

Oussama Abla
Gritta Janka
Editors

Histiocytic Disorders

 Springer

Histiocytic Disorders

Oussama Abla • Gritta Janka
Editors

Histiocytic Disorders

 Springer

Editors

Oussama Abla
University of Toronto
The Hospital for Sick Children
Toronto, Ontario, Canada

Gritta Janka
Pediatric Hematology and Oncology
University Medical Center Hamburg
Eppendorf
Hamburg, Germany

ISBN 978-3-319-59631-0 ISBN 978-3-319-59632-7 (eBook)
<https://doi.org/10.1007/978-3-319-59632-7>

Library of Congress Control Number: 2017958965

© Springer International Publishing AG 2018, corrected publication February 2018

This work is subject to copyright. All rights are reserved by the Publisher, whether the whole or part of the material is concerned, specifically the rights of translation, reprinting, reuse of illustrations, recitation, broadcasting, reproduction on microfilms or in any other physical way, and transmission or information storage and retrieval, electronic adaptation, computer software, or by similar or dissimilar methodology now known or hereafter developed.

The use of general descriptive names, registered names, trademarks, service marks, etc. in this publication does not imply, even in the absence of a specific statement, that such names are exempt from the relevant protective laws and regulations and therefore free for general use.

The publisher, the authors and the editors are safe to assume that the advice and information in this book are believed to be true and accurate at the date of publication. Neither the publisher nor the authors or the editors give a warranty, express or implied, with respect to the material contained herein or for any errors or omissions that may have been made. The publisher remains neutral with regard to jurisdictional claims in published maps and institutional affiliations.

Printed on acid-free paper

This Springer imprint is published by Springer Nature
The registered company is Springer International Publishing AG
The registered company address is: Gewerbestrasse 11, 6330 Cham, Switzerland

Preface

As the second textbook on “histiocytic disorders” is about to be published, the world of histiocytoses has never been more exciting and challenging at the same time. Exceptional advances in molecular and cellular biology have led to rapid changes in diagnostic and therapeutic modalities and have revolutionized the way we view most histiocytic disorders today. Once considered to be disorders of immune regulation, Langerhans cell histiocytosis (LCH) and Erdheim-Chester disease (ECD) are now considered as inflammatory myeloid neoplasms thanks to the discovery of BRAF-V600E and MAP2K mutations in two-thirds of these patients. One of the most important priorities of this textbook is to discuss the new genomic findings in all histiocytic neoplasms and related disorders and to shed more light on the new pathophysiological and genetic findings in hemophagocytic lymphohistiocytosis (HLH). The 2016 revised classification of histiocytic disorders will also be explained, and this will take into account all the most recent molecular and genomic findings merged with clinical categories.

This book will include four sections: the first one is dedicated to the pathology of all histiocytic disorders and is written by the top two world pathology experts on histiocytoses; section 2 is dedicated to LCH in children and adults, central nervous system (CNS) LCH, and first-line treatment of pediatric and adult LCH as well as treatment of refractory and relapsed LCH, with chemotherapy and BRAF inhibitors as well as new hematopoietic stem cell transplantation (HSCT) modalities, with an updated chapter on late effects after LCH. The third section is dedicated to HLH, in particular its diagnostic and clinical features, genetics and pathophysiology, with dedicated chapters on CNS-HLH, EBV-related HLH, malignancy-associated HLH, and macrophage-activation syndrome (MAS). These are followed by chapters on frontline treatment, treatment of refractory/relapsed HLH, HSCT and novel therapies, and finally adult HLH. Section 4 includes the uncommon histiocytic disorders with dedicated chapters on juvenile xanthogranuloma (JXG) and JXG-like disorders, ECD, Rosai-Dorfman disease (RDD), and malignant histiocytoses.

All chapters were written by distinguished experts in each field. We would like to take this opportunity to thank all of them for their efforts and time but also to thank several junior physicians who assisted these experts on specific chapters. We are also very grateful for the editorial assistance of Andy Kwan in New York and of Rahul Kumar Sharma in India, who have shown extraor-

dinary dedication and patience in managing the flow of many manuscripts, figures, and permissions.

We hope this book will serve as a comprehensive and updated tool for all pediatric and adult hematologists, oncologists, immunologists, pathologists, and trainees who will be looking after patients with histiocytic disorders.

Toronto, Canada
Hamburg, Germany

Oussama Abla, MD
Gritta Janka, MD, PhD

Contents

Part I Pathology of Histiocytic Disorders

- 1 Pathology of Histiocytic Disorders and Neoplasms and Related Disorders** 3
Jennifer Picarsic and Ronald Jaffe

Part II Langerhans Cell Histiocytosis (LCH)

- 2 Biology and Genomics of LCH and Related Disorders** 53
Barrett J. Rollins
- 3 Epidemiology and Clinical Manifestations of Langerhans Cell Histiocytosis in Children** 73
Etai Adam, Rima Jubran, and Sheila Weitzman
- 4 Central Nervous System Langerhans Cell Histiocytosis** 87
Milen Minkov, Jennifer Picarsic, and Karoly Lakatos
- 5 First-Line Treatment of Pediatric Langerhans Cell Histiocytosis** 103
Carlos Rodriguez-Galindo and Cor van den Bos
- 6 Treatment of Relapsed and Refractory Langerhans Cell Histiocytosis in Children** 119
Oussama Abla, Carlos Rodriguez-Galindo, and Paul Veys
- 7 Adult Langerhans Cell Histiocytosis** 139
Michael Girschikofsky and Abdellatif Tazi
- 8 Late Effects of Langerhans Cell Histiocytosis and the Association of LCH with Malignancy** 155
Vasanta Nanduri, Lilibeth R. Torno, and Riccardo Haupt

Part III Hemophagocytic Lymphohistiocytosis (HLH)

- 9 Classification, Clinical Manifestations, and Diagnostics of HLH** 173
J. Pachlopnik Schmid, Benjamin Volkmer, and Stephan Ehl

10	CNS Involvement in HLH (CNS-HLH)	189
	AnnaCarin Horne and Karin Beutel	
11	Genetics and Pathogenesis of Hemophagocytic Lymphohistiocytosis	197
	Geneviève de Saint Basile, Despina Moshous, and Alain Fischer	
12	Hemophagocytic Lymphohistiocytosis Associated with Malignancies and with Epstein-Barr Virus	215
	Kai Lehmborg, Fumihiro Ochi, Kim E. Nichols, and Eiichi Ishii	
13	Macrophage Activation Syndrome in Rheumatic Diseases (MAS-HLH)	233
	Alexei A. Grom, AnnaCarin Horne, and Fabrizio De Benedetti	
14	Treatment of Newly Diagnosed HLH and Refractory Disease	247
	Jan-Inge Henter, Rebecca A Marsh, and Tatiana von Bahr Greenwood	
15	Hematopoietic Cell Transplantation and Novel Therapies in Hemophagocytic Lymphohistiocytosis	265
	K. Scott Baker and Michael B. Jordan	
16	HLH in Adults	275
	Paul La Rosée and Rafal Machowicz	
 Part IV Rare Histiocytic Disorders: Non-Langerhans Cell Histiocytosis		
17	Juvenile Xanthogranuloma and Related Non-LCH Disorders	293
	Francesco Ceppi and Oussama Abla	
18	Erdheim-Chester Disease	313
	Eli L. Diamond and Benjamin H. Durham	
19	Rosai–Dorfman Disease	339
	Oussama Abla and Jennifer Picarsic	
20	Malignant Histiocytoses	361
	Eric Jacobsen, Oussama Abla, and Johannes Visser	
	Erratum	E1
	Index	383

Contributors

Oussama Abla, MD Department of Pediatrics, Division of Hematology/Oncology, Hospital for Sick Children and University of Toronto, Toronto, ON, Canada

Etai Adam, MD The Children's Center for Cancer and Blood Diseases, Children's Hospital Los Angeles, Los Angeles, CA, USA

Tatiana von Bahr Greenwood, MD Childhood Cancer Research Unit, Department of Women's and Children's Health, Karolinska Institutet, and Theme of Children's and Women's Health, Karolinska University Hospital, Stockholm, Sweden

Fabrizio De Benedetti, MD Ospedale Pediatrico Bambino Gesù, Rome, Italy

Karin Beutel, MD Pediatric Hematology and Oncology, Children's Hospital München-Schwabing, Städtisches Klinikum München and University Hospital München Rechts der Isar, Technical University München, München, Germany

Cor van den Bos, MD, PhD Emma Children's Hospital/Academic Medical Center, Department of Pediatric Oncology, Amsterdam, The Netherlands

Francesco Ceppi, MD Department Woman-Mother-Child, Divisions of Pediatric Oncology and Hematology, University Hospital of Lausanne, Lausanne, Switzerland

Eli L. Diamond, MD Department of Neurology, Memorial Sloan Kettering Cancer Center, New York, NY, USA

Benjamin H. Durham, MD Department of Neurology, Memorial Sloan Kettering Cancer Center, New York, NY, USA

Stephan Ehl, MD Center for Chronic Immunodeficiency, University Medical Center Freiburg, University of Freiburg, Freiburg, Germany

Alain Fischer, MD, PhD INSERM UMR1163, Paris, France
Paris Descartes University-Sorbonne Paris Cité, Imagine Institute, Paris, France

Paediatric Immunology and Hematology Department, Necker Children's Hospital, AP-HP, Paris, France

Collège de France, Paris, France

Michael Girschikofsky, MD Internal Medicine I, (Hemostasis, Hematology and Stem Cell Transplantation and Medical Oncology), Ordensklinikum Linz - Elisabethinen Hospital, Linz, Austria

Alexei A. Grom, MD Cincinnati Children's Hospital Medical Center, Division of Rheumatology, Cincinnati, OH, USA

Riccardo Haupt, MD Epidemiology and Biostatistics Unit, Istituto Giannina Gaslini, Genoa, Italy

Jan-Inge Henter, MD, PhD Childhood Cancer Research Unit, Department of Women's and Children's Health, Karolinska Institutet, and Theme of Children's and Women's Health, Karolinska University Hospital, Stockholm, Sweden

AnnaCarin Horne, MD, PhD Pediatric Rheumatology Clinic and Childhood Cancer Research Unit, Karolinska universitetets sjukhuset and Karolinska Institutet, Stockholm, Sweden

Eiichi Ishii, MD Department of Pediatrics, Ehime University Graduate School of Medicine, Toon, Ehime, Japan

Eric Jacobsen, MD Department of Medical Oncology, Dana-Farber Cancer Institute, Boston, MA, USA

Ronald Jaffe, MB, BCh Department of Pathology, University of Pittsburgh School of Medicine, Magee Women's Hospital of UPMC, Pittsburgh, PA, USA

Michael B. Jordan, MD Divisions of Immunobiology and Bone Marrow Transplantation and Immune Deficiency, Department of Pediatrics, Cincinnati Children's Hospital Medical Center, University of Cincinnati, Cincinnati, OH, USA

Rima Jubran, MD The Children's Center for Cancer and Blood Diseases, Children's Hospital Los Angeles, Los Angeles, CA, USA

Karoly Lakatos, MD St. Anna Children's Hospital, Department of Pediatrics and Adolescent Medicine, Medical University of Vienna, Vienna, Austria

Kai Lehmborg, MD Department of Pediatric Hematology and Oncology, University Medical Center Hamburg Eppendorf, Hamburg, Germany

Rafal Machowicz, MD, MSc Department of Hematology, Oncology and Internal Diseases, Medical University of Warsaw, Warsaw, Poland

Rebecca A. Marsh, MD Division of Bone Marrow Transplantation and Immune Deficiency, Cincinnati Children's Hospital Medical Center, Cincinnati, OH, USA

Milen Minkov, MD, PhD International LCH Study Reference Center, CCRI, St. Anna Kinderkrebsforschung, Department of Pediatrics and Adolescent Medicine, Medical University of Vienna, Vienna, Austria

St. Anna Children's Hospital, Department of Pediatrics and Adolescent Medicine, Medical University of Vienna, Vienna, Austria

Despina Moshous, MD, PhD INSERM UMR1163, Paris, France

Paris Descartes University-Sorbonne Paris Cité, Imagine Institute, Paris, France

Paediatric Immunology and Hematology Department, Necker Children's Hospital, AP-HP, Paris, France

Vasanta Nanduri, MD, MRCP, FRCPC Department of Paediatrics, Watford General Hospital, Watford, WK, UK

Kim E. Nichols, MD Department of Oncology, St. Jude Children's Research Hospital, Memphis, TN, USA

Fumihiko Ochi, MD Department of Pediatrics, Ehime University Graduate School of Medicine, Toon, Ehime, Japan

J. Pachlopnik Schmid, MD, PhD Division of Immunology, University Children's Hospital, University of Zurich, Zurich, Switzerland

Jennifer Picarsic, MD Department of Pathology, University of Pittsburgh School of Medicine, Children's Hospital of Pittsburgh of UPMC, Pittsburgh, PA, USA

Department of Pathology, Children's Hospital of Pittsburgh of UPMC, Pittsburgh, PA, USA

Carlos Rodriguez-Galindo, MD Departments of Global Pediatric Medicine and Oncology, St. Jude Children's Research Hospital, Memphis, TN, USA

Barrett J. Rollins, MD, PhD Department of Medical Oncology, Dana-Farber Cancer Institute, Department of Medicine, Brigham and Women's Hospital, Harvard Medical School, Boston, MA, USA

Paul La Rosée, MD Klinik für Innere Medizin II, Klinikstr. 11, Schwarzwald-Baar-Klinikum, Villingen-Schwenningen, Germany

Geneviève de Saint Basile, MD, PhD INSERM UMR1163, F-75015, Paris, France

Paris Descartes University-Sorbonne Paris Cité, Imagine Institute, Paris, France

Centre d'Etudes des Déficiés Immunitaires, Assistance Publique-Hôpitaux de Paris, Hôpital Necker, Paris, France

K. Scott Baker, MD, MS Clinical Research Division, Fred Hutchinson Cancer Research Center, Department of Pediatrics, University of Washington, Seattle, WA, USA

Abdellatif Tazi, MD, PhD Publique-Hôpitaux de Paris, Saint-Louis Hospital, National Reference Center for Histiocytoses, Pulmonary Department, Paris, France

University Paris Diderot, Sorbonne Paris Cité, Inserm UMR-1153 (CRESS),
Biostatistics and Clinical Epidemiology Research Team (ECSTRA), Paris,
France

Lilibeth R. Torno, MD After Cancer Treatment Survivorship Program,
Children's Hospital of Orange County, Orange, CA, USA

Paul Veys, MBBS, FRCP, FRCPATH, FRCPCH Blood and Bone
Marrow Transplantation Unit, Great Ormond Street Hospital for Children,
London, UK

Johannes Visser, MB, ChB Cambridge University Hospitals NHS
Foundation Trust, Addenbrooke's Hospital, Cambridge, UK

Benjamin Volkmer, PhD Division of Immunology, University Children's
Hospital, University of Zurich, Zurich, Switzerland

Sheila Weitzman, MB, BCh, FCP(SA), FRCP(C) Division of
Haematology and Oncology, Department of Paediatrics, The Hospital for
Sick Children, University of Toronto, Toronto, ON, Canada

Part I

Pathology of Histiocytic Disorders

Pathology of Histiocytic Disorders and Neoplasms and Related Disorders

1

Jennifer Picarsic and Ronald Jaffe

Introduction

The “histiocytoses” have been a collective description of tissue proliferations of the hematopoietic-derived cells that compose both the monocyte-macrophage and the dendritic cell families. Our understanding of histiocytic disorders has evolved from the first classification published by the Histiocyte Society (HS) Working Group in 1987 that included disorders of Langerhans cells (LC), non-Langerhans cell related, and the malignant histiocytoses (MH) [1]. A more contemporary classification was laid out in 1997 by the World Health Organization (WHO) Committee on Histiocytic/Reticulum Cell Proliferations and the Histiocyte Society Reclassification Working Group (Table 1.1) [2]. These classifications were based on biologic behavior and histopathology, including dendritic cell related (e.g., Langerhans cell histiocytosis

(LCH), juvenile xanthogranuloma (JXG) family), macrophage related (e.g., hemophagocytic syndromes, Rosai-Dorfman disease (RDD)), and malignant disorders, typically grouped by their most common morphologic/immunophenotypic counterpart. The histology together with the clinical features and stage of involvement had resulted in a unifying clinicopathologic diagnosis in most cases [2]. However, the field of histiocytic disorders is now within an era of “molecular enlightenment.” New molecular data are emerging that support the theory that LCH and Erdheim-Chester disease (ECD) (and possibly also systemic JXG lesions with gain of function mutations) are best classified as inflammatory myeloid neoplasms [3–5]. The shared molecular alterations in these histiocytic disorders have blurred the lines between the LCH and “non-LCH” groups. Recent discussion is now focused on a revised classification scheme in which the molecular signature of these disorders is more strongly emphasized and proposes to lump seemingly separate groups (i.e., LCH and ECD) based on common molecular alterations and overlapping clinical presentations [6] (Table 1.2). The proposed 2016 WHO classification of mature lymphoid, histiocytic, and dendritic neoplasms has now separated ECD as its own distinct entity based on integration of clinical, radiology, and histopathologic diagnosis [7] (Table 1.3).

As the molecular signature of the histiocytic disorders/neoplasms is further elucidated, we are

J. Picarsic, MD (✉)

Department of Pathology, University of Pittsburgh
School of Medicine, Children’s Hospital of Pittsburgh
of UPMC, Pittsburgh, PA, USA

Department of Pathology, Children’s Hospital of
Pittsburgh of UPMC, One Children’s Hospital Drive,
4401 Penn Avenue, Main Hospital, B260,
Pittsburgh, PA 15224, USA
e-mail: picarsicj@upmc.edu

R. Jaffe, MB, BCh

Department of Pathology, University of Pittsburgh
School of Medicine, Magee Women’s Hospital
of UPMC, Pittsburgh, PA, USA

Table 1.1 1997 Contemporary classification of histiocytic disorders: by WHO Committee on Histiocytic/Reticulum Cell Proliferations

<i>Disorders of varied biologic behavior</i>
Dendritic cell related
Langerhans cell histiocytosis
Secondary dendritic cell processes
Juvenile xanthogranuloma and related disorders
Solitary histiocytomas of various dendritic cell phenotypes
Macrophage related
Hemophagocytic syndromes
Primary hemophagocytic lymphohistiocytosis (familial and sporadic; commonly elicited by viral infections)
Secondary hemophagocytic syndromes
Infection associated
Malignancy associated
Others
Rosai-Dorfman disease (sinus histiocytosis with massive lymphadenopathy)
Solitary histiocytoma with macrophage phenotype
<i>Malignant disorders</i>
Monocyte related
Leukemias (FAB and revised FAB classifications)
Monocytic leukemia M5A and B
Acute myelomonocytic leukemia M4
Chronic myelomonocytic leukemia
Extramedullary monocytic tumor or sarcoma (monocytic counterpart of granulocytic sarcoma)
Dendritic cell-related histiocytic sarcoma (localized or disseminated)
Specify phenotype, follicular dendritic cell, interdigitating dendritic cell, etc.
Macrophage-related histiocytic sarcoma (localized or disseminated)

Reference: Favara et al. [2]

afforded a better understanding of the putative cell of origin. Transcriptional profiles of LCH share a gene expression profile closely related to circulating dendritic cells (cDCs) and late-stage myeloid progenitor cells, rather than epidermal Langerhans cells, supported by previous reports that LCH is derived from immature myeloid dendritic cells of the bone marrow [3, 8]. In contrast, non-LCH lesions (i.e., JXG, ECD) may share transcriptional profiles more similar to monocytes and earlier hematopoietic stem and progenitor cells in preliminary work [4].

Table 1.2 2016 Revised classification of histiocytoses and neoplasms of the macrophage-dendritic cell lineages based on clinical, radiographic, pathological, phenotypic, genetic, and/or molecular features

L group histiocytoses
Langerhans cell histiocytosis
Indeterminate dendritic cell tumor
Erdheim-Chester disease
Mixed Langerhans cell histiocytosis/Erdheim-Chester disease
C group: non-Langerhans cell histiocytosis of skin and mucosa
<i>Cutaneous non-Langerhans cell histiocytosis</i>
Xanthogranuloma family:
Juvenile xanthogranuloma granuloma
Adult xanthogranuloma granuloma
Solitary reticulohistiocytoma
Benign cephalic histiocytosis
Generalized eruptive histiocytosis
Progressive nodular histiocytosis
Non-xanthogranuloma
Cutaneous Rosai-Dorfman disease
Necrobiotic xanthogranuloma
Cutaneous histiocytosis not otherwise specified
<i>Cutaneous non-Langerhans cell histiocytosis with a major systemic component</i>
Xanthogranuloma family: xanthoma disseminatum
Non-xanthogranuloma family: multicentric reticulohistiocytosis
R group: Rosai-Dorfman disease and miscellaneous noncutaneous, non-Langerhans cell histiocytoses
Familial Rosai-Dorfman disease
Sporadic Rosai-Dorfman disease
Classical (nodal) Rosai-Dorfman disease
Extranodal Rosai-Dorfman disease
Neoplasia-associated Rosai-Dorfman disease
Immune-associated Rosai-Dorfman disease
M group: malignant histiocytoses
Primary malignant histiocytoses, localization and subtype (histiocytic, Langerhans cell, interdigitating, indeterminate cell, or not specified)
Secondary malignant histiocytoses (following or associated with another hematologic neoplasia)
H group: hemophagocytic lymphohistiocytosis and macrophage activation syndrome (HLH/MAS)
Primary HLH: monogenic, Mendelian-inherited conditions leading to HLH
Secondary HLH (apparently non-Mendelian HLH)
HLH of unknown/uncertain origin

Reference: Emile et al. [6]

Table 1.3 Proposed 2016 WHO classification of mature lymphoid, histiocytic, and dendritic neoplasms

Histiocytic and dendritic cell neoplasms
Histiocytic sarcoma
Langerhans cell histiocytosis
Langerhans cell sarcoma
Indeterminate dendritic cell tumor
Interdigitating dendritic cell sarcoma
Follicular dendritic cell sarcoma
Fibroblastic reticular cell tumor
Disseminated juvenile xanthogranuloma
Erdheim-Chester disease ^a

Reference: Swerdlow et al. [7]

^aChanges from the 2008 classification

Thus, while sharing similar mitogen-activated protein kinase (MAPK) pathway mutations, newer transcriptional data with RNA-seq analyses in LCH and non-LCH histiocytoses may still support two separable groups, as originally supported by their divergent immunophenotype [4].

The sustained progress that has been made in the field will continue as we further explore the diverse histopathology, now with a strong emphasis on the molecular underpinnings that may drive these disorders in order to better describe, classify, and ultimately treat these rare disorders/neoplasms. For the purposes of this chapter, we will describe the main histiocytic groups based on their defining histopathologic characteristics, with reference to areas that are in fluidity with regards to the proposed revised classification (Table 1.2) [6].

Langerhans Cell Histiocytosis (LCH)

Morphology

The establishment of LCH requires a tissue diagnosis, which shows a clonal neoplastic proliferation of generally large (15–25 μm) round to oval histiocytes with a complex nuclear contour that often assumes a nuclear groove (“coffee bean” nucleus) (Fig. 1.1). The cells should be distinguished from the inflammatory CD1a+ dendritic cells, which have a branching morphology given their antigen-presenting role.

Immunophenotype

The immunophenotype of LCH (Fig. 1.1, Table 1.4) includes surface CD1a expression [9] and granular cytoplasmic CD207 (langerin) staining, which is a surrogate for Birbeck granules and has replaced the need for ultrastructural confirmation [10]. When still performed, S100 is present with cytoplasmic and nuclear staining. An inflammatory milieu often accompanies but is not required for diagnosis and includes eosinophils, lymphocytes, phagocytic macrophages, and a variable number of lysozyme-rich (CD68+/CD1a-) osteoclastic-type giant cells, especially frequent within bony lesions, while plasma cells are rare. Foci of necrosis and brisk mitoses can be seen but are not unfavorable features, unlike the presence of atypical mitoses, diffuse pleomorphism, and cytologic atypia, which raise concern for Langerhans cell sarcoma (see “Malignant Histiocytic Disorders”). In general, the proliferation index of LCH can be difficult to determine accurately without a dual-staining marker (e.g., CD207/Ki-67) to confirm the LCH cells within an inflammatory milieu; however, the proliferation rate is generally less than 10% when dual staining is applied (Ronald Jaffe, personal observations 1985–2015).

Differential Diagnosis

While it is often overlooked, it is important to remember that the pathologic diagnosis of LCH requires not only the appropriate cytomorphology and phenotype but also the correct pattern of organ involvement. Diagnostic difficulty ensues in chronic inflammatory disorders, most notably of the skin and lymph node, where LC/dendritic cell hyperplasia with increased numbers of CD1a-positive dendritic cells (CD207 can be low or absent) in a non-LCH pattern of involvement (i.e., perivascular distribution in chronic dermatoses or paracortical hyperplasia in dermatopathic lymphadenopathy) leads to a false-positive diagnosis. On the opposite end of the spectrum, diagnostic challenges ensue in cases where LCH cells have been replaced by a

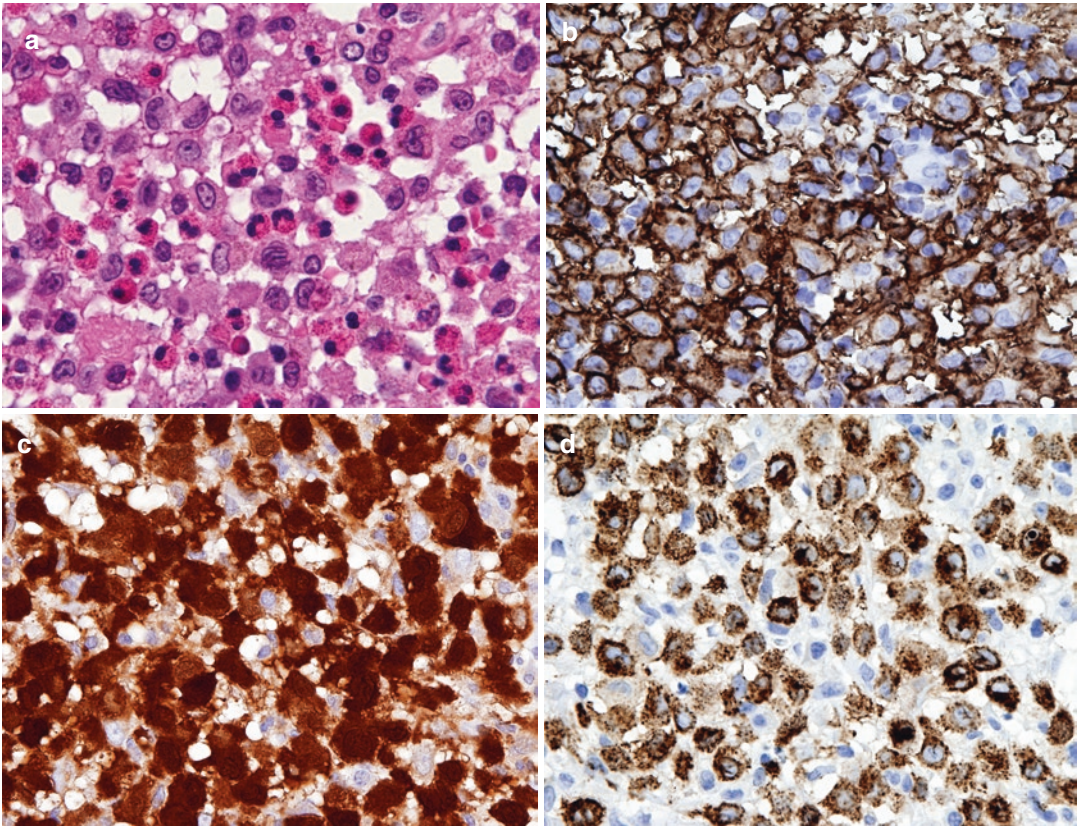


Fig. 1.1 (a) Langerhans cell histiocytosis (LCH) with large ovoid histiocytes and “coffee bean” nuclear groove admixed with eosinophils (hematoxylin and eosin (H&E) stain, 100×). (b) Surface CD1a expression (immunostain, 100×). (c) Nuclear and cytoplasmic S100 expression

(immunostain, 100×). (d) Granular cytoplasmic CD207 (langerin) (immunostain, 100×) expression (Original objective magnification) (Modified from previous publication (Ref. [24]))

fibroxanthomatous inflammatory milieu or limited sampling precludes a diagnosis (false negative). This is most commonly seen in the bone marrow, liver, and small pituitary and other CNS biopsies where very few LCH cells may be sampled on biopsy. Molecular testing may hold promise in these “false-negative” cases. Rare reports have shown small percentages of BRAF mutant-positive (<1%), CD1a-negative myeloid precursor cells in the bone marrows of LCH patients who were known to harbor the *BRAF-V600E* mutation [3]. Further investigation will be needed to delineate if the “molecular microscope” may better signal disease in this “false negative” as opposed to standard histopathology alone.

Ancillary Studies: Insights into Cellular Origin and Diagnostic Testing

Original reports on the *BRAF-V600E* mutation-specific antibody (clone VE1) [11] and subsequent molecular analysis [3] suggest that the co-expression of mutant protein is seen in CD207+ tissue LCH cells, along with circulating and bone marrow-derived CD14+/CD36+ or CD14+/CD11c myeloid cells, which support the role of immature myeloid dendritic cells as the precursor or cell of origin in LCH. The VE1 antibody has an ancillary role, but has not replaced molecular testing, with few studies specifically addressing the comparison of antibody

Table 1.4 Immunohistochemical (IHC) panels and pearls for diagnosis of select histiocytic lesions/neoplasms

Diagnosis	IHC panel	Pearls for diagnosis
Langerhans cell histiocytosis	CD1a (membranous) CD207/ langerin (cytoplasmic) S100 (nuclear and cytoplasmic)	CD207 replaced need for EM and more sensitive than CD1a Correct pattern of involvement for given site is needed
Indeterminate cell histiocytosis	CD1a (membranous) S100 (nuclear and cytoplasmic) Negative for CD207	<i>ETV-NCOA2</i> fusion now described in some
Erdheim-Chester disease	CD163 (surface to cytoplasmic) CD14 (surface) CD68 (granular cytoplasmic) Factor XIIIa (cytoplasmic) Fascin (cytoplasmic)	The morphology and phenotype of “juvenile xanthogranuloma family” have to be correlated with clinical and radiographic images for diagnosis. Factor XIIIa can be lost in heavily xanthomatous cells
Juvenile xanthogranuloma family of lesions	Similar to ECD above	While cutaneous lesions with typical morphologic patterns do not require extensive immunophenotyping, deep and visceral lesions without classic morphology can be aided by IHC
Rosai-Dorfman disease	S100 and fascin positive CD1a and CD207 negative	Large pale histiocytes with a hypochromatic nucleus are diagnostic. Emperipolesis is variable An S100+ lesion in lymph node should exclude metastatic malignant melanoma in an adult and LCH in a child
Histiocytic sarcoma	CD163, CD14, CD4, and CD11c, lysozyme (Golgi dot), CD45, HLA-DR, S100 +/-, CD56 (rare), and variable JXG phenotype Ki-67 proliferation rate > 10%	CD163 in a surface and/or cytoplasmic pattern has high specificity, more so than CD68 that is present in a variety of cell types Cytologic pleomorphism, increased mitoses, including atypical forms
Langerhans cell sarcoma	CD1a (membranous) CD207/ langerin (cytoplasmic) S100 (nuclear and cytoplasmic) Ki-67 proliferation rate > 30%	Cytologic pleomorphism, increased mitoses, including atypical forms

to molecular testing in LCH [11, 12]. According to the US Food and Drug Administration (FDA) definition of *in vitro diagnostic product (IVD) reagents intended for use in diagnostics of disease taken from the human body*, the VE1 antibody could fall under Class II: “providing prognostic or predictive data” which requires more rigorous validation since treatment decisions could be based directly on results [13, 14] (College of American Pathology (CAP) checklist, *available upon request*). In the United States, it is important to ensure that the clinical laboratory offering VE1 testing has rigorously validated the antibody according to FDA/CAP guidelines if used for treatment decisions in lieu of molecular testing.

After the diagnosis of LCH has been confirmed, some centers perform up-front BRAF mutational testing on all LCH cases [15], as

ongoing work is showing its value in predicting refractory or recurrent disease [3], first-line treatment failure, and association with high-risk features [16]. While molecular PCR confirmation is the gold standard, the role of VE1 immunohistochemistry (if properly validated) has significant value in LCH as it has been demonstrated that LCH lesions may have a very low number of lesional cells harboring the BRAF mutation (in many cases below 5% of cells). Conventional PCR sequencing will miss those cases with small allelic fractions and may be considered negative (i.e., typical limit of detection is 20–25% of cells); therefore, sensitive methods of detection including validated VE1 immunohistochemistry and highly sensitive molecular assays (i.e., quantitative real-time PCR (qPCR) or allele-specific PCR/amplification refractory mutation system

(ARMS)) are required to accurately determine the BRAF status in LCH with a limit of detection down to 1% or less for mutated alleles [3, 15, 17]. Other mutations in the MAPK pathway (e.g., *ARAF*, *ERBB3*, *MAP2K1*) and rarely mutations in the phosphoinositide 3-kinase-Akt murine thymoma pathway (*PIK3CA*) have also been discovered in BRAF wild-type LCH lesions with nearly all LCH lesions showing upregulation of ERK phosphorylation [18–23]. A detailed review of the molecular and genomic features of LCH is provided in Chap. 2 and elsewhere [24].

LCH Pattern of Involvement in Specific Organs

Because the diagnosis of LCH requires the combination of morphology, immunophenotype, and correct pattern of organ involvement, we will briefly discuss the salient features in these various organ systems, but refer to other sources for further details [25].

Bone

Clinical

Bone involvement may manifest as an asymptomatic solitary osteolytic lesion that will spontaneously resolve with simple curettage. Multifocal bone involvement, with or without bone pain or bone involvement associated with disseminated multiorgan involvement (MS-LCH), confers a more aggressive disease course. In the cranial bones, it has long been held that involvement of certain “CNS-risk sites” including the temporal bone, maxillofacial bones, and orbital bones confer a higher risk of diabetes insipidus (DI), endocrinopathies, and subsequent CNS neurodegeneration (ND) [26]. Vertebral involvement often leads to collapse (i.e., vertebra plana) with complications arising if there is spinal cord compression.

Pattern of Involvement

Lytic bone lesions are one of the most common sites of involvement, which manifest as sheets of

LCH cells within a rich inflammatory milieu with cortical destruction. In some cases, an aneurysmal bone cyst-like formation occurs with numerous osteoclast-type giant cells lining the periphery of the cystic space [27] (Fig. 1.2). Older lesions may result in extensive fibrosis, which may preclude a diagnosis if the residual small collections of diagnostic LCH cells are not identified.

Ancillary Testing

Bone lesions are a particular challenge for *BRAF* mutational studies, as formic acid decalcification processing irreversibly degrades nucleic acids and renders the specimen inadequate for subsequent PCR molecular studies. Therefore, upfront triage of a fresh frozen tissue in bone lesions with suspected histiocytic disorders should be instituted (i.e., bone curettage and marrow aspirates). Some also propose an alternative fixation/decalcification in EDTA, which is reported to offer the best chance of successful DNA extraction from FFPE decalcified bone specimens [12, 28]. Alternatively, the VE1 antibody appears to be stable in decalcified FFPE sections both with formic acid [29] and EDTA [12, 30]) preparations, which could serve as a surrogate if the antibody has properly been validated (*see above*).

Differential Diagnosis

The differential diagnosis in these cases includes chronic osteomyelitis, fibrohistiocytic lesions, JXG family, and ECD. Reactive conditions, including culture-negative chronic recurrent multifocal osteomyelitis (CRMO), can be challenging to distinguish by histopathology alone, especially in those cases associated with fractures and associated plasma cells. Typically, CRMO lesions present in the metaphyses of long bones and do not involve unusual sites such as the skull bone, nor should they have associated soft tissue lesions or lymphadenopathy; if these features are present on imaging, a repeat biopsy or biopsy of another site may be warranted. In the differential diagnosis of old fibrosing lesions of the long bones, especially in adults, ECD should also be considered with the typical radiographic findings (i.e., bilateral long bone osteosclerosis and retroperitoneal fibrosis). The radiographic

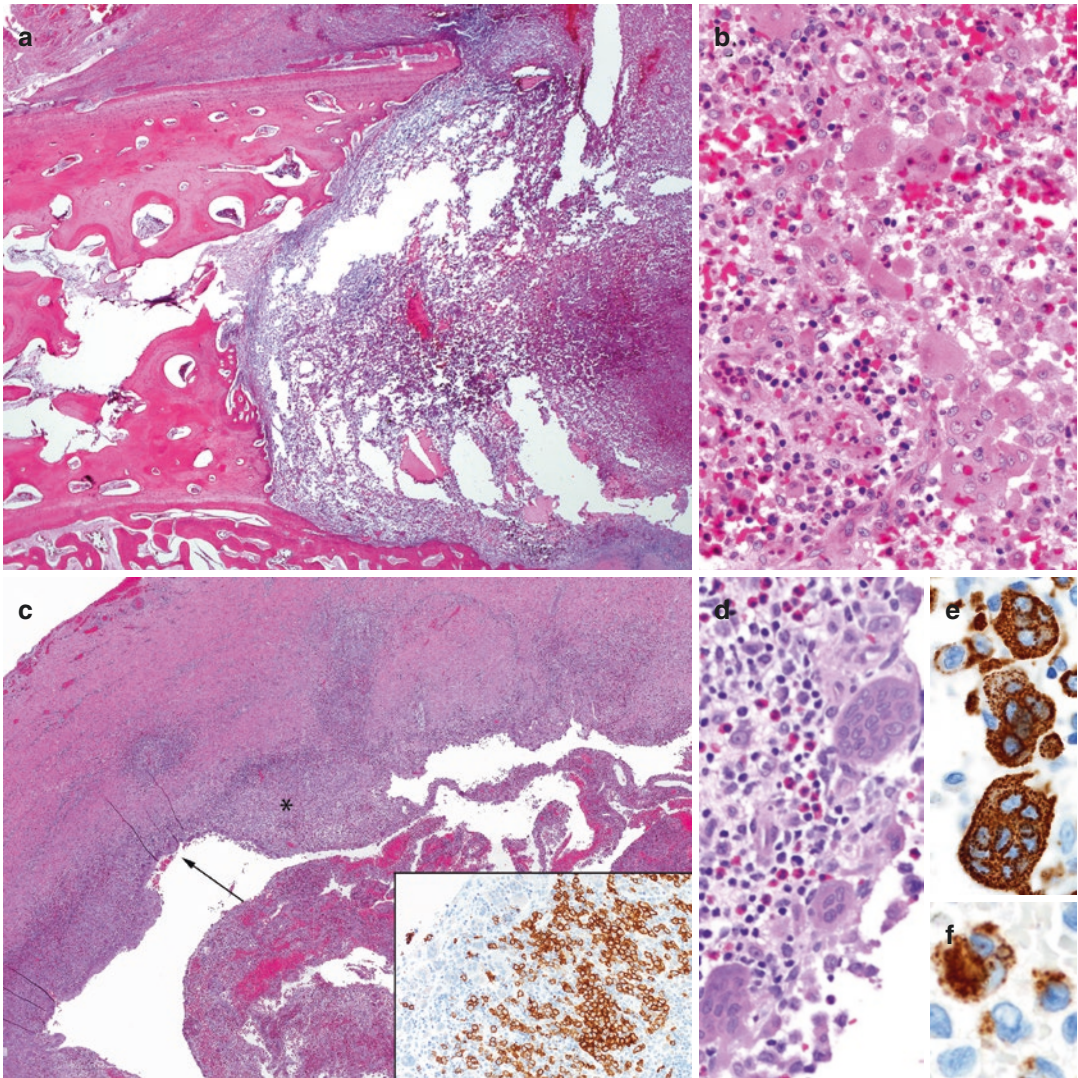


Fig. 1.2 Bone LCH. (a) Cortical destruction of frontal skull bone by LCH (H&E, 2 \times). (b) LCH with a rich inflammatory background including osteoclast-like giant cells (OCGC), eosinophils, and neutrophils (H&E, 40 \times). (c, d) Dural extension with aneurysmal bone cyst-like formation with OCGC lining the leading edge of the lesion (arrow head corresponding to image d) and asterisk indicates the area of CD1a-positive LCH (c. H&E, 2 \times , with inset, immunostain, 20 \times and d. H&E, 40 \times). (e) CD68

positivity in lysosomal rich OCGC (immunostain, 100 \times), with (f) variable paranuclear positivity to negative staining of LCH cells for this lysosomal marker (CD68 immunostain, 100 \times) (Digital whole slide images (WSI) are available here: <http://image.upmc.edu:8080/HistioPathChapter/Abla/view.apml> and hosted courtesy of University of Pittsburgh School of Medicine, Department of Pathology, Division of Informatics)

findings are correlated with the histology showing a JXG immunophenotype with a high content of xanthomatous/foamy cells within a fibrosing stromal background (see below) [31]. The challenge in RDD bone lesions is that bone involvement is rare and demonstration of RDD

cells (e.g., large pale histiocytic cells with a hypochromatic nucleus and variable emperipoleses) may be masked by a fibrosing and inflammatory background rich in plasma cells, which can mimic chronic osteomyelitis including CRMO if multifocal (see below).

Skin

Clinical

LCH involvement of the skin typically presents as eczema/seborrheic dermatitis in young children or papulonodular eruptions of the flexural (axilla, groin), scalp, and genital/perineal areas in adults.

Pattern of Involvement

LCH expands the upper dermis with sheetlike infiltration and epidermotropism and may ulcerate the surface (Fig. 1.3). LCH cells demand the correct cytomorphology (i.e., plump histiocytes with grooved nucleus) and immunophenotype (CD1a+ surface/CD207+ cytoplasmic). Isolated cutaneous LCH involvement in a neonate should be treated as single-system (SS)-LCH only after careful staging has been performed, as a subset of these patients already have or will later present with MS-LCH disease [32].

Ancillary Testing

In children with cutaneous LCH, circulating peripheral blood monocyte/myeloid cells with

BRAF-V600E mutation were noted with much greater frequency (72%) in those with multisystem (MS)-LCH as compared to those with skin-only LCH (8%) [32]. Therefore, a diagnosis of congenital, self-healing Hashimoto-Pritzker disease, or self-healing reticulohistiocytoma, is a diagnosis of clinical exclusion based on retrospective clinical insight, after careful staging and watchful waiting, and should not be made on histologic grounds alone [33]. A highly sensitive qPCR test for circulating and/or bone marrow *BRAF* mutant precursor cells (<1% mutant) may hold promise for predicting and following disease course, although a wild-type *BRAF* status at this point does not necessarily predict indolent behavior and clinical staging is still mandatory in patients with apparent skin-only disease [34].

Differential Diagnosis

Important differential diagnoses include other cutaneous histiocytic lesions (e.g., JXG family, RDD), cutaneous myelomonocytic leukemias, mastocytosis, melanocytic nevi, and immune defects, including the V(D)J recombination activation gene (*RAG1* and 2) defects/severe

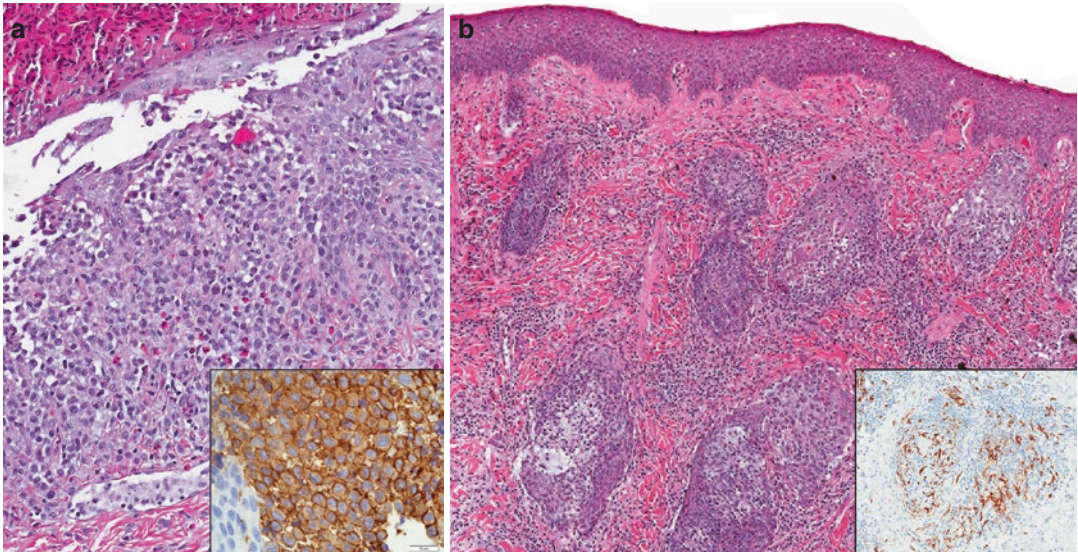


Fig. 1.3 Cutaneous lesions. (a) Skin LCH with epidermotropism and ulceration (H&E, 20×); CD1a (inset, 100×) (b). Chronic dermatitis with folliculitis pattern (H&E, 20×) with mild hyperplasia of CD1a-positive cells, which are branched and spindled, unlike LCH cells (20×)

(Digital whole slide images (WSI) are available here: <http://image.upmc.edu:8080/HistioPathChapter/Abla/view.apml> and hosted courtesy of University of Pittsburgh School of Medicine, Department of Pathology, Division of Informatics)

combined immune defects (SCID) (including Omenn syndrome, OMIM #603554) [35]. These immune defects may have a mixed histiocytic dermal infiltrate with dendritic cell hyperplasia, but are predominately CD1a and langerin negative. Involvement of the skin with a CD1a+ immature myelomonocytic leukemia/sarcoma should be ruled out with a panel including MPO, CD14, lysozyme, CD33, and Ki-67/MiB1, which will have a generally high proliferation rate. In such cases, we also find it helpful to perform both CD68-KP1 (lysosomal **and** an early myeloid marker) and CD68-PGM1 (lysosomal marker only), where KP1 can be informative as a myeloid marker if expression is greater than PGM1, confirming a myeloid predominant population. We have seen a rare example of a CD1a+ myeloid sarcoma and advocate also using CD207, which will be negative. Cutaneous JXG and RDD of the skin are described in their respective sections (see below). Mastocytosis is usually CD117/tryptase positive and CD1a/langerin negative. Melanocytic nevi will express S100 with other melanocytic markers (MelanA, HMB45) and is CD1a/langerin negative. Chronic inflammatory dermatoses, including chronic scabies and pseudo-lymphomatous folliculitis, show a mostly superficial perivascular/perifollicular mononuclear inflammatory infiltrate with dendritic cell hyperplasia. While it does not have the pattern of LCH, the indiscriminate use of immunostains will reveal a population of spindly perivascular dendritic cells that are CD1a+/S100+ with variable CD207+, but should not be diagnosed as LCH (Fig. 1.3).

Lymph Node

Pattern of Involvement

In order to diagnose LCH involvement of the lymph nodes, a sinus pattern must be demonstrated. Secondary involvement of the other zones (i.e., paracortex) occurs in cases with architectural expansion and parenchymal effacement. In such cases, there may be less expression of CD1a/CD207 in the paracortex when compared to the sinus infiltrate (Fig. 1.4a, b).

Differential Diagnosis

Indiscriminate use of immunostains in a reactive lymph node with nodular paracortical hyperplasia (i.e., dermatopathic lymphadenopathy pattern) will reveal an expanded population of CD1a+/CD207+ spindled/dendritic cells, in addition to a rich population of S100+/fascin+ interdigitating dendritic cells within the pale staining interfollicular nodular areas. Occasional melanin pigment-laden macrophages are often noted in the background. In this scenario, recognizing the pattern of CD1a+/CD207+ cells without a sinus pattern together with the paracortical S100+/fascin+ expansion will prevent an erroneous diagnosis of LCH (Fig. 1.4). We advocate the use of both CD1a and CD207 immunostains, as there is an endogenous cell population of CD207+ cells in the medullary sinuses that may additionally cause diagnostic confusion in the node. Langerhans cell sarcoma (LCS) of the lymph nodes can be distinguished from LCH based on high cellularity with nuclear pleomorphism, increased mitoses including atypical forms, and increased Ki-67 index (>30%); the immunophenotype and sinus pattern of involvement are retained in both LCH and LCS. Often there is more architectural effacement in LCS (see below, Fig. 1.17). In RDD, a histiocytic sinus involvement is noted, but the presence of large pale histiocytes with a large hypochromatic nucleus and variable degree of emperipolesis should be readily distinguished from LCH by H&E, and the S100+/fascin+/CD1a-/CD207- phenotype is further confirmatory (see below). Replacement of the nodal architecture with a xanthomatous histiocytic-rich infiltrate can be seen in late LCH involvement with little discernable CD1a+/CD207+ cells. In addition, storage disorders are considered here in which clinical history and discerning use of ancillary stains and ultrastructural analysis can be confirmatory. Nodal JXG involvement is exceptionally rare and may rather raise a suspicion for histiocytic sarcoma if cytologic atypia or atypical/increased mitoses are found. Other malignancies in the differential diagnosis include histiocytic-rich variant of anaplastic large cell lymphoma, for which cytomorphology and phenotype should be readily distinguishable. Other nodal inflammatory conditions included in

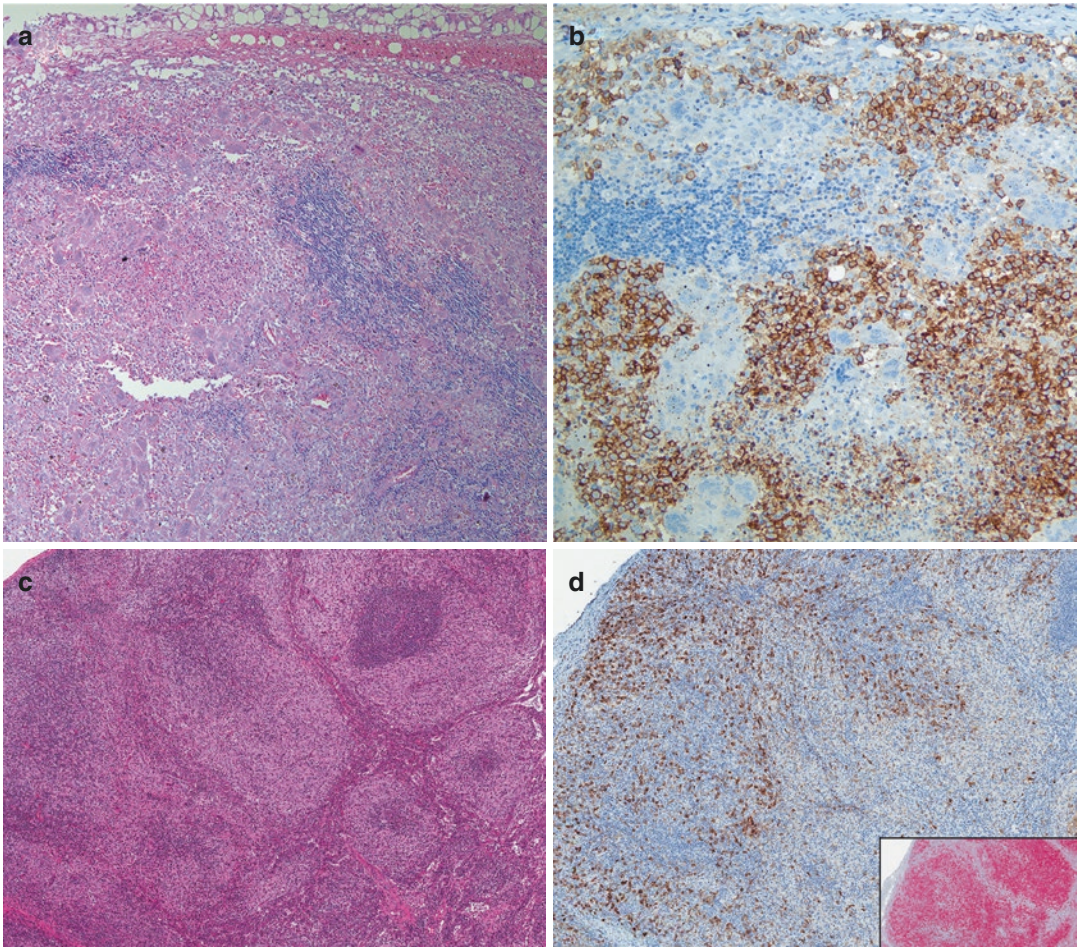


Fig. 1.4 Lymph node lesions. (a) LCH of lymph node with subcapsular sinus involvement and extension into the paracortex (H&E, 20 \times). (b) CD1a shows strong membranous staining of the sinus LCH cells with paracortical infiltration (immunostain). (c) Extensive paracortical dendritic cell hyperplasia consistent with dermatopathic

effect (Digital H&E image, 5 \times). (d) High content of interspersed CD1a+ dendritic Langerhans cells without sinus expansion; the paracortical areas stain strongly for S100+ interdigitating cells (immunostain image, inset, 5 \times) and fascin (not shown)

the differential diagnosis would include Churg-Strauss syndrome (eosinophils), while a vaguely granulomatous/histiocytic lymphadenitis may further raise a differential diagnosis of various immunodeficiency states which needs to be correlated with the clinical scenario (i.e., chronic granulomatous disease (CGD), Blau syndrome, CVID, and certain RAG1 deficiencies) [36–39]. Lastly, microscopic foci of dendritic/Langerhans cells in the context of other lymphoproliferations are best classified as LCH-like lesions, rather than a true LCH lesion. These small foci appear to be an exaggerated reactive response, without the typical

pattern of LCH, and tend to involute when the primary disease is controlled without sequela of LCH [40], and, when tested, appear polyclonal in nature [41]. We have also seen such foci with Hodgkin lymphoma, cutaneous pseudolymphoma, thyroid malignancy, and in the thymus [42].

High-Risk Organ Involvement

In multisystem (MS)-LCH, involvement of the bone marrow, liver, and/or spleen confers a higher risk of death from disease and thus is collectively

referred to as risk organs. In multivariate analysis studies, pulmonary involvement was not an independent variable and is now no longer considered to be a risk organ. [43].

Bone Marrow

Clinical

The clinical definition of bone marrow involvement is based on cytopenias of at least two cell lineages. Since marrow biopsies are generally normocellular [44] or even hypercellular and lack a marrow-replacing infiltrate [45], it is more likely that the cytopenias are cytokine mediated rather than direct LCH replacement.

Pattern of Involvement

True marrow infiltration of LCH, separate from penetration of a destructive cortical-based lesion, is typically seen in association with MS-LCH disease and is often difficult to diagnose by histopathology alone [26, 46]. The marrow in these patients is almost never replaced by an LCH infiltrate, as seen in leukemia. The more typical scenario is one in which a macrophage-rich collection of xanthomatous CD163+/CD68+ cells with (at best) small clusters of CD1a+/CD207+ LCH cells is focally present. In rare cases, the macrophages will be activated with a phagocytic phenotype, and it is important to distinguish LCH involvement from an associated macrophage activation that may have more ominous prognostic implications [45, 47]. However, often the diagnosis cannot be reliably made on bone biopsy in the absence of the LCH cell clusters. The VE1 immunostaining pattern is a work in progress.

Ancillary Testing

Recent studies have shown that highly sensitive qPCR can detect very low allelic fractions of *BRAF-V600E* in CD1a-negative precursor cells (~0.02%) in otherwise “negative” (e.g., CD1a/CD207 negative) bone marrows of LCH patients. These marrows may either show a normal histologic appearance or display a histiocytic-rich infiltrate [3, 15]. It has been advocated that in those patients harboring a *BRAF-V600E*-positive

primary LCH lesion, subsequent bone marrow evaluation and/or peripheral blood testing for the *BRAF-V600E* mutation with a highly sensitive PCR methodology may help follow disease progression [15]. Preliminary studies have shown that the mutation may be associated with a two-fold increase in the risk of treatment failure or reactivation [3, 15].

Differential Diagnosis

JXG only rarely involves the bone marrow, and this is typically seen in systemic JXG [48, 49]. ECD bone involvement may extend into the marrow space and can be difficult to separate from bone involvement, and may also be *BRAF-V600E* positive; therefore, clinical/radiographic correlation is mandatory. RDD within the marrow is also typically a part of systemic disease and shows a variable inflammatory rich to fibrosing pattern with occasional RDD cells (see below). Chronic osteomyelitis remains in the differential, but a plasma cell inflammatory infiltrate is not typical with LCH marrow involvement (see above, bone LCH).

Liver

Clinical

Hepatic LCH involvement presents with hepatomegaly (greater than 3 cm below the costal margin at the midclavicular line with ultrasound confirmation) and obstructive cholangiopathy with elevated bilirubin and gamma-glutamyl transferase (γ GT) greater than twice the normal [26].

Pattern of Involvement

Hepatic LCH involvement is one of large bile duct infiltration and is typically noted in the context of MS-LCH disease (Fig. 1.5a). Typically, a liver biopsy is not required for the diagnosis if the disease has been previously established and there are obstructive cholangiopathy laboratory findings. Diagnostic challenge ensues in atypical cases or in those without a prior diagnosis, as a liver biopsy itself is rarely diagnostic given the preferential large bile duct involvement

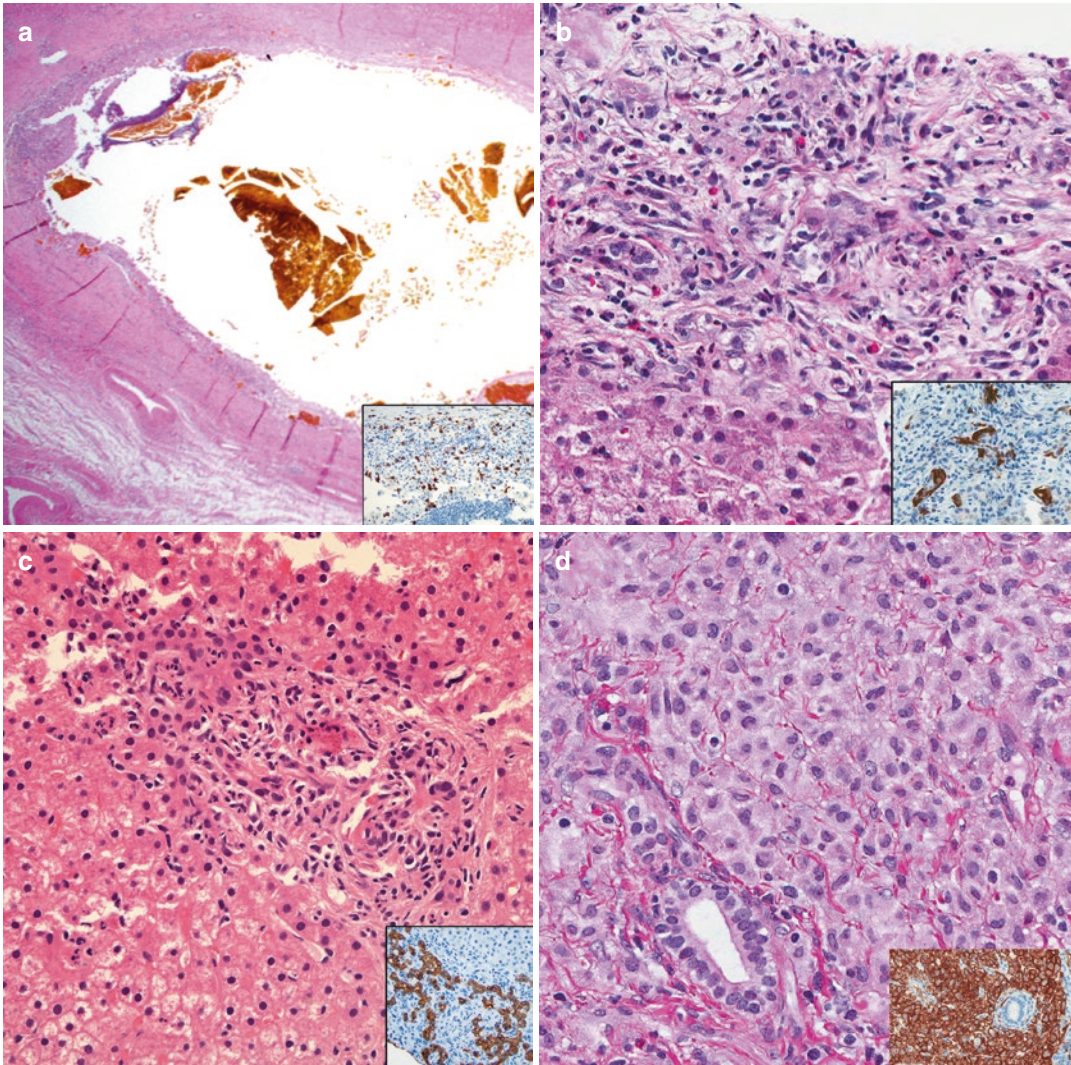


Fig. 1.5 Liver lesions. (a) Large bile duct involvement with LCH (H&E, 2 \times); inset with few CD207-positive LCH cells at explant (immunostain, 10 \times). (b) Rare example of small (distal) bile duct LCH involvement at biopsy with an active obstructive cholangiopathy pattern (H&E, 20 \times), with CD1a-positive LCH cells within the duct epithelium (inset, immunostain 20 \times). (c) Same patient 3 months later with sclerosing cholangitis pattern, nega-

tive for LCH in small ducts (CD1a-/CD207-, not shown) with cytokeratin 7 highlighting proliferating ductules (inlet, immunostain 20 \times). At explant (see a) this patient was shown to have focal, residual LCH only in large hilar bile ducts. (d) Juvenile xanthogranuloma (JXG) involvement and expansion of the portal tracts without biliary involvement (H&E, 20 \times) showing diffuse surface staining for CD163 (inset, immunostain 40 \times)

(Fig. 1.5a). Rarely, one can demonstrate CD1a+/CD207+ LCH infiltration within the distal small bile duct epithelium at biopsy (Fig. 1.5b). However, more often, the biopsy will show an obstructive/destructive cholangiopathy pattern (best highlighted by cytokeratin 7 immunostain) with elevated γ GT and bilirubin (Fig. 1.5c). In

such a scenario, hepatic LCH involvement is likely if a diagnosis has been previously established elsewhere. This determination is more challenging without a prior diagnosis, and other causes of obstructive/sclerosing cholangiopathy need to be ruled out. With advanced disease at the hilar ducts, the distal sclerosing biliary lesions,

which are typically CD1a- and /CD207-, will progress with bridging portal fibrosis to micronodular cirrhosis, which will eventually require liver transplantation. At explant, the larger hilar ducts may rarely show residual LCH (Fig. 1.5a) and should be adequately sampled. In active LCH disease at biopsy, increased portal macrophages and exuberant Kupffer cell activation, with an element of hemophagocytosis, may reflect a systemic cytokine effect in MS-LCH as a consequence of LCH, rather than direct bile duct involvement [47].

Ancillary Testing

Whenever the diagnosis of LCH cannot be definitively made by biopsy, some investigators advocate testing for the *BRAF*-V600E mutation in peripheral blood which may support the diagnosis if positive [15].

Differential Diagnosis

JXG involvement of the liver has a unique pattern of portal expansion without biliary infiltration (Fig. 1.5d, see below). Hepatic RDD is exceedingly rare and should be distinguished from activated sinusoidal macrophages/Kupffer cells, which can acquire a S100+/fascin+ phenotype. Some have shown that these activated reactive S100-positive macrophages are more reactive to S100-alpha subunit, in contrast to the S100-beta subunit expressed in LCH [50]; however, most commercially available polyclonal S100 antibodies have dual-subunit reactivity. Another challenge is in those post-transplant LCH patients with subsequent biliary obstructive changes. Structural post-transplant biliary problems can be challenging to distinguish from LCH recurrence [51]. Clinical/radiographic correlation with the help of ancillary molecular testing is needed in such cases.

Spleen

Clinical

The spleen is rarely biopsied given its high vascularity. Similar to the bone marrow and liver, determination of true LCH involvement in the spleen can be challenging. Splenomegaly is

clinically defined as a spleen size greater than 3 cm below the costal margin at the midclavicular line, confirmed by ultrasound [26].

Pattern of Involvement

While LCH can be demonstrated in the red pulp sinuses [40], macrophage activation and/or extramedullary hematopoiesis of the cords with sinusoid red blood cell congestion may also explain the splenomegaly in LCH patients [52]. Thus, while the dictum of splenomegaly in the context of MS-LCH typically confers splenic involvement, such non-LCH causes of splenomegaly should also be considered.

Lung

Clinical

Pulmonary involvement in adults has been closely linked with cigarette smoking and is often a single site of involvement. In children it is often seen in MS-LCH but is no longer considered a risk organ site.

Pattern of Involvement

The pattern of involvement is primarily that of small airway-centered LCH with extension into the alveolar septa (Fig. 1.6). Over time, tissue destruction progresses with regression of CD1a+/ langerin+ cells, and the fibrotic stellate nodules with interstitial fibrosis lead to honeycomb-like enlargement of the airspaces with hyperinflation and cystic change. Transbronchial biopsy together with bronchoalveolar lavage has variable success in diagnosing the peribronchial infiltrate in a patient with suspicious clinicoradiographic findings, and multiple biopsies (at least six) are usually needed to increase sensitivity [53]. A wedge biopsy of peripheral lesions is often diagnostic (Fig. 1.6).

Differential Diagnosis

The differential diagnosis depends on disease distribution and age of the patient. In adults, upper lobe involvement with cystic lung disease can also be seen with sarcoidosis and centrilobular emphysema; lower lobe involvement can be

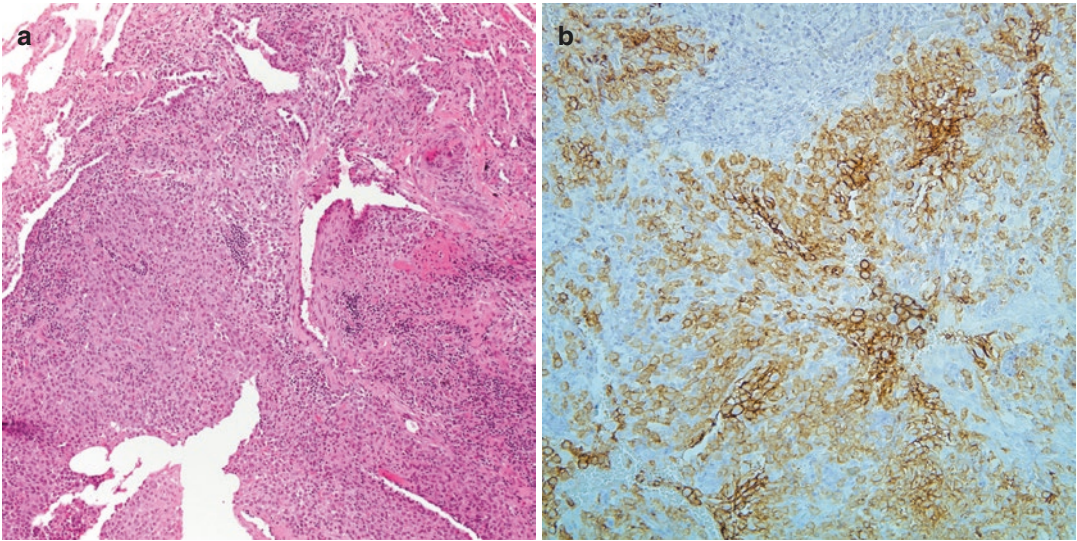


Fig. 1.6 Lung involvement of LCH. (a) An expanded peribronchial nodular infiltrate extending into the adjacent septa (H&E, 10 \times). (b) CD1a highlights the LCH with surface staining (immunostain, 20 \times)

found in patients with Birt-Hogg-Dube syndrome, panacinar emphysema, and usual interstitial pneumonia, while entire lung involvement is usually seen with lymphangioleiomyomatosis, infections, lymphoid interstitial pneumonia, cancer, and bronchiectasis [54]. In children, cystic pulmonary malformation, congenital bronchiectasis, and infections are within the differential diagnosis. Other histiocytic disorders are described in their respective sections, but typically JXG involvement in the lung is rare outside of systemic disease involvement. Pulmonary ECD involvement is a known site of involvement with a septal (e.g., lymphatic/subpleural) distribution and pleural effusions [31, 55].

Central Nervous System

Clinical

Few pathologic studies have systematically studied LCH involvement in the CNS [56, 57] with detailed immunophenotyping [54–56]. Descriptions of CNS-LCH disease prior to immunohistochemistry described both a proliferative phase with transition to a granulomatous and more xanthomatous phase and finally a fibrotic stage [56, 57]. The largest series from the

Histiocyte Society CNS-LCH group included neuropathology from 12 patients with limited immunohistochemistry [58]. The most common site of CNS-LCH involvement is the hypothalamic-pituitary axis (HPA) with infundibular thickening and lack of the posterior pituitary bright spot on T1-weighted MRI images, which clinically manifests with diabetes insipidus and/or anterior pituitary dysfunction [59]. The pattern of a slowly progressive “CD1a-negative” LCH neurodegeneration (ND) is radiographically characterized by variable symmetric MRI signal intensity changes of the cerebellum, basal ganglia, and/or pons along with dilated VRS spaces [59] and clinically is defined as having progressive problems with coordination (ataxia, dysarthria, dysmetria) as well as neurocognitive and psychological difficulties [60] (see also Chap. 4, “Central Nervous System LCH”).

Pattern of Involvement

A diagnostic HPA biopsy will show collections of LCH cells with variable admixture of eosinophils in its proliferative phase (Fig. 1.7). However, obtaining a diagnostic biopsy at this site can be fraught with challenges: (1) biopsy fragments are small and tenuous given the location, (2) samples contain only scant diagnostic cells or none at all,

and (3) perilesional granulomatous histiocytic infiltrates may masquerade as other histiocytic lesions (see below).

Space-occupying intracranial, extra-axial lesions involving the dura/leptomeninges, choroid plexus, and pineal gland are also described, but intraparenchymal involvement is rare [58, 61]. We have noted rare cases of parenchymal CNS-LCH with peculiar perivascular pattern of

LCH cells and a surrounding macrophage-rich inflammatory response (Fig. 1.7). This perivascular rich pattern of involvement was previously described by Kepes in 1979 who noted (without the aid of immunohistochemistry) that “this pattern of development has a course much in common with that of other mesenchymal lesions of the brain, e.g. sarcoidosis, primary malignant lymphomas, etc.” [56]. Thus, LCH in the brain

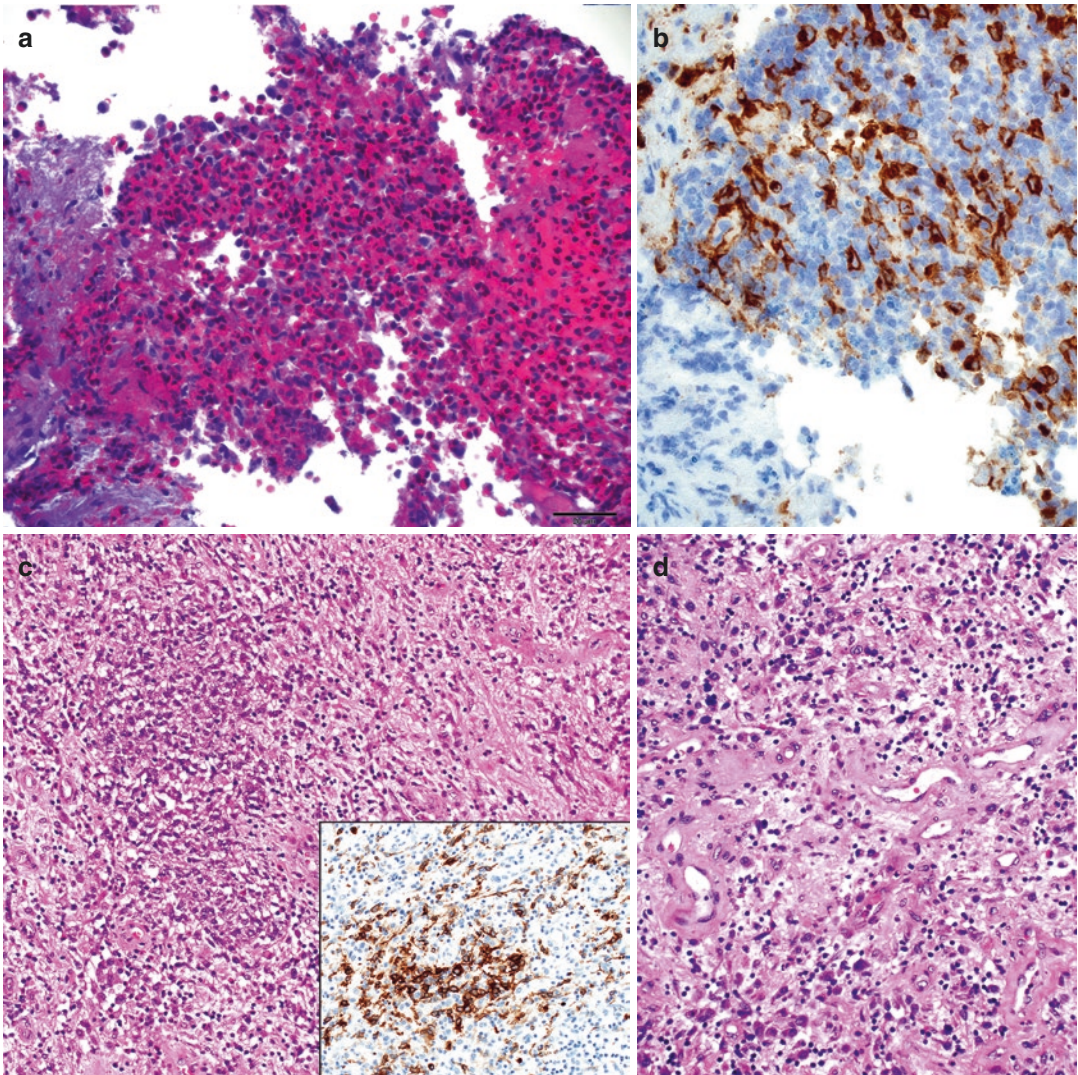


Fig. 1.7 CNS involvement with LCH. (a) Hypothalamic involvement with a granulomatous infiltrate of LCH cells and eosinophils (H&E, 40 \times). (b) CD207 positive (immunostain, 40 \times). (c) Parenchymal cerebellar involvement with perivascular nodules of LCH (H&E, 20 \times); inset CD1a (immunostain 20 \times). (d) Robust surrounding hyper-

vascular/sclerotic inflammatory response with demyelination (H&E, 20 \times) (Digital whole slide images (WSI) are available here: <http://image.upmc.edu:8080/HistioPathChapter/Abla/view.apml> and hosted courtesy of University of Pittsburgh School of Medicine, Department of Pathology, Division of Informatics)

may enter the parenchyma and leptomeninges in a manner similar to primary CNS lymphomas, with an angiocentric proliferation expanding the Virchow-Robin perivascular cuffs, with subsequent invasion into neural parenchyma or subarachnoid spaces, either developing into a mass lesion or with more diffuse infiltration [62, 63], as originally noted by Kepes. Further, ongoing work is in progress to better delineate these findings, specifically in the context of late neurodegenerative LCH (ND-LCH) disease [64]. Only few ND-LCH cases have undergone detailed histopathologic investigation, including a rare published autopsy study [58]. A nonspecific pattern of tissue destruction with loss of neurons (e.g., cerebellar Purkinje cells) and axons and demyelination has been described, with atrophy from loss of axons and neurons and resultant gliosis and inflammation [58]. Older studies without the aid of detailed histochemical analysis describe late-stage disease with a striking fibrous gliosis [56, 57] which may be the histopathologic correlate of ND-LCH. Current ongoing work is further exploring the previously described CNS-LCH histopathologic patterns in the context of new ancillary techniques [62]. This current ongoing work is beginning to challenge the long-standing notion of ND-LCH as a paraneoplastic process, as new data may suggest that CD1a-negative *BRAF-V600E* mutant myeloid/dendritic precursor cell could be the driving cell leading to ongoing, smoldering neuroinflammation, demyelination, and subsequent fibrotic gliosis in the brain [62, 64].

Ancillary Testing

As described above, establishing a diagnosis with the addition of the *BRAF-V600E* mutation may be further confirmatory, especially in cases with rare CD1a and CD207 cells.

Differential Diagnosis

HPA biopsies showing granulomatous infiltrates with xanthomatous histiocytes will cause diagnostic confusion with JXG and ECD (especially if *BRAF-V600E* positive). Other “granulomatous” HPA/infundibular lesions that should be ruled out include germ cell tumors, sarcoidosis,

nonspecific lymphocytic hypophysitis, and tuberculosis, while involvement of the hypothalamus should exclude gliomas, lymphoma, and sarcoidosis [65].

JXG involvement of the CNS can involve the spinal canal and meninges, with predilection for the Meckel’s cave area [66], along with rare intraparenchymal involvement described in the context of systemic disease. The challenge, as previously described, is that active CNS-LCH lesions, regressing lesions, and even treated LCH, particularly of the intracranial extra-axial sites, can often incite a robust xanthomatous inflammatory response closely resembling JXG. Even in active LCH disease, only rare perivascular nodules of LCH may be demonstrated (Fig. 1.8).

Other Sites of Involvement

Other sites of LCH involvement include the gastrointestinal (GI) tract, thymus, and thyroid. We have previously expounded in more detail on these various sites [25, 67]. In the GI tract, LCH can expand the lamina propria, which can extend into the submucosa [68]. Thymic involvement can range from architectural disruption with fibrosis to medullary-restricted LCH infiltrates [42, 69]. Rare cases of mixed LCH-JXG-like histiocytic proliferation have been noted [42], but single, solitary JXG involvement of the thymus has not been described. Of note, the thymus can also show microscopic collections of hyperplastic LCH-like foci in incidental thymectomies that are not diagnostic of LCH involvement [42]. Thyroid involvement can also be seen both in SS and MS-LCH disease, and disease involvement should be distinguished from reports of microscopic LCH-like foci associated with papillary thyroid carcinoma. Various case reports have shown concurrence of papillary thyroid carcinoma and LCH disease both harboring the *BRAF-V600E* mutation [70, 71]. Of note, certain sites including the kidneys and gonads are privileged sites where LCH does not typically occur, unlike the other histiocytic lesions, including ECD, which more commonly involves these sites [72, 73].

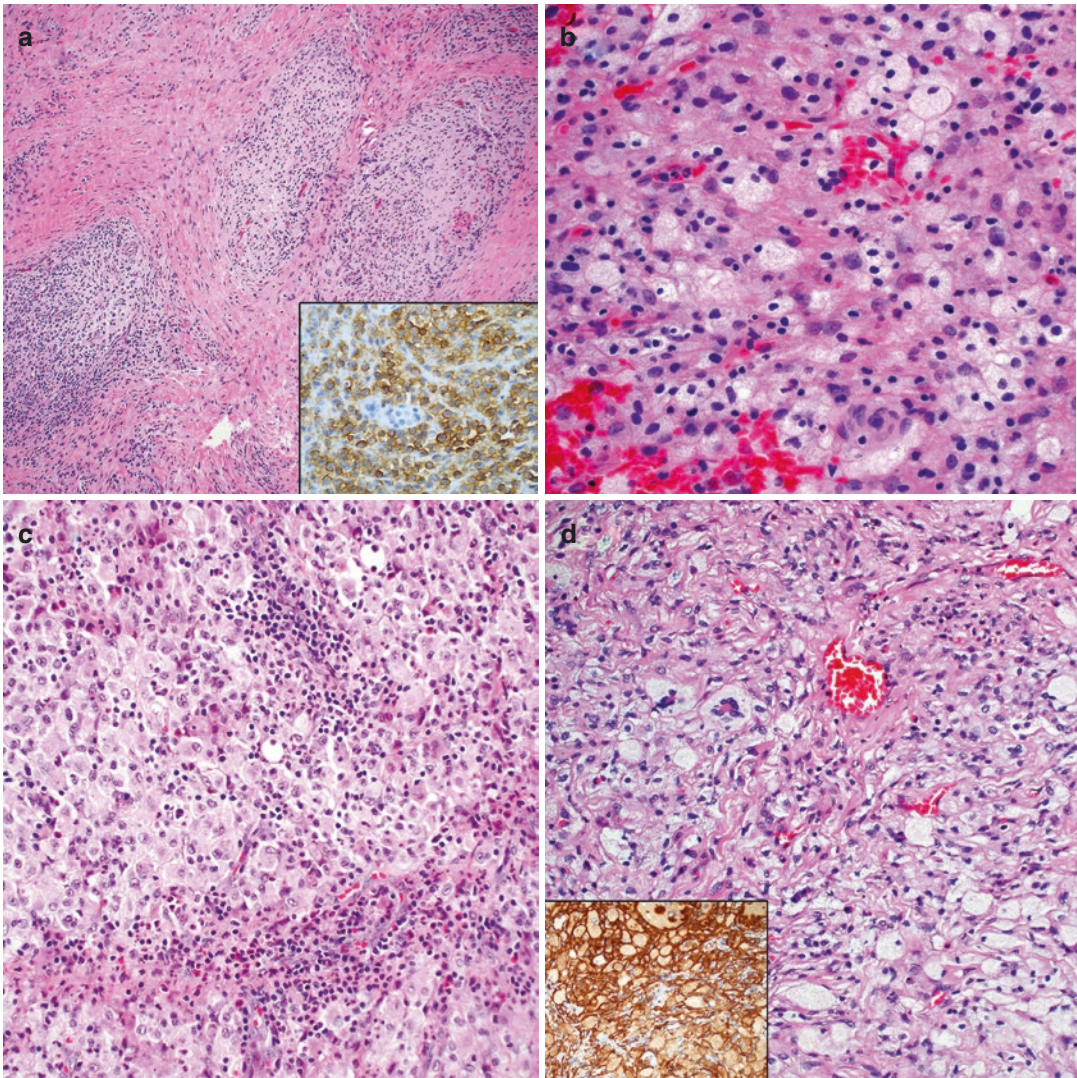


Fig. 1.8 CNS lesions. (a) Dural involvement of small LCH nodules (H&E, 10 \times) that are CD1a positive (inset, immunostain 40 \times) surrounded by fibrosis and (b) xanthomatous inflammatory infiltrates (H&E, 40 \times). (c) Solitary juvenile xanthogranuloma (JXG) of the temporal lobe (H&E, 20 \times). (d) Lesions of the dural, cavernous sinus,

and sella with features of a JXG family of lesions, with foamy macrophages in a sclerosing background with occasional Touton giant cells and diffuse CD163 immunostaining (inset, immunostain 20 \times) that was found to be Erdheim-Chester disease with clinicopathologic correlation and *BRAF-V600E* mutation

Conclusions

The histopathology of LCH is relatively straightforward in most cases with diagnostic CD1a+/CD207+ cells. However, the diagnosis hinges on the correct phenotype and pattern of involvement to prevent erroneous false-positive diagnoses. It is equally important to remember that histopathologic diagnosis may be limited without diagnostic CD1a+/CD207+ LCH cells

present (i.e., false negative). However, at certain sites such as the bone marrow and CNS, our understanding of “LCH involvement” may be evolving beyond the defining CD1a+/CD207+ cell to include *BRAF-V600E* mutant myeloid precursor cells. The refined molecular landscape of LCH should help aid diagnostically challenging cases while also helping to provide more lineage-specific LCH phenotypic

markers as we better define and classify these challenging lesions.

Erdheim-Chester Disease

Historically, Erdheim-Chester disease (ECD) has been grouped under the pathologic category of systemic juvenile xanthogranuloma (JXG) “family” given its shared immunophenotype (CD163, CD68, CD14, factor XIIIa, and fascin, with low to absent S100 (Table 1.4)), although it has been long recognized that it has a distinct clinical and radiographic presentation [74]. However, the current understanding of ECD as a clonal inflammatory myeloid neoplasm [4, 5, 75] has helped distinguish ECD as a distinct entity in the WHO tumors of hematopoietic and lymphoid tissues [7] (Table 1.3). At the same time, however, there are increasing number of reports of LCH and ECD having shared clonal mutations in the mitogen-activated protein kinase (MAPK) pathway [3, 4, 19, 22, 76–78] along with combined LCH/ECD lesions either in the same lesion/site or at different sites within the same patient during their lifetime [71, 76, 79–81]. This has led to the proposal for classifying LCH and ECD together within the “L” (Langerhans) group in the latest revised classification [6] (Table 1.2). For the purposes of this chapter, we opt to leave ECD as its own category acknowledging the shared molecular phenotype with LCH and the shared immunophenotype with JXG family of lesions.

Chapter 18 is devoted to the detailed clinical review of ECD, but we herein share some of pathologic key points in this distinct histiocytic disorder that has molecular and immunophenotypic similarities spanning the LCH and JXG family of lesions.

Pattern of Involvement

The presence of CD68+ xanthomatous cells alone is not enough for a confident diagnosis of ECD. The histopathology often shows a cellular infiltrate of plump epithelioid to variably “xanthomatous” or foamy-appearing histiocytes,

often with a variable number of giant cells with a central ring of nuclei (e.g., Touton giant cells). In most cases, the histiocytic proliferation is within a densely fibrotic stroma admixed with plasma cells, lymphocytes, and rare granulocytes in the background (Figs. 1.9 and 1.10). The epithelioid histiocytes should display a JXG-like immunophenotype (Table 1.4) characterized by surface/membranous staining for monocytic/macrophage markers including CD163 (a hemoglobin-haptoglobin scavenger receptor) and CD14 (monocyte/macrophage receptor that binds lipopolysaccharide), along with granular cytoplasmic staining for CD68 (a lysosomal glycoprotein marker which binds low-density lipoprotein), together with cytoplasmic staining for factor XIIIa (a tissue transglutaminase that was formerly suggested to represent interstitial and interdigitating dendritic cells, now better recognized as dermal macrophage marker [82] and fascin (an actin-bundling protein). Of note, factor XIIIa staining can be diminished in heavily xanthomatous cells [25]. Typically, S100 is negative in ECD, as is CD1a and langerin, although focal and variable S100 positivity can be seen [6]. It is mandatory that the histopathology be correlated with the correct clinical and radiographic features in order to make a unifying diagnosis of ECD. Organ-specific features are described below.

Ancillary Testing

Because of the therapeutic implications, testing of ECD for the *BRAF*-V600E mutation should include sensitive molecular methods for accurate detection, especially given the variable low content of histiocytes in some cases. Recent consensus ECD guidelines urge the confirmation of negative *BRAF*-V600E testing using another genotyping modality and/or genotyping from a different anatomic site, especially if a *BRAF* wild-type bone lesion was originally tested [31]. In cases with mutated *BRAF*-V600E, the VE1 antibody will show a dark cytoplasmic granular staining pattern in the clonal histiocytes [71, 83]. Other mutations in the MAPK pathway include *MAP2K1* and *NRAS* which will also show pERK

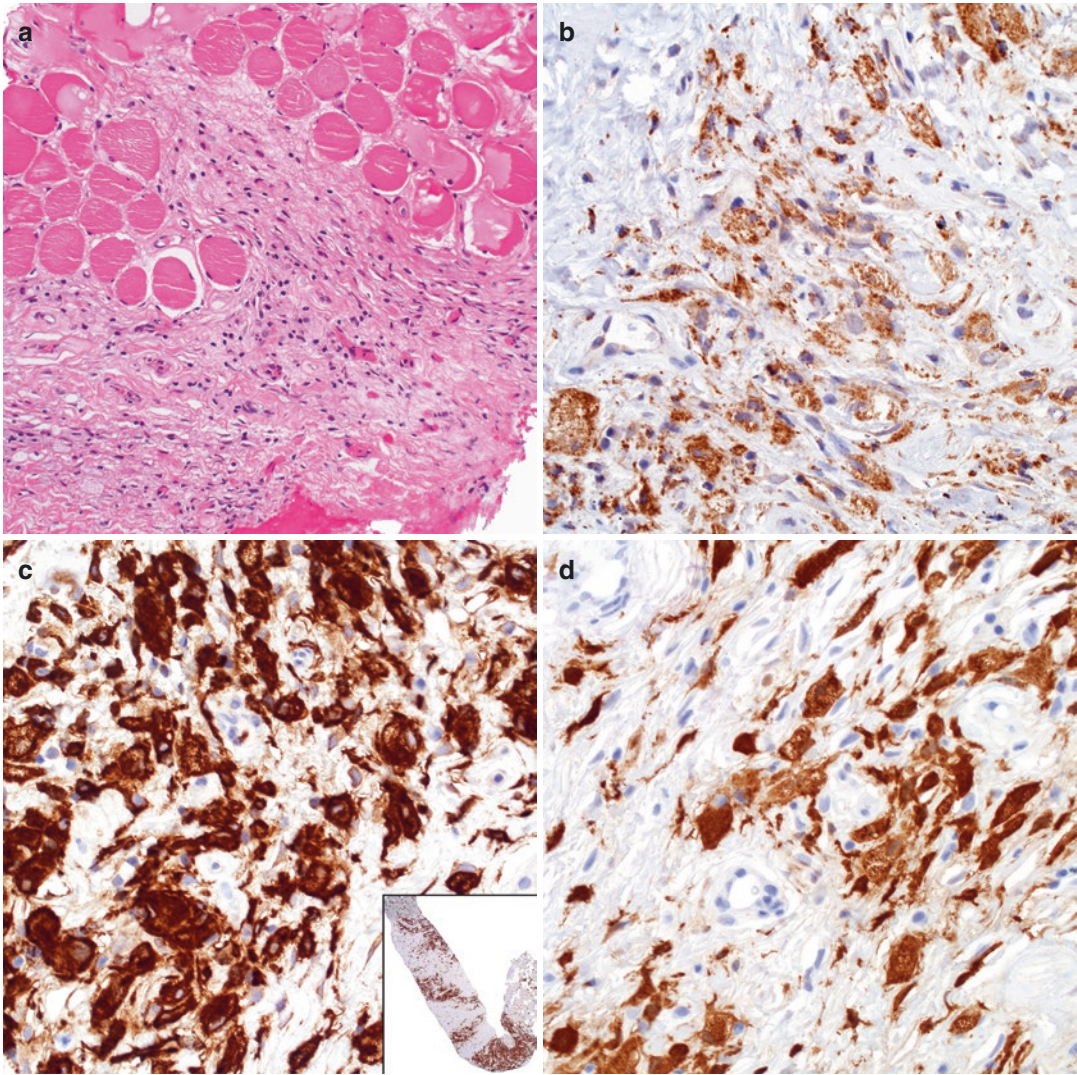


Fig. 1.9 Erdheim-Chester disease of the retroperitoneal soft tissue and muscle. (a) Tissue biopsy showing hyalinized fibrosis alternating with looser fibrotic zones with admixture of plump epithelioid histiocytes and a light chronic inflammatory infiltrate (H&E, 20 \times). (b) CD68

shows cytoplasmic granular staining in the plump histiocytes (immunostain, 40 \times). (c) CD163 highlights the epithelioid histiocytes (immunostain 40 \times , inset immunostain 4 \times). (d) Factor XIIIa highlights cytoplasmic staining of the histiocytes (immunostain, 40 \times)

antibody expression. Reports of *PIK3CA* mutations have also been recently described [4].

Differential Diagnosis

The “age” of the lesion may impact the degree of underlying fibrosis which is most notable, but not exclusive to involved retroperitoneal and bone

sites. To the unwary pathologist, the lesion may be missed as a nonspecific inflammatory or fibrosing process, especially if the clinical and radiographic findings are not correlated. Thus, a histopathologic-based diagnosis of either “fibrohistiocytic lesion” or a “JXG family of lesions” in the correct clinical/radiographic setting is diagnostic of ECD, which is defined by the interplay of clinical, radiographic, and histopathologic

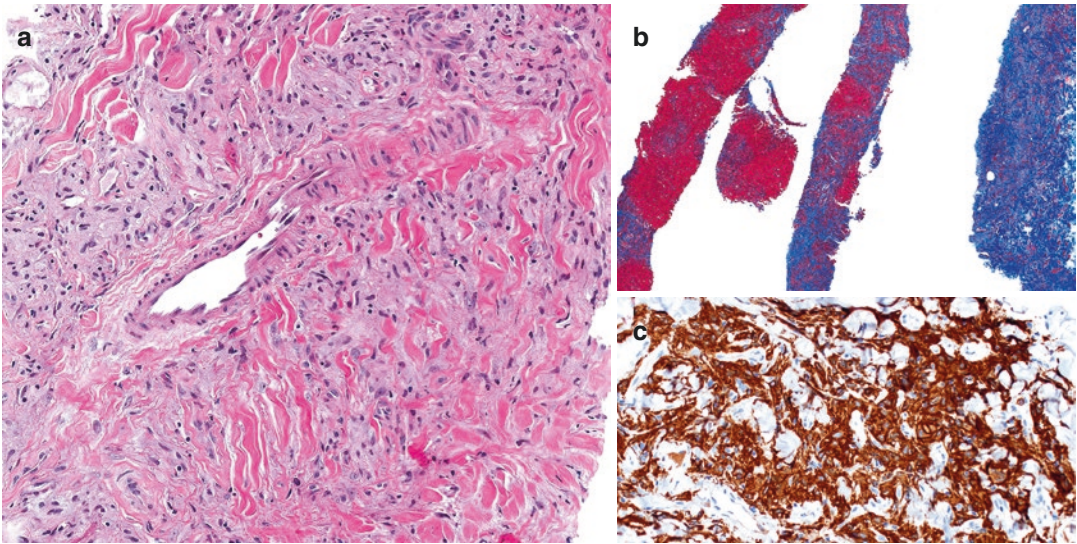


Fig. 1.10 Erdheim-Chester disease of the liver. While not a typical site, the patient had liver lesions in addition to omental and bone involvement. (a) Expanded zone of fibrosis with plump, finely vacuolated, epithelioid histiocytes (H&E, 20 \times). (b) Expanded fibrotic zones imparting

architectural distortion of the liver with bridging portal fibrosis and cirrhosis (Masson trichrome, 4 \times). (c) The CD163 stain highlights the histiocytic proliferation (immunostain, 40 \times)

findings [31]. Further support with BRAF or other ERK pathway mutations solidifies the diagnosis; however, previously treated or late/regressed LCH lesions can enter into the differential diagnosis if classic imaging findings are not found (i.e., bone osteosclerosis, retroperitoneal fibrosis). Treated and/or long-standing LCH lesions may acquire a morphologic and phenotypic overlap with xanthomatous-appearing histiocytes within a densely fibrotic stroma showing little to no CD1a+/CD207+ LCH cells. Some of these cases may even display a JXG-like phenotype with small allelic fractions of mutant *BRAF-V600E*, which has been noted in bone marrow cases of LCH patients [3]. These index cases stress the importance of clinical, radiographic, and pathologic correlation for the diagnosis of ECD while also highlighting the shared histopathologic overlap between some cases of LCH, ECD, and systemic JXG family of lesions. A clear distinction between childhood ECD and disseminated JXG is not always easy, especially in cases with shared molecular mutations but certain clinical/radiographic features, most notably osteosclerosis of the long bones, remain distinctive thus far. Supportive data points toward a CD1a-negative marrow-derived myeloid precursor cell as the

driving cell in LCH, ECD, and possibly also systemic JXG family of lesions with gain of function mutations in the MAPK/ERK activated pathway [3, 5, 6, 75]. Thus, the reclassification proposal of a shared “L group” lesion for these histiocytic disorders may be timely as we begin to understand them as inflammatory myeloid neoplasms (Table 1.2).

Bone

Clinical

Osteosclerotic lesions involving the bilateral distal limbs (e.g., diaphysis and metaphysis of the femur, proximal and distal tibia) are seen in the vast majority of ECD patients, and the small percentage (~4%) of cases lacking classic bone findings should demonstrate other organ involvement with clinical/radiographic/pathologic correlation [84].

Pattern of Involvement

The histopathology may show a medullary sclerosis and cortical thickening with the biopsy showing a fibroxanthomatous replacement of the marrow space.

Ancillary Testing

BRAF-V600E and other mutations in the MAPK/pERK pathway may be further supportive [4], but testing must be done on appropriate material for PCR testing (fresh, frozen, EDTA decalcification) as routine formic acid decalcification is incompatible with nuclei acid amplification.

Retroperitoneum

Clinical and Pattern of Involvement

Typically, ECD involvement of the pelvic/retroperitoneum involves a fibrohistiocytic encasement of the perinephric tissues with a “hairy kidney” appearance on imaging, including encasement of the ureters with narrowing and hydronephrosis, and/or renal arteries with hypertension. The typical immunophenotype of these histiocytic cells is demonstrated (CD163+/CD68+/CD14+/factor XIIIa+/fascin+).

Differential Diagnosis

ECD of the retroperitoneum (Fig. 1.9) may incite a differential diagnosis including retroperitoneal sclerosing diseases, amyloidosis, and xanthogranulomatous inflammation (Fig. 1.11). Xanthogranulomatous pyelonephritis is a chronic pyelonephritis of adults, rarely seen in childhood, in which the robust infectious/inflammatory process can replace much of the kidneys and even extend into the retroperitoneum. These lesions, however, do not display the same JXG phenotype with a more phagocytic appearance and little to no factor XIIIa staining. Loss of factor XIIIa staining occurs more commonly in very xanthomatous ECD lesions.

Skin

Clinical

Cutaneous ECD typically presents as a xanthelasma-like lesion (XLL) with frequent involvement of the periorbital site in 25% of patients; and papulonodular/patch-like lesions of the head/neck, axilla, groin, trunk, and extremities are also common. Cutaneous ECD lesions are clinically and phenotypically indistinguishable

from JXG lesions and classic dyslipidemia-associated xanthelasma palpebrarum (XP) [31, 71, 83].

Pattern of Involvement and Ancillary Testing

Newer reports suggest that certain histopathology findings such as reticular dermis involvement, immunostaining for factor XIIIa in greater than 30% of the histiocytes, and a high density of multinucleated and Touton giant cells, along with a decreased degree of fibrosis, are features that can better discriminate a cutaneous ECD lesion from a classic XP lesion [83]; however, significantly elevated serum lipid levels still appear to be a good clinically discriminating factor for XP, with a high rate of *BRAF*-V600E mutations noted in ECD XLL-like lesions [83]. Cutaneous lesions with a reticulohistiocytoma-like appearance and a large eosinophilic ground-glass cytoplasm positive for the *BRAF*-V600E mutation can also be seen in ECD [71]. Thus, a pathologic diagnosis of a cutaneous xanthogranuloma family of lesions in an adult should prompt further investigation for ECD including confirmatory molecular and radiographic findings, as skin involvement may be the presenting feature [71, 83].

Central Nervous System, Including Orbital

Clinical

Like LCH, ECD has a predilection for pituitary gland involvement. Diabetes insipidus (DI) is a known finding in 25% of patients, but a recent systematic case-control study has shown that anterior endocrinopathies are present in almost all cases, with growth hormone (GH) deficiency, testicular deficiency, and hyperprolactinemia being the most frequently reported [72]. Long-term sequela of ECD may include CNS manifestations (i.e., ataxia, oculomotor difficulties, and dysphagia) outside of direct lesional CNS involvement.

Pattern of Involvement

As described above, a xanthomatous histiocytic-rich lesion in the pituitary of a child with DI and a complete JXG phenotype is largely supportive

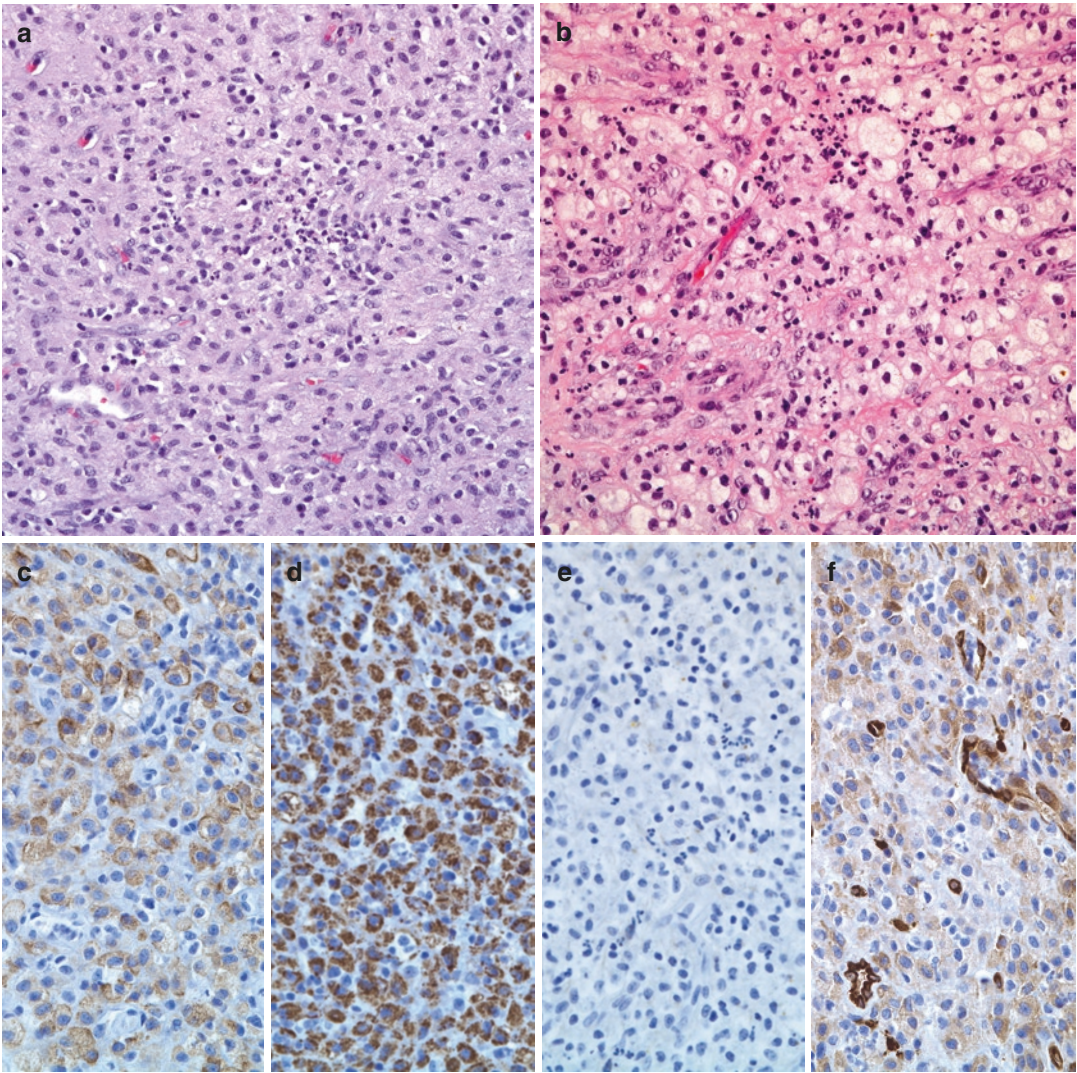


Fig. 1.11 Perinephric/abdominal mass in a child masquerading as a histiocytic lesion. (a) Xanthogranulomatous pattern of inflammation with admixed acute inflammation (H&E, 40×). (b) Histiocytic markers. (c) CD163 with light

surface staining (immunostain, 40×). (d) CD68 with coarse phagocytic cytoplasmic staining (immunostain, 40×). (e) Negative for factor XIIIa (immunostain, 40×). (f) Negative to trace staining with fascin (immunostain, 40×)

of ECD in the absence of other complicating factors, but without complete immunophenotyping and nonsupportive clinicoradiographic findings, the diagnosis may be less clear (see Chap. 18). Parenchymal lesions of the CNS are more common in ECD as compared to LCH and portend a worse outcome [85] but may be difficult to differentiate from JXG lesions in isolation. A solitary JXG lesion of the CNS, typically dural, should not be labeled as ECD without supporting

clinical and imaging findings. Intracranial, extra-axial lesions may also involve the facial bones with osteosclerosis.

Cardiovascular

A fibrohistiocytic encasement around the thoracic and abdominal aortal (“coated aorta”) can be found by imaging in most ECD patients, often

without systemic symptoms. However, pericardial disease typically manifests with signs of pericarditis, effusion, or tamponade and can be a major cause of death. Reports of cardiac involvement with mass lesions or diffuse infiltration of the myocardium are also noted [31, 86], but are rarely biopsied.

Lung

Pulmonary ECD involvement tends to have a particular predilection for the septal lymphatics with pleural and interlobular septal thickening. Patients may be asymptomatic or can present with nonspecific symptoms such as cough and progressive dyspnea. Lung involvement in ECD is rarely biopsied [55]. Pleural effusions will contain variable collections of epithelioid to foamy histiocytes. Immunohistochemistry performed on a cell block preparation reveals the JXG phenotype.

Other Sites of Involvement

Unlike LCH, hepatosplenic involvement is rare in ECD and does not confer increased disease risk. We have seen a rare systemic case of hepatic and omental involvement. Biochemically, the liver enzymes showed a cholestatic pattern with clinical symptoms of abdominal distention secondary to omental thickening and ascites. The liver biopsy revealed large epithelioid cells conferring a JXG phenotype by immunostains within a densely sclerotic stroma, involving and extending out from the portal tracts with severe architectural distortion (Fig. 1.11). Lymph nodes are not a typical site of involvement for either ECD or JXG, and such suspected nodal examples should raise the possibility of a histiocytic sarcoma/malignant histiocytosis of the JXG type (see below, Fig. 1.18).

Conclusions

ECD is a rare histiocytic disorder which is now distinguished as a distinct clonal entity by the WHO. Those in the histiocyte community are

further recognizing it within the spectrum of an inflammatory myeloid neoplasm. The cell of origin is still debatable with overlapping features in both the LCH and JXG family of lesions. For the pathologist, the recognition of a fibrohistiocytic pattern with variable epithelioid to xanthomatous cells having a JXG phenotype (especially in an adult) should be correlated with clinical and directed imaging in order to make a unified clinicopathologic diagnosis of ECD. Ancillary testing with VE1 BRAF antibody staining and confirmatory mutational analysis of the tissue, blood, and even urine can be further helpful [31, 87].

Juvenile Xanthogranuloma Family of Lesions (JXG)

Juvenile xanthogranuloma family of lesions is a pathologic term that we have adopted from the Burgdorf and Zelger (1996) description [88], further refined by Weitzman and Jaffe in their 2005 classification to encompass a range of clinical phenotypes [89]. This is also included in the most recent reclassification of histiocytic disorders with some modifications [6] (Table 1.2). Under the microscope, the JXG “family of lesions” can display a number of histologic patterns (Fig. 1.12) with the common variable being the JXG phenotype, useful in cases when the typical morphology may be obscured (Fig. 1.13). The JXG family phenotype is characterized by surface/membranous CD163 and CD14, granular cytoplasmic CD68 along with cytoplasmic factor XIIIa, and fascin immunostaining (Fig. 1.13). While S100 has typically been noted as a negative stain in these lesions, there are conflicting reports as to whether the variable S100 positivity identified in previous reports [90–92] represents JXG lesional cells versus CD1a dendritic cell staining [93]. However, we [94] and others have noted variable focal to diffuse S100 expression in the mononuclear and giant cells of otherwise diagnostic JXG family of lesions in up to 20% of cases (Ronald Jaffe personal observations 1985–2015).

The cell of origin has been long debated. The first hypothesis made by McDonagh in 1909

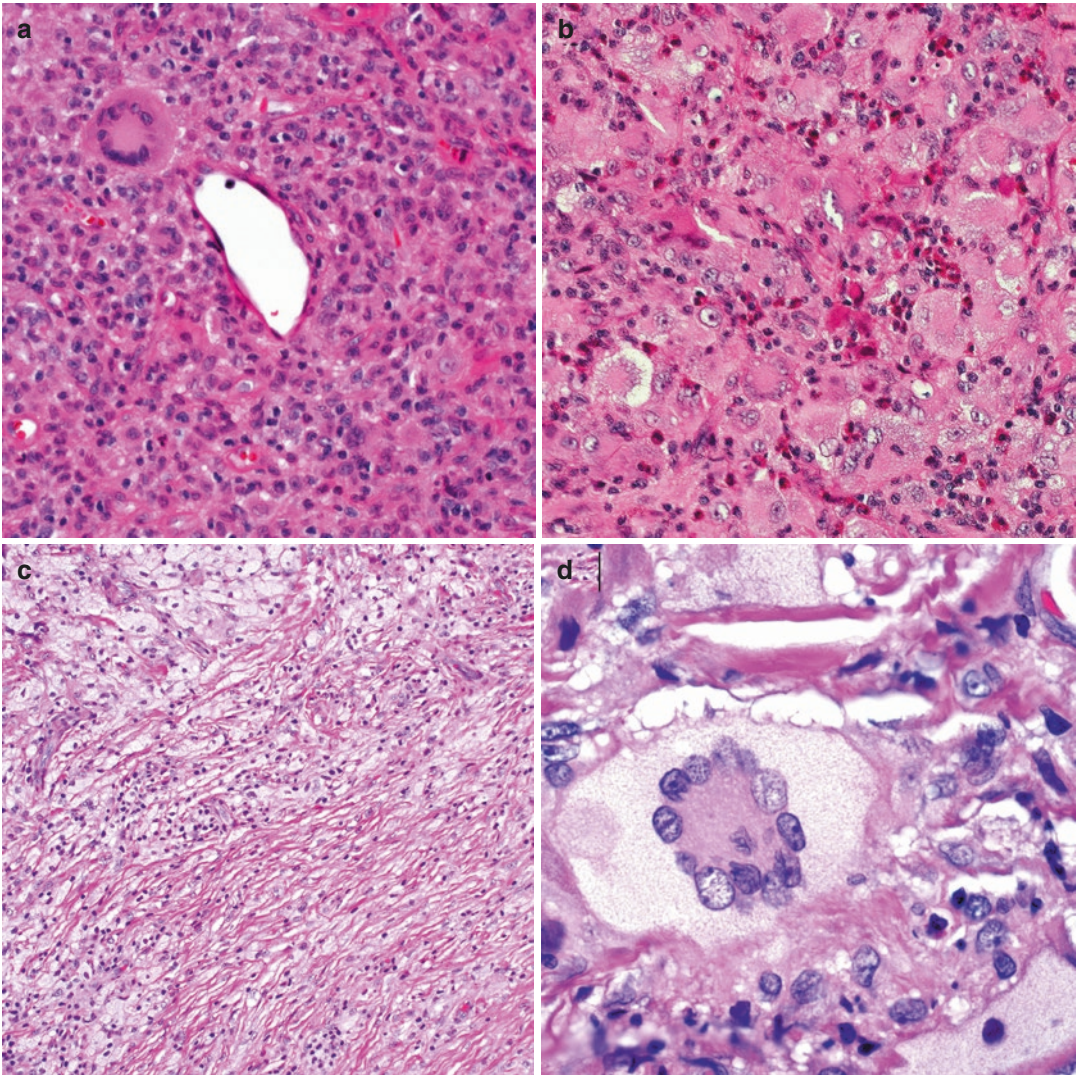


Fig. 1.12 Juvenile xanthogranuloma morphologic patterns. Within the same cutaneous lesion were intermixed patterns including (a) small epithelioid cells with Touton-like giant cells (H&E, 40 \times) and (b) oncocytic cells with a reticulohistiocytoma-like pattern (H&E, 40 \times). (c) Other

patterns include xanthomatous to spindled arrangement with entrapped fibrosis ((H&E, 20 \times). (d) Classic Touton giant cell with finely vacuolated peripheral cytoplasm with a ring of nuclei around a central eosinophilic core (H&E, 100 \times)

was that of an endothelial origin (nevoxantho-endothelioma). Helwig and Hackney in 1954 noted the cutaneous proliferation of spindle and polygonal “xanthomatous-like” cells of young children without lipid abnormalities had variable Touton giant cells and eosinophils [95]. They were the first to coin these lesions as JXG, for which they conclude is a “descriptive term... until the exact etiologic factors are known.” Since that time, the lesional cell was postulated

to be a dermal “dendrocyte” based on its factor XIIIa expression and has been later reclassified as a dermal macrophage marker [82] with co-expression of macrophage/monocyte makers CD163/CD68/CD14 (Table 1.4). While Kraus et al. has postulated that the CD4+ plasmacytoid monocyte is the principal cell of origin, this was never further substantiated [90]. The World Health Organization’s Committee on Histiocytic/Reticulum Cell Proliferations has previously

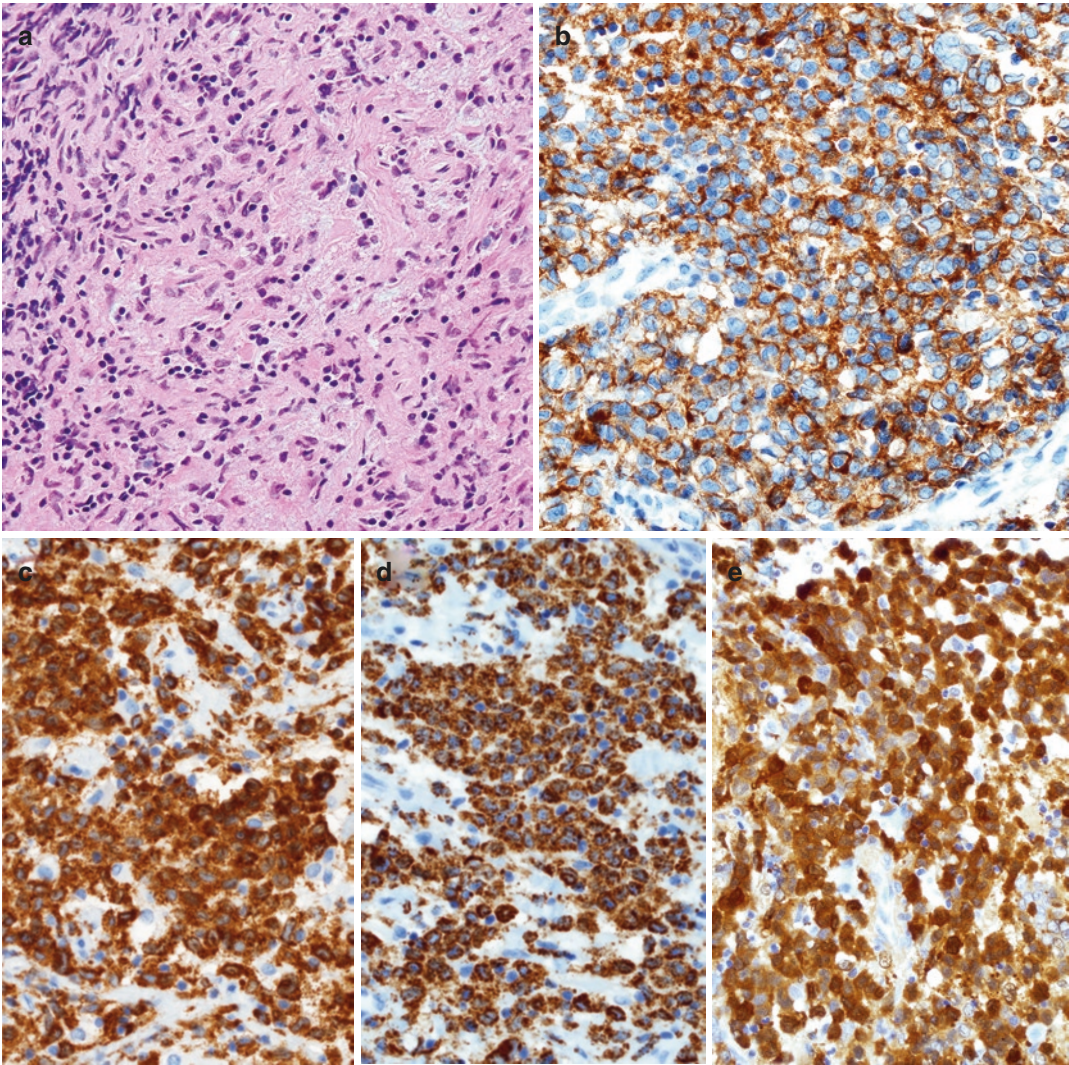


Fig. 1.13 Juvenile xanthogranuloma family immunophenotype is helpful when the typical morphology may be obscured. (a) Brain biopsy of ventricular mass with plump histiocytic cells with variable crush artifact (H&E, 40 \times).

(b) CD14 stains the cell surface (immunostain, 40 \times). (c) CD163 with surface and cytoplasmic staining (immunostain, 40 \times). (d) CD68 with granular staining (immunostain, 40 \times). (e) Factor XIIIa is cytoplasmic (immunostain 40 \times)

considered JXG as a dendritic cell histiocytic disorder [2]. The recent revised classification of histiocytoses and neoplasms of the macrophage-dendritic lineage subscribes to the notion of separating ECD, which may also include systemic JXG with gain of function mutations in the MAPK pathway (L group), from the cutaneous and mucocutaneous histiocytosis (C group) based on disparate molecular and clinical outcomes [6] (Table 1.2). For the purposes of this chapter, the cutaneous and systemic JXG groups are included

together based on their shared pathologic features described herein.

The variable histologic patterns in the JXG family of lesions have been described based on a so-called “temporal-based presentation” (i.e., early vs. late lesions) [92], knowing that it is common to see a spectrum of patterns within the same lesion. We subscribe to the notion that both time course and local tissue factors likely play a role in defining the cellular morphology, as originally proposed, with a wide variety of

monomorphic cell shapes including scalloped, epithelioid, spindle, vacuolated, xanthomatous, and oncocytic, while giant cells usually present as Touton or Touton-like [88, 89, 96–98] (Fig. 1.12). The so-called early-type pattern has small- to intermediate-sized mononuclear histiocytes in a sheetlike infiltrate with little xanthomatous cells but often has finely vacuolated cytoplasm with a folded bland nucleus and rare to no Touton-type giant cells [92]. This pattern may display increased mitoses, especially in the youngest of patients, but is devoid of sarcomatous features including lack of pleomorphism and atypical mitoses, an important distinction from histiocytic sarcoma of JXG type (see Fig. 1.18) [99]. The classic JXG pattern is noted by abundant foamy, xanthomatous (i.e., lipidized) histiocytes and Touton giant cells that display an eosinophilic core with a ring of nuclei and peripheral foamy cytoplasm (Fig. 1.12). The so-called transitional JXG pattern is characterized by the predominance of spindle-shaped cells resembling benign fibrous histiocytoma (BFH) with foamy histiocytes and occasional giant cells. However, unlike JXG family of lesions, BFH has only interspersed dendritic-shaped histiocytes, without uniform expression of JXG immunophenotype. While reticulohistiocytoma (RH), characterized by oncocytic cells with abundant glassy pink cytoplasm, has traditionally been classified as its own entity (more specifically the multicentric form with or without arthropathy, MRH), microscopically, it shares an immunophenotype with the JXG family [98]. We have seen such cases in which the reticulohistiocytoma pattern of oncocytic epithelioid cells was intermixed with more typical JXG-like morphology (Fig. 1.12) and also a case with classic RH morphology with *BRAF* V600E positivity in the context of ECD [71]. The immunophenotype may also show slight variations based on the morphologic pattern (i.e., highly xanthomatous cells “lose” their factor XIIIa expression with more variable surface CD163 staining). In these highly xanthomatous lesions, a peripheral rim of more strongly staining factor XIIIa epithelioid cells often remains at the edge of the lesion.

Thus, we believe that any of these patterns together with a confirmatory immunophenotype establishes the pathologic diagnosis of a “JXG family of lesions.” A simplified but practical approach is that the pathologic diagnosis of “JXG family” should be correlated with the clinical presentation for classifying the lesion, with further distinguishing by the molecular phenotype. Those of the so-called cutaneous/mucocutaneous (“C” group), including those with a major systemic component, are without known gain of function mutations as opposed to those systemic JXG with a gain-of-function mutation (*BRAF*, *NRAS*, *KRAS*, or *MAP2K1*) for which some would consider within the ECD family (“L” group) [6].

Cutaneous and Mucocutaneous JXG Family of Lesions

Pattern of Involvement

The prototypical JXG lesion is that of a cutaneous infiltrate with any of the above described patterns, presenting a dermal or submucosal-based lesion, typically in infancy with self-limited course. Dermal lesions tend to involute slowly over time, and thus involvement of excision margins is typically not of any clinical significance. Cutaneous and mucocutaneous JXG lesions can develop after treatment for LCH [81], and, rarely, combined elements of both are present. As described previously, the presence of *BRAF* mutation in a dermal JXG-type lesion—in the correct clinical/radiographic context—should raise concern for ECD. [71]. Periocular JXG, particularly around the eyelid, is a common site of involvement. While ocular JXG can lead to blindness and glaucoma, it is not clear from the literature if routine ophthalmologic screening in young patients with cutaneous JXG is warranted, unless there are symptomatic ocular changes [100, 101]. There is an eruptive xanthogranuloma member of the JXG family, which is not associated with hyperlipidemic states. Eruptive xanthomas are common in hyperlipidemic diseases and thus should be distinguished clinically for definitive diagnosis [102].

Differential Diagnosis

The differential diagnosis of cutaneous lesions includes LCH, RDD, melanocytic nevi, mastocytosis, and, in older and more spindled lesions, benign dermal fibrous histiocytoma (BFH) or dermatofibroma for which distinguishing immunophenotype should clearly separate these lesions if the cytomorphology is not typical. Single or small clusters of RDD-type cells can be seen in traumatized or previously shaved JXG lesions and are distinguished from cutaneous RDD which typically has a deeper dermal/subcutaneous involvement with surrounding lymphoplasmacytic response and contains more numerous S100-positive histiocytic cells with pale cytoplasm and hypochromatic nucleus.

Systemic JXG Family of Lesions

A more detailed clinical overview of JXG is provided in Chap. 17. Briefly, the diagnosis of a JXG family histiocytic proliferation at an extra-cutaneous site should prompt investigation for other lesions in the context of systemic/disseminated JXG, which is an aggressive disease typically involving infants or very young children and often requiring systemic treatment. Solitary extra-cutaneous lesions do rarely occur [91], which in small series showed a predilection for the head and neck region. There appear to be better outcomes as compared to systemic disease characterized by two or more sites of involvement (i.e., skin and viscera) [85].

Ancillary Testing

New molecular data linking common kinase mutations in both LCH and non-LCH systemic histiocytosis (i.e., *ARAF*, *MAPK* *BRAF-RNF11* fusion) has prompted some to subclassify systemic JXG (“L group”) separately from cutaneous JXG (“C group”) [6]. However, preliminary gene enrichment data based on upregulated gene sets may suggest divergent hematopoietic precursors in LCH (e.g., late-stage myeloid progenitor cells, granulocyte-monocyte progenitors, and classic dendritic cell genes) as compared to non-LCH histiocytoses (e.g., common myeloid progenitors and core macrophage-associated genes) [4].

While deep lesions tend to be more cellular and monotonous with fewer Touton cells [91, 103], no specific pathologic variables per se distinguish systemic and solitary visceral JXG from its cutaneous form, with all sharing a similar immunophenotype.

Special Sites Including Bone, CNS, and Liver

Distinguishing between systemic JXG and rare case of early/childhood ECD under the microscope is impossible, but clinical/radiographic features are helpful for the diagnosis. Systemic JXG is often a neonatal disease without bone involvement, while childhood ECD often will include classic bilateral bone involvement. While the *BRAF-V600E* mutation may be more prevalent in ECD, systemic JXG lesions are now known to harbor mutations in the MAPK pathway, further blurring the diagnostic lines [4]. JXG bone involvement of the axial skeleton, especially with an osteosclerosis pattern, should prompt further clinical and radiologic investigation for ECD [104]. Solitary JXG lesions of the bone, including osteolytic destructive lesions with soft tissue and/or dura involvement, have been rarely noted [105], and a differential diagnosis of regressing and healing phases of LCH, which can often acquire large numbers of xanthoma cells, should always be kept in mind. Furthermore, bone marrow involvement with “JXG” morphology can also be difficult to distinguish from marrow involvement of LCH which often has few CD1a/CD207-positive cells. Berres et al. have reported MS-LCH cases with CD1a/CD207-negative bone marrows harboring a low-level (0.03–0.4%) *BRAF-V600E* mutant alleles, in which the pathology showed JXG morphology [3]. These cases, thus, question our ability to accurately categorize such cases based on histomorphology alone. Other differential diagnoses for bone lesions include RDD (see below) and chronic osteomyelitis.

CNS involvement both in solitary and systemic JXG is described, often involving the dura, spinal canal, or Meckel’s cave (the trigeminal cave at the petrous apex) with parenchymal brain mass lesions often presenting with seizures, headaches, and ataxia [91, 92, 106–110]. The characteristic

immunophenotype is retained, but more variable S100+ can also be present in the mononuclear JXG cells. Orsey et al. provide a nice literature review of 26 cases of CNS JXG with 38% of cases presenting as isolated lesions [108]. However, unlike LCH and ECD, pituitary involvement of JXG with diabetes insipidus is rare [92, 106]. While solitary CNS JXG lesions may have better outcomes given their ability for complete resection, we have encountered rare examples of solitary CNS mass lesions with pleomorphism and increased proliferation (including atypical mitoses) which we have called histiocytic sarcoma (with a JXG phenotype) (Fig. 1.18, see below). Others have noted fatal outcomes in what first appeared to be a primary CNS JXG with meningeal and spinal dissemination [110], while malignant transformation has also been noted in CNS JXG with diffuse leptomeningeal and parenchymal involvement [108].

Liver involvement in JXG has a portal-centric predilection and unlike LCH, does not directly involve the bile ducts (Fig. 1.5d). Rather, the portal tracts are expanded with an infiltrate of plump histiocytic cells with the JXG phenotype and can be associated with macrophage activation, hepatomegaly, and liver dysfunction. Hepatic involvement is often a poor prognostic factor when associated with fulminant hepatic failure in systemic JXG and may be related to a macrophage activation syndrome [91, 92, 106, 111, 112].

Other extra-cutaneous sites include the eye, gastrointestinal tract, spleen, genitourinary tract, and lungs with bronchocentric pattern [91, 92, 101, 106]. Solitary thymic involvement is exceedingly rare, but we have seen examples of mixed histiocytic lesions with both LCH and JXG-like morphologies within the same thymus [42]. Of note, lymph node involvement of JXG is exceedingly rare and outside of contiguous growth, and such involvement should prompt evaluation for a histiocytic sarcoma of JXG type (see below).

Rosai-Dorfman Disease

Also known by its descriptive name, sinus histiocytosis with massive lymphadenopathy (SHML), Rosai-Dorfman disease (RDD) remains a unique

histiocytic disorder with a variable clinical course having solitary, multifocal, and systemic forms. The name first coined by Rosai and Dorfman in 1969 [113, 114] was first noted by Destombes as adenitis with lipid excess [115]. A more detailed overview of RDD is provided in Chap. 19. Briefly, while it has been recognized as a “benign” disorder, often with spontaneous regression, a small subset of cases will have poorer outcomes. While the molecular underpinnings of this histiocytic disorder are at the early stages, additional clues from the “molecular microscope” may help unravel the striking variations in clinical presentation and behavior. New data are emerging that RDD may also harbor kinase mutations similar to LCH, including *NRAS*, *KRAS*, and *ARAF* [4], while a subset are associated with germline mutations (see below). Briefly, the classic clinical presentation is that of enlarged, bilateral cervical lymphadenopathy. However, a wide range of non-nodal sites can also be involved, including skin and subcutaneous tissues, bone, orbit, nasal cavity/paranasal sinuses, salivary glands, and CNS, in particular the meninges, with case reports of multiple different visceral sites of involvement [116–119]. RDD may present with variable systemic symptoms including fever, elevated sedimentation rate, leukocytosis, mild anemia, high ferritin, and polyclonal hyperglobulinemia, with a proportion of patients demonstrating clinical evidence of autoimmune disease [119]. The association of RDD or RDD-like changes are noted in several other conditions including LCH; lymphoma; HIV; autoimmune-related diseases (systemic lupus erythematosus, idiopathic juvenile arthritis, autoimmune hemolytic anemia); ALPS, in particular the type I with heterozygous germline mutation in *TNFRSF6*, the *FAS* gene (OMIM#601859); and histiocytosis-lymphadenopathy plus syndrome with a homozygous or compound heterozygous mutation in the *SLC29A3* gene (OMIM #602782) [79, 120–125] which are further elaborated in Chap. 19.

The pathologic sine qua non is the RDD cell which is a large histiocytic cell characterized by ample pale cytoplasm, often with a “watery-clear” or foamy appearance, and a large hypochromatic nucleus with a prominent nucleolus (Figs. 1.14 and 1.15). Emperipolesis, the trafficking of whole,

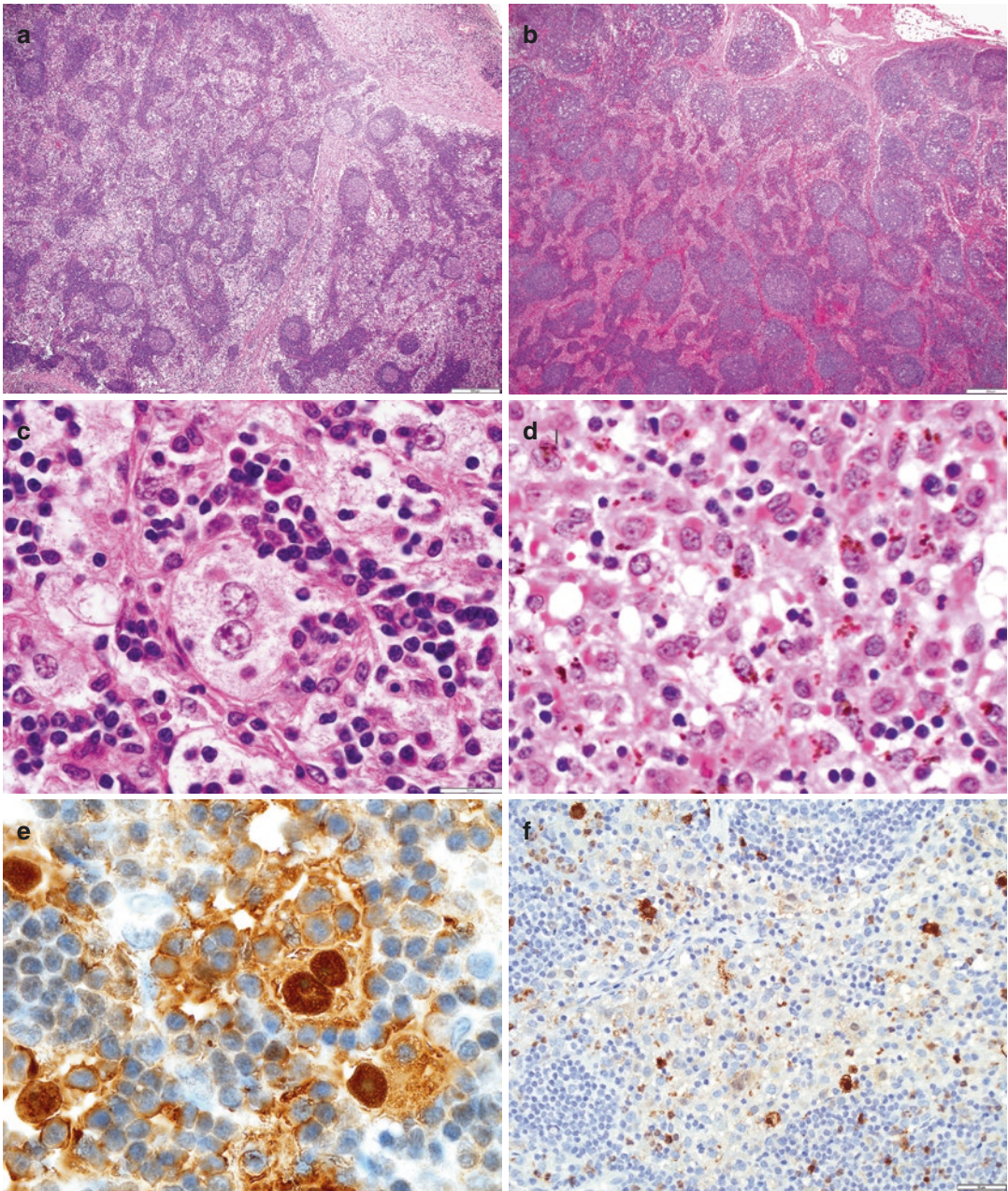


Fig. 1.14 Rosai-Dorfman disease, lymph node with sinus expansion of large pale staining histiocytes with large hypochromatic nucleus, and emperipolesis (**a** H&E, 4x, **c** H&E, 100x, **e** S100 immunostain, 100x). In contrast reactive sinus histiocytosis of a lymph node with small

histiocytes has eosinophilic cytoplasm and a small bland nucleus and is negative for S100 which highlights occasional dendritic cells (**b** H&E, 4x, **d** H&E, 20x, **f** S100 immunostain 40x)

intact leukocytes through the cytoplasm (in contrast to phagocytosis), is a diagnostic finding, but can be focal, especially at extranodal sites, and often is best highlighted on the selective cytoplasmic staining for S100 and fascin of the RDD cells

(Figs. 1.14 and 1.15). The immunophenotype of the large histiocytic cells is characterized by S100, CD68, and fascin, along with variable CD163 and CD14, and is typically CD1a and CD207 negative (Table 1.4). Similar to the other

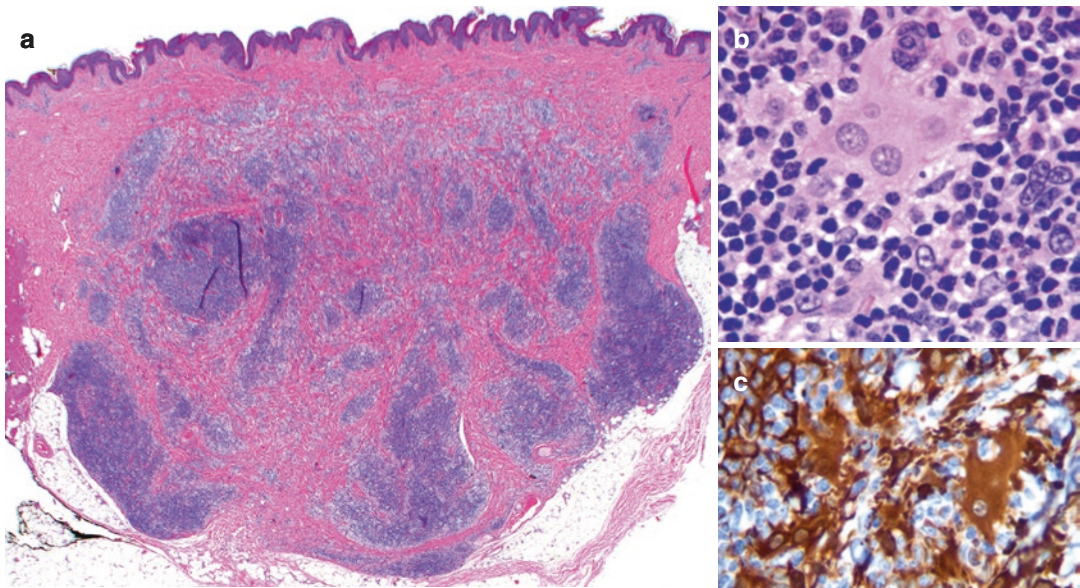


Fig. 1.15 Rosai-Dorfman disease (RDD) of the skin with deep dermal infiltrate and a robust surrounding lymphoplasmacytic infiltrate, simulating a lymph node in the

skin. (a) H&E (2 \times). (b) H&E (100 \times). (c) Fascin immunostain highlighting cytoplasm of a RDD cell with emperipolesis (immunostain, 40 \times)

histiocytic disorders, the cytomorphology and immunophenotype should be taken together with the pattern of involvement.

In the revised classification of histiocytosis and neoplasms of the macrophage-dendritic cell lineage, the “R” group (Table 1.2) includes classic sporadic RDD of the lymph nodes, extranodal involvement by sporadic RDD, and inherited and other conditions predisposing to RDD or RDD-like conditions [6]. We will attempt to outline the pathology based on these subgroups.

Classic Sporadic RDD

Sinus expansion in the lymph node, particularly of the cervical chain, with RDD cells is the most common presentation seen in children and young adults. It is often accompanied by numerous polytypic plasma cells in the medullary cords and around the venules. A thickened capsule is often present. Focal areas of necrosis and suppurative inflammation are not unusual. The nodal architecture is typically preserved, but residual follicles are often compressed due to the massive sinus expansion. Distinguishing between reactive

sinus histiocytosis should not be difficult, as reactive sinus histiocytes do not have the classic RDD cytomorphology which is a criterion for diagnosis (Fig. 1.14) and is usually S100 negative. An important caveat in making the diagnosis of sporadic nodal RDD is excluding any associated pathology both within the node itself or other related conditions (see inherited conditions predisposing to RDD or RDD-like conditions).

Extranodal Involvement

Sporadic RDD most often occurs in the bone, skin, upper respiratory tract, and orbit. In our files, bone and skin/soft tissue are the most frequent sites noted in consultation with rare examples in the eye (conjunctiva and orbital bone), spinal canal, and spleen. Extranodal sites will still retain the same cytomorphology of the RDD cells, albeit less frequent emperipolesis. Typically, a rich lymphoplasmacytic surrounding infiltrate is noted, and stromal fibrosis can be extensive. The combination of plasma cells and fibrosis may spark an investigation for increased IgG4 plasma cells in the context of IgG4-related

disease (RD), which is characterized by IgG4/IgG ratio > 0.4, storiform fibrosis, and obliterative phlebitis. In the most recent classification of histiocytosis, it was recommended to evaluate IgG4/IgG ratio in all RDD (grade D2), although it is still unclear whether RDD should belong in the spectrum of IgG4-RD or as a separate diagnostic subcategory of RDD [6, 126, 127]. If there is an increased IgG4/IgG ratio, serum Ig subsets could be evaluated, although increased IgG4 serum levels are also not specific for IgG4-RD, but are rather a T-helper 2 cell-mediated immune response to various conditions. Evaluation of CD4/FOXP3-positive T-regulatory (Treg) cells may also be a potential future marker with elevated levels in IgG4-RD, reactive lymph nodes, and variable high levels in RDD with elevated IgG4/IgG levels >0.4 [127].

RDD of the bone may mimic an inflammatory process, most notably chronic osteomyelitis (postinfectious and rheumatic-mediated CRMO), further compounded by the rich inflammatory milieu with plasma cells and vague systemic symptoms (i.e., fever, high ESR, leukocytosis). Often the larger positive histiocytic cells can be obscured or focal, especially if S100/fascin stains are not utilized, further leading to false-negative diagnosis. Chronic osteomyelitis, including CRMO, does not typically present with lymphadenopathy, and sampling of lymphadenopathy or soft tissue masses in such cases is warranted, which may reveal the diagnostic RDD cells if the bone is non-diagnostic of RDD.

RDD of the skin is another special site that may cause diagnostic confusion with other histiocytic disorders, inflammatory conditions, and other cutaneous lymphoid lesions. Typically, the RDD cells form a deep dermal to subcutaneous nodule with surrounding lymphoid follicles and plasma cells with a “lymph node in the skin” appearance (Fig. 1.15). Emperipolesis may be less prominent than in nodal sites, and older lesions may have extensive fibrotic stromal changes obscuring the residual diagnostic islands of RDD. The S100 and fascin immunostains may better highlight the lesional cells. We have seen rare cases of RDD with a more superficial dermal extension. It is also not uncommon to

have isolated RDD-type cells within LCH and JXG family of lesions, but typically these are not diagnosed as mixed histiocytic lesions, unless there is a clear distinct area of RDD that could be microdissected from the surrounding lesion (see “Mixed Histiocytic Disorders”).

Inherited Conditions Predisposing to RDD or RDD-Like Conditions

Familial and systemic RDD-like disease is described in Faisalabad histiocytosis. The overlapping *SLC29A3* mutation on chromosome 10q22 and a variable constellation of findings between familial RDD, Faisalabad histiocytosis, H syndrome, and pigmented hypertrichosis with insulin-dependent diabetes mellitus syndrome (e.g., cutaneous, cardiac, and/or endocrine features, joint contractures, and/or deafness) suggest that these four entities comprise the *SLC29A3* spectrum disorder, now listed as histiocytosis-lymphadenopathy plus syndrome, OMIM #602782 [120, 128, 129].

Associated RDD morphology has been noted in up to 41% of cases of autoimmune lymphoproliferative syndrome (ALPS) type I with germline mutation in the *FAS* gene (*TNFRSF6*, OMIM #601859). Features distinct from RDD include paracortical hyperplasia of the lymph node containing double-negative CD4/CD8 T cells and interdigitating S100-positive dendritic cells. These patients tend to have more aggressive manifestations of ALPS, male predominance, and early age at onset, but the RDD-like changes appear to be self-limited in these cases [121].

Neoplasia-Associated RDD

The association of RDD with non-Hodgkin lymphoma (NHL) and Hodgkin lymphoma (HL), including classical and nodular lymphocyte predominant (NLP) HL, has been reported. In the cases of RDD and lymphoma occurring at different sites, RDD either precedes or follows a diagnosis of lymphoma, with NHL predominating [121, 130–140]. In contrast, the simultaneous

involvement of HL and RDD-like changes within the same node/site may represent a distinct phenomenon, as many of the reported cases describe a more focal (<10%) RDD-like involvement of the node [122, 124, 141].

Conclusions

Inherited and neoplasia-associated RDD, along with high prevalence of immune dysregulation in sporadic RDD, suggests a concomitant role of dysfunctional immunity with the expansion of the RDD cell with associated emperipolesis, plasmacytosis, and variable fibrotic response.

Other histiocytic lesions: Indeterminate cell histiocytosis, ALK-positive histiocytosis, and dendritic cell histiocytosis, not otherwise specified

Some histiocytic lesions do not fit nicely into a certain category based on their immunophenotype. It is the hope that we will be able to better diagnose, classify, and ultimately treat these “rare” disorders with the insight gained from the “molecular microscope” of histiocytic disorders. Two such examples include the indeterminate cell histiocytosis with a unique *ETV-NCOA2* fusion [142] and systemic JXG-like ALK-positive histiocytosis seen in early infancy [143].

Indeterminate cell histiocytosis (ICH) is one such lesion that has features of a Langerhans-like

cell with an oval to round shape and a convoluted nucleus with surface CD1a and cytoplasmic/nuclear S100 expression, but lacks Birbeck granules on ultrastructural examination, and thus is also CD207 (langerin) negative by immunohistochemistry (Fig. 1.16) (Table 1.4). Despite being recognized since the early 1980s [144], these lesions have previously received little attention given their rarity, poorly defined origin, and pathogenesis and thus have remained poorly understood. However, the “molecular microscope” has helped in gaining new insights with at least three reported ICH cases harboring a gene fusion *ETV3-NCOA2* [142]. A large series of ICH cases is lacking, but those few reported cases suggest a female predominance in older adults with a variable indolent course and a typical cutaneous presentation [142, 145, 146]. While follow-up in these rare cases is often not extensive, at least a few cases had a fatal outcome with associated lymphoma/leukemia and/or signs of adenopathy/splenomegaly [142, 145].

ALK-positive histiocytosis is another rare histiocytosis, described thus far in infancy, with features of juvenile xanthogranuloma (positive for ALK, CD163, CD68, lysozyme, and variable fascin, factor XIIIa, and S100, but negative for CD30, CD1a, and CD207 immunostains).

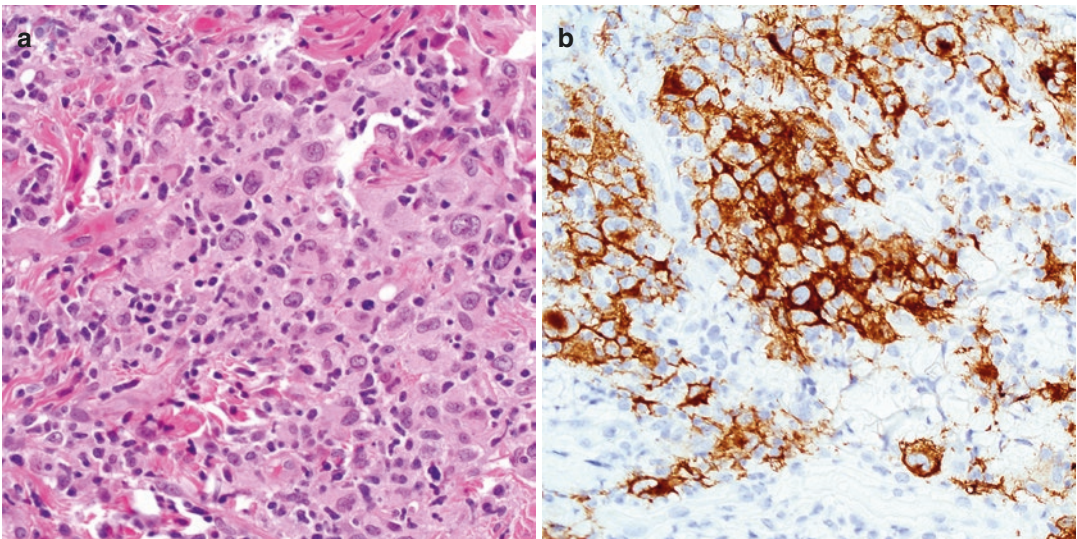


Fig. 1.16 Indeterminate cell histiocytosis with *ETV 3-NCOA2* fusion. (a) Morphologic features of LCH cell (H&E, 40x) with (b) membranous CD1a staining (immunostain, 40x) but CD207 negative (not shown)

These rare ALK-positive histiocytoses harbor the *TPM3-ALK* fusion with positive ALK immunohistochemistry in a membranous and cytoplasmic expression [143]. The three index cases were females with hepatosplenomegaly and sinusoidal infiltrates of ALK-positive histiocytes. The active phase initially showed signs concerning for hemophagocytosis, malignancy, or storage disorder given the hepatosplenomegaly, variable hematologic changes, and large sinusoidal histiocytes. However, the clinical resolution suggests that this is a unique but self-limited form of histiocytosis of infancy [143], distinct from the systemic/visceral JXG lesions. ALK immunohistochemistry may help separate these lesions especially in early infancy period.

Solitary Histiocytomas of the Dendritic Cell Phenotype

The solitary histiocytomas of the dendritic cell phenotype, not otherwise specified [2], have been described as tumoral proliferations of cells that are devoid of malignant features and, while lacking the immunophenotype of LCH or JXG, do have some staining suggestive of a “semi-mature” myeloid dendritic cell lineage (S100+, fascin+, HLA-DR+, and CD68+ but CD1a-, CD207-). Unlike ICH, a small series previously noted more frequency in children with dural and soft tissue unifocal involvement but with a higher rate of local recurrence [147]; however, more detailed studies are lacking. Further investigation is warranted in these cases which may just represent variants rather than a unified group.

Mixed Histiocytic Disorders

The term “mixed histiocytic” disorders is not a well-defined group of disorders, with few case reports [42, 71, 79, 80] and even rarer case series [76]. We have largely subscribed to the notion that two distinct histiocytic lesions are present within the same lesion, in which microdissection of the two lesions could be technically achieved. This serves to distinguish the so-called secondary

histiocytic hyperplasias seen in some disorders. Occasional S100+/fascin+ RDD cells may be found within a JXG family of lesions and should not constitute a “mixed histiocytosis” diagnosis; the same is true with CD1a-positive dendritic cells in other lesions. Some authors expand the definition of “mixed” histiocytic disorders to include more than one histiocytic lesion within the same patient, either concurrently or separable in time, most recently described with LCH and ECD [71, 76].

The mixed histiocytic lesions are distinguished from those histiocytic lesions following lymphoid neoplasms (see “Lymphomas, Leukemias, and Secondary Histiocytic Tumors, Including Secondary Histiocytic Sarcoma”). In histiocytic lesions following acute lymphoblastic leukemia (ALL), a shared molecular or clonal identity could be identified in a subset of patients and tended to show more aggressive behavior as compared to their native “benign” counterpart [148].

The International Rare Histiocytic Disorders Registry (IRHDR) (NCT02285582) is positioned to collect data on disease presentation, treatments, and outcomes of patients with non-LCH histiocytic disorders (<https://clinicaltrials.gov/ct2/show/NCT02285582>). It is only through the dedicated international collaboration of pathologists, clinicians, and scientists that we can continue to make sustained progress in better understanding and developing best-practice treatment regimens for these rare diseases.

Malignant Histiocytic Disorders

Histiocytic Sarcoma

Clinical Course

Most instances of histiocytic sarcoma with “anaplastic” cytologic features are aggressive with patients dying within a year. Tumor size may correlate with outcome. There is a small and poorly defined group of lesions that has relatively low-grade cytologic features, more confined growth potential, and longer survival. These “atypical” histiocytic lesions need to be better demarcated from high-grade histiocytic sarcomas.

Histiocytic sarcoma is defined as a high-grade, progressive tumor that has cellular atypia, mitoses and atypical mitoses (“sarcoma”), and the phenotypic features of histiocytes. Chromosomal gains or losses are rare, and *BRAF* mutations are described in some [149, 150]. While most are primary, some instances arise secondary to lymphomas, leukemias, or other hematologic neoplasms. Extramedullary myeloid tumors that have monocytic differentiation are not included.

Primary Histiocytic Sarcoma

Clinical

All ages can be affected, including infants and children [151], but adults predominate with equal sex distribution. Rare instances follow mediastinal malignant teratomas [152]. Presentation is commonly with “B” symptoms and the discovery of lymphadenopathy, skin, soft tissue, bone, or CNS lesions. Hepatosplenomegaly may be present, more likely as a systemic effect and not infiltration.

Pattern of Involvement

The initial impression is that of a diffuse large cell “lymphoma” that effaces lymph nodes or forms tumors. Cellular pleomorphism is the rule, often with binucleated or multinucleated forms interspersed. Mitotic activity is variable and may include atypical forms in the more anaplastic lesions. Inflammatory cells are generally sparse but present and may include bland histiocytes, lymphocytes, eosinophils and plasma cells. A cytologic clue to the diagnosis is the relatively abundant “macrophage-like” cytoplasm, lightly eosinophilic, though some are more spindly or dendritic cell in appearance. Nuclei are oval, hypochromatic, or vesicular with a single small nucleolus. Multinucleation is common. Tumors at various sites, including CNS, have similar features. It was formerly said that histiocytic lineage was documented only by excluding all other cell types, but phenotypic confirmation of the histiocytic differentiation suffices. It is important to note that a high content of interspersed “benign” histiocytes in this as well as other hematopoietic tumors may be found. Histiocytic sarcoma has the phenotype of

mature tissue macrophages [153] (Table 1.4). Immunostains for CD163 show a surface and cytoplasmic pattern with higher specificity than CD68 that is present in a variety of cell types. Membranous CD14, light CD4, and CD11c are additional histiocytic markers. Lysozyme is seen as a Golgi-type dot rather than the diffuse cytoplasmic stain of myeloid and monocytic lesions. S100 can be present in cases with a more dendritic morphology. CD45 and HLA-DR may be expressed and CD56 is rare. Cases with JXG phenotype, including variable factor XIIIa and fascin, have been described (Fig. 1.18). Few cells expressing CD1a or langerin may be demonstrable.

Differential Diagnosis

Markers that would suggest alternative diagnoses should not be expressed, specifically myeloid leukemia (myeloperoxidases), Langerhans cell (CD1a, CD207), follicular dendritic cell (CD21, CD23, CD35), anaplastic large cell (CD30, EMA, ALK), and epithelial keratins. The Ki-67/Mib proliferation marker may be present in more than 10% of cells. Ultrastructure and enzyme histochemistry have been largely superseded. The differential diagnoses of large cell anaplastic tumors have been covered under the phenotype, but anaplastic tumors with a high content of interspersed macrophages should always be kept in mind. Ancillary molecular testing has shown recurrent molecular mutations in the MEK-ERK1/2 MAPK signaling pathway (e.g., *BRAF*, *HRAS*, *BRAF* gene fusions) of primary histiocytic sarcomas in addition to chromosomal gains or losses [4, 149, 154].

Lymphomas, Leukemias, and Secondary Histiocytic Tumors, Including Secondary Histiocytic Sarcoma

Histiocytic lesions of a wide variety have been noted to follow lymphomas or leukemias, mostly B cell type, and in many instances a clear clonal relationship has been established between the two processes [155, 156]. Some of the histiocytic tumors have been low grade with benign long-term follow-up [157], but others fulfill the

criteria for a wide range of tumors including interdigitating cell sarcoma, Langerhans cell sarcoma, immature undefined histiocytic lesions, and (secondary) histiocytic sarcoma [158].

This intriguing condition has the same diagnostic features as those described for primary histiocytic sarcoma but can follow follicular lymphomas, lymphoid leukemia, and rarely other histiocytoses [159]. In many instances, the molecular genetic signature of the primary tumor has been demonstrated in the subsequent histiocytic sarcoma that suggests “transdifferentiation” or lineage switching. Similar *IGH* gene rearrangements, deletions of positions of chromosome 5, t(14;18), trisomies 8 and 9, and *BCR-ABL1* have been documented in the primary tumor and the histiocytic sarcoma [159–162].

Langerhans Cell Sarcoma

Clinical

Langerhans cell sarcoma (LCS) is more common in adults, mean age 50 years, but cases are described in childhood. Very rare and poorly documented cases of prior Langerhans cell histiocytosis are

described, but the condition probably arises de novo with no connection. Presentation is commonly with a mass lesion in skin, soft tissues, lymph node, or Waldeyer’s ring. Localized disease confers survival advantage with surgical excision, but more disseminated disease is associated with survival of about 2 years [163].

Pattern of Involvement

LCS has the features of a high-grade, cytologically malignant hematopoietic neoplasm with the Langerhans cell phenotype (Fig. 1.17) [163, 164]. The cellular pleomorphic large cell population with high-grade features has a range from moderate pleomorphism to frank anaplasia. The classical nuclear features of the LCH cell, complex folding, and “coffee bean” grooves serve as a clue to establishing the phenotype as atypical mitoses. Cytoplasm is pale and moderately abundant. There may be a light eosinophil presence, but inflammatory cells including interspersed macrophages are sparse. The mitotic rate is generally brisk, and Ki-67 in the CD207+ cells is above 30% (Table 1.4). Similar to histiocytic sarcoma (Fig. 1.18), there are a

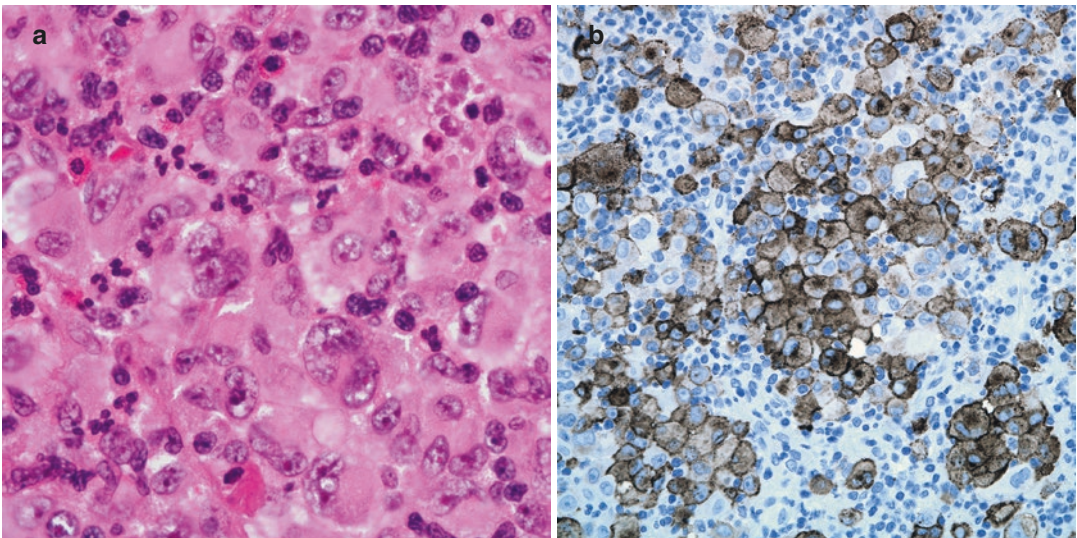


Fig. 1.17 Malignant histiocytosis, features of Langerhans cell sarcoma with architectural effacement. (a) Complex grooved nuclear folds with high cellularity and pleomorphism (H&E, 100×) which have (b) CD207 expression

(immunostain, 40×). Unusual features included diminished CD1a expression. There was also surface staining of CD163, CD14, and cytoplasmic and paranuclear CD68 immunostains (not shown)

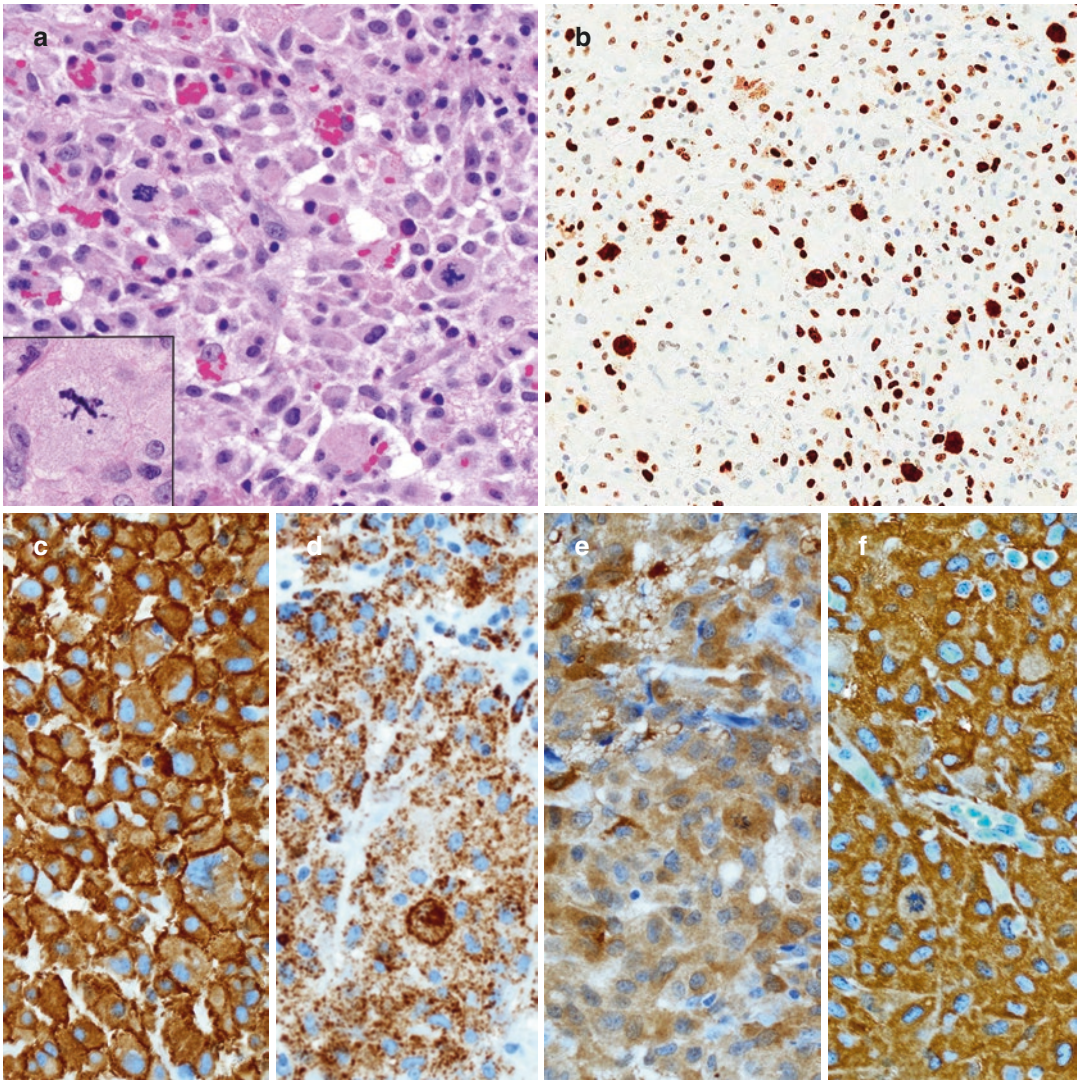


Fig. 1.18 Malignant histiocytosis, histiocytic sarcoma, JXG phenotype. (a) Intermediate to large, histiocytic cells with frequent mitoses including an atypical mitosis with diffuse growth pattern. (b) The Ki-67 proliferation index is very high including large cells (immunostain, 20×). The

cells display a JXG histiocytic phenotype including (c) surface and cytoplasmic CD163 (immunostain, 40×), (d) granular cytoplasmic CD68 (immunostain, 40×), (e) cytoplasmic factor XIIIa (immunostain, 40×), and (f) fascin (immunostain, 40×)

small number of instances in which the pleomorphism and mitotic rate do not reach the cytologic threshold for “sarcoma.” These cases deserve better characterization since the outcome is uncertain. Lymph node involvement, like LCH, is primarily that of a sinus pattern, though it may be lost over time. At other sites, the diagnosis is established based on the cytology and phenotype.

Differential Diagnosis

LCS has the same phenotype as LCH, with CD1a, CD207, and S100 positivity. There is, however, greater variability in the number of cells staining for each, and both CD1a and CD207 can be lost on recurrences. CD68 and HLA-DR can be seen as a paranuclear dot in some. Rarely, CD56 or CD30 is expressed as

well. Demonstration of the ultrastructural Birbeck granule is not required for diagnosis.

The primary differential diagnosis is that of LCH. The excess pleomorphism, high mitotic rate, and atypical mitoses, when present, are diagnostic of LCS. There are rare and poorly characterized instances in which the features fall short. Other diagnostic considerations are excluded by the definitive LCS phenotype. Like LCH, the cell of origin is believed to be myeloid and activating kinase mutations in *BRAF-V600E*, and other MAP kinase pathway mutations have been described [165, 166].

Indeterminate Dendritic Cell Sarcoma

Clinical

Indeterminate dendritic cell sarcoma is rare, affecting primarily older adults. Most cases involve the skin, soft tissue, and lymph nodes. Secondary indeterminate dendritic cell lesions can follow prior lymphomas or leukemias and can share the genetic signature of the primary tumor [145].

Pattern of Involvement

Indeterminate dendritic cell sarcoma is a high-grade lesion with similarities to LCS, but defined by its phenotype that is S100+/CD1a+ and lacks CD207 and the ultrastructural Birbeck granule [167, 168]. The tumors are highly reminiscent of LCS but lack their convoluted nuclear morphology. CD1a is required for the diagnosis, and CD207 is absent by definition. S100 is generally positive but S100-negative cases are reported. CD68 generally has a paranuclear dot. The biological spectrum is wide, from low-grade and localized lesions to more anaplastic high-grade “sarcoma.”

Ancillary Studies

BRAF mutations have been described [169], but more interestingly, three adult patients with indeterminate cell lesions have been shown to harbor a recurrent *ETV3-NCOA2* translocation suggesting

that it is biologically distinct [142], although demonstration in its “sarcoma” form has not yet been described. While indeterminate dendritic cell sarcoma has morphologic similarity to LCS, biological outcome in reported cases has varied, with suggestion of a more aggressive tumor.

Differential Diagnosis

The differential diagnosis includes LCS that by definition is CD207+. However, LCS can progressively lose its markers, such as CD207, and mimic indeterminate dendritic cell sarcoma. Exuberant skin lesions (especially following arthropod bites) can have abundant CD1a reactivity without CD207, as a physiological state. Other CD1a+ /CD207- infiltrates include some myelomonocytic and rare T cell leukemias.

Interdigitating Dendritic Cell Sarcoma (IDCS)

Definition

This is a clinically aggressive, though histologically non-anaplastic, sarcoma that has the phenotype of the lymph node paracortical interdigitating dendritic cell [170]. Because of the disparity between the histopathology and clinical behavior, it is often referred to as the interdigitating dendritic cell tumor rather than sarcoma (herein IDCS). Rare instances accompany or follow low-grade B or T cell lymphomas [158, 171, 172].

The existence of IDCS has recently been challenged because the lesion appears to be indistinguishable on histopathologic and phenotypic grounds from spindle cell melanoma, though ultrastructural differences may apply [170, 173].

Clinical

Tumors present as masses in nodal or extranodal sites, skin, soft tissue, and organ sites predominantly. The clinical progression is aggressive in about half of the patients, but histopathology is not predictive.

Pattern of Involvement

Nodal lesions tend to be paracortical and sharply defined from residual lymphoid tissue, but at the other sites, the spindle cell lesion is diffuse and may have poorly formed fascicles or whorls. Nuclear features are generally bland, rarely anaplastic, and the nuclei are vesicular, oval to plump with a single prominent nucleolus. The cytoplasm is pale, and abundant and has indistinct cell borders. Interspersed small lymphocytes and plasma cells may be noted. Cytologic atypia varies (usually low) and mitoses are not prominent. Ultrastructural features are thought to be informative with complex interdigitating cell processes without formed desmosomes. Distinguishing features such as Birbeck granules, basal lamina, or melanosomes should not be found.

Immunophenotype

The diagnosis of interdigitating dendritic cell sarcoma in a spindle cell mass relies on the phenotype; like the paracortical interdigitating cell of the lymph node, there is moderate and high expression of S100 and fascin, vimentin, and HLA-DR. Conventional histiocytic markers such as CD68, CD163, and CD14 are absent, as are CD45 and lysozyme. Specific subset histiocytic markers like CD21, CD23, CD35, CD1a, and CD207 are absent. HBM45 and cytokeratin are not found. Interspersed lymphocytes are T cells. Ki-67 is reported to be in the 10–20% range. BRAF mutations have been described [169, 174].

Differential Diagnosis

The differential diagnosis of spindle cell tumors is of course wide. The distinction from spindle

cell melanoma has been mentioned, but the expanded phenotype is distinct if other look-alikes are excluded.

Follicular Dendritic Cell Sarcoma

The follicular dendritic cell is reputed to be of mesenchymal, non-hematopoietic origin and is not included in the review of histiocytic lesions nor considered in the revised classification of histiocytoses and neoplasms of macrophage-dendritic cell lineages [6]. Their phenotype is distinctive and includes CD21, CD23, CD35, clusterin, podoplanin, desmoplakin, and claudin-4 [175].

Fibroblastic Reticular Cell Tumor

The fibroblastic reticular cell or cytokeratin-positive interstitial reticulum cell is not believed to belong to the histiocytic family but to be of mesenchymal origin. The cell forms a complex network of channels in the lymph node paracortex. These nodal (rarely splenic) lesions are characterized by their staining for vimentin, actin, and keratin and sometimes also desmin [176].

Hemophagocytic Lymphohistiocytosis and Macrophage Activation Syndrome

Section III is dedicated to the clinical diagnosis, classification, and treatment of hemophagocytic lymphohistiocytosis/macrophage activation syndrome (HLH/MAS). While included herein, it should be stressed that HLH/MAS is not a primary histiocytic defect but rather a regulatory disorder of T cells leading to unbridled macrophage activation. Furthermore, despite the name,

Table 1.5 Histologic hepatic patterns of hemophagocytic lymphohistiocytosis (HLH)/macrophage activation syndrome (MAS)

1. Chronic hepatitis-like pattern with a portal accumulation of T lymphocytes and plump activated histiocytes (“lymphohistiocytosis”) with lymphocytic bile duct injury and endothelialitis. Activated sinusoidal macrophages with hemophagocytosis can accompany
2. A leukemia-like pattern with sinusoidal infiltration of T cell with bile duct damage and endothelialitis
3. A histiocyte storage disorder-like pattern with intravascular and sinusoidal lymphohistiocytic macrophages
4. A neonatal giant cell hepatitis-like pattern with multinucleated giant cell transformation of hepatocytes, extramedullary hematopoiesis, and lymphohistiocytic infiltrates in the portal tracts with bile duct injury and endothelialitis (similar to pattern 1)

Taken from Chen et al. [181]

the pathologic features of hemophagocytosis are neither specific nor sensitive in the overall diagnosis and constitute only one of the eight diagnostic criteria [177]. Hemophagocytosis can be demonstrated after transfusions, surgical interventions, and immunoglobulin infusions. Briefly, in HLH/MAS-activated macrophages, some with hemophagocytosis can be found in the lymph nodes, spleen, central nervous system, liver, bone marrow, and thymus [178]. None of the pathologic features will clearly distinguish between the primary and secondary hemophagocytic syndromes. The lymph nodes may display enlarged activated macrophages in the sinuses and paracortical T-zone areas, whereas lymphoid depletion, particularly of the follicles, may be present in later stages [179, 180]. The spleen is also a prominent site of hemophagocytosis and often will show white pulp depletion in severe cases with enlarged activated macrophages in the cords and sinuses [178]. In the liver, the infiltrate has been described in four patterns (Table 1.5), but

the recognition of a “chronic hepatitis” pattern with lymphohistiocytosis has been long noted. Classically, the portal and sinusoidal infiltrates are composed of activated macrophages with variable hemophagocytosis (CD163+/CD68+, CD1a-) and cytotoxic T cells (CD3+, CD8+, granzyme B+) (Fig. 1.19). Endothelialitis of the portal and central veins is quite typical, often with free-floating macrophages in the lumen of the veins. Lymphocyte-mediated bile duct injury is also a typical feature [178, 180, 181]. In the bone marrow, macrophage activation and hemophagocytosis can be cyclical, and intervening biopsies may be negative at first examination or during troughs of activity (false negative) [177, 180]. In the bone marrow, the PGM-1 CD68 antibody has little cross-reaction with hematopoietic precursors and is therefore a preferred bone marrow macrophage stain if CD163 is not available. When positive, the marrow will display enlarged macrophages, increased in size and number, with variable hemophagocytosis, in contrast to normal oval to spindle-shaped marrow macrophages (Fig. 1.20). An increase of CD3/CD8 T cells is also observed. Early disease often does not show marrow depletion, which suggests that cytopenias are secondary to cytokine effect rather than marrow replacement. Dyserythropoiesis and pseudo-Pelger-Huet change can be noted on aspirates. Late disease, often after systemic therapy, may show marrow depletion with xanthomatous macrophage replacement [178, 182]. A skin biopsy with non-specific rash may show a lymphocytic infiltration with or without hemophagocytosis. The CSF in patients with neurologic symptoms may show pleocytosis with large activated cytoplasmic-rich macrophages that may show hemophagocytosis, along with elevated protein levels.

It should be noted that while pathologic features may further confirm a diagnosis of HLH/MAS, the clinical criteria must be met before such a diagnosis is established.

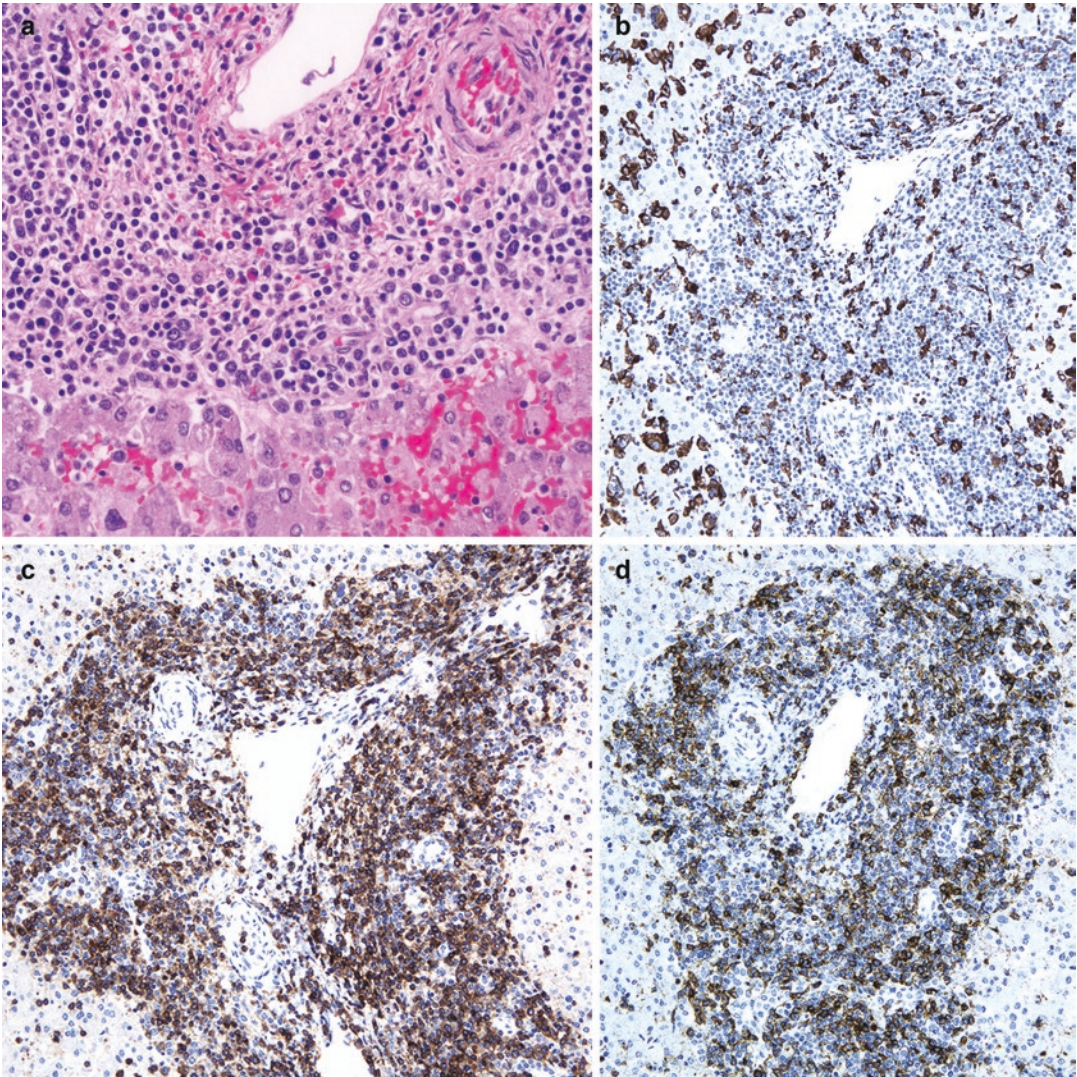


Fig. 1.19 Familial hemophagocytic lymphohistiocytosis (HLH), type 2 perforin deficient. (a) The liver has expanded portal areas and sinusoids with high macrophage content and lymphocytic content. (a) H&E (40×), (b) CD163 immunostain with variable portal macrophages

and enlarged, activated sinusoidal macrophages (immunostain, 20×). (c) Expanded portal infiltrate of CD3 T cells (immunostain, 20×), (d) which are mostly CD8-positive cytotoxic T cells (immunostain, 20×). The perforin immunostain was not detectable on lymphocytes (not shown)

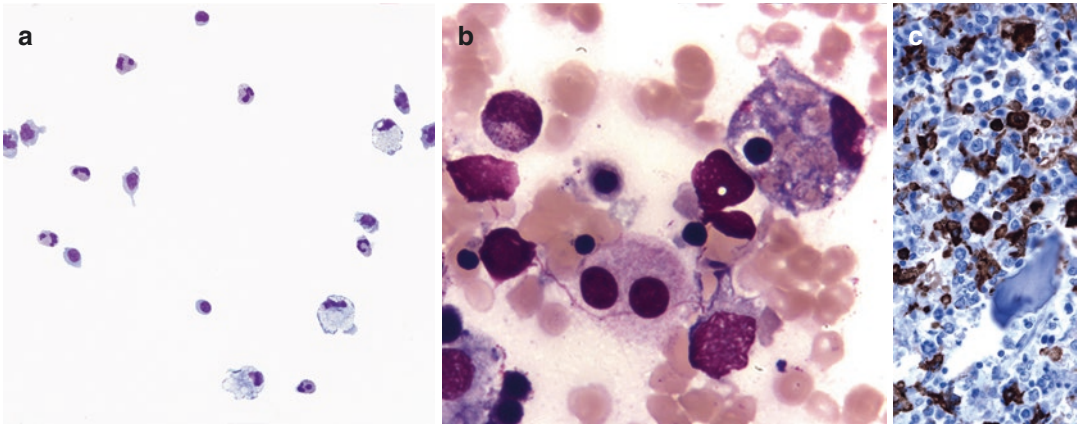


Fig. 1.20 HLH cerebral spinal fluid (CSF) and bone marrow (BM). (a) Predominance of monocytyoid cells and activated macrophages in the CSF of a patient with HLH would indicate CSF HLH involvement (Wright-Giemsa, 40 \times).

(b) BM aspirate with hemophagocytosis (Wright-Giemsa, 100 \times). (c) CD163 immunostain of BM with increased numbers of large macrophages, some showing intracytoplasmic red cells and cell debris (immunostain, 40 \times).

Conclusions

The pathology of histiocytoses and neoplasms of the macrophage-dendritic cell lineages is varied and made more difficult by their rarity in any one practice. The “molecular microscope” of these lesions is further unraveling their biologic potential, which in many cases has also helped to solidify their standing as inflammatory myeloid neoplasms. However, the often overlapping clinical and histologic spectrum among these diseases continues to baffle pathologists, clinicians, and scientists alike as we continue to seek out the cellular origins of this enigmatic group of diseases. The latest attempt to revise the classification of histiocytoses and neoplasms of the macrophage-dendritic cell lineages has proposed grouping this diverse group of over 100 clinical entities into five main groups (see Table 1.2) based on clinical, histologic, and molecular relevance [6]. At the writing of this chapter, the 2016 WHO classification for histiocytoses and neoplasms of the macrophage-dendritic cell lineages has only recently recognized ECD as a separate category [7] (Table 1.3). The clinical/

pathologic relevance of this revised classification will ultimately determine if this new grouping is further adopted into practice as a framework for further study.

References

1. Histiocytosis syndromes in children. Writing group of the Histiocyte Society. *Lancet*. 1987;1(8526):208–9.
2. Favara BE, Feller AC, Pauli M, Jaffe ES, Weiss LM, Arico M, et al. Contemporary classification of histiocytic disorders. The WHO Committee on histiocytic/reticulum cell proliferations. Reclassification Working Group of the Histiocyte Society. *Med Pediatr Oncol*. 1997;29:157.
3. Berres ML, Lim KP, Peters T, Price J, Takizawa H, Salmon H, et al. BRAF-V600E expression in precursor versus differentiated dendritic cells defines clinically distinct LCH risk groups. *J Exp Med*. 2014;211(4):669–83.
4. Diamond EL, Durham BH, Haroche J, Yao Z, Ma J, Parikh SA, et al. Diverse and targetable kinase alterations drive histiocytic neoplasms. *Cancer Discov*. 2016;6(2):154–65.
5. Haroche J, Cohen-Aubart F, Charlotte F, Maksud P, Grenier PA, Cluzel P, et al. The histiocytosis Erdheim-Chester disease is an inflammatory myeloid neoplasm. *Expert Rev Clin Immunol*. 2015;11(9):1033–42.

6. Emile JF, Abla O, Fraitag S, Horne A, Haroche J, Donadieu J, et al. Revised classification of histiocytoses and neoplasms of the macrophage-dendritic cell lineages. *Blood*. 2016;127(22):2672–81.
7. Swerdlow SH, Campo E, Pileri SA, Harris NL, Stein H, Siebert R, et al. The 2016 revision of the World Health Organization (WHO) classification of lymphoid neoplasms. *Blood*. 2016;127:2375.
8. Berres ML, Allen CE, Merad M. Pathological consequence of misguided dendritic cell differentiation in histiocytic diseases. *Adv Immunol*. 2013;120:127–61.
9. Emile JF, Wechsler J, Brousse N, Boulland ML, Cologon R, Fraitag S, et al. Langerhans' cell histiocytosis. Definitive diagnosis with the use of monoclonal antibody O10 on routinely paraffin-embedded samples. *Am J Surg Pathol*. 1995;19(6):636–41.
10. Chikwava K, Jaffe R. Langerin (CD207) staining in normal pediatric tissues, reactive lymph nodes, and childhood histiocytic disorders. *Pediatr Dev Pathol*. 2004;7(6):607–14.
11. Sahm F, Capper D, Preusser M, Meyer J, Stenzinger A, Lasitschka F, et al. BRAFV600E mutant protein is expressed in cells of variable maturation in Langerhans cell histiocytosis. *Blood*. 2012;120(12):e28–34.
12. Mehes G, Irsai G, Bedekovics J, Beke L, Fazakas F, Rozsa T, et al. Activating BRAF V600E mutation in aggressive pediatric langerhans cell histiocytosis: demonstration by allele-specific PCR/direct sequencing and immunohistochemistry. *Am J Surg Pathol*. 2014;38:1644.
13. College of American Pathologists. Anatomic pathology checklist predictive markers 2015 [cited 2016 June 1, 2016]. Available from: <http://www.cap.org/ShowProperty?nodePath=/UCMCon/Contribution%20Folders/WebContent/pdf/accreditation-checklists-full-listing.pdf>.
14. US Food and Drug Administration (FDA). Overview of IVD regulation silver spring, MD. 2015 [updated 3/19/15; cited 2016 June 30]. Available from: <http://www.fda.gov/MedicalDevices/DeviceRegulationandGuidance/IVDRegulatoryAssistance/ucm123682.htm>.
15. Allen CE, Ladisch S, McClain KL. How I treat Langerhans cell histiocytosis. *Blood*. 2015;126(1):26–35.
16. Heritier S, Emile JF, Barkaoui MA, Thomas C, Fraitag S, Boudjemaa S, et al. BRAF mutation correlates with high-risk langerhans cell histiocytosis and increased resistance to first-line therapy. *J Clin Oncol*. 2016;34:3023.
17. Ellison G, Donald E, McWalter G, Knight L, Fletcher L, Sherwood J, et al. A comparison of ARMS and DNA sequencing for mutation analysis in clinical biopsy samples. *J Exp Clin Cancer Res*. 2010;29:132.
18. Badalian-Very G, Vergilio JA, Degar BA, MacConaill LE, Brandner B, Calicchio ML, et al. Recurrent BRAF mutations in Langerhans cell histiocytosis. *Blood*. 2010;116(11):1919–23.
19. Brown NA, Furtado LV, Betz BL, Kiel MJ, Weigelin HC, Lim MS, et al. High prevalence of somatic MAP2K1 mutations in BRAF V600E-negative Langerhans cell histiocytosis. *Blood*. 2014;124(10):1655–8.
20. Nelson DS, Quispel W, Badalian-Very G, van Halteren AG, van den Bos C, Bovee JV, et al. Somatic activating ARAF mutations in Langerhans cell histiocytosis. *Blood*. 2014;123(20):3152–5.
21. Nelson DS, van Halteren A, Quispel WT, van den Bos C, Bovee JVMG, Patel B, et al. MAP2K1 and MAP3K1 mutations in langerhans cell histiocytosis. *Genes Chromosomes Cancer*. 2015;54(6):361–8.
22. Chakraborty R, Hampton OA, Shen X, Simko SJ, Shih A, Abhyankar H, et al. Mutually exclusive recurrent somatic mutations in MAP2K1 and BRAF support a central role for ERK activation in LCH pathogenesis. *Blood*. 2014;124(19):3007–15.
23. Prince HM. Identifying mutant pathways in the histiocytoses. *Blood*. 2014;124(19):2901–3.
24. Rollins BJ. Genomic alterations in Langerhans cell histiocytosis. *Hematol Oncol Clin North Am*. 2015;29(5):839–51.
25. Picarsic J, Jaffe R. Nosology and pathology of Langerhans cell histiocytosis. *Hematol Oncol Clin North Am*. 2015;29(5):799–823.
26. Haupt R, Minkov M, Astigarraga I, Schafer E, Nanduri V, Jubran R, et al. Langerhans cell histiocytosis (LCH): guidelines for diagnosis, clinical work-up, and treatment for patients till the age of 18 years. *Pediatr Blood Cancer*. 2013;60(2):175–84.
27. Roncaroli F, Consales A, Galassi E, Bernardi B, Valeri B. Occipital aneurysmal bone cyst secondary to eosinophilic granuloma. *Pediatr Neurosurg*. 2001;35(2):103–6.
28. Brown RSD, Edwards J, Bartlett JW, Jones C, Dogan A. Routine acid decalcification of bone marrow samples can preserve DNA for FISH and CGH studies in metastatic prostate cancer. *J Histochem Cytochem*. 2002;50(1):113–5.
29. Brown NA, Betz BL, Weigelin HC, Elenitoba-Johnson KS, Lim MS, Bailey NG. Evaluation of allele-specific PCR and immunohistochemistry for the detection of BRAF V600E mutations in hairy cell leukemia. *Am J Clin Pathol*. 2015;143(1):89–99.
30. Andrulis M, Penzel R, Weichert W, von Deimling A, Capper D. Application of a BRAF V600E mutation-specific antibody for the diagnosis of hairy cell leukemia. *Am J Surg Pathol*. 2012;36(12):1796–800.
31. Diamond EL, Dagna L, Hyman DM, Cavalli G, Janku F, Estrada-Veras J, et al. Consensus guidelines for the diagnosis and clinical management of Erdheim-Chester disease. *Blood*. 2014;124(4):483–92.
32. Simko SJ, Garmezy B, Abhyankar H, Lupo PJ, Chakraborty R, Lim KPH, et al. Differentiating skin-limited and multisystem Langerhans cell histiocytosis. *J Pediatr*. 2014;165(5):990–6.
33. Jaffe R. Is there a role for histopathology in predicting the clinical outcome in congenital and infant Langerhans cell disease? *Pediatr Blood Cancer*. 2009;53(6):924–5.
34. Minkov M, Prosch H, Steiner M, Grois N, Potschger U, Kaatsch P, et al. Langerhans cell histiocytosis in neonates. *Pediatr Blood Cancer*. 2005;45(6):802–7.
35. Online Mendelian Inheritance in Man O. OMENN SYNDROME Johns Hopkins University, Baltimore,

- MD.02/11/2014 [updated 02/11/2014]. Available from: <http://omim.org/>.
36. Avila EM, Uzel G, Hsu A, Milner JD, Turner ML, Pittaluga S, et al. Highly variable clinical phenotypes of hypomorphic RAG1 mutations. *Pediatrics*. 2010;126(5):e1248–52.
 37. Schuetz C, Huck K, Gudowius S, Megahed M, Feyen O, Hubner B, et al. An immunodeficiency disease with RAG mutations and granulomas. *N Engl J Med*. 2008;358(19):2030–8.
 38. Wouters CH, Maes A, Foley KP, Bertin J, Rose CD. Blau syndrome, the prototypic auto-inflammatory granulomatous disease. *Pediatr Rheumatol Online J*. 2014;12:33.
 39. Buchbinder D, Baker R, Lee YN, Ravell J, Zhang Y, McElwee J, et al. Identification of patients with RAG mutations previously diagnosed with common variable immunodeficiency disorders. *J Clin Immunol*. 2015;35(2):119–24.
 40. Schmitz L, Favara BE. Nosology and pathology of Langerhans cell histiocytosis. *Hematol Oncol Clin North Am*. 1998;12(2):221–46.
 41. Christie LJ, Evans AT, Bray SE, Smith ME, Kernohan NM, Levison DA, et al. Lesions resembling Langerhans cell histiocytosis in association with other lymphoproliferative disorders: a reactive or neoplastic phenomenon? *Hum Pathol*. 2006;37(1):32–9.
 42. Picarsic J, Egeler RM, Chikwava K, Patterson K, Jaffe R. Histologic patterns of thymic involvement in Langerhans cell proliferations: a clinicopathologic study and review of the literature. *Pediatr Dev Pathol*. 2015;18(2):127–38.
 43. Ronceray L, Potschger U, Janka G, Gadner H, Minkov M. Pulmonary involvement in pediatric-onset multi-system Langerhans cell histiocytosis: effect on course and outcome. *J Pediatr*. 2012;161(1):129–33 e1-3.
 44. Kim HK, Park CJ, Jang S, Cho YU, Park SH, Koh KN, et al. Bone marrow involvement of Langerhans cell histiocytosis: immunohistochemical evaluation of bone marrow for CD1a, Langerin, and S100 expression. *Histopathology*. 2014;65(6):742–8.
 45. Galluzzo ML, Braier J, Rosenzweig SD, Garcia de Davila MT, Rosso D. Bone marrow findings at diagnosis in patients with multisystem langerhans cell histiocytosis. *Pediatr Dev Pathol*. 2010;13(2):101–6.
 46. Minkov M, Potschger U, Grois N, Gadner H, Dworzak MN. Bone marrow assessment in Langerhans cell histiocytosis. *Pediatr Blood Cancer*. 2007;49(5):694–8.
 47. Favara BE, Jaffe R, Egeler RM. Macrophage activation and hemophagocytic syndrome in langerhans cell histiocytosis: report of 30 cases. *Pediatr Dev Pathol*. 2002;5(2):130–40.
 48. Chantranuwat C. Systemic form of juvenile xanthogranuloma: report of a case with liver and bone marrow involvement. *Pediatr Dev Pathol*. 2004;7(6):646–8.
 49. Kesserwan C, Boue DR, Kahwash SB. Isolated juvenile xanthogranuloma in the bone marrow: report of a case and review of the literature. *Pediatr Dev Pathol*. 2007;10(2):161–4.
 50. Takahashi K, Isobe T, Ohtsuki Y, Sonobe H, Takeda I, Akagi T. Immunohistochemical localization and distribution of S-100 proteins in the human lymphoreticular system. *Am J Pathol*. 1984;116(3):497–503.
 51. Hadzic N, Pritchard J, Webb D, Portmann B, Heaton ND, Rela M, et al. Recurrence of Langerhans cell histiocytosis in the graft after pediatric liver transplantation. *Transplantation*. 2000;70(5):815–9.
 52. Christiansen EC, Ellwein M, Neglia JP. Splenomegaly unresponsive to standard and salvage chemotherapy in Langerhans cell histiocytosis: a case of extramedullary hematopoiesis. *Pediatr Blood Cancer*. 2012;58(6):998–9.
 53. Baqir M, Vassallo R, Maldonado F, Yi ES, Ryu JH. Utility of bronchoscopy in pulmonary Langerhans cell histiocytosis. *J Bronchology Interv Pulmonol*. 2013;20(4):309–12.
 54. Roden AC, Yi ES. Pulmonary Langerhans cell histiocytosis: an update from the pathologists' perspective. *Arch Pathol Lab Med*. 2016;140(3):230–40.
 55. Arnaud L, Pierre I, Beigelman-Aubry C, Capron F, Brun AL, Rigolet A, et al. Pulmonary involvement in Erdheim-Chester disease: a single-center study of 34 patients and a review of the literature. *Arthritis Rheum*. 2010;62(11):3504–12.
 56. Kepes J. Histiocytosis X. In: BG VPJ, editor. *Handbook of neurology*, vol. 38. New York: Elsevier Publishing Company; 1979. p. 93–117.
 57. Norman R. The neuronal storage diseases. In: Greenfield J, editor. *Neuropathology*. London: Arnold Publication; 1958. p. 398–9.
 58. Grois N, Prayer D, Prosch H, Lassmann H. Neuropathology of CNS disease in Langerhans cell histiocytosis. *Brain*. 2005;128(Pt 4):829–38.
 59. Grois N, Fahrner B, Arceci RJ, Henter JI, McClain K, Lassmann H, et al. Central nervous system disease in Langerhans cell histiocytosis. *J Pediatr*. 2010;156(6):873–81, 81 e1.
 60. Imashuku S, Arceci RJ. Strategies for the prevention of central nervous system complications in patients with Langerhans cell histiocytosis: the problem of neurodegenerative syndrome. *Hematol Oncol Clin North Am*. 2015;29(5):875–93.
 61. Grois N, Barkovich AJ, Rosenau W, Ablin AR. Central nervous system disease associated with Langerhans' cell histiocytosis. *Am J Pediatr Hematol Oncol*. 1993;15(2):245–54.
 62. Picarsic J. Abstracts from the 32nd Annual Meeting of the Histiocyte Society Dublin, Ireland October 17–19, 2016. *Pediatr Blood Cancer*. 2016;63(S2):S10–65.
 63. Picarsic J, editor. LCH Symposium: Langerhans cell histiocytosis in the central nervous system: Challenges in pathologic diagnosis. *Histiocyte Society 31st Annual Meeting 2015; Athens, Greece*.
 64. Zinn D. Abstracts from the 32nd Annual Meeting of the Histiocyte Society Dublin, Ireland October 17–19, 2016. *Pediatr Blood Cancer*. 2016;63(S2):S10–65.
 65. Grois NG, Favara BE, Mostbeck GH, Prayer D. Central nervous system disease in Langerhans cell histiocytosis. *Hematol Oncol Clin North Am*. 1998;12(2):287–305.
 66. Paulus W, Kirchner T, Michaela M, Kuhl J, Warmuth-Metz M, Sorensen N, et al. Histiocytic tumor of Meckel's cave. An intracranial equivalent of juve-

- nile xanthogranuloma of the skin. *Am J Surg Pathol.* 1992;16(1):76–83.
67. Jaffe R. Langerhans cell histiocytosis and Langerhans cell sarcoma. In: Jaffe ES, Harris NL, Vardiman JW, Campo E, Arber DA, editors. *Hematopathology*. St. Louis: Saunders; 2011.
 68. Singhi AD, Montgomery EA. Gastrointestinal tract Langerhans cell histiocytosis: a clinicopathologic study of 12 patients. *Am J Surg Pathol.* 2011;35(2):305–10.
 69. Favara BE, Jaffe R. The histopathology of Langerhans cell histiocytosis. *Br J Cancer Suppl.* 1994;23:S17–23.
 70. Moschovi M, Adamaki M, Vlahopoulos S, Rodriguez-Galindo C. Synchronous and metachronous thyroid cancer in relation to Langerhans cell histiocytosis; involvement of V600E BRAF-mutation? *Pediatr Blood Cancer.* 2015;62(1):173–4.
 71. Johnson WT, Patel P, Hernandez A, Grandinetti LM, Huen AC, Marks S, et al. Langerhans cell histiocytosis and Erdheim-Chester disease, both with cutaneous presentations, and papillary thyroid carcinoma all harboring the BRAF mutation. *J Cutan Pathol.* 2015;43:270.
 72. Courtillot C, Laugier Robiollle S, Cohen Aubart F, Leban M, Renard-Penna R, Drier A, et al. Endocrine manifestations in a monocentric cohort of 64 patients with Erdheim-Chester disease. *J Clin Endocrinol Metab.* 2016;101(1):305–13.
 73. Haroche J, Arnaud L, Cohen-Aubart F, Hervier B, Charlotte F, Emile JF, et al. Erdheim-Chester disease. *Curr Rheumatol Rep.* 2014;16(4):412.
 74. Jaffe R. Disseminated Juvenile Xanthogranuloma. In: Swerdlow S, Campo E, Lee Harris N, Jaffe ES, Pileri SA, Stein H, et al., editors. *WHO classification of tumours of haematopoietic and lymphoid tissue (IARC WHO classification of Tumours)*. Lyon: International Agency for Research on Cancer (IARC); 2008.
 75. Haroche J, Abla O. Uncommon histiocytic disorders: Rosai-Dorfman, juvenile xanthogranuloma, and Erdheim-Chester disease. *Hematology Am Soc Hematol Educ Program.* 2015;2015:571–8.
 76. Hervier B, Haroche J, Arnaud L, Charlotte F, Donadieu J, Neel A, et al. Association of both Langerhans cell histiocytosis and Erdheim-Chester disease linked to the BRAFV600E mutation: a multicenter study of 23 cases. *Blood.* 2014;124:1119.
 77. Emile JF, Diamond EL, Helias-Rodzewicz Z, Cohen-Aubart F, Charlotte F, Hyman DM, et al. Recurrent RAS and PIK3CA mutations in Erdheim-Chester disease. *Blood.* 2014;124(19):3016–9.
 78. Badalian-Very G. A common progenitor cell in LCH and ECD. *Blood.* 2014. 2014-08-14 00:00:00;124:991–2.
 79. O'Malley DP, Duong A, Barry TS, Chen S, Hibbard MK, Ferry JA, et al. Co-occurrence of Langerhans cell histiocytosis and Rosai-Dorfman disease: possible relationship of two histiocytic disorders in rare cases. *Mod Pathol.* 2010;23(12):1616–23.
 80. Abla O, Halliday W, Laughlin S, Weitzman S. Central nervous system juvenile xanthogranuloma after Langerhans cell histiocytosis. *Pediatr Blood Cancer.* 2013;60(2):342–3.
 81. Bains A, Parham DM. Langerhans cell histiocytosis preceding the development of juvenile xanthogranuloma: a case and review of recent developments. *Pediatr Dev Pathol.* 2011;14(6):480–4.
 82. Zaba LC, Fuentes-Duculan J, Steinman RM, Krueger JG, Lowes MA. Normal human dermis contains distinct populations of CD11c+BDCA-1+ dendritic cells and CD163+FXIIIa+ macrophages. *J Clin Invest.* 2007;117(9):2517–25.
 83. Chasset F, Barete S, Charlotte F, Cohen-Aubart F, Arnaud L, Le Pelletier F, et al. Cutaneous manifestations of Erdheim-Chester disease (ECD): clinical, pathological, and molecular features in a monocentric series of 40 patients. *J Am Acad Dermatol.* 2016;74(3):513–20.
 84. Haroche J, Arnaud L, Cohen-Aubart F, Hervier B, Charlotte F, Emile JF, et al. Erdheim-Chester disease. *Rheum Dis Clin N Am.* 2013;39(2):299–311.
 85. Drier A, Haroche J, Savatovsky J, Godeneche G, Dormont D, Chiras J, et al. Cerebral, facial, and orbital involvement in Erdheim-Chester disease: CT and MR imaging findings. *Radiology.* 2010;255(2):586–94.
 86. Haroche J, Amoura Z, Dion E, Wechsler B, Costedoat-Chalumeau N, Cacoub P, et al. Cardiovascular involvement, an overlooked feature of Erdheim-Chester disease report of 6 new cases and a literature review. *Medicine (Baltimore).* 2004;83(6):371.
 87. Hyman DM, Diamond EL, Vibat CR, Hassaine L, Poole JC, Patel M, et al. Prospective blinded study of BRAFV600E mutation detection in cell-free DNA of patients with systemic histiocytic disorders. *Cancer Discov.* 2015;5(1):64–71.
 88. Burgdorf WH, Zelger B. The non-Langerhans' cell histiocytoses in childhood. *Cutis.* 1996;58(3):201–7.
 89. Weitzman S, Jaffe R. Uncommon histiocytic disorders: the non-Langerhans cell histiocytoses. *Pediatr Blood Cancer.* 2005;45(3):256–64.
 90. Kraus MD, Haley JC, Ruiz R, Essary L, Moran CA, Fletcher CD. "juvenile" xanthogranuloma: an immunophenotypic study with a reappraisal of histogenesis. *Am J Dermatopathol.* 2001;23(2):104–11.
 91. Dehner LP. Juvenile xanthogranulomas in the first two decades of life: a clinicopathologic study of 174 cases with cutaneous and extracutaneous manifestations. *Am J Surg Pathol.* 2003;27(5):579–93.
 92. Janssen D, Harms D. Juvenile xanthogranuloma in childhood and adolescence: a clinicopathologic study of 129 patients from the kiel pediatric tumor registry. *Am J Surg Pathol.* 2005;29(1):21–8.
 93. Sandell RF, Carter JM, Folpe AL. Solitary (juvenile) xanthogranuloma: a comprehensive immunohistochemical study emphasizing recently developed markers of histiocytic lineage. *Hum Pathol.* 2015;46(9):1390–7.
 94. Haynes E, Schmitt L, Guo H, Jaffe R, Picarsic J. Abstracts from the 2017 Spring Society for Pediatric Pathology Meeting, San Antonio, TX, March 3-5, 2017. S100 Immunohistochemistry in 65 localized juvenile xanthogranuloma family lesions: Understanding staining patterns with clinicopathologic correlation. *Pediatric and Developmental Pathology:* S43.

95. Helwig EHV. Juvenile xanthogranuloma (nevo-xanthoendothelioma) proceedings of the American Association of Pathologists and Bacteriologists. *Am J Pathol.* 1954;30(3):625–6.
96. Cline MJ. Histiocytes and histiocytosis. *Blood.* 1994;84(9):2840–53.
97. Marrogi AJ, Dehner LP, Coffin CM, Wick MR. Benign cutaneous histiocytic tumors in childhood and adolescence, excluding Langerhans' cell proliferations. A clinicopathologic and immunohistochemical analysis. *Am J Dermatopathol.* 1992;14(1):8–18.
98. Zelger BW, Sidoroff A, Orchard G, Cerio R. Non-Langerhans cell histiocytoses. A new unifying concept. *Am J Dermatopathol.* 1996;18(5):490–504.
99. Jaffe R. Histiocytic proliferations in childhood. In: Proytcheva M, editor. *Diagnostic pediatric hematopathology.* Illinois/Cambridge: Feinberg School of Medicine, Northwestern University/Cambridge University Press; 2011. p. 504–39.
100. Liu DT, Choi PC, Chan AY. Juvenile xanthogranuloma in childhood and adolescence: a clinicopathologic study of 129 patients from the Kiel pediatric tumor registry. *Am J Surg Pathol.* 2005;29(8):1117. author reply -8
101. Chang MW, Frieden IJ, Good W. The risk intraocular juvenile xanthogranuloma: survey of current practices and assessment of risk. *J Am Acad Dermatol.* 1996;34(3):445–9.
102. Shah AS, Wilson DP. Primary hypertriglyceridemia in children and adolescents. *J Clin Lipidol.* 2015;9(5 Suppl):S20–8.
103. Barroca H, Farinha NJ, Lobo A, Monteiro J, Lopes JM. Deep-seated congenital juvenile xanthogranuloma: report of a case with emphasis on cytologic features. *Acta Cytol.* 2007;51(3):473–6.
104. Globerman H, Burstein S, Girardina PJ, Winchester P, Frankel S. A xanthogranulomatous histiocytosis in a child presenting with short stature. *Am J Pediatr Hematol Oncol.* 1991;13(1):42–6.
105. Zhi Y, Duan Y, Zhang H, Yin X, Qu T, Guan G, et al. Solitary juvenile xanthogranuloma with tibial involvement: a case report. *Int J Clin Exp Pathol.* 2015;8(1):164–70.
106. Freyer DR, Kennedy R, Bostrom BC, Kohut G, Dehner LP. Juvenile xanthogranuloma: forms of systemic disease and their clinical implications. *J Pediatr.* 1996;129(2):227–37.
107. Bostrom J, Janssen G, Messing-Junger M, Felsberg JU, Neuen-Jacob E, Engelbrecht V, et al. Multiple intracranial juvenile xanthogranulomas. Case report. *J Neurosurg.* 2000;93(2):335–41.
108. Orsey A, Paessler M, Lange BJ, Nichols KE. Central nervous system juvenile xanthogranuloma with malignant transformation. *Pediatr Blood Cancer.* 2008;50(4):927–30.
109. Kitchen ND, Davies MS, Taylor W. Juvenile xanthogranuloma of nerve root origin. *Br J Neurosurg.* 1995;9(2):233–7.
110. Ernemann U, Skalej M, Hermisson M, Platten M, Jaffe R, Voigt K. Primary cerebral non-Langerhans cell histiocytosis: MRI and differential diagnosis. *Neuroradiology.* 2002;44(9):759–63.
111. Hu WK, Gilliam AC, Wiersma SR, Dahms BB. Fatal congenital systemic juvenile xanthogranuloma with liver failure. *Pediatr Dev Pathol.* 2004;7(1):71–6.
112. Fan R, Sun J. Neonatal systemic juvenile xanthogranuloma with an ominous presentation and successful treatment. *Clin Med Insights Oncol.* 2011;5:157–61.
113. Rosai J, Dorfman RF. Sinus histiocytosis with massive lymphadenopathy. A newly recognized benign clinicopathological entity. *Arch Pathol.* 1969;87(1):63–70.
114. Rosai J, Dorfman RF. Sinus histiocytosis with massive lymphadenopathy: a pseudolymphomatous benign disorder. Analysis of 34 cases. *Cancer.* 1972;30(5):1174–88.
115. Destombes P. Adenitis with lipid excess, in children or young adults, seen in the Antilles and in Mali. (4 cases). *Bulletin de la Societe de pathologie exotique et de ses filiales.* 1965;58(6):1169–75.
116. Foucar E, Rosai J, Dorfman RF. Sinus histiocytosis with massive lymphadenopathy. *Arch Otolaryngol.* (Chicago, Ill : 1960). 1978;104(12):687–93.
117. Foucar E, Rosai J, Dorfman RF. The ophthalmologic manifestations of sinus histiocytosis with massive lymphadenopathy. *Am J Ophthalmol.* 1979;87(3):354–67.
118. Foucar E, Rosai J, Dorfman RF, Brynes RK. The neurologic manifestations of sinus histiocytosis with massive lymphadenopathy. *Neurology.* 1982;32(4):365–72.
119. Foucar E, Rosai J, Dorfman R. Sinus histiocytosis with massive lymphadenopathy (Rosai-Dorfman disease): review of the entity. *Semin Diagn Pathol.* 1990;7(1):19–73.
120. Online Mendelian Inheritance in Man O. histiocytosis-lymphadenopathy plus syndrome Johns Hopkins University, Baltimore, MD.07/18/2013. Available from: World Wide Web URL: <http://omim.org/>.
121. Maric I, Pittaluga S, Dale JK, Niemela JE, Delsol G, Diment J, et al. Histologic features of sinus histiocytosis with massive lymphadenopathy in patients with autoimmune lymphoproliferative syndrome. *Am J Surg Pathol.* 2005;29(7):903–11.
122. Maia DM, Dorfman RF. Focal changes of sinus histiocytosis with massive lymphadenopathy (Rosai-Dorfman disease) associated with nodular lymphocyte predominant Hodgkin's disease. *Hum Pathol.* 1995;26(12):1378–82.
123. Delacretaz F, Meuge-Moraw C, Anwar D, Borisch B, Chave JP. Sinus histiocytosis with massive lymphadenopathy (Rosai Dorfman disease) in an HIV-positive patient. *Virchows Arch A Pathol Anat Histopathol.* 1991;419(3):251–4.
124. Lu D, Estalilla OC, Manning JT Jr, Medeiros LJ. Sinus histiocytosis with massive lymphadenopathy and malignant lymphoma involving the same

- lymph node: a report of four cases and review of the literature. *Mod Pathol*. 2000;13(4):414–9.
125. OMIM OMiM. Autoimmune lymphoproliferative syndrome Johns Hopkins University, Baltimore, MD.03/01/2016 [cited 2016]. Available from: World Wide Web URL: <http://omim.org/>.
 126. Menon MP, Evbuomwan MO, Rosai J, Jaffe ES, Pittaluga S. A subset of Rosai-Dorfman disease cases show increased IgG4-positive plasma cells: another red herring or a true association with IgG4-related disease? *Histopathology*. 2014;64(3):455–9.
 127. Liu L, Perry AM, Cao W, Smith LM, Hsi ED, Liu X, et al. Relationship between Rosai-Dorfman disease and IgG4-related disease: study of 32 cases. *Am J Clin Pathol*. 2013;140(3):395–402.
 128. Colmenero I, Molho-Pessach V, Torreló A, Zlotogorski A, Requena L. Emperipolesis: an additional common histopathologic finding in H syndrome and Rosai-Dorfman disease. *Am J Dermatopathol*. 2012;34(3):315–20.
 129. Morgan NV, Morris MR, Cangul H, Gleeson D, Straatman-Iwanowska A, Davies N, et al. Mutations in SLC29A3, encoding an equilibrative nucleoside transporter ENT3, cause a familial histiocytosis syndrome (Faisalabad histiocytosis) and familial Rosai-Dorfman disease. *PLoS Genet*. 2010;6(2):e1000833.
 130. Koduru PR, Susin M, Kolitz JE, Soni M, Teichberg S, Siques MJ, et al. Morphological, ultrastructural, and genetic characterization of an unusual T-cell lymphoma in a patient with sinus histiocytosis with massive lymphadenopathy. *Am J Hematol*. 1995;48(3):192–200.
 131. Foucar E, Rosai J, Dorfman RF, Eyman JM. Immunologic abnormalities and their significance in sinus histiocytosis with massive lymphadenopathy. *Am J Clin Pathol*. 1984;82(5):515–25.
 132. Rangwala AF, Zinterhofer LJ, Nyi KM, Ferreira PP. Sinus histiocytosis with massive lymphadenopathy and malignant lymphoma. An unreported association. *Cancer*. 1990;65(4):999–1002.
 133. Krzemieniecki K, Pawlicki M, Marganska K, Parczewska J. The Rosai-Dorfman syndrome in a 17-year-old woman with transformation into high-grade lymphoma. A rare disease presentation. *Ann Oncol*. 1996;7(9):977.
 134. Lossos IS, Okon E, Bogomolski-Yahalom V, Ron N, Polliack A. Sinus histiocytosis with massive lymphadenopathy (Rosai-Dorfman disease): report of a patient with isolated renotesticular involvement after cure of non-Hodgkin's lymphoma. *Ann Hematol*. 1997;74(1):41–4.
 135. Moore JC, Zhao X, Nelson EL. Concomitant sinus histiocytosis with massive lymphadenopathy (Rosai-Dorfman disease) and diffuse large B-cell lymphoma: a case report. *J Med Case Rep*. 2008;2:70.
 136. Shoda H, Oka T, Inoue M, Kusaka S, Tsuneyoshi H, Miyazaki J, et al. Sinus histiocytosis with massive lymphadenopathy associated with malignant lymphoma. *Intern Med*. 2004;43(8):741–5.
 137. Garel L, Lucaya J, Piqueras J. Clinical quiz. Large-cell anaplastic lymphoma coexisting with Rosai-Dorfman disease. *Pediatr Radiol*. 2004;34(6):509–10.
 138. Wu W, Cao L, Li Y, Yu X, Huang H, He J. Primary splenic diffuse large B-cell lymphoma in a patient with thymus Rosai-Dorfman disease. *Am J Med Sci*. 2012;344(2):155–9.
 139. Llamas-Velasco M, Cannata J, Dominguez I, Garcia-Noblejas A, Aragües M, Fraga J, et al. Coexistence of Langerhans cell histiocytosis, Rosai-Dorfman disease and splenic lymphoma with fatal outcome after rapid development of histiocytic sarcoma of the liver. *J Cutan Pathol*. 2012;39(12):1125–30.
 140. Di Tommaso L, Rahal D, Bossi P, Roncalli M. Hepatic rosai-dorfman disease with coincidental lymphoma: report of a case. *Int J Surg Pathol*. 2010;18(6):540–3.
 141. Falk S, Stutte HJ, Frizzera G. Hodgkin's disease and sinus histiocytosis with massive lymphadenopathy-like changes. *Histopathology*. 1991;19(3):221–4.
 142. Brown RA, Kwong BY, McCalmont TH, Ragsdale B, Ma L, Cheung C, et al. ETV3-NCOA2 in indeterminate cell histiocytosis: clonal translocation supports sui generis. *Blood*. 2015;126(20):2344–5.
 143. Chan JK, Lamant L, Algar E, Delsol G, Tsang WY, Lee KC, et al. ALK+ histiocytosis: a novel type of systemic histiocytic proliferative disorder of early infancy. *Blood*. 2008;112(7):2965–8.
 144. Wood GS, Hu CH, Beckstead JH, Turner RR, Winkelmann RK. The indeterminate cell proliferative disorder: report of a case manifesting as an unusual cutaneous histiocytosis. *J Dermatol Surg Oncol*. 1985;11(11):1111–9.
 145. Rezk SA, Spagnolo DV, Brynes RK, Weiss LM. Indeterminate cell tumor: a rare dendritic neoplasm. *Am J Surg Pathol*. 2008;32(12):1868–76.
 146. Roh J, Kim SW, Park CS. Indeterminate dendritic cell tumor: a case report of a rare Langerhans cell lineage disease. *J Pathol Transl Med*. 2016;50(1):78–81.
 147. Jaffe R, Favara B. Non-Langerhans' dendritic cell histiocytosis (abstract). *Pediatr Dev Pathol*. 2002;5:99.
 148. Castro P, Rebocho AP, Soares RJ, Magalhaes J, Roque L, Trovisco V, et al. PAX8-PPARgamma rearrangement is frequently detected in the follicular variant of papillary thyroid carcinoma. *J Clin Endocrinol Metab*. 2006;91(1):213–20.
 149. Go H, Jeon YK, Huh J, Choi SJ, Choi YD, Cha HJ, et al. Frequent detection of BRAF(V600E) mutations in histiocytic and dendritic cell neoplasms. *Histopathology*. 2014;65(2):261–72.
 150. Liu Q, Tomaszewicz K, Hutchinson L, Hornick JL, Woda B, Yu H. Somatic mutations in histiocytic sarcoma identified by next generation sequencing. *Virchows Arch*. 2016;469:233.
 151. Heath JL, Burgett SE, Gaca AM, Jaffe R, Wechsler DS. Successful treatment of pediatric histiocytic sarcoma using abbreviated high-risk leukemia chemotherapy. *Pediatr Blood Cancer*. 2014;61(10):1874–6.

152. Ikdahl T, Josefsen D, Jakobsen E, Delabie J, Fossa SD. Concurrent mediastinal germ-cell tumour and haematological malignancy: case report and short review of literature. *Acta Oncol.* 2008;47(3):466–9.
153. Takahashi E, Nakamura S. Histiocytic sarcoma : an updated literature review based on the 2008 WHO classification. *J Clin Exp Hematop.* 2013;53(1):1–8.
154. Durham BH, Diamond EL, Abdel-Wahab O. Histiocytic neoplasms in the era of personalized genomic medicine. *Curr Opin Hematol.* 2016;23(4):416–25.
155. Kumar R, Khan SP, Joshi DD, Shaw GR, Ketterling RP, Feldman AL. Pediatric histiocytic sarcoma clonally related to precursor B-cell acute lymphoblastic leukemia with homozygous deletion of CDKN2A encoding p16(INK4A). *Pediatr Blood Cancer.* 2010;56:307.
156. Feldman AL. Clonal relationships between malignant lymphomas and histiocytic/dendritic cell tumors. *Surg Pathol Clin.* 2013;6(4):619–29.
157. Castro EC, Blazquez C, Boyd J, Correa H, de Chadarevian JP, Felgar RE, et al. Clinicopathologic features of histiocytic lesions following ALL, with a review of the literature. *Pediatr Dev Pathol.* 2010;13(3):225–37.
158. Shao H, Xi L, Raffeld M, Feldman AL, Ketterling RP, Knudson R, et al. Clonally related histiocytic/dendritic cell sarcoma and chronic lymphocytic leukemia/small lymphocytic lymphoma: a study of seven cases. *Mod Pathol.* 2011;24(11):1421–32.
159. Ansari J, Naqash AR, Munker R, El-Osta H, Master S, Cotelingam JD, et al. Histiocytic sarcoma as a secondary malignancy: pathobiology, diagnosis, and treatment. *Eur J Haematol.* 2016;97(1):9–16.
160. Brown AF, Fan H, Floyd JR, Henry JM, Higgins RA. Primary central nervous system histiocytic sarcoma arising after precursor B-cell acute lymphoblastic leukemia. *J Neuropathol Exp Neurol.* 2015;74(12):1120–6.
161. Fernandez-Pol S, Bangs CD, Cherry A, Arber DA, Gratzinger D. Two cases of histiocytic sarcoma with BCL2 translocations and occult or subsequent follicular lymphoma. *Hum Pathol.* 2016;55:39–43.
162. Hayase E, Kurosawa M, Yonezumi M, Suzuki S, Suzuki H. Aggressive sporadic histiocytic sarcoma with immunoglobulin heavy chain gene rearrangement and t(14;18). *Int J Hematol.* 2010;92(4):659–63.
163. Howard JE, Dwivedi RC, Masterson L, Jani P. Langerhans cell sarcoma: a systematic review. *Cancer Treat Rev.* 2015;41(4):320–31.
164. Zwerdling T, Won E, Shane L, Javahara R, Jaffe R. Langerhans cell sarcoma: case report and review of world literature. *J Pediatr Hematol Oncol.* 2014;36(6):419–25.
165. Mourah S, Lorillon G, Meignin V, Vercellino L, de Margerie-Mellon C, Pages C, et al. Dramatic transient improvement of metastatic BRAF(V600E)-mutated Langerhans cell sarcoma under treatment with dabrafenib. *Blood.* 2015;126(24):2649–52.
166. Chen W, Jaffe R, Zhang L, Hill C, Block AM, Sait S, et al. Langerhans cell sarcoma arising from chronic lymphocytic lymphoma/small lymphocytic leukemia: lineage analysis and BRAF V600E mutation study. *N Am J Med Sci.* 2013;5(6):386–91.
167. Deng A, Lee W, Pfau R, Harrington A, DiGiovani J, Prickett KA, et al. Primary cutaneous Langerhans cell sarcoma without Birbeck granules: indeterminate cell sarcoma? *J Cutan Pathol.* 2008;35(9):849–54.
168. Dalia S, Shao H, Sagatys E, Cualing H, Sokol L. Dendritic cell and histiocytic neoplasms: biology, diagnosis, and treatment. *Cancer Control J Moffitt Cancer Center.* 2014;21(4):290–300.
169. O'Malley DP, Agrawal R, Grimm KE, Hummel J, Glazyrin A, Dim DC, et al. Evidence of BRAF V600E in indeterminate cell tumor and interdigitating dendritic cell sarcoma. *Ann Diagn Pathol.* 2015;19(3):113–6.
170. Lupato V, Romeo S, Franchi A, Mantovani M, Dei Tos AP, Tirelli G, et al. Head and neck extranodal interdigitating dendritic cell sarcoma: case report and review of the literature. *Head Neck Pathol.* 2016;10(2):145–51.
171. Khashab T, Sehgal L, Medeiros LJ, Samaniego F. Spontaneous regression of interdigitating dendritic sarcoma in a patient with concurrent small lymphocytic lymphoma. *BMJ Case Rep.* 2015; 2015. doi: [10.1136/bcr-2014-209014](https://doi.org/10.1136/bcr-2014-209014)
172. Cossu A, Deiana A, Lissia A, Dedola MF, Cocco L, Palmieri G, et al. Synchronous interdigitating dendritic cell sarcoma and B-cell small lymphocytic lymphoma in a lymph node. *Arch Pathol Lab Med.* 2006;130(4):544–7.
173. Stowman AM, Mills SE, Wick MR. Spindle cell melanoma and interdigitating dendritic cell sarcoma: do they represent the same process? *Am J Surg Pathol.* 2016;40:1270.
174. Di Liso E, Pennelli N, Lodovichetti G, Ghiotto C, Dei Tos AP, Conte P, et al. Braf mutation in interdigitating dendritic cell sarcoma: a case report and review of the literature. *Cancer Biol Ther.* 2015;16(8):1128–35.
175. Facchetti F, Lorenzi L. Follicular dendritic cells and related sarcoma. *Semin Diagn Pathol.* 2016;33:262.
176. Andriko JW, Kaldjian EP, Tsokos M, Abbondanzo SL, Jaffe ES. Reticulum cell neoplasms of lymph nodes: a clinicopathologic study of 11 cases with recognition of a new subtype derived from fibroblastic reticular cells. *Am J Surg Pathol.* 1998;22(9):1048–58.
177. Henter JI, Horne A, Arico M, Egeler RM, Filipovich AH, Imashuku S, et al. HLH-2004: diagnostic and therapeutic guidelines for hemophagocytic lymphohistiocytosis. *Pediatr Blood Cancer.* 2007;48(2):124–31.

178. Ost A, Nilsson-Ardnor S, Henter JI. Autopsy findings in 27 children with haemophagocytic lymphohistiocytosis. *Histopathology*. 1998;32(4):310–6.
179. Bernstrand C, Cederlund K, Sandstedt B, Ahstrom L, Lundell M, Dahlquist G, et al. Pulmonary abnormalities at long-term follow-up of patients with Langerhans cell histiocytosis. *Med Pediatr Oncol*. 2001;36(4):459–68.
180. Henter JI, Elinder G, Ost A. Diagnostic guidelines for hemophagocytic lymphohistiocytosis. The FHL study Group of the Histiocyte Society. *Semin Oncol*. 1991;18(1):29–33.
181. Chen JH, Fleming MD, Pinkus GS, Pinkus JL, Nichols KE, Mo JQ, et al. Pathology of the liver in familial hemophagocytic lymphohistiocytosis. *Am J Surg Pathol*. 2010;34(6):852–67.
182. Macheta M, Will AM, Houghton JB, Wynn RF. Prominent dyserythropoiesis in four cases of haemophagocytic lymphohistiocytosis. *J Clin Pathol*. 2001;54(12):961–3.

Part II

Langerhans Cell Histiocytosis (LCH)

Barrett J. Rollins

Introduction

Our understanding and treatment of the diseases known as the histiocytoses have undergone revolutionary changes since the turn of the century. While still recognized as a clinically heterogeneous collection of disorders having a somewhat arcane taxonomy, advances in molecular analyses have revealed pathway abnormalities shared by several of these entities. Other advances in stem cell and lineage analyses have shed light on the biological differences that individuate clinically distinct presentations. Most importantly, these insights have led to new therapeutic opportunities that have so far shown tremendous clinical promise.

The histiocytoses are characterized by the accumulation of cells having morphologic characteristics that are reminiscent of histiocytes. Although histiocytes are technically defined as tissue resident macrophages, the abnormal cells of the histiocytoses are thought to derive both from macrophage and dendritic cell lineages. The clinical and pathological characteristics of histiocytoses are varied, and several attempts have been made over the years to create a rational taxonomy [1, 2]. Thanks to a number of recent

discoveries, some of which are described below, a new classification scheme has been proposed [1] in which histiocytic disorders are grouped into five categories: L Group (Langerhans cell histiocytosis, Erdheim-Chester disease, intermediate cell histiocytosis), C Group (cutaneous non-LCH diseases such as juvenile xanthogranuloma, cutaneous Rosai-Dorfman disease, and others), R Group (non-cutaneous Rosai-Dorfman disease in its many manifestations), M Group (malignant histiocytoses), and H Group (hemophagocytic lymphohistiocytosis). This chapter will address the biology and genomics of the diseases in the L Group.

Pathobiology

Langerhans Cell Histiocytosis The histiocytes in Langerhans cell histiocytosis (LCH) share several features with normal Langerhans cells (LCs) including the expression of CD1a and CD207 (or Langerin) and the presence of cytoplasmic organelles known as Birbeck granules. Some of these characteristics are actually pathognomonic for LCH. As a result, normal LCs have been thought to be the cell of origin for LCH histiocytes [3, 4]. Nonetheless, as discussed below, the presence of morphologic features characteristic of a specific normal cell type does not necessarily prove that the abnormal histiocyte is derived from that cell type.

As described in detail elsewhere in this volume, LCH is predominantly, although not

B.J. Rollins, MD, PhD
Department of Medical Oncology, Dana-Farber Cancer Institute, Department of Medicine, Brigham and Women's Hospital, Harvard Medical School, Boston, MA 02215, USA
e-mail: barrett_rollins@dfci.harvard.edu

exclusively, a disease of childhood with a peak incidence between 5 and 10 years of age [5, 6]. Some versions, such as the one known eponymously as Letterer-Siwe disease, can affect neonates or infants and, in its disseminated form involving skin, lymph nodes, spleen, and liver, can be associated with 20% mortality rate [7, 8]. The most common forms of LCH may typically involve the bone, the skin, and the anterior pituitary with concomitant diabetes insipidus. These forms of LCH are rarely seen in adults, but the more common adult presentation is pulmonary LCH, which usually occurs in smokers.

This broad spectrum of clinical behaviors and outcomes formed the basis of a complex nosology in which each clinical version was considered to be a distinct entity (summarized in [9]). This approach was bolstered by differences in treatment responses [10]. Disseminated Letterer-Siwe disease required more aggressive therapy and had worse outcomes than Hand-Schüller-Christian disease or eosinophilic granuloma. The discovery that the histiocytes in all forms of this disease share attributes of normal LCs was a remarkable advance that suggested that they also share a common pathobiology. However, this grand unification has been unable to shed light on pathogenesis or on the mechanistic basis for the disparate clinical behavior of the various subtypes of LCH.

Erdheim-Chester Disease Unlike LCH, the histiocytes in Erdheim-Chester disease (ECD) have the morphology of foamy macrophages and express macrophage surface markers such as CD68 and CD163 rather than markers that are characteristic of LCH [11]. In many ways, the clinical presentation of ECD could not be more different than LCH [11]. ECD primarily affects adults with a peak incidence between 50 and 70 years of age and is rarer than LCH. The disease affects the long bones, CNS, skin, heart, aorta, and kidneys, the latter often compromised by retroperitoneal fibrosis. Skin involvement is frequently manifested as xanthelasma, consistent with the appearance of fat-laden histiocytes in involved tissues. Despite this very different clinical presentation and the macrophage-like

characteristics of its histiocytes, mixed ECD and LCH may be seen simultaneously in the same patient. In a large ECD cohort from France, this kind of mixed histiocytic picture was observed in 19% of the patients [12]. This is a remarkably high prevalence given the evidence supporting different cells of origin in the two diseases and their disparate clinical presentations and raises the possibility of a shared early precursor.

Indeterminate Cell Histiocytosis Indeterminate cell histiocytosis (ICH) is a rare disease characterized by a generalized cutaneous eruption in adults, although some cases may only involve lymph nodes [13–15]. Based on case reports, ICH appears predominantly to affect women. The lesions consist of a non-epidermotropic infiltration of histiocytes that share some characteristics of LCH histiocytes such as CD1a positivity. In contrast to LCH histiocytes, however, ICH histiocytes do not express CD207 and do not have Birbeck granules. Although this mixed picture had led some investigators to suggest that ICH might be a variant of LCH, recent molecular data, described below, indicates that it is a separate disease entity.

Genomics

Neoplasia vs Inflammatory Disorder

Each of the diseases in the L Group of histiocytoses is remarkable for being associated with a prominent inflammatory infiltrate. For example, LCH lesions commonly contain an impressive number of eosinophils. In fact, the version of LCH that involves a small number of sites in long bones was known as eosinophilic granuloma. Thus, initial hypotheses about pathogenesis suggested that LCH might be an inflammatory disorder. This notion was supported by documented cases of spontaneous remissions even in advanced forms of Letterer-Siwe disease [16, 17]. Further, even though the lesions in histiocytoses are granulomatoid, decades of searching for possible infectious, autoimmune, or exposure associations have

been fruitless. Reports of EBV, CMV, HHV-6, and Merkel cell polyomavirus in LCH samples have not been confirmed [18–20]. While high plasma levels of cytokines that might be associated with inflammatory conditions, such as GM-CSF, M-CSF, FLT-3L, and IL-17A, have been reported in LCH patients, their role in pathogenesis remains uncertain [(21–27)].

As inflammatory or autoimmune mechanisms were serially hypothesized and then excluded in LCH, it became more reasonable to start looking at this disease and, perhaps, some of the other L Group histiocytoses as being neoplasms. In order for a disease process to be considered neoplastic, two criteria must be fulfilled. First, the abnormal cells that drive the disease must be clonal, and, second, the clonal cells should have evidence for recurrent genetic or epigenetic abnormalities. In 1994, two reports described the use of human androgen receptor gene-based X chromosome inactivation assays (HUMARA assays) to demonstrate that the abnormal histiocytes in LCH are clonal [28, 29]. Thus, one of the conditions for LCH to be classified as a neoplasm was met.

Identifying recurrent genetic or epigenetic abnormalities in LCH has been far more challenging. Until recently, assays for single-nucleotide variants (SNVs), copy number variations (CNVs), translocations, or epigenetic modifiers of DNA have required abundant amounts of fresh frozen tissue. Because the incidence of the histiocytoses is so low and the amount of tissue required to make a clinical diagnosis is so small, frozen samples of LCH or other L Group histiocytoses are rarely available in large numbers. This has led to many reports of various molecular abnormalities, but nearly all were either nonrecurrent or have not been reproduced in subsequent studies. These included nonrecurrent cytogenetic abnormalities [30, 31], loss of heterozygosity at a number of loci [32], and fractional allelic loss in patients with advanced disease [33]. Another study found no significant SNVs or CNVs in a large number of samples [31]. In contrast to these one-off or non-reproducible findings, overexpression of p53, the product of the TP53 gene, is observed

frequently by immunohistochemistry. The basis of this overexpression remains obscure, however, because of the very low frequency of mutations in TP53 or the genes such as MDM2 which modulate levels of p53 [31, 34].

Our understanding of the genomic landscape of the histiocytoses was aided by the advent of analytic tools that can identify abnormalities reliably and robustly in formalin-fixed, paraffin-embedded tissue samples. These techniques made available for analysis patient samples in the archives of pathology departments where reasonable numbers of histiocytosis specimens have been stored. One of the first such technologies to be applied to LCH was Sequenom's mass spectrometry-based allelotyping platform [35]. A customized version called OncoMap [36], which tested 983 specific alleles in 115 cancer-related genes, was used to analyze 61 archived LCH cases and demonstrated the presence of the oncogenic mutation encoding the BRAF V600E variant in 57% of the samples [34]. These mutations were confirmed using an orthogonal identification method, namely, pyrosequencing, and a variety of techniques were used to demonstrate that the mutations occurred specifically in the CD1a-positive LCH histiocytes. Thus, LCH cells are clonal, and over half of LCH cases have recurrent oncogenic mutations in BRAF, making LCH a neoplastic disease. (This mutation and others are described more fully, below.)

A similar evolution in thinking about the pathogenesis of Erdheim-Chester disease also occurred. As in LCH, HUMARA assays demonstrated clonality although the sample size was very small [37]. While there has been some dispute about the reliability and reproducibility of the clonality assays in ECD [38, 39], the discovery of mutations encoding BRAF V600E in over 50% of ECD lesions [40] suggests that the histiocytes are clonal and demonstrates the recurrent genetic abnormality that classifies ECD as neoplastic.

A definitive assessment of the neoplastic nature of ICH has been much more difficult to ascertain because it is even rarer and more clinically heterogeneous than LCH or ECD.

The literature contains no direct assessment of clonality and only a single case of ICH carrying the mutation encoding BRAF V600E [41]. However, a recent report described a recurrent translocation in three patients (discussed below) which may be interpreted as supporting a clonal and neoplastic origin for ICH [42].

Recurrent Genomic Abnormalities

Langerhans Cell Histiocytosis

As noted above, the discovery of recurrent *BRAF* mutations contributed to the classification of LCH as a neoplasm. Since then, several groups have used a variety of analytic techniques to interrogate the LCH genome for this and additional abnormalities. Broadly based analyses, such as whole-exome sequencing, reveal a remarkably stable genome having a small number of SNVs compared to most other cancers: an average of six SNVs per patient (0.14/Mb) in the study of Nelson et al. [43] and an average of one SNV per patient (0.03/Mb) in Chakraborty et al. [44]. These mutation prevalences are at the low end of the pan-cancer spectrum, where pediatric tumors such as pilocytic astrocytomas are found, and are lower than prevalences found in acute lymphoblastic leukemia [45]. Nonetheless, a variety of genetic alterations have been reported, and several have important implications for therapy.

BRAF BRAF is a component of a multi-step signal transduction pathway that transmits the effects of extracellular stimuli, such as growth factors, to the nucleus where the response to those stimuli is executed by an induced transcriptional program (Fig. 2.1). The final targets of the pathway are the ERK (extracellular signal-regulated kinase) proteins, ERK1 and ERK2, which are MAPKs (mitogen-activated protein kinases). Each step in the pathway consists of a protein kinase which is activated by being phosphorylated by the next proximal kinase. In general terms, the enzyme that phosphorylates a MAP kinase is a MAP kinase kinase, and the next proximal enzyme is a MAP kinase kinase kinase. BRAF, for example, is a MAP kinase kinase

kinase and is one of the three closely related members of the RAF protein family (Figs. 2.1 and 2.2). When extracellular messengers such as growth factors bind to their receptors, the intrinsic tyrosine kinase activity of the receptor is activated. This results in the activation of a RAS protein family member. Activated RAS proteins activate RAF family members which phosphorylate MEK family members, and this culminates in the phosphorylation of ERKs. Phosphorylated ERK then translocates to the nucleus to stimulate transcription of specific genes. The substitution of glutamate for valine at position 600 of BRAF creates a protein with inherent MEK kinase activity, which is not dependent on upstream activation by RAS. This is the basis for clonal neoplastic proliferation or accumulation of cells carrying the BRAF V600E variant. Mutations in other members of this cascade may occur which also lead to constitutive activation of the signaling cascade. Some of these occur in LCH and are described below. These additional mutations along with the highly prevalent BRAF V600E mutation account for the fact that ERK phosphorylation is observed in nearly all cases of LCH regardless of *BRAF* mutational status [34, 46].

A large number of studies have confirmed the original observation [34] of the high prevalence of the T to A transversion at nucleotide position 1799 of *BRAF* which encodes the oncogenic substitution of glutamate for valine at amino acid position 600 (BRAF V600E) (Table 2.1). Although reported prevalences range from 16% to 64%, the studies which examine the largest cohorts suggest that BRAF V600E occurs in 45–65% of cases [34, 46–49]. Some of the variation in prevalence rates likely reflects the association between the presence of the mutation and younger age [34, 47, 50] although this association has not been seen in all studies [46]. A few studies suggest the possibility that mutation prevalence might be lower in East Asian populations [51, 52], but the number of samples tested is too small to make this a valid inference.

As noted above, pulmonary LCH is a syndrome seen almost exclusively in adult smokers. Because of this exposure history and the multifocal nature of the disease, pulmonary LCH was thought to be primarily an inflammatory

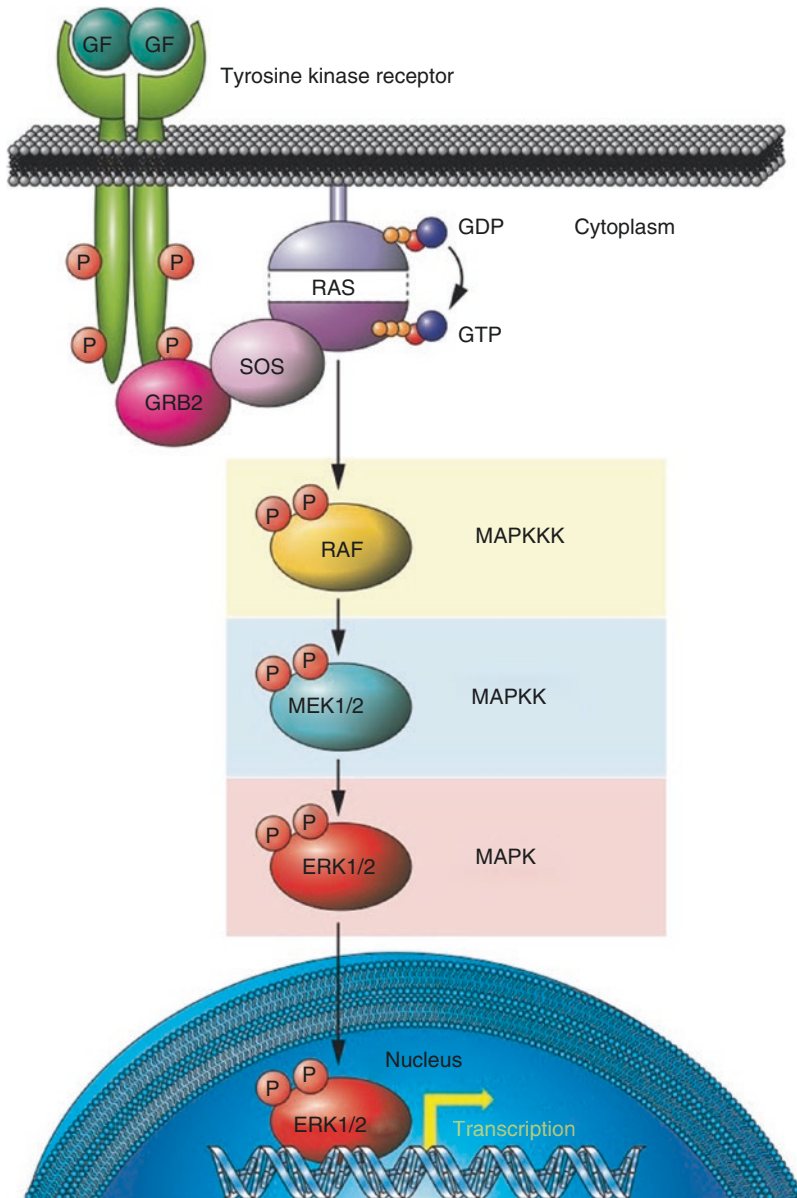


Fig. 2.1 MAP kinase signal transduction pathway. Extracellular stimuli, such as those induced by growth factors (GFs), are transmitted to the nucleus by means of serial activation of kinases. GFs bind to their cognate receptors many of which, as shown here, have intrinsic tyrosine kinase activity which is stimulated by GF binding. Tyrosine kinase receptor activation leads, via GRB2 and SOS, to the exchange of guanosine diphosphate (GDP) for guanosine triphosphate (GTP) bound to RAS. In this form, RAS phosphorylates and activates

RAF family members which are MAP kinase kinase kinases (MAPKKK). Activated RAF kinases phosphorylate and activate MEK1 or MEK2 which are MAP kinase kinases (MAPKK). Activated MEK1 or MEK2 kinases phosphorylate and activate ERK1 or ERK2 which are MAP kinases (MAPK). Phosphorylated ERKs translocate to the nucleus where they stimulate transcription of genes that alter the state of the cell (Reprinted from Rollins [72], with permission from Elsevier)

response to environmental insults. In support of this mechanism, only one third of pulmonary cases have been found to be clonal [53]. Perhaps

surprisingly, then, the prevalence of BRAF V600E in pulmonary LCH approaches that seen in non-pulmonary LCH (Table 2.1). Much, but

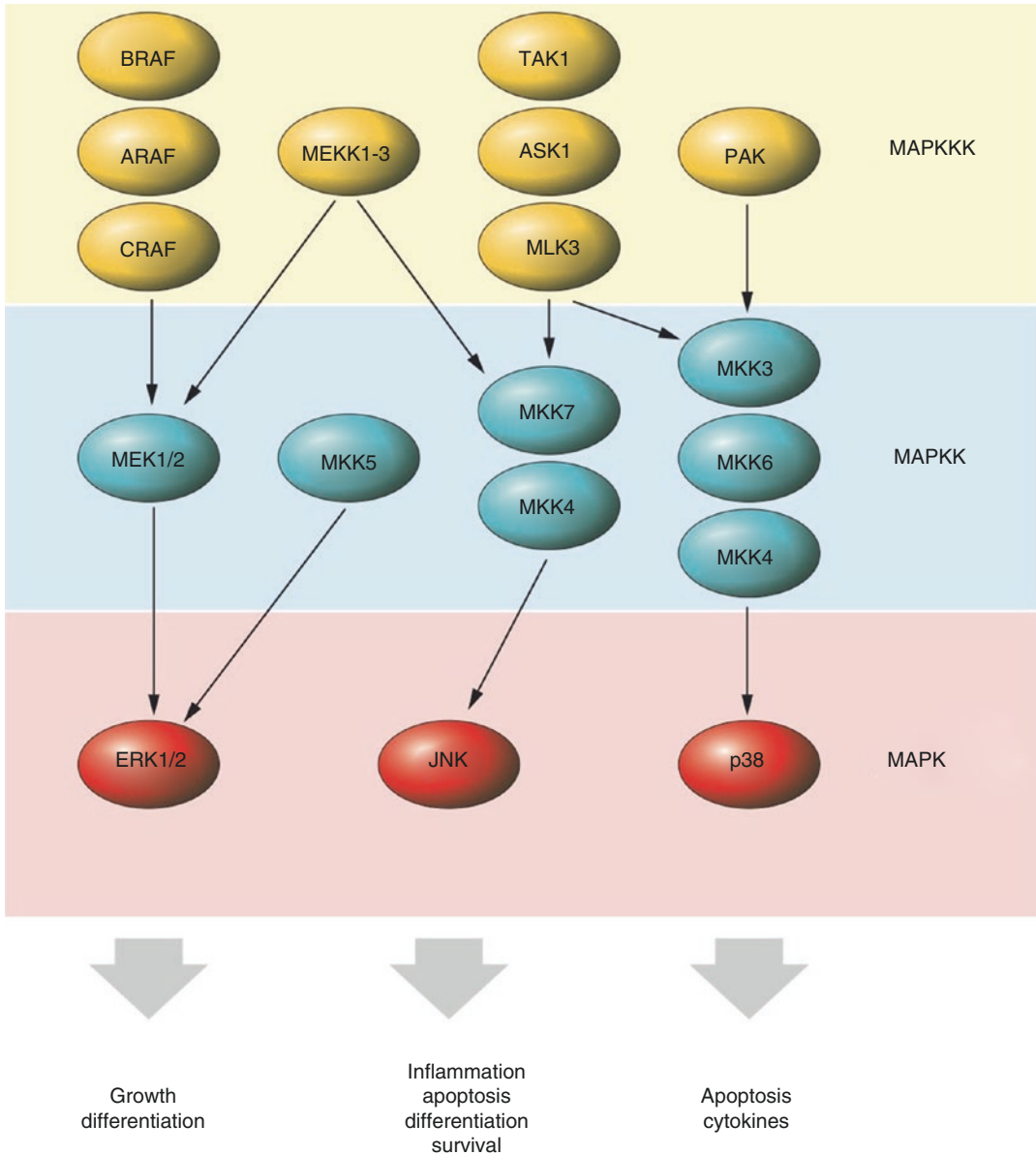


Fig. 2.2 The MAP kinase family. *Arrows* indicate substrates for the indicated kinase. Shown in *yellow* are members of the MAP kinase kinase kinase family. These include RAF family members (BRAF, ARAF, and CRAF) as well as MEKK1–3 and several other structurally related kinases. Shown in *blue* are members of the MAP kinase

kinase family including MEK1 and MEK2 as well as several MKK family members. Shown in *red* are the MAP kinase targets of these pathways including ERK1/2, JNK, and p38. Some of the physiological effects of activation of these MAP kinases are shown below each one (Reprinted from Rollins [72], with permission from Elsevier)

not all, of the prevalence could be accounted for by clonal cases, but the additional mutated cases could be the result of independent clones of LCH in a single patient, all of which carry the *BRAF* mutation.

Early studies examined relatively small patient cohorts, usually fewer than 100, and inferring correlations between the presence of *BRAF* V600E and clinical characteristics was difficult. For example, the original description of *BRAF*

Table 2.1 Prevalence of BRAF V600E in LCH¹

Report (Ref.)	Prevalence ²
Badalian-Very et al. [34]	57% (35/61) 42% (5/12) <i>pulmonary only</i> 61% (30/49) <i>extrapulmonary</i>
Haroche et al. [40]	38% (11/29)
Sahm et al. [106]	38% (34/89) ^{3,4}
Satoh et al. [57]	56% (9/16) ⁴
Wei et al. [49]	56% (28/50) 100% (1/1) <i>pulmonary only</i> 55% (27/49) <i>extrapulmonary</i>
Roden et al. [107]	33% (26/79) 28% (7/25) <i>pulmonary only</i> 35% (19/54) <i>extrapulmonary</i>
Berres et al. [46]	64% (64/100) ⁴
Chilosi et al. [108]	46% (18/38) 63% (12/19) <i>pulmonary only</i> 32% (6/19) <i>extrapulmonary</i>
Méhes et al. [109]	53% (8/15)
Varga et al. [110]	54% (6/11) <i>adult cutaneous</i>
Bubolz et al. [111]	48% (23/48) 25% (1/4) <i>pulmonary only</i> 50% (22/44) <i>extrapulmonary</i>
Brown et al. [64]	45% (18/40)
Go et al. [51]	25% (7/28) ⁵
Héritier et al. [47]	54.6% (173/315) ⁴
Mourah et al. [48]	43% (27/63) 50% (13/26) <i>pulmonary only</i> 38% (14/37) <i>extrapulmonary</i>
Kamionek et al. [65]	34.6% <i>pulmonary only</i>
Sasaki et al. [52]	21% (4/19) ⁶
Alayed et al. [50]	16% (8/50) ⁷
Diamond et al. [63]	60% (6/10)

¹Updated version of Table 2.1 in (72). The prevalence of any mutation in *BRAF* was taken from the indicated reference. When disease involving only the lungs (“pulmonary only”) was described, the prevalence of *BRAF* mutations in that disease subtype is indicated

²Prevalence rate is indicated with actual numbers shown in parentheses (number of cases with mutated *BRAF*/total number of cases)

³Detected by immunohistochemistry using VE-1 antibody

⁴No pulmonary-only cases

⁵Chinese population

⁶Japanese population

⁷Median age 36.5 years; presence of mutation correlated with young age

V600E in LCH reported that the median age of patients carrying the mutation was younger than the age of those who did not; further, the presence of BRAF V600E was associated with

younger age in an unadjusted exact logistic model but not in an adjusted model [34]. Mutational status was also not associated with specific clinical presentations, e.g., single-system disease versus disseminated disease. In a larger study of 100 patients, BRAF V600E was not correlated with young age, but the mutation did predict for disease relapse despite not being correlated with disseminated disease or the clinical definition of high risk [46]. In contrast, a recent report on 315 pediatric patients showed that the presence of BRAF V600E was associated with involvement of so-called risk organs (bone marrow, spleen, or liver) and the skin (but not single-system skin disease with spontaneous regression) with odds ratios of 6.35 and 3.675 [47]. BRAF V600E did not correlate with bone involvement. The presence of the mutation also correlated with disease involvement of the CNS and pituitary. Patients whose histiocytes expressed BRAF V600E were resistant to standard vinblastine/prednisone therapy, had a higher rate of relapse (as in [46]), and had more debilitating long-term complications. Thus, in this large pediatric study, BRAF V600E was present in patients with more aggressive disease. This study also showed a correlation between the presence of the mutation and younger age.

Substitution of glutamate for valine at amino acid position 600 is not the only molecular abnormality that produces a constitutively active BRAF kinase. In melanoma, for example, substitution of another acidic amino acid, aspartate, for valine at this position (V600D) is also an activating mutation [54]. This alteration has been reported in one case of LCH [55]. BRAF V600K, a substitution of lysine for valine at this same position, is seen more commonly in melanoma than V600D [56] but has not been described in LCH to date. An unusual four amino acid substitution for V600, aspartate-leucine-alanine-threonine (DLAT), has been reported in a single LCH case [57]. Like the other substitutions seen in LCH, this is predicted on the basis of structural considerations to lead to a constitutively active kinase. In-frame deletions of *BRAF* were identified in 6 of 25 cases analyzed by whole-exome or targeted sequencing [58]. These deletions are

predicted to shorten the $\beta 3/\alpha C$ -helix and lock it in the so-called “helix-in” conformation that favors dimer formation, a conformation predicted to be resistant to inhibition by vemurafenib, a first generation RAF kinase inhibitor [59, 60]. A single example of a translocation generating a *FAM73A-BRAF* fusion protein has been described [58]. This fusion is predicted to have constitutive BRAF kinase activity because the kinase domain of *BRAF* is intact, while the auto-inhibitory domain has been replaced by the fusion partner. *BRAF* duplications such as those seen in pediatric gliomas [61, 62] have not been described in LCH.

ARAF The RAF kinase family consists of three structurally related members, ARAF, BRAF, and CRAF (or RAF1), all of which phosphorylate members of the MEK family (Fig. 2.2). Because they are so closely related, these proteins, all MAP kinase kinase kinases, may substitute for one another in some circumstances. This may be the case in LCH in which activating mutations of *ARAF* have been found in patients who carry wild-type alleles of *BRAF*. The first such report described an unusual compound mutation in which a single-nucleotide variant results in a substitution of leucine for phenylalanine at amino acid 351 (F351L) accompanied by a six-nucleotide in-frame deletion resulting in loss of amino acids 347 and 348 (Q347_A348del) [43]. Both alterations occur in the kinase domain close to the homolog of amino acid 600 in BRAF. Expressing the ARAF variant in vitro demonstrated that it has constitutive MEK kinase activity. It is also capable of transforming mouse embryo fibroblasts suggesting that it could be an oncogenic driver in this *BRAF* wild-type patient. Notably, the ARAF variant is inhibited by clinically relevant concentrations of vemurafenib, suggesting that mutational screening in the clinical management of LCH should extend beyond *BRAF*. Interestingly, ARAF F351L has been found in a single case of juvenile xanthogranuloma (JXG), a C Group histiocytosis [63].

A different mutation in *ARAF*, namely, methionine substituted for threonine at position 70 (T70M), was described in a case of combined

LCH and ECD [44]. Although this variant has not been examined for constitutive MEK kinase activity, it occurred in a case that carried BRAF V600E suggesting that T70M is likely not to be an activating mutation. No mutations in CRAF have been described to date in LCH.

MAP2K1 *MAP2K1* encodes MEK1, a MAP kinase kinase (Fig. 2.2). Mutations in *MAP2K1* have been described in LCH and, as expected, are found only in cases in which *BRAF* is not mutated suggesting that *BRAF* and *MAP2K1* exert their effects within the same signaling pathway in LCH [44, 50, 64–66]. The prevalence of *MAP2K1* mutations in LCH varies between 10% and 30% (Table 2.2). Differences in prevalence may relate to differences in study cohort composition. Overall, however, *MAP2K1* mutations appear to comprise approximately 50% of the *BRAF* wild-type cases. So far, the presence of *MAP2K1* mutations does not correlate with age or extent of disease.

MAP2K1 mutations in cancers, leukemias, and lymphomas tend to cluster in the N-terminal negative regulatory domain and in the catalytic domain. Mutations in the N-terminal regulatory domain include both single-nucleotide variants as well as in-frame deletions which presumably derepress the kinase. Mutations occurring in the catalytic domain are single-nucleotide variants which lead to amino acid substitutions that activate the kinase [67–71]. *MAP2K1* mutations in

Table 2.2 Prevalence of *MAP2K1* mutations in LCH¹

Report (Ref.)	Prevalence ²
Brown et al. [64]	27.5% (11/40)
Chakraborty et al. [44]	33% (7/21)
Nelson et al. [66]	10% (3/30)
Alayed et al. [50]	12% (6/50)
Kamionek et al. [65]	18% (5/28) ³
Mourah et al. [48]	11.5% (3/26) ³
Diamond et al. [63]	40% (4/10)

¹Prevalence of mutations in *MAP2K1* (encoding MEK1) in ECD. All mutations are included whether or not they have been tested for encoding constitutively active MEK1

²Prevalence rate is indicated with actual numbers shown in parentheses (number of cases with mutated *MAP2K1*/total number of cases)

³All pulmonary cases

LCH map to the same areas and often include previously reported alterations such as a C to G transversion at nucleotide position 362 which results in a substitution of serine for cysteine at amino acid 121 (C121S). This is a frequent alteration in melanoma [70]. However, some LCH mutations are novel. For example, the C121S substitution is created in at least one case by a different nucleotide variant: an A to T transversion at position 361 which creates a different codon but one that still encodes serine at amino acid position 121 [66]. This appears to be a unique mutation in LCH. Many of the deletions in the N-terminal negative regulatory domain in LCH are identical or overlap with deletions reported in other diseases [72].

Many of the MEK1 variants found in LCH samples have been expressed *in vitro* and have constitutive ERK activity [44, 66]. Not all of the deletion variants have been tested, but because they occur in the same region as other deletion variants known to have constitutive kinase activity, they are presumed to be activating mutations as well. One case reported by Nelson et al. [66] was found to have a compound mutation: C121S and G128D. Each variant was tested and found to have constitutive ERK activity *in vitro* (C121S > G128D), but the combination had much more activity than either variant alone.

MAP3K1 Whole-exome sequencing identified two LCH samples with mutations in *MAP3K1*, a MAP kinase kinase kinase that encodes MEKK1 (Fig. 2.2) [66]. In both cases, deletions produced frameshifts that encode truncated proteins: T799fs and L1481fs. Because MEKK1 can phosphorylate MEK1 [73], an attempt was made to test whether the variants were able to do so. However, no stable expression could be achieved, and the mutations are presumed to be null alleles similar to many MEKK1 variants in other cancers, including breast cancer [74]. If these variants contribute to LCH pathogenesis at all, they are unlikely to do so through ERK activation. This inference is supported by the fact that the T799fs variant was found in a case carrying BRAF V600E [66].

RAS Activating mutations of RAS family members could result in constitutive phosphorylation of MEK and ERK and might explain some cases of LCH with wild-type *BRAF* and *MAP2K1*. Interestingly, however, RAS mutations are rare in LCH. One analysis of 30 pulmonary LCH cases found two instances of KRAS mutations (G12A and G12D) [65], and both occurred, as expected, in *BRAF* wild-type backgrounds. A second, independent report on 26 pulmonary LCH cases found one case with KRAS G12V again in a *BRAF* wild-type background [48]. This study may underestimate the true prevalence of *KRAS* mutations since the authors examined single-nucleotide variants only at amino acid position 12. There are no reports to date of *KRAS* mutations in non-pulmonary LCH. This may reflect the more specific mutational effects of smoking on the induction of *KRAS* mutations.

Pathogenetic variants of *NRAS* and, in particular, substitutions of lysine or arginine for glutamine at position 61 (Q61K or Q61R) have been reported in LCH. The same study of pulmonary LCH that identified a single case with KRAS G12V also found that 42% of the cases examined (11 of 26) contained *NRAS* Q61K or Q61R [48]. Notably, seven of these occurred in patients whose total biopsy material also contained single-nucleotide variants encoding BRAF V600E. However, by genotyping individual foci of CD1a-positive LCH histiocytes in several of these patients, the authors could demonstrate that each focus contained cells expressing either BRAF V600E or *NRAS* Q61K/R but not both. Thus, the mutations are mutually exclusive as would be expected based on their convergence on ERK. This observation also supports the notion, described above, that pulmonary LCH may be comprised of multiple independent clones that only appear in the aggregate to be non-clonal. A single case report described an *NRAS* G12D variant in mixed juvenile myelomonocytic leukemia (JMML) and LCH [75]. This mutation is characteristic of JMML, and its presence in this case likely reflects its driver status in that disease and not in LCH, since it was found in blood samples rather than tissue LCH samples, which were not tested.

Of course, the mutation could theoretically promote ERK activation if it were also present in LCH histiocytes.

PI3K/PTEN/AKT/mTOR The PI3K/PTEN/AKT/mTOR pathway converges on many of the same downstream targets as the RAS/RAF/MEK/ERK pathway [76], and it is possible that activating mutations in LCH in the former may produce outcomes similar to mutations in the latter. This possibility was supported by a report that a patient with multisystem LCH enrolled on a clinical trial of an AKT inhibitor had a prolonged clinical response [77]. An LCH-specific trial demonstrated responses in 5 of 17 patients (29%) some of whom had relapsed or refractory disease [78]. However, to date, no mutations in *PTEN*, *AKT*, or *mTOR* have been reported in LCH. Targeted assessment of four hotspot mutations in *PIK3CA* (E542K, E545K, A1046T, and H1047R) was performed in 86 LCH patients and revealed only a single case with the E542K variant in a *BRAF* wild-type background [79]. The low frequency of *PIK3CA* mutations in this allele-specific assessment is likely to be generally true since no *PIK3CA* mutations were described in whole-exome sequencing analyses of LCH performed to date [44, 66].

TP53 Although the histiocytes in most cases of LCH overexpress p53 as determined by immunohistochemistry [80], its mechanistic basis is unclear. Mutations in the *TP53* gene are rare in LCH with only one report of a case with TP53 R175H [34], a presumed oncogenic variant [81–83]. There are no reports of mutations in p53 regulators such as *MDM2*. The role of p53 overexpression in LCH pathogenesis is unknown. On one hand, it could be a driver abnormality that occurs via epigenetic alterations; on the other hand, p53 overexpression could be a response to constitutive ERK activation.

Others Based on the low overall frequency of single-nucleotide variants in clinical LCH samples described above, it is not surprising that few additional DNA variants have been described. In one whole-exome sequencing study of 41 LCH samples, 29 mutations that targeted the RAS/

RAF/MEK/ERK pathway were found [44]. An additional 23 mutations were found in a variety of genes, which might theoretically impact that pathway including *PICK1* and *PIK3R2*, and an ERBB3 P921Q variant in a *BRAF* wild-type background [44].

Translocations and Copy Number Variations An early survey of cytogenetic abnormalities in LCH described a clonal t(7;12)(q11.2;p13) translocation in one case and non-clonal translocations in the same case plus three more; none were recurrent [30]. A subsequent study of 31 cases showed that all were diploid and contained no translocations [31]. As described above, a single example of a translocation producing a *BRAF* fusion protein has been reported [58].

Array comparative genomic hybridization (array CGH), quantitative PCR, and next-generation sequencing have all been used to examine copy number changes in LCH. The array CGH study examined seven bone lesions and described several copy number changes throughout the genome and hints of recurrent loss of heterozygosity at some loci [32]. A separate PCR study found fractional allelic loss at a higher prevalence in multisystem disease than single-system or low-risk disease [33]. However, a later study which used high-density SNP (single-nucleotide polymorphism) arrays failed to confirm these findings [31]. None of the next-generation sequencing studies published to date describe recurrent copy number variations.

Summary Essentially all LCH histiocytes show constitutive activation of ERK. In a little over three quarters of these cases, activation has a genetic explanation: activating mutations of *BRAF* in about 50% (including rare fusion events); activating mutations of *MAP2K1*, in about 20–25%; and a smattering of mutations in *ARAF*, *KRAS*, *NRAS*, and *PIK3CA*. This leaves about 20–25% of LCH without an as yet documented genetic basis for ERK pathway activation. This is the “dark matter” of LCH pathogenesis. Epigenetic alterations may eventually account for much of the missing mechanisms underlying ERK activation. It is also

possible that overexpression of receptor tyrosine kinases or their ligands could provide autocrine or paracrine stimulation of ERK sufficient to cause LCH histiocyte accumulation. This could arise from epigenetic alterations that affect expression levels or from mutations in promoter regions which have not been thoroughly examined in the sequencing projects reported to date.

Erdheim-Chester Disease

As in LCH, the genome of ECD histiocytes is very close to normal: an average of seven SNVs per adult patient and five SNVs per pediatric patient in a whole-exome analysis [63]. However, also like LCH, the discovery of recurrent mutations in the ERK activation pathway places ECD squarely in the neoplastic disease category.

BRAF The prevalence of mutations encoding BRAF V600E in ECD is 50–60% (Table 2.3) and is similar to the prevalence seen in LCH. One study showing 100% of ECD patients expressing this *BRAF* variant examined a very small sample (18 patients), and this prevalence rate has not been reproduced [84]. To date, none of the rarer activating mutations occasionally observed in LCH have been reported in ECD. However, at least two translocations involving *BRAF* have been described [63]. One results in a novel RNF11-BRAF fusion, which produces a constitutively active MEK kinase with about the same

activity as BRAF V600E. The second translocation is also novel and results in a CLIP2-BRAF fusion, which is expressed, but its transforming activity has not been demonstrated [60].

ARAF Whole-exome sequencing, targeted gene panel sequencing, and transcriptome sequencing of 44 *BRAF* wild-type ECD cases found ARAF mutations in ten for a prevalence of 23% [63]. Among unselected ECD cases, one could impute a prevalence of approximately 11% (10/88) which is much higher than the prevalence seen in LCH [43, 44]. The minority of ARAF mutations encoded amino acid substitutions in the kinase domain. Although the effects of these substitutions on ARAF kinase activity are largely unknown, one of the variants (S214A) was reported as an activating mutation in a non-small cell lung cancer case, which responded to treatment with sorafenib [85]. This variant was found in an ECD patient who had relapsed after multiple therapies and was similarly responsive to sorafenib [63].

MAP2K1 Whole-exome and transcriptome sequencing of 14 ECD cases found two with *MAP2K1* mutations; targeted sequencing of 18 archived *BRAF* wild-type cases found nine more for an overall prevalence of about 22% (assuming a 50% prevalence of *BRAF* mutations) [63]. *MAP2K1* mutations are found in 50% of the *BRAF* wild-type ECD cases in this series. These included deletions and SNVs in the N-terminal regulatory domain and kinase domain which overlap those found in LCH. However, the C121S variant commonly observed in LCH was not seen in ECD. As expected, cases with mutations in *MAP2K1* did not contain mutations in *BRAF*, *ARAF*, *NRAS*, *KRAS*, or *PIK3CA*.

RAS Mutations in RAS family members have a significant prevalence in ECD. The first description of a *KRAS* mutant (G12S) came from an analysis of mutations in cell-free DNA from the plasma and urine of histiocytosis patients [86]. This same mutation was documented in tissue taken from a cardiac lesion in the same patient. No *KRAS* mutations were seen in a broader survey of tissues from 44 ECD patients [63].

Table 2.3 Prevalence of *BRAF* mutations in ECD¹

Report (Ref.)	Prevalence ²
Haroche et al. [40] Emile et al. [112] Emile et al. [88]	57.5% (46/80) ³
Cangi et al. [84]	100% (18/18)
Mazor et al. [113]	50% (3/6)
Cao et al. [114]	68.8% (11/16) ⁴
Diamond et al. [63]	50% (7/14)

¹Prevalence of *BRAF* mutations in ECD

²Prevalence rate is indicated with actual numbers shown in parentheses (number of cases with mutated *BRAF*/total number of cases)

³Cumulative prevalence from various components of the 80 patient cohorts reported in these three papers

⁴Chinese population

In contrast, *NRAS* mutations are recurrent in ECD although the prevalence is still low. After a case report from 2013 [87], a French study of 80 patients with ECD found *NRAS* mutations in three (3.7%) [88]. The amino acid substitutions were all known to be activating and included G12D, Q61K, and Q61R. As expected, these appeared in *BRAF* wild-type cases. Another analysis of archived material from 18 *BRAF* wild-type ECD cases found *NRAS* mutations in three, including G12D and Q61K/R variants [63]. This 16.6% prevalence among *BRAF* wild-type cases implies an overall prevalence among all ECD patients of about 8%, similar to the French study.

PIK3CA Through a combination of allele-specific genotyping and exon sequencing, *PIK3CA* mutations were found in 7 of 58 ECD patients in the French cohort (12.1%) [88]. Among the 41 patients with *BRAF* mutations, there were 4 concurrent *PIK3CA* mutations (10.0%) while there were 3 *PIK3CA* mutations in the 17 remaining *BRAF* wild-type patients (17.6%), suggesting that *PIK3CA* mutations occur independently of *BRAF* mutational status. This may mean that the *PIK3CA* mutations in ECD exert their effects in a pathway that does not overlap ERK activation pathways. A second study found three *PIK3CA* mutations in 18 *BRAF* wild-type samples for a prevalence of 16.7% among the *BRAF* wild-type cohorts and an imputed overall prevalence of 3/36 or 8.3% among all ECD patients [63].

Others Whole-exome sequencing of 14 ECD cases revealed nonrecurrent SNVs in a variety of genes that could have a plausible role in pathogenesis [63]. Several occurred in genes encoding members of the JNK/p38 pathway and in genes involved in epigenetic and transcriptional regulation. The contributions of these alterations, if any, to the development or behavior of ECD are unknown.

Translocations and Copy Number Variations Several translocations resulting in potentially actionable protein fusions were discovered in a transcriptome and targeted RNA sequencing analysis of ECD cases [63]. They appeared in *BRAF* wild-type cases and included an

RNF11-BRAF fusion, a *CLIP2-BRAF* fusion, two *KIF5B-ALK* fusions, and an *LMNA-NTRK1* fusion. In all cases, the kinase domain of the downstream partner was intact. The *RNF11-BRAF* fusion imparted factor-independent growth to Ba/F3 cells and made them sensitive to MEK inhibition similar to the effects of *BRAF* fusions in other diseases [89, 90]. Similarly, the *KIF5B-ALK* fusion made Ba/F3 cells factor independent, but, in this case, their growth was sensitive to an ALK inhibitor. There are no published reports of copy number changes in ECD. There is a single report of a balanced translocation t(12;15;20)(q11;q24,p13.3) in an ECD case [39] which has not been reported again.

Summary Like LCH, about half of ECD cases are driven by activating mutations of *BRAF* and another 25% by activating mutations in *MAP2K1*. Unlike LCH, mutations in *ARAF* are somewhat more common as are mutations in *NRAS* and *PIK3CA*. Also more common in ECD are translocations leading to fusions that activate oncogenic driver kinases including, so far, *BRAF*, *ALK*, and *NTRK1*. The result is that there is much less “dark matter,” i.e., cases without identified driver genomic alterations, in ECD. Nonetheless, 8–10% of ECD cases have an unexplained pathogenesis, and it will be important to test some of the rare, one-off mutations for their potential function. Epigenetic mechanisms may also contribute to transformation in ECD, and these have yet to be rigorously investigated.

Indeterminate Cell Histiocytosis

The rarity of ICH and the ongoing disputes about its diagnostic criteria have made molecular analysis of this disease challenging. One report describes a case of mixed angioimmunoblastic T cell lymphoma and ICH in which the ICH cells stained for *BRAF* V600E [41]. If more cases were to be described with *BRAF* mutations, this might lead to a reconsideration of ICH as a variant of LCH, given its CD1a positivity. However, a recent collection of four ICH cases showed same clonal translocation in three which results in a *ETV3-NCOA2* gene fusion [42]. *ETV3* encodes the transcriptional repressor, Ets variant

3 (also known as METS and PE-1 and an ERK2 substrate [91]); *NCOA2* (also known as GRIP1 and TIF2) encodes nuclear receptor coactivator 2 which is a transcriptional coregulator [92]. The pathophysiological role played by this fusion, if any, in ICH is unclear although translocations involving *NCOA2* have been observed in a variety of sarcomas, solid tumors, and hematologic malignancies [93–97]. This recurrent translocation provides substantial support for the idea that ICH is a nosologically distinct histiocytosis.

Implications of Genomic Alterations for Identifying the Cell of Origin in Histiocytic Diseases

Inferences about histiocytoses' cells of origin have been based on the phenotype of the abnormal histiocyte. In the case of LCH, the expression of CD1a and CD207 and the presence of Birbeck granules are features shared by mature LCs, and LCH was presumed to arise as a result of oncogenic activation or inflammatory stimulation of LCs [3, 4]. However, several lines of evidence suggest that this model is incorrect. For example, the pattern of global gene expression by LCH cells is much closer to that of immature myeloid dendritic cells than LCs [98]. In addition, the mutation encoding BRAF V600E was identified in circulating CD14+ monocytes and CD11c+ myeloid DCs in patients with high-risk disease and was also present in CD34+ bone marrow cells in some of the high-risk patients [46]. Interestingly, circulating cells carrying mutated *BRAF* were not detectable in patients with single-system disease and were present only in a few patients with multifocal low-risk disease. This has led to the proposal that the acquisition of the T1799A transversion is a transforming event and can occur in any of the several precursor cells in the myeloid dendritic cell lineage. Transformation in an early precursor (e.g., CD34+ stem cells) leads to multisystem high-risk disease, while transformation in a later, more differentiated cell leads to localized or lower-risk disease. Some support for this hypothesis comes from genetically engineered mouse models in which the

gene encoding BRAF V600E is conditionally expressed [46]. Directed expression of mutated *BRAF* to CD207-expressing cells produces a mild, limited histiocytic disease while directing expression to CD11c-expressing cells results in a systemic histiocytosis.

Similarly, the phenotype of ECD histiocytes has led to the suggestion that they are derived from macrophages. As in LCH, however, mutated *BRAF* [84] and *NRAS* [88] alleles have been found in circulating CD14+ cells of some ECD patients suggesting the possibility that a less mature precursor cell may have undergone transformation. The existence of driver mutations in these disorders will eventually enable a detailed analysis of the transformation state of well-defined stem and precursor cells. This will provide a clearer picture of the ontogeny of histiocytosis cells.

Implications of Genomic Alterations for the Treatment of L Group Histiocytoses

The presence in LCH and ECD of mutations known to be oncogenic drivers in cancer strongly suggests, but does not prove, that they are also drivers in these diseases. Real proof of their driver status comes from the remarkable clinical responses to inhibitors of the activated proteins encoded by these mutations. Unfortunately, no clinical trial outcome data are available yet for the histiocytoses, but a significant number of case reports and descriptions of small cohorts support the efficacy of RAF or MEK inhibition in these diseases [96–102].

The first published report of the effect of treating ECD and LCH with a RAF inhibitor described three patients with refractory BRAF V600E-expressing ECD, two of whom also had LCH involvement of skin or lymph nodes. Treatment with vemurafenib led to major clinical responses in all three patients, and the response persisted for the duration of reported follow-up (4 months) [99]. The same investigators later described a larger cohort of eight BRAF V600E-positive ECD patients, four of whom also had LCH. Again,

all had responses to vemurafenib that lasted for the duration of follow-up (6–16 months) [100]. In both reports, disease activity was easily monitored by PET scanning. Single case reports also describe responses to vemurafenib in specific clinical settings including brainstem involvement by ECD/LCH [101] and spinal cord involvement by ECD [102]. A so-called basket study designed to treat patients having a wide variety of diseases with BRAF variants at position 600 included several with ECD and LCH which were lumped together in the analysis [103]. The overall response rate of the combined diagnostic group was 43% (6 of 14) although some disease regression was observed in 12 of 14 patients and symptomatic improvement occurred in all. Median treatment duration in the study period was 5.9 months, and no patient progressed while on vemurafenib. Four patients discontinued the drug because of adverse events, and one of these patients progressed while off drug. A similar example of treatment-dependent persistence of response was reported in an 8-month-old patient with multisystem LCH [104]. She had a dramatic response to vemurafenib, but when the drug was discontinued after 90 days of treatment, she relapsed in the skin. Re-treatment with vemurafenib was effective. Finally, the only published report of vemurafenib resistance in LCH described an adult patient who had a very good response to vemurafenib for 20 months at which time she progressed on therapy [105].

Similar early signals of efficacy for MEK inhibition have been published. Two ECD patients have been described who had failed multiple lines of conventional therapy and whose histiocytes had *MAP2K1* mutations: K57N and Q56P [63]. Both patients have experienced major and prolonged responses to the MEK inhibitors trametinib, in the first case, and cobimetinib in the second. One note of caution, however, is that some of the *MAP2K1* mutations that occur in LCH, e.g., C121S, have been described as resistant to MEK inhibitors [70] suggesting that not all *MAP2K1* mutations may be biomarkers for sensitivity to MEK inhibitor treatments.

The common threads that run through these scattered reports are as follows: (1) patients

whose histiocytoses carry targetable mutations respond dramatically to cognate inhibitors; (2) patients do not generally develop resistance to the inhibitors, at least during the periods of follow-up described in the reports; and (3) disease reappears when targeted therapies are withdrawn. These observations suggest that LCH and ECD are “single-pathway” diseases, i.e., the proliferative and antiapoptotic thrust depends almost entirely on ERK activation through RAF and MEK family members. Further, the non-emergence of resistance is consistent with the very low frequency of mutations in these diseases (see above). A stable genome is much less likely to generate mutations that permit bypass pathways to appear. In many ways, this scenario is reminiscent of chronic myeloid leukemia and its response to ABL inhibitors. It remains to be determined whether LCH and ECD can be cured by prolonged treatment with targeted agents and whether resistance will eventually emerge through mutations in the target proteins.

Conclusions

The recent discoveries of recurrent genomic abnormalities in the L Group histiocytoses have had several important implications. First, they provide insight into the fundamental nature of these diseases. The fact that so many of the alterations result in activation of authentic oncogenic drivers indicates that these diseases are neoplastic in nature. Second, these discoveries provide new information about pathogenesis and the development of the histiocytoses. The fact that clonal genetic abnormalities can be found in precursor cells, e.g., CD34+ bone marrow cells, indicates that the transforming event can occur early in the ontogeny of the abnormal histiocytes and suggests the possibility that clinical behavior may be determined by the specific precursor population or stem cell that first suffers the mutagenic hit. Finally, these discoveries provide a road map for therapeutics. The histiocytosis community can apply the lessons learned in other ERK-driven diseases such as melanoma to treatment of LCH and ECD. We have already seen early evidence that RAF and

MEK inhibitors have substantial activity in patients whose abnormal histiocytes carry mutations in the genes encoding the targets of those inhibitors. It is now essential to design clinical trials to determine which patient populations might benefit from these targeted therapies. In particular, the reappearance of disease after withdrawing these drugs indicates that, despite their efficacy, single targeted therapies are not curing patients. In contrast, vinblastine and prednisone can cure LCH in the appropriate population. Future goals will be to determine which patients should receive cytotoxic chemotherapy, who should receive single targeted agents, and who should receive combination therapy.

References

- Emile JF, Ablu O, Fraïtag S, Home A, Haroche J, Donadieu J, et al. Revised classification of histiocytoses and neoplasms of the macrophage-dendritic cell lineages. *Blood*. 2016;127(22):2672–81.
- Fletcher CDM, Bridge JA, Hogendoorn PCW, Mertens F. WHO classification of tumours of soft tissue and bone. 4th ed. International Agency for Research on Cancer: Lyon; 2013.
- Nezelof C, Basset F, Rousseau MF. Histiocytosis X: histogenetic arguments for a Langerhans cell origin. *Biomedicine*. 1973;18(5):365–71.
- Writing Group of the Histiocyte Society. Histiocytosis syndromes in children. *Lancet*. 1987;1(8526):208–9.
- Stalemark H, Laurencikas E, Karis J, Gavhed D, Fadeel B, Henter JI. Incidence of Langerhans cell histiocytosis in children: a population-based study. *Pediatr Blood Cancer*. 2008;51(1):76–81.
- Guyot-Goubin A, Donadieu J, Barkaoui M, Bellec S, Thomas C, Clavel J. Descriptive epidemiology of childhood Langerhans cell histiocytosis in France, 2000–2004. *Pediatr Blood Cancer*. 2008;51(1):71–5.
- Gadner H, Heitger A, Grois N, Gatterer-Menz I, Ladisch S. Treatment strategy for disseminated Langerhans cell histiocytosis. DAL HX-83 study group. *Med Pediatr Oncol*. 1994;23(2):72–80.
- Minkov M, Grois N, Heitger A, Potschger U, Westermeier T, Gadner H. Treatment of multisystem Langerhans cell histiocytosis. Results of the DAL-HX 83 and DAL-HX 90 studies. DAL-HX study group. *Klin Padiatr*. 2000;212(4):139–44.
- Badalian-Very G, Vergilio JA, Fleming M, Rollins BJ. Pathogenesis of Langerhans cell histiocytosis. *Annu Rev Pathol*. 2013;8:1–20.
- Degar BA, Fleming MD, Rollins BJ, Rodriguez-Galindo C. Histiocytoses. In: Orkin SH, Fisher DE, Ginsburg D, Look AT, Lux SE, Nathan DG, editors. *Nathan and Orski's hematology and oncology of infancy and childhood*. 8th ed. Philadelphia: Elsevier Saunders; 2015. p. 2100–22.
- Diamond EL, Dagna L, Hyman DM, Cavalli G, Janku F, Estrada-Veras J, et al. Consensus guidelines for the diagnosis and clinical management of Erdheim-Chester disease. *Blood*. 2014;124(4):483–92.
- Hervier B, Haroche J, Arnaud L, Charlotte F, Donadieu J, Neel A, et al. Association of both Langerhans cell histiocytosis and Erdheim-Chester disease linked to the BRAFV600E mutation. *Blood*. 2014;124(7):1119–26.
- Wood GS, Hu CH, Beckstead JH, Turner RR, Winkelmann RK. The indeterminate cell proliferative disorder: report of a case manifesting as an unusual cutaneous histiocytosis. *J Dermatol Surg Oncol*. 1985;11(11):1111–9.
- Sidoroff A, Zelger B, Steiner H, Smith N. Indeterminate cell histiocytosis--a clinicopathological entity with features of both X- and non-X histiocytosis. *Br J Dermatol*. 1996;134(3):525–32.
- Rezk SA, Spagnolo DV, Brynes RK, Weiss LM. Indeterminate cell tumor: a rare dendritic neoplasm. *Am J Surg Pathol*. 2008;32(12):1868–76.
- Broadbent V, Pritchard J, Davies EG, Levinsky RJ, Heaf D, Atherton DJ, et al. Spontaneous remission of multi-system histiocytosis X. *Lancet*. 1984;1(8371):253–4.
- McElligott J, McMichael A, Sanguenza OP, Anthony E, Rose D, McLean TW. Spontaneous regression of Langerhans cell histiocytosis in a neonate with multiple bony lesions. *J Pediatr Hematol Oncol*. 2008;30(1):85–6.
- Jenson HB, McClain KL, Leach CT, Deng JH, Gao SJ. Evaluation of human herpesvirus type 8 infection in childhood Langerhans cell histiocytosis. *Am J Hematol*. 2000;64(4):237–41.
- Jeziorski E, Senechal B, Molina TJ, Devev F, Leruez-Ville M, Morand P, et al. Herpes-virus infection in patients with Langerhans cell histiocytosis: a case-controlled sero-epidemiological study, and in situ analysis. *PLoS One*. 2008;3(9):e3262.
- Murakami I, Matsushita M, Iwasaki T, Kuwamoto S, Kato M, Horie Y, et al. Merkel cell polyomavirus DNA sequences in peripheral blood and tissues from patients with Langerhans cell histiocytosis. *Hum Pathol*. 2014;45(1):119–26.
- de Graaf JH, Tamminga RY, Dam-Meiring A, Kamps WA, Timens W. The presence of cytokines in Langerhans' cell histiocytosis. *J Pathol*. 1996;180(4):400–6.
- Egeler RM, Favara BE, van Meurs M, Laman JD, Claassen E. Differential in situ cytokine profiles of Langerhans-like cells and T cells in Langerhans cell histiocytosis: abundant expression of cytokines relevant to disease and treatment. *Blood*. 1999;94(12):4195–201.

23. Emile JF, Fraitag S, Leborgne M, de Prost Y, Brousse N. Langerhans' cell histiocytosis cells are activated Langerhans' cells. *J Pathol.* 1994;174(2):71–6.
24. Emile JF, Tartour E, Brugieres L, Donadieu J, Le Deist F, Charnoz I, et al. Detection of GM-CSF in the sera of children with Langerhans' cell histiocytosis. *Pediatr Allergy Immunol.* 1994;5(3):162–3.
25. Rolland A, Guyon L, Gill M, Cai YH, Banchereau J, McClain K, et al. Increased blood myeloid dendritic cells and dendritic cell-poietins in Langerhans cell histiocytosis. *J Immunol.* 2005;174(5):3067–71.
26. Coury F, Annels N, Rivollier A, Olsson S, Santoro A, Speziani C, et al. Langerhans cell histiocytosis reveals a new IL-17A-dependent pathway of dendritic cell fusion. *Nat Med.* 2008;14(1):81–7.
27. Hogarty MD. IL-17A in LCH: systemic biomarker, local factor, or none of the above? *Mol Ther J Am Soc Gene Ther.* 2011;19(8):1405–6.
28. Willman CL, Busque L, Griffith BB, Favara BE, McClain KL, Duncan MH, et al. Langerhans'-cell histiocytosis (histiocytosis X)--a clonal proliferative disease. *N Engl J Med.* 1994;331(3):154–60.
29. Yu RC, Chu C, Buluwela L, Chu AC. Clonal proliferation of Langerhans cells in Langerhans cell histiocytosis. *Lancet.* 1994;343(8900):767–8.
30. Betts DR, Leibundgut KE, Feldges A, Pluss HJ, Niggli FK. Cytogenetic abnormalities in Langerhans cell histiocytosis. *Br J Cancer.* 1998;77(4):552–5.
31. da Costa CE, Szuhai K, van Eijk R, Hoogeboom M, Sciot R, Mertens F, et al. No genomic aberrations in Langerhans cell histiocytosis as assessed by diverse molecular technologies. *Genes Chromosomes Cancer.* 2009;48(3):239–49.
32. Murakami I, Gogusev J, Fournet JC, Glorion C, Jaubert F. Detection of molecular cytogenetic aberrations in langerhans cell histiocytosis of bone. *Hum Pathol.* 2002;33(5):555–60.
33. Chikwava KR, Hunt JL, Mantha GS, Murphy JE, Jaffe R. Analysis of loss of heterozygosity in single-system and multisystem Langerhans' cell histiocytosis. *Pediatr Dev Pathol.* 2007;10(1):18–24.
34. Badalian-Very G, Vergilio JA, Degar BA, MacConaill LE, Brandner B, Calicchio ML, et al. Recurrent BRAF mutations in Langerhans cell histiocytosis. *Blood.* 2010;116(11):1919–23.
35. Tang K, Fu D, Kotter S, Cotter RJ, Cantor CR, Koster H. Matrix-assisted laser desorption/ionization mass spectrometry of immobilized duplex DNA probes. *Nucleic Acids Res.* 1995;23(16):3126–31.
36. Thomas RK, Baker AC, Debiasi RM, Winckler W, Laframboise T, Lin WM, et al. High-throughput oncogene mutation profiling in human cancer. *Nat Genet.* 2007;39(3):347–51.
37. Chetritt J, Paradis V, Dargere D, Adle-Biassette H, Maurage CA, Mussini JM, et al. Chester-Erdheim disease: a neoplastic disorder. *Hum Pathol.* 1999;30(9):1093–6.
38. Gong L, He XL, Li YH, Ren KX, Zhang L, Liu XY, et al. Clonal status and clinicopathological feature of Erdheim-Chester disease. *Pathol Res Pract.* 2009;205(9):601–7.
39. Vencio EF, Jenkins RB, Schiller JL, Huynh TV, Wenger DD, Inwards CY, et al. Clonal cytogenetic abnormalities in Erdheim-Chester disease. *Am J Surg Pathol.* 2007;31(2):319–21.
40. Haroche J, Charlotte F, Arnaud L, von Deimling A, Helias-Rodzewicz Z, Hervier B, et al. High prevalence of BRAF V600E mutations in Erdheim-Chester disease but not in other non-Langerhans cell histiocytoses. *Blood.* 2012;120(13):2700–3.
41. O'Malley DP, Agrawal R, Grimm KE, Hummel J, Glazyrin A, Dim DC, et al. Evidence of BRAF V600E in indeterminate cell tumor and interdigitating dendritic cell sarcoma. *Ann Diagn Pathol.* 2015;19(3):113–6.
42. Brown RA, Kwong BY, McCalmont TH, Ragsdale B, Ma L, Cheung C, et al. ETV3-NCOA2 in indeterminate cell histiocytosis: clonal translocation supports sui generis. *Blood.* 2015;126(20):2344–5.
43. Nelson DS, Quispel W, Badalian-Very G, van Halteren AG, van den Bos C, Bovee JV, et al. Somatic activating ARAF mutations in Langerhans cell histiocytosis. *Blood.* 2014;123(20):3152–5.
44. Chakraborty R, Hampton OA, Shen X, Simko SJ, Shih A, Abhyankar H, et al. Mutually exclusive recurrent somatic mutations in MAP2K1 and BRAF support a central role for ERK activation in LCH pathogenesis. *Blood.* 2014;124(19):3007–15.
45. Alexandrov LB, Nik-Zainal S, Wedge DC, Aparicio SA, Behjati S, Biankin AV, et al. Signatures of mutational processes in human cancer. *Nature.* 2013;500(7463):415–21.
46. Berres ML, Lim KP, Peters T, Price J, Takizawa H, Salmon H, et al. BRAF-V600E expression in precursor versus differentiated dendritic cells defines clinically distinct LCH risk groups. *J Exp Med.* 2014;211(4):669–83.
47. Heritier S, Emile JF, Barkaoui MA, Thomas C, Fraitag S, Boudjemaa S, et al. BRAF mutation correlates with high-risk Langerhans cell histiocytosis and increased resistance to first-line therapy. *J Clin Oncol.* 2016;34(25):3023–30.
48. Mourah S, How-Kit A, Meignin V, Gossot D, Lorillon G, Bugnet E, et al. Recurrent NRAS mutations in pulmonary Langerhans cell histiocytosis. *Eur Respir J.* 2016;47(6):1785–96.
49. Wei R, Wang Z, Li X, Shu Y, Fu B. Frequent mutation has no effect on tumor invasiveness in patients with Langerhans cell histiocytosis. *Biomed Rep.* 2013;1(3):365–8.
50. Alayed K, Medeiros LJ, Patel KP, Zuo Z, Li S, Verma S, et al. BRAF and MAP2K1 mutations in Langerhans cell histiocytosis: a study of 50 cases. *Hum Pathol.* 2016;52:61–7.

51. Go H, Jeon YK, Huh J, Choi SJ, Choi YD, Cha HJ, et al. Frequent detection of BRAF(V600E) mutations in histiocytic and dendritic cell neoplasms. *Histopathology*. 2014;65(2):261–72.
52. Sasaki Y, Guo Y, Arakawa F, Miyoshi H, Yoshida N, Koga Y, et al. Analysis of the BRAFV600E mutation in 19 cases of Langerhans cell histiocytosis in Japan. *Hematol Oncol*. 2016; doi: [10.1002/hon.2293](https://doi.org/10.1002/hon.2293).
53. Yousem SA, Colby TV, Chen YY, Chen WG, Weiss LM. Pulmonary Langerhans' cell histiocytosis: molecular analysis of clonality. *Am J Surg Pathol*. 2001;25(5):630–6.
54. Davies H, Bignell GR, Cox C, Stephens P, Edkins S, Clegg S, et al. Mutations of the BRAF gene in human cancer. *Nature*. 2002;417(6892):949–54.
55. Kansal R, Quintanilla-Martinez L, Datta V, Lopategui J, Garshfield G, Nathwani BN. Identification of the V600D mutation in exon 15 of the BRAF oncogene in congenital, benign langerhans cell histiocytosis. *Genes Chromosomes Cancer*. 2013;52(1):99–106.
56. Rubinstein JC, Sznol M, Pavlick AC, Ariyan S, Cheng E, Bacchiocchi A, et al. Incidence of the V600K mutation among melanoma patients with BRAF mutations, and potential therapeutic response to the specific BRAF inhibitor PLX4032. *J Transl Med*. 2010;8:67.
57. Satoh T, Smith A, Sarde A, Lu HC, Mian S, Trouillet C, et al. B-RAF mutant alleles associated with Langerhans cell histiocytosis, a granulomatous pediatric disease. *PLoS One*. 2012;7(4):e33891.
58. Chakraborty R, Burke TM, Hampton OA, Zinn DJ, Lim KP, Abhyankar H, et al. Alternative genetic mechanisms of BRAF activation in Langerhans cell histiocytosis. *Blood*. 2016;128(21):2533–7.
59. Chen SH, Zhang Y, Van Horn RD, Yin T, Buchanan S, Yadav V, et al. Oncogenic BRAF deletions that function as homodimers and are sensitive to inhibition by RAF dimer inhibitor LY3009120. *Cancer Discov*. 2016;6(3):300–15.
60. Foster SA, Whalen DM, Ozen A, Wongchenko MJ, Yin J, Yen I, et al. Activation mechanism of oncogenic deletion mutations in BRAF, EGFR, and HER2. *Cancer Cell*. 2016;29(4):477–93.
61. Jones DT, Kocialkowski S, Liu L, Pearson DM, Backlund LM, Ichimura K, et al. Tandem duplication producing a novel oncogenic BRAF fusion gene defines the majority of pilocytic astrocytomas. *Cancer Res*. 2008;68(21):8673–7.
62. Pfister S, Janzarik WG, Remke M, Ernst A, Werft W, Becker N, et al. BRAF gene duplication constitutes a mechanism of MAPK pathway activation in low-grade astrocytomas. *J Clin Invest*. 2008;118(5):1739–49.
63. Diamond EL, Durham BH, Haroche J, Yao Z, Ma J, Parikh SA, et al. Diverse and targetable kinase alterations drive histiocytic neoplasms. *Cancer Discov*. 2016;6(2):154–65.
64. Brown NA, Furtado LV, Betz BL, Kiel MJ, Weigelin HC, Lim MS, et al. High prevalence of somatic MAP2K1 mutations in BRAF V600E negative Langerhans cell histiocytosis. *Blood*. 2014;124:1655.
65. Kamionek M, Ahmadi Moghaddam P, Sakhdari A, Kovach AE, Welch M, Meng X, et al. Mutually exclusive extracellular signal-regulated kinase pathway mutations are present in different stages of multi-focal pulmonary Langerhans cell histiocytosis supporting clonal nature of the disease. *Histopathology*. 2016;69(3):499–509.
66. Nelson DS, van Halteren A, Quispel WT, van den Bos C, Bovee JV, Patel B, et al. MAP2K1 and MAP3K1 mutations in langerhans cell histiocytosis. *Genes Chromosomes Cancer*. 2015;54(6):361–8.
67. Emery CM, Vijayendran KG, Zipser MC, Sawyer AM, Niu L, Kim JJ, et al. MEK1 mutations confer resistance to MEK and B-RAF inhibition. *Proc Natl Acad Sci U S A*. 2009;106(48):20411–6.
68. Hodis E, Watson IR, Kryukov GV, Arold ST, Imielinski M, Theurillat JP, et al. A landscape of driver mutations in melanoma. *Cell*. 2012;150(2):251–63.
69. Marks JL, Gong Y, Chitale D, Golas B, McLellan MD, Kasai Y, et al. Novel MEK1 mutation identified by mutational analysis of epidermal growth factor receptor signaling pathway genes in lung adenocarcinoma. *Cancer Res*. 2008;68(14):5524–8.
70. Wagle N, Emery C, Berger MF, Davis MJ, Sawyer A, Pochanard P, et al. Dissecting therapeutic resistance to RAF inhibition in melanoma by tumor genomic profiling. *J Clin Oncol*. 2011;29(22):3085–96.
71. Waterfall JJ, Arons E, Walker RL, Pineda M, Roth L, Killian JK, et al. High prevalence of MAP2K1 mutations in variant and IGHV4-34-expressing hairy-cell leukemias. *Nat Genet*. 2014;46(1):8–10.
72. Rollins BJ. Genomic alterations in Langerhans cell histiocytosis. *Hematol Oncol Clin North Am*. 2015;29(5):839–51.
73. Lange-Carter CA, Pleiman CM, Gardner AM, Blumer KJ, Johnson GL. A divergence in the MAP kinase regulatory network defined by MEK kinase and Raf. *Science*. 1993;260(5106):315–9.
74. Ellis MJ, Ding L, Shen D, Luo J, Suman VJ, Wallis JW, et al. Whole-genome analysis informs breast cancer response to aromatase inhibition. *Nature*. 2012;486(7403):353–60.
75. Ozono S, Inada H, Nakagawa S, Ueda K, Matsumura H, Kojima S, et al. Juvenile myelomonocytic leukemia characterized by cutaneous lesion containing Langerhans cell histiocytosis-like cells. *Int J Hematol*. 2011;93(3):389–93.
76. Mendoza MC, Er EE, Blenis J. The Ras-ERK and PI3K-mTOR pathways: cross-talk and compensation. *Trends Biochem Sci*. 2011;36(6):320–8.
77. Spencer A, Yoon SS, Harrison SJ, Morris SR, Smith DA, Brigandi RA, et al. The novel AKT inhibitor afuresertib shows favorable safety, pharmacokinetics, and clinical activity in multiple myeloma. *Blood*. 2014;124(14):2190–5.

78. Arceci RJ, Allen CE, Dunkel I, Jacobsen ED, Whitlock J, Vassallo R, et al. Evaluation of afuresertib, an oral pan-AKT inhibitor, in patients with Langerhans cell histiocytosis. *Blood*. 2013;122(21):2907.
79. Heritier S, Saffroy R, Radosevic-Robin N, Pothin Y, Pacquement H, Peuchmaur M, et al. Common cancer-associated PIK3CA activating mutations rarely occur in Langerhans cell histiocytosis. *Blood*. 2015;125(15):2448–9.
80. Weintraub M, Bhatia KG, Chandra RS, Magrath IT, Ladisch S. p53 expression in Langerhans cell histiocytosis. *J Pediatr Hematol Oncol*. 1998;20(1):12–7.
81. Cao Y, Gao Q, Wazer DE, Band V. Abrogation of wild-type p53-mediated transactivation is insufficient for mutant p53-induced immortalization of normal human mammary epithelial cells. *Cancer Res*. 1997;57(24):5584–9.
82. Hinds PW, Finlay CA, Quartin RS, Baker SJ, Fearon ER, Vogelstein B, et al. Mutant p53 DNA clones from human colon carcinomas cooperate with ras in transforming primary rat cells: a comparison of the “hot spot” mutant phenotypes. *Cell Growth Differ*. 1990;1(12):571–80.
83. Lu X, Liu DP, Xu Y. The gain of function of p53 cancer mutant in promoting mammary tumorigenesis. *Oncogene*. 2013;32(23):2900–6.
84. Cangi MG, Biavasco R, Cavalli G, Grassini G, Dalcin E, Campochiaro C, et al. BRAFV600E-mutation is invariably present and associated to oncogene-induced senescence in Erdheim-Chester disease. *Ann Rheum Dis*. 2015;74(8):1596–602.
85. Imielinski M, Greulich H, Kaplan B, Araujo L, Amann J, Horn L, et al. Oncogenic and sorafenib-sensitive ARAF mutations in lung adenocarcinoma. *J Clin Invest*. 2014;124(4):1582–6.
86. Hyman DM, Diamond EL, Vibat CR, Hassaine L, Poole JC, Patel M, et al. Prospective blinded study of BRAFV600E mutation detection in cell-free DNA of patients with systemic histiocytic disorders. *Cancer Discov*. 2015;5(1):64–71.
87. Diamond EL, Abdel-Wahab O, Pentsova E, Borsu L, Chiu A, Teruya-Feldstein J, et al. Detection of an NRAS mutation in Erdheim-Chester disease. *Blood*. 2013;122(6):1089–91.
88. Emile JF, Diamond EL, Helias-Rodzewicz Z, Cohen-Aubart F, Charlotte F, Hyman DM, et al. Recurrent RAS and PIK3CA mutations in Erdheim-Chester disease. *Blood*. 2014;124(19):3016–9.
89. Hutchinson KE, Lipson D, Stephens PJ, Otto G, Lehmann BD, Lyle PL, et al. BRAF fusions define a distinct molecular subset of melanomas with potential sensitivity to MEK inhibition. *Clin Cancer Res*. 2013;19(24):6696–702.
90. Sievert AJ, Lang SS, Boucher KL, Madsen PJ, Slaunwhite E, Choudhari N, et al. Paradoxical activation and RAF inhibitor resistance of BRAF protein kinase fusions characterizing pediatric astrocytomas. *Proc Natl Acad Sci U S A*. 2013;110(15):5957–62.
91. Carlson SM, Chouinard CR, Labadorf A, Lam CJ, Schmelzle K, Fraenkel E, et al. Large-scale discovery of ERK2 substrates identifies ERK-mediated transcriptional regulation by ETV3. *Sci Signal*. 2011;4(196):rs11.
92. Hong H, Kohli K, Garabedian MJ, Stallcup MR. GRIP1, a transcriptional coactivator for the AF-2 transactivation domain of steroid, thyroid, retinoid, and vitamin D receptors. *Mol Cell Biol*. 1997;17(5):2735–44.
93. Carapeti M, Aguiar RC, Goldman JM, Cross NC. A novel fusion between MOZ and the nuclear receptor coactivator TIF2 in acute myeloid leukemia. *Blood*. 1998;91(9):3127–33.
94. Arbajian E, Magnusson L, Mertens F, Domanski HA, Vult von Steyern F, Nord KH. A novel GTF2I/NCOA2 fusion gene emphasizes the role of NCOA2 in soft tissue angiofibroma development. *Genes Chromosomes Cancer*. 2013;52(3):330–1.
95. Yu J, Wu WK, Liang Q, Zhang N, He J, Li X, et al. Disruption of NCOA2 by recurrent fusion with LACTB2 in colorectal cancer. *Oncogene*. 2016;35(2):187–95.
96. Strehl S, Nebral K, Konig M, Harbott J, Strobl H, Ratei R, et al. ETV6-NCOA2: a novel fusion gene in acute leukemia associated with coexpression of T-lymphoid and myeloid markers and frequent NOTCH1 mutations. *Clin Cancer Res*. 2008;14(4):977–83.
97. Sumegi J, Nishio J, Nelson M, Frayer RW, Perry D, Bridge JA. A novel t(4;22)(q31;q12) produces an EWSR1-SMARCA5 fusion in extraskeletal Ewing sarcoma/primitive neuroectodermal tumor. *Mod Pathol*. 2011;24(3):333–42.
98. Allen CE, Li L, Peters TL, Leung HC, Yu A, Man TK, et al. Cell-specific gene expression in Langerhans cell histiocytosis lesions reveals a distinct profile compared with epidermal Langerhans cells. *J Immunol*. 2010;184(8):4557–67.
99. Haroche J, Cohen-Aubart F, Emile JF, Arnaud L, Maksud P, Charlotte F, et al. Dramatic efficacy of vemurafenib in both multisystemic and refractory Erdheim-Chester disease and Langerhans cell histiocytosis harboring the BRAF V600E mutation. *Blood*. 2013;121(9):1495–500.
100. Haroche J, Cohen-Aubart F, Emile JF, Maksud P, Drier A, Toledano D, et al. Reproducible and sustained efficacy of targeted therapy with vemurafenib in patients with BRAF(V600E)-mutated Erdheim-Chester disease. *J Clin Oncol*. 2015;33(5):411–8.
101. Euskirchen P, Haroche J, Emile JF, Buchert R, Vandersee S, Meisel A. Complete remission of critical neurohistiocytosis by vemurafenib. *Neurol Neuroimmunol Neuroinflamm*. 2015;2(2):e78.
102. Tzoulis C, Schwarzlmuller T, Gjerde IO, Softeland E, Neckelmann G, Biermann M, et al. Excellent response of intramedullary Erdheim-Chester disease to vemurafenib: a case report. *BMC Res Notes*. 2015;8:171.

103. Hyman DM, Puzanov I, Subbiah V, Faris JE, Chau I, Blay JY, et al. Vemurafenib in multiple nonmelanoma cancers with BRAF V600 mutations. *N Engl J Med*. 2015;373(8):726–36.
104. Heritier S, Jehanne M, Leverger G, Emile JF, Alvarez JC, Haroche J, et al. Vemurafenib use in an infant for high-risk Langerhans cell histiocytosis. *JAMA Oncol*. 2015;1(6):836–8.
105. Gandolfi L, Adamo S, Pileri A, Broccoli A, Argnani L, Zinzani PL. Multisystemic and multiresistant Langerhans cell histiocytosis: a case treated with BRAF inhibitor. *J Natl Compr Cancer Netw*. 2015;13(6):715–8.
106. Sahm F, Capper D, Preusser M, Meyer J, Stenzinger A, Lasitschka F, et al. BRAFV600E mutant protein is expressed in cells of variable maturation in Langerhans cell histiocytosis. *Blood*. 2012;120(12):e28–34.
107. Roden AC, Hu X, Kip S, Parrilla Castellar ER, Rumilla KM, Vrana JA, et al. BRAF V600E expression in Langerhans cell histiocytosis: clinical and immunohistochemical study on 25 pulmonary and 54 extrapulmonary cases. *Am J Surg Pathol*. 2014;38(4):548–51.
108. Chilosi M, Facchetti F, Calio A, Zamo A, Brunelli M, Martignoni G, et al. Oncogene-induced senescence distinguishes indolent from aggressive forms of pulmonary and non-pulmonary Langerhans cell histiocytosis. *Leuk Lymphoma*. 2014;55(11):2620–6.
109. Mehes G, Irsai G, Bedekovics J, Beke L, Fazakas F, Rozsa T, et al. Activating BRAF V600E mutation in aggressive pediatric Langerhans cell histiocytosis: demonstration by allele-specific PCR/direct sequencing and immunohistochemistry. *Am J Surg Pathol*. 2014;38(12):1644–8.
110. Varga E, Korom I, Polyanka H, Szabo K, Szell M, Baltas E, et al. BRAFV600E mutation in cutaneous lesions of patients with adult Langerhans cell histiocytosis. *J Eur Acad Dermatol Venereol*. 2014;29:1205.
111. Bubolz AM, Weissinger SE, Stenzinger A, Arndt A, Steinestel K, Bruderlein S, et al. Potential clinical implications of BRAF mutations in histiocytic proliferations. *Oncotarget*. 2014;5(12):4060–70.
112. Emile JF, Charlotte F, Amoura Z, Haroche J. BRAF mutations in Erdheim-Chester disease. *J Clin Oncol*. 2013;31(3):398.
113. Mazor RD, Manevich-Mazor M, Kesler A, Aizenstein O, Eshed I, Jaffe R, et al. Clinical considerations and key issues in the management of patients with Erdheim-Chester disease: a seven case series. *BMC Med*. 2014;12:221.
114. Cao XX, Sun J, Li J, Zhong DR, Niu N, Duan MH, et al. Evaluation of clinicopathologic characteristics and the BRAF V600E mutation in Erdheim-Chester disease among Chinese adults. *Ann Hematol*. 2016;95(5):745–50.

Epidemiology and Clinical Manifestations of Langerhans Cell Histiocytosis in Children

3

Etai Adam, Rima Jubran, and Sheila Weitzman

History of LCH

Introduction

LCH is a rare disease with a variety of presentations and outcomes. Indeed, for most of its history, it was thought to be several different entities until sufficient cases were described that made the spectrum of this disease clearer. The early cases and history of its classification remain instructive to those learning about this disease.

The first modern description of LCH came in 1865 when Dr. Thomas Smith described a child that had impetigo and three large holes in the calvarium, which he thought were a congenital malformation [1].

Hand-Schüller-Christian Disease

In 1893, Dr. Alfred Hand, a medical resident at the Children's Hospital of Philadelphia, described a 3-year-old boy with skull lesions, exophthalmos, polydipsia, and polyuria that he ascribed to

tuberculosis [2]. Kay described a patient in 1905 with the above triad plus chronic ear discharge and tooth exfoliation [3]. Schüller described two patients in 1915 who had exophthalmos and skull lesions – one of them had diabetes insipidus (DI) and the other had adiposogenital dystrophy. This constellation of findings led him to believe that pituitary dysfunction was the root cause of this disease [4]. Five years later, Dr. Henry Christian described a similar case and, being aware of Schüller's hypothesis, treated his patient with a pituitary extract. The "pituitrin" relieved the polyuria and polydipsia (when given subcutaneously but not orally or rectally) but did nothing for the bone lesions [5]. Dr. Hand recognized the similarity of all of these cases and realized that the hypopituitarism could not be the root cause of the disease because pituitary extract therapy only treated the DI and because another case he published subsequently had the features of the disease without the DI or other pituitary dysfunctions. He proposed that the bone lesions were the fundamental problem, causing exophthalmos by mechanical pressure from bone lesions in the orbit and causing hypopituitarism (and subsequent DI) due to changes in the sella turcica that had been noted on Schüller's radiographs [6]. The names Christian syndrome, Hand's disease, Schüller's disease, and others were used for some years before Hand-Schüller-Christian disease became the standard way to describe the constellation of exophthalmos, DI, and bone lesions in children typically over the age of 2 years.

E. Adam, MD • R. Jubran, MD, PhD (✉)
The Children's Center for Cancer and Blood
Diseases, Children's Hospital Los Angeles,
Los Angeles, CA, USA
e-mail: rjubran@chla.usc.edu

S. Weitzman, MB, BCh, FCP(SA), FRCP(C)
Division of Haematology and Oncology, Department
of Paediatrics, The Hospital for Sick Children,
University of Toronto, Toronto, ON, Canada

Letterer-Siwe Disease

In 1924, Erich Letterer published a report of a 6-month-old infant who presented with hepatosplenomegaly, lymphadenopathy, anemia, and purpura who died shortly after presentation [7]. The autopsy showed the lymph nodes, bone marrow, spleen, and liver were infiltrated by large, pale mononuclear cells. In 1933, Siwe described a similar case in a 16-month-old girl and realized the similarity to Letterer's case and several other cases published in the intervening 9 years [8]. He defined a disease marked by hepatosplenomegaly, lymphadenopathy, anemia, localized bone tumors, purpura, and generalized hyperplasia of non-lipoid-storing macrophages in children typically under 2 years old. Three years later, the disease was named "Letterer-Siwe disease" by Abt and Denenholz [9].

The concept of the reticuloendothelial system had been proposed in 1924 by Karl Aschoff [10] to describe the tissues rich in mononuclear phagocytes, and the term "reticuloendotheliosis" was, therefore, applied to diseases with accompanying hepatosplenomegaly, lymphadenopathy, and bone marrow infiltration. Letterer-Siwe disease and Hand-Schüller-Christian disease were both classified vaguely as "reticuloendothelioses," along with a variety of infections, storage diseases, and malignancies. These were distinguished histologically with Letterer-Siwe disease being called a non-lipoid histiocytosis, which distinguished it from the lipoid histiocytoses such as Hand-Schüller-Christian disease, Niemann-Pick disease, and Gaucher's disease. Letterer-Siwe disease was distinguished from the known neoplastic and infectious non-lipoid histiocytoses by the lack of the specific features of those diseases, such as positive bacterial cultures or specific histologic features of known malignancies [9].

Eosinophilic Granuloma of Bone

Cases of isolated bone tumors with histologic features similar to Hand-Schüller-Christian disease were published in 1929 by Finzi [11] and 1930 by Mignon [12]. Finzi described his case as a myeloma of the frontal bone with a prevalence

of eosinophils in a 15-year-old boy, while Mignon described his case as a granulation tumor of the frontal bone. Subsequent publications of isolated bone granulomas of similar description over the next decade described this disease as part of Hand-Schüller-Christian disease until 1940 when Otani and Erlich described a series of seven patients with isolated bone granulomas; these were distinguished from Hand-Schüller-Christian disease due to the lack of birefringent lipid on histology and lack of other system involvement and spontaneous healing they observed in these patients [13].

That same year, Jaffe and Lichtenstein published their experience with the disease, which they called "eosinophilic granuloma of the bone," a name which reflects their manuscript's focus on the eosinophilia in the peripheral blood, bone marrow, and bone lesions of the described patients [14].

Histiocytosis X

As this new distinction was being made, there were steps made toward recognizing the commonality of these three diseases through the recognition of transitional forms between them. It was becoming clear that the clinical spectrum of Hand-Schüller-Christian disease overlapped with that of Letterer-Siwe in terms of presenting symptoms, course of disease, and affected ages. The only concrete distinction became that of cholesterol – seen as a birefringent lipid in the cytoplasm of histiocytes – which was thought to be pathognomonic for Hand-Schüller-Christian (HSC) disease. Opinion was divided over whether the buildup of cholesterol was the driving force of the disease or a secondary effect of the proliferation of histiocytes. Wallgren argued in 1940 that the cholesterol accumulation had to be a secondary effect because some cases of HSC did not show any evidence of cholesterol accumulation; furthermore, even when some tissues had histiocytes with accumulated cholesterol (described as "foam cells"), other tissues in the same patient would have a proliferation of histiocytes without any notable cholesterol buildup – implying that this is not driving the process [15]. He goes on to write that:

Since infiltration of foam cells can hardly be regarded as an essential and primary feature of Schüller-Christian disease but is rather a secondary phenomenon, the boundary line between Schüller-Christian disease and Letterer-Siwe disease, as far as the anatomic basis is concerned, appears to be eliminated.

In 1941, at the meeting of the American Association of Pathologists and Bacteriologists, Sidney Farber argued further that eosinophilic granuloma of the bone was also part of this spectrum [16]. Farber and Green expanded on this line of reasoning in 1942 and provided evidence that the relative differences in the histology of the bone lesions in the three different diseases, in reality, represent different stages of development of the lesion [17]. This led to a period of gradual acceptance of the unification of these diseases on a single spectrum under the name “histiocytosis X” [18]. It was called “histiocytosis” because pathologists felt that this cell was key to the pathogenesis and the “X” highlighted the need for further investigation of the underlying etiology. The names of the individual syndromes of LCH remained in use to describe variations along the spectrum of the disease.

Langerhans Cell Histiocytosis

The Langerhans cell was identified in 1868 by Paul Langerhans who described a dendritic cell in the skin that did not stain with gold chloride [19]. These cells only became associated with histiocytosis X in 1973 due to Nezelof’s

discovery of the pathologic similarity between the histiocytes in the bony lesions of histiocytosis X and Langerhans cells [20] – especially the granules visible on electron microscopy described by Birbeck in 1961 [21] that had not been seen in any other types of cells. This led Nezelof to argue that the Langerhans cell was the cell of origin of histiocytosis X. This idea was controversial at the time, and it took Nezelof several years before a journal finally agreed to publish his results. Based on this finding, Risdall [22] coined the term “Langerhans cell histiocytosis” which was endorsed as a replacement for all prior names by the newly formed Histiocyte Society in 1987 [23].

Epidemiology of LCH

Incidence

The peak incidence of childhood LCH is between 0 and 4 years [24]. Several regional and national studies have attempted to estimate the incidence of LCH, with varied results, as shown in Table 3.1.

The consistent pattern that emerges is that the incidence of LCH peaks in infancy, decreases with age, that there is a male predominance, and that unifocal bone disease is the most common manifestation. While multisystem disease dominates in the first year of life [24–26], single system becomes commoner by age 5 years and thereafter, with the majority of single system LCH being unifocal bone disease [24–26, 30].

Table 3.1 Reported estimated incidence rates

Study author (ref)	<i>n</i>	Ages studied (years)	Incidence	Incidence in infants	Region	Years studied	Male/female
Guyot-Goubin [25]	258	0–15	4.6	15.3	France	2000–2004	1.2
Stalemark [26]	22	0–15	8.9		Stockholm County	1992–2001	1.2
Carstensen [27]	90	0–15	5.4		Denmark	1975–1989	
Alston [24]	101	0–15	2.6	9	NW England	1954–1998	1.1
Muller [28]	111	0–18	2.2		Hungary	1981–2001	1.4
GCR [29]	697	0–14	7 ^a	26	Germany	2005–2014	1.5
Salotti [30]	94	0–16	4.1	9.9	UK and Ireland	2003–2005	1.5

All incidence expressed in cases per million child years

^aAge standardized to Segi world standard population

Associated Factors

Aside from strong evidence linking smoking to pulmonary LCH in adults [31], there are no clear environmental risk factors for LCH. In fact, exposure to tobacco smoke was not found to be associated with pediatric LCH in two epidemiological studies that examined the possibility [32, 33]. There have been several studies looking into different associations in order to gain some insight into the pathogenesis of LCH. Carstensen and Orvold [27] looked at 15 years of data from Denmark retrospectively and checked for correlation with ABO and Rh blood types, route of delivery, previous disease, birth complications, and low birth weight – none were found to be significant in that population. Other studies have found an association between LCH and maternal UTI during pregnancy [34], infections in the neonatal period [32, 33], and a protective effect of childhood vaccinations [32]. Hamre et al. found a link between LCH and feeding problems, blood transfusions, and medication use in the first 6 months of life [34]. One study found thyroid disease in the proband and in the patient's family to be associated with LCH [32], – the association of a family history of thyroid disease did not reach significance in a subsequent study [33]. LCH has been found in conjunction with congenital anomalies such as 22q11 deletion [35], TAR [36], and others [37].

Seasonality

Several epidemiological studies have looked for a seasonal pattern to LCH, as this may provide a clue to an environmental cause. A study in the UK and Ireland found an excess of cases diagnosed from March to June, although there was no seasonal association with either birthdate or month of symptom onset [30]. In the Stockholm County study, 76% of their cases were diagnosed in the fall or winter [26]. A study from Taiwan found a 45% increase in cases (primarily in multifocal bone disease) during an El Nino year when they had excess rainfall, mostly in the summer [38]. All of these studies show a different seasonal peak but were also done in different

countries with different climates; thus, it is difficult to draw a firm conclusion from them. Also, a study of LCH in NW England over 45 years did not show a pattern of seasonal variation [24].

Exposures

Other exposure histories have been evaluated, some of which have shown significant associations, such as alcohol consumption by the parents and occupational exposure of the parents to metal, granite, and wood [33].

LCH and Malignancy

There is a known association between LCH and certain malignancies, including leukemias, lymphomas, and several types of solid tumors. A causal relationship in this association has not been defined, but it's notable that in most of the published cases of patients having lymphoma or lung cancer and LCH, the diagnoses were simultaneous, often both being present in the same lymph node. The most common malignancy associated with LCH is leukemia, and AML appears to be a more common association than ALL [39]. Two reviews of this found that associated cases of AML typically came after the diagnosis of LCH, whereas ALL typically came before. It has been hypothesized that LCH is an inflammatory response to malignancy when it occurs simultaneously or after but that in some cases wherein malignancy comes later, it may be secondary to treatment of the LCH; however, some cases of malignancy occur in patients where the initial LCH was observed without therapy [40]. One survey of family history found an increase in malignancies in first-degree relatives [33], while another did not [34]. There was also a finding of increased benign tumors in relatives of the proband [34].

Association with In Vitro Fertilization

A review of 16,280 children born by in vitro fertilization in Sweden between 1982 and 2002 revealed an increase in cancer overall in this

cohort, but notably they had 5 cases of LCH in this group, whereas they would have expected only 0.9 cases [41]. There was also an overall increased risk of cancer in this population. When the study was expanded to 26,000 patients with more follow-up time in a subsequent study, only one additional case of LCH was found [42], suggesting that this may have been a random cluster.

Familial Clusters

There have been several presumed monozygotic twin pairs concordant for LCH and a few siblings and cousins. The cases of concordant twins with LCH seem to be skewed to younger age at diagnosis. This implies either a strong genetic basis for development of LCH in these children or potentially an in utero transfusion of mutated cells [43]. Still, the lack of family history in the vast majority of LCH implies that a simple genetic basis is not the prime cause in most cases.

Genetics

The two main genetic lesions described in LCH are mutations in BRAF and MAP2K1, both of which cause activation of the MAP/ERK pathway. Studies of LCH have found the *BRAF V600E* mutation in about 60% of tested samples [44, 45], although some studies found a lower percentage [46, 47]. A subsequent study found a 27.5% incidence of MAP2K1 mutation in LCH, all in LCH lesions that do not harbor a BRAF mutation [47]. Notably, LCH lesions appear to show activation of the MAP/ERK pathway regardless of whether or not there is a BRAF or MAP2K1 mutation [47]. See Chap. 2 for more details regarding the genomics of LCH.

Nature of LCH

Before being recognized as a distinct entity, LCH was likely mistaken for other more common diseases. In the past, LCH was presumed to

be a disorder of lipid metabolism, an infection, an inflammatory reaction, or a malignancy. Over the years, its classification as an infection or storage disease lost favor, but still scientists lacked an understanding of the etiology. Today, evidence of the clonality of this disease [48], discovery of *BRAF-V600E* mutations in the lesions, and an association with other malignancies all suggest that LCH is a neoplastic process. Another example suggesting neoplasm is the finding of a clonal relationship between patients with T cell ALL and the LCH they subsequently developed [49]. Nevertheless, LCH does not actually fit into the category of malignancy, as the spectrum of disease includes solitary bone lesions with a benign course, the Langerhans cells from these lesions when isolated in culture tend to mature and do not divide endlessly, there are low levels of proliferation within the lesions, and activating BRAF mutations are also commonly found in nonmalignant lesions such as nevi [50]. Please see Chap. 2 for further discussion on the *BRAF V600E* mutation in LCH.

Clinical Manifestations of LCH in Children

LCH presents in a variety of ways and can affect any organ in the body with the exception of the kidney and gonad (Table 3.2). Children may present with single system (SS) or multisystem (MS) disease. Common sites of disease include the skin, bone, lung, liver, and pituitary gland. Patients are stratified into groups: low risk and high risk depending on the affected organs. Involvement of the liver, spleen, and hematopoietic system (primarily anemia) stratifies the patient into the “risk organ” category as defined by the Histiocyte Society, where “risk” is the risk for mortality [51]. Risk organ involvement is usually seen in children younger than 2 years of age but may be seen in older children and in adults. Multifocal disease without risk organ involvement is usually seen in the 2–5-year age group, while more than 50% of patients with a single bone lesion are diagnosed after the age of 5 years [25, 26, 30].

Table 3.2 Differential diagnosis

Area of involvement	Clinical manifestation	Possible differential diagnoses
Skin	Dermatitis	Seborrheic dermatitis
	Vesicles	Varicella, herpes simplex, erythema toxicum
	Petechiae	
	Ulcerative lesions	Fungal infection
	Nodules	Juvenile xanthogranuloma, infant leukemia, mastocytosis
Bone	Lytic lesions/vertebra plana	Acute osteomyelitis
		Chronic relapsing multifocal osteomyelitis
		Atypical mycobacterial infection
		Bone angiomatosis (Gorham disease)
		Aneurysmal bone cyst
		Juvenile xanthogranuloma
		Malignancy such as Ewing's sarcoma/lymphoma
Lung	Cavitary nodules	Mycobacterial or other infections
		Sarcoidosis
		<i>Pneumocystis jirovecii</i>
Liver	Jaundice/hypoalbuminemia	Hepatitis
		Sclerosing cholangitis
		Metabolic disease
		Malignancy
		Toxic injury
Pituitary	Diabetes insipidus	Central nervous system germ cell tumor
		Hypophysitis

Skin

The skin is a common site of disease in all age groups. LCH may be limited to the skin or may be associated with involvement of other organ systems. A recent report noted that 40% of children presumed to have skin-limited disease were found on further investigation to have other organs affected with LCH. Patients with skin-limited disease had a 3-year progression-free survival of 89% after initial therapy. Patients with skin and other organ involvement had a 44% progression-free survival with therapy [52]. Lesions can present as dermatitis, a vesicular eruption, ulcerative lesions, or petechial rash. Although any area of the skin may be involved, LCH has a predilection for the scalp, axilla, and perineum (Fig. 3.1), and it can also be disseminated (Fig. 3.2). In infants, it commonly presents as a seborrheic dermatitis and can be mistaken for cradle cap as it may occur without the classical petechial component (Fig. 3.3). Older children usually develop the rash in skinfolds (axilla, under the breast, perineum), and it may be misdiagnosed as fungal infection

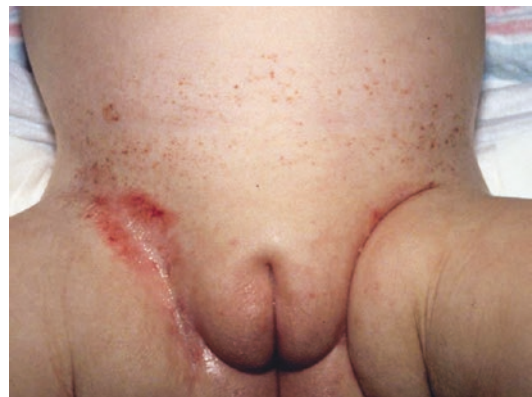

Fig. 3.1 Seborrheic pattern of LCH in the diaper area with scattered petechiae

[53]. Nail involvement is rare and presents as discoloration and hardening of nail beds with grooving and loss of nail tissue [54].

All young infants with skin-only LCH should be carefully followed, although a recent study of 21 patients with self-resolving and 10 patients with nonself-resolving LCH showed that monolesional forms, necrotic lesions, hypopigmented

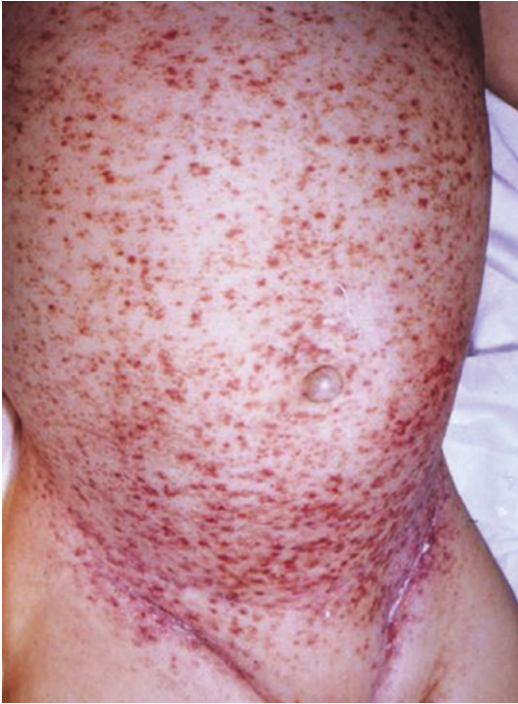

Fig. 3.2 Disseminated skin LCH with petechial papules

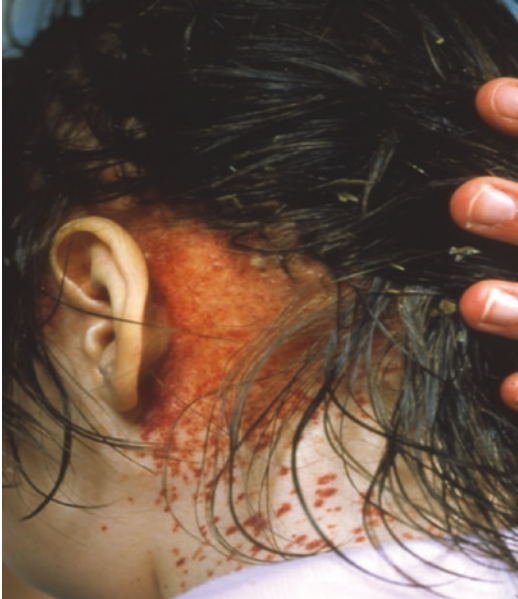

Fig. 3.3 Classic LCH of the scalp with crusting and petechiae

macules at presentation, and distal extremity lesions were seen only in patients with self-resolving cutaneous LCH [55].

Bone

LCH lesions can occur in any bone, although lytic skull lesions in the vault are the most common site of bone involvement in children (Fig. 3.4) [56]. Bone LCH may be unifocal or multifocal. Most commonly, patients complain of pain and/or swelling at the site of involvement. The lesions may be painful or asymptomatic and commonly have a soft tissue mass associated with the lesion which may cause compression of surrounding tissues. In the vertebral bones, advanced disease causes vertebral bone collapse or vertebra plana on X-ray (Fig. 3.5) [57], and paraplegia has been described due to the soft tissue component. Lower extremity and pelvic lesions may cause limping or a fracture and in rare cases may be completely asymptomatic (Fig. 3.6). Patients with bone lesions affecting the orbital, mastoid, and temporal bones are thought to have a higher risk of developing endocrine/CNS involvement. It has been reported that 20% of these patients will develop DI by 15 years post-diagnosis [58].

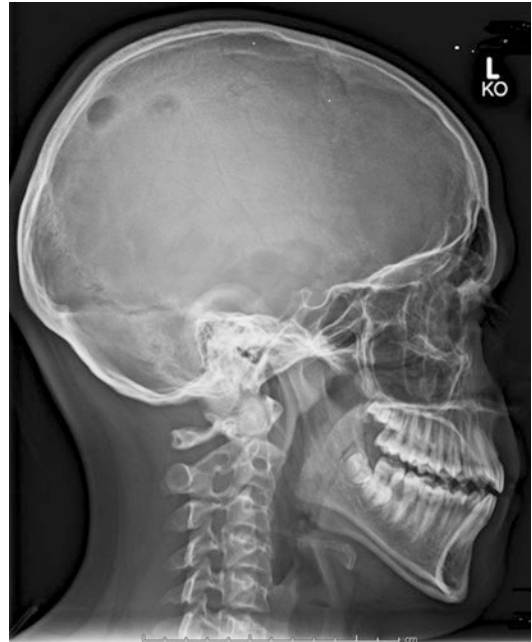

Fig. 3.4 Typical “punched-out” LCH lytic lesions of the skull (Courtesy of Dr. Fariba Goodarzi)

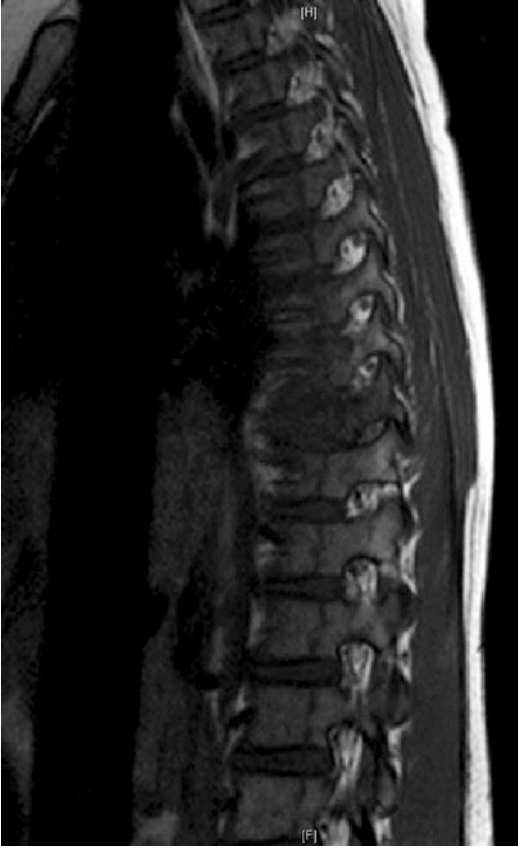

Fig. 3.5 Spinal LCH: vertebra plana with collapse of T10 vertebral body and an enhancing paraspinal soft tissue

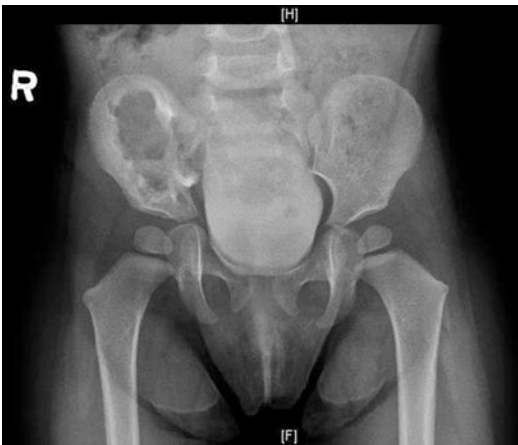

Fig. 3.6 Large LCH lytic lesion in the right iliac bone, with lobulated contours and sclerotic margins

Lungs

Lung involvement can occur in any age group but is more common in young adult smokers [59]. Twenty-five percent of children with multisystem disease present with lung involvement which is no longer considered a “risk” organ for death [51]. Lung involvement can be seen on chest X-ray or CT scan as areas of nodular fibrosis and bullae or blebs formation usually symmetrical and in the upper and middle lobes (Fig. 3.7) [60]. Patients may have no associated pulmonary complaints, or they may complain of cough or shortness of breath. The “smokers lung LCH” seen in adults may improve with smoking cessation, or it may progress to respiratory failure requiring lung transplantation. Spontaneous pneumothorax, commoner in adults, may occur and may be bilateral. Pulse oximetry may indicate hypoxia, and pulmonary function tests may reflect restrictive lung disease if lung damage is advanced [61].

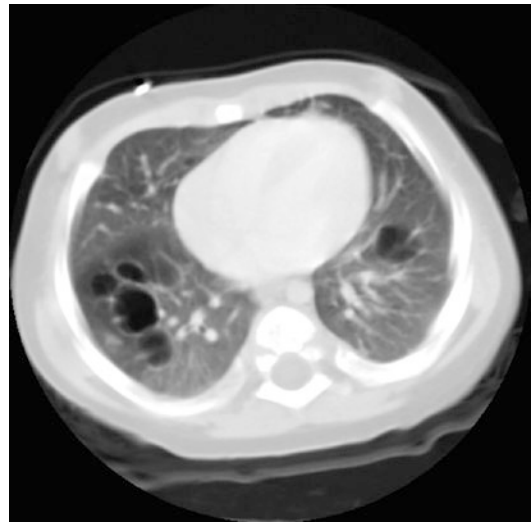


Fig. 3.7 There are multiple air-filled cysts in multiple lobes of the lungs, more prominent at the right base (Courtesy of Dr. Alan Daneman, Hospital for Sick Children, Toronto)

Lymph Nodes

The cervical chain is most commonly affected. Nodes are enlarged and may be soft or hard and matted. Mediastinal involvement is very rare and may be due to thymic or lymph node infiltration [62]. The presence of a skin sinus which may become chronic usually reflects the presence of an underlying nodal LCH.

Oral Cavity

Lesions in the oral cavity are usually ulcers and gingival hypertrophy (Fig. 3.8). Tooth loss can occur if the underlying bone is affected [63]. Pain or swelling of the jaws can occur and may lead to significant local complications.

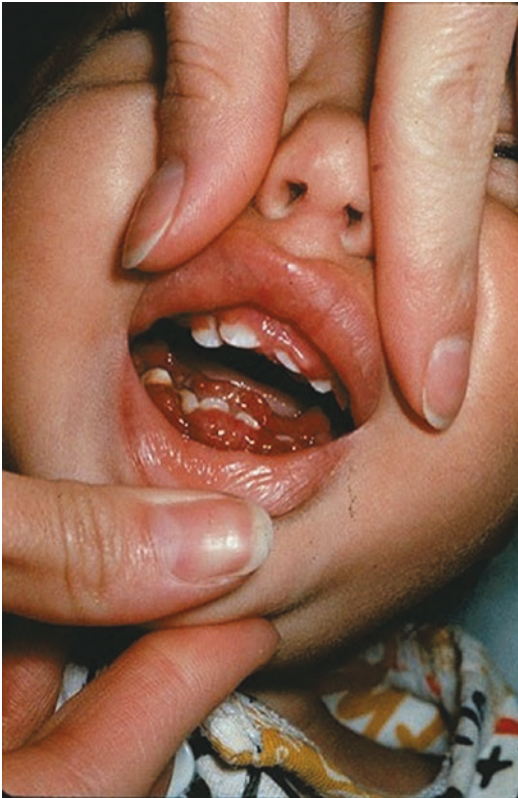

Fig. 3.8 Gum hypertrophy and loose teeth in a child with oral cavity LCH

Central Nervous System and Endocrine

Patients may present with lesions in the hypothalamic-pituitary region, dural-based masses, infiltration in the choroid plexus, or changes in white matter in the basal ganglia and cerebellum [64]. Involvement of the hypothalamic-pituitary region can occur as an isolated event or as a component of multisystem disease. The posterior pituitary is affected first with the most common manifestation being diabetes insipidus (DI). DI can occur several years prior to or following a confirmed diagnosis of LCH. Overall, approximately 24% of patients with LCH have been reported to develop DI [65], with the greatest risk being seen in patients with multisystem disease and craniofacial bone involvement at the time of diagnosis (relative risk 4.6) [58]. On magnetic resonance imaging (MRI), there is loss of the pituitary bright spot on T2-weighted images, and usually a nodular mass or thickening of the pituitary stalk is noted [66]. Studies of patients who present with isolated “idiopathic” DI showed that only 6–19% later develop evidence of LCH [67–69]. Patients who present with isolated DI should not be treated for LCH without biopsy confirmation. It has been reported that 50–80% of patients with proven pituitary LCH and DI will develop other manifestations of LCH [70, 71]. As more of the pituitary becomes involved, anterior pituitary dysfunction may develop, with growth hormone (GH) deficiency being the second most common occurring in 25% of patients with DI [72]. Dural-based mass lesions may be noted incidentally or present with symptoms associated with space-occupying lesions [66].

Neurodegenerative CNS (ND-CNS) LCH develops in approximately 1–4% of patients with LCH. Pathologically this is no longer active LCH, and it may be due to an antibody-antigen reaction or possibly a late cytokine/chemokine effect. Patients with pituitary involvement and craniofacial bone lesions are at higher risk for developing this disorder [73]. Involvement usually starts in the cerebellum,

basal ganglia, and pons. Patients have a variable course and may develop dysmetria, tremor, ataxia, dysarthria, behavioral disturbances, cognitive disorders, and/or psychosis. Imaging on MRI shows hyperintensity on T1-weighted images in the dentate nucleus which may then develop into hyper- or hypointensity on T2-weighted images. Some patients then develop extension into the white matter of the cerebellum. There is frequently an associated hyperintensity noted in the basal ganglia on T1-weighted images. Involvement of the pons with LCH is associated with severe neurologic impairment [64, 74, 75]. For more on CNS LCH, please refer to Chap. 5.

Bone Marrow

Bone marrow involvement in LCH is usually manifested as cytopenias in the setting of multisystem disease. Anemia is the most common presentation followed by thrombocytopenia. Bone marrow biopsies may show hemophagocytosis or large number of macrophages. Bone marrow involvement is associated with a worse prognosis [76–78].

Liver and Gastrointestinal Tract

Liver involvement usually occurs in children younger than 2 years of age. Involvement with LCH typically presents with hepatosplenomegaly and may be confused with leukemic infiltration or metabolic disease. These patients usually have other organs involved, and biopsy from a skin or bone lesion confirms the diagnosis. Transcutaneous biopsy of the liver may be nondiagnostic. LCH granulomas tend to occur around bile ducts and cause ductal sclerosis. Clinically patients may also present with signs of liver dysfunction including direct hyperbilirubinemia, hypoalbuminemia, coagulopathy, and ascites [79, 80]. On radiographic imaging, involvement may be nodular or diffuse infiltration. Less commonly, patients may present with or develop later a sclerosing cholangitis picture thought to be due to cytokine-induced fibrosis. These patients are challenging to treat and may or may not respond

to therapy as the sclerosis may progress despite the LCH no longer being active. Liver transplantation has been used with varying success [81, 82]. Intestinal involvement presents with bloody diarrhea, failure to thrive, and malabsorption. Diagnosis depends on endoscopic biopsy and may be difficult because the disease is patchy [83, 84]. Differential diagnosis includes inflammatory bowel disease and infection. Although not considered a “risk” organ, it is felt that GI involvement may portend a worse prognosis [84].

Spleen

Involvement of the spleen usually occurs with the liver. The organ is enlarged and can cause cytopenias. Splenectomy provides transient relief and should only be performed as a lifesaving measure [85].

Other organs: Thyroid involvement has been reported, and children typically present with thyroid enlargement and hypothyroidism [86]. Eye involvement is extremely rare and can potentially cause blindness [87].

Conclusion

LCH is a disease with a variety of presentations that encompasses the previous descriptions of Hand-Schüller-Christian disease, Letterer-Siwe disease, and eosinophilic granuloma of the bone. The highest incidence is in young children, and the disease can affect any organ system except the kidneys and gonads. While there are some suggestions of risk factors and some known associated genetic lesions, the ultimate causes of LCH remain unknown.

References

1. Smith T. Skull cap showing congenital deficiency of bone. *Trans Pathol Soc of Lond.* 1865;16:224–5.
2. Hand A. Polyuria and tuberculosis. *Arch Pediatr.* 1893;10:673–5.
3. Kay TW. Acquired hydrocephalus with atrophic bone changes, exophthalmos, and polyuria (with presentation of the patient). *Pa Med J.* 1905;9:520–1.

4. Schüller A. Über eigenartige schadeldefekte im jugendalter. Fortschritte Auf der Gebiete Röntgenstrahlen. 1915;23:12–8.
5. Christian HA. Defects in membranous bones, exophthalmos and diabetes insipidus; an unusual syndrome of dyspituitarism. *Med Clin North Am.* 1920;3:849–71.
6. Hand A. Defects of membranous bones, exophthalmos and polyuria in childhood: is it dyspituitarism? *Am J Med Sci.* 1921;162:509–15.
7. Letterer E. Aleukämische Retikulose Ztschr f Path. 1924;30:377.
8. Siwe S. Die reticuloendotheliose - ein neues krankheitsbild unter den hepatosplenomegalien. *Zeitschrift Fur Kinderheilkunde.* 1933;55:212–47.
9. Abt AF, Denenholz EJ. Letterer-Siwe's disease; spleno-hepatomegaly, associated with widespread hyperplasia of non lipid-storing macrophages; discussion of the so-called reticulo-endotheliosis. *Am J Dis Child.* 1936;51(3):499–522.
10. Aschoff L. Das Reticulo-Endotheliale system. *Ergebnisse Inner Medicin und Kinderheilkunde.* 1924;26:1–117.
11. Finzi O. Mieloma con prevalenza delle cellule eosinofile, circoscritto all' osso frontale in un giovane di 15 anni. *Minerva Med.* 1929;9(pt 1):239.
12. Mignon F. Ein granulationstumor des stimbeins. *Fortchritte RoEntgenstrahlen.* 1930;42:749–51.
13. Otani S, Erlich JC. Solitary granuloma of bone simulating primary neoplasm. *Am J Pathol.* 1940;16:479–90.
14. Lichtenstein L, Jaffe H. Eosinophilic granuloma of bone. *Am J Path.* 1940;16:595.
15. Wallgren A. Systemic reticulo-endothelial granuloma. Nonlipid reticuloendotheliosis and Schüller-Christian disease. *Am J Dis Child.* 1940;60(3):471.
16. Farber S. The nature of "solitary or eosinophilic granuloma" of bone. *Am J Pathol.* 1941;17:625–9.
17. Green WT, Farber S. "Eosinophilic or solitary Granuloma" of bone. *J Bone Joint Surg.* 1942;24:499–526.
18. Lichtenstein L. Histiocytosis X; integration of eosinophilic granuloma of bone, Letterer-Siwe disease, and Schuller-Christian disease as related manifestations of a single nosologic entity. *AMA Arch Pathol.* 1953;56(1):84–102.
19. Langerhans P. Ueber die Nerven der menschlichen laut. Über die Nerven der menschlichen Haut *Archive der Pathologischen Anatomie.* 1868;44:325–37.
20. Nezelof C, Basset F, Rousseau MF. Histiocytosis X histogenetic arguments for a Langerhans cell origin. *Biomedicine.* 1973;18(5):365–71.
21. Birbeck MS, Breathnach AS, Everall JD. An electron microscope study of basal melanocytes and high-level clear cells (Langerhans cells) in vitiligo**from the Chester Beatty research institute, Royal Cancer Hospital, London, S.W. 3, and the departments of anatomy, and dermatology, St. Mary's Hospital medical school (University of London) London, W. 2, England. *J Invest Dermatol.* 1961;37(1):51–64.
22. Risdall RJ, Dehner LP, Duray P, Kobrinsky N, Robison L, Nesbit ME Jr. Histiocytosis X (Langerhans' cell histiocytosis). Prognostic role of histopathology. *Arch Pathol Lab Med.* 1983;107(2):59–63.
23. Chu T, D'Angio GJ, Favara B, Ladisch S, Nesbit M, Pritchard J. Histiocytosis syndromes in children. *Lancet.* 1987;2:41–2.
24. Alston RD, Tatevossian RG, McNally RJ, Kelsey A, Birch JM, Eden TO. Incidence and survival of childhood Langerhans cell histiocytosis in Northwest England from 1954 to 1998. *Pediatr Blood Cancer.* 2007;48(5):555–60.
25. Guyot-Goubin A, Donadieu J, Barkaoui M, Bellec S, Thomas C, Clavel J. Descriptive epidemiology of childhood Langerhans cell histiocytosis in France, 2000-2004. *Pediatr Blood Cancer.* 2008;51(1):71–5.
26. Stalemark H, Laurencikas E, Karis J, Gavhed D, Fadeel B, Henter JI. Incidence of Langerhans cell histiocytosis in children: a population-based study. *Pediatr Blood Cancer.* 2008;51(1):76–81.
27. Carstensen H, Ornvold K. The epidemiology of Langerhans cell histiocytosis in children in Denmark, 1975-89. *Med Pediatr Oncol.* 1993;21:385–8.
28. Muller J, Garami M, Hauser P, Schuler D, Csoka M, Kovacs G, et al. Hungarian experience with Langerhans cell histiocytosis in childhood. *Pediatr Hematol Oncol.* 2006;23(2):135–42.
29. German Childhood Cancer Registry. Annual Report 2015. Institute for Biostatistics, Epidemiology and Informatics.
30. Salotti JA, Nanduri V, Pearce MS, Parker L, Lynn R, Windebank KP. Incidence and clinical features of Langerhans cell histiocytosis in the UK and Ireland. *Arch Dis Child.* 2009;94(5):376–80.
31. Watanabe R, Tatsumi K, Hashimoto S, Tamakoshi A, Kuriyama T. Respiratory failure research Group of J. Clinico-epidemiological features of pulmonary histiocytosis X. *Intern Med.* 2001;40(10):998–1003.
32. Bhatia S, Nesbit ME, Egeler RM, Buckley JD, Mertens A, Robison LL. Epidemiologic study of Langerhans cell histiocytosis in children. *J Pediatr.* 1997;130:774–84.
33. Venkatramani R, Rosenberg S, Indramohan G, Jeng M, Jubran R. An exploratory epidemiological study of Langerhans cell histiocytosis. *Pediatr Blood Cancer.* 2012;59(7):1324–6.
34. Hamre M, Hedberg J, Buckley J, Bhatia S, Finlay J, Meadows A, et al. Langerhans cell histiocytosis: an exploratory epidemiological study of 177 cases. *Med Pediatr Oncol.* 1997;28:92–7.
35. Levendoglu-Tugal O, Noto R, Juster F, Brudnicki A, Slim M, Beneck D, et al. Langerhans cell histiocytosis associated with partial DiGeorge syndrome in a newborn. *J Pediatr Hematol Oncol.* 1996;18(4):401–4.
36. Giordano P, Ceginati V, Grassi M, Giordani L, De Mattia D, Santoro N. Langerhans cell histiocytosis in a pediatric patient with thrombocytopenia-absent radius syndrome and 1q21.1 deletion: case report and proposal of a rapid molecular diagnosis of 1q21.1 deletion. *Immunopharmacol Immunotoxicol.* 2011;33(4):754–8.
37. Sheils C, Dover GJ. Frequency of congenital anomalies in patients with histiocytosis X. *Am J Hematol.* 1989;31(2):91–5.

38. Chen RL, Lin KS, Chang WH, Hsieh YL, Chen BW, Jaing TH, et al. Childhood Langerhans cell histiocytosis increased during el Nino 1997-98: a report from the Taiwan pediatric oncology group. *Acta Paediatr Taiwan*. 2003;44(1):14-20.
39. Egeler RM, Neglia JP, Arico M, Favara BE, Heitger A, Nesbit ME, et al. The relation of Langerhans cell histiocytosis to acute leukemia, lymphomas, and other solid tumors. The LCH-malignancy study Group of the Histiocyte Society. *Hematol Oncol Clin North Am*. 1998;12(2):369-78.
40. Egeler RM, Neglia JP, Puccetti DM, Brennan CA, Nesbit ME. Association of Langerhans cell histiocytosis with malignant neoplasms. *Cancer*. 1993;71(3):865-73.
41. Kallen B, Finnstrom O, Nygren KG, Olausson PO. In vitro fertilization in Sweden: child morbidity including cancer risk. *Fertil Steril*. 2005;84(3):605-10.
42. Kallen B, Finnstrom O, Lindam A, Nilsson E, Nygren KG, Olausson PO. Cancer risk in children and young adults conceived by in vitro fertilization. *Pediatrics*. 2010;126(2):270-6.
43. Arico M, Nichols K, Whitlock JA, Arceci R, Haupt R, Mittler U, et al. Familial clustering of Langerhans cell histiocytosis. *Br J Haematol*. 1999;107:883-8.
44. Badalian-Very G, Vergilio JA, Degar BA, MacConaill LE, Brandner B, Calicchio ML, et al. Recurrent BRAF mutations in Langerhans cell histiocytosis. *Blood*. 2010;116(11):1919-23.
45. Berres ML, Lim KP, Peters T, Price J, Takizawa H, Salmon H, et al. BRAF-V600E expression in precursor versus differentiated dendritic cells defines clinically distinct LCH risk groups. *J Exp Med*. 2014;211(4):669-83.
46. Haroche J, Charlotte F, Arnaud L, von Deimling A, Helias-Rodzewicz Z, Hervier B, et al. High prevalence of BRAF V600E mutations in Erdheim-Chester disease but not in other non-Langerhans cell histiocytoses. *Blood*. 2012;120(13):2700-3.
47. Brown NA, Furtado LV, Betz BL, Kiel MJ, Weigelin HC, Lim MS, et al. High prevalence of somatic MAP2K1 mutations in BRAF V600E-negative Langerhans cell histiocytosis. *Blood*. 2014;124(10):1655-8.
48. Willman CL, Busque L, Griffith BB, Favara BE, McClain KL, Duncan MH, et al. Langerhans' cell histiocytosis (Histiocytosis X) - a clonal proliferative disease. *N Engl J Med*. 1994;331:154-60.
49. Rodig SJ, Payne EG, Degar BA, Rollins B, Feldman AL, Jaffe ES, et al. Aggressive Langerhans cell histiocytosis following T-ALL: clonally related neoplasms with persistent expression of constitutively active NOTCH1. *Am J Hematol*. 2008;83(2):116-21.
50. Michaloglou C, Vredevelde LC, Mooi WJ, Peepers DS. BRAF(E600) in benign and malignant human tumours. *Oncogene*. 2008;27(7):877-95.
51. Ronceray L, Potschger U, Janka G, Gadner H, Minkov M, German Society for Pediatric H, et al. Pulmonary involvement in pediatric-onset multisystem Langerhans cell histiocytosis: effect on course and outcome. *J Pediatr*. 2012;161(1):129-33 e1-3.
52. Simko SJ, Garmezzy B, Abhyankar H, Lupo PJ, Chakraborty R, Lim KP, et al. Differentiating skin-limited and multisystem Langerhans cell histiocytosis. *J Pediatr*. 2014;165(5):990-6.
53. Munn S, Chu AC. Langerhans cell histiocytosis of the skin. *Hematol Oncol Clin North Am*. 1998;12(2):269-86.
54. Ashena Z, Alavi S, Arzani MT, Eshghi P. Nail involvement in langerhans cell histiocytosis. *Pediatr Hematol Oncol*. 2007;24(1):45-51.
55. Battistella M, Fraitag S, Teillac DH, Brousse N, de Prost Y, Bodemer C. Neonatal and early infantile cutaneous langerhans cell histiocytosis: comparison of self-regressive and non-self-regressive forms. *Arch Dermatol*. 2010;146(2):149-56.
56. Slater JM, Swarm OJ. Eosinophilic granuloma of bone. *Med Pediatr Oncol*. 1980;8(2):151-64.
57. Peng XS, Pan T, Chen LY, Huang G, Wang J. Langerhans' cell histiocytosis of the spine in children with soft tissue extension and chemotherapy. *Int Orthop*. 2009;33(3):731-6.
58. Grois N, Potschger U, Prosch H, Minkov M, Arico M, Braier J, et al. Risk factors for diabetes insipidus in langerhans cell histiocytosis. *Pediatr Blood Cancer*. 2006;46(2):228-33.
59. Vassallo R, Ryu JH, Colby TV, Hartman T, Limper AH. Pulmonary Langerhans'-cell histiocytosis. *N Engl J Med*. 2000;342(26):1969-78.
60. Abbritti M, Mazzei MA, Bargagli E, Refini RM, Penza F, Perari MG, et al. Utility of spiral CAT scan in the follow-up of patients with pulmonary Langerhans cell histiocytosis. *Eur J Radiol*. 2012;81(8):1907-12.
61. Bernstrand C, Cederlund K, Henter JI. Pulmonary function testing and pulmonary Langerhans cell histiocytosis. *Pediatr Blood Cancer*. 2007;49(3):323-8.
62. Ducassou S, Seyrig F, Thomas C, Lambilliotte A, Marec-Berard P, Berger C, et al. Thymus and mediastinal node involvement in childhood Langerhans cell histiocytosis: long-term follow-up from the French national cohort. *Pediatr Blood Cancer*. 2013;60(11):1759-65.
63. Madrigal-Martinez-Pereda C, Guerrero-Rodriguez V, Guisado-Moya B, Meniz-Garcia C. Langerhans cell histiocytosis: literature review and descriptive analysis of oral manifestations. *Med Oral Patol Oral Cir Bucal*. 2009;14(5):E222-8.
64. Grois NG, Favara BE, Mostbeck GH, Prayer D. Central nervous system disease in Langerhans cell histiocytosis. *Hematol Oncol Clin North Am*. 1998;12(2):287-305.
65. Prosch H, Grois N, Prayer D, Waldhauser F, Steiner M, Minkov M, et al. Central diabetes insipidus as presenting symptom of Langerhans cell histiocytosis. *Pediatr Blood Cancer*. 2004;43(5):594-9.
66. Prayer D, Grois N, Prosch H, Gadner H, Barkovich AJ. MR imaging presentation of intracranial disease associated with Langerhans cell histiocytosis. *AJNR Am J Neuroradiol*. 2004;25(5):880-91.
67. Di Iorgi N, Allegri AE, Napoli F, Calcagno A, Calandra E, Fratantoni N, et al. Central diabetes insipidus in children and young adults: etiological

- diagnosis and long-term outcome of idiopathic cases. *J Clin Endocrinol Metab.* 2014;99(4):1264–72.
68. Richards GE, Thomsett MJ, Boston BA, DiMeglio LA, Shulman DI, Draznin M. Natural history of idiopathic diabetes insipidus. *J Pediatr.* 2011;159(4):566–70.
 69. Maghnie M, Cosi G, Genovese E, Manca-Bitti ML, Cohen A, Zecca S, et al. Central diabetes insipidus in children and young adults. *N Engl J Med.* 2000;343(14):998–1007.
 70. Marchand I, Barkaoui MA, Garel C, Polak M, Donadieu J, Writing C. Central diabetes insipidus as the inaugural manifestation of Langerhans cell histiocytosis: natural history and medical evaluation of 26 children and adolescents. *J Clin Endocrinol Metab.* 2011;96(9):E1352–60.
 71. Dunger DB, Broadbent V, Yeoman E, Seckl JR, Lightman SL, Grant DB, et al. The frequency and natural history of diabetes insipidus in children with Langerhans-cell histiocytosis. *N Engl J Med.* 1989;321(17):1157–62.
 72. Donadieu J, Rolon MA, Thomas C, Brugieres L, Plantaz D, Emile JF, et al. Endocrine involvement in pediatric-onset Langerhans' cell histiocytosis: a population-based study. *J Pediatr.* 2004;144(3):344–50.
 73. Fahrner B, Prosch H, Minkov M, Krischmann M, Gadner H, Prayer D, et al. Long-term outcome of hypothalamic pituitary tumors in Langerhans cell histiocytosis. *Pediatr Blood Cancer.* 2012;58(4):606–10.
 74. Wnorowski M, Prosch H, Prayer D, Janssen G, Gadner H, Grois N. Pattern and course of neurodegeneration in Langerhans cell histiocytosis. *J Pediatr.* 2008;153(1):127–32.
 75. Mittheisz E, Seidl R, Prayer D, Waldenmair M, Neophytou B, Potschger U, et al. Central nervous system-related permanent consequences in patients with Langerhans cell histiocytosis. *Pediatr Blood Cancer.* 2007;48(1):50–6.
 76. McClain K, Ramsay NK, Robison L, Sundberg RD, Nesbit M Jr. Bone marrow involvement in histiocytosis X. *Med Pediatr Oncol.* 1983;11(3):167–71.
 77. Minkov M, Potschger U, Grois N, Gadner H, Dworzak MN. Bone marrow assessment in Langerhans cell histiocytosis. *Pediatr Blood Cancer.* 2007;49(5):694–8.
 78. Galluzzo ML, Braier J, Rosenzweig SD, Garcia de Davila MT, Rosso D. Bone marrow findings at diagnosis in patients with multisystem langerhans cell histiocytosis. *Pediatr Dev Pathol.* 2010;13(2):101–6.
 79. Wong A, Ortiz-Neira CL, Reslan WA, Sharon R, Pinto-Rojas A, Kaura D, et al. Liver involvement in Langerhans cell histiocytosis. *Pediatr Radiol.* 2006;36(10):1105–7.
 80. Jaffe R. Liver involvement in the histiocytic disorders of childhood. *Pediatr Dev Pathol.* 2004;7(3):214–25.
 81. Braier J, Ciocca M, Latella A, de Davila MG, Drajer M, Inventarza O. Cholestasis, sclerosing cholangitis, and liver transplantation in Langerhans cell histiocytosis. *Med Pediatr Oncol.* 2002;38(3):178–82.
 82. Hadzic N, Pritchard J, Webb D, Portmann B, Heaton ND, Rela M, et al. Recurrence of Langerhans cell histiocytosis in the graft after pediatric liver transplantation. *Transplantation.* 2000;70(5):815–9.
 83. Geissmann F, Thomas C, Emile JF, Micheau M, Canioni D, Cerf-Bensussan N, et al. Digestive tract involvement in Langerhans cell histiocytosis. The French Langerhans cell Histiocytosis study group. *J Pediatr.* 1996;129(6):836–45.
 84. Hait E, Liang M, Degar B, Glickman J, Fox VL. Gastrointestinal tract involvement in Langerhans cell histiocytosis: case report and literature review. *Pediatrics.* 2006;118(5):e1593–9.
 85. Akkari V, Donadieu J, Piguet C, Bordigoni P, Michel G, Blanche S, et al. Hematopoietic stem cell transplantation in patients with severe Langerhans cell histiocytosis and hematological dysfunction: experience of the French Langerhans cell study group. *Bone Marrow Transplant.* 2003;31(12):1097–103.
 86. Burnett A, Carney D, Mukhopadhyay S, Scalzetti EM, Leino D, Souid AK. Thyroid involvement with Langerhans cell histiocytosis in a 3-year-old male. *Pediatr Blood Cancer.* 2008;50(3):726–7.
 87. Boztug K, Frimpong-Ansah K, Nanduri VR, Lawson J, Russell-Eggitt I, Brock P. Intraocular Langerhans cell histiocytosis in a neonate resulting in bilateral loss of vision. *Pediatr Blood Cancer.* 2006;47(5):633–5.

Central Nervous System Langerhans Cell Histiocytosis

4

Milen Minkov, Jennifer Picarsic,
and Karoly Lakatos

Abbreviations

CNS	Central nervous system
CSF	Cerebrospinal fluid
DI	Diabetes insipidus
ECD	Erdheim-Chester disease
EDSS	Expanded Disability Status Scale
FDG-PET	Fluorodeoxyglucose positron emission tomography
HPR	Hypothalamic-pituitary region
ICARS	International Cooperative Ataxia Rating Scale
JXG	Juvenile xanthogranuloma
LCH	Langerhans cell histiocytosis
MAPK	Mitogen-activated protein kinase
MRI	Magnetic resonance imaging

MS-LCH	Multisystem LCH
ND	Neurodegeneration
PC	Permanent consequences
RDD	Rosai-Dorfman disease
SS-LCH	Single system LCH

Introduction

LCH is a dendritic cell neoplasm characterized by granulomatous lesions containing lesional cells positive for CD1a, CD207 (langerin), and S100. For decades, LCH has been considered a disease resulting from immune dysregulation. The identification of the recurring activating *BRAF-V600E* mutation [1] followed by identification of further activating mutations alongside the MAPK pathway [2, 3] clearly redefined LCH as a myeloid neoplastic disorder. Further studies revealed that the lesional cells in LCH, while sharing a cell surface phenotype with dendritic cells (particularly with the Langerhans cell of the epidermis), are recruited from the bone marrow and have myeloid origin [4]. It seems that the clinical expression and severity of LCH primarily depend on the maturation stage of myeloid lineage, at which the somatic mutation has been acquired, rather than on the specific mutation itself [4]. Nevertheless, LCH does not clinically behave as a classic malignancy. It has diverse clinical behavior ranging from benign single system disease (SS-LCH) with propensity to spontaneous regression to multisystem disease

M. Minkov, MD, PhD (✉)
International LCH Study Reference Center,
CCRI, St. Anna Kinderkrebsforschung, Department
of Pediatrics and Adolescent Medicine,
Medical University of Vienna, Vienna A-1090, Austria

St. Anna Children's Hospital, Department of
Pediatrics and Adolescent Medicine, Medical
University of Vienna, Vienna A-1090, Austria
e-mail: milen.minkov@stanna.at

J. Picarsic, MD
Department of Pathology, University of Pittsburgh
School of Medicine, Children's Hospital of Pittsburgh
of UPMC, Pittsburgh, PA, USA

K. Lakatos, MD
St. Anna Children's Hospital, Department of
Pediatrics and Adolescent Medicine, Medical
University of Vienna, Vienna A-1090, Austria

(MS-LCH) with unpredictable course. Although spontaneous regression has been rarely observed in MS-LCH [5], most cases will progress if left untreated. The outcome of LCH progressing despite systemic treatment is poor [6]. LCH can occur at any age but is more common in children, of whom two thirds have SS-LCH predominantly in the bone followed by skin, lungs, thyroid, brain, and lymph nodes. MS-LCH, involving two or more systems, has variable course and outcome [7].

Chronically reactivating course could be observed irrespective of systemic treatment and is associated with increased risk for sequelae [8–11]. The spectrum of disease-related permanent consequences (PC) is well described and encompasses orthopedic problems, diabetes insipidus (DI), loss of anterior pituitary hormones, hearing loss, sclerosing cholangitis, lung fibrosis and honeycombing, and neurologic, cognitive, and behavioral deficits [12].

LCH can affect virtually any organ of the human body, particularly the central nervous system (CNS-LCH). CNS-LCH can occur either as isolated LCH of the brain (cerebral SS-LCH) or more frequently in the setting of MS-LCH. Depending on utilized definitions (including or excluding cases with CNS-LCH confined to the hypothalamic-pituitary region; inclusion or exclusion of clinically silent neuroimaging findings) and cohort denominators (total LCH cohort vs. selection for disease extent, observation time, etc.), its prevalence in pediatric-onset LCH series ranges between 4% and 25% [12–17]. The incidence of hypothalamic-pituitary region (HPR) involvement, which most commonly manifests with diabetes insipidus (DI), is well known and ranges between 10% and 15% [13, 18, 19]. The prevalence of clinically manifest CNS-LCH, other than isolated HPR disease, appears to be in the range of 4–10% among patients with pediatric-onset LCH [12, 13].

Mechanisms of CNS-LCH

Typical LCH lesions characterized by granuloma forming inflammatory cells and containing the diagnostic hallmark, CD1a+/CD207+ histiocytic cells, can develop in the brain. Those are most frequently located in the HPR or elsewhere in the

circumventricular organ, but can localize in other brain structures (e.g., choroid plexus and meninges) as well. The clinical manifestations depend on location and are indistinguishable from the manifestations of space-occupying lesions of other origin. This type of CNS-LCH is referred to as “tumorous” or “granulomatous” CNS-LCH. It is most likely to be an inaugural manifestation or to occur early in the LCH course.

Neurological and cognitive deficits or behavioral problems can develop insidiously years after presentation of LCH, even in patients who seem to be in complete remission of the underlying disease. MRI studies usually reveal “neurodegeneration-like” findings, corresponding to gliosis and neuronal loss, with or mostly without accompanying granulomatous lesions. This type of CNS-LCH is called “neurodegenerative” (ND) or “non-granulomatous.” The exact mechanisms leading to progressive damage of the brain tissue and neuronal loss are still not well understood, nor is it frequently biopsied. The role of autoantibodies in this process has not been proven to date. Both CNS tissue specimens and cerebrospinal fluid studies suggest that tissue damage is driven by cytotoxic lymphocytes and mediated by inflammatory cytokines/chemokines [20–22]. A comprehensive overview on available laboratory evidence and hypothetical models of neuroinflammation and neurodegeneration in LCH are provided in a recent paper by Imashuku and Arceci [22]. Current ongoing work, however, is beginning to gain insight into the pathogenesis of ND-CNS-LCH with new data suggesting that a CD1a-negative *BRAF-V600E* mutant myeloid/dendritic precursor cell could be the driving cell leading to ongoing, smoldering neuroinflammation, demyelination, and subsequent fibrotic gliosis in the brain [23, 24].

Risk Factors for CNS-LCH

As far as can be extrapolated from available retrospective institutional series and from the database of the Histiocyte Society, it seems that early age at the diagnosis of LCH, multisystem disease, involvement of the skull base bones, and relapsing disease course are all predisposing factors to CNS-LCH, particularly to ND-CNS-LCH [8, 12, 15–17, 25].

Skull bones are frequently affected by LCH [26]. On conventional radiography, calvarial lesions are most easily recognized and, therefore, most frequently reported. Although they may have large size and be accompanied by soft tissue masses displacing or even eroding the dura, they usually do not affect the brain. Interestingly, osseous lesions of the skull vault are not associated with increased risk for CNS-LCH [8]. On the contrary, lesions of the skull base are usually more complex and can have considerable soft tissue component. Their intracranial extension may be impressive, but usually does not penetrate the dura [27]. Craniofacial lesions of the frontal, sphenoid, ethmoid, temporal, and occipital bones seem to carry a higher risk for CNS-LCH in both the HPR and other locations of the brain [8, 15, 28]. Consequently, the term “CNS-risk lesions” has been coined for such lesions, and systemic treatment has been advocated (even for localized disease), although this concept has been recently questioned by other authors [29–31].

Clinical Spectrum of CNS-LCH

Involvement of the HPR manifesting with diabetes insipidus (DI) and less frequently with dysfunction of the anterior pituitary is a characteristic manifestation of LCH, known since its first descriptions [32–34]. Involvement of other brain structures attracted attention much later, and systematic research has been made possible after clinical implementation of modern techniques, like computed tomography (CT) and magnetic resonance imaging (MRI) of the brain [14, 35, 36]. Particularly important contributions with this regard have been made by the international CNS-LCH Study Group of the Histiocyte Society [21, 27, 28, 37]. It has been shown that patients with DI have increased risk for CNS-LCH outside of the HPR and particularly for ND-CNS-LCH [38, 39].

The spectrum of clinical manifestations of CNS-LCH is wide and ranges from acute presentation (headaches, seizures, symptoms of increased intracranial pressure) to insidious onset (cerebellar, cranial nerve, pyramidal, cognitive, and memory deficits, as well as emotional and behavioral problems) with variable course [28].

Diagnostic Methods and MRI-Based Classification

Standardized neurological examination (i.e., Expanded Disability Status Scale (EDSS), International Cooperative Ataxia Rating Scale (ICARS)) and age-appropriate neuropsychological testing performed initially and at regular intervals are essential for objective longitudinal judgment and clinical decision-making [28].

Patients with manifestations suggestive of hormonal deficit have to be assessed by an endocrinologist for appropriate testing and hormonal substitution.

Cerebrospinal fluid (CSF) is usually nondiagnostic for CNS-LCH, but may be helpful to rule out alternative diagnoses and document inflammatory signature and decay products. CD1a+ histiocytes have been only anecdotally found in the CSF of patients with granulomatous lesions [40]. A recently presented work gives promise that elevated osteopontin in CSF could be a useful marker of LCH for the purposes of differential diagnosis, particularly if combined with the presence of BRAF-V600E-positive cells in blood [24]. Nevertheless, biopsy is recommended, whenever feasible and justifiable combined with evaluation of BRAF-V600E status. It could be essential for diagnosing uncharacteristic granulomatous lesions [23]. Biopsies from non-granulomatous lesions are less likely to be diagnostic, as they usually feature perivascular inflammation, demyelination, and gliosis and lack CD1a+/CD207+ cells [21]. However, the evaluation of BRAF-V600E status on such lesions may indicate ongoing activity despite the absence of diagnostic LCH cells [23, 24].

Magnetic resonance imaging (MRI) has considerably improved our understanding of CNS-LCH, and consistent imaging findings evolved into comprehensive classification [14, 27, 28, 35, 41, 42]. Due to the availability, noninvasive nature, and reproducibility of MRI, and not least due to the available experience, MRI is the mainstay of the diagnostic assessment of CNS-LCH. The role of functional imaging (e.g., FDG-PET, nuclide scans with other tracers, magnetic resonance spectroscopy) for initial evaluation, follow-up, and treatment response of CNS-LCH remains to be defined [43–46].

The classification of the MRI findings in CNS-LCH has been recently refined [28]. It discriminates between granulomatous and non-granulomatous lesions in different anatomic locations (Table 4.1). Brain atrophy is a nonspecific finding, mostly seen in patients with clinically manifest long-lasting neurodegeneration. The relative frequency of the different MRI findings is presented in Fig. 4.1. There is a very good correlation between clinical

Table 4.1 Classification of the radiological findings in CNS-LCH

<i>Granulomatous lesions</i>	
Hypothalamic-pituitary region (hypothalamus, pituitary stalk, anterior and posterior pituitary)	
Pineal gland	
Choroid plexus	
Meninges	
Enhancing parenchymal lesion	
<i>Non-granulomatous lesions</i>	
Cerebellum (dentate nucleus, cerebellar white matter)	
Brain stem, pons	
Basal ganglia	
Supratentorial white matter (“leukoencephalopathy-like”)	
Virchow-Robin spaces (“vascular type”)	
<i>Brain atrophy</i>	
Cerebellar	
Midbrain	
Supratentorial	

Reprinted with permission, Grois et al. [28]




Fig. 4.1 Relative frequency of MRI findings in CNS-LCH

manifestations, imaging, and pathology findings, forming two main patterns of CNS-LCH, namely, tumorous (granulomatous) and neurodegenerative (non-granulomatous) CNS-LCH [28]. In some patients, the lesions of both types can be simultaneously present (Table 4.2).

Granulomatous or “Tumorous” CNS-LCH

Meningeal enhancement caused by the soft tissue component of an adjacent skull bone lesion is a common finding on MRI. The soft tissue mass originating from the bone lesion can be of considerable size and may cause displacement of the dura, although it does not usually penetrate it (Fig. 4.2a, b). Extradural masses accompanying bone lesions of the vault do not seem to increase the risk for ND-CNS-LCH. Therefore, such lesions do not fall into the categories of “CNS-LCH” or “CNS-risk” lesions. On the contrary, soft tissue masses extending from the skull base have been found to increase the risk of DI and ND-CNS-LCH and, therefore, are categorized as “CNS-risk” lesions [8], but are not per se considered CNS-LCH lesions.

Clinical Features

Granulomatous lesions of the HPR and of other extra-axial locations are the most frequently encountered type of CNS-LCH. Depending on location of the lesions, it can manifest with DI (polydipsia and polyuria), focal seizures, or increased intracranial pressure. The typical location on MRI is extra-axial (circumventricular organs, particularly the HPR and the pineal gland, meninges, and choroid plexus). DI is the most common neuroendocrine manifestation of LCH with an incidence of 8–12% [47–49]. Patients with LCH and coexisting DI are at higher risk of developing anterior pituitary dysfunction and ND-CNS-LCH [38, 39]. The clinical manifestations of anterior pituitary dysfunction are growth failure, precocious or delayed puberty,

Table 4.2 Patterns of CNS-LCH based on clinical, imaging, and pathology findings

Pattern	Clinical manifestations	MRI findings
<i>Granulomatous (“tumorous”)-type CNS-LCH</i>		
<i>Isolated HPR lesion</i>	Diabetes insipidus, loss of anterior pituitary hormones	Pituitary stalk thickening, pituitary mass lesion, empty sella, lacking posterior bright spot
<i>Mass lesions of other locations</i>	Increased ICP, site-dependent symptoms (e.g., seizures)	Extra-axial (meninges, circumventricular structures), rarely parenchymal (cerebellar) mass lesions
<i>Non-granulomatous (“neurodegeneration”)-type CNS-LCH</i>		
<i>Radiological neurodegeneration</i>	None	White and gray matter abnormal signal intensity without mass effect (cerebellum, pons, basal ganglia, cortical tracts)
<i>Clinical neurodegeneration</i>	Cerebellar and bulbar signs and symptoms (ataxia, dysarthria, etc.), cognitive and behavioral deficits	
<i>Mixed-type CNS-LCH</i>		
<i>Concurrent granulomatous and non-granulomatous lesions</i>	Various	Mass lesions and signs of neurodegeneration

hypothyroidism, hypogonadism, hypocortisolism, or panhypopituitarism [50, 51]. Patients with predominant involvement of the hypothalamus may present with temperature instability, abnormal eating patterns with weight gain, and/or behavioral problems.

Diagnostic Features

Most characteristic MRI findings of the HPR lesions are distinct thickening of the pituitary stalk or hypothalamic mass lesion, “empty sella,” and lack of posterior pituitary bright spot (Fig. 4.3a, b). Establishing the correct diagnosis in patients with isolated HPR mass can be a challenge [40, 52]. Pragmatic algorithm aiming to find extra-cerebral lesions accessible for biopsy or to rule out the most common differential diagnoses has been proposed [53]. Patients with suspected LCH in whom a pituitary biopsy is not feasible, and in the absence of other sites of disease, may benefit from *BRAF-V600E* mutation testing in the peripheral blood or CSF which may lead to the diagnosis and help identifying potential targets for inhibitor therapy [54]. Extra-axial granulomatous lesions in CNS locations other than the HPR (meninges, choroid plexus, and pineal gland) present as nonspecific mass lesions (Fig. 4.3c, d) and are exceedingly rare (Daniela Prayer, personal

communication). The granulomatous lesions are usually hypo-/isointense in T1-weighted and T2-weighted images, mostly enhancing after contrast application. Tissue biopsy typically reveals granulomas containing CD1a+/CD207+ histiocytes during its proliferative phase [21]; however, such diagnostic biopsies are rarely encountered (Figs. 4.2c, d and 4.3e, f). Typically, biopsies are small with scant diagnostic cells, and perilesional granulomatous histiocytic infiltrates may masquerade as other histiocytic and non-histiocytic lesions. The panel of histiocytic markers including CD1a, CD207, CD163, CD68, factor XIIIa, fascin, and VE1, a *BRAF-V600E* antibody, may be useful in such cases (see also Chap. 1, Pathology of Histiocytic Disorders).

Differential Diagnosis

The most common differential diagnoses are lymphoma, juvenile xanthogranuloma (JXG), Rosai-Dorfman disease (RDD), metastases of other tumors [27, 55], germ cell tumors, craniopharyngioma, and sarcoidosis [28, 41, 55]. In adults with isolated DI, differential diagnosis may also include Erdheim-Chester disease (ECD), especially in those lesions that are *BRAF-V600E* positive. Clinical and radiographic correlation is essential for accurate diagnosis.

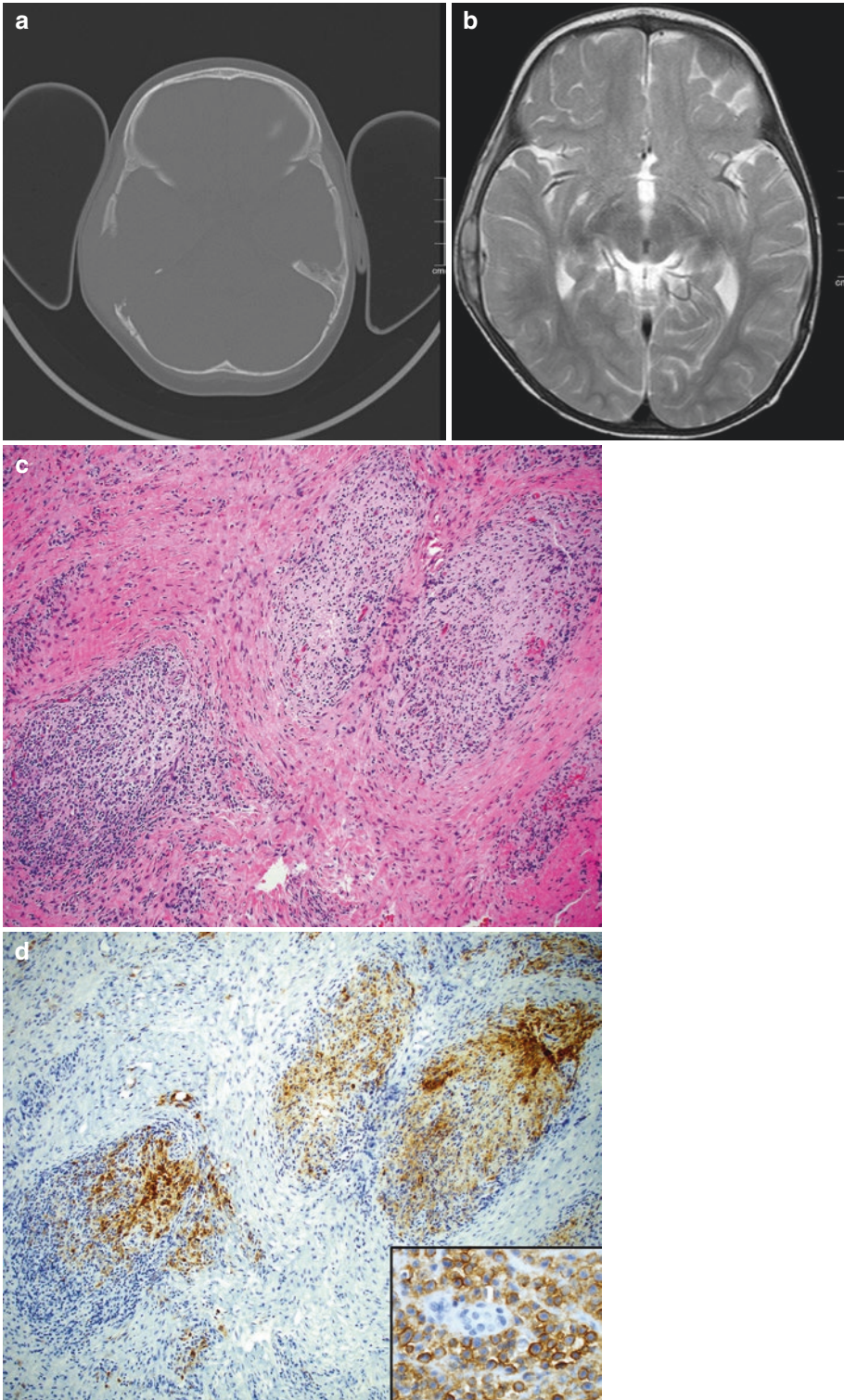


Fig. 4.2 Extradural soft tissues mass accompanying skull bone lesion. (a) CT scan. (b) MRI: axial T1W image. (c) Dural involvement of small LCH nodules sur-

rounded by histiocytic-rich inflammatory infiltrate and fibrosis (H&E, original magnification 10×). (d) CD1a-positive nodules (CD1a immunostain 10×, inlet 40×)

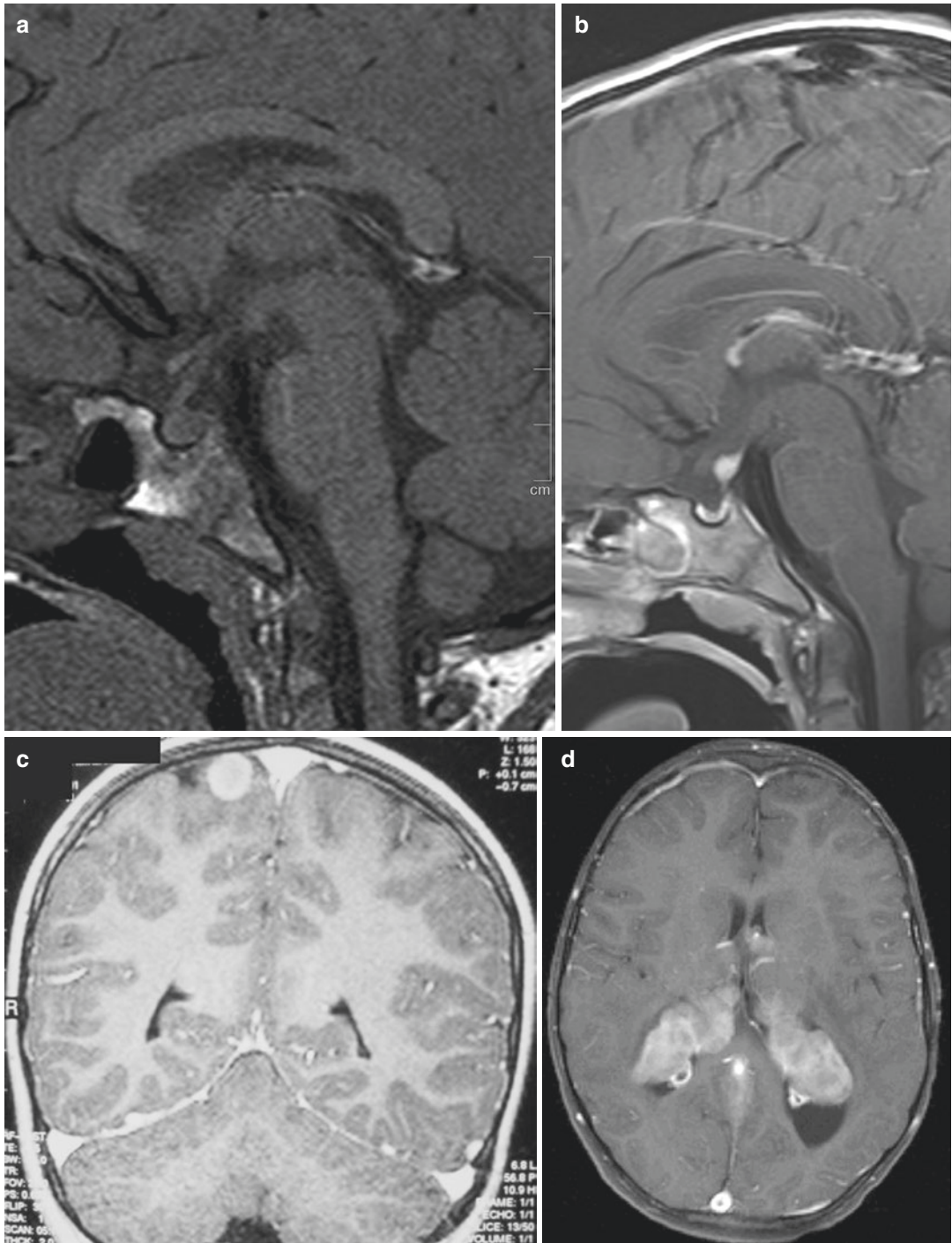
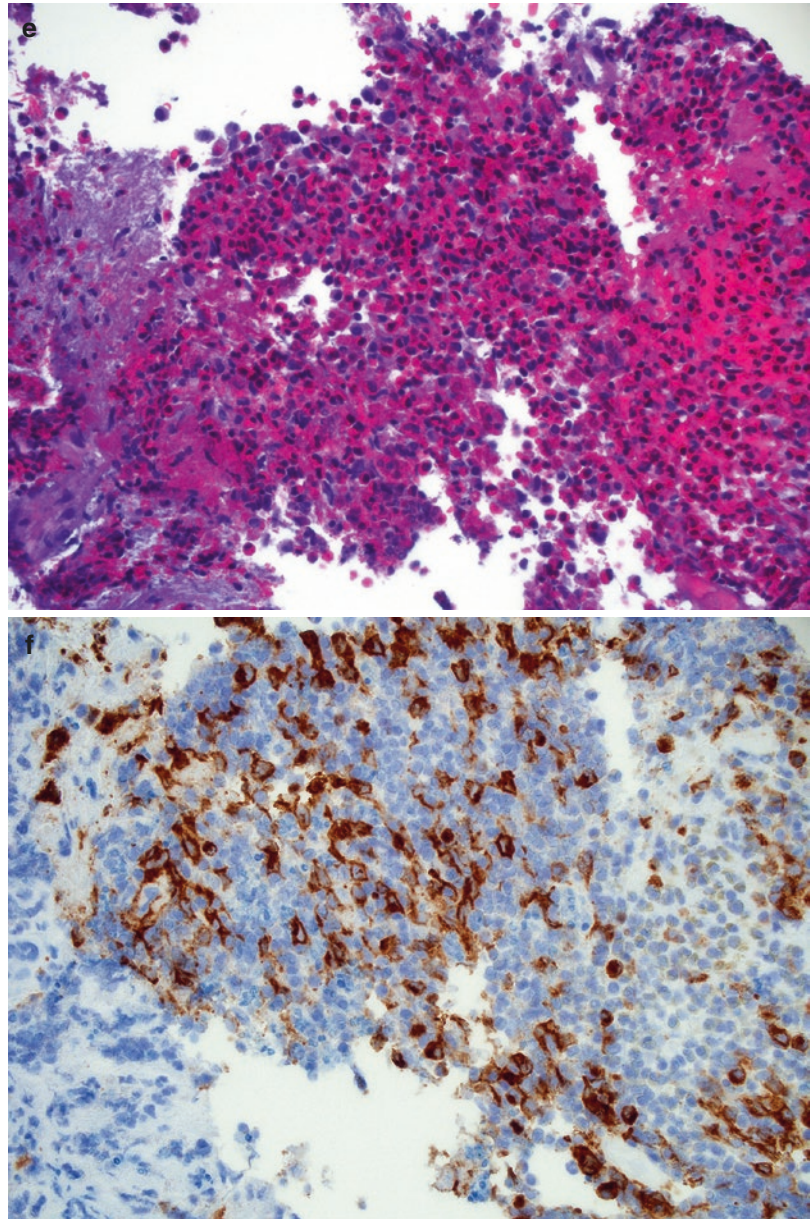


Fig. 4.3 Granulomatous lesions (MRI): **(a)** sagittal T1W image demonstrating lacking posterior bright spot. **(b)** Sagittal contrast-enhanced T1W image demonstrating thickened pituitary stalk and empty sella. **(c)** Coronal contrast-enhanced T1W image showing an enhancing meningeal lesion. **(d)** Axial contrast-enhanced T1W image showing extensive bilateral lesions in the choroid plexus. **(e)** Hypothalamic involvement of the typical granulomatous infiltrate of LCH cells and eosinophils (H&E, 40×); **(f)** CD207-positive histiocytes (CD207 immunostain, 40×)

Fig. 4.3 (continued)

Treatment

Treatment of granulomatous CNS-LCH confined to the HPR and clinically manifesting with isolated DI remains controversial [56]. Systemic treatment in such patients is advocated with the hope of reversing DI and preventing late sequelae, such as ND-CNS-LCH and anterior pituitary dysfunction. However, reversal of DI has been achieved only in anecdotal cases [56, 57], and nearly all patients require a life-long replacement

therapy with desmopressin or DDAVP. The role of systemic treatment in preventing subsequent neurodegeneration has not been addressed by appropriate clinical studies. Granulomatous CNS-LCH lesions of other location than HPR are usually treated with surgery and/or systemic therapy. Parenchymal mass lesions of the brain due to LCH may respond to either single drugs or drug combinations consisting of prednisone, vinblastine, vincristine, cytarabine, cladribine, or clofarabine [58–61]. Vinblastine/prednisone is

an established frontline treatment for multifocal and multisystem LCH including pituitary/hypothalamic location [48]. There are only few papers focusing on CNS-LCH. In a retrospective study, 15/20 (75%) patients with CNS-LCH lesions responded to treatment with weekly vinblastine (6 mg/m²/dose) ± steroids [60]. A recent paper has shown that cytarabine is an effective drug in both untreated and pretreated LCH patients [62]. The progression-free survival in the group of untreated patients was 93%, and it is remarkable that 9 of 16 patients have had pituitary disease. In another series (*n* = 12), cladribine (5–13 mg/m²/day given on 3–5 consecutive days; repeated every 2–8 weeks for 3–12 months) was used to treat patients with CNS-LCH mass lesions. Complete response was achieved in 8 and a sustained partial radiographic response in 4, proving its activity in granulomatous-type CNS-LCH [59]. Clofarabine (25 mg/m²/day for 5 days, repeated monthly for 2–6 months) has been shown to be also an active drug in the treatment of patients with active LCH, who have failed first-line therapy. In that cohort, 5 out of the 11 patients with LCH have had CNS or CNS-risk lesions. While all the above listed drugs have documented activity with respect to resolution of the granulomatous lesions, it remains unproven, whether they are able to prevent subsequent ND-CNS-LCH. In view of the recent advances in understanding the pathobiology of LCH (around 75% of the patients harbor activating BRAF or MEK mutations; BRAF-V600E accounting for the vast majority of them), targeted drugs (e.g., vemurafenib, dabrafenib, cobimetinib, and trametinib) are attractive new options for granulomatous CNS-LCH.

Non-granulomatous or “Neurodegenerative” CNS-LCH (ND-CNS-LCH)

Clinical features

ND-CNS-LCH is a devastating and irreversible complication that may occur many years (even 10 or more) after resolution of extra-cerebral LCH. Typically, it has an insidious onset with cerebellar and bulbar symptoms (ataxia, tremor,

dysmetria, adiadochokinesis, dysarthria, dysphagia, hyperreflexia, spastic tetraparesis, VI and VII cranial nerve palsy) [14, 25, 35, 63], cognitive deficits (particularly short-term memory), behavioral problems, and psychosis [16, 64–68]. The clinical course can vary from spontaneous stabilization to rapid deterioration with loss of motor functions and mental debilitation.

Diagnostic Features

Typical MRI findings are bilateral symmetric lesions in the cerebellum (dentate nucleus and white matter) (Fig. 4.4a, b), pons, and basal ganglia (Fig. 4.4c) and rarely in the supratentorial white matter (Fig. 4.4d). Pontine and cerebellar lesions are characteristically hypointense on T1-weighted and hyperintense on T2-weighted images and can show variable enhancement after application of gadolinium. Supratentorial white matter lesions show the same signal alterations on T1- and T2-weighted images, but they are usually non-enhancing. Lesions in the basal ganglia are hyperintense on T1-weighted and iso-/hypointense on T2-weighted images [14, 27, 35]. MRI signal alterations are consistent with degeneration (neuronal loss and demyelination) of the affected brain tissue. Biopsies of such lesions are rare with only few modern studies describing the histopathology in association with immunohistochemistry studies [21]. The older studies performed without immunohistochemistry described a striking fibrous-type gliosis in late-stage disease (e.g. ND-CNS-LCH) with demyelination and relative sparing of axons along with a more pronounced loss of Purkinje cells and neurons of the dentate nuclei [69]. Even with the aid of immunohistochemistry, these lesions are usually nondiagnostic for LCH (e.g., lack of CD1a+/CD207+ cells) and reveal perivascular inflammatory changes with neuronal loss, demyelination, and gliosis [21], similar to original descriptions by Kepes and others [69]. There can also be CD1a-negative “granulomatous” inflammation with macrophages in the area of active demyelination (Fig. 4.4e-f). Current ongoing work is further exploring the CNS-LCH histopathologic patterns in the context of

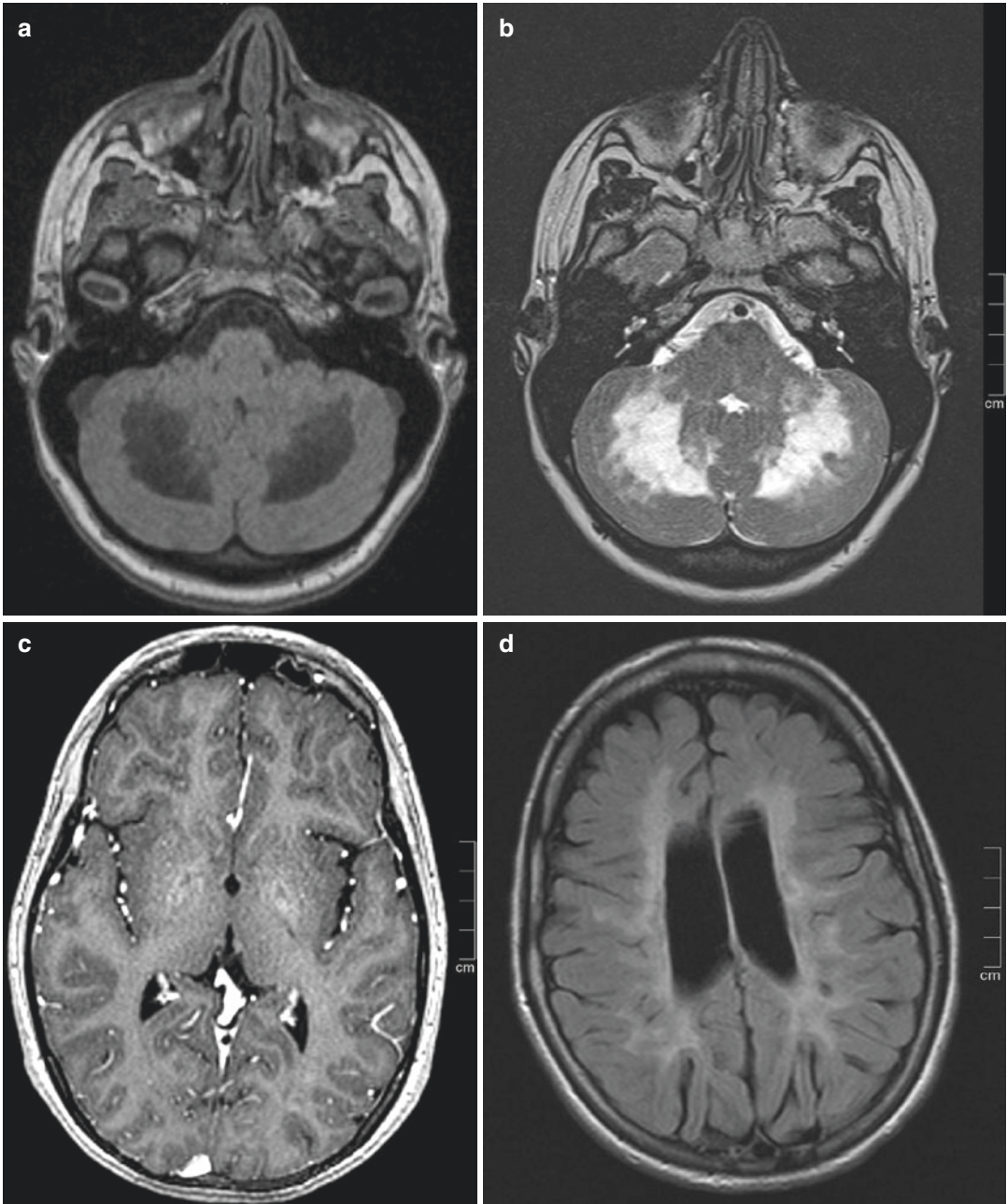
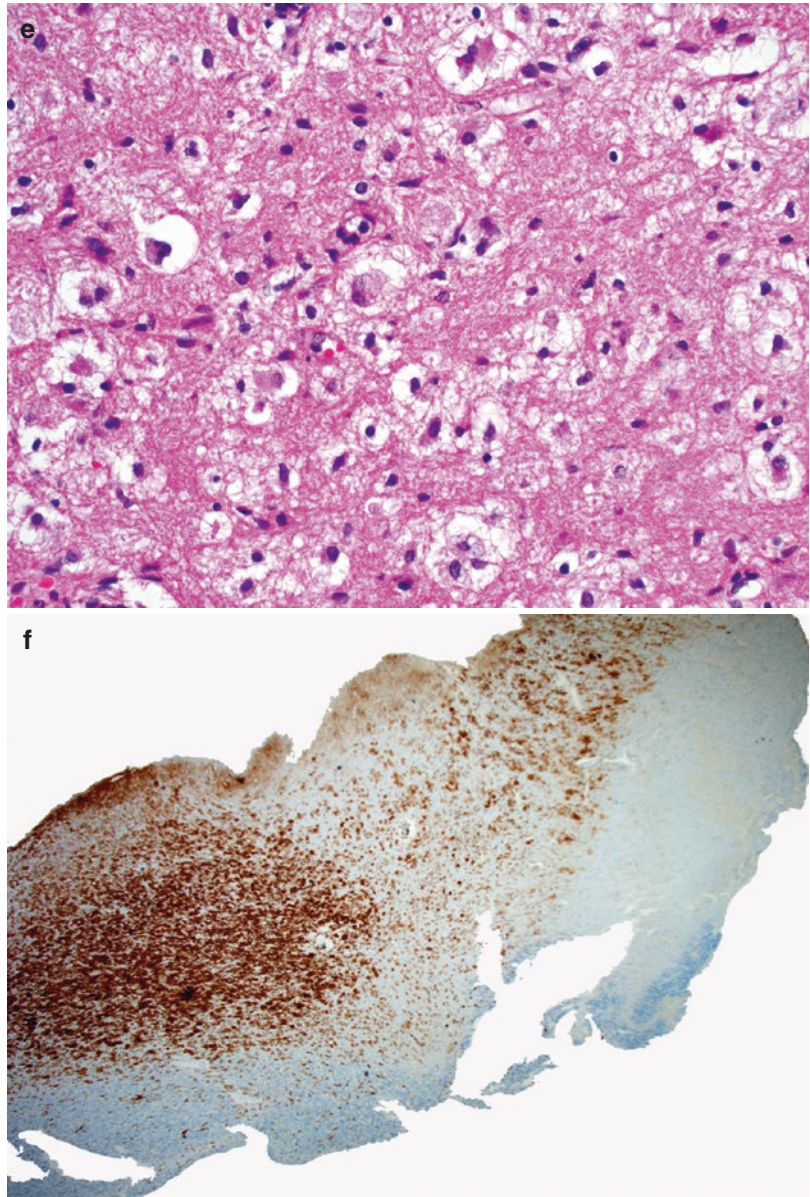


Fig. 4.4 Non-granulomatous lesions (MRI): (a) axial T1-weighted image illustrating extensive (dentate nucleus and white matter) cerebellar neurodegeneration. (b) Axial T2-weighted image of the same lesions as in (a). (c) Axial T1-weighted image showing symmetric hyperintense lesions of the basal ganglia. (d) Axial, FLAIR (fluid-attenuated inversion recovery) sequence demonstrating

bilateral supratentorial white matter lesions (leukoencephalopathy-like pattern). (e) Cerebellar ND-CNS-LCH with foamy histiocytes (H&E 40 \times), negative for CD1a and CD207 (not shown). (f) Low power image showing macrophage-rich infiltrate (IBA1 immunostain for activated microglial and monocytes/macrophages, 2 \times)

Fig. 4.4 (continued)

new ancillary techniques with VE1 BRAF antibody and allele-specific qPCR for BRAF-V600E [23, 24]. These preliminary results suggest that CD1a-negative *BRAF*-V600E mutant myeloid/dendritic precursor cells could be the driving cell leading to ongoing, smoldering neuroinflammation, demyelination, and subsequent fibrotic

gliosis [23, 24]. MRI findings consistent with ND-CNS-LCH (“radiological” ND-CNS-LCH) may precede clinical symptoms by several years. Available data suggests that after a follow-up of 10 or more years, about 25% of the patients with radiological findings will develop overt neurological or cognitive deficits of variable severity

(“clinical” ND-CNS-LCH) [35, 39]. The neuroimaging course can be stable or progressive, but significant regression or complete reversal of radiographic findings has not been observed [42].

Differential Diagnosis

Important differential diagnoses are other inflammatory and demyelinating CNS disorders (e.g., acute disseminated encephalomyelitis, disseminated encephalitis, multiple sclerosis, metabolic disorders, and degenerative brain diseases of various etiologies) [27, 29].

Treatment

Early treatment in patients with clinical ND-CNS-LCH is essential. Intravenous immunoglobulin (IVIG) [70–72] and all-trans retinoic acid (ATRA) [73] have been reported to stabilize progression of ND-CNS-LCH. The rationale for using retinoic acid for treatment of ND-CNS-LCH is its potential to induce differentiation of LCH cell lines in vitro [74]. IVIG is well known for its immunomodulatory effect in autoimmune disorders, particularly in neuroinflammatory disease (e.g., multiple sclerosis). A Japanese group has used monthly IVIG (400 mg/kg) concomitantly to chemotherapy for treating patients with ND-CNS-LCH [71]. The chemotherapy consisting of prednisone, vinblastine, methotrexate, and mercaptopurine was given for at least 1 year, while IVIG was continued alone monthly for up to 2 years and every 2 months thereafter. Stabilization of the clinical signs and symptoms was observed in four out of five patients. A follow-up report of the same group confirmed the initial observation and concluded that IVIG is more effective if started soon after ND-CNS-LCH diagnosis and continued for at least 3 years [70]. Although chemotherapy has been generally ineffective in ND-CNS-LCH, in one series, the combination of vincristine and cytarabine was associated with improvement in clinical symptoms and MRI images in six out of eight patients [58]. Based on those findings, cytarabine (100 mg/m²/day for 5 days, repeated monthly

for at least 6–12 month) is recommended as an alternative treatment for patients with progressive ND-CNS-LCH. Some patients fail to respond to the above listed therapies and have a gradual decline in neurologic function over the course of years. Thus, immunosuppressive and cytotoxic treatment attempts did not result in unequivocal reproducible success. Interpretation of response in the available small series is further complicated by the waxing and waning course of ND-CNS-LCH with phases of natural stabilization. While MAPK inhibitors could be a promising treatment option for patients with granulomatous CNS-LCH [75], it is currently unclear whether BRAF inhibitors will have effect in ND-CNS-LCH. A few initial reports show promising results in select cases [75], but not all patients may show equal benefit [76]. Phase I/II trials are ongoing in pediatrics for the first-generation BRAF inhibitor, dabrafenib (NCT01677741), and results in children with resistant LCH receiving this drug are pending.

In summary, only a limited number of treatment options are currently available for treatment of both granulomatous and non-granulomatous CNS-LCH, and the evidence supporting their activity is of low quality. Therefore, large-scale controlled prospective trials (e.g., LCH-IV) utilizing standardized disease assessment and follow-up, as well as uniform evaluation of treatment response, are essential for further progress on CNS-LCH.

References

1. Badalian-Very G, Vergilio JA, Fleming M, Rollins BJ. Pathogenesis of Langerhans cell histiocytosis. *Annu Rev Pathol.* 2013;8:1–20.
2. Chakraborty R, Hampton OA, Shen X, Simko SJ, Shih A, Abhyankar H, et al. Mutually exclusive recurrent somatic mutations in MAP2K1 and BRAF support a central role for ERK activation in LCH pathogenesis. *Blood.* 2014;124(19):3007–15.
3. Brown NA, Furtado LV, Betz BL, Kiel MJ, Weigelin HC, Lim MS, et al. High prevalence of somatic MAP2K1 mutations in BRAF V600E-negative Langerhans cell histiocytosis. *Blood.* 2014;124(10):1655–8.
4. Berres ML, Lim KP, Peters T, Price J, Takizawa H, Salmon H, et al. BRAF-V600E expression in precursor versus differentiated dendritic cells defines

- clinically distinct LCH risk groups. *J Exp Med.* 2014;211(4):669–83.
5. McLelland J, Broadbent V, Yeomans E, Malone M, Pritchard J. Langerhans cell histiocytosis: the case for conservative treatment. *Arch Dis Child.* 1990;65(3):301–3.
 6. Minkov M, Grois N, Heitger A, Potschger U, Westermeier T, Gadner H, et al. Response to initial treatment of multisystem Langerhans cell histiocytosis: an important prognostic indicator. *Med Pediatr Oncol.* 2002;39(6):581–5.
 7. Minkov M. Multisystem Langerhans cell histiocytosis in children: current treatment and future directions. *Paediatr Drugs.* 2011;13(2):75–86.
 8. Grois N, Potschger U, Prosch H, Minkov M, Arico M, Braier J, et al. Risk factors for diabetes insipidus in langerhans cell histiocytosis. *Pediatr Blood Cancer.* 2006;46(2):228–33.
 9. Minkov M, Steiner M, Potschger U, Arico M, Braier J, Donadieu J, et al. Reactivations in multisystem Langerhans cell histiocytosis: data of the international LCH registry. *J Pediatr.* 2008;153(5):700–5, 5 e1–2.
 10. Morimoto A, Kobayashi R, Maeda M, Asami K, Bessho F, Imashuku S, et al. Impact of reactivation on the sequelae of multi-system Langerhans cell histiocytosis patients. *Pediatr Blood Cancer.* 2008;50(4):931–2. author reply 2
 11. Pollono D, Rey G, Latella A, Rosso D, Chantada G, Braier J. Reactivation and risk of sequelae in Langerhans cell histiocytosis. *Pediatr Blood Cancer.* 2007;48(7):696–9.
 12. Haupt R, Nanduri V, Calevo MG, Bernstrand C, Braier JL, Broadbent V, et al. Permanent consequences in Langerhans cell histiocytosis patients: a pilot study from the Histiocyte Society-late effects study group. *Pediatr Blood Cancer.* 2004;42(5):438–44.
 13. A multicentre retrospective survey of Langerhans' cell histiocytosis: 348 cases observed between 1983 and 1993. The French Langerhans' cell Histiocytosis study group. *Arch Dis Child.* 1996;75(1):17–24.
 14. Grois N, Barkovich AJ, Rosenau W, Ablin AR. Central nervous system disease associated with Langerhans' cell histiocytosis. *Am J Pediatr Hematol Oncol.* 1993;15(2):245–54.
 15. Laurencikas E, Gavhed D, Stalemark H, van't Hoof I, Prayer D, Grois N, et al. Incidence and pattern of radiological central nervous system Langerhans cell histiocytosis in children: a population based study. *Pediatr Blood Cancer.* 2011;56(2):250–7.
 16. Wnorowski M, Prosch H, Prayer D, Janssen G, Gadner H, Grois N. Pattern and course of neurodegeneration in Langerhans cell histiocytosis. *J Pediatr.* 2008;153(1):127–32.
 17. Imashuku S, Shioda Y, Kobayashi R, Hosoi G, Fujino H, Seto S, et al. Neurodegenerative central nervous system disease as late sequelae of Langerhans cell histiocytosis. Report from the Japan LCH study group. *Haematologica.* 2008;93(4):615–8.
 18. Gadner H, Heitger A, Ritter J, Gobel U, Janka GE, Kuhl J, et al. Langerhans cell histiocytosis in childhood--results of the DAL-HX 83 study. *Klin Padiatr.* 1987;199(3):173–82.
 19. Willis B, Ablin A, Weinberg V, Zoger S, Wara WM, Matthay KK. Disease course and late sequelae of Langerhans' cell histiocytosis: 25-year experience at the University of California, san Francisco. *J Clin Oncol Off J Am Soc Clin Oncol.* 1996;14(7):2073–82.
 20. Gavhed D, Akefeldt SO, Osterlundh G, Laurencikas E, Hjorth L, Blennow K, et al. Biomarkers in the cerebrospinal fluid and neurodegeneration in Langerhans cell histiocytosis. *Pediatr Blood Cancer.* 2009;53(7):1264–70.
 21. Grois N, Prayer D, Prosch H, Lassmann H, Group CLC-o. Neuropathology of CNS disease in Langerhans cell histiocytosis. *Brain J Neurol.* 2005;128(Pt 4):829–38.
 22. Imashuku S, Arceci RJ. Strategies for the prevention of central nervous system complications in patients with langerhans cell histiocytosis: the problem of neurodegenerative syndrome. *Hematol Oncol Clin North Am.* 2015;29(5):875–93.
 23. Picarsic J, Murdoch G, Chakraborty R, Castro-Silva F, Panigrahy A, Jaffe R, et al. Revisiting the neuropathology of central nervous system Langerhans cell histiocytosis. Abstracts from the 32nd Annual Meeting of the Histiocyte Society Dublin, Ireland October 17-19, 2016. *Pediatr Blood Cancer.* 2016;63(Suppl 2):S29–30.
 24. Zinn D, Picarsic J, Chakraborty R, Lin H, Abhyankar H, Scull B. Elevated CSF osteopontin and peripheral blood cells with braf mutations in patients with langerhans cell histiocytosis-associated neurodegeneration. Abstracts from the 32nd Annual Meeting of the Histiocyte Society Dublin, Ireland October 17-19, 2016. *Pediatr Blood Cancer.* 2016;63(Suppl 2):S37–8.
 25. Imashuku S, Ishida S, Koike K, Ichikawa M, Minato T, Suzuki Y, et al. Cerebellar ataxia in pediatric patients with Langerhans cell histiocytosis. *J Pediatr Hematol Oncol.* 2004;26(11):735–9.
 26. D'Ambrosio N, Soohoo S, Warshall C, Johnson A, Karimi S. Craniofacial and intracranial manifestations of langerhans cell histiocytosis: report of findings in 100 patients. *AJR Am J Roentgenol.* 2008;191(2):589–97.
 27. Prayer D, Grois N, Prosch H, Gadner H, Barkovich AJ. MR imaging presentation of intracranial disease associated with Langerhans cell histiocytosis. *AJNR Am J Neuroradiol.* 2004;25(5):880–91.
 28. Grois N, Fahrner B, Arceci RJ, Henter JI, McClain K, Lassmann H, et al. Central nervous system disease in Langerhans cell histiocytosis. *J Pediatr.* 2010;156(6):873–81, 81 e1.
 29. Chellapandian D, Shaikh F, van den Bos C, Somers GR, Astigarraga I, Jubran R, et al. Management and outcome of patients with Langerhans cell histiocytosis and single-bone CNS-risk lesions: a multi-institutional retrospective study. *Pediatr Blood Cancer.* 2015;62(12):2162–6.
 30. Harris GJ. Langerhans cell histiocytosis of the orbit: a need for interdisciplinary dialogue. *Am J Ophthalmol.* 2006;141(2):374–8.

31. Harris GJ, Woo KI. Is unifocal Langerhans-cell histiocytosis of the orbit a "CNS-risk" lesion? *Pediatr Blood Cancer*. 2004;43(3):298–9. author reply 300-1
32. Christian HA. Defects in membranous bones, exophthalmos and diabetes insipidus; an unusual syndrome of dyspituitarism: a clinical study. *Horm Res*. 1920;53:61–4.
33. Hand A. Defects of membranous bones, exophthalmos and polyuria in childhood: is it dyspituitarism? *Am J Med Sci*. 1921;162:509–15.
34. Schüller A. Über eigenartige Schädeldefekte im Jugendalter. *Fortschr Geb Röntgenstr*. 1915;23:12–9.
35. Barthez MA, Araujo E, Donadieu J. Langerhans cell histiocytosis and the central nervous system in childhood: evolution and prognostic factors. Results of a collaborative study. *J Child Neurol*. 2000;15(3):150–6.
36. Greenwood SM, Martin JS, Towfighi J. Unifocal eosinophilic granuloma of the temporal lobe. *Surg Neurol*. 1982;17(6):441–4.
37. Report of the Histiocyte Society workshop on "central nervous system (CNS) disease in Langerhans cell histiocytosis (LCH)". *Medical and pediatric oncology*. 1997;29(2):73–78.
38. Donadieu J, Rolon MA, Thomas C, Brugieres L, Plantaz D, Emile JF, et al. Endocrine involvement in pediatric-onset Langerhans' cell histiocytosis: a population-based study. *J Pediatr*. 2004;144(3):344–50.
39. Grois N, Prayer D, Prosch H, Minkov M, Potschger U, Gadner H. Course and clinical impact of magnetic resonance imaging findings in diabetes insipidus associated with Langerhans cell histiocytosis. *Pediatr Blood Cancer*. 2004;43(1):59–65.
40. Prosch H, Feldges A, Grois N, Fretz C, Spieler P, Minkov M, et al. Demonstration of CD1a positive cells in the cerebrospinal fluid—a clue to diagnosis of isolated Langerhans cell histiocytosis of the hypothalamic-pituitary axis? *Med Pediatr Oncol*. 2003;41(5):474–6.
41. Grois NG, Favara BE, Mostbeck GH, Prayer D. Central nervous system disease in Langerhans cell histiocytosis. *Hematol Oncol Clin North Am*. 1998;12(2):287–305.
42. Prosch H, Grois N, Wnorowski M, Steiner M, Prayer D. Long-term MR imaging course of neurodegenerative Langerhans cell histiocytosis. *AJNR Am J Neuroradiol*. 2007;28(6):1022–8.
43. Buchler T, Cervinek L, Belohlavek O, Kantorova I, Mechl M, Nebesky T, et al. Langerhans cell histiocytosis with central nervous system involvement: follow-up by FDG-PET during treatment with cladribine. *Pediatr Blood Cancer*. 2005;44(3):286–8.
44. Calming U, Bemstrand C, Mosskin M, Elander SS, Ingvar M, Henter JL. Brain 18-FDG PET scan in central nervous system langerhans cell histiocytosis. *J Pediatr*. 2002;141(3):435–40.
45. Ribeiro MJ, Idbah A, Thomas C, Remy P, Martin-Duverneuil N, Samson Y, et al. 18F-FDG PET in neurodegenerative Langerhans cell histiocytosis : results and potential interest for an early diagnosis of the disease. *J Neurol*. 2008;255(4):575–80.
46. Steiner M, Prayer D, Asenbaum S, Prosch H, Minkov M, Unger E, et al. Modern imaging methods for the assessment of Langerhans' cell histiocytosis-associated neurodegenerative syndrome: case report. *J Child Neurol*. 2005;20(3):253–7.
47. Gadner H, Heitger A, Grois N, Gatterer-Menz I, Ladisch S. Treatment strategy for disseminated Langerhans cell histiocytosis. DAL HX-83 study group. *Med Pediatr Oncol*. 1994;23(2):72–80.
48. Gadner H, Minkov M, Grois N, Potschger U, Thiem E, Arico M, et al. Therapy prolongation improves outcome in multisystem Langerhans cell histiocytosis. *Blood*. 2013;121(25):5006–14.
49. Grois N, Flucher-Wolfram B, Heitger A, Mostbeck GH, Hofmann J, Gadner H. Diabetes insipidus in Langerhans cell histiocytosis: results from the DAL-HX 83 study. *Med Pediatr Oncol*. 1995;24(4):248–56.
50. Nanduri VR, Bareille P, Pritchard J, Stanhope R. Growth and endocrine disorders in multisystem Langerhans' cell histiocytosis. *Clin Endocrinol*. 2000;53(4):509–15.
51. Nanduri VR, Pritchard J, Levitt G, Glaser AW. Long term morbidity and health related quality of life after multi-system Langerhans cell histiocytosis. *Eur J Cancer*. 2006;42(15):2563–9.
52. Prosch H, Grois N, Bokkerink J, Prayer D, Leuschner I, Minkov M, et al. Central diabetes insipidus: is it Langerhans cell histiocytosis of the pituitary stalk? A diagnostic pitfall. *Pediatr Blood Cancer*. 2006;46(3):363–6.
53. Prosch H, Grois N, Prayer D, Waldhauser F, Steiner M, Minkov M, et al. Central diabetes insipidus as presenting symptom of Langerhans cell histiocytosis. *Pediatr Blood Cancer*. 2004;43(5):594–9.
54. Allen CE, Ladisch S, McClain KL. How I treat Langerhans cell histiocytosis. *Blood*. 2015;126(1):26–35.
55. Gabbay LB, Leite Cda C, Andriola RS, Pinho Pda C, Lucato LT. Histiocytosis: a review focusing on neuroimaging findings. *Arq Neuropsiquiatr*. 2014;72(7):548–58.
56. Ablá O, Weitzman S, Minkov M, McClain KL, Visser J, Filipovich A, et al. Diabetes insipidus in Langerhans cell histiocytosis: when is treatment indicated? *Pediatr Blood Cancer*. 2009;52(5):555–6.
57. Ablá O, Palmert MR. Reversal of LCH-related diabetes insipidus and reappearance of posterior pituitary bright spot with low-dose chemotherapy. *Pediatr Blood Cancer*. 2012;59(1):201–2.
58. Allen CE, Flores R, Rauch R, Dauser R, Murray JC, Puccetti D, et al. Neurodegenerative central nervous system Langerhans cell histiocytosis and coincident hydrocephalus treated with vincristine/cytosine arabinoside. *Pediatr Blood Cancer*. 2010;54(3):416–23.
59. Dhall G, Finlay JL, Dunkel IJ, Ettinger LJ, Kellie SJ, Allen JC, et al. Analysis of outcome for patients with mass lesions of the central nervous system due to Langerhans cell histiocytosis treated with

- 2-chlorodeoxyadenosine. *Pediatr Blood Cancer*. 2008;50(1):72–9.
60. Ng Wing Tin S, Martin-Duverneuil N, Idhah A, Garel C, Ribeiro M, Parker JL, et al. Efficacy of vinblastine in central nervous system Langerhans cell histiocytosis: a nationwide retrospective study. *Orphanet J Rare Dis*. 2011;6(1):83.
61. Simko SJ, Tran HD, Jones J, Bilgi M, Beauhin LK, Coulter D, et al. Clofarabine salvage therapy in refractory multifocal histiocytic disorders, including Langerhans cell histiocytosis, juvenile xanthogranuloma and Rosai-Dorfman disease. *Pediatr Blood Cancer*. 2014;61(3):479–87.
62. Simko SJ, McClain KL, Allen CE. Up-front therapy for LCH: is it time to test an alternative to vinblastine/prednisone? *Br J Haematol*. 2015;169(2):299–301.
63. Grois N, Tsunematsu Y, Barkovich AJ, Favara BE. Central nervous system disease in Langerhans cell histiocytosis. *Br J Cancer Suppl*. 1994;23:S24–8.
64. Mimouni-Bloch A, Schneider C, Politi KE, Konen O, Gothelf D, Stark B, et al. Neuropsychiatric manifestations in Langerhans' cell histiocytosis disease: a case report and review of the literature. *J Child Neurol*. 2010;25(7):884–7.
65. Mittheisz E, Seidl R, Prayer D, Waldenmair M, Neophytou B, Potschger U, et al. Central nervous system-related permanent consequences in patients with Langerhans cell histiocytosis. *Pediatr Blood Cancer*. 2007;48(1):50–6.
66. Van't Hooft I, Gavhed D, Laurencikas E, Henter JI. Neuropsychological sequelae in patients with neurodegenerative Langerhans cell histiocytosis. *Pediatr Blood Cancer*. 2008;51(5):669–74.
67. Vrijmoet-Wiersma CM, Kooloos VM, Koopman HM, Kolk AM, van der Laan I, Grootenhuys MA, et al. Health-related quality of life, cognitive functioning and behaviour problems in children with Langerhans cell histiocytosis. *Pediatr Blood Cancer*. 2009;52(1):116–22.
68. Whitsett SF, Kneppers K, Coppes MJ, Egeler RM. Neuropsychologic deficits in children with Langerhans cell histiocytosis. *Med Pediatr Oncol*. 1999;33(5):486–92.
69. Kepes JJ, Histiocytosis X. In: Vinken PJ, Brujn GW, editors. *Handbook of neurology*, vol. 83. New York: Elsevier; 1979. p. 93–117.
70. Imashuku S, Fujita N, Shioda Y, Noma H, Seto S, Minato T, et al. Follow-up of pediatric patients treated by IVIG for Langerhans cell histiocytosis (LCH)-related neurodegenerative CNS disease. *Int J Hematol*. 2015;101(2):191–7.
71. Imashuku S, Okazaki N, Nakayama M, Fujita N, Fukuyama T, Koike K, et al. Treatment of neurodegenerative CNS disease in Langerhans cell histiocytosis with a combination of intravenous immunoglobulin and chemotherapy. *Pediatr Blood Cancer*. 2008;50(2):308–11.
72. Gavhed D, Laurencikas E, Akefeldt SO, Henter JI. Fifteen years of treatment with intravenous immunoglobulin in central nervous system Langerhans cell histiocytosis. *Acta Paediatr*. 2011;100(7):e36–9.
73. Idhah A, Donadieu J, Barthez MA, Geissmann F, Bertrand Y, Hermine O, et al. Retinoic acid therapy in “degenerative-like” neuro-langerhans cell histiocytosis: a prospective pilot study. *Pediatr Blood Cancer*. 2004;43(1):55–8.
74. Geissmann F, Landman-Parker J, Thomas C, Donadieu J, Brousse N, Hermine O. In vitro effects of retinoic acid on Langerhans cell histiocytosis cells and normal dendritic cells. Abstracts of the Annual Meeting 1997 of the Histiocyte Society. *Pediatr Blood Cancer*. 1998;31(1):49.
75. Euskirchen P, Haroche J, Emile JF, Buchert R, Vandersee S, Meisel A. Complete remission of critical neurohistiocytosis by vemurafenib. *Neurol Neuroimmunol Neuroinflamm*. 2015;2(2):e78.
76. Donadieu J, Visser J, Sieni E, Kabbara N, Jehanne M, Pagnier A, et al. Vemurafenib in children with refractory LCH: 21 patients treated in France, UK, Italy and Lebanon. Abstracts from the 32nd Annual Meeting of the Histiocyte Society Dublin, Ireland October 17-19, 2016. *Pediatr Blood Cancer*. 2016;63(Suppl 2):16.



First-Line Treatment of Pediatric Langerhans Cell Histiocytosis

5

Carlos Rodriguez-Galindo and Cor van den Bos

Abbreviations

2-CdA	Cladribine
6-MP	6-Mercaptopurine
AIEOP	Associazione Italiana Ematologia Oncologia Pediatrica
ARA-C	Cytarabine
BRAF	Gene encoding for B-Raf protein (serine/threonine protein kinase B-Raf)
<i>BRAF-V600E</i>	Mutation of BRAF gene with substitution of glutamate for valine at amino acid position 600
CNS	Central nervous system
ctDNA	Circulating tumor DNA
CXCR-4	CXC chemokine receptor type 4
DAL-HX	Deutsche Arbeitsgemeinschaft für Leukämieforschung und – Behandlung im Kindesalter e.V. – Histiocytose X

DI	Diabetes insipidus
DNA	Deoxyribonucleic acid
EFS	Event-free survival
JLSG	Japan Langerhans Cell Histiocytosis Study Group
LCH	Langerhans Cell Histiocytosis
MEK	Gene encoding for mitogen-activated protein kinase kinase
MRI	Magnetic resonance imaging
MS-LCH	Multisystem Langerhans Cell Histiocytosis
MTX	Methotrexate
NAD	Non-active disease
ND-CNS LCH	Neurodegenerative central nervous system LCH
PDN	Prednisone
POG	Pediatric Oncology Group
PUVA	Psoralen plus ultraviolet A
RO	Risk organ
VBL	Vinblastine
VCR	Vincristine
VP-16	Etoposide

The original version of this chapter was revised.
An erratum to this chapter can be found at
https://doi.org/10.1007/978-3-319-59632-7_21

C. Rodriguez-Galindo, MD
Departments of Global Pediatric Medicine and
Oncology, St. Jude Children's Research Hospital,
Memphis, TN, USA
e-mail: Carlos.Rodriguez-Galindo@STJUDE.ORG

C. van den Bos, MD, PhD. (✉)
Emma Children's Hospital/Academic Medical
Center, Department of Pediatric Oncology,
Amsterdam, The Netherlands
e-mail: c.vandenbos@amc.uva.nl

Introduction

The indications for and the intensity/duration of treatment for Langerhans cell histiocytosis (LCH) in the pediatric age group are largely dependent upon disease manifestations at diagnosis and on treatment response. This reflects the natural history and manifestations of LCH in children, ranging

from single self-limiting lesions to life-threatening systemic disease. In this chapter, the current treatment approaches for both localized and disseminated LCH in children will be discussed. Evidence that has emerged from different clinical trials will be reviewed, and remaining questions with future directions will be discussed.

Treatment of Single-System LCH

In Table 5.1 a summary of the current first-line strategies for LCH is provided, including those for single-system LCH. The treatment options for single-system LCH will be discussed on the basis of the organ system involved.

Table 5.1 Current first-line treatment options for pediatric LCH

Type of LCH	Treatment options
Isolated skin LCH	Observation only (wait-and-watch) [2, 5, 9, 10] Excision [2, 8] Topical steroids [1, 5, 11] <i>In case of failure of very extensive disease:</i> 6-mercaptopurine and methotrexate [11] <i>Others</i> [2, 5, 11]
Single-bone LCH	Observation after biopsy/curettage [2] Excision ^a [2, 11] Intralesional steroids [2, 24] <i>Wait-and-watch without a biopsy</i> [23, 25]
CNS-risk lesions	Vinblastine-based treatment (vinblastine plus corticosteroids) [2]
Multifocal bone LCH	Vinblastine-based treatment (vinblastine plus corticosteroids) [2, 11, 12] Indomethacin [36]
Isolated lung LCH	Smoking cessation [39] Steroids (\pm vinblastine) [2] 2-CdA [2]
Multisystem LCH	Vinblastine-based treatment (vinblastine plus corticosteroids) [37, 45–49] Cytarabine (ARA-C)-based treatment (ARA-C, vincristine, and corticosteroids) [50–52]

^aSee remarks about excision in Ref. [11]

Single-System Skin LCH

Isolated cutaneous LCH can present in a wide range of clinical manifestations, from nodules to blisters, tumorlike lesions, and scaling or purpuric macules [1–5]. One of the most important things to remember in pediatrics is that, particularly in young children under 1 year of age, progression to the potentially lethal multi-system LCH (MS-LCH) has been reported to be quite common [1, 4, 6], necessitating close monitoring for disease progression. In contrast, more recent studies showed that older age, later onset, and a protracted course of the skin lesions were more frequently associated with MS-LCH [1, 7]. It is not uncommon that the diagnosis of LCH is made only after the progression to MS-LCH [4]. Published studies are from referral centers [4, 7] or international collaborative studies [6] and reported by different combinations of dermatologists [1] or pediatric oncologists [4, 6, 7]. It is possible that referral and inclusion biases are responsible for the observed differences. Furthermore, it is recognized that the true incidence of self-healing LCH lesions is unknown and that therefore the risk of progression may be overestimated [4]. It is also possible that in the near future, detection of circulating cells carrying an LCH-related mutation such as the *BRAF-V600E* variant may help to distinguish isolated skin LCH from MS-LCH [7]. Notwithstanding all these uncertainties, it is currently widely recognized that, in general, true skin-only LCH has an excellent prognosis and should not be overtreated [2, 8, 9]. Therefore, a careful wait-and-watch strategy is preferred [2, 5, 9, 10]. An extensive review of treatment modalities in both children and adults was published in 1998 [3]. Among the modalities mentioned in that review, several are still mentioned today, such as: non-mutilating surgery for small isolated lesions [2, 8], topical corticosteroids [1, 5, 11], local application of nitrogen mustard [2, 5, 9, 11, 12], PUVA [5, 11], thalidomide [11], and different chemotherapeutic agents, such as cladribine (2-CdA) [11] and etoposide (VP-16). Other reported treatment modalities are low-dose

methotrexate (MTX) [2], vinblastine (VBL) [2, 11], vincristine (VCR) [11], and topical tacrolimus [5]. It is important to consider that for some treatments, the references provided are old and not always validated with prospective cohorts. The local application of nitrogen mustard, for example, was first described in an adult [13], and subsequently in a case report of two children, of whom one had MS-LCH and only a follow-up of 1 month [14]. Several patients were reported by the group from Great Ormond Street Hospital in London; these reports are quite often used as reference, but also in these studies, some or all of the children with either otitis externa or skin involvement had MS-LCH and also received systemic treatment [15–18]. Hoeger et al. reported that at median follow-up of 114 months, 10 out of 20 patients had no active disease, and skin relapse had occurred in eight [18]. Two patients developed contact dermatitis. A reactivation rate after complete response of approximately 50% was also shown in a more recent report, where six out of 14 patients also developed contact dermatitis [19]. While a systematic review is beyond the scope of this chapter, it is clear that the efficacy of local application of nitrogen mustard in skin-only LCH has not been properly validated and that reactivation rates are well within the normal range for other treatment modalities used in LCH.

There is no reason to assume that this is different for the other treatments. In light of all this, it must be concluded that the published experience with all the treatment modalities is always limited and that “guidelines” are therefore based far more on expert opinion [2], than on solid evidence. Topical steroids are generally well tolerated [1]. If these fail, a well-tolerated combination is MTX and 6-mercaptopurine (6-MP) [11]; however, there is clearly no evidence that this regimen is superior to others.

Single-Bone (“Monostotic”) LCH

The most commonly used approach to single-bone lesions is observation after biopsy.

Other approaches are observation only or intralesional injection of steroids. In the 2013 guidelines the evidence for the different treatment approaches for single-bone lesions is considered to be relatively poor (level C evidence) and based on nonanalytic studies (case reports, case series, small retrospective studies) [2]. However, some large and informative studies have been published. A study published in 1980 reviewed 686 patients that were reported between 1940 and 1974; radiotherapy was included in 198 cases, and there was no evidence of superiority of any form of treatment [20], comparable to the observation in an early case series published in 1960 [21]. Another study evaluating healing characteristics of 42 lesions in 21 patients was also unable to demonstrate a difference between intralesional steroids, chemotherapy, surgery, radiotherapy, and no treatment, i.e., largely biopsy only [22]. Indications for the use of different interventions, such as when to use radiotherapy, were not reported in both studies. The POG 8047 study, which included patients between 1981 and 1984, tried to address some of the open questions. Twenty-three eligible patients were included in the study, and excision/curettage was an effective treatment in 20/23 lesions (87%) [23]. The question about the value of radiotherapy could not be answered in this study, because of insufficient accrual in the study arms. An interesting observation in this study was that bone reactivation occurred in two patients in the second year after treatment, both healing without biopsy or specific therapy [23]. With regard to the use of intralesional steroids, a case series of 8 patients with literature review of 48 additional cases was published in 1992 [24]. All patients with adequate follow-up were reported to have obtained complete resolution of the lesion. Complications were rare. Although there are inevitable biases in these studies, it seems reasonable to conclude that (i) no local therapy is clearly superior, (ii) local radiotherapy can be avoided, and (iii) the indication for the use of intralesional steroids is not completely clear. In the previously mentioned guidelines, the indication for the use of intralesional methylprednisolone is described with equal uncertainty;

“depending on the size and location of the lesion, an intralesional injection of methylprednisolone may be administered to promote healing” [2].

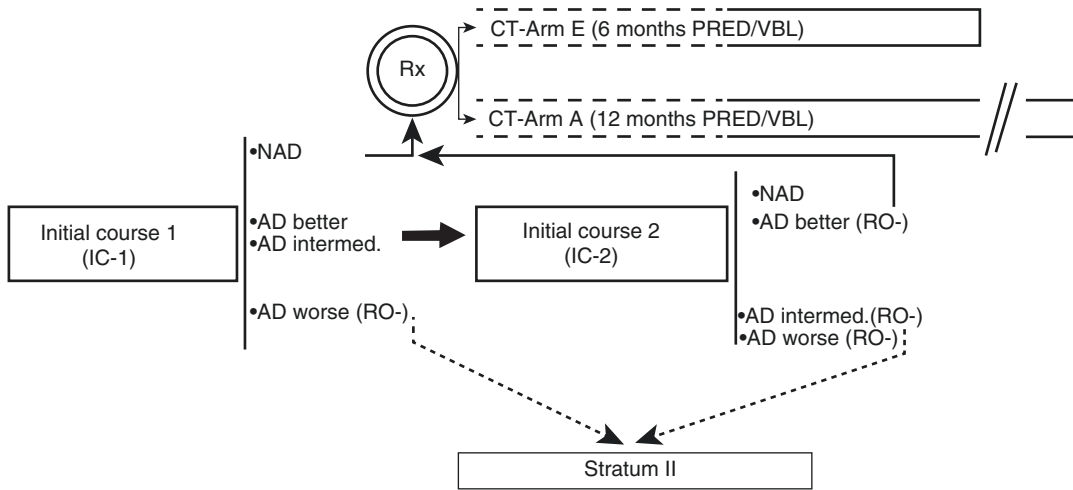
Stratum VI of the current LCH-IV study (EudraCT nr. 2011-001699-2020/NCT02205762) aims to describe the natural history of single-system LCH treated by conservative methods, i.e., a wait-and-watch strategy or local therapy. The primary endpoint of this study arm is reactivation-free survival. Although this study is expected to yield outcome data on a large series of uniformly followed patients, the indication for the use of intralesional steroids is unfortunately not dictated by the protocol. Therefore, this arm cannot be expected to yield unbiased data regarding the differences in outcome between the wait-and-watch strategy and the use of methylprednisolone injection. Considering the good prognosis of this form of LCH and the very low toxicity and complication rate of the use of intralesional steroids, it can however be argued that this is not the most important clinical problem in the treatment of LCH.

An interesting study is currently running in a number of centers in Canada and the United States. In patients with a radiological typical single-bone vault LCH lesion, a wait-and-watch strategy is applied without taking a biopsy. This approach is in line with the widely mentioned clinical experience of self-regressing lesions [23, 25]. It can be argued that without a biopsy the diagnosis cannot be made with a 100% certainty. In the near future, this problem may be solved by the use of circulating cell-free DNA for the detection of the known LCH-associated mutations [26, 27].

Central Nervous System (CNS)-Risk Bone Lesions

Central nervous system (CNS) LCH is discussed in Chap. 4 of this book. Craniofacial bone lesions have been reported to be associated

with an increased risk of diabetes insipidus (DI) [28]. Furthermore, DI/pituitary involvement in LCH has been found to be associated with neurodegenerative CNS (ND-CNS) LCH [29, 30], a devastating permanent consequence [31, 32]. Based on these observations, the concept of CNS-risk lesions was developed and also introduced in the LCH-III study. The concept of CNS-risk lesions is complex and not well defined; some authors have proposed that the occurrence of DI is used as a surrogate marker for neurodegeneration and thus for the estimation of CNS-risk [28, 33]. In the LCH-III study, the CNS risks were defined as: “lesions in the orbital, temporal/mastoid, sphenoidal, zygomatic, ethmoidal bones, maxilla, sinuses or anterior or middle cranial fossa, with intracranial soft tissue extension demonstrated on MRI.” In the current LCH-IV study, lesions at the risk sites, with or without intracranial soft tissue extension, are considered to be CNS-risk lesions. The fact that the intracranial soft tissue extension has been removed from the *definition* illustrates the difficulties in the CNS-risk lesion concept. It has also been observed (see section “Multisystem LCH (MS-LCH)” and Table 5.3) that the duration of treatment in MS-LCH does not seem to influence the risk of developing DI [34]. In a recent multicenter retrospective study on single-bone CNS-risk lesions, no effect of systemic therapy on the occurrence of reactivation and late sequelae could be demonstrated [35], although the data were not derived from a prospective randomized trial. These data are nevertheless considered to at least challenge the indication for systemic therapy in isolated lesions [9]. The most recently published guidelines still indicate CNS-risk lesions as an indication for systemic therapy, albeit only as a grade C recommendation [2]. The standard treatment arm for CNS-risk lesions in the LCH-IV study has a treatment duration of 6 months, with the use of VBL and prednisone (PDN) (Fig. 5.1).



RO-: No disease activity in Risk Organs
 Rx: Randomization time point,

Fig. 5.1 Current strategy for single-system LCH with CNS-risk lesions or multifocal bone lesions within the LCH-IV protocol of the Histiocyte Society

Multifocal Bone LCH

Systemic treatment is usually indicated for patients with multifocal bone disease [2, 11, 12]. It is well recognized that these patients have survival rates of 100% [2]; thus, the most important goal in the treatment is to reduce the risk of reactivations and permanent consequences. The most commonly used strategy is the combination of VBL and PDN [2, 11, 12]. A recognized alternative is the use of the anti-inflammatory drug, indomethacin [36]. The efficacy of this alternative, however, has never been evaluated in a randomized fashion.

The optimal duration of treatment for this group of patients has not been well defined. Extrapolating from patients with MS disease without RO involvement, longer duration (12 vs. 6 months) may be associated with decreased risk of reactivation, as shown in the LCH-III study [37]. In the current LCH-IV protocol, multifocal bone patients are therefore randomized between

a maintenance phase of 6 months (standard arm) and 12 months to evaluate whether prolongation of maintenance in this group of patients will indeed lead to a reduction in reactivation rates and the development of permanent consequences. Preliminary data from the JLSG-96 and JLSG-02 studies, however, show that intensification and prolongation (from 24 weeks to 48 weeks) of treatment in multifocal bone LCH may not result in a lower reactivation rate [38]. Thus, the optimal treatment duration for these patients is yet to be determined.

Isolated Lung LCH

Isolated lung LCH is very rare in children and usually occurs in adolescent smokers. The current therapy recommendation for adults is smoking cessation in all patients [39]. There is no reason to give another recommendation to smoking adolescents. In children with persistent and progressive

lung disease, 2-CdA or the combination of VBL and steroids have been used [2]. In adults, the natural history of pulmonary LCH is very variable, and a favorable outcome is not always dependent on therapy [39]. Steroid treatment [40, 41] had been advised for the nodular form of pulmonary LCH [39]. The use of 2-CdA, reported in small patient series [42–44], is indicated in case of progression under steroid treatment [39].

There are, to our knowledge, no published randomized studies in children or adolescents with isolated pulmonary LCH. Therefore, it seems reasonable to follow the adult guidelines (see Chap. 7).

Multisystem LCH (MS-LCH)

Since the first publication on the use of vinblastine (VBL) in the treatment of LCH [45], considerable progress has been made in the treatment of MS-LCH. The DAL-HX 83 and DAL-HX 90 [46] and the AIEOP-CNR-H.X'83 [47] studies were among the first to consistently apply a risk-adapted approach. These studies were followed by studies of the Histiocyte Society [37, 48, 49] and the Japan Langerhans Cell Histiocytosis Study Group [50, 51].

In the AIEOP-CNR-H.X'83 study, patients without involvement of risk organs (in that study defined as no OD = organ dysfunction) responded well to mono-chemotherapy. VBL and etoposide (VP-16) showed a response rate of 63% and 88%, respectively [47]. The treatment for patients with OD consisted of cycles of prednisone (PDN), doxorubicin, vincristine (VCR), and cyclophosphamide, with a maximum treatment duration of more than a year. The study yielded a low survival rate at 1 year of 46%, which was reported not to be attributable to toxicity of the chemotherapy [47].

The DAL-HX 83 and DAL-HX 90 studies were conducted between 1983 and 1991. Risk categories were defined by the presence of multifocal bone disease (group A), soft tissue involvement without organ dysfunction (group B), and organ dysfunction (group C). Treatment consisted

of a 6-week induction regimen with PDN, VBL, and VP-16, followed by a continuation treatment for a total duration of 12 months. Continuation treatment for group A patients was oral 6-mercaptopurine (6-MP) and pulses of PDN and VBL. For group B, VP-16 was added and for group C, VP-16 and methotrexate (MTX) were added (Table 5.2). For the multisystem patients (groups B and C), a 79% response rate at 6 weeks was obtained, and the 5-year reactivation rates and survival rates were 32% and 81%, respectively (Table 5.3) [46].

The LCH-I study was the first international randomized trial for multisystem LCH (MS-LCH) [48]. It randomized patients to receive 6 months treatment of VBL or VP-16 after a single initial 3-day methylprednisolone pulse. At 3 years follow-up, the two treatment arms had an equal probability of survival (VBL arm 76% and VP-16-arm 83%) and equal reactivation rates (VBL arm 61% and VP-16-arm 55%). In comparison with the preceding DAL-HX studies, LCH-I showed a lower 6-week response rate (53% vs. 79%) and a higher reactivation rate (58% vs. 32%) (Table 5.3). Involvement of the hematopoietic system, lung, liver, and spleen, age at diagnosis less than 2 years old, and poor response at 6 weeks were associated with a poor outcome [48].

The LCH-II study explored in a randomized fashion the addition of VP-16 to a standard 6-week induction with PDN and VBL and a continuation therapy with daily 6-MP and every-3-week pulses of PDN and VBL ± VP-16, for a total of 24 weeks (Tables 5.2 and 5.3) [49]. Both arms (± VP-16) had similar outcomes in terms of 6-week response rates, 5-year survival probability, and disease reactivation rates. However, for patients with risk organ involvement, the more intensive arm with VP-16 resulted in an increased proportion of responses at week 6 (43% in the VBL arm of LCH-I vs. 68% in the VP-16 arm of LCH-II) and a reduced mortality when compared with LCH-I (44% in the VBL of LCH-I vs. 27% in the VP-16 arm of LCH-II). In the LCH-II study, patients younger than 2 years without risk organ involvement had excellent response rates

Table 5.2 Drug doses used in LCH treatment protocols

	First induction	Second induction	Continuation/maintenance
DAL-HX 83 [46]	Prednisone (40 mg/m ² /day for 4 weeks, and taper over 2 weeks), etoposide (60 mg/m ² /day, days 1–3), etoposide (150 mg/m ² four weekly doses), vinblastine (6 mg/m ² four weekly doses)		Group A: 6-mercaptopurine (50 mg/m ² /day) and every-3-week pulses of prednisone (40 mg/m ² /day for 5 days) and vinblastine (6 mg/m ²) for a total of 52 weeks of therapy Group: as group A plus every-3-week etoposide (150 mg/m ²) Group C: as group B plus every-3-week methotrexate (500 mg/m ²)
DAL-HX 90 [46]	Groups A and B: prednisone (40 mg/m ² /day for 4 weeks, and taper over 2 weeks), etoposide (100 mg/m ² /day, days 1–5), etoposide (150 mg/m ² four weekly doses), vinblastine (6 mg/m ² four weekly doses) Group C: prednisone (40 mg/m ² /day for 4 weeks, and taper over 2 weeks), etoposide (150 mg/m ² six weekly doses), vinblastine (6 mg/m ² six weekly doses)		Group A: every-3-week pulses of prednisone (40 mg/m ² /day for 5 days) and etoposide (150 mg/m ²) for a total of 24 weeks of therapy Groups B and C: 6-mercaptopurine (50 mg/m ² /day) and every-3-week pulses of prednisone (40 mg/m ² /day for 5 days), vinblastine (6 mg/m ²), etoposide (150 mg/m ²) (last pulse on week 42) for a total of 52 weeks of therapy
LCH-I [48]	Methylprednisolone 30 mg/kg/day for 3 days with etoposide (150 mg/m ² /day for 3 days) or vinblastine (6 mg/m ² on day 1)		Every-3-week etoposide (150 mg/m ² /day for 3 days) or weekly vinblastine (6 mg/m ²) for a total of 24 weeks of therapy
LCH-II [49]	Prednisone (40 mg/m ² /day for 4 weeks, and taper over 2 weeks) and vinblastine (6 mg/m ² weekly for six doses) Plus/minus etoposide (150 mg/m ² weekly for six doses)		6-mercaptopurine (50 mg/m ² /day) and every-3-week pulses of prednisone (40 mg/m ² /day for 5 days) and vinblastine (6 mg/m ²) Plus/minus etoposide (150 mg/m ² for six doses) for a total of 24 weeks of therapy
LCH-III MS-RO+ [37]	Prednisone (40 mg/m ² /day for 4 weeks, and taper over 2 weeks) and vinblastine (6 mg/m ² weekly for six doses) Plus/minus methotrexate (500 mg/m ²) every other week during induction for a total of three doses	Weekly vinblastine for six doses, weekly pulses of prednisone (40 mg/m ² /day for 3 days) Plus/minus three doses of methotrexate (500 mg/m ² every other week)	6-mercaptopurine (50 mg/m ² /day) and every-3-week pulses of prednisone (40 mg/m ² /day for 5 days) and vinblastine (6 mg/m ²) for a total of 52 weeks of therapy Plus/minus methotrexate (orally 20 mg/m ²) once every week
LCH-MS-RO- [37]	Prednisone (40 mg/m ² /day for 4 weeks, and taper over 2 weeks) and vinblastine (6 mg/m ² weekly for six doses)	Weekly vinblastine for six doses, weekly pulses of prednisone (40 mg/m ² /day for 3 days)	Every-3-week pulses of prednisone (40 mg/m ² /day for 5 days) and vinblastine (6 mg/m ²) for a total of 26 or 52 weeks of therapy (randomization)

(continued)

Table 5.2 (continued)

	First induction	Second induction	Continuation/maintenance
JLSG-96 [50]	Three every-2-week courses of cytarabine (100 mg/m ² /day for 5 days), vincristine (0.05 mg/kg on day 1), and prednisolone (2 mg/kg/day for 5 days),		24-week maintenance phase alternating cycles of cytarabine (150 mg/m ² on day 1), vincristine (0.05 mg/kg on day 1), and prednisolone, (2 mg/kg/day for 4 days), with methotrexate (1 mg/kg for one dose) and prednisolone (2 mg/kg/day for 3 days) every 2 weeks
		For poor responders: Three every-2-week courses of doxorubicin (35 mg/m ² day 1), cyclophosphamide (10 mg/kg/day for 5 days), vincristine (0.05 mg/kg day 1), and prednisolone (2 mg/kg/day for 5 days)	For poor responders: 24-week maintenance phase alternating cycles every 2 weeks of: Doxorubicin (35 mg/m ² day 1), vincristine (0.05 mg/kg day 1), and prednisolone (2 mg/kg/day for 5 days) Methotrexate (3 mg/kg for one dose) and prednisolone (2 mg/kg/day for 3 days) Cyclophosphamide (10 mg/kg day 1), vincristine (0.05 mg/kg day 1), and prednisolone (2 mg/kg/day for 5 days)
JLSG-02 [51]	Prednisone (40 mg/m ² /day for 4 weeks, and taper over 2 weeks) and three every-two-week courses of cytarabine (100 mg/m ² /day for 5 days), vincristine (0.05 mg/kg on day 1)		Maintenance A: 24-week maintenance phase alternating cycles every 2 weeks of: <ul style="list-style-type: none"> • Cytarabine (150 mg/m² day 1), vincristine (0.05 mg/kg on day 1), prednisolone (2 mg/kg/day for 4 days) • Methotrexate (1 mg/kg for one dose) and prednisolone (2 mg/kg/day for 3 days) Maintenance C: 24-week maintenance phase with 6-mercaptopurine (1.5 mg/kg/day orally) and alternating cycles every week of: <ul style="list-style-type: none"> • Prednisolone (2 mg/kg/day for 5 days) and vinblastine (6 mg/m²) • Methotrexate (20 mg/m² orally for one dose)
		For poor responders: Cyclosporine A 3 mg/kg/day for 2 weeks, with three every-2-week courses of doxorubicin (35 mg/m ² day 1), cyclophosphamide (10 mg/kg/day for 5 days), vincristine (0.05 mg/kg day 1), and prednisolone (2 mg/kg/day for 5 days)	For poor responders: Maintenance B: 24-week maintenance phase alternating cycles every 2 weeks of: <ul style="list-style-type: none"> • Doxorubicin (35 mg/m² day 1), vincristine (0.05 mg/kg day 1), and prednisolone (2 mg/kg/day for 5 days) • Methotrexate (3 mg/kg for one dose) and prednisolone (2 mg/kg/day for 3 days) • Cyclophosphamide (10 mg/kg day 1), vincristine (0.05 mg/kg day 1), and prednisolone (2 mg/kg/day for 5 days) Maintenance C

Table 5.2 (continued)

	First induction	Second induction	Continuation/maintenance
EKZ/AMC [§] [52]	Prednisolone 40 mg/m ² /day for 4 weeks Two 2-week courses of cytarabine (100 mg/m ² /day for 4 days), vincristine (1.5 mg/m ² on day 1)		Prednisolone 20 mg/m ² /day for until week 47, and taper over 6 weeks Courses of cytarabine (100 mg/m ² /day for 4 days), vincristine (1.5 mg/m ² on day 1), on weeks 5, 8, 12, 17, 23, 29, 35

§ = as reported by Egeler et al. [52]

and a survival rate of 100%, thereby showing that young age per se is not a risk factor [49].

The LCH-III study tested the efficacy of increasing the treatment intensity by adding in a randomized way MTX for patients with risk organ involvement (defined for LCH-III as involvement of the lungs, liver, spleen, or hematopoietic system), as well as the effect of a second induction course in patients with insufficient response at 6 weeks [37]. A second objective was to evaluate the effect of treatment prolongation for MS-RO– patients (6 vs. 12 months) [37].

Patients with MS-RO+ LCH received standard 6-week induction with PDN and VBL, and continuation with 6-MP and three-week pulses of PDN and VBL for a total duration of 12 months of therapy, and were randomized to the addition of MTX (Table 5.2). Patients with active disease at 6 weeks received a modified re-induction with a duration of 6 weeks, consisting of weekly VBL and PDN pulses with MTX according to the randomization. As shown in Table 5.3, the outcomes in both arms were similar for response rates, reactivation rates, and 5-year probability of survival. Furthermore, historical comparisons revealed superior outcomes compared with LCH-I and LCH-II in terms of survival and reactivation rates. In MS-RO– patients, longer treatment resulted in a significantly lower 5-year reactivation rate (37% vs. 54%). Overall, the LCH-III study allowed for the conclusions that early intensification with a second induction phase for patients with slow responses and therapy prolongation result in significantly improved outcomes for patients with MS-LCH [37].

In the same journal issue that published the results of the AIEOP study [47], the results of a single institution (Emma Children's Hospital,

Amsterdam, the Netherlands) were published [52]. The treatment consisted of PDN, VCR, and cytarabine (ARA-C) for a treatment duration of 12 months (Table 5.2). In a small series of MS-RO+ patients, an overall survival rate of 75% was found, as well as a reactivation rate of 17% (1/6 patients; see also Table 5.3) [52]. The Japan LCH Study Group expanded the experience with LCH treatment on an ARA-C backbone in two studies [50, 51]. The JLSG-96 protocol was a non-randomized response-based trial. All patients received an induction course with courses of ARA-C, VCR, and PDN, comparable to that of the Emma Children's Hospital study [52]. Responding patients subsequently received a maintenance phase with cycles of ARA-C, VCR, and PDN, alternating with MTX and PDN (Table 5.2). Poor responders to induction treatment were switched to second induction phase with doxorubicin, cyclophosphamide, VCR, and PDN and subsequently continued to receive alternating cycles of those agents as maintenance for 24 weeks (Table 5.2). Overall, a good response rate of 89.8% was obtained in the MS-group at any point in the treatment, as well as an overall survival rate of 94.4% (Table 5.3) [50]. Patients who obtained a good response had a reactivation rate of 45.3% [50]. Because of these high reactivation rates, the PDN dose in the induction phase of the JLSG-02 study was increased, and the maintenance phase was increased to a total treatment duration of 12 months [51]. Furthermore, cyclosporine was introduced in the second induction [51]. These measures (Table 5.2) increased the 6-week response rates in MS-RO+ patients from 68.3% to 76.2% (see also Table 5.3) and the event-free survival (EFS) rate from 26.6% to 36.2% [51]. The role of ARA-C in the first-line

Table 5.3 Outcome of treatment protocol for multisystem LCH

	<i>n</i>	Risk groups	Treatment duration (mo)	Response rate at 6 weeks (%)	Overall response rate (NAD) (%)	(Estimated) reactivation rate (%)	(Estimated) survival rate (%)	DI at Dx n & %	DI during & after treatment	DI total
DAL-HX-83&90 [46]	63	MS-LCH	12	79	79	32 at 5 years	81 at 5 years	4/63 = 6%	7/59 = 12%	11/63 = 17%
LCH-I [48]	143	MS-LCH	6	53	62	58 at 3 years	79 at 3 years	16/143 = 12%	18/127 = 14%	34/143 = 24%
LCH-II [49]	146	RO+	6	62	62	44 at 3 years	69 at 5 years	14/193 = 7%	28/179 = 16%	42/193 = 22%
	47	RO ^a	6	83	93	52 at 3 years	100			
LCH-III [37]	120	RO + MTX+	12	65	75	29 at 5 years	82 at 5 years	8/115 = 7%	9/107 = 8%	17/115 = 15%
	115	RO + MTX-	12	66	82	25 at 5 years	87 at 5 years	8/112 = 7%	10/104 = 10%	18/112 = 16%
	98	RO-	6	87 ¹	nd	54 at 5 years	100 at 5 years	16/94 = 17%	9/78 = 11%	25/94 = 27%
	89	RO-	12		nd	37 at 5 years	99 at 5 years	15/85 = 18%	8/70 = 11%	23/85 = 27%
JL-SG-96 [50]	41	RO+	7.5	68	nd	60.7 ²	93 at 5 years	3/59 = 5%	5/56 = 9%	8/59 = 14%
	18	RO-	7.5	94	nd	58.8 ²	100			
JL-SG-02 [51]	84	RO+	12	76	nd	42.2 ²	92 at 5 years	6/84 = 7%	8/78 = 10%	ne
	63	RO-	12	94	nd	25.4 ²	100	16/63 = 25%	5/47 = 11%	ne
EKZ/AMC ³ [52]	8	RO+	12	nd	6/8 = 75%	1/6 = 17%	6/8 = 75%	1/8 = 13%	None	13%

^aIncluded because age < 2 years;

¹Response rate determined in initial group, with 234 out of 269 patients responding *nd* not determined ²In good responders; events rates defined as exacerbation or reactivation during maintenance phase, not attaining good response at the end of protocol therapy, reactivation after completion of therapy, secondary malignancy, or death from any cause *ne* not evaluable, two patients with DI at diagnosis improved, unclear in which group ³As reported by Egeler et al. [52]

management of LCH was also explored in separate institutional case series of 16 patients with de novo LCH, 14 (88%) of whom achieved non-active disease (NAD) by the end of 1 year of therapy, with a 1-year progression-free survival of 93% [53]. In 4 out of the 16 patients, the LCH reactivated either during therapy or within 6 months of therapy completion [53].

An interesting observation among all the treatment protocols is that the improved reactivation rates seem to have had only limited, if any, impact on the occurrence of permanent consequences such as DI (Table 5.3). This was also observed comparing treatment eras within a large national cohort in France [34].

The results of all the multicenter studies [2], as well as the recent report on the French national cohort [34], support the following conclusions: (i) early response is a predictor of survival in MS-RO+ LCH patients [48, 51, 54], (ii) a second induction treatment should be administered to

nonresponding patients [37, 50, 51], (iii) prolongation of treatment decreases the reactivation rate [37, 51], and (iv) isolated pulmonary involvement is rare and is not an independent prognostic factor [51, 55]. Furthermore, a recent evaluation of the patients included in the LCH studies of the Histiocyte Society showed that in MS-LCH patients, the absence of bony lesions at diagnosis is associated with a lower survival [56].

In the current LCH-IV study, MS-LCH patients are eligible for inclusion in Stratum I, group 1 (Fig. 5.2). In line with the observations and conclusions shown above, the aim of the study for MS-LCH patients is to investigate whether mortality can be further decreased by an early switch to more intensive salvage treatment in those patients whose risk organ involvement does not respond to frontline therapy. It also investigates in a randomized fashion whether further prolongation (12 vs 24 months) and intensification of continuation therapy (treatment ±6-MP) will reduce

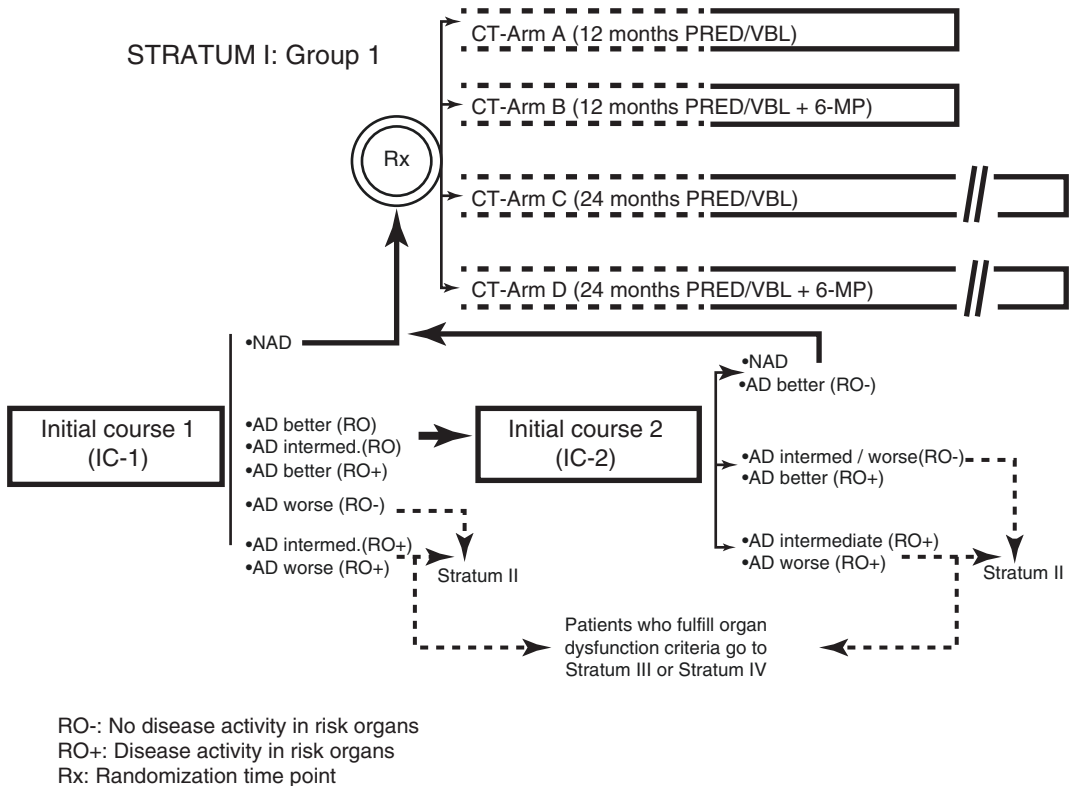


Fig. 5.2 Current strategy for MS-LCH within the LCH-IV protocol of the Histiocyte Society

the reactivation rate and permanent consequences. The LCH-IV study does not include a direct comparison between a VBL and an ARA-C-based induction therapy. However, a separate trial is currently investigating this question in a randomized fashion (NCT02670707).

Indomethacin

In the first report on the anti-inflammatory drug, indomethacin, in LCH, this drug was used to treat hypercalcemia and pain in an infant with multisystem LCH with extensive bony lesions [57]; however, during the treatment there was an increase in the size of the bony lesions [57]. In 1999, a report on a series of ten patients (6 single-system bone disease and 4 with MS-LCH) showed a good response rate, defined as a complete resolution of symptoms for a period of 4 weeks [58]. In this study, evaluation of radiologic response was not required and was only determined in one patient; the authors acknowledged that they could not determine whether the drug influenced the disease process or merely acted as an analgesic [58]. In other studies, indomethacin was compared to MTX-based chemotherapy in a group of patients with skull lesions, where 8 out of 9 had single skull lesions [59], and in a group of 33 patients with other single-bone lesions [60]. For both of these groups, the use of adjuvant therapy is questionable [59, 60]. More favorable responses with indomethacin have more recently been reported by the group from Buenos Aires [36]. Of the 22 patients in that study treated at diagnosis, 16 had only unifocal bone disease. Of the 6 patients with multifocal bone disease at diagnosis, the evaluation after 8 weeks revealed no evidence of active disease in 3, and the other three needed additional treatment [36]. Although published results have thus far not shown a superior effect of indomethacin over more traditional chemotherapeutic approaches, the low toxicity profile of the drug as well as its price are very attractive. Furthermore, there is significant amount of non-published favorable experiences with indomethacin. This has led to the randomization of

indomethacin versus 6-MP/MTX in the maintenance phase of the low-risk reactivation stratum of the LCH-IV study (Stratum II). Results of this study are eagerly awaited and, in case of equal efficacy, it is to be expected that the use of indomethacin in the maintenance phase of primary LCH will be tested in future studies of the Histiocyte Society.

Remaining Questions and Future Directions

In skin-only LCH (see section “[Single-System Skin LCH](#)”), there is a need for a well-designed clinical trial to answer some of the open questions in that clinical entity. Treatment options should be evaluated in a randomized fashion, probably with stratification on the basis of the percentage of involved skin. Ideally, such a study should be a collaborative effort between dermatologists, pediatric oncologists, and probably also primary care physicians, as it is not unlikely that some mild forms of skin-only LCH are currently not detected because no biopsy is taken. Clearly, this will need a huge effort and it is perhaps an unattainable goal in this mild disease. This is probably not the case for young children, where the substantial risk for progression to MS-LCH is well established [1, 4, 6]. For a study in that age group, an effort should be made to evaluate at least those children in primary care where skin rashes do not react as expected to standard of care, to find out whether these children have skin LCH.

The need for systemic treatment in single CNS-risk lesion LCH was recently questioned by a multicenter retrospective study [35]. Although this was not a prospective randomized study and thus had inherent biases, there is a need to try to confirm these data in an independent cohort [9, 35]. The fact that in multisystem LCH the development of DI as a permanent consequence seems not to be influenced by the duration of maintenance treatment underlines this need [34]. For multifocal bone disease (section “[Multifocal Bone LCH](#)”), preliminary data from the JLSG may indicate that prolongation of treatment in

that group of patient does not necessarily lead to a lower reactivation rate [38]. The survival rates of 100% in multifocal bone disease seem to designate this group of patients as one where also the efficacy of indomethacin can be further tested in a randomized fashion. And even if the drug turns out to be a little less efficacious than, e.g., the more traditional 6-MP/MTX combination, it might become the drug of choice in less affluent countries. As mentioned in the previous section, Stratum II of the current LCH-IV study can be expected to shed some light on this issue.

Although for MS-LCH the LCH-III study clearly showed that prolongation of maintenance treatment improved the reactivation-free survival, it cannot be denied that for almost half of the patients, a treatment duration of only 6 months is enough [37]. The common problem here, and in the single-system forms discussed above, is that currently it is very difficult to estimate the risk of reactivation or other outcomes (e.g., death in MS-RO+ LCH) already at diagnosis. Luckily enough, data are appearing that might soon allow for a more refined risk stratification at diagnosis. Lack of bony lesions at diagnosis of MS-LCH was found to be associated with an inferior outcome [56], as was anemia with thrombocytopenia with or without leukopenia and hypoalbuminemia [61]. The expression of CXCR4 at diagnosis was shown to be an independent risk factor for reactivation [62]. Recent evidence from France indicates that the presence of the *BRAF-V600E* mutation correlates with high-risk LCH and also with an increased risk of failure of first-line therapy [63]. In the previous years, other factors that may predict a risk of reactivation have been described, although this might be explained by their association with MS-LCH [64–67]. The current LCH-IV should be used as the platform to evaluate some of these risk factors prospectively in a cohort with a uniform treatment policy.

Lack of early response to treatment in MS-RO+ LCH has been established as a risk factor [48, 51, 54]. The effect of early switch to salvage treatment is tested in the current LCH-IV study. It can be expected that besides clinical evaluations, such as the Disease Activity Score [68], laboratory tests such as the detection or kinetics of ctDNA

[26, 27] will be evaluated for their ability to detect treatment failure early in the course of treatment. BRAF inhibitors have been shown to be effective in patients with *BRAF-V600E* mutated forms of LCH [69–71]. Inhibitors for BRAF and MEK will undoubtedly find their way into the first-line treatment of LCH within a few years, although it is well recognized that issues such as clear indications, optimal inhibitor, best dose, and treatment duration are yet to be defined.

Lastly, it is well recognized that only a randomized study will be able to settle the dispute [53, 72, 73] whether primary treatment should be based on a VBL or on an ARA-C backbone.

References

1. Morren M-A, Vanden Broecke K, Vangeebergen L, Sillevs-Smitt JH, Van Den Berghe P, Hauben E, et al. Diverse cutaneous presentations of langerhans cell histiocytosis in children: a retrospective cohort study. *Pediatr Blood Cancer*. 2016;63(3):486–92.
2. Haupt R, Minkov M, Astigarraga I, Schäfer E, Nanduri V, Jubran R, et al. Langerhans cell histiocytosis (LCH): guidelines for diagnosis, clinical work-up, and treatment for patients till the age of 18 years. *Pediatr Blood Cancer*. 2013;60(2):175–84.
3. Munn S, Chu AC. Langerhans cell histiocytosis of the skin. *Hematol Oncol Clin North Am*. 1998;12(2):269–86.
4. Lau L, Krafchik B, Trebo MM, Weitzman S. Cutaneous Langerhans cell histiocytosis in children under one year. *Pediatr Blood Cancer*. 2006;46(1):66–71.
5. Krafchik B, Pope E, Walsh SR. Histiocytosis of the skin in children and adults. In: Weitzman S, Egeler RM, editors. *Histiocytic disorders of children and adults*. Cambridge: Cambridge University Press; 2005.
6. Minkov M, Prosch H, Steiner M, Grois N, Pötschger U, Kaatsch P, et al. Langerhans cell histiocytosis in neonates. *Pediatr Blood Cancer*. 2005;45(6):802–7.
7. Simko SJ, Garmezay B, Abhyankar H, Lupo PJ, Chakraborty R, Lim KPH, et al. Differentiating skin-limited and multisystem Langerhans cell histiocytosis. *J Pediatr*. 2014;165(5):990–6.
8. Weitzman S, Egeler RM. Langerhans cell histiocytosis: update for the pediatrician. *Curr Opin Pediatr*. 2008;20(1):23–9.
9. Aricò M. Langerhans cell histiocytosis in children: from the bench to bedside for an updated therapy. *Br J Haematol*. 2016;173(5):663–70.
10. Ablá O, Weitzman S. Treatment of Langerhans cell histiocytosis: role of BRAF/MAPK inhibition. *Hematology Am Soc Hematol Educ Program*. 2015;2015(1):565–70.

11. Allen CE, Ladisch S, McClain KL. How I treat Langerhans cell histiocytosis. *Blood*. 2015;126(1):26–35.
12. Windebank K, Visser J, Nanduri V. Advances in the understanding and management of histiocytic disorders 2015. *Paediatr Child Health*. 2016;26(2):73–80.
13. Dolezal JF, Thomson ST. HAnd-schüller-christian disease in a septuagenarian. *Arch Dermatol*. 1978;114(1):85–7.
14. Zachariae H. Histiocytosis X in two infants—treated with topical nitrogen mustard. *Br J Dermatol*. 1979;100(4):433–8.
15. Wong E, Holden CA, Broadbent V, Atherton DJ. Histiocytosis X presenting as intertrigo and responding to topical nitrogen mustard. *Clin Exp Dermatol*. 1986;11(2):183–7.
16. Sheehan MP, Atherton DJ, Broadbent V, Pritchard J. Topical nitrogen mustard: an effective treatment for cutaneous Langerhans cell histiocytosis. *J Pediatr*. 1991;119(2):317–21.
17. Hadfield PJ, Birchall MA, Albert DM. Otitis externa in Langerhans' cell histiocytosis — the successful use of topical nitrogen mustard. *Int J Pediatr Otorhinolaryngol*. 1994;30(2):143–9.
18. Hoeger PH, Nanduri VR, Harper JJ, Atherton DA, Pritchard J. Long term follow up of topical mustine treatment for cutaneous Langerhans cell histiocytosis. *Arch Dis Child*. 2000;82(6):483–7.
19. Lindahl LM, Fenger-Grøn M, Iversen L. Topical nitrogen mustard therapy in patients with Langerhans cell histiocytosis. *Br J Dermatol*. 2012;166(3):642–5.
20. Slater JM, Swarm OJ. Eosinophilic granuloma of bone. *Med Pediatr Oncol*. 1980;8(2):151–64.
21. McGavran MH, Spady HA. Eosinophilic granuloma of bone. A study of twenty-eight cases. *J Bone Joint Surg*. 1960;42(6):979–92.
22. Womer RB, Raney RB, D'Angio GJ. Healing rates of treated and untreated bone lesions in Histiocytosis X. *Pediatrics*. 1985;76(2):286–8.
23. Berry DH, Gresik M, Maybee D, Marcus R. Histiocytosis X in bone only. *Med Pediatr Oncol*. 1990;18(4):292–4.
24. Egeler RM, Thompson RCJ, Voûte PA, Nesbit ME. Intralesional infiltration of corticosteroids in localized langerhans' cell histiocytosis. *J Pediatr Orthop*. 1992;12(6):811–4.
25. Kamimura M, Kinoshita T, Itoh H, Yuzawa Y, Takahashi J, Ohtsuka K. Eosinophilic granuloma of the spine: early spontaneous disappearance of tumor detected on magnetic resonance imaging. *J Neurosurg Spine*. 2000;93(2):312–6.
26. Kobayashi M, Tojo A. The BRAF-V600E mutation in circulating cell-free DNA is a promising biomarker of high-risk adult Langerhans cell histiocytosis. *Blood*. 2014;124(16):2610–1.
27. Hyman DM, Diamond EL, Vibat CRT, Hassaine L, Poole JC, Patel M, et al. Prospective blinded study of BRAFV600E mutation detection in cell-free DNA of patients with systemic histiocytic disorders. *Cancer Discov*. 2015;5(1):64–71.
28. Grois N, Pötschger U, Prosch H, Minkov M, Arico M, Braier J, et al. Risk factors for diabetes insipidus in langerhans cell histiocytosis. *Pediatr Blood Cancer*. 2006;46(2):228–33.
29. Donadieu J, Rolon M-A, Thomas C, Brugieres L, Plantaz D, François Emile J, et al. Endocrine involvement in pediatric-onset langerhans' cell histiocytosis: a population-based study. *J Pediatr*. 2004;144(3):344–50.
30. Fahrner B, Prosch H, Minkov M, Krischmann M, Gadner H, Prayer D, et al. Long-term outcome of hypothalamic pituitary tumors in Langerhans cell histiocytosis. *Pediatr Blood Cancer*. 2012;58(4):606–10.
31. Grois N, Fahrner B, Arceci RJ, Henter J-I, McClain K, Lassmann H, et al. Central nervous system disease in langerhans cell histiocytosis. *J Pediatr*. 2010;156(6):873–81.e1.
32. Barthez M-A, Araujo E, Donadieu J. Langerhans cell histiocytosis and the central nervous system in childhood: evolution and prognostic factors. Results of a collaborative study. *J Child Neurol*. 2000;15(3):150–6.
33. Donadieu J, Chalard F, Jeziorski E. Medical management of langerhans cell histiocytosis from diagnosis to treatment. *Expert Opin Pharmacother*. 2012;13(9):1309–22.
34. Rigaud C, Barkaoui MA, Thomas C, Bertrand Y, Lambilliotte A, Miron J, et al. Langerhans cell histiocytosis: therapeutic strategy and outcome in a 30-year nationwide cohort of 1478 patients under 18 years of age. *Br J Haematol*. 2016;174:887. n/a-n/a
35. Chellapandian D, Shaikh F, van den Bos C, Somers GR, Astigarraga I, Jubran R, et al. Management and outcome of patients with langerhans cell histiocytosis and single-bone CNS-risk lesions: a multi-institutional retrospective study. *Pediatr Blood Cancer*. 2015;62(12):2162–6.
36. Braier J, Rosso D, Pollono D, Rey G, Lagomarsino E, Latella A, et al. Symptomatic bone langerhans cell histiocytosis treated at diagnosis or after reactivation with indomethacin alone. *J Pediatr Hematol Oncol*. 2014;36(5):e280–e4.
37. Gadner H, Minkov M, Grois N, Pötschger U, Thiem E, Aricò M, et al. Therapy prolongation improves outcome in multisystem Langerhans cell histiocytosis. *Blood*. 2013;121(25):5006–14.
38. Morimoto A, Shioda Y, Imamura T, Kudo K, Ishii E, Horibe K, et al. Intensified and prolonged therapy did not improve the outcome in Langerhans cell Histiocytosis with single-system multifocal bone lesions; results of JLSG-02 protocol study. *Pediatr Blood Cancer*. 2015;62:S133.
39. Girschikofsky M, Arico M, Castillo D, Chu A, Doberauer C, Fichter J, et al. Management of adult patients with Langerhans cell histiocytosis: recommendations from an expert panel on behalf of euro-Histio-net. *Orphanet J Rare Dis*. 2013;8(1):1–11.
40. Tazi A. Adult pulmonary Langerhans' cell histiocytosis. *Eur Respir J*. 2006;27(6):1272–85.
41. Vassallo R, Ryu JH, Schroeder DR, Decker PA, Limper AH. Clinical outcomes of pulmonary Langerhans'-cell histiocytosis in adults. *N Engl J Med*. 2002;346(7):484–90.

42. Grobost V, Khouatra C, Lazor R, Cordier J-F, Cottin V. Effectiveness of cladribine therapy in patients with pulmonary Langerhans cell histiocytosis. *Orphanet J Rare Dis.* 2014;9(1):1–8.
43. Lazor R, Etienne-Mastroianni B, Khouatra C, Tazi A, Cottin V, Cordier J-F. Progressive diffuse pulmonary Langerhans cell histiocytosis improved by cladribine chemotherapy. *Thorax.* 2009;64(3):274–5.
44. Lorillon G, Bergeron A, Detournignies L, Jouneau S, Wallaert B, Fria J, et al. Cladribine is effective against cystic pulmonary Langerhans cell histiocytosis. *Am J Respir Crit Care Med.* 2012;186(9):930–2.
45. Beier FR, Thatcher LG, Lahey ME. Treatment of reticuloendotheliosis with vinblastine sulfate. *J Pediatr.* 1963;63(6):1087–92.
46. Minkov M, Grois N, Heitger A, Pötschger U, Westermeier T, Gadner H. Treatment of multisystem Langerhans cell histiocytosis. Results of the DAL-HX 83 and DAL-HX 90 studies. *Klin Padiatr.* 2000;212(04):139–44.
47. Ceci A, De Terlizzi M, Colella R, Loiacono G, Balducci D, Surico G, et al. Langerhans cell histiocytosis in childhood: results from the Italian cooperative AIEOP-CNR-H.X '83 study. *Med Pediatr Oncol.* 1993;21(4):259–64.
48. Gadner H, Grois N, Arico M, Broadbent V, Ceci A, Jakobson A, et al. A randomized trial of treatment for multisystem Langerhans' cell histiocytosis. *J Pediatr.* 2001;138(5):728–34.
49. Gadner H, Grois N, Pötschger U, Minkov M, Arico M, Braier J, et al. Improved outcome in multisystem Langerhans cell histiocytosis is associated with therapy intensification. *Blood.* 2008;111(5):2556–62.
50. Morimoto A, Ikushima S, Kinugawa N, Ishii E, Kohdera U, Sako M, et al. Improved outcome in the treatment of pediatric multifocal Langerhans cell histiocytosis. *Cancer.* 2006;107(3):613–9.
51. Morimoto A, Shioda Y, Imamura T, Kudo K, Kawaguchi H, Sakashita K, et al. Intensified and prolonged therapy comprising cytarabine, vincristine and prednisolone improves outcome in patients with multisystem Langerhans cell histiocytosis: results of the Japan Langerhans cell Histiocytosis study group-02 protocol study. *Int J Hematol.* 2016;104(1):99–109.
52. Egeler RM, De Kraker J, Voüte PA. Cytosine-arabinoside, vincristine, and prednisolone in the treatment of children with disseminated langerhans cell histiocytosis with organ dysfunction: experience at a single institution. *Med Pediatr Oncol.* 1993;21(4):265–70.
53. Simko SJ, McClain KL, Allen CE. Up-front therapy for LCH: is it time to test an alternative to vinblastine/prednisone? *Br J Haematol.* 2015;169(2):299–301.
54. Minkov M, Grois N, Heitger A, Pötschger U, Westermeier T, Gadner H. Response to initial treatment of multisystem langerhans cell histiocytosis: an important prognostic indicator. *Med Pediatr Oncol.* 2002;39(6):581–5.
55. Ronceray L, Pötschger U, Janka G, Gadner H, Minkov M. Pulmonary involvement in pediatric-onset multisystem Langerhans cell Histiocytosis: effect on course and outcome. *J Pediatr.* 2012;161(1):129–33.e3.
56. Aricò M, Astigarraga I, Braier J, Donadieu J, Gadner H, Glogova E, et al. Lack of bone lesions at diagnosis is associated with inferior outcome in multisystem langerhans cell histiocytosis of childhood. *Br J Haematol.* 2015;169(2):241–8.
57. McLean TW, Pritchard J. Langerhans cell histiocytosis and hypercalcemia: clinical response to indomethacin. *J Pediatr Hematol Oncol.* 1996;18(3):318–20.
58. Munn SE, Olliver L, Broadbent V, Pritchard J. Use of indomethacin in Langerhans cell histiocytosis. *Med Pediatr Oncol.* 1999;32(4):247–9.
59. Park SH, Park J, Hwang JH, Hwang SK, Hamm IS, Park YM. Eosinophilic granuloma of the skull: a retrospective analysis. *Pediatr Neurosurg.* 2007;43(2):97–101.
60. Han I, Suh ES, Lee SH, Cho HS, Oh JH, Kim HS. Management of eosinophilic granuloma occurring in the appendicular skeleton in children. *Clin Orthop Surg.* 2009;1(2):63–7.
61. Braier JL, Rosso D, Latella A, Chantada G, Ozuna B, Ripoli M, et al. Importance of multi-lineage hematologic involvement and hypoalbuminemia at diagnosis in patients with “risk-organ” multi-system langerhans cell histiocytosis. *J Pediatr Hematol Oncol.* 2010;32(4):e122–e5.
62. Quispel WT, Stegehuis-Kamp JA, Blijleven L, Santos SJ, Lourda M, van den Bos C, et al. The presence of CXCR4+ CD1a+ cells at onset of Langerhans cell histiocytosis is associated with a less favorable outcome. *Oncoimmunology.* 2016;5(3):e1084463.
63. Héritier S, Emile J-F, Barkaoui M-A, Thomas C, Fraitag S, Boudjemaa S, et al. BRAF mutation correlates with high-risk Langerhans cell histiocytosis and increased resistance to first-line therapy. *J Clin Oncol.* 2016;34:3023.
64. Geissmann F, Emile JF, Andry P, Thomas C, Fraitag S, De Prost Y, et al. Lack of expression of E-cadherin is associated with dissemination of Langerhans' cell histiocytosis and poor outcome. *J Pathol.* 1997;181(3):301–4.
65. Kim S-Y, Kim H-J, Kim H-J, Park M-R, Koh K-N, Im H-J, et al. Role of p16 in the pathogenesis of Langerhans cell histiocytosis. *Korean J Hematol.* 2010;45(4):247–52.
66. Rust R, Kluiver J, Visser L, Harms G, Blokzijl T, Kamps W, et al. Gene expression analysis of dendritic/Langerhans cells and Langerhans cell histiocytosis. *J Pathol.* 2006;209(4):474–83.
67. Seo J-J, Cho T, Kim S-Y, Nassour I, Kim H-J, Lim Y-J, et al. Prognostic significance of gelsolin and MMP12 in Langerhans cell histiocytosis. *Korean J Hematol.* 2012;47(4):267–72.
68. Donadieu J, Piguët C, Bernard F, Barkaoui M, Ouache M, Bertrand Y, et al. A new clinical score for disease activity in Langerhans cell histiocytosis. *Pediatr Blood Cancer.* 2004;43(7):770–6.
69. Haroche J, Cohen-Aubart F, Emile J-F, Arnaud L, Maksud P, Charlotte F, et al. Dramatic efficacy of vemurafenib in both multisystemic and refractory

- Erdheim-Chester disease and Langerhans cell histiocytosis harboring the BRAF V600E mutation. *Blood*. 2013;121(9):1495–500.
70. Héritier S, Jehanne M, Leverger G, et al. VEmurafenib use in an infant for high-risk langerhans cell histiocytosis. *JAMA Oncol*. 2015;1(6):836–8.
 71. Charles J, Beani J-C, Fiandrino G, Busser B. Major response to vemurafenib in patient with severe cutaneous Langerhans cell histiocytosis harboring BRAF V600E mutation. *J Am Acad Dermatol*. 2013;71(3):e97–e9.
 72. Minkov M, Rodriguez-Galindo C. Treatment of Langerhans cell histiocytosis: it is time to learn from the past. *Br J Haematol*. 2015;171(1):148–9.
 73. Allen CE, McClain KL. Treatment of Langerhans cell histiocytosis: it is time to learn from the past: response to Minkov and Rodriguez-Galindo. *Br J Haematol*. 2015;171(1):150–1.

Treatment of Relapsed and Refractory Langerhans Cell Histiocytosis in Children

Oussama Abla, Carlos Rodriguez-Galindo, and Paul Veys

Introduction

A significant improvement in the understanding of the biology of Langerhans cell histiocytosis (LCH) has occurred in the last decade, particularly after the discovery of recurrent somatic activating mutations of the *BRAF-V600E* gene in 57% of LCH cases [1]. Despite this, almost 50% of patients with LCH are refractory to initial treatment or develop reactivation of their disease within 5 years, with most reactivations occurring in the first 2 years [2–4]. Well-known poor prognostic factors in patients with LCH include the involvement of “risk organs” (RO), such as the liver, spleen and haematopoietic system, and failure to respond after 6 weeks of induction therapy [5, 6]. Patients with multisystem (MS) LCH who are RO+ and who fail to respond after two courses of initial therapy (week 12) had a survival probability of 20–34% on the LCH-I and LCH-II

studies and only 10% after the more intensive DAL chemotherapy regimen [6]. Thus, the treatment of patients with MS-LCH who are refractory to initial therapy has been quite challenging, and their outcome is very poor.

The LCH-III trial results showed that prolonging treatment with vinblastine/prednisone in MS-LCH patients was effective in improving the 5-year survival rate to 84% (from 62% on the LCH-I and 69% on the LCH-II trials) and decreasing the 5-year reactivation rate to 27% (from 55% on the LCH-I and 44% on the LCH-II trials) [2]. These improvements were mainly attributed to early switch to salvage therapy in slow early responders, better salvage regimens and better supportive care in recent years.

This chapter will focus on the treatment strategies of children with refractory and relapsed LCH including chemotherapy, immunomodulating agents, targeted therapies and haematopoietic stem cell transplant (HSCT).

O. Abla, MD (✉)
Department of Pediatrics,
Division of Hematology/Oncology, Hospital for Sick
Children, University of Toronto, Toronto,
ON, Canada
e-mail: oussama.abla@sickkids.ca

C. Rodriguez-Galindo, MD
Departments of Global Pediatric Medicine and
Oncology, St. Jude Children’s Research Hospital,
Memphis, TN, USA

P. Veys, MBBS FRCP FRCPath FRCPC
Blood and Bone Marrow Transplantation Unit, Great
Ormond Street Hospital for Children, London, UK

Treatment of Relapsed and Refractory “Low-Risk” LCH

This group includes patients with reactivation of skin-only disease, multifocal bone disease or “low-risk” multisystem disease (RO⁻). Disease reactivation tends to occur in almost one-third of these patients, and they usually respond well to second-line therapy, although multiple reactivations are common. In general, treatment failures in patients

with low-risk LCH are not associated with mortality but with long-term morbidity, and optimal chemotherapeutic strategies are not well defined.

Therapies for Relapsed/Refractory Skin LCH

Relapsed and refractory skin-only LCH can be treated with topical corticosteroids, particularly in cases with severe symptoms or for cosmetic reasons. Failure of complete remission or concerns regarding long-term steroids toxicity will usually dictate a change of therapy. Surgery can be a reasonable option for isolated and small lesions, and it is used more commonly in adults for cosmetic reasons; mutilating surgery should be avoided. Alternative topical treatments include nitrogen mustard, imiquimod and phototherapy.

Topical nitrogen mustard (0.02% mechlorethamine hydrochloride), an alkylating cytostatic agent, has been reported to be effective and safe in children with refractory skin LCH, although relapses are common [7]. However, due to its oncogenic potential and the high rate of contact sensitivity, its use should be limited to severe skin disease or multiply refractory cases [8, 9].

Topical imiquimod, an interferon-inducing agent, has been successfully used in a child with skin LCH who was refractory to topical steroids and topical tacrolimus. The skin rash resolved completely within 5 months with no recurrence after a 2-year follow-up. The drug was well tolerated except for minor bleeding and irritation [10]. Successful use of topical imiquimod has also been reported in adults [11].

Oral 8-methoxypsoralen (8-MOP) plus ultraviolet A (PUVA) therapy (3 times/week for 2 months followed by maintenance therapy at 1–2 times/week) is an effective option for adult patients with extensive and refractory skin LCH [12]. However, due to the increased risk of skin cancer, PUVA is contraindicated in children less than 12 years of age [10].

Narrow band ultraviolet B (NB-UVB) therapy is a safer and effective option in children and

adults. Side effects are usually mild and include burning, itchiness, erythema and xerosis [13, 14]. Nevertheless, it is controversial whether NB-UVB can be associated with an increased risk of skin cancer; therefore, we do not routinely recommend it for a resistant skin-only LCH (personal communication, O. Abła).

Methylaminolevulinate (MAL)-based photodynamic therapy (PDT) was found to be effective in an 18-month-old boy with severe and resistant scalp LCH. Two weeks after PDT, a significant reduction of the inflammation and crusting was noted. Four weeks later, there was an almost complete healing. A control biopsy revealed a complete histological clearing and only some residual CD1a + LC on immunohistochemistry. After a follow-up of 6 months, the scalp was still recurrence-free. The procedure was well tolerated [15]. PDT is an FDA-approved treatment option for superficial basal cell carcinoma, Bowen's disease and actinic keratosis. PDT permits selective destruction of cells accumulating the topical photosensitizer (MAL) and subsequently activated by a light source. Through an unknown mechanism, a ten-fold higher intracellular concentration of the photosensitizer is achieved in metabolically more active cells, such as the LCH cells [15].

Refractory mucocutaneous LCH can also be treated with systemic chemotherapy. Low-dose oral methotrexate (MTX), at 20 mg weekly, was found to be effective in both adults and children with multifocal and resistant skin LCH [16–18]. The combination of alternate-day prednisone (40 mg/m²/day) with weekly oral MTX was similarly effective and tolerated in 13 children with refractory LCH [17]. An alternative regimen is the combined use of weekly oral MTX and daily oral 6-mercaptopurine (50 mg/m²/day), which was beneficial and tolerated in 11 children with relapsed skin and bone LCH [19]. Oral thalidomide (200 mg/day), an anti-TNF alpha agent, was effective for mucocutaneous LCH after 4 weeks of treatment with complete remission after 3 months. Maintenance therapy using 100 mg/day can be recommended to prevent recurrent disease [20].

Therapies of Relapsed and Refractory Bone LCH

Indomethacin

Since prostaglandin (PG) E2 has been identified in the bone lesions of LCH, indomethacin, a potent PG inhibitor, may be useful in patients with symptomatic bony LCH. The drug, at a dose of 1–2.5 mg/kg/day for 1–16 weeks (mean 6 weeks), induced complete remission in eight of ten patients treated in an older series, six with unifocal bone and four with multifocal bone LCH [21]. Braier et al. evaluated the nonrandomised use of oral indomethacin (2 mg/kg/d) in patients with symptomatic single-system bone LCH. Thirty-eight patients were treated for a median of 4 months. Criteria of nonactive disease (NAD) after 8 weeks of treatment were no pain, no soft tissue involvement, no increase of size or no new bone lesions. Twenty-two patients were treated at diagnosis: 18 showed NAD after initial treatment; 3 improved and were with NAD after treatment with indomethacin, steroids or radiotherapy; and 1 patient developed progressive bone disease and he was with NAD after treatment with steroids and chemotherapy. Sixteen patients were treated after reactivation, and all were with NAD after initial treatment: 5 reactivated again and 4 remained with NAD after retreatment with indomethacin. Indomethacin was overall well tolerated, but patients need to be monitored for gastrointestinal side effects [22]. In summary, indomethacin can be effective in reactivated as well as newly diagnosed single-system bone disease. Whether it has any role in slowing disease progression or in preventing late sequelae, or only acts as an analgesic agent, remain to be determined. The optimal duration of indomethacin therapy, however, is yet to be defined. The Histiocyte Society LCH-IV International trial is currently studying the randomised use of indomethacin (2 mg/kg/day with gastric protection) versus 6-mercaptopurine and MTX as continuation therapy for 2 years after second-line treatment with VCR/prednisone and Ara-c in “non-risk” LCH patients.

Bisphosphonates

Bisphosphonates are analogues of pyrophosphates that act by inhibiting osteoclasts and preventing bone resorption [23]. They can be beneficial in bone LCH mostly through a reduction in LCH cell proliferation and reduced formation and function of osteoclasts [24]. Bisphosphonates provide an analgesic effect by decreasing cytokine and prostaglandin production and through an increase in bone structure [24]. In 1989, bisphosphonates were initially found to be effective in multifocal eosinophilic granuloma of the bone [25]. Several other reports confirmed subsequently the beneficial effects of these drugs in bony LCH [24, 26–28]. Da Costa et al. showed, in 2005, that multinucleated giant cells (MGCs) in LCH express several osteoclast markers that are responsible for producing osteoclast-inducing cytokines [29]. These osteolytic cytokines, tumour necrosis factor (TNF)- α and interleukin-1, and other matrix-degrading enzymes produced by the MGCs, are involved in inducing osteolysis.

A nationwide survey from Japan investigated the role of pamidronate in 16 children with reactivated bone LCH; pamidronate was effective in the resolution of bone lesions in 75% of children with a low toxicity profile [30]. More recently, results of a multicentre retrospective study of 13 patients (adults and children) with LCH who had received bisphosphonates, either at diagnosis or at disease reactivation, were reported. Ten patients had unifocal bone disease, while 3 had bone lesions as part of MS-LCH. Four patients received pamidronate, 3 received alendronate and 6 received zoledronate. Significant pain relief was obtained in almost all patients, and 12 patients (92%) achieved resolution of active bone lesions and 10 of these had NAD for 3.5 years. One patient had significant response in skin and soft tissue lesions following pamidronate therapy [31]. Pamidronates have been previously shown to have some efficacy in non-ostotic LCH lesions such as skin and soft tissue lesions [30]. This is compatible with the findings of da Costa et al. who showed the presence of CD68+ osteoclast-like MGCs in non-ostotic lesions that

also co-expressed CD1a [29]. Bisphosphonates were well tolerated in this series except for few episodes of fever after IV pamidronate in one patient and mild elevation in parathyroid hormone (PTH) levels after alendronate in another patient. The other rare but significant side effect associated with IV bisphosphonates is osteonecrosis of the jaw (ONJ) [32], but none of the patients in this series developed ONJ. Other reported side effects of bisphosphonates include nephrotic syndrome with renal failure [33] and visual adverse effects [34].

In summary, both oral and IV bisphosphonates appear to be a safe and effective option to treat bone lesions in LCH at diagnosis and at reactivation, in adults as well as in children. Patients need to have adequate vitamin D repletion prior to starting bisphosphonate therapy with monitoring of serum calcium and PTH pre- and during bisphosphonate therapy. Whether bisphosphonates can help in preventing progression to late CNS or endocrine complications remain to be determined. Prospective long-term studies will be required to answer this question, as well as to determine the optimal dose and duration of therapy and long-term efficacy and safety of bisphosphonates in LCH patients.

Chemotherapy

Anecdotal reports of daily oral 6-mercaptopurine and weekly oral methotrexate in relapsed/refractory low-risk LCH have been reported. A previous report of few cases from Denmark confirmed the benefit and low toxicity of this combination in children with relapsed skin and multifocal bone LCH [19]. Similarly, oral chemotherapy with alternate-day prednisone and weekly MTX was effective and non-toxic in patients with low-risk LCH [17]. Furthermore, intermediate-dose methotrexate (100–175 mg/m² IV every 10–14 days) was found to be effective and well tolerated in children with recurrent low-risk LCH [35].

Treatment of Relapsed and Refractory MS-LCH

Chemotherapy

Based on the recent suggestion that LCH cells derive from immature myeloid precursors [36], it

is reasonable to conclude that nucleoside analogues such as cytarabine, cladribine and clofarabine may have activity against LCH.

Cytarabine (Ara-C) monotherapy or in combination with vincristine and prednisone have been shown to be effective in children with low-risk and RO+ MS disease, either as front-line or as salvage therapy [37–40]. Egeler et al. treated 18 children with new and relapsed LCH (8 RO+ and 10 RO-) with Ara-C, vincristine (VCR) and prednisone (PRED) and observed complete remissions in 13 patients (72%). Two of those with risk organ involvement died within 3 months of therapy. The treatment was overall well tolerated with only two episodes of fever/neutropenia and bacteremia [37]. The Japanese LCH Study Group (JLSG) 02 trial (2002–2009) used a 6-week induction regimen, in patients with MS-LCH, consisting of Ara-C/VCR/PRED followed by an extended maintenance therapy (to 48 weeks) and added cyclosporine to the salvage regimen. Patients with risk organ involvement who were refractory to treatment at week 6 had a mortality rate of 30% [38]. The overall response rate at week 6 was 76% compared to 66% with the vinblastine-prednisone-based LCH-III trial and a long-term mortality of 8% compared to 15% with LCH-III; third and fourth grade cytopenias were, however, much higher (80%) than those seen with the LCH-III trial (28%). The cytopenias, mostly neutropenias, were transient and no life-threatening complications were observed [2, 38]. Stratum 2 of the ongoing LCH-IV trial, designed for RO- MS patients who fail first-line therapy or who initially respond but subsequently develop a reactivation, is studying a 6-month reinduction with Ara-C/VCR/PRED followed by a randomized 18-month continuation with oral indomethacin versus oral 6-mercaptopurine and methotrexate.

An institutional retrospective series reported the successful use of Ara-C monotherapy (100 mg/m²/d x 5d for 6 months) in adults with bone LCH with a relapse rate of only 21%, as opposed to 59% with cladribine and 84% with vinblastine/prednisone [39]. A regimen containing intermediate-dose cytarabine (100–170 mg/m²/day IV for 3–5 days every 3–4 weeks), either as monotherapy or in combination with VCR or with VCR/PRED, was reported by Simko et al. to

be effective in treating LCH patients in first or greater relapse with a 59% (13 of 22) response rate, including 4 of 6 patients who were RO+. The estimated 3-year progression-free (PFS) and overall survival (OS) were 41% and 100%, respectively. The PFS at 1 year was 60% with no difference between RO+ and RO- patients [40]. Toxicity was limited to neutropenia, fever or infrequent infections requiring hospitalisation. The same group tested the efficacy of IV cytarabine (100–170 mg/m²/day IV over 3–5 days, every 3–4 weeks) in 16 patients with newly diagnosed LCH and found that 14 of them (88%) had NAD after 1 year of therapy. Only one patient progressed while on therapy and three (19%) relapsed within 6 months after therapy completion; the OS rate was 100% [40]. A phase III trial at Baylor College of Medicine is currently comparing cytarabine monotherapy versus vinblastine/prednisone in patients with LCH aged <21 years. A longer follow-up period will be required, however, to fully evaluate the impact of this strategy on the rates of reactivation and permanent sequelae.

Nucleoside Analogues

Cladribine, or 2-Chlorodeoxyadenosine (2-CdA), is a nucleoside analogue with a well-known activity in children with relapsed acute myeloid leukaemia (AML) and a response rate of 59% when used as single agent [41]. 2-CdA is resistant to the enzyme adenosine deaminase (ADA), but not to deoxycytidine kinase (dCk) which metabolises deoxyadenosine in ADA-deficient cells. This will cause the accumulation of chlorinated deoxyadenosine nucleotides which can be incorporated into the DNA of dividing cells and a subsequent arrest in the S phase of the cell cycle and activation of apoptosis [42]. Normal mature monocytes express high levels of dCk, and *in vitro* studies have found 2-CdA to be a highly selective anti-monocyte agent which results in decreased monocyte function and decreased IL-6 secretion [43]. Since tissue histiocytes are derived from the same stem cells as circulating monocytes, 2-CdA has been reported as an active agent in the treatment of LCH and other histiocytic

disorders. In adults with relapsed LCH, 2-CdA was associated with excellent clinical responses with an overall response rate of 82% [44].

In children with chronically relapsing low-risk disease, 2-CdA appeared to be very effective with responses in >90% of the patients although further reactivations still occur [45–48]. 2-CdA penetrates the blood-brain-barrier producing cerebrospinal fluid (CSF) levels that are 25% of plasma; thus another benefit of this drug is its effect on active CNS LCH including the anecdotal reversal of diabetes insipidus [49].

Results of the LCH-Salvage-98 protocol of the Histiocyte Society showed that single-agent low-dose 2-CdA (5 mg/m²/d for 5 days per month for 6 months) was effective in inducing a 22% response rate in RO+ patients and 62% in RO- patients who were refractory to front-line therapy. However, only 4% of all patients had NAD by week 24. The 2-year predicted survival (2-year pSU) in RO+ patients was 48% ± 0.08% from the start of 2-CdA (23 of 45 RO+ patients died); the 2-year pSU was 97% ± 0.03% for patients who were RO- at the start of 2-CdA (1 RO- patient died after HSCT) [50]. Prolonged myelosuppression was a limiting factor particularly in RO+ patients and most reported infections occurred in this group; one risk patient developed an EBV-induced lymphoproliferative disease after treatment with 2-CdA, but he was heavily pretreated with many immunosuppressive drugs. Very low toxicity was reported in the low-risk group with only one patient developing a prolonged EBV infection. The study conclusion was that 2-CdA is an active drug in LCH but that as monotherapy it has a higher response rate in patients with low-risk MS or MFB disease. Approximately 30% of risk patients seem to respond to 2-CdA, and mortality from disease in this group is low. Risk patients who fail to respond to 2-CdA, however, have a high risk of mortality [50].

A major limitation of this drug is its toxicity which includes transient myelosuppression and prolonged T-cell immunosuppression. Few serious infections have been reported in patients receiving 2-CdA including recurrent herpes zoster and CMV pneumonia [51]. Others have reported late effects such as chronic myelomonocytic leukaemia (CMML) and EBV-induced

lymphoproliferative disorder after therapy with 2-CdA [44]. Continued surveillance of patients with LCH treated with 2-CdA for the development of late malignancies, such as monosomy 7 and solid tumours (glioblastoma, mucoepidermoid parotid carcinoma), is suggested. Other less common complications after therapy with 2-CdA include early and delayed onset of severe autoimmune hemolytic anaemia, aplastic anaemia [52] and severe skin rash [53]. A careful risk-benefit assessment needs to be performed in each case due to the potential risk of serious side effects from 2-CdA.

Due to the effects of 2-CdA on DNA metabolism, it is reasonable to conclude that it is likely to be synergistic with other cytotoxic drugs and that combination therapy is likely to be more effective than 2-CdA alone. The cytotoxic effect of Ara-C is due to the active metabolite 5'-triphosphate, Ara-CTP [54] and the combination of Ara-C and 2-CdA which results in higher intracellular concentration and increased retention time of Ara-CTP in vitro and in vivo [55]. This synergy and the minimal long-term toxicity of Ara-C make this an attractive combination in resistant LCH cases. An older small series of 10 patients with progressive LCH showed encouraging results. Treatment consisted of at least two courses of Ara-C (1000 mg/m²/d) and 2-CdA (9 mg/m²/d) for 5 days every 4 weeks. Amongst the seven patients who received two courses of therapy, disease activity decreased in six patients and control of disease was achieved in all seven patients after a median delay of 5.5 months.

Significant pancytopenia occurred, however, in all patients. Two septic deaths occurred after the first course of 2-CdA/Ara-C; a third patient was withdrawn from the trial after the first course and subsequently died after allogeneic HSCT [56]. Another small series using the same combination showed similarly encouraging results in relapsed paediatric patients with LCH and risk organ involvement [57]. The Histiocyte Society LCH-S 2005 protocol used a combination of high-dose Ara-C (1 gr/m²/day) and 2-CdA (9 gr/m²/day for 5 days per cycle) in 27 very-high-risk LCH patients (median age 0.7 months).

There was a 92% response rate after 2 cycles (7% had NAD and 85% had AD better); four patients relapsed, some of whom were salvaged by HSCT. There were four deaths (15%), two from toxicity and two from disease progression. Although this regimen proved to be very effective, it was associated with significant toxicity and requires excellent supportive care measures [58]. Rosso et al. used the same combination of drugs and treated a series of nine patients with progressive MS-LCH with a lower dose of 2-CdA (5 mg/m²/d) and a much lower dose of cytarabine (100 mg/m²/d for 4 days per cycle). Six patients achieved remission and one a partial response; three patients reactivated. The overall probability of survival at 3 years was 73% [59]. The studies are not strictly comparable as only five of the nine patients treated in the Rosso series had progressive disease at 6 weeks of LCH therapy, a known very poor prognostic factor. However, these results are encouraging and suggest a worthwhile salvage strategy, particularly for sites that do not have the supportive care required for the high-dose therapy. Stratum 3 of the ongoing Histiocyte Society LCH-IV trial is currently evaluating the efficacy of salvage with 2-CdA/Ara-C combination in MS-LCH patients with risk organ involvement who fail to respond to first-line treatment or who develop reactivation after initial response.

Clofarabine is a second-generation nucleoside analogue with activity in refractory AML [60]. The drug was designed to improve the efficacy and minimise the toxicity of its congeners cladribine and fludarabine. While fludarabine triphosphate mainly inhibits DNA polymerases and cladribine triphosphate particularly inhibits ribonucleotide reductase, clofarabine triphosphate inhibits both DNA polymerases and ribonucleotide reductase in addition to inducing apoptosis through release of mitochondrial cytochrome C [61]. Small case series have shown single-agent clofarabine to be a successful salvage therapy in LCH patients (RO+ and RO-) who failed to achieve durable responses with cladribine or cytarabine [62–64]. Simko et al. reported a one-year progression-free survival of 76% in 11 LCH

patients who had failed a median of three previous chemotherapy regimens, and most patients (64%) had a complete response after 6 months of clofarabine at 25 mg/m²/day for 5 days every 28 days. All patients developed grade 4 neutropenia, and five developed grade 3 bacterial infections [62]. Data from phase I leukaemia studies showed that the maximum tolerated dose of clofarabine in children was 52 mg/m²/day for 5 days. Most patients in the LCH series were treated with either 30 or 25 mg/m²/day (5 days/cycle) for 6 months, and some patients received filgrastim. Prolonged and cumulative cytopenias were not seen, likely because of the lower doses of clofarabine in LCH compared to leukaemia studies. Another issue with clofarabine is its high cost;

however, this could possibly be justified by the potential to avoid HSCT in these refractory patients. A summary of the largest salvage therapy studies for LCH are summarised in Table 6.1. A phase II study of clofarabine in patients with recurrent or refractory LCH (LCH-CLO) is currently being conducted by the North American Consortium for Histiocytic Disorders (NACHO).

In summary, nucleoside analogues have an excellent activity in treating resistant LCH, with dose-dependent effects with regards to therapeutic efficacy and toxicity. Patients with very resistant high-risk LCH despite multiple salvage therapies can be potentially be cured with haematopoietic stem cell transplant.

Table 6.1 Salvage therapies in children with relapsed/refractory LCH

Regimen (Ref)	# of patients	Response		Outcome		Toxicity	
ARA-C/VCR/PRED [40]	22	59%		1-year PFS	60%	Neutropenia	50%
				3-year PFS	41%	Fever	19%
				3-year OS	100%	Infections	12%
ARA-C/VCR/PRED [37] ^a	18	72%		OS	89%	Mild myelosuppression	100%
		RO+	63%			Infections	11%
		RO-	80%				
ARA-C/2-CdA [56]	10	70%		3-year OS	70%	Febrile neutropenia	100%
						Infections	30%
						Neuropathy	30%
2-CdA (5 mg/m ²) [50]	83	RO+	22%	2-year pSU = 48% (RO+)			
		RO-	62%	2-year pSU = 97% (RO-)			
ARA-C(1 g/m ²) + 2-CdA (9 mg/m ²) [58]	27	92%		5-year OS	85%	Febrile neutropenia	100%
				Reactivation	22%	Enteritis	18%
						Infections	11%
						Aspergillosis	11%
						TRM	15%
ARA-C(100 mg/m ²) + 2-CdA 5 (mg/m ²) [59]	9	78%		3-year OS	73%	Febrile neutropenia	100%
				Reactivation	33%	Infections	11%
Clofarabine [40]	11	73%		1-year PFS	76%	Neutropenia	100%
				1-year OS	91%	Infections	45%
						Vomiting	29%
						Drug-related fever	9%
						Capillary leak syndrome	9%

ARA-C cytarabine, VCR vincristine, PRED prednisone, PFS progression-free survival, OS overall survival, pSU predicted survival, RO risk organ, 2-CdA cladribine, TRM treatment-related mortality

^aNewly diagnosed and relapsed LCH

Haematopoietic Stem Cell Transplant

Patients with high-risk LCH, whose disease is refractory to conventional chemotherapy, have a poor outcome with 2-year survival rates <30% [65]. Attempted salvage with allogeneic haematopoietic stem cell transplantation (HSCT) has been explored in these patients because of the strong immunomodulatory effects of HSCT [66, 67]. An initial review of the literature identified 29 paediatric patients with high-risk disease who underwent allogeneic HSCT using myeloablative conditioning [68]. The overall survival was 48%, but transplant-related mortality (TRM) was exceedingly high, at 45%.

Reduced-intensity conditioning (RIC) HSCT regimens have been developed to reduce morbidity and TRM in paediatric patients with non-malignant disorders, particularly in patients with significant comorbidities [69]. This approach was utilised by Steiner et al. in nine high-risk LCH patients [68]. The conditioning was generally well tolerated. Two patients died at 50 and 69 days after transplantation, and seven patients survived free of disease to a median follow-up of 390 days, including one patient who experienced graft rejection with autologous reconstitution. Similarly, good outcomes with RIC regimens and allogeneic transplantation have also been confirmed in a further 13 LCH patients [70–72]. A prospective trial set up to examine the use RIC transplant regimens in LCH (LCH-HCT-2006) had to be closed due to poor recruitment, although many centres utilised the proposed RIC protocol.

While RIC may reduce high rates of TRM following HSCT, some studies in acute myeloid leukaemia have suggested an increased risk of relapse after RIC HSCT [73]. This may be important as the observation made by Badalian-Very et al. that 57% of archived specimens of LCH tissue carried a BRAF mutation [1] and subsequent studies showing that high-risk LCH patients carried BRAF mutations in both bone marrow CD34+ progenitors and circulating CD11c+ and CD14+ blood cells suggests that LCH might be a myeloid neoplasm [36]. Thus, in order to examine

the influence of conditioning intensity on outcome of transplant in LCH, a retrospective analysis was performed of HSCTs reported to the two largest transplant registries: Center for International Blood and Marrow Transplant Research (CIBMTR) and the European Blood and Marrow Transplant (EBMT) [74]. Eighty-seven patients with high-risk LCH underwent HSCT between 1990 and 2013. Prior to the year 2000, most patients underwent HSCT following myeloablative conditioning (MAC): only 5 of 20 patients (25%) survived with a high rate (55%) of transplant-related mortality (TRM). After the year 2000, an increasing number of patients underwent HSCT with RIC, 49/67 (73%) patients survived; however, unlike the situation in haemophagocytic lymphohistiocytosis (HLH) [75], the improved survival was not overtly achieved by the introduction of RIC regimens with similar 3-year probability of survival after MAC (77%) and RIC transplantation (71%) (Fig. 6.1). The improvement over time was most likely due to improved donor selection and general supportive care, the only caveat to this being the possibility that clinicians elected to treat higher risk patients with RIC procedures due to concern over the risk of TRM, which might also explain the apparent lack of benefit from RIC in terms of TRM. Relapse rates were higher after RIC compared to MAC regimens (28% vs 8%, $P = 0.05$) (Fig. 6.1), although most patients relapsing after RIC transplantation could be salvaged with further chemotherapy. The majority of patients achieved 100% donor chimerism, and amongst those with mixed donor chimerism, there was a significant increase in disease progression or relapse; this is again reminiscent of the behaviour of a malignant disease, although, amongst six patients who had autologous reconstitution following graft rejection, only one had recurrence of LCH: a finding previously reported in a single patient by Steiner et al. [68]. The majority of patients achieved sufficient donor chimerism to cure a genetic disease, such as HLH, where 10–20% donor chimerism usually secures ongoing disease remission [76]. Relapse despite good levels of donor chimerism and continuous remission despite autologous reconstitution distinguish LCH from HLH where

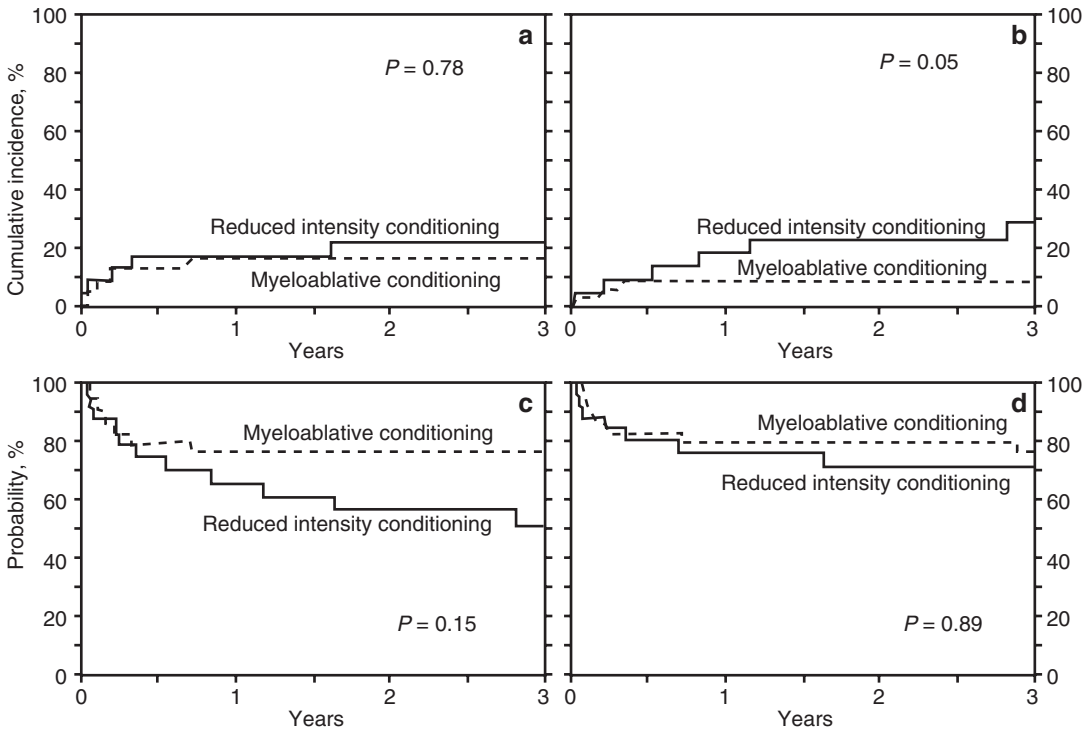


Fig. 6.1 (a) The cumulative incidence of transplant-related mortality by conditioning regimen intensity. (b) The cumulative incidence of disease relapse by conditioning regimen intensity. (c) The probability of

disease-free survival by conditioning regimen intensity. (d) The probability of overall survival by conditioning regimen intensity (Reproduced from Veys et al. [74])

disease control would be expected with mixed donor chimerism and disease recurrence in all patients following graft rejection [77].

If LCH is confirmed to be a myeloid malignancy and on the basis of the findings of the above study, another approach to HSCT in LCH might be via the use of myeloablative but reduced toxicity protocols, such as the addition of thiotepa to fludarabine and melphalan [78] or treosulfan/fludarabine/thiotepa [79].

Another question that remains unanswered is the precise indication and/or timing of HSCT in LCH. Kudo et al. reported a 10-year overall survival rate amongst nine patients with risk organ involvement at diagnosis of 57% (7/9 undergoing HSCT within 12 months of diagnosis), whereas six patients without risk organ involvement have all survived with no evidence of disease (3/6 patients undergoing HSCT 7 years or later after diagnosis) [72]. As a comparison Bernard et al.

reported that 7/10 patients with refractory LCH had achieved sustained complete remission after treatment with 2-chlorodeoxyadenosine and cytarabine alone [56]. In the study by Kudo et al., two patients who failed to respond to the combination of 2-CdA and cytarabine underwent HSCT, and one is alive with no disease after RIC transplantation [72]. Consequently, both 2-CdA/cytarabine salvage therapy and HSCT are reasonable approaches in refractory LCH with disease in risk organs. At the authors' institutions, the current policy is to treat refractory MS-LCH with 2-CdA and cytarabine or with single-agent clofarabine. At the same time, a search is initiated for potential HSCT donors. If there is no response after two courses of salvage chemotherapy and a donor has been identified, patients proceed to HSCT. If there is a partial response to initial treatment, four courses of 2-CdA/cytarabine are given and HSCT considered if response is

inadequate. The situation regarding indication and timing of HSCT in LCH will become even more complicated with the introduction of targeted therapies [80].

In conclusion HSCT may be a curative approach in three out of four patients with high-risk LCH refractory to chemotherapy. The optimal timing of HSCT and choice of HSCT conditioning remain to be determined but should preferably commence prior to the development of significant comorbidities and include reduced intensity or reduced toxicity approaches. Further information may be forthcoming from the LCH-IV International Collaborative Treatment Protocol.

Novel Therapies for Relapsed/ Refractory LCH

The fact that LCH cells originate from immature myeloid cells may also explain the possible efficacy of hydroxyurea in relapsed LCH. Hydroxyurea (HU) is a myelotoxic ribonucleotide reductase inhibitor commonly used for the treatment of patients with chronic myeloid leukaemia (CML). Zinn et al. recently reported the successful use of this drug in 15 LCH patients (adults and children with skin or bone disease, alone or in combination with lymph node) who had refractory/recurrent disease or had intolerance to previous therapies. HU was given for a median time of 10 months (range, 1–24 months). Twelve of 15 patients (80%) had either partial or complete responses with minimal side effects. Thus, HU could be considered as maintenance therapy in resistant low-risk cases, also, because of the added benefits of low cost and ease of administration [81].

Immunomodulatory Therapy

Inflammatory cytokines, like tumour necrosis factor alpha (TNF- α), are an important cause of morbidity in LCH. TNF- α inhibitors (receptor blockers or monoclonal antibodies) can reduce circulating levels of the bioactive TNF- α and to a lesser degree IL-6 and IL-1 [82]. Thalidomide

has shown activity in localised and disseminated skin LCH, in both children and adults, through inhibition of TNF- α , through enhancement of T-cell co-stimulatory activity and through its antiangiogenic and anti-inflammatory activities [83]. It has shown efficacy in patients with cutaneous, mucosal and vulvar LCH [84]. In many patients reported so far, however, LCH lesions tend to recur within variable periods after stopping therapy. Excellent responses of cutaneous and anogenital LCH lesions to thalidomide plus interferon have also been published [85]. A phase II trial of thalidomide in 16 children and adults with refractory LCH showed a 70% response (four complete and three partial responses) in patients with low-risk LCH, while there was no response in all six patients with risk organ involvement with all patients dying from pulmonary, liver or bone marrow failure [86]. The main advantages of thalidomide, in comparison with chemotherapy, are the lower frequency of myelosuppression, alopecia and nausea. However, other dose-related toxicities can still occur and can be debilitating such as neuropathy, somnolence, skin and mucus membrane dryness, skin rash and oedema [86, 87]. Initial treatment doses of thalidomide range between 50 and 200 mg/day with maintenance doses as low as 25 mg twice weekly. Responses can be seen sometimes within 1–3 months [87].

Lenalidomide is another TNF- α inhibitor with antiangiogenic and anti-inflammatory properties. It is a functional analogue of thalidomide but with increased efficacy and less side effects, although myelosuppression is more common and can be a dose-limiting factor [88]. Lenalidomide has shown efficacy in adults with relapsed MS-LCH without significant toxicity [88–90]. Complete remission with a combination of lenalidomide, dexamethasone and etoposide has been reported in an adult with multiply relapsed MS-LCH [91]. Paediatric experience with lenalidomide is, however, more limited. Pulses of lenalidomide and dexamethasone have been used in four children with very resistant LCH. All patients had a complete response at the 15–18 month follow-up time, and no major side effects were reported [92]. One important

consideration is that lenalidomide is not only less toxic but also less expensive than the cladribine/cytarabine combination (\$1000 vs \$7500). A phase II clinical trial of lenalidomide in adult histiocytic disorders is currently enrolling patients.

The literature on other TNF- α inhibitors such as etanercept and infliximab has shown conflicting results. Etanercept, a soluble TNF receptor blocker, was given to an infant with nonresponsive MS-LCH with improvement of clinical symptomatology and no side effects. Nevertheless, the disease relapsed again when the drug was stopped after 6 months but then resolved when therapy was restarted [93]. Chohan et al. reported the successful treatment of an adult with refractory LCH involving the CNS with infliximab [94]. Others, however, have shown further LCH reactivation after treatment with infliximab [95]. Although no side effects were observed with this class of drugs, the associated immunosuppression may predispose to opportunistic infections and secondary lymphoproliferative disorders [96].

Targeted Therapy

Tyrosine Kinase Inhibitors

Imatinib mesylate is a competitive Bcr-Abl tyrosine kinase inhibitor that is very effective for the treatment of patients with CML. It has also been shown to inhibit platelet-derived growth factor receptors (PDGFRA and PDGFRB) and KIT and can inhibit the differentiation of CD34+ progenitors into dendritic cells [97]. Caponetti et al. showed that a group of patients with LCH were positive for PDGFRA and suggested that they could benefit from treatment with tyrosine kinase inhibitors [98]. Refractory cases of MS-LCH with cerebral and lung involvement have shown some response to imatinib, although with mixed results [99–101]. Imatinib has shown similar activity in other histiocytic disorders such as Rosai-Dorfman disease and Erdheim-Chester disease, although responses have been variable [99].

Afuresertib is an oral, potent, highly selective adenosine triphosphate, competitive pan-AKT inhibitor with preclinical and clinical activity

against hematologic malignancies [102]. AKT, also known as protein kinase B, is a serine/threonine protein kinase regulating important cellular processes, including survival, proliferation, tissue invasion and metabolism [103]. Increased AKT phosphorylation has been identified in a small number of LCH biopsy specimens [104]. Further, the differentiation of CD1a + dendritic cells from CD34+ haematopoietic cells has been shown to be dependent on PI3K signalling, which can be reduced by AKT inhibition [105]. A phase II study of afuresertib included ten patients with refractory/recurrent and seven with newly diagnosed LCH. Most patients were treated for more than 24 weeks. The overall response rate was 33% in treatment-naïve patients and 28% in patients with recurrent/refractory LCH, which did not meet the Bayesian criteria for efficacy. Side effects included mild to moderate GI symptoms, fatigue, pain and severe soft tissue necrosis [106].

BRAF/MEK Inhibitors

The identification of *BRAF-V600E* and *MAP2K1* mutations in LCH patients has made the possibility of targeted therapies an obvious strategy in resistant disease. Furthermore, in paediatric LCH, *BRAF-V600E* mutation has been recently associated with high-risk disease, permanent sequelae and a poor short-term response to conventional chemotherapy [107]. The *BRAF-V600E* inhibitor, vemurafenib, has been shown to induce deactivation of the proliferative RAS/RAF/MEK/ERK pathway in *BRAF-V600E*-driven melanoma. The first large histiocytosis series was published by Haroche et al. who reported dramatic responses to vemurafenib in eight adult patients with refractory BRAF-mutated ECD, four of whom had concurrent LCH. Favourable responses were seen despite decreasing the dose of vemurafenib to 50% due to severe cutaneous adverse events seen in the first three patients, one of whom developed squamous cell carcinoma (SCC). All other patients showed a continued response at a median 10 months (range, 6–16) on vemurafenib [108]. Single case reports have also described favourable responses in an adult with CNS LCH/ECD [109] and two adults with severe

refractory skin LCH who achieved a complete remission within 6 months of starting vemurafenib [110, 111]. The basket study was designed to treat non-melanoma patients having a wide variety of diseases with BRAF-V600E mutation and included several patients with LCH and ECD which were analysed together. The overall response rate amongst the LCH/ECD cases was 43% (6 of 14), and 12 of 14 patients had some disease regression, while symptomatic improvement occurred in all patients. No patient progressed while on vemurafenib; four patients discontinued the drug because of side effects and one of them progressed while off therapy [112].

In children, a dramatic response to vemurafenib has been published in an infant with refractory MS-LCH, but when the drug was discontinued after 90 days of treatment, she had a skin reactivation. Retreatment with vemurafenib was effective again [113]. Another child with progressive CNS-ND LCH had a favourable response to vemurafenib [114]. A recent multi-centre retrospective study showed vemurafenib to be very active in systemic RO+ refractory LCH with *BRAF-V600E* mutation (12 of 13 patients had a complete response and 1 partial response by week 6), while it had limited impact on CNS-ND LCH [115].

Although secondary resistance to vemurafenib is observed in most melanoma patients [116], most case series and case reports of patients with histiocytic disorders showed no resistance to the drug (Table 6.2). The only published report of vemurafenib resistance in LCH was in an adult

patient who had a very favourable response to vemurafenib for 20 months at which time she had progressive disease [117]. In melanoma studies, vemurafenib has been associated with severe toxicity profile including cutaneous SCC in over 30% of patients, pancreatic adenocarcinomas and secondary melanomas [118, 119]. The toxicity profile in the LCH/ECD patients was similar to that seen in melanoma trials (Table 6.3). With regards to the dose of vemurafenib, it seems that 20 mg/kg/day (2x 10 mg/kg) is enough in most patients, and at this dose the skin toxicity is minimal (Personal communication, Milen Minkov).

Dabrafenib, an oral BRAF inhibitor, selectively binds to and inhibits the activity of *BRAF-V600E* and is approved for use in patients with *BRAF-V600E*-mutated melanoma. It has similar efficacy to vemurafenib, although at a higher cost. Two children with *BRAF-V600E*+ ND-CNS LCH, with a few years history of neurologic decline, had rapid clinical and radiological improvement after dabrafenib treatment [120]. Although it shares many of the same toxicities as vemurafenib, it seems to be more tolerated with a lower frequency of SCC (7–10% vs 20–44%) and other cutaneous toxicities and no cardiac or liver toxicity [121] (Table 6.3). Patients are advised to have a baseline dermatology assessment and routine follow-up visits; it is very important to keep the skin moisturised regularly, to avoid long and warm baths that can cause skin dryness and to use a powerful sunscreen (above 50 SPF). Paediatric liquid formulations have been developed, and phase I/II trials are ongoing for

Table 6.2 Published treatment of LCH with vemurafenib

Patients features	#of patients	Outcome	Reference
ECD BRAF V600E+ (4 with LCH)	8	Major responses for the duration of follow-up (6–16 mos)	Haroche et al. [108]
Brainstem involvement by ECD/LCH	1	Major response	Euskirchen et al. [109]
ECD or LCH BRAF V600+ (basket study)	14	1 CR 5 PR 12 some disease regression 14 symptomatic improvement	Hyman et al. [112]
8 month old with MS-LCH, BRAD V600E+	1	Major response; recurred off drug; successfully retreated	Heritier et al. [113]
Adult with LCH, BRAF V600E	1	Major response; progressed on drug at 20 mos	Gandolfi et al. [117]

Courtesy of Dr. Barrett Rollins

Table 6.3 Comparison of the different side effects of BRAF inhibitors

	Vemurafenib [108, 109, 112–117]	Dabrafenib [121]
Toxicity hyperkeratosis	24%	37%
Cutaneous squamous cell carcinoma ^a	20–44%	7–10%
Skin rash	37–78%	17–27%
Fatigue	61%	5%
Arthralgia	67%	33%
Hypertension	44%	NR
Alopecia	36–45%	22%
Diarrhoea	33%	11%
Nausea	33%	20%
Photosensitivity	40–50%	3%
Fever	19%	24%
Hyperglycaemia	NR	50%
Hypophosphatemia	NR	37%
Hypokalaemia	Reported	Reported
Hyponatremia	Reported	2%
Acute renal failure	Common	<1%
Elevated LFTs	17%	NR
QTc prolongation	Uncommon	NR

NR no response, LFTs liver function tests

^aUsually well differentiated and easily resected

dabrafenib (NCT01677741); the recommended dose of dabrafenib in children is 5.25 mg/kg/day (divided in 2 doses/day). Results in children with resistant LCH receiving this drug are pending.

Similar reports of efficacy using MEK inhibitors have been recently published in adult ECD patients. Both patients were refractory to multiple previous therapies and harboured *MAP2K1* mutations (K57 N and Q56P). Both patients had a major and prolonged response to trametinib and cobimetinib, respectively [122]. However, some *MAP2K1* mutations that occur in LCH, i.e. C121S, have been shown to be resistant to MEK inhibitors, and this suggests that not all *MAP2K1* mutations have the same sensitivity to MEK inhibitors [123]. Recent melanoma studies have shown that progression-free and overall survival in patients treated with trametinib are comparable to vemurafenib, but the significant benefit with trametinib is that it is not associated with squamous cell carcinoma [124].

The development of cutaneous toxicity of BRAF inhibitors could be explained by the paradoxical activation of the MAPK pathway in wild-type BRAF cells. The presence of oncogenic

RAS mutations causes the formation of homo- or hetero-RAF dimers in wild-type BRAF cells and subsequent activation of MEK which is the major cause of cutaneous side effects of BRAF inhibitors. The high prevalence of RAS mutations (30–70%) in patients who developed SCC with BRAF inhibitor treatment is much higher than that in patients who developed SCC without BRAF inhibitor (3.2%). As a consequence, combination therapy of BRAF and MEK inhibitors in melanoma patients has been shown to improve response to therapy and decrease cutaneous toxicity (especially SCC) compared to BRAF inhibitor monotherapy [121]. Future research studies should evaluate the role of MEK and ARAF inhibitors, as well as combined BRAF/MEK inhibitor therapy in patients with relapsed/refractory LCH.

Other side effects from BRAF inhibitors include acute renal failure, which seems to be related to a tubular interstitial injury, and are more common with vemurafenib than dabrafenib. Electrolyte abnormalities such as hypokalaemia and hyponatremia have been reported with both inhibitors, while hypophosphatemia has been reported only

with dabrafenib [125]. Cardiac toxicity such as QTc prolongation and left ventricular dysfunction, although rare, has been reported mainly with vemurafenib [126]. Ocular toxicity, such as transient retinopathy, has been reported with the use of MEK inhibitors either as monotherapy or in combination with BRAF inhibitors [127]. More studies are needed to determine the long-term safety of these drugs in the paediatric age group.

Although side effects like squamous cell carcinomas and adenomas may likely be tolerated in adults with life-threatening melanomas, the risk of these is hard to justify in children with LCH who almost universally can be cured with chemotherapy. New clinical trials are needed to test novel agents, like BRAF and BRAF/MEK inhibitors, and to test the combination of these with cytotoxic chemotherapy in LCH patients who have refractory or progressive disease after salvage therapy.

Future Directions

Novel therapies targeting other components of LCH pathogenesis require more research. The expression of CD52 by pathologic LCH cells suggests that alemtuzumab, an anti-CD52 monoclonal antibody, may represent a new potential targeted therapy for this disease [128]. Further, the adoption of alemtuzumab in the conditioning regimen for HSCT in high-risk LCH patients may be able to directly target LCH cells for a better disease control [68]. Expression levels of specific matrix metalloproteinase, MMP12, have been associated with disseminated LCH [129]; GM6001, a metalloproteinase inhibitor, may have potential therapeutic benefit in LCH especially in high-risk patients [130]. CR2113, a monoclonal antibody against CD1a, has antitumor activity against cancers expressing CD1a, like T-cell ALL, and might potentially have future therapeutic efficacy in LCH [131].

Conclusions

The treatment of patients with relapsed and refractory LCH has proved to be challenging, and the outcome of these cases, especially

those with risk organ involvement, has been poor. Histiocytoses world experts have yet to agree on a uniform standard of care for these patients. More time is needed to assess the long-term efficacy of nucleoside analogues on the rates of reactivation and permanent sequelae. Large studies are needed to understand what is the optimal BRAF inhibitor, dose and duration to use in children with relapsed/refractory disease and whether the combination of BRAF/MEK inhibitors is more effective in preventing further reactivation or development of resistance and less toxic particularly less tumorigenic. Further, the concept of combining BRAF or BRAF/MEK inhibitors with chemotherapy warrants future investigation.

References

1. Badalian-Very G, Vergilio JA, Degar BA, MacConaill LE, Brandner B, Calicchio ML, et al. Recurrent BRAF mutations in Langerhans cell histiocytosis. *Blood*. 2010;116(11):1919–23.
2. Gardner H, Minkov M, Grois N, Pötschger U, Thiem E, Aricò M, et al. Histiocyte Society. Therapy prolongation improves outcome in multisystem Langerhans cell histiocytosis. *Blood*. 2013;121(25):5006–14.
3. Minkov M, Steiner M, Pötschger U, Aricò M, Braier J, Donadieu J, et al. International LCH study group. Reactivations in multisystem Langerhans cell histiocytosis: data of the international LCH registry. *J Pediatr* 2008; 153(5):700–705., e1–e2.
4. Gardner H, Grois N, Pötschger U, Minkov M, Aricò M, Braier J, et al. Histiocyte Society. Improved outcome in multisystem Langerhans cell histiocytosis is associated with therapy intensification. *Blood*. 2008;111(5):2556–62.
5. Gardner H, Grois N, Arico M, Broadbent V, Ceci A, Jakobson A, et al. A randomized trial of treatment for multisystem Langerhans cell histiocytosis. *J Pediatr*. 2001;138(5):728–34.
6. Minkov M, Grois N, Heitger A, Pötschger U, Westemeier T, Gardner H, DAL-HX Study Group. Response to initial treatment of multisystem Langerhans cell histiocytosis: an important prognostic indicator. *Med Pediatr Oncol*. 2002;39:581–5.
7. Lindahl LM, Fenger-Grøn M, Iversen L. Topical nitrogen mustard therapy in patients with Langerhans cell histiocytosis. *Br J Dermatol*. 2012;166:642–5.
8. Hoeger P, Nanduri V, Harper J, Atherton D, Pritchard J. Long term follow up of topical mustine treatment

- for cutaneous Langerhans cell histiocytosis. *Arch Dis Child*. 2000;82:483–7.
9. Morren M, Vanden Broecke K, Vangeebergen L, Sillevs-Smitt JH, Van Den Bergh P, Hauben E, et al. Diverse Cutaneous presentations of Langerhans cell Histiocytosis in children: a retrospective cohort study. *Pediatr Blood Cancer*. 2016;63:486–92.
 10. Dodd E, Hook K. Topical Imiquimod for the treatment of childhood cutaneous Langerhans cell Histiocytosis. *Pediatr Dermatol*. 2016;33:e184–5.
 11. Okane D, Jenkinson H, Carson J. Langerhans cell histiocytosis associated with breast carcinoma successfully treated with topical imiquimod. *Clin Exp Dermatol*. 2009;34:e829–32.
 12. Kwon OS, Cho KH, Song KY. Primary Cutaneous Langerhans cell Histiocytosis treated with Photochemotherapy. *J Dermatol*. 1997;24:54–6.
 13. Do JE, Lee JY, Kim YC. Successful treatment of cutaneous Langerhans cell histiocytosis with targeted narrowband ultraviolet B phototherapy in an infant. *Clin Exp Dermatol*. 2009;34:e280–1.
 14. Ness MJ, Lowe GC, Davis DMR, Hand JL. Narrowband ultraviolet B light in Langerhans cell histiocytosis: a case report. *Pediatr Dermatol*. 2014;31:e10–2.
 15. Failla V, Wauters O, Caucanas M, Nikkels-Tassoudji N, Nikkels AF. Photodynamic therapy for multi-resistant cutaneous Langerhans cell histiocytosis. *Rare Tumors*. 2010;2:e34.
 16. Steen AE, Steen KH, Bauer R, Bieber T. Successful treatment of cutaneous Langerhans cell histiocytosis with low-dose methotrexate. *Br J Dermatol*. 2001;145:137–40.
 17. Womer RB, Anunciato KR, Chehrena M. Oral methotrexate and alternate-day prednisone for low-risk Langerhans cell histiocytosis. *Med Pediatr Oncol*. 1995;25:70–3.
 18. Carstensen H. Methotrexate and 6-mercaptopurine in the treatment of Langerhans cell histiocytosis (LCH). *J Invest Dermatol*. 2001;117:1020.
 19. Bank MJ, Rengtvad P, Carstensen H, Peterson BL. P53 expression in biopsies from children with Langerhans cell Histiocytosis. *J Pediatr Hematol Oncol*. 2002;24:733–6.
 20. Sander C, Kaatz M, Elsner P. Successful treatment of Cutaneous Langerhans cell Histiocytosis with thalidomide. *Dermatology*. 2004;208:149–52.
 21. Munn SE, Olliver L, Boradvent V, Pritchard J. Use of Indomethacin in Langerhans cell histiocytosis. *Med Pediatr Oncol*. 1999;32:247–9.
 22. Braier J, Rosso D, Pollono D, Rey G, Lagomarsino E, Latella A, et al. Symptomatic bone Langerhans cell Histiocytosis treated at diagnosis or after reactivation with Indomethacin alone. *J Pediatr Hematol Oncol*. 2014;11:e280. (Epub ahead of print)
 23. Shaw NJ, Bishop NJ. Bisphosphonate treatment of bone disease. *Arch Dis Child*. 2005;90:494–9.
 24. Farran RP, Zaretski E, Egeler RM. Treatment of Langerhans cell histiocytosis with pamidronate. *J Pediatr Hematol Oncol*. 2001;23:54–6.
 25. Elomaa I, Blomqvist C, Porkka L, Holmström T. Experiences of clodronate treatment of multifocal eosinophilic granuloma of bone. *J Intern Med*. 1989;225:59–61.
 26. Arzoo K, Sadeghi S, Pullarkat V. Pamidronate for bone pain from osteolytic lesions in Langerhans'-cell histiocytosis. *N Engl J Med*. 2001;345:225.
 27. Kamizono J, Okada Y, Shirahata A, Tanaka Y. Bisphosphonate induces remission of refractory osteolysis in langerhans cell histiocytosis. *J Bone Miner Res*. 2002;17:1926–8.
 28. Montella L, Merola C, Merola G, Petillo L, Palmieri G. Zoledronic acid in treatment of bone lesions by Langerhans cell histiocytosis. *J Bone Miner Metab*. 2009;27:110–3.
 29. da Costa CE, Annelis NE, Faaij CM, Forsyth RG, Hogendoorn PC, Egeler RM. Presence of osteoclast-like multinucleated giant cells in the bone and non-ostotic lesions of Langerhans cell histiocytosis. *J Exp Med*. 2005;201:687–93.
 30. Morimoto A, Shioda Y, Imamura T, Kanegane H, Sato T, Kudo K, et al. Nationwide survey of bisphosphonate therapy for children with reactivated Langerhans cell histiocytosis in Japan. *Pediatr Blood Cancer*. 2011;56:110–5.
 31. Chellapandian D, Makras P, Kaltsas G, van den Bos C, Naccache L, Rampal R, et al. Bisphosphonates in Langerhans cell histiocytosis: An international retrospective case series. *Mediterr J Hematol Infect Dis*. 2016;8(10):e2016033. (E-pub ahead of print)
 32. King AE, Umland EM. Osteonecrosis of the jaw in patients receiving intravenous or oral bisphosphonates. *Pharmacotherapy*. 2008;28:667–77.
 33. Lockridge L, Papac RJ, Perazella MA. Pamidronate-associated nephrotoxicity in a patient with Langerhans histiocytosis. *Am J Kidney Dis*. 2002;40:E2.
 34. Fraunfelder PW, Fraunfelder FT. Bisphosphonates and ocular inflammation. *New Engl J Med*. 2003;348:1187–8.
 35. Carroll C, Collier A, Malempati S, Whitlock J. Intermediate-dose methotrexate for recurrent Langerhans cell histiocytosis: a retrospective analysis. In: Proceedings of the 24th Annual Meeting of the Histiocyte Society, October 1–3, Berlin; 2008.
 36. Berres ML, Lim KP, Peters T, Price J, Takizawa H, Salmon H, et al. BRAF-V600E expression in precursor versus differentiated dendritic cells defines clinically distinct LCH risk groups. *J Exp Med*. 2014;211(4):669–83.
 37. Egeler R, Dekraker J, Voute P. Cytosine-arabioside, Vincristine, and prednisone in the treatment of children with disseminated Langerhans cell histiocytosis with organ dysfunction – experience at a single institution. *Med Pediatr Oncol*. 1993;21:265–70.
 38. Morimoto A, Shioda Y, Imamura T, Kudo K, Kawaguchi H, Sakashita K, et al. Intensified and prolonged therapy comprising cytarabine, vincristine and prednisolone improves outcome in patients with multisystem Langerhans cell histiocytosis: results of

- the Japan Langerhans cell Histiocytosis study group-02 protocol study. *Int J Hematol.* 2016;104:99–109.
39. Cantu MA, Lupo PJ, Bilgi M, Hicks MJ, Allen CE, McClain KL. Optimal therapy for adults with Langerhans cell histiocytosis bone lesions. *PLoS One.* 2012;7:e43257.
 40. Simko SJ, McClain KL, Allen CE. Up-front therapy for LCH: is it time to test an alternative to vinblastine/prednisone? *Br J Haematol.* 2015;169:299–301.
 41. Santana VM, Mirro J, Kearns C, Schell M, Crom W, Blakely RL. 2-chlorodeoxyadenosine produces a high rate of complete hematologic remission in relapsed acute myeloid leukemia. *J Clin Oncol.* 1992;10:364–70.
 42. Robertson LE, Chubb S, Meyn RE, Story M, Ford R, Hittelman WN, et al. Induction of apoptotic cell death in chronic lymphocytic leukemia by 2-chloro-2'-deoxyadenosine and 9-a'-D-arabinosyl-2-fluoroadenine. *Blood.* 1993;81:143–50.
 43. Carrera CJ, Terai C, Lotz M, Curd JG, Piro LD, Beutler E, et al. Potent toxicity of 2-chlorodeoxyadenosine toward human monocytes in vitro and in vivo. *J Clin Invest.* 1990;86:1480–8.
 44. Saven A, Burian C. Cladribine activity in adult Langerhans cell histiocytosis. *Blood.* 1999;93:4125–30.
 45. Rodriguez-Galindo C, Kelly P, Jeng M, Presbury GG, Rieman M, Wang W. Treatment of children with Langerhans cell Histiocytosis with 2-chlorodeoxyadenosine. *Am J Hematol.* 2002;69:179–84.
 46. Mottl H, Stary J, Chanova M, Nekolna M, Drahokoupilova E, Smelhaus V. Treatment of recurrent Langerhans cell histiocytosis in children with 2-chlorodeoxyadenosine. *Leuk Lymphoma.* 2006;47:1881–4.
 47. Weitzman S, Wayne AS, Arceci R, Lipton JM, Whitlock JA, De Rossi G. Nucleoside analogues in the therapy of Langerhans cell histiocytosis: a survey of members of the Histiocyte Society and review of the literature. *Med Pediatr Oncol.* 1999;33:4761–481.
 48. Stine KC, Saylor RL, Saccente S, McClain KL, Becton DL. Efficacy of continuous infusion 2-CDA (cladribine) in pediatric patients with Langerhans cell histiocytosis. *Pediatr Blood Cancer.* 2004;43:81–4.
 49. Ottaviano F, Finlay JL. Diabetes insipidus and Langerhans cell histiocytosis: a case report of reversibility with 2-chlorodeoxyadenosine. *J Pediatr Hematol Oncol.* 2003;25:575–7.
 50. Weitzman S, Braier J, Donadieu J, Egeler RM, Grois N, Ladisch S, et al. 2-Chlorodeoxyadenosine (2-CDA) as salvage therapy for Langerhans cell histiocytosis (LCH). Results of the LCH-98 protocol of the Histiocyte Society. *Pediatr Blood Cancer.* 2009;53:1271–6.
 51. Joshi S, Parisi M, Smogorzewska E, et al. Long term immunodeficiency in a patient with Langerhans cell histiocytosis treated with 2-Chlorodeoxyadenosine. *Med Pediatr Oncol.* 1999;33:523.
 52. Tetrault SA, Saven A. Delayed onset of autoimmune hemolytic anemia complicating cladribine therapy for Waldenstrom cryoglobulinemia. *Leuk Lymphoma.* 2000;37:125–30.
 53. Grey MR, Flanagan NG, Kelsey PR. Severe skin rash in two consecutive patients treated with 2-chlorodeoxyadenosine for hairy cell leukemia. *Clin Lab Haematol.* 2000;22:111–3.
 54. Choi SW, Bangaru BS, Wu CD, Finlay JL. Gastrointestinal involvement in disseminated Langerhans cell histiocytosis (LCH) with durable complete response to 2-chlorodeoxyadenosine and high-dose cytarabine. *J Pediatr Hematol Oncol.* 2003;25:503–6.
 55. Gandhi V, Estey E, Keating MJ, Chucrallah A, Plunkett W. Chlorodeoxyadenosine and arabinosylcytosine in patients with acute myelogenous leukemia: pharmacokinetic, pharmacodynamics and molecular interactions. *Blood.* 1996;87:256–64.
 56. Bernard F, Thomas C, Bertrand Y, Munzer M, Landman Parker J, Ouache M, et al. Multi-centre pilot study of 2- chlorodeoxyadenosine and cytosine arabinoside combined chemotherapy in refractory Langerhans cell histiocytosis with haematological dysfunction. *Eur J Cancer.* 2005;41:2682–9.
 57. Apollonsky N, Lipton JM. Treatment of refractory Langerhans cell histiocytosis (LCH) with a combination of 2-chlorodeoxyadenosine and cytosine arabinoside. *J Pediatr Hematol Oncol.* 2009;31:53–6.
 58. Donadieu J, Bernard F, van Noesel M, Barkaoui M, Bardet O, Mura R, et al. Cladribine and cytarabine in refractory multisystem Langerhans cell histiocytosis: results of an international phase 2 study. *Blood.* 2015;126(12):1415–23.
 59. Rosso D, Amaral D, Latella A, Chantada G, Braier JL. Reduced doses of cladribine and cytarabine regimen was effective and well tolerated in patients with refractory-risk multisystem Langerhans cell histiocytosis. *Br J Hematol.* 2015; doi:10.1111/bjh.13475.
 60. Jeha S, Razzouk B, Rytting M, Rheingold S, Albano E, Kadota R, et al. Phase II study of clofarabine in pediatric patients with refractory or relapsed acute myeloid leukemia. *J Clin Oncol.* 2009;27:4392–7.
 61. Bonate PL, Arthaud L, Cantrell WR, Stephenson K, Secrist JA, Weitman S. Discovery and development of clofarabine: a nucleoside analogue for treating cancer. *Nat Rev Drug Discov.* 2006;5:855–63.
 62. Simko SJ, Tran HD, Jones J, Bilgi M, Beaupin LK, Coulter D, et al. Clofarabine salvage therapy in refractory multifocal histiocytic disorders, including Langerhans cell histiocytosis, juvenile xanthogranuloma and Rosai-Dorfman disease. *Pediatr Blood Cancer.* 2014;61:479–87.
 63. Abraham A, Alsultan A, Jeng M, Rodriguez-Galindo C, Campbell PK. Clofarabine salvage therapy for refractory high-risk Langerhans cell histiocytosis. *Pediatr Blood Cancer.* 2013;60:E19–22.
 64. Rodriguez-Galindo C, Jeng M, Khuu P, McCarville MB, Jeha S. Clofarabine in refractory Langerhans cell histiocytosis. *Pediatr Blood Cancer.* 2008;51:703–6.
 65. Maria Postini A, del Prever AB, Pagano M, Rivetti E, Berger M, Asaftei SD, et al. Langerhans cell

- histiocytosis: 40 years' experience. *J Pediatr Hematol Oncol.* 2012;34:353–8.
66. Ringden O, Ahstrom L, Lonnqvist B, Baryd I, Svedmyr E, Gahrton G. Allogeneic bone marrow transplantation in a patient with chemotherapy-resistant progressive histiocytosis X. *New Engl J Med.* 1987;316:733–5.
 67. Ringden O, Lonnqvist B, Holst M. 12-year follow-up of allogeneic bone-marrow transplant for Langerhans cell histiocytosis. *The Lancet.* 1997;349:476.
 68. Steiner M, Matthes-Martin S, Attarbaschi A, Minkov M, Grois N, Unger E, et al. Improved outcome of treatment-resistant high-risk Langerhans cell histiocytosis after allogeneic stem cell transplantation with reduced-intensity conditioning. *Bone Marrow Transplant.* 2005;36:215–25.
 69. Chiesa R, Veys P. Reduced intensity conditioning in paediatric haematopoietic cell transplantation. In: Thomas AE, Halsey C, editors. *Controversies in Paediatric and Adolescent Haematology.* Basel/Switzerland: Karger; 2014. p. 116–34.
 70. Cooper N, Rao K, Goulden N, Webb D, Amrolia P, Veys P. The use of reduced intensity stem cell transplantation in haemophagocytic lymphohistiocytosis and Langerhans cell histiocytosis. *Bone Marrow Transplant.* 2008;42(Suppl. 2):S47–50.
 71. Hatakeyama N, Hori T, Yamamoto M, Inazawa N, Hirako Y, Tsutsumi H, et al. Successful treatment of refractory Langerhans cell histiocytosis with pulmonary aspergillosis by reduced-intensity conditioning cord blood transplantation. *Pediatric Transplant.* 2010;14:E4–E10.
 72. Kudo K, Ohga S, Morimoto A, Ishida Y, Suzuki N, Hasegawa D, et al. Improved outcome of refractory Langerhans cell histiocytosis in children with hematopoietic stem cell transplantation in Japan. *Bone Marrow Transplant.* 2010;45:901–6.
 73. Schmid C, Labopin M, Nagler A, Niederwieser D, Castagna L, Tabrizi R, et al. Acute Leukaemia working Party of the European Group for blood and marrow transplantation (EBMT). Treatment, risk factors, and outcome of adults with relapsed AML after reduced intensity conditioning for allogeneic stem cell transplantation. *Blood.* 2012;119:1599–606.
 74. Veys PA, Nanduri V, Baker KS, Bandini G, Biondi A, Dalissier A, et al. Haematopoietic stem cell transplantation for refractory Langerhans cell histiocytosis: outcome by intensity of conditioning. *Br J Haematol.* 2015;169:711–8.
 75. Marsh RA, Vaughn G, Kim MO, Li D, Jodele S, Joshi S, et al. Reduced-intensity conditioning significantly improves survival of patients with hemophagocytic lymphohistiocytosis undergoing allogeneic hematopoietic cell transplantation. *Blood.* 2010;116:5824–31.
 76. Terrell CE, Jordan MB. Mixed hematopoietic or T-cell chimerism above a minimal threshold restores perforin-dependent immune regulation in perforin-deficient mice. *Blood.* 2013;122:2618–21.
 77. Ardeshtna K, Hollifield J, Chessells JM, Veys P, Webb DKH. Outcome for children after failed transplant for primary haemophagocytic lymphohistiocytosis. *Br J Haematol.* 2001;115:949–52.
 78. Lang P, Teltschik HM, Feuchtinger T, Müller I, Pfeiffer M, Schumm M, et al. Transplantation of CD3/CD19 depleted allografts from haploidentical family donors in paediatric leukaemia. *Br J Haematol.* 2014;165:688–98.
 79. Bernardo ME, Piras E, Vacca A, Giorgiani G, Zecca M, Bertaina A, et al. Allogeneic hematopoietic stem cell transplantation in thalassemia major: results of a reduced-toxicity conditioning regimen based on the use of treosulfan. *Blood.* 2012;120:473–6.
 80. Aricò M. Langerhans cell histiocytosis in children: from the bench to bedside for an updated therapy. *Br J Haematol.* 2016;23. [Epub ahead of print]. Review
 81. Zinn DJ, Grimes AB, Lin H, Eckstein O, Allen CE, McClain KL. Hydroxyurea: a new old therapy for Langerhans cell histiocytosis. *Blood.* 2016; doi:10.1182-06721993.
 82. Charles P, Elliot MJ, Davis D, Potter A, Kalden JR, Antoni C, et al. Regulation of cytokines, cytokine inhibitors and acute phase proteins following anti-TNF α therapy in rheumatoid arthritis. *J Immunol.* 1999;163:1521–8.
 83. Rizzo F, Cives M, Simone V, Silvestris F. New insights into the molecular pathogenesis of Langerhans cell Histiocytosis. *Oncologist.* 2014;19:151–63.
 84. Claudon A, Dietmann JL, Hamman DCA, Hassler P. Interest in thalidomide in cutaneo-mucous and hypothalamo-hypophyseal involvement of Langerhans cell histiocytosis. *Rev Med Intern.* 2002;23:651–6.
 85. Montero AJ, Diaz-Montero CM, Malpica A, Ramirez PT, Kavanagh JJ. Langerhans cell histiocytosis of the female genital tract: a literature review. *Int J Gynecol Cancer.* 2003;13:381–8.
 86. McClain K, Kozinetz C. A phase II trial using thalidomide for Langerhans cell histiocytosis. *Pediatr Blood Cancer.* 2007;48:44–9.
 87. Broekart SMC, Metzler G, Burgdorf W, Rocken M, Schaller M. Multisystem Langerhans cell histiocytosis: successful treatment with thalidomide. *Am J Clin Dermatol.* 2007;8:311–4.
 88. Szturz P, Adam Z, Reháč Z, Koukalová R, Slaisová R, Stehlíková O, et al. Lenalidomide proved effective in multisystem Langerhans cell histiocytosis. *Acta Oncol.* 2012;51:412–5.
 89. Ibrahim I, Naina H. Treatment of recurrent Langerhans cell histiocytosis of the vulva with Lenalidomide. *J Clin Oncol.* 2013;31:e16555.
 90. Adam Z, Pour L, Krejčí M, Zahradová L, Szturz P, Koukalová R, et al. The effect of lenalidomide on rare blood disorders: Langerhans cell histiocytosis, multicentric Castleman disease, POEMS syndrome. Erdheim-Chester disease and angiomatosis. *Vnitr Lek.* 2012;58:856.
 91. Adam Z, Reháč Z, Koukalová R, Szturz P, Krejčí M, Pour L, et al. Lenalidomide induced therapeutic response in a patient with aggressive multisystem Langerhans cell histiocytosis resistant to 2-chlorodeoxyadenosine and early relapsing after

- high-dose BEAM chemotherapy with autologous peripheral blood stem cell transplantation. *Vnitř Lek.* 2012;58:62.
92. Uppuluri R, Ramachandrakurup S, Subburaj D, Bakane A, Raj R. Excellent remission rates with limited toxicity in relapsed/refractory Langerhans cell histiocytosis with pulse dexamethasone and lenalidomide in children. *Pediatr Blood Cancer.* 2017;64:110–2.
 93. Henter J, Karlen J, Calming U, Bernstrand C, Andersson U, Fadeel B. Successful treatment of Langerhans cell histiocytosis with Etanercept. *New Engl J Med.* 2001;345:1577–8.
 94. Chohan G, Barnett Y, Gibson J, Reddel S, Barnett M. Langerhans cell histiocytosis with refractory central nervous system involvement responsive to infliximab. *J Neurol Neurosurg And Psych.* 2012;83:574–8.
 95. Rodriguez H, Garcia I, Alba A, Igea F. Infliximab-induced reactivated Langerhans cell histiocytosis in a patient with ulcerative colitis. *Inflamm Bowel Dis.* 2009;15:1286–7.
 96. Mahe E, Descamps V, Grossin M, Fraitag S, Crickx B. CD30+ T-cell lymphoma in a patient with psoriasis treated with cyclosporine and infliximab. *Br J Dermatol.* 2003;149:170–3.
 97. Appel S, Boehmler A, Grunebach F, Müller MR, Rupf A, Weck MM, et al. Imatinib mesylate affects the development and function of dendritic cells generated from CD34 (+) peripheral blood progenitor cells. *Blood.* 2004;103:538–44.
 98. Caponetti G, Miranda R, Althof P, Dobesh RC, Sanger WG, Medeiros LJ, et al. Immunohistochemical and molecular cytogenetic evaluation of potential targets for tyrosine kinase inhibitors in Langerhans cell histiocytosis. *Hum Pathol.* 2012;43:2223–8.
 99. Janku F, Amin H, Yang D, Garrido-Laguna I, Trent J, Kurzrock R. Response of Histiocytoses to Imatinib Mesylate: fire to ashes. *J Clin Oncol.* 2010;28:E633–6.
 100. Montella L, Insabato L, Palmieri G. Imatinib mesylate for cerebral Langerhans cell histiocytosis. *N Engl J Med.* 2004;351:1034–5.
 101. Wagner C, Mohme H, Kromer-Olbrisch T, Stadler R, Goerdts S, Kurzen H. Langerhans cell histiocytosis: treatment failure with Imatinib. *Arch Dermatol.* 2009;145:949–50.
 102. Dumble M, Crouthamel MC, Zhang SY, Schaber M, Levy D, Robell K, et al. Discovery of novel AKT inhibitors with enhanced anti-tumor effects in combination with the MEK inhibitor. *PLoS One.* 2014;9:e100880.
 103. Morgensztern D, McLeod HL. PI3K/AKT/mTOR pathway as a target for cancer therapy. *Anti-Cancer Drugs.* 2005;16:797–803.
 104. Brown RE. Brief communication: morphoproteomic analysis of osteolytic Langerhans cell histiocytosis with therapeutic implications. *Ann Clin Lab Sci.* 2005;35:131–6.
 105. van de Laar L, Buitenhuis M, Wensveen FM, Janssen HL, Coffey PJ, Woltman AM. Human CD34-derived myeloid dendritic cell development requires intact phosphatidylinositol 3-kinase protein kinase B mammalian target of rapamycin signaling. *J Immunol.* 2010;184:6600–11.
 106. Arceci RJ, Allen CE, Dunkel IJ, Jacobsen E, Whitlock J, Vassallo R, et al. A phase IIa study of afuresertib, an oral pan-AKT inhibitor, in patients with Langerhans cell histiocytosis. *Pediatr Blood Cancer.* 2016; doi:10.1002/psc.26325. (epub ahead of print)
 107. Heritier S, Emile JF, Barkaoui MA, Thomas C, Fraitag S, Boudjemaa S, et al. *BRAF* mutation correlates with high-risk Langerhans cell Histiocytosis and increased resistance to first-line therapy. *J Clin Oncol.* 2016;34:3023–30.
 108. Haroche J, Cohen-Aubart F, Emile JF, Maksud P, Drier A, Tolédano D, et al. Reproducible and sustained efficacy of targeted therapy with vemurafenib in patients with BRAFV600E-mutated Erdheim-Chester disease. *J Clin Oncol.* 2015;33:411–8.
 109. Euskirchen P, Haroche J, Emile JF, Buchert R, Vandersee S, Meisel A. Complete remission of critical neurohistiocytosis by vemurafenib. *Neuro Immunol & Neuroinflamm.* 2015;2:e78.
 110. Charles J, Beani JC, Fiandrino G, Busser B. Major response to vemurafenib in a patient with severe cutaneous Langerhans cell histiocytosis. *J Am Acad Dermatol.* 2014;71:e97–9.
 111. Bubolz AM, Weissinger SE, Stenzinger A, Arndt A, Steinestel K, Brüderlein S, et al. Potential clinical implications of BRAF mutations in histiocytic proliferations. *Oncotarget.* 2014;5:4060–70.
 112. Hyman D, Puzanov I, Subbiah V, Faries JE, Chau I, Blay JY, et al. Vemurafenib in multiple non-melanoma cancers with BRAF V600E mutations. *New Engl J Med.* 2015;373:726–36.
 113. Heritier S, Jehanne M, Leverger G, Emile JF, Alvarez JC, Haroche J, et al. Vemurafenib use in an infant for high-risk Langerhans cell histiocytosis. *JAMA Oncol.* 2015;1:836–8.
 114. Donadieu J, Armari-Alla C, Templier I, et al. First use of vemurafenib in children LCH with neurodegenerative LCH. In: 30th Annual Histiocyte Society Meeting. Toronto, October 28–30, 2014. Abstract 3, p. 35.
 115. Donadieu J, Visser J, Sieni E, et al. Vemurafenib in children with refractory LCH: 21 Patients treated in France, UK, Italy And Lebanon. In: 32 Annual Histiocyte Society Meeting. Dublin, October 17–19, 2016. Abstract 3, p. 38.
 116. Haroche J, Cohen-Aubart F, Emile JF, Arnaud L, Maksud P, Charlotte F, et al. Dramatic efficacy of vemurafenib in both multisystemic and refractory Erdheim-Chester disease and Langerhans cell histiocytosis harbouring the BRAF V600E mutation. *Blood.* 2013;121:1495–500.

117. Gandolfi L, Adamo S, Pileri A, Broccoli A, Argnani L, Zinzani PL. Multisystemic and Multiresistant Langerhans cell Histiocytosis: a case treated with BRAF inhibitor. *J Natl Compr Cancer Net*. 2015;13:715–8.
118. da Rocha DS, Salmonson T, van Zwieten-Boot B, Jonsson B, Marchetti S, Schellens JH, et al. The European medicines agency review of vemurafenib (Zelboraf) for the treatment of adult patients with BRAF V600 mutation-positive unresectable or metastatic melanoma: summary of the scientific assessment of the Committee for Medicinal Products for human use. *Eur J Cancer*. 2013;49:1654–61.
119. Lipowicz S, Chagnon S, Saiag P. Rapidly growing pancreatic ductal adenocarcinoma in a patient with metastatic melanoma and harbouring CDKN2A germline mutation: a new vemurafenib-induced malignancy? *Melanoma Res*. 2013;23:241.
120. Yeh EA, Leary S, Longoni G, et al. Clinical and Radiographic Improvement of Neurodegenerative Langerhans Cell Histiocytosis (ND-LCH) Following Dabrafenib. The 68th Annual American Academy of Neurology Annual Meeting, April 15–21, Vancouver. 2016.
121. Zhang W. BRAF inhibitors: the current and the future. *Curr Opin Pharmacol*. 2015;23:68–73.
122. Diamond E, Durham B, Haroche J, Yao Z, Ma J, Parikh SA, et al. Diverse and targetable Kinase alterations drive Histiocytic Neoplasms. *Cancer Discov*. 2016;6:154–65.
123. Wagle N, Emery C, Berger MF, Davis MJ, Sawyer A, Pochanard P, et al. Dissecting therapeutic resistance to RAF inhibition in melanoma by tumor genomic profiling. *J Clin Oncol*. 2011;29:3085–96.
124. Flaherty KT, Robert C, Hersey P, Nathan P, Garbe C, et al. Improved survival with MEK inhibition in BRAF-mutated melanoma. *N Engl J Med*. 2012;367:107–14.
125. Jhaveri KD, Sakhiya V, Fishbane S. Nephrotoxicity of the BRAF inhibitors Vemurafenib and Dabrafenib. *JAMA Oncol*. 2015;1(8):1133–4. doi:10.1001/jamaoncol.2015.1713.
126. Bronte E, Bronte G, Novo G, Bronte F, Bavetta MG, Lo RG. What links BRAF to the heart function? New insights from the cardiotoxicity of BRAF inhibitors in cancer treatment. *Oncotarget*. 2015;6:35589–601. doi:10.18632/oncotarget.5853.
127. Niro A, Strippoli S, Alessio G, Sborgia L, Recchimurzo N, Guida M. Ocular toxicity in metastatic melanoma patients treated with mitogen-activated protein kinase kinase inhibitors: a case series. *Am J Ophthalmol*. 2015;160:959–67. doi:10.1016/j.ajo.2015.07.035. e1. Epub 2015 Jul 29
128. Jordan M, McClain K, Yan X, Hicks J, Jaffe R. Anti-CD52 antibody, alemtuzumab, binds to Langerhans cells in Langerhans cell histiocytosis. *Pediatr Blood Cancer*. 2005;44:251–4.
129. Seo J, Cho T, Kim S, Nassour I, Kim HJ, Lim YJ, et al. Prognostic significance of gelsolin and MMP12 in Langerhans cell histiocytosis. *Korean J Hematol*. 2012;47:267–72.
130. Kis-Toth K, Bacskai I, Gogolak P, Mazlo A, Szatmari I, Rajnavolgyi E. Monocyte-derived dendritic cell subpopulations use different types of matrix metalloproteinase inhibited by GM6001. *Immunobiology*. 2013;218:1361–9.
131. Bechan GI, Lee DW, Zajonc DM, Heckel D, Xian R, Throsby M, et al. Phage display generation of a novel human anti-CD1A monoclonal antibody with potent cytolytic activity. *Br J Haematol*. 2012;159:299–310.

Adult Langerhans Cell Histiocytosis

7

Michael Girschikofsky and Abdellatif Tazi

Introduction

Langerhans cell histiocytosis (LCH) is observed in one to two adults per 1 million population [1], but the true incidence is unknown. The number of affected patients is likely to be underestimated, since tertiary care centers are preferably contacted in case of advanced or recurrent disease. The largest number of patients was published in a pooled retrospective analysis from several national registries [2], but in contrast to childhood LCH trials, strong evidence-based recommendations are lacking.

The variety of potentially involved organs results in a large number of different physicians who may be consulted at the time of initial presentation. Thus, in many cases only the apparently affected site is recognized, and a complete

examination, in order to detect the whole extent of the disease, is often not performed. Although the lungs may be affected simultaneously with other organs, an isolated pulmonary LCH may be observed as well and represents a special form of adult LCH. The most frequent non-pulmonary sites include the bone, skin, and pituitary gland and less frequently the lymph nodes, liver, spleen, gut, and central nervous system (CNS), while the bone marrow is rarely involved in adults, as opposed to children [3].

Generally, the clinical manifestations of the disease vary depending on the involved organ or system, ranging from isolated bone or skin lesions to a more severe clinical manifestation affecting the same tissue in multiple sites, or several organs, termed multisystem (MS) LCH [4]. Pediatric studies have shown that disease involvement of the hematopoietic system, spleen, and liver (so-called risk organs, RO) confers worse prognosis and even risk of mortality in patients who are slow early responders [5]. It remains to be determined whether such organs represent true “risk organs” in adults as well.

The clinical course of LCH in adults may vary from a self-limiting to a chronic recurrent disease. The latter form can be similar to rheumatic disorders. Permanent consequences and late effects of the disease and its therapy lead in some cases to severe impairment of the quality of life. A symptom-related approach, to avoid overtreatment that could result in late sequelae, is therefore strictly recommended.

M. Girschikofsky, MD (✉)

Internal Medicine I, (Hemostasis, Hematology and Stem Cell Transplantation and Medical Oncology), Ordensklinikum Linz – Elisabethinen Hospital, Fadingerstraße 1, 4020 Linz, Austria
e-mail: michael.girschikofsky@ordensklinikum.at

A. Tazi, MD, PhD

Assistance Publique-Hôpitaux de Paris, Saint-Louis Hospital, National Reference Center for Histiocytoses, Pulmonary Department, Paris, France

University Paris Diderot, Sorbonne Paris Cité, Inserm UMR-1153 (CRESS), Biostatistics and Clinical Epidemiology Research Team (ECSTRA), Paris, France

e-mail: abdellatif.tazi@aph.fr

Compared to childhood LCH, a rapid progressive form is usually not observed in adults, and accordingly other malignant histiocytic disorders should be ruled out in such cases. Langerhans cell sarcoma (LCS) can occur de novo or after a previous diagnosis of LCH [6]. The term “mixed histiocytosis” describes the case when more than one histiocytic disorder is present in the same patient, such as the coexistence of LCH and Erdheim-Chester disease (ECD) or the development of an ECD after a preexisting LCH [7].

The diagnosis of LCH should be based on histological and immunophenotypic examination of a lesional tissue. The gold standard for the diagnosis is the morphologic identification of the characteristic LCH cells that demonstrate CD1a and Langerin (CD207) positivity [4]. Additional workup may include detection of mutations of the BRAF-ERK pathway, which can offer more treatment options in case of refractory and recurrent disease [8].

Biopsy samples should be taken from the most accessible site, i.e., the skin (if involved), or in case of multifocal bone involvement, the most easily accessible bone lesion should be chosen. The risk versus benefit of a biopsy should be carefully weighed, especially in patients with extended isolated pulmonary LCH [9]. Another possible scenario is that of an isolated pituitary lesion and/or a small and not easily accessible cerebral or spinal lesion on neuroimaging. Without proven diagnosis, both situations do not require initial cytotoxic medication, and close monitoring and reassessment of the need for biopsy is recommended in patients with mild symptoms.

The probability of a diagnosis other than LCH is usually higher in adults; thus in all other situations, performing a biopsy is generally recommended. For example, in case of lytic bone lesions or lymphadenopathy, other clinical conditions that might lead to similar findings, such as multiple myeloma, bone metastases of solid tumors, lymphoma, and leukemia, have to be considered with a higher probability [4]. In summary, LCH in adults is mostly a random and non-expected diagnosis.

Baseline Clinical Evaluation

Initially, patients with LCH are often asymptomatic or show only mild symptoms, most commonly dyspnea and cough, local bone pain, an abnormal growth of soft tissue over the affected area of the bone, exanthema of the skin, and polydipsia. Additional signs may include fatigue, generalized weakness, weight loss, night sweats, nausea, pruritus, and fever [4].

Because of the potential for generalized involvement, a thorough history should be performed and should include a family history (few familial cases have been reported [10]), past medical history, childhood “idiopathic” eczema, lung alterations or bony lesions, thyroid disease, diabetes insipidus and unexplained teeth loss, and smoking habits.

For staging and determination of organ dysfunction, a comprehensive physical examination is recommended. In particular, the skin and the mucous membranes should be inspected. Supplemental neurological and/or psychological investigations are useful in patients presenting with neurological or cognitive impairment.

The laboratory tests to be performed include a complete blood count (CBC), blood chemistry, liver enzymes, albumin, total protein, C-reactive protein, coagulation studies, and urine analysis. Serum levels of cytokines like interleukins, interferon- γ , GM-CSF, TNF- α , and osteopontin have been evaluated by several groups around the world and seem to correlate with disease activity [11]. Detection of circulating cells harboring mutations of the BRAF-ERK pathway might be of additional value [12], but at the moment neither cytokine level analysis nor detection of circulating LCH cells is recommended for routine clinical use.

Only if computerized tomography (CT) scan or positron emission tomography (PET)-CT is not available, a skeletal survey, skull series, and a chest x-ray should be done as the first radiographic examinations, in conjunction with an abdomen ultrasound to rule out hepatic and internal organ abnormalities. A bone scintigraphy (technetium-99) alone is not sufficient for diagnostic purposes [13], while magnetic resonance

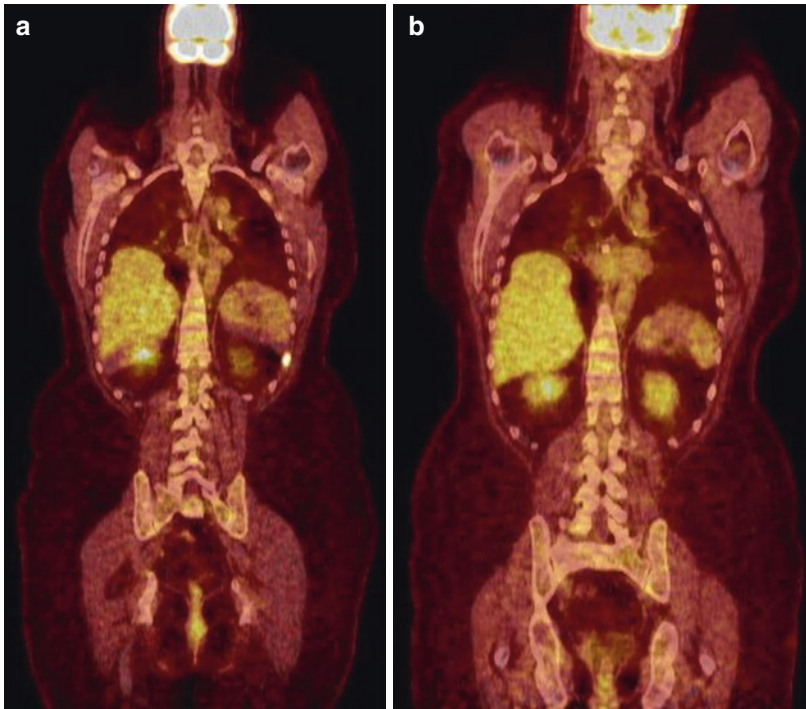


Fig. 7.1 (a, b) 37-year-old female patient with PLCH and an isolated rib lesion 2 years after lung transplantation (a). Sustained remission 16 months after local steroid injection (b)

imaging (MRI) scan can detect soft tissue and additional extra-osseous lesions.

Hypothalamic-pituitary and brain lesions can be ruled out by brain MRI [14]. Any evidence of a pathological thoracic finding should be followed up by a high-resolution chest CT. A FDG-PET scan may identify lesions missed by other modalities, is suitable to document response to therapy (Fig. 7.1a, b), and, thus, is now preferably used in adult LCH patients [15].

Treatment Options in Specific Clinical Scenarios

Single-System (SS) LCH

Bone

In certain scenarios, such as vertebral lesions with intraspinal extension or craniofacial bone lesions with intracranial soft tissue extension, the lesions tend to be located in functionally critical anatomical sites. Isolated disease in these

so-called special sites may justify systemic therapy, especially in childhood. Alternatively, radiotherapy might be considered in adults. These lesions need to be distinguished from other bone lesions. In children, craniofacial bone lesions are also called CNS-risk lesions due to their association with diabetes insipidus [16] and subsequent neurodegenerative CNS (ND-CNS) LCH. It is unclear whether the term “CNS-risk lesions” can be extrapolated to the adult population; in addition, this term is a matter of debate even in childhood LCH [17].

In unifocal bone disease, “non-special sites,” local therapy is the standard of care. Treatment modality depends on the location and size of the lesion and patients’ symptomatology. Complete excision of bone lesions is not always indicated since it may increase the size of the bone defect, delay healing time, and can cause permanent skeletal defects. When tissue sample is taken from a bone lesion, curettage of the center of the lesion is usually sufficient for pathologic diagnosis and may also trigger the

healing process. To accelerate this process, intralesional injection of steroids is suitable, and dosages of 40–160 mg of methylprednisolone have been used [18]. Observation alone can be considered in asymptomatic patients with an isolated bone reactivation.

Radiotherapy (RT) is indicated if there is an impending neurological deficit and a high surgical risk (e.g., lesion in the odontoid peg or cranial base) and should be considered in all locally recurrent lesions. Local control rates after RT ranged from 75% to 100%, while complete remission rates were up to 85% [19]. Thus, in case of a slow response to standard systemic therapy, RT may be considered as an additive treatment for painful lesions, even in multifocal or multisystem disease [4]. The optimal dose of radiotherapy is still controversial, since an exact dose-effect relationship has not been established. There is a wide dose range of applied total doses from 3 Gy up to 50.4 Gy, but in general, a dose range from 10 to 20 Gy is recommended in adults. Such total doses should be delivered in fractions of 1–2 Gy per day, in order to avoid a possibly limited capacity for tissue repair mechanisms in larger single doses [19].

Systemic therapy should be administered for multifocal bone LCH and possibly for bone lesions in “special sites.” Patients with mild symptoms can be treated with low-dose chemotherapy such as oral methotrexate, 6-mercaptopurine, or azathioprine [4]. COX inhibitors, such as indomethacin, are considered effective analgesics against bony pain and can potentially cause regression of LCH lesions [20]. Bisphosphonates can be considered as first-line therapy, but patients have to be aware of the risk of osteonecrosis of the jaw and its prevention (dental hygiene) [21]. In addition, adequate supplementation with calcium and vitamin D should be concomitantly administered, in order to avoid severe hypocalcemia and/or secondary hyperparathyroidism. In case of refractory or multiple recurrent bony disease, systemic therapy (e.g., cytarabine) is a reasonable therapeutic option (Table 7.1) [22].

Table 7.1 First-line systemic therapy options

<i>Mild symptoms, no risk organs involved</i>
Methotrexate 20 mg per week p.o./i.v.
Azathioprine 2 mg/kg/d p.o.
Thalidomide 100 mg/d p.o. in skin or soft tissue multifocal single-system LCH
<i>Additionally in multifocal bone LCH</i>
Zoledronic acid 4 mg i.v., q 1 (–3) month (depending on extent and response)
<i>Symptomatic, no risk organs involved</i>
Cytarabine 100 mg/m ² d1–5 q4w i.v.
Etoposide 100 mg/m ² d1–5 (1–3) q4w i.v.
Vinblastine/prednisolone (pediatric study-based protocol)
<i>Risk organs (liver, CNS – tumorous) involved</i>
2-CDA 6 mg/m ² d1–5 q4w s.c./i.v.

Skin

There is no pathognomonic picture of skin involvement in adult LCH, since it can mimic a number of common dermatoses [23]. Thus, a high level of suspicion and a skin biopsy are required to confirm or rule out skin LCH.

Typical seborrheic dermatitis-like scalp lesions are small translucent papules, 1–2 mm in diameter, slightly raised and rose-yellow in color. Frequently, these lesions show scaling or crusting and petechial hemorrhages (Fig. 7.2). Erythema and erosions in the axillary, inguinal, vulvar, or anogenital regions represent intertriginous involvement and are frequently misdiagnosed as eczema, psoriasis, or candida infection. Generalized skin eruptions may mimic guttate psoriasis with erythematous scaly patches, or prurigo nodularis with small hard papules and nodules, particularly on the trunk [23]. Pure varicella-like vesicular eruptions are rarely observed. Multiple erythematous papules involving mainly the trunk and extending to the extremities may resemble lichen planus or lichenoid dermatitis of different causes. Nail changes include paronychia, onycholysis, subungual hyperkeratosis, and purpuric striae of the nail bed, suggesting a wide panel of conditions that affect the nails. Ulcerative lesions and ulcerated nodules located to the anogenital area combined with severe pruritus are a common presentation of adult LCH. Further mucosal

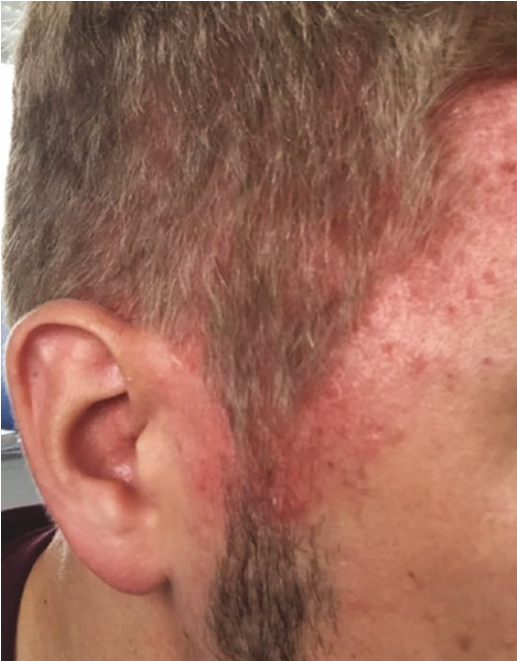

Fig. 7.2 A 30-year-old male patient with MS LCH and chronic recurrent skin involvement

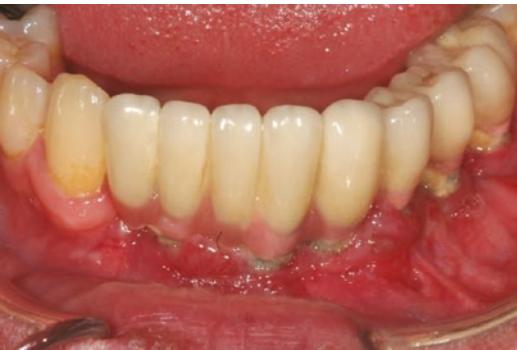

Fig. 7.3 A 42-year-old male patient with MS LCH and chronic recurrent gingival hyperplasia by biopsy-proven LCH

involvement may be observed in terms of ulcerative or non-ulcerative lesions of the gum or gingival hyperplasia, which frequently result in teeth loss (Fig. 7.3) [4].

Surgical excision is indicated in isolated skin lesions (usually appearing as erythematous papules), and no further intervention is required in case of complete resection. Otherwise, mutilating surgeries like hemivulvectomy or multiple teeth

extractions should be strictly avoided [4]. In multifocal skin disease, or in scenarios where the skin fails to respond fully to systemic treatment, there are a number of treatments directed specifically to the skin: topical nitrogen mustard (20%) applied to the skin might be useful, but reactivations are quite common [24] and it is not available in most countries. Psoralen plus ultraviolet A (PUVA) [25] and narrowband ultraviolet (UV) B [26] have been shown to be effective in treating cutaneous LCH in individual case reports, but response of intertriginous or scalp lesions is limited although they may respond to photodynamic therapy [27].

Pegylated interferon alpha can be used in multifocal papular skin involvement [28], while TNF- α antagonists have been shown to be effective in treating cutaneous LCH as well, although poor responses have been seen in high-risk MS disease [29]. Thalidomide, at a dose of 100 mg/day, is generally used in adults, but peripheral neuropathy is a common side effect [29]. Lenalidomide showed activity in multisystem LCH [30], but there is no data about its effectiveness in isolated skin involvement. Azathioprine (or its metabolite, 6-mercaptopurine) is effective in adults with cutaneous LCH as well as in multi-system disease. If available, patients should be tested for thiopurine methyltransferase (TPMT) enzyme activity, and if this is normal, then it can be administered at a dose of 2 mg/kg/day. The drug may take up to 6 weeks to become effective [31]. Methotrexate (MTX) was used successfully at the dosages of 20 mg once weekly [32] either as single agent or in combination with azathioprine or prednisone. Additional folinic acid rescue should be considered during MTX therapy. Despite concerns about the potential of drug-induced secondary leukemia, etoposide (VP-16) usually administered IV at a dose of 100 mg/m² for 3–5 days (repeated every 4 weeks) is a useful treatment option for refractory skin as well as for multisystem LCH [33].

CNS and Neuroendocrine

Tumorous involvement of the hypothalamo-pituitary axis (HPA), with consecutive permanent posterior with or without anterior pituitary

dysfunction, is frequently observed in adult LCH [34]. Diabetes insipidus (DI) is the most common disease-related consequence that can precede the diagnosis or develop anytime during the course of the disease. DI is found in up to 30% of patients but may occur in up to 40% in patients with multisystem disease or 94% in the presence of other pituitary deficiencies [35]. In the presence of polyuria and polydipsia, and/or structural abnormalities of the HPA, plasma osmolality and urine/plasma osmolality ratio have to be quantified to confirm a query DI, whereas a water deprivation test is usually required to reveal cases of partial DI. Desmopressin with individualized timing and dosage should be started immediately. If LCH is unproven (idiopathic DI), repeated brain MRI and clinical follow-up are required; furthermore, a pituitary biopsy in case of pituitary stalk thickening (of at least 7 mm) can be considered [36]. In proven LCH, new-onset DI is a sign of active disease, and systemic therapy (preferably with drugs that can penetrate the CNS) is recommended in order to prevent further damage and late sequelae such as anterior pituitary dysfunction and CNS neurodegeneration. Radiotherapy can be an effective alternative, but the benefit of radiographic improvement has to be balanced against the potential for radiotherapy-related late effects [37].

Anterior pituitary dysfunction (APD) is found in up to 20% of adult patients, is almost always associated with DI, and needs appropriate replacement therapy since it appears to be permanent [35]. Growth hormone deficiency (GHD) is a frequent disease-related APD, diagnosed in up to 50% of patients with DI [34]. In adults, there are no specific GHD-related symptoms that can suggest the diagnosis and it may be missed if not specifically considered. Administration of GH in adults is feasible and may improve quality of life in selected cases [38]. Gonadotropin deficiency leads to menstrual disturbances in women and decreased libido in men; therefore, it usually requires adequate sex steroid replacement therapy [39]. Partial or complete ACTH deficiency

is rarely observed and usually develops in the context of panhypopituitarism and can present with nonspecific symptoms or acute adrenal insufficiency following stressful events. ACTH deficiency should be promptly replaced with daily divided doses of hydrocortisone [39]. Similarly, TSH deficiency is almost always associated with panhypopituitarism and may present with subtle symptoms and signs of hypothyroidism. Levothyroxine replacement therapy should be titrated to achieve mid-normal serum free T4 levels [4]. Moderately elevated prolactin (PRL) levels attributed to pituitary stalk infiltration can cause galactorrhea in females and gonadotropin deficiency in all patients. Dopamine agonists can be used for normalization of PRL levels [39].

Hypothalamic involvement is less common and may lead to pituitary dysfunction, neuropsychiatric and behavioral disorders, disturbances of thermoregulation and sleeping pattern, and autonomic and metabolic abnormalities. The most frequent consequence is severe obesity due to increased appetite, whereas hypothalamic-related adipsia may seriously complicate the management of DI [4]. Other sites of tumorous CNS lesions such as parenchymal, meningeal, or choroid plexus involvement occur less frequently [37]. Isolated tumors can be treated locally with surgery, RT, or radiosurgery. Multifocal CNS involvement usually responds to chemotherapeutic agents such as cladribine (2-CDA) or cytarabine [40].

Non-tumorous, neurodegenerative (ND-CNS LCH) lesions of the cerebellum and/or brain stem are histopathologically different from typical LCH granulomas, with lack of CD1a and predominant presence of CD8+ lymphocytes, which can explain their neuroinflammatory nature [41]. Some of these patients are asymptomatic, and others have clinical signs ranging from mild tremors, dysarthria, dysphagia, and motor spasticity to pronounced ataxia, behavioral problems, and severe psychiatric disease. Unfortunately, none of the published treatment regimens such as intravenous immunoglobulins, retinoic acid, TNF- α inhibitors, and various chemotherapeutic agents [42–45] could sufficiently influence the

course of ND-CNS disease so far. The identification of risk categories based on a combination of serum/CSF biomarkers with electrophysiological and neuroimaging features may be helpful in future targeted therapy trials [46].

Adults with LCH are at high risk of developing other endocrine abnormalities such as impaired glucose tolerance, diabetes mellitus, and metabolic syndrome which can occur as a consequence of the disease's inflammatory process, hormonal deficiencies, and/or concurrent medications and can lead to increased insulin resistance even in the absence of obesity [47]. In addition, patients may present with a low bone mineral density at any age, particularly during periods of active disease. Osteopenia and osteoporosis are commonly observed in postmenopausal women and in men over 50 years old [48]. The thyroid gland may occasionally be involved in the disease process, where fine needle aspiration (FNA) or even histological specimens may be mistaken with thyroid carcinoma [49]. Genital tract involvement, such as the ovaries, is quite rare and usually occurs in the context of disseminated disease [50]. Adrenal infiltration has been described in autopsy series, although without any obvious clinical findings [39]. Pancreatic involvement is also extremely rare, although there are reports of glucose metabolism abnormalities secondary to pancreatic and/or hepatic infiltration and dysfunction [39].

Gastrointestinal Tract

Gastrointestinal (GI) tract involvement by LCH is a rare condition in adults, and endoscopy is not mandatory in asymptomatic patients. It may appear as an incidental solitary colorectal polyp or as multiple granulomatous and/or ulcerative lesions in the upper and lower GI tract [51]. Patients with polyps are usually asymptomatic, whereas extensive disease is associated with diarrhea, weight loss, and abdominal pain mimicking inflammatory bowel disease. In case of an accidental diagnosis by polypectomy, further investigations to rule out MS LCH are required. Multiple lesions are usually associated with MS LCH and require treatment with systemic chemotherapy [4].

Liver and Bile Ducts

Two distinct patterns of liver involvement may be observed, and they can both be detected predominantly in patients with MS LCH. Hepatic tumorous lesions may be revealed accidentally by an abdominal ultrasound, CT, or MRI and are chemosensitive in almost all cases [52]. Patients presenting with cholestasis and/or elevated liver enzymes should undergo magnetic resonance cholangiography (MRC) or endoscopic retrograde cholangiopancreatography (ERCP), which can detect alterations of the biliary tract similar to primary sclerosing cholangitis. Immunohistochemical confirmation of LCH may be difficult especially in advanced fibrosis [52]. Ursodeoxycholic acid is usually helpful in alleviating cholestatic symptoms, while response to chemotherapy is usually very poor. Consequently, progression to secondary biliary cirrhosis and liver failure are known late effects, and finally patients will require liver transplant [53].

Lymph Nodes

In general, a lymph node excision from the most accessible site should be performed instead of an FNA biopsy in order to confirm or rule out LCH or a coexistent lymphoma, which can sometimes be detected in the same lymph node [54]. Isolated involvement of lymph nodes is rare, but spontaneous regressions have been observed. Therefore, in adults with LCH, watchful waiting may be adequate in isolated lymph node involvement and mutilating surgery, such as neck dissection should be strictly avoided [55]. Generalized lymphadenopathy usually indicates multisystem LCH and requires systemic chemotherapy, particularly in patients with severe general symptoms where the disease course is usually more aggressive [30].

Multisystem Disease

There is no consensus regarding the optimal first-line therapy for adults with MS LCH. Patients with mild symptoms may be treated with low-dose chemotherapy such as methotrexate, azathioprine, or 6-mercaptopurine. Vinblastine-prednisone-based

pediatric regimens have been considered as standard therapy, but have not been tested prospectively in adults. An attempt of an international trial in adults failed due to challenges in regulations for academic trials, resulting in a low recruitment rate and premature closing (LCH-A1, EudraCT 2006–002392–40). Nevertheless, vinblastine-prednisone is effective as published in numerous case reports and small series [22, 56], but the risk of neuropathy, especially in patients with coexisting diabetes mellitus, has to be taken into account [22]. Therefore, some experts prefer monotherapy with cytarabine [22], etoposide, or 2-CDA, especially in case of tumorous liver or CNS LCH [57] (Table 7.1). Lymphoma-based multi-agent chemotherapy protocols, like MACOP-B, can be helpful too in MS LCH [58], although they seem not to be more effective than 2-CDA or other single agents in terms of response rates and long-term outcomes.

LCH and Pregnancy

Only a few case reports of LCH and pregnancy have been reported. Changes of clinical symptoms ranged from improvement to worsening with DI as the main cause of morbidity [59]. It is unclear, however, if worsening or onset of DI during pregnancy is really caused by LCH. Subclinical forms of DI may be unmasked, independently from a preexistent histiocytic disorder, by a pregnancy which can trigger an increased vasopressinase activity and decreased responsiveness to vasopressin [60]. In general, it is unpredictable how pregnancy may influence the course of LCH. Nevertheless, women can be reassured that there are no adverse impacts of LCH on pregnancy or delivery, with the exception of the need for cesarean section in case of vulvar involvement [59].

Response Assessment, Follow-Up, and Disease Reactivation

Similarly to pediatric studies, response assessment in adults is routinely performed at 6 weeks after vinblastine-prednisone induction regimens.

When other chemotherapy protocols are being used, early response has to be assessed after 2–3 cycles of chemotherapy, similarly to malignant disorders. Vinblastine-prednisone maintenance therapy is usually given for 6–12 months (every 3 weeks) with the addition of daily oral 6-mercaptopurine. Other drugs, such as cytarabine, etoposide, or 2-CDA, are usually administered for up to six cycles, depending on response [22].

LCH may be quite unpredictable and disease reactivation is possible at any time. The exact rate of reactivation in adults is unknown, but based on registry data, it seems to occur in about at least 1/3 of the patients [4]. Patients may develop multiple reactivations, which seem to be more common in multisystem disease. The choice of treatment options is based on the same principles as for initial disease. In patients with mild or local reactivation (i.e., isolated skin or bone), the possibility of spontaneous regression should be kept in mind. If a reactivation occurs more than 1 year after completion of therapy, re-induction with the previously used regimen may be effective without the need to switch to alternative therapy. Patients responding poorly to conventional chemotherapy might benefit from therapies targeting platelet-derived growth factor receptor (PDGFR) such as imatinib mesylate [61] or BRAF-ERK pathway [8], but optimal dosage and duration of therapy has to be investigated. In the rare case of very aggressive disease, hematopoietic stem cell transplant (HSCT) has been performed successfully as well [62].

Extensive and multiple reactivations may induce organ damage [53]. Moreover, LCH can be associated with hematological malignancies (predominantly lymphoma and leukemia) as well as various solid tumors [63, 64]. Therefore, follow-up investigations and close monitoring of functional impairments are required. Follow-up intervals will depend on the primary extent and activity of disease and may range from 3 to 12 months. The extent of reevaluation is based on disease manifestations and should focus on new complaints of the patients [4].

Primary Pulmonary LCH

Epidemiology

Although lung involvement can be present in systemic forms of LCH, pulmonary LCH (PLCH) in adults commonly occurs as a single-system disease [65]. The prevalence of PLCH is unknown, but it probably accounts for about 3–5% of patients with diffuse infiltrative lung disease. The prevalence of PLCH is probably underestimated, with an increased number of patients being diagnosed through the wide use of chest CT. The most striking epidemiological feature of PLCH is that it occurs predominantly in young smokers or ex-smokers (>90% of cases) of both genders, with a peak incidence between the ages of 20 and 40 years [65, 66].

Pathogenesis

The close association between smoking and PLCH strongly suggests a role for tobacco smoke in the pathogenesis of the disease. The role for smoking in triggering PLCH is highlighted by the finding that children with extrapulmonary LCH who subsequently develop PLCH during adolescence or adulthood are more often smokers [67].

As in other forms of LCH, the presence of the BRAFV600E mutation has been observed in 35–50% of PLCH, as well as MAP2K1 mutations in a subset of BRAF wild-type PLCH lesions [68–71]. Recently, activating NRASQ61K/R mutations have been described in a substantial subset of PLCH lesions, whereas these mutations were not reported in other forms of LCH [69]. Noteworthy, these NRAS mutations occurred concurrently with BRAFV600E mutations in most cases, and both mutations were carried by different cell clones [69].

Clinical Features

PLCH is pleomorphic in its presentation. Symptoms can be minor or absent, and often the

patients attribute their symptoms to smoking. PLCH is usually diagnosed in three main circumstances. (1) Respiratory symptoms such as cough and dyspnea on exertion are present in approximately 2/3 of patients and can be associated with asthenia, fever, night sweats, and weight loss. (2) Spontaneous pneumothorax in 15–20% of cases – pneumothorax may occur at any time during the course of disease and may be bilateral and/or recurrent, raising difficult therapeutic challenges. (3) In 10–25% of cases, PLCH is detected on routine chest radiography. Hemoptysis is uncommon and should not be attributed to PLCH until possible complications (infectious bronchitis, lung cancer, rarely aspergillus colonization of a cystic lung cavity) or alternative diagnoses have been ruled out. Adult PLCH is generally isolated. When present, extrathoracic lesions usually involve the bone, the hypothalamic-pituitary axis (diabetes insipidus), and more rarely the skin. Physical examination is generally normal, except in advanced stages or when associated with extrathoracic involvement.

Diagnostic Evaluation

Standard chest radiographs typically show bilateral symmetric reticulo-micronodular infiltration, in which cysts may sometimes be identified, predominantly involving the upper and middle lung fields. Occasionally, a pneumothorax, or rarely, a lytic lesion in a rib, may be visible. Pleural effusion is not a feature, and mediastinal lymph nodes are very uncommon, although hilar enlargement may be observed in patients with pulmonary hypertension. In rare cases, the chest radiograph is normal. Chest high-resolution computed tomography (HRCT) is mandatory when PLCH is suspected. The typical HRCT pattern combines small poorly limited nodules, cavitated nodules, and thick- and thin-walled cysts predominantly in the upper and middle lung fields with relative sparing of the bases (Fig. 7.4) [65, 66]. The various lung lesions vary with disease duration. As the disease evolves, cystic lesions become a predominant finding [72]. Cysts vary in size and may coalesce to form irregular shapes

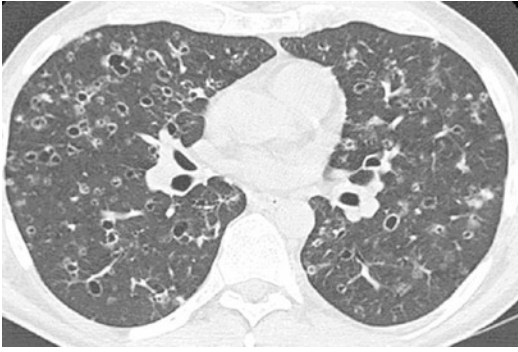

Fig. 7.4 HRCT: Recent PLCH characterized by the typical combination of nodules, cavitated nodules, and thick- and thin-walled cysts

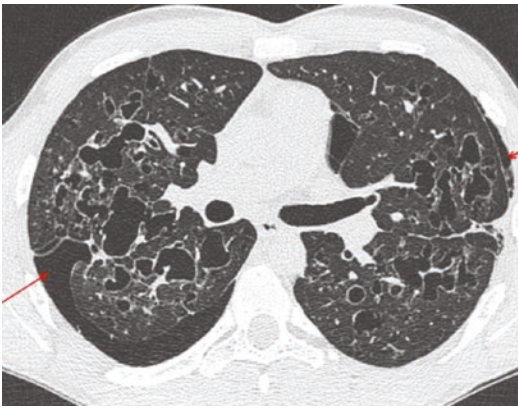


Fig. 7.5 HRCT: More advanced disease with predominant cysts of variable size and irregular shapes (“bizarre cysts”). Note the presence of bilateral partial pneumothorax (arrows)

(“bizarre cysts”) (Fig. 7.5). Other findings in PLCH may include ground-glass opacities or localized emphysema secondary to cigarette smoking. Significantly enlarged mediastinal lymph nodes are rarely observed and should suggest another diagnosis. Pulmonary artery enlargement is suggestive of pulmonary hypertension.

Pulmonary function abnormalities vary according to the extent of cystic involvement and disease duration [72]. The most common abnormality is reduction of the diffuse lung capacity (DLCO), which is observed in 80–90% of cases. Lung volumes are impaired in a majority of patients with a reduction in vital capacity (VC), normal or increased residual volume

(RV), preserved total lung capacity (TLC), and increased or normal RV/TLC ratio (air trapping). An obstructive ventilator defect is observed in a sizable proportion of patients particularly in advanced cystic disease, while restrictive ventilatory defect (defined by a TLC < 80% predicted) is present in a minority. Patients with predominantly nodular HRCT pattern usually have minimal lung function, with an isolated reduction in DLCO [66].

Bronchoscopy is usually macroscopically normal or may reveal nonspecific smoking-related abnormalities. Bronchial mucosal biopsies do not contribute to the diagnosis of PLCH, but are useful to exclude other diseases. Transbronchial lung biopsies have variable diagnostic yields (15 to 40%) due to the focal nature of histological lesions [73, 74]. Bronchoalveolar lavage (BAL) is rarely diagnostic of PLCH in adults, although it can support the diagnosis by showing high alveolar macrophage counts related to smoking. The presence of $\geq 5\%$ of CD1a + cells in BAL has only been reported in PLCH, albeit in a minority of cases. BAL is also useful in atypical cases to exclude other lung diseases and to rule out lung infections, depending on the clinical context [73–75].

Pathology

The definitive diagnosis of PLCH requires a lung biopsy, most commonly through a video-assisted thoracoscopic surgical biopsy guided by HRCT findings. The histological hallmark of PLCH is the accumulation of CD1a + cells organized into loosely formed granulomas, preferentially located in and destroying the wall of distal bronchioles [65, 66]. With progression of the lesions, the number of CD1a + cells decreases and is subsequently replaced by either fibrosis in the form of a characteristic stellate scar or contiguous and confluent cystic cavities surrounded by a fibrous ring [65, 66]. Interestingly, correlations between CT features and pulmonary histopathology have shown that CD1a + cells may still be observed in diffuse cystic forms and that inflammatory cells may persist even inside thin-walled cysts [76]. The indication for a lung biopsy must be

determined in each individual case with careful evaluation of risks and benefits of the procedure. The diagnostic approach is essentially guided by the clinical context and HRCT findings. In a young adult smoker, with mild or no symptoms and a typical HRCT pattern (a combination of nodular and cystic changes), a presumptive diagnosis is acceptable with a close follow-up. In patients with extensive cystic lesions and impaired lung function, the risk of a surgical lung biopsy should be balanced with the need of a definitive diagnosis.

Clinical Course and Follow-Up

A limited but careful medical assessment must be performed following the diagnosis of PLCH. The primary goal of this clinical assessment is to determine the degree of functional and pulmonary impairment and assess for complications like pulmonary hypertension and extrapulmonary manifestations. In patients with clinically isolated PLCH, the systematic search for bone involvement is not usually informative [77]. The natural history and the prognosis of PLCH are not clearly defined and can be quite unpredictable [78]. Approximately half of the patients develop stable disease with little or no progression over time [72]. Partial or complete resolution of the lung HRCT abnormalities may occur without treatment. However, almost 50% of patients will experience impaired pulmonary function over time and develop obstructive lung disease [72]. In some patients, despite regression of the disease, pulmonary function continues to deteriorate as a result of smoking-related COPD.

Pregnancy does not appear to modify the course of PLCH, but certain precautions, such as a cesarean section, are required in women with diffuse cystic lesions and impaired pulmonary function due to the risk of pneumothorax during labor.

In a retrospective study, the median survival of patients with PLCH was found to be significantly shorter than that expected for individuals of the same sex and age [78]. In addition to the association with lymphoma, particularly Hodgkin's

lymphoma, an increased incidence of primary lung cancer (related to ongoing smoking) as well as various other types of malignant tumors has also been reported [78, 79].

Serial lung function tests (including diffusing capacity measurement) are essential for following patients with PLCH. It is recommended that all patients undergo follow-up every 3–6 months for the first year after diagnosis. In a recent multicenter study, an early decline of pulmonary function was observed in a substantial proportion of patients after a median follow-up of 1 year after diagnosis [66]. Interestingly, sequential chest CT scans showed that only about 10% of patients presented significant progression of the extent of pulmonary cystic lesions over the same period [66]. An isolated decline of DLCO should prompt a search for pulmonary hypertension by Doppler echocardiography, which needs to be confirmed by cardiac catheterization [66].

Treatment

Smoking cessation is essential and represents the only intervention necessary in a substantial proportion of patients [56]. In a recent prospective study, persistence in smoking was associated with longitudinal decline in lung function [66]. Individualized smoking cessation strategies should be used to address this powerful addictive behavior. Inhaled corticosteroids and bronchodilator therapy may provide benefit to patients with reactive airway disease and obstructive lung disease which is frequently present. Pneumothorax requires drainage. Pleurodesis is indicated in case of recurrence and should be also considered in case of single large pneumothorax, because of the high rate of recurrence with a conservative approach [80]. Lower respiratory tract infection is a common cause of deterioration of PLCH and should be promptly treated. Annual vaccination against influenza as well as anti-pneumococcal vaccine is recommended in patients with impaired lung function.

Systemic treatment is considered in symptomatic patients with impairment of lung function. Oral corticosteroids are often prescribed in

patients with progressive disease, even though their efficacy in stabilizing or inducing disease remission remains unclear. There is no evidence-based data on the efficacy of vinblastine in PLCH. Cladribine has been demonstrated to induce disease remission when used as a single drug in selected patients with advanced disease [81, 82]. The role of cladribine in the treatment of symptomatic forms of PLCH with impaired pulmonary function is currently under evaluation in a phase II clinical trial (<http://clinicaltrials.gov/NCT01473797>).

Hypoxemia should be treated with supplemental oxygen. The role of vasodilator therapy for the treatment of pulmonary hypertension in PLCH is not well established and should be reserved to centers with expertise in both vascular and advanced lung disease [83]. Patients with advanced PLCH benefit from lung transplantation [84]. Disease relapse in the transplanted lungs has been described, particularly for patients with preoperative extrapulmonary manifestations and in those who resumed smoking following transplantation [84]. The effects of MAPK pathway-targeted therapy in PLCH, particularly on lung function outcomes, have not been yet reported.

References

- Institute NC. Langerhans Cell Histiocytosis Treatment—Health Professional Version. September 25, 2015 [updated September 25, 2015; cited March 22, 2016]; Available from: http://www.cancer.gov/types/langerhans/hp/langerhans-treatment-pdq#link/_141_toc.
- Arico M, Girschikofsky M, Genereau T, Klersy C, McClain K, Grois N, et al. Langerhans cell histiocytosis in adults. Report from the international registry of the Histiocyte society. *Eur J Cancer*. 2003;39(16):2341–8.
- Minkov M, Potschger U, Grois N, Gadner H, Dworzak MN. Bone marrow assessment in Langerhans cell histiocytosis. *Pediatr Blood Cancer*. 2007;49(5):694–8.
- Girschikofsky M, Arico M, Castillo D, Chu A, Doberauer C, Fichter J, et al. Management of adult patients with Langerhans cell histiocytosis: recommendations from an expert panel on behalf of euro-Histio-net. *Orphanet J Rare Dis*. 2013;8:72.
- Gadner H, Minkov M, Grois N, Potschger U, Thiem E, Arico M, et al. Therapy prolongation improves outcome in multisystem Langerhans cell histiocytosis. *Blood*. 2013;121(25):5006–14.
- Mourah S, Lorillon G, Meignin V, Vercellino L, de Margerie-Mellon C, Pages C, et al. Dramatic transient improvement of metastatic BRAF(V600E)-mutated Langerhans cell sarcoma under treatment with dabrafenib. *Blood*. 2015;126(24):2649–52.
- Hervier B, Haroche J, Arnaud L, Charlotte F, Donadieu J, Neel A, et al. Association of both Langerhans cell histiocytosis and Erdheim-Chester disease linked to the BRAFV600E mutation. *Blood*. 2014;124(7):1119–26.
- Hyman DM, Puzanov I, Subbiah V, Faris JE, Chau I, Blay JY, et al. Vemurafenib in multiple Nonmelanoma cancers with BRAF V600 mutations. *N Engl J Med*. 2015;373(8):726–36.
- Tazi A. Adult pulmonary Langerhans' cell histiocytosis. *Eur Respir J*. 2006;27(6):1272–85.
- Arico M, Nichols K, Whitlock JA, Arceci R, Haupt R, Mittler U, et al. Familial clustering of Langerhans cell histiocytosis. *Br J Haematol*. 1999;107(4):883–8.
- Oh Y, Morimoto A, Shioda Y, Imamura T, Kudo K, Imashuku S. High serum osteopontin levels in pediatric patients with high risk Langerhans cell histiocytosis. *Cytokine*. 2014;70(2):194–7.
- Berres ML, Lim KP, Peters T, Price J, Takizawa H, Salmon H, et al. BRAF-V600E expression in precursor versus differentiated dendritic cells defines clinically distinct LCH risk groups. *J Exp Med*. 2014;211(4):669–83.
- Zhou W, Wu H, Han Y, Wang S, Dong Y, Wang Q. Preliminary study on the evaluation of Langerhans cell histiocytosis using F-18-fluoro-deoxy-glucose PET/CT. *Chin Med J*. 2014;127(13):2458–62.
- Prayer D, Grois N, Prosch H, Gadner H, Barkovich AJ. MR imaging presentation of intracranial disease associated with Langerhans cell histiocytosis. *AJNR Am J Neuroradiol*. 2004;25(5):880–91.
- Obert J, Vercellino L, Van Der Gucht A, de Margerie-Mellon C, Bugnet E, Chevret S, et al. 18F-fluorodeoxyglucose positron emission tomography-computed tomography in the management of adult multisystem Langerhans cell histiocytosis. *Eur J Nucl Med Mol Imaging*. 2016;20:598.
- Grois N, Potschger U, Prosch H, Minkov M, Arico M, Braier J, et al. Risk factors for diabetes insipidus in langerhans cell histiocytosis. *Pediatr Blood Cancer*. 2006;46(2):228–33.
- Chellapandian D, Shaikh F, van den Bos C, Somers GR, Astigarraga I, Jubran R, et al. Management and outcome of patients with Langerhans cell Histiocytosis and single-bone CNS-risk lesions: a multi-institutional retrospective study. *Pediatr Blood Cancer*. 2015;62(12):2162–6.
- Putters TF, de Visscher JG, van Veen A, Spijkervet FK. Intralesional infiltration of corticosteroids in the treatment of localised langerhans' cell histiocytosis of the mandible report of known cases and three new cases. *Int J Oral Maxillofac Surg*. 2005;34(5):571–5.

19. Kriz J, Eich HT, Bruns F, Heyd R, Schafer U, Haverkamp U, et al. Radiotherapy in langerhans cell histiocytosis – a rare indication in a rare disease. *Radiat Oncol.* 2013;8:233.
20. Braier J, Rosso D, Pollono D, Rey G, Lagomarsino E, Latella A, et al. Symptomatic bone Langerhans cell Histiocytosis treated at diagnosis or after reactivation with indomethacin alone. *J Pediatr Hematol Oncol.* 2014;11:100.
21. Sivendran S, Harvey H, Lipton A, Drabick J. Treatment of Langerhans cell histiocytosis bone lesions with zoledronic acid: a case series. *Int J Hematol.* 2011;93(6):782–6.
22. Cantu MA, Lupo PJ, Bilgi M, Hicks MJ, Allen CE, McClain KL. Optimal therapy for adults with Langerhans cell histiocytosis bone lesions. *PLoS One.* 2012;7(8):e43257.
23. Caputo R. A text atlas of Histiocytic syndromes. London: Informa Health Care; 1998.
24. Lindahl LM, Fenger-Gron M, Iversen L. Topical nitrogen mustard therapy in patients with Langerhans cell histiocytosis. *Br J Dermatol.* 2012;166(3):642–5.
25. Sakai H, Ibe M, Takahashi H, Matsuo S, Okamoto K, Makino I, et al. Satisfactory remission achieved by PUVA therapy in Langerhans cell histiocytosis in an elderly patient. *J Dermatol.* 1996;23(1):42–6.
26. Imafuku S, Shibata S, Tashiro A, Furue M. Cutaneous Langerhans cell histiocytosis in an elderly man successfully treated with narrowband ultraviolet B. *Br J Dermatol.* 2007;157(6):1277–9.
27. Failla V, Wauters O, Caucanas M, Nikkels-Tassoudji N, Nikkels AF. Photodynamic therapy for multi-resistant cutaneous Langerhans cell histiocytosis. *Rare Tumors.* 2010;2(2):e34.
28. Furudate S, Fujimura T, Kambayashi Y, Kawano M, Ogasawara K, Tsukada A, et al. Successful treatment of adult onset Langerhans cell histiocytosis with bi-weekly administration of pegylated interferon-alpha. *Acta Derm Venereol.* 2014;94(5):611–2.
29. McClain KL, Kozinetz CA. A phase II trial using thalidomide for Langerhans cell histiocytosis. *Pediatr Blood Cancer.* 2007;48(1):44–9.
30. Szturz P, Adam Z, Rehak Z, Koukalova R, Slaisova R, Stehlikova O, et al. Lenalidomide proved effective in multisystem Langerhans cell histiocytosis. *Acta Oncol.* 2012;51(3):412–5.
31. Rao A, Chu A. Langerhans cell histiocytosis: treatment of cutaneous disease with azathiopine. *Br J Dermatol.* [Poster Presentation (P24)]. 2013;169(Suppl 1):30.
32. Steen AE, Steen KH, Bauer R, Bieber T. Successful treatment of cutaneous Langerhans cell histiocytosis with low-dose methotrexate. *Br J Dermatol.* 2001;145(1):137–40.
33. Chu T. Langerhans cell histiocytosis. *Australas J Dermatol.* 2001;42(4):237–42.
34. Makras P, Kaltsas G. Langerhans cell histiocytosis and pituitary function. *Endocrine.* 2015;48(3):728–9.
35. Kaltsas GA, Powles TB, Evanson J, Plowman PN, Drinkwater JE, Jenkins PJ, et al. Hypothalamo-pituitary abnormalities in adult patients with langerhans cell histiocytosis: clinical, endocrinological, and radiological features and response to treatment. *J Clin Endocrinol Metab.* 2000;85(4):1370–6.
36. Jian F, Bian L, Sun S, Yang J, Chen X, Chen Y, et al. Surgical biopsies in patients with central diabetes insipidus and thickened pituitary stalks. *Endocrine.* 2014;47(1):325–35.
37. Grois N, Fahrner B, Arceci RJ, Henter JI, McClain K, Lassmann H, et al. Central nervous system disease in Langerhans cell histiocytosis. *J Pediatr.* 2010;156(6):873–81. 81 e1.
38. Reed ML, Merriam GR, Kargi AY. Adult growth hormone deficiency – benefits, side effects, and risks of growth hormone replacement. *Front Endocrinol (Lausanne).* 2013;4:64.
39. Makras P, Alexandraki KI, Chrousos GP, Grossman AB, Kaltsas GA. Endocrine manifestations in Langerhans cell histiocytosis. *Trends Endocrinol Metab.* 2007;18(6):252–7.
40. Buchler T, Cervinek L, Belohlavek O, Kantorova I, Mechl M, Nebesky T, et al. Langerhans cell histiocytosis with central nervous system involvement: follow-up by FDG-PET during treatment with cladribine. *Pediatr Blood Cancer.* 2005;44(3):286–8.
41. Grois N, Prayer D, Prosch H, Lassmann H. Neuropathology of CNS disease in Langerhans cell histiocytosis. *Brain.* 2005;128(Pt 4):829–38.
42. Imashuku S, Fujita N, Shioda Y, Noma H, Seto S, Minato T, et al. Follow-up of pediatric patients treated by IVIG for Langerhans cell histiocytosis (LCH)-related neurodegenerative CNS disease. *Int J Hematol.* 2015;101(2):191–7.
43. Idbaih A, Donadieu J, Barthez MA, Geissmann F, Bertrand Y, Hermine O, et al. Retinoic acid therapy in “degenerative-like” neuro-langerhans cell histiocytosis: a prospective pilot study. *Pediatr Blood Cancer.* 2004;43(1):55–8.
44. Allen CE, Flores R, Rauch R, Dauser R, Murray JC, Puccetti D, et al. Neurodegenerative central nervous system Langerhans cell histiocytosis and coincident hydrocephalus treated with vincristine/cytosine arabinoside. *Pediatr Blood Cancer.* 2010;54(3):416–23.
45. Chohan G, Barnett Y, Gibson J, Reddel SW, Barnett MH. Langerhans cell histiocytosis with refractory central nervous system involvement responsive to infliximab. *J Neurol Neurosurg Psychiatry.* 2012;83(5):573–5.
46. Imashuku S, Arceci RJ. Strategies for the prevention of central nervous system complications in patients with Langerhans cell Histiocytosis: the problem of neurodegenerative syndrome. *Hematol Oncol Clin North Am.* 2015;29(5):875–93.
47. Alexandraki KI, Makras P, Protogerou AD, Dimitriou K, Stathopoulou A, Papadogias DS, et al. Cardiovascular risk factors in adult patients with multisystem Langerhans-cell histiocytosis: evidence of glucose metabolism abnormalities. *QJM.* 2008;101(1):31–40.

48. Makras P, Terpos E, Kanakis G, Papatheodorou A, Anastasilakis AD, Kokkoris P, et al. Reduced bone mineral density in adult patients with Langerhans cell histiocytosis. *Pediatr Blood Cancer*. 2011;58:819–22.
49. Attakkil A, Thorawade V, Jagade M, Kar R, Parelkar K. Isolated Langerhans Histiocytosis in thyroid: thyroidectomy or chemotherapy? *J Clin Diagn Res*. 2015;9(9):XD01–XD3.
50. Axiotis CA, Merino MJ, Duray PH. Langerhans cell histiocytosis of the female genital tract. *Cancer*. 1991;67(6):1650–60.
51. Singhi AD, Montgomery EA. Gastrointestinal tract langerhans cell histiocytosis: a clinicopathologic study of 12 patients. *Am J Surg Pathol*. 2011;35(2):305–10.
52. Abdallah M, Genereau T, Donadieu J, Emile JF, Chazouilleres O, Gaujoux-Viala C, et al. Langerhans' cell histiocytosis of the liver in adults. *Clin Res Hepatol Gastroenterol*. 2011;35(6–7):475–81.
53. Scanzi J, Goutte M, Teilhet C, Abergel A. When should we consider transplantation in adult patients with sclerosing cholangitis due to multisystem Langerhans' cell histiocytosis? *Dig Liver Dis*. 2015;47(2):176–7.
54. Das DK, Sheikh ZA, Alansary TA, Amir T, Al-Rabiy FN, Junaid TA. A case of Langerhans' cell histiocytosis associated with Hodgkin's lymphoma: fine-needle aspiration cytologic and histopathological features. *Diagn Cytopathol*. 2016;44(2):128–32.
55. Lo WC, Chen CC, Tsai CC, Cheng PW. Isolated adult Langerhans' cell histiocytosis in cervical lymph nodes: should it be treated? *J Laryngol Otol*. 2009;123(9):1055–7.
56. Elia D, Torre O, Cassandro R, Caminati A, Harari S. Pulmonary Langerhans cell histiocytosis: a comprehensive analysis of 40 patients and literature review. *Eur J Intern Med*. 2015;26(5):351–6.
57. Schini M, Makras P, Kanakis G, Voulgarelis M, Kaltsas G. Cladribine therapy in adults with advanced Langerhans cell histiocytosis. *Leuk Lymphoma*. 2013;54(7):1541–3.
58. Derenzini E, Stefoni V, Pellegrini C, Gandolfi L, Broccoli A, Casadei B, et al. High efficacy of the MACOP-B regimen in the treatment of adult Langerhans cell histiocytosis, a 20 year experience. *BMC Cancer*. 2015;15:879.
59. DiMaggio LA, Lippes HA, Lee RV. Histiocytosis X and pregnancy. *Obstet Gynecol*. 1995;85(5 Pt 2):806–9.
60. Ananthkrishnan S. Diabetes insipidus in pregnancy: etiology, evaluation, and management. *Endocr Pract*. 2009;15(4):377–82.
61. Janku F, Amin HM, Yang D, Garrido-Laguna I, Trent JC, Kurzrock R. Response of histiocytoses to imatinib mesylate: fire to ashes. *J Clin Oncol*. 2010;28(31):e633–6.
62. Xicoy B, Ribera JM, Batlle M, Feliu E. Sustained remission in an adult patient with Langerhans cell histiocytosis following T-cell depleted allogeneic cell transplantation. *Med Clin (Barc)*. 2006;127(18):716.
63. Yohe SL, Chenault CB, Torlakovic EE, Asplund SL, McKenna RW. Langerhans cell histiocytosis in acute leukemias of ambiguous or myeloid lineage in adult patients: support for a possible clonal relationship. *Mod Pathol*. 2014;27(5):651–6.
64. Howarth DM, Gilchrist GS, Mullan BP, Wiseman GA, Edmonson JH, Schomberg PJ. Langerhans cell histiocytosis: diagnosis, natural history, management, and outcome. *Cancer*. 1999;85(10):2278–90.
65. Suri HS, Yi ES, Nowakowski GS, Vassallo R. Pulmonary langerhans cell histiocytosis. *Orphanet J Rare Dis*. 2012;7:16.
66. Tazi A, de Margerie C, Naccache JM, Fry S, Dominique S, Jouneau S, et al. The natural history of adult pulmonary Langerhans cell histiocytosis: a prospective multicentre study. *Orphanet J Rare Dis*. 2015;10:30.
67. Bernstrand C, Cederlund K, Sandstedt B, Ahstrom L, Lundell M, Dahlquist G, et al. Pulmonary abnormalities at long-term follow-up of patients with Langerhans cell histiocytosis. *Med Pediatr Oncol*. 2001;36(4):459–68.
68. Badalian-Very G, Vergilio JA, Degar BA, Rodriguez-Galindo C, Rollins BJ. Recent advances in the understanding of Langerhans cell histiocytosis. *Br J Haematol*. 2012;156(2):163–72.
69. Mourah S, How-Kit A, Meignin V, Gossot D, Lorillon G, Bugnet E, et al. Recurrent NRAS mutations in pulmonary Langerhans cell histiocytosis. *Eur Respir J*. 2016;47(6):1785–96.
70. Roden AC, Hu X, Kip S, Parrilla Castellar ER, Rumilla KM, Vrana JA, et al. BRAF V600E expression in Langerhans cell histiocytosis: clinical and immunohistochemical study on 25 pulmonary and 54 extrapulmonary cases. *Am J Surg Pathol*. 2014;38(4):548–51.
71. Yousem SA, Dacic S, Nikiforov YE, Nikiforova M. Pulmonary Langerhans cell histiocytosis: profiling of multifocal tumors using next-generation sequencing identifies concordant occurrence of BRAF V600E mutations. *Chest*. 2013;143(6):1679–84.
72. Tazi A, Marc K, Dominique S, de Bazelaire C, Crestani B, Chinet T, et al. Serial computed tomography and lung function testing in pulmonary Langerhans' cell histiocytosis. *Eur Respir J*. 2012;40(4):905–12.
73. Baqir M, Vassallo R, Maldonado F, Yi ES, Ryu JH. Utility of bronchoscopy in pulmonary Langerhans cell histiocytosis. *J Bronchology Interv Pulmonol*. 2013;20(4):309–12.
74. Harari S, Torre O, Cassandro R, Taveira-DaSilva AM, Moss J. Bronchoscopic diagnosis of Langerhans cell histiocytosis and lymphangioleiomyomatosis. *Respir Med*. 2012;106(9):1286–92.
75. Tazi A, Soler P, Hance AJ. Adult pulmonary Langerhans' cell histiocytosis. *Thorax*. 2000;55(5):405–16.
76. Kim HJ, Lee KS, Johkoh T, Tomiyama N, Lee HY, Han J, et al. Pulmonary Langerhans cell histiocytosis in adults: high-resolution CT-pathology comparisons

- and evolutionary changes at CT. *Eur Radiol.* 2011;21(7):1406–15.
77. Tazi A, de Margerie-Mellon C, Vercellino L, Naccache JM, Fry S, Dominique S, et al. Extrathoracic investigation in adult patients with isolated pulmonary langerhans cell histiocytosis. *Orphanet J Rare Dis.* 2016;11:11.
78. Vassallo R, Ryu JH, Schroeder DR, Decker PA, Limper AH. Clinical outcomes of pulmonary Langerhans'-cell histiocytosis in adults. *N Engl J Med.* 2002;346(7):484–90.
79. Feuillet S, Louis L, Bergeron A, Berezne A, Dubreuil ML, Polivka M, et al. Pulmonary Langerhans cell histiocytosis associated with Hodgkin's lymphoma. *Eur Respir Rev.* 2010;19(115):86–8.
80. Mendez JL, Nadrous HF, Vassallo R, Decker PA, Ryu JH. Pneumothorax in pulmonary Langerhans cell histiocytosis. *Chest.* 2004;125(3):1028–32.
81. Grobost V, Khouatra C, Lazor R, Cordier JF, Cottin V. Effectiveness of cladribine therapy in patients with pulmonary Langerhans cell histiocytosis. *Orphanet J Rare Dis.* 2014;9(1):191.
82. Lorillon G, Bergeron A, Detourmignies L, Jouneau S, Wallaert B, Frija J, et al. Cladribine is effective against cystic pulmonary Langerhans cell histiocytosis. *Am J Respir Crit Care Med.* 2012;186(9):930–2.
83. Le Pavec J, Lorillon G, Jais X, Tcherakian C, Feuillet S, Dorfmueller P, et al. Pulmonary Langerhans cell histiocytosis-associated pulmonary hypertension: clinical characteristics and impact of pulmonary arterial hypertension therapies. *Chest.* 2012;142(5):1150–7.
84. Dauriat G, Mal H, Thabut G, Mornex JF, Bertocchi M, Tronc F, et al. Lung transplantation for pulmonary langerhans' cell histiocytosis: a multicenter analysis. *Transplantation.* 2006;81(5):746–50.

Late Effects of Langerhans Cell Histiocytosis and the Association of LCH with Malignancy

8

Vasanta Nanduri, Lilibeth R. Torno,
and Riccardo Haupt

Introduction

Langerhans cell histiocytosis (LCH), previously considered a benign and treatable condition, is now known to cause long-term consequences in various tissues involved.

For decades, it was recognised that up to half of survivors of LCH may have residual disabilities, which impact the quality of survival [1, 2]. There are now several reports from co-operative groups in countries and from single institutions that describe these outcomes [3–11]. The reported incidence and prevalence of these problems however, vary widely across studies. Factors such as variations in the size of the studies, selection of patient cohorts, referral bias within institutions, treatments used, variability in the diagnosis and investigation of sequelae and the

method used for follow-up assessment (telephone interviews, questionnaire-based studies and clinical examination) account for the differences (Table 8.1).

The majority of published literature on permanent consequences of LCH consists mainly of follow-up studies in subjects who had the disease during childhood. Notably, children have an additional burden of sequelae as the disease may involve organs that are still developing during childhood. Its effects on growth and puberty as well as the protracted development of late effects over the years further complicate the burden of disease outcomes.

In the next sections, we will describe the relevant permanent consequences of LCH in various systems, collated from evidence from published reports and personal communications from experts and researchers in the field of histiocytosis.

V. Nanduri, MD, MRCP, FRCPCH
Department of Paediatrics, Watford General Hospital,
Watford, WD18 0HB, UK

L.R. Torno, MD
After Cancer Treatment Survivorship Program,
Children's Hospital of Orange County,
1201 W. La Veta, Orange, CA 92868, USA

R. Haupt, MD (✉)
Epidemiology and Biostatistics Unit, Istituto Giannina
Gaslini, Via G. Gaslini, 5, 16147 Genoa, Italy
e-mail: riccardohaupt@gaslini.org

Table 8.1 Published comprehensive studies of clinical outcome in LCH

Author, year	No. of long-term survivors	Mean length of follow-up (years)	Prevalence of sequelae (%)	DI (%)	Short stature/GHD (%)	Other endo (%)	Ortho (%)	Dental (%)	Liver (%)	Pulmonary (%)	Hearing (%)	CNS (%)	Low IQ (%)	Psycho (%)	Type of assessment at follow-up
Sims (1977)	29		52	50	17		3			27 3/11 tests	NA	NA	10	NA	Questionnaire and examination
Komp (1980)	60	>5	47	20	10	1.6	15			13	5	12	8	6	Case note review, examination
Ceci (1993)	90		48	20	5		15	3	3						Co-operative National study
Gadner (1994)	96 ^a	6	33 ^b	15	7	8	11	2	3	2	5	1	–	–	Questionnaires to participating institutions
Donadieu (1996)	320	3.3	22	17	5	3	3	1	1	1	3	4 ^a	–	–	Co-operative National study
Willis (1996)	71	8.1	64	25	20	16	42	30	2	8	16	14 ^a	–	–	Case note review, mail, telephone questionnaire
Braier (1999)	123	3	28	14	2		9		5	5	11				Case note review, single institution
Kusumakumary (2000)	41	7.1	29	17	19	–	–	15	–	–	5	–	5	–	Single-institution examination
Haupt (2004)	182	8.8	52	24	9		20	7	0	4	13	4	7	–	Retrospective International Institutions
Kim (2014)	581	8.1	16	8	3	4									Nationwide Survey
Rigaud (2016)	1478	5.1	21.8	15					4.8	1.3	1.9	5.8			Co-operative National study
Morimoto (2016)	125	7.3		26								5.6			Co-operative National study

DI diabetes mellitus, GHD growth hormone deficiency, CNS central nervous system, IQ intelligence quotient

^aSurvivors out of 106 total patients; ^breported in 106 patients

Orthopaedic Disabilities

Since the bony skeleton is the most common site of involvement of LCH, the commonest reported sequelae tend to be orthopaedic, with 42% of long-term survivors affected, and include pathological fractures, malformation, scoliosis and *vertebra plana* [7]. Various other studies reported lower incidence of late complications involving the skeletal system ranging from 2.5% [6] to 5% [12], 15% [1, 4], 20% [8] and 26% [13] in a study on subjects with single-system bone disease. Differences in the reported incidences might be due to selections of patient cohorts, as well as to timing of evaluation. Although in paediatric patients there is often reconstitution and modelling of bones, residual problems, when present, may be more severe than in adult patients because of damage to a growing skeleton. The final assessment of orthopaedic deformities needs to be made after completion of growth, as some problems manifest during periods of rapid growth such as puberty. As radiation is used less often in the treatment of LCH, the specific

radiation-related bone consequences are not as common as previously reported [14].

Abnormalities secondary to LCH involvement of the skull and facial bones, such as depressed skull lesions, asymmetry or proptosis (Fig. 8.1), are often described and may have an impact on appearance and therefore the quality of life of the patient. Facial asymmetry may become more manifest as the child grows, and rarely, major reconstructive surgery may be required. Loss of teeth may be permanent and can result either directly from LCH affecting the jaw or secondary to treatment such as curettage or radiotherapy to the lesion (Fig. 8.1). There may also be abnormal growth of the jaw requiring corrective orthodontic surgery [15].

LCH of the spine can result in compression of the body of the vertebra resulting in *vertebra plana*, and as growth progresses, scoliosis may become apparent (Fig. 8.2) [12].

Involvement of the long bones may result in shortening of one limb or asymmetry. However, limb deformities are infrequent and have not been reported to cause significant morbidity.

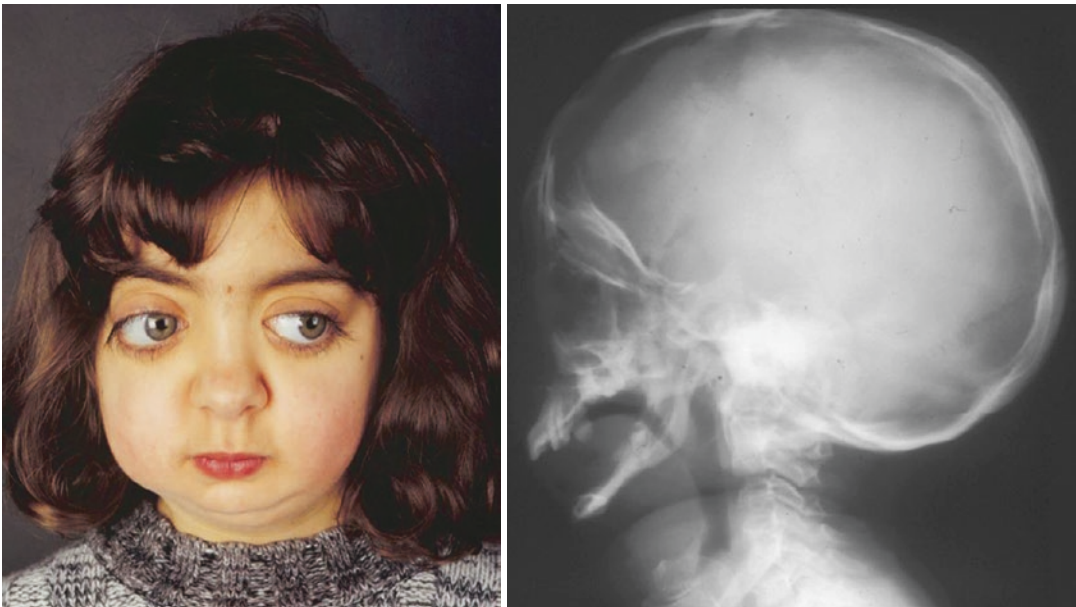

Fig. 8.1 Severe proptosis, facial asymmetry and jaw hypoplasia with almost complete loss of teeth in a patient with single-system multiple sites LCH diagnosed at

18 months of age. This patient also developed diabetes insipidus 16 years after LCH diagnosis

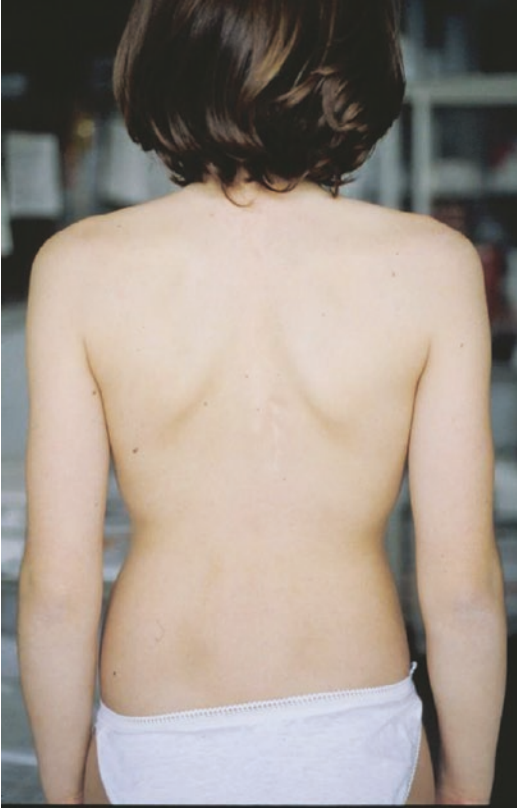

Fig. 8.2 Scoliosis in a patient with single-system single bone vertebral localisation when she was 6 years old

Ears

Mastoid lesions can result in permanent damage and hearing loss with an incidence ranging from 3% to 16% [1, 4–6, 16]. Although deafness is more often conductive, damage to the inner ear and bony labyrinth may result in permanent sensorineural hearing loss and disability [17]. Involvement of the vestibular region is rare but may present with loss of balance in addition to hearing loss. Damage to the bony structures of the inner ear is best seen on CT scan of the

petrous bones; therefore, all children with hearing loss or other symptoms of inner ear involvement should have appropriate imaging performed.

Hearing loss may go undiagnosed resulting in learning problems (see later). Children with ear involvement should thus be carefully followed up with serial audiometry and assessment throughout childhood, since early diagnosis of hearing loss and interventional strategies such as the use of hearing aids can significantly improve outcome.

Skin

Scarring can be seen at sites of previous skin involvement and from surgical procedures. Deposition of fat in skin lesions may result in xanthomatous areas (Fig. 8.3) and concomitant juvenile xanthogranuloma [18]. Treatment with topical mustine hydrochloride was used very effectively in the past and found to be safe with no long-term sequelae [19]. Furthermore, radiation to the area may result in secondary basal cell carcinoma, melanoma or precancerous lesions which need careful follow-up (see later).

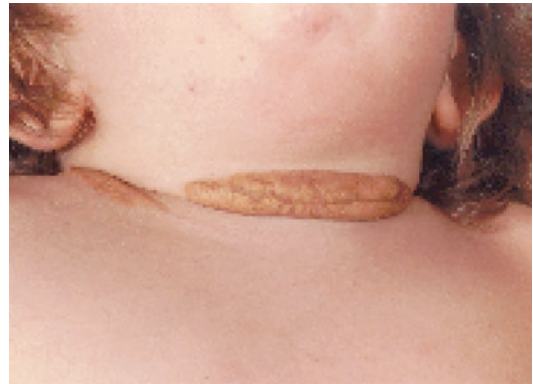

Fig. 8.3 Xanthogranuloma in area of previous LCH rash

Endocrine Sequelae

Diabetes insipidus: LCH has a special predilection for involving the posterior pituitary gland. Diabetes insipidus (DI) can either precede the diagnosis of LCH by many years [20] or become manifest after LCH is diagnosed. The reported incidence of DI ranges from 15% to 50% [5–7, 10, 21], while the reported long-term cumulative risk of developing DI varies between 26% [8] and 42% [22]. The variations in reported incidence of DI may be a reflection of factors such as the referral bias to institutions, differing criteria for establishing the diagnosis ranging from scant clinical history of polyuria and polydipsia, measurement of early morning plasma and/or urine osmolality to water deprivation test with measurement of urinary arginine vasopressin (AVP) levels [23], the latter being the test of choice for diagnosis of DI.

The risk factors for development of DI include multisystem disease and involvement of the craniofacial bones, especially the orbit and base of the skull [24, 25].

DI is usually permanent [26, 27], but there have been a few reports of reversibility of DI with treatment [14, 28, 29]. It is possible that some of these patients might have had partial DI with higher AVP levels. This needs to be fully assessed with appropriate investigations before a conclusive diagnosis is made. Several studies in the literature suggest that the use of intensive chemotherapy at onset of LCH can reduce the development of DI [4, 24]. More studies are needed to validate this approach.

Anterior pituitary dysfunction: Growth hormone deficiency (GHD) is the next most common endocrine abnormality, occurring in up to 20% of subjects, with other hormone deficiencies such as secondary hypothyroidism, gonadotropin deficiency and corticotropin deficiency occurring

less often [8, 30]. Pituitary radiation used in patients with DI does not ameliorate the condition and may, in fact, result in anterior pituitary damage and hormone deficiency and should therefore be avoided.

All children with DI, short stature and poor growth or delayed puberty should have pituitary stimulation tests to measure anterior pituitary hormone function. It should be noted, however, that growth may be affected due to a combination of factors including hormone deficiency, bony involvement, chronic steroid therapy and the effects of the chronic disease itself, resulting in compromised final height [21].

Children with hypothalamic damage may not only have pituitary endocrinopathies but may also develop behavioural problems, the so-called hypothalamic syndrome. Features of this condition include aggressive behaviour, eating disorders, obesity and temperature instability.

The thyroid gland rarely may also be directly affected by LCH resulting in primary hypothyroidism. This has been described predominantly in adults, although there have been a few reports in children [31].

Lungs

Lung involvement may occur during the acute phase of the disease in up to 50% of children with multisystem LCH. However, compared to adults, permanent lung damage is less common in children, ranging in incidence between 1% and 8% according to different reports [8, 10]. This is possibly due to the repair of alveoli in the young child. Lung disease with LCH appears to be predominantly a disease of young adults, particularly in those who smoke [32]. In this long-term follow-up study, 24% of patients, including some in whom LCH was diagnosed during childhood,

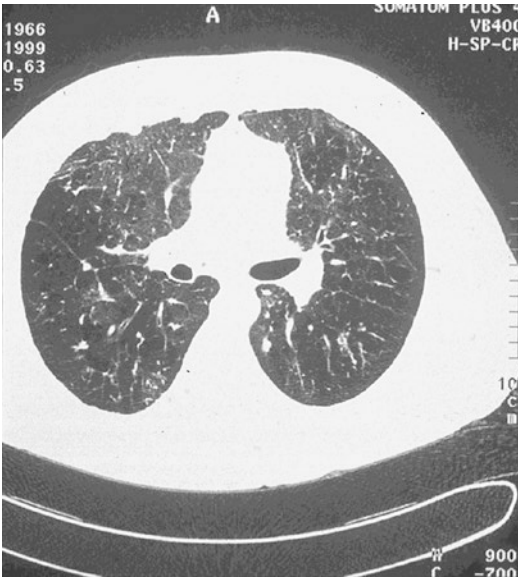


Fig. 8.4 Pulmonary findings of LCH on chest CT

had radiological abnormalities of the lungs, and 70% of these subjects were or had been smokers. Only 20% of these patients were symptomatic. Overall, the natural history of pulmonary disease in the context of LCH is still unknown. In some patients, severe lung fibrosis and emphysema (Fig. 8.4) resulting in restriction of activity may require lung transplantation.

As smoking has been shown by several groups to be the most important risk factor for worsening lung disease [33, 34], patients with LCH should be strongly advised to refrain from smoking. Additionally, all patients with a history of LCH and who are known smokers should have long-term pulmonary follow-up as there is a known association between LCH and lung cancer in patients who smoke (see later) [35].

Brain

Neurological problems such as cerebellar ataxia, psychological problems and learning difficulties can develop concurrently, or more often, several

years after diagnosis of LCH. The natural history of CNS disease in LCH is unclear and the abnormalities may remain stable or progress in time resulting in severe disability. The prevalence of CNS disease varies in different reports depending on the mode of assessment and the depth of investigation.

Cerebellar damage may be seen in up to 12% of all patients with LCH [7], but this increases to 60% in patients with recognised CNS involvement [36, 37].

Learning difficulty has been reported in patients with LCH, but there have only been a few comprehensive studies on this area in the literature. Neuropsychological sequelae of LCH include intellectual loss, learning deficit, poor school performance and emotional disturbance. Detailed testing has shown global deficits in functioning with a drop in intellectual quotient (IQ) [38] and significant cognitive impairment in up to 40% of patients with multisystem disease [39]. CNS involvement in LCH seems to affect general cognitive development, both verbal and non-verbal. Patients have been shown to have problems with immediate auditory verbal memory span and immediate recall of geometric designs. Similarly, the patients also showed increased vulnerability to interference during learning. Deficits in memory can result, further affecting the ability to retain information and learn.

It is recognised that “risk factors” for CNS disease include multisystem involvement, cranio-facial bone lesions and the presence of DI [8, 36]. Patients who belong to these groups should have more careful and frequent follow-up, including brain MRI and neuropsychometric studies, looking specifically for CNS damage.

Although neurological damage may be less common and less overt than other sequelae of LCH, its impact on school performance and ability to lead an independent life and quality of life highlight the importance of assessing every patient in detail on a regular basis, so

that abnormalities can be picked up early and appropriate intervention and rehabilitation can be planned. For more details on CNS-LCH, see Chap. 5.

Liver

Chronic, progressive liver damage may result in sclerosing cholangitis and cirrhosis. This abnormality may be seen quite early in the disease course and may be associated with concurrent active disease in other organs. Sclerosing cholangitis is often fatal and liver transplantation might be the only curative procedure [40]. Recurrence, however, of LCH in the graft has also been reported [41].

Morbidity and Quality of Life

Single-institution studies have shown that overall morbidity can be significant resulting in disability and handicap in over half of survivors of multisystem LCH. Health-related quality of life, which assesses the patient's perspective of the burden of disease, has also been studied in the same patients and found to correlate closely with the morbidity, as measured by professionals. Both parameters were especially affected by the presence of CNS and lung involvement with inability to lead independent lives in the most severely affected patients [42].

LCH and Malignancies

The association of LCH with malignancy has been described in several reports [43–53], and it is clear that the frequency is greater than what could be expected by chance alone. In 1991, members of the Histiocyte Society (HS) formed the LCH-Malignancy Registry with the goal of defining the patterns of occurrence of malignancy and LCH in

the same individual. Information on timing (synchronous or asynchronous) of the two diagnoses, type of malignancy and treatments for the first disease might, in fact, help to generate hypotheses to investigate possible common pathways between the two diseases. The registry is updated through periodic literature review and registration of cases by HS members. Two reports have been published [44, 45], and in this chapter, we have the latest update, discussing the cases observed in subjects in whom LCH occurred in paediatric age (i.e. ≤ 18 years) or during adulthood.

At the last update (2015), 270 cases of LCH-malignancy association have been registered: 117 subjects had their LCH diagnosis under the age of 18, while the remaining 153 were diagnosed as adults (Table 8.2). Solid tumours are the most frequently reported type of malignancy both among children and adults; acute myeloid leukaemias (AML) are the second most frequent type of malignancy among children with LCH, while lymphomas are more frequently reported among adults (Table 8.2, Haupt, 2015, personal communication, unpublished).

As for malignancies observed among subjects diagnosed with LCH before age 18, solid tumours are the most frequent (44 cases reported), followed by AML (32 cases), acute lymphoblastic leukaemias (ALL) (25 cases) and lymphomas (16 cases). In general, there appear to be two patterns of association between LCH and malignancy:

Table 8.2 Number of malignancies reported in subjects with LCH (Haupt, 2015, personal communication)

	Age at LCH diagnosis		Total <i>n</i> (%)
	≤ 18 years <i>n</i> (%)	>18 years <i>n</i> (%)	
Solid tumours	44 (38)	61 (40)	105 (39)
Lymphomas	16 (14)	57 (37)	73 (27)
AML + MDS	32 (27)	33 (22)	65 (24)
ALL	25 (21)	2 (1)	27 (10)
Total	117 (100)	153 (100)	270 (100)

ALL usually precedes LCH, while AML and solid tumours develop after LCH.

Details about specific tumour types and their occurrence with respect to LCH diagnosis are reported in Tables 8.3 and 8.4, stratified by age at LCH diagnosis.

LCH and solid tumours: In most paediatric cases, the LCH diagnosis preceded that of the

associated malignancy and in several of those who received radiotherapy as part of their treatment, the malignancy developed within the radiation field. The development of solid tumours in the radiation field used for LCH treatment indicates that radiotherapy is the oncogenic stimulus in these patients. It is possible that the frequency of this observation will be reduced in the future

Table 8.3 Association of LCH with solid tumours or lymphomas by age at LCH diagnosis (Haupt, 2015, personal communication)

	Age (years) at LCH diagnosis							
	≤18				>18			
	LCH				LCH			
	Precedes	Concurrent	Follows	Total	Precedes	Concurrent	Follows	Total
CNS	8	1	4	13	–	–	1	1
Retinoblastoma	2	1	3	6	–	–	–	–
Neuroblastoma	3	–	3	6	–	–	–	–
Skin	4	–	–	4	–	1	4	5
Bone	4	–	–	4	–	–	–	–
Ewing/PNET	2	–	2	4	–	–	–	–
Breast	1	–	–	1	–	–	6	6
Thyroid	2	–	–	2	–	4	3	7
Lung	1	–	–	1	9	9	5	23
Gastrointestinal	–	–	–	–	–	2	1	3
Tongue	–	–	–	–	–	1	–	1
Pancreas	–	–	–	–	1	–	–	1
Parotid	–	–	–	–	–	1	–	1
Hepatic	1	–	–	1	–	–	–	–
Bladder	–	–	–	–	–	–	2	2
Kidney	–	1	–	1	1	1	–	2
Dysgerminoma	–	–	–	–	–	–	1	1
Testis	–	–	–	–	–	–	3	3
Apudoma	1	–	–	1	–	–	–	–
Fibrous histiocytoma	–	–	–	–	1	–	–	1
Undefined	–	–	–	–	2	1	–	3
Myeloid sarcoma	–	–	–	–	–	1	–	1
Histiocytic sarcoma					1	–	–	1
Myeloma					–	1	2	3
Hodgkin disease	4	1	2	7	2	17	13	32
Non-Hodgkin lymphoma	5	1	3	9	5	13	4	23
Total	35	8	17	60	21	52	45	119

Table 8.4 Association of LCH with leukaemias by age at LCH diagnosis (Haupt, 2015, personal communication)

		Age (years) at LCH diagnosis							
		≤18				>18			
		LCH				LCH			
		Precedes	Concurrent	Follows	Total	Precedes	Concurrent	Follows	Total
ALL	T-ALL	3	1	11	15	–	–	–	–
	B-ALL	2		4	6	–	–	1	1
	Unspecified	2		2	4	–	–	1	1
AML	FAB M1	5			5		1	1	2
	FAB M2	2			2	1	–	1	2
	FAB M3	9			9	–	–	–	–
	FAB M4	1	1		2	4	1	–	5
	FAB M5	3			3	4	–	–	4
	FAB M7	1			1	–	–	–	–
	Unspecified	4	–	–	4	1	1	–	2
Other	MDS	1	4		5	1	1	3	5
	JCML	1			1				
	CMML					5	2	–	7
	Acute basophilic	–	–	–	–	–	1	–	1
	Mixed lineage					–	1	–	1
	CLL					–	1	–	1
	Total	34	6	17	57	16	9	7	32

ALL acute lymphoblastic leukaemia, *AnLL* acute non-lymphoblastic leukaemia, *MDS* myelodysplastic syndrome, *JCML* juvenile chronic myelocytic leukaemia, *CMML* chronic myelomonocytic leukaemia, *CLL* chronic lymphocytic leukaemia

since radiotherapy is now rarely used for treatment of LCH [14].

Among adults, lung cancer is the most frequently reported malignancy often occurring concurrently or shortly after LCH diagnosis. The association of both lung cancer and pulmonary histiocytosis with smoking is well known, and it is likely that LCH represents a reaction either to smoking or the tumour itself [54].

LCH and lymphomas: Lymphomas are more frequently reported among adults with LCH [44], and often, the two diagnoses are almost concurrent (Table 8.2). This suggests that in these cases, LCH represents a reaction to the lymphoma. Among children with LCH, only 16 cases of lymphomas have been reported (7 Hodgkin disease, 9 non-Hodgkin lymphoma).

LCH and leukaemia: Ninety-two patients had LCH in association with leukaemia. Most of the leukaemias reported in subjects with LCH are AML ($n = 65$). In all, except one case who was diagnosed concurrently with LCH, the leukaemia followed LCH. The distribution of the different subtypes is not similar to what is expected in the de novo leukaemia; in particular nine cases of acute promyelocytic leukaemia (APL) have been reported. Most of these cases occurred in subjects either of Latino or Japanese origin; hence, a role of ethnicity has been hypothesised [46]. Another interesting observation comes from cytogenetic analysis of available cases; in fact, besides the classical t(15:17), chromosome 7 abnormalities were reported in an apparently non-random fashion.

It is likely that most of the AML cases were secondary to treatment given for LCH. In fact, all cases except one who was diagnosed 24 years after LCH were previously treated with chemotherapy or radiotherapy or both. Etoposide (VP-16) and other intercalating agents were part of treatment regimens in most cases. These observations, together with the evidence of a minor role of VP-16 in multisystem LCH, led to the exclusion of this drug from the standard front-line treatment for multisystem disease. However, even if most of the LCH-associated AML cases are probably treatment related, LCH patients seem to behave differently from other patients with cancer conditions who develop secondary AML in which FAB M5 subtypes seem to occur more frequently [46].

Acute lymphoblastic leukaemia (ALL) has been associated with LCH in 27 cases, and almost all [25] were diagnosed in patients who developed LCH in paediatric age. Again in the case of ALL, the distribution of different types is not what one would expect in *de novo* ALL. Interestingly, in fact, T-cell leukaemias are the most common immunophenotype and, in general, occur close to LCH diagnosis. In a review by Castro et al. [55], they described the clinico-pathologic features of 15 patients who had histiocytic lesions that followed ALL. The molecular signature of the prior leukaemia and the subsequent histiocytic lesion shared immunoglobulin H or monoclonal TCR gene rearrangements [55]. As most patients with ALL rapidly attain remission on starting treatment, it is felt to be less likely that the LCH develops as a “reaction” to the leukaemia. Another hypothesis, to explain the few cases in which LCH followed ALL, is that chemotherapy-induced immunosuppression may have played a role in the development of at least some cases of LCH.

Side Effects After Treatment with Targeted Therapies Involving BRAF/MAPK Pathways

With the recent identification of activating mutations in the proto-oncogene BRAF V600E noted in 60% of LCH cases as well as MEK and ERK phosphorylation in almost 100% of examined cases, LCH is now considered a myeloid neoplasm in the setting of inflammation [56, 57]. This has led to the use of targeted therapies, specifically agents deactivating RAS/RAF/MEK/ERK pathway similar to the BRAF V600E-driven melanoma treated with the inhibitor vemurafenib [56]. Several other inhibitors such as dabrafenib and various other combinations of BRAF, MEK and PI3K/mTOR inhibitors have shown encouraging results in clinical trials [58]. Since then, the efficacy of vemurafenib in refractory Erdheim-Chester disease (ECD) and LCH harbouring the BRAF V600E mutation has been demonstrated [59].

The use of vemurafenib in melanoma patients has been associated with the development of *de novo* squamous cell carcinoma (SCC) in as many as 25–50% of patients [60, 61]. Although SCC is the most concerning cutaneous effect related to BRAF inhibitor monotherapy, a myriad of other cutaneous side effects have been described including hyperkeratosis and photosensitivity [62]. Skin irritation was nearly universal in the LCH/ECD series, including rash (78%), photosensitivity reaction (28%) and cutaneous SCC (44%) [63]. Other toxicities experienced by adults with ECD and LCH treated with vemurafenib have included fatigue (61%), arthralgia (61%), hypertension (44%), diarrhoea (33%), alopecia (39%) and nausea (33%) [63].

There is increasing evidence for the development of resistance and second cancers after prolonged use of BRAF inhibitors likely due to

paradoxical ERK activation in cells with wild-type BRAF in a RAS-dependent manner [64, 65]. Secondary pancreatic cancers in patients with melanoma and BRAF V600E mutation treated with single inhibitor have also been reported [66].

Jhaveri et al. reviewed the FDA Adverse Event Reporting System's (FAERS) quarterly legacy data file from the third quarter of 2011 to the second quarter of 2014 for vemurafenib use in malignant melanoma [67]. Vemurafenib-related renal adverse event data were extracted from the database. A total of 132 cases of acute kidney injury were reported secondary to vemurafenib. The average age of the men was 65 years and 59 years for the women ($P = 0.0392$). There were six cases of hypokalaemia and eight cases of hyponatraemia reported [67]. With regard to dabrafenib, the European summary of product characteristics of the drug reports that renal failure has been identified in <1% of patients treated with dabrafenib [68].

The association of BRAF inhibitors and QT prolongation, although uncommon, has also been reported [69]. Furthermore, a case of left ventricular dysfunction in a child with relapsed neuroblastoma has also been described [70].

Ocular toxicity such as retinopathy has also been noted, mainly among melanoma patients treated with MEK inhibitors specifically binimetinib [71]. MEK inhibitor as a single agent or in combination with BRAF inhibitor induces transient retinopathy with time-dependent recurrence and usually mild visual symptoms. It is important to investigate all previous ocular disorders, systemic conditions and pharmacologic interactions of MEK inhibitor that may accelerate the onset of associated ocular effects [72].

The possibility of various acute complications requires caution and judicious use of these agents. Little is known of their long-term complications

and patients would require continued surveillance. More studies are needed to ascertain the value of combining targeted agents to ensure optimal efficacy and monitor development of resistance as well as possible adverse effects of these agents especially in the paediatric population.

Conclusions

There is a considerable difference in the reported incidence and prevalence of permanent consequences after LCH in the various sources available. Some of these discrepancies may relate to the widely varying treatment approaches used in the past for the disease we now recognize as LCH. Also, methods for collection of data and criteria for definition of each of the late effects have been different across different studies, leading to a lack of homogeneous data. Therefore, it is difficult to make accurate comparisons regarding risk factors for development of sequelae from LCH and the association of treatment with outcome.

In the past, patients who had LCH were often "lost to follow-up" as LCH was considered a benign condition, and the potential risk for late effects was underestimated. As more information is now known regarding these long-term problems, it is important that all patients and their families are counselled regarding the possibility of developing consequences, especially when the risk factors mentioned above are present.

In a recent multicentre study sponsored by the Histiocyte Society [8], it has been clearly shown that a significant proportion of subjects are lost to follow-up and that among subjects still in follow-up, non-homogeneous criteria are used in the different institutions to assess permanent consequences. It is important to use a "common language" to define late effects/permanent consequences and to

Table 8.5 Proposal for standardised follow-up for permanent consequences in LCH patients [73]

System involvement	Test	Frequency	Notes
All patients	Clinical assessment, height, weight, pubertal status neurological assessment history of thirst, polyuria	End of therapy Every 6 months for 2 years Yearly for 10 years	If thirst or polyuria: water deprivation test with measurement of plasma and urinary osmolarity +/- urinary AVP If poor growth, delayed puberty or DI: growth hormone and other pituitary hormone secretion tests
Bone-axial skeleton and/or limbs	Orthopaedic assessment	End of therapy Yearly until completion of pubertal growth	
Ear, mastoid and skull base	Audiometry or audiometry evoked responses in younger children	End of therapy Before entering school If symptoms develop	If hearing loss: CT scan of petrous temporal bone
Oral tissue and jaw	Dental assessment	Yearly	
CNS positive or skull base Orbital lesions, DI, anterior pituitary deficiency	Neuropsychometric assessment	End of therapy Every 2–3 years or earlier if there are concerns regarding learning	
CNS positive or skull base Orbital lesions, DI, anterior pituitary deficiency	MRI brain with contrast	End of therapy Once every 5 years unless specific concerns regarding balance, gait or learning	If mass lesion present, scan every 6 months until resolution or stable
Lungs	Spirometry	End of therapy Every 6 months for 2 years Every year for 10 years	Dangers of smoking should be explained and smoking avoided if possible. If spirometry is abnormal or chest symptoms: chest X-ray and high-resolution CT scan
Liver	Sonography Bilirubin, GGT, alkaline phosphatase	End of therapy	Repeat if abnormal

For disease-specific monitoring, follow guidelines of the new LCH-IV protocol

develop a consensus for the method of investigations and selection of patients who need specific tests performed. In Table 8.5 we propose a simple outline for standardised, multi-disciplinary follow-up of long-term survivors of LCH.

The consequences reported in the literature are from patients who were treated on the older regimens, and some modalities such as radiotherapy, VP-16 and high doses of alkylat-

ing agents are now used less often for treatment of this disease. It is possible that this may reduce the long-term problems, such as secondary development of solid tumours and AML following treatment. Finally, with increasing shift of treatment options towards more targeted therapies, increasing surveillance for both acute and long-term complications of these agents is imperative.

References

- Komp DM, El Mahdi A, Starling KA, Easley J, Vietti TJ, Berry DH, George SL. Quality of survival in histiocytosis X: a southwest oncology group study. *Med Pediatr Oncol.* 1980;8:35–40.
- Komp DM. Long-term sequelae of histiocytosis X. *Am J Pediatr Hematol Oncol.* 1981;3:165–8.
- Sims DG. Histiocytosis X. Follow-up of 43 cases. *Arch Dis Child.* 1977;52:433–40.
- Ceci A, Terlizzi MD, Colella R, Loiacono G, Balducci D, Surico G, Castello M, Testi AM, Bernardi B, Indolfi P, Macchia P, Madon E, Mancini A, Rosati D. Langerhans cell histiocytosis in childhood: results from the Italian cooperative AIEOP-CNR-H.X '83 study. *Med Pediatr Oncol.* 1993;21:259–64.
- Gadner H, Heitger A, Grois N, Gatterer-Menz I, Ladisch S. Treatment strategy for disseminated Langerhans cell histiocytosis. *Med Pediatr Oncol.* 1994;23:72–80.
- Donadieu J, French LCH Study group. A multi-centre retrospective survey of Langerhans' cell histiocytosis: 348 cases observed between 1983 and 1993. *Arch Dis Child.* 1996;75:17–24.
- Willis B, Ablin A, Weinberg V, Zoger S, Wara WM, Matthay KK. Disease course and late sequelae of Langerhans' cell histiocytosis: 25-year experience at the University of California, San Francisco. *J Clin Oncol.* 1996;14:2073–82.
- Haupt R, Nanduri V, Calevo MG, Bernstrand C, Braier JL, Broadbent V, Rey G, McClain KL, Janka-Schaub G, Egeler M. Permanent consequences in Langerhans cell histiocytosis patients. A pilot study from the histiocyte society – late effects study group. *Pediatr Blood Cancer.* 2004;42:438–44.
- Chellapandian D, Shaikh F, van den Bos C, Somers GR, Astigarraga I, Jubran R, Degar B, Carret AS, Mandel K, Belletrutti M, Dix D, Visser J, Abuhadra N, Chang T, Rollins B, Whitlock J, Weitzman S, Abla O. Management and outcome of patients with Langerhans cell Histiocytosis and single-bone CNS-risk lesions: a multi-institutional retrospective study. *Pediatr Blood Cancer.* 2015;62:2162–6.
- Rigaud C, Barkaoui MA, Thomas C, Bertrand Y, Lambilliotte A, Miron J, Aladjidi N, Plat G, Jeziorski E, Galambrun C, Mansuy L, Lutz P, Deville A, Armari-Alla C, Reguerre Y, Fraïtag S, Coulomb A, Gandemer V, Leboulanger N, Moshous D, Hoang-Xuan K, Tazi A, Heritier S, Emile JF, Donadieu J. Langerhans cell histiocytosis: therapeutic strategy and outcome in a 30-year nationwide cohort of 1478 patients under 18 years of age. *Br J Haematol.* 2016;174:887–98.
- Kim BE, Koh KN, Suh JK, Im HJ, Song JS, Lee JW, et al. Clinical features and treatment outcomes of Langerhans cell Histiocytosis: a Nationwide survey from Korea Histiocytosis working party. *J Pediatr Hematol Oncol.* 2014;36:125–33.
- Lau LM, Stuurman K, Weitzman S. Skeletal Langerhans cell histiocytosis in children: permanent consequences and health-related quality of life in long-term survivors. *Pediatr Blood Cancer.* 2008;50:607–12.
- Lau; Skeletal Langerhans Cell Histiocytosis in Children: Permanent Consequences
- Titgemeyer C, Grois N, Minkov M, Flucher-Wolfman B, Gatterer-Meinz I, Gadner H. Pattern and course of single-system disease in Langerhans cell histiocytosis data from the DAL-HX 83- and 90- study. *Med Pediatr Oncol.* 2001;37:108–14.
- Greenberger JS, Cassady JR, Jaffe N, Vawter G, Crocker AC. Radiation therapy in patients with histiocytosis: management of diabetes insipidus and bone lesions. *Int J Radiat Oncol Biol Phys.* 1979;5:1749–55.
- Henry R, Sweeney E. Langerhans cell Histiocytosis: case reports and literature review. *Pediatr Dent.* 1996;18:11–6.
- Braier J, Chantada G, Rosso D, Bernaldez P, Amaral D, Latella A, Balancini B, Masautis A, Goldberg J. Langerhans cell histiocytosis: retrospective evaluation of 123 patients at a single institution. *Pediatr Hematol Oncol.* 1999;16:377–85.
- Nanduri VR, Pritchard J, Chong WK, Phelps PD, Sirimanna TS, Bailey CM. Labyrinthine involvement in Langerhans' cell histiocytosis. *Int J of Ped Otorhinolaryngology.* 1998;46(1–2):109–15.
- Hoeger PH, Diaz C, Malone M, Pritchard J, Harper JI. Juvenile xanthogranuloma as a sequel to Langerhans cell histiocytosis: a report of three cases. *Clin Exp Dermatol.* 2001;26:391–4.
- Hoeger PH, Nanduri VR, Harper JI, Pritchard J. Long term follow up of topical mustine treatment for cutaneous Langerhans cell histiocytosis. *Arch Dis Child.* 2000;82:483–7.
- Di Iorgi N, Allegri AE, Napoli F, Calcagno A, Calandra E, Fratangeli N, Vannati M, Rossi A, Bagnasco F, Haupt R, Maghnie M. Central diabetes insipidus in children and young adults: etiological diagnosis and long-term outcome of idiopathic cases. *J Clin Endocrinol Metab.* 2014;99:1264–72.
- Nanduri VR, Bareille P, Pritchard J, Stanhope R. Growth and endocrine disorders in Langerhans cell histiocytosis. *Clin Endo.* 2000;53:509–15.
- Dunger DB, Broadbent V, Yeoman E, Seckl JR, Lightman SL, Grant DB, Pritchard J. The frequency and natural history of diabetes insipidus in children with Langerhans-cell histiocytosis. *N Engl J Med.* 1989;321:1157–62.
- Dunger DB, Seckl JR, Grant DB, Yeoman E, Lightman SL. A short water deprivation test incorporating urinary arginine vasopressin estimations for the investigation of posterior pituitary function in children. *Acta Endocrinol.* 1988;117:13–8.
- Grois N, Flucher Wolfram B, Heitger A, Mostbeck GH, Hofmann J, Gadner H. Diabetes insipidus in Langerhans cell histiocytosis: results from the DAL-HX 83 study. *Med Pediatr Oncol.* 1995;24:248–56.

25. Minkov M, Grois N, Heitger A, Potschger U, Westermeyer T, Gadner H. Treatment of multisystem Langerhans cell histiocytosis. Results of the DAL-HX 83 and DAL-HX 90 studies. DAL-HX study group. *Klin Padiatr.* 2000;212:139–44.
26. Broadbent V, Pritchard J. Diabetes insipidus associated with Langerhans cell histiocytosis: is it reversible? *Med Pediatr Oncol.* 1997;28:289–93.
27. Rosenzweig KE, Arceci RJ, Tarbell NJ. Diabetes insipidus secondary to Langerhans' cell histiocytosis: is radiation therapy indicated. *Med Pediatr Oncol.* 1997;29:36–40.
28. Ottaviano F, Finlay JL. Diabetes insipidus and Langerhans cell histiocytosis: a case report of reversibility with 2-chlorodeoxyadenosine. *J Pediatr Hematol Oncol.* 2003;25:575–7. PMID: 23258922
29. Morimoto A, Shioda Y, Imamura T, Kudo K, Kawaguchi H, Sakashita K, Yasui M, Koga Y, Kobayashi R, Ishii E, Fujimoto J, Horibe K, Bessho F, Tsunematsu Y, Imashuku S. Intensified and prolonged therapy comprising cytarabine, vincristine and prednisolone improves outcome in patients with multisystem Langerhans cell histiocytosis: results of the Japan Langerhans cell Histiocytosis study group-02 protocol study. *Int J Hematol.* 2016;104:99–109.
30. Toro Galván S, Planas Vilaseca A, Michalopoulou Alevras T, Torres Díaz A, Suárez Balaguer J, Villabona AC. Endocrine changes in histiocytosis of the hypothalamic-pituitary axis. *Endocrinol Nutr.* 2015;62:72–9.
31. Rami B, Schneider U, Wandl-Vergesslich K, Frisch H, Schober E. Primary hypothyroidism, central diabetes insipidus and growth hormone deficiency in multisystem Langerhans cell histiocytosis: a case report. *Acta Paediatr.* 1998;87:112–4.
32. Bernstrand C, Cederlund K, Sandstedt B, Ahstrom L, Lundell M, Dahlquist G, Henter JI. Pulmonary abnormalities at long-term follow-up of patients with Langerhans cell histiocytosis. *Med Pediatr Oncol.* 2001;36:459–68.
33. Tazi A, de Margerie C, Naccache JM, Fry S, Dominique S, Jouneau S, Lorillon G, Bugnet E, Chiron R, Wallaert B, Valeyre D, Chevret S. The natural history of adult pulmonary Langerhans cell histiocytosis: a prospective multicentre study. *Orphanet J Rare Dis.* 2015;14:10–30.
34. Habib SB, Congleton J, Carr D, Partridge J, Corrin B, Geddes DM, Banner N, Yacoub M, Burke M. Recurrence of recipient Langerhans' cell histiocytosis following bilateral lung transplantation. *Thorax.* 1998;53:323–5.
35. Howarth DM, Gilchrist GS, Mullan BP, Wiseman GA, Edmonson JH, Schomberg PJ. Langerhans cell histiocytosis. Diagnosis, natural history, management, and outcome. *Cancer.* 1999;85:2278–90.
36. Grois NG, Favara BE, Mostbeck GH, Prayer D. Central nervous system disease in Langerhans cell histiocytosis. *Hematol Oncol Clin North Am.* 1998;12:287–305.
37. Grois N, Fahrner B, Arceci RJ, Henter JI, McClain K, Lassmann H, Nanduri V, Prosch H, Prayer D. Central nervous system disease in Langerhans cell histiocytosis. *J Pediatr.* 2010;156:881.
38. Whitsett SF, Kneppers K, Coppes MJ, Egeler RM. Neuropsychological deficits in children with Langerhans cell histiocytosis. *Med Pediatr Oncol.* 1999;33:486–92.
39. Nanduri VR, Lillywhite L, Chapman C, Parry L, Pritchard J, Vargha-Khadem F. Cognitive outcome of long term survivors of multisystem Langerhans cell histiocytosis: a single-institution, cross-sectional study. *J Clin Onc.* 2003;21:2961–7.
40. Braier J, Ciocca M, Latella A, de Davila MG, Drajer M, Inventarza O. Cholestasis, sclerosing cholangitis, and liver transplantation in Langerhans cell Histiocytosis. *Med Pediatr Oncol.* 2002;38:178–82.
41. Hadzic N, Pritchard J, Webb D, Portmann B, Heaton ND, Rela M, Dhawan A, Baker AJ, Mieli VG. Recurrence of Langerhans cell histiocytosis in the graft after pediatric liver transplantation. *Transplantation.* 2000;70:815–9.
42. Nanduri VR, Pritchard J, Levitt G, Glaser AW. Long term morbidity and health related quality of life after multi-system Langerhans cell histiocytosis. *Eur J Cancer.* 2006;42(15):2563–9. Nesbit ME, Keiffer S, D'Angio GJ. (1969). Reconstitution of vertebral height in Histiocytosis X: a long-term follow-up. *J Bone Joint Surg;*51:1360–8.
43. Chiles LR, Christian MM, McCoy DK, Hawkins HK, Yen AH, Raimer SS. Langerhans cell histiocytosis in a child while in remission for acute lymphocytic leukemia. *J Am Acad Dermatol.* 2001;45:S233–4.
44. Egeler RM, Neglia JP, Arico M, Favara BE, Heitger A, Nesbit ME. Acute leukemia in association with Langerhans cell Histiocytosis. *Med Pediatr Oncol.* 1994;2:381–5.
45. Egeler RM, Neglia JP, Arico M, Favara BE, Heitger A, Nesbit ME, Nicholson HS. The relation of Langerhans cell histiocytosis to acute leukemia, lymphomas, and other solid tumors. The LCH-malignancy study Group of the Histiocyte Society. *Hematol Oncol Clin North Am.* 1998;12:369–78.
46. Haupt R, Fears TR, Heise A, Gadner H, Loiacono G, De Terlizzi M, Tucker MA. Risk of secondary leukemia after treatment with etoposide (VP-16) for Langerhans' cell histiocytosis in Italian and Austrian- German populations. *Int J Cancer.* 1997;71:9–13.
47. Kager L, Heise A, Minkov M, Mobius D, Kotte W, Schulte-Overberg U, Henze G, Gadner H. Occurrence of acute nonlymphoblastic leukemia in two girls after treatment of recurrent, disseminated Langerhans cell histiocytosis. *Pediatr Hematol Oncol.* 1999;16:251–6. Review

48. Lopes LF, de Camargo B. Secondary acute promyelocytic leukemia after treatment with etoposide for Langerhans cell histiocytosis (LCH). *Med Pediatr Oncol.* 1999;32:315.
49. Macedo Silva ML, Land MG, Maradei S, Otero L, Veith M, Brito G, Klumb C, Fernandez T, Pombo-de-Oliveira MS. Translocation (11;11)(p13- p15;q23) in a child with therapy-related acute myeloid leukemia following chemotherapy with DNA-topoisomerase II inhibitors for Langerhans cell histiocytosis. *Cancer Genet Cytogenet.* 2002;135:101–2.
50. Raj A, Bendon R, Moriarty T, Suarez C, Bertolone S. Langerhans cell histiocytosis following childhood acute lymphoblastic leukemia. *Am J Hematol.* 2001;68:284–6.
51. Wu JH, Lu MY, Lin KH, Jou ST, Lin DT. Development of acute lymphoblastic leukemia in a child after treatment of Langerhans cell histiocytosis: report of one case. *Acta Paediatr Taiwan.* 1999;40:441–2.
52. Ghosn M, Haddad A, Nassar M, Abadjjian G, El Karak F, Aftimos P. Acute myeloid leukemia and Langerhans cell Histiocytosis: multiple theories for an unusual presentataion. *Leukemia Res.* 2009;34:406–8. doi:10.1016/j.leukres.2009.07.025.
53. Greaves W, Bueso-Ramos C, Fayad L. Classical Hodgkin lymphoma associated with Langerhans cell Histiocytosis: Multiagent chemotherapy resulted in Histologic resolution of both classical Hodgkin lymphoma and Langerhans cell proliferation components. *JCO.* 2011;29(4):e76–8. doi:10.1200/JCO.2010.31.2413.
54. Vassallo R, Ryu J, Schroeder D, Decker P, Limper A. Clinical outcomes of pulmonary Langerhans cell Histiocytosis in adults. *N Engl J Med.* 2002;346:484–90.
55. Castro EC, Blazquez C, Boyd J, Correa H, de Chadarevian JP, Felgar RE. Clinicopathologic features of histiocytic lesions following ALL, with review of the literature. *Pediatr Dev Pathol.* 2010;13:225–37.
56. Abla O, Weitzman S. Treatment of Langerhans cell histiocytosis: role of BRAF/MAPK inhibition. *Hematology Am Soc Hematol Educ Program.* 2015;2015:565–70. doi:10.1182/asheducation-2015.1.565.
57. Badalian-Very G, Vergilio JA, Degar BA, MacConaill LE, Brandner B, Calicchio ML, Kuo FC, Ligon AH, Stevenson KE, Kehoe SM, Garraway LA, Hahn WC, Meyerson M, Fleming MD, Rollins BJ. Recurrent BRAF mutations in Langerhans cell histiocytosis, blood. 2010. Sep 16. 2010;116(11):1919–23.
58. Greger JG, Eastman SD, Zhang V, Bleam MR, Hughes AM, Smitheman KN. Combinations of BRAF, MEK, and PI3K/mTOR inhibitors overcome acquired resistance to the BRAF inhibitor GSK2118436 dabrafenib, mediated by NRAS or MEK mutations. *Mol Cancer Ther.* 2012;11(4):909–20. doi:10.1158/1535-7163.MCT-11-0989. Epub 2012 Mar 2
59. Haroche J, Cohen-Aubart F, Emile JF, Arnaud L, Maksud P, Charlotte F. Dramatic efficacy of vemurafenib in both multisystemic and refractory Erdheim-Chester disease and Langerhans cell histiocytosis harboring the BRAF V600E mutation. *Blood.* 2013;121(9):1495–500. doi:10.1182/blood-2012-07-446286.
60. Sloot S, Fedorenko IV, Smalley KS, Gibney GT. Long-term effects of BRAF inhibitors in melanoma treatment: friend or foe? *Expert Opin Pharmacother.* 2014;15(5):589–92. doi:10.1517/14656566.2014.881471. Epub 2014 Jan 24
61. Oberholzer PA, Kee D, Dziunycz P, et al. RAS mutations are associated with the development of cutaneous squamous cell tumors in patients treated with RAF inhibitors. *J Clin Oncol.* 2012;30:316–21.
62. Carlos G, Anforth R, Clements A, Menzies AM, Carlino MS, Chou S. Cutaneous toxic effects of BRAF inhibitors alone and in combination with MEK inhibitors for metastatic melanoma. *JAMA Dermatol.* 2015;151(10):1103–9. doi:10.1001/jamadermatol.2015.1745.
63. Hyman DM, Puzanov I, Subbiah V, et al. Vemurafenib in multiple nonmelanoma cancers with BRAF V600 mutations. *N Engl J Med.* 2015;373:726–36.
64. Johannessen CM, Boehm JS, Kim SY, Thomas SR, Wardwell L, Johnson LA. COT drives resistance to RAF inhibition through MAP kinase pathway reactivation. *Nature.* 2010;468(7326):968–72. doi:10.1038/nature09627. Epub 2010 Nov 24
65. Poulikakos PI, Zhang C, Bollag G, Shokat KM, Rosen N. RAF inhibitors transactivate RAF dimers and ERK signalling in cells with wild-type BRAF. *Nature.* 2010;464(7287):427–30. doi:10.1038/nature08902.
66. Grey A, Cooper A, McNeil C, O'Toole S, Thompson J, Grimison P. Progression of KRAS mutant pancreatic adenocarcinoma during vemurafenib treatment in a patient with metastatic melanoma. *Intern Med J.* 2014;44(6):597–600. doi:10.1111/imj.12415.
67. Jhaveri KD, Sakhiya V, Fishbane S. Nephrotoxicity of the BRAF inhibitors Vemurafenib and Dabrafenib. *JAMA Oncol.* 2015;1(8):1133–4. doi:10.1001/jamaoncol.2015.1713.
68. US Food and Drug Administration. Tefinlar Highlights of prescribing information. http://www.accessdata.fda.gov/drugsatfda_docs/label/2013/202806s000lbl.pdf Last revised May 2013.
69. Bronte E, Bronte G, Novo G, Bronte F, Bavetta MG, Lo RG. What links BRAF to the heart function? New insights from the cardiotoxicity of BRAF inhibitors in cancer treatment. *Oncotarget.* 2015;6(34):35589–601. doi:10.18632/oncotarget.5853.
70. Modak S, Asante-Korang A, Steinherz LJ, Grana N. Trametinib-induced left ventricular dysfunction in a child with relapsed Neuroblastoma. *J Pediatr Hematol Oncol.* 2015;37(6):e381–3. doi:10.1097/MPH.0000000000000364.
71. Urner-Bloch U, Urner M, Stieger P, Galliker N, Winterton N, Zubel A. Transient MEK

- inhibitor-associated retinopathy in metastatic melanoma. *Ann Oncol.* 2014;25(7):1437–41. doi:[10.1093/annonc/mdu169](https://doi.org/10.1093/annonc/mdu169). Epub 2014 May 26
72. Niro A, Strippoli S, Alessio G, Sborgia L, Recchimurzo N, Guida M. Ocular toxicity in metastatic melanoma patients treated with Mitogen-activated protein Kinase Kinase inhibitors: a case series. *Am J Ophthalmol.* 2015;160(5):959–67. doi:[10.1016/j.ajo.2015.07.035](https://doi.org/10.1016/j.ajo.2015.07.035). e1. Epub 2015 Jul 29
73. LCH-IV International Collaborative Treatment Protocol for Langerhans Cell Histiocytosis. <https://clinicaltrials.gov/ct2/show/NCT02205762>

Part III

Hemophagocytic Lymphohistiocytosis (HLH)



Classification, Clinical Manifestations, and Diagnostics of HLH

9

J. Pachlopnik Schmid, Benjamin Volkmer, and Stephan Ehl

Abbreviations

ADV	Adenovirus
CGD	Chronic granulomatous disease
CHS	Chediak-Higashi syndrome
CNS	Central nervous system
CSF	Cerebrospinal fluid
EBV	Epstein-Barr virus
FHL	Familial HLH
HHV	Human herpes virus
HLH	Hemophagocytic lymphohistiocytosis
HPS	Hermansky-Pudlak syndrome
HSCT	Hematopoietic stem cell transplantation
IFN	Interferon
MAS	Macrophage activation syndrome
MRI	Magnetic resonance imaging
NGS	Next-generation sequencing
PBMCs	Peripheral blood mononuclear cells
PCR	Polymerase chain reaction
PID	Primary immunodeficiency

SAP	Signaling lymphocytic activation molecule-associated protein
sJIA	Systemic juvenile idiopathic arthritis
SLE	Systemic lupus erythematosus
WES	Whole-exome sequencing
WGS	Whole-genome sequencing
XIAP	X-linked inhibitor of apoptosis
XLP	X-linked lymphoproliferative syndrome

Classification of HLH

Hemophagocytic lymphohistiocytosis (HLH) is a life-threatening hyperinflammatory syndrome. HLH is not a single disease, since a variety of conditions can lead to similar clinical hyperinflammatory phenotypes. The terms used to describe HLH and related syndromes have changed since the original description in 1952 [1]. Ideally, HLH would be classified according to the underlying pathophysiology. However, the pathophysiological basis of HLH varies in different conditions and has not been fully characterized in many disease settings.

Because of its important therapeutic implications, the distinction between “primary HLH” and “secondary HLH” (summarized in Table 9.1) is a clinically relevant issue. This implies the need for a rapid diagnosis of a genetic defect in granule-mediated cytotoxicity. Patients with “primary” HLH require allogeneic

The original version of this chapter was revised. An erratum to this chapter can be found at https://doi.org/10.1007/978-3-319-59632-7_21

J. Pachlopnik Schmid, MD, PhD (✉) • B. Volkmer, PhD
Division of Immunology, University Children’s Hospital, University of Zurich, Zurich, Switzerland
e-mail: jana.pachlopnik@kispi.uzh.ch

S. Ehl, MD
Center for Chronic Immunodeficiency,
University Medical Center Freiburg,
University of Freiburg, Freiburg, Germany

Table 9.1 Classification of HLH

Primary HLH	Affected genes
1. <i>Familial hemophagocytic lymphohistiocytosis</i>	<i>PRF1</i> (FHL2), <i>UNC13D</i> (FHL3), <i>STX11</i> (FHL4), and <i>STXBP2</i> (FHL5)
2. <i>Griscelli syndrome type 2</i>	<i>RAB27A</i>
3. <i>Chediak-Higashi syndrome</i>	<i>LYST</i>
4. <i>Hermansky-Pudlak syndrome type 2</i>	<i>AP3B3A</i>
5. <i>X-linked lymphoproliferative disorders</i>	<i>SH2D1A</i> and <i>BIRC4</i>
Secondary HLH	Associated conditions
1. <i>Infection-associated HLH</i>	Viral (including EBV, CMV, ADV, HSV, HHV6, HHV8, VZV, parvovirus B19, influenza, enteroviruses), bacterial (including mycobacteria, BCG, <i>Rickettsia</i> , <i>Staphylococcus</i> , <i>Klebsiella</i> , <i>Ehrlichia</i> , <i>Mycoplasma</i>), parasitic (<i>Leishmania</i> , <i>Plasmodium</i> , and <i>Toxoplasma</i>), and rarely fungal (<i>Histoplasma</i> , <i>Candida</i> , and <i>Cryptococcus</i>) infections
2. <i>Autoinflammatory and autoimmune diseases</i>	sJIA, NLRP4 mutations, Crohn's disease, SLE, Kawasaki disease (very rarely also familial Mediterranean disease, dermatomyositis, rheumatoid arthritis, sarcoidosis, and systemic sclerosis)
3. <i>Acquired immunodeficiency</i>	Immunosuppressive treatments, HIV infection
4. <i>Malignant diseases</i>	Lymphomas, mostly T/NK cell, but also B-cell lymphomas, and leukemia (rarely solid tumors) cf. Chap. 12 of this book
5. <i>Primary immunodeficiencies (other than primary HLH)</i>	CGD, SCID, CID (WAS, X-MEN syndrome, interleukin-2-inducible T-cell kinase deficiency, CD27 deficiencies (very rarely in X-linked agammaglobulinemia, autoimmune lymphoproliferative syndrome, nuclear factor-kappa B essential modulator deficiency syndrome, CTLA-4 haploinsufficiency, and IFN γ receptor deficiency))
6. <i>Metabolic diseases</i>	Lysinuric protein intolerance, galactosemia, Wolman disease (lysosomal acid lipase deficiency), cobalamin C type methylmalonic aciduria with homocystinuria, propionic aciduria, Gaucher's disease, and hydroxycobalamin deficiency

hematopoietic stem cell transplantation (HSCT) [2–5], and the intensity and duration of immunosuppression needed for disease control are frequently lower in patients with “secondary” HLH.

Primary HLH

The term “primary HLH” is used to denote genetic disorders with a genetic defect in perforin-mediated cytotoxicity. This may be caused by mutations in perforin itself or in genes whose products are involved in the degranulation of perforin-containing granules [6]. In some of these genetic defects, HLH is the key disease manifestation, developing in almost 100% of affected patients – often at birth or in the first few years of life. These diseases are

summarized as familial HLH (FHL). Other defects cause syndromic diseases in which HLH is one key manifestation of a more complex syndrome. They are also called immunodeficiencies with albinism. Furthermore, HLH manifesting in the context of immunodeficiency X-linked lymphoproliferative syndrome types 1 and 2 (XLP-1 and XLP-2, with increased vulnerability to Epstein-Barr virus (EBV)) is also classified as “primary.” A large proportion of patients with XLP-1 or XLP-2 (55% and 76%, respectively) will experience HLH at some point in life [7]. Infections may trigger the onset of an HLH episode in primary HLH, although in many cases, no infectious agent can be identified. Strong immunosuppression (to achieve remission from hyperinflammatory, active HLH) followed by allogeneic HSCT is clearly indicated in most patients with primary HLH.

Familial Hemophagocytic Lymphohistiocytosis

Familial hemophagocytic lymphohistiocytosis types 2–5 (FHL2–5) constitute a genetically heterogeneous group of rare, autosomal-recessive diseases with an estimated incidence of 0.12 per 100,000 children [8]. Mutations in the *PRF1* (FHL2), *UNC13D* (FHL3), *STX11* (FHL4), or *STXBP2* (FHL5) genes have been found in these patients [9–13]. The underlying genetic defects affect the cytolytic effector protein perforin or other proteins involved in the transport and/or exocytosis of perforin-containing granules to the lytic immunological synapse (as described in detail in Chap. 11 of this book). FHL2 and FHL3 are the most prevalent types, depending on the ethnic origin: 13–50% of patients have FHL2 and 17–41% have FHL3. FHL4 is mostly found in patients of Turkish origin.

GrisCELLI Syndrome

GrisCELLI syndrome is characterized by hypopigmentation of the skin and hair, the presence of large clumps of pigment in hair shafts, and an accumulation of mature melanosomes within the melanocytes. Autosomal-recessive defects in the *MYO5A*, *RAB27A*, and *MLPH* genes, respectively, are responsible for GrisCELLI syndrome types 1, 2, and 3 [14–16]. Only GrisCELLI syndrome type 2 is associated with an immune disorder that leads to episodes of hemophagocytic syndrome. Rare *RAB27A* mutations have been described that confer a risk for HLH but do not cause albinism.

Chediak-Higashi Syndrome

Chediak-Higashi syndrome (CHS) is caused by autosomal-recessive mutations in the *CHSI* gene (also referred to as lysosomal trafficking regulator, *LYST*) [17]. CHS is also characterized by hypopigmentation of the skin, hair and the eyes. Hair pigmentation abnormalities in CHS differ from the hypopigmentation observed in GrisCELLI syndromes. Moreover, CHS patients show giant lysosomes in neutrophils and other blood cells, which are diagnostic for this disease.

Hermansky-Pudlak Syndrome

Hermansky-Pudlak syndrome (HPS) is characterized by bleeding problems (due to a platelet

function defect) and oculocutaneous albinism. There are ten types of the disorder [18]. HPS2 and HPS10 (caused by mutations in the genes encoding the β 3A subunit and the δ subunit of the adaptor protein 3 complex, respectively) are associated with a cytotoxicity defect, but HLH has so far only been observed very rarely in HPS type 2. Its classification as primary HLH is subject to debate. Preemptive HSCT does not appear to be justified in HPS type 2 [19].

X-Linked Lymphoproliferative Disorders

As mentioned above, the primary immunodeficiencies XLP-1 and XLP-2 are associated with a high risk of developing HLH – particularly in the context of an EBV infection. XLP-1 is caused by mutations in the *SH2D1A* gene (also referred to as signaling lymphocytic activation molecule-associated protein, SAP), whereas XLP-2 is caused by mutations in the gene coding for X-linked inhibitor of apoptosis (XIAP) [7]. In both diseases, manifestations other than HLH (such as immunodeficiency, inflammatory bowel disease, or lymphoma) can dominate the clinical picture.

Secondary HLH

The term “secondary HLH” (also referred to as “sporadic” or “acquired HLH”) has generally been used to describe patients with (i) a disease fulfilling the clinical diagnostic criteria for HLH and (ii) none of the abovementioned genetic defects. Most patients with secondary HLH suffer from an inherited or acquired underlying disease or are receiving treatment that predisposes them to immune dysregulation, as detailed below. However, the majority of patients with these diseases will never experience HLH. Infections or high inflammatory activity may precede the onset, but not always obvious infectious triggers can be identified.

Infection-Associated HLH

Infections have an important role as triggers in both acquired and inherited forms of hemophagocytic syndromes. Immunocompetent

individuals without any underlying disease may develop infection-triggered secondary HLH. The most common triggers are viral infections and particularly herpes virus infections, especially Epstein-Barr virus. The term viral-associated hemophagocytic syndrome has been used to describe this type of secondary HLH occurring in otherwise healthy individuals. HLH has also been described after infection with numerous different bacteria (including *Brucella*, mycobacterium tuberculosis [20]), fungi, and parasites (especially *Leishmania* [21]). Because of the specific therapeutic consequences, it is of particular importance to recognize that visceral leishmaniasis can present with a clinical picture that is indistinguishable from HLH.

Autoinflammatory and Autoimmune Diseases

Secondary HLH can occur in autoinflammatory syndromes and is most frequently reported in systemic juvenile idiopathic arthritis (sJIA). Many rheumatologists prefer to use the term “macrophage activation syndrome” (MAS), rather than secondary HLH. MAS complicates at least 10% of cases of sJIA, although a much higher proportion of patients (30–40%) show signs of subclinical MAS [22]. MAS can also occur in adult-onset Still’s disease. Secondary HLH very rarely occurs in patients with other autoinflammatory syndromes [23, 24]. Recently, a mutation in the nucleotide-binding domain of the inflammasome component NLRC4 was linked to early-onset recurrent MAS [25]. Interestingly, functional assays demonstrated spontaneous inflammasome formation, plus the production of the inflammasome-dependent cytokines IL-1 β and IL-18 at levels higher than those seen in cryopyrin-associated periodic fever syndromes (another group of autoinflammatory syndromes).

Furthermore, patients with Crohn’s disease are more susceptible to HLH. Since patients with XLP-2 may present with a Crohn’s-like disease, the combination of Crohn’s disease with HLH should prompt a diagnostic workup for XLP-2 [7], bearing in mind that gastroenterological problems have also been described in patients with *STXBP2* and *NLRC4* mutations.

Patients with autoimmune disorders and those with vasculitis may also suffer from secondary HLH or MAS. In particular, patients with systemic lupus erythematosus (SLE) have an increased risk of developing this complication [26]. Secondary HLH can occur during the acute phase of Kawasaki disease (KD), a hyperinflammatory syndrome associated with vasculitis [27]. When KD patients present with hepatosplenomegaly and an additional laboratory abnormality consistent with HLH (such as cytopenia, liver dysfunction, hyperferritinemia, elevated serum LDH, hypofibrinogenemia, and hypertriglyceridemia), a diagnosis of HLH should be considered. Sporadically, patients with other rheumatologic diseases (such as dermatomyositis, rheumatoid arthritis, sarcoidosis, and systemic sclerosis) develop secondary HLH [28].

Acquired Immunodeficiencies

Secondary HLH can also arise in acquired immunodeficiencies. Treatments with immunosuppressants and certain biologics have been linked to the development of HLH [29]. Patients with sJIA are especially vulnerable when their immunosuppressive treatment is modified. HLH can also arise after chemotherapy and organ or stem cell transplantation. Kidney transplant recipients are at increased risk of HLH (due to immunosuppression), and most such cases are triggered by infection. The mortality rate is over 50% [30]. Screening for a concomitant infection is mandatory, and specific surveillance for EBV and cytomegalovirus infections and for bacterial infections (including mycobacteria) has been recommended in adult patients receiving biologics [31]. Patients infected with HIV alone or in presence of other opportunistic infections or malignancies have an increased risk of developing HLH, and the latter has also been described in a setting of immune reconstitution inflammatory syndrome [32].

Malignant Diseases

Conditions meeting the criteria for HLH may occur in the context of cancer (as discussed in Chap. 12 of this book).

Primary Immunodeficiencies

Secondary HLH may also be a rare but nonetheless clearly associated complication in some genetic diseases. Patients with primary immunodeficiencies (PIDs) other than cytotoxicity defects or X-linked lymphoproliferative disorders may develop an HLH-like disease. PIDs like chronic granulomatous disease (CGD) and combined immunodeficiencies are overrepresented in reports of secondary HLH, relative to other PIDs [33]. CGD is a genetically heterogeneous condition associated with recurrent, life-threatening bacterial and fungal infections. HLH in CGD is mainly associated with bacterial infections. In patients with severe combined immunodeficiency and partial T-cell deficiencies (such as 22q11 microdeletion and Wiskott-Aldrich syndrome), HLH-like episodes tend to occur in the context of a viral infection. Combined immunodeficiencies in which impaired control of EBV infection is a cardinal feature have been associated with EBV-induced HLH in some cases. This includes X-MEN syndrome (X-linked immunodeficiency with magnesium defect, EBV infection, and neoplasia) [34], patients with interleukin-2-inducible T-cell kinase [35], and CD27 deficiencies [36]. Rarely, patients with other PIDs (such as X-linked agammaglobulinemia, autoimmune lymphoproliferative syndrome, nuclear factor-kappa B essential modulator deficiency syndrome, CTLA-4 haploinsufficiency) [37–40] and even IFN γ receptor deficiency [41] develop secondary HLH.

Metabolic Diseases

Patients with metabolic diseases may suffer from secondary HLH. Lysinuric protein intolerance is associated with *SLC7A7* mutations and may be complicated by severe lung disease with pulmonary alveolar proteinosis, renal disease, and an incompletely characterized immune deficiency with HLH [42, 43]. A clinical picture resembling HLH has also been observed in patients with galactosemia, Wolman disease (lysosomal acid lipase deficiency), cobalamin C type methylmalonic aciduria with homocystinuria [44], propionic aciduria [45], Gaucher's disease [46], and hydroxycobalamin deficiency [47].

Clinical Manifestations of HLH

Although the full-blown clinical picture of HLH is quite characteristic, its initial presentation is variable. The most common form is a sepsis-like febrile illness with multiple organ involvement. The cardinal signs of HLH are fever, (hepato) splenomegaly, and pancytopenia. Characteristic laboratory test results include marked hyperferritinemia, hypofibrinogenemia, hypertriglyceridemia, elevated liver enzymes, and hyponatremia. These symptoms can be explained by (i) a high concentration of inflammatory cytokines and (ii) organ infiltration by activated immune cells. In theory, almost every organ can be affected by HLH. With a few exceptions, there are no clinical and laboratory features that allow to differentiate whether the disease occurs in the presence or absence of an underlying genetic defect.

Age at Presentation

Presentation of primary HLH usually occurs in early infancy. Antenatal presentation has been reported and should be considered in the differential diagnosis of nonimmune hydrops fetalis [50–52] and neonatal cytopenia.

Clinical Features

Systemic Symptoms

Most patients have a severely impaired general condition. Prolonged, persistent, non-circadian fever is usually observed in most patients other than neonates and preterm infants (in whom the incidence of fever may be low [48]) and severely ill patients (who may develop hypothermia).

Splenomegaly

Splenomegaly is common in patients with HLH and belongs to the diagnostic criteria. It has been observed in 97% of pediatric and 67% of adult cases [29, 49].

Hepatic Involvement

Hepatic involvement is present in more than half of the patients and may manifest itself as

hepatomegaly, elevated transaminase levels, increased LDH, and/or hepatic cholestasis. Increased triglycerides are also frequently observed and belong to the diagnostic criteria (see below). Occasionally, acute liver failure may even dominate the clinical presentation. In selected patients with secondary HLH-associated liver failure, liver transplantation has been shown to restore good health in an otherwise lethal condition [56]. Fulminant liver failure has also been reported in neonates [57]. Abnormal coagulation is often seen and may be caused by multiple factors, such as liver dysfunction, fibrinogen degradation, low platelet count, and disseminated intravascular coagulopathy. On autopsy, the livers of patients who have died from HLH show periportal lymphocytic infiltration and in some cases evidence of hemophagocytosis [58].

Kidney

Kidney injury may occur in severely ill patients [57, 58]. Glomerulopathy and nephrotic syndrome may develop [30].

Lung

Lung involvement is common in patients with HLH and is suggestive of a poor prognosis [59].

Central Nervous System Involvement

HLH is typically a systemic disease, which can also be associated with variable degrees of CNS involvement (as detailed in Chap. 10). Cases with predominant CNS involvement or initial, isolated CNS involvement are rare [53, 54]. Neurological signs can range from a meningeal irritation to a severe CNS affection, with tetraparesis or epileptic seizures. Microcephaly may develop over time [55]. At the onset of primary HLH, neurological symptoms are mostly associated with abnormal CSF findings and normal brain MRI. Increased CSF cell counts, protein levels, and hemophagocytic features may be observed. MRI abnormalities can be severe but are unspecific. However, it has been shown that relative to patients with acute disseminated encephalomyelitis, patients with HLH are more likely to show symmetric periventricular lesions that do not affect the thalamus or brainstem and

do not show T1 hypo-intensity; this may help to distinguish between early lesions in HLH and those observed in other inflammatory diseases of the white matter [55].

Additional Clinical Features

Some patients with HLH-causing gene mutations present with additional clinical features. Patients with Griscelli syndrome type 2, CHS, and HPS typically show pigment abnormalities. In patients with CHS, neurological symptoms (which are more likely to be associated with the causal mutation than with HLH) can occur in early adulthood [60, 61].

Around 30% of patients with XLP-1 develop lymphoma, and XLP-2 patients may suffer from Crohn's-like chronic hemorrhagic colitis and recurrent splenomegaly associated with cytopenia and fever (probably corresponding to minimal forms of HLH) [7]. Both patient groups can develop hypogammaglobulinemia leading to recurrent chest infections.

Laboratory Features

Hematological Signs

Cytopenias are seen in more than 80% patients on presentation [62]. Cytokine-mediated bone marrow suppression might well be more important for the pathogenesis of cytopenia than hemophagocytosis alone. In patients with sJIA and MAS, cytopenias may occur later in the course of the disease because these individuals often have elevated blood counts of neutrophilic granulocytes and thrombocytes prior to developing MAS; in this context, a change over time in these laboratory parameters is more valuable than the absolute values for the early diagnosis of MAS [63].

Ferritin

Very high serum ferritin levels are common in HLH. In the HLH-94 study, the median ferritin level was 2950 ng/mL; ferritin levels greater than 500, 5000, and 10,000 ng/mL were seen in, respectively, 93%, 42%, and 25% of the patients [62]. However, the positive predictive value of

hyperferritinemia as a single parameter for HLH is quite low, in particular in adults [64]. Therefore, one should also consider other possible causes, such as liver disease, hematologic malignancy, or chronic transfusion.

Fibrinogen

Hypofibrinogenemia is most probably caused by increased fibrin degradation by activated macrophages [65, 66]. It may also be worsened in patients with liver dysfunction.

Cytokines

Inflammatory cytokines, such as interferon-gamma (IFN-gamma), tumor necrosis factor/cachectin-alpha, interleukin-6 (IL-6), and IL-1, are augmented in active HLH and contribute to the pathogenesis of the disease [67–69]. Soluble IL-2 receptor (sIL-2R or sCD25) is typically elevated in HLH and serves as a diagnostic marker of the disease [3]. The persistent activation of immune cells that occurs in patients with HLH leads to excessive cytokine production. Recently it has been shown how increased cytokine production is linked to the default in target cell death: prolonged target cell survival is due to failed disengagement of perforin- or granzyme A/B--deficient lymphocytes, increasing mean contact time up to fivefold. The prolonged synapse time leads to repetitive Ca²⁺ + –signaling within the effector cell to cytokine hypersecretion by cytotoxic T cells/NK cells, including IFN-gamma that directly activates macrophages [70].

Serum Sodium Level

Hyponatremia is often present and may be associated with CNS disease. However, pseudohyponatremia (caused by severe hypertriglyceridemia) can also be observed [71].

Diagnosis of HLH

Diagnosing an Episode of HLH

Prompt initiation of treatment is essential for the survival of affected patients. Often the greatest barrier to a successful outcome is late diagnosis.

The diagnosis of HLH is difficult because of the rarity of this syndrome, the variable clinical presentation, the similarity to sepsis or flares of an underlying rheumatic disease, and the lack of specific clinical and laboratory findings.

There is no specific test for HLH. Diagnosis is based on the presence of a combination of the various diagnostic features. Hemophagocytosis per se is not sufficient for a diagnosis of hemophagocytic syndrome because macrophages that have engulfed other blood cells (Fig. 9.1) are present in some other conditions and hemophagocytosis can be a late sign even in primary forms of the syndrome. In clinical practice, bone marrow and CSF (or any other biopsy taken in a patient with suspected HLH) should be assessed for hemophagocytosis.

In 1994, the Histiocyte Society proposed a definition of HLH as part of the HLH-94 clinical trial. This definition was later revised for the HLH-2004 trial and currently comprises eight parameters, of which at least five must be met for a diagnosis of HLH [3]. These criteria (with some minor modifications) are listed in Table 9.2.

The diagnostic criteria for HLH as shown in Table 9.2 are appropriate for diagnosing primary HLH and secondary, infection-associated HLH. In some patients with a rheumatic disease, recognition of an HLH episode or MAS may be difficult, due to its resemblance to flares of the

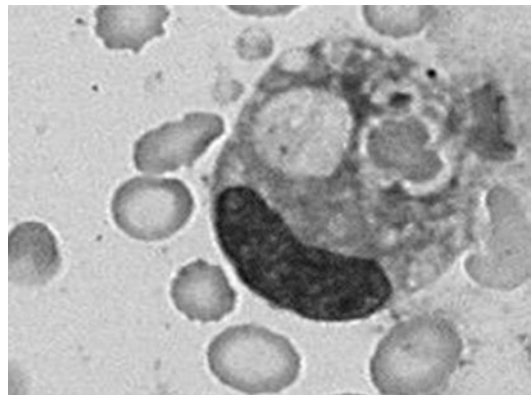


Fig. 9.1 Macrophage with engulfed erythrocytes (i.e., hemophagocytosis) in a bone marrow smear. May-Grunwald-Giemsa stain, light microscope, magnification $\times 1000$ (Adapted from Pachlopnik Schmid and de Saint Basile [92], with permission)

Table 9.2 Diagnostic criteria for HLH

The diagnosis of HLH can be established if (A) and (B) are fulfilled
A. A molecular diagnosis consistent with HLH: disease-causing mutations in <i>PRF1</i> , <i>UNC13D</i> , <i>Munc18-2</i> , <i>STX11</i> , <i>RAB27A</i> , <i>LYST</i> , <i>SH2D1A</i> , or <i>BIRC4</i>
B. Five out of the eight criteria listed below are fulfilled:
1. Fever ≥ 38.5
2. Splenomegaly (palpable below costal margin or increased size by imaging)
3. Cytopenia (affecting ≥ 2 out of the 3 lineages): Hemoglobin (< 90 g/l; in newborns, < 100 g/l) Neutrophilic granulocytes ($< 1.0 \times 10^9/l$) Platelet count ($< 100 \times 10^9/l$)
4. Hemophagocytosis (in the bone marrow or CSF)
5. Hyperferritinemia (≥ 500 $\mu\text{g/l}$)
6. Hypertriglyceridemia (fasting level, ≥ 3.0 mmol/l) or hypofibrinogenemia (≤ 1.5 g/l)
7. Elevated soluble CD25 (≥ 2400 U/ml)
8. Decreased NK-cell cytotoxicity

Adapted from Henter et al. [3]

underlying rheumatic disease. The fibrinogen level and the absolute neutrophil and thrombocyte counts may be misleading in patients with sJIA who experience MAS. In sJIA (in the absence of MAS), elevation of these parameters is typical [72]. In contrast, MAS leads to a relative decrease in fibrinogen and cell counts and might therefore be underdiagnosed since it does not lead to hypofibrinogenemia, neutropenia, or thrombocytopenia in absolute terms. It is noteworthy that sJIA features spikes of fever, whereas MAS tends to be associated with a persistently elevated body temperature.

To aid with the diagnostic process, consensus criteria for the classification of MAS in patients with sJIA have been published [73] as detailed in Chap. 13. The physician must check that the laboratory parameters cannot be explained by other aspects of the patient's condition, such as concomitant immune-related thrombocytopenia, infectious hepatitis, visceral leishmaniasis, or familial hyperlipidemia. Patients with sJIA and recurrent MAS should be screened for primary HLH; they may profit from targeted treatment with IL-1 antagonists or tocilizumab. Autologous hematopoietic stem cell transplantation following

intensive immunosuppressant therapy has been performed in some patients with severe treatment-resistant sJIA. This may include individuals with severe, recurrent MAS [74]. However, HSCT currently remains an experimental therapy targeting the underlying disease in very selected cases rather than an accepted treatment modality for MAS itself.

The assessment of a bone marrow aspirate will help to rule out hematological neoplasia. *Leishmania* infection should be searched by PCR in a bone marrow specimen, since false-negative results may result from PCR of peripheral blood, serology, bone marrow microscopy, and bone marrow culture [21]. In primary HLH, a marrow with normal or increased cellularity (especially for the erythropoietic lineage) is typical. In contrast, MAS in sJIA tends to be associated with an increase in the granulocytic lineage. However, hemophagocytosis in bone marrow may not be present, especially at the beginning of an HLH episode.

Material obtained from other organs (such as CSF) may also be of value in the diagnostic procedure. However, hemophagocytosis is not an obligatory diagnostic criterion, and we do not recommend the performance of liver biopsies in patients with active HLH (due to potential bleeding).

The CSF should be analyzed for cell count, protein level, and hemophagocytic features on a cytopspin preparation. Changes in CSF may precede changes in brain imaging.

Diagnosing the Underlying Disease Associated with an HLH Episode

In recent years, the introduction of new immunologic and genetic analyses has made it easier and faster for the physician to diagnose patients with suspected primary HLH [75]. For example, the identification of novel HLH-associated genes has increased the possibilities to establish a definite diagnosis of primary HLH [11–13]. The results of more specific immunological tests (which may be available within 1–3 days) allow the rapid identification of patients in need of HSCT and

can guide the priorities in targeted genetic analysis [75]. In addition, next-generation sequencing allows more comprehensive genetic analyses and helps to identify novel genes that predispose to HLH [76]. Hence, diagnostic approaches are changing, and the most efficient algorithm has yet to be determined.

Once an HLH episode has been diagnosed, immunologic screening is valuable for guiding the subsequent workup. A possible diagnostic flow sheet is shown in Fig. 9.2. Deficient protein expression or NK-cell degranulation should prompt targeted genetic testing. In some cases, the clinical context can provide additional clues for the diagnosis of inherited vs. acquired disease.

Inherited hemophagocytic syndromes are more frequent among young children (especially <1 year of age) and in cases of severe and/or recurrent disease, parental consanguinity, a family history suggestive of an X-linked disease, and pigmentary anomalies. However, it must be noted that (i) acquired forms can also start early in life and can also be severe and can be recurrent in sJIA and other autoinflammatory diseases, and (ii) inherited forms can start later in life and may be sporadic, attenuated in severity, or even oligo-symptomatic (e.g., with neurological involvement alone). Therefore, even milder forms of HLH, HLH in adult male patients (especially those with a family history suggestive of an

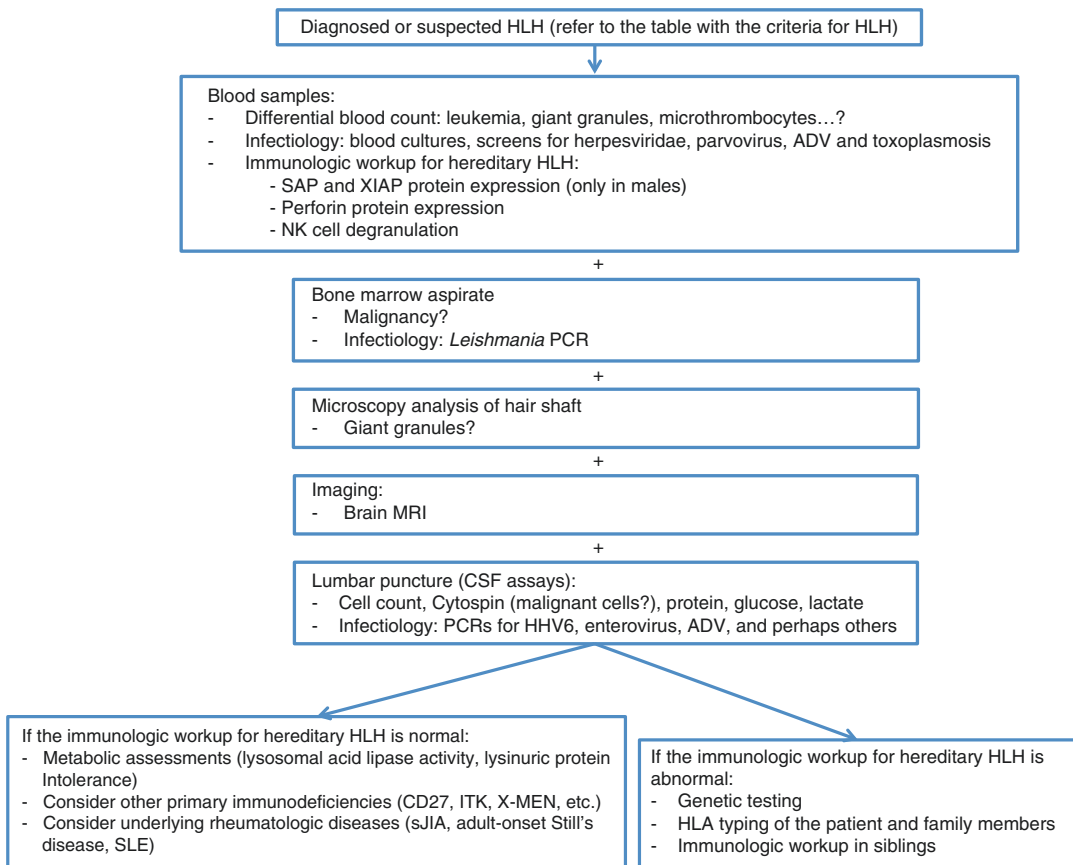


Fig. 9.2 Immunologic testing may support a diagnosis of primary HLH and provide functional data, whereas gene sequencing (typically requiring 3–8 weeks) may define the specific mutations. If a repeatedly abnormal test suggests an underlying functional abnormality, genetic testing should include sequencing of introns, should consider

deletions, and should encompass sequencing of all relevant genes (including the genes associated with albinism even in the absence of this symptom). Normal immunological test results cannot fully exclude a genetic disease, although this is very rare in experienced labs

X-linked disease), and neurological signs with reasonable grounds for suspecting HLH are valid indications to perform diagnostic tests for defects in cell cytotoxicity by degranulation and protein expression assays. However, in these cases the possible benefits of the diagnostic tests should also be weighed against the costs of unnecessary tests and possibly resulting unnecessary follow-up and even treatment.

In view of the iatrogenic lymphopenia that can be induced by the subsequent treatment, immunological tests should be performed early in the disease course. However, valid results can be obtained even under HLH-2004 therapy. Microscopic hair analysis (Fig. 9.3) is a simple analysis and should be carried out in patients with a silvery shine of the hair (even in those with

dark hair) or patients with fair hair (because the silvery shine can be very difficult to recognize in these cases). Furthermore, giant granules should be searched for in the differential blood count because they are pathognomonic for CHS.

Sequential immunological testing, followed by a genetic diagnostic approach, provides the basis for a rapid transplant decision and timely preparation for allogeneic HSCT. Targeted sequencing is currently the most widely used approach. Immunological screening can identify patients with primary HLH but requires specific expertise. With advances in next-generation sequencing, genetic approaches may prove to be technically easier and may prevail in the future.

Patients should also be screened for autoimmune diseases or malignancy with a detailed clinical history, a physical examination, and other appropriate analyses.

In a patient with a PID, an episode of secondary HLH may occur when the PID is diagnosed or may even reveal the PID. PIDs other than disorders of cytotoxicity or XLP are therefore a relevant differential diagnosis in patients presenting with HLH syndrome [33]. It has been reported that patients with an underlying T-cell PID have a significantly higher ferritin/sCD25 ratio (>10 , on average) than patients with FHL and CGD patients (<1 , on average).

In a patient with HLH, it is essential to understand the underlying etiology and to screen extensively for infectious triggers. Extensive immunosuppressive treatment may be needed to control the immune dysregulation. Treatment with immunosuppressants in the absence of anti-infective medications may have serious consequences ranging from unnecessary overtreatment [21] to a potentially lethal outcome.

Screening for infectious agents such as EBV, cytomegalovirus, herpes simplex virus, adenovirus, parvovirus B19, mycobacteria, and *Leishmania* is recommended, since most of these agents are amenable to treatment. The detection of EBV infection has important therapeutic implications because elimination of the main EBV reservoir by B-cell-directed treatment is an important component of therapy in all patients with EBV-associated HLH [77].

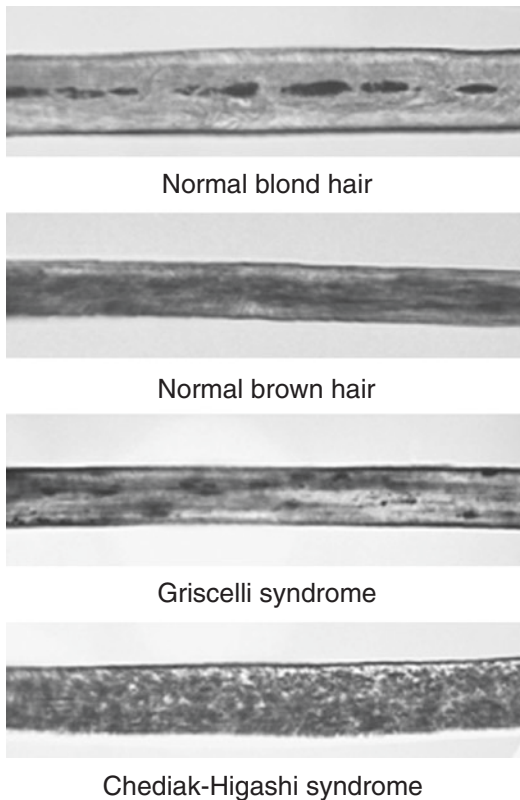


Fig. 9.3 Normal hair shafts (*upper panels*) and characteristic large clumps of pigment in the hair shaft of patients with Griscelli syndrome and Chediak-Higashi syndrome (*lower panels*). Light microscope, magnification $\times 250$ (Adapted from Pachlopnik Schmid and de Saint Basile [92], with permission)

Degranulation Test

Testing the patient's cells for their degranulation capability is becoming a routine procedure in suspected HLH. The results can be obtained within less than 2 days. In immunocompetent individuals, when cytolytic cells such as cytotoxic T lymphocytes (CTL) and natural killer (NK) cells recognize a target cell, they kill the target cells by secreting perforin and granzymes [78–81]. Mutations in the genes *UNC13D*, *STX11*, *STXBP2*, *RAB27A*, *LYST*, and *AP3B1* all affect either vesicle loading, vesicle maturation, or vesicle fusion with the plasma membrane [13, 16, 82–86], thereby preventing proper target cell killing by cytolytic cells. The degranulation test thus determines whether the secretory pathway for lytic proteins is functional.

In the degranulation test, peripheral blood mononuclear cells (PBMCs) are activated by incubation with K562 cells. As K562 cells do not express MHC class I molecules, they are recognized as “missing self” and subsequently killed by NK cells by secretion of their cytotoxic molecules. Successful degranulation of NK cells can be determined based on the presence of CD107a (LAMP1) on the cell surface [87]. The protein CD107a is normally only found on lysosomal membranes but can be detected on the surface of cytotoxic cells after fusion of cytotoxic vesicles with the plasma membrane. The degranulation test is thus based on the appearance of the lysosomal membrane protein CD107a on the surface of activated NK cells, measured by flow cytometry (Fig. 9.4).

Studying the expression of CD107a on NK cells of patients suffering from different forms of primary HLH and healthy individuals allowed Bryceson et al. to evaluate normal and pathogenic degranulation percentages [75]. According to their work, no degranulation defect is present with values above 10%. Degranulation values between 5% and 10% are not conclusive and a repetition of the assay is recommended. Degranulation values below 5% are, however, very suggestive of an inherited defect and warrant further genetic investigation of the known mutations affecting degranulation.

It is important to be aware that functional degranulation still occurs when the genetic cause of HLH can be attributed to either *PRF1*, *SH2D1A*, or *XIAP* [75]. The degranulation assay should therefore routinely be accompanied by an intracellular staining of CTLs or NK cells for perforin, SAP, and XIAP – which can all be performed on the same blood sample used for the degranulation test. In combination, the degranulation test and intracellular staining can detect all currently known HLH-causing gene mutations.

Genetic Analysis

Fulfillment of at least five defined HLH (HLH-2004) criteria out of a set of eight is sufficient for clinical HLH diagnosis. Immunological and genetic tests are needed for diagnosis of inherited HLH. Nowadays Sanger sequencing of known mutations is a relatively cheap, robust, and

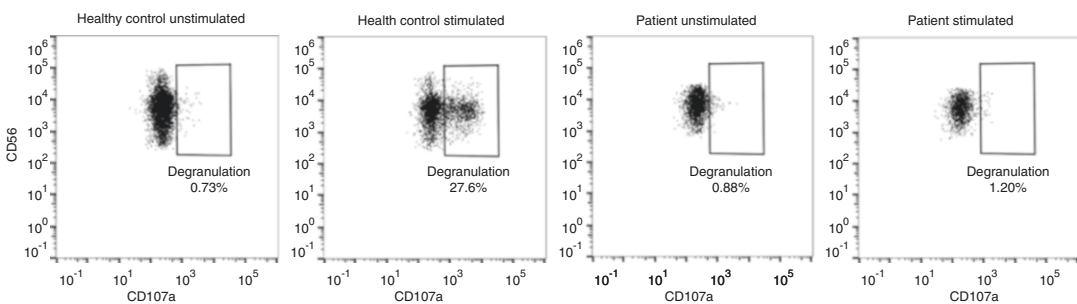


Fig. 9.4 Degranulation test of healthy control and affected patient. Dot plots of NK cells (CD3⁻ CD56⁺) showing degranulation (CD107a⁺) after stimulation with

K562 cells in the healthy control (*left panels*). In the affected patient with Munc13-4 deficiency, degranulation is below 5% (*right panels*)

accepted method for detecting genetic mutations. Minute amounts of DNA extracted from blood are sufficient for sequencing. A drawback of Sanger sequencing is that being a targeted sequencing method, only known mutations are detected. The detection of novel disease-causing mutations is possible by sequencing the whole gene instead of only the regions with known mutations, but this may exaggerate the cost and effort. The advent of next-generation sequencing and its increasing affordability may however fully replace Sanger sequencing in the near future [88, 89].

In contrast to Sanger sequencing, next-generation sequencing (NGS) methods allow to cover large parts of the genome [90]. Whole-exome sequencing (WES) and whole-genome sequencing (WGS) are the best-known methods, and with targeted NGS, sequencing, e.g., all genes linked to immunological disorders, is possible. Compared to Sanger sequencing, NGS currently depends on high throughput for cost-efficiency, and the duration from taking the blood sample to obtaining the sequencing results is longer. Therefore today, WES is especially used for the discovery of novel disease-causing mutations, as it detects mutations in all protein coding regions of the genome [18, 91]. However, filtering all the detected variants and assigning a specific mutation to a patient's phenotype is very challenging and time-consuming. Nevertheless, as NGS is further improved, WES or a customized NGS gene panel might become an important screening tool for HLH patients or other patients with a suspected immunodeficiency [88].

References

- Farquhar JW, Claireaux AE. Familial haemophagocytic reticulosis. *Arch Dis Child*. 1952;27(136):519–25.
- Janka GE, Lehmborg K. Hemophagocytic lymphohistiocytosis: pathogenesis and treatment. *Hematology Am Soc Hematol Educ Program*. 2013;2013:605–11.
- Henter JI, et al. HLH-2004: diagnostic and therapeutic guidelines for hemophagocytic lymphohistiocytosis. *Pediatr Blood Cancer*. 2007;48(2):124–31.
- Ouachee-Charadin M, et al. Hematopoietic stem cell transplantation in hemophagocytic lymphohistiocytosis: a single-center report of 48 patients. *Pediatrics*. 2006;117(4):e743–50.
- Cesaro S, et al. Hematopoietic stem cell transplantation for hemophagocytic lymphohistiocytosis: a retrospective analysis of data from the Italian Association of Pediatric Hematology Oncology (AIEOP). *Haematologica*. 2008;93(11):1694–701.
- Pachlopnik Schmid J, et al. Inherited defects in lymphocyte cytotoxic activity. *Immunol Rev*. 2010;235(1):10–23.
- Pachlopnik Schmid J, et al. Clinical similarities and differences of patients with X-linked lymphoproliferative syndrome type 1 (XLP-1/SAP deficiency) versus type 2 (XLP-2/XIAP deficiency). *Blood*. 2011;117(5):1522–9.
- Henter JI, et al. Incidence in Sweden and clinical features of familial hemophagocytic lymphohistiocytosis. *Acta Paediatr Scand*. 1991;80(4):428–35.
- Stepp SE, et al. Perforin gene defects in familial hemophagocytic lymphohistiocytosis. *Science*. 1999;286(5446):1957–9.
- Feldmann J, et al. Munc13-4 is essential for cytolytic granules fusion and is mutated in a form of familial hemophagocytic lymphohistiocytosis (FHL3). *Cell*. 2003;115(4):461–73.
- Zur Stadt U, et al. Familial hemophagocytic lymphohistiocytosis type 5 (FHL-5) is caused by mutations in Munc18-2 and impaired binding to syntaxin 11. *Am J Hum Genet*. 2009;85(4):482–92.
- Zur SU, et al. Linkage of familial hemophagocytic lymphohistiocytosis (FHL) type-4 to chromosome 6q24 and identification of mutations in syntaxin 11. *Hum Mol Genet*. 2005;14(6):827–34.
- Cote M, et al. Munc18-2 deficiency causes familial hemophagocytic lymphohistiocytosis type 5 and impairs cytotoxic granule exocytosis in patient disease causing mutations. *J Clin Invest*. 2009;119(12):3765–73.
- Menasche G, et al. Griscelli syndrome restricted to hypopigmentation results from a melanophilin defect (GS3) or a MYO5A F-exon deletion (GS1). *J Clin Invest*. 2003;112(3):450–6.
- Menasche G, Fischer A, de Saint Basile G. Griscelli syndrome types 1 and 2. *Am J Hum Genet*. 2002;71(5):1237–8. author reply 1238
- Menasche G, et al. Mutations in RAB27A cause Griscelli syndrome associated with haemophagocytic syndrome. *Nat Genet*. 2000;25(2):173–6.
- Barbosa MD, et al. Identification of mutations in two major mRNA isoforms of the Chediak-Higashi syndrome gene in human and mouse. *Hum Mol Genet*. 1997;6(7):1091–8.
- Ammann S, et al. Mutations in AP3D1 associated with immunodeficiency and seizures define a new type of Hermansky-Pudlak syndrome. *Blood*. 2016;127(8):997–1006.
- Jessen B, et al. The risk of hemophagocytic lymphohistiocytosis in Hermansky-Pudlak syndrome type 2. *Blood*. 2013;121(15):2943–51.
- Rathnayake PV, et al. Disseminated tuberculosis presenting as hemophagocytic lymphohistiocytosis in an immunocompetent adult patient: a case report. *J Med Case Rep*. 2015;9:294.

21. Bode SF, et al. Hemophagocytic lymphohistiocytosis in imported pediatric visceral leishmaniasis in a non-endemic area. *J Pediatr*. 2014;165(1):147–53. e1
22. Behrens EM, et al. Occult macrophage activation syndrome in patients with systemic juvenile idiopathic arthritis. *J Rheumatol*. 2007;34(5):1133–8.
23. Rossi-Semerano L, et al. Macrophage activation syndrome revealing familial Mediterranean fever. *Arthritis Care Res (Hoboken)*. 2011;63(5):780–3.
24. Ter Haar NM, et al. The phenotype and genotype of mevalonate kinase deficiency: a series of 114 cases from the Eurofever registry. *Arthritis Rheumatol*. 2016;68(11):2795.
25. Canna SW, et al. An activating NLRC4 inflammatory mutation causes autoinflammation with recurrent macrophage activation syndrome. *Nat Genet*. 2014;46(10):1140–6.
26. Parodi A, et al. Macrophage activation syndrome in juvenile systemic lupus erythematosus: a multinational multicenter study of thirty-eight patients. *Arthritis Rheum*. 2009;60(11):3388–99.
27. Wang W, et al. Macrophage activation syndrome in Kawasaki disease: more common than we thought? *Semin Arthritis Rheum*. 2015;44(4):405–10.
28. Atteritano M, et al. Haemophagocytic syndrome in rheumatic patients. A systematic review. *Eur Rev Med Pharmacol Sci*. 2012;16(10):1414–24.
29. Ramos-Casals M, et al. Adult haemophagocytic syndrome. *Lancet*. 2014;383(9927):1503–16.
30. Filippone EJ, Farber JL. Hemophagocytic lymphohistiocytosis: an update for nephrologists. *Int Urol Nephrol*. 2016;48(8):1291.
31. Brito-Zeron P, et al. Infection is the major trigger of hemophagocytic syndrome in adult patients treated with biological therapies. *Semin Arthritis Rheum*. 2016;45(4):391–9.
32. Fardet L, et al. Reactive haemophagocytic syndrome in 58 HIV-1-infected patients: clinical features, underlying diseases and prognosis. *AIDS*. 2010;24(9):1299–306.
33. Bode SF, et al. The syndrome of hemophagocytic lymphohistiocytosis in primary immunodeficiencies: implications for differential diagnosis and pathogenesis. *Haematologica*. 2015;100(7):978–88.
34. Li FY, et al. XMEN disease: a new primary immunodeficiency affecting Mg²⁺ regulation of immunity against Epstein-Barr virus. *Blood*. 2014;123(14):2148–52.
35. Ghosh S, et al. Interleukin-2-inducible T-cell kinase (ITK) deficiency - clinical and molecular aspects. *J Clin Immunol*. 2014;34(8):892–9.
36. Alkhairy OK, et al. Novel mutations in TNFRSF7/CD27: clinical, immunologic, and genetic characterization of human CD27 deficiency. *J Allergy Clin Immunol*. 2015;136(3):703–12. e10
37. Pachlopnik Schmid JM, et al. Transient hemophagocytosis with deficient cellular cytotoxicity, monoclonal immunoglobulin M gammopathy, increased T-cell numbers, and hypomorphic NEMO mutation. *Pediatrics*. 2006;117(5):e1049–56.
38. Schultz KA, et al. Familial hemophagocytic lymphohistiocytosis in two brothers with X-linked agammaglobulinemia. *Pediatr Blood Cancer*. 2008;51(2):293–5.
39. Kuijpers TW, et al. Common variable immunodeficiency and hemophagocytic features associated with a FAS gene mutation. *J Allergy Clin Immunol*. 2011;127(6):1411–4. e2
40. Rudman Spergel A, et al. Autoimmune lymphoproliferative syndrome misdiagnosed as hemophagocytic lymphohistiocytosis. *Pediatrics*. 2013;132(5):e1440–4.
41. Tesi B, et al. Hemophagocytic lymphohistiocytosis in 2 patients with underlying IFN-gamma receptor deficiency. *J Allergy Clin Immunol*. 2015;135(6):1638–41.
42. Duval M, et al. Intermittent hemophagocytic lymphohistiocytosis is a regular feature of lysinuric protein intolerance. *J Pediatr*. 1999;134(2):236–9.
43. Ogier de Baulny H, Schiff M, Dionisi-Vici C. *Lysinuric protein intolerance (LPI): a multi organ disease by far more complex than a classic urea cycle disorder*. *Mol Genet Metab*. 2012;106(1):12–7.
44. Wu S, et al. Cobalamin C disease presenting with hemophagocytic lymphohistiocytosis. *Pediatr Hematol Oncol*. 2005;22(8):717–21.
45. Gokce M, et al. Secondary hemophagocytosis in 3 patients with organic acidemia involving propionate metabolism. *Pediatr Hematol Oncol*. 2012;29(1):92–8.
46. Grabowski GA. Phenotype, diagnosis, and treatment of Gaucher's disease. *Lancet*. 2008;372(9645):1263–71.
47. Dokmanovic L, et al. Extreme hypertriglyceridemia in an infant with Hemophagocytic Lymphohistiocytosis and Hydroxycobalamin deficiency. *Srp Arh Celok Lek*. 2015;143(11–12):744–7.
48. Suzuki N, et al. Characteristics of hemophagocytic lymphohistiocytosis in neonates: a nationwide survey in Japan. *J Pediatr*. 2009;155(2):235–8. e1
49. Arico M, et al. Hemophagocytic lymphohistiocytosis. Report of 122 children from the international registry. FHL study group of the Histiocyte society. *Leukemia*. 1996;10(2):197–203.
50. Balta G, et al. Association of nonimmune hydrops fetalis with familial hemophagocytic lymphohistiocytosis in identical twin neonates with perforin His222Arg (c665A>G) mutation. *J Pediatr Hematol Oncol*. 2013;35(8):e332–4.
51. Bechara E, et al. Hemophagocytic lymphohistiocytosis with Munc13-4 mutation: a cause of recurrent fatal hydrops fetalis. *Pediatrics*. 2011;128(1):e251–4.
52. Malloy CA, et al. Hemophagocytic lymphohistiocytosis presenting with nonimmune hydrops fetalis. *J Perinatol*. 2004;24(7):458–60.
53. Feldmann J, et al. Severe and progressive encephalitis as a presenting manifestation of a novel missense perforin mutation and impaired cytolytic activity. *Blood*. 2005;105(7):2658–63.
54. Turtzo LC, et al. A neurologic presentation of familial hemophagocytic lymphohistiocytosis which mimicked septic emboli to the brain. *J Child Neurol*. 2007;22(7):863–8.

55. Deiva K, et al. CNS involvement at the onset of primary hemophagocytic lymphohistiocytosis. *Neurology*. 2012;78(15):1150–6.
56. Amir AZ, et al. Liver transplantation for children with acute liver failure associated with secondary hemophagocytic lymphohistiocytosis. *Liver Transpl*. 2016;22(9):1245–53.
57. Stapp J, et al. Fulminant neonatal liver failure in siblings: probable congenital hemophagocytic lymphohistiocytosis. *Pediatr Dev Pathol*. 2006;9(3):239–44.
58. Ost A, Nilsson-Ardnor S, Henter JI. Autopsy findings in 27 children with haemophagocytic lymphohistiocytosis. *Histopathology*. 1998;32(4):310–6.
59. Seguin A, et al. Pulmonary involvement in patients with Hemophagocytic Lymphohistiocytosis. *Chest*. 2016;149(5):1294–301.
60. Tardieu M, et al. Progressive neurologic dysfunctions 20 years after allogeneic bone marrow transplantation for Chediak-Higashi syndrome. *Blood*. 2005;106(1):40–2.
61. Shimazaki H, et al. Autosomal-recessive complicated spastic paraplegia with a novel lysosomal trafficking regulator gene mutation. *J Neurol Neurosurg Psychiatry*. 2014;85(9):1024–8.
62. Trottestam H, et al. Chemoimmunotherapy for hemophagocytic lymphohistiocytosis: long-term results of the HLH-94 treatment protocol. *Blood*. 2011;118(17):4577–84.
63. Ravelli A, et al. Expert consensus on dynamics of laboratory tests for diagnosis of macrophage activation syndrome complicating systemic juvenile idiopathic arthritis. *RMD Open*. 2016;2(1):e000161.
64. Sackett K, et al. Extreme Hyperferritinemia: causes and impact on diagnostic reasoning. *Am J Clin Pathol*. 2016;145(5):646–50.
65. Motley MP, et al. A CCR2 macrophage endocytic pathway mediates extravascular fibrin clearance in vivo. *Blood*. 2016;127(9):1085–96.
66. Mosser DM, Edwards JP. Exploring the full spectrum of macrophage activation. *Nat Rev Immunol*. 2008;8(12):958–69.
67. Osugi Y, et al. Cytokine production regulating Th1 and Th2 cytokines in hemophagocytic lymphohistiocytosis. *Blood*. 1997;89(11):4100–3.
68. Henter JI, et al. Hypercytokinemia in familial hemophagocytic lymphohistiocytosis. *Blood*. 1991;78(11):2918–22.
69. Billiau AD, et al. Macrophage activation syndrome: characteristic findings on liver biopsy illustrating the key role of activated, IFN-gamma-producing lymphocytes and IL-6- and TNF-alpha-producing macrophages. *Blood*. 2005;105(4):1648–51.
70. Jenkins MR, et al. Failed CTL/NK cell killing and cytokine hypersecretion are directly linked through prolonged synapse time. *J Exp Med*. 2015;212(3):307–17.
71. Milionis HJ, Liamis GL, Elisaf MS. The hyponatremic patient: a systematic approach to laboratory diagnosis. *CMAJ*. 2002;166(8):1056–62.
72. Lehmsberg K, et al. Differentiating macrophage activation syndrome in systemic juvenile idiopathic arthritis from other forms of hemophagocytic lymphohistiocytosis. *J Pediatr*. 2013;162(6):1245–51.
73. Ravelli A, et al. Classification criteria for macrophage activation syndrome complicating systemic juvenile idiopathic arthritis: a European league against rheumatism/American College of Rheumatology/paediatric rheumatology international trials organisation collaborative initiative. *Ann Rheum Dis*. 2016;75(3):481–9.
74. Quartier P. Current treatments for juvenile idiopathic arthritis. *Joint Bone Spine*. 2010;77(6):511–6.
75. Bryceson YT, et al. A prospective evaluation of degranulation assays in the rapid diagnosis of familial hemophagocytic syndromes. *Blood*. 2012;119(12):2754–63.
76. Stranneheim H, Wedell A. Exome and genome sequencing: a revolution for the discovery and diagnosis of monogenic disorders. *J Intern Med*. 2016;279(1):3–15.
77. Chellapandian D, et al. Treatment of Epstein Barr virus-induced haemophagocytic lymphohistiocytosis with rituximab-containing chemo-immunotherapeutic regimens. *Br J Haematol*. 2013;162(3):376–82.
78. Voskoboinik I, Whisstock JC, Trapani JA. Perforin and granzymes: function, dysfunction and human pathology. *Nat Rev Immunol*. 2015;15(6):388–400.
79. Vivier E, et al. Functions of natural killer cells. *Nat Immunol*. 2008;9(5):503–10.
80. Voskoboinik I, et al. Perforin: structure, function, and role in human immunopathology. *Immunol Rev*. 2010;235(1):35–54.
81. Orange JS. Natural killer cell deficiency. *J Allergy Clin Immunol*. 2013;132(3):515–25. quiz 526
82. Neefi M, et al. Munc13-4 is an effector of rab27a and controls secretion of lysosomes in hematopoietic cells. *Mol Biol Cell*. 2005;16(2):731–41.
83. Arneson LN, et al. Cutting edge: syntaxin 11 regulates lymphocyte-mediated secretion and cytotoxicity. *J Immunol*. 2007;179(6):3397–401.
84. Bryceson YT, et al. Defective cytotoxic lymphocyte degranulation in syntaxin-11 deficient familial hemophagocytic lymphohistiocytosis 4 (FHL4) patients. *Blood*. 2007;110(6):1906–15.
85. Barbosa MD, et al. Identification of the homologous beige and Chediak-Higashi syndrome genes. *Nature*. 1996;382(6588):262–5.
86. Dell'Angelica EC, et al. Altered trafficking of lysosomal proteins in Hermansky-Pudlak syndrome due to mutations in the beta 3A subunit of the AP-3 adaptor. *Mol Cell*. 1999;3(1):11–21.
87. Marcenaro S, et al. Analysis of natural killer-cell function in familial hemophagocytic lymphohistiocytosis (FHL): defective CD107a surface expression heralds Munc13-4 defect and discriminates between genetic subtypes of the disease. *Blood*. 2006;108(7):2316–23.
88. Picard C, Fischer A. Contribution of high-throughput DNA sequencing to the study of primary immunodeficiencies. *Eur J Immunol*. 2014;44(10):2854–61.
89. Schuster SC. Next-generation sequencing transforms today's biology. *Nat Methods*. 2008;5(1):16–8.

-
90. Heather JM, Chain B. The sequence of sequencers: the history of sequencing DNA. *Genomics*. 2016;107(1):1–8.
91. Schulert GS, et al. Whole-exome sequencing reveals mutations in genes linked to Hemophagocytic Lymphohistiocytosis and macrophage activation syndrome in fatal cases of H1N1 influenza. *J Infect Dis*. 2016;213(7):1180–8.
92. Pachlopnik Schmid J, de Saint Basile G. *Angeborene hämophagozytische Lymphohistiozytose (HLH)*. *Klin Padiatr*. 2010;222(6):345–50.

AnnaCarin Horne and Karin Beutel

Abbreviations

ADEM	Acute disseminated encephalomyelitis
ANE	Acute necrotizing encephalopathy
ATG	Antithymocyte globulin
CNS	Central nervous system
CSA	Ciclosporin
CSF	Cerebrospinal fluid
CT	Computed tomography
EBV	Epstein-Barr virus
HLH	Hemophagocytic lymphohistiocytosis
HSCT	Hematopoietic stem cell transplantation
IFN- γ	Interferon γ
IT	Intrathecal
JAK1/2	Janus kinase 1/2
MRI	Magnetic resonance imaging
MTX	Methotrexate
NAA	N-acetylaspartate

A. Horne, MD, PhD (✉)
Pediatric Rheumatology Clinic and Childhood
Cancer Research Unit, Karolinska universitets
sjukhuset and Karolinska Institutet,
ALB, Q605, 17176 Stockholm, Sweden
e-mail: annacarin.horne@karolinska.se

K. Beutel, MD
Pediatric Hematology and Oncology, Children's
Hospital München-Schwabing, Städtisches Klinikum
München and University Hospital München Rechts
der Isar, Technical University München,
München, Germany
e-mail: Karin.beutel@mri.tum.de

Introduction

Involvement of the central nervous system (CNS) in hemophagocytic lymphohistiocytosis (HLH) is usually associated with systemic features, but neurological symptoms may be the first and only manifestation of the disease [1–6]. Even if the occurrence of neurological symptoms is not included as a diagnostic criterion, it is important to consider HLH in a child with unexplained neurologic manifestations, especially one with fever, pancytopenia, and hepatosplenomegaly. CNS involvement is a frequent finding in both primary and secondary HLH [7–10]. Overall CNS disease has been reported in 30–73% of all HLH patients, either at presentation or during the course of the disease [7, 8, 11–15].

CNS involvement can cause devastating brain lesions in affected patients and is an important cause of mortality and morbidity in HLH. It is essential for the clinician to have a high suspicion of CNS-HLH and perform a rapid evaluation. Intensive therapy can halt the CNS inflammation and resolve the symptoms [8, 16], whereas progressive inflammation will lead to irreversible neurological lesions, associated with brain parenchymal necrosis [11]. This chapter focuses on the clinical presentation, diagnostic features, treatment, and neurological late effects of CNS-HLH.

Epidemiology

The true epidemiology of CNS-HLH is hampered by the lack of a standard definition. Today most HLH experts agree that an abnormal CSF and/or MRI of the brain, with or without distinct neurological signs or symptoms, defines CNS-HLH. The frequency of CNS involvement has only been evaluated prospectively in a few studies [8, 12–14]. The results from these as well as retrospective studies indicate that CNS-HLH occurs in primary and secondary HLH with a relative frequency of 18–73% of patients with documented systemic HLH [7, 9–13, 15, 17, 18]. However, CNS disease has also been reported as a primary symptom before the onset of systemic disease or in the absence of any systemic HLH features [1–6, 19].

Pathology

As has been shown for systemic disease, HLH in the CNS is considered to be the result of hyperinflammation. In a postmortem histopathological review of 23 HLH patients, lymphocytic and histiocytic infiltration with hemophagocytosis could be demonstrated. The cerebrum and cerebellum were more affected than the brainstem. The extent of infiltration was categorized in four stages ranging from no histopathological findings (stage 0) to focal meningeal infiltration in stage I, more prominent perivascular infiltration with slight tissue infiltration in stage II, and pronounced parenchymal infiltration and multifocal tissue necrosis in stage III. A correlation between the severity of the clinical symptoms and the histopathological changes was observed [11].

Clinical Signs and Symptoms

A wide spectrum of clinical neurological symptoms has been reported in HLH patients. Seizures are the most frequent symptoms [9, 12, 13, 15, 17, 18]. In one series of 25 patients with CNS disease, seizures occurred predominantly in younger infants at the onset of disease, whereas

in older children, ataxia was observed [10]. Unspecific findings described as irritability, disturbed consciousness, or encephalopathy are also among the most common findings. Furthermore opisthotonus or meningismus has been reported in up to a third of the patients. Focal neurologic disturbances include cranial nerve palsies, hemiparesis, and ataxia [10, 12, 13, 20]. Also life-threatening neurological symptoms have been reported [8, 12–14].

Diagnostic Work-Up

The diagnosis of CNS-HLH, especially the isolated form, is notoriously difficult and may lead to delays in treatment or even lack of CNS-directed therapy in patients who are left with severe long-term effects. To initiate proper treatment for CNS-HLH, a correct diagnosis must be made. A diagnostic work-up should include a careful review of the patient's history and a thorough neurological examination. In addition to the blood tests required to make a diagnosis of systemic HLH, a lumbar puncture with cerebrospinal fluid (CSF) analysis and magnetic resonance imaging (MRI) should always be done in all cases regardless of the presence or absence of neurological signs or symptoms.

CSF

CSF findings are usually subtle including mild pleocytosis of mononuclear cells and/or elevated protein levels. Although only mild increases in protein levels are usually found, cases with high values up 10,000 mg/l have been reported [21]. In some cases, hemophagocytosis can be found in the CSF. Additional biomarkers like neopterin [22] or elevated soluble interleukin-2 receptor have been suggested but have not been evaluated in detail.

None of these findings are specific. Other conditions, in particular CNS infection, which can also occur concomitantly, have to be ruled out. Thus, CSF diagnostics should include standard testing: protein, glucose, lactate, cell count, and

microbiological work-up. Morphology determined by a cytospin slide mostly reveals a lymphocytic rather than the granulocytic pattern, which is found in bacterial meningitis. Hemophagocytosis, which is described to be present in 91% of brain biopsies, mostly located in the meninges [11], was less commonly seen in the CSF (39%) of pediatric cases [8]. Whether the degree of hemophagocytosis in the CSF correlates to the duration and severity of disease, as demonstrated in brain tissue, is not known.

Protein differentiation, like electrophoresis, may help to distinguish HLH more precisely from other conditions in which local immunoglobulin production (e.g., viral encephalitis) is present. The relevance of measuring opening pressure is not clear. In case of initial normal findings, repeated lumbar punctures might be necessary to detect CNS involvement, especially in patients with persisting active systemic HLH with ongoing or new neurological symptoms.

Flow cytometry of the CSF also has not been evaluated properly. The presence of activated T cells, however, might be a clue to diagnosis, especially in those patients with CNS disease only.

Imaging

The variety of clinical presentations of CNS disease in HLH is reflected by the wide spectrum of neuroradiological findings which have been described in the literature. However, not all patients with CSF abnormalities and/or neurological symptoms also show abnormalities in imaging. On the other hand, magnetic resonance imaging (MRI) findings have been described in patients without clinical signs or CSF abnormalities [6, 17].

Brain computed tomography (CT) scans might reveal parenchymal volume loss, brain edema, hemorrhage, and hyperdense areas indicating calcification or necrosis [23, 24]. MRI appears to be the most sensitive method. In addition to the findings mentioned above, leptomeningeal and perivascular contrast enhancement, hypointense or T2 hyperintense parenchymal lesions, nodular or ring-enhancing parenchymal lesions,

and subdural fluid collections have been reported [9, 18, 25–27]. Parenchymal lesions are mostly found in the cerebrum and cerebellum, mainly at the junction of white and gray matter, with the brainstem less affected [6, 25, 28]. Bilateral distribution is common, which differentiates the condition from ADEM [9] (Fig. 10.1a–c).

Parenchymal hemorrhage and extra-axial bleeding have been found in one child who also had retinal hemorrhage. A diagnosis of child abuse was made before the final diagnosis was established due to systemic features of HLH [29]. In another case series, hemorrhagic transformation was considered to be due to ischemic injury after perivascular infiltration [25].

Standard MRI techniques have not been defined until now. Due to the unspecific pattern of the lesions, an extended MRI protocol can be recommended including T1-weighted, T2-weighted, FLAIR, diffusion-weighted, and post-contrast imaging. Susceptibility-weighted imaging is particularly useful in demonstrating bleeding or blood components.

In cases with symptoms suggestive of spinal involvement or polyradiculitis, a spinal MRI should be performed [30, 31].

Systematic follow-up imaging has not been done. Few studies indicate that progression or resolution of neurological symptoms is reflected by MRI findings [6, 25, 27].

MRI spectroscopy has been applied in a few cases and has shown an increase in lactate and a decrease in N-acetylaspartate (NAA) in the active phase of the disease, whereas clinical improvement was associated with a decreased lactate peak and a recovery of NAA [25, 27].

Monitoring of disease activity by repeated CSF analysis has been suggested in the HLH trials in 1994 and 2004. Treatment response seems to be evident more rapidly in the CSF than the resolution of neuroradiological findings can be documented [12].

In summary, there are no specific parameters for the diagnosis of CNS disease. Similar neuroradiological findings have been observed in hereditary and acquired HLH [12]. Especially in the absence of systemic HLH features, an extended laboratory and radiological work-up

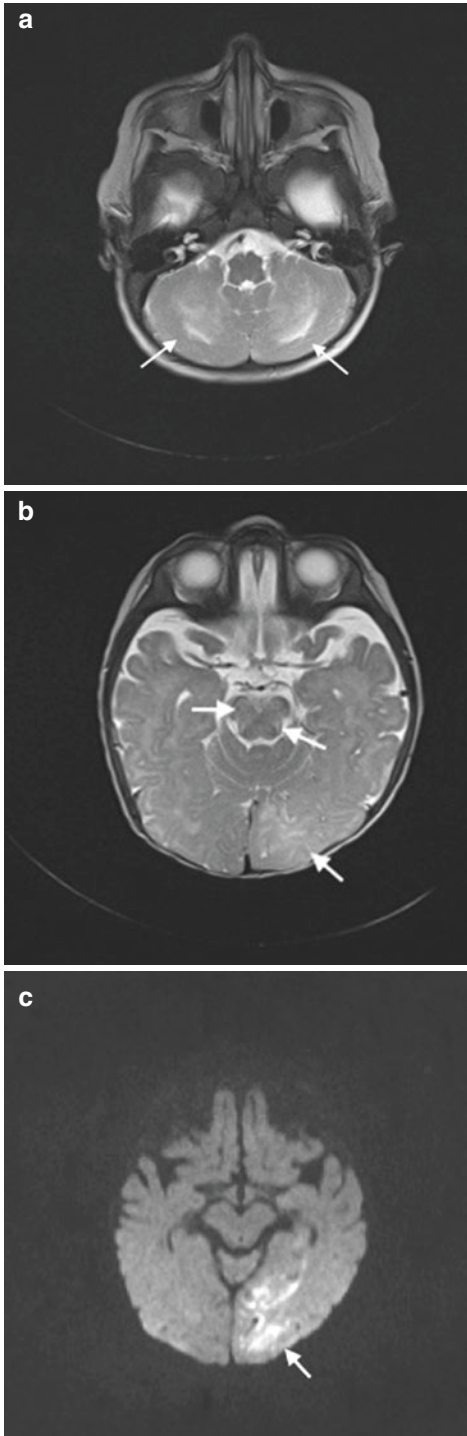


Fig. 10.1 Neuroradiological MRI findings in HLH (arrows are indicating the lesions). (a) T2w image showing bilateral hyperintense lesions in the cerebellum. (b) T2w image with hyperintense signal and edema in the left posterior hemisphere and abnormalities in the brainstem. (c) Diffusion-weighted imaging of the same region as in (b) with lesions imitating cerebral infarction

has to be performed to exclude other conditions like acute disseminated encephalomyelitis (ADEM), acute necrotizing encephalopathy (ANE), CNS vasculitis, multiple sclerosis, encephalitis, CNS manifestations of rheumatologic disease (such as systemic lupus erythematosus), and other genetically mediated CNS inflammatory disorders such as interferonopathies, and child abuse. Both isolated CNS-HLH and CNS involvement in addition to systemic HLH can also mimic CNS infections. Of note, abnormal MRI findings have also been shown as a consequence of HLH therapy. Especially posterior reversible leukoencephalopathy has been demonstrated in association with corticosteroid and ciclosporin A (CSA) treatment [32] but can be distinguished from CNS disease due to its characteristic appearance in MRI [33]. Brain volume loss is considered to be an effect of steroid treatment. Furthermore, infectious complications under the immunosuppressive HLH treatment, for example, CNS aspergillosis, can easily be confounded with CNS involvement of HLH [34].

Treatment

The pathophysiology of CNS-HLH is likely to be similar to that of systemic HLH, i.e., massive hyperinflammation leading to destruction of the brain tissue. Therefore, it is important to constantly reduce inflammatory HLH activity to prevent CNS injury. Deficient cytotoxicity in primary HLH may result in reduced elimination of virus-infected cells; hence, antiviral therapy should be given when possible. The first step is to optimize treatment of systemic disease, which varies depending on the underlying cause and severity of HLH.

The international HLH 1994 study [8] and experience with antithymocyte globulin (ATG) [16, 35] showed that initial CSF findings improved by using systemic therapy only. Systemic therapy reduces cytokine-secreting T cells in the circulation. It can be assumed that these cells also migrate through vessels into the brain, leading to the lymphohistiocytic infiltrate described in brain autopsies. Available treatments to consider include therapies used in

protocols HLH-94 and HLH-2004, including dexamethasone, etoposide, and CSA [8, 36], or treatment with corticosteroids and ATG or alemtuzumab [16, 35, 37].

A steroid, preferably dexamethasone, is of importance in CNS-HLH treatment. Results of clinical studies have shown that dexamethasone has a longer half-life in the CSF and better CSF penetration than prednisone [38, 39]. In prospective randomized trials, dexamethasone yielded better control of CNS leukemia [39]. For EBV-associated HLH, rituximab has been shown to be beneficial; systemic clearance of EBV by rituximab has been reported [40, 41]. It should be used in cases of severe EBV-HLH with CNS involvement in order to reduce inflammatory activity by eliminating the triggering agent. However, it has to be considered that in many EBV-HLH cases, the virus is also found in T cells which will not be affected by rituximab treatment [40–43].

A novel and interesting concept for HLH treatment is the administration of an anti-IFN- γ antibody. This agent is currently being explored in a phase II trial (NCT01818492). It seems also to be of benefit in CNS-HLH (Michael Jordan, personal communication). Another very promising agent is the JAK1/2 inhibitor ruxolitinib, shown to be effective in HLH in two recent studies using different murine models of HLH. In the Rab27a $-/-$ mice, CNS involvement was significantly reduced with ruxolitinib therapy [44, 45].

Often in CNS-HLH, there is a good response to systemic therapy alone. However, intrathecal therapy may be necessary in patients in whom treatment with dexamethasone, etoposide, or ATG offers good control of systemic HLH but not of CNS disease. Intrathecal methotrexate and steroids (as described in HLH-2004 [36]) for CNS-HLH should then be used and be given weekly for at least three doses and preferably until all CSF abnormalities and CNS symptoms normalize. The benefit from the use of intrathecal therapy for CNS-HLH has been witnessed by many HLH experts; however, as of today there are no controlled studies to prove this. CSF abnormalities seem to disappear in most cases, whereas an improvement of neurologic symptoms and neuro-radiological findings is less likely [10, 12].

There are also risks with intrathecal chemotherapy: neurological adverse effects are well described and may be expected [46]. There are ongoing concerns regarding intrathecal drugs as a major contributor to CNS late effects in children [47]. Future studies are required to weigh the benefits and risks of intrathecal therapy in CNS-HLH.

Even if a patient has responded well to initial therapy of HLH, reactivation of CNS-HLH by the time of HSCT is common. Early transplant in HLH can halt the progression of CNS disease [48, 49]. Therefore, even if HLH is still active, an early transplant should be considered as the risk of late effects may be more severe than the risk of transplantation. After a successful HSCT, neurologic manifestations can be reversed, and recurrences can be prevented [48, 49].

In patients who have CNS involvement, pre-transplant close surveillance for reoccurrence is warranted. Analyses of the CSF after donor engraftment are advisable to monitor for recurrent/persistent CSF abnormalities. If CNS-HLH recurs/worsens after HSCT, as indicated by clinical findings or CSF, additional intrathecal and systemic therapy should be considered. Finally, all long-term survivors should have longitudinal follow-up for neurological late effects including cognitive and motor evaluations to initiate early and appropriate support.

Neurological Late Effects in Survivors

Over the last 20 years, survival of primary HLH has improved markedly. Therefore, it has become increasingly important to thoroughly evaluate long-term toxicity, especially long-term effects related to the CNS. A significant proportion of children (10–39%) with HLH have neurologic late effects ranging from mild to severe, despite successful HSCT [8, 9, 13, 50].

Neurological late effects have been shown to be more common in those patients with combined abnormal CSF and neurologic symptoms at diagnosis [13] but do not seem to be influenced by age or type of genetic HLH defect [9].

In the prospective HLH-94 treatment study, the most common neurological late effects were

developmental delay, epilepsy, attention deficit hyperactivity disorder, hearing loss, and hemiplegia [8]. Preliminary data from the next treatment protocol, HLH-2004, indicates unfortunately that this high proportion of neurological late effects in survivors remains.

The first study which systematically evaluated the cognitive and psychosocial outcome of HLH survivors reported that children treated for HLH with HSCT have significantly lower levels of intellectual functions compared to both a normal population and sibling controls [50]. These impairments were identified in 52% despite of no obvious neurologic involvement by the disease itself at diagnosis. In addition to cognitive difficulties, this study also found significant psychosocial (especially emotional and social) difficulties in children transplanted for HLH. These psychosocial difficulties were observed by both parents and teachers. Also the percentage of children with significant neuropsychological problems in this study (30%) was higher than previously reported [50].

The true morbidity of CNS-HLH in survivors is still unknown. Future long-term studies including larger patient numbers are needed to analyze risk factors for adverse neurologic outcomes. Recognition of the risks of CNS disease and immediate early treatment are essential to reduce the numbers of children suffering these late effects.

References

- Feldmann J, Menasche G, Callebaut I, Minard-Colin V, Bader-Meunier B, Le Clainche L, Fischer A, Le Deist F, Tardieu M, de Saint BG. Severe and progressive encephalitis as a presenting manifestation of a novel missense perforin mutation and impaired cytolytic activity. *Blood*. 2005;105:2658–63.
- Shinoda J, Murase S, Takenaka K, Sakai N. Isolated central nervous system hemophagocytic lymphohistiocytosis: case report. *Neurosurgery*. 2005;56:187.
- Moshous D, Feyen O, Lankisch P, Schwarz K, Schaper J, Schneider M, Dilloo D, Laws HJ, Schwahn BC, Niehues T. Primary necrotizing lymphocytic central nervous system vasculitis due to perforin deficiency in a four-year-old girl. *Arthritis Rheum*. 2007;56:995–9.
- Rostasy K, Kolb R, Pohl D, Mueller H, Fels C, Moers AV, Bergmann M, Hanefeld F, Pekrun A, Schulz-Schaeffer W. CNS disease as the main manifestation of hemophagocytic lymphohistiocytosis in two children. *Neuropediatrics*. 2004;35:45–9.
- Henter JI, Elinder G. Cerebrospinal fluid hemophagocytic lymphohistiocytosis. *Lancet*. 1992;339:104–7.
- Kieslich M, Vecchi M, Dr iever PH, Laverda AM, Schwabe D, Jacobi G. Acute encephalopathy as a primary manifestation of haemophagocytic lymphohistiocytosis. *Dev Med Child Neurol*. 2001;43:555–8.
- Ramachandran B, Balasubramanian S, Abhishek N, Ravikumar KG, Ramanan AV. Profile of hemophagocytic lymphohistiocytosis in children in a tertiary care hospital in India. *Indian Pediatr*. 2011;48:31–5.
- Trottestam H, Horne A, Arico M, Egeler RM, Filipovich AH, Gardner H, Imashuku S, Ladisch S, Webb D, Janka G, et al. Chemoimmunotherapy for hemophagocytic lymphohistiocytosis: long-term results of the HLH-94 treatment protocol. *Blood*. 2011;118:4577–84.
- Deiva K, Mahlaoui N, Beaudonnet F, de Saint BG, Caridade G, Moshous D, Mikaeloff Y, Blanche S, Fischer A, Tardieu M. CNS involvement at the onset of primary hemophagocytic lymphohistiocytosis. *Neurology*. 2012;78:1150–6.
- Haddad E, Sulis ML, Jabado N, Blanche S, Fischer A, Tardieu M. Frequency and severity of central nervous system lesions in hemophagocytic lymphohistiocytosis. *Blood*. 1997;89:794–800.
- Henter JI, Nennesmo I. Neuropathologic findings and neurologic symptoms in twenty-three children with hemophagocytic lymphohistiocytosis. *J Pediatr*. 1997;130:358–65.
- Yang S, Zhang L, Jia C, Ma H, Henter JI, Shen K. Frequency and development of CNS involvement in Chinese children with hemophagocytic lymphohistiocytosis. *Pediatr Blood Cancer*. 2010;54:408–15.
- Horne A, Trottestam H, Arico M, Egeler RM, Filipovich AH, Gardner H, Imashuku S, Ladisch S, Webb D, Janka G, et al. Frequency and spectrum of central nervous system involvement in 193 children with haemophagocytic lymphohistiocytosis. *Br J Haematol*. 2008;140:327–35.
- Dao AT, Luong VT, Nguyen TT, Huynh QT, Phan TT, Lam MT, Ngoma AM, Koriyama C. Risk factors for early fatal outcomes among children with hemophagocytic lymphohistiocytosis (HLH): a single-institution case-series in Vietnam. *Pediatr Hematol Oncol*. 2014;31:271–81.
- Gratton SM, Powell TR, Theeler BJ, Hawley JS, Amjad FS, Tornatore C. Neurological involvement and characterization in acquired hemophagocytic lymphohistiocytosis in adulthood. *J Neurol Sci*. 2015;357:136–42.
- Mahlaoui N, Ouachee-Chardin M, de Saint BG, Neven B, Picard C, Blanche S, Fischer A. Immunotherapy of familial hemophagocytic lymphohistiocytosis with antithymocyte globulins: a single-center retrospective report of 38 patients. *Pediatrics*. 2007;120:e622–8.
- Kim MM, Yum MS, Choi HW, Ko TS, Im HJ, Seo JJ, Koh KN. Central nervous system (CNS) involvement

- is a critical prognostic factor for hemophagocytic lymphohistiocytosis. *Korean J Hematol.* 2012;47:273–80.
18. Jovanovic A, Kuzmanovic M, Kravljanc R, Micic D, Jovic M, Gazikalovic S, Pasic S. Central nervous system involvement in hemophagocytic lymphohistiocytosis: a single-center experience. *Pediatr Neurol.* 2014;50:233–7.
 19. Imashuku S. Clinical features and treatment strategies of Epstein-Barr virus-associated hemophagocytic lymphohistiocytosis. *Crit Rev Oncol Hematol.* 2002;44:259–72.
 20. Gurgey A, Aytac S, Balta G, Oguz KK, Gumruk F. Central nervous system involvement in Turkish children with primary hemophagocytic lymphohistiocytosis. *J Child Neurol.* 2008;23:1293–9.
 21. Voeten M, Maes P, Wojciechowski M, Vandenbossche L, Meyts I, Ceulemans B. Extremely elevated cerebrospinal fluid protein levels in a child with neurologic symptoms: beware of haemophagocytic lymphohistiocytosis. *Eur J Paediatr Neurol.* 2014;18:427–9.
 22. Howells DW, Strobel S, Smith I, Levinsky RJ, Hyland K. Central nervous system involvement in the erythrophagocytic disorders of infancy: the role of cerebrospinal fluid neopterin in their differential diagnosis and clinical management. *Pediatr Res.* 1990;28:116–9.
 23. Rettwitz W, Sauer O, Burow HM, Lenard HG, Raute-Kreinsen U, Tornow K. Neurological and neuropathological findings in familial erythrophagocytic lymphohistiocytosis. *Brain and Development.* 1983;5:322–7.
 24. Fitzgerald NE, McClain KL. Imaging characteristics of hemophagocytic lymphohistiocytosis. *Pediatr Radiol.* 2003;33:392–401.
 25. Goo HW, Weon YC. A spectrum of neuroradiological findings in children with haemophagocytic lymphohistiocytosis. *Pediatr Radiol.* 2007;37:1110–7.
 26. Guandalini M, Butler A, Mandelstam S. Spectrum of imaging appearances in Australian children with central nervous system hemophagocytic lymphohistiocytosis. *J Clin Neurosci.* 2014;21:305–10.
 27. Rego I, Severino M, Micalizzi C, Faraci M, Pende D, Dufour C, Arico M, Rossi A. Neuroradiologic findings and follow-up with magnetic resonance imaging of the genetic forms of haemophagocytic lymphohistiocytosis with CNS involvement. *Pediatr Blood Cancer.* 2012;58:810–4.
 28. Decaminada N, Cappellini M, Mortilla M, Del Giudice E, Sieni E, Caselli D, Arico M, Fonda C. Familial hemophagocytic lymphohistiocytosis: clinical and neuroradiological findings and review of the literature. *Childs Nerv Syst.* 2010;26:121–7.
 29. Rooms L, Fitzgerald N, McClain KL. Hemophagocytic lymphohistiocytosis masquerading as child abuse: presentation of three cases and review of central nervous system findings in hemophagocytic lymphohistiocytosis. *Pediatrics.* 2003;111:e636–40.
 30. Chiapparini L, Uziel G, Vallinoto C, Bruzzone MG, Rovelli A, Tricomi G, Bizzi A, Nardocci N, Rizzari C, Savoiaro M. Hemophagocytic lymphohistiocytosis with neurological presentation: MRI findings and a nearly miss diagnosis. *Neurol Sci.* 2011;32:473–7.
 31. Del Giudice E, Savoldi G, Notarangelo LD, Di Benedetto L, Manganelli F, Bruzzese E, Romano A, Santoro L. Acute inflammatory demyelinating polyradiculoneuropathy associated with perforin-deficient familial haemophagocytic lymphohistiocytosis. *Acta Paediatr.* 2003;92:398–401.
 32. Thompson PA, Allen CE, Horton T, Jones JY, Vinks AA, McClain KL. Severe neurologic side effects in patients being treated for hemophagocytic lymphohistiocytosis. *Pediatr Blood Cancer.* 2009;52:621–5.
 33. Lee G, Lee SE, Ryu KH, Yoo ES. Posterior reversible encephalopathy syndrome in pediatric patients undergoing treatment for hemophagocytic lymphohistiocytosis: clinical outcomes and putative risk factors. *Blood Res.* 2013;48:258–65.
 34. Foley JM, Borders H, Kurt BA. A diagnostic dilemma: similarity of neuroradiological findings in central nervous system hemophagocytic lymphohistiocytosis and aspergillosis. *Pediatr Blood Cancer.* 2016;63:1296–9.
 35. Moshous D. The many faces of hemophagocytic lymphohistiocytosis - a challenge in diagnosis and therapy. *Clin Biochem.* 2014;47:726–7.
 36. Henter JI, Horne A, Arico M, Egeler RM, Filipovich AH, Imashuku S, Ladisch S, McClain K, Webb D, Winiarski J, et al. HLH-2004: diagnostic and therapeutic guidelines for hemophagocytic lymphohistiocytosis. *Pediatr Blood Cancer.* 2007;48:124–31.
 37. Marsh RA, Allen CE, McClain KL, Weinstein JL, Kanter J, Skiles J, Lee ND, Khan SP, Lawrence J, Mo JQ, et al. Salvage therapy of refractory hemophagocytic lymphohistiocytosis with alemtuzumab. *Pediatr Blood Cancer.* 2013;60:101–9.
 38. Eadie MJ, Brophy TR, Ohlrich G, Tyrer JH. Dexamethasone: pharmacokinetics in neurological patients. *Clin Exp Neurol.* 1984;20:107–18.
 39. Balis FM, Lester CM, Chrousos GP, Heideman RL, Poplack DG. Differences in cerebrospinal fluid penetration of corticosteroids: possible relationship to the prevention of meningeal leukemia. *J Clin Oncol.* 1987;5:202–7.
 40. Chellapandian D, Das R, Zellek K, Wiener SJ, Zhao H, Teachey DT, Nichols KE. Treatment of Epstein Barr virus-induced hemophagocytic lymphohistiocytosis with rituximab-containing chemo-immunotherapeutic regimens. *Br J Haematol.* 2013;162:376–82.
 41. Balamuth NJ, Nichols KE, Paessler M, Teachey DT. Use of rituximab in conjunction with immunosuppressive chemotherapy as a novel therapy for Epstein Barr virus-associated hemophagocytic lymphohistiocytosis. *J Pediatr Hematol Oncol.* 2007;29:569–73.
 42. So MW, Koo BS, Kim YJ, Kim YG, Lee CK, Yoo B. Successful rituximab treatment of refractory hemophagocytic lymphohistiocytosis and autoimmune hemolytic anemia associated with systemic lupus erythematosus. *Mod Rheumatol.* 2014;24:855–7.
 43. Al Asad O, Salam A, Mannem S, Ninan M, Markowitz A, Jana B. Alternative therapy for epstein-barr virus

- related hemophagocytic lymphohistiocytosis. *Case Rep Oncol Med.* 2015;2015:508387.
44. Maschalidi S, Sepulveda FE, Garrigue A, Fischer A, de Saint BG. Therapeutic effect of JAK1/2 blockade on the manifestations of hemophagocytic lymphohistiocytosis in mice. *Blood.* 2016;128(1):60–71.
 45. Das R, Guan P, Sprague L, Verbist K, Tedrick P, An QA, Cheng C, Kurachi M, Levine R, Wherry EJ, et al. Janus kinase inhibition lessens inflammation and ameliorates disease in murine models of hemophagocytic lymphohistiocytosis. *Blood.* 2016;127:1666–75.
 46. Ruggiero A, Conter V, Milani M, Biagi E, Lazzareschi I, Sparano P, Riccardi R. Intrathecal chemotherapy with antineoplastic agents in children. *Paediatr Drugs.* 2001;3:237–46.
 47. Duffner PK, Armstrong FD, Chen L, Helton KJ, Brecher ML, Bell B, Chauvenet AR. Neurocognitive and neuroradiologic central nervous system late effects in children treated on pediatric oncology group (POG) P9605 (standard risk) and P9201 (lesser risk) acute lymphoblastic leukemia protocols (ACCL0131): a methotrexate consequence? A report from the children's oncology group. *J Pediatr Hematol Oncol.* 2014;36:8–15.
 48. Sparber-Sauer M, Honig M, Schulz AS, zur Stadt U, Schutz C, Debatin KM, Friedrich W. Patients with early relapse of primary hemophagocytic syndromes or with persistent CNS involvement may benefit from immediate hematopoietic stem cell transplantation. *Bone Marrow Transplant.* 2009;44:333–8.
 49. Ouachee-Chardin M, Elie C, de Saint BG, Le Deist F, Mahlaoui N, Picard C, Neven B, Casanova JL, Tardieu M, Cavazzana-Calvo M, et al. Hematopoietic stem cell transplantation in hemophagocytic lymphohistiocytosis: a single-center report of 48 patients. *Pediatrics.* 2006;117:e743–50.
 50. Jackson J, Titman P, Butler S, Bond K, Rao A, Veys P, Chiesa R, Leiper A, Riley L, Gilmour K, et al. Cognitive and psychosocial function post hematopoietic stem cell transplantation in children with hemophagocytic lymphohistiocytosis. *J Allergy Clin Immunol.* 2013;132:889–95. e881–883

Genetics and Pathogenesis of Hemophagocytic Lymphohistiocytosis

11

Geneviève de Saint Basile, Despina Moshous,
and Alain Fischer

List of Abbreviations

APC	Antigen-presenting cell	JIA	Juvenile idiopathic arthritis
BEACH	Beige and Chediak-Higashi	LRBA	Lipopolysaccharide-responsive and beige-like anchor protein
CHS	Chediak-Higashi syndrome	LYST	Lysosomal trafficking regulator
CTL	Cytotoxic T lymphocytes	MAS	Macrophage activation syndrome
CVID	Common variable immune deficiency	MIM	Mendelian inheritance in man
EBV	Epstein-Barr virus	MTOC	Microtubule-organizing centre
FHL	Familial lymphohistiocytosis	NK	Natural killer
GS	Griscelli syndrome	PH	Pleckstrin homology domain
HLH	Hemophagocytic lymphohistiocytosis	PID	Primary immunodeficiency
HPS2	Hermansky-Pudlak syndrome type 2	SNARE	Soluble N-ethylmaleimide-sensitive factor attachment protein receptor
IL-	Interleukin-	TNF	Tumour necrosis factor
INF	Interferon	t-SNARE	Target-SNARE
IS	Immunological synapse	XLP	X-linked lymphoproliferative disease

G. de Saint Basile, MD, PhD (✉)
INSERM UMR1163, F-75015 Paris, France
Paris Descartes University-Sorbonne Paris Cité,
Imagine Institute, F-75015 Paris, France
Centre d'Etudes des Déficits Immunitaires,
Assistance Publique-Hôpitaux de Paris,
Hôpital Necker, Paris, France
e-mail: genevieve.de-saint-basile@inserm.fr
D. Moshous, MD, PhD
INSERM UMR1163, F-75015 Paris, France
Paris Descartes University-Sorbonne Paris Cité,
Imagine Institute, F-75015 Paris, France

Paediatric Immunology and Hematology
Department, Necker Children's Hospital,
AP-HP, Paris, France
A. Fischer, MD, PhD
INSERM UMR1163, F-75015 Paris, France
Paris Descartes University-Sorbonne Paris Cité,
Imagine Institute, F-75015 Paris, France
Paediatric Immunology and Hematology Department,
Necker Children's Hospital, AP-HP, Paris, France
Collège de France, F-75005 Paris, France

Introduction

Several hereditary disorders lead to the development of hemophagocytic lymphohistiocytosis. This syndrome is characterized by the over-activation and proliferation of T cells, mostly CD8⁺ T cells, and macrophages, which produce high levels of pro-inflammatory cytokines and infiltrate many organs. Genetic diseases in which HLH is the key manifestation are referred to as primary or familial lymphohistiocytosis (FHL; MIM 267700) (Table 11.1). Mutations in four genes have been linked to the occurrence of FHL. In other primary conditions, HLH is associated with characteristic hypopigmentation, as in Griscelli syndrome (GS; MIM 214450) and Chediak-Higashi syndrome (CHS; MIM 214500). Furthermore, Hermansky-Pudlak syndrome type 2 (HPS2; MIM 608233), another condition with pigmentary dilution, is occasionally associated with HLH. Moreover, a number of other primary immunodeficiencies (PIDs), particularly those predisposing to susceptibility to Epstein-Barr virus (EBV) infection, such

as X-linked lymphoproliferative disease types 1 and 2 (XLP1; MIM 308240 and XLP2; MIM 300635), are associated with a significant risk of developing HLH. Lastly, a few inborn errors of metabolism and PIDs can predispose to HLH. It is important to note that in addition to primary HLH (conditions in which a genetic contribution has been clearly defined), so-called “secondary” forms of HLH (also referred to as macrophage activation syndrome (MAS)) are reportedly associated with a variety of infections, malignancies and autoimmune diseases [1]. The putative genetic component of secondary HLH remains to be established.

Defective Cytotoxic Function in HLH

A hallmark of most primary forms of HLH is the defective function of cytotoxic T lymphocytes (CTL) and natural killer (NK) cells. CTLs and NK cells contribute to immune protection by identifying and killing virus-infected or transformed cells. Mechanistically, target cell recognition

Table 11.1 Genetic disorders associated with occurrence of HLH

	Gene	Locus	Inheritance	Protein function
<i>1. HLH with cytotoxicity defect</i>				
FHL2	<i>PRF1</i>	10q21–22	AR	Perforin/pore-forming protein
FHL3	<i>UNC13D</i>	17q25	AR	Munc13-14/priming factor
FHL4	<i>STX11</i>	6q24	AR	Syntaxin 11/membrane fusion
FHL5	<i>STXB2</i>	19p13	AR	Munc18-2/syntaxin-binding protein
XLP1	<i>SH2D1A</i>	Xq25	XL	SAP/regulate signalling lymphocyte activation molecule
<i>HLH with hypopigmentation</i>				
GS2	<i>RAB27A</i>	15q21	AR	Rab27a/tethering
CHS	<i>CHS/</i> <i>LYST</i>	1q42–43	AR	Lyst/lysosomal fission-protein sorting
HPS2 ^a	<i>AP3B1</i>	5q14.1	AR	Ap3β1/sorting of lysosomal protein
<i>2. HLH with no evidence of cytotoxicity defect</i>				
XLP2	<i>BIRC4</i>	Xq25	XL	XIAP/Inhibitor of apoptosis
NLRC4	<i>NRCC4</i>	2p22.3	AD/GOF	NLRC4/ innate immune response regulation
<i>3. Metabolic disorders</i>				
Wolman disease	<i>LIPA</i>	10q23.2–23.3	AR	Lipase A/ lysosomal acid hydrolase
Lysinuric protein intolerance	<i>SLC7A7</i>	14q11.2	AR	SLC7A7/cationic amino acid transporter
Others...				

AR autosomal recessive, XL X-linked, AD autosomal dominant, GOF gain of function

^aOnly one typical HLH case has been reported

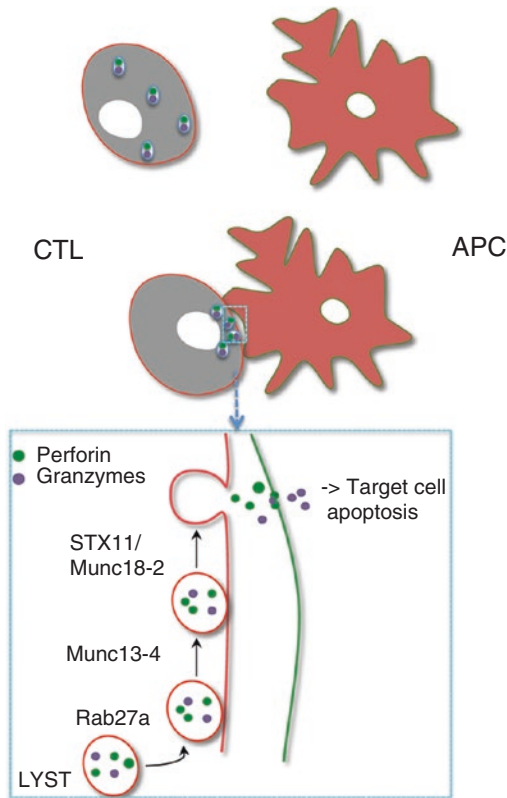


Fig. 11.1 Cytotoxic lymphocytes kill cognate target cells. Cytotoxic lymphocyte recognizing an antigen-presenting cell (APC) forms a transient cell-cell conjugate. Cytotoxic granules containing perforin and granzymes polarized towards the target cell fuse their membrane with the plasma membrane and release their content into an intercellular cleft. Perforin forms a pore in the target membrane, allowing granzymes to enter and induce apoptosis of the target cell. At the plasma membrane, Rab27a allows tethering of cytotoxic granules that are then primed by Munc13-4, while syntaxin 11 and Munc18-2 regulate granule fusion

leads to the transient formation of a cell-cell conjugate, followed by the polarized release of perforin- and granzyme-containing granules from the cytotoxic cell towards the target cell (Fig. 11.1). The secretion of mature cytotoxic granules from CTL and NK cells is a complex molecular process that requires a sequence of coordinated events. These steps include the formation of an immunological synapse (IS) at the site of cell-cell contact, the transport of cytotoxic granules towards the microtubule-organizing centre (MTOC) and the latter's polarization

towards the target cell. Polarized lytic granules dock at a secretory domain on the plasma membrane and then fuse near to where T cell receptor and signalling molecules are clustered [2]. The lytic granule contents are then released into the narrow intercellular cleft formed between the two cells. Perforin's pore-forming activity enables pro-apoptotic granzymes to enter the cytoplasm of the target cell, where they cleave key substrates and thus initiate apoptotic cell death (Fig. 11.1). All the genetic defects causing FHL and the other primary HLH conditions associated with hypopigmentation impair the function of the granule-dependent cytotoxic pathway.

The Genetics of HLH with Impaired Lymphocyte Cytotoxicity

Familial Hemophagocytic Lymphohistiocytosis

Familial hemophagocytic lymphohistiocytosis is inherited as an autosomal recessive disease. It has an annual incidence estimated around 1 per 100,000 children. Isolated, overwhelming HLH is the sole distinguishing feature of most cases of FHL. The symptoms of HLH usually appear within the first 6 months of life but may, in rare cases, develop in utero [3] or at birth [4]. However, familial forms with a later onset (at any time up to adulthood) have also been reported [5–7] HLH mostly occurs in previously healthy young children, which suggests that the clinical manifestations have an exogenous trigger. In susceptible children, infection with intracellular pathogens (notably viral and fungal pathogens) is the most likely trigger [8].

In 1999, the use of linkage analysis and homozygosity mapping led to the identification of a locus (designated FHL1) on chromosome 9q21.3–22 in four inbred FHL families of Pakistani descent [9]. However, no causative gene has been associated with this locus to date, and the robustness of these data has been questioned. Simultaneously, a second locus was found on chromosome 10q21–22 (FHL2), and evidence of the genetic heterogeneity of this

condition was provided [10]. Shortly thereafter, gene candidate screening within the FHL2 locus enabled Stepp et al. to identify the first gene for FHL (*PRF1*, the perforin gene) [11] (Table 11.1 and Fig. 11.1). This rather unexpected finding was decisive because it (i) directly linked the function of the granule-dependent cytotoxic pathway to the pathophysiology of HLH and (ii) suggested additional etiologies for FHL. Similar genetic approaches identified three additional causes of FHL, all of which affect the exocytosis of cytotoxic lymphocyte granules (Table 11.1). FHL3 has been linked to mutations in *UNC13-D* (located on chromosome 17q25) [12] and FHL4 to mutations in syntaxin 11 (located on chromosome 6q24) [13], and lastly, a defect in the gene for syntaxin 11-binding protein STXBP2/Munc18-2 (located on chromosome 19p13) was found to cause FHL5 [14, 15]. Given that these four genes account for approximately 90% of the cases of FHL, other causative genes regulating the cytotoxic function of lymphocytes may still be identified.

Perforin Deficiency Causes FHL2

The cytolytic effector perforin (PRF1) is localized in cytotoxic granules (Fig. 11.1). Mutations in the *PRF1* gene account for about 35–45% of all FHL cases (FHL2, MIM 603553) [11, 16]. Proteolytic cleavage of perforin within granules enables maturation of the protein. Following the release of perforin from cytotoxic granules, the perforin C2 domain binds calcium and interacts with the target membrane. Once bound to the target membrane, perforin oligomerizes to form a pore and allows granzymes to enter the target cell cytoplasm. Rapid apoptotic death of the target cell ensues [17]. The molecular and structural bases for membrane binding and pore formation have been recently characterized [18, 19]. The perforin gene comprises three exons (of which only the second and third are translated) and encodes a 555-amino acid polypeptide [20]. Over 100 different recessive *PRF1* mutations (micro-deletions, nonsense or missense mutations) have been found in FHL2 patients. The mutations are distributed all along the gene sequence. Some perforin mutations are more frequent in particu-

lar ethnic populations, suggesting common ancestry. For example, the Trp374 stop (G1122A) mutation occurs frequently in Turkish families, whereas the Leu17 frameshift (50delT) mutation occurs frequently in African populations [21]. Most of the mutations result in undetectable amounts of perforin in cytotoxic granules, leading to defective cytotoxic activity [8, 11, 22]. Some peculiar mutations of the perforin gene specifically affect proteolytic cleavage and thus maturation of the protein [23] or the calcium-binding ability [24, 25]. Missense mutations that only partially impair perforin function have also been reported. The latter are mainly associated with atypical (mostly late-onset) HLH disease and include the Ala91Val substitution (found in between 4% and 8% of healthy individuals). Ala91Val was initially considered to be a neutral polymorphism [26], but it does result in the partial (50%) loss of PRF1-dependent cytotoxicity. The Ala91Val allele probably confers a predisposition to late-onset disease, with the homozygous state being associated with susceptibility to lymphoma and the compound heterozygous state being associated with FLH (when a second “null” perforin allele is present) [27–29]. Furthermore, a few reports have provided convincing evidence to suggest that temperature-sensitive mutations in perforin may be associated with late-onset FHL and a predisposition to haematological malignancies [5]. A recently proposed structural approach explained the effect of 76 missense mutations identified in FHL2 patients via perforin’s ability to oligomerize – thereby providing an explanation for the observed cytotoxicity defect in these patients [30] and a basis for the observed phenotype/genotype correlation.

Munc13-4 Deficiency Causes FHL3

The clinical features of FHL3 are indistinguishable from those of FHL2. This genetic form of FHL accounts for 30% to 35% of the cases. Although cytolytic granules in CTL and NK cells from FHL3 patients have normal contents, cytotoxicity is impaired. FHL3 was found to be associated with mutations in the gene *UNC13D* coding for Munc13-4, a member of the Munc13-UNC13 family [12]. Lymphocytes that

lack Munc13-4 are able to form normal, stable conjugates with target cells, dock at the plasma membrane and polarize their cytotoxic granules but cannot release their granule contents at the IS (Fig. 11.1) [12]. Indeed, Munc13-4 appears to be mandatory for the priming of docked lytic granules at the IS – probably via regulation of the interaction between the vesicle soluble N-ethylmaleimide-sensitive factor attachment protein receptor (SNARE) and the target (t)-SNARE required for the fusion of the granule with the plasma membrane. As is the case for other members of the Munc13 family of proteins, Munc13-4 may induce a conformational change in the cognate t-SNARE and thus generate its active conformation. The *UNC13D* gene contains 32 exons that encode the 123 kDa Munc13-4 protein. Two calcium-binding (C2) domains are separated by long sequences containing two Munc13-homology domains (MHD1 and MHD2). Most of the mutations so far identified in *UNC13D* are deletions, splice-site mutations or nonsense mutations predicted to result in major changes in the protein. The severity of the mutations may influence the clinical expression of HLH disease. Prenatal disease onset in utero has been described with null mutations [3], whereas an atypical clinical course, reminiscent of common variable immune deficiency (CVID), was associated with missense or splice-site mutations in a few patients [31]. In addition to exonic and splice-site mutations, deep intronic mutations have also been found in populations in northern Europe. These mutations impair *UNC13D* transcription and Munc13-4 expression in cytotoxic cells and thus cause FHL3 [32–34].

Besides its role as a priming factor, Munc13-4 is also known to be involved in the upstream maturation of cytotoxic granules. By facilitating the fusion of two distinct endosomal compartments, Munc13-4 forms a pool of vesicles carrying effectors of the exocytic machinery [35]. Following target cell recognition, the pool of formed vesicles polarizes and coalesces with perforin-containing granules at the IS. This late granule maturation step may limit the proportion of cytotoxic granules that can release their

contents and thus endow cytotoxic cells with serial killing ability.

Syntaxin 11 Deficiency Causes FHL4

In patients with FHL4 (MIM 605014), the mean time of HLH onset is later than in patients with FHL2 or FHL3 [36, 37]. FHL4 Patients carry mutations in the syntaxin 11 gene (*STX11*) [13]. Syntaxin 11 is a member of the t-SNARE family of proteins involved in membrane fusion events. Most of the *STX11* mutations reported to date are null mutations and were first identified in patients of Turkish/Kurdish descent, where they account for approximately 20% of FHL cases [38]. Since then, biallelic syntaxin 11 mutations have been identified in patients of different origins. A few missense mutations have also been reported in FHL4 patients, and examination of their functional consequences has helped to identify the syntaxin 11 domain that interacts with the syntaxin-binding protein Munc18-2 [39, 40]. Although the cytotoxic activity of NK cells in FHL4 patients is markedly defective, syntaxin 11-deficient CTLs are less affected and can be partially restored by IL-2 stimulation [41]. The fact that syntaxin 3 expression in cytotoxic lymphocytes can compensate for a lack of functional syntaxin 11, at least in vitro, may account for this functional restoration [39]. Syntaxin 11 is thus yet another effector of the cytotoxic machinery required for the release of cytotoxic granules contents – probably by regulating membrane fusion events [42]. The syntaxin 11-regulated step in the cytotoxic pathway remains to be characterized, although it is probably involved in the fusion between cytotoxic granules and the plasma membrane at the IS (Fig. 11.1).

Munc18-2 Deficiency Causes FHL5

The most recently identified type of FHL (FHL5, MIM 601717) is caused by mutations in the syntaxin-binding-protein-2 (*STXBP2*) gene encoding Munc18-2 [14, 15]. FHL5 accounts for 15–25% of FHL cases. To date, more than 50 different *STXBP2* mutations have been reported worldwide, including missense, nonsense, splicing, deletion and insertion mutations. In the majority of patients with Munc18-2 deficiency,

HLH usually starts within the first 6 months of life. In these cases, mutations affect protein stability. A few mutations allow some residual protein activity and are associated with a milder disease phenotype; this is the case for the highly prevalent exon 15 splice-site mutation c.1247-1G > C [15, 43]. In these cases, later onset with splenomegaly and unexplained fever or a COVID-like profile have been observed. Development of Hodgkin's lymphoma has also reported in such situation [44].

STXBP2/Munc18-2 belongs to the SM family of fusion accessory proteins. These proteins are SNARE partners and have a complementary role in membrane fusion [45, 46]. STXBP2/Munc18-2 is widely expressed and binds to syntaxin 11 and syntaxin 3 with high affinity [39]. However, only the level of syntaxin 11 is low in STXBP2/Munc18-2-deficient lymphoblasts [15] – indicating that syntaxin 11 is Munc18-2's main partner in lymphocytes and that Munc18-2 is required for stable expression of syntaxin 11. In accordance with the pathophysiological features of FHL, Munc18-2-deficient NK cells and CTLs display impairments in cytotoxic activity [14, 15]. A putative role for Munc18-2 in later stages of the exocytosis pathway is suggested by the observation that perforin-containing granules in Munc18-2-deficient NK cells are normally polarized towards cognate target cells – even though the impairment of exocytosis prevents them from releasing their contents [15]. Recently, it was reported that Munc18-2 is localized predominantly to the cytotoxic granules and is required for delivery of syntaxin 11 to the plasma membrane [47]. Thus, by interacting with syntaxin 11, Munc18-2 probably regulates a late step in cytotoxic granule exocytosis by regulating membrane fusion (Fig. 11.1).

FHL5 appears to slightly differ from the classical manifestations of HLH [43]. Gastrointestinal manifestations, characterized by severe, chronic diarrhoea requiring long-term parenteral nutrition, have been reported in FHL5 patients with early-onset HLH. Diarrhoea is often present before the onset of HLH and persists in most patients having undergone haematopoietic stem cell transplantation – suggesting a primary epithelial defect. Short microvilli and the

accumulation of granules at the enterocytes' apical pole have been reported. Renal tubular dysfunction was also observed in one of these patients [48]. Since Munc18-2 is expressed at high levels in normal gut epithelial cells, the protein is probably involved in the FHL5 patients' gastrointestinal manifestations. Sensorineural hearing loss between the ages of 4 and 17 has been reported in several patients [43].

Pigmentary Dilution Disorders Associated with HLH

The HLH manifestations observed in FHL are also associated with pigmentary dilution in two inherited conditions: Griscelli syndrome type 2 (GS2) and Chediak-Higashi syndrome (CHS). It can also be occasionally associated with Hermansky-Pudlak syndrome type 2 (HPS2).

Rab27a Deficiency Causes GS2

GS2 (MIM 214450) is a rare autosomal-recessive disease that combines HLH with hypopigmentation of the skin and hair. The disease is due to biallelic mutations in the gene encoding Rab27a, a ubiquitously expressed small GTP-binding GTPase protein [49] (Table 11.1). CTLs and NK cells that lack Rab27a exhibit impaired cytotoxicity because polarized cytotoxic granules are unable to reach the IS and dock with the plasma membrane [50]. In GS2, the patients' hypopigmentation is due to the defective release of melanosomes from melanocyte dendrites, which requires the function of the tripartite protein complex, Rab27a-melanophilin-myosinVA. In cytotoxic cells, Munc13-4 interacts with Rab27a [35]. This molecular interaction is critical for lytic granule exocytosis and is probably involved in coordination of the last step in the exocytic process, between the docking and priming of lytic granules [51] (Fig. 11.1). The *RAB27A* gene, located on 15q21 chromosome region, consists of seven exons, the first two being untranslated. Mutations in *RAB27A* have been characterized in more than 100 independent patients [37, 38, 49]. Very few missense mutations have been reported and functionally analysed [52]. The other mutations

are nonsense mutations, deletions or splice-site alterations, all predicting an early protein truncation. In all cases, the location of the stop codon predicts truncation of the protein's consensus carboxyl-terminal motif, involved in Rab protein geranyl-geranylation, and thus should leave Rab27a protein in an inactive state. Recently, a few patients have been found to carry *RAB27A* biallelic mutations affecting residues involved in Rab27a-Munc13-4 interaction but not Rab27a-melanophilin interaction. These patients develop HLH with no clinical evidence of pigmentary dilution [53, 54].

It is noteworthy that the pigmentary dilution observed in GS2, linked to defective release of melanosome contents from melanocyte dendrites, is also found in patients with GS1 and GS3. The GS1 and GS2 disease loci are located close together in the chromosomal region 15q21, whereas GS3 has been located on chromosome 2q37.3. GS1, GS2 and GS3 are due to defects in myosin-Va, Rab27a and melanophilin, respectively. Individuals with the GS1 and GS3 subtypes do not develop HLH.

LYST Deficiency Causes CHS

Chediak-Higashi syndrome (MIM 214500) is characterized clinically, in addition to the manifestations of HLH, by hypopigmentation of the skin and the hair, mild bleeding tendency, recurrent infections and progressive neurodevelopmental abnormalities. The latter is characterized by learning and behavioural deficits in childhood and progressive neurodegeneration in early adulthood, with varying degrees of cerebellar dysfunction, peripheral neuropathy, spasticity and parkinsonism [55–57]. A pathognomonic feature is the presence in many cell types of enlarged inclusion bodies of lysosomal origin. The *CHS1/LYST cDNA* (13.5 kb) [58] encodes a huge cytosolic protein (425 kDa, 3801 amino acids (aa)) [59, 60]. CHS1/LYST belongs to the Beige and Chediak-Higashi (BEACH) family of proteins that share the same three C-terminal domains: a pleckstrin homology domain (PH) [61], a BEACH domain [58] and WD40 repeats. However, the domains' exact functions are unknown, though they are predicted to bind

protein partners [61, 62]. Most of the functional information on CHS1/LYST comes from studies of other members of the BEACH family, defined as vesicle-trafficking regulatory proteins [63]. The BEACH family member LRBA is thought to regulate the trafficking of cytotoxic T lymphocyte antigen-4 (a potent inhibitory immune receptor) and has been linked to autoimmune disease [64]. The CHS1/LYST protein also contains a series of armadillo [65] and HEAT repeat motifs (thought to mediate membrane associations and vesicle transport [66] and a lectin-like domain [67]). LYST's regulation of the exocytosis of cytotoxic granules is not well understood. It was recently suggested that LYST is involved in the trafficking of the exocytosis effectors required for the terminal maturation of perforin-containing vesicles into secretory cytotoxic granules [68] (Fig. 11.1).

CHS results from biallelic mutations in the *LYST* gene (also known as *CHS1*), which consists of 55 exons and is located on chromosome 1q43 [69] [58, 59]. Considering the length of the *LYST* gene, mutation analysis in CHS patients was a difficult task before next-generation sequencing becomes available. Interestingly, most of the mutations reported to date (nonsense and frameshift mutations) result in truncated proteins [58, 59, 70]. There is a reasonably straightforward genotype-phenotype correlation for CHS [69], although similar homozygous mutations were occasionally found to be associated with both typical and milder clinical courses – even within the same family [70, 71]. A correlation, albeit not absolute, has also been shown for disease severity vs. the degree of impairment of cytotoxic activity [71]. Adults with mild forms of CHS, even when they carry biallelic *LYST* variants, may escape the onset of HLH but can develop neurologic involvement [55, 56]. It is therefore likely that factors other than *LYST* gene mutations influence the clinical expression of CHS; these may include environmental factors, such as disease-triggering infections.

Ap3 β 1 Deficiency Causes HPS2

Patients with HPS2 share a common phenotype (hypopigmentation, bleeding disorders and increased susceptibility to infections) as a result

of congenital neutropenia and impaired cytotoxicity. HPS2 results from a mutation in the *AP3B1*, a gene located on chromosome 5q14.1 and that codes for the β chain of the adaptor protein-3 (AP3) complex [72] (Table 11.1). AP3 is a ubiquitous cytoplasmic complex consisting of four different subunits. It shuttles cargo proteins from the trans-Golgi and a tubular endosomal compartment to endosome-lysosome-related organelles [73, 74]. Hence, AP3 assists with protein sorting to lysosomes. Most of the HPS2 patients screened for *AP3B1* mutations to date carry deletions or nonsense mutations, and only a few have missense mutations [75–78]. There is only one published report of a HPS2 patient developing classical HLH, although cytotoxicity is impaired in all tested patients [75]. However, since this patient also carried a heterozygous *RAB27A* mutation that may have contributed to the disease, the risk of developing HLH in HPS2 remains unclear but is certainly much lower than in FHL, GS2 or CHS [75, 78].

Genetics of HLH with Partially Defective or Normal Cytotoxicity

Several forms of HLH are characterized by normal NK cell cytotoxicity against K562 target cells and the induction of normal T cell cytotoxicity by anti-CD3 antibodies. Disease onset is frequently triggered by EBV infection [79]. The best characterized forms are X-linked lymphoproliferative (XLP) syndromes.

XLP Syndromes

XLP syndrome is a very rare immunodeficiency, with an estimated incidence of 1 per 500,000 live births. This condition, formerly also referred to as Purtilo syndrome, is primarily characterized by extreme vulnerability to EBV infection in boys, which triggers HLH and/or malignant lymphoproliferation [80]. There are two genetic forms of XLP: XLP-1 [81–83] and XLP-2 [84] (Table 11.1).

SAP Deficiency Causes XLP-1

XLP-1 results from a deficiency in the signaling lymphocyte activation molecule (SLAM)-associated protein (SAP, encoded by the *SH2D1A* (for SH2 domain-containing protein 1A) gene). SAP is a small adaptor protein produced exclusively in T, NK and NKT cells. SAP uses its SH2 domain to bind with high affinity and specificity to immunoreceptor tyrosine-based switch motifs present in the cytoplasmic domains of SLAM receptors (SLAM-R) [85, 86]. SAP-deficient CTLs and NK cells are selectively impaired in their cytotoxic response to infected B cells; this probably accounts for the exquisite (albeit not constant) role of EBV in triggering HLH in XLP1 patients. The response requires an interaction between SLAM-Rs and subsequent SAP-dependent signalling in T-lymphocytes but not in other cell types [87, 88]. In addition to impaired lymphocyte cytotoxicity towards B cells, other cellular defects have been documented in SAP-deficient patients. These include CD4⁺ T-helper cell cytokine production and function, a blockade of CD1d-restricted NKT cell development, defective antibody production associated with low numbers of switched memory B cells and defects in germinal centre formation [85, 89]. These immune dysfunctions mostly result from changes in signal transduction via SLAM-Rs.

More than 80 XLP-1-causing mutations in the *SH2D1A* gene have been identified, including missense, nonsense and splice-site mutations and micro- and macrodeletions. Most of the missense mutations markedly decrease the stability of the SAP protein and impair its adaptor function. No correlation between *SH2D1A* gene mutations and XLP-1 clinical phenotypes has been found.

XIAP Deficiency Causes XLP-2

XLP-2 results from a lack of the X-linked inhibitor of apoptosis (XIAP, encoded by the *XIAP/BIRC4* gene) [84]. The *SH2D1A* and *XIAP* genes are just 0.4 Mb apart at the same gene locus (Xq25) [84]. More than 20 *XIAP* mutations have been described to date, including missense, nonsense and frameshift mutations and deletions [79, 84, 90, 91]. No correlations between the

genotype, residual XIAP function and the phenotype have been observed – highlighting the importance of the genetic and environmental background in the presentation of XIAP-related disease [92].

XLP2 frequently causes HLH, although lymphoma is not observed. However, a significant proportion of patients develop a Crohn's-like inflammatory bowel disease. The ubiquitously expressed XIAP protein belongs to the inhibitors of apoptosis protein family and is known to be a potent physiological inhibitor of caspases 3, 7 and 9 [93, 94]. XIAP also has a ubiquitin ligase activity [95]. Furthermore, XIAP is involved in multiple signalling pathways: the copper metabolism pathway, activation of the NF- κ B and MAP kinase pathways and signal transduction via the TGF- β receptor, the bone morphogenetic protein receptor and the intracellular pattern recognition receptor NOD2 [96, 97]. In agreement with XIAP's anti-apoptotic role, XIAP-deficient human lymphocytes display enhanced activation-induced cell death [84, 90]. In contrast to XLP-1 patients, XLP-2 patients do not present with NK T cell lymphopenia. However, XIAP probably contributes to lymphocyte survival because non-random X-chromosome inactivation is observed in the leukocytes of female carriers of *XIAP* mutations, with cells preferentially expressing the wild-type *XIAP* allele [84, 90].

The pathophysiology of HLH in XLP-2 is not presently understood and does not fit with the current paradigm in which HLH is resulting from defects in the cytotoxicity pathway. Further studies are required to determine the precise mechanisms underlying HLH in patients with XIAP deficiency, although some hypotheses have been put forward (see below).

NLRC4 Inflammasome Activation Causes HLH

Activating heterozygous mutations in the inflammasome component NLRC4 were recently shown to cause recurrent, severe, systemic inflammation reminiscent of HLH [98–100]

(Table 11.1). These mutations are located in NLRC4's nucleotide-binding domain and result in the spontaneous formation and activation of the NLRC4 inflammasome. In turn, this leads to constitutively high levels of inflammatory cytokines in general and IL18 in particular. It is noteworthy that elevated serum levels of IL18 are also associated with XIAP deficiency. NLRC4 is expressed in monocytes and macrophages and in intestinal epithelial cells. NLRC4 is known to be involved in bacterial sensing via the detection of flagellin or components of the bacterial type 3 secretion system. Accordingly, *NLRC4*-mutated patients can develop a combination of enterocolitis and HLH, which may be related to sensing of the bacterial flora.

Other Conditions that Predispose to HLH

A few inborn errors of metabolism (such as lysosomal acid lipase deficiency (Wolman disease; MIM 278000) [101], multiple sulfatase deficiency (MIM 272200) [102] and lysinuric protein intolerance (MIM 222700) [103]) can predispose to HLH. In these settings, inflammasome activation in macrophages probably results from the accumulation of non-degraded substrates that trigger MAS. Furthermore, patients with PIDs related to defects in pathways other than cytotoxicity or XLP sometimes develop an HLH-like syndrome (Table 11.1). This includes (i) patients with combined immune deficiencies (CIDs) and hypomorphic severe combined immune deficiencies (SCIDs) with various molecular causes (including defects in *IL2GR*, *IL7R*, *CD3e*, *RAG-1*, *WAS*, *CD27* and *ITK*), in whom HLH is mainly triggered by a viral infection, and (ii) patients with chronic granulomatous disease (*p91*, *p47*, *p22*, *DHR*), in whom HLH is mainly triggered by bacterial infections [104]. The development of HLH in hypomorphic SCID and CID patients with a very low T lymphocyte count further indicates that mechanisms other than T cell over-activation can account for the pathophysiology of some secondary forms of this disease.

Understanding the Pathogenesis of HLH

The Pathogenesis of HLH with Impaired Lymphocyte Cytotoxicity

The manifestations of HLH are frequently triggered by an infectious agent, leading to the massive expansion and activation of polyclonal CD8⁺ T cells. The most obvious explanation for the role of cytotoxic activity in the pathogenesis of HLH is the persistence of antigen-presenting cells (APCs), which are not properly eliminated when the granule-dependent cytotoxicity of lymphocytes is impaired. The elimination of APCs should generate strong negative feedback and thus limit T cell-mediated immune responses (Fig. 11.2). An alternative mechanism, which may also occur in parallel with the above-mentioned scenario, involves lymphocyte cytotoxicity having a direct function in killing T cells engaged in a given immune response.

The CTLs may either kill neighbouring T cells that have transiently acquired peptide-MHC class I molecules from the target cells [2, 105] or commit suicide (Fig. 11.3). The latter mechanism is not compatible with the observation that, in a setting of mixed chimerism following haematopoietic stem cell transplantation, a low percentage of functional donor CTLs (20%) is sufficient to control the disease in patients with HLH [106, 107]. Excessive T cell activation leads to the production of high quantities of cytokines (e.g. INF- γ) and induces sustained macrophage activation and a pro-inflammatory cytokine storm. The observation of a direct role of INF- γ in murine models of HLH (see below) has prompted the development of anti-INF- γ therapies, through INF- γ neutralization or inhibition of the signalling pathway. Activated lymphocytes and macrophages produce high levels of IL-6, IL-18 and TNF- α , infiltrate the tissues and have a major role in the various clinical symptoms (cytopenia and coagulopathy), tissue damage and multi-organ dysfunction [108, 109]. Elevated levels of IL1 and IL6,

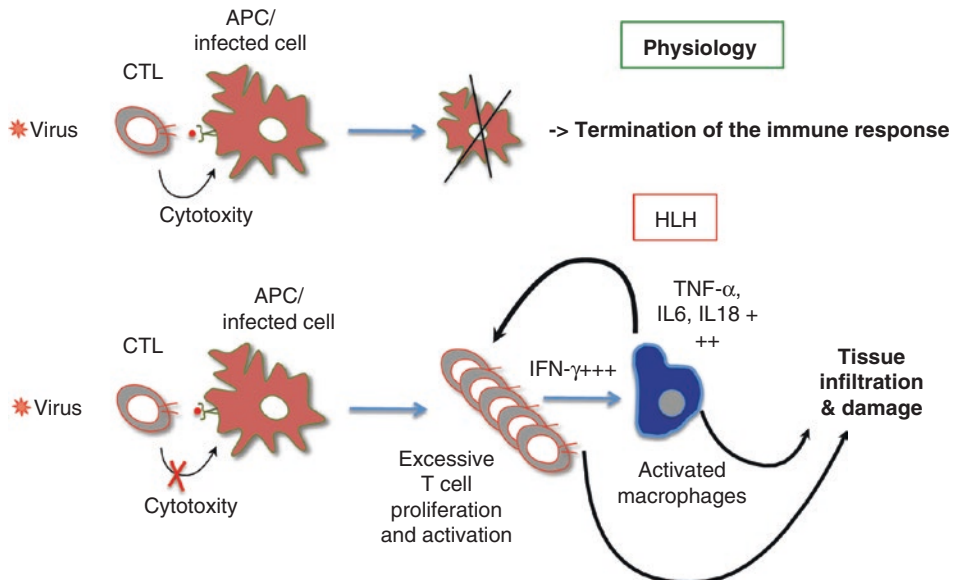


Fig. 11.2 Pathophysiology of HLH. In a physiological setting, cytotoxic T cells (CTL) proliferate in response to a viral infection, secrete inflammatory cytokines (INF- γ) and exert their cytotoxic activity to eliminate the infected and antigen-presenting cells (APC). In an HLH setting, failure of CTL to eliminate the target cells leads to the over-proliferation and over-activation of T lymphocytes

secreting high level of INF γ , which activates macrophages. Over-activated macrophages secrete high levels of inflammatory cytokines (including TNF- α , IL6, IL18) that in turn further activate T lymphocytes, leading to uncontrolled, systemic inflammatory response. Activated lymphocytes and macrophages infiltrate the various organs resulting in massive tissue damage and organ failure

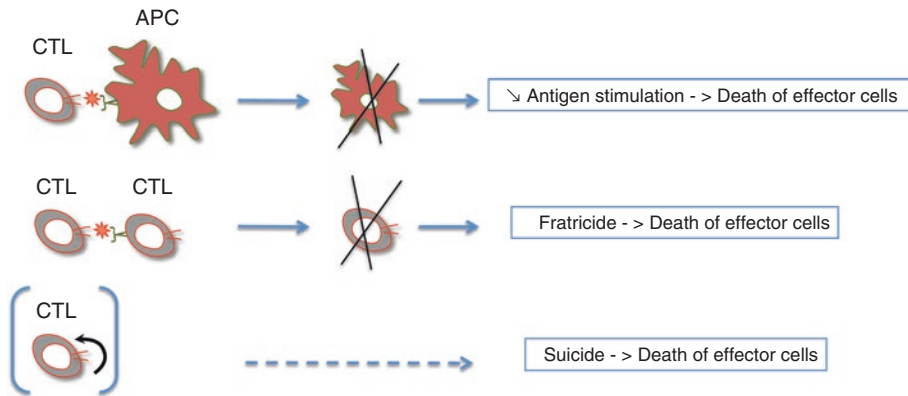


Fig. 11.3 Pathophysiology: how cytotoxic T lymphocytes (CTLs) contribute to the termination of the immune response. CTLs can eliminate antigen-presenting cells (APC) providing an important negative feedback to limit T cell-mediated immune responses. CTLs could either kill

neighbouring T cells (fratricide) that have transiently acquired peptide-MHC class I molecules from the target cells or commit suicide. The latter is not compatible with the transdominant effect of CTLs following haematopoietic stem cell transplantation, hence indicated in brackets

like infection, also induce fever. Elevated TNF- α levels inhibit lipoprotein lipase, leading to hypertriglyceridemia, whereas activated macrophages secrete ferritin and plasminogen activator, leading to hyperfibrinolysis. The cytopenias probably result from TNF- α 's suppressive effect on haematopoiesis and an increase in macrophage haemophagocytosis [108]. The elevated level of CD25s probably reflects lymphocyte activation.

The Pathogenesis of HLH with Normal Lymphocyte Cytotoxicity

As above mentioned, some genetically determined forms of HLH occur in the absence of an obvious defect in cytotoxicity; this seems to be the case for XLP2 deficiency. Indeed, XIAP-deficient CTLs and NK cells exhibit apparently normal *in vitro* cytotoxic responses, regardless of the SLAMF7 dependency, although subtle defects cannot be fully ruled out. Invariant natural killer T (iNKT) cells have a cytotoxic activity that is induced by EBV-infected B cells [110]. One cannot rule out the possibility that the exacerbated apoptosis of XIAP-deficient iNKT cells induced by EBV infection might be involved in the development of HLH in XLP-2. Alternatively, the mechanisms underlying EBV-driven HLH in XLP-2 may differ completely from those

observed in XLP-1 and other inherited forms of HLH. The recent observation that XIAP is a potent downregulator of the NLRP3 inflammasome and pro-inflammatory cytokine production in mice has provided new insights into the immunopathogenesis of HLH [111]. In a context of XIAP deficiency, the accumulation of apoptotic cells and the persistence of EBV-infected cells might trigger abnormal inflammation and contribute to the development of HLH. The importance of inflammasome activation in HLH development is also highlighted by the consequences of an activating mutation in human *NLRP4* that leads to recurrent HLH and autoinflammation [98–100]. In both of these settings (*XIAP* and *NLRP4* mutations), HLH is associated with an extraordinarily high serum level of IL18 [100, 112]. However, the molecular mechanisms linking XIAP deficiency to IL18 overproduction and HLH have not been identified.

Thus, disease-based genetic discovery in patients with HLH manifestations has led to the emergence of two mechanistic paradigms. The first involves cytotoxic lymphocyte dysfunction, excessive lymphocyte activation and then secondary macrophage activation. The second, more recent, is based on primary macrophage activation, as observed in association with *NLRP4* mutants. Primary macrophage activation may also result from not only XIAP deficiency but

also systemic juvenile idiopathic arthritis (sJIA) or Still's disease [113, 114], in which a very high serum level of IL18 is also frequently observed.

Animal Models Help Understand the Pathophysiology of HLH

Murine models of primary HLH, in which cytotoxicity-deficient animals are challenged with a non-lytic virus, have proven to be very useful tools for further understanding the pathogenesis of HLH under defined conditions [115–121]. Experiments in a murine model of perforin deficiency infected with lymphocytic choriomeningitis virus revealed that (i) the persistence of dendritic cells is determinant in the pathogenesis [122] and (ii) the resulting hyperactivated cytotoxic T lymphocytes and high levels of IFN- γ drive systemic macrophage activation and the development of fatal HLH [119]. Recent research has also highlighted the critical regulatory role of perforin-dependent cytotoxicity in NK cells in the regulation of macrophage and CTL activation [121]. Furthermore, IFN- γ -dependent activation of macrophages has been shown to prompt the development of severe, consumptive anaemia and other types of cytopenia, probably through direct changes in the macrophages' endocytic uptake, showing that haemophagocytosis is in fact an appropriate response to sustained inflammation [123].

In mice and humans with defects in the granule-dependent cytotoxic pathway, the magnitude of the cytotoxicity impairment appears to be the best predictor of the development and severity of HLH [37, 120]. In humans, it remains difficult to assess the minimum level of cytotoxic activity required for the maintenance of immune homeostasis. Indeed, adult patients with HLH have been found to carry biallelic hypomorphic mutations that delay the development of HLH. Furthermore, monoallelic mutations in one or more FHL genes have been observed in some adult patients, although the functional impact remains difficult to assess [5, 7, 124–128]. A recent study in mice has demonstrated that the accumulation of monoallelic defects in HLH genes significantly increases the risk of develop-

ing HLH [129]. Based on these results, a polygenic model may also account for some cases of "secondary" HLH observed in humans.

Although cytotoxic lymphocytes have a key role in the development of primary HLH, other genetic factors may also contribute. It has been shown that MyD88, which mediates toll-like receptor and IL1 signalling, is required for HLH in Unc13d-deficient mice – suggesting that innate immune cells contribute to the development of this disease [130]. Moreover, high levels of IL4 or recurrent toll-like receptor 9 stimulation can induce the development of an HLH-like syndrome in wild-type mice [131, 132]. Following the identification of an NLRC4-dependent disease mechanism in human HLH, it is now considered that any regulatory molecule involved in an inflammatory pathway can contribute significantly to the development of the manifestations of HLH.

Lastly, environmental factors, particularly infectious triggers, also contribute to the development of HLH. Experiments in animal models of HLH have clearly demonstrated that even the most severe HLH-predisposing mutations in mice do not lead to active HLH if the animals are never exposed to pathogenic infections. However, a pathogen trigger cannot be identified in many cases, in cytotoxicity-defective newborns or even foetuses that develop primary HLH [3, 133]. Although one cannot exclude that an unknown microorganisms may act as the trigger, it is also possible that the granule-dependent cytotoxic pathway in humans has a role in T cell homeostasis, even in the absence of external stimulus (as the Fas/FasL pathway). In contrast, the potent immune system activator EBV is a major trigger of HLH in older children and adults with residual or even apparently normal cytotoxicity. This suggests that environmental and other genetic factors have greater relative weights in HLH triggering when the cytotoxicity defect is mild. It is tempting to speculate that (i) "extreme" stimuli may be sufficient to induce sporadic HLH development in any individual and (ii) the overall risk is augmented by the accumulation of genetic variants that promote excessive or poorly regulated immune responses – including mutations in genes controlling inflammatory processes (Fig. 11.4).

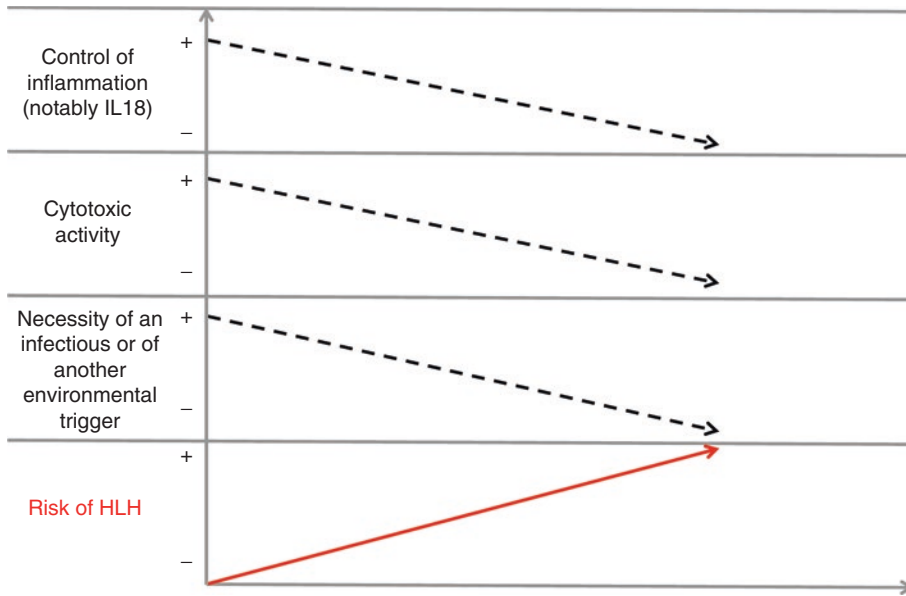


Fig. 11.4 HLH viewed as a single syndrome resulting from the accumulation of underlying risk factors. Genetic factors impairing cytotoxic activity and the control of

inflammation together with an infectious trigger of various forces converge to increase the risk of HLH occurrence

Concluding Remarks

Over the last few decades, characterization of the molecular bases of primary HLH has revealed the critical role of lymphocyte cytotoxicity in the control of immune homeostasis. These studies have identified key effectors of cytotoxic granule exocytosis and have described their specific functions in the cytotoxic pathway. They have also open the way for targeted therapy of HLH patients. Greater knowledge of the scope of HLH's occurrence has generated the hypothesis whereby HLH occurs when the weight of various predisposing genetic and environmental factors exceeds a threshold, above which inflammation is no longer controlled. Some cases of HLH do not appear to be directly related to a cytotoxicity defect – indicating that other genes regulating the same disease pathway, notably those involved in macrophage-related inflammation, also have a role. Characterizing the synergistic connections between the various risk factors for HLH will be a key challenge in the coming years.

References

1. Janka GE. Familial and acquired hemophagocytic lymphohistiocytosis. *Annu Rev Med.* 2012;63:233–46.
2. Stinchcombe JC, Bossi G, Booth S, Griffiths GM. The immunological synapse of CTL contains a secretory domain and membrane bridges. *Immunity.* 2001;15(5):751–61.
3. Bechara E, Dijoud F, de Saint BG, Bertrand Y, Pondarre C. Hemophagocytic lymphohistiocytosis with Munc13-4 mutation: a cause of recurrent fatal hydrops fetalis. *Pediatrics.* 2011;128(1):e251–4.
4. Lipton JM, Westra S, Haverty CE, Roberts D, Harris NL. Case records of the Massachusetts General Hospital. Weekly clinicopathological exercises. Case 28-2004. Newborn twins with thrombocytopenia, coagulation defects, and hepatosplenomegaly. *N Engl J Med.* 2004;351(11):1120–30.
5. Chia J, Yeo KP, Whisstock JC, Dunstone MA, Trapani JA, Voskoboinik I. Temperature sensitivity of human perforin mutants unmasks subtotal loss of cytotoxicity, delayed FHL, and a predisposition to cancer. *Proc Natl Acad Sci U S A.* 2009;106(24):9809–14.
6. Sieni E, Cetica V, Piccin A, Gherlinzoni F, Sasso FC, Rabusin M, et al. Familial hemophagocytic lymphohistiocytosis may present during adulthood: clinical and genetic features of a small series. *PLoS One.* 2012;7(9):e44649.

7. Nagafuji K, Nonami A, Kumano T, Kikushige Y, Yoshimoto G, Takenaka K, et al. Perforin gene mutations in adult-onset hemophagocytic lymphohistiocytosis. *Haematologica*. 2007;92(7):978–81.
8. Feldmann J, Le Deist F, Ouachee-Chardin M, Certain S, Alexander S, Quartier P, et al. Functional consequences of perforin gene mutations in 22 patients with familial haemophagocytic lymphohistiocytosis. *Br J Haematol*. 2002;117(4):965–72.
9. Ohadi M, Lalloz MR, Sham P, Zhao J, Dearlove AM, Shiach C, et al. Localization of a gene for familial hemophagocytic lymphohistiocytosis at chromosome 9q21.3-22 by homozygosity mapping. *Am J Hum Genet*. 1999;64(1):165–71.
10. Dufourcq-Lagelouse R, Jabado N, Le Deist F, Stephan JL, Souillet G, Bruin M, et al. Linkage of familial hemophagocytic lymphohistiocytosis to 10q21-22 and evidence for heterogeneity. *Am J Hum Genet*. 1999;64(1):172–9.
11. Stepp S, Dufourcq-Lagelouse R, Le Deist F, Bhawan S, Certain S, Mathew P, et al. Perforin gene defects in familial hemophagocytic lymphohistiocytosis. *Science*. 1999;286:1957–9.
12. Feldmann J, Callebaut I, Raposo G, Certain S, Bacq D, Dumont C, et al. Munc13-4 is essential for cytolytic granules fusion and is mutated in a form of familial hemophagocytic lymphohistiocytosis (FHL3). *Cell*. 2003;115(4):461–73.
13. zur Stadt U, Schmidt S, Kasper B, Beutel K, Diler AS, Henter JI, et al. Linkage of familial hemophagocytic lymphohistiocytosis (FHL) type-4 to chromosome 6q24 and identification of mutations in syntaxin 11. *Hum Mol Genet*. 2005;14(6):827–34.
14. zur Stadt U, Rohr J, Seifert W, Koch F, Grieve S, Pagel J, et al. Familial hemophagocytic lymphohistiocytosis type 5 (FHL-5) is caused by mutations in Munc18-2 and impaired binding to syntaxin 11. *Am J Hum Genet*. 2009;85(4):482–92.
15. Cote M, Menager MM, Burgess A, Mahlaoui N, Picard C, Schaffner C, et al. Munc18-2 deficiency causes familial hemophagocytic lymphohistiocytosis type 5 and impairs cytotoxic granule exocytosis in patient NK cells. *J Clin Invest*. 2009;119(12):3765–73.
16. Goransdotter Ericson K, Fadeel B, Nilsson-Ardnor S, Soderhall C, Samuelsson A, Janka G, et al. Spectrum of perforin gene mutations in familial hemophagocytic lymphohistiocytosis. *Am J Hum Genet*. 2001;68(3):590–7.
17. Voskoboinik I, Mar J, Camakaris J. Mutational analysis of the Menkes copper P-type ATPase (ATP7A). *Biochem Biophys Res Commun*. 2003;301(2):488–94.
18. Law RH, Lukyanova N, Voskoboinik I, Caradoc-Davies TT, Baran K, Dunstone MA, et al. The structural basis for membrane binding and pore formation by lymphocyte perforin. *Nature*. 2010;468(7322):447–51.
19. Baran K, Dunstone M, Chia J, Ciccone A, Browne KA, Clarke CJ, et al. The molecular basis for perforin oligomerization and transmembrane pore assembly. *Immunity*. 2009;30(5):684–95.
20. Lichtenheld MG, Olsen KJ, Lu P, Lowrey DM, Hameed A, Hengartner H, et al. Structure and function of human perforin. *Nature*. 1988;335(6189):448–51.
21. Lee SM, Sumegi J, Villanueva J, Tabata Y, Zhang K, Chakraborty R, et al. Patients of African ancestry with hemophagocytic lymphohistiocytosis share a common haplotype of PRF1 with a 50delT mutation. *J Pediatr*. 2006;149(1):134–7.
22. Voskoboinik I, Smyth MJ, Trapani JA. Perforin-mediated target-cell death and immune homeostasis. *Nat Rev Immunol*. 2006;6(12):940–52.
23. Katano H, Ali MA, Patera AC, Catalfamo M, Jaffe ES, Kimura H, et al. Chronic active Epstein-Barr virus infection associated with mutations in perforin that impair its maturation. *Blood*. 2004;103(4):1244–52. Epub 2003 Oct 23
24. Feldmann J, Menasche G, Callebaut I, Minard-Colin V, Bader-Meunier B, Le Clainche L, et al. Severe and progressive encephalitis as a presenting manifestation of a novel missense perforin mutation and impaired cytolytic activity. *Blood*. 2005;105(7):2658–63.
25. Voskoboinik I, Thia MC, Fletcher J, Ciccone A, Browne K, Smyth MJ, et al. Calcium-dependent plasma membrane binding and cell lysis by perforin are mediated through its C2 domain: a critical role for aspartate residues 429, 435, 483, and 485 but not 491. *J Biol Chem*. 2005;280(9):8426–34.
26. Zur Stadt U, Beutel K, Weber B, Kabisch H, Schneppenheim R, Janka G. A91V is a polymorphism in the perforin gene not causative of an FHLH phenotype. *Blood*. 2004;104(6):1909. author reply 10
27. Trambas C, Gallo F, Pende D, Marcenaro S, Moretta L, De Fusco C, et al. A single amino acid change, A91V, leads to conformational changes that can impair processing to the active form of perforin. *Blood*. 2005;106(3):932–7.
28. Santoro A, Cannella S, Trizzino A, Lo Nigro L, Corsello G, Arico M. A single amino acid change A91V in perforin: a novel, frequent predisposing factor to childhood acute lymphoblastic leukemia? *Haematologica*. 2005;90(5):697–8.
29. Voskoboinik I, Sutton VR, Ciccone A, House CM, Chia J, Darcy PK, et al. Perforin activity and immune homeostasis: the common A91V polymorphism in perforin results in both presynaptic and postsynaptic defects in function. *Blood*. 2007;110(4):1184–90.
30. An O, Gursoy A, Gurgey A, Keskin O. Structural and functional analysis of perforin mutations in association with clinical data of familial hemophagocytic lymphohistiocytosis type 2 (FHL2) patients. *Protein Sci*. 2013;22(6):823–39.
31. Rohr J, Beutel K, Maul-Pavicic A, Vraetz T, Thiel J, Warnatz K, et al. Atypical familial hemophagocytic lymphohistiocytosis due to mutations in UNC13D and STXBP2 overlaps with primary immunodeficiency diseases. *Haematologica*. 2010;95(12):2080–7.
32. Meeths M, Chiang SC, Wood SM, Entesarian M, Schlums H, Bang B, et al. Familial hemophagocytic lymphohistiocytosis type 3 (FHL3) caused by deep

- intronic mutation and inversion in UNC13D. *Blood*. 2011;118(22):5783–93.
33. Entesarian M, Chiang SC, Schlums H, Meeths M, Chan MY, Mya SN, et al. Novel deep intronic and missense UNC13D mutations in familial haemophagocytic lymphohistiocytosis type 3. *Br J Haematol*. 2013;162(3):415–8.
 34. Cichocki F, Schlums H, Li H, Stache V, Holmes T, Lenvik TR, et al. Transcriptional regulation of Munc13-4 expression in cytotoxic lymphocytes is disrupted by an intronic mutation associated with a primary immunodeficiency. *J Exp Med*. 2014;211(6):1079–91.
 35. Menager MM, Menasche G, Romao M, Knapnougel P, Ho CH, Garfa M, et al. Secretory cytotoxic granule maturation and exocytosis require the effector protein hMunc13-4. *Nat Immunol*. 2007;8:257–67.
 36. Marsh RA, Satake N, Biroeschak J, Jacobs T, Johnson J, Jordan MB, et al. STX11 mutations and clinical phenotypes of familial hemophagocytic lymphohistiocytosis in North America. *Pediatr Blood Cancer*. 2010;55(1):134–40.
 37. Sepulveda FE, Debeurme F, Menasche G, Kurowska M, Cote M, Pachlopnik Schmid J, et al. Distinct severity of HLH in both human and murine mutants with complete loss of cytotoxic effector PRF1, RAB27A, and STX11. *Blood*. 2013;121(4):595–603.
 38. Zur Stadt U, Beutel K, Kolberg S, Schneppenheim R, Kabisch H, Janka G, et al. Mutation spectrum in children with primary hemophagocytic lymphohistiocytosis: molecular and functional analyses of PRF1, UNC13D, STX11, and RAB27A. *Hum Mutat*. 2006;27(1):62–8.
 39. Hackmann Y, Graham SC, Ehl S, Honing S, Lehmberg K, Arico M, et al. Syntaxin binding mechanism and disease-causing mutations in Munc18-2. *Proc Natl Acad Sci U S A*. 2013;110(47):E4482–91.
 40. Muller ML, Chiang SC, Meeths M, Tesi B, Entesarian M, Nilsson D, et al. An N-terminal missense mutation in STX11 causative of FHL4 abrogates Syntaxin-11 binding to Munc18-2. *Front Immunol*. 2014;4:515.
 41. Bryceson YT, Rudd E, Zheng C, Edner J, Ma D, Wood SM, et al. Defective cytotoxic lymphocyte degranulation in syntaxin-11 deficient familial hemophagocytic lymphohistiocytosis 4 (FHL4) patients. *Blood*. 2007;110(6):1906–15.
 42. Arneson LN, Brickshawana A, Segovis CM, Schoon RA, Dick CJ, Leibson PJ. Cutting edge: syntaxin 11 regulates lymphocyte-mediated secretion and cytotoxicity. *J Immunol*. 2007;179(6):3397–401.
 43. Pagel J, Beutel K, Lehmberg K, Koch F, Maul-Pavicic A, Rohlf AK, et al. Distinct mutations in STXBP2 are associated with variable clinical presentations in patients with familial hemophagocytic lymphohistiocytosis type 5 (FHL5). *Blood*. 2012;119(25):6016–24.
 44. Machaczka M, Klimkowska M, Chiang SC, Meeths M, Muller ML, Gustafsson B, et al. Development of classical Hodgkin's lymphoma in an adult with biallelic STXBP2 mutations. *Haematologica*. 2013;98(5):760–4.
 45. Toonen RF, Verhage M. Vesicle trafficking: pleasure and pain from SM genes. *Trends Cell Biol*. 2003;13(4):177–86.
 46. Sudhof TC, Rothman JE. Membrane fusion: grappling with SNARE and SM proteins. *Science*. 2009;323(5913):474–7.
 47. Dieckmann NM, Hackmann Y, Arico M, Griffiths GM. Munc18-2 is required for syntaxin 11 localization on the plasma membrane in cytotoxic T-lymphocytes. *Traffic*. 2015;16(12):1330–41.
 48. Stepensky P, Bartram J, Barth TF, Lehmberg K, Walther P, Amann K, et al. Persistent defective membrane trafficking in epithelial cells of patients with familial hemophagocytic lymphohistiocytosis type 5 due to STXBP2/MUNC18-2 mutations. *Pediatr Blood Cancer*. 2013;60(7):1215–22.
 49. Ménasché G, Pastural E, Feldmann J, Certain S, Ersoy F, Dupuis S, et al. Mutations in RAB27A cause Griscelli syndrome associated with hemophagocytic syndrome. *Nat Genet*. 2000;25:173–6.
 50. Stinchcombe JC, Barral DC, Mules EH, Booth S, Hume AN, Machesky LM, et al. Rab27a is required for regulated secretion in cytotoxic t lymphocytes. *J Cell Biol*. 2001;152(4):825–34.
 51. Elstak ED, Neeft M, Nehme NT, Voortman J, Cheung M, Goodarzi M, et al. The munc13-4-rab27 complex is specifically required for tethering secretory lysosomes at the plasma membrane. *Blood*. 2011;118(6):1570–8.
 52. Menasche G, Feldmann J, Houdusse A, Desaynard C, Fischer A, Goud B, et al. Biochemical and functional characterization of Rab27a mutations occurring in Griscelli syndrome patients. *Blood*. 2003;101(7):2736–42.
 53. Netter P, Chan SK, Banerjee PP, Monaco-Shawver L, Noroski LM, Hanson IC, et al. A novel Rab27a mutation binds melanophilin, but not Munc13-4, causing immunodeficiency without albinism. *J Allergy Clin Immunol*. 2016;138(2):599–601.
 54. Cetica V, Hackmann Y, Grieve S, Sieni E, Ciambotti B, Coniglio ML, et al. Patients with Griscelli syndrome and normal pigmentation identify RAB27A mutations that selectively disrupt MUNC13-4 binding. *J Allergy Clin Immunol*. 2015;135(5):1310–8. e1
 55. Mathis S, Cintas P, de Saint-Basile G, Magy L, Funalot B, Vallat JM. Motor neuropathy in Chediak-Higashi syndrome. *J Neurol Sci*. 2014;344(1–2):203–7.
 56. Introne WJ, Westbroek W, Cullinane AR, Groden CA, Bhambhani V, Golas GA, et al. Neurologic involvement in patients with atypical Chediak-Higashi disease. *Neurology*. 2016;86(14):1320–8.
 57. Tardieu M, Lacroix C, Neven B, Bordigoni P, de Saint BG, Blanche S, et al. Progressive neurologic dysfunctions 20 years after allogeneic bone marrow transplantation for Chediak-Higashi syndrome. *Blood*. 2005;106(1):40–2.
 58. Nagle DL, Karim AM, Woolf EA, Holmgren L, Bork P, Misumi DJ, et al. Identification and mutation analysis of the complete gene for Chediak-Higashi syndrome. *Nat Genet*. 1996;14:307–11.

59. Barbosa MDFS, Nguyen QA, Tchernev VT, Aschley JA, Deter JC, Blaydes SM, et al. Identification of the homologous beige and Chediak-Higashi syndrome genes. *Nature*. 1996;382:262–5.
60. Perou CM, Leslie JD, Green W, Li L, Ward DM, Kaplan J. The Beige/Chediak-Higashi syndrome gene encodes a widely expressed cytosolic protein. *J Biol Chem*. 1997;272(47):29790–4.
61. Jogl G, Shen Y, Gebauer D, Li J, Wiegmann K, Kashkar H, et al. Crystal structure of the BEACH domain reveals an unusual fold and extensive association with a novel PH domain. *EMBO J*. 2002;21(18):4785–95.
62. Gebauer D, Li J, Jogl G, Shen Y, Myszkka DG, Tong L. Crystal structure of the PH-BEACH domains of human LRBA/BGL. *Biochemistry*. 2004;43(47):14873–80.
63. Martens S, McMahon HT. Mechanisms of membrane fusion: disparate players and common principles. *Nat Rev Mol Cell Biol*. 2008;9(7):543–56.
64. Lo B, Zhang K, Lu W, Zheng L, Zhang Q, Kanellopoulou C, et al. AUTOIMMUNE DISEASE. Patients with LRBA deficiency show CTLA4 loss and immune dysregulation responsive to abatacept therapy. *Science*. 2015;349(6246):436–40.
65. Peifer M, Berg S, Reynolds AB. A repeating amino acid motif shared by proteins with diverse cellular roles. *Cell*. 1994;76(5):789–91.
66. Andrade MA, Bork P. HEAT repeats in the Huntington's disease protein. *Nat Genet*. 1995;11(2):115–6.
67. Burgess A, Mornon JP, de Saint-Basile G, Callebaut I. A concanavalin A-like lectin domain in the CHS1/LYST protein, shared by members of the BEACH family. *Bioinformatics*. 2009;25(10):1219–22.
68. Sepulveda FE, Burgess A, Heiligenstein X, Goudin N, Menager MM, Romao M, et al. LYST controls the biogenesis of the endosomal compartment required for secretory lysosome function. *Traffic*. 2015;16(2):191–203.
69. Karim MA, Suzuki K, Fukai K, Oh J, Nagle DL, Moore KJ, et al. Apparent genotype-phenotype correlation in childhood, adolescent, and adult Chediak-Higashi syndrome. *Am J Med Genet*. 2002;108(1):16–22.
70. Certain S, Barrat F, Pastural E, Le Deist F, Goyo-Rivas J, Jabado N, et al. Protein truncation test of LYST reveals heterogeneous mutations in patients with Chediak-Higashi syndrome. *Blood*. 2000;95(3):979–83.
71. Jessen B, Maul-Pavicic A, Ufheil H, Vraetz T, Enders A, Lehmborg K, et al. Subtle differences in CTL cytotoxicity determine susceptibility to hemophagocytic lymphohistiocytosis in mice and humans with Chediak-Higashi syndrome. *Blood*. 2011;118(17):4620–9.
72. Dell'Angelica EC, Shotelersuk V, Aguilar RC, Gahl WA, Bonifacino JS. Altered trafficking of lysosomal proteins in Hermansky-Pudlak syndrome due to mutations in the beta 3A subunit of the AP-3 adaptor. *Mol Cell*. 1999;3(1):11–21.
73. Dell'Angelica EC, Ohno H, Ooi CE, Rabinovich E, Roche KW, Bonifacino JS. AP-3: an adaptor-like protein complex with ubiquitous expression. *EMBO J*. 1997;16(5):917–28.
74. Dell'Angelica EC, Ooi CE, Bonifacino JS. Beta3A-adaptin, a subunit of the adaptor-like complex AP-3. *J Biol Chem*. 1997;272(24):15078–84.
75. Enders A, Zieger B, Schwarz K, Yoshimi A, Speckmann C, Knoepfle EM, et al. Lethal hemophagocytic lymphohistiocytosis in Hermansky-Pudlak syndrome type II. *Blood*. 2006;108(1):81–7.
76. Huizing M, Gahl WA. Disorders of vesicles of lysosomal lineage: the Hermansky-Pudlak syndromes. *Curr Mol Med*. 2002;2(5):451–67.
77. Shotelersuk V, Dell'Angelica EC, Hartnell L, Bonifacino JS, Gahl WA. A new variant of Hermansky-Pudlak syndrome due to mutations in a gene responsible for vesicle formation. *Am J Med*. 2000;108(5):423–7.
78. Jessen B, Bode SF, Ammann S, Chakravorty S, Davies G, Diestelhorst J, et al. The risk of hemophagocytic lymphohistiocytosis in Hermansky-Pudlak syndrome type 2. *Blood*. 2013;121(15):2943–51.
79. Pachlopnik Schmid J, Canioni D, Moshous D, Touzot F, Mahlaoui N, Hauck F, et al. Clinical similarities and differences of patients with X-linked lymphoproliferative syndrome type 1 (XLP-1/SAP deficiency) versus type 2 (XLP-2/XIAP deficiency). *Blood*. 2011;117(5):1522–9.
80. Purtilo DT, Cassel CK, Yang JP, Harper R. X-linked recessive progressive combined variable immunodeficiency (Duncan's disease). *Lancet*. 1975;1(7913):935–40.
81. Coffey AJ, Brooksbank RA, Brandau O, Oohashi T, Howell GR, Bye JM, et al. Host response to EBV infection in X-linked lymphoproliferative disease results from mutations in an SH2-domain encoding gene. *Nat Genet*. 1998;20(2):129–35.
82. Nichols KE, Harkin DP, Levitz S, Krainer M, Kolquist KA, Genovese C, et al. Inactivating mutations in an SH2 domain-encoding gene in X-linked lymphoproliferative syndrome. *Proc Natl Acad Sci U S A*. 1998;95(23):13765–70.
83. Sayos J, Wu C, Morra M, Wang N, Zhang X, Allen D, et al. The X-linked lymphoproliferative-disease gene product SAP regulates signals induced through the co-receptor SLAM. *Nature*. 1998;395(6701):462–9.
84. Rigaud S, Fondaneche MC, Lambert N, Pasquier B, Mateo V, Soulas P, et al. XIAP deficiency in humans causes an X-linked lymphoproliferative syndrome. *Nature*. 2006;444(7115):110–4.
85. Schwartzberg PL, Mueller KL, Qi H, Cannons JL. SLAM receptors and SAP influence lymphocyte interactions, development and function. *Nat Rev Immunol*. 2009;9(1):39–46.
86. Veillette A, Dong Z, Perez-Quintero LA, Zhong MC, Cruz-Munoz ME. Importance and mechanism of 'switch' function of SAP family adapters. *Immunol Rev*. 2009;232(1):229–39.
87. Palendira U, Low C, Chan A, Hislop AD, Ho E, Phan TG, et al. Molecular pathogenesis of EBV susceptibility in XLP as revealed by analysis of female carriers with heterozygous expression of SAP. *PLoS Biol*. 2011;9(11):e1001187.

88. Tangye SG. XLP: clinical features and molecular etiology due to mutations in SH2D1A encoding SAP. *J Clin Immunol*. 2014;34(7):772–9.
89. Dong Z, Cruz-Munoz ME, Zhong MC, Chen R, Latour S, Veillette S. Essential function for SAP family adaptors in the surveillance of hematopoietic cells by natural killer cells. *Nat Immunol*. 2009;10(9):973–80.
90. Marsh RA, Madden L, Kitchen BJ, Mody R, McClimon B, Jordan MB, et al. XIAP deficiency: a unique primary immunodeficiency best classified as X-linked familial hemophagocytic lymphohistiocytosis and not as X-linked lymphoproliferative disease. *Blood*. 2010;116(7):1079–82.
91. Horn PC, Belohradsky BH, Urban C, Weber-Mzell D, Meindl A, Schuster V. Two new families with X-linked inhibitor of apoptosis deficiency and a review of all 26 published cases. *J Allergy Clin Immunol*. 2011;127(2):544–6.
92. Speckmann C, Lehmborg K, Albert MH, Damgaard RB, Fritsch M, Gyrd-Hansen M, et al. X-linked inhibitor of apoptosis (XIAP) deficiency: the spectrum of presenting manifestations beyond hemophagocytic lymphohistiocytosis. *Clin Immunol*. 2013;149(1):133–41.
93. Paulsen M, Ussat S, Jakob M, Scherer G, Lepenies I, Schutze S, et al. Interaction with XIAP prevents full caspase-3/–7 activation in proliferating human T lymphocytes. *Eur J Immunol*. 2008;38(7):1979–87.
94. Eckelman BP, Salvesen GS, Scott FL. Human inhibitor of apoptosis proteins: why XIAP is the black sheep of the family. *EMBO Rep*. 2006;7(10):988–94.
95. Schile AJ, Garcia-Fernandez M, Steller H. Regulation of apoptosis by XIAP ubiquitin-ligase activity. *Genes Dev*. 2008;22(16):2256–66.
96. Dubrez-Daloz L, Dupoux A, Cartier J. IAPs: more than just inhibitors of apoptosis proteins. *Cell Cycle*. 2008;7(8):1036–46.
97. Krieg A, Correa RG, Garrison JB, Le Negrato G, Welsh K, Huang Z, et al. XIAP mediates NOD signaling via interaction with RIP2. *Proc Natl Acad Sci U S A*. 2009;106(34):14524–9.
98. Kitamura A, Sasaki Y, Abe T, Kano H, Yasutomo K. An inherited mutation in NLR4 causes autoinflammation in human and mice. *J Exp Med*. 2014;211(12):2385–96.
99. Romberg N, Al Moussawi K, Nelson-Williams C, Stiegler AL, Loring E, Choi M, et al. Mutation of NLR4 causes a syndrome of enterocolitis and autoinflammation. *Nat Genet*. 2014;46(10):1135–9.
100. Canna SW, de Jesus AA, Gouni S, Brooks SR, Marrero B, Liu Y, et al. An activating NLR4 inflammasome mutation causes autoinflammation with recurrent macrophage activation syndrome. *Nat Genet*. 2014;46(10):1140–6.
101. Taurisano R, Maiorana A, De Benedetti F, Dionisi-Vici C, Boldrini R, Deodato F. Wolman disease associated with hemophagocytic lymphohistiocytosis: attempts for an explanation. *Eur J Pediatr*. 2014;173(10):1391–4.
102. Gokce M, Unal O, Hismi B, Gumruk F, Coskun T, Balta G, et al. Secondary hemophagocytosis in 3 patients with organic acidemia involving propionate metabolism. *Pediatr Hematol Oncol*. 2012;29(1):92–8.
103. Duval M, Fenneteau O, Doireau V, Faye A, Emilie D, Yotnda P, et al. Intermittent hemophagocytic lymphohistiocytosis is a regular feature of lysinuric protein intolerance. *J Pediatr*. 1999;134(2):236–9.
104. Bode SF, Ammann S, Al-Herz W, Bataneant M, Dvorak CC, Gehring S, et al. The syndrome of hemophagocytic lymphohistiocytosis in primary immunodeficiencies: implications for differential diagnosis and pathogenesis. *Haematologica*. 2015;100(7):978–88.
105. Huang JF, Yang Y, Sepulveda H, Shi W, Hwang I, Peterson PA, et al. TCR-mediated internalization of peptide-MHC complexes acquired by T cells. *Science*. 1999;286(5441):952–4.
106. Ouachee-Chardin M, Elie C, de Saint BG, Le Deist F, Mahlaoui N, Picard C, et al. Hematopoietic stem cell transplantation in hemophagocytic lymphohistiocytosis: a single-center report of 48 patients. *Pediatrics*. 2006;117(4):e743–50.
107. Hartz B, Marsh R, Rao K, Henter JI, Jordan M, Filipovich L, et al. The minimum required level of donor chimerism in hereditary hemophagocytic lymphohistiocytosis. *Blood*. 2016;127(25):3281–90.
108. Henter JI, Elinder G, Soder O, Hansson M, Andersson B, Andersson U. Hypercytokinemia in familial hemophagocytic lymphohistiocytosis. *Blood*. 1991;78(11):2918–22.
109. Billiau AD, Roskams T, Van Damme-Lombaerts R, Matthys P, Wouters C. Macrophage activation syndrome: characteristic findings on liver biopsy illustrating the key role of activated, IFN-gamma-producing lymphocytes and IL-6- and TNF-alpha-producing macrophages. *Blood*. 2005;105(4):1648–51.
110. Chung BK, Tsai K, Allan LL, Zheng DJ, Nie JC, Biggs CM, et al. Innate immune control of EBV-infected B cells by invariant natural killer T cells. *Blood*. 2013;122(15):2600–8.
111. Yabal M, Muller N, Adler H, Knies N, Gross CJ, Damgaard RB, et al. XIAP restricts TNF- and RIP3-dependent cell death and inflammasome activation. *Cell Rep*. 2014;7(6):1796–808.
112. Wada T, Kanegane H, Ohta K, Katoh F, Imamura T, Nakazawa Y, et al. Sustained elevation of serum interleukin-18 and its association with hemophagocytic lymphohistiocytosis in XIAP deficiency. *Cytokine*. 2014;65(1):74–8.
113. Shimizu M, Yokoyama T, Yamada K, Kaneda H, Wada H, Wada T, et al. Distinct cytokine profiles of systemic-onset juvenile idiopathic arthritis-associated macrophage activation syndrome with particular emphasis on the role of interleukin-18 in its pathogenesis. *Rheumatology*. 2010;49(9):1645–53.
114. Mazodier K, Marin V, Novick D, Farnarier C, Robitail S, Schleinitz N, et al. Severe imbalance of

- IL-18/IL-18BP in patients with secondary hemophagocytic syndrome. *Blood*. 2005;106(10):3483–9.
115. Binder D, van den Broek MF, Kagi D, Bluethmann H, Fehr J, Hengartner H, et al. Aplastic anemia rescued by exhaustion of cytokine-secreting CD8+ T cells in persistent infection with lymphocytic choriomeningitis virus. *J Exp Med*. 1998;187(11):1903–20.
 116. Kagi D, Odermatt B, Mak TW. Homeostatic regulation of CD8+ T cells by perforin. *Eur J Immunol*. 1999;29(10):3262–72.
 117. Matloubian M, Suresh M, Glass A, Galvan M, Chow K, Whitmire JK, et al. A role for perforin in down-regulating T-cell responses during chronic viral infection. *J Virol*. 1999;73(3):2527–36.
 118. Nansen A, Jensen T, Christensen JP, Andreasen SO, Ropke C, Marker O, et al. Compromised virus control and augmented perforin-mediated immunopathology in IFN-gamma-deficient mice infected with lymphocytic choriomeningitis virus. *J Immunol*. 1999;163(11):6114–22.
 119. Jordan MB, Hildeman D, Kappler J, Marrack P. An animal model of hemophagocytic lymphohistiocytosis (HLH): CD8+ T cells and interferon gamma are essential for the disorder. *Blood*. 2004;104:735–43.
 120. Jessen B, Kogl T, Sepulveda FE, de Saint BG, Aichele P, Ehl S. Graded defects in cytotoxicity determine severity of hemophagocytic lymphohistiocytosis in humans and mice. *Front Immunol*. 2013;4:448.
 121. Sepulveda FE, Maschalidi S, Vosshenrich CA, Garrigue A, Kurowska M, Menasche G, et al. A novel immunoregulatory role for NK-cell cytotoxicity in protection from HLH-like immunopathology in mice. *Blood*. 2015;125(9):1427–34.
 122. Terrell C, Zoller E, Jordan M. Perforin-dependent cytotoxicity regulates the immune response in trans: how much donor chimerism is enough? *Bilbao: Histiocyte Society*;2009. September 15–17.
 123. Zoller EE, Lykens JE, Terrell CE, Aliberti J, Filipovich AH, Henson PM, et al. Hemophagocytosis causes a consumptive anemia of inflammation. *J Exp Med*. 2011;208(6):1203–14.
 124. Mancebo E, Allende LM, Guzman M, Paz-Artal E, Gil J, Urrea-Moreno R, et al. Familial hemophagocytic lymphohistiocytosis in an adult patient homozygous for A91V in the perforin gene, with tuberculosis infection. *Haematologica*. 2006;91(9):1257–60.
 125. Shabbir M, Lucas J, Lazarchick J, Shirai K. Secondary hemophagocytic syndrome in adults: a case series of 18 patients in a single institution and a review of literature. *Hematol Oncol*. 2011;29(2):100–6.
 126. Zhang M, Behrens EM, Atkinson TP, Shakoory B, Grom AA, Cron RQ. Genetic defects in cytolysis in macrophage activation syndrome. *Curr Rheumatol Rep*. 2014;16(9):439.
 127. Zhang K, Jordan MB, Marsh RA, Johnson JA, Kissell D, Meller J, et al. Hypomorphic mutations in PRF1, MUNC13-4, and STXBP2 are associated with adult-onset familial HLH. *Blood*. 2011;118(22):5794–8.
 128. Zhang K, Chandrakasan S, Chapman H, Valencia CA, Husami A, Kissell D, et al. Synergistic defects of different molecules in the cytotoxic pathway lead to clinical familial hemophagocytic lymphohistiocytosis. *Blood*. 2014;124(8):1331–4.
 129. Sepulveda FE, Garrigue A, Maschalidi S, Garfa-Traore M, Menasche G, Fischer A, et al. Polygenic mutations in the cytotoxicity pathway increase susceptibility to develop HLH immunopathology in mice. *Blood*. 2016;127(17):2113–21.
 130. Krebs P, Crozat K, Popkin D, Oldstone MB, Beutler B. Disruption of MyD88 signaling suppresses hemophagocytic lymphohistiocytosis in mice. *Blood*. 2011;117(24):6582–8.
 131. Milner JD, Orekov T, Ward JM, Cheng L, Torres-Velez F, Junttila I, et al. Sustained IL-4 exposure leads to a novel pathway for hemophagocytosis, inflammation, and tissue macrophage accumulation. *Blood*. 2010;116(14):2476–83.
 132. Behrens EM, Canna SW, Slade K, Rao S, Kreiger PA, Paessler M, et al. Repeated TLR9 stimulation results in macrophage activation syndrome-like disease in mice. *J Clin Invest*. 2011;121(6):2264–77.
 133. Levendoglu-Tugal O, Ozkaynak MF, LaGamma E, Sherbany A, Sandoval C, Jayabose S. Hemophagocytic lymphohistiocytosis presenting with thrombocytopenia in the newborn. *J Pediatr Hematol Oncol*. 2002;24(5):405–9.

Hemophagocytic Lymphohistiocytosis Associated with Malignancies and with Epstein-Barr Virus

Kai Lehmborg, Fumihiko Ochi, Kim E. Nichols, and Eiichi Ishii

Abbreviations

CAEBV	Chronic active EBV infection	PTLD	Post-transplantation lymphoproliferative disorder
CMV	Cytomegalovirus	RIC	Reduced intensity conditioning
CTL	Cytotoxic T cells	sCD25	Soluble IL2 receptor
EBNA	Epstein-Barr nuclear antigen	TBI	Total body irradiation
EBV	Epstein-Barr virus	TCR	T cell receptor
FHL	Familial HLH	TGF	Transforming growth factor
FIM	Fulminant mononucleosis	UCBT	Unrelated donor cord blood transplantation
HIV	Human immune deficiency virus	VCA	Virus capsid antigen
HLH	Hemophagocytic lymphohistiocytosis	XLP	X-linked lymphoproliferative disease
HSCT	Hematopoietic stem cell transplantation		
IFN	Interferon		
IM	Infectious mononucleosis		
ITK	Inducible T cell kinase		
MAC	Myeloablative conditioning		
MAGT1	Magnesium transporter 1		
MRI	Magnetic resonance imaging		
NK	Natural killer		
PBMNC	Peripheral blood mononuclear cells		

Hemophagocytic Lymphohistiocytosis Associated with Malignancy

Malignancy-Triggered HLH Versus HLH During Chemotherapy

The association of the hyperinflammatory syndrome hemophagocytic lymphohistiocytosis (HLH) and malignant diseases has been recognized for decades [1]. Patients with neoplasms may display the typical HLH features of fever, organomegaly, cytopenia, consumptive hypofibrinogenemia, and hemophagocytosis in bone marrow or lymph nodes. As of 2014, more than 1000 cases have been reported for adults alone [2]. A clear differentiation must be made between two distinct situations in which HLH may occur in relation to cancer [3]:

K. Lehmborg, MD (✉)
Department of Pediatric Hematology and Oncology,
University Medical Center Hamburg Eppendorf,
Hamburg, Germany
e-mail: klehmborg@uke.de

F. Ochi, MD • E. Ishii, MD
Department of Pediatrics, Ehime University Graduate
School of Medicine, Toon, Ehime, Japan

K.E. Nichols, MD
Department of Oncology, St. Jude Children's
Research Hospital, 62 Danny Thomas Place,
Memphis, TN, USA

In *malignancy-triggered HLH*, hyperinflammation typically occurs at first presentation or relapse of cancer and is considered driven by the underlying neoplasm. The pathophysiology of malignancy-triggered HLH is poorly understood. In vitro experiments with lymphoma cell lines suggest that malignant cells secrete cytokines such as interferon- γ and interleukin-6, which play a key role in the development of HLH [4, 5]. Elevated soluble interleukin-2 receptor (sCD25) is a marker of both HLH and tumor burden in non-Hodgkin lymphoma [6, 7], which points at the overlap between these two conditions. Viruses can act as co-triggers, particularly in Epstein-Barr virus (EBV)-related lymphomas [8].

In *HLH during chemotherapy*, most patients are already in remission of the malignancy, which renders the neoplasm an unlikely driving factor. HLH is believed to occur primarily due to triggering infections, while patients are under strong immune suppression caused by chemotherapy. This suggests that the underlying pathology substantially differs from malignancy-triggered HLH and rather resembles infection-associated HLH in the context of long-term immune suppression. Infections as triggers of HLH in immunocompromised patients have been well described in organ transplant recipients [9]. The microbiological spectrum is not restricted to viral triggers (e.g., EBV and cytomegalovirus (CMV)) but includes invasive fungi and bacteria as well [10–12].

The distinction between malignancy-triggered HLH and HLH during chemotherapy cannot be always easily made, and coexistence is possible when infectious agents boost malignancy-triggered HLH. However, both for clinical purposes and for scientific evaluation, the differentiation must be attempted and is feasible in most cases. Unfortunately, the distinction is not always made in the literature, which renders interpretation of results difficult.

Neoplastic Entities in Malignancy-Triggered HLH

In adults, the most frequently reported malignancies are T and NK cell lymphomas (35%) and B cell lymphomas (32%), followed by leukemias

(6%), Hodgkin lymphomas (6%), other hematologic cancers (14%), solid tumors (3%), and other malignancies (3%) [2]. In reports from Western countries and Japan, B cell lymphoma is the leading triggering entity in adults [13, 14], while T cell neoplasms are predominant in China and Korea [15–17]. T cell malignancies constitute the majority in the pediatric cohort [18, 19].

Mature T cell sub-entities display a particular propensity to elicit HLH [20] (peripheral T cell lymphoma including subcutaneous panniculitis-like T cell lymphoma, primary cutaneous $\gamma\delta$ -T cell lymphoma, anaplastic large cell lymphoma), whereas lymphoblastic T cell malignancies have been reported less frequently [18, 19]. In the group of B cell neoplasms, diffuse large B cell lymphoma is the predominant entity, particularly in the elderly. Far East Asian patients with intravascular large B cell lymphoma appear to be particularly prone to HLH [21]. B-precursor malignancies have only rarely been reported [22]. Among the rarely occurring solid tumors, mediastinal germ-cell tumors stand out [23].

EBV as co-trigger is found in up to 90% of HLH cases associated with Hodgkin lymphoma [8, 24], less frequently (approx. one third) with peripheral T cell lymphoma [14, 16], and only rarely with diffuse large B cell lymphoma [25, 26].

The spectrum of differential diagnoses for malignancy-triggered HLH is broad and includes Langerhans cell histiocytosis [11], multicentric Castleman disease in the context of human immune deficiency virus (HIV) infection [27], EBV-driven T and NK cell lymphoproliferative disorders (particularly in Far East Asia) [28–30], and cytophagic histiocytic panniculitis [31].

Chemotherapy Regimens Associated with HLH During Chemotherapy

HLH in this patient cohort occurs when patients are usually already in remission of the underlying malignancy. In 75–100% of cases, an infectious trigger can be found, including fungi [10, 11, 19, 22, 32, 33]. Patients under aggressive chemotherapeutic regimens for hematological malignancies carry the highest risk [10]. While HLH often occurs during induction and consolidation therapy,

it can also occur during maintenance therapy [19]. Cytokine release syndromes can frequently be observed after administration of T cell engaging therapies for B-precursor neoplasms (chimeric antigen receptor-modified T cells and bispecific T cell engaging antibodies). These syndromes can be considered as an iatrogenic subtype of HLH [34].

Diagnosis

Figure 12.1 displays a flow chart for the diagnostic work-up and therapeutic decisions for different scenarios involving HLH in the context of malignancies. Scenario 1a: Exclusion of an underlying malignancy in a patient with confirmed HLH. Scenario 1b: Exclusion of HLH in a patient with confirmed malignancy. Scenario 2: Exclusion of HLH in a patient during chemotherapy.

The diagnosis of HLH is based on a set of clinical features and laboratory parameters. Currently, the HLH-2004 criteria [35] are the most commonly used tool. These criteria include fever, splenomegaly, decreased blood counts and fibrinogen, elevated ferritin, triglycerides, and sCD25 (see Chap. 9). Elevated lactate dehydrogenase, transaminases, d-dimers, and decreased albumin may support the diagnosis. However, this set of criteria has shortcomings as it was designed originally for pediatric patients with primary and virus-associated secondary HLH. Several features may per se be fulfilled in patients with hematological malignancies at presentation or during treatment (e.g., fever, cytopenia, organomegaly). Even the eponymous hemophagocytosis in bone marrow or lymph nodes is neither highly specific nor sensitive [36] and can thus only make a small contribution to the diagnosis of HLH. A high sCD25/ferritin ratio can point toward an underlying lymphoma in HLH patients [37]. Several modified criteria have been proposed for HLH in adults, reviewed in [38], including a scoring system based on a cohort in which almost half of patients had malignancy-associated HLH [39] as well as criteria for HLH during therapy for acute myeloid leukemia [10]. However, it

remains to be determined whether these tools will gain wider acceptance.

Given the challenges related to a lack of formal criteria, it is important for clinical purposes to subjectively judge if the triad of (i) combination, (ii) extent, and (iii) progression of parameters is unusual, unexpected, and unexplained [3], compared to other cases of malignancies. Combination: Every single feature of HLH may occur in many other circumstances. However, the combination is abnormal. Extent: In HLH, the derangement of laboratory parameters is typically excessive. Progression: If left untreated, there is usually substantial momentum in the evolution of features. It is essential to make the diagnosis in time.

In any patient with HLH, underlying malignant disease (particularly lymphoma) should be considered and baseline diagnostic procedures be performed (cytology of peripheral blood and bone marrow, ultrasound of abdomen and lymph nodes, chest x-ray). If other etiologies can be identified (e.g., HLH in hereditary, autoimmune, autoinflammatory, or infectious conditions), underlying malignancy is less likely, but not excluded. This is especially true for the finding of EBV or HIV [40], as tumors may be EBV-driven or based on acquired immune deficiency. If the etiology of HLH is otherwise not well explained, diagnostic work-up must be extended, including computed tomography, magnetic resonance imaging (MRI), positron emission tomography [41], and lymph node biopsy. The risk of bleeding complications following organ biopsies must be weighed against the benefits, especially if coagulation is disturbed and thrombocytopenia profound. Cerebral MRI and cerebrospinal fluid investigations are recommended to exclude central nervous system involvement, particularly in patients with clinical neurological abnormalities.

HLH parameters can be used for follow-up to determine disease activity and treatment response. Obviously, differentiation of features of persistent disease activity and treatment toxicity (in particular if aggressive malignancy-directed protocols are used) may prove difficult. Platelets tend to quickly improve in patients with good response. Even if patients respond to treatment, normalization of ferritin usually

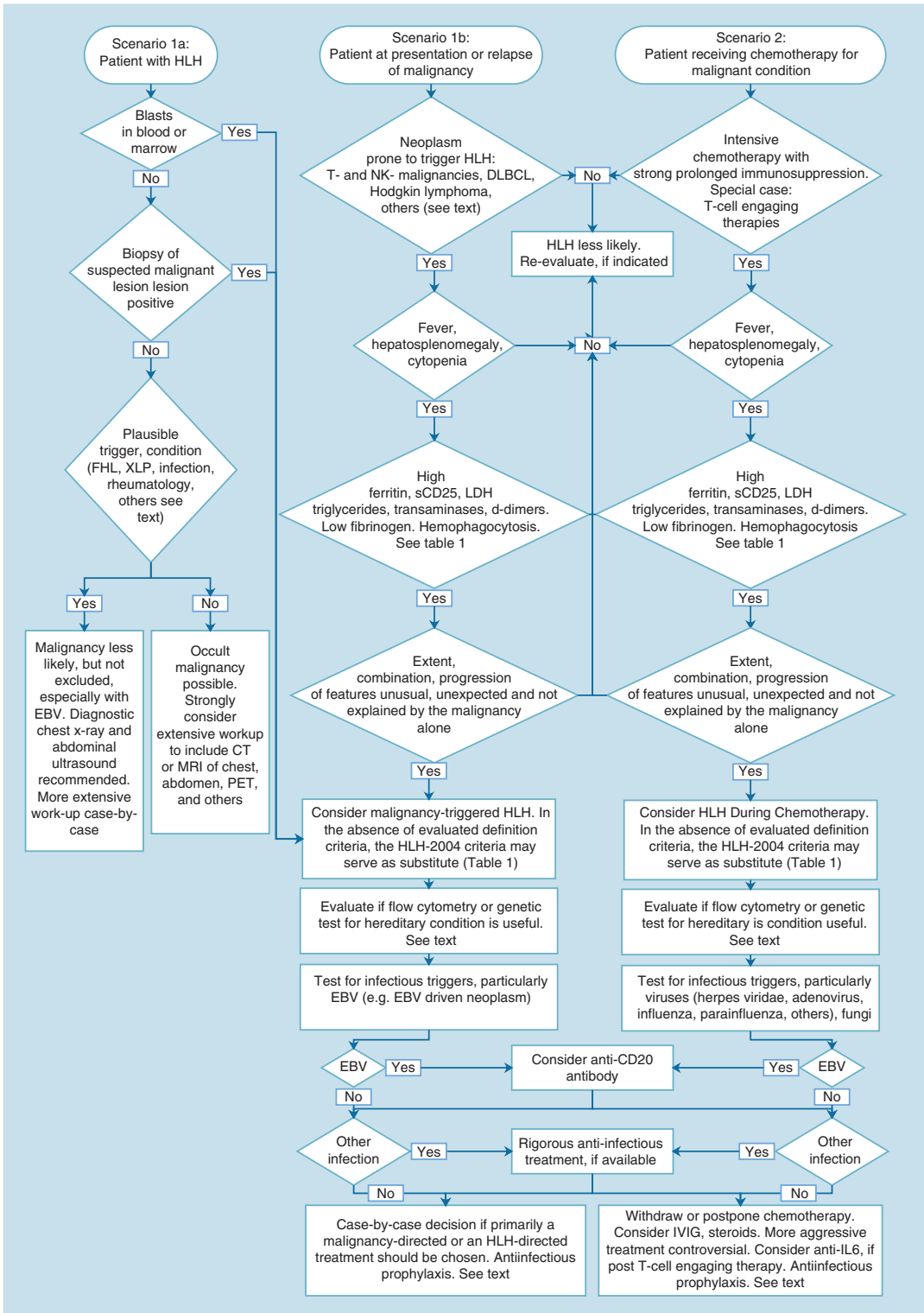


Fig. 12.1 Diagnosis and Management of HLH associated with malignancies. From [3], with kind permission of Haematologica

takes several weeks or even months [42]. Follow-up bone marrow cytology may help to distinguish HLH-related cytopenias from treatment-associated cytopenias.

Role of Genetic Defects

A variable degree of predisposition to malignancies appears to be present in various genetic defects associated with hereditary HLH. This is most striking in X-linked lymphoproliferative syndrome type (XLP) 1 where in the largest study approx. 40% of patients had overwhelming HLH at primary EBV infection as first manifestation. However, B cell lymphoma was the presenting feature in 14% and occurred in a quarter of patients at any time [43]. A history of EBV-associated HLH and B cell lymphoma is thus suggestive of XLP1 in male patients. XLP2, in contrast, does not seem to be associated with lymphoma [44]. Several genetic defects conferring inappropriate control of EBV, which may resemble HLH, additionally confer a predisposition to lymphoma, e.g., deficiencies of the magnesium transporter 1 (MAGT1), inducible T cell kinase (ITK), and CD27 [45].

The association of perforin and degranulation defects (see Chap. 11) with malignant conditions is less pronounced. However, defects in the underlying genes may contribute not only to the pathogenesis of HLH but also to the development malignancies, even though some of the data are conflicting. FHL mouse models reveal an increased incidence of lymphoma [46]. In humans, hypomorphic mutations in perforin are associated both with HLH and hematologic malignancies [47, 48]. The role of the hypomorphic perforin mutation A91V in hematological malignancies is debated [49, 50]. Hematological malignancies were not shown to be statistically more frequent in heterozygous carriers of (familial hemophagocytic lymphohistiocytosis) FHL mutations [51]. Several case reports describe an association of inherited cytotoxicity defects and Hodgkin lymphoma [52–55], with or without EBV. Somatic loss of heterozygosity in the region 6q24, which includes STX11

(the gene mutated in FHL4), has been found in adult peripheral T cell lymphoma cells [56]. Similarly, evidence regarding solid tumors is inconsistent: An increased incidence of gynecological tumors has been shown for heterozygous carriers of mutations conferring familial HLH [51]. However, no increased frequency of perforin mutations was detected in a series of patients with colorectal and ovarian carcinoma [57].

It is debatable if a predisposing hereditary defect is to be excluded in every patient with malignancy-associated HLH. As a practical approach, a case-by-case decision can be made. Factors increasing the likelihood of an underlying defect include young age, previous episodes of full or partial HLH, and a positive family history. A positive antibody titer to Epstein-Barr nuclear antigen (EBNA) indicates that primary EBV infection has occurred previously. A positive EBNA without prior HLH renders a genetic defect less likely, as EBV is considered the most potent trigger of HLH in cytotoxicity defects. Flow cytometry (protein stains and degranulation assays) has been proven an effective screening tool to test for the pertinent defects [58, 59] (see Chap. 9). In case of abnormalities, targeted sequencing or gene panel sequencing can detect relevant mutations. Exome or genome sequencing approaches may be indicated in special cases.

Treatment and Prognosis of Malignancy-Triggered HLH

Therapy should be instituted promptly in patients with malignancy-triggered HLH. However, it is currently unknown if primarily HLH-directed treatment or malignancy-directed treatment or a combination of both is most effective. Consequently, decisions must be taken on a case-by-case basis. In patients where initially an HLH-directed approach is pursued, a regimen addressing the neoplasm must follow once HLH parameters have stabilized or resolved.

There is substantial overlap in the agents used for treatment of malignancies and HLH. Etoposide and glucocorticosteroids, in particular, are used for both conditions. Cytostatic medications that

have shown efficacy in murine models of primary HLH include etoposide, cyclophosphamide, and methotrexate [60]. Etoposide has been shown to selectively ablate activated T cells [60] which play a key role in HLH. Malignancy-directed protocols containing dexamethasone, etoposide, or cyclophosphamide may thus constitute the preferred treatment option to address HLH when it occurs in the context of a neoplasm. In some patients with poor general condition, initial HLH-directed immunosuppressive treatment may pave the road for more aggressive malignancy-directed therapy after clinical improvement. Liposomal doxorubicin, methylprednisolone, and etoposide are currently the only regimen that has been prospectively studied in 29 adult patients with lymphoma-triggered HLH unsuccessfully treated with HLH94 for at least 2 weeks. Response was complete (i.e., normalization of parameters) in 17%, partial (i.e., moderate improvement of parameters) in 59%, and absent in 24% of patients [61]. Some retrospective studies and case series have indicated better survival if etoposide was administered; substantial limitations of these analyses however preclude generalization [62, 63]. Cyclosporine A has shown beneficial effects in HLH in conjunction with cytophagic histiocytic panniculitis and subcutaneous panniculitis-like T cell lymphoma [31, 64]. The janus kinase inhibitor ruxolitinib was effective in mouse models of primary and secondary HLH [65, 66]. Its role for the treatment of HLH in the context of malignancies remains to be determined. In patients with a relevant underlying hereditary defect, hematopoietic stem cell transplantation after resolution of HLH is usually indicated.

When treating individuals with malignancy-triggered HLH, it is important that extensive anti-infectious treatment of viruses, bacteria, and fungi, as well as anti-infectious prophylaxis (including *Pneumocystis jirovecii*), and frequent screening for fungi and viruses (EBV, CMV, adenovirus) be pursued to avoid additional triggering factors. In highly replicative EBV infection, rituximab is recommended to address this strong co-trigger by elimination of B cells [67]. If the neoplasm is CD20 positive, an additional anti-tumor effect can be expected. Prevalence of acute

kidney failure in patients with malignancy-triggered HLH particularly in adults is high. Adjustments of treatment doses and renal replacement therapy are frequently required [68].

The interpretation of outcome data may prove difficult because it is often not possible to distinguish whether HLH or the underlying malignancy or both are the major cause of death. The prognosis of the HLH in this patient cohort is biased by the often per se dismal prognosis of the underlying neoplasm. This contributes to the poorer outcome of HLH in the context of malignancy as compared to other subtypes of HLH. The prognosis of HLH in B cell lymphomas is superior in comparison to T cell malignancies. HLH is a poor prognostic indicator in malignancy patients. Depending on the subtype of the underlying neoplasm in adults, the 30-day survival of the acute phase of HLH is reported to be 56–70%, the median overall survival 36–230 days, and the 3-year survival 18–55% [14, 16, 17, 61–63, 69–72]. Outcome data from pediatric patients are better, with survival of the acute phase of HLH measuring 56–67% and median overall survival approximately 1 year [18, 19].

Treatment and Prognosis of HLH During Chemotherapy

There is even less evidence regarding treatment for HLH during chemotherapy. Antiviral, antibacterial, and antifungal treatment directed at the identified pathogen is a mainstay of management. Rituximab may improve EBV-driven HLH [67] and should thus be considered in patients with EBV viremia. In addition, antimicrobial prophylaxis against other viruses, fungi, and bacteria is strongly recommended, as patients with HLH during chemotherapy are usually profoundly neutropenic and lymphopenic and consequently prone to further aggravating infections. Aspergilli should be included in the spectrum of antifungals.

As chemotherapy-induced immune suppression is the most likely basis for the occurrence of HLH, further chemotherapeutic courses should be postponed or maintenance medication interrupted

until the HLH comes under control. The benefit-risk ratio can be assumed positive for immunoglobulins; in addition glucocorticosteroids can be administered [10, 19]. It is a matter of debate whether further immune suppression (such as etoposide (19)) is beneficial or counterproductive. It is thus advisable to take this decision case by case. The anti-interleukin 6 antibody tocilizumab has shown efficacy against cytokine-release syndromes triggered by T cell engaging therapies [34]. In adult patients treated for acute myeloid leukemia, overall survival was significantly lower in patients where features of HLH occurred (1.3 years) [10]. In a small pediatric cohort of HLH during chemotherapy mainly for leukemia, overall survival was 0.9 years [19].

Conclusions for HLH Associated with Malignancies

Malignancy-triggered HLH and HLH during chemotherapy constitute a major challenge in hematology. The criteria used for the definition of HLH in the context of malignancies need refinement. However, awareness of the condition may facilitate timely initiation of therapy. Since it is unknown if initial HLH-directed or malignancy-directed treatment is better, therapy must be tailored on a case-by-case basis.

Hemophagocytic Lymphohistiocytosis Associated with Epstein-Barr Virus

EBV, also known as human herpesvirus 4, is one of the most common viruses to infect humans. EBV infection is associated with a wide spectrum of illnesses, including infectious mononucleosis (IM), hemophagocytic lymphohistiocytosis (HLH), chronic active EBV infection (CAEBV), posttransplantation lymphoproliferative disorders (PTLD), and B and NK/T cell lymphomas [73]. EBV first infects and proliferates in epithelial cells of the nasopharynx. Subsequently, it enters B cells that circulate throughout these tissues. Natural killer (NK) cells initially control

EBV-infected B cells followed by EBV-specific cytotoxic T cells (CTL) [74]. Accordingly, individuals with defects in NK cell and/or CTL number or function are at risk to develop EBV-induced disorders [45]. As one example, males with X-linked lymphoproliferative disease, type 1 (XLP1), who exhibit altered T and NK function due to germline mutations in the *SH2D1A* gene, are at increased risk to develop an overwhelming form of EBV infection known as fulminant IM (FIM) [75].

The development of EBV-associated disorders is related to the age of the individual and stage of infection. IM, EBV-HLH, and XLP-associated FIM generally occur in younger children during primary EBV infection. In contrast, EBV-PTLD or CAEBV usually develop in older children during the persistent or reactivation phase of infection [73]. Apart from these diseases, two cutaneous disorders, hydroa vacciniforme and severe mosquito bite allergy, are closely associated with EBV-infected T or NK cells [29].

Epidemiology

The true incidence of EBV-HLH is difficult to determine because the clinical and laboratory findings are similar to those observed in other inflammatory disorders [76]. In a literature review of adult HLH cases, the prevalence of EBV as trigger was 15% [2]. In adults from Asia this rate is twice as high [77]. Most studies in EBV-associated HLH come from pediatric centers in Asia, where EBV-HLH has been the focus of intense investigation. Imashuku et al. [78] estimated that 51.7 cases of childhood HLH are diagnosed every year in Japan, with half of these cases due to EBV. Subsequently, Ishii et al. [14] reported that 64 children developed HLH per year in Japan for an estimated annual incidence of 1 in 800,000 individuals. Forty percent of these individuals had EBV-driven disease. More recent studies by Kogawa et al. report a similar annual incidence of HLH in Japan of 25 cases per year [79]. The Korean Society collected 251 children with HLH between 1996 and 2011 for an annual estimated incidence of 16.7 [80]. Among

these, 42% had evidence of EBV. The incidence of EBV-HLH is thought to be lower in non-Asian countries, although published data are limited. Gurgey et al. [81] describe 18 Turkish children with secondary HLH diagnosed between 1998 and 2005, of whom only one (5.5%) had evidence for EBV. The higher incidence in Asia suggests that certain genetic factors found in this ethnic group may promote the development of EBV-HLH.

Diagnostic Findings

EBV-HLH exhibits manifestations that are often indistinguishable from those seen in other inflammatory disorders. Physical signs and symptoms consist of persistent fever resistant to antibiotics, hepatosplenomegaly, lymphadenopathy, rash, jaundice, dyspnea or tachypnea, and neurological abnormalities including irritability, disturbances in the level of consciousness, and convulsions [82]. As with other forms of HLH, laboratory findings include cytopenias (affecting ≥ 2 of three blood cell lineages), hypertriglyceridemia and/or hypofibrinogenemia (often with evidence for disseminated intravascular coagulation), hyperferritinemia, liver dysfunction with high LDH, and hyponatremia (see Chap. 9). Hemophagocytosis in the bone marrow, spleen, and/or lymph nodes can be detected in most patients. Pleocytosis with an increased protein level in the cerebrospinal fluid or abnormal radiological findings of the brain may be observed at the onset or during the course of the disease, despite the absence of neurological abnormalities [82].

Diagnostic criteria for HLH have been put forth in two clinical studies of the Histiocyte Society (HLH-94, HLH-2004) [35, 83]; however, the sensitivity and specificity of these criteria have not been determined [84]. Regardless, these criteria have been widely used for the diagnosis of HLH. Ishii et al. [85] analyzed the clinical features of 43 children with HLH and observed that each of the HLH-94 or HLH-2004 diagnostic criteria were identified in $>50\%$ of patients, indicating the potential reliability of each criterion for establishing the diagnosis. As biological mark-

ers, a high soluble IL-2 receptor (sCD25) and impaired NK cell activity are often used for diagnosing HLH [35]. Interestingly, while sCD25 is usually increased in EBV-HLH, NK cell activity is normal or only minimally reduced [14].

The diagnosis of EBV-HLH is made in individuals who meet HLH criteria and have evidence for EBV infection. Of note, the finding of EBV does not exclude a lymphoma, as this may be EBV-driven. It is important to recognize that increased titers of certain anti-EBV antibodies are not always seen in patients with EBV-HLH. In 94 Japanese patients with EBV-HLH showing positive VCA-IgG, only a third of the patients clearly had the first exposure to EBV by positive VCA IgM or EADR-IgG, whereas the remaining two thirds showed non-specific patterns, negative VCA IgM/EADR-IgG or positive EBNA, indicating that serological anti-EBV response may be of limited use for the diagnosis of EBV-HLH [78]. Patients with EBV-HLH harbor significantly higher viral loads in plasma and peripheral blood mononuclear cells (PBMNC) than individuals with IM, and these viral loads decreased more slowly over time [86]. In patients with IM, the mean viral load in PBMNC was 10^{2-3} copies of EBV genome/ μg PBMNC DNA, which disappeared within 4–5 weeks [87]. This is in contrast to patients with EBV-HLH, where the viral load was 1–3 logs higher at 10^{3-6} copies of EBV genome/ μg PBMNC DNA which only gradually decreased over the course of treatment. In a survey of EBV-HLH patients by Kogawa et al., the median viral load in plasma, white blood cells, and whole blood were similarly elevated at 1.4×10^6 copies/ml, 1.1×10^5 copies/ μg DNA, and 5.0×10^5 copies of EBV genome/ml, respectively [79]. The characteristics for the diagnosis of EBV-HLH are displayed in Table 12.1.

Pathogenesis of EBV-HLH

There are two major cytotoxic pathways in CTL and NK cells which culminate in the induction of target cell apoptosis [88]. In the perforin/granzyme pathway, perforin is secreted and forms pores in the target cell plasma membrane.

Table 12.1 Characteristics of EBV-HLH

<i>A. Features of HLH</i>	
1	Clinical Fever, liver dysfunction, splenomegaly, bleeding tendency
2	Laboratory Cytopenia, elevated ferritin, elevated LDH, increased triglyceride, decreased fibrinogen
3	Histology Hemophagocytosis without malignant findings
<i>B. Definition of EBV infection</i>	
1	Apparent primary infection or reactivation with EBV
2	Elevated EBV DNA in plasma, WBC, or whole blood
3	EBER-positive cells in bone marrow, lymph nodes, or other organs

This allows for the entry of granzymes A and B, which subsequently trigger apoptosis. In the Fas/Fas ligand pathway, CTL expressing Fas ligand trigger apoptosis of Fas-expressing target cells. In most primary forms of HLH, CTL and NK cells are unable to kill virus-infected cells and activated antigen-presenting cells, resulting in the sustained activation of CTL and macrophages [89]. The overproduction of pro-inflammatory cytokines by these cell lineages leads to hypotension, vascular leak, and tissue damage, resulting in the many signs and symptoms of HLH.

Consistent with this notion, EBV is a known trigger of disease in children with the familial form of HLH or with primary immunodeficiency disorders that affect T and/or NK cell signaling or cytolytic function [45, 90]. In a Chinese study, eight out of 67 (12%) children with EBV-HLH were found to carry monoallelic or biallelic mutations characteristic of FHL [91]. XLP1 is a classic example of a primary immunodeficiency characterized by a unique susceptibility of affected males to EBV infection. In XLP1, mutations in *SH2D1A* (which encodes the signaling lymphocytic activation molecule-associated protein or SAP) lead to impaired T and NK cell signaling. As a consequence, patients fail to develop proper EBV-specific cytotoxic responses, which, in combination with other XLP-associated immune defects, results in the polyclonal B cell proliferation that manifests as FIM (Fig. 12.2) [92].

The pathogenesis of EBV-HLH occurring outside the realm of familial HLH or primary immunodeficiency disorders is not well understood. For unclear reasons, EBV predominantly infects CD8⁺ T cells in Asian patients with EBV-HLH (Fig. 12.2) [93, 94]. In support of this finding, Toga et al. [95] observed a clonal proliferation of EBV-infected CD8⁺ T cells with downregulation of CD5 in patients with the disease. In contrast, EBV is reported to infect T and B cells equally in EBV-HLH patients of European origin [96]. Interestingly, in vitro studies show that forced expression of EBV latent membrane protein-1 (LMP1) in T cell lines suppresses expression of the XLP1 gene product SAP, leading to T cell activation, increased IFN γ secretion, and decreased apoptosis [97, 98]. In separate studies, Lay et al. [99] showed that EBV-infected T lymphoma cells upregulate TNF α expression. Finally, Kawanishi et al. showed that expression of LMP1 in Jurkat T cells provides resistance against apoptosis [100]. Currently, it is not known whether responses similar to those shown in vitro also occur in vivo. However, based on these findings, one can speculate that EBV infection of CD8⁺ T cells might contribute to HLH by promoting T cell activation and pro-inflammatory cytokine production while at the same time facilitating accumulation through the inhibition of apoptosis. Of note, spontaneous outgrowth of EBV⁺ B cells can be seen during the recovery phase or remission of EBV-HLH, indicating that EBV infection of B cells does indeed occur in Japanese patients but may be delayed and occur later in the course of the illness [101].

Several investigators have confirmed the clonality of virus-infected T lymphocytes in EBV-HLH. This clonality can be evaluated by assessing the uniformity of the EBV genome and/or the monoclonality of T cell receptor (TCR) gene rearrangement [102, 103]. In studies by Kogawa et al., 62% of EBV-HLH patients exhibited clonality of EBV-infected T cells [79]. From a clinical perspective, the monitoring of TCR clonality patterns combined with the quantification of EBV load may provide useful information to detect and enumerate proliferating EBV⁺ T cells in patients with EBV-HLH.

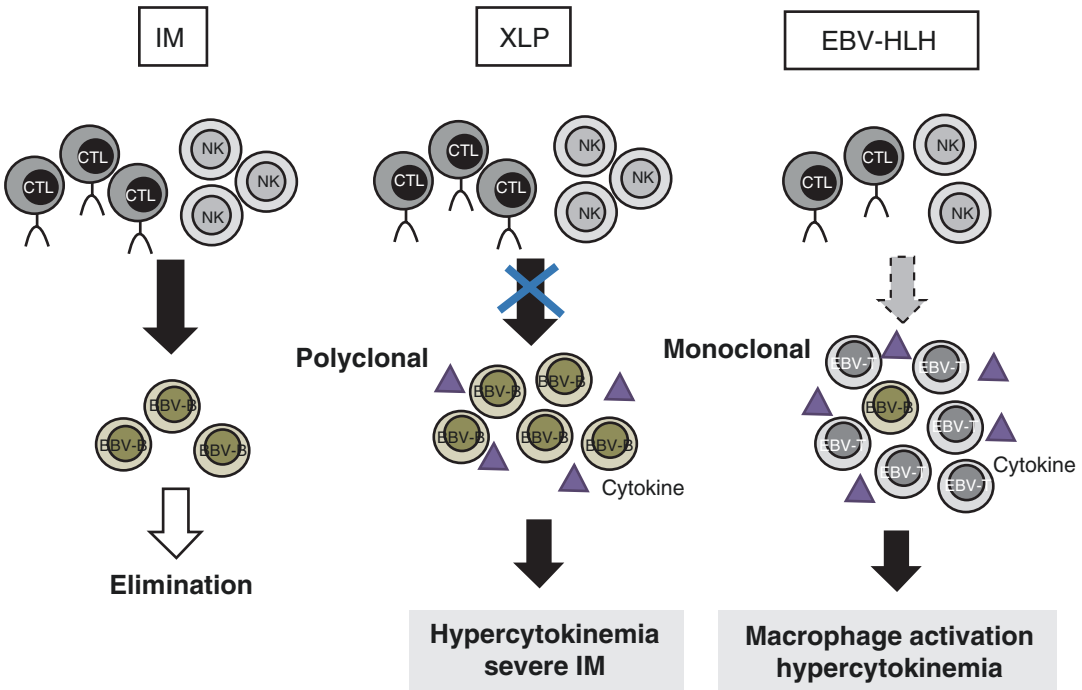


Fig. 12.2 Schema depicting the possible pathogenesis of IM, FIM, and EBV-HLH. When B cells are infected with EBV during primary infection, NK and cytotoxic T lymphocytes (CTL) are activated and EBV-infected B cells are eliminated (IM). Patients with XLP exhibit impaired development of EBV-specific cytotoxic responses, and

this results in a polyclonal proliferation of B cells and the features of FIM (XLP). In EBV-HLH, EBV predominantly infects CD8⁺ T cells. Cytokines produced by EBV-infected T cells are responsible for macrophage activation and subsequent development of HLH (EBV-HLH)

It is not well understood how EBV infects T or NK cells in EBV-HLH. Initially, EBV infects B cells by interaction of viral surface glycoproteins with CD21, also known as complement receptor 2 [74, 101]. Viral entry into B cells is then mediated by HLA class II and other co-receptors [96]. Although T cells express mRNA encoding CD21, they do not express detectable levels of the protein at the cell surface [104]. NK cells also do not express CD21. Accordingly, it has remained puzzling as to how EBV infects these cell types. Toward this end, recent data suggest that NK cells acquire receptor molecules by synaptic transfer from EBV-infected B cells and subsequently acquire the ability to bind EBV [105]. Similar mechanisms of transfer of target cell membrane proteins to CTL have also been described [106]. It is plausible, therefore, that NK and CTL that come in close contact with

EBV-infected B cells acquire CD21 and thus become susceptible to EBV infection [29].

To understand the genetic factors associated with EBV-HLH, Hatta et al. analyzed polymorphisms within genes encoding cytokines produced by CTL and their receptors in patients with IM, EBV-HLH, and CAEBV and in healthy controls [107]. These investigators identified a polymorphism in the gene encoding transforming growth factor-beta 1 (TGFβ1) that was overrepresented and one in the gene encoding IL-1α that was underrepresented in EBV-HLH patients. Based on these observations, the investigators speculate that patients harboring these polymorphisms might express higher levels of TGF-β1, which could suppress the immune reaction to EBV, and lower levels of IL-1α, which would further dampen the antiviral immune response. Collectively, these effects could impair virus elimination and enable development of

HLH. Henderson et al. [93] reported that expression of the viral homologue of Bcl-2, a molecule known as BHRF1, inhibits apoptosis of EBV-infected T cells, and thus EBV infection of this cell lineage may promote sustained proliferation and cytokine production.

Treatment of EBV-HLH

Although the prognosis for EBV-HLH has improved over time, it can be fatal in a substantial proportion of cases. Imashuku et al. [108] reported that the early use of etoposide within 4 weeks from EBV-HLH diagnosis significantly improved survival. Subsequently, this group also showed that the combination of etoposide, dexamethasone, and cyclosporine A could effectively achieve long-term control of EBV-HLH [109, 110]. Nonetheless, chemotherapy containing regimens may not always be needed, and in rare cases, spontaneous recovery can occur even in patients with severe disease. In support of this notion, Shiraishi et al. [111] reported that 14 of 22 patients with EBV-HLH (64%) improved without etoposide. Kogawa et al. [79] also showed that 37 of 93 with EBV-HLH (40%) were treated without etoposide-containing regimens, and the overall survival rate was not different between those treated or not with etoposide. These findings suggest that about half of Japanese EBV-HLH patients can be successfully treated without etoposide.

The identification of prognostic factors in EBV-HLH has been a major focus of investigation. Ishii et al. reported that an adult age, EBV reactivation, and multidrug chemotherapy were associated with a poor clinical outcome in patients with EBV-HLH [14]. Kogawa and colleagues completed a retrospective analysis of 98 children with EBV-HLH [79], most of whom were treated with a chemotherapeutic regimen including corticosteroids, etoposide, and cyclosporine. After initial treatment, 90.3% of patients were in remission, while 7 patients experienced recurrence of EBV-HLH. The 3-year overall survival (OS) and progression-free survival (PFS) rates were 91.2% and 79.3%, respectively.

Among several prognostic factors analyzed, hyperbilirubinemia ($>50 \mu\text{mol/L}$) and hyperferritinemia ($>2000 \mu\text{g/L}$) at the time of diagnosis conferred significantly poorer prognosis. Henter's group identified similar findings [112] and reported that hyperbilirubinemia, hyperferritinemia, and cerebrospinal fluid pleocytosis at diagnosis, as well as thrombocytopenia and hyperferritinemia 2 weeks after the initiation of treatment, adversely affect the outcome of HLH. In contrast, EBV load, NK cell activity, the type of cell infected by EBV (T/NK versus B), and the presence of clonality at the onset of disease were not associated with a poorer outcome in EBV-HLH [14, 79]. Of note, in these studies, some patients who had completed initial treatment remained in a durable remission of HLH without further therapy despite persistently elevated EBV loads. The early identification of those who respond poorly to initial therapy may be beneficial by allowing for a change in treatment approach.

With this in mind, one interesting concept is to deplete EBV-infected B cells using the B cell-targeting monoclonal antibody rituximab. The EBV-HLH Rituximab Study Group of the Histiocyte Society completed a retrospective analysis of 42 patients with EBV-HLH who had received a rituximab-containing regimen [67]. On average, patients received three rituximab infusions (range 1–10) with a median dose of 375 mg/m^2 . Rituximab was always given in conjunction with corticosteroids, etoposide, and/or cyclosporine [67]. Rituximab-containing regimens appeared well-tolerated and improved the clinical status in 43% of patients. Treatment with rituximab-containing regimens significantly reduced EBV load and serum ferritin levels, leading the authors to conclude that combination therapies containing rituximab may improve symptoms, reduce viral load, and diminish inflammation in patients with EBV-HLH.

Allogeneic hematopoietic stem cell transplantation (HSCT) for acquired EBV-HLH must be reserved for patients who relapse or show persistent disease despite treatment. In a retrospective study by Imashuku et al., 14 patients with EBV-HLH underwent HSCT, including unrelated

donor cord blood transplantation (UCBT) in half of the cases [113]. The 10-year overall survival rate was $85.7 \pm 9.4\%$, with the survival of UCBT recipients $>65\%$. However, HSCT with myeloablative conditioning (MAC) is associated with high transplantation-related mortality [114]. Recently, reduced-intensity conditioning (RIC), which is less toxic and associated with a lower incidence of long-term sequelae, has been used for primary HLH. Conditioning regimens with alemtuzumab, fludarabine, and melphalan or treosulfan lead to improved outcomes in HSCT for HLH, with a 75% or better survival rate [115–117]. Recent studies describe unrelated cord blood transplantation with RIC, including fludarabine and melphalan with or without low-dose total-body irradiation (TBI) for both primary and EBV-HLH, with successful results [113, 118, 119].

The current treatment strategy for EBV-HLH in Japan is described in Fig. 12.3. In this strategy, patients are categorized into low- and high-risk groups according to the initial treatment response to corticosteroids. Low-risk patients with a good response, defined as resolution of fever within several days, continue with corticosteroids and γ -globulin. Those with a poor response, defined as no resolution of fever within several days, are treated with additional therapy based on the

HLH-2004 protocol which is used from the beginning in the poor-risk group. Rituximab can be also be added to remove proliferating EBV-infected B cells. If disease is still active despite HLH-2004-based treatment and possibly rituximab, other cytotoxic drugs or allogeneic HSCT should be initiated. Other possible risk factors, including high ferritin or bilirubin levels, and high EBV loads at onset or during the treatment, should be clarified by this or other prospective studies.

Conclusions for EBV-HLH

In summary, the last two decades have witnessed great strides in the awareness and understanding of EBV-HLH, where it is now recognized that this syndrome is associated with a spectrum of disease severity and caused by the entry of EBV into non-B as well as B cells. Despite these advances, many questions remain unanswered. Accordingly, the goals for future research are plentiful and include: (1) deciphering the genetic or other risk factors that influence disease susceptibility and treatment response; (2) identifying and further characterizing the mechanisms by which EBV enters into and influences the functions of NK, T

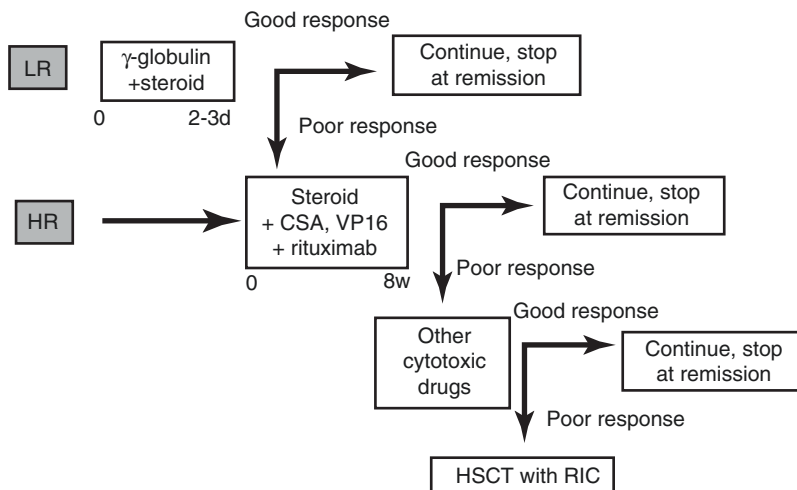


Fig. 12.3 Treatment strategy for EBV-HLH. Patients without risk factors (as defined in the text) should be initially treated with corticosteroids and γ -globulin. If fever does not resolve within several days or for those with risk

factors, immunochemotherapy and possibly also rituximab should be used. If the disease is still active despite these approaches, other cytotoxic drugs or HSCT should be considered

and B cells; and (3) developing novel and rational therapeutic strategies to further improve the cure rate for children and adults who experience this often devastating disease.

References

1. Warnke RA, Kim H, Dorfman RF. Malignant histiocytosis (histiocytic medullary reticulosis). I. Clinicopathologic study of 29 cases. *Cancer*. 1975;35(1):215–30.
2. Ramos-Casals M, Brito-Zeron P, Lopez-Guillermo A, Khamashta MA, Bosch X. Adult haemophagocytic syndrome. *Lancet*. 2014;383(9927):1503–16.
3. Lehmborg K, Nichols KE, Henter JI, Girschikofsky M, Greenwood T, Jordan M, et al. Consensus recommendations for the diagnosis and management of hemophagocytic lymphohistiocytosis associated with malignancies. *Haematologica*. 2015;100(8):997–1004.
4. Al-Hashmi I, Decoteau J, Gruss HJ, Zielenska M, Thorner P, Poon A, et al. Establishment of a cytokine-producing anaplastic large-cell lymphoma cell line containing the t(2;5) translocation: potential role of cytokines in clinical manifestations. *Leuk Lymphoma*. 2001;40(5–6):599–611.
5. Siebert S, Amos N, Williams BD, Lawson TM. Cytokine production by hepatic anaplastic large-cell lymphoma presenting as a rheumatic syndrome. *Semin Arthritis Rheum*. 2007;37(1):63–7.
6. Perez-Encinas M, Villamayor M, Campos A, Gonzalez S, Bello JL. Tumor burden and serum level of soluble CD25, CD8, CD23, CD54 and CD44 in non-Hodgkin's lymphoma. *Haematologica*. 1998;83(8):752–4.
7. Janik JE, Morris JC, Pittaluga S, McDonald K, Raffeld M, Jaffe ES, et al. Elevated serum-soluble interleukin-2 receptor levels in patients with anaplastic large cell lymphoma. *Blood*. 2004;104(10):3355–7.
8. Menard F, Besson C, Rince P, Lambotte O, Lazure T, Canioni D, et al. Hodgkin lymphoma-associated hemophagocytic syndrome: a disorder strongly correlated with Epstein-Barr virus. *Clin Infect Dis*. 2008;47(4):531–4.
9. Risdall RJ, McKenna RW, Nesbit ME, Krivit W, Balfour HH Jr, Simmons RL, et al. Virus-associated hemophagocytic syndrome: a benign histiocytic proliferation distinct from malignant histiocytosis. *Cancer*. 1979;44(3):993–1002.
10. Delavigne K, Berard E, Bertoli S, Corre J, Duchayne E, Demur C, et al. Hemophagocytic syndrome in patients with acute myeloid leukemia undergoing intensive chemotherapy. *Haematologica*. 2014;99(3):474–80.
11. Celkan T, Berrak S, Kazanci E, Ozyurek E, Unal S, Ucar C, et al. Malignancy-associated hemophagocytic lymphohistiocytosis in pediatric cases: a multicenter study from Turkey. *Turk J Pediatr*. 2009;51(3):207–13.
12. Lehmborg K, Sprekels B, Nichols KE, Woessmann W, Müller I, Suttorp M, Bernig T, Beutel K, Bode SFN, Kentouche K, Kolb R, Längler A, Minkov M, Schillign FH, Schmid I, Vieth S, Ehl S, Zur Stadt U, Janka GE. Malignancy-associated haemophagocytic lymphohistiocytosis in children and adolescents. *B J Haematol*. 2015;170(4):539–49.
13. Riviere S, Galicier L, Coppo P, Marzac C, Aumont C, Lambotte O, et al. Reactive hemophagocytic syndrome in adults: a multicenter retrospective analysis of 162 patients. *Am J Med*. 2014;127(11):1118–25.
14. Ishii E, Ohga S, Imashuku S, Yasukawa M, Tsuda H, Miura I, et al. Nationwide survey of hemophagocytic lymphohistiocytosis in Japan. *Int J Hematol*. 2007;86(1):58–65.
15. Li J, Wang Q, Zheng W, Ma J, Zhang W, Wang W, et al. Hemophagocytic lymphohistiocytosis: clinical analysis of 103 adult patients. *Medicine*. 2014;93(2):100–5.
16. Yu JT, Wang CY, Yang Y, Wang RC, Chang KH, Hwang WL, et al. Lymphoma-associated hemophagocytic lymphohistiocytosis: experience in adults from a single institution. *Ann Hematol*. 2013;92(11):1529–36.
17. Han AR, Lee HR, Park BB, Hwang IG, Park S, Lee SC, et al. Lymphoma-associated hemophagocytic syndrome: clinical features and treatment outcome. *Ann Hematol*. 2007;86(7):493–8.
18. Veerakul G, Sanpakit K, Tanphaichitr VS, Mahasandana C, Jirattanasopa N. Secondary hemophagocytic lymphohistiocytosis in children: an analysis of etiology and outcome. *J Med Assoc Thai*. 2002;85(Suppl 2):S530–41.
19. Lehmborg K, Sprekels B, Nichols KE, Woessmann W, Müller I, Suttorp M, et al. Malignancy-associated haemophagocytic lymphohistiocytosis in children and adolescents. *Br J Haematol*. 2015;170(4):539–49.
20. Go RS, Wester SM. Immunophenotypic and molecular features, clinical outcomes, treatments, and prognostic factors associated with subcutaneous panniculitis-like T-cell lymphoma: a systematic analysis of 156 patients reported in the literature. *Cancer*. 2004;101(6):1404–13.
21. Ferreri AJ, Dognini GP, Campo E, Willemze R, Seymour JF, Bairey O, et al. Variations in clinical presentation, frequency of hemophagocytosis and clinical behavior of intravascular lymphoma diagnosed in different geographical regions. *Haematologica*. 2007;92(4):486–92.
22. Kelly C, Salvi S, McClain K, Hayani A. Hemophagocytic lymphohistiocytosis associated with precursor B acute lymphoblastic leukemia. *Pediatr Blood Cancer*. 2011;56(4):658–60.
23. Nichols CR, Roth BJ, Heerema N, Griep J, Tricot G. Hematologic neoplasia associated with primary mediastinal germ-cell tumors. *N Engl J Med*. 1990;322(20):1425–9.
24. Chang YH, Lu PJ, Lu MY, Wang JS, Tung CL, Shaw CF. Sequential transplants for respective relapse of Hodgkin disease and hemophago-

- cytic lymphohistiocytosis: a treatment dilemma. *J Pediatr Hematol Oncol.* 2009;31(10):778–81.
25. Shimazaki C, Inaba T, Nakagawa M. B-cell lymphoma-associated hemophagocytic syndrome. *Leuk Lymphoma.* 2000;38(1–2):121–30.
 26. Murase T, Nakamura S, Kawauchi K, Matsuzaki H, Sakai C, Inaba T, et al. An Asian variant of intravascular large B-cell lymphoma: clinical, pathological and cytogenetic approaches to diffuse large B-cell lymphoma associated with haemophagocytic syndrome. *Br J Haematol.* 2000;111(3):826–34.
 27. Stebbing J, Ngan S, Ibrahim H, Charles P, Nelson M, Kelleher P, et al. The successful treatment of haemophagocytic syndrome in patients with human immunodeficiency virus-associated multi-centric Castleman's disease. *Clin Exp Immunol.* 2008;154(3):399–405.
 28. Hong M, Ko YH, Yoo KH, Koo HH, Kim SJ, Kim WS, et al. EBV-positive T/NK-cell Lymphoproliferative disease of childhood. *Korean J Pathol.* 2013;47(2):137–47.
 29. Kimura H, Ito Y, Kawabe S, Gotoh K, Takahashi Y, Kojima S, et al. EBV-associated T/NK-cell lymphoproliferative diseases in nonimmunocompromised hosts: prospective analysis of 108 cases. *Blood.* 2012;119(3):673–86.
 30. Paik JH, Choe JY, Kim H, Lee JO, Kang HJ, Shin HY, et al. Clinicopathological categorization of Epstein-Barr virus-positive T/NK-cell lymphoproliferative disease: an analysis of 42 cases with an emphasis on prognostic implications. *Leuk Lymphoma.* 2017;58(1):53–63. Epub 2016 May 9.
 31. Aronson IK, Worobec SM. Cytophagic histiocytic panniculitis and hemophagocytic lymphohistiocytosis: an overview. *Dermatol Ther.* 2010;23(4):389–402.
 32. Trebo MM, Attarbaschi A, Mann G, Minkov M, Kornmuller R, Gadner H. Histiocytosis following T-acute lymphoblastic leukemia: a BFM study. *Leuk Lymphoma.* 2005;46(12):1735–41.
 33. Lackner H, Urban C, Sovinz P, Benesch M, Moser A, Schwinger W. Hemophagocytic lymphohistiocytosis as severe adverse event of antineoplastic treatment in children. *Haematologica.* 2008;93(2):291–4.
 34. Teachey DT, Rheingold SR, Maude SL, Zugmaier G, Barrett DM, Seif AE, et al. Cytokine release syndrome after blinatumomab treatment related to abnormal macrophage activation and ameliorated with cytokine-directed therapy. *Blood.* 2013;121(26):5154–7.
 35. Henter JI, Horne A, Arico M, Egeler RM, Filipovich AH, Imashuku S, et al. HLH-2004: diagnostic and therapeutic guidelines for hemophagocytic lymphohistiocytosis. *Pediatr Blood Cancer.* 2007;48(2):124–31.
 36. Gupta A, Tyrrell P, Valani R, Benseler S, Weitzman S, Abdelhaleem M. The role of the initial bone marrow aspirate in the diagnosis of hemophagocytic lymphohistiocytosis. *Pediatr Blood Cancer.* 2008;51(3):402–4.
 37. Tsuji T, Hirano T, Yamasaki H, Tsuji M, Tsuda H. A high sIL-2R/ferritin ratio is a useful marker for the diagnosis of lymphoma-associated hemophagocytic syndrome. *Ann Hematol.* 2014;93(5):821–6.
 38. Hayden A, Park S, Giustini D, Lee AY, Chen LY. Hemophagocytic syndromes (HPSs) including hemophagocytic lymphohistiocytosis (HLH) in adults: a systematic scoping review. *Blood Rev.* 2016;30(6):411–20.
 39. Fardet L, Galicier L, Lambotte O, Marzac C, Aumont C, Chahwan D, et al. Development and validation of the HScore, a score for the diagnosis of reactive hemophagocytic syndrome. *Arthritis Rheumatol.* 2014;66(9):2613–20.
 40. Fardet L, Lambotte O, Meynard JL, Kamouh W, Galicier L, Marzac C, et al. Reactive haemophagocytic syndrome in 58 HIV-1-infected patients: clinical features, underlying diseases and prognosis. *AIDS.* (London, England). 2010;24(9):1299–306.
 41. Wang J, Wang D, Zhang Q, Duan L, Tian T, Zhang X, et al. The significance of pre-therapeutic F-18-FDG PET-CT in lymphoma-associated hemophagocytic lymphohistiocytosis when pathological evidence is unavailable. *J Cancer Res Clin Oncol.* 2016;142(4):859–71.
 42. LehMBERG K, Ehl S. Diagnostic evaluation of patients with suspected hemophagocytic lymphohistiocytosis. *Br J Haematol.* 2012;160(3):275–87.
 43. Booth C, Gilmour KC, Veys P, Gennery AR, Slatter MA, Chapel H, et al. X-linked lymphoproliferative disease due to SAP/SH2D1A deficiency: a multicenter study on the manifestations, management and outcome of the disease. *Blood.* 2011;117(1):53–62.
 44. Speckmann C, LehMBERG K, Albert MH, Damgaard RB, Fritsch M, Gyrd-Hansen M, et al. X-linked inhibitor of apoptosis (XIAP) deficiency: the spectrum of presenting manifestations beyond hemophagocytic lymphohistiocytosis. *Clin Immunol.* 2013;149(1):133–41.
 45. Cohen JI. Primary immunodeficiencies associated with EBV disease. *Curr Top Microbiol Immunol.* 2015;390(Pt 1):241–65.
 46. Smyth MJ, Thia KY, Street SE, MacGregor D, Godfrey DI, Trapani JA. Perforin-mediated cytotoxicity is critical for surveillance of spontaneous lymphoma. *J Exp Med.* 2000;192(5):755–60.
 47. Chia J, Yeo KP, Whisstock JC, Dunstone MA, Trapani JA, Voskoboinik I. Temperature sensitivity of human perforin mutants unmasks subtotal loss of cytotoxicity, delayed FHL, and a predisposition to cancer. *Proc Natl Acad Sci U S A.* 2009;106(24):9809–14.
 48. Clementi R, Locatelli F, Dupre L, Garaventa A, Emmi L, Bregni M, et al. A proportion of patients with lymphoma may harbor mutations of the perforin gene. *Blood.* 2005;105(11):4424–8.
 49. Santoro A, Cannella S, Trizzino A, Lo Nigro L, Corsello G, Arico M. A single amino acid change A91V in perforin: a novel, frequent predisposing factor to childhood acute lymphoblastic leukemia? *Haematologica.* 2005;90(5):697–8.
 50. Mehta PA, Davies SM, Kumar A, Devidas M, Lee S, Zamzow T, et al. Perforin polymorphism A91V and susceptibility to B-precursor childhood acute lymphoblastic leukemia: a report from the children's oncology group. *Leukemia.* 2006;20(9):1539–41.

51. Lofstedt A, Chiang SC, Onelov E, Bryceson YT, Meeths M, Henter JI. Cancer risk in relatives of patients with a primary disorder of lymphocyte cytotoxicity: a retrospective cohort study. *Lancet Haematol.* 2015;2(12):e536–42.
52. Machaczka M, Klimkowska M, Chiang SC, Meeths M, Muller ML, Gustafsson B, et al. Development of classical Hodgkin's lymphoma in an adult with biallelic STXBP2 mutations. *Haematologica.* 2013;98(5):760–4.
53. Lorenzi L, Tabellini G, Vermi W, Moratto D, Porta F, Notarangelo LD, et al. Occurrence of nodular lymphocyte-predominant hodgkin lymphoma in herman-sky-pudlak type 2 syndrome is associated to natural killer and natural killer T cell defects. *PLoS One.* 2013;8(11):e80131.
54. Nagai K, Ochi F, Terui K, Maeda M, Ohga S, Kanegane H, et al. Clinical characteristics and outcomes of chediak-Higashi syndrome: a nationwide survey of Japan. *Pediatr Blood Cancer.* 2013;60(10):1582–6.
55. Pagel J, Beutel K, Lehmborg K, Koch F, Maul-Pavicic A, Rohlf AK, et al. Distinct mutations in STXBP2 are associated with variable clinical presentations in patients with familial hemophagocytic lymphohistiocytosis type 5 (FHL5). *Blood.* 2012;119(25):6016–24.
56. Yoshida N, Tsuzuki S, Karube K, Takahara T, Suguro M, Miyoshi H, et al. STX11 functions as a novel tumor suppressor gene in peripheral T-cell lymphomas. *Cancer Sci.* 2015;106(10):1455–62.
57. Trapani JA, Thia KY, Andrews M, Davis ID, Gedye C, Parente P, et al. Human perforin mutations and susceptibility to multiple primary cancers. *Oncoimmunology.* 2013;2(4):e24185.
58. Bryceson YT, Pende D, Maul-Pavicic A, Gilmour KC, Ufheil H, Vraetz T, et al. A prospective evaluation of degranulation assays in the rapid diagnosis of familial hemophagocytic syndromes. *Blood.* 2012;119(12):2754–63.
59. Marsh RA, Bleesing JJ, Filipovich AH. Flow cytometric measurement of SLAM-associated protein and X-linked inhibitor of apoptosis. *Methods Mol Biol.* 2013;979:189–97.
60. Johnson TS, Terrell CE, Millen SH, Katz JD, Hildeman DA, Jordan MB. Etoposide selectively ablates activated T cells to control the immunoregulatory disorder hemophagocytic lymphohistiocytosis. *J Immunol.* 2014;192(1):84–91.
61. Wang Y, Huang W, Hu L, Cen X, Li L, Wang J, et al. Multicenter study of combination DEP regimen as a salvage therapy for adult refractory hemophagocytic lymphohistiocytosis. *Blood.* 2015;126(19):2186–92.
62. Arca M, Fardet L, Galicier L, Riviere S, Marzac C, Aumont C, et al. Prognostic factors of early death in a cohort of 162 adult haemophagocytic syndrome: impact of triggering disease and early treatment with etoposide. *Br J Haematol.* 2014;168(1):63–8.
63. Schram AM, Comstock P, Campo M, Gorovets D, Mullally A, Bodio K, et al. Haemophagocytic lymphohistiocytosis in adults: a multicentre case series over 7 years. *Br J Haematol.* 2016;172(3):412–9.
64. Mizutani S, Kuroda J, Shimura Y, Kobayashi T, Tsutsumi Y, Yamashita M, et al. Cyclosporine A for chemotherapy-resistant subcutaneous panniculitis-like T cell lymphoma with hemophagocytic syndrome. *Acta Haematol.* 2011;126(1):8–12.
65. Maschalidi S, Sepulveda FE, Garrigue A, Fischer A, de Saint Basile G. Therapeutic effect of JAK1/2 blockade on the manifestations of hemophagocytic lymphohistiocytosis in mice. *Blood.* 2016;128(1):60–71.
66. Das R, Guan P, Sprague L, Verbist K, Tedrick P, An QA, et al. Janus kinase inhibition lessens inflammation and ameliorates disease in murine models of hemophagocytic lymphohistiocytosis. *Blood.* 2016;127(13):1666–75.
67. Chellapandian D, Das R, Zelle K, Wiener SJ, Zhao H, Teachey DT, et al. Treatment of Epstein Barr virus-induced haemophagocytic lymphohistiocytosis with rituximab-containing chemo-immunotherapeutic regimens. *Br J Haematol.* 2013;162(3):376–82.
68. Aulagnon F, Lapidus N, Canet E, Galicier L, Boutboul D, Peraldi MN, et al. Acute kidney injury in adults with hemophagocytic lymphohistiocytosis. *Am J Kidney Dis.* 2015;65(6):851–9.
69. Takahashi N, Chubachi A, Kume M, Hatano Y, Komatsuda A, Kawabata Y, et al. A clinical analysis of 52 adult patients with hemophagocytic syndrome: the prognostic significance of the underlying diseases. *Int J Hematol.* 2001;74(2):209–13.
70. Parikh SA, Kapoor P, Letendre L, Kumar S, Wolanskyj AP. Prognostic factors and outcomes of adults with hemophagocytic lymphohistiocytosis. *Mayo Clin Proc.* 2014;89(4):484–92.
71. Tong H, Ren Y, Liu H, Xiao F, Mai W, Meng H, et al. Clinical characteristics of T-cell lymphoma associated with hemophagocytic syndrome: comparison of T-cell lymphoma with and without hemophagocytic syndrome. *Leuk Lymphoma.* 2008;49(1):81–7.
72. Buyse S, Teixeira L, Galicier L, Mariotte E, Lemiale V, Seguin A, et al. Critical care management of patients with hemophagocytic lymphohistiocytosis. *Intensive Care Med.* 2010;36(10):1695–702.
73. Kawa K. Epstein-Barr virus--associated diseases in humans. *Int J Hematol.* 2000;71(2):108–17.
74. Cohen JI. Epstein-Barr virus infection. *N Engl J Med.* 2000;343(7):481–92.
75. Zhang K, Wakefield E, Marsh R. Lymphoproliferative disease, X-Linked. In: Pagon RA, Adam MP, Ardinger HH, Wallace SE, Amemiya A, Bean LJH, et al., editors. *GeneReviews(R)*. Seattle;1993.
76. Castillo L, Carcillo J. Secondary hemophagocytic lymphohistiocytosis and severe sepsis/ systemic inflammatory response syndrome/multiorgan dysfunction syndrome/macrophage activation syndrome share common intermediate phenotypes on a spectrum of inflammation. *Pediatr Crit Care Med.* 2009;10(3):387–92.
77. Chen J, Wang X, He P, Li Y, Si M, Fan Z, et al. Viral etiology, clinical and laboratory features of adult hemophagocytic lymphohistiocytosis. *J Med Virol.* 2016;88(3):541–9.

78. Imashuku S, Ikushima S, Hibi S, Todo S. Langerhans cell histiocytosis and hemophagocytic syndrome in Japan: epidemiological studies. *Int J Pediatr Hematol Oncol.* 1994;1:241–6.
79. Kogawa K, Sato H, Asano T, Ohga S, Kudo K, Morimoto A, et al. Prognostic factors of Epstein-Barr virus-associated hemophagocytic lymphohistiocytosis in children: report of the Japan Histiocytosis Study Group. *Pediatr Blood Cancer.* 2014;61(7):1257–62.
80. Koh KN, Im HJ, Chung NG, Cho B, Kang HJ, Shin HY, et al. Clinical features, genetics, and outcome of pediatric patients with hemophagocytic lymphohistiocytosis in Korea: report of a nationwide survey from Korea Histiocytosis Working Party. *Eur J Haematol.* 2015;94(1):51–9.
81. Gurgey A, Secmeer G, Tavil B, Ceyhan M, Kuskonmaz B, Cengiz B, et al. Secondary hemophagocytic lymphohistiocytosis in Turkish children. *Pediatr Infect Dis J.* 2005;24(12):1116–7.
82. Ishii E, Ohga S, Imashuku S, Kimura N, Ueda I, Morimoto A, et al. Review of hemophagocytic lymphohistiocytosis (HLH) in children with focus on Japanese experiences. *Crit Rev Oncol Hematol.* 2005;53(3):209–23.
83. Henter JL, Arico M, Egeler RM, Elinder G, Favara BE, Filipovich AH, et al. HLH-94: a treatment protocol for hemophagocytic lymphohistiocytosis. HLH study Group of the Histiocyte Society. *Med Pediatr Oncol.* 1997;28(5):342–7.
84. Allen CE, McClain KL. Pathophysiology and epidemiology of hemophagocytic lymphohistiocytosis. *Hematology Am Soc Hematol Educ Program.* 2015;2015:177–82.
85. Ishii E, Ohga S, Tanimura M, Imashuku S, Sako M, Mizutani S, et al. Clinical and epidemiologic studies of familial hemophagocytic lymphohistiocytosis in Japan. Japan LCH Study Group. *Med Pediatr Oncol.* 1998;30(5):276–83.
86. Kimura H, Hoshino Y, Hara S, Nishikawa K, Sako M, Hirayama M, et al. Viral load in Epstein-Barr virus-associated hemophagocytic syndrome. *Microbiol Immunol.* 2002;46(8):579–82.
87. Yamashita N, Kimura H, Morishima T. Virological aspects of Epstein-Barr virus infections. *Acta Med Okayama.* 2005;59(6):239–46.
88. Fadeel B, Orrenius S, Henter JL. Familial hemophagocytic lymphohistiocytosis: too little cell death can seriously damage your health. *Leuk Lymphoma.* 2001;42(1–2):13–20.
89. de Saint BG, Sepulveda FE, Maschalidi S, Fischer A. Cytotoxic granule secretion by lymphocytes and its link to immune homeostasis. *F1000Res.* 2015;4(F1000 Faculty Rev):930.
90. Parvaneh N, Filipovich AH, Borkhardt A. Primary immunodeficiencies predisposed to Epstein-Barr virus-driven hematological diseases. *Br J Haematol.* 2013;162(5):573–86.
91. Zhizhuo H, Junmei X, Yuelin S, Qiang Q, Chunyan L, Zhengde X, et al. Screening the PRF1, UNC13D, STX11, SH2D1A, XIAP, and ITK gene mutations in Chinese children with Epstein-Barr virus-associated hemophagocytic lymphohistiocytosis. *Pediatr Blood Cancer.* 2012;58(3):410–4.
92. Dupre L, Andolfi G, Tangye SG, Clementi R, Locatelli F, Arico M, et al. SAP controls the cytolytic activity of CD8+ T cells against EBV-infected cells. *Blood.* 2005;105(11):4383–9.
93. Kasahara Y, Yachie A, Takei K, Kanegane C, Okada K, Ohta K, et al. Differential cellular targets of Epstein-Barr virus (EBV) infection between acute EBV-associated hemophagocytic lymphohistiocytosis and chronic active EBV infection. *Blood.* 2001;98(6):1882–8.
94. Wada T, Kurokawa T, Toma T, Shibata F, Tone Y, Hashida Y, et al. Immunophenotypic analysis of Epstein-Barr virus (EBV)-infected CD8(+) T cells in a patient with EBV-associated hemophagocytic lymphohistiocytosis. *Eur J Haematol.* 2007;79(1):72–5.
95. Toga A, Wada T, Sakakibara Y, Mase S, Araki R, Tone Y, et al. Clinical significance of cloned expansion and CD5 down-regulation in Epstein-Barr Virus (EBV)-infected CD8+ T lymphocytes in EBV-associated hemophagocytic lymphohistiocytosis. *J Infect Dis.* 2010;201(12):1923–32.
96. Beutel K, Gross-Wieltsch U, Wiesel T, Stadt UZ, Janka G, Wagner HJ. Infection of T lymphocytes in Epstein-Barr virus-associated hemophagocytic lymphohistiocytosis in children of non-Asian origin. *Pediatr Blood Cancer.* 2009;53(2):184–90.
97. Chuang HC, Lay JD, Hsieh WC, Wang HC, Chang Y, Chuang SE, et al. Epstein-Barr virus LMP1 inhibits the expression of SAP gene and upregulates Th1 cytokines in the pathogenesis of hemophagocytic syndrome. *Blood.* 2005;106(9):3090–6.
98. Nagy N, Matskova L, Kis LL, Hellman U, Klein G, Klein E. The proapoptotic function of SAP provides a clue to the clinical picture of X-linked lymphoproliferative disease. *Proc Natl Acad Sci U S A.* 2009;106(29):11966–71.
99. Lay JD, Chuang SE, Rowe M, Su IJ. Epstein-barr virus latent membrane protein-1 mediates upregulation of tumor necrosis factor- α in EBV-infected T cells: implications for the pathogenesis of hemophagocytic syndrome. *J Biomed Sci.* 2003;10(1):146–55.
100. Kawanishi M. Expression of Epstein-Barr virus latent membrane protein 1 protects Jurkat T cells from apoptosis induced by serum deprivation. *Virology.* 1997;228(2):244–50.
101. Kasahara Y, Yachie A. Cell type specific infection of Epstein-Barr virus (EBV) in EBV-associated hemophagocytic lymphohistiocytosis and chronic active EBV infection. *Crit Rev Oncol Hematol.* 2002;44(3):283–94.

102. Owen G, Webb DK. Evidence of clonality in a child with haemophagocytic lymphohistiocytosis. *Br J Haematol.* 1995;89(3):681–2.
103. Matsuda K, Nakazawa Y, Yanagisawa R, Honda T, Ishii E, Koike K. Detection of T-cell receptor gene rearrangement in children with Epstein-Barr virus-associated hemophagocytic lymphohistiocytosis using the BIOMED-2 multiplex polymerase chain reaction combined with GeneScan analysis. *Clin Chim Acta.* 2011;412(17–18):1554–8.
104. Braun M, Melchers I, Peter HH, Illges H. Human B and T lymphocytes have similar amounts of CD21 mRNA, but differ in surface expression of the CD21 glycoprotein. *Int Immunol.* 1998;10(8):1197–202.
105. Tabiasco J, Vercellone A, Meggetto F, Hudrisier D, Brousset P, Fournie JJ. Acquisition of viral receptor by NK cells through immunological synapse. *J Immunol.* 2003;170(12):5993–8.
106. Stinchcombe JC, Bossi G, Booth S, Griffiths GM. The immunological synapse of CTL contains a secretory domain and membrane bridges. *Immunity.* 2001;15(5):751–61.
107. Hatta K, Morimoto A, Ishii E, Kimura H, Ueda I, Hibi S, et al. Association of transforming growth factor-beta1 gene polymorphism in the development of Epstein-Barr virus-related hematologic diseases. *Haematologica.* 2007;92(11):1470–4.
108. Imashuku S, Kuriyama K, Teramura T, Ishii E, Kinugawa N, Kato M, et al. Requirement for etoposide in the treatment of Epstein-Barr virus-associated hemophagocytic lymphohistiocytosis. *J Clin Oncol.* 2001;19(10):2665–73.
109. Imashuku S, Hibi S, Ohara T, Iwai A, Sako M, Kato M, et al. Effective control of Epstein-Barr virus-related hemophagocytic lymphohistiocytosis with immunochemotherapy. *Histiocyte Society. Blood.* 1999;93(6):1869–74.
110. Imashuku S, Teramura T, Tauchi H, Ishida Y, Otoh Y, Sawada M, et al. Longitudinal follow-up of patients with Epstein-Barr virus-associated hemophagocytic lymphohistiocytosis. *Haematologica.* 2004;89(2):183–8.
111. Shiraishi A, Ohga S, Doi T, Ishimura M, Takimoto T, Takada H, et al. Treatment choice of immunotherapy or further chemotherapy for Epstein-Barr virus-associated hemophagocytic lymphohistiocytosis. *Pediatr Blood Cancer.* 2012;59(2):265–70.
112. Trottestam H, Berglof E, Horne A, Onelov E, Beutel K, Lehmberg K, et al. Risk factors for early death in children with haemophagocytic lymphohistiocytosis. *Acta Paediatr.* 2012;101(3):313–8.
113. Ohga S, Kudo K, Ishii E, Honjo S, Morimoto A, Osugi Y, et al. Hematopoietic stem cell transplantation for familial hemophagocytic lymphohistiocytosis and Epstein-Barr virus-associated hemophagocytic lymphohistiocytosis in Japan. *Pediatr Blood Cancer.* 2010;54(2):299–306.
114. Chandrakasan S, Filipovich AH. Hemophagocytic lymphohistiocytosis: advances in pathophysiology, diagnosis, and treatment. *J Pediatr.* 2013;163(5):1253–9.
115. Cooper N, Rao K, Gilmour K, Hadad L, Adams S, Cale C, et al. Stem cell transplantation with reduced-intensity conditioning for hemophagocytic lymphohistiocytosis. *Blood.* 2006;107(3):1233–6.
116. Marsh RA, Vaughn G, Kim MO, Li D, Jodele S, Joshi S, et al. Reduced-intensity conditioning significantly improves survival of patients with hemophagocytic lymphohistiocytosis undergoing allogeneic hematopoietic cell transplantation. *Blood.* 2010;116(26):5824–31.
117. Lehmberg K, Albert MH, Beier R, Beutel K, Gruhn B, Kroger N, et al. Treosulfan-based conditioning regimen for children and adolescents with hemophagocytic lymphohistiocytosis. *Haematologica.* 2014;99(1):180–4.
118. Sawada A, Ohga S, Ishii E, Inoue M, Okada K, Inagaki J, et al. Feasibility of reduced-intensity conditioning followed by unrelated cord blood transplantation for primary hemophagocytic lymphohistiocytosis: a nationwide retrospective analysis in Japan. *Int J Hematol.* 2013;98(2):223–30.
119. Nishi M, Nishimura R, Suzuki N, Sawada A, Okamura T, Fujita N, et al. Reduced-intensity conditioning in unrelated donor cord blood transplantation for familial hemophagocytic lymphohistiocytosis. *Am J Hematol.* 2012;87(6):637–9.

Macrophage Activation Syndrome in Rheumatic Diseases (MAS-HLH)

13

Alexei A. Grom, AnnaCarin Horne,
and Fabrizio De Benedetti

List of Abbreviations

MAS	macrophage activation syndrome
HLH	hemophagocytic lymphohistiocytosis
SJIA	systemic juvenile idiopathic arthritis
AOSD	adult-onset Still's disease
SLE	systemic lupus erythematosus
DIC	disseminated intravascular coagulation
EBV	Epstein-Barr virus
CMV	cytomegalovirus
NK	natural killer
ESR	erythrocyte sedimentation rate
CRP	C-reactive protein
sIL2Ra	soluble IL-2 receptor alpha chain
LCMV	lymphocytic choriomeningitis virus
TLR	Toll-like receptor
LPS	lipopolysaccharides
ATG	antithymocyte globulin

Definitions

The term *macrophage activation syndrome* (MAS) refers to hemophagocytic syndromes presenting as a complication of a rheumatic disease. Like other hemophagocytic syndromes, it is caused by excessive activation and expansion of T lymphocytes and macrophagic histiocytes that exhibit hemophagocytic activity (Fig. 13.1). In MAS, excessive activation and expansion of T lymphocytes and macrophagic histiocytes lead to a hyperinflammatory state associated with three cardinal features: cytopenias, liver dysfunction, and coagulopathy resembling disseminated intravascular coagulation [1–6]. Extreme hyperferritinemia is another striking laboratory feature of MAS. It is a life-threatening condition and may progress to multiple organ failure. The reported mortality rates reach 20–30% [7, 8].

Epidemiology

Although MAS has been reported in association with many inflammatory disorders, it is seen most frequently in SJIA and, in its adult equivalent, adult-onset Still's disease (AOSD) [7, 9, 10]. The pathophysiology of SJIA and AOSD seems to be driven by continuous activation of innate immune pathways leading to dysregulated production of proinflammatory cytokines, mainly IL-1 β [11, 12] and IL-6 [13–15]. Therefore, many pediatric rheumatologists view SJIA as an

A.A. Grom, MD (✉)
Cincinnati Children's Hospital Medical Center,
Division of Rheumatology, ML 4010,
3333 Burnet Ave, Cincinnati, OH 45229, USA
e-mail: alexei.grom@cchmc.org

A. Horne, MD, PhD
Karolinska University Hospital Solna,
Stockholm, Sweden

F. De Benedetti, MD
Ospedale Pediatrico Bambino Gesù, Rome, Italy

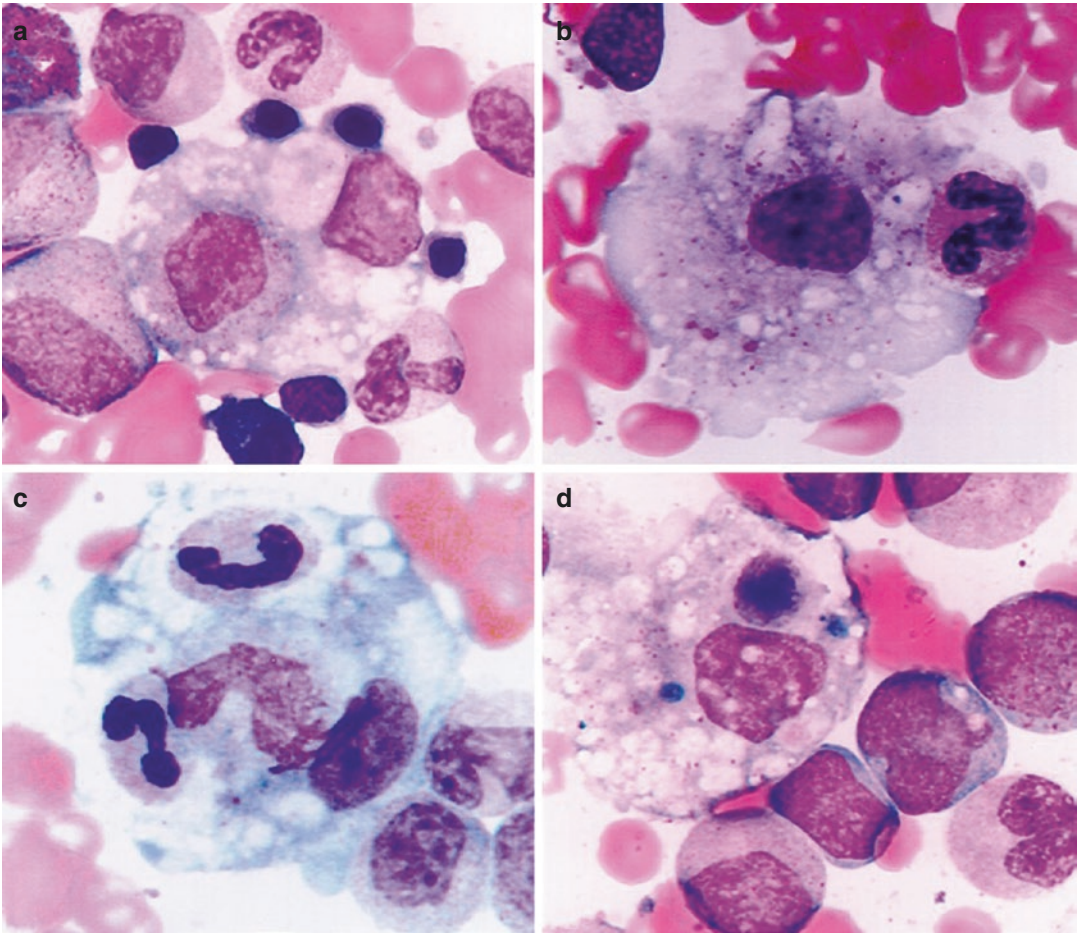


Fig. 13.1 Bone marrow hemophagocytic macrophages in MAS. Bone marrow aspirate specimen revealing activated macrophages (H&E stain, original magnification $\times 1000$). (a) Myelocyte within activated macrophage. In addition, there are multiple adherent red blood cell and myeloid precursors. (b). Activated macrophage engulfing

a neutrophilic band form. (c) Neutrophilic band forms and metamyelocyte within an activated macrophage. Nuclei of band forms appear condensed. (d) Activated macrophage with hemosiderin deposits and a degenerating phagocytosed nucleated cell (With permission from Prahalad et al. [23])

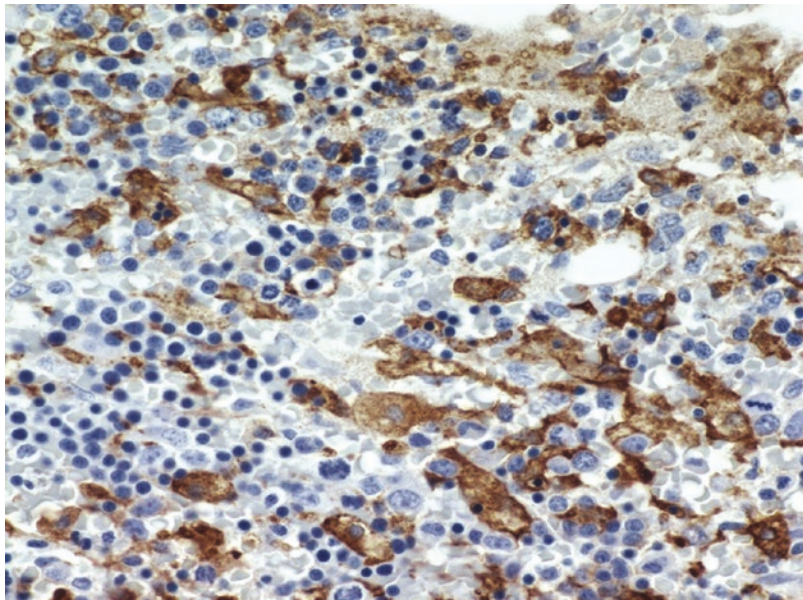
autoinflammatory disorder rather than a classic autoimmune disease [16].

Besides SJIA, systemic lupus erythematosus (SLE) and Kawasaki disease are two other rheumatologic conditions in which MAS appears to occur somewhat more frequently than in other rheumatic diseases [17]. Most patients develop this syndrome at some time during the course of their primary rheumatic disease, but MAS occurring at the initial presentation of a rheumatic illness is not uncommon [18]. In a large retrospective, multicenter survey, about 25% of the episodes were reported as occurring at SJIA

onset with diagnoses of MAS and SJIA being established simultaneously [19]. In adults, based on some limited epidemiologic studies, MAS is seen most frequently in association with adult-onset Still's disease, SLE, and various vasculitic syndromes.

The epidemiologic studies of MAS have been complicated by the lack of defined diagnostic criteria. Based on several reports originating from large pediatric rheumatology centers, approximately 7–17% of patients with SJIA develop full-blown MAS [8, 20], while mild “subclinical” MAS may be seen in as many as one third of

Fig. 13.2 Bone marrow biopsy from an SJIA patient with subclinical MAS. Immunostaining with monoclonal antibodies specific for CD 163. *Brown* staining identifies CD163 + cells many of which have foamy cytoplasm reflecting highly activated status (With permission from Hinze et al. (2010))



patients with active systemic disease [21, 22]. Bone marrow examination in patients with “sub-clinical MAS” typically reveals extensive expansion of highly activated macrophages with only few of these cells exhibiting overt hemophagocytic activity. Additional staining with monoclonal antibodies specific for CD163 might be necessary to highlight such macrophagic expansion (Fig. 13.2). The Division of Rheumatology at Cincinnati Children’s Hospital, a large tertiary center in the USA, is following approximately 50 patients with SJIA, and this number has been relatively stable over the last 10 years. At this center, 2–3 patients are diagnosed with MAS every year, suggesting a crude incidence of MAS in SJIA to be in the range between 4 and 6 MAS cases per 100 patient/years (Grom, unpublished observations).

MAS and HLH

The abundance of tissue macrophages, or *histiocytes*, exhibiting hemophagocytic activity in inflammatory lesions in MAS, suggests that this syndrome belongs to a group of histiocytic disorders collectively known as *hemophagocytic lymphohistiocytosis* or *HLH* [23, 24]. HLH is a more general term that describes a spectrum of disease

processes characterized by accumulations of histologically benign well-differentiated mononuclear cells with a macrophage phenotype [25, 26]. The current classification of histiocytic disorders distinguishes *primary*, or *familial*, *HLH* and *secondary*, or *reactive*, *HLH* (see Chap. 9). Clinically, however, they may be difficult to distinguish from each other. *Primary hemophagocytic lymphohistiocytosis* (*pHLH*) is a constellation or rare autosomal recessive immune disorder linked to genetic defects in various genes all affecting the cytolytic pathway (see Chap. 11). The clinical symptoms of *pHLH* usually become evident within the first months of life. Secondary HLH tends to occur in older children. It may be associated with an identifiable infectious episode, most often Epstein-Barr virus (EBV) or cytomegalovirus (CMV) infection. The group of secondary hemophagocytic disorders also includes *malignancy-associated HLH*. The distinction between primary and secondary HLH is becoming increasingly blurred as new genetic causes are identified, some of which are associated with less severe and somewhat more distinct clinical presentations [27]. Some of these may present later in life due to heterozygous or compound heterozygous mutations in cytolytic pathway genes that confer a partial dominant

negative effect on the cytolytic function [28]. The exact relationship between HLH and MAS is an area of extensive investigations, and some rheumatologists believe that MAS should be categorized as *secondary HLH occurring in a setting of a rheumatic disease* (or MAS-HLH).

Genetic Defects in Primary HLH

In primary HLH, the uncontrolled proliferation of T cells and macrophages has been linked to various genetic defects leading to decreased natural killer (NK) cell and cytotoxic T cell function. These defects, which are described in more detail in Chap. 11, have also been implicated in the development of MAS-HLH. Therefore, their role in cytolytic function is briefly summarized. In about 30% of FHLH patients, the cytolytic defect is due to mutations in the gene encoding perforin [29]. Perforin is a protein which cytolytic cells utilize to induce apoptosis of target cells such as tumor cells or cells infected by viruses. In about 10% of patients with primary HLH, the disease is caused by mutations in another gene, *MUNC13-4* [30]. The protein encoded by this gene is involved in the release of perforin into the immune synapse with a target cell. Although the cytolytic cells of patients with *MUNC13-4* mutations produce sufficient amounts of perforin, their ability to kill target cells is greatly diminished. More recently, mutations in two other genes encoding proteins that facilitate granule fusion in intracellular trafficking events leading to the release of perforin have been linked to the development of primary HLH: *syntaxin 11*, a member of the SNARE protein family [31], and *syntaxin-binding protein 2* (*STXBP2*, known as *MUNC18-2*) [32]. In addition, several immunodeficiency syndromes, including Griscelli syndrome type 2 and Chediak-Higashi syndrome, present frequently with HLH as well.

Cytolytic Dysfunction in MAS

Similar to primary HLH, depressed cytolytic function is observed in SJIA patients with MAS

[33], although this impairment tends to improve with better control of the activity of the underlying SJIA [34], suggesting that background inflammation is a contributing factor. Indeed, IL-6, a pivotal proinflammatory cytokine in SJIA, has been shown to induce defective expression of perforin and decreased NK cell cytotoxic activity [35]. Heterozygous hypomorphic mutations in HLH-associated genes are detected in approximately one third of these patients [36, 37]. Functional studies of some of these mutations show that these variants might partially reduce cytolytic activity [38, 39] that could be further suppressed by the SJIA inflammatory milieu. Although patients with such variants appear at a higher risk for MAS recurrence, their pathogenic significance still needs to be clarified [36].

Clinical and Laboratory Manifestations

The clinical findings in MAS may evolve rapidly and often mimic the picture of sepsis. Patients become acutely ill and develop high persistent fever, hepatosplenomegaly, generalized lymphadenopathy, mental status changes, and coagulopathy resembling disseminated intravascular coagulation (DIC) [1–6]. Hemorrhagic skin rashes are common. Mild petechiae and ecchymotic lesions are seen early in the course of MAS. At later stages, patients may develop epistaxis and hematemesis secondary to upper gastrointestinal bleeding as well as rectal bleeding. Encephalopathy is another frequently reported clinical feature of MAS [19]. Mental status changes, seizures, and coma are the most common manifestations of the central nervous system disease. Cerebrospinal fluid examination usually reveals pleocytosis with mildly elevated protein [2–4]. Renal involvement with deterioration in renal function has been noted in several series and was associated with particularly high mortality in one report [8]. Pulmonary infiltrates have been observed in some patients, and hemophagocytic macrophages can be found in bronchoalveolar lavage. In a large international collection of MAS cases in patients with SJIA, 25 percent of

the reported episodes occurred at SJIA onset [19]. While in a patient known to have SJIA, the clinical suspicion of MAS in the presence of the above-described clinical manifestation may be relatively obvious, when MAS occurs at SJIA onset, it is important to differentiate it from primary HLH [40].

The early features that should raise the immediate suspicion for MAS symptoms are typically found in laboratory evaluation. Sharp fall in at least two of three blood cell lines (leukocytes, erythrocytes, or platelets) is one of the early findings. Sudden fall in erythrocyte sedimentation rate (ESR) despite persistently high C-reactive protein (CRP) is another characteristic laboratory feature. Falling ESR usually parallels decreasing serum levels of fibrinogen secondary to fibrinogen consumption and liver dysfunction. Liver dysfunction can be very prominent in MAS. Most patients with MAS develop marked hepatomegaly. Some develop mild jaundice. Liver function tests often reveal high serum transaminases activity but

only mildly elevated levels of serum bilirubin. Moderate hypoalbuminemia has been reported as well. Serum ammonia levels are typically normal or only mildly elevated, a feature that may help distinguish MAS from Reye's syndrome. Liver biopsies in these patients typically show sinusoidal and periportal infiltration with T cells and histiocytes. The histiocytes are highly activated and some exhibit hemophagocytic activity.

One of the most striking laboratory findings in MAS is serum hyperferritinemia. Presumably, it occurs in response to the need to sequester free iron released during erythrophagocytosis (Fig. 13.3). As a general rule, strikingly high levels of serum ferritin (>5000 ng/L) are highly suggestive of MAS, although lower levels could be seen in a sizable proportion of these patients.

Additional laboratory findings in MAS include highly elevated serum levels of triglycerides. Highly increased lactate dehydrogenase concentration is typical. Another laboratory test that may help with the diagnosis is markedly elevated

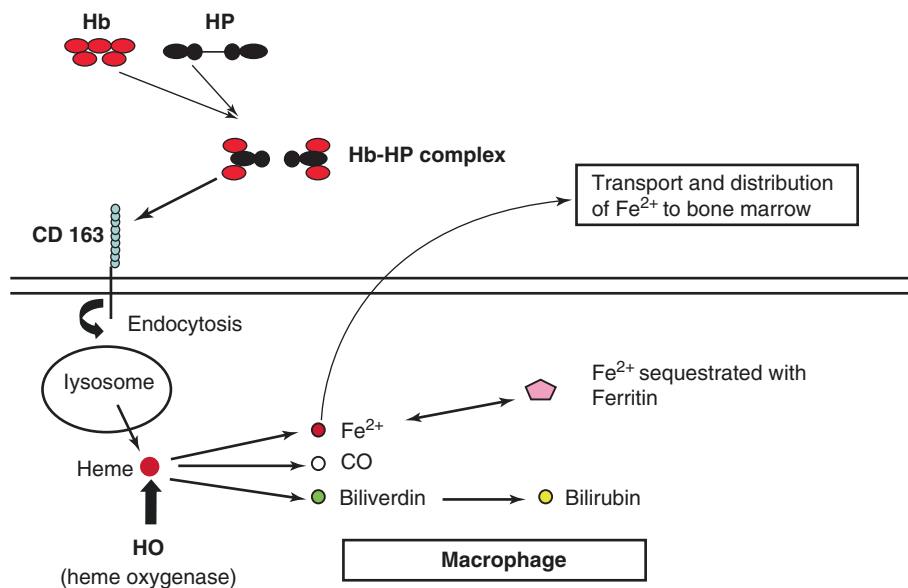


Fig. 13.3 Hemoglobin-haptoglobin scavenger receptor CD163, heme oxygenases and ferritin in adaptation to oxidative stress induced by free heme and iron. Free heme is a source of redox active iron. To prevent cell damage caused by iron-derived reactive oxygen species, haptoglobin forms a complex with free hemoglobin. The Hp-Hb complexes bind to CD163 and are internalized by the macrophage. Endocytosis of Hp-Hb complexes

leads to upregulation of heme oxygenase (HO) enzymatic activity. HO degrades the heme subunit of Hb into biliverdin that is subsequently converted to bilirubin, carbon monoxide (CO), and free iron. The free iron is either sequestered in association with ferritin within the cell or transported and distributed to red blood cell precursors in the bone marrow (With permission from Fall et al. [49])

serum levels of sIL2Ra chains presumably originating from overly activated T cells [21].

Increasingly MAS is being recognized as a complication of SLE [17], but the diagnosis of MAS in these patients might be very challenging. Many characteristic features of MAS such as fever, cytopenias, and raised liver enzymes can be seen as part of disease activity in SLE itself. Raised levels of serum ferritin and lactate dehydrogenase could help discriminate between active lupus and MAS complicating lupus.

General Diagnostic Approach

The early diagnosis of MAS is often difficult due to the fact that many clinical features of MAS overlap with those seen in the underlying rheumatic diseases. Some clinical features of MAS also overlap with sepsis-like syndromes associated with infection. This is further complicated by the fact that MAS may also be triggered by a flare of the underlying rheumatic disease or infection. As a general rule in a patient with active underlying rheumatologic disease, persistent fevers, and a fall in the ESR and platelet count, particularly in a combination with increase in serum D-dimer and ferritin levels, MAS should be included in the differential diagnosis. Bone marrow biopsy may help establish the diagnosis. Indeed, the presence of increased hemophagocytosis in bone marrow is the pathognomonic feature of MAS. However, the demonstration of hemophagocytosis may be difficult due to sampling error, particularly at the early stages of the syndrome. In such cases, additional staining of the bone marrow with anti-CD163 antibodies may be helpful. In the setting of MAS, such staining usually reveals massive expansion of highly activated histiocytes (Fig. 13.2), and the absence of overt hemophagocytosis does not rule out the diagnosis of MAS in these patients.

The recognition that MAS is clinically similar to HLH has led some to recommend the use of the HLH-2004 diagnostic guidelines developed by the HLH Study Group of the International Histiocyte Society [41]. However, the HLH-2004 diagnostic guidelines when applied to SJIA

patients with suspected MAS are highly specific but not sufficiently sensitive to diagnose the condition in its early stages when further deterioration could be prevented with relatively mild treatment. Some of the HLH markers, such as splenomegaly and hyperferritinemia, are common features of active SJIA itself and, therefore, do not distinguish MAS from a conventional SJIA flare. Other HLH criteria, such as cytopenias and hypofibrinogenemia, become evident only in the later stages of MAS as SJIA patients often have increased white blood cell and platelet counts as well as serum levels of fibrinogen as a part of the inflammatory response. Therefore, when they develop MAS, these counts decrease and reach the degree of cytopenias and hypofibrinogenemia seen in HLH only later in the clinical course [40]. Attempts to modify the HLH criteria to increase their sensitivity and specificity for the diagnosis of MAS in rheumatic conditions including SJIA have been initiated. In 2014, a set of classification criteria for MAS complicating systemic JIA was developed through a combination of expert consensus and analysis of patient data (Table 13.1). In cross-validation analyses, the criteria revealed a sensitivity of 0.72–0.76 and a specificity 0.97–0.99 [42]. Prospective validation is still required to further scrutinize the performance of the new criteria. Another point to consider is that these criteria were developed using clinical data generated prior to the introduction of IL-1 and IL-6 inhibitors now widely used for the treatment of SJIA. Preliminary

Table 13.1 The classification criteria for macrophage activation syndrome in systemic juvenile idiopathic arthritis

A febrile patient with known or suspected systemic juvenile idiopathic arthritis is classified as having macrophage activation syndrome if the following criteria are met

Ferritin >684 ng/ml
and
Any two of the following
Platelet count $\leq 181 \times 10^9/l$
Aspartate aminotransferase >48 U/l
Triglycerides >156 mg/dl
Fibrinogen ≤ 360 mg/dl

evidence suggests that IL-6 inhibition tends to decrease ferritin levels and some patients treated with tocilizumab develop neutropenia, liver enzyme elevation, and thrombocytopenia. Therefore, it is not clear, how, at this stage, these criteria will perform in patients who develop MAS while treated with biologic therapy.

Pathophysiology

The main pathophysiologic feature of MAS is excessive activation and expansion of predominantly cytotoxic CD8+ T cells and macrophages [43]. These activated immune cells produce large amounts of proinflammatory cytokines creating “a cytokine storm.” In clinically similar primary HLH, the uncontrolled expansion of T cells and macrophages has been linked to decreased NK cell and cytotoxic T cell function. Depressed cytolytic activity has been seen in MAS as well [9, 33]. Normally, cytotoxic cells induce apoptosis of cells infected with intracellular microbes or cells undergoing malignant transformation. In some circumstances, cytotoxic cells may also be directly involved in induction of apoptosis of activated macrophages and T cells during the contraction stage of the immune response. It has been proposed that in both HLH and MAS, failure to induce apoptosis due to cytotoxic dysfunction leads to prolonged expansion of T cells and macrophages and escalating production of proinflammatory cytokines [44, 45]. Hemophagocytic activity of macrophages, the pathognomonic feature of MAS, appears to be induced by chronic stimulation of macrophages with cytokines. Identification of cytokines that play the pivotal role in this process is an area of active research, since selectively targeting these cytokines may be a very effective therapeutic strategy.

Findings in Animal Models

Some clues are provided by the observations in animal models of HLH and MAS. First, Jordan et al. demonstrated that perforin-deficient mice infected with lymphocytic choriomeningitis

virus (LCMV) developed fevers, splenomegaly, pancytopenia, extreme hyperferritinemia, and hypercytokinemia, as well as histological features including hemophagocytosis characteristic of HLH [46]. More importantly, these clinical features were abolished by the administration of anti-CD8 antibodies or neutralization of IFN- γ , while antibodies against CD4 and the neutralization of other inflammatory cytokines, including TNF α , had no effect. These results suggest that IFN- γ -producing CD8+ T cells are central in the pathogenesis of the hemophagocytic syndrome in this model [46]. This idea was also consistent with the demonstration of abundance of IFN- γ -producing CD8+ T cells in inflammatory lesions in MAS and HLH patients [43] as well as with the fact that cyclosporine A, a therapeutic agent that acts predominantly on T cells, was very effective in the treatment of the majority of MAS patients [4]. Similar results have been obtained in mice deficient in other HLH-associated genes including *Rab27a* [47]. These animals also developed an HLH-like picture upon infection with LCMV in an IFN- γ -dependent manner. Based on these studies, the neutralization of IFN- γ has been proposed as a potential alternative treatment of HLH in humans, and the first clinical trial of neutralizing anti-IFN- γ antibodies is now in progress.

In all these models, however, the HLH-like clinical features emerge only in response to LCMV infection. Although a viral illness is a very common trigger of hemophagocytic syndromes, MAS is often associated with a flare of underlying SJIA rather than infection [19]. These considerations prompted a search for other animal models that would not be dependent on a viral infection. Recent reports showing the critical need for the TLR signaling adaptor MyD88 in the development of HLH-like disease in LCMV-infected *MUNC13-4*-deficient mice [48] combined with the evidence of persistently activated Toll-like receptor (TLR) and IL1R signaling pathways in SJIA [11, 49] provided a rationale for repeated activation of TLR to replicate the environment that would allow MAS to develop in a genetically predisposed host. Indeed, mice given repeated TLR9 stimulation with CpG develop some HLH features [50]. Although serum ferritin levels are

only mildly elevated in these animals and to induce hemophagocytosis additional blockade of IL-10 is required, many clinical features seen in this model are reminiscent of MAS (such as cytopenias and liver dysfunction) [50]. The role of IFN- γ in this model has been assessed by several groups. Behrens et al. demonstrated that in these animals, IFN- γ was produced mainly by dendritic cells and NK cells rather than CD8 T lymphocytes [50]. Interestingly, in a later study by the same group, IFN- γ knockout mice developed immunopathologies and hemophagocytosis comparable to wild-type mice [51]. However, IFN- γ knockout mice did not become anemic and also had greater numbers of splenic erythroid precursors, suggesting that in this model IFN- γ contributes to the development of anemia but might not be required for other MAS features [51]. In a more recent study, using the same model, Buatois et al. neutralized IFN- γ through repeated administration of anti-IFN- γ antibodies. In this study, neutralization of IFN- γ not only prevented the development of anemia but also led to the resolution of splenomegaly, hyperferritinemia, cytopenia, and liver inflammation [52]. Despite some discrepancies, all the described studies utilizing the CpG model of HLH clearly link chronic TLR stimulation and development of HLH-like clinical features. These findings might be relevant for the pathogenesis of MAS, as gene expression signatures reflecting continuous activation of TLR-IL1R-induced signaling pathways have also been reported in SJIA [49].

In contrast, in another model of secondary HLH where immunocompetent BALB/c mice are infected with the β -herpesvirus murine CMV, IFN- γ -deficient animals developed more severe clinical phenotype [53]. This observation suggests that in some forms of secondary HLH, IFN- γ might play an immunoregulatory role.

Other observations potentially relevant to MAS have been made in mice genetically modified to overproduce IL-6 [54]. The rationale for the development of this animal model was based on data implicating IL-6 as a major cytokine in the pathogenesis of SJIA [13–15]. Findings in the mice overproducing IL-6 might reflect the pathology of MAS occurring in the setting of

autoinflammation or autoimmunity more accurately than other animal models of hemophagocytic syndromes. In this model, features of MAS are induced by mimicking an acute infection with administration of lipopolysaccharides (LPS), or other TLR ligands, on a background of high IL-6 levels, recapitulating what occurs in patients with SJIA in whom an infection may trigger MAS on a background of high inflammation as what occurs during active disease. Indeed, macrophages chronically exposed to IL-6 have been shown to have an exaggerated response to TLR stimulation. Survival in these animals was decreased compared to the wild-type mice, and they developed MAS-like features including cytopenia and increased serum levels of ferritin. These observations suggest that IL-6-driven background inflammation as seen in SJIA can lead to exaggerated responses of macrophages to inflammatory stimuli induced by infection and thus contributes to MAS development. Background inflammatory activity also seems to have a role in the emergence of MAS-like phenotypes in patients with a gain-of-function mutation in the *NLRC4* gene leading to overproduction of IL-1 β and IL-18 [55].

“Cytokine Storm” in MAS

The term “cytokine storm” has been used to characterize hyperinflammation seen in MAS. Indeed, cytokines derived from lymphocytes such as IFN- γ and IL-2 as well as cytokines originating from monocyte and macrophage including IL-1 β , TNF α , IL-6, and IL-18 are strikingly high in these patients. With growing numbers of available biologics targeting cytokines and small molecules inhibiting cytokine signaling such as JAK/STAT inhibitors, the interest in relative significance of various cytokines in MAS is increasing.

IFN- γ The role of IFN- γ in SJIA-associated MAS has not yet been fully characterized. Interestingly, IFN- γ does not seem to play a major role in the pathogenesis of SJIA itself. Levels of serum IFN- γ have been reported to be within the normal range in patients with SJIA, independent of disease activity [56]. Three independent gene expression studies have failed to

find a prominent IFN- γ -induced signature in the peripheral blood monocytes of children with active SJIA in the absence of clinical features of MAS [49, 57, 58]. The absence of IFN- γ activity is not limited to only the peripheral blood and could be observed in the inflamed tissues as well [56]. Thus, expression of IFN- γ -induced chemokines (CXCL9 and CXCL10) in synovial tissue from SJIA patients is hardly detectable, in contrast to very high levels of these chemokines in tissue from patients with oligoarticular or polyarticular JIA [56]. The absence of the IFN- γ signature in SJIA does not seem to be caused by abnormal responsiveness to IFN- γ . In fact, monocytes from SJIA patients incubated with exogenous IFN- γ often have exaggerated responses to this cytokine [56].

In contrast to SJIA, preliminary evidence suggests that IFN- γ is essential for the pathogenesis of MAS [59]. Episodes of MAS in SJIA commonly occur when elicited by viral infections, which are known to activate IFN- γ -induced pathways. Furthermore, children with MAS exhibit increased levels of neopterin, a product normally released by macrophages stimulated with IFNs [60]. A recent assessment of longitudinal cytokine changes in serum of SJIA patients has demonstrated that IFN- γ itself and IFN- γ -induced chemokines increased markedly with the emergence of clinical features of MAS and return to normal ranges after resolution of this complication [61]. Furthermore, such increase was associated with activation of IFN-induced signaling pathways based on increased STAT1 phosphorylation in freshly isolated unmanipulated monocytes. In fact activation of these pathways might distinguish *acute MAS* versus *conventional flare of SJIA*. In addition, IFN- γ and IFN- γ -induced chemokines (CXCL9 in particular) strongly correlated with many laboratory features of MAS in patients with clinical features of MAS, but not in patients with a conventional SJIA flare without MAS [61]. No similar correlations were observed with TNF and IL-6.

IL-1 and IL-6 IL-1 β [11, 12] and IL-6 [13–15] have been implicated as essential cytokines in SJIA, and adequate control of the underlying

disease using biologics neutralizing IL-1 or IL-6 was expected to protect against MAS. The observed MAS rates in the phase III clinical trials of tocilizumab (anti-IL6R antibody) and canakinumab (anti-IL-1 β antibody) have shown, however, that therapeutic strategies aimed at the inhibition of either IL-1 β or IL-6 do not provide full protection against MAS even if the underlying SJIA is well controlled [62–64]. One possible conclusion is that neither IL-1 β nor IL-6 alone is the key driver contributing to the development of MAS. Reports describing successful treatment of MAS with anakinra, recombinant IL-1 receptor antagonist that blocks activity of both IL-1 β and IL-1 α , suggest a potential role for IL-1 α [65–67]. However, the fact that MAS has been seen in patients treated with rilonacept [68], which also neutralizes IL-1 α , makes this possibility less likely. Alternatively, the fact that some SJIA/MAS patients respond to IL-1 blockade while others develop MAS during continuous treatment with IL-1 blocking biologics suggests some MAS pathophysiologic heterogeneity that needs to be explored further.

IL-18 Over the last 5 years, interest in the role of IL-18 in the pathogenesis of SJIA in general, and in MAS in particular, has increased. Strikingly high serum levels of IL-18 have been observed in patients with SJIA [69–71], in sharp contrast to only moderately elevated levels of IL-18 seen in other rheumatic diseases [72]. Patients with high levels of IL-18 more often have systemic manifestations rather than arthritis as the predominant feature of SJIA and also seem to be more likely to develop MAS [69]. The emergence of MAS features in these patients corresponds with a further increase of IL-18 levels. Levels of IL-18 possibly reflect the extent of macrophage activation as macrophages seem to be the main source of IL-18 in patients with MAS [70]. The role of IL-18 has been examined in perforin-deficient mice infected with murine CMV. Uncontrolled viral replication in these mice is associated with many features of HLH and MAS including pancytopenia, hepatic dysfunction, hemophagocytosis, and death [73]. Administration of synthetic IL-18BP ameliorated

liver damage in these mice; however, production of proinflammatory cytokines was considerable, and no change in overall survival was observed.

Treatment

Most Common Treatments

MAS is a life-threatening condition associated with high mortality rates. Therefore, early recognition and immediate therapeutic intervention to produce a rapid response are critical. Standardized treatment guidelines for MAS are currently lacking, but management commonly starts with high-dose glucocorticoids. This may include intravenous methylprednisolone pulse therapy (e.g., 30 mg/kg for 3 consecutive days) followed by 2–3 mg/kg/day in four divided doses. If response to glucocorticoids is not satisfactory, cyclosporine A (2–7 mg/kg/day) is usually initiated based on several reports describing rapid resolution of features of MAS in response to cyclosporine over the course of a few days [4, 6, 7, 74]. Cyclosporine is preferentially used orally (with trough levels in the 150–200 ng/ml range), and careful monitoring for toxicity is required, especially if it is administered intravenously. If MAS remains active, despite the use of glucocorticoids and cyclosporine A, the HLH-2004 treatment protocol developed by the HLH Study Group of the International Histiocyte Society [41] might be considered. This protocol, in addition to steroids and cyclosporine A, includes etoposide (or VP16), a podophyllotoxin derivative that inhibits DNA synthesis by forming a complex with topoisomerase II and DNA. Etoposide is metabolized by the liver, and then both unchanged drug and its metabolites are excreted through the kidneys. Since patients who may require the use of etoposide are very likely to have renal and renal involvement, caution should be exercised to properly adjust the dosage and thus limit the potential side effects such as severe bone marrow suppression. Although successful use of etoposide in MAS has been reported, potential toxicity of the drug is a major concern, particularly in patients with renal impairment. Reports describing deaths with the use of etoposide caused by severe bone

marrow suppression and overwhelming infections have been published. Recently, it also has been suggested that in unresponsive patients, antithymocyte globulin (ATG) might be an alternative to etoposide [75, 76].

Biologic Agents

The utility of biologic drugs in MAS treatment remains unclear. Although TNF α -inhibiting agents have been reported to be effective in occasional MAS patients, other reports describe patients in whom MAS developed while they were on TNF α -inhibiting agents. Since, at least in SJIA, MAS episodes are often triggered by the disease flare, biologics that neutralize IL-1, a cytokine that plays a pivotal role in SJIA pathogenesis, have been tried by many authors with conflicting results. Recent case series have suggested that anakinra might be effective at least in some patients with SJIA-associated MAS, particularly when used in higher doses. It should however be pointed out that in established SJIA, continuous treatment with standard doses of anti-IL-1 and IL-6 biologic therapies does not appear to prevent completely the occurrence of MAS even if the underlying disease responds well to the treatment.

Intravenous immune globulin treatment has been used with some success in virus-associated reactive HLH [77]. Rituximab, a treatment that depletes B lymphocytes, the main type of cells harboring EBV virus, has been successfully used in EBV-induced lymphoproliferative disease [78, 79] and could be considered in EBV-driven MAS.

Findings in animal models and translational studies in HLH patients support IFN- γ blockade as novel therapy for primary HLH: a phase II–III trial of an anti-IFN- γ antibody is currently underway, and a pilot trial in MAS patients unresponsive to standard treatment is planned.

Prognosis

MAS is a life-threatening condition with significant morbidity and mortality. Due to increasing awareness of this syndrome, early diagnosis and

appropriate interventions have resulted in improved outcomes. A proportion of MAS patients may experience recurrent episodes, and these patients may require closer monitoring. In the future, the use of novel biomarkers to identify the children and adults with rheumatic disease who are at greatest risk of MAS will hopefully lead to better therapies and outcomes.

References

- Silverman ED, Miller JJ 3rd, Bernstein B, et al. Consumption coagulopathy associated with systemic juvenile rheumatoid arthritis. *J Pediatr*. 1983;103:872–6.
- Hadchouel M, Prieur AM, Griscelli C. Acute hemorrhagic, hepatic, and neurologic manifestations in juvenile rheumatoid arthritis: possible relationship to drugs or infection. *J Pediatr*. 1985;106:561–6.
- Stephan JL, Zeller J, Hubert P, Herbelin C, Dayer JM, Prieur AM. Macrophage activation syndrome and rheumatic disease in childhood: a report of four new cases. *Clin Exp Rheumatol*. 1993;11:451–6.
- Mouy R, Stephan JL, Pillet P, et al. Efficacy of cyclosporine A in the treatment of macrophage activation syndrome in juvenile arthritis: report of five cases. *J Pediatr*. 1996;129:750–4.
- Grom AA, Passo MH. Macrophage activation syndrome in systemic juvenile idiopathic arthritis. *J Pediatr*. 1996;129:630–2.
- Ravelli A, De Benedetti F, Viola S, et al. Macrophage activation syndrome in systemic juvenile rheumatoid arthritis successfully treated with cyclosporine. *J Pediatr*. 1996;128:275–8.
- Stephan JL, Kone-Paut, I, Galambrun C et al. Reactive haemophagocytic syndrome in children with inflammatory disorders. A retrospective study of 24 patients. *Rheumatology (Oxford)*. 2001;40(11):1285–92.
- Sawhney S, Woo P, Murray KJ. Macrophage activation syndrome: a potentially fatal complication of rheumatic disorders. *Arch Dis Child*. 2001;85:421–6.
- Grom AA. NK dysfunction: a common pathway in systemic onset juvenile rheumatoid arthritis, macrophage activation syndrome, and hemophagocytic lymphohistiocytosis. *Arthritis Rheum*. 2004;50:689–98.
- Ariet JB, Le Thi Huong D, Marinho A, et al. Reactive haemophagocytic syndrome in adult-onset Still's disease: a report of six patients and a review of the literature. *Ann Rheum Dis*. 2006;65:1596–601.
- Pascual V, Allantaz F, Arce E, et al. Role of interleukin-1 (IL-1) in the pathogenesis of systemic onset juvenile idiopathic arthritis and clinical response to IL-1 blockade. *J Exp Med*. 2005;201:1479–86.
- Ruperto N, Brunner HI, Quartier P, Constantin T, Wulfraat N, Horneff G, Brik R, McCann L, Nistala K, Wouters C, Cimaz R, Ferrandiz MA, Flato B, Grom AA, Magnusson OS, Abrams K, Kim D, Martini A, Lovell DJ. Two randomized trials of canakinumab in systemic juvenile idiopathic arthritis. *N Engl J Med*. 2012;367:2396–406.
- De Benedetti F, Martini A. Is systemic juvenile rheumatoid arthritis an IL-6 mediated disease. *J Rheumatol*. 1998;25:203–7.
- Yokota S, Imagawa T, Mori M, et al. Efficacy and safety of tocilizumab in patients with systemic-onset juvenile idiopathic arthritis: a randomised, double-blind, placebo-controlled, withdrawal phase III trial. *Lancet*. 2008;371:998–1006.
- De Benedetti F, Brunner HI, Ruperto N, Kenwright A, Ravelli A, Schneider WP, Wouters C, Zemel L, Burgos-Vargas R, Dolezalova P, Grom AA, Wulfraat N, Zuber Z, Zulian F, Lovell D, Martini A. Randomized trial of tocilizumab in systemic juvenile idiopathic arthritis. *N Engl J Med*. 2012;367:2385–95.
- Rigante D, Cantarini L. The systemic onset variant of juvenile idiopathic arthritis needs to be recorded as an autoinflammatory syndrome: comment on the review by Nigrovic. *Arthritis Rheumatol*. 2014;66:2645.
- Parodi A, Davì S, Pringe AB, Pistorio A, Ruperto N, Magni-Manzoni S, Miettunen P, Bader-Meunier B, Espada G, Sterba G, Ozen S, Wright D, Saad Magalhães C, Khubchandani R, Michels H, Woo P, Toro Gutiérrez CE, Guseinova D, Cortis E, Hayward K, Wouters C, Grom AA, Vivarelli M, Fischer KA, Martini A, Ravelli A. Macrophage activation syndrome in juvenile systemic lupus erythematosus. Multinational multicenter study of 38 patients. *Arthritis Rheum*. 2009;60:3388–99.
- Avcin T, Tse SML, Schneider R, et al. Macrophage activation syndrome as the presenting manifestation of rheumatic diseases in childhood. *J Pediatr*. 2006;148:683–6.
- Minoia F, Davì S, Horne A, Demirkaya E, Bovis F, Li C, Lehmborg K, Weitzman S, Insalaco A, Wouters C, Shenoi S, Espada G, Ozen S, Anton J, Khubchandani R, Russo R, Pal P, Kasapcopur O, Miettunen P, Maritsi D, Merino R, Shakoory B, Alessio M, Chasnyk V, Sanner H, Gao Y, Huasong Z, Kitoh T, Avcin T, Fischbach M, Frosch M, Grom AA, Huber A, Jelusic M, Sawhney S, Uziel Y, Ruperto N, Martini A, Cron RQ, Ravelli A. Clinical features, treatment and outcome of macrophage activation syndrome complicating systemic juvenile idiopathic arthritis A multinational, multicenter study of 362 patients. *Arthritis Rheumatol*. 2014;66:3160–9.
- Moradinejad MH, Ziaee V. The incidence of macrophage activation syndrome in children with rheumatic disorders. *Minerva Pediatr*. 2011;63:459–66.
- Bleesing J, Prada A, Siegel DM, et al. The diagnostic significance of soluble CD163 and soluble interleukin-2 receptor alpha-chain in macrophage activation syndrome and untreated new-onset systemic juvenile idiopathic arthritis. *Arthritis Rheum*. 2007;56:965–71.
- Behrens EM, Beukelman T, Paessler M et al. Occult macrophage activation syndrome in patients with systemic juvenile idiopathic arthritis. *J Rheumatol*. 2007;34:1133–8. Page: 1446.

23. Prahalad S, Bove KE, Dickens D et al. Etanercept in the treatment of macrophage activation syndrome. *J Rheumatol* 2001;28:2120–4. Page: 1446.
24. Ramanan AV, Baildam EM. Macrophage activation syndrome is hemophagocytic lymphohistiocytosis—need for the right terminology. *J Rheumatol*. 2002;29:1105.
25. Favara BE, Feller AC, Pauli M, et al. Contemporary classification of histiocytic disorders. The WHO Committee on Histiocytic/Reticulum Cell Proliferations. Reclassification Working Group of the Histiocyte Society. *Med Pediatr Oncol*. 1997;29:157–66.
26. Filipovich HA. Hemophagocytic lymphohistiocytosis. *Immunol Allergy Clin N Am*. 2002;22:281–300.
27. Jordan MB, Allen CE, Weitzman S, et al. How I treat hemophagocytic lymphohistiocytosis. *Blood*. 2011;118:4041–52.
28. Zhang K, Jordan MB, Marsh RA, et al. Hypomorphic mutations in PRF1, MUNC13–4, and STXBP2 are associated with adult-onset familial HLH. *Blood*. 2011;118:5794–8.
29. Stepp SE, Dufourcq-Lagelouse R, Le Deist F, et al. Perforin gene defects in familial hemophagocytic lymphohistiocytosis. *Science*. 1999;286:1957–9.
30. Feldmann J, Callebaut I, Raposo G, et al. MUNC13–4 is essential for cytolytic granules fusion and is mutated in a form of familial hemophagocytic lymphohistiocytosis (FHL3). *Cell*. 2003;115:461–73.
31. zur Stadt U, Schmidt S, Kasper B, et al. Linkage of familial hemophagocytic lymphohistiocytosis (FHL) type-4 to chromosome 6q24 and identification of mutations in syntaxin 11. *Hum Mol Genet*. 2005;14:827–34.
32. zur Stadt U, Rohr J, Seifert W, et al. Familial hemophagocytic lymphohistiocytosis type 5 (FHL-5) is caused by mutations in Munc18–2 and impaired binding to syntaxin 11. *Am J Hum Genet*. 2009;85:482–92.
33. Grom AA, Villanueva J, Lee S, et al. Natural killer cell dysfunction in patients with systemic-onset juvenile rheumatoid arthritis and macrophage activation syndrome. *J Pediatr*. 2003;142:292–6.
34. Vastert SJ, van Wijk, R, D'Urbano, LE et al. Mutations in the perforin gene can be linked to macrophage activation syndrome in patients with systemic onset juvenile idiopathic arthritis. *Rheumatology (Oxford)*. 2010;49:441–9.
35. Cifaldi L, Prencipe G, Caiello I, Bracaglia C, Strippoli R, De Benedetti F. Inhibition of natural killer cell cytotoxicity by interleukin-6: implications for the pathogenesis of macrophage activation syndrome. *Arthritis Rheumatol*. 2015;67:3037–46.
36. Kaufman KM, Linghu B, Szustakowski JD, et al. Whole exome sequencing reveals overlap between macrophage activation syndrome in systemic juvenile idiopathic arthritis and familial hemophagocytic lymphohistiocytosis. *Arthritis Rheum*. 2014;66:3486–95.
37. Bracaglia C, Sieni E, Da Ros M, De Fusco C, Micalizzi C, Cetica V, Ciambotti B, Coniglio ML, Insalaco A, De Benedetti F, Maurizio A. Mutations of familial hemophagocytic lymphohistiocytosis related genes and abnormalities of cytotoxicity function tests in patients with macrophage activation syndrome (MAS) occurring in systemic juvenile idiopathic arthritis. *Pediatr Rheumatol*. 2014;12(Suppl 1):53.
38. Zhang M, Bracaglia C, Prencipe G, Bemrich-Stolz CJ, Beukelman T, Dimmitt RA, Chatham WW, Zhang K, Li H, Walter MR, De Benedetti F, Grom AA, Cron RQ. A single copy RAB27a mutation leading to decreased NK cell cytolytic function and hemophagocytic lymphohistiocytosis. *J Immunol*. 2016;196(6):2492–503.
39. Schulert GS, Zhang M, Fall N, Husami A, Kissell D, Hanosh A, Zhang K, Davis K, Jentzen JM, Siddiqui J, Smith LB, Harms PW, Grom AA, Cron RQ. Whole exome sequencing reveals mutations in hemophagocytic lymphohistiocytosis linked genes among fatal cases of H1N1 infection. *J Infect Dis*. 2016;213:1180–8.
40. Lehmberg K, Pink I, Eulenburg C, Beutel K, Maul-Pavicic A, Janka G. Differentiating macrophage activation syndrome in systemic juvenile idiopathic arthritis from other forms of hemophagocytic lymphohistiocytosis. *J Pediatr*. 2013;162:1245–51.
41. Henter JI, Horne A, Arico M, et al. HLH-2004: diagnostic and therapeutic guidelines for hemophagocytic lymphohistiocytosis. *Pediatr Blood Cancer*. 2007;48:124–31.
42. Ravelli A, Minoia F, Davì S, Horne AC, Bovis F, Pistorio P, Aricò M, Avcin T, Behrens EM, De Benedetti F, Filipovic AH, Grom AA, Henter JI, Ilowite NT, Jordan MB, Khubchandani R, Kitoh T, Lehmberg K, Lovell D, Miettunen P, Nichols K, Ozen S, Pachlopnick J, Ramanan AV, Russo R, Schneider R, Sterba G, Uziel Y, Wallace W, Wouters C, Demirkaya E, Brunner HI, Martini A, Ruperto N, RQ Cron, on behalf of the Pediatric Rheumatology International Trials Organization, the Childhood Arthritis & Rheumatology Research Alliance, the Pediatric Rheumatology Collaborative Study Group, the Histiocyte Society. Development and initial validation of classification criteria for macrophage activation syndrome complicating systemic juvenile idiopathic arthritis. *Arthritis Rheumatol*. 2016;68:566–76.
43. Billiau AD, Roskams T, Van Damme-Lombaerts R, et al. Macrophage activation syndrome: characteristic findings on liver biopsy illustrating the key role of activated, IFN-gamma-producing lymphocytes and IL-6- and TNF-alpha-producing macrophages. *Blood*. 2005;105:1648.
44. Kagi D, Odermatt B, Mak TW. Homeostatic regulation of CD8+ T cells by perforin. *Eur J Immunol*. 1999;29:3262–72.
45. Lykens JE, Terrell CE, Zoller EE, Risma K, Jordan MB. Perforin is a critical physiologic regulator of T-cell activation. *Blood*. 2011;118:618–26.
46. Jordan MB, Hildeman D, Kappler J, Marrack P. An animal model of hemophagocytic lymphohistiocytosis (HLH): CD8+ T cells and interferon gamma are essential for the disorder. *Blood*. 2004;104:735–43.

47. Pachlopnik Schmid J, Ho CH, Chretien F, et al. Neutralization of IFN γ defeats haemophagocytosis in LCMV-infected perforin- and Rab27a-deficient mice. *EMBO Mol Med*. 2009;1:112–24.
48. Krebs P, Crozat K, Popkin D, et al. Disruption of MyD88 signaling suppresses hemophagocytic lymphohistiocytosis in mice. *Blood*. 2011;117:6582–8.
49. Fall N, Barnes M, Thornton S, et al. Gene expression profiling of peripheral blood from patients with untreated new-onset systemic juvenile idiopathic arthritis reveals molecular heterogeneity that may predict macrophage activation syndrome. *Arthritis Rheum*. 2007;56:3793–804.
50. Behrens EM, Canna SW, Slade K, et al. Repeated TLR9 stimulation results in macrophage activation syndrome-like disease in mice. *J Clin Invest*. 2011;121:2264–77.
51. Canna SW, Wrobel J, Chu N, Kreiger PA, Paessler M, Behrens EM. Interferon- γ mediates anemia but is dispensable for fulminant toll-like receptor 9-induced macrophage activation syndrome and hemophagocytosis in mice. *Arthritis Rheum*. 2013;65:1764–75.
52. Buatois V, Chatel L, Cons L Lory S, Richard F, Bracaglia C, De Benedetti F, Kosco-Vilbois M, Ferlin W, de Min C. IFN- γ drives disease in TLR9-mediated secondary hemophagocytic lymphohistiocytosis. *Transl Res*. 2016. pii: S1931-5244(16)30157-8. doi:10.1016/j.trsl.2016.07.023.
53. Brisse E, Imbrechts M, Put K, et al. Mouse cytomegalovirus infection in BALB/c mice resembles virus-associated secondary hemophagocytic lymphohistiocytosis and shows a pathogenesis distinct from primary hemophagocytic lymphohistiocytosis. *J Immunol*. 2016;196:3124–34.
54. Strippoli R, Carvello F, Scianaro R, et al. Amplification of the response to toll-like receptor ligands by prolonged exposure to interleukin-6 in mice: implication for the pathogenesis of macrophage activation syndrome. *Arthritis Rheum*. 2012;64:1680–8.
55. Canna SW, de Jesus AA, Gouni S, Brooks SR, Marrero B, Liu Y, DiMattia MA, Zaal KJ, Sanchez GA, Kim H, Chapelle D, Plass N, Huang Y, Villarino AV, Biancotto A, Fleisher TA, Duncan JA, O'Shea JJ, Benseler S, Grom AA, Deng Z, Laxer RM, Goldbach-Mansky R. An activating NLRC4 inflammasome mutation causes autoinflammation with recurrent macrophage activation syndrome. *Nat Genet*. 2014;46:1140–6.
56. Sikora KA, Fall N, Thornton S, Grom AA. The limited role of interferon-gamma in systemic juvenile idiopathic arthritis cannot be explained by cellular hyporesponsiveness. *Arthritis Rheum*. 2012;64:3799–808.
57. Allantaz F, Chaussabel D, Stichweh D, Bennett L, Allman W, Mejias A, Ardura M, Chung W, Smith E, Wise C, Palucka K, Ramilo O, Punaro M, Banchereau J, Pascual V. Blood leukocyte microarrays to diagnose systemic onset juvenile idiopathic arthritis and follow the response to IL-1 blockade. *J Exp Med*. 2007;204:2131–44.
58. Ogilvie EM, Khan A, Hubank M, et al. Specific gene expression profiles in systemic juvenile idiopathic arthritis. *Arthritis Rheum*. 2007;56:1954–65.
59. Put K, Avau A, Brisse E, Mitera T, Put S, Proost P, Bader-Meunier B, Westhovens R, Van den Eynde BJ, Orabona C, Fallarino F, De Somer L, Tousseyn T, Quartier P, Wouters C, Matthys P. Cytokines in systemic juvenile idiopathic arthritis and haemophagocytic lymphohistiocytosis: tipping the balance between interleukin-18 and interferon- γ . *Rheumatology (Oxford)*. 2015 Mar 12. pii: keu524. [Epub ahead of print].
60. Ibarra MF, Klein-Gitelman M, Morgan E, et al. Serum neopterin levels as a diagnostic marker of hemophagocytic lymphohistiocytosis syndrome. *Clin Vaccine Immunol*. 2011;18:609–14.
61. Bracaglia C, Kathy de Graaf K, Marafon DP, D'Ario G, Guilhot F, Ferlin W, Prencipe G, Caiello I, Davi D, Schulert G, Ravelli A, Grom AA, De Benedetti F. Elevated circulating levels of interferon- γ and interferon- γ induced chemokines characterize patients with macrophage activation syndrome complicating systemic JIA. *Ann Rheum Dis*. 2016;76:166–72.
62. Ravelli A, Schneider R, Weitzman S, Devlin C, Daimaru K, Yokota S, Takei S, De Benedetti F. Macrophage activation syndrome in patients with systemic juvenile idiopathic arthritis treated with tocilizumab. *Arthritis Rheumatol*. 2014;66(Suppl):83–4.
63. Yokota S, Itoh Y, Morio T, Sumitomo N, Daimaru K, Minota S. Macrophage activation syndrome in patients with systemic juvenile idiopathic arthritis under treatment with tocilizumab. *J Rheumatol*. 2015;42:712–22.
64. Grom AA, Ilowite NT, Pascual V, Brunner HI, Martinin A, Lovell D, Ruperto N, Leon K, Lheritier K, Abrams K. Canakinumab in systemic juvenile idiopathic arthritis: impact on the rate and clinical presentation of macrophage activation syndrome. *Arthritis Rheumatol*. 2016;68:218–28.
65. Miettunen PM, Narendran A, Jayanthan A, et al. Successful treatment of severe paediatric rheumatic disease-associated macrophage activation syndrome with interleukin-1 inhibition following conventional immunosuppressive therapy: case series with 12 patients. *Rheumatology*. 2011;50:417–9.
66. Durand M, Troyanov Y, Laflamme P, Gregoire G. Macrophage activation syndrome treated with anakinra. *J Rheumatol*. 2010;37:879–80.
67. Nigrovic PA, Mannion M, Prince FH, et al. Anakinra as first-line disease-modifying therapy in systemic juvenile idiopathic arthritis: report of forty-six patients from an international multicenter series. *Arthritis Rheum*. 2011;63:545–55.
68. Ilowite NT, Prather K, Lokhnygina Y, Schanberg LE, Elder M, Milojevic D, Verbsky JW, Spalding SJ, Kimura Y, Imundo LF, Punaro MG, Sherry DD, Tarvin SE, Zemel LS, Birmingham JD, Gottlieb BS, Miller ML, O'Neil K, Ruth NM, Wallace CA, Singer NG, Sandborg CI. Randomized, double-blind, placebo-controlled trial of the efficacy and safety of rilonacept in the treatment of systemic

- juvenile idiopathic arthritis. *Arthritis Rheumatol.* 2014;66:2570–9.
69. Shimizu M, Yokoyama T, Yamada K, et al. Distinct cytokine profiles of systemic-onset juvenile idiopathic arthritis-associated macrophage activation syndrome with particular emphasis on the role of interleukin-18 in its pathogenesis. *Rheumatology.* 2010;49:1645–53.
 70. Maeno N, Takei S, Imanaka H, et al. Increased interleukin-18 expression in bone marrow of a patient with systemic juvenile idiopathic arthritis and unrecognized macrophage-activation syndrome. *Arthritis Rheum.* 2004;50:1935–8.
 71. Kawashima M, Yamamura M, Taniai M, et al. Levels of interleukin-18 and its binding inhibitors in the blood circulation of patients with adult-onset Still's disease. *Arthritis Rheum.* 2001;44:550–60.
 72. Novick D, Elbirt D, Miller G, et al. High circulating levels of free interleukin-18 in patients with active SLE in the presence of elevated levels of interleukin-18 binding protein. *Cytokine.* 2009;48:103–4.
 73. Chiossone L, Audonnet S, Chetaille B, et al. Protection from inflammatory organ damage in a murine model of hemophagocytic lymphohistiocytosis using treatment with IL-18 binding protein. *Front Immunol.* 2012;3:239–49.
 74. Quesnel B, Catteau B, Aznar V, Bauters F, Fenaux P. Successful treatment of juvenile rheumatoid arthritis associated haemophagocytic syndrome by cyclosporin A with transient exacerbation by conventional-dose G-CSF. *Br J Haematol.* 1997;97:508–10.
 75. Mahlaoui N, Ouachee-Chardin M, de Saint Basile G, et al. Immunotherapy of familial hemophagocytic lymphohistiocytosis with antithymocyte globulins: a single-center retrospective report of 38 patients. *Pediatrics.* 2007;120:e622–8.
 76. Coca A, Bundy KW, Marston B, et al. Macrophage activation syndrome: serological markers and treatment with anti-thymocyte globulin. *Clin Immunol.* 2009;132:10–8.
 77. Tristano AG, Casanova-Escalona L, Torres A, Rodriguez MA. Macrophage activation syndrome in a patient with systemic onset rheumatoid arthritis: rescue with intravenous immunoglobulin therapy. *J Clin Rheumatol.* 2003;9:253–8.
 78. Balamuth NJ, Nichols KE, Paessler M, Teachey DT. Use of rituximab in conjunction with immunosuppressive chemotherapy as a novel therapy for Epstein Barr virus-associated hemophagocytic lymphohistiocytosis. *J Pediatr Hematol Oncol.* 2007;29:569–73.
 79. Bosman G, Langemeijer SM, Hebeda KM, et al. The role of rituximab in a case of EBV-related lymphoproliferative disease presenting with haemophagocytosis. *Neth J Med.* 2009;67:364–5.

Jan-Inge Henter, Rebecca A Marsh,
and Tatiana von Bahr Greenwood

Abbreviations

ATG	Antithymocyte globulin
CSA	Cyclosporine A
DEP	Doxorubicin, etoposide, and methylprednisolone
EBV	Epstein-Barr virus
FHL	Familial hemophagocytic lymphohistiocytosis
HLH	Hemophagocytic lymphohistiocytosis
IFN	Interferon
IL	Interleukin
IVIG	Intravenous immunoglobulin
MAS	Macrophage activation syndrome
SCT	Hematopoietic stem cell transplantation
sHLH	Secondary HLH

Introduction

Historical Background

Familial hemophagocytic lymphohistiocytosis (FHL) is typically a rapidly fatal illness with a median survival of less than 2 months if not treated adequately [1]. Early treatment attempts included corticosteroids, mostly with short responses, and splenectomy, with transient clinical improvement reported in some patients. With regard to cytotoxic drugs, treatment including vinca alkaloids, mostly vinblastine in combination with corticosteroids, was reported to induce response in a few patients [1]. Repeated plasma or blood exchange also induced resolution in some patients [1, 2].

During the 1980s, the use of the epipodophylotoxin derivatives etoposide and teniposide was shown to induce prolonged resolution in combination with corticosteroids [3, 4]. A treatment protocol including etoposide in pulses, corticosteroids, intrathecal methotrexate, and cranial irradiation was shown to be successful in inducing resolution and prolonged survival [5]. In 1991, a therapeutic regimen (HLH-91) including guidelines for maintenance therapy as well as reactivations was published; it was based on similar drugs, but the cranial irradiation had been excluded and the cytotoxic treatment was administered regularly instead of in pulses (Fig. 14.1) [6]. This therapeutic regimen, which was successful in inducing resolution in four of five

J.-I. Henter, MD, PhD (✉) • T. von Bahr Greenwood, MD
Childhood Cancer Research Unit, Department of
Women's and Children's Health, Karolinska Institutet,
and Theme of Children's and Women's Health,
Karolinska University Hospital, Stockholm, Sweden
e-mail: Jan-Inge.Henter@ki.se

R.A. Marsh, MD
Division of Bone Marrow Transplantation and
Immune Deficiency, Cincinnati Children's Hospital
Medical Center, Cincinnati, OH, USA

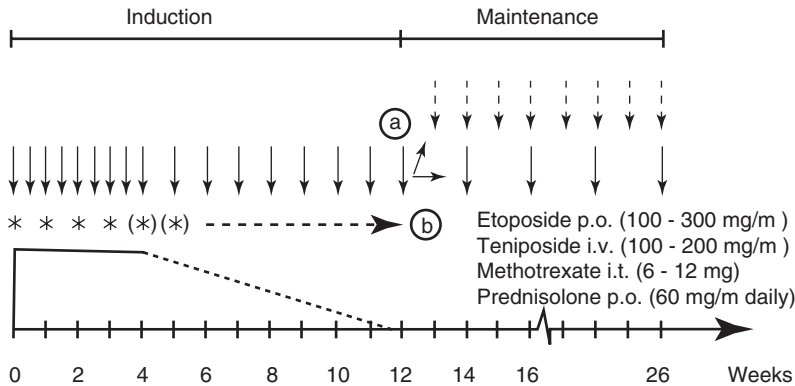


Fig. 14.1 The HLH-91 treatment protocol. This protocol was used in five Swedish patients, of whom four (80%) achieved remission [6]. It resembles HLH-94, in which prednisolone was changed to dexamethasone, the induction phase reduced from 12 weeks to 8 weeks and biweekly cytotoxic therapy from 4 weeks to 2 weeks, intrathecal therapy introduced week 3 instead of upfront, teniposide changed to resembling etoposide, cyclosporine A introduced, and oral maintenance therapy abandoned. In HLH-91, maintenance therapy was administered

(a) either as a weekly dose oral etoposide 100–300 mg/m² (dashed arrow) or as a biweekly dose intravenous teniposide 100–200 mg/m² body surface area (solid arrow). Intrathecal methotrexate doses by age: <1 year = 6 mg, 1 year = 8 mg, 2 years = 10 mg, ≥3 years = 12 mg. (b) Four additional doses of intrathecal methotrexate were given once spinal fluid cell number had reached <10×10⁶ cells/L and active cerebromeningeal symptoms no longer were present. Prednisolone p.o. (60 mg/m² daily). (Adapted from: Henter and Elinder [6])

patients (80%), formed a basis for the pretransplant therapy in the subsequent treatment protocols (HLH-94 and HLH-2004).

Epipodophyllotoxin derivatives (etoposide), corticosteroids, and intrathecal methotrexate are still commonly used drugs in the treatment of primary HLH. Although this treatment has been effective in prolongation of survival, in some patients >5 years after onset [6], it has not been possible to ultimately cure any child with verified primary HLH using immunochemotherapy only. It was therefore a major therapeutic breakthrough when allogeneic hematopoietic stem cell transplantation (SCT) was shown to cure HLH [7, 8].

Various forms of immunotherapy attained increasing interest during the early 1990s when the T-cell suppressive drugs cyclosporine A (CSA) and antithymocyte globulin (ATG) were reported to be successful in inducing remission [9, 10]. In 1991, markedly elevated levels of interferon (IFN)-gamma were reported in active HLH disease and, consequently, a role for cytokine inhibitors in HLH was suggested [11]. In 1994, the first international clinical trial was launched (HLH-94),

which resulted in markedly pronounced survival, and it was succeeded by HLH-2004. Despite the pronounced improvement of long-term survival from around zero to around two out of three, there is still room for improvement, and ongoing studies on novel treatments such as alemtuzumab, JAK inhibitors, and anti-IFN-gamma therapy are welcome.

Virus-associated HLH was first described by Risdall et al. in 1979 after which it was initially recommended to avoid chemotherapy in this condition [12]. However, it was later shown that the presence of a virus infection in a child with HLH may be a concomitant finding that does not rule out an inherited disease, i.e. FHL, suggesting HLH-directed therapy may be essential even in the presence of an infection [13]. Moreover, effective control of severe Epstein-Barr virus (EBV)-related HLH with immunochemotherapy was later convincingly reported, mostly in patients with presumed secondary HLH (sHLH) [14]. Increased awareness and knowledge of secondary (acquired) HLH has, in recent years, modified its treatment to adapt it to triggering factors, severity of symptoms and response to therapy.

General Principles of HLH Treatment

Based on the experiences outlined above and others, principles for the treatment of HLH have been developed, aimed mainly at suppression of hyperinflammation and related hypercytokinemia and elimination of activated immune cells and antigen-presenting cells by immunosuppressive, immunomodulatory, and cytotoxic drugs [15]. These principles include the administration of different combinations of the following drugs as the initial therapy in newly diagnosed patients with primary HLH: corticosteroids, etoposide, CSA, IVIG, T-cell antibodies (ATG, alemtuzumab), B-cell antibodies (rituximab), and anticytokine agents (anti-IFN-gamma). These treatment options are presented below, except anti-IFN-gamma that is discussed in a subsequent chapter on stem cell transplantation and novel therapies. Additional general therapeutic approaches include elimination of HLH triggers, supportive therapy and, for primary HLH, replacement of the defective immune system by SCT.

Diagnose and Initiate Treatment Promptly

Since the clinical course of HLH may be rapidly fatal and the presentation so variable, it is important for clinicians in many medical fields to be aware of this condition for prompt evaluation and diagnosis. In 1991, the HLH Study Group of the Histiocyte Society presented the first international diagnostic guidelines for HLH [16]. At that time, there were no conclusive clinical, laboratory (functional or genetic tests) or histopathological methods available to distinguish primary and secondary HLH, so these entities were not separated. The diagnostic criteria were revised for the HLH-2004 treatment protocol with the addition of newly available laboratory analysis of NK-cell activity and molecular diagnosis to help identify genetic HLH [17].

Despite these diagnostic advancements, in a newly diagnosed patient with HLH, the underlying cause is often unknown. Nonetheless, prompt

initiation of treatment is crucial to suppress hyperinflammation and hypercytokinemia that leads to multi-organ failure, CNS inflammation, coagulopathy, irreversible organ damage, and ultimately death. For patients with primary HLH, it also stabilizes the patient for the curative SCT. CNS involvement causes the most common severe late effects in HLH and can affect patients with primary as well as secondary HLH [18, 19]. Since regenerative capacity of the CNS is limited, it is very important to initiate timely appropriate systemic HLH-specific treatment to avoid accumulating CNS damage. Knowledge of the underlying cause of HLH is not necessary to start initial treatment but must be identified as soon as possible to help decide adequate continuation treatment as well as search for a donor for patients requiring SCT.

Further need for HLH-directed therapy (length of continuation treatment and SCT) depends on whether the HLH is resolved on the treatment provided and if the patient is finally diagnosed with primary or secondary HLH. Secondary HLH generally only needs treatment until the HLH is in resolution and rarely requires SCT, whereas a primary HLH normally requires continuation treatment until SCT. In these patients, the search for a suitable SCT donor should start promptly to shorten the time to curative SCT and thus decrease the risk of complications of immunosuppressive treatment, HLH reactivation, and CNS damage.

Choice of Acute Therapy

In patients with primary (genetic) HLH, therapy in line with HLH-94/HLH-2004 [17, 20–22] can currently be regarded as standard of care [23], with the addition of rituximab in case of associated EBV infection [24]. This treatment is appropriate in pediatric patients with severe HLH that fulfill the diagnostic criteria for HLH, in particular if functional analyses indicate findings in line with primary HLH, such as decreased cytotoxic function, degranulation defects, or reduced perforin expression. Choice of treatment is more controversial when the diagnostic criteria for

HLH are not fulfilled, in particular if results of laboratory tests are pending and the type of HLH is unclear. One option may be to administer dexamethasone, an important anti-inflammatory drug in HLH, in line with the HLH-94/HLH-2004 protocols while awaiting further laboratory results. In patients with less aggressive HLH, in particular in sHLH, corticosteroids and immunomodulatory drugs such as CSA or IVIG may be sufficient, but these patients must be followed carefully [15]. It is the severity of the symptoms of HLH that should dictate the intensity of initial HLH-directed therapy, not whether it is primary or secondary which, however, is important for guidance in the decision of appropriate continued therapy. Treatment of adults with HLH is discussed in detail in a separate chapter.

Anti-infectious and Supportive Therapy

Infections may trigger both primary and secondary HLH, as well as bouts of the disease, wherefore search for treatable infections is imperative. The most common trigger is viral infections, in particular with EBV, but bacteria, fungi, and parasites may also trigger HLH. Treatment of a triggering infection is an essential part of the overall therapeutic strategy to achieve control of the vicious circle of hyperinflammation in HLH, in primary as well as secondary forms of HLH. Importantly, however, evidence of an associated infection does most often not exclude appropriate HLH-specific therapy, except in *Leishmania*-associated HLH where liposomal amphotericin B is recommended. EBV-associated HLH may be particularly severe and associated with a high mortality, for which the anti-CD20 antibody rituximab, which depletes B cells, has been reported to have a therapeutic value [24]. Moreover, individuals without apparent immunodeficiency may still develop chronic EBV infection with persistent, life-threatening, infectious mononucleosis-like symptoms with high EBV-DNA load in the peripheral blood and systemic clonal expansion of EBV-infected T cells or natural killer cells. The term chronic active EBV

(CAEBV) infection, which may develop to malignant lymphoma, is now often used for this severe condition and is important to identify since treatment with SCT has been reported to have improved outcome markedly [25, 26].

Since HLH patients often are severely ill, maximal supportive care is recommended, including appropriate broad-spectrum antibiotics (until culture results are available), prophylactic cotrimoxazole (5 mg/kg of trimethoprim, two to three times weekly), antimycotic therapy, antiviral therapy in patients with ongoing treatable viral infections, gastroprotection at least during weeks 1–9, and IVIG (0.5 g/kg iv) once every 4 weeks (during the initial and continuation therapy), according to the HLH-2004 protocol. Note that as much as half of fatalities in primary HLH have been reported to be associated with invasive fungal infection, in particular invasive aspergillosis and disseminated candidiasis, highlighting the value of antimycotic prophylaxis and that it should also be directed against *Aspergillus* [27].

Etoposide-Based Treatment, Including HLH-94 and HLH-2004

The Treatment Protocols HLH-94 and HLH-2004

Etoposide and Dexamethasone

HLH-94 and HLH-2004 are designed to induce and maintain a state of resolution of the disease in order to ultimately cure primary, persistent, and relapsing forms of HLH by SCT [17, 20]. The protocols include an initial intensive therapy with immunosuppressive and cytotoxic agents for 8 weeks, with the aim to induce resolution of disease activity (Figs. 14.2 and 14.3). Etoposide 150 mg/m² is administered twice weekly during the first 2 weeks and then weekly, in combination with dexamethasone (initially 10 mg/m² for 2 weeks followed by 5 mg/m² for 2 weeks, 2.5 mg/m² for 2 weeks, 1.25 mg/m² for 1 week, and 1 week of tapering). Corticosteroids are important anti-inflammatory drugs for HLH, and dexamethasone is preferred due to better penetration into the CSF. The choice of etoposide

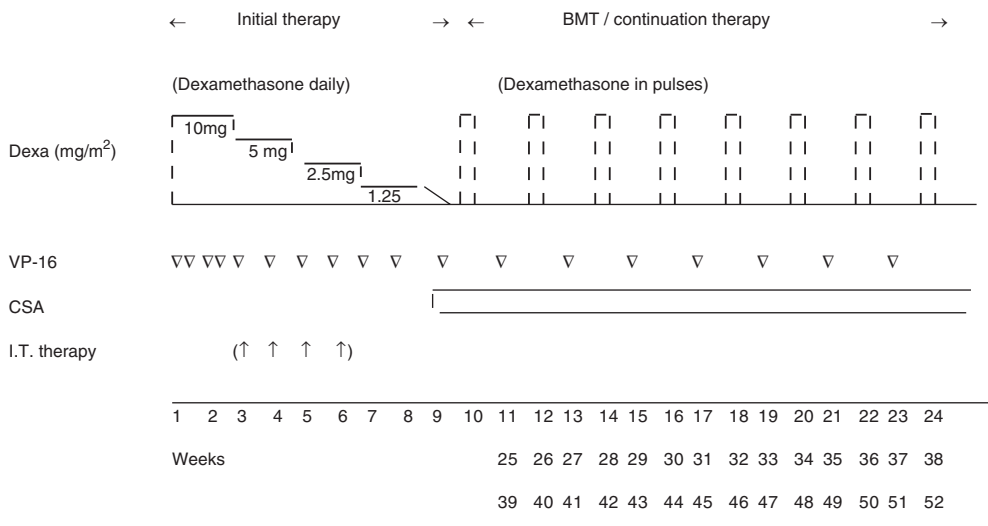


Fig. 14.2 The HLH-94 treatment protocol. The treatment is described in the paragraph “Etoposide-based treatment, including HLH-94 and HLH-2004”. Dexa = Dexamethasone daily with 10 mg/m² for 2 weeks, 5 mg/m² for 2 weeks, 2.5 mg/m² for 2 weeks, 1.25 mg/m² for 1 week; then taper and discontinue during the eighth week. Then pulses starting every second week with 10 mg/m²/day for 3 days, week 10–52. VP-16 = Etoposide 150 mg/m² i.v. is administered twice weekly during the first 2 weeks and then weekly. CSA = Cyclosporine A aiming at blood levels of around

200 µg/L (monoclonal, trough value). Start after 8 weeks with 6 mg/kg daily perorally (divided in 2 daily doses). I.T. therapy = methotrexate doses: <1 year 6 mg, 1–2 years 8 mg, 2–3 years 10 mg, >3 years 12 mg each dose. Maximum four doses prior to re-evaluation, but start only if progressive neurological symptoms or if an abnormal CSF has not improved (Originally published in Blood: Trottestam et al. [22]. Copyright © the American Society of Hematology. Reprinted by permission of the American Society of Hematology)

was empiric, but later laboratory studies showed that etoposide can compensate for the inherited cytotoxic defect in FHL [28]. Notably, if lymphocytes isolated from FHL patients were subjected to etoposide in vitro, this elicited a normalized apoptotic response in FHL patient cells when compared to healthy controls [28]. Later, in a murine model of HLH, it was found that etoposide substantially alleviated all symptoms of murine HLH and the therapeutic mechanism involved potent selective deletion of activated T cells and efficient suppression of inflammatory cytokine production [29].

Cyclosporine A

The immune suppressor CSA lowers the activity of T cells and their immune response. Moreover, HLH is associated with very high IFN-gamma levels and CSA has been reported to also inhibit the production of IFN-gamma [13, 30]. In HLH-94, CSA was therefore used as an immunosuppressive drug, administered in the continuation

treatment starting after the first 8 weeks of induction therapy. When reviewing the results of HLH-94, 35 of the 249 patients included (14%) were reported to have died during the first 2 months of treatment, with most deaths considered to be due to HLH by the reporting physicians, while only 17 died during the subsequent 4 months, i.e., after initiating CSA, but the role of CSA in this lower mortality rate could not be determined [22]. CSA has also been reported by Japanese investigators to be clinically beneficial in the initial treatment of HLH [31]. Therefore, in HLH-2004 the treatment intensity was increased during the first 2 months of therapy by administering CSA already upfront in order to increase immunosuppression without inducing additional myelotoxicity, aiming for CSA trough levels in plasma around 200 microgram/L (Fig. 14.3) [17].

Intrathecal Therapy

Intrathecal therapy (methotrexate in HLH-94, with the addition of corticosteroids in HLH-2004) is

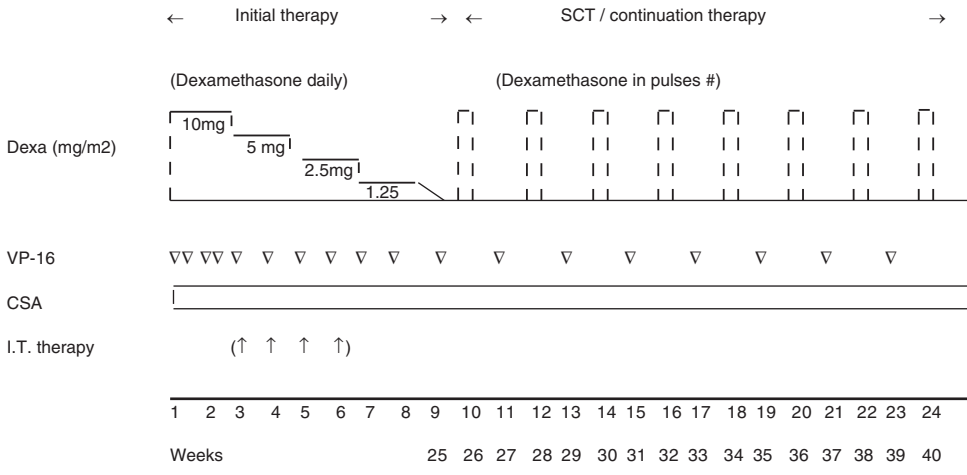


Fig. 14.3 The HLH-2004 treatment protocol. The treatment is described in the paragraph “Etoposide-based treatment, including HLH-94 and HLH-2004”. Dexa = Dexamethasone daily with 10 mg/m² for 2 weeks, 5 mg/m² for 2 weeks, 2.5 mg/m² for 2 weeks, 1.25 mg/m² for 1 week; then taper and discontinue during the eighth week. # = Pulses every second week with 10 mg/m²/day for 3 days during the continuation therapy. VP-16 = Etoposide 150 mg/m² i.v., twice weekly for the first 2 weeks, then weekly during the initial therapy and every second week during the continuation therapy. CSA = Cyclosporin A aiming at levels around 200 µg/L (monoclonal, trough value). Start with 6 mg/kg daily orally (divide in 2 daily doses), if normal kidney func-

tion. I.T. therapy: ↑ = methotrexate doses by age: <1 year 6 mg, 1–2 years 8 mg, 2–3 years 10 mg, >3 years 12 mg each dose. Prednisolone doses by age: <1 year 4 mg, 1–2 years 6 mg, 2–3 years 8 mg, >3 years 10 mg each dose. Maximum four doses are suggested, but start only if progressive neurological symptoms or if an abnormal CSF has not improved. Supportive therapy: Cotrimoxazole, eq 5 mg/kg of trimethoprim, 2–3 times weekly (week 1 and onwards). An oral antimycotic from week 1 to week 9. IvIG (0.5 g/kg iv) q 4 weeks. Gastroprotection suggested week 1–9 (Originally published in: Henter et al. [17]. Copyright © 2006 Wiley-Liss, Inc. Reprinted by permission of John Wiley & Sons, Inc.)

recommended for patients with progressive neurological symptoms and/or persisting abnormal CSF findings [17, 20]. The dosage of the intrathecal therapy is age dependent: for methotrexate <1 year, 6 mg; 1–2 years, 8 mg; 2–3 years, 10 mg; and >3 years, 12 mg, and for prednisolone <1 year, 4 mg; 1–2 years, 6 mg; 2–3 years, 8 mg; and >3 years, 10 mg. In countries where the intrathecal formulation of prednisolone is not commercially available, hydrocortisone can be used instead.

Continuation Therapy and Stem Cell Transplantation

In patients where primary disease is unlikely and the disease resolves after 8 weeks, it is suggested to then stop treatment and restart only if signs of reactivation occur, in order to avoid prolonged therapy and SCT for patients with secondary HLH. For patients with primary, persistent, or relapsing

disease, continuation therapy is recommended to keep the patient in remission until an allogeneic SCT can be performed. The continuation therapy consists of etoposide 150 mg/m² iv every second week and dexamethasone pulses 10 mg/m²/day for 3 days every alternating second week, in combination with continuous CSA. Allogeneic SCT in HLH, as well as gene therapy, an alternative curative option, is discussed in detail in the next chapter.

Results of the HLH-94 and HLH-2004 Studies and Current Recommendations

Results of HLH-94

The overall 5-year cumulative probability of survival in the HLH-94 study was 54% (95% CI ±6%). Altogether, 71% had permanent remission or were

alive until transplant. After the initial treatment of 2 months, 214 patients (86%) were alive. Overall, 114 patients (46%) died; 72 were never transplanted, and 64 of these (89%) died within the first year. The 5-year cumulative survival post-SCT was $66 \pm 8\%$, $74 \pm 16\%$ with matched related donors ($n = 31$), $76 \pm 12\%$ with matched unrelated donors ($n = 46$), $61 \pm 23\%$ with mismatched unrelated donors ($n = 18$), and $43 \pm 21\%$ with family haploidentical donors ($n = 21$) (donor type missing $n = 8$) [22].

Clinically relevant sequelae were reported in 37/133 survivors (28%). Neurological late effects were reported in 19% and included severe mental retardation, cranial and non-cranial nerve palsies, epilepsy, speech delay, learning difficulties, and attention-deficit/hyperactivity disorder (ADHD). Non-neurological late effects were reported in 16%, including nutritional problems and/or growth retardation, hypertension, impaired renal function, obstructive bronchiolitis, and hearing impairment. One patient developed acute myelogenous leukemia (AML) 6 months after treatment start, was transplanted and survived [22].

Results of HLH-2004 and Current Recommendations

The results of the HLH-2004 study are not published at the time of writing this text. However, when comparing preliminary HLH-2004 data with those of the HLH-94 study, it could not be statistically shown that the HLH-2004 treatment was superior to that of HLH-94 with regard to overall survival, survival at 8 weeks, survival before SCT, or survival post-SCT nor with regard to number of patients that displayed neurological symptom at 2 months after start of therapy or at transplantation. Therefore, the HLH-2004 Study Group and the HLH Steering Committee of the Histiocyte Society both recommend the HLH-94 protocol as standard of care. Note that with regard to diagnostics, the HLH-2004 diagnostic criteria are still recommended.

Further Improvements of HLH-94/HLH-2004

The HLH-94/HLH-2004 protocols can likely be improved further by using accumulated clinical

knowledge, by improving CNS-HLH therapy and monitoring, and by adapting to modern diagnostics, to data on risk factors, and to the increasing number of patients diagnosed with secondary HLH, as well as by revising SCT guidelines and salvage recommendations.

It is beyond the scope of this chapter to detail these suggestions, but we want to highlight that in patients with verified primary HLH, the authors suggest not to taper dexamethasone to zero after 8 weeks of therapy but instead maintain a low dose until SCT. Moreover, if using HLH-2004, it is suggested to initiate CSA not earlier than 2 weeks after start of therapy instead of upfront. Finally, for patients with presumed sHLH who may benefit from etoposide, we suggest individualized therapy, such as (1) less frequent etoposide treatments (typically once weekly), (2) weekly decisions on continuation of etoposide treatment, and (3) lower etoposide dose in adolescents and adults (50–100 mg/m²), according to severity of symptoms and response to therapy [32].

ATG-Based Treatment

The HLH group in Paris, France, developed an immunotherapeutic approach, based on the pathophysiologic features of the condition, of ATG in combination with corticosteroids and CSA, with additional intrathecal therapy (methotrexate with or without corticosteroids). More specifically, the regimen included rabbit-ATG, 5 (or 10) mg/kg per day for 5 days, and methylprednisolone (4 mg/kg per day while on ATG, then weaned), followed by a continuation therapy consisting of CSA and intermittent prednisolone, until SCT was performed. Individuals with CNS involvement also received intrathecal therapy [9, 33].

In a retrospective analysis of 38 consecutive patients the treatment led to rapid and complete response of FHL in 73% of the patients, partial response in 24% and no response in 1 patient (3%). The median duration of the complete response was 1.3 months (range 0.5–18 months) in the patients who did not receive a transplant

shortly after ATG therapy. Out of the 38 patients, 30 (79%) underwent a SCT, and the median time between onset of therapy and SCT was 6 weeks (range 4–32 weeks). An overall survival of 21 of the 38 (55%) patients was obtained in this highly experienced center, with 4 toxic deaths [33].

With regard to risk factors, neurological signs indicated a poorer response, and it was concluded that this may be related to the fact that ATG does not cross the blood-brain barrier efficiently and that presence of neurological disease possibly reflects a more severe FHL. Risk factor analysis also showed that first-line ATG therapy had a higher chance of inducing complete remission (82%), whereas second-line ATG therapy was fully efficient in only half of the cases. It was also observed that administration of ATG in patients having had corticosteroids or other immunosuppressive agents ($n = 10$), or ATG ($n = 6$), or both ($n = 1$) carried a significant risk (3/17, 17.5%) for EBV-induced B lymphoproliferative disorders [33].

Two related studies, HIT-HLH and Euro-HIT-HLH, have combined ATG with etoposide and dexamethasone, with additional intrathecal therapy of methotrexate and corticosteroids. Data on outcome and side effects are not yet published.

Alemtuzumab-Based Treatment

The Paris HLH group that developed ATG treatment has also initiated a study including the monoclonal CD52-antibody alemtuzumab as first-line treatment in combination with methylprednisolone and CSA. This proposition is based on the hypothesis that alemtuzumab, capable of killing T lymphocytes efficiently in vivo, should be better tolerated than ATG since, in contrast to the mechanism of action of ATG, alemtuzumab does not activate T lymphocytes when killing them. While data on front-line therapy in HLH still is limited, the use of alemtuzumab in HLH does appear interesting. Alemtuzumab has also been reported to be an effective salvage agent for refractory HLH as described later in this chapter [34].

CNS-HLH-Directed Therapy

Most patients with primary HLH have CNS involvement, which is common also in sHLH [18, 19]. Importantly, patients with FHL-associated genetic aberrations may present with CNS disease only, most often during a reactivation pre- or post-SCT.

Today intrathecal therapy with methotrexate and corticosteroids is included in many treatment protocols for HLH. However, firm evidence on the value of intrathecal therapy in HLH patients with CNS involvement is limited. In the HLH-94 study, neurological alterations were reported in 35 of 109 (32%) patients at onset [21]. In these 35 affected individuals, symptoms normalized in 21 of 31 (67%) survivors after 2 months of HLH-94 therapy. The rate of normalization was similar whether intrathecal therapy was used or not as an additional treatment to systemic etoposide, corticosteroids, and CSA (10/15 versus 10/15, respectively). However, intrathecal methotrexate was not administered in a randomized fashion, and it is possible that the patients who received intrathecal therapy were more seriously affected. Hence, additional analyses are required to better evaluate the value of intrathecal therapy in CNS-HLH.

Secondary HLH

Simply diagnosing HLH is a challenge in itself, not least sHLH. It requires much awareness by the treating physician and, furthermore, must be distinguished from other similar hyperinflammatory conditions in critically ill patients for a timely and appropriately directed therapy. None of the diagnostic criteria for HLH are specific, and the clinical presentation of HLH overlaps the clinical presentation seen in systemic inflammatory response syndrome, sepsis, multi-organ dysfunction syndrome, as well as genetic disorders of metabolism and immunodeficiencies [35]. Additionally, not all diagnostic criteria may be present in the early phase of HLH, and the criteria may not be optimal for patients with sHLH or adults with HLH [36]. Diagnostic uncertainty due

to incomplete evidence of HLH may unnecessarily delay treatment of the uncontrolled inflammation and subsequent potentially life-threatening irreversible organ damage.

As discussed above, a generally accepted standard of care is available for primary HLH. However, treatment of sHLH is less established. Distinguishing between primary (genetic/familial) and secondary (acquired) HLH is often not possible at diagnosis and at the critical time point of initiating therapy. Age may be of some guidance since neonates and infants are more likely to have primary HLH, whereas the likelihood of sHLH increases with age, in particular malignancy-associated HLH. However, hypomorphic monoallelic and biallelic mutations in HLH-causing genes have recently been identified in adolescents and adults [37]. Furthermore, infection-associated sHLH can be found in all ages. In Asia, >90% of children with HLH have sHLH with an average age of 2–3 years [38]. Importantly, as mentioned previously, evidence of an active infection does not exclude a genetic cause of HLH, since infections often trigger a “dormant” primary HLH.

Despite initial diagnostic challenges, it is essential that the hyperinflammation be controlled, and, as mentioned previously, it is the severity of the symptoms of HLH that should dictate the intensity of initial HLH-directed therapy, not whether it is primary or secondary which, however, is important for guidance in the decision of appropriate continued therapy. Of note, in particular in sHLH, it is important to avoid unnecessarily prolonged immunochemotherapy. In adults, the most common forms are infection-associated and malignancy-associated HLH, followed by rheuma-/autoimmune-associated HLH (also called macrophage activation syndrome, MAS) and posttransplant HLH [36]. In children, infection-associated HLH is most common, followed by rheuma-associated HLH (MAS) [39]. The text below focuses on children; for adults, see Chap. 16.

As in primary HLH, it is important also in sHLH to suppress damaging hyperinflammation and hypercytokinemia, to avoid multi-organ failure, CNS inflammation, coagulopathy, irreversible organ damage, and death. For treatment

of virus-associated HLH, see “Choice of Acute Therapy” and “Anti-infectious and Supportive Therapy” above. Addition of plasma exchange (plasmapheresis) to critically ill patients with sHLH has also been reported to be beneficial in some patients [2, 39]. Whether also patients with bacterial septicemia and HLH should be treated with HLH-directed therapy is not well studied, but a short course of corticosteroids and/or IVIG has been suggested and others have added etoposide when corticosteroids were not sufficient [15, 40].

In rheuma-associated HLH (MAS), first-line treatment includes corticosteroids in high doses and CSA. Second-line therapy includes the interleukin (IL)-1 inhibitor anakinra, for which published reports are favorable, and the IL-6 inhibitor tocilizumab, for which the efficacy is unclear at present, and an unclear role of IVIG, cyclophosphamide, etoposide, and plasma exchange has also been reported [41]. However, other reports indicate that etoposide may be efficient in selected cases of severe rheuma-associated HLH (MAS) [42]. For more detailed information on MAS-HLH, see separate chapter.

Malignancy-associated HLH comes in two forms, “malignancy-triggered HLH” and “HLH during chemotherapy” [43]. With regard to “malignancy-triggered HLH,” it is reported to be uncertain if a malignancy-directed or an HLH-directed regimen should be used primarily, but the authors suggest that a regimen including etoposide and corticosteroids likely is valuable, at least in patients with florid HLH. In “HLH during chemotherapy,” delay or interruption of ongoing cancer therapy should be strongly considered, except for in the event of a relapse. In addition, infectious triggers require rigorous treatment, and the addition of rituximab is suggested in highly replicative EBV infection [24, 43].

Prognostic Factors in Newly Diagnosed HLH

Based on data retrieved in patients treated with HLH-94 and HLH-2004 ($n = 232$), risk factors for early fatal outcome have been identified [44]. The following features at onset were significantly

associated with early pre-SCT mortality (aHR = adjusted hazard ratio): hyperbilirubinaemia $>50 \mu\text{mol/L}$ (aHR 3.2; 95% CI 1.3–8.1, $p = 0.011$), hyperferritinemia $>2000 \mu\text{g/L}$ (aHR 3.2; CI 1.2–8.6, $p = 0.019$), and CSF pleocytosis $>100 \times 10^6/\text{L}$ (aHR 5.1; CI 1.4–18.5, $p = 0.012$). Moreover, the following features at 2 weeks into treatment were significantly associated with adverse early pre-SCT outcome: thrombocytopenia $<40 \times 10^9/\text{L}$ (aHR 3.4; CI 1.1–10.7, $p = 0.033$) and hyperferritinemia $>2000 \mu\text{g/L}$ (aHR 10.6; CI 1.2–96.4, $p = 0.037$).

Refractory HLH Treatment

FHL is more or less a continuous disease characterized by frequent reactivations, particularly if the therapeutic intensity is reduced, that is not cured until SCT has been performed. The definition of refractory disease is therefore difficult, as supported by data from clinical studies. Following 2 months of treatment with HLH-94 ($n = 113$), 56 patients (53%) achieved a resolution (7 of whom had had a reactivation), and 34 (32%) improved but had no resolution, whereas only 4 (4%) did not improve and 12 (11%) died (missing data in 7 patients) [21]. Similarly, following treatment with ATG with methylprednisolone, 73% had a complete response, 24% a partial response, and 3% failed to respond, but all patients with a complete response who were not promptly treated with SCT ($n = 7$) experienced a relapse [33]. Importantly, in contrast to many malignant diseases, a reactivation will often respond to an intensification of the ordinary therapy [21, 33]. Moreover, SCT can still be successful despite persisting HLH activity at SCT (3-year survival 54%, as compared to 71% with non-active disease at SCT) [45]. Accordingly, in the HLH-2004 protocol, the suggested action if the patient develops a reactivation is to intensify therapy with etoposide and dexamethasone and add intrathecal therapy in case of CNS reactivation. In summary, reactivations are frequent in HLH, but these have to be separated from failure to respond to therapy, which is less common. The patients who fail to respond to standard-of-

care treatment will need to be treated with additional therapy or alternative “salvage” therapies. Recently, a working group was formed within the Histiocyte Society to review the published experience with salvage therapies for HLH. The results of this group’s efforts are pending at the time of writing.

For the purpose of this chapter, we have attempted to summarize the more recent literature (from the year 2000 through early 2016) regarding the therapy of patients with HLH who were reported to have failed to respond adequately to standard-of-care regimens that contain corticosteroids and etoposide or ATG. Unfortunately, the existing reports have many limitations as there are varying patient populations, a lack of standard timelines for response assessments, and last but not least a lack of consistency with regard to defining refractory disease that includes both reactivations and failures to respond. These reports, therefore, have to be interpreted with caution. Except for etoposide, which has been widely used, only four therapeutic agents or regimens have been reported in the English literature since the year 2000 to have been used in more than one patient with disease reported to be refractory to standard therapy. These agents/regimens include anakinra, alemtuzumab, ATG, and a regimen consisting of doxorubicin, etoposide, and methylprednisolone (DEP). The clinical data or criteria used for authors’ assessments of response are summarized in Table 14.1, and we summarize the authors’ results below and in Table 14.2.

Anakinra

Three patients have been reported to have received anakinra for salvage therapy of HLH following treatment with steroids and etoposide (Table 14.2). These three patients were considered to have secondary HLH or MAS by the authors due to having underlying rheumatologic or other disease. A 14-year-old with cytophagic histiocytic panniculitis and sHLH was reported to fail treatment with methylprednisolone (1 g daily), a single dose of etoposide, and CSA. Anakinra at a dose of 2 mg/kg/day was started, and the authors reported

improvement in laboratory studies, resolution of need for blood transfusions, resolution of organomegaly, successful extubation, and improvement in mental status [46]. A second report described the use of anakinra in patients with rheuma-associated HLH (MAS). One patient in this series with Kawasaki disease and one with systemic juvenile idiopathic arthritis were treated with anakinra following methylprednisolone, cyclosporine, and etoposide, and both patients were reported to experience resolution of HLH following anakinra [47].

ATG

Two patients received ATG within the original French report as a second-line therapy following steroids and etoposide (Table 14.2) [33]. These patients were reported within a group of ten patients with a diagnosis of primary HLH who received second-line ATG following various agents. Methylprednisolone (4 mg/kg per day) was given with the ATG and then tapered. Within the group of 10 patients, 5/10 achieved a complete response. Four of the remaining patients had a

Table 14.1 Definitions or descriptions of complete and partial responses in salvage literature (not including etoposide)

Salvage agent and reference	N	Partial response description or definition	Complete response description or definition
<i>Anakinra</i>			
Behrens et al. [46]	1		Improvement in laboratory studies, no need for further blood transfusions, improvement in mental status, resolution of organomegaly
Miettunen et al. [47]	2 (following steroids and etoposide)		Resolution of MAS
<i>ATG</i>			
Mahlaoui et al. [33]	2 (following steroids and etoposide) 7 (following previous steroids and ATG)	A significant but incomplete improvement of clinical and/or biological manifestations of HLH. Clinical manifestations included mainly fever, hepatosplenomegaly, neurologic symptoms, and bleeding. Biological manifestations included cytopenia, hypertriglyceridemia, hypofibrinogenemia, hyperferritinemia; high blood levels of liver enzymes, cerebrospinal pleocytosis or high levels of protein, and excess HLA DR + CD8+ T cells in the blood and/or cerebrospinal fluid	Complete disappearance of clinical and biological signs of HLH. Clinical manifestations included mainly fever, hepatosplenomegaly, neurologic symptoms, and bleeding. Biological manifestations included cytopenia, hypertriglyceridemia, hypofibrinogenemia, hyperferritinemia; high blood levels of liver enzymes, cerebrospinal pleocytosis or high levels of protein, and excess HLA DR + CD8+ T cells in the blood and/or cerebrospinal fluid
<i>Alemtuzumab</i>			
Strout et al. [48]	1	Fever resolved, blood counts improved but platelets did not normalize, lymphohistiocytic infiltrate on bone marrow biopsy resolved	
Gerard et al. [49]	1	Normalization of the absolute neutrophil count, a rise in the platelet count to $50 \times 10^9/L$, a fall of ferritin from 4756 to 1500 ug/L, and regression of hemophagocytosis in marrow samples	

(continued)

Table 14.1 (continued)

Salvage agent and reference	N	Partial response description or definition	Complete response description or definition
Marsh et al. [34]	22	At least a 25% improvement in two or more quantifiable symptoms and laboratory markers by 2 weeks following alemtuzumab as follows. Soluble IL-2 receptor response was defined as a greater than a 1.5-fold decrease. Ferritin and triglyceride responses were defined as decreases of at least 25%. For patients with an initial ANC $<0.5 \times 10^9/L$, a response was defined as an increase of ANC by at least 100% to $>0.5 \times 10^9/L$. For patients with an ANC $0.5-2.0 \times 10^9/L$, an increase by at least 100% to $>5 \times 10^9/L$. For patients with transaminitis with an ALT greater than 400 U/L, an ALT response was defined as a decrease of ALT of at least 50%. For patients with hemophagocytosis noted on a biopsy specimen within 4 weeks of alemtuzumab, a response was defined as resolution of hemophagocytosis following alemtuzumab. For patients with refractory CNS-HLH and altered level of consciousness, a response was defined as a normal level of consciousness following alemtuzumab	Normalization of all listed at left
<i>DEP</i>			
Wang et al. [50]	34 (patients with lymphoma-associated HLH were excluded here)	At least a 25% improvement in two or more quantifiable symptoms and laboratory markers by 2 weeks following DEP regimen as follows: sCD25 response was 1.5-fold decrease; ferritin and triglyceride decrease of at least 25%; for patients with an initial neutrophil count of $<0.5 \times 10^9/L$, a response was defined as an increase by at least 100% to $>0.5 \times 10^9/L$; for patients with a neutrophil count of $0.5-2.0 \times 10^9/L$, an increase by at least 100% to $>2.0 \times 10^9/L$ was considered a response; and for patients with ALT 400 U/L, response was defined as an ALT decrease of at least 50%. Fever resolution	Normalization of all of the quantifiable symptoms and laboratory markers of HLH, including levels of sCD25, ferritin, and triglycerides; hemoglobin; neutrophil counts; platelet counts; and alanine aminotransferase (ALT). Fever resolution

partial response, and one patient failed to respond. Personal communication with the authors (Alain Fischer) revealed that the two patients who were treated with ATG following steroids and etoposide both achieved a complete response. In a second round of therapy with ATG to seven patients who had received a previous course of ATG (following a complete response and relapse ($n = 6$), and following a partial response and relapse ($n = 1$)), six out of seven patients achieved a

complete response and one patient achieved a partial response (Table 14.2) [33].

Alemtuzumab

Two case reports describe the use of alemtuzumab in adults with refractory HLH (Table 14.2). One adult initially treated with IVIG, CSA, dexamethasone, infliximab, and etoposide was treated

Table 14.2 Salvage therapy regimens and responses, except for etoposide

Salvage agent	N	Dosing regimen(s) ^a	Time of response assessment or description of response	CR	PR	NR
<i>Anakinra</i>						
Behrens et al. [46]	1	2 mg/kg/day	1 week (less for some symptoms)	1		
Miettunen et al. [47]	2 (12 patients reported in the series but only 2 received anakinra following steroids and etoposide)	2 mg/kg/day	10 days	2		
<i>ATG</i>						
Mahlaoui et al. [33]	2 (2 received ATG following steroids and etoposide) 7 (2 received ATG following previous steroids and ATG)	ATG: 25 or 50 mg/kg divided over 5 consecutive days. Methylprednisolone: 4 mg/kg per day given with the ATG and then tapered	For all patients included in the report ($n = 45$), CR was achieved in a median time of 8 days (range 4–15 days)	2 6	 1	
<i>Alemtuzumab</i>						
Strout et al. [48]	1	30 mg subcut three times a week	1 week		1	
Gerard et al. [49]	1	30 mg subcut three times a week	1 and 2 weeks		1	
Marsh et al. [34]	22	Median 1 mg/kg (range 0.1–8.9 mg/kg) divided over a median of 4 days (range 2–10 days) as a first or only course	2 weeks		14	8 ^b
<i>DEP</i>						
Wang et al. [50]	34 (patients with lymphoma-associated HLH were excluded here)	In the first month: Liposomal doxorubicin 25 mg/m ² on day 1; Etoposide 100 mg/m ² on the first day of every week; Methylprednisolone 15 mg/kg days 1–3, 2 mg/kg days 4–6, 1 mg/kg days 7–10, 0.75 mg/kg days 11–14, 0.5 mg/kg days 15–21, and 0.4 mg/kg days 22–28	2 and 4 weeks	12	14	8

^aMany patients were also continued on previous HLH-directed therapies

^bSome patients had improvement in one sign or symptom of HLH

with alemtuzumab, and within 1 week, the authors reported fever resolution, blood count improvement, and resolution of lymphohistiocytic infiltrate on bone marrow biopsy (Table 14.2) [48]. Another adult was previously treated with dexamethasone, CSA, etoposide, IVIG, methylprednisolone, and plasmapheresis, but CSA and etoposide were held due to toxicities. This patient was reported to experience a normalization of the absolute neutrophil count

and a rise in the platelet count to $50 \times 10^9/L$ along with a fall of ferritin from 4756 to 1500 ug/L within 2 weeks of alemtuzumab initiation [49].

A larger case series ($n = 22$) described the use of alemtuzumab for the salvage treatment of pediatric and young adult patients with primary HLH (Table 14.2) [34]. The patients had previously been treated with dexamethasone and etoposide, but etoposide had been held in 23% of patients due to intolerance with marrow

suppression/neutropenia. Additional therapies received by patients during the 2 weeks prior to alemtuzumab included cyclosporine, intrathecal hydrocortisone +/- methotrexate, methylprednisolone, and rituximab in 36%, 23%, 9%, and 14% of patients, respectively. A first or only course of alemtuzumab at a median dose of 1 mg/kg was given subcutaneously over a median of 4 days. At the time of response assessment (2 weeks), a partial response had been achieved in 14/22 patients (64%). No patients achieved a complete response at that time point. The remaining patients had improvement in only one sign or symptom of HLH or failed to respond [34].

Doxorubicin, Etoposide, and Methylprednisolone (DEP)

A prospective study of doxorubicin, etoposide, and methylprednisolone (DEP) was reported by Wang et al. (Table 14.2) [50]. The authors treated 63 patients aged 18 years and older who failed to achieve a partial remission after at least 2 weeks of HLH-94 treatment with or without rituximab (in EBV-HLH patients). Many patients had lymphoma-associated HLH, but 34 patients were treated for HLH not associated with lymphoma. Following DEP, 12 of 34 patients (35%) achieved a complete response, 14 patients (41%) achieved a partial response, and 8 (24%) patients failed to respond [50].

Toxicities and Complications of Salvage Therapies

The three patients who were reported to receive anakinra were not reported to have serious side effects following treatment. Toxicities and complications were common following ATG but were not reported individually for the patients that received ATG following corticosteroids and either etoposide or ATG [33]. Following the entire reported 45 courses of ATG, 20 were complicated by immediate adverse effects including fever and chills (40%), neutropenia (16%),

neurological symptoms (4%), or other (11%) complications. Infections occurred in 22% of the entire cohort, including bacterial, fungal, and viral infections. EBV-associated lymphoproliferative disorder occurred in three patients. Four patients died following either disseminated fungal infection or EBV-induced B lymphoproliferative disorder [33]. The case series of alemtuzumab reported fever in four patients (18%), urticaria in one patient (5%), transient worsening of neutropenia in four patients (18%), and transient worsening of thrombocytopenia in two patients (9%). Viral reactivations were common: CMV, adenovirus, and EBV viremia occurred following alemtuzumab in 32%, 23%, and 23% of patients, respectively. Bacteremia or candidemia occurred in nine patients [34]. The authors of the DEP study noted transient worsening of cytopenias in a minority of patients which improved by 4 weeks. They reported that they did not observe new or worsening infections directly induced by the DEP regimen [50].

Concluding Remarks

Conclusions Regarding Newly Diagnosed Patients

The principles for the treatment of HLH include suppression of hyperinflammation and related hypercytokinemia and elimination of activated immune cells and antigen-presenting cells by immunosuppressive, immunomodulatory, and cytotoxic drugs. These principles include the administration of different combinations of the following drugs as the initial therapy in newly diagnosed patients with primary HLH: corticosteroids, etoposide, CSA, IVIG, T-cell antibodies (ATG, alemtuzumab), B-cell antibodies (rituximab), and anticytokine agents (anti-IFN-gamma). In patients with familial (primary) HLH, therapy in line with HLH-94/HLH-2004 can currently be regarded as standard of care, with the addition of rituximab in case of associated EBV infection. The choice of treatment is more controversial when the diagnostic criteria

for HLH are not fulfilled, in particular if results of laboratory tests are pending. Diagnostic uncertainty may unnecessarily delay treatment of the uncontrolled inflammation where prompt initiation of therapy is crucial. One option may be to administer dexamethasone in line with the HLH-94/HLH-2004 protocols. In patients with less aggressive HLH, in particular sHLH, corticosteroids and CSA or IVIG may be sufficient. It is the severity of the symptoms of HLH that should dictate the intensity of initial HLH-directed therapy, not whether it is primary or secondary. Furthermore, treatment of concomitant infections or other triggering factors of HLH and maximal supportive care is essential.

Conclusions Regarding Refractory HLH Treatment

FHL is more or less a continuous disease characterized by frequent reactivations particularly if the therapeutic intensity is reduced, that is, not cured until SCT has been performed. The definition of refractory disease is therefore difficult, and reactivations, which often can respond to intensification of ordinary therapy, have to be separated from failure to respond to therapy, which is less common. Overall, there is little literature upon which to base decisions regarding therapy for patients that fail to respond. While anakinra appears to be a potentially promising agent without serious side effects for patients with rheuma-associated HLH (MAS), its effectiveness in patients with primary HLH and other forms of sHLH is uncertain. ATG and alemtuzumab have been associated with complete or partial responses in many patients, respectively, but carry significant risks of complications. The DEP regimen is similar to traditional corticosteroid and etoposide treatment, and it is possible that continued corticosteroid and etoposide treatment might have led to similar responses. Overall, clinicians must continue to weigh the pros and cons of individual immunosuppressive agents for each patient with refractory disease until appropriate prospective clinical trials are performed.

References

1. Janka GE. Familial hemophagocytic lymphohistiocytosis. *Eur J Pediatr*. 1983;140(3):221–30.
2. Ladisch S, Ho W, Matheson D, Pilkington R, Hartman G. Immunologic and clinical effects of repeated blood exchange in familial erythrophagocytic lymphohistiocytosis. *Blood*. 1982;60(4):814–21.
3. Ambruso DR, Hays T, Zwartjes WJ, Tubergen DG, Favara BE. Successful treatment of lymphohistiocytic reticulosis with phagocytosis with epipodophyllotoxin VP 16-213. *Cancer*. 1980;45(10):2516–20.
4. Henter JI, Elinder G, Finkel Y, Söder O. Successful induction with chemotherapy including teniposide in familial erythrophagocytic lymphohistiocytosis. *Lancet*. 1986;2(8520):1402.
5. Fischer A, Virelizier JL, Arenzana-Seisdedos F, Perez A, Nezelof C, Griscelli C. Treatment of four patients with erythrophagocytic lymphohistiocytosis by a combination of epipodophyllotoxin, steroids, intrathecal methotrexate and cranial irradiation. *Pediatrics*. 1985;76(2):263–8.
6. Henter JI, Elinder G. Familial hemophagocytic lymphohistiocytosis. Clinical review based on the findings in seven children. *Acta Paediatr Scand*. 1991;80(3):269–77.
7. Fischer A, Cerf-Bensussan N, Blanche S, LeDeist F, Bremard-Oury C, Leverger G, et al. Allogeneic bone marrow transplantation for erythrophagocytic lymphohistiocytosis. *J Pediatr*. 1986;108(2):267–70.
8. Blanche S, Caniglia M, Girault D, Landman J, Griscelli C, Fischer A. Treatment of hemophagocytic lymphohistiocytosis with chemotherapy and bone marrow transplantation: a single center study of 22 cases. *Blood*. 1991;78(1):51–4.
9. Stephan JL, Donadieu J, Ledeist F, Blanche S, Griscelli FA. Treatment of familial hemophagocytic lymphohistiocytosis with antithymocyte globulins, steroids and cyclosporin A. *Blood*. 1993;82(8):2319–23.
10. Loechelt BJ, Egeler RM, Filipovich AH, Jyonouchi H, Shapiro RS. Immunosuppression: an alternative maintenance therapy for familial hemophagocytic lymphohistiocytosis (FHL): preliminary results. *Med Pediatr Oncol*. 1994;22(5):325–8.
11. Henter JI, Söder O, Hansson M, Elinder G, Andersson B, Andersson U. Hypercytokinemia in familial hemophagocytic lymphohistiocytosis. *Blood*. 1991;78(11):2918–22.
12. Risdall RJ, McKenna RW, Nesbit ME, Krivit W, Balfour HH Jr, Simmons RL, et al. Virus-associated hemophagocytic syndrome. A benign histiocytic proliferation distinct from malignant histiocytosis. *Cancer*. 1979;44(3):993–1002.
13. Henter JI, Ehrnst A, Andersson J, Elinder G. Familial hemophagocytic lymphohistiocytosis and viral infections. *Acta Paediatr*. 1993;82(4):369–72.
14. Imashuku S, Hibi S, Ohara T, Iwai A, Sako M, Kato M, et al. Effective control of Epstein-Barr virus-related

- hemophagocytic lymphohistiocytosis with immuno-chemotherapy. *Blood*. 1999;93(6):1869–74.
15. Janka GE, Lehmborg K. Hemophagocytic lymphohistiocytosis: pathogenesis and treatment. *Hematology Am Soc Hematol Educ Program*. 2013;2013(1):605–11.
 16. Henter JI, Elinder G, Öst Å; the HLH Study Group of the Histiocyte Society. Diagnostic guidelines for hemophagocytic lymphohistiocytosis. *Semin Oncol*. 1991;18(1):29–33.
 17. Henter JI, Horne AC, Aricó M, Egeler RM, Filipovich AH, Imashuku S, et al. HLH-2004: diagnostic and therapeutic guidelines for hemophagocytic lymphohistiocytosis. *Pediatr Blood Cancer*. 2007;48(2):124–31.
 18. Horne AC, Trottestam H, Aricó M, Egeler RM, Filipovich AH, Gardner H, et al. Frequency and spectrum of CNS involvement in 193 children with hemophagocytic lymphohistiocytosis. *Br J Haematol*. 2008;140(3):327–35.
 19. Yang S, Zhang L, Jia C, Ma H, Henter JI, Shen K. Frequency and development of CNS involvement in Chinese children with hemophagocytic lymphohistiocytosis. *Pediatr Blood Cancer*. 2010;54(3):408–15.
 20. Henter JI, Arico M, Egeler M, Elinder G, Filipovich A, Favara B, et al. HLH-94: a treatment protocol for hemophagocytic lymphohistiocytosis. *Med Pediatr Oncol*. 1997;28(5):342–7.
 21. Henter JI, Samuelsson-Horne AC, Arico M, Egeler RM, Elinder G, Filipovich AH, et al. Treatment of hemophagocytic lymphohistiocytosis with HLH-94 immuno-chemotherapy and bone marrow transplantation. *Blood*. 2002;100(7):2367–73.
 22. Trottestam H, Horne AC, Aricó M, Egeler RM, Filipovich AH, Gardner H, et al. Chemo-immunotherapy for hemophagocytic lymphohistiocytosis: long-term results of the HLH-94 treatment protocol. *Blood*. 2011;118(17):4577–84.
 23. Janka GE, Lehmborg K. Hemophagocytic syndromes – an update. *Blood Rev*. 2014;28(4):135–42.
 24. Chellapandian D, Das R, Zellek K, Wiener SJ, Zhao H, Teachey DT, et al; EBV-HLH Rituximab Study Group. Treatment of Epstein Barr virus-induced haemophagocytic lymphohistiocytosis with rituximab-containing chemo-immunotherapeutic regimens. *Br J Haematol*. 2013;162(3):376–82.
 25. Fujiwara S, Kimura H, Imadome K, Arai A, Kodama E, Morio T, et al. Current research on chronic active Epstein-Barr virus infection in Japan. *Pediatr Int*. 2014;56(2):159–66.
 26. Kawa K, Sawada A, Sato M, Okamura T, Sakata N, Kondo O, et al. Excellent outcome of allogeneic hematopoietic SCT with reduced-intensity conditioning for the treatment of chronic active EBV infection. *Bone Marrow Transplant*. 2011;46(1):77–83.
 27. Sung L, King SM, Carcao M, Trebo M, Weitzman SS. Adverse outcomes in primary hemophagocytic lymphohistiocytosis. *J Pediatr Hematol Oncol*. 2002;24(7):550–4.
 28. Fadeel B, Orrenius S, Henter JI. Induction of apoptosis and caspase activation in cells obtained from familial haemophagocytic lymphohistiocytosis patients. *Br J Haematol*. 1999;106(2):406–15.
 29. Johnson TS, Terrell CE, Millen SH, Katz JD, Hildeman DA, Jordan MB. Etoposide selectively ablates activated T cells to control the immunoregulatory disorder hemophagocytic lymphohistiocytosis. *J Immunol*. 2014;192(1):84–91.
 30. Kalman VK, Klimpel GR. Cyclosporin A inhibits the production of gamma interferon (IFN gamma), but does not inhibit production of virus-induced IFN alpha/beta. *Cell Immunol*. 1983;78(1):122–9.
 31. Imashuku S, Hibi S, Kuriyama K, Tabata Y, Hashida T, Iwai A, et al. Management of severe neutropenia with cyclosporin during initial treatment of Epstein-Barr virus-related hemophagocytic lymphohistiocytosis. *Leuk Lymphoma*. 2000;36(3–4):339–46.
 32. Henter JI, Chow CB, Leung CW, Lau YL. Cytotoxic therapy for severe avian influenza A (H5N1) infection. *Lancet*. 2006;367(9513):870–3.
 33. Mahlaoui N, Ouaché-Chardin M, de Saint BG, Neven B, Picard C, Blanche S, et al. Immunotherapy of familial hemophagocytic lymphohistiocytosis with antithymocyte globulins: a single center retrospective report of 38 patients. *Pediatrics*. 2007;120(3):622–8.
 34. Marsh RA, Allen CE, McClain KL, Weinstein JL, Kanter J, Skiles J, et al. Salvage therapy of refractory hemophagocytic lymphohistiocytosis with alemtuzumab. *Pediatr Blood Cancer*. 2013;60(1):101–9.
 35. Lehmborg K, Ehl S. Diagnostic evaluation of patients with suspected haemophagocytic lymphohistiocytosis. *Br J Haematol*. 2013;133(3):289–98.
 36. Ramos-Casals M, Brito-Zerón P, López-Guillermo A, Khamashta MA, Bosch X. Adult haemophagocytic syndrome. *Lancet*. 2014;383(9927):1503–16.
 37. Zhang K, Jordan MB, Marsh RA, Johnson JA, Kissell D, Meller J, et al. Hypomorphic mutations in PRF1, MUNC13-4, and STXBP2 are associated with adult-onset familial HLH. *Blood*. 2011;118(22):5794–8.
 38. Ishii E, Ohga S, Imashuku S, Yasukawa M, Tsuda H, Miura I, et al. Nationwide survey of hemophagocytic lymphohistiocytosis in Japan. *Int J Hematol*. 2007;86(1):58–65.
 39. Demirkol D, Yildizdas D, Bayrakci B, Karapinar B, Kendirli T, Koroglu TF, et al; Turkish Secondary HLH/MAS Critical Care Study Group. Hyperferritinemia in the critically ill child with secondary hemophagocytic lymphohistiocytosis/sepsis/multiple organ dysfunction syndrome/macrophage activation syndrome: what is the treatment? *Crit Care*. 2012;16(2):R52.
 40. Edner J, Rudd E, Zheng C, Dahlander A, Eksborg S, Edner A, et al. Severe bacteria-associated hemophagocytic lymphohistiocytosis in an extremely premature infant. *Acta Paediatr*. 2007 Nov;96(11):1703–6.
 41. Ravelli A, Grom AA, Behrens EM, Cron RQ. Macrophage activation syndrome as part of systemic juvenile idiopathic arthritis: diagnosis, genetics, pathophysiology and treatment. *Genes Immun*. 2012 Jun;13(4):289–98.
 42. Palmblad K, Schierbeck H, Sundberg E, Horne AC, Erlandsson Harris H, et al. High systemic levels of

- the cytokine-inducing HMGB1 isoform secreted in severe macrophage activation syndrome. *Mol Med*. 2015;20(1):538–47.
43. Lehmsberg K, Nichols KE, Henter JI, Girschikofsky M, Greenwood T, Jordan M, et al; the Study Group on Hemophagocytic Lymphohistiocytosis Subtypes of the Histiocyte Society. Consensus recommendations for the diagnosis and management of hemophagocytic lymphohistiocytosis associated with malignancies. *Haematologica*. 2015;100(8):997–1004.
44. Trottestam H, Berglöf E, Horne AC, Beutel K, Lehmsberg K, Sieni E, et al. Risk factors for early death in patients with hemophagocytic lymphohistiocytosis. *Acta Paediatr*. 2012;101(3):313–8.
45. Horne AC, Janka G, Egeler RM, Gadner H, Imashuku S, Ladisch S, et al. Hematopoietic stem cell transplantation in hemophagocytic lymphohistiocytosis. *Br J Haematol*. 2005;129(5):622–30.
46. Behrens EM, Kreiger PA, Cherian S, Cron RQ. Interleukin 1 receptor antagonist to treat cytotoxic histiocytic panniculitis with secondary hemophagocytic lymphohistiocytosis. *J Rheumatol*. 2006;33(10):2081–4.
47. Miettunen PM, Narendran A, Jayanthan A, Behrens EM, Cron RQ. Successful treatment of severe paediatric rheumatic disease-associated macrophage activation syndrome with interleukin-1 inhibition following conventional immunosuppressive therapy: case series with 12 patients. *Rheumatology (Oxford)*. 2011;50(2):417–9.
48. Strout MP, Seropian S, Berliner N. Alemtuzumab as a bridge to allogeneic SCT in atypical hemophagocytic lymphohistiocytosis. *Nat Rev Clin Oncol*. 2010;7(7):415–20.
49. Gerard LM1, Xing K, Sherifi I, Granton J, Barth D, Abdelhaleem M, et al. Adult hemophagocytic lymphohistiocytosis with severe pulmonary hypertension and a novel perforin gene mutation. *Int J Hematol*. 2012;95(4):445–50.
50. Wang Y, Huang W, Hu L, Cen X, Li L, Wang J, et al. Multicenter study of combination DEP regimen as a salvage therapy for adult refractory hemophagocytic lymphohistiocytosis. *Blood*. 2015;126(19):2186–92.

Hematopoietic Cell Transplantation and Novel Therapies in Hemophagocytic Lymphohistiocytosis

K. Scott Baker and Michael B. Jordan

Abbreviations

CNS	Central nervous system
GVHD	Graft-versus-host disease
HCT	Hematopoietic cell transplantation
HLH	Hemophagocytic lymphohistiocytosis
MAC	Myeloablative conditioning
RIC	Reduced intensity conditioning
UCB	Umbilical cord blood
VOD	Veno-occlusive disease

Hematopoietic Cell Transplantation (HCT) for HLH

Background and Rationale

As described in previous chapters, the recognition of HLH as an immunoregulatory disorder, which was fatal in the majority of cases despite immunosuppressive and cytotoxic therapy, led to

the hypothesis that HLH, like many other disorders of immune function, could be treated and potentially cured by providing the patient with a new functional immune system through the process of allogeneic HCT. Furthermore, the ultimate discovery of the genetic basis for several inherited defects in cytotoxic killing in the disease, as described elsewhere in this book, further supported the rationale for treatment of HLH with HCT. The first case of successful allogeneic HCT utilizing a matched sibling donor for HLH was reported in 1986 [1]. Subsequently over the next 10 years, the use of HCT continued to be explored. In 1996, Arico et al. published a collection of 122 cases of HLH that had been reported to an international registry within the Histiocyte Society and found a clear survival advantage for patients receiving HCT (66%) compared to only 10.1% for those treated with chemotherapy alone. [2] Additional early experience with HCT reported in the late 1990s further defined the utility of HCT for treating HLH but also the unique challenges that were observed as discussed further below.

K. Scott Baker, MD, MS
Clinical Research Division, Fred Hutchinson Cancer Research Center, Department of Pediatrics, University of Washington, Seattle, WA, USA

M.B. Jordan, MD (✉)
Divisions of Immunobiology, and Bone Marrow Transplantation and Immune Deficiency, Department of Pediatrics, Cincinnati Children's Hospital Medical Center, University of Cincinnati, Cincinnati, OH, USA
e-mail: Michael.Jordan@cchmc.org

Indications for HCT in HLH and Donor Sources

Clinical Indications

Indication for HCT in patients with HLH in whom a disease-associated mutation has been

identified is straightforward, in that all of these patients should proceed to HCT with the best available donor once adequate disease control has been achieved. The difficulties that arise are twofold. The first is whether patients should proceed to HCT when a diagnosis of primary HLH is suspected (e.g., based on age at diagnosis, lack of any associated infectious trigger, or persistently abnormal functional assay such as NK function/degranulation) but cannot be clearly confirmed (i.e., no family history or HLH-associated mutations can be identified). Patients with HLH secondary to malignancy or rheumatologic conditions would not ordinarily proceed to HCT unless the HLH was recurrent and severe (in the case of rheumatologic disorders) or for treatment of the malignancy. With an uncertain diagnosis of primary HLH, a “wait and watch” approach may be most reasonable. If the response to therapy is prompt, disease markers normalize, and treatment can be tapered off without a flare of disease activity, then careful monitoring of those patients for any signs of reactivation can be done and treatment reinstated if needed. Recurrent disease would strongly suggest that the disease is primary in nature and thereby justify proceeding to HCT. However, physicians must weigh the severity of the patient’s initial HLH and how readily it responded to treatment, when considering a risk-benefit analysis balancing the risks of HCT vs. potentially recurrent HLH. Indirect evidence that HLH is primary may be sufficient to justify the risks of HCT. Historically, age of onset below 2 years was thought to suggest primary HLH. In the author’s experience, an age of onset below the age of 1 year appears to be a stronger indicator of primary HLH. Persistently abnormal functional assays (NK function or CD107 mobilization/degranulation) may also provide support for HCT. In this case it is wise to assess parents and siblings (even those not considered as donors) to determine how clearly the functional defect correlates with clinical HLH. The true specificity of these functional assays is not known, and in the author’s experience, some “well” parents may have similar defects.

The second issue complicating HCT decisions is whether patients should proceed to HCT with active disease when HCT is indicated, but adequate disease control cannot be achieved. For patients with ongoing active disease, all reasonable attempts to achieve a quiescent state of disease activity (see Novel Therapies below) should be pursued prior to HCT as inferior outcomes have been reported for patients who enter HCT with active disease [3]. However, without HCT patients with inherited HLH have no chance of survival, and thus assuming that basic organ function is acceptable, the newer reduced intensity conditioning regimens which are highly immunosuppressive should be pursued even with imperfect disease control.

Donor Choice

For any HCT, stem cells collected from an HLA-identical sibling donor remain the optimal donor choice. For patients with genetic disorders, however, utilization of a sibling not only requires that they be HLA identical but also that they be screened for the genetic condition identified in the affected sibling (assuming one was identified). In autosomal recessive conditions such as HLH, “carrier” donors with heterozygous mutations are suitable for patients with homozygous or compound heterozygous mutations. When the genetic etiology of HLH is unknown or partially known (e.g., patient has only a heterozygous mutation in a disease-causing gene), consideration of a potential sibling donor is challenging. It requires a careful clinical and family history, examination of HLH laboratory markers including NK function or CD107 mobilization/degranulation, and possibly consideration of the age of the potential donor and likelihood that disease may still manifest in the sibling. If these studies are normal, then it is still reasonable to proceed with using the sibling donor, particularly if they have evidence of past infection with Epstein-Barr virus and cytomegalovirus which may provide additional reassurance of an intact immune system.

If a matched related donor is not available, then a suitable unrelated donor should be identified. The use of umbilical cord blood (UCB) has been explored although little published data regarding this experience exists. The primary concern with UCB has been the risk of graft failure and the potential need for myeloablative conditioning (MAC) in order to reduce this risk. However, as the field has moved away from MAC regimens in this disease, there has been more hesitancy to utilize UCB, partly due to the inability to deliver donor lymphocyte infusions (DLI) posttransplant for treatment of falling chimerism. A report from Japan included 28 cases of HLH who underwent UCB after either MA or reduced intensity conditioning (RIC) [4]. The survival of UCB recipients was 65%, although four cases required second UCB transplant due to graft failure. A second report from Japan included 38 patients who underwent UCB transplant, 25 cases after MAC and 13 cases after RIC [5]. Event-free survival (EFS) at 2 years was 59% after MAC and 46% after RIC ($p = 0.35$); overall survival (OS) also did not differ between the two groups, 63% vs. 61%, respectively ($p = 0.66$). Mixed chimerism was present in 32% in the MAC group and 60% of those receiving RIC. Five patients (3 MAC, 2 RIC) had graft failure.

Conditioning Regimen Choices and Outcomes

Myeloablative Conditioning

In the late 1990s, the first few publications of small series of patients who received myeloablative HCT for HLH were reported (14, 17, and 20 cases each) [3, 6, 7]. In all three the majority of cases received a preparative regimen of busulfan (BU) and cyclophosphamide (CY) with or without etoposide and anti-thymocyte globulin (ATG). While these series established HCT as definitive therapy for HLH, all had a high incidence of transplant-related mortality and overall survival rates of only between 45% and 64%. Deaths in these early series were

attributed to disease recurrence, hepatic sinusoidal obstructive syndrome (then termed veno-occlusive disease), infections, and multi-organ failure. Importantly, at this point in time, all BU dosing was oral, and pharmacokinetically based adjustments of BU dosing were not widely available. In all series, disease recurrence was a predominant cause of mortality. In the series by Baker et al., only 17% of cases with active disease at the time of HCT survived, whereas all patients who had active CNS disease at the time of HCT survived [3]. This collective experience has generally led to more aggressive attempts to achieve better disease control prior to HCT, as well as moving to HCT more quickly to avoid disease flares that may be more difficult to control.

Following these initial reports, larger studies began to be published in the 2000s, and all continued to report the use of myeloablative conditioning regimens, again the majority with BU/CY \pm etoposide and \pm ATG. The Histiocyte Society had completed the HLH-1994 study and reported the results in 2002 [8]. At the time of diagnosis, patients ($n = 113$) were treated with combined chemotherapy and immunotherapy (dexamethasone, etoposide, cyclosporine, and intrathecal methotrexate if CNS disease was present). Of these, 65 patients went on to receive either matched related (10/15 alive), matched unrelated (17/25 alive), mismatched unrelated (1/4 alive), haploidentical (6/14 alive), or cord blood (4/5 alive) transplants (data missing on 2 related donor cases, both alive). The 3-year probability of survival after HCT was 62% ($\pm 12\%$). Transplant-related mortality in this study was significant (32% at 100 days) and due to typical HCT-related complications ($n = 17$) and HLH reactivation ($n = 3$). Interestingly one late death occurred at day +422 from a secondary acute myeloid leukemia, but no data was provided on whether this was in donor or recipient cells. A subsequent study included 91 cases of HLH reported to the Center for Blood and Marrow Transplantation Research (CIBMTR) [9]. All patients underwent unrelated donor HCT between 1989 and 2005, and the majority

received the BU/CY/etoposide \pm ATG preparative regimen. The 5-year overall survival was 45%. Data on pre-HCT disease status was only available on 51 cases; 43/51 were in clinical systemic and CNS remission, 4 had active systemic disease without CNS involvement, 3 had only active CNS disease, and 1 patient had active systemic and CNS disease. The 5-year OS in those in remission at time of HCT was 49%. Only one of five with active systemic disease at time of HCT was alive. The risk of 100-day mortality was high at 35% with similar causes of death to what had been noted previously. The probability of grade 2–4 acute graft-versus-host disease (aGVHD) was 41%, and grade 3–4 was 24%. Given the era of these transplants, low-resolution typing was available for HLA A and B and high-resolution typing only for DRB1 alleles; 32/91 (35%) were single-locus mismatched, and 4 were two-loci mismatched. Compared to current DNA-based HLA typing standards and considering HLA-C and DQ matching, there was likely a significant degree of HLA disparity in the majority of these patients. As detailed in Table 15.1, other cohorts of patients have been reported by Horne [10] in 2005 ($n = 86$), Ouachee-Chardin [11] in 2006 ($n = 48$), and Cesaro [12] in 2008. These again all included the BU/CY \pm etoposide and \pm ATG preparative regimen and reported overall survival rates of 64% at 3 years, 59% at 10 years, and 59% at 8 years, respectively. High rates of transplant-related mortality remained a major limitation to improved outcome in all of these studies.

The conclusion of the collective experience of myeloablative HCT for patients with HLH was clearly that the toxicity of the BU, CY, and etoposide regimen was unacceptable and that alternative approaches were needed. Engraftment rates are generally good with this approach in the vast majority of cases, although mixed chimerism was still found in 10–20%. This had led to the exploration of reduced toxicity and/or reduced intensity conditioning (RIC) regimens which have transformed the field of HLH transplantation, although leading to some challenges of their own in dealing with a significantly higher degree of mixed chimerism.

Reduced Intensity Conditioning (RIC) Regimens

Because transplant outcomes have historically been relatively poor for patients with HLH, investigators began to utilize reduced intensity conditioning (RIC) regimens for these patients in the mid-2000s. Table 15.1 lists published case series of patients with HLH receiving myeloablative conditioning (MAC) and RIC regimens. Cooper et al. first reported good outcomes in a small series of patients with HLH treated with RIC in 2006 [13]. In 2010, Marsh et al. described a large series of patients with HLH receiving RIC or MAC regimens at a single institution [14]. In this series, patients receiving RIC regimens experienced a near doubling of overall survival. These results have inspired an ongoing multicenter clinical trial, testing a RIC regimen in patients with HLH and other immune disorders (<https://clinicaltrials.gov/ct2/show/NCT01998633>).

The reasons for the substantial improvement in survival of patients after RIC-based HCT are not entirely clear but are likely manifold. Most MAC regimens have employed cyclophosphamide and busulfan, \pm ATG and etoposide. Historically, posttransplant mortality in patients with HLH treated with MAC has been reported to be unusually high for a nonmalignant disorder. Mortality is due to multiple reported factors, including infection, GVHD, and multi-organ failure. However, veno-occlusive disease (VOD), idiopathic pulmonary syndrome, and primary graft rejection are also reported at unusually high rates. The reduction in mortality in RIC-treated patients is associated with reduced rates of all of these complications, though reductions in VOD are most obvious. It may be speculated that RIC regimens are superior due to reduction of chemotherapy-associated liver/vascular toxicities in patients with preexisting (perhaps subclinical) damage of a similar sort and the potentially more profound suppression of the dysfunctional HLH immune system achieved with the combination of alemtuzumab and fludarabine.

Most HLH patients receiving RIC-HCTs have received an alemtuzumab-, fludarabine-,

Table 15.1 Larger published series describing HCT for patients with HLH

Reference	N	MAC or RIC	MRD/ MUD	MMRD/ MMUD	Haplo	Engrafted (%)	Mixed chimerism (%)	Acute GVHD (Gr II-IV)	TRM (by Day + 100)	Survival
Horne et al. [10]	86	MAC	66%	15%	19%	90	19%	32%	27%	64% (3 year)
Ouachee-Chardin et al. [11]	48	MAC	38%	2%	60%	78	50%	17%	NS	59% (10 year)
Eapen et al. ^a [28]	35	MAC	60%	29%	11%	94	23%	52%	26%	62% (5 year)
Baker et al. [3]	91	MAC	59%	39%	0%	91	10%	41%	35%	45% (5 year)
Cesaro et al. [12]	61	MAC	NS	NS	NS	95	21%	31%	18%	59% (8 year)
Yoon et al. [29]	19	MAC	74%	26%	0%	84	NS	26%	26%	73% (5 year)
Ohga et al. [4]	43	MAC	65%	28%	5%	83	19%	NS	17%	65% (10 year)
Cooper et al. [13]	12	RIC	50%	25%	25%	100	33%	33%	NS	75% (2.5 year)
Cooper et al. [30]	25	RIC	40%	44%	16%	100	29%	NS	NS	84% (3 year)
Marsh et al. [14]	14/26	MAC/RIC	64/73%	35/27%	0%	100	18/65%	14/23%	29/0%	43/92% (3 year)
Marsh et al. [15]	23	RIC	88%	13%	0%	96	31%	12%	4%	80% (1 year)
Marsh et al. ^b [31]	8/11	MAC/RIC	58%	42%	0%	100	32%	21%	45/10%	14%/55%
Marsh et al. ^c [32]	16	RIC	87%	13%	0%	100	31%	6%	4%	80% (1 year)

Abbreviations: *GVHD* Graft-versus-host disease, *Haplo* Haploidentical, *MAC* Myeloablative conditioning, *MMRD* Mismatched related donor, *MMUD* Mismatched unrelated donor, *MRD* Matched related donor, *MUD* Matched unrelated donor, *NS* not specified, *RIC* reduced intensity conditioning, *TRM* transplant-related mortality

Notes:

^aChediak-Higashi patients only

^bXLP2 patients only

^cXLP1 patients only

and melphalan-based regimen. While the application of fludarabine and melphalan has been generally uniform, several variations in the dose and timing of alemtuzumab as part of HCT conditioning for patients with HLH and other disorders have been published. While overall survival has not been shown to be clearly affected by these variations, use of >1 mg/kg of alemtuzumab is associated with lower rates of GVHD but higher rates of mixed chimerism and graft rejection. This is likely due to *in vivo* depletion of graft T cells by residual alemtuzumab. Most centers currently employ a 14-day RIC regimen in which alemtuzumab is given subcutaneously at 0.2 mg/kg on days -14, -13, -12, -11, and -10.

While initial engraftment rates are reported to be high (>95% of patients achieve initial donor engraftment), the subsequent development of mixed chimerism, sometimes leading to graft loss, occurs at substantial rates in RIC-treated HLH patients. In a recently published single-center case series, the development of mixed chimerism after a 14-day RIC regimen was reported to be 31% [15]. Results from the ongoing multi-center trial (NCT01998633) of this regimen are not yet known but are likely to reveal a somewhat higher rate of mixed chimerism development. Due to the high rate of mixed chimerism after RIC-HCT for HLH, umbilical cord cells are not a preferred stem cell source, as they are associated with higher rates of graft failure, and DLI is not an option for managing mixed chimerism (see below).

Other reduced intensity or “reduced toxicity” HCT preparative regimens have been utilized in patients with HLH. A reduced toxicity myeloablative preparative regimen incorporating treosulfan, fludarabine, and alemtuzumab has been reported in a recently published series of patients [16]. With follow-up of 7–31 months, 19 patients experienced 100% disease-free survival, though two patients required a second transplant and six required subsequent donor lymphocyte infusions to reverse falling chimerism. Further study of treosulfan-based or other reduced toxicity regimens appears warranted.

Special Considerations

Management of Mixed Chimerism

Historically, HCT for HLH has been associated with a relatively high rate of primary graft rejection. In the current context of RIC-HCT, while primary non-engraftment appears quite rare, the development of mixed chimerism is a common complication. Haines et al. noted that the development of mixed chimerism after RIC-HCT, in a series of patients with HLH or other nonmalignant disorders, was more likely to lead to loss of adequate chimerism and/or require intervention if it occurred earlier after HCT [17]. Similarly, mixed chimerism developing greater than 6 months post HCT was rarely associated with graft loss or HLH recurrence. It is important to treat mixed chimerism in order to prevent a decline of donor chimerism below 20–30%, which is associated with recurrence of HLH [18]. It is thought that mixed chimerism develops due to excessive depletion of donor T cells from persisting alemtuzumab levels. The lack of donor T cells, combined with immune suppression (IS) for GVHD prophylaxis, hobbles graft anti-host marrow responses. In the absence of an adequate anti-host marrow response, residual host stem cells (likely the most quiescent ones pretransplant) are able to regrow and, along with residual host T cells, outcompete and/or reject donor marrow and lymphocytes. Therefore, the appropriate counter-maneuver is to promote graft-versus-host hematopoiesis. This can be achieved by at least three methods. The first strategy is to withdraw immune suppression (IS) given for GVHD prophylaxis. Because chimerism may fall very rapidly, withdrawal of IS after mixed chimerism is detected should be performed quickly, over only a matter of days. A more typical wean (over many weeks) is likely to occur too slowly to prevent loss of adequate chimerism. Withdrawal of immune suppression may restore donor chimerism, with or without precipitating GVHD. If GVHD occurs, it should be treated without delay in a conventional fashion. In most cases, patients developing GVHD experience rapid restoration

of full donor chimerism, which is not affected by treating the GVHD, though rare cases of GVHD with persistently poor chimerism do exist. The second strategy for managing mixed chimerism is donor lymphocyte infusions (DLI). Because chimerism reversal and GVHD may not be evident for up to 3 weeks after IS withdrawal, DLI should not commence for 2–3 weeks after IS has been withdrawn. Furthermore, DLI given in this context should be different from that given for treatment of leukemic relapse. Because leukemic relapse is an urgent, often emergent problem, starting doses are typically in excess of 1×10^6 CD3+ cells/kg. In the context of HLH, a sensible strategy balancing the risks of GVHD and graft loss would include frequent monitoring of donor chimerism (initially weekly) and prompt initiation of DLI once mixed chimerism is detected. Starting doses of donor lymphocytes are relatively low ($1\text{--}3 \times 10^5$ CD3+ cells/kg). Repeated infusions are used every 3–4 weeks for worsening donor chimerism in the absence of GVHD, increasing the cell dose relatively rapidly (approximately threefold) with each infusion. The third strategy for managing mixed chimerism after RIC-HCT is a second infusion of hematopoietic stem cells, either an infusion of purified CD34+ cells (without preparative chemotherapy) or a second complete transplant (including a preparative regimen). Infusion of CD34 selected cells may be a useful adjunct to DLI, especially if mixed chimerism is associated with cytopenias and a hypocellular marrow. A second complete transplant should be considered if donor T cell chimerism falls below 10–20%. Limited experience suggests that use of a RIC preparative regimen for retransplantation within 6 months of the first transplant is likely to lead to sustained engraftment.

HLH Reactivations After HCT

HLH reactivation after HCT is well described. There are at least two contexts in which this may occur. First, HLH occurring early after engraftment in patients that may or may not have had

HLH prior to HCT [19]. By description in the literature, this diagnosis of HLH is difficult to distinguish from a severe engraftment syndrome. In our experience, this early HLH/severe engraftment syndrome is responsive to corticosteroid therapy, though published reports describe therapy with etoposide or other agents [20]. Second, systemic HLH may recur in the context of graft rejection or waning donor chimerism. In this case it should be viewed as the same disease process observed pre-HCT and treated accordingly.

CNS HLH and HCT

While HCT conditioning may help to treat active CNS HLH, recurrent CNS inflammation after HCT is a problem requiring distinct management. CNS HLH may occur in two patterns: persistent CNS disease may flair early post HCT despite full donor chimerism, or CNS HLH may recur somewhat more distantly in the setting of graft rejection or waning donor chimerism. Isolated CNS disease recurrence despite good donor chimerism may be severe and/or fatal and may be seen for up to 6 months after HCT, though usually it occurs within the first month or two. Disease manifestations are similar to pretransplant HLH, and similar to that situation, infectious triggers are not necessarily detectable. Because of this possibility, a surveillance LP should be considered within a week or two of engraftment in all patients with CNS HLH prior to HCT and subsequently if CNS symptoms develop. If abnormal, (increased protein or WBC count) repeat examinations may be appropriate, and treatment with intrathecal methotrexate is sometimes needed for worsening CSF signs or clinical evidence of disease.

Long-Term Sequelae After HCT

There have not been specific studies examining the long-term sequelae of HLH patients after HCT. However, HLH survivors are potentially at risk for the same complications that have

been seen in patients with malignant disorders who have received myeloablative conditioning with busulfan and cyclophosphamide, including pulmonary fibrosis, ovarian and testicular failure, infertility, growth abnormalities, and dental complications. However, given the fact that the current approach to transplantation of the vast majority of patients with HLH is with reduced intensity conditioning regimens, it can be anticipated that the majority of the late effects seen after myeloablative conditioning regimens will be significantly reduced or eliminated. At this point in time, the length of follow-up of HLH patients who have received reduced intensity transplants is insufficient to provide meaningful data.

The other issue to be considered is that there are disease-related factors such as the involvement of the CNS prior to HCT that can lead to varying degrees of neurocognitive impairment and/or ongoing seizure disorders in HLH survivors. Post HCT follow-up magnetic resonance imaging and neurocognitive testing are required in these individuals. Some patients have also been exposed to long periods of high-dose steroids either before or after HCT that can lead to cardiac hypertrophy (pretransplant dexamethasone), bone mineral deficits, adrenal insufficiency, insulin resistance, and hypertension. Thus monitoring of these potential issues post HCT is important. While there are not likely high risks for endocrine complications in patients after RIC, these survivors should still be monitored closely for growth, pubertal delay, and ultimately for fertility. It is also unlikely that they will experience any significant long-term lung and heart problems. Hepatic dysfunction is not anticipated as well, although monitoring would be indicated in patients who had significant hepatic involvement related to HLH or for those who may have developed sinusoidal obstruction syndrome during HCT. Patients who have received a large number of transfusions of packed red blood cells over the course of their treatment should also be evaluated for possible iron overload. Finally, while the risk of new malignancies is an important issue for HCT survivors, the risk of these

developing in patients who have not received myeloablative conditioning regimens, particularly without total body irradiation, is unknown but presumably much less. For patients who have received RIC transplantation and who do not achieve full donor myeloid chimerism, there is a theoretical risk of secondary acute myeloid leukemia arising in recipient cells exposed to epipodophyllotoxins. However, there has been sufficient follow-up of a large enough number of patients at this point, and this has not been reported to be an issue to date.

There is a significant need for research into long-term outcomes and late effects in patients with HLH surviving after HCT, and such efforts are currently underway to examine this further within the HLH Subcommittee of the Histiocyte Society.

Novel Therapies

Experimental Treatment of HLH

Standard of care therapy for HLH has been relatively unchanged since the 1990s, relying on etoposide and corticosteroids. Experimental studies into the development and treatment of HLH have demonstrated a critical role for interferon gamma in the pathogenesis of HLH [21]. An initial report in 2004, followed by independent confirmatory studies, led to the development of an anti-IFN-gamma monoclonal antibody, currently called NI-0501 (Novimmune), for the treatment of HLH. Clinical studies are ongoing (NCT01818492), but initial results reported in abstract form have suggested that this may be a viable therapy for HLH. As such, it would be the first targeted therapy designed specifically for HLH. Similarly, experimental studies in mice have recently demonstrated that inhibition of JAK kinases, critical signaling molecules downstream of IFN-gamma and other cytokines, may have utility as a treatment for HLH [22, 23]. No HLH patients have been treated to date with these agents, though post HCT use of ruxolitinib for the treatment of graft-versus-host disease suggests that myelosuppression will be a major concern in the context of HLH.

Gene Therapy

Curative therapy for HLH currently requires HCT. However, as detailed above, HCT carries substantial risks for these patients. Because familial HLH is due in most cases to defects of perforin-dependent lymphocyte cytotoxicity, correction of the defective genes in this pathway could be an alternative to HCT. Animal studies have demonstrated that perforin-dependent regulation of the immune response functions dominantly, such that normal perforin expression in only a fraction of lymphocytes (>10–20%) is sufficient to restore normal immune regulation [24]. Subsequent surveys of patients with mixed chimerism after HCT have confirmed a similar threshold effect, suggesting that >20% chimerism is sufficient to protect from recurrent HLH [18]. Thus, there appears to be a potentially achievable threshold for genetic correction of HLH-associated defects. Three animal studies have demonstrated that lentiviral mediated gene correction (of SH2D1A or perforin) can give at least partial correction of the HLH phenotype [25–27]. In the case of perforin gene correction, high levels of perforin protein expression per cell are needed for optimal correction, suggesting that it will be difficult to mimic the dynamic and complex regulation of endogenous perforin using lentiviral vectors. Further studies will be needed to understand how to best apply this technology to the treatment of patients with HLH.

References

1. Fischer A, et al. Allogeneic bone marrow transplantation for erythrophagocytic lymphohistiocytosis. *J Pediatr*. 1986;108(2):267–70.
2. Arico M, et al. Hemophagocytic lymphohistiocytosis. Report of 122 children from the International Registry. FHL Study Group of the Histiocyte Society. *Leukemia*. 1996;10(2):197–203.
3. Baker KS, et al. Successful correction of hemophagocytic lymphohistiocytosis with related or unrelated bone marrow transplantation. *Blood*. 1997;89(10):3857–63.
4. Ohga S, et al. Hematopoietic stem cell transplantation for familial hemophagocytic lymphohistiocytosis and Epstein-Barr virus-associated hemophagocytic lymphohistiocytosis in Japan. *Pediatr Blood Cancer*. 2010;54(2):299–306.
5. Sawada A, et al. Feasibility of reduced-intensity conditioning followed by unrelated cord blood transplantation for primary hemophagocytic lymphohistiocytosis: a nationwide retrospective analysis in Japan. *Int J Hematol*. 2013;98(2):223–30.
6. Jabado N, et al. Treatment of familial hemophagocytic lymphohistiocytosis with bone marrow transplantation from HLA genetically nonidentical donors. *Blood*. 1997;90(12):4743–8.
7. Imashuku S, et al. Allogeneic hematopoietic stem cell transplantation for patients with hemophagocytic syndrome (HPS) in Japan. *Bone Marrow Transplant*. 1999;23(6):569–72.
8. Henter JI, et al. Treatment of hemophagocytic lymphohistiocytosis with HLH-94 immunochemotherapy and bone marrow transplantation. *Blood*. 2002;100(7):2367–73.
9. Baker KS, et al. Unrelated donor hematopoietic cell transplantation for hemophagocytic lymphohistiocytosis. *Bone Marrow Transplant*. 2008;42(3):175–80.
10. Horne A, et al. Haematopoietic stem cell transplantation in haemophagocytic lymphohistiocytosis. *Br J Haematol*. 2005;129(5):622–30.
11. Ouachee-Chardin M, et al. Hematopoietic stem cell transplantation in hemophagocytic lymphohistiocytosis: a single-center report of 48 patients. *Pediatrics*. 2006;117(4):e743–50.
12. Cesaro S, et al. Hematopoietic stem cell transplantation for hemophagocytic lymphohistiocytosis: a retrospective analysis of data from the Italian Association of Pediatric Hematology Oncology (AIEOP). *Haematologica*. 2008;93(11):1694–701.
13. Cooper N, et al. Stem cell transplantation with reduced-intensity conditioning for hemophagocytic lymphohistiocytosis. *Blood*. 2006;107(3):1233–6.
14. Marsh RA, et al. Reduced-intensity conditioning significantly improves survival of patients with hemophagocytic lymphohistiocytosis undergoing allogeneic hematopoietic cell transplantation. *Blood*. 2010;116(26):5824–31.
15. Marsh RA, et al. An intermediate alemtuzumab schedule reduces the incidence of mixed chimerism following reduced-intensity conditioning hematopoietic cell transplantation for hemophagocytic lymphohistiocytosis. *Biol Blood Marrow Transplant*. 2013;19(11):1625–31.
16. Lehmborg K, et al. Treosulfan-based conditioning regimen for children and adolescents with hemophagocytic lymphohistiocytosis. *Haematologica*. 2014;99(1):180–4.
17. Haines HL, et al. Outcomes of donor lymphocyte infusion for treatment of mixed donor chimerism after a reduced-intensity preparative regimen for pediatric patients with nonmalignant diseases. *Biol Blood Marrow Transplant*. 2015;21(2):288–92.
18. Hartz B, et al. The minimum required level of donor chimerism in hereditary hemophagocytic lymphohistiocytosis. *Blood*. 2016;127(25):3281–90.
19. Jaiswal SR, et al. Hemophagocytic syndrome following haploidentical peripheral blood stem cell

- transplantation with post-transplant cyclophosphamide. *Int J Hematol.* 2016;103(2):234–42.
20. Koyama M, et al. Encouraging results of low-dose etoposide in the treatment of early-onset hemophagocytic syndrome following allogeneic hematopoietic stem cell transplantation. *Int J Hematol.* 2007;86(5):466–7.
 21. Jordan MB, et al. An animal model of hemophagocytic lymphohistiocytosis (HLH): CD8+ T cells and interferon gamma are essential for the disorder. *Blood.* 2004;104(3):735–43.
 22. Das R, et al. Janus kinase inhibition lessens inflammation and ameliorates disease in murine models of hemophagocytic lymphohistiocytosis. *Blood.* 2016;127(13):1666–75.
 23. Maschalidi S, et al. Therapeutic effect of JAK1/2 blockade on the manifestations of hemophagocytic lymphohistiocytosis in mice. *Blood.* 2016;128(1):60–71.
 24. Terrell CE, Jordan MB. Mixed hematopoietic or T-cell chimerism above a minimal threshold restores perforin-dependent immune regulation in perforin-deficient mice. *Blood.* 2013;122(15):2618–21.
 25. Rivat C, et al. SAP gene transfer restores cellular and humoral immune function in a murine model of X-linked lymphoproliferative disease. *Blood.* 2013;121(7):1073–6.
 26. Tiwari S, et al. High level of perforin expression is required for effective correction of hemophagocytic lymphohistiocytosis. *Hum Gene Ther.* 2016.
 27. Carmo M, et al. Perforin gene transfer into hematopoietic stem cells improves immune dysregulation in murine models of perforin deficiency. *Mol Ther.* 2015;23(4):737–45.
 28. Eapen M, et al. Hematopoietic cell transplantation for Chediak-Higashi syndrome. *Bone Marrow Transplant.* 2007;39(7):411–5.
 29. Yoon HS, et al. The outcome of hematopoietic stem cell transplantation in Korean children with hemophagocytic lymphohistiocytosis. *Pediatr Transplant.* 2010;14(6):735–40.
 30. Cooper N, et al. The use of reduced-intensity stem cell transplantation in haemophagocytic lymphohistiocytosis and Langerhans cell histiocytosis. *Bone Marrow Transplant.* 2008;42(Suppl 2):S47–50.
 31. Marsh RA, et al. Allogeneic hematopoietic cell transplantation for XIAP deficiency: an international survey reveals poor outcomes. *Blood.* 2013;121(6):877–83.
 32. Marsh RA, et al. Reduced-intensity conditioning hematopoietic cell transplantation is an effective treatment for patients with SLAM-associated protein deficiency/X-linked lymphoproliferative disease type 1. *Biol Blood Marrow Transplant.* 2014;20(10):1641–5.

Paul La Rosée and Rafal Machowicz

Abbreviations

aHLH	adult hemophagocytic lymphohistiocytosis
AOSD	adult-onset Still's disease
CS	corticosteroids
CsA	cyclosporin A
CTL	cytotoxic T lymphocyte
DEX	dexamethasone
EBMT	European Society of Blood and Marrow Transplantation
EBV	Epstein-Barr virus
FHL	familial HLH
HLH	hemophagocytic lymphohistiocytosis
LA-HLH	lymphoma-associated HLH
MAS	macrophage activation syndrome
MOF	multiorgan failure
NK cell	natural killer cell
PVIG	polyvalent intravenous immunoglobulin
sCD25	soluble interleukin-2 receptor

Introduction

Hemophagocytic lymphohistiocytosis in adults (aHLH) is a rare syndrome of uncontrolled hyperinflammation, which, if unstopped, leads to irreversible organ damage and death. Symptoms initially do not differ from any other inflammation, but are extremely pronounced and lead to rapid deterioration of the patient's condition. The clinical picture and abnormalities are caused by a self-propelling cytokine storm. Patients are almost uniformly febrile. Cytopenias cause fatigue, provoke secondary infections, and contribute to bleeding associated with hypofibrinogenemia. Extreme acute-phase reaction causes multiple laboratory abnormalities including hyperferritinemia, hypertriglyceridemia, and elevated transaminases. Without therapeutic intervention, inflammatory lymphoproliferation and macrophage activation lead to irreversible organ damage causing multiorgan failure (MOF) with a high probability of death. The clinical picture does not differ much from complicated infections resulting in sepsis and septic shock. The full clinical picture of HLH may be preceded by several weeks of fevers and unspecific symptoms. The variability of time periods between initial symptoms and full-blown HLH multiplied by numerous potential triggering conditions creates a wide spectrum of initial presentation. The heterogeneity explains diagnostic delay or even nihilism with deadly consequences, which calls for urgent efforts to increase awareness of HLH.

P. La Rosée, MD (✉)
 Klinik für Innere Medizin II, Klinikstr. 11,
 Schwarzwald-Baar-Klinikum,
 Villingen-Schwenningen, Germany
 e-mail: paul.larosee@sbk-vs.de

R. Machowicz, MD, MSc
 Department of Hematology, Oncology and Internal
 Diseases, Medical University of Warsaw,
 ul. Banacha 1a, 02-097 Warsaw, Poland
 e-mail: r.machowicz@wp.pl

In 1939, Scott and Robb-Smith published a case series of four adult patients presenting with fever and wasting. By relating their case series to six published cases, they identified a disease pattern which they called *histiocytic medullary reticulosis* [1]: “The clinical course is characterized by fever, wasting, generalized lymphadenopathy, splenomegaly and hepatic enlargement. In the terminal stages jaundice, purpura, anaemia and profound leucopenia are common. All cases ended fatally.”

The term familial hemophagocytic lymphohistiocytosis (FHL) has its roots in the 1952 publication of Farquhar and Claireaux, who reported siblings with a deadly course of HLH long before genetic testing allowed us to detect hereditary disease [2]. Since then, hemophagocytic lymphohistiocytosis (HLH) was commonly regarded as a rare, pediatric syndrome. Until today, HLH in the context of adult patients (aHLH) is hard to find in textbooks of hematology or internal medicine. Hence, with no surprise HLH patients outside of pediatric centers have been at high risk of not being diagnosed and treated for this fatal disease. Due to a number of factors, case reports and series on aHLH have exploded recently [3–12]. Whether this reflects a true increase of incidence or is the result of increased awareness is unclear. Widened use of immunosuppressive treatment, chronicification of malignant and autoimmune disorders by novel therapies, global circulation of infectious diseases, rising organ and stem cell transplantation numbers, and accelerated knowledge spread are all likely explanations for this observation.

Recognition that familial HLH is not only a matter of newborns and toddlers, but also occurs in early adulthood, further pushed interest in the pathophysiology of aHLH [13]. With the discovery of HLH-associated perforin mutations in 1999 [14], a new diagnostic tool had been developed. It removed the theoretical age limit for hereditary HLH as mutations were found at any age (e.g., a 62-year-old patient [15]). Besides supporting the notion that HLH is not only a pediatric syndrome, these results contributed to another important paradigm shift. HLH was artificially divided into primary (familial, genetic) and secondary/acquired HLH (induced by some

triggering factors). While primary HLH was attributed to children, secondary or acquired HLH was perceived as a domain of adults. With the genetic data at hand, we know that there is significant overlap with mutant HLH-associated genes detected in all age groups [16, 17].

As HLH is a syndrome with a high proportion of patients suffering from severe infections that trigger HLH, the concept of treating HLH with chemotherapy and immunosuppression combined with specific treatment addressing the underlying condition is counterintuitive. In 1979, Risdal and colleagues reported a series of patients with virus-associated HLH and concluded: “Immunosuppressive and cytotoxic therapy may be contraindicated in the treatment of this virus-associated syndrome.” And indeed, tailoring the balance between effectively inhibiting the detrimental lymphohistiocytic proliferation by chemotherapy and steroids and allowing immune reconstitution to clear the infection is the major therapeutic challenge [18].

This chapter aims at summarizing current knowledge about aHLH with focus on differences between pediatric and adult HLH that impact our approach to patients. Despite a lack of standardized consensus recommendations, we provide our concept of adapting pediatric diagnostic criteria and treatment algorithms to the needs of adult HLH patients.

Epidemiology

HLH in adults very likely is severely underdiagnosed. Data from a Japanese nationwide survey estimate one confirmed case of HLH per 800,000 annually in the general population. Forty-four percent of those patients were over 15 and 19% over 60 years of age [7]. In Sweden, the incidence of malignancy-associated HLH in adults is estimated at 3.6 per million annually [19]. A minimal estimate for primary HLH in children less than 15 years of age is 1.2 per million annually [20]. The relative incidence of HLH also depends on the hospital experience and referral pattern. In a tertiary pediatric center in Texas, 1 in 3000 patients was admitted with HLH [21].

Underlying Conditions that Lead to HLH in Adults

The spectrum of underlying conditions and triggering factors in aHLH differs compared to children. Pathophysiology of HLH in adults is complex with defects in cytolytic degranulation in some patients, aberrant inflammasome regulation, T-cell exhaustion, accumulation of reactive oxygen species (i.e., trauma associated), coincidence of genetic predisposition (presumed polymorphisms), immune evasion strategies of infectious agents, or malignant cell clones (for genetics see paragraph 4.) [22]. In Fig. 16.1, we have focused on recent case series from the USA, Europe, and China with >50 patients each depicting the triggering factors [3, 4, 8–10, 23]. Heterogeneity in

underlying diseases (T-cell lymphoma in China (in green), more B-cell lymphomas in Europe and the USA (in red), varying numbers of idiopathic/unknown triggering conditions (in light purple), and the important role of infectious diseases (viral infections in orange)) in all registries is shown. We believe that all data sets are biased not only by the method chosen to retrieve patients but also by physician vigilance and expertise in subspecialties of medicine such as hematology and intensive care medicine, involvement of pediatric expertise, and the true differences in the global distribution of infectious agents, disease epidemiology of cancer, and ethnically modified pathophysiology. Ramos-Casals et al. have tried to summarize the global perspective of HLH triggers and underlying conditions in adults by analyzing published

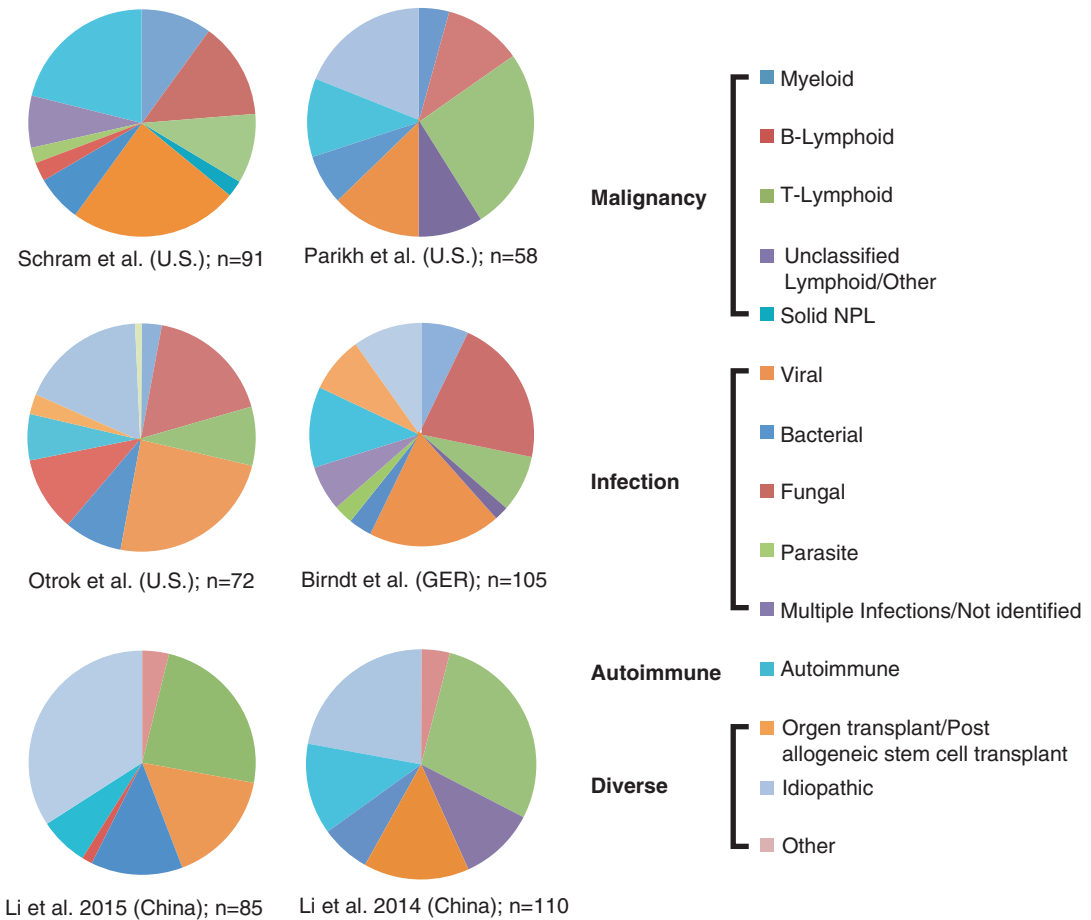


Fig. 16.1 Underlying conditions that lead to HLH in adults: Recently published case series from the USA, Europe, and China with >50 included patients

case reports and case series. They collected 2197 patients and identified five categories of triggers: (1) infections, (2) neoplasms, (3) autoimmune diseases, (4) other conditions or diseases, and (5) idiopathic or unknown [12]. Infections, in particular viral infections (35%; HIV, EBV, herpesviruses, and CMV), represented about 50% of all triggering factors. Malignancies were second in the global data set with 1047/2197 patients affected (47%).

Genetics

The concept of primary HLH as a pediatric disorder and acquired or secondary HLH as a disease of adults has partially been challenged by genetic data. Whereas enrichment of hereditary disease in >60% of newborns and toddlers with HLH supports the previous concept, recent data have demonstrated that mutant HLH-associated genes are also detectable in adults. Registry data from the USA, Italy, and China need careful interpretation, as regions with differing ethnicity, patient cohorts, and methods of mutation detection and *in silico* validation differ significantly (Table 16.1). In Italy, 25% (11/44) of adults (age > 18 years) in a pediatric registry showed typical biallelic mutations [24]. In the USA a rate of 7% (12/175: ten patients with biallelic mutations, two patients with monoallelic mutations in two different genes) was reported for the same age group [17]; an additional 13 patients had monoallelic mutations. The predominant locus was the A91V mutation in the perforin gene, which is considered a hypomorphic mutation. The Chinese registry which is focusing primarily on adult patients determined a rate of 7% (18/252) for patients over 13 years of age [16].

In only 3% (7/252), the mutations were biallelic. Modern genetic diagnostics will facilitate our efforts to rapidly detect sequence variants in HLH-related genes as demonstrated by Tesi et al. using high-throughput sequencing [25].

Hence, patients can be diagnosed with genetic predisposition at any age. Detection of a mutant gene with varying impact on disease severity and an obvious gene-dose effect governed by monoallelic vs biallelic or nonsense vs missense mutations have modified our dichotomous view (primary vs secondary) more toward a continuum: The extremes are null mutations vs genetically “normal” patients, and the continuum is built by those with hypomorphic or monoallelic or missense mutations with more or less residual protein function or folding defects in the case of perforin. Additional genetic factors and the broad variability of disease-triggering factors then define onset and severity of disease [24, 26]. Whether a patient is prone to develop HLH in response to a certain trigger very likely is not a mono-vector function of genes, but depends on pro-HLH propensity governed by comorbidities, co-medications, environment, genetic background, and coincidence of such factors. Time-dependent variability of disease outbreak even in siblings with familial HLH highlights the multi-causal pathophysiology of HLH [24]. An analogy may be found in a novel “The Chain of Chance” by Stanislaw Lem (a Polish science fiction writer and trained physician), where a series of deaths of unrelated people was at first attributed to a mysterious poisoner, but the common motif was lacking. Finally, it turned out that it was an interaction of multiple everyday use chemicals (including cosmetics and medications), which caused serious depressive and eventually suicidal reactions. In HLH there is no mysterious killer

Table 16.1 Selected studies on sequence variants (mono- or biallelic) in HLH-associated genes in adult HLH

Reference	Mut. rate	<i>PRF1</i>	<i>STXBP2</i>	<i>SH2DIA</i>	<i>UNC13D</i>	<i>STX11</i>	Age
Sieni et al. [78]	n/a	6	1	2	2	ns	23 (18–43)
Zhang et al. [17]	14%	18	2	ns	7	ns	> 18
Wang et al. [16]	7%	9	ns	1	1	7	20 (13–56)
Cetica et al. [24]	25%	Only biallelic mutations rated. Specific mutant site not reported for the >18 years subgroup					>18

Mut. rate mutation rate, ns not stated

(gene), but in some of the HLH patients, we are facing such accumulation of pro-HLH factors that an unnoticeable blow of butterfly wings can initiate a cytokine storm.

Diagnostic Criteria

Diagnosing HLH in adults is a dilemma. We are using the pediatric HLH-2004 criteria with variables and thresholds developed and validated in the pediatric setting [27]. The broad clinical picture of HLH in adults, however, explains the uncertainty clinicians experience when the patient “looks like having HLH” but does not meet at least five out of eight criteria. A similar and related diagnostic dilemma is the diagnosis of sepsis: In the 2001 consensus criteria, the authors’ intention was “to codify the physical and laboratory findings that prompt an experienced clinician to conclude that an infected patient <<looks septic>>” [28]. In HLH, many physicians have their own intuition leading them to a conclusion that a patient “looks like having HLH.” This diagnostic uncertainty creates conflicts and dogmatic debates between “believers” and “nonbelievers,” which directly affects the approach to a critically ill patient. For this reason, the use of the HLH-2004 diagnostic criteria supports the daily routine by offering a defined diagnostic code, but clinical practice teaches us that a new consensus for diagnosing HLH in adults is needed.

“Hemophagocytic Syndrome”

Some authors report patients in severe clinical condition with proven hemophagocytosis as having a “hemophagocytic syndrome.” Hemophagocytosis may be a good start to assess the remaining HLH criteria, yet hemophagocytosis by itself is an unspecific phenomenon. It is observed in many inflammatory conditions: sepsis, influenza, leishmaniasis, malaria, leukemia, active autoimmune disorders, and after blood transfusions [29]. Moreover, it was found in 83% of patients who died from sepsis [30] and in 64%

in a prospective study on septic and thrombocytopenic patients [31].

Overemphasis of hemophagocytosis as central diagnostic criterion could invoke the risk not to include HLH as a differential diagnosis in patients without detectable hemophagocytosis. In the pediatric experience, hemophagocytosis is a late symptom, and in many cases, repeated biopsies would be required to finally observe it [32]. Even the French HLH registry which is the source data for the recently published *HScore* to calculate HLH probability registered histologically confirmed hemophagocytosis in only 70% of HLH patients despite the fact that the term “hemophagocytosis” in the diagnosis list was required for patient inclusion [33, 34].

In summary, hemophagocytosis alone is not sufficient, is unspecific, and – if absent – does not exclude HLH. Therefore, diagnosis of “hemophagocytic syndrome” based solely on this phenomenon should not be used.

HLH-2004 Criteria

Currently, the HLH-2004 criteria developed by the Histiocyte Society are applied in most centers as a standard diagnostic tool for adult HLH although they had been established for the pediatric HLH trials (Table 16.2) [27]. They have evolved from the first criteria established in 1994 by the addition of three parameters: hyperferritinemia, low NK-cell activity, and high sCD25 concentration. Five out of eight criteria enable the diagnosis of HLH. Additionally, mutations in HLH-characteristic genes confirm the diagnosis in a symptomatic patient. While the role of HLH-2004 criteria as a cornerstone for diagnosis of HLH cannot be overestimated, here we would like to focus on some limitations with regard to adult patients.

A ferritin threshold of 500 ng/ml seems too low to be characteristic for HLH. In a recent study, a higher value of 2000 ng/ml was found to be optimal for diagnosis in children [35]. In adults, various preexisting conditions like hemochromatosis, hemolysis, dialysis, malignancy, or liver failure may be sufficient to reach this

Table 16.2 Comparison of HLH-2004 and HLH-1994 diagnostic criteria

	HLH-2004	HLH-1994
	<i>Genetic diagnosis</i>	x
1	<i>Fever</i>	
2	<i>Splenomegaly</i>	
3	<i>Cytopenia of ≥ 2 out of 3 lineages</i>	
	Neutrophils $<1.0 \times 10^9/L$	
	Hb < 9.0 g/dL	
	PLT $< 100 \times 10^9/L$	
4	<i>Hypofibrinogenemia and/or hypertriglyceridemia</i>	
	Fibrinogen <1.5 g/L	
	Trig > 3.0 mmol/L (265 mg/dl)	Trig > 2.0 mmol/L or ≥ 3 SD
5	<i>Hemophagocytosis</i>	
6	<i>Ferritin > 500 ng/ml</i>	X
7	<i>Low NK-cell activity</i>	X
8	<i>sCD25 > 2400 U/mL</i>	X

threshold even without inflammation [36]. It should be underlined that hyperferritinemia has two roles in the diagnostic process. First, it is the best alarming factor which should always prompt to include HLH in the differential diagnosis [37]. The ferritin values characteristic for HLH in adults are often above 7–10,000 ng/ml and may surpass even 100,000 ng/ml; however, these extreme levels are seen in the minority of patients. There is no ferritin threshold value pathognomonic for HLH [36]. Secondly, hyperferritinemia is one of the eight equally important diagnostic criteria; however, adult patients are also diagnosed with ferritin values only slightly surpassing or some even below 500 ng/ml [3].

The HLH-2004 criteria were developed for children; they are not validated formally for adults and remain an expert opinion. On a global perspective, two of these criteria, i.e., sCD25 concentration and NK-cell activity, are available only in reference centers. In order not to delay lifesaving therapy, we then recommend to use 6 criteria only and to make a diagnosis of HLH if 4/6 criteria are positive, provided that ferritin exceeds 2000 ng/ml. In addition other clinical and laboratory findings should support the diagnosis of HLH as outlined below.

The HLH-2004 criteria remain a gold standard for the diagnosis of HLH. Most of the data provided in this chapter are based on these

diagnostic criteria, and diagnostic difficulties in the “Special Considerations” subchapter are HLH-2004 oriented.

Henter and the HLH-2004 coauthors provided additional clinical findings supporting HLH such as spinal fluid pleocytosis (mononuclear cells) and/or elevated spinal fluid protein, cerebrospinal fluid symptoms, lymph node enlargement, jaundice, hepatic enzyme abnormalities, a histological picture in the liver resembling chronic persistent hepatitis, edema, skin rash, hypoproteinemia, hyponatremia, elevated VLDL, and low HDL [27]. *In our view these additional HLH symptoms and parameters support the notion that the daily clinical reassessment at the bedside of the critically ill patient is most important for diagnosis.* Patients with unclassified inflammation presenting with only three out of eight HLH-2004 criteria on admission may develop HLH over a short period of time and therefore need daily whole-body examination. Using a literature survey, Tamamyian et al. added additional parameters, in particular due to limited availability of some of the HLH-2004 criteria, and used renal failure (creatinine $>50\%$ above baseline), coagulopathy (prothrombin time ≥ 1.5 times the upper limit of normal and/or partial thromboplastin time ≥ 1.5 times the upper limit of normal, and/or D-dimer ≥ 10 $\mu\text{g/mL}$, hypoalbuminemia (<3.5 g/L), elevated lactate dehydrogenase (≥ 2.5 times the upper limit of normal), and elevated $\beta 2$ -microglobulin (≥ 2 mg/L) to retrieve HLH patients from their clinical database [38]. For integration of each diagnostic criterion into the time-dependent evolution of diagnosing HLH, Lehmborg suggested to ask “whether:

1. The combination
2. The extent, and
3. The progression of the mentioned clinical and laboratory abnormalities are unusual, unexpected and otherwise unexplained” [39].

The HScore

Developed in 2013 in Paris, the HScore (Table 16.3) aims at solving the limitations of the HLH-2004 criteria at least partially, as discussed

Table 16.3 The *HScore* [34]

Parameter	No. of points (criteria for scoring)
Known underlying immunosuppression ^a	0 (no) or 18 (yes)
Temperature (°C)	0 (<38.4), 33 (38.4–39.4), or 49 (>39.4)
Organomegaly	0 (no), 23 (hepatomegaly or splenomegaly), or 38 (hepatomegaly and splenomegaly)
No. of cytopenias ^b	0 (1 lineage), 24 (2 lineages), or 34 (3 lineages)
Ferritin (ng/ml)	0 (<2000), 35 (2000–6000), or 50 (>6000)
Triglyceride (mmol/L)	0 (<1.5), 44 (1.5–4), or 64 (>4)
Fibrinogen (g/L)	0 (>2.5) or 30 (≤2.5)
AST (SGOT = serum glutamic oxaloacetic transaminase) (IU/liter)	0 (<30) or 19 (≥30)
Hemophagocytosis features on bone marrow aspirate	0 (no) or 35 (yes)

^aHuman immunodeficiency virus positive or receiving long-term immunosuppressive therapy (i.e., glucocorticoids, cyclosporin, azathioprine)

^bDefined as a hemoglobin level of ≤9.2 g/dL and/or a leukocyte count of ≤5 × 10⁹/L and/or a platelet count of ≤110 × 10⁹/L

previously [34]. The first step in its creation was a Delphi survey in which 26 HLH experts (authors of published HLH cases) answered questions regarding 26 diagnostic criteria and their “necessity” for diagnosing HLH [40]. Authors were also asked to judge the availability and practicability of a specific test in their hands, which led to the exclusion of NK-cell activity and sCD25 concentration due to limited availability. The parameters chosen by the experts were tested on a group of 209 out of 312 patients (developmental cohort) with hemophagocytosis or hemophagocytic syndrome as the coding diagnosis. Three experts from the study center classified the patients as “positive,” “negative,” and “undetermined status” with a fourth expert solving cases where a consensus had not been reached. Based on these categories, and using a logistic regression model in the developmental and a subsequent validation cohort (27 patients), the authors developed a score allowing to determine the

likelihood of having HLH (Table 16.3). A score of 169 points was found optimal with a sensitivity of 93%, specificity of 86%, and accurate classification of 90% of the patients.

The *HScore* estimates the probability of hemophagocytic syndrome by quantitative grading of diagnostic variables. It is not a tool to increase vigilance at the bedside due to its complexity, but can easily be calculated online (<http://saintantoine.aphp.fr/score/>). We regard it as a confirmatory/supportive diagnostic tool after HLH has been diagnosed using the HLH-2004 criteria.

Treatment

Treatment of adults with HLH has its specific challenges that differ from HLH in newborns and children. Adult and especially elderly patients may have (multiple) chronic comorbidities (e.g., renal insufficiency, liver or heart failure, diminished hematopoietic reserve) which make those patients even more vulnerable to the deleterious effects of the cytokine storm in HLH but also limit treatment intensity as used in pediatric protocols. The challenges for physicians treating adult patients with HLH are caring for patients with a very rare disease, caring for patients with a syndrome evolving from a multitude of underlying conditions, and the limited availability of validated treatment protocols. The pediatric treatment protocols derived from prospective trials, namely, HLH-1994 and HLH-2004, are most frequently used as a reference but may harm adult patients regarding toxicity and long-term immunosuppression, when not adapted [27, 41, 42]. HLH-specific treatment is targeted against the deranged immune response to a certain trigger. The trigger becomes the central focus of treatment, as soon as organ dysfunction caused by HLH is in (partial) remission. Questions that need to be addressed prior to treatment initiation are:

1. Is the diagnosis HLH confirmed or very likely?
2. What is the current stage/severity of HLH? Is immediate treatment required (imminent organ dysfunction)?

3. Has – after comprehensive workup – a trigger been detected?
4. Is there a need to send material for functional testing prior to lymphocyte depletion by immunosuppressive agents (testing in lymphopenic patients very likely does not deliver meaningful results). This is to consider particularly in male patients with EBV infection (XLP-1, XLP-2) or patients with albinism, as well as in patients with a (family) history potentially indicating genetic disease [43].
5. Have all efforts been undertaken to exclude infections which frequently present with symptoms of HLH but require specific antimicrobial treatment instead of immunosuppression (e.g., *Leishmania*, tuberculosis) [44, 45]?

Ad 1: In some patients HLH diagnosis may be very likely but may not be confirmed by 5/8 positive HLH-2004 criteria. Yet the clinical decision to start treatment depends on the timely and repeated assessment of organ function to prevent irreversible organ damage. Time is life as shown in pediatric as well as in adult cohorts. Prognosis in patients receiving etoposide within 4 weeks of symptom onset was significantly better compared to delayed administration [46, 47].

Ad 2: If HLH is likely, but inflammation still is in control, a treatment delay to allow comprehensive diagnostics may be advisable. Ishii et al. provided a severity score taking into account ferritin levels, impairment of liver function, platelet count, serum LDH level, and presence of coagulopathy. They classified HLH as mild, moderate, and severe (Table 16.4). Mild cases may transiently fulfill the diagnostic criteria with a resolution of HLH without immunosuppression [48].

Ad 3: Detection of a trigger, most often an infection or malignancy, has the highest priority for tailoring HLH treatment. If treatment has to start immediately without a detected

trigger, repeated diagnostic workup, including repeated tissue biopsies, is mandatory to allow disease-specific treatment. In particular in relapsed HLH, reassessment of potentially undetected triggers and search for secondary infections are crucial.

Ad 4: Diagnostics to determine the function of NK cells and CTLs by degranulation and assessment of perforin expression is not needed routinely, as sporadic HLH is the predominant subtype in adults. Of note, if a decision toward functional diagnostics has been made, treatment delay due to outstanding laboratory results should be avoided by any means. Classification of HLH as a hereditary disease with a degranulation defect has no impact on the selection of induction treatment, but rather may determine consolidation treatment at later stages of the disease course.

Ad 5: Infections that target the mononuclear phagocyte system (also known as reticuloendothelial compartment) may present with an HLH phenotype. Global mobility spreads infections. *Leishmania*, for example, is endemic in large parts of the world affecting population and tourists around the world (http://apps.who.int/neglected_diseases/ntddata/leishmaniasis/leishmaniasis.html) (see below). In patients with preceding immunosuppression, secondary infections triggering HLH need to be differentiated from HLH secondary to the underlying condition that prompted immunosuppression. The French HLH registry found 50% of HLH patients being immunosuppressed prior to the onset of HLH [33].

Adaptation of HLH-1994 for Adults

The heterogeneity of HLH in adults obviously prohibits a “one-size-fits-all protocol.” In children where hereditary HLH is enriched, prolonged treatment and bridging to allogeneic stem cell

Table 16.4 Severity assessment of HLH by Ishii et al. [7]

	Mild	Moderate	Severe
ASAT/ALAT ratio	< 2	> 2	
Ferritin (ng/mL)	< 10.000	≥ 10.000	
LDH (U/L)	< 1000	> 1000	
Platelet/ μ l	≥ 100.000	< 100.000	+ Coagulopathy

transplantation by cyclosporin A (CsA) is the rule. HLH-1994 changed the formally deadly prognosis in children to a long-term survival >50% [41]. Of note, only children up to 17 years of age were included. Prospective evaluation of HLH-1994 in adult patients is not available. Treatment recommendations therefore rely on personal experience and expert opinion. The core of the pediatric protocols is an initial treatment with corticosteroids (CS) and etoposide to delete activated T-cells and suppress inflammatory cytokine production. Dexamethasone (DEX) has been chosen for it penetrates into the cerebrospinal fluid, which frequently is affected by overt immune activation. Etoposide is a chemotherapeutic agent with high specificity against T-cell proliferation and cytokine secretion in mice [49]. HLH-2004 was designed to optimize induction treatment used in HLH-1994, as a significant proportion of patients died prior to transplantation due to active HLH. CsA was started up front to enhance T-cell-directed activity. The trial awaits final analysis, but there are some data that the combination of high-dose steroids and CSA may produce some untoward side effects. The unpublished recommendation of the HLH Study Group is to use HLH-1994 as treatment protocol outside from trials (J.I. Henter, oral presentation Annual Meeting of the Histiocyte Society 2015, Athens). What are

potential indications for the HLH-1994 treatment plan in adult patients (personal opinion)?

1. Severe aHLH with unknown trigger
2. Known hereditary HLH (with the full picture of severe HLH)
3. Relapsed HLH (relapse should prompt the search for an infection such as sepsis or a (reactivated) viral infection)

For toxicity reasons, we usually limit the etoposide dose to 100 mg/m² maximum dose and prefer once weekly administration (instead of twice weekly in the first 2 weeks). The term “HLH-1994-like” treatment is frequently applied in situations, where single elements (etoposide, dexamethasone, CsA) are employed on a case-by-case basis, to overcome overt inflammation with imminent respiratory, hepatic, renal, or hematopoietic failure. Henter et al. have proposed a modified HLH-1994 protocol for patients with reactive HLH, infected by the avian flu (H1N5), which contains tapered DEX with weekly (x8) etoposide infusions [50]. We propose an adaptation of the Henter scheme by adding therapeutic dosing of polyvalent immunoglobulins and consistent application of broad antimicrobial prophylaxis against *Pneumocystis jirovecii*, fungi, and viruses due to severe T-cell depletion (Fig. 16.2).

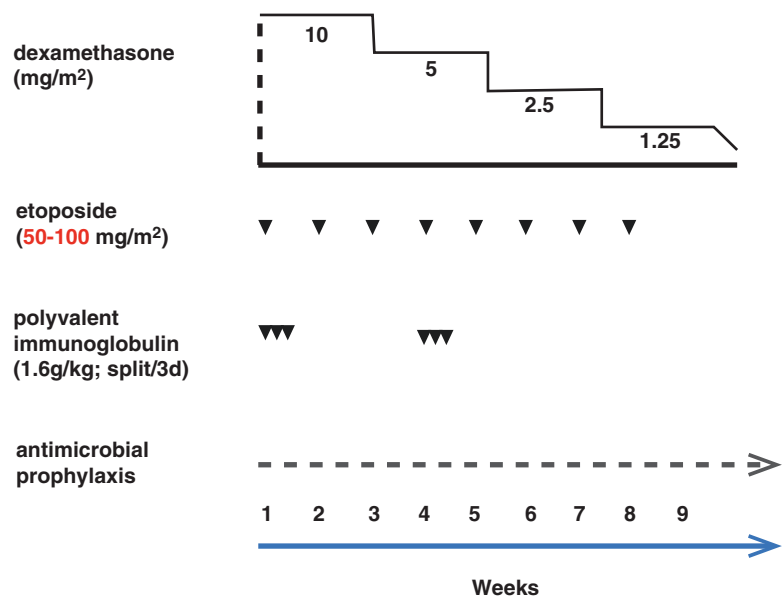


Fig. 16.2 Suggested treatment schedule for use of HLH-1994 components in adult HLH patients

In our hands monitoring HLH activity via ferritin serum levels is a sensitive and cost-effective way to measure response within days. Wang et al. used fever and the HLH laboratory criteria to monitor response within 2 weeks after the start of HLH-1994 including serum levels of sCD25, ferritin, triglycerides, hemoglobin, neutrophils, platelets, and alanine aminotransferase (ALAT) [51]. Fever and alanine aminotransferase (ALAT) were also included. After partial remission has been achieved, it has to be decided whether etoposide needs to be continued or CsA should be included to control T-cell activity. CsA can be replaced by tacrolimus, but both need careful drug-level monitoring and toxicity assessment [52].

Polyvalent Immunoglobulins

Polyvalent immunoglobulins (PVIG) have anti-inflammatory potential by inhibiting complement activation, by blocking antibody Fc-fragments and macrophage Fc-receptors, and by neutralizing cytokines [53, 54]. In HLH, treatment with PVIG may be aimed at two directions: combined anti-inflammatory treatment together with dexamethasone to suppress overt inflammation using therapeutic dosing (up to 1.6 g/kg in split doses over 2–3 days) and support of defective humoral immunity in patients with Ig deficiency. There is no consensus on whether PVIG is active in specific subtypes of HLH, whether it is not beneficial in some subtypes such as lymphoma-associated or EBV-triggered HLH, whether its efficacy depends on the time of applications to block macrophage activation, and whether the distinct pathophysiology of HLH in children vs adults explains differential efficacy observed in these populations [54]. PVIG combined with CsA are an option in HLH patients with moderate severity. In particular, HLH triggered by infections may only require combined CsA/PVIG with targeted antimicrobial treatment without additional etoposide. As Ig deficiency frequently is observed in patients with lymphoma-triggered HLH, replacement treatment to achieve IgG levels >5 g/L is intended to support anti-infective treatment. As patients remain heavily immunosuppressed during HLH

treatment, we regard regular PVIG substitution as a very useful treatment component.

Refractory HLH

Depending on the underlying triggering condition, a substantial fraction of patients does not sufficiently respond to HLH-1994-adapted treatment. Mortality in adult HLH ranges between 20% and 88% (with the majority of retrospective data sets indicating mortality >50%) which is due to primarily refractory HLH, secondary infections, and relapse of the underlying disease [55]. After failure of HLH-1994 within 2 weeks of treatment, Wang et al. used the DEP protocol containing liposomal doxorubicin, etoposide, and high-dose methylprednisolone to fight refractory HLH [51]. In a cohort of 63 patients with lymphoma-associated HLH (LA-HLH, $n = 29$), EBV-associated HLH ($n = 22$), FHL ($n = 4$), and HLH with unknown trigger ($n = 8$), they saw a 24% mortality rate within 4 weeks, a CR rate of 27%, and a PR rate of 49% (overall response rate 76%). In 13 of 63 patients, this served as bridge to allogeneic stem cell transplantation. The limited response in nearly 50% of patients with LA-HLH to HLH-1994 illustrates clearly that as soon as the trigger has been determined, disease-specific treatment is pivotal to overcome HLH. Doxorubicin is part of lymphoma protocols, which have been shown to effectively overcome HLH when applied in time, albeit the overall prognosis of LA-HLH is exceptionally dismal [46].

Early disease-specific treatment with HLH-oriented pre-phase treatment should be applied. A potentially helpful laboratory parameter to recognize LA-HLH is the use of the sCD25/ferritin ratio since sCD25 levels in lymphomas are exceptionally high [56].

The Chinese adult HLH group has also shown that refractory HLH can successfully be overcome by splenectomy, which in some cases is also helpful to resolve the problem of identifying the trigger [57]. Splenectomy is also included in our therapeutic algorithm (Fig. 16.3). In 18 retrospectively analyzed patients with refractory HLH who underwent splenectomy, a survival rate of

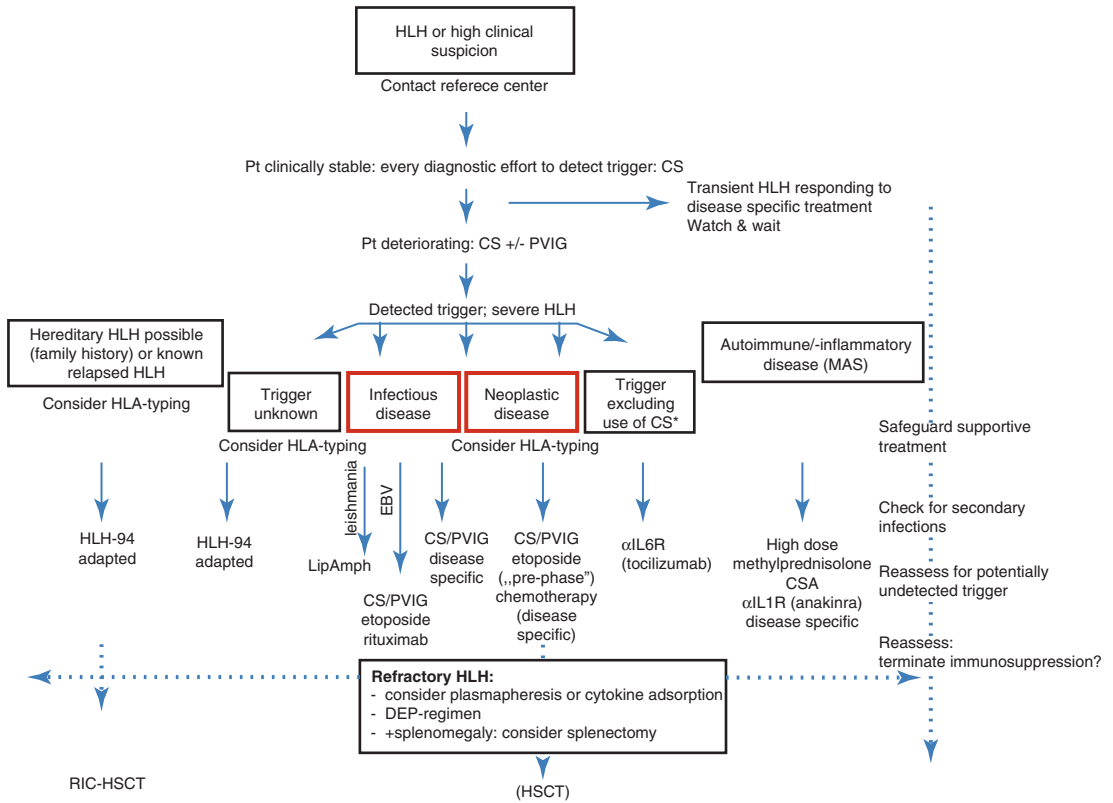


Fig. 16.3 Work in progress: An HLH treatment algorithm for adults

61% was demonstrated with a median follow-up of 25 months. All patients had enlarged spleens, and in 6/8 patients with signal enhancement in PET-CT, lymphoma was histopathologically confirmed. Lymphoma was also detected in a patient with normal metabolic activity and in three patients with an inconclusive PET report.

Another approach to effectively fight a refractory cytokine storm is to remove cytokines via adsorption columns that may be used combined with hemodialysis in critically ill patients [58].

alemtuzumab in a median dose of 1 mg/kg split over a median of 4 days has been shown to be a feasible way to allow disease control in refractory patients [60, 61]. Again, in adults a standardized approach including transplant cannot be recommended as hereditary HLH is rare; the clinical course of patients with sequence variants in HLH-associated genes is heterogeneous, as is the underlying trigger of HLH. Systematic data in adults are lacking. An EBMT registry is ongoing. A case-by-case decision with contact to a HLH reference center is currently recommended.

Stem Cell Transplantation

Allogeneic stem cell transplantation in children with hereditary HLH is the rule and has dramatically improved outcome [18]. High transplant-related mortality was reduced by introducing reduced intensity conditioning [59]. Disease control prior to transplant is important for successful transplant outcome. The CD52 antibody

Special Considerations

Macrophage Activation Syndrome (MAS)

MAS is a commonly used name for HLH induced by autoimmune and autoinflammatory diseases. Frequent causes for MAS are Still's disease

(adult-onset Still's disease (AOSD)) and lupus erythematosus. HLH-2004 criteria are of limited diagnostic utility, as the disease pattern in particular in AOSD includes leukocytosis and hyperfibrinogenemia with a gradual decline as AOSD-associated MAS progresses [62]. The 2016 published new MAS criteria for pediatric patients with suspected systemic-onset juvenile idiopathic arthritis (sJIA) guide diagnosis in a febrile patient using ferritin >684 ng/ml and at least two of the following items: (i) platelets $<181 \times 10^9/L$, (ii) aspartate aminotransferase $>48 U/L$, (iii) triglycerides $>156 \text{ mg/dl}$, or (iv) fibrinogen $\leq 360 \text{ mg/dl}$. Of note, these criteria are validated for pediatric patients only. Yet, they help to foster diagnostic vigilance in patients with severe inflammation, joint pain, and rash to recognize macrophage activation syndrome in patients not fulfilling the HLH-2004 criteria.

Treatment of MAS relies on pulse methylprednisolone (30 mg/kg for 3 days followed by 2–3 mg/kg/day in two to four divided doses) [63]. CsA can be given in patients with insufficient response; alternatively tacrolimus may be selected. In refractory patients, the interleukin-1 receptor antibody anakinra has been used successfully [64]. As many MAS patients have a prior history of immunosuppression, all patients should be evaluated for infectious triggers.

Liver Failure

Liver failure may be the leading symptom in patients with HLH. Patients may present with elevated transaminases or hyperbilirubinemia and eventually progress to liver failure. Hepatic disease other than HLH can be difficult to discriminate, as it can mimic many of the HLH criteria (high ferritin, coagulopathy, thrombocytopenia). Liver damage may lead to ferritin levels beyond 10,000 ng/ml or even 50,000 ng/ml [36]. Patient's history may help to unveil preexisting liver damage. Liver damage in HLH is caused by a periportal lymphohistiocytic infiltrate with biliary duct obstruction leading to jaundice and, if not treated in time, to biliary tract sclerosis with irreversible organ dysfunction [65]. Hepatic impairment with

prominent cholestasis is often a matter of concern with regard to the use of etoposide. Etoposide is metabolized by the liver; however, major excretion is by the kidney [66]. Timely application reverses histiocytic proliferation and cytokine storm, reversing liver dysfunction. In patients with renal failure, dose reduction, but otherwise application without delay, is recommended.

Sepsis or HLH?

Sepsis is a state of aberrant inflammation caused by an infection. This definition is very broad and thereby includes HLH patients, who develop a sepsis-like cytokine storm disease secondary to infections. Clinically, HLH and sepsis have an overlapping phenotype making it sometimes very difficult to start immunosuppression as the necessary therapeutic intervention for HLH patients. Vigilance for HLH on intensive care units is needed to not miss the estimated 5–10% HLH patients in the cohort of the routine ICU sepsis patients [67, 68]. Of note, bacterial sepsis may act as a trigger for HLH, making those patients refractory to conventional sepsis treatment. This is why we favor ferritin to be part of the ICU admission lab panel.

Ferritinemia over 500 ng/ml is frequent among patients with sepsis, but sepsis as a single cause of a concentration over 10,000 ng/ml is unlikely [68, 69]. Splenomegaly, if antibiotics are used, also should not occur [70]. Hypertriglyceridemia in sepsis also tends to be lower compared to HLH, with maximal values around 180 mg/dl (2.0 mmol/l) [71]. Hypofibrinogenemia (as well as thrombocytopenia) can be strongly affected by the presence of DIC (disseminated intravascular coagulation), which is associated with sepsis. Pancytopenia is usually more pronounced in HLH compared to sepsis. Of note, NK-cell activity can be diminished in sepsis and thus is not useful as discriminator [72]. The concentration of sCD25 is elevated in sepsis (particularly in acute kidney injury) [73] and thus has limited value for differentiation except if there are extremely high values, where HLH may be more probable.

HLH patients secondary to sepsis require immunosuppression +/- PVIG +/- cytokine adsorption simultaneously with sepsis treatment. Etoposide and other chemotherapeutics should be avoided in such situation [18]. It is a matter of debate whether steroids should be applied in septic shock refractory to fluid resuscitation and vasopressors. In patients with an HLH-like picture, the demonstration of a benefit from timely application of corticosteroids will depend on the number of undetected HLH patients in the sepsis cohort [74, 75]. In the Surviving Sepsis guidelines, the maximum steroid dose is 200 mg of hydrocortisone i.v. daily [74]. We recommend steroids to be administered as early as the HLH suspicion is confirmed. Higher doses (and change to dexamethasone or methylprednisolone) have to be considered, since 200 mg of hydrocortisone is unlikely to effectively interfere with the HLH cytokine storm. Dexamethasone as used in the HLH-2004 protocol (10 mg/m² daily during the first 2 weeks) would be an equivalent to 400–500 mg of hydrocortisone. An important piece of evidence for undetected HLH patients on ICU is a post hoc analysis of anakinra in a large cohort of sepsis patients: in this analysis patients with HLH-associated criteria were shown to respond to anakinra in contrast to “sepsis-only” patients [76]. Ferritin, organomegaly, hemophagocytosis, highly increased sCD25, and cytopenias are red flags to reduce missed diagnoses of HLH [77].

The Age-Dependent View on HLH

There is a large overlapping group of adolescents and young adults, which to some extent differs from very young and elderly patients. Here, close collaboration between pediatricians and physicians caring for adults is of utmost importance.

As the diagnostic approach and treatment need to reflect on age-dependent HLH specifics, we propose acronyms that summarize key characteristics in the differing age groups: GENESIS, RELy, and RELy ON (Table. 16.5). This might help to share basic HLH concepts with non-expert physicians who very rarely are exposed to HLH patients.

Table 16.5 Key characteristics of HLH in children, adolescents/young adults, and adult patients

GENESIS – children	
GEN	GENetic background frequent – genetic analyses indicated
E	EBV – scan for viruses
S	SCT may be needed after induction treatment – search for donor
I	Infection triggers hyperinflammation
S	Siblings may be at risk
RELy – adolescents/young adults	
Based on the patient, many items of GENESIS may be true, but main triggers are different	
R	Rheumatic-autoimmune disease (MAS)
E	EBV – and other viruses
Ly	Lymphoma
RELy ON – adults	
RELy	RELy is always true, but...
O	Oncology
N	Neoplasm ^a – always search for malignancy!

^aIt could have been only ON for oncology, but it is so important that it requires two letters

Conclusions

As children are not miniatures of adults, so are adults not just enlarged children. Transferred to HLH, lessons from the pediatric setting need adaptation, not copy-pasting into the adult setting. Raising awareness for HLH in adults is crucial to save lives. Interaction between pediatric specialists, hematologists, and ICU specialists caring for adult patients is needed, as HLH is a rare disease requiring expert specialists for individual treatment decisions.

References

1. Scott RBR-S, A.H.T. Histiocytic medullary reticulosis. *Lancet*. 1939;2(6047):194–8.
2. Farquhar JW, Claireaux AE. Familial haemophagocytic reticulosis. *Arch Dis Child*. 1952;27(136):519–25.
3. Schram AM, Comstock P, Campo M, Gorovets D, Mullally A, Bodio K, et al. Haemophagocytic lymphohistiocytosis in adults: a multicentre case series over 7 years. *Br J Haematol*. 2016;172(3):412–9.
4. Otrock ZK, Eby CS. Clinical characteristics, prognostic factors, and outcomes of adult patients with

- hemophagocytic lymphohistiocytosis. *Am J Hematol*. 2015;90(3):220–4.
5. Delavigne K, Berard E, Bertoli S, Corre J, Duchayne E, Demur C, et al. Hemophagocytic syndrome in patients with acute myeloid leukemia undergoing intensive chemotherapy. *Haematologica*. 2014;99(3):474–80.
 6. Fardet L, Lambotte O, Meynard JL, Kamouh W, Galicier L, Marzac C, et al. Reactive haemophagocytic syndrome in 58 HIV-1-infected patients: clinical features, underlying diseases and prognosis. *AIDS*. 2010;24(9):1299–306.
 7. Ishii E, Ohga S, Imashuku S, Yasukawa M, Tsuda H, Miura I, et al. Nationwide survey of hemophagocytic lymphohistiocytosis in Japan. *Int J Hematol*. 2007;86(1):58–65.
 8. Li F, Yang Y, Jin F, Dehoedt C, Rao J, Zhou Y, et al. Clinical characteristics and prognostic factors of adult hemophagocytic syndrome patients: a retrospective study of increasing awareness of a disease from a single-center in China. *Orphanet J Rare Dis*. 2015;10(1):20.
 9. Li J, Wang Q, Zheng W, Ma J, Zhang W, Wang W, et al. Hemophagocytic lymphohistiocytosis: clinical analysis of 103 adult patients. *Medicine*. 2014;93(2):100–5.
 10. Parikh SA, Kapoor P, Letendre L, Kumar S, Wolanskyj AP. Prognostic factors and outcomes of adults with hemophagocytic lymphohistiocytosis. *Mayo Clin Proc*. 2014;89(4):484–92.
 11. Park HS, Kim DY, Lee JH, Lee JH, Kim SD, Park YH, et al. Clinical features of adult patients with secondary hemophagocytic lymphohistiocytosis from causes other than lymphoma: an analysis of treatment outcome and prognostic factors. *Ann Hematol*. 2012;91(6):897–904.
 12. Ramos-Casals M, Brito-Zeron P, Lopez-Guillermo A, Khamashta MA, Bosch X. Adult haemophagocytic syndrome. *Lancet*. 2014;383(9927):1503–16.
 13. Allen M, De Fusco C, Legrand F, Clementi R, Conter V, Danesino C, et al. Familial hemophagocytic lymphohistiocytosis: how late can the onset be? *Haematologica*. 2001;86(5):499–503.
 14. Stepp SE, Dufourcq-Lagelouse R, Le Deist F, Bhawan S, Certain S, Mathew PA, et al. Perforin gene defects in familial hemophagocytic lymphohistiocytosis. *Science*. 1999;286(5446):1957–9.
 15. Nagafuji K, Nonami A, Kumano T, Kikushige Y, Yoshimoto G, Takenaka K, et al. Perforin gene mutations in adult-onset hemophagocytic lymphohistiocytosis. *Haematologica*. 2007;92(7):978–81.
 16. Wang Y, Wang Z, Zhang J, Wei Q, Tang R, Qi J, et al. Genetic features of late onset primary hemophagocytic lymphohistiocytosis in adolescence or adulthood. *PLoS One*. 2014;9(9):e107386.
 17. Zhang K, Jordan MB, Marsh RA, Johnson JA, Kissell D, Meller J, et al. Hypomorphic mutations in PRF1, MUNC13-4, and STXBP2 are associated with adult-onset familial HLH. *Blood*. 2011;118(22):5794–8.
 18. Janka GE, Lehmborg K. Hemophagocytic lymphohistiocytosis: pathogenesis and treatment. *Hematology Am Soc Hematol Educ Program*. 2013;2013:605–11.
 19. Machaczka M, Vaktinas J, Klimkowska M, Hagglund H. Malignancy-associated hemophagocytic lymphohistiocytosis in adults: a retrospective population-based analysis from a single center. *Leuk Lymphoma*. 2011;52(4):613–9.
 20. Meeths M, Horne A, Sabel M, Bryceson YT, Henter JI. Incidence and clinical presentation of primary hemophagocytic lymphohistiocytosis in Sweden. *Pediatr Blood Cancer*. 2014.
 21. Allen CE, Yu X, Kozinetz CA, McClain KL. Highly elevated ferritin levels and the diagnosis of hemophagocytic lymphohistiocytosis. *Pediatr Blood Cancer*. 2008;50(6):1227–35.
 22. Janka GE, Lehmborg K. Hemophagocytic syndromes – an update. *Blood Rev*. 2014;28(4):135–42.
 23. Birndt S, Schenk T, Brunkhorst FM, Maschmeyer G, Rothmann F, Weber T, Müller M, Panse J, Schroers R, Braess J, Frickhofen N, Janka G, Lehmborg K, Hochhaus A, Ernst T, La Rosée P. Hemophagocytic Lymphohistiocytosis in adults (aHLH): results from the German HLH registry. *Blood*. 2016;128:2523 (abstract).
 24. Cetica V, Sieni E, Pende D, Danesino C, De Fusco C, Locatelli F, et al. Genetic predisposition to hemophagocytic lymphohistiocytosis: report on 500 patients from the Italian registry. *J Allergy Clin Immunol*. 2016;137(1):188–96 e4.
 25. Tesi B, Lagerstedt-Robinson K, Chiang SC, Ben Bdira E, Abboud M, Belen B, et al. Targeted high-throughput sequencing for genetic diagnostics of hemophagocytic lymphohistiocytosis. *Genome Med*. 2015;7:130.
 26. Risma K, Jordan MB. Hemophagocytic lymphohistiocytosis: updates and evolving concepts. *Curr Opin Pediatr*. 2012;24(1):9–15.
 27. Henter JI, Horne A, Arico M, Egeler RM, Filipovich AH, Imashuku S, et al. HLH-2004: diagnostic and therapeutic guidelines for hemophagocytic lymphohistiocytosis. *Pediatr Blood Cancer*. 2007;48(2):124–31.
 28. Levy MM, Fink MP, Marshall JC, Abraham E, Angus D, Cook D, et al. 2001 SCCM/ESICM/ACCP/ATS/SIS international sepsis definitions conference. *Crit Care Med*. 2003;31(4):1250–6.
 29. Zoller EE, Lykens JE, Terrell CE, Aliberti J, Filipovich AH, Henson PM, et al. Hemophagocytosis causes a consumptive anemia of inflammation. *J Exp Med*. 2011;208(6):1203–14.
 30. Strauss R, Neureiter D, Westenburger B, Wehler M, Kirchner T, Hahn EG. Multifactorial risk analysis of bone marrow histiocytic hyperplasia with hemophagocytosis in critically ill medical patients – a post-mortem clinicopathologic analysis. *Crit Care Med*. 2004;32(6):1316–21.
 31. Francois B, Trimoreau F, Vignon P, Fixe P, Praloran V, Gastinne H. Thrombocytopenia in the sepsis syndrome: role of hemophagocytosis and macrophage colony-stimulating factor. *Am J Med*. 1997;103(2):114–20.

32. Janka GE, Schneider EM. Modern management of children with haemophagocytic lymphohistiocytosis. *Br J Haematol*. 2004;124(1):4–14.
33. Riviere S, Galicier L, Coppo P, Marzac C, Aumont C, Lambotte O, et al. Reactive hemophagocytic syndrome in adults: a retrospective analysis of 162 patients. *Am J Med*. 2014;127(11):1118–25.
34. Fardet L, Galicier L, Lambotte O, Marzac C, Aumont C, Chahwan D, et al. Development and validation of the HScore, a score for the diagnosis of reactive hemophagocytic syndrome. *Arthritis Rheumatol*. 2014;66(9):2613–20.
35. Lehmborg K, McClain KL, Janka GE, Allen CE. Determination of an appropriate cut-off value for ferritin in the diagnosis of hemophagocytic lymphohistiocytosis. *Pediatr Blood Cancer*. 2014;61(11):2101–3.
36. Schram AM, Campigotto F, Mullally A, Fogerty A, Massarotti E, Neuberg D, et al. Marked hyperferritinemia does not predict for HLH in the adult population. *Blood*. 2015;125(10):1548–52.
37. Machowicz R, Kröger N, Krieger T, Zborowska H, Rejowski S, Gorka M, et al. Hyperferritinemia in adult HLH: the best what we have, so far. *Blood*. 2015;125. <http://www.bloodjournal.org/content/125/10/1548/tab-e-letters#hyperferritinemia-in-adult-hlh-the-best-what-we-have-so-far>.
38. Tamamyan GN, Kantarjian HM, Ning J, Jain P, Sasaki K, McClain KL, et al. Malignancy-associated hemophagocytic lymphohistiocytosis in adults: relation to hemophagocytosis, characteristics, and outcomes. *Cancer*. 2016;31.
39. Lehmborg K, Nichols KE, Henter JI, Girschikofsky M, Greenwood T, Jordan M, et al. Consensus recommendations for the diagnosis and management of hemophagocytic lymphohistiocytosis associated with malignancies. *Haematologica*. 2015;100(8):997–1004.
40. Hejblum G, Lambotte O, Galicier L, Coppo P, Marzac C, Aumont C, et al. A web-based delphi study for eliciting helpful criteria in the positive diagnosis of hemophagocytic syndrome in adult patients. *PLoS One*. 2014;9(4):e94024.
41. Trottestam H, Horne A, Arico M, Egeler RM, Filipovich AH, Gadner H, et al. Chemoimmunotherapy for hemophagocytic lymphohistiocytosis: long-term results of the HLH-94 treatment protocol. *Blood*. 2011;118(17):4577–84.
42. La Rosee P. Treatment of hemophagocytic lymphohistiocytosis in adults. *Hematology Am Soc Hematol Educ Program*. 2015;2015(1):190–6.
43. Lehmborg K, Ehl S. Diagnostic evaluation of patients with suspected haemophagocytic lymphohistiocytosis. *Br J Haematol*. 2013;160(3):275–87.
44. Roupael NG, Talati NJ, Vaughan C, Cunningham K, Moreira R, Gould C. Infections associated with haemophagocytic syndrome. *Lancet Infect Dis*. 2007;7(12):814–22.
45. Bode SF, Bogdan C, Beutel K, Behnisch W, Greiner J, Henning S, et al. Hemophagocytic lymphohistiocytosis in imported pediatric visceral leishmaniasis in a nonendemic area. *J Pediatr*. 2014;165(1):147–53 e1.
46. Arca M, Fardet L, Galicier L, Riviere S, Marzac C, Aumont C, et al. Prognostic factors of early death in a cohort of 162 adult haemophagocytic syndrome: impact of triggering disease and early treatment with etoposide. *Br J Haematol*. 2015;168(1):63–8.
47. Imashuku S, Kuriyama K, Sakai R, Nakao Y, Masuda S, Yasuda N, et al. Treatment of Epstein-Barr virus-associated hemophagocytic lymphohistiocytosis (EBV-HLH) in young adults: a report from the HLH study center. *Med Pediatr Oncol*. 2003;41(2):103–9.
48. Berliner N, Kurra C, Chou D, CASE RECORDS of the MASSACHUSETTS GENERAL HOSPITAL. Case 1-2016. An 18-year-old man with fever, abdominal pain, and thrombocytopenia. *N Engl J Med*. 2016;374(2):165–73.
49. Johnson TS, Terrell CE, Millen SH, Katz JD, Hildeman DA, Jordan MB. Etoposide selectively ablates activated T cells to control the immunoregulatory disorder hemophagocytic lymphohistiocytosis. *J Immunol*. 2014;192(1):84–91.
50. Henter JI, Chow CB, Leung CW, Lau YL. Cytotoxic therapy for severe avian influenza A (H5N1) infection. *Lancet*. 2006;367(9513):870–3.
51. Wang Y, Huang W, Hu L, Cen X, Li L, Wang J, et al. Multi-center study of combination DEP regimen as a salvage therapy for adult refractory hemophagocytic lymphohistiocytosis. *Blood*. 2015;126(19):2186–92.
52. Schram AM, Berliner N. How I treat hemophagocytic lymphohistiocytosis in the adult patient. *Blood*. 2015;125(19):2908–14.
53. Larroche C, Bruneel F, Andre MH, Bader-Meunier B, Baruchel A, Tribout B, et al. Intravenously administered gamma-globulins in reactive hemaphagocytic syndrome. Multicenter study to assess their importance, by the immunoglobulins group of experts of CEDIT of the AP-HP. *Annales de medecine interne*. 2000;151(7):533–9.
54. Emmenegger U, Spaeth PJ, Neffel KA. Intravenous immunoglobulin for hemophagocytic lymphohistiocytosis? *J Clin Oncol*. 2002;20(2):599–601.
55. Hayden A, Park S, Giustini D, Lee AY, Chen LY. Hemophagocytic syndromes (HPSs) including hemophagocytic lymphohistiocytosis (HLH) in adults: a systematic scoping review. *Blood Rev*. 2016;30(6):411–20.
56. Tabata C, Tabata R. Possible prediction of underlying lymphoma by high sIL-2R/ferritin ratio in hemophagocytic syndrome. *Ann Hematol*. 2012;91(1):63–71.
57. Jing-Shi W, Yi-Ni W, Lin W, Zhao W. Splenectomy as a treatment for adults with relapsed hemophagocytic lymphohistiocytosis of unknown cause. *Ann Hematol*. 2015;94(5):753–60.
58. Frimmel S, Schipper J, Henschel J, Yu TT, Mitzner SR, Koball S. First description of single-pass albumin dialysis combined with cytokine adsorption in fulminant liver failure and hemophagocytic syndrome resulting from generalized herpes simplex virus 1 infection. *Liver Transpl*. 2014;20(12):1523–4.
59. Marsh RA, Vaughn G, Kim MO, Li D, Jodele S, Joshi S, et al. Reduced-intensity conditioning significantly improves survival of patients with hemophagocytic

- lymphohistiocytosis undergoing allogeneic hematopoietic cell transplantation. *Blood*. 2010;116(26):5824–31.
60. Marsh RA, Allen CE, McClain KL, Weinstein JL, Kanter J, Skiles J, et al. Salvage therapy of refractory hemophagocytic lymphohistiocytosis with alemtuzumab. *Pediatr Blood Cancer*. 2013;60(1):101–9.
 61. Strout MP, Seropian S, Berliner N. Alemtuzumab as a bridge to allogeneic SCT in atypical hemophagocytic lymphohistiocytosis. *Nat Rev Clin Oncol*. 2010;7(7):415–20.
 62. Ravelli A, Minoia F, Davi S, Horne A, Bovis F, Pistorio A, et al. 2016 classification criteria for macrophage activation syndrome complicating systemic juvenile idiopathic arthritis: a European league against rheumatism/American College of Rheumatology/Paediatric rheumatology international trials organisation collaborative initiative. *Ann Rheum Dis*. 2016;75(3):481–9.
 63. Schulert GS, Grom AA. Macrophage activation syndrome and cytokine-directed therapies. *Best Pract Res Clin Rheumatol*. 2014;28(2):277–92.
 64. Miettunen PM, Narendran A, Jayanthan A, Behrens EM, Cron RQ. Successful treatment of severe paediatric rheumatic disease-associated macrophage activation syndrome with interleukin-1 inhibition following conventional immunosuppressive therapy: case series with 12 patients. *Rheumatology*. 2011;50(2):417–9.
 65. de Kerguenec C, Hillaire S, Molinie V, Gardin C, Degott C, Erlinger S, et al. Hepatic manifestations of hemophagocytic syndrome: a study of 30 cases. *Am J Gastroenterol*. 2001;96(3):852–7.
 66. Hande KR, Wolff SN, Greco FA, Hainsworth JD, Reed G, Johnson DH. Etoposide kinetics in patients with obstructive jaundice. *J Clin Oncol*. 1990;8(6):1101–7.
 67. Halacli B, Unver N, Halacli SO, Canpinar H, Ersoy EO, Ocal S, et al. Investigation of hemophagocytic lymphohistiocytosis in severe sepsis patients. *J Crit Care*. 2016;35:185–90.
 68. Machowicz R, Janka G, Wiktor-Jedrzejczak W. Your critical care patient may have HLH (hemophagocytic lymphohistiocytosis). *Crit Care*. 2016;20(1):215.
 69. Machowicz RJ, Janka G, Wiktor-Jedrzejczak W. Similar but not the same: differential diagnosis of HLH and sepsis. submitted for publication. *Crit Rev Oncol Hematol*. 2017;114:1–12.
 70. Feig JA, Cina SJ. Evaluation of characteristics associated with acute splenitis (septic spleen) as markers of systemic infection. *Arch Pathol Lab Med*. 2001;125(7):888–91.
 71. Berbee JF, van der Hoogt CC, de Haas CJ, van Kessel KP, Dallinga-Thie GM, Romijn JA, et al. Plasma apolipoprotein CI correlates with increased survival in patients with severe sepsis. *Intensive Care Med*. 2008;34(5):907–11.
 72. von Muller L, Klemm A, Durmus N, Weiss M, Suger-Wiedeck H, Schneider M, et al. Cellular immunity and active human cytomegalovirus infection in patients with septic shock. *J Infect Dis*. 2007;196(9):1288–95.
 73. Cho E, Lee JH, Lim HJ, Oh SW, Jo SK, Cho WY, et al. Soluble CD25 is increased in patients with sepsis-induced acute kidney injury. *Nephrology*. 2014;19(6):318–24.
 74. Dellinger RP, Levy MM, Rhodes A, Annane D, Gerlach H, Opal SM, et al. Surviving sepsis campaign: international guidelines for management of severe sepsis and septic shock: 2012. *Crit Care Med*. 2013;41(2):580–637.
 75. Annane D. Corticosteroids for severe sepsis: an evidence-based guide for physicians. *Ann Intensive Care*. 2011;1(1):7.
 76. Shakoory B, Carcillo JA, Chatham WW, Amdur RL, Zhao H, Dinarello CA, et al. Interleukin-1 receptor blockade is associated with reduced mortality in sepsis patients with features of macrophage activation syndrome: reanalysis of a prior phase III trial. *Crit Care Med*. 2016;44(2):275–81.
 77. Lachmann G, La Rosée P, Schenk T, Brunkhorst FM, Spies C. Hemophagocytic lymphohistiocytosis: a diagnostic challenge on the ICU. *Der Anaesthesist*. 2016;65(10):776–86.
 78. Sieni E, Cetica V, Piccin A, Gherlinzoni F, Sasso FC, Rabusin M, et al. Familial hemophagocytic lymphohistiocytosis may present during adulthood: clinical and genetic features of a small series. *PLoS One*. 2012;7(9):e44649.

Part IV

Rare Histiocytic Disorders: Non-Langerhans Cell Histiocytosis

Francesco Ceppi and Oussama Abl

Introduction

The rare histiocytic disorders (RHD) are a group of conditions known as the non-Langerhans cell histiocytoses (non-LCH), most of which arise from either a dendritic cell (DC) or a macrophage/monocytic cell, although overlap may exist in some entities.

The classification of the histiocytic disorders, including the rare histiocytoses, is in continuous evolution. In 2005, Weitzman and Jaffe divided the RHD into three clinical groups: those that are predominantly cutaneous (cutaneous juvenile xanthogranuloma (JXG) family, reticulohistiocytoma, and cutaneous Rosai-Dorfman disease (RDD)), those that are cutaneous but have a major systemic component (xanthoma disseminatum and multicentric reticulohistiocytosis), and those that are mainly systemic although the skin may be part of the disease (Erdheim-Chester disease (ECD), systemic JXG, and systemic RDD) [1]. However, this classification did not include the very rare entities such as the malignant histiocytoses and preceded the recognition of the role of the

BRAF/MAPK kinase pathway in histiocytoses and the notion that LCH, ECD, and JXG are currently considered as inflammatory myeloid neoplasms (see Chap. 1, “Pathology of Histiocytic Disorders,” and Chap. 2, “Genomics of LCH and Related Disorders”).

This chapter will focus on JXG and related JXG disorders, while ECD, RDD, and the malignant histiocytoses will be discussed in the following chapters.

The Juvenile Xanthogranuloma Family

JXG is best described today as a macrophage disorder with positivity for CD14, CD68, CD163, fascin, and factor XIIIa, with negative or low S100 and negative CD1a and langerin. Factor XIIIa was originally thought to stain dendritic-shaped dermal “dendritic cells” (DC), but more detailed examination found factor XIIIa-positive dermal cells to be macrophages (2 = Zaba et al., 2007). Most of the cutaneous non-LCH disorders such as JXG, benign cephalic histiocytosis (BCH), generalized eruptive histiocytosis (GEH), xanthoma disseminatum (XD), progressive nodular histiocytosis (PNH), and their localized counterparts, as well as ECD, share an identical immunophenotype with JXG [2, 3]. Despite their clinical differences and heterogeneity, these entities represent a spectrum of the same disorder of which xanthogranuloma (XG) is the archetype [4].

F. Ceppi, MD (✉)

Department Woman-Mother-Child, Divisions of Pediatric Oncology and Hematology, University Hospital of Lausanne, Lausanne, Switzerland
e-mail: francesco.ceppi@chuv.ch

O. Abl, MD

Department of Pediatrics, Division of Hematology/Oncology, Hospital for Sick Children, University of Toronto, Toronto, ON, Canada

JXG

Introduction

Juvenile xanthogranuloma (JXG), the commonest of the non-LCH histiocytic disorders, is a benign proliferative pediatric histiocytosis that usually resolves spontaneously [1]. Factors responsible for the spontaneous involution are unknown, although an immune response to the lesion may play a role. The prognosis depends on the extent of extracutaneous involvement. Dermal JXG lesions generally occur early in life, predominantly as solitary cutaneous lesions that regress slowly without treatment.

JXG histology is common to a wide range of clinical conditions with manifestations that can be similar to LCH. Clinically, JXG involves primarily the skin but may be localized to a single extracutaneous site without any skin disease or may be disseminated and life threatening. JXG used to be misdiagnosed as LCH in over 20% of cases, in one study [5]; however, this is not true anymore given how ubiquitous CD1a and langerin testing is now. JXG and LCH share several clinical similarities, including a predisposition for naturally regressing dermal lesions and the potential for systemic presentation in early childhood [6, 7]. In contrast to JXG, LCH often involves bone and lymph nodes and commonly causes diabetes insipidus [6]. There have been rare reports of concomitant JXG and LCH and also LCH followed by JXG after chemotherapy, supporting the possibility of a common progenitor [8]. Immunohistochemical analysis is the most reliable method of distinguishing between these conditions [7].

Epidemiology

JXG is a disease of young children (median age 2 years) and may be present at birth. There is a male preponderance, especially in children with multiple skin lesions [7]. Incidence is presumed to be at one case/million children [5], but it could be higher because solitary regressing lesions may often be not reported. Two large retrospective studies of JXG reported a frequency of single-lesion

JXG as between 83% and 89.5% of cases [5, 7]. The median age of presentation with solitary skin nodules is 2 years compared to 5 months for multiple skin lesions, in one large series [7].

Pathogenesis

The cell of origin has been long debated. The first hypothesis made by McDonagh in 1909 was that of an endothelial origin (nevus-xantho-endothelioma). Helwig and Hackney in 1954 noted the cutaneous proliferation of spindle and polygonal “xanthomatous-like” cells of young children without lipid abnormalities had variable Touton giant cells and eosinophils [9]. They were the first to coin these lesions as JXG, which they concluded is a “descriptive term...until the exact etiologic factors are known.” Since that time, the lesional cell was postulated to be a dermal “dendrocyte” based on its factor XIIIa expression, but which has been reclassified as a dermal macrophage marker [10] with co-expression of macrophage/monocyte markers CD163/CD68/CD14 (Table 1.4, Chap. 1). Kraus et al. have postulated that the CD4+ plasmacytoid monocyte is the principal cell of origin, but this has never been further substantiated [11]. The World Health Organization’s Committee on Histiocytic/Reticulum Cell Proliferations has previously considered JXG to be a dendritic cell histiocytic disorder [2]. The pathogenesis of JXG is unknown, but recent whole-exome sequencing (WES) studies suggest a role for pathologic ERK activation. One study identified 17 somatic mutations by WES in four JXG lesions, and although no *BRAF-V600E* mutations were identified in these lesions, a *PI3KCD* mutation was identified in one patient and a germline *NF1* mutation was found in another one with neurofibromatosis type 1 (NF1) and JXG [12]. Indeed, JXG has been associated with NF1 and juvenile myelomonocytic leukemia (JMML). In these patients, the JXG usually precedes or occurs concurrently with JMML. Children with JXG and NF1 have 20- to 32-fold increased risk of JMML compared to patients with NF1 alone [13].

More recently, an *ARAF F351L* mutation has been found in a single case of JXG [14]. The *ARAF*

variant can potentially be inhibited by vemurafenib, a RAF kinase inhibitor, which suggests that mutational screening can also be useful in the clinical management of patients with JXG. A more widespread molecular and genetic screening of JXG patients is, however, needed for a better elucidation of JXG pathogenesis.

Histopathology

JXG diagnosis is confirmed by biopsy to rule out LCH or other benign histiocytoses, dermatofibromas, or mastocytosis. Many cases of skin JXG are diagnosed on clinical grounds without histologic confirmation, which is the routine practice when the lesions are typical.

Zelger was the first to point out the unifying features of histologically disparate lesions, composed of bland oval histiocytes (Fig. 17.1a) that became progressively more lipidized over time until they were completely xanthomatous (Fig. 17.1b). Some had elements or a predominance of spindle cells (spindle cell JXG) (Fig. 17.1d), scalloped cells (xanthoma disseminatum), or oncocytic cells (reticulohistiocytoma and multicentric reticulohistiocytosis). Giant cells of the Touton variety (Fig. 17.1c) are common but not required. A unifying feature of the lesions has been their consistent phenotype that is given as positive for CD14, CD68 (Fig. 17.2a), CD163 (Fig. 17.2b), factor XIIIa (Fig. 17.2c), and fascin, with S100 being absent or low variable in 20% of cases (Fig. 17.2d). Langerhans cell markers such as CD1a and langerin are, by definition, absent. There is always a light inflammatory component with lymphocytes and occasionally some eosinophils. Mitoses are rare but can be occasionally seen in the deep lesions which is never an atypical finding.

Clinical Features

Cutaneous JXG

Cutaneous JXG can present as a single (commonest presentation) or multiple brown or yellow papules or nodules, predominantly localized on

the face, head, and neck, followed by upper torso and upper and lower extremities (Fig. 17.3). It can present at any site, including the nails, penis, clitoris, eyelid, lips, palms, and soles. During infancy, JXG more commonly presents as multiple, ranging from a few to hundred lesions. Oral JXG can occur as a solitary lesion, without systemic disease and usually at an older age (9 years), and excision is usually curative [15]. Giant JXG is defined as 2 cm or more in diameter [4] and occurs most commonly in females, less than 14 months of age, on the proximal extremity or upper back and may be preceded by a congenital precursor lesion leading to misdiagnosis as hemangioma [16]. Giant JXG usually involutes over time and should not be overtreated. Cutaneous JXG usually has a benign course, progressing to yellow-brown lesions followed by gradual involution over months to years [16]. In infants with multiple lesions, old and new lesions may coexist and regression may occur at different rates. Lesions may resolve completely or may leave a residual atrophic or hyperpigmented scar.

Systemic JXG

Systemic JXG occurs in 4% of children with JXG and has an overall mortality of 5–10% [7]. Median age is usually 3 months and almost one-half of the patients have no skin lesions. Systemic JXG frequently affects two or more organ systems in unpredictable numbers and combinations of sites. Some sites may be asymptomatic initially but may later cause clinical problems. For new patients with cutaneous JXG, clinicians must at least be aware of the possibility of coexisting systemic disease and remain alert to the development of suspicious clinical or laboratory findings needing further investigation [17]. The most common presentation is lesions in the deeper soft tissues, followed by the liver, spleen, lung, eyes/orbits, oropharynx, muscles, bone marrow, and CNS. Clinical presentations of liver JXG are jaundice, hepatosplenomegaly, ascites, and liver enzyme alterations and are likely caused by macrophage activation syndrome (MAS) rather than a direct effect of JXG [18]. Pulmonary lesions are usually multiple solid nodules of varying sizes, thus mimicking metastases [17]. JXG should be

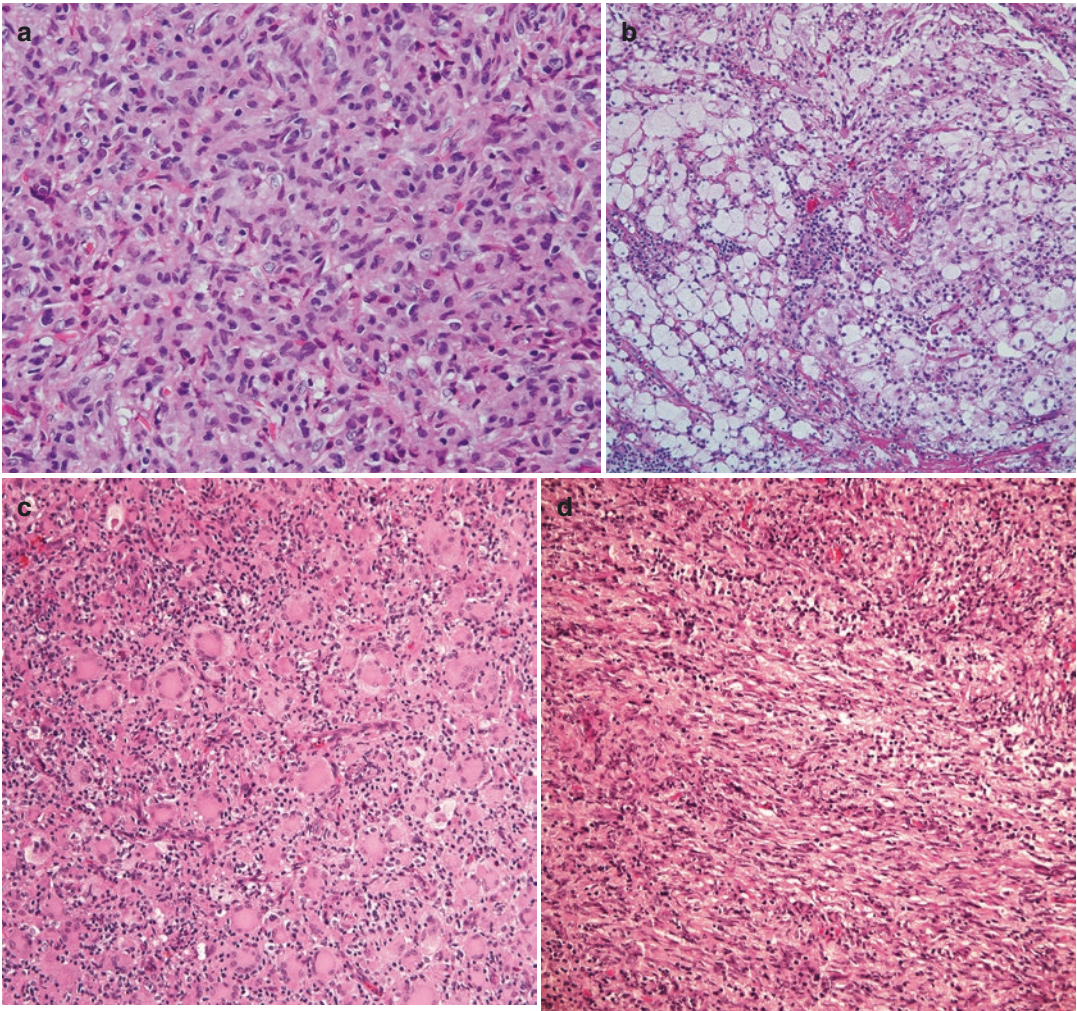


Fig. 17.1 There is a wide spectrum of histologic appearances to the JXG family of lesions. **(a)** The prototypical lesion has small histiocytes with oval nuclei and a modest amount of eosinophilic cytoplasm. The characteristic immunophenotype of this deep soft tissue JXG is illustrated in Fig. 17.2 (H&E-OMx400). **(b)** Xanthomatous foamy histiocytes can predominate in some older lesions

(H&E-OMx200). The light inflammatory presence is also usual. **(c)** Larger cytoplasm-rich histiocytes have Touton-type giant cell features (H&E-OMx200). **(d)** Some JXG lesions that have the expected immunophenotype are more spindled in appearance, simulating the fibrohistiocytic disorders (H&E-OMx200) (Courtesy of Dr. Ronald Jaffe)

considered in the differential diagnosis of cytopenias and bone marrow failure in early infancy [17]. It may regress spontaneously, whereas it can also lead to significant multiorgan deterioration and even death. For patients with isolated and accessible lesions, surgical excision appears curative. The greatest challenge seems to be posed by patients with symptoms who have unresectable disease (e.g., those with deep diffuse visceral infiltration). Visceral JXG requires treatment only in

the presence of vital organ dysfunction, because of the potential self-limiting nature of JXG.

Rarely, fatal cases of systemic JXG have been reported as a consequence of hepatic failure [7] or progressive CNS disease [17].

Intraocular JXG

Ocular JXG occurs in 1% of children with cutaneous JXG, and it occurs mainly in infants younger than 1 year and less commonly in older

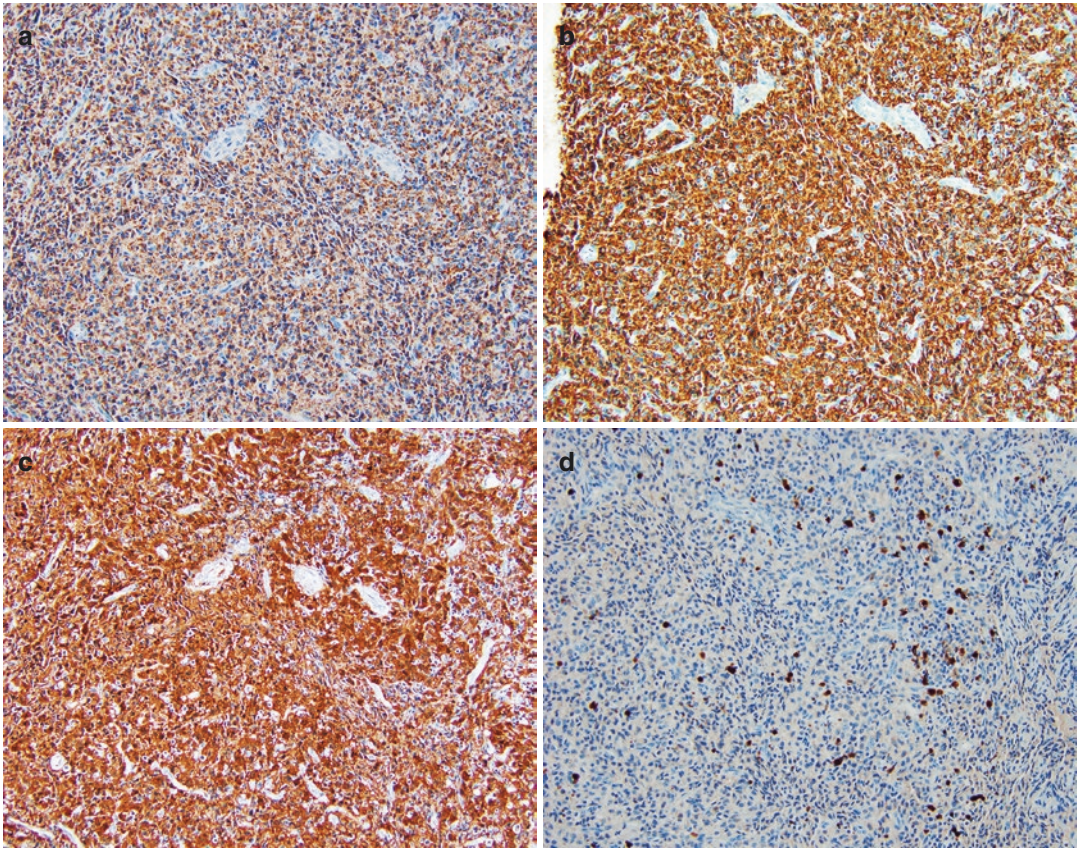


Fig. 17.2 Immunohistochemistry of the JXG family of lesions (OMx200). (a) CD68, PGM-1 clone. There is a finely granular intracytoplasmic pattern. (b) CD163. Staining is intense with a surface and cytoplasmic component. (c) Factor XIIIa. A diffuse cytoplasmic staining pattern is noted. In some lesions the peripheral cells stain

most strongly with less or absent staining at the center. (d) S100. Most are negative, highlighting only intervening (dendritic) cells. Up to 20%, however, can have light and variable staining of the JXG histiocytes (Courtesy of Dr. Ronald Jaffe). *OM* original magnification. Digital editing and publication choices affect the final magnification

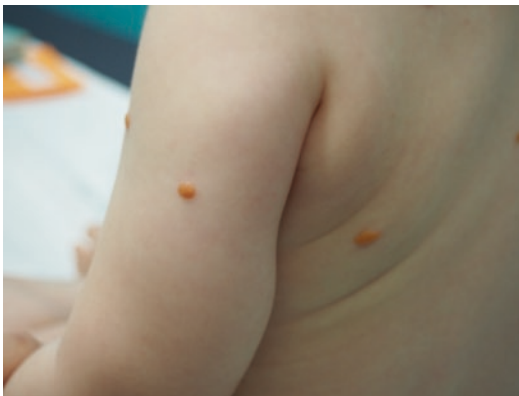

Fig. 17.3 Cutaneous JXG in a child: typical yellow nodules (Courtesy of Dr. Elena Pope, Hospital for Sick Children, Toronto)

children and adults, 90% of the patients being less than 2 years old [5]. Eye involvement is mostly unilateral with red eye and uveitis, glaucoma, spontaneous hyphema, and rarely retina or optic nerve involvement, which can lead to blindness. Of the 36 reported cases of ocular JXG, 16 had corneoscleral limbal involvement, 13 had iris involvement, 1 had conjunctival involvement, and only 11 had skin involvement [20].

Early diagnosis and treatment of intraocular JXG is essential and will eventually determine the final visual outcome.

Intracranial JXG

JXGs involving the nervous system account for only 1–2% of JXG [5]. Most intracranial JXGs

(88%) present in young children (<12 years old). Males (72%) were affected more often than females [20]. Clinically, the differential diagnosis and management of intracranial JXGs are difficult, particularly in the absence of pathologically confirmed cutaneous lesions. CNS involvement with JXG may result in significant complications such as seizures, increased intracranial pressure, diabetes insipidus, developmental delay, and blindness. Radiographically, patients with CNS disease may have leptomeningeal involvement, single, or multiple intracranial or spinal cord lesions. There seems to be a predilection for Meckel's cave involvement [21]. Enhancement on brain MRI following administration of gadolinium is a more reliable feature of these lesions [20, 22–24]. Overall, most of intracranial JXG manifests iso-intense T1- and T2-weighted imaging, homogenous enhancement. Thus, histopathologic examination remains the “gold standard” for the diagnosis of JXG.

Wang et al. have reported four children with intracranial JXG without cutaneous lesions and reviewed 39 previous reports of pediatric intracranial JXGs [26]. There was no significant association between resection of intracranial lesions, multiple intracranial lesions, systemic lesions, and clinical outcome [20]. When feasible, total surgical resection of intracranial lesions may be curative. Disseminated CNS lesions are not amenable for surgical resection and should be considered for systemic chemotherapy [25–27].

Treatment

In general, JXG has an excellent prognosis. For patients with isolated and accessible skin lesions, surgical excision is curative although most childhood cutaneous lesions tend to disappear spontaneously.

Most children with JXG require no therapy, but an extensive diagnostic workup is needed in patients in whom systemic involvement is suspected. Frequent follow-up visits in young children (<4 years), particularly those with concurrent NF1, should always include a complete

blood count (CBC) with differential and blood smear to monitor for JMML. Ophthalmological consultation is recommended for high-risk patients (those <2 years of age) who should undergo screening at diagnosis and every 3 or 6 months until age 2 years. Ocular involvement may require therapy with topical, intralesional, and subconjunctival corticosteroids. Surgery or systemic steroids may be required to treat complications, such as glaucoma or hyphema [19]. Persistent ocular forms with major visual impact can be treated with chemotherapy similar to that used in LCH, such as vinblastine and prednisone. Methotrexate has been used to treat JXG in a child with recurrent symptomatic uveitis and iris tumor [28]. Ashkenazy et al. reported two children with ocular JXG, refractory to local corticosteroid therapy, who were successfully treated with intraocular bevacizumab [29].

The standard treatment for solitary and symptomatic CNS JXG is surgical resection, provided that surgery is feasible. Patients with unresectable or multifocal cranial JXG have been successfully treated with cladribine [30] and vinblastine [31]. One pediatric review suggested that symptomatic cases of multisystem JXG, including CNS disease, can successfully be treated with LCH-based regimens [32]. Cranial radiation therapy can be considered for unresectable and refractory CNS disease [33] although due to its potentially severe side effects in young children, it is preferable to leave this modality as the last resource.

Clofarabine, as a therapeutic option in children with recurrent or refractory systemic JXG, has shown interesting results [34]. Simko et al. reported 18 patients treated with clofarabine administered at 25 mg/m²/day for 5 days for LCH, JXG, or RDD at Texas Children's Hospital. Patients were treated with a median of three chemotherapeutic regimens prior to clofarabine. Seventeen of 18 patients were alive at the time of the report. All surviving patients showed demonstrable improvement after 2–4 cycles of therapy, with 11 (61%) complete responses, 4 (22%) partial responses, and two patients still receiving therapy. All patients with JXG and RDD had complete or partial response at conclusion

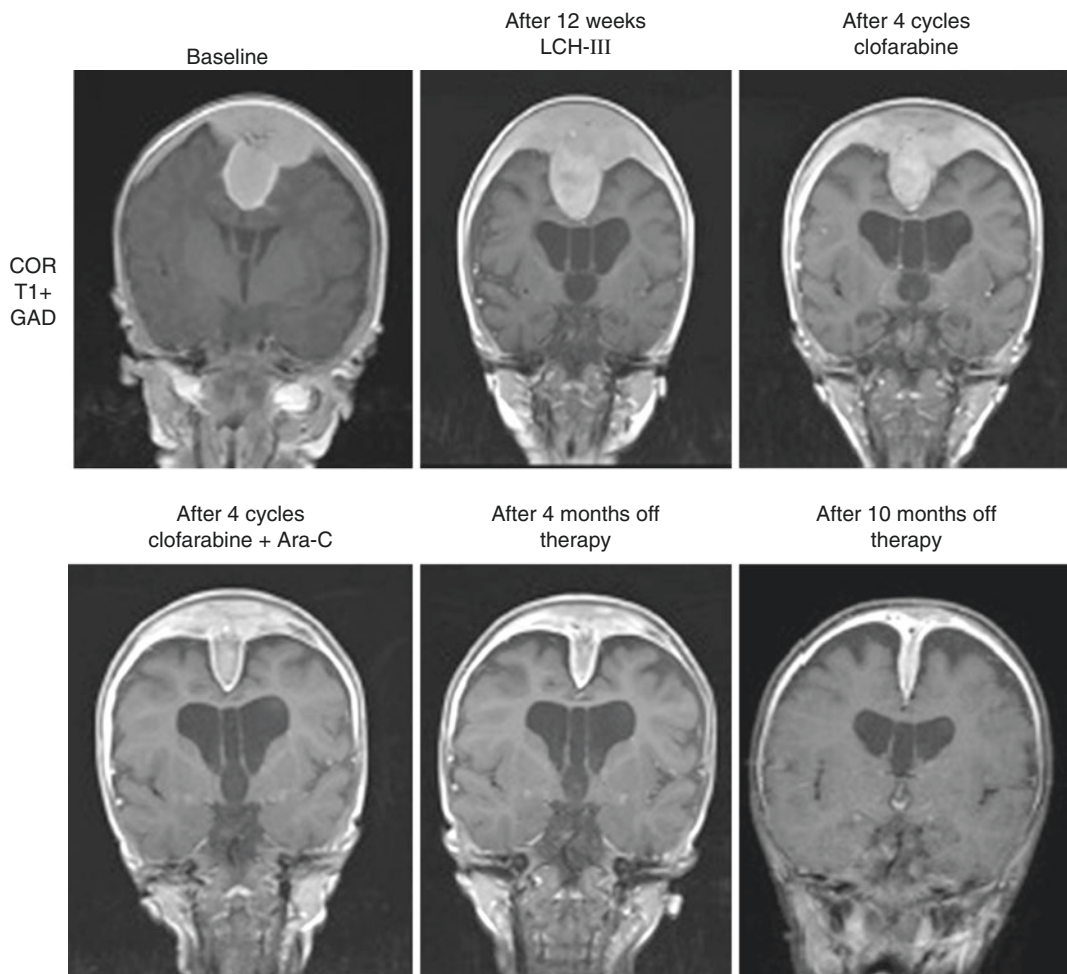


Fig. 17.4 Brain MRI from a child with intracranial JXG: Improvement of the intracranial mass size over the course of treatment with clofarabine-based regimen (Courtesy of Dr. Ronald Anderson, Alberta Children's Hospital, Calgary)

of therapy [34]. In our experience, we have seen a very good remission with clofarabine and cytarabine in a child with refractory CNS JXG (Fig. 17.4) (personal communication, O. Abl).

In general, decisions regarding the use of adjuvant therapy require careful attention to potential toxicity in young infants, thus reserving chemotherapy for patients with life-threatening or multiple relapsed/refractory disease. It remains to be determined whether ongoing and future WES studies of systemic JXG cases will lead to the discovery of new mutations of the ERK pathway that can ultimately be targeted by BRAF or MEK inhibitors.

Course and Prognosis

Patients with skin- or soft tissue-only JXG all survive, and their lesions will eventually resolve over time in most cases. Patients, and particularly infants, with liver, CNS, bone marrow, or large retroperitoneal disease will usually require systemic chemotherapy for survival. Nevertheless, in a review by Stover et al., 2 of 17 patients with multisystem JXG died of their disease despite intensive chemotherapy [32].

Children with intracranial JXG may often be left with a mild neurodevelopmental delay, which will need a long-term neurological and neuropsychological follow-up. Children with

intraocular JXG need to be followed at least yearly by an ophthalmologist.

Adult XG

XG in adults commonly occurs as solitary skin lesions, mostly affecting 20–40-year-old patients. Typical lesions have been described up to 80 years of age [35]. Adult XG affects both genders and predominates in the head and neck region and more commonly as single lesions, with no reports of adult XG on the lower extremities [16]. Pathologically, there is no difference between juvenile and adult forms, but as a rule adult XG either does not resolve spontaneously [4] or regresses more slowly, and most skin lesions are cured by surgical excision. Adult XG presents most commonly as a solitary lesion without systemic manifestations. However, occasionally it can be cutaneous disseminated that can rarely regress spontaneously [36] or systemic XG involving the lungs, long bones, and peritoneum and must therefore be differentiated from other histiocytic disorders [16]. CNS and pericardial disease is associated with a poor prognosis. Chemotherapy and radiotherapy often have no impact on the disease course [1]. In spite of its rarity, adult XG is characterized by an association with hematological disorders including acute lymphoblastic leukemia (ALL) and myelodysplastic syndrome (MDS) [37, 38]. In general, treatment of adult XG should be fairly conservative, although a workup for lymphoproliferative disorders should be considered in systemic cases [39].

Cutaneous JXG-Like Disorders

Benign Cephalic Histiocytosis (BCH)

BCH is a rare and early form of JXG, characterized by a benign course and tendency toward spontaneous remission, and is not usually associated with systemic involvement. Pathologically the lesions vary over time and with age [4]. Patients are typically young children with

multiple small lesions (red-brown macules and papules) on the cheeks, forehead, and upper trunk and without any internal organ involvement [40]. Pathologically, BCH lesions have the common histopathology of JXG, and immunohistochemically they are identical to JXG. On electron microscopy, they may show “wormlike” cytoplasmic inclusions (composed of wormlike membranous profiles, without Birbeck granules) [41]. Most children are otherwise healthy and developmentally normal [40]; however, diabetes insipidus has been reported in some children with BCH [42]. BCH is usually self-limited and treatment is not recommended because of spontaneous remission of the disease [40].

Generalized Eruptive Histiocytosis (GEH)

GEH is a rare benign histiocytic disorder characterized by asymptomatic, frequently symmetrical small red-brown papules on the face, trunk, and arms, usually sparing the flexures and sometimes involving mucosa. By definition, hyperlipidemia should be excluded. GEH mainly affects adults, but pediatric cases have been described [43], ranging in age from 1 month to 9 years [44–46]. The distinguishing feature is the relatively rapid appearance of crops of lesions, which disappear completely or resolve leaving a brown scar. New and old lesions may be present concurrently [45]. On histopathology, early GEH lacks the lipid-laden foamy cells and multinucleated giant cells that are characteristic of other non-LCH disorders, such as xanthoma disseminatum. Usually, GEH lesions have the same immunohistological features as JXG. One pediatric case demonstrated healing in sun-exposed areas, suggesting the value of ultraviolet therapy, if treatment is necessary [47, 48]. Although GEH usually has a benign and self-healing course, four adult cases of GEH have been reported in association with acute monocytic leukemia or chronic myelomonocytic leukemia [49–52]. Ziegler et al. described a 20-year-old patient with GEH associated with *FIP1L1-PDGFR*A-positive chronic eosinophilic leukemia. The patient was treated with imatinib

and achieved a complete clinical remission of both the leukemia and the GEH [53].

Progressive Nodular Histiocytosis (PNH)

PNH consists of two types of lesions – superficial xanthomas showing foamy macrophages and deeper subcutaneous nodules consisting of spindle-shaped histiocytosis with the same immunostaining as JXG [4]. The disease occurs in different age groups, but adults are more affected than children, and both genders are equally affected [54]. It is characterized by the clinical appearance of yellow papules and larger nodules on the head, trunk, and extremities [55]. These skin lesions are neither painful nor pruritic. Marked cosmetic deformity is the usual complaint, and functional disability may occur in some cases as a result of large lesions on the extremities. The oral, laryngeal, pharyngeal, and conjunctival mucosa may be involved [56]. The disease is usually progressive with no tendency to spontaneous involution and with time may cause severe disfigurement. Involvement of internal organs or systemic complications have not been reported. Effective treatment of PNH is not yet available. Large disfiguring or painful lesions are usually removed surgically, but recurrences are common [57]. Carbon dioxide laser has been used to ablate skin nodules [58]. Chemotherapy drugs such as cyclophosphamide, vincristine, and prednisone have been tried without success [59, 60]. Chu suggested that early stages of XD and PNH may be more sensitive to chemotherapy and radiation therapy and that early aggressive treatment may help. This, however, remains to be proven [3].

Mixed Histiocytosis

JXG-type lesions can follow LCH, although it has not been determined whether these lesions share the molecular signal of the LCH. Combined LCH and JXG have been described in which zones of one and the other coexist [68].

Cutaneous Disorders with a Major Systemic Component

Xanthoma Disseminatum (XD)

XD is a variant of JXG, most often occurring in young adult males (less than 25 years old). It presents with widespread symmetrically distributed, rapidly coalescing cutaneous papules, initially red-brown then yellow, involving the face, trunk, flexural, and intertriginous areas [61]. The lesions continue to grow forming distinctive plaques and nodules [62–64]. Occasional involvement of mucous membranes, including conjunctivae, lips, tongue, buccal mucosa, gingiva, and palate, has been reported and almost any organ may be affected [65]. XD also tends to involve the upper respiratory tract (trachea and larynx) and may cause airway obstruction. Ocular, CNS, and meningeal involvement can cause significant morbidity (exophthalmos, hydrocephalus, ataxia). DI occurs in 30–50% of cases due to lesions compressing the hypothalamic-pituitary axis, although it tends to be transient [62]. CNS involvement with DI has been associated with a progressive clinical pattern, while involvement of other areas of the brain occurs in less than 5% of XD [66]. Progressive CNS lesions carry a poor prognosis, and the mortality rate has been reported to be 63% in patients with intracranial disease outside the pituitary/hypothalamus and 100% in patients with posterior fossa involvement [67].

Three clinical patterns of XD have been described: a common persistent form, a less common progressive form with systemic involvement (which may be fatal), and a rare spontaneous regression form [74].

In XD, several treatment strategies showed disappointing results (or were successful in isolated cases), including lipid-lowering agents, prednisone, interferon- α , and immunosuppressive and chemotherapy agents [68–77]. Campero et al. reported a patient with XD who was successfully treated with an interleukin-1 receptor antagonist (anakinra) [78]. Recently, an anecdotal case of response to imatinib has been reported in a refractory case of XD [79]. Table 17.1 illustrates a summary of the treatment strategies for patients with XD.

Table 17.1 Summary of systemic treatments for XD

Treatment/reference	Extracutaneous sites	Outcome
Prednisone/vinblastine [70]	Oral mucosae/lips/eyelids, bones/bone marrow/liver, and spleen	Failure
Thalidomide	Pharynx/larynx/trachea	Failure
Cyclophosphamide		Failure
Vinblastine [76]		VGPR
Cyclophosphamide [77]	Eye/laryngeal mucosae/pituitary gland/CNS	PR
Prednisone/azathioprine [69]	Liver	Failure
HLH-94	Liver/bone marrow	Failure
High-dose chemotherapy (carmustine/etoposide/cytarabine/melphalan) and allogeneic HSCT [95]		CR
Doxycycline [96]	Conjunctiva/nasopharynx	Good regression
Etoposide/IFN- α	Bone/conjunctiva/nasopharyngeal and buccal mucosae	Failure
Rosiglitazone/simvastatin [71]		Failure
Steroids/cyclophosphamide	Oral mucosae/soft palate	Failure
Rosiglitazone/simvastatin [74]		PR
Cladribine [72]	5 patients with variably associated soft palate/eye, pituitary gland involvement	Good partial remission marked in cutaneous lesions (2 patients) or failure (3 patients)
Statins/fenofibrate/cyclophosphamide [73]	Pituitary gland with DI	Partial remission of the pituitary gland involvement, but failure in skin lesions
Doxycycline	Not applicable	Failure
Cyclosporine, doxycycline [75]		PR
Corticosteroids/thalidomide [78]	Stomach/lungs/bone	Good outcome, more marked on cutaneous lesions
Cranial radiotherapy [79]	Pituitary/CNS	Failure
Anakinra [79]		CR
Imatinib [80]	Oral mucosae/DI	VGPR

Legend: *VGPR* very good partial remission, *PR* partial remission, *CR* complete remission, *HSCT* hematopoietic stem cell transplant, *IFN- α* interferon alpha, *DI* diabetes insipidus

Non-LCH Disorders Related to JXG

Cutaneous

Solitary Reticulohistiocytoma

Solitary reticulohistiocytoma (SRH), also known as solitary cutaneous reticulohistiocytosis, is morphologically the localized variant of multicentric reticulohistiocytosis (MRH). SRH usually presents as a yellow to reddish-brown, smooth-surfaced, firm nodule that favors the trunk and extremities. SRH affected young male adults without preference to site but may occur in the newborn where differentiation from LCH is important. Immunohistochemically it is S100 and CD1a negative [79]. SRH is routinely treated by surgical excision.

Cutaneous with a Major Systemic Component

Multicentric Reticulohistiocytosis (MRH)

MRH is a rare multisystem disorder characterized by cutaneous involvement (usually papulo-nodular eruption), mucosal lesions, and a destructive

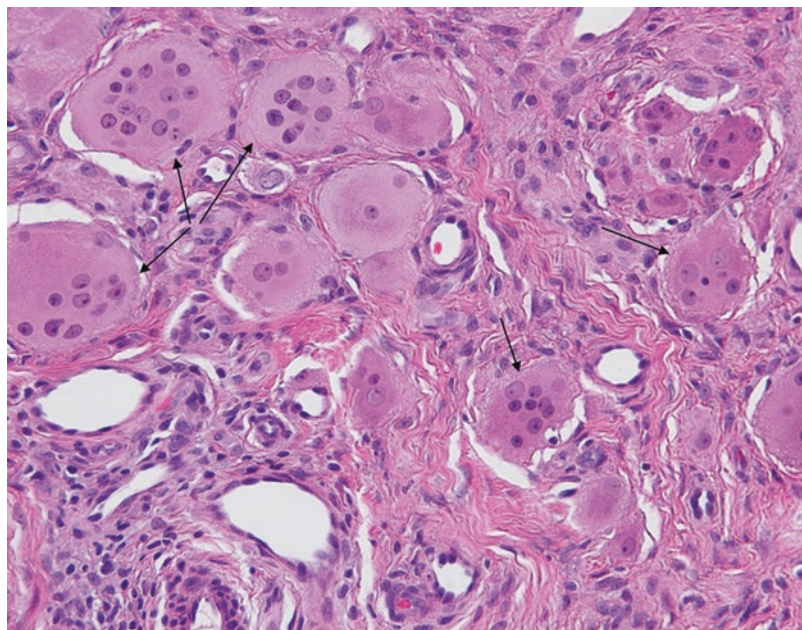
osteoarthropathy. It can rarely affect internal organs such as the lungs (resulting in pleural effusion) and heart (case reports of pericardial effusion and congestive heart failure).

MRH is a disease of older adults with 85% of cases reported in Caucasians [80]. MRH predominately affects female individuals (ratio of 3:1), both in the adult and pediatric populations [81]. At least 14 pediatric cases have been reported, with the youngest case being diagnosed at the age of 3 months [80, 82–84]. Early and accurate diagnosis of MRH is crucial. When untreated, MRH can cause erosive arthritis with potential progression to arthritis mutilans.

Pathology

In MRH, pathology is characterised by nodular infiltrate of plump histiocytes with abundant finely granular eosinophilic cytoplasm and multinucleated giant cells, and usually PAS positivity (Fig. 17.5). Unlike other non-LCH disorders, MRH histiocytes are factor XIIIa negative; immunostaining for CD68 and CD163 is positive, while CD1a and S100 stains are negative.

Fig. 17.5 Multicentric reticulohistiocytosis: The multinucleated histiocytes (arrows) are large with an eosinophilic and finely granular “ground-glass” cytoplasm. The nuclei tend to favor the center of the cells. A CD163 stain was diffusely positive and the cells were focally PAS positive (not shown) (Courtesy of Tariq S. et al., SpringerPlus, 2016, 5:180)



Pathogenesis

The pathogenesis of MRH is unknown; however, there is evidence of histiocytic proliferation with an increase in lesional cytokines such as interleukin (IL)-12, tumor necrosis factor (TNF)- α , and IL-1 β , produced predominantly by activated macrophages. The disease can be associated with an underlying malignancy (breast cancer, ovarian cancer, cutaneous squamous cell carcinoma, melanoma, papillary serous endometrial cancer, nasopharyngeal cancer, and hepatocellular carcinoma) in about 28% of cases, hyperlipidemia in 30–58%, and autoimmune disease in 6–17% and tuberculosis [80, 85, 86].

Clinical Features

Tariq et al. reviewed MRH cases reported between 1991 and 2014 and extracted 52 individual cases. They found cutaneous involvement in 50 cases (96%), arthritis in 43 (82%), weight loss in 10 (19%), weakness in 8 (15%), dysphagia in 5 (9.6%), fatigue in 5 (9.6%), fever in 5 (9.6%), tenosynovitis in 3 (5.75%), hoarseness in 3 (5.75%), dry eye in 3 (5.75%), myalgia in 2 (3.8%), muscle atrophy in 2 (3.8%), mucosal lesions in 2 (3.8%), and pleural effusion in 2 (3.8%) (Table 17.2) [81]. Concomitant medical conditions included Sjogren's syndrome (3 cases), thyroid disease (2), hepatitis B (1), systemic lupus erythematosus (1), hypercholesterolemia (1), cardiac failure (1), ulcerative colitis (1), primary biliary cirrhosis (1), and multiple sclerosis (1) [81].

The most common cutaneous manifestation of MRH is a papulo-nodular rash followed by peri-ungual telangiectasia, reddish-brown nodules, papules with a "coral bead" appearance, pruritis, nonspecific erythematous rash, xanthelasma, photosensitive rash, and eyelid lesions [82]. Mucosal lesions occur in at least 30% of cases, and 15% may have vermicular lesions bordering the nostrils [87]. The arthritis is a polyarticular symmetric erosive one (Fig. 17.6), which may involve any joint. The hand is the most common area affected by MRH with an almost equal involvement of the proximal and distal interphalangeal joints, while the knee is the second most

Table 17.2 Frequency of different clinical features in MRH reported

Clinical features	n = 52
Arthritis	43
Erosive disease	23
Arthralgia	5
Arthritis mutilans	4
Tenosynovitis	3
Skin lesions	50
Pseudoptosis	1
Weight loss	10
Weakness	8
Dysphagia	5
Fatigue	5
Fever	5
Nodules on epiglottis	3
Hoarseness	3
Sicca syndrome	3
Nodules in larynx	2
Muscle atrophy	2
Myalgia	2
Mucosal lesions	2
Macroglossia	1
Parotid enlargement	1
URI symptoms	1
PPD+	1
Lymphadenopathy	1
Raynaud's phenomenon	1
Splenomegaly	1

Courtesy of Tariq S. et al., SpringerPlus, 2016, 5:180

commonly involved joint with MRH [82]. Findings of inflammatory arthritis from 43 cases are described by Tariq et al. In this series erosions were seen within the radiographs in 23 (55%) cases and arthritis mutilans was reported in 4 (9.3%) cases. Arthralgia alone was reported in 5 (11.6%) cases, while tenosynovitis was seen in 3 (7%) cases. Periarticular osteopenia was seen in 3 (7%), while flexion deformities from long-standing disease were seen in 6 (14%) cases of arthritis [81].

It has been postulated that release of urokinase from the histiocytes plays a role in the erosion of cartilage and bone and may explain the disparity between mildness of symptoms and extent of joint destruction [87]. Other symptoms like fever, weight loss, and malaise may develop as well. Differentiation of MRH from rheumatoid arthritis

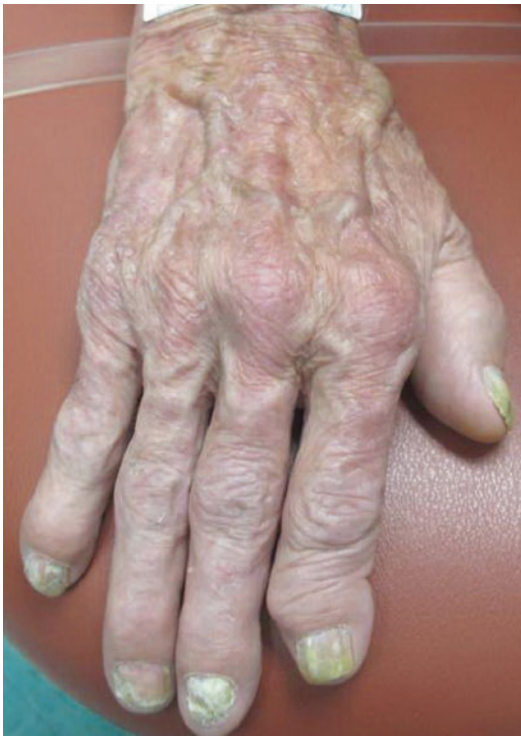

Fig. 17.6 Arthropathy in a patient with MRH: The patient's right dorsal hand is shown with visible swelling of all the distal, proximal interphalangeal, and metacarpophalangeal joints (Courtesy of Tariq S. et al., SpringerPlus, 2016, 5:180)

is important, because of symmetric involvement frequently involving the interphalangeal joints of the hands, which may lead to a characteristic widening and shortening of the fingers known as the “opera-glass” hand [80]. Some patients, including most of the children, will have a self-limited disease with non-deforming arthritis [80].

Treatment

Exclusion of an underlying disease is important, although eradication does not usually influence the disease course [88]. Resolution of MRH was seen in a patient with renal cell carcinoma after nephrectomy [89]. Disease activity may fluctuate spontaneously, and it is difficult to assess effects of therapy. Some patients, including most of the children, have self-limited disease with non-deforming arthritis. Anti-inflammatory drugs and corticosteroid can be helpful as palliative measures but

usually have little or no effect on disease progression [82, 87, 88].

Tariq et al. have critically analyzed and graded relative treatment efficacy used for skin and joint manifestations [81]. The grades were 0 = worse, 1 = no benefit/condition remained same, 2 = improvement without resolution, and 3 = resolution. The different treatments used and relative benefits are summarized in Table 17.3. The most effective initial disease-modifying antirheumatic drug (DMARD) to use is methotrexate, which controlled arthritis symptoms (score 3) in 28% of cases and skin lesions in 38%. Additionally, it showed partial disease control (score 2) in joints in 44% and skin lesions in 28% of cases, respectively [81]. Other DMARDs such as leflunomide or azathioprine could be considered in cases with a contraindication to methotrexate. Other agents like hydroxychloroquine and sulfasalazine were not of significant benefit [81]. Cyclophosphamide was found to be of significant benefit with 20% of cases with complete (score 3) arthritis resolution and 27% of cases of skin lesions. Additionally partial arthritis and skin disease control (score 2) were seen in 40% and 45% of cases, respectively. In order to avoid its potential side effects, however, cyclophosphamide can be kept in reserve for refractory diseases or in cases of major extra-articular manifestations. Recent studies have demonstrated good response with anti-TNF- α drugs (etanercept, infliximab), interleukin-1 receptor antagonists (anakinra), and interleukin-6 antagonists (tocilizumab) both in adult and pediatric cases [90–93]. Recently, Jha et al. reported an infant with MRH who responded well to vinblastine and prednisone [84]. A patient with systemic lupus erythematosus and MRH and a 6-year-old girl with severe erosive arthritis responded well to cyclosporine after failing standard therapy [94]. Bisphosphonates should be considered as “add-on” agents in cases of poor disease control or in cases of concomitant osteopenia (or osteoporosis) and/or steroid use. Tariq review suggests clear benefit from the use of these agents [81].

A treatment algorithm is proposed by Tariq et al. for MRH on the basis of literature review (Fig. 17.7) [81].

Table 17.3 Summary of the different treatments used with relative benefit

Medical treatments and indication	<i>n</i> total	<i>n</i> (%) for score 3 = resolution of the condition	<i>n</i> (%) for score 2 = improvement without resolution	<i>n</i> (%) for score 1 = no benefit/condition remained same	<i>n</i> (%) for score 0 = worse than prior to treatment
Methotrexate for arthritis	25	7 (28)	11 (44)	3 (12)	4 (16)
Methotrexate for skin	26	10 (38)	10 (28)	3 (11)	3 (11)
Hydroxychloroquine for arthritis	7	0 (0)	1 (14)	3 (43)	3 (43)
Hydroxychloroquine for skin	7	0 (0)	1 (14)	3 (43)	3 (43)
Thalidomide	1		1 (100)		
Sulfasalazine for arthritis	1				1 (100)
Sulfasalazine for skin	1				1 (100)
Leflunomide for arthritis	2	2 (100)			
Leflunomide for skin	2	2 (100)			
Azathioprine for arthritis	2	1 (50)		1 (50)	
Azathioprine for skin	2	1 (50)	1 (50)		
Cyclophosphamide for arthritis	10	2 (20)	4 (40)	4 (40)	
Cyclophosphamide for skin	11	3 (27)	5 (45)	3 (27)	
Cyclosporine for arthritis	1	1 (100)			
Cyclosporine for skin	2	1 (50)		1 (50)	
Etanercept for arthritis	6	3 (50)	2 (33)	1 (17)	
Etanercept for skin	6	3 (50)	2 (33)	1 (17)	
Adalimumab for arthritis	2	2 (100)			
Adalimumab for skin	2	2 (100)			
Infliximab for arthritis	3	1 (33)	2 (67)		
Infliximab for skin	3	1 (33)	2 (67)		
Alendronate for arthritis	4	1 (25)	2 (50)	1 (25)	
Alendronate for skin	4	2 (50)	1 (25)	1 (25)	
Zoledronic acid for arthritis	3	1 (33)	2 (67)		
Zoledronic acid for skin	2	1 (50)	1 (50)		
Pamidronate for arthritis	1		1 (100)		
Pamidronate for skin	1			1 (100)	
Chlorambucil for arthritis	1				1 (100)
Chlorambucil for skin	1				1 (100)
Sodium aurothiomalate	1			1 (100)	
Naproxen	1	1 (100)			
Prednisone for arthritis	2		2 (100)		
Prednisone for skin	2	1 (50)	1 (50)		

Courtesy of Tariq S. et al., SpringerPlus, 2016, 5:180

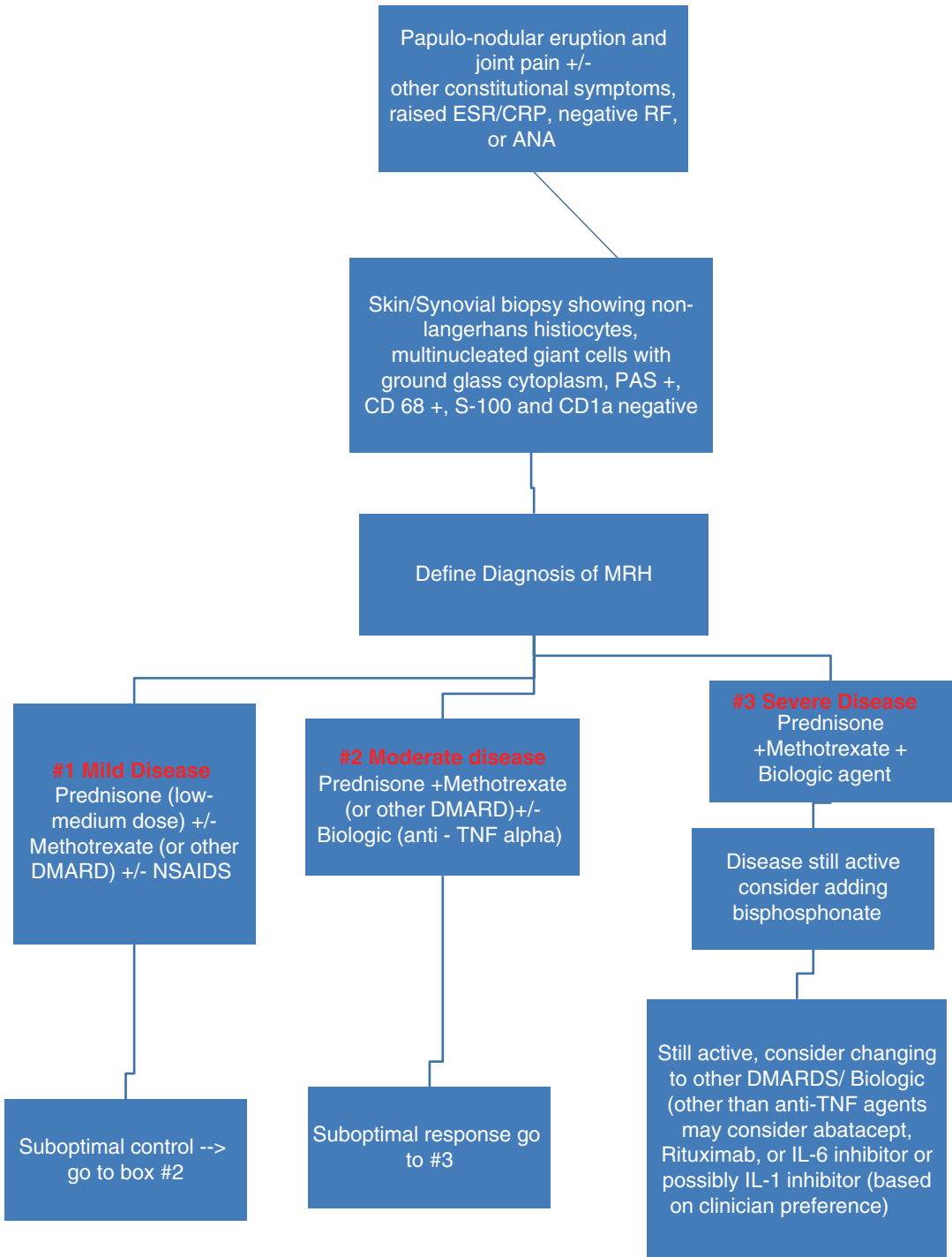


Fig. 17.7 Treatment algorithm for MRH: The algorithm summarizes the proposed treatment algorithm. For mild cases NSAIDs can be started but the disease is aggressive in most cases requiring steroids in varying doses and DMARDs. The methotrexate can be used once the diagnosis is secured with biopsy. Given the erosive nature of

the disease with possibility of joint mutilation and good response to biologic agents seen in multiple case reports especially the anti-TNF agents, step-up therapy should be considered in patients with suboptimal response to DMARDs (Courtesy of Tariq S. et al., SpringerPlus, 2016, 5:180)

References

- Weitzman S, Jaffe R. Uncommon histiocytic disorders: the non-Langerhans cell histiocytoses. *Pediatr Blood Cancer*. 2005;45(3):256–64.
- Favara BE, Feller AC, Pauli M, Jaffe ES, Weiss LM, Arico M, et al. Contemporary classification of histiocytic disorders. The WHO Committee on Histiocytic/Reticulum Cell proliferations. Reclassification Working group of the Histiocyte Society. *Med Pediatr Oncol*. 1997;29(3):157–66.
- Chu AC. The confusing state of the histiocytoses. *Br J Dermatol*. 2000;143(3):475–6.
- Zelger BW, Cerio R. Xanthogranuloma is the archetype of non-Langerhans cell histiocytoses. *Br J Dermatol*. 2001;145(2):369–71.
- Janssen D, Harms D. Juvenile xanthogranuloma in childhood and adolescence: a clinicopathologic study of 129 patients from the kiel pediatric tumor registry. *Am J Surg Pathol*. 2005;29(1):21–8.
- Egeler RM, D'Angio GJ. Langerhans cell histiocytosis. *J Pediatr*. 1995;127(1):1–11.
- Dehner LP. Juvenile xanthogranulomas in the first two decades of life: a clinicopathologic study of 174 cases with cutaneous and extracutaneous manifestations. *Am J Surg Pathol*. 2003;27(5):579–93.
- Patrizi A, Neri I, Bianchi F, Guerrini V, Misciali C, Paone G, et al. Langerhans cell histiocytosis and juvenile xanthogranuloma. Two case reports. *Dermatology (Basel, Switzerland)*. 2004;209(1):57–61.
- Helwig EAHV. Juvenile xanthogranuloma (nevo-xanthoendothelioma) proceedings of the American Association of Pathologists and Bacteriologists. *Am J Pathol*. 1954;30(3):625–6.
- Zaba LC, Fuentes-Duculan J, Steinman RM, Krueger JG, Lowes MA. Normal human dermis contains distinct populations of CD11c+B220+ dendritic cells and CD163+FXIIIa+ macrophages. *J Clin Invest*. 2007;117(9):2517–25.
- Kraus MD, Haley JC, Ruiz R, Essary L, Moran CA, Fletcher CD. "Juvenile" xanthogranuloma: an immunophenotypic study with a reappraisal of histogenesis. *Am J Dermatopathol*. 2001;23(2):104–11.
- Chakraborty R, Hampton OA, Shen X, Simko SJ, Shih A, Abhyankar H, et al. Mutually exclusive recurrent somatic mutations in MAP2K1 and BRAF support a central role for ERK activation in LCH pathogenesis. *Blood*. 2014;124(19):3007–15.
- Zvulunov A, Barak Y, Metzker A. Juvenile xanthogranuloma, neurofibromatosis, and juvenile chronic myelogenous leukemia. World statistical analysis. *Arch Dermatol*. 1995;131(8):904–8.
- Diamond EL, Durham BH, Haroche J, Yao Z, Ma J, Parikh SA, et al. Diverse and targetable kinase alterations drive histiocytic neoplasms. *Cancer Discov*. 2016;6(2):154–65.
- Flaitz C, Allen C, Neville B, Hicks J. Juvenile xanthogranuloma of the oral cavity in children: a clinicopathologic study. *Oral Surg Oral Med Oral Pathol Oral Radiol Endod*. 2002;94(3):345–52.
- Chang MW. Update on juvenile xanthogranuloma: unusual cutaneous and systemic variants. *Semin Cutan Med Surg*. 1999;18(3):195–205.
- Freyer DR, Kennedy R, Bostrom BC, Kohut G, Dehner LP. Juvenile xanthogranuloma: forms of systemic disease and their clinical implications. *J Pediatr*. 1996;129(2):227–37.
- Papadakis V, Volonaki E, Katsibardi K, Stefanaki K, Valari M, Anagnostakou M, et al. A rare case of neonatal systemic xanthogranulomatosis with severe hepatic disease and metachronous skin involvement. *J Pediatr Hematol Oncol*. 2012;34(3):226–8.
- Niu L, Zhang C, Meng F, Cai R, Bi Y, Wang Y, et al. Ocular juvenile xanthogranuloma. *Optom Vis Sci (official publication of the American Academy of Optometry)*. 2015;92(6):e126–33.
- Wang B, Jin H, Zhao Y, Ma J. The clinical diagnosis and management options for intracranial juvenile xanthogranuloma in children: based on four cases and another 39 patients in the literature. *Acta Neurochir*. 2016;158:1289–97.
- Tamir I, Davir R, Fellig Y, Weintraub M, Constantini S, Spektor S. Solitary juvenile xanthogranuloma mimicking intracranial tumor in children. *J Clin Neurosci (official Journal of the Neurosurgical Society of Australasia)*. 2013;20(1):183–8.
- Kwak ES, Marrero DE, Pfannl R, Erbay SH. Sterile brain abscess due to juvenile xanthogranuloma: DWI characteristics. *J Neuroimaging (official Journal of the American Society of Neuroimaging)*. 2013;23(3):437–40.
- Lesniak MS, Viglione MP, Weingart J. Multicentric parenchymal xanthogranuloma in a child: case report and review of the literature. *Neurosurgery*. 2002;51(6):1493–8. discussion 8.
- Ashley WW Jr, Narayan P, Park TS, Tu PH, Perry A, Leonard JR. Incidental pediatric intraparenchymal xanthogranuloma: case report and review of the literature. *J Neurosurg*. 2005;102(3 Suppl):307–10.
- Nakatani T, Morimoto A, Kato R, Tokuda S, Sugimoto T, Tokiwa K, et al. Successful treatment of congenital systemic juvenile xanthogranuloma with Langerhans cell histiocytosis-based chemotherapy. *J Pediatr Hematol Oncol*. 2004;26(6):371–4.
- Dolken R, Weigel S, Schroder H, Hartwig M, Harms D, Beck JF. Treatment of severe disseminated juvenile systemic xanthogranuloma with multiple lesions in the central nervous system. *J Pediatr Hematol Oncol*. 2006;28(2):95–7.
- Orsey A, Paessler M, Lange BJ, Nichols KE. Central nervous system juvenile xanthogranuloma with malignant transformation. *Pediatr Blood Cancer*. 2008;50(4):927–30.
- Longmuir S, Dumitrescu A, Kwon Y, Boldt HC, Hong S. Juvenile xanthogranulomatosis with bilateral and multifocal ocular lesions of the iris, corneal scleral limbus, and choroid. *J AAPOS (the official publication of the American Association for Pediatric Ophthalmology and Strabismus / American Association for Pediatric Ophthalmology and Strabismus)*. 2011;15(6):598–600.

29. Ashkenazy N, Henry CR, Abbey AM, McKeown CA, Berrocal AM, Murray TG. Successful treatment of juvenile xanthogranuloma using bevacizumab. *J AAPOS* (the official publication of the American Association for Pediatric Ophthalmology and Strabismus / American Association for Pediatric Ophthalmology and Strabismus). 2014;18(3):295–7.
30. Rajendra B, Duncan A, Parslew R, Pizer BL. Successful treatment of central nervous system juvenile xanthogranulomatosis with cladribine. *Pediatr Blood Cancer*. 2009;52(3):413–5.
31. Auvin S, Cuvelier JC, Vinchon M, Defoort-Dhellemes S, Soto-Ares G, Nelken B, et al. Subdural effusion in a CNS involvement of systemic juvenile xanthogranuloma: a case report treated with vinblastin. *Brain Dev*. 2008;30(2):164–8.
32. Stover DG, Alapati S, Regueira O, Turner C, Whitlock JA. Treatment of juvenile xanthogranuloma. *Pediatr Blood Cancer*. 2008;51(1):130–3.
33. Yamada K, Yasui M, Sawada A, Inoue M, Nakayama M, Kawa K. Severe persistent bone marrow failure following therapy with 2-chlorodeoxyadenosine for relapsing juvenile xanthogranuloma of the brain. *Pediatr Blood Cancer*. 2012;58(2):300–2.
34. Simko SJ, Tran HD, Jones J, Bilgi M, Beaupin LK, Coulter D, et al. Clofarabine salvage therapy in refractory multifocal histiocytic disorders, including Langerhans cell histiocytosis, juvenile xanthogranuloma and Rosai-Dorfman disease. *Pediatr Blood Cancer*. 2014;61(3):479–87.
35. Tahan SR, Pastel-Levy C, Bhan AK, Mihm MC Jr. Juvenile xanthogranuloma. Clinical and pathologic characterization. *Arch Pathol Lab Med*. 1989;113(9):1057–61.
36. Asarch A, Thiele JJ, Ashby-Richardson H, Norden PS. Cutaneous disseminated xanthogranuloma in an adult: case report and review of the literature. *Cutis*. 2009;83(5):243–9.
37. Namiki T, Miura K, Yokozeki H. Multiple CD163(+) adult xanthogranuloma associated with myelodysplastic syndrome. *J Dermatol*. 2015;42(11):1106–7.
38. Shoo BA, Shinkai K, McCalmont TH, Fox LP. Xanthogranulomas associated with hematologic malignancy in adulthood. *J Am Acad Dermatol*. 2008;59(3):488–93.
39. Chisolm SS, Schulman JM, Fox LP. Adult xanthogranuloma, reticulohistiocytosis, and Rosai-Dorfman disease. *Dermatol Clin*. 2015;33(3):465–72; discussion 73.
40. Lange M, Izycka-Swieszewska E, Michajlowski I, Baranska-Rybak W. Benign cephalic histiocytosis. *Cutis*. 2015;95(6):E15–7.
41. Gianotti F, Caputo R, Ermacora E. Singular “infantile histiocytosis with cells with intracytoplasmic vermiform particles”. *Bull Soc Fr Dermatol Syphiligr*. 1971;78(3):232–3.
42. Weston WL, Travers SH, Mierau GW, Heasley D, Fitzpatrick J. Benign cephalic histiocytosis with diabetes insipidus. *Pediatr Dermatol*. 2000;17(4):296–8.
43. Jang KA, Ahn SJ, Choi JH, Sung KJ, Moon KC, Koh JK. Histiocytic disorders with spontaneous regression in infancy. *Pediatr Dermatol*. 2000;17(5):364–8.
44. Jang KA, Lee HJ, Choi JH, Sung KJ, Koh JK, Moon KC. Generalized eruptive histiocytoma of childhood. *Br J Dermatol*. 1999;140(1):174–6.
45. Wee SH, Kim HS, Chang SN, Kim DK, Park WH. Generalized eruptive histiocytoma: a pediatric case. *Pediatr Dermatol*. 2000;17(6):453–5.
46. Chern E, Yau D, Ho JC. Generalized eruptive histiocytosis in an infant. *Acta Derm Venereol*. 2010;90(2):204–5.
47. Misery L, Kanitakis J, Hermier C, Cambazard F. Generalized eruptive histiocytoma in an infant with healing in summer: long-term follow-up. *Br J Dermatol*. 2001;144(2):435–7.
48. Lan Ma H, Metze D, Luger TA, Steinhoff M. Successful treatment of generalized eruptive histiocytoma with PUVA. *J Dtsch Dermatol Ges*. 2007;5(2):131–4.
49. Shon W, Peters MS, Reed KB, Ketterling RP, Dogan A, Gibson LE. Atypical generalized eruptive histiocytosis clonally related to chronic myelomonocytic leukemia with loss of Y chromosome. *J Cutan Pathol*. 2013;40(8):725–9.
50. Montero I, Gutierrez-Gonzalez E, Ginarte M, Toribio J. Generalized eruptive histiocytosis in a patient with chronic myelomonocytic leukemia. *Actas Dermosifiliogr*. 2012;103(7):643–4.
51. Klemke CD, Dippel E, Geilen CC, Koenigsman MP, Thiel E, Orfanos CE, et al. Atypical generalized eruptive histiocytosis associated with acute monocytic leukemia. *J Am Acad Dermatol*. 2003;49(5 Suppl):S233–6.
52. Satham BN, Fairris GM, Cotterill JA. Atypical eruptive histiocytosis – a marker of underlying malignancy? *Br J Dermatol*. 1984;110(1):103–5.
53. Ziegler B, Peitsch WK, Reiter A, Marx A, Goerd S, Geraud C. Generalized eruptive Histiocytosis associated with FIP1L1-PDGFRA-positive chronic eosinophilic leukemia. *JAMA Dermatol*. 2015;151(7):766–9.
54. Zelger BW, Staudacher C, Orchard G, Wilson-Jones E, Burgdorf WH. Solitary and generalized variants of spindle cell xanthogranuloma (progressive nodular histiocytosis). *Histopathology*. 1995;27(1):11–9.
55. Taunton OD, Yeshurun D, Jarratt M. Progressive nodular histiocytoma. *Arch Dermatol*. 1978;114(10):1505–8.
56. Nofal A, Assaf M, Tawfik A, Elsayed N, Nofal E, Elnakib N, et al. Progressive nodular histiocytosis: a case report and literature review. *Int J Dermatol*. 2011;50(12):1546–51.
57. Glavin FL, Chhatwall H, Karimi K. Progressive nodular histiocytosis: a case report with literature review, and discussion of differential diagnosis and classification. *J Cutan Pathol*. 2009;36(12):1286–92.
58. Gonzalez Ruiz A, Bernal Ruiz AI, Aragonese Fraile H, Peral Martinez I, Garcia MM. Progressive nodular histiocytosis accompanied by systemic disorders. *Br J Dermatol*. 2000;143(3):628–31.
59. Watanabe T, Watanabe D, Tamada Y, Matsumoto Y. Progressive nodular histiocytosis – a five-year follow up. *Eur J Dermatol*. 2008;18(2):200–2.

60. Vadoud-Seyedi J, Vadoud-Seyedi R, De Dobbeleer G. Progressive nodular histiocytomas. *Br J Dermatol.* 2000;143(3):678–9.
61. Szekeres E, Tiba A, Korom I. Xanthoma disseminatum: a rare condition with non-X, non-lipid cutaneous histiocytopathy. *J Dermatol Surg Oncol.* 1988;14(9):1021–4.
62. Zelger B, Burgdorf WH. The cutaneous “histiocytoses”. *Adv Dermatol.* 2001;17:77–114.
63. Nanda A, Kanwar AJ, Kapoor MM, Radotra BD, Kaur S. Xanthoma disseminatum. *Int J Dermatol.* 1990;29(10):727–8.
64. Coldiron BM, Cruz PD Jr, Freeman RG, Sontheimer RD. Benign non-X histiocytosis: a unique case bridging several of the non-X histiocytic syndromes. *J Am Acad Dermatol.* 1988;18(6):1282–9.
65. Ferrando J, Campo-Voegeli A, Soler-Carrillo J, Munoz E, Sole M, Palou J, et al. Systemic xanthohistocytoma: a variant of xanthoma disseminatum? *Br J Dermatol.* 1998;138(1):155–60.
66. Oka M, Oniki S, Komatsu M, Ikeda T, Matsuo M, Miyamoto Y, et al. Xanthoma disseminatum with intracranial involvement: case report and literature review. *Int J Dermatol.* 2010;49(2):193–9.
67. Hammond RR, Mackenzie IR. Xanthoma disseminatum with massive intracranial involvement. *Clin Neuropathol.* 1995;14(6):314–21.
68. Buyukavci M, Selimoglu A, Yildirim U, Ertekin V, Atasoy M. Xanthoma disseminatum with hepatic involvement in a child. *Pediatr Dermatol.* 2005;22(6):550–3.
69. Calverly DC, Wismer J, Rosenthal D, de Sa D, Barr RD. Xanthoma disseminatum in an infant with skeletal and marrow involvement. *J Pediatr Hematol Oncol.* 1995;17(1):61–5.
70. Eisendle K, Linder D, Ratzinger G, Zelger B, Philipp W, Piza H, et al. Inflammation and lipid accumulation in xanthoma disseminatum: therapeutic considerations. *J Am Acad Dermatol.* 2008;58(2 Suppl):S47–9.
71. Khezri F, Gibson LE, Tefferi A. Xanthoma disseminatum: effective therapy with 2-chlorodeoxyadenosine in a case series. *Arch Dermatol.* 2011;147(4):459–64.
72. Kim WJ, Ko HC, Kim BS, Kim MB. Successful treatment of xanthoma disseminatum with combined lipid lowering agents. *Ann Dermatol.* 2012;24(3):380–2.
73. Lee EH, Kang TW, Kim SC. Successful treatment of xanthoma disseminatum with simvastatin. *J Dermatol.* 2011;38(10):1015–7.
74. Park M, Boone B, Devos S. Xanthoma disseminatum: case report and mini-review of the literature. *Acta Dermatovenerol Croat.* 2014;22(2):150–4.
75. Pruvost C, Picard-Dahan C, Bonnefond B, Grossin M, Gehanno P, Souteyrand P, et al. Vinblastine treatment for extensive non-X histiocytosis (xanthoma disseminatum). *Annales de dermatologie et de venerologie.* 2004;131(3):271–3.
76. Seaton ED, Pillai GJ, Chu AC. Treatment of xanthoma disseminatum with cyclophosphamide. *Br J Dermatol.* 2004;150(2):346–9.
77. Zinoun M, Hali F, Marnissi F, Lazaar S, Benchikhi H. Xanthoma disseminatum with asymptomatic multisystem involvement. *Annales de dermatologie et de venerologie.* 2015;142(4):276–80.
78. Campero M, Campero S, Guerrero J, Aouba A, Castro A. Cerebral and cutaneous involvements of xanthoma disseminatum successfully treated with an interleukin-1 receptor antagonist: a case report and minireview. *Dermatology (Basel, Switzerland).* 2016;232(2):171–6.
79. Jaffe R. The histiocytoses. *Clin Lab Med.* 1999;19(1):135–55.
80. Outland JD, Keiran SJ, Schikler KN, Callen JP. Multicentric reticulohistiocytosis in a 14-year-old girl. *Pediatr Dermatol.* 2002;19(6):527–31.
81. Tariq S, Hugenberg ST, Hirano-Ali SA, Tariq H. Multicentric reticulohistiocytosis (MRH): case report with review of literature between 1991 and 2014 with in depth analysis of various treatment regimens and outcomes. *SpringerPlus.* 2016;5:180.
82. Havill S, Duffill M, Rademaker M. Multicentric reticulohistiocytosis in a child. *Australas J Dermatol.* 1999;40(1):44–6.
83. Raphael SA, Cowdery SL, Faerber EN, Lischner HW, Schumacher HR, Tourtellotte CD. Multicentric reticulohistiocytosis in a child. *J Pediatr.* 1989;114(2):266–9.
84. Jha VK, Kumar R, Kunwar A, Singh A, Kumar M, Kumar M, et al. Efficacy of vinblastine and prednisone in multicentric reticulohistiocytosis with onset in infancy. *Pediatrics.* 2016;137(6):e20152118.
85. Gorman JD, Danning C, Schumacher HR, Klippel JH, Davis JC Jr. Multicentric reticulohistiocytosis: case report with immunohistochemical analysis and literature review. *Arthritis Rheum.* 2000;43(4):930–8.
86. Campbell DA, Edwards NL. Multicentric reticulohistiocytosis: systemic macrophage disorder. *Baillieres Clin Rheumatol.* 1991;5(2):301–19.
87. Luz FB, Gaspar TAP, Kalil-Gaspar N, Ramos-e-Silva M. Multicentric reticulohistiocytosis. *J Eur Acad Dermatol Venerol.* 2001;15(6):524–31.
88. Liang GC, Granston AS. Complete remission of multicentric reticulohistiocytosis with combination therapy of steroid, cyclophosphamide, and low-dose pulse methotrexate. Case report, review of the literature, and proposal for treatment. *Arthritis Rheum.* 1996;39(1):171–4.
89. Jansen TL, Kruithof IG. Diagnostic image (141) nodules in a patient with rheumatoid arthritis. Multicentric

- reticulohistiocytosis as a paraneoplastic manifestation. *Ned Tijdschr Geneeskd.* 2003;147(22):1067.
90. Olson J, Mann JA, White K, Cartwright VW, Bauer J, Nolt D. Multicentric reticulohistiocytosis: a case report of an atypical presentation in a 2-year-old. *Pediatr Dermatol.* 2015;32(3):e70–3.
91. Aouba A, Leclerc-Mercier S, Fraitag S, Martin-Silva N, Bienvenu B, Georgin-Lavialle S. Assessment and effective targeting of interleukin-1 in multicentric reticulohistiocytosis. *Joint Bone Spine.* 2015;82(4):280–3.
92. Pacheco-Tena C, Reyes-Cordero G, Ochoa-Albiztegui R, Rios-Barrera V, Gonzalez-Chavez SA. Treatment of multicentric reticulohistiocytosis with tocilizumab. *J Clin Rheumatol (Practical Reports on Rheumatic & Musculoskeletal Diseases).* 2013;19(5):272–6.
93. Yeter KC, Arkfeld DG. Treatment of multicentric reticulohistiocytosis with adalimumab, minocycline, methotrexate. *Int J Rheum Dis.* 2013;16(1):105–6.
94. Chalom EC, Rosenstein ED, Kramer N. Cyclosporine as a treatment for multicentric reticulohistiocytosis. *J Rheumatol.* 2000;27(2):556.
95. Savasan S, Smith L, Scheer, Dansey R, Abella E. Successful bone marrow transplantation for life threatening xanthogranuloma disseminatum in neurofibromatosis type-1. *Pediatr Transplant* 2005;9:534–6.
96. Bastida J, Camacho-Galan R, Armesto-Fernandez MA, Diaz-Casajoc. Adult disseminated primary papular xanthoma treated with doxycycline. *Arch Dermatol.*



Eli L. Diamond, and Benjamin H. Durham

Introduction

Erdheim-Chester disease (ECD) is a rare non-Langerhans cell histiocytosis (non-LCH) with a wide spectrum of clinical manifestations, from mild and asymptomatic to life-threatening and multisystem forms. Involved tissues are infiltrated by foamy CD1a (–) histiocytes with varying amounts of admixed acute and chronic inflammation, as well as fibrosis. ECD was previously classified as a member of the juvenile xanthogranuloma family of the non-LCH disorders [1] but in a recent reclassification of the histiocytic neoplasms has been grouped in the “L” (Langerhans) histiocytosis group [2]. ECD was initially described in 1930 by Jakob Erdheim and William Chester [3], and since that time approximately 700 cases have been reported [4]. The number of ECD-related publications has risen significantly in recent years, likely because of increased recognition of the disease. Since 2004, the heterogeneous manifestations of ECD across organ systems have been meticulously characterized by Dr. Julien Haroche and colleagues at the Pitié-Salpêtrière Hospital in

Paris, where the largest cohort of patients is followed and treated. Scientific and clinical investigations in recent years have brought about significant changes in both the understanding and therapy of ECD. For many years, the etiology of ECD was not certain, although it was considered most likely an autoimmune granulomatous disease. There remained an enduring question of whether ECD was primarily a clonal disorder, however, and the identification of recurrent *BRAF* V600E mutations in lesional tissue of both ECD and Langerhans cell histiocytosis (LCH) brought into focus the underlying neoplastic etiology of these diseases [5–7]. Subsequently, the discovery of diverse kinase alterations in ECD lesional tissue has led to the reconceptualization of ECD as a myeloid neoplasm driven predominantly by activating mutations of the mitogen-activating protein kinase (MAPK) pathway [8]. This has opened a new era of therapeutic possibilities for ECD with evidence for robust efficacy of *BRAF* inhibitors and other targeted therapies, although the ideal context in which to implement these treatments remains uncertain.

Alongside developments in the understanding and treatment of ECD, there has been increased physicians’ awareness, multi-institutional collaboration, and patient advocacy for the disease. The Erdheim-Chester Disease Global Alliance (ECDGA; <http://erdheim-chester.org>) is an advocacy organization based in the United States that has organized four annual

The original version of this chapter was revised.
An erratum to this chapter can be found at
https://doi.org/10.1007/978-3-319-59632-7_21

E.L. Diamond, MD (✉) • B.H. Durham
Department of Neurology, Memorial Sloan Kettering
Cancer Center, New York, NY, USA
e-mail: diamone1@mskcc.org

International Medical Symposia on ECD. These meetings have stimulated several collaborative projects, including the first and only consensus guidelines for the diagnosis and clinical management of ECD [9]. Furthermore, there is a worldwide network of recognized referral centers led by physicians with expertise in ECD, and these are listed on the website of the ECDGA. Also, the National Genome Research Institute of the National Institutes of Health is conducting an observational study of ECD patients (NCT01417520), providing comprehensive and longitudinal evaluation for participants and capturing data about the natural history of ECD. Furthermore, there is a rare histiocytosis registry (The International Rare Histiocytic Disorders Registry) centered at the Hospital for Sick Children in Toronto that is collecting data on ECD patients (NCT02285582).

This chapter will review the current research and collective expertise about the epidemiology, diagnosis, clinical features, and treatment of ECD.

Epidemiology

The cohort with the richest epidemiologic data for ECD is followed at the Pitié-Salpêtrière Hospital in Paris and comprises 122 patients as of a recent report [4]. In this cohort, 75% of patients are men, and the mean age at diagnosis is 56.1 years (± 14.7) with an age range of 5–80 years. There is often a significant time period that elapses between patients' initial ECD presentation and their diagnosis, most likely the result of ECD's rarity and protean manifestations. In this most recent series from the French group, the mean time from symptom onset and diagnosis was 49.8 months, although periods of up to 25 years have been observed. ECD has been reported in only a very small number of children [10–16], in one of these cases with concomitant LCH [17] and another with concomitant acute lymphocytic leukemia [18]. A mixed form of histiocytosis with the clinical phenotype and pathologic findings of ECD and LCH occurs in up to

12% of ECD cases [19–23], and thus far, this syndrome is defined by the presence of the *BRAF* V600E mutation in lesional tissue.

Pathogenesis and Cell of Origin of ECD

Molecular Pathogenesis

The pathophysiology of ECD has long been obscure, and it was previously unclear as to whether or not this histiocytic disorder represented an autoimmune or a clonal, neoplastic disorder [9, 24]. However, since 2012, a series of recurrent activating kinase mutations and fusions involving the canonical MAPK and PI3K-AKT pathways (Fig. 18.1a) have been discovered in a large proportion of patients affected by this disorder. ECD was the first non-LCH neoplasm to reveal a high frequency of *BRAF*V600E mutations [8, 25]. A summary of all somatic alterations identified thus far in ECD is provided in Table 18.1.

BRAF

BRAF mutations were first described in the non-LCH neoplasms in 2012 when Haroche et al. discovered recurrent *BRAF* V600E mutations in 54% (13 of 24) of archived ECD samples using pyrosequencing [5]. The first combined WES and RNA sequencing study of the histiocytic neoplasms identified that 51% of ECD cases demonstrated recurrent *BRAF* V600E mutations, which is similar to the frequency of *BRAF* V600E mutations in ECD observed by pyrosequencing [8]. As previously described for LCH, the *BRAF* V600E mutation occurs in the activation segment of the BRAF kinase domain (Fig. 18.1b) and leads to constitutive activation of the BRAF kinase and hyperactivation of the RAS-ERK signaling cascade and its downstream transcription of genes involved in cellular processes such as proliferation. This discovery also provided firm evidence that ECD is a clonal neoplastic disorder driven by constitutive MAPK signaling and

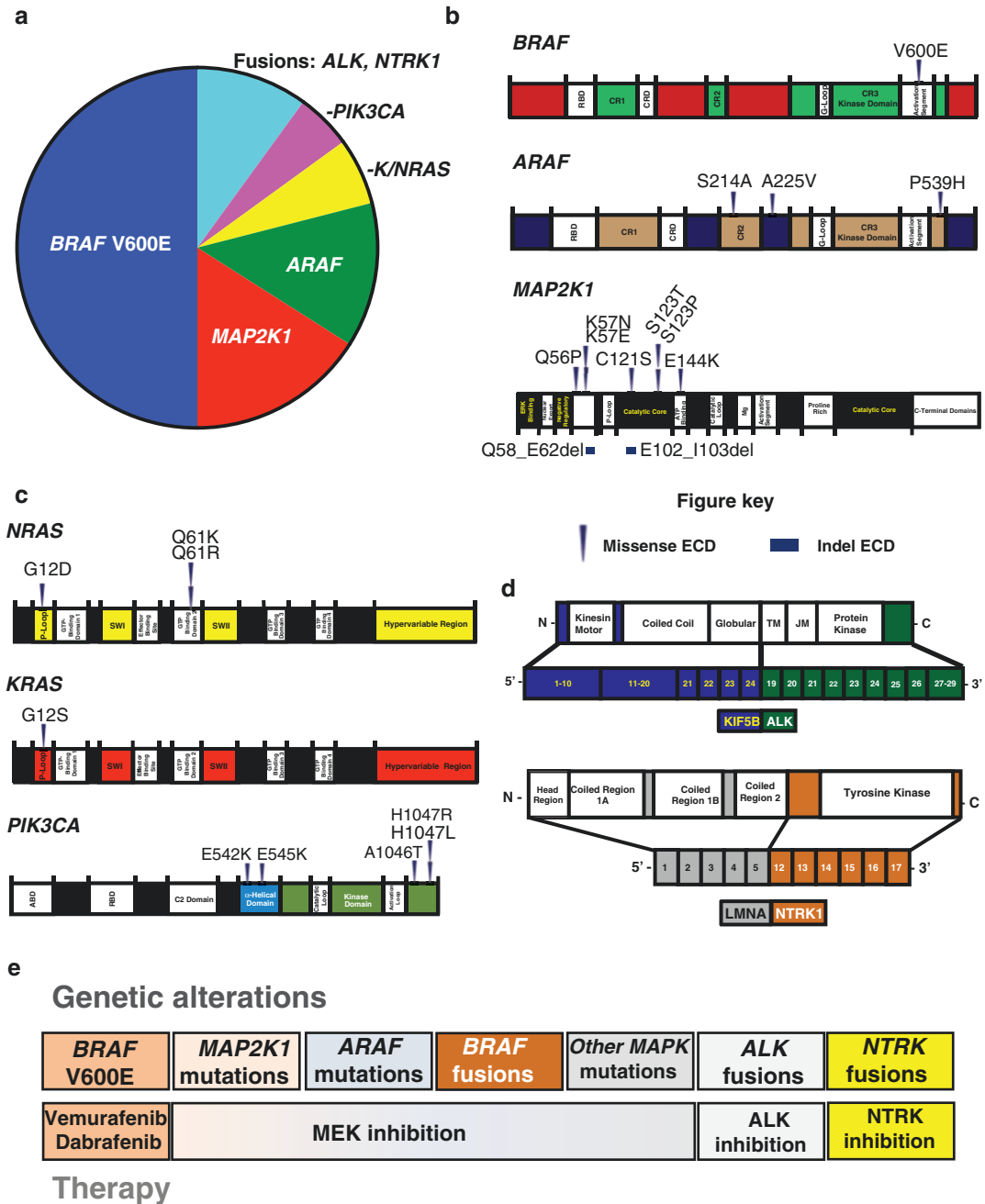


Fig. 18.1 Summary of the diverse kinase alterations documented in Erdheim-Chester disease. (a) Pie chart illustrating the known activating kinase alterations in ECD. Diagrams of somatic mutations described in (b) *BRAF*, *ARAF*, and *MAP2K1*; (c) *NRAS*, *KRAS*, and *PIK3CA*; and kinase fusions involving (d) *ALK* and *NTRK1*. (e) Diagram summarizing the potential targeted therapies that have or may demonstrate clinical efficacy

in histiocytic neoplasms. The RAF inhibitors vemurafenib or dabrafenib have already demonstrated efficacy in *BRAF* V600E-mutant ECD. MEK inhibition may have an important role in ECD and other histiocytoses, regardless of *BRAF* V600E mutational status. ALK and NTRK inhibitors need to be studied for the potential role in the therapy of *ALK* or *NTRK* fusion ECD specifically

Table 18.1 Kinase alterations reported in Erdheim-Chester disease

Source	Gene alteration(s)	Comment
Haroche et al. [5]; Emile et al. [6]; Blombery et al. [7]	<i>BRAF</i> p.V600E	Successful targeted treatment of <i>BRAF</i> -mutated ECD has been reported in cases, retrospective series, and one prospective clinical trial
Diamond et al. [26]; Aitken et al. [27]; Emile et al. [28]	<i>NRAS</i> p.Q61R <i>NRAS</i> p.Q61K	<i>NRAS</i> p.Q61R mutation was detected in peripheral CD14+ monocytes
Emile et al. [28]	<i>PIK3CA</i> p.E542K <i>PIK3CA</i> p.E545K <i>PIK3CA</i> p.A1046T <i>PIK3CA</i> p.H1047R	Treatment of ECD with an mTOR pathway inhibitor (sirolimus) has been studied in a clinical trial [29] Four of seven patients with mutations in <i>PIK3CA</i> also had <i>BRAF</i> V600E mutations
Hyman et al. [30]	<i>KRAS</i> p.G12S	Quantifiable allelic burden of circulating <i>KRAS</i> mutation was identified in the urine and plasma of this patient
Diamond et al. [8]; Diamond et al. [31]	<i>ARAF</i> p.S214A <i>ARAF</i> p. A225V <i>NRAS</i> p.G12D <i>MAP2K1</i> p.Q56P <i>MAP2K1</i> p.K57N <i>MAP2K1</i> p.K57E <i>MAP2K1</i> p.C121S <i>MAP2K1</i> p.S123 T <i>MAP2K1</i> p.S123P <i>MAP2K1</i> p.E144K <i>MAP2K1</i> Q58_E62del <i>MAP2K1</i> E102_I103del <i>KIF5B-ALK</i> fusion <i>LMNA-NTRK1</i> fusion	Successful treatment with sorafenib was reported for a patient with <i>ARAF</i> p.S214A-mutated ECD Successful treatment with cobimetinib was reported for a patient with <i>MAP2K1</i> p.Q56P-mutated ECD Successful treatment with trametinib was reported for a patient with <i>MAP2K1</i> p.K57N-mutated ECD

provided one of the first targets for molecular therapeutics in the non-LCH histiocytoses [5].

ARAF

ARAF mutations were first described in ECD in 2015 when a study discovered three activating *ARAF* somatic mutations in 21% (3 of 14) of fresh-frozen ECD cases [8]. However, only two of the *ARAF* mutations were mutually exclusive of *BRAF* V600E. The mutations were *ARAF* S214A, which involved the critical region 2 (CR2) of the *ARAF* protein, *ARAF* A225V, *ARAF* P529H, and *ARAF* P539P, which involved the kinase domain of the *ARAF* protein (Fig. 18.1b) [8]. Of note, activating alterations in *ARAF* have been identified in LCH as well [32]. A larger cohort of ECD cases needs to be evaluated for *ARAF* mutations to better determine the true frequency of *ARAF* mutations in ECD. Also, evaluation of the functional genomic role of somatic *ARAF* mutations in the histiocytic neoplasms and their optimal targeted therapy is necessary using isogenic cell lines and murine models.

MAP2K1

MAP2K1 mutations were first discovered in ECD in 2015 when a study uncovered activating *MAP2K1* somatic mutations in 14% (2 of 14) of fresh-frozen ECD cases. An additional nine activating *MAP2K1* mutations were discovered in 50% (9 of 18) of *BRAF* V600E-wild-type, archived ECD cases evaluated by targeted sequencing in a validation cohort in this study [8]. The mutations cluster in the N-terminal negative regulatory domain encoded by exon 2 and the N-terminal catalytic core of the kinase domain encoded by exon 3 (Fig. 18.1b), as seen in LCH.

Mutations described in the N-terminal negative regulatory domain of *MAP2K1* are the following: *MAP2K1* E51_Q58, *MAP2K1* Q56P, *MAP2K1* K57N, *MAP2K1* K57E, and *MAP2K1* Q58_E62del (Fig. 18.1b). Mutations described in the N-terminal catalytic core of the kinase

domain of MAP2K1 are the following: *MAP2K1* E103_I102del, *MAP2K1* C121S, *MAP2K1* S123 T, and *MAP2K1* S123P. A recurrent activating mutation (*MAP2K1* E144K) has also been described in the ATP-binding domain of the MAP2K1 protein (Fig. 18.1b and Table 18.1) [8, 25, 31].

These *MAP2K1* mutations have been demonstrated biochemically to cause constitutive activation of MEK1 [8]; however, several *MAP2K1* mutations still need to be evaluated as to their impact on MEK1 signaling and their functional genomic role in ECD through the development of isogenic cell lines and murine models. Furthermore, these *MAP2K1* mutations need evaluation as to whether or not they will be responsive to MEK inhibition.

RAS Isoforms

NRAS mutations were first described in ECD in 2013 in a case report by Diamond et al. that used targeted sequencing with the Sequenom MassARRAY system. They described an activating mutation in *NRAS* that was a missense mutation in the GTP-binding domain 2 of *NRAS* (*NRAS* Q61R) (Fig. 18.1c) [26]. A larger study by Emile et al. in 2014 discovered *NRAS* mutations in 3.7% (3 of 80) of archived ECD cases using targeted sequencing approaches that included pyrosequencing, Sequenom mass spectrometric-based genotyping assays, and targeted-capture, next-generation sequencing using the Illumina MiSeq [28]. In 2015, *NRAS* mutations were discovered in 7% (1 of 14) fresh-frozen ECD cases and in 17% (3 of 18) *BRAF* V600E-wild-type, archived ECD cases evaluated by targeted sequencing in a validation cohort in this study [8]. These activating *NRAS* mutations affected the GTP-binding domain 1 (*NRAS* G12D) and the GTP-binding domain 2 (*NRAS* Q61R, *NRAS* Q61K) of *NRAS* (Fig. 18.1c and Table 18.1). An activating *KRAS* mutation (*KRAS* G12S) affecting the GTP-binding domain 1 of *KRAS* has also been described in ECD (Fig. 18.1c) [30]. To better understand the frequency of RAS mutations in ECD, a larger cohort of cases should be evaluated, and the activating

NRAS mutations in ECD need to undergo functional genomic analysis as to how they impact ECD pathogenesis and respond to MEK inhibition.

PIK3CA

PIK3CA mutations were first discovered in ECD in 2014 by Emile et al. in 10.9% of archived ECD cases using targeted sequencing approaches that included Sequenom mass spectrometric-based genotyping assays and targeted-capture, next-generation sequencing using the Illumina MiSeq [28]. In 2015 *PIK3CA* mutations were discovered in 17% (3 of 18) of *BRAF* V600E-wild-type, archived ECD cases evaluated by targeted sequencing in a validation cohort from this study [8]. *PIK3CA* mutations clustered in the α -helical domain (*PIK3CA* E542K; *PIK3CA* E545K) and the kinase domain (*PIK3CA* A1046T; *PIK3CA* H1047R; *PIK3CA* H1047L) of the *PIK3CA* protein (Fig. 18.1c) [8, 28]. Larger cohorts of ECD still need to be evaluated for *PIK3CA* mutations to better determine the frequency of *PIK3CA* mutations in ECD, the role of *PIK3CA* in the pathogenesis of ECD using isogenic cell lines and murine models, and the relevancy of PI3K inhibitors in potential ECD treatment. There has been one clinical trial of sirolimus and prednisolone for ECD, with promising results, although not in the context of *PIK3CA*-mutated disease (see *Treatment* section below).

KIF5B-ALK

In 2015 *KIF5B-ALK* fusions were discovered in ECD using RNA sequencing analysis. These kinase fusions were confirmed using RT-PCR followed by Sanger sequencing, interphase FISH using *ALK* break apart probes, and *ALK* immunohistochemistry. The *KIF5B-ALK* fusions were confirmed to be in-frame fusions involving exons 1–24 of *KIF5B* (kinesin family member 5B) and either exons 19–29 or exons 20–29 of *ALK* (anaplastic lymphoma receptor tyrosine kinase), which leads to the fusion of the N-terminal

coiled-coil domain of KIF5B to the intact kinase domain of ALK and results in the inappropriate expression and constitutive activation of ALK (Fig. 18.1d) [8]. The *KIF5B-ALK* fusions have similar configurations to previously described *KIF5B-ALK* fusions in non-small cell lung cancer [33] and are functionally activating kinase fusions that show sensitivity to ALK inhibition in vitro, which is consistent with results from similar analyses of other *ALK* fusions in the literature [8, 34, 35]. Nonetheless, more functional genomic characterization of the role of the *KIF5B-ALK* fusions in the pathogenesis of ECD and its responsiveness to ALK inhibition is required.

LMNA-NTRK1

In 2015 an *LMNA-NTRK1* fusion was uncovered in ECD by RNA sequencing analysis. This kinase fusion was confirmed using RT-PCR followed by Sanger sequencing, interphase FISH using *NTRK1* break apart probes, and NTRK1 immunohistochemistry. The *LMNA-NTRK1* fusion was confirmed to be an in-frame fusion involving exons 1–5 of *LMNA* (lamin A/C) and exons 12–17 of *NTRK1* (neurotrophic tyrosine kinase receptor type I), which leads to the fusion of the N-terminal coiled-coil domain of LMNA to the intact kinase domain of NTRK1 and results in the inappropriate expression and constitutive activation of NTRK1 (Fig. 18.1d) [8]. The *LMNA-NTRK1* fusion has a similar configuration to previously described *LMNA-NTRK1* fusions in spitzoid neoplasms [36] and is functionally an activating kinase fusion in both the MAPK and PI3K-AKT pathways [8, 25, 36]. More functional genomic characterization of the role of the *LMNA-NTRK1* fusion in the pathogenesis of histiocytic neoplasms and its responsiveness to NTRK inhibition is required.

Cell of Origin

Historically, the literature has pointed to near-mature cells as the cells of origin for non-LCH histiocytic neoplasms [24, 37, 38]. The World

Health Organization describes the non-LCH neoplasms (histiocytic sarcoma, ECD, JXG) as having a terminally differentiated monocyte or macrophage cell of origin [9, 24]. Interestingly, recent work performed differential gene expression analysis of RNA from LCH and non-LCH neoplastic cells by RNA sequencing. Gene set enrichment analysis of this data suggested that systemic LCH has a transcriptional profile most consistent with classical dendritic cells (cDCs) and late-stage, myeloid progenitor cells, which confirms prior reports that systemic LCH neoplasms arise from immature myeloid dendritic cells [8, 39–42]. Meanwhile, in this first attempt to elucidate the cell of origin of ECD using RNA sequencing, systemic non-LCH neoplasms had transcriptional profiles similar to monocytes, hematopoietic stem cells, and early-stage, myeloid progenitor cells [8]. Although these initial studies have started to advance knowledge of the cellular pathogenesis and histogenesis of ECD, more research into the existing *BRAF* V600E murine models [42] and the development of other isogenic murine models using newly identified activating kinase mutations and gene fusions in ECD will be necessary to further progress knowledge in the cellular pathogenesis and histogenesis of ECD [8, 43, 44].

Diagnosis of ECD

Diagnostic Criteria and Histopathologic Findings

The diagnosis of ECD is made by the identification of [1] distinctive histopathologic and immunophenotypic features of lesional material in [2] the appropriate clinical-radiologic context (Fig. 18.2). Classically, ECD histologically shows xanthogranulomatous histiocytes with small nuclei with surrounding fibrosis (Fig. 18.2c) that also demonstrate the presence of multinucleated giant cells, as well as Touton giant cells, often in a milieu of reactive lymphocytes, plasma cells, and neutrophils. The neoplastic histiocytes are immunoreactive for CD14, CD68 (Fig. 18.2d, upper panel), CD163 (Fig. 18.2d, lower panel),

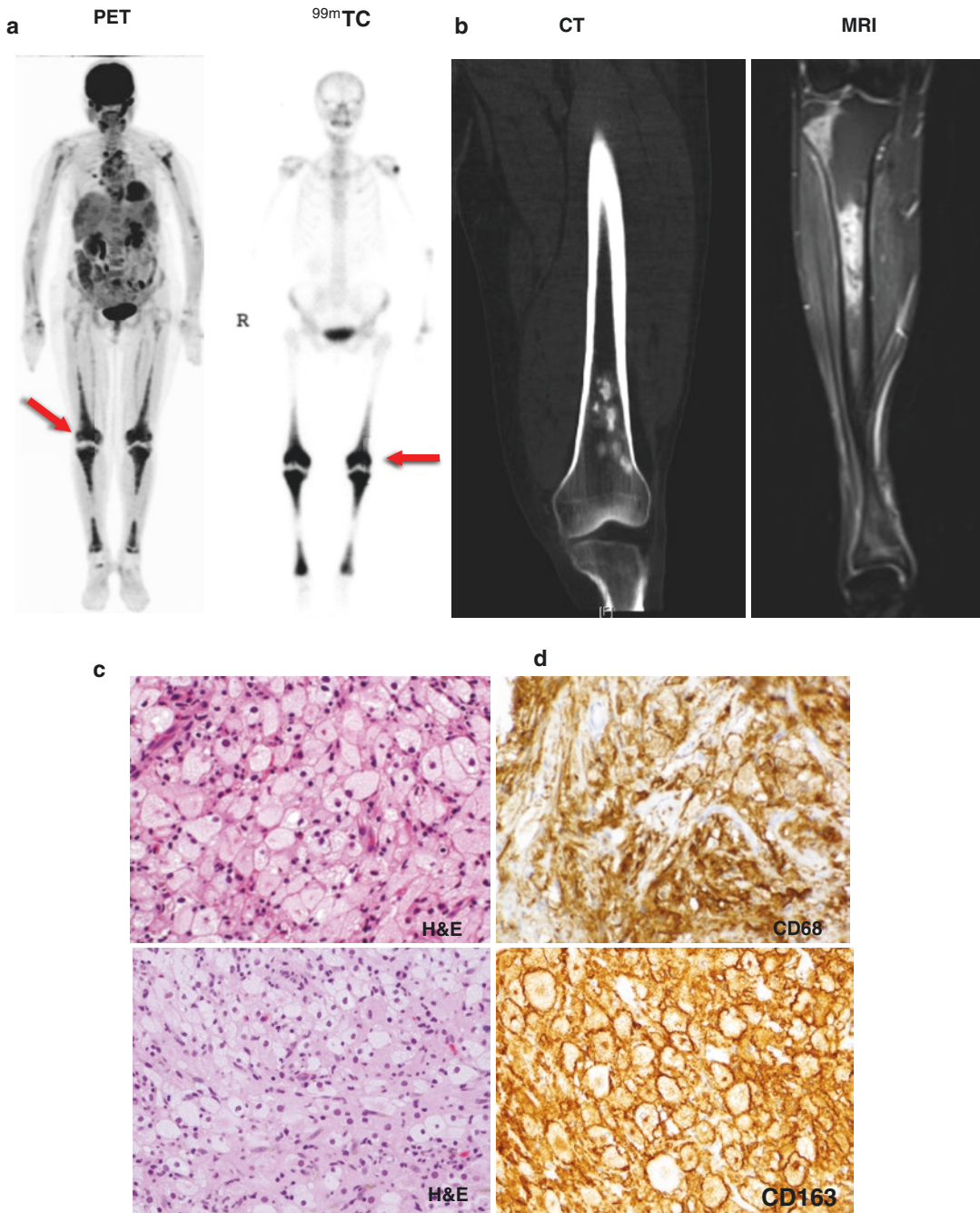


Fig. 18.2 Classical radiographic and histopathological features of Erdheim-Chester disease. (a) FDG-PET (left) and ^{99m}Tc bone scan (right) imaging demonstrating symmetric abnormal diametaphyseal radiotracer uptake in the long bones of the legs (red arrows) commonly observed in ECD patients. “R” indicates the patient’s right side. (b) CT (left) and MRI (right) scans of revealing sclerotic lesions of the metaphyses of the femur (left) and tibia (right) (yellow arrows). (c) Hematoxylin-eosin-stained biopsy section demonstrate xanthogranulomatous histiocytes in the most classical histological appearance of

non-Langerhans cell histiocytic neoplasms such as ECD (top) with intervening areas of fibrosis with a milieu of mixed inflammatory cells consisting of lymphocytes, plasma cells, and eosinophils (bottom). (d) Immunohistochemistry showing immunoreactivity of histiocytes to CD68 (top) and the monocyte-/macrophage-specific marker CD163 (bottom). This figure was originally published in *Blood*. Diamond et al. Consensus guidelines for the diagnosis and clinical management of Erdheim-Chester disease. *Blood*. 2014;124(4):483–92. © the American Society of Hematology

factor XIIIa, and fascin with rare immunoreactivity to S100 and no immunoreactivity for CD1a or CD207 (langerin). Also, there is an absence of Birbeck granules on electron microscopy [1, 9, 24, 45]. By contrast, LCH lesional tissue is positive for CD1a and langerin. S100 staining is positive in LCH, is positive in Rosai-Dorfman disease (RDD), and is classically negative in ECD; however weak or focal S100 positivity has been observed in ECD and should not be thought to exclude an ECD diagnosis. On morphologic and immunohistochemical grounds, ECD histiocytes are identical to those seen in juvenile xanthogranuloma (JXG), and it has been postulated that ECD is a predominantly non-cutaneous variant of JXG [46]. While the presence of classic histology (i.e., abundant foamy histiocytes) has been cited to be present in all ECD cases [4], we have found this feature not to be invariably present. In fact, ECD has a spectrum of nonclassical histopathological features (Fig. 18.3) that include predominantly fibrotic lamellae with only scattered foci of xanthogranulomatous histiocytes and rare Touton giant cells embedded in the fibrotic lamellae (Fig. 18.3a); a florid lymphohistiocytic infiltrate with only scattered foci of pale, non-xanthogranulomatous histiocytes (Fig. 18.3b); and fibrous tissue with a scant, mixed inflammatory infiltrate with rare Touton giant cells and scant histiocytes, which is a pattern that can often be seen when ECD involves the perinephric adipose tissue (Fig. 18.3c), among others. These nonclassical histopathological patterns underscore the importance of immunohistochemical and molecular studies of lesional material and also highlight the paramount importance of the clinical and radiological setting for each patient.

A defining and nearly universal feature of ECD is the presence of symmetric diaphyseal and metaphyseal osteosclerosis in the legs (Fig. 18.2a, b). These lesions are iconically present in the distal ends of the femurs and the proximal and distal tibia, although not necessarily in all of these locations. These abnormalities can be visualized by many modalities, including ^{99m}Tc bone scan, ^{18}F -fluorodeoxyglucose (FDG) positron emission tomography (PET), computed tomography (CT), or magnetic resonance imaging (MRI). While it has been posited that ^{99m}Tc may be

the most sensitive for detecting bone lesions [47–49], this kind of imaging is almost always insufficient as the sole evaluation for ECD because of the need to visualize other organ structures. If FDG-PET is being performed in the evaluation of possible ECD, the study must be conscientiously ordered to include the distal extremities as the conventional “skull-to-thigh” acquisition will not include these osseous regions. In the French cohort, five of 122 patients had no evidence of osseous abnormalities in the femurs or tibia by any imaging study, and in this case the diagnosis was established on the basis of histopathologic findings and radiologic involvement of other classic organs (these are described in the sections below). Rendering a diagnosis of ECD is most challenging in the setting of equivocal pathology, atypical or absent osseous lesions, or both. In these cases, the treating physician must rely on the constellation of ancillary features—in aggregate—to suggest the diagnosis or not, such as location and distribution of other organ abnormalities and the presence of *BRAF* or other MAPK pathway mutations in lesional tissue. Formal or informal consultation with a specialist who is familiar with the spectrum of ECD manifestations (see above regarding the Erdheim-Chester Disease Global Alliance and its network of referral centers) may help clarify ambiguities of particular cases. In all cases, the diagnosis of ECD should not rest upon typical or suggestive clinical and radiologic characteristics alone; rather, tissue biopsy is always necessary both to confirm the diagnosis and to establish the disease’s mutational status.

Clinical and Radiologic Manifestations by Organ System

The sites most commonly affected by ECD include the skeleton, retroperitoneum, orbit, cardiovascular structures, lungs and pleura, intracranial structures, and endocrine systems, although histiocytic infiltration has been documented in virtually every body structure. It should be noted that severity of symptoms and/or end-organ dysfunction is not necessarily proportionate to the radiologic burden of disease (e.g., renal dysfunction in relation to extent of visible retroperitoneal infiltrates).

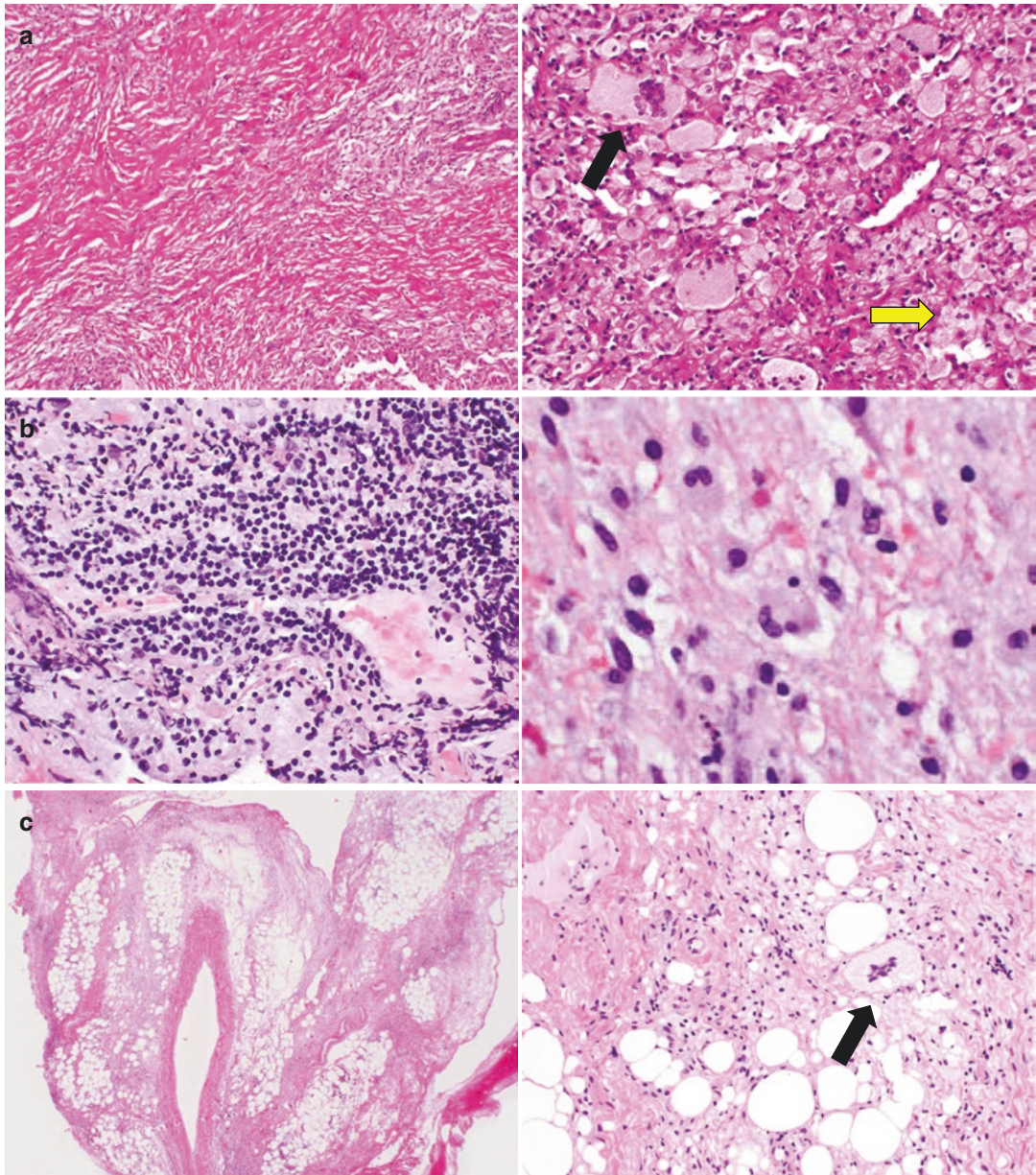


Fig. 18.3 Heterogeneous histopathological features of Erdheim-Chester disease (ECD). (a) Brain biopsy with fibrotic lamellae (*left*) with embedded, scattered foci of xanthogranulomatous histiocytes (*yellow arrow*) and rare Touton giant cells (*black arrow*) (*right*). (b) Central nervous system biopsy with a florid lymphohistiocytic infiltrate (*left*) and foci of pale, non-xanthogranulomatous histiocytes (*right*). (c) Perinephric biopsy with perirenal

adipose tissue widened by fibrous tissue with a scant, mixed inflammatory cell infiltrate (*left*) with higher magnification showing a rare Touton giant cell (*black arrow*) but few other histiocytes (*right*). This figure was originally published in *Blood*. Diamond et al. Consensus guidelines for the diagnosis and clinical management of Erdheim-Chester disease. *Blood*. 2014;124(4):483–92. © the American Society of Hematology

This is noted in each section below which discusses each organ system in detail. The radiologic findings observed with common ECD manifestations

are presented in Fig. 18.4, while Fig. 18.5 demonstrates an array of uncommon sites of ECD involvement in patients treated at our center.

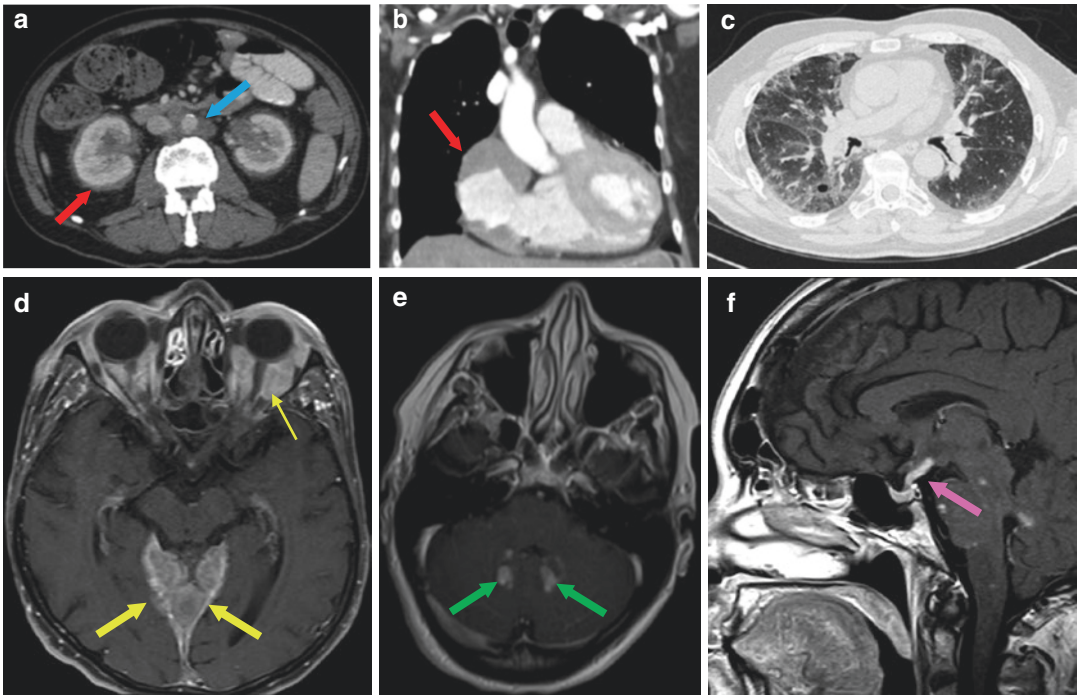


Fig. 18.4 Radiographic findings in common manifestations of Erdheim-Chester disease. (a) Axial CT scan of the abdomen demonstrating dense infiltration of perinephric fat, referred to as a “hairy kidney” appearance (*red arrow*). Circumferential soft-tissue sheathing of the thoracic aorta seen is referred to as a “coated aorta” (*blue arrow*). (b) Coronal CT scan of the chest demonstrates a mass lesion in the right atrium (*red arrow*). (c) Parenchymal pulmonary infiltration on axial chest CT in an ECD patient. (d) Axial post-gadolinium T1 MRI demonstrates expansile

enhancement of the pachymeninges (*thick arrows*), as well as orbital masses (*thin arrow*). (e) Axial post-gadolinium T1-weighted MRI shows enhancing lesions in the dentate nuclei of the cerebellum. (f) Sagittal post-gadolinium T1-weighted MRI demonstrates thickening and enhancement of the pituitary stalk (*pink arrow*). This figure was originally published in Blood. Diamond et al. Consensus guidelines for the diagnosis and clinical management of Erdheim-Chester disease. *Blood*. 2014;124(4):483–92. © the American Society of Hematology

Osseous Manifestations

Bone involvement is nearly invariably present in ECD patients [9], and as mentioned above, the classical location of infiltration is the femurs and the tibia. Only 50% or less of patients, however, report bone pain [4], and it has been our experience that the presence or severity of pain is not predicted by the burden of osseous disease as represented by imaging studies. The distribution of osseous lesions in ECD is conventionally differentiated from that of LCH by the notion that LCH more often involves the craniofacial bones, proximal limbs, pelvis, and scapula [50]; while this is generally true, there are several reports of ECD involvement of the spine and pelvis, uncommonly causing fractures [51–53],

as well as many cases of infiltration of the maxilla, mandible, and periodontal regions, causing bone loss or periodontitis [54–57].

Cardiovascular Manifestations

Involvement of the cardiovascular structures is detected by CT or MRI, and it can be clinically asymptomatic or have life-threatening consequences. The most commonly seen abnormality is circumferential soft-tissue sheathing or encasement of the thoracic and abdominal aorta, present in up to two-thirds of patients (Fig. 18.4a). In cases of unclear diagnosis but for which ECD is being considered, the presence of this “coated aorta” can be helpful in steering the diagnosis

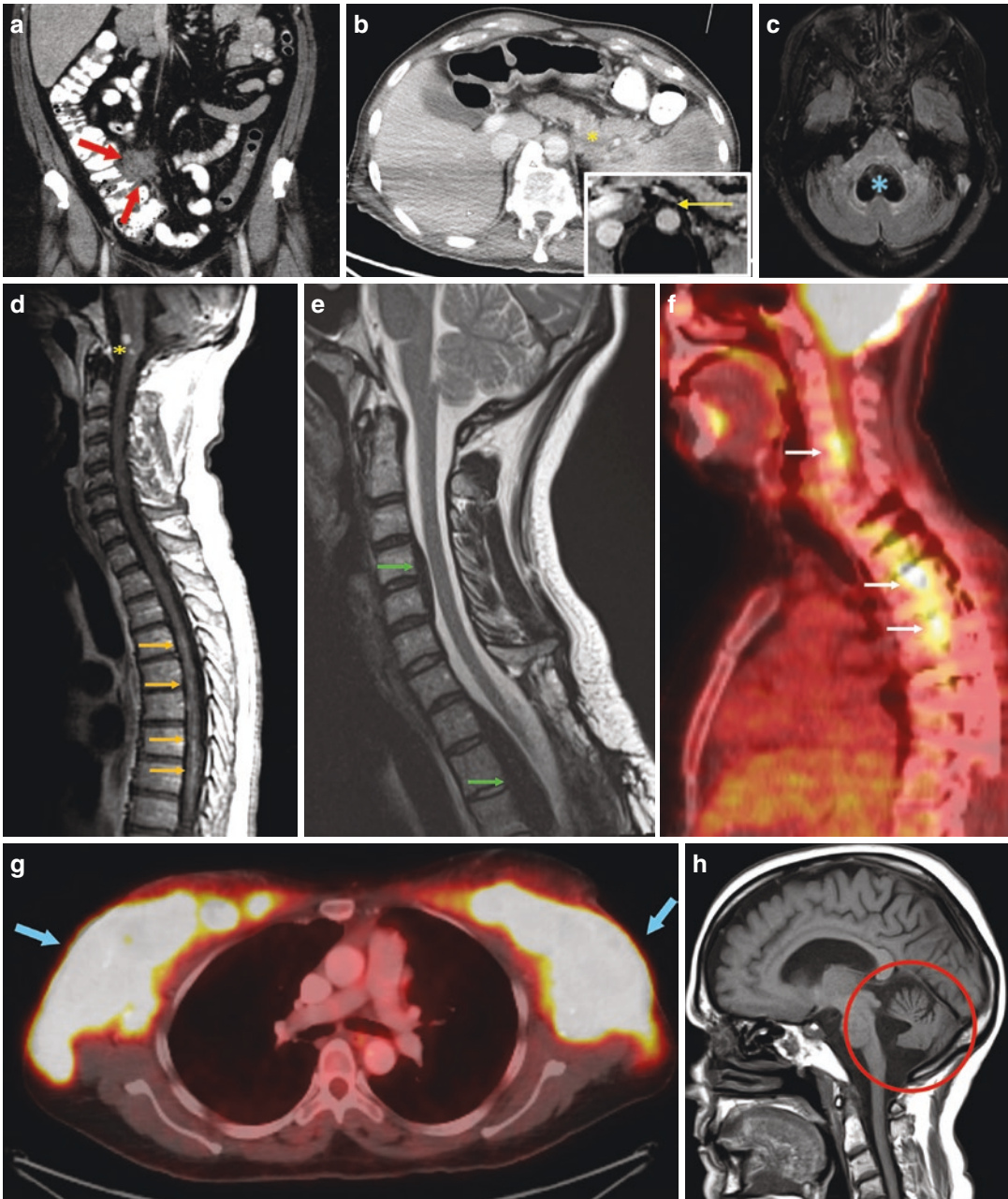


Fig. 18.5 Uncommon organ localizations and findings in Erdheim-Chester disease. (a) Coronal abdominal CT scan demonstrates a mesenteric mass in the right lower quadrant (*red arrows*). (b) Axial CT scan demonstrates peri-aortic soft-tissue mass (*yellow star*), and MR angiogram (*inset*) demonstrates severe stenosis of the origin of the celiac artery (*yellow arrow*). (c) Axial T2 fluid-attenuated inversion recovery (FLAIR) MRI demonstrates marked cerebellar atrophy with ex vacuo dilatation of the fourth ventricle (*blue star*). No tumors are present. (d) Scattered intramedullary lesions, seen on sagittal post-gadolinium

T1-weighted MRI of the spine, are present in the brain-stem (*yellow star*) and throughout the parenchyma of the spinal cord (*yellow arrows*). (e) Expansile lesions of the spinal dura (*green arrows*) with impingement of the thoracic spinal cord are seen on sagittal T2-weighted MRI. (f) Sagittal FDG-PET/CT demonstrates these dural lesions to be hypermetabolic (*white arrows*). (g) Large, hypermetabolic subcutaneous masses are seen on axial FDG-PET/CT (*blue arrows*). (h) Severe cerebellar atrophy (*red circle*) without tumorous lesions is demonstrated by sagittal T1-weighted MRI

toward ECD because it is atypical both for other histiocytoses and for other diseases generally. Aortic sheathing can be clinically silent or can cause vascular compromise of the aortic branches with various manifestations. If this involves the renal arteries, renovascular hypertension may develop and require stenting; of note, this may be an early presentation of ECD, preceding manifestations in other organs. Also of note, periarterial infiltrates around the renal arteries may not be readily visible by CT scan, and the identification of renal artery stenosis may require ultrasound or CT/MR angiogram. Coronary artery disease with myocardial infarction has been described in ECD but is probably uncommon [58–60]. Involvement of the splanchnic arteries leading to ischemia has been observed (Fig. 18.5b), but not published to date. Clinical aortitis and vasculitis, per se, have been reported in single cases of ECD, respectively [61, 62]. Pericardial infiltration occurs in up to 40–45% of ECD patients, and this can present clinically with pericarditis, pericardiac effusion, and even with tamponade that can be fatal. The right atrium is the most common cardiac site of mass-like infiltration (Fig. 18.4b), although diffuse involvement of the interatrial septum [63] or myocardium has also been described [64]. Clinically, these infiltrates can lead to conduction abnormalities, valvular dysfunction, and at times, overt heart failure.

Pulmonary Manifestations

Pulmonary involvement of ECD is most often asymptomatic but can be detected radiologically in up to one half of cases, with abnormalities of the pleura or lung parenchyma [15, 45]. Plain films are typically unrevealing, but high-resolution CT scans can demonstrate ground-glass opacities, centrilobular opacities, or interlobular septal thickening (Fig. 18.4c). These findings can be present anywhere in the lungs, as opposed to LCH, which typically involves the lung apices. Macrophages and foamy histiocytes may be seen in fluid from bronchoalveolar lavage in this if performed. Clinically, pulmonary ECD can manifest as cough or dyspnea. Even in

asymptomatic patients, pulmonary function tests may demonstrate restrictive features and/or decreased diffusion capacity. Discrete masses in the lungs are uncommon in ECD, although they have been seen; therefore, an independent primary lung neoplasm should at least be considered if this is seen in an ECD patient, depending on the clinical context.

Neurologic, Orbital, and Neuroendocrine Manifestations

There are many potential intracranial manifestations of ECD that require understanding. The frequency of “neurologic” involvement of ECD (including the dura and orbits) has been estimated to be from 25% to 50%, although infiltration of the true central nervous system (the parenchyma of the brain and spinal cord) is probably less common than this. Parenchymal CNS disease is a significant cause of functional disability in ECD and, in the French cohort, has been found to be an independent predictor of death [65]. ECD lesions can be seen throughout the neuraxis, in both the intra-axial and extra-axial compartments, leading to a variety of clinical phenotypes. Dural disease is manifest as expansile, contrast-enhancing lesions of the pachymeninges (Fig. 18.4d), and this can occur overlying the cerebral hemispheres or in the cerebellar tentorium, although the latter seems to be particularly common. These dural lesions can be discrete and mimic a meningioma or can be diffuse and appear like granulomatous disease or some vasculitides. Radiologically, pachymeningeal ECD is fairly similar to that caused by LCH or RDD. Diffuse meningeal disease can be asymptomatic if the burden of disease is low or alternatively can cause global neurologic decline with dementia and deterioration of gait when tumors are bulky. Dural or epidural disease of the spine is not common, but this has been reported and can be a cause of spinal cord compression (Fig. 18.5c, f) [66, 67]. Involvement of the trigeminal nerve, mimicking a schwannoma, has been reported in one case [16], and bilateral hearing loss attributed to involvement of the auditory nerves has also been

reported once [68]. In the brain parenchyma, the classic localization for ECD is in the posterior fossa, specifically the dentate nuclei of the cerebellum (Fig. 18.4e), the cerebellar peduncles, or the pons, and this causes a cerebellar syndrome of ataxia and dysarthria and less commonly brainstem symptoms such as oculomotor abnormalities. Supratentorial lesions are less common but can occur throughout the cerebral hemispheres, and intramedullary lesions in the spinal cord do occur rarely (Fig. 18.5d) [69]. Parenchymal ECD lesions are contrast enhancing and can be initially mistaken for primary or metastatic tumors, demyelinating or other inflammatory disorders, or leukodystrophies. Similar lesions have been described in intracranial XJG [70], and LCH lesions are similar to ECD lesions in their distribution and appearance with the exceptions that (1) pachymeningeal lesions are often bulkier in ECD and (2) the spinal cord parenchyma is spared in LCH. The intracranial vasculature can be affected by ECD, although stroke has been only rarely attributed to disease by this mechanism [71].

The phenomenon of non-tumor-related or non-infiltrative neurodegeneration in ECD is poorly understood and is in need of further study. The entity of neurodegenerative LCH is uncommon but well described and is manifest as an atrophic process of the posterior fossa structures (Fig. 18.5c, h), most commonly, or of the entire brain [72]. The etiology of this process in LCH is not clear. In ECD, there are rare examples of florid cerebellar degeneration without tumorous lesions. Aside from this, however, it has been informally observed that ECD patients suffer cognitive difficulties and dysregulation of mood and behavior, even in the absence of neurologic involvement as evidenced by a normal brain MRI. Thus far this has been investigated in one volumetric MRI study of 11 ECD patients without CNS disease, in which brain volumes were quantitatively compared to volumes in age-matched healthy controls [73]. This study found diffuse reduction of cerebral gray matter volumes in ECD patients, corroborating the observation that there may be non-infiltrative phenomena in ECD to explain the clinical observations of

ECD-treating clinicians. This is an area that requires further systematic study.

ECD can cause tumorous infiltration of the orbits, unilaterally or bilaterally, and this occurs in approximately 20% of cases in the French cohort [4], causing exophthalmos (Fig. 18.4d). Other symptoms include retro-orbital pain, oculomotor abnormalities, and blindness. These lesions can be mistaken for other causes of orbital pseudotumor including Graves' disease, granulomatous disease, lymphoma, and giant cell arteritis. Orbital ECD can extend and infiltrate locally in an impressive manner, and involvement of the cavernous sinus, lacrimal glands, and the choroid itself has been observed [8, 74–76].

ECD is associated with a variety of neuroendocrine and endocrine abnormalities. Like LCH, ECD patients can have diabetes insipidus (DI), with a frequency of 25–33% of cases, and DI can precede other clinical manifestations of disease by years or even decades [4, 77]. Endocrine function has been meticulously characterized in a subset of the French cohort, and it was found that multiple abnormalities exist, including somatotrophic deficiency in 79% of patients, hyperprolactinemia in 44%, and gonadotropic deficiency in 22%. Thyrotropin deficiency was relatively uncommon (10%), but testosterone deficiency was found in 53% of cases. In terms of radiologic manifestations, midline structures such as the pituitary gland, stalk, hypothalamus, and pineal gland can be enlarged and demonstrate abnormal enhancement (Fig. 18.4f) [78, 79]. It must be noted, however, that there can be clinical-radiologic dissociation in this aspect of ECD, which is to say that imaging can be robustly normal in the setting of endocrinopathy. Conversely, there can be a dense burden of visible disease that is clinically silent.

Retroperitoneal and Urologic Manifestations

One-quarter to one-third of ECD patients will demonstrate retroperitoneal infiltrates that can mimic retroperitoneal fibrosis [4, 9]. In a series of ECD cases from the Mayo clinic, however, 37 of 47

(79%) of patients were found to have urologic involvement of some kind [80]. The classic radiologic appearance of these infiltrates, seen on axial CT or MRI, has been described as the “hairy kidney” because of the stranded and septated appearance of the lesions from this view (Fig. 18.4a). Retroperitoneal ECD can cause unilateral or bilateral hydronephrosis, which can require ureteral stenting or even nephrostomy. In the Mayo series, 28% of patients required a urologic surgery of some kind because of ECD. One feature of retroperitoneal ECD, which may differentiate it from idiopathic retroperitoneal fibrosis, is that the ECD infiltrates are circumferential around the aorta, while the posterior aortic wall is typically spared in other processes [4]. In the French series, testicular infiltration as evidenced by abnormal ultrasound was present in 29% of men.

Cutaneous Manifestations

In the French cohort, 32% of ECD patients had cutaneous involvement of some kind [81]. The most common site of disease is around the eyelids where lesions appear as xanthelasma. Skin lesions elsewhere have a heterogeneous distribution and can involve the neck, axilla, trunk, and groin, as well as other sites [9]. Lesions can appear as scaly plaques or as yellow or red-brown papulonodular lesions. ECD and JXG lesions cannot be differentiated on the basis of clinical examination alone; rather, JXG is less commonly a multisystem disease, and as mentioned above, ECD almost invariably involves the bones of the legs [82]. ECD skin lesions, and in particular xanthelasma, should be evaluated completely because they can be a rich source of lesional material for genotyping that can be obtained with minimal procedural risk.

Other Sites of ECD Involvement

The organ systems discussed above are the most commonly involved with ECD, although disease involvement has been reported in virtually every organ system. ECD has been documented in the

breast [83–85], thyroid [86], muscle [87], pelvic cavity [88], Achilles tendons [89], and other sites. We have observed ECD on many occasions in the subcutaneous soft tissues in a variety of sites (Fig. 18.5g). While ECD has been reported rarely in the alimentary tract [90], liver [91], and mesentery [92], our experience has been that involvement of the gastrointestinal tract, mesentery (Fig. 18.5a), and omentum may be underappreciated.

Baseline Evaluations and MAPK Pathway Mutational Assessment

The goal of the baseline ECD assessment is to characterize and capture the entire burden of disease and also to bring into focus abnormalities that may be clinically relevant in the future. Initial comprehensive assessment of the newly diagnosed ECD patient is presented in Table 18.2. CT scan of the chest, abdomen, and pelvis (with contrast if possible), FDG-PET of the entire body including the brain and distal extremities, MRI of the brain with gadolinium with detailed examination of the pituitary gland, and cardiac MRI are recommended in all patients regardless of symptoms. Even when a ⁹⁹Tc bone scan has been performed in the diagnostic workup for an ECD patient, the sensitivity of PET scans for extraosseous involvement has rendered FDG-PET the nuclear medicine study of choice for evaluation of overall ECD burden and for selection of biopsy targets [93–95].

As written above, confirmation of ECD diagnosis by tissue biopsy is strongly recommended, which also acquires lesional tissue for mutational testing. Selection of biopsy sites is challenging, however. Common sites of biopsy include osseous lesions, as well as soft-tissue lesions in the abdomen such as perinephric infiltrates, and this is usually performed by percutaneous needle biopsy with CT guidance. If FDG-PET has been performed in conjunction with CT, we suggest sampling abnormalities of greater FDG avidity if possible, especially with bony lesions, as areas of non-avid sclerosis may have scant histiocyte content. There is no firm evidence, however, that this practice increases biopsy yield. Regardless

Table 18.2 Baseline clinical evaluation recommendations for patients with Erdheim-Chester disease

<i>Medical history</i>	<i>Radiological evaluation</i>
Constitutional: fevers, night sweats, fatigue HEENT: double vision, retro-orbital pain Cardiovascular: dyspnea, orthopnea Pulmonary: dyspnea, cough Musculoskeletal: bone pain Dermatologic: xanthelasma, rash Endocrine: polydipsia/polyuria, gynecomastia, decreased libido Neurologic: ataxia, dysarthria, dysphagia, cognitive decline Psychiatric: depression, anxiety, disinhibition, inappropriate laughing or crying	All patients: CT chest, abdomen, and pelvis with contrast PET/CT including distal extremities MRI brain with contrast and detailed examination of the sella turcica Cardiac MRI Selected patients based on symptoms or organ involvement MRI orbit with contrast Renal artery ultrasound High-resolution CT chest Pulmonary function tests Testicular ultrasound Electromyography
<i>Physical examination</i>	<i>Laboratory evaluation</i>
HEENT: xanthelasma, exophthalmos Cardiac: hypertension, irregular pulse, cardiomegaly, murmurs, ECG abnormalities Pulmonary: diminished aeration, rales Neurologic: disconjugate gaze, cranial nerve palsies, dysarthria, ataxic or magnetic gait, hyperreflexia Psychiatric: pseudobulbar affect	Complete blood count with differential Comprehensive metabolic panel Erythrocyte sedimentation rate C-reactive protein Morning urine osmolality Morning serum cortisol TSH and free T4 Prolactin, testosterone (males), LH, FSH Vitamin B12, thiamine levels <i>BRAF</i> V600 genotyping (in lesional tissue or by urinary cell-free DNA analysis) Targeted-capture, next-generation sequencing of lesional tissue from <i>BRAF</i> V600-wild-type ECD for mutations in <i>ARAF</i> , <i>NRAS</i> , <i>KRAS</i> , <i>MAP2K1</i> , and <i>PIK3CA</i>

This table was originally published in Blood. Diamond et al. Consensus guidelines for the diagnosis and clinical management of Erdheim-Chester disease. Blood. 2014;124(4):483–92. © the American Society of Hematology

of biopsy site, it is suggested that multiple cores are obtained during a biopsy procedure, if not cores from multiple sites, in order to maximize the yield of diagnostic tissue and histiocyte content for histological and mutational analysis. If a bone sample is collected, one must remember that decalcification performed for histopathologic interpretation renders a sample unsuitable for genotyping; therefore, additional cores must be taken and flagged to be processed without decalcification or to undergo decalcification using an EDTA-based method so that they can later be used for DNA extraction and mutation testing. If skin lesions are present, such as xanthelasmas, these should be considered first for biopsy as the procedure is minimally invasive and these lesions typically provide rich diagnostic tissue. Additionally, subcutaneous nodules can be sampled with little procedural risk and also often present adequate biopsy material.

BRAF and Other Mutational Assessment

Assessment for the presence of the *BRAF* V600E mutation in ECD tissue should be performed for all patients, if possible, given its therapeutic implications. ECD lesions often possess variable histiocyte content, and as mentioned above, lesional material is often obtained from bone biopsies, and both of these can present challenges to excluding the presence of *BRAF* mutations with reliable sensitivity. For this reason, it is recommended to confirm negative *BRAF* V600E testing using more than one genotyping modality and/or more than one biopsy site, preferably not a bone biopsy unless it is snap frozen and not decalcified or unless decalcified using an EDTA-based decalcification method. There are several screening tests available to determine *BRAF* mutational status, including immunohistochemistry, pyrosequencing methods, and polymerase chain reaction (PCR)-based methods. Immunohistochemistry using a *BRAF* V600E antibody clone that has been appropriately validated for clinical use in pathology at the diagnosing institution is the cheapest method and should

be used on all histiocytoses samples; however, due to the potential for false-positive expression and the variability in interpretation based on the experience of the reviewing pathologist, all samples should be tested using another molecular method such as allele-specific PCR for the *BRAF* V600E mutation, pyrosequencing, or a targeted-capture, next-generation sequencing platform. A targeted-capture next-generation sequencing platform will be the most sensitive for detecting the *BRAF* V600E mutation, followed by pyrosequencing, and then allele-specific PCR for *BRAF* V600E. It is important to note that a commercial urine-based cell-free DNA assay has also been validated as highly sensitive and specific in the context of untreated ECD [30]. Any *BRAF* V600E-wild-type ECD sample should be evaluated for other kinase alterations (*KRAS*, *NRAS*, *ARAF*, *MAP2K1*, and *PIK3CA*) using a targeted-capture, next-generation sequencing approach screening for the diverse mutations in these kinase genes (Fig. 18.1a–c and Table 18.1). Ideally, a separate biopsy should be acquired and snap frozen for DNA and RNA extraction, which would also provide a means for using targeted-capture, RNA-sequencing to also screen for kinase fusions discovered in ECD (Fig. 18.1d and Table 18.1); however, a more universal approach will be to provide 20 formalin-fixed, paraffin-embedded (FFPE) tissue curls at 15 micrometer thickness from the diagnostic ECD paraffin block(s) for DNA extraction and subsequent evaluation using a targeted-capture, next-generation sequencing panel to screen for the diverse kinase mutations in ECD (Table 18.1).

Treatment

There have been few prospective therapeutic trials for ECD, although these are increasing in recent years with the advent of “basket trials” and other studies whose design incorporates treatment of multiple tumor pathologies. As a general rule, treatment of ECD is recommended over observation alone with the uncommon exception of patients with minimal and asymptomatic disease. Until recently, interferon-alpha (IFN- α) or anakinra-based regimens have been considered

first-line therapy for ECD, with either cytotoxic chemotherapy or targeted treatments such as *BRAF* inhibitors reserved for disease that is refractory to these therapies. However, *BRAF* inhibitors have been used more frequently as initial therapy for ECD most recently given their robust efficacy, especially for severe forms of disease. Below we summarize the evidence for various therapeutic strategies for ECD and currently ongoing clinical trials (also in Table 18.3). Treatment in the setting of a clinical trial is recommended when possible in light of the dearth of prospective data supporting ECD therapies. An algorithm for ECD therapy in light of *BRAF* mutational status, disease severity, and availability of clinical trials and targeted therapies is presented in Fig. 18.6. Treatment regimens are detailed in Table 18.3 and a proposed treatment algorithm is presented in Fig. 18.6.

Interferon-Alpha and Pegylated Interferon-Alpha

Albeit retrospective, there is a wealth of supporting evidence for treatment of ECD with interferon- α -2a (IFN- α) and pegylated- α -2a (PEG-IFN- α). The mechanism of IFN- α 's action in ECD is not known, although it is thought to have a variety of antineoplastic and immunomodulatory effects, including promoting differentiation of host immune cells to possess antitumor immunity [122]. The first successful treatment of ECD with IFN- α was observed in 2005, and since that time, treatment with more than 60 ECD patients has been reported [104–108]. In the French cohort, a prospective, nonrandomized, observational cohort study of 53 patients—46 treated with IFN- α or PEG-IFN- α —demonstrated that IFN therapy was associated with greater overall survival as compared to other treatments [109]. There is firm dose equivalence between IFN- α and PEG-IFN- α ; the dosing of IFN- α ranges from 3 to 9 million units (mIU) three times per week, and the dosing of PEG-IFN- α ranges from 90 to 180mcg weekly. PEG-IFN- α is thought to be generally better tolerated and in one study was more effective in achieving a sustained virologic response in the context of treating hepatitis C at a dose of 135mcg weekly as compared to 9mIU

Table 18.3 Treatment recommendations for Erdheim-Chester disease patients

Class of treatment	Medication	Dose and schedule	Comment
BRAF inhibitors	Vemurafenib	480–960 mg twice daily	Robust and sustained efficacy has been demonstrated in several case reports, in series, and in one prospective clinical trial [96–103]. The FDA-approved dose is 960 mg twice daily, although dose reduction is often needed, and treatment success has been observed at lower doses
	Dabrafenib	75–150 mg twice daily	Successful treatment reported in one case [30], but anecdotal experience reflects similar efficacy to vemurafenib
First-line conventional therapy	Pegylated-IFN- α	135 μ g SC/week (standard dose) or 180 μ g SC/week (high dose)	Currently the therapy with largest clinical evidence base in ECD [104–109]. Case series have demonstrated survival benefit with the use of some form of IFN- α . High-dose IFN- α ended for patients with CNS or cardiac involvement
	Interferon- α	3mIU SC TIW (standard dose) or 6–9mIU SC TIW (high dose)	
	Anakinra	100 mg SC daily or up to 2 mg/kg/day	Growing experience and several case reports of successful treatment, mainly of less severe forms of ECD [12, 110–115], but limited reports of CNS [31] or cardiac disease [116] with favorable response. Poor efficacy in patients previously treated with IFN- α in one series [117]. Especially effective for bone pain and constitutional symptoms
Second-line conventional therapy	Cladribine	6 mg/m ² IV daily for 5 days Q4weeks	Used frequently in clinical therapy of systemic Langerhans cell histiocytosis and ECD but published reports of its efficacy are few
	Sirolimus and prednisone	Sirolimus dosed to level of 8–12 ng/mL	Eight of ten patients had a favorable response in a prospective clinical trial [29]
	Imatinib	400 mg PO daily	Mixed results in 7 ECD patients treated with imatinib [118, 119]. Appears that it may be more effective in less severe forms of disease
	Infliximab	5 mg/mg IV Q6weeks	Four patients with cardiac disease refractory to treatment with IFN- α had clinical improvement when treated with infliximab [120, 121]
ECD clinical trials	Cobimetinib (NCT02649972)	Per trial guidelines	Two cases of dramatic response to single-agent MEK inhibitor therapy in ECD patients with <i>MAP2K1</i> mutations [8]
	Dabrafenib and trametinib (NCT02281760)	Per trial guidelines	First trial of combined BRAF/MEK inhibition for <i>BRAF</i> -mutated ECD
	Lenalidomide (NCT02523050)	Per trial guidelines	For patients with ECD, LCH, or histiocytic sarcoma. There is one case report of ECD treated with lenalidomide in combination with cladribine

Adding references on each of these studies will be helpful. This table was originally published in Blood. Diamond et al. Consensus guidelines for the diagnosis and clinical management of Erdheim-Chester disease. Blood. 2014;124(4):483–92. © the American Society of Hematology

of IFN- α three times per week. There is no established optimal dose for IFN- α or PEG-IFN- α in ECD, although the lowest dose that has been shown to decrease lesional burden is 3 million

units (mIU) of IFN- α given three times per week [104, 105, 108]. In a case series of eight patients with cardiac or CNS ECD, high-dose treatment (≥ 9 mIU IFN- α or ≥ 180 mcg PEG-IFN- α) was

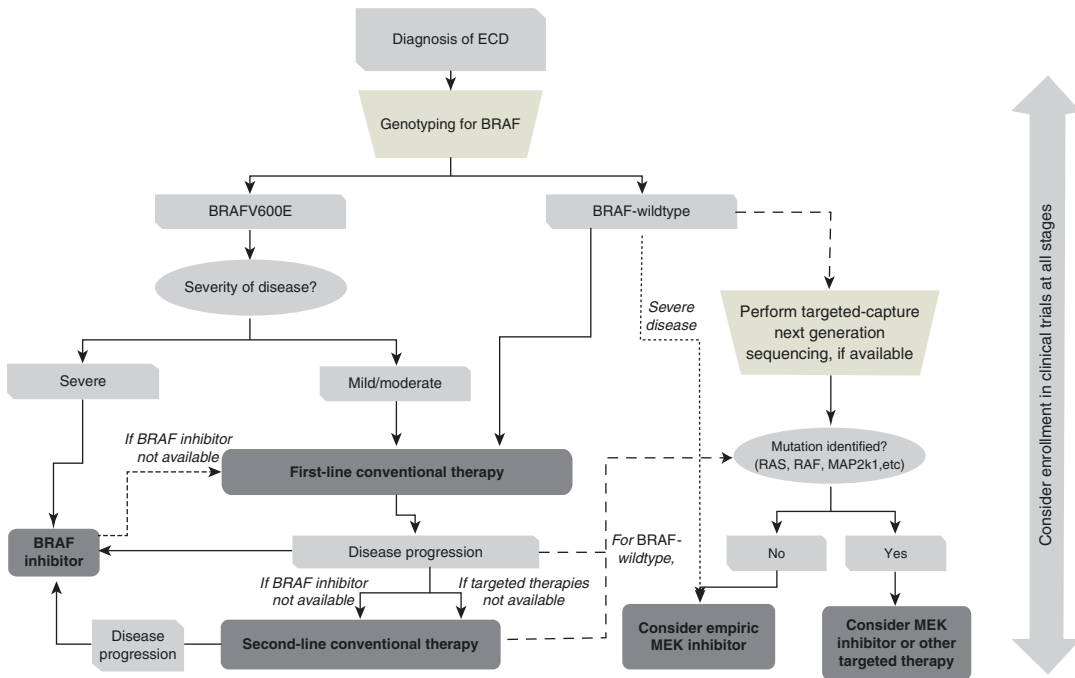


Fig. 18.6 Treatment algorithm for patients with Erdheim-Chester disease. *BRAF* mutational status, if available, and severity of disease determine initial therapy. Genomic profiling should be performed when possible for *BRAF*-

wild-type ECD to allow for optimal consideration of treatment options if first-line therapy fails. Clinical trial participation is recommended at any stage of illness, if possible

needed to achieve efficacy when lower doses were not effective. Duration of treatment is not defined but up to 3 years of therapy has been described to lead to stabilization or improvement in both CNS (64% of cases) and cardiac (79% of cases) ECD in one study of 24 patients [107]. Both forms of IFN- α have many potential toxicities including depression and other neuropsychiatric symptoms, constitutional symptoms (fever, fatigue, malaise, myalgias, arthralgias), gastrointestinal symptoms, alopecia, pruritus, pneumonitis, transaminitis, and myelosuppression.

Cytokine-Directed Therapy

The recombinant interleukin-1 (IL-1) receptor antagonist anakinra has been found in a small number of reported cases to have been efficacious in ECD and in recent years has been used increasingly in unreported experiences. Reduction in both ECD lesions and in inflammatory cytokines have been observed in eight reported ECD

cases with relatively mild phenotypes involving predominantly bones and retroperitoneum [12, 110–115]. In the largest case series to date of 12 ECD patients treated with anakinra, all previously treated with IFN- α , 3 patients had a favorable response by FDG-PET, and the remainder stopped treatment for disease progression or toxicity. One patient had progressive CNS disease on treatment, while another died of pericardial tamponade. Outside of the context of patients previously treated with IFN- α , however, there has been one case of cardiac ECD treated effectively [116] and two patients with robust improvement of intracranial disease with anakinra [31]. The standard dose of anakinra is 100 mg/day, injected subcutaneously, although doses up to 2 mg/kg/day have been used in other contexts. Common side effects include injection site reactions, headache, arthralgias, and nasopharyngitis. Altogether, anakinra can be viewed as reasonable first-line therapy for ECD patients with prominent osseous or constitutional symptoms; the evidence is mixed with regard to more severe forms

of disease, although favorable examples exist in the context of patients untreated with IFN- α .

There is very limited experience with other cytokine-directed treatments. Canakinumab is an IL-1R- β receptor antagonist that has been reported successfully in one case of pediatric ECD, interestingly in the instance of disease progression on anakinra [123]. Four patients with cardiac ECD, refractory to IFN- α , were treated with infliximab, with resulting clinical improvement and reduction in circulating cytokine levels. A clinical trial of tocilizumab, a humanized monoclonal antibody against the IL-6 receptor, was performed (NCT01727206), although results have yet to be formally reported.

Immunosuppressive Agents, Cytotoxic Chemotherapy, Radiotherapy, and Surgery

Many chemotherapeutic regimens have been reported in cases or small series [124–131]. Corticosteroids are not considered effective monotherapy for ECD, although they may ameliorate acute edema such as in the instance of severe orbital disease causing visual impairment. Cladribine, a purine analogue chemotherapy that is used frequently in the treatment of LCH, has been used in a handful of reported cases of ECD [132–134] and can be considered in the context of refractory disease when a targeted therapy is not available or contraindicated. In contrast to LCH, in the context of which radiotherapy can offer definitive therapy for isolated lesions, radiation has been found to confer short-term palliation at best in ECD and is not recommended [135, 136]. There was a prospective, open-label clinical trial of combined sirolimus (dosed to a target level of 8–12 ng/mL) and prednisolone, in which ten ECD patients were treated. Eight of the ten achieved disease stabilization or radiologic response, although two of three patients with CNS disease died of disease progression (one responded). Furthermore, correlative studies demonstrated mTOR pathway activation in lesional histiocytes, although no patients were found to have *PIK3CA* mutations in ECD tissue. This may represent a promising ECD therapy,

although further study into the mechanism of efficacy in ECD would be of interest [137]. Because ECD is multifocal and requires systemic treatment, surgery is infrequently appropriate in ECD with the exception of severe orbital lesions, resectable intracranial lesions, or large tumors with end-organ dysfunction for which debulking would be beneficial.

Serine/Threonine Kinase Inhibitors

Following the discovery of the presence of the *BRAF* V600E mutation in ECD tissue, three patients with refractory disease harboring the mutation were treated with vemurafenib in Paris with dramatic efficacy [96], and subsequently, the favorable and durable response to vemurafenib in eight patients at the Pitié-Salpêtrière Hospital was reported as well [97]. Furthermore, 14 histiocytosis patients with *BRAF*-mutated disease were treated in a phase 2, histology-independent, “basket” trial; 12 patients enjoyed regression of their tumors and there were no instances of disease progression on study [98]. Numerous other cases of efficacious treatment with vemurafenib [99–103] and one with dabrafenib [30] have been published as well. The FDA-approved doses of these medications are 960 mg BID and 150 mg BID, respectively, although therapeutic responses have been observed at lower doses. Common toxicities of BRAF inhibitors include fatigue, arthralgias, headache, and multiple skin complications including squamous cell carcinomas. While it is now well established that ongoing BRAF inhibition can achieve a meaningful and durable response in *BRAF*-mutated ECD, there remain unanswered questions about the optimal duration of therapy, long-term toxicity of treatment, parameters for dose reduction or tapering in the setting of remission, and the sequelae of drug discontinuation. There is an ongoing prospective, observational study of ECD patients in the context of discontinuation of vemurafenib (NCT02089724). There is no published experience along these lines, but the informal observation has been that disease relapses in the setting of indefinite discontinuation of treatment. Strategies for intermittent treatment with BRAF inhibitors,

or changing treatment to a longer-term “maintenance” or “suppression” regimen, are reasonable notions but have not been pursued systematically.

A key remaining question in the initial treatment of *BRAF*-mutated ECD is whether to attempt treatment with “conventional” therapies (such as IFN- α or anakinra) before *BRAF* inhibitors or to use the latter as first-line treatment. The competing priorities in this dilemma are the marked efficacy of *BRAF* inhibition on the one hand but the uncertainties of both toxicities and of the treatment trajectory in the long term, on the other hand. In particular, indefinite treatment with *BRAF* inhibitors carries the risk of accelerating premalignant RAS-mediated neoplasms [138]. Because of the morbidity and mortality associated with severe forms of ECD, especially CNS infiltration or instances of other severe organ compromise, it is reasonable to use *BRAF* inhibitors as first-line therapy in that setting. Conversely, conventional treatment is most often appropriate initial therapy for limited and mild disease. For cases of moderate severity, a constellation of factors should be considered such as the degree of organ compromise, the clinical need for cytoreduction that a targeted therapy is more likely to achieve, and the specifics of the patient and her/his medications and comorbidities that present relative contraindications to the different approaches. Consultation with an experienced ECD clinician is often helpful and therefore advised for purposes of formulating an initial treatment plan.

The experience with targeted therapies for *BRAF*-wild-type disease remains limited. Two patients with heavily pretreated and refractory ECD with *MAP2K1* mutations (p.Q56P and p.K57N) enjoyed robust responses to treatment with cobimetinib and trametinib, respectively, and one patient with refractory ECD harboring an *ARAF* S214A mutation responded to treatment with sorafenib [8]. Treatment with MEK inhibition for *BRAF*-wild-type ECD is currently ongoing in the form of a clinical trial (see section below).

There has been limited experience with imatinib mesylate for treatment of ECD, and mixed results have been reported in seven patients [118, 119]. Efforts to treat ECD with imatinib are

reasonable both on the basis of experience with treatment of other histiocytoses [139, 140] and the observation of abundant PDGFR- β expression in lesional ECD tissue [118]. Imatinib is probably a less attractive treatment option in the era of targeted therapies but may have a role in the second-line setting if these are not available or contraindicated.

Clinical Trials for ECD

There are presently a handful of registered clinical trials accepting ECD patients. For patients with *BRAF* V600E-mutated disease, there is an ongoing trial of combined *BRAF*/*MEK* inhibition at the National Institutes of Health (NCT02281760), a trial of a novel *BRAF* inhibitor (PLX8394) at MD Anderson Cancer Center (NCT02428712), and an observational study at the Pitié-Salpêtrière Hospital of patients off treatment after initial therapy with vemurafenib (NCT02089724). There is a phase 2 trial of single-agent cobimetinib (*MEK* inhibitor) for patients with *BRAF*-wild-type ECD, as well as *BRAF* V600E-mutated ECD patients who can either not access or tolerate *BRAF* inhibitor therapy at Memorial Sloan Kettering Cancer Center (NCT02649972). A basket trial of a novel *ERK* inhibitor (BVD-523) is accepting patients with *BRAF* or *MEK* mutations (NCT01781429) at MD Anderson Cancer Center. Also, there is a phase 2 trial of lenalidomide for ECD patients of any mutational status at Dana-Farber Cancer Institute (NCT02523040). Finally, two trials of targeted therapies for mixed cancer histologies (DCC-2618 and DCC-2701) are accepting ECD patients regardless of mutational status at MD Anderson Cancer Center (NCT02571036 and NCT02228811).

Response Assessment and Disease Surveillance

It is generally recommended that treatment be continued indefinitely for ECD, if tolerated; however, attempting cessation of treatment for

patients with minimal or stable disease can be considered for individual patients. There are no formal criteria for response assessment in ECD. FDG-PET is the most informative test for assessment of overall disease status and should be performed approximately every 3–6 months for all patients. The degree of FDG avidity is highly variable both between patients and between lesions within a single patient; therefore, response should be considered in light of relative change for individual lesions. For example, avidity is typically the most intense for cerebral lesions. Complete normalization of FDG avidity of all lesions is optimal but does not need to be achieved in order to consider a therapy efficacious. Moreover, FDG avidity can fluctuate to a limited degree over time, even in the setting of overall stable disease; thus, small FDG changes in single tumors should not be understood necessarily to indicate treatment failure. Organ-specific imaging with CT or MRI should be performed every 3 months after beginning treatment or every 6 months in the context of stable disease. Since ECD lesions are heterogeneous and may contain significant areas of fibrosis, some tumors may not significantly regress in their dimensions, even with effective therapy, such as abdominal and retroperitoneal infiltrates. For such lesions, modest regression of a tumor by measurements may indicate efficacy, and FDG-PET may constitute a more helpful response assessment. In terms of biomarkers, C-reactive protein (CRP) is elevated in 80% of ECD cases at the time of diagnosis, and following levels may be helpful in monitoring response to treatment [9]. For *BRAF*-mutated disease, quantified allelic burden of mutated urinary cell-free DNA has been shown in one prospective study to correlate strongly with response of *BRAF* inhibitor therapy [30], and this is a commercially available assay provided by Trovogene, Inc. (San Diego, CA).

Conclusions

ECD is a rare multisystem disorder that presents many diagnostic and therapeutic challenges. For this reason, multidisciplinary collaboration is often vital to the evaluation and management of ECD patients. A diagnosis

of ECD rests upon biopsy of lesional material demonstrating characteristic histopathologic findings in the appropriate clinical and radiologic context. Comprehensive ECD evaluation involves careful medical history, physical examination, imaging studies, laboratory evaluation, and mutational testing for *BRAF* V600E and other MAPK pathway alterations. The palette of ECD treatments is growing as targeted therapies gain relevance alongside conventional immunomodulatory and antineoplastic agents. Clinical trials are under way to evaluate these therapies, although additional prospective studies are essential. Treatment is recommended for nearly all patients, and consultation with an ECD specialist at a referral center is advised whenever possible.

References

- Weitzman S, Jaffe R. Uncommon histiocytic disorders: the non-Langerhans cell histiocytoses. *Pediatr Blood Cancer*. 2005;45(3):256–64.
- Emile JF, Ablu O, Fraitag S, Horne A, Haroche J, Donadieu J, et al. Revised classification of histiocytoses and neoplasms of the macrophage-dendritic cell lineages. *Blood*. 2016;127:2672–81.
- Chester W. Uber lipidgranulomatose. *Virchows Arch Pathol Anat*. 1930;279:561–602.
- Haroche J, Cohen-Aubart F, Charlotte F, Maksud P, Grenier PA, Cluzel P, et al. The histiocytosis Erdheim-Chester disease is an inflammatory myeloid neoplasm. *Expert Rev Clin Immunol*. 2015;11(9):1033–42.
- Haroche J, Charlotte F, Arnaud L, von Deimling A, Helias-Rodzewicz Z, Hervier B, et al. High prevalence of *BRAF* V600E mutations in Erdheim-Chester disease but not in other non-Langerhans cell histiocytoses. *Blood*. 2012;120(13):2700–3.
- Emile JF, Charlotte F, Amoura Z, Haroche J. *BRAF* mutations in Erdheim-Chester disease. *J Clin Oncol (Official Journal of the American Society of Clinical Oncology)*. 2013;31(3):398.
- Blombery P, Wong SQ, Lade S, Prince HM. Erdheim-Chester disease harboring the *BRAF* V600E mutation. *J Clin Oncol (Official Journal of the American Society of Clinical Oncology)*. 2012;30(32):e331–2.
- Diamond EL, Durham BH, Haroche J, Yao Z, Ma J, Parikh SA, et al. Diverse and targetable kinase alterations drive histiocytic neoplasms. *Cancer Discov*. 2016;6(2):154–65.
- Diamond EL, Dagna L, Hyman DM, Cavalli G, Janku F, Estrada-Veras J, et al. Consensus guidelines for the diagnosis and clinical management of Erdheim-Chester disease. *Blood*. 2014;124(4):483–92.

10. Sohn MH, Kim MW, Kang YH, Jeong HJ. Tc-99m MDP bone and Ga-67 citrate scintigraphy of Erdheim-Chester disease in a child. *Clin Nucl Med*. 2006;31(2):90–2.
11. Joo CU, Go YS, Kim IH, Kim CS, Lee SY. Erdheim-Chester disease in a child with MR imaging showing regression of marrow changes. *Skelet Radiol*. 2005;34(5):299–302.
12. Tran TA, Pariente D, Lecron JC, Delwail A, Taoufik Y, Meinzer U. Treatment of pediatric Erdheim-Chester disease with interleukin-1-targeting drugs. *Arthritis Rheum*. 2011;63(12):4031–2.
13. Song SY, Lee SW, Ryu KH, Sung SH. Erdheim-Chester disease with multisystem involvement in a 4-year-old. *Pediatr Radiol*. 2012;42(5):632–5.
14. Tran TA, Fabre M, Pariente D, Craiu I, Haroche J, Charlotte F, et al. Erdheim-Chester disease in childhood: a challenging diagnosis and treatment. *J Pediatr Hematol Oncol*. 2009;31(10):782–6.
15. Clerico A, Ragni G, Cappelli C, Schiavetti A, Gonfiantini M, Uccini S. Erdheim-Chester disease in a child. *Med Pediatr Oncol*. 2003;41(6):575–7.
16. Alimohamadi M, Hartmann C, Paterno V, Samii M. Erdheim-Chester disease mimicking an intracranial trigeminal schwannoma: case report. *J Neurosurg Pediatr*. 2015;15(5):493–8.
17. Kim S, Lee M, Shin HJ, Lee J, Suh YL. Coexistence of intracranial Langerhans cell histiocytosis and Erdheim-Chester disease in a pediatric patient: a case report. *Childs Nerv Syst (ChNS: Official Journal of the International Society for Pediatric Neurosurgery)*. 2016;32(5):893–6.
18. Krishna VV, James TE, Chang KT, Yen SS. Erdheim-Chester disease with rare radiological features in a 14-year old girl with pre-B acute lymphocytic leukemia and diabetes mellitus. *J Radiol Case Rep*. 2014;8(8):7–15.
19. Haroche J, Arnaud L, Cohen-Aubart F, Hervier B, Charlotte F, Emile JF, et al. Erdheim-Chester disease. *Rheum Dis Clin N Am*. 2013;39(2):299–311.
20. Furmanczyk PS, Bruckner JD, Gillespy T 3rd, Rubin BP. An unusual case of Erdheim-Chester disease with features of Langerhans cell histiocytosis. *Skelet Radiol*. 2007;36(9):885–9.
21. Tsai JW, Tsou JH, Hung LY, Wu HB, Chang KC. Combined Erdheim-Chester disease and Langerhans cell histiocytosis of skin are both monoclonal: a rare case with human androgen-receptor gene analysis. *J Am Acad Dermatol*. 2010;63(2):284–91.
22. Naruse H, Shoda H, Okamoto A, Oka T, Yamamoto K. A case of Osteoarthropathy due to Erdheim-Chester disease with overlapping Langerhans' cell infiltration. *Intern Med*. 2010;49(12):1225–8.
23. Caoduro C, Ungureanu CM, Rudenko B, Angoue O, Blagosklonov O, Paycha F, et al. 18F-fluoride PET/CT aspect of an unusual case of Erdheim-Chester disease with histologic features of Langerhans cell histiocytosis. *Clin Nucl Med*. 2013;38(7):541–2.
24. Swerdlow SH, Campo E, Harris NL, Jaffe ES, Pileri SA, Stein H, Thiele J, Vardiman JW. WHO classification of tumours of haematopoietic and lymphoid tissues. 4th ed. Lyon: WHO Press; 2008.
25. Durham BH, Diamond EL, Abdel-Wahab O. Histiocytic neoplasms in the era of personalized genomic medicine. *Curr Opin Hematol*. 2016;23(4):416–25.
26. Diamond EL, Abdel-Wahab O, Pentsova E, Borsu L, Chiu A, Teruya-Feldstein J, et al. Detection of an NRAS mutation in Erdheim-Chester disease. *Blood*. 2013;122(6):1089–91.
27. Aitken SJ, Presneau N, Tirabosco R, Amary MF, O'Donnell P, Flanagan AM. An NRAS mutation in a case of Erdheim-Chester disease. *Histopathology*. 2015;66(2):316–9.
28. Emile JF, Diamond EL, Helias-Rodzewicz Z, Cohen-Aubart F, Charlotte F, Hyman DM, et al. Recurrent RAS and PIK3CA mutations in Erdheim-Chester disease. *Blood*. 2014;124(19):3016–9.
29. Gianfreda D, Nicastro M, Galetti M, Alberici F, Corradi D, Becchi G, et al. Sirolimus plus prednisone for Erdheim-Chester disease: an open-label trial. *Blood*. 2015;126(10):1163–71.
30. Hyman DM, Diamond EL, Vibat CR, Hassaine L, Poole JC, Patel M, et al. Prospective blinded study of BRAFV600E mutation detection in cell-free DNA of patients with systemic histiocytic disorders. *Cancer Discov*. 2015;5(1):64–71.
31. Diamond EL, Abdel-Wahab O, Durham BH, Dogan A, Ozkaya N, Brody L, et al. Anakinra as efficacious therapy for two cases of intracranial Erdheim-Chester disease. *Blood*. 2016;128:1896–8.
32. Nelson DS, Quispel W, Badalian-Very G, van Halteren AG, van den Bos C, Bovee JV, et al. Somatic activating ARAF mutations in Langerhans cell histiocytosis. *Blood*. 2014;123(20):3152–5.
33. Takeuchi K, Choi YL, Togashi Y, Soda M, Hatano S, Inamura K, et al. KIF5B-ALK, a novel fusion oncogene identified by an immunohistochemistry-based diagnostic system for ALK-positive lung cancer. *Clin Cancer Res*. 2009;15(9):3143–9.
34. Takeuchi T, Sato M, Sonomura T, Itakura T. Erdheim-Chester disease associated with intramedullary spinal cord lesion. *Br J Radiol*. 2012;85(1011):e62–4.
35. Mano H. ALKoma: a cancer subtype with a shared target. *Cancer Discov*. 2012;2(6):495–502.
36. Wiesner T, He J, Yelensky R, Esteve-Puig R, Botton T, Yeh I, et al. Kinase fusions are frequent in Spitz tumours and spitzoid melanomas. *Nat Commun*. 2014;5:3116.
37. Berres ML, Merad M, Allen CE. Progress in understanding the pathogenesis of Langerhans cell histiocytosis: back to Histiocytosis X? *Br J Haematol*. 2015;169(1):3–13.
38. Badalian-Very G. A common progenitor cell in LCH and ECD. *Blood*. 2014;124(7):991–2.
39. Allen CE, Parsons DW. Biological and clinical significance of somatic mutations in Langerhans cell histiocytosis and related histiocytic neoplastic disorders. *Hematology Am Soc Hematol Educ Program*. 2015;2015:559–64.

40. Collin M, Bigley V, McClain KL, Allen CE. Cell(s) of origin of langerhans cell histiocytosis. *Hematol Oncol Clin North Am.* 2015;29(5):825–38.
41. Allen CE, Li L, Peters TL, Leung HC, Yu A, Man TK, et al. Cell-specific gene expression in Langerhans cell histiocytosis lesions reveals a distinct profile compared with epidermal Langerhans cells. *J Immunol.* 2010;184(8):4557–67.
42. Berres ML, Lim KP, Peters T, Price J, Takizawa H, Salmon H, et al. BRAF-V600E expression in precursor versus differentiated dendritic cells defines clinically distinct LCH risk groups. *J Exp Med.* 2014;211:669–83.
43. Chakraborty R, Hampton OA, Shen X, Simko SJ, Shih A, Abhyankar H, et al. Mutually exclusive recurrent somatic mutations in MAP2K1 and BRAF support a central role for ERK activation in LCH pathogenesis. *Blood.* 2014;124(19):3007–15.
44. Hervier B, Haroche J, Arnaud L, Charlotte F, Donadieu J, Neel A, et al. Association of both Langerhans cell histiocytosis and Erdheim-Chester disease linked to the BRAFV600E mutation. *Blood.* 2014;124(7):1119–26.
45. Haroche J, Abla O. Uncommon histiocytic disorders: Rosai-Dorfman, juvenile xanthogranuloma, and Erdheim-Chester disease. *Hematology Am Soc Hematol Educ Program.* 2015;2015:571–8.
46. Breuil V, Brocq O, Pellegrino C, Grimaud A, Euler-Ziegler L. Erdheim-Chester disease: typical radiological bone features for a rare xanthogranulomatosis. *Ann Rheum Dis.* 2002;61(3):199–200.
47. Garcia-Gomez FJ, Acevedo-Banez I, Martinez-Castillo R, Tirado-Hospital JL, Cuenca-Cuenca JJ, Pachon-Garrudo VM, et al. The role of 18FDG, 18FDOPA PET/CT and 99mTc bone scintigraphy imaging in Erdheim-Chester disease. *Eur J Radiol.* 2015;84(8):1586–92.
48. Garcia-Gomez FJ, Cambil-Molina T, Rios-Martin JJ, de la Riva-Perez PA, Calvo-Moron C, Castro-Montano J. Bone scintigraphy as cornerstone in the diagnosis of Erdheim-Chester disease. *Rev Esp Med Nucl Imagen Mol.* 2016;35(3):193–6.
49. Gotthardt M, Welcke U, Brandt D, Tontsch D, Barth PJ, Schaefer J, et al. The role of bone scintigraphy in patients with Erdheim-Chester disease. *Clin Nucl Med.* 2000;25(6):414–20.
50. Wilejto M, Abla O. Langerhans cell histiocytosis and Erdheim-Chester disease. *Curr Opin Rheumatol.* 2012;24(1):90–6.
51. Allmendinger AM, Krauthamer AV, Spektor V, Aziz MS, Zablou B. Atypical spine involvement of Erdheim-Chester disease in an elderly male. *J Neurosurg Spine.* 2010;12(3):257–60.
52. Caglar E, Aktas E, Aribas BK, Sahin B, Terzi A. Erdheim-Chester disease in thoracic spine: a rare case of compression fracture. *Spine J (Official Journal of the North American Spine Society).* 2016;16(4):e257–8.
53. Klieger MR, Schultz E, Elkowitz DE, Arlen M, Hajdu SI. Erdheim-Chester disease: a unique presentation with multiple osteolytic lesions of the spine and pelvis that spared the appendicular skeleton. *AJR Am J Roentgenol.* 2002;178(2):429–32.
54. Nagatsuka H, Han PP, Taguchi K, Tsujigiwa H, Gunduz M, Fukunaga J, et al. Erdheim-Chester disease in a child presenting with multiple jaw lesions. *J Oral Pathol Med (Official Publication of the International Association of Oral Pathologists and the American Academy of Oral Pathology).* 2005;34(7):420–2.
55. Petrikowski CG, McGaw WT. Erdheim-Chester disease of the jaws: literature review and case report. *Oral Surg Oral Med Oral Pathol Oral Radiol Endod.* 2000;90(3):389–98.
56. Valdez IH, Katz RW, Travis WD. Premature alveolar bone loss in Erdheim-Chester disease. *Oral Surg Oral Med Oral Pathol.* 1990;70(3):294–6.
57. Blomstrand L, Thor A, Hagberg H. Erdheim-Chester disease presenting as periodontal disease: experience of treatment with cladribine, interferon- α , local radiotherapy and anakinra. *Acta Oncol.* 2016;55(2):248–50.
58. Fink MG, Levinson DJ, Brown NL, Sreekanth S, Sobel GW. Erdheim-Chester disease. Case report with autopsy findings. *Arch Pathol Lab Med.* 1991;115(6):619–23.
59. Loeffler AG, Memoli VA. Myocardial involvement in Erdheim-Chester disease. *Arch Pathol Lab Med.* 2004;128(6):682–5.
60. Serratrice J, Granel B, De Roux C, Pellissier JF, Swiader L, Bartoli JM, et al. “Coated aorta”: a new sign of Erdheim-Chester disease. *J Rheumatol.* 2000;27(6):1550–3.
61. Rodriguez Sanchez D, Saura Espin D, Bas BA. Erdheim-Chester syndrome with Periaortitis. *Revista espanola de cardiologia.* 2016;69(1):72.
62. Windisch C, Petersen I, Schulz B, Winkens T, Lopatta E, Oelzner P, et al. Erdheim-Chester disease with vascular involvement mimics large vessel vasculitis. *Postgrad Med J.* 2016;92:687–8.
63. Raptis DA, Raptis CA, Jakerst C, Bhalla S. Erdheim-Chester disease with interatrial septum involvement. *J Thorac Imaging.* 2012;27(5):W105–7.
64. de Miguel CJ, Aguilera Del Hoyo LF, Garcia Del Salto L, Cueva Perez E, Casado Cerrada J, Nieto Llanos S, et al. Case 224: cardiac involvement in Erdheim-Chester disease. *Radiology.* 2015;277(3):916–21.
65. Arnaud L, Hervier B, Neel A, Hamidou MA, Kahn JE, Wechsler B, et al. CNS involvement and treatment with interferon- α are independent prognostic factors in Erdheim-Chester disease: a multicenter survival analysis of 53 patients. *Blood.* 2011;117(10):2778–82.
66. Hwang BY, Liu A, Kern J, Goodwin CR, Wolinsky JP, Desai A. Epidural spinal involvement of Erdheim-Chester disease causing myelopathy. *J Clin Neurosci (Official Journal of the Neurosurgical Society of Australasia).* 2015;22(9):1532–6.
67. Albayram S, Kizilkilic O, Zulfikar Z, Islak C, Kocer N. Spinal dural involvement in Erdheim-Chester disease: MRI findings. *Neuroradiology.* 2002;44(12):1004–7.
68. Querat C, Thai-Van H, Durand DV, Cotton F, Gallego S, Truy E. Hearing rehabilitation with a binaural

- cochlear implant in a patient with Erdheim-Chester disease. *Cochlear Implants Int.* 2015;16(5):295–300.
69. Pego-Reigosa R, Branas-Fernandez F, Martinez-Vazquez F, Rivas-Bande MJ, Sanjuanbenito L, Garcia-Villanueva M, et al. Erdheim-Chester disease with spinal cord manifestations. *Eur Neurol.* 2000;43(4):242–4.
 70. Lalitha P, Reddy M, Reddy KJ. Extensive intracranial juvenile xanthogranulomas. *AJNR Am J Neuroradiol.* 2011;32(7):E132–3.
 71. Sagnier S, Debruxelles S, Lepreux S, Sibon I. Erdheim-Chester disease: an unusual cause of intracranial Vasculitis and progressive leukoencephalopathy. *J stroke Cerebrovasc Dis (The Official Journal of National Stroke Association).* 2016;25(5):e63–5.
 72. Grois N, Fahrner B, Arceci RJ, Henter JI, McClain K, Lassmann H, et al. Central nervous system disease in Langerhans cell histiocytosis. *J Pediatr.* 2010;156(6):873–81, 81 e1.
 73. Diamond EL. Diffuse reduction of cerebral grey matter volumes in Erdheim-Chester disease. *Orphanet J Rare Dis.* 2016;11(1):109.
 74. Merritt H, Pfeiffer ML, Richani K, Phillips ME. Erdheim-Chester disease with orbital involvement: case report and ophthalmic literature review. *Orbit.* 2016;35(4):221–6.
 75. Karcioğlu ZA, Sharara N, Boles TL, Nasr AM. Orbital xanthogranuloma: clinical and morphologic features in eight patients. *Ophthalm Plast Reconstr Surg.* 2003;19(5):372–81.
 76. Abdellatif A, Mason CM, Ytterberg SR, Boorjian SA, Salomao DR, Pulido J. Choroidal involvement in Erdheim-Chester disease. *Ophthalmic Surg Lasers Imaging Retina.* 2015;46(6):674–6.
 77. Courtillot C, Laugier Robiolle S, Cohen Aubart F, Leban M, Renard-Penna R, Drier A, et al. Endocrine manifestations in a monocentric cohort of 64 patients with Erdheim-Chester disease. *J Clin Endocrinol Metab.* 2016;101(1):305–13.
 78. Sedrak P, Ketonen L, Hou P, Guha-Thakurta N, Williams MD, Kurzrock R, et al. Erdheim-Chester disease of the central nervous system: new manifestations of a rare disease. *Am J Neuroradiol.* 2011;32(11):2126–31.
 79. Mukherjee A, Dhull VS, Karunanithi S, Sharma P, Durgapal P, Kumar R. Pineal gland involvement in Erdheim-Chester disease detected on (18)F-FDG PET-CT imaging: a case report and review of literature. *Clin Imaging.* 2014;38(3):367–71.
 80. Yelfimov DA, Lightner DJ, Tollefson MK. Urologic manifestations of Erdheim-Chester disease. *Urology.* 2014;84(1):218–21.
 81. Chasset F, Barette S, Charlotte F, Cohen-Aubart F, Arnaud L, Le Pelletier F, et al. Cutaneous manifestations of Erdheim-Chester disease (ECD): clinical, pathological, and molecular features in a monocentric series of 40 patients. *J Am Acad Dermatol.* 2016;74(3):513–20.
 82. Caputo R, Marzano AV, Passoni E, Berti E. Unusual variants of non-Langerhans cell histiocytoses. *J Am Acad Dermatol.* 2007;57(6):1031–45.
 83. Barnes PJ, Foyle A, Hache KA, Langley RG, Burrell S, Juskevicius R. Erdheim-Chester disease of the breast: a case report and review of the literature. *Breast J.* 2005;11(6):462–7.
 84. Provenzano E, Barter SJ, Wright PA, Forouhi P, Allibone R, Ellis IO. Erdheim-Chester disease presenting as bilateral clinically malignant breast masses. *Am J Surg Pathol.* 2010;34(4):584–8.
 85. Ferrozzi F, Bova D, Tognini G, Zuccoli G. Pseudotumoral bilateral involvement of the breast in Erdheim-Chester disease: CT appearance. *J Comput Assist Tomogr.* 2000;24(2):281–3.
 86. Sheu SY, Wenzel RR, Kersting C, Merten R, Otterbach F, Schmid KW. Erdheim-Chester disease: case report with multisystemic manifestations including testes, thyroid, and lymph nodes, and a review of literature. *J Clin Pathol.* 2004;57(11):1225–8.
 87. Yamamoto T, Mizuno K. Erdheim-Chester disease with intramuscular lipogranuloma. *Skelet Radiol.* 2000;29(4):227–30.
 88. Taguchi S, Kishida Y, Tamura K, Nose Y, Sato T, Ishikawa A, et al. Intrapelvic bulky tumor as an unusual presentation of Erdheim-Chester disease. *Internal Med (Tokyo, Japan).* 2015;54(24):3241–5.
 89. Nadjiri J, Woertler K, Specht K, Harrasser N, Toepfer A. Erdheim-Chester disease with bilateral Achilles tendon involvement. *Skelet Radiol.* 2016:1–6.
 90. Pan A, Doyle T, Schlup M, Lubcke R, Schultz M. Unusual manifestation of Erdheim-Chester disease. *BMC Gastroenterol.* 2011;11:77.
 91. Ivan D, Neto A, Lemos L, Gupta A. Erdheim-Chester disease: a unique presentation with liver involvement and vertebral osteolytic lesions. *Arch Pathol Lab Med.* 2003;127(8):e337–9.
 92. Moore FO, Berne JD, Fox AD. Mesenteric panniculitis and Erdheim-Chester disease: xanthogranulomatous diseases confused with malignancy. *J Am Coll Surg.* 2007;204(2):326–7.
 93. Namwongprom S, Nunez R, Kim EE, Macapinlac HA. Tc-99m MDP bone scintigraphy and positron emission tomography/computed tomography (PET/CT) imaging in Erdheim-Chester disease. *Clin Nucl Med.* 2007;32(1):35–8.
 94. Lin E. FDG PET/CT for biopsy guidance in Erdheim-Chester disease. *Clin Nucl Med.* 2007;32(11):860–1.
 95. Stenova E, Steno B, Povinec P, Ondrias F, Rampalova J. FDG-PET in the Erdheim-Chester disease: its diagnostic and follow-up role. *Rheumatol Int.* 2012;32(3):675–8.
 96. Haroche J, Cohen-Aubart F, Emile JF, Arnaud L, Maksud P, Charlotte F, et al. Dramatic efficacy of vemurafenib in both multisystemic and refractory Erdheim-Chester disease and Langerhans cell histiocytosis harboring the BRAF V600E mutation. *Blood.* 2013;121(9):1495–500.
 97. Haroche J, Cohen-Aubart F, Emile JF, Maksud P, Drier A, Toledano D, et al. Reproducible and sustained efficacy of targeted therapy with vemurafenib in patients with BRAF(V600E)-mutated Erdheim-Chester disease. *J Clin Oncol (Official Journal of the American Society of Clinical Oncology).* 2015;33(5):411–8.

98. Hyman DM, Puzanov I, Subbiah V, Faris JE, Chau I, Blay JY, et al. Vemurafenib in multiple Nonmelanoma Cancers with BRAF V600 Mutations. *N Engl J Med*. 2015;373(8):726–36.
99. Cohen-Aubart F, Emile JF, Maksud P, Galanaud D, Idbah A, Chauvet D, et al. Marked efficacy of vemurafenib in suprasellar Erdheim-Chester disease. *Neurology*. 2014;83(14):1294–6.
100. Euskirchen P, Haroche J, Emile JF, Buchert R, Vandersee S, Meisel A. Complete remission of critical neurohistiocytosis by vemurafenib. *Neurol Neuroimmunol Neuroinflamm*. 2015;2(2):e78.
101. Franconieri F, Martin-Silva N, de Boysson H, Galateau-Salle F, Emile JF, Biennu B, et al. Superior efficacy and tolerance of reduced doses of vemurafenib plus anakinra in Erdheim-Chester disease: towards the paradigm of combined targeting and immune therapies. *Acta Oncol*. 2016;55(7):930–2.
102. Tzoulis C, Schwarzlmuller T, Gjerde IO, Softeland E, Neckelmann G, Biermann M, et al. Excellent response of intramedullary Erdheim-Chester disease to vemurafenib: a case report. *BMC Res Notes*. 2015;8:171.
103. Borys D, Nystrom L, Song A, Lomasney LM. Erdheim Chester disease with appendicular skeletal, renal and pleural involvement responding to Zelboraf (BRAF inhibitor) treatment: case report. *Skelet Radiol*. 2016;45(10):1397–402.
104. Braiteh F, Boxrud C, Esmaeli B, Kurzrock R. Successful treatment of Erdheim-Chester disease, a non-Langerhans-cell histiocytosis, with interferon-alpha. *Blood*. 2005;106(9):2992–4.
105. Suzuki HI, Hosoya N, Miyagawa K, Ota S, Nakashima H, Makita N, et al. Erdheim-Chester disease: multisystem involvement and management with interferon-alpha. *Leuk Res*. 2010;34(1):e21–4.
106. Haroche J, Amoura Z, Trad SG, Wechsler B, Cluzel P, Grenier PA, et al. Variability in the efficacy of interferon-alpha in Erdheim-Chester disease by patient and site of involvement: results in eight patients. *Arthritis Rheum*. 2006;54(10):3330–6.
107. Hervier B, Arnaud L, Charlotte F, Wechsler B, Piette JC, Amoura Z, et al. Treatment of Erdheim-Chester disease with long-term high-dose interferon-alpha. *Semin Arthritis Rheum*. 2012;41(6):907–13.
108. Esmaeli B, Ahmadi A, Tang R, Schiffman J, Kurzrock R. Interferon therapy for orbital infiltration secondary to Erdheim-Chester disease. *Am J Ophthalmol*. 2001;132(6):945–7.
109. Arnaud L, Hervier B, Neel A, Hamidou MA, Kahn JE, Wechsler B, et al. CNS involvement and treatment with interferon-alpha are independent prognostic factors in Erdheim-Chester disease: a multicenter survival analysis of 53 patients. *Blood*. 2011;117(10):2778–82.
110. Aouba A, Georgin-Lavialle S, Pagnoux C, Martin Silva N, Renand A, Galateau-Salle F, et al. Rationale and efficacy of interleukin-1 targeting in Erdheim-Chester disease. *Blood*. 2010;116(20):4070–6.
111. Aubert O, Aouba A, Deshayes S, Georgin-Lavialle S, Rieu P, Hermine O. Favorable radiological outcome of skeletal Erdheim-Chester disease involvement with anakinra. *Joint Bone Spine*. 2013;80(2):206–7.
112. Darstein F, Kirschev S, Heckl S, Rahman F, Schwarting A, Schuchmann M, et al. Successful treatment of Erdheim-Chester disease with combination of interleukin-1-targeting drugs and high-dose glucocorticoids. *Intern Med J*. 2014;44(1):90–2.
113. Sevcikova S, Kubiczkova L, Sedlarikova L, Rihova L, Kryukov F, Szturz P, et al. Impact of anakinra treatment on cytokine and lymphocytes/ monocytes profile of an Erdheim-Chester patient. *Klin Onkol*. 2014;27(4):276–82.
114. Podesta MA, Graziani G, Reggiani F, Buemi M, Badalamenti S, Ponticelli C. Improvement of Erdheim-Chester disease-related renal failure after treatment with anakinra. *Kidney Res Clin Pract*. 2014;33(3):165–7.
115. Courcoul A, Vignot E, Chapurlat R. Successful treatment of Erdheim-Chester disease by interleukin-1 receptor antagonist protein. *Joint Bone Spine*. 2014;81(2):175–7.
116. Killu AM, Liang JJ, Jaffe AS. Erdheim-Chester disease with cardiac involvement successfully treated with anakinra. *Int J Cardiol*. 2013;167(5):e115–7.
117. Cohen-Aubart F, Maksud P, Saadoun D, Drier A, Charlotte F, Cluzel P, et al. Variability in the efficacy of the IL1 receptor antagonist anakinra for treating Erdheim-Chester disease. *Blood*. 2016;127(11):1509–12.
118. Haroche J, Amoura Z, Charlotte F, Salvatierra J, Wechsler B, Graux C, et al. Imatinib mesylate for platelet-derived growth factor receptor-beta-positive Erdheim-Chester histiocytosis. *Blood*. 2008;111(11):5413–5.
119. Janku F, Amin HM, Yang D, Garrido-Laguna I, Trent JC, Kurzrock R. Response of histiocytoses to imatinib mesylate: fire to ashes. *J Clin Oncol*. 2010;28(31):e633–6.
120. Dagna L, Corti A, Langheim S, Guglielmi B, De Cobelli F, Doglioni C, et al. Tumor necrosis factor alpha as a master regulator of inflammation in Erdheim-Chester disease: rationale for the treatment of patients with infliximab. *J Clin Oncol (Official Journal of the American Society of Clinical Oncology)*. 2012;30(28):e286–90.
121. Ferrero E, Belloni D, Corti A, Doglioni C, Dagna L, Ferrarini M. TNF-alpha in Erdheim-Chester disease pericardial effusion promotes endothelial leakage in vitro and is neutralized by infliximab. *Rheumatology*. 2014;53(1):198–200.
122. Ferrantini M, Capone I, Belardelli F. Interferon-alpha and cancer: mechanisms of action and new perspectives of clinical use. *Biochimie*. 2007;89(6–7):884–93.
123. Tran TA, Pariente D, Guitton C, Delwail A, Barathouari M, Meinzer U. Treatment of Erdheim-Chester disease with canakinumab. *Rheumatology*. 2014;53(12):2312–4.
124. Jendro MC, Zeidler H, Rosenthal H, Haller H, Schwarz A. Improvement of Erdheim-Chester

- disease in two patients by sequential treatment with vinblastine and mycophenolate mofetil. *Clin Rheumatol.* 2004;23(1):52–6.
125. Broccoli A, Stefoni V, Faccioli L, Agostinelli C, Spinardi L, Pastore Trossello M, et al. Bilateral orbital Erdheim-Chester disease treated with 12 weekly administrations of VNCOP-B chemotherapy: a case report and a review of literature. *Rheumatol Int.* 2012;32(7):2209–13.
 126. Boissel N, Wechsler B, Leblond V. Treatment of refractory Erdheim-Chester disease with double autologous hematopoietic stem-cell transplantation. *Ann Intern Med.* 2001;135(9):844–5.
 127. Bourke SC, Nicholson AG, Gibson GJ. Erdheim-Chester disease: pulmonary infiltration responding to cyclophosphamide and prednisolone. *Thorax.* 2003;58(11):1004–5.
 128. Yano S, Kobayashi K, Kato K, Tokuda Y, Ikeda T, Takeyama H. A case of Erdheim-Chester disease effectively treated by cyclophosphamide and prednisolone. *Nihon Kokyuki Gakkai Zasshi.* 2007;45(1):43–8.
 129. Gaspar N, Boudou P, Haroche J, Wechsler B, Van Den Neste E, Hoang-Xuan K, et al. High-dose chemotherapy followed by autologous hematopoietic stem cell transplantation for adult histiocytic disorders with central nervous system involvement. *Haematologica.* 2006;91(8):1121–5.
 130. Ho P, Smith C. High-dose methotrexate for the treatment of relapsed central nervous system erdheim-chester disease. *Case Rep Hematol.* 2014;53(1):198–200.
 131. Jeon IS, Lee SS, Lee MK. Chemotherapy and interferon-alpha treatment of Erdheim-Chester disease. *Pediatr Blood Cancer.* 2010;55(4):745–7.
 132. Myra C, Sloper L, Tighe PJ, McIntosh RS, Stevens SE, Gregson RH, et al. Treatment of Erdheim-Chester disease with cladribine: a rational approach. *Br J Ophthalmol.* 2004;88(6):844–7.
 133. Adam Z, Sprlakova A, Rehak Z, Koukalova R, Szturz P, Krejci M, et al. Partial regression of CNS lesions of Erdheim-Chester disease after treatment with 2-chlorodeoxadenosine and their full remission following treatment with lenalidomide. *Klin Onkol.* 2011;24(5):367–81.
 134. Azadeh N, Tazelaar HD, Gotway MB, Mookadam F, Fonseca R. Erdheim Chester disease treated successfully with cladribine. *Respiratory Med Case Rep.* 2016;18:37–40.
 135. Mascalchi M, Nencini P, Nistri M, Sarti C, Santoni R. Failure of radiation therapy for brain involvement in Erdheim Chester disease. *J Neuro-Oncol.* 2002;59(2):169–72.
 136. Miller RC, Villà S, Kamer S, Pasquier D, Poortmans P, Mücke O, et al. Palliative treatment of Erdheim-Chester disease with radiotherapy: a rare cancer network study. *Radiother Oncol.* 2006;80(3):323–6.
 137. Haroche J, Amoura Z. mTOR: a new target in Erdheim-Chester disease? *Blood.* 2015;126(10):1151–2.
 138. Callahan MK, Rampal R, Harding JJ, Klimek VM, Chung YR, Merghoub T, et al. Progression of RAS-mutant leukemia during RAF inhibitor treatment. *N Engl J Med.* 2012;367(24):2316–21.
 139. Montella L, Insabato L, Palmieri G. Imatinib mesylate for cerebral Langerhans'-cell histiocytosis. *N Engl J Med.* 2004;351(10):1034–5.
 140. Utikal J, Ugurel S, Kurzen H, Erben P, Reiter A, Hochhaus A, et al. Imatinib as a treatment option for systemic non-Langerhans cell histiocytoses. *Arch Dermatol.* 2007;143(6):736–40.

Introduction

Rosai–Dorfman disease (RDD) is a rare histiocytic disorder described as a unique entity by Rosai and Dorfman in 1969 under the name of “sinus histiocytosis with massive lymphadenopathy” or SHML [1]. It was initially identified in 1965 by Dr. Destombes, who reported two African cases with lymphadenopathy and sinus histiocytosis [2]. Historically, RDD has been considered a benign and self-limited non-Langerhans cell histiocytosis (non-LCH) disorder of unknown etiology, although a small number of patients seem to have a poor outcome [3]. Clinically, patients with classic RDD present with enlarged bilateral cervical lymphadenopathy. Extranodal sites can also be involved including skin and soft tissues, bone, orbit, salivary glands, CNS, and liver [3].

In the revised classification of histiocytosis and neoplasms of the macrophage–dendritic cell lineage, RDD is included in the “R” group as classic sporadic RDD of the lymph nodes,

extranodal involvement by sporadic RDD, and inherited conditions predisposing to RDD or RDD-like conditions and in the “C” group as cutaneous RDD [4].

Epidemiology

RDD is a very rare disease with a reported prevalence of 1:200,000 [5] and an estimated 100 new cases per year in the United States [6]. It is more frequently seen in children and young adults (mean age of 20.6 years), although it has been reported up to age 74 years. Older patients (mean age 37.5 years) usually present with isolated intracranial disease [5]. RDD is slightly more common in males (58%) and in individuals of African descent. The cutaneous form of RDD seems to be more common in adult females of Asian ethnicity [7].

Pathogenesis

The etiology of RDD is not well defined. Historical molecular studies suggested that RDD is a polyclonal, reactive, and nonneoplastic disorder [8]. The search for a viral link to the disease has been conflicting. Some studies had suggested that human herpes virus-6 (HHV-6), parvovirus B19, and Epstein–Barr virus (EBV) may have a role in the pathogenesis. In fact, HHV-6 antigen has been found to be expressed in RDD

O. Abla, MD (✉)

Department of Pediatrics, Division of Hematology/
Oncology, Hospital for Sick Children,
University of Toronto, Toronto, ON, Canada
e-mail: oussama.abla@sickkids.ca

J. Picarsic, MD

Department of Pathology, University of Pittsburgh
School of Medicine, Children’s Hospital of Pittsburgh
of UPMC, Pittsburgh, PA, USA

histiocytes, whereas EBV and parvovirus were found in the lymphocytes phagocytosed by histiocytes. However, in situ hybridization studies failed to show EBV-encoded RNA in the RDD histiocytes [9]. RDD has also been associated with HIV infection [10]. Therefore, while the viral hypothesis in RDD has been abandoned, it is possible that a viral infection could be the immunological trigger in some cases [11].

In 10% of the patients, RDD can coexist with an immunological disease [3]. In fact, the disease has been associated with systemic lupus erythematosus (SLE), juvenile idiopathic arthritis (JIA), autoimmune hemolytic anemia (AHA) [12], and autoimmune lymphoproliferative syndrome (ALPS), in particular the type I with heterozygous germline mutation in *TNFRSF6*, the *FAS* gene [13].

In addition, RDD has been reported in patients with Hodgkin lymphoma (classic and nodular lymphocyte predominant types) and non-Hodgkin lymphoma (follicular lymphoma), with RDD and lymphoma either preceding or following each other or sometimes occurring in the same node [14]. Furthermore, RDD has been reported after myelodysplastic syndrome [15], after bone marrow transplant for acute leukemia [16], and in concurrence or after LCH [17].

The French Histiocytic Study Group recently analyzed the phenotype of 47 cases of RDD, and no somatic mutations of *BRAF-V600E* were identified [18]. Similarly, Chakraborty et al. did not identify any *BRAF-V600E* mutations by whole-exome sequencing in the lesions obtained from four RDD cases [19]. However, recent studies have reported that *NRAS*, *KRAS*, and *ARAF* mutations were found in a subset of patients with RDD [20].

Associated Diseases

IgG4-Related RDD

Some forms of extranodal RDD, such as those involving the liver, lungs, or colon, have been reported to be associated with an increased number of IgG4-positive plasma cells [21–24].

Although RDD has been described in patients with IgG4-related disease, there is currently no proof that the two disorders share the same pathogenesis. A recent analysis of 29 patients with RDD showed that a low number of IgG4-positive plasma cells and low IgG4/IgG ratios were present compared with IgG4-related disease samples [23]. Evaluation of CD4/FOXP3-positive T-regulatory (T-reg) cells may also be a potential future marker with elevated levels in IgG4-RD, reactive lymph nodes, and variable high levels in RDD with elevated IgG4/IgG levels >0.4 [23]. In the most recent classification of histiocytosis, it was recommended to evaluate IgG4/IgG ratio in all RDD patients, although it is still unclear whether RDD should belong in the spectrum of IgG4-RD or as a separate diagnostic subcategory of RDD [4, 23, 24]. See also Chap. 1.

Inherited Conditions Predisposing to RDD or RDD-Like Entities

Congenital cases of RDD presenting with anemia, thrombocytopenia, and hepatosplenomegaly have been reported [25, 26]. The frequent observation of these congenital cases together with the growing reports of familial RDD suggests a genetic predisposition in some patients with RDD. Germline mutations in *SLC29A3* have been reported in patients with familial RDD. The *SLC29A3* (solute carrier family 29) is a nucleoside transporter, expressed in lysosomal and mitochondrial membranes, with a high expression in cells of the monocytic lineage. Pathogenic mutations of this gene can lead to decreased adenosine transport in these two organelles, leading to impaired phagocytic function in cells of the monocytic lineage with widespread mitochondrial dysfunction [27]. These molecular alterations may partially explain the pleiotropy seen in the *SLC29A3* disease spectrum which includes familial histiocytosis (Faisalabad histiocytosis seen in twin siblings from Pakistan, but lately described in Turkish and Middle Eastern families) [28] H syndrome [28, 29], and pigmented hypertrichotic dermatosis with insulin-dependent diabetes, all currently described as

histiocytosis-lymphadenopathy plus syndrome (MIM602782) [27–30].

Associated RDD morphology has been noted in up to 41% of cases of ALPS type I with germline mutation in the FAS gene (*TNFRSF6*, OMIM #601859). These patients tend to have more aggressive manifestations of ALPS, male predominance, and early age at onset, but the RDD-like changes appear to be self-limited in these cases [13].

Because of the presence of a Rosai–Dorfman pattern in hereditary, autoimmune, and malignant conditions, RDD could be considered today as a pattern rather than a single entity. Based on this notion, RDD can be classified into five categories: familial, classical (SHML), extranodal, malignancy associated, and autoimmune associated (Table 19.1).

Pathology

The diagnostic pathologic feature of nodal RDD includes the sinus expansion of large histiocytic cells characterized by ample pale cytoplasm, often described as “watery-clear,” with a large hypochromatic nucleus and a prominent nucleolus (Fig. 19.1). Nodal RDD is often accompanied

with numerous polytypic plasma cells in the medullary cords and around the venules (Fig. 19.2). A thickened capsule is often present, and focal areas of necrosis and suppurative inflammation are not unusual. While the nodal architecture is typically preserved, the residual follicles are often compressed due to the massive sinus expansion of the RDD cells. Distinguishing between reactive sinus histiocytosis and RDD should not be difficult, as reactive sinus histiocytes do not have the classic RDD cytomorphology which is a criterion for diagnosis. Other sites of involvement are described in further detail (see Chap. 1), but consistent features, regardless of the site, include the cytomorphology of the large pale histiocytes and S100/fascin positivity. Emperipolesis, the trafficking of whole, intact leukocytes through the cytoplasm, is also a diagnostic finding, but can be focal, especially at extranodal sites, and is not required for diagnosis. The immunophenotype of the large histiocytic RDD cells is characterized by S100 and fascin along with CD68 and variable CD163 and CD14 positivity. The cells are CD1a and CD207 negative in contrast to the sinus pattern of nodal LCH. Similar to the other histiocytic lesions, the cytomorphology and immunophenotype should be taken together with the pattern of involvement for diagnosis. An important caveat in making the diagnosis of sporadic nodal RDD is excluding any associated pathology, both within the node itself or other related conditions [4, 31–33]. The differential diagnosis includes lymphomas, infections (EBV, CMV, HHV-6, or HIV), progressive transformation of germinal centers (PTGC), LCH/other histiocytic disorder, or sinus hyperplasia where histiocytes are positive for CD68 and CD163 but negative for S100 (see also Chap. 1).

Table 19.1 Proposed new classification of Rosai–Dorfman disease

Familial RDD	Faisalabad syndrome, H syndrome, FAS deficiency (ALPS)
Classic	Sinus histiocytosis with massive lymphadenopathy (SHML)
Extranodal RDD	Skin Bone CNS IgG4-associated Multisystem
Malignancy-associated RDD	Leukemia Lymphoma LCH Histiocytic sarcoma
Autoimmune-associated RDD	Systemic lupus erythematosus (SLE) Juvenile idiopathic arthritis (JIA) Autoimmune hemolytic anemia (AIHA)

Adapted with permission from Haroche and Ablu [142]

Baseline Evaluations

In addition to histopathological features, the diagnostic workup of patients with suspicious RDD should include a detailed history (personal and family history of autoimmune diseases or malignancy) and physical examination to rule out other causes of lymphadenopathy. Hepatosplenomegaly

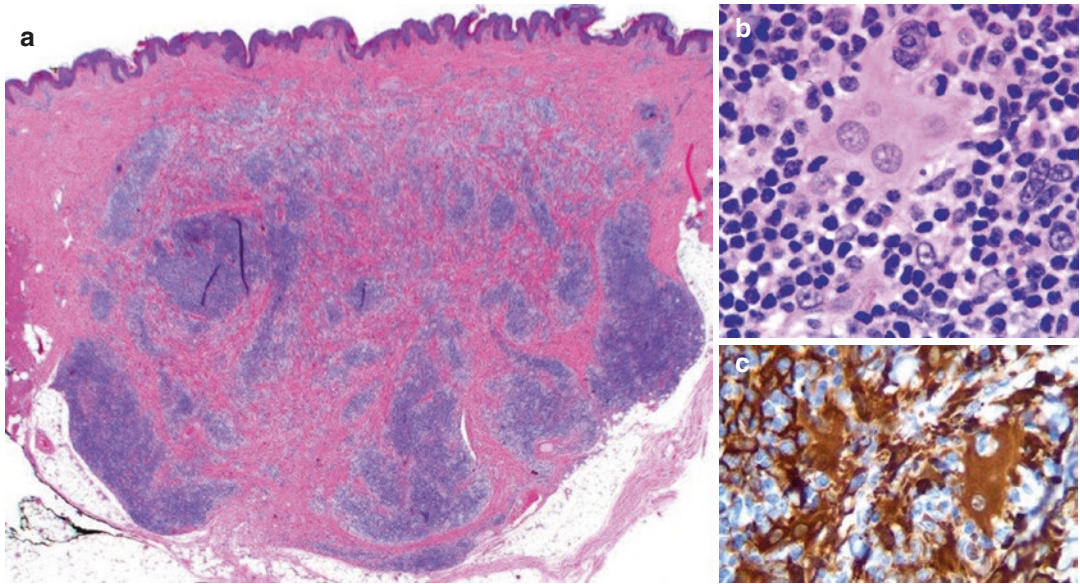


Fig. 19.1 Rosai–Dorfman disease of the skin with. (a) an expanded deep dermal infiltrate composed of RDD cells surrounded by nodular lymphoplasmacytic inflammatory infiltrates (H&E 4×). (b) The cytomorphology of the RDD cells is constant which includes large histiocytes with

ample cytoplasm and a large hypochochromatic nucleus; emperipolesis is not present in all cells (H&E 100×). (c) Immunostains may help highlight the nonstaining cells of emperipolesis (S100 immunostain, 100×) (Courtesy of Dr. Jennifer Picarsic, Pittsburg, PA, USA)

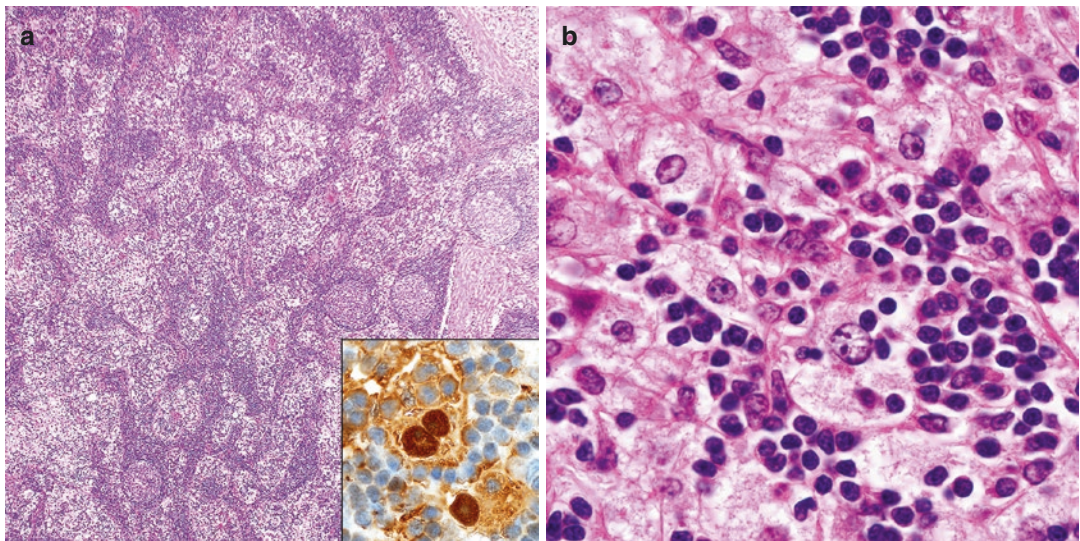


Fig. 19.2 Rosai–Dorfman disease, lymph node with (a) sinus expansion by large pale staining histiocytes (H&E 4×); inlet RDD cells with emperipolesis (S100 immunos-

tain,100×). (b) RDD cells with pale staining cytoplasm and a large hypochochromatic nucleus (H&E 100×) (Courtesy of Dr. Jennifer Picarsic, Pittsburg, PA, USA)

is rare in RDD while it is more common in other histiocytic disorders. Staging should include a contrast CT scan of the neck, chest, abdomen, and pelvis. Positron emission tomography (PET) with FDG can be added if bony disease is suspected,

although it can also be helpful if other extranodal sites are suspected. Blood work should include a complete blood count (CBC), an erythrocyte sedimentation rate (ESR), and immunoglobulin levels. Leukocytosis, hypergammaglobulinemia,

and an elevated ESR are all nonspecific findings in RDD. A normochromic normocytic anemia, a positive rheumatoid factor, and antinuclear antibody have been reported. Hemolytic anemia and eosinophilia have been reported in association with RDD. Further, blood work to exclude ALPS is recommended in all RDD patients, along with flow cytometry of the lymph node; renal and liver function tests should be checked due to the rare renal and hepatic presentations. Bone marrow aspirate and biopsy are required only for patients with cytopenias or abnormal peripheral blood cells. Patients with orbital or neurological symptoms should have a brain MRI, and those with symptoms suspicious for spinal cord compression will require a spinal MRI with diffusion-weighted imaging (DWI). A rare case of treatment-refractory systemic RDD with only immunohistochemical expression of “platelet-derived growth factors (PDGF)- α and PDGF- β ” and *c-kit* showed sensitivity to imatinib therapy despite no evidence of associated molecular alterations [34]. Such rare cases highlight the need to explore alternative therapies that may hold promise in refractory disease for some cases. In addition, genomic sequencing of lesional tissue might help identify MAPK pathway mutations which if positive can lead to targeted therapies in resistant cases.

Clinical Features

Classic RDD

Most patients with RDD present, in otherwise good health, with bilateral, massive, and painless cervical lymphadenopathy (90%) (Fig. 19.3) with or without intermittent fevers, night sweats, and weight loss [11]. Mediastinal (30%), axillary (38%), and inguinal nodes (44%) may also be involved. Retroperitoneal lymphadenopathy has been reported in a small number of patients [35].

Extranodal RDD

Extranodal involvement has been reported in up to 43% of cases [3]. Although infiltration of almost every organ system has been reported in RDD, the

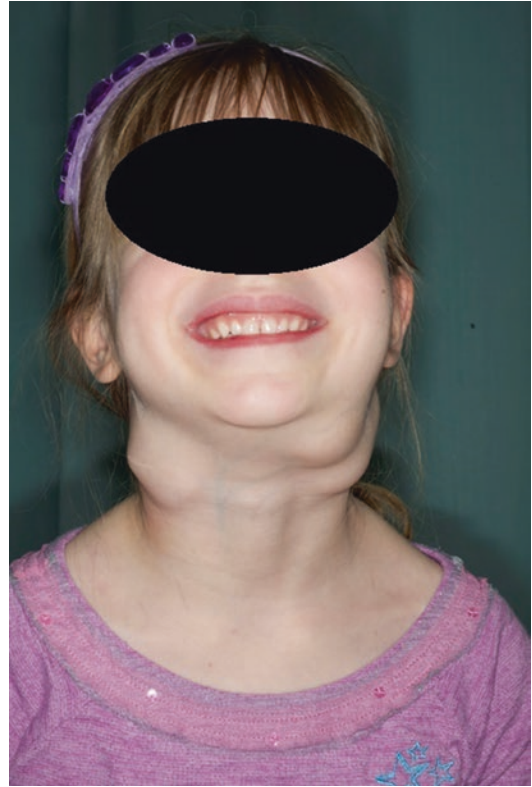

Fig. 19.3 A child with immunodeficiency and Rosai–Dorfman disease with massive cervical lymphadenopathy

most commonly affected sites are the upper respiratory tract (nasal cavities and paranasal sinuses), deep soft tissues, skin, eyes, and retro-orbital tissue. Salivary glands and central nervous system (CNS) have been reported less frequently. Localizations of RDD in the lungs, genitourinary and gastrointestinal tract/liver, breast, thyroid, and even heart and bone have also been documented. Below is a discussion of the systems affected by RDD with a section on a differential diagnosis consideration for each site presentation.

Cutaneous Manifestations

The skin is involved in 10% of RDD cases, and 3% of cases are limited to the skin without nodal or other extranodal lesions [3]. Cutaneous lesions can be variable, but are typically nodules (Fig. 19.4), plaques, or papules, yellow, red to brown, or skin-colored. The lesions are usually painless but can rarely be painful and itchy.

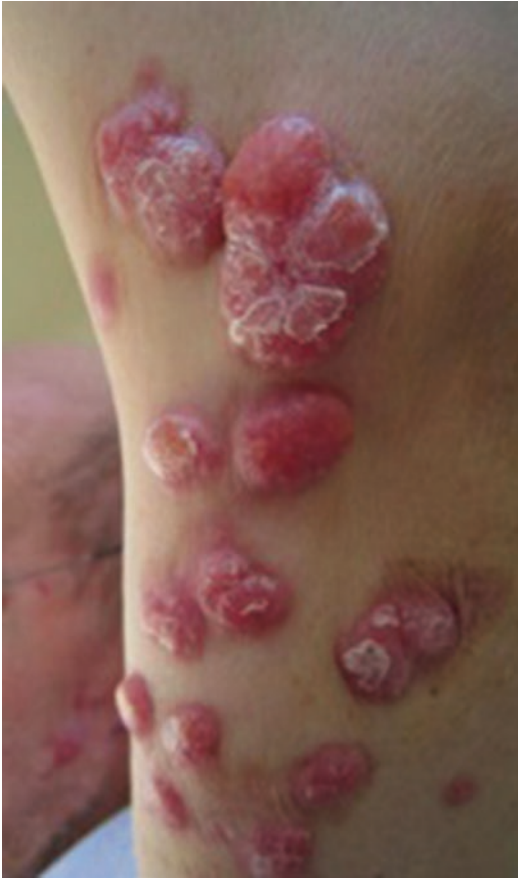

Fig. 19.4 Rosai–Dorfman disease of the skin showing red nodular lesions (Courtesy of Dr. Julien Haroche, Paris, France)

Cutaneous RDD (C-RDD) tends to occur at an older age, has a female preponderance, and has a higher prevalence in Asians compared with classic systemic RDD. Patients with C-RDD are generally in normal health and do not routinely have lymphadenopathy or fever [36]. Rare cases of combined C-RDD and cutaneous small LCH-like aggregates have been reported [36]. In some cases of C-RDD, the presence of abundant IgG4-positive plasma cells and stromal fibrosis was suggested to be a link to IgG4-related sclerosing disease [37]. The most commonly affected skin areas are the face (cheeks and periorbital area), chest, abdomen, back, and upper and lower limbs. Facial C-RDD lesions usually present as multiple, non-ulcerative, asymptomatic, red nodular plaques with duration ranging from 1 month to a

few years. The histology typically shows a mid to deep dermal infiltrate with surrounding lymphoid cells and plasma cells (see above).

The differential diagnosis includes granuloma facial, acne vulgaris, sarcoidosis, scleroderma, varicella zoster, leprosy, and cutaneous metastasis. Many methods have been tried for the treatment of C-RDD (antibiotics, corticosteroids, chemotherapy, radiotherapy, retinoids, thalidomide, laser, and cryotherapy). The most effective treatment appears to be surgical excision, with an 80% cure rate with no evidence of recurrence (see section “[Treatment](#)”). Spontaneous resolution can occur in many C-RDD cases regardless of the treatment modality [38].

After a diagnostic incisional biopsy, it seems reasonable to leave C-RDD under a “watch and wait” strategy with the hope for a spontaneous regression. Nevertheless, some patients may require active treatment for cosmetically disfiguring, painful, or itchy cutaneous lesions.

Soft Tissues

Isolated soft tissue RDD is very rare. The review by Foucar et al. reported that only 13 (3%) out of 423 patients with RDD had extranodal soft tissue RDD without lymph node involvement [3]. Extranodal lesions including soft tissues are usually associated with more fibrosis, fewer histiocytes, and less emperipolesis which can make the diagnosis of RDD more difficult.

Central Nervous Manifestations

Central nervous system (CNS) involvement in RDD is rare and occurs in <5% of cases. Among these, 75% occur as intracranial lesions, while 25% present with intraspinal lesions. CNS RDD has a predilection for men during the fourth to fifth decades of life. Isolated intracranial RDD lesion without lymphadenopathy is very rare, and only 21 pediatric cases of isolated intracranial RDD have been reported until 2015 [39–41]. The most typical appearance is a dura-based (Fig. 19.5), extra-axial, homogeneously enhancing mass

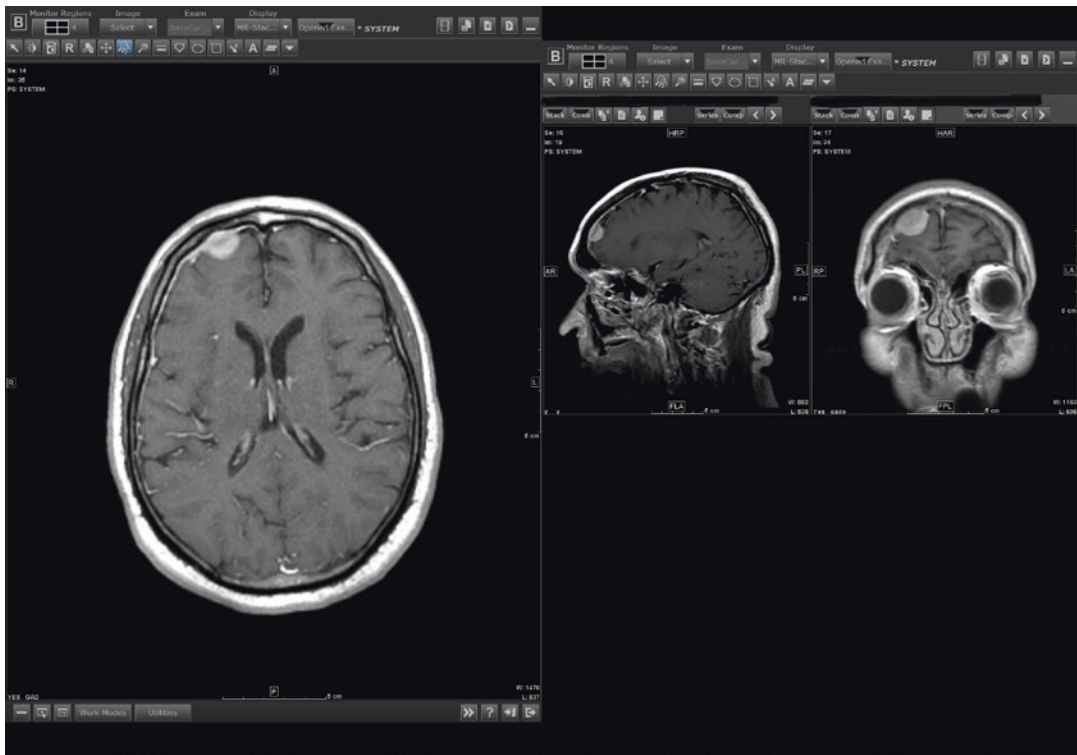

Fig. 19.5 Rosai–Dorfman disease of the brain dura: axial, coronal, and sagittal gadolinium-enhanced T1-weighted MRI demonstrates an enhancing dural-based

mass overlying the right frontal lobe (Courtesy of Dr. Eli Diamond, New York, USA)

that is associated with surrounding vasogenic edema, mimicking a meningioma. Common presenting symptoms include headaches, seizures, limb weakness, and cranial nerve deficits, based on the location of the lesions. CNS RDD most commonly present with a single lesion, although multifocal lesions have been reported [42]. The most common intracranial sites are the cerebral convexities, cavernous sinuses, suprasellar and petroclival region, and the orbits. On MRI, RDD lesion is usually hypo-isointense on T1-weighted images with very low signal intensity on T2-weighted images. An RDD lesion may have a dural tail as seen in the case of meningioma. However, the presence of internal low signal intensity areas on T2-weighted images and the lack of hypervascularity on angiogram can help distinguishing an RDD from a meningioma [43]. The presence of emperipolesis in the CSF can also be helpful in distinguishing RDD from a meningioma. Patients with CNS RDD can rarely present

with intraparenchymal (brain stem, pontine) [39] (Fig. 19.6) or intraventricular lesions [44].

The differential diagnosis of CNS RDD includes meningiomas, malignant gliomas, CNS lymphomas, LCH, sarcoidosis, tuberculosis, metastatic tumors, and neurofibromatosis. Although the course of most intracranial RDD lesions is generally benign, no spontaneous regression has been reported so far. Most patients will have a favorable outcome after a radical surgical resection. A review of 43 cases of CNS RDD showed that 58% of patients were alive at the time of report [45]. Another small series showed that 9 out of 11 patients lived 2–42 months (mean 15 months), with no patient having disease recurrence even with subtotal resection [46]. Nevertheless, intracranial RDD can rarely have an aggressive and fatal course [46–48].

Ophthalmic manifestations occur in 10% of RDD cases, often involving the orbital soft tissues, eyelid, lacrimal gland, conjunctiva/subconjunctiva, and cornea, uveitis, and optic nerve

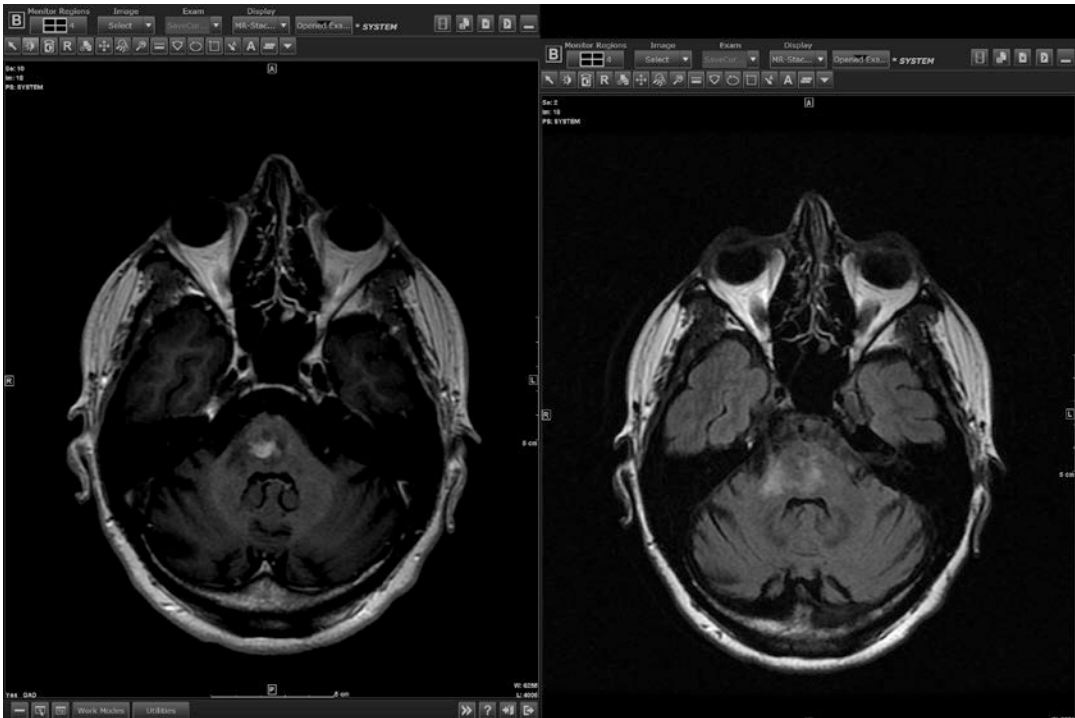


Fig. 19.6 Rosai–Dorfman disease of the brain stem: axial t2-FLAIR and gadolinium-enhanced T1-weighted MRI demonstrates enhancing and non-enhancing abnor-

malities in the pons and cerebellar peduncle (Courtesy of Dr. Eli Diamond, New York, USA)

compressive neuropathy [3]. Visual impairment may occur and is usually partial, although complete blindness has been rarely reported [49]. Epibulbar mass involvement, bilateral or unilateral, has been described and usually presents as pink, salmon-colored, and fleshy masses [50].

Rarely, intracranial RDD can extend in the prepontine area causing mild compression of the adjacent pons, with subsequent damage to the auditory nerve pathway and deafness [51]. Rare reports of sensorineural hearing loss due to intracranial RDD (one of them involving two siblings) have been published [52, 53]. Furthermore, many familial cases of RDD have been associated with sensorineural hearing loss [27–30].

Intraspinal involvement with RDD has been reported in more than 50 case reports [54] (Fig. 19.7). At least 15 of these reported cases were isolated to the spine. Spinal RDD can manifest with epidural, intradural, or intramedullary disease in the spinal cord. The lesions most commonly occur in the thoracic or cervical spinal areas. Patients commonly present

with progressive onset of limb paraparesis, limb sensory deficits, gait difficulty, back pain, and urinary and bowel incontinence. Usually, these symptoms would develop over the course of weeks or months, although rarely they can develop over days [55]. Neuroimaging findings for isolated spinal RDD usually show a well-circumscribed dural or extradural masses on MRI. On T1-weighted images, most lesions are isointense to the spinal cord, although hyperintense and hypointense lesions have been reported. The main differential diagnosis of epidural spine RDD includes hematoma, abscess or phlegmon, meningioma, metastasis, lymphoma, sarcoidosis, or IgG4-related meningeal disease. Surgical debulking is the first treatment approach for spinal RDD.

Head and Neck Manifestations

Commonly involved extranodal sites of the head and neck are the nasal cavity and paranasal sinuses

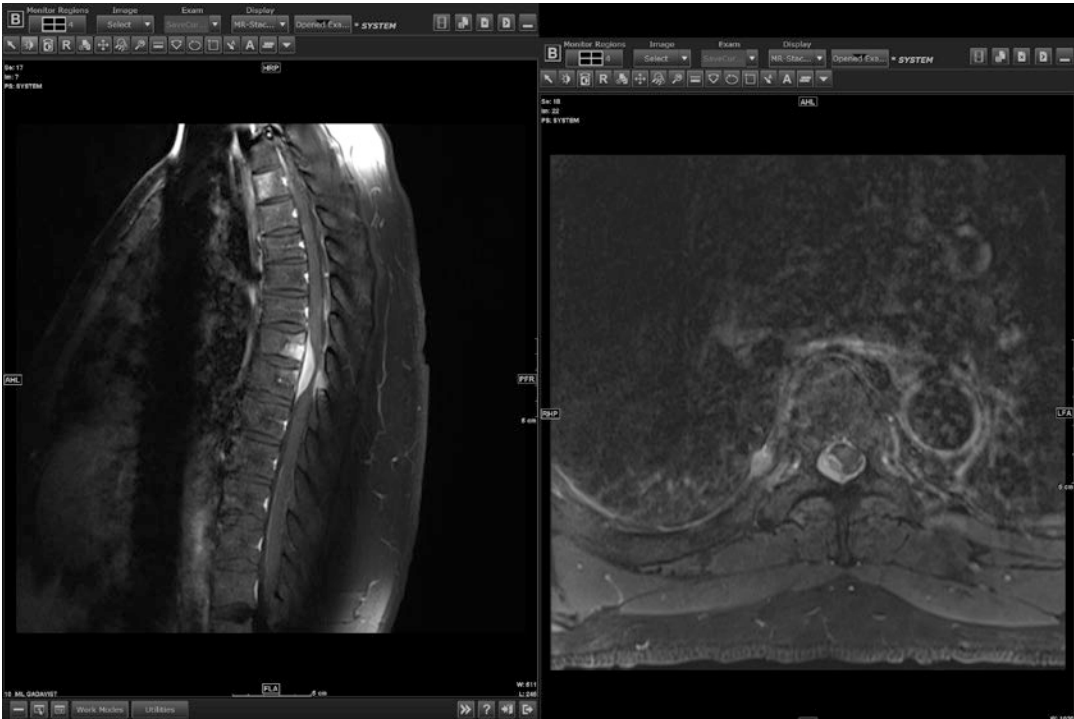


Fig. 19.7 Rosai–Dorfman disease of the spine: sagittal/axial gadolinium-enhanced T1-weighted MRI shows an expansile dural-based mass with compression of the spinal cord (Courtesy of Dr. Eli Diamond, New York, USA)

which has been reported in 11% of cases [3] and appears to be more common in Asians [56, 57]. Based on the lesion sites, sinonasal RDD can be divided into the anterior and posterior sinonasal groups, respectively [57]. Symptoms of sinonasal RDD include nasal obstruction, epistaxis, hyposmia, nasal dorsum deformity, dyspnea, facial asymmetry, decreased vision, and aural fullness [57]. Although recurrences can still occur after endoscopic surgery, this procedure can induce short-term symptomatic control and restoration of function.

Oral cavity involvement can also occur in RDD, most frequently presenting with soft and hard palate nodules, gingival and oral mucosa swelling, tongue enlargement, thickened mucosa of the oropharynx, enlarged tonsils, and frequent episodes of tonsillitis [3]. Most patients with oral cavity RDD will usually have lymph node involvement, and almost 90% have some form of extranodal disease, most commonly nasal cavity and paranasal sinuses. The oral cavity may seem to be an unfavorable site of RDD, since 9% of the patients, in the series by Foucar et al., died

although RDD was not the direct cause of death in these patients [3].

Other less frequently involved extranodal sites include the salivary glands (parotid and submandibular enlargement), larynx, pharynx, thymus, and thyroid gland [11, 58, 59]. More than 30 cases of RDD in the larynx have been reported, and at least one case involved the paraglottic space [59]. Patients with masses of the upper respiratory tract present with dysphagia, dyspnea, a foreign body sensation, voice changes, cough, and stridor. Differential diagnosis of laryngeal masses includes laryngeal cancer, hemangiomas, lipomas, chondromas, LCH, and metastatic carcinomas. RDD lesions tend to be slow-growing masses that are often present for long periods before causing any symptoms. The mainstay of therapy for laryngeal RDD is surgical resection.

Thyroid involvement with RDD is very rare. Patients may present with subacute thyroiditis, with a diffusely enlarged and tender thyroid gland. Thyroid involvement can also occur secondary to local extension from adjacent lymph

nodes [3]. Fine-needle aspiration cytology was found to be a useful diagnostic procedure and can potentially avoid an unnecessary thyroidectomy [58].

The prognosis of patients with head and neck RDD is variable. Previous reports showed that 2 of 14 patients (14.3%) with extranodal RDD of the head and neck and 6 of 126 patients (4.8%) with sinonasal disease died with RDD, respectively [57, 60].

Intrathoracic Manifestations

Intrathoracic RDD is described in only 2% of patients, and mediastinal lymphadenopathy is the most common manifestation. Other presentations include airway disease, interstitial lung disease, pulmonary nodules and cysts, tracheobronchial disease, and pleural effusions. Patients usually present with a history of chronic dry cough, progressive dyspnea, or acute respiratory failure. All RDD patients with lower respiratory tract disease in the series by Foucar et al. had evidence of nodal involvement; however, rare cases of pulmonary RDD in the absence of nodal disease have been published [61–63], although nodal disease was later diagnosed in one report [61]. Rare cases of pulmonary IgG4+ RDD have been reported [61, 63], although the IgG4/Ig ratio was not clear from these reports. Lung biopsy usually shows a significant proportion of IgG4-positive plasma cells. The presence of pleural effusions in RDD can be a result of an invasion of the pleural lymphatics by histiocytes causing a loss of pleural resorption. Pseudotumor nodular presentation in the lungs can manifest as hypermetabolic pulmonary nodules on PET scan. Pulmonary RDD can mimic pulmonary LCH or ECD; negative immunohistochemical staining for CD1a, Langerin, CD163, and factor XIII-a can help excluding these other histiocytoses (see Chap. 1). The absence of granulomas and negative stains will help ruling out sarcoidosis and mycobacterial and fungal infections.

Infiltration of the tracheobronchial tree with RDD lesions may cause an obstructive pattern on pulmonary function tests. Tracheal RDD can

mimic tracheal carcinoma, plasmacytoma, papilloma, or more rarely granulomatous lesions (tracheal amyloidosis) [64]. Patients with a chronic aggressive form of RDD affecting the lower respiratory tract may have a poor prognosis. Indeed, almost 45% of these patients, in the series by Foucar et al., died of their disease [3]. Patients with pulmonary or tracheobronchial RDD can be treated with either tracheostomy, debulking resection by rigid bronchoscopy, laser resection, surgery, or corticosteroids [61, 64–66]. Recurrence of tracheobronchial RDD is common, which justifies the long-term follow-up of these patients.

Breast involvement with RDD can occur in the form of subcutaneous lesions over the breast or as intraparenchymal breast mass with or without axillary lymphadenopathy [3].

Cardiac Manifestations

Cardiac involvement in RDD is very rare, occurring in 0.1–0.2% of cases [67]. Most common symptoms include chest pain, palpitations, fever, hypotension, shortness of breath, syncope, dry cough, edema, fatigue, and atrial flutter; the disease can rarely present as an incidental finding on cardiac imaging. Different patterns of cardiac involvement have been identified: an intracardiac mass with or without underlying infiltration, pericardial/epicardial involvement, tricuspid or pulmonary valve involvement, and a pulmonary arterial mass. Left ventricular hypertrophy, a low left ventricular ejection fraction, and conduction abnormalities are frequent findings on echocardiogram and ECG. A recent literature review reported 18 cases of cardiac RDD (15 adults and 3 children) treated with either steroids or surgery. Five deaths occurred in this cohort (one pediatric patient and four adults). Among the deaths, three were related to cardiac RDD, one died during an invasive biopsy procedure, and one died of other causes [67].

The differential diagnosis of cardiac RDD includes sarcoma, benign atrial myxoma, granulomatous disease, and lymphoma. While a computed tomography (CT) scan can delineate the

anatomical extent, magnetic resonance (MR) imaging and positron emission tomography (PET) can analyze the morphology and metabolic activity of the mass. Further, PET scan is also a sensitive indicator for early prediction of treatment response in RDD [68]. The literature review suggested that successful surgical resection of cardiac RDD leads to a favorable prognosis. We have seen a teenage girl with isolated cardiac RDD, who is now in complete remission at 3 years after surgical resection (personal communication, O. Ablá).

Genitourinary Manifestations

The most common site of genitourinary (GU) involvement by RDD is the kidney followed by the testis [3]. Kidney involvement is rare and seen in only 4% of patients [69]. Patients may present with fever, weight loss, hematuria, flank pain, abdominal fullness due to a large mass [70], acute renal failure [71], nephrotic syndrome caused by a generalized amyloidosis, or renal vein thrombosis with subsequent pulmonary thromboembolism [72]. Some patients with kidney involvement may have concurrent nodal disease, which in some cases may impinge on the urinary system. Rare cases have been reported in association with adenocarcinoma of the prostate [69, 73]. Hypercalcemia, due to extrarenal calcitriol overproduction, was reported in a hemodialysis adult patient who was later diagnosed with nodal RDD [74]. Radiologically, the renal involvement can present as discrete nodal masses, infiltrative lesions around the capsule, lobular irregularly enlarged kidneys with distorted calyces, and large para-aortic lymph nodes [75]; hydronephrosis and ureteral obstruction are common complications [76]. The differential diagnosis of renal RDD includes ECD, leukemia, lymphoma, renal cell carcinoma, storage disease, tuberculosis, or a metastatic tumor such as malignant melanoma, given the S100 staining positivity. Of note, LCH does not seem to involve the kidneys which are considered as privileged sites. Patients with RDD renal involvement have been associated with poorer outcomes, with 40% of

them dying with RDD and the remainder having persistent disease [3].

Testicular involvement with RDD is very rare. Patients may present with a testicular pain and an intrascrotal mass (swollen and tender) or an enlargement of the epididymis [3, 77]. Differential diagnosis should include seminoma, germ cell tumor, Leydig cell tumor, metastasis, or focal epididymitis. LCH does not usually involve the gonads, and these are also considered as privileged sites. Treatment with orchiectomy is usually curative in most patients. RDD can also affect the genital skin around the scrotum, epididymis, and vulva [3].

Adrenal gland involvement is a very rare extranodal manifestation of RDD. Patients may present with a unilateral or bilateral fibrotic infiltrates surrounding the adrenals, with sometimes an infrahilar nodal involvement [78]. Surgical resection of the adrenal gland is an effective treatment strategy.

Gastrointestinal Tract Manifestations

Gastrointestinal (GI) tract involvement in RDD is very rare, occurring in less than 1% of all extranodal cases [3]. GI RDD seems to affect mainly middle-aged female patients, can be solitary or segmental, and has a predilection for ileocecal area, appendix, and distal colon, with most cases being located beyond the pylorus [21, 79]. An involvement of the whole GI tract including the esophagus, stomach, duodenum, ileum, colon, and rectum has been rarely reported [80]. Most cases of GI RDD are associated with nodal or other extranodal manifestations, although rarely the disease can be restricted to the digestive system. Presenting symptoms include fever, hematochezia, constipation, abdominal pain, abdominal mass, and intestinal occlusion, which can sometimes mimic colonic diverticulitis [15]. Sometimes patients may be asymptomatic, and RDD is discovered incidentally on colonoscopy as an isolated polyp [81], autopsy, or in an appendectomy specimen.

Although RDD involving the GI tract has similar morphological features to nodal disease, more

fibrosis and fewer histiocytes with emperipolesis are encountered which may make the diagnosis difficult. Also, described cases only rarely involve the mucosa, with deeper lesions more often described, making diagnosis by endo-/colonoscopy difficult [22, 79]. The differential diagnosis of RDD of the GI tract includes LCH, ECD, and follicular dendritic cell sarcoma [21, 82].

IgG4-related RDD can occur all over the body including the GI tract. A case of cecal RDD was reported and showed histologic features of IgG4-related disease including areas of storiform fibrosis and numerous IgG4 positive plasma cells with elevated ratio of IgG4 to IgG [22].

RDD involving the GI tract does not usually undergo spontaneous remission. Of the reported patients for whom follow-up data of >12 months were available, almost 20% died from disease complications, while the remaining patients were alive with disease [21].

Pancreatic localization of RDD is extremely rare, with only seven cases being reported in the literature so far [79, 83–88]. Pancreatic RDD is characterized by nonspecific symptoms, such as abdominal or back pain and endocrine insufficiency like hyperglycemia. The main differential diagnosis includes pancreatic malignancy, IgG4-disease-related autoimmune pancreatitis, LCH, and other histiocytic disorders. The most common treatment approach in pancreatic RDD is surgical resection.

Liver Manifestations

Hepatic involvement is seen in only 1% of RDD cases [3]. Usually, the liver is affected as a part of systemic RDD with nodal and extensive extranodal involvement as shown by Lauwers et al. [79]. In this case series of 11 patients with RDD of the digestive system, 5 cases of hepatic RDD were documented. The presentation varied from a well-circumscribed firm white nodule in the right lobe, liver scan showing several areas of decreased radioactivity in a normal sized liver and tender hepatomegaly. In four of the five cases with pathologic evaluation, the histology ranged from granulomatous hepatic nodules to localized

portocentric histiocytic infiltrates [79]. Of note, S100+ sinusoidal histiocytes can be seen in a number of liver pathologies and should not serve as evidence of hepatic RDD involvement. Among these five patients in the Lauwers series, two died of disease, two were alive with disease, and one was lost to follow-up. Cirrhosis of the liver has been reported in at least three case reports in recent years [71, 89, 90].

The differential diagnosis of hepatic RDD includes LCH, ECD, and JXG; other focal lesions in the liver such as hepatic cysts, abscess, hemangioma, adenoma, and lymphoma have to be ruled out as well. However, hepatic involvement of histiocytic lesions has a particular pattern of involvement which should be taken into account (LCH-biliary; JXG-portal centric without destructive biliary lesions; see also Chap. 1). A case of hepatic RDD with concurrent relapsing nodal follicular lymphoma has been reported [91].

The previously reported cases of RDD involving the liver showed that 7% died with disease [79, 90]. However, these cases were always reported in the setting of systemic RDD [79, 90]. The case of an isolated hepatic RDD with follicular lymphoma was alive and well at the time of report, despite the relapsing lymphoma [91]. This indicates that the prognosis of RDD is dependent on the number of extranodal sites involved by the disease rather than its specific site.

Bone Manifestations

Bone involvement with RDD occurs in 5–10% of cases in association with nodal disease [3, 92]. Isolated bone involvement in RDD is very rare, with less than 50 cases reported in the literature [92]. Typically, patients present with bone pain, tenderness, a bone mass, and rarely pathological fractures [71]. Radiologically, bony RDD lesions are usually osteolytic or mixed lytic sclerotic, often with a narrow zone of transition. However, lesions can sometimes look more aggressive with soft tissue extension. The usual location is metaphyseal or diaphyseal. The lesions can easily be confused with LCH or ECD bony disease.

Other differential diagnoses based on imaging include chronic osteomyelitis (including chronic recurrent multifocal osteomyelitis), lymphoma, metastasis, giant cell tumor, fibrous dysplasia, and Ewing sarcoma. Typically histology will easily differentiate on biopsy.

Similarly to other lymphoproliferative disorders, RDD lesions are known to be FDG-avid. There are few reports of FDG avidity of RDD lesions in the skeletal system (Fig. 19.8) [93] and in other extranodal areas such as the liver, pancreas [87], heart [68] and brain [94, 95]. PET-CT scan can also be helpful in monitoring response to therapy [95].

Although the lesions usually undergo spontaneous resolution, many cases of RDD tend to follow a “waxing and waning” clinical course [96]. In general, the prognosis of primary bony RDD is good. Most reported cases of isolated skeletal RDD healed completely after the totally surgical curettage or resection [97]. Radiotherapy might be helpful in patients whose symptoms recur

after surgery or for those who are unsuitable candidates for surgery [98].

Hematological and Bone Marrow Manifestations

Common hematological abnormalities in RDD patients include normochromic normocytic anemia (reported in 67% of cases), leukocytosis (in about 60%, more often neutrophilia), thrombocytopenia, and a raised ESR. Rare cases of congenital RDD with anemia, thrombocytopenia, and hepatosplenomegaly without lymphadenopathy have been reported. Both cases recovered spontaneously with conservative management [25, 26].

The most common immune dysfunction in RDD is autoimmune hemolytic anemia. Although most patients with RDD tend to have spontaneous resolution of their disease, those with associated autoimmune manifestations have a particularly poor prognosis. A review of the RDD

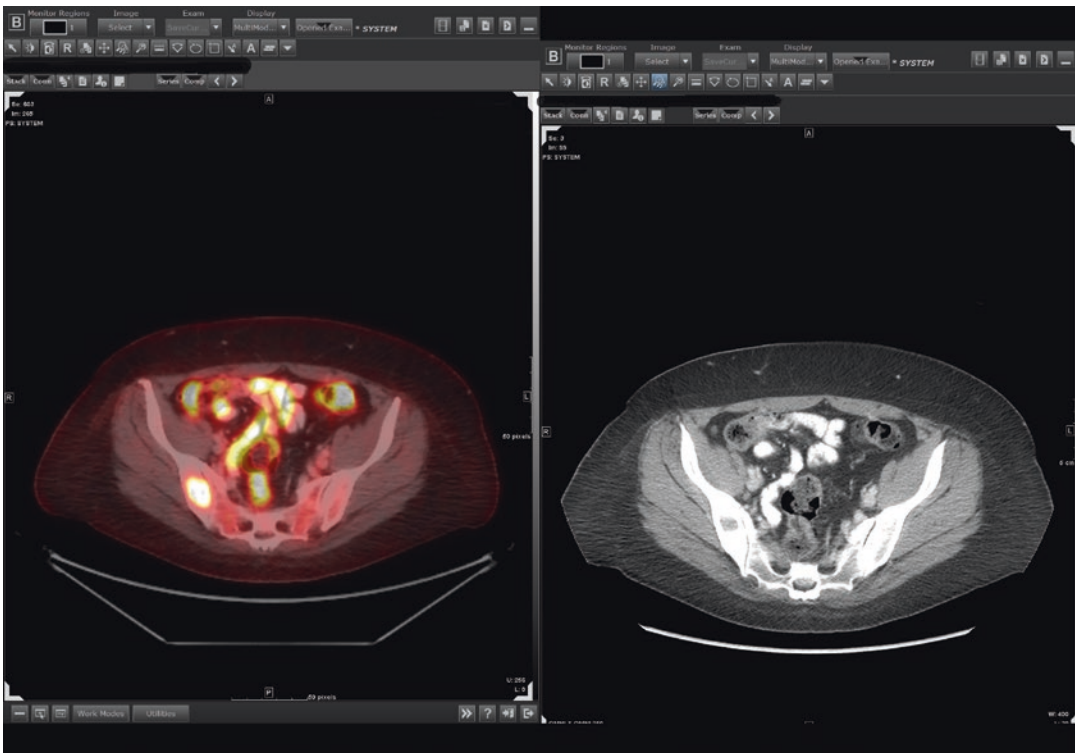


Fig. 19.8 Rosai–Dorfman disease of the bones: axial-fused FDG-PET/CT demonstrates a hypermetabolic lesion in the right iliac bone (Courtesy of Dr. Eli Diamond, New York, USA)

registry by Foucar et al. (400 patients) found that none of the 13% of patients with associated autoimmune disease achieved a complete remission, and patients with autoimmunity represented >50% of the registry's fatalities [3].

Despite the common hematological abnormalities associated with RDD, actual bone marrow (BM) involvement with RDD is extremely rare. Huang et al. reported the case of an adult with a history of idiopathic thrombocytopenic purpura, where his BM showed involvement by extranodal RDD [99]. However, the presence of focal BM involvement might hinder the detection of RDD. Another limitation is the fact that extranodal RDD infiltrates are usually associated with marked fibrosis, fewer emperipolesis, and inflammatory lymphoid cells which may suggest a chronic inflammation rather than RDD. Conventional MRI with DWI is a better tool in identifying focal bone marrow infiltration by RDD [100, 101].

Treatment

Because of the heterogeneous clinical presentations of RDD patients, treatment is usually restricted for symptomatic disease or life-threatening vital organ involvement. The number of cases who have spontaneous remission without any therapy varies between 20% and 50% [65, 102].

Surgery is usually limited to biopsy, although debulking may be warranted in cases with impending upper airway obstruction, spinal cord compression, intracranial resectable lesions, or localized cutaneous or bone RDD. Long-term remissions with surgery alone have been reported in isolated intracranial disease [103, 104]. Surgical excision of resectable lesions led to a complete remission in eight out of nine patients [65]. A surgical approach can, however, be associated with morbidity in some cases, but most patients will have a prolonged disease-free survival [65, 104]. In the absence of post-op residual neurological symptoms, a "wait and watch" strategy can be followed after partial resection of CNS RDD lesions [105]. Patients with residual CNS symptoms may benefit from external beam or stereotactic radiotherapy [105].

Radiotherapy has limited efficacy in RDD, although it can be beneficial in refractory soft tissue and orbital bone disease with visual compromise [106, 107] and resistant airway obstruction or as a palliative option for symptomatic disease [65, 108]. Radiotherapy has also been recommended in patients whose symptoms persist or recur after surgical intervention or for those who are not suitable candidates for surgery [98]. No standard doses of radiotherapy have been established, but a lymphoma-like total dose between 30 and 50 Gy has been employed [108]. Due to the acute and long-term toxicity of radiotherapy in children, it is preferable to use this modality only as a last therapeutic resource for urgent or palliative pediatric RDD cases.

Whenever treatment for RDD is required, many histiocytosis experts consider systemic steroids as the first-line therapeutic option, at least in children. Steroids are usually helpful in reducing nodal size and symptoms, although responses to these drugs have been variable and unpredictable. The optimal type of steroid (prednisone or dexamethasone), dose, and duration has not been well defined. Prednisone, at a dose ranging between 40 and 70 mg/day, has produced complete or partial responses in cases of orbital, CNS, bone RDD and AHA-associated disease [109, 110]. Similarly, dexamethasone at doses ranging between 8 and 20 mg/day has been effective in cases of CNS RDD and hilar lymphadenopathy [111, 112]. Intralesional injection of steroids in an adult case with orbital RDD and optic nerve compression has been effective [113]. Nevertheless, other reports of orbital, tracheal, renal, or soft tissue RDD failed to show any response to steroids [114–116]. In addition, steroids can be quite immunosuppressive and have many unpleasant side effects (especially mood changes, weight gain, myopathy, hyperglycemia, and hypertension). Further, relapses of RDD lesions can always happen after a short period of interruption. Patients and parents need to be aware of the implications of steroid therapy including their side effects, quality of life, and the unpredictable responses. Also, decisions regarding steroid therapy should not be taken because of cosmetic reasons only.

Responses to chemotherapy in RDD have also been quite unpredictable. Anthracyclines and alkylating agents seem to have little efficacy, while vinca alkaloids have shown variable responses [65]. The combination of low-dose methotrexate (MTX) and 6-mercaptopurine (6-MP) was effective in only a few patients [65, 117]. In other series, a few patients achieved sustainable remissions after regimens containing vinblastine/MTX/6-MP and 6-thioguanine [118], vinblastine/prednisone/MTX/6-MP [119], or vinorelbine/MTX [120]. Single-agent 6-MP was effective in stopping disease progression in an adult with orbital and intracranial RDD [121]. Further, long-term remission of intracranial RDD has been reported after postsurgical maintenance with CHOP-like regimens [122]. Anecdotal reports of efficacy with cytarabine or cyclophosphamide have been published [123], but our own experience with these agents has been disappointing. A multiply relapsed and refractory nodal RDD case with debilitating symptoms has shown response to cytarabine/prednisone/vincristine followed by MTX/6-MP maintenance [123]. Anecdotal successful treatment of refractory cutaneous RDD has been reported with single-agent vincristine [124] and low-dose MTX [125]. In addition, azathiopurine and interferon- α have been shown to induce long-term remissions in patients with RDD [126–128]. However, the use of interferon- α in combination with chemotherapy failed to induce any response in another report [65].

Nucleoside analogues, such as cladribine (2-CdA) and clofarabine, have shown favorable responses in RDD [71, 129–132]. They decrease the viability and impair the function of monocytes through inhibition of IL-6, IL1- β , and TNF- α production. Cladribine was effective in inducing prolonged remissions in cases of recurrent, refractory systemic RDD [71, 129–131], while clofarabine (at 25 mg/m²/day for 5 days and every 28 days for 6 months) was effective as salvage therapy in refractory/relapsed RDD with an 86% response rate [132].

Targeted therapies have shown some activity in RDD patients. The efficacy of rituximab, an anti-CD20 monoclonal antibody, has been

described especially in autoimmune-related RDD cases [133], although refractoriness [123], and recurrences after a complete response [107], have been seen. The exact mechanism of action of rituximab is not clear, but it is possible that the drug is capable of preventing the emperipolesis of CD20+ lymphocytes by the RDD histiocytes [134]. Imatinib mesylate, a tyrosine kinase inhibitor, has also shown anecdotal activity in RDD. One report described an adult patient with refractory RDD who showed a rapid and a complete response to imatinib. The patients' histiocytes were positive for the imatinib target proteins PDGFRB and *c-kit* by immunohistochemistry, but no concurrent mutation was found [34]. Further, imatinib can inhibit the differentiation of CD34+ progenitors into dendritic cell precursors [135]. However, responses to imatinib have been variable with another case of skin RDD who was refractory to this drug [136].

Immunomodulatory therapy, with TNF- α inhibitors, has shown promising results in patients with RDD. Thalidomide is a TNF- α inhibitor with antiangiogenic and anti-inflammatory properties. Because of the high levels of TNF- α and IL-6 found in RDD patients, it is reasonable to conclude that these drugs could be effective. Several reports have shown low-dose oral thalidomide (100 mg/day) to be effective in refractory cutaneous RDD [137–139]. Responses to thalidomide, however, have not been universal, and patients need to be monitored for side effects such as skin rashes, peripheral neuropathy (which can be persistent at a cumulative dose of 20 grams), and fatigue. Furthermore, the optimal dose and duration of this drug in adults and children remain unknown. Lenalidomide, a thalidomide analogue, has recently shown an excellent response in an adult with multiply refractory nodal and bone RDD. The drug seems to be more tolerated than thalidomide (less skin rashes and less neuropathy), although it can be more myelo-suppressive [140].

Sirolimus, an *mTOR* inhibitor, is a new attractive option for patients with autoimmune-related RDD. *mTOR* is a critical pathway for the control of proliferation and cytokine production from immune cells. In RDD, there is a dysregulation of

the PI(3)K/AKT/*mTOR* pathway which is essential for the normal development of histiocytic precursors; thus, *mTOR* inhibition leads to a significant reduction of these cells in vitro. Sirolimus was found to be beneficial in a child with resistant RDD and recurrent autoimmune cytopenias [141] and represents an ideal therapeutic option in patients with ALPS-related RDD.

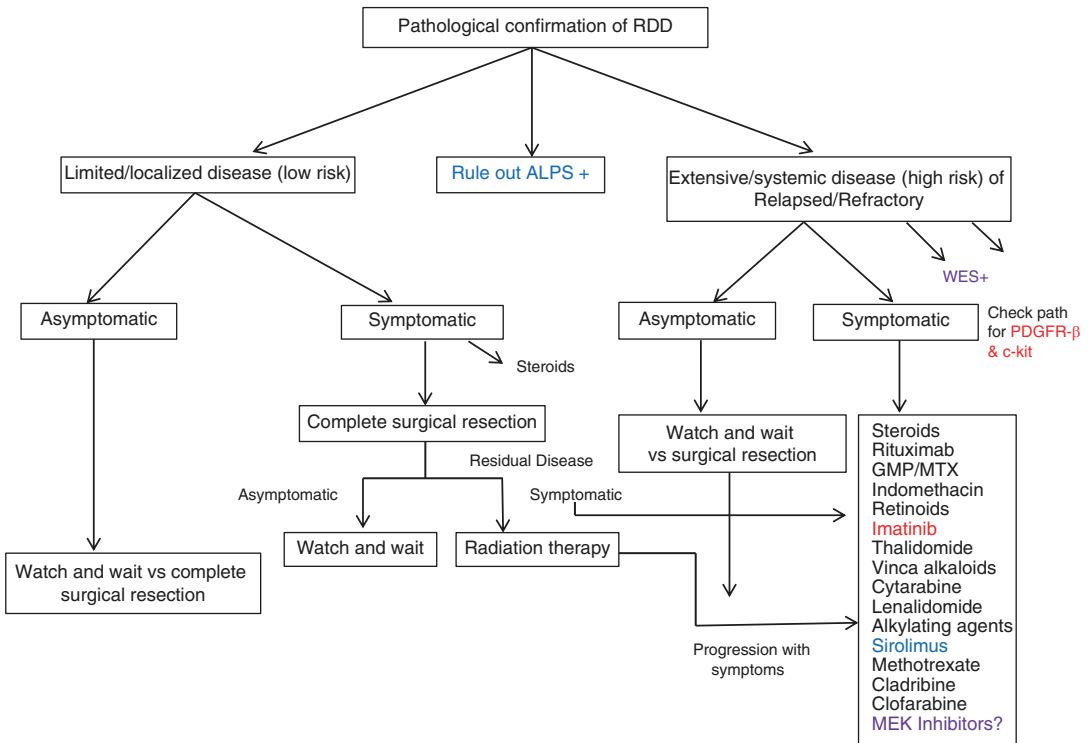
Due to the absence of *BRAF-V600E* mutations in RDD, there are no reports on the use of BRAF inhibitors in this disease. There is currently a phase 2 trial of single-agent cobimetinib (MEK inhibitor) for patients with *BRAF* wild-type ECD at Memorial Sloan Kettering Cancer Center (NCT02649972) that is also accepting patients with RDD. Lastly, due to the rarity of RDD, the role of hematopoietic stem cell transplant in severe cases has not been explored yet.

A proposed treatment algorithm is shown in Table 19.2, and treatment recommendations for newly diagnosed and refractory/relapsed patients are shown in Table 19.3.

Course and Prognosis

Many patients with RDD tend to have an unpredictable clinical course, with alternated periods of remissions and reactivations that may last years. The outcome of most patients is usually favorable as the disease is often self-limiting. However, 7–12% of patients die from disease. In the biggest study on RDD by Foucar et al. in 1990, among 238 patients with RDD, 17 (7%) died of their disease [3]. In a literature review by Pulsoni et al. in 2002, 10 of 80 patients (12%) died from RDD; one of these patients died of amyloidosis and renal failure [65]. Patients with multiple locations of extranodal RDD, those with kidney, liver, or lower respiratory tract disease and those with immunologic abnormalities have an unfavorable prognosis and can be considered as having “high-risk RDD” [3, 142]. These patients tend to have a protracted clinical course with frequent relapses over the years. Thus, it is justifiable to treat this high-risk group with moderate or intensive

Table 19.2 Treatment algorithm for RDD patients



Adapted with permission from Dhalia et al. Cancer Control, 2014

Table 19.3 Treatment recommendations for Rosai–Dorfman disease patients

Class of treatment	Treatment	Indications and comments
First-line conventional therapy	Observation	Uncomplicated lymphadenopathy. Starting therapy for cosmetic reasons is not recommended
	Steroids	High fevers, tracheal compression, or vital organ compromise Effective in immune-related RDD and bone, CNS, and orbital disease Once therapy is discontinued, monitor closely for recurrence
	Surgery	Resectable intracranial lesions, orbital RDD, or vital organ compression (\pm steroids), localized bone RDD
	Vinca alkaloids	Front line multisystem RDD (\pm prednisone)
	6-MP/methotrexate	CNS RDD, or as maintenance after steroids
	Cladribine	Multifocal bone, multisystem (unwell)
	Thalidomide	Skin RDD (upfront or refractory)
	Retinoids	Skin RDD (upfront or refractory)
	Sirolimus	Autoimmune cytopenias or ALPS-related RDD
Second-line conventional therapy	Rituximab	Autoimmune related, or in relapsed/refractory RDD
	Cladribine	Relapsed disease, multisystem, non-resectable CNS, or immune-related RDD
	Clofarabine	Relapsed disease, multisystem, non-resectable CNS, or immune-related RDD
	Methotrexate	Refractory skin or systemic RDD (\pm prednisone)
	Methotrexate	Refractory skin or systemic RDD (\pm prednisone)
	Lenalidomide	Refractory/relapsed disease, skin RDD
	Imatinib	Refractory/relapsed disease; mainly PDGFR+ cases, but could work in any refractory RDD, although unlikely to work in all patients More effective in less severe disease
Radiotherapy	Has limited efficacy, but could help in refractory orbital/bone RDD Should be given only if surgery is not possible	
Clinical trial	MEK inhibitor	Results pending

Adapted with permission from Haroche and Abla [142]

systemic chemotherapy, such as nucleoside analogues, or novel targeted or immune therapy. Patients with isolated and asymptomatic nodal RDD, who can be classified as “low-risk RDD,” typically have periods of enlargement and spontaneous regressions over few years; some of them have mild lymphadenopathy for years that eventually disappears without further recurrences. These patients can be followed closely with a “watch and wait” strategy every 3–6 months for the first 2 years, with a yearly follow-up thereafter to monitor for late recurrences or for the development of lymphomas.

Conclusions

Rosai–Dorfman disease is a benign histiocytic disorder that tends to be self-limited in most cases. Nevertheless, the fatality rate of at least 7% and the association with ALPS/

autoimmune and malignant diseases highlight the clinical heterogeneity of RDD and help identifying a subset of RDD patients with unfavorable outcomes.

The recent identification of *MAPK* pathway mutations in a small group of RDD patients [20] indicates potential response of resistant cases to MEK inhibitors despite absence of *BRAF-V600E* known mutations. Future genomic studies of RDD lesions may lead to the discovery of other *MAPK* pathway mutations, which might lead to more effective, and potentially less toxic, targeted therapies for “high-risk” patients. In the meantime, health-care professionals should refer patients with RDD to tertiary care centers if systemic chemotherapy is required. Because of the rarity of RDD, prospective multicenter studies are challenging. The International

Rare Histiocytic Disorders Registry, IRHDR (ClinicalTrials.gov; NCT02285582), has been enrolling patients since 2015 and aims to better understand the clinicopathological features, treatment strategies, and the outcome of patients with RDD and other non-LCH disorders. A biobank is an additional component of the IRHDR, and this could help identifying new molecular features that can eventually be treated with targeted therapies and possibly correlated with future clinical outcome and response to therapy.

References

- Rosai J, Dorfman R. Sinus histiocytosis with massive lymphadenopathy. *Arch Pathol.* 1969;87(1):63–70.
- Destombes P. Ade'nites avec surcharge lipidique, de l'enfant ou de l'adulte jeune, observe'es aux Antilles et au Mali. *Bull Soc Pathol Exot.* 1965;58(6):1169–75.
- Foucar E, Rosai J, Dorfman R. Sinus histiocytosis with massive lymphadenopathy (Rosai-Dorfman disease): review of the entity. *Semin Diagn Pathol.* 1990;7(1):19–73.
- Emile JF, Abla O, Fraitag S, et al. Revised classification of histiocytoses and neoplasms of the macrophage-dendritic cell lineages. *Blood.* 2016;127(22):2672–81.
- Mahzoni P, Zavareh MHT, Bagheri M, Neda Hani N, Moqtader B. Intracranial ROSAI-DORFMAN disease. *J Res Med Sci.* 2012;17(3):304–7.
- Warrier R, Chauhan A, Jewan Y, Bansal S, Craver R. Rosai-Dorfman disease with central nervous system involvement. *Clin Adv Hematol Oncol.* 2012;10(3):196–8.
- Kutlubay Z, Bairamov O, Sevim A, Demirkesen C, Mat MC. Rosai-Dorfman disease: a case report with nodal and cutaneous involvement and review of the literature. *Am J Dermatopathol.* 2013;36:1–5.
- Paulli M, Bergamaschi G, Tonon L, et al. Evidence for a polyclonal nature of the cell infiltrate in sinus histiocytosis with massive lymphadenopathy (rosai-dorfman disease). *Br J Haematol.* 1195;91(2):415–8.
- Dalia S, Sagatys E, Sokol L, Kubal T. Rosai-Dorfman disease: tumor biology, clinical features, pathology, and treatment. *Cancer Control.* 2014;21(4):322–7.
- Delacretaz F, Meuge-Moraw C, Anwar D, Borisch B, Chave JP. Sinus histiocytosis with massive lymphadenopathy (Rosai Dorfman disease) in an HIV-positive patient. *Virchows Arch A Pathol Anat Histopathol.* 1991;419(3):251–4.
- di Dio F, Mariotti I, Coccolini E, Bruzzi P, Predieri B, Lughetti L. Unusual presentation of Rosai-Dorfman disease in a 14-month-old Italian child: a case report and review of the literature. *BMC Pediatr.* 2016;16:62. doi:10.1186/s12887-016-0595-9.
- Vaiselbuh SR, Bryceson YT, Allen CE, Whitlock JA, Abla O. Updates on histiocytic disorders. *Pediatr Blood Cancer.* 2014;61(7):1329–35.
- Maric I, Pittaluga S, Dale JK, et al. Histologic features of sinus histiocytosis with massive lymphadenopathy in patients with autoimmune lymphoproliferative syndrome. *Am J Surg Pathol.* 2005;29(7):903–11.
- Lu D, Estalilla OC, Manning JT Jr, Medeiros LJ. Sinus histiocytosis with massive lymphadenopathy and malignant lymphoma involving the same lymph node: a report of four cases and review of the literature. *Mod Pathol.* 2000;13(4):414–9.
- Long E, Lassalle S, Cheikh-Rouhou R, Hofman V, Lacour JP, Hofman P. Intestinal occlusion caused by Rosai-Dorfman disease mimicking colonic diverticulitis. *Pathol Res Pract.* 2007;203:233–7.
- Ambati S, Chamyam G, Restrepo R, et al. Rosai-Dorfman disease following bone marrow transplantation for pre-B cell acute lymphoblastic leukemia. *Pediatr Blood Cancer.* 2008;51(3):433–5.
- O'Malley DP, Duong A, Barry TS, et al. Co-occurrence of Langerhans cell histiocytosis and Rosai-Dorfman disease: possible relationship of two histiocytic disorders in rare cases. *Mod Pathol.* 2010;23:1616–23.
- Cohen-Aubart F, Haroche J, De Risi T, et al. La maladie de Rosai-Dorfman-Destombes est une histiocytose inflammatoire polymorphe: etude phenotypique multicentrique de 47 patients. *Orale Communication at the 71st Congress of the Societe' Nationale Franc_aise de Medecine Interne (SNFMI).* June 10–12, 2015. Besancon.
- Chakraborty R, Hampton OA, Shen X, et al. Mutually exclusive recurrent somatic mutations in *MAP2K1* and *BRAF* support a central role for ERK activation in LCH pathogenesis. *Blood.* 2014;124(19):3007–15.
- Diamond EL, Durham BH, Haroche J, Yao Z, Ma J, Parikh SA, et al. Diverse and targetable kinase alterations drive histiocytic neoplasms. *Cancer Discov.* 2016;6(2):154–65.
- Zhao M, Li C, Zheng J, et al. Extranodal Rosai-Dorfman disease involving appendix and mesenteric nodes with protracted course: a report of a rare case lacking relationship to IgG4-related disease and review of the literature. *Int J Clin Exp Pathol.* 2013;6(11):2569–77.
- Wimmer DB, Ro JY, Lewis A, et al. Extranodal Rosai-Dorfman disease associated with increased numbers of immunoglobulin g4 plasma cells involving the colon: case report with literature review. *Arch Pathol Lab Med.* 2013;137(7):999–1004.
- Liu L, Perry AM, Cao W, et al. Relationship between Rosai-Dorfman disease and IgG4-related disease: study of 32 cases. *Am J Clin Pathol.* 2013;140(3):395–402.
- Menon MP, Evbuomwan MO, Rosai J, Jaffe ES, Pittaluga S. A subset of Rosai-Dorfman disease cases show increased IgG4-positive plasma cells: another red herring or a true association with IgG4-related disease? *Histopathology.* 2014;64(3):455–9.
- Iwabuchi H, Kakihara T, Tanaka A, Uchiyama M, Shibuya H, Umezuh H. Congenital Rosai-Dorfman

- disease without lymphadenopathy. *Pediatr Pathol Mol Med*. 2003;22:399–403.
26. Chow CP, Ho HK, Chan GCF, Cheung AN, Ha SY. Congenital Rosai–Dorfman disease presenting with anemia, thrombocytopenia and hepatomegaly. *Pediatr Blood Cancer*. 2009;52:415–7.
 27. Morgan NV, Morris MR, Cangul H, Gleeson D, Straatman-Iwanowska A, Davies N, et al. Mutations in SLC29A3, encoding an equilibrative nucleoside transporter ENT3, cause a familial histiocytosis syndrome (Faisalabad histiocytosis) and familial Rosai–Dorfman disease. *PLoS Genet*. 2010;6(2):e1000833.
 28. Avitan-Hersh E, Mandel H, Indelman M, et al. A case of H syndrome showing immunophenotype similarities to Rosai–Dorfman disease. *Am J Dermatopathol*. 2011;33(1):47–51.
 29. Colmenero I, Molho-Pessach V, Torrelo A, Zlotogorski A, Requena L. Emperipolesis: an additional common histopathologic finding in H syndrome and Rosai–Dorfman disease. *Am J Dermatopathol*. 2012;34(3):315–20.
 30. Rosssbach HC, Dalence C, Wynn T, Tebbi C. Faisalabad histiocytosis mimics Rosai–Dorfman disease: brothers with lymphadenopathy, intrauterine fractures, short stature and sensorineural deafness. *Pediatr Blood Cancer*. 2006;47(5):629–32.
 31. Jaffe R. Histiocytic proliferations in childhood. In: Proytcheva M, editor. *Diagnostic pediatric hematopathology*. Illinois: Feinberg School of Medicine, Northwestern University, Cambridge University Press; 2011. p. 504–39.
 32. Picarsic J, Chikwava K. In: Hsi ED, editor. *Disorders of histiocytes hematopathology*. 3rd ed. Philadelphia: Elsevier Saunders; 2017. (in press).
 33. Picarsic J, Jaffe R. *Nosology and pathology of Langerhans cell histiocytosis*. *Hematol Oncol Clin North Am*. 2015;29(5):799–823.
 34. Utikal J, Ugurel S, Kurzen H, et al. Imatinib as a treatment option for systemic non-Langerhans cell histiocytoses. *Arch Dermatol*. 2007;143:736–40.
 35. Sodhi KS, Suri S, Nijhawan R, Kang M, Gautam V. Rosai–Dorfman disease: unusual cause of diffuse and massive retroperitoneal lymphadenopathy. *Br J Radiol*. 2005;78(933):845–7.
 36. Litzner BR, Subtil A, Vidal CI. Combined cutaneous Rosai–Dorfman disease and localized cutaneous Langerhans cell histiocytosis within a single subcutaneous nodule. *Am J Dermatopathol*. 2015;37(12):936–9.
 37. Kuo TT, Chen TC, Lee LY, Lu PH. IgG4-positive plasma cells in cutaneous Rosai–Dorfman disease: an additional immunohistochemical feature and possible relationship to IgG4-related sclerosing disease. *J Cutan Pathol*. 2009;36(10):1069–73.
 38. Al-Khateeb TH. Cutaneous Rosai–Dorfman disease of the face: a comprehensive literature review and case report. *J Oral Maxillofac Surg*. 2016;74:528–40.
 39. Varan A, Sen H, Akalan N, et al. Pontine Rosai–Dorfman disease in a child. *Child Nerv Syst*. 2015;31:971–5.
 40. Ludemann W, Banan R, Samii A, et al. Cerebral Rosai–Dorfman disease. *Child Nerv Syst*. 2015;31:529–32.
 41. Gupta K, Bagdi N, Sunitha P, et al. Isolated intracranial Rosai–Dorfman disease mimicking meningioma in a child: a case report and review of the literature. *Br J Radiol*. 2011;84:e138–41.
 42. Raslan O, Ketonen LM, Fuller GN, Schellingerhout D. Intracranial Rosai–Dorfman disease with relapsing spinal lesions. *J Clin Oncol*. 2008;26:3087–9.
 43. Zhu H, Qiu LH, Dou YE, et al. Imaging characteristics of Rosai–Dorfman disease in the central nervous system. *Eur J Radiol*. 2012;81:1265–72.
 44. Morandi X, Godey B, Riffaud L, et al. Isolated Rosai–Dorfman disease of the fourth ventricle. Case illustration. *J Neurosurg*. 2000;92:890.
 45. Konishi E, Ibayashi N, Yamamoto S, Scheithauer BW. Isolated intracranial Rosai–Dorfman disease (sinus histiocytosis with massive lymphadenopathy). *Am J Neuroradiol*. 2003;24:515–8.
 46. Andriko JAW, Morrison A, Colegial CH, Davis BJ, Jones RV. Rosai–Dorfman disease isolated to the central nervous system: a report of 11 cases. *Mod Pathol*. 2001;14:172–8.
 47. Ramos AA, Vega MAA, Alles JVD, Garcia JA, Martinez AM. Multiple involvement of the central nervous system in Rosai–Dorfman disease. *Pediatr Neurol*. 2012;46:54–6.
 48. Petzold A, Thom M, Powell M, Plant GT. Relapsing intracranial Rosai–Dorfman disease. *J Neurol Neurosurg Psychiatry*. 2001;71:538–41.
 49. Md T, Khair A, Begum F, Akhter S, Farooq S, Kamal M. Isolated intracranial Rosai–Dorfman disease. *Case Reports in Neuro Med*. 2016;1972594:4.
 50. Tran HM, Chinichian S, Storkersen K, Tokuhara K. An unusual case of extranodal Rosai–Dorfman disease manifesting as an Epibulbar mass. *Case Rep Ophthalmol*. 2015;6:351–5.
 51. Nalini A, Jitender S, Anantaram G, Santosh V. Rosai–Dorfman disease: case with extensive dural involvement and cerebrospinal fluid pleocytosis. *J Neurol Sci*. 2012;314:152–4.
 52. Yetsir S, Cekin E, Tosun F, Yildirim A. Rosai–Dorfman disease associated with neurosensorial hearing loss in two siblings. *Int J Pediatr Otorino*. 2004;68:1095–100.
 53. Ahsan SF, Madgy DN, Poulik J. Otolaryngologic manifestations of Rosai–Dorfman disease. *Int J Pediatr Otorino*. 2001;59:221–7.
 54. Kozak B, Talbott J, Uzelac A, Rehani B. Rosai–Dorfman disease isolated to the thoracic epidural spine. *Radiol Case*. 2015;9:6–16.
 55. Chen CW, Kachramanoglou C, Revesz T, Choi D. Rosai–Dorfman disease presenting as a thoracic intradural extramedullary spinal tumor but without extraspinal manifestations. *Acta Neurochir (Wein)*. 2012;154:367–8.
 56. Chen HH, Zhou SH, Wang SQ, Teng XD, Fan J. Factors associated with recurrence and therapeutic strategies for sinonasal Rosai–Dorfman disease. *Head Neck*. 2012;34:1504–13.

57. Duan HG, Zheng CQ, Wang DH, et al. Extranodal sino-nasal Rosai-Dorfman disease: a clinical study of 10 cases. *Eur Arch Otorhinolaryngol*. 2015;272:2313–8.
58. Vujhini SK, Kolte SS, Satarkar RN, Srikanth S. Fine needle aspiration diagnosis of Rosai-Dorfman disease involving thyroid. *J Cytol*. 2012;29:83–5.
59. Ma YL, Liang ZP, Xu SE, et al. Rosai-Dorfman disease (RDD) in the paraglottic space: report of a case and review of the literature. *Int J Clin Exp Pathol*. 2015;8:13532–8.
60. Wenig BM, Abbondazo SL, Childers EL, Kapadia SB, Heffner DR. Extranodal sinus histiocytosis with massive lymphadenopathy (Rosai-Dorfman disease) of the head and neck. *Hum Pathol*. 1993;24:483–92.
61. El-Kersh K, Perez RL, Guardiola J. Pulmonary IgG4+ Rosai-Dorfman disease. *BMJ Case Rep*. 2013;2013:bcr2012008324. doi:10.1136/bcr-2012-008324.
62. Campana M, Goupil de Bouille J, De Muret A, et al. Pulmonary manifestations revealing Rosai-Dorfman disease. *Sarcoidosis Vasc Diffuse Lung Dis*. 2015;32:275–7.
63. Roberts SS, Attanoos RL. IgG4+ Rosai-Dorfman disease of the lung. *Histopathology*. 2010;56:662–4.
64. Boissiere L, Patey M, Toubas O, et al. Tracheobronchial involvement of Rosai-Dorfman disease. *Medicine*. 2016;95:1–5.
65. Pulsoni A, Anghel G, Falcucci P, et al. Treatment of sinus histiocytosis with massive lymphadenopathy (Rosai-Dorfman disease): report of a case and literature review. *Am J Hematol*. 2002;69(1):67–71.
66. Ocheni S, Ibegbulam OG, Okafor OC, et al. Usefulness of oral corticosteroids in Rosai-Dorfman disease. *Eur J Cancer Care (Engl)*. 2007;16:286–8.
67. O'Gallagher K, Dancy L, Sinha A, Sado D. Rosai-Dorfman disease of the heart. *Intractable Rare Dis Res*. 2016;5:1–5.
68. Daruwalla V, Parekh K, Tahir H, Collins JD, Carr J. Extranodal Rosai-Dorfman disease involving the left atrium: cardiac MRI, CT, and PET scan findings. *Case Rep Radiol*. 2015;2015:753160.
69. Krishnan A, Nassar A, Nieh P. Rosai-Dorfman disease presenting as extranodal mass. *Urology*. 2005;66:1317–9.
70. El Majdoub A, El Houari A, Chbani L, El Fatemi H, Khallouk A, Farihi MH. Isolated localization of Rosai-Dorfman disease as renal mass: a case report and review of the literature. *Pan Afr Med J*. 2016;24(64):1–5.
71. Sasaki K, Pemmaraju N, Westin JR, et al. A single case of Rosai-Dorfman disease marked by pathologic fractures, kidney failure, and liver cirrhosis treated with single-agent cladribine. *Front Oncol*. 2014;297:1–3.
72. Rocken C, Wieker K, Grote HJ, Muller G, Franke A, Roessner A. Rosai-Dorfman disease and generalized AA amyloidosis: a case report. *Hum Pathol*. 2000;31:621–4.
73. Harik L, Nassar A. Extranodal Rosai-Dorfman disease of the kidney and coexistent poorly differentiated prostatic adenocarcinoma. *Arch Pathol Lab Med*. 2006;130:1223–6.
74. Yamada S, Uemura M, Tokumoto M, et al. Hypercalcemia induced by Rosai-Dorfman disease in a hemodialysis patient: histological evidence of Extrarenal Calcitriol overproduction. *Intern Med*. 2014;53:2783–7.
75. Karaosmanoglu AD, Onur MR, Shirkhoda A, Ozmen M, Hahn PF. Unusual benign solid neoplasms of the kidney: cross-sectional imaging findings. *Diagn Interv Radiol*. 2015;21:376–81.
76. Izadyar S, Samiei F, Gholamrezaezhad A. Sinus histiocytosis with massive lymphadenopathy (Rosai-Dorfman disease) – imaging manifestations of renal involvement. *Nuclear Med Rev*. 2014;17:44–6.
77. Rodriguez Torres C, Fantova GR, Martinez IE, Castillo Escudero JJ, Arias CDA. Rosai-Dorfman disease with atypical intrascrotal involvement. *Int J Urol*. 2015;22:794–6.
78. Flores-Carrillo VM, Santaella-Torres F, Sanchez-Martinez LC, et al. Rosai-Dorfman disease presented with involvement of the adrenal gland. A clinical case reported. *Rev Med Inst Mex Seguro Soc*. 2014;52:224–7.
79. Lauwers GY, Perez-Atayde A, Dorfman RF, Rosai J. The digestive system manifestations of Rosai-Dorfman disease (sinus histiocytosis with massive lymphadenopathy): review of 11 cases. *Hum Pathol*. 2000;31:380–5.
80. Baran B, Karaca C, Soyer OM, et al. Rosai-Dorfman disease with diffuse gastrointestinal involvement. *Eur J Gastroenterol Hepatol*. 2013;25:869–74.
81. Ide M, Asao T, Yoshida T, et al. Rosai-Dorfman disease of the colon presented as small solitary polypoid lesion. *Rare Tumors*. 2010;31(2):e2.
82. Hollowood K, Stamp G, Zouvani I, Fletcher CD. Extranodal follicular dendritic cell sarcoma of the gastrointestinal tract. Morphologic, immunohistochemical and ultrastructural analysis of two cases. *Am J Clin Pathol*. 1995;103:90–7.
83. Esquivel J, Krishnan J, Jundi M, et al. Rosai-Dorfman disease (sinus histiocytosis with massive lymphadenopathy) of the pancreas: first case report. *Hepatogastroenterol*. 1999;46:1202–5.
84. Zivin SP, Atieh M, Mosier M, et al. Rosai-Dorfman disease (sinus histiocytosis with massive lymphadenopathy) of the pancreas: second case report. *J Gastrointest Surg*. 2009;13:806–9.
85. Podberezin M, Angeles R, Guzman G, Peace D, Gaitonde S. Primary pancreatic sinus histiocytosis with massive lymphadenopathy (Rosai-Dorfman disease) an unusual extranodal manifestation clinically simulating malignancy. *Arch Pathol Lab Med*. 2010;134:276–8.
86. Romero Arenas MA, Singhi AD, Hruban RH, et al. Rosai-Dorfman disease (sinus histiocytosis with massive lymphadenopathy) of the pancreas: third reported occurrence. *J Gastrointest Cancer*. 2012;43:626–9.
87. Shaikh F, Awan O, Mohiuddin S, Farooqui S, Kahn SA, McCartney W. 18F-FDG PET /CT imaging of extranodal Rosai-Dorfman disease with hepatopancreatic involvement: a pictorial and literature review. *Cureus*. 2015;7:e392. doi:10.7759/cureus.392.

88. Mantilla JG, Goldberg-Stein S, Wang Y. Extranodal Rosai-Dorfman disease. Clinicopathologic series of 10 patients with radiologic correlation and review of the literature. *Am J Clin Pathol*. 2016;145:211–21.
89. Melikyan AC, Kovringina AM, Gilyazildinova EA, Gittis MK. A case of sinus histiocytosis with massive lymphadenopathy in a patient with diffuse large cell lymphoma and chronic hepatitis B infection. *Ter Arch*. 2012;84:66–70.
90. Kgomomo MK, Elnagar AA, Jeske C, Nagel J. Sinus histiocytosis with massive lymphadenopathy (Rosai-Dorfman disease) and cirrhosis of the liver: a case report and literature review. *S Afr Med J*. 2016;106:463–4.
91. Di Tommaso L, Rahal D, Bossi P, Roncalli M. Hepatic Rosai-Dorfman disease with coincidental lymphoma: report of a case. *Int J Surg Pathol*. 2010;18:540–3.
92. Patel MH, Jambhekar KR, Pandey T, Ram R. A rare case of extranodal Rosai-Dorfman disease with isolated multifocal osseous manifestation. *Indian J Radiol Imaging*. 2015;25:284–7.
93. Tsang JS, Anthony MP, Wong MP, Wong CS. The use of FDG-PET/CT in extranodal Rosai-Dorfman disease of bone. *Skelet Radiol*. 2012;41:715–7.
94. Deshayes E, Le Berre JP, Joanneau E, Vasiljevic A, Raverot G, Seve P. 18F-FDG PET/CT findings in a patient with isolated intracranial Rosai-Dorfman disease. *Clin Nucl Med*. 2013;38:e50–2.
95. Albano D, Bosio G, Bertagna F. 18F-FDG PET/CT of Rosai-Dorfman disease. *Clin Nucl Med*. 2015;40:e40–2.
96. Gupta P, Babyn P. Sinus histiocytosis with massive lymphadenopathy (Rosai-Dorfman disease): a clinicoradiological profile of three cases including two with skeletal disease. *Pediatr Radiol*. 2008;38:721–8. quiz 821–822
97. Demicco EG, Rosenberg AE, Bjornsson J, et al. Primary Rosai-Dorfman disease of bone: a clinicopathological study of 15 cases. *Am J Surg Pathol*. 2010;34:1324–33.
98. Paryani NN, Daugherty LC, O'Connor MI, Jiang L. Extranodal Rosai-Dorfman disease of the bone treated with surgery and radiotherapy. *Rare Tumors*. 2014;6(5531):132–4.
99. Huang Q, Chang KL, Weiss LM. Extranodal Rosai-Dorfman disease involving the bone marrow: a case report. *Am J Surg Pathol*. 2006;30:1189–92.
100. Huang BY, Liu HL, Yu CJ. Isolated Intramedullary spinal Rosai-Dorfman disease: a case report and literature review. *World Neurosurg*. 2016;88:694. e.11-694.e15
101. Oner AY, Akpek S, Tali T. Rosai-Dorfman disease with epidural and spinal bone marrow involvement: magnetic resonance imaging and diffusion-weighted imaging features. *Acta Radiol*. 2007;48:331–4.
102. Lima FB, Barcelos PS, Constância AP, Nogueira CD, Melo-Filho AA. Rosai-Dorfman disease with spontaneous resolution: case report of a child. *Rev Bras Hematol Hemoter*. 2011;33:312–4.
103. Purav P, Ganapathy K, Mallikarjuna VS, et al. Rosai-Dorfman disease of the central nervous system. *J Clin Neurosci*. 2005;12:656–9.
104. Forest F, N'guyen AT, Fesselet J, et al. Meningeal Rosai-Dorfman disease mimicking meningioma. *Ann Hematol*. 2014;93:937–40.
105. Sandoval-Sus JD, Sandoval-Leon AC, Chapman JR, et al. Rosai-Dorfman disease of the central nervous system: report of 6 cases and review of the literature. *Medicine (Baltimore)*. 2014;93:165–75.
106. Cooper SL, Chavis PS, Fortney JA, Watkins JM, Caplan MJ, Jenrette JM 3rd. A case of orbital Rosai-Dorfman disease responding to radiotherapy. *J Pediatr Hematol Oncol*. 2008;30:744–8.
107. Maklad AM, Bayoumi Y, Tunio M, Alshakweer W, Dahar MA, Akbar SA. Steroid-resistant extranodal rosai-dorfman disease of cheek mass and ptosis treated with radiation therapy. *Case Rep Hematol*. 2013;2013:428297. doi:10.1155/2013/428297.
108. Toguri D, Louie AV, Rizkalla K, Franklin J, Rodrigues G, Venkatesan V. Radiotherapy for steroid-resistant laryngeal Rosai-Dorfman disease. *Curr Oncol*. 2011;18:e158–62.
109. Z'Graggen WJ, Sturzenegger M, Mariani L, Keserue B, Kappeler A, Vajtai I. Isolated Rosai-Dorfman disease of intracranial meninges. *Pathol Res Pract*. 2006;202:165–70.
110. Shulman S, Katzenstein H, Abramowsky C, Broecker J, Wulkan M, Shehata B. Unusual presentation of Rosai-Dorfman disease (RDD) in the bone in adolescents. *Fetal Pediatr Pathol*. 2011;30:442–7.
111. McPherson CM, Brown J, Kim AW, DeMonte F. Regression of intracranial rosai-dorfman disease following corticosteroid therapy. Case report. *J Neurosurg*. 2006;104:840–4.
112. Adeleye AO, Amir G, Fraifeld S, Shoshan Y, Umansky F, Spektor S. Diagnosis and management of Rosai-Dorfman disease involving the central nervous system. *Neurol Res*. 2010;32:572–8.
113. Petrushkin H, Salisbury J, O'Sullivan E. Intralesional steroid for orbital manifestations of Rosai-Dorfman disease. *Clin Exp Ophthalmol*. 2015;43:483–5.
114. Ottaviano G, Doro D, Marioni G, et al. Extranodal Rosai-Dorfman disease: involvement of eye, nose and trachea. *Acta Otolaryngol*. 2006;126:657–60.
115. Sakallioğlu O, Gok F, Kalman S, et al. Minimal change nephropathy in a 7-year-old boy with Rosai-Dorfman disease. *J Nephrol*. 2006;19:211–4.
116. Saboo SS, Jagannathan JP, Krajewski KM, et al. Symptomatic extranodal Rosai-Dorfman disease treated with steroids, radiation, and surgery. *J Clin Oncol*. 2011;29:e772–5.
117. Horneff G, Jurgens H, Hort W, et al. Sinus histiocytosis with massive lymphadenopathy (Rosai-Dorfman disease): response to methotrexate and mercaptopurine. *Med Pediatr Oncol*. 1996;27:187–92.
118. Scheel MM, Rady PL, Tying SK, et al. Sinus histiocytosis with massive lymphadenopathy: presentation as giant granuloma annulare and detection of human herpesvirus 6. *J Am Acad Dermatol*. 1997;37:643–6.

119. Jabali Y, Smrcka V, Pradna J. Rosai-Dorfman disease: successful long-term results by combination chemotherapy with prednisone, 6-mercaptopurine, methotrexate, and vinblastine: a case report. *Int J Surg Pathol*. 2005;13:285–9.
120. Inoue S, Onwuzurike N. Venorelbine and methotrexate for the treatment of Rosai-Dorfman disease. *Pediatr Blood Cancer*. 2005;45(1):84–5.
121. Arnao V, Riolo M, Savettieri G, Aridon P. Mercaptopurine treatment in an adult man with orbital and intracranial Rosai-Dorfman disease. *Case Rep Neurol Med*. 2016;2016:1030478. doi:10.1155/2016/1030478. 5 pages
122. Rivera D, Pérez-Castillo M, Fernández B, Stoeter P. Long-term follow-up in two cases of intracranial Rosai-Dorfman disease complicated by incomplete resection and recurrence. *Surg Neurol Int*. 2014;5:30. doi:10.4103/2152-7806.128003.
123. Visser J, Dyer MJ. Refractory, atypical Rosai-Dorfman disease successfully treated with a Cytarabine-containing Langerhans cell Histiocytosis treatment regimen—a case report. *Pediatr Blood Cancer*. 2014;61(11):2142.
124. Liu P, Wang P, Du J, Zhang J. Successful treatment of refractory cutaneous Rosai-Dorfman disease with vincristine. *J Dermatol*. 2015;42:97–8.
125. Nadal M, Kervarrec T, Machet MC, Petrella T, Machet L. Cutaneous Rosai-Dorfman disease located on the breast: rapid effectiveness of methotrexate after failure of topical corticosteroids. *Acitretin and thalidomide*. *Acta Derm Venereol*. 2015;95:758–9.
126. Le Guenno G, Galicier L, Uro-Coste E, et al. Successful treatment with azathioprine of relapsing Rosai-Dorfman disease of the central nervous system. *J Neurosurg*. 2012;117:486–9.
127. Lohr HF, Godderz W, Wolfe T, et al. Long-term survival in a patient with Rosai-Dorfman disease treated with interferon-alpha. *Eur J Cancer*. 1995;31A:2427–8.
128. Le Guenno G, Galicier L, Fieschi C, et al. Dramatic efficiency of pegylated interferon in sinus histiocytosis with massive lymphadenopathy. *Br J Dermatol*. 2011;164:213–5.
129. Konca C, Ozkurt ZN, Deger M, et al. Extranodal multifocal Rosai-Dorfman disease: response to 2-chlorodeoxyadenosine treatment. *Int J Hematol*. 2009;89:58–62.
130. Aouba A, Terrier B, Vasiliu V, et al. Dramatic clinical efficacy of cladribine in Rosai-Dorfman disease and evolution of the cytokine profile: towards a new therapeutic approach. *Haematologica*. 2006;91(12 Suppl):ECR52.
131. Tasso M, Esquembre C, Blanco E, et al. Sinus histiocytosis with massive lymphadenopathy (Rosai-Dorfman disease) treated with 2-chlorodeoxyadenosine. *Pediatr Blood Cancer*. 2006;47:612–5.
132. Simko SJ, Tran HD, Jones J, et al. Clofarabine salvage therapy in refractory multifocal histiocytic disorders, including Langerhans cell histiocytosis, juvenile xanthogranuloma and Rosai-Dorfman disease. *Pediatr Blood Cancer*. 2014;61:479–87.
133. Petschner F, Walker UA, Schmitt-Graff A, et al. “Catastrophic systemic lupus erythematosus” with Rosai-Dorfman sinus histiocytosis: successful treatment with anti-CD20/rituximab. *Dtsch Med Wochenschr*. 2001;126:998–1001.
134. Pagel JM, Lionberger J, Gopal AK, et al. Therapeutic use of rituximab for sinus histiocytosis with massive lymphadenopathy (Rosai-Dorfman disease). *Am J Hematol*. 2007;82:1121–2.
135. Appel S, Boehmler AM, Grunebach F, et al. Imatinib mesylate affects the development and function of dendritic cells generated from CD34 peripheral blood progenitor cells. *Blood*. 2004;103:538–44.
136. Gebhardt C, Averbeck M, Paasch U, et al. A case of cutaneous Rosai-Dorfman disease refractory to imatinib therapy. *Arch Dermatol*. 2009;145:571–4.
137. Li X, Hong Y, An Q, et al. Successful treatment of Rosai-Dorfman disease with low-dose oral thalidomide. *JAMA Dermatol*. 2013;149:992–3.
138. Wang F, Zhou H, Luo DQ, Han JD, Chen MK. Dermatoscopic findings in cutaneous Rosai-Dorfman disease and response to low-dose thalidomide. *J Dtsch Dermatol Ges*. 2014;12:350–2.
139. Chen E, Pavlidakey P, Sami N. Rosai-Dorfman disease successfully treated with thalidomide. *JAAD Case Rep*. 2016;2:369–72.
140. Rubinstein M, Assal A, Scherba M, et al. Lenalidomide in the treatment of Rosai Dorfman disease – a first in use report. *Am J Hematol*. 2016;91:E1. doi:10.1002/ajh.24225.
141. Cooper SL, Arceci RJ, Gamper CJ, Teachey DT, Schafer ES. Successful treatment of recurrent autoimmune cytopenias in the context of sinus histiocytosis with massive lymphadenopathy using sirolimus. *Pediatr Blood Cancer*. 2016;63:358–60.
142. Haroche J, Ablá O. Uncommon histiocytic disorders: Rosai-Dorfman, juvenile xanthogranuloma, and Erdheim-Chester disease. *Hematology Am Soc Hematol Educ Program*. 2015;2015:571–8.

Eric Jacobsen, Oussama Abla,
and Johannes Visser

Introduction

The malignant histiocytoses (MH) are extremely rare tumors that originate from the dendritic and macrophage/histiocyte lineages (mononuclear phagocyte system). Dendritic cells are antigen-presenting cells, and macrophages are involved in the clearance of cellular debris and pathogens. Although the morphological term “histiocyte” refers to resident macrophages, its derivative “histiocytoses” is used in this context to refer to tumors of dendritic and macrophage/histiocyte origin. The following conditions are discussed in this chapter (cellular counterparts in brackets):

- *Histiocytic sarcoma* (myeloid-derived macrophages)
- *Langerhans cell sarcoma* (myeloid-derived dendritic cells)

- *Indeterminate dendritic cell tumor* (myeloid-derived dendritic cells)
- *Interdigitating dendritic cell sarcoma* (myeloid-derived dendritic cells)

Classification

Historically, the classification of dendritic and histiocytic neoplasms has been confusing and complicated by difficulties in identifying the histiocytic derivation of the neoplastic cell and by difficulties in establishing clonality. The rarity of these tumors, together with a previous lack of characteristic immunohistochemical markers (in fixed tissue sections) and the inconsistent nomenclature, hampered progress. As pathology techniques improved, several tumors previously thought to be histiocytic neoplasms upon reevaluation proved to represent a range of non-histiocytic tumors including anaplastic large cell lymphoma, peripheral T-cell lymphoma, and histiocyte-rich variants of B-cell, T-cell, and Hodgkin lymphoma. The term “malignant histiocytosis” was also sometimes used to describe what we would now recognize as hemophagocytic lymphohistiocytosis (HLH), which is characterized by large numbers of nonneoplastic histiocytes [1, 2].

In 2002, the International Lymphoma Study Group initiated a process to better classify tumors of histiocytes and dendritic cells by reviewing 61

E. Jacobsen, MD (✉)
Department of Medical Oncology, Dana-Farber
Cancer Institute, Boston, MA, USA
e-mail: Eric_Jacobsen@dfci.harvard.edu

O. Abla, MD
Department of Pediatrics, Division of Hematology/
Oncology, Hospital for Sick Children, University of
Toronto, Toronto, ON, Canada

J. Visser, MB, ChB
Cambridge University Hospitals NHS Foundation
Trust, Addenbrooke's Hospital, Cambridge, UK

cases of histiocytic and dendritic cell tumors using the latest available techniques. The result was a proposed classification based on systematic histological evaluation, combining immunophenotype and morphology. Six groups of tumors were proposed: (i) histiocytic sarcoma (HS), (ii) Langerhans cell tumor, (iii) Langerhans cell sarcoma (LCS), (iv) interdigitating dendritic cell tumor/sarcoma (IDCS), (v) follicular dendritic cell tumor/sarcoma (FDCS), and (vi) unclassifiable [2]. In the 2008 WHO classification of hematological malignancies, very similar terminology was used to describe the histiocytic and dendritic cell neoplasms. Two additional rare dendritic cell tumors, indeterminate dendritic cell tumor and fibroblastic reticular cell tumor, were added as was disseminated juvenile xanthogranuloma [1]. In the 2016 revision of the WHO classification, Erdheim-Chester disease was added to the histiocytic and dendritic cell neoplasms to distinguish it from the other members of the juvenile xanthogranuloma family [3] (Table 20.1). Langerhans cell histiocytosis (LCH), juvenile xanthogranuloma (JXG), and Erdheim-Chester disease (ECD) are not characterized by anaplastic histology and are discussed elsewhere in this textbook.

The WHO nomenclature informs ICD-O coding which forms the basis of cancer registration and the study of cancer epidemiology. ICD-O-3 (2000) included specific codes for histiocytic sarcoma, Langerhans cell sarcoma, interdigitating dendritic cell sarcoma, and follicular dendritic cell sarcoma. In ICD-O-3.1 (2011 update of ICD-O-3), a code for fibroblastic reticular cell tumor

was added (Table 20.1). It is notable that only one code is assigned to interdigitating dendritic cell sarcoma, indeterminate dendritic cell sarcoma, and dendritic cell sarcoma not otherwise specified [4]. This lack of specificity hampers the study of rare subtypes. The stability of nomenclature used in the revised 2016 WHO classification is likely to lead to stability in ICD-O coding for the foreseeable future providing the opportunity to study the epidemiology of these rare pathological entities over a sustained period of time.

The histiocytic and dendritic cell neoplasms form part of the wider group of disorders of macrophage-dendritic cell lineages. The first classification of this wider group of histiocytosis syndromes was published in 1987 by the Working Group of the Histiocyte Society and consisted of three categories: Langerhans cell related, non-Langerhans cell related, and malignant histiocytic disorders. The malignant histiocytic category at that stage included acute monocytic leukemia, malignant histiocytosis, and so-called true histiocytic lymphomas [5]. Subsequently, it was determined that monocytic leukemia is best classified among the acute myeloid leukemias and the nomenclature for the other conditions has changed significantly since then.

The 2016 revised classification of this wider group of disorders (histiocytoses and neoplasms of the macrophage-dendritic cell lineages) groups the tumors with anaplastic histology together (M Group) and proposes naming these malignant histiocytoses (MH) (see Chap. 1, Pathology of Histiocytic Disorders). MH can be localized or disseminated and can occur *de novo* (primary) or simultaneously/after other hematological neoplasms or other histiocytoses (secondary). The MH are divided into a number of subtypes based upon cell of origin: histiocytic MH (macrophage lineage), interdigitating cell MH, Langerhans cell MH, indeterminate cell MH (dendritic cell lineage), and not specified [1, 6] (Table 20.2). It is notable that this classification excludes the tumors which originate from stromal-derived rather than myeloid-derived dendritic cells, namely, follicular dendritic cell sarcoma and fibroblastic reticular cell tumor. A return to the old term “malignant histiocytosis” may create a

Table 20.1 Histiocytic and dendritic cell neoplasms – 2016 revision of the WHO classification of hematological malignancies (ICD-O-3.1 code in brackets) [4]

<i>Histiocytic sarcoma</i> (9755/3)
<i>Langerhans cell histiocytosis</i> (9751/3)
<i>Langerhans cell sarcoma</i> (9756/3)
<i>Indeterminate dendritic cell tumor</i> (9757/3)
<i>Interdigitating dendritic cell sarcoma</i> (9757/3)
<i>Follicular dendritic sarcoma</i> (9758/3)
<i>Fibroblastic reticular cell tumor</i> (9759/3)
<i>Disseminate juvenile xanthogranuloma</i>
<i>Erdheim-Chester disease</i>

Table 20.2 Malignant histiocytoses (MH) – revised classification of histiocytoses and neoplasms of the macrophage-dendritic cell lineages (2016)

Malignant histiocytoses	Localization	Subtype
<i>Primary MH</i>	<i>Localized to organ/system</i>	Histiocytic MH
<i>Secondary MH to:</i>	Skin	Interdigitating cell MH
Follicular lymphoma	Lymph node	Langerhans cell MH
Lymphocytic leukemia/lymphoma	Digestive system	Indeterminate cell MH
Hairy cell leukemia	CNS	Not specified
Acute lymphoblastic leukemia	Other	
Histiocytosis (LCH, RDD, others)	<i>Disseminated</i>	
Other hematological neoplasia		

degree of nomenclature confusion, though a move away from the term “sarcoma,” for what are essentially tumors of myeloid stem cell origin, is of value. This approach, however, is not reflected in the revised WHO classification which continues to use a mixture of the terms “sarcoma” and “tumor” to describe the histiocytic and dendritic cell neoplasms (Table 20.1).

The WHO terms will predominantly be used in the text of this chapter, and the malignant histiocytosis term will be shown in brackets next to the relevant headings.

Epidemiology

Using pooled data from 89 population-based European cancer registries (1995–2002), the “Surveillance of Rare Cancers in Europe” project (RARECARE) estimated that the dendritic cell and histiocytic neoplasms as a group have an estimated crude incidence of 0.5/1,00,000 per year [7]. The RARECAREnet project updated this estimate using data from patients diagnosed during the period 2000–2007 reported to 94 population-based cancer registries in 24 European countries. The estimated incidence of histiocytic sarcoma, interdigitating dendritic cell sarcoma, and follicular dendritic cell sarcoma as a group is <0.01/1,00,000 per year. Langerhans cell sarcoma and Langerhans cell histiocytosis are grouped together, and their incidence is estimated as <0.04/1,00,000 per year [8].

These tumors are most often reported in adult patients but occasionally occur in children. During the 9-year period 2002–2011, only four patients (<15 years) with MH (three HS and one

IDCS) were registered in the UK children’s cancer registry, representing an age standardized incidence of MH of 0.004/1,00,000 per year (personal communication – Dr. Charles Stiller).

Population-based information on possible gender, race, or geographic predilection is limited. There are no known hereditary genetic or environmental factors predisposing to the development of the MH.

Pathogenesis

The pathogenesis of dendritic cell and histiocytic neoplasms remains unclear. These tumors can occur in isolation, in association with other histiocytoses, or in the presence of other hematological neoplasms (see below) [9].

The means by which a primary hematopoietic neoplasm gives rise to a secondary malignant histiocytosis remains an area of active investigation. The process has been studied best in the setting of secondary MH with follicular lymphoma, and at least three hypotheses have been put forward. The leading hypothesis is direct transdifferentiation of a cell, such as a B cell, into a cell of histiocyte/dendritic cell lineage. In one study of eight patients with follicular lymphoma (FL) and a concomitant malignant histiocytosis, PCR and sequencing identified identical IGH gene rearrangements or BCL2 gene breakpoints in both processes in all patients tested. All of the malignant histiocytoses lacked PAX5 and had upregulation of CEBP β and PU.1 [10]. Similar findings were reported in a case series of seven patients with chronic lymphocytic leukemia (CLL) and a concomitant MH. In two of these cases, the CLL and malignant histiocytosis shared

a cytogenetic abnormality (deletion 17p), while in general, the malignant histiocytoses were largely negative for PAX5. One finding in the study of CLL patients with MH, the variable and weak expression of CEBP β , was different than that in MH occurring secondary to FL where CEBP β expression was more uniform, but strong expression of PU.1 was a feature of secondary MH occurring in the context of CLL as it was in secondary MH occurring in follicular lymphoma [11]. These findings corroborated *in vitro* studies demonstrating that transdifferentiation of B cells into macrophages could be achieved by forced expression of CEBP β and CEBP α and inhibition of PAX5. PU.1 played a synergistic role in this process [12]. Conversely, forced expression of PAX5 prevented myeloid transdifferentiation of B cells [13].

A second hypothesis invokes a shared hematopoietic precursor that develops along both lymphoid or myeloid and histiocyte/dendritic cell lineages at different times. This does not explain situations such as the co-occurrence of follicular lymphoma and histiocytic sarcoma sharing the same immunoglobulin heavy chain mutation and t(14;18) since these changes occur at the pre-B-cell stage of development; however, it is certainly possible that more than one mechanism could be responsible for the development of secondary MH [14]. Finally, a third theory invokes a two-step process of dedifferentiation of neoplastic hematopoietic cells to early progenitors with subsequent redifferentiation to the histiocyte/dendritic cell lineage [14]. This possibility is supported by studies demonstrating that conditional deletion of PAX5 caused dedifferentiation of mature B cells into uncommitted hematopoietic precursors *in vitro* [15]. This mechanism of shared lineage is the most complex and therefore not likely to be the primary mechanism of secondary MH. The possible mechanisms of secondary MH occurring outside of B-cell neoplasms have not been studied thoroughly, but the same principles likely apply.

Mutations in the RAS/RAF pathway are important in the pathogenesis of many histiocyte disorders though exactly how or why this triggers a malignant histiocytosis remains unclear. *BRAF-V600E* mutations have been demonstrated in a

number of dendritic cell and histiocytic tumors. In one series, 5 out of 8 histiocytic sarcoma (62.5%) and 5 out of 27 follicular dendritic cell sarcoma (18.5%) harbored the *BRAF-V600E* mutation [16]. The *BRAF-V600E* mutation has also been reported in some cases of Langerhans cell sarcoma, interdigitating dendritic cell sarcoma, and indeterminate dendritic cell tumor [17–19]. It is interesting to note that hairy cell leukemia (HCL), a condition in which the *BRAF-V600E* mutation is considered the disease-defining mutation, has been reported to precede the development of Langerhans cell sarcoma in two case reports. The BRAF status of the HCL and LCS was unfortunately not reported, but identical immunoglobulin gene rearrangements in both cases, and almost identical karyotypes in one case, suggested that the HCL and LCS had a common origin [20, 21].

Importantly, other mutations in BRAF have been recently identified in clinical samples from patients with histiocytic sarcoma. One group reported a gain-of-function mutation in the DFG motif of BRAF [BRAF(F595L)] that cooperates with mutant RAS to promote oncogenic signaling. This interaction could be inhibited by pan-RAF and MEK inhibitors [22]. A second group utilized next-generation sequencing to identify BRAF mutations in three out of five cases of histiocytic sarcoma including activating mutations at G464V and G466R and a somatic mutation (N581S) located in the catalytic loop of the BRAF kinase domain but of unknown functional significance [23]. These studies highlight the importance of assessing for a wide variety of BRAF mutations and the therapeutic possibilities of RAS,RAF, MEK, and/or ERK inhibitors in patients with variant BRAF mutations or perhaps even in patients who do not harbor a BRAF mutation (wild-type BRAF).

Diagnosis and Differential Diagnosis

The diagnosis of dendritic and histiocytic tumors presents particular challenges to the pathologist. These tumors are rare and can present in many

different organs. There are only a small number of phenotypic markers unique to dendritic cells and macrophages requiring the pathologist to combine these markers with a panel of other immunophenotypic and molecular markers to exclude multiple other lineages including T-cell, B-cell, NK-cell, stromal, melanocytic, and epithelial lineages. The MH have anaplastic morphology and a range of possible ultrastructural findings. Morphology, ultrastructure, and immunophenotyping are combined with the clinical context to reach a diagnosis. The clinical context needs specific consideration. For instance, MH should be distinguished from myeloid sarcoma which is caused by infiltrates of leukemic cells with no/minimal cytologic differences from the bone marrow/circulating leukemia cells [1, 6]. In addition, Emile and colleagues demonstrated that a few patients with typical MH histology have unexpectedly proven to have nonprogressive or spontaneously regressive tumors making the label of MH inappropriate [6]. The pathologist should be provided with all the relevant clinical information to assist in the diagnostic process. Although the diagnosis of MH may be possible on fine needle aspiration or core needle biopsy, incisional or excisional biopsies are generally preferred [24].

Histiocytic sarcoma, interdigitating dendritic cell sarcoma, Langerhans cell sarcoma, and indeterminate cell sarcoma are expected to be positive for at least two of the following histiocyte/dendritic cell markers: CD68, CD163, CD4, and lysozyme. These entities are expected to be negative for keratins and EMA (positive in carcinomas), Melan-A and HMB45 (positive in melanoma), B and T lymphocyte markers (positive in lymphoma), as well as follicular dendritic cell markers (positive in follicular dendritic cell tumors). Staining with S100 protein, CD1a and CD207 (langerin) are used to distinguish between the different MH [5]. Although CD207 staining has replaced the need for electron microscopy to detect Birbeck granules, ultrastructural findings (e.g., presence/absence of lysosomes, desmosomes, interdigitating cell processes) may contribute to the process of distinguishing between the different MH [1, 2]. Some cases have features of more than one MH or have an atypical

phenotype that defies specific classification [24, 25]. The need to carefully consider and exclude a range of differential diagnoses and distinguish between different MH may lead to a prolonged diagnostic process.

Staging

These tumors may present as localized or as disseminated disease which may have prognostic and therapeutic implications. The organs/systems most commonly affected vary between the different histological types. In addition to a careful history and clinical examination, laboratory studies (including complete blood count, serum electrolytes, liver and renal function), cross-sectional imaging \pm functional imaging are usually indicated. Histiocytic sarcoma, Langerhans cell sarcoma, interdigitating dendritic cell sarcoma, and follicular dendritic cell sarcoma have been reported to be FDG-PET avid [26–32]. Bone marrow aspirate and trephine biopsy are indicated in patients with otherwise unexplained cytopenias [33].

Management and Prognosis

Histiocytic sarcoma, Langerhans cell sarcoma, and interdigitating dendritic cell sarcoma are usually aggressive malignancies with >50% mortality rate [1, 14, 34]. Limited information is available regarding possible risk factors, and the optimal treatment for these conditions remains unknown. In the absence of clinical trials or treatment guidelines, clinicians often rely on case reports, case series, literature reviews, and expert advice to inform treatment decisions.

Histiocytic Sarcoma (Histiocytic Malignant Histiocytosis)

Epidemiology

Histiocytic sarcoma generally presents in patients between the ages of 40 and 60, but has been reported in pediatric populations [2, 35].

HS can be a *de novo* entity or occur in the context of other hematopoietic or even germ cell neoplasms [36]. There are no identified risk factors nor is there a predilection based upon gender or race [2]. The clinical presentation of HS varies dramatically depending upon the organs involved. Most patients present with a rapidly enlarging mass and symptoms due to unifocal or multifocal extranodal disease, most commonly involving the intestinal tract, skin, and soft tissues although the bone, lymph nodes, liver, spleen, lungs (Fig. 20.1a, c),

adrenals (Fig. 20.1b, c), and nervous system can be affected [1]. Isolated involvement of the lymph nodes is uncommon and occurs in fewer than 20% of cases [1, 2]. Skin involvement can manifest as a nonspecific rash or tumors. Systemic symptoms such as fevers and weight loss are common. Laboratory abnormalities depend on the organ system affected. Approximately one-third of patients will have cytopenias due to bone marrow involvement, and a small percentage of patients have hemophagocytosis [33].

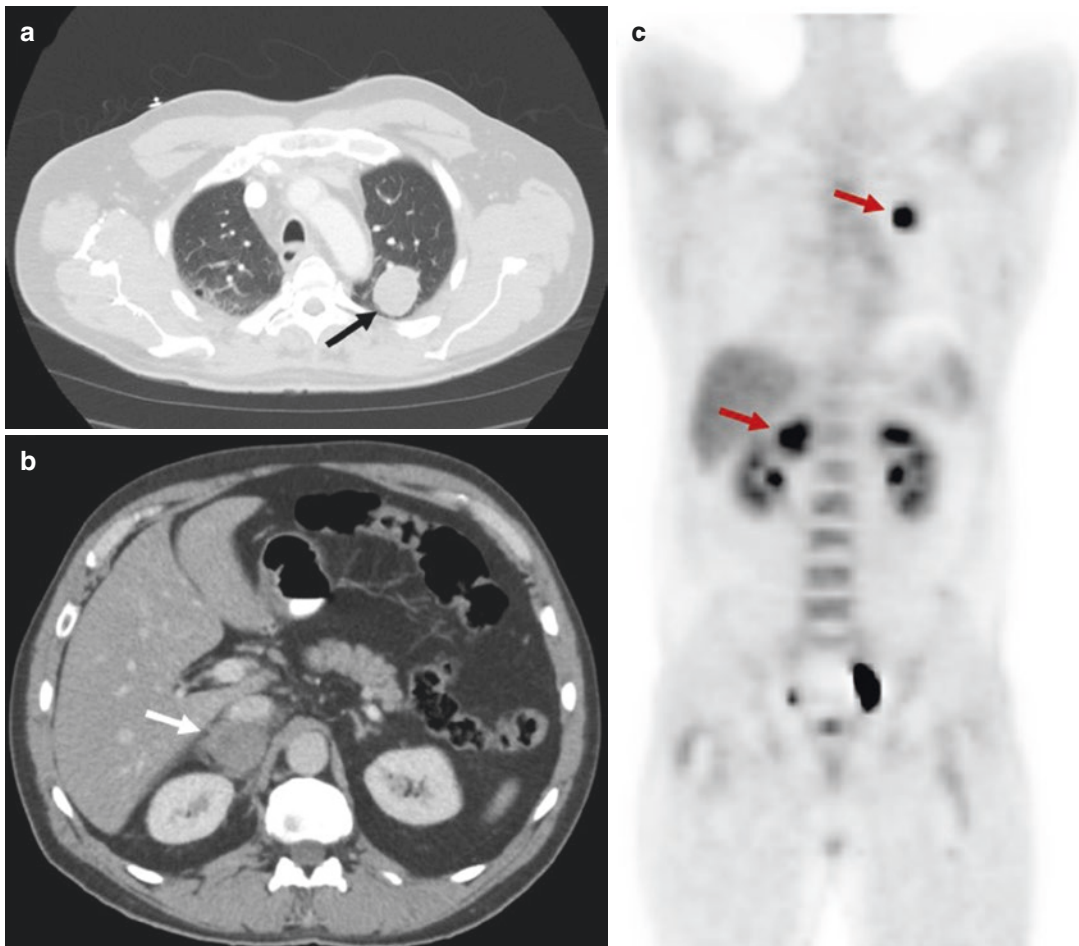


Fig. 20.1 A 54-year-old man with BRAF-negative histiocytic sarcoma. (a) Contrast-enhanced axial CT image of the chest demonstrates a well-defined round mass in the left upper lobe (*black arrow*). (b) Axial CT image of the upper abdomen obtained during portal venous phase shows a rounded left adrenal hypo-enhancing mass

(*white arrow*) with mild perilesional fat stranding. (c) Maximum intensity projection (MIP) PET/CT image shows the FDG-avid lung and adrenal mass (*red arrows*) (Courtesy of Dr. Francesco Alessandrino, Department of Radiology, Brigham and Women's Hospital, Boston, MA, USA)

Pathology

Histiocytic sarcoma (HS) is an extremely rare and generally aggressive malignancy typically comprised of non-cohesive, large cells that are polygonal or ovoid with spindling and abundant eosinophilic cytoplasm (Fig. 20.2a). Occasionally, the neoplastic cells can have a foamy appearance, but this is not nearly as pronounced as in ECD. There is typically a

prominent inflammatory infiltrate, but necrosis is minimal. Hemophagocytosis may occasionally be present. The malignant cells usually express CD68, lysozyme, CD4 and CD11c, membranous CD14 (Fig. 20.2b), and CD163 (Fig. 20.2c). CD1a, S100, and T- and B-cell markers, aside from CD4, and epithelial markers are usually absent. Birbeck granules are usually lacking. A high Ki-67/MIB1 proliferation rate index is usually present (Fig. 20.2d). A clonal

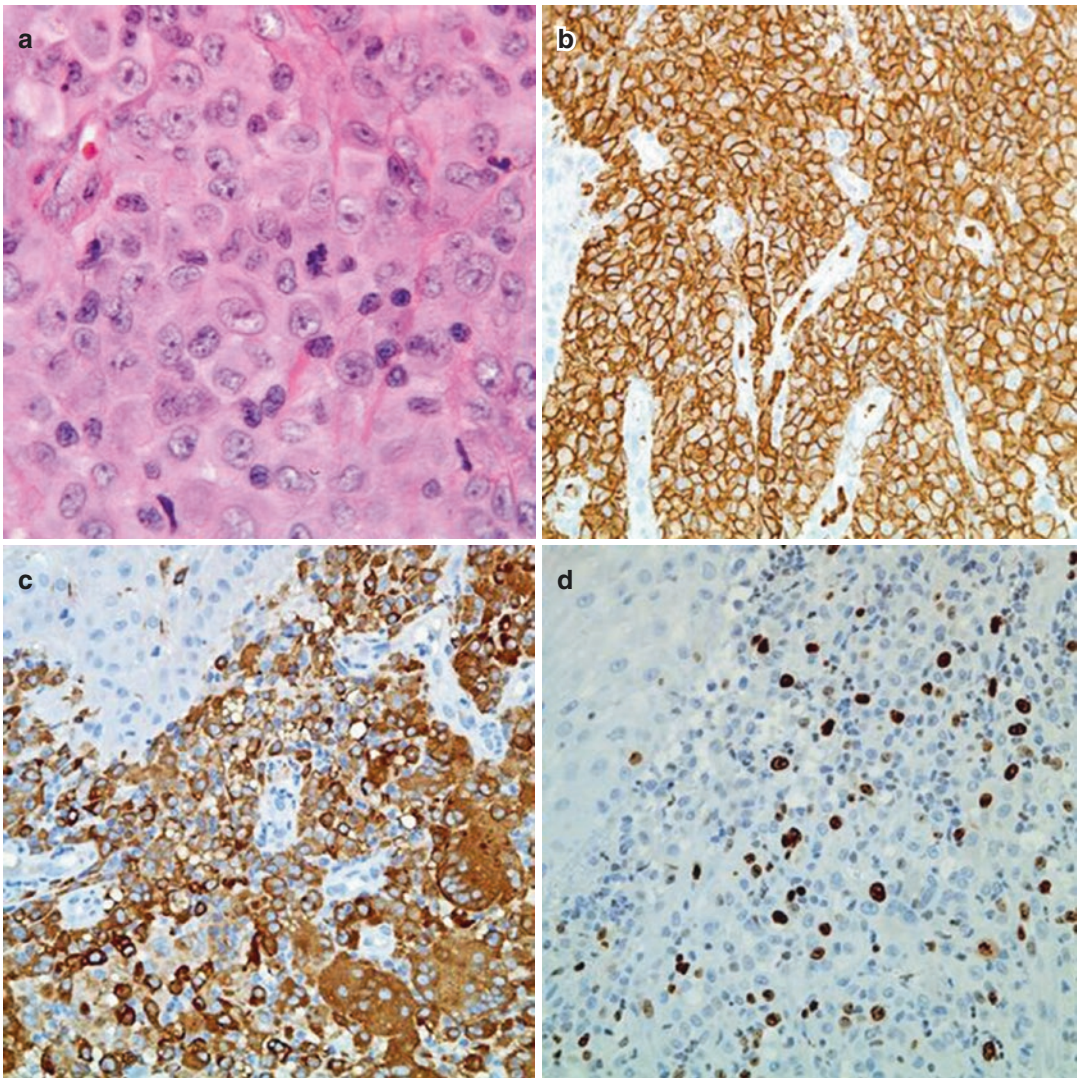


Fig. 20.2 Histiocytic sarcoma with (a) monotonous oval nuclei, prominent nucleoli, a fairly brisk mitotic rate, and abundant pale cytoplasm (H&E 100 \times). The cells have a macrophage phenotype with (b) surface CD14 and (c)

cytoplasmic and surface CD163, along with granular cytoplasmic CD68 (not shown). (d) High Ki-67/MIB1 proliferation rate index (immunostains, 40 \times) (Courtesy of Dr. Jennifer Picarsic)

immunoglobulin heavy chain gene rearrangement can be present with or without a concomitant follicular lymphoma [1, 6].

Pathogenesis

The pathogenesis of histiocytic sarcoma is unknown. The disease is much more common in dogs (particularly Bernese Mountain Dogs and flat-coated retrievers) than in humans. One study assessed recurrent copy number alterations in tumors from these two breeds and found similarities including deletions of the tumor suppressor genes *CDKN2A/CDNK2B*, *RB1*, and *PTEN* [37]. Human and mouse histiocytic sarcoma tumors also demonstrate genetic or epigenetic inactivation of *PTEN* in addition to *p16(INK4A)* and *p14(ARF)* [38]. In another murine study, Sleeping Beauty mutagenesis targeted to myeloid cell lines identified a number of mutations of interest, among them *RAF1*, *MYC*, and *PTEN* [39]. Additionally, in primary canine tumors and cell lines, increased expression of survivin correlated with decreased survival and resistance to chemotherapy. Treatment of cell lines with the survivin inhibitor YM155 suppressed cell growth and blocked resistance to lomustine by inhibiting the activity of ATP-binding cassette transporters [40]. The above findings are hypothesis generating, but at present, their exact role in the pathogenesis of histiocytic sarcoma remains to be defined.

The clonal association between histiocytic sarcoma and other hematological neoplasms is well described. Secondary histiocytic sarcoma is most commonly reported in the setting of follicular lymphoma but has also been described in association with B- and T-cell acute lymphoblastic leukemia [41], various B-cell non-Hodgkin lymphomas [42], Hodgkin lymphoma [43], chronic lymphocytic leukemia [11], chronic myeloid leukemias [44], and hairy cell leukemia [45]. Histiocytic sarcoma has also been described in conjunction with acute myeloid leukemia [46], and germ cell tumors [47] and on occasion all three malignancies occur in the same patient [46]. In some circumstances, a clonal relationship

between the associated hematopoietic neoplasm and histiocytic sarcoma has been well elucidated. For instance, in one study of eight patients who were diagnosed with both follicular lymphoma and malignant histiocytosis (seven patients with histiocytic sarcoma and one patient with interdigitating dendritic cell sarcoma), all eight cases of the secondary malignant histiocytosis harbored a *t(14;18)*. Three of the patients had simultaneous follicular lymphoma and malignant histiocytosis, while in the other five patients, the malignant histiocytosis developed 2 months to 12 years after the follicular lymphoma [10]. However, clonal immunoglobulin receptor gene rearrangements can occur in a high percentage of sporadic histiocytic sarcoma demonstrating that these tumors may arise from cells of the B-cell lineage without presenting with a concomitant B-cell lymphoma [48]. The means by which primary hematopoietic neoplasm give rise to secondary malignant histiocytosis is unclear, and the different hypotheses are described above (page 363, section "Pathogenesis").

For purposes of treatment decision-making, clinicians need to consider whether the patient has localized or disseminated disease and whether he/she has primary or secondary histiocytic sarcoma.

Localized Histiocytic Sarcoma

Patients with unifocal disease are thought to have a better prognosis, although in one series of 15 patients, there was no difference in survival between those with localized disease and those with disseminated disease. This finding is likely due to the small number of patients examined, rather than a lack of difference in prognosis between localized and multifocal disease [49].

Surgical resection is the preferred treatment for primary histiocytic sarcoma with localized disease. In two series that included a total of nine patients treated by surgical resection alone, six did not experience a recurrence, while one experienced a localized recurrence that was successfully treated with repeat resection and radiation [49, 50].

The role of adjuvant radiotherapy after surgical resection is unclear but is favored by the authors. In one report in which three patients were treated with surgical resection and adjuvant radiation, none had a local recurrence although one did develop a distant recurrence [50]. Despite the limited data, we favor adjuvant radiation for localized disease due to the poor prognosis of histiocytic sarcoma.

Combined modality therapy may not be appropriate for all patients due to potential toxicity of either radiation or surgery. If the patient is not a surgical candidate due to comorbidities or other factors, primary radiotherapy would be the treatment of choice for localized disease. Conversely, if radiation is expected to have excessive morbidity, it is reasonable to utilize surgical resection alone without adjuvant radiation. The optimal dose of radiation is not defined, though higher doses than the 12–20 Gy most commonly used in Langerhans cell histiocytosis are recommended.

There is no clear role for adjuvant chemotherapy following resection and/or radiation. In the series published by researchers at Brigham and Women's Hospital, two of the six patients who received adjuvant chemotherapy developed distant metastases within weeks of treatment. This recurrence rate was similar to those treated without chemotherapy [50]. Similarly, in the Memorial Sloan Kettering Cancer Center series, adjuvant or neoadjuvant chemotherapy did not improve overall survival [49].

Intracranial Histiocytic Sarcoma

Most CNS HS tumors are unresectable due to their location and number. Total excision, if possible, should always be considered as it may provide a better prognosis with survival up to 1 year after complete resection [51]. Steroids may relieve the symptoms temporarily by their anti-edematous and oncolytic effects, but should be avoided before a biopsy as they may interfere with an accurate diagnosis [52].

Chemotherapy for intracranial HS has usually been unsuccessful [10]. High doses of methotrexate and cytarabine were found to be ineffective in

one case report of CNS HS [52]. Nevertheless, a more recent case of intracranial HS responded well to a high-dose methotrexate-based chemotherapy regimen [53]. A dramatic response to vemurafenib has been recently reported in a *BRAF-V600E*-mutated primary CNS HS [54]. Whole brain radiotherapy in CNS HS may improve the response to chemotherapy and may decrease local recurrence rates, but is not curative, and the rate of neurotoxicity is high [55].

Disseminated or Recurrent Histiocytic Sarcoma

Multifocal disease typically requires systemic therapy, although patients that have a limited number of metastases may do well with resection. An isolated recurrence after localized therapy can be treated by surgical resection and/or radiation with systemic therapy reserved for more widespread recurrences.

Unfortunately, histiocytic sarcoma generally does not respond well to cytotoxic chemotherapy, and the outcome for patients with multifocal disease is poor. No standard systemic therapy exists, and most clinicians utilize regimens developed for aggressive non-Hodgkin lymphomas. Some of the responses described with these regimens originate from a time when limited diagnostic techniques were available and aggressive lymphomas may have been misdiagnosed as histiocytic sarcoma. Nonetheless, these regimens remain widely used. The two most commonly utilized regimens are cyclophosphamide, doxorubicin, vincristine, and prednisone (CHOP) or ifosfamide, carboplatin, and etoposide (ICE) with mesna. The authors favor the ICE regimen, although this is based solely on personal experience and there is no evidence in the literature that conclusively demonstrates that ICE is superior to other regimens.

Due to the high recurrence rate after chemotherapy, hematopoietic stem cell transplantation (HSCT) is considered in appropriate patients with multifocal disease who achieve a remission with chemotherapy. However, there is very little data demonstrating the efficacy of either

autologous or allogeneic HSCT for histiocytic sarcoma [56]. There are case reports of long-term remissions following both allogeneic and autologous HSCT [57]. However, if transplantation is considered, the authors generally favor allogeneic HSCT given the inherent chemoresistance of histiocytic sarcoma.

Treatment options for patients with relapsed or refractory disease following frontline therapy are poorly defined. Initial reports suggested that the BRAF-V600E mutations did not occur in histiocytic sarcoma. However, subsequent analyses have identified this mutation in a small proportion of patients. Given the success of BRAF inhibitors in LCH and ECD [58, 59] and case reports describing responses to BRAF inhibitors in Langerhans sarcoma and histiocytic sarcoma [18, 60], the authors favor BRAF inhibitors as second-line therapy if the BRAF-V600E mutation is present even though the exact response rate and duration of response remain unknown. Treatment options for patients who do not respond to BRAF inhibitors or who did not harbor the BRAF mutation are poorly defined. There are case reports detailing responses to thalidomide [61]-, alemtuzumab [62]-, and cladribine-based regimens [63]. There is not sufficient data on any of these treatments to recommend one

over the other, and treatment selection should be based upon patient comorbidities, physician preference, and, in the case of alemtuzumab, on the presence or absence of CD52 on the malignant cell. More recently, PD-L1 expression has been demonstrated in histiocytic sarcoma creating the possibility that immunotherapy with PD-L1 or PD-1 inhibitors may be a potential option [64]. At present, however, there is no published clinical experience with these immunotherapies in histiocytic sarcoma. Please see Table 20.3 for a summary of treatment options for HS.

Treatment of Histiocytic Sarcoma Secondary to Other Malignancies

There is extremely limited data examining the optimal treatment of patients with HS secondary to other malignancies. In general, treatment should be directed at the most aggressive process, either the histiocytic sarcoma or the concomitant primary malignancy. For instance, in a patient with histiocytic sarcoma secondary to acute lymphoblastic leukemia (ALL), treatment should be directed at the acute leukemia. One exception would be if the HS were localized and amenable to surgical resection and/or radiation. In that

Table 20.3 Treatment of histiocytic sarcoma

Localized disease	Intracranial disease	Multifocal disease
1. Combined modality therapy (surgery and radiation) preferred [49, 50]	Solitary site – surgical resection preferred, radiation if surgery not possible [51]	If only two sites involved, surgery preferred
2. Surgical resection alone or radiation alone if combined modality therapy not feasible	Multiple sites BRAF inhibitor if BRAF mutation present [54] Cytarabine with or without methotrexate if BRAF inhibitor ineffective or BRAF mutation not detected [53]	If more than 2 sites then chemotherapy: ICE CHOP Allogeneic transplant in appropriate patients with chemosensitive disease [56, 57]
Adjuvant chemotherapy not suggested	Recurrent disease or patient not candidate for systemic therapy: Whole brain radiation [55] Best supportive care	Relapsed/refractory disease: BRAF inhibitor if mutation present [18, 60] Alemtuzumab (if CD52+) [62] Thalidomide or lenalidomide [61] Cladribine [63] MEK inhibitor (efficacy unknown) PD-1 or PD-L1 inhibitor if PD-L1+ (efficacy unknown) [64] Cytarabine (efficacy unknown) Clofarabine (efficacy unknown)

circumstance, localized treatment against HS prior to or concomitant with treatment directed at the primary neoplasm would be appropriate. For example, in cases of HS diagnosed concomitantly with follicular lymphoma, for which watchful waiting or directed therapies such as rituximab may otherwise be appropriate, the primary treatment selection should be directed at the HS since it is generally the more aggressive process. There also may be circumstances in which the presence of a shared mutation may tailor therapy. One example would be the HS occurring with hairy cell leukemia when both harbor the BRAF-V600E mutation [20, 21]. In such a scenario, treatment with a BRAF inhibitor could address the pathophysiology of both entities.

Langerhans Cell Sarcoma (Langerhans Cell Malignant Histiocytosis)

Pathology

Langerhans cell sarcoma (LCS) is a rare aggressive neoplasm distinct from the usually clinically benign condition, LCH. In contrast to LCH, the Langerhans cells in LCS have overt malignant

cytological features characterized by increased nuclear/cytoplasmic ratio, nuclear pleomorphism, clumped chromatin, conspicuous nucleoli, and a high mitotic rate (Fig. 20.3a). It is only with the help of immunophenotyping, such as CD1a (Fig. 20.3b), S100, and CD207 positivity, that these anaplastic cells are revealed to have the features of Langerhans cells [1, 17]. It is important to note that not all LCS tumors are CD207 positive (contain Birbeck granules) [17].

Epidemiology

LCS is predominantly a disease of adulthood. A review of 53 published cases revealed a median age of 57 years and an age range of 7–88 years. The majority of reported cases are male (M/F ratio 1.5:1) [17]. Population-based demographic data is lacking.

Pathogenesis

The pathogenesis of LCS remains unclear. It usually presents as a spontaneous illness but has been reported after liver transplant in at least two patients (6 and 12 years after transplant,

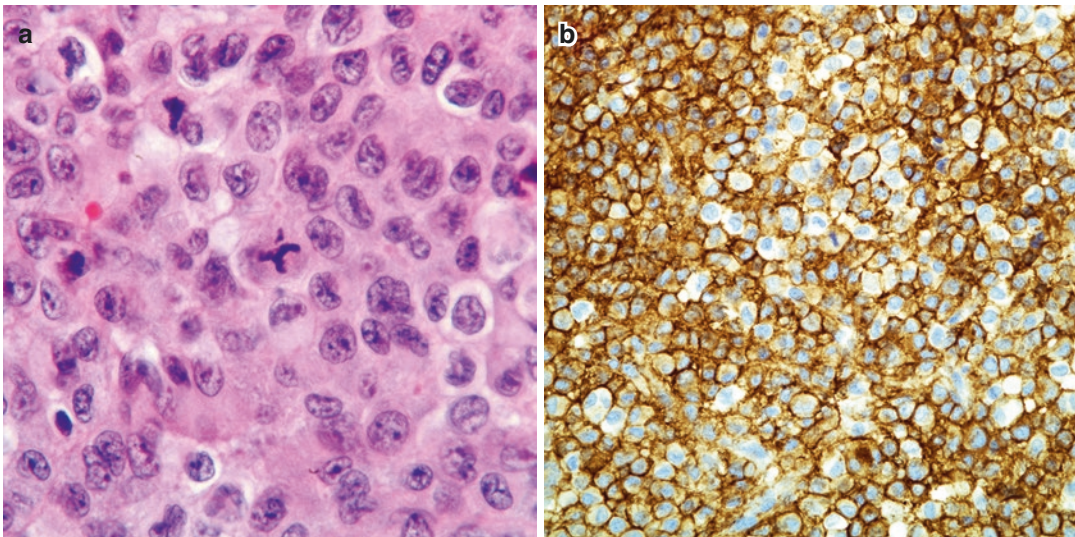


Fig. 20.3 Langerhans cell sarcoma with (a) grooved nuclear folds, high cellularity, mild pleomorphism, and an atypical mitosis (H&E, 100 \times) and (b) CD1a expression (immunostain 40 \times) (Courtesy of Dr. Jennifer Picarsic)

respectively) [26, 65]. Preceding LCH skin lesions have been rarely reported, and there is one report of a preceding and concurrent pulmonary LCH [26, 66, 67].

Preceding/concurrent hematological malignancies including chronic myeloid leukemia [68], chronic lymphocytic leukemia/small lymphocytic lymphoma [69], hairy cell leukemia [20, 21], precursor B-cell acute lymphoblastic leukemia [70], T-cell acute lymphoblastic leukemia [61], myelodysplastic/myeloproliferative syndrome [71], acute myeloid leukemia [72], nodal marginal zone lymphoma [73], and follicular lymphoma [74] have been reported. In some of these cases, a clonal relationship between the hematological neoplasm and the LCS has been demonstrated. In one case where the LCS and chronic lymphocytic leukemia/small lymphocytic lymphoma occurred in the same lymph node, a 6q23 deletion was detected in cells from both diseases, while the BRAF-V600E was only present in the LCS cells [69]. In another example, identical immunoglobulin rearrangements have been demonstrated in the LCS and hairy cell leukemia occurring in the same patient [20]. Exactly how primary hematopoietic neoplasms give rise to secondary malignant histiocyto-

sis remains unclear, and the different hypotheses are described above (page 363, section “Pathogenesis”).

The BRAF-V600E mutation, which is found in 57% of LCH cases, has been found in some patients with LCS though the exact percentage of LCS that harbor this mutation is unclear [17, 18, 75, 76]. The possible role of this activating mutation in the development of some cases of LCS warrants further investigation.

Clinical Manifestations and Prognosis

A review of 53 published cases suggests that the most common sites of disease are the lymph nodes and skin. Other sites include bone (Fig. 20.4a, b), bone marrow, lung, liver, spleen, and soft tissue. The majority of cases (53%) are reported to have single site/organ disease. Outcome was reported in 47/53 cases. Of the 28 patients with localized disease, 7 had died (25%), 5 were alive with disease, 11 were in remission, and insufficient data was available on 5 patients. In contrast, 16 of the 25 patients with multiorgan/multisite disease had died (64%), 3 were alive with disease, 5 were in remission, and insufficient data was available on 1

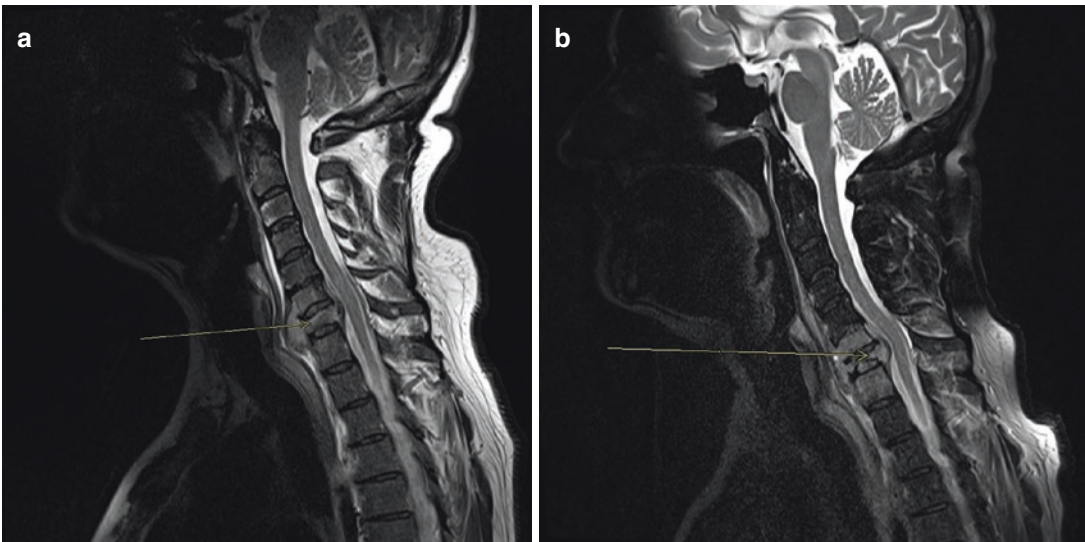


Fig. 20.4 Adult patient with Langerhans cell sarcoma progression in cervical spine. **(a)** Loss of height of C7 vertebral body with soft tissue infiltration of C7 and C6.

(b) Collapse of C7 vertebral body and progressive invasion of C6 after a 6-week interval (Courtesy of Dr. Fiona Dickinson)

patient. Most cases were reported with very short follow-up, and it is likely that the mortality will be higher with longer follow-up (several reported to be alive with disease) [17]. Population-based information on prognosis is lacking, and estimates of prognosis on the basis of published outcomes are compromised by publication bias, incomplete data, and short follow-up.

Treatment

The optimal treatment for LCS is not known. Case reports and summaries of treatment and outcomes reported in the literature provide little insight into which modalities/combinations are most likely to be successful. In the first instance, clinicians need to consider whether the patient has primary or secondary Langerhans cell sarcoma and whether the patient has localized or multifocal disease. The principles for the treatment of secondary MH described in the histiocytic sarcoma section also apply here (see page 370).

Localized Langerhans Cell Sarcoma

Localized disease usually affects a lymph node or manifests as a single skin lesion. This is most often managed with complete resection as first-line therapy although adjuvant chemotherapy and radiotherapy are often used. The value of adjuvant therapy is however unclear, and resection alone can be curative in some cases [65, 67, 77, 78]. Unfortunately, local and systemic recurrence after surgery is common. Single modality treatment with radiotherapy has been successful in treating localized disease in a lymph node in one reported case. The optimal dose of radiotherapy for LCS is not well defined, but it is noted that 59.4Gy was used in this case [28]. In light of the poor prognosis of LCS and relative insensitivity to chemotherapy, the authors suggest that complete resection and adjuvant radiotherapy are considered when feasible in patients with localized disease. If surgery is not possible, radiotherapy may be a suitable alternative.

Multifocal or Recurrent Langerhans Cell Sarcoma

The mainstay of treatment of multisite/multiorgan LCS is chemotherapy. There is, however, no established effective treatment regimen. CHOP (cyclophosphamide, doxorubicin, vincristine, and prednisolone) chemotherapy is often used, but reported responses and outcomes are not encouraging [18, 26, 27, 79, 80]. Drugs and combinations of drugs successfully used in LCH treatment, including vinblastine + prednisolone, cladribine monotherapy, and cladribine + cytarabine, have also been disappointing in the treatment of LCS [29, 68, 81]. Although the follow-up data is very limited, there are anecdotal reports of responses to some ifosfamide-based regimens, namely, ICE (ifosfamide, carboplatin, etoposide), EPIG (etoposide, cisplatin, ifosfamide, gemcitabine), and Adriamycin + ifosfamide [82–84]. A regimen of gemcitabine + docetaxel was not effective in one reported case [21]. Two patients who later went on to have allogeneic HSCT had dexamethasone and etoposide (HLH2004) as first-line therapy and achieved a 16-month CR and a 12-month PR, respectively, before they relapsed/progressed [82]. There is not enough published data to make a recommendation regarding specific chemotherapy combinations, but ifosfamide- and etoposide-containing regimens may warrant further investigation. The reported CR achieved with AML-type treatment (decitabine, daunorubicin, and cytarabine) described below is also of note [72].

The poor record of systemic chemotherapy in LCS suggests that new approaches are needed. Patients with tumors that carry the BRAF-V600E mutations could be considered for treatment with BRAF inhibitors. Dramatic response to dabrafenib has been reported but was short-lived, and combined BRAF and MEK inhibition may need to be considered [18].

In the light of the poor prognosis of patients with multifocal or recurrent LCS, allogeneic HSCT may require consideration in patients who respond to treatment. There is, however, little published evidence to support its use.

Two patients who received allogeneic HSCT were still alive at last follow-up (see above). They were alive for a period of >16 months (in CR) and >24 months (status unknown) from diagnosis, respectively. The interval between the transplant and last follow-up was not reported. Both were treated with HLH2004 treatment (etoposide and dexamethasone) as first-line therapy with transient response and different second-line treatments. It is also not clear what conditioning regimens were used [82]. Another patient had an allogeneic HSCT after cyclophosphamide + total body irradiation conditioning regimen and remains in CR at 52 months from diagnosis (13 months since transplant) [70]. A patient who developed AML and localized skin LCS at the same time achieved CR with AML-type treatment with decitabine, daunorubicin, and cytarabine before receiving an allogeneic HSCT, remaining alive in CR at 62 months from diagnosis [72]. See Table 20.4 for a summary of treatment options for LCS.

Interdigitating Dendritic Cell Sarcoma (Interdigitating Cell Malignant Histiocytosis)

Pathology

Interdigitating dendritic cell sarcoma (IDCS) develops in the paracortical region of lymph nodes and has a storiform or whorled fascicular growth pattern. The tumor cells are spindle to ovoid in shape, have abundant cytoplasm, and often have indistinct borders (Fig. 20.5a). The nuclei are oval or spindle and have distinct nucleoli. The degree of cytologic atypia varies. The mitotic rate is low (<5 per 10 high-power fields) in the majority of patients. There is often an associated infiltrate of T lymphocytes. Immunophenotyping is needed to make a specific diagnosis. Tumor cells are consistently positive for S100 (Fig. 20.5b) and vimentin. Fascin (Fig. 20.5c) is also often positive. Expression of CD68, lysozyme, and CD45 is variable. CD1a and CD207 are negative, and the Ki67 proliferative index is low [1, 2, 85]. The intermixed mononuclear round cells are positive for CD163, but lesional spindle cells are CD163 negative (Fig. 20.5d).

Table 20.4 Treatment of Langerhans cell sarcoma

Localized disease	Multifocal disease
Combined modality therapy with surgery and radiation preferred Surgery alone or radiation alone is acceptable if potential morbidity precludes combined modality therapy Adjuvant chemotherapy not recommended	Optimal treatment unknown. <i>Multiagent regimens (preferred):</i> CHOP [18, 26, 27, 79, 80] ICE [82] EPIG [83] Adriamycin + ifosfamide [84] Cladribine + cytarabine [68] <i>Single agents:</i> Vinblastine + prednisone [29] Cladribine [81] BRAF inhibitors are favored for patients with relapsed/refractory disease and BRAF-V600E mutation [18] MEK inhibitors could be considered but efficacy unknown <i>Consider allogeneic transplant in appropriate patients who respond to treatment [72]</i>

Epidemiology

Pooled data from reported cases demonstrates a wide age range (21 months to 88 years) and a median age of 56.5 years. There was a slight predominance of males (M/F ratio of 1.38:1) among the reported cases [85]. SEER registry data covering the period 2001–2008 demonstrated a similar median age (64 years) and a similar male predominance (M/F ratio 1.5:1) [34].

Pathogenesis

The pathogenesis of this tumor remains unclear. At least 12% of patients with IDCS develop another hematological malignancy and 9% another solid organ tumor during their lifetime [85]. Of note, a clonal relationship between

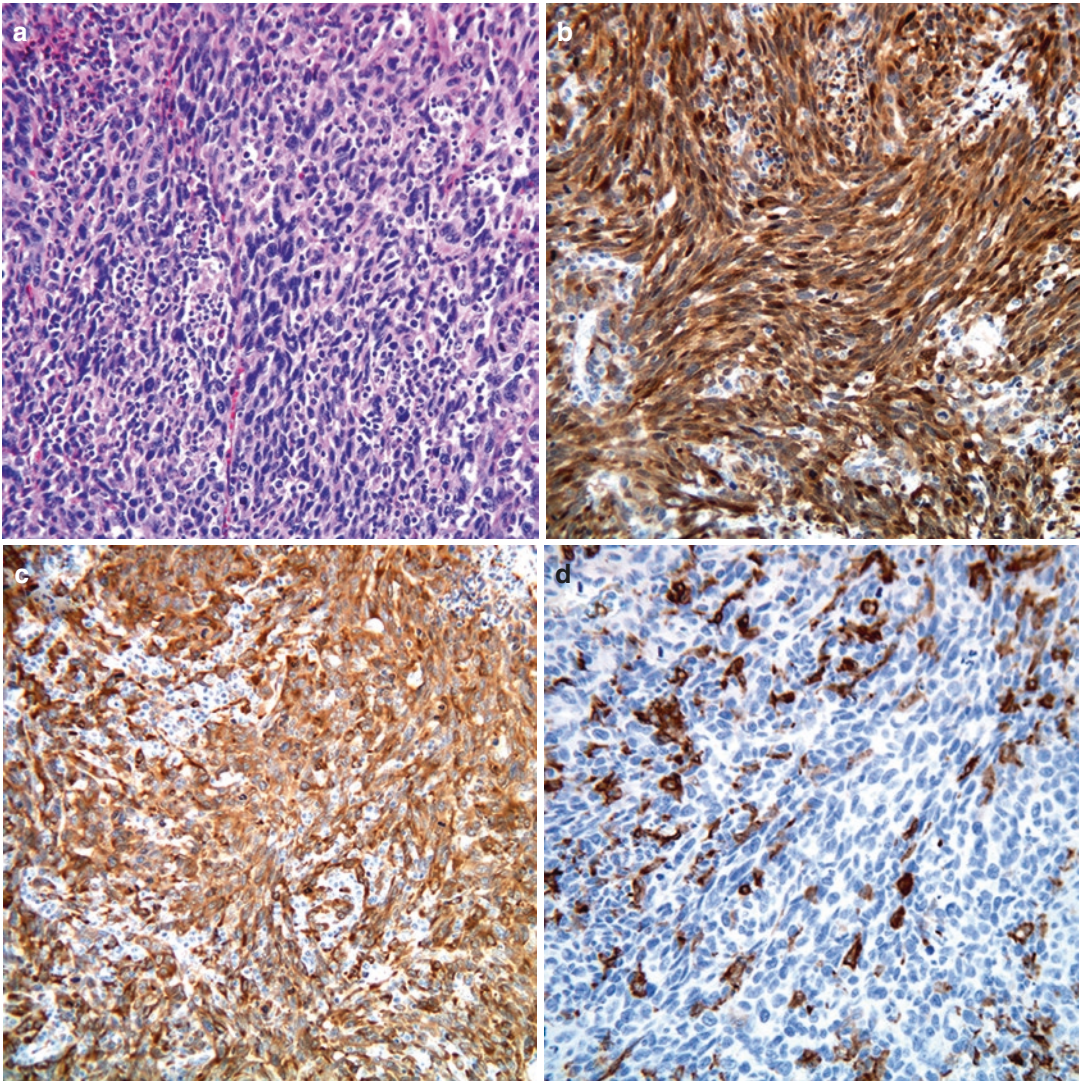


Fig. 20.5 Interdigitating cell sarcoma. (a) Spindle cell lesion composed of ovoid to elongated nuclei without prominent nucleoli (H&E 40×). Lesional cells stain strongly for (b) S100 (immunostain, 40×), (c) fascin

(immunostain, 40×), and vimentin (not shown). (d) The intermixed mononuclear round cells are positive for CD163, but lesional spindle cells are negative (Courtesy of Dr. Jennifer Picarsic)

IDCS and low-grade B-cell lymphomas has been demonstrated in some patients who experienced both diseases synchronously or metachronously [10, 11, 86]. Hypotheses on how this relationship may come about are described above (page 363, section “Pathogenesis”). Some IDCS cases harbor the *BRAF-V600E* mutation, and this may provide a focus for further investigations into the pathogenesis of these rare tumors [19, 87].

Clinical Manifestations and Prognosis

The majority of patients (55%) have localized disease at diagnosis (SEER data) [34]. Patients most often present with painless solitary lymphadenopathy. Systemic symptoms including fever, night sweats, weight loss, and fatigue have been reported, most often in patients with both nodal and extranodal disease. Isolated nodal disease

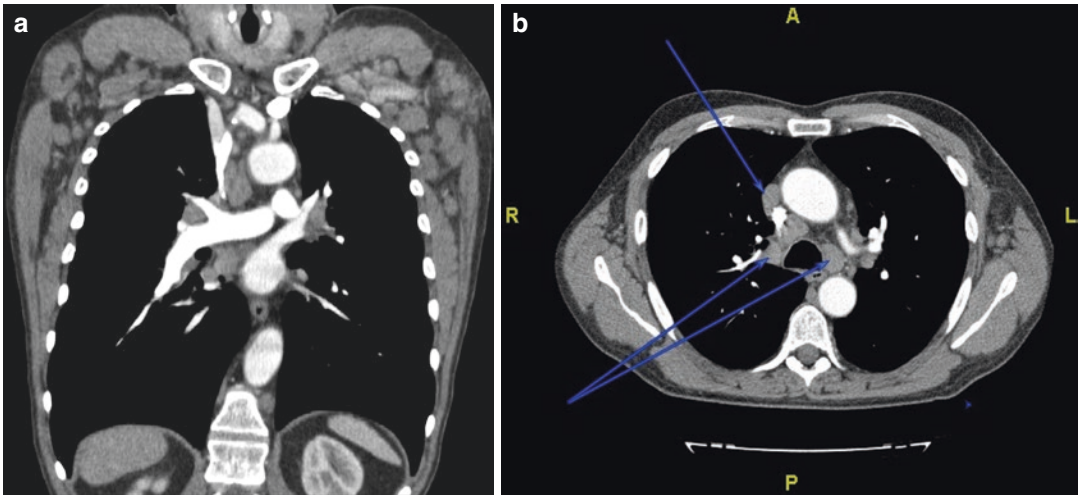


Fig. 20.6 Adult patient with multifocal interdigitating dendritic cell sarcoma. (a) Extensive axillary, mediastinal, and hilar lymphadenopathy. (b) Mediastinal lymphade-

nopathy with the largest nodes in the pre- and paratracheal regions (Courtesy of Dr. Rachael Holmes)

makes up 47% of reported cases, isolated extranodal disease 25%, and combined nodal and extranodal 28% [85] (Fig. 20.6a, b). Extranodal sites include the liver, spleen, tonsils, bone marrow, lungs, skin, soft tissue, bowel, and bladder.

Pooled data from reported cases demonstrated a significantly lower overall survival in patients with metastatic disease (38.46% at 1 year, 15.8% at 2 years) compared to localized disease (84.8% at 1 year, 68.1% at 2 years). The median survival for patients with metastatic disease was 9 months (0.25–72 months). The majority of patients with localized disease were still alive at last follow-up (82%), and median survival was not reached [85]. The SEER registry data revealed a similar pattern with a median survival of 10 months in patients with metastatic disease, while the median survival was not reached in those with localized disease [34]. Younger patients and those with intra-abdominal disease appear to have a higher risk of relapse or death [85].

Treatment

The optimal treatment for patients with IDCS is not well defined. Clinicians need to consider whether the patient has primary or secondary IDCS and whether the patient has

localized or multifocal disease. The principles for the treatment of secondary MH described in the histiocytic sarcoma section also apply here (see page 370).

Localized Disease

The abovementioned review of pooled published cases demonstrates that surgery is the mainstay of treatment in patients with localized disease (34/45). Surgery was combined with adjuvant radiotherapy (10/34), adjuvant chemotherapy (3/34), and adjuvant radiotherapy/chemotherapy (2/34) in some patients. The remainder of cases were treated with radiotherapy (6 out of 11 patients), chemotherapy (3 out of 11 patients), or radiotherapy and chemotherapy (1 out of 11). At a median follow-up of 13 months, 10/11 of these patients were alive. There was no difference in overall survival between those treated with surgery alone, those treated with surgery and radiotherapy, and those treated with other modalities [85]. The SEER dataset included 11 patients with localized disease. Six were treated with surgery (one of them had adjuvant radiotherapy). Those who did not have surgery ($n = 5$) also did not have radiotherapy (the SEER data does not include information on chemotherapy). Patients

treated with surgery had a significantly better prognosis than those who did not have surgery or radiotherapy [34]. The small number of patients and the degree of missing data limit the conclusions that can be drawn from the published cases and the registry. In view of the relatively good prognosis of localized disease, it is reasonable to consider surgery as single modality first-line treatment, when feasible. Radiotherapy is a reasonable alternative if surgery is not considered appropriate.

Multifocal or Recurrent Disease

Patients with metastatic disease are usually treated with chemotherapy (given to 23 out of 27 patients in a pooled analysis of published cases) though the outcome is quite poor [85]. ABVD (doxorubicin, bleomycin, vinblastine, dacarbazine) appears to be the most promising option, with a slowly growing number of case reports showing response to this combination [88–91]. It is encouraging that in three of these cases, patients with disseminated disease experienced complete remission which was maintained for a prolonged period (at least 12 months in two cases and at least 24 months in one case) [89, 90]. However, the small number of reports since the first report of successful treatment with ABVD in 2002 and a recent report of only transient partial response in one case suggest that this approach is not always successful [92]. A range of other chemotherapy regimens have been reported in the literature, although responses have been often absent and short-lived or the reported follow-up is very short. These include CHOP (cyclophosphamide, doxorubicin, vincristine, and prednisolone) [32, 93, 94]; epirubicin + ifosfamide [95], IMEP (ifosfamide, methotrexate, etoposide, and prednisolone) [32]; vincristine + actinomycin + cyclophosphamide + adriamycin [93]; and docetaxel + gemcitabine [96]. A response to vemurafenib has been reported in a patient who had a tumor expressing the BRAF-V600E mutation [95]. Patients with an abnormally activated MAPK/ERK pathway may benefit from appropriate targeted therapy. See Table 20.5 for a

Table 20.5 Treatment of interdigitating dendritic cell sarcoma

Localized disease	Multifocal disease
Surgery preferred, radiation if surgical resection not possible [34] No role for adjuvant chemotherapy	Optimal treatment unknown. Options include: ABVD [88–91] CHOP [32, 93, 94] Epirubicin + ifosfamide [95] IMEP [32] Docetaxel + gemcitabine [96] BRAF inhibitor should be considered in patients with relapsed/refractory disease and BRAF-V600E mutation MEK inhibitors could be considered in relapsed/refractory disease regardless of mutation status though efficacy unknown

summary of treatment options for interdigitating dendritic cell sarcoma.

Indeterminate Dendritic Cell Tumor (Indeterminate Cell Malignant Histiocytosis)

Indeterminate dendritic cell tumors (IDCT) are also known as indeterminate dendritic cell sarcomas. These are high-grade lesions with similarities to LCS and are described in Chapter 1 (see page 39). The tumors are S100+/CD1a+ but lacks CD207. Only a small number of cases have been described in the literature. It affects older adults and is usually involves the skin and/or lymph nodes. It can occur de novo or in the context of current or previous lymphoma [97]. The prognosis is uncertain and optimal treatment has not been defined.

Conclusions and Future Perspectives

The malignant histiocytoses are extremely rare and have variable clinical behavior. Therefore, in most cases, the optimal treatment has not been clearly defined. Patients with disseminated disease appear to have a particularly poor prognosis.

The study of the epidemiology of malignant histiocytoses is hampered by the small number of cases and by changes in the classification, nomenclature, and ICD coding over time. The need for cancer registries to collaborate when studying extremely rare cancers is clearly demonstrated by this group of disorders [6].

The lack of systematic data on treatment and outcomes frustrates efforts to improve the care of these patients. There are no published trials and no prospect of undertaking randomized trials due to the rarity of these conditions. As possible sources of evidence, the published case reports and case series suffer from inevitable publication bias, lack of complete data, and often very short follow-up periods. The small number of cases prevents individual clinicians from gaining more than anecdotal experience and limits the ability of researchers to obtain sufficient material for basic and translational research.

The Histiocyte Society International Rare Histiocytic Disorder Registry (IRHDR) was launched in 2015 to address some of these challenges. Cases presented for inclusion in the registry undergo expert pathology review. The outcome of this review is combined with clinical, treatment, response, and follow-up data for each patient. The registry will provide a growing repository of information which may inform future therapeutic recommendations. <http://www.histiocytesociety.org/main-website-pages/clinical-trials/clinical-studies/IRHDR>

In the absence of clear treatment recommendations or resistant disease, consideration should be given to participation in early phase clinical trials. Systematic genome sequencing and high-throughput drug sensitivity testing may also be able to aid treatment decisions in the future. Contributing tumor tissue to a tumor bank will allow samples from these very rare tumors to be available for future basic and translational research.

References

1. Swerdlow SH, Campo E, Harris NL, Jaffe ES, Pileri SA, Stein H, et al., editors. WHO classification of tumours of haematopoietic and lymphoid tissue (IARC WHO classification of tumours). Geneva: WHO; 2008.
2. Pileri SA, Grogan TM, Harris NL, Banks P, Campo E, Chan JK, et al. Tumours of histiocytes and accessory dendritic cells: an immunohistochemical approach to classification from the International lymphoma study group based on 61 cases. *Histopathology*. 2002;41(1):1–29.
3. Swerdlow SH, Campo E, Pileri SA, Harris NL, Stein H, Siebert R, et al. The 2016 revision of the World Health Organization classification of lymphoid neoplasms. *Blood*. 2016;127(20):2375–90.
4. <http://codes.iarc.fr/codegroup/2>.
5. Histiocytosis syndromes in children. Writing Group of the Histiocyte Society. *Lancet*. 1987;1(8526):208–9.
6. Emile JF, Abia O, Fraitag S, Horne A, Haroche J, Donadieu J, et al. Revised classification of histiocytoses and neoplasms of the macrophage-dendritic cell lineages. *Blood*. 2016;127(22):2672–81.
7. Gatta G, van der Zwan JM, Casali PG, Siesling S, Dei Tos AP, Kunkler I, et al. Rare cancers are not so rare: the rare cancer burden in Europe. *Eur J Cancer*. 2011;47(17):2493–511.
8. <http://www.rarecarenet.eu/rarecarenet/index.php/cancerlist>.
9. O'Malley DP, Zuckerberg L, Smith LB, et al. The genetics of interdigitating dendritic cell sarcoma share some changes with Langerhans cell histiocytosis in select cases. *Ann Diagn Pathol*. 2014;18(1):18–20.
10. Feldman AL, Arber DA, Pittaluga S, Martinez A, Burke JS, Raffeld M, et al. Clonally related follicular lymphomas and histiocytic/dendritic cell sarcomas: evidence for transdifferentiation of the follicular lymphoma clone. *Blood*. 2008;111(12):5433–9.
11. Shao H, Xi L, Raffeld M, Feldman AL, Ketterling RP, Knudson R, et al. Clonally related histiocytic/dendritic cell sarcoma and chronic lymphocytic leukemia/small lymphocytic lymphoma: a study of seven cases. *Mod Pathol*. 2011;24(11):1421–32.
12. Xie H, Ye M, Feng R, Graf T. Stepwise reprogramming of B cells into macrophages. *Cell*. 2004;117(5):663–76.
13. Yu D, Allman D, Goldschmidt MH, Atchison ML, Monroe JG, Thomas-Tikhonenko A. Oscillation between B-lymphoid and myeloid lineages in Myc-induced hematopoietic tumors following spontaneous silencing/reactivation of the EBF/Pax5 pathway. *Blood*. 2003;101(5):1950–5.
14. Ansari J, Naqash AR, Munker R, El-Osta H, Master S, Cotelingam JD, et al. Histiocytic sarcoma as a secondary malignancy: pathobiology, diagnosis, and treatment. *Eur J Haematol*. 2016;97(1):9–16.
15. Cobaleda C, Jochum W, Busslinger M. Conversion of mature B cells into T cells by dedifferentiation to uncommitted progenitors. *Nature*. 2007;449(7161):473–7.
16. Go H, Jeon YK, Huh J, Choi SJ, Choi YD, Cha HJ, et al. Frequent detection of BRAF(V600E) mutations in histiocytic and dendritic cell neoplasms. *Histopathology*. 2014;65(2):261–72.

17. Zwerdling T. Langerhans cell sarcoma: case report and review of world literature. *J Pediatr Hematol Oncol.* 2014;36(6):419–25.
18. Mourah S, Lorillon G, Meignin V, Vercellino L, de Margerie-Mellon C, Pages C, et al. Dramatic transient improvement of metastatic BRAF(V600E)-mutated Langerhans cell sarcoma under treatment with dabrafenib. *Blood.* 2015;126(24):2649–52.
19. O'Malley DP, Agrawal R, Grimm KE, Hummel J, Glazyrin A, Dim DC, et al. Evidence of BRAF V600E in indeterminate cell tumor and interdigitating dendritic cell sarcoma. *Ann Diagn Pathol.* 2015;19(3):113–6.
20. Furmanczyk PS, Lisle AE, Caldwell RB, Kraemer KG, Mercer SE, George E, et al. Langerhans cell sarcoma in a patient with hairy cell leukemia: common clonal origin indicated by identical immunoglobulin gene rearrangements. *J Cutan Pathol.* 2012;39(6):644–50.
21. Muslimani A, Chisti MM, Blenc AM, Boxwala I, Micale MA, Jaiyesimi I. Langerhans/dendritic cell sarcoma arising from hairy cell leukemia: a rare phenomenon. *Ann Hematol.* 2012;91(9):1485–7.
22. Kordes M, Roring M, Heining C, Braun S, Hutter B, Richter D, et al. Cooperation of BRAF(F595L) and mutant HRAS in histiocytic sarcoma provides new insights into oncogenic BRAF signaling. *Leukemia.* 2016;30(4):937–46.
23. Liu Q, Tomaszewicz K, Hutchinson L, Hornick JL, Woda B, Yu H. Somatic mutations in histiocytic sarcoma identified by next generation sequencing. *Virchows Arch.* 2016;469(2):233–41.
24. Johnson RL, Boisot S, Ball ED, Wang HY. A case of interdigitating dendritic cell sarcoma/histiocytic sarcoma—a diagnostic pitfall. *Int J Clin Exp Pathol.* 2013;7(1):378–85.
25. Porter DW, Gupte GL, Brown RM, Spray C, English MW, deVille DeGoyet J, et al. Histiocytic sarcoma with interdigitating dendritic cell differentiation. *J Pediatr Hematol Oncol.* 2004;26(12):827–30.
26. Yoshimi A, Kumano K, Motokura T, Takazawa Y, Oota S, Chiba S, et al. ESHAP therapy effective in a patient with Langerhans cell sarcoma. *Int J Hematol.* 2008;87(5):532–7.
27. Yang CJ, Lee JY, Wu CC, Yin HL, Lien CT, Liu YC. An unusual pulmonary mass with mediastinal invasion and multiple intrapulmonary nodules in a 52-year-old man. *Chest.* 2012;141(1):253–8.
28. Nakayama M, Takahashi K, Hori M, Okumura T, Saito M, Yamakawa M, et al. Langerhans cell sarcoma of the cervical lymph node: a case report and literature review. *Auris Nasus Larynx.* 2010;37(6):750–3.
29. Keklik M, Sivgin S, Kontas O, Abdulrezzak U, Kaynar L, Cetin M. Langerhans cell sarcoma of the nasopharynx: a rare case. *Scott Med J.* 2013;58(4):e17–20.
30. Yaman E, Ozturk B, Erdem O, Gokcora N, Coskun U, Uluoglu O, et al. Histiocytic sarcoma: PET-CT evaluation of a rare entity. *Ann Nucl Med.* 2008;22(8):715–7.
31. Dong A, Wang Y, Zuo C. FDG PET/CT in follicular dendritic cell sarcoma with extensive peritoneal involvement. *Clin Nucl Med.* 2014;39(6):534–6.
32. Han HS, Lee OJ, Lim SN, An JY, Lee KM, Choe KH, et al. Extranodal interdigitating dendritic cell sarcoma presenting in the pleura: a case report. *J Korean Med Sci.* 2011;26(2):304–7.
33. Oka K, Nakamine H, Maeda K, et al. Primary histiocytic sarcoma of the spleen associated with hemophagocytosis. *Int J Hematol.* 2008;87(4):405.
34. Perkins SM, Shinohara ET. Interdigitating and follicular dendritic cell sarcomas: a SEER analysis. *Am J Clin Oncol.* 2013;36(4):395–8.
35. Heath JL, Burgett SE, Gaca AM, Jaffe R, Wechsler DS. Successful treatment of pediatric histiocytic sarcoma using abbreviated high-risk leukemia chemotherapy. *Pediatr Blood Cancer.* 2014;61(10):1874–6.
36. Fang LH, Shih LS, Lee PI, Chen WT, Chen RL. Mediastinal germ cell tumor-associated histiocytic proliferations treated with thalidomide plus chemotherapy followed by Alemtuzumab-containing reduced intensity allogeneic peripheral blood stem cell transplantation: a case report. *Medicine (Baltimore).* 2016;95(2):e2515.
37. Hedan B, Thomas R, Motsinger-Reif A, Abadie J, Andre C, Cullen J, et al. Molecular cytogenetic characterization of canine histiocytic sarcoma: a spontaneous model for human histiocytic cancer identifies deletion of tumor suppressor genes and highlights influence of genetic background on tumor behavior. *BMC Cancer.* 2011;11:201,2407-11-201.
38. Carrasco DR, Fenton T, Sukhdeo K, Protopopova M, Enos M, You MJ, et al. The PTEN and INK4A/ARF tumor suppressors maintain myelolymphoid homeostasis and cooperate to constrain histiocytic sarcoma development in humans. *Cancer Cell.* 2006;9(5):379–90.
39. Been RA, Linden MA, Hager CJ, DeCoursin KJ, Abrahamte JE, Landman SR, et al. Genetic signature of histiocytic sarcoma revealed by a sleeping beauty transposon genetic screen in mice. *PLoS One.* 2014;9(5):e97280.
40. Yamazaki H, Takagi S, Hosoya K, Okumura M. Influence of a survivin suppressor YM155 on the chemoresistance of canine histiocytic sarcoma cells. *Vet J.* 2015;205(3):375–80.
41. McClure R, Khoury J, Feldman A, Ketterling R. Clonal relationship between precursor B-cell acute lymphoblastic leukemia and histiocytic sarcoma: a case report and discussion in the context of similar cases. *Leuk Res.* 2010;34(2):e71–3.
42. Hure MC, Elco CP, Ward D, Hutchinson L, Meng X, Dorfman DM, et al. Histiocytic sarcoma arising from clonally related mantle cell lymphoma. *J Clin Oncol.* 2012;30(5):e49–53.
43. Murarescu ED, Lighezan R, Negru D, Chiselita IR, Plamadeala P, Mihailovici MS. Histiocytic sarcoma associated with Hodgkin's disease. *Romanian J Morphol Embryol.* 2005;46(3):183–7.
44. Mori M, Matsushita A, Takiuchi Y, Arima H, Nagano S, Shimoji S, et al. Histiocytic sarcoma and underlying chronic myelomonocytic leukemia: a proposal

- for the developmental classification of histiocytic sarcoma. *Int J Hematol*. 2010;92(1):168–73.
45. Michonneau D, Kaltenbach S, Derriex C, Trinquand A, Brouzes C, Gibault L, et al. BRAF(V600E) mutation in a histiocytic sarcoma arising from hairy cell leukemia. *J Clin Oncol*. 2014;32(35):e117–21.
 46. Vaishampayan U, Dan ME, Hussain M. Unusual hematologic malignancies. Case 2. Mediastinal germ cell tumor, malignant histiocytosis, and acute leukemia. *J Clin Oncol*. 2002;20(17):3739–42.
 47. Ikdahl T, Josefsen D, Jakobsen E, Delabie J, Fossa SD. Concurrent mediastinal germ-cell tumour and haematological malignancy: case report and short review of literature. *Acta Oncol*. 2008;47(3):466–9.
 48. Chen W, Lau SK, Fong D, Wang J, Wang E, Arber DA, et al. High frequency of clonal immunoglobulin receptor gene rearrangements in sporadic histiocytic/dendritic cell sarcomas. *Am J Surg Pathol*. 2009;33(6):863–73.
 49. Gounder M, Desai V, Kuk D, Agaram N, Arcila M, Durham B, et al. Impact of surgery, radiation and systemic therapy on the outcomes of patients with dendritic cell and histiocytic sarcomas. *Eur J Cancer*. 2015;51(16):2413–22.
 50. Hornick JL, Jaffe ES, Fletcher CD. Extranodal histiocytic sarcoma: clinicopathologic analysis of 14 cases of a rare epithelioid malignancy. *Am J Surg Pathol*. 2004;28(9):1133–44.
 51. Bell SL, Hanzely Z, Alakandy LM, et al. Primary meningeal histiocytic sarcoma: a report of two unusual cases. *Neuropathol Appl Neurobiol*. 2012;38:111–4.
 52. So H, Kim SA, Yoon DH, et al. Primary histiocytic sarcoma of the central nervous system. *Cancer Res Treat*. 2014;47(2):322–8.
 53. Curry RC, Faivre G, Akkari L, et al. High-dose methotrexate-based chemotherapy as treatment for histiocytic sarcoma of the central nervous system. *Leuk Lymph*. 2016;57(8):1961–4.
 54. Idbaih A, Mokhtari K, Emile JF, et al. Dramatic response of a BRAF V600E-mutated primary CNS histiocytic sarcoma to vemurafenib. *Neurology*. 2014;83:1478–80.
 55. Dalia S, Shao H, Sagatys E, Cualing H, Sokol L. Dendritic cell and histiocytic neoplasms: biology, diagnosis, and treatment. *Cancer Control*. 2014;21:290–300.
 56. Tsujimura H, Miyaki T, Yamada S, Sugawara T, Ise M, Iwata S, et al. Successful treatment of histiocytic sarcoma with induction chemotherapy consisting of dose-escalated CHOP plus etoposide and upfront consolidation auto-transplantation. *Int J Hematol*. 2014;100(5):507–10.
 57. Zeidan AM, Forde PM, Symons H, Chen A, Smith BD, Pratz K, et al. HLA-haploidentical donor lymphocyte infusions for patients with relapsed hematologic malignancies after related HLA-haploidentical bone marrow transplantation. *Biol Blood Marrow Transplant*. 2014;20(3):314–8.
 58. Hyman DM, Puzanov I, Subbiah V, Faris JE, Chau I, Blay JY, et al. Vemurafenib in multiple nonmelanoma cancers with BRAF V600 mutations. *N Engl J Med*. 2015;373(8):726–36.
 59. Haroche J, Cohen-Aubart F, Emile JF, Maksud P, Drier A, Toledano D, et al. Reproducible and sustained efficacy of targeted therapy with vemurafenib in patients with BRAF(V600E)-mutated Erdheim-Chester disease. *J Clin Oncol*. 2015;33(5):411–8.
 60. Idbaih A, Mokhtari K, Emile JF, Galanaud D, Belaid H, de Bernard S, et al. Dramatic response of a BRAF V600E-mutated primary CNS histiocytic sarcoma to vemurafenib. *Neurology*. 2014;83(16):1478–80.
 61. Abidi MH, Tove I, Ibrahim RB, Maria D, Peres E. Thalidomide for the treatment of histiocytic sarcoma after hematopoietic stem cell transplant. *Am J Hematol*. 2007;82(10):932–3.
 62. Shukla N, Kobos R, Renaud T, Teruya-Feldstein J, Price A, McAllister-Lucas L, et al. Successful treatment of refractory metastatic histiocytic sarcoma with alemtuzumab. *Cancer*. 2012;118(15):3719–24.
 63. Tomlin J, Orosco RK, Boles S, Tipps A, Wang HY, Husseman J, et al. Successful Treatment of Multifocal Histiocytic Sarcoma Occurring after Renal Transplantation with Cladribine, High-Dose Cytarabine, G-CSF, and Mitoxantrone (CLAG-M) Followed by Allogeneic Hematopoietic Stem Cell Transplantation. *Case Rep Hematol*. 2015;2015:728260.
 64. Gatalica Z, Bilalovic N, Palazzo JP, Bender RP, Swensen J, Millis SZ, et al. Disseminated histiocytoses biomarkers beyond BRAFV600E: frequent expression of PD-L1. *Oncotarget*. 2015;6(23):19819–25.
 65. Diaz-Sarrio C, Salvatella-Danes N, Castro-Forns M, Nadal A. Langerhans cell sarcoma in a patient who underwent transplantation. *J Eur Acad Dermatol Venereol*. 2007;21(7):973–6.
 66. Rodig SJ, Payne EG, Degar BA, Rollins B, Feldman AL, Jaffe ES, et al. Aggressive Langerhans cell histiocytosis following T-ALL: clonally related neoplasms with persistent expression of constitutively active NOTCH1. *Am J Hematol*. 2008;83(2):116–21.
 67. Lee JS, Ko GH, Kim HC, Jang IS, Jeon KN, Lee JH. Langerhans cell sarcoma arising from Langerhans cell histiocytosis: a case report. *J Korean Med Sci*. 2006;21(3):577–80.
 68. Chang NY, Wang J, Wen MC, Lee FY. Langerhans cell sarcoma in a chronic myelogenous leukemia patient undergoing imatinib mesylate therapy: a case study and review of the literature. *Int J Surg Pathol*. 2014;22(5):456–63.
 69. Chen W, Jaffe R, Zhang L, Hill C, Block AM, Sait S, et al. Langerhans cell sarcoma arising from chronic lymphocytic lymphoma/small lymphocytic leukemia: lineage analysis and BRAF V600E mutation study. *N Am J Med Sci*. 2013;5(6):386–91.
 70. Ratei R, Hummel M, Anagnostopoulos I, Jahne D, Arnold R, Dorken B, et al. Common clonal origin of an acute B-lymphoblastic leukemia and a Langerhans'

- cell sarcoma: evidence for hematopoietic plasticity. *Haematologica*. 2010;95(9):1461–6.
71. Valentin-Nogueras SM, Seijo-Montes R, Montalvan-Miro E, Sanchez JL. Langerhans cell sarcoma: a case report. *J Cutan Pathol*. 2013;40(7):670–5.
 72. Sagrafsky MJ, Deng AC, Magro CM. Primary cutaneous langerhans cell sarcoma: a report of four cases and review of the literature. *Am J Dermatopathol*. 2013;35(2):196–204.
 73. Ambrosio MR, De Falco G, Rocca BJ, Barone A, Amato T, Bellan C, et al. Langerhans cell sarcoma following marginal zone lymphoma: expanding the knowledge on mature B cell plasticity. *Virchows Arch*. 2015;467(4):471–80.
 74. West DS, Dogan A, Quint PS, Tricker-Klar ML, Porcher JC, Ketterling RP, et al. Clonally related follicular lymphomas and Langerhans cell neoplasms: expanding the spectrum of transdifferentiation. *Am J Surg Pathol*. 2013;37(7):978–86.
 75. Badalian-Very G, Vergilio JA, Degar BA, MacConaill LE, Brandner B, Calicchio ML, et al. Recurrent BRAF mutations in Langerhans cell histiocytosis. *Blood*. 2010;116(11):1919–23.
 76. Go H, Jeon YK, Huh J, Choi SJ, Choi YD, Cha HJ, et al. Frequent detection of BRAF(V600E) mutations in histiocytic and dendritic cell neoplasms. *Histopathology*. 2014;65(2):261–72.
 77. Misery L, Godard W, Hamzeh H, Levigne V, Vincent C, Perrot JL, et al. Malignant Langerhans cell tumor: a case with a favorable outcome associated with the absence of blood dendritic cell proliferation. *J Am Acad Dermatol*. 2003;49(3):527–9.
 78. Jimura N, Matsushita S, Baba N, Kubo H, Takeda K, Fukushige T, et al. Rare case of Langerhans cell sarcoma with cutaneous manifestation arising on the inguinal region. *J Dermatol*. 2014;41(12):1127–8.
 79. Kawase T, Hamazaki M, Ogura M, Kawase Y, Murayama T, Mori Y, et al. CD56/NCAM-positive Langerhans cell sarcoma: a clinicopathologic study of 4 cases. *Int J Hematol*. 2005;81(4):323–9.
 80. Wang C, Chen Y, Gao C, Yin J, Li H. Multifocal Langerhans cell sarcoma involving epidermis: a case report and review. *Diagn Pathol*. 2012;7:99,1596-7-99.
 81. Bohn OL, Ruiz-Arguelles G, Navarro L, Saldivar J, Sanchez-Sosa S. Cutaneous Langerhans cell sarcoma: a case report and review of the literature. *Int J Hematol*. 2007;85(2):116–20.
 82. Chung WD, Im SA, Chung NG, Park GS. Langerhans cell sarcoma in two young children: imaging findings on initial presentation and recurrence. *Korean J Radiol*. 2013;14(3):520–4.
 83. Kwong YL. Cutaneous Langerhans cell sarcoma relapsing systemically: complete remission with the EPIG regimen. *Ann Hematol*. 2015;94(4):697–9.
 84. Ferringer T, Banks PM, Metcalf JS. Langerhans cell sarcoma. *Am J Dermatopathol*. 2006;28(1):36–9.
 85. Saygin C, Uzunaslan D, Ozguroglu M, Senocak M, Tuzuner N. Dendritic cell sarcoma: a pooled analysis including 462 cases with presentation of our case series. *Crit Rev Oncol Hematol*. 2013;88(2):253–71.
 86. Fraser CR, Wang W, Gomez M, Zhang T, Mathew S, Furman RR, et al. Transformation of chronic lymphocytic leukemia/small lymphocytic lymphoma to interdigitating dendritic cell sarcoma: evidence for transdifferentiation of the lymphoma clone. *Am J Clin Pathol*. 2009;132(6):928–39.
 87. Pokuri VK, Merzianu M, Gandhi S, Baqai J, Loree TR, Bhat S. Interdigitating dendritic cell sarcoma. *J Natl Compr Cancer Netw*. 2015;13(2):128–32.
 88. Kyogoku C, Seki M, Ogawa S, Miyamoto K, Ito Y, Kurita N, et al. Complete remission in systemic skin interdigitating dendritic cell sarcoma after ABVD chemotherapy. *J Clin Exp Hematop*. 2015;55(1):33–7.
 89. Olnes MJ, Nicol T, Duncan M, Bohlman M, Erlich R. Interdigitating dendritic cell sarcoma: a rare malignancy responsive to ABVD chemotherapy. *Leuk Lymphoma*. 2002;43(4):817–21.
 90. Lee SY, Lee SR, Chang WJ, Kim HS, Kim BS, Kim IS. Successful treatment of disseminated interdigitating dendritic cell sarcoma with adriamycin, bleomycin, vinblastine, and dacarbazine chemotherapy. *Korean J Hematol*. 2012;47(2):150–3.
 91. Helbig G, Wichary R, Pajak J, Budny M, Makowska M, Machura K, et al. Sustained remission after ABVD treatment for interdigitating dendritic cell sarcoma. *Contemp Oncol (Pozn)*. 2015;19(1):83–5.
 92. Gao WJ, Zhang R, Qiu HX, Shen YM, Zhang XH, Xue SL, et al. Interdigitating dendritic cell sarcoma: a case report with literature review. *Zhonghua Xue Ye Xue Za Zhi*. 2005;26(4):232–4.
 93. Pillay K, Solomon R, Daubenton JD, Sinclair-Smith CC. Interdigitating dendritic cell sarcoma: a report of four paediatric cases and review of the literature. *Histopathology*. 2004;44(3):283–91.
 94. Liu X, Deng Y, Zhang X, Mukherjee R, Huang W, Zhang G, et al. Interdigitating dendritic cell sarcoma following adult liver transplantation: case report and literature review. *Pathol Oncol Res*. 2011;17(2):397–402.
 95. Di Liso E, Pennelli N, Lodovichetti G, Ghiotto C, Dei Tos AP, Conte P, et al. Braf mutation in interdigitating dendritic cell sarcoma: a case report and review of the literature. *Cancer Biol Ther*. 2015;16(8):1128–35.
 96. Nguyen CM, Cassarino D. Primary cutaneous interdigitating dendritic cell sarcoma: a case report and review of the literature. *Am J Dermatopathol*. 2016;38(8):628–31.
 97. Rezk SA, Spagnolo DV, Brynes RK, Weiss LM. Indeterminate cell tumor: a rare dendritic neoplasm. *Am J Surg Pathol*. 2008;32(12):1868–76.



Erratum to: Histiocytic Disorders

Oussama Abla and Gritta Janka

Errata to: Histiocytic Disorders

This book was inadvertently published without updating the following corrections:

On the title page of Chapter 5, the degrees listed for Cor van den Bos were incomplete. The degrees have been revised on the chapter title page and the Contributor's List so that it now reads: "C. van den Bos, MD, PhD."

The above mentioned correction is also updated in List of Contributors.

On the title page of Chapter 9, the author's name is incorrectly displayed as "Schmid" in the affiliation area. Now we have corrected it to "J. Pachlopnik Schmid".

The co-author information on the chapter opening page of chapter 18 was missing.

Co-authors for this chapter were:

Eli L. Diamond, Benjamin H. Durham

The above mentioned correction is also updated in Table of Contents and List of Contributors.

The email address of the corresponding author was wrong on the chapter opening page and has been updated to diamone1@mskcc.org

The updated online version of this chapters can be found at

https://doi.org/10.1007/978-3-319-59632-7_5

https://doi.org/10.1007/978-3-319-59632-7_9

https://doi.org/10.1007/978-3-319-59632-7_18

O. Abla (✉)

University of Toronto, The Hospital for Sick Children, Toronto, Ontario, Canada

G. Janka

Pediatric Hematology & Oncology, University Medical Center Hamburg Eppendorf,
Hamburg, Hamburg, Germany

Index

A

- Acute lymphoblastic leukemia
(ALL), 157, 159, 160, 362
- Acute myeloid leukaemias (AML), 157, 159, 160
- Adalimumab, 298
- Adjuvant radiotherapy, 361, 368
- Adult hemophagocytic lymphohistiocytosis (aHLH)
age-dependent, 281
diagnosis
 hemophagocytic syndrome, 273
 HLH-1994 criteria, 274
 HLH-2004 criteria, 273–274
 HScore, 274–275
epidemiology, 270
genetics, 272–273
histiocytic medullary reticulosis, 270
liver failure, 280
MAS, 279–280
sepsis, 280–281
symptoms, 269
treatment, 275–276
 HLH-1994, adaptation of, 276–278
 PVIg, 278
 refractory HLH, 278–279
 stem cell transplantation, 279
underlying conditions, 271–272
- Adult LCH
baseline clinical evaluation, 136–137
clinical course, 135
clinical manifestations, 135
diagnosis, 136
disease reactivation, 142
follow-up investigations, 142
LCS, 136
non-pulmonary sites, 135
and pregnancy, 142
primary pulmonary
 LCH (*see* Primary pulmonary LCH)
response assessment, 142
SS-LCH treatment
 APD, 140
 bone, 137–138
 diabetes insipidus, 140
 endocrine abnormalities, 141
 GI tract, 141
 hypothalamic involvement, 140
 hypothalamo-pituitary axis, 139–140
 liver and bile ducts, 141
 lymph node, 141
 multisystem disease, 141–142
 ND-CNS LCH, 140–141
 skin, 138–139
- Adult-onset Still's disease (AOSD), 227, 280
- aHLH. *See* Adult hemophagocytic lymphohistiocytosis (aHLH)
- Alemtuzumab, 248
aHLH, 279
EBV, 220
HS, 362
primary HLH, 243
refractory HLH treatment, 252–254
RIC-HLH, 262, 264
- Alendronate, 298
- ALK-positive histiocytosis, 32–33
- ALL. *See* Acute lymphoblastic leukemia (ALL)
- AML. *See* Acute myeloid leukaemias (AML)
- Anakinra, 250–251, 322
- Anterior pituitary dysfunction (APD), 140
- Antithymocyte globulin (ATG), 247–248
MAS, 236
primary HLH, 242
refractory HLH treatment, 250–253
- AOSD. *See* Adult-onset Still's disease (AOSD)
- Arthropathy, 296, 297
- ATG. *See* Antithymocyte globulin (ATG)
- Autoimmune lymphoproliferative syndrome (ALPS), 31
- Azathioprine, 297, 298

B

- Benign cephalic histiocytosis (bch), 292
- Bisphosphonates, 117–118, 297
- Busulfan (BU), 261, 262, 266

C

- Canakinumab, 235, 323
- 2-CdA. *See* Cladribine (2-CdA)

- Central nervous system in hemophagocytic lymphohistiocytosis (CNS-HLH), 183, 248
 clinical signs and symptoms, 184
 diagnostic work-up
 CSF findings, 184–185
 imaging, 185–186
 epidemiology, 184
 HCT, 265
 pathology, 184
 survivors, neurological late effects in, 187–188
 treatment, 186–187
- Central nervous system-LCH (CNS-LCH)
 age-appropriate neuropsychological testing, 85
 ancillary testing, 16
 cerebrospinal fluid, 85
 clinical definition, 14
 clinical spectrum, 85
 diagnostic biopsy, 14–15
 differential diagnosis, 16, 17
 GI tract, 16
 HPR involvement, 84
 ICARS, 85
 MRI findings, 85–86
 neurodegenerative LCH disease, 16
 neurodegenerative/non-granulomatous CNS-LCH
 (*see* Non-granulomatous/neurodegenerative CNS-LCH (ND-CNS-LCH))
 parenchymal CNS-LCH, 15
 prevalence, 84
 risk factors, 84–85
 standardized neurological examination, 85
 thymic involvement, 16
 thyroid involvement, 16
 tumorous/granulomatous CNS-LCH (*see* Granulomatous/tumorous CNS-LCH)
 Virchow-Robin perivascular cuffs, 16
- Chediak-Higashi syndrome (CHS), 169, 197
- Chemotherapy
 bone LCH, 117–118
 cytotoxic chemotherapy, 323
 malignancy
 chemotherapy regimens, 210–211
 vs. malignancy-triggered HLH, 209–210
 prognosis, 214–215
 treatment, 214–215
 relapsed and refractory MS-LCH treatment, 118–119
- Chlorambucil, 298
- Chronic granulomatous disease (CGD), 171
- Chronic lymphocytic leukemia (CLL), 355–356
- CHS. *See* Chediak-Higashi syndrome (CHS)
- Cyclosporin A (CSA)
 LH-94 and HLH-2004, 245, 246, 247
 posterior reversible leukoencephalopathy, 186
 in rheuma-associated HLH, 249
- Cladribine (2-CdA), 323, 345, 362, 366
- Clofarabine, 290, 291, 345, 362
- CNS-HLH. *See* Central nervous system in hemophagocytic lymphohistiocytosis (CNS-HLH)
- CNS-LCH. *See* Central nervous system-LCH (CNS-LCH)
- Cobimetinib, 127, 346
- Combined immune deficiencies (CIDs), 199
- Crohn's disease, 170
- CSA. *See* Cyclosporin A (CSA)
- CsA. *See* Cyclosporin A (CsA)
- CY. *See* Cyclophosphamide (CY)
- Cyclophosphamide (CY), 261, 262, 266, 293, 297, 298
- Cyclophosphamide, doxorubicin, vincristine, and prednisone (CHOP), 361, 365, 369, 370
- Cyclosporin A (CsA), 298
 aHLH, 277, 278
 malignancy-triggered HLH, 214
 MAS, 236
 primary HLH, 242, 243
- Cytarabine, 291, 361, 362
- Cytokine-directed therapy, 322–323
- Cytokine release syndromes, 211
- Cytokine storm, 233
 IFN- γ , 234–235
 IL-18, 235–236
 IL-1 and IL-6, 235
- Cytotoxic chemotherapy, 323
- D**
- Dabrafenib, 126, 127
- Dexamethasone (DEX), 365
 aHLH, 276, 281
 CNS-HLH, 187
 HLH-94 and HLH-2004, 244–246
 refractory HLH treatment, 250
- Diabetes insipidus (DI), 140, 155
- Doxorubicin, 278
- Doxorubicin, etoposide, and methylprednisolone (DEP), 254
- E**
- EBV. *See* Epstein-Barr virus (EBV)
- ECD. *See* Erdheim-Chester disease (ECD)
- Eosinophilic granuloma of bone, 70
- Epstein-Barr virus (EBV), 198
 alemtuzumab, 220
 HLH, 192, 201, 215–221
 malignancy, HLH with, 210, 213
- Erdheim-Chester disease (ECD), 318, 354
 ancillary testing, 18–19
 ARAF mutations, 59
 baseline evaluations, 318–319
 bone involvement, 20–21
 BRAF mutations, 59
 cardiovascular involvement, 22–23
 cardiovascular manifestations, 314, 316
 cell of origin, 310
 central nervous system involvement, 21–22
 classification, 305
 clonal inflammatory myeloid neoplasm, 18

- clonality assays, 51
 - cutaneous manifestations, 318
 - diagnosis of, 310–313
 - differential diagnosis, 19–20
 - disease surveillance, 324–325
 - epidemiology, 306
 - genomic alterations, 61
 - hepatosplenic involvement, 23
 - JNK/p38 pathway, 60
 - of liver, 18, 20
 - MAP2K1* mutations, 59, 62
 - MAPK pathway mutational assessment, 318–319
 - molecular pathogenesis, 306, 307
 - ARAF* mutations, 307, 308
 - BRAF* mutations, 305, 306, 308, 319–320
 - KIF5B-ALK* fusions, 309–310
 - LMNA-NTRK1* fusion, 310
 - MAP2K1* mutations, 307–309
 - PIK3CA* mutations, 309
 - RAS isoforms, 307, 309
 - neuroendocrine endocrine abnormalities, 313–17
 - neurologic, 316–317
 - orbital manifestations, 317
 - osseous manifestations, 314
 - pathobiology, 50
 - PIK3CA* mutations, 60
 - pulmonary involvement, 23
 - pulmonary manifestations, 316
 - radiologic findings, 313–314
 - RAF inhibitor, 61
 - RAS mutations, 59–60
 - response assessment, 324–325
 - retroperitoneal manifestations, 317–318
 - retroperitoneum involvement
 - differential diagnosis, 21, 22
 - fibrohistiocytic encasement, 21
 - histiocytic proliferation, 18, 19
 - skin involvement, 21
 - translocations and copy number variations, 60
 - treatment, 320, 321, 322
 - clinical trials, 324
 - cytokine-directed therapy, 322–323
 - cytotoxic chemotherapy, 323
 - IFN- α , 320–322
 - immunosuppressive agents, 323
 - PEG-IFN- α , 320–322
 - radiotherapy, 323
 - serine/threonine kinase inhibitors, 323–324
 - surgery, 323
 - uncommon organ localizations and findings, 315
 - urologic manifestations, 317–318
 - vemurafenib, 61, 62
 - Etanercept, 124, 297, 298
 - Etoposide, 241
 - aHLH, 276, 278, 281
 - CNS-HLH, 187
 - HLH-94 and HLH-2004, 244–245, 244–246
 - malignancy-triggered HLH, 214
 - MAS, 236
 - myeloablative HCT, 261, 262
 - primary HLH, 242, 243
 - refractory HLH treatment, 250, 253
 - Etoposide, cisplatin, ifosfamide, gemcitabine (EPIG), 365
- F**
- Faisalabad histiocytosis, 31
 - Familial hemophagocytic lymphohistiocytosis (FHL), 241, 270
 - incidence, 193
 - locus, 193–194
 - Munc13-4 deficiency, FHL3, 194–195
 - Munc18-2 deficiency, FHL5, 195–196
 - perforin deficiency, FHL2, 194
 - syntaxin 11 deficiency, FHL4, 195
 - Fibroblastic reticular cell tumor, 38
 - Fludarabine, 220, 262
 - Follicular dendritic cell tumor/sarcoma (FDCS), 38, 354
 - Fulminant IM (FIM), 215
- G**
- Generalized eruptive histiocytosis (GEH), 292–293
 - Gene therapy, 267
 - Glucocorticosteroids, 213, 215
 - Graft-*versus*-host disease (GVHD), 264–265
 - Granulomatous/tumorous CNS-LCH
 - clinical features, 86–87
 - clinical manifestations, 86, 87
 - diagnostic features, 87–90
 - differential diagnosis, 87
 - extradural soft tissues mass, 86, 88
 - MRI findings, 86, 87
 - treatment, 90–91
 - Griscelli syndrome, 169
 - Griscelli syndrome type 2 (GS2), 196–197
 - GVHD. *See* Graft-*versus*-host disease (GVHD)
- H**
- Hairy cell leukemia (HCL), 356
 - Hand-Schüller-Christian disease, 69
 - Hematopoietic cell transplantation (HCT), 259
 - clinical indications, 259–261
 - CNS HLH, 265
 - donor choice, 260–261
 - experimental treatment, 266
 - gene therapy, 267
 - long-term sequelae, 265–266
 - MAC, 261–262
 - mixed chimerism, management of, 264–265
 - reactivation of, HLH, 265
 - RIC, 262–264
 - Hematopoietic stem cell transplantation (HSCT)
 - autologous/allogeneic HSCT, 362, 366
 - EBV-HLH, 219–220
 - primary HLH, 167
 - relapsed and refractory LCH, 122–124

- Hemolytic anemia, 335
- Hemophagocytic lymphohistiocytosis (HLH), 353
 - acute therapy, 243–244
 - aHLH (*see* Adult hemophagocytic lymphohistiocytosis (aHLH))
 - alemtuzumab-based treatment, 248
 - antenatal presentation, 171
 - anti-infectious and supportive therapy, 244
 - ATG-based treatment, 247–248
 - bone marrow, 39, 41
 - cerebral spinal fluid, 39, 41
 - characterization, 192
 - clinical manifestations, 171
 - CNS-HLH-directed therapy, 248
 - CNS involvement, 172
 - defective cytotoxic function, 192–193
 - diagnosis, 174, 243
 - CSF, 174
 - degranulation test, 177
 - genetic analysis, 177–178
 - immunologic testing, 175
 - infectious agents screening, 176
 - laboratory parameters, 174
 - microscopic hair analysis, 176
 - neurological signs, 176
 - sequential immunological testing, 176
 - targeted sequencing, 176
 - in early infancy, 171
 - EBV, 220–221
 - diagnostic findings, 216
 - disorders, 215
 - epidemiology, 215–217
 - pathogenesis, 216–219
 - treatment of, 219–220
 - HCT, 259
 - clinical indications, 259–260
 - CNS HLH, 265
 - donor choice, 260–261
 - experimental treatment, 266
 - gene therapy, 267
 - long-term sequelae, 265–266
 - MAC, 261–262
 - mixed chimerism, management of, 264–265
 - reactivation of, HLH, 265
 - RIC, 262–264
 - hepatic involvement, 171–172
 - histologic hepatic patterns, 39
 - HLH-94 and HLH-2004, 246–247
 - continuation therapy, 246
 - CSA, 245, 246
 - dexamethasone, 244–246
 - etoposide, 244–246
 - intrathecal therapy, 245–246
 - stem cell transplantation, 246
 - HLH-91 treatment protocol, 241–242
 - with impaired lymphocyte cytotoxicity
 - FHL, 193–196
 - pathogenesis, 200–201
 - pigmentary dilution disorders, 196–198
 - initiate treatment, 243
 - kidney injury, 172
 - laboratory features
 - cytokines, 173
 - ferritin, 172–173
 - fibrinogen, 173
 - serum sodium level, 173
 - lung involvement, 172
 - lymphocyte-mediated bile duct injury, 39
 - with malignancy (*see* Malignancy)
 - normal lymphocyte cytotoxicity
 - NLRC4 inflammasome activation, 199
 - pathogenesis, 201–202
 - predispose to, 199
 - XLP syndrome, 198–199
 - pathologic features, 39
 - pathophysiology, animal models, 202–203
 - PGM-1 CD68 antibody, 39
 - primary HLH, 192
 - CHS, 169
 - classification, 167, 168
 - familial hemophagocytic lymphohistiocytosis, 169
 - Griscelli syndrome, 169
 - HPS, 169
 - HSCT, 167
 - X-linked lymphoproliferative disorders, 169
 - prognostic factors, 249–250
 - refractory HLH treatment, 254–255
 - alemtuzumab, 252–254
 - anakinra, 250–251
 - ATG, 251–252
 - DEP, 254
 - salvage therapy, 251–254
 - secondary HLH, 192, 248–249
 - acquired immunodeficiencies, 170
 - autoinflammatory and autoimmune diseases, 170
 - classification, 167, 168
 - infection-associated HLH, 169–170
 - malignant diseases, 170
 - metabolic diseases, 171
 - primary immunodeficiencies, 171
 - splenomegaly, 171
 - systemic symptoms, 171
 - treatment, 243
 - type 2 perforin deficient, 39, 40
 - virus-associated HLH, 242
- Hemophagocytic syndrome, 273
- Hepatosplenomegaly, 333–334
- Hermansky-Pudlak syndrome (HPS), 169
- Hermansky-Pudlak syndrome type 2 (HPS2), 197–198
- Histiocyte Society Reclassification Working Group, 1, 2
- Histiocytic medullary reticulosis, 270
- Histiocytic/Reticulum Cell Proliferations, 1, 2
- Histiocytic sarcoma (HS)
 - clinical course, 33–34
 - disseminated/recurrent, 361–362
 - epidemiology, 357–358
 - intracranial, 361
 - localized disease, 360–361
 - mortality rate, 357
 - pathogenesis, 360

pathology, 359–360
 primary HS, 34
 treatment of, 362–363
 Histiocytosis X, 70–71
 HLH. *See* Hemophagocytic lymphohistiocytosis (HLH)
 HPS2. *See* Hermansky-Pudlak syndrome type 2 (HPS2)
 HS. *See* Histiocytic sarcoma (HS)
 HScore, 274–275
 HSCT. *See* Hematopoietic stem cell transplantation (HSCT)
 Human androgen receptor gene-based X chromosome
 inactivation (HUMARA) assays, 51
 Human herpesvirus 4. *See* Epstein-Barr virus (EBV)
 Hydroxychloroquine, 297, 298
 Hydroxyurea, 124
 Hypercalcemia, 341
 Hyperferritinemia, 216, 219, 231, 232, 233, 250, 274
 Hypertriglyceridemia, 216, 280
 Hypofibrinogenemia, 216, 232, 280
 Hypothalamic-pituitary region (HPR) involvement, 84

I

ICARS. *See* International Cooperative Ataxia Rating
 Scale (ICARS)
 ICE. *See* Ifosfamide, carboplatin, and etoposide (ICE)
 ICH. *See* Indeterminate cell histiocytosis (ICH)
 IDCS. *See* Interdigitating dendritic cell sarcoma (IDCS)
 IDCT. *See* Indeterminate dendritic cell tumors (IDCT)
 Ifosfamide, carboplatin, and etoposide (ICE), 361, 365
 Imatinib mesylate, 345
 Immunomodulatory therapy, 124–125
 Indeterminate cell histiocytosis (ICH), 32
 pathobiology, 50
 recurrent genomic abnormalities, 60–61
 Indeterminate dendritic cell tumors (IDCT)
 clinical manifestations, 370
 epidemiology, 369
 pathogenesis, 370
 pathology, 369, 370
 prognosis, 370
 treatment, 370
 Indomethacin
 bone LCH, 117
 pediatric LCH, 110
 Infliximab, 298
 Interdigitating dendritic cell sarcoma (IDCS), 354
 clinical manifestations, 367–368
 clinical progression, 37
 definition, 37
 differential diagnosis, 38
 epidemiology, 366
 immunophenotype, 38
 localized disease, 368–369
 multifocal/recurrent disease, 369
 pathogenesis, 366–367
 pathology, 366, 367
 pattern of involvement, 38
 prognosis, 367–368
 treatment, 368
 Interferon- α -2a (IFN- α), 320–322

Interferon-gamma, 245, 266
 International Cooperative Ataxia Rating Scale (ICARS), 85
 The International Rare Histiocytic Disorders Registry
 (IRHDR), 33
 Intrathecal methotrexate, 187, 241, 242, 245–246, 248, 265
 Intrathecal therapy, 250
 Intravenous methylprednisolone pulse therapy, 236
 In vitro diagnostic product (IVD) reagents, 5

J

Juvenile myelomonocytic leukemia (JMML), 286
 Juvenile xanthogranuloma (JXG)
 ancillary testing, 27
 bone involvement, 27
 CD4+ plasmacytoid monocyte, 24
 classic JXG pattern, 26
 clinical/radiographic features, 27
 CNS, 27–28
 course, 291–292
 cutaneous
 BCH, 292
 GEH, 292–293
 MRH, 295–299
 PNH, 293
 SRH, 295
 XD, 293–294
 yellow-brown lesions, 287, 289
 cutaneous and mucocutaneous lesions
 BRAF mutation, 26
 dermal lesions, 26
 differential diagnosis, 27
 ocular JXG, 26
 periocular JXG, 26
 systemic JXG family of lesions, 27
 ECD, 312
 epidemiology, 286
 extra-cutaneous sites, 28
 family, 285
 giant, 287
 histologic patterns, 23, 24
 histology, 286
 histopathology, 287, 288, 289
 intracranial, 289–290
 intraocular, 288–289
 LCH, 286
 liver involvement, 28
 mixed histiocytosis, 293
 morphology, 23, 25
 oral, 287
 pathogenesis, 286–287
 pathologic diagnosis, 26
 prognosis, 291–292
 S100 positivity, 23
 systemic, 27, 287–288
 temporal-based presentation, 25
 thymic involvement, 28
 transitional JXG pattern, 26
 treatment, 290–291
 JXG. *See* Juvenile xanthogranuloma (JXG)

K

Kawasaki disease (KD), 170, 228

L

Langerhans cell histiocytosis (LCH)

in adult (*see* Adult LCH)

AML, 72

ARAF mutation, 56

associated factors, 72

bone involvement

ancillary testing, 6

aneurysmal bone cyst-like formation, 6, 7

clinical definition, 6

CNS-risk sites, 6

differential diagnosis, 6–7

vertebral involvement, 6

bone marrow

ancillary testing, 11

clinical definition, 11

differential diagnosis, 11

macrophage-rich collection of xanthomatous, 11

VE1 immunostaining pattern, 11

BRAF mutation

BRAF V600E variant, 52, 54–55

BRAF V600K, 55

FAM73A-BRAF fusion protein, 56

MAP kinase family, 52, 54

prevalence, 53–55

transcriptional program, 52, 53

central nervous system involvement

ancillary testing, 16

clinical definition, 14

diagnostic biopsy, 14–15

differential diagnosis, 16, 17

GI tract, 16

neurodegenerative LCH disease, 16

parenchymal CNS-LCH, 15

thymic involvement, 16

thyroid involvement, 16

Virchow-Robin perivascular cuffs, 16

cerebellar damage, 156

in children

bone, 75–76

bone marrow, 78

central nervous system and endocrine, 77–78

common sites, 73

liver and gastrointestinal tract, 78

lungs, 76

lymph nodes, 77

oral cavity, 77

risk organ involvement, 73

skin, 74–75

spleen, 78

clinical outcomes, 151, 152

CNS involvement, 156

differential diagnosis, 3–4

endocrine sequelae, 155

eosinophilic granuloma, 50

exposure histories, 72

familial clusters, 73

follow-up studies, 151, 162

genetics, 73

genomic alterations, 61

health-related quality of life, 157

hearing loss, 154

history of, 69, 71

HUMARA assays, 51

immature myeloid dendritic cells, 4

immunophenotype, 3, 5

incidence, 71

inflammatory conditions, 51

in vitro fertilization children, 72–73

IVD reagents, 5

leukemia, 72

liver involvement

ancillary testing, 13

CD1a+/CD207+ LCH infiltration, 12

cirrhosis, 157

clinical definition, 11

differential diagnosis, 13

distal sclerosing biliary lesions, 12

MS-LCH disease, 11, 12

obstructive/destructive cholangiopathy pattern, 12

sclerosing cholangitis, 157

lung involvement, 13–14, 155–156

lymph node involvement

CD1a+/CD207 expression, 9, 10

differential diagnosis, 9–10

high-risk organ involvement, 10–11

sinus pattern, 9, 10

with malignancies

ALL, 157, 159, 160

AML, 157, 159, 160

LCH-Malignancy Registry, 157

lymphomas, 157–158, 159

solid tumours, 157–158

MAP2K1 mutation, 56–57

MAP3K1 mutation, 57

morbidity, 157

morphology, 3, 4

neoplastic etiology, 305

neurodegenerative LCH, 317

neurological damage, 156

nonrecurrent cytogenetic abnormalities, 51

NRAS G12D variant, 57

OncoMap, 51

orthopaedic disabilities, 153, 154

pathobiology, 49–50

in pediatric age group (*see* Pediatric LCH)

PI3K/PTEN/AKT/mTOR pathway, 58

pyrosequencing, 51

RAF inhibitor, 61

RAS/RAF/MEK/ERK pathway, 58

relapsed and refractory LCH (*see* Relapsed and refractory LCH)

seasonality, 72

Sequenom's mass spectrometry, 51

skin involvement

ancillary testing, 8

- clinical definition, 8
- cutaneous lesions, 8
- differential diagnosis, 8–9
- scarring, 154
- single-system-LCH, 8
- xanthogranuloma, 154
- spleen involvement, 13
- targeted therapies, side effects, 160–161
- T cell ALL, 73
- TP53* mutations, 58
- transcriptional profiles, 2
- translocations and copy number variations, 58
- VE1 antibody, 4, 5
- vemurafenib, 61, 62
- Langerhans cell sarcoma (LCS), 136, 354
 - clinical definition, 35
 - clinical manifestations, 364–365
 - differential diagnosis, 36–37
 - epidemiology, 363
 - features, 35
 - histiocytic sarcoma, 35, 36
 - localized disease, 365
 - multifocal/recurrent, 365–366
 - pathogenesis, 363–364
 - pathology, 363
 - prognosis, 364–365
 - treatment, 365
- Langerhans cell tumor, 354
- LCH. *See* Langerhans cell histiocytosis (LCH)
- LCS. *See* Langerhans cell sarcoma (LCS)
- Leflunomide, 297, 298
- Leishmania* infection, 174
- Lenalidomide, 124, 345, 362
- Letterer-Siwe disease, 50, 70
- Leukemias, 34–35
- Liposomal doxorubicin, 214, 278
- Lymphomas, 34–35
- M**
- Macrophage activation syndrome (MAS). *See also* Hemophagocytic lymphohistiocytosis (HLH)
 - aHLH, 279–280
 - clinical and laboratory manifestations, 230–232
 - cytolytic dysfunction, 230
 - definition, 227, 228
 - diagnosis of, 232–233
 - epidemiology, 227–229
 - pathophysiology, 233–236
 - pHLH, 229, 230
 - prognosis, 236–237
 - secondary HLH, 229
 - treatment, 236
- Macrophage activation syndrome in rheumatic diseases (MAS-HLH). *See* Macrophage activation syndrome (MAS)
- Macrophage-dendritic cell lineages, 1, 2
- Malignancy
 - during chemotherapy
 - chemotherapy regimens, 210–211
 - vs. malignancy-triggered HLH, 209–210
 - prognosis, 214–215
 - treatment, 214–215
- diagnosis, 211–213
- genetic defects, role of, 213
- malignancy-triggered HLH, 209–210
 - vs. during chemotherapy, 209–210
 - neoplastic entities in, 210
 - prognosis, 213–214
 - treatment, 213–214
- Malignant histiocytoses (MH)
 - classification, 353–355
 - diagnosis, 356–357
 - differential diagnosis, 356–357
 - epidemiology, 355
 - high-throughput drug sensitivity testing, 371
 - histiocytic sarcoma
 - clinical course, 33–34
 - disseminated/recurrent, 361–362
 - epidemiology, 357–358
 - intracranial, 361
 - localized disease, 360–361
 - pathogenesis, 360
 - pathology, 359–360
 - primary histiocytic sarcoma, 34
 - treatment of, 362–363
- IDCS
 - clinical manifestations, 367–368
 - epidemiology, 366
 - localized disease, 368–369
 - multifocal/recurrent disease, 369
 - pathogenesis, 366–367
 - pathology, 366, 367
 - prognosis, 367–368
 - treatment, 368
- IDCT
 - clinical manifestations, 370
 - epidemiology, 369
 - pathogenesis, 370
 - pathology, 369, 370
 - prognosis, 370
 - treatment, 370
- IRHD, 371
- LCS
 - clinical manifestations, 364–365
 - epidemiology, 363
 - localized disease, 365
 - multifocal/recurrent, 365–366
 - pathogenesis, 363–364
 - pathology, 363
 - prognosis, 364–365
 - treatment, 365
 - management, 357
 - PAX5 expression, 356
 - prognosis, 357
 - RAS/RAF pathway, 356
 - systematic genome sequencing, 371
- MAS. *See* Macrophage activation syndrome (MAS)
- Mature lymphoid, histiocytic, and dendritic neoplasms, 1, 3
- Melphalan, 220, 264

- 6-Mercaptopurine (6-MP), 345
 Methotrexate (MTX), 290, 298, 299, 345, 361, 362
 Methylprednisolone
 aHLH, 278, 280
 malignancy-triggered HLH, 214
 refractory HLH treatment, 250
 MH. *See* Malignant histiocytoses (MH)
 Mixed histiocytosis, 33, 136, 293
 MRH. *See* Multicentric reticulohistiocytosis (MRH)
 MS-LCH. *See* Multisystem LCH (MS-LCH)
 Multicentric reticulohistiocytosis (MRH)
 clinical features, 296–297
 incidence, 295
 pathogenesis, 296
 pathology, 295
 treatment, 297–299
 Multisystem LCH (MS-LCH)
 CNS, 84
 pediatric LCH
 AIEOP-CNR-H.X'83, 104
 DAL-HX 83, 104
 DAL-HX 90, 104
 drug doses, 104–107
 JLSG-96 protocol, 107
 LCH-I study, 104
 LCH-II study, 104, 107
 LCH-III study, 107, 111
 LCH-IV study, 109, 111
 outcomes, 104, 108
 vinblastine, 104
 relapsed and refractory LCH
 chemotherapy, 118–119
 haematopoietic stem cell transplant, 122–124
 nucleoside analogues, 119–121
 spontaneous regression, 84
 survival probability, 115
 Myeloablative conditioning (MAC) regimens, 220, 261–262
- N**
 Naproxen, 298
 ND-CNS-LCH. *See* Non-granulomatous/
 neurodegenerative CNS-LCH
 (ND-CNS-LCH)
 Neoplasia-associated RDD, 31–32
 Non-granulomatous/neurodegenerative CNS-LCH
 (ND-CNS-LCH), 140–141
 clinical features, 91
 clinical manifestations, 86, 87
 diagnostic features, 91–94
 differential diagnosis, 94
 MRI findings, 86, 87
 treatment, 94
 Non-Langerhans cell histiocytoses (Non-LCH), 285
 adult XG, 292
 ECD (*see* Erdheim-Chester disease (ECD))
 JXG, 285
 course, 291–292
 JXG, cutaneous, 287, 289
 BCH, 292
- GEH, 292–293
 MRH, 295–299
 PNH, 293
 SRH, 295
 XD, 293–294
 epidemiology, 286
 giant, 287
 histology, 286
 histopathology, 287, 288, 289
 intracranial, 289–290
 intraocular, 288–289
 LCH, 286
 mixed histiocytosis, 293
 oral, 287
 pathogenesis, 286–287
 prognosis, 291–292
 systemic, 287–288
 treatment, 290–291
 Normochromic normocytic anemia, 335
 Novimmune (NI-0501), 266
- O**
 OncoMap, 51
- P**
 Pamidronate, 298
 Pediatric LCH
 indomethacin, 110
 multisystem LCH treatment
 AIEOP-CNR-H.X'83, 104
 DAL-HX 83, 104
 DAL-HX 90, 104
 drug doses, 104–107
 JLSG-96 protocol, 107
 LCH-I study, 104
 LCH-II study, 104, 107
 LCH-III study, 107, 111
 LCH-IV study, 109, 111
 outcomes, 104, 108
 vinblastine, 104
 single-system LCH treatment
 CNS-risk bone lesions, 102, 103, 110
 first-line options, 100
 isolated lung LCH, 103–104
 multifocal bone LCH, 103
 single-bone/monostotic LCH, 101–102
 single-system skin LCH, 100–101, 110
 Pegylated- α -2a (PEG-IFN- α), 320–322
 Perforin, 213, 230
 Polyvalent immunoglobulins (PVIG), 278
 Prednisolone, 246, 323
 Prednisone, 290, 293, 298
 Primary histiocytic sarcoma, 34
 Primary HLH
 CHS, 169
 classification, 167, 168
 familial hemophagocytic lymphohistiocytosis, 169
 Griscelli syndrome, 169

- HPS, 169
 HSCT, 167
 X-linked lymphoproliferative disorders, 169
- Primary immunodeficiencies (PIDs), 171
- Primary pulmonary LCH
 clinical course, 145
 clinical features, 143
 diagnostic evaluation, 143–144
 epidemiology, 143
 follow-up, 145
 pathogenesis, 143
 pathology, 144–145
 treatment, 145–146
- Progressive nodular histiocytosis (PNH), 293
- Prophylactic cotrimoxazole, 244
- Pulmonary LCH, 52–54
- Purtilo syndrome, 198
- R**
- Rare histiocytic disorders (RHD), 285
- RDD. *See* Rosai–Dorfman disease (RDD)
- Reduced-intensity conditioning (RIC)
 regimens, 220, 262–265
- Relapsed and refractory LCH
 BRAF/MEK inhibitors
 cobimetinib, 127
 dabrafenib, 126, 127
 side effects, 127–128
 trametinib, 127
 vemurafenib, 125, 126
 hydroxyurea, 124
 immunomodulatory therapy, 124–125
 low-risk LCH treatment
 bone LCH, 117–118
 skin LCH, 116
 MS-LCH treatment
 chemotherapy, 118–119
 HSCT, 122–124
 nucleoside analogues, 119–121
 tyrosine kinase inhibitors, 125
- Reticuloendotheliosis, 70
- Retroperitoneal lymphadenopathy, 335
- RIC. *See* Reduced-intensity conditioning (RIC) regimens
- Rituximab, 244, 345
 CNS-HLH, 187
 EBV, 219, 220
 MAS, 236
 primary HLH, 243
- Rosai–Dorfman disease (RDD)
 ALK-positive histiocytosis, 32–33
 ALPS, 31
 baseline evaluations, 333–335
 “C” group, 331
 classic sporadic RDD, 30
 clinical features
 bone manifestations, 342–343
 bone marrow manifestations, 343–344
 cardiac manifestations, 340–341
 central nervous manifestations, 337–339
 classic, 335
 cutaneous manifestations, 335–336
 extranodal, 335
 gastrointestinal tract manifestations, 341–342
 genitourinary manifestations, 341
 head and neck manifestations, 338–340
 hematological manifestations, 343–344
 intrathoracic manifestations, 340
 liver manifestations, 342
 soft tissues, 336
 course, 346–347
 epidemiology, 331
 extranodal involvement, 30–31
 Faisalabad histiocytosis, 31
 ICH, 32
 IgG4-related, 332
 immunophenotype, 29
 inherited conditions, 332–333
 kinase mutations, 28
 neoplasia-associated RDD, 31–32
 pathogenesis, 331–332
 pathologic sine qua non, 28–30
 pathology, 333
 prognosis, 346–347
 “R” group, 331
 symptoms, 28
 treatment, 344–347
- Ruxolitinib, 187, 266
- S**
- SCIDs. *See* Severe combined immune deficiencies (SCIDs)
- Secondary histiocytic sarcoma, 35
- Secondary HLH
 acquired immunodeficiencies, 170
 autoinflammatory and autoimmune diseases, 170
 classification, 167, 168
 infection-associated HLH, 169–170
 malignant diseases, 170
 metabolic diseases, 171
 primary immunodeficiencies, 171
- Sepsis, 280–281
- Sequenom’s mass spectrometry, 51
- Serine/threonine kinase inhibitors, 323–324
- Severe combined immune deficiencies (SCIDs), 199
- Single system LCH (SS-LCH)
 adult LCH
 APD, 140
 bone, 137–138
 diabetes insipidus, 140
 endocrine abnormalities, 141
 GI tract, 141
 hypothalamic involvement, 140
 hypothalamo-pituitary axis, 139–140
 liver and bile ducts, 141
 lymph node, 141
 multisystem disease, 141–142
 ND-CNS LCH, 140–141
 skin, 138–139
 cerebral SS-LCH, 84

Sirolimus, 323, 345–346
sJIA. *See* Systemic juvenile idiopathic arthritis (sJIA)
SLE. *See* Systemic lupus erythematosus (SLE)
Sodium aurothiomalate, 298
Solitary histiocytomas, 33
Solitary reticulohistiocytoma (SRH), 295
Splenectomy, 278–279
Splenomegaly, 171
SS-LCH. *See* Single system LCH (SS-LCH)
Stem cell transplantation (SCT), 246, 279
Sulfasalazine, 297, 298
Systemic juvenile idiopathic arthritis (sJIA)
 cytopenias, 172
 in febrile patient, 280
 IL-18, 235
 MAS, 228, 230, 231
 bone marrow biopsy, 229
 classification criteria, 232
 IFN- γ , 234, 235
 IL-1 and IL-6, 235
 pathophysiology of, 227
 primary HLH, 174
Systemic lupus erythematosus (SLE), 170, 228, 232

T

Tacrolimus, 278, 280
Teniposide, 241
Thalidomide, 298, 345, 362

Tocilizumab, 215, 235, 323
Trametinib, 127

U

Umbilical cord blood (UCB), 261

V

Vemurafenib, 61, 62, 125, 126, 361, 369
Vinblastine, 290
Vinblastine-prednisone-based pediatric
 regimens, 141–142
Vincristine, 293

X

Xanthoma disseminatum (XD), 293–294
X-linked inhibitor of apoptosis (XIAP)
 deficiency, 198–199, 201
X-linked lymphoproliferative (XLP) syndromes
 incidence, 198
 SAP deficiency, XLP-1, 198
 XIAP deficiency, XLP-2, 198–199
X-MEN syndrome, 171

Z

Zoledronic acid, 298