

Laser-Assisted Multi-tissue Management During Aesthetic or Restorative Procedures

Donald J. Coluzzi

- 15.1 Introduction – 318**
- 15.2 Review of Laser Wavelengths and Tissue Interaction – 318**
 - 15.2.1 Diode and Nd:YAG Lasers – 318
 - 15.2.2 Erbium Lasers – 318
 - 15.2.3 Carbon Dioxide Lasers – 318
 - 15.2.4 For Soft Tissue Surgery Procedures, the Following Points Should be Considered – 318
 - 15.2.5 For Procedures Involving Alveolar Bone, the Important Points to Remember Are – 319
- 15.3 Gingival Biotype – 319**
- 15.4 Biologic Width and the Dentogingival Complex – 319**
- 15.5 Emergence Profile – 320**
 - 15.5.1 Clinical Cases Illustrating Emergence Profile – 321
- 15.6 Crown Lengthening – 321**
- 15.7 Soft Tissue Crown Lengthening – 322**
 - 15.7.1 Soft Tissue Crown Lengthening for Aesthetics – 322
 - 15.7.2 Soft Tissue Crown Lengthening for Restorative Dentistry – 322
 - 15.7.3 Clinical Cases of Soft Tissue Crown Lengthening – 323
- 15.8 Osseous Crown Lengthening – 325**
 - 15.8.1 Lasers for Osseous Crown Lengthening – 326
 - 15.8.2 Osseous Crown Lengthening for Aesthetics – 326
 - 15.8.3 Osseous Crown Lengthening for Restorative Dentistry – 326
 - 15.8.4 Clinical Cases of Osseous Crown Lengthening – 326
- 15.9 Soft Tissue Management for Placement of Direct or Indirect Restorations – 330**
- 15.10 Tissue Preparation for a Fixed Prosthodontic Pontic Restoration – 333**
- References – 334**

Core Message

Whether treating new carious lesions or planning extensive prosthodontics, the dental clinician must consider how the restoration will harmonize with the periodontium so that the result will be both healthy and maintainable. Likewise, recontouring the gingiva and the underlying supporting bone for improved aesthetics must entail the same deliberation. Dental lasers can be used for modification of soft or hard supporting tissue. The appropriate wavelength and operating parameters must be chosen for the specific tissue, but the result can be very predictable and biologically compatible with the restoration.

15.1 Introduction

This chapter will describe the use of multiple laser wavelengths to alter and improve hard and soft dental tissues for improved aesthetics and successful restoration placement. While this chapter's intention is to not exhaustively review all aspects of periodontal surgery, fundamental concepts of soft tissue anatomy such as biotype and biologic width will be discussed. The basic principle is that, after any alteration to soft or hard tissue, good physiologic contour must be restored. Predictable tissue management primarily relies on the clinician's choice of the proper wavelength to interact with the target tissue, while using appropriate parameters and techniques to maximize the efficiency of tissue removal, establish proper contour, and minimize any collateral damage. ► Chaps. 3 and 4 discuss these concepts in great detail.

15.2 Review of Laser Wavelengths and Tissue Interaction

15.2.1 Diode and Nd:YAG Lasers

These near-infrared wavelengths produce photonic energy that is generally scattered in soft tissue and is transmissive through water but will be absorbed by pigmented and/or inflamed areas. These lasers are for soft tissue only; they have virtually no interaction with healthy tooth structure and should not be used on bone. They work well in well-vascularized tissue and provide excellent hemostasis. As noted previously, Nd:YAG instruments operate in a free-running pulsed mode, producing very high peak powers; some diode lasers also can operate with relatively short pulse durations and moderate peak power output. This pulsing modality can help to control collateral thermal damage.

15.2.2 Erbium Lasers

The two wavelengths of these mid-infrared instruments have the highest absorption by water compared to any other available lasers, with a smaller secondary interaction with the mineral components of hard tissue. These lasers employ a

free-running pulsed emission, and their high peak power is primarily and rapidly absorbed into water. In soft tissue, this produces a shallow area of ablation. In hard tissue, there is superheating of the water content of the tooth or bone, resulting in an explosive expansion. This disrupts and ejects whole fragments of the calcified structure, resulting in a «cavity.» The mineral remains unchanged. The term «all-tissue laser» implies that an erbium instrument can perform soft tissue excisions, tooth preparation, and osseous procedures.

15.2.3 Carbon Dioxide Lasers

There are also two far-infrared wavelengths in this category. Both are highly absorbed by hard tissue and secondarily by water. Current developments in technology allow the 9300 nm machine to remove carious lesions and prepare teeth, contour bone, and perform soft tissue surgery. The 10,600 nm device can only be used for soft tissue procedures in its present form.

15.2.4 For Soft Tissue Surgery Procedures, the Following Points Should be Considered

- Very fibrous gingival tissue surrounding chronic inflammation due to a margin discrepancy of a crown will be much more difficult to incise with the near-infrared wavelengths because of their photonic energy's preference for melanin or hemoglobin in the tissue. Moreover, these wavelengths can cause some conductive heat buildup in tissue distant to the surgical area with possible peripheral edema. Lasers with longer wavelengths, such as carbon dioxide, would be much better instruments for that type of tissue.
- Alternatively, acutely inflamed gingiva with its well-vascularized structure would be easily ablated by the same near-infrared lasers.
- A water spray can be used to control the tissue temperature during ablation. This irrigation can either be emitted from the laser (erbium and 9300 nm carbon dioxide instruments) or from other sources such as the operatory triplex syringe. The near-infrared wavelengths are generally transmitted through water, but the mid- and far-infrared photonic energy is highly interactive. While the water will cool the tissue, it would reduce the average power at the target tissue when using erbium or carbon dioxide wavelengths, since some of the laser energy will be actively absorbed.
- When using all-tissue lasers, care must be exercised while removing soft tissue to avoid unintentional removal of tooth structure. The laser beam must be aimed as precisely as possible and a suitable physical barrier (such as a matrix band or plastic instrument)

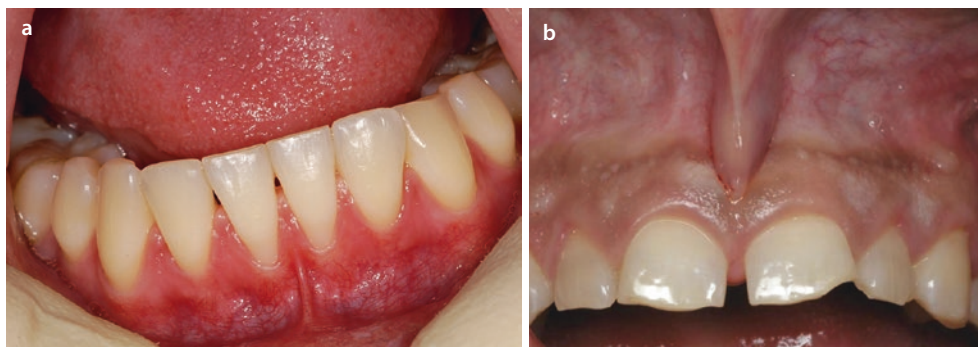
could greatly aid in only ablating the target tissue. This precaution is especially important with some noncontact laser delivery systems.

- While performing a gingivectomy, the clinician must strive to match the healthy physiologic contour of the adjacent gingiva. The desired goal is that the healed site will not only be harmonious with the patient's periodontium, but will retain its shape with a healthy attachment. One benefit of using a laser for the procedure is that small areas of tissue can be treated in steps until the desired contour is achieved. This precision is easier to accomplish compared to tissue removed with a surgical blade.

15.2.5 For Procedures Involving Alveolar Bone, the Important Points to Remember Are

- During osseous surgery, care must be taken to avoid overheating the bone and compromising its vascularity. The appropriate lasers for this procedure use a water spray, and the clinician should ensure that the irrigation is properly directed toward the target tissue.
- When performing osseous crown lengthening, an open flap or closed flap technique may be used. With the absence of visualization during a closed flap procedure, the clinician must use maximum tactile sense while excising and contouring the bone, while simultaneously avoiding alterations to the healthy root surface.
- Whether an open or closed flap is chosen, it is recommended that the soft tissue modification proceed first. It is much more difficult to excise and reshape the gingival tissue after the new bone form is established.
- Similar to soft tissue surgery, the laser beam's placement should be as precise as possible. The bony tissue must be properly contoured so that there are no remaining defects, troughs, or unusual anatomy. The underlying bone will determine the ultimate contour of the soft tissue covering it.

■ Fig. 15.1 a An example of thin biotype tissue in the mandibular incisor area. Note the narrow zone of keratinized tissue. b An example of thick biotype tissue with a large area of attached gingiva



15.3 Gingival Biotype

Gingival anatomy has been generally described and categorized as either thin or thick [1, 2]. Variations of those terms sometimes appear in print as «thin-scalloped» or «thick-flat,» and current terminology is phrased thick or thin biotype. Although somewhat difficult to determine visually, the disappearance of the tip of the periodontal probe into the sulcus usually indicates a thick tissue biotype. Other characteristics can aid in the classification:

- The *thin biotype* is generally less than 1.5 mm in thickness with a width of 3.5–5 mm and is characterized by a narrow zone of keratinized tissue with thin marginal bone surrounding teeth with triangular anatomic crowns. An example is shown in ■ Fig. 15.1a.
- The *thick biotype* is at least 2 mm in thickness with a width of 5–6 mm and features a large amount of keratinized tissue, thick marginal bone, and bony plates surrounding square anatomic crowns. An example is shown in ■ Fig. 15.1b.

The alveolar crest position and labial cortical plate thickness has a significant correlation with the gingival biotype [3]. It has been shown that patients with thin biotype tissue had a great prevalence of gingival recession [4], whereas patients with thick biotype are less likely to experience those changes after surgical or restorative therapy [5]. Thus the laser clinician should identify the gingival biotype before treatment and take special care with cases of thin anatomy.

15.4 Biologic Width and the Dentogingival Complex

This term is defined as the dimensions of the soft tissue attachments of the soft tissue to the portion of the tooth coronal to the crestal alveolar bone. Based on measurements first published by Gargiulo [6], biologic width is generally stated as approximately 2 mm—the sum of the width of the epithelial and the connective tissue attachments. There are some variations in different studies of that 2 mm value, and clinicians also find the same variety. This can be due to many factors such as the position of the tooth in the alveolus, the anatomy of the roots, and especially the health of the

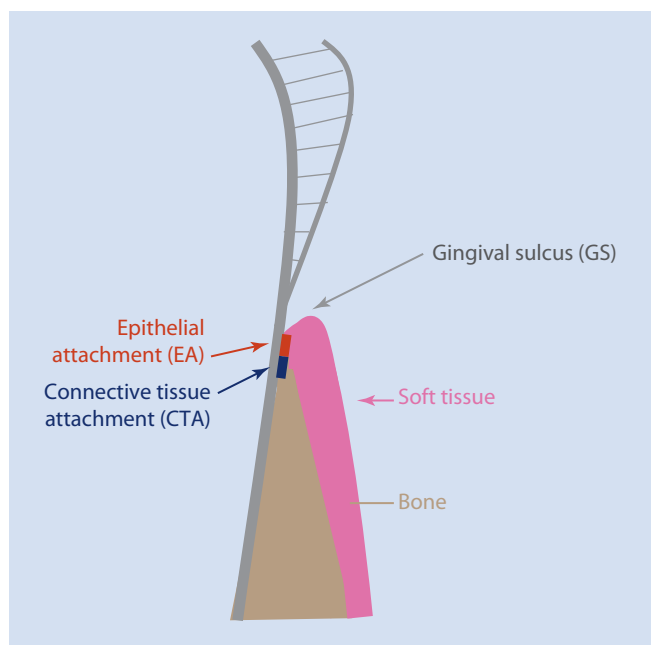


Fig. 15.2 A graphic depiction of the dentogingival complex (DGC) and the biologic width (W). BW is composed of the epithelial attachment (EA) and the connective tissue attachment (CTA) and usually measured as a total of 2.0 mm. The DGC includes the gingival sulcus (GS) with a minimum depth of 1.0 mm

periodontium [7]. Most practitioners generally use the term dentogingival complex which includes the gingival sulcular depth when discussing biologic width for ease of measurement. The literature states that 3.0 mm is the ideal distance from the free gingival margin to the alveolar crest on the facial aspect of anterior teeth and from 3.0 to 5.0 mm measured interproximally [8, 9]. Thus the apical aspect or bottom of the sulcus can be viewed as the top of the attachment. Therefore the clinician can account for any variation in the attachment position by ensuring proper measurements.

Figure 15.2 illustrates the ideal dentogingival complex and measurements.

As the clinician designs the restoration, this concept will guide the placement of the margin relative to the attachment and bone to ensure optimal periodontal health [10]. This can be a critical decision in the aesthetic zone, where one of the treatment objectives is to mask the junction of the margin with the tooth. Other situations such as creating adequate resistance and retention form or to make significant alterations to

the shape of the restoration will dictate the apical extension of the preparation. However, placement of the apical margin of the restoration within the biologic width can produce inflammatory periodontal disease [10]. This subgingival margin location can create the greatest biologic risk, and the best practice is to place that margin a maximum of 0.5 mm into the sulcus. This distance will minimize any chronic inflammation by not impinging on the biologic width. From another perspective, this would mean that the margin should be a minimum of 2 mm away from the alveolar crest.

For aesthetic procedures where only the periodontium is altered without placing any restorations, the new soft tissue must still retain an optimum biologic width so that there will be long-term stability.

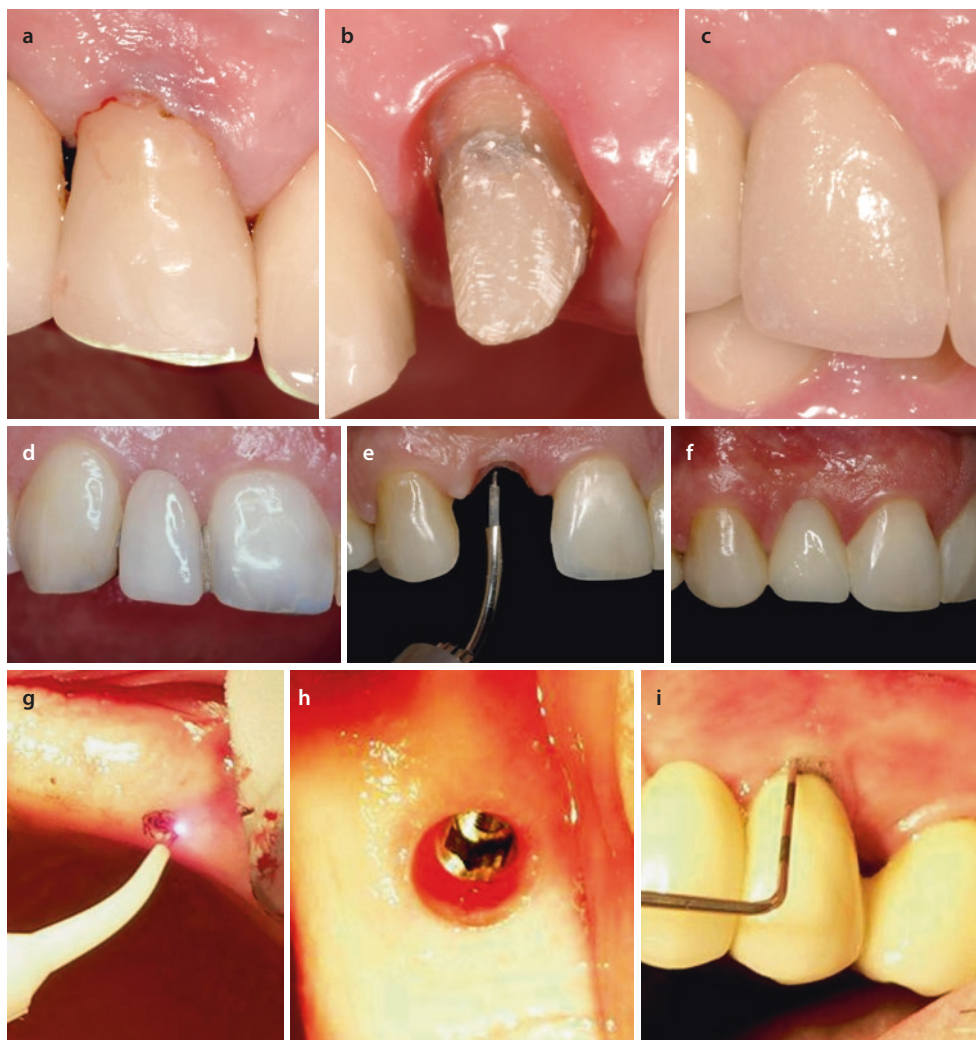Thus any restorative or aesthetic procedure that alters hard or soft tissue must establish a new healthy biologic width and dentogingival complex.

15.5 Emergence Profile

The emergence profile is that portion of the clinical crown's contour extending from the base of the gingival sulcus to the proximal contacts and to the height of contour on the facial and lingual surfaces [11]. This circumferential shape of the tooth or restoration in relation to the surrounding soft tissue is crucial for both periodontal health and aesthetics. The emergence profile must be scrutinized on each axial surface depending on various clinical situations ranging from a diastema closure and height of contours of partial denture abutments to placement of interproximal contact areas and all subgingival margins. In all situations, the final restoration on an implant abutment or a pontic in a fixed bridge must harmonize with the rest of the patient's dentition.

The reestablishment of a normal embrasure with a restoration is particularly challenging when there is no papilla, as in pontic or implant spaces and some diastema areas [12]. Adding width to close a space generally necessitates a deeper subgingival margin of the restoration [13]. Of course, the final result must achieve periodontal health. Various techniques are necessary such as troughing the gingiva to add additional restorative material, contouring the edentulous ridge, and troughing around the implant fixture. All of these are ideal procedures that can be performed with a laser.

Fig. 15.3 **a** Preoperative view of a crown restoration with a recurrent carious lesion at the gingival margin. **b** A 2-week postoperative view showing the healed tissue after crown lengthening and troughing with an Nd:YAG laser using a 320 micron fiber and an average power of 2.0 W (100 mJ at 20 Hz). **c** Four-week postoperative view showing the crown delivery. Note the emergence profile. **d** Pre-operative view of a bonded pontic replacing the maxillary lateral incisor. **e** An Er:YAG laser used with a 400 micron tip and an average power of 2.0 W (40 mJ per pulse at 50 Hz) without water spray to produce an ovate pontic concavity on the soft tissue. **f** Four-week postoperative view with new restoration in place. Note the much improved gingival embrasures and papillae due to the improved emergence profile. **g** A 810 nm diode laser used with a 400 micron tip at 1.0 W continuous wave begins to uncover an implant fixture. **h** A 2-week postoperative view of the healed gingival contour. **i** A 6-week postoperative view of the restored implant. Note the healthy gingival tissue (Implant case courtesy of Dr. Steven Parker)



15.5.1 Clinical Cases Illustrating Emergence Profile

Figure 15.3 shows three different clinical situations where a laser was used to create a new emergence profile. In each case the soft tissue needed careful contouring so that the final restoration could be constructed with ideal axial surfaces to restore both function and health

15.6 Crown Lengthening

This term is used to describe the intentional surgical removal of periodontal tissues for both aesthetic improvements and/or proper and predictable placement of a restoration. Many

clinical conditions can be indications for crown lengthening, such as subgingival carious lesion, subgingival fracture of tooth structure, inadequate axial height of a preparation, unequal gingival levels, altered passive eruption, and short clinical crowns due to wear [14].

The primary goal is to attain a healthy biologic width around the total circumference of the tooth. There are other important objectives such as achieving the proper aesthetic tooth form or providing sufficient tooth structure for a successful restoration. For aesthetic procedures, the clinician can achieve the desired result of a more pleasing smile by applying the principles of maintaining a healthy dentogingival complex. Crown lengthening can be limited to soft tissue only, or both soft and hard tissue can be contoured.

15.7 Soft Tissue Crown Lengthening

This surgery consists of two procedures—the excision of the gingival tissue to the desired height (gingivectomy) and the recontouring of that newly established marginal tissue to match the adjacent anatomy (gingivoplasty.) The amount of gingivoplasty will depend on the tissue biotype: thin biotype will need less contouring than a thicker anatomic form. After ensuring that biologic width is adequate, it is essential to restore the physiologic contours after soft tissue crown lengthening. This combination of removal and sculpting should produce a harmonious gingival outline segment and will also minimize any «rebound» or undesired tissue regrowth. ■ Figure 15.4 demonstrates how a laser is used for both procedures.

Any available dental laser can be used, keeping in mind how it interacts with the target tissue and adjusting the parameters for optimum ablation. When using erbium or carbon dioxide wavelengths, caution should be taken to avoid any tooth interaction until needed. In ■ Fig. 15.2a, the diode laser can be aimed directly at the enamel, since that wavelength has minimal interaction with healthy tooth structure. However, the beam of erbium and carbon dioxide wavelengths should be placed parallel to the enamel to avoid unintended removal of the enamel, as shown in ■ Fig. 15.2b. As noted, biologic width must be considered both when planning this surgery and after it is completed. After soft tissue crown lengthening, the clinician should determine if adequate biologic width remains; if not, then osseous crown lengthening must be performed.

15.7.1 Soft Tissue Crown Lengthening for Aesthetics

Before any gingival surgery, proper treatment planning is essential. Aesthetic gingival procedures should consider the overall design of the smile that exists and how the

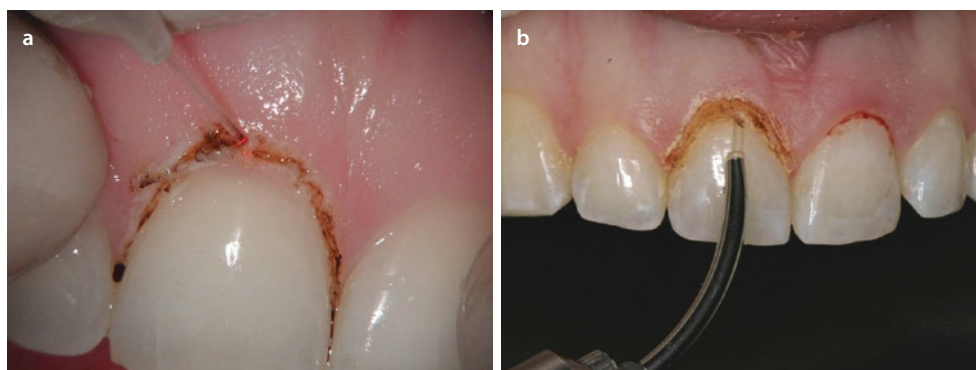
practitioner can change that form. Clearly, there are personal interpretations of aesthetics, and those can have a wide variance among patients both individually and culturally. Moreover, the clinician may have specific opinions. In the end, the treatment objectives are to produce a pleasing and healthy result for the patient.

The starting point for any smile design is the clinical crown profile of the maxillary central incisors and the corresponding gingival shape surrounding them [15]. If the patient desires some alteration, for example, for a «gummy smile,» then the biologic width must be located. After that, the surgical plan would be to create good symmetry on both sides of the midline. The zenith or apical most point of the gingival outline should ideally be the same height on the central and cuspid, while the lateral incisor's height can be 1–2 mm shorter [16].

The ideal gingival contour has a scalloped shape, and all of the interdental papillae fully occupy the interproximal embrasures. During gingival surgery, care should be taken to not produce a less scalloped, flatter gingival margin, since that could result in shorter interdental papilla and the opening of the embrasure spaces. The latter condition is sometimes referred to as «black triangles,» and that would be a compromised aesthetic outcome. The most predictable gingival response will occur when the new postoperative outline follows the smile design principles as well as providing optimum periodontal health.

15.7.2 Soft Tissue Crown Lengthening for Restorative Dentistry

The traditional restorative requirements of adequate and sound tooth structure can be problematic when a carious lesion extends subgingivally. The clinician must be able to visualize and remove the diseased tooth structure, while analyzing the periodontal condition. In addition, an acceptable emergence profile must be produced.



■ Fig. 15.4 a The diode laser is used for a gingivectomy and subsequent gingivoplasty on a maxillary central incisor. Note that the beam can be directed toward the tooth with minimum interaction or damage potential. b An Er:YAG laser is performing the gingivoplasty

on the maxillary right central incisor. The gingivectomy was already performed on both central incisors. Since this wavelength can also be used for tooth preparation, the tip should not be aimed directly at the tooth surface during the soft tissue crown lengthening

Retraction or removal of gingiva impinging on a lesion is essential for thorough caries removal. If biologic width is adequate after the preparation is complete, then the clinician must decide if the margin placement will aid or hinder the patient's ability to maintain oral hygiene to try to prevent another lesion [17]. In both cases, a laser can be used.

15.7.3 Clinical Cases of Soft Tissue Crown Lengthening

■ Figure 15.5 shows the use of an erbium laser to improve gingival aesthetics. Excessive gingiva results in the appearance of short clinical crowns. After biologic width is measured, it was determined that soft tissue crown lengthening could proceed. A tissue marker provided a «layout» to guide the clinician for the procedure. Note that the laser is used parallel to the labial surface to avoid any interaction with the enamel. The immediate postoperative view shows good tissue contour (Clinical case courtesy of Dr. David Hornbrook).

■ Figure 15.6 illustrates a case of porcelain veneers placed to improve aesthetics and to close the diastema of the maxillary incisors. The patient opted out of orthodontic treatment as a first step. A harmonious gingival architecture to produce a pleasing smile along with a good emergence

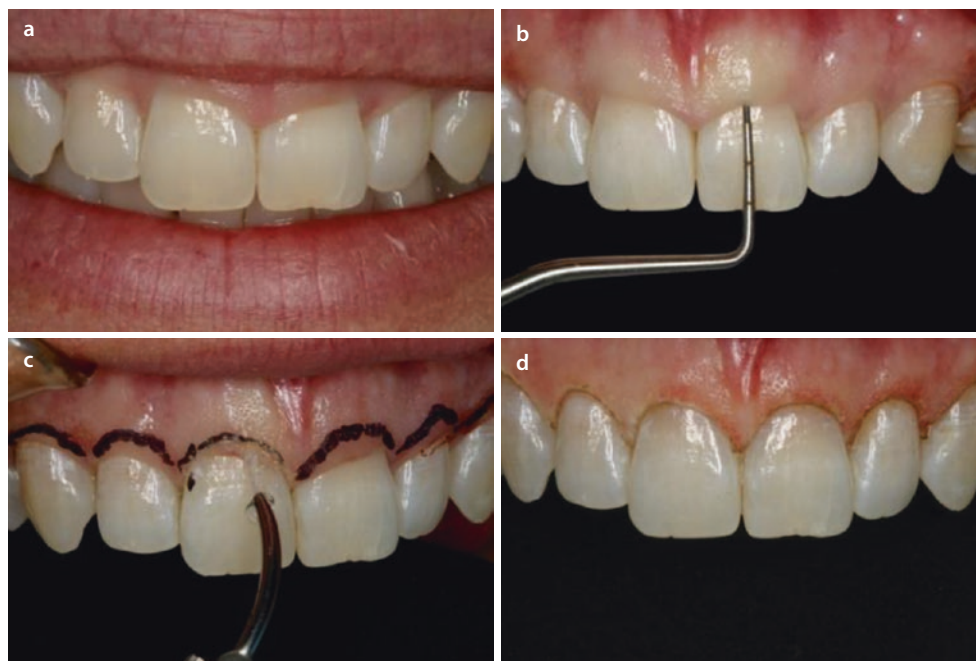
profile for the restorations was meticulously planned. A diode laser was used.

■ Figure 15.7 illustrates another case of aesthetic crown lengthening utilizing an Nd:YAG laser. Adequate biologic width was measured, and the laser performed a gingivectomy and gingivoplasty. The Nd:YAG wavelength produces a similar tissue interaction result to a diode laser, although the free-running pulse emission mode produces very short duration pulses with a low emission cycle. The relatively long intervals of non-emission are periods of thermal relaxation for the tissue during the surgery, which is an advantage for thinner tissue biotype.

■ Figure 15.8 shows the use of a diode laser to remove gingiva at an abfraction lesion in order to finish the apical extent of the preparation. The laser can easily recontour the tissue and maintain a dry field for placement of the restoration. As noted above, the diode wavelength has no interaction with the tooth structure. In addition, the new gingival level will facilitate the patient's oral hygiene in that area.

■ Figure 15.9 depicts a recurrent carious lesion around an existing restoration on bicuspid. The inflamed marginal gingiva prevents total access to the lesion. A carbon dioxide laser was used to remove the tissue, repositioning it more apically so that a new composite could be placed. The 9300 nm instrument also removed the carious lesion, and that discussion can be found in ▶ Chap. 8 (Clinical case courtesy of Dr. Josh Weintraub).

■ **Fig. 15.5** a Preoperative view showing uneven gingival contour, with pronounced differences in the zeniths of the maxillary central incisors. b A periodontal probe is used for the determination of biologic width and the overall dimensions of the dentogingival complex. c After tissue is marked, an Er:YAG laser with a 600 micron tip is used with an average power of 2.0 W (40 mJ per pulse at 50 Hz) without a water spray to perform the gingivectomy and gingivoplasty on all six maxillary anterior teeth. d Immediate postoperative view showing excellent hemostasis and tissue contour (Clinical case courtesy of Dr. David Hornbrook)



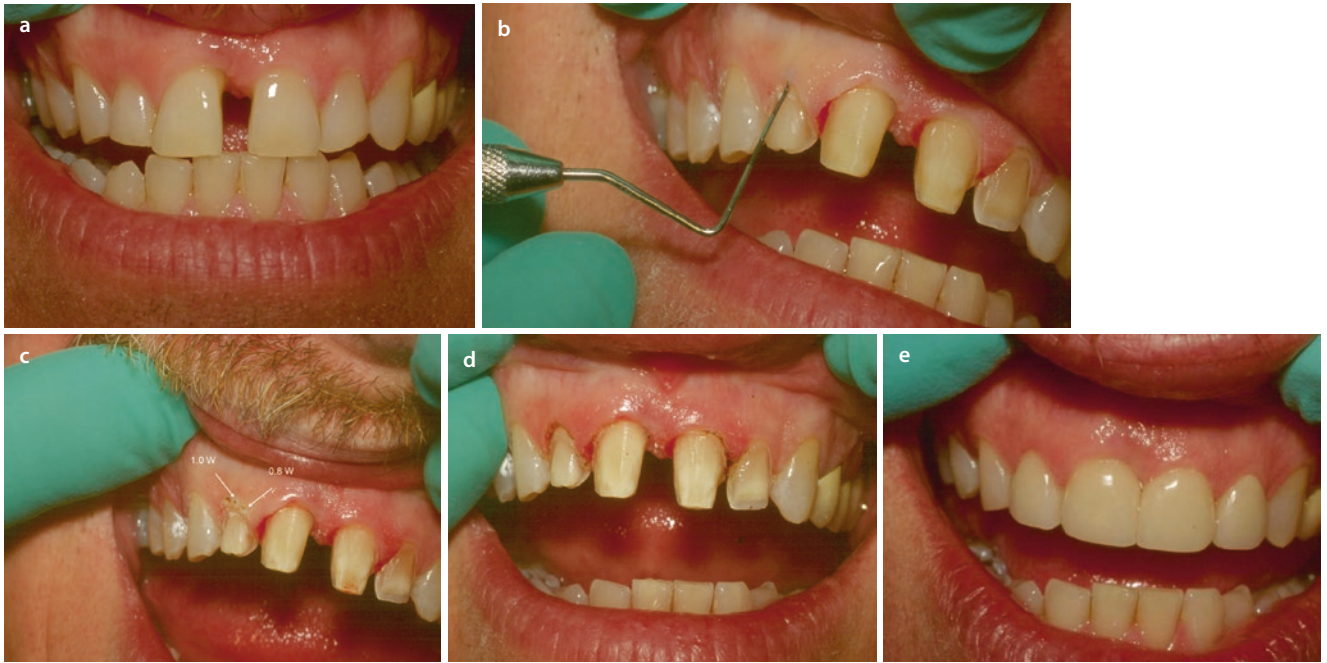


Fig. 15.6 **a** Preoperative view of the maxillary anterior segment with a large diastema between the central incisors and uneven gingival height of all incisors. **b** Biologic width determination and analysis of the dentogingival complex is performed with a periodontal probe. **c** After verifying the periodontal condition, soft tissue crown lengthening was performed with an 810 nm diode laser using a 400 micron bare fiber. In order to lay out the intended new gingival form, a 400 micron diameter «dot» was placed at the new gingival zenith using a power of 1.0 W continuous wave. Careful inspection of that small area of ablation revealed slight carbonization, which indicates the tissue temperature was excessive. The laser parameter was adjusted to 0.8 W

continuous wave and other dot was placed. That area showed normal ablation and that parameter was chosen to utilize for the surgery. **d** The immediate postoperative view shows the completed crown lengthening and finished preparations. Note that the central incisors were reduced on their mesial aspect and a subgingival trough was placed. Both of those procedures will enable new porcelain contours so that the diastema can be closed. **e** Six-month postoperative view demonstrates how the laser adjunctively fulfilled the principles smile design and emergence profile while creating a healthy periodontal condition

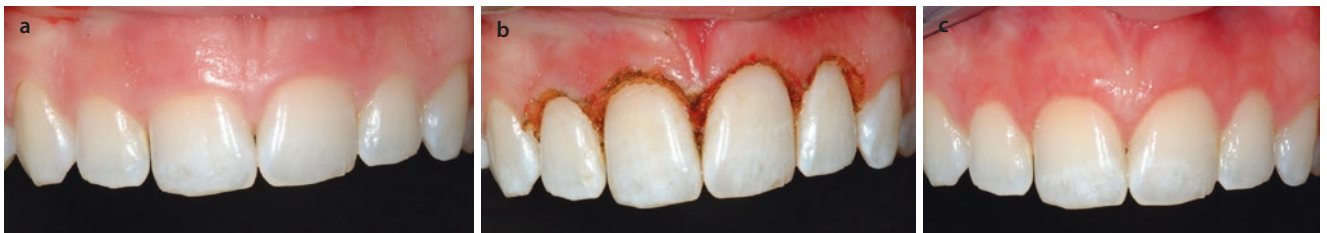

Fig. 15.7 **a** Preoperative view of the anterior maxillary sextant with asymmetrical gingival scalloping. Biologic width measurements revealed adequate tissue available for soft tissue crown lengthening. Note the thinner biotype on the lateral incisors compared to the central incisors. An Nd:YAG laser was used with a 320 micron fiber at an average power of 1.8 W (60 mJ per pulse at 30 Hz). **b** Immediate postop-

erative view. The laser's free-running pulse mode emission allows for thermal relaxation of the tissue, particularly on the lateral incisors' thinner biotype. Note the areas of gingivoplasty for new tissue form and outline. **c** Three-week postoperative view showing improved aesthetics with a more harmonious gingival scallop and embrasures

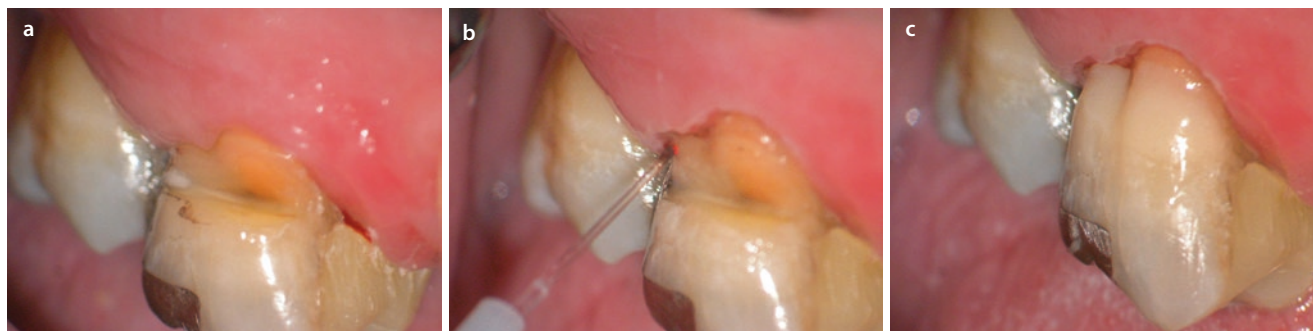

Fig. 15.8 **a** Preoperative view showing abfraction lesion on a maxillary molar. The gingival tissue has proliferated over the apical aspect of the lesion. **b** An 810 nm diode laser with a 400 micron bare fiber is used with an average power of 1.0 W to remove the gingival tissue and reestablish proper contour. The lesion can then be prepared

and restored. **c** Immediate postoperative view of the final restoration. The laser created a dry field with lack of any bleeding from the tissue to aid in the placement of the restorative material. The final margin placement should allow easy patient access for maintenance

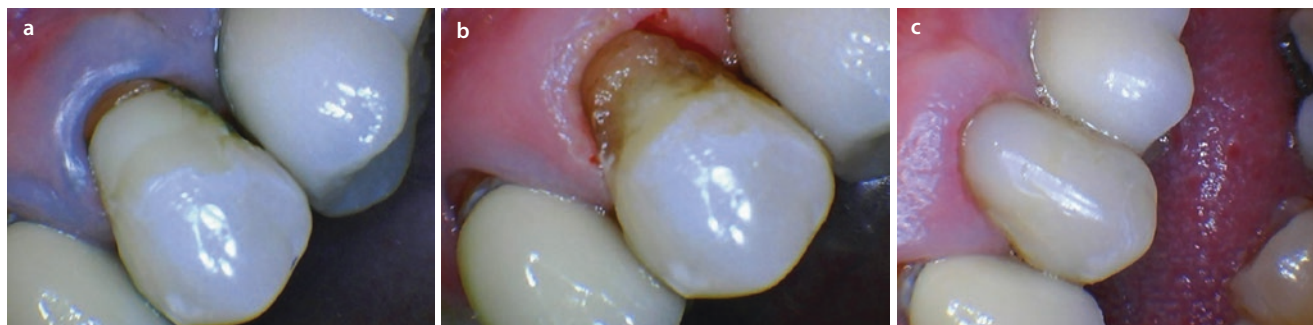

Fig. 15.9 **a** Preoperative view showing a recurrent carious lesion with inflamed gingival tissue. The carious lesion extends subgingivally. **b** The gingiva was recontoured with a 9300 nm carbon dioxide laser using 0.25 mm spot size, a 65 μ s pulse duration, and a cutting speed between 10% and 30% with minimal water spray. **c** The immediate

postoperative view showing the new tissue contour with the margin of the new composite restoration placed at the free gingival margin. Note how the laser achieved good control of tissue fluids to aid in the composite placement

15.8 Osseous Crown Lengthening

If the intended crown lengthening will compromise the biologic width, an osseous procedure will be required. The desired goal is to shape the osseous crest to match the gingival scallop outline form, and both should parallel the restorative margin [18]. As implied above, in general, soft tissue crown lengthening is performed first before the osseous procedure. The clinician must consider whether to proceed by raising a flap in an «open flap» surgical approach or operate without elevating any soft tissue—the so-called closed flap or flapless technique. A contact laser tip can transmit tactile information to guide the clinician in the procedure; however, laser energy does not easily distinguish between bone and root surface cementum and/or dentin. Conventional flap reflection may be necessary to both visualize and properly contour bone, especially in large areas of missing tooth structure or in multiple adjacent sites. In a localized area, for example, with a subgingivally fractured cusp, a closed flap osteotomy and osteoplasty can be performed. In either case, the bone must be contoured as close to an ideal physiologic form as possible—without

ledges, craters, or other deviations. Meticulous attention to creating proper anatomical form is much more challenging without flap access [19]. The overlying principle of biologic width dictates the amount of hard tissue removal along with the maintenance of adequate periodontal support.

The typical surgery begins with designing the new gingival outline and determining the initial biologic width. In this case, it is assumed that both soft and osseous crown lengthening will be performed. Next, the gingival tissue is excised and contoured to achieve that new sculpture. That may result in destruction of all or part of the soft tissue attachments. If possible, the existing osseous crest should be sounded. Then the clinician makes the decision about raising a flap. Removal of 2–3 mm of osseous resection is generally required to reestablish new biologic width [20]. Similar to soft tissue crown lengthening, an osteotomy and osteoplasty should be performed, resulting in a stable anatomic scaffold for the overlying gingiva. If an open flap procedure was used, the soft tissue flap is usually apically repositioned and sutured. In a flapless technique, the clinician should ensure that the soft tissue is well approximated on the tooth surface [21].

15.8.1 Lasers for Osseous Crown Lengthening

As mentioned above, only the erbium family and the 9300 nm carbon dioxide lasers are currently indicated for bone procedures. The Er,Cr:YSGG (2780 nm) and the Er:YAG (2940 nm) instruments primarily target the water component in osseous tissue, whereas the 9300 nm carbon dioxide energy interacts the hydroxyapatite. All three wavelengths utilize free-running pulse emission with very short pulse durations. Each features a water spray to help minimize any overheated areas of ablation. To guide the beam, some instruments have contact tips and others have small cylindrical guides used out of contact.

15.8.2 Osseous Crown Lengthening for Aesthetics

All of the concepts of smile design must be considered before any surgery begins. If any restorations will be placed, their gingival margin position should also be planned. Typically multiple teeth are involved in aesthetic dentistry, and harmony among them must be achieved. A diagnostic wax up can certainly aid in visualization of the desired treatment outcome. In addition, approximate areas of laser excision and contouring can be simulated.

15.8.3 Osseous Crown Lengthening for Restorative Dentistry

As a tooth preparation extends deeply into the gingival sulcus, the clinician must evaluate how and where the bone will be repositioned. The restoration's margin and the surrounding periodontium will correspond to each other; therefore the immediate postoperative tissue position, form, and contour will dictate the ultimate result.

15.8.4 Clinical Cases of Osseous Crown Lengthening

Figure 15.10 depicts a typical clinical dilemma where an existing crown restoration has fractured off with an inadequate amount of clinical crown remaining. Osseous crown lengthening was performed in an open flap procedure using an Er:YAG laser. The successful procedure resulted in sufficient tooth structure for a new crown to be constructed.

Figure 15.11 demonstrates an open flap osseous crown lengthening procedure so that the two posterior teeth can be restored. The 9300 nm carbon dioxide laser was used, and a 5-month postoperative photo shows good healing with the reestablishment of biologic width (Clinical case courtesy of Dr. Josh Weintraub).

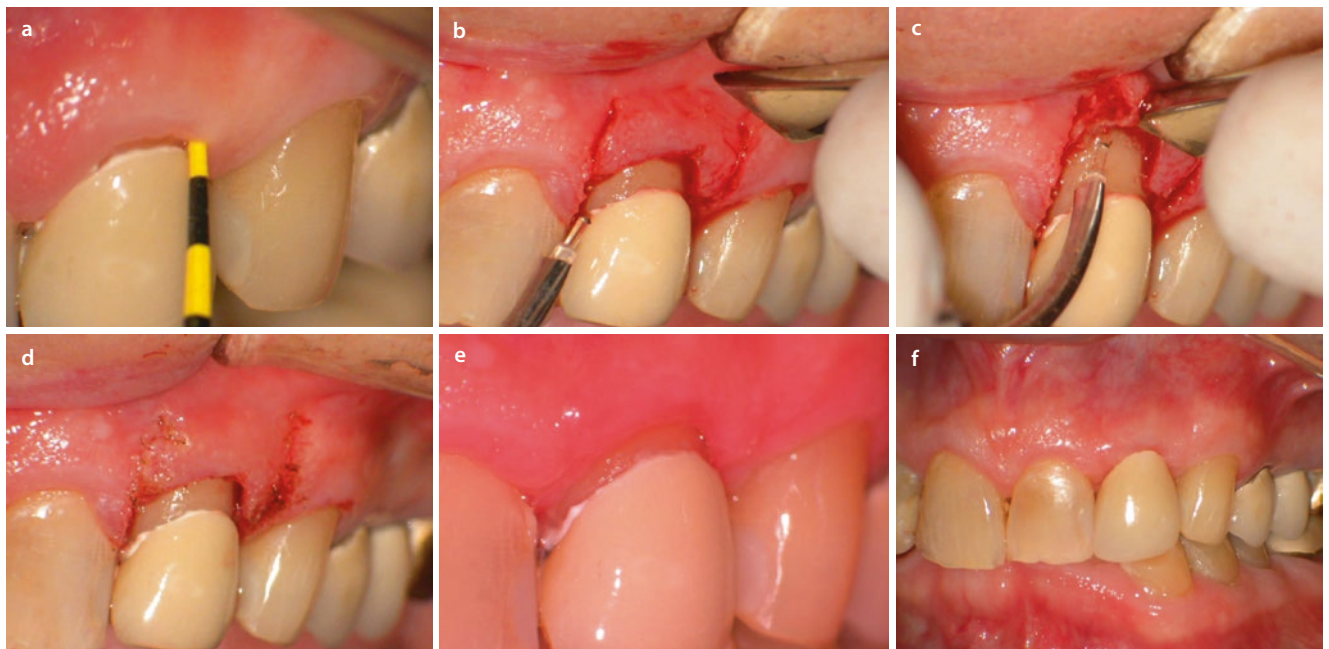


Fig. 15.10 **a** Preoperative view. The patient presented with a porcelain fused to metal crown that had become dislodged. The incisal one-third of the preparation had also fractured. The crown was recemented, and it was determined that osseous crown lengthening would be necessary because of the inadequate biologic width. **b** An Er:YAG laser was used with a 400 micron tip with an average power of 2.4 w (80 mJ at 30 Hz) with a copious water spray to apically reposition the gingival margin, achieving the soft tissue portion of the crown lengthening. **c** After raising a flap with conventional instruments, the same

laser parameters were used to remove and reposition the osseous crest. Note that the tip is aimed at the bone, avoiding contact with the root. **d** The immediate postoperative view of the flap repositioned with new tooth form revealed. **e** One-month postoperative view shows the healed attachment and new gingival height. A new crown preparation can proceed with adequate ferule for good retention form. **f** Two weeks later, the crown is delivered, and the tissue should continue to heal for a successful restorative result

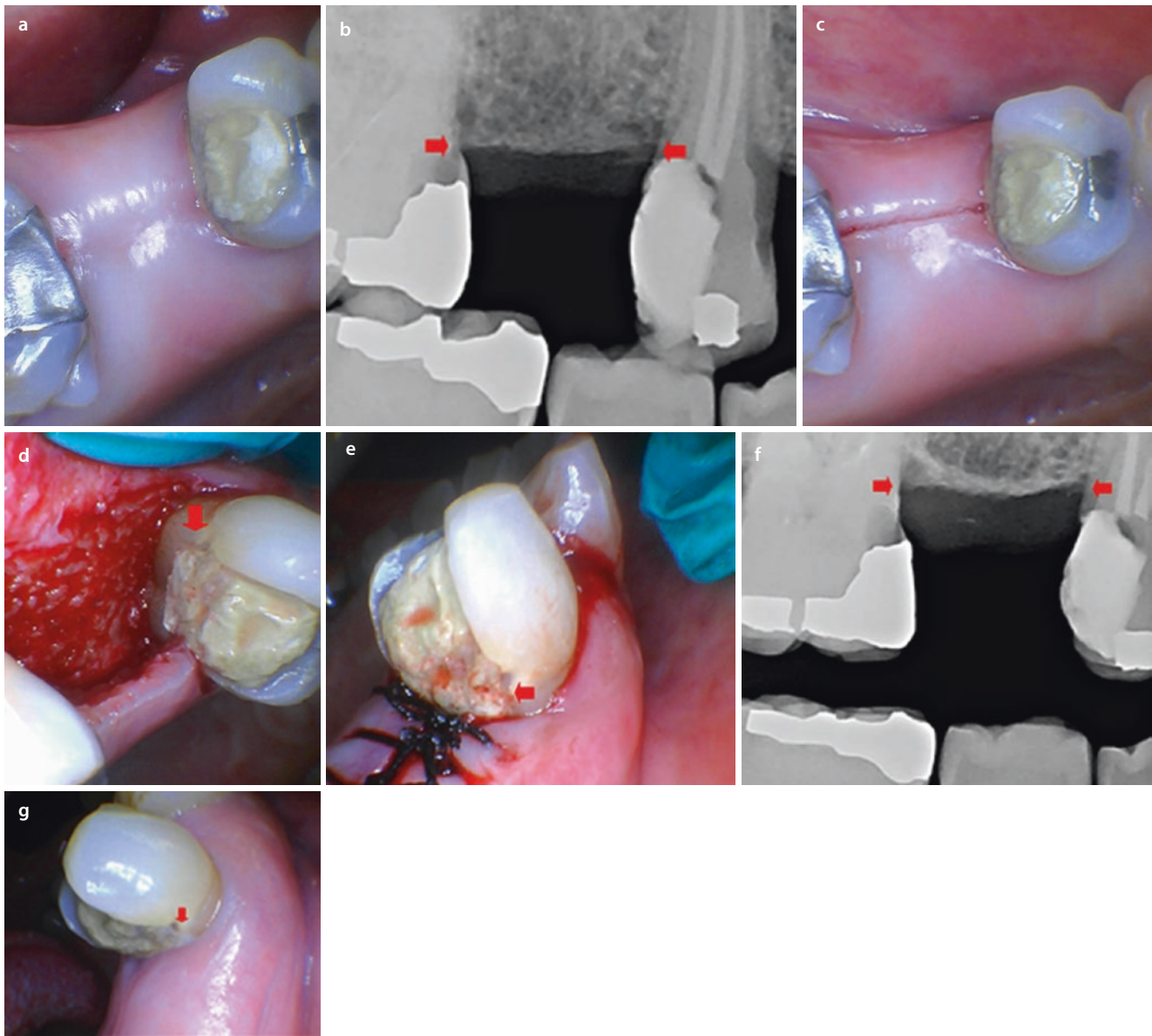


Fig. 15.11 **a** Preoperative view of a maxillary posterior segment of edentulous ridge between a bicuspid and molar that will be restored because of recurrent carious lesions. The patient was considering treatment options for replacing the missing tooth. **b** The preoperative radiograph shows that the carious lesions are violating the biologic width zone and indicated by the red arrows. Thus osseous crown lengthening is indicated. **c** The 9300 nm carbon dioxide laser was used in its noncontact mode with a 0.25 mm spot size, a 65 μ s pulse duration, 50–100% speed, and minimal water spray to perform the soft tissue incision. The flap extended to the proximal surfaces of both teeth. Note the minimal bleeding and the clean, linear cut. **d** After the flap was raised with traditional periodontal instruments, a 1.0 mm spot size, 75 μ s pulse duration, and 50–100% speed, with full water spray for the

initial alveolar bone ablation. The spot size was reduced to 0.25 mm for the final contour of the osseous tissue adjacent to the tooth. The red arrow indicates the previous tissue level, and sufficient bone has been removed to reestablish biologic width. The alveolar ridge adjacent to the molar received the same treatment. Note the good vascularity of the ablated osseous structure. **e** Immediate postoperative view with the gingival tissue sutured in place. The red arrow shows the preoperative gingival level. **f** Immediate postoperative radiograph showing a smooth osseous contour and a clear gain in clinical crown length, indicated by the red arrows. **g** A 5-month postoperative view showing complete tissue healing after osseous crown lengthening. A new restoration can now be constructed without a biologic width violation (Clinical case courtesy of Dr. Josh Weintraub)

■ Figure 15.12 shows a case of varied gingival heights and contour of some maxillary teeth. Closed flap gingival and osseous crown lengthening were accomplished with an Er:YAG laser, and then porcelain veneers were placed. The clinical photos show a portion of that procedure on the cuspid. A 4-year postoperative view shows healthy periodontium and excellent aesthetics (Clinical case courtesy of Dr. David Hornbrook).

■ Figure 15.13 depicts a case of severely worn maxillary and mandibular anterior teeth. Closed flap gingival and osseous crown lengthening were performed with an Er,Cr:YSGG laser followed by porcelain restorations. At the 6-month postoperative review appointment, a biologic width violation was discovered around the maxillary right central incisor. The laser was used again to correct the discrepancy in the tissues and the problem was resolved (Clinical case courtesy of Dr. Mark Cronshaw).

■ **Fig. 15.12** a Preoperative view of varied gingival architecture around existing porcelain crowns. b An Er:YAG laser was used with a 400 micron tip with an average power of 2.0 W (40 mj at 50 Hz) without water spray and was used for the soft tissue removal. This photo shows that procedure in progress on the cuspid, and perio-probing on that tooth shows that there will be a violation of biologic width in order to establish the intended new gingival outline and to place the margin of the restoration. Osseous crown lengthening is necessary on the labial surface, and a close flap technique was used. The Er:YAG was used with the same parameters—2.0 W (40 mj 50 Hz) but with a water spray. c The crown lengthening is completed on all of the teeth. d Four-year postoperative view shows excellent periodontal health along with good smile design (Clinical case courtesy of Dr. David Hornbrook)

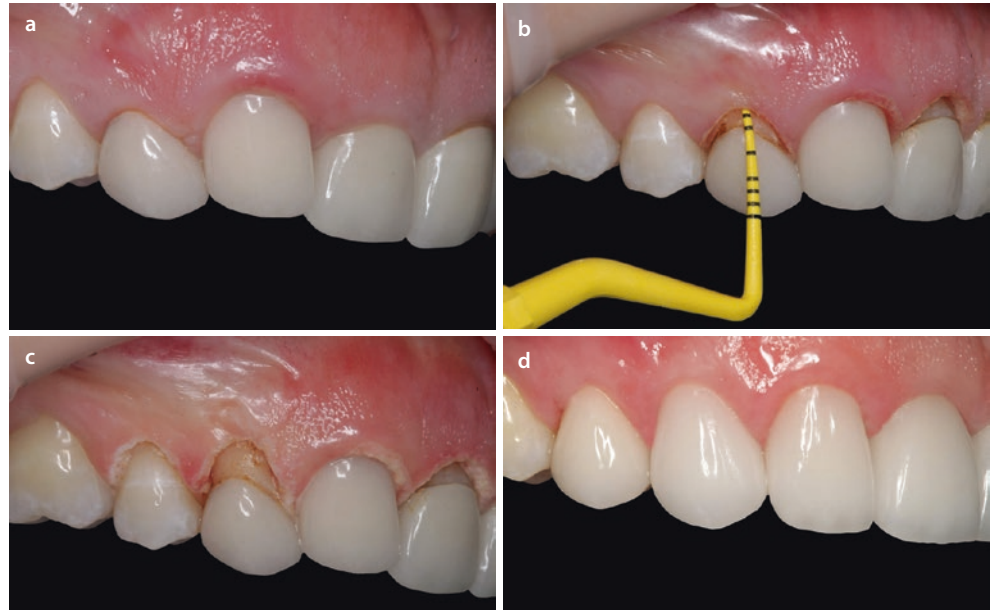

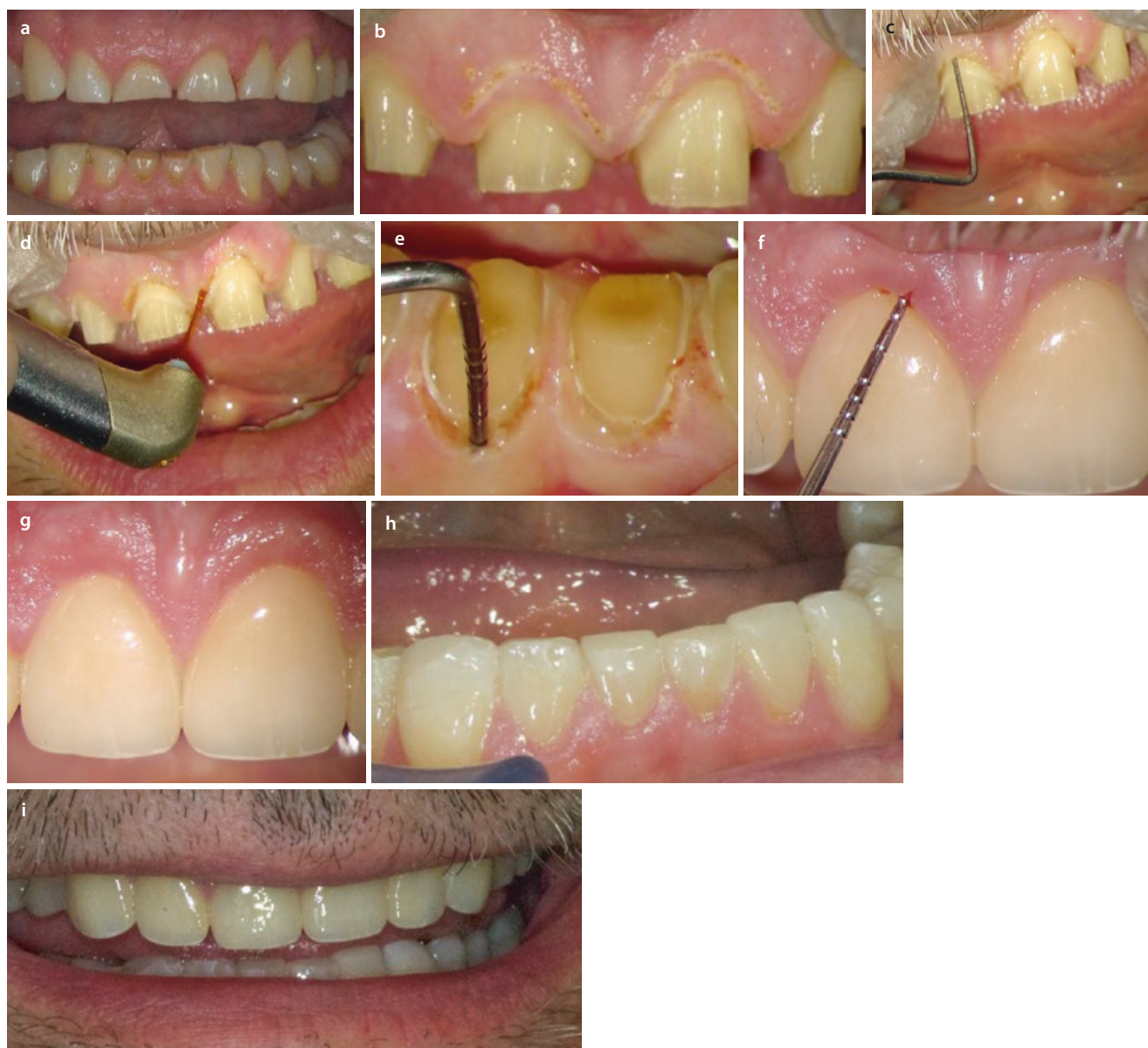


Fig. 15.13 a Preoperative view of severely worn anterior dentition. The treatment plan consisted of porcelain restorations for those teeth after the appropriate crown lengthening. b After the initial preparation of teeth, the desired new gingival outline is placed. The Er,Cr:YSGG laser was used for the gingivectomy with a 600 micron diameter zirconia tip at an average power of 2 W (80 mJ, 25 pps, 20% air, 40% water, 60 μ s pulse duration). c Probing the existing osseous crest shows that osseous crown lengthening must be performed to establish a healthy dentogingival complex and biologic width. d Closed flap osseous contouring was then accomplished. The photo shows the careful placement of the 600 micron zirconia tip aiming toward the osseous crest. The laser parameters were 3 W of average power (100 mJ, 30 pps, 60%

air, 60% water, 60 μ s pulse duration.) A Wedelstaedt bone chisel and a piezo device subsequently smoothed the bone contour. e Probing confirms reestablishment of biologic width. f Six-month postoperative close-up view shows residual inflammation around the right central restoration. The perio-probe indicates a biologic width violation remains. The Er,Cr:YSGG laser was used with the previous parameters b, d to refine the gingival and osseous tissue. g Two weeks later, the tissues have healed. h Six-month postoperative view of completed mandibular restorations. i Six-month postoperative view of reestablished smile line and vertical dimension of occlusion (Clinical case courtesy of Dr. Mark Cronshaw)

15.9 Soft Tissue Management for Placement of Direct or Indirect Restorations

Manipulation of soft tissue with various wavelengths and subgingival margin placement has been discussed earlier in this chapter. The restorative dentist must consider and apply all of those principles while preparing the tooth. Modern dental direct restorative materials generally require meticulous control of moisture and bleeding to ensure a good bonding environment. Successful fabrication of indirect restorations involves many factors. One important one is to duplicate the finished preparation with as much accuracy as possible. Whether for direct fillings, impressions, or optical scanning, any available dental laser can accomplish soft tissue management, moisture control, debridement, and hemostasis.

■ Figure 15.14 depicts a molar carious lesion with distal tissue overgrowth. A carbon dioxide laser was used to remove the tissue so that a core buildup material could be placed. The laser beam was aimed directly at the gingiva. The 9300 nm instrument also removed the carious lesion, and that discussion can be found in ► Chap. 8 (Clinical case courtesy of Dr. Josh Weintraub).

■ Figure 15.15 shows how an Nd:YAG laser is used for troughing around two preparations during the construction of new crowns. The laser is gently placed in the sulcus and aimed toward the gingival soft tissue. It offers excellent tissue management which facilitates any impression technique.

■ Figure 15.16 depicts an Er,Cr:YSGG laser used for troughing around a molar. The rigid tip was aimed at the soft tissue in the sulcus, being careful to avoid contact with the preparation margins. The impression precisely captured all the marginal detail (Clinical case courtesy of Dr. Glenn van As).

■ Figure 15.17 shows a comparison between diode laser tissue retraction and conventional cord technique during full crown preparations on adjacent maxillary premolars. Using careful technique and proper parameters, the laser easily reveals the subgingival margins with excellent bleeding control (Clinical case courtesy of Dr. Glenn van As).

■ Figure 15.18 shows how a carbon dioxide laser is used to retract the tissue around a central incisor. The 10,600 nm wavelength is very effective in soft tissue removal while achieving excellent hemostasis (Clinical case courtesy of Dr. Steven Parker).

■ **Fig. 15.14** a Preoperative view showing a large carious lesion with gingival overgrowth. b The gingiva was recontoured with a 9300 nm carbon dioxide laser using 0.5 mm spot size and a 45 pulse setting with minimal water spray. c The immediate postoperative view showing good tissue contour around the core buildup material. Note good moisture control to aid in the composite placement. d A postoperative radiograph showing no biologic width violations. The crown preparation margins should be easily placed while maintaining gingival health (Clinical case courtesy of Dr. Josh Weintraub)

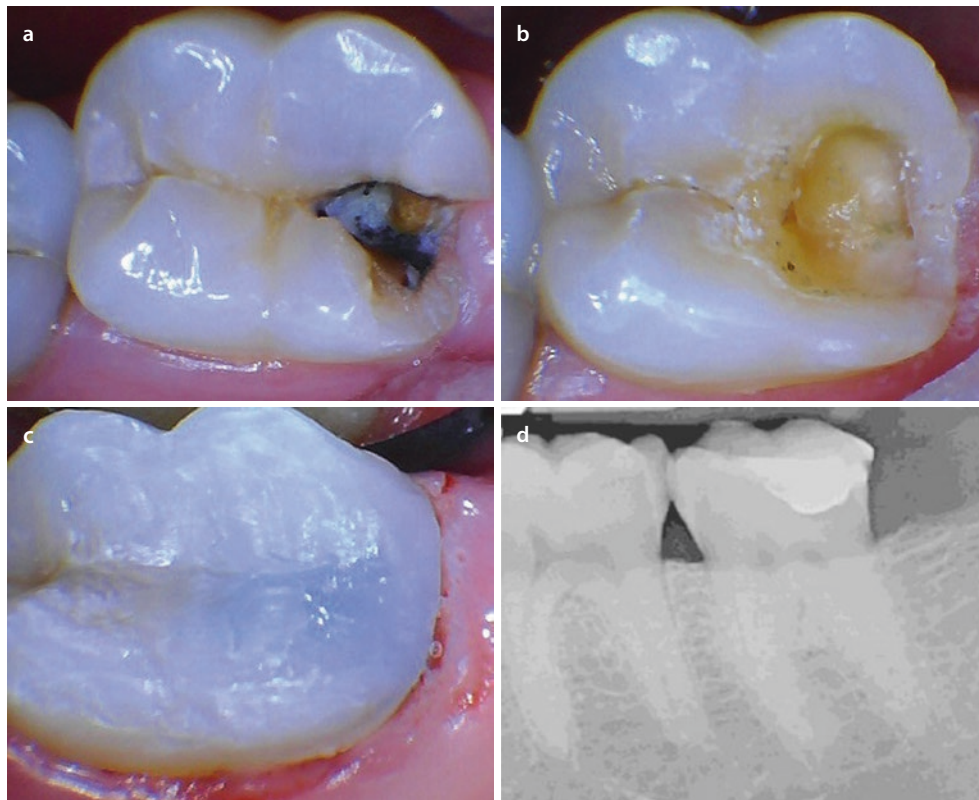


Fig. 15.15 **a** Preoperative view of the maxillary left central and lateral incisors which will be prepared for porcelain crowns. **b** Immediate postoperative view of the laser troughing. An Nd:YAG laser was used with a 320 micron bare fiber at an average power of 1.2 W (40 mJ at 30 Hz) in the sulcus, aimed at the soft tissue side of the pocket with gentle pressure. The fiber is used in short arcs of a circle, interacting with small segments of the tissue at a time. The goal was to gently retract and debride the tissue space along with controlling bleeding so that the impression material can accurately capture the subgingival margins. The interdental papilla was also slightly contoured. This average power is less than the parameters generally used for incisions since there is no need for any tissue removal. **c** The resulting impression shows accurate marginal detail. **d** Three-week postoperative and 1-week post-delivery view of the completed restorations showing an excellent tissue response

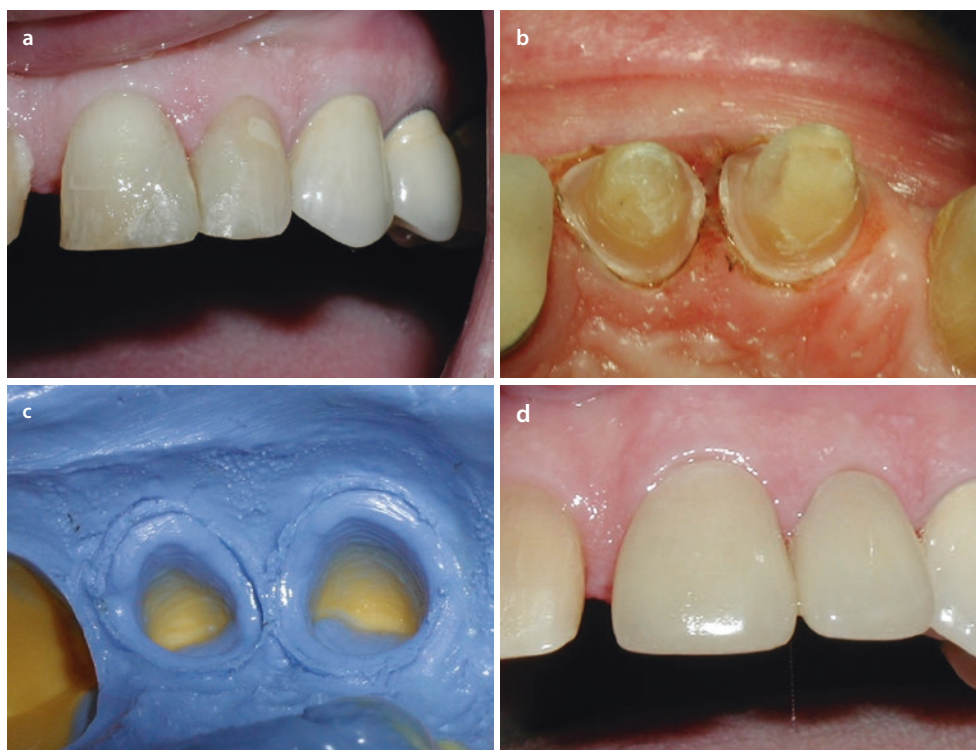

Fig. 15.16 **a** Preoperative mirror view of a maxillary molar defective crown restoration. A new crown will be constructed. **b** Immediate postoperative mirror view of the laser troughing. After the tooth was prepared, an Er,Cr:YSGG laser was used with an MZ 5 tip at an average power of 2.25 W (75 mJ per pulse at 30 Hz) in the sulcus with minimal water spray. The tip was moved around the tooth in short arcs of a circle to debride and widen the sulcular tissue so that the subgingival margins were revealed. **c** A photo of the final impression. Note the clear margin definition. **d** The final crown was delivered with excellent results including gingival health (Clinical case courtesy of Dr. Glenn van As)

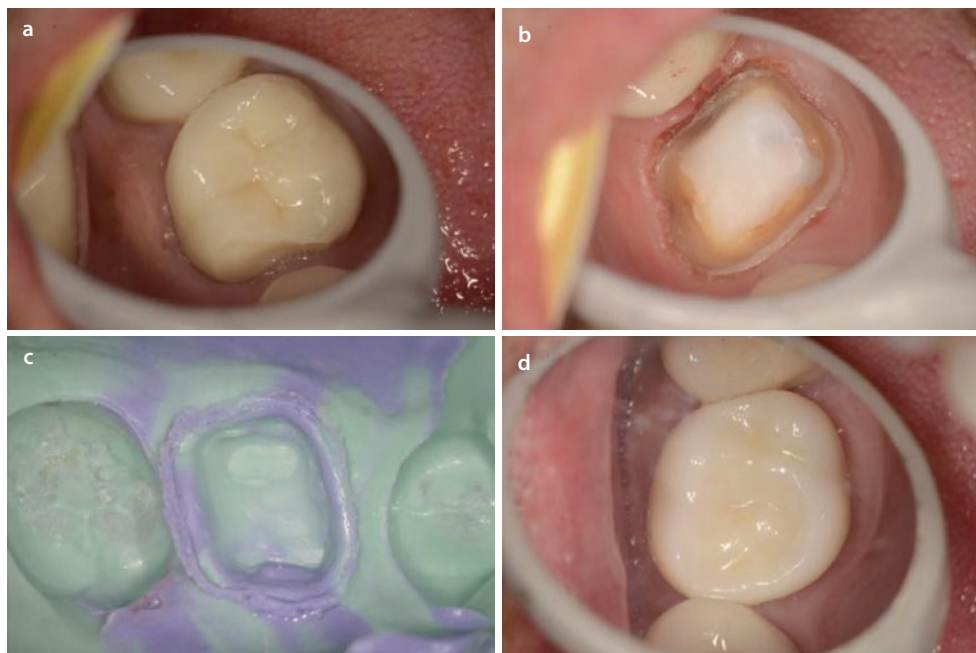

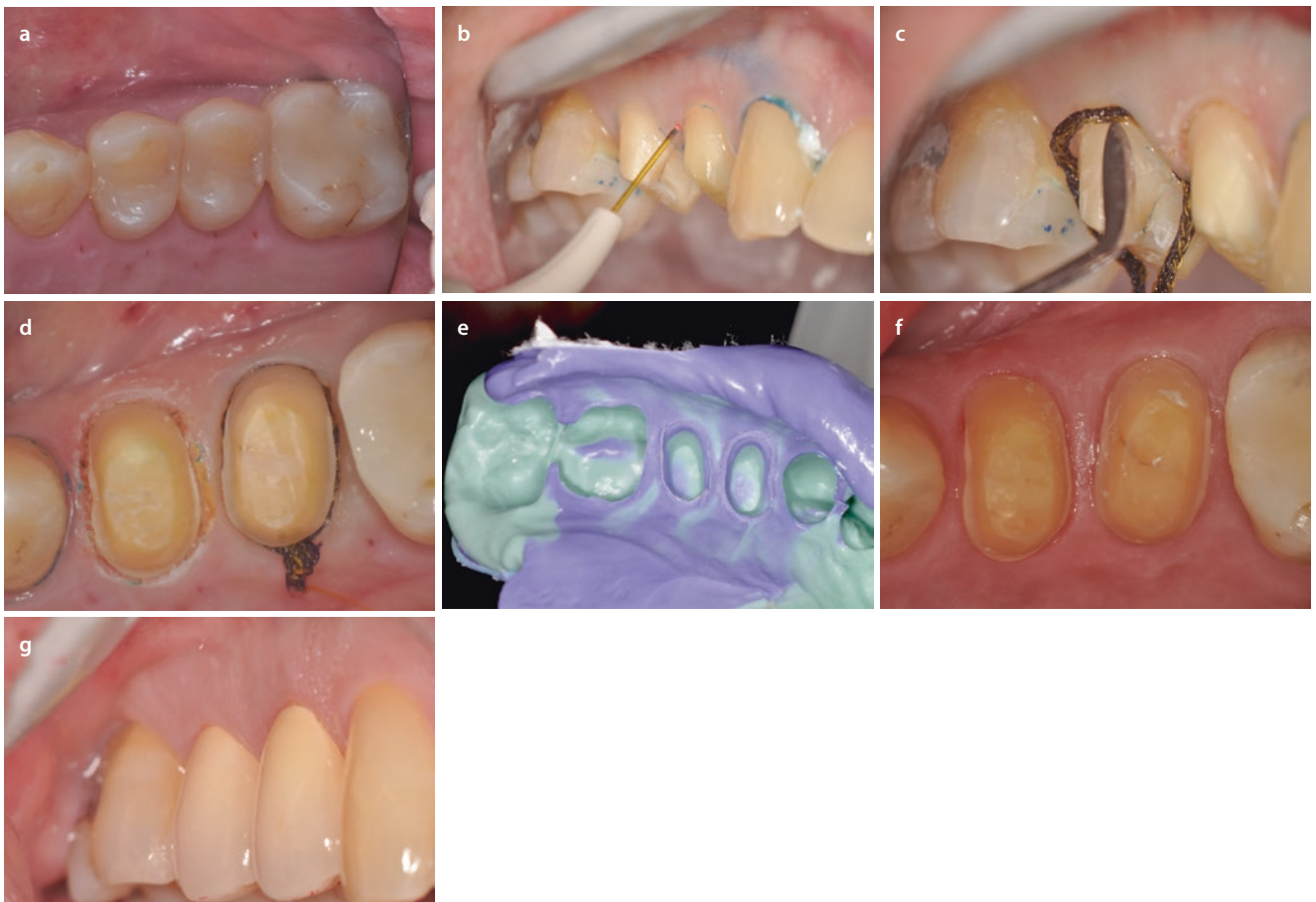


Fig. 15.17 a The mirror view of two maxillary premolar teeth that will receive full porcelain crown restorations. b A diode laser with a 400 micron bare fiber and an average power of 0.8 W is used parallel to the long axis of the preparation of the first premolar to expose the margins and debride the sulcus. The fiber is used in short arcs of a circle. c Retraction cord is placed in the sulcus of the second premolar. d The preparations are ready for the impression. Note the excellent control of

bleeding and tissue retraction on the first premolar's gingiva after the laser use. e View of the final impression showing excellent capture of both preparations. f Two-week postoperative view of the preparations, after the provisional restorations are removed, showing adequate gingival health. g Three-week postoperative view of the final restorations showing an excellent result (Clinical case courtesy of Dr. Glenn van As)

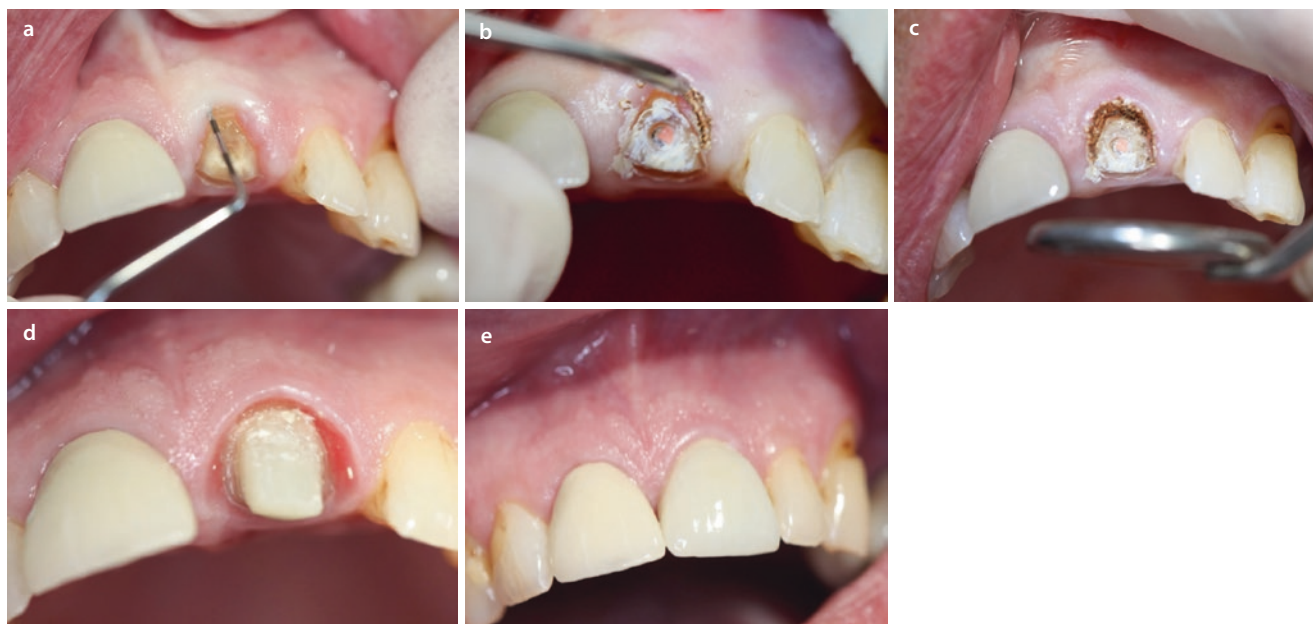


Fig. 15.18 **a** Preoperative view of a crown preparation in progress while determining the dentogingival complex measurement. **b** A 10600 nm carbon dioxide laser used with a 600 micron beam diameter in noncontact at a power of 1.0 W continuous wave. The beam was aimed precisely at the soft tissue while avoiding interaction with any tooth structure. **c** Immediate postoperative view. The small area of

tissue removal that appears carbonized will be rinsed away; however, the hemostasis is excellent. **d** Two-week postoperative view shows the healed tissue contour which will facilitate the good emergence profile of the restoration. **e** View with crown delivered (Clinical Case courtesy of Dr. Steven Parker)

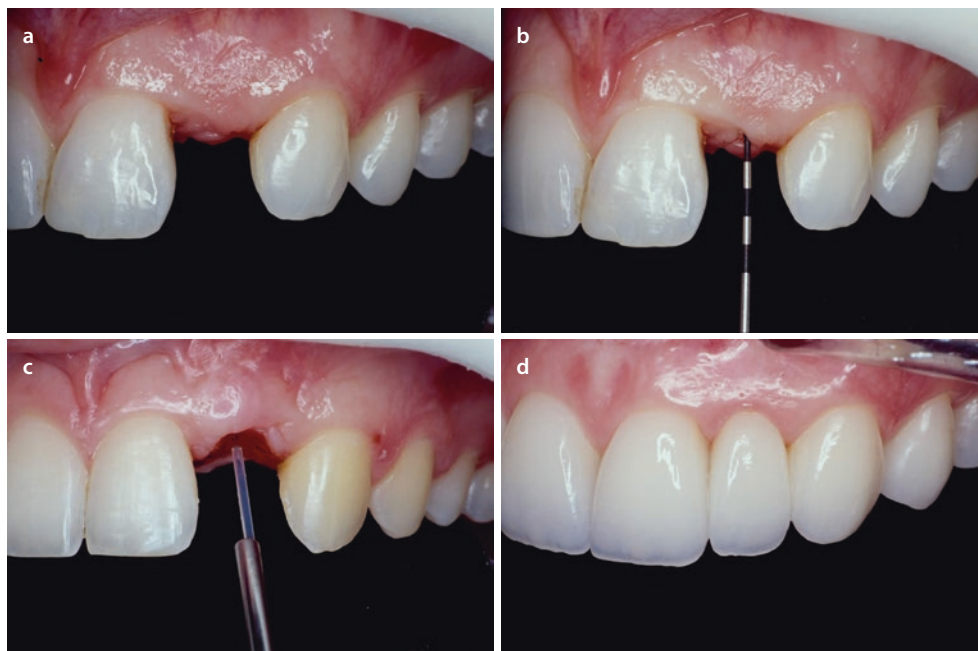
15.10 Tissue Preparation for a Fixed Prosthodontic Pontic Restoration

As discussed, the emergence profile ultimately determines the periodontal and aesthetic success of the dentition. Toward that end, the periodontal tissues can be manipulated with dental lasers to provide a stable and healthy foundation to guide the axial contours of the restoration or natural tooth. Crown lengthening can be used to perform these alterations. In the case of a fixed bridge pontic, the edentulous ridge can be prepared with a concave area so that the apical portion of the pontic can be made into a convex

surface. This avoids a «ridge-lap» design which usually prevents the patient from adequate oral hygiene in the area. Instead a more natural appearing prosthodontic restoration can be fabricated.

Figure 15.19 shows the development of an ovate pontic area prior to replacing a fixed bridge. The tissue surface of the previous pontic was poorly contoured which resulted in chronically inflamed tissue. A diode laser was used to remove and reshape the soft tissue. The long-term (15-year) picture demonstrates how this procedure allowed the patient to maintain periodontal health (Case courtesy of Dr. David Hornbrook).

Fig. 15.19 a Preoperative view of edentulous ridge after removal of a bonded bridge. Note the chronic inflammation of the tissue due to the ridge-lap design of the previous pontic, which prevented the patient from adequately cleaning the area. b A periodontal probe is used to measure the tissue thickness. There is sufficient tissue to allow removal for an ovate pontic design. c A diode laser is used with a bare 400 micron fiber at 1.0 W continuous wave emission to sculpt the concavity where the convex pontic will be positioned. The laser shaping can proceed with small amounts of tissue removal, but the clinician must be careful to leave at least 1.0 mm of tissue covering the bone. d A 15-year postoperative view showing excellent periodontal health with the new bridge restoration with its ovate pontic. The patient can easily maintain the pontic space and adjacent tissue (Clinical case courtesy of Dr. David Hornbrook)



Conclusion

The purpose of this chapter is to demonstrate that utilization of the variety of dental wavelengths allows the clinician to precisely and predictably manage the soft and hard tissue surrounding the teeth. Any available dental surgical laser will incise and ablate soft tissue, although the interaction can vary among the emission wavelengths. For removal and contour of osseous tissue, the available choice of instruments is more limited to the erbium family and the 9300 nm carbon dioxide ones. These latter «all-tissue» lasers can facilitate treatment by allowing incremental removal of the tissues so that the target treatment section can harmonize with the adjacent areas. However, careful placement of the laser beam is essential to avoid unintended removal of one tissue while treating the other.

As always, thorough diagnosis and detailed treatment planning of a well-chosen case are highly important. It is equally important that the clinician be familiar with current periodontal surgical therapies and protocol, which can be found in any textbook [22]. The treatment phase must pay attention to several biologic principles so that the dentogingival complex and the tooth and/or restoration are harmonious and allow the patient to maintain good oral hygiene. Elective aesthetic procedures require the same principles along with elements of smile design and other dentofacial aesthetic details. In order to provide sufficient tooth structure for a successful restoration, the biologic width must be respected.

Thus for successful placement of restorations and pleasing aesthetic procedures, a dental laser is a beneficial and significant addition to the clinician's armamentarium.

References

- Ochsenbein C, Ross S. A re-evaluation of osseous surgery. *Dent Clin North Am.* 1969;13(1):87–102.
- Seibert JL, Lindhe J. Esthetics and periodontal therapy. In: Lindhe J, editor. *Textbook of clinical periodontology*. 2nd ed. Copenhagen: Munksgaard; 1989. p. 477–514.
- Cook DR, et al. Relationship between clinical periodontal biotype and labial plate thickness: an in vivo study. *Int J Periodontics Restorative Dent.* 2011;31(4):345–54.
- Serino G, et al. The prevalence and distribution of gingival recession in subjects with a high standard of oral hygiene. *J Clin Periodontol.* 1994;21(1):57–63.
- Pontoriero R, Carnevale G. Surgical crown lengthening: a 12-month clinical wound healing study. *J Periodontol.* 2001;72(7):841–8.
- Gargiulo AW, et al. Dimensions and relations of the dentogingival junction in humans. *J Periodontol.* 1961;32(3):261–7.
- Schmidt JC, et al. Biologic width dimensions—a systematic review. *J Clin Periodontol.* 2013;40(5):493–504.
- Rosenberg ES, et al. Crown lengthening revisited. *Compend Contin Educ Dent.* 1999;20:527.
- Kois JC. Altering gingival levels: the restorative connection. Part 1: biologic variables. *J Esthet Dent.* 1994;6(1):3–9.
- Gunay H, Seeger A, et al. Placement of the preparation line and periodontal health— a prospective two-year clinical study. *Int J Periodontics Restorative Dent.* 2000;20(2):171–81.
- Croll BM. Emergence profiles in natural tooth contour. Part I: photographic observations. *J Prosthet Dent.* 1989;62(1):4–10.
- Tarnow D, Magner A, Fletcher P. The effect of the distance from the contact point to the crest of bone on the presence or absence of the interproximal dental papilla. *J Periodontol.* 1992;63(12):995–6.
- Oquendo A, Brea L, David S. Diastema: correction of excessive spaces in the esthetic zone. *Dent Clin North Am.* 2011;55(2):265–81.
- Camargo P, et al. Clinical crown lengthening in the esthetic zone. *J Calif Dent Assoc.* 2007;35(7):487–98.

15. Okuda W. Smile design 2.0: evolving from our past to be successful in treating the modern cosmetic patient. *Gen Dent.* 2016;64(1):10–3.
16. Garber D, Salama M. The aesthetic smile: diagnosis and treatment. *Periodontol 2000.* 1996;11:18–28.
17. Kois J. The restorative-periodontal interface: biological parameters. *Periodontol 2000.* 1996;11:29–38.
18. Flax H, Radz G. Closed-flap laser-assisted esthetic dentistry using Er:YSGG technology. *Compendium.* 2004;25(8):622–8.
19. Cobb C. Lasers in periodontics: a review of the literature. *J Periodontol.* 2006;77(4):545–64.
20. Kao R, et al. Esthetic crown lengthening: appropriate diagnosis for achieving gingival balance. *J Calif Dent Assoc.* 2008;36(3):187–91.
21. McGuire M, Scheyer ET. Laser-assisted flapless crown lengthening: a case series. *Int J Periodontics Restorative Dent.* 2011;31(4):357–64.
22. Newman M, Takei H, Klokkevold P, Carranza F. *Carranza's clinical periodontology.* 11th ed. St Louis: Elsevier Saunders; 2012.