

Endocrinology

*Series Editor:* Andrea Lenzi

*Series Co-Editor:* Emmanuele A. Jannini

SPRINGER  
REFERENCE

Manuela Simoni

Ilpo T. Huhtaniemi *Editors*

# Endocrinology of the Testis and Male Reproduction

 Springer

---

# Endocrinology

## Volume 1

### **Series Editor**

Andrea Lenzi

Chair of Endocrinology

Department of Experimental Medicine,

Section of Medical Pathophysiology

Food Science and Endocrinology

Sapienza University of Rome

Rome, Italy

### **Series Co-Editor**

Emmanuele A. Jannini

Chair of Endocrinology & Medical Sexology (ENDOSEX)

Department of Systems Medicine

University of Rome Tor Vergata

Rome, Italy

Within the health sciences, Endocrinology has a unique and pivotal role. This old, but continuously new science is the study of the various hormones and their actions and disorders in the body. The matter of Endocrinology are the glands, i.e., the organs that produce hormones, active on the metabolism, reproduction, food absorption and utilization, growth and development, behavior control, and several other complex functions of the organisms. Since hormones interact, affect, regulate, and control virtually all body functions, Endocrinology not only is a very complex science, multidisciplinary in nature, but is one with the highest scientific turnover. Knowledge in the Endocrinological sciences is continuously changing and growing. In fact, the field of Endocrinology and Metabolism is one where the highest number of scientific publications continuously flourishes. The number of scientific journals dealing with hormones and the regulation of body chemistry is dramatically high. Furthermore, Endocrinology is directly related to genetics, neurology, immunology, rheumatology, gastroenterology, nephrology, orthopedics, cardiology, oncology, gland surgery, sexology and sexual medicine, psychology, psychiatry, internal medicine, and basic sciences. All these fields are interested in updates in Endocrinology. The aim of the MRW in Endocrinology is to update the Endocrinological matter using the knowledge of the best experts in each section of Endocrinology: basic endocrinology, neuroendocrinology, endocrinological oncology, pancreas with diabetes and other metabolic disorders, thyroid, parathyroid and bone metabolism, adrenals and endocrine hypertension, sexuality, reproduction, and behavior.

More information about this series at <http://www.springer.com/series/14021>

---

Manuela Simoni • Ilpo T. Huhtaniemi  
Editors

# Endocrinology of the Testis and Male Reproduction

With 127 Figures and 73 Tables

 Springer

*Editors*

Manuela Simoni  
Unit of Endocrinology  
Department of Biomedical  
Metabolic and Neural Sciences  
University of Modena and Reggio Emilia  
Modena, Italy

Ilpo T. Huhtaniemi  
Faculty of Medicine  
Department of Surgery and Cancer  
Imperial College London  
London, UK

ISBN 978-3-319-44440-6 ISBN 978-3-319-44441-3 (eBook)

ISBN 978-3-319-44442-0 (print and electronic bundle)

<https://doi.org/10.1007/978-3-319-44441-3>

Library of Congress Control Number: 2017948013

© Springer International Publishing AG 2017

This work is subject to copyright. All rights are reserved by the Publisher, whether the whole or part of the material is concerned, specifically the rights of translation, reprinting, reuse of illustrations, recitation, broadcasting, reproduction on microfilms or in any other physical way, and transmission or information storage and retrieval, electronic adaptation, computer software, or by similar or dissimilar methodology now known or hereafter developed.

The use of general descriptive names, registered names, trademarks, service marks, etc. in this publication does not imply, even in the absence of a specific statement, that such names are exempt from the relevant protective laws and regulations and therefore free for general use.

The publisher, the authors and the editors are safe to assume that the advice and information in this book are believed to be true and accurate at the date of publication. Neither the publisher nor the authors or the editors give a warranty, express or implied, with respect to the material contained herein or for any errors or omissions that may have been made. The publisher remains neutral with regard to jurisdictional claims in published maps and institutional affiliations.

Printed on acid-free paper

This Springer imprint is published by Springer Nature

The registered company is Springer International Publishing AG

The registered company address is: Gewerbestrasse 11, 6330 Cham, Switzerland

---

## Series Preface

Is there an unmet need for a new MRW series in Endocrinology and Metabolism? It might not seem so! The vast number of existing textbooks, monographs, and scientific journals suggest that the field of hormones (from genetic, molecular, biochemical, and translational to physiological, behavioral, and clinical aspects) is one of the largest in biomedicine, producing a simply huge scientific output. However, we are sure that this new series will be of interest for scientists, academics, students, physicians, and specialists alike.

The knowledge in Endocrinology and Metabolism limited to the two main (from an epidemiological perspective) diseases, namely hypo/hyperthyroidism and diabetes mellitus, now seems outdated and perhaps closer to the practical interests of the general practitioner than to those of the specialist. This has led to endocrinology and metabolism being increasingly considered as a subsection of internal medicine rather than an autonomous specialization. But endocrinology is much more than this.

We are proposing this series as the *manifesto* for **Endocrinology 2.0**, embracing the fields of medicine in which hormones play a major part but which, for various historical and cultural reasons, have thus far been “ignored” by endocrinologists. Hence, this MRW comprises “traditional” (but no less important or investigated) topics: from the molecular actions of hormones to the pathophysiology and management of pituitary, thyroid, adrenal, pancreatic, and gonadal diseases, as well as less usual and common arguments. Endocrinology 2.0 is, in fact, the science of hormones, but it is also the medicine of sexuality and reproduction, the medicine of gender differences, and the medicine of well-being. These aspects of Endocrinology have to date been considered of little interest, as they are young and relatively unexplored sciences. But this is no longer the case. The large scientific production in these fields coupled with the impressive social interest of patients in these topics is stimulating a new and fascinating challenge for Endocrinology.

The aim of the **MRW in Endocrinology** is thus to update the subject with the knowledge of the best experts in each field: basic endocrinology, neuroendocrinology, endocrinological oncology, pancreatic disorders, diabetes and other metabolic disorders, thyroid, parathyroid and bone metabolism, adrenal and endocrine

hypertension, sexuality, reproduction, and behavior. We are sure that this ambitious aim, covering for the first time the whole spectrum of Endocrinology 2.0, will be fulfilled in this vast Springer MRW in Endocrinology Series.

Andrea Lenzi  
Emmanuele A. Jannini

---

## Volume Preface

Generally speaking, the ultimate scope of life is maintenance of the species, which is ensured by reproduction. Reproduction depends on exquisite endocrine signals, which start during fetal life, are dormant during childhood, mature and attain full function at the end of puberty, and variably decline thereafter in a gender-dependent fashion. Therefore, if hormones are essential for life of individuals, reproductive hormones are in addition essential for the maintenance of species. Turned in another way, if some hormonal defects are deadly for the individual, reproductive failure may be deadly for the species. This book illustrates what hormones do for male reproduction, in which way they govern the pathophysiology of the hypothalamo-pituitary-gonadal axis, and, more generally, how they are implicated in the maintenance of the human species.

The book has been compiled by the world experts of the field, both in basic and clinical science. It aims at providing a comprehensive view of the current knowledge ranging from molecular, genetic, and cellular mechanisms to clinical manifestations of male reproductive physiology and its disorders to therapeutic perspectives. Male reproduction is a sensitive issue, with wide socioeconomical and ethical implications, which has been covered as well.

Each chapter of this book is meant to stand on itself as a reference work in its field. It has been written with human male reproduction in mind, but it also covers the animal research relevant to understand the clinical problems andrologists and male reproductive endocrinologists may encounter in their everyday practice.

We are grateful to all distinguished colleagues who generously contributed to this work with their knowledge and experience. We are confident that the readership will find clear answers to their curiosity, to improve their clinical skills and to stimulate them to more creative research in this fascinating field.

Manuela Simoni  
Ilpo T. Huhtaniemi



---

# Contents

## Volume 1

<b>Part I Physiology of the Hypothalamus-Pituitary-Gonadal Axis, the Testis, and Testicular Function</b> .....	<b>1</b>
<b>1 Control of GnRH Secretion</b> .....	<b>3</b>
Marco Bonomi, Valeria Vezzoli, and Anna Cariboni	
<b>2 GnRH Action</b> .....	<b>35</b>
Kathryn L. Garner, Krasimira Tsaneva-Atanasova, and Craig A. McArdle	
<b>3 Gonadotropins</b> .....	<b>71</b>
Alfredo Ulloa-Aguirre, James A. Dias, and George R. Bousfield	
<b>4 Gonadotropin Receptors</b> .....	<b>123</b>
Livio Casarini, Ilpo T. Huhtaniemi, Manuela Simoni, and Adolfo Rivero-Müller	
<b>5 Sex Determination</b> .....	<b>169</b>
Sarah J. Potter, Deepti Lava Kumar, and Tony DeFalco	
<b>6 Male Sexual Differentiation</b> .....	<b>217</b>
Catherine H. Sterling, Dagmar Wilhelm, and Stefan Bagheri-Fam	
<b>7 Endocrinology of the Fetal Testis</b> .....	<b>245</b>
Richard Ivell, Ravinder Anand-Ivell, and Steven D. Morley	
<b>8 Testis Development and Descent</b> .....	<b>273</b>
Girolamo Mattioli, Pietro Lazzeroni, Irene Paraboschi, Natascia Di Iorgi, Flavia Napoli, and Mohamad Maghnie	
<b>9 Functional Anatomy and Histology of the Testis</b> .....	<b>313</b>
D. Fietz and M. Bergmann	
<b>10 Testicular Steroidogenesis</b> .....	<b>343</b>
Christa E. Flück and Amit V. Pandey	

<b>11 Anabolic and Metabolic Effects of Testosterone and Other Androgens: Direct Effects and Role of Testosterone Metabolic Products</b> .....	373
Jonas Čeponis, Christina Wang, Ronald S. Swerdloff, and Peter Y. Liu	
<b>12 Androgen Receptor</b> .....	395
Päivi Sutinen, Marjo Malinen, and Jorma J. Palvimo	
<b>13 Spermatogenesis</b> .....	417
Juho-Antti Mäkelä and Jorma Toppari	
<b>14 Epididymal Sperm Transport and Fertilization</b> .....	457
S. Marchiani, L. Tamburrino, M. Muratori, and E. Baldi	
<b>Part II Clinical Approach to the Disorders of Male Reproduction</b> .....	<b>479</b>
<b>15 Anamnesis and Physical Examination</b> .....	481
Francesco Lombardo, Francesco Pallotti, Francesco Cargnelutti, and Andrea Lenzi	
<b>16 Hormonal Laboratory Examination</b> .....	495
Uberto Pagotto, Flaminia Fanelli, and Antonio Raffaele Granata	
<b>17 Genetic Analysis in Male Infertility</b> .....	517
Csilla Krausz	
<b>18 The Semen Analysis: The Investigation of the Human Ejaculate</b> .....	535
Lars Björndahl and Rebecka Holmberg	
<b>19 Color-Doppler Ultrasound and New Imaging Techniques in Andrological Examination</b> .....	555
Francesco Lotti and Mario Maggi	
<b>20 Histopathological Evaluation of Testicular Biopsy</b> .....	623
Ewa Rajpert-De Meyts, Kenneth M. Grigor, and Niels E. Skakkebaek	
<b>Volume 2</b>	
<b>Part III Disorders of Sexual Development and Male Hypogonadism</b> .....	<b>643</b>
<b>21 Classification and Epidemiology of Hypogonadism</b> .....	645
George A. Kanakis and Dimitrios G. Goulis	

<b>22</b>	<b>Clinical Manifestation and Diagnosis of Androgen Deficiency</b> . . . .	<b>669</b>
	Agnieszka Swiecicka and Frederick Wu	
<b>23</b>	<b>Primary and Secondary Hypogonadism</b> . . . . .	<b>687</b>
	Daniele Santi and Giovanni Corona	
<b>24</b>	<b>Delayed Puberty</b> . . . . .	<b>749</b>
	Nanna Kolby, Alexander S. Busch, and Anders Juul	
<b>25</b>	<b>Androgen Resistance</b> . . . . .	<b>773</b>
	Jarmo Jääskeläinen	
<b>26</b>	<b>Estrogen Deficiency in Men</b> . . . . .	<b>797</b>
	Vincenzo Rochira and Cesare Carani	
<b>27</b>	<b>Hypogonadism in Systemic Diseases</b> . . . . .	<b>829</b>
	Vincenzo Rochira	
<b>28</b>	<b>Effect of Cancer Treatments on Testicular Function</b> . . . . .	<b>881</b>
	Aleksander Giwercman	
<b>29</b>	<b>Gynecomastia</b> . . . . .	<b>899</b>
	Marco Zavattaro, Giovanna Motta, Stefano Allasia, and Fabio Lanfranco	
<b>30</b>	<b>Late-Onset Hypogonadism</b> . . . . .	<b>921</b>
	Giulia Rastrelli and Gianni Forti	
<b>31</b>	<b>Treatment of Hypogonadism</b> . . . . .	<b>945</b>
	Giulia Rastrelli and Mario Maggi	
<b>Part IV</b>	<b>Male Infertility</b> . . . . .	<b>979</b>
<b>32</b>	<b>Pre-Testicular, Testicular, and Post-Testicular Causes of Male Infertility</b> . . . . .	<b>981</b>
	Fotios Dimitriadis, George Adonakis, Apostolos Kaponis, Charalampos Mamoulakis, Atsushi Takenaka, and Nikolaos Sofikitis	
<b>33</b>	<b>Genetics of Male Infertility</b> . . . . .	<b>1029</b>
	Frank Tüttelmann and Albrecht Röpke	
<b>34</b>	<b>Infectious and Immunological Aspects of Male Infertility</b> . . . . .	<b>1051</b>
	Qian Jiang and Daishu Han	
<b>35</b>	<b>Hormonal Treatment of Male Infertility: Gonadotropins and Beyond</b> . . . . .	<b>1071</b>
	Andrea M. Isidori, Andrea Sansone, and Daniele Gianfrilli	

<b>36</b>	<b>Nonhormonal Medical Treatment of Male Infertility</b> .....	1091
	Aldo E. Calogero, Rosita A. Condorelli, and Sandro La Vignera	
<b>37</b>	<b>Varicocele</b> .....	1115
	M.W. Ragab and S. Kliesch	
<b>38</b>	<b>Assisted Reproduction for Male Infertility</b> .....	1145
	Biljana Popovic-Todorovic and Herman Tournaye	
<b>39</b>	<b>Intratesticular Sperm Extraction</b> .....	1177
	Davide Oreggia, Eugenio Ventimiglia, and Andrea Salonia	
<b>40</b>	<b>Therapy with Antiandrogens in Gender Dysphoric Natal Males</b> .....	1199
	Giulia Gava, Renato Seracchioli, and Maria Cristina Merigiola	
<b>Part V</b>	<b>Miscellaneous Aspects</b> .....	<b>1211</b>
<b>41</b>	<b>Male Contraception</b> .....	1213
	Bradley D. Anawalt and Stephanie T. Page	
<b>42</b>	<b>Cryopreservation of Spermatozoa</b> .....	1235
	Loredana Gandini, Francesco Pallotti, Donatella Paoli, and Andrea Lenzi	
<b>43</b>	<b>Use, Misuse, and Abuse of Androgens</b> .....	1251
	David J. Handelsman	
<b>44</b>	<b>Psychological Aspects of Infertility Among Men</b> .....	1287
	Jane Fisher and Karin Hammarberg	
<b>45</b>	<b>Ethical Aspects of Male Reproductive Disorders and Their Treatment</b> .....	1319
	Maurizio Mori	
<b>Index</b> .....		<b>1351</b>

---

## About the Editors



**Manuela Simoni, M.D., Ph.D.**, trained as a clinical endocrinologist at the Unit of Endocrinology of the University of Modena, Italy, between 1982 and 1990 and, thereafter, as molecular endocrinologist at the Institute of Reproductive Medicine of the University of Münster, Germany, where she was Professor for Endocrinology and Molecular Biology of Reproduction from 1998 to 2008.

Since 2008, she is Full Professor of Endocrinology at the University of Modena and Reggio Emilia, Italy.

Currently, she holds the following positions: Director of the Clinical Unit of Endocrinology at the Ospedale Civile of Modena, Director of the School of Specialization in Endocrinology and Metabolism, Deputy Director of the Department of Biomedical, Metabolic and Neural Sciences, and Director of the Center for Genomic Research of the University of Modena and Reggio Emilia.

Her research interests are gonadotropin and androgen action, testicular function, male infertility, endocrinology, and pathophysiology of reproduction.

She is member of several societies, including the European Academy of Andrology (EAA) and the European Society of Endocrinology (ESE, serving as the Secretary), and is active in the editorial boards of several journals in the fields of endocrinology and reproduction. Since January 2017, she is Co-Editor-in-Chief of ANDROLOGY, the official journal of the European Academy of Andrology and the American Society of Andrology.



**Ilpo T. Huhtaniemi** received his M.D. and Ph.D. from the University of Helsinki, Finland, did postdoctoral training in USA (UC San Francisco and NIH, Bethesda), and has been on sabbatical leave in Germany, USA, and Scotland. From 1986 to 2002, he held the post of Professor and Chairman of Physiology at University of Turku, Finland. He moved in 2002 to UK as a Chair in Reproductive Endocrinology at Imperial College London, from which post he retired in 2015. He has received several national and international honors, among them a Fellowship of the Academy of Medical Sciences (UK) and a Doctor Honoris Causa of the Medical University Lodz, Poland, and University of Szeged, Hungary. He has been the Chief Managing Editor of *Mol Cell Endocrinol* (1999–2017), has served in the Editorial Board of *Endocrinology* and *Endocr Rev*, and is/has been the Editor or Editorial Board Member of several other scientific journals (e.g., *Eur J Endocrinol*, *Clin Endocrinol*, *Hum Reprod Update*, *J Endocrinol*, *Mol Hum Reprod*, *Reproduction*, *Asian J Androl*, *J Endocr Soc*). He has held positions of trust in many international scientific organizations (e.g., Past President of International Society of Andrology; Executive Committee of European Society of Endocrinology). His research interests include clinical and basic reproductive endocrinology, in particular the function of gonadotrophins and male reproductive endocrinology. He also has long-term interests in male contraception, hormone-dependent cancer, and the endocrinology of aging.

---

## Contributors

**George Adonakis** Department of Ob/Gyn, School of Medicine, Patras University, Patras, Greece

**Stefano Allasia** Department of Medical Sciences, Division of Endocrinology, Diabetology and Metabolism, University of Torino, Torino, Italy

**Ravinder Anand-Ivell** School of Biosciences, University of Nottingham, Nottingham, UK

**Bradley D. Anawalt** Department of Medicine- Metabolism, Endocrinology and Nutrition, University of Washington, Seattle, WA, USA

**Stefan Bagheri-Fam** Department of Anatomy and Neuroscience, The University of Melbourne, Melbourne, VIC, Australia

**E. Baldi** Dipartimento di Medicina Sperimentale e Clinica, University of Florence, Florence, Italy

**M. Bergmann** Institute for Veterinary Anatomy, Histology and Embryology, Justus Liebig University Giessen, Giessen, Germany

**Lars Björndahl** ANOVA – Andrology, Sexual Medicine and Transgender Medicine, Karolinska University Hospital and Karolinska Institute, Stockholm, Sweden

**Marco Bonomi** Department of Clinical Sciences and Community Health, University of Milan, Milan, Italy

Division of Endocrine and Metabolic Diseases and Laboratory of Endocrine and Metabolic Research, IRCCS Istituto Auxologico Italiano, Ospedale San Luca, Milan, Italy

**George R. Bousfield** Department of Biology, Wichita State University, Wichita, KS, USA

**Alexander S. Busch** Department of Growth and Reproduction, Rigshospitalet, University of Copenhagen, Copenhagen Ø, Denmark

International Research and Research Training Centre in Endocrine Disruption of Male Reproduction and Child Health (EDMaRC), Rigshospitalet, University of Copenhagen, Copenhagen Ø, Denmark

**Aldo E. Calogero** Department of Clinical and Experimental Medicine, University of Catania, Catania, Italy

**Cesare Carani** Department of Biomedical, Metabolic and Neural Sciences, University of Modena and Reggio Emilia, Modena, Italy

**Francesco Cargnelutti** Department of Experimental Medicine, University of Rome “La Sapienza”, Rome, Italy

**Anna Cariboni** Department of Pharmacological and Biomolecular Sciences, University of Milan, Milan, Italy

**Livio Casarini** Unit of Endocrinology, Department of Biomedical, Metabolic and Neural Sciences, University of Modena and Reggio Emilia, Modena, Italy

**Jonas Čeponis** Los Angeles Biomedical Research Institute at Harbor-UCLA Medical Center, Torrance, CA, USA

Institute of Endocrinology, Lithuanian University of Health Sciences, Kaunas, Lithuania

**Rosita A. Condorelli** Department of Clinical and Experimental Medicine, University of Catania, Catania, Italy

**Giovanni Corona** Endocrinology Unit, Medical Department, Azienda USL Bologna Maggiore-Bellaria Hospital, Bologna, Italy

**Tony DeFalco** Division of Reproductive Sciences, Cincinnati Children’s Hospital Medical Center, Cincinnati, OH, USA

**Natascia Di Iorgi** Department of Pediatrics, Istituto Giannina Gaslini, University of Genova, Genova, Italy

**James A. Dias** Department of Biomedical Sciences, State University of New York at Albany, Albany, NY, USA

**Fotios Dimitriadis** Department of Urology, School of Medicine, Aristotle University, Thessaloniki, Greece

**Flaminia Fanelli** Endocrinology Unit and Center for Applied Biomedical Research, Department of Medical and Surgical Sciences, University of Bologna – S. Orsola-Malpighi Hospital, Bologna, Italy

**D. Fietz** Institute for Veterinary Anatomy, Histology and Embryology, Justus Liebig University Giessen, Giessen, Germany

**Jane Fisher** Jean Hailes Research Unit, School of Public Health and Preventive Medicine, Monash University, Melbourne, VIC, Australia

**Christa E. Flück** Pediatric Endocrinology and Diabetology Department of Pediatrics, Bern University Hospital, and Department of Clinical Research, University of Bern, Bern, Switzerland



**Gianni Forti** Endocrinology Unit, Department of Experimental and Clinical Biomedical Sciences, University of Florence, Florence, Italy

**Loredana Gandini** Department of Experimental Medicine, Laboratory of Semiology-Sperm Bank, University of Rome “La Sapienza”, Rome, Italy

**Kathryn L. Garner** Laboratories for Integrative Neuroscience and Endocrinology, School of Clinical Sciences, University of Bristol, Bristol, UK

**Giulia Gava** Gynecology and Physiopathology of Human Reproduction, S. Orsola-Malpighi Hospital, Department of Medical and Surgical Science, University of Bologna, Bologna, Italy

**Daniele Gianfrilli** Department of Experimental Medicine, Section of Medical Pathophysiology, Food Science and Endocrinology, Sapienza University of Rome, Rome, Italy

**Aleksander Giwercman** Translational Medicine, Lund University, Malmö, Sweden

Molecular Reproductive Medicine, Department of Translational Medicine, Lund University, Malmö, Sweden

**Dimitrios G. Goulis** Unit of Reproductive Endocrinology, First Department of Obstetrics and Gynaecology, Medical School, Aristotle University of Thessaloniki, Thessaloniki, Greece

**Antonio Raffaele Granata** Endocrinology Unit, Department of Internal Medicine, Endocrinology, Metabolism and Geriatry, Azienda Ospedaliero Universitaria, Modena, Italy

**Kenneth M. Grigor** Department of Pathology, University of Edinburgh, Edinburgh, Scotland, UK

**Karin Hammarberg** Jean Hailes Research Unit, School of Public Health and Preventive Medicine, Monash University, Melbourne, VIC, Australia

**Daishu Han** Department of Cell Biology, Institute of Basic Medical Sciences, Chinese Academy of Medical Sciences, School of Basic Medicine, Peking Union Medical College, Beijing, China

**David J. Handelsman** ANZAC Research Institute, University of Sydney, Sydney, Australia

Andrology Department, Concord Hospital, Sydney, Australia

**Rebecka Holmberg** ANOVA – Andrology, Sexual Medicine and Transgender Medicine, Karolinska University Hospital and Karolinska Institute, Stockholm, Sweden

**Ipo T. Huhtaniemi** Faculty of Medicine, Department of Surgery and Cancer, Imperial College London, London, UK

**Andrea M. Isidori** Department of Experimental Medicine, Section of Medical Pathophysiology, Food Science and Endocrinology, Sapienza University of Rome, Rome, Italy

**Richard Ivell** School of Biosciences and School of Veterinary Medicine and Science, University of Nottingham, Nottingham, UK

**Jarmo Jääskeläinen** Institute of Clinical Medicine, Department of Pediatrics, Kuopio University Hospital and University of Eastern Finland, Kuopio, Finland

**Qian Jiang** Department of Cell Biology, Institute of Basic Medical Sciences, Chinese Academy of Medical Sciences, School of Basic Medicine, Peking Union Medical College, Beijing, China

**Anders Juul** Department of Growth and Reproduction, Rigshospitalet, University of Copenhagen, Copenhagen Ø, Denmark

International Research and Research Training Centre in Endocrine Disruption of Male Reproduction and Child Health (EDMaRC), Rigshospitalet, University of Copenhagen, Copenhagen Ø, Denmark

**George A. Kanakis** Unit of Reproductive Endocrinology, First Department of Obstetrics and Gynaecology, Medical School, Aristotle University of Thessaloniki, Thessaloniki, Greece

**Apostolos Kaponis** Department of Ob/Gyn, School of Medicine, Patras University, Patras, Greece

**S. Kliesch** Department of Clinical and Surgical Andrology, Center of Reproductive Medicine and Andrology, University Hospital, Münster, Germany  
WHO Collaborating Center, EAA Training Center, Münster, Germany

**Nanna Kolby** Department of Growth and Reproduction, Rigshospitalet, University of Copenhagen, Copenhagen Ø, Denmark

International Research and Research Training Centre in Endocrine Disruption of Male Reproduction and Child Health (EDMaRC), Rigshospitalet, University of Copenhagen, Copenhagen Ø, Denmark

**Csilla Krausz** Department of Experimental and Clinical Biomedical Sciences “Mario Serio”, University of Florence, Florence, Italy

**Sandro La Vignera** Department of Clinical and Experimental Medicine, University of Catania, Catania, Italy

**Deepti Lava Kumar** Division of Reproductive Sciences, Cincinnati Children’s Hospital Medical Center, Cincinnati, OH, USA

**Fabio Lanfranco** Department of Medical Sciences, Division of Endocrinology, Diabetology and Metabolism, University of Torino, Torino, Italy

**Pietro Lazzeroni** Department of Pediatrics, Istituto Giannina Gaslini, University of Genova, Genova, Italy

**Andrea Lenzi** Department of Experimental Medicine, Laboratory of Seminology-Sperm Bank, University of Rome “La Sapienza”, Rome, Italy

**Peter Y. Liu** Los Angeles Biomedical Research Institute at Harbor-UCLA Medical Center, Torrance, CA, USA

David Geffen School of Medicine at UCLA, Harbor-UCLA Medical Center, Torrance, CA, USA

**Francesco Lombardo** Department of Experimental Medicine, University of Rome “La Sapienza”, Rome, Italy

**Francesco Lotti** Sexual Medicine and Andrology Unit, Department of Experimental and Clinical Biomedical Sciences, University of Florence, Florence, Italy

**Mario Maggi** Sexual Medicine and Andrology Unit, Department of Experimental and Clinical Biomedical Sciences, University of Florence, Florence, Italy

**Mohamad Maghnie** Department of Pediatrics, Istituto Giannina Gaslini, University of Genova, Genova, Italy

**Juho-Antti Mäkelä** Department of Physiology, Institute of Biomedicine, University of Turku, Turku, Finland

**Marjo Malinen** Institute of Biomedicine, University of Eastern Finland, Kuopio, Finland

**Charalampos Mamoulakis** Department of Urology, School of Medicine, University of Crete, Heraklion, Crete, Greece

**S. Marchiani** Dipartimento di Scienze Biomediche, Sperimentali e Cliniche, Università di Firenze, Florence, Italy

**Girolamo Mattioli** Department of Surgery, Istituto Giannina Gaslini, University of Genova, Genova, Italy

**Craig A. McArdle** Laboratories for Integrative Neuroscience and Endocrinology, School of Clinical Sciences, University of Bristol, Bristol, UK

**Maria Cristina Meriggiola** Gynecology and Physiopathology of Human Reproduction, S. Orsola-Malpighi Hospital, Department of Medical and Surgical Science, University of Bologna, Bologna, Italy

**Maurizio Mori** Università di Torino, Consulta di Bioetica Onlus, Turin, Italy

**Steven D. Morley** Division of Health Sciences, University of Edinburgh Medical School, Edinburgh, UK

**Giovanna Motta** Department of Medical Sciences, Division of Endocrinology, Diabetology and Metabolism, University of Torino, Torino, Italy

**M. Muratori** Dipartimento di Scienze Biomediche, Sperimentali e Cliniche, Università di Firenze, Florence, Italy

**Flavia Napoli** Department of Pediatrics, Istituto Giannina Gaslini, University of Genova, Genova, Italy

**Davide Oreggia** University Vita-Salute San Raffaele, Milan, Italy  
Division of Experimental Oncology/Unit of Urology, URI-Urological Research Institute, IRCCS Ospedale San Raffaele, Milan, Italy

**Stephanie T. Page** Department of Medicine- Metabolism, Endocrinology and Nutrition, University of Washington, Seattle, WA, USA

**Uberto Pagotto** Endocrinology Unit and Center for Applied Biomedical Research, Department of Medical and Surgical Sciences, University of Bologna – S. Orsola-Malpighi Hospital, Bologna, Italy

**Francesco Pallotti** Department of Experimental Medicine, Laboratory of Semiology-Sperm Bank, University of Rome “La Sapienza”, Rome, Italy

**Jorma J. Palvimo** Institute of Biomedicine, University of Eastern Finland, Kuopio, Finland

**Amit V. Pandey** Pediatric Endocrinology and Diabetology Department of Pediatrics, Bern University Hospital, and Department of Clinical Research, University of Bern, Bern, Switzerland

**Donatella Paoli** Department of Experimental Medicine, Laboratory of Semiology-Sperm Bank, University of Rome “La Sapienza”, Rome, Italy

**Irene Paraboschi** Department of Surgery, Istituto Giannina Gaslini, University of Genova, Genova, Italy

**Biljana Popovic-Todorovic** Centre for Reproductive Medicine, UZ Brussel, Brussel, Belgium

**Sarah J. Potter** Division of Reproductive Sciences, Cincinnati Children’s Hospital Medical Center, Cincinnati, OH, USA

**M. W. Ragab** Department of Clinical and Surgical Andrology, Center of Reproductive Medicine and Andrology, University Hospital, Münster, Germany  
Department of Andrology, Faculty of Medicine, Cairo University, Cairo, Egypt

**Ewa Rajpert-De Meyts** Department of Growth and Reproduction, Rigshospitalet, University of Copenhagen and EDMaRC, Copenhagen, Denmark

**Giulia Rastrelli** Sexual Medicine and Andrology Unit, Department of Experimental and Clinical Biomedical Sciences, University of Florence, Florence, Italy

**Adolfo Rivero-Müller** Department of Physiology, Institute of Biomedicine, University of Turku, Turku, Finland

**Vincenzo Rochira** Department of Biomedical, Metabolic and Neural Sciences, University of Modena and Reggio Emilia, Azienda Ospedaliero-Universitaria di Modena, Ospedale Civile di Baggiovara, Modena, Italy

**Albrecht Röpke** Institute of Human Genetics, University of Münster, Münster, Germany

**Andrea Salonia** University Vita-Salute San Raffaele, Milan, Italy

Division of Experimental Oncology/Unit of Urology, URI-Urological Research Institute, IRCCS Ospedale San Raffaele, Milan, Italy

**Andrea Sansone** Department of Experimental Medicine, Section of Medical Pathophysiology, Food Science and Endocrinology, Sapienza University of Rome, Rome, Italy

**Daniele Santi** Unit of Endocrinology, Department of Biomedical, Metabolic and Neural Sciences, University of Modena and Reggio Emilia, Modena, Italy

**Renato Seracchioli** Gynecology and Physiopathology of Human Reproduction, S. Orsola-Malpighi Hospital, Department of Medical and Surgical Science, University of Bologna, Bologna, Italy

**Manuela Simoni** Unit of Endocrinology, Department of Biomedical, Metabolic and Neural Sciences, University of Modena and Reggio Emilia, Modena, Italy

**Niels E. Skakkebaek** Department of Growth and Reproduction, Rigshospitalet, University of Copenhagen and EDMaRC, Copenhagen, Denmark

**Nikolaos Sofikitis** Department of Urology, School of Medicine, Ioannina University, Ioannina, Greece

**Catherine H. Sterling** Department of Anatomy and Neuroscience, The University of Melbourne, Melbourne, VIC, Australia

**Päivi Sutinen** Institute of Biomedicine, University of Eastern Finland, Kuopio, Finland

FinVector Vision Therapies Oy, Kuopio, Finland

**Ronald S. Swerdloff** Los Angeles Biomedical Research Institute at Harbor-UCLA Medical Center, Torrance, CA, USA

David Geffen School of Medicine at UCLA, Harbor-UCLA Medical Center, Torrance, CA, USA

**Agnieszka Swiecicka** Andrology Research Unit, Faculty of Biology, Medicine and Health, The University of Manchester, Manchester, UK

**Atsushi Takenaka** Department of Urology, School of Medicine, Tottori University, Yonago, Japan

**L. Tamburrino** Dipartimento di Scienze Biomediche, Sperimentali e Cliniche, Università di Firenze, Florence, Italy

**Jorma Toppari** Department of Pediatrics, Turku University Hospital, Turku, Finland

Department of Physiology, Institute of Biomedicine, University of Turku, Turku, Finland

**Herman Tournaye** Centre for Reproductive Medicine, UZ Brussel, Brussel, Belgium

**Krasimira Tsaneva-Atanasova** Department of Mathematics, College of Engineering, Mathematics and Physical Sciences, University of Exeter, Exeter, UK

EPSRC Centre for Predictive Modelling in Healthcare, University of Exeter, Exeter, UK

**Frank Tüttelmann** Institute of Human Genetics, University of Münster, Münster, Germany

**Alfredo Ulloa-Aguirre** Red de Apoyo a la Investigación, Coordinación de la Investigación Científica, Universidad Nacional Autónoma de México (UNAM), Mexico City, Mexico

Red de Apoyo a la Investigación, Instituto Nacional de Ciencias Médicas y Nutrición SZ, Mexico City, Mexico

**Eugenio Ventimiglia** University Vita-Salute San Raffaele, Milan, Italy

Division of Experimental Oncology/Unit of Urology, URI-Urological Research Institute, IRCCS Ospedale San Raffaele, Milan, Italy

**Valeria Vezzoli** Laboratory of Endocrine and Metabolic Research, IRCCS Istituto Auxologico Italiano, Cusano Milanino, Milan, Italy

**Christina Wang** Los Angeles Biomedical Research Institute at Harbor-UCLA Medical Center, Torrance, CA, USA

David Geffen School of Medicine at UCLA, Harbor-UCLA Medical Center, Torrance, CA, USA

**Dagmar Wilhelm** Department of Anatomy and Neuroscience, The University of Melbourne, Melbourne, VIC, Australia

**Frederick Wu** Andrology Research Unit, Faculty of Biology, Medicine and Health, The University of Manchester, Manchester, UK

**Marco Zavattaro** Department of Translational Medicine, Division of Endocrinology, University of Eastern Piedmont, Novara, Italy

---

## Part I

# Physiology of the Hypothalamus- Pituitary-Gonadal Axis, the Testis, and Testicular Function

Marco Bonomi, Valeria Vezzoli, and Anna Cariboni

## Abstract

Human reproduction and fertility are completely dependent upon neuroendocrine control of the hypothalamus-pituitary-gonadal (HPG) axis and its hierarchy of secreted hormones. The human reproductive system is controlled by the hypothalamus through the decapeptide gonadotropin-releasing hormone (GnRH), which displays a remarkable conservation over millions of years of evolution in the different species. The neurosecretion of GnRH depends on less than 4,000 GnRH-secreting neurons, which have an extracranial origin and finally migrate into the hypothalamic preoptic area. They secrete GnRH starting from the tenth week of gestation till the first 4–6 months of life, when GnRH secretion is “switched-off” until puberty. At puberty, the GnRH secretion is switched back “on” with a characteristic pulsatile manner that is maintained during adulthood. Regulation of GnRH-secreting neuron activity through the lifespan is not completely understood, but is clearly the result of a sophisticated network of stimulatory and inhibitory inputs, that include centrally different subgroups of neurons afferent to the GnRH-secreting neurons and peripherally the gonadal steroid feedback. The present chapter of the Textbook will focus on the ontogeny

---

M. Bonomi (✉)

Department of Clinical Sciences and Community Health, University of Milan, Milan, Italy

Division of Endocrine and Metabolic Diseases and Laboratory of Endocrine and Metabolic Research, IRCCS Istituto Auxologico Italiano, Ospedale San Luca, Milan, Italy

e-mail: [marco.bonomi@unimi.it](mailto:marco.bonomi@unimi.it); [m.bonomi@auxologico.it](mailto:m.bonomi@auxologico.it)

V. Vezzoli

Laboratory of Endocrine and Metabolic Research, IRCCS Istituto Auxologico Italiano, Cusano Milanino, Milan, Italy

e-mail: [v.vezzoli@auxologico.it](mailto:v.vezzoli@auxologico.it)

A. Cariboni

Department of Pharmacological and Biomolecular Sciences, University of Milan, Milan, Italy

e-mail: [anna.cariboni@unimi.it](mailto:anna.cariboni@unimi.it)



of the GnRH-secreting neurons and the mechanisms so far known to be implicated in regulating their neurosecretory activity.

### Keywords

Gonadotropin-releasing hormone • GnRH receptor • GnRH-secreting neurons • Kisspeptin • KNDy

### Contents

Development and Migration of GnRH-Secreting Neurons .....	6
GnRH-Secreting Neuron Function and GnRH Secretion .....	10
Pulsatile GnRH Secretion Throughout Lifespan .....	10
Regulation of GnRH Secretion .....	11
Summary .....	20
Cross-References .....	20
References .....	21

Neuroendocrine control of the hypothalamus-pituitary-gonadal (HPG) axis and hormones forms the base of human reproduction and fertility. A small number of neurons, scattered throughout different hypothalamic areas, secrete the neurohormone gonadotropin-releasing hormone (GnRH), which subsequently reaches the adenohypophysis through the pituitary portal vessels. Inside the pituitary, GnRH stimulates synthesis and release of the two gonadotropins, the luteinizing hormone (LH) and the follicle-stimulating hormone (FSH), by interacting with its specific receptor, the GnRHR which is expressed on the membrane of the gonadotrope cells. The two gonadotropins enter the systemic circulation and reach the gonads where they promote steroidogenesis (estrogen, progesterone, and androgens) and gametogenesis (oocytes and spermatozoa). Gonadal steroids, in turn, autoregulate their own secretion through a feedback mechanism, which determines a decrease of GnRH and gonadotropin secretion at the central level of the HPG axis.

The first suggestion of a hypothalamic site of control of the reproductive system came from the original findings of Harris in 1937 and his following “neurohumoral theory” (Harris 1955), which postulated that the secretion of each adenohypophyseal hormone would be controlled by a corresponding hypothalamic neuropeptide. Indeed, only some years later, the first such hypothalamic releasing hormone was identified, thyrotropin-releasing hormone (TRH) (Boler et al. 1969; Burgus et al. 1970), closely followed by the discovery and purification of GnRH (Amoss et al. 1971; Baba et al. 1971; Matsuo et al. 1971; Schally et al. 1971). Following this, the role of GnRH as a crucial regulator of the HPG axis became progressively clearer (Conn and Crowley 1994; Millar et al. 2001).

Comparison of the GnRH sequence from different species reveals a remarkable evolutionary conservation of over millions of years in the peptide length (ten amino acids), the N-terminus (Glu-His-Trp-Ser) and the C-terminus (Pro-Gly-NH<sub>2</sub>) (Fig. 1), supporting the crucial role of these sequences in receptor binding and activation. In humans, the gene encoding GnRH consists of four exons and is mapped to 8p.11.2-p.2p21 (Fig. 2) (Yang-Feng et al. 1986; Radovick et al. 1990). GnRH cDNA comprises an open reading frame of 276 base pairs, which encodes a

a

	1	2	3	4	5	6	7	8	9	10	
<b>Mammalian</b>	pGlu-	His-	Trp-	Ser-	Tyr-	Gly-	Leu-	Arg-	Pro-	Gly-	NH <sub>2</sub>
<b>Guinea Pig</b>	pGlu-	His-	Tyr-	Ser-	Tyr-	Gly-	Val-	Arg-	Pro-	Gly-	NH <sub>2</sub>
<b>Chicken I</b>	pGlu-	His-	Trp-	Ser-	Tyr-	Gly-	Leu-	Gln-	Pro-	Gly-	NH <sub>2</sub>
<b>Chicken II</b>	pGlu-	His-	Trp-	Ser-	His-	Gly-	Trp-	Tyr-	Pro-	Gly-	NH <sub>2</sub>
<b>Salmon</b>	pGlu-	His-	Trp-	Ser-	Tyr-	Gly-	Trp-	Leu-	Pro-	Gly-	NH <sub>2</sub>
<b>Dogfish</b>	pGlu-	His-	Trp-	Ser-	His-	Gly-	Trp-	Leu-	Pro-	Gly-	NH <sub>2</sub>
<b>Catfish</b>	pGlu-	His-	Trp-	Ser-	His-	Gly-	Leu-	Gln-	Pro-	Gly-	NH <sub>2</sub>
<b>Herring</b>	pGlu-	His-	Trp-	Ser-	His-	Gly-	Leu-	Ser-	Pro-	Gly-	NH <sub>2</sub>
<b>Medaka</b>	pGlu-	His-	Trp-	Ser-	His-	Gly-	Leu-	Ser-	Pro-	Gly-	NH <sub>2</sub>
<b>Lamprey I</b>	pGlu-	His-	Tyr-	Ser-	Leu-	Glu-	Trp-	Lys-	Pro-	Gly-	NH <sub>2</sub>
<b>Lamprey II</b>	pGlu-	His-	Trp-	Ser-	His-	Gly-	Trp-	Phe-	Pro-	Gly-	NH <sub>2</sub>
<b>Lamprey III</b>	pGlu-	His-	Trp-	Ser-	His-	Asp-	Trp-	Lys-	Pro-	Gly-	NH <sub>2</sub>
<b>Frog</b>	pGlu-	His-	Trp-	Ser-	Tyr-	Gly-	Leu-	Trp-	Pro-	Gly-	NH <sub>2</sub>
<b>Seabream</b>	pGlu-	His-	Trp-	Ser-	Tyr-	Gly-	Met-	Ser-	Pro-	Gly-	NH <sub>2</sub>
<b>Tunicate I</b>	pGlu-	His-	Trp-	Ser-	Asp-	Tyr-	Phe-	Lys-	Pro-	Gly-	NH <sub>2</sub>
<b>Tunicate II</b>	pGlu-	His-	Trp-	Ser-	Leu-	Cys-	His-	Ala-	Pro-	Gly-	NH <sub>2</sub>
<b>Whitefish</b>	pGlu-	His-	Trp-	Ser-	Tyr-	Gly-	Met-	Asn-	Pro-	Gly-	NH <sub>2</sub>

b

**GnRH-I**pGlu-His-Trp-Ser-Tyr-Gly-Leu-Arg-Pro-Gly-NH<sub>2</sub>

1 2 3 4 5 6 7 8 9 10

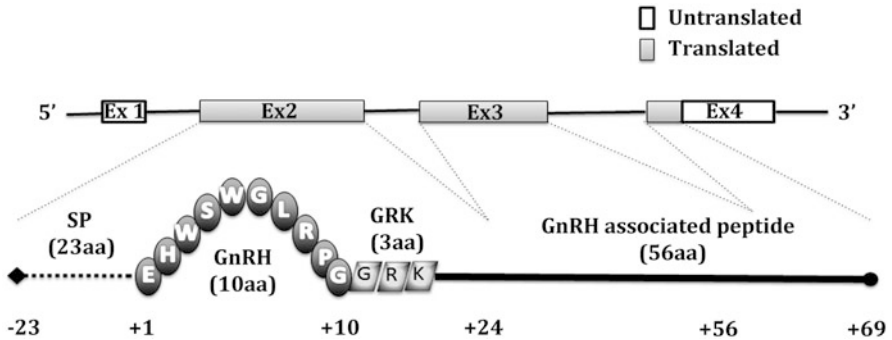
**GnRH-II**pGlu-His-Trp-Ser-His-Gly-Trp-Tyr-Pro-Gly-NH<sub>2</sub>

1 2 3 4 5 6 7 8 9 10

**Fig. 1** (a) Comparison of GnRH amino acid sequences through evolution of protochordates to mammals. Grey regions indicate conserved N- and C-terminal residues throughout the evolution, indicating their important functional role. (b) GnRH isoform in humans

precursor protein, subsequently cleaved and processed by a peptidase into secretory granules. The initial 23 amino acids of the prohormone correspond to a signal sequence, which is followed by the mature GnRH, the GKR sequence, and the 56-amino acid GnRH-associated protein, GAP (Fig. 2). The precise role of GAP is not known but is believed to have prolactin release inhibitory activity (Nikolics et al. 1985; Chavali et al. 1997).

Other GnRH isoforms exist and are expressed together with the “classic” type 1 GnRH (GnRH1) (Fig. 1). GnRH2 isoform presents a different amino acid sequence at positions 5, 7, and 8 and is expressed in humans, while GnRH3 has thus far only been found in some classes of fish. In humans, the gene encoding *GnRH2* has been cloned and mapped to chromosome 20p13. It consists of four exons, separated by three introns, encoding a predicted prohormone similarly organized to that of the GnRH1 precursor. However, the human *GnRH1* gene (5 kb) is longer than the *GnRH2* gene (2.1 kb) due to larger introns 2 and 3. The expression of the *GnRH1* and *GnRH2* genes is controlled by different promoters, suggesting different transcriptional regulations (White et al. 1998; Kim 2007). The two GnRH isoforms exhibit an overlapping pattern of tissue expression, which includes the central



**Fig. 2** Human GnRH gene consisting of four exons located on the short arm of chromosome 8. Exon 1 encodes a 5' untranslated region (5'UTR); Exon 2 encodes the 23 amino acid Signal Peptide (SP), the GnRH decapeptide, the GKR processing sequence, and initial 11 amino acid of the GnRH-associated peptide (GAP); Exon 3 encodes the next 32 amino acid of GAP; Exon 4 encodes the remainder of GAP and an 3'UTR

nervous system and the reproductive organs (ovary, prostate, endometrium, breast, and placenta) (Hong et al. 2008), but GnRH2 is also expressed more widely outside the CNS (Skinner et al. 2009). Indeed, the expression of GnRH2 is primarily detectable in the kidney, prostate, and bone marrow, suggesting both reproductive and nonreproductive roles for this isoform. On the other hand, GnRH1 immunoreactivity is detected not only in the hypothalamus but also in some specific human pituitary cell types, such as thyrotropes and somatotropes, thus indicating a possible supplementary role in the pituitary. Moreover, GnRH2 neurons do not show the same origin of GnRH1 neurons in the olfactory placode and, to a lesser extent, the neural crest (see also below), and the two neuronal populations undergo different regulation by gonadal steroids (Khosravi and Leung 2003).

The short half-life (approximately few minutes) is due to its rapid cleavage exerted by specific peptidases. Since GnRH is rapidly degraded and largely diluted, it is not possible to precisely measure it in the peripheral bloodstream once it has left the hypophyseoportal circulation. Thus, in humans, the measurement of the two gonadotropins (LH and FSH) is commonly used in the clinical practice as marker of the regular GnRH hypothalamic secretion. Of the two gonadotropins, LH pulses more accurately mirror the GnRH pulses in frequency and amplitude, as also demonstrated in the ewes (Clarke and Cummins 1985), because the longer half-life of FSH can mask FSH secretory troughs between pulses.

## Development and Migration of GnRH-Secreting Neurons

Despite their anatomical position within the adult brain, during development GnRH neurons have an extracranial origin. The embryonic development of these cells, which is a conserved process that involves few hundred neurons per hemisphere in

mice (a few thousand in humans), has been extensively studied in mice and other species and is extremely important for the establishment and maintenance of reproduction (Wray 2010). Such studies have highlighted the physical and molecular connection of GnRH neurons with the olfactory system. Thus, GnRH neurons, which can be visualized on sections with *in situ* hybridization and/or immunohistochemistry protocols, are first detected in mice in the nasal placode, a structure which gives rise to the vomeronasal organ (VNO) and the olfactory epithelium at around embryonic day (E) 10.5. Whether GnRH neurons originated entirely within the nasal placode, or were just associated with this region, was for a long time a theme of debate; the current prevailing view is that neural crest-, as well as placodal-derived, cells also contribute to the mature GnRH neuron population.

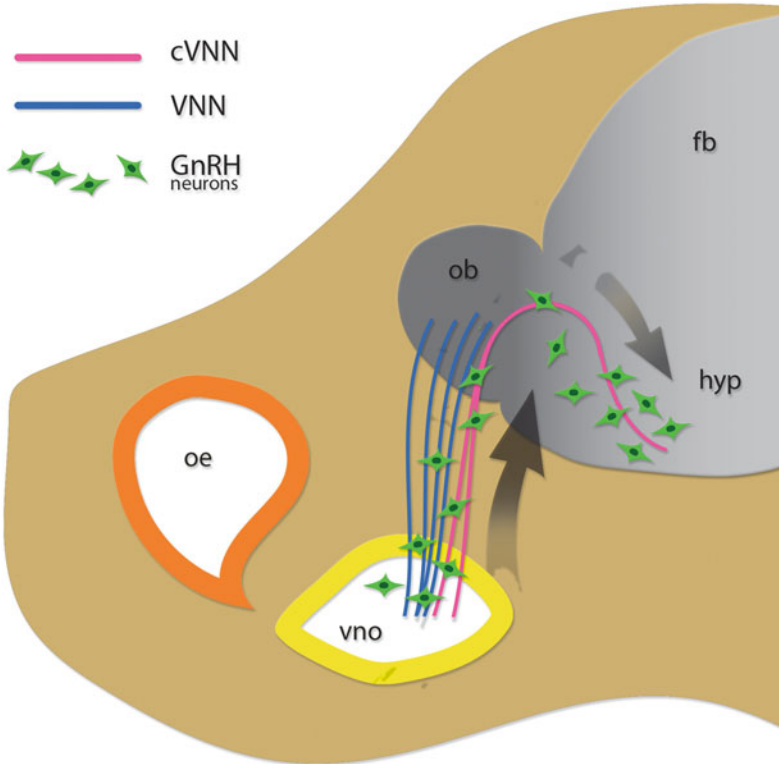
Following fate specification, GnRH neurons migrate in association with axons of the olfactory/terminal/vomeronasal nerves within the nasal section to reach their definitive position in the forebrain (Hutchins et al. 2013). It is also well established that GnRH neurons co-migrate with other cell populations including other neurons (Fornaro et al. 2003) and neural crest-derived olfactory ensheathing cells (OECs) (Geller et al. 2013; Raucci et al. 2013).

Specifically, GnRH neurons first migrate within the nasal compartment along the intermingled olfactory and terminal-vomeronasal axons, whose cell bodies are located in the olfactory epithelium (OE) and VNO, respectively. Then, once they have reached the nasal-forebrain junction, GnRH neurons make a pause and enter the brain close to the olfactory bulbs. Within the brain, GnRH neurons associate with a transient axonal scaffold, formed by the caudal ramification of the vomeronasal nerve (Fig. 3), which drive the neurons toward the future hypothalamus, where they will set, in mice, at around E18.5. GnRH neuron migration is axophilic, in which the axons of the olfactory and vomeronasal nerves form a scaffold along which GnRH neurons migrate (Marin and Rubenstein 2003). The development of the GnRH-neuroendocrine system is also dependent on the olfactory system. In mammals, olfaction depends on sensory neuronal cells located in the OE and in the VNO, two epithelial structures present in the nose (Mombaerts 2001). The sensory neurons located in the OE are specifically detecting volatile substances and provide information on the external environment. Instead, the neurons placed in the VNO, at least in animals, perceive pheromones, which are not volatile chemicals that mediate reproductive and social behaviors, as well as changes in the neuroendocrine system.

Olfactory neurons send their axons to the principal olfactory bulb, where they are connecting with tufted and mitral cells to form the “glomeruli” (Farbman and Buchholz 1992). Similarly, the vomeronasal neurons are projecting to the accessory olfactory bulb. In humans, it has been recently reported the existence of a potential VNO, which role is still controversial (Dulac and Axel 1995; Stern and McClintock 1998).

Despite the possible functional role of the VNO in humans, it is now established that GnRH neuron maturation and therefore fertility depend on olfactory and vomeronasal neuron development.

In addition to extending olfactory and vomeronasal neuron axons, other cells leave the nasal placode and migrate toward the forebrain. Altogether, the migratory



**Fig. 3** Schematic drawing of a mouse sagittal section showing the migration of GnRH neurons (green cells), olfactory ensheathing cells (OECs, blue cells), and the patterning of olfactory and vomeronasal axons (orange, pink, and blue lines), emerging from the olfactory epithelium (oe) and the vomeronasal organ (vno). To enter the forebrain (fb) and position in the hypothalamus (hyp), GnRH neurons follow the caudal branch of the vomeronasal nerve (cVNN)

cells and the extending axons form the so-called migratory mass. A first population of GnRH-negative neurons emerges from the nasal placode before the extension of olfactory axons; the role of these early migratory cells is to establish a scaffold used by the extending olfactory axons later on (Croucher and Tickle 1989; De Carlos et al. 1995; Maier and Gunhaga 2009). Cell populations that migrate later include GnRH neurons, OMP-positive and acetylcholine esterase-positive cells, and glial OECs (De Carlos et al. 1995; Miller et al. 2010).

OECs are the glial cell component of the olfactory system and derive from neural crest. Recent studies (Barraud et al. 2013; Geller et al. 2013) have highlighted that OECs form a microenvironment suitable for GnRH neuron migration, by secreting trophic factors; these cells also ensheath olfactory neurons and regulate their fasciculation/defasciculation and subsequently the correct formation of the scaffold along which GnRH neurons migrate.

Interestingly, the discovery of OECs as neural crest derivatives is offering novel insights into the etiopathogenesis of human diseases such as Kallmann syndrome (KS) that, besides GnRH deficiency, often displays several neural crest defects.

In humans, the time of GnRH neuron appearance and their pattern of migration have been determined by performing immunolocalization studies on human embryos (Schwanzel-Fukuda et al. 1996). In embryos of 42 days of development, GnRH immunoreactivity is revealed in epithelial cells of the medial nasal placode, in cells along the terminal nerve in the nasal septum with a similar trajectory observed in mouse embryos toward the forebrain. Concomitant to the migrating GnRH neurons, bundles of fibers expressing the adhesion molecule N-CAM and serving as guides for migrating GnRH neurons are found to elongate from the olfactory pit into the forebrain.

Further evidence of the origin and initial migration of GnRH neurons arises from the analysis of a human fetus, the single so far analyzed, carrying a mutation in the *KAL1/ANOS1* gene, which causes the X-linked form of KS; in this fetus, GnRH neurons did not enter the forebrain, and they gathered together in the cribriform plate in a tangle of neurons and olfactory/vomer nasal nerves (Schwanzel-Fukuda et al. 1989).

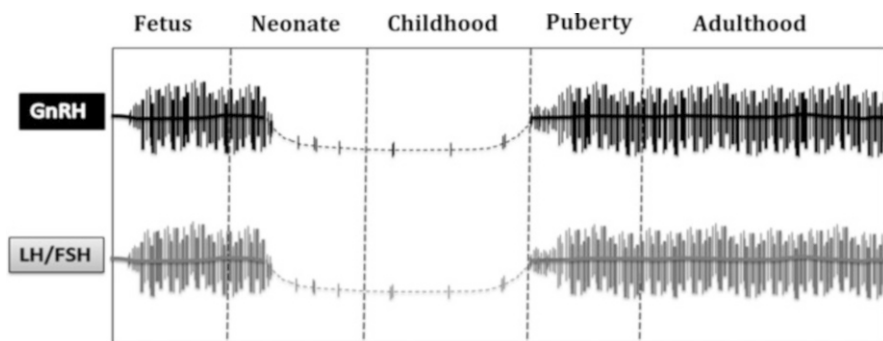
Besides *KAL1/ANOS1* other causal genes have been discovered so far in patients with GnRH deficiency (Vezzoli et al. 2016), and they account, altogether, for only 35–45% of the cases. This is because genetic linkage studies have proven difficult to identify further causative genes, as most pedigrees are small due to infertility, and because sporadic mutations cannot be identified with this technique. Thus, researchers in the field have adopted different experimental paradigms, including immortalized GnRH neuron cell lines (Cariboni et al. 2004), nasal explants (Fueshko and Wray 1994; Tobet et al. 1996) and genetically modified mouse models, to study the molecular mechanisms of GnRH neuron development and, ultimately, to predict new candidate causative genes underlying the etiopathogenesis of KS and hypogonadotropic hypogonadism (HH). These studies have identified some of the molecular mechanisms that directly or indirectly regulate GnRH neuron development: these include transcription factors, i.e., *Ebf2* (Corradi et al. 2003), neurotransmitters, i.e., GABA (Wray et al. 1996), adhesion molecules, i.e., N-CAM (Yoshida et al. 1999), and classical secreted cues such as semaphorins (Giacobini et al. 2008; Cariboni et al. 2011, 2015; Messina et al. 2011), Slits (Cariboni et al. 2012), ephrins (Gamble et al. 2005), and SDF-1 (Schwartz et al. 2006).

For example, by applying mouse models and cell lines, it has been recently proved that the semaphorin *SEMA3A* is playing a key role in axon guidance in mice during development of the GnRH neuron (Cariboni et al. 2011), and subsequently genetic variations in *SEMA3A* in patients with KS have been identified (Hanchate et al. 2012; Young et al. 2012). These and other studies (Pitteloud et al. 2010) show that genetic mouse models are esteemed tools to uncover new causal genes for HH/KS and, when combined to next-generation sequencing (NGS) techniques, will help to validate the functional relevance of the novel genes in the GnRH system.

## GnRH-Secreting Neuron Function and GnRH Secretion

### Pulsatile GnRH Secretion Throughout Lifespan

The activity of human GnRH-secreting neurons is detectable in the hypothalamus by the tenth week of gestation followed by secretion of the two gonadotropins, which are present by the 10th–13th week of gestation when the hypophyseal portal system has developed (Fig. 4). Their secretion continues until the mid-gestation period when the typical surge of the placental steroids, via a negative feedback mechanism, causes a decrease, which is maintained until delivery. Indeed, after birth, the lack of this inhibition gives rise to a new surge in GnRH secretion. This central stimulation of the HPG axis is typical of the first 12–24 or 6 months of life in girls and boys, respectively, and it is so-called minipuberty. Subsequently and due to inhibitory mechanisms that are not fully understood and might involve the neurotransmitters  $\gamma$ -aminobutyric acid (GABA) and the neuropeptide Y (NPY), GnRH, LH, and FSH levels decrease and remain suppressed until puberty (Fig. 4) (Waldhauser et al. 1981; Blogowska et al. 2003). At puberty, GnRH and gonadotropin secretion resumes with a typical pulsatile manner, which is controlled by the GnRH pulse generator. The neurobiological origins and the precise location of this pulse generation are not yet fully elucidated. Recent work supports two possible hypotheses: (i) the GnRH-secreting neurons are able to generate autonomously the secreting pulses; (ii) the pulse generator is due to the influence of peptidergic neurons usually positioned in the infundibular region (INF) and in the hypothalamic arcuate nucleus (ARC) (Piet et al. 2015; Plant 2015). The pulsatile secretion of GnRH at puberty begins first at night with a low amplitude and slow frequency, and then both amplitude and frequency increase during pubertal development to achieve the normal pattern in adulthood (Fig. 4) (McCartney 2010). In adult men, GnRH secretion is characterized by pulses occurring approximately every 2 h, whereas in the fertile female, the frequency of GnRH pulse is more complicated and is intrinsically dependent on the timing of the ovulatory cycle. GnRH pulsatility is crucial in regulating the synthesis, secretion, and ratio release of the two gonadotropins from



**Fig. 4** Representation of the GnRH pulsatile secretion variation during the male lifespan

the pituitary (Fig. 4) (Reame et al. 1984; Nippoldt et al. 1989; Hall et al. 1992), and it is dependent on the fine-tuned modulation of the GnRH-secreting neurons as firstly demonstrated by Knobil and colleagues (Knobil 1992). Indeed, in patients affected by isolated GnRH deficiency, the substitutive use of pulsatile exogenous GnRH allows the pubertal development to occur (Marshall and Kelch 1979; Hoffman and Crowley 1982) and reproduces the hormonal changes normally seen in the menstrual cycle, thus stimulating the ovulation (Crowley and McArthur 1980). On the contrary, when GnRH is infused continuously, it is inhibiting the gonadotropin secretion, while the return to a pulsing stimulation is able to revert this negative effect. The molecular explanation for this phenomenon resides in the downregulation of the GnRHR (Loumaye and Catt 1982; Cheng et al. 2000; McArdle 2012), and this characteristic is currently used in the clinic to temporarily block the HPG axis through the administration of long-acting GnRH agonists. This downregulation of the GnRHR on the gonadotrope cells, when continuously stimulated, gives reason of the importance of the normal pulsatile GnRH secretion in order to induce the synthesis and release of the two gonadotropins from the pituitary.

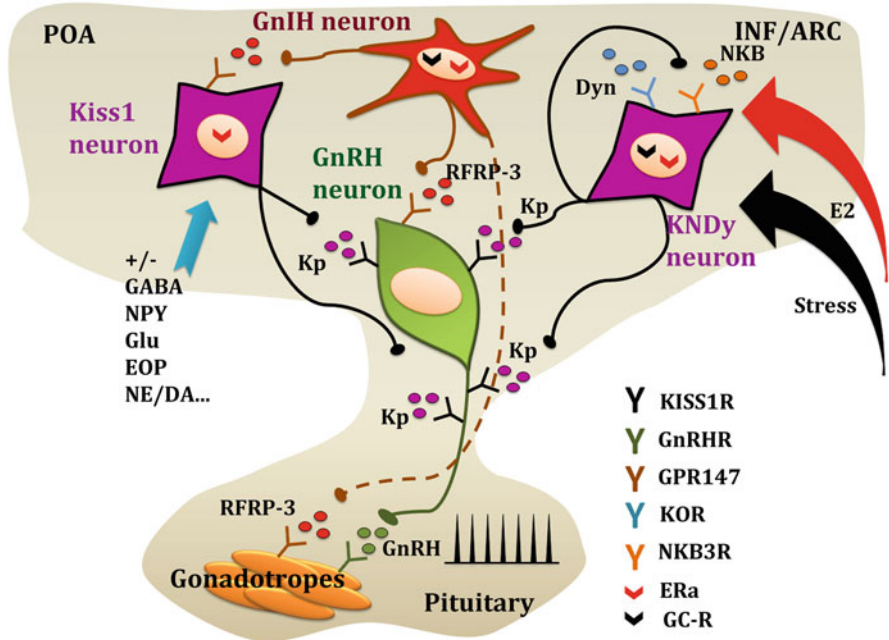
## Regulation of GnRH Secretion

The mechanisms regulating GnRH secretion are extremely complex. Studies on immortalized GnRH-secreting neurons (GT1) (Mellon et al. 1990), on primary GnRH neurons (Tobet et al. 1996; Maurer and Wray 1997), and in animal models (Negro-Vilar et al. 1982; Gore and Terasawa 1991; Levine et al. 1995) show that GnRH secretion is modulated by a network of excitatory and inhibitory inputs that include either a central control exerted by distinct subgroups of neurons afferent to the GnRH-secreting neurons or the peripheral gonadal steroid feedback (Fig. 5) (Ojeda et al. 2006; Christian and Moenter 2010; Herbison 2016).

### Central Control by Kisspeptin Neuronal System

The identification of the hypothalamic kisspeptin neuronal network has deeply changed our perceptions of the control and activation of GnRH-secreting neurons at puberty. Indeed, kisspeptin (formerly known as metastin) is a strong activator of the hypothalamic-pituitary-gonadal axis in humans and animal models. It is encoded by the *KISS1* gene (chromosome 1q32) which consists of two untranslated and two coding exons. *KISS1* gene encodes a precursor of 145 amino acid, which cleavage generates a 54 amino acid peptide (West et al. 1998), subsequently processed in two smaller fragments, kisspeptin-13 and kisspeptin-14. Kisspeptin binds to GPR54 (now termed KISS1R) (Gottsch et al. 2004), described both in the rat and in human brain (Lee et al. 1999; Muir et al. 2001; Ohtaki et al. 2001). The five exons of the *KISS1 receptor* gene (chromosome 19p13.3) encode for a 398 amino acid G-protein-coupled receptor (Muir et al. 2001). Kisspeptin-mediated KISS1R activation (Muir et al. 2001; Liu et al. 2008; Constantin et al. 2009) determines a biphasic surge of cytosolic  $Ca^{2+}$  concentration with a more persistent second phase (Min et al. 2014). In order to support this second phase and to prevent receptor desensitization





**Fig. 5** Summary of the physiological mechanisms possibly involved in the control of GnRH secretion and its action on gonadotrope cells. *POA* preoptic area, *INF* infundibular region, *ARC* arcuate nucleus, *Kp* Kisspeptin, *NKB* neurokinin B, *DYN* dynorphin, *RFRP-3* RFamide-related peptide, *E2* estradiol, *GABA* gamma aminobutyric acids, *NPY* neuropeptide Y, *NA* noradrenaline, *EOP* endogenous opioid peptides, *NE/DA* Norepinephrine/Dopamine, *KISS1R* Kiss1 receptor, *GnRHR* GnRH receptor, *GPR147* RFP-3 receptor, *KOR* kappa-opioid receptor, *NKB3R* neurokinin B receptor, *ER $\alpha$*  estrogen receptor alpha, *GC-R* Glucocorticoid receptor.

following the first activation, an intense KISS1R trafficking is needed (Min et al. 2014).

The key role played by kisspeptin system became evident from studies performed in a model of human disease which is represented by patients with congenital GnRH deficiency. Indeed, patients with inactivating allelic variants of either *KISS1R* or *KISS1* resulted in idiopathic hypogonadotropic hypogonadism (de Roux et al. 2003; Seminara et al. 2003; Topaloglu et al. 2012). This evidence was supported by studies in knockout mouse models for either the *Kiss1r* or the *Kiss1* genes, which phenotype the human GnRH congenital deficiency (d'Anglemont de Tassigny et al. 2007; Lapatto et al. 2007; Chan et al. 2009). Thus, the crucial importance of the kisspeptin effect on the GnRH secretion became evident across mammalian species. Moreover, clinical studies involving the administration of kisspeptin to both healthy controls and patients with idiopathic hypogonadotropic hypogonadism further confirmed the importance of the kisspeptin system in the control of the GnRH neuron activity (Dhillon et al. 2005; Jayasena et al. 2009, 2010, 2011; George et al. 2011; Chan et al. 2012; Young et al. 2013). Indeed, the acute injection of exogenous kisspeptin is able

to induce the rise of LH and FSH in male healthy volunteers, while its action in female is variably dependent on the period of the menstrual cycle. Furthermore, non-chronical administration of kisspeptin (in order to avoid the receptor desensitization) is also effective in stimulating GnRH secretion in men with acquired hypogonadotropic hypogonadism associated with obesity and type 2 diabetes (George et al. 2010) and in female with hypothalamic amenorrhea (Jayasena et al. 2010).

### **Kisspeptin Neurons**

The majority of the studies on the Kisspeptin system have been performed in rodents, but many correlations with higher mammals have been found. Kisspeptin neurons are positioned in the infundibular (INF)/arcuate (ARC) nucleus in all species and in the rostral preoptic area (POA) with a species-specific distribution (Clarkson and Herbison 2006; Pompolo et al. 2006; Ramaswamy et al. 2008; Clarkson et al. 2009; Hrabovszky et al. 2010): in rodents, they are positioned in the periventricular nucleus (PeN) and the anteroventral periventricular nucleus (AVPV) (Clarkson and Herbison 2006; Clarkson et al. 2009), while in humans and ruminants, their cell bodies are more sprinkled within the POA (Pompolo et al. 2006; Rometo et al. 2007; Oakley et al. 2009; Hrabovszky et al. 2010). Moreover, in humans there is also a sexual dimorphism in respect to the kisspeptin neuron distribution and numerosity. Female hypothalamus have considerably more kisspeptin fibers and cell bodies in the INF nucleus compared to men hypothalamus (Hrabovszky et al. 2010). Furthermore, kisspeptin cells are detected in the rostral periventricular area only in female (Hrabovszky et al. 2010). This different hypothalamic architecture of the kisspeptin system in male and female, as discussed in the next section of the chapter, has been linked to the different effect of the sex steroids on this cell population.

Kisspeptin neurons may act both directly or transsynaptically through neurotransmitters (Skorupskaite et al. 2014). The close proximity between the kisspeptin- and GnRH-secreting neurons seen in rodents, sheep, and monkeys was also seen in humans, where kisspeptin axons form dense pericapillary plexus in the pituitary stalk, engaging contacts with the GnRH neuron cell body, axons, and dendritic spine (Hrabovszky et al. 2010) (Fig. 5). However, in humans the occurrence of these connections seems lower, and not all GnRH neurons receive kisspeptin neuronal contacts (Clarkson and Herbison 2006; Ramaswamy et al. 2008; Smith et al. 2008a; Hrabovszky et al. 2010). This indicates a fine modulation of GnRH release by kisspeptin and other neuropeptides. Indeed, in the hypothalamus an interconnected and composite system of modulators of kisspeptin neurons has been identified, including neuroendocrine factors and sex steroids (see below), that guarantees the correct gonadotropic function (Fig. 5).

### **KNDy Neurons**

Inside the hypothalamus, two kisspeptin neuron populations are present with a differential expression of neuropeptides (Fig. 5) and distinct functions (Ojeda et al. 2010). In addition to neurons that exclusively express and secrete kisspeptin, there

are other neurons, designated as KNDy neurons (Cheng et al. 2010), which are co-expressing kisspeptin (KP), neurokinin B (NKB), and dynorphin (Dyn) (Lehman et al. 2010; Hrabovszky et al. 2012; Navarro 2012; Skrapits et al. 2015). KNDy neurons are preserved among species and are localized in the ARC nucleus of sheep and rodents and in the corresponding INF region of humans (Burke et al. 2006; Goodman et al. 2007; Navarro et al. 2009). The three secreted KNDy neuropeptides shape kisspeptin secretion through paracrine/autocrine action, operating in a coordinated fashion (Fig. 5). KNDy neurons in the ARC form a complex system where individual neurons are interconnected to each other and project the median eminence (ME) (Lehman et al. 2010). Moreover in humans it was observed that KNDy neurons are in straight relationship with GnRH neuron cell body and dendrites (Ciofi et al. 1994; Krajewski et al. 2005; Clarkson and Herbison 2006; Ramaswamy et al. 2008; Dahl et al. 2009). This distribution suggests that KNDy neurons located in ARC/INF act as a central hub for the regulation of GnRH release. They stimulated GnRH neurons via the release of kisspeptins, but they also participate in the mutual (auto)-regulation of kisspeptin system through the secretion of NKB and Dyn (Navarro et al. 2009; Wakabayashi et al. 2010). NKB pathway is able to stimulate LH release, which mirrors GnRH release (Billings et al. 2010; Navarro et al. 2011). These stimulatory activities are in accordance with the altered reproductive defects observed in TAC3- and TACR3-mutated patients (Topaloglu et al. 2009; Gianetti et al. 2010; Young et al. 2010). In contrast, dynorphin, working via K-opioid receptors (KOR), exerts its inhibitory control on pulsatile GnRH release (Wakabayashi et al. 2010) by mediating the negative feedback of progesterone, as discussed in the next section (Goodman et al. 2004; Foradori et al. 2005). Additionally, although the principal target of kisspeptin stimulation pathway is the control of GnRH secretion (Gottsch et al. 2004; Irwig et al. 2004; Smith et al. 2008b), the expression of *KISS1* and *KISS1R* genes in the gonadotropes suggests a possible direct effect of kisspeptin on gonadotrope functionality. Indeed some studies have demonstrated that pituitary explants stimulated with kisspeptin secrete gonadotropins (Kotani et al. 2001; Navarro et al. 2005; Gutierrez-Pascual et al. 2007; Richard et al. 2008) and that in the sheep low amount of kisspeptin is present in the pituitary portal vessels (Smith et al. 2008b).

### **Gonadal Steroid Regulation**

Another important mechanism that controls dynamically the GnRH synthesis and release from the GnRH-secreting neurons is represented by the gonadal steroid feedback. Indeed, in both sexes the severe deprivation of estrogens (E), androgens (A), and progesterone (P), such as in human females menopause, after castration or due to gonadal dysgenesis, triggers an increase in the secretion of GnRH and of gonadotropins, which, in turn, is controverted by the substitutive therapy (Kalra and Kalra 1989; Herbison 2016). The idea that sex steroids modulate the release of GnRH and gonadotropins was postulated for the first time in the 1930s, although several aspects concerning their precise molecular mechanisms of action are still not fully understood. Whether the sex steroids exert their regulatory functions on the GnRH neurons directly or through intermediate connected pathways or neurons is

still debated. Direct action of gonadal steroids on the GnRH cells would imply the expression of specific receptors. Indeed, estrogens bind to two specific nuclear receptors isoforms: the estrogen receptor alpha (ER $\alpha$ ) and the estrogen receptor beta (ER $\beta$ ), but the presence of the ER $\alpha$  on the GnRH-secreting neurons is still debated, and only recently some studies were detecting the ER $\alpha$  mRNA in these cells (Herbison and Pape 2001; Hu et al. 2008). In addition, after the discovery of a second ER isoform, the ER $\beta$  (Kuiper et al. 1996; Mosselman et al. 1996), a small subgroup of GnRH neuron, was found to express this isoform (Butler et al. 1999; Skynner et al. 1999; Hrabovszky et al. 2000; Kallo et al. 2001). Moreover, in vitro studies have demonstrated the presence of ERs in the immortalized GT1 cell line. Therefore, it is also possible that GnRH neurons are temporally expressing the ERs, and the direct action of E on these neurons might exist only during embryogenesis and/or during the early stages of postnatal life. This possibility could be also extended to the A receptor, AR, which is not expressed in vivo in GnRH neurons (Huang and Harlan 1993), while detectable in vitro in the GT1 cells (Poletti et al. 1994; Belsham et al. 1998). Nevertheless, regarding the effects of A on GnRH secretion, we have to consider that testosterone is enzymatically converted through a specific aromatase into E, which is mediating its principal negative effect on the HPG axis. Lastly, even the expression of the P receptor, PR, on the GnRH neurons is still controversial, thus keeping open the question whether the P regulatory effect is directly exerted on GnRH neurons or indirectly through neuronal intermediates. P is important in the regulation of the GnRH secretion at the hypothalamic level (Ramirez et al. 1980; Kim et al. 1989), although its action occurs mainly at the pituitary level where, acting in synergy with E, it induces a full gonadotrope response to GnRH (Nippoldt et al. 1987; Mahesh and Brann 1998).

Following the characterization of the kisspeptin system, further important improvements in our comprehension of the central control of reproduction became possible, including the elucidation of the molecular mechanisms underlying the sex steroid feedback on GnRH neuronal activity. Indeed, kisspeptin system is implicated in the transmission of both negative and positive feedback of sex steroids on GnRH neurons. Accordingly the majority of the hypothalamic kisspeptin-secreting cells, including KNDy neurons, express ER $\alpha$ , AR, PR, and, in a small proportion, ER $\beta$ , while GnRH neurons do not (Smith et al. 2005a, b, 2006, 2007, Franceschini et al. 2006; Adachi et al. 2007; Clarkson et al. 2008, 2012). Moreover, *Kiss1* mRNA expression level in the ARC/INF is upregulated following gonadectomy, in accordance with the rise of the gonadotropins levels, while this effect is prevented by the estradiol replacement (Smith et al. 2006; Adachi et al. 2007; Clarkson et al. 2008; Oakley et al. 2009; Lehman et al. 2010). Additionally, KissR inactivation, either as in the KO animal model (Dungan et al. 2007) or in the presence of a specific Kiss1 antagonist (Roseweir et al. 2009), mitigates the rise in circulating LH after gonadectomy. The E negative feedback on the kisspeptin system is mainly dependent upon ER $\alpha$ . Indeed, the administration of an ER $\alpha$ -selective agonist suppresses Kiss1 mRNA expression and LH blood concentrations in castrated animals (Navarro et al. 2004), while the LH increase after castration is absent only in the ER $\alpha$  KO mice and still present in the ER $\beta$  null mice (Dungan et al. 2007). Thus, E exerts its

negative feedback on the kisspeptin system, mainly through the ER $\alpha$ , by inhibiting kisspeptin and neurokinin B secretion, which, in turn, lowers their synergic stimulation on the GnRH neurons (Fig. 5). Moreover, dynorphin, which is normally co-secreted with kisspeptin and neurokinin B from the KNDy neurons, is able to inhibit GnRH pulsatility following progesterone administration, while the progesterone receptor expression is upregulated from the E (Nippoldt et al. 1989; Soules et al. 1984). Thus, E also mediates the inhibiting effect on the GnRH secretion by enhancing the dynorphin secretion and action.

The E negative feedback effect so far described is dependent on constant low levels of the hormone, since it is well known that a rapid increase in estradiol levels, such as at the end of the follicular phase in the female menstrual cycle, accompanied by the upregulation of the PR, characteristically switches the feedback from inhibitory (negative feedback) to stimulatory (positive feedback). This E positive feedback is a key point in the determination of the GnRH preovulatory surge which allows the LH peak and the following ovulation. The neuroendocrine mechanisms based on such positive feedback of E are less well characterized, compared to the negative ones, and appear to be more site- and species-specific. Experimental data in humans and animal models indicate that at least a subgroup of kisspeptin-secreting neurons plays a key role in mediating the E positive feedback. Indeed, in humans, the administration of kisspeptin, instead of hCG, was effective in generating the ovulatory LH surge and in triggering the oocyte maturation (Jayasena et al. 2010). A more precise characterization of this positive feedback comes from experimental data on female rodents (Roa et al. 2009). In these animal model, estradiol is able to enhance the *Kiss1* mRNA level in the AVPV/RPV3 nucleus (Smith et al. 2005b), and this is associated with the observation that AVPV kisspeptin neurons are stimulated during the preovulatory sex steroid-induced LH surge (Smith et al. 2006). Further, these kisspeptin neurons in the AVPV are connected with the GnRH neurons (Clarkson and Herbison 2006), and the offsetting of kisspeptin in the POA eliminates the preovulatory LH peak (Kinoshita et al. 2005). Furthermore, the KO animal models for *Kiss1* and *Kiss1R* genes are characterized by an anovulatory state, and specific kisspeptin antagonists are able to markedly inhibit the gonadotropin preovulatory surge (Pineda et al. 2010a). Altogether these data indicate a key role of the kisspeptin neurons of the AVPV hypothalamic nucleus in mediating the positive feedback control of the GnRH secretion in rodents. In humans, the homologous of the AVPV kisspeptin neurons has so far not been identified (Rometo et al. 2007; Oakley et al. 2009). Nevertheless, this sexual dimorphism, observed in the kisspeptin pathway in the INF region, might be related to E positive feedback. Indeed, E positive feedback occurs only in females, where the system appears more represented and might be constituted by distinct kisspeptin neurons mediating the negative or the positive E feedback on the GnRH secretion. As for the positive feedback, the effect seems to be mediated by the ER $\alpha$  since the selective elimination of this signaling in the kisspeptin cells in vivo is associated with a lack of the E action on the AVPV neurons and subsequently the absence of ovulation (Mayer et al. 2010).

To summarize the data so far accumulated regarding the sexual steroid action on the GnRH secretion, we can conclude that the negative and positive feedbacks are

surely mediated by the kisspeptin system, although a certain direct effect through specific receptors has to be considered and might be better characterized in the future.

### Neurotransmitters and Neuropeptide Regulation

As demonstrated either *in vivo* or *in vitro*, the GnRH secretion and pulsatility is also modulated by local release of different neurotransmitters and neuropeptides, which are also interrelated with other control systems such as the KNDy neurons and the gonadal steroids.

Two of the first neurotransmitters able to stimulate the GnRH secretion are represented by norepinephrine and dopamine (Herbison 1997). The initial evidence came from *in vitro* studies of the GT1 GnRH neuron cell line that expresses  $\beta$ 1-adrenergic and D1-dopaminergic receptors and whose activity is pharmacologically interfered by the treatment with specific agonists and antagonists of the so far mentioned receptors (Martinez de la Escalera et al. 1992; Findell et al. 1993; Uemura et al. 1997). Subsequently, experimental data in humans and primates have confirmed the modulation of the GnRH pulsatile secretion by norepinephrine and dopamine also *in vivo*. Indeed, the  $\alpha$ -adrenergic receptor blocking agents (i.e., phentolamine or prazosin) and the dopamine antagonist (i.e., metoclopramide) are able to arrest or at least inhibit the GnRH pulse generator in ovariectomized rhesus monkey (Kaufman et al. 1985; Gearing and Terasawa 1991). Furthermore, in humans, while the administration of dopamine and its agonists has been shown to be able to decrease the mean LH circulating levels, the  $\alpha$ -adrenergic receptor blocking agents do not alter the LH pulsatile frequency (Leblanc et al. 1976; Lachelin et al. 1977; Pehrson et al. 1983).

Glutamate represents another important excitatory neurotransmitter in the hypothalamus, and its role in the stimulation of the GnRH secretion has been demonstrated in several species (Goldsmith et al. 1994; Dhandapani and Brann 2000; Gore 2001; Ottem et al. 2002; Lin et al. 2003; Pompolo et al. 2003). Glutamate mediates its role by binding to the N-methyl-D-aspartate (NMDA) receptors which are expressed on GnRH neurons (Gore 2001). Additionally, since the GABA agonists and the opioids agents are able to act at presynaptic NMDA receptor to inhibit the glutamate exocytosis (Potashner 1979; Weisskopf et al. 1993), an interaction between the glutamate and the opioid neurons may occur in the regulation of the GnRH control (Brann and Mahesh 1997). Indeed, in GT1 cells, GABA<sub>A</sub> and GABA<sub>B</sub> NMDA receptors have been identified (Stojilkovic et al. 1994).

GABA, in contrast to the previously described stimulatory neurotransmitters, inhibits GnRH secretion through the binding of the GABA<sub>A</sub> receptor (Urbanski and Ojeda 1987; Herbison 1998). This was demonstrated both *in vivo* and *in vitro* experimental models following the treatment with specific agonist and antagonist of the GABA<sub>A</sub> receptor (Li and Pelletier 1993; Leonhardt et al. 1995; Han et al. 2004).

Among the different neuropeptides, an important inhibitory role on the GnRH secretion is surely played by the opioids (Kalra and Kalra 1984; Grosser et al. 1993). Indeed, *in vitro* experimental evidences revealed that opioids weaken the adrenergic stimulation on GT1 cell line (Nazian et al. 1994), and this inhibitory effect can be solved by the use of the opiate antagonist, naloxone (Ferlin et al. 1982; Van Vugt

et al. 1989; Williams et al. 1990). Moreover, the in vivo data demonstrate that the activation of endogenous opioids mediate the suppression of the GnRH secretion following the treatment with corticotropin-releasing hormone (CRH) (Knobil 1989; Williams et al. 1990), although this effect was not observed in humans (Fischer et al. 1992).

Neuropeptide Y (NPY), galanin, and aspartate represent other putative neuromodulators of the GnRH system, although only the last one stimulates directly the GnRH pulse generator, whereas the first two are gonadal steroid dependent for their action (Woller and Terasawa 1992; Brann et al. 1993). Indeed, studies on the effect of NPY on the GnRH secretion reveal a complex picture. Central injection of NPY in intact animal (or castrated animal substituted with sex steroids) leads to the stimulation, while in castrated animal to the inhibition of the GnRH secretion. This bimodal action of NYP on the GnRH system is then sex steroid dependent. Nevertheless, the *NPY* null animal models present a relatively normal reproductive function, indicating that the role played by NPY in reproduction is only one of several inputs and it is part of a highly redundant network.

Another important peptide in regulating the GnRH secretion is leptin, a peptide hormone secreted by the adipose tissue that helps to regulate the energy balance and mirrors the amount of energy reserve. Thus, leptin might play a key role either by signaling to the central nervous system the information regarding the amount of fat stores that are present or by enabling the activation of the HPG axis through the GnRH secretion when convenient. Specifically, it has been demonstrated that leptin is able to stimulate the GnRH secretion either increasing the release of aspartate or reducing the release of GABA in peri-pubertal rats, whereas in the prepubertal rats, it increases the release of GABA (Reynoso et al. 2003). Furthermore, the exogenous replacement therapy with leptin in leptin-deficient prepubertal girls results in a LH/FSH secretory pattern consistent with an early puberty, thus confirming the stimulation of the GnRH secretion (Farooqi et al. 1999).

## GnIH

The neuronal network that regulates the HPG axis is additionally complicated by gonadotropin inhibitory hormone (GnIH), a novel neuropeptide capable of inhibiting gonadotropin synthesis and secretion, which was first identified in birds (Tsutsui et al. 2000). GnIH is synthesized as a 173 amino acid precursor that is proteolytically processed into three peptides, respectively, named GnIH, GnIH-1, and GnIH-2 (Satake et al. 2001). These peptides share a carboxyl-terminal LPXRF-amide structure, in which X might be replaced by L or Q. Two perfectly conserved peptides of the RF-amide family, RFRP-1 and RFRP-3, were also reported in mammals. Intriguingly, even if RFRP-1 peptide exhibits greater structural homology with GnIH (Kriegsfeld et al. 2006), the RFRP-3 appears as the mammalian functional ortholog of avian GnIH (Pineda et al. 2010b; Smith and Clarke 2010). Both RFRP-1 and RFRP-3 act primarily by binding NPF1R (also termed Gpr147), a G-protein-coupled receptor. Moreover the two peptides are able to signal binding the NPF2R receptor (also named Gpr74) (Clarke et al. 2009). In mammals RFRP-3 neurons are principally identified in the hypothalamic dorsomedial nucleus (DMN)

or adjacent areas, where they project to different districts of the hypothalamus, such as the ARC, the ventromedial nucleus (VMN), the lateral hypothalamus, and the paraventricular nucleus (PVN). It is well known that these regions play crucial functions in the regulation of fertility and energy equilibrium (Qi et al. 2009). In this scenario, recent experimental data suggest a possible function of GnIH/RFRP peptide as a connecting hub, together with leptin, between reproductive and metabolic homeostasis. Overall the pharmacological data so far available are in favor of an orexigenic role for RFRP-3. Considering that orexigenic mediators are turned on in negative energy balance conditions (e.g., to promote food intake), it is reasonable to suppose that RFRP mediates the suppression of reproductive function during an energy absence state (Clarke et al. 2012).

Even though the link between the GnIH/RFRP and the physiology of reproduction was described in animal models (Tsutsumi et al. 2010), a possible regulation of human pubertal development by the RFRP-3/GPR147 system was only recently suggested (Maggi et al. 2016). While the experimental evidences collected until now suggest a main inhibitory effect exerted by GnIH/RFRP on LH/FSH release among mammals, several arguments persist concerning the nature (stimulatory in some instance), preferential area of action (pituitary vs. hypothalamic), and significance (in relation with different neuropeptides) of the GnIH/RFRP network in the control of the hypothalamic-pituitary-gonadal axis (Fig. 5). Equally, the relationship between the RFRP and the other mediators with crucial roles in the physiology of reproduction, including kisspeptins (Fig. 5), was proposed, but additional evidence is required in order to have a complete picture of the main interaction and connections between GnIH/RFRP peptides and central/peripheral actors involved in the regulation of the hypothalamic-pituitary-gonadal axis.

### **Other Factors Influence on GnRH Regulation**

Other factors may influence the GnRH secretion including various stressors as infection, malnutrition, anxiety, depression, and chronic illness. Indeed, in humans and in animal models, acute fasting is able to induce infertility throughout the inhibition of the GnRH secretion (Bergendahl et al. 1998). Similar effect was demonstrated in animal models treated with intravenous lipopolysaccharide, a bacterial endotoxin that mimics an infectious stress (Takeuchi et al. 1997; Yoo et al. 1997; Refojo et al. 1998). Finally, men affected with prolonged critical illness present a decrease and a blunted 24 h pulsatile profile of the LH secretion, which causes a reduced androgen circulating levels with the settle of an acquired central hypogonadism (Van den Berghe et al. 1994).

All these chronic stressors trigger a rise in glucocorticoids, which are the classic endocrine response to stress. GC suppresses reproductive function at different levels of the HPG axis (Collu et al. 1984; Rabin et al. 1988) mainly through the inhibition of the GnRH secretion (Dubey and Plant 1985; Kamel and Kubajak 1987), which, in turn, leads to a reduced LH release (Briski and Sylvester 1991). This is consistent with the observation that in Cushing's disease, a disorder characterized by hypercortisolemia, the presence of an associated hypogonadism is a common aspect. Moreover, hypothalamic neurons are known to express the glucocorticoid receptor



(GC-R) (Chandran et al. 1994), and the treatment of the GT1 cell line with GC results in the inhibition of both the GnRH-mRNA levels and the transcriptional activity of transfected GnRH promoter-reporter gene vectors (Chandran et al. 1996). Additionally, the downregulation of the GnRH secretion exerted by the GC is mediated through the interaction with the GnIH/RFRP system (Fig. 5). Indeed, acute and chronic stress stimulates expression of RFRP in the adult male rat hypothalamus, where expression of RFRP and GC-R overlap (Kirby et al. 2009), and systemic administration of RFRP combined to stress suppresses the LH release and the sexual behavior. On the other hand, adrenalectomy prevents the stress-induced increase of the RFRP expression in the hypothalamus and in turn also the suppression of LH secretion.

On the opposite, in response to acute stress, endogenous GC may protect gonadotropin secretion (Matsuwaki et al. 2006). This is related to the secretion of prostaglandins (PGs) in the central nervous system, which inhibit the LH pulses, as reported in the case of several stress factors such as infections, hypoglycemia, and restriction (Konsman et al. 2004). The increased secretion of GC may balance the effects of stress-induced PG synthesis in order to support, instead to inhibit, the reproductive function in response to acute stress circumstances.

---

## Summary

Reproduction is crucial for species survival and is fully dependent on a complex axis involving different organs such as hypothalamus, pituitary, gonads, and genitalia. This network is controlled by neuroendocrine mechanisms which are not fully characterized but surely interacting at the hypothalamic level where relatively few neurons secrete the neurohormone GnRH. In the last decades, advances have been made to better understand the action of GnRH either in physiologic or pathologic conditions. Researchers are progressively starting to better understand which factors are mandatory for GnRH neuronal migration, the mechanisms involved in the starting of the pulsatile GnRH secretion at puberty, and the maintenance of the normal adult reproductive function.

---

## Cross-References

- ▶ [Anabolic and Metabolic Effects of Testosterone and Other Androgens: Direct Effects and Role of Testosterone Metabolic Products](#)
- ▶ [Androgen Receptor](#)
- ▶ [Androgen Resistance](#)
- ▶ [Classification and Epidemiology of Hypogonadism](#)
- ▶ [Clinical Manifestation and Diagnosis of Androgen Deficiency](#)
- ▶ [Delayed Puberty](#)
- ▶ [Estrogen Deficiency in Men](#)
- ▶ [Genetic Analysis in Male Infertility](#)

- ▶ [GnRH Action](#)
- ▶ [Gonadotropins](#)
- ▶ [Hormonal Laboratory Examination](#)
- ▶ [Primary and Secondary Hypogonadism](#)
- ▶ [Testicular Steroidogenesis](#)

---

## References

- Adachi S, Yamada S, Takatsu Y, Matsui H, Kinoshita M, Takase K, Sugiura H, Ohtaki T, Matsumoto H, Uenoyama Y, Tsukamura H, Inoue K, Maeda K. Involvement of anteroventral periventricular metastin/kisspeptin neurons in estrogen positive feedback action on luteinizing hormone release in female rats. *J Reprod Dev.* 2007;53(2):367–78.
- Amoss M, Burgus R, Blackwell R, Vale W, Fellows R, Guillemin R. Purification, amino acid composition and N-terminus of the hypothalamic luteinizing hormone releasing factor (LRF) of ovine origin. *Biochem Biophys Res Commun.* 1971;44(1):205–10.
- Baba Y, Matsuo H, Schally AV. Structure of the porcine LH- and FSH-releasing hormone. II. Confirmation of the proposed structure by conventional sequential analyses. *Biochem Biophys Res Commun.* 1971;44(2):459–63.
- Barraud P, John JAS, Stolt CC, Wegner M, Baker CV. Olfactory ensheathing glia are required for embryonic olfactory axon targeting and the migration of gonadotropin-releasing hormone neurons. *Biol Open.* 2013;2(7):750–9.
- Belsham DD, Evangelou A, Roy D, Duc VL, Brown TJ. Regulation of gonadotropin-releasing hormone (GnRH) gene expression by 5alpha-dihydrotestosterone in GnRH-secreting GT1-7 hypothalamic neurons. *Endocrinology.* 1998;139(3):1108–14.
- Bergendahl M, Aloji JA, Iranmanesh A, Mulligan TM, Veldhuis JD. Fasting suppresses pulsatile luteinizing hormone (LH) secretion and enhances orderliness of LH release in young but not older men. *J Clin Endocrinol Metab.* 1998;83(6):1967–75.
- Billings HJ, Connors JM, Altman SN, Hileman SM, Holaskova I, Lehman MN, McManus CJ, Nestor CC, Jacobs BH, Goodman RL. Neurokinin B acts via the neurokinin-3 receptor in the retchiasmatic area to stimulate luteinizing hormone secretion in sheep. *Endocrinology.* 2010;151(8):3836–46.
- Blogowska A, Rzepka-Gorska I, Krzyzanowska-Swiniarska B, Zoltowski S, Kosmowska B. Leptin, neuropeptide Y, beta-endorphin, gonadotropin, and estradiol levels in girls before menarche. *Gynecol Endocrinol.* 2003;17(1):7–12.
- Boler J, Enzmann F, Folkers K, Bowers CY, Schally AV. The identity of chemical and hormonal properties of the thyrotropin releasing hormone and pyroglutamyl-histidyl-proline amide. *Biochem Biophys Res Commun.* 1969;37(4):705–10.
- Brann DW, Mahesh VB. Excitatory amino acids: evidence for a role in the control of reproduction and anterior pituitary hormone secretion. *Endocr Rev.* 1997;18(5):678–700.
- Brann DW, Chorich LP, Mahesh VB. Effect of progesterone on galanin mRNA levels in the hypothalamus and the pituitary: correlation with the gonadotropin surge. *Neuroendocrinology.* 1993;58(5):531–8.
- Briski KP, Sylvester PW. Acute inhibition of pituitary LH release in the male rat by the glucocorticoid agonist decadron phosphate. *Neuroendocrinology.* 1991;54(4):313–20.
- Burgus R, Dunn TF, Desiderio D, Ward DN, Vale W, Guillemin R. Characterization of ovine hypothalamic hypophysiotropic TSH-releasing factor. *Nature.* 1970;226(5243):321–5.
- Burke MC, Letts PA, Krajewski SJ, Rance NE. Coexpression of dynorphin and neurokinin B immunoreactivity in the rat hypothalamus: morphologic evidence of interrelated function within the arcuate nucleus. *J Comp Neurol.* 2006;498(5):712–26.
- Butler JA, Sjoberg M, Coen CW. Evidence for oestrogen receptor alpha-immunoreactivity in gonadotrophin-releasing hormone-expressing neurones. *J Neuroendocrinol.* 1999;11(5):331–5.

- Cariboni A, Pimpinelli F, Colamarino S, Zaninetti R, Piccolella M, Rumio C, Piva F, Rugarli EI, Maggi R. The product of X-linked Kallmann's syndrome gene (KAL1) affects the migratory activity of gonadotropin-releasing hormone (GnRH)-producing neurons. *Hum Mol Genet.* 2004;13(22):2781–91.
- Cariboni A, Davidson K, Rakic S, Maggi R, Parnavelas JG, Ruhrberg C. Defective gonadotropin-releasing hormone neuron migration in mice lacking SEMA3A signalling through NRP1 and NRP2: implications for the aetiology of hypogonadotropic hypogonadism. *Hum Mol Genet.* 2011;20(2):336–44.
- Cariboni A, Andrews WD, Memi F, Ypsilanti AR, Zelina P, Chedotal A, Parnavelas JG. Slit2 and Robo3 modulate the migration of GnRH-secreting neurons. *Development.* 2012;139(18):3326–31.
- Cariboni A, Andre V, Chauvet S, Cassatella D, Davidson K, Caramello A, Fantin A, Bouloux P, Mann F, Ruhrberg C. Dysfunctional SEMA3E signaling underlies gonadotropin-releasing hormone neuron deficiency in Kallmann syndrome. *J Clin Invest.* 2015;125(6):2413–28.
- Chan YM, Broder-Fingert S, Wong KM, Seminara SB. Kisspeptin/Gpr54-independent gonadotropin-releasing hormone activity in Kiss1 and Gpr54 mutant mice. *J Neuroendocrinol.* 2009;21(12):1015–23.
- Chan YM, Butler JP, Sidhoum VF, Pinnell NE, Seminara SB. Kisspeptin administration to women: a window into endogenous kisspeptin secretion and GnRH responsiveness across the menstrual cycle. *J Clin Endocrinol Metab.* 2012;97(8):E1458–67.
- Chandran UR, Attardi B, Friedman R, Dong KW, Roberts JL, DeFranco DB. Glucocorticoid receptor-mediated repression of gonadotropin-releasing hormone promoter activity in GT1 hypothalamic cell lines. *Endocrinology.* 1994;134(3):1467–74.
- Chandran UR, Attardi B, Friedman R, Zheng Z, Roberts JL, DeFranco DB. Glucocorticoid repression of the mouse gonadotropin-releasing hormone gene is mediated by promoter elements that are recognized by heteromeric complexes containing glucocorticoid receptor. *J Biol Chem.* 1996;271(34):20412–20.
- Chavali GB, Nagpal S, Majumdar SS, Singh O, Salunke DM. Helix-loop-helix motif in GnRH associated peptide is critical for negative regulation of prolactin secretion. *J Mol Biol.* 1997;272(5):731–40.
- Cheng KW, Nathwani PS, Leung PC. Regulation of human gonadotropin-releasing hormone receptor gene expression in placental cells. *Endocrinology.* 2000;141(7):2340–9.
- Cheng G, Coolen LM, Padmanabhan V, Goodman RL, Lehman MN. The kisspeptin/neurokinin B/dynorphin (KNDy) cell population of the arcuate nucleus: sex differences and effects of prenatal testosterone in sheep. *Endocrinology.* 2010;151(1):301–11.
- Christian CA, Moenter SM. The neurobiology of preovulatory and estradiol-induced gonadotropin-releasing hormone surges. *Endocr Rev.* 2010;31(4):544–77.
- Ciofi P, Krause JE, Prins GS, Mazzuca M. Presence of nuclear androgen receptor-like immunoreactivity in neurokinin B-containing neurons of the hypothalamic arcuate nucleus of the adult male rat. *Neurosci Lett.* 1994;182(2):193–6.
- Clarke IJ, Cummins JT. GnRH pulse frequency determines LH pulse amplitude by altering the amount of releasable LH in the pituitary glands of ewes. *J Reprod Fertil.* 1985;73(2):425–31.
- Clarke IJ, Qi Y, Puspita Sari I, Smith JT. Evidence that RF-amide related peptides are inhibitors of reproduction in mammals. *Front Neuroendocrinol.* 2009;30(3):371–8.
- Clarke IJ, Smith JT, Henry BA, Oldfield BJ, Stefanidis A, Millar RP, Sari IP, Chng K, Fabre-Nys C, Caraty A, Ang BT, Chan L, Fraley GS. Gonadotropin-inhibitory hormone is a hypothalamic peptide that provides a molecular switch between reproduction and feeding. *Neuroendocrinology.* 2012;95(4):305–16.
- Clarkson J, Herbison AE. Postnatal development of kisspeptin neurons in mouse hypothalamus; sexual dimorphism and projections to gonadotropin-releasing hormone neurons. *Endocrinology.* 2006;147(12):5817–25.

- Clarkson J, d'Anglemont de Tassigny X, Moreno AS, Colledge WH, Herbison AE. Kisspeptin-GPR54 signaling is essential for preovulatory gonadotropin-releasing hormone neuron activation and the luteinizing hormone surge. *J Neurosci*. 2008;28(35):8691–7.
- Clarkson J, d'Anglemont de Tassigny X, Colledge WH, Caraty A, Herbison AE. Distribution of kisspeptin neurones in the adult female mouse brain. *J Neuroendocrinol*. 2009;21(8):673–82.
- Clarkson J, Shamas S, Mallinson S, Herbison AE. Gonadal steroid induction of kisspeptin peptide expression in the rostral periventricular area of the third ventricle during postnatal development in the male mouse. *J Neuroendocrinol*. 2012;24(6):907–15.
- Collu R, Gibb W, Ducharme JR. Effects of stress on the gonadal function. *J Endocrinol Investig*. 1984;7(5):529–37.
- Conn PM, Crowley Jr WF. Gonadotropin-releasing hormone and its analogs. *Annu Rev Med*. 1994;45:391–405.
- Constantin S, Caligioni CS, Stojilkovic S, Wray S. Kisspeptin-10 facilitates a plasma membrane-driven calcium oscillator in gonadotropin-releasing hormone-1 neurons. *Endocrinology*. 2009;150(3):1400–12.
- Corradi A, Croci L, Broccoli V, Zecchini S, Previtali S, Wurst W, Amadio S, Maggi R, Quattrini A, Consalez GG. Hypogonadotropic hypogonadism and peripheral neuropathy in *Ebf2*-null mice. *Development*. 2003;130(2):401–10.
- Croucher SJ, Tickle C. Characterization of epithelial domains in the nasal passages of chick embryos: spatial and temporal mapping of a range of extracellular matrix and cell surface molecules during development of the nasal placode. *Development*. 1989;106(3):493–509.
- Crowley Jr WF, McArthur JW. Simulation of the normal menstrual cycle in Kallman's syndrome by pulsatile administration of luteinizing hormone-releasing hormone (LHRH). *J Clin Endocrinol Metab*. 1980;51(1):173–5.
- d'Anglemont de Tassigny X, Fagg LA, Dixon JP, Day K, Leitch HG, Hendrick AG, Zahn D, Franceschini I, Caraty A, Carlton MB, Aparicio SA, Colledge WH. Hypogonadotropic hypogonadism in mice lacking a functional *Kiss1* gene. *Proc Natl Acad Sci U S A*. 2007;104(25):10714–9.
- Dahl SK, Amstalden M, Coolen L, Fitzgerald M, Lehman M. Dynorphin immunoreactive fibers contact GnRH neurons in the human hypothalamus. *Reprod Sci*. 2009;16(8):781–7.
- De Carlos JA, Schlaggar BL, O'Leary DD. Development of acetylcholinesterase-positive thalamic and basal forebrain afferents to embryonic rat neocortex. *Exp Brain Res*. 1995;104(3):385–401.
- de Roux N, Genin E, Carel JC, Matsuda F, Chaussain JL, Milgrom E. Hypogonadotropic hypogonadism due to loss of function of the *KISS1*-derived peptide receptor GPR54. *Proc Natl Acad Sci U S A*. 2003;100(19):10972–6.
- Dhandapani KM, Brann DW. The role of glutamate and nitric oxide in the reproductive neuroendocrine system. *Biochem Cell Biol*. 2000;78(3):165–79.
- Dhillon WS, Chaudhri OB, Patterson M, Thompson EL, Murphy KG, Badman MK, McGowan BM, Amber V, Patel S, Ghatei MA, Bloom SR. Kisspeptin-54 stimulates the hypothalamic-pituitary gonadal axis in human males. *J Clin Endocrinol Metab*. 2005;90(12):6609–15.
- Dubey AK, Plant TM. A suppression of gonadotropin secretion by cortisol in castrated male rhesus monkeys (*Macaca mulatta*) mediated by the interruption of hypothalamic gonadotropin-releasing hormone release. *Biol Reprod*. 1985;33(2):423–31.
- Dulac C, Axel R. A novel family of genes encoding putative pheromone receptors in mammals. *Cell*. 1995;83(2):195–206.
- Dungan HM, Gottsch ML, Zeng H, Gragerov A, Bergmann JE, Vassilatis DK, Clifton DK, Steiner RA. The role of kisspeptin-GPR54 signaling in the tonic regulation and surge release of gonadotropin-releasing hormone/luteinizing hormone. *J Neurosci*. 2007;27(44):12088–95.
- Farbman AI, Buchholz JA. Growth of olfactory epithelial tissue in vitro: lectin staining of axons. *Microsc Res Tech*. 1992;23(2):173–80.

- Farooqi IS, Jebb SA, Langmack G, Lawrence E, Cheetham CH, Prentice AM, Hughes IA, McCamish MA, O'Rahilly S. Effects of recombinant leptin therapy in a child with congenital leptin deficiency. *N Engl J Med*. 1999;341(12):879–84.
- Ferin M, Wehrenberg WB, Lam NY, Alston EJ, Vande Wiele RL. Effects and site of action of morphine on gonadotropin secretion in the female rhesus monkey. *Endocrinology*. 1982;111(5):1652–6.
- Findell PR, Wong KH, Jackman JK, Daniels DV. Beta 1-adrenergic and dopamine (D1)-receptors coupled to adenylyl cyclase activation in GT1 gonadotropin-releasing hormone neurosecretory cells. *Endocrinology*. 1993;132(2):682–8.
- Fischer UG, Wood SH, Bruhn J, Roseff SJ, Mortola J, Rivier JE, Yen SS. Effect of human corticotropin-releasing hormone on gonadotropin secretion in cycling and postmenopausal women. *Fertil Steril*. 1992;58(6):1108–12.
- Foradori CD, Goodman RL, Adams VL, Valent M, Lehman MN. Progesterone increases dynorphin concentrations in cerebrospinal fluid and preprodynorphin messenger ribonucleic acid levels in a subset of dynorphin neurons in the sheep. *Endocrinology*. 2005;146(4):1835–42.
- Fornaro M, Geuna S, Fasolo A, Giacobini-Robecchi MG. HuC/D confocal imaging points to olfactory migratory cells as the first cell population that expresses a post-mitotic neuronal phenotype in the chick embryo. *Neuroscience*. 2003;122(1):123–8.
- Franceschini I, Lomet D, Cateau M, Delsol G, Tillet Y, Caraty A. Kisspeptin immunoreactive cells of the ovine preoptic area and arcuate nucleus co-express estrogen receptor alpha. *Neurosci Lett*. 2006;401(3):225–30.
- Fueshko S, Wray S. LHRH cells migrate on peripherin fibers in embryonic olfactory explant cultures: an in vitro model for neurophilic neuronal migration. *Dev Biol*. 1994;166(1):331–48.
- Harris GW. The induction of ovulation in the rabbit, by electrical stimulation of the hypothalamo-hypophysial mechanism. *Proc Roy Soc Ser B*. 1937;122:374–94.
- Gamble JA, Karunadasa DK, Pape JR, Skynner MJ, Todman MG, Bicknell RJ, Allen JP, Herbison AE. Disruption of ephrin signaling associates with disordered axophilic migration of the gonadotropin-releasing hormone neurons. *J Neurosci*. 2005;25(12):3142–50.
- Gearing M, Terasawa E. The alpha-1-adrenergic neuronal system is involved in the pulsatile release of luteinizing hormone-releasing hormone in the ovariectomized female rhesus monkey. *Neuroendocrinology*. 1991;53(4):373–81.
- Geller S, Kolasa E, Tillet Y, Duittoz A, Vaudin P. Olfactory ensheathing cells form the microenvironment of migrating GnRH-1 neurons during mouse development. *Glia*. 2013;61(4):550–66.
- George JT, Millar RP, Anderson RA. Hypothesis: kisspeptin mediates male hypogonadism in obesity and type 2 diabetes. *Neuroendocrinology*. 2010;91(4):302–7.
- George JT, Veldhuis JD, Roseweir AK, Newton CL, Faccenda E, Millar RP, Anderson RA. Kisspeptin-10 is a potent stimulator of LH and increases pulse frequency in men. *J Clin Endocrinol Metab*. 2011;96(8):E1228–36.
- Giacobini P, Messina A, Morello F, Ferraris N, Corso S, Penachioni J, Giordano S, Tamagnone L, Fasolo A. Semaphorin 4D regulates gonadotropin hormone-releasing hormone-1 neuronal migration through PlexinB1-Met complex. *J Cell Biol*. 2008;183(3):555–66.
- Gianetti E, Tusset C, Noel SD, Au MG, Dwyer AA, Hughes VA, Abreu AP, Carroll J, Trarbach E, Silveira LF, Costa EM, de Mendonca BB, de Castro M, Lofrano A, Hall JE, Bolu E, Ozata M, Quinton R, Amory JK, Stewart SE, Arlt W, Cole TR, Crowley WF, Kaiser UB, Latronico AC, Seminara SB. TAC3/TACR3 mutations reveal preferential activation of gonadotropin-releasing hormone release by neurokinin B in neonatal life followed by reversal in adulthood. *J Clin Endocrinol Metab*. 2010;95(6):2857–67.
- Goldsmith PC, Thind KK, Perera AD, Plant TM. Glutamate-immunoreactive neurons and their gonadotropin-releasing hormone-neuronal interactions in the monkey hypothalamus. *Endocrinology*. 1994;134(2):858–68.
- Goodman RL, Coolen LM, Anderson GM, Hardy SL, Valent M, Connors JM, Fitzgerald ME, Lehman MN. Evidence that dynorphin plays a major role in mediating progesterone negative

- feedback on gonadotropin-releasing hormone neurons in sheep. *Endocrinology*. 2004;145(6):2959–67.
- Goodman RL, Lehman MN, Smith JT, Coolen LM, de Oliveira CV, Jafarzadehshirazi MR, Pereira A, Iqbal J, Caraty A, Ciofi P, Clarke IJ. Kisspeptin neurons in the arcuate nucleus of the ewe express both dynorphin A and neurokinin B. *Endocrinology*. 2007;148(12):5752–60.
- Gore AC. Gonadotropin-releasing hormone neurons, NMDA receptors, and their regulation by steroid hormones across the reproductive life cycle. *Brain Res Brain Res Rev*. 2001;37(1–3):235–48.
- Gore AC, Terasawa E. A study of the hypothalamic pulse-generating mechanism responsible for LH release: electrical stimulation of the medial basal hypothalamus in the ovariectomized guinea pig. *Brain Res*. 1991;560(1–2):268–75.
- Gottsch ML, Cunningham MJ, Smith JT, Popa SM, Acohido BV, Crowley WF, Seminara S, Clifton DK, Steiner RA. A role for kisspeptins in the regulation of gonadotropin secretion in the mouse. *Endocrinology*. 2004;145(9):4073–7.
- Grosser PM, O'Byrne KT, Williams CL, Thalabard JC, Hotchkiss J, Knobil E. Effects of naloxone on estrogen-induced changes in hypothalamic gonadotropin-releasing hormone pulse generator activity in the rhesus monkey. *Neuroendocrinology*. 1993;57(1):115–9.
- Gutierrez-Pascual E, Martinez-Fuentes AJ, Pinilla L, Tena-Sempere M, Malagon MM, Castano JP. Direct pituitary effects of kisspeptin: activation of gonadotrophs and somatotrophs and stimulation of luteinising hormone and growth hormone secretion. *J Neuroendocrinol*. 2007;19(7):521–30.
- Hall JE, Schoenfeld DA, Martin KA, Crowley Jr WF. Hypothalamic gonadotropin-releasing hormone secretion and follicle-stimulating hormone dynamics during the luteal-follicular transition. *J Clin Endocrinol Metab*. 1992;74(3):600–7.
- Han SK, Todman MG, Herbison AE. Endogenous GABA release inhibits the firing of adult gonadotropin-releasing hormone neurons. *Endocrinology*. 2004;145(2):495–9.
- Hanchate NK, Giacobini P, Lhuillier P, Parkash J, Espy C, Fouveaut C, Leroy C, Baron S, Campagne C, Vanacker C, Collier F, Cruaud C, Meyer V, Garcia-Pinero A, Dewailly D, Cortet-Rudelli C, Gersak K, Metz C, Chabrier G, Pugeat M, Young J, Hardelin JP, Prevot V, Dode C. SEMA3A, a gene involved in axonal pathfinding, is mutated in patients with Kallmann syndrome. *PLoS Genet*. 2012;8(8):e1002896.
- Harris GW. Neural control of the pituitary gland. London: Edward Arnold Ltd; 1955.
- Herbison AE. Noradrenergic regulation of cyclic GnRH secretion. *Rev Reprod*. 1997;2(1):1–6.
- Herbison AE. Multimodal influence of estrogen upon gonadotropin-releasing hormone neurons. *Endocr Rev*. 1998;19(3):302–30.
- Herbison AE. Control of puberty onset and fertility by gonadotropin-releasing hormone neurons. *Nat Rev Endocrinol*. 2016;12:452–66.
- Herbison AE, Pape JR. New evidence for estrogen receptors in gonadotropin-releasing hormone neurons. *Front Neuroendocrinol*. 2001;22(4):292–308.
- Hoffman AR, Crowley Jr WF. Induction of puberty in men by long-term pulsatile administration of low-dose gonadotropin-releasing hormone. *N Engl J Med*. 1982;307(20):1237–41.
- Hong IS, Cheung AP, Leung PC. Gonadotropin-releasing hormones I and II induce apoptosis in human granulosa cells. *J Clin Endocrinol Metab*. 2008;93(8):3179–85.
- Hrabovszky E, Shughrue PJ, Merchenthaler I, Hajszan T, Carpenter CD, Liposits Z, Petersen SL. Detection of estrogen receptor-beta messenger ribonucleic acid and 125I-estrogen binding sites in luteinizing hormone-releasing hormone neurons of the rat brain. *Endocrinology*. 2000;141(9):3506–9.
- Hrabovszky E, Ciofi P, Vida B, Horvath MC, Keller E, Caraty A, Bloom SR, Ghatel MA, Dhillon WS, Liposits Z, Kallo I. The kisspeptin system of the human hypothalamus: sexual dimorphism and relationship with gonadotropin-releasing hormone and neurokinin B neurons. *Eur J Neurosci*. 2010;31(11):1984–98.
- Hrabovszky E, Sipos MT, Molnar CS, Ciofi P, Borsay BA, Gergely P, Herczeg L, Bloom SR, Ghatel MA, Dhillon WS, Liposits Z. Low degree of overlap between kisspeptin, neurokinin B, and

- dynorphin immunoreactivities in the infundibular nucleus of young male human subjects challenges the KNDy neuron concept. *Endocrinology*. 2012;153(10):4978–89.
- Hu L, Gustafson RL, Feng H, Leung PK, Mores N, Krsmanovic LZ, Catt KJ. Converse regulatory functions of estrogen receptor- $\alpha$  and - $\beta$  subtypes expressed in hypothalamic gonadotropin-releasing hormone neurons. *Mol Endocrinol*. 2008;22(10):2250–9.
- Huang X, Harlan RE. Absence of androgen receptors in LHRH immunoreactive neurons. *Brain Res*. 1993;624(1–2):309–11.
- Hutchins BI, Klenke U, Wray S. Calcium release-dependent actin flow in the leading process mediates axophilic migration. *J Neurosci*. 2013;33(28):11361–71.
- Irwig MS, Fraley GS, Smith JT, Acohido BV, Popa SM, Cunningham MJ, Gottsch ML, Clifton DK, Steiner RA. Kisspeptin activation of gonadotropin releasing hormone neurons and regulation of KiSS-1 mRNA in the male rat. *Neuroendocrinology*. 2004;80(4):264–72.
- Jayasena CN, Nijher GM, Chaudhri OB, Murphy KG, Ranger A, Lim A, Patel D, Mehta A, Todd C, Ramachandran R, Salem V, Stamp GW, Donaldson M, Ghatei MA, Bloom SR, Dhillon WS. Subcutaneous injection of kisspeptin-54 acutely stimulates gonadotropin secretion in women with hypothalamic amenorrhea, but chronic administration causes tachyphylaxis. *J Clin Endocrinol Metab*. 2009;94(11):4315–23.
- Jayasena CN, Nijher GM, Abbara A, Murphy KG, Lim A, Patel D, Mehta A, Todd C, Donaldson M, Trew GH, Ghatei MA, Bloom SR, Dhillon WS. Twice-weekly administration of kisspeptin-54 for 8 weeks stimulates release of reproductive hormones in women with hypothalamic amenorrhea. *Clin Pharmacol Ther*. 2010;88(6):840–7.
- Jayasena CN, Nijher GM, Cominos AN, Abbara A, Januszewski A, Vaal ML, Sriskandarajah L, Murphy KG, Farzad Z, Ghatei MA, Bloom SR, Dhillon WS. The effects of kisspeptin-10 on reproductive hormone release show sexual dimorphism in humans. *J Clin Endocrinol Metab*. 2011;96(12):E1963–72.
- Kallo I, Butler JA, Barkovics-Kallo M, Goubillon ML, Coen CW. Oestrogen receptor beta-immunoreactivity in gonadotropin releasing hormone-expressing neurones: regulation by oestrogen. *J Neuroendocrinol*. 2001;13(9):741–8.
- Kalra SP, Kalra PS. Opioid-adrenergic-steroid connection in regulation of luteinizing hormone secretion in the rat. *Neuroendocrinology*. 1984;38(5):418–26.
- Kalra SP, Kalra PS. Do testosterone and estradiol-17 beta enforce inhibition or stimulation of luteinizing hormone-releasing hormone secretion? *Biol Reprod*. 1989;41(4):559–70.
- Kamel F, Kubajak CL. Modulation of gonadotropin secretion by corticosterone: interaction with gonadal steroids and mechanism of action. *Endocrinology*. 1987;121(2):561–8.
- Kaufman JM, Kesner JS, Wilson RC, Knobil E. Electrophysiological manifestation of luteinizing hormone-releasing hormone pulse generator activity in the rhesus monkey: influence of alpha-adrenergic and dopaminergic blocking agents. *Endocrinology*. 1985;116(4):1327–33.
- Khosravi S, Leung PC. Differential regulation of gonadotropin-releasing hormone (GnRH)I and GnRHII messenger ribonucleic acid by gonadal steroids in human granulosa luteal cells. *J Clin Endocrinol Metab*. 2003;88(2):663–72.
- Kim HH. Regulation of gonadotropin-releasing hormone gene expression. *Semin Reprod Med*. 2007;25(5):313–25.
- Kim K, Lee BJ, Park Y, Cho WK. Progesterone increases messenger ribonucleic acid (mRNA) encoding luteinizing hormone releasing hormone (LHRH) level in the hypothalamus of ovariectomized estradiol-primed prepubertal rats. *Brain Res Mol Brain Res*. 1989;6(2–3):151–8.
- Kinoshita M, Tsukamura H, Adachi S, Matsui H, Uenoyama Y, Iwata K, Yamada S, Inoue K, Ohtaki T, Matsumoto H, Maeda K. Involvement of central metastin in the regulation of preovulatory luteinizing hormone surge and estrous cyclicity in female rats. *Endocrinology*. 2005;146(10):4431–6.
- Kirby ED, Geraghty AC, Ubuka T, Bentley GE, Kaufer D. Stress increases putative gonadotropin inhibitory hormone and decreases luteinizing hormone in male rats. *Proc Natl Acad Sci U S A*. 2009;106(27):11324–9.

- Knobil E. The electrophysiology of the GnRH pulse generator in the rhesus monkey. *J Steroid Biochem.* 1989;33(4b):669–71.
- Knobil E. Remembrance: the discovery of the hypothalamic gonadotropin-releasing hormone pulse generator and of its physiological significance. *Endocrinology.* 1992;131(3):1005–6.
- Konsman JP, Vignes S, Mackerlova L, Bristow A, Blomqvist A. Rat brain vascular distribution of interleukin-1 type-1 receptor immunoreactivity: relationship to patterns of inducible cyclooxygenase expression by peripheral inflammatory stimuli. *J Comp Neurol.* 2004;472(1):113–29.
- Kotani M, Dethoux M, Vandenbogaerde A, Communi D, Vanderwinden JM, Le Poul E, Brezillon S, Tyldesley R, Suarez-Huerta N, Vandeput F, Blanpain C, Schiffmann SN, Vassart G, Parmentier M. The metastasis suppressor gene KiSS-1 encodes kisspeptins, the natural ligands of the orphan G protein-coupled receptor GPR54. *J Biol Chem.* 2001;276(37):34631–6.
- Krajewski SJ, Anderson MJ, Iles-Shih L, Chen KJ, Urbanski HF, Rance NE. Morphologic evidence that neurokinin B modulates gonadotropin-releasing hormone secretion via neurokinin 3 receptors in the rat median eminence. *J Comp Neurol.* 2005;489(3):372–86.
- Kriegsfeld LJ, Mei DF, Bentley GE, Ubuka T, Mason AO, Inoue K, Ukena K, Tsutsui K, Silver R. Identification and characterization of a gonadotropin-inhibitory system in the brains of mammals. *Proc Natl Acad Sci U S A.* 2006;103(7):2410–5.
- Kuiper GG, Enmark E, Peltö-Huikko M, Nilsson S, Gustafsson JA. Cloning of a novel receptor expressed in rat prostate and ovary. *Proc Natl Acad Sci U S A.* 1996;93(12):5925–30.
- Lachelin GC, Leblanc H, Yen SS. The inhibitory effect of dopamine agonists on LH release in women. *J Clin Endocrinol Metab.* 1977;44(4):728–32.
- Lapatto R, Pallais JC, Zhang D, Chan YM, Mahan A, Cerrato F, Le WW, Hoffman GE, Seminara SB. Kiss1<sup>-/-</sup> mice exhibit more variable hypogonadism than Gpr54<sup>-/-</sup> mice. *Endocrinology.* 2007;148(10):4927–36.
- Leblanc H, Lachelin GC, Abu-Fadil S, Yen SS. Effects of dopamine infusion on pituitary hormone secretion in humans. *J Clin Endocrinol Metab.* 1976;43(3):668–74.
- Lee DK, Nguyen T, O'Neill GP, Cheng R, Liu Y, Howard AD, Coulombe N, Tan CP, Tang-Nguyen AT, George SR, O'Dowd BF. Discovery of a receptor related to the galanin receptors. *FEBS Lett.* 1999;446(1):103–7.
- Lehman MN, Coolen LM, Goodman RL. Minireview: kisspeptin/neurokinin B/dynorphin (KNDy) cells of the arcuate nucleus: a central node in the control of gonadotropin-releasing hormone secretion. *Endocrinology.* 2010;151(8):3479–89.
- Leonhardt S, Seong JY, Kim K, Thorun Y, Wuttke W, Jarry H. Activation of central GABAA-but not of GABAB-receptors rapidly reduces pituitary LH release and GnRH gene expression in the preoptic/anterior hypothalamic area of ovariectomized rats. *Neuroendocrinology.* 1995;61(6):655–62.
- Levine JE, Chappell P, Besecky LM, Bauer-Dantoin AC, Wolfe AM, Porkka-Heiskanen T, Urban JH. Amplitude and frequency modulation of pulsatile luteinizing hormone-releasing hormone release. *Cell Mol Neurobiol.* 1995;15(1):117–39.
- Li S, Pelletier G. Chronic administration of muscimol and pentobarbital decreases gonadotropin-releasing hormone mRNA levels in the male rat hypothalamus determined by quantitative in situ hybridization. *Neuroendocrinology.* 1993;58(1):136–9.
- Lin W, McKinney K, Liu L, Lakhani S, Jennes L. Distribution of vesicular glutamate transporter-2 messenger ribonucleic Acid and protein in the septum-hypothalamus of the rat. *Endocrinology.* 2003;144(2):662–70.
- Liu X, Lee K, Herbison AE. Kisspeptin excites gonadotropin-releasing hormone neurons through a phospholipase C/calcium-dependent pathway regulating multiple ion channels. *Endocrinology.* 2008;149(9):4605–14.
- Loumaye E, Catt KJ. Homologous regulation of gonadotropin-releasing hormone receptors in cultured pituitary cells. *Science.* 1982;215(4535):983–5.
- Maggi R, Cariboni AM, Marelli MM, Moretti RM, Andre V, Marzagalli M, Limonta P. GnRH and GnRH receptors in the pathophysiology of the human female reproductive system. *Hum Reprod Update.* 2016;22(3):358–81.



- Mahesh VB, Brann DW. Neuroendocrine mechanisms underlying the control of gonadotropin secretion by steroids. *Steroids*. 1998;63(5–6):252–6.
- Maier E, Gunhaga L. Dynamic expression of neurogenic markers in the developing chick olfactory epithelium. *Dev Dyn*. 2009;238(6):1617–25.
- Marin O, Rubenstein JL. Cell migration in the forebrain. *Annu Rev Neurosci*. 2003;26:441–83.
- Marshall JC, Kelch RP. Low dose pulsatile gonadotropin-releasing hormone in anorexia nervosa: a model of human pubertal development. *J Clin Endocrinol Metab*. 1979;49(5):712–8.
- Martinez de la Escalera G, Gallo F, Choi AL, Weiner RI. Dopaminergic regulation of the GT1 gonadotropin-releasing hormone (GnRH) neuronal cell lines: stimulation of GnRH release via D1-receptors positively coupled to adenylate cyclase. *Endocrinology*. 1992;131(6):2965–71.
- Matsuo H, Baba Y, Nair RM, Arimura A, Schally AV. Structure of the porcine LH- and FSH-releasing hormone. I. The proposed amino acid sequence. *Biochem Biophys Res Commun*. 1971;43(6):1334–9.
- Matsuwaki T, Kayasuga Y, Yamanouchi K, Nishihara M. Maintenance of gonadotropin secretion by glucocorticoids under stress conditions through the inhibition of prostaglandin synthesis in the brain. *Endocrinology*. 2006;147(3):1087–93.
- Maurer JA, Wray S. Luteinizing hormone-releasing hormone (LHRH) neurons maintained in hypothalamic slice explant cultures exhibit a rapid LHRH mRNA turnover rate. *J Neurosci*. 1997;17(24):9481–91.
- Mayer C, Acosta-Martinez M, Dubois SL, Wolfe A, Radovick S, Boehm U, Levine JE. Timing and completion of puberty in female mice depend on estrogen receptor alpha-signaling in kisspeptin neurons. *Proc Natl Acad Sci U S A*. 2010;107(52):22693–8.
- McArdle CA. Gonadotropin-releasing hormone receptor signaling: biased and unbiased. *Mini-Rev Med Chem*. 2012;12(9):841–50.
- McCartney CR. Maturation of sleep-wake gonadotrophin-releasing hormone secretion across puberty in girls: potential mechanisms and relevance to the pathogenesis of polycystic ovary syndrome. *J Neuroendocrinol*. 2010;22(7):701–9.
- Mellon PL, Windle JJ, Goldsmith PC, Padula CA, Roberts JL, Weiner RI. Immortalization of hypothalamic GnRH neurons by genetically targeted tumorigenesis. *Neuron*. 1990;5(1):1–10.
- Messina A, Ferraris N, Wray S, Cagnoni G, Donohue DE, Casoni F, Kramer PR, Derijck AA, Adolfs Y, Fasolo A, Pasterkamp RJ, Giacobini P. Dysregulation of Semaphorin7A/beta1-integrin signaling leads to defective GnRH-1 cell migration, abnormal gonadal development and altered fertility. *Hum Mol Genet*. 2011;20(24):4759–74.
- Millar R, Lowe S, Conklin D, Pawson A, Maudsley S, Troskie B, Ott T, Millar M, Lincoln G, Sellar R, Faurholm B, Scobie G, Kuestner R, Terasawa E, Katz A. A novel mammalian receptor for the evolutionarily conserved type II GnRH. *Proc Natl Acad Sci U S A*. 2001;98(17):9636–41.
- Miller AM, Treloar HB, Greer CA. Composition of the migratory mass during development of the olfactory nerve. *J Comp Neurol*. 2010;518(24):4825–41.
- Min L, Soltis K, Reis AC, Xu S, Kuohung W, Jain M, Carroll RS, Kaiser UB. Dynamic kisspeptin receptor trafficking modulates kisspeptin-mediated calcium signaling. *Mol Endocrinol*. 2014;28(1):16–27.
- Mombaerts P. How smell develops. *Nat Neurosci*. 2001;4(Suppl):1192–8.
- Mosselman S, Polman J, Dijkema R. ER beta: identification and characterization of a novel human estrogen receptor. *FEBS Lett*. 1996;392(1):49–53.
- Muir AI, Chamberlain L, Elshourbagy NA, Michalovich D, Moore DJ, Calamari A, Szekeres PG, Sarau HM, Chambers JK, Murdock P, Steplewski K, Shabon U, Miller JE, Middleton SE, Darker JG, Larminie CG, Wilson S, Bergsma DJ, Emson P, Faull R, Philpott KL, Harrison DC. AXOR12, a novel human G protein-coupled receptor, activated by the peptide KiSS-1. *J Biol Chem*. 2001;276(31):28969–75.
- Navarro VM. New insights into the control of pulsatile GnRH release: the role of Kiss1/neurokinin B neurons. *Front Endocrinol (Lausanne)*. 2012;3:48.

- Navarro VM, Castellano JM, Fernandez-Fernandez R, Barreiro ML, Roa J, Sanchez-Criado JE, Aguilar E, Dieguez C, Pinilla L, Tena-Sempere M. Developmental and hormonally regulated messenger ribonucleic acid expression of KiSS-1 and its putative receptor, GPR54, in rat hypothalamus and potent luteinizing hormone-releasing activity of KiSS-1 peptide. *Endocrinology*. 2004;145(10):4565–74.
- Navarro VM, Castellano JM, Fernandez-Fernandez R, Tovar S, Roa J, Mayen A, Nogueiras R, Vazquez MJ, Barreiro ML, Magni P, Aguilar E, Dieguez C, Pinilla L, Tena-Sempere M. Characterization of the potent luteinizing hormone-releasing activity of KiSS-1 peptide, the natural ligand of GPR54. *Endocrinology*. 2005;146(1):156–63.
- Navarro VM, Gottsch ML, Chavkin C, Okamura H, Clifton DK, Steiner RA. Regulation of gonadotropin-releasing hormone secretion by kisspeptin/dynorphin/neurokinin B neurons in the arcuate nucleus of the mouse. *J Neurosci*. 2009;29(38):11859–66.
- Navarro VM, Castellano JM, McConkey SM, Pineda R, Ruiz-Pino F, Pinilla L, Clifton DK, Tena-Sempere M, Steiner RA. Interactions between kisspeptin and neurokinin B in the control of GnRH secretion in the female rat. *Am J Physiol Endocrinol Metab*. 2011;300(1):E202–10.
- Nazian SJ, Landon CS, Muffly KE, Cameron DF. Opioid inhibition of adrenergic and dopaminergic but not serotonergic stimulation of luteinizing hormone releasing hormone release from immortalized hypothalamic neurons. *Mol Cell Neurosci*. 1994;5(6):642–8.
- Negro-Vilar A, Advis JP, Ojeda SR, McCann SM. Pulsatile luteinizing hormone (LH) patterns in ovariectomized rats: involvement of norepinephrine and dopamine in the release of LH-releasing hormone and LH. *Endocrinology*. 1982;111(3):932–8.
- Nikolics K, Mason AJ, Szonyi E, Ramachandran J, Seeburg PH. A prolactin-inhibiting factor within the precursor for human gonadotropin-releasing hormone. *Nature*. 1985;316(6028):511–7.
- Nippoldt TB, Khoury S, Barkan A, Kelch RP, Marshall JC. Gonadotrophin responses to GnRH pulses in hypogonadotropic hypogonadism: LH responsiveness is maintained in the presence of luteal phase concentrations of oestrogen and progesterone. *Clin Endocrinol*. 1987;26(3):293–301.
- Nippoldt TB, Reame NE, Kelch RP, Marshall JC. The roles of estradiol and progesterone in decreasing luteinizing hormone pulse frequency in the luteal phase of the menstrual cycle. *J Clin Endocrinol Metab*. 1989;69(1):67–76.
- Oakley AE, Clifton DK, Steiner RA. Kisspeptin signaling in the brain. *Endocr Rev*. 2009;30(6):713–43.
- Ohtaki T, Shintani Y, Honda S, Matsumoto H, Hori A, Kanehashi K, Terao Y, Kumano S, Takatsu Y, Masuda Y, Ishibashi Y, Watanabe T, Asada M, Yamada T, Suenaga M, Kitada C, Usuki S, Kurokawa T, Onda H, Nishimura O, Fujino M. Metastasis suppressor gene KiSS-1 encodes peptide ligand of a G-protein-coupled receptor. *Nature*. 2001;411(6837):613–7.
- Ojeda SR, Roth C, Mungenast A, Heger S, Mastronardi C, Parent AS, Lomniczi A, Jung H. Neuroendocrine mechanisms controlling female puberty: new approaches, new concepts. *Int J Androl*. 2006;29(1):256–63 .discussion 286–290
- Ojeda SR, Dubay C, Lomniczi A, Kaidar G, Matagne V, Sandau US, Dissen GA. Gene networks and the neuroendocrine regulation of puberty. *Mol Cell Endocrinol*. 2010;324(1–2):3–11.
- Ottm EN, Godwin JG, Petersen SL. Glutamatergic signaling through the N-methyl-D-aspartate receptor directly activates medial subpopulations of luteinizing hormone-releasing hormone (LHRH) neurons, but does not appear to mediate the effects of estradiol on LHRH gene expression. *Endocrinology*. 2002;143(12):4837–45.
- Pehrson JJ, Jaffee WL, Vaitukaitis JL. Effect of dopamine on gonadotropin-releasing hormone-induced gonadotropin secretion in postmenopausal women. *J Clin Endocrinol Metab*. 1983;56(5):889–92.
- Piet R, de Croft S, Liu X, Herbison AE. Electrical properties of kisspeptin neurons and their regulation of GnRH neurons. *Front Neuroendocrinol*. 2015;36:15–27.
- Pineda R, Garcia-Galiano D, Roseweir A, Romero M, Sanchez-Garrido MA, Ruiz-Pino F, Morgan K, Pinilla L, Millar RP, Tena-Sempere M. Critical roles of kisspeptins in female puberty

- and preovulatory gonadotropin surges as revealed by a novel antagonist. *Endocrinology*. 2010a;151(2):722–30.
- Pineda R, Garcia-Galiano D, Sanchez-Garrido MA, Romero M, Ruiz-Pino F, Aguilar E, Dijcks FA, Blomenrohr M, Pinilla L, van Noord PL, Tena-Sempere M. Characterization of the inhibitory roles of RFRP3, the mammalian ortholog of GnIH, in the control of gonadotropin secretion in the rat: in vivo and in vitro studies. *Am J Physiol Endocrinol Metab*. 2010b;299(1):E39–46.
- Pitteloud N, Durrani S, Raivio T, Sykiotis GP. Complex genetics in idiopathic hypogonadotropic hypogonadism. *Front Horm Res*. 2010;39:142–53.
- Plant TM. Neuroendocrine control of the onset of puberty. *Front Neuroendocrinol*. 2015;38:73–88.
- Poletti A, Melcangi RC, Negri-Cesi P, Maggi R, Martini L. Steroid binding and metabolism in the luteinizing hormone-releasing hormone-producing neuronal cell line GT1-1. *Endocrinology*. 1994;135(6):2623–8.
- Pompolo S, Pereira A, Scott CJ, Fujiyama F, Clarke IJ. Evidence for estrogenic regulation of gonadotropin-releasing hormone neurons by glutamatergic neurons in the ewe brain: an immunohistochemical study using an antibody against vesicular glutamate transporter-2. *J Comp Neurol*. 2003;465(1):136–44.
- Pompolo S, Pereira A, Estrada KM, Clarke IJ. Colocalization of kisspeptin and gonadotropin-releasing hormone in the ovine brain. *Endocrinology*. 2006;147(2):804–10.
- Potashner SJ. Baclofen: effects on amino acid release and metabolism in slices of guinea pig cerebral cortex. *J Neurochem*. 1979;32(1):103–9.
- Qi Y, Oldfield BJ, Clarke IJ. Projections of RFamide-related peptide-3 neurones in the ovine hypothalamus, with special reference to regions regulating energy balance and reproduction. *J Neuroendocrinol*. 2009;21(8):690–7.
- Rabin D, Gold PW, Margioris AN, Chrousos GP. Stress and reproduction: physiologic and pathophysiologic interactions between the stress and reproductive axes. *Adv Exp Med Biol*. 1988;245:377–87.
- Radovick S, Wondisford FE, Nakayama Y, Yamada M, Cutler Jr GB, Weintraub BD. Isolation and characterization of the human gonadotropin-releasing hormone gene in the hypothalamus and placenta. *Mol Endocrinol*. 1990;4(3):476–80.
- Ramaswamy S, Guerriero KA, Gibbs RB, Plant TM. Structural interactions between kisspeptin and GnRH neurons in the mediobasal hypothalamus of the male rhesus monkey (*Macaca mulatta*) as revealed by double immunofluorescence and confocal microscopy. *Endocrinology*. 2008;149(9):4387–95.
- Ramirez VD, Dluzen D, Lin D. Progesterone administration in vivo stimulates release of luteinizing hormone-releasing hormone in vitro. *Science*. 1980;208(4447):1037–9.
- Rauci F, Tiong JD, Wray S. P75 nerve growth factor receptors modulate development of GnRH neurons and olfactory ensheathing cells. *Front Neurosci*. 2013;7:262.
- Reame N, Sauder SE, Kelch RP, Marshall JC. Pulsatile gonadotropin secretion during the human menstrual cycle: evidence for altered frequency of gonadotropin-releasing hormone secretion. *J Clin Endocrinol Metab*. 1984;59(2):328–37.
- Refojo D, Arias P, Moguilevsky JA, Feleder C. Effect of bacterial endotoxin on in vivo pulsatile gonadotropin secretion in adult male rats. *Neuroendocrinology*. 1998;67(4):275–81.
- Reynoso R, Ponzio OJ, Szwarcfarb B, Rondina D, Carbone S, Rimoldi G, Scacchi P, Moguilevsky JA. Effect of leptin on hypothalamic release of GnRH and neurotransmitter amino acids during sexual maturation in female rats. *Exp Clin Endocrinol Diabetes*. 2003;111(5):274–7.
- Richard N, Galmiche G, Corvaisier S, Caraty A, Kottler ML. Kiss-1 and GPR54 genes are co-expressed in rat gonadotrophs and differentially regulated in vivo by oestradiol and gonadotrophin-releasing hormone. *J Neuroendocrinol*. 2008;20(3):381–93.
- Roa J, Castellano JM, Navarro VM, Handelsman DJ, Pinilla L, Tena-Sempere M. Kisspeptins and the control of gonadotropin secretion in male and female rodents. *Peptides*. 2009;30(1):57–66.
- Romero AM, Krajewski SJ, Voytko ML, Rance NE. Hypertrophy and increased kisspeptin gene expression in the hypothalamic infundibular nucleus of postmenopausal women and ovariectomized monkeys. *J Clin Endocrinol Metab*. 2007;92(7):2744–50.

- Roseweir AK, Kauffman AS, Smith JT, Guerriero KA, Morgan K, Pielecka-Fortuna J, Pineda R, Gottsch ML, Tena-Sempere M, Moenter SM, Terasawa E, Clarke IJ, Steiner RA, Millar RP. Discovery of potent kisspeptin antagonists delineate physiological mechanisms of gonadotropin regulation. *J Neurosci*. 2009;29(12):3920–9.
- Satake H, Hisada M, Kawada T, Minakata H, Ukena K, Tsutsui K. Characterization of a cDNA encoding a novel avian hypothalamic neuropeptide exerting an inhibitory effect on gonadotropin release. *Biochem J*. 2001;354(Pt 2):379–85.
- Schally AV, Arimura A, Baba Y, Nair RM, Matsuo H, Redding TW, Debeljuk L. Isolation and properties of the FSH and LH-releasing hormone. *Biochem Biophys Res Commun*. 1971;43(2):393–9.
- Schwanzel-Fukuda M, Bick D, Pfaff DW. Luteinizing hormone-releasing hormone (LHRH)-expressing cells do not migrate normally in an inherited hypogonadal (Kallmann) syndrome. *Brain Res Mol Brain Res*. 1989;6(4):311–26.
- Schwanzel-Fukuda M, Crossin KL, Pfaff DW, Bouloux PM, Hardelin JP, Petit C. Migration of luteinizing hormone-releasing hormone (LHRH) neurons in early human embryos. *J Comp Neurol*. 1996;366(3):547–57.
- Schwartz GA, Henion TR, Nugent JD, Caplan B, Tobet S. Stromal cell-derived factor-1 (chemokine C-X-C motif ligand 12) and chemokine C-X-C motif receptor 4 are required for migration of gonadotropin-releasing hormone neurons to the forebrain. *J Neurosci*. 2006;26(25):6834–40.
- Seminara SB, Messager S, Chatzidakis EE, Thresher RR, Acierno Jr JS, Shagoury JK, Bo-Abbas Y, Kuohung W, Schwinof KM, Hendrick AG, Zahn D, Dixon J, Kaiser UB, Slaugenhaupt SA, Gusella JF, O’Rahilly S, Carlton MB, Crowley Jr WF, Aparicio SA, Colledge WH. The GPR54 gene as a regulator of puberty. *N Engl J Med*. 2003;349(17):1614–27.
- Skinner DC, Albertson AJ, Navratil A, Smith A, Mignot M, Talbott H, Scanlan-Blake N. Effects of gonadotrophin-releasing hormone outside the hypothalamic-pituitary-reproductive axis. *J Neuroendocrinol*. 2009;21(4):282–92.
- Skorupskaitė K, George JT, Anderson RA. The kisspeptin-GnRH pathway in human reproductive health and disease. *Hum Reprod Update*. 2014;20(4):485–500.
- Skrapits K, Borsay BA, Herczeg L, Ciofi P, Liposits Z, Hrabovszky E. Neuropeptide co-expression in hypothalamic kisspeptin neurons of laboratory animals and the human. *Front Neurosci*. 2015;9:29.
- Skyrner MJ, Sim JA, Herbison AE. Detection of estrogen receptor alpha and beta messenger ribonucleic acids in adult gonadotropin-releasing hormone neurons. *Endocrinology*. 1999;140(11):5195–201.
- Smith JT, Clarke IJ. Gonadotropin inhibitory hormone function in mammals. *Trends Endocrinol Metab*. 2010;21(4):255–60.
- Smith JT, Cunningham MJ, Rissman EF, Clifton DK, Steiner RA. Regulation of Kiss1 gene expression in the brain of the female mouse. *Endocrinology*. 2005a;146(9):3686–92.
- Smith JT, Dungan HM, Stoll EA, Gottsch ML, Braun RE, Eacker SM, Clifton DK, Steiner RA. Differential regulation of KiSS-1 mRNA expression by sex steroids in the brain of the male mouse. *Endocrinology*. 2005b;146(7):2976–84.
- Smith JT, Pota SM, Clifton DK, Hoffman GE, Steiner RA. Kiss1 neurons in the forebrain as central processors for generating the preovulatory luteinizing hormone surge. *J Neurosci*. 2006;26(25):6687–94.
- Smith JT, Clay CM, Caraty A, Clarke IJ. KiSS-1 messenger ribonucleic acid expression in the hypothalamus of the ewe is regulated by sex steroids and season. *Endocrinology*. 2007;148(3):1150–7.
- Smith JT, Coolen LM, Kriegsfeld LJ, Sari IP, Jaafarzadehshirazi MR, Maltby M, Bateman K, Goodman RL, Tilbrook AJ, Ubuka T, Bentley GE, Clarke IJ, Lehman MN. Variation in kisspeptin and RFamide-related peptide (RFRP) expression and terminal connections to gonadotropin-releasing hormone neurons in the brain: a novel medium for seasonal breeding in the sheep. *Endocrinology*. 2008a;149(11):5770–82.

- Smith JT, Rao A, Pereira A, Caraty A, Millar RP, Clarke IJ. Kisspeptin is present in ovine hypophysial portal blood but does not increase during the preovulatory luteinizing hormone surge: evidence that gonadotropes are not direct targets of kisspeptin in vivo. *Endocrinology*. 2008b;149(4):1951–9.
- Soules MR, Steiner RA, Clifton DK, Cohen NL, Aksel S, Bremner WJ. Progesterone modulation of pulsatile luteinizing hormone secretion in normal women. *J Clin Endocrinol Metab*. 1984; 58(2):378–83.
- Stern K, McClintock MK. Regulation of ovulation by human pheromones. *Nature*. 1998;392 (6672):177–9.
- Stojilkovic SS, Krmanovic LZ, Spergel DJ, Catt KJ. Gonadotropin-releasing hormone neurons: intrinsic pulsatility and receptor-mediated regulation. *Trends Endocrinol Metab*. 1994; 5(5):201–9.
- Takeuchi Y, Nagabukuro H, Kizumi O, Mori Y. Lipopolysaccharide-induced suppression of the hypothalamic gonadotropin-releasing hormone pulse generator in ovariectomized goats. *J Vet Med Sci*. 1997;59(2):93–6.
- Tobet SA, Hanna IK, Schwarting GA. Migration of neurons containing gonadotropin releasing hormone (GnRH) in slices from embryonic nasal compartment and forebrain. *Brain Res Dev Brain Res*. 1996;97(2):287–92.
- Topaloglu AK, Reimann F, Guclu M, Yalin AS, Kotan LD, Porter KM, Serin A, Mungan NO, Cook JR, Ozbek MN, Imamoglu S, Akalin NS, Yuksel B, O'Rahilly S, Semple RK. TAC3 and TACR3 mutations in familial hypogonadotropic hypogonadism reveal a key role for Neurokinin B in the central control of reproduction. *Nat Genet*. 2009;41(3):354–8.
- Topaloglu AK, Tello JA, Kotan LD, Ozbek MN, Yilmaz MB, Erdogan S, Gurbuz F, Temiz F, Millar RP, Yuksel B. Inactivating KISS1 mutation and hypogonadotropic hypogonadism. *N Engl J Med*. 2012;366(7):629–35.
- Tsutsui K, Saigoh E, Ukena K, Teranishi H, Fujisawa Y, Kikuchi M, Ishii S, Sharp PJ. A novel avian hypothalamic peptide inhibiting gonadotropin release. *Biochem Biophys Res Commun*. 2000;275(2):661–7.
- Tsutsumi R, Mistry D, Webster NJ. Signaling responses to pulsatile gonadotropin-releasing hormone in LbetaT2 gonadotrope cells. *J Biol Chem*. 2010;285(26):20262–72.
- Uemura T, Nishimura J, Yamaguchi H, Hiruma H, Kimura F, Minaguchi H. Effects of noradrenaline on GnRH-secreting immortalized hypothalamic (GT1-7) neurons. *Endocr J*. 1997;44(1):73–8.
- Urbanski HF, Ojeda SR. Activation of luteinizing hormone-releasing hormone release advances the onset of female puberty. *Neuroendocrinology*. 1987;46(3):273–6.
- Van den Berghe G, de Zegher F, Lauwers P, Veldhuis JD. Luteinizing hormone secretion and hypoandrogenaemia in critically ill men: effect of dopamine. *Clin Endocrinol*. 1994; 41(5):563–9.
- Van Vugt DA, Baby N, Stewart M, Reid RL. The paradoxical stimulatory effect of morphine on LH secretion is dose-dependent and naloxone-reversible. *Neuroendocrinology*. 1989;50(1):109–16.
- Vezzoli V, Duminuco P, Bassi I, Guizzardi F, Persani L, Bonomi M. The complex genetic basis of congenital hypogonadotropic hypogonadism. *Minerva Endocrinol*. 2016;41(2):223–39.
- Wakabayashi Y, Nakada T, Murata K, Ohkura S, Mogi K, Navarro VM, Clifton DK, Mori Y, Tsukamura H, Maeda K, Steiner RA, Okamura H. Neurokinin B and dynorphin A in kisspeptin neurons of the arcuate nucleus participate in generation of periodic oscillation of neural activity driving pulsatile gonadotropin-releasing hormone secretion in the goat. *J Neurosci*. 2010; 30(8):3124–32.
- Waldhauser F, Weissenbacher G, Frisch H, Pollak A. Pulsatile secretion of gonadotropins in early infancy. *Eur J Pediatr*. 1981;137(1):71–4.
- Weisskopf MG, Zalutsky RA, Nicoll RA. The opioid peptide dynorphin mediates heterosynaptic depression of hippocampal mossy fibre synapses and modulates long-term potentiation. *Nature*. 1993;362(6419):423–7.
- West A, Vojta PJ, Welch DR, Weissman BE. Chromosome localization and genomic structure of the KiSS-1 metastasis suppressor gene (KISS1). *Genomics*. 1998;54(1):145–8.

- White RB, Eisen JA, Kasten TL, Fernald RD. Second gene for gonadotropin-releasing hormone in humans. *Proc Natl Acad Sci U S A*. 1998;95(1):305–9.
- Williams CL, Nishihara M, Thalabard JC, O'Byrne KT, Grosser PM, Hotchkiss J, Knobil E. Duration and frequency of multiunit electrical activity associated with the hypothalamic gonadotropin releasing hormone pulse generator in the rhesus monkey: differential effects of morphine. *Neuroendocrinology*. 1990;52(3):225–8.
- Woller MJ, Terasawa E. Estradiol enhances the action of neuropeptide Y on in vivo luteinizing hormone-releasing hormone release in the ovariectomized rhesus monkey. *Neuroendocrinology*. 1992;56(6):921–5.
- Wray S. From nose to brain: development of gonadotrophin-releasing hormone-1 neurones. *J Neuroendocrinol*. 2010;22(7):743–53.
- Wray S, Fueshko SM, Kusano K, Gainer H. GABAergic neurons in the embryonic olfactory pit/vomeronasal organ: maintenance of functional GABAergic synapses in olfactory explants. *Dev Biol*. 1996;180(2):631–45.
- Yang-Feng TL, Seeburg PH, Francke U. Human luteinizing hormone-releasing hormone gene (LHRH) is located on short arm of chromosome 8 (region 8p11.2—p21). *Somat Cell Mol Genet*. 1986;12(1):95–100.
- Yoo MJ, Nishihara M, Takahashi M. Tumor necrosis factor-alpha mediates endotoxin induced suppression of gonadotropin-releasing hormone pulse generator activity in the rat. *Endocr J*. 1997;44(1):141–8.
- Yoshida K, Rutishauser U, Crandall JE, Schwarting GA. Polysialic acid facilitates migration of luteinizing hormone-releasing hormone neurons on vomeronasal axons. *J Neurosci*. 1999;19(2):794–801.
- Young J, Bouligand J, Francou B, Raffin-Sanson ML, Gaillez S, Jeanpierre M, Grynberg M, Kamenicky P, Chanson P, Brailly-Tabard S, Guiochon-Mantel A. TAC3 and TACR3 defects cause hypothalamic congenital hypogonadotropic hypogonadism in humans. *J Clin Endocrinol Metab*. 2010;95(5):2287–95.
- Young J, Metay C, Bouligand J, Tou B, Francou B, Maione L, Tosca L, Sarfati J, Brioude F, Esteva B, Briand-Suleau A, Brisset S, Goossens M, Tachdjian G, Guiochon-Mantel A. SEMA3A deletion in a family with Kallmann syndrome validates the role of semaphorin 3A in human puberty and olfactory system development. *Hum Reprod*. 2012;27(5):1460–5.
- Young J, George JT, Tello JA, Francou B, Bouligand J, Guiochon-Mantel A, Brailly-Tabard S, Anderson RA, Millar RP. Kisspeptin restores pulsatile LH secretion in patients with neurokinin B signaling deficiencies: physiological, pathophysiological and therapeutic implications. *Neuroendocrinology*. 2013;97(2):193–202.

## GnRH Signaling

Kathryn L. Garner, Krasimira Tsaneva-Atanasova, and  
Craig A. McArdle

### Abstract

Gonadotropin-releasing hormone (GnRH) mediates central control of reproductive function by activation of G-protein-coupled receptors on pituitary gonadotropes. These  $G_q$ -coupled receptors mediate acute effects of GnRH on the exocytotic secretion of luteinizing hormone and follicle-stimulating hormone and also chronic regulation of the synthesis of these gonadotropin hormones. GnRH is secreted in brief pulses and GnRH effects on its target cells are dependent upon the characteristics of these pulses. Here we provide an overview of GnRH receptors and their signaling network, emphasizing novel and atypical functional features of GnRH signaling, and mechanisms mediating pulsatile hormone signaling.

### Keywords

GnRH • GnRH receptors • G-proteins • Phospholipase C • ERK • NFAT • MAPK

### Contents

Gonadotropin-Releasing Hormone (GnRH) and Its Receptors .....	36
GnRHR Signaling and Gonadotropin Secretion .....	37
GnRH Signaling and Gene Expression .....	39
Trafficking, Compartmentalization, and Desensitization of GnRHR .....	42
Extrapituitary GnRHR, Context Dependence, and Ligand Bias .....	44

K.L. Garner • C.A. McArdle (✉)

Laboratories for Integrative Neuroscience and Endocrinology, School of Clinical Sciences,  
University of Bristol, Bristol, UK

e-mail: [craig.mcardle@bristol.ac.uk](mailto:craig.mcardle@bristol.ac.uk)

K. Tsaneva-Atanasova

Department of Mathematics, College of Engineering, Mathematics and Physical Sciences,  
University of Exeter, Exeter, UK

EPSRC Centre for Predictive Modelling in Healthcare, University of Exeter, Exeter, UK

Additional Hormonal and Local Regulators of Gonadotropes .....	47
Pulsatile GnRH Signaling .....	49
An Information Theoretic Approach to GnRH Signaling .....	55
Summary .....	57
References .....	58

---

## Gonadotropin-Releasing Hormone (GnRH) and Its Receptors

Gonadotropin-releasing hormone, (pGlu-His-Trp-Ser-Tyr-Gly-Leu-Arg-Pro-Gly-NH<sub>2</sub>), also known as luteinizing hormone-releasing hormone (LHRH) or GnRH-I, is a peptide that is synthesized in hypothalamic neurons. It is secreted into the hypothalamic-hypophyseal portal circulation in pulses each lasting for a few minutes (Belchetz et al. 1978; Clarke and Cummins 1985; Wildt et al. 1981), with the secretory activity of GnRH neurons being controlled largely by input from kisspeptin-containing neuronal circuits. After secretion GnRH exits the portal circulation and binds to its cognate receptors (GnRHRs) on the surface of anterior pituitary gonadotropes. It causes them to synthesize and secrete luteinizing hormone (LH) and follicle-stimulating hormone (FSH); these two gonadotropin hormones then control gametogenesis and steroidogenesis in the gonads (Cheng and Leung 2005; Ciccone and Kaiser 2009; McArdle and Roberson 2015; Millar et al. 2004; Naor 2009; Sealfon et al. 1997; Stojilkovic et al. 2010b; Wang et al. 2010). LH and FSH are heterodimeric glycoprotein hormones with distinct  $\beta$ -subunits (LH $\beta$  and FSH $\beta$ ) and a common  $\alpha$ -gonadotropin subunit ( $\alpha$ GSU). The mature protein hormones are packaged into secretory vesicles for release from gonadotropes. Acutely GnRH regulates vesicle fusion with the plasma membrane whereas chronically, it increases synthesis of gonadotropins and thereby influences the hormone content of these vesicles. Together, these effects on synthesis and secretion underpin the central control of reproduction by GnRH.

The importance of this system is illustrated by the fact that GnRH and its receptors are both absolutely essential for mammalian reproduction (Cattanach et al. 1977; de Roux et al. 1997; Mason et al. 1986), but comparative studies have revealed multiple forms of GnRH and GnRHR. There are three distinct forms of the hormone: GnRH-I (often known simply as GnRH), GnRH-II, and GnRH-III. These have a common ancestral origin that predates vertebrates (Fernald and White 1999). Most classes of vertebrate have GnRH-I and GnRH-II, but GnRH-III is specific for teleosts (Cheng and Leung 2005; Millar et al. 2004; Schneider and Rissman 2008). GnRHRs are members of the rhodopsin-like G-protein-coupled receptor (GPCR) family and have a characteristic seven-transmembrane  $\alpha$ -helical domain structure. They have been cloned from multiple species and can be classified into three groups based on sequence homology. All of the cloned mammalian GnRHRs are in groups I or II (Millar et al. 2004; Morgan and Millar 2004), and the type I GnRHRs of humans, rats, mice, pigs, sheep, and horses have >80% amino acid sequence identity. Some primates (notably rhesus and green monkeys and marmosets) express functional type II GnRHR (as well as type I GnRHR), but in humans there is a

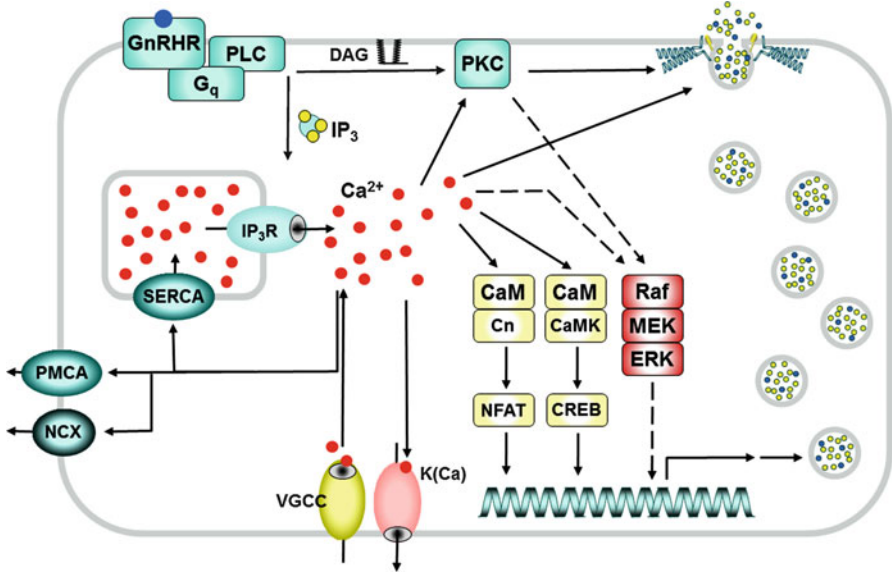


frameshift mutation and a premature stop codon in the GnRHR II (pseudo)gene so that a functional type II GnRHR is not expressed (Morgan and Millar 2004; Stewart et al. 2009; Wang et al. 2010). Accordingly, for humans, central control of reproduction is mediated by GnRH-I from the hypothalamus acting on type I GnRHR in gonadotropes. Further evidence of the importance of this system lies in the fact that GnRHRs are established therapeutic targets for manipulation with agonist and antagonist analogues of GnRH for assisted reproduction technology (Al-Inany et al. 2016; Siristatidis et al. 2015). In general, stimulatory effects of endogenous GnRH pulses can be mimicked with pulsatile agonists to induce ovulation or spermatogenesis. Alternatively, effects of endogenous GnRH can be blocked with GnRH antagonists to reduce circulating levels of gonadotropins and gonadal steroids and thereby treat sex hormone-dependent neoplasms such as those of the prostate, ovary, endometrium, or mammary glands (Chengalvala et al. 2003; Conn and Crowley 1994; Schally 1999). Paradoxically, sustained stimulation with GnRH agonists causes stimulation followed by desensitization of GnRHR-mediated gonadotropin secretion, and this is also exploited to treat sex steroid-dependent cancers (Cheng and Leung 2005; Ciccone and Kaiser 2009; McArdle and Roberson 2015; Millar et al. 2004; Naor 2009; Sealton et al. 1997; Stojilkovic and Catt 1995; Wang et al. 2010).

---

## GnRHR Signaling and Gonadotropin Secretion

In gonadotropes, GnRHR signaling (Fig. 1) is primarily mediated by activation of the heterotrimeric G-protein  $G_q$  which, in turn, activates the effector enzyme phospholipase C (PLC). PLC cleaves phosphatidylinositol (4,5)-bisphosphate to produce the second messengers inositol (1,4,5)-trisphosphate ( $IP_3$ ) and diacylglycerol (DAG).  $IP_3$  acts via its own intracellular receptors to increase  $Ca^{2+}$  release from intracellular stores, whereas DAG activates isozymes of protein kinase C (PKC).  $Ca^{2+}$  mobilization is followed by  $Ca^{2+}$  influx via L-type voltage-gated  $Ca^{2+}$  channels, and it is this  $Ca^{2+}$  entry across the plasma membrane that supports a more sustained increase in cytoplasmic  $Ca^{2+}$  concentration on continuous GnRH exposure (Ciccone and Kaiser 2009; Naor 2009; Stojilkovic and Catt 1995; Stojilkovic et al. 2010b). In some models, GnRH causes oscillations in cytoplasmic  $Ca^{2+}$ , and the type of response depends on the model system and on GnRH concentration, with low concentrations having subthreshold effects, intermediate concentrations causing oscillatory responses, and high concentrations causing biphasic (spike-plateau) responses (Leong and Thorner 1991; Stojilkovic et al. 1991). For the latter, the initial spike phase is due to mobilization of  $Ca^{2+}$  from intracellular stores, whereas the plateau is dependent on  $Ca^{2+}$  entry through voltage-gated  $Ca^{2+}$  channels (Hansen et al. 1987; Izumi et al. 1989). For the oscillatory responses, a cytoplasmic oscillator model has been described, and with either response pattern, rapid effects of GnRH on gonadotropin secretion are driven by elevation of cytoplasmic  $Ca^{2+}$  (Hansen et al. 1987; Hille et al. 1994; Izumi et al. 1989; Stojilkovic et al. 1994).



**Fig. 1 A simplified GnRHR signaling network.** GnRHR acts primarily via Gq, activating phospholipase C (*PLC*) to generate IP<sub>3</sub> which drives IP<sub>3</sub> receptor (IP<sub>3</sub>R)-mediated mobilization of Ca<sup>2+</sup> from intracellular stores, and diacylglycerol (DAG) which, along with Ca<sup>2+</sup>, activates conventional PKC isozymes. Additional proteins involved in the control of the cytoplasmic Ca<sup>2+</sup> ion concentration include Ca<sup>2+</sup> sequestering sarcoplasmic and endoplasmic reticulum Ca<sup>2+</sup> ATPase (*SERCA*), plasma membrane ATPase (*PMCA*), plasma membrane Na<sup>+</sup>/Ca<sup>2+</sup> exchanger (*NCX*), Ca<sup>2+</sup>-sensitive K<sup>+</sup> channels (*K(Ca)*), and voltage-gated Ca<sup>2+</sup> channels (*VGCC*); GnRH increases cytoplasmic Ca<sup>2+</sup> by coordinated effects on mobilization from intracellular stores and entry across the plasma membrane. Ca<sup>2+</sup> is the primary driver for regulated release of gonadotropins that are contained in secretory vesicles and secreted largely by regulated exocytosis. Ca<sup>2+</sup> also activates calmodulin (*CaM*), which activates CaM-dependent protein kinases (*CaMK*), which in turn phosphorylate and regulate effectors including CREB (cAMP response element binding protein). CaM also activates the protein phosphatase calcineurin (*Cn*), which activates a number of effectors including the Ca<sup>2+</sup>-dependent transcription factor NFAT (nuclear factor of activated T-cells). Furthermore, GnRH activates MAPK cascades, including the (largely PKC-mediated) activation of the Raf/MEK/ERK cascade shown. NFAT, CREB, and ERK-activated transcription factors are among the many inputs to the transcriptome mediating combinatorial control of gene expression. This includes the genes encoding the gonadotropin subunits, so GnRH has both acute effects on the rate of vesicle fusion with the plasma membrane and chronic effects on the gonadotropin synthesis to influence the content of these vesicles. This is a greatly simplified view of some of the network components and more detailed GnRH signaling models are described elsewhere (Bliss et al. 2010; Ciccone and Kaiser 2009; Fink et al. 2010; McArdle and Roberson 2015; Millar et al. 2004; Navratil et al. 2010; Stojilkovic and Catt 1995; Wang et al. 2010; Wurmbach et al. 2001)

The Ca<sup>2+</sup> sensors mediating this regulated exocytosis have not been explored in detail, but early work implicated calmodulin as a mediator of GnRH-stimulated LH secretion (Conn et al. 1981) and also showed that PKC activation can mimic and modulate secretory effects of GnRH (McArdle et al. 1987; Stojilkovic et al. 1991; Zhu et al. 2002). Here, it is important to recognize that although Ca<sup>2+</sup> drives

regulated exocytosis, a proportion of gonadotropin secretion is via the constitutive pathway so that physiologically, pulses of GnRH-stimulated gonadotropin secretion overlay significant basal secretion (Pawson and McNeilly 2005). Indeed, the proportion of FSH secreted constitutively exceeds that for LH and when gonadotropins were measured in hypophyseal and peripheral blood, there was a high degree of synchrony between pulses of GnRH and LH, whereas FSH pulses are only associated with a small proportion of GnRH pulses (Clarke et al. 2002). LH and FSH are present in the same gonadotrope (Crawford and McNeilly 2002) so this requires sorting of the gonadotropins into distinct vesicles. Here it is noteworthy that only vesicles containing LH are associated with the storage protein secretogranin II and that the amount of LH stored in the pituitary can be 10–50 times higher than that of FSH (Pawson and McNeilly 2005). Thus, GnRH-stimulated  $\text{Ca}^{2+}$  transients drive regulated exocytotic release of storage vesicles containing LH, but have a less pronounced effect on FSH secretion, because FSH is less abundant in these vesicles and is directed largely for constitutive secretion (Pawson and McNeilly 2005).

---

## GnRH Signaling and Gene Expression

Array studies have revealed that GnRH influences expression of many genes, several of which encode transcription factors, including c-Fos, Egr1, and ATF-3 (Ruf et al. 2003; Yuen et al. 2009; Yuen et al. 2002), but most work in this area has focused on transcriptional control of the gonadotrope signature genes for  $\alpha$ GSU, LH $\beta$ , FSH $\beta$ , and GnRHR. GnRH increases transcription of each of these genes, and mechanistic studies have revealed regulatory roles for  $\text{Ca}^{2+}$ -regulated proteins and also for mitogen-activated protein kinase (MAPK) cascades (McArdle and Roberson 2015). The most extensively studied MAPK is ERK, which phosphorylates and regulates numerous cytoplasmic and nuclear target proteins including Ets, ELK1, and SAP1 transcription factors. The ERK cascade is classically engaged by growth factors via tyrosine kinase receptors, but many other stimuli, including GPCR agonists, feed into the cascade (Caunt et al. 2006b). The mechanisms of GnRHR-mediated ERK activation differ between model systems, but it is largely mediated by PKC in  $\alpha$ T3-1 and L $\beta$ T2 gonadotropes (Naor 2009), and both PKC and ERK mediate transcriptional effects of GnRH on  $\alpha$ GSU (Fowkes et al. 2002; Harris et al. 2003; Roberson et al. 1995; Weck et al. 1998), as well as LH $\beta$  (Call and Wolfe 1999; Harris et al. 2002; Kanasaki et al. 2005; Liu et al. 2002a) and FSH $\beta$  (Bonfil et al. 2004; Kanasaki et al. 2005; Vasilyev et al. 2002; Wang et al. 2008) subunits. However, other reports suggest roles for  $\text{Ca}^{2+}$  rather than ERK in GnRH-mediated LH $\beta$  (Weck et al. 1998) or  $\alpha$ GSU expression (Ferris et al. 2007; Kowase et al. 2007). Moreover, in some models, GnRH engages the canonical ERK activation pathway by causing a PKC-dependent proteolytic release of membrane bound epidermal growth factor (EGF) receptor ligands, thereby activating EGF receptors (Cheng and Leung 2005; Kraus et al. 2001), whereas in others EGF receptor activation is not involved (Bonfil et al. 2004; Naor 2009). A particularly interesting feature here is that gene knockouts targeting the  $\alpha$ GSU-expressing cells of the mouse

pituitary revealed a requirement for ERK1 and/or ERK2 for ovulation and fertility in females but not for fertility in males (Bliss et al. 2009). These effects were attributed to LH insufficiency because LH $\beta$  transcript levels were reduced by knockout in females (but not in males) and levels of transcripts for other gonadotropin subunits and for the GnRHR were indistinguishable between control and knockout animals of either gender (Bliss et al. 2009). It is also important to recognize that GnRH can also activate other MAPKs. Thus, in rat pituitaries,  $\alpha$ T3-1 and L $\beta$ T2 cells, GnRH increases c-Jun N-terminal kinase (JNK) activity (Burger et al. 2004, 2009; Naor 2009), and JNK can mediate GnRH effects on  $\alpha$ GSU expression as well as transcriptional activation of LH $\beta$  and FSH $\beta$  expression (Bonfil et al. 2004; Burger et al. 2009; Haisenleder et al. 2008). Similarly, GnRH activates p38 (also known as stress-activated protein kinase, SAPK) in these three model systems (Coss et al. 2007; Roberson et al. 1999), and this has been reported to have no role in LH $\beta$ , FSH $\beta$ , or  $\alpha$ GSU subunit transcription (Haisenleder et al. 2008; Liu et al. 2002a; Roberson et al. 1999) or to mediate GnRH effects on FSH $\beta$  transcription in L $\beta$ T2 cells (Bonfil et al. 2004; Coss et al. 2007). GnRH also activates ERK5, and this is thought to contribute to activation of FSH $\beta$  transcription in L $\beta$ T2 cells (Lim et al. 2009).

Although G<sub>q</sub> is the major mediator of GnRHR action, there is also evidence for regulation of the adenylyl cyclase/cyclic AMP (cAMP)/protein kinase A (PKA) pathway via G<sub>s</sub> or G<sub>i</sub>. GnRH was reported to increase cAMP production by pituitary cells (Borgeat et al. 1972), by gonadotrope-derived L $\beta$ T2 cells (Lariviere et al. 2007; Liu et al. 2002b), and in heterologous GnRHR expression systems (Arora et al. 1998). GnRHR coupling to G<sub>s</sub> has however remained controversial, because it was reported not to increase cAMP in some models (Conn et al. 1979; Horn et al. 1991), and where it does, some reports emphasize mediation by G<sub>s</sub> (Liu et al. 2002b; Stanislaus et al. 1998), whereas others show GnRHR coupling exclusively to G<sub>q</sub> (Grosse et al. 2000) or cAMP accumulation mediated by Ca<sup>2+</sup>/calmodulin-sensitive adenylyl cyclases (Lariviere et al. 2007). GnRHR apparently activate G<sub>i</sub> in some cancer cell lines including JEG-3 human choriocarcinoma cells and BPH-1 human benign prostate hyperplasia cells (Maudsley et al. 2004), but perhaps the most compelling evidence for GnRHR coupling to multiple G-proteins comes from work with immortalized GnRH-expressing neurons where the endogenous mouse GnRHR of GT1-7 cells mediates the activation of G<sub>s</sub>, G<sub>i</sub>, and G<sub>q</sub> as revealed by GnRH-stimulated release of G-protein subunits from membranes as well as associated functional responses (Krsmanovic et al. 2003). In L $\beta$ T2 cells, a cAMP FRET sensor study (Tsutsumi et al. 2010) revealed that GnRH pulses cause pulsatile increases in cAMP and also that with constant stimulation, effects of GnRH on cAMP were more transient than its effects on Ca<sup>2+</sup> or DAG (Tsutsumi et al. 2010). Furthermore, more recent work revealed that the GnRHRs interact directly with the proto-oncogene SET and that, in L $\beta$ T2 cells, the SET protein facilitates cAMP production while inhibiting GnRHR-mediated elevation of cytoplasmic Ca<sup>2+</sup> concentration (Avet et al. 2013).

Together, such studies highlight the possibility that GnRHR mediate effects on multiple heterotrimeric G-proteins and that the balance of signaling via these effectors varies with cell context and stimulation paradigm.

Regulation of cAMP levels by GnRH appears to have little or no acute effect on gonadotropin secretion but gonadotropin subunit promoters contain CREs (cAMP response elements), providing a direct mechanism for regulation by the cAMP/PKA pathway. In  $\alpha$ T3-1 cells GnRH caused a 4–5-fold increase in phospho-CREB (CRE-binding protein) binding (Duan et al. 1999), and cAMP stimulates transcription of the mouse, rat, and human  $\alpha$ GSU genes (Delegeane et al. 1987; Maurer et al. 1999). Moreover, a cAMP analogue increased  $\alpha$ GSU mRNA in rat pituitary cells, although it did not alter mRNA levels for LH $\beta$  or FSH $\beta$  (Haisenleder et al. 1992). Nevertheless, it is possible that the ERK cascade mediates gonadotropin promoter CRE activation rather than the cAMP/PKA pathway (Brown and McNeilly 1999; Burger et al. 2004; Counis et al. 2005; Harris et al. 2002; Levi et al. 1998) as CREB integrates multiple inputs, being regulated not only by PKA but also by MAPKs, CaMKs, and PKC (Berridge 2012). Two known substrates of JNK (c-Jun and ATF-2) bind the CRE domain of the  $\alpha$ GSU promoter (Haisenleder et al. 2005). Indeed, GnRH acts via p38 and JNK to phosphorylate ATF-2 and upon phosphorylation ATF-2 binds the CRE element within the c-Jun proximal promoter. Functional ATF-2 is needed for GnRH-mediated induction of both c-Jun and FSH $\beta$  (Fox et al. 2009). GnRH also increases ATF-3 expression, and ATF-3 is recruited along with c-Jun and c-Fos to CREs on the  $\alpha$ GSU promoter that are essential for GnRH-stimulated  $\alpha$ GSU gene expression (Chu et al. 2009).

In addition to the canonical  $G_q$  pathway that mediates GnRH effects on gonadotropin synthesis and secretion, it is important to recognize that GnRH activates additional signaling intermediates for which physiological roles are largely unknown. Thus, in addition to PLC, GnRH activates phospholipases D and A2 (Naor 2009), which hydrolyze phosphatidylcholine to produce phosphatidic acid (PA) and arachidonic acid (AA), respectively. PA and AA products (prostaglandins, thromboxanes, and leukotrienes) are thought to mediate GnRH signaling, and, conversely, GnRH can activate a DAG kinase that phosphorylates DAG to produce PA (Davidson et al. 2004a). Similarly, although most work on cyclic nucleotide signaling has focused on cAMP, gonadotropes also express neuronal nitric oxide synthase (nNOS) which generates nitric oxide (NO), and thereby stimulates cyclic GMP production by NO activation of soluble guanylyl cyclase. Of particular interest here is that GnRH is not only able to increase expression of nNOS but would also be expected to cause a  $Ca^{2+}$ /CaM-dependent activation of nNOS and that NO (which is membrane permeant and labile) has the potential to regulate guanylyl cyclase in gonadotropes and in neighboring cells (Garrel et al. 1997; Lozach et al. 1998). It has also been shown that GnRHRs mediate activation of the Wnt/ $\beta$ -catenin signaling pathway (Gardner et al. 2007), as well as proline-rich tyrosine kinase-2 (Davidson et al. 2004b) and AMP-activated protein kinase (AMPK), and the latter effect is implicated in control of LH $\beta$  gene transcription providing a potential common link between GnRH regulation and reproductive disorders due to metabolic dysregulation of gene expression (Andrade et al. 2013). Another particularly interesting feature here is that localization within the plasma membrane is crucial for GnRHR signaling. Indeed, GnRHRs are constitutively expressed in specialized plasma membrane micro-domains termed rafts, where they are co-localized with

important effectors and GnRHR signaling (at least to ERK) is dependent on the integrity of such rafts (Bliss et al. 2007; Navratil et al. 2003; Navratil et al. 2010). A comprehensive overview of the signaling network in L $\beta$ T2 cells (Fink et al. 2010) is available as a process diagram at [http://tsb.mssm.edu/pathwayPublisher/GnRHR\\_Pathway/GnRHR\\_Pathway\\_index.html](http://tsb.mssm.edu/pathwayPublisher/GnRHR_Pathway/GnRHR_Pathway_index.html).

---

## Trafficking, Compartmentalization, and Desensitization of GnRHR

It has long been known that sustained agonist exposure causes activation followed by desensitization of GnRH-stimulated gonadotropin secretion that can be avoided with pulsatile stimulation. Indeed, early physiological studies revealed that GnRH pulses support circulating gonadotropin levels in ovariectomized primates, whereas sustained stimulation caused them to plummet, an effect that is reversed on return to pulsatile stimulation (Belchetz et al. 1978). GnRH causes GnRHR internalization, and this could certainly contribute to desensitization of GnRH-stimulated gonadotropin secretion. Sustained stimulation of GPCRs typically elicits a process known as rapid homologous receptor desensitization, in which G-protein receptor kinases phosphorylate Ser and Thr residues, most often within the receptor's COOH-terminal tail, facilitating binding of nonvisual arrestins (arrestins 2 and 3). The arrestins prevent G-protein activation and also target the desensitized receptors for internalization, most often via clathrin-coated vesicles (CCVs) (Bockaert et al. 2003; Pierce and Lefkowitz 2001). Although GnRH was known to cause GnRHR internalization via CCVs (Hazum et al. 1980; Jennes et al. 1984), the cloning of mammalian type I GnRHR revealed most remarkably the complete absence of a COOH-terminal tail (Millar et al. 2004; Sealfon et al. 1997; Tsutsumi et al. 1992). Equally remarkable is the fact that all nonmammalian GnRHRs cloned to date have such tails, indicating that mammalian type I have undergone a period of rapidly accelerated molecular evolution with the advent of mammals being associated with the loss of COOH-terminal tails. In fact, it was established that type I mammalian GnRHR (where explored) do not rapidly desensitize or undergo agonist-induced phosphorylation or arrestin binding. Moreover, although they do show agonist-induced internalization, the process is relatively slow and is arrestin independent (Blomenrohr et al. 2002; Chen et al. 1995; Davidson et al. 1994; Finch et al. 2009; Heding et al. 1998; Hislop et al. 2000, 2001; McArdle et al. 1999; Pawson et al. 1998; Vrecl et al. 1998). Conversely, nonmammalian GnRHRs or type II mammalian GnRHRs (with COOH-terminal tails) do undergo agonist-induced phosphorylation, arrestin binding, and/or arrestin-dependent rapid homologous desensitization and are desensitized and internalized more rapidly than type I mammalian GnRHR. Furthermore, fusing the COOH-terminal of various nonmammalian GnRHRs to type I mammalian GnRHR can facilitate rapid desensitization, arrestin binding, and internalization (Finch et al. 2009; Hanyaloglu et al. 2001; Heding et al. 1998, 2000; Hislop et al. 2005). The fact that GnRH effects do undergo homologous desensitization seems initially at odds with the lack of desensitization of type I mammalian

GnRH, but in reality just points to the importance of alternative downstream mechanisms as discussed in more detail below.

Arrestins are well known as terminators of GPCR signaling, but they can also act as scaffolds to mediate signaling (Pierce and Lefkowitz 2001). Notably, they bind MAPK cascade components so that some GPCRs can switch between two distinct modes of signaling with two waves of ERK activation, the first mediated by G-protein activation and the second reflecting G-protein-independent activation of arrestin-scaffolded ERK (Luttrell and Lefkowitz 2002; Shenoy and Lefkowitz 2003). This raised the possibility that the latter might be selectively engaged by GnRHR with COOH-terminal tails and consistent with this, it was shown that heterologously expressed mouse GnRHR mediate only G-protein-dependent ERK activation whereas a *Xenopus laevis* GnRHR (XGnRHR) provoked both G-protein- and arrestin-mediated ERK activation (Caunt et al. 2006a, c). A third area in which the absence or presence of GnRHR C-tails is important is for cell surface GnRHR expression. Here the key observation is that a large proportion of GnRHRs are actually intracellular (Brothers et al. 2006; Finch et al. 2009; Finch et al. 2008; Janovick and Conn 2010a, b; Janovick et al. 2012; Sedgley et al. 2006), as shown by work with human (h)GnRHR mutants that cause infertility and were found to be nonfunctional because of impaired trafficking rather than impaired signaling (Conn and Janovick 2009; Conn and Ulloa-Aguirre 2010; Janovick et al. 2009; Tao and Conn 2014; Ulloa-Aguirre and Conn 2009). Even wild-type hGnRHRs are relatively poorly expressed at the cell surface, and the presence of a primate specific Lys<sup>191</sup>, the absence of a second N-terminal glycosylation site, and the absence of a COOH-tail are all implicated in poor cell surface expression of hGnRHR (Conn and Janovick 2009; Conn and Ulloa-Aguirre 2010; Davidson et al. 1995; Janovick et al. 2009; Tao and Conn 2014; Ulloa-Aguirre and Conn 2009). Indeed, quantitative immunofluorescence revealed that <5% of HA-tagged GnRHRs are at the cell surface in several heterologous expression systems and that this value can be increased as much as 10–50-fold for GnRHR with COOH-terminal tails (Finch et al. 2008, 2010). Cell-permeant GnRHR ligands are currently being developed as potential orally active GnRHR antagonists (Betz et al. 2008) and the proportion of hGnRHRs at the cell surface can also be increased (10–20-fold) by non-peptide indole antagonists (Finch et al. 2008, 2010). Such compounds can rescue signaling by trafficking-impaired GnRHR mutants, acting as pharmacological chaperones (pharmacoperones) to aid the folding of endoplasmic reticulum (ER)-resident GnRHR into a suitable conformation to meet ER exit quality control criteria, thereby facilitating GnRHR trafficking to the cell surface (Conn and Janovick 2009; Conn and Ulloa-Aguirre 2010; Janovick and Conn 2010b; Janovick et al. 2009; Ulloa-Aguirre and Conn 2009). Perhaps the most exciting aspect of this work is the potential for such compounds to be used clinically to restore function of mutant receptors with impaired trafficking, and recent work provided proof of concept, using a knock-in mouse model with a recessive E90K mutation in the GnRHR (Stewart et al. 2012). This mutation impairs trafficking of GnRHR to the cell surface by causing ER retention. This causes

hypogonadotropic hypogonadism in humans as well as in the mice, and pharmacoperone therapy restored testis function in this misfolded GnRHR model (Janovick et al. 2013).

---

## Extrapituitary GnRHR, Context Dependence, and Ligand Bias

GnRHR expression is not restricted to the pituitary as they are found in many normal and neoplastic tissues. Thus, GnRHRs have been found in the brain, placenta, endometrium, ovary, breast, testes, and prostate, where they may be activated by locally produced GnRH (Harrison et al. 2004). Here, some of the earliest studies suggested a paracrine role with GnRHR expression in Leydig cells and GnRH production by Sertoli cells as well as effects of GnRH agonists on steroidogenesis in cultured testes (Bahk et al. 1995; Botte et al. 1998; Dufau et al. 1984; Harrison et al. 2004). Interestingly, rat testes have been shown to express high-affinity GnRHRs that mediate GnRH effects on steroidogenesis *in vitro* (Huhtaniemi et al. 1985), but blockade of testicular GnRHR did not alter Leydig cell function *in vivo* (Huhtaniemi et al. 1987) and early work showed that GnRHRs are not present in human gonadal tissues (Clayton and Huhtaniemi 1982). In general, physiological roles for extrapituitary GnRHR remain elusive, but interest in this field is fueled by the fact that GnRH analogs can stimulate apoptosis and can inhibit proliferation and migration, in cell lines derived from cancers of such tissues (Eidne et al. 1987). Thus, GnRH agonists can inhibit proliferation and/or migration of prostate cancer cell lines which together with evidence for GnRHR expression in reproductive duct cancers suggests a local role in tumor growth and metastasis (Cheng and Leung 2005; Cheung and Wong 2008; Franklin et al. 2003; Limonta et al. 2012; Limonta et al. 2003; Montagnani Marelli et al. 2009; Wang et al. 2010). There is also considerable interest in the possibility that such receptors may be targeted with cytotoxins conjugated to GnRH analogs. Notably a cytotoxin consisting of the agonist D-Lys<sup>6</sup>GnRH covalently coupled to doxorubicin (AEZS-108) is undergoing clinical trials for treatment of breast, endometrial, ovarian, and prostate cancers (Engel et al. 2012, 2016).

Interestingly, major functional differences have been reported between pituitary and extrapituitary GnRHR, most notable in early work suggesting that extrapituitary GnRHRs have lower affinity for peptide ligands than their pituitary counterparts, signal via G<sub>i</sub> rather than via G<sub>q</sub>, and are unable to distinguish agonists from antagonists in the same way as pituitary GnRHR do (Emons et al. 1998; Everest et al. 2001; Franklin et al. 2003; Grundker et al. 2001; Imai et al. 1997; Limonta et al. 2012). It was initially suspected that this reflected expression and activation of distinct receptors in different cell types, but this seems unlikely because, as noted above, the type II GnRHR pseudogene that does not encode functional GnRHR (Stewart et al. 2009), and in some hormone-dependent cancer cell line effects of GnRH (and, indeed, effects of GnRH-II), can be prevented by knockdown of type I GnRHR (Montagnani Marelli et al. 2009). The simplest alternative possibility is that GnRHRs are capable of activating multiple upstream



effectors (i.e., G-proteins), that the efficiency with which they do so is dependent on the relative amounts of such effectors in their immediate vicinity, and that this varies from one cell type to another. Although the endogenous GnRHR of breast cancer (MCF7) and prostate cancer (PC3) cells has been shown to mediate direct antiproliferative effects of GnRHR ligands, in our hands these cells did not express measurable GnRHR, as judged by binding and functional assays (Everest et al. 2001; Finch et al. 2004; Franklin et al. 2003). However, when recombinant adenovirus was used to express type I GnRHR in them, the heterologously expressed GnRHR had similar binding affinity, ligand specificity, and  $G_q$  coupling to the native GnRHR in gonadotropes. Moreover, activation of these receptors did reduce proliferation with effects apparently mediated by  $G_q$  rather than  $G_i$ . These experiments are consistent with a role for extrapituitary GnRHRs as regulators of cell fate in hormone-dependent cancer cells, but it remains unclear why the native type I GnRHR of GnRHR-positive breast and prostate cancer cells should mediate proliferation inhibition by a distinct mechanism to the type I GnRHR expressed heterologously in GnRHR-negative versions of the same cells. Cell context-dependent behavior was also seen when fluorescence microscopy was used to explore receptor compartmentalization, however (Finch et al. 2008; Sedgley et al. 2006). This revealed that <1% of HA-tagged hGnRHRs are at the cell surface in MCF7 and prostate cancer (DU145) cell lines and that this proportion is >5-fold higher in gonadotrope-lineage L $\beta$ T2 cells.

Receptor dimerization may also be relevant to context-dependent GnRHR signaling as it is now well established that many GPCRs form dimers of higher-order oligomers and that such oligomerization can facilitate signaling and may be either constitutive or ligand induced. In some of the earliest work supporting this idea, Conn's groups showed that GnRH antagonists could be converted to agonists by addition of bivalent antibodies to the ligand. No such effect was seen with monovalent antibodies so the simplest interpretation is that antibody-mediated GnRHR cross-linking is sufficient for activation (Conn et al. 1982), presumably because this cross-linking facilitates or mimics GnRHR dimerization. There is also now considerable evidence that agonists (but not antagonists) cause GnRHR oligomerization or at least bring GnRHR sufficiently close to one another to mediate FRET or BRET (Cornea et al. 2001; Horvat et al. 2001; Kroeger et al. 2003). However, the cellular compartments in which GnRHR oligomers form and the regulation of oligomer assembly remain poorly understood, and it has not been shown that oligomerization is required for GnRH signaling. It is also now well established that many GPCRs can form heterodimers (or higher-order oligomers) with other GPCRs. For example, type V somatostatin receptors (SSTR5) form heterodimers with type II dopamine receptors (D2R), both of which are  $G_i$ -coupled GPCRs (Rocheville et al. 2000). Some of the best evidence for this comes from early functional rescue studies showing, for example, that when signal dead (C-terminal truncated) SSTR5 are co-expressed with D2R, this rescues the ability of SST to activate  $G_i$  (Rocheville et al. 2000). To our knowledge dimerization of GnRHR with other GPCRs has not been explored, but if this were to occur, it could potentially facilitate GnRH signaling to G-proteins activated by the partner GPCR, and this

could confer context-dependent signaling as the repertoire of partner GPCRs available would presumably also be dependent on cell type.

Finally, ligand bias (also known as biased signaling or pluridimensional efficacy) is another concept that may be important for cell context-dependent GnRHR signaling. Here, the fundamental idea is that GPCRs actually have multiple active conformations that may couple differentially to different effectors. They may also be differentially stabilized by different ligands, such that different ligands can bias signaling toward different effectors (Kenakin 2011; McArdle 2012). The simplest scenario is that there are two distinct active conformations, but in reality, for any given GPCR, there are thought to be many different tertiary structures in related groups of preferred conformations known as receptor ensembles (Kenakin 2011). If the effect of a given ligand on the distribution of receptors between possible conformations differs from one cell type to another (because other features of the receptors' environments differ), ligand bias would itself be dependent on cell context. For cell context-dependent GnRHR effects, some experimental data cannot be easily explained without distinct active conformations of a single GnRHR type. Thus, the peptide "antagonist" cetrorelix is a pure antagonist of GnRH effects on inositol phosphate (IP) accumulation and gonadotropin secretion in pituitary cells, but it actually mimics antiproliferative effects of GnRH in some models (Grundker et al. 2004; Maudsley et al. 2004). Similarly, GnRH-I is more potent than GnRH-II at stimulation of IP accumulation by type I GnRHR in pituitary cells, which is the reverse of the situation for inhibition of proliferation in some models (Cheung and Wong 2008; Enomoto et al. 2004; Grundker et al. 2004; Hislop et al. 2000; Wang et al. 2010). Indeed, with only a single receptor target, ligand bias appears the most likely explanation for much data showing differences in ligand specificity when native GnRHR-mediated effects have been compared in different cell types (McArdle 2012). More direct evidence for ligand bias has been obtained in a number of models (Caunt et al. 2004; Davidson et al. 2004b; Lopez de Maturana et al. 2008; Maudsley et al. 2004) including a study comparing effects of GnRH analogues on different type I mammalian GnRHR-mediated responses. A series of GnRHR ligands all inhibited proliferation in JEG-3 cells and BPH-1 cells (both with native hGnRHR) and in SCL60 cells (which have exogenous rat GnRHR). They all apparently activated  $G_i$  and caused  $G_i$ -dependent inhibition of proliferation (Maudsley et al. 2004), and marked ligand bias was observed because GnRH-I stimulated IP accumulation; activated ERK, p38, and JNK; and inhibited proliferation, whereas a GnRH analogue (135–25) mimicked all other GnRH-I effects but failed to increase IP accumulation (Maudsley et al. 2004). Ligand bias at GnRHR is also evident in work on GnRHR localization and trafficking. As noted above, non-peptide pharmacoperones can increase GnRHR trafficking to the cell surface so work with these compounds provides a marked example of pluridimensional efficacy with non-peptide ligands acting as antagonists in terms of cell surface GnRHR signaling, but as agonists in terms of anterograde trafficking. This also indicates that the cell surface and intracellular GnRHRs have different conformations, which is not unexpected as most GnRHRs within the cell have apparently failed quality control criteria for ER exit, whereas those at the cell surface evidently

have not. Experiments were performed with two peptide antagonists (antide and cetrorelix), which, being membrane-impermeant, did not have access to intracellular GnRHR and, as expected, had no effect on the proportion of hGnRHR at the cell surface (Finch et al. 2008). However, when the XGnRHR COOH-tail was added to the hGnRHR in order to increase cell surface expression, the peptide antagonists further increased cell surface expression of the chimeric receptor. Although the effect was modest, it raised the possibility that the peptides might act at the surface to increase GnRHR number by slowing internalization. Indeed, a pronounced synergism can occur when a non-peptide chaperone is used to increase GnRHR trafficking to the cell surface and a peptide antagonist is used to slow internalization from the cell surface (Finch et al. 2010). Thus, although the mechanisms are not known, this work clearly demonstrates that the cetrorelix-occupied hGnRHR is functionally distinct from the unoccupied receptor and that cetrorelix can be a pure antagonist for GnRH-I-stimulated IP accumulation and  $\text{Ca}^{2+}$  signaling and an inverse agonist for GnRHR internalization. Importantly, this form of ligand bias was seen with a compound that is used clinically and in gonadotropes, the only proven targets for GnRHR-directed therapy. Ligand bias has a number of implications for understanding and manipulating GnRHR signaling in pituitary and extrapituitary sites, but most importantly, it raises the exciting possibility of developing ligands that more selectively engage therapeutically beneficial responses. Here an obvious strategy would be to develop GnRHR ligands that are antagonists for  $G_q$ -mediated stimulation of gonadotropin secretion from the pituitary and agonists for direct  $G_i$ -mediated anti-proliferative effects on hormone-dependent cancers.

---

## Additional Hormonal and Local Regulators of Gonadotropes

In addition to GnRH, gonadotropes are targets for numerous other hormonal and local regulators. It is well established, for example, that gonadal steroids (estrogen, progesterone, and testosterone) mediate feedback within the hypothalamic-gonadal axis, acting centrally to influence GnRH secretion and at the pituitary to modulate GnRH effects on gonadotropes. In females estrogen exerts positive and negative feedback effects with positive feedback at the pituitary level being crucial for the preovulatory gonadotropin surge, whereas in males, testosterone exerts negative feedback effects both centrally and at the pituitary. At the pituitary level, testosterone influences expression of GnRHR, gonadotropin subunit expression, and GnRH signaling (Clayton and Catt 1981; Kaiser et al. 1993; Winters et al. 1992), and modulation of GnRH effects on cytoplasmic  $\text{Ca}^{2+}$  was shown to be dependent on local conversion of testosterone to dihydrotestosterone by  $5\alpha$ -reductase (Tobin and Canny 1998). Interestingly, a recent study in which the male reproductive axis of sheep was modeled mathematically incorporated regulation of GnRH pulsatility by central testosterone-mediated negative feedback (but not feedback at the pituitary) and illustrated the importance of a time delay that was attributed to conversion of testosterone to estrogen (Ferasyi et al. 2016). The proteins inhibin and activin also feedback from the gonads to inhibit and activate (respectively) FSH production but,

in addition to this endocrine loop, are also synthesized in gonadotropes and act locally to regulate FSH synthesis. They are members of the TGF- $\beta$  family and act via receptors with intrinsic serine/threonine kinase activity to exert effects that are modulated by locally produced follistatin (Bilezikjian et al. 2006).

Pituitary adenylyl cyclase-activating polypeptide (PACAP) is another ligand thought to mediate both endocrine and local regulation of gonadotropes. It was isolated from hypothalamic extracts based on its ability to stimulate cAMP production in pituitary cell cultures (Miyata et al. 1989) and has higher concentration in the portal circulation than in the periphery, supporting a hypothalamic-hypophysiotrophic hormone role (Counis et al. 2007; Rawlings and Hezareh 1996; Schomerus et al. 1994; Winters and Moore 2011). It has two major forms (PACAP27 and PACAP38) which act via three GPCRs: VPAC<sub>1</sub> and VPAC<sub>2</sub> that have similar affinity for PACAP and VIP (vasoactive polypeptide) and PAC<sub>1</sub> that has higher affinity for PACAP than for VIP. PACAP causes a PAC<sub>1</sub>-mediated activation of both G<sub>s</sub> and G<sub>q</sub> in gonadotropes and gonadotrope-derived cell lines and influences gonadotropin secretion and synthesis both alone and by modulation of GnRH effects. It also targets PAC<sub>1</sub> receptors on folliculo-stellate cells and evidence exists for its production by folliculo-stellate cells and gonadotropes, suggesting it to be an autocrine regulator of both (Denef 2008; Winters and Moore 2011). Interestingly, PACAP increases follistatin expression by folliculo-stellate cells and gonadotropes and may thereby modulate activin signaling in the pituitary (Winters and Moore 2011). Other ligands that act via GPCRs on gonadotropes include oxytocin, endothelin 1, galanin,  $\beta$ -endorphin, neuropeptide Y, and nucleotides (Denef 2008). The latter are of particular interest as ATP, ADP, uridine 5' diphosphate, and uridine 5' triphosphate (UDP and UTP) act via purinergic receptors that include both GPCRs and ligand-gated ion channels. P2X receptors (P2XRs) are ATP-activated ligand-gated ion channels that are permeable to Na<sup>+</sup>, K<sup>+</sup>, and Ca<sup>2+</sup> so their activation characteristically increases Ca<sup>2+</sup> entry across the plasma membrane either directly or as a consequence of membrane depolarization. P2Y receptors (P2YRs) and adenosine receptors (ARs) are GPCRs that are preferentially activated by ATP and adenosine (respectively), and since both classes include G<sub>q</sub>-coupled receptors, their activation is also often associated with elevation of cytoplasmic Ca<sup>2+</sup>. Anterior pituitary cell expresses at least six types of P2XRs, two types of P2YR, and all four types of AR (Stojilkovic et al. 2010a; Stojilkovic and Koshimizu 2001). Early work revealed that ATP and UTP act via P2YRs in gonadotropes to drive a G<sub>q</sub>-mediated increase in cytoplasmic Ca<sup>2+</sup> (Chen et al. 1994, 1995), whereas later work revealed expression of P2XR in gonadotropes and, indeed, in all secretory cell types of the pituitary (Stojilkovic et al. 2010a, b; Stojilkovic and Koshimizu 2001). Pituitary cells store ATP in secretory vesicles and co-release it with hormones during agonist-stimulated exocytosis (Denef 2008), underlining the potential for a positive feedback loop in which GnRH stimulates ATP secretion and ATP stimulates LH secretion, either alone or by amplification of GnRH-mediated LH secretion (Denef 2008). As noted above, GnRH increases nNOS expression and thereby increases cGMP production mediated by NO and soluble guanylyl cyclase, but pituitary cells are also responsive to natriuretic peptides that act via cell surface receptors with

intrinsic guanylyl cyclase activity (Fowkes and McArdle 2000). Of particular interest here is C-type natriuretic peptide (CNP) that specifically activates NPR-2 (natriuretic peptide receptor 2, also known as guanylyl cyclase B) to increase cGMP levels in primary cultures of pituitary cells and in gonadotrope-derived cell lines (Fowkes and McArdle 2000; McArdle et al. 1994a; Thompson et al. 2009). CNP is highly expressed in the pituitary with particularly strong expression in gonadotropes where it is located largely in secretory vesicles (McArdle et al. 1996). Deletion of genes encoding both CNP and NPR-2 causes infertility (Chusho et al. 2001; Tamura et al. 2004), and although CNP does not stimulate LH secretion, it can stimulate the  $\alpha$ GUSU promoter (Thompson et al. 2009). Together these data suggest that autocrine and/or paracrine regulation of both particulate and soluble guanylyl cyclases influences gonadotrope function.

Gonadotropes (like all cells) sense multiple chemicals in their environment, and these different inputs act in combination. The importance of this combinatorial input is illustrated by cyclic nucleotide signaling; although GnRH increases cAMP and cGMP production in some models, its effects are much less pronounced than those of PACAP and CNP, and in the presence of PACAP, GnRH actually inhibits cAMP production (McArdle and Counis 1996; McArdle et al. 1994b), just as it actually inhibits cGMP production in the presence of CNP in gonadotrope cell lines (McArdle et al. 1994a). This raises the question of which effects predominate in normal gonadotropes and more generally, the issue that effects of GnRH seen in isolation and in vitro may differ from those seen in more complex and physiologically relevant extracellular environments. Furthermore, gonadotropes not only sense and respond to their environment but also influence it, as highlighted above for ATP, NO, CNP, PACAP, and inhibin, all of which are likely secreted in response to GnRH (Denef 2008). Recent work has shown how GnRH-stimulated secretion of inhibin and of growth differentiation factor 9 form incoherent feedforward loops controlling FSH production, highlighting the fact that the extracellular space can also mediate GnRH signaling in a concept that was termed “outside the box signaling” (Choi et al. 2012, 2014; Pincas et al. 2014).

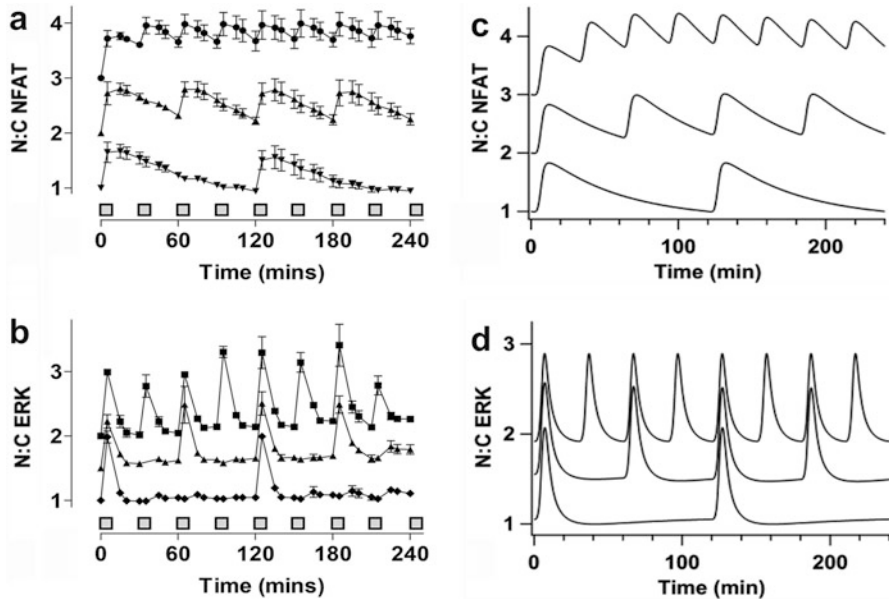
---

## Pulsatile GnRH Signaling

GnRH is secreted from hypothalamic neurons in pulses that drive pulses of gonadotropin release and are essential for normal reproduction (Clarke and Cummins 1982; Dierschke et al. 1970). Its effects are dependent on pulse frequency, as shown in early studies in which constant GnRH suppressed LH and FSH secretion, whereas restoration of GnRH pulses restored gonadotropin secretion (Belchetz et al. 1978; Knobil 1980; Wildt et al. 1981). In humans and other primates, GnRH pulses have a duration of a few minutes and intervals of 30 min to several hours, with pulse frequency differing under different physiological conditions. For example, changes in GnRH pulse frequency drive changes in reproductive status during development, with an increase in pulse frequency driving the increased gametogenesis and gonadal steroid production at puberty (Sisk and Foster 2004). Similarly, GnRH pulse

frequency varies through the menstrual cycle, increasing before ovulation and contributing to generation of the preovulatory gonadotropin surge (Ferris and Shupnik 2006; Marshall et al. 1993). Moreover, stimulation paradigm is crucial for therapeutic intervention because agonist pulses can maintain or increase circulating gonadotropin levels whereas sustained agonist stimulation (after initial activation) reduces them, causing the chemical castration that is exploited in treatment of breast cancer, prostate cancer, and other sex steroid hormone-dependent conditions (Bliss et al. 2010; Ferris and Shupnik 2006; Marshall et al. 1993; Millar et al. 2004). Similar mechanisms mediate responses to sustained and pulsatile GnRH as for both, GnRH activates  $G_q$  and effectors including the  $Ca^{2+}$ /calmodulin/calciurein/NFAT module and ERK (Armstrong et al. 2009a, b; Bliss et al. 2009, 2010; Ciccone and Kaiser 2009; Ferris and Shupnik 2006; Millar et al. 2004). Moreover, pituitary ERK is essential for reproduction (Bliss et al. 2009) consistent with its role as an effector of pulsatile GnRHR in vivo.

A fundamental question here is why GnRH is secreted in pulses, and we have explored this by monitoring effects of pulsatile GnRH on the nuclear translocation of ERK2-GFP as a readout for Raf/MEK/ERK activation and of NFAT-EFP as a readout for  $Ca^{2+}$ /calmodulin activation (Fig. 2). We found that each 5 min pulse of GnRH elicits a rapid and transient ERK2-GFP translocation response and a somewhat slower NFAT-EFP translocation response (Armstrong et al. 2009a, 2010). With 30 min pulse intervals, there was insufficient time for the NFAT-EFP reporter to return to pre-stimulation values so that a cumulative or “saw-tooth” response was observed. Indeed, the NFAT-EFP translocation response to GnRH pulses was comparable to that seen with constant stimulation (Armstrong et al. 2009a), whereas the ERK2-GFP translocation response was not. This demonstrates two fundamental reasons why pulsatile signals are so prevalent in biological systems: first, the increase in efficiency (similar system output with pulsatile vs. constant stimulation) and, second, the possibility for selective effector activation (with 30 min pulses of GnRH causing maximal NFAT translocation and submaximal ERK activation). To explore this further, we developed an ordinary differential equation-based mathematical model of a GnRHR signaling network that was trained on experimental data (Perrett et al. 2014; Tsaneva-Atanasova et al. 2012) (Fig. 2). Model simulations were used to predict responses with varied GnRH concentration, pulse width and pulse frequency in order to explore system sensitivity to these distinct features of the dynamic input (Perrett et al. 2014; Tsaneva-Atanasova et al. 2012). These simulations revealed that a tenfold increase in GnRH concentration does not cause a tenfold increase in responses, primarily because it does not cause a tenfold increase in GnRHR occupancy. Moreover, increases in system outputs caused by a tenfold increase in GnRH pulse width are less than the increases caused by a tenfold increase in pulse frequency. Thus, the system is an integrative tracker (in that it is sensitive to pulse amplitude, frequency, and width, all of which influence the integral of the input), but there is certainly not a simple 1:1 relationship between integrated input and output. Instead, the kinetics of receptor occupancy and downstream effector activation create a system that is relatively robust to changes in pulse width and



**Fig. 2** Live cell monitoring and mathematical modelling of pulsatile GnRH signaling to ERK and NFAT. Panels **A** and **B**: HeLa cells were transduced with recombinant adenovirus for expression of ERK2-GFP or NFAT-EFP (as indicated), both of which translocate to the nucleus on activation. Live cell imaging was used to capture responses during 5 min pulses of  $10^{-7}$  M GnRH at intervals of 30 min (circles), 60 min (upright triangles) or 120 min (inverted triangles). Nuclear:cytoplasmic ratios were calculated for each reporter. These were normalized to the value at time 0 and are offset on the vertical axes for clarity (i.e., NFAT-EFP data are offset by 0, 1, or 2 and ERK2-GFP values are offset by 0, 0.5 or 1). Note that each GnRH pulse caused nuclear translocation of each reporter (although the ERK2-GFP translocation responses had more rapid onset and offset) and that with high pulse frequencies, there was insufficient time for the NFAT-EFP to return to the pre-stimulation value. Note also, that there was no obvious desensitization, in that amplitudes did not reduce over time. Panels **C** and **D**: An ordinary differential equation-based model for GnRH signaling was developed and trained against wet lab data for pulsatile GnRH signaling to ERK and NFAT. The data shown are simulations for ERK and NFAT translocation in cells receiving 5 min pulses of  $10^{-7}$  M GnRH offset precisely as described for panels **A** and **B** to illustrate the close agreement between the wet lab data and the model predictions (Adapted from Tsaneva-Atanasova et al. 2012)

concentration but is highly sensitive to changes in pulse frequency, the input variable known to vary under different physiological conditions in vivo (Perrett et al. 2014).

Another fundamentally important feature of the system is that responses can be maximal at submaximal pulse frequency (Bedecarrats and Kaiser 2003; Ciccone and Kaiser 2009; Ciccone et al. 2010; Dalkin et al. 1989; Ferris and Shupnik 2006; Haisenleder et al. 1991; Kaiser et al. 1993; Kanasaki et al. 2005; Shupnik 1990; Weiss et al. 1990). Moreover, the frequency eliciting maximal responses is dependent on the output measured, as seen in work with luciferase reporters for gonadotrope signature genes (Bedecarrats and Kaiser 2003), where optimal GnRH

pulse frequencies for expression of LH $\beta$ , FSH $\beta$ ,  $\alpha$ GSU, and GnRHR reporters differ (maximal responses at pulse intervals of 2 h for LH $\beta$  and FSH $\beta$ , 0.5 h for  $\alpha$ GSU, and 1 h for GnRHR, in L $\beta$ T2 cells). In ovariectomized rhesus monkeys bearing hypothalamic lesions which reduced circulating LH and FSH to undetectable levels, hourly GnRH pulses favored LH secretion whereas pulses every 3 h favored FSH secretion (Wildt et al. 1981). Additional *in vivo* studies with GnRH-deficient men recapitulated this observation (Gross et al. 1987; Spratt et al. 1987), as do *in vitro* studies using pituitary cultures (Bedecarrats and Kaiser 2003; Dalkin et al. 1989; Ferris and Shupnik 2006; Haisenleder et al. 1991; Kaiser et al. 1993; Shupnik 1990; Weiss et al. 1990; Yasin et al. 1995). Moreover, in polycystic ovarian syndrome, the most common cause of infertility in women of reproductive age, there is an increase in GnRH activity and predominance of high-frequency GnRH pulses that are thought to drive the observed elevation of LH and suppression of FSH and the associated disruption of reproductive cycles (Ciccone et al. 2010; Hoffman and Ehrmann 2008).

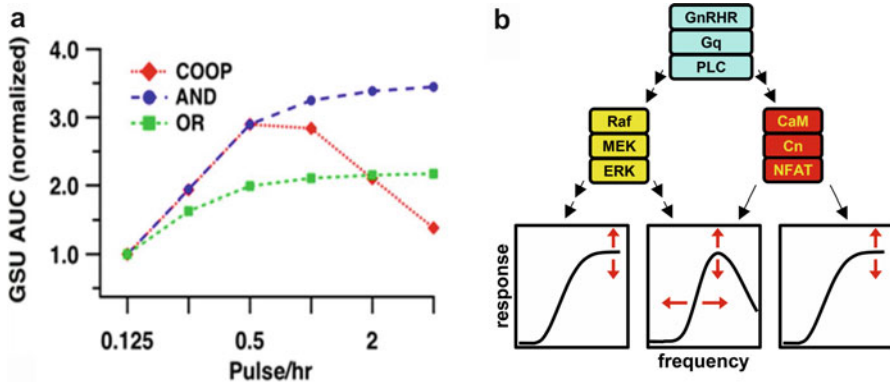
In essence, the data above all illustrate the fact that for many GnRH effects, there is a non-monotonic (bell-shaped) pulse frequency-response curve. This could reflect the existence of feedback or feedforward loops (Krakauer et al. 2002), but the nature of these loops is unclear. Rapid homologous receptor desensitization can be excluded as a potential negative feedback loop because type I mammalian GnRHR do not show this behavior (as discussed earlier). However, GnRH does downregulate cell surface GnRHR, and a mathematical model of GnRH signaling predicts pulse frequency-dependent desensitization of upstream signals as a consequence of GnRHR downregulation (Washington et al. 2004). Alternative possible mechanisms for desensitization to GnRH have been described, including GnRHR-mediated induction of RGS-2 (regulator of G-protein signaling-2) which displays GTPase-activating protein activity and is known to inhibit G $\alpha$  signaling (Karakoula et al. 2008; Wurmbach et al. 2001), direct interaction of GnRHR with SET protein which can inhibit G $\alpha$  binding (Avet et al. 2013), induction of MAPK phosphatases (MKPs) which would modulate GnRHR-mediated ERK signaling (Lim et al. 2009), downregulation of IP<sub>3</sub> receptors (Willars et al. 2001; Wojcikiewicz et al. 2003), induced expression of calmodulin-dependent small G-protein Kir/Gem (kinase-inducible Ras-like protein/GTP-binding protein overexpressed in skeletal muscle) (Ferris and Shupnik 2006), and ERK-mediated negative feedback (Armstrong et al. 2009b; Caunt et al. 2006a). However, such responses have been explored primarily with constant stimulation paradigms and may well have little or no effect with pulsatile stimulation. A thorough theoretical examination of pulse frequency decoding mechanisms also revealed how receptor dimerization can generate non-monotonic frequency-response relationships (Fletcher et al. 2014), and this is of particular interest in light of early studies suggesting that dimerization of GnRHR could elicit signaling (Conn et al. 1982, 1987), as well as work showing that agonists (but not antagonists) bring GnRHR closer to one another (Cornea et al. 2001; Navratil et al. 2006). However, as noted above, it is not established that dimerization of normal GnRHR is a prerequisite for signaling; the live cell imaging experiments



described above also provide some insight here, as the ERK2-GFP and NFAT-EFP translocation responses were both reproducible with repeated GnRH pulses (Fig. 2) and the signals passing from the cytoplasm to the nucleus showed increasing monotonic frequency-response relationships. In support of this, Egr-1-responsive and NFAT-responsive luciferase reporters used as transcriptional readouts for ERK and NFAT activation both show maximal responses at maximal GnRH pulse frequency (Armstrong et al. 2009a, 2010).

If signaling inputs to the nucleus show increasing monotonic frequency-response relationships, the obvious possibility is that feedback and/or feedforward regulatory loops within the nucleus underlie the observed non-monotonic frequency-response relationships for gene expression. This has been explored most extensively for the FSH $\beta$  promoter, for which a number of incoherent feedforward loops have been described. These are signaling modules that fan out from an upstream node and reconverge at a downstream node and for which the two divergent branches have different overall signs (i.e., positive and negative effects). Thus, for example, stimulation of FSH $\beta$  gene expression by GnRH is, in part, mediated by its ability to phosphorylate and activate the transcription factor CREB, but GnRH can also increase expression of the inducible cAMP early repressor (ICER), which inhibits the effect of CREB, providing both positive and negative inputs to the promoter (Ciccone et al. 2010; Thompson et al. 2013). As noted above, pulsatile stimulation provides the potential for specificity in effector activation, and the inhibitory (ICER-mediated) loop is preferentially activated at high GnRH pulse frequency so that transcriptional activation is greatest at submaximal pulse frequency. Similarly, it was shown that expression of Fos and Jun (positive regulators of FSH $\beta$  expression) is increased at lower GnRH pulse frequencies than needed for expression of negative regulators (the co-repressors SKIL, CREM, and TGIF1) suggesting regulation by an alternative incoherent feedforward loop in which SKIL and/or TGIF1 inhibits activation by AP-1 factors Fos and Jun (Mistry et al. 2011). In addition to these nuclear mechanisms, incoherent feedforward loops have been described in which the inhibitory branch is due to GnRH-stimulated protein secretion. In the first, it is mediated by secretion of inhibin- $\alpha$ , which has long been known to suppress FSH expression, and in the second, it is mediated by inhibition of the secretion of growth differentiation factor 9, an autocrine inducer of FSH $\beta$  expression in L $\beta$ T2 cells (Choi et al. 2012, 2014; Pincas et al. 2014). These studies are of particular interest as they effectively extend the GnRH signaling network to the extracellular space (as outlined above for autocrine regulation).

We have also used mathematical modeling to explore possible frequency decoding mechanisms, taking our model trained against NFAT-EFP and ERK2-GFP translocation data (Figs. 2 and 3), so that these could then be used as inputs to the transcriptome. In doing so, it was assumed that two transcription factors act at separate sites on a common gene promoter (using NFAT as the first transcription factor and an undefined ERK-dependent transcription factor as the second one). Three distinct logic gates were considered: an “and-gate,” an “or-gate” or a “cooperative gate.” This model predicted bell-shaped frequency-response relationships



**Fig. 3 Generation of bell-shaped pulse frequency-response relationships by convergent signaling.** A previously described mathematical model for GnRH signaling (Tsaneva-Atanasova et al. 2012) was used to simulate transcriptional responses driven by ERK and NFAT assuming that they converge at a common promoter with one of three logic gates: an “and-gate,” an “or-gate,” or a “cooperative” gate. Predicted transcriptional responses (area under the curve for time-course data) are shown in panel A, as a function of pulse frequency (5 min pulses of  $10^{-7}$  M GnRH) for the target gene (here given the generic term GSU, but not indicating any particular gonadotropin subunit gene). Such simulations always yielded increasing monotonic frequency-response relationships when a single pathway was considered or when convergence was modelled with an and-gate or an or-gate. Bell-shaped frequency-response relationships were only obtained with cooperative convergence of these two pathways at the transcriptome (panels A and B) (Adapted from Tsaneva-Atanasova et al. 2012)

when two transcription factors act cooperatively. The characteristic feature of maximal response at submaximal frequency was never seen with the and-gate or with the or-gate, and this behavior was predicted without negative feedback (Tsaneva-Atanasova et al. 2012). A particularly interesting feature of these simulations is that they revealed GnRH pulse frequency-response relationship may be plastic, in that varying rate constants for transcription factor activation and inactivation, or varying balance of signaling via NFAT and ERK-dependent transcription factors, influenced the frequencies at which maximal response occurred (Tsaneva-Atanasova et al. 2012). This modelling clearly does not show that the bell-shaped frequency-response relationships seen for transcriptional effects of GnRH are mediated by convergence of NFAT and ERK-dependent transcription factors. In fact, multiple pathways converge to mediate GnRH effects on transcription (Nelson et al. 1998), and the relative importance and mechanisms of integration of these inputs are undoubtedly promoter/enhancer specific. Moreover, the bell-shaped frequency-response relationships seen in this model rely on a mathematical description of cooperative convergence for which biological substrates have not been identified, so it will be important to develop and test mathematical models for the biological pathways described above. Nevertheless, a common feature of much work in this field is that it highlights mechanisms for generation of non-monotonic frequency-response relationships in the absence of upstream negative feedback. Indeed, it

seems likely that pulsatile GnRH secretion and the resistance of type I mammalian GnRHR to desensitization both serve to minimize negative feedback and thereby place increasing reliance on such alternative mechanisms.

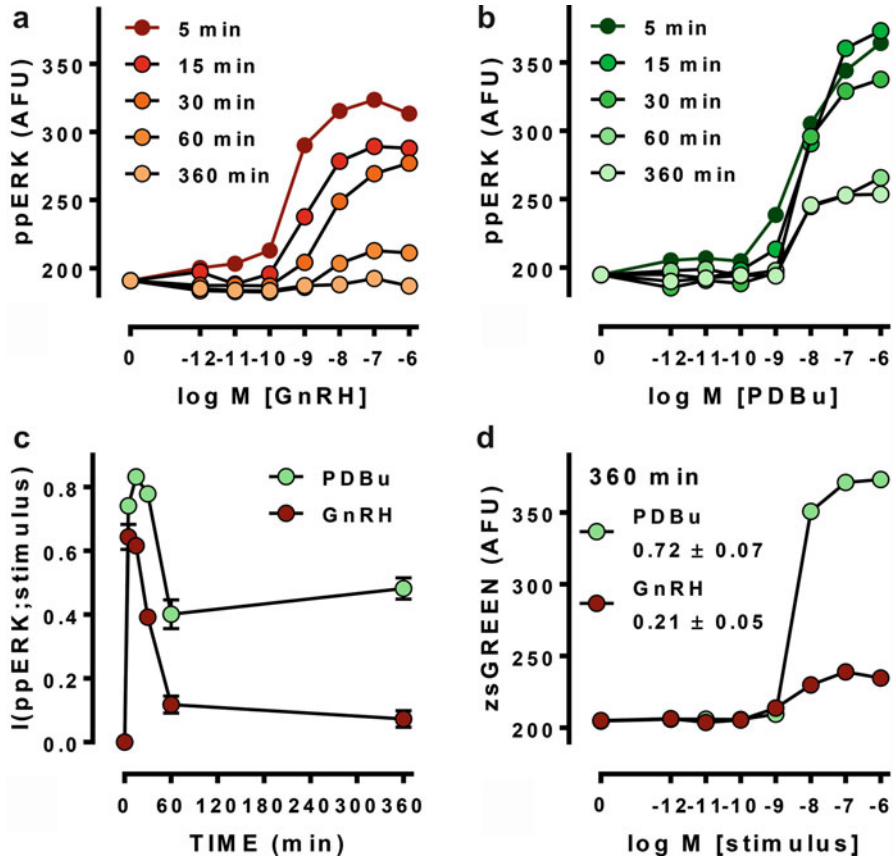
---

## **An Information Theoretic Approach to GnRH Signaling**

Most work on GnRH signaling has entailed measurement of average responses from populations of cells, and the mechanistic modelling outlined above effectively considers the behavior of a single cell, assuming it to be representative of the population. These approaches ignore cell-cell variation but such variation is in fact inevitable because cell signaling is inherently stochastic. It is also crucial for the behavior of cell populations (Bowsher and Swain 2014) because each individual cell has to sense its environment and make appropriate decisions (to express or suppress given genes, to survive or die, to proliferate or differentiate, etc.). Cell-cell variation in response to GnRH has been documented for many years, from early work on gonadotropin secretion and  $\text{Ca}^{2+}$  mobilization (Lewis et al. 1989; McArdle et al. 1992; Stojilkovic and Catt 1995) and more recent studies using transcriptional readouts and/or high content imaging (Armstrong et al. 2009a, b, 2010; Caunt et al. 2012; Garner et al. 2016; Ruf et al. 2006, 2007). Information theory was developed to analyze electronic communication but can also be applied to biological systems, where it provides tools with which the influence of cell-cell variation on the reliability of sensing can be determined (Bowsher and Swain 2014; Bowsher et al. 2013; Brennan et al. 2012; Cheong et al. 2011; Selimkhanov et al. 2014; Uda et al. 2013; Voliotis et al. 2014). In this context, information is defined as the uncertainty about the environment that is reduced by signaling and can be quantified as the mutual information (MI) between two stochastic variables (Bowsher and Swain 2014). MI measures the quality of the inference (or “prediction”) of the signal from the response. It is measured in bits with an MI of 1 bit indicating that the system can unambiguously distinguish between two equally probable states of the environment. Importantly, estimation of MI doesn’t require knowledge of the mechanism by which information is transferred, and MI values are unaffected by transformations of the signal or response (Bowsher and Swain 2014). Several groups have applied information theoretic approaches to analysis of cell signaling, treating signaling pathways as noisy communication channels and quantifying the information that they do (or could) carry. The value of this approach can be illustrated by considering a signaling pathway with multiple levels, such as a MAPK cascade. It is well established that signal amplification can occur from one tier to the next in the cascade, but it is less well recognized that information about the input cannot actually increase from one level in the cascade to the next. In fact there is normally loss (and never gain) of information through signaling cascades and any increase in numbers of activated molecules must therefore be associated with increased variability (noise) through the cascade. There is considerable interest in understanding how cells mitigate loss of information through signaling pathways, and here negative feedback loops are of particular interest because they can

reduce information transfer (by reducing dynamic range of the output) or protect it (by reducing cell-cell variability).

In a recent study, ppERK and nuclear translocation of NFAT-EFP were measured as activation readouts, and *Egr1*- and NFAT response element-driven fluorophore expression were measured as transcription activation by ERK and NFAT. Responses were measured in large numbers of individual GnRH-stimulated cells (Garner et al. 2016) and used to calculate MI between GnRH concentration and ppERK ( $I(\text{ppERK};\text{GnRH})$ ). This revealed information transfer between GnRHR and ERK to be  $<1$  Bit in HeLa cells transduced with Ad-GnRHR (Fig. 4). This is comparable to values obtained for cytokine and growth factor signaling in other systems (Garner et al. 2016), but is still surprisingly low for two reasons. First, the cells were typically stimulated with eight GnRH concentrations so there was a 3 Bit input, of which  $<1$  Bit of information was transferred. Second, population-averaged measures consistently show responses to GnRH being graded over a wide range of GnRH concentrations, yet an MI of  $<1$  implies that single cells cannot unambiguously distinguish between just two inputs (i.e., with and without GnRH). This was not due to use of a heterologous expression system because information transfer values were similar in HeLa cells (with exogenous GnRHR) and L $\beta$ T2 gonadotropes (with endogenous GnRHR). It was also not restricted to the ERK pathway because information transfer from GnRHR to NFAT was  $<0.5$  Bits in both cell models (Garner et al. 2016). Another possible explanation for low information transfer is that single time-point measures underestimate information transfer. This would be expected where cells infer inputs (i.e., GnRH concentrations) from trajectories of outputs (i.e., ppERK levels) over time (Selimkhanov et al. 2014). For example, time-course experiments revealed that  $I(\text{ppERK};\text{GnRH})$  is higher at 5 than at 360 min (Fig. 4), but this clearly does not mean that a cell obtains less information over 360 min than it had over 5 min. Instead, it shows that the 360 min snapshot underestimates information transferred over the 360 min stimulation. Measuring MI for ERK-driven transcription is an alternative approach that could be sensitive to ppERK trajectory, and, consistent with this, work with imaging readouts for ERK-driven transcription revealed more reliable sensing of PDBu than of GnRH in HeLa cells (Fig. 4), presumably because PDBu has a more sustained effect than GnRH on ppERK and causes a more marked increase in *Egr1*-driven zsGREEN expression (Garner et al. 2016). Thus the system senses sustained stimulation more reliably and must therefore be sensitive to the dynamics of ERK activation. This information theoretic approach was also applied to consider possible effects of negative feedback, focusing on ERK-dependent feedback (i.e., rapid transcription-independent and slow transcription-dependent feedback) and on receptor desensitization (i.e., by comparison of type I mammalian GnRHRs that do not rapidly desensitize and XGnRHRs that do). The overriding observation from these first statistical measures of information transfer via GnRHR is that it is not measurably influenced by the occurrence or absence of rapid receptor desensitization, but is influenced by downstream adaptive processes (i.e., ERK-mediated feedback) with optimal GnRH sensing at intermediate feedback intensities.



**Fig. 4 MI as an information theoretic measure of GnRH sensing.** Panels A and B show concentration and time-dependent effects of GnRH and phorbol 12,13 dibutyrate (PDBu) on ERK activity in L $\beta$ T2 cells, with nuclear ppERK reported in arbitrary fluorescence units (AFU). Single cell measures underlying these plots were also used to calculate MI between ppERK and each of these stimuli and these values are plotted (MI in Bits on vertical axis) against time in panel C. The cells were also transduced with recombinant adenovirus for expression of an ERK-driven transcription reporter (Egr1-zsGREEN). Panel D shows the concentration-dependence of GnRH and PDBu on zsGREEN expression (in AFU) at 360 min and the MI between zsGREEN and each of these stimuli is also shown for this time (Adapted from Garner et al. 2016)

## Summary

Since GnRH was isolated and sequenced in the 1970s, there have been immense advances in our understanding of GnRH signaling. This ranges from the early work identifying  $\text{Ca}^{2+}$  as a mediator of stimulus-secretion coupling through subsequent work mapping the GnRH signaling network as well as the extensive studies of gene expression focusing on gonadotrope signature genes or using omics approaches to

elucidate regulatory networks. The ever-increasing complexity of GnRHR signaling networks highlights the necessity for mathematical and statistical analyses as illustrated by recent information theoretic work on GnRH signaling, where emphasis was on the amount of information transferred rather than identifying components of the paths through which it is conveyed. From the outset the system has provided remarkable surprises. Notably, the initial paradoxical observation that a peptide purified as a gonadotropin-releasing factor actually reduces circulating gonadotropins and causes chemical castration on sustained stimulation *in vivo*. With receptor cloning came the equally surprising observation that mammalian type I GnRHR lack COOH-terminal tails and do not rapidly desensitize, so alternative mechanisms must underlie the desensitization of GnRH-stimulated gonadotropin secretion. Compartmentalization has also emerged as a crucial determinant of GnRHR function, as highlighted by the discovery that most hGnRHRs are actually intracellular as well as the fact that GnRHR signaling is dependent upon its location within the plane of the plasma membrane. Similarly, the importance of dynamics cannot be overestimated because the CNS provides GnRH pulses as a frequency-encoded signal to be decoded by gonadotropes. We still do not have a detailed understanding of how they do so or how GnRHR compartmentalization is controlled, let alone how these systems may be modulated by other hormonal or local inputs. Accordingly, the authors believe that a major research challenge for future work is to overlay space and time on existing schema for GnRH action, whereas the clinical challenge lies in translating the large amount of mechanistic information into genuine therapeutic benefit.

**Acknowledgments** This work was funded Project Grants from MRC (93447) and the BBSRC (J014699). KTA gratefully acknowledges the financial support of the EPSRC via grant EP/N014391/1.

---

## References

- Al-Inany HG, Youssef MA, Ayeleke RO, Brown J, Lam WS, Broekmans FJ. Gonadotrophin-releasing hormone antagonists for assisted reproductive technology. *Cochrane Database Syst Rev*. 2016;4:CD001750.
- Andrade J, Quinn J, Becker RZ, Shupnik MA. AMP-activated protein kinase is a key intermediary in GnRH-stimulated LHbeta gene transcription. *Mol Endocrinol*. 2013;27:828–39.
- Armstrong SP, Caunt CJ, Fowkes RC, Tsaneva-Atanasova K, McArdle CA. Pulsatile and sustained gonadotropin-releasing hormone (GnRH) receptor signaling: does the Ca<sup>2+</sup>/NFAT signaling pathway decode GnRH pulse frequency? *J Biol Chem*. 2009a;284:35746–57.
- Armstrong SP, Caunt CJ, McArdle CA. Gonadotropin-releasing hormone and protein kinase C signaling to ERK: spatiotemporal regulation of ERK by docking domains and dual-specificity phosphatases. *Mol Endocrinol*. 2009b;23:510–9.
- Armstrong SP, Caunt CJ, Fowkes RC, Tsaneva-Atanasova K, McArdle CA. Pulsatile and sustained gonadotropin-releasing hormone (GnRH) receptor signaling: does the ERK signaling pathway decode GnRH pulse frequency? *J Biol Chem*. 2010;285:24360–71.

- Arora KK, Kršmanovic LZ, Mores N, O'Farrell H, Catt KJ. Mediation of cyclic AMP signaling by the first intracellular loop of the gonadotropin-releasing hormone receptor. *J Biol Chem.* 1998;273:25581–6.
- Avet C, Garrel G, Denoyelle C, Laverriere JN, Counis R, Cohen-Tannoudji J, Simon V. SET protein interacts with intracellular domains of the gonadotropin-releasing hormone receptor and differentially regulates receptor signaling to cAMP and calcium in gonadotrope cells. *J Biol Chem.* 2013;288:2641–54.
- Bahk JY, Hyun JS, Chung SH, Lee H, Kim MO, Lee BH, Choi WS. Stage specific identification of the expression of GnRH mRNA and localization of the GnRH receptor in mature rat and adult human testis. *J Urol.* 1995;154:1958–61.
- Bedecarrats GY, Kaiser UB. Differential regulation of gonadotropin subunit gene promoter activity by pulsatile gonadotropin-releasing hormone (GnRH) in perfused L beta T2 cells: role of GnRH receptor concentration. *Endocrinology.* 2003;144:1802–11.
- Belchetz PE, Plant TM, Nakai Y, Keogh EJ, Knobil E. Hypophyseal responses to continuous and intermittent delivery of hypothalamic gonadotropin-releasing hormone. *Science.* 1978;202:631–3.
- Berridge MJ. *Cell signalling biology.* 2012.
- Betz SF, Zhu YF, Chen C, Struthers RS. Non-peptide gonadotropin-releasing hormone receptor antagonists. *J Med Chem.* 2008;51:3331–48.
- Bilezikjian LM, Blount AL, Donaldson CJ, Vale WW. Pituitary actions of ligands of the TGF-beta family: activins and inhibins. *Reproduction.* 2006;132:207–15.
- Bliss SP, Navratil AM, Breed M, Skinner DC, Clay CM, Roberson MS. Signaling complexes associated with the type I gonadotropin-releasing hormone (GnRH) receptor: colocalization of extracellularly regulated kinase 2 and GnRH receptor within membrane rafts. *Mol Endocrinol.* 2007;21:538–49.
- Bliss SP, Miller A, Navratil AM, Xie J, McDonough SP, Fisher PJ, Landreth GE, Roberson MS. ERK signaling in the pituitary is required for female but not male fertility. *Mol Endocrinol.* 2009;23:1092–101.
- Bliss SP, Navratil AM, Xie J, Roberson MS. GnRH signaling, the gonadotrope and endocrine control of fertility. *Front Neuroendocrinol.* 2010;31:322–40.
- Blomenrohr M, Bogerd J, Leurs R, Goos H. Differences in structure-function relations between nonmammalian and mammalian GnRH receptors: what we have learnt from the African catfish GnRH receptor. *Prog Brain Res.* 2002;141:87–93.
- Bockaert J, Marin P, Dumuis A, Fagni L. The 'magic tail' of G protein-coupled receptors: an anchorage for functional protein networks. *FEBS Lett.* 2003;546:65–72.
- Bonfil D, Chuderland D, Kraus S, Shahbazian D, Friedberg I, Seger R, Naor Z. Extracellular signal-regulated kinase, Jun N-terminal kinase, p38, and c-Src are involved in gonadotropin-releasing hormone-stimulated activity of the glycoprotein hormone follicle-stimulating hormone beta-subunit promoter. *Endocrinology.* 2004;145:2228–44.
- Borgeat P, Chavancy G, Dupont A, Labrie F, Arimura A, Schally AV. Stimulation of adenosine 3':5'-cyclic monophosphate accumulation in anterior pituitary gland in vitro by synthetic luteinizing hormone-releasing hormone. *Proc Natl Acad Sci U S A.* 1972;69:2677–81.
- Botte MC, Chamagne AM, Carre MC, Counis R, Kottler ML. Fetal expression of GnRH and GnRH receptor genes in rat testis and ovary. *J Endocrinol.* 1998;159:179–89.
- Bowsher CG, Swain PS. Environmental sensing, information transfer, and cellular decision-making. *Curr Opin Biotechnol.* 2014;28:149–55.
- Bowsher CG, Voliotis M, Swain PS. The fidelity of dynamic signaling by noisy biomolecular networks. *PLoS Comput Biol.* 2013;9:e1002965.
- Brennan MD, Cheong R, Levchenko A. Systems biology. How information theory handles cell signaling and uncertainty. *Science.* 2012;338:334–5.
- Brothers SP, Janovick JA, Conn PM. Calnexin regulated gonadotropin-releasing hormone receptor plasma membrane expression. *J Mol Endocrinol.* 2006;37:479–88.

- Brown P, McNeilly AS. Transcriptional regulation of pituitary gonadotrophin subunit genes. *Rev Reprod.* 1999;4:117–24.
- Burger LL, Haisenleder DJ, Dalkin AC, Marshall JC. Regulation of gonadotropin subunit gene transcription. *J Mol Endocrinol.* 2004;33:559–84.
- Burger LL, Haisenleder DJ, Aylor KW, Marshall JC. Regulation of Lhb and Egr1 gene expression by GNRH pulses in rat pituitaries is both c-Jun N-terminal kinase (JNK)- and extracellular signal-regulated kinase (ERK)-dependent. *Biol Reprod.* 2009;81:1206–15.
- Call GB, Wolfe MW. Gonadotropin-releasing hormone activates the equine luteinizing hormone beta promoter through a protein kinase C/mitogen-activated protein kinase pathway. *Biol Reprod.* 1999;61:715–23.
- Cattanach BM, Iddon CA, Charlton HM, Chiappa SA, Fink G. Gonadotrophin-releasing hormone deficiency in a mutant mouse with hypogonadism. *Nature.* 1977;269:338–40.
- Caunt CJ, Hislop JN, Kelly E, Matharu AL, Green LD, Sedgley KR, Finch AR, McArdle CA. Regulation of gonadotropin-releasing hormone receptors by protein kinase C: inside out signalling and evidence for multiple active conformations. *Endocrinology.* 2004;145:3594–602.
- Caunt CJ, Finch AR, Sedgley KR, McArdle CA. GnRH receptor signalling to ERK: kinetics and compartmentalization. *Trends Endocrinol Metab.* 2006a;17:308–13.
- Caunt CJ, Finch AR, Sedgley KR, McArdle CA. Seven-transmembrane receptor signalling and ERK compartmentalization. *Trends Endocrinol Metab.* 2006b;17:276–83.
- Caunt CJ, Finch AR, Sedgley KR, Oakley L, Luttrell LM, McArdle CA. Arrestin-mediated ERK activation by gonadotropin-releasing hormone receptors: receptor-specific activation mechanisms and compartmentalization. *J Biol Chem.* 2006c;281:2701–10.
- Caunt CJ, Perett RM, Fowkes RC, McArdle CA. Mechanisms of GnRH-induced extracellular signal-regulated kinase nuclear localization. *PLoS One.* 2012;7:e40077.
- Chen ZP, Levy A, McArdle CA, Lightman SL. Pituitary ATP receptors: characterization and functional localization to gonadotropes. *Endocrinology.* 1994;135:1280–3.
- Chen ZP, Kratzmeier M, Levy A, McArdle CA, Poch A, Day A, Mukhopadhyay AK, Lightman SL. Evidence for a role of pituitary ATP receptors in the regulation of pituitary function. *Proc Natl Acad Sci U S A.* 1995;92:5219–23.
- Cheng CK, Leung PC. Molecular biology of gonadotropin-releasing hormone (GnRH)-I, GnRH-II, and their receptors in humans. *Endocr Rev.* 2005;26:283–306.
- Chengalvala MV, Pelletier JC, Kopf GS. GnRH agonists and antagonists in cancer therapy. *Curr Med Chem Anticancer Agents.* 2003;3:399–410.
- Cheong R, Rhee A, Wang CJ, Nemenman I, Levchenko A. Information transduction capacity of noisy biochemical signaling networks. *Science.* 2011;334:354–8.
- Cheung LW, Wong AS. Gonadotropin-releasing hormone: GnRH receptor signaling in extra-pituitary tissues. *FEBS J.* 2008;275:5479–95.
- Choi SG, Jia J, Pfeffer RL, Sealfon SC. G proteins and autocrine signaling differentially regulate gonadotropin subunit expression in pituitary gonadotrope. *J Biol Chem.* 2012;287:21550–60.
- Choi SG, Wang Q, Jia J, Pincas H, Turgeon JL, Sealfon SC. Growth differentiation factor 9 (GDF9) forms an incoherent feed-forward loop modulating follicle-stimulating hormone beta-subunit (FSHbeta) gene expression. *J Biol Chem.* 2014;289:16164–75.
- Chu Z, Andrade J, Shupnik MA, Moenter SM. Differential regulation of gonadotropin-releasing hormone neuron activity and membrane properties by acutely applied estradiol: dependence on dose and estrogen receptor subtype. *J Neurosci.* 2009;29:5616–27.
- Chusho H, Tamura N, Ogawa Y, Yasoda A, Suda M, Miyazawa T, Nakamura K, Nakao K, Kurihara T, Komatsu Y, et al. Dwarfism and early death in mice lacking C-type natriuretic peptide. *Proc Natl Acad Sci U S A.* 2001;98:4016–21.
- Ciccone NA, Kaiser UB. The biology of gonadotroph regulation. *Curr Opin Endocrinol Diabetes Obes.* 2009;16:321–7.
- Ciccone NA, Xu S, Lacza CT, Carroll RS, Kaiser UB. Frequency-dependent regulation of follicle-stimulating hormone beta by pulsatile gonadotropin-releasing hormone is mediated by functional antagonism of bZIP transcription factors. *Mol Cell Biol.* 2010;30:1028–40.



- Clarke IJ, Cummins JT. The temporal relationship between gonadotropin releasing hormone (GnRH) and luteinizing hormone (LH) secretion in ovariectomized ewes. *Endocrinology*. 1982;111:1737–9.
- Clarke IJ, Cummins JT. Increased gonadotropin-releasing hormone pulse frequency associated with estrogen-induced luteinizing hormone surges in ovariectomized ewes. *Endocrinology*. 1985;116:2376–83.
- Clarke I, Moore L, Veldhuis J. Intensive direct cavernous sinus sampling identifies high-frequency, nearly random patterns of FSH secretion in ovariectomized ewes: combined appraisal by RIA and bioassay. *Endocrinology*. 2002;143:117–29.
- Clayton RN, Catt KJ. Regulation of pituitary gonadotropin-releasing hormone receptors by gonadal hormones. *Endocrinology*. 1981;108:887–95.
- Clayton RN, Huhtaniemi IT. Absence of gonadotropin-releasing hormone receptors in human gonadal tissue. *Nature*. 1982;299:56–9.
- Conn PM, Crowley Jr WF. Gonadotropin-releasing hormone and its analogs. *Annu Rev Med*. 1994;45:391–405.
- Conn PM, Janovick JA. Trafficking and quality control of the gonadotropin releasing hormone receptor in health and disease. *Mol Cell Endocrinol*. 2009;299:137–45.
- Conn PM, Ulloa-Aguirre A. Trafficking of G-protein-coupled receptors to the plasma membrane: insights for pharmacoperone drugs. *Trends Endocrinol Metab*. 2010;21:190–7.
- Conn PM, Morrell DV, Dufau ML, Catt KJ. Gonadotropin-releasing hormone action in cultured pituitary cells: independence of luteinizing hormone release and adenosine 3',5'-monophosphate production. *Endocrinology*. 1979;104:448–53.
- Conn PM, Chafouleas JG, Rogers D, Means AR. Gonadotropin releasing hormone stimulates calmodulin redistribution in rat pituitary. *Nature*. 1981;292:264–5.
- Conn PM, Rogers DC, Stewart JM, Niedel J, Sheffield T. Conversion of a gonadotropin-releasing hormone antagonist to an agonist. *Nature*. 1982;296:653–5.
- Conn PM, Huckle WR, Andrews WV, McArdle CA. The molecular mechanism of action of gonadotropin releasing hormone (GnRH) in the pituitary. *Recent Prog Horm Res*. 1987;43:29–68.
- Comea A, Janovick JA, Maya-Nunez G, Conn PM. Gonadotropin-releasing hormone receptor microaggregation. Rate monitored by fluorescence resonance energy transfer. *J Biol Chem*. 2001;276:2153–8.
- Coss D, Hand CM, Yaphockun KK, Ely HA, Mellon PL. p38 mitogen-activated protein kinase is critical for synergistic induction of the FSH(beta) gene by gonadotropin-releasing hormone and activin through augmentation of c-Fos induction and Smad phosphorylation. *Mol Endocrinol*. 2007;21:3071–86.
- Counis R, Laverriere JN, Garrel G, Bleux C, Cohen-Tannoudji J, Lerrant Y, Kottler ML, Magre S. Gonadotropin-releasing hormone and the control of gonadotrope function. *Reprod Nutr Dev*. 2005;45:243–54.
- Counis R, Laverriere JN, Garrel-Lazayres G, Cohen-Tannoudji J, Lariviere S, Bleux C, Magre S. What is the role of PACAP in gonadotrope function? *Peptides*. 2007;28:1797–804.
- Crawford JL, McNeilly AS. Co-localisation of gonadotrophins and granins in gonadotrophs at different stages of the oestrous cycle in sheep. *J Endocrinol*. 2002;174:179–94.
- Dalkin AC, Haisenleder DJ, Ortolano GA, Ellis TR, Marshall JC. The frequency of gonadotropin-releasing-hormone stimulation differentially regulates gonadotropin subunit messenger ribonucleic acid expression. *Endocrinology*. 1989;125:917–24.
- Davidson JS, Wakefield IK, Millar RP. Absence of rapid desensitization of the mouse gonadotropin-releasing hormone receptor. *Biochem J*. 1994;300(Pt 2):299–302.
- Davidson JS, Flanagan CA, Zhou W, Becker II, Elario R, Emeran W, Sealson SC, Millar RP. Identification of N-glycosylation sites in the gonadotropin-releasing hormone receptor: role in receptor expression but not ligand binding. *Mol Cell Endocrinol*. 1995;107:241–5.
- Davidson L, Pawson AJ, Lopez de Maturana R, Freestone SH, Barran P, Millar RP, Maudsley S. Gonadotropin-releasing hormone-induced activation of diacylglycerol kinase-zeta and its association with active c-src. *J Biol Chem*. 2004a;279:11906–16.

- Davidson L, Pawson AJ, Millar RP, Maudsley S. Cytoskeletal reorganization dependence of signaling by the gonadotropin-releasing hormone receptor. *J Biol Chem.* 2004b;279:1980–93.
- de Roux N, Young J, Misrahi M, Genet R, Chanson P, Schaison G, Milgrom E. A family with hypogonadotropic hypogonadism and mutations in the gonadotropin-releasing hormone receptor. *N Engl J Med.* 1997;337:1597–602.
- Deleage AM, Ferland LH, Mellon PL. Tissue-specific enhancer of the human glycoprotein hormone alpha-subunit gene: dependence on cyclic AMP-inducible elements. *Mol Cell Biol.* 1987;7:3994–4002.
- Denef C. Paracrinicity: the story of 30 years of cellular pituitary crosstalk. *J Neuroendocrinol.* 2008;20:1–70.
- Dierschke DJ, Bhattacharya AN, Atkinson LE, Knobil E. Circoral oscillations of plasma LH levels in the ovariectomized rhesus monkey. *Endocrinology.* 1970;87:850–3.
- Duan WR, Shin JL, Jameson JL. Estradiol suppresses phosphorylation of cyclic adenosine 3',5'-monophosphate response element binding protein (CREB) in the pituitary: evidence for indirect action via gonadotropin-releasing hormone. *Mol Endocrinol.* 1999;13:1338–52.
- Dufau ML, Warren DW, Knox GF, Loumaye E, Castellon ML, Luna S, Catt KJ. Receptors and inhibitory actions of gonadotropin-releasing hormone in the fetal Leydig cell. *J Biol Chem.* 1984;259:2896–9.
- Eidne KA, Flanagan CA, Harris NS, Millar RP. Gonadotropin-releasing hormone (GnRH)-binding sites in human breast cancer cell lines and inhibitory effects of GnRH antagonists. *J Clin Endocrinol Metab.* 1987;64:425–32.
- Emons G, Muller V, Ortmann O, Schulz KD. Effects of LHRH-analogues on mitogenic signal transduction in cancer cells. *J Steroid Biochem Mol Biol.* 1998;65:199–206.
- Engel J, Emons G, Pinski J, Schally AV. AEZS-108: a targeted cytotoxic analog of LHRH for the treatment of cancers positive for LHRH receptors. *Expert Opin Investig Drugs.* 2012;21:891–9.
- Engel JB, Tinneberg HR, Rick FG, Berkes E, Schally AV. Targeting of peptide cytotoxins to LHRH receptors for treatment of cancer. *Curr Drug Targets.* 2016;17:488–94.
- Enomoto M, Endo D, Kawashima S, Park MK. Human type II GnRH receptor mediates effects of GnRH on cell proliferation. *Zool Sci.* 2004;21:763–70.
- Everest HM, Hislop JN, Harding T, Uney JB, Flynn A, Millar RP, McArdle CA. Signaling and antiproliferative effects mediated by GnRH receptors after expression in breast cancer cells using recombinant adenovirus. *Endocrinology.* 2001;142:4663–72.
- Ferasyi TR, Barrett PH, Blache D, Martin GB. Modeling the male reproductive endocrine axis: potential role for a delay mechanism in the inhibitory action of gonadal steroids on GnRH pulse frequency. *Endocrinology.* 2016;157:2080–92.
- Fernald RD, White RB. Gonadotropin-releasing hormone genes: phylogeny, structure, and functions. *Front Neuroendocrinol.* 1999;20:224–40.
- Ferris HA, Shupnik MA. Mechanisms for pulsatile regulation of the gonadotropin subunit genes by GnRH1. *Biol Reprod.* 2006;74:993–8.
- Ferris HA, Walsh HE, Stevens J, Fallest PC, Shupnik MA. Luteinizing hormone beta promoter stimulation by adenylyl cyclase and cooperation with gonadotropin-releasing hormone 1 in transgenic mice and LBetaT2 Cells. *Biol Reprod.* 2007;77:1073–80.
- Finch AR, Green L, Hislop JN, Kelly E, McArdle CA. Signaling and antiproliferative effects of type I and II gonadotropin-releasing hormone receptors in breast cancer cells. *J Clin Endocrinol Metab.* 2004;89:1823–32.
- Finch AR, Sedgley KR, Caunt CJ, McArdle CA. Plasma membrane expression of GnRH receptors: regulation by antagonists in breast, prostate, and gonadotrope cell lines. *J Endocrinol.* 2008;196:353–67.
- Finch AR, Caunt CJ, Armstrong SP, McArdle CA. Agonist-induced internalization and down-regulation of gonadotropin-releasing hormone receptors. *Am J Physiol Cell Physiol.* 2009;297:C591–600.

- Finch AR, Caunt CJ, Armstrong SP, McArdle CA. Plasma membrane expression of gonadotropin-releasing hormone receptors: regulation by peptide and nonpeptide antagonists. *Mol Endocrinol.* 2010;24:423–35.
- Fink MY, Pincas H, Choi SG, Nudelman G, Sealfon SC. Research resource: gonadotropin-releasing hormone receptor-mediated signaling network in LbetaT2 cells: a pathway-based web-accessible knowledgebase. *Mol Endocrinol.* 2010;24:1863–71.
- Fletcher PA, Clement F, Vidal A, Tabak J, Bertram R. Interpreting frequency responses to dose-conserved pulsatile input signals in simple cell signaling motifs. *PLoS One.* 2014;9:e95613.
- Fowkes RC, McArdle CA. C-type natriuretic peptide: an important neuroendocrine regulator? *Trends Endocrinol Metab.* 2000;11:333–8.
- Fowkes RC, King P, Burrin JM. Regulation of human glycoprotein hormone alpha-subunit gene transcription in LbetaT2 gonadotropes by protein kinase C and extracellular signal-regulated kinase 1/2. *Biol Reprod.* 2002;67:725–34.
- Fox EM, Andrade J, Shupnik MA. Novel actions of estrogen to promote proliferation: integration of cytoplasmic and nuclear pathways. *Steroids.* 2009;74:622–7.
- Franklin J, Hislop J, Flynn A, McArdle CA. Signalling and anti-proliferative effects mediated by gonadotrophin-releasing hormone receptors after expression in prostate cancer cells using recombinant adenovirus. *J Endocrinol.* 2003;176:275–84.
- Gardner S, Maudsley S, Millar RP, Pawson AJ. Nuclear stabilization of beta-catenin and inactivation of glycogen synthase kinase-3beta by gonadotropin-releasing hormone: targeting Wnt signaling in the pituitary gonadotrope. *Mol Endocrinol.* 2007;21:3028–38.
- Garner KL, Perrett RM, Voliotis M, Bowsher C, Pope GR, Pham T, Caunt CJ, Tsaneva-Atanasova-K, McArdle CA. Information Transfer in Gonadotropin-releasing Hormone (GnRH) Signaling: extracellular signal-regulated kinase (ERK)-mediated feedback loops control hormone sensing. *J Biol Chem.* 2016;291:2246–59.
- Garrel G, McArdle CA, Hemmings BA, Counis R. Gonadotropin-releasing hormone and pituitary adenylate cyclase-activating polypeptide affect levels of cyclic adenosine 3',5'-monophosphate-dependent protein kinase A (PKA) subunits in the clonal gonadotrope alphaT3-1 cells: evidence for cross-talk between PKA and protein kinase C pathways. *Endocrinology.* 1997;138:2259–66.
- Gross KM, Matsumoto AM, Bremner WJ. Differential control of luteinizing hormone and follicle-stimulating hormone secretion by luteinizing hormone-releasing hormone pulse frequency in man. *J Clin Endocrinol Metab.* 1987;64:675–80.
- Grosse R, Schmid A, Schoneberg T, Herrlich A, Muhn P, Schultz G, Gudermann T. Gonadotropin-releasing hormone receptor initiates multiple signaling pathways by exclusively coupling to G (q/11) proteins. *J Biol Chem.* 2000;275:9193–200.
- Grundker C, Volker P, Emons G. Antiproliferative signaling of luteinizing hormone-releasing hormone in human endometrial and ovarian cancer cells through G protein alpha(I)-mediated activation of phosphotyrosine phosphatase. *Endocrinology.* 2001;142:2369–80.
- Grundker C, Schlotawa L, Viereck V, Eicke N, Horst A, Kairies B, Emons G. Antiproliferative effects of the GnRH antagonist cetrorelix and of GnRH-II on human endometrial and ovarian cancer cells are not mediated through the GnRH type I receptor. *Eur J Endocrinol.* 2004;151:141–9.
- Haisenleder DJ, Dalkin AC, Ortolano GA, Marshall JC, Shupnik MA. A pulsatile gonadotropin-releasing hormone stimulus is required to increase transcription of the gonadotropin subunit genes: evidence for differential regulation of transcription by pulse frequency in vivo. *Endocrinology.* 1991;128:509–17.
- Haisenleder DJ, Yasin M, Marshall JC. Enhanced effectiveness of pulsatile 3',5'-cyclic adenosine monophosphate in stimulating prolactin and alpha-subunit gene expression. *Endocrinology.* 1992;131:3027–33.
- Haisenleder DJ, Burger LL, Aylor KW, Dalkin AC, Walsh HE, Shupnik MA, Marshall JC. Testosterone stimulates follicle-stimulating hormone beta transcription via activation of extracellular signal-regulated kinase: evidence in rat pituitary cells. *Biol Reprod.* 2005;72:523–9.

- Haisenleder DJ, Burger LL, Walsh HE, Stevens J, Aylor KW, Shupnik MA, Marshall JC. Pulsatile gonadotropin-releasing hormone stimulation of gonadotropin subunit transcription in rat pituitaries: evidence for the involvement of Jun N-terminal kinase but not p38. *Endocrinology*. 2008;149:139–45.
- Hansen JR, McArdle CA, Conn PM. Relative roles of calcium derived from intra- and extracellular sources in dynamic luteinizing hormone release from perfused pituitary cells. *Mol Endocrinol*. 1987;1:808–15.
- Hanyaloglu AC, Vrecl M, Kroeger KM, Miles LE, Qian H, Thomas WG, Eidne KA. Casein kinase II sites in the intracellular C-terminal domain of the thyrotropin-releasing hormone receptor and chimeric gonadotropin-releasing hormone receptors contribute to beta-arrestin-dependent internalization. *J Biol Chem*. 2001;276:18066–74.
- Harris D, Bonfil D, Chuderland D, Kraus S, Seger R, Naor Z. Activation of MAPK cascades by GnRH: ERK and Jun N-terminal kinase are involved in basal and GnRH-stimulated activity of the glycoprotein hormone LHBeta-subunit promoter. *Endocrinology*. 2002;143:1018–25.
- Harris D, Chuderland D, Bonfil D, Kraus S, Seger R, Naor Z. Extracellular signal-regulated kinase and c-Src, but not Jun N-terminal kinase, are involved in basal and gonadotropin-releasing hormone-stimulated activity of the glycoprotein hormone alpha-subunit promoter. *Endocrinology*. 2003;144:612–22.
- Harrison GS, Wierman ME, Nett TM, Glode LM. Gonadotropin-releasing hormone and its receptor in normal and malignant cells. *Endocr Relat Cancer*. 2004;11:725–48.
- Hazum E, Cuatrecasas P, Marian J, Conn PM. Receptor-mediated internalization of fluorescent gonadotropin-releasing hormone by pituitary gonadotropes. *Proc Natl Acad Sci U S A*. 1980;77:6692–5.
- Heding A, Vrecl M, Bogerd J, McGregor A, Sellar R, Taylor PL, Eidne KA. Gonadotropin-releasing hormone receptors with intracellular carboxyl-terminal tails undergo acute desensitization of total inositol phosphate production and exhibit accelerated internalization kinetics. *J Biol Chem*. 1998;273:11472–7.
- Heding A, Vrecl M, Hanyaloglu AC, Sellar R, Taylor PL, Eidne KA. The rat gonadotropin-releasing hormone receptor internalizes via a beta-arrestin-independent, but dynamin-dependent, pathway: addition of a carboxyl-terminal tail confers beta-arrestin dependency. *Endocrinology*. 2000;141:299–306.
- Hille B, Tse A, Tse FW, Almers W. Calcium oscillations and exocytosis in pituitary gonadotropes. *Ann N Y Acad Sci*. 1994;710:261–70.
- Hislop JN, Madziva MT, Everest HM, Harding T, Uney JB, Willars GB, Millar RP, Troskie BE, Davidson JS, McArdle CA. Desensitization and internalization of human and xenopus gonadotropin-releasing hormone receptors expressed in alphaT4 pituitary cells using recombinant adenovirus. *Endocrinology*. 2000;141:4564–75.
- Hislop JN, Everest HM, Flynn A, Harding T, Uney JB, Troskie BE, Millar RP, McArdle CA. Differential internalization of mammalian and non-mammalian gonadotropin-releasing hormone receptors. Uncoupling of dynamin-dependent internalization from mitogen-activated protein kinase signaling. *J Biol Chem*. 2001;276:39685–94.
- Hislop JN, Caunt CJ, Sedgley KR, Kelly E, Mundell S, Green LD, McArdle CA. Internalization of gonadotropin-releasing hormone receptors (GnRHRs): does arrestin binding to the C-terminal tail target GnRHRs for dynamin-dependent internalization? *J Mol Endocrinol*. 2005;35:177–89.
- Hoffman LK, Ehrmann DA. Cardiometabolic features of polycystic ovary syndrome. *Nat Clin Pract Endocrinol Metab*. 2008;4:215–22.
- Horn F, Bilezikjian LM, Perrin MH, Bosma MM, Windle JJ, Huber KS, Blount AL, Hille B, Vale W, Mellon PL. Intracellular responses to gonadotropin-releasing hormone in a clonal cell line of the gonadotrope lineage. *Mol Endocrinol*. 1991;5:347–55.
- Horvat RD, Roess DA, Nelson SE, Barisas BG, Clay CM. Binding of agonist but not antagonist leads to fluorescence resonance energy transfer between intrinsically fluorescent gonadotropin-releasing hormone receptors. *Mol Endocrinol*. 2001;15:695–703.

- Huhtaniemi IT, Catt KJ, Clayton RN. Newborn and immature rat testes contain gonadotropin-releasing hormone (GnRH) receptors, and their testosterone production is stimulated by a GnRH agonist in vitro. *Mol Cell Endocrinol.* 1985;40:41–4.
- Huhtaniemi IT, Nikula H, Detta A, Stewart JM, Clayton RN. Blockade of rat testicular gonadotropin releasing hormone (GnRH) receptors by infusion of a GnRH antagonist has no major effects of Leydig cell function in vivo. *Mol Cell Endocrinol.* 1987;49:89–97.
- Imai A, Horibe S, Takagi A, Tamaya T. Gi protein activation of gonadotropin-releasing hormone-mediated protein dephosphorylation in human endometrial carcinoma. *Am J Obstet Gynecol.* 1997;176:371–6.
- Izumi S, Stojilkovic SS, Catt KJ. Calcium mobilization and influx during the biphasic cytosolic calcium and secretory responses in agonist-stimulated pituitary gonadotrophs. *Arch Biochem Biophys.* 1989;275:410–28.
- Janovick JA, Conn PM. Salt bridge integrates GPCR activation with protein trafficking. *Proc Natl Acad Sci U S A.* 2010a;107:4454–8.
- Janovick JA, Conn PM. Use of pharmacoperones to reveal GPCR structural changes associated with constitutive activation and trafficking. *Methods Enzymol.* 2010b;485:277–92.
- Janovick JA, Patny A, Mosley R, Goulet MT, Altman MD, Rush 3rd TS, Cornea A, Conn PM. Molecular mechanism of action of pharmacoperone rescue of misrouted GPCR mutants: the GnRH receptor. *Mol Endocrinol.* 2009;23:157–68.
- Janovick JA, Pogozheva ID, Mosberg HI, Cornea A, Conn PM. Rescue of misrouted GnRHR mutants reveals its constitutive activity. *Mol Endocrinol.* 2012;26:1179–88.
- Janovick JA, Stewart MD, Jacob D, Martin LD, Deng JM, Stewart CA, Wang Y, Cornea A, Chavali L, Lopez S, et al. Restoration of testis function in hypogonadotropic hypogonadal mice harboring a misfolded GnRHR mutant by pharmacoperone drug therapy. *Proc Natl Acad Sci U S A.* 2013;110:21030–5.
- Jennes L, Stumpf WE, Conn PM. Receptor-mediated binding and uptake of GnRH agonist and antagonist by pituitary cells. *Peptides.* 1984;5(Suppl 1):215–20.
- Kaiser UB, Jakubowiak A, Steinberger A, Chin WW. Regulation of rat pituitary gonadotropin-releasing hormone receptor mRNA levels in vivo and in vitro. *Endocrinology.* 1993;133:931–4.
- Kanasaki H, Bedecarrats GY, Kam KY, Xu S, Kaiser UB. Gonadotropin-releasing hormone pulse frequency-dependent activation of extracellular signal-regulated kinase pathways in perfused LbetaT2 cells. *Endocrinology.* 2005;146:5503–13.
- Karakoula A, Tovey SC, Brighton PJ, Willars GB. Lack of receptor-selective effects of either RGS2, RGS3 or RGS4 on muscarinic M3- and gonadotropin-releasing hormone receptor-mediated signalling through G alpha q/11. *Eur J Pharmacol.* 2008;587:16–24.
- Kenakin T. Functional selectivity and biased receptor signaling. *J Pharmacol Exp Ther.* 2011;336:296–302.
- Knobil E. The neuroendocrine control of the menstrual cycle. *Recent Prog Horm Res.* 1980;36:53–88.
- Kowase T, Walsh HE, Darling DS, Shupnik MA. Estrogen enhances gonadotropin-releasing hormone-stimulated transcription of the luteinizing hormone subunit promoters via altered expression of stimulatory and suppressive transcription factors. *Endocrinology.* 2007;148:6083–91.
- Krakauer DC, Page KM, Sealton S. Module dynamics of the GnRH signal transduction network. *J Theor Biol.* 2002;218:457–70.
- Kraus S, Naor Z, Seger R. Intracellular signaling pathways mediated by the gonadotropin-releasing hormone (GnRH) receptor. *Arch Med Res.* 2001;32:499–509.
- Kroeger KM, Pflieger KD, Eidne KA. G-protein coupled receptor oligomerization in neuroendocrine pathways. *Front Neuroendocrinol.* 2003;24:254–78.
- Krsmanovic LZ, Mores N, Navarro CE, Arora KK, Catt KJ. An agonist-induced switch in G protein coupling of the gonadotropin-releasing hormone receptor regulates pulsatile neuropeptide secretion. *Proc Natl Acad Sci U S A.* 2003;100:2969–74.

- Lariviere S, Garrel G, Simon V, Soh JW, Laverriere JN, Counis R, Cohen-Tannoudji J. Gonadotropin-RELEASING hormone couples to 3',5'-cyclic adenosine-5'-monophosphate pathway through novel protein kinase Cdelta and -epsilon in LbetaT2 gonadotrope cells. *Endocrinology*. 2007;148:1099–107.
- Leong DA, Thorner MO. A potential code of luteinizing hormone-releasing hormone-induced calcium ion responses in the regulation of luteinizing hormone secretion among individual gonadotropes. *J Biol Chem*. 1991;266:9016–22.
- Levi NL, Hanoch T, Benard O, Rozenblat M, Harris D, Reiss N, Naor Z, Seger R. Stimulation of Jun N-terminal kinase (JNK) by gonadotropin-releasing hormone in pituitary alpha T3-1 cell line is mediated by protein kinase C, c-Src, and CDC42. *Mol Endocrinol*. 1998;12:815–24.
- Lewis CE, Richards PS, Morris JF. Heterogeneity of responses to LH-releasing hormone and phorbol ester among rat gonadotrophs: a study using a reverse haemolytic plaque assay for LH. *J Mol Endocrinol*. 1989;2:55–63.
- Lim S, Pnueli L, Tan JH, Naor Z, Rajagopal G, Melamed P. Negative feedback governs gonadotrope frequency-decoding of gonadotropin releasing hormone pulse-frequency. *PLoS One*. 2009;4:e7244.
- Limonta P, Moretti RM, Montagnani Marelli M, Motta M. The biology of gonadotropin hormone-releasing hormone: role in the control of tumor growth and progression in humans. *Front Neuroendocrinol*. 2003;24:279–95.
- Limonta P, Montagnani Marelli M, Mai S, Motta M, Martini L, Moretti RM. GnRH receptors in cancer: from cell biology to novel targeted therapeutic strategies. *Endocr Rev*. 2012. doi:10.1210/er.2012-1014.
- Liu F, Austin DA, Mellon PL, Olefsky JM, Webster NJ. GnRH activates ERK1/2 leading to the induction of c-fos and LHbeta protein expression in LbetaT2 cells. *Mol Endocrinol*. 2002a;16:419–34.
- Liu F, Usui I, Evans LG, Austin DA, Mellon PL, Olefsky JM, Webster NJ. Involvement of both G(q/11) and G(s) proteins in gonadotropin-releasing hormone receptor-mediated signaling in L beta T2 cells. *J Biol Chem*. 2002b;277:32099–108.
- Lopez de Maturana R, Pawson AJ, Lu ZL, Davidson L, Maudsley S, Morgan K, Langdon SP, Millar RP. Gonadotropin-releasing hormone analog structural determinants of selectivity for inhibition of cell growth: support for the concept of ligand-induced selective signaling. *Mol Endocrinol*. 2008;22:1711–22.
- Lozach A, Garrel G, Lerrant Y, Berault A, Counis R. GnRH-dependent up-regulation of nitric oxide synthase I level in pituitary gonadotrophs mediates cGMP elevation during rat proestrus. *Mol Cell Endocrinol*. 1998;143:43–51.
- Luttrell LM, Lefkowitz RJ. The role of beta-arrestins in the termination and transduction of G-protein-coupled receptor signals. *J Cell Sci*. 2002;115:455–65.
- Marshall JC, Dalkin AC, Haisenleder DJ, Griffin ML, Kelch RP. GnRH pulses – the regulators of human reproduction. *Trans Am Clin Climatol Assoc*. 1993;104:31–46.
- Mason AJ, Hayflick JS, Zoeller RT, Young 3rd WS, Phillips HS, Nikolics K, Seeburg PH. A deletion truncating the gonadotropin-releasing hormone gene is responsible for hypogonadism in the hpg mouse. *Science*. 1986;234:1366–71.
- Maudsley S, Davidson L, Pawson AJ, Chan R, Lopez de Maturana R, Millar RP. Gonadotropin-releasing hormone (GnRH) antagonists promote proapoptotic signaling in peripheral reproductive tumor cells by activating a Galpha<sub>i</sub>-coupling state of the type I GnRH receptor. *Cancer Res*. 2004;64:7533–44.
- Maurer RA, Kim KE, Schoderbek WE, Roberson MS, Glenn DJ. Regulation of glycoprotein hormone alpha-subunit gene expression. *Recent Prog Horm Res*. 1999;54:455–84; discussion 485.
- McArdle CA. Gonadotropin-releasing hormone receptor signaling: biased and unbiased. *Mini Rev Med Chem*. 2012;12:841–50.

- McArdle CA, Counis R. GnRH and PACAP action in gonadotropes: cross-talk between phosphoinositidase C and adenylyl cyclase mediated signaling pathways. *Trends Endocrinol Metab.* 1996;7:168–75.
- McArdle CA, Roberson MS. Gonadotropes and gonadotropin-releasing hormone signaling. In: Plant TM, editor. *Knobil and Neill's physiology of reproduction*. 4th ed. Amsterdam: Elsevier; 2015. p. 335–97.
- McArdle CA, Huckle WR, Conn PM. Phorbol esters reduce gonadotrope responsiveness to protein kinase C activators but not to  $Ca^{2+}$ -mobilizing secretagogues. Does protein kinase C mediate gonadotropin-releasing hormone action? *J Biol Chem.* 1987;262:5028–35.
- McArdle CA, Bunting R, Mason WT. Dynamic video imaging of cytosolic  $Ca(2+)$  in the alphaT3-1, gonadotrope-derived cell line. *Mol Cell Neurosci.* 1992;3:124–32.
- McArdle CA, Olcese J, Schmidt C, Poch A, Kratzmeier M, Middendorff R. C-type natriuretic peptide (CNP) in the pituitary: is CNP an autocrine regulator of gonadotropes? *Endocrinology.* 1994a;135:2794–801.
- McArdle CA, Poch A, Schomerus E, Kratzmeier M. Pituitary adenylate cyclase-activating polypeptide effects in pituitary cells: modulation by gonadotropin-releasing hormone in alpha T3-1 cells. *Endocrinology.* 1994b;134:2599–605.
- McArdle CA, Willars GB, Fowkes RC, Nahorski SR, Davidson JS, Forrest-Owen W. Desensitization of gonadotropin-releasing hormone action in alphaT3-1 cells due to uncoupling of inositol 1,4,5-trisphosphate generation and  $Ca^{2+}$  mobilization. *J Biol Chem.* 1996;271:23711–7.
- McArdle CA, Davidson JS, Willars GB. The tail of the gonadotrophin-releasing hormone receptor: desensitization at, and distal to, G protein-coupled receptors. *Mol Cell Endocrinol.* 1999;151:129–36.
- Millar RP, Lu ZL, Pawson AJ, Flanagan CA, Morgan K, Maudsley SR. Gonadotropin-releasing hormone receptors. *Endocr Rev.* 2004;25:235–75.
- Mistry DS, Tsutsumi R, Fernandez M, Sharma S, Cardenas SA, Lawson MA, Webster NJ. Gonadotropin-releasing hormone pulse sensitivity of follicle-stimulating hormone-beta gene is mediated by differential expression of positive regulatory activator protein 1 factors and corepressors SKIL and TGIF1. *Mol Endocrinol.* 2011;25:1387–403.
- Miyata A, Arimura A, Dahl RR, Minamino N, Uehara A, Jiang L, Culler MD, Coy DH. Isolation of a novel 38 residue-hypothalamic polypeptide which stimulates adenylate cyclase in pituitary cells. *Biochem Biophys Res Commun.* 1989;164:567–74.
- Montagnani Marelli M, Moretti RM, Mai S, Januskiewicz-Caulier J, Motta M, Limonta P. Type I gonadotropin-releasing hormone receptor mediates the antiproliferative effects of GnRH-II on prostate cancer cells. *J Clin Endocrinol Metab.* 2009;94:1761–7.
- Morgan K, Millar RP. Evolution of GnRH ligand precursors and GnRH receptors in protochordate and vertebrate species. *Gen Comp Endocrinol.* 2004;139:191–7.
- Naor Z. Signaling by G-protein-coupled receptor (GPCR): studies on the GnRH receptor. *Front Neuroendocrinol.* 2009;30:10–29.
- Navratil AM, Bliss SP, Berghorn KA, Haughian JM, Farmerie TA, Graham JK, Clay CM, Roberson MS. Constitutive localization of the gonadotropin-releasing hormone (GnRH) receptor to low density membrane microdomains is necessary for GnRH signaling to ERK. *J Biol Chem.* 2003;278:31593–602.
- Navratil AM, Farmerie TA, Bogerd J, Nett TM, Clay CM. Differential impact of intracellular carboxyl terminal domains on lipid raft localization of the murine gonadotropin-releasing hormone receptor. *Biol Reprod.* 2006;74:788–97.
- Navratil AM, Bliss SP, Roberson MS. Membrane rafts and GnRH receptor signaling. *Brain Res.* 2010;1364:53–61.
- Nelson SB, Eraly SA, Mellon PL. The GnRH promoter: target of transcription factors, hormones, and signaling pathways. *Mol Cell Endocrinol.* 1998;140:151–5.
- Pawson AJ, McNeilly AS. The pituitary effects of GnRH. *Anim Reprod Sci.* 2005;88:75–94.

- Pawson AJ, Katz A, Sun YM, Lopes J, Illing N, Millar RP, Davidson JS. Contrasting internalization kinetics of human and chicken gonadotropin-releasing hormone receptors mediated by C-terminal tail. *J Endocrinol.* 1998;156:R9–12.
- Perrett RM, Voliotis M, Armstrong SP, Fowkes RC, Pope GR, Tsaneva-Atanasova K, McArdle CA. Pulsatile hormonal signaling to extracellular signal-regulated kinase: exploring system sensitivity to gonadotropin-releasing hormone pulse frequency and width. *J Biol Chem.* 2014;289:7873–83.
- Pierce KL, Lefkowitz RJ. Classical and new roles of beta-arrestins in the regulation of G-protein-coupled receptors. *Nat Rev Neurosci.* 2001;2:727–33.
- Pincas H, Choi SG, Wang Q, Jia J, Turgeon JL, Sealfon SC. Outside the box signaling: secreted factors modulate GnRH receptor-mediated gonadotropin regulation. *Mol Cell Endocrinol.* 2014;385:56–61.
- Rawlings SR, Hezareh M. Pituitary adenylate cyclase-activating polypeptide (PACAP) and PACAP/vasoactive intestinal polypeptide receptors: actions on the anterior pituitary gland. *Endocr Rev.* 1996;17:4–29.
- Roberson MS, Misra-Press A, Laurance ME, Stork PJ, Maurer RA. A role for mitogen-activated protein kinase in mediating activation of the glycoprotein hormone alpha-subunit promoter by gonadotropin-releasing hormone. *Mol Cell Biol.* 1995;15:3531–9.
- Roberson MS, Zhang T, Li HL, Mulvaney JM. Activation of the p38 mitogen-activated protein kinase pathway by gonadotropin-releasing hormone. *Endocrinology.* 1999;140:1310–8.
- Rocheville M, Lange DC, Kumar U, Patel SC, Patel RC, Patel YC. Receptors for dopamine and somatostatin: formation of hetero-oligomers with enhanced functional activity. *Science.* 2000;288:154–7.
- Ruf F, Fink MY, Sealfon SC. Structure of the GnRH receptor-stimulated signaling network: insights from genomics. *Front Neuroendocrinol.* 2003;24:181–99.
- Ruf F, Park MJ, Hayot F, Lin G, Roysam B, Ge Y, Sealfon SC. Mixed analog/digital gonadotrope biosynthetic response to gonadotropin-releasing hormone. *J Biol Chem.* 2006;281:30967–78.
- Ruf F, Hayot F, Park MJ, Ge Y, Lin G, Roysam B, Sealfon SC. Noise propagation and scaling in regulation of gonadotrope biosynthesis. *Biophys J.* 2007;93:4474–80.
- Schally AV. LH-RH analogues: I. Their impact on reproductive medicine. *Gynecol Endocrinol.* 1999;13:401–9.
- Schneider JS, Rissman EF. Gonadotropin-releasing hormone II: a multi-purpose neuropeptide. *Integr Comp Biol.* 2008;48:588–95.
- Schomerus E, Poch A, Bunting R, Mason WT, McArdle CA. Effects of pituitary adenylate cyclase-activating polypeptide in the pituitary: activation of two signal transduction pathways in the gonadotrope-derived alpha T3-1 cell line. *Endocrinology.* 1994;134:315–23.
- Sealfon SC, Weinstein H, Millar RP. Molecular mechanisms of ligand interaction with the gonadotropin-releasing hormone receptor. *Endocr Rev.* 1997;18:180–205.
- Sedgley KR, Finch AR, Caunt CJ, McArdle CA. Intracellular gonadotropin-releasing hormone receptors in breast cancer and gonadotrope lineage cells. *J Endocrinol.* 2006;191:625–36.
- Selimkhanov J, Taylor B, Yao J, Pilko A, Albeck J, Hoffmann A, Tsimring L, Wollman R. Systems biology. Accurate information transmission through dynamic biochemical signaling networks. *Science.* 2014;346:1370–3.
- Shenoy SK, Lefkowitz RJ. Multifaceted roles of beta-arrestins in the regulation of seven-membrane-spanning receptor trafficking and signalling. *Biochem J.* 2003;375:503–15.
- Shupnik MA. Effects of gonadotropin-releasing hormone on rat gonadotropin gene transcription in vitro: requirement for pulsatile administration for luteinizing hormone-beta gene stimulation. *Mol Endocrinol.* 1990;4:1444–50.
- Siristatidis CS, Gibreel A, Basios G, Maheshwari A & Bhattacharya S. Gonadotrophin-releasing hormone agonist protocols for pituitary suppression in assisted reproduction. *Cochrane Database Syst Rev.* 2015; CD006919.
- Sisk CL, Foster DL. The neural basis of puberty and adolescence. *Nat Neurosci.* 2004;7:1040–7.



- Spratt DI, Finkelstein JS, Butler JP, Badger TM, Crowley Jr WF. Effects of increasing the frequency of low doses of gonadotropin-releasing hormone (GnRH) on gonadotropin secretion in GnRH-deficient men. *J Clin Endocrinol Metab.* 1987;64:1179–86.
- Stanislaus D, Ponder S, Ji TH, Conn PM. Gonadotropin-releasing hormone receptor couples to multiple G proteins in rat gonadotrophs and in GGH3 cells: evidence from palmitoylation and overexpression of G proteins. *Biol Reprod.* 1998;59:579–86.
- Stewart AJ, Katz AA, Millar RP, Morgan K. Retention and silencing of prepro-GnRH-II and type II GnRH receptor genes in mammals. *Neuroendocrinology.* 2009;90:416–32.
- Stewart MD, Deng JM, Stewart CA, Mullen RD, Wang Y, Lopez S, Serna MK, Huang CC, Janovick JA, Pask AJ, et al. Mice harboring *Gnrhr* E90K, a mutation that causes protein misfolding and hypogonadotropic hypogonadism in humans, exhibit testis size reduction and ovulation failure. *Mol Endocrinol.* 2012;26:1847–56.
- Stojilkovic SS, Catt KJ. Novel aspects of GnRH-induced intracellular signaling and secretion in pituitary gonadotrophs. *J Neuroendocrinol.* 1995;7:739–57.
- Stojilkovic SS, Koshimizu T. Signaling by extracellular nucleotides in anterior pituitary cells. *Trends Endocrinol Metab.* 2001;12:218–25.
- Stojilkovic SS, Iida T, Merelli F, Torsello A, Krsmanovic LZ, Catt KJ. Interactions between calcium and protein kinase C in the control of signaling and secretion in pituitary gonadotrophs. *J Biol Chem.* 1991;266:10377–84.
- Stojilkovic SS, Tomic M, Kukuljan M, Catt KJ. Control of calcium spiking frequency in pituitary gonadotrophs by a single-pool cytoplasmic oscillator. *Mol Pharmacol.* 1994;45:1013–21.
- Stojilkovic SS, He ML, Koshimizu TA, Balik A, Zemkova H. Signaling by purinergic receptors and channels in the pituitary gland. *Mol Cell Endocrinol.* 2010a;314:184–91.
- Stojilkovic SS, Tabak J, Bertram R. Ion channels and signaling in the pituitary gland. *Endocr Rev.* 2010b;31:845–915.
- Tamura N, Doolittle LK, Hammer RE, Shelton JM, Richardson JA, Garbers DL. Critical roles of the guanylyl cyclase B receptor in endochondral ossification and development of female reproductive organs. *Proc Natl Acad Sci U S A.* 2004;101:17300–5.
- Tao YX, Conn PM. Chaperoning G protein-coupled receptors: from cell biology to therapeutics. *Endocr Rev.* 2014;35:602–47.
- Thompson IR, Chand AN, Jonas KC, Burrin JM, Steinhilper ME, Wheeler-Jones CP, McArdle CA, Fowkes RC. Molecular characterisation and functional interrogation of a local natriuretic peptide system in rodent pituitaries,  $\alpha$ T3-1 and L $\beta$ T2 gonadotroph cells. *J Endocrinol.* 2009;203:215–29.
- Thompson IR, Ciccone NA, Xu S, Zaytseva S, Carroll RS, Kaiser UB. GnRH pulse frequency-dependent stimulation of FSH $\beta$  transcription is mediated via activation of PKA and CREB. *Mol Endocrinol.* 2013;27:606–18.
- Tobin VA, Canny BJ. The regulation of gonadotropin-releasing hormone-induced calcium signals in male rat gonadotrophs by testosterone is mediated by dihydrotestosterone. *Endocrinology.* 1998;139:1038–45.
- Tsaneva-Atanasova K, Mina P, Caunt CJ, Armstrong SP, McArdle CA. Decoding GnRH neurohormone pulse frequency by convergent signalling modules. *J R Soc Interface.* 2012;9:170–82.
- Tsutsumi M, Zhou W, Millar RP, Mellon PL, Roberts JL, Flanagan CA, Dong K, Gillo B, Sealfon SC. Cloning and functional expression of a mouse gonadotropin-releasing hormone receptor. *Mol Endocrinol.* 1992;6:1163–9.
- Tsutsumi R, Mistry D, Webster NJ. Signaling responses to pulsatile gonadotropin-releasing hormone in L $\beta$ T2 gonadotrope cells. *J Biol Chem.* 2010;285:20262–72.
- Uda S, Saito TH, Kudo T, Kokaji T, Tsuchiya T, Kubota H, Komori Y, Kuroda S. Robustness and compensation of information transmission of signaling pathways. *Science.* 2013;341:558–61.
- Ulloa-Aguirre A, Conn PM. Targeting of G protein-coupled receptors to the plasma membrane in health and disease. *Front Biosci.* 2009;14:973–94.

- Vasilyev VV, Pernasetti F, Rosenberg SB, Barsoum MJ, Austin DA, Webster NJ, Mellon PL. Transcriptional activation of the ovine follicle-stimulating hormone-beta gene by gonadotropin-releasing hormone involves multiple signal transduction pathways. *Endocrinology*. 2002;143:1651–9.
- Voliotis M, Perrett RM, McWilliams C, McArdle CA, Bowsher CG. Information transfer by leaky, heterogeneous, protein kinase signaling systems. *Proc Natl Acad Sci U S A*. 2014;111:E326–33.
- Vrecl M, Anderson L, Hanyaloglu A, McGregor AM, Groarke AD, Milligan G, Taylor PL, Eidne KA. Agonist-induced endocytosis and recycling of the gonadotropin-releasing hormone receptor: effect of beta-arrestin on internalization kinetics. *Mol Endocrinol*. 1998;12:1818–29.
- Wang Y, Fortin J, Lamba P, Bonomi M, Persani L, Roberson MS, Bernard DJ. Activator protein-1 and smad proteins synergistically regulate human follicle-stimulating hormone beta-promoter activity. *Endocrinology*. 2008;149:5577–91.
- Wang L, Chadwick W, Park SS, Zhou Y, Silver N, Martin B, Maudsley S. Gonadotropin-releasing hormone receptor system: modulatory role in aging and neurodegeneration. *CNS Neurol Disord Drug Targets*. 2010;9:651–60.
- Washington TM, Blum JJ, Reed MC, Conn PM. A mathematical model for LH release in response to continuous and pulsatile exposure of gonadotrophs to GnRH. *Theor Biol Med Model*. 2004;1:9.
- Weck J, Fallest PC, Pitt LK, Shupnik MA. Differential gonadotropin-releasing hormone stimulation of rat luteinizing hormone subunit gene transcription by calcium influx and mitogen-activated protein kinase-signaling pathways. *Mol Endocrinol*. 1998;12:451–7.
- Weiss J, Jameson JL, Burrin JM, Crowley Jr WF. Divergent responses of gonadotropin subunit messenger RNAs to continuous versus pulsatile gonadotropin-releasing hormone in vitro. *Mol Endocrinol*. 1990;4:557–64.
- Wildt L, Hausler A, Marshall G, Hutchison JS, Plant TM, Belchetz PE, Knobil E. Frequency and amplitude of gonadotropin-releasing hormone stimulation and gonadotropin secretion in the rhesus monkey. *Endocrinology*. 1981;109:376–85.
- Willars GB, Royall JE, Nahorski SR, El-Gehani F, Everest H, McArdle CA. Rapid down-regulation of the type I inositol 1,4,5-trisphosphate receptor and desensitization of gonadotropin-releasing hormone-mediated Ca<sup>2+</sup> responses in alpha T3-1 gonadotrophs. *J Biol Chem*. 2001;276:3123–9.
- Winters SJ, Moore Jr JP. PACAP, an autocrine/paracrine regulator of gonadotrophs. *Biol Reprod*. 2011;84:844–50.
- Winters SJ, Ishizaka K, Kitahara S, Troen P, Attardi B. Effects of testosterone on gonadotropin subunit messenger ribonucleic acids in the presence or absence of gonadotropin-releasing hormone. *Endocrinology*. 1992;130:726–34.
- Wojcikiewicz RJ, Xu Q, Webster JM, Alzayady K, Gao C. Ubiquitination and proteasomal degradation of endogenous and exogenous inositol 1,4,5-trisphosphate receptors in alpha T3-1 anterior pituitary cells. *J Biol Chem*. 2003;278:940–7.
- Wurbach E, Yuen T, Ebersole BJ, Sealfon SC. Gonadotropin-releasing hormone receptor-coupled gene network organization. *J Biol Chem*. 2001;276:47195–201.
- Yasin M, Dalkin AC, Haisenleder DJ, Kerrigan JR, Marshall JC. Gonadotropin-releasing hormone (GnRH) pulse pattern regulates GnRH receptor gene expression: augmentation by estradiol. *Endocrinology*. 1995;136:1559–64.
- Yuen T, Wurbach E, Ebersole BJ, Ruf F, Pfeiffer RL, Sealfon SC. Coupling of GnRH concentration and the GnRH receptor-activated gene program. *Mol Endocrinol*. 2002;16:1145–53.
- Yuen T, Ruf F, Chu T, Sealfon SC. Microtranscriptome regulation by gonadotropin-releasing hormone. *Mol Cell Endocrinol*. 2009;302:12–7.
- Zhu H, Hille B, Xu T. Sensitization of regulated exocytosis by protein kinase C. *Proc Natl Acad Sci U S A*. 2002;99:17055–9.

Alfredo Ulloa-Aguirre, James A. Dias, and George R. Bousfield

## Abstract

The gonadotropins, luteinizing hormone (LH), follicle-stimulating hormone (FSH), and chorionic gonadotropin hormone (CG) play an essential role in reproduction. LH and FSH are synthesized in the gonadotropes of the anterior pituitary gland, while CG is synthesized by the placental syncytiotrophoblasts. Gonadotropins, together with thyroid-stimulating hormone (TSH) synthesized by the thyrotropes of the adenohypophysis, belong to the glycoprotein hormone family. The glycoprotein hormones are complex heterodimers consisting of a common  $\alpha$ -subunit non-covalently associated with a  $\beta$ -subunit, which is structurally unique in its peptide sequence to each member of the family and that confers binding specificity at the receptor level. Both subunits are decorated with oligosaccharide chains, whose number vary depending on the particular glycoprotein hormone, and that are involved in many functional aspects, including folding and secretion of the heterodimer, as well as plasma half-life and bioactivity of the hormone at the target cell. The synthesis and

---

A. Ulloa-Aguirre (✉)

Red de Apoyo a la Investigación, Coordinación de la Investigación Científica, Universidad Nacional Autónoma de México (UNAM), Mexico City, Mexico

Red de Apoyo a la Investigación, Instituto Nacional de Ciencias Médicas y Nutrición SZ, Mexico City, Mexico

e-mail: [aulloa@unam.mx](mailto:aulloa@unam.mx)

J.A. Dias

Department of Biomedical Sciences, State University of New York at Albany, Albany, NY, USA

e-mail: [jdias@albany.edu](mailto:jdias@albany.edu)

G.R. Bousfield

Department of Biology, Wichita State University, Wichita, KS, USA

e-mail: [george.bousfield@wichita.edu](mailto:george.bousfield@wichita.edu)

secretion of gonadotropins are regulated by the concerted action of several endocrine, paracrine, and autocrine factors of diverse chemical structure, the main player being the hypothalamic decapeptide gonadotropin-releasing hormone (GnRH). Gonadotropins interact with their cognate receptors (the FSH receptor and the LH/CG receptor) in the ovary and the testes. In the ovary, FSH regulates the growth and maturation of the ovarian follicles as well as estrogen production by the granulosa cells, whereas in the testes FSH stimulates the Sertoli cells lining the seminiferous tubules to influence spermatogenesis. The target cells of LH are the theca cells of the ovarian follicles and the corpus luteum, where it promotes the synthesis of sex steroid hormones and the ovulatory process. In the testes, LH stimulates Leydig cell steroidogenesis, mainly testosterone production, to promote sexual maturation and function, and spermatogenesis. Mutations in the  $\beta$ -subunit genes of LH and FSH leading to gonadotropin deficiency are very rare. When they occur in LH $\beta$ , they are clinically manifested by lack of pubertal maturation and infertility in men and infertility in women, whereas mutations in FSH $\beta$  may lead to azoospermia in men and absent or partial puberty and infertility in women. Several natural and recombinant preparations of gonadotropins are currently available for therapeutic purposes. Given that glycosylation is well known to vary in a cell- and tissue-specific manner, the main difference between natural and the currently available recombinant preparations massively produced in Chinese hamster ovary cells for commercial purposes lies in the abundance of some of the carbohydrates that comprise the complex glycans attached to the protein core. Because of the functional and pharmacological similarities between natural and recombinant compounds, both may be employed in the clinical arena to treat diseases characterized by gonadotropin deficiency as well as infertility.

### Keywords

Luteinizing hormone • Follicle-stimulating hormone • Chorionic gonadotropin hormone • Glycoproteins • Glycoprotein hormones • Gonadotropins • Gonadal function • Macroheterogeneity • Microheterogeneity • Reproductive function • Ovary • Testes

### Contents

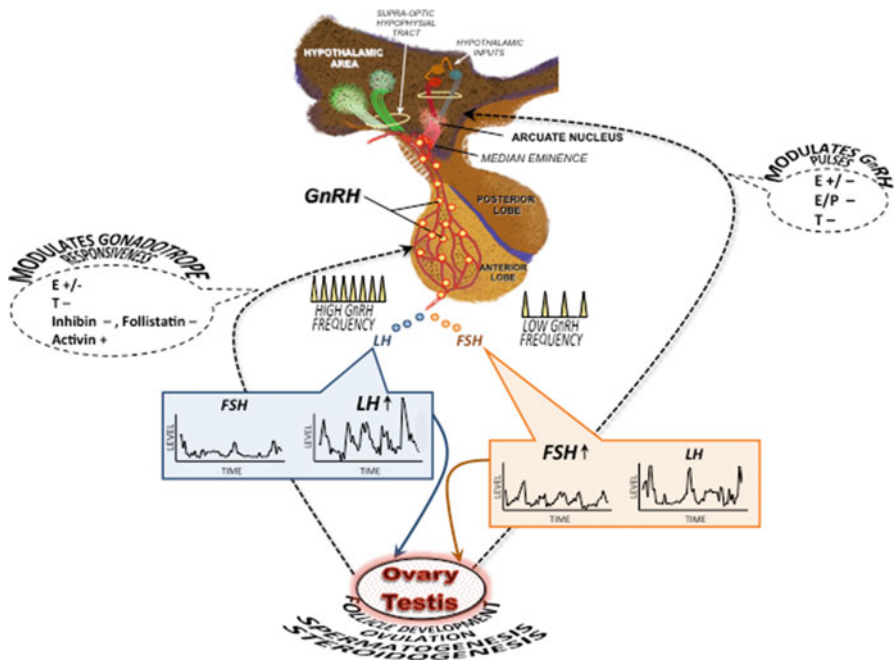
Introduction .....	73
Structural Features of the Gonadotropins .....	75
Gonadotropin Genes .....	75
Gene Sequences .....	76
Amino Acid Sequences of the Mature Hormone Subunits .....	77
Three-Dimensional Structures of CG and Human FSH Receptor (FSHR) .....	80
Carbohydrate Structures Attached to Gonadotropins .....	83
Biosynthesis of the Gonadotropins .....	87
Signaling Pathways and Transcriptional Regulation of the $\alpha$ - and $\beta$ -Subunit Genes .....	87

Gonadotropin Subunit Assembly, Processing, and Secretion .....	93
Gonadotropin Subunit Assembly .....	93
Processing .....	96
Secretion .....	97
Pharmacokinetics of Gonadotropins .....	98
Biological Effects of Gonadotropins .....	101
Binding to Receptors .....	101
Biological Effects .....	102
Recombinant Gonadotropins .....	103
Structural Abnormalities of Gonadotropins .....	104
Mutations in LHB gene .....	104
Mutations in FSHB gene .....	105
Summary .....	107
References .....	107

---

## Introduction

In mammals, reproductive function is governed by the hypothalamic-pituitary-gonadal axis, which comprises a functional unit (Fig. 1). Sexual maturation and development of reproductive competence depend on the coordinated function of this axis, whose components communicate with each other through endocrine signals. Among the components of this axis are the pituitary gonadotropins, follicle-stimulating hormone (or follitropin, FSH), and luteinizing hormone (or lutropin, LH), which together with chorionic gonadotropin (CG), synthesized by the placental trophoblasts, and thyroid-stimulating hormone (or thyrotropin, TSH), produced in the thyrotrophs, comprise the glycoprotein hormone (GPH) family. All GPHs are heterodimeric and consist of a common  $\alpha$ -subunit non-covalently associated with a unique  $\beta$ -subunit, which is structurally distinct in its peptide sequence for each member of the GPH family. Both subunits are decorated with *N*- (and *O*-linked, in the case of CG) oligosaccharide chains, whose number vary depending on the GPH, and that play important roles in determining the plasma half-life of the glycoprotein as well as its bioactivity at the target cell level. Pituitary gonadotropin production and secretion are governed by the concerted action of hypothalamic and gonadal factors that regulate the transcriptional regulation of their subunit genes (Bernard et al. 2010; Ulloa-Aguirre and Timossi 2000), translation of corresponding mRNAs, posttranslational processing and assembly, intracellular traffic, packaging, and secretion (Bousfield and Dias 2011). The granulosa cells of the ovary and the Sertoli cells lining the seminiferous tubules are the primary targets of FSH, whereas the theca and granulosa cells and the corpus luteum of the ovary and the Leydig cells of the testis are the primary targets of LH. In these cells, gonadotropins play a fundamental role in regulating gonadal function and thereby control reproduction (Huhtaniemi 2015; Richards and Pangas 2010). Although receptors for both LH and FSH also have been detected in a number of extragonadal tissues



**Fig. 1** Functional relations of the hypothalamic-pituitary-gonadal axis. Gonadotropin-releasing hormone (*GnRH*) is synthesized and secreted by neurons located mainly in the arcuate nucleus of the medial basal hypothalamus and the preoptic area of the anterior hypothalamus. The synthesis and secretion of GnRH are under the regulation of KNDy (kisspeptin, neurokinin B, and dynorphin) neurons located immediately above the arcuate nucleus. GnRH-producing neurons project to the median eminence where they terminate in a plexus of boutons on the primary portal vessel that delivers GnRH (*yellow balls*) to the gonadotrope of the adenohypophysis. The secretion and interaction of GnRH with its cognate receptor occur in a pulsatile and intermittent manner; such episodic signaling allows distinct rates and patterns of synthesis and episodic release of luteinizing hormone (*LH*) and follicle-stimulating hormone (*FSH*). High and low pulse GnRH frequencies favor LH and FSH synthesis and release, respectively. Gonadotropin hormones bind their target receptors in the ovary and the testes to promote follicular development, ovulation, spermatogenesis, and steroidogenesis. The transcriptional regulation of the gonadotropin subunit genes as well as the secretion of both gonadotropins is controlled by GnRH as well as by positive (+) and/or negative (–) feedback from steroid hormones and other factors produced in the gonads in response to gonadotropins. *E* estrogens, *P* progesterone, *T* testosterone

(Bukovsky et al. 2003; Kumar 2014), their functional role is controversial and still remains to be clarified.

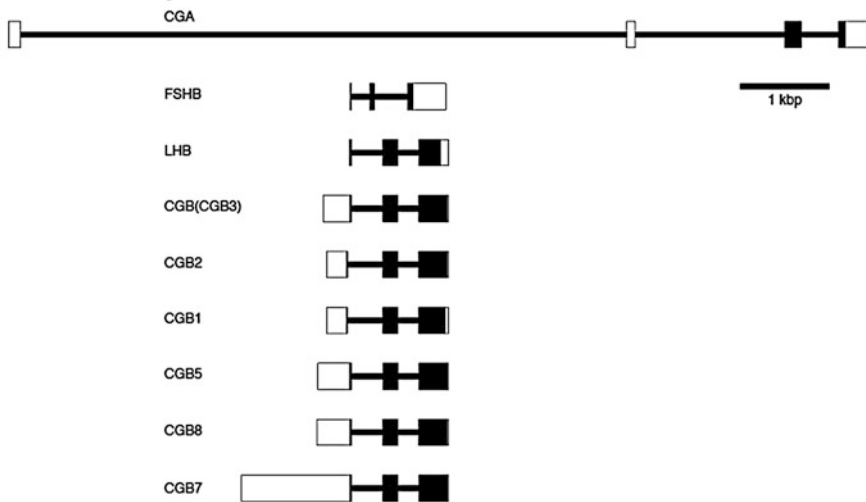
This chapter concentrates on the structure, biosynthesis, and structure-function correlates of the three gonadotropic hormones, LH, FSH, and CG. Although emphasis is given to human(h)gonadotropins, available data from other mammalian species are also provided for informative and/or comparative purposes.

## Structural Features of the Gonadotropins

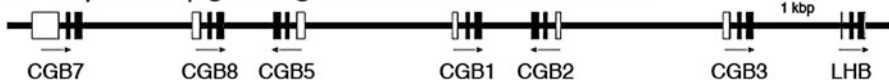### Gonadotropin Genes

The gonadotropins are encoded by several genes. In humans, these are designated *CGA*, *FSHB*, *LHB*, and *CGB* for the common  $\alpha$ , FSH $\beta$ , LH $\beta$ , and CG $\beta$  subunits, respectively (Fig. 2). All but the LH $\beta$  and CG $\beta$  genes reside on separate chromosomes. The common  $\alpha$ -subunit *CGA* gene is found on human chromosome 6 at 6q14.3. According to the Ensemble database (release 84), the human *CGA* gene has six transcripts with five predicted translation products consisting of 62–147 amino acid residues (Cunningham et al. 2015). The canonical *CGA* translation product, CGA001, comprises 116 residues, of which 92 constitute the mature protein. The longest predicted protein, CGA003, includes a 31-residue N-terminal insert between Gln<sup>4</sup> and Cys<sup>6</sup>, which might be tolerated, as it merely extends the amino terminus.

#### a Gonadotropin Subunit Genes



#### b CG $\beta$ and LH $\beta$ gene organization on chromosome 19



**Fig. 2** Gonadotropin subunit genes. (a) Individual subunit genes: *CGA*, common  $\alpha$ -subunit; *FSHB*, hFSH $\beta$  subunit; *LHB*, hLH $\beta$  subunit; *CGB*, hCG $\beta$  subunit genes, with each gene identified by number. Exons are indicated by open or closed *rectangles* and introns by *solid lines*. *Open rectangles* indicate untranslated, and *closed rectangles* represent translated exons or portions of exons. (b) Map of the hLH $\beta$  and hCG $\beta$  gene cluster on chromosome 19. The *arrows* indicate the direction of transcription

It is tempting to speculate that this accounts for reports of large human  $\alpha$ -subunit not attributed to glycosylation (Posillico et al. 1983). The two truncated peptides, CGA004 and CGA005, lack the C-terminal Cys knot motif, Cys-His-Cys, and would not fold properly.

The FSH hormone-specific FSH $\beta$  subunit *FSHB* is found on human chromosome 11, at 11p13. According to the Ensemble database, the *FSHB* has three transcripts, which affect the size of the 5' untranslated region, but encode the same 129-residue preprotein and 111-residue mature protein. The LH hormone-specific LH $\beta$  subunit is encoded by a gene that was duplicated, mutated, and duplicated again during primate evolution (Boorstein et al. 1982; Fiddes and Goodman 1980). In the human, the *LHB* is located on chromosome 19 at the same location, 19q13.32, as the six CG  $\beta$ -subunit genes. The Ensemble database lists two human LH $\beta$  gene transcripts. One is predicted to yield the classical protein sequence, while the alternative transcript predicts a shortened signal peptide at the N-terminus, the same mature core sequence as human LH $\beta$ , with a C-terminal extension, similar to that of human CG $\beta$ . In new-world monkeys, common marmoset, squirrel, and owl monkeys (*Callithrix jacchus*, *Saimiri sp.*, and *Aotus sp.*), the LH $\beta$  gene is not expressed in the pituitary gland for reasons not completely understood (Müller et al. 2004; Scammell et al. 2008). Pituitary-expressed *CGB* has assumed the functions of LHB in these species. A single LH/CGB gene is found in the equids (Sherman et al. 1992).

The chorionic gonadotropin  $\beta$ -subunit genes are all located on chromosome 19, the same chromosome where the *LHB* is located. Primates vary in the number of CGB genes, as macaques possess three genes, orangutans four, and chimpanzees five, while humans possess six (Maston and Ruvolo 2002; Nagiraja et al. 2010). The equids, horses, donkeys, and zebras possess a single LH/CGB gene, which is expressed in both pituitary and placenta (Sherman et al. 1992). This appears to differ from new-world monkeys in which an unexpressed *LHB* remains detectable, however, separated from the *CGB* by 20 kbp, instead of the usual 2–3 kbp seen in other species (Müller et al. 2004). Perhaps this separates the LHB gene from important promoter elements located near the *CGB*. In the equids it appears that the mutations that enable 3'-read through occurred without the subsequent gene duplication events that took place during primate CG $\beta$  evolution.

## Gene Sequences

The structures of the canonical gonadotropin genes are shown in Fig. 2. The *CGA* gene consists of 9,650 bp comprising four exons and three introns. Mammalian intron 1 is variable in size, ranging from 6.8 kbp in humans to 13.2 kbp in rhesus macaque. In zebrafish, *CGA* intron 1 is 2.1 kbp.

The *FSHB* consists of three exons and two introns. The first intron varies in size, although not to the same extent as *CGA* intron 1. Compared with other gonadotropin genes, *FSHB* possesses the largest 3'-untranslated region, 509–1,477 bp. The *LHB* consists of three exons and two introns. The introns are fairly small, as compared with other gonadotropin genes. There is some variation in the size of intron 1.

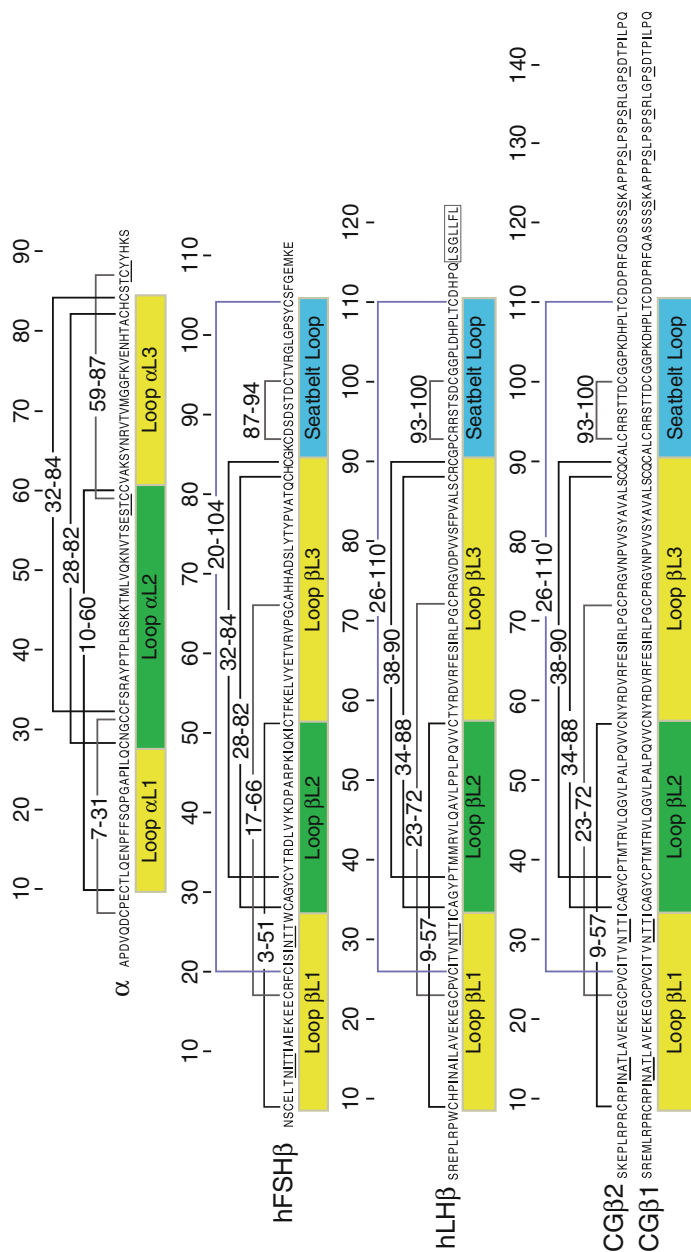


The related CGB genes possess the same three-exon, two-intron structure of the ancestral LHB gene. However, there is a larger, 364–403 bp untranslated region at the 5' end that is larger than the 8 bp untranslated region of *LHB* exon 1. The 3' untranslated region is reduced from 88 to 17 bp to accommodate the C-terminal extension. Six CGB genes are shown, four of which are believed to be expressed during normal pregnancy in order of expression level CGB8 > > CGB5 > CGB3 > CGB7 (Rull and Laan 2005).

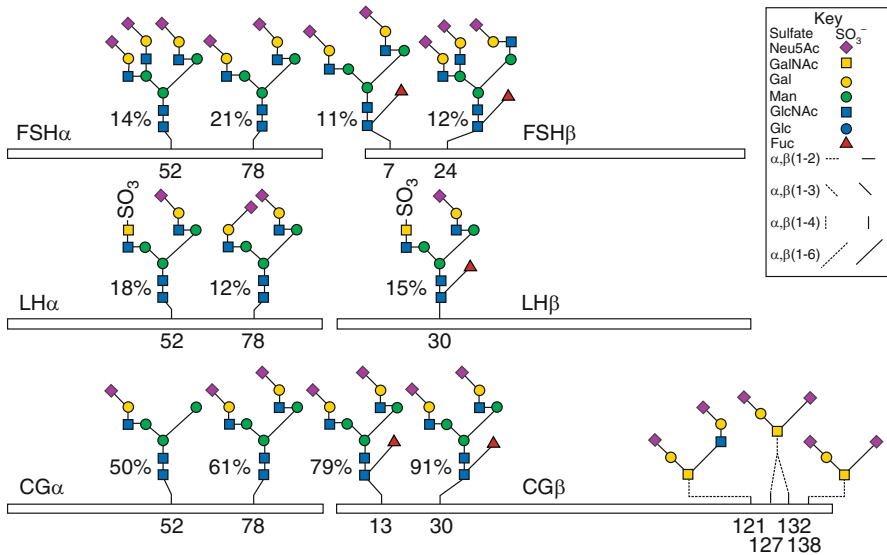
## Amino Acid Sequences of the Mature Hormone Subunits

Mature human  $\alpha$ -subunit comprises only 92 amino acid residues, due to a shift in exon 1–exon 2 splice site that eliminates four residues from the amino terminus (Chin et al. 1983) as compared with other mammalian  $\alpha$ -subunits (Fig. 3). N-terminal heterogeneity is observed in  $\alpha$ -subunits from all hormone preparations. Pituitary human FSH $\alpha$  begins with Val<sup>4</sup> (Shome and Parlow 1974), human LH $\alpha$  begins with Val<sup>4</sup> (Keutmann et al. 1978; Shome and Parlow 1974), and 70% of CG $\alpha$  sequences begin with Ala<sup>1</sup>, 10% begin with Asp<sup>3</sup>, and 30% start at Val<sup>4</sup> (Morgan et al. 1975). In the pre-SDS-PAGE era, gonadotropin subunits seldom met the single N-terminal residue standard of purity (Ward et al. 1989). The  $\alpha$ -subunit possesses quantitatively glycosylated N-glycosylation sites, –N<sup>52</sup>VT– and –N<sup>78</sup>HT– (Fig. 4). The N-glycan populations differ depending on the presence or absence of a  $\beta$ -subunit and on the nature of the  $\beta$ -subunit. Thus, common  $\alpha$ -subunit structural identity applies only to the polypeptide chains (Figs. 3 and 4). The glycan populations can be used to identify the hormone of origin (Gotschall and Bousfield 1996). The five  $\alpha$ -subunit disulfide bonds (Fig. 3) were not firmly established until the crystal structures of CG and human FSH (hFSH) demonstrated identical disulfide bond patterns (Fox et al. 2001; Laphorn et al. 1994; Wu et al. 1994). The cystine knot ring disulfides are formed between Cys<sup>28</sup>–Cys<sup>82</sup> and Cys<sup>32</sup>–Cys<sup>84</sup>. The associated sequences, –C<sup>28</sup>MGC<sup>32</sup>–Cys– and –C<sup>82</sup>HC<sup>84</sup>–, are highly conserved. Only the Met residue varies in the CMGC motif, while His is replaced with Tyr in CHC only in the equid  $\alpha$ -subunits (Stewart et al. 1987; Ward et al. 1982). The disulfide bond that connects the other two strands to “tie” the knot is Cys<sup>10</sup>–Cys<sup>60</sup>. The remaining disulfide bonds, Cys<sup>7</sup>–Cys<sup>31</sup> and Cys<sup>59</sup>–Cys<sup>87</sup>, tether the N- and C-terminal peptides, respectively, to the alpha subunit core.

FSH $\beta$  subunit N-terminal heterogeneity results from alternate cleavage by signal peptidase (Walton et al. 2001). The initial hFSH $\beta$  sequencing studies revealed two N-termini, one at the canonical Asn<sup>1</sup> residue and the other at the Cys<sup>3</sup> residue (Sairam et al. 1972; Shome and Parlow 1974). Subsequently, only 20% of hFSH $\beta$  chains possessed all 111 residues (Walton et al. 2001). The remaining 80% comprised 109 residues. Prediction of FSH $\beta$  cleavage sites by SignalP 4.1 Server web tool analysis of pre-hFSH $\beta$  indicated Asn<sup>2</sup>–Cys<sup>3</sup> as the primary cleavage site and Cys<sup>1</sup>–Asn<sup>1</sup> as a secondary site (Petersen et al. 2011). This mechanism does not appear to apply to  $\alpha$ -subunit N-terminal heterogeneity because SignalP predicts a single cleavage site at the known N-terminus. N-terminal heterogeneity encountered



**Fig. 3** Amino acid sequences for the gonadotropin subunits. The sequences are indicated using the single-letter code for amino acid residues. Brackets above each sequence indicate disulfide bonds between Cys residues. These are numbered for convenience. The three *thick brackets* indicate Cys knot disulfide bonds. The *blue line* indicates the  $\beta$ -subunit seat belt loop. Loops L1 and L3 are highlighted in *yellow*, as they are on the same side of the Cys knot. Loop L2 is shaded *green*. The seat belt loop is shaded *cyan*. The seven-residue sequence in hLH $\beta$  responsible for targeting this hormone to the regulated secretory pathway is *boxed*. N- and O-glycosylation sites are indicated by underlining the N-X-T sequence for the former and individual Ser residues for the latter. Two CG $\beta$  sequences are shown, CG $\beta$ 2, the product of CGB3, 5, and 8, and CG $\beta$ 1, the product of CGB7



**Fig. 4** Diagrammatic representation of gonadotropin glycosylation. The common  $\alpha$ -subunits are indicated by *open bars* on the *left*, with both N-glycosylation sites numbered. The hormone-specific  $\beta$ -subunits are indicated on the *right*, with glycosylation sites numbered. The homologous N-glycosylation sites are aligned. The hCG $\beta$  O-glycosylation sites are indicated at the C-terminal end. Only three are shown as glycosylation at Ser<sup>127</sup> or Ser<sup>132</sup> which appears to be mutually exclusive. Glycans are the most abundant species at each glycosylation site, as indicated by percentage. Glycan abundance was determined by mass spectrometry for hFSH and by NMR for hLH and hCG (Weisshaar et al. 1991a, b). Diagrams of each FSH glycoform are shown below. The oligosaccharide structures use the color scheme adopted by the Consortium for Glycoscience for monosaccharide residues (GlcNAc = blue squares, Man = green circles, Gal = yellow circles, Neu5Ac (sialic acid) = purple diamonds, Fuc = red triangles) and the Oxford Glycobiology Institute system for indicating linkages (Varki et al. 2015)

during protein sequence studies was considered a by-product of postmortem degradation in the pituitary gland. However, recombinant hFSH $\beta$  recovered from conditioned tissue culture medium also exhibits the same 20/80 ratio of Asn<sup>1</sup>/Cys<sup>3</sup> N-terminal residues as the pituitary-derived subunit (Butnev et al. 2015). Human FSH $\beta$  disulfide bonds were established by the crystal structure reported in 2001 (Fox et al. 2001). The Cys knot ring sequences are  $-C^{28}AGYC^{32}-$  and  $-C^{82}HC^{84}-$ . The disulfide bonds forming the ring are Cys<sup>28</sup>-Cys<sup>82</sup> and Cys<sup>32</sup>-Cys<sup>84</sup>. The disulfide bond tying the knot was Cys<sup>3</sup>-Cys<sup>51</sup>. A Cys<sup>17</sup>-Cys<sup>66</sup> disulfide bond linked loop  $\beta$ L1 to  $\beta$ L3 and probably accounts for the greater structural stability of the  $\beta$ -subunit as compared with the  $\alpha$ -subunit. In the latter,  $\alpha$ L1 and  $\alpha$ L3 loops are stabilized by non-covalent bonds between the  $\alpha$ Asn<sup>78</sup> N-acetylglucosamine (GlcNAc) residues and amino acid side chains in both loops (Lapthorn et al. 1994). The determinant loop disulfide bond in FSH $\beta$  is Cys<sup>87</sup>-Cys<sup>94</sup>, and the seat belt latch disulfide is Cys<sup>20</sup>-Cys<sup>104</sup>. FSH $\beta$  possesses two potential N-glycosylated Asn residues  $-N^7ITI-$  and  $-N^{24}TTW-$  (Figs. 3 and 4). Partial glycosylation of FSH $\beta$  occurs in several species,

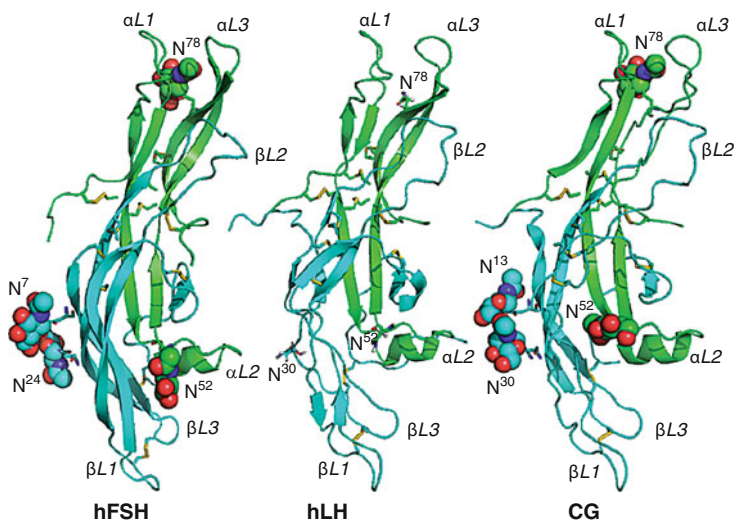
including humans (Bousfield et al. 2007, 2014b). Because both glycosylation sites are of the NXT-type, the middle residue does not affect the efficiency of transferring the preformed oligosaccharide to the nascent chain (Shakin-Eshleman et al. 1986). However, the Trp residue following Thr<sup>26</sup> may reduce oligosaccharide transfer efficiency to Asn<sup>24</sup> almost 20%, while the Ile residue following Thr<sup>9</sup> may reduce transfer to Asn<sup>7</sup> by 10% (Mellquist et al. 1998).

The LH $\beta$  subunit possesses 118 residues in the predicted mature sequence (Talmadge et al. 1983). A C-terminal, 7-residue, hydrophobic peptide was identified by predicting the *LHB* translation product. This peptide (LSGLLFL) was missed during protein sequencing studies of hLH $\beta$  as no consensus C-terminal sequence emerged (Keutmann et al. 1979; Sairam and Li 1975; Shome and Parlow 1973). Nevertheless, it has been shown that this peptide directs LH to the regulated secretory pathway (Jablonka-Shariff et al. 2008; Muyan et al. 1994) (see below). As there is no crystal structure for LH $\beta$ , its disulfide bond placements are unknown, but probably the same as those for CG $\beta$  as instead of is discussed below. Human LH $\beta$  possesses a single N-glycosylation site,  $-N^{30}TT-$ , that differs from all other mammalian LH $\beta$  subunits, which are glycosylated at Asn<sup>13</sup> (Bousfield et al. 2006) (Fig. 4). An alternative LH $\beta$  subunit allele is expressed in some human populations that encodes two N-glycosylation sites, Asn<sup>13</sup> and Asn<sup>30</sup> (Haavisto et al. 1995). Pituitary hLH usually is nicked in  $\beta$ L2, which results in a 100-fold reduction in affinity for the LH receptor (Hartree and Showkeen 1991; Ward et al. 1986); therefore, biological and biochemical studies employed LH preparations derived from other species.

The most obvious feature of the CG $\beta$  subunit is the C-terminal extension of 25 amino acid residues. A less obvious feature is the presence of two N-glycans rather than the usual single N-linked oligosaccharide, one attached to Asn<sup>13</sup>, like most LH $\beta$  subunits, and the other attached to Asn<sup>30</sup>, like hLH $\beta$ . The CG $\beta$  C-terminal peptide (CTP) possesses up to four O-linked oligosaccharides attached to Ser residues 121, 127, 132, and 138 (Birken and Canfield 1977; Kessler et al. 1979a). Partial glycosylation at Asn<sup>13</sup>, Ser<sup>121</sup>, and Ser<sup>138</sup> has been detected by liquid chromatography-mass spectrometry (LC-MS) and electrospray ionization-mass spectrometry (ESI-MS) analysis of several CG preparations (Valmu et al. 2006). As in hLH $\beta$ , the cysteine knot ring-forming sequences are  $-C^{34}AGYC^{38}-$ , at the  $\beta$ L1/ $\beta$ L2 boundary, and  $-C^{88}QC^{90}-$  at the  $\beta$ L2/ $\beta$ L3 boundary. The ring disulfide bonds are Cys<sup>34</sup>-Cys<sup>88</sup> and Cys<sup>38</sup>-Cys<sup>90</sup>. The disulfide bond that “ties” the knot is Cys<sup>9</sup>-Cys<sup>57</sup>. The  $\beta$ L1- $\beta$ L3 disulfide bond is Cys<sup>23</sup>-Cys<sup>72</sup>, the determinant loop disulfide is Cys<sup>93</sup>-Cys<sup>100</sup>, and the seat belt latch disulfide is Cys<sup>26</sup>-Cys<sup>110</sup> (Fig. 3).

### Three-Dimensional Structures of CG and Human FSH Receptor (FSHR)

Gonadotropin three-dimensional structure determinations provided insight into their interactions with their cognate receptors and receptor activation (Jiang et al. 2013). Three-dimensional structures exist for two gonadotropins,



**Fig. 5** Three-dimensional structures of the gonadotropin core regions. The proteins are indicated as cartoons using PyMol. The  $\alpha$ -subunits are green and the  $\beta$ -subunits are cyan. Disulfide bonds are shown as sticks, in which the yellow sticks indicate the sulfur atoms. The GlcNAc residues, N<sup>52</sup>, N<sup>78</sup>, N<sup>7</sup>, and N<sup>24</sup>, attached to the N-glycosylation sites in human FSH and CG are shown as spheres with the carbon atoms colored according to the corresponding subunit. The Asn residues are shown as sticks. The Cys knot loops, L1, L2, and L3, are identified by subunit. The FSH model was extracted from pdb file 1xwd, the CG model from 1hcn. The human LH model is a homology model generated using Tripos Sybyl-X with CG as a template

CG (Lapthorn et al. 1994; Wu et al. 1994) and hFSH (Fox et al. 2001), which are shown in Fig. 5. Chemically deglycosylated, urinary, or recombinant CG structures were reported in 1994 (Lapthorn et al. 1994; Wu et al. 1994). The pregnancy urine CG structure was determined at 3.0 Å resolution (Lapthorn et al. 1994). The recombinant CG was expressed as a selenomethionine derivative (Lustbader et al. 1995) and its structure determined at 2.6 Å resolution (Wu et al. 1994). A 3.0 Å resolution structure for recombinant, insect cell-expressed hFSH was reported in 2001 (Fox et al. 2001). To facilitate crystallization, the second FSH $\beta$  N-glycosylation site, Asn<sup>24</sup>, was silenced by mutating Thr<sup>26</sup> to Ala, thereby eliminating partial glycosylation at this site. Deglycosylation was unnecessary. In 2005, the 2.9 Å resolution structure of co-crystallized single-chain hFSH bound to the high-affinity binding site of the FSHR extracellular domain was reported (Fan and Hendrickson 2005). The 2.5 Å resolution structure of the entire hFSHR extracellular domain, with single-chain FSH bound, was reported in 2012 (Jiang et al. 2012). In both FSHR structures (Fan and Hendrickson 2005; Jiang et al. 2013), digestion with endoglycosidase F was necessary to obtain diffractable crystals. The resulting FSH in these two hormone-receptor complexes was very similar but not identical to the fully glycosylated FSH structure (Fox et al. 2001) as it differs from the latter particularly in the shift in the alpha subunit C-terminus.

The 3D structures resolved conflicting disulfide bond assignments. For the  $\alpha$ -subunits, all reported disulfide bond placements were incorrect. For the  $\beta$ -subunits, disulfide bond placements, 34–88, 38–57, 9–90, 23–72, 93–100, and 26–110 initially proposed for ovine LH $\beta$  (Tsunasawa et al. 1977) and subsequently for CG $\beta$  (Mise and Bahl 1980), were successfully used to guide following CG $\beta$  folding studies (Huth et al. 1992). However, two disulfide bonds, 38–57 and 9–90, differed from those in the CG crystal structures (Laphorn et al. 1994; Wu et al. 1994). Subsequent studies supported a model in which the initial disulfide bond assignments were correct for immature CG $\beta$ . A subsequent disulfide bond rearrangement produced the mature pattern of 9–57 and 38–90 (Ruddon et al. 1996). In both subunits, the disulfide bonds organized a structural motif called the cystine knot.

First discovered in the nerve growth factor (NGF) crystal structure (McDonald et al. 1991), the cystine knot motif consists of a pair of disulfide bonds between two parallel strands, which form a ring that a third disulfide bond connected to two different strands passes through. This motif defines an elliptical molecule with two loops designated L1 and L3, on one side of the knot, and a single loop, L2, on the other side. Cystine knot motifs define three protein superfamilies, the inhibitor cystine knots, cyclic cystine knots, and cystine knot growth factor (CKGF) superfamily, including gonadotropins (Roch and Sherwood 2014). CKGF cystine knots differ from those in the other two superfamilies by the use of Cys I and Cys IV disulfide bond to penetrate the ring. The gonadotropins, TSH, and thyrostimulin form one of the six groups in the CKGF superfamily. The other groups are bursicon hormone, bone morphogenic protein antagonist family, transforming growth factor beta family, platelet-derived growth factor family (which includes vascular endothelial growth factors), and the nerve growth factor family (Roch and Sherwood 2014). CKGF motifs are found in other multi-domain proteins, such as the mucins, which employ them as dimerization domains.

Both hCG  $\alpha$ - and  $\beta$ -subunits are cystine knot proteins (Fig. 3). While the conserved arrangement of Cys residues underlies the sequence homology pointed out by Dayhoff (Dayhoff 1976), the surrounding sequences appear to be subunit specific. While swapping  $\alpha$ -subunit cystine knot sequences CMGCC and CHC for the corresponding  $\beta$ -subunit sequences, CAGYC and CQC, permitted subunit folding, heterodimer formation was effectively blocked (Darling et al. 2001). Cystine knot proteins are generally dimers organized in parallel or non-parallel, homo- or heterodimeric, non-covalently or covalently associated via intermolecular disulfide bonds. The gonadotropins are all antiparallel heterodimers connected non-covalently by a fourth  $\beta$ -subunit loop, the seat belt loop (Laphorn et al. 1994), or cystine noose (Arnold et al. 1998). This loop embraces the  $\alpha$ -subunit loop, L2, and latched by an intramolecular disulfide bond. Embedded in the seat belt loop is an octapeptide loop between Cys residues 93–100 (CG $\beta$  and presumably LH $\beta$ ) and 87–94 (FSH $\beta$ ), called the determinant loop. First proposed to distinguish LH from FSH and TSH (Moore et al. 1980), subsequent studies confirmed it as an LH determinant. The adjacent, C-terminal portion of the seat belt loop is the FSH determinant, which confers FSH binding activity on chicken LH (Moyle et al. 1994). Missing from both hCG structures was the CTP.

The structure of hFSH confirmed the cystine knot structure for the gonadotropin family (Fox et al. 2001). FSH $\alpha$  subunit disulfide bonds matched those in CG $\alpha$ . Those in FSH $\beta$  were homologous to CG $\beta$ . Two FSH molecules were in the asymmetric unit, which revealed flexibility. A small difference in the angle of the  $\beta$ -subunits, when the  $\alpha$ -subunits were aligned, suggested flexibility in subunit association. Other flexible regions were the tips of the L1 and L3 loops and subunit N- and C-termini. Similar patterns of flexibility were observed during molecular dynamics simulations of FSH models (Meher et al. 2015). Co-crystallization of FSH with portions of its cognate receptor revealed receptor-induced conformational changes (Fan and Hendrickson 2005; Jiang et al. 2012).

Human FSH-FSHR interaction (Jiang et al. 2013) included a progressive loss of FSH flexibility. Binding the high-affinity site on the FSHR induced helix formation at the FSH $\alpha$  C-terminus, defining the positions of the last few residues missing in the FSH crystal structure. Fewer residues exhibited  $>1$  Å differences at the tips of loops L1 and L3 in both subunits, and there were no significant differences in positions of these residues between the three FSH ligands bound to the entire FSHR extracellular domain. This is consistent with receptor binding studies in which FSH does not dissociate from its receptor on its own (Urizar et al. 2005), even after prolonged incubation (Cheng 1975), but requires 1,000-fold excess hormone to partially displace it (Krishnamurthy et al. 2003).

The structure of hFSH bound to the high-affinity site of the hFSHR extracellular domain (Fan and Hendrickson 2005) revealed an absolute requirement for heterodimer structure in order to engage the high-affinity binding site. Cystine knot L2 loops in each subunit bound opposite sides of the receptor and made important contacts with the leucine-rich repeat (LRR) connecting loops. A proteolytic nick in L2 loops in either subunit resulted in a 100-fold reduction in receptor binding affinity, but the critical role for both L2 loops was unknown (Bousfield and Ward 1988; Ward et al. 1986). A conformational change at the  $\alpha/\beta$  interface was noted; however, its significance was not realized until the entire FSHR extracellular domain was co-crystallized with FSH (Jiang et al. 2012). The FSHR hinge region was revealed as a LRR extension plus a partially defined loop that included a highly conserved sulfated Tyr residue, shown to be essential for glycoprotein hormone receptor activation (Costagliola et al. 2002). The conformational change in FSH attending high-affinity binding to the LRR domain created a pocket the sulfo-Tyr bound. The corresponding FSHR conformational change was proposed to release receptor inhibition when a helical region, disulfide bonded to the sulfo-Tyr-containing loop, altered its position near the FSHR transmembrane domain (Jiang et al. 2013).

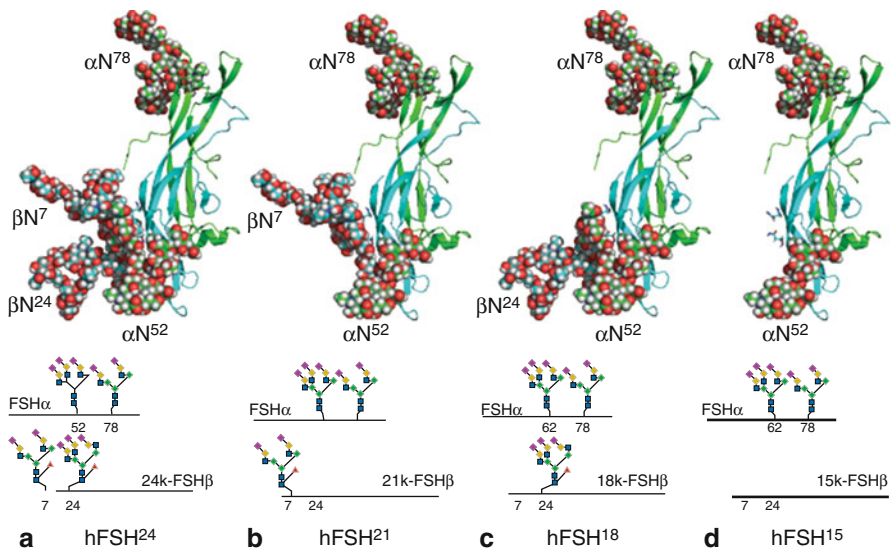
## Carbohydrate Structures Attached to Gonadotropins

Glycosylation is an important posttranslational glycoprotein hormone modification that impacts folding, stability, clearance, receptor-binding affinity, and receptor activation. Heterogeneity comes in two forms, macroheterogeneity resulting from the absence of one or more oligosaccharide chains from a hormone variant and

microheterogeneity resulting from variation in the structures of glycans attached to the hormone.

All LH N-glycosylation sites are quantitatively occupied by oligosaccharides. In equine LH from the horse, 12, partially O-glycosylated Ser and Thr residues have been reported (Bousfield et al. 2001). There is a variant *LHB* allele in the human population (see below), in which both Asn<sup>13</sup> and Asn<sup>30</sup> glycosylation sites are present (Haavisto et al. 1995). This variant exhibits shortened survival in the circulation (Suganuma et al. 1996). Macroheterogeneity in CG occurs at both the N-glycosylated core and in the O-glycosylated CTP (Bedows et al. 1992). Structural evaluation of CG from several sources has indicated that partial CG $\beta$  N-glycosylation occurs only at Asn<sup>13</sup> (Valmu et al. 2006), while partial O-glycosylation occurs at either Ser<sup>127</sup> or Ser<sup>132</sup> (Liu and Bowers 1997; Valmu et al. 2006). Exactly which Ser residue lacks carbohydrate is unknown because both residues reside in the same peptide.

FSH macroheterogeneity occurs at either one or both FSH $\beta$  N-glycosylation sites (Davis et al. 2014) (Fig. 6). Two FSH $\beta$  bands appear in Western blots: a 24 kDa band that possesses both Asn<sup>7</sup> and Asn<sup>24</sup> N-glycans (designated as fully glycosylated, 24 k-FSH $\beta$ ) and a 21 kDa band that lacks Asn<sup>24</sup> glycan (hypo-glycosylated, 21 k-FSH $\beta$ ) (Bousfield et al. 2014b; Walton et al. 2001) (Fig. 6). The corresponding FSH heterodimers are designated FSH<sup>24</sup> and FSH<sup>21</sup>, respectively. Purified FSH<sup>21</sup>



**Fig. 6** Human FSH glycoform models. The protein moieties are indicated as cartoons, with FSH $\alpha$  colored *green* and FSH $\beta$  colored *cyan*. The oligosaccharide models are shown as *spheres*. Each model was built by attaching the most abundant glycan at each site using the web-based tool GLYCAM-Web (Woods Group. (2005–2016) GLYCAM Web. Complex Carbohydrate Research Center, University of Georgia, Athens, GA. (<http://glycam.org>)) (See Fig. 4 and Varki et al. 2015) for symbols)



preparations include a second hypo-glycosylated variant, 18 k-FSH $\beta$ , which lacks the Asn<sup>7</sup> glycan. The corresponding heterodimer is designated as FSH<sup>18</sup>. A completely non-glycosylated hFSH $\beta$  subunit variant was detected in 21 kDa-FSH $\beta$  and 24 kDa-FSH $\beta$  preparations by matrix-assisted laser desorption (MALDI)-MS (Walton et al. 2001). A 15 kDa-FSH $\beta$  subunit band was detected in pituitary extracts from transgenic mice that expressed a double glycosylation mutant hFSH $\beta$  (Wang et al. 2016a). This variant was designated FSH<sup>15</sup>. Despite pituitary expression of 15 kDa-FSH $\beta$ , very little FSH<sup>15</sup> was found in the circulation. Under nonreducing conditions, FSH<sup>15</sup> heterodimer was undetectable in FSH $\beta$  Western blots, as if the absence of carbohydrate affected heterodimer formation and/or stability. Thus, there appear to be three physiologically relevant FSH variants, FSH<sup>24</sup>, FSH<sup>21</sup>, and FSH<sup>18</sup>.

*In vitro* and *in silico* studies have shown that hypo-glycosylated pituitary hFSH preparations exhibit higher FSHR binding activity and bioactivity as compared to fully glycosylated FSH (Bousfield et al. 2014a; Jiang et al. 2015; Meher et al. 2015). Thus, similar to the influence of microheterogeneity on the ability of the gonadotropins to activate and trigger intracellular signaling, FSH $\beta$  macroheterogeneity may also contribute to its bioactivity. In fact, recent *in silico* studies on complexes between the hormone-binding domain of the hFSHR (Fan and Hendrickson 2005) and different FSH glycoforms revealed that FSHR complexed with FSH<sup>15</sup> exhibited greater conformational flexibility and more favorable kinetic profile than FSH<sup>24</sup>. Greater binding free energy was indicated, due to formation of closer and more persistent salt bridges of both variant  $\alpha$ - and  $\beta$ -subunits with the receptor (Meher et al. 2015). Thus, a more stable FSHR interaction with hypo-glycosylated FSH relative to fully glycosylated FSH suggests mechanisms for the differences in biological effects for fully and partially glycosylated FSH *in vivo* and *in vitro* (Bousfield et al. 2014a; Jiang et al. 2015). Further, the recent model of the FSHR as a functional trimer (see below) (Jiang et al. 2014b) supports *in vitro* data showing that binding of bulky, fully glycosylated FSH to the FSHR is delayed and occurs at a slower rate compared to that shown by a more compact hypo-glycosylated variant possessing largely oligomannose glycans (Bousfield et al. 2014a). In this model, FSH<sup>24</sup> with 3–4-branch glycans requires more time to fit the  $\alpha$ Asn<sup>52</sup> glycan into the central cavity of the receptor trimer than the hypo-glycosylated FSH variants bearing truncated, 2-branch glycans at this position (Jiang et al. 2014b). This model may also explain the different receptor binding activities and *in vitro* biological potencies of distinct FSH glycoforms with variations in sialic acid content, internal structure of the carbohydrate chains, and complexity of glycans (Ulloa-Aguirre et al. 1995; Creus et al. 2001). Human FSH macroheterogeneity is of physiological significance as FSH<sup>24</sup> represents approximately 80% of hFSH in pooled pituitary and urinary hFSH samples from postmenopausal women, while FSH<sup>21</sup> represents 52–70% pituitary FSH derived from autopsies of reproductive age women (Bousfield et al. 2007, 2014a, b). Further, FSH<sup>21</sup> abundance is correlated with the age of the donor: FSH<sup>21</sup> abundance is greater in pituitaries of younger women and decreases over reproductive life. In postmenopausal women hFSH<sup>24</sup> is the dominant glycoform (Bousfield et al. 2014a). Recent studies showing circulating levels of hypo- and fully glycosylated FSH and LH varying across the menstrual cycle suggest hormonal

control of glycosylation (Wide and Eriksson 2013). Recombinant hFSH<sup>15</sup> was found to be cleared from the circulation faster than recombinant FSH<sup>24</sup> (Bishop et al. 1995). Studies of human pituitary extracts revealed that pituitary FSH from young, cycling women cleared more rapidly than FSH from postmenopausal women (Wide and Wide 1984). These findings may have important implications for the pharmacological treatment of infertility in assisted reproduction, particularly considering that the relative abundance of hypoglycosylated FSH in recombinant FSH preparations produced in CHO cells is comparatively lower than that present in the pituitary of young women.

Microheterogeneity at each N-glycosylation site has been evaluated by nuclear magnetic resonance (NMR) for CG, hLH, and human TSH (Hiyama et al. 1992; Weisshaar et al. 1991a, b). NMR provides quantitation and the least ambiguity in structure determination, provided sufficient material of acceptable purity is available for study. The same 14 bi-antennary oligosaccharides were observed at each hLH glycosylation site (Weisshaar et al. 1991b). The relative proportion of each glycan differed at each site, and  $\alpha$ -subunit glycans lacked core-linked fucose, while LH $\beta$  glycans possessed it (Fig. 4). Human LH possessed significant sialic acid content, in contrast to other mammalian LH preparations, in which sialic acid is rare (Green and Baenziger 1988). A novel characteristic of hLH glycans was sialic acid linked to Gal residues by both  $\alpha(2-6)$  and  $\alpha(2-3)$  linkages (Weisshaar et al. 1991b). In CG, all sialic acids were  $\alpha(2-3)$  linked. Sialic acid was also linked to hLH GalNAc residues (Renwick et al. 1987), so that in this gonadotropin sialic acid is attached to both Gal and GalNAc. In other glycoprotein hormones, GalNAc usually is sulfated. Ion mobility mass spectrometry has identified at least 82 oligosaccharides in two samples of LH glycans from each glycosylation site. Both  $\beta$ Asn<sup>30</sup> and  $\alpha$ Asn<sup>78</sup> glycan populations consisted of 64–65 oligosaccharides, while  $\alpha$ Asn<sup>52</sup> possessed 74 glycans. Oligosaccharide structures ranged from mono-antennary to either tetra-antennary or tri-antennary with lactosamine repeats. The larger glycans were low in abundance, rarely exceeding 1% relative abundance, with 4% the highest level observed in the  $\alpha$ Asn<sup>52</sup> glycan samples. The most abundant glycans were bi-antennary and terminated with sulfate, sialic acid, or both. Sulfated glycans were lowest in abundance (20–30%) at  $\alpha$ Asn<sup>78</sup>. Sulfate decorated almost half of  $\beta$ Asn<sup>30</sup> glycans, and these were more abundant than sialylated  $\alpha$ Asn<sup>52</sup> glycans. Both glycans are located at one end of LH, while  $\alpha$ Asn<sup>78</sup> oligosaccharides are at the opposite end. The most abundant glycan detected by NMR at each site was among the more abundant, if not the most abundant, structure for the corresponding site that was identified by mass spectrometry.

An early study of CG N-glycans reported four bi-antennary structures and one mono-antennary (Endo et al. 1979). The bi-antennary structures differed by the presence of core fucose in those derived from CG $\beta$ , no fucose in those derived from CG $\alpha$ , and either one or two sialic acid residues. Another early report of CG N-glycans detected only a disialylated, bi-antennary N-glycan at all four sites, with core fucose only attached to those derived from the  $\beta$ -subunit (Kessler et al. 1979b). In CG $\alpha$ , NMR identified four Asn<sup>52</sup> N-glycans, and a sialylated, mono-antennary glycan represented 50% of this population (Fig. 4). Two hybrid-type

oligosaccharides accounted for 29%, while a disialylated, bi-antennary glycan represented 18%. The latter structure represented 61% of the Asn<sup>78</sup> glycan population and a mono-antennary glycan the remaining 39%. For CG $\beta$ , disialylated, bi-antennary glycans formed the majority of the glycan populations at both sites; however 100% Asn<sup>13</sup> and 30% Asn<sup>30</sup> glycans were core fucosylated. The other glycan at these sites was a mono-antennary glycan like that at Asn<sup>52</sup>, plus fucose. Mass spectrometry analysis confirmed the Asn<sup>30</sup> populations (Liu and Bowers 1997). However, seven N-glycans were found at Asn<sup>13</sup>, including tri-antennary glycans, like those reported previously for choriocarcinoma CG (Endo et al. 1988; Mizuochi et al. 1983). The major N-glycan was like that at  $\alpha$ Asn<sup>78</sup>, disialylated, bi-antennary, and lacking core fucose. This glycan was also the most abundant pregnancy CG $\beta$  Asn<sup>13</sup> glycan identified by a more recent mass spectrometry report that identified 14 N-glycans, largely lacking core fucose (Valmu et al. 2006). Invasive mole- and testicular cancer-derived CG $\beta$  Asn<sup>13</sup> glycans exhibited increased mono- and tri-antennary glycan abundance, along with increased core fucosylation. At Asn<sup>30</sup>, mass spectrometry confirmed a reduced level of heterogeneity relative to that at Asn<sup>13</sup>. Initially only two fucosylated, bi-antennary glycans possessing either one or two sialic acids were found (Liu and Bowers 1997). A subsequent study identified small amounts of nine additional glycans (Valmu et al. 2006). These remain the most abundant in cancer CG, despite increased mono- and tri-antennary glycan abundance.

Until the development of suitable mass spectrometry procedures, hFSH micro-heterogeneity was only evaluated at the whole molecule level (Green and Baenziger 1988; Renwick et al. 1987). Proteinase K glycopeptide mass spectrometry studies identified as many as 11 oligosaccharides at  $\beta$ Asn<sup>24</sup> and  $\alpha$ Asn<sup>52</sup>, but only 2–4 at  $\beta$ Asn<sup>7</sup> and  $\alpha$ Asn<sup>78</sup> (Dalpathado et al. 2006). Mass spectrometry analysis of  $\alpha$ Asn<sup>52</sup> oligosaccharides released from intact hFSH $\alpha$  with peptide-N-glycanase F (PNGaseF) identified 109 unique glycan structures. These were sialic acid derivatives of about 30 core glycan structures. Many possess the same number of sialic acid residues, but differ by their position on the glycan branches or by linkage to the Gal or GalNAc residues. Site-specific pituitary FSH oligosaccharide analysis revealed core fucose in over 95% of FSH $\beta$  oligosaccharides, but less than 5% FSH $\alpha$  oligosaccharides. The relative abundance of each FSH glycan shown in Fig. 4 is relatively low because of the degree of heterogeneity, as 67 glycans were identified in the FSH $\beta$  samples and 48 in the FSH $\alpha$  samples.

---

## Biosynthesis of the Gonadotropins

### Signaling Pathways and Transcriptional Regulation of the $\alpha$ - and $\beta$ -Subunit Genes

As mentioned previously, control of LH and FSH synthesis and secretion is complex and involves a coordinated interplay between the gonads, the pituitary, and the hypothalamus (Fig. 1). The hypothalamic component is represented by the

decapeptide gonadotropin-releasing hormone (GnRH), synthesized by specialized neurons predominantly located in the arcuate nucleus of the mediobasal hypothalamus and in the preoptic area of the anterior hypothalamus. The axons of these neurons project either to various regions of the brain, where GnRH acts as a neurotransmitter or neuromodulator of reproductive behavior, or to the median eminence; here, the decapeptide enters the portal circulation to reach the pituitary gonadotropes of the adenohypophysis (Ulloa-Aguirre and Timossi 2000). The secretion of GnRH into hypophyseal portal circulation occurs in a pulsatile manner (Knobil 1980; Marshall et al. 1991; Wildt et al. 1981); the episodic GnRH secretion is finely regulated by the coordinated interaction between hypothalamic neurons of the arcuate nucleus that co-express kisspeptins, neurokinin B, and dynorphin (KNDy neurons) and the GnRH-producing neurons. Neurokinin-B and dynorphin operate reciprocally as major positive and negative regulators of the episodic release of kisspeptin, which in turn is the effector of this neuronal complex for the stimulation of the neurosecretory activity of GnRH neurons via interaction with its receptor, KISS1R (Skorupskaite et al. 2014).

Once in the gonadotrope cells, GnRH interacts with its cognate receptor (GnRHR) to induce gene expression as well as stimulus secretion of gonadotropins (Ciccone and Kaiser 2009). In fact, GnRH-regulated expression of gonadotropin  $\alpha$ - and  $\beta$ -subunits provides a genomic signature unique to functional gonadotropes. Nevertheless, many pathways need to converge to achieve the complexity and, more importantly, the differential regulation of LH and FSH subunit expression, a first step toward production and secretion. The activation of signaling pathways promoting the interaction of distinct transcription factors with specific response elements, present in the gonadotropin subunit promoters, to control differential gonadotropin gene transcription, varies depending on the cell context and experimental conditions (Grosse et al. 2000; Stanislaus et al. 1997, 1998; Sviridonov et al. 2013). In primary pituitary cultures, G-GH<sub>3</sub>, and L $\beta$ T2 cells, the GnRHR couples to G<sub>s</sub> and G<sub>q/11</sub> proteins but not G<sub>i</sub>, whereas in  $\alpha$ T3-1 pituitary precursor cells, Chinese hamster ovary (CHO)-K1 cells, and COS-7 cells, the GnRHR appears to couple almost exclusively to the G<sub>q/11</sub> protein (Grosse et al. 2000; Han and Conn 1999; Liu et al. 2002; Tsutsumi et al. 2010). Coupling to other G proteins has also been reported (Kraus et al. 2001; Naor and Huhtaniemi 2013). Consequently, increases in a number of distinct second messengers including cAMP, inositol 1,4,5-trisphosphate, Ca<sup>2+</sup>, and diacylglycerol (DAG), as well as activation of multiple protein kinase-mediated signaling pathways following GnRH exposure, are important for decoding the GnRH signal by the gonadotrope and stimulate frequency-dependent, differential LH and FSH synthesis and secretion (Naor and Huhtaniemi 2013). Nevertheless, some of these studies employed acute tonic treatment rather than the natural pulsatile stimulation, which is known to be fundamental for gonadotropin gene transcription (Ferris and Shupnik 2006; Shupnik 1990). More specifically, the gonadotrope responds to pulsatile GnRH stimulation activating signaling cascades mediated by MAPKs (mitogen-activated protein kinases), including ERK1/2, (extracellular signal-regulated kinase), JNK (jun N-terminal kinase), and p38 (Kanasaki et al. 2005; Naor 2009). In particular, it seems that ERK1/2 phosphorylation and

translocation to the nucleus are involved in differential transcriptional regulation of LH $\beta$  and FSH $\beta$  genes through GnRH-provoked activation of MAPK phosphatases, particularly DUSP1 (dual-specificity kinase), which allow for differential activation patterns of these kinases (Purwana et al. 2011; Zhang and Roberson 2006). Additional signaling cascades involved in differential synthesis of gonadotropin  $\beta$ -subunits include those dependent on either the PKA/cAMP pathway (see below); the Ca<sup>2+</sup>/calmodulin/calcineurin pathway, which allows nuclear translocation of the nuclear factor of activated T cells (NFAT) upon cell exposure to GnRH (Armstrong et al. 2009; Tsaneva-Atanasova et al. 2012); or the WNT/ $\beta$ -catenin signaling pathway (Salisbury et al. 2008).

### **Transcriptional Regulation of the Common $\alpha$ -Subunit Gene ( $\alpha$ GSU)**

Although the  $\alpha$ -subunit is produced in excess of the gonadotropin  $\beta$ -subunits and  $\alpha$ GSU transcription does not appear to be tightly regulated by GnRH pulse frequency, as occurs with the  $\beta$ -subunits, some studies have indicated that  $\alpha$ -subunit transcription is favored by fast-frequency (interpulse interval 8–30 min) GnRH pulses (Haisenleder et al. 1991; Shupnik 1996) and that it can be regulated by gonadal factors (Heckert et al. 1997). The best-characterized mechanism for transcriptional activation of the  $\alpha$ -subunit gene is the cAMP/PKA pathway (Haisenleder et al. 1992). In the human gonadotrope, the  $\alpha$ -subunit promoter exhibits two tandemly repeated cAMP/PKA response elements (CRE) located at positions –146 to –111 relative to the transcription initiation site (Jameson et al. 1986), which binds the nuclear CRE-binding proteins, including CREB, CRE modulator, and c-Jun/ATF2 heterodimers, to activate gene transcription. Other regulatory elements involved in basal transcription of the  $\alpha$ GSU include the homeobox 1 (Pitx1) response element (Jorgensen et al. 2004; Quirk et al. 2001) and GSE (gonadotrope-specific element) (Barnhart and Mellon 1994; Horn et al. 1992; Ingraham et al. 1994), as well as the GnRH-responsive unit at the distal 5' regulatory region (which also defines  $\alpha$ GSU expression in a cell-specific manner) comprised by elements PGBE,  $\alpha$ BE1 and 2, and Ets binding sequence, which bind several factors including members of the LIM homeodomain family  $\alpha$ BP1 and 2, and Ets (Heckert et al. 1995; Jorgensen et al. 2004). Meanwhile, the  $\alpha$ GSU promoter regions implicated in GnRH-regulated  $\alpha$ GSU transcription mainly include PGBE,  $\alpha$ BE, and the Ets sequence, with CRE at the proximal promoter region interacting with the former elements.

A number of regulatory elements have a key role on the transcriptional regulation of  $\alpha$ GSU in trophoblasts; these include JRE (junctional regulatory element, which binds Distal-less 3 or Dlx3), TSE (trophoblast-specific element, which binds activating protein 2 or AP2), and the CCAAT box, as well as CRE and  $\alpha$ ACT (with the latter binding GATA-binding proteins 2 and -3) (Bokar et al. 1989; Budworth et al. 1997; Johnson et al. 1997; Knofler et al. 2000, 2001; Nilson et al. 1989; Pittman et al. 1994; Steger et al. 1994).

### **Transcriptional Regulation of the Specific $\beta$ -Subunit Genes**

Several transcription factors participate in the cell-specific activation and hormone-regulated differential expression of the  $\beta$ -subunits. In the case of the FSH $\beta$ , synthesis

of this subunit represents the rate-limiting step for FSH dimer synthesis and constitutive secretion from the gonadotrope. The FSH $\beta$  gene promoter contains in its 5' proximal flanking region a half cAMP-response element/AP1 site, which binds CREB as well as c-Fos and c-Jun, both members of the AP1 family. In fact, the CREB consensus binding sequence (TGACGTCA) is very similar to that of AP1. This GnRH-responsive element and inducible cAMP early repressor (ICER) have been implicated in the regulation of murine FSH $\beta$  gene expression. CREB binds to cAMP response elements on the FSH $\beta$  gene promoter and could give rise to the differential GnRH pulse effect on gonadotropin gene expression by recruiting CREB binding protein (CBP) at slow pulse frequency of the decapeptide. In this scenario, high pulse frequency of GnRH may increase ICER, which binds to CRE on the FSH $\beta$  gene promoter, thereby dampening gene transcription (Ciccone et al. 2010). Thus, the induction of this, and other negative regulatory transcription factors (such as SKIL and TGIF1 (Mistry et al. 2011)), could potentially provide a mechanism for the differential regulation of gonadotropin gene expression under low and high GnRH pulse frequency. Low pulse (interpulse interval 120–240 min) favors and high pulse represses FSH $\beta$  gene transcription. Distal to the GnRH-responsive element described above is a *cis*-element that binds Nur77, which seems to regulate GnRH-induced derepression of the murine FSH $\beta$  gene (Lim et al. 2007; Wurmbach et al. 2001).

As discussed above, LH $\beta$  subunit gene transcription is promoted by high frequency GnRH pulses (interpulse interval ~60 min in *in vitro* systems (Lawson et al. 2007)), which in turn provoke MAPK activation and LH $\beta$  transcription through rapid induction of the immediate early gene Egr-1 which interacts with basal factors to induce LH $\beta$  transcription (reviewed in (Jorgensen et al. 2004)). In rodents, Egr-1 sites are located in tandem with SF-1 sites at either site of homeodomain element (HD) that interacts with Ptx1 (Tremblay et al. 1999); these three elements act synergistically to promote GnRH-induced LH $\beta$  transcription and also interact with  $\beta$ -catenin to increase LH $\beta$  transcription (Salisbury et al. 2008). Meanwhile, the scaffold protein p300 allows interaction between these proximal promoter sites and the more distally located SP-1 and CArG elements, also involved in pulsatile LH $\beta$  transcription (Mouillet et al. 2004). Apparently, the GnRH frequency-regulated LH $\beta$  transcription is governed by the interplay between ubiquitin, which establishes on-off cycling of SF-1 and Egr-1 factors at the LH $\beta$  promoter, and the Egr repressor proteins Nab1/2 (NGFI-A binding proteins) which are induced by low frequency GnRH pulses (Lawson et al. 2007).

The dynamics of gonadotropin synthesis is complex and includes the interplay among several endocrine, paracrine, and autocrine factors that may directly influence on the gonadotrope response to the GnRH stimulus. It is known that sex steroid hormones and glucocorticoids regulate gonadotropin synthesis and secretion by acting at the hypothalamus and the pituitary. Estrogens exert both positive and negative feedback on gonadotropin synthesis and secretion, with the negative feedback occurring mainly at the hypothalamic level through inhibiting kisspeptin and neurokinin B release from KNDy neurons, thereby reducing their stimulatory input to GnRH neurons, which lack estrogen receptor- $\alpha$  (Garcia-Galiano et al. 2012;

Shupnik and Fallest 1994; Skorupskaite et al. 2014). Although the positive feedback of estrogens also occurs through effects at the hypothalamus KNDy neurons (Garcia-Galiano et al. 2012), it has been demonstrated that estrogens, acting via the estrogen receptor- $\alpha$ , promote LH $\beta$  gene transcription either directly through binding an imperfect estrogen response element in the distal LH $\beta$  promoter of the rat gene (Shupnik and Rosenzweig 1991) or interacting with SF-1 and Ptx1 (Luo et al. 2005) or indirectly by influencing expression of activators (e.g., Egr-1) and repressors of transcription (Kowase et al. 2007). Although estrogens exert a suppressive effect on FSH $\beta$  gene transcription by interaction with the estrogen receptor- $\alpha$ , the mechanism through which this is effected is still unclear. Progesterone, another steroid hormone produced by the gonads, mainly by the corpus luteum and placenta, regulates gonadotropin synthesis and secretion through effects at the hypothalamus and the pituitary. The effects at the gonadotrope level have been difficult to analyze due to the need of estrogens to induce the progesterone receptor. In L $\beta$ T2 cells over-expressing the progesterone receptor, exposure to progesterone suppressed basal and GnRH-induced LH $\beta$  gene expression, an effect that required the presence of elements within -300/-150 of the LH $\beta$  promoter but not direct interaction of the steroid-progesterone receptor B complex with the promoter (Thackray et al. 2009; Thackray et al. 2010). By contrast, progesterone exerts facilitatory effects on FSH $\beta$  gene transcription through direct interactions of the activated progesterone receptor with hormone response elements of the FSH $\beta$  promoter (Thackray et al. 2006). A similar effect has been observed for androgens and glucocorticoids, which may downregulate and upregulate, respectively, LH $\beta$  and FSH $\beta$  transcriptional activation through direct interactions of the activated androgen receptor with either rat Sp1 or bovine SF-1 factors (to repress GnRH-induced LH $\beta$  gene transcriptional activation) or with hormone response elements (to promote FSH $\beta$  gene transcription) (Jorgensen et al. 2004; Spady et al. 2004; Thackray et al. 2006). In both human and mouse  $\alpha$ GSU promoters, androgens suppress transcriptional activation of the  $\alpha$ GSU gene through interaction with CRE-binding proteins (Jorgensen et al. 2004).

Another endocrine factor that regulates gonadotropin  $\beta$ -subunit expression is leptin, a protein hormone mainly synthesized in adipose tissue. In addition to regulating appetite and metabolism, in several animal species, including humans, leptin is also important in regulating reproductive function by acting at both the hypothalamus and the pituitary (Clement et al. 1998; Issad et al. 1998; Strobel et al. 1998). In the pituitary, leptin increases the synthesis and secretion of LH and FSH, and its effects on the transcriptional regulation of LH $\beta$  and FSH $\beta$  genes are mediated by the LIM-homeodomain transcription factor Isl-1 gene (Wu et al. 2010). This effect on gonadotropin synthesis may apparently be counteracted by central leptin resistance in conditions of energy excess, such as obesity, which is frequently associated with low serum gonadotropin levels, hypogonadism, and subfertility (Chou and Mantzoros 2014).

There is compelling evidence that activin as well as growth differentiation factor 9 (GDF9) and bone morphogenetic proteins (BMP), all members of the transforming growth factor  $\beta$  (TGF $\beta$ ) superfamily, act synergistically with GnRH to regulate transcriptional activation and mRNA expression of *FSHB* in an autocrine manner.

Activins are protein factors produced in multiple tissues, including the gonads and the pituitary gland, where they act in an autocrine/paracrine manner (Bilezikjian et al. 2004; Knight and Glistler 2001). Activin, produced by the gonadotropes, binds to type I/type II serine/threonine receptor kinases to activate the SMAD signaling cascade (SMAD2 and -3, which partner with the common SMAD 4 and translocate to the nucleus) to regulate gene transcription (Gregory and Kaiser 2004). In *in vitro* and *in vivo* murine models, activin-activated SMADs regulate transcription of at least two genes: the FSH $\beta$  gene and the follistatin gene (which binds activin, thereby inhibiting its effects on the gonadotrope) and also probably the GnRHR gene (reviewed in (Fortin et al. 2015)). The effect of activin on the increase in FSH $\beta$  gene transcription is exerted through binding of SMADs to SMAD-binding elements (SBE) as well as to forkhead-binding elements (FBE) in complex with the transcription factor forkhead box L2 (FOXL2) (Bernard and Tran 2013; Blount et al. 2009; Lamba et al. 2009; Tran et al. 2013; Zawel et al. 1998). Meanwhile, activin regulates follistatin gene expression apparently through binding of SMADs and FOXL2 to an enhancer located at the 3'-end of intron 1 (Blount et al. 2008). In contrast to activin, the structurally related hormone inhibin (which is mainly synthesized in the gonads, but also in the pituitary) prevents activation of the activin-mediated SMAD signaling pathway and consequently FSH $\beta$  gene transcription by blocking, complexed with the TGF $\beta$ -type III receptor (betaglycan), the binding of activin to its type-II receptor (Lewis et al. 2000; MacConell et al. 2002). Another member of the TGF $\beta$  superfamily, GDF9, is also expressed in primary pituitary cultures and gonadotrope cell lines (Wang et al. 2009). It has been shown that GDF9 is an autocrine inducer of mouse FSH $\beta$  gene transcription acting via Smad2/3 activation. Since GDF9 expression is preferentially suppressed by high frequency GnRH pulses, this particular factor has been proposed as an additional local regulator of GnRH frequency-dependent expression of this gonadotropin subunit (Choi et al. 2014; Pincas et al. 2014). Finally, bone morphogenetic proteins (BMPs), specifically BMP4, 6, and 7, can modify activin- as well as GnRH-mediated gonadotropin release by increasing mRNA levels of FSH $\beta$  subunits (Nicol et al. 2008; Takeda et al. 2012). Thus, there is an important functional link between all these members of the TGF $\beta$  superfamily and GnRH stimulation, providing short-loop feedback and thereby fine-tuning FSH $\beta$  gene expression.

Pituitary adenylate cyclase-activating polypeptide (PACAP) belongs to the vaso-active intestinal peptide-secretin-glucagon peptide superfamily and is produced in both the hypothalamus and the pituitary. It is now recognized that PACAP acts either alone or with GnRH to stimulate expression of each gonadotropin subunit as well as transcription of GnRHR. In L $\beta$ T3 cells, expression of PACAP and its receptor are increased at low-frequency GnRH pulses leading to preferential increase in FSH $\beta$  expression, as opposed to cells exposed to high-frequency GnRH pulses, where follistatin mRNA is increased without modifications in PACAP receptor expression, provoking preferential increase in LH $\beta$  gene transcription (Kanasaki et al. 2009, 2013). Like GnRH, differential regulation of gonadotropin gene expression can be achieved by modulation of the signal frequency of PACAP; although both LH $\beta$  and FSH $\beta$  genes expression may be upregulated by pulsed administration of PACAP,



high-frequency pulses increase LH $\beta$  gene expression more than FSH $\beta$  gene expression, while low-frequency pulses have the opposite effect (Kanasaki et al. 2009).

The regulation of chorionic gonadotropin  $\beta$ -subunit transcription in the placenta has been studied in some detail. As mentioned previously, the CG $\beta$  subunit is encoded by at least six nonallelic genes (*CGB*) named *CGB1–2* (both pseudogenes), *CGB3*, *CGB5*, and *CGB7–8* (Policastro et al. 1983), with *CGB8* and *CGB5* being the most actively transcribed in the placenta (Cocquebert et al. 2012; Nagirnaja et al. 2010; Rull and Laan 2005). Transcription of this subunit is stimulated by multiple factors including steroid hormones (i.e., progesterone and corticoids), small peptides (GnRH) and growth factors (EGF), cytokines (IL6), leptin, PPAR $\delta$ , and activators of the cAMP signaling pathway (reviewed in (Fournier et al. 2015)). The synthesis of the CG $\beta$  subunit is mainly controlled by response elements located in the proximal (–315 to +114) region of the promoter that bind AP2 $\alpha$  and Sp1 and 2 transcription factors, with AP2 $\alpha$  binding promoted by cAMP and with distinct expression patterns of Sp factors, depending on the stage of gestation (Knofler et al. 2004).

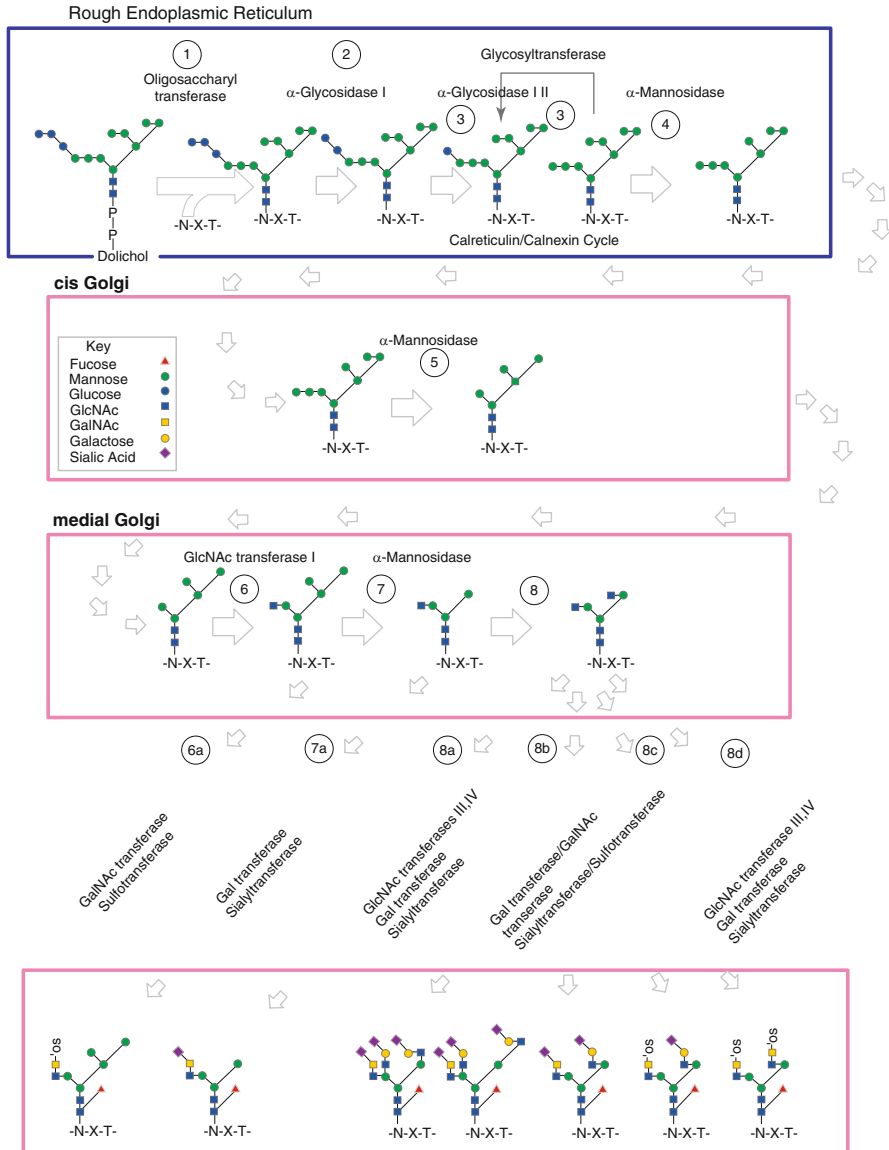
---

## Gonadotropin Subunit Assembly, Processing, and Secretion

As described above, initiation of events that lead to pituitary gonadotropin gene expression rests at the level of secretagogues and is modulated by several factors. The biosynthesis of the gonadotropin subunits can be considered in three steps: (a) translation involving the cytoplasm and the endoplasmic reticulum (ER), (b) glycosylation and assembly taking place in the ER (Fig. 7), and (c) processing, packaging, and secretion, which occurs in the the Golgi and secretory vesicles. In GPHs, both subunits are glycosylated, and the timing of glycosylation relative to translation and transfer to the ER, as well as protein folding and assembly, is still incompletely understood. Since the glycoprotein hormones are heterodimeric, it could be anticipated that expression of the genes that encode the  $\alpha$ - and  $\beta$ -subunits is coordinated; in fact, expression of the pituitary gonadotropin subunits is regulated by GnRH frequency-determined triggering of signaling pathways in the gonadotrope. Moreover, production of either subunit alone would be in vain without a partner to form the active hormone heterodimer. There also appears to be an interdependent relationship between glycosylation and dimer formation; glycosylation is essential for subunit association, and conversely, association is important for glycan processing and maturation (Matzuk and Boime 1988a, b, 1989; Wang et al. 2016a). In fact, failure of the  $\alpha$ -subunit to associate with the  $\beta$ -subunit leads to aberrant glycosylation of the former (see below).

### Gonadotropin Subunit Assembly

Folding and assembly of gonadotropin subunits occur in the ER. As discussed above, each gonadotropin subunit is divided into three large loops by the so-called cystine knots, which are critical for establishing subunit conformation. The crystal structures



**Fig. 7** Generation of gonadotropin oligosaccharide diversity. A preformed N-glycan precursor, GlcNAc<sub>2</sub>Man<sub>9</sub>Glc<sub>3</sub>, is transferred en bloc from dolichol pyrophosphate to an Asn residue in the -Asn-Xaa-Thr- sequence found at highly conserved, homologous positions in the nascent α- or β-subunit chain by the enzyme complex oligosaccharyl transferase. Glucose trimming leads to calnexin- or calreticulin-mediated chaperone recruitment and subunit folding. Folded subunits lose one Man residue, which enables them to be loaded into transfer vesicles bound for the cis Golgi. Mannosidase trimming removes three more residues. In the medial Golgi, GlcNAc transferase I adds the first residue of a complex branch, and this is generally followed by α-mannosidase trimming of two more Man residues. The precursor is decorated with additional GlcNAc residues

of human CG and hFSH show that the subunits of the  $\alpha/\beta$  heterodimer are arranged in an antiparallel fashion, with three cystine-knot loops at opposite ends (Fox et al. 2001; Laphorn et al. 1994; Wu et al. 1994). The  $\alpha$ - and  $\beta$ -subunit cystine-knot domains orient in a head-to-tail 2–1/1–2 manner and the  $\beta$ -subunit carboxy-terminal tail is wrapped around the  $\alpha$ -subunit; during heterodimer assembly, the  $\alpha$ -subunit loop L2 is surrounded by residues located in the core of the  $\beta$ -subunit as well as by residues on the other side that have been likened to a seat belt, whose carboxyl-terminus is *latched* by a disulfide bond to a cysteine residue in loop 1 of the  $\beta$ -subunit (Bousfield and Dias 2011). The earliest model of assembly proposed that heterodimer assembly occurred by a wraparound mechanism with the *seat belt latched after subunit docking* (Ruddon et al. 1996). In this model, the folded  $\alpha$ -subunit is ready for association, whereas the  $\beta$ -subunit needs formation of a disulfide bond between residues 93–100 to limit the flexibility of its carboxyl-terminus and become dimerization competent. Thereafter the subunits dock, forming an  $\alpha/\beta$  dimer which becomes conformationally active upon formation of a 26–110 disulfide bridge that stabilizes functional CG (Ruddon et al. 1996). In a series of elegant mutagenesis studies, Moyle's group later proposed alternative models for subunit assembly of the GPHs CG, hFSH, and human TSH in which assembly occurs *after the seat belt is latched* (Xing et al. 2001a, b, 2004b, c), as well as for differential pathways for CG and hLH subunit assembly (Bernard et al. 2014). Heterodimer assembly is driven by subunit contacts that allow formation of a parallel  $\beta$ -sheet composed of  $\alpha$ - and  $\beta$ -subunit loop 2 residues as shown by the three-dimensional structures of CG and hFSH (Fox et al. 2001; Laphorn et al. 1994; Wu et al. 1994). In the threading mechanism proposed (Xing et al. 2001b, 2004a;), the 26–100 seat belt loop disulfide bond in the folded CG $\beta$  has already been formed while the 93–100 disulfide bridge (which stabilizes a small loop in the amino-terminal end of the seat belt) is disrupted (a process that will facilitate the subsequent threading of the  $\alpha$ -subunit) leading to enlargement of the seat belt loop. Then the  $\alpha$ -subunit with a compact glycan (at  $\alpha$ Asn<sup>52</sup>) threads through the enlarged seat belt loop, leading to an inactive  $\alpha/\beta$  dimer. Active CG conformation in the  $\alpha$ -subunit loop L2 is achieved when the 93–100 disulfide bridge reforms. In contrast to CG, in the case of hLH subunit assembly, the  $\beta$ -subunit is incompletely folded as it remains attached to the molecular chaperone BiP (Meunier et al. 2002; Ulloa-Aguirre et al. 2004). Folding of the  $\beta$ -subunit requires the mandatory presence of the  $\alpha$ -subunit, which acts as a chaperone, as well as disruption of the  $\alpha$ 7–31 disulfide bridge, which then will allow assembly of the heterodimer after the  $\beta$ -subunit has folded by a wraparound mechanism (Bernard et al. 2014). Thus, assembly of hLH is different from that of CG. The more complex LH heterodimer



**Fig. 7** (continued) to initiate the second, third, or fourth glycan branch. A specific GlcNAc transferase initiates each branch. In the trans Golgi, the branches are extended by addition of Gal or GalNAc residues and the branches terminated with Neu5Ac or sulfate, respectively, although in LH and FSH, some GalNAc residues are sialylated. Fucose is also added in this compartment (See Fig. 4 and (Varki et al. 2015) for symbols)

formation, including the  $\alpha$ -subunit dependency of  $\beta$ -subunit folding, explains why unasssembled, free CG $\beta$  may be secreted, whereas free LH $\beta$  is not.

## Processing

Glycosylation is the most important posttranslational modification in GPHs, since it influences many processes and functions of the hormone before and after secretion. *In vitro* studies in CHO cells expressing mutant CG $\alpha$ - or CG $\beta$  have revealed that glycans in the  $\beta$ -subunit are both important for assembly with the  $\alpha$ -subunit and for secretion of the hormone, whereas carbohydrates at positions  $\alpha$ Asn<sup>78</sup> and  $\alpha$ Asn<sup>52</sup> seem important for subunit stability and dimer secretion, respectively (Matzuk and Boime 1988b, a). Further, recent studies in transgenic mice lacking glycans on FSH  $\beta$ -subunit showed that N-linked glycans on this subunit are essential for both its efficient assembly with the  $\alpha$ -subunit to form  $\alpha/\beta$ FSH heterodimer and for FSH secretion (Wang et al. 2016a).

Glycosylation of GPHs begins in the rough ER (RER) with the co-translational transfer of a dolichol-linked oligosaccharide precursor to asparagine residues at Asn-X-Ser/Thr N-glycosylation consensus sites (Baenziger and Green 1988; Helenius and Aebi 2001) (Fig. 7). While the identity of the “X” amino acid residue in Asn-X-Ser sequences can significantly affect glycosylation efficiency (Shakin-Eshleman et al. 1986), all gonadotropin glycosylation sites are Asn-X-Thr-type, which are not affected by the middle residue. Further modifications by exoglucosidases and by  $\alpha$ -mannosidases yield a common core composed of two N-acetyl glucosamine (GlcNAc) residues linked to three mannose (Man) residues. Dimer formation (discussed above) and trimming of glucose and mannose residues to a Man<sub>8</sub>GlcNAc<sub>2</sub> occur in the RER. Mannose trimming concludes in the cis-Golgi apparatus and is followed by extensive processing of the oligosaccharides attached to the protein core in the medial and trans-Golgi, leading to formation of mature glycans (Helenius and Aebi 2001).

Multiple enzymes are involved in the glycosylation of glycoprotein hormones and include glucosidases and mannosidases as well as a group of glycosyltransferases [N-acetyl galactosamine (GalNAc)-transferases, N-acetyl glucosamine-transferases, galactosyl- or galactose (Gal)-transferases, sialyltransferases, and sulfotransferases] that markedly influence glycoprotein hormone glycosylation and sulfation (Damian-Matsumura et al. 1999; Smith and Baenziger 1988, 1990, 1992) (Fig. 7). Some of these enzymes require a specific recognition site in the primary sequence of the protein in order to add a new carbohydrate residue to the nascent oligosaccharide chain, while others may add it in a nonspecific manner (Smith and Baenziger 1988, 1990, 1992). A particular GalNAc-transferase recognizes the -Pro-Xaa-Arg/Lys- motif in the  $\alpha$ -subunit when associated as an LH $\alpha/\beta$  dimer, adding a GalNAc residue to its glycans yielding a terminally sulfated sequence (Smith and Baenziger 1988, 1992), which is a characteristic feature of glycans in hLH. The particular peptide sequence for this GalNAc-transferase is present in the  $\alpha$ -subunit as well as in specific locations in LH $\beta$  and CG $\beta$ . Human FSH $\beta$  is minimally sulfated (Dalpathado et al. 2006) despite

bearing a Pro-Leu-Arg sequence, which is ignored by the GalNAc-transferase probably because its location differs from that of LH $\beta$  and CG $\beta$ . On the other hand, significantly higher levels of sulfated glycans are associated with bovine, ovine, porcine, and equine FSH preparations (Dalpathado et al. 2006; Green and Baenziger 1988). This specific GalNAc-transferase has been detected in the pituitary but not in placental cells; hence, pituitary CG differs from that synthesized by placental trophoblasts in that placental CG does not bear terminal sulfate residues (Baenziger and Green 1988). Human LH oligosaccharides are terminally processed by the consecutive actions of a GalNAc-transferase and a sulfotransferase, which act as a catalyst for terminal sulfate transfer (Dharmesh et al. 1993); since these particular enzymes are absent in CHO cells, recombinant hLH produced by these cells is instead sialylated (Olivares et al. 2000).

The regulation of the remarkably different distribution of sialylated and sulfated oligosaccharides in LH and FSH is of particular interest considering that both glycoprotein hormones are synthesized within the same cell. In fact, it has been shown that the  $\beta$ -subunits influence the oligosaccharide processing of the bound  $\alpha$ -subunit, particularly of the  $\alpha$ Asn<sup>52</sup> oligosaccharide, thus accounting in part for the differences in N-linked glycosylation between these gonadotropins (Bielinska et al. 1989; Corless et al. 1987). In this regard, it has been proposed that the presence of the  $\beta$ -subunit may hinder the action of some processing enzymes or, alternatively, that conformational changes between free and combined  $\alpha$ -subunits may be distinctly recognized by glycosidases and glycotransferases (Bielinska et al. 1989).

In general, oligosaccharides on the  $\beta$ -subunits play a major role in determining the metabolic clearance rate of gonadotropins (Bishop et al. 1995), whereas the oligosaccharide in position  $\alpha$ Asn<sup>52</sup> is more important for the activation of the receptor/signal transducer (G proteins) system and the subsequent biological response (Matzuk et al. 1989; Sairam 1989; Sairam and Bhargavi 1985; Valove et al. 1994). A potential role for the  $\alpha$ Asn<sup>78</sup> glycan in FSH-mediated signal transduction has been also proposed by two mutagenesis studies (Bishop et al. 1994; Flack et al. 1994).

## Secretion

As discussed in the preceding sections, differential regulation of LH and FSH synthesis and secretion is modulated by GnRH pulse frequency and by changes in inhibins, activins, follistatins, and sex steroids. The secretion of the gonadotropic hormones has been studied *in vitro* by pulse-chase techniques, followed by immunoprecipitation of the heterodimer and analysis of the labeled subunits by gel electrophoresis, as well as *in vivo* by frequent sampling from the peripheral and/or hypophyseal portal circulation (Flores et al. 1990; Jablonka-Shariff and Boime 2004; Jablonka-Shariff et al. 2002; Padmanabhan et al. 1997). One of the first differences in secretion noted actually came from a comparison of CG and hLH, which are very similar except for a  $\beta$ -subunit carboxyl-terminal extension that is O-glycosylated in CG and is absent in LH. Using a cell line that exhibits apical/basal secretion, it has been shown that CG is secreted apically whereas LH is secreted basally (Jablonka-Shariff et al. 2002). Also known is

that the apical secretion of CG is constitutive when compared to heterodimeric LH and that the carboxyl-terminal tail of CG $\beta$ , which is not present in hLH, is necessary for the constitutive apical secretion of CG (Jablonka-Shariff and Boime 2009). When compared to LH, FSH is found to sort *into both* apical and basolateral secretory compartments, and in LH the signal for basolateral secretion is localized in the last seven amino acids of the  $\beta$ -subunit (Jablonka-Shariff and Boime 2004). In contrast to LH, which is stored in complex secretory granules, secreted in pulses, and associated with a midcycle release from the gonadotrope upon GnRH stimulation, FSH is transported to the plasma membrane in vesicles and then released to the portal circulation. Thus, the secretion of FSH is constitutive, whereas that of LH is regulated by GnRH stimulation. *In vitro* studies have determined that this difference is due to the hydrophobic stretch of seven amino acids (LSGLLFL) in the LH $\beta$  tail described above (Jablonka-Shariff et al. 2008). In fact, FSH secretion could be switched from the constitutive to the regulated pathway both *in vitro* and *in vivo* by fusing that sequence to the carboxyl-terminal subunit tail of FSH (Pearl et al. 2010; Wang et al. 2014). Further, experimentally modified FSH $\beta$  possessing this peptide sequence directed FSH to the regulated secretory pathway with the interesting physiological consequence of inducing superovulation at every cycle (Wang et al. 2014). Nevertheless, frequent and simultaneous sampling from peripheral and/or hypophyseal portal circulation has found that although the constitutive (basal) component of FSH secretion predominates, low-frequency GnRH stimulation leads to coincident release of FSH in discrete pulses, which can not be detected in peripheral circulation due to the low concentration of FSH and its relatively long plasma half-life ( $t_{0.5}$ ), unless deconvolution techniques are applied (Padmanabhan et al. 1997; Veldhuis et al. 1987, 1990).

In the majority of mammalian species studied, the GnRH-dependent secretion of LH occurs in a pulsatile manner, and the frequency of pulses detected in peripheral circulation varies depending on the sex, age, phase of the menstrual (estrous) cycle, and the particular method employed for pulse analysis (Evans et al. 1992; Faria et al. 1992; Filicori et al. 1986; Spratt et al. 1987; Urban et al. 1988; Veldhuis et al. 1990). In general, LH pulses are more frequent during the late follicular phase and midcycle (one pulse every ~60 min) than during the early follicular phase (one pulse every 90–100 min) (Adams et al. 1994; Evans et al. 1992); immediately after the LH surge, LH pulse frequency decreases (to one pulse every ~70 min) and becomes slower, but with high peak amplitude during the ensuing luteal phase. Finally, the LH pulse frequency increases again during the luteal-follicular transition, paralleling the slow increase in circulating FSH concentrations (Hall et al. 1992). In adult men, LH pulses may be detected at frequencies of 7–16 pulses/24 h or 23–26 pulses/24 h (i.e., one pulse every ~55 min), depending on the method of pulse analysis applied (Spratt et al. 1987; Urban et al. 1988; Veldhuis et al. 1990).

---

## Pharmacokinetics of Gonadotropins

The role of carbohydrates in GPHs in the metabolic clearance rate (MCR) and the *in vivo* biological potency of the gonadotropins have been studied extensively. Both functions are highly dependent on the amount of glycans attached to the protein and

specific type of terminal residues present in their oligosaccharide structures. As described above, oligosaccharides present in hFSH and CG predominantly terminate in sialic acid; this monosaccharide, and particularly the number of exposed terminal galactose residues, are key factors in determining hormone survival in the circulation (Morell et al. 1971). Exposure of terminal galactose residues dramatically increases glycoprotein clearance from plasma through a mechanism that involves hepatocyte receptors for the asialo galactose-terminated complex molecules. However, this mechanism appears to be irrelevant for CG clearance, as blocking the hepatocyte receptors with asialoglycoproteins has no effect on intact CG clearance (Lefort et al. 1984) and apparently kidney clearance appears to be a more important mechanism (Nisula et al. 1989). Heavily sialylated glycoproteins circulate for longer periods than those with less sialylated or sulfated glycans (Barrios-De-Tomasi et al. 2002; Diaz-Cueto et al. 1996; Ulloa-Aguirre et al. 1992; Ulloa-Aguirre and Timossi 2000; Wide 1986), whereas sulfated glycans, such as those present in hLH and minimally in hFSH, or oligosaccharides bearing terminal mannose or GlcNAc accelerate clearance of the molecule by specific receptors present in hepatic endothelial and Kupffer cells (Fiete and Baenziger 1997; Fiete et al. 1991). The plasma  $t_{0.5}$  of hFSH and CG is therefore longer than that of hLH (see below). Recombinant asialo-gonadotropin variants as well as deglycosylated FSH are rapidly cleared from the circulation and are practically inactive *in vivo* when compared to the corresponding intact variants (Legardinier et al. 2005). Conversely, recombinant hFSH possessing a hybrid  $\beta$ -subunit composed of the  $\beta$ -subunit of FSH and the hCG $\beta$  carboxyl-terminal peptide [(FSH-CTP), which possesses up to four O-linked sialylated glycans], or to which additional glycosylation sites have been added, exhibits a prolonged plasma  $t_{0.5}$  (approximately two to four times longer) than intact recombinant FSH (Bouloux et al. 2001; Duijkers et al. 2002; Perlman et al. 2003; Weenen et al. 2004). The half-life of the different charge variants of hFSH and hLH also has been analyzed in some detail. In FSH, the more acidic/sialylated variants exhibit higher circulatory survival than the less acidic counterparts (Ulloa-Aguirre et al. 1995; Ulloa-Aguirre and Timossi 1998, 2000; Ulloa-Aguirre et al. 1999; Wide 1986). The plasma disappearance of endogenous LH is slower in postmenopausal than in young women (Sharpless et al. 1999), which is likely due to the increased sialylation of the gonadotropin that occurs after the menopause (Wide 1985a, b; Wide et al. 2007). The mechanism for this shift is probably more complicated than solely the addition of GalNAc instead of Gal to partially synthesized glycans because, as discussed above, sialylated GalNAc has been reported for hLH (Weisshaar et al. 1991b). Differences in half-lives among the different glycosylation variants that comprise circulating FSH also explain why *in vivo* and *in vitro* administration of a more acidic/sialylated mix of FSH isoforms or sequential administration of more acidic/sialylated FSH followed by a less sialylated variant more effectively stimulates follicular maturation and 17 $\beta$ -estradiol production than a poorly sialylated preparation (Colacurci et al. 2014; Nayudu et al. 2002; West et al. 2002). Although gonadotropins are also degraded in the kidney (as demonstrated for hCG), the specific structural requirements that promote their renal uptake are still unknown. Gonadotropin molecules that have not been metabolized by the liver are excreted in urine in forms that still are highly bioactive. This characteristic has allowed the isolation, purification, and clinical

application of urinary gonadotropins from postmenopausal and pregnant women for the exogenous induction of follicular maturation and ovulation. The free subunits of gonadotropins are more rapidly eliminated from the circulation than the desialylated dimers or molecules with fused subunits, which suggests that alternative pathways, different to those described above, may also determine the metabolic fate of gonadotropins.

Several pharmacokinetic studies on human gonadotropins have been performed (le Cotonnec et al. 1993, 1994, 1995, 1998a, b, c; Porchet et al. 1994, 1995). However, the results vary depending on the specific preparation employed (recombinant vs urinary or pituitary extracts), methods of measurement of the circulating hormone, parameters reported, and routes of administration (*i.v.*, *i.m.*, or *s.c.*). In general, the  $t_{0.5}$  of CG is longer than that exhibited by LH, whereas that of FSH is intermediate between CG and LH. When calculated as a single exponential, the initial plasma  $t_{0.5}$  of urinary FSH after its *i.v.* administration varies from 4.7 to 6.9 h, whereas for biexponential kinetics the initial  $t_{0.5}$  ranges from 1.5 to 2 h and the slow phase  $t_{0.5}$  from 15 to 17 h. Despite differences in sialylation (Timossi et al. 1998), the pharmacokinetics of urinary FSH and recombinant FSH produced by CHO cells is quite similar, indicating that such differences in terminal sialylation do not significantly impact the metabolic clearance of the hormone administered (le Cotonnec et al. 1993). Urinary and recombinant FSH is eliminated in the urine in proportions of 20% and 10% of the initial dose administered (renal clearances  $0.1 \pm 0.05$  L/h and  $0.07 \pm 0.04$  L/h), respectively, and their estimated total clearance approximates 0.5 L/h (le Cotonnec et al. 1995). These renal clearance values, which are below the glomerular filtration rate, suggest either hFSH is reabsorbed after filtration, the glycosylated molecule is too large to be freely excreted, or the FSH molecule is subject to a certain degree of metabolism by the kidney. Subcutaneous administration of highly purified preparations of urinary or recombinant hFSH (produced by CHO cells) has yielded nearly similar elimination half-lives (around 30–40 h) and bioavailability values (le Cotonnec et al. 1994, 1995; Porchet et al. 1993, 1995).

The pharmacokinetic parameters of recombinant (CHO cell produced) and urinary LH from postmenopausal women are similar, which is in agreement with the higher sialic acid content of the former (Olivares et al. 2000). Following *i.v.* administration, the initial and terminal plasma  $t_{0.5}$  of both preparations are approximately 1.2 h and 10–12 h, respectively. The total plasma clearance rate of urinary LH is  $\sim 1.2$  L/h, whereas for the recombinant preparation is  $\sim 1.7$  L/h; renal clearances are  $0.3 \pm 0.2$  L/h and  $0.03 \pm 0.02$  L/h, respectively (le Cotonnec et al. 1998a). The contribution of the kidney to the total clearance of urinary LH is  $\sim 30\%$ , a value which is significantly higher than that for recombinant LH ( $\sim 4\%$ ). Despite these differences, the bioavailability of both preparations is quite similar (le Cotonnec et al. 1998c).

The net *in vivo* biological potency of different gonadotropin preparations is intimately related to their circulatory half-lives, albeit other factors such as glycan composition, receptor binding capacity, and potency of their corresponding isoforms to activate their cognate receptor and induce a subsequent intracellular signal transduction also seem important (Barrios-De-Tomasi et al. 2002; Timossi et al. 1998).



In fact, despite the fact that recombinant- and urinary-derived FSH preparations exhibit similar pharmacokinetic and clinical profiles in assisted reproduction therapy (where pharmacological doses of gonadotropins are administered to induce multiple follicular maturation (reviewed in (Smits et al. 2015)), sequential administration of urinary FSH (highly sialylated) followed by recombinant FSH produced in CHO cells (less sialylated) (Timossi et al. 1998) (to mimick what has been observed across the natural follicular phase of the menstrual cycle (Zambrano et al. 1995)) is associated with higher proportions of MII oocytes, implantation rate, and pregnancy rate than recombinant FSH administered alone during the induction cycle (Colacurci et al. 2014; Selman et al. 2010, 2013).

The plasma  $t_{0.5}$  of endogenous CG has been mainly analyzed by determining its clearance from the circulation immediately after term placental extraction. Kinetic analyses have shown that CG circulating in term pregnancies has a short (approximately 5 h) initial plasma  $t_{0.5}$  and a terminal  $t_{0.5}$  of 30–36 h (Campbell 2005). In women that underwent legal abortion during the first trimester of pregnancy, CG showed a longer plasma  $t_{0.5}$ , of 30 and 65 h, probably due to the presence of highly sialylated isoforms during the early stages of pregnancy (Diaz-Cueto et al. 1996). The plasma  $t_{0.5}$  of CG after its intramuscular administration is approximately 60 h.

---

## Biological Effects of Gonadotropins

### Binding to Receptors

The gonadotropin receptors, FSHR and LH/CGR, belong to the superfamily of G protein-coupled receptors (GPCR), specifically to the so-called Rhodopsin-like family (Ascoli et al. 2002; Simoni et al. 1997). Structural data exist only for FSH-FSHR binding the extracellular domain (Fan and Hendrickson 2005; Jiang et al. 2012, 2015). FSH binding to the extracellular domain of the FSHR and how that may result in receptor activation is comprehensively summarized by Jiang et al. (Jiang et al. 2013). FSH engages the high-affinity binding site in the FSHR hormone binding domain via the C-terminal regions of both subunits and the  $\alpha$ L2 and  $\beta$ L2 loops in an interaction likened to a hand clasp (Fan and Hendrickson 2005). High-affinity binding causes a conformational change at the FSH $\alpha$ /FSH $\beta$  interface, forming a binding pocket for a highly conserved sulfo-Tyr residue located in the thumb loop in the FSHR hinge domain (Jiang et al. 2012). This second binding step may alter the conformation of a helix in the hinge region to release the antagonistic effect of the FSHR extracellular domain on the transmembrane domain. Although it seems that the other glycoprotein hormone/glycoprotein hormone receptor pairs follow a similar binding and activation mechanism as that characterized for the hFSH/hFSHR pair, further studies are still required to confirm that this is so. Nevertheless, neither Fan's or Jiang's model indicates how carbohydrates allow full activation of the FSHR (Bishop et al. 1994; Calvo et al. 1986; Flack et al. 1994; Sairam and Manjunath 1982). This is an intriguing question given that according to the crystal structure of the FSHR ectodomain, FSH glycans play no role in the

binding interface of the FSH/FSHR complex, but rather appear to be sequestered in the periphery of the complex (Dias 2005; Fan and Hendrickson 2005; Jiang et al. 2014a, 2012). In this vein, the structures of FSH and the FSHR ectodomain in complex with FSH (Dias 2005; Fan and Hendrickson 2005; Fox et al. 2001) predict contact between the GlcNAc1 residue at  $\alpha$ Asn<sup>52</sup> (which is indispensable for signaling (Flack et al. 1994; Matzuk and Boime 1989; Matzuk et al. 1989)) and Tyr<sup>58</sup> in FSH $\beta$ . It is thus possible that structural variations in the  $\alpha$ Asn<sup>52</sup> glycan may influence the stability and/or conformation of the FSH ligand, thereby compromising the ability of the FSH/FSHR complex to affect signal transduction. The FSHR model as a functional trimer additionally supports a role for glycans in FSH on receptor binding and activation (Jiang et al. 2014b). The structure and function of the gonadotropin receptors are described in greater detail in ► [Chap. 4, “Gonadotropin Receptors”](#).

## Biological Effects

Following binding of gonadotropins, receptor-mediated activation of a number of intracellular signaling cascades is triggered either in parallel or sequentially. The canonical G<sub>S</sub> $\alpha$ /cAMP/PKA signaling pathway, which subsequently activates CREB, thereby modulating gene transcription, has been recognized for more than two decades as a key effector mechanism of gonadotropin biological action (Ulloa-Aguirre and Zariñán, 2016). However, in recent years it has become evident that the gonadotropin receptors are rather connected to a nonlinear, complex signaling network mediated either by other G protein subtypes, including the G<sub>i</sub>, G<sub>q/11</sub>, and G<sub>h</sub> proteins, or other types of receptors (e.g., the epidermal growth factor receptor and the insulin-like growth factor 1 receptor) (Ulloa-Aguirre et al. 2011; Ulloa-Aguirre and Zariñán, 2016), which in concert regulate the net biological effects of the gonadotropins at their corresponding target cells. The granulosa cells of the ovary and the Sertoli cells lining the seminiferous tubules are the primary targets of FSH. In the former, FSH regulates granulosa cell function, including growth and maturation of ovarian follicles, estrogen production from theca cell-produced androgens, oocyte maturation, and, in concert with LH, the ovulatory process (Richards et al. 2002). In the testis, FSH regulates Sertoli cell function, thereby supporting spermatogenesis (Huhtaniemi 2015). The precise role of FSH in spermatogenesis, particularly in humans, is still uncertain, and apparently its role is more related to maintain the quality of sperm cells, being testosterone a major player necessary to achieve full spermatogenesis and fertility potential (Huhtaniemi 2015). The primary targets of LH are the theca cells of the ovarian follicles, as well as the corpus luteum, where this gonadotropin regulates steroidogenesis, mainly androgen biosynthesis and progesterone production, respectively. In the male, LH is involved in Leydig cell survival and proliferation and stimulation of testosterone production, thereby promoting spermatogenesis (Shiraishi and Ascoli 2007; Tai et al. 2009). Under gonadotropin stimulation, the gonads also produce nonsteroidal (polypeptide) factors, which, together with the steroid hormones synthesized in response to gonadotropins,

regulate the functions of the rest of the hypothalamic-gonadotropic axis (Gregory and Kaiser 2004). CG and LH share the same receptor (the LH/CGR); CG has many end-target tissues including the corpus luteum, syncytiotrophoblast cells, uterus, immune system, and fetal Leydig cells (Shi et al. 1993; Ambrus and Rao 1994; Doheny et al. 2003; Eta et al. 1994; Kane et al. 2009; Muzzio et al. 2014; Schumacher et al. 2013; Wan et al. 2007). Characterization of multiple CG isoforms, native CG, hyperglycosylated CG, and the  $\beta$ -subunit of the hyperglycosylated hCG has allowed investigators to assign extragonadal functional roles to CG under both normal and pathological conditions (Cole 2010; Fournier et al. 2015; Berndt et al. 2009; Herr et al. 2007; Zygmunt et al. 2002).

► Chapters 4, “Gonadotropin Receptors,” ► 10, “Testicular Steroidogenesis,” and ► 13, “Spermatogenesis” provide a detailed description of the biological effects of gonadotropins.

---

## Recombinant Gonadotropins

Recombinant gonadotropins possess the same protein moieties as their pituitary counterparts (Fig. 3). However, as glycosylation is well known to vary in a cell- and tissue-specific manner, differences in glycosylation occur. These have been mentioned with regard to functional aspects in other parts of this chapter. Recombinant gonadotropins used as pharmaceuticals are expressed in Chinese hamster ovarian (CHO) cells. Using nanoES-ITMS, N-glycans of recombinant CG, hLH, and hFSH were characterized (Gervais et al. 2003). In CG, bi-, tri-, and tetra-antennary glycans were detected. The most abundant class was the bi-antennary type. In hLH and hFSH, penta-antennary glycans were observed in addition to the other three types of glycans. Seven of ten reported O-glycans (Liu and Bowers 1997; Valmu et al. 2006) were found in recombinant CG $\beta$ , along with two fucosylated glycans not seen in either pregnancy or tumor-associated CG $\beta$ . For hLH, the biggest difference between pituitary and urinary hLH glycans and recombinant hLH glycans is the absence of sulfate, as the enzymes required for sulfation are not expressed in CHO cells. However, as hLH already possesses a significant amount of sialic acid, as described above, this is not as big as the difference between recombinant ovine, bovine, or porcine LH, which possess almost exclusively sulfated glycans. Recombinant hFSH glycosylation has been characterized by NMR and mass spectrometry and compared with urinary hFSH glycosylation. Hypo-glycosylated hFSH comprises only 14% of urinary hFSH, but 23–27% of recombinant hFSH (Bousfield et al. 2014b). Pituitary and urinary hFSH glycans are 33–56% bi-antennary, 26–35% tri-antennary, and 20% tetra-antennary (Bousfield et al. 2015; Wang et al. 2016b). Recombinant hFSH glycans were 55–72% bi-antennary, 12–30% tri-antennary, while tetra-antennary glycans were not detected (Bousfield et al. 2015; Wang et al. 2016b). From the above discussion, it is evident that recombinant and naturally occurring hFSH are not structurally identical. Whether recombinant preparations produced in CHO cells are equally or less effective for infertility treatment than novel preparations obtained from human cell lines, still remains to be more

extensively investigated. Meanwhile CHO cell-produced recombinant FSH should not be considered as representative of the most physiologically relevant form of FSH.

---

## Structural Abnormalities of Gonadotropins

Structural alterations in gonadotropins due to mutations in  $\beta$ -subunits leading to gonadotropin deficiency are very rare. When they occur in LH $\beta$ , they are clinically manifested by delayed puberty and infertility in homozygous males and infertility in affected women (Achard et al. 2009; Arnhold et al. 2009; Basciani et al. 2012; Lofrano-Porto et al. 2007; Valdes-Socin et al. 2004, 2009; Weiss et al. 1992). The fact that males bearing homozygous mutations in *LHB* exhibit a normal male phenotype at birth illustrates the role of CG during fetal life on Leydig cell proliferation, differentiation, and androgen production. *FSHB* mutations are also rare; male homozygous subjects bearing mutations in FSH $\beta$  present normal or impaired puberty and azoospermia, whereas homozygous females exhibit absent or partial puberty and infertility. The phenotype in men with mutations in *FSHB* contrasts with its counterpart in mice, in which the absence of this subunit (or the FSHR) does not lead to infertility (Kumar et al. 1997, 1999). It also contrasts with findings in men bearing loss-of-function mutations in the FSHR gene, in whom fertility is variably preserved (Tapanainen et al. 1997).

## Mutations in LHB gene

Several mutations in LH $\beta$  have been described. These include:

- (a) The missense mutation Gly36Asp, which disrupts a five-amino acid motif (CAGYC) important for the formation of the cystine knot (Fig. 3) (Valdes-Socin et al. 2004, 2009). Thus, the abnormal subunit does not heterodimerize with the common  $\alpha$ -subunit. The male subject bearing this mutation presented hypogonadism, delayed puberty, undetectable serum LH, low testosterone levels, and azoospermia, despite elevated serum FSH, underlining the critical role of intratesticular testosterone for normal spermatogenesis.
- (b) In the Gln54Arg mutation, although  $\alpha/\beta$  heterodimerization occurs, the resulting dimer does not bind to its cognate receptor (Weiss et al. 1992). The reported adult homozygous male patient with this mutation exhibited absence of puberty and infertility, with high concentrations of immunoreactive LH, whereas in heterozygous males, puberty was normal but fertility reduced. Heterozygous women with this mutation exhibited no reproductive abnormalities (Weiss et al. 1992).
- (c) The IVS2+1G $\rightarrow$ C, which disrupts intron 2 splicing, leads to inclusion of the entire intron and disruption of exon 3 reading frame, yielding a highly abnormal mRNA and, theoretically, an aberrant protein with additional 79 amino acids

inserted after the Met41 residue unable to form the seat belt loop of the subunit (Lofrano-Porto et al. 2007). Male subjects bearing this mutation presented delayed puberty and infertility, whereas the affected woman presented normal puberty but secondary amenorrhea and infertility. As expected, serum LH was undetectable, and testosterone levels were very low.

- (d) The 12 nucleotide deletion (28\_39del) at the LH $\beta$  signal peptide leads to deletion of four leucines at positions 10–13 (Leu10 $\Delta$ 12 bp) and thus in failure of normal  $\beta$ -subunit processing (Basciani et al. 2012). This mutation was reported in a compound heterozygous man who also had the IVS2+1G $\rightarrow$ C mutation described above. The two sisters of the proband had the same mutations and presented normal puberty and oligomenorrhea (Basciani et al. 2012).
- (e) The nine base deletion in exon 2, which impairs cystine knot formation, leads to a  $\beta$ -subunit lacking amino acids 10–12 and a LH molecule with residual activity sufficient to permit intratesticular testosterone to reach adequate concentrations. Thus, the affected man with this mutation exhibited normal spermatogenesis (Achard et al. 2009).
- (f) The recently reported in-frame deletion of Lys40 in the mature polypeptide was detected in two brothers homozygous for the mutation, who exhibited pubertal delay, hypogonadism, and undetectable LH. *In vitro* studies revealed that the mutation led to intracellular retention of the gonadotropin, without affecting either dimerization of the mutant subunit with the common- $\alpha$  subunit or its ability to activate its cognate receptor. Interestingly, mutagenesis studies revealed that the sequence 39Glu-Lys-Glu41 in LH $\beta$  plays an important role in the traffic of the gonadotropin through the secretory pathway (Potorac et al. 2016).

## Mutations in FSHB gene

Mutations in *FSHB* occur in exon 3 and lead to impaired disulfide bond formation, severely altered three-dimensional structure of the protein, and inability of the FSH  $\beta$ -subunit to heterodimerize with the common  $\alpha$ -subunit. The *FSHB* mutations described so far are the following:

- (a) The Val61X mutation, in which a two-nucleotide deletion in codon 61 affects the amino acid sequence 61–86 followed by a premature stop codon (Val61 $\Delta$ 2 bp/87X), eliminating amino acid residues 87–111 of the subunit (Fig. 3) (Layman et al. 2002; Matthews et al. 1993; Phillip et al. 1998)
- (b) The Cys51Gly mutation, which was reported in a compound heterozygous woman bearing also the Val61X mutation (Layman et al. 2002)
- (c) The Tyr76X nonsense mutation, which predicts a translated protein missing amino acid residues 76–111 (Layman et al. 2002)
- (d) The Ala79X, a single nucleotide deletion at codon 79 (c.289delG) leading to a frameshift and a premature stop at codon 109 (A79fs108X) (Kottler et al. 2010)

- (e) The Cys82Arg mutation, which, similar to the Cys51Gly substitution, alters the cystine knot structure of the  $\beta$ -subunit (Lindstedt et al. 1998)
- (f) The Cys122Arg (Cys104Arg not considering the signal peptide) mutation (Simsek et al. 2016), which disrupts a disulfide bond that is part of the “seat belt” that wraps around the  $\alpha$ -subunit (Fox et al. 2001)

Several polymorphisms in the  $\beta$ -subunit genes of the gonadotropins, associated with potential impact in gonadotropin action, have been described. These include the Trp8Arg/Ile15Thr, Gly102Ser, and Ala-3Thr polymorphisms in the *LHB* and the -211G/T polymorphism in *FSHB*. The most widely studied *LHB* polymorphism is the Trp8Arg/Ile15Thr combination in exon 2, which is in complete linkage disequilibrium (Furui et al. 1994; Okuda et al. 1994). This polymorphism has a worldwide distribution and presents varying frequencies depending on the particular ethnic group screened. The polymorphic LH molecule (named LH-V) is not recognized by specific immunoassays (particularly those using monoclonal antibodies recognizing the LH $\alpha$ / $\beta$  dimer) nor is it, in general, strongly linked with fertility or endocrine disturbances, although a few studies suggest that it might do so (Furui et al. 1994; Lamminen and Huhtaniemi 2001; Raivio et al. 1996; Takahashi et al. 1998, 1999). The glycosylation of this LH variant differs from that exhibited by the wild-type variant (introduction of an additional glycosylation site at Asn13 $\beta$ ) which leads to differences in plasma half-life and *in vitro* biological activity (reviewed in (Lamminen and Huhtaniemi 2001)). The Gly102Ser in exon 3 is a low-frequency polymorphism that has been associated in some populations with infertility in men and menstrual disturbances in women (Lamminen et al. 2002; Ramanujam et al. 1999, 2000). Finally, in the Ala-3Thr variant, three residues are changed before the signal peptide cleavage (Jiang et al. 2002); this is an interesting variant that has been reported to behave as a biased agonist *in vitro*, exhibiting reduced potency for stimulation of cAMP production and greater potency for provoking phosphatidylinositol turnover. Meanwhile, the -211G/T *FSHB* variant in the promoter region of the subunit gene has been associated with varying levels of circulating FSH; in several populations, TT-genotype carriers exhibit lower serum FSH, inhibin B, and testosterone levels as well as lower testicular volume than the GG carriers, and the former genotype has been associated with infertility in men (Simoni and Casarini 2014).

No germ line loss-of-function mutations have been reported in the common  $\alpha$ -subunit or CG $\beta$  subunits as they yield inactive CG, which is crucial for pregnancy and embryo survival. In fact, several rare polymorphic variants in the two most actively transcribed loci of the four CG $\beta$ -duplicate genes (*CGB5* and *CGB8*) have been identified as associated with either recurrent pregnancy loss (Val56Leu in *CGB5* and Pro73Arg, Arg8Trp, and T>A (located 4 bp before the transcription start site) in *CGB8*) or reduction in recurrent miscarriage (1,038C>T (in intron 2), -155G>C, -147G>del, -144T>C, and -142T>A (in the promoter region) in *CGB5* as well as 1,045C>T (in intron 2) in *CGB8*) in two different European populations (Rull et al. 2008).

## Summary

Gonadotropins are heterodimeric glycoprotein hormones synthesized by the anterior pituitary gland and the placenta. They are composed by two dissimilar subunits, the  $\alpha$ -subunit, which is common to all gonadotropins, and the  $\beta$ -subunit which is unique for each hormone. Each gonadotropin is decorated with glycans which regulate a variety of functions of the hormone including folding, heterodimerization, secretion, circulatory survival, and bioactivity. Gonadotropins exert a variety of functions when acting on the ovary and the testes, all related to gametogenesis and steroidogenesis, and thus are essential for reproduction. Although the main regulator of the synthesis and secretion of the pituitary gonadotropins is GnRH, other factors of gonadal and pituitary origin play an important role in modulating the effects of GnRH. Gonadotropin deficiency may lead to reproductive disorders, which are amenable to treatment with either natural or recombinant gonadotropins.

---

## References

- Achard C, et al. Normal spermatogenesis in a man with mutant luteinizing hormone. *N Engl J Med.* 2009;361:1856–63.
- Adams JM, Taylor AE, Schoenfeld DA, Crowley Jr WF, Hall JE. The midcycle gonadotropin surge in normal women occurs in the face of an unchanging gonadotropin-releasing hormone pulse frequency. *J Clin Endocrinol Metab.* 1994;79:858–64.
- Ambrus G, Rao CV. Novel regulation of pregnant human myometrial smooth muscle cell gap junctions by human chorionic gonadotropin. *Endocrinology.* 1994;135:2772–9.
- Armstrong SP, Caunt CJ, Fowkes RC, Tsaneva-Atanasova K, McArdle CA. Pulsatile and sustained gonadotropin-releasing hormone (GnRH) receptor signaling: does the Ca<sup>2+</sup>/NFAT signaling pathway decode GnRH pulse frequency? *J Biol Chem.* 2009;284:35746–57.
- Arnhold IJ, Lofrano-Porto A, Latronico AC. Inactivating mutations of luteinizing hormone beta-subunit or luteinizing hormone receptor cause oligo-amenorrhea and infertility in women. *Horm Res.* 2009;71:75–82.
- Arnold CJ, Liu C, Lindau-Shepard B, Losavio ML, Patrascu MT, Dias JA. The human follitropin  $\alpha$ -subunit C terminus collaborates with a  $\beta$ -subunit cystine noose and an  $\alpha$ -subunit loop to assemble a receptor-binding domain competent for signal transduction. *Biochemistry.* 1998;37:1762–8.
- Ascoli M, Fanelli F, Segaloff DL. The lutropin/choriogonadotropin receptor, a 2002 perspective. *Endocr Rev.* 2002;23:141–74.
- Baenziger JU, Green ED. Pituitary glycoprotein hormone oligosaccharides: structure, synthesis and function of the asparagine-linked oligosaccharides on lutropin, follitropin and thyrotropin. *Biochim Biophys Acta.* 1988;947:287–306.
- Barnhart KM, Mellon PL. The orphan nuclear receptor, steroidogenic factor-1, regulates the glycoprotein hormone alpha-subunit gene in pituitary gonadotropes. *Mol Endocrinol.* 1994;8:878–85.
- Barrios-De-Tomasi J, et al. Assessment of the *in vitro* and *in vivo* biological activities of the human follicle-stimulating isohormones. *Mol Cell Endocrinol.* 2002;186:189–98.
- Basciani S, et al. Hypogonadism in a patient with two novel mutations of the luteinizing hormone beta-subunit gene expressed in a compound heterozygous form. *J Clin Endocrinol Metab.* 2012;97:3031–8.

- Bedows E, Huth JR, Ruddon RW. Kinetics of folding and assembly of the human chorionic gonadotropin  $\beta$  subunit in transfected chinese hamster ovary cells. *J Biol Chem.* 1992;267:8880–6.
- Bernard DJ, Tran S. Mechanisms of activin-stimulated FSH synthesis: the story of a pig and a FOX. *Biol Reprod.* 2013;88:78.
- Bernard DJ, Fortin J, Wang Y, Lamba P. Mechanisms of FSH synthesis: what we know, what we don't, and why you should care. *Fertil Steril.* 2010;93:2465–85.
- Bernard MP, Lin W, Kholodovych V, Moyle WR. Human lutropin (hLH) and choriogonadotropin (CG) are assembled by different pathways: a model of LH assembly. *J Biol Chem.* 2014;289:14360–9.
- Berndt S, et al. Chorionic gonadotropin stimulation of angiogenesis and pericyte recruitment. *J Clin Endocrinol Metab.* 2009;94:4567–74.
- Bielinska M, Matzuk MM, Boime I. Site-specific processing of the N-linked oligosaccharides of the human chorionic gonadotropin  $\alpha$  subunit. *J Biol Chem.* 1989;264:17113–8.
- Bilezikjian LM, Blount AL, Leal AM, Donaldson CJ, Fischer WH, Vale WW. Autocrine/paracrine regulation of pituitary function by activin, inhibin and follistatin. *Mol Cell Endocrinol.* 2004;225:29–36.
- Birken S, Canfield RE. Isolation and amino acid sequence of COOH-terminal fragments from the  $\beta$  subunit of human choriogonadotropin. *J Biol Chem.* 1977;252:5386–92.
- Bishop LA, Robertson DM, Cahir N, Schofield PR. Specific roles for the asparagine-linked carbohydrate residues of recombinant human follicle stimulating hormone in receptor binding and signal transduction. *J Mol Endocrinol.* 1994;8:722–31.
- Bishop LA, Nguyen TV, Schofield PR. Both of the  $\beta$ -subunit carbohydrate residues of follicle-stimulating hormone determine the metabolic clearance rate and *in vivo* potency. *Endocrinology.* 1995;136:2635–40.
- Blount AL, Vaughan JM, Vale WW, Bilezikjian LM. A Smad-binding element in intron 1 participates in activin-dependent regulation of the follistatin gene. *J Biol Chem.* 2008;283:7016–26.
- Blount AL, Schmidt K, Justice NJ, Vale WW, Fischer WH, Bilezikjian LM. FoxL2 and Smad3 coordinately regulate follistatin gene transcription. *J Biol Chem.* 2009;284:7631–45.
- Bokar JA, et al. Expression of the glycoprotein hormone  $\alpha$ -subunit gene in the placenta requires a functional cyclic AMP response element, whereas a different cis-acting element mediates pituitary-specific expression. *Mol Cell Biol.* 1989;9:5113–22.
- Boorstein WR, Vamvakopoulos NC, Fiddes JC. Human chorionic gonadotropin  $\beta$ -subunit is encoded by at least eight genes arranged in tandem and inverted pairs. *Nature.* 1982;300:419–22.
- Bouloux PM, et al. First human exposure to FSH-CTP in hypogonadotrophic hypogonadal males. *Hum Reprod.* 2001;16:1592–7.
- Bousfield GR, Dias JA. Synthesis and secretion of gonadotropins including structure-function correlates. *Rev Endocr Metab Disord.* 2011;12:289–302.
- Bousfield GR, Ward DN. Selective proteolysis of ovine lutropin or its b subunit by endoproteinase Arg-C. *J Biol Chem.* 1988;263:12602–7.
- Bousfield GR, Baker VL, Gotschall RR, Butnev VY, Butnev VY. Carbohydrate analysis of glycoprotein hormones. *Methods.* 2000;21:15–39.
- Bousfield GR, Butnev VY, Butnev VY. Identification of twelve-O-glycosylation sites in eCG $\beta$  and eLH $\beta$  by solid-phase Edman degradation. *Biol Reprod.* 2001;64:136–47.
- Bousfield GR, Jia L, Ward DN. Gonadotropins: chemistry and biosynthesis. In: Neill JD, editor. *Knobil and Neill: physiology of reproduction.* San Diego: Elsevier; 2006. p. 1581–634.
- Bousfield GR, et al. All-or-none N-glycosylation in primate follicle-stimulating hormone beta-subunits. *Mol Cell Endocrinol.* 2007;260-262:40–8.
- Bousfield GR, Butnev VY, Rueda-Santos MA, Brown A, Smalter Hall A, Harvey DJ. Macro and micro heterogeneity in pituitary and urinary follicle-stimulating hormone glycosylation. *J Glycomics Lipidomics.* 2014a;4:125.



- Bousfield GR, Butnev VY, Butnev VY, Hiromasa Y, Harvey DJ, May JV. Hypo-glycosylated human follicle-stimulating hormone (hFSH21/18) is much more active *in vitro* than fully-glycosylated hFSH (hFSH24). *Mol Cell Endocrinol.* 2014b;382:989–97.
- Bousfield GR, Butnev VY, White WK, Smalter Hall A, Harvey DJ. Comparison of follicle-stimulating hormone glycosylation microheterogeneity by quantitative negative mode nano-electrospray mass spectrometry of peptide-N-glycanase-released oligosaccharides. *J Glycomics Lipidomics.* 2015;5:129.
- Budworth PR, Quinn PG, Nilson JH. Multiple characteristics of a pentameric regulatory array endow the human alpha-subunit glycoprotein hormone promoter with trophoblast specificity and maximal activity. *Mol Endocrinol.* 1997;11:1669–80.
- Bukovsky A, et al. Multiple luteinizing hormone receptor (LHR) protein variants, interspecies reactivity of anti-LHR mAb clone 3B5, subcellular localization of LHR in human placenta, pelvic floor and brain, and possible role for LHR in the development of abnormal pregnancy, pelvic floor disorders and Alzheimer's disease. *Reprod Biol Endocrinol.* 2003;1:46.
- Butnev VY, et al. Production, purification, and characterization of recombinant hFSH glycoforms for functional studies. *Mol Cell Endocrinol.* 2015;405:41–52.
- Calvo FO, Keutmann HT, Bergert ER, Ryan RJ. Deglycosylated human follitropin: characterization and effects on adenosine cyclic 3',5'-phosphate production in porcine granulosa cells. *Biochemistry.* 1986;25:3938–43.
- Campbell RK. Molecular pharmacology of gonadotropins. *Endocrine.* 2005;26:291–6.
- Cheng K-W. Properties of follicle-stimulating-hormone receptor in cell membranes of bovine testes. *Biochem J.* 1975;149:123–32.
- Chin WW, Maizel Jr JV, Habener JF. Difference in sizes of human compared to murine  $\alpha$ -subunits of the glycoprotein hormones arises by a four-codon gene deletion or insertion. *Endocrinology.* 1983;112:482–5.
- Choi SG, Wang Q, Jia J, Pincas H, Turgeon JL, Sealfon SC. Growth differentiation factor 9 (GDF9) forms an incoherent feed-forward loop modulating follicle-stimulating hormone beta-subunit (FSHbeta) gene expression. *J Biol Chem.* 2014;289:16164–75.
- Chou SH, Mantzoros C. 20 years of leptin: role of leptin in human reproductive disorders. *J Endocrinol.* 2014;223:T49–62.
- Ciccone NA, Kaiser UB. The biology of gonadotroph regulation. *Curr Opin Endocrinol Diabetes Obes.* 2009;16:321–7.
- Ciccone NA, Xu S, Lacza CT, Carroll RS, Kaiser UB. Frequency-dependent regulation of follicle-stimulating hormone beta by pulsatile gonadotropin-releasing hormone is mediated by functional antagonism of bZIP transcription factors. *Mol Cell Biol.* 2010;30:1028–40.
- Clement K, et al. A mutation in the human leptin receptor gene causes obesity and pituitary dysfunction. *Nature.* 1998;392:398–401.
- Cocquebert M, et al. Comparative expression of hCG  $\beta$ -genes in human trophoblast from early and late first-trimester placentas. *Am J Physiol Endocrinol Metab.* 2012;303:E950–8.
- Colacurci N, et al. Sequential protocol with urinary-FSH/recombinant-FSH versus standard protocol with recombinant-FSH in women of advanced age undergoing IVF. *Gynecol Endocrinol.* 2014;30:730–3.
- Cole LA. Hyperglycosylated hCG, a review. *Placenta.* 2010;31:653–64.
- Corless CL, et al. Gonadotropin alpha subunit. Differential processing of free and combined forms in human trophoblast and transfected mouse cells. *J Biol Chem.* 1987;262:14197–203.
- Costagliola S, et al. Tyrosine sulfation is required for agonist recognition by glycoprotein hormone receptors. *EMBO J.* 2002;21:504–13.
- Creus S, Chaia, Z, Pellizzari ER, Cigorraga SB, Ulloa-Aguirre A, Campo S. Human FSH isoforms: carbohydrate complexity as determinant of in-vitro bioactivity. *Mol Cell Endocrinol.* 2001;174:41–49.
- Cunningham F, et al. *Ensembl* 2015. *Nucleic Acids Res.* 2015;43:D662–9.

- Dalpathado DS, et al. Comparative glycomics of the glycoprotein follicle stimulating hormone: glycopeptide analysis of isolates from two mammalian species. *Biochemistry*. 2006;45:8665–73.
- Damian-Matsumura P, Zaga V, Maldonado A, Sanchez-Hernandez C, Timossi C, Ulloa-Aguirre A. Oestrogens regulate pituitary alpha2,3-sialyltransferase messenger ribonucleic acid levels in the female rat. *J Mol Endocrinol*. 1999;23:153–65.
- Darling RJ, et al. Functional contributions of noncysteine residues within the cystine knots of human chorionic gonadotropin subunits. *J Biol Chem*. 2001;276:10692–9.
- Davis JS, Kumar TR, May JV, Bousfield GR. Naturally occurring follicle-stimulating hormone glycosylation variants. *J Glycomics Lipidomics*. 2014;4:e117.
- Dayhoff MO. Atlas of protein sequence and structure (Volume 5, Suppl. 2). Washington, DC: National Biomedical Research Foundation; 1976. p. 122.
- Dharmesh SM, Skelton TP, Baenziger JU. Co-ordinate and restricted expression of the ProXaaArg/Lys-specific GalNAc-transferase and the GalNAcb1,4GlcNAcb1,2Mana-4-sulfotransferase. *J Biol Chem*. 1993;268:17096–102.
- Dias JA. Endocrinology: fertility hormone in repose. *Nature*. 2005;433:203–4.
- Diaz-Cueto L, Barrios-de-Tomasi J, Timossi C, Mendez JP, Ulloa-Aguirre A. More *in-vitro* bioactive, shorter-lived human chorionic gonadotrophin charge isoforms increase at the end of the first and during the third trimesters of gestation. *Mol Hum Reprod*. 1996;2:643–50.
- Doheny HC, Houlihan DD, Ravikumar N, Smith TJ, Morrison JJ. Human chorionic gonadotrophin relaxation of human pregnant myometrium and activation of the BKCa channel. *J Clin Endocrinol Metab*. 2003;88:4310–5.
- Duijkers IJ, Klipping C, Boerrigter PJ, Machielsen CS, De Bie JJ, Voortman G. Single dose pharmacokinetics and effects on follicular growth and serum hormones of a long-acting recombinant FSH preparation (FSH-CTP) in healthy pituitary-suppressed females. *Hum Reprod*. 2002;17:1987–93.
- Endo Y, Yamashita K, Tachibana Y, Tojo S, Kobata A. Structures of the asparagine-linked sugar chains of human chorionic gonadotropin. *J Biochem*. 1979;85:669–79.
- Endo T, Nishimura R, Mochizuki M, Kochibe N, Kobata A. Altered glycosylation is induced in both  $\alpha$ - and  $\beta$ -subunits of human chorionic gonadotropin produced by choriocarcinoma. *J Biochem*. 1988;103:1035–8.
- Eta E, Ambrus G, Rao CV. Direct regulation of human myometrial contractions by human chorionic gonadotropin. *J Clin Endocrinol Metab*. 1994;79:1582–6.
- Evans WS, et al. Contemporary aspects of discrete peak-detection algorithms. II. The paradigm of the luteinizing hormone pulse signal in women. *Endocr Rev*. 1992;13:81–104.
- Fan QR, Hendrickson WA. Structure of human follicle-stimulating hormone in complex with its receptor. *Nature*. 2005;433:269–77.
- Faria AC, et al. Pulsatile growth hormone release in normal women during the menstrual cycle. *Clin Endocrinol*. 1992;36:591–6.
- Ferris HA, Shupnik MA. Mechanisms for pulsatile regulation of the gonadotropin subunit genes by GNRH1. *Biol Reprod*. 2006;74:993–8.
- Fiddes JC, Goodman HM. The cDNA for the  $\beta$ -subunit of human chorionic gonadotropin suggests evolution of a gene by readthrough into the 3'-untranslated region. *Nature*. 1980;286:684–7.
- Fiete D, Baenziger JU. Isolation of the SO<sub>4</sub>-4-GalNAcb1,4GlcNAcb1,2Mana-specific receptor from rat liver. *J Biol Chem*. 1997;272:14629–37.
- Fiete D, Srivastava V, Hinds Gaul O, Baenziger JU. A hepatic reticuloendothelial cell receptor specific for SO<sub>4</sub>-4GalNAcb1,4GlcNAcb1,2Man $\alpha$  that mediates rapid clearance of lutropin. *Cell*. 1991;67:1103–10.
- Filicori M, Santoro N, Merriam GR, Crowley Jr WF. Characterization of the physiological pattern of episodic gonadotropin secretion throughout the human menstrual cycle. *J Clin Endocrinol Metab*. 1986;62:1136–44.

- Flack MR, Froehlich J, Bennet AP, Anasti J, Nisula BC. Site-directed mutagenesis defines the individual roles of the glycosylation sites on follicle-stimulating hormone. *J Biol Chem.* 1994;269:14015–20.
- Flores JA, Veldhuis JD, Leong DA. Follicle-stimulating hormone evokes an increase in intracellular free calcium ion concentrations in single ovarian (granulosa) cells. *Endocrinology.* 1990;127:3172–9.
- Fortin J, et al. Minireview: activin signaling in gonadotropes: what does the FOX say... to the SMAD? *Mol Endocrinol.* 2015;29:963–77.
- Fournier T, Guibourdenche J, Evain-Brion D. Review: hCGs: different sources of production, different glycoforms and functions. *Placenta.* 2015;36(Suppl 1):S60–5.
- Fox KM, Dias JA, Van Roey P. Three-dimensional structure of human follicle-stimulating hormone. *Mol Endocrinol.* 2001;15:378–89.
- Furui K, et al. Identification of two point mutations in the gene encoding luteinizing hormone (LH) b-subunit, associated with immunologically anomalous LH variants. *J Clin Endocrinol Metab.* 1994;78:107–13.
- Garcia-Galiano D, Pinilla L, Tena-Sempere M. Sex steroids and the control of the Kiss1 system: developmental roles and major regulatory actions. *J Neuroendocrinol.* 2012;24:22–33.
- Gervais A, et al. Glycosylation of human recombinant gonadotrophins: characterization and batch-to-batch consistency. *Glycobiology.* 2003;13:179–89.
- Gotschall RR, Bousfield GR. Oligosaccharide mapping reveals hormone-specific glycosylation patterns on equine gonadotropin  $\alpha$ -subunit Asn<sup>56</sup>. *Endocrinology.* 1996;137:2543–57.
- Green ED, Baenziger JU. Asparagine-linked oligosaccharides on lutropin, follitropin, and thyrotropin. II. Distributions of sulfated and sialylated oligosaccharides on bovine, ovine, and human pituitary glycoprotein hormones. *J Biol Chem.* 1988;263:36–44.
- Gregory SJ, Kaiser UB. Regulation of gonadotropins by inhibin and activin. *Semin Reprod Med.* 2004;22:253–67.
- Grosse R, et al. Gonadotropin-releasing hormone receptor initiates multiple signaling pathways by exclusively coupling to G(q/11) proteins. *J Biol Chem.* 2000;275:9193–200.
- Haavisto A-M, Pettersson K, Bergendahl M, Virkamaki A, Huhtaniemi I. Occurrence and biological properties of a common genetic variant of luteinizing hormone. *J Clin Endocrinol Metab.* 1995;80:1257–63.
- Haisenleder DJ, Dalkin AC, Ortolano GA, Marshall JC, Shupnik MA. A pulsatile gonadotropin-releasing hormone stimulus is required to increase transcription of the gonadotropin subunit genes: evidence for differential regulation of transcription by pulse frequency in vivo. *Endocrinology.* 1991;128:509–17.
- Haisenleder DJ, Yasin M, Marshall JC. Enhanced effectiveness of pulsatile 3',5'-cyclic adenosine monophosphate in stimulating prolactin and alpha-subunit gene expression. *Endocrinology.* 1992;131:3027–33.
- Hall JE, Schoenfeld DA, Martin KA, Crowley Jr WF. Hypothalamic gonadotropin-releasing hormone secretion and follicle-stimulating hormone dynamics during the luteal-follicular transition. *J Clin Endocrinol Metab.* 1992;74:600–7.
- Han XB, Conn PM. The role of protein kinases A and C pathways in the regulation of mitogen-activated protein kinase activation in response to gonadotropin-releasing hormone receptor activation. *Endocrinology.* 1999;140:2241–51.
- Hartree AS, Showkeen RC. Studies of human pituitary lutropin containing internally cleaved beta subunit. *J Mol Endocrinol.* 1991;6:101–9.
- Heckert LL, Schultz K, Nilson JH. Different composite regulatory elements direct expression of the human  $\alpha$  subunit gene to pituitary and placenta. *J Biol Chem.* 1995;270:26497–504.
- Heckert LL, Wilson EM, Nilson JH. Transcriptional repression of the alpha-subunit gene by androgen receptor occurs independently of DNA binding but requires the DNA-binding and ligand-binding domains of the receptor. *Mol Endocrinol.* 1997;11:1497–506.
- Helenius A, Aebi M. Intracellular functions of N-linked glycans. *Science.* 2001;291:2364–9.

- Herr F, et al. HCG in the regulation of placental angiogenesis. Results of an *in vitro* study. *Placenta*. 2007; 28 Suppl A:S85–93.
- Hiyama J, Weisshaar G, Renwick AGC. The asparagine-linked oligosaccharides at individual glycosylation sites in human thyrotropin. *Glycobiology*. 1992;2:401–9.
- Horn F, Windle JJ, Barnhart KM, Mellon PL. Tissue-specific gene expression in the pituitary: the glycoprotein hormone alpha-subunit gene is regulated by a gonadotrope-specific protein. *Mol Cell Biol*. 1992;12:2143–53.
- Huhtaniemi I. A short evolutionary history of FSH-stimulated spermatogenesis. *Hormones (Athens)*. 2015; 14:468–478.
- Huth JR, Mountjoy K, Perini F, Bedows E, Ruddon RW. Domain-dependent protein folding is indicated by the intracellular kinetics of disulfide bond formation of human chorionic gonadotropin  $\beta$  subunit. *J Biol Chem*. 1992;267:21396–403.
- Ingraham HA, et al. The nuclear receptor steroidogenic factor 1 acts at multiple levels of the reproductive axis. *Genes Dev*. 1994;8:2302–12.
- Issad T, Strobel A, Camoin L, Ozata M, Strosberg AD. Leptin and puberty in humans: hypothesis of the critical adipose mass revisited. *Diabete Metab*. 1998;24:376–8.
- Jablonka-Shariff A, Boime I. Luteinizing hormone and follicle-stimulating hormone exhibit different secretion patterns from cultured Madin-Darby canine kidney cells. *Biol Reprod*. 2004;70:649–55.
- Jablonka-Shariff A, Boime I. Secretory trafficking signal encoded in the carboxyl-terminal region of the CGbeta-subunit. *Mol Endocrinol*. 2009;23:316–23.
- Jablonka-Shariff A, Garcia-Campayo V, Boime I. Evolution of lutropin to chorionic gonadotropin generates a specific routing signal for apical release *in vivo*. *J Biol Chem*. 2002;277:879–82.
- Jablonka-Shariff A, Pearl CA, Comstock A, Boime I. A carboxyl-terminal sequence in the lutropin beta subunit contributes to the sorting of lutropin to the regulated pathway. *J Biol Chem*. 2008;283:11485–92.
- Jameson JL, Lindell CM, Habener JF. Evolution of different transcriptional start sites in the human luteinizing hormone and chorionic gonadotropin beta-subunit genes. *DNA*. 1986;5:227–34.
- Jiang M, et al. A novel Ala(–3)Thr mutation in the signal peptide of human luteinizing hormone beta-subunit: potentiation of the inositol phosphate signalling pathway and attenuation of the adenylate cyclase pathway by recombinant variant hormone. *Mol Hum Reprod*. 2002;8:201–12.
- Jiang X, et al. Structure of follicle-stimulating hormone in complex with the entire ectodomain of its receptor. *Proc Natl Acad Sci U S A*. 2012;109:12491–6.
- Jiang X, Dias JA, He X. Structural biology of glycoprotein hormones and their receptors: insights to signaling. *Mol Cell Endocrinol*. 2013;108:7172–6.
- Jiang X, Dias JA, He X. Structural biology of glycoprotein hormones and their receptors: Insights to signaling. *Mol Cell Endocrinol*. 2014a;382:424–51.
- Jiang X, et al. Evidence for follicle-stimulating hormone receptor as a functional trimer. *J Biol Chem*. 2014b;289:14273–82.
- Jiang C, et al. Hypo-glycosylated hFSH has greater bioactivity than fully-glycosylated recombinant hFSH in human granulosa cells. *J Clin Endocrinol Metab*. 2015;100:E852–60.
- Johnson W, Albanese C, Handwerger S, Williams T, Pestell RG, Jameson JL. Regulation of the human chorionic gonadotropin alpha- and beta-subunit promoters by AP-2. *J Biol Chem*. 1997;272:15405–12.
- Jorgensen JS, Quirk CC, Nilson JH. Multiple and overlapping combinatorial codes orchestrate hormonal responsiveness and dictate cell-specific expression of the genes encoding luteinizing hormone. *Endocr Rev*. 2004;25:521–42.
- Kanasaki H, Bedecarrats GY, Kam KY, Xu S, Kaiser UB. Gonadotropin-releasing hormone pulse frequency-dependent activation of extracellular signal-regulated kinase pathways in perfused LbetaT2 cells. *Endocrinology*. 2005;146:5503–13.
- Kanasaki H, Mutiara S, Oride A, Purwana IN, Miyazaki K. Pulse frequency-dependent gonadotropin gene expression by adenylate cyclase-activating polypeptide 1 in perfused mouse pituitary gonadotroph LbetaT2 cells. *Biol Reprod*. 2009;81:465–72.

- Kanasaki H, Purwana IN, Miyazaki K. Possible role of PACAP and its PAC1 receptor in the differential regulation of pituitary LHbeta- and FSHbeta-subunit gene expression by pulsatile GnRH stimulation. *Biol Reprod.* 2013;88:35.
- Kane N, Kelly R, Saunders PT, Critchley HO. Proliferation of uterine natural killer cells is induced by human chorionic gonadotropin and mediated via the mannose receptor. *Endocrinology.* 2009;150:2882–8.
- Kessler MJ, Mise T, Ghai RD, Bahl OP. Structure and location of the O-glycosidic carbohydrate units of human chorionic gonadotropin. *J Biol Chem.* 1979a;254:7909–14.
- Kessler MJ, Reddy MS, Shah RH, Bahl OP. Structures of the N-Glycosidic carbohydrate units of human chorionic gonadotropin. *J Biol Chem.* 1979b;254:7901–8.
- Keutmann HT, Dawsom B, Bishop WH, Ryan RJ. Structure of human luteinizing hormone alpha subunit. *Endocr Res Commun.* 1978;5:57–70.
- Keutmann HT, Williams RM, Ryan RJ. Structure of human luteinizing hormone beta subunit: evidence for a related carboxy-terminal sequence among certain peptide hormones. *Biochem Biophys Res Commun.* 1979;90:842–8.
- Knight PG, Glistler C. Potential local regulatory functions of inhibins, activins and follistatin in the ovary. *Reproduction.* 2001;121:503–12.
- Knobil E. The neuroendocrine control of the menstrual cycle. *Recent Prog Horm Res.* 1980;36:53–88.
- Knofler M, et al. Promoter elements and transcription factors involved in differentiation-dependent human chorionic gonadotrophin-alpha messenger ribonucleic acid expression of term villous trophoblasts. *Endocrinology.* 2000;141:3737–48.
- Knofler M, Vasicek R, Schreiber M. Key regulatory transcription factors involved in placental trophoblast development – a review. *Placenta.* 2001; 22 Suppl A:S83–92.
- Knofler M, et al. Transcriptional regulation of the human chorionic gonadotropin beta gene during villous trophoblast differentiation. *Endocrinology.* 2004;145:1685–94.
- Kottler ML, et al. A new FSHbeta mutation in a 29-year-old woman with primary amenorrhea and isolated FSH deficiency: functional characterization and ovarian response to human recombinant FSH. *Eur J Endocrinol.* 2010;162:633–41.
- Kowase T, Walsh HE, Darling DS, Shupnik MA. Estrogen enhances gonadotropin-releasing hormone-stimulated transcription of the luteinizing hormone subunit promoters via altered expression of stimulatory and suppressive transcription factors. *Endocrinology.* 2007;148:6083–91.
- Kraus S, Naor Z, Seger R. Intracellular signaling pathways mediated by the gonadotropin-releasing hormone (GnRH) receptor. *Arch Med Res.* 2001;32:499–509.
- Krishnamurthy H, Galet C, Ascoli M. The association of arrestin-3 with the follitropin receptor depends on receptor activation and phosphorylation. *Mol Cell Endocrinol.* 2003;204:127–40.
- Kumar TR. Extragonadal FSH receptor: is it real? *Biol Reprod* 2014; 91:99.
- Kumar TR, Wang Y, Lu N, Matzuk MM. Follicle stimulating hormone is required for ovarian follicle maturation but not male fertility. *Nat Genet.* 1997;15:201–4.
- Kumar TR, et al. Transgenic models to study gonadotropin function: the role of follicle-stimulating hormone in gonadal growth and tumorigenesis. *Mol Endocrinol.* 1999;13:851–65.
- Lamba P, Fortin J, Tran S, Wang Y, Bernard DJ. A novel role for the forkhead transcription factor FOXL2 in activin A-regulated follicle-stimulating hormone beta subunit transcription. *Mol Endocrinol.* 2009;23:1001–13.
- Lamminen T, Huhtaniemi I. A common genetic variant of luteinizing hormone; relation to normal and aberrant pituitary-gonadal function. *Eur J Pharmacol.* 2001;414:1–7.
- Lamminen T, et al. Functional study of a recombinant form of human LHbeta-subunit variant carrying the Gly(102)Ser mutation found in Asian populations. *Mol Hum Reprod.* 2002;8:887–92.
- Lapthorn AJ, et al. Crystal structure of human chorionic gonadotropin. *Nature.* 1994;369:455–61.
- Lawson MA, et al. Pulse sensitivity of the luteinizing hormone beta promoter is determined by a negative feedback loop involving early growth response-1 and Ngfi-A binding protein 1 and 2. *Mol Endocrinol.* 2007;21:1175–91.

- Layman LC, et al. FSH beta gene mutations in a female with partial breast development and a male sibling with normal puberty and azoospermia. *J Clin Endocrinol Metab.* 2002;87:3702–7.
- le Cotonnec JY, Porchet HC, Beltrami V, Howles C. Comparative pharmacokinetics of two urinary human follicle stimulating hormone preparations in healthy female and male volunteers. *Hum Reprod.* 1993;8:1604–11.
- le Cotonnec JY, Porchet HC, Beltrami V, Khan A, Toon S, Rowland M. Clinical pharmacology of recombinant human follicle-stimulating hormone (FSH). I. Comparative pharmacokinetics with urinary human FSH. *Fertil Steril.* 1994;61:669–78.
- le Cotonnec JY, Porchet HC, Beltrami V, Khan A, Toon S, Rowland M. Comprehensive pharmacokinetics of urinary human follicle stimulating hormone in healthy female volunteers. *Pharm Res.* 1995;12:844–50.
- le Cotonnec JY, Porchet HC, Beltrami V, Munafo A. Clinical pharmacology of recombinant human luteinizing hormone: Part II. Bioavailability of recombinant human luteinizing hormone assessed with an immunoassay and an *in vitro* bioassay. *Fertil Steril.* 1998a;69:195–200.
- le Cotonnec JY, Porchet HC, Beltrami V, Munafo A. Clinical pharmacology of recombinant human luteinizing hormone: Part I. Pharmacokinetics after intravenous administration to healthy female volunteers and comparison with urinary human luteinizing hormone. *Fertil Steril.* 1998b;69:189–94.
- le Cotonnec JY, Loumaye E, Porchet HC, Beltrami V, Munafo A. Pharmacokinetic and pharmacodynamic interactions between recombinant human luteinizing hormone and recombinant human follicle-stimulating hormone. *Fertil Steril.* 1998c;69:201–9.
- Lefort GP, Stolk JM, Nisula BC. Evidence that desialylation and uptake by hepatic receptors for galactose-terminated glycoproteins are immaterial to the metabolism of human chorionic gonadotropin in the rat. *Endocrinology.* 1984;115:1551–7.
- Legardinier S, Duonor-Cerutti M, Devauchelle G, Combarnous Y, Cahoreau C. Biological activities of recombinant equine luteinizing hormone/chorionic gonadotropin (eLH/CG) expressed in Sf9 and Mimic insect cell lines. *J Mol Endocrinol.* 2005;34:47–60.
- Lewis KA, et al. Betaglycan binds inhibin and can mediate functional antagonism of activin signalling. *Nature.* 2000;404:411–4.
- Lim S, et al. Distinct mechanisms involving diverse histone deacetylases repress expression of the two gonadotropin beta-subunit genes in immature gonadotropes, and their actions are overcome by gonadotropin-releasing hormone. *Mol Cell Biol.* 2007;27:4105–20.
- Lindstedt G, Nystrom E, Matthews C, Ernest I, Janson PO, Chatterjee K. Follitropin (FSH) deficiency in an infertile male due to FSHbeta gene mutation. A syndrome of normal puberty and virilization but underdeveloped testicles with azoospermia, low FSH but high lutropin and normal serum testosterone concentrations. *Clin Chem Lab Med.* 1998;36:663–5.
- Liu C, Bowers LD. Mass spectrometric characterization of the beta-subunit of human chorionic gonadotropin. *J Mass Spectrom.* 1997;32:33–42.
- Liu F, et al. Involvement of both G(q/11) and G(s) proteins in gonadotropin-releasing hormone receptor-mediated signaling in L beta T2 cells. *J Biol Chem.* 2002;277:32099–108.
- Lofrano-Porto A, et al. Luteinizing hormone beta mutation and hypogonadism in men and women. *N Engl J Med.* 2007;357:897–904.
- Luo M, Koh M, Feng J, Wu Q, Melamed P. Cross talk in hormonally regulated gene transcription through induction of estrogen receptor ubiquitylation. *Mol Cell Biol.* 2005;25:7386–98.
- Lustbader JW, et al. The expression, characterization, and crystallization of wild-type and selenomethionyl human chorionic gonadotropin. *Endocrinology.* 1995;136:640–50.
- MacConell LA, Leal AM, Vale WW. The distribution of betaglycan protein and mRNA in rat brain, pituitary, and gonads: implications for a role for betaglycan in inhibin-mediated reproductive functions. *Endocrinology.* 2002;143:1066–75.
- Marshall JC, Dalkin AC, Haisenleder DJ, Paul SJ, Ortolano GA, Kelch RP. Gonadotropin-releasing hormone pulses: regulators of gonadotropin synthesis and ovulatory cycles. *Recent Prog Horm Res.* 1991;47:155–87. discussion 188-9

- Maston GA, Ruvolo M. Chorionic gonadotropin has a recent origin within primates and an evolutionary history of selection. *Mol Biol Evol.* 2002;19:320–35.
- Matthews CH, et al. Primary amenorrhoea and infertility due to a mutation in the beta-subunit of follicle-stimulating hormone. *Nat Genet.* 1993;5:83–6.
- Matzuk MM, Boime I. The role of the asparagine-linked oligosaccharides of the  $\alpha$  subunit in the secretion and assembly of human chorionic gonadotropin. *J Cell Biol.* 1988b;106:1049–59.
- Matzuk MM, Boime I. Site-specific mutagenesis defines the intracellular role of the asparagine-linked oligosaccharides of chorionic gonadotropin beta subunit. *J Biol Chem.* 1988a;263:17106–11.
- Matzuk MM, Boime I. Mutagenesis and gene transfer define site-specific roles of the gonadotropin oligosaccharides. *Biol Reprod.* 1989;40:48–53.
- Matzuk MM, Keene JL, Boime I. Site specificity of the chorionic gonadotropin N-linked oligosaccharides in signal transduction. *J Biol Chem.* 1989;264:2409–14.
- McDonald NQ, Lapatto R, Murray-Rust J, Gunning J, Wlodawer A, Blundell TL. New protein fold revealed by a 2.3-Å resolution crystal structure of nerve growth factor. *Nature.* 1991;354:411–4.
- Meher BR, Dixit A, Bousfield GR, Lushington GH. Glycosylation effects on FSH-FSHR interaction dynamics: a case study of different FSH glycoforms by molecular dynamics simulations. *PLoS ONE.* 2015;10:e0137897.
- Mellquist JL, Kasturi L, Spitalnik SL, Shakin-Eshleman SH. The amino acid following an asn-X-Ser/Thr sequon is an important determinant of N-linked core glycosylation efficiency. *Biochemistry.* 1998;37:6833–7.
- Meunier L, Usherwood YK, Chung KT, Hendershot LM. A subset of chaperones and folding enzymes form multiprotein complexes in endoplasmic reticulum to bind nascent proteins. *Mol Biol Cell.* 2002;13:4456–69.
- Mise T, Bahl OP. Assignment of disulfide bonds in the  $\alpha$  subunit of human chorionic gonadotropin. *J Biol Chem.* 1980;255:8516–22.
- Mistry DS, et al. Gonadotropin-releasing hormone pulse sensitivity of follicle-stimulating hormone-beta gene is mediated by differential expression of positive regulatory activator protein 1 factors and corepressors SKIL and TGIF1. *Mol Endocrinol.* 2011;25:1387–403.
- Mizuochi T, et al. Structures of the asparagine-linked sugar chains of human chorionic gonadotropin produced in choriocarcinoma: appearance of triantennary sugar chains and unique biantennary sugar chains. *J Biol Chem.* 1983;258:14126–9.
- Moore Jr WT, Burleigh BD, Ward DN. Chorionic gonadotropins: comparative studies and comments on relationships to other glycoprotein hormones. In: Segal SJ, editor. *Chorionic gonadotropin.* New York: Plenum Press; 1980. p. 89–126.
- Morell AG, Gregoriadis G, Scheinberg IH, Hickman J, Ashwell G. The role of sialic acid in determining the survival of glycoproteins in the circulation. *J Biol Chem.* 1971;246:1461–7.
- Morgan FJ, Birken S, Canfield RE. The amino acid sequence of human chorionic gonadotropin. The alpha subunit and beta subunit. *J Biol Chem.* 1975;250:5247–58.
- Mouillet JF, Sonnenberg-Hirche C, Yan X, Sadovsky Y. p300 regulates the synergy of steroidogenic factor-1 and early growth response-1 in activating luteinizing hormone-beta subunit gene. *J Biol Chem.* 2004;279:7832–9.
- Moyle WR, Campbell RK, Myers RV, Bernard MP, Han Y, Wang X. Co-evolution of ligand-receptor pairs. *Nature.* 1994;368:251–5.
- Müller T, et al. Chorionic gonadotrophin beta subunit mRNA but not luteinising hormone beta subunit mRNA is expressed in the pituitary of the common marmoset (*Callithrix jacchus*). *J Mol Endocrinol.* 2004;32:115–28.
- Muyan M, Ryzmkiewicz DM, Boime I. Secretion of lutropin and follitropin from transfected GH3 cells: evidence for separate secretory pathways. *Mol Endocrinol.* 1994;8:1789–97.
- Muzzio D, Zygmunt M, Jensen F. The role of pregnancy-associated hormones in the development and function of regulatory B cells. *Front Endocrinol (Lausanne).* 2014;5(39).

- Nagirnaja L, Rull K, Uusküla L, Hallast P, Grigorova M, Laan M. Genomics and genetics of gonadotropin beta-subunit genes: Unique FSHB and duplicated LHB/CGB loci. *Mol Cell Endocrinol.* 2010;329:4–16.
- Naor Z. Signaling by G-protein-coupled receptor (GPCR): studies on the GnRH receptor. *Front Neuroendocrinol.* 2009;30:10–29.
- Naor Z, Huhtaniemi I. Interactions of the GnRH receptor with heterotrimeric G proteins. *Front Neuroendocrinol.* 2013;34:88–94.
- Nayudu PL, Vitt UA, Barrios De Tomasi J, Pancharatna K, Ulloa-Aguirre A. Intact follicle culture: what it can tell us about the roles of FSH glycoforms during follicle development. *Reprod BioMed Online.* 2002;5:240–53.
- Nicol L, Faure MO, McNeilly JR, Fontaine J, Taragnat C, McNeilly AS. Bone morphogenetic protein-4 interacts with activin and GnRH to modulate gonadotrophin secretion in LbetaT2 gonadotrophs. *J Endocrinol.* 2008;196:497–507.
- Nilson JH, et al. CRE-binding proteins interact cooperatively to enhance placental-specific expression of the glycoprotein hormone alpha-subunit gene. *Ann N Y Acad Sci.* 1989;564:77–85.
- Nisula BC, Bliethe DL, Akar A, Lefort G, Wehmann RE. Metabolic fate of human choriongonadotropin. *J Steroid Biochem.* 1989;33:733–7.
- Okuda K, Takamatsu J, Okazaki T, Yamada T, Saeki M, Sugimoto O. Hereditary abnormality of luteinizing hormone resulting in discrepant serum concentrations determined by different assays. *Endocr J.* 1994;41:639–44.
- Olivares A, Cardenas M, Timossi C, Zarinan T, Diaz-Sanchez V, Ulloa-Aguirre A. Reactivity of different LH and FSH standards and preparations in the world health organization matched reagents for enzyme-linked immunoassays of gonadotrophins. *Hum Reprod.* 2000;15:2285–91.
- Padmanabhan V, McFadden K, Mauger DT, Karsch FJ, Midgley ARJ. Neuroendocrine control of follicle-stimulating hormone (FSH) secretion. I. Direct evidence for separate episodic and basal components of FSH secretion. *Endocrinology.* 1997;138:424–32.
- Pearl CA, Jablonka-Shariff A, Boime I. Rerouting of a follicle-stimulating hormone analog to the regulated secretory pathway. *Endocrinology.* 2010;151:388–93.
- Perlman S, et al. Glycosylation of an N-terminal extension prolongs the half-life and increases the in vivo activity of follicle stimulating hormone. *J Clin Endocrinol Metab.* 2003;88:3227–35.
- Petersen TN, Brunak S, von Heijne G, Nielsen H. SignalP 4.0: discriminating signal peptides from transmembrane regions. *Nat Methods.* 2011;8:785–6.
- Phillip M, Arbell JE, Segev Y, Parvari R. Male hypogonadism due to a mutation in the gene for the beta-subunit of follicle-stimulating hormone. *N Engl J Med.* 1998;338:1729–32.
- Pincas H, Choi SG, Wang Q, Jia J, Turgeon JL, Sealfon SC. Outside the box signaling: secreted factors modulate GnRH receptor-mediated gonadotropin regulation. *Mol Cell Endocrinol.* 2014;385:56–61.
- Pittman RH, Clay CM, Farmerie TA, Nilson JH. Functional analysis of the placenta-specific enhancer of the human glycoprotein hormone alpha subunit gene. Emergence of a new element. *J Biol Chem.* 1994;269:19360–8.
- PolICASTRO P, Ovitt CE, Hoshima M, Fukuoka H, Boothby MR, Boime I. The  $\beta$  subunit of human chorionic gonadotropin is encoded by multiple genes. *J Biol Chem.* 1983;258:11492–9.
- Porchet HC, Le Cotonnec JY, Canali S, Zanol G. Pharmacokinetics of recombinant human follicle stimulating hormone after intravenous, intramuscular, and subcutaneous administration in monkeys, and comparison with intravenous administration of urinary follicle stimulating hormone. *Drug Metab Dispos.* 1993;21:144–50.
- Porchet HC, le Cotonnec JY, Loumaye E. Clinical pharmacology of recombinant human follicle-stimulating hormone. III. Pharmacokinetic-pharmacodynamic modeling after repeated subcutaneous administration. *Fertil Steril.* 1994;61:687–95.
- Porchet HC, Le Cotonnec JY, Neuteboom B, Canali S, Zanol G. Pharmacokinetics of recombinant human luteinizing hormone after intravenous, intramuscular, and subcutaneous administration in monkeys and comparison with intravenous administration of pituitary human luteinizing hormone. *J Clin Endocrinol Metab.* 1995;80:667–73.



- Posillico EG, Handwerger S, Tyrey L. Demonstration of intracellular and secreted forms of large human chorionic gonadotrophin alpha subunit in cultures of normal placental tissue. *Placenta*. 1983;4:439–48.
- Potorac I, et al. A vital region for human glycoprotein hormone trafficking revealed by an LHB mutation. *J Endocrinol* 2016;231:197–207.
- Purwana IN, Kanasaki H, Mijiddorj T, Oride A, Miyazaki K. Induction of dual-specificity phosphatase 1 (DUSP1) by pulsatile gonadotropin-releasing hormone stimulation: role for gonadotropin subunit expression in mouse pituitary LbetaT2 cells. *Biol Reprod*. 2011;84:996–1004.
- Quirk CC, Lozada KL, Keri RA, Nilson JH. A single Pitx1 binding site is essential for activity of the LHBeta promoter in transgenic mice. *Mol Endocrinol*. 2001;15:734–46.
- Raivio T, et al. The role of luteinizing hormone-beta gene polymorphism in the onset and progression of puberty in healthy boys. *J Clin Endocrinol Metab*. 1996;81:3278–82.
- Ramanujam LN, Liao WX, Roy AC, Loganath A, Goh HH, Ng SC. Association of molecular variants of luteinizing hormone with menstrual disorders. *Clin Endocrinol*. 1999; 51:243–6.
- Ramanujam LN, Liao WX, Roy AC, Ng SC. Association of molecular variants of luteinizing hormone with male infertility. *Hum Reprod*. 2000;15:925–8.
- Renwick AGC, Mizuochi T, Kochibe N, Kobata A. The asparagine-linked sugar chains of human follicle-stimulating hormone. *J Biochem*. 1987;101:1209–21.
- Richards JS, Pangas SA. The ovary: basic biology and clinical implications. *J Clin Invest*. 2010;120:963–72.
- Richards JS, et al. Novel signaling pathways that control ovarian follicular development, ovulation, and luteinization. *Recent Prog Horm Res*. 2002;57:195–220.
- Roch GJ, Sherwood NM. Glycoprotein hormones and their receptors emerged at the origin of metazoans. *Genome Biol Evol*. 2014;6:1466–79.
- Ruddon RW, Sherman SA, Bedows E. Protein folding in the endoplasmic reticulum: lessons from the human chorionic gonadotropin  $\beta$  subunit. *Protein Sci*. 1996;5:1443–52.
- Rull K, Laan M. Expression of beta-subunit of HCG genes during normal and failed pregnancy. *Hum Reprod*. 2005;20:3360–8.
- Rull K, et al. Chorionic gonadotropin beta-gene variants are associated with recurrent miscarriage in two European populations. *J Clin Endocrinol Metab*. 2008;93:4697–706.
- Sairam MR. Role of carbohydrates in glycoprotein hormone signal transduction. *FASEB J*. 1989;3:1915–26.
- Sairam MR, Bhargavi GN. A role for glycosylation of the alpha subunit in transduction of biological signal in glycoprotein hormones. *Science*. 1985;229:65–7.
- Sairam MR, Li CH. Human pituitary lutropin: isolation, properties, and the complete amino acid sequence of the  $\beta$ -subunit. *Biochim Biophys Acta*. 1975;412:70–81.
- Sairam MR, Manjunath P. Studies on pituitary follitropin. XI. Induction of hormonal antagonistic activity by chemical deglycosylation. *Mol Cell Endocrinol*. 1982;28:139–50.
- Sairam MR, Papkoff H, Li CH. Human pituitary interstitial cell stimulating hormone: primary structure of the  $\alpha$  subunit. *Biochem Biophys Res Commun*. 1972;48:530–7.
- Salisbury TB, Binder AK, Nilson JH. Welcoming beta-catenin to the gonadotropin-releasing hormone transcriptional network in gonadotropes. *Mol Endocrinol*. 2008;22:1295–303.
- Scammell JG, Funkhouser JD, Moyer FS, Gibson SV, Willis DL. Molecular cloning of pituitary glycoprotein alpha-subunit and follicle stimulating hormone and chorionic gonadotropin beta-subunits from New World squirrel monkey and owl monkey. *Gen Comp Endocrinol*. 2008;155:534–41.
- Schumacher A, et al. Human chorionic gonadotropin as a central regulator of pregnancy immune tolerance. *J Immunol*. 2013;190:2650–8.
- Selman H, Pacchiarotti A, El-Danasouri I. Ovarian stimulation protocols based on follicle-stimulating hormone glycosylation pattern: impact on oocyte quality and clinical outcome. *Fertil Steril*. 2010;94:1782–6.

- Selman H, et al. Simultaneous administration of human acidic and recombinant less acidic follicle-stimulating hormone for ovarian stimulation improves oocyte and embryo quality and clinical outcome in patients with repeated IVF failures. *Eur Rev Med Pharmacol Sci.* 2013;17:1814–9.
- Shakin-Eshleman SH, Spitalnik SL, Kasturi L. The amino acid at the X position of an Asn-X-Ser sequon is an important determinant of N-linked core glycosylation efficiency. *J Biol Chem.* 1986;271:6363–6.
- Sharpless JL, Supko JG, Martin KA, Hall JE. Disappearance of endogenous luteinizing hormone is prolonged in postmenopausal women. *J Clin Endocrinol Metab.* 1999;84:688–94.
- Sherman GB, et al. A single gene encodes the  $\beta$ -subunits of equine luteinizing hormone and chorionic gonadotropin. *Mol Endocrinol.* 1992;6:951–9.
- Shi QJ, Lei ZM, Rao CV, Lin J. Novel role of human chorionic gonadotropin in differentiation of human cytotrophoblasts. *Endocrinology.* 1993;132:1387–95.
- Shiraishi K, Ascoli M. Lutropin/choriogonadotropin stimulate the proliferation of primary cultures of rat Leydig cells through a pathway that involves activation of the extracellularly regulated kinase 1/2 cascade. *Endocrinology.* 2007;148:3214–25.
- Shome B, Parlow AF. The primary structure of the hormone-specific, beta subunit of human pituitary luteinizing hormone (hLH). *J Clin Endocrinol Metab.* 1973;36:618–21.
- Shome B, Parlow AF. Human follicle stimulating hormone (hFSH): first proposal for the amino acid sequence of the  $\alpha$ -subunit (hFSH $\alpha$ ) and first demonstration of its identity with the  $\alpha$ -subunit of human luteinizing hormone (hLH $\alpha$ ). *J Clin Endocrinol Metab.* 1974;39:199–202.
- Shupnik MA. Effects of gonadotropin-releasing hormone on rat gonadotropin gene transcription *in vitro*: requirement for pulsatile administration for luteinizing hormone-beta gene stimulation. *Mol Endocrinol.* 1990;4:1444–50.
- Shupnik MA. Gonadotropin gene modulation by steroids and gonadotropin-releasing hormone. *Biol Reprod.* 1996;54:279–86.
- Shupnik MA, Fallest PC. Pulsatile GnRH regulation of gonadotropin subunit gene transcription. *Neurosci Biobehav Rev.* 1994;18:597–9.
- Shupnik MA, Rosenzweig BA. Identification of an estrogen-responsive element in the rat LH beta gene. DNA-estrogen receptor interactions and functional analysis. *J Biol Chem.* 1991;266:17084–91.
- Simoni M, Casarini L. Mechanisms in endocrinology: genetics of FSH action: a 2014-and-beyond view. *Eur J Endocrinol.* 2014;170:R91–107.
- Simoni M, Gromoll J, Nieschlag E. The follicle-stimulating hormone receptor: biochemistry, molecular biology, physiology, and pathophysiology. *Endocr Rev.* 1997;18:739–73.
- Simsek E, Montenegro LR, Binay C, Demiral M, Acikalin MF, Latronico AC. Clinical and hormonal features of a male adolescent with congenital isolated follicle-stimulating hormone deficiency. *Horm Res Paediatr.* 2016;85:207–12.
- Skorupskaitė K, George JT, Anderson RA. The kisspeptin-GnRH pathway in human reproductive health and disease. *Hum Reprod Update.* 2014;20:485–500.
- Smith PL, Baenziger JU. A pituitary N-acetylgalactosamine transferase that specifically recognizes glycoprotein hormones. *Science.* 1988;242:930–3.
- Smith PL, Baenziger JU. Recognition by the glycoprotein hormone-specific N-acetylgalactosaminetransferase is independent of hormone native conformation. *Proc Natl Acad Sci U S A.* 1990;87:7275–9.
- Smith PL, Baenziger JU. Molecular basis of recognition by the glycoprotein hormone-specific N-acetylgalactosamine-transferase. *Proc Natl Acad Sci U S A.* 1992;89:329–33.
- Smitz J, Wolfenson C, Chappel S, Ruman J. Follicle-stimulating hormone: a review of form and function in the treatment of infertility. *Reprod Sci.* 2015.
- Spady TJ, Shayya R, Thackray VG, Ehrensberger L, Bailey JS, Mellon PL. Androgen regulates follicle-stimulating hormone beta gene expression in an activin-dependent manner in immortalized gonadotropes. *Mol Endocrinol.* 2004;18:925–40.
- Spratt DI, Carr DB, Merriam GR, Scully RE, Rao PN, Crowley Jr WF. The spectrum of abnormal patterns of gonadotropin-releasing hormone secretion in men with idiopathic

- hypogonadotropic hypogonadism: clinical and laboratory correlations. *J Clin Endocrinol Metab.* 1987;64:283–91.
- Stanislaus D, Janovick JA, Brothers S, Conn PM. Regulation of G(q/11)alpha by the gonadotropin-releasing hormone receptor. *Mol Endocrinol.* 1997;11:738–46.
- Stanislaus D, Ponder S, Ji TH, Conn PM. Gonadotropin-releasing hormone receptor couples to multiple G proteins in rat gonadotrophs and in GGH3 cells: evidence from palmitoylation and overexpression of G proteins. *Biol Reprod.* 1998;59:579–86.
- Steger DJ, Hecht JH, Mellon PL. GATA-binding proteins regulate the human gonadotropin alpha-subunit gene in the placenta and pituitary gland. *Mol Cell Biol.* 1994;14:5592–602.
- Stewart F, Thomson JA, Leigh SEA, Warwick JM. Nucleotide (cDNA) sequence encoding the horse gonadotropin  $\alpha$ -subunit. *J Endocrinol.* 1987;115:341–6.
- Strobel A, Issad T, Camoin L, Ozata M, Strosberg AD. A leptin missense mutation associated with hypogonadism and morbid obesity. *Nat Genet.* 1998;18:213–5.
- Suganuma N, Furui K, Kikkawa F, Tomoda Y, Furuhashi M. Effects of the mutations (Trp(8)->Arg and Ile(15)->Thr) in human luteinizing hormone (LH) beta-subunit on LH bioactivity *in vitro* and *in vivo*. *Endocrinology.* 1996;137:831–8.
- Sviridonov L, et al. Differential signaling of the GnRH receptor in pituitary gonadotrope cell lines and prostate cancer cell lines. *Mol Cell Endocrinol.* 2013;369:107–18.
- Tai P, Shiraishi K, Ascoli M. Activation of the lutropin/choriogonadotropin receptor inhibits apoptosis of immature Leydig cells in primary culture. *Endocrinology.* 2009;150:3766–73.
- Takahashi K, et al. Increased prevalence of luteinizing hormone beta-subunit variant in Japanese infertility patients. *Hum Reprod.* 1998;13:3338–44.
- Takahashi K, Ozaki T, Okada M, Kurioka H, Kanasaki H, Miyazaki K. Increased prevalence of luteinizing hormone beta-subunit variant in patients with premature ovarian failure. *Fertil Steril.* 1999;71:96–101.
- Takeda M, et al. Interaction between gonadotropin-releasing hormone and bone morphogenetic protein-6 and -7 signaling in LbetaT2 gonadotrope cells. *Mol Cell Endocrinol.* 2012;348:147–54.
- Talmadge K, Boorstein WR, Fiddes JC. The human genome contains seven genes for the  $\beta$ -subunit of chorionic gonadotropin but only one gene for the  $\beta$ -subunit of luteinizing hormone. *DNA.* 1983;2:281–9.
- Tapanainen JS, Aittomaki K, Min J, Vaskivuo T, Huhtaniemi IT. Men homozygous for an inactivating mutation of the follicle-stimulating hormone (FSH) receptor gene present variable suppression of spermatogenesis and fertility. *Nat Genet.* 1997;15:205–6.
- Thackray VG, McGillivray SM, Mellon PL. Androgens, progestins, and glucocorticoids induce follicle-stimulating hormone beta-subunit gene expression at the level of the gonadotrope. *Mol Endocrinol.* 2006;20:2062–79.
- Thackray VG, Hunnicutt JL, Memon AK, Ghochani Y, Mellon PL. Progesterone Inhibits basal and gonadotropin-releasing hormone induction of luteinizing hormone beta-subunit gene expression. *Endocrinology.* 2009;150:2395–403.
- Thackray VG, Mellon PL, Coss D. Hormones in synergy: regulation of the pituitary gonadotropin genes. *Mol Cell Endocrinol.* 2010;314:192–203.
- Timossi C, Damian-Matsumura P, Dominguez-Gonzalez A, Ulloa-Aguirre A. A less acidic human follicle-stimulating hormone preparation induces tissue-type plasminogen activator enzyme activity earlier than a predominantly acidic analogue in phenobarbital-blocked pro-oestrous rats. *Mol Hum Reprod.* 1998;4:1032–8.
- Tran S, et al. Impaired fertility and FSH synthesis in gonadotrope-specific Foxl2 knockout mice. *Mol Endocrinol.* 2013;27:407–21.
- Tremblay JJ, Marciel A, Gauthier Y, Drouin J. Ptx1 regulates SF-1 activity by an interaction that mimics the role of the ligand-binding domain. *EMBO J.* 1999;18:3431–41.
- Tsaneva-Atanasova K, Caunt CJ, Armstrong SP, Perrett RM, McArdle CA. Decoding neurohormone pulse frequency by convergent signalling modules. *Biochem Soc Trans.* 2012;40:273–8.
- Tsunasawa S, Liu W-K, Burleigh BD, Ward DN. Studies of disulfide bond location in ovine lutropin  $\beta$  subunit. *Biochim Biophys Acta.* 1977;492:340–56.

- Tsutsumi R, Mistry D, Webster NJ. Signaling responses to pulsatile gonadotropin-releasing hormone in LbetaT2 gonadotrope cells. *J Biol Chem*. 2010;285:20262–72.
- Ulloa-Aguirre A, Timossi C. Structure-function relationship of follicle-stimulating hormone and its receptor. *Hum Reprod Update*. 1998;4:260–83.
- Ulloa-Aguirre A, Timossi C. Biochemical and functional aspects of gonadotrophin-releasing hormone and gonadotrophins. *Reprod BioMed Online*. 2000;1:48–62.
- Ulloa-Aguirre A, Cravioto A, Damian-Matsumura P, Jimenez M, Zambrano E, Diaz-Sanchez V. Biological characterization of the naturally occurring analogues of intrapituitary human follicle-stimulating hormone. *Hum Reprod*. 1992;7:23–30.
- Ulloa-Aguirre A, Midgley Jr AR, Beitins IZ, Padmanbhan V. Follicle-stimulating isohormones: characterization and physiological relevance. *Endocr Rev*. 1995;16:765–87.
- Ulloa-Aguirre A, Timossi C, Damian-Matsumura P, Dias JA. Role of glycosylation in function of follicle-stimulating hormone. *Endocrine*. 1999;11:205–15.
- Ulloa-Aguirre A, Janovick JA, Brothers SP, Conn PM. Pharmacologic rescue of conformationally-defective proteins: implications for the treatment of human disease. *Traffic*. 2004;5:821–37.
- Ulloa-Aguirre A, Crepieux P, Poupon A, Maurel MC, Reiter E. Novel pathways in gonadotropin receptor signaling and biased agonism. *Rev Endocr Metab Disord*. 2011;12:259–74.
- Ulloa-Aguirre A, Zarinan T. The follitropin receptor: matching structure and function. *Mol Pharmacol*. 2016;90:596–608.
- Urban RJ, Evans WS, Rogol AD, Kaiser DL, Johnson ML, Veldhuis JD. Contemporary aspects of discrete peak-detection algorithms. I. The paradigm of the luteinizing hormone pulse signal in men. *Endocr Rev*. 1988;9:3–37.
- Urizar E, et al. Glycoprotein hormone receptors: link between receptor homodimerization and negative cooperativity. *EMBO J*. 2005;24:1954–64.
- Valdes-Socin H, et al. Hypogonadism in a patient with a mutation in the luteinizing hormone beta-subunit gene. *N Engl J Med*. 2004;351:2619–25.
- Valdes-Socin H, et al. Testicular effects of isolated luteinizing hormone deficiency and reversal by long-term human chorionic gonadotropin treatment. *J Clin Endocrinol Metab*. 2009;94:3–4.
- Valmu L, Alfthan H, Hotakainen K, Birken S, Stenman UH. Site-specific glycan analysis of human chorionic gonadotropin beta-subunit from malignancies and pregnancy by liquid chromatography – electrospray mass spectrometry. *Glycobiology*. 2006;16:1207–18.
- Valove FM, Finch C, Anasti JN, Froehlich J, Flack MR. Receptor binding and signal transduction are dissociable functions requiring different sites on follicle-stimulating hormone. *Endocrinology*. 1994;135:2657–61.
- Varki A, et al. Symbol nomenclature for graphical representation of glycans. *Glycobiology*. 2015;25:1323–4.
- Veldhuis JD, Carlson ML, Johnson ML. The pituitary gland secretes in bursts: appraising the nature of glandular secretory impulses by simultaneous multiple-parameter deconvolution of plasma hormone concentrations. *Proc Natl Acad Sci U S A*. 1987;84:7686–90.
- Veldhuis JD, Iranmanesh A, Johnson ML, Lizarralde G. Twenty-four-hour rhythms in plasma concentrations of adenohypophyseal hormones are generated by distinct amplitude and/or frequency modulation of underlying pituitary secretory bursts. *J Clin Endocrinol Metab*. 1990;71:1616–23.
- Walton WJ, Nguyen VT, Butnev VY, Singh V, Moore WT, Bousfield GR. Characterization of human follicle-stimulating hormone isoforms reveals a non-glycosylated  $\beta$ -subunit in addition to the conventional glycosylated  $\beta$ -subunit. *J Clin Endocrinol Metab*. 2001;86:3675–85.
- Wan H, et al. Chorionic gonadotropin can enhance innate immunity by stimulating macrophage function. *J Leukoc Biol*. 2007;82:926–33.
- Wang Y, et al. Extra-ovarian expression and activity of growth differentiation factor 9. *J Endocrinol*. 2009;202:419–30.
- Wang H, et al. Redirecting intracellular trafficking and the section of pattern of FSH dramatically enhances ovarian function in mice. *Proc Natl Acad Sci U S A*. 2014;111:5735–40.

- Wang H, et al. Comparative assessment of glycosylation of a recombinant human FSH and a highly purified FSH extracted from human urine. *J Proteome Res.* 2016a;15:923–32.
- Wang H, Butnev VY, Bousfield GR, Kumar TR. A human FSHB transgene encoding the double N-glycosylation mutant (Asn7 $\Delta$  Asn25 $\Delta$ ) FSHb fails to rescue Fshb null mice. *Mol Cell Endocrinol.* 2016b; xx:1–12.
- Ward DN, Moore Jr WT, Burleigh BD. Structural studies on equine chorionic gonadotropin. *J Protein Chem.* 1982;1:263–80.
- Ward DN, Glenn SD, Nahm HS, Wen T. Characterization of cleavage products in selected human lutropin preparations. *Int J Pept Protein Res.* 1986;27:70–8.
- Ward DN, Bousfield GR, Gordon WL, Sugino H. Chemistry of the peptide components of glycoprotein hormones. In: Keel BA, Grotjan HE Jr, editors. *Microheterogeneity of glycoprotein hormones.* Boca Raton: CRC Press; 1989. p. 1–21.
- Weenen C, et al. Long-acting follicle-stimulating hormone analogs containing N-linked glycosylation exhibited increased bioactivity compared with o-linked analogs in female rats. *J Clin Endocrinol Metab.* 2004;89:5204–12.
- Weiss J, Axelrod L, Whitcomb RW, Harris PE, Crowley WF, Jameson JL. Hypogonadism caused by a single amino acid substitution in the beta subunit of luteinizing hormone. *N Engl J Med.* 1992;326:179–83.
- Weisshaar G, Hiyama J, Renwick AG. Site-specific N-glycosylation of human chorionic gonadotropin – structural analysis of glycopeptides by one- and two-dimensional 1H NMR spectroscopy. *Glycobiology.* 1991a;1:393–404.
- Weisshaar G, Hiyama J, Renwick AG, Nimtz M. NMR investigations of the N-linked oligosaccharides at individual glycosylation sites of human lutropin. *Eur J Biochem.* 1991b;195:257–68.
- West CR, et al. Acidic mix of FSH isoforms are better facilitators of ovarian follicular maturation and E2 production than the less acidic. *Endocrinology.* 2002;143:107–16.
- Wide L. Median charge and charge heterogeneity of human pituitary FSH, LH and TSH. II. Relationship to sex and age. *Acta Endocrinol.* 1985a;109:190–7.
- Wide L. Median charge and charge heterogeneity of human pituitary FSH, LH and TSH. I. Zone electrophoresis in agarose suspension. *Acta Endocrinol.* 1985b;109:181–9.
- Wide L. The regulation of metabolic clearance rate of human FSH in mice by variation of the molecular structure of the hormone. *Acta Endocrinol.* 1986;112:336–44.
- Wide L, Eriksson K. Dynamic changes in glycosylation and glycan composition of serum FSH and LH during natural ovarian stimulation. *Ups J Med Sci.* 2013;118:153–64.
- Wide L, Wide M. Higher plasma disappearance rate in the mouse for pituitary follicle-stimulating hormone of young women compared to that of men and elderly women. *J Clin Endocrinol Metab.* 1984;58:426–9.
- Wide L, Naessén T, Sundström-Poromaa I, Eriksson K. Sulfonation and sialylation of gonadotropins in women during the menstrual cycle, after menopause, and with polycystic ovarian syndrome and in men. *J Clin Endocrinol Metab.* 2007;92:4410–7.
- Wildt L, et al. Frequency and amplitude of gonadotropin-releasing hormone stimulation and gonadotropin secretion in the rhesus monkey. *Endocrinology.* 1981;109:376–85.
- Wu H, Lustbader JW, Liu Y, Canfield RE, Hendrickson WA. Structure of human chorionic gonadotropin at 2.6 Å resolution from MAD analysis of the selenomethionyl protein. *Structure.* 1994;2:545–58.
- Wu Y, Luo H, Liu J, Kang D, McNeilly AS, Cui S. LIM homeodomain transcription factor Isl-1 enhances follicle stimulating hormone-beta and luteinizing hormone-beta gene expression and mediates the activation of leptin on gonadotropin synthesis. *Endocrinology.* 2010;151:4787–800.
- Wurbach E, Yuen T, Ebersole BJ, Sealson SC. Gonadotropin-releasing hormone receptor-coupled gene network organization. *J Biol Chem.* 2001;276:47195–201.
- Xing Y, et al. Alternatively folded choriogonadotropin analogs. Implications for hormone folding and biological activity. *J Biol Chem.* 2001a;276:46953–60.

- Xing Y, et al. Threading of a glycosylated protein loop through a protein hole: implications for combination of human chorionic gonadotropin subunits. *Protein Sci.* 2001b;10:226–35.
- Xing Y, et al. Glycoprotein hormone assembly in the endoplasmic reticulum: IV. Probable mechanism of subunit docking and completion of assembly. *J Biol Chem.* 2004a;279:35458–68.
- Xing Y, et al. Glycoprotein hormone assembly in the endoplasmic reticulum: II. Multiple roles of a redox sensitive beta-subunit disulfide switch. *J Biol Chem.* 2004b;279:35437–48.
- Xing Y, et al. Glycoprotein hormone assembly in the endoplasmic reticulum: I. The glycosylated end of human alpha-subunit loop 2 is threaded through a beta-subunit hole. *J Biol Chem.* 2004c;279:35426–36.
- Zambrano E, et al. Dynamics of basal and gonadotropin-releasing hormone-releasable serum follicle-stimulating hormone charge isoform distribution throughout the human menstrual cycle. *J Clin Endocrinol Metab.* 1995;80:1647–56.
- Zawel L, et al. Human Smad3 and Smad4 are sequence-specific transcription activators. *Mol Cell.* 1998;1:611–7.
- Zhang T, Roberson MS. Role of MAP kinase phosphatases in GnRH-dependent activation of MAP kinases. *J Mol Endocrinol.* 2006;36:41–50.
- Zygmunt M, et al. Characterization of human chorionic gonadotropin as a novel angiogenic factor. *J Clin Endocrinol Metab.* 2002;87:5290–6.

Livio Casarini, Ilpo T. Huhtaniemi, Manuela Simoni, and Adolfo Rivero-Müller

## Abstract

The two gonadotrophin receptors (GnRs), luteinizing hormone receptor (LHCGR) and follicle-stimulating receptor (FSHR), belong to the glycoprotein hormone receptor subgroup of type A G protein-coupled receptors (GPCRs). LHCGR binds specifically the two structurally similar gonadotrophins, luteinizing hormone (LH) and human chorionic gonadotrophin (hCG), and FSHR binds follicle-stimulating hormone (FSH). The receptors reside on plasma membrane and transmit the gonadotrophin signal to target cells using the classical Gs/adenylyl cyclase/cyclic AMP/protein kinase A signaling cascade. Other signaling pathways (e.g., inositol phosphate, calcium) are activated at pharmacological hormone concentrations or at high receptor density. LHCGR is expressed in testicular Leydig cells and in ovarian theca, luteinizing granulosa and luteal cells. FSHR is expressed in testicular Sertoli cells and ovarian granulosa cells. LHCGR activation stimulated Leydig cell steroidogenesis, in particular testosterone production, while FSHR maintains Sertoli cell metabolism, thereby indirectly stimulating spermatogenesis. Recent basic research, using GnR, expressing cells in vitro and genetically modified mice in vivo, has elucidated novel aspects of the molecular mechanisms of gonadotrophin receptor function. The crystal structure of GnRs has also been partly resolved. Numerous inactivating and activating GnR mutations that have been discovered in patients have unraveled the molecular basis of hypogonadism and other aberrations of reproductive

---

L. Casarini • M. Simoni

Unit of Endocrinology, Department of Biomedical, Metabolic and Neural Sciences, University of Modena and Reggio Emilia, Modena, Italy

e-mail: [livio.casarini@unimore.it](mailto:livio.casarini@unimore.it); [manuela.simoni@unimore.it](mailto:manuela.simoni@unimore.it)

I.T. Huhtaniemi

Faculty of Medicine, Department of Surgery and Cancer, Imperial College London, London, UK

e-mail: [ilpo.huhtaniemi@imperial.ac.uk](mailto:ilpo.huhtaniemi@imperial.ac.uk)

A. Rivero-Müller (✉)

Department of Physiology, Institute of Biomedicine, University of Turku, Turku, Finland

endocrine functions. The purpose of this chapter is to review the recent trends of GnR research and how it has elucidated the molecular mechanisms of GnR function and the role of GnR in human reproductive physiology and pathophysiology.

---

### Keywords

FSH • Gonadotrophins • hCG • LH • Polymorphism

## Contents

Introduction .....	124
The GPCR Superfamily (Evolution and Structure) .....	124
GnR Functions: Evolutionary, Physiological, Ligand-Dependent, Extragonadal .....	128
Structure of the Human FSHR and LHCGR Genes and Proteins .....	131
Ligand-Receptor Binding (and Relationship with Structures) .....	132
Ligand-Specific Signal Transduction (and Surface Expression) .....	136
Post-Endocytotic Trafficking and Signaling .....	138
Receptor Di/Oligomerization: <i>Cis/Trans</i> activation .....	140
Gonadotrophin Receptor Mutations and Polymorphisms .....	142
Common Single-Nucleotide Polymorphisms .....	142
Receptor Mutations .....	145
Clinical Studies and In Vitro Analyses to Study Receptor Activity and Function .....	147
Transgenic Models for Receptor Functional Studies .....	150
Conclusive Remarks .....	153
References .....	154

---

## Introduction

Gonadotrophins are glycoprotein hormones produced by the anterior pituitary gland and placental trophoblast cells regulating the development and mature reproductive functions in mammals. They act through specific receptors almost exclusively located in the gonads and sharing high sequence similarity, suggesting that they originated from a common ancestor gene. The similarities occurring among the genes are reflected in the molecular structures of the cognate receptor proteins, resulting in conserved functioning which relies on G proteins as their main intracellular signal transduction mediators. However, evolutionary divergences do exist, especially in primates, where species-specific receptor isoforms and additional ligands exist allowing further endocrine adaptation upon reproduction and pregnancy. Recent advancements in the structure-function relationships of gonadotrophin receptor mutations in patients and genetically modified animal models have greatly advanced our knowledge about the function upon normal reproduction and its disturbances.

---

## The GPCR Superfamily (Evolution and Structure)

There are two gonadotrophin receptors (GnRs) in vertebrates: the luteinizing hormone (LH)/chorionic gonadotrophin (CG) receptor (LHCGR) and the follicle-stimulating hormone (FSH) receptor (FSHR). As their names indicate, they are the



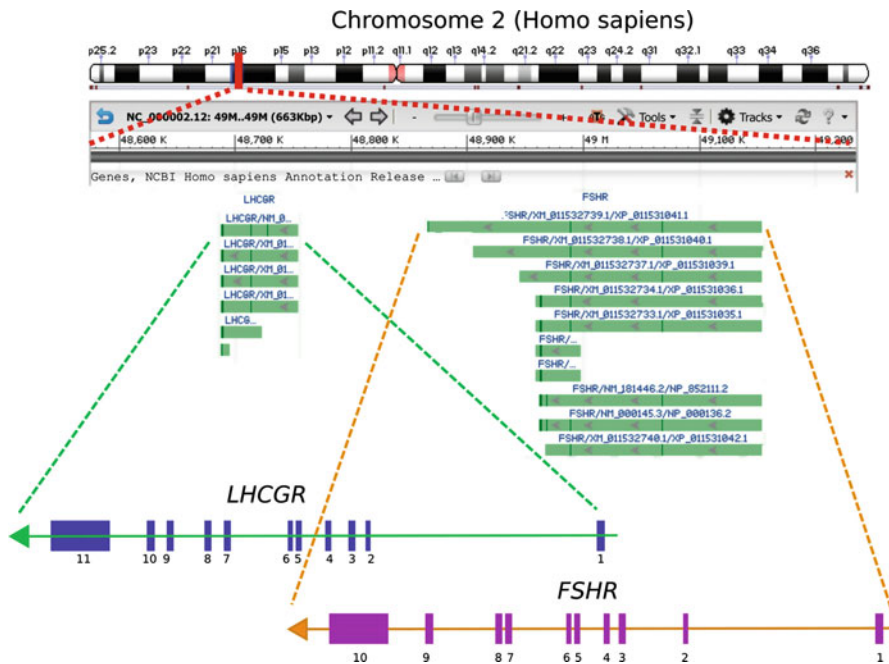
receptors for hormones that stimulate the gonads. The GnRs are G protein-coupled receptors (GPCRs) of the class A subfamily. All GPCR members, around 800 in humans, have a distinctive 7 serpentine-transmembrane domain (TMD). Their *N*-termini are exposed to the extracellular environment, and the *C*-termini are located intracellularly. Yet, the GnRs are characterized by a large extracellular domain (ECD) (see below), and their ligands are large pituitary (or placental) glycoproteins (see previous chapter).

The FSHR and LHCGR do not only look alike on the *outside*, but they are highly similar at the structural, molecular, genetic, and genomic levels. This, together with the similarity and, in some cases, promiscuity of their ligands, suggests that these two receptor genes resulted from a gene duplication during evolution. Indeed, in support of this, the *LHCGR* and the *FSHR* genes reside next to each other in most annotated tetrapod genomes (George et al. 2011; Heckert et al. 1992), their hormones share a common subunit (common glycoprotein alpha, CGA), and their specific subunits have high similarity (LH-FSH 41% identical).

Additionally, in humans, both receptor genes are located on the short arm of chromosome 2 as a single copy and separate by some 200 kb. Structurally the genomic sequences are also similar; these two receptor genes have a series of short exons (nine for *FSHR* and ten for *LHCGR*) encoding the ECDs, followed by the last (10th or 11th, respectively) large exon which encodes the 7-transmembrane and intracellular domains (Fig. 1).

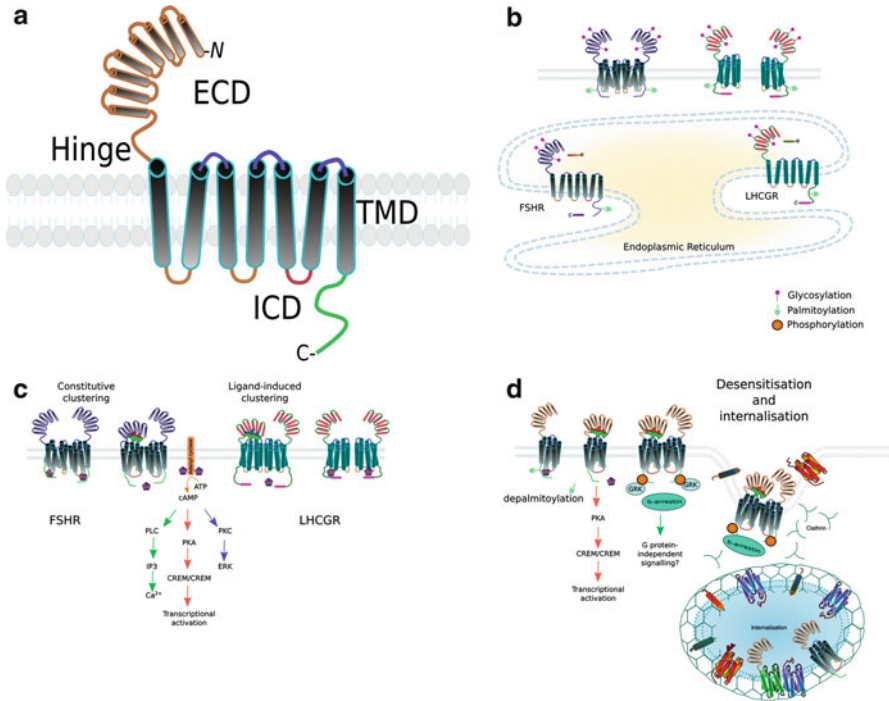
At the protein level, both LHCGR and FSHR have large extracellular *N*-termini which are responsible for ligand binding and are composed of repeats of leucine-rich regions (LRRs). These large extracellular domains are followed by a “hinge” sequence that seems to be partially responsible for changes in the transmembrane region before and during activation (Agrawal and Dighe 2009; Jiang et al. 2012). As all GPCRs, these two receptors have a 7 serpentine-transmembrane structure that is organized as a barrel (see for more detailed information) (Fig. 2a). While both receptors have an intracellular *C*-terminus, the mature LHCGR retains its entire coded sequence, while FSHR undergoes a proteolytic step where the *C*-terminus is partially chopped off (see the posttranscriptional modifications section and Fig. 2b).

As one would expect if a gene became duplicated, these receptors can be promiscuous to their hormones, and they are more promiscuous in fish and much less promiscuous in mammals or birds which suggest an evolution of function. Moreover, while the extracellular domains (ECDs) of these receptors have only 46% identity, the transmembrane domains (TMDs) still share 72% identity (Costagliola et al. 2005), which suggests the hormone binding region, at the ECD, is the region that must evolve to selectiveness to distinct ligand, while the TMDs only need to accommodate the ECD/ligand heterodimer complex for activation, where one large CGA subunit is the same in both hormones. Moreover, some LHCGR and FSHR mutants become more promiscuous to the wrong ligand, and activating mutations of either receptor can occur at the corresponding amino acids (see below). To add to this, two LHCGR ligands have evolved (LH and hCG) in higher primates, including humans, which is a subject of a previous chapter in this book (chapter 3). Yet, in equids, the family of horses, donkeys, and zebras, the *LHB* gene is extraordinarily expressed in the chorion where it is differentially



**Fig. 1** Localization and structure of the *LHCGR* and *FSHR* genes. Both genes are localized in the short arm of chromosome 2 in humans. Both GnRs are coded in the same direction; in the image they are coded from *right to left*. While *FSHR* is coded in 10 exons (purple boxes), the *LHCGR* is coded in 11 (blue boxes). In both cases, all exons but last are short and code for the extracellular domain and part of the hinge. The last large exon codes for the rest of the hinge, TMD, and intracellular domains. Alternative transcripts are depicted in the image as green lines, whereas dark green areas represent exons (in many cases so thin that cannot be seen). The image has been based from the genomic region at NCBI database

glycosylated. This *chorionic LH* is often referred to as pregnant mare serum gonadotropin (PMSG) or as equine chorionic gonadotrophin (eCG) although it has no evolutionary relationship with that of primates. What makes PMSG most interesting is that it can activate both the *LHCGR* and *FSHR* in most mammals (Guillou and Combarrous 1983; Stewart and Allen 1981), except for the equids where only LH receptor is activated, in a similar fashion as CG activates *LHCGR* in primates during pregnancy (Stewart and Allen 1979). The diversity of *LHCGR* variants and the peculiarity of their interaction with lineage-specific molecules, such as LH and CG, triggered the proposal of a new nomenclature to replace that previously existing, which used the term “*LHCGR*” to define all the LH receptors (Troppmann et al. 2013). Given the existence of CG molecules only in primates (except equids), “*LHCGR* type 1” should indicate the receptor of primates, while “*Lhr*” should be used for the LH receptor of other mammals. “*LHCGR* type 2” is the receptor of new world monkeys, as primates lacking exon 10 of the receptor gene (see below).



**Fig. 2** Structure, biosynthesis, signaling, and regulation of GnRs. A representation of the general structure of gonadotrophin receptors (**a**) showing the extracellular domain (ECD), hinge, 7-transmembrane domain (TMD), and intracellular domain (ICD). (**b**) Post-transcriptional modifications (PTMs) of the GnRs during biosynthesis. Both receptors are glycosylated on the ECD and palmitoylated at the ICD. The FSHR forms clusters during biosynthesis, and its C-terminal is cleaved, while the LHCGR does not. (**c**) Both GnRs transduce intracellular signaling upon ligand activation via  $G_{\alpha s}$  protein. The release of  $G_{\alpha s}$  triggers the production of cAMP from ATP by adenylyl cyclase, which in turn activates a series of downstream responses and the activation of different signaling pathways (PKA, PLC, PKC) which results in cellular and metabolic changes. No PTMs are depicted in (**c**) for clarity. The FSHR forms constitutive clusters, while the LHCGR forms dimer/multimers in response to ligand binding. (**d**) After activation the GnRs are desensitized first by phosphorylation, likely by GRKs, and then depalmitoylated. Phosphorylation induced the binding to arrestins ( $\beta$ -arrestin) which might trigger other intracellular responses unrelated to G protein signaling and then the receptors internalized in clathrin-coated vesicles together with other receptors as well as other membrane proteins. The receptors are then either recycled to the membrane or become ubiquitinated and degraded by the proteasome (not shown)

The reason for the need of two ligands for LHCGR in primates and equine is not clear at the moment. Many studies have shown that although both LH and CG activate the LHCGR, they do so with a different duration and strength. Moreover, there are fine-tuned signaling differences between the two ligands (Casarini et al. 2012). Nevertheless, the lack of LH can be clinically (pharmacologically) compensated for by hCG in patients lacking the former – and theoretically the reciprocal is

possible although there is no report of the lack of hCG in a single patient – probably due to its crucial role in pregnancy maintenance and due to the multiple copies of the *CGB* gene in the genome. Indeed, in primates CG plays a central role in placentation and stimulation of testosterone production by the fetal testes, a function that can be bypassed in rodents by promiscuous stimulation of fetal Leydig cells by a number of non-gonadotrophic hormones (see the animal model section below). There are even cases of LHCGR mutants where the resulting receptor does not respond to LH but is responsive to hCG (see “receptor mutants” below).

More evidence has been produced by a patient suffering from a homozygous deletion of exon 10 of *LHCGR*. The resulting receptor turned out to be responsive to hCG but not to LH (Gromoll et al. 2000). This suggests that hCG and LH act slightly differently on the LHCGR although their responses have been thought to be equal, except for the duration of the stimulation which is longer by hCG than LH, likely as an effect of higher hCG binding affinity due to low dissociation rate (Huhtaniemi and Catt 1981). Interestingly, in New World monkeys, the pituitary LH synthesis is inactivated, and its role has been overtaken by CG, which acts both as a reproductive and a pregnancy hormone in this primate species (Müller et al. 2004). Accordingly, their *LHCGR* mRNA lacks the coding sequence exon 10, which is totally spliced off the transcript, although at the genomic level, at least part of exon 10 is present (Zhang et al. 1997). In these primates, *LHB* gene is not transcribed, and instead *CG beta* (*CGB*) gene is de novo secreted by the pituitary as well as by placenta thus taking a dual role similar to that of LH in other mammals (Müller et al. 2004).

All this together, points to duplication of the pre-*LHCGR/FSHR* with later acquisition and separation of function for each receptor and their ligands. Especially, receptor-specific functions may have driven the gonadotrophin dependence of gametogenesis, which is primarily supported by either LH or FSH – depending on the species (Huhtaniemi 2015). The functions of these receptors will be detailed in the next sections.

---

## **GnR Functions: Evolutionary, Physiological, Ligand-Dependent, Extragonadal**

As mentioned above the main role of the GnRs is the induction of sexual differentiation in utero, acquisition of the mature male and female phenotype at puberty, and the maintenance of sex hormone production, spermatogenesis, and ovulation. Moreover, these receptors are expressed in several tissues other than gonads. The physiological, or pathophysiological, functions of the extragonadal GnRs remain a matter of debate. As it will be presented below, in some cases the expression of these receptors may participate in function of the pituitary-gonadal axis, while in some species, they clearly have functions unrelated to reproduction yet connected to sexual dimorphism and behavior.

The expression of GnRs is tightly regulated at the transcriptional and posttranscriptional levels. The former is partially self-regulated by a feedback loop (see below), the latter will be described in the next section.

The *FSHR* promoter is regulated by transcription factors (TFs) such as the steroidogenic factor 1 (SF1, aka NR5A1), SMAD3, E2f, USF1, USF2, POU2F1, and GATA factors, the latter recognizing an enhancer in the large intron 1. Activation of the *FSHR* by FSH results in the expression of ID2 which, in turn, reduces the binding of TFs, USF1, and 2, to its promoter resulting in decreased *FSHR* expression. Despite two decades of studies, many of the regulatory factors of *FSHR* expression are still unknown, in particular the distal regulatory sequences/elements since transgenic mice carrying yeast artificial chromosomes (YACs) encoding the *FSHR* gene flanked by over 50 Kb of promoter, and 30 Kb of 3' sequences were not expressed in Sertoli cells as would have been expected [reviewed in (George et al. 2011)].

Unlike *FSHR*, the *LHCGR* promoter is better understood. The minimal *LHCGR* promoter is about 175 nucleotides long (–175 nucleotides), and within it there are binding sites for Sp1 and Sp3 transactivators, complemented by histone deacetylase complexes (HDACs) that induce transcriptional activation. Upstream of this region, there is an almost 2,000 nucleotide-inhibitory region (–176/–2,056 nts) that regulates the transcription of the *LHCGR* gene. In rodents this region completely inhibits expression of the gene, while in humans it only reduces the overall expression (Zhang and Dufau 2003). This has been further proven in animal models where *beta-galactosidase* ( $\beta$ Gal, *LacZ*) was placed under different lengths of the promoter (175 bp, 2.1 Kb, and 7.4 Kb, respectively). The expression of the reporter gene in Leydig and granulosa cells was inversely correlated to the length of the promoter (Hamalainen et al. 2001).

*LHCGR* and *FSHR* expression thwart each other, which means that cells expressing one receptor rarely express the other. As often in biology, there is at least one exception: preovulatory granulosa cells, where both receptors are co-expressed and play important physiological roles. In granulosa cells, the highest expression of *LHCGR* is in preovulatory follicles just before ovulation, which is in line with FSH stimulation of the *LHCGR* gene transcription, which is accompanied by expression of the *aromatase* gene (*CYP19A1*), at the highest peak of estradiol and progesterone production (Jeppesen et al. 2012). FSH is known to induce *CYP19A1* expression (Garverick et al. 2002) which is tentatively how in granulosa cells the *LHCGR* is transcribed at the right time.

The GnRs have long been considered specific for gonadal somatic cells. However, there is a physiological and physical problem posing the question of how can the large peptide hormones in plasma reach these receptors on the membrane of cells that are not in direct contact with the bloodstream. Indeed, LH or FSH, both secreted by the pituitary, are not able to cross the vascular endothelial barrier to find their target receptors on the membrane of Leydig (LC), Sertoli (SC), granulosa, theca, and luteal cells. The answer to this question involves the GnRs themselves. Endothelial cells around the target tissues, as well as in the periphery of tumors (see “extra-gonadal actions”), express GnRs that serve not as ordinary extracellular signaling antennas but as highly specialized transporters of glycoprotein hormones from the blood-face of the endothelial cell to the interstitial or intertubular regions where the hormones are then released to bind another receptor on the *target* cells (LC, SC, granulosa, or theca) (Ghinea et al. 1994; Vu Hai et al. 2004).

This suggests that the GnRs are not solely expressed in gonadal somatic cells but also have other, sometimes unknown and unexpected, functions. GnRs are normally found in the uterus, placenta, brain, endothelial cells, and adrenals at very low expression levels (human protein atlas: <http://www.proteinatlas.org/ENSG00000138039-LHCGR/tissue>). At least in some cases, we have clues of what these receptors do in these tissues: in South African clawed frogs, for example, the LHCGR expression in the brain seems to be a functional male-driven factor of male behavior (Yang et al. 2007). Likewise, expression of the LHCGR in rat brain has also been reported (Apaja et al. 2004). The physiological function of extragonadal LHGCR remains open largely due to lack of conclusive evidence from animal models and clinical cases (Pakarainen et al. 2007) (see below).

In patients a subclass of adrenal tumors shows ectopic expression of LHCGR, usually after chronically elevated gonadotrophin levels, e.g., after gonadectomy or menopause, which results in LH-/hCG-dependent adrenal hyperplasia. This suggests that the low constitutive expression of LHCGR in adrenals increases after chronic stimulation and due to autocrine factors such as Wnt signaling (Teo et al. 2015), and/or the LHCGR-positive cells proliferate under high gonadotrophin stimulation to become the main cell type in the hyperplastic tissue. An additional mechanism could well be the lack of gonadal factors such as inhibin or activin that normally work as repressors of gonadotrophin action. Also cases of pregnancy-associated adrenal hyperplasia have been described, where the hCG is the stimulus causing the adrenal overgrowth (Monticone et al. 2012). Ectopic expression of several GPCRs is a phenomenon whose mechanism and significance are still poorly understood.

Moreover, the FSHR has been found in the perivascular endothelium of several tumor types (Radu et al. 2010), although its function, if any, has not been discovered. One could suggest that if FSHR is expressed in tumor cells, and there is some evidence for breast and prostate cancer cells (Hong et al. 2015), then in order to be activated by FSH, the expression of the FSHR is essential around tumor vasculature. An interesting question with therapeutic potential would be whether blockage of FSHR would suppress growth of such tumors. More important, however, would be to understand how this process is regulated at molecular level as implanted human tumors into mice also result in such perivascular expression of FSHR, where normal mouse vasculature, indirectly related to the tumor, responds to tumor growth and probably hypoxia (Radu et al. 2010).

The LHCGR has been found in the uterus in several species (Agrawal et al. 2012; Ziecik et al. 1992), including humans (Bukovsky et al. 2003), as well as in the placenta (Minegishi et al. 1997), where it has been suggested to receptor play an essential role in placentation and/or maintenance of pregnancy. This hypothesis been recently been challenged by a case of a woman suffering from primary infertility who successfully underwent full-term pregnancy with a donor oocyte. She was later found to be a composite heterozygote where both *LHCGR* alleles had inactivating *LHCGR* mutations (Mitri et al. 2014). Nevertheless, the presence of wild-type (WT) LHCGR in the donor embryo and thus in the placenta in addition to maternal hCG was sufficient to maintain pregnancy and embryo development.

## Structure of the Human FSHR and LHCGR Genes and Proteins

As mentioned above, the GnRs are likely derived from a common ancestor gene, and thus they share similar amino acid coding sequences and protein structures (Ascoli et al. 2002; Simoni et al. 1997). The first isolation of an *FSHR* cDNA was obtained using a rat Sertoli cell cDNA library, as a specific target cells of FSH action, by cDNA probes of the LH receptor (Sprengel et al. 1990). The molecular cloning of the human receptor was performed in the year 1990, and an overall 89% sequence identity to the rat receptor was found (Minegishi et al. 1991). The human FSHR was characterized as a molecule structurally similar to other GPCRs, featured by a 359 amino acid extracellular domain containing four *N*-linked glycosylation sites and seven highly conserved transmembrane regions. The functional characterization of the receptor was done in transfected human embryonic kidney (HEK) cells by FSH dose-response experiments, demonstrating hormone-dependent intracellular cAMP increase.

The *FSHR* gene promoter was identified within about 2,000 bp upstream to the transcriptional starting site and is characterized by core cAMP regulatory elements with basal activity in the absence of hormone. In contrast to the *LHCGR*, the *FSHR* gene promoter has no CG-islands. The FSHR protein consists of 695 amino acids resulting in a molecular mass of about 76 KDa. The ECD is fundamental for ligand binding; it spans 349 amino acids enclosing a 12 LRR region forming the hydrophobic core, similar to that of the LHCGR and TSHR. The ECD is connected to the transmembrane domains by a hinge region. The LRRs are structured in alternating  $\alpha$ -helices and parallel  $\beta$ -sheets involved in strong protein-protein interactions (Kobe and Deisenhofer 1993), with the highest binding specificity probably localized between repeats 5 and 10, while the hinge region is essential for the transmission of conformational changes to the TMD upon hormone binding, as well as ligand recognition. Several cysteine residues are located at the ECD, of which eight are conserved in the LHCGR and TSHR likely to preserve the complex conformational structure of the glycoprotein hormone receptors. Moreover, three of the four phylogenetically conserved sites for *N*-linked glycosylation fall at positions 191, 199, and 293, as essential requirement for protein folding and receptor trafficking to the membrane.

The 7-transmembrane  $\alpha$ -helices span 20–25 amino acids, hydrophobic stretches connected by intra- and extracellular loops to follow the typical structure of the GPCRs. Several cytoplasmic interactors coupling to multiple domains contact the intracellular loops and the *C*-terminus of the receptor, contributing to modulate intracellular signaling cascades (Jiang et al. 2014a). Especially, the second intracellular loop is fundamental in maintaining the receptor in an inactive conformation and for  $G\alpha s$  protein coupling (Timossi et al. 2002) and subsequent intracellular cAMP increase, as major modulator of steroidogenesis.

The first purification of a target cDNA of *LHCGR* occurred in 1989 (Ascoli and Segaloff 1989; McFarland et al. 1989). Using an affinity chromatography and PCR approach, the rat LH receptor (*Lhr*) was cloned from an ovarian cDNA library and inserted in a cell system engineered to induce its expression. The receptor showed high binding affinity for hCG and increased intracellular cAMP upon exposure to

hormone. The cloning of the human LH/CG receptor occurred the subsequent year, demonstrating an overall 85–87% sequence identity with the previously cloned rat and porcine receptors and a 335 amino acid extracellular domain featured by six *N*-linked glycosylation sites (Minegishi et al. 1990). The transcriptional regulatory elements Sp1 and Sp3 binding sites were identified about 200 bp upstream the transcription start triplet, while an inhibitory region at about 2,000 bp upstream (Geng et al. 1999; Huhtaniemi et al. 1992). The human *LHCGR* gene is characterized by 11 exons and 10 introns spanning a total genomic region of about 70 Kb at position 2p21 (Ascoli et al. 2002). Exons 1–10 encode for the ECD and the *N*-terminal portion of the hinge region, while the TMD and the *C*-terminus tail arise from exon 11. Especially, exon 10 is unique in *LHCGR*, in spite of overall similarity among the glycoprotein hormone receptor genes, and confers high binding affinity for LH rather than CG (Zhang et al. 1997). The amino acid sequence encoded by exon 10 falls to the hinge region, between the LRR and the TMD domains, and is crucial for the LH-, but not the CG-induced signaling (Grzesik et al. 2015). Curiously, exon 10 is spliced out of the mature mRNA in the New World monkey lineage (Platyrrhini), who use pituitary CG as a single multitasking hormone (Gromoll et al. 2003).

Moreover, a cryptic exon localized between exons 6 and 7, named 6A, has been identified in primates and produces transcripts triggering *nonsense-mediated mRNA decay* (NMD) (Kossack et al. 2008). Mutations in exon 6A may be associated to Leydig cell hypoplasia in men, revealing the importance of these transcript variants despite overall unknown physiological functions. The *LHCGR* TMD encompasses the classical structure of the rhodopsin-like GPCRs and conserves two sites of palmitoylation and phosphorylation at the *C*-terminus tail, which are involved in internalization of the receptor (Kawate and Menon 1994) (see below). The intracellular domain of *LHCGR* overlaps, in large part, with the *FSHR* molecular structure, resulting in similar intracellular signaling, although each receptor also generates specific second messengers, and results in differential gene expression and steroid synthesis (Lee et al. 2002b).

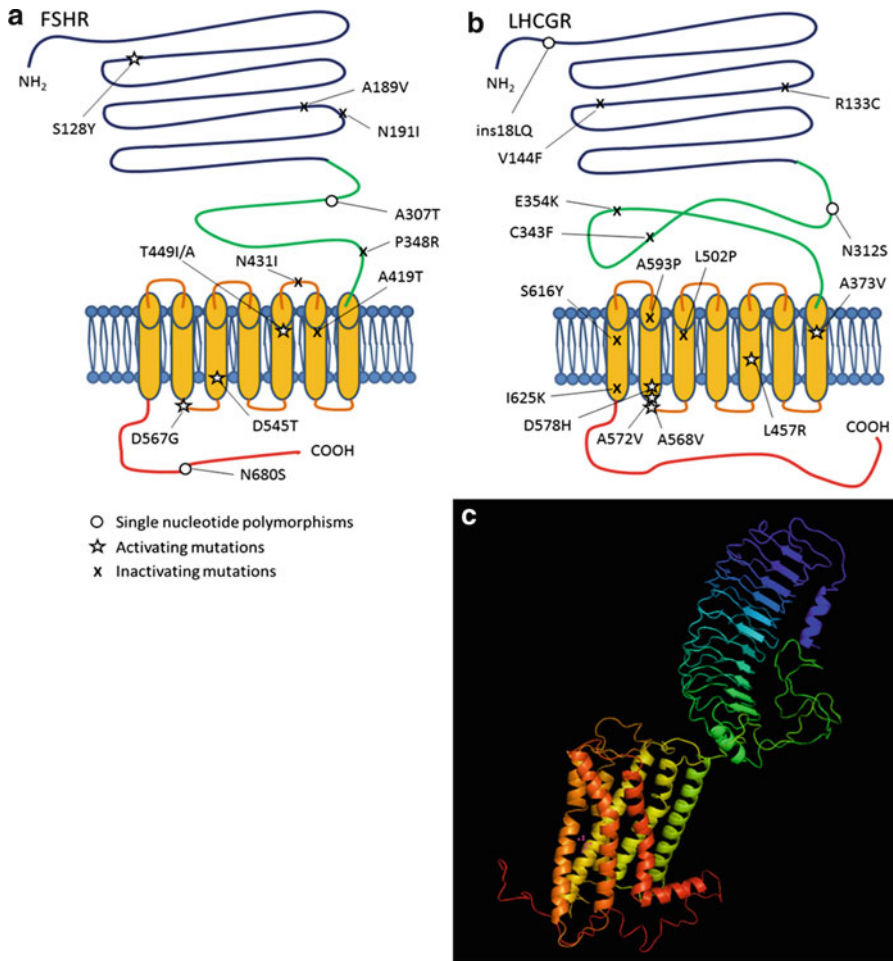
---

## Ligand-Receptor Binding (and Relationship with Structures)

The first step toward the comprehension of the molecular features and functioning of GPCRs consisted of characterization of the tridimensional structure of rhodopsin by crystallography (Palczewski et al. 2000). Due to high structural similarity among the GPCRs, the rhodopsin structure served as template for modeling *FSHR* (Fig. 3) and *LHCGR* structures and allowed to derive parallels to other receptors from the same superfamily. This discovery was a milestone in understanding the biophysical properties and mechanisms of signal transduction of other GPCRs and was followed by crystallographic structures of the active conformation of several other GPCRs as ligand-receptor complexes.

The structures of FSH bound to the ECD of *FSHR* and to the entire ECD were finally determined in the years 2005 (Fan and Hendrickson 2005) and 2012 (Jiang





**Fig. 3** Mutations and polymorphisms in the FSHR and LHCGR proteins. **(a)** Representative image of the FSHR protein chain indicating the position of the most common SNPs and mutations. Legend: *blue* = ligand-specific LRRs domain, *green* = hinge region, *orange* = intra- and extracellular loops and 7-TMD domains, *red* = C-terminal region. **(b)** LHCGR protein chain. **(c)** Modeling of the FSHR inferred by the rhodopsin receptor using the online database SwissModel (<http://swissmodel.expasy.org>) and visually represented by the PyMOL software (<https://www.pymol.org>). The three-dimensional structure of this receptor is similar to that of the other GPCRs, such as LHCGR and TSHR. Legend: *blue/light blue* = ligand-specific LRRs domain, *green* = hinge region, *yellow/orange* = intra- and extracellular loops and 7-TMD domains, *red* = C-terminal region

et al. 2012), respectively, providing new insights into GnR functioning. The ligand specificity of FSHR is mainly determined by residues at positions 55, 76, 101, 179, and 222, which join noncovalently to the hormone. Especially, the residues at positions 55 and 179 interact with the discriminating “seat-belt” region of FSH $\beta$ ,

distinguishing the binding to FSH *versus* LH/hCG, while those at positions 76, 101, and 222 establish the selectivity of the receptor for the natural ligand against TSH. As expected, the common, *nonspecific*  $\alpha$  subunit (CGA) of the gonadotrophins plays a role in hormone binding and signal transduction. Since the CGA is common for all the glycoprotein hormones, one could assume that key contact residues are conserved within the receptor ECDs. Indeed, nine amino acid residues falling in  $\beta$ -strands 2, 4, and 5 of FSHR, highly conserved in LHCGR and TSHR, are the main contact sites for CGA. However, mutagenesis of six of these residues (Lys74, Tyr124, Asn129, Thr130, Asp150, Asp153) did not affect FSH binding but still resulted in a significant decrease of cAMP production (Angelova et al. 2010) revealing the role of CGA in cell signaling activation. Moreover, the extracellular loops 1 and 3 may serve as secondary binding sites for CGA (Dupakuntla and Mahale 2010).

Although some data suggest that GPCRs may exist in several, functionally distinct conformations, the classical biophysical view indicates a two-state mechanism of receptor inactivation and activation. The inactive state is stably maintained by *N*- and *C*-terminal cysteine-rich regions until hormone binding to the receptor ECD, which triggers a conformational change resulting in G protein activation at the intracellular level. The inner concave area of LRRs 1–8 is involved in the initial FSH recruitment through high-affinity interaction, resulting in the LRR 2  $\beta$ -sheet folding and exposure of a further hydrophobic interaction site to the hormone (Jiang et al. 2012). The hinge region is a key player of the receptor conformational change. It is a structurally integral part of the ECD, participating in hormone binding, likely via a sulfated tyrosine residue as an additional interaction site, and contributing to stabilization of the active state of the receptor. This tyrosine residue is highly conserved among the glycoprotein hormone receptors, and it is fundamental for their function (Costagliola et al. 2002). Thereafter follows signal transmission of the ligand-receptor complex to the TMD through mechanisms involving the extracellular loops. Extracellular loop 2 of the TMD in particular is crucial for the ligand-mediated signaling and FSHR internalization (Dupakuntla et al. 2012), as well as to discriminate between LH and hCG binding to LHCGR (Grzesik et al. 2015).

Since the specificity for the ligand binding is determined by a few key amino acid residues within the  $\beta$ -strands of the glycoprotein hormone receptors, mutated residues at the fifth and seventh LRRs of the FSHR and TSHR result in relaxed sensitivity toward hCG and loss of sensitivity for their natural ligands (Smits et al. 2003a). However, naturally occurring cross interactions between glycoprotein hormones and their receptors have been described. Firstly, the case of LH and hCG, both acting on the same receptor, depicts an interesting example of versatility of the GPCRs and supports the historical inaccurate concept that the two hormones are equivalent despite molecular, physiological, and evolutionary issues (Choi and Smitz 2014; Grzesik et al. 2014). Some experimental evidence suggested that hCG may have higher binding affinity and lower dissociation rate constant than LH for the rat receptor (Huhtaniemi and Catt 1981), although this point should be revisited using new experimental techniques. However, the hormone-specific interaction sites of LHCGR have been identified, supporting the fact that LH and hCG activate

the intracellular signaling cascades *in vitro* differently despite binding to the same receptor (Casarini et al. 2012). This observation reflects the different physiological roles of LH and hCG, which regulate sex steroid production and gametogenesis during the fertile age of males and females and support the pregnancy, respectively. The production of hCG progressively increases during the first trimester of pregnancy, inducing a dramatic drop of the serum TSH levels and subsequent rise of the thyroid hormones T3 and T4, and occasional transient hyperthyroidism, as a result of the TSH-like activity of choriogonadotrophin on TSHR. Both TSHR and FSHR are cross activated *in vitro* by high hCG concentrations, which mimics the natural ligand of the receptors (Schubert et al. 2003).

Several groups have focused on the hCG glycosylation isoforms as an interesting model of ligand-receptor cross interaction. It was hypothesized that hyperglycosylated hCG isoforms produced by trophoblast cells during the first 2 weeks of pregnancy may exert angiogenic actions by acting through the transforming growth factor  $\beta$  receptor type II (TGF $\beta$ RII), rather than LHCGR (Cole 2012). Since TGF $\beta$ RII does not belong to the superfamily of GPCRs and is structurally different to LHCGR, a high rate of glycosylation should confer a severe shift of the biochemical properties of the ligand and radically change their binding affinity. Although further experimental evidence is required to confirm this issue, it is indicative of the growing interest toward the role of glycosylation on receptor binding, which has been studied for long time (Butnev et al. 1996). As mentioned above, the existence of eCG which is able to activate both LHCGR and FSHR in other mammals provides another example of the potential promiscuity of the GnRs for their ligands. The binding affinity of the equine CG depends on the rate of *O*-linked oligosaccharides, which negatively impact on receptor binding. Similar observations arose using differently glycosylated FSH isoforms, which induced intracellular cAMP increase and steroid synthesis *in vitro* in an inverse, glycosylation-dependent manner (Jiang et al. 2015). Radioligand assays revealed that hypo-glycosylated FSH has greater activity *in vitro* than fully glycosylated FSH, due to the higher availability of binding sites, even resulting in more rapid receptor binding (Bousfield et al. 2014).

Increasing interest exists in allosteric modulators of the glycoprotein hormone receptors. They are molecules with low molecular weight capable to modulate the specific gonadotrophin-mediated signaling by selective interaction with the receptors at sites distinct from that of the natural agonist. In human granulosa cells, which naturally express FSHR, allosteric modulators may amplify the FSH-induced intracellular cAMP response and steroid synthesis, but not other signaling pathways simultaneously activated by the receptor (van Koppen et al. 2013), resulting in unbalanced (biased) signal transduction. Due to their interference with the hormone system, several allosteric compounds are also known to be endocrine disruptors, but they could be used in clinical practice for hormone replacement. An example of how allosteric modulators may modify the cell response to gonadotrophin has been recently provided *in vitro* (Munier et al. 2016). In FSHR-transfected CHO cells, the endocrine disruptor p,p'-DDT amplified the maximal cAMP response to FSH treatment and increase the FSHR sensitivity to hCG by interacting with the TMD.

Interestingly, the action of this endocrine disruptor is receptor specific, since it did not interfere with LHCGR activity.

---

## Ligand-Specific Signal Transduction (and Surface Expression)

FSHR and LHCGR activate multiple signaling pathways simultaneously. Translated receptors are anchored within the cell membrane, as a rate-limiting step for hormone functions, by specific signal peptides located at the *N*-terminal portion (Fig. 2b) and identified within the first 17 and 24 amino acid residues of FSHR and LHCGR, respectively. Receptors at the cell membrane are activated upon ligand binding, and several intracytoplasmic interactors mediate the gonadotrophin-specific signaling (Gloaguen et al. 2011). Overall, FSHR and LHCGR retain a huge potential to regulate greatly different, sometimes opposite physiologic effects, and the gonadotrophin-mediated signaling may be summarized as focused in steroid synthesis and cell growth, closely connected by complex intracellular cross talks. Therefore, the proliferative response to gonadotrophins characterizing the gametogenesis is the net result of a balance between life and death signals arising simultaneously.

The classical knowledge provides that G proteins are primarily involved in FSHR and LHCGR signal transduction as heterotrimeric complexes coupled to the receptors. These proteins consist the stable  $\beta$ - $\gamma$  dimeric complex and an  $\alpha$  subunit, existing in several isoforms. G proteins are activated in response to a conformational change of the FSHR or LHCGR at the TMD, inducing the replacement of the intracellularly bound guanosine diphosphate (GDP) with a guanosine triphosphate (GTP). It leads to the dissociation of the GTP/G $\alpha$  from the negative regulator  $\beta$ - $\gamma$  complex and subsequent activation of different signaling cascades (Ulloa-Aguirre et al. 2013). Among the different classes of G $\alpha$  proteins, the G $\alpha$ s is best known and classically the most studied because of its relationship with the gonadotrophin and other hormones signaling through cAMP. The G $\alpha$ s protein action is exerted through direct activation of the membrane-associated enzyme adenylyl cyclase, which, in turn, catalyzes the conversion of ATP to the second messenger cAMP and pyrophosphate. The increase in intracellular cAMP is rapid, within 2–5 min, and mediates various events, such as the activation of protein kinase A (PKA) and the exchange protein directly activated by cAMP (EPAC). cAMP production is counterbalanced by the activity of phosphodiesterases (PDEs) catalyzing the conversion of cAMP to AMP. Interestingly, the FSHR-mediated intracellular cAMP increase is biphasic and featured by a first rapid cAMP response and a second wave occurring after several hours from ligand binding, while that specific LHCGR-mediated is a unique, large stimulation followed by cAMP downregulation (Conti 2002).

Since PKA has a wide range of targets, such as the stress-related P38 mitogen-activated protein kinases (p38 MAPK), the activation of this kinase is a key step of the gonadotrophin signal transduction. Especially, the activation of the GTPase ras and the subsequent mitogen-activated kinase (MEK) cascades by sequential phosphorylations occur in both FSH- and LH-responsive cells and lead to the activation

of extracellular signal-regulated kinases (ERK1/2). Since this signaling pathway, known as “MAPK/ERK,” regulates the activity of transcription factors modulating the cell cycle (e.g., c-Myc), it is traditionally associated to cell growth, including cancer development and tumor progression. The cAMP response element-binding protein (CREB) is a further transcription factor activated through ERK1/2 by phosphorylation and, at least in part, directly through PKA, as an important cAMP-dependent downstream event. It is involved in the transcription of gonadotrophin target genes, such as *STARD1*, as key mediators of steroidogenesis and, in turn, of gametogenesis. The function of the cAMP/PKA pathway is parallel to that mediated by EPAC, which triggers anti-apoptotic events exerted via protein kinase B (AKT), in the modulation of pro-apoptotic stimuli through the p38 MAPK pathway and the regulation of steroid secretion (Aivatiadou et al. 2009). Especially, the phosphorylation of AKT occurs even in a cAMP-independent manner (Meroni et al. 2002), through the activation of phosphatidylinositol-4,5-bisphosphate 3-kinase (PI3K) via G $\alpha$ s protein, and results in the regulation of steroid synthesis, cell cycle, and proliferation, further demonstrating the complexity of the pathways simultaneously activated by G proteins. PI3K indirectly mediates the activation mammalian target of rapamycin (mTOR), a protein kinase regulating cell growth and motility, proliferation, and survival and therefore involved in aging and cancer. In addition to the canonical G protein signal transduction, AKT- and ERK1/2-pathways are activated by DCC-interacting protein 13-alpha (APPL1) through interaction with intracellular loops 1 and 2, which are alternative sites for G protein docking and mediate the FSH-dependent signaling (Thomas et al. 2011).

Beside the canonical G $\alpha$ s-mediated signaling, the  $\beta$ - $\gamma$  dimeric complex triggers the activation of the phospholipase C  $\beta$  (PLC) enzymes, which, in turn, catalyze the formation of inositol 1,4,5-trisphosphate (IP $_3$ ) and diacylglycerol (DAG) using Ca $^{2+}$  ions as a cofactor. Protein kinase C (PKC) activation occurs as a downstream event of the  $\beta$ - $\gamma$ -mediated signaling and exerts an inhibitory role on cAMP formation (Eikvar et al. 1993) despite supporting the basal PKA-independent steroidogenic activity (Jo et al. 2005) (Fig. 2). Finally, the positive modulation of growth and migration of certain cancer cells by gonadotrophins (Mertens-Walker et al. 2010) is exerted via ERK1/2-mediated mechanisms requiring the activation of PKC, highlighting the role of this kinase in cell cycle regulation.

The stimulatory role of the G $\alpha$ s protein, mainly exerted by the potent increase in intracellular cAMP, is counterbalanced by the inhibitory action mediated through the G $\alpha$ i protein. Together with the downregulation of the cAMP/PKA pathway, G $\alpha$ i protein triggers the phosphorylation of ERK1/2 and is accompanied by rapid depolarization of the cell membrane and Ca $^{2+}$  ion uptake (Loss et al. 2011). The intracellular Ca $^{2+}$  increase is a signal for PDE recruitment, as a mechanism of cAMP/PKA-pathway desensitization. However, Ca $^{2+}$  is an additional LHCGR-specific second messenger, rather than FSHR-specific second messenger, revealing that the two receptors utilize similar, but not identical intracellular signal transduction pathways. Moreover, a further LHCGR-specific inhibitory mechanism has been described, where ERK1/2 mediates an increase of *LHCGR* mRNA binding protein (LRBP) which induces the degradation of receptor mRNA (Menon et al. 2011).

Therefore, ERK1/2 exerts a dual role on steroid synthesis; it is fundamental to attain CREB phosphorylation and StAR expression (Manna and Stocco 2011), as a rate-limiting step for steroid synthesis, although it triggers GPCR downregulation by phosphorylation through recruitment of G protein-coupled receptor kinases (GRKs) on the other side (Pitcher et al. 1999). After all, intracellular mechanisms “turning off” the steroidogenic signals may be required to counteract the negative impact of high intracellular cAMP levels on cell viability (Insel et al. 2012).

Besides G proteins, other molecular players interact with FSHR and LHCGR at the intracellular level. Most remarkable are the  $\beta$ -arrestins that belong to a family of proteins classically associated with GPCRs desensitization, internalization, and recycling (Lohse et al. 1990) and more recently described as signal transducers (Reiter and Lefkowitz 2006) (Fig. 2d).

$\beta$ -Arrestins are recruited to the GRK-phosphorylated receptor, as a consequence of GPCR occupancy by the ligand. However,  $\beta$ -arrestins directly activate a slower but more prolonged ERK1/2 signaling pathway than the G proteins. The positive effect on ERK1/2 phosphorylation triggered by these molecules reveals their inhibitory role on the steroidogenic cAMP/post-meiotic and the shift of the signaling cascade toward proliferative events. Interestingly, the receptor density at the cell membrane is the determinant for preferential recruitment of  $\beta$ -arrestins against G proteins signaling (Tranchant et al. 2011), suggesting that proliferative or steroidogenic gonadotrophin-mediated signals may be differently predominant during gametogenesis, depending on the receptor number.

---

## Post-Endocytotic Trafficking and Signaling

Both GnRs undergo a series of receptor-specific modifications (PTM), at the mRNA and protein levels. The first PTM occurring to the GnRs is alternative splicing, where in some cases, some exons are skipped or alternative exons are used instead (Fig. 1). This results in receptors lacking small fragments (see the next section “receptor variants”). RNA splicing allows several gene products from one (genomic) gene, and although in some cases it is unclear why “nonfunctional” splice variants, those producing truncated proteins, serve the organism.

The level of expression of the GnRs is directly regulated by extracellular and intracellular factors, which include cAMP and hormones such as activin and inhibin. Activin, for example, regulates the stabilization of *FSHR*'s mRNA which results in higher receptor number (Tano et al. 1997). As mentioned above a similar mechanism on *LHCGR* mRNA is exerted by LRBP.

At protein level, the most frequent PTMs in GnRs is glycosylation, and this PTM allows the receptor to be transported to the cell membrane and be functional. Glycosylation takes place during biosynthesis at the endoplasmic reticulum and seems to be important for folding and interacting with chaperones (Menon and Menon 2012). Although all vertebrate GnRs seem to have six putative glycosylation sites, their glycosylation seems to be species specific. There is no consensus in the effect of these glycosylation sites; on one hand in most cases, mutagenesis of the

glycosylation sites results in lower ligand binding, although in most cases, a single glycosylation site is sufficient for proper biosynthesis (Zhang et al. 1995).

One very clear difference between the two GnRs is that during biosynthesis, the FSHR's *C*-terminal is proteolytically cleaved, while the LHCGR is expressed in full length. A chimeric receptor of the FSHR and the *C*-terminal of the LHCGR – FSHR's first 611 amino acids fused to the *C*-terminal of the LHCGR (amino acids 604-674) – is able to retain its *C*-terminus without affecting its signaling functions (Mazurkiewicz et al. 2015).

The *C*-termini tails of LHCGR and FSHR are palmitoylated at 2 and 3 cysteines, respectively. While in FSHR the ablation of one palmitoylated residue results in lower membrane expression (Uribe et al. 2008), palmitoylation does not aid anchoring of LHCGR to the plasma membrane. Additional research has shown that mutagenesis of these cysteines had no effect on ligand binding and signaling. However, ligand-induced internalization is enhanced in palmitoylation-free LHCGRs, a common feature among several GPCRs (Qanbar and Bouvier 2003), which suggests that depalmitoylation might be a step in the internalization process. This is supported by constitutively activated LHCGR mutants that are less readily palmitoylated than WT receptors and have a tendency for rapid internalization (reviewed in Menon et al. 2004) (Fig. 2b).

Upon ligand binding the receptor activation involves rearrangement of the barrel structure of the GnRs, as is the case in most GPCRs, by dissociation of interbonding of the seven helices (Fig. 2c). Particularly important bonds are present within the sixth helix, and thus disruption of this structure can result in inactivating or activating mutations; indeed, most activating mutants are found within this region in both receptors (Fig. 3).

As mentioned above, ligand activation of the GnRs primarily induces the generation of cAMP via adenylyl cyclases. The cAMP-dependent pathways could be divided in short-term and longer-term effects. Short-term effects are, e.g., activation of ion channels and protein kinase A (PKA) which then further phosphorylates a number of protein targets and morphological changes. Long(er)-term effects involve activation of transcription factors, such as cAMP response element-binding protein (CREB) and cAMP response element-binding modulator (CREM), and gene transcription regulation (Fig. 2c).

Both LHCGR and FSHR can be found phosphorylated at serine residues at their *C*-termini in several cell lines after ligand activation (reviewed in Menon and Menon 2012). Phosphorylation results in receptor inactivation and internalization probably due to interaction with arrestins. G protein-coupled kinases (GRKs) are able to phosphorylate a variety of GPCRs including LHCGR and FSHR. The GRK family has several members, and it is under discussion which one(s) act on the GnRs in physiological conditions as most GRK studies have been conducted *in vitro* using exogenous GnRs and/or GRKs (Premont et al. 1996) (Fig. 2d).

Ubiquitination, the addition of one or several ubiquitin residues by ubiquitin ligases, is a PTM that either targets the tagged protein for proteasomal degradation (polyubiquitination) or changes its localization, interactions, or activity of a tagged protein (monoubiquitination). LHCGR is found ubiquitinated already at the

endoplasmic reticulum of rat cells, a tag that directs the receptor to the proteasome for degradation, in a quality- and quantity-controlled manner (Pietilä et al. 2005). Ubiquitination plays an important mechanism to avoid protein misfolding in the endoplasmic reticulum to congest biosynthesis causing endoplasmic reticulum stress, transcription blockade, and cell death. A mutation that causes intracellular retention of LHCGR can also cause retention of the WT counterpart, and thus ubiquitination of the misfolded receptors as an endoplasmic reticulum quality control is essential for proper function of the cell (Apaja et al. 2006; Richter-Unruh et al. 2004; Rivero-Müller et al. 2015). After activation, the FSHR either internalizes and recycles to the cell membrane or becomes ubiquitinated and routed to the proteasome for degradation. The intracellular third loop regulates ubiquitination, although it is not the sole location where this tagging occurs, as shown using a mutant (K555R) where the only lysine (K) in this loop was replaced for arginine (R), yet this did not completely block ubiquitination of the receptor (Cohen et al. 2011). Receptor ubiquitination does not seem to affect internalization or signaling. It is rather a control for membrane expression at the pre- and post-activation time.

Additional factors can influence the downstream responses of LHCGR. For example, epidermal growth factor receptor (EGFR) plays a supportive role to the LHCGR-induced steroidogenesis. When the EGFR is blocked, or its ligand amphiregulin (AREG) is knocked down, LHCGR is unable to induce steroidogenic acute regulatory protein (StAR) expression and the production of progesterone (Fang et al. 2016).

While both GnRs trigger cAMP generation, the downstream cascades are significantly different (Donadeu and Ascoli 2005), in particular the activation of inositol phosphate and the downstream activation of CREB/CREM. These latter two transcription factors have several spliced isoforms that define their function as transcriptional activators/repressors. Their target genes, not fully mapped to date, include the genes for protamines and other components of postmeiotic spermiocytes. FSH/FSHR seems to regulate CREM expression via activation of alternative polyA of the *CREM*'s mRNA which results in higher stability and thus more translated protein (Foulkes et al. 1992; Walker and Habener 2016). The responses of the GnRs can also be influenced by other receptors on the cell membrane, receptor-receptor interactions, clustering, and dimerization.

---

## Receptor Di/Oligomerization: *Cis/Trans*activation

Most GPCRs can function as monomers, i.e., as single ligand-single receptor pairs, and thus for a long time, di/oligomerization of these receptors was considered an artefact found in immunoblots. This view has slowly been changing following early observations by Watanabe and collaborators where the presence of a second type of receptor influenced the ligand-binding abilities of the first type (Watanabe et al. 1978). Such an effect prompted Nigel Birdsall to suggest that a ligand to one receptor can allosterically affect a second receptor by changing the latter receptor's ability to



bind its own ligand (Birdsall 1982). This indicates that di/oligomerization is not just an oddity, but it also has a physiological function. In fact, many, if not most, GPCRs dimerize with other GPCRs, of the same or different kind, and/or with other membrane proteins. The effects of these interactions result in either *positive* or *negative cooperativity*, which means that ligand binding by one protomer increases the affinity for a ligand (positive) or it reduces the ligand's affinity for the second protomer.

With the advance of biochemical techniques in the 1990s, GPCRs were found more often than not in complexes that corresponded to their double, triple, quadruple size suggesting di/oligomers. GnRs were no exception, because dimers of both receptors have been found by a plethora of groups (Lei et al. 2007; Roess et al. 2000; Tao et al. 2004; Urizar et al. 2005). LHCGR in particular has been shown to cluster during LH and hCG activation (Hunzicker-Dunn et al. 2003; Jonas et al. 2015), but it also constitutively multimerizes in constitutively active mutants D578Y and D578H in contrast to the unliganded WT receptor (Lei et al. 2007). This suggests that dimerization, or clustering, plays a role in signaling, signal termination, desensitization, and/or internalization of these receptors.

FSHR also dimerizes, although its consequences remain unclear. In fact the crystal structure of the extracellular domain – bound by ligand, the first gonadotropin receptor crystal structure – shows a dimer of FSHR molecules intertwined like shaking hands (Fan and Hendrickson 2005). The FSHR is found in clusters of receptors at the cell membrane in unbound and bound states as well as already at the endoplasmic reticulum (Thomas et al. 2007; Urizar et al. 2005). Thomas and colleagues further suggested that the effect of FSHR mutants with trafficking defects could be ameliorated by WT FSHR as they will multimerize and be transported as a group to the membrane (Fig. 2b, c). Recent crystallographic and mutagenesis data suggested that FSHR may act as a functional trimer, increasing their capacity to bind deglycosylated FSH and resulting in quantitatively different signaling activities (Jiang et al. 2014b).

One limitation to observe the ligand-induced FSHR clustering is due to the tagging problems using fluorescent proteins due to the C-terminal cleavage (Thomas et al. 2007). Using a different approach, Thomas and collaborators used antibodies against FSHRs differentially tagged to N-termini, and by FRET they could determine that this receptor is found as di/oligomers. Surprisingly, the addition of ligand did not increase the rate of di/oligomerization nor induced dissociation (Thomas et al. 2007).

Dimerization seems to occur early in the biosynthesis process, so already in the endoplasmic reticulum FSHR, LHCGR, and FSHR/LHCGR can be found by a variety of techniques such as immunoprecipitation, FRET, BRET, fluorescent protein-tagged receptors, and co-localization using immunocytochemistry or immunofluorescence (Jonas et al. 2012). Yet, as mentioned above the LHCGR polymerizes further after ligand activation and desensitization, while clusters of FSHRs do not seem to be affected by ligand activation or desensitization.

Elegantly, Ji and collaborators have shown that the extracellular domain of an FSHR anchored to the cell membrane via a transmembrane protein, or to glycosyl

phosphatidyl inositol, was able to bind FSH and transactivate a ligand-deficient FSHR (Jeoung et al. 2007). Interestingly enough, depending on the inactivating mutation of the ligand-binding-deficient FSHR, such mutants were located at the extracellular domain (e.g., D26A and L27A), resulting in either cAMP generation or phospholipase C activation, respectively (Ji et al. 2004). This suggests that a single receptor-ligand moiety can cause the activation of multiple receptors in its proximity. In support of this view, Ji and collaborators also showed that a signaling-deficient mutant of the LHCGR can transactivate a ligand-deficient one (Lee et al. 2002a).

Additionally, an LHCGR patient mutation, truncated at TM5, can partially rescue the signaling by a ligand-deficient LHCGR, in this particular case a FSHR-LHCGR chimera which is unable to bind hCG but has intact TM domains and C-terminal (Osuga et al. 1997). Such *transactivation*, we prefer to call it *intermolecular cooperation*, might have a physiological role in GnRs signaling. It reveals that these receptors are highly flexible and amicable to other molecules in their vicinity. An important note is that dimerization might mean transient interactions (*kiss and run*) rather than covalent ones, which is probably one of the reasons for the heated debate and controversy about dimerization of GnRs.

Instead of trying to study intermolecular cooperation in cells expressing mutant receptors, we took the challenge to tackle the physiological relevance of this phenomenon. In our approach a ligand-deficient LHCGR (LHCGR<sup>LH-</sup>) and a signal-deficient LHCGR (LHCGR<sup>cAMP-</sup>) were generated using bacterial artificial chromosomes (BACs) carrying the mouse genomic *LHCGR* flanked by >50 Kb at both 5' and 3' ends, in order to achieve the spatiotemporal expression of the endogenous gene. These transgenic lines were crossed with the *LHCGR* knockout mouse (LuRKO) to obtain mice having either mutant receptor or both expressed in the LHCGR-null background. While neither LHCGR<sup>LH-</sup> nor LHCGR<sup>cAMP-</sup> expression alone had any effect on the hypogonadal LuRKO phenotype, when both receptors were expressed together, intermolecular cooperation could rescue the eugonadal and fertile phenotype of male mice (Rivero-Müller et al. 2010). This was not only the first physiologically functional example of a GnRs dimer but the first *in vivo* proof of dimerization of any class A GPCR. Further research has corroborated that complementary LHCGRs form dimers, as evidenced by tracking single receptor molecules and signal upon ligand binding (Jonas et al. 2015).

---

## Gonadotrophin Receptor Mutations and Polymorphisms

### Common Single-Nucleotide Polymorphisms

Both the *FSHR* and *LHCGR* genes carry several single-nucleotide polymorphisms (SNPs) (Casarini et al. 2011). SNPs originated as point mutations which were fixed as genetic variants achieving a frequency  $\geq 1\%$  among the human populations. Although most of these SNPs are synonymous, not implying an amino acid change at the protein level, some of these genetic variants affect the receptor functioning

(Fig. 3a, b). In few cases, SNPs modulate the physiological response to gonadotrophins, resulting in receptor isoforms differing for sensitivity to hormone stimulation.

Due to their relevance for clinical practice, in particular during the ovarian stimulation protocols for assisted reproduction, polymorphisms within the *FSHR* gene have been extensively studied. The most common *FSHR* SNP is registered as rs6166 in the National Center for Biotechnology Information (NCBI) database (<http://www.ncbi.nlm.nih.gov/pubmed>) and falls within exon 10 of the receptor gene. It is featured by nucleotide change A to G at position 2039 of the receptor gene (c.2039A>G), leading to an asparagine (N) to serine (S) change at position 680 of the amino acid chain (p.N680S). The N amino acid is considered the ancestral allele due to its overall higher frequency than the S allele worldwide. In fact, the polymorphism p.N680S is evolutionarily recent, and the N allele is present in almost all other mammals, while the S allele likely appeared in *Homo sapiens* and *Homo neanderthalensis*. However, the two receptor variants are differently distributed within populations, where higher prevalence of the N allele in people of African, European, and East Asian ancestry (about 60% of prevalence), while in Oceania and South-Central Asia, the S variant achieves about 50% prevalence (Simoni and Casarini 2014). The *FSHR* p.N680S N variants achieve 60–75% of prevalence in some ethnic groups, such as Kalash from Pakistan, Yakuts from East Siberia, and Melanesians from South Pacific Islands. Interestingly, p.N680S S homozygous women have slightly higher serum FSH levels and menstrual cycle length than the N homozygous carriers, revealing that the S amino acid makes the receptor less sensitive to endogenous FSH than N (Greb et al. 2005). This is observed during assisted reproduction, when women homozygous for p.N680S S require higher doses of exogenous FSH than the N homozygous carriers, to achieve equal ovarian stimulation. In fact, these two receptor variants display different short-term kinetics in the response to FSH *in vitro*, in terms of cAMP/PKA- and ERK1/2-pathway activation, and progesterone production over 24 h (Casarini et al. 2014). The amino acid change from asparagine to serine at position 680 creates an additional phosphorylation site at the C-terminal portion of the receptor, conferring higher potential for basal receptor desensitization *via* GRK enzymes. The *FSHR* p.N680S S variant evokes slower cAMP response and downstream signaling than the N variant, although this difference is flattened at saturation, and is reflected in progesterone synthesis. Therefore, the rs6166 SNP affects *FSHR* signaling which implies consequences at the physiological level. For instance, *FSHR* p.N680S N homozygous genotype is linked to higher testes volume than S homozygous in Baltic men (Grigorova et al. 2013). Interestingly, a recent multicentric study demonstrated that the polymorphism p.N680S is a marker of DNA fragmentation index in men undergoing clinical FSH treatment for idiopathic infertility, leading to a better outcome for N than S homozygous carriers (Simoni et al. 2016). The polymorphism p.N680S is in strong linkage disequilibrium with another common *FSHR* SNP in exon 10 (rs6165), characterized by the nucleotide change c.919G>A, resulting in amino acid change from alanine to threonine (p.A307T) in the ECD (Simoni et al. 1999). Linkage disequilibrium defines the *nonrandom* association of alleles at different *loci* to be higher than what expected from independent alleles. Therefore,

FSHR exists in two main discrete isoforms resulting in the receptor phenotypes T307-N680 and A307-S680 featured by different *in vivo* and *in vitro* activities. Recently meta-analyzed data indeed revealed increased risk of infertility resulting to a combinatory effects of these two polymorphisms in men (Wu et al. 2015).

A third common *FSHR* polymorphism is located in the promoter region (rs1394205; c.-29G>A). The minor allele frequency ranges from about 50–70% in East Asia and Europe, respectively, reflecting the wide distribution of this SNP among humans. Homozygous c.-29G>A women undergoing assisted reproduction display poorer ovarian response to exogenous FSH, due to lower levels of *FSHR* mRNA (and protein) expression (Desai et al. 2011), while male homozygous A carriers have smaller testicular volume than G homozygotes (Lend et al. 2010).

To date, the most severe impact on human phenotype may result from the combination of *FSHR* SNPs linked to “FSH-resistant” phenotypes. For instance, c.-29G>A together with c.2039A>G homozygosity should be a genotype associated with poorer response to FSH, compared to other genotype carriers, due to the additive effect of low expression levels and response to hormone. The combined effect of *FSHR* haplotype, together with a *FSHB* promoter polymorphism (-211G>T; rs10835638) resulting in the modulation of the gene transcription, is evaluated in men, where specific SNP combinations affect male parameters, i.e., serum FSH and LH levels, and bitesticular volume (Grigorova et al. 2014; Tüttelmann et al. 2012).

The most common polymorphism of the *LHCGR* gene is the addition of the two amino acids, leucine (L) and glutamine (Q), within exon 1 at codons 19–20 (Piersma et al. 2006), which originates from a CTCCAG insertion at positions 55–60 of the *LHCGR* gene. This receptor variant, known as “ins18LQ,” is common among Caucasians but absent in Japan. The two-amino acid insertion does not severely affect the sensitivity to LH and hCG, in terms of cAMP production (Rodien et al. 1998). However, when present as homozygous, it is related to the age of onset, risk, and phenotype of ovarian and testicular germ cell cancers (Brokken et al. 2012; Powell et al. 2003), revealing a role for *LHCGR* function in endocrine malignancies. However, the molecular mechanism by which the polymorphism affects the receptor functioning is still unknown.

Another SNP in exon 10 of the *LHCGR* gene, p.N312S (rs2293275), is associated with spermatogenic damage due to its high prevalence among male infertile patients (Simoni et al. 2008). The molecular mechanisms behind this SNP are under investigation.

Overall, the contribution of *LHCGR* SNPs to characteristic phenotypes is still weak, and clear phenotypic markers within this gene and impact on the male reproductive functions are still lacking. Rather, genetic hot spots for polycystic ovary syndrome (PCOS) within the *LHCGR* and *FSHR* genes were found by genome-wide association studies (GWAS) in Han Chinese as sample population (Chen et al. 2011; Shi et al. 2012). PCOS is a common endocrine disorder affecting the 4–12% of women worldwide, depending on ethnicity and lifestyle, which are characterized by some phenotypic features identified as hyperandrogenism, polycystic ovaries, and/or metabolic dysfunctions (low insulin sensitivity). The

evidences emerged from GWAS were further confirmed in *non*-Chinese populations, emphasizing the importance of LHCGR and FSHR signaling networks in granulosa and theca cells in the pathogenesis of PCOS (McAllister et al. 2015).

## Receptor Mutations

Differing from SNPs, a mutation occurs when its frequency is <1% in the population, due to relatively recent appearance or deleterious, often dominant phenotypic effects. Although point mutations may be linked to pathologic conditions, they provide useful information on the structure-function relationships of the receptor. Several activating or inactivating mutations have been described for FSHR and LHCGR, resulting in a wide range of phenotypes. In general, activating mutations of FSHR are rare and mainly consist in different grades of severity of pregnancy-associated ovarian hyperstimulation syndrome (OHSS) in females, due to FSHR acquiring hCG binding, while their effects in males are not completely understood, due to only two reported cases (Casas-González et al. 2012; Gromoll et al. 1996c). Especially, some of these mutations are linked to constitutive activity of the receptor through a molecular mechanism affecting the interaction ability between transmembrane domains 3, 5, 6 and the highly conserved E/DRY/W amino acid sequence (Ulloa-Aguirre et al. 2014). Indeed, the first activating mutation of FSHR was an aspartic acid (D) to glycine (G) amino acid change at position 567 (D567G) found in a hypogonadotropic man (due to hypophysectomy because of acromegaly) subjected to testosterone treatment (Gromoll et al. 1996c). Although he had normal testes volume and semen parameters, his mutant receptor displayed constitutive activity *in vitro*. The finding was confirmed by studying the effects of the FSHR D567G mutation in a woman with pregnancy-associated ovarian hyperstimulation syndrome (OHSS) due to high basal activity of the receptor (Smits et al. 2003b). In that case, mutant FSHR responded also to hCG or TSH treatment. Although the mutant FSHR displayed marginal constitutive activity, the phenotype was apparently caused by the responsiveness of the mutant receptor to hCG, explaining the pregnancy association of the ovarian hyperstimulation in the patient. The mutation falls within the third intracellular loop and involves the amino acid aspartic acid present also in LHCGR and TSHR, which plays an important role in glycoprotein receptor function. Mutation analysis of LHCGR and TSHR revealed that this amino acid residue also results in constitutive activity and is linked to gonadotrophin-independent male-limited precocious puberty and thyroid adenomas, respectively.

Other mutations falling within the TMD of FSHR have been associated with OHSS in women (Desai et al. 2013). Especially, the substitution I545T results in constitutive activity and cross activation of the receptor by hCG and TSH *in vitro* and was detected in a woman affected by OHSS during pregnancy, when hCG levels are almost 1,000 times higher. Similar FSHR-mediated basal activity and cross interaction with hCG and TSH were described for the T449I and T449A mutations, although the FSHR T449I mutant did not mediate TSH-dependent signaling. OHSS was also found in association with the mutation S128Y in the ECD of the receptor

(De Leener et al. 2008), once again resulting in increased sensitivity to hCG. Therefore, the amino acid tyrosine, instead of serine at position 128, determines high binding affinity of FSHR for hCG, while the affinity for TSH was increased by replacing serine 128 with isoleucine or valine in mutagenesis experiments. Curiously, activating mutations may also be asymptomatic. In vitro functional analysis of FSHR carrying the amino acid replacement asparagine to isoleucine at position 431 (N431I) revealed that the constitutive activity of the mutant receptor counterbalanced the potential deleterious effects of decreased cell surface expression. Therefore, the male carrier of the FSHR mutation had normal spermatogenesis and testicular functions in spite of suppressed serum FSH level (Casas-González et al. 2012).

FSHR-inactivating mutations have also been described. They have negative impact on ligand binding especially when they occur at the ECD. Mutations falling within other domains of the receptor may affect trafficking or signal transduction capability, resulting in the impairment of FSH-dependent signals. The C566T transition at the exon 7 of the *FSHR* gene provides an example of inactivating mutations. It results in the substitution of amino acid alanine to valine within the ECD, at position 189, which causes hypergonadotropic hypogonadism and infertility in homozygous women (Aittomäki et al. 1995). High serum levels of FSH occur as a consequences of the absence of negative feedback on pituitary gonadotrophin production. The mutant receptor retains normal binding affinity for FSH but reduced binding capacity and cAMP production due to low trafficking and receptor density at the cell membrane. Amino acids 189–193 in FSHR, known as the “AFNGT motif,” are highly conserved in all species and in other glycoprotein hormone receptors. Curiously, the A189V mutation has an unexpected high frequency among the Finnish population. The AFNGT sequence carries a putative glycosylation site and is fundamental for the trafficking of the mature receptor and its structural integrity. Another mutation within this sequence (N191I) leads to failure of FSH-dependent cAMP production (Gromoll et al. 1996c). However, homozygous men carrying the A189V mutated receptor show phenotypes with variable suppression of testis weight and spermatogenesis, and surprisingly none on the five men homozygous for the mutation were azoospermic, and two of them had fathered two children each (Tapanainen et al. 1997). It remains a conundrum why the three men identified with inactivating FSHB mutation are all azoospermic, whereas the five men with inactivating FSHR mutation, as well as knockout mice for *fshb* or *fshr* (Krishnamurthy et al. 2000; Shetty et al. 2006), are oligo- or normozoospermic.

Interestingly, inactivating mutations at the hinge region of FSHR ECD, such as the proline to arginine substitution at position 348 (Allen et al. 2003), potentially abolish both the receptor binding and signaling, reflecting the involvement of this region in the regulation of several properties of receptor function.

Inactivating mutations within the transmembrane domain of FSHR result in a wide spectrum of alterations, depending on the type and position of the amino acid change. The FSHR A419T substitution was found in a Finnish female patient with primary amenorrhea (Doherty et al. 2002). The mutation localized to the second transmembrane stretch of the receptor and resulted in normal hormone binding in the

face of absent cAMP response. Several other mutations within the transmembrane regions have been described, confirming that the TMD is fundamental for signal transduction. However, some of these mutations are partially inactivating, i.e., decreasing of cAMP production or ligand selectivity (Montanelli et al. 2004), resulting in a variety of phenotypes, ranging from primary ovarian failure (Bramble et al. 2016) to ovarian hyperstimulation syndrome (Chauhan et al. 2015), FSH resistance, primary amenorrhea, or disturbed folliculogenesis (Kuechler et al. 2010).

Several LHCGR mutations have been described, and they lead to a variety of phenotypes and pathologies. In general, activating germline mutations are involved in male-limited gonadotrophin-independent precocious puberty (testotoxicosis) (Kawate et al. 1995), while no phenotypes were associated with LHCGR-activating mutations in females. In addition, testicular Leydig cell tumors have been detected due to somatic mutations (Sangkhathat et al. 2010). A well-known activating *LHCGR* mutation is the G to C substitution at position 1732 of the receptor gene, resulting in the amino acid change D578H of the protein falling within the sixth transmembrane stretch. It was found in the tumor cells of three boys with early pubertal development (Liu et al. 1999) and independently confirmed by the discovery of the same somatic mutation in two boys affected by Leydig cell adenoma hypersecreting testosterone (Canto et al. 2002). These findings reveal that the maintenance of the intact sixth transmembrane region of the receptor is important for the control of the cAMP production, and mutations within this area result in constitutive activation of the G $\alpha$ s protein/adenylyl cyclase signaling. Interestingly, no phenotype has been detected in women carriers of activating LHCGR mutations, for reasons not understood. A likely explanation is that the ovaries do not express LHCGR before the onset of puberty, when their expression is induced by FSH and estradiol. An activating receptor mutation cannot induce phenotype before it is expressed.

In males, inactivating mutations of the LHCGR are linked to well-established LH/hCG unresponsive phenotypes featured by primary hypogonadism, the absence of Leydig cells, and disorder of sexual differentiation (Latronico et al. 1996). The typical clinical picture of these patients includes complete lack of masculinization with female external genitalia and lack of pubertal maturation, today referred to as Leydig cell hypoplasia type 1 (LHC1). As well as for FSHR, the loss of Leydig cell functioning is amenable to mutations affecting hormone binding, receptor transport at the cell membrane, and G protein activation (Kremer et al. 1995).

---

## Clinical Studies and In Vitro Analyses to Study Receptor Activity and Function

Both LHCGR and FSHR respond upon ligand binding by G protein activation, which further activates a cascade of intracellular events, most notably the production of cAMP. In fact, measuring cAMP is still considered the most useful functional assay in GPCR studies. There are many practical ways to measure cAMP, starting from classical immunoassays such as enzyme-linked immunoassay (ELISA) and radioimmunoassays (RIA). More recently, molecular biology has taken over the

field, and the discovery of cAMP-binding proteins allowed the engineering of sensor-chimeric proteins that change function upon cAMP binding resulting in measuring signals such as fluorescence or luminescence readouts [reviewed in (Paramonov et al. 2015)]. A limitation of this modern assays is that cells need to be transfected with the genetic probes, particularly limiting their use to cell lines. Trehan et al. and Klarenbeek et al. solved this by hypothesizing that cAMP can be transferred between cells through gap junctions, and thus having cells expressing a reporter system could detect cAMP produced in neighboring cells (Klarenbeek et al. 2011; Trehan et al. 2014). Additionally, it was shown that cAMP can be transferred between different cell types and more strikingly, cells of different animal species (Trehan et al. 2014).

In clinical diagnostics the activation of the LHCGR is usually measured as testosterone response in male patients, which is a rather accurate way to measure the bioactivity of Leydig cells expressing this receptor. Since FSH contributes to the stimulation of spermatogenesis by acting on Sertoli cells, sperm quality may give some indication of FSHR activity, as well as serum inhibin B levels. Clinical suspicion of gonadotrophin receptor dysfunction arises usually in patients with disturbances in sexual development or maturation, or hypogonadism and infertility. In these cases, hormonal levels are measured (testosterone, estradiol, LH, FSH, inhibin, anti-Müllerian hormone). If the testosterone levels are low, the first test is to stimulate the release of LH and testosterone by using GnRH or its agonist, followed by LH and testosterone measurements. Thereafter (or before the GnRH test), the patient should be challenged with hCG to stimulate directly Leydig cells, and the testosterone response is measured. If both tests yield negative responses, then the problem can be in nonfunctional LHCGR, which, however, is extremely rare. The next step is to sequence the patient's DNA for mutations in the *LHCGR* gene. If the receptor has inactivating mutation, then the diagnosis is Leydig cell hypoplasia type 1 (LCH1) which is characterized by disorders of sex development (DSD) and lack of pubertal sexual development (Reviewed in (Furtado et al. 2012)). Partially responsive LHCGR mutants, for example, those responding the hCG but not to LH, will result in Leydig cell hypoplasia type 2 (LCH2) with a variable phenotype including hypospadias, cryptorchidism, micropenis, and/or hypogonadism, like those having mutation of the *LHB* gene resulting in a nonfunctional LH.

Mutational analysis of FSHR and LHCGR has been traditionally performed by measuring the second messenger cAMP by ELISA or RIA in cell lines transfected with the mutant receptor. It was due to the relatively easy-to-handle detection methods used in the practice of research laboratories and incomplete knowledge of the GPCR-mediated cell signaling. Thus, cAMP is the standard parameter of receptor functionality in almost all in vitro studies from the 1990s and, in large part, even in the subsequent decade (Boot et al. 2011; Doherty et al. 2002; Gromoll et al. 1996c, 2002). The discovery of alternative GPCR signaling mediators as indicator of receptor functionality, such as  $\beta$ -arrestins (Lohse et al. 1990), provided new targets for mutational analysis. For example, FSHR A189V mutation was characterized in the year 1995 (Aittomäki et al. 1995) and was linked to lower spermatogenesis in



homozygous than WT males and impaired cAMP production in vitro; however, the discovery of an association between the mutation and cAMP/PKA-independent phosphorylation of ERK1/2 through  $\beta$ -arrestins occurred much more recently (Tranchant et al. 2011). Cell-based assays, such as BRET-/FRET-based methods, are promising tools for the improvement of GnR mutational studies (Ayoub et al. 2015), allowing the detection of several intracellular mediators in the same transfected cell system.

New insights in mutational analysis may be provided by whole exome sequencing, as primary method for detection of naturally occurring mutations, followed by in vitro validation of signal transduction and/or flow cytometry. This procedure was used to detect a *FSHR* mutation (c.1222G>T; p.Asp408Tyr) in two Turkish sisters with hypergonadotropic primary amenorrhea. Using transfected HEK293 cells, in vitro analysis of the mutant receptor revealed an approximate 50% reduction of the cell surface expression and cAMP production upon FSH treatment, providing the validation of the finding by experimental evidence (Bramble et al. 2016).

The first step to study in more detail, a receptor mutant is to clone or generate the receptor mutant by in vitro mutagenesis. For this there is a variety of methods, including commercial mutagenesis kits. Alternatively, a simplified protocol to generate mutants has been created by Trehan and collaborators, which has been used in reports on the mutagenesis of multiple *FSHR* and *LHCGR* mutants (Trehan et al. 2015).

As the complexity of signaling and interactions are beyond mere cAMP generation, there are a variety of other functional assays depending on what is the desired phenomenon to be studied. For example, receptor dimerization is often studied by FRET or BRET assays, while internalization is often studied by  $\beta$ -arrestin binding assays, receptor localization is studied by flow cytometry and immunocytochemistry, and other signaling pathways are often studied by Western blot analyses, phospho-arrays, ELISA, metabolomics, or cell-based assays (reviewed in (Jonas et al. 2012)). Below we describe some of the most common assays in more detail.

In the case of signaling cascades, there is no assay that covers them all; instead single assay per pathway is the usual manner to study them, although there are new approaches using “omics” (metabolomics, proteomics, transcriptomics) trying to cover as many cellular changes as possible [reviewed in (Yao et al. 2015)]. There is a whole suite of them, most of them immunoassays, although some biosensors have been recently developed for some of them. A common approach are calcium measurements, which are an indirect way to measure GPCR activation popular due to their simplicity. Yet, these assays often result in rapid changes that do not represent the kinetics of receptor activation. For further reading on this subject, refer to Jonas et al. (2012) and Zhang and Xie (2012).

As there are only few good antibodies recognizing the extracellular domain of the WT *LHCGR* or *FSHR*, localization studies are often performed using tagged receptors. The tag, a small peptide sequence for which good antibodies are available (HA, FLAG, V5, and Myc are the most commonly used), needs to be placed after the membrane localization signal as this signal peptide is removed during receptor biosynthesis (see Fig. 2b). The tag is then left fused to the mature receptor, and so

far there are no reports suggesting that such short tags might have any effect on ligand binding or receptor activation. The living cells are often “fed” with the primary antibody against the tag, then incubated for an hour, and washed with PBS. In some cases, the cells are fixed, while in most cases, the secondary fluorescently tagged antibody is added just after resuspending the cells and then washed and run in flow cytometer. The fluorescent intensity is directly proportional to the number of receptor molecules on the surface, and thus this method does not only show that the receptor is located on the cell membrane but also provides an approximate number of molecules per cell. If no receptor is found on the membrane, the cells are resuspended, fixed, permeabilized, and then incubated with the primary and secondary antibodies (as before). This will determine if the mutant receptor is normally expressed but has problems during biosynthesis and localization. For example, a mutant LHCGR having misfunctional transmembrane domain 7 and C-termini (cT) is retained in the endoplasmic reticulum, which further triggers endoplasmic reticulum stress. This is a cellular response to misfolded proteins jamming the endoplasmic reticulum machinery and reducing gene expression as a survival mechanism (Rivero-Müller et al. 2015).

Another modern approach to detect receptor expression and localization is the use of intracellular fluorescent protein tags such as green fluorescent protein (GFP) or far-red fluorescent protein mCherry. Tagging of the LHCGR using FPs has been performed, and the receptor does not seem to be affected by such carryover (Smith et al. 2006). Yet FSHR was unable to be tagged using fluorescent proteins, something that was later found due to proteolysis of the cT. This has been recently solved by swapping its intracellular domain for that of the LHCGR. While the FSHR-cT-LHCGR chimera retains FSHR functionality, fluorescent protein tags can be used for tracking the receptor, a technique that also allowed the tracking of single molecules and observing LHCGR/FSHR heterodimers (Mazurkiewicz et al. 2015).

One additional approach to measure receptor activation is the visualization or quantification of the arrestins recruited upon activation (Fig. 2d). There are academic as well as commercial systems to perform this, although in most cases, they require the modification of the C-terminal of the receptor under study. This limits such assays to cell cultures and exogenous receptors, and in some cases, as with FSHR, they would require the use of chimeric proteins. Aggregation of fluorescently tagged arrestins is also used even if it is not optimal for quantification, although it allows confocal microscopy and visualization of internalization complexes.

---

## Transgenic Models for Receptor Functional Studies

In order to study the physiological roles of proteins, we are left with two options, the serendipitous discovery of mutations in human patients or the engineered generation of organisms lacking or overexpressing certain components such as the ligand or the receptor. This also includes the generation of mutant receptors or downstream components in order to elucidate the function and interactions between the different players.

While we always have to remember that animal models are just models that in some cases only distantly resemble the human condition and thus the results gained from animal models have to be carefully analyzed before translated into human conditions, yet more often than not, the results obtained in animal models faithfully phenocopy those in humans, and this is no exception in the GnR field.

Transgenic mice overexpressing either the *hCGB* gene or the former plus the *CGA* subunit under *ubiquitin* promoter were expected to model the phenotype of humans with activating mutations of the LHCGR. Surprisingly, these mice resulted in the opposite phenotype: while in human females are asymptomatic to constitutively active LHCGR mutations, men develop precocious puberty and tumorigenesis (testotoxicosis). Unexpectedly, male mice overexpressing hCG presented with normal phenotypes, while female mice presented precocious puberty, became obese (twice the weight of WT at 4 months of age), and had luteinized ovaries with luteomas and hemorrhagic cysts (Rulli et al. 2002). These mice also developed a series of non-gonadal problems such as prolactin-secreting pituitary adenomas, mammary tumors, pseudopregnancy, and uterine hyperstimulation (reviewed in Peltoketo et al. 2010). Female mice overexpressing a chimeric LHB and carboxyl terminal peptide (CTP) of hCG (LH $\beta$ -CTP), to increase the half-life of this moiety, presented polycystic ovaries and high estradiol and testosterone and developed granulosa cell tumors (Clay et al. 1995). In contrast, overexpression of the *FSHB* gene resulted in indistinguishable phenotypes of male or females to WT littermates (Kumar 2007).

The first gonadotrophin-related gene to be knocked out was the common *CGA* subunit. The phenotypes matched well the expectations, as the mice were hypogonadal and presented hypothyroidism due to lack of LH, FSH, and TSH hormones (Kendall et al. 1995). Because mice do not have chorionic gonadotrophin (i.e., a dimer of CGA and CGB), pregnancy of the knockout mice was not compromised. In order to identify the physiological roles of each beta subunit, they were knocked out one by one, starting with the *FSHB* which was performed by Kumar and collaborators (1997) who found that male mice have smaller testes, yet they were fertile. Female KO mice were infertile due to lack of preantral stimulation, and probably FSH-dependent LHCGR expression.

The *LHB* knockout mouse model was also generated by the same lab (Kumar and Matzuk), although this time the model recapitulated the human condition more faithfully. *LHB KO* mice presented with hypogonadism, with very few hypoplastic Leydig cells and thus very low testosterone levels but normal serum FSH. Females likewise were infertile due to, among other issues, anovulation and degeneration of antral follicles (Ma et al. 2004).

The knockout models of *FSHR* or *LHCGR* showed identical phenotypes with the cognate ligand KOs. The *LHCGR KO* (LuRKO) did not fully mirror the human condition where the fully inactivated *LHCGR* results in LCH1 and hermaphroditism, while in rodents, there is a gonadotrophin-independent pathway for the production of testosterone during fetal life (O'Shaughnessy et al. 2003). Namely, numerous endocrine and paracrine non-gonadotrophic factors are able to stimulate fetal Leydig cell testosterone production in the absence of LH or LHCGR (El-Gehani et al. 1998).

Thus the knockout mice are born similar to WT but lack postnatal sexual maturation in the absence of LH-stimulated testosterone production. Interestingly, in old age (12-month old), these mice develop qualitatively full, though quantitatively minor, spermatogenesis, as a sign of biological effect of the residual LH-independent testosterone production of their testes (Zhang et al. 2003).

In teleosts, the group including most fish, the *Lhr* and *Fshr* are promiscuous to their ligands. Surprisingly in many species of fish, e.g., African catfish and zebra fish, *Fshr* binds indiscriminately to FSH and LH, whereas the *Lhr* binds only LH (So et al. 2005; Vischer et al. 2003), while in other fish species, *Fshr* binds only to FSH, but *Lhr* binds strongly to LH and weakly to Fsh (Oba et al. 1999). The GnRs have also less stringent expression pattern as in mammals, as the *Fshr* and *Lhr* are both expressed in Leydig cells (García-López et al. 2010).

Using gene editing techniques, two research groups generated zebra fish lacking either the *LhB* or the *FshB*. Zebra fish depleted of FSH had a clear delay in folliculogenesis and spermatogenesis, yet LH is able to rescue the phenotype, probably due to the promiscuity of this fish's *Fshr* (Zhang et al. 2015b). On the other hand, lack of LH resulted in no changes in gonadal growth, despite this female fish rendered infertile due to a blockade in oocyte maturation as well as ovulation (Chu et al. 2014; Zhang et al. 2015b). The same groups generated KOs of the GnRs as well, in one of the studies, they showed that *Fshr* KO female fish fails in the first wave of follicular activation and responds by reversing the males, surprisingly these males were fertile. In males *Fshr* depletion resulted in a delay in the initiation of spermatogenesis, but once started they were fully fertile. Since *Lhr* KO fish had no effect on either gender (Chu et al. 2014), these fishes were crossed with *Fshr* KO, double KO fish of both GnRs, resulting in infertile male offspring (Zhang et al. 2015a).

Potential constitutively active mutants of LHCGR and FSHR found in the clinic need to be tested in vitro and eventually in vivo, in particular FSHR mutations since FSHR constitutively active mutations usually have a low baseline activity (cAMP generation), while mutant LHCGRs have a much higher baseline. For example, in order to study the functional role of the FSHR-D567G in vivo, Haywood and colleagues took a very elegant approach. Knockout mouse embryos for the gonadotrophin-releasing hormone (*hpg* mice) were microinjected with a transgene for the expression of the *FSHR-D567G* mutant under a Sertoli cell-specific promoter (*anti-Müllerian hormone*). Since the *hpg* mice have neither LH nor FSH production, their testes are underdeveloped, and spermatogenesis is arrested at the premeiotic stage, yet *hpg* mice also carrying the *FSHR-D567G* transgene showed an increase in testes weight and postmeiotic germ cells demonstrating the constitutive activity of this mutant receptor. Moreover, isolated Sertoli cells from these mice had twice higher cAMP basal activity (Haywood et al. 2002). Further studies where FSHR-D567G receptor was expressed in the *hpg*- and LHCGR-*null* mice demonstrated that, in rodents, FSHR activity alone is able to accomplish Sertoli cell proliferation, further demonstrated by injecting FSH in *hpg* mice achieving a similar effect (Allan et al. 2004). Female mice expressing the FSHR D567H mutation responded with increase fertility (litter size), which is in agreement with other data showing that folliculogenesis requires FSH/FSHR signaling. Activating FSHR mutations in males

apparently have marginal phenotype in the WT background, and therefore their functionality can only be demonstrated in the gonadotrophin-deficient background like *hpg*. Apparently for the same reason, the only activating FSHR mutation detected in a human male was in a hypophysectomized man maintaining normal spermatogenesis in the absence of circulating gonadotrophins (Casas-González et al. 2012; Gromoll et al. 1996b).

While in men the LHCGR-dependent testosterone production is essential to spermatogenesis, lack of either FSH or FSHR can still be compensated for as long as testosterone levels are sufficient. Despite smaller testicular volume, this very same finding has been made by using knockout rodent models of *FSHR* or *FSHB* (Abel et al. 2000; Kumar et al. 1997).

Very little evidence exists on the extragonadal role of GnRs, at least in mammals. One of the very few animal models showing the importance of a GnRs in non-gonadal tissues was a study on adrenal glands. Experimental mice over-expressing transcription factor GATA4 under the *21-hydroxylase* (*Cyp21a1*, *21-OH*) promoter developed adrenal hyperplasia after gonadectomy. There were clearly two types of cells within the lesions: *A cells* that were steroidogenically silent and *B cells* that were LHCGR positive and, as expected, steroidogenically active (Chruscziel et al. 2013). These data support clinical and experimental data suggesting that lack of gonadal factors and increased LH levels result in the hyperproliferation of LHCGR-positive cells (B cells) and that secreted factors produced by these cells support the proliferation and survival of neighboring A cells. As described above, the overexpression of hCG alone does not result in adrenal tumors. On the other hand, orthotopic transplantation of WT ovarian tissue to LuRKO mice allowed them to attain fertility, which indicates that extragonadal LHR expression is not needed for female mouse fertility (Pakarainen et al. 2005). Similarly, ovum donation to a female with inactivating LHCGR mutation allowed her to foster the donated embryo to term, also in the absence of extragonadal LHCGR (Mitre et al. 2014).

Understanding the physiological roles of gonadotrophin actions requires animal models, which, in most cases, phenocopy the human health and disease conditions. However, interspecies differences are fascinating in their own right and could well teach us how to bypass or circumvent clinical problems for which medications are nonexistent.

---

## Conclusive Remarks

The GnRs play essential role in the communication between the pituitary gland and gonadal cells and forward to pregnancy, sex development, and gametogenesis. Several decades of studies have not yet provided a complete picture of the GnR molecular features, which go far beyond the classical view of the cAMP-mediated stimulation of gonadal-limited steroidogenesis. GnRs activate numerous signaling cascades modulating a wide range of effects at the cellular level and resulting in a complex regulation of the reproductive endocrine functions. These receptors specifically recognize the ligand through highly conserved interaction sites; thus,

artificially induced or naturally occurring mutations can dramatically affect such binding. Unique signaling cascades are likewise activated upon recognition of the ligand by peculiar, species-specific residues located at the hinge region and TMD of the receptors. Moreover, recently discovered GnR features have revealed that these molecules act, besides monomers, as functional homo-/heterodimers or oligomers, as well as other GPCRs, suggesting that the modulation of the intracellular signaling may occur at different levels and is physiologically relevant, as confirmed by transgenic mouse models *in vivo*. Thus, GnRs regulate a wide spectrum of physiological functions, likely not exclusively exerted at the gonadal level, which may be individually modulated by widespread SNPs among human populations and resulting in various endocrine ethnic backgrounds. Yet GnRs have also clearly defined additional roles in physiology or pathological conditions. Numerous activating and inactivating GnR mutations have been described in humans, resulting in pathological, often sex-limited, phenotypes with differing range of severity, depending on the location and entity of the alteration. Thanks to carefully detailed studies on the molecular biology of these molecules as well as clinical cases and animal models, a clearer picture of the similarities and differences between these receptors, their hormones, and regulation has emerged. New insights in the understanding of the functional complexity of GnRs may provide new pharmacological approaches for personalized treatment of hypogonadism and infertility, as well as effective tools to be used for health care of endocrine and cancer patients.

---

## References

- Abel MH, Wootton AN, Wilkins V, Huhtaniemi I, Knight PG, Charlton HM. The effect of a null mutation in the follicle-stimulating hormone receptor gene on mouse reproduction. *Endocrinology* [Internet]. 2000;141(5):1795–803. Cited 2 May 2016. Available from: <http://www.ncbi.nlm.nih.gov/pubmed/10803590>.
- Agrawal G, Dighe RR. Critical involvement of the hinge region of the follicle-stimulating hormone receptor in the activation of the receptor. *J Biol Chem*. 2009;284(5):2636–47.
- Agrawal V, Jaiswal MK, Jaiswal YK. Gonadal and nongonadal FSHR and LHR dysfunction during lipopolysaccharide induced failure of blastocyst implantation in mouse. *J Assist Reprod Genet* [Internet]. 2012;29(2):163–73. Cited 29 June 2016. Available from: <http://www.ncbi.nlm.nih.gov/pubmed/22193751>.
- Aittomäki K, Lucena JL, Pakarinen P, Sistonen P, Tapanainen J, Gromoll J, et al. Mutation in the follicle-stimulating hormone receptor gene causes hereditary hypergonadotropic ovarian failure. *Cell* [Internet]. 1995;82(6):959–68. Cited 5 May 2016. Available from: <http://www.ncbi.nlm.nih.gov/pubmed/7553856>.
- Aivatiadou E, Ripolone M, Brunetti F, Berruti G. cAMP-Epac2-mediated activation of Rap1 in developing male germ cells: RA-RhoGAP as a possible direct down-stream effector- PubMed – NCBI. *Mol Reprod Dev*. 2009;76(4):407–16.
- Allan CM, Garcia A, Spaliviero J, Zhang F-P, Jimenez M, Huhtaniemi I, et al. Complete Sertoli cell proliferation induced by follicle-stimulating hormone (FSH) independently of luteinizing hormone activity: evidence from genetic models of isolated FSH action. *Endocrinology* [Internet]. 2004;145(4):1587–93. Cited 19 Apr 2016. Available from: <http://www.ncbi.nlm.nih.gov/pubmed/14726449>.

- Allen LA, Achermann JC, Pakarinen P, Kotlar TJ, Huhtaniemi IT, Jameson JL, et al. A novel loss of function mutation in exon 10 of the FSH receptor gene causing hypergonadotrophic hypogonadism: clinical and molecular characteristics. *Hum Reprod* [Internet]. 2003;18(2):251–6. Cited 5 May 2016. Available from: <http://www.ncbi.nlm.nih.gov/pubmed/12571157>.
- Angelova K, de Jonge H, Granneman JCM, Puett D, Bogerd J. Functional differences of invariant and highly conserved residues in the extracellular domain of the glycoprotein hormone receptors. *J Biol Chem*. 2010;285(45):34813–27.
- Apaja PM, Harju KT, Aatsinki JT, Petaja-Repo UE, Rajaniemi HJ. Identification and structural characterization of the neuronal luteinizing hormone receptor associated with sensory systems. *J Biol Chem* [Internet]. 2004;279(3):1899–906. Cited 23 May 2016. Available from: <http://www.ncbi.nlm.nih.gov/pubmed/14581462>.
- Apaja PM, Tuusa JT, Pietilä EM, Rajaniemi HJ, Petäjä-Repo UE. Luteinizing hormone receptor ectodomain splice variant misroutes the full-length receptor into a subcompartment of the endoplasmic reticulum. *Mol Biol Cell* [Internet]. 2006;17(5):2243–55. Cited 25 May 2016. Available from: <http://www.pubmedcentral.nih.gov/articlerender.fcgi?artid=1446094&tool=pmcentrez&rendertype=abstract>.
- Ascoli M, Segaloff D. On the structure of the luteinizing hormone/chorionic gonadotropin receptor\*. *Endocr Rev* [Internet]. 1989;10(1):27–44. Cited 28 June 2016. Available from: <http://www.ncbi.nlm.nih.gov/pubmed/2666109>.
- Ascoli M, Fanelli F, Segaloff DL. The lutropin/choriogonadotropin receptor, a 2002 perspective. *Endocr Rev*. 2002;23(2):141–74.
- Ayoub MA, Landomiel F, Gallay N, Jégot G, Poupon A, Crépieux P, et al. Assessing gonadotropin receptor function by resonance energy transfer-based assays. *Front Endocrinol (Lausanne)* [Internet]. 2015;6:130. Cited 4 July 2016. Available from: <http://www.pubmedcentral.nih.gov/articlerender.fcgi?artid=4550792&tool=pmcentrez&rendertype=abstract>.
- Birdsall NJM. Can different receptors interact directly with each other? *Trends Neurosci*. 1982;5:137–8.
- Boot AM, Lumbroso S, Verhoef-Post M, Richter-Unruh A, Looijenga LHI, Funaro A, et al. Mutation analysis of the LH receptor gene in Leydig cell adenoma and hyperplasia and functional and biochemical studies of activating mutations of the LH receptor gene. *J Clin Endocrinol Metab* [Internet]. 2011;96(7):E1197–205. Cited 4 July 2016. Available from: <http://www.pubmedcentral.nih.gov/articlerender.fcgi?artid=3135199&tool=pmcentrez&rendertype=abstract>.
- Bousfield GR, Butnev VY, Butnev VY, Hiromasa Y, Harvey DJ, May JV. Hypo-glycosylated human follicle-stimulating hormone (hFSH(21/18)) is much more active in vitro than fully-glycosylated hFSH (hFSH(24)). *Mol Cell Endocrinol*. 2014;382(2):989–97.
- Bramble MS, Goldstein EH, Lipson A, Ngun T, Eskin A, Gosschalk JE, et al. A novel follicle-stimulating hormone receptor mutation causing primary ovarian failure: a fertility application of whole exome sequencing. *Hum Reprod* [Internet]. 2016;31(4):905–14. Cited 6 May 2016. Available from: <http://www.ncbi.nlm.nih.gov/pubmed/26911863>.
- Brokken LJS, Lundberg-Giwercman Y, Rajpert De-Meyts E, Eberhard J, Ståhl O, Cohn-Cedermark G, et al. Association of polymorphisms in genes encoding hormone receptors ESR1, ESR2 and LHCGR with the risk and clinical features of testicular germ cell cancer. *Mol Cell Endocrinol* [Internet]. 2012;351(2):279–85. Cited 3 May 2016. Available from: <http://www.ncbi.nlm.nih.gov/pubmed/22245602>.
- Bukovsky A, Indrapichate K, Fujiwara H, Cekanova M, Ayala ME, Dominguez R, et al. Multiple luteinizing hormone receptor (LHR) protein variants, interspecies reactivity of anti-LHR mAb clone 3B5, subcellular localization of LHR in human placenta, pelvic floor and brain, and possible role for LHR in the development of abnormal pregnancy. *Reprod Biol Endocrinol* [Internet]. 2003;1:46. Cited 25 May 2016. Available from: <http://www.pubmedcentral.nih.gov/articlerender.fcgi?artid=161821&tool=pmcentrez&rendertype=abstract>.
- Butnev VY, Gotschall RR, Baker VL, Moore WT, Bousfield GR. Negative influence of O-linked oligosaccharides of high molecular weight equine chorionic gonadotropin on its luteinizing

- hormone and follicle-stimulating hormone receptor-binding activities. *Endocrinology*. 1996;137(6):2530–42.
- Canto P, Soderlund D, Ramon G, Nishimura E, Mendez JP. Mutational analysis of the luteinizing hormone receptor gene in two individuals with Leydig cell tumors. *Am J Med Genet* [Internet]. 2002;108(2):148–52. 2002/02/22 ed. Available from: [http://www.ncbi.nlm.nih.gov/entrez/query.fcgi?cmd=Retrieve&db=PubMed&dopt=Citation&list\\_uids=11857565](http://www.ncbi.nlm.nih.gov/entrez/query.fcgi?cmd=Retrieve&db=PubMed&dopt=Citation&list_uids=11857565).
- Casarini L, Pignatti E, Simoni M. Effects of polymorphisms in gonadotropin and gonadotropin receptor genes on reproductive function. *Rev Endocr Metab Disord* [Internet]. 2011;12(4):303–21. Cited 28 Apr 2016. Available from: <http://www.ncbi.nlm.nih.gov/pubmed/21912887>.
- Casarini L, Lispi M, Longobardi S, Milosa F, La Marca A, Tagliasacchi D, et al. LH and hCG action on the same receptor results in quantitatively and qualitatively different intracellular signalling. *PLoS ONE* [Internet]. Public Library of Science. 2012;7(10):e46682. Cited 22 Apr 2016. Available from: <http://journals.plos.org/plosone/article?id=10.1371/journal.pone.0046682>.
- Casarini L, Moriondo V, Marino M, Adversi F, Capodanno F, Grisolia C, et al. FSHR polymorphism p.N680S mediates different responses to FSH in vitro. *Mol Cell Endocrinol* [Internet]. 2014;393(1–2):83–91. Cited 29 Apr 2016. Available from: <http://www.ncbi.nlm.nih.gov/pubmed/24970684>.
- Casas-González P, Scaglia HE, Pérez-Solís MA, Durand G, Scaglia J, Zariñán T, et al. Normal testicular function without detectable follicle-stimulating hormone. A novel mutation in the follicle-stimulating hormone receptor gene leading to apparent constitutive activity and impaired agonist-induced desensitization and internalization. *Mol Cell Endocrinol* [Internet]. 2012;364(1–2):71–82. Cited 6 May 2016. Available from: <http://www.ncbi.nlm.nih.gov/pubmed/22954680>.
- Chauhan AR, Prasad M, Chamariya S, Achrekar S, Mahale SD, Mittal K. Novel FSH receptor mutation in a case of spontaneous ovarian hyperstimulation syndrome with successful pregnancy outcome. *J Hum Reprod Sci* [Internet]. 2015;8(4):230–3. Cited 17 Mar 2016. Available from: <http://www.pubmedcentral.nih.gov/articlerender.fcgi?artid=4691976&tool=pmcentrez&rendertype=abstract>.
- Chen Z-J, Zhao H, He L, Shi Y, Qin Y, Shi Y, et al. Genome-wide association study identifies susceptibility loci for polycystic ovary syndrome on chromosome 2p16.3, 2p21 and 9q33.3. *Nat Genet* [Internet]. 2011;43(1):55–9. Cited 28 Mar 2016. Available from: <http://www.ncbi.nlm.nih.gov/pubmed/21151128>.
- Choi J, Smitz J. Luteinizing hormone and human chorionic gonadotropin: origins of difference. *Mol Cell Endocrinol*. 2014;383(1–2):203–13.
- Chrusciel M, Vuorenoja S, Mohanty B, Rivero-Müller A, Li X, Toppari J, et al. Transgenic GATA-4 expression induces adrenocortical tumorigenesis in C57Bl/6 mice. *J Cell Sci* [Internet]. The Company of Biologists Ltd; 2013;126(8):1845–57. Cited 25 Sept 2015. Available from: <http://www.pubmedcentral.nih.gov/articlerender.fcgi?artid=3678410&tool=pmcentrez&rendertype=abstract>.
- Chu L, Li J, Liu Y, Hu W, Cheng CH. Targeted gene disruption in zebrafish reveals noncanonical functions of LH signaling in reproduction. *Mol Endocrinol*. 2014;28(11):1785–95.
- Cohen BD, Bariteau JT, Magenis LM, Dias JA. Regulation of follitropin receptor cell surface residency by the ubiquitin-proteasome pathway. *Endocrinology* [Internet]. Endocr Soc. 2011. Cited 26 May 2016. Available from: <http://press.endocrine.org/doi/full/10.1210/en.2002-0063>.
- Cole LA. hCG, the wonder of today's science. *Reprod Biol Endocrinol*. 2012;10:24.
- Conti M. Specificity of the cyclic adenosine 3',5'-monophosphate signal in granulosa cell function. *Biol Reprod* [Internet]. 2002;67(6):1653–61. Cited 26 Apr 2016. Available from: <http://www.ncbi.nlm.nih.gov/pubmed/12444038>.
- Costagliola S, Panneels V, Bonomi M, Koch J, Many MC, Smits G, et al. Tyrosine sulfation is required for agonist recognition by glycoprotein hormone receptors. *EMBO J*. 2002;21(4):504–13.



- Costagliola S, Urizar E, Mendive F, Vassart G. Specificity and promiscuity of gonadotropin receptors. *Reproduction* [Internet]. 2005;130(3):275–81. Cited 25 May 2016. Available from: <http://www.reproduction-online.org/content/130/3/275.full>.
- De Leener A, Caltabiano G, Erkan S, Idil M, Vassart G, Pardo L, et al. Identification of the first germline mutation in the extracellular domain of the follitropin receptor responsible for spontaneous ovarian hyperstimulation syndrome. *Hum Mutat* [Internet]. 2008 ;29(1):91–8. Cited 4 May 2016. Available from: <http://www.ncbi.nlm.nih.gov/pubmed/17721928>.
- Desai SS, Achrekar SK, Pathak BR, Desai SK, Mangoli VS, Mangoli R V, et al. Follicle-stimulating hormone receptor polymorphism (G-29A) is associated with altered level of receptor expression in granulosa cells. *J Clin Endocrinol Metab* [Internet]. 2011;96(9):2805–12. Cited 29 Apr 2016. Available from: <http://www.ncbi.nlm.nih.gov/pubmed/21752882>.
- Desai SS, Roy BS, Mahale SD. Mutations and polymorphisms in FSH receptor: functional implications in human reproduction. *Reproduction* [Internet]. 2013;146(6):R235–48. Cited 4 May 2016. Available from: <http://www.ncbi.nlm.nih.gov/pubmed/24051057>.
- Doherty E, Pakarinen P, Tiitinen A, Kiilavuori A, Huhtaniemi I, Forrest S, et al. A Novel mutation in the FSH receptor inhibiting signal transduction and causing primary ovarian failure. *J Clin Endocrinol Metab* [Internet]. 2002;87(3):1151–5. Cited 6 May 2016. Available from: <http://www.ncbi.nlm.nih.gov/pubmed/11889179>.
- Donadeu FX, Ascoli M. The differential effects of the gonadotropin receptors on aromatase expression in primary cultures of immature rat granulosa cells are highly dependent on the density of receptors expressed and the activation of the inositol phosphate cascade. *Endocrinology* [Internet]. 2005;146(9):3907–16. Cited 23 May 2016. Available from: <http://www.pubmedcentral.nih.gov/articlerender.fcgi?artid=1262674&tool=pmcentrez&rendertype=abstract>.
- Dupakuntla M, Mahale SD. Accessibility of the extracellular loops of follicle stimulating hormone receptor and their role in hormone-receptor interaction. *Mol Cell Endocrinol*. 2010;315(1–2):131–7.
- Dupakuntla M, Pathak B, Roy BS, Mahale SD. Extracellular loop 2 in the FSH receptor is crucial for ligand mediated receptor activation. *Mol Cell Endocrinol*. 2012;362(1–2):60–8.
- Eikvar L, Taskén KA, Eskild W, Hansson V. Protein kinase C activation and positive and negative agonist regulation of 3',5'-cyclic adenosine monophosphate levels in cultured rat Sertoli cells. *Acta Endocrinol (Copenh)* [Internet]. 1993;128(6):568–72. Cited 27 Apr 2016. Available from: <http://www.ncbi.nlm.nih.gov/pubmed/7687809>.
- El-Gehani F, Zhang FP, Pakarinen P, Rannikko A, Huhtaniemi I. Gonadotropin-independent regulation of steroidogenesis in the fetal rat testis. *Biol Reprod* [Internet]. 1998;58(1):116–23. Cited 11 July 2016. Available from: <http://www.ncbi.nlm.nih.gov/pubmed/9472931>.
- Fan QR, Hendrickson WA. Structure of human follicle-stimulating hormone in complex with its receptor. *Nature* [Internet]. 2005;433(7023):269–77. Available from: [http://www.ncbi.nlm.nih.gov/entrez/query.fcgi?cmd=Retrieve&db=PubMed&dopt=Citation&list\\_uids=15662415](http://www.ncbi.nlm.nih.gov/entrez/query.fcgi?cmd=Retrieve&db=PubMed&dopt=Citation&list_uids=15662415).
- Fang L, Yu Y, Zhang R, He J, Sun Y-P. Amphiregulin mediates hCG-induced StAR expression and progesterone production in human granulosa cells. *Sci Rep* [Internet]. Nature Publishing Group. 2016;6:24917. Cited 5 May 2016. Available from: <http://www.nature.com/srep/2016/160426/srep24917/full/srep24917.html>.
- Foulkes NS, Mellström B, Benusiglio E, Sassone-Corsi P. Developmental switch of CREM function during spermatogenesis: from antagonist to activator. *Nature* [Internet]. 1992;355(6355):80–4. Cited 23 May 2016. Available from: <http://www.ncbi.nlm.nih.gov/pubmed/1370576>.
- Furtado PS, Moraes F, Lago R, Barros LO, Toralles MB, Barroso U. Gender dysphoria associated with disorders of sex development. *Nat Rev Urol* [Internet]. Nature Publishing Group, a division of Macmillan Publishers Limited. All Rights Reserved.; 2012;9(11):620–7. Cited 30 May 2016. Available from: <http://dx.doi.org/10.1038/nrurol.2012.182>.
- García-López A, de Jonge H, Nóbrega RH, de Waal PP, van Dijk W, Hemrika W, et al. Studies in zebrafish reveal unusual cellular expression patterns of gonadotropin receptor messenger

- ribonucleic acids in the testis and unexpected functional differentiation of the gonadotropins. *Endocrinology* [Internet]. 2010;151(5):2349–60. Cited 27 May 2014. Available from: <http://www.pubmedcentral.nih.gov/articlerender.fcgi?artid=2869266&tool=pmcentrez&rendertype=abstract>.
- Garverick HA, Baxter G, Gong J, Armstrong DG, Campbell BK, Gutierrez CG, et al. Regulation of expression of ovarian mRNA encoding steroidogenic enzymes and gonadotrophin receptors by FSH and GH in hypogonadotrophic cattle. *Reproduction* [Internet]. 2002;123(5):651–61. Cited 25 May 2016. Available from: <http://www.ncbi.nlm.nih.gov/pubmed/12006093>.
- Geng Y, Tsai-Morris CH, Zhang Y, Dufau ML. The human luteinizing hormone receptor gene promoter: activation by Sp1 and Sp3 and inhibitory regulation.- *PubMed - NCBI. Biochem Biophys Res Commun.* 1999;263(2):366–71.
- George JW, Dille EA, Heckert LL. Current concepts of follicle-stimulating hormone receptor gene regulation. *Biol Reprod* [Internet]. 2011;84(1):7–17. Cited 10 Feb 2016. Available from: <http://www.biolreprod.org/content/84/1/7.full>.
- Ghinea N, Mai T V, Groyer-Picard MT, Milgrom E. How protein hormones reach their target cells. Receptor-mediated transcytosis of hCG through endothelial cells. *J Cell Biol* [Internet]. 1994;125(1):87–97. Cited 25 May 2016. Available from: <http://www.pubmedcentral.nih.gov/articlerender.fcgi?artid=2120011&tool=pmcentrez&rendertype=abstract>.
- Gloaguen P, Crépieux P, Heitzler D, Poupon A, Reiter E. Mapping the follicle-stimulating hormone-induced signaling networks. *Front Endocrinol (Lausanne)* [Internet]. 2011;2:45. Cited 26 Apr 2016. Available from: <http://www.pubmedcentral.nih.gov/articlerender.fcgi?artid=3364461&tool=pmcentrez&rendertype=abstract>.
- Greb RR, Behre HM, Simoni M. Pharmacogenetics in ovarian stimulation – current concepts and future options. *Reprod BioMed Online* [Internet]. 2005;11(5):589–600. Cited 28 Apr 2016. Available from: <http://www.ncbi.nlm.nih.gov/pubmed/16409708>.
- Grigороva M, Punab M, Poolamets O, Söber S, Vihljajev V, Žilaitienė B, et al. Study in 1790 Baltic men: FSHR Asn680Ser polymorphism affects total testes volume. *Andrology* [Internet]. 2013;1(2):293–300. Cited 11 July 2016. Available from: <http://www.pubmedcentral.nih.gov/articlerender.fcgi?artid=3674532&tool=pmcentrez&rendertype=abstract>.
- Grigороva M, Punab M, Punab AM, Poolamets O, Vihljajev V, Žilaitienė B, et al. Reproductive physiology in young men is cumulatively affected by FSH-action modulating genetic variants: FSHR -29G/A and c.2039 A/G, FSHB -211G/T. *PLoS ONE* [Internet]. 2014;9(4):e94244. Cited 11 July 2016. Available from: <http://www.pubmedcentral.nih.gov/articlerender.fcgi?artid=3981791&tool=pmcentrez&rendertype=abstract>.
- Gromoll J, Pekel E, Nieschlag E. The structure and organization of the human follicle-stimulating hormone receptor (FSHR) gene. *Genomics* [Internet]. 1996a;35(2):308–11. Cited 5 May 2016. Available from: <http://www.ncbi.nlm.nih.gov/pubmed/8661143>.
- Gromoll J, Simoni M, Nieschlag E. An activating mutation of the follicle-stimulating hormone receptor autonomously sustains spermatogenesis in a hypophysectomized man. *J Clin Endocrinol Metab* [Internet]. 1996/04/01 ed. 1996b;81(4):1367–70. Available from: [http://www.ncbi.nlm.nih.gov/entrez/query.fcgi?cmd=Retrieve&db=PubMed&dopt=Citation&list\\_uids=8636335](http://www.ncbi.nlm.nih.gov/entrez/query.fcgi?cmd=Retrieve&db=PubMed&dopt=Citation&list_uids=8636335).
- Gromoll J, Simoni M, Nordhoff V, Behre HM, De Geyter C, Nieschlag E. Functional and clinical consequences of mutations in the FSH receptor. *Mol Cell Endocrinol* [Internet]. 1996c;125(1–2):177–82. Cited 4 May 2016. Available from: <http://www.ncbi.nlm.nih.gov/pubmed/9027356>.
- Gromoll J, Eiholzer U, Nieschlag E, Simoni M. Male hypogonadism caused by homozygous deletion of exon 10 of the luteinizing hormone (LH) receptor: differential action of human chorionic gonadotropin and LH. *J Clin Endocrinol Metab* [Internet]. 2000/06/14 ed. 2000;85(6):2281–6. Available from: [http://www.ncbi.nlm.nih.gov/entrez/query.fcgi?cmd=Retrieve&db=PubMed&dopt=Citation&list\\_uids=10852464](http://www.ncbi.nlm.nih.gov/entrez/query.fcgi?cmd=Retrieve&db=PubMed&dopt=Citation&list_uids=10852464).
- Gromoll J, Schulz A, Borta H, Gudermann T, Teerds KJ, Greschniok A, et al. Homozygous mutation within the conserved Ala-Phe-Asn-Glu-Thr motif of exon 7 of the LH receptor causes

- male pseudohermaphroditism. *Eur J Endocrinol* [Internet]. 2002;147(5):597–608. Cited 4 July 2016. Available from: <http://www.ncbi.nlm.nih.gov/pubmed/12444891>.
- Gromoll J, Wistuba J, Terwort N, Godmann M, Müller T, Simoni M, et al. A new subclass of the luteinizing hormone/chorionic gonadotropin receptor lacking exon 10 messenger RNA in the New World monkey (Platyrrhini) lineage. *Biol Reprod* [Internet]. 2003/02/28 ed. 2003;69(1):75–80. Cited 20 Apr 2016. Available from: [http://www.ncbi.nlm.nih.gov/entrez/query.fcgi?cmd=Retrieve&db=PubMed&dopt=Citation&list\\_uids=12606382](http://www.ncbi.nlm.nih.gov/entrez/query.fcgi?cmd=Retrieve&db=PubMed&dopt=Citation&list_uids=12606382).
- Grzesik P, Teichmann A, Furkert J, Rutz C, Wiesner B, Kleinau G, et al. Differences between lutropin-mediated and choriongonadotropin-mediated receptor activation. *FEBS J*. 2014;281(5):1479–92.
- Grzesik P, Kreuchwig A, Rutz C, Furkert J, Wiesner B, Schuelein R, et al. Differences in signal activation by LH and hCG are mediated by the LH/CG receptor's extracellular hinge region. *Front Endocrinol (Lausanne)*. 2015;6:140.
- Guillou F, Combarnous Y. Purification of equine gonadotropins and comparative study of their acid-dissociation and receptor-binding specificity. *Biochim Biophys Acta* [Internet]. 1983/01/25 ed. 1983;755(2):229–36. Available from: [http://www.ncbi.nlm.nih.gov/entrez/query.fcgi?cmd=Retrieve&db=PubMed&dopt=Citation&list\\_uids=6299370](http://www.ncbi.nlm.nih.gov/entrez/query.fcgi?cmd=Retrieve&db=PubMed&dopt=Citation&list_uids=6299370).
- Hamalainen T, Poutanen M, Huhtaniemi I. Promoter function of different lengths of the murine luteinizing hormone receptor gene 5'-flanking region in transfected gonadal cells and in transgenic mice. *Endocrinology* [Internet]. 2001;142(6):2427–34. Available from: [http://www.ncbi.nlm.nih.gov/entrez/query.fcgi?cmd=Retrieve&db=PubMed&dopt=Citation&list\\_uids=11356691](http://www.ncbi.nlm.nih.gov/entrez/query.fcgi?cmd=Retrieve&db=PubMed&dopt=Citation&list_uids=11356691).
- Haywood M, Tymchenko N, Spaliviero J, Koch A, Jimenez M, Gromoll J, et al. An activated human follicle-stimulating hormone (FSH) receptor stimulates FSH-like activity in gonadotropin-deficient transgenic mice. *Mol Endocrinol* [Internet]. Endocrine Society. 2002 ;16(11):2582–91. Cited 3 May 2016. Available from: [http://press.endocrine.org/doi/10.1210/me.2002-0032?url\\_ver=Z39.88-2003&rft\\_id=ori:rid:crossref.org&rft\\_dat=cr\\_pub%3dpubmed](http://press.endocrine.org/doi/10.1210/me.2002-0032?url_ver=Z39.88-2003&rft_id=ori:rid:crossref.org&rft_dat=cr_pub%3dpubmed).
- Heckert LL, Daley IJ, Griswold MD. Structural organization of the follicle-stimulating hormone receptor gene. *Mol Endocrinol* [Internet]. 1992;6(1):70–80. Available from: <http://www.ncbi.nlm.nih.gov/pubmed/1738373>.
- Hong H, Yan Y, Shi S, Graves SA, Krasteva LK, Nickles RJ, et al. PET of follicle-stimulating hormone receptor: broad applicability to cancer imaging. *Mol Pharm* [Internet]. 2015;12(2):403–10. Cited 25 May 2016. Available from: <http://www.pubmedcentral.nih.gov/articlerender.fcgi?artid=4351720&tool=pmcentrez&rendertype=abstract>.
- Huhtaniemi I. A short evolutionary history of FSH-stimulated spermatogenesis. *Hormones (Athens)* [Internet]. 2015;14(4):468–78. Cited 28 June 2016. Available from: <http://www.ncbi.nlm.nih.gov/pubmed/26732152>.
- Huhtaniemi IT, Catt KJ. Differential binding affinities of rat testis luteinizing hormone (LH) receptors for human chorionic gonadotropin, human LH, and ovine LH. *Endocrinology* [Internet]. 1981;108(5):1931–8. Cited 28 June 2016. Available from: <http://www.ncbi.nlm.nih.gov/pubmed/6260468>.
- Huhtaniemi IT, Eskola V, Pakarinen P, Matikainen T, Sprengel R. The murine luteinizing hormone and follicle-stimulating hormone receptor genes: transcription initiation sites, putative promoter sequences and promoter activity. *Mol Cell Endocrinol*. 1992;88(1):55–66.
- Hunzicker-Dunn M, Barisas G, Song J, Roess DA. Membrane organization of luteinizing hormone receptors differs between actively signaling and desensitized receptors. *J Biol Chem* [Internet]. 2003;278(44):42744–9. Available from: [http://www.ncbi.nlm.nih.gov/entrez/query.fcgi?cmd=Retrieve&db=PubMed&dopt=Citation&list\\_uids=12930832](http://www.ncbi.nlm.nih.gov/entrez/query.fcgi?cmd=Retrieve&db=PubMed&dopt=Citation&list_uids=12930832).
- Insel PA, Zhang L, Murray F, Yokouchi H, Zambon AC. Cyclic AMP is both a pro-apoptotic and anti-apoptotic second messenger. *Acta Physiol (Oxf)* [Internet]. 2012;204(2):277–87. Cited 27 Apr 2016. Available from: <http://www.pubmedcentral.nih.gov/articlerender.fcgi?artid=3125423&tool=pmcentrez&rendertype=abstract>.

- Jeoung M, Lee C, Ji I, Ji TH. Trans-activation, cis-activation and signal selection of gonadotropin receptors. *Mol Cell Endocrinol* [Internet]. 2007;260–262:137–43. Available from: [http://www.ncbi.nlm.nih.gov/entrez/query.fcgi?cmd=Retrieve&db=PubMed&dopt=Citation&list\\_uids=17055146](http://www.ncbi.nlm.nih.gov/entrez/query.fcgi?cmd=Retrieve&db=PubMed&dopt=Citation&list_uids=17055146).
- Jeppesen JV, Kristensen SG, Nielsen ME, Humaidan P, Dal Canto M, Fadini R, et al. LH-receptor gene expression in human granulosa and cumulus cells from antral and preovulatory follicles. *J Clin Endocrinol Metab* [Internet]. The Endocrine Society. 2012;97(8):E1524–31. Cited 25 May 2016. Available from: <http://pubmed.ncbi.nlm.nih.gov/23410279/>?report=abstract.
- Ji I, Lee C, Jeoung M, Koo Y, Sievert GA, Ji TH. Trans-activation of mutant follicle-stimulating hormone receptors selectively generates only one of two hormone signals. *Mol Endocrinol* [Internet]. 2004;18(4):968–78. Available from: [http://www.ncbi.nlm.nih.gov/entrez/query.fcgi?cmd=Retrieve&db=PubMed&dopt=Citation&list\\_uids=14726491](http://www.ncbi.nlm.nih.gov/entrez/query.fcgi?cmd=Retrieve&db=PubMed&dopt=Citation&list_uids=14726491).
- Jiang X, Liu H, Chen X, Chen P-H, Fischer D, Sriraman V, et al. Structure of follicle-stimulating hormone in complex with the entire ectodomain of its receptor. *Proc Natl Acad Sci USA*. 2012;109(31):12491–6.
- Jiang X, Dias JA, He X. Structural biology of glycoprotein hormones and their receptors: insights to signaling. *Mol Cell Endocrinol*. 2014a;382(1):424–51.
- Jiang X, Fischer D, Chen X, McKenna SD, Liu H, Sriraman V, et al. Evidence for follicle-stimulating hormone receptor as a functional trimer. *J Biol Chem* [Internet]. 2014b;289(20):14273–82. Cited 28 June 2016. Available from: <http://www.pubmedcentral.nih.gov/articlerender.fcgi?artid=4022893&tool=pmcentrez&rendertype=abstract>.
- Jiang C, Hou X, Wang C, May JV, Butnev VY, Bousfield GR, et al. Hypoglycosylated hFSH has greater bioactivity than fully glycosylated recombinant hFSH in human granulosa cells. *J Clin Endocrinol Metab*. 2015;100(6):E852–60.
- Jo Y, King SR, Khan SA, Stocco DM. Involvement of protein kinase C and cyclic adenosine 3',5'-monophosphate-dependent kinase in steroidogenic acute regulatory protein expression and steroid biosynthesis in Leydig cells. *Biol Reprod* [Internet]. 2005;73(2):244–55. Cited 27 Apr 2016. Available from: <http://www.ncbi.nlm.nih.gov/pubmed/15814901>.
- Jonas KC, Rivero-Müller A, Huhtaniemi IT, Hanyaloglu AC. G protein-coupled receptor trans-activation: from molecules to mice. *Methods Cell Biol* [Internet]. 2012;117:433–50. Cited 6 Oct 2014. Available from: <http://www.sciencedirect.com/science/article/pii/B9780124081437000232>.
- Jonas KC, Fanelli F, Huhtaniemi IT, Hanyaloglu AC. Single molecule analysis of functionally asymmetric G protein-coupled receptor (GPCR) oligomers reveals diverse spatial and structural assemblies. *J Biol Chem* [Internet]. 2015;290(7):3875–92. Cited 15 Feb 2016. Available from: <http://www.pubmedcentral.nih.gov/articlerender.fcgi?artid=4326798&tool=pmcentrez&rendertype=abstract>.
- Kawate N, Menon KM. Palmitoylation of luteinizing hormone/human choriogonadotropin receptors in transfected cells. Abolition of palmitoylation by mutation of Cys-621 and Cys-622 residues in the cytoplasmic tail increases ligand-induced internalization of the receptor. *J Biol Chem*. 1994;269(48):30651–8.
- Kawate N, Kletter GB, Wilson BE, Netzloff ML, Menon KM. Identification of constitutively activating mutation of the luteinizing hormone receptor in a family with male limited gonadotropin independent precocious puberty (testotoxicosis). *J Med Genet* [Internet]. 1995;32(7):553–4. Cited 28 June 2016. Available from: <http://www.pubmedcentral.nih.gov/articlerender.fcgi?artid=1050550&tool=pmcentrez&rendertype=abstract>.
- Kendall SK, Samuelson LC, Saunders TL, Wood RI, Camper SA. Targeted disruption of the pituitary glycoprotein hormone alpha-subunit produces hypogonadal and hypothyroid mice. *Genes Dev* [Internet]. 1995;9(16):2007–19. Cited 26 May 2016. Available from: <http://genesdev.cshlp.org/content/9/16/2007.abstract>.
- Klarenbeek JB, Goedhart J, Hink MA, Gadella TWJ, Jalink K. A mTurquoise-based cAMP sensor for both FLIM and ratiometric read-out has improved dynamic range. *PLoS ONE* [Internet]. 2011 ed. 2011 Jan 29;6(4):e19170. Cited 31 Oct 2012. Available from: [http://www.ncbi.nlm.nih.gov/entrez/query.fcgi?cmd=Retrieve&db=PubMed&dopt=Citation&list\\_uids=21559477](http://www.ncbi.nlm.nih.gov/entrez/query.fcgi?cmd=Retrieve&db=PubMed&dopt=Citation&list_uids=21559477).

- Kobe B, Deisenhofer J. Crystal structure of porcine ribonuclease inhibitor, a protein with leucine-rich repeats. *Nature*. 1993;366(6457):751–6.
- Kossack N, Simoni M, Richter-Unruh A, Themmen APN, Gromoll J. Mutations in a novel, cryptic exon of the luteinizing hormone/chorionic gonadotropin receptor gene cause male pseudohermaphroditism. *PLoS Med*. 2008;5(4):e88.
- Kremer H, Kraaij R, Toledo SP, Post M, Fridman JB, Hayashida CY, et al. Male pseudohermaphroditism due to a homozygous missense mutation of the luteinizing hormone receptor gene. *Nat Genet* [Internet]. 1995;9(2):160–4. Cited 19 May 2016. Available from: <http://www.ncbi.nlm.nih.gov/pubmed/7719343>.
- Krishnamurthy H, Danilovich N, Morales CR, Sairam MR. Qualitative and quantitative decline in spermatogenesis of the follicle-stimulating hormone receptor knockout (FORKO) mouse. *Biol Reprod* [Internet]. 2000;62(5):1146–59. Cited 28 June 2016. Available from: <http://www.ncbi.nlm.nih.gov/pubmed/10775161>.
- Kuechler A, Hauffa BP, Köninger A, Kleinau G, Albrecht B, Horsthemke B, et al. An unbalanced translocation unmasks a recessive mutation in the follicle-stimulating hormone receptor (FSHR) gene and causes FSH resistance. *Eur J Hum Genet* [Internet]. 2010;18(6):656–61. Cited 6 May 2016. Available from: <http://www.pubmedcentral.nih.gov/articlerender.fcgi?artid=2987335&tool=pmcentrez&rendertype=abstract>.
- Kumar TR. Mouse models for gonadotropins: a 15-year saga. *Mol Cell Endocrinol* [Internet]. 2007;260–262:249–54. Cited 26 May 2016. Available from: <http://www.sciencedirect.com/science/article/pii/S0303720706004229>.
- Kumar TR, Wang Y, Lu N, Matzuk MM. Follicle stimulating hormone is required for ovarian follicle maturation but not male fertility. *Nat Genet* [Internet]. 1997;15(2):201–4. Cited 14 May 2016. Available from: <http://www.ncbi.nlm.nih.gov/pubmed/9020850>.
- Latronico AC, Anasti J, Arnold IJ, Rapaport R, Mendonca BB, Bloise W, et al. Brief report: testicular and ovarian resistance to luteinizing hormone caused by inactivating mutations of the luteinizing hormone-receptor gene. *N Engl J Med* [Internet]. 1996;334(8):507–12. Cited 19 May 2016. Available from: <http://www.ncbi.nlm.nih.gov/pubmed/8559204>.
- Lee C, Ji I, Ryu K, Song Y, Conn PM, Ji TH. Two defective heterozygous luteinizing hormone receptors can rescue hormone action. *J Biol Chem* [Internet]. 2002a;277(18):15795–800. Available from: [http://www.ncbi.nlm.nih.gov/entrez/query.fcgi?cmd=Retrieve&db=PubMed&dopt=Citation&list\\_uids=11859079](http://www.ncbi.nlm.nih.gov/entrez/query.fcgi?cmd=Retrieve&db=PubMed&dopt=Citation&list_uids=11859079).
- Lee PSN, Buchan AMJ, Hsueh AJW, Yuen BH, Leung PCK. Intracellular calcium mobilization in response to the activation of human wild-type and chimeric gonadotropin receptors. *Endocrinology*. 2002b;143(5):1732–40.
- Lei Y, Hagen GM, Smith SML, Liu J, Barisas G, Roess DA. Constitutively-active human LH receptors are self-associated and located in rafts. *Mol Cell Endocrinol* [Internet]. 2007;260–262:65–72. Cited 1 Mar 2016. Available from: <http://www.pubmedcentral.nih.gov/articlerender.fcgi?artid=1904512&tool=pmcentrez&rendertype=abstract>.
- Lend AK, Belousova A, Haller-Kikkatalo K, Punab M, Poolamets O, Peters M, et al. Follicle-stimulating hormone receptor gene haplotypes and male infertility in Estonian population and meta-analysis. *Syst Biol Reprod Med* [Internet]. 2010;56(1):84–90. Cited 4 May 2016. Available from: <http://www.ncbi.nlm.nih.gov/pubmed/20170288>.
- Liu G, Duranteau L, Carel JC, Monroe J, Doyle DA, Shenker A. Leydig-cell tumors caused by an activating mutation of the gene encoding the luteinizing hormone receptor. *N Engl J Med* [Internet]. 1999/12/02 ed. 1999;341(23):1731–6. Cited 17 May 2016. Available from: <http://www.ncbi.nlm.nih.gov/pubmed/10580072>.
- Lohse MJ, Benovic JL, Codina J, Caron MG, Lefkowitz RJ. Beta-arrestin: a protein that regulates beta-adrenergic receptor function. *Science* [Internet]. 1990;248(4962):1547–50. Cited 27 Apr 2016. Available from: <http://www.ncbi.nlm.nih.gov/pubmed/2163110>.
- Loss ES, Jacobus AP, Wassermann GF. Rapid signaling responses in Sertoli cell membranes induced by follicle stimulating hormone and testosterone: calcium inflow and electrophysiological changes.

- Life Sci [Internet]. 2011 . ;89(15–16):577–83. Cited 26 Apr 2016. Available from: <http://www.ncbi.nlm.nih.gov/pubmed/21703282>.
- Ma X, Dong Y, Matzuk MM, Kumar TR. Targeted disruption of luteinizing hormone beta-subunit leads to hypogonadism, defects in gonadal steroidogenesis, and infertility. *Proc Natl Acad Sci U S A* [Internet]. 2004;101(49):17294–9. Cited 26 May 2016. Available from: <http://www.pubmedcentral.nih.gov/articlerender.fcgi?artid=535369&tool=pmcentrez&rendertype=abstract>.
- Manna PR, Stocco DM. The role of specific mitogen-activated protein kinase signaling cascades in the regulation of steroidogenesis. *J Signal Transduct* [Internet]. 2011;2011:821615. Cited 27 Apr 2016. Available from: <http://www.pubmedcentral.nih.gov/articlerender.fcgi?artid=3100650&tool=pmcentrez&rendertype=abstract>.
- Mazurkiewicz JE, Herrick-Davis K, Barroso M, Ulloa-Aguirre A, Lindau-Shepard B, Thomas RM, et al. Single-molecule analyses of fully functional fluorescent protein-tagged follitropin receptor reveal homodimerization and specific heterodimerization with lutropin receptor. *Biol Reprod* [Internet]. 2015;92(4):100. Cited 1 Mar 2016. Available from: <http://www.ncbi.nlm.nih.gov/pubmed/25761594>.
- McAllister JM, Legro RS, Modi BP, Strauss JF. Functional genomics of PCOS: from GWAS to molecular mechanisms. *Trends Endocrinol Metab* [Internet]. 2015;26(3):118–24. Cited 3 May 2016. Available from: <http://www.pubmedcentral.nih.gov/articlerender.fcgi?artid=4346470&tool=pmcentrez&rendertype=abstract>.
- McFarland KC, Sprengel R, Phillips HS, Köhler M, Rosemblit N, Nikolics K, et al. Lutropin-choriogonadotropin receptor: an unusual member of the G protein-coupled receptor family. *Science*. 1989;245(4917):494–9.
- Menon KMJ, Menon B. Structure, function and regulation of gonadotropin receptors – a perspective. *Mol Cell Endocrinol* [Internet]. 2012;356(1–2):88–97. Cited 25 May 2016. Available from: <http://www.pubmedcentral.nih.gov/articlerender.fcgi?artid=3327826&tool=pmcentrez&rendertype=abstract>.
- Menon KMJ, Munshi UM, Clouser CL, Nair AK. Regulation of luteinizing hormone/human chorionic gonadotropin receptor expression: a perspective. *Biol Reprod* [Internet]. 2004;70(4):861–6. Cited 23 May 2016. Available from: <http://www.biolreprod.org/content/70/4/861.abstract>.
- Menon B, Franzo-Romain M, Damanpour S, Menon KMJ. Luteinizing hormone receptor mRNA down-regulation is mediated through ERK-dependent induction of RNA binding protein. *Mol Endocrinol* [Internet]. 2011 ;25(2):282–90. Cited 26 Apr 2016. Available from: <http://www.pubmedcentral.nih.gov/articlerender.fcgi?artid=3386540&tool=pmcentrez&rendertype=abstract>.
- Meroni SB, Riera MF, Pellizzari EH, Cigorraga SB. Regulation of rat Sertoli cell function by FSH: possible role of phosphatidylinositol 3-kinase/protein kinase B pathway.- *PubMed - NCBI. J Endocrinol* [Internet]. 2002;174(2):195–204. Cited 26 Apr 2016. Available from: <http://www.ncbi.nlm.nih.gov/pubmed/12176658>.
- Mertens-Walker I, Bolitho C, Baxter RC, Marsh DJ. Gonadotropin-induced ovarian cancer cell migration and proliferation require extracellular signal-regulated kinase 1/2 activation regulated by calcium and protein kinase C{delta}. *Endocr Relat Cancer* [Internet]. 2010;17(2):335–49. Cited 27 Apr 2016. Available from: <http://www.ncbi.nlm.nih.gov/pubmed/20215102>.
- Minegishi T, Nakamura K, Takakura Y, Miyamoto K, Hasegawa Y, Ibuki Y, et al. Cloning and sequencing of human LH/hCG receptor cDNA. *Biochem Biophys Res Commun*. 1990;172(3):1049–54.
- Minegishi T, Nakamura K, Takakura Y, Ibuki Y, Igarashi M, Minegish T [corrected to Minegishi T]. Cloning and sequencing of human FSH receptor cDNA. *Biochem Biophys Res Commun*. 1991;175(3):1125–30.
- Minegishi T, Tano M, Abe Y, Nakamura K, Ibuki Y, Miyamoto K. Expression of luteinizing hormone/human chorionic gonadotropin (LH/HCG) receptor mRNA in the human ovary. *Mol Hum Reprod* [Internet]. 1997;3(2):101–7. Cited 28 June 2016. Available from: <http://www.ncbi.nlm.nih.gov/pubmed/9239715>.

- Mitri F, Bentov Y, Behan LA, Esfandiari N, Casper RF. A novel compound heterozygous mutation of the luteinizing hormone receptor -implications for fertility. *J Assist Reprod Genet* [Internet]. 2014;31(7):787–94. Cited 18 May 2016. Available from: <http://www.pubmedcentral.nih.gov/articlerender.fcgi?artid=4096877&tool=pmcentrez&rendertype=abstract>.
- Montanelli L, Van Durme JJJ, Smits G, Bonomi M, Rodien P, Devor EJ, et al. Modulation of ligand selectivity associated with activation of the transmembrane region of the human follitropin receptor. *Mol Endocrinol* [Internet]. 2004;18(8):2061–73. Cited 6 May 2016. Available from: <http://www.ncbi.nlm.nih.gov/pubmed/15166252>.
- Monticone S, Auchus RJ, Rainey WE. Adrenal disorders in pregnancy. *Nat Rev Endocrinol* [Internet]. 2012;8(11):668–78. Available from: <http://www.ncbi.nlm.nih.gov/pubmed/22965163>.
- Müller T, Simoni M, Pekel E, Luetjens CM, Chandolia R, Amato F, et al. Chorionic gonadotrophin beta subunit mRNA but not luteinising hormone beta subunit mRNA is expressed in the pituitary of the common marmoset (*Callithrix jacchus*). *J Mol Endocrinol* [Internet]. 2004 ed. 2004 Feb;32(1):115–28. Cited 28 Apr 2016. Available from: [http://www.ncbi.nlm.nih.gov/entrez/query.fcgi?cmd=Retrieve&db=PubMed&dopt=Citation&list\\_uids=14765996](http://www.ncbi.nlm.nih.gov/entrez/query.fcgi?cmd=Retrieve&db=PubMed&dopt=Citation&list_uids=14765996).
- Munier M, Grouleff J, Gourdin L, Fauchard M, Chantreau V, Henrion D, et al. In vitro effects of the endocrine disruptor p,p’DDT on human follitropin receptor. *Environ Health Perspect* [Internet]. 2016;124(7):991–9. Cited 11 July 2016. Available from: <http://www.ncbi.nlm.nih.gov/pubmed/26895433>.
- O’Shaughnessy PJ, Fleming LM, Jackson G, Hochgeschwender U, Reed P, Baker PJ. *Endocrinology* [Internet]. 2003;144(8):3279–84. Cited 15 Feb 2016. Available from: <http://www.ncbi.nlm.nih.gov/pubmed/12865302>.
- Oba Y, Hirai T, Yoshiura Y, Yoshikuni M, HNY K. The duality of fish gonadotropin receptors: cloning and functional characterization of a second gonadotropin receptor cDNA expressed in the ovary and testis of amago salmon (*Oncorhynchus rhodurus*). *Biochem Biophys Res Commun*. 1999;265(2):366–71.
- Osuga Y, Hayashi M, Kudo M, Conti M, Kobilka B, Hsueh AJ. Co-expression of defective luteinizing hormone receptor fragments partially reconstitutes ligand-induced signal generation. *J Biol Chem* [Internet]. 1997;272(40):25006–12. Available from: [http://www.ncbi.nlm.nih.gov/entrez/query.fcgi?cmd=Retrieve&db=PubMed&dopt=Citation&list\\_uids=9312107](http://www.ncbi.nlm.nih.gov/entrez/query.fcgi?cmd=Retrieve&db=PubMed&dopt=Citation&list_uids=9312107).
- Pakarainen T, Zhang FP, Poutanen M, Huhtaniemi I. Fertility in luteinizing hormone receptor-knockout mice after wild-type ovary transplantation demonstrates redundancy of extragonadal luteinizing hormone action. *J Clin Invest* [Internet] 2005;115(7):1862–8. Available from: [http://www.ncbi.nlm.nih.gov/entrez/query.fcgi?cmd=Retrieve&db=PubMed&dopt=Citation&list\\_uids=15951841](http://www.ncbi.nlm.nih.gov/entrez/query.fcgi?cmd=Retrieve&db=PubMed&dopt=Citation&list_uids=15951841).
- Pakarainen T, Ahtiainen P, Zhang F-P, Rulli S, Poutanen M, Huhtaniemi I. Extragonadal LH/hCG action—not yet time to rewrite textbooks. *Mol Cell Endocrinol* [Internet]. 2007;269(1–2):9–16. Cited 2016 Jun 28. Available from: <http://www.ncbi.nlm.nih.gov/pubmed/17350753>.
- Palczewski K, Kumasaka T, Hori T, Behnke CA, Motoshima H, Fox BA, et al. Crystal structure of rhodopsin: a G protein-coupled receptor. *Science*. 2000;289(5480):739–45.
- Paramonov VM, Mamaeva V, Sahlgren C, Rivero-Müller A. Genetically-encoded tools for cAMP probing and modulation in living systems. *Front Pharmacol* [Internet]. 2015;6:196. Cited 30 Oct 2015. Available from: <http://www.pubmedcentral.nih.gov/articlerender.fcgi?artid=4569861&tool=pmcentrez&rendertype=abstract>.
- Peltoketo H, Rivero-Muller A, Ahtiainen P, Poutanen M, Huhtaniemi I, Rivero-Müller A. Consequences of genetic manipulations of gonadotrophins and gonadotrophin receptors in mice. *Ann Endocrinol* [Internet]. 2010/04/07 ed. 2010;71(3):170–6. Cited 30 May 2012. Available from: <http://www.ncbi.nlm.nih.gov/pubmed/20362970>.
- Piersma D, Berns EM, Verhoef-Post M, Uitterlinden AG, Braakman I, Pols HA, et al. A common polymorphism renders the luteinizing hormone receptor protein more active by improving signal peptide function and predicts adverse outcome in breast cancer patients. *J Clin Endocrinol*

- Metab [Internet]. 2006;91(4):1470–6. Available from: [http://www.ncbi.nlm.nih.gov/entrez/query.fcgi?cmd=Retrieve&db=PubMed&dopt=Citation&list\\_uids=16464948](http://www.ncbi.nlm.nih.gov/entrez/query.fcgi?cmd=Retrieve&db=PubMed&dopt=Citation&list_uids=16464948).
- Pietilä EM, Tuusa JT, Apaja PM, Aatsinki JT, Hakalahti AE, Rajaniemi HJ, et al. Inefficient maturation of the rat luteinizing hormone receptor. A putative way to regulate receptor numbers at the cell surface. *J Biol Chem* [Internet]. 2005;280(28):26622–9. Cited 26 May 2016. Available from: <http://www.jbc.org/content/280/28/26622.full>.
- Pitcher JA, Tesmer JJ, Freeman JL, Capel WD, Stone WC, Lefkowitz RJ. Feedback inhibition of G protein-coupled receptor kinase 2 (GRK2) activity by extracellular signal-regulated kinases. *J Biol Chem* [Internet]. 1999;274(49):34531–4. Cited 27 Apr 2016. Available from: <http://www.ncbi.nlm.nih.gov/pubmed/10574913>.
- Powell BL, Piersma D, Kevenaar ME, van Staveren IL, Themmen APN, Iacopetta BJ, et al. Luteinizing hormone signaling and breast cancer: polymorphisms and age of onset. *J Clin Endocrinol Metab* [Internet]. 2003;88(4):1653–7. Cited 3 May 2016. Available from: <http://www.ncbi.nlm.nih.gov/pubmed/12679452>.
- Premont RT, Macrae AD, Stoffel RH, Chung N, Pitcher JA, Ambrose C, et al. Characterization of the G protein-coupled receptor kinase GRK4. Identification of four splice variants. *J Biol Chem* [Internet]. 1996 ed. 1996 Mar 15;271(11):6403–10. Cited 25 May 2016. Available from: [http://www.ncbi.nlm.nih.gov/entrez/query.fcgi?cmd=Retrieve&db=PubMed&dopt=Citation&list\\_uids=8626439](http://www.ncbi.nlm.nih.gov/entrez/query.fcgi?cmd=Retrieve&db=PubMed&dopt=Citation&list_uids=8626439).
- Qanbar R, Bouvier M. Role of palmitoylation/depalmitoylation reactions in G-protein-coupled receptor function. *Pharmacol Ther* [Internet]. 2003;97(1):1–33. Cited 23 May 2016. Available from: <http://www.ncbi.nlm.nih.gov/pubmed/12493533>.
- Radu A, Pichon C, Camparo P, Antoine M, Allory Y, Couvelard A, et al. Expression of follicle-stimulating hormone receptor in tumor blood vessels. *N Engl J Med* [Internet]. 2010/10/22 ed. 2010;363(17):1621–30. Cited 13 Feb 2016. Available from: [http://www.ncbi.nlm.nih.gov/entrez/query.fcgi?cmd=Retrieve&db=PubMed&dopt=Citation&list\\_uids=20961245](http://www.ncbi.nlm.nih.gov/entrez/query.fcgi?cmd=Retrieve&db=PubMed&dopt=Citation&list_uids=20961245).
- Reiter E, Lefkowitz RJ. GRKs and beta-arrestins: roles in receptor silencing, trafficking and signaling. *Trends Endocrinol Metab* [Internet]. 2006;17(4):159–65. Cited 1 Apr 2016. Available from: <http://www.ncbi.nlm.nih.gov/pubmed/16595179>.
- Richter-Unruh A, Verhoef-Post M, Malak S, Homoki J, Hauffa BP, Themmen APN. Leydig cell hypoplasia: absent luteinizing hormone receptor cell surface expression caused by a novel homozygous mutation in the extracellular domain. *J Clin Endocrinol Metab* [Internet]. 2004;89(10):5161–7. Cited 25 May 2016. Available from: <http://www.ncbi.nlm.nih.gov/pubmed/15472221>.
- Risma KA, Clay CM, Nett TM, Wagner T, Yun J, Nilson JH. Targeted overexpression of luteinizing hormone in transgenic mice leads to infertility, polycystic ovaries, and ovarian tumors. *Proc Natl Acad Sci U S A* [Internet]. National Academy of Sciences. 1995;92(5):1322–6. Cited 11 July 2016. Available from: <http://www.ncbi.nlm.nih.gov/pubmed/7877975>.
- Rivero-Müller A, Chou Y-YY-Y, Ji I, Lajic S, Hanyaloglu AC, Jonas K, et al. Rescue of defective G protein-coupled receptor function in vivo by intermolecular cooperation. *Proc Natl Acad Sci U S A* [Internet]. 2010 ed. National Acad Sciences. 2010;107(5):2319–24. Cited 16 Mar 2012. Available from: [http://www.ncbi.nlm.nih.gov/entrez/query.fcgi?cmd=Retrieve&db=PubMed&dopt=Citation&list\\_uids=20080658](http://www.ncbi.nlm.nih.gov/entrez/query.fcgi?cmd=Retrieve&db=PubMed&dopt=Citation&list_uids=20080658).
- Rivero-Müller A, Potorac I, Pintiaux A, Daly AF, Thiry A, Rydlewski C, et al. A novel inactivating mutation of the LH/chorionic gonadotrophin receptor with impaired membrane trafficking leading to Leydig cell hypoplasia type 1. *Eur J Endocrinol* [Internet]. 2015;172(6):K27–36. Cited 25 Sept 2015. Available from: <http://www.ncbi.nlm.nih.gov/pubmed/25795638>.
- Rodien P, Cetani F, Costagliola S, Tonacchera M, Duprez L, Minegishi T, et al. Evidences for an allelic variant of the human LC/CG receptor rather than a gene duplication: functional comparison of wild-type and variant receptors. *J Clin Endocrinol Metab* [Internet]. 1998;83(12):4431–4. Cited 3 May 2016. Available from: <http://www.ncbi.nlm.nih.gov/pubmed/9851790>.



- Roess DA, Horvat RD, Munnely H, Barisas BG. Luteinizing hormone receptors are self-associated in the plasma membrane. *Endocrinology* [Internet]. 2000;141(12):4518–23. Cited 1 Mar 2016. Available from: <http://www.ncbi.nlm.nih.gov/pubmed/11108263>.
- Rulli SB, Kuorelahti A, Karaer O, Pelliniemi LJ, Poutanen M, Huhtaniemi I. Reproductive disturbances, pituitary lactotrope adenomas, and mammary gland tumors in transgenic female mice producing high levels of human chorionic gonadotropin. *Endocrinology* [Internet]. 2002;143(10):4084–95. Available from: [http://www.ncbi.nlm.nih.gov/entrez/query.fcgi?cmd=Retrieve&db=PubMed&dopt=Citation&list\\_uids=12239120](http://www.ncbi.nlm.nih.gov/entrez/query.fcgi?cmd=Retrieve&db=PubMed&dopt=Citation&list_uids=12239120).
- Sangkhatthath S, Kanngum S, Jaruratanasirikul S, Tubtawee T, Chaiyapan W, Patrapinyokul S, et al. Peripheral precocious puberty in a male caused by Leydig cell adenoma harboring a somatic mutation of the LHR gene: report of a case. *J Med Assoc Thai* [Internet]. 2010;93(9):1093–7. Cited 28 June 2016. Available from: <http://www.ncbi.nlm.nih.gov/pubmed/20873084>.
- Schubert RL, Narayan P, Puett D. Specificity of cognate ligand-receptor interactions: fusion proteins of human chorionic gonadotropin and the heptahelical receptors for human luteinizing hormone, thyroid-stimulating hormone, and follicle-stimulating hormone. *Endocrinology*. 2003;144(1):129–37.
- Shetty G, Weng CCY, Porter KL, Zhang Z, Pakarinen P, Kumar TR, et al. Spermatogonial differentiation in juvenile spermatogonial depletion (jsd) mice with androgen receptor or follicle-stimulating hormone mutations. *Endocrinology* [Internet]. 2006;147(7):3563–70. Cited 28 June 2016. Available from: <http://www.ncbi.nlm.nih.gov/pubmed/16627582>.
- Shi Y, Zhao H, Shi Y, Cao Y, Yang D, Li Z, et al. Genome-wide association study identifies eight new risk loci for polycystic ovary syndrome. *Nat Genet* [Internet]. 2012;44(9):1020–1025. Cited 3 May 2016. Available from: <http://www.ncbi.nlm.nih.gov/pubmed/22885925>.
- Simoni M, Casarini L. Mechanisms in endocrinology: genetics of FSH action: a 2014-and-beyond view. *Eur J Endocrinol* [Internet]. 2014;170(3):R91–107. Cited 28 Apr 2016. Available from: <http://www.ncbi.nlm.nih.gov/pubmed/24288354>.
- Simoni M, Gromoll J, Nieschlag E. The follicle-stimulating hormone receptor: biochemistry, molecular biology, physiology, and pathophysiology. *Endocr Rev*. 1997;18(6):739–73.
- Simoni M, Gromoll J, Höppner W, Kamischke A, Krafft T, Stähle D, et al. Mutational analysis of the follicle-stimulating hormone (FSH) receptor in normal and infertile men: identification and characterization of two discrete FSH receptor isoforms. *J Clin Endocrinol Metab* [Internet]. 1999;84(2):751–5. Cited 29 Apr 2016. Available from: <http://www.ncbi.nlm.nih.gov/pubmed/10022448>.
- Simoni M, Tüttelmann F, Michel C, Böckenfeld Y, Nieschlag E, Gromoll J. Polymorphisms of the luteinizing hormone/chorionic gonadotropin receptor gene: association with maldescended testes and male infertility. *Pharmacogenet Genomics* [Internet]. 2008;18(3):193–200. Cited 3 May 2016. Available from: <http://www.ncbi.nlm.nih.gov/pubmed/18300940>.
- Simoni M, Santi D, Negri L, Hoffmann I, Muratori M, Baldi E, et al. Treatment with human, recombinant FSH improves sperm DNA fragmentation in idiopathic infertile men depending on the FSH receptor polymorphism p.N680S: a pharmacogenetic study. *Hum Reprod*. 2016;31:1960.
- Smith SM, Lei Y, Liu J, Cahill ME, Hagen GM, Barisas BG, et al. Luteinizing hormone receptors translocate to plasma membrane microdomains after binding of human chorionic gonadotropin. *Endocrinology* [Internet]. 2006;147(4):1789–95. Available from: [http://www.ncbi.nlm.nih.gov/entrez/query.fcgi?cmd=Retrieve&db=PubMed&dopt=Citation&list\\_uids=16410308](http://www.ncbi.nlm.nih.gov/entrez/query.fcgi?cmd=Retrieve&db=PubMed&dopt=Citation&list_uids=16410308).
- Smits G, Campillo M, Govaerts C, Janssens V, Richter C, Vassart G, et al. Glycoprotein hormone receptors: determinants in leucine-rich repeats responsible for ligand specificity. *EMBO J*. 2003a;22(11):2692–703.
- Smits G, Olatunbosun O, Delbaere A, Pierson R, Vassart G, Costagliola S. Ovarian hyperstimulation syndrome due to a mutation in the follicle-stimulating hormone receptor. *N Engl J Med* [Internet]. 2003b;349(8):760–6. Available from: [http://www.ncbi.nlm.nih.gov/entrez/query.fcgi?cmd=Retrieve&db=PubMed&dopt=Citation&list\\_uids=12930928](http://www.ncbi.nlm.nih.gov/entrez/query.fcgi?cmd=Retrieve&db=PubMed&dopt=Citation&list_uids=12930928).

- So W-K, Kwok H-F, Ge W. Zebrafish gonadotropins and their receptors: II. Cloning and characterization of zebrafish follicle-stimulating hormone and luteinizing hormone subunits – their spatial-temporal expression patterns and receptor specificity. *Biol Reprod* [Internet]. 2005;72(6):1382–96. Cited 1 July 2016. Available from: <http://www.ncbi.nlm.nih.gov/pubmed/15728794>.
- Sprengel R, Braun T, Nikolics K, Segaloff DL, Seeburg PH. The testicular receptor for follicle stimulating hormone: structure and functional expression of cloned cDNA. *Mol Endocrinol*. 1990;4(4):525–30.
- Stewart F, Allen WR. The binding of FSH, LH and PMSG to equine gonadal tissues. *J Reprod Fertil Suppl* [Internet]. 1979 ed. 1979;(27):431–40. Available from: [http://www.ncbi.nlm.nih.gov/entrez/query.fcgi?cmd=Retrieve&db=PubMed&dopt=Citation&list\\_uids=225496](http://www.ncbi.nlm.nih.gov/entrez/query.fcgi?cmd=Retrieve&db=PubMed&dopt=Citation&list_uids=225496).
- Stewart F, Allen WR. Biological functions and receptor binding activities of equine chorionic gonadotrophins. *J Reprod Fertil* [Internet]. 1981 ed. 1981;62(2):527–36. Available from: [http://www.ncbi.nlm.nih.gov/entrez/query.fcgi?cmd=Retrieve&db=PubMed&dopt=Citation&list\\_uids=6265633](http://www.ncbi.nlm.nih.gov/entrez/query.fcgi?cmd=Retrieve&db=PubMed&dopt=Citation&list_uids=6265633).
- Tano M, Minegishi T, Nakamura K, Karino S, Ibuki Y, Miyamoto K. Transcriptional and post-transcriptional regulation of FSH receptor in rat granulosa cells by cyclic AMP and activin. *J Endocrinol* [Internet]. 1997;153(3):465–73. Cited 23 May 2016. Available from: <http://www.ncbi.nlm.nih.gov/pubmed/9204001>.
- Tao Y-XX, Johnson NB, Segaloff DL. Constitutive and agonist-dependent self-association of the cell surface human lutropin receptor. *J Biol Chem* [Internet]. 2004;279(7):5904–14. Cited 1 Mar 2016. Available from: <http://www.ncbi.nlm.nih.gov/pubmed/14594799>.
- Tapanainen JS, Aittomäki K, Min J, Vaskivuo T, Huhtaniemi IT. Men homozygous for an inactivating mutation of the follicle-stimulating hormone (FSH) receptor gene present variable suppression of spermatogenesis and fertility. *Nat Genet* [Internet]. 1997;15(2):205–6. Cited 28 Mar 2016. Available from: <http://www.ncbi.nlm.nih.gov/pubmed/9020851>.
- Teo AED, Garg S, Shaikh LH, Zhou J, Karet Frankl FE, Gurnell M, et al. Pregnancy, primary aldosteronism, and adrenal CTNNB1 mutations. *N Engl J Med* [Internet]. Massachusetts Medical Society; 2015;373(15):1429–36. Cited 26 May 2016. Available from: <http://www.nejm.org/doi/full/10.1056/NEJMoa1504869?rss=searchAndBrowse#t=article>.
- Thomas RM, Nechamen CA, Mazurkiewicz JE, Muda M, Palmer S, Dias JA. Follicle-stimulating hormone receptor forms oligomers and shows evidence of carboxyl-terminal proteolytic processing. *Endocrinology* [Internet]. 2007 ed. 2007;148(5):1987–95. Available from: [http://www.ncbi.nlm.nih.gov/entrez/query.fcgi?cmd=Retrieve&db=PubMed&dopt=Citation&list\\_uids=17272391](http://www.ncbi.nlm.nih.gov/entrez/query.fcgi?cmd=Retrieve&db=PubMed&dopt=Citation&list_uids=17272391).
- Thomas RM, Nechamen CA, Mazurkiewicz JE, Ulloa-Aguirre A, Dias JA. The adapter protein APPL1 links FSH receptor to inositol 1,4,5-trisphosphate production and is implicated in intracellular Ca(2+) mobilization. *Endocrinology* [Internet]. 2011. Cited 27 Apr 2016;152(4):1691–701. Available from: <http://www.pubmedcentral.nih.gov/articlerender.fcgi?artid=3060640&tool=pmcentrez&rendertype=abstract>.
- Timossi C, Maldonado D, Vizcaino A, Lindau-Shepard B, Conn PM, Ulloa-Aguirre A. Structural determinants in the second intracellular loop of the human follicle-stimulating hormone receptor are involved in nnnn(s) protein activation. *Mol Cell Endocrinol* [Internet]. 2002 ed. 2002;189(1–2):157–68. Available from: [http://www.ncbi.nlm.nih.gov/entrez/query.fcgi?cmd=Retrieve&db=PubMed&dopt=Citation&list\\_uids=12039074](http://www.ncbi.nlm.nih.gov/entrez/query.fcgi?cmd=Retrieve&db=PubMed&dopt=Citation&list_uids=12039074).
- Tranchant T, Durand G, Gauthier C, Crépieux P, Ulloa-Aguirre A, Royère D, et al. Preferential  $\beta$ -arrestin signalling at low receptor density revealed by functional characterization of the human FSH receptor A189 V mutation. *Mol Cell Endocrinol* [Internet]. 2011.;331(1):109–18. Cited 27 Apr 2016. Available from: <http://www.ncbi.nlm.nih.gov/pubmed/20801186>.
- Trehan A, Rotgers E, Coffey ETE, Huhtaniemi I, Rivero-Müller A. CANDLES assay for monitoring GPCR induced cAMP generation in cell cultures. *Cell Commun Signal* [Internet]. 2014;12:70. Cited 25 Nov 2014. Available from: <http://www.biosignaling.com/content/12/1/70>.

- Trehan A, Kielbus M, Czapinski J, Stepulak A, Huhtaniemi IT, Rivero-Müller A. REPLACR-mutagenesis, a one-step method for site-directed mutagenesis by recombineering. *Sci Rep [Internet]*. Macmillan Publishers Limited. 2015;5:19121. Available from: <http://dx.doi.org/10.1038/srep19121>.
- Troppmann B, Kleinau G, Krause G, Gromoll J. Structural and functional plasticity of the luteinizing hormone/choriogonadotrophin receptor. *Hum Reprod Update*. 2013;19(5):583–602.
- Tüttelmann F, Laan M, Grigorova M, Punab M, Söber S, Gromoll J. Combined effects of the variants FSHB –211G>T and FSHR 2039A>G on male reproductive parameters. *J Clin Endocrinol Metab [Internet]*. 2012;97(10):3639–47. Cited 28 June 2016. Available from: <http://www.ncbi.nlm.nih.gov/pubmed/22791757>.
- Ulloa-Aguirre A, Dias JA, Bousfield G, Huhtaniemi I, Reiter E. Trafficking of the follitropin receptor. *Methods Enzymol [Internet]*. 2013;521:17–45. Cited 27 Apr 2016. Available from: <http://www.pubmedcentral.nih.gov/articlerender.fcgi?artid=4503599&tool=pmcentrez&rendertype=abstract>.
- Ulloa-Aguirre A, Reiter E, Bousfield G, Dias JA, Huhtaniemi I. Constitutive activity in gonadotropin receptors. *Adv Pharmacol [Internet]*. 2014;70:37–80. Cited 4 May 2016. Available from: <http://www.ncbi.nlm.nih.gov/pubmed/24931192>.
- Uribe A, Zariñán T, Pérez-Solis MA, Gutiérrez-Sagal R, Jardón-Valadez E, Piñeiro A, et al. Functional and structural roles of conserved cysteine residues in the carboxyl-terminal domain of the follicle-stimulating hormone receptor in human embryonic kidney 293 cells. *Biol Reprod [Internet]*. 2008 ed. 2008 May 1 ;78(5):869–82. Cited 23 May 2016. Available from: [http://www.ncbi.nlm.nih.gov/entrez/query.fcgi?cmd=Retrieve&db=PubMed&dopt=Citation&list\\_uids=18199880](http://www.ncbi.nlm.nih.gov/entrez/query.fcgi?cmd=Retrieve&db=PubMed&dopt=Citation&list_uids=18199880).
- Urizar E, Montanelli L, Loy T, Bonomi M, Swillens S, Gales C, et al. Glycoprotein hormone receptors: link between receptor homodimerization and negative cooperativity. *EMBO J [Internet]*. 2005;24(11):1954–64. Available from: [http://www.ncbi.nlm.nih.gov/entrez/query.fcgi?cmd=Retrieve&db=PubMed&dopt=Citation&list\\_uids=15889138](http://www.ncbi.nlm.nih.gov/entrez/query.fcgi?cmd=Retrieve&db=PubMed&dopt=Citation&list_uids=15889138).
- van Koppen CJ, Verboost PM, van de Lagemaat R, Karstens W-JF, Loozen HJJ, van Achterberg TAE, et al. Signaling of an allosteric, nanomolar potent, low molecular weight agonist for the follicle-stimulating hormone receptor. *Biochem Pharmacol*. 2013;85(8):1162–70.
- Vischer HF, Granneman JCM, Linskens MHK, Schulz RW, Bogerd J. Both recombinant African catfish LH and FSH are able to activate the African catfish FSH receptor. *J Mol Endocrinol [Internet]*. 2003;31(1):133–40. Cited 1 July 2016. Available from: <http://www.ncbi.nlm.nih.gov/pubmed/12914531>.
- Vu Hai MT, Lescop P, Loosfelt H, Ghinea N. Receptor-mediated transcytosis of follicle-stimulating hormone through the rat testicular microvasculature. *Biol Cell [Internet]*. 2004;96(2):133–44. Cited 25 May 2016. Available from: <http://www.ncbi.nlm.nih.gov/pubmed/15050368>.
- Walker WH, Habener JF. Role of transcription factors CREB and CREM in cAMP-regulated transcription during spermatogenesis. *Trends Endocrinol Metab*. 1996 [Internet];7(4):133–8. Cited 23 Jan 2016. Available from: <http://www.ncbi.nlm.nih.gov/pubmed/18406739>.
- Watanabe AM, McConnaughey MM, Strawbridge RA, Fleming JW, Jones LR, Besch Jr. HR. Muscarinic cholinergic receptor modulation of beta-adrenergic receptor affinity for catecholamines. *J Biol Chem [Internet]*. 1978 ed. 1978;253(14):4833–6. Available from: [http://www.ncbi.nlm.nih.gov/entrez/query.fcgi?cmd=Retrieve&db=PubMed&dopt=Citation&list\\_uids=209018](http://www.ncbi.nlm.nih.gov/entrez/query.fcgi?cmd=Retrieve&db=PubMed&dopt=Citation&list_uids=209018).
- Wu XQ, Xu SM, Wang YQ, Li Q, Wang ZQ, Zhang CL, et al. FSHR gene Thr307Ala and Asn680Ser polymorphisms in infertile men: an association study in North China and meta-analysis. *Genet Mol Res [Internet]*. 2015;14(2):5592–601. Cited 11 July 2016. Available from: <http://www.ncbi.nlm.nih.gov/pubmed/26125757>.
- Yang E-J, Nasipak BT, Kelley DB. Direct action of gonadotropin in brain integrates behavioral and reproductive functions. *Proc Natl Acad Sci USA [Internet]*. 2007;104(7):2477–82. Cited 23 May 2016. Available from: <http://www.pubmedcentral.nih.gov/articlerender.fcgi?artid=1893001&tool=pmcentrez&rendertype=abstract>.

- Yao Z, Petschnigg J, Ketteler R, Stagljar I. Application guide for omics approaches to cell signaling. *Nat Chem Biol*. Nature Publishing Group. 2015;11(6):387.
- Zhang Y, Dufau ML. Dual mechanisms of regulation of transcription of luteinizing hormone receptor gene by nuclear orphan receptors and histone deacetylase complexes. *J Steroid Biochem Mol Biol* [Internet]. 2003;85(2–5):401–414. Cited 25 May 2016. Available from: <http://www.ncbi.nlm.nih.gov/pubmed/12943729>.
- Zhang R, Xie X. Tools for GPCR drug discovery. *Acta Pharmacol Sin* [Internet]. Nature Publishing Group. 2012;33(3):372–84. Cited 3 July 2016. Available from: <http://www.ncbi.nlm.nih.gov/pubmed/22266728>.
- Zhang R, Cai H, Fatima N, Buczko E, Dufau ML. Functional glycosylation sites of the rat luteinizing hormone receptor required for ligand binding. *J Biol Chem* [Internet]. 1995;270(37):21722–8. Cited 26 May 2016. Available from: <http://www.ncbi.nlm.nih.gov/pubmed/7665591>.
- Zhang FP, Rannikko AS, Manna PR, Fraser HM, Huhtaniemi IT. Cloning and functional expression of the luteinizing hormone receptor complementary deoxyribonucleic acid from the marmoset monkey testis: absence of sequences encoding exon 10 in other species. *Endocrinology*. 1997;138(6):2481–90.
- Zhang F-P, Pakarainen T, Poutanen M, Toppari J, Huhtaniemi I. The low gonadotropin-independent constitutive production of testicular testosterone is sufficient to maintain spermatogenesis. *Proc Natl Acad Sci USA* [Internet]. 2003;100(23):13692–7. Cited 14 May 2016. Available from: <http://www.pubmedcentral.nih.gov/articlerender.fcgi?artid=263875&tool=pmcentrez&rendertype=abstract>.
- Zhang Z, Lau S-W, Zhang L, Ge W. Disruption of zebrafish follicle-stimulating hormone receptor (fshr) But not luteinizing hormone receptor (lhcg) gene by TALEN leads to failed follicle activation in females followed by sexual reversal to males. *Endocrinology*. 2015a;156:3747–62. <http://dx.doi.org/10.1210/en.2015-1039>. Endocrine Society Chevy Chase, MD.
- Zhang Z, Zhu B, Ge W. Genetic analysis of zebrafish gonadotropin (FSH and LH) functions by TALEN-mediated gene disruption. *Mol Endocrinol* [Internet]. 2015b;29(1):76–98. Cited 1 July 2016. Available from: <http://www.ncbi.nlm.nih.gov/pubmed/25396299>.
- Ziecik AJ, Jedlinska M, Rzucidlo SJ. Effect of estradiol and progesterone on myometrial LH/hCG receptors in pigs. *Eur J Endocrinol* [Internet]. *Eur Soc Endocrinol*. 1992;127(2):185–8. Cited 28 June 2016. Available from: <http://www.eje-online.org/cgi/doi/10.1530/acta.0.1270185>.

Sarah J. Potter, Deepti Lava Kumar, and Tony DeFalco

---

## Abstract

In mammals, the decision to become male or female is initiated in the gonad by the sex determination pathway, which drives and instructs the differentiation of the gonad into a testis or ovary. The gonad develops as an undifferentiated primordium that is initially indistinguishable between XX (female) and XY (male) embryos; the gonad is a uniquely bipotential organ in its ability to give rise to a testis or ovary. Prior to sex determination, the establishment of the gonadal anlage (i.e., the setup of genetic and cellular programs promoting its identity) by a set of specification factors is critical. The master switch of mammalian sex determination, the *Sry* gene on the Y chromosome, is the genetic trigger that sets sex determination in motion and launches the testis program in the gonad. *Sry* is necessary and sufficient for male development, while the ovarian pathway (under the control of a female-specific program) ensues in the absence of *Sry* expression during a critical developmental time window. In this chapter, we will cover the processes of gonad specification and sex determination, focusing on major factors and signaling pathways involved in the male-versus-female decision and the establishment of sexual dimorphism in the gonad. Additionally, we will briefly discuss evolutionarily conserved aspects of chromosomal sex determination mechanisms and environmental influences that potentially impact sex determination and sex ratio in mammals.

---

## Keywords

Gonad specification • Sex determination • Genital ridge • GATA4 • ZFPM2/FOG2 • WT1 • OSR1 • SIX1 • SIX4 • NR5A1/SF1 • INSR • IGF1R • TCF21 •

---

Sarah J. Potter and Deepti Lava Kumar contributed equally to this work.

S.J. Potter • D.L. Kumar • T. DeFalco (✉)

Division of Reproductive Sciences, Cincinnati Children's Hospital Medical Center, Cincinnati, OH, USA

e-mail: [sarah.potter@cchmc.org](mailto:sarah.potter@cchmc.org); [deepti.lava.kumar@cchmc.org](mailto:deepti.lava.kumar@cchmc.org); [tony.defalco@cchmc.org](mailto:tony.defalco@cchmc.org)

CITED2 • CBX2 • LHX9 • PBX1 • EMX2 • MFGE8 • WNT4 • RSPO1 • Sex chromosomes • XX/XY system • ZZ/ZW system • SRY • DMRT1 • Doublesex • MAB-3 • DM-domain proteins • Haplodiploidy sex determination • SOX9 • TGF-beta • Sertoli cells • MAP3K4 • GADD45g • FGF9 • PTGDS • NR0B1/DAX1 • Beta-catenin/CTNNB1 • FOXL2

## Contents

Gonad Specification .....	170
Origins of the Bipotential Gonadal Primordium .....	170
Genital Ridge Formation and Specification Factors .....	171
Sex Determination .....	183
Role of Chromosomes in Sex Determination .....	183
Chromosomal Sex Determination Mechanisms .....	184
Mammalian Testicular Sex Determination Genes .....	189
Mammalian Ovarian Sex Determination Genes .....	195
Environmental Influences in Mammalian Sex Determination/Sex Ratio .....	197
Conclusions and Future Areas of Research in the Field .....	203
References .....	204

## Gonad Specification

### Origins of the Bipotential Gonadal Primordium

Both the urinary and reproductive tract organs form from the same cellular source, the intermediate mesoderm. Within the intermediate mesoderm, the adreno-gonadal primordium (AGP) arises at 9.5 days post coitus (dpc) in the mouse; soon thereafter, the adrenal gland and gonad separate to form independent organs. At first the defined region of the gonad is referred to as the “genital ridge,” which represents the gonad anlage, i.e., the newly formed layers of cells on the surface of the mesonephros. The process of gonad specification by targeted cellular recruitment and cell fate specification starts to occur by 10.0–10.5 dpc in mice (McLaren 2000; Swain and Lovell-Badge 1999). The gonad is comprised of both somatic cells and germ cells. Germ cells migrate from the allantois via the gut tube, along the dorsal mesentery, and through the mesonephros to colonize the forming gonad between 10.5 and 11.5 dpc (discussed in ► [Chap. 6, “Male Sexual Differentiation”](#)). Germ cell colonization is not absolutely essential for early gonad formation and somatic cell development; however, the somatic cells are important for germ cell survival and proliferation (Kimble and White 1981). This chapter will focus specifically on the development of the somatic cell lineage. The gonad is a unique organ in that its primordium is bipotential, with the capability to become either a testis or an ovary, dependent on the presence or absence of sex-specific factors. Section “[Gonad Specification](#)” focuses on the factors important for the initial formation of the genital ridge, while section “[Sex Determination](#)” will cover the factors involved in sex determination within the gonad.

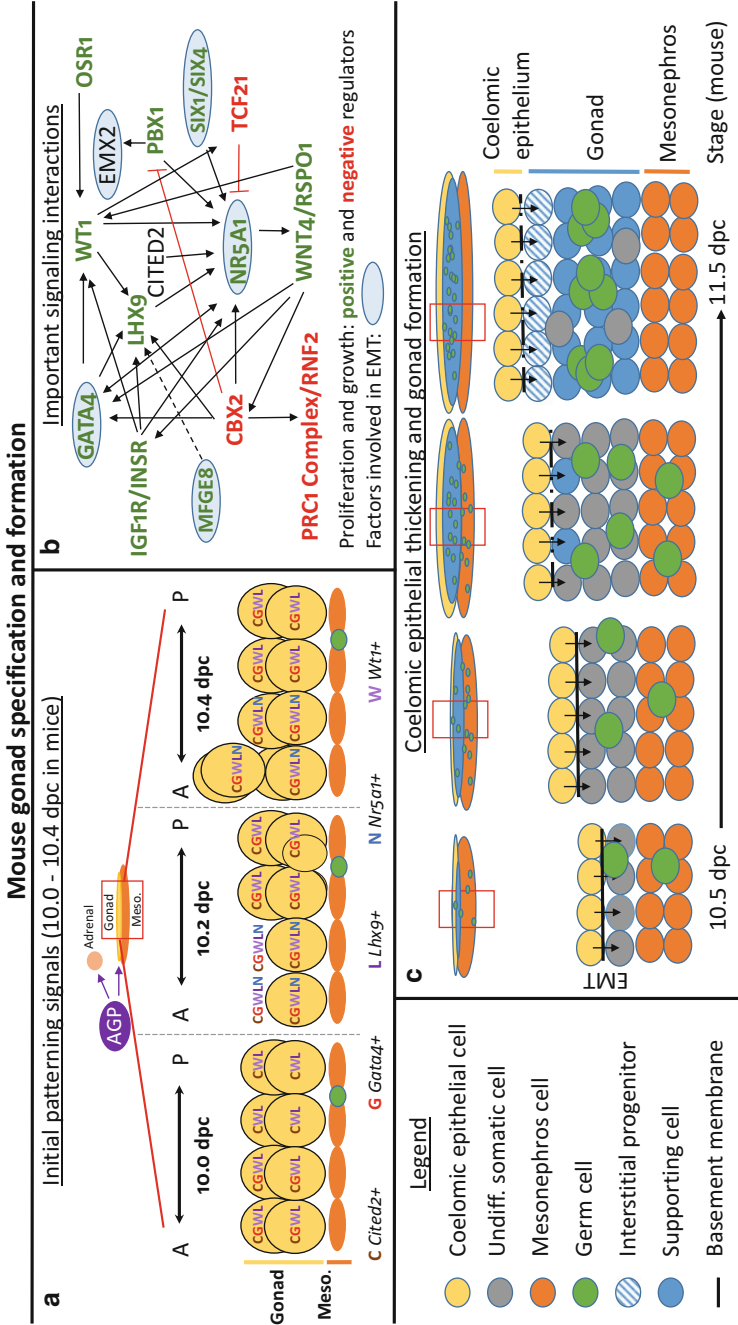
## Genital Ridge Formation and Specification Factors

Both cell migration and cell proliferation contribute to the initial formation of the coelomic epithelium on the surface of the mesonephros. Subsequent proliferation of the coelomic epithelium promotes the formation of the gonad, and a host of factors are important for the specification of the gonad fate (Fig. 1). After cellular migration helps form the epithelium, proliferation of the epithelium and subsequent epithelial-to-mesenchymal transition (EMT) drive the expansion of the forming gonad. Cells arising from early epithelial proliferation have the potential to become supporting cells; however, later epithelial divisions give rise to interstitial cells (Karl and Capel 1998). The underlying mechanisms for these events will be discussed in more detail in ► Chap. 6, “Male Sexual Differentiation.”

Many factors are important to the process of gonad specification and formation (Fig. 1); some of the major ones are included in this chapter, including GATA-binding protein 4 (GATA4); Wilms' tumor 1 (WT1); nuclear receptor subfamily 5, group A, member 1 (NR5A1); sine oculis-related homeobox members SIX1/SIX4; odd-skipped related 1 (OSR1); chromobox 2 (CBX2); LIM homeobox protein 9 (LHX9); empty spiracles homeobox 2 (EMX2); pre-B-cell leukemia homeobox 1 (PBX1); insulin receptor (INSR) and insulin-like growth factor 1 receptor (IGF1R); milk fat globule-EGF factor 8 protein (MFG8); wingless-type MMTV integration site family 4 (WNT4); and R-spondin 1 (RSPO1). Mutations in most of these genes usually result in a structure called a “streak gonad,” which fails to develop beyond the bipotential state and contains mostly fibrous, undifferentiated tissue; alternatively, they may alter the gonadal primordium such that the development of the testis or ovary is particularly hindered. This section will discuss each factor in detail and the known interactions between them.

### GATA-Binding Protein 4 (GATA4)

GATA4, named after the GATA DNA sequence to which it binds, is an important zinc finger transcription factor for genital ridge development and is expressed in gonadal somatic cells regardless of later sexual fate (Heikinheimo et al. 1997; Viger et al. 1998). Mice with systemic mutations in *Gata4* are embryonic lethal by 8.5–10.5 dpc, and, therefore, gonad development cannot be studied in these models; however, the conditional loss of *Gata4* (through a tamoxifen-inducible Cre/LoxP system removing *Gata4* after 8.75 dpc) results in the lack of gonadal ridge formation/thickening, demonstrating its functional importance in gonad specification (Molkentin et al. 1997; Hu et al. 2013). *Gata* family members are expressed at various stages of gonad development, such as *Gata1*, *Gata4*, and *Gata6*; however, only *Gata4* is expressed during gonad formation (Heikinheimo et al. 1997; Viger et al. 1998; Ketola et al. 1999). GATA4-positive cells within the splanchnic mesoderm cells of the hindgut, a dorsal mesentery region continuous with the coelomic epithelium, migrate toward explanted gonads in culture (McCoard et al. 2001); therefore, it is presumed that a released gonadal factor creates a chemotactic gradient to recruit GATA4-positive cells to the forming gonad; however, the role of GATA4 in



**Fig. 1** Initial gonad specification and formation. **(a)** Initial signaling pathways involved in progenitor cell formation and gonad specification in mammals (10.0–10.4 dpc of mouse development). Diagram depicts expression of gonad specification factors involved in the development of the adreno-gonadal primordium and the formation of the early gonad. **(b)** Important signaling interactions for gonad formation, focusing on factors involved in the growth, proliferation, and migration of cells during gonadogenesis. Factors in *red text* are suppressors of proliferation or growth, whereas factors in *green text* promote



survival or proliferation cannot be discounted within this model (McCoard et al. 2001). Interestingly, no GATA4 was observed in the mesonephric structures, so GATA4 may be more specific for gonad specification, rather than overall urogenital development, at this stage. Upon the formation of the genital ridge at 9.25 dpc, GATA4 is initially expressed anteriorly, after which it expands in an anterior-to-posterior fashion within the epithelium of the gonad (Hu et al. 2013).

The function of GATA4 has been well characterized in the development of the heart. GATA4 regulates the cell cycle transition between G1 and S phases and proliferation through direct binding to the promoter regions of the cell cycle genes *Cyclin D2* (*Ccnd2*) and *Cyclin-dependent kinase 4* (*Cdk4*). Additionally, GATA4 has been shown to influence EMT through mitogen-activated protein kinase 1 (MAPK1) and Erb-b2 receptor tyrosine kinase 3 (ERBB3) signaling (Rojas et al. 2008; Rivera-Feliciano et al. 2006). The overall importance of GATA4 during gonad formation has been demonstrated through GATA4-mediated *Nr5a1* and *Lhx9* activation, in which GATA4 may directly or indirectly interact to influence coelomic epithelial thickening (Hu et al. 2013). Additionally, the *Gata4* locus contains binding sites for the transcription factors WT1 and NR5A1, and its expression is localized within WT1- and NR5A1-expressing cells. Through elucidation of the interaction of *Nr5a1* and GATA4, it has been determined that GATA4 can only transactivate *Nr5a1* in some cell types, such as alphaT3-1 and MSC-1 cell lines, but was very poor at transactivation in L, TM3, or Y-1 cells. This GATA4-dependent activation of *Nr5a1* occurs through the GATA element and not the minimal promoter, implicating that the presence of cell-specific cofactors or posttranslational modifications might contribute to transcriptional activation differences in different tissues or cell lines. It could be speculated that these cofactors or posttranslational modifications could also occur during a particular developmental time window of activation; therefore, additional positive or negative regulatory elements may control this interaction (Tremblay and Viger 2001). Additionally, a feedback loop between NR5A1 and GATA4 may regulate *Gata4* expression, as a binding site in the *Gata4* promoter specific for NR5A1 has been identified (Tremblay and Viger 2001). GATA4 can autoregulate through the binding of itself on the *Gata4* exon 1b (E1b) promoter (Mazaud-Guittot et al. 2014). The difference between the *Gata4* E1b transcript, as compared to the transcript containing exon 1a (E1a), is that E1b allows regulation of GATA4 by itself, whereas E1a transcripts require other more ubiquitous factors binding to either the GC- or E-box motif through different promoter regions (Mazaud-Guittot et al. 2014). *Gata4* E1b-based transcriptional autoregulation of itself is repressed by interaction of GATA4 with zinc finger protein, multitype 2 (ZFPM2, also known as FOG2)



**Fig. 1** (continued) proliferation or growth. Additionally, *round circles* specify factors involved in epithelial-to-mesenchymal transition (EMT). (c) Diagram of coelomic epithelial thickening and gonad formation in mammals. Schematic depicts three areas: the coelomic epithelium, gonad, and mesonephros between 10.5 and 11.5 dpc, when sex determination occurs. The gonad forms by the expansion of the coelomic epithelium and through epithelial-to-mesenchymal transition. Additionally, at that time germ cells begin to arrive and colonize the gonad

(Mazaud-Guittot et al. 2014). This interaction is most likely why *Gata4* auto-regulation occurs during initial gonadal formation, but not during later stages when ZFPM2 is present (Lakshmaiah et al. 2010; Tevosian et al. 2002), which will be discussed in more detail in a later section of this chapter.

### **Wilms' Tumor 1 (WT1)**

WT1 is an important transcription factor required for development of the urogenital tract, especially the gonad and kidney, as mice mutant for *Wt1* lack both these organs (Kreidberg et al. 1993). Two known mutations in human *WT1*, one at 11p13 affecting structural integrity of the WT1 protein and the other a dominant point mutation disrupting its zinc finger domains, lead to Wilms' tumor-aniridia-genital anomalies-retardation (WAGR) and Denys-Drash syndromes, respectively. Both syndromes have overlapping symptoms of abnormal genitalia and predisposition to Wilms' tumors, which are characteristic of *WT1* mutations (Glaser et al. 1989; Pelletier et al. 1991). Mice with a homozygous mutation for *Wt1* are embryonic lethal (Kreidberg et al. 1993). *Wt1* is expressed throughout early fetal development in the adreno-gonadal primordium starting at 9.0 dpc, and its expression continues into genital ridge formation. At early stages, such as 9.5 dpc, WT1 expression is throughout the urogenital ridge. Although initially also in the adrenal gland, adrenal WT1 expression is decreased after adrenal-gonad separation, while the gonad continues to express WT1 even at later stages, including 11.5–12.5 dpc (Bandiera et al. 2013). In the absence of *Wt1* function, the thickening of the coelomic epithelium of the gonad is reduced by 11.0 dpc, and gonad formation is stunted and resultant apoptosis causes massive degeneration of the gonad by 14.0 dpc (Kreidberg et al. 1993). The impact of *Wt1* deficiency was limited to somatic cells, as germ cell migration was normal in these mutants (Kreidberg et al. 1993).

WT1 can potentially exist as 36 different isoforms due to splice variations and differential start sites; however, there are two specific WT1 isoforms that are involved in gonad specification, which either contain (WT1+KTS) or lack (WT1-KTS) a tripeptide of lysine, threonine, and serine (Hohenstein and Hastie 2006). The presence of the KTS region alters WT1 function, as the insertion of these three amino acids is between the third and fourth zinc fingers and affects WT1's ability to bind DNA. When present, the KTS sequence prevents zinc finger function due to increased flexibility of the linker between the third and fourth zinc fingers and abrogates the binding of the fourth zinc finger in the major groove of DNA; these changes drastically reduce DNA binding, so the WT1+KTS isoform instead preferentially binds to RNA and thus is involved in RNA metabolism (by shuttling between the nucleus and cytoplasm and associating with ribonucleoproteins and actively translating polysomes) (Caricasole et al. 1996; Kennedy et al. 1996; Niksic et al. 2004). In contrast, WT1-KTS regulates gene expression and chromatin architecture, as it has a high affinity for DNA. The ratio of these two isoforms is thought to be of importance because Frasier syndrome patients have a loss of the WT1+KTS isoform; however, this syndrome seems to be linked to sex determination-associated defects (rather than initial gonadal formation defects) due to its role in *Sry* and *anti-Müllerian hormone (Amh)* gene regulation. In addition, GATA4 cooperative binding

with WT1 on the *Amh* promoter requires the WT1-KTS isoform (Miyamoto et al. 2008).

WT1-KTS binds to the same DNA sequence as early growth response 1 (EGR1), but, unlike EGR1, which activates insulin growth factor II and platelet-derived growth factor A chain, WT1-KTS represses the activity of these genes (Drummond et al. 1992; Wang et al. 1992). WT1-KTS also has a binding site for *Nr5a1* (Wilhelm and Englert 2002), which is another gene crucial for gonad development (discussed in more detail later in this section). Additionally, WT1 can activate various genes, including but not limited to cell cycle and apoptosis genes, such as *Cyclin-dependent kinase inhibitor 1A* (also known as *P21*) and *B-cell leukemia/lymphoma 2* (*Bcl2*); G-protein coupled receptor genes (*Syndecan 1*); genes encoding transcription factors, such as *nuclear receptor subfamily 0, group B, member 1* (also known as *Dax1*) and *Paired box 2* (*Pax2*); and genes encoding growth factors/mitogens (*Amphiregulin*) in other cellular systems, demonstrating its diverse role in cellular functions (Kreidberg et al. 1993; Cook et al. 1996; Englert et al. 1997; Kim et al. 1999; Lee et al. 1999; Mayo et al. 1999). One of the more important roles of WT1 in the gonad and adrenal gland, as demonstrated through ectopic expression of WT1-KTS, is that WT1 without KTS can prevent differentiation of AGP WT1-positive precursor cells into steroidogenic cells through its regulation of proposed *Nr5a1* repressors, *GLI-Kruppel family member GLI1* (*Gli1*) and *transcription factor 21* (*Tcf21*), demonstrating the importance of the isoform in development (Bandiera et al. 2013). TCF21 has a known involvement in gonadal formation, as the lack of *Tcf21* causes impaired gonadal growth (shortened gonadal length).

### **Odd-Skipped Related 1 (OSR1)**

OSR1, also known as ODD1, is a transcription factor containing zinc finger motifs, whose mRNA is expressed starting as early as 7.5–8.5 dpc, during the earliest stage of intermediate mesoderm development (So and Danielian 1999). OSR1 plays a role in p53-mediated apoptosis in zebrafish, but increased apoptosis was restricted to specific regions of the embryo, rather than widespread apoptosis (Huang et al. 2004). This role in apoptosis is likely the reason for agenesis of the kidney and gonad in *Osr1* knockout mice. Between 9.5 and 10.5 dpc, a massive Caspase3-driven apoptosis occurs in the gonad (Wang et al. 2005; Fernandez-Teran et al. 1997), resulting in gonadal loss. Interestingly, overexpression or continuous expression of *Osr1* mRNA in the kidney leads to ectopic or expanded kidney formation in *Danio rerio* (zebrafish), *Xenopus* (frog), and *Gallus* (chicken) without nephrogenic differentiation. Although the gonad has not been analyzed as of yet, we speculate that similarly to the kidney that arises from all *Osr1*-positive cells, *Osr1* may play a role in promoting the cellular expansion of gonadal progenitor cells (James et al. 2006; Tena et al. 2007). *Osr1* and *Wt1* knockout mice have similar defects in embryonic development (Kreidberg et al. 1993; Wang et al. 2005), including both heart and urogenital abnormalities (Wang et al. 2005). OSR1 may act upstream or in concert with WT1, as OSR1 is expressed earlier than WT1 during mesoderm differentiation; WT1 is downregulated in *Osr1* mutants, and *Osr1* knockouts produce less developed kidneys than *Wt1* knockouts

(Wang et al. 2005; Armstrong et al. 1993). Whether these factors are part of the same signaling pathway needs to be elucidated further.

### **Sine Oculis-Related Homeobox 1 (SIX) SIX1 and SIX4**

There are six member genes of the Six family, all of which regulate cell fate. Two of these members, SIX1 and SIX4, are transcription factors that work in concert for gonad primordium formation and testicular differentiation by influencing two downstream targets, *Nr5a1* and *Zfp2* (also known as *Fog2*), respectively (Fujimoto et al. 2013). Both SIX1 and SIX4 were expressed in the coelomic epithelium and co-localized in cells displaying NR5A1 expression (Fujimoto et al. 2013). Mice lacking *Six1* die at birth due to multiple organ malformations (Xu et al. 2003; Ozaki et al. 2004; Laclef et al. 2003a, b); however, mice lacking *Six4* do not show any major developmental deficiencies (Ozaki et al. 2004). Interestingly, mice lacking both *Six1* and *Six4* have more severe defects, including kidney agenesis (Kobayashi et al. 2007). Mice lacking both *Six1* and *Six4* have defective upregulation of NR5A1 as early as 9.5 dpc, which influences gonad primordium development and subsequently leads to decreased gonadal size (Fujimoto et al. 2013). Furthermore, decreased gonadal size (and possibly delayed development) was observed at later stages (such as 11.5 dpc) in *Six1/Six4* double-knockout mice; therefore, the deficit of SIX1 and SIX4 goes uncompensated. SIX1 and SIX4 regulate *Nr5a1* independently of the later sex differentiation factor, *Zfp2*. Unchanged levels of *Nr5a1* in *Zfp2*-mutant mice further demonstrate that *Nr5a1*-independent signaling pathways that occur during gonadal formation are separated from later deficiencies (Tevosian et al. 2002). Furthermore, *Six1* and *Six4* knockout mice had normal expression of other important genital ridge formation genes, such as *Lhx9*, *Emx2*, *Cbx2*, *Gata4*, or *Wt1*-KTS, so this influence seems to be specific for *Nr5a1* at 10.5 dpc (Fujimoto et al. 2013).

### **Nuclear Receptor Subfamily 5, Group A, Member 1 (NR5A1)**

NR5A1 is an important nuclear receptor for development of all steroid-producing tissues, including the gonad and adrenal glands, as mice lacking *Nr5a1* lack both organs (Luo et al. 1994). *Nr5a1* is not expressed within the adjacent mesonephros and is restricted to the gonad. The homolog of NR5A1 in *Bos taurus*, named adrenal 4-binding protein (AD4BP), has a functional role in the regulation of cytochrome P450 steroid hydroxylase genes, through a generally conserved sequence 5'-AGGTC A-3' (with some variation) within the proximal promoter; therefore, NR5A1 is commonly known as its functional name, steroidogenic factor 1 (SF1) (Taketo et al. 1995; Morohashi et al. 1992).

*Nr5a1* function may rely on the activation of its downstream targets, as it plays a role in activation of genes involved in steroidogenesis (Honda et al. 1993; Lala et al. 1992; Morohashi et al. 1993), proliferation (Nash et al. 1998; Wang et al. 2014), and differentiation (Combes et al. 2010; Tran et al. 2006). NR5A1 is already expressed by 9.0 dpc, separating into two populations with either low or high expression by 10.0 dpc; however, the number of NR5A1-high cells seemingly continues to increase during the development of the gonad and adrenal gland from 10.5 to

11.5 dpc. A homozygous deletion of the entire *Nr5a1* gene leads to apoptosis of gonadal somatic cells by 12.5 dpc. These mice die by postnatal day 8, and it has been proposed that this lethality is due to adrenal defects (Luo et al. 1994). Rescue experiments with overexpressed *Nr5a1* in *Nr5a1*-deficient animals further confirm that gonad development directly requires *Nr5a1* (Fatchiyah et al. 2006). Interestingly, NR5A1 acts in a dose-dependent manner, as a heterozygous mutation of *Nr5a1* results in reduced, but not absent, gonads (Bland et al. 2004). NR5A1 is a unique nuclear factor in that it binds monomerically, rather as a homo- or heterodimer. This unique aspect was demonstrated by the loss of 30–40% of NR5A1 DNA binding upon a homozygous point mutation (R92Q) in the A-box region of the DNA binding domain of human NR5A1, resulting in reduced transcriptional activity; however, individuals with a heterozygous point mutation remained phenotypically normal (Achermann et al. 2002). When compared to a P-box mutation, which yields sex reversal phenotypes upon a heterozygous mutation (G35E), the A-box mutation may disrupt a secondary DNA-binding domain and also reveals how dosage could be involved in NR5A1 functionality (Achermann et al. 2002). This region has been suggested to interact with the minor DNA groove to stabilize the interaction of NR5A1 with DNA (Achermann et al. 2002). As this reduction in binding is only partial, other transcription factors known to bind may further stabilize the NR5A1-DNA interaction.

In the adrenal gland, as early as 11.5 dpc, pre-B-cell leukemia homeobox 1 (PBX1) (covered in more detail later in this chapter) is essential for *Nr5a1* expression, as mice deficient in *Pbx1* had reduced levels of *Nr5a1*, and both PBX1-homeobox superfamily (HOX) and PBX1-Pbx/knotted 1 homeobox (PKNOX1; also known as PREP1) complexes can bind the fetal adrenal enhancer (FAe) to initiate *Nr5a1* expression (Zubair et al. 2006). PBX1 and empty spiracles homeobox 2 (EMX2) work cooperatively to activate NR5A1 (their interaction will be discussed in further detail in the PBX1 section). Additionally, *Nr5a1* is proposed to be initiated by GATA4. The maintenance of NR5A1 expression has been shown to be by SIX1 and SIX4 and also by NR5A1 autoregulation (through its FAe). *Six1* and *Six4* double-deficient mice have a reduced number of NR5A1-positive cells as compared to GATA4-expressing cells (Fujimoto et al. 2013). This reduction in *Nr5a1* was observed as early as 9.5 dpc in the coelomic epithelium, and both gene and protein expression were further reduced by 10.0 dpc through 11.5 dpc. Conversely, *Six1/Six4* transgene overexpression induced *Nr5a1* gene expression, further confirming the relationship between NR5A1 and SIX1/SIX4 (Fujimoto et al. 2013).

### **Insulin Receptor (INSR) and Insulin-Like Growth Factor 1 Receptor (IGF1R)**

INSR and IGF1R pathways are important signaling mechanisms for overall body growth, cellular proliferation, and differentiation. When analyzed at 10.5 dpc, mice deficient in both *Insr* and *Igf1r* had no considerable size defects, but over the next 2 days, progression of overall body size decreased. Due to their reduced size, mice lacking both *Insr* and *Igf1r* were analyzed to determine if their overall developmental programming was delayed. Interestingly, tail somites and other

developmental structures, such as limbs, were normal in later developmental stages. Genes encoding receptor tyrosine kinases in the insulin pathway (INSR and IGF1R) are required for proliferation of the somatic progenitor cells within the gonad. Mice lacking *Insr* and *Igfr* lead to reduced NR5A1, WT1, and LHX9 expression (Pitetti et al. 2013), thereby influencing gonad development. *Insr* and *Igfr*, in conjunction with *insulin receptor-related receptor* (*Insr*, also known as *Irr*), have an additional critical role in later aspects of male sex determination and differentiation, such as regulating *Sry* expression (Nef et al. 2003); these functions will be discussed later in this chapter.

### **Cbp/p300-Interacting Transactivator, with Glu-/Asp-Rich Carboxy-Terminal Domain, 2 (CITED2)**

*Cited2* is expressed in the coelomic epithelium and adjacent mesenchyme at 10.0 dpc (Val et al. 2007). During the separation of the AGP at 10.5 dpc, *Cited2* expression decreased in the coelomic epithelium and was barely detectable by 12.0 dpc. No changes in *Cited2*-deficient mice were observed in proliferation, apoptosis or in laminin expression at 10.5 or 11.5 dpc; however, there was an *Nr5a1*-specific transcriptional delay in gonad development at 11.5 dpc, which resulted in additional later disruptions of gonad morphology. *Cited2*-deficient mice have reduced expression of the gonadal formation gene *Nr5a1*, as well as a reduction in expression of a sex determination gene expressed in Sertoli cells, *Sox9*, at 11.5 dpc. Additionally, the expression of a Leydig cell-specific gene, *cytochrome P450, family 11, subfamily a, polypeptide 1* (*Cyp11a1*), is also decreased at 13.5 dpc (Combes et al. 2010). However, transcription of *Sox9*, *Cyp11a1*, and *Nr5a1* all recovered in *Cited2*-deficient gonads by 13.5 dpc, indicating that later differentiation and structure in both male and female gonads are normal (Combes et al. 2010).

*Cited2*-deficient mice have normal levels of WT1 and LHX9; therefore, CITED2 might be acting downstream of these two gonadogenesis factors. CITED2 is a non-DNA-binding cofactor for WT1 in the stimulation of *Nr5a1* within the adreno-gonadal primordium (Val et al. 2007). The cooperation between WT1 and CITED2 leads to an expression increase of NR5A1 in the adreno-gonadal primordium, and this expression of NR5A1 over the required threshold allows for adrenal and gonad development (Val et al. 2007). Although CITED2 has been demonstrated to bind to both isoforms of WT1, the WT1-KTS has shown preferential binding (Val et al. 2007).

### **Chromobox 2 (CBX2)**

CBX2 (also known as M33; known in *Drosophila melanogaster* as Polycomb), a regulator of homeotic gene expression, is important for development of the gonad, adrenal, and spleen, as well as for sexual differentiation (Katoh-Fukui et al. 1998). CBX2 may regulate the differentiation of embryonic stem cells (ESCs), as increased CBX2 protein expression was observed in later differentiated stages of ESCs and retinoic acid-treated ESCs. Furthermore, ChIP sequencing and ESC teratoma formation experiments demonstrate a germ layer specification preference toward mesoderm and endoderm with the expression of CBX2 (Morey et al. 2012). *Cbx2* and

*Polycomb ring finger oncogene (Bmi1)* work synergistically to regulate mesodermal genes, as demonstrated by double-knockout experiments.

A Polycomb group (PcG) assembly of either PRC1 (polycomb repressive complex 1) or PRC2 (polycomb repressive complex 2) is crucial for developmental epigenetic regulation (via histone modifications) and for maintenance of gene repression. CBX2 directly recognizes modified histones, such as H3K27me<sub>3</sub>, through its chromodomain and recruits other members of the PRC1 complex. Phosphorylation of CBX2 provides its functionality, as phosphorylation is important for its nuclear translocation and interaction with H3K27me<sub>3</sub> by increasing its affinity for H3K27me<sub>3</sub> (Hatano et al. 2010). The interaction of CBX2 with the E3 ligase ring finger protein 2 (RNF2, also known as RING1B), which is another transcriptional repressor in the PRC1 complex, brings RNF2 in the proximity to H3K27me<sub>3</sub>, inducing chromatin modification through RNF2 ubiquitination of H2A at lysine 119, thereby furthering repression of the gene locus (Kaustov et al. 2011; van der Stoop et al. 2008). CBX2 is the only CBX family member known to induce chromatin compaction (Grau et al. 2011). Loss of *Cbx2* results in reduced cellular proliferation through impaired regulation of H3K27me<sub>3</sub>. This effect is expected, as CBX family proteins have the shared function of repressing the INK4a-ARF locus, known to be an inhibitor of cell cycle, and, specifically, CBX2 in embryonic fibroblasts controls the entry into S phase during proliferation (as demonstrated by BrdU incorporation studies) (Core et al. 2004). In humans, two isoforms of CBX2, CBX2.1 and CBX2.2, have been observed, with different lengths (the latter being shorter than the former); both can functionally repress transcription. Both isoforms contain the chromodomain; however, only CBX2.1 contains the Polycomb box shown to directly bind to RNF2; therefore, the binding of the PRC1 complex is altered with CBX2.2 (Volkel et al. 2012). Similarly, zebrafish have *Cbx* loci coding for isoforms with and without the Polycomb box (Le Faou et al. 2011). Within the gonad, CBX2 expression is strong in epithelial cells (as defined by a single layer of cells lining the coelomic space), but is weak in gonadal mesenchymal cells (Katoh-Fukui et al. 2012).

The loss of *Cbx2* results in underdeveloped and small gonads, with later sex differentiation defects. Defects in *Cbx2*-mutant gonads are most likely due to reduced mesenchymal proliferation, rather than migration defects, as *Cbx2*-deficient gonads demonstrated decreased mesenchymal proliferation (via BrdU incorporation assays), but exhibited no change in epithelial proliferation, overall apoptosis, or laminin expression (important for basement membrane formation) (Katoh-Fukui et al. 2012). Additional studies confirm CBX2 playing a role in the regulation of gonadal proliferation, as CBX2 accumulates and binds to an upstream promoter region of *Nr5a1* in both mouse and human cells, and overexpression of NR5A1 has been demonstrated in chicken embryos to upregulate Cyclin D1, a known player involved in driving the G1/S phase transition (Ishimaru et al. 2008). CBX2 is an important nuclear receptor for genital ridge development and has been implicated in the regulation of NR5A1, as a human mutation in *CBX2* failed to regulate NR5A1; decreased expression was observed in the gonad of a murine *Cbx2* knockout, and CBX2 can accumulate and bind the promoter region of *Nr5a1* (Katoh-Fukui et al.

1998, 2005; Biason-Lauber et al. 2009). Additional studies using DNA adenine methyltransferase identification (DamID) coupled to high-throughput sequencing (DamID-seq) demonstrated that overexpression or knocking down CBX2 via transfection methods in a NT-2D1 cell line resulted in increased or decreased NR5A1 expression, respectively (Eid et al. 2015). CBX2 is also known to influence other gonad formation-associated transcription factors, such as LHX9 and GATA4. LHX9, GATA4, and EMX2 are downregulated in *Cbx2*-deficient mouse gonads (Katoh-Fukui et al. 2012). However, other gonadal transcription factors, such as WT1 and CITED2, are unaffected in *Cbx2*-deficient gonads (Katoh-Fukui et al. 2012); therefore, CBX2 regulation of transcription factors may be selective for LHX9, GATA4, and EMX2 function.

### **LIM Homeobox Protein 9 (LHX9)**

LHX9, part of the LIN11-ISLET1-MEC3 (LIM) homeodomain family, is an important transcription factor for genital ridge development, as *Lhx9* knockout mice fail to develop bipotential gonads (Birk et al. 2000). LHX9, like most of the other family members, regulates transcription; they are characterized by their two LIM domains containing a total of four cysteine-rich zinc fingers that are important for protein-protein interactions and a homeobox domain crucial for DNA binding. *Lhx9* is involved in proliferation of the gonad anlage; *Lhx9* exon2-/exon3-deficient mice (removal of the first two LIM domains) have a reduced proliferation rate, but no changes in apoptosis, in LHX9-positive cells. LHX9 is expressed at 9.5 dpc in both the epithelial and mesenchymal cells (Birk et al. 2000). *Lhx9* is subsequently (11.5 dpc) expressed at high levels in both the coelomic epithelium and the superficial mesenchyme that later becomes the tunica albuginea, but is expressed at lower levels within the deeper mesenchyme (Birk et al. 2000). LHX9 cooperates with WT1 to bind and transactivate *Nr5a1* (Wilhelm and Englert 2002; Birk et al. 2000). Furthermore, the impact of LHX9 on *Nr5a1* is demonstrated by the *Lhx9*-exon2-/exon3-deficient mouse displaying reduced levels of *Nr5a1* (Birk et al. 2000); however, the reduction of proliferation of these *Nr5a1*-positive cells (as they overlap with *Lhx9*-positive cells) may be the indirect cause of LHX9 on these reduced levels. The GATA4/ZFPM2 complex has been shown to activate *Lhx9* in the heart; however, as ZFPM2 is not required for *Gata4* function in gonad formation, there is no effect of the mutant GATA4/ZFPM2 complex on *Lhx9* expression in the gonad (Tevosian et al. 2002; Smagulova et al. 2008). In other embryonic tissues, such as the central nervous system and limbs, the expression of *Lhx2*, which has similar structure and overlaps with *Lhx9* expression, may compensate for the lack of *Lhx9* function in the *Lhx9* exon2/exon3 mutant; however, since *Lhx2* is not expressed within the gonad, that is likely why gonadal-specific defects are observed in *Lhx9*-mutant mice (Birk et al. 2000; Bertuzzi et al. 1999).

### **Pre-B-cell Leukemia Transcription Factor1 (Pbx1)**

The pre-B-cell leukemia transcription factor (PBX) family encodes three amino acid loop extension (TALE) homeodomain proteins, whose TALE domain allows them to form trimeric complexes with DNA (Burglin 1997; Ferretti et al. 2000; Jacobs et al.



1999). Of the four subclasses, only PBX1 (and weakly PBX3, which demonstrates an overlapping embryonic expression pattern with PBX1) is expressed in the gonad (Di Giacomo et al. 2006). PBX1 is a HOX cofactor (increasing HOX DNA-binding specificity/selectivity) that can be expressed as either of two splice variants (PBX1a and PBX1b) (Mann and Affolter 1998; Schnabel et al. 2001). PBX1b expression is localized to both nuclei and cytoplasm of gonadal cells (Ota et al. 2008). PBX1 is expressed in the adreno-gonadal primordium and the coelomic epithelium by 10.0 dpc, followed by later expression in the gonad interstitium after sex determination (Schnabel et al. 2003). *Pbx1*-knockout mice lack adrenal glands and Müllerian ducts, have problems with gonad development, have reduced kidney size, and are embryonic lethal by 15.5–16.5 dpc (Schnabel et al. 2001, 2003). PBX1 is not essential for the generation of mesoderm, but rather functions later in the development of the urogenital organs, likely through its involvement in cell cycle regulation (Schnabel et al. 2003; DiMartino et al. 2001; Kim et al. 2002; Selleri et al. 2001). The size of the genital ridge is severely decreased, mostly attributable to reduced adrenogenital precursor proliferation (as demonstrated by BrdU incorporation assays) in *Pbx1*-knockout mice as compared to control mice (Schnabel et al. 2003).

NR5A1 expression is reduced in *Pbx1*-deficient mice, resulting in only a few NR5A1-positive cells in the coelomic epithelium at 10.0 dpc, which persisted in some Sertoli and Leydig cells later at 13.0 dpc (Schnabel et al. 2003). This gonadal reduction in NR5A1 has been postulated to be caused by a reduction in gonadal proliferation (Schnabel et al. 2003). The role of PBX1 in modulating NR5A1 expression is more prominent in the adrenal gland, as *Pbx1*-deficient mice lack NR5A1-positive cells, although different mechanisms may occur in different tissues (Schnabel et al. 2003). Even though PBX1 may play a role in regulating NR5A1 expression, PBX1 does not seem to impact WT1 expression (Schnabel et al. 2003). Another interacting partner of PBX1 (although only analyzed in other tissue and cell systems) known to bind DNA as a cooperative partner with PBX1 is EMX2. In *Pbx1/Pbx2/Pbx3* mutants, EMX2 is completely lost, and proliferation is reduced (Capellini et al. 2010); EMX2 is also important in genital ridge formation (see next section). EMX2 and PBX1 together in cell lines, such as COX and P13, have the ability to bind the DNA consensus sequence 5'-CTTTAATGAT-3' as a heterodimer to activate transcription of genes; one example is the scapular patterning genes. Furthermore, the transcriptional activation of genes relied on cooperation between the two proteins, as separately neither PBX1 nor EMX2 could activate transcription (Capellini et al. 2010). Therefore, we speculate that *Pbx1* is important in patterning and proliferation within the newly formed gonad.

### **Empty Spiracles Homeobox 2 (EMX2)**

EMX2 is an important transcription factor for development of the urogenital tract, including the gonad, kidneys, ureters, and genital tracts, as *Emx2* mutant mice lack these organs (Miyamoto et al. 1997). EMX2 expression has been observed in the coelomic epithelium at 10.5–11.5 dpc. Mice lacking *Emx2* exhibit defective gonad formation with sparse cells comprising the coelomic epithelium at 11.5 dpc. Through

scanning electron microscopy, it was determined that *Emx2*-knockout gonads have irregular clustering of cells, rather than the smooth surface epithelium seen in controls (Kusaka et al. 2010). Later at 12.5 dpc, the gonad is lost through apoptosis in *Emx2*-deficient mice (Miyamoto et al. 1997).

*Emx2*-mutant gonads have ectopic tight junction formation, which inhibits EMT required during early gonad development, in which coelomic epithelial cells become the gonadal mesenchyme. EMT is normally controlled by epidermal growth factor receptor (EGFR) through the regulation of sarcoma viral oncogene homolog tyrosine (SRC) phosphorylation. Within *Emx2*-knockout gonads, phosphorylation of both SRC and EGFR increases, and subsequently EGFR expression is upregulated (Kusaka et al. 2010).

### **Milk Fat Globule-EGF Factor 8 Protein (MFGE8)**

A factor involved in genital ridge formation that is associated with epidermal growth factor signaling is MFGE8 (also known as lactadherin). *Mfge8* encodes a soluble integrin-binding protein that mediates cellular interaction through two binding interactions: one interaction is through integrin beta 3, and the other is through either phosphatidylserine or phosphatidylethanolamine (Hanayama et al. 2002; Kanai et al. 2000). Similar to EGF-like repeats and discoidin I-like domain 3 (also known as Dell), the functionality of MFGE8 in cellular adhesion occurs through its binding to integrin beta 3 using the arginine-glycine-aspartic acid (RGD) motif of its second EGF domain; another region of MFGE8, the discoidin domain, is able to bind to phosphatidylserine and phosphatidylethanolamine. MFGE8 is expressed in both fetal and adult tissues and is known for mediating cellular adhesion during macrophage phagocytosis of apoptotic cells and maintaining cells within a niche location (Hanayama et al. 2002; Kanai et al. 2000). However, MFGE8 has also been known to play a role in a variety of other contexts, including mammary gland branching morphogenesis, sperm-oocyte adhesion, and angiogenesis (Hanayama et al. 2002; Ensslin and Shur 2007; Motegi et al. 2011; Uchiyama et al. 2014).

During fetal stages, MFGE8 expression is restricted to the urogenital ridge, the nervous system, and the bone (Kanai et al. 2000). *Mfge8* RNA is first observed in the coelomic epithelium at 10.0 dpc (protein expressed by 10.5 dpc); then by 10.5 dpc *Mfge8* RNA is localized to the region below the coelomic epithelium containing mesenchymal cells (Kanai et al. 2000). By 11.5–12.5 dpc, the expression of *Mfge8* is restricted to the border region between the gonad and the mesonephros and in stromal tissues that eventually develop into the tunica albuginea; however, by 15.5 dpc *Mfge8* was no longer expressed within the developing gonad (Kanai et al. 2000).

Ishii et al. (2005) demonstrated that MFGE8 is important for gonadal cell-cell adhesion during the critical stages of gonad morphogenesis between 11.5 and 12.5 dpc, as higher binding activity is observed in alkaline phosphatase-positive germ cells, as well as both NR5A1-positive and NR5A1-negative somatic cells, as compared to other time ranges including 10.5 dpc or 15.5 dpc using ex vivo binding assays. These cell types can bind to both of MFGE8's domains (the two EGF and the two discoidin regions) through a mechanism described above (Ishii et al. 2005). Interestingly, *Mfge8* expression partially overlaps with that of *Lhx9*, but not *Wtl* or

*Emx2*, at 11.5 dpc (Kanai et al. 2000). Further elucidation of the interaction between LHX9 and MFGE8 is required to understand how these two factors may synergize for gonad development.

### **Wingless-Type MMTV Integration Site Family 4 (WNT4) and Roof Plate-Specific Spondin (RSPO1)**

Although WNT4 and RSPO1 are associated with female sex differentiation (and shown to play a role in the same pathway), these factors also play a role in initial gonad formation. For more information regarding their roles in sexual differentiation of the gonad, please read section “[Forkhead Box L2 \(Foxl2\)](#)”. *Wnt4* is important in kidney, adrenal gland, mammary gland, and reproductive tract morphogenesis by regulating endothelial and steroidogenic cell migration (Jeays-Ward et al. 2003). WNT4 is important in kidney formation, as it is involved in EMT; additionally, *Wnt4*-knockout mice lack kidneys and die shortly after birth (Kispert et al. 1998). RSPO1 has also been described in other systems to induce WNT/CTNNB1 ( $\beta$ -catenin) signaling, generally associated with increased proliferation (Kazanskaya et al. 2004). *Wnt4* expression occurs as early as 9.5 dpc, and WNT4 has been observed in the forming gonad between 10 and 11.5 dpc, after which female-specific expression is observed (Vainio et al. 1999). In males, WNT4 is decreased after 11.5 dpc, whereas in females both RSPO1 and WNT4 are upregulated (Vainio et al. 1999; Barrionuevo et al. 2006). Both *Wnt4* and *Rspo1* lead to gonad cellular proliferation between 10.5 and 11.5 dpc (Chassot et al. 2012). The exact mechanism of interaction between WNT4 and RSPO1 is unclear both during early gonad formation and later in sex determination. Although *Rspo1*-knockout mice do not have any observable defects in initial gonad formation, there is a known influence of *Rspo1* and CTNNB1 on later *Wnt4* expression (11.5 dpc) (Chassot et al. 2008; Liu et al. 2009; Tomizuka et al. 2008).

Synergy between RSPO1 and WNT4 was observed in *Rspo1/Wnt4* double-knockout mice, which have a more severe gonadal phenotype with a hypoplastic testis and a reduced number of Sertoli cells (and reduced number of seminiferous tubules), most likely due to a decreased proliferation of the coelomic epithelium which gives rise to Sertoli cells (Chassot et al. 2012). *Insr/Igf1r* double-knockout mutants demonstrate a decrease in *Wnt4*, and *Wnt4/Rspo1* double-knockout mutants have decreased *Igf1r* levels; therefore, there is likely a mutual interaction or feedback loop between these two pathways within the forming gonad (Pitetti et al. 2013; Chassot et al. 2012). WNT4 and RSPO1 do not influence *Nr5a1*; therefore, WNT4/RSPO1 likely functions downstream of *Nr5a1* (Chassot et al. 2012).

---

## **Sex Determination**

### **Role of Chromosomes in Sex Determination**

Ancient theories, such as those put forth by Aristotle, posited that the heat of the man’s sperm or the male’s “principle” drives sex determination (Haqq and Donahoe 1998). These ideas persisted for many centuries until modern science in the past two

centuries revealed the role of chromosomes in heredity; of particular importance was the discovery of the role of chromosomes in sex determination by Clarence Erwin McClung (McClung 1918). As an expansion to this early work, genetic analyses have shown that a network of factors encoded on chromosomes (both sex chromosomes and autosomes) is important for sex determination. Sex determination occurs when cells are progressively restricted in their developmental potential and led down a particular lineage path to their resulting end fate, in this case male (testis) or female (ovary). Once the fate of a cell has been “determined,” it normally does not change, except if there are defects in the network of genes that maintain sexual fate or if there is an external influence by environmental factors (e.g., hormones in nonmammalian species).

Sexual development occurs at various steps: sex determination, which is the mechanism that triggers the male-versus-female choice and sets that pathway into motion (often, but not always, encoded genetically); and sexual differentiation (gonadal and extra-gonadal), which is downstream of sex determination and is the phenotypic manifestation of male and female identity. This chapter will cover sex determination, while sexual differentiation will be discussed in ► [Chap. 6, “Male Sexual Differentiation”](#)

## Chromosomal Sex Determination Mechanisms

For centuries, the mechanisms that drove the decision in utero for the embryo to develop as a male or female were a source of great debate. Early ideas centered on the environment playing a major role in sex determination. During the nineteenth century, studies by Mendel and others put forth the idea that heritable factors are responsible for determining genetic traits of offspring, including possibly their sex. The discovery of chromosomes as the vessels for genetic material was a critical step in securing a model of chromosomal sex determination. In particular, the observation that the karyotype of males and females of certain species (those with heteromorphic sex chromosomes) was different sparked a new area of research focusing on uncovering the genetic mechanisms driving sex determination.

Sex-specific chromosomes were first described for their role in sex determination at the turn of the twentieth century, due in large part to research on insect model systems. Clarence Edward McClung, who was studying spermatogenesis in the grasshopper *Xiphidium fasciatum*, first proposed in 1901 that a particular “nuclear element” (which McClung demonstrated was in fact a chromosome) was responsible for sex determination (McClung 1918). While he was not the first to describe that the karyotypes of sperm were different from one another and one-half of sperm contained a unique chromosome, he was among the first to propose that chromosomal makeup was directly linked to sex determination. A few years later, while studying the fruit fly, Nettie Stevens and Edmund Beecher Wilson in 1905 confirmed this idea by defining sex-specific chromosomes through the observation that chromosomal karyotype correlated with the sex of the individual (Wilson 1905). These findings launched the idea that there was a chromosomal basis for sex determination.

### **Chromosomal Sex Determination in Mammals (XX/XY System)**

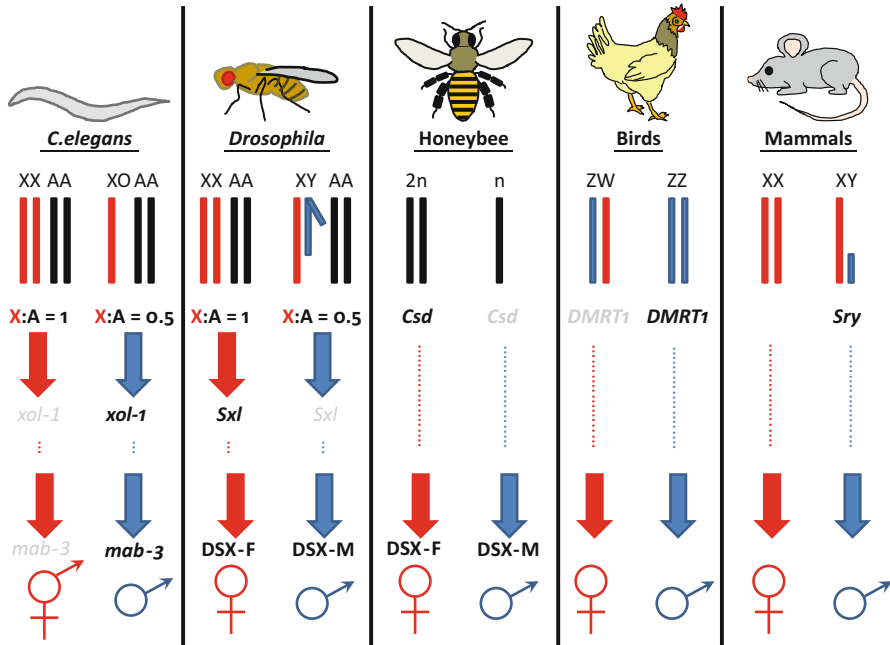
Almost half a century after the work of Stevens and Wilson, the research of Alfred Jost pushed the field of sex determination even further by defining the gonad as the central factor which determines the sex of the embryo in mammals. In his groundbreaking experiments, Jost removed gonads from fetal rabbits in utero early during gestation (i.e., before sex determination took place) and found that gonadectomized embryos invariably developed as females in terms of reproductive tract and external genital development (Jost 1947). In his research, Jost showed that the testis was sufficient to induce male-specific development of the reproductive tract and external genitalia by secreting essential signals for sexual differentiation (later shown to be testosterone and anti-Müllerian hormone) (Jost 1953). Several years later, clinical studies revealed that sex chromosomal aberrations were likely the basis for Klinefelter's (XXY males) and Turner's (XO females) syndromes in humans (Ford et al. 1959; Jacobs and Strong 1959); soon thereafter, it was reported that partial deletions of the Y chromosome likely were responsible for sexual differentiation phenotypes in humans (Conen et al. 1961). These data led to and supported the hypothesis that the Y chromosome was the major determinant of sex determination in mammals.

It was only recently discovered in 1990 that the dominant factor in sex determination was a gene on the Y chromosome, named *Sry* (*sex-determining region of chromosome Y*), which encodes a HMG-box transcription factor necessary and sufficient for male sex determination (Koopman et al. 1990, 1991; Sinclair et al. 1990) (see later in this chapter). This gene on the Y chromosome, when placed on an autosome in an XX mouse, was sufficient to endow a fully male phenotype (however, the XX/*Sry* mouse was sterile since the Y chromosome also contains other genes required for spermatogenesis and XX germ cells in a XY-like somatic environment have difficulty completing gametogenesis) (Koopman et al. 1991). Finally, the evidence was conceptualized in a model in which sex determination in mammals was a XX/XY system, where females are the homogametic sex (XX) and males are the heterogametic sex (XY), and, additionally, the Y chromosome is the major determining chromosomal component for male sex determination.

### **Other Chromosomal Sex Determination Mechanisms**

While the most familiar system of chromosomal sex determination is the XY system, such as used by humans, there are a variety of genetic mechanisms that drive sex determination among animal species (Fig. 2). These systems vary not only in the identity and makeup of the sex chromosomes themselves but also the mechanisms downstream of the chromosomal trigger that drives the decision to undertake male-specific or female-specific development (described in further detail in the upcoming section).

In avian species, the males are the homogametic sex (ZZ) and females are the heterogametic sex (ZW) (Ayers et al. 2013). Therefore, this system has been termed ZZ/ZW, in contrast to XX/XY, to emphasize the consensus in the field that the mammalian X and Y sex chromosomes are unrelated to the avian Z and W sex



**Fig. 2** Chromosomal sex determination pathways in diverse animal species. Cartoon representing key genetic triggers in sex determination of *Caenorhabditis elegans*, *Drosophila melanogaster*, the honeybee *Apis mellifera*, chickens, and mammals. Bars on top row represent chromosomes, in which female-specific sex chromosomes are red, male-specific sex chromosomes are blue, and autosomes are black. The ratio of X chromosomes to autosomes is the genetic trigger in *C. elegans* and *Drosophila*, which leads to the expression of *xol-1* and *Sxl*, respectively, which subsequently drives sex-specific regulation of *mab-3* and *dsx*, respectively. In honeybees, the haploid/diploid state and the hetero-/hemi-/homozygosity of *Csd* lead to sex-specific development. In birds and mammals, a master gene (*DMRT1* or *Sry*, respectively) sets off the male pathway

chromosomes (Fridolfsson et al. 1998; Matsubara et al. 2006). Similarly to SRY in the XX/XY system, it has been suggested that transcription factor, DMRT1 (Doublesex- and MAB-3-related transcription factor 1), acts as the master sex determination factor in birds (Smith et al. 2009); however, DMRT1 is different from *Sry* in that avian *DMRT1* likely acts in a dosage-dependent manner in which two copies are required for male sex determination (since *DMRT1* is located on the Z chromosome). The *DMRT1* gene and its homologs are present in most vertebrate species examined and also have significant evolutionary conservation among invertebrates, such as *Drosophila* and *C. elegans*, suggesting that this gene family has a more ancestral role in this process (Raymond et al. 1998, 1999) (see more discussion below).

The molecular mechanism underlying the chromosomal-based system of *Drosophila* and *C. elegans* sex determination is a “counting mechanism” in which

the ratio of X chromosomes to autosomes drives a regulatory gene cascade. The X:autosome ratio drives the expression (or repression) of the master regulator genes *Sex lethal (Sxl)* in *Drosophila* and *XO lethal-1 (xol-1)* in *C. elegans*, which ultimately leads to sex-specific expression of target genes responsible for sexual dimorphism, such as *doublesex (dsx)* in *Drosophila* and *male abnormal-3 (mab-3)* in *C. elegans*, both of which encode a DM-domain homolog of mammalian DMRT1 (reviewed in Salz and Erickson 2010; Zarkower 2006).

Lastly, in the haplodiploidy system of honeybees and some other insect species, sex chromosomes with unique genetic information are not required for sex determination; instead, sex-specific development is controlled via a dose-dependent signal from a single or two different alleles of the *complementary sex determiner (Csd)* gene, in which male or female sex determination depends on whether the embryo is homozygous (nonreproducing male), heterozygous (female), or hemizygous (male) at the *Csd* locus (Beye et al. 2003). Therefore, males develop from haploid unfertilized eggs and females develop from diploid fertilized eggs.

### Evolutionarily Conserved Aspects of Chromosomal Sex Determination

It is clear the upstream “trigger” that launches sex determination has rapidly evolved over the course of time; the labile nature of this process is demonstrated by the fact that certain mammalian species have lost *Sry* and that the closely related species Japanese medaka and Luzon ricefish (*Oryzias latipes* and *Oryzias luzonensis*, respectively) have different master sex determination triggers (a DMRT1-like transcription factor versus a transforming growth factor-beta (TGF- $\beta$ ) secreted factor) (Matsuda et al. 2002; Myosho et al. 2012). While the upstream mechanisms are widely diverged in the animal kingdom, many parts of the molecular machinery involved in sex determination are conserved among animals.

The DMRT1 family of transcription factors, as the name suggests (Doublesex- and MAB-3-related transcription factor 1), is a central part of sex determination mechanisms in a number of animal phyla (Matson and Zarkower 2012). This transcription factor is the homolog of two factors involved in sexual development in invertebrates: DSX in *Drosophila* and MAB-3 in *C. elegans*, all of which contain a DM (Doublesex and MAB-3) domain, which is a novel zinc finger DNA-binding motif (Zhu et al. 2000). Recently, DM-domain homologs of DMRT1 have been implicated as key sex determination factors in birds, the Japanese medaka, Chinese tongue sole, and frog (*Xenopus*) (Smith et al. 2009; Matsuda et al. 2002; Chen et al. 2014; Yoshimoto et al. 2008). Genomic deletion of the distal short arm of chromosome 9 (9p) in humans, a region which contains *DMRT1*, is associated with gonadal dysgenesis and XY sex reversal phenotypes (Onesimo et al. 2012), suggesting that human *DMRT1* is critical for male sex determination. XY mice with mutations in *Dmrt1* do not show a sex reversal phenotype and are born with normal testes (Raymond et al. 2000), indicating that *Dmrt1* is not required for mouse primary sex determination; however, in post-natal stages *Dmrt1* has been shown to be important for sexual differentiation and maintenance (discussed in the next chapter of this volume).

A factor central to mammalian sex determination is *Sox9*, which encodes a SoxE group transcription factor necessary and sufficient for male sex determination (Barrionuevo et al. 2006; Vidal et al. 2001). SOX9 protein and its homologs are specifically expressed within the testes (not ovaries) in a number of species, such as *Gallus gallus* (chicken), *Danio rerio* (zebrafish), and *Drosophila* (Chiang et al. 2001; DeFalco et al. 2003; Kent et al. 1996). *Sox9* plays a key role in male development in mammals as it is a direct downstream molecular target of SRY (Sekido et al. 2004). In particular, as a determinant of Sertoli cells, *Sox9* is important for forming testis cords, the embryonic precursors of the seminiferous tubules (the sites of spermatogenesis in the gonads of many vertebrate species); experiments in mice deleting *Sox9* and its closely related gene family member *Sox8* after sex determination has already occurred reveal that *Sox* gene function is required for maintenance of seminiferous tubule integrity (Barrionuevo et al. 2009). The *Drosophila* homolog of *Sox9*, *Sox100B*, is not required for primary sex determination in flies, but does play a role in adult testicular morphogenesis (Nanda et al. 2009), suggesting that there is broad evolutionary conservation of *Sox9* function in male-specific development.

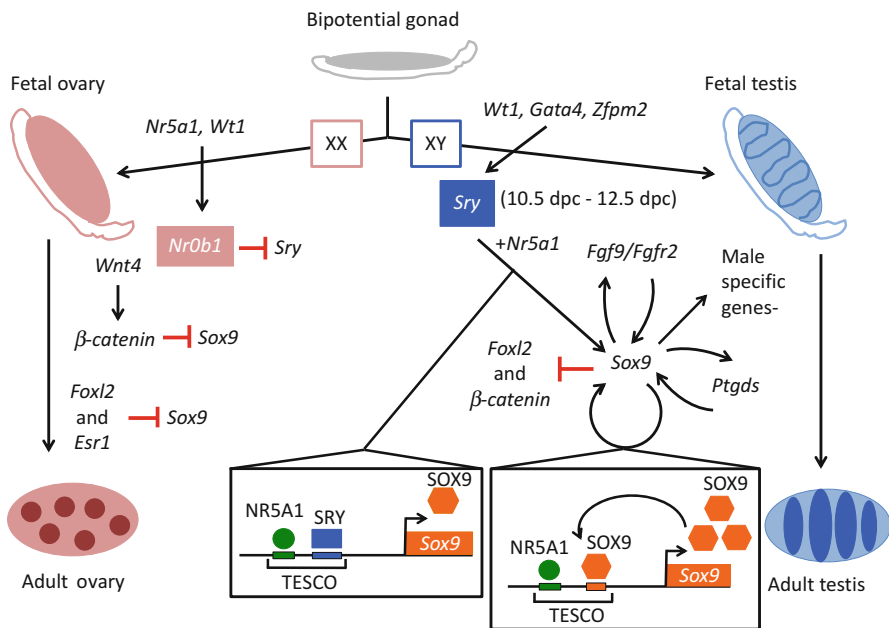
Throughout evolution, it is common to see the same extracellular signaling pathways used in different contexts. An example of one such pathway is TGF- $\beta$ . While TGF- $\beta$  is used in multiple developmental processes, it also plays a role in sex determination in different species. In particular, the involvement of homologs of the TGF- $\beta$  factor anti-Müllerian hormone (*Amh*) is widespread in sex determination of various animal species, especially in fish. In the medaka, *Oryzias latipes*, the *hotei* mutation (in the *Amh* receptor type II) revealed that disruption of *Amh* signaling drives excessive germ cell proliferation and male-to-female sex reversal (Morinaga et al. 2007). *Amh* pathway member homologs are also sex-determining factors in tiger pufferfish (fugu; *Takifugu rubripes*), Luzon ricefish (*Oryzias luzonensis*; closely related to Japanese medaka), Patagonian pejerrey (*Odontesthes hatcheri*), and sablefish (*Anoplopoma fimbria*) (Myosho et al. 2012; Hattori et al. 2012; Kamiya et al. 2012; Rondeau et al. 2013). Interestingly, mammalian *Amh* is not involved in primary sex determination and instead is critical for sexual dimorphism of the reproductive tract and for ovarian follicular development (Behringer et al. 1994; Durlinger et al. 1999). However, this later role for *Amh* in mammals is likely an exception among animals, since in most other species examined, such as alligators and birds, *Amh* is expressed prior to *Sox9* (Oreal et al. 1998; Western et al. 1999); therefore, *Amh* and related TGF- $\beta$  factors likely play a more central, ancestral role in sex determination in some animal species (rather than in differentiation as in mammals).

Regardless of the chromosomal systems used to trigger testicular or ovarian development, many of the downstream factors are evolutionarily conserved. Further examination of these factors that drive gonad specification and formation should shed light on the basic mechanisms responsible for sex determination, as well as how perturbations in these pathways play a role in disorders of sexual development and other congenital conditions within the reproductive system.



## Mammalian Testicular Sex Determination Genes

In mammals, sex determination is equivalent to gonad determination, in that the gonad is the initial and primary site where the male-versus-female decision is triggered, with profound downstream effects on the rest of the reproductive system and body. In the developing mouse embryo, the gonadal primordium arises at around 10.0 dpc (Kashimada and Koopman 2010). At this stage the genital ridges are morphologically indistinguishable between XX and XY embryos. The main trigger for sex determination is the expression of *Sry* in somatic cells of the XY gonadal ridge starting at 10.0–10.5 dpc (Hacker et al. 1995), which triggers male sex determination and directs the bipotential gonad toward testicular differentiation (Fig. 3); in the absence of *Sry* expression, the gonad develops into an ovary, under



**Fig. 3** Overview of the mammalian sex determination pathway. In mice, the bipotential gonad (*gray*) arises by 10.5 dpc and is morphologically indistinguishable between XX and XY embryos. *Sry* expression (triggered by *Wt1*, *Gata4*, and *Zfp2*) at 10.5 dpc (filled blue box) in the somatic cells of the XY gonad triggers male-specific gonad development (*right side* of the figure). SRY, along with SF1, upregulates its downstream target *Sox9* (schematic in the *left bottom inset*) in pre-Sertoli cells to trigger testis development. SOX9 expression is sustained by positive feedback loops involving *Fgf9*, *Ptgs*, and SOX9 itself (schematic in the *right bottom inset*). This feedback loop ensures continued *Sox9* expression which is required to activate male-specific genes during development and sustains expression of *Sox9* in the postnatal and adult testis. In the absence of *Sry* (*left side* of the figure), expression of female-specific genes such as *Nr0b1*, *Wnt4*, and *Foxl2* ensures proper ovarian development. *Abbreviations*: *Fgfr2* fibroblast growth factor receptor 2, *Esr1* estrogen receptor 1

the influence of signaling by the WNT4/ $\beta$ -catenin pathway and NR0B1/DAX1. This section of the chapter discusses the major genes involved in both testicular and ovarian sex determination in mammals.

### **Sex-Determining Region of Chromosome Y (*Sry*)**

*Sry*, the master gene in the mammalian sex determination pathway, encodes a protein that belongs to the SOX (SRY-related HMG box) family of transcription factors. Evolutionary studies have revealed that *Sry* is a recently arisen mammal-specific gene, which likely evolved from the *Sox3* gene currently on the mammalian X chromosome (Foster and Graves 1994), and *Sry* does not exist in other animal classes such as birds. Consistent with the idea that *Sry* function evolved from *Sox3* (and potentially replaced *Sry* as a central sex-determining gene), it was shown that ectopic expression or genomic duplication of *Sox3* results in XX male sex reversal in mice and humans (Haines et al. 2015; Moalem et al. 2012; Sutton et al. 2011), while mutation of *Sox3* alone (in mice) does not affect sex determination (Weiss et al. 2003).

The discovery of two human disorders of sexual development (DSDs), namely Turner's syndrome (XO females) and Klinefelter's syndrome (XXY males) (Ford et al. 1959; Jacobs and Strong 1959), led to the identification of a sex-determining region on the Y chromosome in humans. This region was thought to carry a gene that determines maleness. Almost 30 years later, the *Sry* gene was discovered. The human *SRY* gene was discovered while searching for conserved regions in translocated Y chromosomal DNA from XX male patients (Sinclair et al. 1990). Subsequently, the homologous Y chromosome sequence from mouse was cloned, leading to the discovery of *Sry* as the testis-determining gene in mice (Koopman et al. 1990). The role of *Sry* as a master regulator in male sex determination in mammals was determined using sex reversal experiments in which XX mice developed as males following ectopic expression of *Sry* (Koopman et al. 1991). Additionally, loss of *Sry* function in mice and humans led to XY gonadal dysgenesis or Turner's syndrome with XO/XY mosaicism (Zhao and Koopman 2012), confirming the essential role of *Sry* in mammalian sex determination.

The expression of *Sry* in mice is tightly regulated during gonad development. Its expression begins at approximately 10.5 dpc in the supporting cells (pre-Sertoli cells) of the XY genital ridges, peaks at around 11.5 dpc, and then gradually declines by 12.5 dpc (Koopman et al. 1990; Hacker et al. 1995; Ballejos et al. 2001; Jeske et al. 1995; Wilhelm et al. 2005). The expression pattern of *Sry* is unique, with its expression initiating in pre-Sertoli cells at the center of the genital ridge and gradually expanding to the poles of the gonad (not via migration, but rather via new expression in pre-Sertoli cells), eventually occupying the entire length of the gonad over a period of several hours. This center-to-pole expansion of *Sry* expression in the pre-Sertoli cells of the gonad was shown to be essential for proper center-to-pole expansion of testicular development (Hiramatsu et al. 2010). Furthermore, using partition culture assays (where the genital ridge was partitioned into anterior and posterior domains), it was shown that center-to-pole progression of testis cord formation was mediated by FGF signaling (Hiramatsu et al. 2010). In

addition to its unique expression pattern, a critical threshold of *Sry* expression is required for Sertoli cell specification (Kashimada and Koopman 2010). As the expression of *Sry* is highly dynamic and transient, it was suggested that *Sry* functions during a critical time window limited to 6 h (which corresponds to 11.0–11.25 dpc) in the developing gonad (Hiramatsu et al. 2009). Using transgenic mice in which the *Sry* expression was driven by a *heat shock protein 70.3* (*Hsp70.3*; official name is *Hspa1a*) promoter that allows for experimental induction of *Sry* expression at different time points, a delay of 6 h in *Sry* expression in XX embryos resulted in failure to initiate the testis development pathway and shifted the balance toward the female pathway, as visualized by a lack of testis cord formation, low levels of proliferation in the coelomic epithelium, reduced male-specific gene expression, and induction of female-specific genes such as *Wnt4* (Hiramatsu et al. 2009). The significance for a critical window during which *Sry* expression occurs could be to suppress the ovarian pathway and activate the testicular development pathway.

Although the regulation of *Sry* expression is not well understood, several genes have been implicated in its regulation; some of these genes include *Wt1*, *Cbx2*, *Gata4*, *Zfp2*, *mitogen-activated protein kinase kinase kinase 4* (*Map3k4*), *Insrr*, *Irr*, and *Igf1r* (Tevosian et al. 2002; Nef et al. 2003; Katoh-Fukui et al. 1998; Biason-Laubert et al. 2009; Barboux et al. 1997; Bogani et al. 2009; Hammes et al. 2001). Targeted deletion of these genes in mice resulted in reduced expression of *Sry* and XY sex reversal phenotypes, in which testis cord formation does not take place and female-specific gene expression is observed. The precise mechanism of how loss of function of these genes results in reduced *Sry* expression is unclear, as some of these genes (such as *Cbx2*, *Gadd45γ*, *Map3k4*, and insulin receptors) do not encode for transcription factors and therefore mostly act indirectly to affect *Sry* expression (Kashimada and Koopman 2010). Of all the genes listed above, much of the work has been focused on WT1+KTS as the main regulator of *Sry* expression. In humans, reduced expression of WT1+KTS causes XY sex reversal accompanied by a condition called Frasier syndrome (Barboux et al. 1997). In vitro studies using luciferase reporter assays have shown that the WT1+KTS isoform, along with GATA4, cooperatively activates transcription from the mouse *Sry* promoter (Miyamoto et al. 2008; Hossain and Saunders 2001; Shimamura et al. 1997). Interestingly, studies have shown that WT1+KTS preferentially binds to mRNA targets during mRNA processing, thereby regulating gene expression at the RNA level (Morrison et al. 2008). Whether WT1+KTS regulates *Sry* expression at the RNA level is still unclear and requires further investigation.

In addition to WT1+KTS, studies have shown that *Map3k4* and *Gadd45γ* also regulate *Sry* expression in the early mouse gonad (Warr et al. 2012). MAP3K4 is a mitogen-activated protein kinase that is involved in p38 MAPK and JNK signaling pathways to regulate a number of cellular processes such as proliferation, differentiation, apoptosis, and inflammatory response (Gerwins et al. 1997; Takekawa et al. 1997). XY embryos lacking functional MAP3K4 have reduced levels of *Sry* expression in pre-Sertoli cells, absence of Sertoli cell differentiation, and defective testis cord formation (Bogani et al. 2009). Furthermore, the mutant gonads developed ovarian morphology at stage 14.5 dpc and exhibited very low levels of *Sox9* (Sertoli

cell marker) expression and high levels of *Stra8* and *Wnt4* expression. High levels of *Stra8* and *Wnt4* expression are indicative of germ cell entry into meiosis and activation of the ovarian pathway in the absence of functional MAP3K4 (Bogani et al. 2009). In all, these data indicate that MAP3K4 signaling is essential for sex determination in mice.

MAP3K4 is known to interact with a number of proteins, one of them being GADD45, a growth arrest and DNA damage response protein family member (Takekawa and Saito 1998). Studies have shown that GADD45 activates MAP3K4 by disrupting the autoinhibitory domain of the MAP3K4 protein (Miyake et al. 2007). This interaction leads to the formation of an active dimer and induces autophosphorylation of MAP3K4 (Miyake et al. 2007). Of the three related proteins (namely, GADD45 $\alpha$ , GADD45 $\beta$ , and GADD45 $\gamma$ ) in the *GADD45* family, GADD45 $\gamma$  is known to activate p38 MAPK and JNK pathways in T-cells (Lu et al. 2001) and interacts with MAP3K4 to regulate the production of the cytokine interferon gamma (IFN $\gamma$ ) in T-cells in vitro (Chi et al. 2004). GADD45 $\gamma$  is also known to be required for testis determination, as mice lacking functional GADD45 $\gamma$  displayed reduced levels of *Sry* expression and XY gonadal sex reversal (Warr et al. 2012). Furthermore, it was shown that *Gadd45 $\gamma$*  and *Map3k4* interact to regulate *Sry* expression through a p38- and MAPK-mediated pathway and thereby regulate testis determination (Warr et al. 2012).

### **Sex-Determining Region Y (SRY)-Box 9 (Sox9)**

SOX9 also belongs to the SOX family of transcription factors. It is widely expressed in the developing heart, kidney skeleton, brain, and gonads (Wright et al. 1995). It is thought to be the major downstream target of SRY during mammalian sex determination. In the mouse XY gonad, the expression of *Sox9* is initiated in the bipotential genital ridge at 11.5 dpc and is upregulated in the pre-Sertoli cells immediately after initiation of *Sry* expression. The expression of *Sox9* within pre-Sertoli cells initiates at the center of the gonad and gradually expands toward the poles of the gonad, mimicking the *Sry* expression pattern (Kent et al. 1996; Sekido et al. 2004; Wilhelm et al. 2005; Ballejos and Koopman 2005; Morais da Silva et al. 1996). Despite their similar expression, *Sox9* expression, unlike *Sry*, is maintained in the gonad beyond fetal stages and throughout postnatal and adult life (Kent et al. 1996; Morais da Silva et al. 1996). This sustained expression of *Sox9* might be associated with maintenance of Sertoli cell fate or identity in the gonad (DiNapoli and Capel 2008).

The role of *Sox9* in sex determination was revealed when loss-of-function mutation in human *SOX9* was shown to cause a male-to-female sex reversal phenotype in 75% of males, accompanied by a skeletal defect called campomelic dysplasia (CD) (Foster et al. 1994; Wagner et al. 1994). Sex reversal phenotypes of XY *Sox9*-null mice and XX *Sox9*-overexpressing mice have confirmed the essential role of *Sox9* in testis determination (Barrionuevo et al. 2006; Vidal et al. 2001; Bishop et al. 2000). Furthermore, *Sox9*-overexpressing XX gonads have a similar phenotype as *Sry*-overexpressing gonads (Kashimada and Koopman 2010), indicating that *Sox9* is the major target of *Sry* that is required for activation of the downstream testicular program in Sertoli cells. Despite a long-standing speculation

that SRY regulates the expression of *Sox9*, it took more than a decade to demonstrate definitively that SRY regulates *Sox9* expression. The discovery of a gonad-specific enhancer of mouse *Sox9* called TESCO (testis-specific enhancer of mouse *Sox9* core) was crucial in the quest to determine how SRY upregulates *Sox9* expression (Sekido and Lovell-Badge 2008). TESCO is a 1.4-kb (kilobase) sequence that lies 11–13 kb upstream of the *Sox9* transcription start site and is highly conserved in mammals (Sekido and Lovell-Badge 2008). Sekido and Lovell-Badge (2008) showed that SRY and SF1 directly bind to TESCO and act synergistically to upregulate *Sox9* expression (Fig. 3). This was the first report demonstrating that SRY acts as a transcriptional activator in vivo. After *Sry* expression starts to decrease at 12.5 dpc, SOX9 itself is able to recognize and bind to sites previously bound by SRY in TESCO along with NR5A1, ensuring its continued expression in a positive autoregulatory feedback loop (Sekido and Lovell-Badge 2008) (Fig. 3). Thus, the positive feedback loop not only ensures that *Sox9* expression is sustained long after *Sry* expression ceases but also ensures that *Sry* signal is amplified in each of the developing Sertoli cells. Other positive feedback loops known to maintain *Sox9* expression in the gonad involve FGF9 signaling and PGD2 signaling from the Sertoli cells (discussed below).

### **Fibroblast Growth Factor 9 (Fgf9)**

FGF9 is one of the members of the fibroblast growth factor (FGF) family that plays essential roles in growth, morphogenesis, and differentiation during development. *Fgf9* is widely expressed in the mouse embryo and is initially expressed in both XY and XX gonads (Colvin et al. 2001). However, following *Sry* expression, *Fgf9* expression becomes male specific and is expressed in the Sertoli cells of the developing testis. In order to determine the in vivo role of *Fgf9*, Colvin and colleagues generated a deletion of *Fgf9* in mice. They reported an overrepresentation of phenotypically female embryos in mice lacking functional *Fgf9*, which ultimately led to the identification of a novel role for *Fgf9* in sex determination and testis development (Colvin et al. 2001). Loss of *Fgf9* led to male-to-female sex reversal in 18.5 dpc embryos, accompanied by disruption of male-specific events, including cell proliferation, mesonephric cell migration, differentiation of Sertoli cells, and testis cord formation (Colvin et al. 2001). Further studies revealed that *Fgf9* acts downstream of *Sry* and is required for promoting proliferation of Sertoli cell precursors. Following up on this study, it was shown that loss of *Fgf9* did not affect the expression of *Sry* or the initial upregulation of *Sox9* expression (Kim et al. 2006). However, *Fgf9*-null gonads did not maintain *Sox9* expression, indicating that FGF9 signaling is required for maintaining *Sox9* expression in the fetal gonad. The authors suggested that a feedback loop involving FGF9 is important in upregulating *Sox9* expression and that *Sox9* expression in turn is required for upregulation of FGF9 in the XY gonad (Fig. 3) (Kim et al. 2006). Recently, it was reported that aberrant expression of testicular FGF9 is associated with Sertoli cell-only (SCO) syndrome (patients with SCO are azoospermic and have atrophic testis and hypogonadism), indicating that *Fgf9* may play an important role in male factor infertility (Chung et al. 2013).

### Prostaglandin D2 Synthase (Ptgds)

The *Ptgds* gene encodes for an enzyme that is involved in the synthesis of prostaglandin D<sub>2</sub> (PGD<sub>2</sub>), which is critical for various physiological processes including male sex determination, platelet aggregation, bronchoconstriction, allergy, and inflammation (Moniot et al. 2011). Studies have reported the presence of a male-specific *Ptgds* gene called lipocalin-type Ptgds (*L-Ptgds*) (Malki et al. 2005). Its expression begins in the developing gonad between 11.5 and 12.5 dpc (Adams and McLaren 2002) and is mainly restricted to Sertoli cells and germ cells (Adams and McLaren 2002). PGD<sub>2</sub> signaling is involved in a positive feedback loop with SOX9 (Fig. 3). It has been shown that SOX9 initiates the transcriptional activation of *Ptgds*, which results in production of PGD<sub>2</sub> that then activates PKA (cAMP-dependent protein kinase A). PKA then phosphorylates SOX9; phosphorylation of SOX9 facilitates its nuclear localization where the SOX9 binds to its own promoter, thereby maintaining its expression (Sekido and Lovell-Badge 2008; Malki et al. 2005). Targeted deletion of *L-Ptgds* results in abnormal SOX9 protein localization and reduced *Sox9* gene expression and, hence, delayed testis cord formation until 14.5 dpc (She and Yang 2014). Additionally, *Sox9*-null gonads have reduced levels of L-PTGDS, indicating that SOX9 is required to maintain the expression of *L-Ptgds* (She and Yang 2014). *L-Ptgds* in turn functions in a positive feedback loop to maintain SOX9 expression in the developing testis.

### Gata4 and Zinc Finger Protein, Multitype 2 (Zfpm2/Fog2)

GATA4 belongs to the zinc finger family of transcription factors that recognizes the consensus sequence (T/A)GATA(A/G) (Tevosian et al. 2002). The GATA zinc finger transcription factors are known to play critical roles during development, including differentiation of hematopoietic cells, cardiac and coronary vascular development, and morphogenesis of various tissues like the liver, lung, and gut (Tevosian et al. 2002). In the developing gonadal ridge, GATA4 expression is restricted to somatic cells only. At 11.5 dpc both XX and XY gonads express GATA4. By 13.5 dpc *Gata4* is expressed at high levels in the Sertoli cells and low levels in the interstitial cells of the XY gonads; however in XX gonads, its expression is low in all cells (Tevosian et al. 2002). Studies have shown that GATA4, along with its cofactor ZFPM2, is required for normal gonad differentiation, as homozygous *Zfpm2*-null mice show failure of testis differentiation, lack of testis cord development, and significantly reduced gonad size (Tevosian et al. 2002). Furthermore, it was shown that *Sry* expression was significantly downregulated in *Zfpm2*-null gonads at 11.5 dpc, the time point when *Sry* expression normally peaks (Tevosian et al. 2002). Additionally, homozygous targeted mutation in *Gata4* (*Gata4<sup>ki</sup>*) that abolishes the interaction between GATA4 and its cofactor ZFPM2 also resulted in loss of Sertoli cell differentiation and abnormal testis development (Tevosian et al. 2002; Manuylov et al. 2011). Detailed analysis of *Zfpm2*-null XY gonads and *Gata4<sup>ki</sup>* XY gonads revealed that expression of genes involved in Sertoli cell differentiation (such as *Sox9*, *Amh*, and *Dhh*) and genes involved in androgen biosynthesis (*Cyp11a1*, *Hsd3b1*, and *Cyp17a1*) was absent. These results indicate that the interaction

between GATA4 and ZFPM2 is essential for normal Sertoli cell development and Leydig cell development (Tevosian et al. 2002). Recently, it was reported that a disruption of the human ZFPM2 protein resulted in failure of direct ZFPM2 and GATA4 interaction, which led to abnormal sex determination and gonadal dysgenesis in humans (Bashamboo et al. 2014). In all, GATA4 and ZFPM2 are essential for male gonadogenesis, and their direct physical interaction is essential for maintaining normal *Sry* expression during testis differentiation (Fig. 3).

## Mammalian Ovarian Sex Determination Genes

### Wingless-Type MMTV Integration Site Family, Member 4 (Wnt4)

WNT4 is a growth factor that plays essential roles during mammalian embryogenesis. In mice, *Wnt4* is expressed in the mesonephros of the early gonad (9.5–10.5 dpc) of both sexes. By 12.5 dpc, its expression becomes restricted to the mesenchyme cells surrounding the Müllerian duct epithelium in the mesonephros (Binnerts et al. 2007). Once sex determination events are initiated, the expression of *Wnt4* is restricted to the female gonad. Loss of *Wnt4* in mice results in a partial sex reversal phenotype in the female reproductive system, indicating that *Wnt4* is a female determinant. *Wnt4* is essential for the development of the Müllerian duct, inhibition of steroidogenic cell differentiation, inhibition of testis-specific vascular remodeling, and development of normal oocytes (Jeays-Ward et al. 2003; Vainio et al. 1999). Furthermore, loss of *Wnt4* also resulted in a transient increase in the expression of both *Sox9* and *Fgf9* in the absence of *Sry*, thus indicating that FGF9 and WNT4 function as antagonistic signals that regulate mammalian sex determination. *Fgf9* downregulates WNT4 signaling to support testis development, while *Wnt4* downregulates FGF9 signaling to support normal ovarian development (Kim et al. 2006). In addition, targeted deletion of *Wnt4* in the granulosa cells of the ovary revealed that *Wnt4* is required for normal follicular development and regulation of steroidogenesis in granulosa cells (Boyer et al. 2010).

Studies have shown that *Wnt4* plays an essential role during various aspects of both male and female sexual development (Boyer et al. 2010; Coveney et al. 2008; Jeays-Ward et al. 2004). *Wnt4*-null testes show defects in Sertoli cell differentiation, and these defects were shown to occur downstream of *Sry* but upstream of *Sox9* and *Dhh*. Additionally, *Wnt4*-null testes were smaller in size and had disorganized testis cords. These studies indicate that *Wnt4* is required for normal testis development (Jeays-Ward et al. 2004). Genome-wide microarray analysis of *Wnt4*-null XX gonads led to the identification of several candidate genes (*Tcf21*, *Igfbp7*, *Cbln1*, *Sostdc1*, *Gpc3*, and *Sulf2*) that may be involved in testis vascular development (Coveney et al. 2008). Additionally, loss of *Wnt4* affected the expression of genes expressed in testis cords (*Robo1*, *Pitx2*, and *Spp1*) or related to germ cell development (Coveney et al. 2008). In all, these data suggest that WNT signaling is essential for testis differentiation. Recently, *Wnt4*-null mice were used to identify several candidate *Wnt4* downstream target genes that might be important for both female and male gonadogenesis (Naillat et al. 2015). *Notum*, *Phlda2*, *Runx1*, and *Msx1* genes

were identified as candidate target genes for female reproductive development. In addition, the authors reported that WNT4 signaling might also regulate genes associated with the male testicular developmental pathway. These genes include *Osr2*, *Dach2*, *Pitx2*, and *Tacr3* (Naillat et al. 2015). These studies have identified a number of potential target genes that may be subject to regulation by WNT4 signaling during mammalian sex determination and development.

WNT4 likely acts through the canonical  $\beta$ -catenin signaling pathway. The disruption of  $\beta$ -catenin signaling in the XX gonad leads to a partial female-to-male sex reversal (Liu et al. 2009), similar to *Wnt4* mutants (Jeays-Ward et al. 2003; Vainio et al. 1999), while ectopic  $\beta$ -catenin signaling in XY gonads results in male-to-female sex reversal (Maatouk et al. 2008). Mutants for *Rspo1*, another positive effector of  $\beta$ -catenin signaling, also show a partial female-to-male sex reversal phenotype reminiscent of *Wnt4* and  $\beta$ -catenin mutants (Chassot et al. 2008). These findings demonstrate that  $\beta$ -catenin signaling, downstream of WNT4 and RSPO1 activity, is required for ovarian determination and differentiation.

### **Forkhead Box L2 (Foxl2)**

FOXL2 belongs to the forkhead/winged-helix family of transcription factors. Studies have shown that FOXL2 is essential for granulosa cell differentiation and normal ovarian development in mice, but is not required for primary sex determination (Schmidt et al. 2004; Uda et al. 2004). Its expression begins at 12.5 dpc in the pre-granulosa cells of the developing gonad. In humans, loss-of-function mutation in the *FOXL2* gene results in the autosomal disorder blepharophimosis/ptosis/epicanthus inversus syndrome (BPES) and premature ovarian failure in adults (Uhlenhaut and Treier 2006). *Foxl2* has also been implicated in the polled intersex syndrome (PIS) of goats, and a recent study revealed that *Foxl2* is required for primary sex determination in that species (Boulanger et al. 2014). Female mice with targeted deletion of *Foxl2* displayed premature disruption of the primordial follicular pool, inhibition of granulosa cell differentiation, and complete absence of secondary follicles (Ottolenghi et al. 2007). Furthermore, it was shown that male-specific genes involved in male sex determination (such as *Sox9*, *Fgf9*, *Fgfr2*, *Nr5a1*, and *Gata4*) were upregulated in *Foxl2*-null ovaries. This indicates that *Foxl2* functions to repress the pathway that regulates male sex determination in mammals (Ottolenghi et al. 2007). Conditional deletion of *Foxl2* in the adult ovarian follicles has shown that *Foxl2* is required to prevent the transdifferentiation of adult ovary granulosa and theca cells into their testicular counterparts (Uhlenhaut et al. 2009). In vitro studies have shown that FOXL2, together with estrogen receptor 1 (ESR1), negatively regulates the expression of SOX9 (Fig. 3). The exact mechanism of *Foxl2* in this transdifferentiation process is discussed in greater detail in the subsequent chapter of this volume.

### **Nuclear Receptor Subfamily 0, Group B, Member 1 (Nr0b1/Dax1)**

*Nr0b1*, also known as *Dax1*, encodes an orphan nuclear receptor that is expressed in the developing gonad, adrenal gland, pituitary, and hypothalamus (Luo et al. 1994; Shinoda et al. 1995). In both mouse and human, DAX1 is coexpressed with NR5A1/SF1



in male and female gonads prior to gonad differentiation. In mice *Dax1* expression is upregulated in the Sertoli cells of the XY gonad at 12.5 dpc (Ikeda et al. 2001). Its expression declines soon after in the Sertoli cells but increases in the interstitial cells between 13.5 and 17.5 dpc. In XX gonads *Dax1* is expressed between 12.5 and 14.5 dpc. DAX1 was originally thought to act like an “anti-testis” factor (Swain et al. 1998); however, it was later reported that *Dax1* plays an essential role in testis differentiation (Meeks et al. 2003). Human XY individuals with *DAX1* duplications exhibited male-to-female sex reversal (dosage-sensitive sex reversal). Transgenic mice carrying duplication of the *Dax1* gene exhibited decreased *Sry* expression and delayed testis development, resulting in a XY sex reversal phenotype (Ludbrook and Harley 2004). Hence, it was concluded that *Dax1* antagonizes *Sry* expression to regulate sex determination (Swain et al. 1998). Targeted deletion of *Dax1* in mice resulted in disorganized testis structure, although Sertoli cells and fetal Leydig cells were present and appeared to function normally. Additionally, mutation in the *Dax1* gene was associated with testicular dysgenesis and abnormal peritubular myoid cell differentiation (Meeks et al. 2003).

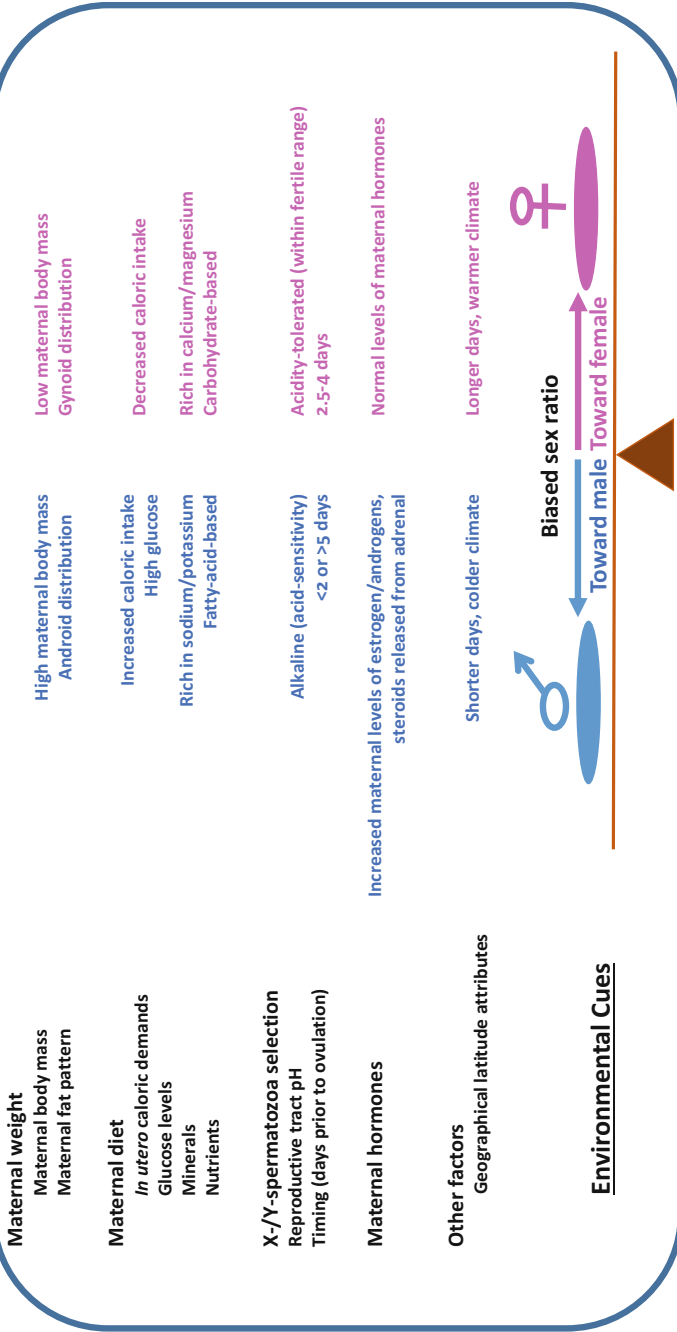
## **Environmental Influences in Mammalian Sex Determination/Sex Ratio**

While mammals utilize sex determination pathways and machinery outlined in previous sections of this chapter, other organisms that lack sex chromosomes or a genetic sex determination mechanism rely on the environment to determine the sex of an organism. Additionally, there are organisms that have a combination of both environmental and genetic components driving their sex determination (Yamamoto et al. 2014). *Sry* (a major male-determining gene, described above) is present in virtually all mammals; however, it is not found in nonmammalian species (such as birds, fish, or reptiles), whose sex determination is sensitive to environmental cues rather than solely relying on genetic information. In some cases, even though *Sry* is absent, the balance of sex-specific downstream signaling, such as FGF-versus-WNT signaling, still regulates sex determination. Some species use environmental sex determination, rather than chromosomal methods, while others utilize external influences to override or coincide with chromosomal sex determination (Quinn et al. 2007; Radder et al. 2008), relying on environmental, hormonal, and/or behavioral switches. Genetic factors play an essential role in sex determination in mammals (described in previous sections); however, the maternal environment may also be important for sex determination and/or sex ratio. This section will highlight examples of how certain environmental cues, such as maternal influence on the pre-conception environment and other external factors, can influence sex ratio and/or determination in mammals (Fig. 4).

### **Pre-conception Maternal Environment (pH)**

The uterus is a controlled environment that allows the fetus to develop and was generally thought to be a passive player in embryonic sexual development; however,

## Environmental influences on sex determination/ratio in mammals



**Fig. 4** Environmental influences on sex determination/ratio in mammals. A list of environmental cues influencing sex determination and/or sex ratio and how changes in these factors promote male or female offspring

it has been demonstrated that the maternal environment before, during, and after conception can influence both long-term health and the sex (and sex ratio) of the offspring. The Trivers-Willard hypothesis of sex ratio is based on the idea that pregnant females can alter the sex of their offspring based on their health condition in terms of nutrition, body size, as well as dominance characteristics (covered later in section) and their parental ability to invest in their offspring to outcompete others for increased offspring in the following generation (also termed the maternal dominance hypothesis). This theory states if the maternal condition is poor, mothers tend to produce a higher ratio of females to males (Trivers and Willard 1973). This sex skewing due to maternal condition was found to be a potential consequence of maternal glucose levels, which differentially supports male-versus-female blastocysts (Larson et al. 2001). This principle was subsequently built upon by a controversial concept that human couples can influence the sex of their offspring, first introduced by Kleegman, but then popularized as Shettles' method in the 1970s (Shettles 1973).

Shettles' concept is based on the timing of coitus in proximity to ovulation, in addition to sexual position during intercourse, as the X- and the Y-spermatozoa have different speeds and sensitivities to acidity (e.g., within the vaginal/cervical environment). His theory states that for male offspring to be created, intercourse must be performed closest (<2 days) to ovulation, compared to female offspring (optimal at 2.5–3 days); this idea is based on the ability of Y-spermatozoa to swim faster than X-spermatozoa due to their physical differences (X-spermatozoa have smaller heads and longer tails) and that Y-sperm are more sensitive to acidic environments. Therefore, this increased time in the cervix will result in removal of male-determining sperm due to the acidity (Shettles 1973). However, this theory is still controversial as others have not been able to determine any significant differences, besides DNA content, between X- and Y-bearing spermatozoa.

The cervix is the major passageway for sperm to move from the vagina to the uterine cavity; therefore, differences in the mucous composition or pH can "select" or control the sperm that travel through it. The cervix is most well known as a barrier against pathogens and also prevents entry of abnormal sperm. The cervical mucus exits into the vaginal cavity, and the whole process of entry into the uterine cavity is influenced by this mucus environment. Since the pH of the cervix changes according to the stages of ovulation due to reproduction-associated hormones (including estrogen, progesterone, and luteinizing hormone), the different time windows relative to ovulation, according to his theory, may allow the pH of the woman's cervical mucus to play a role in sex ratios (Bott et al. 2006). During pre-ovulation/midcycle, the levels of estradiol are high, physically changing the size and decreasing the firmness of the cervix itself and increasing water content, which leads to decreased mucus viscosity and alkaline pH, thereby becoming more hospitable to sperm (Bigelow et al. 2004; Kopito et al. 1973). The chemical composition of the mucus, including the ratios and amounts of specific electrolytes, such as sodium, changes over the course of the cycle (Gould and Ansari 1981), which can influence the overall pH of the cervix.

## Maternal Diet

Both the number and sex ratio of offspring produced can be influenced by overall food intake and/or the presence of nutrients during both preconception and early pregnancy (Schmidt and Hood 2012). Studies have shown that in humans, the sex ratio of the fetus can be influenced by the maternal diet at the time of conception (Mathews et al. 2008). The nutrition of the mother greatly influences sex ratio of her offspring, as mothers with malnutrition produce increased numbers of female offspring, whereas higher caloric intake resulted in male-biased offspring. In Western countries, the human male-female offspring ratio is already skewed slightly toward males, possibly caused by population-wide obesity in these cultures (the influence of fat on sex ratios will be discussed later in this chapter). Human male offspring have higher in utero caloric demands than females (Tamimi et al. 2003). Although this skewing may be due to energy requirements for each sex (causing sex-selective spontaneous abortion or miscarriage), it also can be related to sex determination (genetic machinery discussed in early sections of this chapter). In humans, analysis of maternal caloric intake around the time of conception revealed 56% of the highest energy intake group had sons, compared with 45% in the lowest energy intake group (Mathews et al. 2008). This study has been similarly replicated in ruminants and rodents with increased skewed ratios. Diets high in lipids, fats (e.g., lard), and dietary fatty acids (including foods high in omega-3 (n-3) polyunsaturated essential fatty acids) are linked to increases in male births in mammalian species, whereas a carbohydrate-based diet (high in sugars and complex carbohydrates) or diets rich in omega-6 (n-6) fatty acids increased female births (Austad and Sunquist 1986; Crawford et al. 1987; Fountain et al. 2008; Gulliver et al. 2013a, b; Rosenfeld and Roberts 2004). As many of these diet-based studies did not result in any malnutrition or decreased litter size, it demonstrates that diet can skew sex ratios without sex-selective miscarriage being the major cause in this shift. A few of these studies noted that older/more mature mothers showed a greater response to changes in the diet than younger mothers (Rosenfeld et al. 2003). Other studies investigating low-fat diets still had skewing toward females, but in addition resulted in smaller litter sizes; therefore, male-selective losses may also play a role in cases of malnutrition and/or lower caloric intake (Meikle and Drickamer 1986; Rivers and Crawford 1974). Interestingly, mouse placentas associated with female embryos demonstrate a higher sensitivity to the maternal diet, by changes in gene expression, compared to their male counterparts (Mao et al. 2010).

In humans and other mammals (such as roe deer, reindeer, mature ewes, Barbary sheep, domestic pigs, and other species), greater maternal body mass and a particular maternal fat distribution (an android pattern in which fat is mainly in the upper trunk portion of the body) are associated with increased male offspring (Cassinello 1996; Kent 1995; Kojola and Eloranta 1989; Meikle et al. 1996; Wauters et al. 1995; Singh and Zambarano 1997). As adipose tissue is a major location for hormone biosynthesis and metabolism, these changes may have hormonal origins. Interestingly, a diet free of fatty acids resulted in a more acidic vaginal environment (Whyte et al. 2007). These studies further highlight how the maternal diet impacts the overall

cervical/vaginal environment, thereby influencing the selectivity of the sperm and overall sex ratio of the offspring.

Minerals in the maternal diet are essential for production of offspring and for normal sex ratios. One example of this is that female white-footed mice fed on a low-calcium diet from reproductive age until senescence had a poor skeletal condition and produced smaller female-biased litters (Schmidt and Hood 2012), demonstrating that calcium intake influences reproductive output and sex ratios. The mechanism underlying the relationship between calcium in the maternal diet and skewed sex ratios in the offspring is unclear, but as calcium has been found to be important for sperm motility, fertilization, and oocyte activation (Homa et al. 1993; Hong et al. 1984). Additionally, it has been speculated that the female reproductive tract milieu influences the functionality of the sperm (in terms of motility and fertilization capacity), perhaps in a sex-specific manner, leading to a biased sex ratio (see earlier in this section). Interestingly, the ratio of monovalent ions (potassium/sodium) to divalent ions (calcium/magnesium) plays a role in sex ratios, whereby higher calcium/magnesium intake is associated with an increase in female offspring, whereas increased potassium/sodium corresponds to more male offspring (Mathews et al. 2008; Bolet et al. 1982; Oun et al. 2016; Stolkowski and Choukroun 1981; Stolkowski and Lorrain 1980; Vahidi and Sheikha 2007). In all, a wide range of dietary factors work together to regulate sex determination in a species-specific manner.

### **Maternal Menstrual Cycle**

A study in humans controlling the timing between coitus and ovulation, in combination with maintaining a strict mineral-containing diet (low in sodium, high in calcium), demonstrated that the time window 3–4 days before ovulation skews the offspring toward female, while any variation/shift in this coitus time window (<2 days or >5 days prior to ovulation) while still on the diet resulted in a decreased female offspring ratio (Noorlander et al. 2010). This study had stringent compliance efforts; therefore, those that did not comply were compared for their contribution to the sex ratio based on their noncompliant status. Previous to this study, many studies were performed providing results either stating there was a difference based on ovulation or there was simply no difference; however, this data aligns with other studies that also report a higher likelihood of male offspring if copulation occurs closer to ovulation, whereas there will be an increased likelihood of female offspring if copulation occurs 3 days prior to ovulation, which is consistent with this time window.

### **Maternal Dominance and Sex Hormones**

The theory of maternal dominance (in which a dominant female is defined as an authoritative and influential female, not to be confused with other personality traits, such as aggressive or domineering) states that a maternal masculine phenotype before conception causes sex skewing toward male offspring (Grant 1996; Sadalla et al. 1987). For example, in social mammalian species, females displaying dominant personalities produce more male offspring as compared to subordinate females.

Interestingly, this trend disappeared at higher population densities (and for animals in captivity) as the number of males born each year is inversely correlated with the population density and can be attributed to the amount of winter rainfall (Kruuk et al. 1999). These changes could be linked to stress caused by competition for resources and/or nutrition (discussed in other sections of this chapter). In another case, some species of temperature-dependent sex-determining fish born earlier in the birthing season in the northern latitudes have a strong female bias to allow females access to a longer feeding season, permitting females to become larger and grants them a competitive edge (via dominance) that promotes both survival and fecundity (Conover 1984). Both these scenarios represent types of environmental variables that are associated with nutritional stress and fecundity that leads to changes in sex ratios.

The basis for maternal dominance sex skewing is that the levels of sex hormones at the time of conception are correlated with sex-specific skewing of births. For example, a mother who has high estrogen and androgen levels may display masculine-like behavioral characteristics, both of which are correlated to a higher production of male offspring (James 1990). Interestingly, under conditions of chronic stress, females respond differently than males, by increasing their testosterone levels, rather than decreasing them (Gray 1992). The cause of this difference is that the adrenal glands normally produce small amounts of androgens (including the precursor to testosterone, androstenedione), but in response to stress only the female adrenal gland increases its production, in addition to cortisol (Mazur and Petrenko 1997), thereby leading to increased maternal testosterone levels.

Stress causes the mother's adrenal glands to release high levels of stress hormones into the blood, which can cross the placental barrier and can interfere with the fetus's production of sex hormones temporarily. One sex hormone most notably influenced by stress hormone levels is testosterone (Ellis and Cole-Harding 2001). Later during testicular development, testosterone is required for masculinization, demonstrated by problems with secondary sex characteristics in testosterone-deficient or androgen receptor-deficient models. Interestingly, maternal levels of testosterone during the time of conception can also further skew the sex bias, by selectively tilting the sex ratio. Female testosterone can also be produced intrafollicularly within the ovary, and these local levels of testosterone have been linked to sex ratios, thought to influence fertilization by X- versus Y-bearing spermatozoa (Grant and Irwin 2005; Grant et al. 2008). The mechanism behind this selection may be due to the influence of maternal hormones on uterine responsiveness, which influences the survival of the fertilized blastocyst, leading to sex-specific resorption, mortality, and, ultimately, sex skewing of offspring (Krackow 1995).

### **Other External Factors**

In addition to the maternal pre-conception environment, other external factors, such as external stress and geographic location (e.g., latitude), have been reported to affect sex ratio. Stress in humans influences sex ratio such that more male offspring are produced in the absence of stress (Masukume and Grech 2015). An example of this

is the increased number of male newborns in South Africa 9 months after the 2010 FIFA World Cup soccer tournament was held in that country. The authors reasoned that the increased male sex ratio was most likely due to increased sexual intercourse during the tournament (Masukume and Grech 2015). Additional causes for the skewed ratio toward males may also be associated with decreased male fetal deaths and the quality of sperm (Masukume and Grech 2015). During negatively stressful situations, however, such as after an earthquake, the inverse sex ratio skewing occurs, tilting toward more female births. An example of this is 9 months following a devastating earthquake in Kobe, Japan, in which more females were born. Acute stress may decrease sperm motility, reduce fertility, and thus reduce male sex ratios (Fukuda et al. 1998).

Other conditions of stress, such as war, lead to small but significant increases in male offspring. More male births were reported during and after wars (including World War I and II and the Korean and Vietnam wars) (Ellis and Bonin 2004; Hesketh and Xing 2006). The reasoning for the skewed sex ratio is that the physiological state of mothers during war caused the release of stress hormones, such as cortisol and adrenaline, potentially inducing a higher rate of miscarriages; however, male fetuses are more prone to miscarriages than female fetuses, which contradicts this argument (Ellis and Bonin 2004).

Another factor potentially influencing sex ratio in humans is geographical latitude, with more female births occurring at tropical latitudes than at temperate and subarctic latitudes (Navara 2009). The relationship between sex allocation and latitude was attributed to latitude-dependent factors, such as length of the day and temperature; a study reported that human sex ratio may be influenced by these factors (Navara 2009). The authors suggested that the quality of the semen and miscarriage rates may vary with latitude and, hence, indirectly affect sex ratio. Confirming that both temperature and day length are important for sex ratios in mammals, other species (such as hamsters, mice, and meadow voles) are also influenced by length of the day and temperature, with more male offspring produced during shorter days or colder weather (Drickamer 1990; Mcshea and Madison 1986). In all, a wide range of environmental factors work together to regulate sex determination and sex ratios in a species-specific manner.

---

## Conclusions and Future Areas of Research in the Field

Sex determination is critical for reproduction and for the survival of sexually reproducing species. While virtually all mammals, such as humans, use the Y chromosome-encoded gene *Sry* as the genetic trigger for sex determination, the molecular mechanism by which sex is determined is highly variable across different animal classes. For those species whose sex determination is sensitive to external influences, such as exogenous hormones, elucidating how environmental contaminants impact reproductive fitness is of major interest for the fields of ecology and reproductive biology. Studying these model systems has the additional potential to

inform us of the imminent consequences of endocrine-disrupting compounds on human health and sexual development.

In mammals, *Sry* is the master switch gene that launches the undifferentiated bipotential gonad into the testis program. Although much is known about *Sry*, several things are still not completely understood, such as the mechanism of its regulation, the proteins with which SRY interacts, and all the downstream genes it directly or indirectly targets. Additionally, genome-wide studies and genetic analyses have led to the identification of several other genes with sex-specific expression patterns that play important roles in sex determination. How these genes function in a network to regulate sex determination is still unclear and is a matter for further investigation. Only about 20% of human cases of reproductive system abnormalities have a defined molecular diagnosis (i.e., a known causative genetic factor) (Hughes et al. 2006), so it is clear that more research is needed into defining the mechanisms that promote the development of the fetal testis and ovary. Understanding the molecular pathways regulating sex determination is essential to gaining insight into some of the yet unidentified causes of human sexual disorders of development, such as gonadal dysgenesis and malformation, ambiguous genitalia, and sex reversal.

**Acknowledgments** This work was supported by Cincinnati Children's Hospital Medical Center (CCHMC) developmental funds and a March of Dimes Basil O'Connor Starter Scholar Award to T.D.; S.J.P. and D.L.K. were also supported by a CCHMC Research Innovation and Pilot Funding Award.

---

## References

- Achermann JC, Ozisik G, Ito M, Orun UA, Harmanci K, Gurakan B, et al. Gonadal determination and adrenal development are regulated by the orphan nuclear receptor steroidogenic factor-1, in a dose-dependent manner. *J Clin Endocrinol Metab.* 2002;87(4):1829–33.
- Adams IR, McLaren A. Sexually dimorphic development of mouse primordial germ cells: switching from oogenesis to spermatogenesis. *Development.* 2002;129(5):1155–64.
- Armstrong JF, Pritchard-Jones K, Bickmore WA, Hastie ND, Bard JB. The expression of the Wilms' tumour gene, WT1, in the developing mammalian embryo. *Mech Dev.* 1993; 40(1–2):85–97.
- Austad S, Sunquist M. Sex-ratio manipulation in the common opossum. *Nature.* 1986;324:58–60.
- Ayers KL, Smith CA, Lambeth LS. The molecular genetics of avian sex determination and its manipulation. *Genesis.* 2013;51(5):325–36.
- Bandiera R, Vidal VP, Motamedi FJ, Clarkson M, Sahut-Barnola I, von Gise A, et al. WT1 maintains adrenal-gonadal primordium identity and marks a population of AGP-like progenitors within the adrenal gland. *Dev Cell.* 2013;27(1):5–18.
- Barboux S, Niaudet P, Gubler MC, Grunfeld JP, Jaubert F, Kuttann F, et al. Donor splice-site mutations in WT1 are responsible for Frasier syndrome. *Nat Genet.* 1997;17(4):467–70.
- Barrionuevo F, Bagheri-Fam S, Klattig J, Kist R, Taketo MM, Englert C, et al. Homozygous inactivation of *Sox9* causes complete XY sex reversal in mice. *Biol Reprod.* 2006; 74(1):195–201.



- Barrionuevo F, Georg I, Scherthan H, Lecureuil C, Guillou F, Wegner M, et al. Testis cord differentiation after the sex determination stage is independent of Sox9 but fails in the combined absence of Sox9 and Sox8. *Dev Biol.* 2009;327(2):301–12.
- Bashamboo A, Brauner R, Bignon-Topalovic J, Lortat-Jacob S, Karageorgou V, Lourenco D, et al. Mutations in the FOG2/ZFPM2 gene are associated with anomalies of human testis determination. *Hum Mol Genet.* 2014;23(14):3657–65.
- Behringer RR, Finegold MJ, Cate RL. Mullerian-inhibiting substance function during mammalian sexual development. *Cell.* 1994;79(3):415–25.
- Bertuzzi S, Porter FD, Pitts A, Kumar M, Agulnick A, Wassif C, et al. Characterization of Lhx9, a novel LIM/homeobox gene expressed by the pioneer neurons in the mouse cerebral cortex. *Mech Dev.* 1999;81(1–2):193–8.
- Beye M, Hasselmann M, Fondrk MK, Page RE, Omholt SW. The gene *csd* is the primary signal for sexual development in the honeybee and encodes an SR-type protein. *Cell.* 2003;114(4):419–29.
- Biason-Laubert A, Konrad D, Meyer M, DeBeaufort C, Schoenle EJ. Ovaries and female phenotype in a girl with 46, XY karyotype and mutations in the CBX2 gene. *Am J Hum Genet.* 2009;84(5):658–63.
- Bigelow JL, Dunson DB, Stanford JB, Ecochard R, Gnoth C, Colombo B. Mucus observations in the fertile window: a better predictor of conception than timing of intercourse. *Hum Reprod.* 2004;19(4):889–92.
- Binnerts ME, Kim KA, Bright JM, Patel SM, Tran K, Zhou M, et al. R-Spondin1 regulates Wnt signaling by inhibiting internalization of LRP6. *Proc Natl Acad Sci U S A.* 2007;104(37):14700–5.
- Birk OS, Casiano DE, Wassif CA, Cogliati T, Zhao L, Zhao Y, et al. The LIM homeobox gene *Lhx9* is essential for mouse gonad formation. *Nature.* 2000;403(6772):909–13.
- Bishop CE, Whitworth DJ, Qin Y, Agoulnik AI, Agoulnik IU, Harrison WR, et al. A transgenic insertion upstream of *sox9* is associated with dominant XX sex reversal in the mouse. *Nat Genet.* 2000;26(4):490–4.
- Bland ML, Fowkes RC, Ingraham HA. Differential requirement for steroidogenic factor-1 gene dosage in adrenal development versus endocrine function. *Mol Endocrinol.* 2004;18(4):941–52.
- Bogani D, Siggers P, Brixey R, Warr N, Beddow S, Edwards J, et al. Loss of mitogen-activated protein kinase kinase kinase 4 (MAP3K4) reveals a requirement for MAPK signalling in mouse sex determination. *PLoS Biol.* 2009;7(9):e1000196.
- Bolet G, Gueguen L, Dando P, Ollivier L. Influence of mineral diet of the sow on the sex ratio of the newborn. *Reprod Nutr Dev.* 1982;22(6):1073–81.
- Bott EM, Young IR, Jenkin G, McLaren WJ. Detection of morphological changes of the ovine cervix in response to sex steroids using a fluorescence confocal endomicroscope. *Am J Obstet Gynecol.* 2006;194(1):105–12.
- Boulanger L, Pannetier M, Gall L, Allais-Bonnet A, Elzaïat M, Le Bourhis D, et al. FOXL2 is a female sex-determining gene in the goat. *Curr Biol.* 2014;24(4):404–8.
- Boyer A, Goff AK, Boerboom D. WNT signaling in ovarian follicle biology and tumorigenesis. *Trends Endocrinol Metab.* 2010;21(1):25–32.
- Bullejos M, Koopman P. Delayed Sry and Sox9 expression in developing mouse gonads underlies B6-Y(DOM) sex reversal. *Dev Biol.* 2005;278(2):473–81.
- Bullejos M, Bowles J, Koopman P. Searching for missing pieces of the sex-determination puzzle. *J Exp Zool.* 2001;290(5):517–22.
- Burglin TR. Analysis of TALE superclass homeobox genes (MEIS, PBC, KNOX, Iroquois, TGIF) reveals a novel domain conserved between plants and animals. *Nucleic Acids Res.* 1997;25(21):4173–80.
- Capellini TD, Vaccari G, Ferretti E, Fantini S, He M, Pellegrini M, et al. Scapula development is governed by genetic interactions of Pbx1 with its family members and with Emx2 via their cooperative control of Alx1. *Development.* 2010;137(15):2559–69.

- Caricasole A, Duarte A, Larsson SH, Hastie ND, Little M, Holmes G, et al. RNA binding by the Wilms tumor suppressor zinc finger proteins. *Proc Natl Acad Sci U S A*. 1996;93(15):7562–6.
- Cassinello J. High-ranking females bias their investment in favour of male calves in captive *Ammotragus lervia*. *Behav Ecol Sociobiol*. 1996;38(6):417–24.
- Chassot AA, Ranc F, Gregoire EP, Roepers-Gajadien HL, Taketo MM, Camerino G, et al. Activation of beta-catenin signaling by Rspo1 controls differentiation of the mammalian ovary. *Hum Mol Genet*. 2008;17(9):1264–77.
- Chassot AA, Bradford ST, Auguste A, Gregoire EP, Pailhoux E, de Rooij DG, et al. WNT4 and RSP01 together are required for cell proliferation in the early mouse gonad. *Development*. 2012;139(23):4461–72.
- Chen S, Zhang G, Shao C, Huang Q, Liu G, Zhang P, et al. Whole-genome sequence of a flatfish provides insights into ZW sex chromosome evolution and adaptation to a benthic lifestyle. *Nat Genet*. 2014;46(3):253–60.
- Chi H, Lu B, Takekawa M, Davis RJ, Flavell RA. GADD45beta/GADD45gamma and MEKK4 comprise a genetic pathway mediating STAT4-independent IFN gamma production in T cells. *EMBO J*. 2004;23(7):1576–86.
- Chiang EF, Pai CI, Wyatt M, Yan YL, Postlethwait J, Chung B. Two sox9 genes on duplicated zebrafish chromosomes: expression of similar transcription activators in distinct sites. *Dev Biol*. 2001;231(1):149–63.
- Chung CL, Lu CW, Cheng YS, Lin CY, Sun HS, Lin YM. Association of aberrant expression of sex-determining gene fibroblast growth factor 9 with Sertoli cell-only syndrome. *Fertil Steril*. 2013;100(6):1547–54. e1–4
- Colvin JS, Green RP, Schmahl J, Capel B, Ornitz DM. Male-to-female sex reversal in mice lacking fibroblast growth factor 9. *Cell*. 2001;104(6):875–89.
- Combes AN, Spiller CM, Harley VR, Sinclair AH, Dunwoodie SL, Wilhelm D, et al. Gonadal defects in Cited 2-mutant mice indicate a role for SF1 in both testis and ovary differentiation. *Int J Dev Biol*. 2010;54(4):683–9.
- Conen PE, Bailey JD, Allemang WH, Thompson DW, Ezrin C. A probable partial deletion of the Y chromosome in an intersex patient. *Lancet*. 1961;2(7197):294–5.
- Conover DO. Adaptive significance of temperature-dependent sex determination in a fish. *Am Nat*. 1984;123(3):297–313.
- Cook DM, Hinkes MT, Bernfield M, Rauscher 3rd FJ. Transcriptional activation of the syndecan-1 promoter by the Wilms' tumor protein WT1. *Oncogene*. 1996;13(8):1789–99.
- Core N, Joly F, Boned A, Djabali M. Disruption of E2F signaling suppresses the INK4a-induced proliferative defect in M33-deficient mice. *Oncogene*. 2004;23(46):7660–8.
- Coveney D, Ross AJ, Slone JD, Capel B. A microarray analysis of the XX Wnt4 mutant gonad targeted at the identification of genes involved in testis vascular differentiation. *Gene Expr Patterns*. 2008;8(7–8):529–37.
- Crawford MA, Doyle W, Meadows N. Gender differences at birth and differences in fetal growth. *Hum Reprod*. 1987;2(6):517–20.
- DeFalco TJ, Verney G, Jenkins AB, McCaffery JM, Russell S, Van Doren M. Sex-specific apoptosis regulates sexual dimorphism in the *Drosophila* embryonic gonad. *Dev Cell*. 2003;5(2):205–16.
- Di Giacomo G, Koss M, Capellini TD, Brendolan A, Popperl H, Selleri L. Spatio-temporal expression of Pbx3 during mouse organogenesis. *Gene Expr Patterns*. 2006;6(7):747–57.
- DiMartino JF, Selleri L, Traver D, Firpo MT, Rhee J, Warnke R, et al. The Hox cofactor and proto-oncogene Pbx1 is required for maintenance of definitive hematopoiesis in the fetal liver. *Blood*. 2001;98(3):618–26.
- DiNapoli L, Capel B. SRY and the standoff in sex determination. *Mol Endocrinol*. 2008;22(1):1–9.
- Drickamer LC. Seasonal-variation in fertility, fecundity and litter sex-ratio in laboratory and wild stocks of house mice (*Mus-Domesticus*). *Lab Anim Sci*. 1990;40(3):284–8.
- Drummond IA, Madden SL, Rohwer-Nutter P, Bell GI, Sukhatme VP, Rauscher 3rd FJ. Repression of the insulin-like growth factor II gene by the Wilms tumor suppressor WT1. *Science*. 1992;257(5070):674–8.

- Durlinger AL, Kramer P, Karels B, de Jong FH, Uilenbroek JT, Grootegoed JA, et al. Control of primordial follicle recruitment by anti-Mullerian hormone in the mouse ovary. *Endocrinology*. 1999;140(12):5789–96.
- Eid W, Opitz L, Biason-Lauber A. Genome-wide identification of CBX2 targets: insights in the human sex development network. *Mol Endocrinol*. 2015;29(2):247–57.
- Ellis L, Bonin S. War and the secondary sex ratio: are they related? *Soc Sci Inf*. 2004;43(1):115–22.
- Ellis L, Cole-Harding S. The effects of prenatal stress, and of prenatal alcohol and nicotine exposure, on human sexual orientation. *Physiol Behav*. 2001;74(1–2):213–26.
- Englert C, Maheswaran S, Garvin AJ, Kreidberg J, Haber DA. Induction of p21 by the Wilms' tumor suppressor gene WT1. *Cancer Res*. 1997;57(8):1429–34.
- Ensslin MA, Shur BD. The EGF repeat and discoidin domain protein, SED1/MFG-E8, is required for mammary gland branching morphogenesis. *Proc Natl Acad Sci U S A*. 2007;104(8):2715–20.
- Fatchiyah, Zubair M, Shima Y, Oka S, Ishihara S, Fukui-Katoh Y, et al. Differential gene dosage effects of Ad4BP/SF-1 on target tissue development. *Biochem Biophys Res Commun*. 2006;341(4):1036–45.
- Fernandez-Teran M, Piedra ME, Simandl BK, Fallon JF, Ros MA. Limb initiation and development is normal in the absence of the mesonephros. *Dev Biol*. 1997;189(2):246–55.
- Ferretti E, Marshall H, Popperl H, Maconochie M, Krumlauf R, Blasi F. Segmental expression of Hoxb 2 in r4 requires two separate sites that integrate cooperative interactions between Prep 1, Pbx and Hox proteins. *Development*. 2000;127(1):155–66.
- Ford CE, Jones KW, Polani PE, De Almeida JC, Briggs JH. A sex-chromosome anomaly in a case of gonadal dysgenesis (Turner's syndrome). *Lancet*. 1959;1(7075):711–3.
- Foster JW, Graves JA. An SRY-related sequence on the marsupial X chromosome: implications for the evolution of the mammalian testis-determining gene. *Proc Natl Acad Sci U S A*. 1994;91(5):1927–31.
- Foster JW, Dominguez-Steglich MA, Guioli S, Kwok C, Weller PA, Stevanovic M, et al. Campomelic dysplasia and autosomal sex reversal caused by mutations in an SRY-related gene. *Nature*. 1994;372(6506):525–30.
- Fountain ED, Mao J, Whyte JJ, Mueller KE, Ellersieck MR, Will MJ, et al. Effects of diets enriched in omega-3 and omega-6 polyunsaturated fatty acids on offspring sex-ratio and maternal behavior in mice. *Biol Reprod*. 2008;78(2):211–7.
- Fridolfsson AK, Cheng H, Copeland NG, Jenkins NA, Liu HC, Raudsepp T, et al. Evolution of the avian sex chromosomes from an ancestral pair of autosomes. *Proc Natl Acad Sci U S A*. 1998;95(14):8147–52.
- Fujimoto Y, Tanaka SS, Yamaguchi YL, Kobayashi H, Kuroki S, Tachibana M, et al. Homeoproteins Six1 and Six4 regulate male sex determination and mouse gonad development. *Dev Cell*. 2013;26(4):416–30.
- Fukuda M, Fukuda K, Shimizu T, Moller H. Decline in sex ratio at birth after Kobe earthquake. *Hum Reprod*. 1998;13(8):2321–2.
- Gerwins P, Blank JL, Johnson GL. Cloning of a novel mitogen-activated protein kinase kinase kinase, MEKK4, that selectively regulates the c-Jun amino terminal kinase pathway. *J Biol Chem*. 1997;272(13):8288–95.
- Glaser T, Driscoll DJ, Antonarakis S, Valle D, Housman D. A highly polymorphic locus cloned from the breakpoint of a chromosome 11p13 deletion associated with the WAGR syndrome. *Genomics*. 1989;5(4):880–93.
- Gould KG, Ansari AH. Electrolyte interactions in cervical mucus and their relationship to circulating hormone levels. *Contraception*. 1981;23(5):507–16.
- Grant VJ. Sex determination and the maternal dominance hypothesis. *Hum Reprod*. 1996;11(11):2371–5.
- Grant VJ, Irwin RJ. Follicular fluid steroid levels and subsequent sex of bovine embryos. *J Exp Zool A Comp Exp Biol*. 2005;303(12):1120–5.

- Grant VJ, Irwin RJ, Standley NT, Shelling AN, Chamley LW. Sex of bovine embryos may be related to mothers' preovulatory follicular testosterone. *Biol Reprod.* 2008;78(5):812–5.
- Grau DJ, Chapman BA, Garlick JD, Borowsky M, Francis NJ, Kingston RE. Compaction of chromatin by diverse polycomb group proteins requires localized regions of high charge. *Genes Dev.* 2011;25(20):2210–21.
- Gray RH. In: Sheppard KE, Boublik JH, Funder JW, editors. *Stress and reproduction: an epidemiological perspective.* New York: Raven Press; 1992.
- Gulliver CE, Friend MA, King BJ, Robertson SM, Wilkins JF, Clayton EH. Increased prostaglandin response to oxytocin in ewes fed a diet high in omega-6 polyunsaturated fatty acids. *Lipids.* 2013a;48(2):177–83.
- Gulliver CE, Friend MA, King BJ, Clayton EH. A higher proportion of female lambs when ewes were fed oats and cottonseed meal prior to and following conception. *Anim Prod Sci.* 2013b; 53(5):464–71.
- Hacker A, Capel B, Goodfellow P, Lovell-Badge R. Expression of Sry, the mouse sex determining gene. *Development.* 1995;121(6):1603–14.
- Haines B, Hughes J, Corbett M, Shaw M, Innes J, Patel L, et al. Interchromosomal insertional translocation at Xq26.3 alters SOX3 expression in an individual with XX male sex reversal. *J Clin Endocrinol Metab.* 2015;100(5):E815–20.
- Hammes A, Guo JK, Lutsch G, Leheste JR, Landrock D, Ziegler U, et al. Two splice variants of the Wilms' tumor 1 gene have distinct functions during sex determination and nephron formation. *Cell.* 2001;106(3):319–29.
- Hanayama R, Tanaka M, Miwa K, Shinohara A, Iwamatsu A, Nagata S. Identification of a factor that links apoptotic cells to phagocytes. *Nature.* 2002;417(6885):182–7.
- Haqq CM, Donahoe PK. Regulation of sexual dimorphism in mammals. *Physiol Rev.* 1998;78(1): 1–33.
- Hatano A, Matsumoto M, Higashinakagawa T, Nakayama KI. Phosphorylation of the chromodomain changes the binding specificity of Cbx2 for methylated histone H3. *Biochem Biophys Res Commun.* 2010;397(1):93–9.
- Hattori RS, Murai Y, Oura M, Masuda S, Majhi SK, Sakamoto T, et al. A Y-linked anti-Mullerian hormone duplication takes over a critical role in sex determination. *Proc Natl Acad Sci U S A.* 2012;109(8):2955–9.
- Heikinheimo M, Ermolaeva M, Bielinska M, Rahman NA, Narita N, Huhtaniemi IT, et al. Expression and hormonal regulation of transcription factors GATA-4 and GATA-6 in the mouse ovary. *Endocrinology.* 1997;138(8):3505–14.
- Hesketh T, Xing ZW. Abnormal sex ratios in human populations: causes and consequences. *Proc Natl Acad Sci U S A.* 2006;103(36):13271–5.
- Hiramatsu R, Matoba S, Kanai-Azuma M, Tsunekawa N, Katoh-Fukui Y, Kurohmaru M, et al. A critical time window of Sry action in gonadal sex determination in mice. *Development.* 2009;136(1):129–38.
- Hiramatsu R, Harikae K, Tsunekawa N, Kurohmaru M, Matsuo I, Kanai Y. FGF signaling directs a center-to-pole expansion of tubulogenesis in mouse testis differentiation. *Development.* 2010;137(2):303–12.
- Hohenstein P, Hastie ND. The many facets of the Wilms' tumour gene, WT1. *Hum Mol Genet.* 2006;15(Spec No 2):R196–201.
- Homa ST, Carroll J, Swann K. The role of calcium in mammalian oocyte maturation and egg activation. *Hum Reprod.* 1993;8(8):1274–81.
- Honda S, Morohashi K, Nomura M, Takeya H, Kitajima M, Omura T. Ad4BP regulating steroidogenic P-450 gene is a member of steroid hormone receptor superfamily. *J Biol Chem.* 1993; 268(10):7494–502.
- Hong CY, Chiang BN, Turner P. Calcium ion is the key regulator of human sperm function. *Lancet.* 1984;2(8417–8418):1449–51.
- Hossain A, Saunders GF. The human sex-determining gene SRY is a direct target of WT1. *J Biol Chem.* 2001;276(20):16817–23.
- Hu YC, Okumura LM, Page DC. Gata4 is required for formation of the genital ridge in mice. *PLoS Genet.* 2013;9(7):e1003629.

- Huang Q, Raya A, DeJesus P, Chao SH, Quon KC, Caldwell JS, et al. Identification of p53 regulators by genome-wide functional analysis. *Proc Natl Acad Sci U S A*. 2004;101(10):3456–61.
- Hughes IA, Houk C, Ahmed SF, Lee PA. Consensus statement on management of intersex disorders. *Arch Dis Child*. 2006;91(7):554–63.
- Ikeda Y, Takeda Y, Shikayama T, Mukai T, Hisano S, Morohashi KI. Comparative localization of Dax-1 and Ad4BP/SF-1 during development of the hypothalamic-pituitary-gonadal axis suggests their closely related and distinct functions. *Dev Dyn*. 2001;220(4):363–76.
- Ishii M, Kanai Y, Kanai-Azuma M, Tajima Y, Wei TT, Kidokoro T, et al. Adhesion activity of fetal gonadal cells to EGF and discoidin domains of milk fat globule-EGF factor 8 (MFG-E8), a secreted integrin-binding protein which is transiently expressed in mouse early gonadogenesis. *Anat Embryol (Berl)*. 2005;209(6):485–94.
- Ishimaru Y, Komatsu T, Kasahara M, Katoh-Fukui Y, Ogawa H, Toyama Y, et al. Mechanism of asymmetric ovarian development in chick embryos. *Development*. 2008;135(4):677–85.
- Jacobs PA, Strong JA. A case of human intersexuality having a possible XXY sex-determining mechanism. *Nature*. 1959;183(4657):302–3.
- Jacobs Y, Schnabel CA, Cleary ML. Trimeric association of Hox and TALE homeodomain proteins mediates Hoxb2 hindbrain enhancer activity. *Mol Cell Biol*. 1999;19(7):5134–42.
- James WH. The hypothesized hormonal control of human sex ratio at birth – an update. *J Theor Biol*. 1990;143(4):555–64.
- James RG, Kamei CN, Wang Q, Jiang R, Schultheiss TM. Odd-skipped related 1 is required for development of the metanephric kidney and regulates formation and differentiation of kidney precursor cells. *Development*. 2006;133(15):2995–3004.
- Jeays-Ward K, Hoyle C, Brennan J, Dandonneau M, Alldus G, Capel B, et al. Endothelial and steroidogenic cell migration are regulated by WNT4 in the developing mammalian gonad. *Development*. 2003;130(16):3663–70.
- Jeays-Ward K, Dandonneau M, Swain A. Wnt4 is required for proper male as well as female sexual development. *Dev Biol*. 2004;276(2):431–40.
- Jeske YW, Bowles J, Greenfield A, Koopman P. Expression of a linear Sry transcript in the mouse genital ridge. *Nat Genet*. 1995;10(4):480–2.
- Jost A. Recherches sur la différenciation sexuelle de l'embryon de lapin. *Arch Anat Microsc Morph Exp*. 1947;36:271–315.
- Jost A. Problems of fetal endocrinology: the gonadal and hypophyseal hormones. *Recent Prog Horm Res*. 1953;8:379–418.
- Kamiya T, Kai W, Tasumi S, Oka A, Matsunaga T, Mizuno N, et al. A trans-species missense SNP in *Amhr2* is associated with sex determination in the tiger pufferfish, *Takifugu rubripes* (fugu). *PLoS Genet*. 2012;8(7):e1002798.
- Kanai Y, Kanai-Azuma M, Tajima Y, Birk OS, Hayashi Y, Sanai Y. Identification of a stromal cell type characterized by the secretion of a soluble integrin-binding protein, MFG-E8, in mouse early gonadogenesis. *Mech Dev*. 2000;96(2):223–7.
- Karl J, Capel B. Sertoli cells of the mouse testis originate from the coelomic epithelium. *Dev Biol*. 1998;203(2):323–33.
- Kashimada K, Koopman P. Sry: the master switch in mammalian sex determination. *Development*. 2010;137(23):3921–30.
- Katoh-Fukui Y, Tsuchiya R, Shiroishi T, Nakahara Y, Hashimoto N, Noguchi K, et al. Male-to-female sex reversal in M33 mutant mice. *Nature*. 1998;393(6686):688–92.
- Katoh-Fukui Y, Owaki A, Toyama Y, Kusaka M, Shinohara Y, Maekawa M, et al. Mouse Polycomb M33 is required for splenic vascular and adrenal gland formation through regulating Ad4BP/SF1 expression. *Blood*. 2005;106(5):1612–20.
- Katoh-Fukui Y, Miyabayashi K, Komatsu T, Owaki A, Baba T, Shima Y, et al. Cbx2, a polycomb group gene, is required for Sry gene expression in mice. *Endocrinology*. 2012;153(2):913–24.
- Kaustov L, Ouyang H, Amaya M, Lemak A, Nady N, Duan S, et al. Recognition and specificity determinants of the human cbx chromodomains. *J Biol Chem*. 2011;286(1):521–9.
- Kazanskaya O, Glinka A, del Barco Barrantes I, Stannek P, Niehrs C, Wu W. R-Spondin2 is a secreted activator of Wnt/beta-catenin signaling and is required for *Xenopus* myogenesis. *Dev Cell*. 2004;7(4):525–34.

- Kennedy D, Ramsdale T, Mattick J, Little M. An RNA recognition motif in Wilms' tumour protein (WT1) revealed by structural modelling. *Nat Genet.* 1996;12(3):329–31.
- Kent JP. Birth sex-ratios in sheep over 9 lambing seasons – years 7–9 and the effects of aging. *Behav Ecol Sociobiol.* 1995;36(2):101–4.
- Kent J, Wheatley SC, Andrews JE, Sinclair AH, Koopman P. A male-specific role for SOX9 in vertebrate sex determination. *Development.* 1996;122(9):2813–22.
- Ketola I, Rahman N, Toppari J, Bielinska M, Porter-Tinge SB, Tapanainen JS, et al. Expression and regulation of transcription factors GATA-4 and GATA-6 in developing mouse testis. *Endocrinology.* 1999;140(3):1470–80.
- Kim J, Prawitt D, Bardeesy N, Torban E, Vicaner C, Goodyer P, et al. The Wilms' tumor suppressor gene (*wt1*) product regulates *Dax-1* gene expression during gonadal differentiation. *Mol Cell Biol.* 1999;19(3):2289–99.
- Kim SK, Selleri L, Lee JS, Zhang AY, Gu X, Jacobs Y, et al. *Pbx1* inactivation disrupts pancreas development and in *Ipfl*-deficient mice promotes diabetes mellitus. *Nat Genet.* 2002;30(4):430–5.
- Kim Y, Kobayashi A, Sekido R, DiNapoli L, Brennan J, Chaboissier MC, et al. *Fgf9* and *Wnt4* act as antagonistic signals to regulate mammalian sex determination. *PLoS Biol.* 2006;4(6):1000–9.
- Kimble JE, White JG. On the control of germ cell development in *Caenorhabditis elegans*. *Dev Biol.* 1981;81(2):208–19.
- Kispert A, Vainio S, McMahon AP. *Wnt-4* is a mesenchymal signal for epithelial transformation of metanephric mesenchyme in the developing kidney. *Development.* 1998;125(21):4225–34.
- Kobayashi H, Kawakami K, Asashima M, Nishinakamura R. *Six1* and *Six4* are essential for *Gdnf* expression in the metanephric mesenchyme and ureteric bud formation, while *Six1* deficiency alone causes mesonephric-tubule defects. *Mech Dev.* 2007;124(4):290–303.
- Kojola I, Eloranta E. Influences of maternal body-weight, age, and parity on sex-ratio in semidomesticated reindeer (*Rangifer-Tarandus-Tarandus*). *Evolution.* 1989;43(6):1331–6.
- Koopman P, Munsterberg A, Capel B, Vivian N, Lovell-Badge R. Expression of a candidate sex-determining gene during mouse testis differentiation. *Nature.* 1990;348(6300):450–2.
- Koopman P, Gubbay J, Vivian N, Goodfellow P, Lovell-Badge R. Male development of chromosomally female mice transgenic for *Sry*. *Nature.* 1991;351(6322):117–21.
- Kopito LE, Kosasky HJ, Sturgis SH, Lieberman BL, Shwachman H. Water and electrolytes in human cervical mucus. *Fertil Steril.* 1973;24(7):499–506.
- Krackow S. The developmental asynchrony hypothesis for sex ratio manipulation. *J Theor Biol.* 1995;176(2):273–80.
- Kreidberg JA, Sariola H, Loring JM, Maeda M, Pelletier J, Housman D, et al. *WT-1* is required for early kidney development. *Cell.* 1993;74(4):679–91.
- Kruuk LEB, Clutton-Brock TH, Albon SD, Pemberton JM, Guinness FE. Population density affects sex ratio variation in red deer. *Nature.* 1999;399(6735):459–61.
- Kusaka M, Katoh-Fukui Y, Ogawa H, Miyabayashi K, Baba T, Shima Y, et al. Abnormal epithelial cell polarity and ectopic epidermal growth factor receptor (EGFR) expression induced in *Emx2* KO embryonic gonads. *Endocrinology.* 2010;151(12):5893–904.
- Laclef C, Souil E, Demignon J, Maire P. Thymus, kidney and craniofacial abnormalities in *Six1* deficient mice. *Mech Dev.* 2003a;120(6):669–79.
- Laclef C, Hamard G, Demignon J, Souil E, Houbron C, Maire P. Altered myogenesis in *Six1*-deficient mice. *Development.* 2003b;130(10):2239–52.
- Lakshmaiah KC, Saini KS, Singh T, Jain A, Kumar RV, SK V, et al. Primary synovial sarcoma of kidney—a report of 2 cases and review of literature. *J Egypt Natl Cancer Inst.* 2010;22(3):149–53.
- Lala DS, Rice DA, Parker KL. Steroidogenic factor I, a key regulator of steroidogenic enzyme expression, is the mouse homolog of fushi tarazu-factor I. *Mol Endocrinol.* 1992;6(8):1249–58.
- Larson MA, Kimura K, Kubisch HM, Roberts RM. Sexual dimorphism among bovine embryos in their ability to make the transition to expanded blastocyst and in the expression of the signaling molecule IFN-tau. *Proc Natl Acad Sci U S A.* 2001;98(17):9677–82.
- Le Faou P, Volkel P, Angrand PO. The zebrafish genes encoding the Polycomb repressive complex (PRC) 1. *Gene.* 2011;475(1):10–21.

- Lee SB, Huang K, Palmer R, Truong VB, Herzlinger D, Kolquist KA, et al. The Wilms tumor suppressor WT1 encodes a transcriptional activator of amphiregulin. *Cell*. 1999;98(5):663–73.
- Liu CF, Bingham N, Parker K, Yao HH. Sex-specific roles of beta-catenin in mouse gonad development. *Hum Mol Genet*. 2009;18(3):405–17.
- Lu B, Yu H, Chow C, Li B, Zheng W, Davis RJ, et al. GADD45gamma mediates the activation of the p38 and JNK MAP kinase pathways and cytokine production in effector TH1 cells. *Immunity*. 2001;14(5):583–90.
- Ludbrook LM, Harley VR. Sex determination: a ‘window’ of DAX1 activity. *Trends Endocrinol Metab*. 2004;15(3):116–21.
- Luo X, Ikeda Y, Parker KL. A cell-specific nuclear receptor is essential for adrenal and gonad development and sexual differentiation. *Cell*. 1994;77(4):481–90.
- Maatouk DM, DiNapoli L, Alvers A, Parker KL, Taketo MM, Capel B. Stabilization of beta-catenin in XY gonads causes male-to-female sex-reversal. *Hum Mol Genet*. 2008;17(19):2949–55.
- Malki S, Nef S, Notarnicola C, Thevenet L, Gasca S, Mejean C, et al. Prostaglandin D2 induces nuclear import of the sex-determining factor SOX9 via its cAMP-PKA phosphorylation. *EMBO J*. 2005;24(10):1798–809.
- Mann RS, Affolter M. Hox proteins meet more partners. *Curr Opin Genet Dev*. 1998;8(4):423–9.
- Manuylov NL, Zhou B, Ma Q, Fox SC, Pu WT, Tevosian SG. Conditional ablation of Gata4 and Fog2 genes in mice reveals their distinct roles in mammalian sexual differentiation. *Dev Biol*. 2011;353(2):229–41.
- Mao J, Zhang X, Sieli PT, Falduto MT, Torres KE, Rosenfeld CS. Contrasting effects of different maternal diets on sexually dimorphic gene expression in the murine placenta. *Proc Natl Acad Sci U S A*. 2010;107(12):5557–62.
- Masukume G, Grech V. The sex ratio at birth in South Africa increased 9 months after the 2010 FIFA World Cup. *Early Hum Dev*. 2015;91(12):807–9.
- Mathews F, Johnson PJ, Neil A. You are what your mother eats: evidence for maternal preconception diet influencing foetal sex in humans. *Proc Biol Sci*. 2008;275(1643):1661–8.
- Matson CK, Zarkower D. Sex and the singular DM domain: insights into sexual regulation, evolution and plasticity. *Nat Rev Genet*. 2012;13(3):163–74.
- Matsubara K, Tarui H, Toriba M, Yamada K, Nishida-Umehara C, Agata K, et al. Evidence for different origin of sex chromosomes in snakes, birds, and mammals and step-wise differentiation of snake sex chromosomes. *Proc Natl Acad Sci U S A*. 2006;103(48):18190–5.
- Matsuda M, Nagahama Y, Shinomiya A, Sato T, Matsuda C, Kobayashi T, et al. DMY is a Y-specific DM-domain gene required for male development in the medaka fish. *Nature*. 2002;417(6888):559–63.
- Mayo MW, Wang CY, Drouin SS, Madrid LV, Marshall AF, Reed JC, et al. WT1 modulates apoptosis by transcriptionally upregulating the bcl-2 proto-oncogene. *EMBO J*. 1999;18(14):3990–4003.
- Mazaud-Guittot S, Prud’homme B, Bouchard MF, Bergeron F, Daems C, Tevosian SG, et al. GATA4 autoregulates its own expression in mouse gonadal cells via its distal 1b promoter. *Biol Reprod*. 2014;90(2):25.
- Mazur SP, Petrenko A. Sex differences in biotransformation of the xenobiotic p-nitroanisole in isolated rat hepatocyte under the influence of phenobarbital. *Biochemistry (Mosc)*. 1997;62(4):362–3.
- McClung CE. Possible action of the sex-determining mechanism. *Proc Natl Acad Sci U S A*. 1918;4(6):160–3.
- McCoard SA, Wise TH, Fahrenkrug SC, Ford JJ. Temporal and spatial localization patterns of Gata4 during porcine gonadogenesis. *Biol Reprod*. 2001;65(2):366–74.
- McLaren A. Germ and somatic cell lineages in the developing gonad. *Mol Cell Endocrinol*. 2000;163(1–2):3–9.
- Mcshea WJ, Madison DM. Sex-ratio shifts within litters of meadow voles (*Microtus pennsylvanicus*). *Behav Ecol Sociobiol*. 1986;18(6):431–6.
- Meeks JJ, Crawford SE, Russell TA, Morohashi K, Weiss J, Jameson JL. Dax1 regulates testis cord organization during gonadal differentiation. *Development*. 2003;130(5):1029–36.

- Meikle DB, Drickamer LC. Food availability and secondary sex ratio variation in wild and laboratory house mice (*Mus musculus*). *J Reprod Fertil.* 1986;78(2):587–91.
- Meikle DB, Drickamer LC, Vessey SH, Arthur RD, Rosenthal TL. Dominance rank and parental investment in swine (*Sus scrofa domestica*). *Ethology.* 1996;102(12):969–78.
- Miyake Z, Takekawa M, Ge Q, Saito H. Activation of MTK1/MEKK4 by GADD45 through induced N-C dissociation and dimerization-mediated trans autophosphorylation of the MTK1 kinase domain. *Mol Cell Biol.* 2007;27(7):2765–76.
- Miyamoto N, Yoshida M, Kuratani S, Matsuo I, Aizawa S. Defects of urogenital development in mice lacking *Emx2*. *Development.* 1997;124(9):1653–64.
- Miyamoto Y, Taniguchi H, Hamel F, Silversides DW, Viger RS. A GATA4/WT1 cooperation regulates transcription of genes required for mammalian sex determination and differentiation. *BMC Mol Biol.* 2008;9:44.
- Moalem S, Babul-Hirji R, Stavropoulos DJ, Wherrett D, Bagli DJ, Thomas P, et al. XX male sex reversal with genital abnormalities associated with a de novo SOX3 gene duplication. *Am J Med Genet A.* 2012;158A(7):1759–64.
- Molkentin JD, Lin Q, Duncan SA, Olson EN. Requirement of the transcription factor GATA4 for heart tube formation and ventral morphogenesis. *Genes Dev.* 1997;11(8):1061–72.
- Moniot B, Farhat A, Aritake K, Declosmenil F, Nef S, Eguchi N, et al. Hematopoietic prostaglandin D synthase (H-Pgds) is expressed in the early embryonic gonad and participates to the initial nuclear translocation of the SOX9 protein. *Dev Dyn.* 2011;240(10):2335–43.
- Morais da Silva S, Hacker A, Harley V, Goodfellow P, Swain A, Lovell-Badge R. Sox9 expression during gonad development implies a conserved role for the gene in testis differentiation in mammals and birds. *Nat Genet.* 1996;14(1):62–8.
- Morey L, Pascual G, Cozzuto L, Roma G, Wutz A, Benitah SA, et al. Nonoverlapping functions of the Polycomb group Cbx family of proteins in embryonic stem cells. *Cell Stem Cell.* 2012;10(1):47–62.
- Morinaga C, Saito D, Nakamura S, Sasaki T, Asakawa S, Shimizu N, et al. The *hotei* mutation of medaka in the anti-Mullerian hormone receptor causes the dysregulation of germ cell and sexual development. *Proc Natl Acad Sci U S A.* 2007;104(23):9691–6.
- Morohashi K, Honda S, Inomata Y, Handa H, Omura T. A common trans-acting factor, Ad4-binding protein, to the promoters of steroidogenic P-450s. *J Biol Chem.* 1992;267(25):17913–9.
- Morohashi K, Zanger UM, Honda S, Hara M, Waterman MR, Omura T. Activation of CYP11A and CYP11B gene promoters by the steroidogenic cell-specific transcription factor, Ad4BP. *Mol Endocrinol.* 1993;7(9):1196–204.
- Morrison AA, Viney RL, Ladomery MR. The post-transcriptional roles of WT1, a multifunctional zinc-finger protein. *Biochim Biophys Acta.* 2008;1785(1):55–62.
- Motegi S, Leitner WW, Lu M, Tada Y, Sardy M, Wu C, et al. Pericyte-derived MFG-E8 regulates pathologic angiogenesis. *Arterioscler Thromb Vasc Biol.* 2011;31(9):2024–34.
- Myosho T, Otake H, Masuyama H, Matsuda M, Kuroki Y, Fujiyama A, et al. Tracing the emergence of a novel sex-determining gene in medaka, *Oryzias luzonensis*. *Genetics.* 2012;191(1):163–70.
- Naillat F, Yan W, Karjalainen R, Liakhovitskaia A, Samoilenko A, Xu Q, et al. Identification of the genes regulated by Wnt-4, a critical signal for commitment of the ovary. *Exp Cell Res.* 2015;332(2):163–78.
- Nanda S, DeFalco TJ, Loh SH, Phochanukul N, Camara N, Van Doren M, et al. Sox100B, a *Drosophila* group E Sox-domain gene, is required for somatic testis differentiation. *Sex Dev.* 2009;3(1):26–37.
- Nash DM, Hess SA, White BA, Peluso JJ. Steroidogenic factor-1 regulates the rate of proliferation of normal and neoplastic rat ovarian surface epithelial cells in vitro. *Endocrinology.* 1998;139(11):4663–71.
- Navara KJ. Humans at tropical latitudes produce more females. *Biol Lett.* 2009;5(4):524–7.
- Nef S, Verma-Kurvari S, Merenmies J, Vassalli JD, Efstratiadis A, Accili D, et al. Testis determination requires insulin receptor family function in mice. *Nature.* 2003;426(6964):291–5.



- Niksic M, Slight J, Sanford JR, Caceres JF, Hastie ND. The Wilms' tumour protein (WT1) shuttles between nucleus and cytoplasm and is present in functional polysomes. *Hum Mol Genet.* 2004;13(4):463–71.
- Noorlander AM, Geraedts JP, Melissen JB. Female gender pre-selection by maternal diet in combination with timing of sexual intercourse – a prospective study. *Reprod BioMed Online.* 2010;21(6):794–802.
- Onesimo R, Ortzeschi D, Scalzone M, Rossodivita A, Nanni L, Zannoni GF, et al. Chromosome 9p deletion syndrome and sex reversal: novel findings and redefinition of the critically deleted regions. *Am J Med Genet A.* 2012;158A(9):2266–71.
- Oreal E, Pieau C, Mattei MG, Josso N, Picard JY, Carre-Eusebe D, et al. Early expression of AMH in chicken embryonic gonads precedes testicular SOX9 expression. *Dev Dyn.* 1998;212(4):522–32.
- Ota T, Asahina H, Park SH, Huang Q, Minegishi T, Auersperg N, et al. HOX cofactors expression and regulation in the human ovary. *Reprod Biol Endocrinol.* 2008;6:49.
- Ottolenghi C, Pelosi E, Tran J, Colombino M, Douglass E, Nedorezov T, et al. Loss of Wnt4 and Foxl2 leads to female-to-male sex reversal extending to germ cells. *Hum Mol Genet.* 2007;16(23):2795–804.
- Oun AE, Barkry S, Soltan S, Taha A, Kadry E. Preconceptional minerals administration skewed sex ration in rat offspring. *Res Obstet Gynecol.* 2016;4(1):11–5.
- Ozaki H, Nakamura K, Funahashi J, Ikeda K, Yamada G, Tokano H, et al. Six1 controls patterning of the mouse otic vesicle. *Development.* 2004;131(3):551–62.
- Pelletier J, Bruening W, Kashtan CE, Mauer SM, Manivel JC, Striegel JE, et al. Germline mutations in the Wilms' tumor suppressor gene are associated with abnormal urogenital development in Denys-Drash syndrome. *Cell.* 1991;67(2):437–47.
- Pitetti JL, Calvel P, Romero Y, Conne B, Truong V, Papaioannou MD, et al. Insulin and IGF1 receptors are essential for XX and XY gonadal differentiation and adrenal development in mice. *PLoS Genet.* 2013;9(1):e1003160.
- Quinn AE, Georges A, Sarre SD, Guarino F, Ezaz T, Graves JA. Temperature sex reversal implies sex gene dosage in a reptile. *Science.* 2007;316(5823):411.
- Radder RS, Quinn AE, Georges A, Sarre SD, Shine R. Genetic evidence for co-occurrence of chromosomal and thermal sex-determining systems in a lizard. *Biol Lett.* 2008;4(2):176–8.
- Raymond CS, Shamu CE, Shen MM, Seifert KJ, Hirsch B, Hodgkin J, et al. Evidence for evolutionary conservation of sex-determining genes. *Nature.* 1998;391(6668):691–5.
- Raymond CS, Kettlewell JR, Hirsch B, Bardwell VJ, Zarkower D. Expression of Dmrt1 in the genital ridge of mouse and chicken embryos suggests a role in vertebrate sexual development. *Dev Biol.* 1999;215(2):208–20.
- Raymond CS, Murphy MW, O'Sullivan MG, Bardwell VJ, Zarkower D. Dmrt1, a gene related to worm and fly sexual regulators, is required for mammalian testis differentiation. *Genes Dev.* 2000;14(20):2587–95.
- Rivera-Feliciano J, Lee KH, Kong SW, Rajagopal S, Ma Q, Springer Z, et al. Development of heart valves requires Gata4 expression in endothelial-derived cells. *Development.* 2006;133(18):3607–18.
- Rivers JP, Crawford MA. Maternal nutrition and the sex ratio at birth. *Nature.* 1974;252(5481):297–8.
- Rojas A, Kong SW, Agarwal P, Gilliss B, Pu WT, Black BL. GATA4 is a direct transcriptional activator of cyclin D2 and Cdk4 and is required for cardiomyocyte proliferation in anterior heart field-derived myocardium. *Mol Cell Biol.* 2008;28(17):5420–31.
- Rondeau EB, Messmer AM, Sanderson DS, Jantzen SG, von Schalburg KR, Minkley DR, et al. Genomics of sablefish (*Anoplopoma fimbria*): expressed genes, mitochondrial phylogeny, linkage map and identification of a putative sex gene. *BMC Genomics.* 2013;14:452.
- Rosenfeld CS, Roberts RM. Maternal diet and other factors affecting offspring sex ratio: a review. *Biol Reprod.* 2004;71(4):1063–70.
- Rosenfeld CS, Grimm KM, Livingston KA, Brokman AM, Lamberson WE, Roberts RM. Striking variation in the sex ratio of pups born to mice according to whether maternal diet is high in fat or carbohydrate. *Proc Natl Acad Sci U S A.* 2003;100(8):4628–32.

- Sadalla EK, Kenrich DT, Vershure B. Dominance and heterosexual attraction. *J Pers Soc Psychol.* 1987;52:730–8.
- Salz HK, Erickson JW. Sex determination in *Drosophila*: the view from the top. *Fly (Austin).* 2010;4(1):60–70.
- Schmidt CM, Hood WR. Calcium availability influences litter size and sex ratio in white-footed mice (*Peromyscus leucopus*). *PLoS ONE.* 2012;7(8):e41402.
- Schmidt D, Ovitt CE, Anlag K, Fehsenfeld S, Gredsted L, Treier AC, et al. The murine winged-helix transcription factor Foxl2 is required for granulosa cell differentiation and ovary maintenance. *Development.* 2004;131(4):933–42.
- Schnabel CA, Selleri L, Jacobs Y, Warnke R, Cleary ML. Expression of Pbx1b during mammalian organogenesis. *Mech Dev.* 2001;100(1):131–5.
- Schnabel CA, Selleri L, Cleary ML. Pbx1 is essential for adrenal development and urogenital differentiation. *Genesis.* 2003;37(3):123–30.
- Sekido R, Lovell-Badge R. Sex determination involves synergistic action of SRY and SF1 on a specific Sox9 enhancer. *Nature.* 2008;453(7197):930–4.
- Sekido R, Bar I, Narvaez V, Penny G, Lovell-Badge R. SOX9 is up-regulated by the transient expression of SRY specifically in Sertoli cell precursors. *Dev Biol.* 2004;274(2):271–9.
- Selleri L, Depew MJ, Jacobs Y, Chanda SK, Tsang KY, Cheah KS, et al. Requirement for Pbx1 in skeletal patterning and programming chondrocyte proliferation and differentiation. *Development.* 2001;128(18):3543–57.
- She ZY, Yang WX. Molecular mechanisms involved in mammalian primary sex determination. *J Mol Endocrinol.* 2014;53(1):R21–37.
- Shettles LB. Sperm morphology, cervical milieu, time of insemination and sex ratios (author's transl). *Andrologie.* 1973;5(3):227–30.
- Shimamura R, Fraizer GC, Trapman J, Lau Yf C, Saunders GF. The Wilms' tumor gene WT1 can regulate genes involved in sex determination and differentiation: SRY, Mullerian-inhibiting substance, and the androgen receptor. *Clin Cancer Res.* 1997;3(12 Pt 2):2571–80.
- Shinoda K, Lei H, Yoshii H, Nomura M, Nagano M, Shiba H, et al. Developmental defects of the ventromedial hypothalamic nucleus and pituitary gonadotroph in the Ftz-F1 disrupted mice. *Dev Dyn.* 1995;204(1):22–9.
- Sinclair AH, Berta P, Palmer MS, Hawkins JR, Griffiths BL, Smith MJ, et al. A gene from the human sex-determining region encodes a protein with homology to a conserved DNA-binding motif. *Nature.* 1990;346(6281):240–4.
- Singh D, Zambarano RJ. Offspring sex ratio in women with android body fat distribution. *Hum Biol.* 1997;69(4):545–56.
- Smagulova FO, Manuylov NL, Leach LL, Tevosian SG. GATA4/FOG2 transcriptional complex regulates Lhx9 gene expression in murine heart development. *BMC Dev Biol.* 2008;8:67.
- Smith CA, Roeszler KN, Ohnesorg T, Cummins DM, Farlie PG, Doran TJ, et al. The avian Z-linked gene DMRT1 is required for male sex determination in the chicken. *Nature.* 2009;461(7261):267–71.
- So PL, Danielian PS. Cloning and expression analysis of a mouse gene related to *Drosophila* odd-skipped. *Mech Dev.* 1999;84(1–2):157–60.
- Stolkowski J, Choukroun J. Preconception selection of sex in man. *Isr J Med Sci.* 1981;17(11):1061–7.
- Stolkowski J, Lorrain J. Preconceptional selection of fetal sex. *Int J Gynaecol Obstet.* 1980;18(6):440–3.
- Sutton E, Hughes J, White S, Sekido R, Tan J, Arboleda V, et al. Identification of SOX3 as an XX male sex reversal gene in mice and humans. *J Clin Invest.* 2011;121(1):328–41.
- Swain A, Lovell-Badge R. Mammalian sex determination: a molecular drama. *Genes Dev.* 1999;13(7):755–67.
- Swain A, Narvaez V, Burgoyne P, Camerino G, Lovell-Badge R. Dax1 antagonizes Sry action in mammalian sex determination. *Nature.* 1998;391(6669):761–7.
- Takekawa M, Saito H. A family of stress-inducible GADD45-like proteins mediate activation of the stress-responsive MTK1/MEKK4 MAPKKK. *Cell.* 1998;95(4):521–30.

- Takekawa M, Posas F, Saito H. A human homolog of the yeast Ssk2/Ssk22 MAP kinase kinase kinases, MTK1, mediates stress-induced activation of the p38 and JNK pathways. *EMBO J*. 1997;16(16):4973–82.
- Takeeto M, Parker KL, Howard TA, Tsukiyama T, Wong M, Niwa O, et al. Homologs of *Drosophila* fushi-tarazu factor 1 map to mouse chromosome 2 and human chromosome 9q33. *Genomics*. 1995;25(2):565–7.
- Tamimi RM, Lagiou P, Mucci LA, Hsieh CC, Adami HO, Trichopoulos D. Average energy intake among pregnant women carrying a boy compared with a girl. *BMJ*. 2003;326(7401):1245–6.
- Tena JJ, Neto A, de la Calle-Mustienes E, Bras-Pereira C, Casares F, Gomez-Skarmeta JL. Odd-skipped genes encode repressors that control kidney development. *Dev Biol*. 2007;301(2):518–31.
- Tevosian SG, Albrecht KH, Crispino JD, Fujiwara Y, Eicher EM, Orkin SH. Gonadal differentiation, sex determination and normal Sry expression in mice require direct interaction between transcription partners GATA4 and FOG2. *Development*. 2002;129(19):4627–34.
- Tomizuka K, Horikoshi K, Kitada R, Sugawara Y, Iba Y, Kojima A, et al. R-spondin1 plays an essential role in ovarian development through positively regulating Wnt-4 signaling. *Hum Mol Genet*. 2008;17(9):1278–91.
- Tran PV, Akana SF, Malkovska I, Dallman MF, Parada LF, Ingraham HA. Diminished hypothalamic bdnf expression and impaired VMH function are associated with reduced SF-1 gene dosage. *J Comp Neurol*. 2006;498(5):637–48.
- Tremblay JJ, Viger RS. GATA factors differentially activate multiple gonadal promoters through conserved GATA regulatory elements. *Endocrinology*. 2001;142(3):977–86.
- Trivers RL, Willard DE. Natural selection of parental ability to vary the sex ratio of offspring. *Science*. 1973;179(4068):90–2.
- Uchiyama A, Yamada K, Ogino S, Yokoyama Y, Takeuchi Y, Udey MC, et al. MFG-E8 regulates angiogenesis in cutaneous wound healing. *Am J Pathol*. 2014;184(7):1981–90.
- Uda M, Ottolenghi C, Crisponi L, Garcia JE, Deiana M, Kimber W, et al. Foxl2 disruption causes mouse ovarian failure by pervasive blockage of follicle development. *Hum Mol Genet*. 2004;13(11):1171–81.
- Uhlenhaut NH, Treier M. Foxl2 function in ovarian development. *Mol Genet Metab*. 2006;88(3):225–34.
- Uhlenhaut NH, Jakob S, Anlag K, Eisenberger T, Sekido R, Kress J, et al. Somatic sex reprogramming of adult ovaries to testes by FOXL2 ablation. *Cell*. 2009;139(6):1130–42.
- Vahidi AR, Sheikhha MH. Comparing the effects of sodium and potassium diet with calcium and magnesium diet on sex ratio of rats' offspring. *Asian Netw Sci Inf*. 2007;6(1):44–8.
- Vainio S, Heikkila M, Kispert A, Chin N, McMahon AP. Female development in mammals is regulated by Wnt-4 signalling. *Nature*. 1999;397(6718):405–9.
- Val P, Martinez-Barbera JP, Swain A. Adrenal development is initiated by Cited 2 and Wt1 through modulation of Sf-1 dosage. *Development*. 2007;134(12):2349–58.
- van der Stoop P, Boutsma EA, Hulsman D, Noback S, Heimerikx M, Kerkhoven RM, et al. Ubiquitin E3 ligase ring 1b/Rnf2 of polycomb repressive complex 1 contributes to stable maintenance of mouse embryonic stem cells. *PLoS ONE*. 2008;3(5):e 2235.
- Vidal VP, Chaboissier MC, de Rooij DG, Schedl A. Sox9 induces testis development in XX transgenic mice. *Nat Genet*. 2001;28(3):216–7.
- Viger RS, Mertineit C, Trasler JM, Nemer M. Transcription factor GATA-4 is expressed in a sexually dimorphic pattern during mouse gonad development and is a potent activator of the Mullerian inhibiting substance promoter. *Development*. 1998;125(14):2665–75.
- Volkel P, Le Faou P, Vandamme J, Pira D, Angrand PO. A human Polycomb isoform lacking the Pc box does not participate to PRC1 complexes but forms protein assemblies and represses transcription. *Epigenetics*. 2012;7(5):482–91.
- Wagner T, Wirth J, Meyer J, Zabel B, Held M, Zimmer J, et al. Autosomal sex reversal and campomelic dysplasia are caused by mutations in and around the SRY-related gene SOX9. *Cell*. 1994;79(6):1111–20.

- Wang ZY, Madden SL, Deuel TF, Rauscher 3rd FJ. The Wilms' tumor gene product, WT1, represses transcription of the platelet-derived growth factor A-chain gene. *J Biol Chem.* 1992;267(31):21999–2002.
- Wang Q, Lan Y, Cho ES, Maltby KM, Jiang R. Odd-skipped related 1 (Odd 1) is an essential regulator of heart and urogenital development. *Dev Biol.* 2005;288(2):582–94.
- Wang CY, Lai PY, Chen TY, Chung BC. NR5A1 prevents centriole splitting by inhibiting centrosomal DNA-PK activation and beta-catenin accumulation. *Cell Commun Signal.* 2014;12:55.
- Warr N, Carre GA, Siggers P, Faleato JV, Brixey R, Pope M, et al. Gadd45gamma and Map3k4 interactions regulate mouse testis determination via p38 MAPK-mediated control of Sry expression. *Dev Cell.* 2012;23(5):1020–31.
- Wauters LA, Decrombrugghe SA, Nour N, Matthysen E. Do female roe deer in good condition produce more sons than daughters. *Behav Ecol Sociobiol.* 1995;37(3):189–93.
- Weiss J, Meeks JJ, Hurley L, Raverot G, Frassetto A, Jameson JL. Sox3 is required for gonadal function, but not sex determination, in males and females. *Mol Cell Biol.* 2003;23(22):8084–91.
- Western PS, Harry JL, Graves JA, Sinclair AH. Temperature-dependent sex determination in the American alligator: AMH precedes SOX9 expression. *Dev Dyn.* 1999;216(4–5):411–9.
- Whyte JJ, Alexenko AP, Davis AM, Eilersieck MR, Fountain ED, Rosenfeld CS. Maternal diet composition alters serum steroid and free fatty acid concentrations and vaginal pH in mice. *J Endocrinol.* 2007;192(1):75–81.
- Wilhelm D, Englert C. The Wilms tumor suppressor WT1 regulates early gonad development by activation of Sfl. *Genes Dev.* 2002;16(14):1839–51.
- Wilhelm D, Martinson F, Bradford S, Wilson MJ, Combes AN, Beverdam A, et al. Sertoli cell differentiation is induced both cell-autonomously and through prostaglandin signaling during mammalian sex determination. *Dev Biol.* 2005;287(1):111–24.
- Wilson EB. The chromosomes in relation to the determination of sex in insects. *Science.* 1905;22(564):500–2.
- Wright E, Hargrave MR, Christiansen J, Cooper L, Kun J, Evans T, et al. The Sry-related gene Sox9 is expressed during chondrogenesis in mouse embryos. *Nat Genet.* 1995;9(1):15–20.
- Xu PX, Zheng W, Huang L, Maire P, Laclef C, Silviu D. Six1 is required for the early organogenesis of mammalian kidney. *Development.* 2003;130(14):3085–94.
- Yamamoto Y, Zhang Y, Sarida M, Hattori RS, Strussmann CA. Coexistence of genotypic and temperature-dependent sex determination in pejerrey *Odontesthes bonariensis*. *PLoS ONE.* 2014;9(7):e102574.
- Yoshimoto S, Okada E, Umemoto H, Tamura K, Uno Y, Nishida-Umehara C, et al. A W-linked DM-domain gene, DM-W, participates in primary ovary development in *Xenopus laevis*. *Proc Natl Acad Sci U S A.* 2008;105(7):2469–74.
- Zarkower D. Somatic sex determination (February 10, 2006), *WormBook*, ed. The C. elegans Research Community, WormBook, doi:10.1895/wormbook.1.84.1, <http://www.wormbook.org>.
- Zhao L, Koopman P. SRY protein function in sex determination: thinking outside the box. *Chromosom Res.* 2012;20(1):153–62.
- Zhu L, Wilken J, Phillips NB, Narendra U, Chan G, Stratton SM, et al. Sexual dimorphism in diverse metazoans is regulated by a novel class of intertwined zinc fingers. *Genes Dev.* 2000;14(14):1750–64.
- Zubair M, Ishihara S, Oka S, Okumura K, Morohashi K. Two-step regulation of Ad4BP/SF-1 gene transcription during fetal adrenal development: initiation by a Hox-Pbx1-Prep 1 complex and maintenance via autoregulation by Ad4BP/SF-1. *Mol Cell Biol.* 2006;26(11):4111–21.

Catherine H. Sterling, Dagmar Wilhelm, and Stefan Bagheri-Fam

---

## Abstract

In mammals, the bipotential genital ridges develop into the testes or ovaries depending on the presence or absence of the Y chromosome. The genital ridges contain three main types of bipotential precursor cells: supporting cells, which in the developing testis differentiate into Sertoli cells, steroidogenic cells giving rise to Leydig cells, and primordial germ cells developing into sperm. Each of these cell types play a critical role in the development and function of adult testes. Expression of the sex-determining region Y gene (*Sry*) in the supporting cells of the undifferentiated genital ridges initiates a molecular cascade leading to testis differentiation. During this process, carefully orchestrated genetic and physical interactions within and among the cell types residing in the developing testis lead to compartmentalization into two distinct regions, the testis cords and the interstitial space, and ultimately to the full development of the testis. Intriguingly, once determined, gonadal sex and therefore the male or female phenotype must be maintained through active repression of the molecular pathways determining the opposite sex. In this chapter, we will discuss the genetic and cellular mechanisms driving the development of a testis as well as the molecular pathways involved in maintaining gonadal sex.

---

## Keywords

Sex determination • Testis • Testis differentiation • Transdifferentiation • Genital ridge • Gonad • Testis cords • Sertoli cells • Peritubular myoid cells • Germ cells • Leydig cells • Endothelial cells • *Sry* • *Sox9* • *Fgf9* • *Dmrt1* • Ovary • Granulosa cells • Estrogen signaling • *Foxl2*

---

C.H. Sterling • D. Wilhelm • S. Bagheri-Fam (✉)  
Department of Anatomy and Neuroscience, The University of Melbourne, Melbourne, VIC,  
Australia  
e-mail: [stefan.bagheri@unimelb.edu.au](mailto:stefan.bagheri@unimelb.edu.au)

## Contents

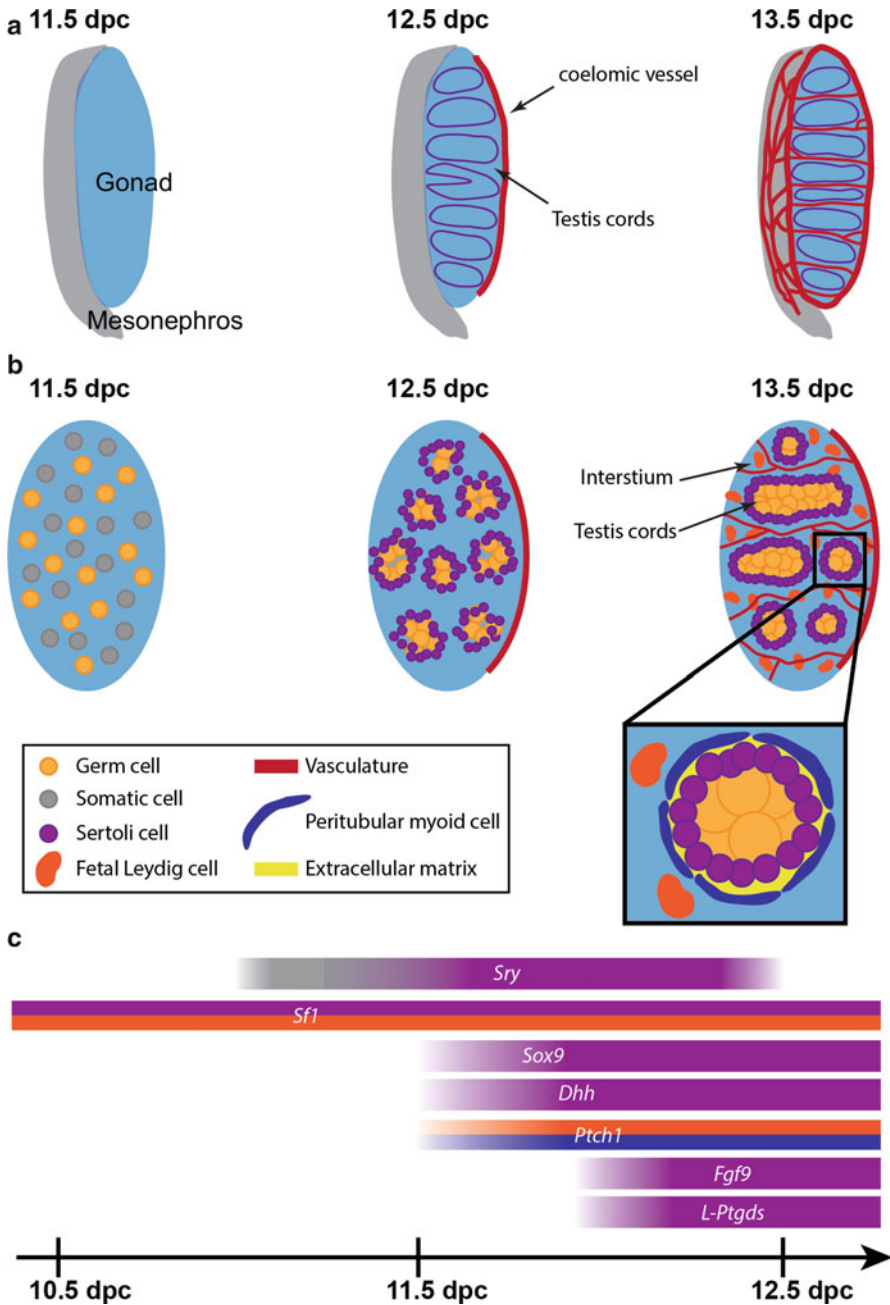
Introduction Testis Development and Function .....	218
Sertoli Cell Differentiation .....	220
Testis Cord Formation .....	222
Leydig Cell Differentiation .....	224
Germ Cell Differentiation .....	225
Sexual Transdifferentiation .....	227
Estrogen Signaling in Ovary-to-Testis Transdifferentiation .....	227
The Role of FOXL2 in Ovary-to-Testis Transdifferentiation .....	228
Mechanisms of Granulosa-to-Sertoli Cell Transdifferentiation .....	229
The Role of <i>DMRT1</i> in Testis-to-Ovary Transdifferentiation .....	231
The Role of SOX9 in Testis-to-Ovary Transdifferentiation .....	232
Mechanisms of Sertoli to Granulosa Cell Transdifferentiation .....	233
Summary .....	234
Conclusions .....	235
References .....	236

---

## Introduction Testis Development and Function

Depending on the chromosomal constitution, the bipotential genital ridge in mammals develops into either a testis (XY) or an ovary (XX). The genital ridge harbors three major bipotential cell types, the supporting cells (Sertoli and granulosa cells), steroidogenic cells (Leydig and theca cells), and primordial germ cells (sperm and eggs) (Fig. 1). Sex is determined in the supporting cell lineage by the antagonistic actions of the male and female gonadal pathways (► Chap. 5, “Sex Determination”) followed by sexual differentiation of the other cell lineages. Testes and ovaries develop into distinct organs until adulthood harboring the sperm-producing seminiferous tubules and egg-releasing ovarian follicles, respectively.

In XY gonads, the supporting cells express *Sry* and *Sox9*, which drive the differentiation of Sertoli cells (Albrecht and Eicher 2001; Chaboissier et al. 2004; Wilhelm et al. 2005; Barrionuevo et al. 2006). Sertoli cells trigger a rapid structural organization of the developing testis with the appearance of testis cords separated by interstitial cells (Fig. 1). The testis cords are outlined by a well-defined basal lamina with juxtaposed myoid cells located at the periphery of the cords. Inside the testis cords, in close association with the basal lamina, a single layer of Sertoli cells encloses the germ cells, which go into mitotic arrest and do not enter meiosis until puberty (Fig. 1). In the interstitial space, the steroidogenic cell lineage differentiates into Leydig cells triggered by paracrine action of the Sertoli cells (Fig. 1) (Pierucci-Alves et al. 2001; Yao et al. 2002; Barsoum et al. 2009). Sertoli and Leydig cells work in concert to ensure masculinization of the XY fetus. AMH (anti-Müllerian hormone) secreted by Sertoli cells inhibits the development of the female reproductive tract, while testosterone produced by the Leydig cells promotes the development of the male reproductive tract and external genitalia. After birth, testis cords develop into the seminiferous tubules of the adult testis in which Sertoli cells structurally support and nurture germ cells during spermatogenesis (► Chaps. 9, “Functional



**Fig. 1** The development of the mouse testis. (a) At 11.5 dpc, the bipotential gonad (blue) lays adjacent to the mesonephros (grey). Within 24 h, cell migration, differential gene expression, and cellular differentiation result in the formation of testis cords (purple) and of the coelomic blood

**Anatomy and Histology of the Testis”** and ▶ 13, “**Spermatogenesis”**). In XX gonads, two largely independent female pathways (*Rspo1/Wnt4* and *Foxl2*) are activated (Ottolenghi et al. 2007; Chassot et al. 2008), which trigger the bipotential supporting cells to differentiate into granulosa cells. Subsequently, the steroidogenic cell lineage differentiates into theca cells, and germ cells go into meiotic arrest. In contrast to the fetal testis, the fetal ovary is largely unstructured, and follicles do not develop until after birth. In the mature follicles of the adult ovary, multiple layers of granulosa cells, encircled by a thin basal lamina, surround the single oocyte. The thin basal lamina separates granulosa cells from layers of theca cells located at the periphery of the follicles. Theca cells provide androgens, which are converted by granulosa cells into estrogens by the aromatase enzyme (Hillier et al. 1994; Young and McNeilly 2010).

Disturbances in testis development can lead to disorders/differences of sex development (DSD) (Hughes et al. 2006; Baxter and Vilain 2013; Ostrer 2014). One such condition, 46,XY gonadal dysgenesis (46,XY GD), is caused by mutations in genes of the testis-determining network such as *SRY* and *SOX9* (Sinclair et al. 1990; Foster et al. 1994; Wagner et al. 1994). 46,XY GD is often associated with tumors and infertility, and defects range from hypospadias, ambiguous genitalia where the child’s sex is indeterminate, to complete male-to-female sex reversal. To date, a molecular diagnosis is made in only ~30 % of these cases (Eggers and Sinclair 2012; Ono and Harley 2013). The search for novel DSD genes is ongoing to improve diagnosis and clinical management of DSDs, as well as to better understand the underlying causes of male infertility.

---

## Sertoli Cell Differentiation

Sertoli cells are the first cells to differentiate within the developing testis and are considered the organizing centers for all other differentiation processes via secretion of a number of factors (Skinner 1993; reviewed in França et al. 2016). Sertoli cells



**Fig. 1** (continued) vessel (*red*). By 13.5 dpc, the testis is compartmentalized into testis cords and interstitial space, and significant vasculature is established. **(b)** Cross-sections of the testes illustrate the progression from an unorganized mixture of somatic cells (*grey*) and germ cells (*peach*) toward a differentiated cord-containing testis. Notably, by 13.5 dpc, vasculature (*red*) and differentiated steroidogenic fetal Leydig cells (*orange*) reside within the interstitium (*blue*). Germ cell (*peach*)-containing testis cords are surrounded by Sertoli cells (*purple*) and further outlined by a basal lamina (*yellow*) and peritubular myoid cells (*blue*) (inset of testis cord). All schematics in **(a, b)** are oriented with anterior (*top*) and posterior (*bottom*). **(c)** Timeline of the expression of key genes involved in testis differentiation from 10.5–12.5 dpc and in testis cord formation. *Colors within bars* indicate the cell type in which genes are initially and primarily expressed. Differentiation of testes is first driven by expression of *Sry* and *Sfl*, leading to upregulation of *Sox9* and several other factors involved in controlling cellular and, therefore, testis differentiation (see text).



were first described in the mid-1800s by Enrico Sertoli for their support role in sperm development (Sertoli 1865). Since then, much has been learnt about their differentiation, maturation, and function.

In the XY gonad, the differentiation of the bipotential supporting cell lineage into Sertoli cells is triggered by the expression of the Y-chromosome-located sex-determining switch gene *SRY/Sry*. In humans, *SRY* expression starts between 41 and 44 days post-ovulation (d.p.o.) with a peak at 44 d.p.o., concomitant with the development of sex cords, and *SRY* expression persists at lower levels within sex cords throughout development (Hanley et al. 2000). In contrast, in the mouse, the *Sry* transcript is expressed only transiently at the time of testis determination. *Sry* expression is initiated at 11.0 days post coitum (dpc) in the center of the gonad (Fig. 1), expands toward the anterior and posterior poles by 11.5 dpc, and becomes rapidly downregulated by 12.5 dpc (Bullejos and Koopman 2001). Activation of the testis differentiation pathway occurs when SRY, together with the transcription factor steroidogenic factor 1 (SF1, official name NR5A1), directly upregulates the expression of the transcription factor gene *Sox9*, (Fig. 1) a couple of hours after *Sry* expression in the same center-to-pole pattern as that of *Sry* (Bullejos and Koopman 2005; Sekido and Lovell-Badge 2008). After upregulation by SRY/SF1, *Sox9* expression is maintained via a positive SOX9 autoregulatory feedback loop as well as by two independent positive feedback loops involving L-PTGDS/PGD<sub>2</sub> and FGF9/FGFR2 (Malki et al. 2005; Wilhelm et al. 2005, 2007; Kim et al. 2006; Kim et al. 2007; Bagheri-Fam et al. 2008; Moniot et al. 2009). SRY and SOX9 are critical for Sertoli cell differentiation both in humans and mice. In humans, mutations in *SRY* or *SOX9* lead to 46,XY GD (Foster et al. 1994; Wagner et al. 1994), while in the mouse, *Sry* and *Sox9* are both necessary and sufficient for testis determination (Koopman et al. 1991; Bishop et al. 2000; Vidal et al. 2001; Chaboissier et al. 2004; Barrionuevo et al. 2006; Kato et al. 2013) (see ► Chap. 5, “Sex Determination” for a more detailed discussion about testis determination).

Sertoli cell differentiation requires a high-energy metabolic rate. One of the earliest testis-specific cellular events downstream of *Sry* is the deposition of glycogen in pre-Sertoli cells, which starts around 11.2 and peaks at 11.5 dpc (Matoba et al. 2005; 2008). Similar to the expression of SRY and SOX9, the accumulation of glycogen occurs in a center-to-pole pattern within the developing XY gonad. In glucose-deprived ex vivo cultured XY genital ridges, upregulation of SRY and SOX9 expression is unaffected. However, SOX9 expression is not maintained leading to a failure in testis cord formation. As such, glycogen deposition in pre-Sertoli cells may serve as a readily available energy source to ensure maintenance of SOX9 expression (Matoba et al. 2008).

In summary, differentiation of the supporting cell lineage into Sertoli cells is required for testis development. This process is driven by multiple factors including SRY, SF1, SOX9, PTGDS/PGD<sub>2</sub>, FGF9/FGFR2, and mechanisms to allow for increased metabolic rate. Failure to promote development of Sertoli cells results in aberrant testis formation with phenotypes ranging from altered testis cord structure, ovotestes, to complete XY sex reversal.

## Testis Cord Formation

The differentiation of supporting precursor cells into Sertoli cells, marked by SOX9 expression, triggers several cellular processes that are specific for the developing testis and do not occur in the developing ovary. Significant SRY-induced proliferation (Schmahl et al. 2000; Schmahl and Capel 2003), together with cells migrating in from the underlying mesonephros (Merchant-Larios et al. 1993; Buehr et al. 1993a; Combes et al. 2009b), results in a rapid testis-specific increase in gonad size. Sertoli cells assemble around clusters of germ cells (Griswold 1995; França et al. 2016) to form testis cords. They undergo mesenchymal-to-epithelial transition and become polarized with the nucleus orienting toward the basal surface and basement membrane, while the apical surface is oriented toward the center of the tubule (Hadley et al. 1985). Importantly, the formation of testis cords is critical for proper structure and function of the testis. Cord formation is dependent on the increase in cellular proliferation as blocking proliferation between 10.5 and 11.5 dpc in the mouse XY gonad results in a lack of testis cords (Schmahl and Capel 2003). In the 12–24 h following Sertoli cell differentiation, approximately a dozen testis cords are formed (Combes et al. 2009a). These cords elongate concordant with Sertoli cell proliferation and Sertoli cell-germ cell cluster formation (Nel-Themaat et al. 2011). By 13.0 dpc, cords become toroidal structures and recruit an outer layer of peritubular myoid (PM) cells. PM cells contact the basal surface of Sertoli cells and, together with Sertoli cells, form and deposit extracellular matrix and basal lamina components that are involved in maintaining testis cord integrity (Maekawa et al. 1996).

Differentiation of PM cells is induced by the Sertoli cell-secreted factor desert hedgehog (DHH) that binds to its interstitial cell-expressed receptor patched 1 (PTCH1). In humans, heterozygous and homozygous mutations in *DHH* have been found in 46,XY DSD patients with partial or complete GD (Das et al. 2011; Umehara et al. 2000; Canto et al. 2004). In the mouse, deposition of the basal lamina surrounding testis cords is dependent upon DHH as the absence of DHH or blocking DHH signaling leads to the disruption of normal PM cell differentiation and subsequent disruption of the testis-cord-associated basal lamina (Clark et al. 2000; Pierucci-Alves et al. 2001). At later stages, PM cells become contractile and are important for the transport of sperm from the testis to the epididymis (Maekawa et al. 1996; Tripiciano et al. 1996). In addition, it has been shown in mice and humans that Sertoli cell-produced DHH is also required for fetal Leydig cell differentiation (Yao et al. 2002; Callier et al. 2014) (see below).

Maintenance of fetal testis cords requires the continued expression of the transcription factor Wilms' tumor suppressor 1 (WT1). In humans, mutations in *WT1* lead to two syndromes with 46,XY GD, Denys-Drash, and Frasier syndrome. 46,XY Frasier syndrome patients display complete GD and have female genitalia (Barboux et al. 1997), while 46,XY Denys-Drash syndrome patients have partial or complete GD with ambiguous or female external genitalia (Jadresic et al. 1990; Pelletier et al. 1991; Lee et al. 2011). Conditional deletion of *Wt1* in Sertoli cells at 14.5 dpc in mice leads to major disruption of testicular structure with only a few testis cords remaining by 15.5 dpc (Gao et al. 2006). Intriguingly, in these mice, Sertoli cells appear to

switch from expressing SOX9/SOX8 to expressing 3 $\beta$ -hydroxysteroid dehydrogenase (3 $\beta$ HSD), an enzyme that catalyzes the biosynthesis of hormones including androstenedione and a marker of Leydig cells, suggesting that Sertoli cells transdifferentiate into Leydig-like cells (Zhang et al. 2015). Thus, WT1 appears to be a major regulator of somatic cell fate promoting Sertoli cell differentiation.

Continued growth of cords within the confined space of the testis results in cord buckling and outward expansion of the testis between 15.5 and 17.5 dpc (Combes et al. 2009a; Nel-Themaat et al. 2009, 2011). During this phase, testis cord development is also controlled by paracrine action of the interstitial Leydig cells (Archambeault and Yao 2010). Mice with Leydig cell-specific ablation of activin A, a member of the TGF $\beta$  protein superfamily, showed reduced Sertoli cell proliferation and a failure of testis cord elongation and expansion by 17.5 dpc. A highly similar phenotype was observed with targeted inhibition of activin receptors and in mice with Sertoli cell-specific ablation of SMAD4, a key protein of TGF $\beta$  signaling. These results indicated that activin A secreted from Leydig cells directly acts on Sertoli cells to promote their proliferation and thus testis cord development (Archambeault and Yao 2010; Miles et al. 2013). In human fetal testis, activin B is expressed in Sertoli and Leydig cells (Majdic et al. 1997), as well as the activin receptors ALK2, ALK4, and ActRIIB in Sertoli cells (Dias et al. 2008), suggesting that a similar mechanism of control of Sertoli cell proliferation is present in humans.

Cord formation also requires the migration of mesonephric cells into the developing testis (Smith et al. 2005; Combes et al. 2009b). It was previously believed that this migrating cell population consisted of at least three different cell types, endothelial cells, peritubular myoid cells, and vascular-associated cells (Merchant-Larios et al. 1993; Buehr et al. 1993a; Martineau et al. 1997; Merchant-Larios and Moreno-Mendoza 1998; Nishino et al. 2001). However, recent experiments using *ex vivo* cell migration assays in which the migration of GFP (green fluorescence protein)-labeled cells was monitored identified that migrating cells are solely endothelial in nature due to their polygonal shape and expression of the endothelial-specific cell marker platelet endothelial cell adhesion molecule 1 (PECAM1) (Cool et al. 2008; Combes et al. 2009b). In support of these findings, independent work by Cool et al. excluded peritubular myoid cells as part of the migrating cell population during testis cord formation (Cool et al. 2008). Importantly, the migration of endothelial cells is not required for the differentiation of testis-specific cell types; Sertoli and Leydig cells differentiate normally within gonads cultured without the neighboring mesonephros (Buehr et al. 1993a; Martineau et al. 1997). Further support comes from studies performed by Combes and co-workers who showed that inhibition of cell migration disrupted testis cord formation but not Sertoli cell differentiation as demonstrated by maintained SOX9 expression (Combes et al. 2009b). A current model proposes that intercellular interactions between migrating endothelial cells drive testis cord formation by creating partitions between evenly spaced Sertoli cell/germ cell clusters thereby initiating the formation of cord-forming units (Coveney et al. 2008; Combes et al. 2009b).

In addition to cord formation, endothelial cell migration, initiated at 11.5 dpc, leads to major testis-specific vascularization and remodeling by 12.5 dpc (Brennan

et al. 2002), including the formation of a hallmark testis-specific vein, the coelomic blood vessel (Brennan et al. 2002; Coveney et al. 2008) (Fig. 1). This vascularization has been found to play a critical role in cord development as demonstrated by the ability to disrupt cord formation via antibody-mediated inhibition of testis vasculature (Combes et al. 2009b).

Although testis cords form in the absence of germ cells (Hashimoto et al. 1990), germ cells do influence cord formation as made evident in studies of  $W^c/W^c$  mice. Homozygous mutants at the white spotting locus ( $W^c/W^c$ ), which have lost the cKIT tyrosine kinase, exhibit blocked primordial germ cell migration, resulting in gonads without germ cells. These mutants also have significantly reduced numbers of Sertoli cells and defects in testis cord organization, indicating the importance of primordial germ cells for proper cord formation to occur (Rios-Rojas et al. 2016).

In summary, a number of changes must occur in the indifferent gonad for testis cords to be formed. These testis-specific changes are marked by cellular proliferation and endothelial cell migration resulting in increased gonad size as well as partitioning of the gonad into the testis tubules and interstitial compartment and the formation of the testis-specific vasculature. Ex vivo culture experiments of gonads with neighboring mesonephros as well as examination of mouse knockout models revealed the critical role of endothelial cell migration and the influence of TGF $\beta$  pathway paracrine factors released from Leydig cells in testis cord development.

---

## Leydig Cell Differentiation

The testis cords separate the testis into two defined compartments: the germ cell-containing cords and the interstitial space in between the cords. The main cell type in the interstitium is Leydig cells, the most important cell type for the endocrine function of the testis. Two distinct populations of Leydig cells are recognized, fetal and adult Leydig cells. They possibly arise from different precursor cell lineages with distinct cellular origins and functions. Fetal Leydig cells differentiate in the mouse at 12.5 dpc and at around 6 weeks of gestation in human, degenerate after birth, and are replaced by adult Leydig cells (Wen et al. 2011, 2014). The main role of both fetal and adult Leydig cells is to produce androgens in order to promote masculinization (O'Shaughnessy et al. 2000, 2006; Shima et al. 2013) (see also ► Chaps. 7, “Endocrinology of the Fetal Testis,” and “► 10, “Testicular Steroidogenesis”).

Although fetal Leydig cell precursors are present in the gonad by 11.5 dpc (Merchant-Larios et al. 1993; Moreno-Mendoza et al. 1995), induction of steroidogenic fetal Leydig cells within the testis interstitium is dependent on factors secreted from Sertoli cells. These fetal Leydig cell precursors have been suggested to be derived from a number of sources (reviewed in Wen et al. 2011), notably from the gonad/mesonephros and the coelomic epithelium (DeFalco et al. 2011) as revealed by lineage tracing experiments (Karl and Capel 1998; Schmahl et al. 2000). Differentiation of these precursor cells into fetal Leydig cells is influenced by several molecular factors. Sertoli cell-produced DHH is not only important for PM cell

differentiation but also promotes fetal Leydig cell development (Pierucci-Alves et al. 2001; Yao et al. 2002). In fact, fetal Leydig differentiation is dependent on the coordinate expression of the transcription factor SF1 and the cell-signaling molecule DHH, demonstrated by observations that *Sfl*<sup>+/-</sup>; *Dhh*<sup>-/-</sup> mice have impaired Leydig development (Park et al. 2007). Interestingly, hedgehog signaling is not only necessary but also sufficient for Leydig cell development; ectopic activation of this signaling pathway in XX mice results in the differentiation of somatic ovarian cells into functional Leydig cells within the developing XX gonad (Barsoum et al. 2009). While HH signaling appears to be important for the initiation of Leydig cell differentiation, another signaling pathway, namely, the Notch pathway, regulates the number of cells that are recruited to the Leydig cell fate. Activation of Notch signaling in the developing testis results in a reduced number, whereas inhibition leads to an increased number of fetal Leydig cells (Tang et al. 2008).

A third factor, the X-linked aristaless-related homeodomain protein (ARX), has been found to promote differentiation of steroidogenic progenitor cells into fetal Leydig cells (Kitamura et al. 2002). Compared to wild-type animals, *Arx*-knockout mice displayed a marked reduction in fetal Leydig cell number as well as other testicular phenotypes including smaller testes, hypoplastic seminal vesicles, and delayed coelomic blood vessel development (Miyabayashi et al. 2013). Similarly in humans, mutations in *ARX* are associated with XLAG (X-linked lissencephaly with abnormal genitalia), in which also only a small number of Leydig cells were observed in testes (Ogata et al. 2000). In addition, it has been reported that fetal Leydig differentiation also requires platelet-derived growth factor receptor  $\alpha$  (PDGFR $\alpha$ ) and its ligand PDGFA as *Pdgfra* mutant animals have significantly reduced Leydig cell numbers. This, however, could also be an indirect effect due to the reduction in Sertoli cell proliferation observed in *Pdgfra* mutants (Brennan et al. 2003).

In summary, fetal Leydig cell development is dependent on Sertoli cells and several signaling pathways, including the Hedgehog and Notch, as well as transcription factors such as ARX. The absence of these components results in decreased Leydig cell numbers and therefore impacts testis development and germ cell maturation.

---

## Germ Cell Differentiation

Primordial germ cells (PGCs) are established early during development and are the precursors for both male (spermatogonia) and female (oocyte) gametes (reviewed in Saitou and Yamaji 2010). In the mouse, PGCs are specified through an inductive mechanism by which surrounding cells secrete members of the bone morphogenic protein (BMP) family (reviewed in Saitou 2009a; Ewen and Koopman 2010), resulting in suppression of the somatic mesodermal program, reacquisition of pluripotency, and epigenetic reprogramming (Saitou 2009b). Interestingly, for human PGC development, a member of the SOX family of transcription factors, SOX17, appears to be an essential factor (Irie et al. 2015). In contrast, in mice,

SOX17 does not play a role in PGC development, highlighting important differences between these species in germ cell specification. However, the transcriptional changes of hundreds of germ cell specification and somatic program genes are driven in both species largely by the transcriptional regulators PR domain zinc finger protein 1 (PRDM1, also known as BLIMP1) and PR domain containing 14 (PRDM14) (Kurimoto et al. 2008; Yamaji et al. 2008; Irie et al. 2015). In the mouse, at 6.25 dpc, the first primordial germ cell precursors can be identified, and by 7.25 dpc, or at the end of the third week in humans, primordial germ cells have been specified as a cluster of alkalinephosphatase-positive cells at the base of the allantois (Saitou et al. 2005; Kurimoto et al. 2008). These cells then migrate along the developing hind gut and the dorsal mesentery to the developing genital ridges (Molyneaux et al. 2001). Continuous proliferation during this time period results in a final population of approximately 25,000 germ cells in the mouse embryo (Mintz and Russell 1957; Tam and Snow 1981; Vergouwen et al. 1991) and approximately 150,000 in male human fetuses (Bendsen et al. 2003; O'Shaughnessy et al. 2007; Mamsen et al. 2011). The migration of primordial germ cells occurs via passive mechanisms as they are carried along with the invaginating endoderm (McLaren 2003), as well as active mechanisms guided by cell adhesion molecules, including laminin, integrins, and E-cadherin (García-Castro et al. 1997; Anderson et al. 1999; Di Carlo and De Felici 2000; Bendel-Stenzel et al. 2000), and chemotrophic signaling pathways involving the receptor/ligand combinations SDF1/CXCR4 and cKIT/KITL (McCoshen and McCallion 1975; Buehr et al. 1993b; Ara et al. 2003; Molyneaux et al. 2003; Mahakali Zama et al. 2005; Runyan et al. 2006).

Once arriving at the developing genital ridges, between 10.5 and 11.5 dpc in mice and around the end of the fifth week to the beginning of the sixth week in humans, primordial germ cells cease migration and coalesce with somatic cells, but proliferation continues via mitotic division until 12.5–13.5 dpc in mice (Western et al. 2008) and until approximately the end of the first trimester (10–12 weeks) in humans (De Felici 2013). As described above, enclosure of primordial germ cells by Sertoli cells forms the testis cords, a process which is critically important for the correct differentiation of primordial germ cells toward the male fate. In an ovary, germ cells remain distributed within somatic cells and start entering meiosis I initiated by retinoic acid (RA) produced by the mesonephros in the mouse (Bowles et al. 2006; Koubova et al. 2006) and by the ovary itself in humans (Childs et al. 2011). In mice, RA is also produced in the XY mesonephros; however, SOX9 in Sertoli cells upregulates transcription of *Cyp26b1* (Kashimada et al. 2011), encoding an RA-degrading enzyme, which protects germ cells from entering meiosis in the developing testis (Bowles et al. 2006; MacLean et al. 2007). Instead, germ cells enter mitotic arrest in G0/G1 as prospermatogonia marked by the modulation of several G1/S-phase cell cycle regulators including p27<sup>KIP1</sup>, p15<sup>INK4B</sup>, pRB, and cyclin E (Western et al. 2008; Spiller et al. 2009, 2010). Somatic factors such as transforming growth factor beta (TGFβ) and activin A (Godin and Wylie 1991; Richards et al. 1999) play a role in this cell cycle arrest. Specifically, TGFβ has been shown both in vitro and in vivo to play a role in regulating testicular fetal germ cell

quiescence by inhibiting proliferation (Moreno et al. 2010), and testis expression of activin A from 12.5 dpc until birth is involved in establishing optimal fertility and overall testis function by maintaining a proper ratio of germ cells to Sertoli cells through inhibition of gonocyte proliferation and promotion of Sertoli cell proliferation (Richards et al. 1999; Western et al. 2008; Mendis et al. 2011).

In summary, the enclosure of mitotically arrested germ cells within cords is a hallmark feature of the testis. In addition to CYP26B1-mediated protection from meiotic entry, mitotic arrest of prospermatogonia is determined by multiple proteins working in concert to promote maximal testis function and fertility.

---

## Sexual Transdifferentiation

It is well established that the male and female molecular pathways within the developing gonads suppress each other during the critical phase of sex determination in fetal life to ensure testicular and ovarian development, respectively. For example, in XY *Sox9*-null gonads, expression of *Rspo1*, *Wnt4*, and *Foxl2* is upregulated leading to ovarian development (Barrionuevo et al. 2006; Lavery et al. 2012), while in XX *Wnt4/Foxl2* double-knockout gonads, expression of *Sox9* is upregulated leading to testicular development (Ottolenghi et al. 2007). It was always assumed that once gonads have terminally differentiated, the sexual fate is permanent and thus could not be reversed. However, over the past few years, comprehensive studies in knockout mice of two transcription factors with opposing roles in sexual differentiation provided evidence that maintenance of gonadal sex requires active repression of the genetic program of the opposite sex throughout life. For example, loss of DMRT1 (doublesex and mab-3-related transcription factor 1) in the adult testis leads to upregulation of forkhead box L2 (FOXL2) in Sertoli cells, resulting in the reprogramming of these cells into granulosa-like cells, and seminiferous tubules transdifferentiate into follicle-like structures (Matson et al. 2011). Conversely, loss of FOXL2 in the adult ovary results in upregulation of DMRT1 in granulosa cells, resulting in the reprogramming of these cells into Sertoli-like cells, and follicles transdifferentiate into seminiferous tubule-like structures (Uhlenhaut et al. 2009). These studies demonstrated that terminally differentiated adult Sertoli and granulosa cell retain the ability to reprogram into the cell fate of the opposite sex.

---

## Estrogen Signaling in Ovary-to-Testis Transdifferentiation

Estrogens are primarily produced in granulosa cells of the ovary through conversion of androgens by the aromatase enzyme, which is encoded by the *Cyp19a1* gene. Estrogens bind to two nuclear receptors, ESR1 (ER $\alpha$ ) and ESR2 (ER $\beta$ ), which show distinct expression patterns in the immature and adult ovary. ESR1 is predominantly expressed in stromal and theca cells, while ESR2 is predominantly found in granulosa cells (Sar and Welsch 1999; Fitzpatrick et al. 1999).

Estrogens influence sex determination in the marsupial tammar wallaby since estradiol can induce partial or complete male-to-female gonadal sex reversal (Coveney et al. 2001; Pask et al. 2010). In eutherian mammals, early ovarian development is independent of estrogens. However, after birth, estrogen signaling becomes critical for the maintenance of female gonadal sex (Couse et al. 1999; Dupont et al. 2000, 2003; Britt et al. 2001). Studies in XX mice lacking both estrogen receptors (*Esr1/Esr2*-null) revealed that during puberty, granulosa cells are reprogrammed into *Sox9*-expressing Sertoli-like cells with subsequent transdifferentiation of follicles into seminiferous tubule-like structures (Couse et al. 1999; Dupont et al. 2000, 2003). These tubules retain the basal lamina of the former follicles but lack the multiple layers of granulosa cells typically seen in follicles, and the single oocyte is either degenerating or is absent. Within the tubules, the Sertoli-like cells are in close association with the basal lamina. A highly similar phenotype was observed in XX mice lacking aromatase (ArKO mice), which are unable to produce estrogens (Britt et al. 2001). In XX ArKO gonads, follicles transdifferentiate into seminiferous-like tubules, which lack germ cells and express *Sox9* levels very similar to wild-type testes. Remarkably, sex reversal extends to the differentiation of interstitial Leydig-like cells (Britt et al. 2001). The studies of XX *Esr1/Esr2*-null mice by Couse et al. provided the first evidence that adult granulosa cells retain the ability to reprogram into Sertoli-like cells (Couse et al. 1999). While at the time it was concluded that the appearance of Sertoli-like cells in XX *Esr1/Esr2*-null mice was due to loss of oocytes, current knowledge obtained from studies of postnatally sex reversed XX *Foxl2*-null gonads favors an oocyte-independent mechanism; the cell-autonomous derepression of the testicular pathway in granulosa cells (Uhlenhaut et al. 2009).

In summary, these studies showed that estrogen signaling plays a crucial role for the maintenance of granulosa cell fate and thus for female gonadal sex.

---

## The Role of FOXL2 in Ovary-to-Testis Transdifferentiation

FOXL2 is a winged helix/forkhead domain transcription factor with a conserved role in mammalian ovarian development. In humans, *FOXL2* is mutated in blepharophimosis/ptosis/epicanthus inversus syndrome (BPES), which is associated with premature ovarian failure (POF) in females (Crisponi et al. 2001). In a goat model, loss of FOXL2 results in XX female-to-male sex reversal, indicating that FOXL2 is a female sex-determining gene in goats (Pailhoux et al. 2001; Boulanger et al. 2014).

In the mouse, *Foxl2* is expressed in granulosa cells of the ovary from 12.5 dpc persisting through adulthood (Schmidt et al. 2004) but has a redundant role during primary sex determination since female-to-male sex reversal, and upregulation of SOX9 protein expression in XX fetal gonads is only observed in the combined absence of *Foxl2* and *Wnt4* (Ottolenghi et al. 2007) or *Foxl2* and *Rspo1* (Auguste et al. 2011). A function for FOXL2 in repressing early testis differentiation in the mouse was also revealed in fetal XY *Foxl2*-transgenic mice, which display ovotestis-like structures, disorganized testis cords, upregulation of ovarian genes such as the



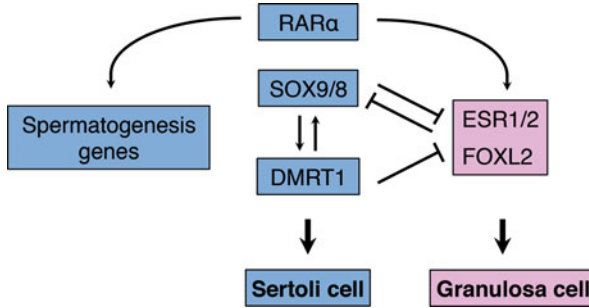
aromatase gene *Cyp19a1*, and repression of Sertoli cell genes including *Sox9*, *Amh*, and *Dhh* (Ottolenghi et al. 2007; Garcia-Ortiz et al. 2009). However, after birth, FOXL2 becomes essential for the maintenance of granulosa cell fate and female gonadal sex in mice as demonstrated in two *Foxl2*-knockout mouse models (Ottolenghi et al. 2005; Uhlenhaut et al. 2009). In constitutive XX *Foxl2*-null gonads, a subpopulation of granulosa cells transdifferentiate into SOX9-expressing Sertoli-like cells during the first week after birth, leading to partial female-to-male sex reversal with the appearance of seminiferous tubule-like structures (Ottolenghi et al. 2005). Conditional inactivation of *Foxl2* in adult mice results in widespread XX gonadal sex reversal with major structural and molecular changes (Uhlenhaut et al. 2009). Following loss of FOXL2, expression of SOX9 and DMRT1 is rapidly upregulated in granulosa cells, which are reprogrammed into Sertoli-like cells closely associated with the basal lamina, and follicles transdifferentiate into seminiferous tubule-like structures, which are vastly devoid of germ cells. Remarkably, sex-reversed conditional XX *Foxl2*-null mice are able to produce testosterone levels similar to wild-type males due to transdifferentiation of theca cells into HSD17B3-positive Leydig-like cells, which surround the seminiferous tubule-like structures similar to wild-type testes (Uhlenhaut et al. 2009). It remains to be determined whether transdifferentiation of theca to Leydig-like cells was caused by paracrine effects of the transdifferentiated supporting cell lineage, or by a cell autonomous effect due to loss of FOXL2 expression within theca cells (Uhlenhaut et al. 2009).

In summary, these studies identified FOXL2 as a critical factor for the maintenance of postnatal and adult granulosa cells and thus for female gonadal sex. Intriguingly, loss of FOXL2 at adult stages demonstrated that a fully differentiated functional adult ovary retains the ability to transdifferentiate into a testis-like organ with seminiferous tubule-like structures and the development of steroidogenic Leydig-like cells able to produce testosterone levels similar to control testes.

---

## Mechanisms of Granulosa-to-Sertoli Cell Transdifferentiation

*Foxl2*-null, ArKO, *Esr1/Esr2*-null, and mice lacking *Esr1* and one *Foxl2* allele all show upregulation of the primary testis determining protein SOX9 with subsequent granulosa to Sertoli-like cell transdifferentiation (Couse et al. 1999; Britt et al. 2001; Dupont et al. 2003; Uhlenhaut et al. 2009), which suggests that FOXL2 and estrogen signaling share similar mechanisms in the maintenance of postnatal granulosa cell fate. Indeed, Uhlenhaut et al. found that FOXL2 cooperates with ESR1 in the direct repression of *Sox9* (Fig. 2) (Uhlenhaut et al. 2009). Specifically, FOXL2 and ESR1 interact at the protein level, they directly bind to the testis-specific enhancer of *Sox9* (*TESCO*) (Sekido and Lovell-Badge 2008) in the adult mouse ovary, and together they inhibit *TESCO* activity in a synergistic manner in reporter gene assays. In addition, combined deletion of putative forkhead and estrogen receptor binding sites within *TESCO* abolishes inhibition in vitro and leads to derepression of a *TESCO*-CFP reporter construct in the follicles of transgenic mice (Uhlenhaut et al. 2009). The latter finding illustrates the critical role for FOXL2 and estrogen



**Fig. 2** Model for the antagonisms of the male and female gonadal sex maintenance networks. *Maintenance of male gonadal sex:* SOX9 and SOX8 maintain Sertoli cell identity through repression of the female gonadal sex maintenance network both via maintaining DMRT1 expression and in cooperation with DMRT1. SOX9/SOX8 ensure sustained expression of DMRT1. DMRT1 in turn reinforces SOX9/SOX8 expression and directly inhibits the expression of the female maintenance genes *Esr1/Esr2* and *FoxL2*, which otherwise would be activated by RAR $\alpha$  required for the expression of spermatogenesis genes. SOX9/SOX8 also represses the female maintenance pathway independent of DMRT1 since postnatal transdifferentiation observed in XY *Dmrt1* single mutant gonads is exacerbated in *Dmrt1/Sox9* double mutant mice. *Maintenance of female gonadal sex:* Estrogen signaling via ESR1/ESR2 and FOXL2 maintain granulosa cell identity through repression of the male gonadal sex maintenance gene *Sox9*. FOXL2 represses *Sox9* expression directly together with ESR1 and indirectly via estrogen signaling by direct activation of *Esr2* expression

signaling in silencing *Sox9* expression via *TESCO* in vivo (Fig. 2). Recent experimental evidence suggests that FOXL2 also indirectly represses *Sox9* expression through activation of estrogen signaling. In conditional *Foxl2*-null gonads and upon knockdown of FOXL2 in murine primary granulosa cells, expression of *Esr2* and the aromatase gene *Cyp19a1* is downregulated, while knockdown of ESR2 in turn results in upregulation of *Sox9* expression (Georges et al. 2014). Furthermore, FOXL2 directly binds to a newly identified enhancer within intron 8 of the *Esr2* gene in primary follicular cells, which is activated by FOXL2, ESR2, and SMAD3 in a synergistic manner in reporter gene assays. Taken together, these data indicate that FOXL2 represses *Sox9* expression directly together with ESR1 and through estrogen signaling by direct activation of *Esr2* expression.

Conditional XX *Foxl2*-null mice also show upregulation of the Sertoli cell protein DMRT1 (not examined in ArKO, *Esr1/Esr2* KO mice), which is required for the maintenance of postnatal male gonadal sex (Fig. 2) (Matson et al. 2011; Minkina et al. 2014). Similar to SOX9, DMRT1 is rapidly upregulated in granulosa cells following loss of FOXL2. However, upregulation of SOX9 protein precedes that of DMRT1 (Uhlenhaut et al. 2009), suggesting that SOX9 may directly or indirectly activate *Dmrt1* expression to induce transdifferentiation (Fig. 2). Consistent with this, recent experimental evidence shows that ectopic expression of DMRT1 can almost fully account for the transdifferentiation phenotype observed in conditional *Foxl2*-null mice (Lindeman et al. 2015). Overexpression of DMRT1 in the fetal mouse ovary results in a switch from FOXL2 to SOX9 expression starting at postnatal day 10, followed by transdifferentiation of granulosa to Sertoli-like cells

and the development of seminiferous tubule-like structures. Similarly, in mice with overexpression of DMRT1 in the adult ovary, FOXL2 is repressed leading to SOX9-positive Sertoli-like cells (Lindeman et al. 2015). Intriguingly, DMRT1 can down-regulate FOXL2 expression and induce transdifferentiation of granulosa to Sertoli-like cells even in the absence of SOX9 (Lindeman et al. 2015), enforcing the notion that SOX9 acts upstream of DMRT1 during transdifferentiation (Fig. 2). An alternative explanation for DMRT1-mediated transdifferentiation in the absence of SOX9 is that SOX9 may act redundantly in relation to DMRT1 similar to its role in the maintenance of Sertoli cell fate (Fig. 2) (see below) (Minkina et al. 2014). In support of this hypothesis, both SOX9 and DMRT1 can induce testis development in fetal XX transgenic mice (Vidal et al. 2001; Zhao et al. 2015). Although SOX9 has been long regarded as indispensable for mammalian testis development, testis differentiation without SOX9 is not without precedence. XX mice lacking both the ovary-promoting gene *Rspo1* and the testis-promoting gene *Sox9* (*Rspo1*;*Sox9*-null) initially develop undifferentiated gonads, but at 16.5 dpc, DMRT1-positive cells appear with subsequent formation of testis cords (Lavery et al. 2012). Given the potent function of DMRT1 in granulosa-to-Sertoli cell differentiation in postnatal and adult ovaries, it is quite possible that DMRT1 also induces testis differentiation in *Rspo1*;*Sox9*-double-null mice.

---

## The Role of *DMRT1* in Testis-to-Ovary Transdifferentiation

DMRT1 is a sequence-specific transcription factor containing a highly conserved zinc finger-like DNA-binding domain (DM domain) (Raymond et al. 1998; Murphy et al. 2010). DMRT1 and its closely related orthologues play important functions in vertebrate testis development and independently evolved as the testis-determining switch factors in at least two non-mammalian species (teleost fish medaka and chicken) with different chromosomal sex-determining systems (Matsuda et al. 2002, 2007; Nanda et al. 2002; Smith et al. 2009; Yoshimoto et al. 2010; Otake et al. 2010; Lambeth et al. 2014).

In mammals, DMRT1 does not appear to be required during primary testis determination. Although in mice, *Dmrt1* is expressed in Sertoli cells from the time of sex determination (Raymond et al. 1999, 2000; Lei et al. 2007), XY *Dmrt1*-null mice are born with normal testes (Raymond et al. 2000; Fahrioglu et al. 2007; Kim et al. 2007). In humans, *DMRT1* is also expressed in Sertoli cells at the time of testis determination (Moniot et al. 2000) and is deleted in patients with 46,XY sex reversal harboring distal deletions of chromosome 9p (Raymond et al. 1999). However, since the critical region also contains *DMRT2*, sex reversal in these patients is might be due to the combined loss of these two genes. While dispensable for testis determination, overexpression of *Dmrt1* in fetal XX mouse gonads can trigger Sertoli cell differentiation and female-to-male sex reversal (Zhao et al. 2015). Thus, current evidence in mice and humans suggests a conserved but redundant role for *Dmrt1* in mammalian testis determination (Zhao et al. 2015). In contrast, over the past few years, comprehensive studies of XY *Dmrt1* mutant mouse models have uncovered a

critical role for DMRT1 in the maintenance of the Sertoli cell phenotype and male gonadal sex during early postnatal and adult life (Matson et al. 2011; Minkina et al. 2014). Mice with conditional deletion of *Dmrt1* in fetal Sertoli cells (*SCDmrt1KO* mice) show extensive postnatal testis-to-ovary transdifferentiation with seminiferous tubules developing into follicle-like structures (Kim et al. 2007; Matson et al. 2011). The driving force for this transformation is a reprogramming process from Sertoli to granulosa-like cells, which switch from SOX9 to FOXL2 expression between P8 and P28 and show a significant upregulation of many genes expressed in granulosa cells and required for ovarian development or function (Matson et al. 2011; Minkina et al. 2014). In the follicle-like structures, the granulosa-like cells are not associated with the basal lamina and instead densely populate the whole tubule due to increased proliferation, a typical feature of granulosa cells within ovarian follicles (Fahrioglu et al. 2007; Kim et al. 2007). In line with elevated levels of CYP19A1/aromatase protein in granulosa-like cells, *SCDmrt1KO* mice show increased estradiol and decreased androgen serum levels when compared to control males (Matson et al. 2011). Sex reversal in XY *SCDmrt1KO* gonads also extends to the theca and germ cell lineages, the other two cell types of ovarian follicles (Matson et al. 2011). The follicle-like structures in *SCDmrt1KO* mice contain cells expressing both FOXL2 and alpha smooth muscle actin ( $\alpha$ SMA), a typical feature of ovarian theca cells. These cells likely originated either from the transdifferentiated FOXL2-positive granulosa-like cells or the testicular  $\alpha$ SMA-positive peritubular myoid cells (Matson et al. 2011). Furthermore, gonadotropin-treated XY *SCDmrt1KO* but not XY control gonads contain some feminized germ cells, which express the oocyte markers MATER and ZP2 (Matson et al. 2011). To test whether loss of DMRT1 can cause reprogramming also in adult Sertoli cells, Matson et al. conditionally deleted *Dmrt1* in the adult testis. Indeed, 1 month after deletion, the *Dmrt1* mutant testes exhibit a subpopulation of tubular cells expressing FOXL2 but not SOX9 with typical morphological characteristics of granulosa cells (Matson et al. 2011).

In summary, these studies identify DMRT1 as a major player in the maintenance of postnatal male gonadal sex. They illustrate that transdifferentiation of Sertoli to granulosa-like cells at early postnatal stages can transform seminiferous tubules into follicle-like structures. Moreover, transdifferentiation of Sertoli cells into granulosa-like cells in adult *SCDmrt1KO* mice indicates that Sertoli cells retain the ability to change cell fate even after terminal differentiation.

---

## The Role of SOX9 in Testis-to-Ovary Transdifferentiation

While SOX9 is both sufficient and required for testis determination in mice (Vidal et al. 2001; Chaboissier et al. 2004; Barrionuevo et al. 2006; Lavery et al. 2012), it appears to be dispensable for subsequent testis differentiation as evidenced by normal testis development in mice with inactivation of *Sox9* shortly after the sex determination period at 13.5 dpc (XY *Sox9<sup>Δ/Δ</sup>* mice) (Barrionuevo et al. 2009). However, studies of these mice on a *Sox8*-null background revealed that SOX9 is in fact redundantly involved in fetal testis cord maintenance. XY *Sox9<sup>Δ/Δ</sup>*; *Sox8<sup>-/-</sup>*

testes at 17.5 dpc have fewer cords when compared to wild-type testes which become disorganized shortly after birth (Barrionuevo et al. 2009). Concomitant with these defects, fetal Sertoli cells sequentially transdifferentiate into granulosa-like cells as demonstrated by down- and upregulation of DMRT1 and FOXL2 expression, respectively (Georg et al. 2012). Recently, it was discovered that SOX9 and SOX8 are also redundantly required for the maintenance of adult male gonadal sex (Barrionuevo et al. 2016). In mice with conditional inactivation of *Sox9* in the adult testis on a *Sox8*-null background, many Sertoli cells are reprogrammed into granulosa-like cells, which switch from DMRT1 to FOXL2 expression. Thus, DMRT1 and SOX9/SOX8 are required to maintain Sertoli cell fate in the adult testis.

---

## Mechanisms of Sertoli to Granulosa Cell Transdifferentiation

SOX9 (on a *Sox8*-null background) and DMRT1 are both required for the maintenance of adult male gonadal sex in mice (Matson et al. 2011; Minkina et al. 2014; Barrionuevo et al. 2016). However, the regulatory relationship between these two proteins is still not fully understood. Current evidence favors a model in which SOX9 prevents Sertoli cell reprogramming via both maintaining DMRT1 expression and in cooperation with DMRT1 (Fig. 2). In relation to the former mechanism, DMRT1 expression is lost in adult *Sox9/8*-null mice (Barrionuevo et al. 2016), while DMRT1 can downregulate FOXL2 expression and induce postnatal granulosa to Sertoli cell transdifferentiation in the absence of SOX9/SOX8 (Lindeman et al. 2015). This is consistent with the strong binding of DMRT1 near the *Foxl2* gene in postnatal testes, indicative of direct transcriptional repression of *Foxl2* by DMRT1 (Fig. 2) (Matson et al. 2011). Sertoli cell fate maintenance by SOX9 independent of DMRT1 was illustrated in *Dmrt1/Sox9* double mutant mice, which show more rapid and complete postnatal transdifferentiation from Sertoli to granulosa cells when compared to XY *Dmrt1* single mutant gonads (Minkina et al. 2014). This suggested that DMRT1 cooperates with SOX9 in the repression of the ovarian pathway in Sertoli cells (Fig. 2). DMRT1 might also directly reinforce SOX9 expression in the adult testis (Fig. 2). Evidence for this notion comes from the facts that DMRT1 binds near the *Sox9* gene in postnatal testes and that SOX9 expression is not maintained in XY *SCDmrt1KO* gonads (Matson et al. 2011). However, since *Sox9* is also a direct target of FOXL2, being repressed in the postnatal ovary (Uhlenhaut et al. 2009), it is possible that loss of SOX9 expression in XY *SCDmrt1KO* gonads is due to upregulation of FOXL2 (Fig. 2).

Considerable progress has been made in understanding the role of DMRT1 in repressing the ovarian molecular pathways in Sertoli cells. DMRT1 strongly binds near the ovarian-promoting genes *Foxl2*, *Esr1*, *Esr2*, *Rspo1*, and *Wnt4*, and their expression is upregulated in XY *SCDmrt1KO* gonads (Matson et al. 2011). During sex determination, the RSP01/WNT4 pathway promotes ovarian development through the stabilization of  $\beta$ -catenin (Chassot et al. 2008) encoded by the *Ctnnb1* gene. In line with upregulation of *Rspo1* and *Wnt4* gene expression, *SCDmrt1KO* gonads have also increased nuclear  $\beta$ -catenin in the granulosa-like cells (Matson

et al. 2011). To determine the relative contribution of these genes to male-to-female transdifferentiation in *Dmrt1* mutant testes, Minkina et al. generated a series of *Dmrt1*-knockout mouse models lacking these genes individually (Minkina et al. 2014). In XY *Dmrt1* mutant gonads lacking *Foxl2*, the transdifferentiation phenotype is completely rescued, identifying FOXL2 as a critical factor during transdifferentiation (Fig. 2). XY *Dmrt1/Esr1* double mutant mice retain full feminization of the gonads. However, in *Dmrt1/Esr2* double mutant gonads lacking also one or both copies of *Esr1* feminization is greatly suppressed, though some Sertoli cells are still able to transdifferentiate into FOXL2-positive granulosa cells (Minkina et al. 2014). While these latter mouse crosses provided evidence for an important role of ESR2 in transdifferentiation (Fig. 2), the role of ESR1 remains unclear since *Dmrt1/Esr2* double mutant gonads on an *Esr1*-wild-type background could not be generated (Minkina et al. 2014). XY *Dmrt1* mutant gonads lacking  $\beta$ -catenin show a near-complete block in transdifferentiation, similar to the *Dmrt1/Esr2* double mutant gonads lacking one or both copies of *Esr1* (Minkina et al. 2014). These data demonstrated that FOXL2, estrogen signaling, and WNT signaling drive gonadal transdifferentiation in XY *Dmrt1* mutant mice, with FOXL2 being the most critical factor. A model has been proposed in which DMRT1 has to repress these ovarian-promoting pathways in postnatal Sertoli cells to prevent transdifferentiation since otherwise they would be activated by RA signaling via the nuclear receptor and transcription factor RAR $\alpha$  (Fig. 2) (Minkina et al. 2014). RA signaling within Sertoli cells promotes their differentiation at puberty and is essential for their cyclic activity and for the establishment of paracrine pathways that control spermatogonia differentiation (Fig. 2) (Ghyselinck et al. 2006; Raverdeau et al. 2012; Hasegawa and Saga 2012; Nicholls et al. 2013). Intriguingly, Minkina et al. found that RA signaling in Sertoli cells is also likely to be the main switch for postnatal transdifferentiation in testes when lacking DMRT1 (Minkina et al. 2014). Firstly, increasing and decreasing RA signaling in *Dmrt1* mutant pups shortly after birth enhances and suppresses postnatal Sertoli-to-granulosa cell transdifferentiation, respectively. Secondly, deletion of *Dmrt1/Rara* specifically in Sertoli cells strongly suppresses feminization. Finally, in the absence of DMRT1, RA can induce the expression of genes, such as *Foxl2*, *Esr2*, and *Wnt4* (Fig. 2), all of the three ovarian-promoting pathways that are activated in *Dmrt1* mutant testes (Minkina et al. 2014). Taken together, these data indicated that DMRT1 has a highly specific role in postnatal Sertoli cells in directly suppressing the activation of a subset of RAR $\alpha$  target genes involved in granulosa cell differentiation thereby suppressing transdifferentiation, while still allowing the expression of RAR $\alpha$  target genes required for Sertoli cell function and thus spermatogenesis (Fig. 2).

---

## Summary

Because both the testis and the ovary are derived from the genital ridge, which contains three major bipotential precursor cell lineages, sexual differentiation requires the initiation and maintenance of a number of genetic and molecular factors.

Testis formation is dependent upon coordinated interactions of SF1 and SRY to drive expression of *Sox9* and initiate the testis-specific developmental program. In doing so, precursor lineages develop into testis-specific Sertoli and Leydig cells, testis-specific structures such as the coelomic vessel and testis cords are formed, and mitotically arrested germ cells are contained within the developed cords, primed for postnatal differentiation into sperm (► Chaps. 9, “Functional Anatomy and Histology of the Testis” and “► 13, “Spermatogenesis”). Elegant experiments using mouse models have demonstrated that failure to initiate or maintain the testis developmental program results in a phenotypes ranging from minor aberrations in testis cord development to complete XY sex reversal.

Studies in mouse models of postnatal sexual transdifferentiation demonstrated that the male and female gonadal sex maintenance networks suppress each other throughout postnatal life and drive gonadal transdifferentiation when activated in the opposite sex. For example, DMRT1 maintains male gonadal sex through direct suppression of the female gonadal sex maintenance genes *Foxl2* and *Esr2*, while FOXL2 maintains female gonadal sex through inhibition of the testis maintenance gene *Dmrt1*. The male (DMRT1 and SOX9/SOX8) and female (FOXL2 and beta-catenin) gonadal sex maintenance/transdifferentiation networks in postnatal gonads show a striking overlap with the sex determination network active in fetal gonads. Thus, at least part of the sex determination network established at fetal stages is maintained throughout life. However, the importance of these factors for the establishment/ maintenance of sexual cell fate greatly varies between fetal and adult stages. For example, *Sox9* is critical for fetal testis determination but acts redundantly with *Sox8* in the maintenance of postnatal male gonadal sex. In contrast, *Dmrt1* and *Foxl2* are redundant during fetal sex determination but become critical for the maintenance of postnatal gonadal sex. These differences might be a reflection of subtle gene expression differences in both male and female gonads throughout development, rendering particular factors more or less critical in the repression of the genetic program of the opposite sex.

---

## Conclusions

Since the discovery of the human testis-determining gene *SRY* in 1990, considerable progress has been made in elucidating the sex-determining gene network both in humans and mice, and mutations in these genes have been shown to lead to 46,XY DSD with associated tumors, infertility, and genital defects. Despite this apparently almost complete picture of the molecular network of sex differentiation, to date, approximately 70 % of 46,XY DSD cases are still unresolved at the molecular level, suggesting that several players and/or regulatory mechanism driving the differentiation of the human testis are still unknown. The search for novel players/pathways in the human testis continues using targeted and unbiased whole exome/genome approaches to improve diagnosis of DSD patients.

## References

- Albrecht KH, Eicher EM. Evidence that Sry is expressed in pre-Sertoli cells and Sertoli and granulosa cells have a common precursor. *Dev Biol.* 2001;240:92–107.
- Anderson R, Fässler R, Georges-Labouesse E, et al. Mouse primordial germ cells lacking beta1 integrins enter the germline but fail to migrate normally to the gonads. *Development.* 1999;126:1655–64.
- Ara T, Nakamura Y, Egawa T, et al. Impaired colonization of the gonads by primordial germ cells in mice lacking a chemokine, stromal cell-derived factor-1 (SDF-1). *Proc Natl Acad Sci U S A.* 2003;100:5319–23. doi:10.1073/pnas.0730719100.
- Archambeault DR, Yao HH. Activin A, a product of fetal Leydig cells, is a unique paracrine regulator of Sertoli cell proliferation and fetal testis cord expansion. *Proc Natl Acad Sci U S A.* 2010;107:10526–31. doi:10.1073/pnas.1000318107.
- Auguste A, Chassot A-A, Grégoire EP, et al. Loss of R-spondin1 and Foxl2 amplifies female-to-male sex reversal in XX mice. *Sex Dev.* 2011;5:304–17. doi:10.1159/000334517.
- Bagheri-Fam S, Sim H, Bernard P, Jayakody I, Taketo MM, Scherer G, Harley VR. Loss of Fgfr2 leads to partial XY sex reversal. *Dev Biol.* 2008;314:71–83. doi:10.1016/j.ydbio.2007.11.010.
- Barboux S, Niaudet P, Gubler MC, et al. Donor splice-site mutations in WT1 are responsible for Frasier syndrome. *Nat Genet.* 1997;17:467–70. doi:10.1038/ng1297-467.
- Barrionuevo F, Bagheri-Fam S, Klattig J, et al. Homozygous inactivation of Sox9 causes complete XY sex reversal in mice. *Biol Reprod.* 2006;74:195–201. doi:10.1095/biolreprod.105.045930.
- Barrionuevo F, Georg I, Scherthan H, et al. Testis cord differentiation after the sex determination stage is independent of Sox9 but fails in the combined absence of Sox9 and Sox8. *Dev Biol.* 2009;327:301–12. doi:10.1016/j.ydbio.2008.12.011 S0012-1606(08)01414-0 [pii].
- Barrionuevo FJ, Hurtado A, Kim G-J, et al. Sox9 and Sox8 protect the adult testis from male-to-female genetic reprogramming and complete degeneration. *Elife.* 2016. doi:10.7554/eLife.15635.
- Barsoum IB, Bingham NC, Parker KL, et al. Activation of the Hedgehog pathway in the mouse fetal ovary leads to ectopic appearance of fetal Leydig cells and female pseudohermaphroditism. *Dev Biol.* 2009;329:96–103. doi:10.1016/j.ydbio.2009.02.025 S0012-1606(09)00155-9 [pii].
- Baxter RM, Vilain E. Translational genetics for diagnosis of human disorders of sex development. *Annu Rev Genomics Hum Genet.* 2013;14:371–92. doi:10.1146/annurev-genom-091212-153417.
- Bendel-Stenzel MR, Gomperts M, Anderson R, et al. The role of cadherins during primordial germ cell migration and early gonad formation in the mouse. *Mech Dev.* 2000;91:143–52.
- Bendsen E, Byskov AG, Laursen SB, et al. (2003) Number of germ cells and somatic cells in human fetal testes during the first weeks after sex differentiation. *Hum Reprod* 18:13–8.
- Bishop CE, Whitworth DJ, Qin Y, et al. A transgenic insertion upstream of Sox9 is associated with dominant XX sex reversal in the mouse. *Nat Genet.* 2000;26:490–4.
- Boulanger L, Pannetier M, Gall L, et al. FOXL2 is a female sex-determining gene in the goat. *Curr Biol.* 2014;24:404–8.
- Bowles J, Knight D, Smith C, et al. Retinoid signaling determines germ cell fate in mice. *Science* (80- ). 2006;312:596–600.
- Brennan J, Karl J, Capel B. Divergent vascular mechanisms downstream of Sry establish the arterial system in the XY gonad. *Dev Biol.* 2002;244:418–28.
- Brennan J, Tilmann C, Capel B. Pdgfr-alpha mediates testis cord organization and fetal Leydig cell development in the XY gonad. *Genes Dev.* 2003;17:800–10.
- Britt KL, Drummond AE, Dyson M, et al. The ovarian phenotype of the aromatase knockout (ArKO) mouse. *J Steroid Biochem Mol Biol.* 2001;79:181–5. doi:10.1016/S0960-0760(01)00158-3.



- Buehr M, Gu S, McLaren A. Mesonephric contribution to testis differentiation in the fetal mouse. *Development*. 1993a;117:273–81.
- Buehr M, McLaren A, Bartley A, Darling S. Proliferation and migration of primordial germ cells in We/We mouse embryos. *Dev Dyn*. 1993b;198:182–9. doi:10.1002/aja.1001980304.
- Bullejos M, Koopman P. Spatially dynamic expression of Sry in mouse genital ridges. *Dev Dyn*. 2001;221:201–5.
- Bullejos M, Koopman P. Delayed Sry and Sox9 expression in developing mouse gonads underlies B6-Y(DOM) sex reversal. *Dev Biol*. 2005;278:473–81.
- Callier P, Calvel P, Matevossian A, et al. Loss of function mutation in the palmitoyl-transferase HHAT leads to syndromic 46,XY disorder of sex development by impeding Hedgehog protein palmitoylation and signaling. *PLoS Genet*. 2014;10:e1004340. doi:10.1371/journal.pgen.1004340.
- Canto P, Soderlund D, Reyes E, Mendez JP. Mutations in the desert hedgehog (DHH) gene in patients with 46,XY complete pure gonadal dysgenesis. *J Clin Endocrinol Metab*. 2004;89:4480–3. doi:10.1210/jc.2004-0863.
- Chaboissier MC, Kobayashi A, Vidal VI, et al. Functional analysis of Sox8 and Sox9 during sex determination in the mouse. *Development*. 2004;131:1891–901. doi:10.1242/dev.01087.
- Chassot AA, Ranc F, Gregoire EP, et al. Activation of beta-catenin signaling by Rspo1 controls differentiation of the mammalian ovary. *Hum Mol Genet*. 2008;17:1264–77. doi:10.1093/hmg/ddn016.
- Childs AJ, Cowan G, Kinnell HL, et al. Retinoic acid signalling and the control of meiotic entry in the human fetal gonad. *PLoS One*. 2011;6:e20249. doi:10.1371/journal.pone.0020249.
- Clark AM, Garland KK, Russell LD. Desert hedgehog (Dhh) gene is required in the mouse testis for formation of adult-type Leydig cells and normal development of peritubular cells and seminiferous tubules. *Biol Reprod*. 2000;63:1825–38.
- Combes AN, Lesieur E, Harley VR, et al. Three-dimensional visualization of testis cord morphogenesis, a novel tubulogenic mechanism in development. *Dev Dyn*. 2009a;238:1033–41. doi:10.1002/dvdy.21925.
- Combes AN, Wilhelm D, Davidson T, et al. Endothelial cell migration directs testis cord formation. *Dev Biol*. 2009b;326:112–20. doi:10.1016/j.ydbio.2008.10.040.
- Cool J, Carmona FD, Szucsik JC, Capel B. Peritubular myoid cells are not the migrating population required for testis cord formation in the XY gonad. *Sex Dev*. 2008;2:128–33. doi:10.1159/000143430.
- Couse JF, Hewitt SC, Bunch DO, et al. Postnatal sex reversal of the ovaries in mice lacking estrogen receptors alpha and beta. *Science*. 1999;286:2328–31.
- Coveney D, Shaw G, Renfree MB. Estrogen-induced gonadal sex reversal in the tammar wallaby. *Biol Reprod*. 2001;65:613–21.
- Coveney D, Cool J, Oliver T, Capel B. Four-dimensional analysis of vascularization during primary development of an organ, the gonad. *Proc Natl Acad Sci U S A*. 2008;105:7212–7. doi:10.1073/pnas.0707674105 0707674105 [pii].
- Crisponi L, Deiana M, Loi A, et al. The putative forkhead transcription factor FOXL2 is mutated in blepharophimosis/ptosis/epicanthus inversus syndrome. *Nat Genet*. 2001;27:159–66. doi:10.1038/84781.
- Das DK, Sanghavi D, Gawde H, et al. Novel homozygous mutations in Desert hedgehog gene in patients with 46,XY complete gonadal dysgenesis and prediction of its structural and functional implications by computational methods. *Eur J Med Genet*. 2011;54:e529–34. doi:10.1016/j.ejmg.2011.04.010.
- De Felici M. Origin, migration, and proliferation of human primordial germ cells. In: Cotichchio G, Albertini DF, Santis L, editors. *Oogenesis*. London: Springer; 2013. p. 19–37.
- DeFalco T, Takahashi S, Capel B. Two distinct origins for Leydig cell progenitors in the fetal testis. *Dev Biol*. 2011;352:14–26. doi:10.1016/j.ydbio.2011.01.011.

- Di Carlo A, De Felici M. A role for E-cadherin in mouse primordial germ cell development. *Dev Biol.* 2000;226:209–19. doi:10.1006/dbio.2000.9861S0012-1606(00)99861-0 [pii].
- Dias V, Meachem S, Rajpert-De Meyts E, et al. Activin receptor subunits in normal and dysfunctional adult human testis. *Hum Reprod.* 2008;23:412–20. doi:10.1093/humrep/dem343.
- Dupont S, Krust A, Gansmuller A, et al. Effect of single and compound knockouts of estrogen receptors alpha (ERalpha) and beta (ERbeta) on mouse reproductive phenotypes. *Development.* 2000;127:4277–91.
- Dupont S, Dennefeld C, Krust A, et al. Expression of Sox9 in granulosa cells lacking the estrogen receptors, ERalpha and ERbeta. *Dev Dyn.* 2003;226:103–6.
- Eggers S, Sinclair A. Mammalian sex determination—insights from humans and mice. *Chromosome Res.* 2012;20:215–38. doi:10.1007/s10577-012-9274-3.
- Ewen KA, Koopman P. Mouse germ cell development: from specification to sex determination. *Mol Cell Endocrinol.* 2010;323:76–93. doi:10.1016/j.mce.2009.12.013.
- Fahrioglu U, Murphy MW, Zarkower D, Bardwell VJ. mRNA expression analysis and the molecular basis of neonatal testis defects in Dmrt1 mutant mice. *Sex Dev.* 2007;1:42–58. doi:10.1159/000096238.
- Fitzpatrick SL, Funkhouser JM, Sindoni DM, et al. Expression of estrogen receptor-beta protein in rodent ovary. *Endocrinology.* 1999;140:2581–91. doi:10.1210/endo.140.6.6928.
- Foster JW, Dominguez-Steglich MA, Guioli S, et al. Campomelic dysplasia and autosomal sex reversal caused by mutations in an SRY-related gene. *Nature.* 1994;372:525–30.
- França LR, Hess RA, Dufour JM, et al. The Sertoli cell: one hundred fifty years of beauty and plasticity. *Andrology.* 2016;4:189–212. doi:10.1111/andr.12165.
- Gao F, Maiti S, Alam N, et al. The Wilms tumor gene, Wt1, is required for Sox9 expression and maintenance of tubular architecture in the developing testis. *Proc Natl Acad Sci U S A.* 2006;103:11987–92.
- García-Castro MI, Anderson R, Heasman J, Wylie C. Interactions between germ cells and extracellular matrix glycoproteins during migration and gonad assembly in the mouse embryo. *J Cell Biol.* 1997;138:471–80.
- García-Ortiz JE, Pelosi E, Omari S, et al. Foxl2 functions in sex determination and histogenesis throughout mouse ovary development. *BMC Dev Biol.* 2009;9:36. doi:10.1186/1471-213X-9-36.
- Georg I, Barrionuevo F, Wiech T, Scherer G. Sox9 and Sox8 are required for basal lamina integrity of testis cords and for suppression of FOXL2 during embryonic testis development in mice. *Biol Reprod.* 2012;87:99. doi:10.1095/biolreprod.112.101907.
- Georges A, L'Hôte D, Todeschini AL, et al. The transcription factor FOXL2 mobilizes estrogen signaling to maintain the identity of ovarian granulosa cells. *Elife.* 2014. doi:10.7554/eLife.04207.
- Ghyselinck NB, Vernet N, Dennefeld C, et al. Retinoids and spermatogenesis: lessons from mutant mice lacking the plasma retinol binding protein. *Dev Dyn.* 2006;235:1608–22. doi:10.1002/dvdy.20795.
- Godin I, Wylie CC. TGFbeta inhibits proliferation and has a chemotrophic effect on mouse primordial germ cells in culture. *Development.* 1991;113:1451–7.
- Griswold MD. Interactions between germ cells and Sertoli cells in the testis. *Biol Reprod.* 1995;52:211–6.
- Hadley MA, Byers SW, Suárez-Quian CA, et al. Extracellular matrix regulates Sertoli cell differentiation, testicular cord formation, and germ cell development in vitro. *J Cell Biol.* 1985;101:1511–22.
- Hanley NA, Hagan DM, Clement-Jones M, Ball SG, Strachan T, Salas-Cortés L, McElreavey K, Lindsay S, Robson S, Bullen P, Ostrer H, Wilson DI. SRY, SOX9, and DAX1 expression patterns during human sex determination and gonadal development. *Mech Dev.* 2000; 91:403–7. doi: 10.1016/S0925-4773(99)00307-X.

- Hasegawa K, Saga Y. Retinoic acid signaling in Sertoli cells regulates organization of the blood-testis barrier through cyclical changes in gene expression. *Development*. 2012;139:4347–55. doi:10.1242/dev.080119.
- Hashimoto N, Kubokawa R, Yamazaki K, et al. Germ cell deficiency causes testis cord differentiation in reconstituted mouse fetal ovaries. *J Exp Zool*. 1990;253:61–70. doi:10.1002/jez.1402530109.
- Hillier SG, Whitelaw PF, Smyth CD. Follicular oestrogen synthesis: the “two-cell, two-gonadotrophin” model revisited. *Mol Cell Endocrinol*. 1994;100:51–4.
- Hughes IA, Houk C, Ahmed SF, et al. Consensus statement on management of intersex disorders. *J Pediatr Urol*. 2006;2:148–62. doi:10.1016/j.jpuro.2006.03.004.
- Irie N, Weinberger L, Tang WWC, et al. SOX17 is a critical specifier of human primordial germ cell fate. *Cell*. 2015;160:253–68. doi:10.1016/j.cell.2014.12.013.
- Jadresic L, Leake J, Gordon I, et al. Clinicopathologic review of twelve children with nephropathy, Wilms tumor, and genital abnormalities (Drash syndrome). *J Pediatr*. 1990;117:717–25.
- Karl J, Capel B. Sertoli cells of the mouse testis originate from the coelomic epithelium. *Dev Biol*. 1998;203:323–33.
- Kashimada K, Svingen T, Feng CW, et al. Antagonistic regulation of Cyp26b1 by transcription factors SOX9/SF1 and FOXL2 during gonadal development in mice. *FASEB J*. 2011;25:3561–9.
- Kato T, Miyata K, Sonobe M, et al. Production of Sry knockout mouse using TALEN via oocyte injection. *Sci Rep*. 2013;3:3136. doi:10.1038/srep03136.
- Kim Y, Kobayashi A, Sekido R, et al. Fgf9 and Wnt4 act as antagonistic signals to regulate mammalian sex determination. *PLoS Biol*. 2006;4:e187.
- Kim Y, Bingham N, Sekido R, Parker KL, Lovell-Badge R, Capel B. Fibroblast growth factor receptor 2 regulates proliferation and Sertoli differentiation during male sex determination. *Proc Natl Acad Sci U S A*. 2007;104:16558–63. doi:10.1073/pnas.0702581104.
- Kim S, Bardwell VJ, Zarkower D. Cell type-autonomous and non-autonomous requirements for Dmrt1 in postnatal testis differentiation. *Dev Biol*. 2007;307:314–27. doi:10.1016/j.ydbio.2007.04.046 S0012-1606(07)00869-X [pii].
- Kitamura K, Yanazawa M, Sugiyama N, et al. Mutation of ARX causes abnormal development of forebrain and testes in mice and X-linked lissencephaly with abnormal genitalia in humans. *Nat Genet*. 2002; 32:359–69. doi:10.1038/ng1009 ng1009 [pii].
- Koopman P, Gubbay J, Vivian N, et al. Male development of chromosomally female mice transgenic for Sry. *Nature*. 1991;351:117–21.
- Koubova J, Menke DB, Zhou Q, et al. Retinoic acid regulates sex-specific timing of meiotic initiation in mice. *Proc Natl Acad Sci U S A*. 2006;103:2474–9.
- Kurimoto K, Yabuta Y, Ohinata Y, et al. Complex genome-wide transcription dynamics orchestrated by Blimp1 for the specification of the germ cell lineage in mice. *Genes Dev*. 2008;22:1617–35. doi:10.1101/gad.1649908.
- Lambeth LS, Raymond CS, Roeszler KN, et al. Over-expression of DMRT1 induces the male pathway in embryonic chicken gonads. *Dev Biol*. 2014;389:160–72. doi:10.1016/j.ydbio.2014.02.012.
- Lavery R, Chassot AA, Pauper E, et al. Testicular differentiation occurs in absence of R-spondin1 and Sox9 in mouse sex reversals. *PLoS Genet*. 2012;8:e1003170. doi:10.1371/journal.pgen.1003170.
- Lee D-G, Han DH, Park KH, Baek M. A novel WT1 gene mutation in a patient with Wilms’ tumor and 46, XY gonadal dysgenesis. *Eur J Pediatr*. 2011;170:1079–82. doi:10.1007/s00431-011-1439-0.
- Lei N, Hornbaker KI, Rice DA, et al. Sex-specific differences in mouse DMRT1 expression are both cell type- and stage-dependent during gonad development. *Biol Reprod*. 2007;77:466–75. doi:10.1095/biolreprod.106.058784.

- Lindeman RE, Gearhart MD, Minkina A, et al. Sexual cell-fate reprogramming in the ovary by DMRT1. *Curr Biol.* 2015;25:764–71.
- MacLean G, Li H, Metzger D, et al. Apoptotic extinction of germ cells in testes of Cyp26b1 knockout mice. *Endocrinology.* 2007;148:4560–7. doi:10.1210/en.2007-0492.
- Maekawa M, Kamimura K, Nagano T. Peritubular myoid cells in the testis: their structure and function. *Arch Histol Cytol.* 1996;59:1–13.
- Mahakali Zama A, Hudson FP, Bedell MA. Analysis of hypomorphic KitlSl mutants suggests different requirements for KITL in proliferation and migration of mouse primordial germ cells. *Biol Reprod.* 2005;73:639–47. doi:10.1095/biolreprod.105.042846.
- Majdic G, McNeilly AS, Sharpe RM, et al. Testicular expression of inhibin and activin subunits and follistatin in the rat and human fetus and neonate and during postnatal development in the rat. *Endocrinology.* 1997;138:2136–47. doi:10.1210/endo.138.5.5135.
- Malki S, Nef S, Notarnicola C, et al. Prostaglandin D2 induces nuclear import of the sex-determining factor SOX9 via its cAMP-PKA phosphorylation. *EMBO J.* 2005;24:1798–809.
- Mamsen LS, Lutterodt MC, Andersen EW, et al. Germ cell numbers in human embryonic and fetal gonads during the first two trimesters of pregnancy: analysis of six published studies. *Hum Reprod.* 2011;26:2140–5. doi:10.1093/humrep/der149.
- Martineau J, Nordqvist K, Tilmann C, et al. Male-specific cell migration into the developing gonad. *Curr Biol.* 1997;7:958–68.
- Matoba S, Kanai Y, Kidokoro T, et al. A novel Sry-downstream cellular event which preserves the readily available energy source of glycogen in mouse sex differentiation. *J Cell Sci.* 2005;118:1449–59. doi:10.1242/jcs.01738.
- Matoba S, Hiramatsu R, Kanai-Azuma M, et al. Establishment of testis-specific SOX9 activation requires high-glucose metabolism in mouse sex differentiation. *Dev Biol.* 2008;324:76–87. doi:10.1016/j.ydbio.2008.09.004.
- Matson CK, Murphy MW, Sarver AL, et al. DMRT1 prevents female reprogramming in the postnatal mammalian testis. *Nature.* 2011;476:101–4. doi:10.1038/nature10239.
- Matsuda M, Nagahama Y, Shinomiya A, et al. DMY is a Y-specific DM-domain gene required for male development in the medaka fish. *Nature.* 2002;417:559–63.
- Matsuda M, Shinomiya A, Kinoshita M, et al. DMY gene induces male development in genetically female (XX) medaka fish. *Proc Natl Acad Sci U S A.* 2007;104:3865–70. doi:10.1073/pnas.0611707104.
- McCoshen JA, McCallion DJ. A study of the primordial germ cells during their migratory phase in Steel mutant mice. *Experientia.* 1975;31:589–90.
- McLaren A. Primordial germ cells in the mouse. *Dev Biol.* 2003;262:1–15.
- Mendis SH, Meachem SJ, Sarraj MA, Loveland KL. Activin A balances Sertoli and germ cell proliferation in the fetal mouse testis. *Biol Reprod.* 2011;84:379–91. doi:10.1095/biolreprod.110.086231.
- Merchant-Larios H, Moreno-Mendoza N. Mesonephric stromal cells differentiate into Leydig cells in the mouse fetal testis. *Exp Cell Res.* 1998;244:230–8. doi:10.1006/excr.1998.4215. S0014-4827(98)94215-X [pii].
- Merchant-Larios H, Moreno-Mendoza N, Buehr M. The role of the mesonephros in cell differentiation and morphogenesis of the mouse fetal testis. *Int J Dev Biol.* 1993;37:407–15.
- Miles DC, Wakeling SI, Stringer JM, et al. Signaling through the TGF beta-activin receptors ALK4/5/7 regulates testis formation and male germ cell development. *PLoS One.* 2013;8:e54606.
- Minkina A, Matson CK, Lindeman RE, et al. DMRT1 protects male gonadal cells from retinoid-dependent sexual transdifferentiation. *Dev Cell.* 2014;29:511–20. doi:10.1016/j.devcel.2014.04.017.
- Mintz B, Russell ES. Gene-induced embryological modifications of primordial germ cells in the mouse. *J Exp Zool.* 1957;134:207–37.

- Miyabayashi K, Katoh-Fukui Y, Ogawa H, et al. Aristaless related homeobox gene, *Arx*, is implicated in mouse fetal Leydig cell differentiation possibly through expressing in the progenitor cells. *PLoS One*. 2013;8:e68050. doi:10.1371/journal.pone.0068050.
- Molyneux KA, Stallock J, Schaible K, Wylie C. Time-lapse analysis of living mouse germ cell migration. *Dev Biol*. 2001;240:488–98. doi:10.1006/dbio.2001.0436.
- Molyneux KA, Zinszner H, Kunwar PS, et al. The chemokine SDF1/CXCL12 and its receptor CXCR4 regulate mouse germ cell migration and survival. *Development*. 2003;130:4279–86.
- Moniot B, Berta P, Scherer G, et al. Male specific expression suggests role of DMRT1 in human sex determination. *Mech Dev*. 2000;91:323–5.
- Moniot B, Declosmenil F, Barrionuevo F, et al. The PGD2 pathway, independently of FGF9, amplifies SOX9 activity in Sertoli cells during male sexual differentiation. *Development*. 2009;136:1813–21. doi:10.1242/dev.032631 136/11/1813 [pii].
- Moreno SG, Attali M, Allemand I, et al. TGFbeta signaling in male germ cells regulates gonocyte quiescence and fertility in mice. *Dev Biol*. 2010;342:74–84. doi:10.1016/j.ydbio.2010.03.007.
- Moreno-Mendoza N, Herrera-Muñoz J, Merchant-Larios H. Limb bud mesenchyme permits seminiferous cord formation in the mouse fetal testis but subsequent testosterone output is markedly affected by the sex of the donor stromal tissue. *Dev Biol*. 1995;169:51–6. doi:10.1006/dbio.1995.1125.
- Murphy MW, Sarver AL, Rice D, et al. Genome-wide analysis of DNA binding and transcriptional regulation by the mammalian Doublesex homolog DMRT1 in the juvenile testis. *Proc Natl Acad Sci U S A*. 2010;107:13360–5. doi:10.1073/pnas.1006243107.
- Nanda I, Kondo M, Hornung U, et al. A duplicated copy of DMRT1 in the sex-determining region of the Y chromosome of the medaka, *Oryzias latipes*. *Proc Natl Acad Sci U S A*. 2002;99:11778–83.
- Nel-Themaat L, Vadakkan TJ, Wang Y, et al. Morphometric analysis of testis cord formation in Sox9-EGFP mice. *Dev Dyn*. 2009;238:1100–10. doi:10.1002/dvdy.21954.
- Nel-Themaat L, Jang C-W, Stewart MD, et al. Sertoli cell behaviors in developing testis cords and postnatal seminiferous tubules of the mouse. *Biol Reprod*. 2011;84:342–50. doi:10.1095/biolreprod.110.086900.
- Nicholls PK, Harrison CA, Rainczuk KE, et al. Retinoic acid promotes Sertoli cell differentiation and antagonises activin-induced proliferation. *Mol Cell Endocrinol*. 2013;377:33–43. doi:10.1016/j.mce.2013.06.034.
- Nishino K, Yamanouchi K, Naito K, Tojo H. Characterization of mesonephric cells that migrate into the XY gonad during testis differentiation. *Exp Cell Res*. 2001;267:225–32. doi:10.1006/excr.2001.5238S0014-4827(01)95238-3 [pii].
- O'Shaughnessy PJ, Baker PJ, Heikkilä M, et al. Localization of 17beta-hydroxysteroid dehydrogenase/17-ketosteroid reductase isoform expression in the developing mouse testis – androstenedione is the major androgen secreted by fetal/neonatal leydig cells. *Endocrinology*. 2000;141:2631–7. doi:10.1210/endo.141.7.7545.
- O'Shaughnessy PJ, Baker PJ, Johnston H. The foetal Leydig cell– differentiation, function and regulation. *Int J Androl*. 2006;29:90–5. doi:10.1111/j.1365-2605.2005.00555.x. discussion 105–8.
- O'Shaughnessy PJ, Baker PJ, Monteiro A, et al. Developmental changes in human fetal testicular cell numbers and messenger ribonucleic acid levels during the second trimester. *J Clin Endocrinol Metab*. 2007;92:4792–801. doi:10.1210/jc.2007-1690.
- Ogata T, Matsuo N, Hiraoka N, Hata JI. X-linked lissencephaly with ambiguous genitalia: delineation of further case. *Am J Med Genet*. 2000;94:174–6.
- Ono M, Harley VR. Disorders of sex development: new genes, new concepts. *Nat Rev Endocrinol*. 2013;9:79–91. doi:10.1038/nrendo.2012.235.
- Ostrer H. Disorders of sex development (DSDs): an update. *J Clin Endocrinol Metab*. 2014;99:1503–9. doi:10.1210/jc.2013-3690.

- Otake H, Masuyama H, Mashima Y, et al. Heritable artificial sex chromosomes in the medaka, *Oryzias latipes*. *Heredity* (Edinb). 2010;105:247–56. doi:10.1038/hdy.2009.174.
- Ottolenghi C, Omari S, Garcia-Ortiz JE, et al. Foxl2 is required for commitment to ovary differentiation. *Hum Mol Genet*. 2005;14:2053–62. doi:10.1093/hmg/ddi210.
- Ottolenghi C, Pelosi E, Tran J, et al. Loss of Wnt4 and Foxl2 leads to female-to-male sex reversal extending to germ cells. *Hum Mol Genet*. 2007;16:2795–804. doi:10.1093/hmg/ddm235 ddm235 [pii].
- Pailhoux E, Vigier B, Chaffaux S, et al. A 11.7-kb deletion triggers intersexuality and polledness in goats. *Nat Genet*. 2001;29:453–8. doi:10.1038/ng769.
- Park SY, Tong M, Jameson JL. Distinct roles for steroidogenic factor 1 and desert hedgehog pathways in fetal and adult Leydig cell development. *Endocrinology*. 2007;148:3704–10. doi:10.1210/en.2006-1731.
- Pask AJ, Calatayud NE, Shaw G, et al. Oestrogen blocks the nuclear entry of SOX9 in the developing gonad of a marsupial mammal. *BMC Biol*. 2010;8:113. doi:10.1186/1741-7007-8-113.
- Pelletier J, Bruening W, Kashtan CE, et al. Germline mutations in the Wilms' tumor suppressor gene are associated with abnormal urogenital development in Denys-Drash syndrome. *Cell*. 1991;67:437–47.
- Pierucci-Alves F, Clark AM, Russell LD. A developmental study of the Desert hedgehog-null mouse testis. *Biol Reprod*. 2001;65:1392–402.
- Raverdeau M, Gely-Pernot A, Feret B, et al. Retinoic acid induces Sertoli cell paracrine signals for spermatogonia differentiation but cell autonomously drives spermatocyte meiosis. *Proc Natl Acad Sci*. 2012;109:16582–7. doi:10.1073/pnas.1214936109.
- Raymond CS, Shamu CE, Shen MM, et al. Evidence for evolutionary conservation of sex-determining genes. *Nature*. 1998;391:691–5.
- Raymond CS, Kettlewell JR, Hirsch B, et al. Expression of Dmrt1 in the genital ridge of mouse and chicken embryos suggests a role in vertebrate sexual development. *Dev Biol*. 1999;215:208–20. doi:10.1006/dbio.1999.9461.
- Raymond CS, Murphy MW, O'Sullivan MG, et al. Dmrt1, a gene related to worm and fly sexual regulators, is required for mammalian testis differentiation. *Genes Dev*. 2000;14:2587–95.
- Richards AJ, Enders GC, Resnick JL. Activin and TGFbeta limit murine primordial germ cell proliferation. *Dev Biol*. 1999;207:470–5. doi:10.1006/dbio.1998.9174.
- Rios-Rojas C, Spiller C, Bowles J, Koopman P. Germ cells influence cord formation and leydig cell gene expression during mouse testis development. *Dev Dyn*. 2016;245:433–44. doi:10.1002/dvdy.24371.
- Runyan C, Schaible K, Molyneaux K, et al. Steel factor controls midline cell death of primordial germ cells and is essential for their normal proliferation and migration. *Development*. 2006;133:4861–9. doi:10.1242/dev.026888.
- Saitou M. Specification of the germ cell lineage in mice. *Front Biosci* (Landmark Ed). 2009;14:1068–87.
- Saitou M. Germ cell specification in mice. *Curr Opin Genet Dev*. 2009;19:386–95. doi:10.1016/j.gde.2009.06.003.
- Saitou M, Yamaji M. Germ cell specification in mice: signaling, transcription regulation, and epigenetic consequences. *Reproduction*. 2010;139:931–42. doi:10.1530/REP-10-0043.
- Saitou M, Payer B, O'Carroll D, et al. Blimp1 and the emergence of the germ line during development in the mouse. *Cell Cycle*. 2005;4:1736–40. doi:10.4161/cc.4.12.2209.
- Sar M, Welsch F. Differential expression of estrogen receptor-beta and estrogen receptor-alpha in the rat ovary. *Endocrinology*. 1999;140:963–71. doi:10.1210/endo.140.2.6533.
- Schmahl J, Capel B. Cell proliferation is necessary for the determination of male fate in the gonad. *Dev Biol*. 2003;258:264–76. doi:10.1016/S0012-1606(03)00122-2.
- Schmahl J, Eicher E, Washburn L, Capel B. Sry induces cell proliferation in the mouse gonad. *Development*. 2000;127:65–73.

- Schmidt D, Ovitt CE, Anlag K, et al. The murine winged-helix transcription factor Foxl2 is required for granulosa cell differentiation and ovary maintenance. *Development*. 2004;131:933–42.
- Sekido R, Lovell-Badge R. Sex determination involves synergistic action of SRY and SF1 on a specific Sox9 enhancer. *Nature*. 2008;453:930–4.
- Sertoli E. Dell'esistenza di particolari cellule ramificate nei canalicoli seminiferi del testicolo umano. *Morgagni*. 1865;7:31–40.
- Shima Y, Miyabayashi K, Haraguchi S, et al. Contribution of Leydig and Sertoli cells to testosterone production in mouse fetal testes. *Mol Endocrinol*. 2013;27:63–73. doi:10.1210/me.2012-1256.
- Sinclair AH, Berta P, Palmer MS, et al. A gene from the human sex-determining region encodes a protein with homology to a conserved DNA-binding motif. *Nature*. 1990;346:240–4.
- Skinner MK. Secretion of growth factors and other regulatory factors. In: Russell LD, Griswold MD, editors. *The Sertoli cell*. Clearwater: Cache River Press; 1993. p. 237–47.
- Smith CA, McClive PJ, Hudson Q, Sinclair AH. Male-specific cell migration into the developing gonad is a conserved process involving PDGF signalling. *Dev Biol*. 2005;284:337–50.
- Smith CA, Roeszler KN, Ohnesorg T, et al. The avian Z-linked gene DMRT1 is required for male sex determination in the chicken. *Nature*. 2009;461:267–71. doi:10.1038/nature08298 nature08298 [pii].
- Spiller C, Wilhelm D, Koopman P. Cell cycle analysis of fetal germ cells during sex differentiation in mice. *Biol Cell*. 2009;101:587–98. doi:10.1042/BC20090021.
- Spiller CM, Wilhelm D, Koopman P. Retinoblastoma 1 protein modulates XY germ cell entry into G1/G0 arrest during fetal development in mice. *Biol Reprod*. 2010;82:433–43. doi:10.1095/biolreprod.109.078691.
- Tam PP, Snow MH. Proliferation and migration of primordial germ cells during compensatory growth in mouse embryos. *J Embryol Exp Morpholog*. 1981;64:133–47.
- Tang H, Brennan J, Karl J, et al. Notch signaling maintains Leydig progenitor cells in the mouse testis. *Development*. 2008;135:3745–53. doi:10.1242/dev.024786 dev.024786 [pii].
- Tripiciano A, Filippini A, Giustiniani Q, Palombi F. Direct visualization of rat peritubular myoid cell contraction in response to endothelin. *Biol Reprod*. 1996;55:25–31.
- Uhlenhaut NH, Jakob S, Anlag K, et al. Somatic sex reprogramming of adult ovaries to testes by FOXL2 ablation. *Cell*. 2009;139:1130–42. doi:10.1016/j.cell.2009.11.021 S0092-8674(09)01433-0 [pii].
- Umehara F, Tate G, Itoh K, et al. A novel mutation of desert hedgehog in a patient with 46,XY partial gonadal dysgenesis accompanied by minifascicular neuropathy. *Am J Hum Genet*. 2000;67:1302–5. doi:10.1016/S0002-9297(07)62958-9.
- Vergouwen RP, Jacobs SG, Huiskamp R, et al. Proliferative activity of gonocytes, Sertoli cells and interstitial cells during testicular development in mice. *J Reprod Fertil*. 1991;93:233–43.
- Vidal VPI, Chaboissier MC, de Rooij DG, Schedl A. Sox9 induces testis development in XX transgenic mice. *Nat Genet*. 2001;28:216–7.
- Wagner T, Wirth J, Meyer J, et al. Autosomal sex reversal and campomelic dysplasia are caused by mutations in and around the SRY-related gene SOX9. *Cell*. 1994;79:1111–20.
- Wen Q, Liu Y, Gao F. Fate determination of fetal Leydig cells. *Front Biol (Beijing)*. 2011;6:12–8. doi:10.1007/s11515-011-1100-3.
- Wen Q, Zheng Q-S, Li X-X, et al. Wt1 dictates the fate of fetal and adult Leydig cells during development in the mouse testis. *Am J Physiol Endocrinol Metab*. 2014;307:E1131–43. doi:10.1152/ajpendo.00425.2014.
- Western PS, Miles DC, van den Bergen JA, et al. Dynamic regulation of mitotic arrest in fetal male germ cells. *Stem Cells*. 2008;26:339–47. doi:10.1634/stemcells.2007-0622.
- Wilhelm D, Martinson F, Bradford S, et al. Sertoli cell differentiation is induced both cell-autonomously and through prostaglandin signaling during mammalian sex determination. *Dev Biol*. 2005;287:111–24. doi:10.1016/j.ydbio.2005.08.039.
- Wilhelm D, Hiramatsu R, Mizusaki H, et al. SOX9 regulates prostaglandin D synthase gene transcription in vivo to ensure testis development. *J Biol Chem*. 2007;282:10553–60.

- Yamaji M, Seki Y, Kurimoto K, et al. Critical function of Prdm14 for the establishment of the germ cell lineage in mice. *Nat Genet.* 2008;40:1016–22. doi:10.1038/ng.186.
- Yao HH-C, Capel B. Disruption of testis cords by cyclopamine or forskolin reveals independent cellular pathways in testis organogenesis. *Dev Biol.* 2002;246:356–65. doi:10.1006/dbio.2002.0663.
- Yao HH-C, Whoriskey W, Capel B. Desert Hedgehog/Patched 1 signaling specifies fetal Leydig cell fate in testis organogenesis. *Genes Dev.* 2002;16:1433–40. doi:10.1101/gad.981202.
- Yoshimoto S, Ikeda N, Izutsu Y, et al. Opposite roles of DMRT1 and its W-linked paralogue, DM-W, in sexual dimorphism of *Xenopus laevis*: implications of a ZZ/ZW-type sex-determining system. *Development.* 2010;137:2519–26. doi:10.1242/dev.048751.
- Young JM, McNeilly AS. Theca: the forgotten cell of the ovarian follicle. *Reproduction.* 2010;140:489–504. doi:10.1530/REP-10-0094.
- Zhang L, Chen M, Wen Q, et al. Reprogramming of Sertoli cells to fetal-like Leydig cells by Wt1 ablation. *Proc Natl Acad Sci U S A.* 2015;112:4003–8. doi:10.1073/pnas.1422371112.
- Zhao L, Svingen T, Ng ET, Koopman P. Female-to-male sex reversal in mice caused by transgenic overexpression of Dmrt1. *Development.* 2015;142:1083–8. doi:10.1242/dev.122184.



Richard Ivell, Ravinder Anand-Ivell, and Steven D. Morley

## Abstract

The human fetus, already at a very early stage in its development, is hormonally active, with the testis and adrenal gland being major contributors. Following sex determination at around weeks 5–6, the somatic cells of the testis begin to differentiate into hormone-producing Sertoli and Leydig cells. The latter cells share similar origins to the steroidogenic cells of the adrenal cortex and fetal zones which at this stage of human development are located close to the testis. This changes following testis descent to the inguinal region caused by Leydig cell production of androgens and INSL3. In the first half of pregnancy, fetal hormones act more as paracrine systems diffusing locally within the fetus and amniotic fluid; consequently understanding fetal steroidogenesis at this stage requires knowledge of both testis and adrenal metabolism. Much of fetal testis development is governed and orchestrated by feedforward and feedback processes, combining with irreversible effects, such as the involution of the Mullerian ducts, the development of the Wolffian system, and testis descent. These processes and the timing of hormone and receptor expression are what lead to the high precision that results in the extremely low frequency of nongenetic disorders of sex development. This is now being challenged by in utero low-level exposure to a range of anthropogenic chemicals which appear capable of disrupting normal development.

---

R. Ivell (✉)

School of Biosciences & School of Veterinary Medicine and Science, University of Nottingham, Nottingham, UK

e-mail: [richard.ivell@nottingham.ac.uk](mailto:richard.ivell@nottingham.ac.uk)

R. Anand-Ivell

School of Biosciences, University of Nottingham, Nottingham, UK

S.D. Morley

Division of Health Sciences, University of Edinburgh Medical School, Edinburgh, UK

---

**Keywords**

 Fetal • Testis • Adrenal • INSL3 • AMH • RXFP2 • Androstenedione • Steroid
 

---

**Contents**

Introduction .....	246
The Fetal Context .....	247
Sex Determination .....	248
Fetal Steroidogenesis .....	250
The Role of Androgens in the Fetus .....	255
The Fetal Adrenal Cortex as a Possible Source of Fetal Androgens .....	256
The Importance of Estrogens in the Male Fetus .....	258
Paracrine- and Endocrine-Acting Hormones and Growth Factors .....	258
Desert Hedgehog (DHH) .....	258
Platelet-Derived Growth Factor A (PDGF-A) .....	259
Vascular Endothelial Growth Factor (VEGF) .....	259
Insulin-Like Growth Factor 1 (IGF1) .....	259
Prostaglandins .....	259
Corticotropin Releasing Factor (CRH) .....	260
Anti-Mullerian Hormone (AMH) .....	260
Inhibins and Activins .....	261
Pituitary Adenylyl Cyclase-Activating Polypeptide (PACAP) .....	261
Natriuretic Peptides .....	262
Insulin-Like Peptide 3 (INSL3) .....	262
Endocrine Control of the Fetal Testis .....	263
Importance of Feedback and Feedforward Regulation .....	264
Environmental Endocrine Disruption of Fetal Development .....	265
Concluding Remarks .....	266
References .....	267

---

**Introduction**

The development of a human individual from a single cell to an infant weighing several kilograms and with most organ systems fully differentiated and physiologically functioning is an awe-inspiring phenomenon, especially when one considers how little divergence from the basic developmental template occurs under normal circumstances. This very dynamic process is only possible because of the evolution of numerous endocrine and paracrine/autocrine regulatory systems, which govern and orchestrate every aspect of fetal development. Because mammals are viviparous, all of this development occurs within the mother during pregnancy and is thus largely inaccessible to direct experimental measurement. This is especially true in the period before elective abortion is most frequently practiced, when most organ systems are established, and the testes become hormonally active in determining the sex-dependent phenotype of the XY offspring. Consequently, much of our knowledge about the endocrinology of the fetal testes derives from animal models, including genetically modified rodents, or from spontaneous or elective abortion material, or the consequences of human genetic aberrations. In this chapter we aim to distil such information to provide an overview of the normal endocrinology of the

healthy human male fetus as pertaining to gonadal development and sex differentiation. Importantly, while focusing on the testes, we also consider the wider fetal context which necessarily includes endocrine steroidogenic activity of the fetal adrenal gland and placenta.

---

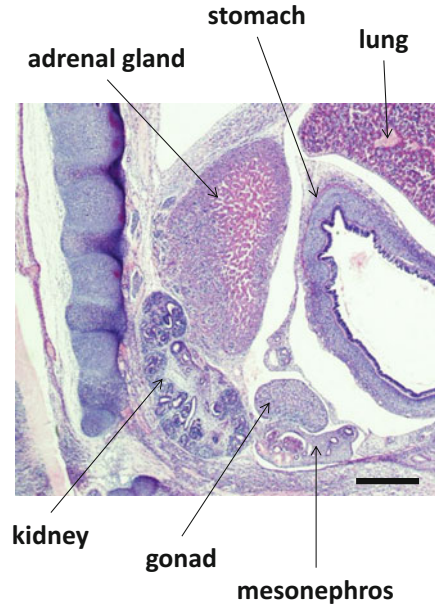
## The Fetal Context

In the first 6 weeks post implantation, a human embryo grows from a single fertilized oocyte to an organism of approximately 4 mm length. In the ensuing 2 weeks, this embryo has grown to 13 mm length, and by 10–12 weeks has attained a size of 30–80 mm, with development of all key organ systems initiated if not fully mature, including the appearance of the external genitalia, which are more or less completed by week 15. During this time, the fetus is enclosed within a growing amniotic sac whose fluid volume increases from about 25 ml at week 10 to about 400 ml at week 20. Up to week 20, the fetal skin has not yet keratinized and become impermeable, and the fetal kidney has barely begun functioning, so that amniotic fluid is largely composed of fetal exudate combined with the secretions of the fetal membranes. Its hormonal content should therefore largely reflect the environment of the growing fetus and its organs, albeit in a dilute form, since at 10 weeks there is approximately 25 times greater amniotic fluid volume than fetal volume, only about 10% of which is fetal blood. This will be supplemented by hormones from the placenta.

Most of the steroidogenic cells of the gonads and adrenal cortex share a common origin in an adrenal-gonadal primordium (AGP), originating from an accumulation of dorsal coelomic epithelial cells in the region of the mesonephros around fetal weeks 3–4 (Mesiano and Jaffe 1997). Following separation of the AGP into distinct adrenal and gonadal primordia at around weeks 4–6, differentiation of migrating adrenocortical cells into fetal and then definitive zones commences around weeks 7–8. This is complemented by the development of vascular connections and a network of sinusoidal capillaries between the cords of the fetal zone, inward migration of neural crest cells giving rise to islands of chromaffin cells destined to form the adrenal medulla, and encapsulation of the developing adrenal gland by specialized mesenchymal cells migrating from the region of the Bowman's capsule.

By the end of the first trimester, the developing adrenal gland is as large as the fetal kidney and highly steroidogenically active, producing large quantities of adrenal androgens, principally dehydroepiandrosterone-sulphate (DHEAS). These are further metabolized by the fetal liver and then converted to estrogens by the placenta, illuminating the role of the “feto-placental unit” in maintaining the high estrogenic milieu of pregnancy (Diczfalusy 1964; Rainey et al. 2004; Ishimoto and Jaffe 2011). Arising from their common origin and prior to testicular descent, the fetal adrenals and male gonads develop in relatively close proximity over the period of fetal weeks 5–10 (Fig. 1), raising the possibility that developing gonadal cells may be subject to significant adrenal paracrine and/or endocrine influence in addition to their own endocrinology. Both early feedback inhibition of pituitary activity by

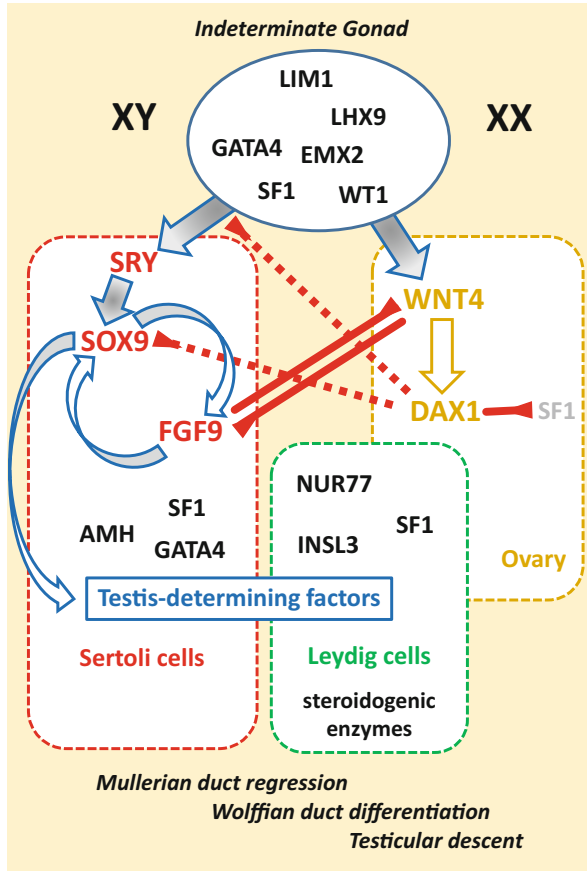
**Fig. 1** Sagittal section through an approximately 8-week human fetus, showing the relative positions of the adrenal gland, kidney, gonad (testis) and mesonephros. Note the close proximity of the adrenal and gonad at this early stage of development. *Size bar* represents 0.5 mm (Modified after Hayashi et al. (2011). Image courtesy of Dr. Shogo Hayashi, Tokyo)



transient cortisol synthesis around weeks 7–8 and subsequent placental metabolism of adrenal steroids may limit adrenal androgen influence on gonadal development (Goto et al. 2006; White 2006; Miller and Auchus 2011); however, fetal virilization and masculinization occurring in androgen excess syndromes, such as 21-hydroxylase-deficient congenital adrenal hyperplasia (21-OHD CAH; Speiser and White 2003), suggest that this may not offer complete protection across all time frames.

## Sex Determination

As noted above, the gonads share a common origin with the adrenal cortex, having their origin in a ridge-like accumulation of coelomic epithelial cells on the dorsal wall of the coelomic cavity around fetal weeks 3–4. Primordial germ cells migrate into this gonadal ridge from the yolk sac, where they have been epigenetically isolated, via the hind gut at around week 6 in the human fetus (GD 8 in the mouse). At this time, the gonads are still of completely indeterminate sex. Between weeks 6 and 8 of human pregnancy, the coelomic epithelial cells adjacent to the arriving germ cells in a male fetus begin to express the SRY gene, form sex cords enclosing the germ cells, and become pre-Sertoli cells. SRY is a key transcription factor which then induces another transcription factor SOX9, which in turn initiates the male sex determination cascade (Fig. 2), including the expression of the major steroid regulatory transcription factor SF-1 (also in pre-Sertoli cells). Parallel to the differentiation of the pre-Sertoli cells, other coelomic epithelial cells congregate around the sex cords to become steroidogenic interstitial cells. These are joined by



**Fig. 2** Molecular basis of sex determination in mammals. The indeterminate gonad already expresses specific transcription factors (blue ellipse), which in the XY karyotype lead to expression of the sex-determining gene on the Y chromosome SRY in the pre-Sertoli cells. SRY in turn activates SOX9, which itself drives expression of FGF9 as part of a feedforward loop maintaining and increasing its expression. In turn SOX9 together with other transcription factors, such as SF1 and/or GATA4, induce expression of specific testis-determining factors, such as AMH. Such factors also lead to differentiation of the Leydig cells, together leading to the production of hormones essential for further testis differentiation, Mullerian duct regression, Wolffian duct development, and testicular descent. In the XX karyotype, WNT4 is expressed which in turn induces the inhibitory transcription factor DAX1, which effectively retards SRY expression, and inhibits both SOX9 and SF1 action. WNT4 and FGF9 are also mutually inhibitory. Thus under normal conditions, the XY-pathway and the XX-pathway are mutually inhibitory and exclusive, with the male pathway being active and dominant, and explaining how in the absence of SRY and SOX9, the female pathway becomes the default

mesenchyme cells similar to those populating the developing adrenal gland migrating in from the adjacent mesonephros. Together these two cell types form what are to become the steroidogenic Leydig cells of the fetal testes, also expressing SF-1. Other interstitial cells immediately surrounding the sex cords become fetal peritubular

cells. In the human fetus, Leydig cells are sufficiently differentiated by week 8 that the relatively Leydig cell-specific steroid testosterone is already measurable at that time. The details of these events have mostly been defined using the mouse model (GD 8–10).

In the female fetus, while there is a similar movement of germ cells into the gonadal ridge, there is no sex cord formation. Instead the primordial ovary remains relatively undifferentiated until about weeks 10–12, when interstitial cells are expressing the inhibitory transcription factor DAX1 and the germ cells form primordial follicles, enter meiosis I and arrest (Fig. 2). The ovaries then remain largely hormonally quiescent throughout pregnancy (Voutilainen and Miller 1986).

---

## Fetal Steroidogenesis

The principal functions of the fetal testes are (a) to make steroid and peptide hormones needed to direct sex-specific differentiation of the male fetus, in particular the accessory sex glands and tissues, the external genitalia, and the brain and (b) to generate appropriate numbers of healthy primordial germ cells which can become gonocytes ready for spermatogenic differentiation during postnatal life and in puberty. Whereas differentiation of male accessory glands and external genitalia appears to require androgens early in pregnancy (mostly weeks 8–16), the brain acquires its gender-specific phenotype later in gestation. According to measurement of amniotic fluid steroids, there appears to be little quantitative variation in individual sex steroid concentration across mid gestation, although there are some gender differences mentioned below (Table 1). This appears to be in contrast to concentrations of steroids measured directly in human fetal testis tissue, which declined consistently in the latter half of gestation after achieving a maximum at about week 14 (Tapanainen et al. 1981), though these data do not take account of the relative growth of the testes in relation to fetal and amniotic volumes. Our understanding of fetal steroidogenesis is based largely on the tissue-specific expression of steroidogenic enzymes, on steroids extracted from fetal tissues and fluids, and on the consequences in humans and rodents of specific mutations in genes for key steroidogenic enzymes. Unfortunately, many of the excellent reviews of fetal steroidogenesis suffer by being treated in an adrenal- or testis-specific manner, without discussing steroid production as a whole. Steroids formed in one tissue (e.g., fetal adrenal) can be substrates for other tissues (e.g., placenta; Miller and Auchus 2011). Importantly, androgens such as testosterone, thought of as almost exclusively testicular in origin, are also made in significant amounts by the adrenal gland. This is easiest to see when comparing steroid concentrations in amniotic fluid of early male and female human fetuses (Table 1). Most of these steroids, measured either by the latest ID/GC-MS technique or immunoassay, show no differences between male and

**Table 1** Amniotic fluid steroid concentration (ng/ml) in the mid-gestation (weeks 12–24) human fetus

Steroid	Male		Female		Sig.	Reference
	Mean $\pm$ SD	Range	Mean $\pm$ SD	Range		
Testosterone	0.24 <sup>a</sup>	0.00–0.50	0.00 <sup>a</sup>	0.00–0.27	Yes	Wudy et al. (1999)
	0.22 $\pm$ 0.01	0.14–0.37 <sup>b</sup>	0.04 $\pm$ 0.002	0.03–0.07 <sup>b</sup>	Yes	Robinson et al. (1977)
	0.23		0.05		Yes	Forest et al. (1980)
	0.30 $\pm$ 0.02		0.08 $\pm$ 0.01		Yes	Carson et al. (1982)
Androstenedione	0.93 <sup>a</sup>	0.29–1.98	0.53 <sup>a</sup>	0.00–2.71	Yes	Wudy et al. (1999)
	1.02 $\pm$ 0.05		0.67 $\pm$ 0.04		Yes	Robinson et al. (1977)
	0.66	0.45–0.97 <sup>b</sup>	0.39	0.25–0.60 <sup>b</sup>	Yes	Forest et al. (1980)
	0.96 $\pm$ 0.60		0.56 $\pm$ 0.04		Yes	Carson et al. (1982)
	0.79 $\pm$ 0.39		0.48 $\pm$ 0.18		Yes	Pang et al. (1980)
Androstanediol	<0.24		<0.10		No	Wudy et al. (1999)
	0.60	0.10–1.38 <sup>b</sup>	1.01	0.73–1.38 <sup>b</sup>	Yes	Forest et al. (1980)
Pregnenolone	1.54	1.16–2.03 <sup>b</sup>	1.87	1.24–2.83 <sup>b</sup>	Yes	Forest et al. (1980)
Progesterone	46.39	18.41–116.90 <sup>b</sup>	47.21	21.35–104.37 <sup>b</sup>	No	Forest et al. (1980)
	56.10 $\pm$ 5.40		59.50 $\pm$ 5.80		No	Carson et al. (1982)

*(continued)*

**Table 1** (continued)

Steroid	Male		Female		Sig.	Reference
	Mean $\pm$ SD	Range	Mean $\pm$ SD	Range		
17OH-prog.	1.48 <sup>a</sup>	0.21–4.96	no sex difference <sup>c</sup>		No	Wudy et al. (1999)
	0.99	0.75–1.34 <sup>b</sup>	1.21	0.98–1.49 <sup>b</sup>	Yes	Forest et al. (1980)
	2.15 $\pm$ 0.16		2.02 $\pm$ 0.10		No	Carson et al. (1982)
17OH-pregn.	1.16	0.85–1.58 <sup>b</sup>	1.57	1.23–2.00 <sup>b</sup>	Yes	Forest et al. (1980)
DHEA	0.47 <sup>a</sup>	0.19–1.77	no sex difference <sup>c</sup>		No	Wudy et al. (1999)
	0.21	0.15–0.30 <sup>b</sup>	0.27	0.17–0.43 <sup>b</sup>	Yes	Forest et al. (1980)
	0.57 $\pm$ 0.04		0.54 $\pm$ 0.02		No	Carson et al. (1982)
DHEA-S	8.80 $\pm$ 0.70		10.10 $\pm$ 0.74		No	Forest et al. (1980)
Cortisol	4.66	2.58–8.39 <sup>b</sup>	4.97	2.64–9.36 <sup>b</sup>	No	Forest et al. (1980)
Cortisone	15.00	11.69–19.25 <sup>b</sup>	17.37	4.17–21.29 <sup>b</sup>	No	Forest et al. (1980)
	11.20 $\pm$ 0.93		12.60 $\pm$ 1.08		No	Carson et al. (1982)
Estrone	0.35 $\pm$ 0.03		0.33 $\pm$ 0.03		No	Robinson et al. (1977)
	0.24	0.16–0.35 <sup>b</sup>	0.24	0.16–0.37 <sup>b</sup>	No	Forest et al. (1980)
Estradiol	0.06 $\pm$ 0.004		0.10 $\pm$ 0.008		Yes	Robinson et al. (1977)
	0.04	0.02–0.11 <sup>b</sup>	0.06	0.04–0.09 <sup>b</sup>	No	Forest et al. (1980)

(continued)



**Table 1** (continued)

Steroid	Male		Female		Sig.	Reference
	Mean $\pm$ SD	Range	Mean $\pm$ SD	Range		
DHT	<0.19		<0.10		No	Wudy et al. (1999)

Wudy et al. (1999) used ID/GC-MS to analyze the steroids; all other studies used specific immunoassays

*17OH-prog.* 17-hydroxy-progesterone, *17-OH-pregn.* 17-hydroxy-pregnenalone, *DHEA* dehydro-epiandrosterone, *DHEA-S* dehydroepiandrosterone-sulfate, *DHT* dehydro-testosterone

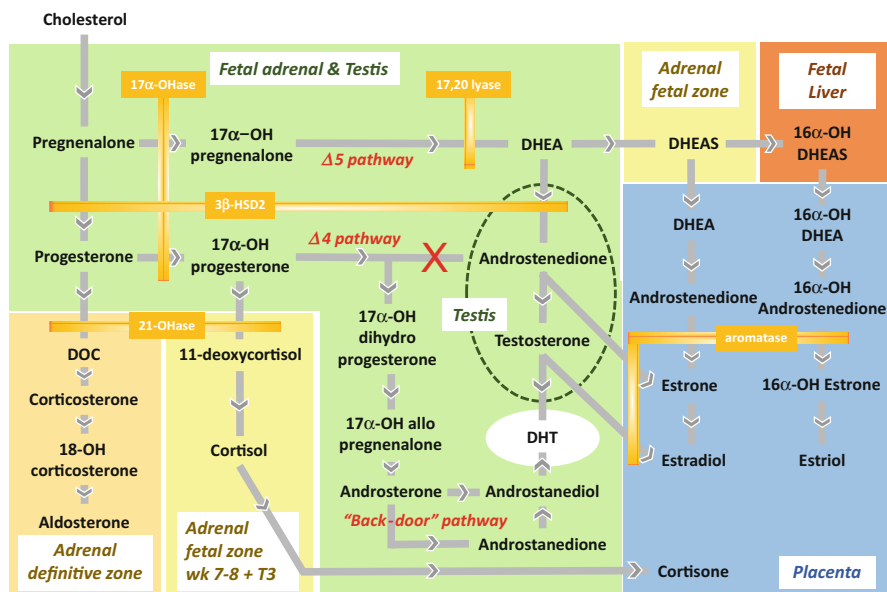
<sup>a</sup>Median

<sup>b</sup>95% confidence intervals

<sup>c</sup>Values for male and female fetuses are combined

female fetuses implying that they are not the product of gonad-specific steroid synthesis or conversion, but are mainly of adrenal or placental origin. Only androstenedione and testosterone show sex-specific differences (Table 1); but even here there is substantial overlap between male and female fetuses in their median and/or range for both steroids, suggesting that, in addition to DHEAS, the female adrenal gland also produces lower but significant concentrations of these androgens which, when not converted to estrogens by the placenta, may be sufficient to activate androgen receptors when these are expressed. As a consequence of this, Wudy et al. (1999) stated categorically that “no reliance should be placed on amniotic fluid testosterone measurement for the determination of fetal sex.” The extent of a maternal or placental contribution is not clear. Older studies comparing maternal, amniotic, and fetal concentrations of testosterone, for example, indeed suggest that both the adrenal gland and placenta may be contributing to testosterone levels in the female fetus (Rodeck et al. 1985).

For the male fetus, there are two principal routes for the production of testosterone and its more potent derivative, dihydrotestosterone (DHT). In the classic pathway cholesterol, either synthesized de novo or taken up via LDL receptors, is first converted into pregnenolone by the P450 side-chain cleavage enzyme CYP11A1 and thence to testosterone via DHEA and the  $\Delta 5$  pathway (Fig. 3). In humans, this appears to occur uniquely within Leydig cells. In mice the alternative  $\Delta 4$  pathway via progesterone and androstenedione is mostly used. It should be noted, however, that in contrast to testosterone synthesis in adult-type Leydig cells, the fetal conversion of androstenedione to testosterone, involving the enzyme 17 $\beta$ HSD3 of the  $\Delta 4$  pathway in the mouse, takes place in Sertoli cells (Carney et al. 2014). It should be recalled that both Sertoli and Leydig cells in the fetus express the key transcription factor SF-1 which is responsible for the permissive upregulation of a number of steroidogenic genes. Similar pathways are also likely to be functional within the fetal adrenal gland of mice and humans, thus explaining the presence of substantial androstenedione and testosterone also in female fetuses (Table 1). These androgens are themselves not the most important androgen receptor agonists, since



**Fig. 3** Tissue and temporal patterns of fetal steroid synthesis. Steroid synthetic conversions active in fetal tissues are denoted by *arrows*, while the inefficient conversion in the human of  $17\alpha$ -OH progesterone to androstenedione by 17,20-lyase is indicated by a red cross. For clarity, only certain key enzymes that determine the secretion of androgens and estrogens have been included. Details of enzyme definitions and enzymes catalyzing additional steroid conversions can be obtained from references cited in the text. Note that most components of the androgenic pathway leading to DHEA, androstenedione, and testosterone are shared between the adrenal and the developing testis; the latter, however, specifically encourages the expression of androgens as end-points (*green oval*; see also Table 1), whereas in the adrenal fetal zone, the favored end-points are DHEAS peaking at the end of the first trimester and cortisol synthesized transiently in weeks 7–8 and then increasing again in the third trimester (T3)

they have a relatively low potency and can be easily inactivated; however, a proportion of the testosterone produced in fetal Leydig cells and released into the circulation could avoid conversion into estrogens by the placenta and instead be converted in target tissues into the more stable and highly potent androgen, DHT, by the action of locally expressed  $5\alpha$ -reductase. This gives rise to the notion that a specific component of total fetal steroid production might exert specific localized tissue effects.

Recently, an alternative so-called “backdoor” pathway for DHT has been described (Biaison-Lauber et al. 2013; Fukami et al. 2013). This generates DHT via progesterone, allopregnanolone, and androsterone, quite independently of the DHEA, androstenedione, or testosterone of the  $\Delta 4$  and  $\Delta 5$  pathways (Fig. 3; Fukami et al. 2013; Flück and Pandey 2014). It has been suggested for the human fetus that up to half of fetal DHT may be produced in this way already in the fetal testes

(Biason-Lauber et al. 2013) and possibly the adrenal glands (Kamrath et al. 2012; Auchus and Miller 2012).

---

## The Role of Androgens in the Fetus

The presence of external female genitalia in androgen receptor-deficient humans and knockout mice, despite the presence of testes and abundant androgens (this term is used here to describe androgen receptor (AR) agonists and probably includes DHT, testosterone, and possibly androstenedione), demonstrates their indispensable nature to normal male development (Wilson et al. 1981). They are essential in the male fetus to stabilize Wolffian duct derivatives in the formation of the accessory sex glands (epididymis, prostate, seminal vesicle, bulbourethral gland, etc.) and the formation of the penis from the urethral folds. This is usually complete by week 16 of human pregnancy. They are also needed to induce dissolution of the cranial suspensory ligaments (weeks 8–10) which retain the undifferentiated gonads in a peri-renal position (Lee and Hutson 1999); if this does not occur, then the first transabdominal phase of testicular descent cannot take place (see later). Androgens are later required also for the second inguino-scrotal phase (weeks 20–36) of testicular descent (Klonisch et al. 2004), as well as for androgenization of the fetal brain (Bao and Swaab 2011).

An important question here is that of specificity. How much androgen is required to achieve these effects, especially given the relatively high concentrations of androgens pervading the mid-gestation female human fetus? In experimental *in vitro* systems dependent on a classically functioning AR, <1 nM testosterone is sufficient to achieve significant activity, a concentration which is close to that measured in the amniotic fluid of female fetuses (Table 1). There are few data directly comparing concentrations of sex steroids in female fetal plasma with those in amniotic fluid. Rodeck et al. (1985) found a concentration of  $1.02 \pm 0.30$  (range 1.65–0.51;  $n = 15$ ) ng/ml testosterone in female fetal plasma from mid gestation (ca. week 20), compared to  $0.73 \pm 0.26$  (range 1.38–0.32;  $n = 21$ ) ng/ml in amniotic fluid from the same fetuses. Although these results are based on older immunoassays, they nevertheless support the view that amniotic fluid may indeed reflect circulating fetal steroid levels. A further indication is provided by the prevalence of obvious virilization in 46XX CAH (congenital adrenal hyperplasia) patients whose amniotic fluid testosterone levels (of adrenal origin) are about 0.2–0.3 ng/ml (Wudy et al. 1999). It should be noted, however, that toward the end of the first trimester, when androgen-dependent masculinization of the genitals and gonadal accessory organs is occurring, the target tissues are all in very close juxtaposition to both testicular and adrenal sources of steroids (Fig. 1), whose local concentration is likely to be much higher. Moreover, inspection of the timing of these events in gestation suggests that the triggering androgen-dependent events are all temporally very close to the initial synthesis of the steroids. This implies that the specificity of

what is likely to be an irreversible morphological action may be due simply to the target receptors being activated during that first local production of steroids and that later and greater steroid exposure is unimportant for these events. This would also help to define the concept of the “fetal programming window” (Welsh et al. 2014).

---

## The Fetal Adrenal Cortex as a Possible Source of Fetal Androgens

As for the testis, the key to understanding adrenal steroid hormone action lies in the temporal and spatial pattern of steroidogenic gene expression in specific adrenocortical zones, coupled with pre-receptor conversion to more or less active products and target tissue responsiveness within a particular developmental time frame. Based on cell morphology, the fetal adrenal cortex is divided into a specialized inner “fetal” zone, first apparent around week 8 of gestation and representing approximately 85% of the cortical volume by the end of the first trimester, a narrower subcapsular “definitive” zone first apparent around week 9 as an outer “rim” of densely packed basophilic cells below the developing capsule (Fig. 1) which gradually begins to broaden toward the end of gestation, and a “transitional” zone appearing between the fetal and definitive zones later in gestation (Mesiano and Jaffe 1997; Rainey et al. 2004). The relative contributions of the fetal, definitive, and transitional zones to fetal steroidogenesis at different stages of development still need to be clarified. However, fetal adrenal steroid synthesis commences around 8 weeks of gestation (i.e., the same time that testosterone is first produced in the developing testis), with the fetal zone expressing high levels of cholesterol side-chain cleavage enzyme and 17 $\alpha$ -hydroxylase/17,20-lyase (17 $\alpha$ -OHase/17,20-lyase) that convert the steroidogenic precursor cholesterol via pregnenolone and 17OH-pregnenolone to DHEA, and steroid sulfotransferase (SULT2A1) which converts DHEA to DHEAS (Fig. 3). Crucially, 3 $\beta$ -hydroxysteroid dehydrogenase type 2 (3 $\beta$ -HSD2) is expressed for a short period in the fetal zone around weeks 7–8, allowing transient cortisol synthesis to suppress ACTH release from the pituitary gland, which would otherwise drive high levels of adrenal testosterone production from DHEA and androstenedione via 17 $\beta$ -hydroxysteroid dehydrogenase type 5 expressed in the fetal cortex. This prevents the inappropriate masculinization of a 46XX female fetus (Goto et al. 2006; White 2006). 3 $\beta$ -HSD2 declines thereafter, returning only in late gestation, thus enhancing flux through 17-hydroxypregnenolone and DHEA to DHEAS at these early stages (Fig. 3). The last of these is not a substrate for 3 $\beta$ -HSD2 and therefore becomes the principal fetal adrenal steroid secreted into the circulation by the end of the first trimester. The majority of circulating DHEAS, and also any DHEA which has escaped sulfation, is subjected to 16 $\alpha$ -hydroxylation in the fetal liver and then taken up by the placenta (which is unable to synthesize 17 $\alpha$ -hydroxylated steroids de novo). Both DHEAS and 16 $\alpha$ -OH DHEAS are then converted via androstenedione and estrone and their 16 $\alpha$ -hydroxylated counterparts, to estradiol and estriol (Fig. 3).

The latter represents a unique marker of fetal adrenal steroidogenic activity that can be measured in the maternal circulation first at around 8 weeks of gestation (Mesiano and Jaffe 1997; Miller and Auchus 2011). The robust aromatase activity of the placenta converts androstenedione to estrone and also any testosterone secreted from the fetal adrenal gland, acting as a further buffer to limit inappropriate masculinization or virilization of the developing fetus; however, the presence of significant amounts of unconverted steroids in the circulation may allow for the possibility of uptake and conversion by other peripheral tissues.

Much can be learned about the potential effects of fetal adrenal androgens on other tissues from 21-OHD CAH, an autosomal recessive disorder in which a partial or complete inactivation of steroid 21 hydroxylase (21-OHase), the penultimate adrenal enzyme in the cortisol synthetic pathway (Fig. 3), redirects steroid intermediates toward androgen production, causing inappropriate masculinization or precocious virilization of the developing fetus (Speiser and White 2003; Hanley and Arlt 2006). Conventional wisdom suggests that the block in production of 11-deoxycortisol from 17-hydroxy progesterone (17OHP) by 21-OHD CAH allows 17OHP to accumulate and be redirected to androstenedione and testosterone which are then secreted and converted to DHT in other tissues in the crucial early weeks of fetal development. The difficulty with this view is that the  $\Delta 4$  pathway conversion of 17OHP to androstenedione by CYP17 is extremely inefficient in humans, and furthermore, the accumulation of 17OHP is likely to feedback-inhibit  $3\beta$ -HSD2 (also inhibited by placental estradiol) which might otherwise convert any DHEA formed via the  $\Delta 5$  pathway to androstenedione. Also, any DHEA synthesized in the fetal adrenal is likely to be sulfated, secreted, and converted to estradiol in the placenta. More recently it has become clear that the so-called “backdoor” pathway for the production of DHT might be responsible for a substantial part of fetal DHT synthesis in 21-OHD CAH (Kamrath et al. 2012; Auchus and Miller 2012), also raising the possibility that this pathway might be operative in the normal fetal adrenal gland. Another intriguing possibility, yet to be fully evaluated, is that the fetal adrenal could short-circuit the requirement for  $3\beta$ -HSD2 in supplying steroidogenic intermediates for backdoor DHT synthesis by using progesterone released from the placenta following the luteal-placental shift at around 8–9 weeks of gestation. Together with the “protective” expression in the fetal adrenal of  $3\beta$ -HSD2 during sex determination in gestational weeks 7–8, described previously, this may explain why affected 21-OHD CAH 46,XY males and 46,XX females undergo normal sex determination, with masculinization and virilization of accessory glands and external genitalia commencing around week 9 of gestation and being essentially complete by weeks 12–16 (Miller and Auchus 2011). This suggests that adrenal androgens are unlikely to affect sex determination around weeks 7–8 of gestation but that their influence on fetal sexual differentiation during weeks 9–16 in genotypically normal males and females, as well as 21-OHD CAH individuals, is likely to be physiologically important.

## The Importance of Estrogens in the Male Fetus

Under normal circumstances, the enzyme aromatase is expressed only at a very low level within the male fetus (Tapanainen et al. 1989). However, as noted previously, estrogens are produced in very large amounts by the feto-placental unit largely using DHEAS from the fetal adrenal gland as substrate (Ishimoto and Jaffe 2011; Miller and Auchus 2011). How much estradiol the fetal testes is exposed to is not clear, except that it is well established that disorders of sexual development (DSDs) can be induced in male fetal rodents by exogenous maternal administration of estrogens such as diethylstilbestrol (DES) or bisphenol A (BPA) and that these effects can be reduced following embryonic deletion of the nuclear estrogen receptors (Cederroth et al. 2007). Whereas ER $\beta$  (estrogen receptor  $\beta$ ) is expressed in Sertoli, Leydig, and germ cells of both human and mouse fetal testes, in the former as two different alternatively spliced variants, ER $\alpha$  appears to be expressed mostly in interstitial Leydig and peritubular cells, and possibly also germ cells, at least in the mouse or rat. For the human, ER $\alpha$  expression is less obvious (Gaskell et al. 2003; Shapiro et al. 2005). ER $\beta$  expression appears to be involved in determining final gonocyte number at birth, and ER $\alpha$  may regulate Leydig cell function, with estrogens acting as inhibitors of fetal androgen or INSL3 (see later) production (Lassarguère et al. 2003; Delbès et al. 2005). These influences of fetal estrogens have, however, only been clearly demonstrated in rodents; for the human fetal testis, results are less secure (N'Tumba-Byn et al. 2012; Mitchell et al. 2013).

The question remains, however, as to the source of fetal estrogens and their impact in the healthy growing testis. Since aromatase is poorly expressed in the normal male fetus, it seems unlikely that local estradiol is the principal ligand for ER $\alpha$  or ER $\beta$  during gestation. While speculative, it should not be forgotten in this context that androstenedione, which is present at moderate concentration in the fetal testis is not only a weak androgen but also activates ER $\alpha$  and ER $\beta$  at modest concentrations (Miller et al. 2013). Interestingly, boys born with X-linked ichthyosis due to a deficiency in steroid sulfatase – and consequently very reduced estrogen levels at birth and increased precursor levels, such as androstenedione – show a significant association with both testis cancer and cryptorchidism (Traupe and Happle 1983; Lykkesfeldt et al. 1991). This would imply a link between fetal estrogens and testis development (see also later).

---

## Paracrine- and Endocrine-Acting Hormones and Growth Factors

### Desert Hedgehog (DHH)

The peptide desert hedgehog (DHH) appears to be the earliest informational molecule to be secreted by pre-Sertoli cells following activation of SOX9 and is responsible via its specific receptor called patched for inducing a Leydig cell phenotype in the neighboring interstitial cells (Fowler et al. 2008).

## **Platelet-Derived Growth Factor A (PDGF-A)**

The tyrosine kinase linked receptor for the PDGF family of growth factors, PDGFR-A, is highly expressed in the early fetal mouse and human testis (Basciani et al. 2002; Brennan et al. 2003), and deletion experiments in mice show that PDGFR ligands are playing a crucial role in the differentiation of early Leydig cells and in testis cord formation immediately following SRY expression (Brennan et al. 2003), with most evidence pointing to early Sertoli cells as a principal source of PDGF-A (Basciani et al. 2010). The key receptor PDGFR-A appears to be expressed on those coelomic epithelial cells destined to become interstitial Leydig cells of the developing testes as well as on interstitial cells already within the early testes. But it does not appear to be expressed in migrating mesonephric cells, nor in equivalent cells of the fetal adrenal gland (Brennan et al. 2003).

## **Vascular Endothelial Growth Factor (VEGF)**

VEGF-A is a secreted ligand which induces angiogenesis and the formation of endothelial-derived blood vessels. It is expressed at a high level in the interstitial cells of the very early fetal mouse testis and appears to be responsible for the incursion of the initial blood vessels migrating in from the coelomic surface (Cool et al. 2011). Importantly, the correct and timely expression of the VEGF system in the early testis is responsible for the early segmentation of the testis cords and its general morphology (Cool et al. 2011). Like VEGF-A in the mouse, a new VEGF variant, EG-VEGF, appears to be expressed in the early human fetal testis (from week 14) with a very similar pattern of expression (Samson et al. 2004), suggesting that the human fetal testis may develop in a similar manner.

## **Insulin-Like Growth Factor 1 (IGF1)**

It has been shown for the fetal rat that IGF1 is made locally by the mid-gestation fetal testis and at least in vitro in explant cultures can act on Leydig cells to increase testosterone production as well as to augment cell proliferation (Rouiller-Fabre et al. 1998).

## **Prostaglandins**

The role of prostaglandins in fetal testis development is relatively under-explored. However, it has recently been shown that prostaglandin D2 which appears to be synthesized by both somatic and germ cell compartments of the fetal testis, at least in rodents (Moniot et al. 2014), plays a role in germ cell mitotic arrest and repression of pluripotency, leading to the specific upregulation of the master transcription factor *Nanos2* and entry into the appropriate germ cell differentiation

pathway. Prostaglandins have gained importance by the finding in humans and rats that specific cyclooxygenase inhibitors, such as the analgesics paracetamol and indomethacin, can significantly impact on human fetal testis function during the critical masculinization window (Mazaud-Guittot et al. 2013; van den Driesche et al. 2015a).

### **Corticotropin Releasing Factor (CRH)**

While it is not known whether CRH is locally produced within the fetal testis, there is evidence to suggest that in the rodent and human fetus, substantial levels of CRH are being produced by the fetal hypothalamus-pituitary system and especially by the placenta, leading to significant levels in amniotic fluid. Why this is important for the fetal testis is that it has been shown that fetal Leydig cells express high levels of the CRH receptor, CRHR1, and that CRH can significantly induce in ex vivo fetal testes a number of steroidogenic genes (McDowell et al. 2012).

### **Anti-Mullerian Hormone (AMH)**

The anti-Mullerian hormone (AMH; also referred to as Mullerian inhibiting substance, MIS) is a member of the TGF $\beta$  family of peptide hormones and like these specifically activates a membrane-linked serine/threonine kinase receptor (Josso et al. 2005). It is specifically secreted as a 140 kD processed homodimer by the pre-Sertoli cells beginning at week 6 of human pregnancy shortly after SRY activation and the induction of SOX9 and SF1, both of which are involved in AMH gene expression (Shen et al. 1994). It has recently been shown that in second-trimester human male fetal serum, it predominantly circulates as the active precursor (the co-called pro-mature form) rather than as the shorter active C-terminal metabolite (Mamsen et al. 2015) as had been earlier assumed. Its main function in the male fetus is to induce the sex-specific involution of the Mullerian duct, which in females gives rise to the adult oviduct and uterus. AMH receptors on the Mullerian duct stop being expressed already by week 7 (Josso et al. 1993), illustrating the importance of temporal coordination in the endocrine control of fetal morphogenesis. Moreover, the AMH-induced involution of the Mullerian duct only occurs ipsilaterally (Nistal et al. 2015), emphasizing the significance of local hormone diffusion at this early stage of fetal development, rather than any generalized systemic effects, in spite of small fetal size. Whereas in humans AMH interacts with the type 2 AMH receptor (AMHR2) to achieve its anti-Mullerian effect, the homologous receptor does not appear to subserve this role in mice. Instead the related receptor BMPRIa fulfils this role (Jamin et al. 2002). Besides its anti-Mullerian function, fetal AMH inhibits the entry of spermatogonia into meiosis (Münsterberg and Lovell-Badge 1991) and may additionally modulate Leydig cell function (Rouiller-Fabre et al. 1998). There is also evidence to suggest that, at least in rodents, AMH can synergize with INSL3 and



androgens to influence gubernacular cells during testicular descent (Kubota et al. 2002).

### **Inhibins and Activins**

Activin is a homodimeric peptide hormone of the TGF $\beta$  family, and inhibin a related heterodimeric peptide which appears to function as a natural antagonist of activin at their common serine protein kinase-type membrane receptor. In each species, there is one activin gene product, activin A, and two inhibin gene products, inhibins A and B. They were first described from the adult pituitary and HPG axis, where especially inhibin B is now recognized as a major component of hormonal feedback to the anterior pituitary of Sertoli cell functional status. In the mid-gestation human fetal testis, both A and B subunits have been detected by immunohistochemistry in some, though not all interstitial Leydig cells, and in vitro their expression could be increased by hCG (Rabinovici et al. 1991; Majdic et al. 1997). The A subunit has also been detected in fetal Sertoli cells in rhesus macaques and in sheep (Rabinovici et al. 1991; Thomas et al. 1995; Jarred et al. 1999) and in one study also in the fetal human testis (Majdic et al. 1997). In the mid-gestation fetal horse, this system appears to be very active with much higher concentrations of inhibin measurable in fetal serum than in maternal serum and marked expression of inhibin and activin peptides in both interstitial and Sertoli cells (Tanaka et al. 2002). Within the pituitary, the activin/inhibin system is further modulated by the expression of an activin-binding protein called follistatin. Studies in both rodents and humans fail to find evidence for any follistatin expression in the fetal testis (Roberts 1997; Majdic et al. 1997). New results from the mouse now show that homodimeric activin produced by the fetal Leydig cells is essential for supporting Sertoli cell proliferation in mid-late gestation and is also responsible for maintaining tubule structure in that phase of pregnancy, since either conditional knockout of Leydig cell-specific activin A or of Sertoli cell expression of the downstream effector Smad4 leads to testis cord dysgenesis (Archambeault and Yao 2010). Taken together, these results point to an important role for activin, produced by fetal Leydig and/or Sertoli cells, in promoting appropriate testis cord geometry. In addition, it seems likely that where the HPG axis is already established in the fetus (see later), the inhibin/activin system may be involved in feedback regulation, though more research is needed to support this conjecture.

### **Pituitary Adenylyl Cyclase-Activating Polypeptide (PACAP)**

PACAP belongs to the secretin/VIP/glucagon family of hormones and was first identified as a hypothalamic peptide able to induce cAMP in pituitary cells via action on a cognate G protein-coupled receptor (GPCR) (Fahrenkrug 2006). Using rat fetal testis tissue and cells, it was shown that PACAP is also made locally within

the mid-gestation fetal testis and can positively influence steroidogenesis in fetal Leydig cells with considerable potency ( $10^{-18}$  M) (El-Gehani et al. 2000).

## Natriuretic Peptides

There are three so-called natriuretic peptides, ANP, BNP and CNP, which have been mostly characterized in the context of cardiovascular and brain physiology (Kuhn 2004). These peptides act through membrane-linked guanylyl cyclase receptors to induce an up-regulation of cGMP within target cells. ANP has been identified at moderate concentration in fetal rat plasma (Wei et al. 1987), and both BNP and CNP mRNA have been detected in mid-gestation rat fetal testes (El-Gehani et al. 2001). Moreover all three peptides are able to stimulate steroidogenesis by rat fetal Leydig cells in vitro (El-Gehani et al. 2001) implying an active natriuretic paracrine system within the fetal testis. No information is available on these peptides in regard to the human fetal testis.

Both fetal and adult-type Leydig cells appear to respond to a wide range of bioactive peptides, many of which are also synthesized by Leydig cells. This has been noted before and hypothesized to represent part of a “biochemical radar” system by which the developing cells can recognize and respond to their environment (Ivell et al. 1992).

## Insulin-Like Peptide 3 (INSL3)

INSL3 is a member of the relaxin family of peptide hormones and in most mammals (Ivell and Anand-Ivell 2009), including the human, interacts very specifically with a GPCR called RXFP2 (relaxin family peptide receptor 2; previously referred to as LGR8 or GREAT). Deletion of either INSL3 or its receptor in mice leads to bilateral cryptorchidism due to a failure of the first transabdominal phase of testicular descent (Nef and Parada 1999; Zimmermann et al. 1999), and a recessive inactivating mutation of the RXFP2 receptor in humans is also associated with cryptorchidism (Ferlin et al. 2009). INSL3 is produced in large amounts by the fetal Leydig cells with the earliest detection in human amniotic fluid at week 11 (Anand-Ivell unpublished). Levels in amniotic fluid are maximal between weeks 12 and 16 (Anand-Ivell et al. 2008), reflecting its role in testicular descent. This is achieved by interaction of the peptide with RXFP2 receptors on the mesenchymal cells of the gubernacular ligament. These thereby proliferate and expand the ligament causing this to anchor the testes in the inguinal region at a time when the fetus is elongating and other organ systems including the kidney and adrenal gland are moving relatively in an antero-dorsal direction. Androgens are also involved in this process, firstly to induce involution of the cranial suspensory ligament, which would otherwise retain the fetal testes in a more dorsal peri-renal location (Lee and Hutson 1999), and secondly because it is believed that the RXFP2 receptor may be under androgen control, at least in rodents (Emmen et al. 2000; Yuan et al. 2010).

INSL3 levels in human amniotic fluid decrease in the second half of pregnancy to almost undetectable amounts (Anand-Ivell et al. 2008). Whether this reflects the concentration in human fetal serum is not known, although measurements of INSL3 in cord blood at birth (Bay et al. 2007; Fénelichel et al. 2015) indicate that there may still be some low level expression. In other species (rat, bull, pig), where parallel data are available, amniotic fluid levels during gestation appear to represent about 10% of that in fetal blood (Anand-Ivell et al. 2011; Anand-Ivell and Ivell 2014; Vernunft et al. 2016). Surprisingly, a recent study in pigs has shown that INSL3 from male fetuses is able to move from one fetus to another within a single uterine horn and cause significant detection within female fetuses (Vernunft et al. 2016). This supports an earlier study in the bovine which showed that in mid-gestation INSL3 of male fetal origin was able to cross the placenta and enter the maternal bloodstream (Anand-Ivell et al. 2011).

Although cryptorchidism is a relatively common perinatal occurrence, very few cases can be attributed to a genetic disruption of the INSL3/RXFP2 system (Ferlin et al. 2009), although there is some evidence to suggest an impact of endocrine-disrupting agents by maternal exposure on INSL3 expression (see later).

---

## Endocrine Control of the Fetal Testis

Whereas it is well established that the pubertal and adult testes are extrinsically regulated by the hormones of the HPG axis, specifically the gonadotropins LH and FSH, this is less clear for fetal testes. For mice, it would appear that fetal Leydig cells require neither LH nor FSH from the fetal pituitary for their differentiation and expression during gestation (O'Shaughnessy and Fowler 2011, 2014; Teerds and Huhtaniemi 2015). To illustrate this, levels of the Leydig cell hormone INSL3 in the fetal Leydig cells at birth are identical in the *hpg* mouse, which is deficient in GnRH and hence pituitary gonadotropins, to those in normal wild-type mice (Balvers et al. 1998). Similar observations have been made in the LHR knockout mouse (Zhang et al. 2001). Instead, there is some evidence to suggest that, at least for some fetal Leydig cells in the mouse, these can respond to the adrenocorticotropic hormone ACTH (O'Shaughnessy et al. 2003), again supporting the possible common origin of such cells with the steroidogenic cells of the fetal adrenal gland.

For the human fetus, all evidence supports the notion that the fetal testis is extrinsically regulated by LH and probably FSH from the fetal pituitary from mid gestation onward (O'Shaughnessy and Fowler 2011). Prior to that time (weeks 1–20), the trophoblast cells of the placenta are generating large amounts of the gonadotropin hCG, and inspection of testes from anencephalic fetuses, which lacks both hypothalamus and pituitary, appears to indicate that these tissues are not required for normal testis differentiation up to mid pregnancy (Baker and Scrimgeour 1980; Molsberry et al. 1982; Teerds and Huhtaniemi 2015). It appears therefore that for the human fetus, hCG is sufficient and essential to drive most testis differentiation *in vivo* up to mid gestation. Similarly, using human fetal testis explant cultures (N'Tumba-Byn et al. 2012), or tissues xenografted into castrated mice

(Mitchell et al. 2013), shows that the early human fetal testis requires either LH or hCG for normal development and differentiation, at least in regard to steroidogenesis. These experimental observations are supported by clinical studies of men with an inactivating mutation in the LH beta subunit. Such men have more or less normal external genitalia, and the resultant hypogonadotropic hypogonadism can be partially rescued by testosterone and/or hCG therapy, leading to partial spermatogenesis (Valdes-Socin et al. 2004). This implies that arrest was at a prepubertal state and that LH is not absolutely required until puberty. In contrast individuals with an inactivating mutation of the LH/CG receptor exhibit complete genital feminization, implying a need for receptor signaling already at an early stage in fetal development (Richter-Unruh et al. 2005). There is little specific information, however, regarding the role of fetal FSH in human testis differentiation, although there is some suggestion from mice that FSH may be required for determining Sertoli cell proliferation and hence fetal testis size (Migrenne et al. 2012). Research in sheep suggests that the fetal pituitary first expresses LH and sometime later FSH (Brooks et al. 1995).

---

## Importance of Feedback and Feedforward Regulation

Study of the endocrinology and development of the fetal testis firstly indicates that there is an extreme precision in both temporal and spatial differentiation of the component cells and tissues during pregnancy, implying a significant orchestration of the processes involved. Moreover, perturbation of this developmental trajectory can lead to marked disorders of sexual development. And yet measurement of hormones in different fetal compartments and at different times in gestation suggests that there is considerable quantitative variation and overlap between male and female fetuses, implying that precision in hormone synthesis may not be the chief factor responsible. It seems likely that several factors contribute together to ensure the necessary developmental precision and lead to the so-called male programming window (Scott et al. 2008). Firstly, early gonadal development is distinguished by the expression of reciprocal, mutually inhibiting feedforward loops (Fig. 2; Kim and Capel 2006). So, for example, the expression by the male fetus of SOX9-induced FGF9 drives more SOX9 production, and in turn the transcription factor SF-1, while at the same time it inhibits Wnt4, whereas in the female fetus reduced FGF9 allows the increased expression of Wnt4 and in turn encourages the expression of DAX1, which then inhibits any possible expression of SF-1 activated genes (Jordan et al. 2001; Kim and Capel 2006). Secondly, it seems likely that the precise timing of hormone receptor expression in specific cell types and not others, to coincide with the initial expression of the hormone, is playing a critical role, for example, the androgen-dependent expression of RXFP2 in gubernacular cells in the first trimester. Thirdly, we should not forget that testis development is associated within the fetus with largely irreversible morphological events, e.g., loss of the Mullerian duct and cranial suspensory ligament, or transabdominal testis “descent” to the inguinal region.

Finally, many of these processes, at least in the early fetus, are probably localized events, limited by rates of paracrine hormone diffusion rather than by global fetal hormone concentration, as illustrated by the ipsilateral nature of Mullerian duct involution (Nistal et al. 2015). This might explain, for example, why the majority of cases of cryptorchidism are unilateral, rather than bilateral; while differential hormone expression might be playing a role here, it is more likely that asynchrony in an irreversible morphological process allowing a unilateral interposition of some disrupting ligament or tissue could be involved.

---

## Environmental Endocrine Disruption of Fetal Development

There is increasing evidence suggesting that important hormonally regulated events in early gestation may be disrupted by maternal exposure to chemical substances in our environment (Gore et al. 2015). These come from a variety of sources including common additives to cosmetics and household products, pesticides, fire retardants, some plastics, and common city pollutants, besides workplace exposures. It is believed that even very low environmental concentrations, especially if additive as mixtures, may interfere with endogenous hormones, transcription factors, and enzymes which are part of the natural machinery precisely regulating the development of the early fetus. Some of these substances evidently impact on the development of the male reproductive system, leading to what in humans has been described as a testicular dysgenesis syndrome (TDS; Skakkebaek et al. 2016). The reason for this focus on male reproduction is simply that the testes are differentiating at a time in early pregnancy when the fetus is particularly vulnerable to maternal factors and that the consequences of such endocrine disruption are easily visible and quantifiable, even in the neonate (cryptorchidism, hypospadias, reduced anogenital distance) or young adult (testis carcinoma, reduced sperm counts). Many such substances, such as phthalates, are referred to as antiandrogens, not because they directly interact with androgen signaling, but by disrupting Leydig cell differentiation, they can temporarily cause a phenotypic androgen deficiency during a critical programming window (Scott et al. 2009). Similarly, interfering with early Sertoli cell development and proliferation can impact on gonocyte and stem cell physiology.

Environmental endocrine disruption can be very subtle. It can impact on other fetal organ systems, such as the thyroid and the brain (Gore et al. 2015) with less easily quantifiable end-points. Moreover, conventional toxicity testing paradigms using cell systems or laboratory animals may be inappropriate, because of species specificity of response and the temporal complexity of some developmental responses. Certainly, recent epidemiological studies in large human cohorts are suggesting that substances may be impacting on the male fetal reproductive system at much lower concentrations than previously considered problematic (Marsee et al. 2006; Jensen et al. 2015; Skakkebaek et al. 2016). Finally, in addition to the substance classes listed above, preliminary evidence is also indicating that some simple pharmaceuticals, previously considered harmless to the fetus, such as paracetamol, may also disrupt appropriate fetal male development (Mazaud-Guittot et al.

2013; van den Driesche et al. 2015a), presumably by interfering with the testis prostanoid system, though this remains to be proven.

The notion of endocrine-disrupting chemicals in the environment is not without its critics. Apart from the obvious conflicting interests attached to one or other contender, part of the problem is that experimental animal models often require high doses of a chemical to see effects within ethically acceptable numbers of animals. Yet for exposed humans, we are often referring to a significant incidence of a particular condition as low as 0.01% of the population (e.g., hypospadias), a penetrance which cannot be reproduced in the laboratory. Thus large epidemiological studies are often the only source of evidence. What is inescapable are the considerable secular changes in many human parameters, including reproductive ones, for which currently environmental or lifestyle factors offer the only explanation. One of the more convincing recent studies assessed a real-life maternal exposure of sheep grazing on pasture fertilized with conventional sewage sludge (with its contaminating chemicals) or with equivalent inorganic fertilizer. The male offspring of such exposed sheep indicated significantly impaired male reproductive function due to the low level contamination of the sewage sludge (Bellingham et al. 2012).

---

## Concluding Remarks

The fetal testis is one of the earliest organ systems to develop to a high degree of complexity within the human fetus. It is also a system which differentiates both spatially as well as temporally, with highly coordinated gross morphological changes supported by specific hormone systems. Early in gestation, shortly after sex determination, the fetal testis is in very close proximity to the growing adrenal gland, and since diffusion kinetics are likely to be more relevant at this time than later in gestation, adrenal endocrinology should not be ignored during this early programming window. Later in gestation, when all organ systems have grown and spatially diverged, when skin permeability has been reduced by keratinization, and when the circulatory system is more established, then the fetal testes can be considered more independently.

Precision in fetal testis endocrinology and its programming effects can best be explained by considering both the timing of first hormone expression, the regulation of specific receptor expression, and especially the rapidly changing spatial coordination of hormone source and target. The often drastic and irreversible nature of downstream hormone actions, particularly morphological changes (loss of ducts and ligaments, testicular descent), lends weight to the notion of a precise male programming window.

However, it should be noted that there may be large differences in both endocrinology and development between species. Whereas in the human fetus, testis development is initiated and mostly completed in the first trimester, the equivalent time in rodents or dogs is much later, in late gestation and the neonatal period (O'Shaughnessy and Fowler 2011; Anand-Ivell and Ivell 2014). Consequently, the

male programming window in the human fetus is quite early (weeks 6–20), unlike, for example, in the rat (GD 13–21). Some endocrine parameters are also very different. The rodent fetal testis appears to develop more or less autonomously, whereas the human fetal testis is more dependent on gonadotropin (especially hCG) input during pregnancy. The response of the fetal testis to environmental endocrine disruptors, such as phthalates, may also be different between humans and rodents (Hallmark et al. 2007; Habert et al. 2014; van den Driesche et al. 2015b). This knowledge is important in providing essential context by which to judge the effects of exogenous factors on testis development and its pathology.

---

## References

- Anand-Ivell R, Ivell R. Insulin-like factor 3 as a monitor of endocrine disruption. *Reproduction*. 2014;147:R87–95.
- Anand-Ivell R, Ivell R, Driscoll DA, Manson J. INSL3 Levels in amniotic fluid from human male fetuses. *Hum Reprod*. 2008;23:1180–6.
- Anand-Ivell R, Hiendleder S, Viñoles C, Martin GB, Fitzsimmons C, Eurich A, Hafen B, Ivell R. INSL3 in the ruminant: a powerful indicator of gender- and genetic-specific fetomaternal dialogue. *PLoS One*. 2011;6:e19821.
- Archambeault DR, Yao HH. Activin A, a product of fetal Leydig cells, is a unique paracrine regulator of Sertoli cell proliferation and fetal testis cord expansion. *Proc Natl Acad Sci USA*. 2010;107:10526–31.
- Auchus RJ, Miller WL. Congenital adrenal hyperplasia – more dogma bites the dust. *J Clin Endocrinol Metab*. 2012;97:772–5.
- Baker TG, Scrimgeour JB. Development of the gonad in normal and anencephalic human fetuses. *J Reprod Fertil*. 1980;60:193–9.
- Balvers M, Spiess AN, Domagalski R, Hunt N, Kilic E, Mukhopadhyay AK, Hanks E, Charlton HM, Ivell R. Relaxin like factor (RLF) expression as a marker of differentiation in the mouse testis and ovary. *Endocrinology*. 1998;139:2960–70.
- Bao AM, Swaab DF. Sexual differentiation of the human brain: relation to gender identity, sexual orientation and neuropsychiatric disorders. *Front Neuroendocrinol*. 2011;32:214–26.
- Basciani S, Mariani S, Arizzi M, Ullisse S, Rucci N, Jannini EA, Della Rocca C, Manicone A, Carani C, Spera G, Gnassi L. Expression of platelet-derived growth factor-A (PDGF-A), PDGF-B and PDGF receptor- alpha and -beta during human testicular development and disease. *J Clin Endocrinol Metab*. 2002;87:2310–9.
- Basciani S, Mariani S, Spera G, Gnassi L. Role of platelet-derived growth factors in the testis. *Endocr Rev*. 2010;31:916–39.
- Bay K, Virtanen HE, Hartung S, Ivell R, Main KM, Skakkebaek NE, Andersson AM, The Nordic Cryptorchidism Study Group, Toppari J. Insulin-like Factor 3 levels in cord blood and serum from children: effects of age, postnatal hypothalamic-pituitary-gonadal axis activation, and cryptorchidism. *J Clin Endocrinol Metab*. 2007;92:4020–7.
- Bellingham M, McKinnell C, Fowler PA, Amezaga MR, Zhang Z, Rhind SM, Cotinot C, Mandon-Pepin B, Evans NP, Sharpe RM. Foetal and post-natal exposure of sheep to sewage sludge chemicals disrupts sperm production in adulthood in a subset of animals. *Int J Androl*. 2012;35:317–29.
- Biason-Lauber A, Miller WL, Pandey AV, Flück CE. Of marsupials and men: “Backdoor” dihydrotestosterone synthesis in male sexual differentiation. *Mol Cell Endocrinol*. 2013;371:124–32.
- Brennan J, Tilmann C, Capel B. Pdgfr- $\alpha$  mediates testis cord organization and fetal Leydig cell development in the XY gonad. *Genes Dev*. 2003;17:800–10.

- Brooks AN, McNeilly A, Thomas GB. Role of GnRH in the ontogeny and regulation of the fetal hypothalamo-pituitary-gonadal axis in sheep. *J Reprod Fertil Suppl.* 1995;49:163–75.
- Carney CM, Muszynski JL, Strotman LN, Lewis SR, O'Connell RL, Beebe DJ, Theberge AB, Jorgensen JS. Cellular microenvironment dictates androgen production by murine fetal Leydig cells in primary culture. *Biol Reprod.* 2014;91:85.
- Carson D, Okuno A, Lee PA, Stetten G, Didolkar SM, Migeon C. Amniotic fluid steroid levels. *Am J Dis Child.* 1982;136:218–22.
- Cederroth CR, Schaad O, Descombes P, Chambon P, Vassalli JD, Nef S. Estrogen receptor alpha is a major contributor to estrogen-mediated fetal testis dysgenesis and cryptorchidism. *Endocrinology.* 2007;148:5507–19.
- Cool J, DeFalco TJ, Capel B. Vascular-mesenchymal cross-talk through Vegf and Pdgf drives organ patterning. *Proc Natl Acad Sci U S A.* 2011;108:167–72.
- Delbès G, Levacher C, Duquenne C, Racine C, Pakarinen P, Habert R. Endogenous estrogens inhibit mouse fetal Leydig cell development via estrogen receptor alpha. *Endocrinology.* 2005;146:2454–61.
- Diczfalusy E. Endocrine functions of the human fetoplacental unit. *Fed Proc.* 1964;23:791–8.
- El-Gehani F, Tena-Sempere M, Huhtaniemi I. Evidence that pituitary adenylate cyclase-activating polypeptide is a potent regulator of fetal rat testicular steroidogenesis. *Biol Reprod.* 2000;63:1482–9.
- El-Gehani F, Tena-Sempere M, Ruskoaho H, Huhtaniemi I. Matriuretic peptides stimulate steroidogenesis in the fetal rat testis. *Biol Reprod.* 2001;65:595–600.
- Emmen JM, McLuskey A, Adham IM, Engel W, Grootegoed JA, Brinkmann AO. Hormonal control of gubernaculum development during testis descent: gubernaculum outgrowth in vitro requires both insulin-like factor and androgen. *Endocrinology.* 2000;141:4720–7.
- Fahrenkrug J. PACAP – a multifaceted neuropeptide. *Chronobiol Int.* 2006;23:53–61.
- Fénichel P, Lahlou N, Coquillard P, Panaïa-Ferrari P, Wagner-Mahler K, Brucker-Davis F. Cord blood insulin-like peptide 3 (INSL3) but not testosterone is reduced in idiopathic cryptorchidism. *Clin Endocrinol.* 2015;82:242–7.
- Ferlin A, Zuccarello D, Garolla A, Selice R, Vinanzi C, Ganz F, Zanon GF, Zuccarello B, Foresta C. Mutations in INSL3 and RXFP2 genes in cryptorchid boys. *Ann N Y Acad Sci.* 2009;1160:213–4.
- Flück CE, Pandey AV. Steroidogenesis of the testis – new genes and pathways. *Ann Endocrinol (Paris).* 2014;75:40–7.
- Forest MG, De Peretti E, Lecoq A, Cadillon E, Zabot MT, Thoulon JM. Concentration of 14 steroid hormones in human amniotic fluid of midpregnancy. *J Clin Endocrinol Metab.* 1980;51:816–22.
- Fowler PA, Cassie S, Rhind SM, Brewer MJ, Collinson JM, Lea RG, Baker PJ, Bhattacharya S, O'Shaughnessy PJ. Maternal smoking during pregnancy specifically reduces human fetal desert hedgehog gene expression during testis development. *J Clin Endocrinol Metab.* 2008;93:619–26.
- Fukami M, Homma K, Hasegawa T, Ogata T. Backdoor pathway for dihydrotestosterone biosynthesis: implications for normal and abnormal human sex development. *Dev Dyn.* 2013;242:320–9.
- Gaskell TL, Robinson LL, Groome NP, Anderson RA, Saunders PT. Differential expression of two estrogen receptor beta isoforms in the human fetal testis during the second trimester of pregnancy. *J Clin Endocrinol Metab.* 2003;88:424–32.
- Gore AC, Chappell VA, Fenton SE, Flaws JA, Nadal A, Prins GS, Toppari J, Zoeller RT. EDC-2: The Endocrine Society's Second Scientific Statement on Endocrine-Disrupting Chemicals. *Endocr Rev.* 2015;36:E1–E150.
- Goto M, Piper Hanley K, Marcos J, Wood PJ, Wright S, Postle AD, Cameron IT, Mason JI, Wilson DI, Hanley NA. In humans, early cortisol biosynthesis provides a mechanism to safeguard female sexual development. *J Clin Invest.* 2006;116:953–60.
- Habert R, Livera G, Rouiller-Fabre V. Man is not a big rat: concerns with traditional human risk assessment of phthalates based on their anti-androgenic effects observed in the rat foetus. *Basic Clin Androl.* 2014;24:14.
- Hallmark N, Walker M, McKinnell C, Mahood IK, Scott H, Bayne R, Coutts S, Anderson RA, Greig I, Morris K, Sharpe RM. Effects of monobutyl and di(n-butyl) phthalate in vitro on



- steroidogenesis and Leydig cell aggregation in fetal testis explants from the rat: comparison with effects in vivo in the fetal rat and neonatal marmoset and in vitro in the human. *Environ Health Perspect.* 2007;115:390–6.
- Hanley NA, Arlt W. The human fetal adrenal cortex and the window of sexual differentiation. *Trends Endocrinol Metab.* 2006;17:391–7.
- Hayashi S, Fuzukawa Y, Rodriguez-Vazquez JF, Cho BH, Verdugo-Lopez S, Murukami G, Nakano T. Pleuroperitoneal canal closure and the fetal adrenal gland. *Anat Rec.* 2011;294:633–44.
- Ishimoto H, Jaffe RB. Development and function of the human fetal adrenal cortex: a key component in the fetoplacental unit. *Endocr Rev.* 2011;32:317–55.
- Ivell R, Anand-Ivell R. The biology of Insulin-like Factor 3 (INSL3) in human reproduction. *Hum Reprod Update.* 2009;15:463–76.
- Ivell R, Hunt N, Hardy M, Nicholson H, Pickering B. Vasopressin biosynthesis in rodent Leydig cells. *Mol Cell Endocrinol.* 1992;89:59–66.
- Jamin SP, Arango NA, Mishina Y, Hanks MC, Behringer RR. Requirement of *Bmpr1a* for Mullerian duct regression during male sexual development. *Nat Genet.* 2002;32:408–10.
- Jarred RA, Cancilla B, Richards M, Groome NP, McNatty KP, Risbridger GP. Differential localization of inhibin subunit proteins in the ovine testis during fetal gonadal development. *Endocrinology.* 1999;140:979–86.
- Jensen MS, Anand-Ivell R, Nørgaard-Pedersen B, BAG J, Bonde JP, Hougaard DM, Cohen A, Lindh CH, Ivell R, Thulstrup AM, Toft G. Second trimester amniotic fluid DEHP and DiNP metabolite levels: associations with fetal Leydig cell function, cryptorchidism and hypospadias. *Epidemiology.* 2015;26:91–9.
- Jordan BK, Mohammed M, Ching ST, Delot E, Chen XN, Dewing P, Swain A, Rai PN, Elejalde BR, Vilain E. Up-regulation of WNT-4 signaling and dosage-sensitive sex reversal in humans. *Am J Hum Genet.* 2001;68:1102–9.
- Josso N, Lamarre I, Picard JY, Berta P, Davies N, Morichon N, Peschanski M, Jeny R. Anti-müllerian hormone in early human development. *Early Hum Dev.* 1993;33:91–9.
- Josso N, Belville C, di Clemente N, Picard JY. AMH and AMH receptor defects in persistent Müllerian duct syndrome. *Hum Reprod Update.* 2005;11:351–6.
- Kamrath C, Hochberg Z, Hartmann MF, Remer T, Wudy SA. Increased activation of the alternative “backdoor” pathway in patients with 21-hydroxylase deficiency: evidence from urinary steroid hormone analysis. *J Clin Endocrinol Metab.* 2012;97:E367–75.
- Kim Y, Capel B. Balancing the bipotential gonad between alternative organ fates: a new perspective on an old problem. *Dev Dyn.* 2006;235:2292–300.
- Klonisch T, Fowler PA, Hombach-Klonisch S. Molecular and genetic regulation of testis descent and external genitalia development. *Dev Biol.* 2004;270:1–18.
- Kubota Y, Temelcos C, Bathgate RA, Smith KJ, Scott D, Zhao C, Hutson JM. The role of insulin 3, testosterone, Müllerian inhibiting substance and relaxin in rat gubernacular growth. *Mol Hum Reprod.* 2002;8:900–5.
- Kuhn M. Molecular physiology of natriuretic peptide signalling. *Basic Res Cardiol.* 2004;99:76–82.
- Lassurguère J, Livera G, Habert R, Jégou B. Time- and dose-related effects of estradiol and diethylstilbestrol on the morphology and function of the fetal rat testis in culture. *Toxicol Sci.* 2003;73:160–9.
- Lee SM, Hutson JM. Effect of androgens on the cranial suspensory ligament and ovarian position. *Anat Rec.* 1999;255:306–15.
- Lykkesfeldt G, Bennett P, Lykkesfeldt AE, Micic S, Rorth M, Skakkebaek NE, Svenstrup B. Testis cancer. Ichthyosis constitutes a significant risk factor. *Cancer.* 1991;67:730–4.
- Majdic G, McNeilly AS, Sharpe RM, Evans LR, Groome NP, Saunders PT. Testicular expression of inhibin and activating subunits and follistatin in the rat and human fetus and neonate and during postnatal development in the rat. *Endocrinology.* 1997;138:2136–47.
- Mamsen LS, Petersen TS, Jeppesen JV, Mollgard K, Grondahl ML, Larsen A, Ernst E, Oxvig C, Kumar A, Kalra B, Andersen CY. Proteolytic processing of anti-Müllerian hormone differs between human fetal testes and adult ovaries. *Mol Hum Reprod.* 2015;21:571–82.

- Marsee K, Woodruff TJ, Axelrad DA, Calafat AM, Swan SH. Estimated daily phthalate exposures in a population of mothers of male infants exhibiting reduced anogenital distance. *Environ Health Perspect*. 2006;114:805–9.
- Mazaud-Guittot S, Nicolas Nicolaz C, Desdoits-Lethimonier C, Coiffec I, Ben Maamar M, Balaguier P, Kristensen DM, Chevrier C, Lavoue V, Poulain P, Dejuq-Rainsford N, Jegou B. Paracetamol, aspirin, and indomethacin induce endocrine disturbances in the human fetal testis capable of interfering with testicular descent. *J Clin Endocrinol Metab*. 2013;98:1757–67.
- McDowell EN, Kisielewski AE, Pike JW, Franco HL, Yao HH, Johnson KJ. A transcriptome-wide screen for mRNAs enriched in fetal Leydig cells: CRHR1 agonism stimulates rat and mouse fetal testis steroidogenesis. *PLoS One*. 2012;7:e47359.
- Mesiano S, Jaffe RB. Developmental and functional biology of the primate fetal adrenal cortex. *Endocr Rev*. 1997;18:378–403.
- Migrenne S, Moreau E, Pakarinen P, Dierich A, Merlet J, Habert R, Racine C. Mouse testis development and function are differently regulated by follicle-stimulating hormone receptors signaling during fetal and prepubertal life. *PLoS One*. 2012;7:e53257.
- Miller WL, Auchus RJ. The molecular biology, biochemistry, and physiology of human steroidogenesis and its disorders. *Endocr Rev*. 2011;32:1–151.
- Miller KMM, Al-Rayyan N, Ivanova MM, Mattingly KA, Ripp SL, Klinge CM, Prough RA. DHEA metabolites activate estrogen receptors alpha and beta. *Steroids*. 2013;78:15–25.
- Mitchell RT, Sharpe RM, Anderson RA, McKinnell C, Macpherson S, Smith LB, Wallace WH, Kelnar CJ, van den Driesche S. Diethylstilboestrol exposure does not reduce testosterone production in human fetal testis xenografts. *PLoS One*. 2013;8:e61726.
- Molsberry RL, Carr BR, Mendelson CR, Simpson ER. Human chorionic gonadotropin binding to human fetal testes as a function of gestational age. *J Clin Endocrinol Metab*. 1982;55:791–4.
- Moniot B, Ujjan S, Champagne J, Hirai H, Aritake K, Nagata K, Dubois E, Nidelet S, Nakamura M, Urade Y, Poulat F, Boizet-Bonhoure B. Prostaglandin D2 acts through the Dp2 receptor to influence male germ cell differentiation in the foetal mouse testis. *Development*. 2014;141:3561–71.
- Münsterberg A, Lovell-Badge R. Expression of the mouse anti-müllerian hormone gene suggests a role in both male and female sexual differentiation. *Development*. 1991;113:613–24.
- N'Tumba-Byn T, Moison D, Lacroix M, Lecureuil C, Lesage L, Prud'homme SM, Pozzi-Gaudin S, Frydman R, Benachi A, Livera G, Rouiller-Fabre V, Habert R. Differential effects of bisphenol A and diethylstilbestrol on human, rat and mouse fetal leydig cell function. *PLoS One*. 2012;7:e51579.
- Nef S, Parada LF. Cryptorchidism in mice mutant for *Insl3*. *Nat Genet*. 1999;22:295–9.
- Nistal M, Paniagua R, Gonzalez-Peramato P, Reyes-Mugica M. Perspectives in pediatric pathology, Chapter 1. Normal development of testicular structures: from the bipotential gonad to the fetal testis. *Pediatr Dev Pathol*. 2015;18:88–102.
- O'Shaughnessy PJ, Fowler PA. Endocrinology of the mammalian testis. *Reproduction*. 2011;141:37–46.
- O'Shaughnessy PJ, Fowler PA. Development of the human fetal testis. *Ann Endocrinol (Paris)*. 2014;75:48–53.
- O'Shaughnessy PJ, Fleming LM, Jackson G, Hochgeschwender U, Reed P, Baker PJ. Adrenocorticotropic hormone directly stimulates testosterone production by the fetal and neonatal mouse testis. *Endocrinology*. 2003;144:3279–84.
- Pang S, Levine LS, Cederqvist LL, Fuentes M, Riccardi VM, Holcombe JH, Nitowsky HM, Sachs G, Anderson CE, Duchon MA, Owens R, Merkatz I, New MI. Amniotic fluid concentrations of delta 5 and delta 4 steroids in fetuses with congenital adrenal hyperplasia due to 21 hydroxylase deficiency and in anencephalic fetuses. *J Clin Endocrinol Metab*. 1980;51:223–9.
- Rabinovici J, Goldsmith PC, Roberts VJ, Vaughan J, Vale W, Jaffe RB. Localization and secretion of inhibin/activating subunits in the human and subhuman primate fetal gonads. *J Clin Endocrinol Metab*. 1991;73:1141–9.

- Rainey WE, Rehman KS, Carr BR. The human fetal adrenal: making adrenal androgens for placental estrogens. *Semin Reprod Med.* 2004;22:327–36.
- Richter-Unruh A, Korsch E, Hjiort O, Holterhus PM, Themmen AP, Wudy SA. Novel insertion frameshift mutation of the LH receptor gene: problematic clinical distinction of Leydig cell hypoplasia from enzyme defects primarily affecting testosterone biosynthesis. *Eur J Endocrinol.* 2005;152:255–9.
- Roberts VJ. Tissue-specific expression of inhibin/activin subunit and follistatin mRNAs in mid- to late-gestational age human fetal testis and epididymis. *Endocrine.* 1997;6:85–90.
- Robinson JD, Judd HL, Young PE, Jones OW, Yen S. Amniotic fluid androgens and estrogens in midgestation. *J Clin Endocrinol Metab.* 1977;45:755–756.
- Rodeck CH, Gill D, Rosenberg DA, Collins WP. Testosterone levels in midtrimester maternal and fetal plasma and amniotic fluid. *Prenat Diagn.* 1985;5:175–81.
- Rouiller-Fabre V, Carmona S, Merhi RA, Cate R, Habert R, Vigier B. Effect of anti-Mullerian hormone on Sertoli and Leydig cell functions in fetal and immature rats. *Endocrinology.* 1998;139:1213–20.
- Samson M, Peale Jr FV, Frantz G, Rioux-Leclercq N, Rajpert-De Meyts E, Ferrara N. Human endocrine gland-derived vascular endothelial growth factor: expression early in development and in Leydig cell tumors suggests roles in normal and pathological testis angiogenesis. *J Clin Endocrinol Metab.* 2004;89:4078–88.
- Scott HM, Hutchison GR, Jobling MS, McKinnell C, Drake AJ, Sharpe RM. Relationship between androgen action in the “male programming window,” fetal sertoli cell number, and adult testis size in the rat. *Endocrinology.* 2008;149:5280–7.
- Scott HM, Mason JI, Sharpe RM. Steroidogenesis in the fetal testis and its susceptibility to disruption by exogenous compounds. *Endocr Rev.* 2009;30:883–925.
- Shapiro E, Huang H, Masch RJ, McFadden DE, Wu XR, Ostrer H. Immunolocalization of androgen receptor and estrogen receptors alpha and beta in human fetal testis and epididymis. *J Urol.* 2005;174:1695–8.
- Shen WH, Moore CC, Ikeda Y, Parker KL, Ingraham HA. Nuclear receptor steroidogenic factor 1 regulates the müllerian inhibiting substance gene: a link to the sex determination cascade. *Cell.* 1994;77:651–61.
- Skakkebaek NE, Rajpert-De Meyts E, Buck Louis GM, Toppari J, Andersson AM, Eisenberg ML, Kold Jensen T, Jorgensen N, Swan SH, Sapra KJ, Ziebe S, Proskorn L, Juul A. Male reproductive disorders and fertility trends: influences of environment and genetic susceptibility. *Physiol Rev.* 2016;96:55–97.
- Speiser PW, White PC. Congenital adrenal hyperplasia. *N Engl J Med.* 2003;349:776–88.
- Tanaka Y, Taniyama H, Tsunoda N, Shinbo H, Nagamine N, Nambo Y, Nagata SI, Watanabe G, Herath CB, Groome NP, Taya K. The testis as a major source of circulating inhibins in the male equine fetus during the second half of gestation. *J Androl.* 2002;23:229–36.
- Tapanainen J, Kellokumpu-Lehtinen P, Pelliniemi L, Huhtaniemi I. Age-related changes in endogenous steroids of human fetal testis during early and midpregnancy. *J Clin Endocrinol Metab.* 1981;52:98–102.
- Tapanainen J, Voutilainen R, Jaffe RB. Low aromatase activity and gene expression in human fetal testes. *J Steroid Biochem.* 1989;33:7–11.
- Teerds KJ, Huhtaniemi IT. Morphological and functional maturation of Leydig cells: from rodent models to primates. *Hum Reprod Update.* 2015;21:310–28.
- Thomas GB, Davidson EJ, Engelhardt H, Baird DT, McNeilly AS, Brooks AN. Expression of mRNA and immunocytochemical localization of inhibin  $\alpha$ - and inhibin  $\beta_A$ -subunits in the fetal sheep testis. *J Endocrinol.* 1995;145:35–42.
- Traupe H, Happle R. Clinical spectrum of steroid sulfatase deficiency: X-linked recessive ichthyosis, birth complications and cryptorchidism. *Eur J Pediatr.* 1983;140:19–21.
- Valdes-Socin H, Salvi R, Daly AF, Gaillard RC, Quatresooz P, Tebeu PM, Pralong FP, Beckers A. Hypogonadism in a patient with a mutation in the luteinizing hormone beta-subunit gene. *N Engl J Med.* 2004;351:2619–5.

- van den Driesche S, Macdonald J, Anderson RA, Johnston ZC, Chetty T, Smith LB, McKinnell C, Dean A, Homer NZ, Jorgensen A, Camacho-Moll ME, Sharpe RM, Mitchell RT. Prolonged exposure to acetaminophen reduces testosterone production by the human fetal testis in a xenograft model. *Sci Transl Med*. 2015a;7:288ra80.
- van den Driesche S, McKinnell C, Calarrão A, Kennedy L, Hutchison GR, Hrabalkova L, Jobling MS, Macpherson S, Anderson RA, Sharpe RM, Mitchell RT. Comparative effects of di(n-butyl) phthalate exposure on fetal germ cell development in the rat and in human fetal testis xenografts. *Environ Health Perspect*. 2015b;123:223–30.
- Vernunft A, Ivell R, Heng K, Anand-Ivell R. The male fetal biomarker INSL3 reveals substantial hormone exchange between fetuses in early pig gestation. *PLoS One*. 2016;11:e0152689.
- Voutilainen R, Miller WL. Developmental expression of genes for the steroidogenic enzymes P450scc (20,22-desmolase), P450c17 (17 alpha-hydroxylase/17,20-lyase), and P450c21 (21-hydroxylase) in the human fetus. *J Clin Endocrinol Metab*. 1986;63:1145–50.
- Wei YF, Rodi CP, Day ML, Wiegand RC, Needleman LD, Cole BR, Needleman P. Developmental changes in the rat atriopeptin hormonal system. *J Clin Invest*. 1987;79:1325–9.
- Welsh M, Suzuki H, Yamada G. The masculinization programming window. *Endocr Dev*. 2014;27:17–27.
- White PC. Ontogeny of adrenal steroid biosynthesis: why girls will be girls. *J Clin Invest*. 2006;116:872–4.
- Wilson JD, George FW, Griffin JE. The hormonal control of sexual development. *Science*. 1981;211:1278–84.
- Wudy SA, Dörr HG, Solleder C, Djalali M, Homoki J. Profiling steroid hormones in amniotic fluid of midpregnancy by routine stable isotope dilution/gas chromatography-mass spectrometry: reference values and concentrations in fetuses at risk for 21-hydroxylase deficiency. *J Clin Endocrinol Metab*. 1999;84:2724–8.
- Yuan FP, Li X, Lin J, Schwabe C, Büllsbach EE, Rao CV, Lei ZM. The role of RXFP2 in mediating androgen-induced inguinoscrotal testis descent in LH receptor knockout mice. *Reproduction*. 2010;139:759–69.
- Zhang FP, Poutanen M, Wilbertz J, Huhtaniemi I. Normal prenatal but arrested postnatal sexual development of luteinizing hormone receptor knockout (LuRKO) mice. *Mol Endocrinol*. 2001;15:172–183.
- Zimmermann S, Steding G, Emmen JM, Brinkmann AO, Nayernia K, Holstein AF, et al. Targeted disruption of the *Insl3* gene causes bilateral cryptorchidism. *Mol Endocrinol*. 1999;13:681–91.

Girolamo Mattioli, Pietro Lazzeroni, Irene Paraboschi,  
Nataschia Di Iorgi, Flavia Napoli, and Mohamad Maghnie

### Abstract

Fetal development of reproductive system is a complex process which can be divided in two main stages: sex determination and sexual differentiation. During sex determination, the bipotential gonadal primordium develops – according to chromosomal sex – into either testis or ovary. Sexual differentiation subsequently involves fetal gonadal production of peptide and steroid hormones that are responsible for male or female phenotype.

This process occurs during a brief window of time and is based on sex-specific expression of transcription factors and signaling molecules that in turn drive cell fate commitment by regulating migration, proliferation, and patterning of somatic and germ cells into testis and ovary.

Pathway to maleness relies on mechanisms that have recently been shown to both promote testis development and simultaneously antagonize ovarian fate. Our understanding of these pathways has grown over the past few years, and novel players involved in sexual development, such as epigenetic regulators, have arisen.

Enlightenment of these networks is critical for a better characterization of conditions such as disorders of sex development (DSD), infertility, and gonadal cancer.

---

G. Mattioli • I. Paraboschi

Department of Surgery, Istituto Giannina Gaslini, University of Genova, Genova, Italy  
e-mail: [girolamomattioli@gaslini.org](mailto:girolamomattioli@gaslini.org); [girolamomattioli@ospedale-gaslini.ge.it](mailto:girolamomattioli@ospedale-gaslini.ge.it);  
[irene.paraboschi@hotmail.com](mailto:irene.paraboschi@hotmail.com)

P. Lazzeroni • N. Di Iorgi • F. Napoli • M. Maghnie (✉)

Department of Pediatrics, Istituto Giannina Gaslini, University of Genova, Genova, Italy  
e-mail: [pietrolazze@libero.it](mailto:pietrolazze@libero.it); [natasciadiiorgi@gaslini.org](mailto:natasciadiiorgi@gaslini.org); [flavianapoli@gaslini.org](mailto:flavianapoli@gaslini.org);  
[mohamadmaghnie@gaslini.org](mailto:mohamadmaghnie@gaslini.org); [Mohamad.Maghnie@unige.it](mailto:Mohamad.Maghnie@unige.it)

---

**Keywords**

Testis • Transcription factors • Bipotential gonads • SRY • SOX9 • Sertoli cells • Leydig cells • INSL3 • Cryptorchidism

---

**Abbreviations**

DSD Disorders of Sex Development

**Contents**

The Bipotential Gonad .....	274
The Road to Maleness .....	276
Sertoli Cell Commitment .....	276
Testis Cord Formation .....	278
Role of the Interstitium: Endothelial Cells and Peritubular Myoid Cells .....	279
Germ Cell Commitment .....	280
Establishing Androgen Production: Role of Fetal Leydig Cells .....	282
Undescended Testis .....	283
Definition .....	283
Etiology .....	283
Classification .....	284
Differential Diagnosis .....	285
Epidemiology .....	286
Diagnosis .....	286
Complications of Cryptorchidism .....	288
Indications for Surgical Treatment .....	294
Timing of Surgical Treatment .....	294
Surgical Treatment .....	295
Follow-Up .....	300
Complications of Surgery .....	300
Medical Therapy .....	301
Other Urogenital Malformations .....	302
Hypospadias .....	302
Micropenis .....	305
Epispadias .....	305
References .....	306

---

**The Bipotential Gonad**

Mammalian bipotential gonad originates from a thickening of the coelomic epithelium overlying the region of the intermediate mesoderm of urogenital ridge called mesonephros. In humans this process begins at approximately 4–5 weeks of gestation, and the primordial gonad remains undifferentiated until about 40 days of gestation.

During mouse embryogenesis – one of the most studied models for testicular development – bipotential primordium first appears at embryonic day E 10.5. This region is composed of cells derived from both the coelomic epithelium and the mesonephros, and contributes to at least two distinct bipotential somatic precursors:

supporting cells, which differentiates into Sertoli cells in the testis and granulosa cells in the ovary, and steroidogenic cells, giving rise to Leydig cells in males and theca cells in females. Precursors of primordial germ cells are identified, in mice, since 6–6.5 days post coitum (dpc) in the proximal part of the epiblast of blastocyst (Kolasa et al. 2012) and reach the urogenital ridge by E.10.5.

Several genes and transcription factors are crucial to establish the bipotential population of somatic cells in the gonad; mutations of these genes determine the development of nonfunctional structures that fail to differentiate beyond the embryonic stage. Table 1 summarizes main genes involved in bipotential gonad origin and highlights the phenotypes related to mutations of these genes.

During the narrow window of time between E10.5 and E11.2, transcriptomes of XY and XX gonadal somatic and germ cells are almost identical. At this stage, key genes involved in testis (SOX9, FGF9) and ovary development (WNT4, RSPO1) are expressed at similar levels irrespective of chromosomal sex (Munger et al. 2013).

These data suggest that plasticity of bipotential gonad depends on a transient balanced transcriptional state between male and female pathway genes. Male sex determination starts when this balance slopes towards the increasing expression of the Y-linked gene SRY.

**Table 1** Main genes involved in bipotential gonad origin and phenotype related to mutations

Gene	Protein	Locus	Function	Phenotype	Reference
WT1	Transcription factor	11p13	Early gonadal and urogenital development	Severe hypospadias, cryptorchidism, vanishing testes syndrome, renal abnormalities, gonadal tumors	Kohler et al. 2011
NR5A1	Nuclear receptor	9q33	Adrenal and gonadal development	Gonadal dysgenesis, primary adrenal failure, ambiguous or female genitalia	Kohler and Achermann 2010
CBX2	Transcription factor	17q25	Gonadal development	Male to female sex reversal	Biason-Lauber et al. 2009
Lhx9	Transcription factor	1q31	Gonadal development, CNS development	Male to female sex reversal, gonadal agenesis	Birk et al. 2000
EMX2	Transcription factor	10q25	Urogenital development, CNS development	Hypospadias, cryptorchidism, male to female sex reversal, CNS abnormalities, renal abnormalities	Piard et al. 2014

## The Road to Maleness

In mammals, development of testis depends on differentiation and assembly of several cell types arising from different structures: somatic cells, which originate from coelomic epithelium and mesonephros, and primordial germ cells, arising from the epiblast of blastocyst and subsequently migrating towards the urogenital ridge. The differentiation of these cell lineages does not proceed independently, since gonadal fate seems to depend on the determination of a somatic cell, the supporting cell lineage, which commits to Sertoli cell and then orchestrates the behavior of all other cells within the organ.

This process starts with the expression of sex-determining region of the Y chromosome (**SRY gene**) – a Sox family transcription factor – in the somatic supporting cell, and results in the differentiation of male-specific cell types, formation of testis cords, and development of sex-specific vascular structures. SRY gene seems therefore to be the master regulator of testis determination in mammals. Interestingly, germ cells are not required in the initial morphogenesis of the testis.

In this chapter the role of these different cell types in the developing male gonad will be highlighted with focus on the genetic factors and the signaling pathways involved. Unless otherwise indicated, we will refer to the events that occur in the mouse, as this is the model which most authors describe in details in the literature.

### Sertoli Cell Commitment

As stated above, SRY expression initiates the process of Sertoli cell differentiation. Cell-tracing studies suggest that the supporting cell lineage originates from coelomic epithelium and enters into both XX and XY genital ridge either by active migration or through high proliferation rate of surface epithelial cells (Svingen and Koopman 2013; Schmahl et al. 2000). SRY expression is activated in XY genital ridge only after this process.

In mice, SRY is detected in somatic supporting cells of XY gonad from E10.5, and its expression peaks at around E11.5; by E12.5 SRY expression is no longer detected (Cool and Capel 2009). SRY interacts with DNA through the high mobility group domain (HMG) and upregulates the expression of *Sox9*, another member of SOX transcription factor family (Svingen and Koopman 2013). *Sox9* seems to be the earliest gene upregulated in the male pathway (Lin and Capel 2015) with a temporal pattern delayed by around 10 hours as compared to *Sry* (Svingen and Koopman 2013). Sertoli cells do not differentiate synchronously in all parts of the gonad, but they rather develop following a wave from the middle third towards the poles.

In mammals, SRY-positive cells are indeed first detected in the center of the gonad with subsequent extension towards the poles. The impairment of this spatial pattern of expression of SRY may generate consequences such as the development of ovotestes, i.e., mixed gonads with both testicular and ovarian structures; in ovotestes testicular cords typically develop in the center, and ovarian structures develop at the poles within the same gonad.



SRY and SOX9 integrity are necessary but not always sufficient to drive the normal testis organogenesis. A threshold level of SRY expression and SOX9 positive cells within the developing gonad is indeed required for proper sex determination. If this level is not reached, the gonad develops either to an ovary or to an ovotestis (Lin and Capel 2015). The same fate occurs when the expression of SRY is delayed beyond E11.25 (Hiramatsu et al. 2009).

These observations suggest that a critical threshold level of male signals is necessary to establish testis fate and draw the attention to the existence of a narrow time interval within which supporting cells are capable to respond to SRY signaling and upregulate SOX9 pathway.

SOX9 expression continues beyond E12.5, time in which SRY expression ceases; this phenomenon highlights the necessary existence of autocrine and paracrine mechanisms in the regulation of SOX9 expression and in reinforcing male signaling pathways.

Fibroblast growth factors (FGFs), prostaglandins, rapid growth proliferation rate of supporting cell lineage driven by *Sry* and, perhaps, other genes such as *Cbx2* (Katoh-Fukui et al. 2012) seem to have a crucial role in these processes. Recent evidences support a model of gonadal development in which these key factors not only promote male fate but are also crucial for active repression of the opposite. This mutual antagonism is sustained by feed-forward mechanisms and creates the basis for a rapid commitment of the gonad towards male or female fate.

**Fibroblast growth factor** signaling is involved in embryonic development through regulation of cellular differentiation, migration, and morphogenesis. Within FGFs, **FGF9**, initially expressed under SOX9 influence, seems to be required for Sertoli cell commitment and male-specific cell proliferation and migration.

*Fgf9* null mice present male to female sex reversal (Colvin et al. 2001). Moreover, loss of FGF9 signaling, albeit not affecting initial expression of *Sry* or *Sox9*, subsequently determines gradual reduction of *Sox9* expression. FGF9 is also involved in spatial upregulation of *Sox9* from the central part of the gonad towards the two ends. These observations suggest that FGF9 is engaged in an autocrine/paracrine feed-forward loop with SOX9 that may maximize the number of SOX9 supporting cells until the achievement of the critical threshold.

Furthermore, recent evidences suggest a role for FGF9 in active repressing of female fate. In vivo studies show how FGF9 mutant mice fail to silence female transcription factors such as WNT4. On the other hand, exogenous in vitro treatment of XX gonadal cells with FGF9 represses WNT4 signaling (Kim et al. 2006).

FGF9 seems to act in male developing gonad through **FGFR2 nuclear receptor**. FGFR2 is expressed in the coelomic epithelium cells of both XX and XY gonads but localizes to the nucleus only of a subset of XY cell after E11.0 (Schmahl et al. 2004). Moreover FGFR2 mutations in the gonad resemble FGF9 mutant phenotype (Bagheri-Fam et al. 2008).

**Prostaglandin D2** (PGD2) may be another factor involved in the enhancement of SOX9 expression.

Prostaglandins are a family of diffusible signaling molecules generated from arachidonic acid via a multistep reaction mediated by cyclooxygenases 1 and

2 (COX1-COX2) and prostaglandin synthetases (PGDS). They take part in several processes such as bone development and vasoconstriction. PGD2 is produced by **PTGDS**, a prostaglandin synthetase specific to male gonad. PTGDS promoter presents binding sites for both *Sry* and *Sox9*. PGD2 seems to be a paracrine signal by which Sertoli cells recruit each other in order to augment SOX9 expression (Wilhelm et al. 2005). PGD2 may therefore have both an upstream and a downstream role in the regulation of SOX9 expression. Moreover, PGD2 interaction with its receptor DP1 promotes cytoplasmic SOX9 protein entry into the nucleus to influence Sertoli cell gene expression (Sargent et al. 2015).

Despite these regulatory effects demonstrated by in vitro studies, PGD mutations do not seem to affect testicular development, confirming the presence of redundant signaling pathways in the regulation of SOX9 expression (Lofin et al. 2002).

## Testis Cord Formation

At the same time of Sertoli cells determination, profound morphological changes occur in the gonad resulting in partition of Sertoli and germ cells from the interstitium and formation of proto-cords. Testis cord formation is the key morphogenetic event in testis development. Testis cords have several crucial functions in testis embryology and physiology. During fetal testicular development they segregate endocrine function from spermatogenesis and physically separate primordial gonadal cells from interstitium, avoiding male germ cells to enter meiosis too early; they are also responsible, in adult testis, for the maturation and export of sperm.

At E12.5 in mice Sertoli cells polarize and proliferate, developing strong contacts around germ cell cluster (Nel-Themaat et al. 2011). By E13.0, Sertoli cells mature assuming an epithelial-like morphology. The nature of initial aggregation events seems to be stochastic, and triggering molecular mechanisms involved in initial cord tubularization is still largely unknown. Some authors have proposed a role for FGF9 and for neurotrophic tyrosine kinase receptor 3 (NTRK3) and its ligand NTF3; they are both expressed by Sertoli cells at the beginning of cord formation, and they seem to act through the formation of adhesive contacts between cells (Svingen and Koopman 2013). Moreover, *Ntrk3* knockout mice present derangement of seminiferous cord structure (Cupp et al. 2000).

Initial cord formation seems to proceed de novo from the aggregations described above, rather than sprouting from preexisting tubular structure. Proto-cords then start to remodel assuming relatively uniform thickness and adopting the distinctive epithelial morphology (Svingen and Koopman 2013; Nel-Themaat et al. 2009).

According to the evidences coming from in vivo and in vitro studies, Sertoli cell specification is not sufficient for cord formation. It is clear that several interstitial cell types are involved in this process. The most important and most studied interstitial gonadal cell types include vascular endothelial cells, peritubular myoid cells, and fetal Leydig cells.

Interestingly, germ cells are not necessary for cord formation, and testicular development may proceed in the absence of germ cells. Several studies indeed show how normal testicular morphology and endocrine function can be achieved in mouse germ cell deficient models (Svingen and Koopman 2013).

### **Role of the Interstitium: Endothelial Cells and Peritubular Myoid Cells**

Migration of cells from mesonephros to the interstitium of developing testis is necessary for the peculiar testicular vascularization and cord formation as this process is impaired when cell migration is blocked (Cool and Capel 2009). First dimorphic vascular structures start to remodel around E11.5 in mouse models.

Interstitial cell lineages essential for vascular and cord formation are basically endothelial cells and peritubular myoid cells. Endothelial cell migration and subsequent sex-specific vascular development represent a milestone in testis embryology and are one of the first steps driving cord formation (Sargent et al. 2015). Unfortunately, the lack of cell-specific early markers makes it currently difficult to track interstitial cell origin and, despite the advances in our understanding of fetal testis development, the debate whether interstitial cells migrate from mesonephros or develop from a somatic precursor cell within the gonad remains unanswered.

Recent evidences show how all migrating cells differentiate towards endothelial fate, as most of the cells migrating from the mesonephros express endothelial cell markers, while peritubular myoid cells, firstly recognizable at around E13.5, seem to be induced within the gonad (Cool et al. 2008; Combes et al. 2009).

According to some authors, Sertoli cells would produce angiogenic factors able to induce endothelial cell migration and male-specific vascular network (Bott et al. 2010). At present, our understanding of molecular mechanisms and signaling factors involved in this phenomenon is far to be complete.

Evidences regarding the role of some of these factors, such as vascular endothelial growth factors (VEGFs), platelet-derived growth factors (PDGFs), hedgehogs (HHs), and neurotrophins will be briefly summarized. The **VEGF** family is involved in migration, proliferation, differentiation, and survival of vascular cells within developing organs. VEGFA is the most studied family member and has been shown to be critical for angiogenic processes as mutations in this factor cause early embryonic lethality (Ferrara et al. 1996).

According to *in vitro* experiments, both inhibition of VEGFA signal and excess of VEGFA isoforms in testis organ cultures result in profound impairment of vascular development and cord formation (Sargent et al. 2015). Despite *in vitro* evidences, *in vivo* mouse models of *Vegfa* knockout in both Sertoli and germ cells present normal vascular and cord structures at birth, even if this process may be delayed embryonically (Lu et al. 2013). The only phenotype displayed by these models is infertility. VEGFA cannot therefore be the only signal involved in endothelial cell migration, testis angiogenesis, and cord formation.

**PDGFs** are diffusible extracellular molecules that interact with specific tyrosine kinase receptors PDGFR $\alpha$  and PDGFR $\beta$ . PDGFR $\alpha$  is expressed in the interstitium of developing testis while PDGFR $\beta$  is expressed within the vasculature. In vivo studies have demonstrated how gain of function of these receptors is able to induce cell migration and female to male sex reversal in XX gonad; moreover, XY *Pdgfra* mutants display severe impairment of cord and vascular structures and lack fetal Leydig cells. (Cool and Capel 2009; Gnessi et al. 2000; Brennan et al. 2003).

**Hedgehogs**, morphogen molecules that regulate organ patterning and growth, act through binding to transmembrane receptors of the Patched family (PCT). Among this family, **Desert hedgehog** (DHH) has been shown to have a role in testis development.

Sertoli cells express DHH from E11.5. Dhh protein binds to its receptor PTC1 that is expressed at E12.5 by interstitial cells (Cool and Capel 2009). The histology of XY *Dhh* mutants is characterized by irregular cord formation, interstitial cell and extracellular matrix defects, and absence of Leydig cells. This general testicular patterning derangement results in infertility (Clark et al. 2000; Yao et al. 2002).

Another transcription factor family potentially involved in signaling between Sertoli cells and interstitium is the **Neurotrophin** family. Neurotrophins are secreted growth factors that are posttranslationally cleaved and able to bind with high affinity to receptors of the tyrosine kinase family. Among neurotrophins, Ntf3 and its receptor TrkC have been shown to be enriched in XY gonad. Ntf3 is expressed by Sertoli cells, whereas TrkC is expressed by interstitial cells.

In vitro studies suggested a role for Ntf3 and TrkC in cord formation through the regulation of mesonephric cells migration into the XY gonad. However, as already discussed with the VEGFA pathway mutations, in vivo experiments showed how NT mutations result in very subtle phenotype (Cupp et al. 2003).

These data again suggest how mesonephric migration and vascular and cord formation seem to be regulated and orchestrated by different independent factors, and how this functional redundancy may rescue normal testis development when one of these signals is deficient.

## Germ Cell Commitment

As mentioned above, progenitor of primordial germ cells (PGCs) develop in the proximal part of the epiblast of blastocyst at around E6.0–E6.5 in mice. These cells start then to migrate and reach at around E7.8–E8.5 the base of the allantois, which is located in the extraembryonic mesoderm, from where they are enclosed in the epithelium of the midgut. Primordial germ cells continue their migration through the dorsal mesentery and reach the genital ridges at E11.5.

PGCs' migration occurs in human between 5 and 8 weeks of gestation.

PGCs' journey, which occurs due to specific amoeboid movement, is regulated by factors expressed by PGCs themselves, but also by cells of embryonic tissues through which germ cells migrate, that constitute a sort of "travelling niche."

While travelling, PGCs strongly express Oct4, transcription factor involved in regulation of apoptosis and survival of migrating cells.

Somatic cells along the migratory pathway express steel factor and stromal cell-derived factor 1 (SDF-1). These molecules bind to specific receptors (respectively CXCR4 and c-Kit-R) on PGCs, and this signal is crucial for control of normal migration, proliferation, and apoptosis of PGCs.

After their arrival to the genital ridge, PGCs are enclosed in clusters around Sertoli cells forming protocords (Kolasa et al. 2012). At this stage, PGCs have very similar transcriptomes and are able to differentiate both as spermatogonia and ovogonia, regardless of their genetic sex, depending on specific male or female signaling factors in the embryonic gonadal environment (Munger et al. 2013).

Developmental timing of PGCs' commitment has been shown to be different in male and female embryos: in XY gonad, PGCs' fate is fixed by E12.5, whereas germ cells in XX gonad are committed to the female pathway by E13.5 (Adams and McLaren 2002).

After E13.5, the first morphological signs of germ cells sex-specific commitment can be demonstrated as meiotic changes appear in female germ cells, whereas male germ cells assume a status of quiescence that they maintain until after birth (Kocer et al. 2009). At present, the existence and the nature of the environmental signaling molecules responsible of germ cell fate commitment has not been clearly established. Some authors have proposed the presence of a female meiosis inducing signaling factor (Byskov et al. 1993), and others have postulated the existence of a repressor of meiosis in XY gonad (McLaren and Southee 1997).

**Retinoic acid (RA)** has been extensively investigated as a molecular candidate, due to its action in inducing meiosis. RA is synthesized in the mesonephros, and it diffuses into the gonad from the anterior to the posterior pole. RA induces the expression of *Stra8* (Stimulated by RA gene 8), a gene involved in the initiation of meiosis, which is indeed upregulated following an anterior to posterior wave in XX gonad.

In XY gonad, the early expression of the P450 enzyme CYP 26B1 is responsible for the degradation of RA, impeding *Stra8* activation, and preventing PGCs meiosis (Kocer et al. 2009; Lin and Capel 2015). Evidence of meiotic germ cells found in embryonic testes of *Cyp26b1* knockout mice supports this hypothesis (MacLean et al. 2007). However, according to other authors, RA may primarily influence germ cells proliferation and survival rather than meiotic processes, either directly or through regulation of gonadal somatic cells (Morita and Tilly 1999).

Additional factors for the regulation of PGCs differentiation, such as WNT4 and FGF9, have been proposed. WNT4 has been shown to promote XX germ cells entry into meiosis (Chassot et al. 2011). *Fgf9* mutations lead to upregulation of meiotic markers and to apoptosis of male germ cells (Bowles et al. 2010). FGF9 seems to act through its downstream target *Nanos2*, a RNA-binding protein involved in the degradation of transcripts of meiotic genes, such as *Stra8*, and in the regulation of the expression of negative regulators of cell cycle.

Accumulation of these factors in germ cells leads to male sex specific mitotic arrest which is crucial for establishing spermatogonial fate and to repress pluripotency (Suzuki et al. 2014; Cook et al. 2011).

## **Establishing Androgen Production: Role of Fetal Leydig Cells**

Fetal Leydig cells (FLCs) are essential for male sex differentiation, as their main function is to produce androgens and other factors, such as insulin-like 3 (INSL3), necessary for Wolffian ducts and external genitalia development, testicular descent, and, potentially, sex-specific brain patterning. FLCs represent genetically, morphologically, and functionally a distinct population compared to adult Leydig cells.

In humans, fetal androgen production starts at around 6–7 weeks of gestation and peaks at around 13–14 weeks (O’Shaughnessy et al. 2005). Androgens induce masculinization of external genitalia and Wolffian duct stabilization. FLCs are also responsible for testicular descent via secretion of INSL3. INSL3 is involved in the first step of testicular descent (transabdominal phase) while the second step (inguinoscrotal phase) is driven by androgens.

Although FLC population performs a crucial role in fetal sexual development, its origin and regulation remain at present uncertain and vigorously debated. Interestingly, it also remains uncertain whether fetal and adult Leydig cells share a common progenitor or not. FLC population is first detected at E12.5 in mouse models (around 6 weeks in humans), after the appearance of Sry positive cells in the gonad; from E12.5 to E15.5 the number of fetal Leydig cells increases dramatically.

Some authors suggest that FLCs may originate from mesonephric migrating cells: This theory is built on the observation, by E11.5, in rats, at the cranial end of the mesonephros, of a population of Sf1 (orphan nuclear receptor steroidogenic factor 1) positive cells, which is a marker expressed by differentiating steroidogenic tissues (O’Shaughnessy et al. 2005; Hatano et al. 1996). These cells would then divide into two distinct populations, one located in the region of the primordium of adrenal cortex and the other one close to coelomic epithelium. According to these authors, fetal Leydig cells and adrenal cells would therefore share a common origin.

Other authors, conversely, by performing tissue recombination in ex vivo culture studies, demonstrated how FLC precursor arises within gonadal tissue – and not from migratory population – from a progenitor cell in common with supporting cell lineage and other interstitial cells, such as peritubular myoid cells (Brennan et al. 2003).

However, irrespective of their origin, FLC differentiation seems to be triggered by Sertoli cell via paracrine regulation. Key signaling factors between Sertoli and FLCs seem to be the above mentioned Desert hedgehog (Dhh) and platelet-derived growth factor A (PDGFA) (O’Shaughnessy et al. 2005). These molecules are involved in fetal Leydig cell differentiation and in expansion of fetal Leydig cell precursors.

Another factor involved in FLC differentiation in mice seems to be Notch signal. Some authors showed how loss of Notch function results in a reduction of FLC

number, whether gain of function of this signal increases the number of these cells (Tang et al. 2008). Moreover, interstitial cells like peritubular myoid cells, endothelial cells, and interstitial fibroblast may also be involved in fetal Leydig cell development. This influence occurs through the expression, by these cells, of *Arx* gene (X-linked aristaless-related homeobox gene) whose transcript has been shown to be essential for normal FLC differentiation (Kitamura et al. 2002).

Regulation of fetal Leydig cells function remains at present not entirely understood.

In humans, evidences from patients affected by inactivating mutations of LH/CG receptor (LHCGR) show how hCG is involved in fetal Leydig cell development and regulation. These patients present a reduction in FLC number and an impairment in androgen production resulting in a male-to-female sex reversal phenotype. In these patients, however, a certain extent of androgen exposure has occurred, as they present some development of epididymis and ductus deferens. This suggests the presence of other mechanisms involved in the regulation of FLCs (Kremer et al. 1995; O'Shaughnessy et al. 2005).

Mc2r, melanocortin receptor specific to ACTH, is differentially expressed in the fetal testis, thus suggesting a role for ACTH in regulation of fetal androgen production. However, mutant mice studies show how ACTH mutations alone do not affect fetal androgen production. ACTH is therefore not necessary for fetal androgen production (O'Shaughnessy et al. 2006).

ACTH may be implicated in androgen production by Leydig cells also in humans, under some circumstances. This postulate arises from data collected from patients affected by congenital adrenal hypoplasia due to *Dax1* mutation: In these patients, ACTH chronic exposure may be able to stimulate Leydig androgen production (Domenice et al. 2001).

These observations suggest the role of multiple endocrine and paracrine redundant factors in the regulation of fetal Leydig cell function, and this mechanism seems to be able to guarantee an adequate androgen production even when one of these signals is missing (Teerds and Huhtaniemi 2015).

---

## Undescended Testis

### Definition

Undescended testis can be described as a testicle that has not moved into its proper position in the lower scrotum before birth. Sometimes it can be stretched into the bottom of the scrotum only by producing high tension on the spermatic cord.

### Etiology

Testicular descent normally occurs in two sequential steps: transabdominal and inguinoscrotal. The first phase begins at about 10 weeks of gestation. It consists of

the initial movement of the testis from the urogenital ridge to the inguinal region: The gubernaculum enlarges and anchors the testis to the inguinal region while the embryo is growing. The testis keeps this position until the seventh month of life, when the second phase occurs. It consists of the migration of the gubernaculum from the inguinal canal into the scrotum, which is usually completed by the third trimester.

The normal testicular descent is controlled by hormones. Androgens seem to stimulate the regression of the cranial suspensory ligament, whereas the enlargement of the gubernaculum seems to be controlled by INSL3 produced by the Leydig cells. The role of the anti-Müllerian hormone has also been proposed as a secondary factor in the first step. The genitofemoral nerve seems to be involved in the second step: It releases the calcitonin gene related peptide (CGRP), which is implicated in the normal inguinoscrotal migration of the testis. A multitude of causes has been proposed for undescended testes: Hormone deficiency or lack of anatomical regulators may affect each step of the normal testicular migration causing a broad spectrum of abnormal positions (Hutson and Hasthorpe 2005).

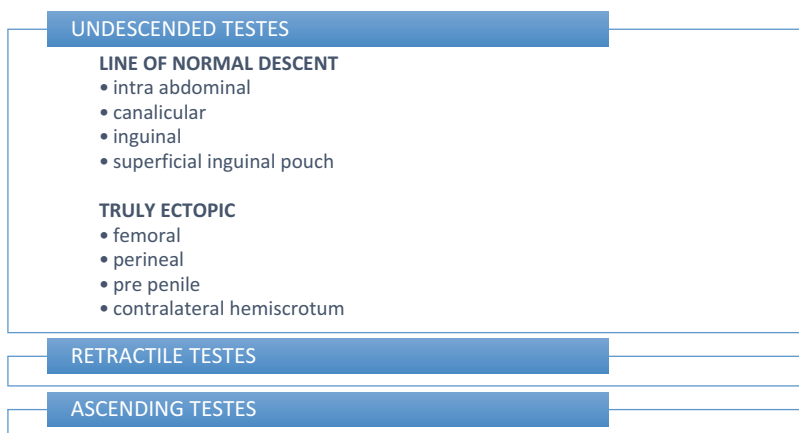
## Classification

At first, undescended testes can be classified by their positions in two distinctive groups, depending on their etiopathogeneses (Fig. 1):

### 1. Those in the normal line of descent

- Intra-abdominal testes (uncommon)

They are usually located within a few centimeters behind the internal inguinal ring, with the vas deferens and the testicular vessels travelling extraperitoneally.



**Fig. 1** Classification and differential diagnosis of undescended testes



They are impalpable through external examination but are easily identified by laparoscopy.

- Canalicular testes

They lie within the inguinal canal but may be difficult to palpate because of the overlying musculature. Such gonads may emerge from the external inguinal ring only after being squeezed out of the inguinal canal.

- Inguinal testes

They are palpable in the groin beyond the external ring.

- Superficial inguinal pouch testes (most common)

They lie laterally and a little above the external inguinal ring, outside the abdominal musculature in the superficial inguinal pouch: the space (originally described by Browne) created by the tunica vaginalis in the groin, limited superficially by Scarpa's fascia, caudally to the inguinal ligament.

2. Those in truly ectopic positions (quite rare)

They could be located in the perineum, femoral region or prepenile region, or in the contralateral hemiscrotum (known as transverse ectopia).

## Differential Diagnosis

Undescended testes should be distinguished from other conditions, such as:

- Retractable testes

They show an overactive cremasteric reflex, which is a normal superficial reflex elicited by lightly stroking or poking the superior and medial part of the thigh. The normal response is an immediate contraction of the cremaster muscle that pulls up the ipsilateral testis in order to protect it from extrinsic trauma and to regulate its temperature. The normal retractile reflex is weak at birth and more pronounced later in childhood. Usually it becomes less elicited with the onset of puberty, due to higher androgen levels.

They require careful follow-up, because the excessive contractility of the cremaster muscle in some children may cause the failure of the spermatic cord to elongate with age and may produce secondary ascending testes.

They could be distinct from undescended testes, because their volume and their hemiscrotum are normal in size, and they can be brought fully to the bottom of the scrotum without difficulty and remain there spontaneously.

- Ascending testes

They are acquired maldescent testes: They descend into the scrotum within the first 3 months postnatal, but then ascend from the scrotum later in childhood.

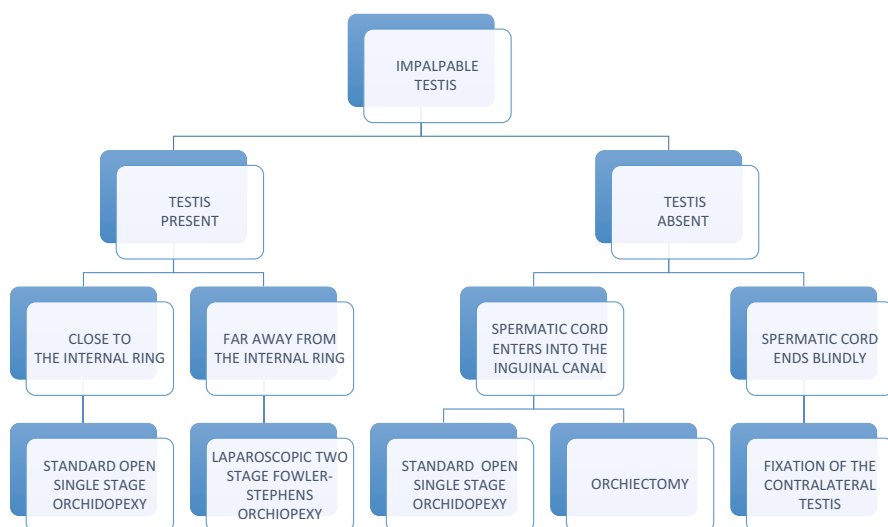
The pathogenesis appears to be due to a failure of natural elongation of cord structures in proportion to body growth due to the incomplete disappearance of the processus vaginalis (either as a patent hernia or an obliterated remnant). In fact, its transection allows adequate elongation of the adjacent vas deferens and testicular vessels.

## Epidemiology

The John Radcliffe Hospital Cryptorchidism Study Group (Ansell et al. 1992) examined a total of 7441 boys for cryptorchidism at birth and, if present, again at 3 months. At birth 3.0% of boys have unilateral and 1.92% have bilateral undescended testes. The right side (70%) is affected more often than the left (30%). At 3 months, the overall rate is 1.55%. Spontaneous descent occurred postnatally in the first 3 months; beyond that time, it is rare. Descent by 3 months is more likely the lower the testis is along the normal pathway of descent. Babies with low birth weight, bilateral cryptorchidism, and normal scrotal size are more likely to have normally descended testes by 3 months. In babies weighing less than 2000 g, 2000–2499 g, and greater than or equal to 2500 g proportions are 7.7%, 2.5%, and 1.41%, respectively. An independent effect of gestational age is suggested: cryptorchid babies of less than 37 weeks gestation are more likely to have normally descended testes at 3 months than babies of higher gestational age. Undescended testes frequently have strong familial clustering with 6–10% incidences within siblings.

## Diagnosis

All newborn males should be examined carefully to demonstrate the presence of each testis within the scrotum (Fig. 2). If during this routinely clinical examination at birth, the testis is not located at the bottom of the ipsilateral scrotal bursa, at 12 weeks of age one more testicular examination is mandatory. At this time, testes that are now



**Fig. 2** Diagnosis and management of impalpable testis

descended spontaneously need regular annual follow-up, because there is a risk that they may reascend out of the scrotum in later childhood. Conversely, for those that are still out of the scrotum, a certain diagnosis of congenital undescended testis should be made. The clinical examination should identify the presence of the gonad and determine the lowest position that it will sit without undue tension. It is important to observe the scrotum before palpation in order to prevent eliciting the cremasteric reflex. With the child relaxed on the examination table, the genitalia and the appearance of the scrotum should be inspected. In infants, if the testis is lying within the scrotum, it is usually visible through the thin scrotal skin. Hypoplasia of the hemiscrotum suggests that the testis has never been within it. It is also important to pay attention to any sign of inguinal swelling that could suggest an associated hernia. If it is present, it should be reduced by manual compression in order to identify the true position of the undescended testis. Since the testis is contained within the tunica vaginalis, it is mobile. Therefore it could be helpful to begin the examination by blocking the internal inguinal ring with one hand and press down toward the external ring to prevent the testis from being displaced up into the inguinal canal on palpation. Once the mobile testis has been identified in the groin, one hand of the examiner attempts to push the testis toward the scrotum while the other hand attempts to grasp it through the thin scrotal skin. The aim of this maneuver is to determine the lowest level to which the testis can be manipulated without undue tension. To locate a testis in the superficial inguinal pouch, light palpation with the flat of the hand is most effective. If palpation is too hard, this often displaces the testis from under the fingers, so it may be missed. It is also important to consider ectopic sites (femoral, perineal, or pubo-penile region) during physical examination. At least 80–90% of testes are palpable in the inguinal region, or can be squeezed out of the inguinal canal and felt at the external ring by pressing firmly on the abdominal wall laterally near the anterosuperior iliac spine and pressing downward and medially toward the scrotum. Intra-abdominal or canalicular testes that cannot be delivered outside the external ring are uncommon. A third of these impalpable testes were found at operation in the abdomen, a third in the inguinal canal, and a quarter in the superficial inguinal pouch. One percent of all testes and 7% of impalpable testes are totally absent, resulting from intrauterine torsion of the spermatic cord during migration of the gubernaculum to the scrotum (known as vanishing testis syndrome or testicular regression syndrome). In this case, the contralateral testis is commonly enlarged. Of the many possible means of investigation and imaging techniques recommended to identify the position of impalpable testes, laparoscopy remains the single most definitive means of locating an intra-abdominal testis and of excluding the possibility of secondary atrophy. Diagnostic laparoscopy has been commonly used for the assessment of a nonpalpable testis, with the accuracy of testicular localization reported to be greater than 95%. Radiological imaging studies carried out to identify a nonpalpable testis carry unacceptable false-negative and false-positive rates. Inguinal ultrasound rarely localizes a true nonpalpable testis and in only 18% of cases correctly identified testes located in the inguinal canal (Elder 2002). Magnetic resonance imaging has been shown to be an effective method of detection in 37% of cases. Radiographic imaging is also

inadequately sensitive to determine the quality of the testis when compared with direct visualization. This includes assessing whether the testis is dysmorphic or hypoplastic or whether epididymal or vessel nonunion anomalies coexist that would ultimately have an impact on the type of surgical procedure performed. The technique used to localize the undescended testis must be highly accurate, because the fate of a missed intra-abdominal testis is potentially serious with respect to preserving testicular function and can be catastrophic because of the risk of malignancy. Diagnostic laparoscopy has also been shown to be useful in the management of a previous inconclusive open exploration for a nonpalpable testis. There are distinct possibilities and courses of action that can arise when diagnostic laparoscopy is used to assess a nonpalpable testis.

1. Spermatic vessels and vas deferens are present and enter into the inguinal canal (canalicular testis or scrotal atrophic testis). In this case, an inguinoscrotal exploration must be performed and a standard orchidopexy or an orchiectomy should be performed in relation to the testicular size and shape.
2. Spermatic vessels and vas deferens end blindly usually within a few centimeters of the internal ring (vanishing testis). In this case no further surgical intervention is necessary, although consideration should be given to performing a transscrotal testicular fixation procedure on the normally descended contralateral testis, because of the reported risk for abnormal testicular fixation.
3. Intra-abdominal testis is seen within a few centimeters of the internal ring. In this condition one-stage orchiopexy is mandatory.
4. Intra-abdominal testis is immobile, beyond 2.5 cm from the internal ring, closer to the iliac vessels. In such condition, a two-stage Fowler-Stephens orchidopexy is usually scheduled.

## **Complications of Cryptorchidism**

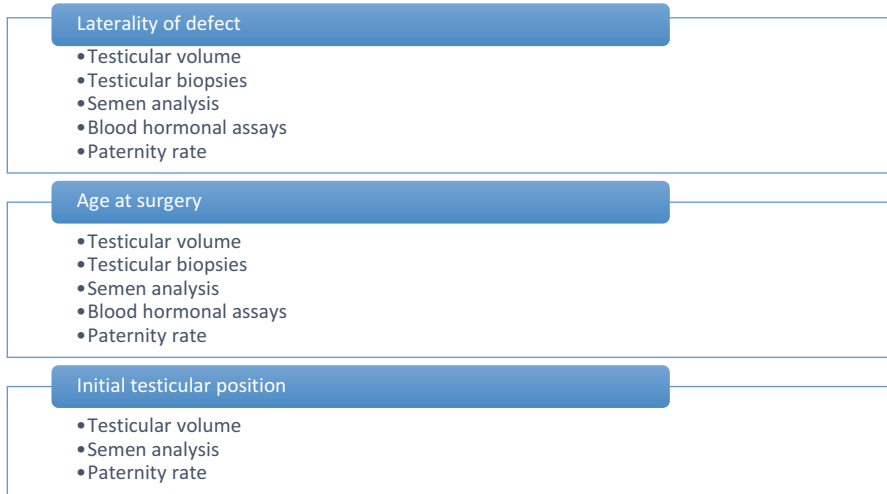### **Infertility**

A significant number of studies have evaluated fertility in men with previous diagnosis of undescended testis. Different features are considered risk factors for infertility in men with a history of cryptorchidism: such as laterality, age at surgery, and initial testicular position. Testicular volume, testicular histology, semen analysis, endocrine production, and finally paternity rate are all markers used to assess the potential for fertility (Fig. 3).

### **Laterality of defect**

- Testicular volume

As the bulk of the testis is composed of seminiferous tubules, testicular volume has been used to estimate tubular function and spermatogenesis, although it has proven to be a poor predictor of germ cell count. Reduced testicular volume is more marked in children with a past history of cryptorchidism:  $18.6 \text{ ml} \pm 4$  is the



**Fig. 3** Risk factors and indicators for infertility in men with undescended testis

testicular volume in normal adults, compared to 17.6 in case of unilateral undescended testis and 16.0 ml  $\pm$  4.9 in bilateral undescended testes (Schreiber et al. 1981).

- **Testicular biopsies**  
Cortes et al. (2001) biopsied 698 cryptorchid testes at surgery: lack of germ cells appears in 18% (88/496) of unilateral and 30% (61/202) of bilateral cases.
- **Semen analysis**  
Numerous studies have addressed the outcome for orchidopexy by semen analysis. Lee (2005) in his study enrolls 101 men who underwent orchiopexy for either unilateral ( $n = 93$ ) or bilateral ( $n = 8$ ) cryptorchidism during childhood. Controls are men who underwent other surgery in the same hospital ( $n = 47$ ), matched for age and surgical date. Although the percentages of normal motility and morphology were similar, the sperm density varied considerably among the three groups: in the unilateral group 83% had normal sperm density with 9% having less than 5 million/mL (the level below which fertility is believed to be impossible). Conversely, 19% of formerly bilateral cryptorchid men had normal sperm density, and 54% had a sperm density of less than 5 million/mL.
- **Blood hormonal assays**  
Previously published research in fertile and infertile men indicates that inhibin B and FSH are biomarkers of the integrity of the seminiferous tubule. In the previous cited study, Lee (2005) found considerable variation for the hormonal levels among the unilateral and bilateral cryptorchid groups, particularly inhibin B and FSH, which tended to be low and high, respectively. However, a statistically significant difference was found only for inhibin B, which was greater among the control group than the entire cryptorchid group ( $P < 0.001$ ).

Although compromised fertility is suggested by elevated FSH and low inhibin B levels alone, their combination with decreased sperm density is the parameter that clearly indicates a higher risk of infertility.

- Paternity rate

The most valid index to assess fertility is to document successful paternity. Since studies quote that 15–30% of paternity tests reveal that the father named on the birth certificate is not the genetic father, paternity results in cryptorchidism should be interpreted with caution. Lee (2005) calculated the portion of men with a previous history of cryptorchidism who had fathered one or more children or had attempted for more than 12 months: In the bilateral cryptorchid group, 65% were successful at paternity, as were 89.7% in the unilateral cryptorchid group, and 93.2% in the control group. Paternity rates were not significantly different between the unilateral and control groups, but the rate for the bilateral group was significantly less than both of the other groups (RR 5.3,  $P = 0.0001$ ).

### Age at surgery

Clear data is not yet available to confirm that earlier treatment is associated with better fertility outcome. Whether orchidopexy in infancy ultimately achieves a significantly improved rate of fertility remains to be seen.

- Testicular volume

Engeler et al. (2000) compared two age groups of 32 patients who had bilateral inguinal cryptorchidism: 12 patients underwent surgery before 2 years of age and 20 patients underwent it between 2 years of age and puberty. There is a highly significant ( $P < 0.001$ ) inverse correlation between the mean age at surgery and the total testicular volume at follow-up.

- Testicular biopsies

Hadziselimovic et al. (1975) histologically assessed 72 intra-abdominal testes, which were biopsied at the time of fixation, and compared them to 94 normally descended controls in order to assess normal and cryptorchid development. The abdominal testes were histologically normal up to 6 months, and then showed a sharp decline in the spermatogonia, with empty interstitium appearing after 2 years and a complete lack of germ cells occurring in 64% of those older than 3 years. Atrophy was also seen in relation to Sertoli cells. Ultrastructural changes such as degeneration of mitochondria, loss of cytoplasmic ribosomes, and smooth endoplasmic reticulum appear by the second year of life and are not seen before 1 year of age.

Engeler et al. (2000) found that the patient's age at orchiopexy directly correlates with the mean germ cell count per 50 tubules of both sides: The mean of the spermatogonia per 50 tubules was 32 (14–88) in the 13 patients who underwent orchidopexy before the age of 2 years, and 2 (0–59) in the 21 patients who underwent orchidopexy after the 2 years of age ( $p < 0.001$ ).

McAleer et al. (1995) calculated fertility index by counting the number of spermatogonia per tubule in 50 tubules examined at 300X magnification and compares the two sides in cases of unilateral undescended testes. Patient age

groups are defined as 1 year or younger, 1.5 years (13–18 months inclusive), 2 years (19–24 months inclusive), 2–6 years (25 months to 6 years inclusive), and older. The one-year-old and younger group have similar fertility index values while all other groups have marked differences between the descended and undescended fertility index measurements ( $p$  less than 0.05) suggesting that earlier orchiopexy may be indicated. If surgery is performed before or by the age of 1 year, the potential exists for maximal salvage of active germinal tissue.

Cortes in his study (2001) demonstrates that the lack of germ cells appeared from 18 months, and this frequency increased with age at surgery.

- Semen analysis

Mandat et al. (1994) found that, with increasing age at the time of unilateral orchidopexy (112 cases), the fraction of patients with normospermia decreases, and the average number of spermatozoa both in 1 ml and in the sperm liquid as a whole reduces. In the smaller group of the bilateral orchidopexy patients (23 cases) the differences are not statistically significant. They concluded that, since the fertility potential is higher among the earlier operated patients, orchidopexy performed as early as possible (preferably between 1 and 2 years of age) may improve the results of treatment.

- Blood hormonal assays

Coughlin et al. (1999) suggested to determine whether there are differences in hormone levels (inhibin B, follicle-stimulating hormone, luteinizing hormone, and testosterone) in 84 men with a history of unilateral cryptorchidism as stratified by age at orchiopexy (range from 1 month to the age of 11). Results showed that age at orchiopexy significantly correlated inversely with inhibin B ( $r = -0.274$ ,  $p = 0.012$ ) and positively correlated with FSH ( $r = 0.229$ ,  $p = 0.036$ ), suggesting a negative effect of late orchiopexy regarding hormone profiles in adulthood. Patients who underwent surgery by age 2 years have higher inhibin B levels than those in the three groups that underwent surgery between ages 2 through 11 years. This difference may be evidence for a beneficial effect of early correction of cryptorchidism in the youngest age group. Also, an inverse ratio was found between the age at surgery and testosterone levels. Data indicating that there are higher inhibin B levels in the youngest age group than in the other groups as well as significant linear trends in mean inhibin B and testosterone levels suggest that early orchiopexy is beneficial.

- Paternity rate

Ludwig and Potempa (1975) showed that fertility rate is greater the younger the patient is at the time of operation, best results being noted in those operated upon during the first or second year of life: Boys who are operated on in the first two years of life have a 90% rate of fertility, in contrast to those operated at the age 3–5 years (50%) and to those who had operations at the age of 9–12 year (30%).

### Initial testicular position

Testes initially located beyond the inguinal canal have a good prognosis for fertility. No data is available comparing testicular histology and hormone production in relation to the initial position of the testes.

- Testicular volume  
Puri and Sparnon (1990) showed that the most important factor in relation to subsequent testicular size is whether or not the testes are palpable:  $4.9 \text{ ml} \pm 3.5$  is the volume of abdominal tests;  $9.8 \text{ ml} \pm 5.4$  is the volume of the canalicular one whereas  $17.0 \pm 4.9$  is the volume of the superficial inguinal pouch one (approximately 85% of normal testicular volume).
- Semen analysis  
Cortes and Thorup (1991) found that patients with both testes originally placed in the superficial inguinal pouch at surgical exploration have a higher maximal sperm density than those that were intracanalicular or abdominal. Mayr et al. (1996) confirm that the pretreatment testicular position (“testicular position value”) has a high prognostic value for prediction of subsequent sperm analysis.
- Paternity rate  
Testes initially located beyond the inguinal canal have a good prognosis for fertility, although relatively location does not change outcome for unilateral cases.

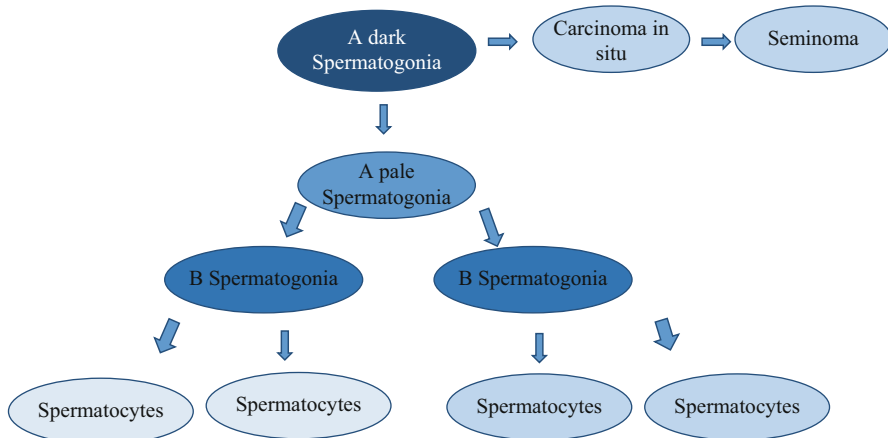
## Malignancy

Prevalence of testicular cancer consists of 1% of the male population. It is the most common solid tumor in the age of 15–34. The association between cryptorchidism and testicular germ cell tumors (TGCT) is well documented: Cryptorchidism has a relative risk of 3.7–7.5 times higher than in men with a normal testis position. Conversely, 5–10% of men who develop testicular cancer were or are cryptorchid (Thorup et al. 2010).

Two fundamental steps in maturation of germ cells normally occur in the prepubertal testis: the disappearance of gonocytes (the fetal stem cell pool) and the appearance of adult dark spermatogonia (the adult stem cell pool) at 2–3 months of age and the appearance of primary spermatocytes (the onset of meiosis) at 4–5 years.

By examining sections of testicular biopsies taken at orchidopexy in early infancy, Huff et al. (2001) demonstrated that gonocytes did not disappear and adult dark spermatogonia did not appear in undescended testes under 1 year of age, which indicates a defect in the first step in maturation at 2–3 months that results in failure to establish an adequate adult stem cell pool. Primary spermatocytes did not appear in the undescended testes and appeared in only 19% of contralateral descended testes at 4–5 years of age. The untransformed gonocytes then degenerate, causing the fall of the number of germ cells. The testicular germ cell tumor most commonly associated with cryptorchidism is seminoma. It is reported that the classical seminomas develop from the intratubular germ cell neoplasia (or carcinoma in situ, CIS). The CIS cells seem to develop following degeneration of neonatal gonocytes which have failed to transform into type A spermatogonia. Furthermore, the depletion of the spermatogonial stem cells pool leads to the complete loss of germ cells in the cryptorchid testis, which explains the infertility risk of these patients (Huff et al. 2001; Ferguson and Agoulnik 2013; Fig. 4).





**Fig. 4** Normal spermatogonial stem cells (SSCs) A (*dark*) and A (*pale*) either undergo a cycle of self-renewal or begin to differentiate and are controlled by the expression of somatic growth factors. Classical seminomas are derived from carcinoma in situ cells (CIS)

Different features are pointed as risk factors for malignancy in men with a history of cryptorchidism: such as laterality, age at orchiopexy, and initial testicular position.

### Laterality

In epidemiologic studies of testicular germ-cell cancer by Moller et al. (1996), cancer risk associated with cryptorchidism was found to be higher in bilateral than in unilateral cryptorchidism (RR, 4.9 and 2.9, respectively). Of the 21 cases with unilateral cryptorchidism, the cancer occurred in the undescended (ipsilateral) testis in 14 cases and in the normally descended (contralateral) testis in 7 cases. The relative cancer risk was therefore 3.9 in the ipsilateral and 1.9 in the contralateral testis. This also supports the finding that in some cases, unilateral cryptorchidism may be a bilateral disease, thus carrying a risk of bilateral neoplasia.

### Age at surgery

The risk of developing testicular cancer in cryptorchid men is not eliminated by orchidopexy, but surgery appears to decrease the risk. Petterson et al. (2007) found that the risk of testicular cancer among men who were treated at 13 years old or older (RR 5.40, 95% CI 3.20–8.53) was approximately twice than among men who underwent orchidopexy before age of 13 (RR 2.23 95% CI, 1.58–3.06). It seems that the younger the boy was at operation, the lower the RR for later testicular cancer: For boys 0–9 years at surgery RR was 0, for boys 10–14 years at surgery RR was 3.9, and for boys older than 15 years at surgery RR was 20.3 (Moller et al. 1996). Although preservation of fertility and self-examination are important, this indication is equally important for early surgical intervention. Based on such data in recent years, the recommended age of surgical correction was reduced and now is usually performed before the age of 6 months.

### **Initial testicular position**

The other factor that appears to play a role in tumor incidence is the relative position of the cryptorchid testes, and hence the degree of environment insults on the gonads, such as heat. It was shown that an abdominal testis presents a greater risk for malignancy than an inguinal testis (Cortes et al. 2001).

### **Inguinal Hernia**

In the perinatal period, after testicular descent, the processus vaginalis normally obliterates. Undescended testes are often associated with a patent processus vaginalis and consequent inguinal hernia. A clinically evident hernia present with a cryptorchid testis is an indication for immediate simultaneous intervention.

### **Torsion**

There is a high incidence of up to 20% for torsion in unoperated undescended testes. The mobility of a testis within the tunica vaginalis in the superficial inguinal pouch may predispose to torsion, but the exact frequency is difficult to determine.

### **Testicular Abnormality**

Separation between the body of the undescended testis and the epididymis is common. The risk of abnormal fusion is greater in intra-abdominal and in high inguinal testes than for those lying at the neck of the scrotum. These abnormalities may be related to underlying androgen deficiency in utero, and in a percentage of these the abnormality may be sufficient to interfere with fertility. Also abnormalities of the vas deferens occur commonly in boys with criptorchid testes (Murphy et al. 2007).

### **Psychological Factors**

Cryptorchidism is a major psychological problem because the obvious physical abnormality of the genitalia promotes parental anxiety about subsequent fertility.

### **Indications for Surgical Treatment**

- To preserve endogenous hormone production
- To preserve normal spermatogenesis
- To reduce the risk of malignancy – both directly and indirectly – by allowing early detection of neoplasia by self-examination
- To avoid complications such as testicular torsion and inguinal hernia
- To provide a normal genital appearance, avoiding psychological distress to the child and the family and enhancing the development of a normal body image

### **Timing of Surgical Treatment**

Controversy persists about whether the maldescent leads to the secondary abnormality of the testis or they coexist. Current management is based on the evidence that

the main abnormalities seen postnatally in undescended testes are secondary to high temperature and can be prevented by early intervention. Testicular thermoregulation is important to maintain testicular temperature within an optimal range for spermatogenesis (Durairajanayagam et al. 2015). Increases in scrotal temperature negatively affect sperm quality. An increase of 1 °C entails a 14% drop in spermatogenesis and consequently poorer sperm production. Spermatogenesis, especially the differentiation and maturation of spermatocytes and spermatids, is temperature-sensitive. Spermatogenesis should occur ideally at a minimum of 2 °C below core body temperature. Elevated scrotal temperature causes testicular germinal atrophy, spermatogenic arrest, and decreased levels of inhibin B (a biochemical marker of spermatogenesis) which leads to lower sperm counts. The severity with which cryptorchidism affects fertility depends on: whether one or both testes had failed to descend fully, positioning itself along the inguinal canal; the cause of the incomplete descent; and the length of time before surgical intervention to reposition the affected testicle into the scrotal sac. Recent evidence shows that testicular function is preserved only when surgery is done in early infancy as long-lasting high temperature leads the testis to undergo progressive alteration causing suffering of the early postnatal germ cells. Surgery should be performed before any irreversible changes in testicular morphology. In intra-abdominal testes, early degeneration of testicular germ cells starts in the first 6 months, derangements in hormone production in the first year of life, tubular dysplasia within the second years, light microscopic changes in the third years, and finally macroscopic atrophy at school age leading to irreversible azoospermia after puberty. According to this evidence, orchidopexy is now recommended at 6–9 months of age, especially in specialized pediatric surgical centers, where a younger age does not increase the risk of complications. In centers with less experience, surgery between 12 and 18 months may be safer. Nevertheless, some authors have shown an increase in the risk of damage to the spermatic cord structures in early operation, resulting in gonadal atrophy. Wilson-Storey et al. (1990) reviewed 200 patients: 100 had orchidopexy before and 100 after their second birthday. From the case records and from long-term review, they found that 5% of the testes in each group became atrophic. Some testes, which were “normal” at the 6-month review, had subsequently failed to increase in size, whereas some which were initially diagnosed as “atrophic” had grown, by long-term follow-up to a similar, normal size compared with the contralateral organ. This study suggests that the risk of postoperative atrophy is not directly related to age in pediatric surgical centers, and the timing for orchidopexy has therefore been a compromise between the potentially increasing risk of testicular dysplasia with age compared with the potentially increased risk of postoperative atrophy in younger children.

## **Surgical Treatment**

### **Standard Open Single-Stage Orchidopexy**

For inguinal undescended testes, it is the treatment of choice.

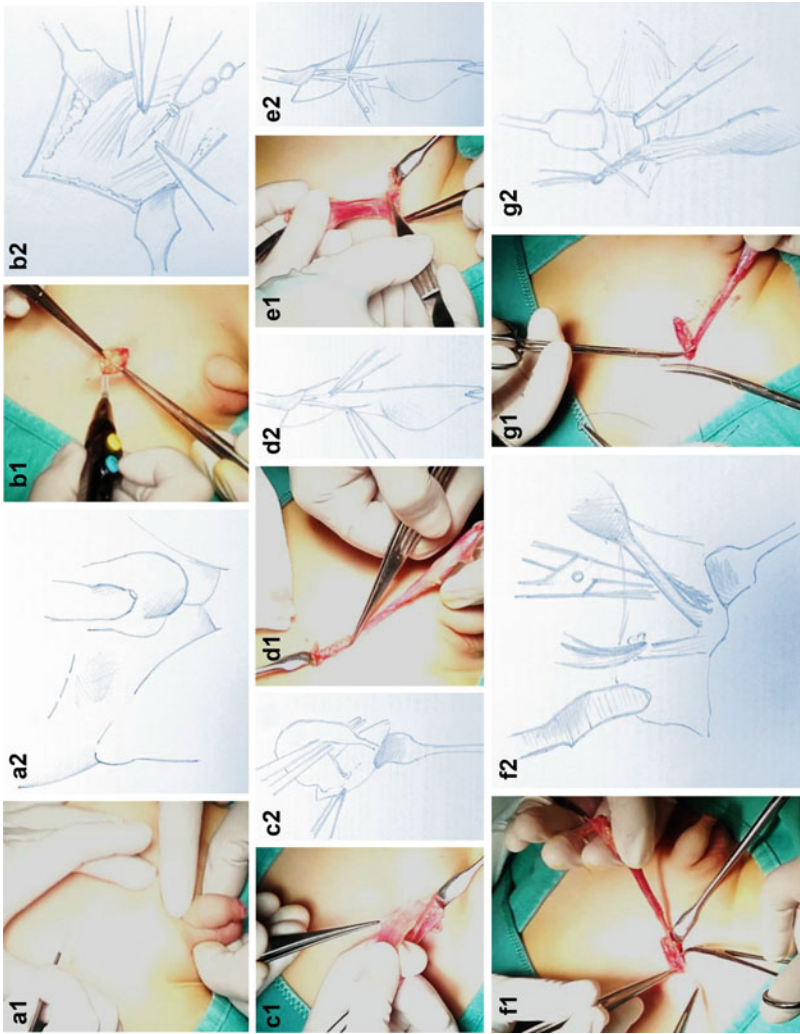
It involves two distinct stages: at first, an inguinal incision with a full exposure of the inguinal canal, the separation of the processus vaginalis, and the mobilization of the testis and the spermatic cord is mandatory; then the procedure ends with the orchidopexy itself, or fixation of the testis in the scrotum.

- Mobilization of the testis

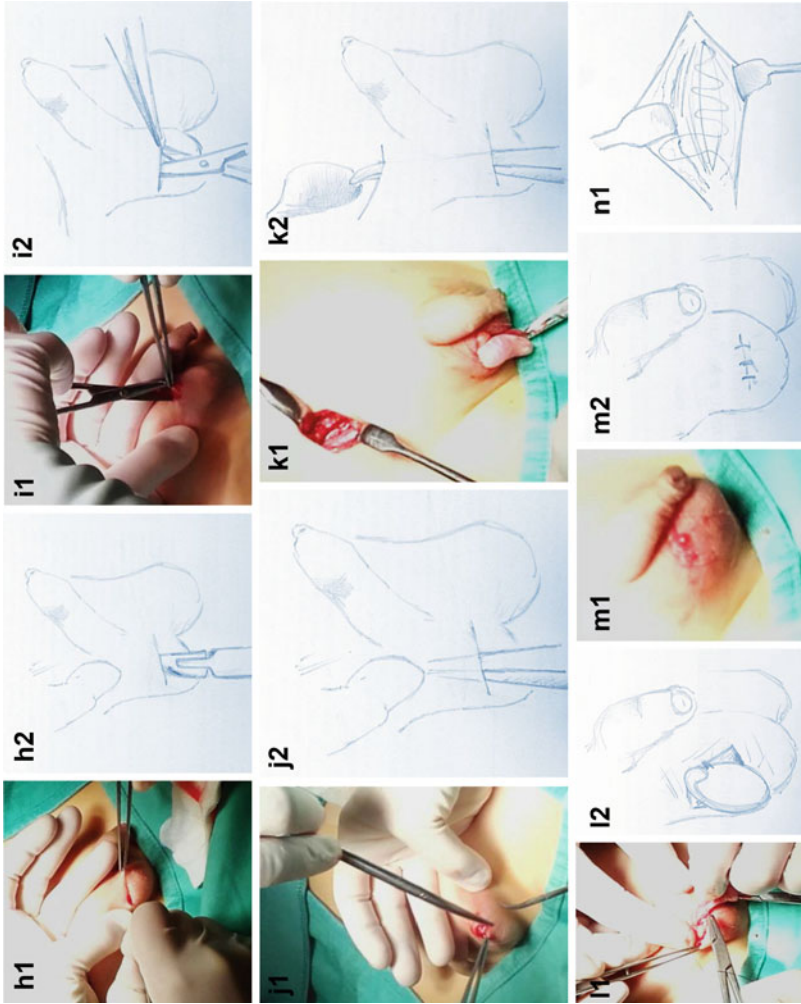
A transverse skin incision is made over the inguinal canal starting from the mid-inguinal point ending to the pubic tubercle (Fig. 5a1–a2). Helping with diathermy, the incision is deepened through the subcutaneous fatty tissue. The superficial fascia is made up of two layers: at first a more superficial fatty one (known as Camper's fascia) and then a deeper fibrous one (known as Scarpa's fascia). The superficial inferior epigastric vein runs in the subcutaneous tissue under the superficial layer so it should be coagulated by diathermy and divided (Fig. 5b1–b2). The external oblique aponeurosis is recognized by the oblique orientation of its fibers. Square retractors show its lower border where the inguinal ligament lies and the site of the external inguinal ring. A scalpel incision in the external oblique aponeurosis followed. This incision can be extended with scissors by cutting the fibers medially towards the external ring or by cutting laterally from the external ring. The ilioinguinal nerve that runs at this level should be identified and avoided since this accidental transaction could produce a sensory deficit in the region of the anterior scrotum (Fig. 5c1–c2). Finally, the spermatic cord is found by blunt dissection of the inner layer of the external oblique aponeurosis. Spermatic cord and testis are then delivered out of the wound. The gubernacular attachment is cut with scissors taking care to structures such as the testicular vessels and the vas deferens (Fig. 5d1–d2). The gubernacular attachment is placed on tension by a small artery forceps (Fig. 5e1–e2). The processus vaginalis is commonly widely patent in the undescended testis. Careful separation of this structure from the vas deferens and the testicular vessels is an important part of the procedure in order to increase the effective length of the spermatic cord. The processus vaginalis is stretched over the index finger while round-ended forceps gently sweep off the other structures avoiding direct application of strength to the vas deferens and the testicular vessels, which should be visualized clearly before the dissection of the sac (Fig. 5f1–f2). With the entire cord held on traction, the sac is then divided with scissors immediately distal to the artery forceps. The testicular vessels and vas deferens are separated with blunt dissection from posterior surface of the sac right up to the internal ring where the translucent processus vaginalis becomes a peritoneal opaque white membrane. This should allow adequate length of the spermatic cord to reach the scrotum (Fig. 5g1–g2). The processus vaginalis is twisted up to the internal ring; it is transfixed and ligated. Traction on the testis is finally stopped.

- Fixation of the testis

Through the inguinal incision, the index finger is introduced down to the scrotum, breaking any fascial layers while the thumb is immobilizing the scrotal skin (Fig. 5h1–h2). A horizontal scrotal incision is then made (Fig. 5i11–i12).



**Fig. 5** (continued)



**Fig. 5** Standard, open single-stage orchidopexy

A pair of scissors is used to develop a subcutaneous pouch (Fig. 5j1–j2). A fine artery forceps is placed through the scrotal incision and pressed internally to the inguinal one in order to break any residual fascial plane and grasps the gubernacular attachments of the testis (Fig. 5k1–k2). The testis is then drawn gently down through the track made by blunt dissection and delivered through the scrotal incision (Fig. 5l1–l2). Then an absorbable suture anchors the body of the testis to the midline scrotal septum in order to prevent its retraction through the inguinal canal. The testis epididymis and the adjacent coverings are then placed in the subcutaneous scrotal pouch, making sure that the cord structures are not twisted (Fig. 5m1–m2). The scrotal incision is closed (Fig. 5n1). Finally the external oblique aponeurosis is reconstituted. The retractors are removed from the inguinal wound, and the fibrous subcutaneous fascia is closed with one or two interrupted sutures. The skin is approximated with 4/0 subcuticular suture.

### **Open Two-Stage Orchidopexy**

When the testis is felt within the inguinal canal or into the abdomen, the spermatic cord may have insufficient length to reach the scrotum despite the maneuvers described previously. In this circumstance, when the testis has been dissected but does not reach the scrotum, it can be sutured in the groin at the lower point where it reaches comfortably as a first-stage procedure, and a second attempt is made 6–12 months later. Success rates for this two-stage orchidopexy have been quoted to be 70–90%.

### **Laparoscopic Fowler Stephens Two-Stage Orchidopexy**

Laparoscopy is the gold standard to diagnose and management of impalpable testes (Mehendale et al. 2013). Laparoscopic two-stage Fowler Stephens orchidopexy consists of clipping the internal spermatic vessels and returning 6 months later to mobilize the testis on collateral vessels and the deferential artery. The first stage begins with patient in supine position with 30° Trendelenburg tilt. Access is gained with a Veress needle technique. The peritoneal layer is opened sharply and the trocar placed usually between the obliterated umbilical arteries. Pneumoperitoneum is created with CO<sub>2</sub> at a flow rate between 8 and 10 L/min with a pressure limit of 8–10 mmHg. The pediatric laparoscope is introduced to view the intraperitoneal pelvic anatomy. Two 5-mm ports are inserted: one in the right iliac fossa and one in the left iliac fossa along the midclavicular line to facilitate dissection. The entire abdomen should be inspected at the time of diagnostic laparoscopy. The various anatomical landmarks are identified which include the bladder and the urachal ligament, lateral umbilical ligaments, inferior epigastric vessels, internal ring, vas deferens, and spermatic vessels. Examining the side opposite the pathology is useful for comparing normal anatomy. The testicular vessels are encircled. The testicular artery and vein are clipped with two titanium clips at this point away from the testis. The second stage of the orchidopexy is usually completed 6 months later. It allows the testis to be mobilized on the enlarged collateral vessels from the vas deferens, which then usually reach the scrotum. It can be performed in either open or laparoscopic fashion. The same principles apply as with an open second-stage

procedure is performed laparoscopically. Dissection begins in the area where the spermatic vessels were earlier clipped. The vessels are now divided below the level of previously applied clips. The retroperitoneum is incised with a 1-cm margin laterally to the testis and medially alongside the vas deferens. The peritoneal flap remains pedicled to the vas deferens. All the vessels around the vas deferens and the peritoneal plane between the vas and vessels are left intact. The gubernaculum is dissected as far distally as possible. The testis is mobilized carefully from the psoas fascia towards the inguinal ring. A new internal ring is created medially to the epigastric vessels. An incision is made at the lower pole of the scrotum, and a dartos pouch is created. A laparoscopic grasper is guided through a tunnel to the new internal ring, and the mobilized testis is pulled into the scrotum. Both stages of the operation are performed as a day case procedure. Routine follow-up is at approximately 6 months and 1 year. At this point, if the testis is of good size and within the scrotum, the patient is then discharged back to the general practitioner. In follow-up studies of this two-stage procedure, researchers report 70–90% scrotal position without atrophy (Stedman et al. 2015).

### **Orchiectomy**

It is typically reserved for post pubescent males with a contralateral normally descended testis when the cryptorchid testis is either anatomically or morphologically abnormal or too far from scrotum to allow for tension-free placement without compromising the vascular integrity of the testis.

### **Follow-Up**

After orchidopexy, the child is usually reexamined 1 week later to remove the dressing and assess the short-term outcome. A further follow-up examination is performed 6–12 months later to determine whether there has been any significant atrophy. The end result and appearance are satisfactory in the majority of instances.

### **Complications of Surgery**

After orchidopexy, nearly 96% of all testes reach the scrotum at operation, and this figure included 69% of abdominal and 94% of canalicular testes. Relapse with ascent of the testis out of the scrotum is a poor secondary condition due to wound infection, poor mobilization of the cord, or inadequate fixation of the testis within the scrotal pouch. In experienced hands, complications are less than 5%. Hemorrhage from poor hemostasis with complete infarction of the testis occurred in approximately 3% of patients with an impalpable testis. Atrophy caused by intraoperative damage of testicular vessels is a serious possible complication that could occur especially in children with concomitant strangulated inguinal hernia and in 15–20% of patients with a high intra-abdominal testis. Damage with occlusion of the lumen of the vas deferens is also described. Lymphedema tends to resolve spontaneously.



## Medical Therapy

Since the 1970s, hormonal treatment with gonadotropin releasing hormone (GnRH) analogs and/or human chorionic gonadotropin (hCG) has been proposed for cryptorchidism, the rationale for hormonal therapy being the increase in circulating androgens that may promote testicular descent. hCG stimulates endogenous testosterone production and is administered by intramuscular injection. Several dose and administration schedules have been reported. GnRH analogues (e.g., buserelin and gonadorelin) are available as nasal sprays, thus allowing to avoid painful intramuscular injections. A typical GnRH analogue dosage regimen consists of 1.2 mg/day in three divided doses, for 4 weeks.

Treatment with either hCG or GnRH stimulates testicular growth and initiation of spermatogenesis both in the cryptorchid and descended testes. Part of the growth after hCG treatment is related to inflammatory reaction. Apoptosis of germ cells can be observed after cessation of hCG treatment and may cause a reduction of the testes size (Cortes et al. 2000). hCG treatment has also been reported to cause potential harm to germ cells.

Several studies assessed the effectiveness of medical therapy as the treatment for cryptorchidism. Unfortunately, most studies were of poor quality, with heterogeneous patient populations, age, testis location, and schedules of hormonal administration, thus precluding definitive conclusions for any hormone or combination therapy. Few studies provided cancer or fertility outcomes, and long-term data are lacking (Rajfer et al. 1986; Penson et al. 2013). The efficacy of hormonal treatments in randomized controlled trials has been only around 20%, and 20% of descended may reascend. Reasons for failure include the presence of a “surgical cause” of the incomplete testicular descent. Some studies suggested that lower initial location of the testicle is associated with a greater likelihood of success.

As to side effects of hormonal treatment, some studies reported virilizing effects, including increased penile length, erections, scrotal erythema, and pigmentation and testicular enlargement, although these side effects were transitory.

In 2004, a systematic review and meta-analysis of randomized controlled trials on hormonal cryptorchidism treatment was done using the methodology of Cochrane Collaboration, and concluded that, because evidence was based on few trials, with small sample sizes and moderated risk of bias, this treatment could not be recommended for everyone (Henna et al. 2004).

Some authors reported successful descent and/or better sperm counts with combined hCG and GnRH therapy in up to 38–59% of undescended testes. Further data on combined therapy are lacking (Lala et al. 1993; Giannopoulos et al. 2001).

In 1997, Hadziselimovic and Herzog advocated GnRH therapy as an adjuvant treatment after orchiopexy, because they observed improved sperm production in patients who have type A dark spermatogonia in testicular biopsy and following GnRH treatment in patients with paucity of germ cells (Hadziselimovic and Herzog 1997). It was suggested that additional hormonal treatment may be beneficial for a special subgroup of cryptorchid patients, but further studies were recommended to identify such a group. The same author in 2008 demonstrated a normal sperm count

in 87% of 15 adults who had received buserelin treatment postoperatively, compared with 33% normal sperm count in 15 nontreated patients (Hadziselimovic 2008).

There may be specific cases where hormone therapy with GnRH may facilitate germ cell maturation after early orchidopexy, as was suggested also by Cortes et al. in their study on hormonal therapy (recombinant FSH or buserelin); the authors conclude that it may be indicated in patients with normal FSH and bilateral cryptorchidism with few germ cells or unilateral cryptorchidism with no germ cells in the biopsy at orchidopexy (Cortes et al. 2003).

In 2014, a systematic review and metaanalysis confirmed that a subset of boys with cryptorchidism may benefit from GnRH as adjunctive to orchidopexy in improving the fertility index, but quality evidences were still lacking to generalize and strongly recommend this approach (Chua et al. 2014).

In 2016, a review article proposed small doses of adjuvant gonadotropin-releasing hormone (GnRH) treatment for bilateral cryptorchid boys at early surgery without evidence of normal maturation of gonocytes into Ad spermatogonia, and without compensatory increase of gonadotropins (Cortes et al. 2016).

The identification of boys with undescended testes resulting from a disrupted hypothalamic-pituitary–testicular axis, who would benefit from hormonal therapy, is difficult. The identification of this subset of patients requires serum gonadotropin and inhibin B assessment, and it implies the need for testicular biopsy at the time of surgery (Thorup et al. 2015). The possible risks of testicular biopsies such as bleeding, infection, atrophy or loss of testis, and other parenchymal changes must be taken into account and weighed against possible benefits (Kraft et al. 2012).

Neither the Nordic nor American guidelines recommend hormonal treatment in cryptorchidism (Ritzén et al. 2007; Kolon et al. 2014). The 2016 European Society for Pediatric Urology guidelines do not recommend hormonal treatment of cryptorchidism to achieve testicular descent either; nevertheless, the authors state that adjuvant or neo-adjuvant hormonal treatment may improve fertility index, which may be a predictor for fertility later in life, though it still needs to be confirmed whether this effect on testicular histology persists into adulthood (Radmayr et al. 2016).

Hormonal therapy remains therefore extremely controversial, with evidence both for and against. Further studies of GnRH-supplementary treatment should include testicular biopsy at surgery and at follow-up in childhood as well as examinations of fertility potential and cancer risk in adulthood (Virtanen and Toppari 2015; Bu et al. 2016).

---

## Other Urogenital Malformations

### Hypospadias

In newborn males, hypospadias is the second most common congenital anomaly after undescended testes, and it represents the most common congenital malformation of the penis (Ságodi et al. 2014). Hypospadias is a congenital malformation of

the penis characterized by a ventral occurrence of urethral opening and hypoplasia of the ventral tissues in varying degrees. These abnormalities can be associated to penile curvature and excessive prepuce.

Hypospadias is caused by abnormal or incomplete urethral closure during the early weeks of embryonic development. In the last consensus on definition of disorders of sexual development (DSDs), hypospadias was included as a form of 46 XY DSD (Hughes et al. 2006).

The severity of the hypospadias is defined according to the location of the opening. In mild forms (distal hypospadias), the urethra opens in the glans or at the border between the glans and the shaft (corona and sulcus). More severe forms are represented by middle or penile hypospadias, in which the opening of the urethra is located on the shaft of the penis, and proximal hypospadias, in which the opening can be found in the penoscrotal area. Distal forms of hypospadias represent 70% of cases, and middle and proximal cases account for the remaining 30% (Carmichael et al. 2012).

Incidence of hypospadias is between 1/200 and 1/300 live male births (Kraft et al. 2010). According to a recent review on epidemiology of hypospadias, the prevalence of this condition shows a huge variability among different countries, ranging from 0.6/10,000 births in Malaysia to 464/10,000 births in Northern Europe (Denmark). However, the majority of studies reported a prevalence of 5–50/10,000 births. Moreover, there have been numerous worldwide studies showing an increasing prevalence of hypospadias over the last three decades, especially in developed countries (Springer et al. 2016). Epidemiological differences among areas have raised a major debate over the potential effects of environmental factors in the development of this condition.

It is generally accepted that hypospadias is a highly heterogeneous condition secondary to multiple genetic and environmental factors. Male external genital development is an androgen-dependent process. In particular, penile development during early fetal life is driven by dihydrotestosterone that is produced locally from testosterone by 5 $\alpha$ -reductase. It has been hypothesized that an impairment of androgen production or action, or the exposure to exogenous anti-androgenic agents or estrogens during pregnancy might result in hypospadias (Skakkebaek et al. 2016).

Mutations known to be associated to hypospadias are typically linked to disorders of testicular differentiation, testosterone synthesis, conversion of testosterone to dihydrotestosterone, or androgen receptor action (Kalfa et al. 2009). The association of bilateral cryptorchidism – undetectable testes at birth – and hypospadias suggests a 46XX DSD with virilization (congenital adrenal hyperplasia – 21 hydroxylase deficiency or other), and requires immediate investigations because of the risk of adrenal insufficiency and life-threatening salt-wasting forms.

However, a genetic cause for isolated hypospadias can be found only in a minority of hypospadias cases (Ságođi et al. 2014), and an endocrine abnormality is diagnosed only in 20% of the patients (Rey et al. 2005).

As stated above, the increasing incidence of hypospadias, particularly in developed countries, has led to the hypothesis that elevated exposure to estrogenic and

anti-androgenic environmental factors may contribute to its etiology. Agents involved may include molecules that interfere with synthesis, transport, or metabolism of endogenous hormones, such as xeno-estrogens or endocrine-disrupting compounds (EDCs). Many other chemicals have been identified as toxic for the urogenital tract, such as phthalates, bisphenol A, phytoestrogens, mycoestrogens, epichlorohydrin, atrazine, and furans, and many of them have pro-estrogenic or anti-androgenic effects (Bouty et al. 2015). Environmental factors can also change transcriptional activity via epigenetic modifications to the genome. It is therefore reasonable to state that certain environmental exposures may not only induce hypospadias in the exposed individual, but may also create long-lasting epigenetic changes that continue to increase the hypospadias risk for generations to come. (Bredfeldt et al. 2010; Wong and Walker 2013).

Hypospadias repair is now considered a safe and reliable procedure with a very high reported success rate, also in consequence of recent advances in surgical techniques and materials. The goal of hypospadias surgical repair is to achieve both functional and cosmetic normality. These objectives may be realized by a single procedure or with a staged approach. Main aim of hypospadias repair consists of the creation of a straight penis, with a uniform caliber of neourethra, which terminates in a natural meatus at the top of a naturally configured glans. Proximal hypospadias is the most challenging condition, and its surgical repair consists of urethral reconstruction, penile curvature correction, and penoscrotal transposition. The choice of surgical technique is driven by single patient anatomical characteristics, such as foreskin and glans configuration, urethral plate conditions, penile size and curvature, meatal position, and scrotum morphology. However, surgical procedures are based more on the quality and development of the urethral plate, rather than the location of the meatus (Manzoni et al. 2004). While advantages have been established for each technique, the current evidences cannot definitively identify an optimal method for individual patients (Springer et al. 2011). The one-stage repair consists of urethral plate tubularization (glans approximation or Snodgrass procedures) and urethral plate augmentation (onlay flap technique, Snod-graft technique). The two-stage repair is represented by urethral plate substitution (Bracka procedure).

Timing of intervention is also debated. Recommendations from the Section of Urology of the American Academy of Pediatrics recently suggested that the optimum time for elective surgery for hypospadias is either in the second 6 months of life or during the fourth year of life (Manzoni et al. 2004).

Hypospadias itself and its surgical repair are associated with future complications. Overall, most common complaints in patients with hypospadias or following its correction are lower urinary tract symptoms, spraying, urethrocuteaneous fistula, recurrent urinary tract infections, urethral stricture, and chordee (ventral curvature of the penis). Sexual dysfunction, such as erectile and ejaculatory dysfunction, may also be a consequence of hypospadias (Hoy and Rourke 2017). Onset of these complications may be either in childhood or in adult

life. Complications may be caused by poor surgical technique, postoperative infection, wound dehiscence, poor healing of the reconstructed tissue, and urine extravasation.

## **Micropenis**

Micropenis is a condition characterized by penile length smaller than 2.5 standard deviations (SD) below the mean (Aaronson 1994). The incidence of micropenis was reported as 1.5/10, 000 males (Nelson et al. 2005). Micropenis may occur as an isolated abnormality or as part of a syndromic picture and may be idiopathic or recognize a specific cause.

Differential diagnoses in patients with micropenis include primary testicular failure, impaired androgen production, hypogonadotrophic hypogonadism, and defects in testosterone action or developmental anomalies such as cloacal exstrophy (Wood and Woodhouse 2011).

An isolated micropenis occurs more commonly with a gonadotrophin deficiency, while those associated with androgen production impairment often present with hypospadias.

Micropenis provides different management challenges. The aims of treatment are to provide a good cosmetic outcome and to enable the patient to have a normal sexual function. Treatment of micropenis may be medical or surgical. Medical treatment is based on topical or systemic androgen administration. Testosterone may be administered by intramuscular injection or topical application. Topical application of dihydrotestosterone gel is usually addressed to prepubertal patients with partial androgen insensitivity syndrome. If the penis does not reach an adequate length despite medical interventions, surgical reconstructive treatment options may be considered (Hatipoğlu and Kurtoğlu 2013).

## **Epispadias**

Epispadias is a condition characterized by failure of the urethral plate to tubularize on the dorsum of the penis. Epispadias is a rare condition and commonly presents in association with bladder exstrophy. Its prevalence in male, when presenting as an isolated malformation, is 1/117,000 (Frimberger 2011).

The anatomic classification is based on the location of the urethral meatus, with the defect ranging from glanular to penile and penopubic. Penopubic epispadias involves the urethra and striated sphincter, starting from the bladder neck, and is often cause of incontinence and poor bladder capacity. Distal epispadias patients present urinary incontinence less frequently, although some authors report prevalence of this problem in up to 75% of cases (Kramer and Kelalis 1982).

Patients with epispadias may additionally present suprapubic or urogenital malformation such as dorsal chordee, pubic diastasis, bladder neck abnormalities, and vesicoureteral reflux.

Surgical correction aims at creation of functional genitalia with placement of the meatus in its anatomical position and good cosmetic outcomes. There is debate as to approach epispadias repair in one or multiple stages. In most simple distal cases, repair may be achieved in one stage. Penopubic epispadias may instead require more than one procedure to be corrected (Cho and Cendron 2014).

---

## References

- Aaronson IA. Micropenis: medical and surgical implications. *J Urol*. 1994;152(1):4–14.
- Adams IR, McLaren A. Sexually dimorphic development of mouse primordial germ cells: switching from oogenesis to spermatogenesis. *Development*. 2002;129(5):1155–64.
- Ansell PE, Bennett VJ, Bone DM, Bull DJ, Jackson MB, Pike LA, Chilvers CED, Dudley NE, Cough MH, Griffiths DM, Redman C, Wilkinson AR, Macfarlane A, Coupland CAC. Cryptorchidism: a prospective study of 7500 consecutive male births, 1984–8. *Arch Dis Child*. 1992;67(7):892–9.
- Bagheri-Fam S, Sim H, Bernard P, Jayakody I, Taketo MM, Scherer G, Harley VR. Loss of *Fgfr2* leads to partial XY sex reversal. *Dev Biol*. 2008;314(1):71–83.
- Biason-Laubert A, Konrad D, Meyer M, DeBeaufort C, Schoenle EJ. Ovaries and female phenotype in a girl with 46,XY karyotype and mutations in the *CBX2* gene. *Am J Hum Genet*. 2009;84(5):658–63.
- Birk OS, Casiano DE, Wassif CA, Cogliati T, Zhao L, Zhao Y, Grinberg A, Huang S, Kreidberg JA, Parker KL, Porter FD, Westphal H. The LIM homeobox gene *Lhx9* is essential for mouse gonad formation. *Nature*. 2000;403(6772):909–13.
- Bott RC, Clopton DT, Fuller AM, McFee RM, Lu N, McFee RM, Cupp AS. *KDR-LacZ*-expressing cells are involved in ovarian and testis-specific vascular development, suggesting a role for VEGFA in the regulation of this vasculature. *Cell Tissue Res*. 2010;342(1):117–30.
- Bouty A, Ayers KL, Pask A, Heloury Y, Sinclair AH. The genetic and environmental factors underlying hypospadias. *Sex Dev*. 2015;9(5):239–59.
- Bowles J, Feng CW, Spiller C, Davidson TL, Jackson A, Koopman P. *FGF9* suppresses meiosis and promotes male germ cell fate in mice. *Dev Cell*. 2010;19(3):440–9.
- Bredfeldt TG, Greathouse KL, Safe SH, Hung MC, Bedford MT, Walker CL. Xenoestrogen-induced regulation of *EZH2* and histone methylation via estrogen receptor signaling to *PI3K/AKT*. *Mol Endocrinol*. 2010;24(5):993–1006.
- Brennan J, Tilmann C, Capel B. *Pdgfr-alpha* mediates testis cord organization and fetal Leydig cell development in the XY gonad. *Genes Dev*. 2003;17(6):800–10.
- Bu Q, Pan Z, Jiang S, Wang A, Cheng H. The effectiveness of hCG and LHRH in boys with cryptorchidism: a meta-analysis of randomized controlled trials. *Horm Metab Res*. 2016;48(5):318–24.
- Byskov AG, Fenger M, Westergaard L, Andersen CY. Forskolin and the meiosis inducing substance synergistically initiate meiosis in fetal male germ cells. *Mol Reprod Dev*. 1993;34(1):47–52.
- Carmichael SL, Shaw GM, Lammer EJ. Environmental and genetic contributors to hypospadias: a review of the epidemiologic evidence. *Birth Defects Res A Clin Mol Teratol*. 2012;94:499–510.
- Chassot AA, Gregoire EP, Lavery R, Taketo MM, de Rooij DG, Adams IR, Chaboissier MC. *RSPO1/β-catenin* signaling pathway regulates oogonia differentiation and entry into meiosis in the mouse fetal ovary. *PLoS One*. 2011;6(10):e25641.

- Cho P, Cendron M. The surgical management of male epispadias in the new millennium. *Curr Urol Rep.* 2014;15(12):472.
- Chua ME, Mendoza JS, Gaston MJ, Luna Jr SL, Morales Jr ML. Hormonal therapy using gonadotropin releasing hormone for improvement of fertility index among children with cryptorchidism: a meta-analysis and systematic review. *J Pediatr Surg.* 2014;49(11):1659–67.
- Clark AM, Garland KK, Russell LD. Desert hedgehog (Dhh) gene is required in the mouse testis for formation of adult-type Leydig cells and normal development of peritubular cells and seminiferous tubules. *Biol Reprod.* 2000;63(6):1825–38.
- Colvin JS, Green RP, Schmahl J, Capel B, Ornitz DM. Male-to-female sex reversal in mice lacking fibroblast growth factor 9. *Cell.* 2001;104(6):875–89.
- Combes AN, Wilhelm D, Davidson T, Dejana E, Harley V, Sinclair A, Koopman P. Endothelial cell migration directs testis cord formation. *Dev Biol.* 2009;326(1):112–20.
- Cook MS, Munger SC, Nadeau JH, Capel B. Regulation of male germ cell cycle arrest and differentiation by DND1 is modulated by genetic background. *Development.* 2011;138(1):23–32.
- Cool J, Capel B. Mixed signals: development of the testis. *Semin Reprod Med.* 2009;27(1):5–13.
- Cool J, Carmona FD, Szucsik JC, Capel B. Peritubular myoid cells are not the migrating population required for testis cord formation in the XY gonad. *Sex Dev.* 2008;2(3):128–33.
- Cortes D, Thorup J. Histology of testicular biopsies taken at operation for bilateral maldescended testes in relation to fertility in adulthood. *Br J Urol.* 1991;68(3):285–91.
- Cortes D, Thorup J, Visfeldt J. Hormonal treatment may harm the germ cells in 1 to 3-year-old boys with cryptorchidism. *J Urol.* 2000;163(4):1290–2.
- Cortes D, Thorup JM, Visfeldt J. Cryptorchidism: aspects of fertility and neoplasms. A study including data of 1,335 consecutive boys who underwent testicular biopsy simultaneously with surgery for cryptorchidism. *Horm Res.* 2001;55(1):21–7.
- Cortes D, Thorup J, Lindenberg S, et al. Infertility despite surgery for cryptorchidism in childhood can be classified by patients with normal or elevated follicle-stimulating hormone and identified at orchidopexy. *BJU Int.* 2003;91(7):670–4.
- Cortes D, Holt R, de Knegt VE. Hormonal aspects of the pathogenesis and treatment of cryptorchidism. *Eur J Pediatr Surg.* 2016;26(5):409–17.
- Coughlin MT, Bellinger MF, Lee PA. Age at unilateral orchiopexy: effect on hormone levels and sperm count in adulthood. *J Urol.* 1999;162(3 Pt 2):986–8.
- Cupp AS, Kim GH, Skinner MK. Expression and action of neurotrophin-3 and nerve growth factor in embryonic and early postnatal rat testis development. *Biol Reprod.* 2000;63(6):1617–28.
- Cupp AS, Uzumcu M, Skinner MK. Chemotactic role of neurotrophin 3 in the embryonic testis that facilitates male sex determination. *Biol Reprod.* 2003;68(6):2033–7.
- Domenice S, Latronico AC, Brito VN, Arnhold IJ, Kok F, Mendonca BB. Adrenocorticotropin-dependent precocious puberty of testicular origin in a boy with X-linked adrenal hypoplasia congenita due to a novel mutation in the DAX1 gene. *J Clin Endocrinol Metab.* 2001;86(9):4068–71.
- Durairajanayagam D, Agarwal A, Ong C. Causes, effects and molecular mechanisms of testicular heat stress. *Reprod BioMed Online.* 2015;30(1):14–27.
- Elder JS. Ultrasonography is unnecessary in evaluating boys with a nonpalpable testis. *Pediatrics.* 2002;110(4):748–51.
- Engeler DS, Hösli PO, John H, Bannwart F, Sulser T, Amin MB, Heitz PU, Hailemariam S. Early orchiopexy: prepubertal intratubular germ cell neoplasia and fertility outcome. *Urology.* 2000;56(1):144–8.
- Ferguson L, Agoulnik AI. Testicular cancer and cryptorchidism. *Front Endocrinol.* 2013;4:32.
- Ferrara N, Carver-Moore K, Chen H, Dowd M, Lu L, O'Shea KS, Powell-Braxton L, Hillan KJ, Moore MW. Heterozygous embryonic lethality induced by targeted inactivation of the VEGF gene. *Nature.* 1996;380(6573):439–42.
- Frimberger D. Diagnosis and management of epispadias. *Semin Pediatr Surg.* 2011;20(2):85–90.

- Giannopoulos MF, Vlachakis IG, Charissis GC. 13 years' experience with the combined hormonal therapy of cryptorchidism. *Horm Res.* 2001;55(1):33–7.
- Gnessi L, Basciani S, Mariani S, Arizzi M, Spera G, Wang C, Bondjers C, Karlsson L, Betsholtz C. Leydig cell loss and spermatogenic arrest in platelet-derived growth factor (PDGF)-A-deficient mice. *J Cell Biol.* 2000;149(5):1019–26.
- Hadziselimovic F. Successful treatment of unilateral cryptorchid boys risking infertility with LH-RH analogue. *Int Braz J Urol.* 2008;34(3):319–26.
- Hadziselimovic F, Herzog B. Treatment with a luteinizing hormone-releasing hormone analogue after successful orchiopexy markedly improves the chance of fertility later in life. *J Urol.* 1997;158(3 Pt 2):1193–5.
- Hadziselimovic F, Herzog B, Seguchi H. Surgical correction of cryptorchism at 2 years: electron microscopic and morphometric investigations. *J Pediatr Surg.* 1975;10(1):19–26.
- Hatano O, Takakusu A, Nomura M, Morohashi K. Identical origin of adrenal cortex and gonad revealed by expression profiles of Ad4BP/SF-1. *Genes Cells.* 1996;1(7):663–71.
- Hatipoğlu N, Kurtoglu S. Micropenis: etiology, diagnosis and treatment approaches. *J Clin Res Pediatr Endocrinol.* 2013;5(4):217–23.
- Henna MR, Del Nero RG, Sampaio CZ, et al. Hormonal cryptorchidism therapy: systematic review with meta-analysis of randomized clinical trials. *Pediatr Surg Int.* 2004;20(5):357–9.
- Hiramatsu R, Matoba S, Kanai-Azuma M, Tsunekawa N, Katoh-Fukui Y, Kurohmaru M, Morohashi K, Wilhelm D, Koopman P, Kanai Y. A critical time window of SRY action in gonadal sex determination in mice. *Development.* 2009;136(1):129–38.
- Hoy NY, Rourke KF. Better defining the spectrum of adult hypospadias: examining the effect of childhood surgery on adult presentation. *Urology.* 2017;99:281–6.
- Huff DS, Fenig DM, Canning DA, Carr MG, Zderic SA, Snyder 3rd HM. Abnormal germ cell development in cryptorchidism. *Horm Res.* 2001;55(1):11–7.
- Hughes IA, Houk C, Ahmed SF, Lee PA. Lawson Wilkins Pediatric Endocrine Society/European Society for Paediatric Endocrinology Consensus Group: consensus statement on management of intersex disorders. *J Pediatr Urol.* 2006;2:148–62.
- Hutson JM, Hasthorpe S. Testicular descent and cryptorchidism: the state of the art in 2004. *J Pediatr Surg.* 2005;40(2):297–302.
- Kalfa N, Philibert P, Sultan C. Is hypospadias a genetic, endocrine or environmental disease, or still an unexplained malformation? *Int J Androl.* 2009;32(3):187–97.
- Katoh-Fukui Y, Miyabayashi K, Komatsu T, Owaki A, Baba T, Shima Y, Kidokoro T, Kanai Y, Schedl A, Wilhelm D, Koopman P, Okuno Y, Morohashi K. Cbx2, a polycomb group gene, is required for SRY gene expression in mice. *Endocrinology.* 2012;153(2):913–24.
- Kim Y, Kobayashi A, Sekido R, DiNapoli L, Brennan J, Chaboissier MC, Poulat F, Behringer RR, Lovell-Badge R, Capel B. FGF9 and WNT4 act as antagonistic signals to regulate mammalian sex determination. *PLoS Biol.* 2006;4(6):e187.
- Kitamura K, Yanazawa M, Sugiyama N, Miura H, Iizuka-Kogo A, Kusaka M, Omichi K, Suzuki R, Kato-Fukui Y, Kamiirisa K, Matsuo M, Kamijo S, Kasahara M, Yoshioka H, Ogata T, Fukuda T, Kondo I, Kato M, Dobyns WB, Yokoyama M, Morohashi K. Mutation of ARX causes abnormal development of forebrain and testes in mice and X-linked lissencephaly with abnormal genitalia in humans. *Nat Genet.* 2002;32(3):359–69.
- Kocer A, Reichmann J, Best D, Adams IR. Germ cell sex determination in mammals. *Mol Hum Reprod.* 2009;15(4):205–13.
- Köhler B, Achermann JC. Update—steroidogenic factor 1 (SF-1, NR5A1). *Minerva Endocrinol.* 2010;35(2):73–86.
- Köhler B, Biebermann H, Friedsam V, Gellermann J, Maier RF, Pohl M, Wieacker P, Hiort O, Grüters A, Krude H. Analysis of the Wilms' tumor suppressor gene (WT1) in patients 46,XY disorders of sex development. *J Clin Endocrinol Metab.* 2011;96(7):E1131–6.
- Kolasa A, Misiakiewicz K, Marchlewicz M, Wiszniewska B. The generation of spermatogonial stem cells and spermatogonia in mammals. *Reprod Biol.* 2012;12(1):5–23.



- Kolon TF, Herndon CDA, Baker LA, et al. American Urological Association. Evaluation and treatment of cryptorchidism: AUA guideline. *J Urol*. 2014;192(2):337–45.
- Kraft KH, Shukla AR, Canning DA. Hypospadias. *Urol Clin North Am*. 2010;37(2):167–81.
- Kraft KH, Canning DA, Snyder 3rd HM, Kolon TF. Undescended testis histology correlation with adult hormone levels and semen analysis. *J Urol*. 2012;188:1429e35.
- Kramer SA, Kelalis PP. Assessment of urinary continence in epispadias: review of 94 patients. *J Urol*. 1982;128(2):290–3.
- Kremer H, Kraaij R, Toledo SP, Post M, Fridman JB, Hayashida CY, van Reen M, Milgrom E, Ropers HH, Mariman E. Male pseudohermaphroditism due to a homozygous missense mutation of the luteinizing hormone receptor gene. *Nat Genet*. 1995;9(2):160–4.
- Lala R, Matarazzo P, Chiabotto P, de Sanctis C, Canavese F, Hadziselimovic F. Combined therapy with LHRH and HCG in cryptorchid infants. *Eur J Pediatr*. 1993;152(Suppl. 2):S31e3.
- Lee PA. Fertility after cryptorchidism: epidemiology and other outcome studies. *Urology*. 2005;66(2):427–31.
- Lin YT, Capel B. Cell fate commitment during mammalian sex determination. *Curr Opin Genet Dev*. 2015;32:144–52.
- Loftin CD, Tian HF, Langenbach R. Phenotypes of the COX-deficient mice indicate physiological and pathophysiological roles for COX-1 and COX-2. *Prostaglandins Other Lipid Mediat*. 2002;68–69:177–85.
- Lu N, Sargent KM, Clopton DT, Pohlmeier WE, Brauer VM, McFee RM, Weber JS, Ferrara N, Silversides DW, Cupp AS. Loss of vascular endothelial growth factor A (VEGFA) isoforms in the testes of male mice causes subfertility, reduces sperm numbers, and alters expression of genes that regulate undifferentiated spermatogonia. *Endocrinology*. 2013;154(12):4790–802.
- Ludwig G, Potempa J. Optimal time for treating cryptorchism. *Dtsch Med Wochenschr*. 1975;100(13):680–3.
- MacLean G, Li H, Metzger D, Chambon P, Petkovich M. Apoptotic extinction of germ cells in testes of Cyp26b1 knockout mice. *Endocrinology*. 2007;148(10):4560–7.
- Mandat KM, Wiczorkiewicz B, Gubała-Kacała M, Sypniewski J, Bujok G. Semen analysis of patients who had orchidopexy in childhood. *Eur J Pediatr Surg*. 1994;4(2):94–7.
- Manzoni G, Bracka A, Palminteri E, Marrocco G. Hypospadias surgery: when, what and by whom? *BJU Int*. 2004;94(8):1188–95.
- Mayr J, Pusch HH, Schimpl G, Reitinger T, Sorantin E, Mayr-Koci M. Semen quality and gonadotropin levels in patients operated upon for cryptorchidism. *Pediatr Surg Int*. 1996;11(5–6):354–8.
- McAleer IM, Packer MG, Kaplan GW, Scherz HC, Krous HF, Billman GF. Fertility index analysis in cryptorchidism. *J Urol*. 1995;153(4):1255–8.
- McLaren A, Southee D. Entry of mouse embryonic germ cells into meiosis. *Dev Biol*. 1997;187(1):107–13.
- Mehendale VG, Shenoy SN, Shah RS, Chaudhari NC, Mehendale AV. Laparoscopic management of impalpable undescended testes: 20 years' experience. *J Minim Access Surg*. 2013;9(4):149–53.
- Møller H, Prener A, Skakkebaek NE. Testicular cancer, cryptorchidism, inguinal hernia, testicular atrophy, and genital malformations: case-control studies in Denmark. *Cancer Causes Control*. 1996;7(2):264–74.
- Morita Y, Tilly JL. Segregation of retinoic acid effects on fetal ovarian germ cell mitosis versus apoptosis by requirement for new macromolecular synthesis. *Endocrinology*. 1999;140(6):2696–703.
- Munger SC, Natarajan A, Looger LL, Ohler U, Capel B. Fine time course expression analysis identifies cascades of activation and repression and maps a putative regulator of mammalian sex determination. *PLoS Genet*. 2013;9(7):e1003630.
- Murphy F, Paran TS, Puri P. Orchidopexy and its impact on fertility. *Pediatr Surg Int*. 2007;23(7):625–32.

- Nelson CP, Park JM, Wan J, Bloom DA, Dunn RL, Wei JT. The increasing incidence of congenital penile anomalies in the United States. *J Urol.* 2005;174:1573–6.
- Nel-Themaat L, Vadakkan TJ, Wang Y, Dickinson ME, Akiyama H, Behringer RR. Morphometric analysis of testis cord formation in SOX9-EGFP mice. *Dev Dyn.* 2009;238(5):1100–10.
- Nel-Themaat L, Jang CW, Stewart MD, Akiyama H, Viger RS, Behringer RR. Sertoli cell behaviors in developing testis cords and postnatal seminiferous tubules of the mouse. *Biol Reprod.* 2011;84(2):342–50.
- O'Shaughnessy PJ, Baker PJ, Johnston H. Neuroendocrine regulation of Leydig cell development. *Ann N Y Acad Sci.* 2005;1061:109–19.
- O'Shaughnessy PJ, Baker PJ, Johnston H. The foetal Leydig cell – differentiation, function and regulation. *Int J Androl.* 2006;29(1):90–5. discussion 105–8.
- Penson D, Krishnaswami S, Jules A, McPheeters ML. Effectiveness of hormonal and surgical therapies for cryptorchidism: a systematic review. *Pediatrics.* 2013;131(6):e1897–907.
- Pettersson A, Richiardi L, Nordenskjöld A, Kaijser M, Akre O. Age at surgery for undescended testis and risk of testicular cancer. *N Engl J Med.* 2007;356(18):1835–41.
- Piard J, Mignot B, Arbez-Gindre F, Aubert D, Morel Y, McElreavy K, Jonveaux P, Valduga M, Van Maldergem L. Severe sex differentiation disorder in a boy with a 3.8 Mb 10q25.3-q26.12 microdeletion encompassing EMX2. *Am J Med Genet A.* 2014;164A(10):2618–22.
- Puri P, Sparnon A. Relationship of primary site of testis to final testicular size in cryptorchid patients. *Br J Urol.* 1990;66(2):208–10.
- Radmayr C, Dogan HS, Hoebcke P, Kocvara R, Nijman R, Stein R, Undre S, Tekgul S. Management of undescended testes: European Association of Urology/European Society for Paediatric Urology Guidelines. *J Pediatr Urol.* 2016;12:335e343.
- Rajfer J, Handelsman DJ, Swerdloff RS, Hurwitz R, Kaplan H, Vandergast T, et al. Hormonal therapy of cryptorchidism. A randomized, double-blind study comparing human chorionic gonadotropin and gonadotropin-releasing hormone. *New Engl J Med.* 1986;314:466e70.
- Rey RA, Codner E, Iñiguez G, Bedecarrás P, Trigo R, Okuma C, Gottlieb S, Bergadá I, Campo SM, Cassorla FG. Low risk of impaired testicular Sertoli and Leydig cell functions in boys with isolated hypospadias. *J Clin Endocrinol Metab.* 2005;90(11):6035–40.
- Ritzén EM, Bergh A, Bjerknes R, et al. Nordic consensus on treatment of undescended testes. *Acta Paediatr.* 2007;96(5):638–43.
- Ságodi L, Kiss A, Kiss-Tóth E, Barkai L. Prevalence and possible causes of hypospadias (in Hungarian). *Orv Hetil.* 2014;155:978–85.
- Sargent KM, McFee RM, Spuri Gomes R, Cupp AS. Vascular endothelial growth factor A: just one of multiple mechanisms for sex-specific vascular development within the testis? *J Endocrinol.* 2015;227(2):R31–50.
- Schmahl J, Eicher EM, Washburn LL, Capel B. SRY induces cell proliferation in the mouse gonad. *Development.* 2000;127(1):65–73.
- Schmahl J, Kim Y, Colvin JS, Ornitz DM, Capel B. FGF9 induces proliferation and nuclear localization of FGFR2 in Sertoli precursors during male sex determination. *Development.* 2004;131(15):3627–36.
- Schreiber K, Menardi G, Marberger H, et al. Late results after surgical treatment of maldescended testes with special regard to exocrine and endocrine testicular function. *Eur Urol.* 1981;7:268–73.
- Skakkebaek NE, Rajpert-De Meyts E, Buck Louis GM, Toppari J, Andersson AM, Eisenberg ML, Jensen TK, Jørgensen N, Swan SH, Sapra KJ, Ziebe S, Priskorn L, Juul A. Male reproductive disorders and fertility trends: influences of environment and genetic susceptibility. *Physiol Rev.* 2016;96(1):55–97.
- Springer A, Krois W, Horcher E. Trends in hypospadias surgery: results of a worldwide survey. *Eur Urol.* 2011;60:1184e9.
- Springer A, van den Heijkant M, Baumann S. Worldwide prevalence of hypospadias. *J Pediatr Urol.* 2016;12(3):152.e1–7.

- Stedman F, Bradshaw CJ, Kufeji D. Current practice and outcomes in the management of intra-abdominal testes. *Eur J Pediatr Surg.* 2015;25(5):409–13.
- Suzuki A, Niimi Y, Saga Y. Interaction of NANOS2 and NANOS3 with different components of the CNOT complex may contribute to the functional differences in mouse male germ cells. *Biol Open.* 2014;3(12):1207–16.
- Svingen T, Koopman P. Building the mammalian testis: origins, differentiation, and assembly of the component cell populations. *Genes Dev.* 2013;27(22):2409–26.
- Tang H, Brennan J, Karl J, Hamada Y, Raetzman L, Capel B. Notch signaling maintains Leydig progenitor cells in the mouse testis. *Development.* 2008;135(22):3745–53.
- Teerds KJ, Huhtaniemi IT. Morphological and functional maturation of Leydig cells: from rodent models to primates. *Hum Reprod Update.* 2015;21(3):310–28.
- Thorup J, McLachlan R, Cortes D, Nation TR, Balic A, Southwell BR, Hutson JM. What is new in cryptorchidism and hypospadias – a critical review on the testicular dysgenesis hypothesis. *J Pediatr Surg.* 2010;45(10):2074–86.
- Thorup J, Clasen-Linde E, Thorup SC, et al. Pre- and postoperative status of gonadotropins (FSH and LH) and inhibin B in relation to testicular histopathology at orchidopexy in infant boys with unilateral undescended testes. *J Pediatr Urol.* 2015;11(1):25.e1–5.
- Virtanen HE, Toppari J. Cryptorchidism and fertility. *Endocrinol Metab Clin North Am.* 2015;44(4):751–60.
- Wilhelm D, Martinson F, Bradford S, Wilson MJ, Combes AN, Beverdam A, Bowles J, Mizusaki H, Koopman P. Sertoli cell differentiation is induced both cell-autonomously and through prostaglandin signaling during mammalian sex determination. *Dev Biol.* 2005;287(1):111–24.
- Wilson-Storey D, McGenity K, Dickson JA. Orchidopexy: the younger the better? *J R Coll Surg Edinb.* 1990;35(6):362–4.
- Wong RL, Walker CL. Molecular pathways: environmental estrogens activate nongenomic signaling to developmentally reprogram the epigenome. *Clin Cancer Res.* 2013;19(14):3732–7.
- Wood D, Woodhouse C. Penile anomalies in adolescence. *ScientificWorldJournal.* 2011;11:614–23.
- Yao HH, Whoriskey W, Capel B. Desert Hedgehog/Patched 1 signaling specifies fetal Leydig cell fate in testis organogenesis. *Genes Dev.* 2002;16(11):1433–40.

D. Fietz and M. Bergmann

## Abstract

The human testis is a paired endocrine and exocrine organ producing sex steroid hormones and mature haploid sperm. The latter are transported into the epididymis for further maturation and storage.

Especially the endocrine function requires a specific anatomical and histological structure of the testis, i.e., a special “location” of the testis outside the body in the scrotum, a sophisticated blood supply, and the development of lobes within the testis containing seminiferous tubules surrounded by the interstitial compartment.

Within the seminiferous tubules, both somatic Sertoli cells and different germ cell developmental stages can be described. As “nursery cells,” Sertoli cells build up the blood-testis barrier. This is required for preventing the meiotic germ cells from the own immune system and for creating a microenvironment essential for the germ cells development. Certain hormone receptors, such as androgen and estrogen receptors, specific secretions products, such as androgen binding protein, and special structural features are provided by Sertoli cells. Most interestingly, structural features of the Sertoli cells include basal and apical ectoplasmic specializations. These are required both for blood-testis barrier formation and for linking elongated spermatids within the Sertoli cell cytoplasm until sperm release. As an important part of the functional histology of the testis, Sertoli cell structure and function will be discussed in this chapter.

Additionally, stages of spermatogenesis with the different germ cell differentiation steps will be described for a broad overview of testicular histology. Within the interstitial compartment, not only well-known steroid-producing Leydig cells

---

D. Fietz (✉) • M. Bergmann

Institute for Veterinary Anatomy, Histology and Embryology, Justus Liebig University Giessen, Giessen, Germany

e-mail: [daniela.fietz@vetmed.uni-giessen.de](mailto:daniela.fietz@vetmed.uni-giessen.de); [martin.bergmann@vetmed.uni-giessen.de](mailto:martin.bergmann@vetmed.uni-giessen.de)

are present but also certain cells of the immune system (mainly macrophages), lymph and blood vessels, as well as rarely seen nerve fibers.

### Keywords

Testis • Anatomy and histology • Sertoli cells • Germ cells • Spermatogenesis • Hormone receptors

## Contents

Scrotum .....	314
Processus Vaginalis ( <i>Cavum serosum scroti</i> ) .....	315
Ligaments .....	315
Vascularization/Innervation .....	316
Testis .....	317
External Appearance, Tunica Albuginea/Septula Testes .....	317
Interstitial Compartment .....	318
Seminiferous Tubules .....	322
Rete Testis .....	335
Ductuli Efferentes Testis .....	336
Summary .....	336
Cross-References .....	338
References .....	338

## Scrotum

The scrotum belongs to the secondary sex organs. It develops by administration of sex hormones, which are secreted by the fetal testes later in embryonic life. The scrotum is developmentally homologous to the labia majora in the female. During the fifth week after fertilization, the gonadal ridge grows behind the peritoneal membrane. By week 6, string-like tissues called primary sex cords form due to the enlarging gonadal ridge. Externally, the genital tubercle appears over the cloacal membrane. By starting testosterone secretion in week 8 after fertilization, the labioscrotal folds are closed into the scrotum, a process called “masculinization.” The outer scrotal raphe as well as the inner scrotal septum is formed when the urethral groove closes by week 12.

The scrotum is continuous to the abdominal skin located directly behind the penis and in front of the perineum. The two more or less symmetrical chambers, build by scrotal raphe and septum of scrotum (*raphe* and *septum scroti*), contain one *processus vaginalis* (see section “[Processus Vaginalis \(\*Cavum serosum scroti\*\)](#)”) each. The scrotal sac is constituted of a thin layer of external skin, which contains more pigment than the surrounding skin, many sebaceous and sweat glands as well as some hair. Below the outer skin, we find a modified subcutaneous tissue, the dartos fascia (*tunica dartos*). This layer contains a lot of smooth muscle cells (*dartos muscle*), which proceed into the scrotal septum and are essential for thermoregulation as they can contract or relax the scrotal skin. The deepest layer of the scrotum is built by the external spermatic fascia (*fascia spermatica externa*), which derives from the superficial fascia.

The scrotum protects the testes and keeps them at a temperature several degrees below the normal body temperature as it protrudes from the body wall and may contract or relax by its smooth muscle within the subcutaneous layer. By high feverish infections, the higher temperature within the testes might lead to a temporarily decreased fertility, which can be restored after recovery.

### **Processus Vaginalis (*Cavum serosum scroti*)**

The *processus vaginalis* is a protrusion of the transverse fascia (*transversalis fascia*, called internal spermatic fascia in this area) as well as the parietal peritoneum (*tunica vaginalis*) through the inguinal canal out of the abdominal cavity into the scrotum. Within this pouch we can locate the testis, epididymis, spermatic cord, and ductus deferens. As a derivation of the inner oblique muscle and the transverse abdominal muscle, the cremasteric muscle (*musculus cremaster*) attaches to the vaginal process to be able to lift the testis as a second mechanism for thermoregulation and in case of danger.

The *processus vaginalis* appears at about 13 weeks of development as an outpouching of the transverse fascia and the parietal peritoneum. This developing tunnel moves medial and caudal between the internal and external abdominal oblique muscles (building the inner and outer inguinal ring by their aponeuroses) and into the scrotum. Leaving the abdominal cavity requires an increased intra-abdominal pressure. The descending testes stay at the opening of the vaginal process for about 10–12 weeks. At week 26–34 of gestation, testis and epididymis proceed into the vaginal process drawn by the gubernaculum. The distal part of the vaginal process directly surrounding testis and epididymis is called *tunica vaginalis*. This structure consists of two layers, a parietal layer on the “wall” of the scrotal sac as well as a visceral layer onto the organs. Between these two layers, the serous cavity called *cavum serosum scroti* is located, containing little amounts of serous fluid. The *processus vaginalis* fuses afterward with the posterior layers of the scrotum and prevents the testis from rotating.

In contrast to other mammals as livestock and pet animals, the *processus vaginalis* closes in human males around week 37–40 (full term). By this, an open communication between the abdominal cavity, the inguinal canal, and the scrotum does not exist anymore. Whereas especially rabbits are able to retract the testes within the abdominal cavity in case of danger by contraction of the cremaster muscle, this is impossible in adult men. A failure of the *processus vaginalis* to close accounts for nearly all inguinal hernias in childhood, but also for other common congenital conditions of childhood as scrotal hydroceles (an accumulation of abdominal fluid within the vaginal cavity) and encysted hydroceles of the cord, but also hernia in later life might occur (for review see Hutson et al. 1997).

### **Ligaments**

The *gubernaculum* or caudal genital ligament adheres to the caudal pole of the developing testis during embryogenesis and guides the testis from the inner inguinal

ring into the vaginal cavity. Therefore, it facilitates the testis descent (*descensus testis*). In adult life, the upper part of the gubernaculum regresses, whereas the lower part remains as scrotal ligaments. As shown by Shafik (1977), parts of the scrotal ligaments were found in 20 of 22 adult men. They tightly connect the lower pole of testis and epididymis to the ground of the vaginal cavity. As reviewed by Migaleddu et al. (2012), the gubernaculum testis is very short and tight in most men. A long, loose scrotal ligament might be a predisposition for testicular torsions. As reviewed most recently by Shimizu et al. (2016), testicular torsion is a urological emergency affecting mostly children and young men. Besides scrotal pain, ischemia of the testis leads to an impaired spermatogenesis and – if not diagnosed and treated promptly – a loss of the affected testis which makes testicular torsion to one cause for acquired (unilateral) anorchia (for review, see Nieschlag et al. 2010).

In other mammals, the scrotal ligament may clearly be divided into two ligaments: (1) *ligamentum testis proprium* from the caudal pole of the testis toward the tail of the epididymis and (2) *ligamentum caudae epididymidis* from the tail of the epididymis to the bottom of the processus vaginalis (for review, see Dyce et al. 2002).

## Vascularization/Innervation

### Blood Supply

The scrotum is vascularized by the superficial and deep external pudendal artery, scrotal branches of the internal pudendal artery, as well as the cremasteric artery, a branch of the inferior epigastric artery. Whereas the external pudendal artery (*arteria pudenda externa*) derives from the medial side of the femoral artery (*arteria femoralis*), the internal pudendal artery (*arteria pudenda interna*) branches off the internal iliac artery (*arteria iliaca interna*).

The blood supply of the testis is provided by the testicular artery (*arteria testicularis*). This artery derives from the abdominal aorta at the level of L2 vertebra. It passes the deep inguinal ring, traverses the inguinal canal within the spermatic cord in a tortuous manner, and reaches the testis within the vaginal cavity. At the posterior border of the testis (see section “[External Appearance, Tunica albuginea/Septula Testes](#)”), the testicular artery is divided into two large (medial and lateral) branches. The latter pierces the *tunica albuginea*, ramifies on the surface of the testis, and forms the *tunica vasculosa* beneath the fibrous capsule. Within the testis, the smaller branches of the artery follow the fibrous septa (*septula testes*) toward the *rete testis* and supply the testicular tissue as recurrent arteries (*arteriae recurrentes*). Testicular veins, forming the spermatic cord together with the arteries, build up the pampiniform venous plexus (*plexus pampiniformis*) to cool the arterial blood. The plexus ascends at the superficial inguinal ring, forming four veins. After passing the inguinal canal, two testicular veins are formed at the deep inguinal ring, accompanying the testicular artery. The right testicular vein drains into the postcava (*vena cava inferior*), whereas the left testicular vein drains into the left renal vein at a right

angle. A disturbed venous drain can be responsible for one of the most common male factor fertility problem, the varicocele. As reviewed by Comhaire and Mahmoud (2006), a reflux of blood in the internal spermatic veins is responsible for testicular and epididymal malfunction caused by a clinically palpable or also subclinical varicocele. Commonly the left testis is affected for the anatomical reasons displayed above, but varicoceles also occur on the right side. The epididymis is supplied with blood by an end artery of the testicular artery anastomosed with the artery to the ductus deferens. The latter originates from the internal iliac artery (reviewed in Gray 1918; Singh 2014).

### Innervation

The nerves for the scrotum can be differentiated into nerves for the anterior one-third and the posterior two-thirds. The anterior one-third is supplied by the ilioinguinal as well as the genital branch of the genitofemoral nerve (L1) whereas the posterior two-thirds are supplied by the scrotal branches of the perineal nerve and the perineal branch of the posterior cutaneous nerve of the thigh (S3). The dartos muscle is supplied by sympathetic fibers of the genital branch of the genitofemoral nerve. Nervous fibers of the autonomic nerve system reach the testis from the celiac plexus by accompanying the testicular artery (reviewed in Gray 1918; Singh 2014).

---

## Testis

### External Appearance, Tunica Albuginea/Septula Testes

The testis is an endocrine (production of sex hormones during steroidogenesis by interstitial Leydig cells, see section “[Leydig Cells](#)”) as well as an exocrine gland (production of sperm or spermatozoa by spermatogenesis, see section “[Germ Cells and Principle of Spermatogenesis](#)”).

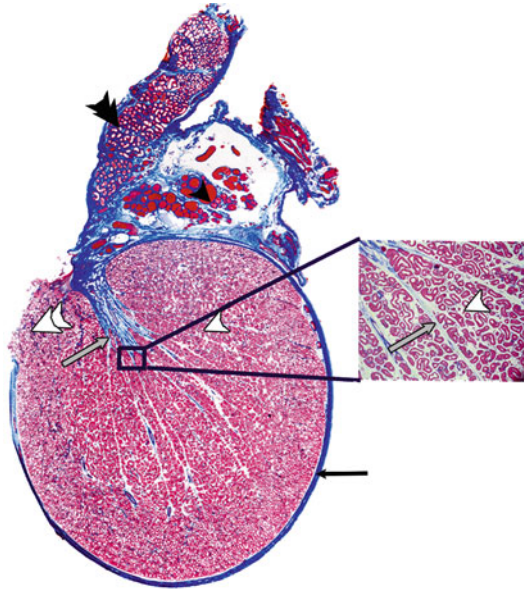
The testis is a paired organ suspended in the scrotum by the spermatic cords. The left testis is hanging a little bit lower than the right one. The average dimensions of the testes are average length of 4–5 cm, an average width of 2.5–3 cm, and a thickness of approx. 1.8–2.4 cm with a volume of approx. 20–25 mL. Each testis is of an oval form and compressed laterally with a kind of oblique position in the scrotum. The upper extremity is directed forward and a bit lateralward; the lower extremity is headed backward and a little to the medialward. The anterior convex border looks forward and downward; the posterior border, which is straight and where the cord is attached, looks backward and upward. Beside the posterior border, all sites of the testis are convex, smooth, and covered with the visceral layer of the *tunica vaginalis*. The epididymis is located along the posterior testicular border.

The testis itself is surrounded by a dense fibrous capsule, the *tunica albuginea* which is of bluish white color and through which the testicular vessels may be seen. It is applied onto the *tunica vasculosa*, the layer between the *tunica albuginea* and the soft parenchyma of the testis. Radially extending *septula testes* move into the



**Fig. 1** Testis histology (modified from Weinbauer et al. 2010)

Transverse section of whole human testis. The testis is surrounded by the *tunica albuginea* (black arrow), sending septa into the testicular tissue (gray arrow). Note the lobular architecture of the testis (white arrowhead) as also shown in the detail. The preparation also includes parts of the efferent ducts (double white arrowhead) as well as the epididymis (double black arrowhead) and the pampiniform venous plexus (black arrowhead)



testicular tissue and meet in the interior as an incomplete vertical septum called *mediastinum testis* which extends from the upper to the lower extremity of the testis with a wider upper and a narrower lower side. The imperfect septa meeting in the *mediastinum testis* subdivide the testicular tissue into approx. 250–350 lobules, which contain about 500–800 strongly twisted and looped tubules (*tubuli seminiferi contorti*) with an average diameter of 180–280  $\mu\text{m}$  (Fig. 1). In these tubules, spermatogenesis takes place (see section “Seminiferous Tubules”). The twisted seminiferous tubules merge into straightly running tubules (*tubuli seminiferi recti*) and meet within the *rete testis*, which is located within the *mediastinum testis*. The latter forms an incomplete vertical septum, extending from the upper to near the lower extremity of the testis. Twelve to fourteen efferent ductules, derived from the mesonephric duct, connect the rete testis with the epididymal duct in the head of the epididymis (reviewed by Gray 1918; Singh 2014).

## Interstitial Compartment

The interstitial compartment is composed of loose connective tissue with many blood and lymph vessels as well as nerve fibers and cells of the lymphatic system. Its proportion on the testicular volume varies. In the human, the interstitial compartment represents approx. 12–15% of the testicular volume, which is comparable to the situation in the ram and the bull. In contrast to that, the interstitial compartment in the boar and the stallion represents approx. 40% of the testicular volume (for review, see Weinbauer et al. 2010; Dyce et al. 2002). In laboratory rodents, presenting rather small testes, the interstitial compartment is comparably sparse and comprises of

small groups of Leydig cells gathering around blood vessels (for review, see Setchell and Breed 2006).

### Leydig Cells

About 10–20% of the interstitial compartment consists of Leydig cells. Human testes contain approx.  $200 \times 10^6$  Leydig cells which were firstly described in 1850 by Franz von Leydig (1850, for review, see Christensen 2007). These cells produce the most important testicular sex hormone testosterone and smaller amounts of estrogens and insulin-like factor 3 (INSL 3) and may be found either in smaller groups or alone, mostly located around the blood vessels in a perivascular sheath. From the developmental, morphological, and functional points of view, different Leydig cell types may be distinguished: Stem Leydig cells are founder cells, progenitor Leydig cells are determined stem cells, fetal Leydig cells are already terminally differentiated in the fetus, and adult Leydig cells are the definite and functional Leydig cells within the adult testis (for review, see Svechnikov et al. 2010). The origin of Leydig cell progenitors is not fully elucidated. It has been shown that they originate from a common primordium with steroidogenic cells of the adrenal gland, located between the dorsal aorta and the dorsal coelomic epithelia of the primitive urogenital ridge (Hatano et al. 1996, for review, see Wen et al. 2016). After differentiation of the male genital ridge into the testis, the interstitial compartment holds the steroidogenic fetal Leydig cells as well as other interstitial somatic cells. Therefore, fetal Leydig cells are thought to originate from cells of the coelomic epithelia or the gonad-mesonephros border (for review, see Wen et al. 2016). As reviewed by Davidoff et al. (2009), the first fetal Leydig cells appear in humans at weeks 7–8 of pregnancy (also called “baby puberty”) and give rise to adult Leydig cells (Davidoff et al. 2009). The main function of fetal Leydig cells is the production of androgens needed for masculinization of the fetus. As fetal Leydig cells do not express 17 $\beta$ -hydroxysteroid dehydrogenase (17 $\beta$ -HSD), they secrete androstenedione, which is afterward converted to testosterone by 17 $\beta$ -HSD expressed by fetal Sertoli cells. Contrary to the common opinion, fetal Leydig cells have been shown to persist in the adult testis of genetic tracing mouse models, making up about 20% of total Leydig cells (for review, see Wen et al. 2016). The main product of adult Leydig cells is testosterone, essential for masculinization, initiation, as well as maintenance of spermatogenesis by its action on the AR (for review, see Gelmann 2002). As steroidogenic active cells, Leydig cells contain large amounts of smooth endothelial reticulum and mitochondria with tubular cristae as well as lipid droplets, storage sites of cholesterol. Beside sex hormones, the Leydig cells also produce insulin-like factor 3 (INSL3), a marker for Leydig cell differentiation and onset of puberty (Ferlin et al. 2006). The activity of Leydig cells is not only influenced by LH but also growth factors as well as differentiation factors secreted by Sertoli cells (for review, see Weinbauer et al. 2010).

### Other Cells of the Interstitial Compartment

Besides Leydig cells, the interstitial compartment also contains fibroblasts, macrophages, mast cells, as well as single lymphocytes.

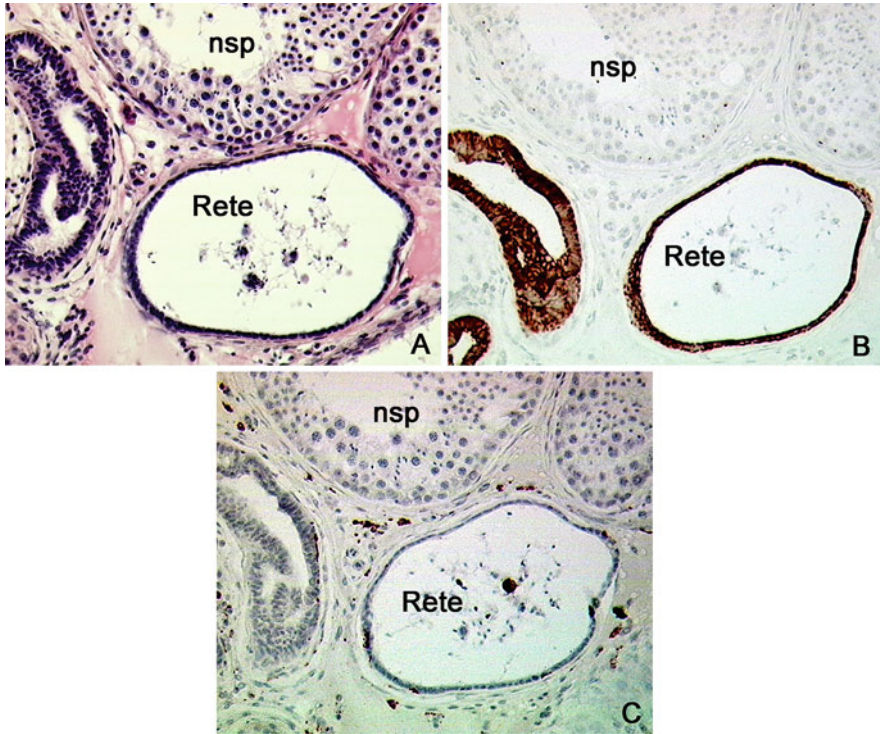
## Fibroblasts

Fibroblasts in the testis are maintaining the interstitial compartment by secretion of collagen fibers building up the loose connective tissue to hold other (free) cells as macrophages, mast cells, and white blood cells but also blood vessels, lymphatic vessels, and nerve fibers. Factors released by mast cells (see below) are able to influence fibroblast activity, cumulating in an excessive collagen production, fibrosis, and thickening of the tubular walls in infertile men (Welter et al. 2013).

## Cells of the Immune System and Immune Privilege of the Testis

During early embryonic life, gonocytes migrate from the yolk sac wall into the fetal gonad, starting to proliferate in a distinct number of proliferation waves and then become quiescent until puberty (Tu et al. 2007). After onset of puberty, spermatogonia start to differentiate into spermatozoa (see section “[Germ Cells and Principle of Spermatogenesis](#)”). By this time, the immune system has matured and a systemic self-tolerance has already been established. Newly developing germ cells would therefore be recognized as “foreign” cells, as they express new surface markers as well as intracellular proteins which might get in contact with cells of the immune system. To avoid a fatal reaction of the immune system, adjacent Sertoli cells form the blood-testis barrier (BTB, see section “[Sertoli Cells](#)”) and maintain a certain immune-privileged environment. But even outside the BTB, the testis remains immune privileged, which was shown by transplantation of allo- or even xenografts (Gores et al. 2003; Isaac et al. 2005; for review, see Fijak et al. 2011). Nevertheless, the testis is able to produce a proper immunoreaction as shown in autoimmune orchitis, which is one of the etiologies for male infertility (for review, see Schuppe and Meinhardt 2005). As the BTB is starting to disintegrate within the rete testis, most inflammatory events are started in this region of the testis (Johnson 1970; Naito and Itoh 2008). Here, many antigen-presenting macrophages can be detected, also in noninflamed testes in direct vicinity of normal spermatogenesis tubules (Fig. 2).

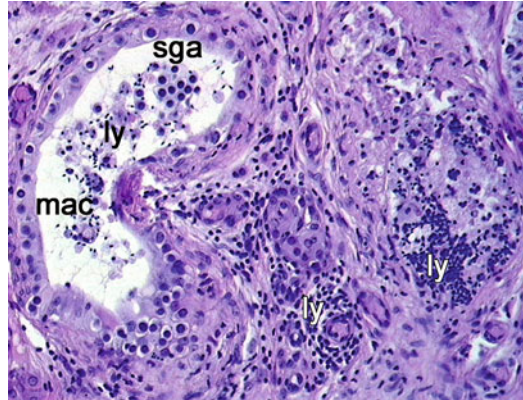
Reasons for the special immune status of the testis are still under investigation. As shown by Fijak et al. (2015) in an *in vitro* approach in the rat, testosterone is able to modulate the immune response by generation and differentiation of regulatory T lymphocytes. Lower testosterone levels are associated with an increased immune response capacity. Cytokines produced by various immune cells (macrophages, mast cells, monocytes, dendritic cells, as well as T and B lymphocytes) build up the immunosuppressed environment. Macrophages are large white blood cells which phagocytose cell debris, foreign cells, and bacteria. About 25% of interstitial cells are macrophages within the interstitial compartment. Testicular macrophages are similar to macrophages in other organs but nevertheless show a reduced capacity for IL-1 $\beta$ , IL-6, and TNF $\alpha$  secretion (for review, see Schuppe and Meinhardt 2005) which are pro-inflammatory cytokines. Macrophages are also thought to influence Leydig cell function, namely, their proliferation activity, differentiation, and steroid production. The second most common immune cell type found in the testis are mast cells, which play an important role in the innate immune system as well as in acquired immune responses (for review, see Schuppe and Meinhardt 2005). Mast cells release a wide range of pro-inflammatory mediators as histamine, tryptase,



**Fig. 2** The presence of macrophages in the *rete testis*  
**(a)** H&E staining of the *rete testis* (*Rete*) and seminiferous tubule showing normal spermatogenesis (*nsp*)  
**(b)** The same sections stained with the marker cytokeratin 18 (CK-18) by immunohistochemistry clearly show the epithelial character of the *rete testis*  
**(c)** Within the *rete testis* as well as in the connective tissue of the mediastinum, macrophages can be detected by immunohistochemistry (*brown color*). Counterstaining with hematoxylin  
**(a-c)** Primary magnification  $\times 20$

leukotrienes, and other cytokines (Albrecht et al. 2005). Histamine is a mitogen for fibroblasts and leads to a testicular fibrosis as stated above. But not only fibroblasts are a target for mast cell products, but their receptors are also expressed in peritubular cells (PTCs) (Albrecht et al. 2006) as well as germ cells (Windschüttl et al. 2014). Compared to macrophages and mast cells, other immune cells as dendritic cells, T and B lymphocytes are found to a much lesser extent in the testis. About 15% of immune cells in the testis are lymphocytes, mostly T lymphocytes, whereas B lymphocytes were not detectable in normal rat testes. Similar results have been reported from sparse investigation in the human (for review, see Schuppe and Meinhardt 2005). For example, see Fig. 3.

Recent findings show that in normal spermatogenesis, T but no B lymphocytes or dendritic cells are present in the human testis; most interestingly, B lymphocytes and dendritic cells have been detected in testicular germ cell neoplasia, driven by a



**Fig. 3** Focal infiltration with immune cells in the interstitial compartment as well as in the tubule. Focal infiltration with lymphocytes was detected either in the interstitial compartment as well as within the tubule (*ly*). Additionally, macrophages (*mac*) were detected within the tubule, which shows an arrest of spermatogenesis at the level of spermatogonia (*sga*). H&E staining, primary magnification  $\times 40$

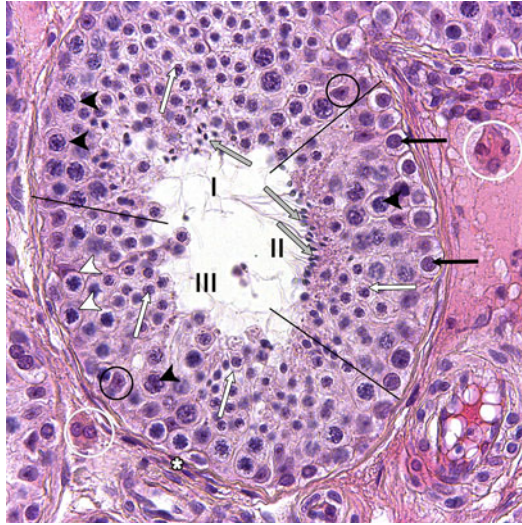
highly pro-inflammatory cytokine environment, created by T helper cell type 1 (Th1) (Klein et al. 2016).

## Seminiferous Tubules

Seminiferous tubules are the site of spermatogenesis in the testis. They make up to 60–80% of testicular volume and are surrounded by a layered wall of collagen fibers and myofibroblastic cells called *lamina propria* with embedded peritubular cells (PTC). The seminiferous epithelium contains all stages of germ cell differentiation as well as somatic Sertoli cells and is separated from the *lamina propria* by a basal membrane (Fig. 4).

### Lamina Propria and Peritubular Cells

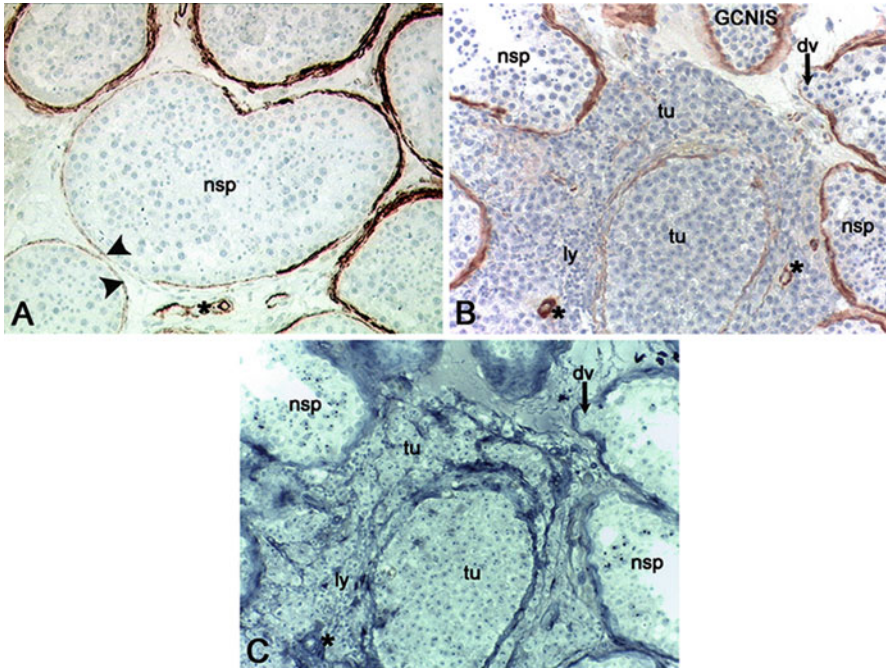
In the human testis, the *lamina propria* consists of 4–5 layers of peritubular cells (PTC), whereas in rodents, only one layer of these cells surrounds the tubular walls. PCTs are myofibroblast cells expressing either fibroblast or smooth muscle cell markers: CD90/Thy-1, CD34, vimentin, desmin, calponin, myosin heavy chain, and smooth muscle actin. By this, PCTs are cells able to contract and transport spermatozoa to the *rete testis* and toward the epididymis (see review by Albrecht 2009). Moreover, PCTs secrete various components of the intercellular matrix as collagens (I, VI, XVIII), laminin, and fibronectin and therefore are also referred to as structural cells. These factors are also thought to be involved in tubulogenesis during embryogenesis. Additionally, various factors influencing the other testicular cell populations are secreted by PCTs, as, for example, nerve



**Fig. 4** Organization of the seminiferous tubules

Surrounded by the *lamina propria* with peritubular myoid cells (*asterisk*), the seminiferous epithelium is organized in different stages (see sections “[Sertoli Cells](#),” “[Germ Cells and Principle of Spermatogenesis](#),” “[Spermiation](#)” and “[Stages of Spermatogenesis](#)”), indicated by *Roman numerals*. Stages I, II, and III are simultaneously present in the tubule, which is called “multistage arrangement” (Luetjens et al. 2005). The germ cells inside the epithelium are spermatogonia (*black arrows*), spermatocytes (leptotene = *white arrowheads*, pachytene = *black arrowheads*), and spermatids (round spermatids = *white arrow*, elongated spermatids = *gray arrow*). Somatic cells inside the tubules are Sertoli cells (*black circle*). In the interstitial compartment, Leydig cells (*white circle*) can be seen. H&E staining, primary magnification  $\times 40$

growth factor (NGF), monocyte chemoattractant protein 1 (MCP-1), as well as inflammatory molecules such as IL-6. The secretion of these is regulated by  $\text{TNF}\alpha$ , a cytokine synthesized especially by mast cells (see section “[Other Cells of the Interstitial Compartment](#)”, for review, see Albrecht 2009). Besides these secreted factors, PTCs also express the androgen receptor (AR) and are therefore considered as androgen-dependent cells. In impaired spermatogenesis, for example, Sertoli-cell-only syndrome or maturation arrests, a thickened *lamina propria* is often found (Sato et al. 2008). In this pathological condition of germ cell loss and differentiation failure, an increase of collagen II fibers may be detected, culminating in so-called tubular shadows, where only a massive *lamina propria* but no seminiferous epithelium is left. As shown by Donner et al. (2004), integrity and functionality of the tubular wall are affected in carcinoma in situ (CIS). This preinvasive form of germ cell neoplasia was recently renamed in germ cell neoplasia in situ (GCNIS) (Berney et al. 2016). Immunohistological stainings for smooth muscle actin and lamin revealed a decreased expression of contractile elements within the dedifferentiated peritubular cells combined with a preserved basal membrane shown by unchanged lamin expression (Fig. 5).



**Fig. 5** Expression of *lamina propria* marker actin in normal spermatogenesis, seminoma, and preinvasive GCNIS

(a) In normal spermatogenesis (*nsp*), the *lamina propria* is clearly detectable by immunohistochemistry for smooth muscle actin. Note the positive staining signal in the smooth muscle layer around small arterioles (*asterisk*). Note that even in *nsp* tubules, expression of smooth muscle actin is not consistently in the *lamina propria* (*arrowheads*)

(b) In this section, interstitial as well as intratubular seminoma cells (*tu*) can be detected. Additionally, tubules with preinvasive GCNIS as well as normal spermatogenesis (*nsp*) are present. Staining for smooth muscle actin is weaker to completely absent in the tumor area, indicating dedifferentiation of myoid cells as shown by Donner et al. (2004). In this staining, tumor cells seem to emigrate the remnant tubule. Note the lymphatic infiltrates (*ly*) and the preserved actin-positive staining of arteriole walls (*asterisk*). *dv* diverticle of the tubular wall (*arrow*)

(c) In the same section as shown in (b), basal membrane is still intact around all tubules regardless tumor or *nsp* status as shown by positive lamin staining. Preserved tubular walls indicate that tumor cells do not emigrate the tubular compartment into the interstitial compartment

Immunohistochemistry, counterstain hematoxylin (a, b), primary magnification  $\times 20$

## Sertoli Cells

Sertoli cells were firstly described by Enrico Sertoli 1865 (Sertoli 1865, for review, see Griswold 1998) as branched cells surrounding different germ cell stages. As the presence of Sertoli cells is a pivotal prerequisite for initiation and maintenance of spermatogenesis, Sertoli cells were also described as “nursery cells” (for review, see Griswold 1998). Sertoli cells are derived from the coelomic epithelium and are the first differentiating cells in the fetal gonad, which enables seminiferous cord formation, colonization of the fetal gonad with gonocytes, differentiation, as well as

function of Leydig cells (for review, see Sharpe et al. 2003; Cupp and Skinner 2005). An important marker gene and protein for immature Sertoli cells is anti-Müllerian hormone (AMH). AMH secretion by Sertoli cells ensures the regression of the Müllerian ducts during fetal development. During puberty, the role of Sertoli cells becomes supporting germ cell differentiation and therefore maintenance of spermatogenesis. In the human adult testis, each Sertoli cell is in close contact to about ten germ cells or 1.5 spermatozoa (Zhengwei et al. 1998), whereas in the macaque monkey, each Sertoli cell is associated with 22 germ cells or 2.7 spermatozoa (Zhengwei et al. 1997). The daily sperm outcome therefore clearly correlates with the number of Sertoli cells within the seminiferous epithelium. As hypothesized by Sharpe et al. (2003), a decreasing Sertoli cell number in later life might be responsible for decreased fertility in these men as well as a dedifferentiation, also called testicular dysgenesis syndrome (TDS).

Sertoli cells are located directly on the basal membrane of the seminiferous tubules and surround different germ cell stages with their cytoplasm. These cells are the only ones to reach from the basal membrane to the tubular lumen. To differentiate Sertoli cells and germ cells within the seminiferous epithelium, nuclear morphology may be assessed easily: immature Sertoli cells exhibit a dark, round nucleus and less cytoplasmic branches (as there are only few gonocytes within the epithelium by this time), whereas adult Sertoli cells can be recognized by their oval-shaped to triangular nucleus, deep nuclear notches and a prominent nucleolus. The nuclear volume of adult Sertoli cells in normal spermatogenesis is approx.  $410 \mu\text{m}^3$  and the cell surface approx.  $430 \mu\text{m}^2$  (Bruning et al. 1993). Morphological changes start at the onset of puberty and have been described by Sharpe et al. (2003) as one prerequisite of Sertoli cell maturation. The other characteristic changes are the establishment of the blood-testis barrier and a decrease in proliferation activity. The latter is under increased investigation nowadays as Sertoli cells have always been described as post-mitotically terminal-differentiated cells for a long time. New studies suggest an ability of proliferation as well as DNA repair also in adult Sertoli cells (Ahmed et al. 2009; Tarulli et al. 2012). The formation of the blood-testis barrier (BTB) is undeniably the most important feature of matured Sertoli cells. The BTB forms between two adjacent Sertoli cells to maintain the immune privilege of the testis after onset of spermatogenesis (see section “Other Cells of the Interstitial Compartment”). Therefore complex intercellular contact zones are established consisting of tight junctions (*zonulae occludentes*), actin filaments, and specializations of the Sertoli cell membrane, called “ectoplasmic specializations” (ES). Tight junctions can be described as bands with literally no existing intercellular space, as the membrane of two adjacent Sertoli cells touch in this area and are connected by transmembrane proteins as claudins (human and rodents) and occludin (rodents). These proteins extend into the intercellular space and are connected with intracellular peripheral proteins as zonula occludens 1 (ZO-1, Fig. 6), ZO-2, and ZO-3. These intracellular proteins are themselves connected to the actin cytoskeleton (for review, see Mruk and Cheng 2010). Next to the actin filaments, cisternae of the endoplasmic reticulum are located, studded with ribosomes just on the averted side (for review, see Pelletier 2011). A schematic drawing of intact BTB can be taken from Fig. 6.

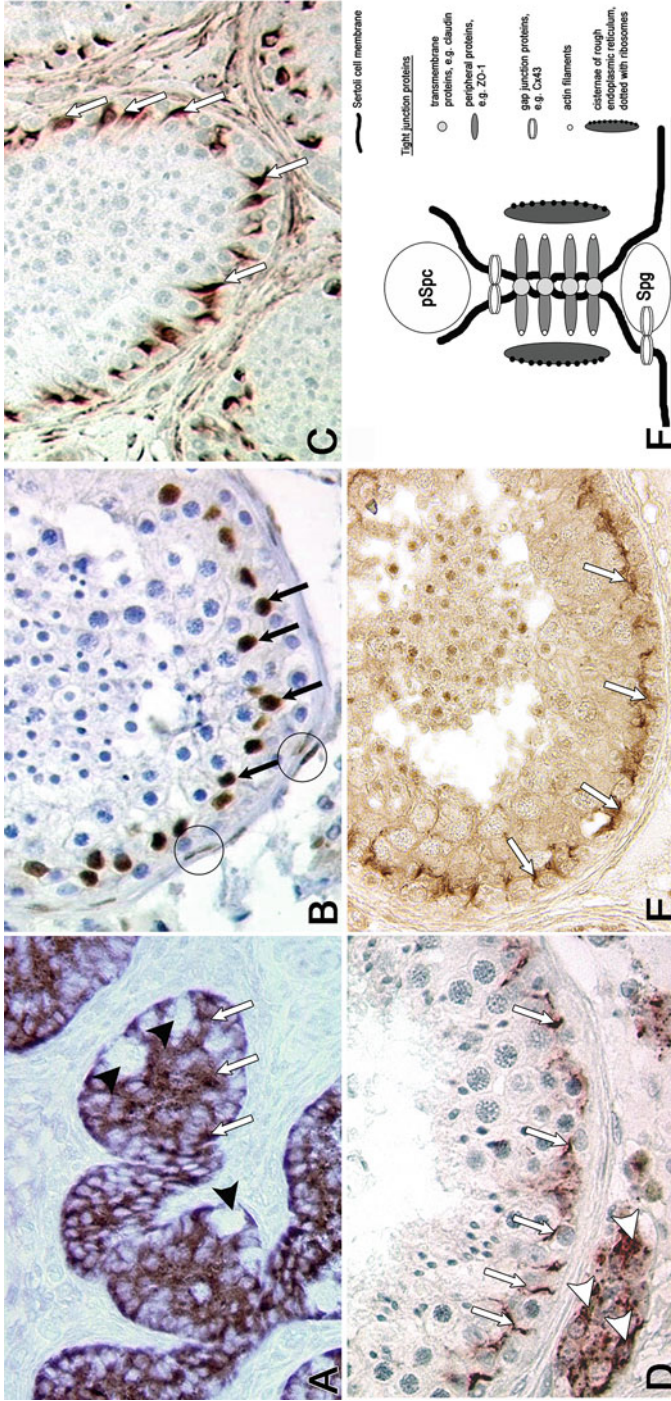


This barrier divides the seminiferous epithelium into a basal compartment, including only diploid spermatogonia and an adluminal compartment, containing the other germ cells types. Surface markers of developing spermatocytes, spermatids, and sperm therefore are separated from the immune system. Dym and Fawcett (1970) were the first to describe this immunological barrier in the rat, and Bergmann et al. (1989) described the BTB in the human testis. As shown by Bergmann and Dierichs (1983) in the rat, BTB is established when the first wave of spermatogenesis reaches the pachytene stage of primary spermatocytes.

By this compartmentalization, a free exchange of molecules and metabolites from the blood system and the basal compartment of the seminiferous epithelium into the adluminal compartment strongly depends on molecular weight and is severely limited or even impossible. Therefore, Sertoli cells not only protect developing germ cells from endo- or exogenous substances and the immune system but also take over nutritive and endocrine functions, by secreting the intratubular fluid. This shows a different composition as it contains more potassium and less sodium ions compared to the plasma (Tuck et al. 1970). By this, Sertoli cells generate a special microenvironment in which the germ cells may develop properly. Proteins secreted by Sertoli cells not only maintain this special environment but also contribute to the stability of the seminiferous epithelium (secretion of intermediary filaments as components of the cytoskeleton: cytokeratin 18 in fetal and vimentin in adult live), act as hormones (AMH in fetal, inhibin B in adult live), and also cell-cell contact and communication (connexin 43) (Wang et al. 2006; for review, see Weider et al. 2011). Moreover, by expressing the androgen receptor, Sertoli cells convey the testosterone action toward germ cells, which do not express this receptor themselves. Two important, androgen-dependent proteins are transferrin, which is essential for iron ion transport and germ cell differentiation as well as androgen-binding protein (ABP), which is pivotal for androgen distribution, either in the testis itself or throughout the body (Skinner et al. 1989). An example of Sertoli cell markers is given in Fig. 6.

These functions of Sertoli cells are important not only during spermatogenesis but also at the end of this process. When the residual body is removed as one of the last steps of spermiogenesis, Sertoli cells phagocytose this excess cytoplasm and are also involved in the sperm release by modification of the apical ectoplasmic specializations (aES, for review see, Berruti and Paiardi 2014).

During impaired spermatogenesis, morphological as well as molecular biological changes in Sertoli cells occur and might also be used as a marker for disturbed spermatogenesis. For example, the nuclear volume of approx.  $410 \mu\text{m}^3$  and the cell surface of approx.  $430 \mu\text{m}^2$  can be correlated with the differentiation status and may be altered in impaired spermatogenesis, e.g., to a volume of approx.  $280 \mu\text{m}^3$  and a cell surface of approx.  $230 \mu\text{m}^2$  in mixed atrophy of spermatogenesis (Sigg 1979; Bruning et al. 1993). Cytokeratin 18 as a differentiation marker has been observed to be reexpressed in Sertoli cells in contact with GCNIS (Kliesch et al. 1998). Sertoli cells of patients showing testicular dysgenesis syndrome (TDS) express the immaturity marker AMH also in adult life (Bergmann and Kliesch 1994; for review, see Sharpe et al. 2003).



**Fig. 6** Sertoli cell markers and blood-testis barrier (BTB) formation (a) In this testicular section originating from a male patient showing testicular feminization (androgen resistance), immature seminiferous tubules with juvenile Sertoli cells can be seen. In this section, immunostaining for AMH revealed a cytoplasmic staining within Sertoli cells (white arrows). Note single gonocytes, which are negative for AMH (black arrowheads). Immunohistochemistry, primary magnification  $\times 40$  (b) Immunohistochemistry using an antibody against androgen receptor in normal spermatogenesis; a positive staining can be detected in Sertoli cell nuclei (black arrows) as well as in peritubular cells (circles), but no germ cells are stained. Leydig cells which are also positive for AR are not shown in this detail. Immunohistochemistry, hematoxylin counterstain, primary magnification  $\times 40$

## Germ Cells and Principle of Spermatogenesis

By the third week of gestation, primordial germ cells (PGCs) move from the primary ectoderm into the yolk sac wall by amoeboid manner and gather near the exit of the allantois (for review, see de Felici 2016). Within the ento- and the mesoderm of the yolk sac, the PGCs are safe until the fetal gonad has formed around the fifth week after fertilization by the proliferation of the coelomic epithelium and the thickening of the underlying mesenchymal tissue. The so-called gonadal ridge is a gender-unspecific structure, whose final differentiation is initiated by the immigration of the primordial germ cells. Therefore, the PGCs move back into the embryo between the fourth and sixth week of gestation. This migration is facilitated by a craniocaudal and lateralward folding of the embryo, certain chemotactic factors, as well as an active amoeboid movement. After crossing the dorsal mesentery, the primordial germ cells colonize the gonadal ridge and keep on multiplying during their journey as well as within the fetal gonad by mitosis. Up to the sixth week of gestation, male and female gonads cannot be distinguished.

The first step to develop from a gender-unspecific gonad into a testis is made by differentiation and mitotic proliferation of Sertoli cells, which originate from the coelomic epithelium of the gonadal ridge. These fetal Sertoli cells surround and aggregate with PGCs to form seminiferous cords (for review, see Cupp and Skinner 2005; de Felici 2016). PGCs settle to the basal membrane of the seminiferous tubule and are then called spermatogonial stem cells, which are able to divide mitotically to further colonize the testis. Until puberty, spermatogonial stem cells are characterized as large cells with a big round nucleus and a rather large amount of cytoplasm.



**Fig. 6** (continued) **(c)** In normal spermatogenesis, cytoskeleton marker vimentin can be detected in Sertoli cell cytoplasm (*white arrows*). Note the branched appearance of Sertoli cell cytoplasm surrounding different germ cell stages. Immunohistochemistry, hematoxylin counterstain, primary magnification  $\times 20$

**(d)** Gap junction marker connexin 43 (Cx43) is detected either in Sertoli cell cytoplasm (*white arrows*) or in interstitial Leydig cells (*white arrowhead*) within normal spermatogenesis. Note the basal staining of Cx43, indicating an involvement in the regulation of blood-testis barrier function (for review, see Weider et al. 2011). Immunohistochemistry, hematoxylin counterstain, primary magnification  $\times 40$

**(e)** As an example for both, Sertoli cell marker and integral component of the BTB, tight junction protein ZO-1 is shown. Specific membrane staining was shown between Sertoli cells in the basal third of the seminiferous epithelium (*white arrows*). Immunohistochemistry, primary magnification  $\times 40$

**(f)** Schematic drawing of blood-testis barrier between two adjacent Sertoli cells. Tight junctions either comprise of transmembrane proteins as claudins (human) or occludin (human and rodents) spanning the intercellular space, peripheral proteins such as ZO-1 and ectoplasmic specializations. ZO-1 interlinks tight junction proteins to the actin cytoskeleton. Beside the actin filaments, cisternae of endoplasmic reticulum dotted with ribosomes on the adverted side. In this region, both Sertoli cell membranes closely merge, and no intercellular space is detectable. Gap junctions such as Cx43 are not part of the tight junctions but connect either Sertoli cells or Sertoli cells and germ cells. *Spg* spermatogonium, *pSpc* pachytene spermatocyte

After onset of puberty, spermatogenesis (i.e., the wave-like development and differentiation of a certain cohort of spermatogonia) takes place, and different stages of germ cell differentiation may be found within the seminiferous epithelium, surrounded by the Sertoli cell cytoplasm. On the onset of meiosis in type B spermatogonia, intercellular bridges between are formed that developmentally connect these cells. Therefore, they may be referred to as clones and mature in cohorts. In the rat, these bridges persist until step 19 spermatids shortly before spermiation (Weber and Russell 1987; for review, see Greenbaum et al. 2011). Also in human-elongated spermatids, intercellular bridges can be detected (for review, see Holstein and Roosen-Runge 1981). The development of germ cells proceeds from the basal to the adluminal compartment so that, in intact spermatogenesis, different spermatogenic stages may be found in a cross-section of seminiferous tubules. These different stages are easily distinguishable by their nuclear shape and position within the seminiferous epithelium. The different germ cell types are:

### 1. Spermatogonia

Spermatogonia are diploid cells (46XY, 2n2C DNA) and present with two subtypes in the seminiferous epithelium, type A and type B spermatogonia.

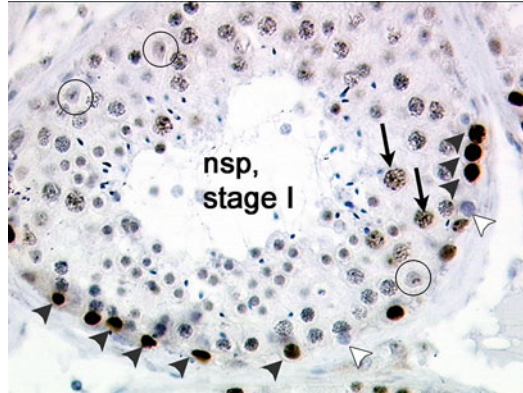
Type A spermatogonia can be further distinguished into  $A_{\text{pale}}$  and  $A_{\text{dark}}$  spermatogonia by their nuclear appearance (Clermont 1963).  $A_{\text{pale}}$  spermatogonia exhibit a round to ovoid, rather pale nucleus due to loosely packed euchromatic DNA, while  $A_{\text{dark}}$  spermatogonia show a darker nucleus with a central brighter area. Both type A spermatogonia are referred to as stem cells, but as  $A_{\text{dark}}$  spermatogonia exhibit only a basal mitotic activity. They are thought to be the resident stem cells of the seminiferous epithelium. In contrast to  $A_{\text{dark}}$ ,  $A_{\text{pale}}$  spermatogonia proliferate into  $A_{\text{pale}}$  and type B spermatogonia (for review, see Ehmecke et al. 2006).

Type B spermatogonia are round cells and display a rather dark heterochromatic nucleus. B spermatogonia show a higher mitotic activity than type A spermatogonia, which was shown by Ki-67 and PCNA staining (Steger et al. 1998). An example for proliferation activity of germ cells can be seen in Fig. 7. Type B spermatogonia enter meiosis.

Meiosis is an essential process in germ cell development as it reduces the diploid chromosome set to a haploid one. A schematic overview of meiosis can be seen in Fig. 8. Only after successful meiosis, haploid gametes are formed which can fuse in fertilization and become a new, diploid zygote. Meiosis takes place in two consecutive divisions, of which each can be subdivided into prophase, metaphase, anaphase, and telophase. Prophase I of the first meiotic division starts with a replication of DNA in B spermatogonia. These preleptotene cells are histologically similar to B spermatogonia but have detached from the basal membrane and are called primary spermatocytes.

### 2. Spermatocytes

Primary spermatocytes are still diploid but reveal a doubled chromatin (46XY, 2n4C DNA). During prophase I, which is the longest phase in meiosis taking approx. 1–3 weeks, essential processes as condensation of chromatin, synapsis, and pairing of

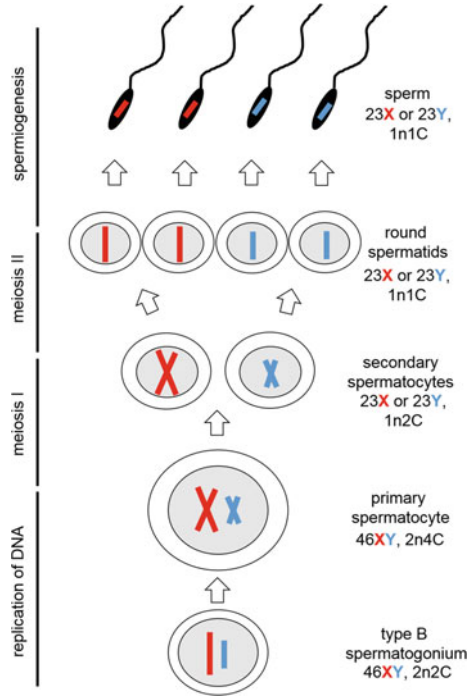


**Fig. 7** Ki-67 expression as proliferation marker in normal spermatogenesis

Immunopositive staining with Ki-67 antibody in spermatogonia (*black arrowheads*) indicates proliferation of germ cells in this stage of normal spermatogenesis (*nsp, stage I*). Note single not stained spermatogonia (*white arrowheads*). Sertoli cells are not stained (*circles*) as usual for mature testis. Note false-positive staining in pachytene spermatocytes (*arrow*). Ki-67 immunohistochemistry, hematoxylin counterstain, primary magnification  $\times 40$

homologous chromosomes as well as homologous recombination (crossing over) with a possible exchange of genetic material take place. Therefore, prophase I can be subdivided into four phases which can be clearly differentiated during spermatogenesis by nuclear morphology. Within **leptotene stage**, single chromosomes become visible and form thin band-like structures within the nucleus. Both sister chromatids are closely connected and cannot be distinguished from each other. The leptotene stage is rather short. **Zygotene primary spermatocytes** already show homologous chromosome pairs, visible as synaptonemal complex in transmission electron microscopy. In light microscopy, the nucleus appears to be coarse grained. In **pachytene stage**, the chromosomal crossing over occurs by building a tetrad formation of homologous chromosomes. Non-sister chromosomes might exchange genetic material during this stage. In light microscopy, big round nuclei containing short, thick chromatin strands are visible. During pachytene stage, the longest in prophase I, the nuclei become even bigger, so that earlier and later pachytene spermatocytes may be differentiated easily. In **diplotene primary spermatocytes**, the chromosomes are separated from each other by degradation of the synaptonemal complex. These cells show big round nuclei with short, thick chromatin material. At the end of prophase I, the nuclear membrane of primary spermatocytes break up in **diakinesis stage**. Subsequently, metaphase, anaphase, and telophase follow as usual. As a result, one primary spermatocyte divides into two **secondary spermatocytes**.

The resulting secondary spermatocytes are already haploid, but the sister chromatids are still paired (23X or 23Y, 1n2C DNA). Secondary spermatocytes are round cells with heterochromatic nuclei; this makes them similar to early round spermatids and therefore difficult to detect. These cells enter the second meiotic division without any DNA replication and are therefore only present during a short period of time



**Fig. 8** Schematic overview of meiosis

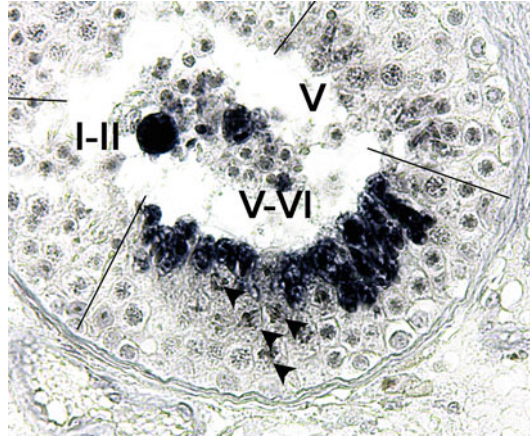
Meiosis begins with a diploid spermatogonium, which contains two copies of each homologous chromosome, either maternal (*red*) or paternal (*blue*) with one chromatid (46XY, 2n2C). First, DNA replication leads to identical sister chromatids connected by their centromere (*red* or *blue* “X”) within the primary spermatocyte (46XY, 2n4C). In prophase of meiosis I, homologous recombination may take place (not depicted here). First meiotic division leads to segregation of homologous chromosomes; one primary spermatocyte divides into two secondary spermatocytes with a haploid either maternal or paternal chromosome set (23X or 23Y, 1n2C). The second meiotic division takes place shortly after the first one, in which separation of sister chromatids results in four round spermatids (23X or 23Y, 1n1C). These germ cells are afterward transformed during spermiogenesis into four sperms (23X or 23Y, 1n1C), which are then released from the seminiferous epithelium

within the seminiferous epithelium (approx. 1–2 days). During the second meiotic division, the sister chromatids are separated and four **round spermatids** are generated (for review, see Weinbauer et al. 2010).

### 3. Spermatids

Spermatids are haploid cells with a single chromatin (23X or 23Y, 1n1C DNA) and may be recognized by their round, homogenous nucleus and the early forming acrosome vesicle. The development from round to elongating to elongated spermatids and afterward mature spermatozoa is called **spermiogenesis**. Three processes occurring more or less simultaneously are necessary to transform round immotile spermatids into spermatozoa:

**Fig. 9** Expression of protamine 1 mRNA in normal spermatogenesis  
 By in situ hybridization, PRM1 mRNA was detected in spermatids of transitional stage V–VI. Note mitotic figures (*arrowheads*), indicating the first meiotic division. In stage V of spermatogenesis, spermatids are still negative for PRM1 as well as in stages I–II. NTB/BCIP staining, primary magnification  $\times 40$



- **Condensation of the nucleus**
- **Formation of the acrosome**
- **Formation of the flagellum**

**Condensation of DNA and Nucleus** In common cells, DNA is packaged and ordered into nucleosomes by nuclear proteins, called histones. These act like spools around which DNA loosely winds and play a pivotal role in gene regulation as they may be modified translationally (acetylation, methylation), resulting in increased or decreased transcriptional activity. In spermatids, nuclear histones are firstly exchanged by transition proteins (TP1, TP2) and in a second step by protamines. There are two isoforms of protamines, PRM1 and PRM2 (Steger et al. 2000). In man, the histone-protamine exchange is 85% complete, leaving approx. 15% of DNA stays with histones. Both are expressed in a clearly stage-dependent manner (example of PRM1 expression in Fig. 9). After this histone-protamine exchange, no transcription is possible anymore, so that translation only takes place with “stored” mRNA. The ratio of PRM1 to PRM2 is a suitable biomarker for the fertilizing potential of men taking part in an ART program (Rogenhofer et al. 2013) as sperm protamine deficiency has a clear impact on human male fertility (for review, see Ni et al. 2016). By nuclear condensation, the elongating and elongated spermatids become visible by their darker and smaller nucleus.

**Formation of the Acrosome and the Flagellum** The acrosome is a cap-like structure sitting on the spermatozoa nucleus. Surrounded by the inner and outer acrosomal membrane, various enzymes essential for acrosome reaction and therefore fertilization are stored there. In the first phase called Golgi phase, the round spermatids are beginning to develop a polarity, as on the one site of the nucleus acrosomal vesicles start to form and to fuse. On the other site of the nucleus, the flagellum starts to form. During the cap phase, the nucleus is surrounded by a

cap-like acrosome vesicle, which elongates to both sides of the flattening nucleus to form the definite acrosome in the acrosome phase. Within the acrosome, hydrolytic enzymes are stored (hyaluronidases, acrosin) which are essential for decomposition of the corona radiata around the oocyte as well as for dissolving the zona pellucida. The excess cytoplasm and all organelles except the mitochondria are removed from the elongated spermatids and phagocytosed by the Sertoli cells as a so-called residual body.

The formation of the flagellum is a time-consuming process, which already starts in the Golgi phase. The axoneme has two central microtubules in addition to the nine outer doublets (called a 9 + 2 axoneme), located on a pair of centrioles.

#### 4. Spermatozoa (Sperm)

At the end of the seminiferous cycle, matured elongated spermatids are released into the tubular lumen and are then referred to as spermatozoa or sperm. This process is called spermiation (see section “[Spermiation](#)”).

Theoretically, one spermatogonium gives rise to four spermatids. Due to germ cell loss during meiosis in man (Johnson et al. 1992), only two spermatids are present which undergo spermiogenesis afterward. As reviewed by Amann (2008), the efficacy of spermatogenesis, given as daily sperm production (DSP), is about  $6 \times 10^6$  sperm per gram testis tissue and day.

#### Spermiation

Spermiation is a process during which elongated spermatids are released from the Sertoli cell cytoplasm into the lumen of seminiferous tubules and afterward transported to the epididymis. As reviewed by O'Donnell et al. (2011), spermiation is a critical determinant of the sperm number entering the epididymis and therefore the sperm in the ejaculate.

Spermiation takes place in a certain stage of spermatogenesis (see section “[Stages of Spermatogenesis](#)”), i.e., stage II in the human (Clermont 1963) and stage VII/VIII in the rodents (for review, see Russell 1993). Prerequisites for spermiation procedure are production of streamlined spermatozoa, removal of ectoplasmic specialization (ES) junctions between Sertoli cells and spermatozoa, retraction of the Sertoli cell cytoplasm, and extension of spermatids into the tubular lumen. The morphological and also ultrastructural events taking place during spermiation are well conserved in rodents, monkeys, and humans (Russell 1991; for review, see Russell 1993). Ectoplasmic specializations are a subsurface modification of the Sertoli cell, composed of actin filament bundles and the endoplasmic reticulum (Russell 1977). They occur on the apical Sertoli cell creating a contact zone between Sertoli cells and elongating spermatids (apical ES, aES) and also basally between Sertoli cells (basal ES). After initiation of spermiation process, aES start to disassemble, and tubulobulbar complexes are formed at the same time to replace the missing aES (Russell and Clermont 1976; for review, see Russell 1993). This “anchoring” of spermatids within the Sertoli cell in a small pouch aids in the removal of Sertoli cell cytoplasm and intercellular aES.



At the end of spermiation process, sperm release takes place. As reviewed by O'Donnell et al. (2011), this releasing step is not easy to assess in testicular histology as the freed sperm are rapidly taken away by the intratubular fluid into the rete testis (see section “[Rete Testis](#)”), the efferent ducts (see section “[Ductuli Efferentes Testis](#)”), and afterward into the head of the epididymis.

## Stages of Spermatogenesis

In normal spermatogenesis of man, six different spermatogenic stages (I–VI) can be distinguished following Clermont (1963) (for review, see Bergmann and Kliesch 2010). Stages of spermatogenesis are characterized by a distinct association of germ cell differentiation stages whereas the term “step” (e.g., step 1 spermatid) describes a certain germ cell generation. Numbering of steps depends on spermatid maturation and starts with early round spermatids within the Golgi phase after the second meiotic division. Stages of spermatogenesis in man can be defined as follows:

### 1. Stage I

This stage is characterized by early round spermatids just after the second meiotic division containing an acrosome vesicle. Within the seminiferous epithelium, type A and B spermatogonia, pachytene primary spermatocytes, round (step 1), as well as elongating spermatids (step 7) are present.

### 2. Stage II

This stages consists of type A and B spermatogonia, pachytene primary spermatocytes, round (step 2), and elongating spermatids (step 8). Within the Sertoli cells, excess spermatid cytoplasm is visible as the residual body. At the end of stage II, sperm release takes place.

### 3. Stage III

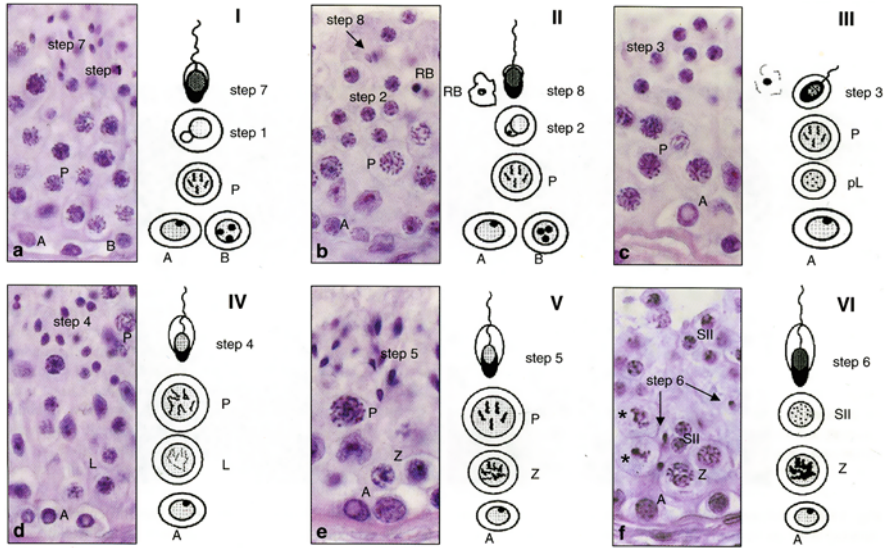
Type B spermatogonia enter meiosis in this stage, starting with a replication of DNA. These cells are called preleptotene primary spermatocytes and are in a so-called intermediate compartment between Sertoli cells and therefore separated from the basal compartment (Bergmann et al. 1989). Moreover, round spermatids (step 3) start with nuclear condensation.

### 4. Stage IV and V

During these stages, only type A spermatogonia are present, and two generations of primary spermatocytes (leptotene and pachytene in stage IV, zygotene and pachytene in stage V) are detectable. Nuclear condensation in step 4 and 5 spermatids, respectively, proceeds due to intense histone-protamine exchange. At the end of stage V, pachytene spermatocytes enter diakinesis and undergo the first meiotic division.

### 5. Stage VI

The last stage of the seminiferous cycle is always characterized by the appearance of secondary spermatocytes. After a short interphase of approx. 6 h, the second meiotic divisions follows, so that stage VI is rarely seen in histological sections. Other cells during this stage are type A spermatogonia, early pachytene primary spermatocytes, and elongating spermatids (step 6).



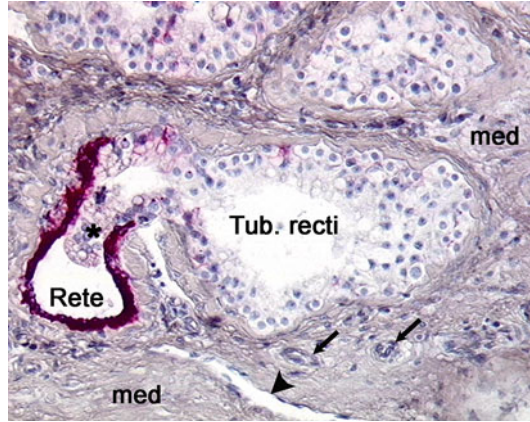
**Fig. 10** Germ cell stages in human spermatogenesis (Bergmann and Kliesch 2010)  
 Normal spermatogenesis in men comprises six spermatogenic stages (a–f). *A, B* type A and type B spermatogonia, *pL* preleptotene primary spermatocytes, *L* leptotene primary spermatocytes, *Z* zygotene primary spermatocytes, *P* pachytene primary spermatocytes (distinguishable in early, mid, and late), *SII* secondary spermatocytes, step 1–8: spermatid differentiation steps/steps of spermiogenesis (step 1–3, round spermatids; step 4–6, elongating spermatids; step 7–8, elongated spermatids), *RB* residual body, \* cells in the first meiotic division. H&E staining, primary magnification  $\times 40$

The different germ cell stages are depicted in Figs. 4, 7, 9, and 10. Human seminiferous epithelium shows a “multistage arrangement,” i.e., more than one stage may be found in a given cross-section showing normal spermatogenesis (for review, see Luetjens et al. 2005). In contrast to that, rodents as mouse and rat display only one spermatogenic stage within a given cross-section of one tubule (“single-stage arrangement”) (for review, see Russell et al. 1990). In men, all stages are passed which is called spermatogenic cycle within 16 days. The time period, in which one spermatogonium gives rise to a mature sperm takes about 4.6 spermatogenic cycles, that is, 74 days. For passing the epididymis, approx. 12 days are needed, so that after about 86 days, first sperm are expected in the ejaculate after onset of spermatogenesis at puberty and from thereon.

### Rete Testis

After sperm release at the end of stage II, mature sperm are within the seminiferous tubules and transported by peristaltic contractions (testicular sperm are neither motile nor able to fertilize an egg) into 20–30 straight *tubuli recti* which discharge

**Fig. 11** *Rete testis* and *tubuli recti* within the mediastinum  
 As shown in this picture, the straight *tubuli recti* (*Tub. recti*) bulge (*asterisk*) into the *rete testis* (*Rete*). The epithelium of the latter is stained with the epithelial marker CK-18 (*red color*). Both structures are embedded in the mediastinum (*med*) containing blood (*arrow*) and lymph vessels (*arrowhead*). Primary magnification  $\times 20$



into the *rete testis* located within the mediastinum. Whereas *tubuli recti* show a flattening seminiferous epithelium with only Sertoli cells left, the *rete testis* is characterized by a low cuboidal or flattened epithelium. The epithelia cells bear microvilli. Interestingly, the epithelium reaches into the funnel-shaped *rete testis* like a weir (Fig. 11) (for review, see Hostein and Roosen-Runge 1981). The *rete testis* is surrounded by the loose connective tissue of the mediastinum, vessels, and nerves and shows no proper *lamina propria* or smooth muscle cells (for review, see Singh 2011). As shown in Fig. 11, the epithelium of *rete testis* is positive for the endothelial marker CK-18.

## Ductuli Efferentes Testis

At the upper end of the mediastinum, the rete testis terminates in 15–20 ducts called *ductuli efferentes (testis)* deriving from the mesonephros during fetal development. The efferent ducts are lined by a ciliated columnar epithelium; some non-ciliated cells are also present and exhibit microvilli on their apical cell membrane. The wall of these ducts shows some smooth muscle cells, important for the peristaltic transport of sperm from the testis. For this, the efferent ducts perforate the *tunica albuginea* and carry sperm as well as seminal fluid into the head of the epididymis. There, they converge into the *ductus epididymidis*, forming the head, body, and tail of the epididymis (for review, see Singh 2011).

## Summary

The mammalian testis is a paired organ, which is located within the scrotal sac surrounded by the *processus vaginalis*. During fetal development, the testis descends into its cavity by shortening of the *gubernaculum* or caudal genital ligament. This process is essential to lower the testicular temperature about 1–2 °C, a prerequisite

for proper spermatogenesis. Additionally to a location outside the abdominal cavity, the testicular blood supply contributes to lowering the temperature as arteries are arranged spiral winded and are surrounded by the testicular veins. Due to the special venous draining, the left testis exhibits a predisposition for developing a varicocele, one of the most important reasons for male infertility conditions. The testis is fixed to the scrotal sac and *processus vaginalis* by remnants of the *gubernaculum*. Elongation of this ligament may be associated with torsions of the testis, mostly affecting young men.

The testis itself is surrounded by a firm fibrous capsule called *tunica albuginea*, sending out septa of connective tissue to subdivide the testicular tissue into various lobules containing either seminiferous tubules or interstitial tissue. Inside the testis, the septa meet and form the mediastinum surrounding either straight tubules as well as the rete testis. From this rete testis, efferent tubules transport the mature sperm (which are neither motile nor capable of fertilization at this moment) into the head of the epididymis.

The interstitial compartment of the testis consists of loose connective tissue surrounding many blood and lymph vessels, rarely seen nerve fibers, and interstitial cells. There, Leydig cells represent the most prominent group of cells and are capable of de novo steroidogenesis to produce various sex steroid hormones from precursor molecules. Moreover, Leydig cells produce insulin-like factor 3, which is essential for testicular descent. Other cells of the interstitial compartment are fibroblasts building up the connective tissue and cells of the immune system. Most immune cells found here are macrophages, followed by mast cells and some lymphocytes. The testis is an immune-privileged organ, as meiotic and post-meiotic germ cells develop way after the establishment of systemic self-tolerance and have to be protected from the immune systems. Therefore, Sertoli cells create the blood-testis barrier, which divides the seminiferous epithelium into a basal and an adluminal compartment, the latter containing the meiotic cells.

The seminiferous tubules are surrounded by the *lamina propria* with embedded peritubular cells and contain either somatic Sertoli cells or different germ cell stages. Sertoli cells are known as “nursery cells” creating a microenvironment for the germ cells by building the blood-testis barrier, secreting the tubular fluid and conveying hormonal stimuli to the germ cells. All germ cell stages are embedded in the Sertoli cell cytoplasm, and these cells play a pivotal role in releasing the matured sperm into the tubular lumen. Sertoli cells can be characterized by various fetal and adult markers.

Spermatogenesis can be divided in two consecutive processes, (1) meiotic divisions to create haploid spermatids from diploid spermatogonia and (2) spermiogenesis to mature round spermatids into elongated sperm. Elongated spermatids are then released by spermiation into the tubular lumen. Germ cell development can be divided into different spermatogenic stages, i.e., six in the human, showing a multistage arrangement inside the seminiferous tubules.

Testicular function is regulated by various factors, i.e., hormones and hormone receptors, but also growth factors and factors secreted by immune cells play a pivotal role in management of spermatogenesis on the one, and steroidogenesis on the other hand.

## Cross-References

- ▶ [Anabolic and Metabolic Effects of Testosterone and Other Androgens: Direct Effects and Role of Testosterone Metabolic Products](#)
- ▶ [Androgen Receptor](#)
- ▶ [Control of GnRH Secretion](#)
- ▶ [GnRH Action](#)
- ▶ [Gonadotropin Receptors](#)
- ▶ [Gonadotropins](#)
- ▶ [Testicular Steroidogenesis](#)

## References

- Ahmed EA, Barten-van Rijbroek AD, Kal HB, Sadri-Ardekani H, Mizrak SC, van Pelt AMM, de Rooij DG. Proliferative activity in vitro and DNA repair indicate that adult mouse and human Sertoli cells are not terminally differentiated, quiescent cells. *Biol Reprod.* 2009;80:1084–91. doi:10.1095/biolreprod.108.071662.
- Albrecht M. Insights into the nature of human testicular peritubular cells. *Ann Anat.* 2009;191:532–40. doi:10.1016/j.aanat.2009.08.002.
- Albrecht M, Frungieri MB, Gonzalez-Calvar S, Meineke V, Köhn FM, Mayerhofer A. Evidence for a histaminergic system in the human testis. *Fertil Steril.* 2005;83:1060–3. doi:10.1016/j.fertnstert.2004.12.002.
- Albrecht M, Rämisch R, Köhn FM, Schwarzer JU, Mayerhofer A. Isolation and cultivation of human testicular peritubular cells: a new model for the investigation of fibrotic processes in the human testis and male infertility. *J Clin Endocrinol Metab.* 2006;91:1956–60. doi:10.1210/jc.2005-2169.
- Amann RP. The cycle of the seminiferous epithelium in humans: a need to revisit? *J Androl.* 2008;29:469–87. doi:10.2164/jandrol.107.004655.
- Bergmann M, Dierichs R. Postnatal formation of the blood-testis barrier in the rat with special reference to the initiation of meiosis. *Anat Embryol.* 1983;168:269–75.
- Bergmann M, Kliesch S. The distribution pattern of cytokeratin and vimentin immunoreactivity in testicular biopsies of infertile men. *Anat Embryol.* 1994;190:515–20.
- Bergmann M, Kliesch S. Testicular biopsy and histology. In: Nieschlag E, Behre HM, Nieschlag S, editors. *Andrology. Male reproductive health and dysfunction.* 3rd ed. Berlin/Heidelberg: Springer; 2010. p. 155–67.
- Bergmann M, Nashan D, Nieschlag E. Pattern of compartmentation in human seminiferous tubules showing dislocation of spermatogonia. *Cell Tissue Res.* 1989;256:183–90.
- Berney DM, Looijenga LHJ, Idrees M, Rajpert-De Meyts E, Ulbright TM, Skakkebaek NE. Germ cell neoplasia in situ (GCNIS): evolution of the current nomenclature for testicular pre-invasive germ cell malignancy. *Histopathology.* 2016;69:7–10. doi:10.1111/his.12958.
- Berruti G, Paiardi C. The dynamic of the apical ectoplasmic specialization between spermatids and Sertoli cells: the case of the small GTPase Rap1. *Biomed Res Int.* 2014;635979. doi:10.1155/2014/635979.
- Bruning G, Dierichs R, Stümpel C, Bergmann M. Sertoli cell nuclear changes in human testicular biopsies as revealed by three dimensional reconstruction. *Andrologia.* 1993;25:311–6.
- Christensen AK. A history of Leydig cell research. In: Payne AH, Hardy MP, editors. *The Leydig cell in health and disease.* Totowa: Humana Press; 2007. p. 3–31.

- Clermont Y. The cycle of the seminiferous epithelium in man. *Am J Anat.* 1963;112:35–51. doi:10.1002/aja.1001120103.
- Comhaire F, Mahmoud A. Cause: varicocele. In: Schill W, Comhaire FH, Hargreave TB, editors. *Andrology for the clinician.* New York: Springer; 2006. p. 68–71.
- Cupp AS, Skinner MK. Embryonic Sertoli cell differentiation. In: Skinner MK, Griswold MD, editors. *Sertoli cell biology.* Amsterdam/Boston: Elsevier Academic Press; 2005. p. 43–70.
- Davidoff MS, Middendorff R, Müller D, Holstein AF. Fetal and adult Leydig cells are of common orig. In: *The neuroendocrine Leydig cells and their stem cell progenitors, the pericytes.* Berlin/Heidelberg: Springer; 2009. p. 89–103.
- de Felici M. The formation and migration of primordial germ cells in mouse and man. *Results Probl Cell Differ.* 2016;58:23–46. doi:10.1007/978-3-319-31973-5\_2.
- Donner J, Kliesch S, Brehm R, Bergmann M. From carcinoma in situ to testicular germ cell tumour. *APMIS.* 2004;112:79–88. doi:10.1111/j.1600-0463.2004.apm1120201.x.
- Dyce KM, Sack WO, Wensing CJG. The urogenital apparatus. In: Dyce KM, Sack WO, Wensing CJG, editors. *Textbook of veterinary anatomy.* 3rd ed. Philadelphia: Saunders; 2002. p. 166–209.
- Dym M, Fawcett DW. The blood-testis barrier in the rat and the physiological compartmentation of the seminiferous epithelium. *Biol Reprod.* 1970;3:308–26.
- Ehmcke J, Wistuba J, Schlatt S. Spermatogonial stem cells: questions, models and perspectives. *Hum Reprod Update.* 2006;12:275–82. doi:10.1093/humupd/dmk001.
- Ferlin A, Arredi B, Zuccarello D, Garolla A, Selice R, Foresta C. Paracrine and endocrine roles of insulin-like factor 3. *J Endocrinol Investig.* 2006;29:657–64. doi:10.1007/BF03344168.
- Fijak M, Bhushan S, Meinhardt A. Immunoprivileged sites: the testis. *Methods Mol Biol.* 2011;677:459–70. doi:10.1007/978-1-60761-869-0\_29.
- Fijak M, Damm L, Wenzel J, Aslani F, Walecki M, Wähle E, Eisel F, Bhushan S, Hackstein H, Baal N, Schuler G, Konrad L, Rafiq A, O'Hara L, Smith LB, Meinhardt A. Influence of testosterone on inflammatory response in testicular cells and expression of transcription factor Foxp3 in T cells. *Am J Reprod Immunol.* 2015;74:12–25. doi:10.1111/aji.12363.
- Gelmann EP. Molecular biology of the androgen receptor. *J Clin Oncol.* 2002;20:3001–15.
- Gores PF, Hayes DH, Copeland MJ, Korbitt GS, Halberstadt C, Kirkpatrick SA, Rajotte RV. Long-term survival of intratesticular porcine islets in nonimmunosuppressed beagles. *Transplantation.* 2003;75:613–8. doi:10.1097/01.TP.0000052376.89400.8D.
- Gray H. *Anatomy of the human body.* 20th ed. Philadelphia: Bartleby; 1918.
- Greenbaum MP, Iwamori T, Buchold GM, Matzuk MM. Germ cell intercellular bridges. *Cold Spring Harb Perspect Biol.* 2011;3:a005850. doi:10.1101/cshperspect.a005850.
- Griswold MD. The central role of Sertoli cells in spermatogenesis. *Semin Cell Dev Biol.* 1998;9:411–6. doi:10.1006/scdb.1998.0203.
- Hatano O, Takakusu A, Nomura M, Morohashi K-I. Identical origin of adrenal cortex and gonad revealed by expression profiles of Ad4BP/SF-1. *Genes Cells.* 1996;1(7):663–71.
- Holstein AF, Roosen-Runge EC. *Atlas of human spermatogenesis.* Berlin: Grosse; 1981.
- Hutson JM, Hasthorpe S, Heyns CF. Anatomical and functional aspects of testicular descent and cryptorchidism. *Endocr Rev.* 1997;18:259–80. doi:10.1210/edrv.18.2.0298.
- Isaac JR, Skinner S, Elliot R, Salto-Tellez M, Garkavenko O, Khoo A, Lee KO, Calne R, Wang DZ. Transplantation of neonatal porcine islets and Sertoli cells into nonimmunosuppressed nonhuman primates. *Transplant Proc.* 2005;37:487–8. doi:10.1016/j.transproceed.2004.11.062.
- Johnson MH. An immunological barrier in the guinea-pig testis. *J Pathol.* 1970;101:129–39. doi:10.1002/path.1711010208.
- Johnson L, Chaturvedi PK, Williams JD. Missing generations of spermatocytes and spermatids in seminiferous epithelium contribute to low efficiency of spermatogenesis in humans. *Biol Reprod.* 1992;47:1091–8.
- Klein B, Haggene T, Fietz D, Indumathy S, Loveland K, Hedger M, Kliesch S, Weidner W, Bergmann M, Schuppe H. Specific immune cell and cytokine characteristics of human testicular germ cell neoplasia. *Hum Reprod.* 2016;31(10):2192–202.

- Kliesch S, Behre HM, Hertle L, Bergmann M. Alteration of Sertoli cell differentiation in the presence of carcinoma in situ in human testes. *J Urol.* 1998;160:1894–8.
- Leydig F. Zur Anatomie der männlichen Geschlechtsorgane und Analdrüsen der Säugetiere. *Z Wiss Zool.* 1850;2:1–57.
- Luetjens CM, Weinbauer GF, Wistuba J. Primate spermatogenesis: new insights into comparative testicular organisation, spermatogenic efficiency and endocrine control. *Biol Rev Camb Philos Soc.* 2005;80:475–88.
- Migaletto V, Virgilio G, Del Prato A, Bertolotto M. Sonographic scrotal anatomy. In: Bertolotto M, Trombetta C, editors. *Scrotal pathology.* Berlin/Heidelberg: Springer; 2012. p. 41–54.
- Mruk DD, Cheng CY. Tight junctions in the testis: new perspectives. *Philos Trans R Soc Lond Ser B Biol Sci.* 2010;365:1621–35. doi:10.1098/rstb.2010.0010.
- Naito M, Itoh M. Patterns of infiltration of lymphocytes into the testis under normal and pathological conditions in mice. *Am J Reprod Immunol.* 2008;59:55–61. doi:10.1111/j.1600-0897.2007.00556.x.
- Ni K, Spiess A, Schuppe H, Steger K. The impact of sperm protamine deficiency and sperm DNA damage on human male fertility: a systematic review and meta-analysis. *Andrology.* 2016;4:789–99. doi:10.1111/andr.12216.
- Nieschlag E, Behre HM, Wieacker P, Meschede D, Kamischke A, Kliesch S. Disorders at the testicular level. In: Nieschlag E, Behre HM, Nieschlag S, editors. *Andrology. Male reproductive health and dysfunction.* 3rd ed. Berlin/Heidelberg: Springer; 2010. p. 194–238.
- O'Donnell L, Nicholls PK, O'Bryan MK, McLachlan RI, Stanton PG. Spermiation: the process of sperm release. *Spermatogenesis.* 2011;1:14–35. doi:10.4161/spmg.1.1.14525.
- Pelletier R. The blood-testis barrier: the junctional permeability, the proteins and the lipids. *Prog Histochem Cytochem.* 2011;46:49–127. doi:10.1016/j.proghi.2011.05.001.
- Rogenhofer N, Dansranjav T, Schorsch M, Spiess A, Wang H, von Schonfeldt V, Cappallo-Obermann H, Baukloh V, Yang H, Paradowska A, Chen B, Thaler CJ, Weidner W, Schuppe H, Steger K. The sperm protamine mRNA ratio as a clinical parameter to estimate the fertilizing potential of men taking part in an ART programme. *Hum Reprod.* 2013;28:969–78. doi:10.1093/humrep/des471.
- Russell L. Observations on rat Sertoli ectoplasmic ('junctional') specializations in their association with germ cells of the rat testis. *Tissue Cell.* 1977;9:475–98.
- Russell LD. The perils of sperm release—'let my children go'. *Int J Androl.* 1991;14:307–11.
- Russell L. Role in spermiation. In: Russell LD, Griswold MD, editors. *The Sertoli cell.* 1st ed. Clearwater: Cache River Press; 1993. p. 269–302.
- Russell L, Clermont Y. Anchoring device between Sertoli cells and late spermatids in rat seminiferous tubules. *Anat Rec.* 1976;185:259–78. doi:10.1002/ar.1091850302.
- Russell LD, Ettl RA, Sinha Hikim AP, Clegg ED. The classification and timing of spermatogenesis. In: Russell LD, editor. *Histological and histopathological evaluation of the testis.* 1st ed. Clearwater: Cache River Press; 1990. p. 41–58.
- Sato Y, Nozawa S, Iwamoto T. Study of spermatogenesis and thickening of lamina propria in the human seminiferous tubules. *Fertil Steril.* 2008;90:1310–2. doi:10.1016/j.fertnstert.2007.10.019.
- Schuppe H, Meinhardt A. Immune privilege and inflammation of the testis. *Chem Immunol Allergy.* 2005;88:1–14. doi:10.1159/000087816.
- Sertoli E. Dell' esistenza di particolari cellule ramificanti nei cunicoli seminiferi del testicolo umano. *Morgagni.* 1865;7:31–40.
- Setchell BB, Breed WG. Anatomy, vasculature, and innervation of the male reproductive tract. In: Knobil and Neill's physiology of reproduction. 3rd ed. Amsterdam: Elsevier/Academic Press; 2006. p. 771–825.
- Shafik A. Anatomy and function of scrotal ligament. *Urology.* 1977;9(6):651–5.
- Sharpe RM, McKinnell C, Kivlin C, Fisher JS. Proliferation and functional maturation of Sertoli cells, and their relevance to disorders of testis function in adulthood. *Reproduction.* 2003;125:769–84.

- Shimizu S, Tsounapi P, Dimitriadis F, Higashi Y, Shimizu T, Saito M. Testicular torsion-detorsion and potential therapeutic treatments: a possible role for ischemic postconditioning. *Int J Urol*. 2016;23:454–63. doi:10.1111/iju.13110.
- Sigg C. Classification of tubular testicular atrophies in the diagnosis of sterility. Significance of the so-called “bunte Atrophie”. *Schweiz Med Wochenschr*. 1979;109:1284–93.
- Singh I. The male reproductive organs. In: Singh I, editor. *Textbook of human histology*. 6th ed. New Delhi/St. Louis: Jaypee Brothers Medical Publishers; 2011. p. 290–303.
- Singh V. *Textbook of anatomy. Abdomen and lower limb*. 2nd ed. New Delhi: Elsevier; 2014.
- Skinner MK, Schlitz SM, Anthony CT. Regulation of Sertoli cell differentiated function: testicular transferrin and androgen-binding protein expression. *Endocrinology*. 1989;124:3015–24. doi:10.1210/endo-124-6-3015.
- Steger K, Aleithe I, Behre H, Bergmann M. The proliferation of spermatogonia in normal and pathological human seminiferous epithelium: an immunohistochemical study using monoclonal antibodies against Ki-67 protein and proliferating cell nuclear antigen. *Mol Hum Reprod*. 1998;4:227–33.
- Steger K, Pauls K, Klonisch T, Franke FE, Bergmann M. Expression of protamine-1 and -2 mRNA during human spermiogenesis. *Mol Hum Reprod*. 2000;6:219–25.
- Svechnikov K, Landreh L, Weisser J, Izzo G, Colón E, Svechnikova I, Söder O. Origin, development and regulation of human Leydig cells. *Horm Res Paediatr*. 2010;73:93–101. doi:10.1159/000277141.
- Tarulli GA, Stanton PG, Meachem SJ. Is the adult Sertoli cell terminally differentiated? *Biol Reprod*. 2012;87(1):13,1–11. doi:10.1095/biolreprod.111.095091.
- Tu J, Fan L, Tao K, Zhu W, Li J, Lu G. Stem cell factor affects fate determination of human gonocytes in vitro. *Reproduction*. 2007;134:757–65. doi:10.1530/REP-07-0161.
- Tuck RR, Setchell BP, Waites GM, Young JA. The composition of fluid collected by micropuncture and catheterization from the seminiferous tubules and rete testis of rats. *Pflugers Arch*. 1970;318(3):225–43.
- Wang R, Yeh S, Chen L, Lin H, Zhang C, Ni J, Wu C, Di Sant’Agnese PA, de Mesy-Bentley KL, Tzeng C, Chang C. Androgen receptor in Sertoli cell is essential for germ cell nursery and junctional complex formation in mouse testes. *Endocrinology*. 2006;147:5624–33. doi:10.1210/en.2006-0138.
- Weber JE, Russell LD. A study of intercellular bridges during spermatogenesis in the rat. *Am J Anat*. 1987;180:1–24. doi:10.1002/aja.1001800102.
- Weider K, Bergmann M, Brehm R. Connexin 43: its regulatory role in testicular junction dynamics and spermatogenesis. *Histol Histopathol*. 2011;26:1343–52.
- Weinbauer G, Luetjens C, Simoni M, Nieschlag E. Physiology of testicular function. In: Nieschlag E, Behre HM, Nieschlag S, editors. *Andrology. Male reproductive health and dysfunction*. 3rd ed. Berlin/Heidelberg: Springer; 2010. p. 11–59.
- Welter H, Kampfer C, Lauf S, Feil R, Schwarzer JU, Kohn F, Mayerhofer A. Partial loss of contractile marker proteins in human testicular peritubular cells in infertility patients. *Andrology*. 2013;1:318–24. doi:10.1111/j.2047-2927.2012.00030.x.
- Wen Q, Cheng CY, Liu Y-X. Development, function and fate of fetal Leydig cells. *Semin Cell Dev Biol*. 2016;59:89–98.
- Windschüttl S, Nettersheim D, Schlatt S, Huber A, Welter H, Schwarzer JU, Köhn FM, Schorle H, Mayerhofer A. Are testicular mast cells involved in the regulation of germ cells in man? *Andrology*. 2014;2:615–22. doi:10.1111/j.2047-2927.2014.00227.x.
- Zhengwei Y, McLachlan RI, Bremner WJ, Wreford NG. Quantitative (stereological) study of the normal spermatogenesis in the adult monkey (*Macaca fascicularis*). *J Androl*. 1997;18:681–7.
- Zhengwei Y, Wreford NG, Royce P, Kretser DM de, McLachlan RI. Stereological evaluation of human spermatogenesis after suppression by testosterone treatment: heterogeneous pattern of spermatogenic impairment. *J Clin Endocrinol Metab* 1998;83:1284-1291.



Christa E. Flück and Amit V. Pandey

## Abstract

Testosterone is the major androgen in circulation in male humans, produced primarily in the Leydig cells of the testis. Biosynthesis of testosterone from cholesterol occurs via a series of enzymatic reactions. Testosterone may be further metabolized into a more potent androgen, dihydrotestosterone. In recent years an alternate pathway of dihydrotestosterone biosynthesis without using testosterone as a precursor has emerged. Majority of classically studied effects of androgens are thought to be mediated via nuclear receptor-dependent long-term transcriptional effects, but there also exist membrane receptor-based effects of androgens which are being uncovered from recent studies that may explain rapid effects of androgens in many cases. In this chapter we are describing the biosynthesis, mechanism of action, and therapeutic effects of testosterone and related androgens.

## Keywords

Androgens • Anabolic steroids • Androgen receptor • Testosterone • CYP17A1 • SRD5A1 • Dihydrotestosterone

## Contents

Introduction: Testosterone Synthesis Throughout Life .....	344
Steroidogenesis in the Testis .....	347
The Classic Pathway of T Synthesis .....	347
The Alternative, Backdoor Pathway for DHT Synthesis .....	349
Testosterone .....	353
Biochemistry of T, DHT, and Their Physiologic Precursors .....	353
Action of T, DHT, and Androgen Receptor .....	354

C.E. Flück (✉) • A.V. Pandey

Pediatric Endocrinology and Diabetology Department of Pediatrics, Bern University Hospital, and Department of Clinical Research, University of Bern, Bern, Switzerland

e-mail: [christa.flueck@dkf.unibe.ch](mailto:christa.flueck@dkf.unibe.ch); [amit@pandeylab.org](mailto:amit@pandeylab.org)

© Springer International Publishing AG 2017

343

M. Simoni, I.T. Huhtaniemi (eds.), *Endocrinology of the Testis and Male Reproduction*, Endocrinology 1, [https://doi.org/10.1007/978-3-319-44441-3\\_10](https://doi.org/10.1007/978-3-319-44441-3_10)

Nonclassical Actions of T/DHT .....	356
T Metabolism/Inactivation .....	357
Genetic Disorders of Testicular Steroidogenesis .....	358
Classic Androgen Biosynthesis Defects that May Also Cause Adrenal Insufficiency (StAR, CYP11A1, HSD3B2, CYP17A1) .....	358
Classic Androgen Biosynthesis Defects Without Adrenal Insufficiency (HSD17B3, SRD5A2) .....	360
Redox Partner Defects (POR, CYB5) .....	361
Genetic Defects of the Backdoor Pathway: Human AKR1C2/4 Mutations .....	363
Steroidogenic Factor 1 (SF1)/NR5A1 Deficiency .....	364
Other Genetic Defects Affecting Testosterone Biosynthesis .....	364
Effects of Disordered Steroidogenesis on Testis Histology, Fertility, and Spermatogenesis ..	365
Outlook, What Do We Not Know? .....	366
Summary .....	367
References .....	368

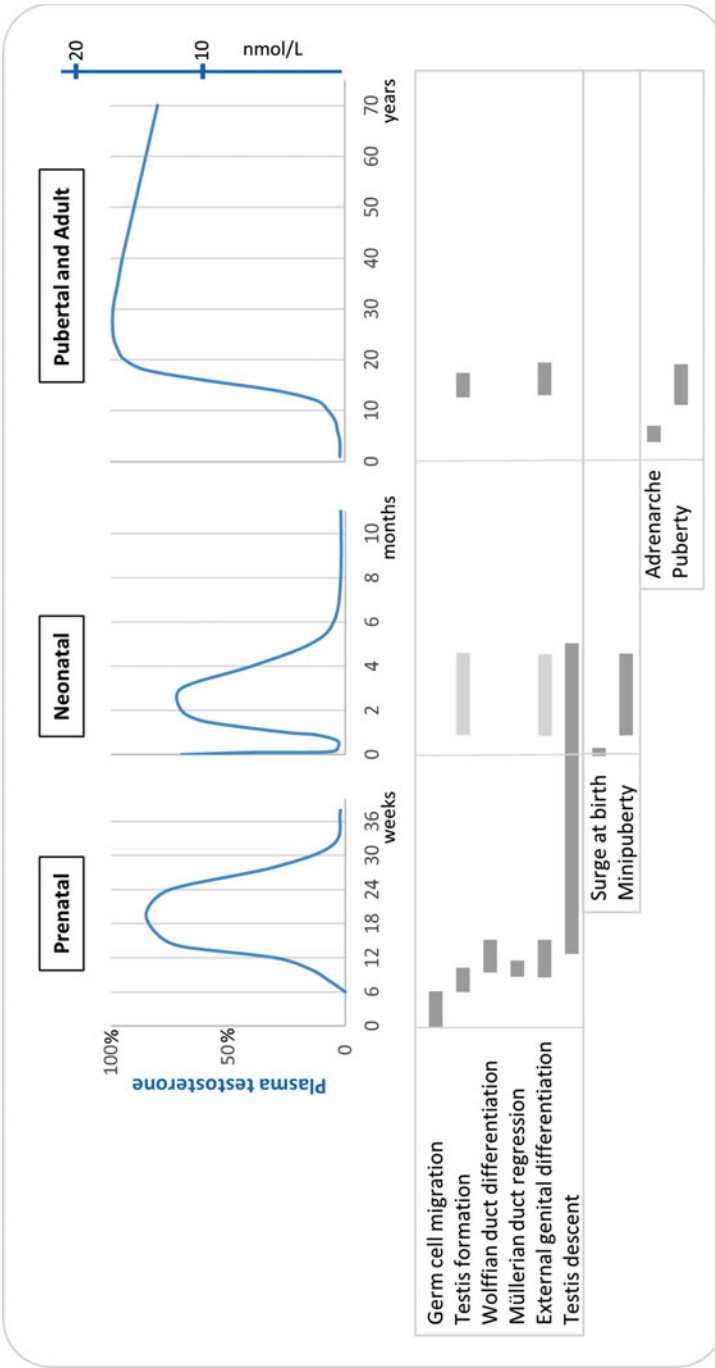
---

## Introduction: Testosterone Synthesis Throughout Life

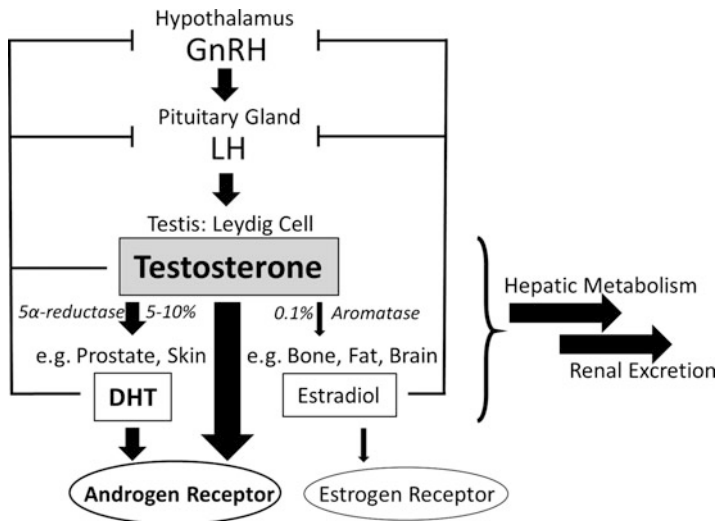
The human testis is a male specific organ, which is key to male sexual differentiation, function, and reproduction. It consists of two distinct functional units comprising of (1) the Leydig cells in the interstitial unit, which are responsible for androgen biosynthesis, and (2) the Sertoli cells of the seminiferous tubules, which are responsible for nourishing spermatogenesis. Hereby, seminiferous tubules make around 90% of the testis volume.

During human development the gonad is first formed as a neutral anlage, but with 46,XY genotype, it is genetically determined to form testes very early in fetal life by around 4–5 weeks of gestation. The testis then produces testosterone (T) and insulin-like 3 (INSL3) in Leydig cells, anti-Müllerian hormone (AMH) in Sertoli cells, and other sex differentiating paracrine factors for normal male sexual differentiation (Fig. 1). While AMH mainly helps to suppress the female Müllerian structures and also helps to maintain and develop male Wolffian duct structures through regulating T production, T and especially its highly potent metabolite 5 $\alpha$ -dihydrotestosterone (DHT) virilize the neutral external genitalia by the end of the first trimester. Thus, T production in the male fetus will reach almost adult peak levels by the second trimester of pregnancy in order to promote full masculinization including testicular descent. Only by the third trimester T production is low until the end of pregnancy (Fig. 1).

At birth, with a general hormonal surge in the newborn in the first 24–48 hours, T levels are shortly high again before showing low levels until the event of “minipuberty” between days 30–100 of life. This event seems rather specific to boys, is centrally stimulated, and may serve for further (male) sexual development (Kuiri-Hanninen et al. 2014). Clinical observations during minipuberty may include descent of the testes and increase in its volume due to an underlying increase in seminiferous tubules, as well as phallic growth. Biochemically, androgens such as T, DHT, and androsterone rise significantly (Dhayat et al. 2015, 2016). Although the exact function of minipuberty remains unknown, it offers a diagnostic window of



**Fig. 1** Testosterone (T) biosynthesis lifetime curve and associated developmental events. Prenatal period: Sex determination of the fetal gonad occurs at 6 weeks gestation. Then the fetal testis starts to produce T in the Leydig cells for sexual differentiation of the male sex organs, predominantly the external genitalia. Sertoli cells produce anti-Müllerian hormone (AMH) for the regression of the Müllerian ducts and for the differentiation of the Wolffian ducts. T production in the first and second trimesters may reach adult peak levels for fetal masculinization, but decreases during the third trimester of pregnancy. Neonatal period: In the first 72 hours after birth, T levels are high due to the surge of hormones (LH/FSH a.o.) at birth. Similarly, between days 30–100 of life, T levels are



**Fig. 2** Schematic diagram of the hypothalamic-pituitary-gonadal axis and of testosterone (*T*) actions. *T* is produced upon central GnRH - LH stimulation in the testicular Leydig cell at a daily rate of 5–7 mg. Circulating *T* (>95% of testis, <5% of adrenal origin) reaches the target organs and exerts its effect via the androgen receptor (*AR*). 5–10% of *T* will be amplified to dihydrotestosterone (*DHT*) by 5α-reductase II (*SRD5A2*) in the sebaceous skin unit and in the prostate gland. *DHT* is 5–10 times more potent on the *AR* than *T*. By contrast, little amount of *T* (0.1%) is converted to estrogens by aromatase (*CYP19A1*) activity in peripheral tissues (e.g., fat, bone, brain, mammary gland). Eventually, all steroids (androgens and estrogens) are metabolized through oxidation and conjugation in the liver and excreted mainly through the kidneys into the urine (>95%). Only few inactive metabolites are excreted into the bile

opportunity for functional testing of the testis, before it becomes hormonally quiescent until puberty.

At puberty, at around 12 years of age in boys, the hypothalamic-pituitary gonadal axis becomes reactivated. The hypothalamic GnRH pulse generator stimulates gonadotropin secretion (LH/FSH) from the pituitary gland and promotes the pubertal development of the testis (Fig. 2). The testicular volume increases during puberty, first predominantly through increase of the proportion of seminiferous tubules. Leydig cells will resume androgen biosynthesis, which will prompt the development of secondary male sex characteristics like further phallic growth, male-type hair growth, breaking of the voice, male-type growth spurt, and adult height as well

←

**Fig. 1** (continued) high, stimulated by LH during “minipuberty.” Pubertal and adult period: After 6–8 years of age, androgens (predominantly DHEA/S) rise slightly due to adrenarache, the functional activation of the zona reticularis of the adrenal cortex. However, the activation of the hypothalamic-pituitary-gonadal (*HPG*) axis only occurs after 12 years in boys (mean). At a testis volume of 6–8 ml, *T* production rises constantly to reach peak adult values between the second and fourth decade of life. With aging *T* production decreases, especially with chronic diseases influencing the *HPG* axis

as male-type body composition (more muscle and bone mass, less fat mass). The mature adult testis finally reaches a volume of 15–25 ml and produces about 5–7 mg testosterone per day, corresponding to serum concentrations of about 12–41.5 nmol/l (348–1197 ng/dl; measured by HPLC-MS/MS; [www.questdiagnostics.com](http://www.questdiagnostics.com)) total testosterone in adults 20–50 years of age. Spermatogenesis nurtured by Sertoli cells is also activated at puberty, and functioning sperms in spontaneously produced ejaculates are detected at a mean age of 13.5 years, long before completion of puberty.

After puberty, the mature testis plays a pivotal role for allowing full sexual functioning and reproduction. Generally, highest T production is observed in the third and fourth decades of life in males and starts to decrease slowly thereafter (Fig. 1). But sexual function and reproduction may be preserved until death. Aging of the testis function is poorly understood and may rather be secondary to general health problems related to metabolic or cardiovascular disorders (see related chapters).

Thus, given the important role of T in males throughout life, it is clear that abnormalities in androgen biosynthesis cause disorders of sex development (DSD) including puberty, as well as sexual function and reproduction. In the following section, we will summarize the current knowledge on androgen biosynthesis in health and disease, and provide insight into the biochemistry and action of T and some other biologic and synthetic androgens.

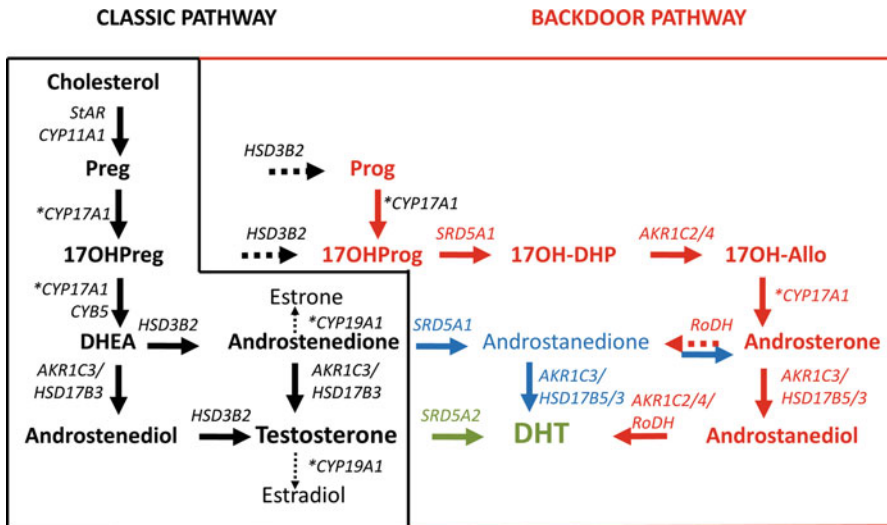
---

## Steroidogenesis in the Testis

The biochemistry of T synthesis is a long known process, but the recent discovery of an alternative, so-called backdoor pathway for the production of DHT has brought some novel aspects to the field and evoked numerous unsolved questions.

### The Classic Pathway of T Synthesis

T is an androgen, which is produced like all other steroid hormones from cholesterol. In males, more than 95% of circulating T is produced in the testes; only little is produced in the adrenal cortex and in peripheral organs through conversion of precursor steroids. The testicular Leydig cell is highly specialized for T production and expresses all required genes that are common to T-producing organs (Miller and Auchus 2011). Upon stimulation by LH, the Leydig cell enhances its steroid production. In a first step, cholesterol molecules are transported to the inner mitochondrial membrane by the steroidogenic acute regulatory protein (StAR). At the inner mitochondrial membrane, the side chain cleavage system comprised of enzyme CYP11A1 (P450<sub>scc</sub>) and its redox partners ferredoxin (FDX1) and ferredoxin-reductase (FDR) convert cholesterol to pregnenolone (Fig. 3). Pregnenolone is then converted through the delta 5 pathway to 17 $\alpha$ -hydroxypregnenolone (17OHPreg) and dehydroepiandrosterone (DHEA). Both conversions are supported



**Fig. 3** Androgen biosynthesis pathways. The *classic* testosterone biosynthesis pathway of the Leydig cell is shown in *black*, the more recently described *alternative, backdoor* pathway in *red*. Cholesterol is transported to the inner mitochondrial membrane by steroidogenic factor 1 (*StAR*). At the inner mitochondrial membrane cholesterol is cleaved to pregnenolone (*Preg*) by the side-chain cleavage catalytic unit consisting of the enzyme *CYP11A1* and its redox partners adrenodoxin/adrenodoxin reductase. *Preg* is then converted by *CYP17A1* in two steps to 17-hydroxypregnenolone (*17OHPreg*) and dehydroepiandrosterone (*DHEA*), both supported by P450 oxidoreductase, the redox partner of cytochrome P450 proteins in the endoplasmic reticulum, the second step, which is the lyase reaction, also requires cytochrome b5 (*CYB5*). *DHEA* is then converted either through the intermediacy of androstenedione and androstenedione to testosterone (*T*) by the enzymes *HSD3B2* and *HSD17B3/AKR1C3*. Small amounts of *T* or androstenedione are converted to estrogens in the testis by aromatase (*CYP19A1*) activity. Recent immunohistochemical findings also suggest that the Leydig cell expresses small amounts of 5 $\alpha$ -reductase for the conversion of *T* to dihydrotestosterone (*DHT*) (see also Fig. 3). However, this conversion is mainly done by in peripheral tissues such as the skin and the prostate. The Leydig cell expresses only little *HSD3B2*, but 17-hydroxyprogesterone (*17OHP*) produced from *17OHPreg* or from *Preg* through progesterone (*Prog*) may feed into the alternative, backdoor pathway for *DHT* synthesis. 5 $\alpha$ -reductase type I (*SRD5A1*) is the gate-keeper to the backdoor. It will convert *17OHP* to 17-hydroxy-dihydroprogesterone (*17OH-DHP*), and 3 $\alpha$ -hydroxysteroid-dehydrogenase activity of *AKR1C2/4* will yield 17-hydroxy-allopregnanolone (*17OH-Allo*); this is then converted to androsterone by *CYP17*. Further conversion by *AKR1C3/HSD17B3* leads to androstenedione and by *AKR1C2/4* or *RoDH* finally to *DHT*. Work from polycystic ovary disease and castration-resistant prostate cancer suggests that there is also a short loop to *DHT* via androstenedione and androsterone (given in *blue*)

by the enzyme *CYP17A1* (P450c17). While the first reaction requires only the 17 $\alpha$ -hydroxylase activity of the enzyme and electron donation by cofactor P450 oxidoreductase (POR), the second reaction requires not only POR support for 17,20-lyase activity, but also cytochrome b5 (*CYB5*) for facilitating optimal allosteric conformation. *DHEA* is then turned over step-wise to *T* through androstenedione or androstenediol catalyzed either first by 3 $\beta$ -hydroxysteroid dehydrogenase type II

(HSD3B2/3 $\beta$ HSDII) or 17 $\beta$ -hydroxysteroid dehydrogenase 3 (HSD17B3/17 $\beta$ HSD3/AKR1C3). In the classic view, in genital skin and the prostate, T may be converted to DHT, which has about 10 times more affinity for the androgen receptor. This T to DHT conversion is catalyzed by 5 $\alpha$ -reductase type II (SRD5A2/5 $\alpha$ Red2). By contrast, very small amounts of androstenedione and T are converted to estrone and estradiol in the testis through aromatase activity (CYP19A1). In humans, only little conversion of pregnenolone to androstenedione occurs in the testis through the delta 4 pathway originating from progesterone (Prog) and 17-hydroxyprogesterone (17OHP) (Fig. 3), because 17,20-lyase activity is poor on the substrate 17OHP compared to 17OHPreg and because HSD3B2 activity is less abundant (Flück et al. 2003). By contrast, rodents produce T predominantly via the delta 4 pathway (Fevold et al. 1989).

In comparison, the human adrenal cortex also expresses all enzymes needed for T production in the zona reticularis. However, because the expression of HSD3B2 is low and that of HSD17B5 extremely low, it produces predominantly DHEA and androstenedione as adrenal androgens. In addition, the adrenal cortex also produces mineralocorticoids and glucocorticoids from cholesterol. These steroid hormones regulate water, salt, and glucose homeostasis and are thus essential for life. The initial steps of biosynthesis are common to all steroid hormones. Therefore, genetic defects in genes involved in the initial steps of steroidogenesis shared by the adrenal cortex and the gonads affect steroid production of both organs and may lead to disorders of sexual development and function in both sexes as well as adrenal insufficiency, also known as congenital adrenal hyperplasia (CAH) in the medical literature (Table 1) (Miller and Auchus 2011; Miller and Flück 2014). Importantly, biosynthesis of the androgen precursors DHEA and androstenedione is also crucial for the production of all estrogens. Therefore, steroid biosynthetic defects such as CYP17A1 deficiency or HSD3B2 deficiency may not only lead to androgen deficiency, but also cause estrogen deficiency and thus lack of pubertal development and infertility in 46,XX females.

### The Alternative, Backdoor Pathway for DHT Synthesis

About 15 years ago, studies of sex development in the tammar wallaby revealed predominance of an alternative pathway for DHT production within the testis of the pouch young (Fig. 3) (Auchus 2004). It was named “backdoor pathway” as it diverges off from common precursors of the classic pathway without using T as the intermediate to produce DHT. In detail, in the backdoor pathway 17OHP is 5 $\alpha$ -reduced (SRD5A1) to 17OH-dihydroprogesterone (17OH-DHP) and 3 $\alpha$ -reduced (AKR1C2/4) to 17OH-allopregnanolone (17OH-Allo). 17OH-Allo is an excellent substrate for 17,20-lyase (CYP17A1/POR) to form androsterone, which is further converted to androstanediol (by AKR1C3/HSD17B3), and finally oxidized (by AKR1C2/4 or RoDH) to DHT. Alternatively, androsterone may be first oxidized to androstenedione before being converted to DHT. The characteristic of this backdoor pathway is that the steroid flux bypasses conventional intermediates of

**Table 1** Androgen biosynthetic defects causing disordered sexual development (DSD) and maturation with and without adrenal insufficiency

Disorder	Gene	OMIM	Adrenal insufficiency	46,XY DSD phenotype (T deficiency)	Spermatogenesis	Other features
Lipoid congenital adrenal hyperplasia (LCAH)	StAR	201710	YES	<i>Classic form</i> : 46,XY DSD, gonadal insufficiency <i>Nonclassic form</i> : None	Absent	
P450 side chain cleavage syndrome (CAH)	CYP11A1	118485	YES	<i>Classic form</i> : 46,XY DSD, gonadal insufficiency <i>Nonclassic form</i> : None	Unknown	
3 $\beta$ -hydroxysteroid dehydrogenase II deficiency (CAH)	HSD3B2	201810	YES	46,XY DSD, gonadal insufficiency <i>Nonclassic form</i> : No DSD, but premature adrenarche	Absent	
Combined 17-hydroxylase, 17,20-lyase deficiency (CAH)	CYP17A1	202110	Rare	46,XY DSD, gonadal insufficiency	Unknown	Hypertension and hypokalemic alkalosis (not seen with isolated lyase deficiency)
P450 oxidoreductase deficiency (CAH)	POR	124015 201750	Variable	46,XY DSD, gonadal insufficiency	Unknown	Maternal virilization during pregnancy; Antley-Bixler skeletal malformation syndrome; changes in drug metabolism



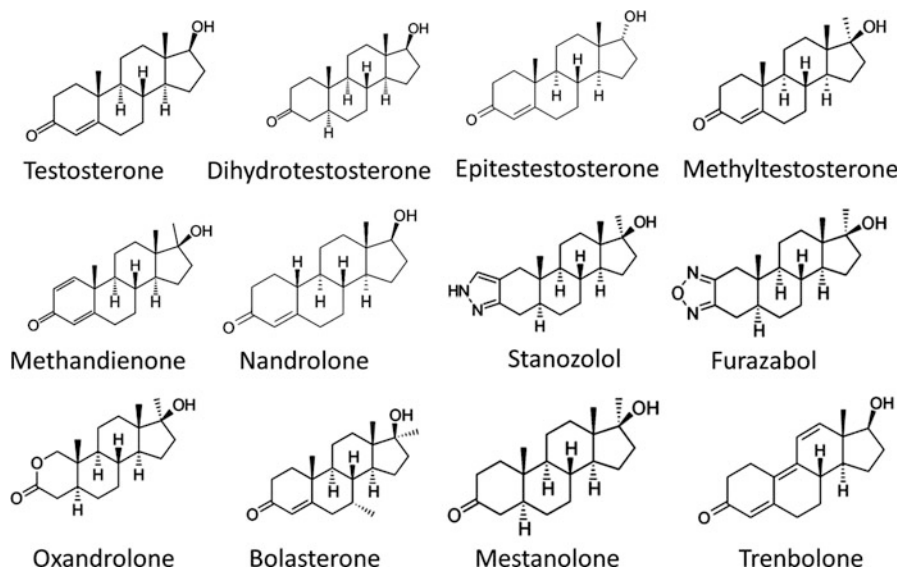
Cytochrome b5 deficiency	CYB5A	613218	NO	46,XY DSD	Unknown	
17 $\beta$ -hydroxysteroid dehydrogenase III deficiency/ 17-ketosteroid reductase deficiency	HSD17B3	264300	NO	46,XY DSD; progressive virilization and gynecomastia at puberty	Decreased or absent	
5 $\alpha$ -reductase II deficiency	SRD5A2	607306	NO	46,XY DSD; progressive virilization and gynecomastia at puberty	Impaired	Methemoglobinemia
3 $\alpha$ -hydroxysteroid dehydrogenase deficiency	AKR1C2/4	600450 600451	NO	46,XY DSD; gonadal insufficiency	Unknown	
Steroidogenic factor 1	NR5A1/SF1	184757	Rare	46,XY DSD; gonadal insufficiency – very variable	Incomplete	

the classic pathway (e.g., DHEA, androstenedione, T) and uses different enzymes (SRD5A1, AKR1C2/4, RoDH/HSD17B6) for DHT production.

As this pathway was also found in rodents, its existence in human (fetuses) was suspected (Auchus 2004). Urine steroid analysis of patients suffering from POR deficiency (PORD) showing variable signs of androgen excess and deficiency revealed first hints (Fukami et al. 2013). Intermediates of the backdoor pathway (17OH-Allo and androsterone) were disproportionately increased in PORD patients. Similar findings were seen in untreated patients with 21OH-ase deficiency (due to CYP21A2 mutations). Urine steroid profiling revealed an elevated androstanediol and an elevated androsterone/etiocholanolone ratio in the neonatal period, suggesting an increased steroid flux through the backdoor pathway in this disease state (Kamrath et al. 2012). It is therefore likely that in utero virilization of girls (46,XX DSD) with PORD or 21-hydroxylase deficiency might be promoted by increased 17OHP being processed to DHT through the backdoor pathway (Auchus 2004; Fukami et al. 2013). Final proof for a role of the backdoor pathway in human sexual development came from 46,XY patients suffering from moderate to severe undervirilization (DSD) with mutations in the genes for AKR1C2/4, but no mutations in genes comprised in the classic pathway (Biaison-Lauber et al. 2013). However, a detailed biochemical analysis of such patients is still missing, and the question remains, why the classic pathway cannot compensate for a defect in the backdoor pathway. Similarly, severe undervirilization of the external genitalia at birth with 46,XY DSD due to 5 $\alpha$ -reductase (SRD5A2) deficiency appears illogical when suggesting an alternative backdoor pathway that is able to produce DHT without depending on SRD5A2 during fetal life.

At present, the discovery of the backdoor pathway leaves us with more open than solved questions in the field of androgen biosynthesis. Recent findings from steroid metabolomics studies during fetal-neonatal transition and gene expression studies of fetal versus adult testis tissues suggest that the activity of the backdoor pathway changes from fetal to postnatal to adult life and varies with disease states. In addition, genes of the backdoor pathway were found to be expressed in a tissue- and developmental stage-specific manner (Flück et al. 2011; Marti et al. 2016), illustrating that there is a fetal to adult shift in the gene expression pattern of backdoor pathway genes in the human testis (Fig. 4).

Yet another alternate pathway for DHT production directly from androstenedione, through 5 $\alpha$ -reductase activity (SRD5A1) which produces androstanedione as intermediate (Fig. 2), has recently been described in castration-resistant prostate cancers (Chang et al. 2011), and was also suggested from steroid profiling in PCOS patients (Fassnacht et al. 2003). Furthermore, 11 $\beta$ -hydroxyandrostenedione, an inactive C19 metabolite which is produced abundantly and secreted into circulation by the human adrenal cortex, may be further metabolized into potent, active androgens as shown again in prostate cancer studies (Swart and Storbeck 2015). Whether all these novel pathways and androgen metabolites are important for normal androgen physiology remains to be studied in detail. However, these novel findings illustrate that T and the classic T biosynthetic pathway alone may no longer suffice for understanding human androgen biology.



**Fig. 4** Chemical structures of natural and synthetic androgens. Several synthetic analogues of T and DHT have been available since 1930s and have been widely used in treatment of anemia, starvation, and bone disorders as well as in body building and sports doping. All known androgen analogues have adverse side effects that range from behavioral changes to acute cardiovascular defects, and precaution is needed in their usage after consideration of benefits and risks

## Testosterone

### Biochemistry of T, DHT, and Their Physiologic Precursors

Similar to all androgens, the biosynthesis of T also starts from cholesterol (see section “[The Classic Pathway of T Synthesis](#)”). Pregnenolone derived from cholesterol metabolism is converted to DHEA in two steps by CYP17A1. In the next steps DHEA is converted to androstenedione by HSD3B2 and then HSD17B enzymes produce testosterone. After the secretion from the testes, T gets distributed rapidly in peripheral tissues. Several steroid-binding proteins may dictate the amount of T availability, act as storage media, and slow down the degradation of T by liver enzymes. T is further metabolized into the highly potent dihydrotestosterone by 5 $\alpha$ -reductase (SRD5A1). Aromatase also metabolizes T and converts a small percentage of T into estradiol, but DHT is not metabolized by aromatase. Depending on tissue level bioavailability of T and enzymes present, different metabolites of T may be produced. Higher levels of SRD5A1 expression is directly associated with increased DHT concentration, while lower levels of 3 $\alpha$  and 3 $\beta$  hydroxysteroid dehydrogenases reduce further metabolism of DHT. In the prostate HSD17B2 can convert T into androstenedione. Therefore, peripheral concentrations of T or DHT may not be used as an indicator of their bioavailability, which is heavily dependent

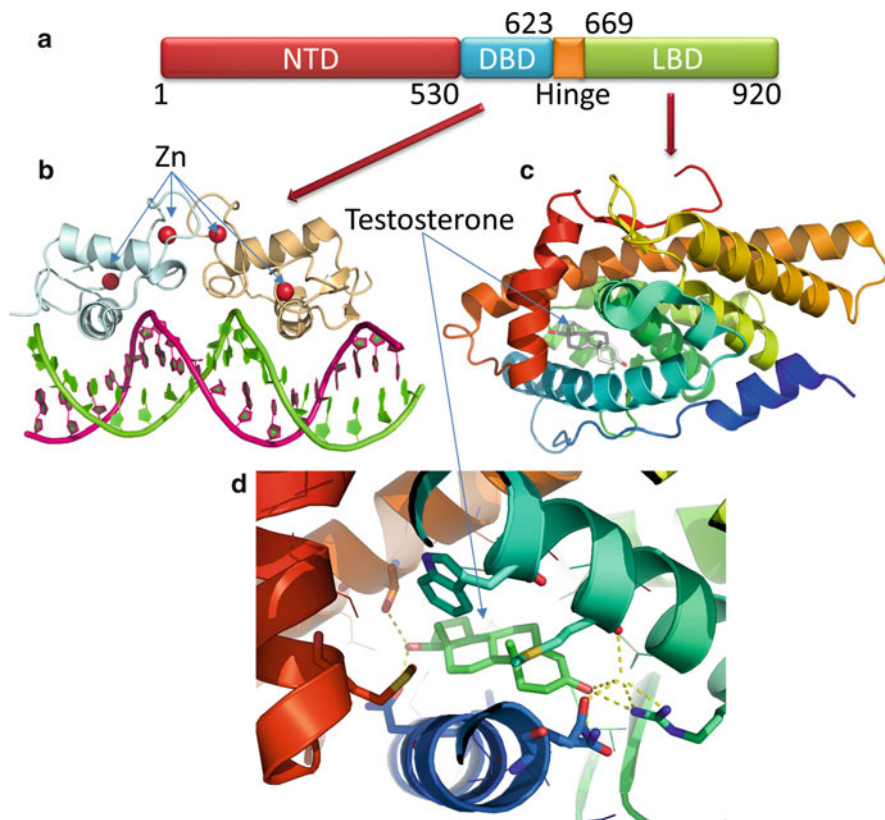
on expression of other enzymes that may further metabolize these two androgens and impact the actual local concentrations in different tissues.

Many synthetic analogues of T have been produced to increase the potency of anabolic effects and bioavailability of T. Commonly used anabolic steroids include nandrolone (available as nandrolone phenylpropionate and nandrolone decanoate), methandienone, stanozolol, oxandrolone, methenolone, and trenbolone (Fig. 4). Among these nandrolone and stanozolol have been used frequently in sports doping. However, the main approved clinical uses of both nandrolone and stanozolol have been for treatment of anemia and osteoporosis. Nandrolone has been proposed to be less toxic than many T metabolites/derivatives and is also a poor substrate for aromatase, which reduces some of the undesirable side effects due to estrogen production from excess of T. However, many adverse side effects associated with use of anabolic steroids are still associated with nandrolone analogues including erectile dysfunction and cardiovascular damage. Stanozolol have also been associated with major adverse effects (see ► Chap. 43, “Use, Misuse, and Abuse of Androgens” by Handelsman).

### Action of T, DHT, and Androgen Receptor

The majority of androgen effects are routed through androgen receptor (AR, NR3C4), which belongs to the nuclear receptor gene family reviewed in Matsumoto et al. (2013) and Davey and Grossmann (2016) (A detailed account of androgen is given in a separate ► Chap. 12, “Androgen Receptor” by Sutinen, Malinen, and Palvimo). After the binding of androgens, AR is activated and regulates the expression of multiple target genes and small RNAs at a tissue-specific level. The AR is a ligand-dependent transcription factor which upon being activated by binding of androgens forms complexes with androgen response elements located on target genes (Govindan 1990; Davey and Grossmann 2016). AR is expressed in numerous tissues including male reproductive organs. In the absence of a ligand AR protein is primarily located in the cytoplasm and is found in complex with heat-shock proteins (HSPs). Once the AR is occupied by androgens/androgen analogues a signaling cascade starts, where the first step is the dissociation of AR from HSPs, followed by translocation of the AR to the nucleus. This mechanism of relocation of AR into the nucleus, triggered by ligand binding, provides a target for the regulation of AR activity. Based on total AR and ligand availability, less than 50% of the individual AR units seem to form complexes with androgens for nuclear transport and start the process to transcriptional regulation (Davey and Grossmann 2016). A large amount of unbound AR molecules are indicated to participate in other metabolic events, and there are implications of ligand-free AR effecting the cell cycle (Ueda et al. 2002). Most of the studies on AR have focused on androgen binding and transcriptional regulation, and roles of unbound AR in alternate cellular processes are not well known.

The AR gene (NR3C4) is located on the X chromosome at the locus Xq11–12 (NC\_000023, 67,644,032...67730619). The protein coding region of the AR gene



**Fig. 5** Structure of AR protein. (a): The AR has distinct functional domains similar to other members of steroid-binding nuclear receptors. The NTD, DBD, and LBD have precise functional requirements and are needed for the function of AR. (b): Structure of DBD bound to androgen response elements. The AR functions as a dimer, and two zinc-binding motifs consisting of four cysteine residues each are located in each DBD unit. DNA is shown as *green and pink ribbons*, two distinct DBD from different AR proteins are shown as *ribbons diagram in light blue and light orange*. Zinc ions are shown as *red spheres*. Structure is from x-ray crystal data from rat AR DBD (PDB: 1R4I) (c): Ligand-binding domain of AR in complex with T based on x-ray crystal data (PDB: 2AM9). (d): A close-up of the ligand-binding pocket of AR

contains 2763 nucleotides (NCBI# NM\_000044) distributed among 8 exons, which encode a 99-kDa protein (NCBI# NP\_000035) consisting of 920 amino acids (Fig. 5a). The AR structure can be divided into distinct domains. The distinct subdomains of the AR structure include the N-terminal domain (NTD, residues 1–530), the DNA-binding domain (DBD, residues 530–623), and a hinge region (residues 623–669) which joins the DBD to the C-terminus ligand-binding domain (LBD, residues 669–920) (Fig. 5a). All three domains of AR are required for its function. The NTD accounts for more than half the size of total AR protein and is encoded by a single exon. The structure of NTD is not known so far and based on

predictions, it is proposed to have a highly disordered structure, which may alternate between several different conformations. The disordered nature of NTD may be crucial for its capacity to form complexes with a wide range of coactivators and transcription factors.

The DBD of AR is a cysteine-rich region and contains two zinc finger motifs which participate in direct binding of AR to DNA recognition elements (termed androgen response elements, ARE) in target genes. Based on crystal data the formation of these zinc-binding motifs comprises of four cysteine each that coordinate the zinc ions (Fig. 5b). AR proteins recognize AREs consisting of some variations of a repeat consensus palindromic sequence 5'-AGGTCA NNN TGACCT-3'. Towards the end of DBD there is a nuclear localization signal (NLS, residues 617–633), which sits between DBD and hinge region and is responsible for the transport of AR to nucleus. In addition, the hinge region has been found to be required for DNA and coactivator binding, emphasizing the fact that whole AR structure is required for its functional activities. The LBD of AR is located at the C-terminus and is a globular structure, which has been well characterized from x-ray crystallographic studies (Fig. 5c). The core structure of LBD is formed by 11 distinct helices which surround the hydrophobic ligand-binding pocket (Fig. 5d). Ligand binding to AR triggers conformational changes in protein structure, causing a shift of the terminal helix of LBD. This ligand-induced structural shift of the terminal helix has been proposed as necessary for complex formations with coregulators (van de Wijngaert et al. 2012). Therefore, binding of T/DHT/androgen analogues changes the conformation and induces the interaction of AR with its coregulatory proteins. The signaling cascades continue by the removal of repression elements and their replacement by coactivators. X-ray crystal structures of AR reveal that the changes in the terminal helix of LBD can be variable based on which ligand is bound with natural ligands, AR agonists, and antagonists showing different patterns of structural shifts, which may be responsible for the differences in the action of different ligands. Posttranslational modifications of the AR (e.g., phosphorylation) may also regulate its activities.

## Nonclassical Actions of T/DHT

There are indications of some nuclear androgen receptor-independent pathways of T/DHT action (Foradori et al. 2008). In general, effects of androgens could be divided into two broad categories, the first being nuclear receptor-mediated long-term transcriptional effects and the second being the membrane receptor-mediated effects that resemble rapid signaling events (Walker 2010). Several reports showing rapid effects of androgens indicate that there may exist mechanisms of T/DHT action that do not use binding to AR as the first step. A key difference between these effects is the requirement for constant presence of androgens for membrane-mediated effects. Some examples of such rapid effect of androgens are effects on kinase

phosphorylation/signaling, secretions of prostate-specific antigen, and GnRH and calcium flux (Walker 2010). T and its synthetic analogue nandrolone has been shown to cause rapid induction of calcium influx which may play a role in rapid power burst and recovery situations and suggests a major role in sports (Cavalari et al. 2012; de Castro et al. 2013). Constant high levels of androgens in female athletes produced by genetic mutations may have a role in aiding performance without the role of nuclear receptor-mediated long-term effects. Membrane receptors with much lower affinity for androgens than AR (GPCR6A, ZIP9) have been identified (Papakonstanti et al. 2003; Hatzoglou et al. 2005; Pi et al. 2010; Ko et al. 2014), and separate mechanisms requiring low or high concentrations of androgens may exist in different cell/tissues (Simoncini and Genazzani 2003). The major non-classical effects of T seem to be mediated through increased intracellular calcium, inositol 1,4,5-triphosphate, and diacylglycerol (Lieberherr and Grosse 1994; Papakonstanti et al. 2003; Loss et al. 2004; Cavalari et al. 2012). Signaling pathways triggered by membrane effects of androgens could be further linked to nuclear receptor-mediated effects by a network of signaling pathways which seem to be linked. Therefore, some of these effects may not start with nuclear receptors but may still converge through intermediary networks (Walker 2010; Ko et al. 2014; Wang et al. 2014).

## T Metabolism/Inactivation

Most of the T in plasma is protein bound and is found to be attached to gonadal steroid-binding globulin, sex steroid-binding globulin, or albumin. In the liver several cytochrome P450 enzymes including CYP2C9, CYP2C19, and CYP3A4 perform  $\beta$ -hydroxylations of testosterone to produce 2 $\beta$ -, 6 $\beta$ -, 11 $\beta$ -, and 16 $\beta$ -hydroxytestosterone (Choi et al. 2005). The major androgenic metabolite of T is DHT, which is formed by the action of SRD5A1 activity as described earlier. DHT is a much more potent androgen than T and binds to AR with even higher affinity than T. Conversion of T to DHT has been a target of drug development to produce inhibitors of DHT biosynthesis for treatment of prostate cancer, male-pattern baldness, and hirsutism. Among the compounds inhibiting 5 $\alpha$ -reductase activities are finasteride, alfatradiol, and dutasteride. However, there are several adverse drug reactions associated with these inhibitors that include impotence, decreased libido, etc. DHT is inactivated by 3 $\alpha$ / $\beta$  hydroxysteroid dehydrogenases into 3 $\alpha$ -androstenediol and 3 $\beta$ -androstenediol. Steroids are often found as sulfate conjugates, a transformation carried out by steroid sulfotransferases (Strott 1996). For example, most of the DHEA produced in adrenals is found in sulfonated form mediated by action of SULT2A1 (Neunzig et al. 2014). Several other cytochrome P450 proteins, including CYP3A5 and CYP3A7, can perform hydroxylation reactions on T/DHT. In addition, Uridine 5'-diphospho-glucuronosyltransferases (UGTs) can perform bioconjugation reactions on T/DHT to create inactive androgens.

## Genetic Disorders of Testicular Steroidogenesis

### Classic Androgen Biosynthesis Defects that May Also Cause Adrenal Insufficiency (StAR, CYP11A1, HSD3B2, CYP17A1)

These genetic defects affect early steps in steroid biosynthesis, which are essential for mineralocorticoid, glucocorticoid, and sex steroid biosynthesis. They cause adrenal insufficiency and sex hormone deficiency, and are therefore also known as congenital adrenal hyperplasias (CAH).

#### StAR and CYP11A1

Patients with severe defects in the genes for *StAR* or *CYP11A1* have clinically indistinguishable features. They suffer from adrenal insufficiency including mineralocorticoid and glucocorticoid deficiency, as well as 46,XY DSD and gonadal insufficiency due to missing androgen production (Table 1) (Miller and Flück 2014). *StAR* facilitates the import of cholesterol from the outer to the inner mitochondrial membrane, where cholesterol is the essential initial substrate for the side chain cleavage system (*CYP11A1/FDX1/FDXR*) for all steroid biosynthesis (Miller and Auchus 2011). In 1955, Prader described a complete sex reversal 46,XY DSD patient who died from an adrenal crisis very early in life and was found to have grossly enlarged, fatty transformed adrenal glands (Prader and Gurtner 1955). The clinical findings prompted him to name this disorder lipid CAH (LCAH). However, the underlying genetic defect of LCAH and the mechanism of the disease were only described years later, after the *StAR* gene had been cloned (Bose et al. 1996). Infants with severe *StAR* mutations (=classic lipid CAH) manifest with adrenal insufficiency soon after birth, latest within the first year of life. Affected 46,XY babies present with female external genitalia (Miller and Flück 2014). Milder *StAR* mutations, in which activity is partially retained, cause nonclassic LCAH. They usually present after 4 years of age to adulthood with late-onset primary adrenal insufficiency only, and do not affect (male) sex development (Flück et al. 2011; Miller and Flück 2014). The mechanism of disease action of *StAR* deficiency has been described by a “two hit model” (Bose et al. 1996). In this model the first hit consists of the actual loss of *StAR* activity for cholesterol import into the mitochondrion of the affected cell. However, as about 10% of cholesterol import occurs *StAR*-independent, a second hit is necessary to explain a severe phenotype. Thus, the second hit consists of the destruction of the steroidogenic cell through accumulation of cholesterol and cholesterol esters. Consistent with this model, the testis Leydig cell, which produces androgens early in fetal life, will be damaged early, resulting in 46,XY DSD. By contrast, the ovary, which is basically inactive in steroidogenesis until puberty, might be only affected by *StAR* deficiency beyond puberty. Affected females may therefore present with normal pubertal development and menses for a certain time, until the second hit strikes (Miller and Flück 2014).

Human *CYP11A1* mutations manifest clinically identical to *StAR* mutations (Miller and Flück 2014). They occur as a classic form with severe mutations and as a nonclassic form with partial loss of enzyme activity. In contrast to *StAR*



mutations, which usually present with adrenal enlargement in adrenal imaging, this finding is not observed in CYP11A1 deficiency. The serum or urine steroid profile of patients with classic StAR or CYP11A1 deficiency is characterized by overall (very) low production of all steroids (mineralocorticoids, glucocorticoids, and sex steroids). However, the exact diagnosis is made by genetic testing.

### **HSD3B2**

The biochemical profile of HSD3B2 deficiency has been described more than 50 years ago (Bongiovanni 1962). Severe HSD3B2 deficiency causes mineralocorticoid and glucocorticoid deficiency as well as (partial) androgen deficiency and results in 46,XY undervirilization and 46,XX virilization (Miller and Flück 2014). This is due to the fact that in humans there are two functional *HSD3B* genes, which express enzymes with similar activity. While *HSD3B2* is exclusively expressed in the gonads and the adrenals, *HSD3B1* is more widely expressed in the placenta and in peripheral tissues including liver and skin. Mutations in the human *HSD3B1* gene have not been described. But in case of HSD3B2 deficiency, peripheral enzyme activity of HSD3B1 may convert circulating androgen precursors secreted from the adrenals or gonads into more active androgens. This may cause virilization of 46,XX females. Likewise, in severe HSD3B2 deficiency massively increased 17OHPreg may be converted to 17OHP through peripheral HSD3B1 activity, and affected newborns may therefore be picked up in the neonatal screening for 21-hydroxylase deficiency. In general, 3 $\beta$ -hydroxysteroid dehydrogenases (3 $\beta$ HSDs/HSD3Bs) convert delta 5 steroids (Preg, 17OHPreg, DHEA, androstenediol) to delta 4 steroids (Prog, 17OHP, androstenedione, T) (Fig. 3). Thus high ratios of the delta 5 over the delta 4 steroids are characteristic for HSD3B2 deficiency. Although the steroid profile of HSD3B2 deficiency is very characteristic, genetic analysis of the *HSD3B2* gene is recommended to confirm the diagnosis.

### **CYP17A1**

CYP17A1 is the qualitative regulator of steroidogenesis in humans and has two distinct enzyme activities. Therefore, CYP17A1 deficiency exists in two forms. The first, more frequent form consists of combined loss of both 17 $\alpha$ -hydroxylase and 17,20-lyase activities and results in glucocorticoid and sex hormone deficiency. The second form consists of an isolated loss of 17,20-lyase activity, which is described only in few patients so far and affects androgen biosynthesis exclusively (Table 1, Fig. 3) (Miller 2012; Miller and Flück 2014). Thus both forms cause 46,XY DSD and gonadal insufficiency. Clinical presentation of 46,XY DSD due to CYP17 deficiency varies from apparently female to undervirilized male with absence of Müllerian structures, hypoplastic Wolffian structures, and intra-abdominal or maldescended testes. Pubertal development is missing. Gynecomastia is only seen in partial insufficiency. With severe 17-hydroxylase deficiency, the mineralocorticoid synthesis pathway of steroidogenesis is functional, and the CYP17 enzyme block will lead to increased production of corticosterone and 11-deoxycorticosterone (DOC), which both have mineralocorticoid properties. This will suppress renin and result in hypertension and hypokalemic alkalosis in the patient. As corticosterone

also has glucocorticoid activity, patients do not generally suffer from clinically relevant adrenal insufficiency, although ACTH is mildly elevated. Thus the typical steroid profile of combined CYP17 deficiency consists of high DOC, but low(ish) cortisol and low androgens.

By contrast, isolated 17,20-lyase deficiency caused by rare *CYP17A1* mutations is due to the loss of the 17,20-lyase activity of the enzyme. This activity is essential for androgen production of the classic and backdoor pathway (Fig. 3). Lyase activity requires POR and CYB5 for its full functionality. So far, only mutations at locations E305, R347, and R358 of the CYP17A1 protein have been shown to cause isolated lyase deficiency (Miller and Auchus 2011; Miller 2012). But specific mutations in *POR* and *CYB5A* may also cause isolated lyase deficiency.

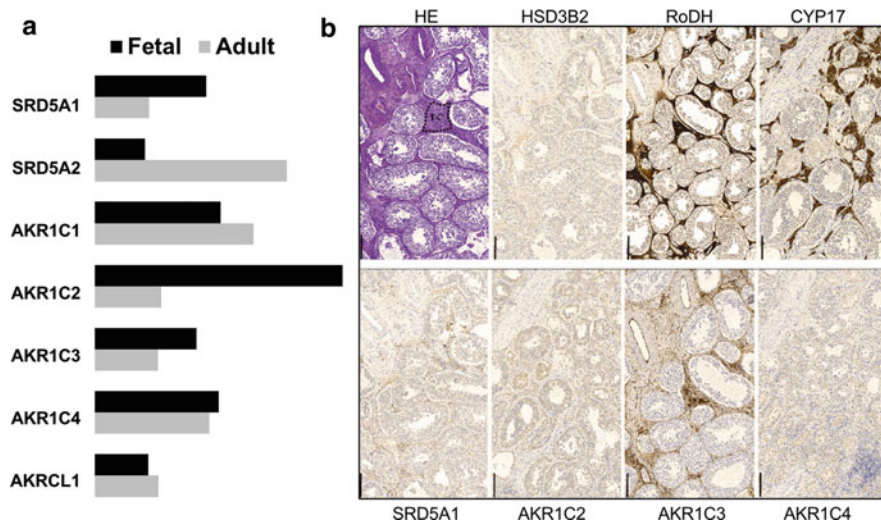
## **Classic Androgen Biosynthesis Defects Without Adrenal Insufficiency (HSD17B3, SRD5A2)**

### **HSD17B3**

There are maybe more than 14 isoforms of human 17 $\beta$ -hydroxysteroid dehydrogenases (17 $\beta$ HSDs), which have variable physiological functions. Some isoforms are preferentially reductases, others oxidases. Human mutations are only known for the *HSD17B3* gene and cause 46,XY DSD due to 17-ketosteroid reductase/17 $\beta$ HSD3 deficiency. Type 3 17 $\beta$ HSD (HSD17B3) is exclusively expressed in the testes, where it reduces androstenedione to T, DHEA to androstenediol, androstanedione to DHT, and androsterone to androstanediol (Fig. 3). Thus HSD17B3 deficiency is a male sex-limited disorder causing 46,XY DSD with severe to complete undervirilization of the external genitalia with a blind vaginal pouch. Müllerian structures are absent while Wolffian structures are present. Testicular descent is disturbed, and testes are often located inguinally. When patients with HSD17B3 deficiency are raised as females, they virilize at puberty as redundant other 17 $\beta$ HSD isoform enzyme activities convert testicular androstenedione to T in the periphery. The diagnostic steroid pattern for HSD17B3 deficiency is a low ratio of T over androstenedione either basally or after hCG stimulation (T/AD <0.8 after hCG) (Faisal Ahmed et al. 2000). Genetic confirmation is recommended.

### **SRD5A2**

In humans, there are two functionally active 5 $\alpha$ -reductases (5 $\alpha$ -Red). Both convert T to more potent DHT (Fig. 3). The type I enzyme (5 $\alpha$ -Red1) is encoded by the gene *SRD5A1* located on chromosome 5p15 and expressed in peripheral tissues such as the skin. The type II enzyme (5 $\alpha$ -Red2) is encoded by *SRD5A2* on chromosome 2p23 and is predominantly expressed in male reproductive tissues (Miller and Flück 2014). The well-known syndrome of 5 $\alpha$ -reductase deficiency is caused by numerous mutations in the *SRD5A2* gene. Typically, affected 46,XY individuals manifest at birth with female-appearing external genitalia, as the virilization of the external genitalia seems to depend largely on DHT; although it remains unsolved why DHT production through the backdoor pathway, which depends on 5 $\alpha$ -Red1, may



**Fig. 6** Expression pattern of backdoor pathway genes in the human testis. **(a)** Fetal versus adult testis. Quantitative RT-PCR shows developmental changes in the expression of SRD5A1 and SRD5A2, as well as for AKR1C2 with the fetal testis expressing higher amounts of SRD5A1 and AKR1C2. **(b)** Immunohistochemical staining showing the expression and localization of backdoor pathway genes in an adult testis. Note that Leydig cells express CYP17, RoDH, and AKR1C3 abundantly, and SRD5A1, AKR1C2/4, and HSD3B2 at low levels

not compensate. Apart from the severe under/nonvirilization of the external genitalia, patients with SRD5A2 deficiency show a rather normal male sex determination and differentiation during fetal development. At puberty, progressive virilization and gynecomastia occur spontaneously due to intact peripheral activity of  $5\alpha$ -Red1. This may prompt a change in gender role to male in individuals raised as female. Diagnosis of  $5\alpha$ -reductase deficiency may be suggested when a high serum T/DHT ratio (basal and hCG stimulated) is observed. However, assessment of a whole steroid profile (GCMS, LCMSMS) is even more informative as  $5\alpha$ -Reds are also important for the reduction of a variety of steroids (e.g., C21 steroids) in their metabolism, and this can be seen in the profile in addition (Miller and Auchus 2011). Human mutations in *SRD5A1* have not been described. Overall, the type 1 and 2 genes show a complex pattern of developmental regulation of expression, which is thought to also play a role in fetal androgen biosynthesis through the classic versus the alternative backdoor pathway in the testis (Figs. 3 and 6) (Flück et al. 2011; Miller and Auchus 2011).

### Redox Partner Defects (POR, CYB5)

Basic studies of isolated lyase deficiency have elucidated the important role of redox partner POR and CYB5 for the enzymatic reaction of CYP17A1 (Miller 2012). As a matter of fact, the same clinical phenotype seen with isolated 17,20-lyase deficiency

due to specific *CYP17A1* mutations may be mimicked by certain *POR* or *CYB5* mutations (Hershkovitz et al. 2008; Idkowiak et al. 2012; Miller 2012).

### **POR**

POR is the obligate electron donor to all microsomal type 2 cytochrome P450s, which comprise many proteins involved in steroidogenesis and xenobiotic metabolism, heme catabolism, bile acid synthesis, as well as prostaglandin and retinoic acid synthesis (comprehensively reviewed in Pandey and Flück 2013; Pandey and Sproll 2014; Burkhard et al. 2017). For adrenal and gonadal steroidogenesis, reactions catalyzed by enzymes CYP21A2 (21-hydroxylase), CYP17A1, and CYP19A1 (aromatase) depend on POR for electron transfer from NADPH. The phenotype of POR deficiency (PORD) was first described 1985 in a 46,XY DSD patient with a steroid profile showing combined 21- and 17-hydroxylase deficiency (Peterson et al. 1985). Years later the underlying defect was then identified to lie within the human *POR* gene (Flück et al. 2004). POR mutations manifest clinically with a very broad phenotype ranging from 46,XY and 46,XX DSD, adrenal insufficiency and skeletal malformations (known as Antley Bixler syndrome) with severe mutations to a polycystic ovary syndrome-like phenotype with milder mutations. This broad phenotype may be explained by two facts: one, different mutations in the POR protein affect the electron transfer to its partners to different degrees; two, the same POR mutation affects the activity of different P450 partners also to different degrees as their interaction might differ (Pandey et al. 2007; Nicolo et al. 2010; Pandey and Flück 2013; Flück and Pandey 2017). For example, a severe POR mutation, which destroys electron transfer to all P450s (e.g., R457H), may be found in patients with either 46,XY or 46,XX DSD, adrenal insufficiency and skeletal malformations, and virilization of the mother during pregnancy may occur (Flück et al. 2004). By contrast, the *POR* mutation G539R for instance, which has been shown to affect predominantly 17,20-lyase activity, will have a milder phenotype and resemble isolated 17,20-lyase deficiency (Hershkovitz et al. 2008). PORD cannot be diagnosed from the clinical picture alone, but the steroid profile from urine or plasma (GCMS or LCMSMS) can be used for diagnosis. Interestingly, steroid metabolites of the backdoor pathway have been found elevated in patients with PORD, and it has been suggested that these steroids contribute towards the observed intrauterine virilization of an affected female fetus and the mother during pregnancy (Homma et al. 2006). Final proof of the diagnosis of PORD however requires genetic testing and laboratory analysis of mutations (Parween et al. 2016; Burkhard et al. 2017).

### **CYB5**

Human *CYB5* mutations have been found in very rare cases of 46,XY patients with low androgens and gonadal insufficiency, but normal mineralocorticoid and glucocorticoid production due to apparent isolated 17,20-lyase deficiency, when genetic mutations in the *CYP17A1* and *POR* genes were not found (Idkowiak et al. 2012). *CYB5* was thought to support 17,20-lyase activity by facilitating the allosteric interaction between the proteins POR and CYP17A1 (Miller 2012; Miller and Flück 2014) but recently has also been shown to act as a redox partner (Duggal

et al. 2016). Only two *CYB5* mutations (W28X, H44L) have been described in 46,XY DSD individuals so far (Idkowiak et al. 2012).

### Genetic Defects of the Backdoor Pathway: Human *AKR1C2/4* Mutations

The backdoor pathway requires reductive and oxidative  $3\alpha$ -hydroxysteroid dehydrogenase ( $3\alpha$ HSD) activities for androgen production (Fig. 3). The four major human  $3\alpha$ HSDs are aldoketoreductases of the AKR1C family and have in principle reductive activity (Miller and Auchus 2011). AKR1C1–4 are located on chromosome 10p14–15 and have specific tissue distribution and specific catalytic characteristics. AKR1C3 is also known as  $17\beta$ HSD5 (HSD17B5) and catalyzes the conversion of androstenedione to T in the adrenals and ovaries, and in non-steroidogenic tissues. Expression of AKR1C3 is higher in the human fetal adrenal and testis and may participate (together with  $17\beta$ HSD3/HSD17B3) in the conversion of androsterone to androstenediol in the backdoor pathway (Fig. 6). Both AKR1C2 and AKR1C4 are able to convert 17OH-DHP to 17OH-Allo. They are both expressed in testes and adrenals, but the fetal testis expresses more AKR1C2 than AKR1C4 (Fig. 6) (Flück et al. 2011). By contrast, AKR1C2/4 harbor both only minimal oxidative activity. Therefore, in the fetal testis the conversion of androstenediol to DHT is unlikely supported by these enzymes, but rather by the oxidative HSD17B6/RoDH (retinol dehydrogenase), which is also abundantly expressed in the human prostate. Recently, we have identified first combined mutations in *AKR1C2/4* in patients with a phenotype similar to isolated  $17,20$ -lyase deficiency manifesting with moderate to severe forms of 46,XY DSD. In these patients mutations in the *CYP17A1*, *POR*, *CYB5*, and *SRD5A2* genes were excluded (Zachmann 1996; Flück et al. 2011). The index family presented initially two 46,XY DSD patients, one with cryptorchidism and genital undervirilization (raised male) and the other with an apparent female phenotype and no uterus (raised female) (Zachmann 1996). Family history revealed an aunt with severe 46,XY DSD (female gender, tall stature, primary amenorrhea) and a cousin with 46,XY DSD with moderate undervirilization (raised male). Adrenal insufficiency was excluded in all. At first, genetic analysis of the genes of the backdoor pathway for androgen production revealed *AKR1C2* mutations in the affected individuals and suggested an autosomal recessive, male sex-limited pattern of inheritance. Wide phenotypical variability and functional studies of identified *AKR1C2* mutants showing only moderate activity loss of 20–80% of the enzymes did not satisfy to explain the disease and prompted to search for a second hit. Linkage analysis picked up the *AKR1C* locus, which contains five closely related *AKR1C* genes. Further investigations of these genes revealed a second hit. Affected patients were all found to harbor a splicing mutation in *AKR1C4* together with the *AKR1C2* (I79V) mutation. In another severely affected 46,XY DSD patient with female external genitalia and intra-abdominal testes, a complex chromosomal rearrangement in the *AKR1C* locus was found. This included an unequal crossing over between the

*AKR1C2* and the *AKR1C1* genes, and an additional missense mutation (H222Q) in the *AKR1C2* gene, which was inactive in functional tests (Flück et al. 2011). These multigenic defects found in the backdoor pathway of androgen biosynthesis in 46,XY DSD patients provide convincing evidence that the backdoor pathway plays a crucial role for human fetal male sex development, even though we do not understand the exact interplay with the classic pathway and do not know its impact in postnatal life yet. Also, in contrast to notes in current textbooks, the fetal testis expresses in the Leydig cells *SRD5A1* and thus seems able to produce DHT (Figs. 3 and 4). However, why testicular or peripheral *SRD5A1* may not compensate for *SRD5A2* deficiency during fetal sex development remains to be explained.

### **Steroidogenic Factor 1 (SF1)/NR5A1 Deficiency**

Steroidogenic factor 1 (SF1/NR5A1) was originally identified in 1991 as an important transcription factor regulating genes of steroidogenesis including *Star*, *CYP11A1*, and *CYP17A1* (Suntharalingham et al. 2015). The knockout mouse model revealed a phenotype of complete sex reversal and adrenal insufficiency (due to a lack of adrenal glands) in males. This phenotype was also found in a first patient with 46,XY DSD and cortisol deficiency harboring a heterozygote *NR5A1* mutation. Meanwhile numerous patients are described, most of them with an isolated 46,XY DSD phenotype only, encompassing a wide spectrum from mild hypospadias to complete sex reversal, which remains poorly understood (Camats et al. 2012). Adrenal insufficiency with *NR5A1* deficiency seems very rare. Genetically, most patients harbor heterozygous mutations, which manifest variably even within families. SF1 deficiency may also cause gonadotropins deficiency and asplenia (Suntharalingham et al. 2015). Affected females may present with primary ovarian insufficiency. Testicular steroidogenesis is mostly disturbed with SF1 mutations and T production is therefore low. However, as SF1 is also critically involved in early sex determination and differentiation, not only steroidogenesis of the Leydig cell may be disturbed, but the overall development of the gonad may show severe abnormalities, presenting as streak gonad in worst case. Müllerian structures are variably persistent reflecting variable AMH levels with SF1 mutations. Overall, a characteristic clinical or biochemical presentation of SF1 deficiency does not exist; therefore the diagnosis must be made by genetic analysis.

Similarly, the transcription factor GATA4, which regulates many steroidogenic genes in collaboration with SF1, may also cause 46,XY DSD with low T production (Lourenco et al. 2011). Characteristically, these patients also manifest with congenital heart defects.

### **Other Genetic Defects Affecting Testosterone Biosynthesis**

In principal, steroidogenesis of the testis may be disturbed by any (genetic) disorder of testis development. These defects often result in severe forms of 46,XY DSD (e.g., *SRY*, *SOX9* mutations) with low or absent androgen biosynthesis. Additionally, genetic defects of the hypothalamic-pituitary gonadal (HPG) axis (e.g., GnRH

receptor, *KALI*, *FGFR1/FGF8*, *ROKR2/PROK2*, etc., mutations), which controls gonadal functions (Fig. 2), may also affect testicular steroidogenesis. However, these defects do not generally present with a DSD phenotype at birth, although with missing stimulation the male external genitalia may appear small at birth, qualifying as microgenitalia. Typically, these defects manifest after 10 years of age for failure of pubertal development due to T deficiency in boys and require T replacement therapy.

By contrast, mutations in the LH receptor (*LHCGR* gene), which do not transmit the HP stimulus to the gonad and result in Leydig cell aplasia or hypoplasia, lead to a moderate to severe DSD phenotype at birth, depending on the severity of LHCGR inactivation. LH levels are typically elevated, and T levels are low.

Furthermore, testicular steroidogenesis may also be impaired by any disorder affecting the overall cholesterol biosynthesis, as all steroid hormones are produced from cholesterol. A typical example for this is the Smith Lemli Opitz (SLO) syndrome, in which mild genital anomalies (bilateral cryptorchidism, hypospadias) are seen in 50% of 46,XY individuals. SLO is caused by dehydrocholesterol reductase (DHCR) deficiency and leads to a block in the last step of cholesterol biosynthesis. Cholesterol is not only essential for steroid hormone biosynthesis, but also for processing of sonic hedgehog. This is important for pattern formation of the limbs, face, and nervous system. DHCR deficiency therefore causes a multitude of syndromic features and impairs cognitive functions to variable degrees.

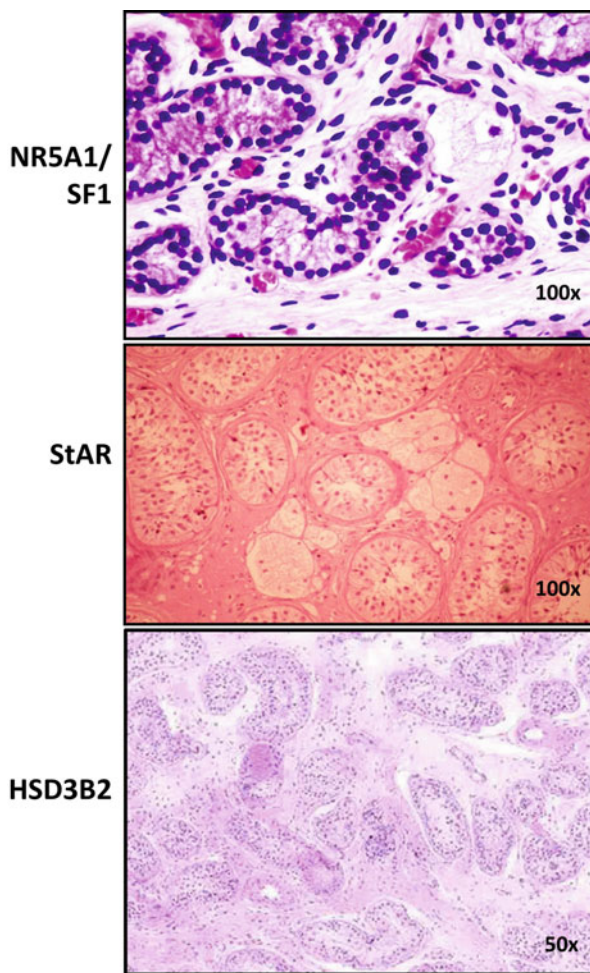
A transient T biosynthetic defect during fetal development is also suggested to explain the 46,XY DSD phenotype at birth with X-linked *MAMLD1* (mastermind-like domain-containing 1) mutations. Observed genital anomalies are often milder (hypospadias), and postnatal testicular function is reported to be normal. Finally, it is important to note here briefly that androgen production may only be effective, if the hormonal receptor is intact (Fig. 2). Mutations in the androgen receptor (or thus far unidentified comodulators) lead to complete or partial androgen insensitive syndromes (also called 46,XY DSD of androgen action), which resemble phenotypically the androgen deficiency syndromes described above. However, with AR mutations T levels are usually elevated.

---

## Effects of Disordered Steroidogenesis on Testis Histology, Fertility, and Spermatogenesis

Little is known on testis histology, fertility, and malignancy risk in 46,XY DSD due to androgen biosynthetic defects. A summary of the literature (mostly case reports) has been reported recently (Burckhardt et al. 2015). Overall, defects in T synthesis seem to affect predominantly Leydig cells, which might be absent or reduced and with vacuoles and fat accumulation (Fig. 7). However, anomalies in seminiferous tubules containing Sertoli cells and germ cells are also observed to different degrees. A characteristic picture for specific enzymatic defects is not observed. Spermatogenesis seems impaired or even absent in many cases and contributes towards infertility together with androgen deficiency. These findings confirm that androgens are needed in the testis itself for normal sperm production, and that there must be an

**Fig. 7** Histology of testis tissues from patients diagnosed with congenital androgen biosynthetic disorders, NR5A1/SF1, StAR, and HSD3B2. General histology with hematoxylin and eosin stain (HE) shows well-developed seminiferous tubules with few germ cells and few Leydig cells. Leydig cells present with cytoplasmic vacuoles in SF1 and StAR deficiency. Overall, a Sertoli-cell-only pattern is characteristic



indispensable interplay between Leydig and Sertoli cells. Concerning malignancy risk with 46,XY DSD due to androgen deficiency, data are even more scarce. Evaluation in very few cases suggested probably low risk, but further studies are needed to conclude on this question.

## Outlook, What Do We Not Know?

Androgen metabolism has been a constantly growing field for a long time. There is large interest in use of androgens as antiaging agents, and novel synthetic androgens that do not possess undesirable side effects and toxicity of natural androgens are being synthesized since 1930s. Use of androgens to slow down or reverse “andropause” is actively being pursued in several large clinical studies. However, recent reports of severe side effects of T usage have dampened the enthusiasm, and



less toxic, perhaps synthetic androgens (or selective androgen receptor modulators, SARMs) may be investigated in future to bypass the side effects associated with T/DHT usage. Despite heavy research on synthesis and metabolism of androgens, there are several aspects of androgen regulation and tissue level bioavailability that need further studies. A major area of research is the fate of androgens during aging. It is known that DHEA levels start rising around puberty and reach a peak during 20–25 years of age then slowly decline throughout life in a phenomenon known as adrenopause. A simplistic extrapolation would deduce that levels of T and DHT would also severely decline with age. However, not much is known about differential expression of different enzymes that activate T or deactivate T and DHT in different tissues. Since a wide range of combinations of activating and inactivating enzymes may influence the actual level of T/DHT in a particular cell/tissue, further studies are needed to have a systems biology approach towards androgen production and regulation through different stages of life. The  $3\alpha/3\beta$  hydroxysteroid dehydrogenases,  $17\beta$  hydroxydehydrogenases,  $5\alpha/5\beta$  reductases, and catabolic cytochrome P450 enzymes that use T/DHT as a substrate (CYP3A4, CYP3A5, CYP3A7, etc.) dictate the actual availability of androgens. From the alternate pathway we have learned that DHT can also be produced from indirect sources and existence/activity of these enzymes, especially in aging and different physiological conditions requires further studies. It is possible that the alternate pathway exists to provide the more potent androgen, DHT, even under limiting T availability to keep the important androgen-dependent pathways functioning. Another aspect of androgen action that is not precisely clear is activation of AR by androgens. Very low quantities of DHT that are an order of magnitude lower than binding constants of androgens for AR have been known to cause AR activation. A partial activation theory and phosphorylation of AR have been proposed to be responsible for these observations, but exact mechanisms that may govern AR activation and whether different physiological conditions affect these mechanisms need further studies. Role of UGTs and sulfokinases in bioconjugation of androgens have not received much focus, and majority of androgen metabolism studies have focused on direct metabolism of androgens by steroid dehydrogenases and cytochrome P450 proteins. Recent works from Yuji Ishi and colleagues from Fukuoka has suggested that protein-protein interactions between P450s and UGTs can influence metabolic processes (Ishii et al. 2010, 2014). Here also a systemic look at such combinations and changes under different physiological conditions require further studies. Nonclassical roles of androgens that does not involve nuclear translocation upon the activation of AR as the first step of androgen signaling also need more investigation. Several novel compounds that may bind to AR but stop its relocation to nucleus, i.e., anti-androgens, have been developed.

---

## Summary

T is a major circulating androgen, but there are more potent metabolites like DHT which have much higher affinity for AR. The classical pathway of T biosynthesis starts from import of cholesterol into mitochondria and then proceeds through

several enzymes to form T/DHT. In addition to direct conversion of T to DHT by  $5\alpha$ -reductase, some alternate pathways of DHT production have recently been identified, especially in fetal life and under disease states like CAH, PCOS, and prostate cancer. Genetic disorders in any of the enzymes and their partner proteins like CYP11A1, CYP17A1, POR, CYB5A, HSD17B, and SRD5A1 may directly influence androgen levels and availability. Most of the T is bound to proteins, which may also control its bioavailability and degradation. The local expression of  $3\alpha/\beta$  hydroxysteroid dehydrogenases,  $5\alpha$ -reductase, and  $17\beta$ -hydroxydehydrogenases, which can activate/inactivate T/DHT, may govern the actual amount of T/DHT in a particular cellular environment, and general estimations based on peripheral measurements in blood/saliva may not provide a full picture of androgen bioavailability. Impact of physiological conditions like aging and different disease states may create difference in cellular environments that could influence androgen production and bioavailability and require further investigation. In addition to long-term post-translational effect of androgens through nuclear localization of AR upon androgen binding, there are also membrane receptor-based effects of androgens which result in rapid response to androgen exposure, an example being rapid calcium influx in muscle. Many synthetic analogues of T/DHT have been produced, and improvements to natural androgens are constantly being pursued to increase bioavailability and minimize the side effects associated with exposure to anabolic steroids. More research into the mechanism of action of androgens and bioavailability is required to potentially develop treatments to reverse the effects in men whose androgen levels drop upon aging.

**Acknowledgments** This work has been supported by the Swiss National Science Foundation grant 320030-146127.

---

## References

- Auchus RJ. The backdoor pathway to dihydrotestosterone. *Trends Endocrinol Metab.* 2004;15:432–8.
- Biason-Laubier A, Miller WL, et al. Of marsupials and men: "backdoor" dihydrotestosterone synthesis in male sexual differentiation. *Mol Cell Endocrinol.* 2013;371(1–2):124–32.
- Bongiovanni AM. The adrenogenital syndrome with deficiency of 3 beta-hydroxysteroid dehydrogenase. *J Clin Invest.* 1962;41:2086–92.
- Bose HS, Sugawara T, et al. The pathophysiology and genetics of congenital lipoid adrenal hyperplasia. *N Engl J Med.* 1996;335(25):1870–8.
- Burckhardt MA, Udhane S, et al. Human 3beta-hydroxysteroid-dehydrogenase deficiency seems to affect fertility but may not harbor a tumor risk: lesson from an experiment of nature. *Eur J Endocrinol.* 2015;173(5):K1–K12.
- Burkhard FZ, Parween S, et al. P450 oxidoreductase deficiency: analysis of mutations and polymorphisms. *J Steroid Biochem Mol Biol.* 2017;165(Pt A):38–50.
- Camats N, Pandey AV, et al. Ten novel mutations in the NR5A1 gene cause disordered sex development in 46,XY and ovarian insufficiency in 46,XX individuals. *J Clin Endocrinol Metab.* 2012;97(7):E1294–306.
- de Castro AL, Cavalari FC, et al. Epitestosterone and testosterone have similar nonclassical actions on membrane of Sertoli cells in whole seminiferous tubules. *Horm Metab Res.* 2013;45(01):15–21.

- Cavalari FC, de Castro AL, et al. Non-classic androgen actions in JSertoli cell membrane in whole seminiferous tubules: effects of nandrolone decanoate and catechin. *Steroids*. 2012;77(1–2):118–25.
- Chang KH, Li R, et al. Dihydrotestosterone synthesis bypasses testosterone to drive castration-resistant prostate cancer. *Proc Natl Acad Sci USA*. 2011;108(33):13728–33.
- Choi MH, Skipper PL, et al. Characterization of testosterone 11 $\beta$ -hydroxylation catalyzed by human liver microsomal cytochromes p450. *Drug Metab Dispos*. 2005;33(6):714–8.
- Davey RA, Grossmann M. Androgen receptor structure, function and biology: from bench to bedside. *Clin Biochem Rev*. 2016;37(1):3–15.
- Dhayat NA, Frey AC, et al. Estimation of reference curves for the urinary steroid metabolome in the first year of life in healthy children: tracing the complexity of human postnatal steroidogenesis. *J Steroid Biochem Mol Biol*. 2015;154:226–36.
- Dhayat NA, Dick B, et al. Androgen biosynthesis during minipuberty favors the backdoor pathway over the classic pathway: insights into enzyme activities and steroid fluxes in healthy infants during the first year of life from the urinary steroid metabolome. *J Steroid Biochem Mol Biol*. 2017;165:312–322.
- Duggal R, Liu Y, et al. Evidence that cytochrome b5 acts as a redox donor in CYP17A1 mediated androgen synthesis. *Biochem Biophys Res Commun*. 2016;477(2):202–8.
- Faisal Ahmed S, Iqbal A, et al. The testosterone:androstenedione ratio in male undermasculinization. *Clin Endocrinol*. 2000;53(6):697–702.
- Fassnacht M, Schlenz N, et al. Beyond adrenal and ovarian androgen generation: increased peripheral 5 alpha-reductase activity in women with polycystic ovary syndrome. *J Clin Endocrinol Metab*. 2003;88(6):2760–6.
- Fevold HR, Lorence MC, et al. Rat P450(17 alpha) from testis: characterization of a full-length cDNA encoding a unique steroid hydroxylase capable of catalyzing both delta 4- and delta 5-steroid-17,20-lyase reactions. *Mol Endocrinol*. 1989;3(6):968–75.
- Flück CE, Pandey AV. Impact on CYP19A1 activity by mutations in NADPH cytochrome P450 oxidoreductase. *J Steroid Biochem Mol Biol*. 2017;165(Pt A):64–70.
- Flück CE, Miller WL, et al. The 17, 20-lyase activity of cytochrome P450c17 from human fetal testis favors the  $\Delta$ 5 steroidogenic pathway. *J Clin Endocrinol Metab*. 2003;88(8):3762–6.
- Flück CE, Tajima T, et al. Mutant P450 oxidoreductase causes disordered steroidogenesis with and without Antley-Bixler syndrome. *Nat Genet*. 2004;36(3):228–30.
- Flück CE, Meyer-Boni M, et al. Why boys will be boys: two pathways of fetal testicular androgen biosynthesis are needed for male sexual differentiation. *Am J Hum Genet*. 2011;89:201–18.
- Flück CE, Pandey AV, et al. Characterization of novel StAR (steroidogenic acute regulatory protein) mutations causing non-classic lipoid adrenal hyperplasia. *PLoS One*. 2011;6(5):e20178.
- Foradori CD, Weiser MJ, et al. Non-genomic actions of androgens. *Front Neuroendocrinol*. 2008;29(2):169–81.
- Fukami M, Homma K, et al. Backdoor pathway for dihydrotestosterone biosynthesis: implications for normal and abnormal human sex development. *Dev Dyn*. 2013;242(4):320–9.
- Govindan MV. Specific region in hormone binding domain is essential for hormone binding and trans-activation by human androgen receptor. *Mol Endocrinol*. 1990;4(3):417–27.
- Hatzoglou A, Kampa M, et al. Membrane androgen receptor activation induces apoptotic regression of human prostate cancer cells in vitro and in vivo. *J Clin Endocrinol Metab*. 2005;90(2):893–903.
- Hershkovitz E, Parvari R, et al. Homozygous mutation G539R in the gene for P450 oxidoreductase in a family previously diagnosed as having 17,20-lyase deficiency. *J Clin Endocrinol Metab*. 2008;93(9):3584–8.
- Homma K, Hasegawa T, et al. Urine steroid hormone profile analysis in cytochrome P450 oxidoreductase deficiency: implication for the backdoor pathway to dihydrotestosterone. *J Clin Endocrinol Metab*. 2006;91(7):2643–9.
- Idkowiak J, Randell T, et al. A missense mutation in the human cytochrome b5 gene causes 46,XY disorder of sex development due to true isolated 17,20 lyase deficiency. *J Clin Endocrinol Metab*. 2012;97(3):E465–75.

- Ishii Y, Nurrochmad A, et al. Modulation of UDP-glucuronosyltransferase activity by endogenous compounds. *Drug Metab Pharmacokinet.* 2010;25(2):134–48.
- Ishii Y, Koba H, et al. Alteration of the function of the UDP-glucuronosyltransferase 1A subfamily by cytochrome P450 3A4: different susceptibility for UGT isoforms and UGT1A1/7 variants. *Drug Metab Dispos.* 2014;42(2):229–38.
- Kamrath C, Hochberg Z, et al. Increased activation of the alternative "backdoor" pathway in patients with 21-hydroxylase deficiency: evidence from urinary steroid hormone analysis. *J Clin Endocrinol Metab.* 2012;97(3):E367–75.
- Ko E, Choi H, et al. Testosterone stimulates Duox1 activity through GPRC6A in skin keratinocytes. *J Biol Chem.* 2014;289(42):28835–45.
- Kuiri-Hanninen T, Sankilampi U, et al. Activation of the hypothalamic-pituitary-gonadal axis in infancy: minipuberty. *Hormone research in paediatrics.* 2014;82(2):73–80.
- Lieberherr M, Grosse B. Androgens increase intracellular calcium concentration and inositol 1,4,5-trisphosphate and diacylglycerol formation via a pertussis toxin-sensitive G-protein. *J Biol Chem.* 1994;269(10):7217–23.
- Loss ES, Jacobsen M, et al. Testosterone modulates K<sup>+</sup>ATP channels in Sertoli cell membrane via the PLC-PIP2 pathway. *Horm Metab Res.* 2004;36(08):519–25.
- Lourenco D, Brauner R, et al. Loss-of-function mutation in GATA4 causes anomalies of human testicular development. *Proc Natl Acad Sci USA.* 2011;108(4):1597–602.
- Marti N, Galvan JA, et al. Genes and proteins of the alternative steroid backdoor pathway for dihydrotestosterone synthesis are expressed in the human ovary and seem enhanced in the polycystic ovary syndrome. *Mol Cell Endocrinol.* 2016;441:116–23.
- Matsumoto T, Sakari M, et al. The androgen receptor in health and disease. *Annu Rev Physiol.* 2013;75(1):201–24.
- Miller WL. The syndrome of 17,20 lyase deficiency. *J Clin Endocrinol Metab.* 2012;97(1):59–67.
- Miller WL, Auchus RJ. The molecular biology, biochemistry, and physiology of human steroidogenesis and its disorders. *Endocr Rev.* 2011;32(1):81–151.
- Miller WL, Flück CE. Adrenal cortex and its disorders. In: Sperling MA, editor. *Pediatric endocrinology.* Philadelphia: Saunders; 2014.
- Neunzig J, Sánchez-Guijo A, et al. A steroidogenic pathway for sulfonated steroids: the metabolism of pregnenolone sulfate. *J Steroid Biochem Mol Biol.* 2014;144(Part B):324–33.
- Nicolo C, Flück CE, et al. Restoration of mutant cytochrome P450 reductase activity by external flavin. *Mol Cell Endocrinol.* 2010;321(2):245–52.
- Pandey AV, Flück CE. NADPH P450 oxidoreductase: structure, function, and pathology of diseases. *Pharmacol Ther.* 2013;138(2):229–54.
- Pandey AV, Sproll P. Pharmacogenomics of human P450 oxidoreductase. *Front Pharmacol.* 2014;5:103.
- Pandey AV, Kempna P, et al. Modulation of human CYP19A1 activity by mutant NADPH P450 oxidoreductase. *Mol Endocrinol.* 2007;21(10):2579–95.
- Papakonstanti EA, Kampa M, et al. A rapid, nongenomic, signaling pathway regulates the actin reorganization induced by activation of membrane testosterone receptors. *Mol Endocrinol.* 2003;17(5):870–81.
- Parween S, Roucher-Boulez F, et al. P450 oxidoreductase deficiency: loss of activity caused by protein instability from a novel L374H mutation. *J Clin Endocrinol Metab.* 2016;101(12):4789–98.
- Peterson RE, Imperato-McGinley J, et al. Male pseudohermaphroditism due to multiple defects in steroid-biosynthetic microsomal mixed-function oxidases. A new variant of congenital adrenal hyperplasia. *N Engl J Med.* 1985;313(19):1182–91.
- Pi M, Parrill AL, et al. GPRC6A mediates the non-genomic effects of steroids. *J Biol Chem.* 2010;285(51):39953–64.
- Prader A, Gurtner HP. The syndrome of male pseudohermaphroditism in congenital adrenocortical hyperplasia without overproduction of androgens (adrenal male pseudohermaphroditism). *Helv Paediatr Acta.* 1955;10(4):397–412.

- Simoncini T, Genazzani A. Non-genomic actions of sex steroid hormones. *Eur J Endocrinol.* 2003;148(3):281–92.
- Strott CA. Steroid sulfotransferases. *Endocr Rev.* 1996;17(6):670–97.
- Suntharalingham JP, Buonocore F, et al. DAX-1 (NR0B1) and steroidogenic factor-1 (SF-1, NR5A1) in human disease. *Best Pract Res Clin Endocrinol Metab.* 2015;29(4):607–19.
- Swart AC, Storbeck KH. 11beta-Hydroxyandrostenedione: downstream metabolism by 11betaHSD, 17betaHSD and SRD5A produces novel substrates in familiar pathways. *Mol Cell Endocrinol.* 2015;408:114–23.
- Ueda T, Mawji NR, et al. Ligand-independent activation of the androgen receptor by Interleukin-6 and the role of steroid receptor coactivator-1 in prostate cancer cells. *J Biol Chem.* 2002;277(41):38087–94.
- Walker WH. Non-classical actions of testosterone and spermatogenesis. *Philos Trans R Soc B: Biol Sci.* 2010;365(1546):1557–69.
- Wang C, Liu Y, et al. G protein-coupled receptors: extranuclear mediators for the non-genomic actions of steroids. *Int J Mol Sci.* 2014;15(9):15412.
- van de Wijngaert DJ, Dubbink HJ, et al. Androgen receptor coregulators: recruitment via the coactivator binding groove. *Mol Cell Endocrinol.* 2012;352(1–2):57–69.
- Zachmann M. Prismatic cases: 17,20-desmolase (17,20-lyase) deficiency. *J Clin Endocrinol Metab.* 1996;81(2):457–9.

---

# Anabolic and Metabolic Effects of Testosterone and Other Androgens: Direct Effects and Role of Testosterone Metabolic Products

# 11

Jonas Čeponis, Christina Wang, Ronald S. Swerdloff, and Peter Y. Liu

---

## Abstract

Sex hormones play a major role throughout the body starting from gender differentiation in utero to senescence. While they are undoubtedly important for development and conservation of reproductive function, their importance has been shown in most systems by experimental and clinical models. While testosterone (T) is considered to be the most important androgen in circulation, it may either directly exert effects on target tissues or be metabolized by 5 $\alpha$ -reductase into dihydrotestosterone (DHT) or aromatized to estradiol (E2). Differential effects of T and its metabolites are not well known and are a topic of scientific debate. These pleiotropic effects lead to variable phenotypes, clinical manifestations, and significance throughout life and may be more pronounced in some systems (such as bone and reproductive organs) or stages (such as puberty) than in others. This chapter focuses on the available clinical evidence of the androgen effects on several important systems.

---

## Keywords

Male • Androgen • Testosterone • Estradiol • Dihydrotestosterone • Effect • Action • Aromatase • 5 $\alpha$ -reductase • Sex hormone

---

J. Čeponis

Los Angeles Biomedical Research Institute at Harbor-UCLA Medical Center, Torrance, CA, USA

Institute of Endocrinology, Lithuanian University of Health Sciences, Kaunas, Lithuania

e-mail: [Jonas.Ceponis@lsmuni.lt](mailto:Jonas.Ceponis@lsmuni.lt); [jceponis@labiomed.org](mailto:jceponis@labiomed.org)

C. Wang • R.S. Swerdloff • P.Y. Liu (✉)

Los Angeles Biomedical Research Institute at Harbor-UCLA Medical Center, Torrance, CA, USA

David Geffen School of Medicine at UCLA, Harbor-UCLA Medical Center, Torrance, CA, USA

e-mail: [wang@labiomed.org](mailto:wang@labiomed.org); [swerdloff@labiomed.org](mailto:swerdloff@labiomed.org); [pliu@labiomed.org](mailto:pliu@labiomed.org)

## Contents

Introduction .....	374
Androgen Levels Throughout Life Span .....	376
Androgen Effects on Bone .....	376
Studies in Healthy Men with Induced Hypogonadism .....	377
Studies in Hypogonadal Men: Testosterone Replacement and Use of Aromatase Inhibitors .....	378
Effects on Body Composition and Muscle Strength .....	379
Studies in Healthy Men with Induced Hypogonadism .....	379
Studies in Hypogonadal Men .....	382
Metabolic Effects .....	384
Effects on Erythropoiesis .....	385
Possible Mechanisms of Action of T on Erythropoiesis .....	385
Clinical Studies of T, DHT, and E2 Effects on Hematopoiesis in Men .....	388
Conclusion .....	389
References .....	389

## Introduction

The most important circulating androgen – testosterone (T) – is mainly produced by the testis with minimal amounts being secreted by *zona reticularis* in the adrenals. The androgens that are predominantly secreted by the adrenal gland are dehydroepiandrosterone (DHEA) and androstenedione.

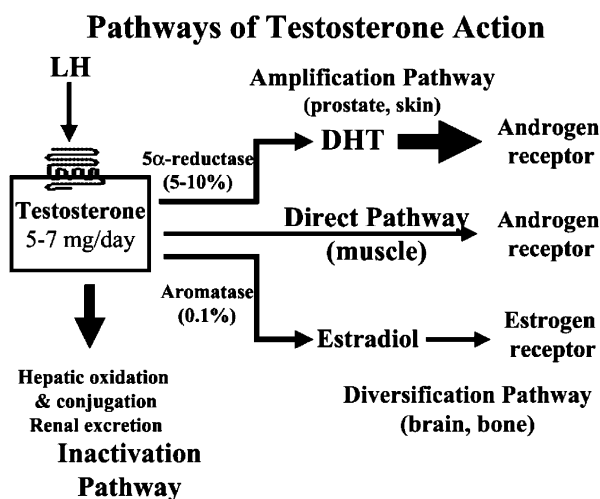
Approximately 98% of circulating T is bound to protein – 60% loosely bound to albumin, while 40% is tightly bound to sex hormone-binding globulin (SHBG). The remaining 2–3% is free or unbound testosterone. The classic understanding is that only free T is biologically active, while albumin-bound T is easily dissociated; thus both of these forms are available to tissues and are usually referred to as bioavailable T. Unlike T, most of the adrenal androgens (about 90%) are bound to albumin with only 3% bound to SHBG.

T may either directly exert effects on target tissues or be metabolized by 5 $\alpha$ -reductase into dihydrotestosterone (DHT) or aromatized to estradiol (E2). Both T and DHT bind to an androgen receptor; however DHT has a stronger binding affinity than T and may have more androgenic effect in certain tissues at lower levels. 5 $\alpha$ -reductase is mostly found in reproductive tissues, prostate, and skin. Aromatase is mostly found in fat tissue, the liver, and some nuclei of the central nervous system (Mooradian et al. 1987). E2 diversifies androgen action through binding to the estrogen receptor. In addition, this diversification is further increased because of the two estrogen receptors,  $\alpha$  and  $\beta$ . Therefore, potentially T may exert variable effects on the same tissue through its product steroids and diverse receptor action. Functions and targets of T and its major metabolites overlap; however their significance and equilibrium in each of those targets are still debated. (See Fig. 1)

There are multiple factors that may impact tissue sensitivity to androgens, such as a number of polyglutamine repeats in the androgen receptor-encoding gene, variable androgen receptor, and its coactivator and corepressor expression or hormonal

action/metabolism differences in tissues, as well as variation in the role of androgen or metabolites in eliciting target tissue responses (Finkelstein et al. 2013).

T effects on reproductive organs and sperm production are described elsewhere in this book. Nonreproductive effects of T on bone, body composition, hematopoiesis, and metabolism are subjects of scientific discussion, especially in the adult and aging male. While there is wealth of data from observational studies, their results are often unequivocal; therefore this review will focus on randomized clinical trials and physiological clinical studies in healthy subjects.



**Fig. 1** Pathways of testosterone action. In men, most (>95%) testosterone is produced under LH stimulation through its specific receptor, a heptahelical G protein-coupled receptor located on the surface membrane of the steroidogenic Leydig cells. The daily production of testosterone (5–7 mg) is disposed along one of four major pathways. The direct pathway of testosterone action is characteristic of skeletal muscle in which testosterone itself binds to and activates the AR. In such tissues, there is little metabolism of testosterone to biologically active metabolites. The amplification pathway is characteristic of the prostate and hair follicle in which testosterone is converted by the type 2 5 $\alpha$ -reductase enzyme into the more potent androgen, DHT. This pathway produces local tissue-based enhancement of androgen action in specific tissues according to where this pathway is operative. The local amplification mechanism was the basis for the development of prostate-selective inhibitors of androgen action via 5 $\alpha$ -reductase inhibition, the forerunner being finasteride. The diversification pathway of testosterone action allows testosterone to modulate its biological effects via estrogenic effects that often differ from AR-mediated effects. The diversification pathway, characteristic of bone and brain, involves the conversion of testosterone to estradiol by the enzyme aromatase, which then interacts with ER $\alpha$  and/or ER $\beta$ . Finally, the inactivation pathway occurs mainly in the liver, with oxidation and conjugation to biologically inactive metabolites that are excreted by the liver into the bile and by the kidney into the urine (Figure and legend from Peter Y. Liu et al. *Androgens and Cardiovascular Disease*. *Endocrine Reviews* (2003) 24 (3): 313-340 by permission of Oxford University Press on behalf of the Endocrine Society)



## Androgen Levels Throughout Life Span

In a male fetus, production of testosterone (T) starts around seventh week of gestation, and high concentrations are sustained during the first half of the gestational period. During fetal development T is required for the development of the Wolffian duct structures, and DHT is needed for development and growth of the external genitalia. Androgen levels drop at the end of gestation and are only slightly higher than in girls at birth. The rise of T levels after the birth (“mini-puberty”) is sustained for 3 months after which they fall to levels slightly above that of girls until puberty. Androgen effects in early development are described in ► [Chaps. 5, “Sex Determination,”](#) ► [6, “Male Sexual Differentiation,”](#) ► [7, “Endocrinology of the Fetal Testis,”](#) and ► [8, “Testis Development and Descent.”](#)

During puberty T gradually rises to adult male levels. Early pre-peripuberty increases in T result in increased sebaceous gland secretion, bone growth maturation leading to growth spurt, pubarche, and axillary and facial hair growth. Adult levels of T after puberty are stable until about 40 years when there is a gradual decrease, which may be accelerated by obesity and concomitant comorbidities (Wu et al. [2010](#)).

---

## Androgen Effects on Bone

Bone metabolism is a balance between bone formation by osteoblasts and resorption by osteoclasts with different components dominating during different parts of the life span. In addition to sex hormones, complex signaling and control mechanisms involve calcium homeostasis, parathyroid hormone, growth hormone, vitamin D, cytokines, and growth factors. Importance of sex hormones in bone formation and maturation during puberty has been established empirically. In adult men, several cross-sectional and longitudinal observational studies found that serum estradiol was more strongly associated with bone mineral density (BMD) and fracture risk than T (Amin et al. [2000](#); Khosla et al. [1998](#); Orwoll et al. [2006](#); Ohlsson et al. [2012](#)). However, most of circulating E2 in men is directly aromatized from T. Therefore, such studies are not effective in discerning differential effects of sex hormones. Moreover, BMD in older men is determined both by bone formation (acquired bone mass) during youth and bone loss that dominates later.

An in-depth overview of the steroid action on bone structure in men by Vanderschueren et al. ([2014](#)) concludes that male cortical and trabecular peak bone mass acquisition is dependent on both AR and ER $\alpha$  actions, while a definite role for ER $\beta$  in humans has not been confirmed; there are also data suggesting importance of non-genomic signaling. While it is known that ER $\alpha$  exerts direct effects in osteoblasts, osteocytes, osteoclasts, and chondrocytes, and AR affects osteoblasts and osteocytes, full mechanisms for these actions are not completely known.

Models for elucidating differential effects of sex hormones include studies of null gene mutations in estrogen or androgen receptor or aromatase in both human and animal models where a specific mutation in ER, AR, or the aromatase results in

significant osteoporosis (Smith et al. 1994; Marcus et al. 2000; Carani et al. 1997; Morishima et al. 1995). E2 replacement in aromatase-deficient males led to increase in bone mineral density. These models provide important insights about impact of elimination of specific regulatory pathways, especially during the developmental stage. However, they are not suitable for evaluation of effects of declining sex hormone levels in adult men.

## Studies in Healthy Men with Induced Hypogonadism

Similar concept of selective hormone deprivation in healthy men may help to determine specific targets of hormone effects and pathophysiology of their failure. These randomized control trials (RCTs) have certain specific traits – the participants are generally healthy; they undergo pharmacological inhibition of endogenous steroidogenesis with replacement of selected hormones to specified levels. Such trials allow mimicking different hormonal equilibrium scenarios and examine their effects on the presumptive targets.

The first study of this kind by Falahati-Nini et al. (2000) reported that in 59 elderly men (mean age 68 years) where endogenous steroid production was suppressed by a long-acting GnRH agonist (leuprolide acetate) and aromatization inhibited by letrozole, T and E2 were replaced to physiologic levels for 3 weeks and then randomized to full substitution or withdrawal of either or both of the sex hormones for another 3 weeks. The most significant increase in both resorption markers and decrease in bone formation markers were observed in men who discontinued all replacement, with smaller changes in those continuing T only, followed by those on E2 but not T. No changes were observed in those who continued full replacement. Similar results were observed in a study by Leder et al. (2003) in 70 men aged 20–44 years, when over 12 weeks deprivation of both hormones led to increased resorption and decreased formation markers compared with replacement of T only, while patients with full replacement displayed no changes in the measured markers. In contrast to previous study, there was no exogenous E2 replacement, and differential E2 effect was only evaluated through inhibition of aromatization in one of the groups. In a recent study, Finkelstein et al. (2016) induced hypogonadism in 189 younger men with GnRH agonist and, by using graded doses of T replacement, showed that bone mineral density decreased with decreasing dose or serum level of T, but the decrease was more marked when T replacement was administered with an aromatase inhibitor. Moreover, as long as E2 levels remained low, bone resorption increased significantly, despite normal or even elevated T levels. Results of this study also showed that serum level of T above 200 ng/dL and E2 above 10 pg/mL appeared to be sufficient for preventing increased bone resorption and BMD decreases in men. The study also showed that E2 deficiency primarily affected cortical bone through increased cortical porosity with minimal effects on trabecular structure. This is in line with findings in animal models, which showed that while E2 mostly affects cortical bone, androgen effects are exerted on trabecular bone directly through AR (Notini et al. 2007; Khosla 2015; Ucer et al. 2015).

Increase in bone turnover after sex hormone deprivation was also observed in a study of 58 men aged 20–45 randomized to differential add-back of sex hormones. Additionally, PTH infusion stimulated bone resorption markers significantly more in those with sex hormone deprivation, especially in groups with no E2 add-back (Lee et al. 2006). Similar findings were observed in postmenopausal women, where lack of E2 was attributed to sensitizing skeleton to bone resorptive effect of PTH (Cosman et al. 1993; Joborn et al. 1991). The continuous versus pulsatile effect of PTH on bone has been shown earlier – while PTH infusion seems to stimulate bone resorption (Leder et al. 2001), intermittent subcutaneous administration increases bone mass (Orwoll et al. 2003).

Yet these randomized clinical trials in healthy men with induced sex hormone deprivation that are specifically designed to elucidate physiological actions of T and its metabolites have certain limitations: First, to ensure safety of the participants these, studies are short in duration, demonstrating acute, rather than chronic effects of hypogonadism. Second, changes in body mineral density develop over a long term, and most available methods may not be sufficiently sensitive to detect subtle changes occurring over a short period of time. Third, measurement of bone metabolism markers (either bone resorption or formation) is an indirect representation of changes in bone turnover; however use of more invasive alternatives would be ethically unacceptable in these groups of subjects. Fourth, there may be age-dependent variations in response; however most studies are performed within wide age ranges, while some, however, specifically analyzed changes in young or old men. Finally, there are differences in sex hormone requirements and skin permeation that were not addressed as all subjects received the same replacement doses and hormone levels were assessed by immunoassay, which is known to be unreliable for T and E2, especially at the lower end of sex hormone spectrum.

## **Studies in Hypogonadal Men: Testosterone Replacement and Use of Aromatase Inhibitors**

A number of studies have shown that androgen replacement increases BMD in men with hypogonadism (Katznelson et al. 1996; Snyder et al. 1999; Amory et al. 2004), although long-term fracture data are lacking. The two randomized controlled trials of T replacement in men with osteoporosis were not sufficiently powered to examine bone fracture rates; moreover, they did not show consistent beneficial T effects on BMD. The failure to exhibit this effect may have been due to the fact that in both studies non-aromatizable androgens were used for treatment. Inkovaara et al. treated 327 subjects with methandienone 2.5 mg daily or placebo for 9 months (Inkovaara et al. 1983), while Hamdy et al. enrolled 21 men administered with nandrolone decanoate 50 mg once weekly or no treatment in addition to calcium carbonate for 12 months (Hamdy et al. 1998).

The androgen effect does not require  $5\alpha$ -reduction. A study in which 50 hypogonadal men over 65 years were randomized to either T plus  $5\alpha$ -reductase inhibitor finasteride, T plus placebo, or placebo alone for 36 months showed similar

improvements in bone metabolism markers after 6 months and BMD at the end of the study in both T replacement groups (Amory et al. 2004). Another study of similar design in 40 patients over 60 years old showed increases in lumbar spine and hip BMD over 12 months of treatment, and this was not affected by finasteride administration (Borst et al. 2014). In both of these studies E2 levels and aromatization were intact in all groups, and studies were not designed to assess impact of T aromatization to E2 on bone. As DHT levels rendered by finasteride were lower (by about 50%) yet still measurable, a possibility that low DHT levels may exert some bone effect could not be fully excluded. In an RCT where 114 healthy men (>50 years) were randomized to receive DHT (a non-aromatizable androgen) or placebo for 24 months that resulted in suppressed T and E2 in the active treatment group, a progressive decrease of lumbar spine BMD was observed compared to placebo (Sartorius et al. 2014). The rate of BMD decrease at femoral neck was similar in both groups, which suggested possible differential effects on cortical and trabecular bone. These studies suggest that the androgenic effects on bone are mainly exerted via estrogens.

When older men with borderline low T levels were given aromatase inhibitor for 1 year, this resulted in increased T and slight decrease in E2 levels (from  $15 \pm 4$  to  $12 \pm 4$  pg/mL). At the end of study, their spine BMD was lower compared to placebo group with other sites showing the same trend but not statistically significant, suggesting that even slight decrease in E2 levels may have significant effect on the bone or that local aromatization in bone is important (Burnett-Bowie et al. 2009). On the other hand, the baseline E2 values of these men were low, and it is well known that immunoassays cannot accurately measure E2 levels in men (Rosner et al. 2013).

In conclusion, current data seem to support that sex hormones have significant impact on bone mineralization and metabolism with E2 playing the major role, while T seems to have a weaker independent effect. Direct effects of DHT on bone are unlikely in men. The effect of T and its metabolites on preventing fractures is not known.

---

## Effects on Body Composition and Muscle Strength

Low T levels are associated with increased adipose tissue and decreased lean body mass in epidemiological studies (Bann et al. 2015; Vandenput et al. 2010). Increased adiposity has been related to increased risk of atherosclerosis progression, dyslipidemia, and hypertension.

## Studies in Healthy Men with Induced Hypogonadism

A small uncontrolled study in six healthy young men treated with a GnRH analog to induce hypogonadism over 10 weeks resulted in decreased fat-free mass and an increase in percent fat mass with decreased rates of lipid oxidation and resting energy

expenditure, as well as decreased muscle strength measured by isokinetic dynamometry of leg extensors at 60° and 180° per second (Mauras et al. 1998). As described in this section, the androgen effects on fat and muscle have been reinforced by a number of studies in both healthy and hypogonadal individuals.

Bhasin et al. (2001) studied 54 healthy young (aged 18–35 years) men with pharmacologically induced hypogonadism. They were randomized to one of five treatment regimens with T enanthate (25, 50, 125, 300, 600 mg per week, respectively), which resulted in T serum values ranging from sub-physiological to supra-physiological (T nadir values ranging from 253 to 2370 ng/dL) levels for 20 weeks. Lean mass did not change significantly in the two low-dose T replacement groups, while the increase in other three groups was dependent on T dose and serum levels. Analogous changes were observed in thigh muscle volumes. Conversely, fat mass increased significantly in two low T replacement groups but did not change in any of the groups of higher levels of replacement. Significant increase in leg muscle strength and power was observed in two higher-dose groups. Further analysis based on the same set of subjects evaluated effects of graded T doses on fat localization (Woodhouse et al. 2004). Supraphysiological doses of T led to decrease in total fat mass, and these changes were evenly distributed between the trunk and the limbs. Higher absolute increase in fat mass was observed in subcutaneous rather than deep intramuscular stores of the thigh and was significant in two lower T dose groups and in 50 mg/week for the abdominal subcutaneous fat. Difference in percent fat mass changes between subcutaneous and intra-abdominal fat compartments was also significant in the latter group. T replacement in the three highest groups was associated with greater relative loss of fat in the deeper intermuscular than in subcutaneous tissues of the thigh with no differences observed in the abdomen. A report on histological analysis of muscle biopsies in 39 men (Sinha-Hikim et al. 2002) revealed T dose and concentration-dependent increase in myonuclear number and cross-sectional area but not in number of both type I and type II fibers with changes from baseline reaching significance in 300 mg and 600 mg for type I and in 600 mg group for type II fibers.

A similar study was later performed in 44 older (60–75 years old) healthy individuals – after induction of hypogonadism with GnRH analog and replacement with the same doses of T enanthate as in younger men (Storer et al. 2008). The highest replacement group (600 mg per week) was discontinued due to high frequency of erythrocytosis and leg edema. Of the remaining groups, the two lowest replacement doses (25 and 50 mg/week) resulted in nadir T levels (176 and 274 ng/dL, respectively) that were lower than baseline, and the two highest were higher than the baseline (852 and 1,784 ng/dL, respectively). Increase in muscle mass and strength was dose dependent. Skeletal muscle mass increased in the two groups of highest replacement (125 and 300 mg) compared to baseline and the two lower concentration groups. Increase in muscle power was only significant in the 300 ng/dL group. No changes were observed in muscle fatigability or performance-based measures of physical function, such as stair climbing and walking tests. The study, however, may have been of insufficient duration for these changes to be exhibited; also it was only powered to detect changes in muscle mass and strength but not

differences in physical function. In a larger set of subjects in the same study, 102 participants underwent MRI to evaluate changes in thigh muscle volume, and in 36 men *vastus lateralis* muscle biopsies were performed to evaluate for changes in muscle fiber area, satellite cell number, and replication (Sinha-Hikim et al. 2006). While the relative proportion of the different types of fibers did not change, a dose-dependent increase in cross-sectional area for both type I and II muscle fibers was observed in two highest concentrations of T compared to baseline and to those treated with the lowest concentration. Increases in myonuclear and satellite cell numbers were also T dose dependent. Compared to baseline, they were significantly greater in the three highest concentration groups for myonuclear and in the highest concentration group for satellite cells. Immunohistochemical staining for proliferating cell nuclear antigen (PCNA), a marker for recruitment of these myogenic precursor cells into cell cycle, showed increased numbers of fibers with PCNA-activated nuclei after T treatment. Notch activation and myogenin protein expression were only assessed in 300 mg/week group and were found to be higher than at baseline. The data is consistent with the hypothesis that T induces muscle hypertrophy through promotion of satellite cell replication and activation, leading to higher numbers of myogenically committed satellite cells (Joubert and Tobin 1995; Mulvaney et al. 1988). Compared to young men, proportion of type II fibers was lower, and cross-sectional area of type II but not type I fibers was significantly smaller in older men; however changes in hypertrophy of satellite cells after T administration were not different in these two studies. While these two studies did show potential effects of androgens and their deficiency on adipose tissue and muscle, they were not designed to differentiate effects of T and its metabolites.

A more recent study by Finkelstein et al. (2013) was designed to examine the relative effects of T versus E2 on muscle and adipose tissue mass. The study consisted of two cohorts of healthy young (20–50 years) men with GnRH agonist-induced hypogonadism who received daily graded doses of T gel (0, 1.25, 2.5, 5, and 10 g, respectively). While one cohort received T replacement only, the same doses of T treatment were supplemented by an aromatase inhibitor in cohort 2; thus differences between the cohorts in the same T dose groups could be attributed to E2 effect. Resulting T values were consistent with hypogonadal levels in placebo and 1.25 g group, and within normal range in 5 and 10 g groups, with 2.5 g group resulting in low normal levels. Effects seen in cohort 1 were similar to previously described studies with T replacement levels in three lowest groups leading to increased adipose tissue, while the highest T dose resulted in decreased fat mass. Significant changes were observed in subcutaneous but not in the intra-abdominal fat area. Consistent with earlier studies, lean mass decreased in low-dose T groups. Thigh muscle area decreased in two lowest groups and increased in the highest T group, while muscle strength decreased in those receiving placebo. Inhibition of aromatization led to increased body fat in all groups, and the magnitude of the increase was similar in all but the 10 g group, suggesting a predominantly E2 effect on adipose tissue. Increase in subcutaneous fat area was different between 1.25 and 10 g groups. Differences in lean mass were preserved between groups after blocked aromatization. Also similarly to cohort 1, thigh muscle area and muscle strength in placebo group decreased

significantly in comparison with other groups. The data suggest an effect of T on muscle that is independent of aromatization. These findings were reaffirmed in inter-cohort analysis as the cohort T dose interaction, as well as differences between the respective groups of the cohorts, was significant for percentage of body fat, intra-abdominal fat area, and subcutaneous fat area indicating independent E2 effects on those parameters but not on lean body mass or any muscle parameters.

Even such an elegantly designed study cannot unequivocally differentiate androgen/estrogen effects on fat and muscle. It has been argued that the observed effect may have not been exerted directly through estrogen action on fat/bone tissue but rather through estrogen-stimulated growth hormone secretion (Birzniece 2013), as it has been shown previously that aromatase inhibitors reduce T-stimulated growth hormone secretion in men (Veldhuis et al. 2009).

## Studies in Hypogonadal Men

A recent meta-analysis by Corona et al. (2016) focused on effects of T treatment on body composition. Of the 104 studies evaluated, 59 were RCTs with 3029 subjects in T replacement and 2049 in placebo arms, respectively. T treatment was associated with reduction of fat and increase in lean mass but not with reduction in body weight, waist circumference, or body mass index. These effects were consistent even when only the most robust methods were considered (limited to hypogonadal subjects, body composition by DEXA, and RCTs). Transdermal and parenteral but not oral preparations were associated with significant increase in muscle and decrease in fat mass; parenteral formulations showed slightly greater effect than transdermal and T undecanoate – better than other parenteral formulations. The difference seen among formulations, however, may be due to difference in achieved T levels – parenteral preparations were associated with slightly greater increase in levels of circulating T than transdermal preparations and significantly greater than oral preparations (by 7.69 nmol/l, 7.57 nmol/l, and 2.39 nmol/l over placebo, respectively).

Intervention using several doses of T gel and a patch for 6 months in 227 hypogonadal (serum T <300 ng/dL) men aged 19–68 years who were free of chronic illness resulted in increased overall and lean body mass with most pronounced differences observed in the higher T dose groups. While the same held true for decrease of fat mass for T gel recipients, in T patch group, however, no significant changes in fat mass were observed (Wang et al. 2000). Arm and especially leg muscle strength improved in all treatment groups similarly. These changes in body composition were sustained when the study was extended for 3 years (Wang et al. 2004).

Interestingly, a recently published The T Trials study where 705 hypogonadal men (serum T <275 ng/dL) over 65 years old were randomized to T gel or placebo for 1 year found no improvement in the 6-min walk assessment in the 387 men with impaired mobility who were specifically enrolled to the physical function trial (with physical functioning subscale (PF-10) of 36-Item Short Form Health Survey (SF-36)

showing borderline benefit,  $p = 0.03$ ), while significant improvement was observed in all T gel-treated men (men with  $\geq 50$  m improvement in 6-min test, distance in 6-min test, improvement  $\geq 8$  in PF-10, PF, and overall 10 score) (Snyder et al. 2016). This may be explained by the lack of power in the smaller group with impaired mobility, or that these men may need longer period of treatment to exhibit any response, or that their baseline function has deteriorated so much that it is no longer reversible.

Potential independent DHT action on body composition and muscle strength was assessed by evaluating effects of suppressed T conversion into DHT by using  $5\alpha$ -reductase inhibitors in RCTs in elderly hypogonadal as well as healthy men with pharmacologically induced hypogonadism. Fifty elderly (aged 65–83 years) men with T  $< 350$  ng/dL were randomized to receive either 200 mg T enanthate every 2 weeks and finasteride daily, the same dose of T enanthate and placebo, or placebo only for 36 months (Page et al. 2005). Improvement of physical performance function (rising from a chair, walking, stair climbing, opening or closing a door) in subjects receiving T was observed by month 12 versus baseline and by month 24 versus placebo, and these changes were mostly sustained for the duration of the study. Similar changes were observed for handgrip strength and lean body mass (with a concordant decrease in fat mass resulting in null net body weight change); however isokinetic lower extremity strength measured at the ankle or knee was not affected by the treatment. Decrease of fat mass was similar in the leg and in the trunk in both T treatment groups; thus no independent DHT effect was observed on any of the outcome measures (Page et al. 2005). These results were replicated in a 52-week study where 60 hypogonadal (total T  $< 300$  ng/dL or bioavailable T  $< 70$  ng/dL) men over 60 years old were treated with graded doses of T with finasteride or placebo (Borst et al. 2014). T treatment reduced total body fat mass, trunk fat, and android fat mass and increased single repetition muscle strength in leg press, knee extension, knee flexion, chest press, triceps extension, and grip tests. Again, DHT did not seem to exhibit an independent effect.

In another study (Bhasin et al. 2012), healthy 18–50-year-old men with GnRH agonist (leuprolide acetate)-induced hypogonadism were randomized to various doses of T enanthate replacement (50, 125, 300, or 600 mg per week) with or without addition of a  $5\alpha$ -reductase inhibitor dutasteride for 20 weeks. Lean body mass and muscle (leg press and chest press) strength increased dose dependently in both groups with no significant differences between those receiving dutasteride and placebo.

On the other hand, when DHT was given to eugonadal men (over 50 years) for 24 months, despite suppressed T and E2 levels, this resulted in an increase in lean mass and decrease in fat mass each by 1.0–1.5 kg suggesting an independent effect of DHT on body composition (Idan et al. 2010).

Other mechanisms of T, such as effect on protein synthesis, have also been investigated (Ferrando et al. 1998), but no confirmatory data in humans is available to date.

In summary, T increases muscle mass and strength, and this effect is mostly dependent of T. These changes are dose dependent; therefore, route of administration



may also be important. A relatively long duration of treatment may be required to exhibit benefit, especially in real-life functional assessment and in older men. T also decreases fat mass, and this seems to be dependent on E2, while DHT has no added effect. However, DHT seems to exhibit an independent effect on both fat and lean mass that is similar to T. To date, there is insufficient data to unequivocally determine if there is difference in the localization of these changes both in limbs versus trunk and subcutaneous versus visceral fat.

---

## Metabolic Effects

Potential metabolic effects attributed to T include its effect on insulin sensitivity, glucose and lipid metabolism, as well as blood pressure regulation. In cross-sectional and observational studies, pharmacological androgen deprivation for prostate cancer treatment has been associated with impaired insulin sensitivity (Hamilton et al. 2011; Smith et al. 2006), increased risk for developing or worsening of existing type 2 diabetes (Keating et al. 2010; Derweesh et al. 2007), metabolic syndrome (Braga-Basaria et al. 2006), and cardiovascular disease (Keating et al. 2010).

A recent meta-analysis (Corona et al. 2016) evaluated 23 RCTs where T treatment was administered to older men with lower T level and provided data on fasting glucose. T compared to placebo was associated with significant reduction in fasting glucose and HOMA index. No improvement in glucose levels was observed in oral T users, whereas users of transdermal and parenteral preparations had significant decreases with the parenteral preparations showing the largest effect. Multivariate linear regression analysis showed that differences in fasting glycemia and HOMA-IR index were related to a change in lean but not in fat mass. While the meta-analysis found no T effect on total cholesterol, HDL, triglyceride levels, and systolic or diastolic blood pressure in all studies, when placebo controlled RCTs in men with serum T <12 nmol/l were evaluated, T decreased both total cholesterol and triglyceride levels. Better metabolic outcome was observed in younger individuals (median age <60 years). Although no difference in T levels at end point was observed between obese (BMI >30 mg/m<sup>2</sup>) and nonobese subjects, T resulted in greater decrease in glycemia in obese subjects. The statistical significance of these findings, however, was borderline, and these results need further validation.

A physiological study in 22 healthy men aged 18–55 with GnRh antagonist-induced hypogonadism was randomized to either transdermal T replacement plus aromatase inhibitor anastrozole, T alone, or placebo for 28 days (Rubinow et al. 2012a). Suppression of T was associated with increased fasting insulin concentration, HOMA insulin resistance, and quantitative insulin sensitivity check index without changes in glucose levels, BMI, or body weight. Serum adipokine and leptin levels also increased. All changes returned to baseline at day 56 when hormone levels were normalized suggesting direct relation. Further analysis (Rubinow et al. 2012b) that focused on lipid metabolism revealed significant increase in HDL cholesterol, cholesterol efflux, and changes in HDL protein composition (increase in HDL-associated clusterin apolipoprotein A-IV) in T-depleted

group with all changes returning to baseline after normalization of sex hormone levels. No changes were observed in any of the groups receiving T replacement in both analyses.

Another recent study evaluated effect of estrogens on insulin sensitivity using an aromatase inhibitor, anastrozole, in 17 healthy 18–50-year-old men for 6 weeks (Gibb et al. 2016) in a double blind, randomized, controlled, crossover study with a 2-week washout between the interventions. Glucose disposal and lipolysis rate as measured during a stepwise hyperinsulinemic euglycemic clamp showed that 50% suppression of estradiol (from 102 to 59.9 pmol/l) and small increase in T (from 21.4 to 25.8 nmol/l) were associated with lower glucose infusion rate suggesting a decrease in insulin sensitivity and no change in lipolysis, endogenous glucose production, or serum glucose levels. Systolic but not diastolic blood pressure was slightly increased, and heart rate was decreased in the anastrozole group. A decrease in leptin and total cholesterol (with a nonsignificant trend for decrease in both HDL and LDL) levels was also observed with aromatase inhibition. The authors suggested that aromatase inhibitors could suppress estrogen action in skeletal muscle, which would adversely affect glucose metabolism and that local estrogen deficiency could be the cause of insulin resistance in hypogonadal men. Conversely, several studies of similar design with letrozole resulted in improved insulin sensitivity, and it is unknown, whether these inconsistencies were medication dependent or due to methodological shortcomings (Lapauw et al. 2009; Lapauw and Ouwens 2010). Moreover, the clinical implications of these quantitatively small changes are not certain.

In conclusion, while there is data suggesting that sex hormones exert metabolic effects, currently available information is inconsistent and insufficient to pinpoint main targets or exact mechanisms for such effects.

---

## Effects on Erythropoiesis

### Possible Mechanisms of Action of T on Erythropoiesis

Hematocrit and hemoglobin levels are lower in women than men. Androgen deficiency in men is associated with a lower hemoglobin and hematocrit levels compared to eugonadal men. While there has been considerable attention on erythrocytosis as an adverse effect of testosterone overtreatment, little effort has been directed to the role of testosterone in anemia of hypogonadal men.

Androgens have been historically used to stimulate erythropoiesis before the advent of synthetic erythropoietin. The erythropoietic effect of androgens is thought to be exerted through at least two pathways: stimulation of erythropoietin production and direct action on erythroblasts that express androgen receptors (Claustres and Sultan 1985, 1988; Mirand et al. 1965; Shahani et al. 2009). As the effect of androgens was significantly diminished in patients with end-stage renal disease, it was hypothesized that the main mechanism of action is through stimulation of erythropoietin that could be exerted either through induction of hypoxia or hypoxic

sensing or by directly stimulating expression of hypoxia-inducible factors, regulators of erythropoietin transcription or secretion (Haase 2013). Another potential effect could be directly on erythropoietin secretion from renal peritubular fibroblasts (Pan et al. 2011). Increased erythropoietin levels led to increased iron utilization; additionally, based on previous data (Moriyama and Fisher 1975; Malgor et al. 1998), T may also heighten sensitivity of erythroid progenitor cells to erythropoietin thus further increasing hemopoiesis.

When graded doses (25–600 mg/week) of T enanthate were administered over 20 weeks in young (18–35 years) and older (60–75 years) healthy men with GnRh agonist-induced hypogonadism, hemoglobin and hematocrit increased in a linear dose-dependent fashion in both age groups (Coviello et al. 2008). For every dose group the increase in hematocrit and hemoglobin levels was greater in older men, and this remained highly significant after adjusting for total and free T levels. Changes in erythropoietin and soluble transferrin receptor (sTR) levels were not different either between young and old or among any of the treatment doses suggesting a pathway independent of erythropoietin production. Further analysis by this group (Bachman et al. 2010) suggested that T treatment suppressed serum hepcidin levels. Hepcidin is a liver-derived peptide that binds to and degrades iron channel ferroportin; thus its suppression results in higher bioavailability of iron (Fleming 2008). Initial GnRH agonist administration caused a flare in serum T, which resulted in at least 50% suppression of hepcidin in all groups within the first week. After reaching stable T levels throughout the rest of the study, hepcidin remained significantly suppressed. Furthermore, after discontinuation of the treatment when endogenous T levels were still low, serum hepcidin levels have either returned to or were above the baseline with men in the highest-dose groups showing the highest rebound effect. While, compared to young men, older men had higher baseline hepcidin levels, they suppressed significantly more both overall and for every dose of treatment. In both young and older men, T effect on hepcidin plateaued at a dose of 300 mg per week with 600 mg per week resulting in no further suppression. Changes in hepcidin preceded and were predictive of those in hematocrit suggesting a possible causality.

In a later study, the same team characterized temporal changes in erythropoietin and hepcidin levels in relation to hematologic and sex hormone values in 166 older (over 65 years) hypogonadal men with mobility limitations who were randomized to T or placebo treatment for 6 months and followed up for 3 months after the treatment (Bachman et al. 2014). Hemoglobin and hematocrit peaked at month 3 of treatment with an average increase of 1.1 g/dL and 4.4%, respectively, and remained at these levels for the duration of the treatment. The values returned to normal 3 months after treatment. T administration increased erythropoietin levels by 58% at month 1 and sustained significance at month 3 with continued trend toward baseline throughout treatment. This may have been a result of balance between continued T replacement and suppressive effect of elevated hemoglobin and hematocrit levels. In comparison with a previously described erythropoietin and hemoglobin association (Beguín et al. 1991), at each level of hemoglobin, erythropoietin levels were greater by about 30% after T administration than at

baseline, and this was true even in subjects with erythrocytosis. Authors suggested that T administration may “recalibrate” this set point to allow for higher erythropoietin levels, which has also been observed in posttransplant erythrocytosis (Vlahakos et al. 2003). Similarly to an earlier study, T administration resulted in significant suppression of hepcidin levels compared to baseline and placebo at months 1 and 3; however differences disappeared by month 6, and after discontinuation of the treatment a slight rebound effect was observed. Similar trends were observed for sTR and ferritin with ferritin exhibiting a rebound effect after treatment discontinuation. The same changes were observed in a subgroup analysis of men with anemia.

Although erythropoietin and hepcidin regulation are interrelated, T seems to affect both independently. Increase in sTR and reduction in serum ferritin indicate that stored iron is utilized for erythropoiesis in response to T treatment underlining relevance of hepcidin suppression. Exact mechanism for hepcidin suppression is not known; a hypothesized IL-6 effect, which is known to regulate hepcidin, has not been confirmed as IL-6 and other evaluated inflammation markers did not change with T treatment. Previous studies have shown that estradiol regulates hepcidin levels *in vitro* and *in vivo* (Ikeda et al. 2012; Hou et al. 2012; Yang et al. 2012). After controlling for T, estradiol and estrone levels were associated with decreases in hepcidin levels suggesting some T-independent effect. On the other hand, it is unlikely that suppression of hepcidin alone could explain development of polycythemia: while inactivation of hepcidin 1 gene in mice has caused transient polycythemia in the first months, hematologic parameters normalized at 6 months of age (Lesbordes-Brion et al. 2006). In humans, inactivating hepcidin gene mutations result in hemochromatosis but not polycythemia (Pietrangelo 2007).

A recent study in patients with telomere diseases suggested another potential mechanism of action of androgens on blood cells (Townsend et al. 2016). Twelve of 27 patients with genetic telomerase diseases including women who received a 19-nortestosterone derivative, danazol, completed the study that showed reduction in telomere attrition rate in leukocytes. Eleven subjects showed elongation of telomeres at 24 months with comparable increases at 6 and 12 months. Hemoglobin increased by a mean of 3.3 g/dL in those with hemoglobin <9.5 g/dL at baseline. While the study showed that substantial telomere elongation may be achieved by an androgen, data on telomere function and effects of attrition have been inconsistent. This androgen effect on telomeres may potentially be relevant in other phenotypes and diseases linked to telomere defects such as in aging as it is related to shortening of chromosomal telomeres. T and E2 have shown to regulate telomerase expression and activity *in vitro* in lymphocytes and liver, heart, brain, breast, and prostate cells (Calado et al. 2009; Cen et al. 2015; Sato et al. 2004; Jacob et al. 2016). Moreover, an epidemiological study in 980 men from The Western Australian Busselton Health Survey showed that serum DHT and E2 correlated with leukocyte telomere length independent of age and identified three alleles of aromatase gene polymorphisms that were associated with lower serum E2 and shorter telomere length (Yeap et al. 2016). Further research is needed to validate that sex hormones may have modifiable action on aging via telomerase length and function.

## Clinical Studies of T, DHT, and E2 Effects on Hematopoiesis in Men

In what was probably the first attempt to discriminate effects of different T preparations on hematopoiesis, an open-label study in 55 hypogonadal subjects was randomized to receive either oral T undecanoate, oral mesterolone (a DHT derivative), T enanthate, or T pellets for 210 days and followed up for 90 additional days (Jockenhovel et al. 1997). Such T replacement resulted in normalized T levels in T enanthate and pellet groups, subnormal trough levels in T undecanoate group, and minimal change in mesterolone group. DHT levels were increased in all groups. Hemoglobin and hematocrit levels increased nonsignificantly in mesterolone group; persistent elevations were observed in T enanthate and T pellets group. While increase in hemoglobin and hematocrit correlated well with area under the curve for serum testosterone levels in TU and TE groups, further increase in serum T resulting from T pellets did not induce further rise of hemoglobin. The authors hypothesized there may be a plateau in the effect at low normal levels of T. As later studies showed no such plateau, this may be attributed to variable effects of different medications.

Differential effects of T and DHT were evaluated in a study by Beggs et al. (2014) where 60 hypogonadal men aged  $\geq 60$  years were randomized to receive either T enanthate, finasteride (a 5- $\alpha$ -reductase inhibitor), both, or placebo for 52 weeks. Starting within the first 3 months of treatment and throughout the study, T enanthate significantly elevated red blood cell count, hematocrit, and hemoglobin (by 9%, 4%, and 8%, respectively) and suppressed hepcidin levels by 57% compared to baseline. None of the variables were significantly altered by coadministration of finasteride. Similarly, treatment with finasteride without T enanthate did not alter any of the measures. After the first 3 months of treatment, serum ferritin was reduced by 32% in those receiving T enanthate, and finasteride coadministration had no further effect. Interestingly, a change in E2 levels correlated significantly with a change in red blood cells and hemoglobin levels within the first 3 months; however no correlation was observed for changes in T or DHT levels. While this and previously described data suggest that E2 may be responsible for at least some of the effects observed, further studies are needed for clarification. It is unlikely that erythropoietic effect would be exerted exclusively through aromatization as a role of non-aromatized T as an important regulator in hematopoiesis has been shown. In two aromatase-deficient men, administration of T resulted in elevated hemoglobin, hematocrit, and red blood cell counts, while administration of E2 has not shown such an effect (Rochira et al. 2009). Another study in 23 boys with constitutional delay of puberty showed that administration of T with an aromatase inhibitor letrozole resulted in similar hematological effects as T treatment alone with estimated red blood cell volume increasing more in the group of blocked aromatization, probably because of higher serum T levels (Hero et al. 2005). In a 24-month RCT 110 men received DHT or placebo, which resulted in decreased T and E2 levels compared to baseline and placebo; DHT also resulted in a consistent 1.0–1.5 g/dL increase in hemoglobin versus placebo which returned to baseline 3 months after cessation of the treatment, showing an independent effect of DHT on erythropoiesis (Idan et al. 2010).

In summary, testosterone has a direct stimulatory effect on hematopoiesis, probably through numerous mechanisms including erythropoietin stimulation, hepcidin suppression leading to higher iron availability, and possibly direct stimulatory effect on the bone marrow. Other mechanisms, such as direct action on bone marrow cells by increasing telomerase activity and increasing telomere length, have yet to be fully elucidated. T appears to be the main actor as inhibition of conversion into either E2 or DHT has had no additional effect; however E2 may have an independent effect on hepcidin suppression, and DHT has shown to independently increase hemoglobin levels. Erythropoietic stimulation may be more pronounced in older than in young men. Due to differences in pharmacokinetics, different medications may result in a variable degree of erythropoiesis stimulation even at the same serum T levels.

---

## Conclusion

In general, T and its metabolites exhibit pleiotropic effects throughout the body. These effects lead to variable phenotypes, clinical manifestations, and significance throughout life and may be more pronounced in some systems (such as bone and reproductive organs) or stages (such as puberty) than in others. Diversification through conversion to estrogens appears to be important for bone mass and adipose tissues. Evidence provided by experiments of nature (aromatase and 5 alpha-reduction gene modifications) and induced deficiencies or excess in adult men show that diversification through conversion to E2 is important for bone and adipose tissue health and amplification through DHT to be important in development of the external genitalia and prostate growth. However, there is also evidence that androgen effects vary with age, health status, and other factors. Through complex interaction with other metabolically active substances, including inflammatory and growth factors, sex hormones have significant effects on most systems; however due to complexity of those interactions and numerous confounders, the mechanisms of those effects are yet to be fully elucidated. Likewise, in treating hypogonadal men, different medications may exhibit variable effects due to resulting different serum T levels, as well as specific medication effects. Further research is warranted in this field.

---

## References

- Amin S, Zhang Y, Sawin CT, Evans SR, Hannan MT, Kiel DP, et al. Association of hypogonadism and estradiol levels with bone mineral density in elderly men from the Framingham study. *Ann Intern Med.* 2000;133(12):951–63.
- Amory JK, Watts NB, Easley KA, Sutton PR, Anawalt BD, Matsumoto AM, et al. Exogenous testosterone or testosterone with finasteride increases bone mineral density in older men with low serum testosterone. *J Clin Endocrinol Metab.* 2004;89(2):503–10.
- Bachman E, Feng R, Travison T, Li M, Olbina G, Ostland V, et al. Testosterone suppresses hepcidin in men: a potential mechanism for testosterone-induced erythrocytosis. *J Clin Endocrinol Metab.* 2010;95(10):4743–7.

- Bachman E, Travison TG, Basaria S, Davda MN, Guo W, Li M, et al. Testosterone induces erythrocytosis via increased erythropoietin and suppressed hepcidin: evidence for a new erythropoietin/hemoglobin set point. *J Gerontol A Biol Sci Med Sci*. 2014;69(6):725–35.
- Bann D, Wu FC, Keevil B, Lashen H, Adams J, Hardy R, et al. Changes in testosterone related to body composition in late midlife: findings from the 1946 British birth cohort study. *Obesity (Silver Spring)*. 2015;23(7):1486–92.
- Beggs LA, Yarrow JF, Conover CF, Meuleman JR, Beck DT, Morrow M, et al. Testosterone alters iron metabolism and stimulates red blood cell production independently of dihydrotestosterone. *Am J Physiol Endocrinol Metab*. 2014;307(5):E456–61.
- Beguín Y, Clemons GK, Oris R, Fillet G. Circulating erythropoietin levels after bone marrow transplantation: inappropriate response to anemia in allogeneic transplants. *Blood*. 1991;77(4):868–73.
- Bhasin S, Woodhouse L, Casaburi R, Singh AB, Bhasin D, Berman N, et al. Testosterone dose-response relationships in healthy young men. *Am J Physiol Endocrinol Metab*. 2001;281(6):E1172–81.
- Bhasin S, Travison TG, Storer TW, Lakshman K, Kaushik M, Mazer NA, et al. Effect of testosterone supplementation with and without a dual 5 $\alpha$ -reductase inhibitor on fat-free mass in men with suppressed testosterone production: a randomized controlled trial. *J Am Med Assoc*. 2012;307(9):931–9.
- Birzniece V. Gonadal steroids and body composition, strength, and sexual function in men. *N Engl J Med*. 2013;369(25):2455.
- Borst SE, Yarrow JF, Conover CF, Nseyo U, Meuleman JR, Lipinska JA, et al. Musculoskeletal and prostate effects of combined testosterone and finasteride administration in older hypogonadal men: a randomized, controlled trial. *Am J Physiol Endocrinol Metab*. 2014;306(4):E433–42.
- Braga-Basaria M, Dobs AS, Muller DC, Carducci MA, John M, Egan J, et al. Metabolic syndrome in men with prostate cancer undergoing long-term androgen-deprivation therapy. *J Clin Oncol*. 2006;24(24):3979–83.
- Burnett-Bowie SA, McKay EA, Lee H, Leder BZ. Effects of aromatase inhibition on bone mineral density and bone turnover in older men with low testosterone levels. *J Clin Endocrinol Metab*. 2009;94(12):4785–92.
- Calado RT, Yewdell WT, Wilkerson KL, Regal JA, Kajigaya S, Stratakis CA, et al. Sex hormones, acting on the TERT gene, increase telomerase activity in human primary hematopoietic cells. *Blood*. 2009;114(11):2236–43.
- Carani C, Qin K, Simoni M, Faustini-Fustini M, Serpente S, Boyd J, et al. Effect of testosterone and estradiol in a man with aromatase deficiency. *N Engl J Med*. 1997;337(2):91–5.
- Cen J, Zhang H, Liu Y, Deng M, Tang S, Liu W, et al. Anti-aging effect of estrogen on telomerase activity in ovariectomised rats – animal model for menopause. *Gynecol Endocrinol*. 2015;31(7):582–5.
- Claustres M, Sultan C. Demonstration of a nuclear androgen receptor in erythroblasts obtained by culture of human bone marrow. *C R Seances Soc Biol Fil*. 1985;179(5):645–55.
- Claustres M, Sultan C. Androgen and erythropoiesis: evidence for an androgen receptor in erythroblasts from human bone marrow cultures. *Horm Res*. 1988;29(1):17–22.
- Corona G, Giagulli VA, Maseroli E, Vignozzi L, Aversa A, Zitzmann M, et al. Therapy of endocrine disease: testosterone supplementation and body composition: results from a meta-analysis study. *Eur J Endocrinol*. 2016;174(3):R99–116.
- Cosman F, Shen V, Xie F, Seibel M, Ratcliffe A, Lindsay R. Estrogen protection against bone resorbing effects of parathyroid hormone infusion. Assessment by use of biochemical markers. *Ann Intern Med*. 1993;118(5):337–43.
- Coviello AD, Kaplan B, Lakshman KM, Chen T, Singh AB, Bhasin S. Effects of graded doses of testosterone on erythropoiesis in healthy young and older men. *J Clin Endocrinol Metab*. 2008;93(3):914–9.
- Derweesh IH, Diblasio CJ, Kincade MC, Malcolm JB, Lamar KD, Patterson AL, et al. Risk of new-onset diabetes mellitus and worsening glycaemic variables for established diabetes in men undergoing androgen-deprivation therapy for prostate cancer. *BJU Int*. 2007;100(5):1060–5.

- Falahati-Nini A, Riggs BL, Atkinson EJ, O'Fallon WM, Eastell R, Khosla S. Relative contributions of testosterone and estrogen in regulating bone resorption and formation in normal elderly men. *J Clin Invest.* 2000;106(12):1553–60.
- Ferrando AA, Tipton KD, Doyle D, Phillips SM, Cortiella J, Wolfe RR. Testosterone injection stimulates net protein synthesis but not tissue amino acid transport. *Am J Phys.* 1998;275(5 Pt 1): E864–71.
- Finkelstein JS, Lee H, Burnett-Bowie SA, Pallais JC, Yu EW, Borges LF, et al. Gonadal steroids and body composition, strength, and sexual function in men. *N Engl J Med.* 2013;369(11):1011–22.
- Finkelstein JS, Lee H, Leder BZ, Burnett-Bowie SA, Goldstein DW, Hahn CW, et al. Gonadal steroid-dependent effects on bone turnover and bone mineral density in men. *J Clin Invest.* 2016;126(3):1114–25.
- Fleming MD. The regulation of hepcidin and its effects on systemic and cellular iron metabolism. *Hematol/Educ Program Am Soc Hematol Am Soc Hematol Educ Program.* 2008;2008:151–8.
- Gibb FW, Homer NZ, Faqehi AM, Upreti R, Livingstone DE, McInnes KJ, et al. Aromatase inhibition reduces insulin sensitivity in healthy men. *J Clin Endocrinol Metab.* 2016;101(5): 2040–6.
- Haase VH. Regulation of erythropoiesis by hypoxia-inducible factors. *Blood Rev.* 2013;27(1): 41–53.
- Hamdy RC, Moore SW, Whalen KE, Landy C. Nandrolone decanoate for men with osteoporosis. *Am J Ther.* 1998;5(2):89–95.
- Hamilton EJ, Gianatti E, Strauss BJ, Wentworth J, Lim-Joon D, Bolton D, et al. Increase in visceral and subcutaneous abdominal fat in men with prostate cancer treated with androgen deprivation therapy. *Clin Endocrinol.* 2011;74(3):377–83.
- Hero M, Wickman S, Hanhijarvi R, Siimes MA, Dunkel L. Pubertal upregulation of erythropoiesis in boys is determined primarily by androgen. *J Pediatr.* 2005;146(2):245–52.
- Hou Y, Zhang S, Wang L, Li J, Qu G, He J, et al. Estrogen regulates iron homeostasis through governing hepatic hepcidin expression via an estrogen response element. *Gene.* 2012;511(2): 398–403.
- Idan A, Griffiths KA, Harwood DT, Seibel MJ, Turner L, Conway AJ, et al. Long-term effects of dihydrotestosterone treatment on prostate growth in healthy, middle-aged men without prostate disease: a randomized, placebo-controlled trial. *Ann Intern Med.* 2010;153(10):621–32.
- Ikeda Y, Tajima S, Izawa-Ishizawa Y, Kihira Y, Ishizawa K, Tomita S, et al. Estrogen regulates hepcidin expression via GPR30-BMP6-dependent signaling in hepatocytes. *PLoS One.* 2012;7(7): e40465.
- Inkovaara J, Gothoni G, Halttula R, Heikinheimo R, Tokola O. Calcium, vitamin D and anabolic steroid in treatment of aged bones: double-blind placebo-controlled long-term clinical trial. *Age Ageing.* 1983;12:124–30.
- Jacob S, Nayak S, Kakar R, Chaudhari UK, Joshi D, Vundinti BR, et al. A triad of telomerase, androgen receptor and early growth response 1 in prostate cancer cells. *Cancer Biol Ther.* 2016;17(4):439–48.
- Joborn C, Ljunghall S, Larsson K, Lindh E, Naessen T, Wide L, et al. Skeletal responsiveness to parathyroid hormone in healthy females: relationship to menopause and oestrogen replacement. *Clin Endocrinol.* 1991;34(5):335–9.
- Jockenhovel F, Vogel E, Reinhardt W, Reinwein D. Effects of various modes of androgen substitution therapy on erythropoiesis. *Eur J Med Res.* 1997;2(7):293–8.
- Joubert Y, Tobin C. Testosterone treatment results in quiescent satellite cells being activated and recruited into cell cycle in rat levator ani muscle. *Dev Biol.* 1995;169(1):286–94.
- Katznelson L, Finkelstein JS, Schoenfeld DA, Rosenthal DI, Anderson EJ, Klibanski A. Increase in bone density and lean body mass during testosterone administration in men with acquired hypogonadism. *J Clin Endocrinol Metab.* 1996;81(12):4358–65.
- Keating NL, O'Malley AJ, Freedland SJ, Smith MR. Diabetes and cardiovascular disease during androgen deprivation therapy: observational study of veterans with prostate cancer. *J Natl Cancer Inst.* 2010;102(1):39–46.



- Khosla S. New insights into androgen and estrogen receptor regulation of the male skeleton. *J Bone Miner Res.* 2015;30(7):1134–7.
- Khosla S, Melton 3rd LJ, Atkinson EJ, O'Fallon WM, Klee GG, Riggs BL. Relationship of serum sex steroid levels and bone turnover markers with bone mineral density in men and women: a key role for bioavailable estrogen. *J Clin Endocrinol Metab.* 1998;83(7):2266–74.
- Lapauw B, T'Sjoen G, Mahmoud A, Kaufman JM, Ruige JB. Short-term aromatase inhibition: effects on glucose metabolism and serum leptin levels in young and elderly men. *Eur J Endocrinol.* 2009;160(3):397–402.
- Lapauw B, Ouwens M, T'Hart LM, Wuyts B, Holst JJ, T'Sjoen G, et al. Sex steroids affect triglyceride handling, glucose-dependent insulinotropic polypeptide, and insulin sensitivity: a 1-week randomized clinical trial in healthy young men. *Diabetes Care.* 2010;33(8):1831–3.
- Leder BZ, Smith MR, Fallon MA, Lee ML, Finkelstein JS. Effects of gonadal steroid suppression on skeletal sensitivity to parathyroid hormone in men. *J Clin Endocrinol Metab.* 2001;86(2):511–6.
- Leder BZ, LeBlanc KM, Schoenfeld DA, Eastell R, Finkelstein JS. Differential effects of androgens and estrogens on bone turnover in normal men. *J Clin Endocrinol Metab.* 2003;88(1):204–10.
- Lee H, Finkelstein JS, Miller M, Comeaux SJ, Cohen RI, Leder BZ. Effects of selective testosterone and estradiol withdrawal on skeletal sensitivity to parathyroid hormone in men. *J Clin Endocrinol Metab.* 2006;91(3):1069–75.
- Lesbordes-Brion JC, Viatte L, Bennoun M, Lou DQ, Ramey G, Houbroun C, et al. Targeted disruption of the hepcidin 1 gene results in severe hemochromatosis. *Blood.* 2006;108(4):1402–5.
- Malgor LA, Valsecia M, Verges E, De Markowsky EE. Blockade of the in vitro effects of testosterone and erythropoietin on CfU-E and Bfu-E proliferation by pretreatment of the donor rats with cyproterone and flutamide. *Acta Physiol, Pharmacol Ther Latinoam: organo Asoc Latinoam Cienc Fisiologicas [de] la Asoc Latinoam Farmacol.* 1998;48(2):99–105.
- Marcus R, Leary D, Schneider DL, Shane E, Favus M, Quigley CA. The contribution of testosterone to skeletal development and maintenance: lessons from the androgen insensitivity syndrome. *J Clin Endocrinol Metab.* 2000;85(3):1032–7.
- Mauras N, Hayes V, Welch S, Rini A, Helgeson K, Dokler M, et al. Testosterone deficiency in young men: marked alterations in whole body protein kinetics, strength, and adiposity. *J Clin Endocrinol Metab.* 1998;83(6):1886–92.
- Mirand EA, Gordon AS, Wenig J. Mechanism of testosterone action in erythropoiesis. *Nature.* 1965;206(981):270–2.
- Mooradian AD, Morley JE, Korenman SG. Biological actions of androgens. *Endo Rev.* 1987;8(1):1–28.
- Morishima A, Grumbach MM, Simpson ER, Fisher C, Qin K. Aromatase deficiency in male and female siblings caused by a novel mutation and the physiological role of estrogens. *J Clin Endocrinol Metab.* 1995;80:3689–98.
- Moriyama Y, Fisher JW. Effects of testosterone and erythropoietin on erythroid colony formation in human bone marrow cultures. *Blood.* 1975;45(5):665–70.
- Mulvaney DR, Marple DN, Merkel RA. Proliferation of skeletal muscle satellite cells after castration and administration of testosterone propionate. *Proc Soc Exp Biol Med.* 1988;188(1):40–5.
- Notini AJ, McManus JF, Moore A, Bouxsein M, Jimenez M, Chiu WS, et al. Osteoblast deletion of exon 3 of the androgen receptor gene results in trabecular bone loss in adult male mice. *J Bone Miner Res.* 2007;22(3):347–56.
- Ohlsson C, Borjesson AE, Vandenput L. Sex steroids and bone health in men. *Bonekey Rep.* 2012;1:2.
- Orwoll ES, Scheele WH, Paul S, Adami S, Syversen U, Diez-Perez A, et al. The effect of teriparatide [human parathyroid hormone (1-34)] therapy on bone density in men with osteoporosis. *J Bone Miner Res.* 2003;18(1):9–17.
- Orwoll E, Lambert LC, Marshall LM, Phipps K, Blank J, Barrett-Connor E, et al. Testosterone and estradiol among older men. *J Clin Endocrinol Metab.* 2006;91(4):1336–44.

- Page ST, Amory JK, Bowman FD, Anawalt BD, Matsumoto AM, Bremner WJ, et al. Exogenous testosterone (T) alone or with finasteride increases physical performance, grip strength, and lean body mass in older men with low serum T. *J Clin Endocrinol Metab.* 2005;90(3):1502–10.
- Pan X, Suzuki N, Hirano I, Yamazaki S, Minegishi N, Yamamoto M. Isolation and characterization of renal erythropoietin-producing cells from genetically produced anemia mice. *PLoS One.* 2011;6(10):e25839.
- Pietrangelo A. Hemochromatosis: an endocrine liver disease. *Hepatology.* 2007;46(4):1291–301.
- Rochira V, Zirilli L, Madeo B, Maffei L, Carani C. Testosterone action on erythropoiesis does not require its aromatization to estrogen: insights from the testosterone and estrogen treatment of two aromatase-deficient men. *J Steroid Biochem Mol Biol.* 2009;113(3–5):189–94.
- Rosner W, Hankinson SE, Sluss PM, Vesper HW, Wierman ME. Challenges to the measurement of estradiol: an endocrine society position statement. *J Clin Endocrinol Metab.* 2013;98(4):1376–87.
- Rubinow KB, Snyder CN, Amory JK, Hoofnagle AN, Page ST. Acute testosterone deprivation reduces insulin sensitivity in men. *Clin Endocrinol.* 2012a;76(2):281–8.
- Rubinow KB, Tang C, Hoofnagle AN, Snyder CN, Amory JK, Heinecke JW, et al. Acute sex steroid withdrawal increases cholesterol efflux capacity and HDL-associated clusterin in men. *Steroids.* 2012b;77(5):454–60.
- Sartorius GA, Ly LP, Handelsman DJ. Male sexual function can be maintained without aromatization: randomized placebo-controlled trial of dihydrotestosterone (DHT) in healthy, older men for 24 months. *J Sex Med.* 2014;11(10):2562–70.
- Sato R, Maesawa C, Fujisawa K, Wada K, Oikawa K, Takikawa Y, et al. Prevention of critical telomere shortening by oestradiol in human normal hepatic cultured cells and carbon tetrachloride induced rat liver fibrosis. *Gut.* 2004;53(7):1001–9.
- Shahani S, Braga-Basaria M, Maggio M, Basaria S. Androgens and erythropoiesis: past and present. *J Endocrinol Investig.* 2009;32(8):704–16.
- Sinha-Hikim I, Artaza J, Woodhouse L, Gonzalez-Cadavid N, Singh AB, Lee MI, et al. Testosterone-induced increase in muscle size in healthy young men is associated with muscle fiber hypertrophy. *Am J Physiol Endocrinol Metab.* 2002;283(1):E154–64.
- Sinha-Hikim I, Cornford M, Gaytan H, Lee ML, Bhasin S. Effects of testosterone supplementation on skeletal muscle fiber hypertrophy and satellite cells in community-dwelling older men. *J Clin Endocrinol Metab.* 2006;91(8):3024–33.
- Smith EP, Boyd J, Frank GR, Takahashi H, Cohen RM, Specker B, et al. Estrogen resistance caused by a mutation in the estrogen-receptor gene in a man. *N Engl J Med.* 1994;331:1056–61.
- Smith MR, Lee H, Nathan DM. Insulin sensitivity during combined androgen blockade for prostate cancer. *J Clin Endocrinol Metab.* 2006;91(4):1305–8.
- Snyder PJ, Peachey H, Hannoush P, Berlin JA, Loh L, Holmes JH, et al. Effect of testosterone treatment on bone mineral density in men over 65 years of age. *J Clin Endocrinol Metab.* 1999;84(6):1966–72.
- Snyder PJ, Bhasin S, Cunningham GR, Matsumoto AM, Stephens-Shields AJ, Cauley JA, et al. Effects of testosterone treatment in older men. *N Engl J Med.* 2016;374(7):611–24.
- Storer TW, Woodhouse L, Magliano L, Singh AB, Dzekov C, Dzekov J, et al. Changes in muscle mass, muscle strength, and power but not physical function are related to testosterone dose in healthy older men. *J Am Geriatr Soc.* 2008;56(11):1991–9.
- Townsley DM, Dumitriu B, Liu D, Biancotto A, Weinstein B, Chen C, et al. Danazol treatment for telomere diseases. *N Engl J Med.* 2016;374(20):1922–31.
- Ucer S, Iyer S, Bartell SM, Martin-Millan M, Han L, Kim HN, et al. The effects of androgens on murine cortical bone do not require AR or ERalpha signaling in osteoblasts and osteoclasts. *J Bone Miner Res.* 2015;30(7):1138–49.
- Vandenput L, Mellstrom D, Karlsson MK, Orwoll E, Labrie F, Ljunggren O, et al. Serum estradiol is associated with lean mass in elderly Swedish men. *Eur J Endocrinol.* 2010;162(4):737–45.

- Vanderschueren D, Laurent MR, Claessens F, Gielen E, Lagerquist MK, Vandemput L, et al. Sex steroid actions in male bone. *Endocr Rev.* 2014;35(6):906–60.
- Veldhuis JD, Mielke KL, Cosma M, Soares-Welch C, Paulo R, Miles JM, et al. Aromatase and 5 $\alpha$ -reductase inhibition during an exogenous testosterone clamp unveils selective sex steroid modulation of somatostatin and growth hormone secretagogue actions in healthy older men. *J Clin Endocrinol Metab.* 2009;94(3):973–81.
- Vlahakos DV, Marathias KP, Agroyannis B, Madias NE. Posttransplant erythrocytosis. *Kidney Int.* 2003;63(4):1187–94.
- Wang C, Swerdloff RS, Iranmanesh A, Dobs A, Snyder PJ, Cunningham G, et al. Transdermal testosterone gel improves sexual function, mood, muscle strength, and body composition parameters in hypogonadal men. *J Clin Endocrinol Metab.* 2000;85(8):2839–53.
- Wang C, Cunningham G, Dobs A, Iranmanesh A, Matsumoto AM, Snyder PJ, et al. Long-term testosterone gel (AndroGel) treatment maintains beneficial effects on sexual function and mood, lean and fat mass, and bone mineral density in hypogonadal men. *J Clin Endocrinol Metab.* 2004;89(5):2085–98.
- Woodhouse LJ, Gupta N, Bhasin M, Singh AB, Ross R, Phillips J, et al. Dose-dependent effects of testosterone on regional adipose tissue distribution in healthy young men. *J Clin Endocrinol Metab.* 2004;89(2):718–26.
- Wu FC, Tajar A, Beynon JM, Pye SR, Silman AJ, Finn JD, et al. Identification of late-onset hypogonadism in middle-aged and elderly men. *N Engl J Med.* 2010;363(2):123–35.
- Yang Q, Jian J, Katz S, Abramson SB, Huang X. 17 $\beta$ -Estradiol inhibits iron hormone hepcidin through an estrogen responsive element half-site. *Endocrinology.* 2012;153(7):3170–8.
- Yeap BB, Knuiman MW, Divitini ML, Hui J, Arscott GM, Handelsman DJ, et al. Epidemiological and Mendelian randomization studies of dihydrotestosterone and estradiol and leukocyte telomere length in men. *J Clin Endocrinol Metab.* 2016;101(3):1299–306.

Päivi Sutinen, Marjo Malinen, and Jorma J. Palvimo

---

## Abstract

Androgen receptor (AR) belongs to the steroid hormone receptor family of the nuclear receptor superfamily and acts as a hormone-controlled transcription factor that conveys the messages of both natural and synthetic androgens to the genes and gene programs. The androgen-regulated genes have a central role in the development and maintenance of the male phenotype and reproductive physiology. AR gene resides on the X chromosome, and mutations in the gene lead to a wide array of androgen insensitivity disorders in males. AR-mediated gene regulation is a rigorously regulated process that involves a coordinated interaction of AR with other DNA sequence-specific transcription factors, such as pioneer factor forkhead box1 and coregulator proteins, including PIAS1. AR signaling starts in the cytosol where hormone binding releases the receptor from a chaperone complex, leading to receptor homodimerization and nuclear translocation and binding to androgen response elements in the regulatory regions of AR target genes. Classic models of AR action view the AR chromatin-binding sites as upstream regulatory elements in gene promoters, but recent genome-wide methods have revealed that the AR regulates transcription mostly from the distal chromatin-binding sites, enhancers. This highlights the importance of chromatin structure and long-range chromatin interactions in the regulation of transcription by AR. In addition to androgens, the AR activity is regulated by several posttranslational modifications, such as SUMOylation, which influence the chromatin binding, protein stability, and interaction of the receptor with other proteins.

---

P. Sutinen

Institute of Biomedicine, University of Eastern Finland, Kuopio, Finland

FinVector Vision Therapies Oy, Kuopio, Finland

e-mail: [Paivi.Sutinen@finvector.com](mailto:Paivi.Sutinen@finvector.com)

M. Malinen • J.J. Palvimo (✉)

Institute of Biomedicine, University of Eastern Finland, Kuopio, Finland

e-mail: [Marjo.Malinen@uef.fi](mailto:Marjo.Malinen@uef.fi); [Jorma.Palvimo@uef.fi](mailto:Jorma.Palvimo@uef.fi)

## Keywords

Androgen receptor • Chromatin • Transcription • Pioneer factor • Coregulator • Enhancer • Testis

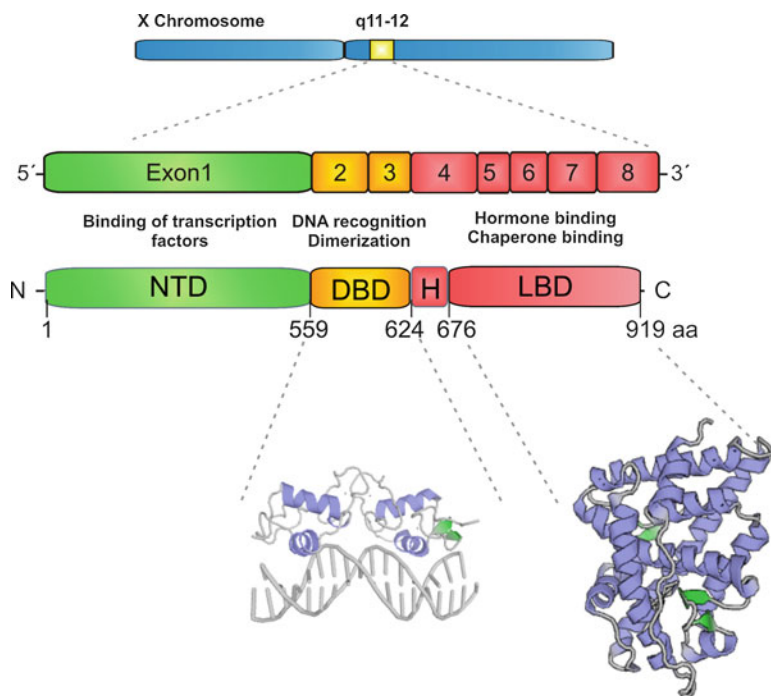
## Contents

Androgen Receptor Gene and Protein .....	396
Androgen Receptor-Mediated Regulation of Transcription .....	400
Nongenomic Androgen Action .....	402
Androgen Receptor Target Genes .....	402
Androgen Receptor Collaborating Transcription Factors .....	404
AR Coregulators .....	405
Enhancer RNAs in AR-Regulated Transcription .....	407
Posttranslational Modifications of the AR .....	407
Summary .....	409
References .....	409

## Androgen Receptor Gene and Protein

The androgen receptor (AR), also known as NR3C4 (nuclear receptor subfamily 3, group C, member 4), is a ligand-dependent transcription factor (TF) belonging to the steroid hormone receptor (SR) group of the nuclear receptor (NR) superfamily. In humans, this superfamily contains 48 NRs. The human AR gene is located on the X chromosome. It consists of eight exons which are separated by relatively long introns (Fig. 1). The AR promoter region lacks a TATA box and a CCAAT box, but contains binding sites for Sp1, NFκB, and c-MYC (Burnstein 2005; Shiota et al. 2011). The retinoblastoma/E2F pathway that controls genes that are essential for DNA synthesis and cell cycle progression inhibits the AR expression via the AR gene promoter (Davis et al. 2006; Valdez et al. 2011). Expression of the AR gene is regulated by androgens, but response to androgens varies in a tissue- and cell-type-specific fashion. Interestingly, loss of an enhancer in the human AR locus is associated with anatomical loss of androgen-dependent sensory vibrissae and penile spines in the human lineage compared to closely related species, including chimpanzees (McLean et al. 2011).

Androgens control male sexual development during embryogenesis and sexual maturation at puberty and maintain reproductive functions and behavior in the adult. AR mRNAs are detectable in male and female mouse embryos from E11 to E12.5 onward, shortly before embryonic hormone synthesis starts (Crocoll et al. 1998; Young and Chang 1998). The male reproductive tissues, such as epididymis and prostate, show the highest AR expression. Both basal and luminal epithelium of human prostate express the AR, with the luminal cells showing higher levels than the basal cells (Abate-Shen and Shen 2000). Rodent prostate gland has a multilobular structure, and expression of AR varies with age and lobe (Banerjee et al. 2001; Sugimura et al. 1986). Interestingly, increased expression of AR has been shown to correlate with development of age-dependent, spontaneous hyperplasia of rat



**Fig. 1** Genomic organization of the androgen receptor (AR) gene and functional domain structure of the AR protein. The AR gene contains eight exons and it encodes for a 919-amino acid-long protein consisting of four major functional domains: N-terminal domain (NTD), DNA-binding domain (DBD), hinge region (H), and ligand-binding domain (LBD). The principal functions of the domains are also shown. Bottom, crystal structure of the AR DBD (PDB: 1R4I) and the AR LBD (PDB: 1E3G)

prostate (Banerjee et al. 2001; Prins and Putz 2008). Whether such changes in the expression of AR occur in human prostate is not known.

In addition to the reproductive tissues, AR is expressed at low level in almost all tissues, including the brain. In mouse, hypothalamic expression of AR is sex, age, and region dependent, with the expression levels increasing toward adulthood and adult males showing higher levels than the females (Brock et al. 2015). In aged male rats, hypothalamic expression of the AR has been found to rise, which may be a compensatory consequence of reduced testosterone concentrations (Munetomo et al. 2015; Wu and Gore 2010). Analogous information of the hypothalamic expression of AR in humans is not available (Harman et al. 2001). Androgens seem to also directly regulate the development of cortex and hippocampus, both of them showing a robust increase in the AR expression during the first 3 weeks after birth of mouse (Tsai et al. 2015).

The AR plays an important role in female reproduction as well, being expressed in various ovarian cell types. In addition to the patients suffering from the androgen

insensitivity syndrome (AIS), the AR's fundamental role for male sexual differentiation and reproductive function has been demonstrated with AR knockout mouse models (Jääskeläinen 2012; Wang et al. 2005). Global AR knockout male mice, similar to complete AIS-suffering patients, have female external genitalia and are infertile, lacking normal spermatogenesis (Yeh et al. 2002). In female mice, global AR knockout results in changes in ovarian function with compromised fertility as well as retarded development of mammary glands (Hu et al. 2004; Walters 2015). Moreover, cell-selective AR knockout models with Cre/loxP technology have revealed tissue- and cell-specific functions of AR in both male and female animals (De Gendt and Verhoeven 2012; Zhou 2010). The AR has important biological actions also in the immune, bone, cardiovascular, hematopoietic systems, and skeletal muscle. The AR is expressed widely in different types of muscle cells, including in myoblasts, myofibers, and satellite cells. Androgen-induced increase in muscle mass is due to hypertrophy of both slow- and fast-twitch muscle fibers (Finkelstein et al. 2013; Kadi et al. 2000; Sinha-Hikim et al. 2004). However, the molecular mechanisms underlying the anabolic effects of androgens in muscle hypertrophy are not completely solved. They seem to be diverse and mediated via several cellular targets and biochemical pathways.

The AR gene encodes a 110-kDa protein composed of 919 amino acid residues, although the number of amino acid residues can vary between individuals due to the presence of polymorphic polyglutamine and polyglycine stretches (Palazzolo et al. 2008). Two AR isoforms, the full-length receptor and an amino-terminally truncated form, have been identified in normal human tissues, but the functional significance of the smaller AR is not established (Ahrens-Fath et al. 2005). The AR has also several splice variants that have been detected in cell- and animal-based models and tissues from prostate cancer patients. The variants commonly lack the C-terminal region of the receptor, which leads to constitutive activity due to the absence of ligand-binding domain and therefore also resistance to antiandrogens (Daniel and Dehm 2016).

The AR is structurally and functionally related to other SRs, glucocorticoid receptor (GR), progesterone receptor (PR), mineralocorticoid receptor (MR), and two estrogen receptors (ER)  $\alpha$  and  $\beta$ , from which all but the ERs share in principle the same DNA-binding sites, although specific sites are also found (Huang et al. 2010). SRs' structures can be roughly divided into four distinct domains: N-terminal-activating domain (NTD), DNA-binding domain (DBD), hinge region, and C-terminal ligand-binding domain (LBD) (Fig. 1).

The AR NTD includes ~60% of the protein's amino acids (558 residues), and it contains the polyglutamine (poly-Q) and polyglycine repeat sequences. Normally, the number of glutamines in the poly-Q repeats ranges from 8 to 31, and repeats with lengths over 40 can cause spinal and bulbar muscular atrophy (Kennedy's disease) (La Spada et al. 1991). The shorter poly-Q repeats commonly impose a higher AR transactivation activity, while longer repeats reduce the activity. The NTD is the most variable domain within the SRs, and the AR NTD shows only limited amino

acid sequence homology with the other SRs. For example, the sequence similarity between AR NTD and PR NTD is only 20%. The NTD is therefore likely to markedly contribute to the specificity of the AR. The NTD that on its own is lacking a well-defined three-dimensional structure interacts in an androgen-dependent manner with the C-terminal LBD (N/C interaction), which stabilizes the transcriptionally active AR dimer complex. This interaction is required for the full transcriptional potential of AR. The NTD is also a site for the interaction between the AR and many structurally diverse coregulators (Davey and Grossmann 2016). The NTD contains a ligand-independent activation function (AF)-1 that is required for the maximal activity of the AR, and in the absence of the LBD, the AF-1 becomes constitutively active. The AF-1 also mediates direct interdomain interactions between the NTD and the LBD, which also stabilizes the AR dimer and reduces the rate of hormone dissociation (McEwan 2004).

The DBD that is a relatively small (~100 amino acids) protein domain is the best conserved region among the NRs. The amino acid sequence of the AR DBD is 76–79% identical with those of its closest relatives, GR, MR, and PR. The AR DBD consists of two  $\alpha$ -helices that are arranged into two structurally and functionally different zinc finger domains (Helsen et al. 2012). The helices are located at the C-terminal ends of the zinc fingers. They are oriented vertically to each other and form the base of a hydrophobic core. Both zinc fingers contain four cysteine residues which coordinate one zinc ion. The N-terminal zinc finger is making direct contacts with the DNA, and the C-terminal one creates a dimerization interface by forming salt bridges with the corresponding region of another AR molecule, resulting in stabilization of DNA binding (Jakob et al. 2007; Shaffer et al. 2004). The amino acids in the first zinc finger's DNA recognition helix, the so-called P box, responsible for the sequence-specific DNA contacts are identical in the corresponding positions of the GR, the MR, and the PR. The hinge region located between the DBD and the LBD contains the main nuclear localization signal for the import of the receptor into the nucleus as well as a nuclear export signal that mediates the export of the AR to the cytoplasm upon ligand removal. The hinge region also mediates interaction with heat shock chaperone proteins when androgen is not bound to receptor (Huang et al. 2010).

The AR LBD consists of 11  $\alpha$ -helices and two antiparallel  $\beta$ -sheets which form a ligand-binding pocket (LBP) as in other members of the SR family. Ligand binding induces a conformational change in the LBD, causing rearrangement of  $\alpha$ -helix 12 harboring ligand-dependent AF-2. The AF-2 acts as a lid to close the LBP upon ligand binding. There are 18 amino acid residues critical for the receptor's interaction with androgen (Matias et al. 2000; Sack et al. 2001). The AF-2 is also involved in the recruitment of coactivators and corepressors. Deletion of LBD leads to a constitutively active AR (Jenster et al. 1991). Several amino acid substitutions in or around AR LBD  $\alpha$ -helices 3, 4, 5, and 11 of AIS patients have been found to disrupt the interaction of the LBD with the NTD, even though the mutations have no severe effects on hormone binding (Thompson et al. 2001).

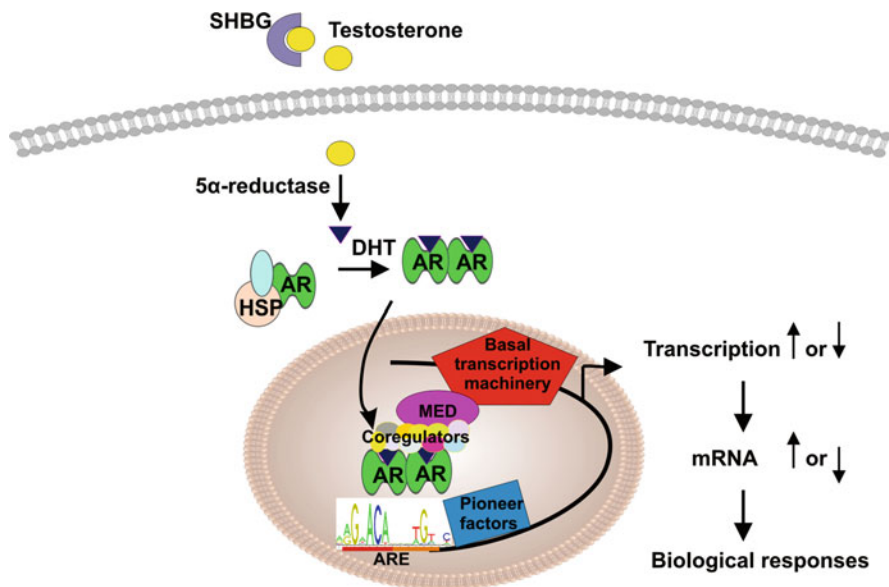


## Androgen Receptor-Mediated Regulation of Transcription

Androgen binding initiates a conformational change in the AR and a subsequent transfer of the receptor dimer to the nucleus where it binds to specific androgen response elements (AREs) on the regulatory regions of its target genes. In this way, the AR conveys the message of androgens directly to the level of genetic programs (Gao et al. 2005; Green et al. 2012; Sampson et al. 2013). In the absence of ligand, AR exists mainly in the cytosol in a multiprotein chaperone complex with heat shock proteins, such as heat shock protein 90, immunophilins, p23, FKBP51, FKBP52 and Cyp40, and serine/threonine phosphatase 5 (Fig. 2) (Echeverria and Picard 2010). The androgen-induced conformational change in the AR releases the receptor from its chaperone protein complex, leading to receptor phosphorylation, homodimerization, and nuclear translocation (Fig. 2) (McEwan 2004; Palvimo 2012). The AR moves into the nucleus very rapidly; it can be detected on chromatin within a few minutes after androgen exposure with maximal binding present at 2 h (Massie et al. 2011). In the nucleus, the AR dimer binds to AREs in the regulatory regions of its target genes (Pihlajamaa et al. 2014; Sahu et al. 2011). This initiates the formation of a multiprotein complex which exerts the activation or repression of AR target genes. If the AR binds to promoter regions, the receptor may interact directly with general transcription machinery components TFIIB and TFIIF associated with RNA polymerase II (Pol II) (Lavery and McEwan 2008; Lee and Chang 2003; Roy and Singer 2015). The multiprotein complexes residing on distal regulatory regions, enhancers, are likely to consist of both directly DNA-binding collaborating TFs and non-DNA-binding coregulators, such as steroid receptor coactivators (SRC) 1, 2, and 3 and cAMP response element-binding protein (CBP)/300 as well as Mediator complex bridging interactions with the Pol II transcription apparatus. (Shang et al. 2002; Wang et al. 2007). In this way, androgen signaling alters gene transcription and ultimately leads to specific biological responses (Fig. 2).

Recently, chromatin immunoprecipitation (ChIP) combined with massively parallel DNA sequencing (ChIP-seq) has enabled investigation and mapping of a given TF's targets at the level of the whole genome. ChIP-seq studies that thus far have mostly been carried out in a few prostate cancer cell lines have typically revealed tens of thousands of androgen-binding sites (ARBs) across the human genome (Massie et al. 2011; Sahu et al. 2011; Toropainen et al. 2015). The collection of ARBs in a given cell line or tissue is termed AR cistrome. Interestingly, the majority of ARBs reside in distal intronic and intergenic regions relative far away from the promoter regions of the target genes. Chromosome conformation capture assays have further demonstrated that the distally bound AR can communicate with promoters through chromatin looping (Wang et al. 2007). Therefore, the classic model of AR binding to the proximal promoter of target genes has been revised. The AR cistromes exhibit cell-type-specific features. ChIP-seq profiling of ARBs in the prostate, epididymis, and kidney has found evidence for only a minor overlap, highlighting tissue specificity of the AR cistromes (Pihlajamaa et al. 2014).

ChIP-seq studies have also uncovered more details about the AREs. Motif analyses of the AR-bound DNA sequences have confirmed that the AR binds mainly



**Fig. 2** Androgen receptor (AR)-mediated signaling. After synthesis, testosterone bound to serum sex hormone-binding globulin (SHBG) is transported to target tissues, such as prostate. In prostate cells, it is converted to 5 $\alpha$ -dihydrotestosterone (DHT) by 5 $\alpha$ -reductase. Binding of DHT to the AR induces a conformational change in the receptor, resulting in release of chaperone heat shock proteins (HSP), dimerization, and translocation of the AR to the nucleus. There, the receptor binds to the androgen-response elements (ARE) under the guidance of pioneer factors and it interacts with coregulators and Mediator complex (MED), which alters, induces, or represses, target gene transcription

to two types of elements. The “classic,” canonical AREs containing two 5′-AGAACA-3′ inverted half-sites, or hexamer repeats, with a three-nucleotide spacer (Mangelsdorf et al. 1995; Roche et al. 1992) are found from ~60 % of the ARBs (Massie et al. 2011; Toropainen et al. 2015). In keeping with the sequence similarity between the closely related SRs, the classic AREs can be recognized also by the GR, the PR, and the MR, and AR and GR cistromes overlap significantly (Sahu et al. 2011). Notably, the best characterized androgen-regulated genes are not generally regulated by perfect inverted repeat-containing AREs. The “selective” AREs in turn resemble more the direct repeats of the same hexamer, and they are not recognized by the GR or the MR (Denayer et al. 2010; Sahu et al. 2014). Interestingly, the selective chromatin binding is achieved through a less stringent sequence requirement for the 3′-hexamer with its second zinc finger of the AR being important for determining the selectivity (Sahu et al. 2014). Thus, the AR seems to use surprisingly relaxed response element stringency for selective chromatin binding and transcriptional regulation *in vivo*.

The role of AREs in the transcriptional repression by the AR is poorly defined in comparison to the transcriptional activation. Previous single target gene- and

reporter gene-based assays have indicated that the AR can repress transcription without directly binding to DNA, but by binding and inhibiting the activity of activator protein 1 (AP-1) and nuclear factor  $\kappa$ B (NF $\kappa$ B) subunit RelA. Competition for the CBP can also contribute to the transcriptional interference between the AR and the AP-1 and the NF $\kappa$ B (Foradori et al. 2008; Kallio et al. 1995; Lu et al. 2000; Palvimo et al. 1996).

---

## Nongenomic Androgen Action

Some effects of androgens are too rapid (occur in seconds to minutes) to be mediated via regulation of gene transcription by the AR. In the literature actions which require neither AR nuclear translocation nor AR DNA binding have been commonly referred to as “nongenomic,” “nonclassical,” or “noncanonical” AR signaling. Cytoplasmic AR may facilitate activation of various kinase-signaling cascades, including the Src family kinases, Ras-Raf-1, phosphatidylinositol 3-kinase/Akt, and protein kinase C, leading the activation of mitogen-activated protein kinase (MAPK)/extracellular signal-regulated kinase (ERK) (Zarif and Miranti 2016). The activated ERK may in turn phosphorylate the AR, which may enhance AR’s genomic activity (Foradori et al. 2008; Liao et al. 2013). Activation of the Src-Raf-1 signal-transducing pathway by nongenomic AR signaling has been reported to lead to S-phase entry and cell proliferation. Moreover, androgens, possibly through membrane-associated AR, have been shown to rapidly increase intracellular calcium which functions as a ubiquitous secondary messenger. However, more studies are needed to establish and complete the mechanistic picture of nongenomic AR action.

---

## Androgen Receptor Target Genes

The AR is capable of regulating thousands of genes whose products are involved in many important cellular functions (Lamont and Tindall 2010). AR target gene classification simply based on AR chromatin-binding events is demanding, because the AR-binding enhancers may reside many hundreds of kilobases or even megabases away from the transcription start sites of the AR target genes. Although AR-regulated gene programs are in a cell-, tissue-, and developmental stage-specific fashion involved in several biological processes and pathways, they seem to share “core” target genes. Many genes of the latter group are involved in the regulation of cell cycle and apoptosis, increasing cell proliferation and inhibiting apoptosis. Many of them also play a role in cellular differentiation. The AR also regulates anabolic gene programs in glucose consumption, lipid turnover, and muscle biomass production. Genome-wide data from murine prostate, kidney, and epididymis confirm that the AR-regulated transcription programs *in vivo* are tissue specific, regulating distinct biological pathways (Pihlajamaa et al. 2014).

The testis is not only the main source of androgens but also numerous genes in the tissue are regulated by androgens. Spermatogenesis is controlled by a hierarchical network of regulatory systems, and androgens play a critical role in it. The cell junction dynamics and cytoskeletal elements are among the AR targets. The genes of this group include claudin-11, occludin, gelsolin, and vimentin (Wang et al. 2006). Biological functions, such as signal transduction, MAPK activity, cell adhesion, calcium binding, and insulin-like growth factor binding, are also regulated by the AR in mouse testis (Verhoeven et al. 2010). Reproductive homeobox X-linked gene 5 (Rhox5) that in addition to the testis is expressed in the epididymis and ovary is induced by androgens through several AREs (Hu et al. 2007). Rhox5 encodes for a TF critical for germ cell development, sperm production, sperm motility, and fertility (Maclean et al. 2005). Moreover, the expression of testis-specific X-linked gene (Tsx) and dopamine receptor 4 (Drd4) are upregulated by the AR (Schauwaers et al. 2007).

Genome-wide identification of AR-regulated genes in mouse epididymis has confirmed several AR target genes which are, for instance, involved in metabolism, signal transduction, biological regulation, localization, development, and transport (Hu et al. 2010; Sipilä et al. 2006). Among those genes are glutathione peroxidase 5, an antioxidant scavenger that protects spermatozoa from damaging effects (Chabory et al. 2009); sperm-associated antigen 1 gene involved in fertilization; and cysteine-rich secretory protein 1 that is needed for the sperm-egg fusion (Roberts et al. 2008). Many of beta-defensing family members' genes that have important roles in sperm maturation and fertility are also AR targets (Hu et al. 2014).

The prostate gland is secreting semen fluid factors which enhance sperm viability. The AR is needed for the embryonic development, growth, and maturation of the prostate. In normal adult prostate, the primary function of the AR is to induce expression of genes required to promote differentiation, suppress proliferation, and promote secretion (Sensibar 1995; Yadav and Heemers 2012). In prostate cancer cells, AR upregulates the expression of cell cycle regulators, including cell division cycling 25A, cyclin-dependent kinase 6, and E2F transcription factor 1. In addition, the AR regulates anabolic programs through genes of enzymes involved in glycolytic flux, such as hexokinase II, and utilization of glycolysis metabolites in the production of lipids, e.g., fatty acid synthase, and nucleotides, e.g., ADP-ribose pyrophosphatase (Massie et al. 2011; Sharma et al. 2013).

Androgens increase skeletal muscle mass. Insulin-like growth factor 1 (IGF-1) gene is one of the important AR targets in skeletal muscle. IGF-1 is upregulated by androgens and promotes myogenesis and maintenance growth of muscle fiber (Chen et al. 2005; Gentile et al. 2010; Serra et al. 2011). In the skeletal muscle, androgens also enhance the expression of follistatin and hepatocyte growth factor, but decrease the expression of GR, myogenin, calcineurin, and c-Myc (MacKrell et al. 2015; Rana et al. 2014). Myostatin that is a negative regulator of skeletal muscle growth is surprisingly also upregulated by androgens (Dubois et al. 2014). This may be a mechanism by which androgens restrain their own anabolic effects in the skeletal muscle.

## Androgen Receptor Collaborating Transcription Factors

The function of AR in transcriptional regulation is tightly associated with that of other TFs. Recent genome-wide ChIP-seq studies have highlighted the role of other TFs, especially that of so-called AR-collaborating TFs, in the regulation of AR target gene transcription. It seems that the AR cistromes differ to a much lesser extent between cell lines and tissues than the AR-regulated transcriptomes. This strongly suggests that other TFs and coregulators are critically involved in determining the specificity of AR-mediated gene regulation. Several TFs, including AP-1, ERG, HOXB13, FOXA1, GATA2, OCT-1, RXR, ETS1, and HNF-4 $\alpha$ , have been shown to interact physically and functionally with the AR (Heemers and Tindall 2007). ChIP-seq studies have confirmed the predicted de novo co-occupancy between the AR and several collaborating TFs (<http://genome.ucsc.edu/ENCODE/>).

Pioneer factors are TFs that are able to access their own DNA recognition motifs even in transcriptionally silent, compact chromatin (Zaret and Carroll 2011). They are thought to displace nucleosomes to loosen chromatin and bind to the genome for a period prior to the binding of other factors. Thus, they enable the binding of other TFs that cannot on their own access to their target sequences in compacted chromatin. The binding of pioneer factors can also lead to formation of compact chromatin with binding of corepressors. Forkhead box A1 (FOXA1) and GATA-binding protein 4 (GATA4) were the first pioneer factors to be identified during development of the liver and heart, respectively, where they have especially crucial roles (Holtzinger and Evans 2005; Lee et al. 2005). In addition to the FOXA family members and GATA2, 3, and 4, several TFs, including TLE factors, PU.1, AP-2 $\alpha$ , and - $\gamma$ , have been shown to possess similar pioneer factor properties.

Pioneer factors significantly contribute to recognition of SR targets on chromatin (Carroll et al. 2006; Hurtado et al. 2011; Laganieri et al. 2005; Yu et al. 2005). In particular, FOX and GATA motifs are enriched within AR- and ER-binding sites. The FOXA1 shows tissue specificity in its function (Pihlajamaa et al. 2014). FOXA1 is a proven key pioneer factor for the AR. It can both facilitate AR-mediated gene activation and function in AR-mediated gene repression (Gao et al. 2003; Lupien et al. 2008). The role of the FOXA1 in AR regulation is versatile, but the function of the FOXA1 not only depends on target genes but also on the equilibrium between the two TFs (Jin et al. 2014). Interestingly, silencing of the FOXA1 in prostate cancer cells led to a global redistribution of ARBs, creating new ARBs and initiating new transcriptional programs (Sahu et al. 2011). Thus, FOXA1 can facilitate binding of AR to some chromatin regions and block the binding to other regions, and there is a class of AR-binding sites that is independent of FOXA1. In the absence of FOXA1, AR binds to more “specific” ARE motifs devoid of the forkhead-binding sites in their close proximity (Jin et al. 2014). These FOXA1 data are derived almost exclusively from prostate cancer cells. Notably, data from murine prostate, kidney, and epididymis indicate that tissue-specific pioneer TFs indeed associate with AR cistromes and transcription programs: hepatocyte nuclear factor 4 $\alpha$  (Hnf4 $\alpha$ ) in the kidney and activating enhancer-binding protein 2 $\alpha$  (AP-2 $\alpha$ ) in the epididymis define tissue-specific AR recruitment, whereas in the mouse prostate as in the prostate

cancer cells, FOXA1 serves for the same purpose. These pioneering factors are constitutively bound to chromatin and guide AR to specific genomic loci upon hormone exposure. These data indicate that hormone-bound AR and AREs are required but not sufficient for tissue-specific AR gene programs (Hu et al. 2010; Pihlajamaa et al. 2014).

---

## AR Coregulators

In addition to the pioneer TFs and general Pol II transcription apparatus, AR-interacting coregulators are required for the AR to enable regulation of target genes. Hormone-bound AR interacts with the coregulator proteins, coactivators, and corepressors, either prior to its chromatin binding or on the chromatin to enhance or repress AR target gene transcription. Whether a given coregulator functions as an activator or a repressor can depend on the target gene and cell context. In contrast to collaborating TFs, coregulator levels are not thought to significantly alter the basal rate of the AR target gene transcription. In addition to binding directly to the AR, coregulators in many cases interact and communicate with other transcription regulatory proteins without interacting directly with the DNA. AR has been reported to interact with more than 200 putative coregulators (Heemers and Tindall 2007). The majority of these coregulators are postulated to associate directly with the AR. This could be due to sequential binding and their interaction with different domains of the AR. However, the biological significance of a relatively small number of the coregulators has been validated. It is also likely that there is a lot of redundancy among the coregulators. Coregulators are often, probably in most cases, components of multi-subunit coregulator complexes possessing a multitude of enzymatic activities. As most of the putative AR coregulators are also able to modulate transcription mediated by several NRs plus other types of TFs, the number of truly AR-specific coregulators is likely to be very small. The AR coregulators have versatile functions, but they can be divided into two families: those which facilitate AR's DNA occupancy, chromatin remodeling, and recruitment of basal transcription machinery and those which modulate the AR protein itself.

Chromatin remodeling complexes alter chromatin structure and unwrap the histone-DNA complexes to render them more permissive for transcription, or, conversely, they can condense the chromatin structure and promote gene repression (Li et al. 2007). Many of the AR coregulators are components of the chromatin-remodeling complexes. AR-interacting protein (ARIP) 4 is a member of the SNF2-like family, which is known for its chromatin-remodeling properties. ARIP4 contains the SNF2 domain and is an active DNA-dependent ATPase able to generate superhelical torsion on linear DNA fragments (Rouleau et al. 2002). In addition, coregulators can covalently modify, acetylate, phosphorylate, methylate, ubiquitinate, and SUMOylate histone residues, i.e., they write histone marks. Specific combinations of covalent histone modifications can loosen or tighten the DNA-histone interactions and create binding surfaces for other chromatin and transcription regulatory proteins that read histone marks (Li et al. 2007). Together

these histone marks have been suggested to form a histone code for the regulation of gene transcription. Many NR coregulators possess histone acetylase, deacetylase, methylase, or demethylase activity, i.e., they erase histone marks. Increased histone N-terminal tail acetylation and histone acetyltransferase (HAT) activity are generally associated with transcriptional activation (Barth and Imhof 2010; Fullgrabe et al. 2011). Steroid receptor coactivator 1, 2, and 3 (members of p160/SRC gene family) and CBP/p300 are recognized AR-interacting HATs (Wang et al. 2011). The role of histone methyl marks is more complex than that of acetyl marks. Active enhancer regions, for example, show high levels of H3K4me2 and H3K4me3 (H3 lysine 4 di- and trimethylation) as well as H3K36me2 and H3K36me3, but are devoid of H3K27me3 and H4K20me3 (Barth and Imhof 2010). Demethylases, such as lysine-specific demethylase 1 (LSD1/KDM1A), are also known to interact with AR (Yamane et al. 2006). The coactivator activity of LSD1 may derive from its ability to demethylate repressive H3K9me2 and H3K9me3, but it may also demethylate H3K4, leading to repression of genes. Mediator complex bridging interactions to Pol II transcription apparatus are also shown to be important in AR-dependent transcription, as, e.g., MED1 (TRAP220) coactivates AR activity (Taatjes 2010).

Other coregulators may affect AR-dependent transcription by modulating appropriate folding, hormone binding, N/C interaction, stability, or correct subcellular localization of the AR. These coregulators are often recruited to the hinge region or the AR NTD, especially in AF-1 (Heemers and Tindall 2007). For example, filamin can facilitate the translocation of the ligand-bound receptor to the nucleus. AF-1 can bind to an LxxLL motif (where L is leucine and x any amino acid), which is commonly present in coregulators (van de Wijngaart et al. 2012). The AR-associated protein of 70 kDa is an example of this category of coregulators. It can stabilize the ligand-bound receptor (Heinlein and Chang 2002). Some coregulators, such as PIAS proteins, can promote posttranslational modifications in AR, which regulate AR's transcriptional activity. Recent genome-wide studies suggest that protein inhibitor of activate STAT 1 (PIAS1) functions as a genuine and chromatin-bound AR coregulator, interacting also with FOXA1 and regulating AR target genes in prostate cancer cells (Toropainen et al. 2015).

Similarly, corepressors utilize various mechanisms for repressing AR-dependent transcription. Histone deacetylases (HDAC) remove acetyl group, which leads to the formation of a condensed nucleosomal structure and silencing of transcriptional activity. For example 5'TG3'-interacting factor can repress AR-mediated transcription by forming a complex with Sin3A and HDAC1 (Sharma and Sun 2001). Corepressors, such as RAD9, may regulate AR N/C interaction, inhibiting ligand binding and competing for coactivator recruitment (Hsu et al. 2005). Nuclear receptor corepressor (NCOR) 1 and 2 may also interfere with the AR N/C interaction, but their effect on the repression of AR-dependent transcription is likely to be more important through corepressor complexes harboring HDACs. Proteins, such as PTEN, may prevent AR's nuclear translocation by sequestering the AR in the cytoplasm (Burd et al. 2006).

Taken together, it seems that AR-collaborating pioneer TFs and coregulators ultimately determine the AR's binding site selection on chromatin and

transcriptional activity in a cell- and tissue-specific manner. Different tissues and cells display different patterns of pioneer TFs and coregulators, which are thought to significantly contribute to distinct androgen-regulated gene programs in different tissues.

---

## Enhancer RNAs in AR-Regulated Transcription

High-throughput sequencing techniques have recently uncovered a widespread transcription from enhancers (Lam et al. 2014). These enhancer RNAs (eRNAs) produced by Pol II are typically bidirectional from enhancer regions, and the majority of them are not spliced or polyadenylated. The enhancer-associated transcript levels correlate positively with the expression of the nearest genes (De Santa et al. 2010; Li et al. 2013). Transcription of the eRNAs can be dynamically regulated by NRs, including the AR. The eRNAs may participate in enhancer-promoter loop formation and chromatin remodeling. Chromatin looping in transcriptional activation by the AR can involve interactions with the Mediator complex, offering scaffolds for AR-associated protein complexes for further contributing specific regulation of AR transcription programs (De Santa et al. 2010; Kaikkonen et al. 2013a). Interestingly, topoisomerase I was recently found to be modulating eRNA synthesis and AR-driven enhancer activation through its DNA-nicking activity (Puc et al. 2015).

---

## Posttranslational Modifications of the AR

In addition to the androgenic hormones, the activity of AR is regulated by post-translational modifications (PTMs), phosphorylation and lysine modifications, acetylation, methylation, ubiquitination, and SUMOylation. The PTMs are likely to cross talk with each other, thus providing a complex regulatory code for the AR action (Gioeli and Paschal 2012).

Altogether 17 amino acid residues have been reported to be phosphorylated in the AR. As several phosphorylation sites may influence each other, the complexity of phosphorylation-based regulation of the AR is potentially huge. Most of the AR phosphorylation sites reside in the NTD (Koryakina et al. 2014). Depending on phosphorylation sites, the phosphorylation can occur either in the absence or presence of androgen. The AR is phosphorylated within 15 min of its synthesis, which is thought to allow ligand binding, and binding of androgen induces further phosphorylation events. For example, several cyclin-dependent kinases (CDKs) are able to phosphorylate the AR NTD. Similarly, growth factors can induce the AR phosphorylation (Gioeli and Paschal 2012). MAPK phosphorylates many sites of AR, including S650 in the hinge domain, which regulates the nuclear transport of the receptor (Gioeli et al. 2006; Koryakina et al. 2014). Phosphorylation of the AR is a reversible process. Two protein phosphatases, PP1 and PP2, have been found to dephosphorylate the AR (Chen et al. 2009; Ikonen et al. 1994). Despite intense research on AR



phosphorylation, there is scanty information of the role of the phosphorylation in the regulation of AR target genes. However, for example, phosphorylation of AR S308 by CDK5 has been recently demonstrated to result in differential expression of AR target genes, including several growth-priming TF genes (Lindqvist et al. 2015).

The AR has been reported to be acetylated in three lysines located in the hinge region in the motif 630-KLKK-633 partly overlapping with the major nuclear localization signal of the receptor. Acetyltransferases p300 and p300/CBP, Tat-interacting protein 60 kDa, and N-acetyltransferase arrest-defect 1 protein can directly acetylate AR and thereby increase its activity (Coffey and Robson 2012). Conversely, HDAC1 is able to deacetylate AR and suppress its activity. The acetylation may modulate the AR's transcriptional activity by favoring its nuclear translocation and by shifting the balance between coactivator and corepressor binding. The modification may affect the capability of the AR to regulate cellular growth and apoptosis and is thus potentially physiologically important. Interestingly, the AR hinge region lysines K630 and K632 are also prone to methylation by SET domain-containing protein 9 (SET9) (Ko et al. 2011). SET9 seems to also coactivate the AR by facilitating the AR N/C interaction. The demethylase(s) targeting the AR have not yet been reported.

Ubiquitination, conjugation of ubiquitin to lysine residues, is an essential mechanism to control the turnover of proteins, but the versatile modification also affects signaling pathways without promoting proteins to degradation. AR, like other SRs, seems to be degraded via the ubiquitin-proteasome system. All ubiquitinated lysines in the AR have not yet been definitely established, but at least K845 and K847 in the LBD represent two conserved ubiquitin acceptors. Ubiquitin E3 ligases mouse double minute 2 homolog (MDM2), C-terminus of HSP70-interacting protein (CHIP), and ring finger protein (RNF6) have been reported to promote the ubiquitination of the AR (Chymkowitch et al. 2011; Xu et al. 2009). Interestingly, RNF6-induced AR K6/27 ubiquitination enhances the transcriptional activity of the receptor, while MDM2- or CHIP-mediated ubiquitination promotes the AR degradation without influencing its transcriptional activity (Xu et al. 2009).

The AR was the first NR shown to be modified by small ubiquitin-related modifier (SUMO), i.e., SUMOylated (Knutson et al. 2012; Poukka et al. 2000; Tian et al. 2002; Treuter and Venteclef 2011). The SUMOylation pathway is analogous to ubiquitination, but it does not generally promote protein degradation but regulates protein-protein interactions, and cells possess distinct machinery for the modification. AR SUMOylation sites, K386 and K520, are located in the NTD which is the domain harboring the SUMOylation sites also in GR and PR (Tian et al. 2002; Treuter and Venteclef 2011; Knutson et al. 2012). Agonist-induced conformation of the AR favors receptor SUMOylation (Kaikkonen et al. 2009; Rytinki et al. 2012). Due to the rapid turnover and highly dynamic nature of SUMOylation, the steady-state level of endogenous AR SUMO conjugates is very low, but cell stress, such as heat shock or heavy metal exposure, dramatically augments AR SUMOylation (Kaikkonen et al. 2013b; Rytinki et al. 2012). The modification modulates the transcriptional activity of AR in a target gene- and pathway-selective fashion (Poukka et al. 2000; Sutinen et al. 2014a; Treuter and Venteclef 2011).

SUMOylation is likely to affect the AR target gene selection via regulating the receptor's interactions with other TFs, including FOXA1. Interestingly, SUMOylation also regulates the transcriptional activity and chromatin occupancy of FOXA1 (Sutinen et al. 2014b), and components of the SUMOylation machinery function as coregulators for AR (Kotaja et al. 2000; Kaikkonen et al. 2009). Notably, PIAS1 acts as a chromatin-bound AR coregulator that also interacts with the FOXA1, functioning either as a coactivator or a corepressor in an AR target gene-selective fashion (Toropainen et al. 2015).

---

## Summary

The AR is mandatory for the development and maintenance of male reproductive tissues and secondary sexual characteristics. The receptor is also expressed outside the reproductive tissues, and it has important biological actions also the immune, neural, cardiovascular, and hemopoietic systems both in health and disease. Testosterone and 5 $\alpha$ -dihydrotestosterone bind to the AR with a strong affinity at the low nanomolar range, which drives the androgen-AR dimer complex into the nucleus to the regulatory regions of genes, mostly to distal enhancers, to modulate, either activate or repress, transcription. Recent genome-wide methods have revealed a coordinated network of transcriptional changes orchestrated by the AR together with coregulator proteins and other sequence-specific TFs in prostate cancer cells. However, there is still scanty genome-wide information of AR's chromatin occupancy and target gene programs in normal androgen target tissues *in vivo*. It is therefore essential to expand the systematic genome-wide analyses to male reproductive tissues. In this way, it will be possible to reveal the true, *in vivo* "coregulator and pioneer TF code" that defines the AR function in a cell- and tissue-specific fashion. A better understanding of the tissue-specific mechanisms of AR function should also contribute to the development of improved treatments for androgen-linked diseases.

**Acknowledgments** The work in J.J.P. laboratory is supported by the Academy of Finland, the Sigrid Jusélius Foundation and the Finnish Cancer Organisations.

---

## References

- Abate-Shen C, Shen MM. Molecular genetics of prostate cancer. *Genes Dev.* 2000;14:2410–34.
- Ahrens-Fath I, Politz O, Geserick C, Haendler B. Androgen receptor function is modulated by the tissue-specific AR45 variant. *FEBS J.* 2005;272:74–84.
- Banerjee PP, Banerjee S, Brown TR. Increased androgen receptor expression correlates with development of age-dependent, lobe-specific spontaneous hyperplasia of the brown Norway rat prostate. *Endocrinology.* 2001;142:4066–75.
- Barth TK, Imhof A. Fast signals and slow marks: the dynamics of histone modifications. *Trends Biochem Sci.* 2010;35:618–26.

- Brock O, De Mees C, Bakker J. Hypothalamic expression of oestrogen receptor alpha and androgen receptor is sex-, age- and region-dependent in mice. *J Neuroendocrinol.* 2015;27:264–76.
- Burd CJ, Morey LM, Knudsen KE. Androgen receptor corepressors and prostate cancer. *Endocr Relat Cancer.* 2006;13:979–94.
- Burnstein KL. Regulation of androgen receptor levels: implications for prostate cancer progression and therapy. *J Cell Biochem.* 2005;95:657–69.
- Carroll JS, Meyer CA, Song J, Li W, Geistlinger TR, Eeckhoutte J, Brodsky AS, Keeton EK, Fertuck KC, Hall GF, et al. Genome-wide analysis of estrogen receptor binding sites. *Nat Genet.* 2006;38:1289–97.
- Chabory E, Damon C, Lenoir A, Kauselmann G, Kern H, Zevnik B, Garrel C, Saez F, Cadet R, Henry-Berger J, et al. Epididymis seleno-independent glutathione peroxidase 5 maintains sperm DNA integrity in mice. *J Clin Invest.* 2009;119:2074–85.
- Chen Y, Zajac JD, MacLean HE. Androgen regulation of satellite cell function. *J Endocrinol.* 2005;186:21–31.
- Chen S, Kesler CT, Paschal BM, Balk SP. Androgen receptor phosphorylation and activity are regulated by an association with protein phosphatase 1. *J Biol Chem.* 2009;284:25576–84.
- Chymkowitz P, Le May N, Charneau P, Compe E, Egly JM. The phosphorylation of the androgen receptor by TFIID directs the ubiquitin/proteasome process. *EMBO J.* 2011;30:468–79.
- Coffey K, Robson CN. Regulation of the androgen receptor by post-translational modifications. *J Endocrinol.* 2012;215:221–37.
- Crocoll A, Zhu CC, Cato AC, Blum M. Expression of androgen receptor mRNA during mouse embryogenesis. *Mech Dev.* 1998;72:175–8.
- Daniel M, Dehm SM. Lessons from tissue compartment-specific analysis of androgen receptor alterations in prostate cancer. *J Steroid Biochem Mol Biol.* 2016. doi:10.1016/j.jsbmb.2016.04.016.
- Davey RA, Grossmann M. Androgen receptor structure, function and biology: from bench to bedside. *Clin Biochem Rev.* 2016;37:3–15.
- Davis JN, Wojno KJ, Daignault S, Hofer MD, Kuefer R, Rubin MA, Day ML. Elevated E2F1 inhibits transcription of the androgen receptor in metastatic hormone-resistant prostate cancer. *Cancer Res.* 2006;66:11897–906.
- De Gendt K, Verhoeven G. Tissue- and cell-specific functions of the androgen receptor revealed through conditional knockout models in mice. *Mol Cell Endocrinol.* 2012;352:13–25.
- De Santa F, Barozzi I, Mietton F, Ghisletti S, Polletti S, Tusi BK, Muller H, Ragoussis J, Wei CL, Natoli G. A large fraction of extragenic RNA pol II transcription sites overlap enhancers. *PLoS Biol.* 2010;8:e1000384.
- Denayer S, Helsen C, Thorrez L, Haelens A, Claessens F. The rules of DNA recognition by the androgen receptor. *Mol Endocrinol.* 2010;24:898–913.
- Dubois V, Laurent MR, Sinnesael M, Cielen N, Helsen C, Clinckemalie L, Spans L, Gayan-Ramirez-G, Deldicque L, Hespel P, et al. A satellite cell-specific knockout of the androgen receptor reveals myostatin as a direct androgen target in skeletal muscle. *FASEB J.* 2014;28:2979–94.
- Echeverria PC, Picard D. Molecular chaperones, essential partners of steroid hormone receptors for activity and mobility. *Biochim Biophys Acta.* 2010;1803:641–9.
- Finkelstein JS, Lee H, Burnett-Bowie SA, Pallais JC, Yu EW, Borges LF, Jones BF, Barry CV, Wulczyn KE, Thomas BJ, Leder BZ. Gonadal steroids and body composition, strength, and sexual function in men. *N Engl J Med.* 2013;369:1011–22.
- Foradori CD, Weiser MJ, Handa RJ. Non-genomic actions of androgens. *Front Neuroendocrinol.* 2008;29:169–81.
- Fullgrabe J, Kavanagh E, Joseph B. Histone onco-modifications. *Oncogene.* 2011;30:3391–403.
- Gao N, Zhang J, Rao MA, Case TC, Mirosevich J, Wang Y, Jin R, Gupta A, Rennie PS, Matusik RJ. The role of hepatocyte nuclear factor-3 alpha (Forkhead Box A1) and androgen receptor in transcriptional regulation of prostatic genes. *Mol Endocrinol.* 2003;17:1484–507.
- Gao W, Bohl CE, Dalton JT. Chemistry and structural biology of androgen receptor. *Chem Rev.* 2005;105:3352–70.

- Gentile MA, Nantermet PV, Vogel RL, Phillips R, Holder D, Hodor P, Cheng C, Dai H, Freedman LP, Ray WJ. Androgen-mediated improvement of body composition and muscle function involves a novel early transcriptional program including IGF1, mechano growth factor, and induction of {beta}-catenin. *J Mol Endocrinol*. 2010;44:55–73.
- Gioeli D, Paschal BM. Post-translational modification of the androgen receptor. *Mol Cell Endocrinol*. 2012;352:70–8.
- Gioeli D, Black BE, Gordon V, Spencer A, Kesler CT, Eblen ST, Paschal BM, Weber MJ. Stress kinase signaling regulates androgen receptor phosphorylation, transcription, and localization. *Mol Endocrinol*. 2006;20:503–15.
- Green SM, Mostaghel EA, Nelson PS. Androgen action and metabolism in prostate cancer. *Mol Cell Endocrinol*. 2012;360:3–13.
- Harman SM, Metter EJ, Tobin JD, Pearson J, Blackman MR, Baltimore Longitudinal Study of Aging. Longitudinal effects of aging on serum total and free testosterone levels in healthy men. Baltimore Longitudinal Study of Aging. *J Clin Endocrinol Metab*. 2001;86:724–31.
- Heemers HV, Tindall DJ. Androgen receptor (AR) coregulators: a diversity of functions converging on and regulating the AR transcriptional complex. *Endocr Rev*. 2007;28:778–808.
- Heinlein CA, Chang C. Androgen receptor (AR) coregulators: an overview. *Endocr Rev*. 2002;23:175–200.
- Helsen C, Kerkhofs S, Clinckemalie L, Spans L, Laurent M, Boonen S, Vanderschueren D, Claessens F. Structural basis for nuclear hormone receptor DNA binding. *Mol Cell Endocrinol*. 2012;348:411–7.
- Holtzinger A, Evans T. Gata4 regulates the formation of multiple organs. *Development*. 2005;132:4005–14.
- Hsu CL, Chen YL, Ting HJ, Lin WJ, Yang Z, Zhang Y, Wang L, Wu CT, Chang HC, Yeh S, Pimplikar SW, Chang C. Androgen receptor (AR) NH<sub>2</sub>- and COOH-terminal interactions result in the differential influences on the AR-mediated transactivation and cell growth. *Mol Endocrinol*. 2005;19:350–61.
- Hu YC, Wang PH, Yeh S, Wang RS, Xie C, Xu Q, Zhou X, Chao HT, Tsai MY, Chang C. Subfertility and defective folliculogenesis in female mice lacking androgen receptor. *Proc Natl Acad Sci USA*. 2004;101:11209–14.
- Hu Z, MacLean JA, Bhardwaj A, Wilkinson MF. Regulation and function of the Rhox5 homeobox gene. *Ann N Y Acad Sci*. 2007;1120:72–83.
- Hu S, Yao G, Guan X, Ni Z, Ma W, Wilson EM, French FS, Liu Q, Zhang Y. Research resource: genome-wide mapping of in vivo androgen receptor binding sites in mouse epididymis. *Mol Endocrinol*. 2010;24:2392–405.
- Hu SG, Zou M, Yao GX, Ma WB, Zhu QL, Li XQ, Chen ZJ, Sun Y. Androgenic regulation of beta-defensins in the mouse epididymis. *Reprod Biol Endocrinol*. 2014;12:76. doi:10.1186/1477-7827-12-76.
- Huang P, Chandra V, Rastinejad F. Structural overview of the nuclear receptor superfamily: insights into physiology and therapeutics. *Annu Rev Physiol*. 2010;72:247–72.
- Hurtado A, Holmes KA, Ross-Innes CS, Schmidt D, Carroll JS. FOXA1 is a key determinant of estrogen receptor function and endocrine response. *Nat Genet*. 2011;43:27–33.
- Ikonen T, Palvimo JJ, Kallio PJ, Reinikainen P, Jänne OA. Stimulation of androgen-regulated transactivation by modulators of protein phosphorylation. *Endocrinology*. 1994;135:1359–66.
- Jääskeläinen J. Molecular biology of androgen insensitivity. *Mol Cell Endocrinol*. 2012;352:4–12.
- Jakob M, Kolodziejczyk R, Orlowski M, Krzywda S, Kowalska A, Dutko-Gwozdz J, Gwozdz T, Kochman M, Jaskolski M, Ozyhar A. Novel DNA-binding element within the C-terminal extension of the nuclear receptor DNA-binding domain. *Nucleic Acids Res*. 2007;35:2705–18.
- Jenster G, van der Korput HA, van Vroonhoven C, van der Kwast TH, Trapman J, Brinkmann AO. Domains of the human androgen receptor involved in steroid binding, transcriptional activation, and subcellular localization. *Mol Endocrinol*. 1991;5:1396–404.
- Jin HJ, Zhao JC, Wu L, Kim J, Yu J. Cooperativity and equilibrium with FOXA1 define the androgen receptor transcriptional program. *Nat Commun*. 2014;5:3972.

- Kadi F, Bonnerud P, Eriksson A, Thornell LE. The expression of androgen receptors in human neck and limb muscles: effects of training and self-administration of androgenic-anabolic steroids. *Histochem Cell Biol.* 2000;113:25–9.
- Kaikkonen S, Jääskeläinen T, Karvonen U, Rytinki MM, Makkonen H, Gioeli D, Paschal BM, Palvimo JJ. SUMO-specific protease 1 (SENPI) reverses the hormone-augmented SUMOylation of androgen receptor and modulates gene responses in prostate cancer cells. *Mol Endocrinol.* 2009;23:292–307.
- Kaikkonen MU, Spann NJ, Heinz S, Romanoski CE, Allison KA, Stender JD, Chun HB, Tough DF, Prinjha RK, Benner C, Glass CK. Remodeling of the enhancer landscape during macrophage activation is coupled to enhancer transcription. *Mol Cell.* 2013a;51:310–25.
- Kaikkonen S, Paakinaho V, Sutinen P, Levonen A, Palvimo JJ. Prostaglandin 15d-PGJ(2) Inhibits Androgen Receptor Signaling in Prostate Cancer Cells. *Mol Endocrinol.* 2013b;27:212–23.
- Kallio PJ, Poukka H, Moilanen A, Jänne OA, Palvimo JJ. Androgen receptor-mediated transcriptional regulation in the absence of direct interaction with a specific DNA element. *Mol Endocrinol.* 1995;9:1017–28.
- Knutson TP, Daniel AR, Fan D, Silverstein KA, Covington KR, Fuqua SA, Lange CA. Phosphorylated and sumoylation-deficient progesterone receptors drive proliferative gene signatures during breast cancer progression. *Breast Cancer Res.* 2012;14:R95.
- Ko S, Ahn J, Song CS, Kim S, Knapczyk-Stwora K, Chatterjee B. Lysine methylation and functional modulation of androgen receptor by Set9 methyltransferase. *Mol Endocrinol.* 2011;25:433–44.
- Koryakina Y, Ta HQ, Gioeli D. Androgen receptor phosphorylation: biological context and functional consequences. *Endocr Relat Cancer.* 2014;21:T131–45.
- Kotaja N, Aittomäki S, Silvennoinen O, Palvimo JJ, Jänne OA. ARIP3 (androgen receptor-interacting protein 3) and other PIAS (protein inhibitor of activated STAT) proteins differ in their ability to modulate steroid receptor-dependent transcriptional activation. *Mol Endocrinol.* 2000;14:1986–2000.
- La Spada AR, Wilson EM, Lubahn DB, Harding AE, Fischbeck KH. Androgen receptor gene mutations in X-linked spinal and bulbar muscular atrophy. *Nature.* 1991;352:77–9.
- Laganier J, Deblois G, Lefebvre C, Bataille AR, Robert F, Giguere V. From the cover: location analysis of estrogen receptor alpha target promoters reveals that FOXA1 defines a domain of the estrogen response. *Proc Natl Acad Sci USA.* 2005;102:11651–6.
- Lam MT, Li W, Rosenfeld MG, Glass CK. Enhancer RNAs and regulated transcriptional programs. *Trends Biochem Sci.* 2014;39:170–82.
- Lamont KR, Tindall DJ. Androgen regulation of gene expression. *Adv Cancer Res.* 2010;107:137–62.
- Lavery DN, McEwan IJ. Functional characterization of the native NH<sub>2</sub>-terminal transactivation domain of the human androgen receptor: binding kinetics for interactions with TFIIF and SRC-1a. *Biochemistry.* 2008;47:3352–9.
- Lee DK, Chang C. Molecular communication between androgen receptor and general transcription machinery. *J Steroid Biochem Mol Biol.* 2003;84:41–9.
- Lee CS, Friedman JR, Fulmer JT, Kaestner KH. The initiation of liver development is dependent on Foxa transcription factors. *Nature.* 2005;435:944–7.
- Li B, Carey M, Workman JL. The role of chromatin during transcription. *Cell.* 2007;128:707–19.
- Li W, Notani D, Ma Q, Tanasa B, Nunez E, Chen AY, Merkurjev D, Zhang J, Ohgi K, Song X, et al. Functional roles of enhancer RNAs for oestrogen-dependent transcriptional activation. *Nature.* 2013;498:516–20.
- Liao RS, Ma S, Miao L, Li R, Yin Y, Raj GV. Androgen receptor-mediated non-genomic regulation of prostate cancer cell proliferation. *Transl Androl Urol.* 2013;2:187–96.
- Lindqvist J, Imanishi SY, Torvaldson E, Malinen M, Remes M, Om F, Palvimo JJ, Eriksson JE. Cyclin-dependent kinase 5 acts as a critical determinant of AKT-dependent proliferation and regulates differential gene expression by the androgen receptor in prostate cancer cells. *Mol Biol Cell.* 2015;26:1971–84.

- Lu S, Jenster G, Epner DE. Androgen induction of cyclin-dependent kinase inhibitor p21 gene: role of androgen receptor and transcription factor Sp1 complex. *Mol Endocrinol.* 2000;14:753–60.
- Lupien M, Eeckhoutte J, Meyer CA, Wang Q, Zhang Y, Li W, Carroll JS, Liu XS, Brown M. FoxA1 translates epigenetic signatures into enhancer-driven lineage-specific transcription. *Cell.* 2008;132:958–70.
- MacKrell JG, Yaden BC, Bullock H, Chen K, Shetler P, Bryant HU, Krishnan V. Molecular targets of androgen signaling that characterize skeletal muscle recovery and regeneration. *Nucl Recept Signal.* 2015;13:e005.
- Maclean 2nd JA, Chen MA, Wayne CM, Bruce SR, Rao M, Meistrich ML, Macleod C, Wilkinson MF. RhoX: a new homeobox gene cluster. *Cell.* 2005;120:369–82.
- Mangelsdorf DJ, Thummel C, Beato M, Herrlich P, Schutz G, Umesono K, Blumberg B, Kastner P, Mark M, Chambon P, Evans RM. The nuclear receptor superfamily: the second decade. *Cell.* 1995;83:835–9.
- Massie CE, Lynch A, Ramos-Montoya A, Boren J, Stark R, Fazli L, Warren A, Scott H, Madhu B, Sharma N, et al. The androgen receptor fuels prostate cancer by regulating central metabolism and biosynthesis. *EMBO J.* 2011;30:2719–33.
- Matias PM, Donner P, Coelho R, Thomaz M, Peixoto C, Macedo S, Otto N, Joschko S, Scholz P, Wegg A, et al. Structural evidence for ligand specificity in the binding domain of the human androgen receptor. Implications for pathogenic gene mutations. *J Biol Chem.* 2000;275:26164–71.
- McEwan IJ. Molecular mechanisms of androgen receptor-mediated gene regulation: structure-function analysis of the AF-1 domain. *Endocr Relat Cancer.* 2004;11:281–93.
- McLean CY, Reno PL, Pollen AA, Bassan AI, Capellini TD, Guenther C, Indjeian VB, Lim X, Menke DB, Schaar BT, et al. Human-specific loss of regulatory DNA and the evolution of human-specific traits. *Nature.* 2011;471:216–9.
- Munetomo A, Hojo Y, Higo S, Kato A, Yoshida K, Shirasawa T, Shimizu T, Barron A, Kimoto T, Kawato S. Aging-induced changes in sex-steroidogenic enzymes and sex-steroid receptors in the cortex, hypothalamus and cerebellum. *J Physiol Sci.* 2015;65:253–63.
- Palazzolo I, Gliozzi A, Rusmini P, Sau D, Crippa V, Simonini F, Onesto E, Bolzoni E, Poletti A. The role of the polyglutamine tract in androgen receptor. *J Steroid Biochem Mol Biol.* 2008;108:245–53.
- Palvimo JJ. The androgen receptor. *Mol Cell Endocrinol.* 2012;352:1–3.
- Palvimo JJ, Reinikainen P, Ikonen T, Kallio PJ, Moilanen A, Jänne OA. Mutual transcriptional interference between RelA and androgen receptor. *J Biol Chem.* 1996;271:24151–6.
- Pihlajamaa P, Sahu B, Lyly L, Aittomäki V, Hautaniemi S, Jänne OA. Tissue-specific pioneer factors associate with androgen receptor cisomes and transcription programs. *EMBO J.* 2014;33:312–26.
- Poukka H, Karvonen U, Jänne O, Palvimo J. Covalent modification of the androgen receptor by small ubiquitin-like modifier 1 (SUMO-1). *Proc Natl Acad Sci USA.* 2000;97:14145–50.
- Prins GS, Putz O. Molecular signaling pathways that regulate prostate gland development. *Differentiation.* 2008;76:641–59.
- Puc J, Kozbial P, Li W, Tan Y, Liu Z, Suter T, Ohgi KA, Zhang J, Aggarwal AK, Rosenfeld MG. Ligand-dependent enhancer activation regulated by topoisomerase-I activity. *Cell.* 2015;160:367–80.
- Rana K, Lee NK, Zajac JD, MacLean HE. Expression of androgen receptor target genes in skeletal muscle. *Asian J Androl.* 2014;16:675–83.
- Roberts KP, Ensrud-Bowlin KM, Piehl LB, Parent KR, Bernhardt ML, Hamilton DW. Association of the protein D and protein E forms of rat CRISP1 with epididymal sperm. *Biol Reprod.* 2008;79:1046–53.
- Roche PJ, Hoare SA, Parker MG. A consensus DNA-binding site for the androgen receptor. *Mol Endocrinol.* 1992;6:2229–35.
- Rouleau N, Domans'kyi A, Reeben M, Moilanen AM, Havas K, Kang Z, Owen-Hughes T, Palvimo JJ, Jänne OA. Novel ATPase of SNF2-like protein family interacts with androgen receptor and modulates androgen-dependent transcription. *Mol Biol Cell.* 2002;13:2106–19.

- Roy AL, Singer DS. Core promoters in transcription: old problem, new insights. *Trends Biochem Sci.* 2015;40:165–71.
- Rytinki M, Kaikkonen S, Sutinen P, Paakinaho V, Rahkama V, Palvimo JJ. Dynamic SUMOylation Is Linked to the Activity Cycles of Androgen Receptor in the Cell Nucleus. *Mol Cell Biol.* 2012;32:4195–205.
- Sack JS, Kish KF, Wang C, Attar RM, Kiefer SE, An Y, Wu GY, Scheffler JE, Salvati ME, Krystek Jr SR, Weinmann R, Einspahr HM. Crystallographic structures of the ligand-binding domains of the androgen receptor and its T877A mutant complexed with the natural agonist dihydrotestosterone. *Proc Natl Acad Sci USA.* 2001;98:4904–9.
- Sahu B, Laakso M, Ovaska K, Mirtti T, Lundin J, Rannikko A, Sankila A, Turunen JP, Lundin M, Konsti J, et al. Dual role of FoxA1 in androgen receptor binding to chromatin, androgen signalling and prostate cancer. *EMBO J.* 2011;30:3962–76.
- Sahu B, Pihlajamaa P, Dubois V, Kerkhofs S, Claessens F, Jänne OA. Androgen receptor uses relaxed response element stringency for selective chromatin binding and transcriptional regulation in vivo. *Nucleic Acids Res.* 2014;42:4230–40.
- Sampson N, Neuwirt H, Pühr M, Klocker H, Eder IE. In vitro model systems to study androgen receptor signaling in prostate cancer. *Endocr Relat Cancer.* 2013;20:R49–64.
- Schauwaers K, De Gendt K, Saunders PT, Atanassova N, Haelens A, Callewaert L, Moehren U, Swinnen JV, Verhoeven G, Verrijdt G, Claessens F. Loss of androgen receptor binding to selective androgen response elements causes a reproductive phenotype in a knockin mouse model. *Proc Natl Acad Sci USA.* 2007;104:4961–6.
- Sensibar JA. Analysis of cell death and cell proliferation in embryonic stages, normal adult, and aging prostates in human and animals. *Microsc Res Tech.* 1995;30:342–50.
- Serra C, Bhasin S, Tangherlini F, Barton ER, Ganno M, Zhang A, Shansky J, Vandenberg HH, Travison TG, Jasuja R, Morris C. The role of GH and IGF-I in mediating anabolic effects of testosterone on androgen-responsive muscle. *Endocrinology.* 2011;152:193–206.
- Shaffer PL, Jivan A, Dollins DE, Claessens F, Gewirth DT. Structural basis of androgen receptor binding to selective androgen response elements. *Proc Natl Acad Sci USA.* 2004;101:4758–63.
- Shang Y, Myers M, Brown M. Formation of the androgen receptor transcription complex. *Mol Cell.* 2002;9:601–10.
- Sharma M, Sun Z. 5'TG3' interacting factor interacts with Sin3A and represses AR-mediated transcription. *Mol Endocrinol.* 2001;15:1918–28.
- Sharma NL, Massie CE, Ramos-Montoya A, Zecchini V, Scott HE, Lamb AD, MacArthur S, Stark R, Warren AY, Mills IG, Neal DE. The androgen receptor induces a distinct transcriptional program in castration-resistant prostate cancer in man. *Cancer Cell.* 2013;23:35–47.
- Shiota M, Yokomizo A, Naito S. Increased androgen receptor transcription: a cause of castration-resistant prostate cancer and a possible therapeutic target. *J Mol Endocrinol.* 2011;47:R25–41.
- Sinha-Hikim I, Taylor WE, Gonzalez-Cadavid NF, Zheng W, Bhasin S. Androgen receptor in human skeletal muscle and cultured muscle satellite cells: up-regulation by androgen treatment. *J Clin Endocrinol Metab.* 2004;89:5245–55.
- Sipilä P, Pujianto DA, Shariatmadari R, Nikkilä J, Lehtoranta M, Huhtaniemi IT, Poutanen M. Differential endocrine regulation of genes enriched in initial segment and distal caput of the mouse epididymis as revealed by genome-wide expression profiling. *Biol Reprod.* 2006;75:240–51.
- Sugimura Y, Cunha GR, Donjacour AA. Morphological and histological study of castration-induced degeneration and androgen-induced regeneration in the mouse prostate. *Biol Reprod.* 1986;34:973–83.
- Sutinen P, Malinen M, Heikkinen S, Palvimo JJ. SUMOylation modulates the transcriptional activity of androgen receptor in a target gene and pathway selective manner. *Nucleic Acids Res.* 2014a;42:8310–9.
- Sutinen P, Rahkama V, Rytinki M, Palvimo JJ. The nuclear mobility and activity of FOXA1 with androgen receptor are regulated by SUMOylation. *Mol Endocrinol.* 2014b. doi:[10.1210/me20141035](https://doi.org/10.1210/me20141035).

- Taatjes DJ. The human Mediator complex: a versatile, genome-wide regulator of transcription. *Trends Biochem Sci.* 2010;35:315–22.
- Thompson J, Saatcioglu F, Jänne OA, Palvimo JJ. Disrupted amino- and carboxyl-terminal interactions of the androgen receptor are linked to androgen insensitivity. *Mol Endocrinol.* 2001;15:923–35.
- Tian S, Poukka H, Palvimo JJ, Jänne OA. Small ubiquitin-related modifier-1 (SUMO-1) modification of the glucocorticoid receptor. *Biochem J.* 2002;367:907–11.
- Toropainen S, Malinen M, Kaikkonen S, Rytinki M, Jääskeläinen T, Sahu B, Jänne OA, Palvimo JJ. SUMO ligase PIAS1 functions as a target gene selective androgen receptor coregulator on prostate cancer cell chromatin. *Nucleic Acids Res.* 2015;43:848–61.
- Treuter E, Venticlef N. Transcriptional control of metabolic and inflammatory pathways by nuclear receptor SUMOylation. *Biochim Biophys Acta.* 2011;1812:909–18.
- Tsai HW, Taniguchi S, Samoza J, Ridder A. Age- and sex-dependent changes in androgen receptor expression in the developing mouse cortex and hippocampus. *Neuroradiol J.* 2015;2015:525369.
- Valdez CD, Davis JN, Odeh HM, Layfield TL, Cousineau CS, Berton TR, Johnson DG, Wojno KJ, Day ML. Repression of androgen receptor transcription through the E2F1/DNMT1 axis. *PLoS One.* 2011;6:e25187.
- van de Wijngaart DJ, Dubbink HJ, van Royen ME, Trapman J, Jenster G. Androgen receptor coregulators: recruitment via the coactivator binding groove. *Mol Cell Endocrinol.* 2012;352:57–69.
- Verhoeven G, Willems A, Denolet E, Swinnen JV, De Gendt K. Androgens and spermatogenesis: lessons from transgenic mouse models. *Philos Trans R Soc Lond Ser B Biol Sci.* 2010;365:1537–56.
- Walters KA. Role of androgens in normal and pathological ovarian function. *Reproduction.* 2015;149:R193–218.
- Wang Q, Carroll JS, Brown M. Spatial and temporal recruitment of androgen receptor and its coactivators involves chromosomal looping and polymerase tracking. *Mol Cell.* 2005;19:631–42.
- Wang RS, Yeh S, Chen LM, Lin HY, Zhang C, Ni J, Wu CC, di Sant’Agnese PA, deMesy-Bentley KL, Tzeng CR, Chang C. Androgen receptor in sertoli cell is essential for germ cell nursery and junctional complex formation in mouse testes. *Endocrinology.* 2006;147:5624–33.
- Wang Q, Li W, Liu XS, Carroll JS, Jänne OA, Keeton EK, Chinnaiyan AM, Pienta KJ, Brown M. A hierarchical network of transcription factors governs androgen receptor-dependent prostate cancer growth. *Mol Cell.* 2007;27:380–92.
- Wang C, Tian L, Popov VM, Pestell RG. Acetylation and nuclear receptor action. *J Steroid Biochem Mol Biol.* 2011;123:91–100.
- Wu D, Gore AC. Changes in androgen receptor, estrogen receptor alpha, and sexual behavior with aging and testosterone in male rats. *Horm Behav.* 2010;58:306–16.
- Xu K, Shimelis H, Linn DE, Jiang R, Yang X, Sun F, Guo Z, Chen H, Li W, Chen H, et al. Regulation of androgen receptor transcriptional activity and specificity by RNF6-induced ubiquitination. *Cancer Cell.* 2009;15:270–82.
- Yadav N, Heemers HV. Androgen action in the prostate gland. *Minerva Urol Nefrol.* 2012;64:35–49.
- Yamane K, Toumazou C, Tsukada Y, Erdjument-Bromage H, Tempst P, Wong J, Zhang Y. JHDM2A, a JmjC-containing H3K9 demethylase, facilitates transcription activation by androgen receptor. *Cell.* 2006;125:483–95.
- Yeh S, Tsai MY, Xu Q, Mu XM, Lardy H, Huang KE, Lin H, Yeh SD, Altuwajri S, Zhou X, et al. Generation and characterization of androgen receptor knockout (ARKO) mice: an in vivo model for the study of androgen functions in selective tissues. *Proc Natl Acad Sci USA.* 2002;99:13498–503.
- Young WJ, Chang C. Ontogeny and autoregulation of androgen receptor mRNA expression in the nervous system. *Endocrine.* 1998;9:79–88.



- Yu X, Gupta A, Wang Y, Suzuki K, Mirosevich J, Orgebin-Crist MC, Matusik RJ. Foxa1 and Foxa2 interact with the androgen receptor to regulate prostate and epididymal genes differentially. *Ann N Y Acad Sci.* 2005;1061:77–93.
- Zaret KS, Carroll JS. Pioneer transcription factors: establishing competence for gene expression. *Genes Dev.* 2011;25:2227–41.
- Zarif JC, Miranti CK. The importance of non-nuclear AR signaling in prostate cancer progression and therapeutic resistance. *Cell Signal.* 2016;28:348–56.
- Zhou X. Roles of androgen receptor in male and female reproduction: lessons from global and cell-specific androgen receptor knockout (ARKO) mice. *J Androl.* 2010;31:235–43.

Juho-Antti Mäkelä and Jorma Toppari

## Abstract

Production of male gametes, i.e., spermatogenesis, takes place in the seminiferous tubules of the testis. It is a multifaceted, process that takes 2.5 months to complete in man and results in formation of the most highly specialized cell type in the human body, the sperm. The seminiferous epithelium is in constant turnover as new generations of germ cells start to differentiate on the basal lamina and mature gametes are released from the apical part to the tubular lumen. Different generations of germ cells ensue spermatogenesis in synchrony and therefore over a period of time, called the cycle, the seminiferous epithelium has the same appearance. Ability to produce sperm spans the lifetime of sexually mature males and ultimately depends on germ-line stem cell (GSC) self-renewal. GSCs are maintained in a niche created by somatic cells and tissue microenvironment. Transmission of genetic information to subsequent generations and perpetuation of the species ultimately depend on GSC maintenance and the delicate balance between GSC self-renewal and differentiation. Spermatogenesis needs to be kept at a quantitatively normal level to sustain male fertility. Sertoli cells are the somatic component of the seminiferous epithelium, and they create the microenvironment that enables germ cells to survive, proliferate, and differentiate. Sertoli cells show unparalleled plasticity in gene expression and function during development and across the cycle of the seminiferous epithelium, and germ cells are dependent on management of their differentiation by Sertoli cells. Sertoli cells are targets of pituitary-derived follicle-stimulating hormone (FSH) and testosterone,

J.-A. Mäkelä (✉)

Department of Physiology, Institute of Biomedicine, University of Turku, Turku, Finland  
e-mail: [juho-antti.makela@utu.fi](mailto:juho-antti.makela@utu.fi)

J. Toppari

Department of Pediatrics, Turku University Hospital, Turku, Finland

Department of Physiology, Institute of Biomedicine, University of Turku, Turku, Finland  
e-mail: [jorma.toppari@utu.fi](mailto:jorma.toppari@utu.fi); [jortop@utu.fi](mailto:jortop@utu.fi)

produced in Leydig cells of testicular interstitium under control of luteinizing hormone (LH), and they transduce these signals and other stimuli into paracrine regulation of spermatogenesis and coordinate gene expression in germ cells. The transcriptome of male germ cells presents one of the widest among all cell types including not only thousands of protein-coding RNAs but also a wide range of short noncoding RNAs that play a pivotal role in posttranscriptional control of gene expression. Many hormones and factors control spermatogenesis and GSC maintenance, but testosterone, retinoic acid (RA), and FSH action are needed to optimize sperm production. FSH mainly affects premeiotic germ cells, whereas testosterone and RA act throughout male germ cell differentiation. However, quantitatively and qualitatively normal spermatogenesis requires all of them.

### Keywords

Spermatogenesis • Germ cell • Sertoli cell • Human • Spermatogonial stem cell • FSH • Testosterone • LH • GDNF • KIT • Retinoic acid • DHH

### Abbreviations

A <sub>al4-16</sub>	Undifferentiated spermatogonia A-aligned 4-16
ABP	Androgen-binding protein
A <sub>dark</sub>	Type A-dark spermatogonia
A <sub>differentiating</sub>	Differentiating type A spermatogonia
AKT	AKT serine/threonine kinase 1
AMH	Anti-Müllerian hormone
AP1	Activator protein 1
A <sub>pale</sub>	Type A-pale spermatogonia
A <sub>pr</sub>	Undifferentiated spermatogonia A-paired
A <sub>progenitor</sub>	Progenitor type A spermatogonia
AR	Androgen receptor
ARE	Androgen responsive element
A <sub>s</sub>	Undifferentiated spermatogonia A-single
A <sub>stem</sub>	Stem type A spermatogonia
A <sub>transition</sub>	Transitional type A spermatogonia
A <sub>undiff</sub>	Undifferentiated type A spermatogonia
BAX	BCL2 associated X
BCL6b	B-cell CLL/lymphoma 6B
BCL-W	BCL2 like 2
BCL-XL	BCL2-like 1
BMP4	Bone morphogenetic protein 4
BMPR	Bone morphogenetic protein receptor
cAMP	Cyclic adenosine monophosphate
CCND1	Cyclin D1
CCND3	Cyclin D3
CK18	Cytokeratin 18
CREB	cAMP response element-binding
CSF1	Colony stimulating factor 1

---

CSF1R	Colony stimulating factor 1 receptor
CXCL12	C-X-C motif chemokine ligand 12
CXCR4	C-X-C motif chemokine receptor 4
DHH	Desert hedgehog
DMRT1	Doublesex and mab-3 related transcription factor 1
DNMT3a/b	DNA methyltransferase 3 alpha/beta
E2F3	E2F transcription factor 3
ERa/b	Estrogen receptor alpha/beta
ERM	Ets-related molecule
ESYT3	Extended synaptotagmin 3
FGF2	Fibroblast growth factor 2
FGFR	Fibroblast growth factor receptor
FOXL2	Forkhead box L2
FOXO1	Forkhead box O1
FSH	Follicle stimulating hormone
FSHR	Follicle stimulating hormone receptor
FST	Follistatin
G <sub>0</sub>	G zero phase
GDNF	Glial cell derived neurotrophic factor
GFRa1	GDNF family receptor alpha 1
GJA6	Gap junction protein, alpha 6
GnRH	Gonadotropin releasing hormone
GSC	Germ-line stem cell
hCG	Human chorionic gonadotropin
ID4	Inhibitor of DNA binding 4
IGF1	Insulin-like growth factor 1
IL-1b	Interleukin 1 beta
INHA	Inhibin alpha
INHBB	Inhibin beta B
ITT	Intratesticular testosterone
KIT	KIT proto-oncogene receptor tyrosine kinase
LC	Leydig cell
LH	Luteinizing hormone
LHCGR	Luteinizing hormone/choriogonadotropin receptor
LHR	Luteinizing hormone receptor
LHX1	LIM homeobox 1
LuRKO	Luteinizing hormone receptor knockout
MAP2K1	Mitogen-activated protein kinase kinase 1
MAPK	Mitogen-activated protein kinase
MCF2	MCF.2 cell line derived transforming sequence
miR221/2	microRNA 221/2
miRNA	microRNA
mRNA	Messenger RNA
mTORC1	Mammalian target of rapamycin complex 1
NANOS2	Nanos C2HC-type zinc finger 2

NF-kB	Nuclear factor kappa-light-chain-enhancer of activated B cells
NGN3	Neurogenin 3
NR5a2	Nuclear receptor subfamily 5 group A member 2
NXF3	Nuclear RNA export factor 3
PKD1	Pyruvate dehydrogenase kinase 1
PGC	Primordial germ cell
PI3-K	Phosphoinositide 3-kinase
PKA	Protein kinase A
PLZF	Promyelocytic leukemia zinc finger
PTCH	Patched
PTM	Peritubular myoid cell
RA	Retinoic acid
RARg	Retinoic acid receptor gamma
RB	Retinoblastoma protein
Redd1	Regulated in development and DNA damage 1
Ret	Rearranged during transfection
RHOX5	Reproductive homeobox 5
RXRb	Retinoid X receptor beta
SALL4	Spalt-like transcription factor 4
SCF	Stem cell factor
SMAD2/3	SMAD family member 2/3
SOHLH1/2	Spermatogenesis and oogenesis specific basic helix-loop-helix 1/2
SOX3	SRY-box 3
SOX9	SRY-box 9
SRY	Sex determining region Y
SSC	Spermatogonial stem cell
SSPC	Spermatogonial stem and progenitor cell
STRA8	Stimulated by retinoic acid gene 8
T	Testosterone
TAF4b	TATA-box binding protein associated factor 4b
TF	Transferrin
TFIID	Transcription factor II D
TGFb	Transforming growth factor beta
TGFb2	Transforming growth factor beta 2
TNFa	Tumor necrosis factor alpha
tr-KIT	Truncated KIT
VAD	Vitamin A deficient
WNT5a	Wnt family member 5A

## Contents

Introduction .....	421
Testis Development .....	424
Cellular Organization and Cycle of the Seminiferous Epithelium .....	425
The Sertoli Cell .....	429

Spermatogonial Stem Cells .....	430
Germ Cell Differentiation During Spermatogenesis .....	434
Mitotic Phase .....	434
Meiotic Phase .....	435
Spermiogenic Phase .....	436
Endocrine Control of Spermatogenesis .....	436
FSH .....	437
LH→Testosterone .....	438
Paracrine Control of Spermatogenesis .....	440
Stem Cell Factor (SCF) .....	440
Retinoic Acid (RA) .....	442
Desert Hedgehog (DHH) .....	443
Activin, Inhibin, and Follistatin .....	444
Estrogen .....	444
References .....	444

---

## Introduction

The spermatogenic differentiation program of spherical diploid spermatogonia into haploid fully elongated spermatids takes 74 days to complete. It can be divided into three phases: mitotic (proliferative), meiotic, and spermiogenic (postmeiotic) phase (Heller and Clermont 1964). During the course of spermatogenesis male germ cells undergo a succession of cytological events and dramatic changes in cell shape, size, and biochemistry. Spermatogenesis starts when stem spermatogonia (undifferentiated spermatogonia or spermatogonial stem and progenitor cells, SSPCs) commit to differentiate. Exit from the self-renewing state and consequent differentiation commitment are the first steps on a long road of spermatogenesis. This particular step is a battlefield of competing antagonistic GDNF (glial cell-derived neurotrophic factor) and RA (retinoic acid) signaling pathways and also involves active miRNA regulation of mRNA stability (van den Driesche et al. 2014). GDNF has started to lose control on SSPCs as its receptor levels have reduced and expression of RAR $\gamma$  (retinoic acid receptor gamma) equips the cells with ability to receive the differentiation-inducing stimuli (Ikami et al. 2015). Differentiating spermatogonia then go through a number of mitotic divisions in a species-dependent manner, and then enter meiosis as primary spermatocytes (Clermont 1962). Two sequential meiotic divisions quadruple the cell number and give rise to haploid round spermatids that enter a multifaceted differentiation program that includes chromatin repacking and condensation, formation of the acrosome and flagellum, and near complete reduction of cytoplasm volume (Clermont et al. 1993; Stern 1993).

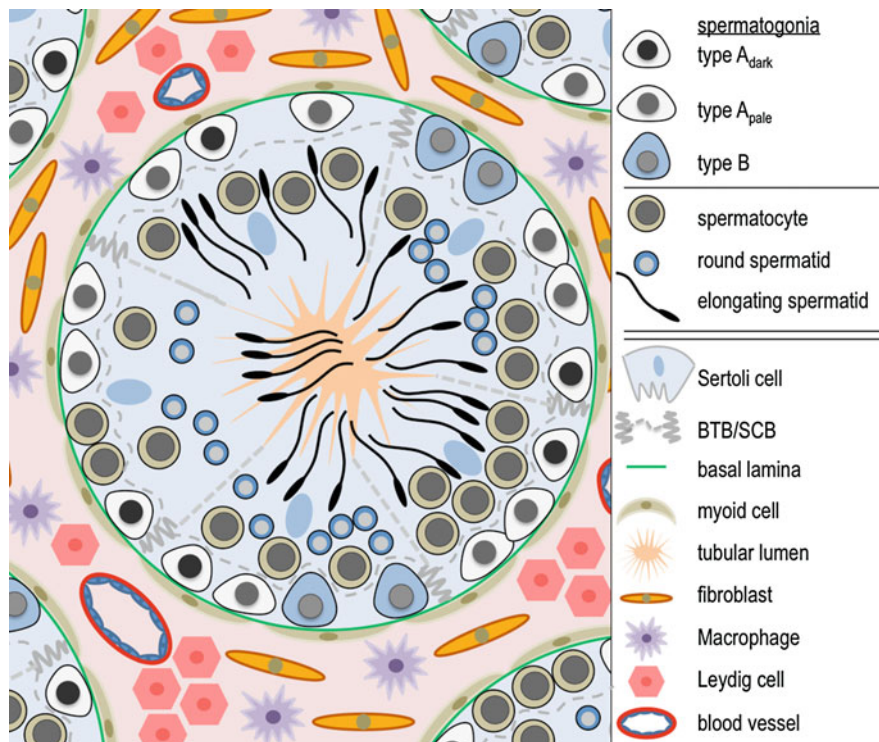
Successful spermatogenesis depends on balance between many different cellular processes, such as self-renewal versus differentiation of SSPCs. Excessive self-renewal would lead to accumulation of undifferentiated spermatogonia and low sperm production output, whereas lack of self-renewal stimuli would ultimately result in testis devoid of germ cells. Spermatogenesis is prone to error, and apoptosis is a common event during male germ cell maturation (Allan et al. 1992; Huckins 1978). The lower the level in the differentiation hierarchy the error takes place, the

more profound effect it has on sperm count because germ cell number multiplies during the process up to a theoretical maximum of 4096-fold increase in the mouse.

Spermatogonia (type  $A_{\text{dark}}$ ,  $A_{\text{pale}}$  and B) and early spermatocytes lie on the basement membrane of the seminiferous tubules surrounded by Sertoli cells. As meiosis proceeds germ cells lose contact to the basement membrane and are engulfed by Sertoli cells. Sertoli cell is like a mother and a guardian angel for the germ cells, supporting and nourishing them through the complex cascade of male germ cell differentiation and maintaining the lifelong capacity to do so by providing the niche for SSPCs. At the end of spermatogenesis, fully matured spermatids are released from the apical tips of Sertoli cells to the tubular lumen. Contractile peritubular myoid (PTM) cells form the structural framework of seminiferous tubules, contribute to the basal lamina, and are a vital part of testis paracrine signaling network. Seminiferous tubules are convoluted and occasionally branching loops that are connected at their tips to the rete testis, the proximal part of the excurrent duct system that transports sperm to the epididymis. Seminiferous tubules form the main part of testis parenchyma but are surrounded by interstitial tissue that consists of blood vessels, nerves, lymphatic vessels, testosterone-producing Leydig cells (LC), fibroblasts, and cells of the immune system (Fig. 1).

Follicle-stimulating hormone (FSH) and androgens act together to maximize the number of sperm produced. The importance of pituitary-derived FSH and LH (luteinizing hormone), and testosterone that is produced in an LH-dependent manner in Leydig cells, has been known for a long time. The only step in germ cell development that seems to be independent of androgen or gonadotropin action takes place prenatally as the predecessors of spermatogonia, the gonocytes, are formed (O'Shaughnessy et al. 2012). The next big step in male germ-line development to be completed peripubertally, namely the formation of the stem cell pool and production of the differentiating spermatogonia for the first cycle of spermatogenesis, is characterized by roughly 50% loss of germ cells in the absence of functional androgen and gonadotropin receptors (O'Shaughnessy et al. 2012). The mechanisms and outcomes of FSH and androgen action have been studied intensively. However, there are at least two shortcomings in the experimental settings of past research: (1) difficulty to discern the effects of a single hormone on the studied parameters as hormones interact on many levels and (2) inability to address the role of different hormones at different developmental stages as the used genetically modified mouse models have lacked functional receptors from the beginning (O'Shaughnessy 2014). Creation of inducible knockout models is therefore needed to dissect the action of these hormones at different phases of testis development and adult spermatogenesis.

Despite considerable variation among different mammalian species in the dynamics of male germ cell differentiation both pre- and postnatally, Amann has been able to characterize overarching features of spermatogenesis that are similar from species to species: (1) germ cell development is temporally tightly regulated; (2) commitment to differentiate takes place synchronously at a certain stage of the seminiferous cycle; (3) progeny of differentiation-committed germ cells are connected by cytoplasmic bridges that ensure synchronous progress of cohort of cells; (4) Sertoli cells nurse many generations of germ cells simultaneously which leads to layering of the



**Fig. 1** Illustration of a cross section of human adult testicular tissue. Majority of testicular tissue is formed by seminiferous tubules that are surrounded by neighboring tubules and testicular interstitial tissue. Testosterone-producing Leydig cells, blood vessels, nerves, fibroblasts, and immune system cells are present in the intertubular space. Peritubular myoid cells limit seminiferous tubules from the interstitium and contribute to formation of basal lamina together with Sertoli cells. Blood-testis barrier (*BTB*), also known as Sertoli cell barrier (*SCB*), divides the seminiferous epithelium into basal compartment where spermatogonia and early primary spermatocytes lie on the basal lamina, and adluminal compartment where meiotic divisions and spermiogenesis take place. Primary spermatocytes at the leptotene phase penetrate the BTB. Sertoli cells extend from basal lamina to the tubular lumen. Germ cells on the adluminal side of BTB are engulfed by the Sertoli cells. Spermatogenesis ends at spermiation when the contact between germ cells and Sertoli cells is lost as mature spermatids are disengaged from the epithelium

seminiferous epithelium; (5) certain developmental states of different cohorts of germ cells always exist at a circumscribed location in a tubule, called a stage of the seminiferous epithelial cycle; (6) at a specific location in the tubule stages progress continuously and in orderly fashion; and (7) apoptosis is a common event during spermatogenesis and reduces the theoretical maximum of sperm production (Amann 2008).

Limited availability of human testicular tissue material for research especially from embryonic, fetal, and early postnatal developmental stages, and lack of efficient culture system for human SSPCs partly explain why there are so many unanswered questions concerning human spermatogenesis. Despite obvious differences between



rodent and human with respect to dynamics and timing of germ cell development both pre- and postnatally, testis descent, changes in hormonal milieu (minipuberty), premeiotic germ cell expansion, and sperm production efficiency, for instance, there are far more common features than separating ones. In the following sections we focus on spermatogenesis as a whole, starting from testis development, then immersing into spermatogenesis as a continuum of cytological events, the central role of Sertoli cells and germ-line stem cells, and endocrine and paracrine control of the process. Most of the presented data is based on research made on rodents but when possible we relate these findings to the human context.

---

## Testis Development

Foundation for lifelong sperm production is laid during early development as primordial germ cells (PGCs) are specified around the time of gastrulation (Irie et al. 2014). Nascent PGCs proliferate and migrate to the bipotential gonadal primordium that assumes sex-specific differentiation in an SRY (sex-determining region of Y) dependent manner (Brennan and Capel 2004). PGCs, or gonocytes as they are called in this developmental phase, are engulfed into cords formed by somatic cells of the developing male gonad. In the mouse, they remain mitotically quiescent until birth, whereas in human they do not enter total quiescence although show varying proliferative activity (Manku and Culty 2015). Gonocytes also undergo genome-wide reprogramming of the epigenome during the latter half of gestation to acquire male-specific genomic imprinting (Sasaki and Matsui 2008). Interestingly, this period is associated with very low mitotic activity in human gonocytes, as well, suggesting that cell cycle needs to arrest for DNA (de)methylation to occur in a desired manner (Galetzka et al. 2007). In rodents, gonocytes start to proliferate and migrate from the lumen to the basement membrane of the seminiferous tubule during the first days of postnatal life (Clermont and Perey 1957). Gaining contact to the basal lamina is crucial for the survival and differentiation of gonocytes (Roosen-Runge and Leik 1968). In rodents this event takes place in a concerted fashion during quite a narrow time window, whereas in human and marmoset the process takes months to complete (McKinnell et al. 2013). Gonocytes that reach the basement membrane form spermatogonial stem cell (SSC) population and give rise to the differentiating spermatogonia of the first cycle of the seminiferous epithelium. In rodents, spermatogenesis succeeds without delay, whereas in humans more than 10 years separate these events. All future cycles differ from the first one with regard to dynamics and efficiency and SSC self-renewal dependency (Yoshida et al. 2006; Jahnukainen et al. 2004).

The testis grows in size after the onset of spermatogenesis. This is due to expansion of the seminiferous tubule diameter and length as a result of Sertoli cell proliferation and appearance of differentiating germ cells. In mammals, Sertoli cells proliferate during fetal, neonatal, and peripubertal periods even though variation in the mitotic activity is vast between different species, and developmental stages (Sharpe et al. 2003). In the mouse, Sertoli cells are mitotically active until day

12 and enter  $G_0$  phase of the cell cycle (Kluin et al. 1984). Interaction between retinoblastoma protein (RB) and E2F3, the only E2F transcription factor expressed in Sertoli cells, controls the exit of Sertoli cells from the cell cycle (Rotgers et al. 2014). Cell cycle arrest is associated with Sertoli cell maturation as their transcriptome changes, and they start to express genes that are associated with adult-type Sertoli cells (such as androgen receptor [*AR*] and *Gata-1*) and cease to express genes linked to the juvenile state (such as cytokeratin-18 [*CK18*] and anti-Müllerian hormone [*AMH*]) (Sharpe et al. 2003). Despite some obvious and functionally significant changes in their transcriptome, most genes are expressed in Sertoli cells in an age-independent manner (De Gendt et al. 2014). Sertoli cells in the adult are regarded terminally differentiated and mitotically quiescent (except for seasonal breeders, like the Djungarian hamster) but whether they retain the ability to divide is a matter of debate (Tarulli et al. 2006; Makela et al. 2014; Eddy and Kahri 1976; Ahmed et al. 2009). The blood-testis barrier (BTB) is formed as a result of Sertoli cell functional maturation and it divides the seminiferous epithelium to basal compartment where mitotic and early meiotic preleptotene spermatocytes reside, and to the immune-privileged adluminal side – the scene for meiotic divisions and post-meiotic germ cell differentiation (Dym and Fawcett 1970).

In the interstitium a similar process takes place and fetal-type Leydig cells are replaced by adult-type LCs whose absolute number increases until early adulthood (Bortolussi et al. 1990). The architecture of the vasculature is also reorganized (Kormano 1967). Before germ cell maturation can commence, the ambient temperature has to fall by a couple of degrees. This is achieved by descent of testis from the abdominal cavity to the scrotum and heat loss through the scrotal skin, and maintained by a countercurrent heat exchange system between the main testicular veins and arteries. A cryptorchid testis is not able to produce sperm and possesses a greater susceptibility for testicular cancer formation when compared to a normally descended testis (Toppari and Kaleva 1999). In boys, testes descend by 6 months of age in >95% of cases but only rarely thereafter (Toppari et al. 2001). If spontaneous descent does not occur, orchiopexy is needed. What inhibits germ cell differentiation at body temperature is not currently well understood, but it may have to do with alternative protein folding enabled by a lower temperature.

---

## Cellular Organization and Cycle of the Seminiferous Epithelium

Before the onset of spermatogenic differentiation there are just two different cell populations present in the seminiferous tubule: Sertoli cells and type A (undifferentiated) spermatogonia. In primates, including man, the type A spermatogonia are subdivided into  $A_{\text{dark}}$  and  $A_{\text{pale}}$  populations (Clermont and Leblond 1959). Discernment between these two cell types is based on functional criteria and staining properties, as their names imply. Distinguishing between  $A_{\text{dark}}$  and  $A_{\text{pale}}$  is often considered a challenge, and many type A human spermatogonia exhibit an intermediate morphology between  $A_{\text{dark}}$  and  $A_{\text{pale}}$  states (Muciaccia et al. 2013; Ehmcke and Schlatt 2006). Therefore an additional  $A_{\text{transition}}$  classification has been suggested,

but due to lack of specific markers for either of the populations or to the proposed one, a new scheme still awaits validation.

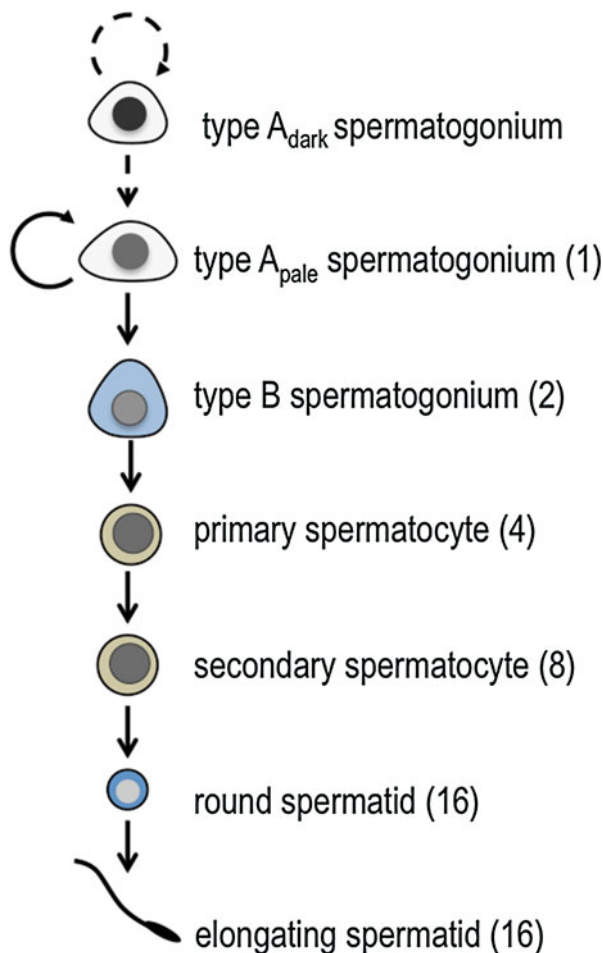
In prepubertal testis,  $A_{\text{dark}}$  spermatogonia proliferate actively and contribute to the formation of spermatogonial stem cell pool (Simorangkir et al. 2005). In adult, however,  $A_{\text{dark}}$  spermatogonia divide rarely and are thought to serve as reserve stem cells responsible for repopulation of the seminiferous epithelium in case of cytotoxic stress and apoptosis of differentiating cells (Ehmcke et al. 2005a, b; van Alphen et al. 1988). As spermatogenesis starts, new generations of germ cells start to appear. Division of  $A_{\text{pale}}$  spermatogonia gives rise to new  $A_{\text{pale}}$  spermatogonia (self-renewal) or type B spermatogonia (differentiation commitment), the first cell type in man that is destined to differentiate into sperm according to a rigid timetable. Self-renewal capacity of  $A_{\text{pale}}$  spermatogonia is likely limited and the population needs to be replenished by differentiation division of  $A_{\text{dark}}$  spermatogonia (Amann 2008; Ehmcke and Schlatt 2006).  $A_{\text{pale}}$  spermatogonia cannot therefore be considered true stem cells but rather transit-amplifying progenitor cells. Based on functional criteria, it is evident that the  $A_{\text{pale}}$  spermatogonial population can be subdivided into  $A_{\text{pale}}$ -progenitor (self-renewing) and  $A_{\text{pale}}$ -committed (differentiating) spermatogonia. What regulates cell fate decisions among human type A spermatogonia is currently not known.

The progeny of type B spermatogonia enter meiosis as spermatocytes, detach from the basal lamina and enter the adluminal compartment, and undergo meiotic divisions to produce fourfold number of spermatids. These cells then gradually differentiate into elongated spermatids and are finally washed off from the apical tips of Sertoli cells by the tubular fluid flow. Schematic presentation of human spermatogenesis is provided in Fig. 2.

Spermatogenesis is a unidirectional process but it also has a cyclic nature. After specific, species-dependent intervals a certain area in the tubule always has similar characteristics. This time interval is known as a cycle of the seminiferous epithelium. During every cycle differentiating germ cells move one level higher in the differentiation hierarchy and spermatogenic differentiation takes 4–5 cycles (depending on the species) to complete. The cycle can be divided into stages or “cell(ular) associations,” a term that is used interchangeably with “stage” in the literature. Cell association actually describes well what stages are all about. A stage is defined by the presence of specific types of germ cells at a specific phase of differentiation. Spermatogenic stage VI in human, for example, is defined by the presence of  $A_{\text{dark}}$ ,  $A_{\text{pale}}$ , and preleptotene spermatocytes on the basal lamina, mid-pachytene spermatocytes, step 6 round spermatids, and mature step 12 elongated spermatids (Muciaccia et al. 2013). It deserves to be mentioned that stages are defined under a microscope by the observer and do not present stagnant check point states during spermatogenesis, but are actually in constant progress.


Cycle of the seminiferous epithelium differs in length among different species. In the mouse it takes 8.6 days to complete one full cycle, whereas in rat and human the duration is 12.9 and 16 days, respectively (Leblond and Clermont 1952; Oakberg 1956; Heller and Clermont 1963). As mentioned above, differentiation of the male germ cell from a differentiating spermatogonium to a spermatozoon,

**Fig. 2** Schematic model of human spermatogenesis. Stem  $A_{\text{dark}}$  spermatogonia divide only rarely. Their division produces new  $A_{\text{dark}}$  spermatogonia (self-renewal) or  $A_{\text{pale}}$  spermatogonia (differentiation). Transit-amplifying  $A_{\text{pale}}$  spermatogonia can undergo a limited number of self-renewal divisions or give rise to type B spermatogonia. Type B spermatogonia are committed to differentiate and their division produces meiotic primary spermatocytes. Short-lived secondary spermatocytes emerge as result of the first meiotic division. The second meiotic division gives rise to haploid spermatids that differentiate into elongating spermatids. Mature elongated spermatids are released to the tubular lumen. The number in parenthesis refers to theoretical fold increase in cell number during spermatogenesis. In reality, the amplification in cell number might be less due to apoptosis



i.e., spermatogenesis, includes many cycles and takes 35, 52, and 74 days to complete in mouse, rat, and human, respectively (Heller and Clermont 1964; Clermont 1972). Until recently human spermatogenesis was thought to consist of six different stages based on spermatid nuclear morphology (Clermont 1963). However, a novel combination of testicular tissue fixation, embedding, and acrosin protein immunohistochemical staining allowed a detailed analysis of the development of the acrosomal complex, and enabled researchers to discern 12 stages, as is the case in many different mammalian species (Muciaccia et al. 2013) (Fig. 3).

According to the new stage classification by Muciaccia et al.,  $A_{\text{dark}}$  and  $A_{\text{pale}}$  spermatogonia are present at every stage. Division of  $A_{\text{pale}}$  spermatogonia at stage XII gives rise to type B spermatogonia first observed at stage I. Type B spermatogonia then undergo the last mitotic division at stage IV to produce preleptonema spermatocytes first visible at stage V. Leptonema starts at stage VII. Pachytene



**Fig. 3** The stages of the human seminiferous epithelial cycle. The cell associations in the vertical columns represent the 12 different stages of the human seminiferous epithelial cycle according to Muciaccia et al. (2013), and they are named after Roman numerals I–XII. Arabic numerals 1–12 refer to different steps of spermiogenesis. *Ad* type  $A_{\text{dark}}$  spermatogonium, *Ap* type  $A_{\text{pale}}$  spermatogonium, *B* type B spermatogonium, *PI* preleptotene spermatocyte, *L* leptotene spermatocyte, *Z* zygotene spermatocyte, *eP*–*mP*–*IP* early, mid and late pachytene spermatocyte, *Di* diplotene spermatocyte, *SS* secondary spermatocyte. Drawn by MSc Sheyla Estefani Cisneros-Montalvo

spermatocytes are present from stage I to stage X followed by diplotene spermatocytes at stage XI, and diakinesis and two meiotic divisions at stage XII. Spermiogenesis is initiated at stage I, spermatid elongation at stage IX, and fully matured spermatozoa are released at stage VI–VII. The duration of every stage in man is roughly 1–1.5 days (Muciaccia et al. 2013). The frequency at which a specific stage is observed in a histological specimen is directly proportional to its length in time and therefore stage VII is recorded twice as often as stage XI, for instance.

The new classification has its merits and makes human spermatogenesis easier to approach, comprehend, and study. The classification is distinctively different from the rodent ones. Most remarkably a similar hot spot of cellular events (differentiation commitment of spermatogonia, meiotic entry, start of spermatid elongation and release) as stage VII–VIII is in rodent spermatogenesis does not seem to exist in human. This may indicate that RA does not have as centrally important role in human spermatogenesis as it has in rodents, as discussed later.

Stages of the seminiferous epithelium are ordered in a segmental fashion in rodents along the length of the tubule, whereas in human the arrangement of stages is more complicated and each cross section contains several stages when viewed under a microscope. This difference is probably due to considerably fewer mitotic

divisions of differentiating spermatogonia in human versus rodent, and therefore the area that is occupied by progeny of differentiation committed cells is smaller. A typical round cross section of human seminiferous tubule contains 2–4 stages, whereas there is usually just one stage present in rodent or bull tubule cross section (Amann 2008). In rodents, as the observer moves along the tubule, the stages follow one another in a numerical order. Different stages can be identified under a stereomicroscope by their light absorption characteristics. Transillumination of the tubules reveals darker and paler zones as a result of differential chromatin condensation and germ cell localization between stages (Parvinen 1982; Toppari and Parvinen 1985; Kotaja et al. 2004).

---

## The Sertoli Cell

The number of Sertoli cells is a determinant of sperm production capacity and thus testis size. This is because a Sertoli cell has a fixed, species-dependent capacity for the number of germ cells that it can nurture (Sharpe 1994; Orth et al. 1988). Sertoli cells extend from the basal lamina to the tubular lumen. During spermatogenic differentiation the physical contact between Sertoli cells and germ cells is uninterrupted and differentiating germ cells are fully dependent on the maturation and survival-promoting microenvironment created by the Sertoli cells. This is particularly true for germ cells in the adluminal compartment. Even their basic metabolism is subject to nutrient supply from the Sertoli cells (Franca et al. 2016).

The functions and responsibilities of Sertoli cells during testis development and spermatogenesis are numerous, starting from initiation of testis development by expression of SRY and SOX9 (SRY-box 9), determining the potential of sperm production, and maintaining the ability to do so by providing a niche for germ-line stem cells, being both the target and mediator of hormone effects in the testis, and intimately guiding male germ cells through the complicated steps of spermatogenesis and finally actively disengaging mature spermatids from the seminiferous epithelium, to name but a few (Franca et al. 2016; Russell et al. 1990). The fascinating role that Sertoli cells play in testis immune regulation and the creation of immune-privileged adluminal side of the seminiferous epithelium has been reviewed in great detail elsewhere (Franca et al. 2016). Later in the text we will focus especially on the role of Sertoli cells in transducing endocrine FSH and androgen signals and other cellular cues into paracrine regulation of germ cell development.

Sertoli cells are proliferatively active until puberty in most mammalian species, including man. After that the cell cycle is halted and Sertoli cells in an adult organism are considered terminally differentiated, quiescent cells. Under certain circumstances they can be induced to proliferate and this is associated with adoption of characteristics of juvenile Sertoli cells (Makela et al. 2014; Ahmed et al. 2009). A defining feature of Sertoli cells is their plasticity and cyclic nature in regard to function and gene expression. Many genes expressed in Sertoli cells (such as *GDNF*, *SCF* [stem cell factor], *DHH* [desert hedgehog]) show stage-dependent

pattern of expression (Ventela et al. 2012; Makela et al. 2011; Hakovirta et al. 1999). There are at least three explanations for the cyclicity of gene expression in Sertoli cells: (1) endocrine regulation stimulates Sertoli cells in a stage-dependent manner, (2) the cycle is prefigured in Sertoli cells during fetal development, or (3) it is the outcome of presence of different populations of germ cells that are in a constant turnover and depend on the microenvironment created and fine-tuned by Sertoli cells. These explanations are not mutually exclusive and many different factors probably take part in adjusting the Sertoli cell function. DMRT1 (doublesex and mab-3 related transcription factor 1) has been characterized as a Sertoli cell autonomous factor needed to sustain cell identity and thus maintain the spatiotemporal pattern of gene expression typical for the cell type. It goes without saying that DMRT1 is therefore crucial for progression and completion of spermatogenesis (Matson et al. 2011).

Previously it has been thought that it is the Sertoli cell that sets the pace for germ cell differentiation. Sertoli cells display at least some aspects of cyclicity even after germ cell depletion or in congenitally germ cell deficient testes (Timmons et al. 2002; Sugimoto et al. 2012). Timmons et al. further suggest that the spermatogenic wave and seminiferous epithelial cycle are prefigured in Sertoli cells during fetal development (Timmons et al. 2002). However, a recent report by Sugimoto et al. challenges this view. They suggest that spermatocytes and spermatids have the primary role in local regulation of RA metabolism, and it would be the differentiating meiotic and postmeiotic germ cells that control the Sertoli cell cycle and ensure appropriate timing of SSPC differentiation commitment (Sugimoto et al. 2012). Conversely, when rat and mouse spermatogonia are transplanted into mouse testis, germ cells differentiate according to their own species-dependent regime (Franca et al. 1998). Germ cells thus follow their intrinsic clock and take benefit of the surrounding somatic environment to do so. It is also possible that in germ cell-depleted testes (such as in vitamin A deficient mice, VAD) Sertoli cells do not actually cycle, despite observation of varying levels of stage-dependent gene expression, but are arrested at a random stage of the cycle (Sugimoto et al. 2012). Interestingly, administration of vitamin A to VAD or differentiation deficient testis was proposed to reset Sertoli cell clock to stage VII (Sugimoto et al. 2012). Involvement of germ cells in modification of Sertoli cell function has also been reported previously, and removal of differentiating germ cells has an impact on Sertoli cell cycling (Kaipia et al. 1991). Despite being a potent agent, it is nonetheless unlikely that RA alone would be able to fully reset the Sertoli cell cycle, and many factors probably take part in adjusting it.

---

## Spermatogonial Stem Cells

Stem cells in the adult are responsible for organ homeostasis by maintaining, repairing, and regenerating many different tissues. Stem cells of the male germline, spermatogonial stem cells (SSCs), reside on the basement membrane of the seminiferous epithelium in a niche created by the surrounding Sertoli cells,

interstitium, and vasculature (Meng et al. 2000; Chiarini-Garcia et al. 2001, 2003; Yoshida et al. 2007). Much of the male germ-line research done during the past 15 years has focused on mouse SSCs, their *in vivo* maintenance and *in vitro* propagation and derivation of other cell types, including embryonic stem cell-like cells, from these cells. In the mouse testis, SSCs exist as solitary isolated single cells, known as A-single or  $A_s$  spermatogonia, or as cysts of cells composed of 2 (A-paired,  $A_{pr}$ ), 4, 8, or 16 (A-aligned,  $A_{al4}$ ,  $A_{al8}$ ,  $A_{al16}$ ) cells connected by a cytoplasmic bridge. These cells are commonly referred to as undifferentiated spermatogonia ( $A_{undiff}$ ) but especially in *in vitro* setting also as spermatogonial stem and progenitor cells (SSPCs). The latter name carries the important distinction that not all undifferentiated spermatogonia are self-renewing and despite retaining the ability to self-renew they do not normally do so but are bound to differentiation commitment. SSPCs, or  $A_{undiff}$ , represent therefore a heterogeneous population of cells in terms of propensity to self-renewal or differentiation. What defines these differences at molecular level is still poorly understood although a group of markers are differentially expressed within the SSPC population (Phillips et al. 2010).

Division of  $A_s$  cells is rarely complete and the daughter cells are connected by a cytoplasmic bridge ( $A_{pr}$ ) (Hara et al. 2014).  $A_{pr}$  cells then give rise to  $A_{al4}$  and so on. New  $A_s$  cells mainly derive from fragmentation of  $A_{pr}$  and  $A_{al4}$  as they divide (Hara et al. 2014). The longer the cyst length is, the greater is the likelihood of exiting the self-renewing state (Schrans-Stassen et al. 1999). GFRa1-expressing  $A_s$  cells tend to exist in proximity of the vasculature and interstitium (Chiarini-Garcia et al. 2003; Yoshida et al. 2007). However, their movement in these areas does not seem to follow any pattern but is somewhat random (Hara et al. 2014). Whether they move actively or are pushed to a different position as the result of expansion of differentiating spermatogonial cell population (or both) is not known. It has been shown, however, that GDNF, the key regulator of SSPC cell fate decision, is a chemo-attractant for freshly isolated undifferentiated spermatogonia and cultured SSPCs (Dovere et al. 2013) and could therefore stimulate chemotactic movement of SSPCs to areas of high GDNF.

It is an intriguing hypothesis that proximity of vasculature and testicular interstitium would provide the microenvironment for maintenance of self-renewal ability of the undifferentiated spermatogonia, i.e., the testis stem cell niche. Having moved out of the niche, actively or passively,  $A_{undiff}$  would be destined to differentiate. How it is decided on cellular level is probably a function of enabling microenvironment and inhibiting cell density as  $A_{undiff}$  rarely if ever cluster. The distribution of  $A_{undiff}$  is nevertheless not random but follows the cycle of the seminiferous epithelium. The highest numbers are seen during mid-stages in rodents when a subset of  $A_{undiff}$  (mainly  $A_{al4-16}$ ) prepares for differentiation and the lowest number just after stage VII–VIII when most  $A_{undiff}$  found are  $A_s$  or  $A_{pr}$  (Schrans-Stassen et al. 1999; Tegelenbosch and de Rooij 1993). Despite their seemingly unipotent nature, germ-line stem cells also possess a pluripotent capacity. This is demonstrated by both *in vitro* (formation of embryonic stem cell-like cells and transdifferentiation into many different cell types) and *in vivo* (formation of teratomas) findings both in human and mouse (Hai et al. 2014). It is not known if the propensity to manifest pluripotent features is restricted to a



certain subpopulation of SSPCs and the underlying mechanisms remain a mystery as yet. Interestingly, SSPCs probably employ an active mechanism to fight the process as induction of pluripotency in these cells in vitro using the Yamanaka factors has surprisingly proved unsuccessful (Corbinau et al. 2016).

A number of growth factors and signaling pathways have been suggested to play a role in SSPC self-renewal and differentiation (Franca et al. 2016; Simon et al. 2007). The two most studied and probably the most important ones as well are GDNF (Meng et al. 2000) and fibroblast growth factor 2 (FGF2) (Ishii et al. 2012). Sertoli cell-derived GDNF belongs to the TGF $\beta$  (transforming growth factor beta) superfamily of growth factors and it signals through a receptor complex that consists of GFR $\alpha$ 1 (GDNF family receptor alpha 1) cell membrane protein and Ret (rearranged during transfection) transmembrane tyrosine kinase protein (Jing et al. 1996; Treanor et al. 1996). Activation of the receptor complex by GDNF binding affects many different cell signaling pathways (Airaksinen and Saarma 2002). SSPC proliferation is stimulated by signaling via SRC kinases and activation of PI3-K/AKT, SMAD2/3, and RAS signaling pathways (He et al. 2009). GDNF expression in Sertoli cells is stimulated by FSH but FGF2, TNF $\alpha$ , and IL-1 $\beta$  might regulate its expression at paracrine level (Simon et al. 2007; Tadokoro et al. 2002). The role of GDNF in mouse spermatogonial stem cell maintenance both in tissue and in culture is crucial (Meng et al. 2000; Kubota et al. 2004). Lack of GDNF leads to depletion of germ cells due to stem cell loss, whereas overexpression of GDNF or activation of RAS signaling in transplanted cells results in accumulation of SSPCs and formation of a seminomatous tumor (Ventela et al. 2012; Meng et al. 2000; Creemers et al. 2002; Yomogida et al. 2003; Lee et al. 2009). *NANOS2*, *ID4*, *CXCR4*, *ERM*, *LHX1* and *BCL6B* are GDNF signaling target genes, and they have been shown to maintain the self-renewing state and/or prevent differentiation (Sada et al. 2012; Chen et al. 2005; Oatley et al. 2006, 2007, 2011; Yang et al. 2013a). In addition, there are at least three genes whose expression is not under direct GDNF control but are still needed for maintenance of the SSPC pool: PLZF, FOXO1, and TAF4b.

PLZF (promyelocytic leukemia zinc finger) is probably the best-characterized cell autonomous factor responsible for SSPC survival, maintenance, and self-renewal. Male mice lacking functional PLZF undergo a progressive germ cell loss and testicular atrophy and are therefore infertile (Costoya et al. 2004; Buaas et al. 2004). PLZF promotes SSPC self-renewal by inducing *Redd1* and thus indirectly inhibiting the mTORC1 pathway, a key regulator of SSPC fate decision (Hobbs et al. 2010, 2015). *SALL4* antagonizes PLZF and permits expression of KIT, the receptor of survival and proliferation-promoting stem cell factor (Rossi et al. 1993; Yan et al. 2000a), thus supporting differentiation of SSPCs (Hobbs et al. 2012). On the contrary, PLZF represses expression of KIT in spermatogonia and therefore promotes the undifferentiated state (Filipponi et al. 2007). The critical role of PLZF in germ-line function is underlined by testicular hypoplasia observed in a patient lacking functional PLZF (Fischer et al. 2008). A severe disruption of the seminiferous epithelium and azoospermia are outcomes of FOXO1 (forkhead box O1) deficiency (Goertz et al. 2011). FOXO1 stimulates expression of self-renewal-associated genes, most notably Ret, a part of GDNF receptor complex

(Goertz et al. 2011). Interestingly, both PLZF and FOXO1 have been assigned to a tumor suppressor role (Fu and Tindall 2008; Suliman et al. 2012). TAF4b (TATA-box binding protein associated factor 4b) is a gonad-specific subunit of transcription initiation factor TFIID. Stem cell maintenance in TAF4b null mice is perturbed, and the testis displays progressive loss of germ cells leading to Sertoli cell only phenotype by 3 months of age (Falender et al. 2005). Truncating mutations in TAF4B have been associated with azoospermia in human as well (Ayhan et al. 2014). Besides GDNF and FGF2, at least three other paracrine factors promote SSPC survival and/or self-renewal: Sertoli cell-derived WNT5a and CXCL12, and CSF-1 that is secreted by Leydig and peritubular myoid cells (Yang et al. 2013a; Yeh et al. 2011; Oatley et al. 2009).

Long-term culture method for mouse SSPCs has been available for almost two decades (Nagano et al. 1998). More recently the minimal requirements of SSPC survival in vitro and the culture conditions enabling their virtually indefinite expansion have been defined in greater detail (Kubota et al. 2004; Kanatsu-Shinohara et al. 2011). Efficient derivation and amplification of SSPCs is fully dependent on the GDNF/GFRA1-RET-PI3K-AKT signaling pathway but FGF2/MAP2K1 activation clearly works in synergy (Ishii et al. 2012; Lee et al. 2007; Takashima et al. 2015). An efficient method for long-term propagation of human SSPCs in vitro is yet to be achieved. This implies that there must be some obvious differences in the survival and growth requirements between mouse and human SSPCs. The gene expression profiles of SSPC predecessors (i.e., mouse gonocytes and human prepubertal spermatogonia) are strikingly similar and this applies both to intracellular and surface markers (Wu et al. 2009). Furthermore, most of the key genes (including *GFRa1*, *Ret*, and *PLZF*) are expressed both in mouse and human SSPCs (Kossack et al. 2009; Izadyar et al. 2011; Guo et al. 2014). These data suggest that the basic mechanisms of germ-line stem cell self-renewal and maintenance are conserved between human and mouse. Transplantation of human SSPCs into seminiferous tubules of immunodeficient mice does not result in production of viable gametes but only allows long-term maintenance of human spermatogonia (Nagano et al. 2002). These data demonstrate that human spermatogonia are able to home into mouse testis stem cell niche, and survive and amplify to a certain extent on the seminiferous epithelium of mouse testis. Inability to give rise to meiotic or postmeiotic germ cells is not necessarily a surprise considering the profound difference in the dynamics of premeiotic germ cell expansion and cycling of the seminiferous epithelium. Human differentiating spermatogonia undergo two to three mitotic divisions, whereas differentiating spermatogonia in mouse undergo six mitotic divisions before the onset of meiosis (Ehmcke and Schlatt 2006). These divisions are strictly coordinated and bound to be progress of the seminiferous epithelial cycle.

An additive level of gene expression regulation is brought about by microRNAs that target mRNAs for degradation or otherwise inhibit their translation. The significance of miRNAs for spermatogenesis is highlighted by the fact that lack of DICER, a key protein in miRNA biogenesis, in germ cells results in spermatogenic failure (Romero et al. 2011; Korhonen et al. 2011). A number of miRNAs are involved in adult germ cell development at different levels, from SSPC maintenance to

spermatid elongation (reviewed by de Mateo and Sassone-Corsi (2014)). A better understanding of the role of testicular miRNome might also provide answers to many puzzling questions about SSPC survival, self-renewal, and differentiation and the species-specific differences behind them.

Establishment of an efficient long-term culture system for human SSPCs is essential for the progress human reproductive and regenerative medicine, and would help bypass the issues of limited research material availability. Even though mouse SSPCs can nowadays be propagated in high numbers, there is still much we do not know about SSPC growth-limiting factors. The reason for this statement lies behind the fact that we can establish and maintain cultures only from mice of specific genetic backgrounds, and culture of SSPCs from one of the most used backgrounds, C57BL/6, for instance, is very difficult (Kanatsu-Shinohara et al. 2003).

---

## Germ Cell Differentiation During Spermatogenesis

Mammalian spermatogenesis is classically divided into three phases: (1) mitotic (proliferative) phase, (2) meiotic phase, and (3) spermiogenic phase. Some authors favor an approach where disengagement of mature spermatids from the seminiferous epithelium, i.e., spermiation, is considered a separate, fourth phase.

### Mitotic Phase

Mitotic divisions of spermatogonia form the basis of sperm production capacity. The number of mitoses that differentiating spermatogonia undergo varies a lot between different species; man and mouse/rat are the two extremes. The first generation of differentiating spermatogonia in mouse is called type A1 spermatogonia. They divide six times (A1→A2→A3→A4→Intermediate→B→preleptotene spermatocyte) before entering meiosis, whereas in man only two divisions take place (Apale→B→preleptotene spermatocyte) (Ehmcke and Schlatt 2006). Divisions of differentiating spermatogonia are tightly bound to the progress of the seminiferous epithelial cycle.

The mitotic phase in rodents has been characterized well. Exit from the self-renewal-retaining state (SSPCs or undifferentiated spermatogonia) is controlled by retinoic acid (RA) both at the onset of spermatogenesis during puberty and in adult (Sugimoto et al. 2012; Snyder et al. 2010). Although the differences in morphology between mouse SSPCs and differentiating spermatogonia are subtle, they diverge in pattern of gene expression. Therefore separation of these two populations by surface antigen expression (such as KIT, only present in the latter) followed by flow cytometry is highly efficient (Shinohara et al. 1999; Kubota et al. 2003). The role of KIT in the testis is interesting for besides having a crucial role in survival, proliferation, and differentiation of differentiating spermatogonia, it is also expressed in gonocytes, Leydig cells, spermatocytes, and in a truncated form in

spermatids and spermatozoa (Hakovirta et al. 1999; Yan et al. 2000a; Orth et al. 1996; Dym et al. 1995; Albanesi et al. 1996; Schrans-Stassen et al. 1999; Manova et al. 1990; Feng et al. 2000; Ohta et al. 2000). The transition from self-renewing to differentiating state is associated with an epigenetic shift in the male germ line (Shirakawa et al. 2013). Alongside KIT, differentiating spermatogonia start to express DNA methyltransferases (DNMT) and exhibit altered histone modifications when compared to SSPCs (Shirakawa et al. 2013). This probably contributes to inability of differentiating spermatogonia to reprogram to a naïve state.

## Meiotic Phase

Besides playing a crucial role in SSPC differentiation commitment, RA also regulates the meiotic entry of type B spermatogonia (Anderson et al. 2008). *STR48* (stimulated by retinoic acid gene 8) is one of the genes upregulated by RA upon onset of meiosis and it plays an essential role in chromosomal rearrangement prior to meiotic divisions (Anderson et al. 2008). At the beginning of meiotic phase, preleptotene spermatocytes replicate their DNA, enter prophase I of meiosis and penetrate through Sertoli cell tight junctions from basal compartment to the immune-privileged adluminal side of the seminiferous epithelium (Smith and Braun 2012). Spermatocytes and their nucleus grow in size during prophase I that takes 2–3 weeks to complete depending on the mammalian species. Prophase I can be subdivided into five different phases based on nuclear morphology: leptotema, zygonema, pachynema, diplonema, and diakinesis. (Spermatocytes at different phases of prophase I are referred to with “-tene” suffix. For example, primary spermatocytes at pachynema are called pachytene spermatocytes.) During leptotema, chromosomes that consist of two sister chromatids condense into strands and the synaptonemal complex starts to assemble. In zygotene spermatocytes, the homologous chromosomes pair. In pachynema, crossing-over takes place as nonsister chromatids of homologous chromosomes exchange DNA. During diplonema, chiasmata, the sites where crossing-over has occurred, become visible as the synaptonemal complex disintegrates and the chromosomes separate from each other. Diakinesis is characterized by disintegration of the nuclear membrane and beginning of meiotic spindle formation. Metaphase, anaphase, and telophase follow and are completed rather quickly giving rise to secondary spermatocytes. As a result of meiosis I homologous chromosomes become segregated, germ cell ploidy is reduced from diploid to haploid and two secondary spermatocytes are formed. They are short-lived cells and undergo the second meiotic division rapidly to produce round spermatids (Stern 1993). Meiosis I is called a reductional division because it halves ploidy. As an equational division, meiosis II is mechanically analogous to mitosis and sister chromatids of chromosomes are segregated into daughter cells. Meiotic divisions thus quadruple germ cell number and significantly amplify gamete production efficiency in all species but especially in those with low number of premeiotic cell divisions, such as human (Fig. 2).

## Spermiogenic Phase

Spermiogenesis represents probably the most remarkable cell differentiation process in the human body. During the 2.5-week spermiogenic phase, haploid spermatids undergo a dramatic change in cell morphology and size, pack their DNA tightly, and develop a flagellum and an acrosome (Clermont et al. 1993). The final step of spermiogenesis is the release of fully matured spermatids to the tubular lumen, i.e., spermiation. It involves active breaking of bonds and structures that anchor a mature spermatid to a Sertoli cell. Testosterone is the master regulator of spermiogenesis and perturbation of androgen action can result in spermiogenic block, premature spermiation or elongating spermatid retention with subsequent phagocytosis by Sertoli cells (O'Donnell et al. 1996; Saito et al. 2000; Zhang et al. 2001). At least in rodents, RA also takes part in spermiation (Huang and Marshall 1983).

Condensation of chromatin structure brings about cessation of transcription at two phases during spermatogenesis: first during homologous recombination of meiotic prophase, then during spermatid elongation (Paronetto and Sette 2010). This creates a need to synthesize and store RNAs for the periods when DNA structure impedes transcription. The spermiogenic phase of male germ cell differentiation is characterized by the appearance of chromatoid bodies (CB): non-membranous ribonucleoprotein granules located in the cytoplasm of round spermatids. CB was discovered for more than a century ago but its structure, components, and function have remained unknown only until recently (von Brunn 1876; Benda 1891). Molecular composition of CB has been characterized lately (Meikar et al. 2010, 2014; Meikar and Kotaja 2014). Majority of the proteins found in CBs are characterized by RNA binding activity or involvement in RNA regulatory pathways (Meikar et al. 2014). CB also hosts a wide range of RNAs of which piRNAs are most characteristic of CB (Meikar et al. 2014). These findings strongly support the hypothesis that CBs participate in posttranscriptional RNA regulation and especially piRNA-targeted regulation of RNAs.

---

## Endocrine Control of Spermatogenesis

Spermatogenesis is under endocrine control. Hypothalamic gonadotropin-releasing hormone (GnRH) controls secretion of LH and FSH from the pituitary. LH and FSH exert their effects on testicular tissues by binding to receptors located on Leydig and Sertoli cell surface, respectively (Zhang et al. 1994; Heckert and Griswold 1991, 1993). It is worth pointing out that germ cells are not influenced by these hormones directly, but LH and FSH do have a pivotal indirect effect on germ cell survival, proliferation, and differentiation. LH stimulates testosterone synthesis in Leydig cells and FSH is a major regulator of Sertoli cell transcriptome and function (Moyle and Armstrong 1970; McLean et al. 2002). Testosterone and Sertoli cell-derived inhibin act negatively on LH and FSH release, respectively, and form thus a negative feedback system that keeps the levels of these hormones in check (hypothalamus-pituitary-gonadal axis). While FSH and testosterone exert their effects

independently on spermatogenesis, their concerted action is needed for complete and quantitatively normal sperm production.

## FSH

The effect that FSH has depends on the developmental status of Sertoli cells (juvenile or adult) and stage of the seminiferous epithelial cycle (Kangasniemi et al. 1990; Orth 1984; Meehan et al. 2000). FSH stimulates proliferation of immature Sertoli cells and regulates transcription of many genes in the adult mitotically quiescent Sertoli cells in an epithelial stage-dependent manner. FSH receptor (FSHR) activation by FSH binding triggers production of intracellular cAMP (cyclic adenosine monophosphate) by adenylate cyclase. Concurrent activation of cell membrane channel proteins has a synergistic effect on FSH-induced cAMP production and the action of these proteins might therefore modulate and potentiate the FSH influence on intracellular signaling (Fok et al. 2014). Cyclic AMP is a potent secondary messenger in Sertoli cells, and it activates directly and indirectly a number of intracellular events: cAMP/PKA, MAPK, and PI3-K/PDK1 signaling pathways, influx of calcium, and synthesis of prostaglandins (Walker and Cheng 2005). Signaling via cAMP/PKA forms the backbone of the FSH intracellular response. CREB, NF- $\kappa$ B, and AP1 are among the transcription factors that take the FSH effect to the transcriptomic level (Walker and Cheng 2005). FSH has an influence on expression of a number of genes, including *GDNF*, *SCF*, *IGF1* (insulin like growth factor 1); *FGF2*, *DHH*, *FSHR*, *AR* (androgen receptor); *ABP* (androgen binding protein); and *TF* (transferrin) (Makela et al. 2011; Tadokoro et al. 2002; Yan et al. 1999; Pitetti et al. 2013; Mullaney and Skinner 1992; Maguire et al. 1997; Skinner et al. 1989; Sylvester and Griswold 1984; Verhoeven and Cailleau 1988; Blok et al. 1989).

Despite its role as a key regulator of Sertoli cell function, FSH is dispensable for qualitatively but not quantitatively normal spermatogenesis both in man and rodents. Men with mutations of the *FSHR* are diagnosed with severely disrupted spermatogenesis and subfertility (Tapanainen et al. 1997). In the literature there are three reports of azoospermic patients with a mutation in the gene encoding the beta subunit of dimeric FSH (Lindstedt et al. 1998; Phillip et al. 1998; Layman et al. 2002). It has been speculated though that the inactivating FSH mutation might not be the primary cause for infertility in these patients. Similar mutations in mice do not cause an equally severe reproductive phenotype (Kumar et al. 1997; Dierich et al. 1998). Interestingly, stimulation of testosterone production by exogenous hLH or hCG (human chorionic gonadotropin, an LH agonist) in gonadotropin-suppressed men, who lack FSH action, restores qualitatively normal spermatogenesis (Bremner et al. 1981; Matsumoto et al. 1984). Sperm counts in these cases were less than half of the normal, but in a couple of individuals they returned to the control range in the hCG study (Bremner et al. 1981; Matsumoto et al. 1984). These data strongly support the idea that FSH is not a pivotal regulator of spermatogenesis and sufficient level of sperm production can be achieved without it. Similarly, several lines of

evidence suggest that lack of androgens can be compensated by a very strong activation of the FSH receptor (Huhtaniemi 2015). This brings us to a conclusion that FSH and testosterone can totally compensate for each other if the level of stimulation of the remaining hormone is high enough (Huhtaniemi 2015).

## LH→Testosterone

LH exerts its effect on spermatogenesis secondarily via testosterone. LH binds to LH receptor (LHR or LHCGR) on the surface of Leydig cells in the testicular interstitial tissue and stimulates production of testosterone. Testosterone is a relative small fat-soluble steroid hormone that reaches its targets by diffusion in the testis. Testosterone does not thus strictly speaking fulfill the criteria of an endocrine factor in the testis, but its secretion is under endocrine control nonetheless, and it affects a number of extragonadal tissues in an endocrine fashion. Intratesticular testosterone (ITT) levels are roughly one to two orders of magnitude higher than testosterone levels in circulation (Hammond et al. 1977; Huhtaniemi et al. 1985). Classically, high ITT is regarded a prerequisite for the onset and maintenance of spermatogenesis and exogenous testosterone has been used as a male contraceptive due to its suppressive effect on endogenous testosterone production resulting in low ITT (Huhtaniemi 2010). Recently, however, Oduwole et al. showed quite elegantly that high ITT is not needed and normal spermatogenesis succeeds at a testosterone concentration of approximately 5 nmol/l that is measured in plasma and that is 20 times lower than the normal ITT (Oduwole et al. 2014). These data offer an explanation why clinical contraceptive testosterone trials have failed to suppress spermatogenesis in a uniform manner.

Receptor for testosterone, the androgen receptor (AR), is expressed by most cell types in the testis, the remarkable exception being the germ cells (Zhou et al. 2002). Cell type-specific AR ablation studies in the mouse have demonstrated that AR signaling via Sertoli and peritubular myoid (PTM) cells is crucial for normal sperm production and fertility (De Gendt et al. 2004; Chang et al. 2004; Welsh et al. 2009). Activation of AR by testosterone binding and dimerization has two ways of action: first, the classical pathway that involves translocation of the receptor complex to the nucleus and initiation of transcription by binding to androgen response elements (AREs) in gene regulatory regions, and second, the nonclassical nongenomic pathway that leads to activation of cell signaling pathways, most notably the MAP kinase cascade (Walker 2009, 2010). Both the classical and nonclassical pathways are required for normal spermatogenesis. Even though the modes of action of the two pathways are different, the outcomes appear to be similar in some cases, and they converge on stimulation of a well-characterized Sertoli cell AR target gene, *Rhox5* (reproductive homeobox 5), expression, for instance (Toocheck et al. 2016).

Once again, most of the data comes from research done on rodents and especially mouse. However, the importance of androgens for sexual development and fertility in man has been very well documented, and perturbation of AR function due to mutations in the AR locus is a common cause of male reproductive problems. By

January 2017, at least 1111 AR mutations have been identified (Gottlieb et al. 2012). These mutations result in varying degrees of androgen action loss and a spectrum of disorders classified as complete, partial, or mild androgen insufficiency syndromes (Mongan et al. 2015).

AR expression is regulated in a dynamic fashion in the human testis. AR staining in Sertoli cells is weak in infants and boys until 6–8 years of age, whereas PTM and Leydig cells show a variable but in many cases detectable level of AR (Chemes et al. 2008). In adulthood AR is strongly expressed in these three cell types (Chemes et al. 2008). In Sertoli cells, AR is expressed in a stage-dependent fashion showing the highest level at stage VI (according to the 2013 classification (Muciaccia et al. 2013)) of the human seminiferous epithelial cycle (Suarez-Quian et al. 1999). This is in accord with stage VI–VII expression pattern of AR in the mouse testis and suggests that androgens play a role in mid-stages of the cycle – such as start of spermatid elongation and spermiation (Zhou et al. 2002). Isolation of ribosome-bound RNA and use of next-generation sequencing allowed de Gendt et al. identify hundreds of genes that are regulated by AR in Sertoli cells (De Gendt et al. 2014). According to DAVID analysis, the molecular functions of the proteins encoded by these differentially expressed genes included calcium ion binding, cytoskeleton protein binding, actin binding, biological adhesion functions, and location at the plasma membrane, stereocilia, cell-cell junctions, and anchoring junctions. The gene whose expression is most severely downregulated by AR signaling was *FOXL2*, a transcription factor needed for development and maintenance of the ovaries (Uhlenhaut et al. 2009). As discussed previously, *DMRT1* is needed for Sertoli cell identity. Loss of *DMRT1* results in activation of *FOXL2* expression in fetal Sertoli cells and postnatal testis (Matson et al. 2011). Acquisition of AR expression by prepubertal Sertoli cells results in downregulation of *FOXL2* mRNA levels and contributes to adoption of adult Sertoli cell identity. Therefore postnatal androgen signaling might be needed for Sertoli cells to suppress the female theca/granulosa cell expression program. Thus functional antagonism between *FOXL2* and *DMRT1* seems to define the sexual identity of gonadal somatic cells, i.e., Sertoli vs. granulosa/theca cell, in an AR-dependent manner.

Male mice lacking either LH receptor (LuRKO) or the beta subunit of LH are infertile (Zhang et al. 2001; Ma et al. 2004). These data suggest that LH-stimulated testosterone production is indispensable for spermatogenesis. Despite lack of sperm, spermatogenesis in young LuRKO mice was able to proceed to round spermatid stage (Zhang et al. 2001). This was made possible by low, residual level of testosterone in these mice indicating that only low levels of testosterone are needed for production of round spermatids and spermiogenesis can succeed only at somewhat higher testosterone level. However, cryptorchidism that is observed in these mice makes these statements weak as spermatogenesis is inhibited at body temperature. Universal AR knock-out mice or mice lacking functional AR also show a block in testis growth and descent and therefore lack postmeiotic germ cells (Gaspar et al. 1991; Yeh et al. 2002). These setbacks have created a need to create mouse models where AR function can be ablated in (a) specific cell type(s), testis descent is normal, and androgen signaling is blocked only in the desired cells.



SCARKO mice lacking functional AR in Sertoli cells were created by subjecting Cre recombinase to regulation of *Amh* promoter that is active in immature Sertoli cells (De Gendt et al. 2004; Chang et al. 2004). SCARKO mice display normal prepubertal development but fail to produce germ cells beyond primary spermatocytes of the pachynema phase (De Gendt et al. 2004; Chang et al. 2004). Spermatogonial cell numbers are normal in SCARKO mice, whereas mice with AR loss-of-function in peritubular myoid cells (PTM-ARKO) have a reduced number of all germ cells, including spermatogonia (De Gendt et al. 2004; Welsh et al. 2009). It is noteworthy that Sertoli cell proliferation is not disrupted in either of the knock-out mouse models and reduction of germ cell numbers is thus not due to smaller population of supporting cells (Welsh et al. 2009; Tan et al. 2005). The lessons that we have learned from cell specific AR ablation studies have been reviewed recently by O'Hara and Smith (2015). It is evident from those studies and decades of research on testosterone-stimulated spermatogenesis that testosterone is vitally important for sperm production. The functions of testosterone in the testis are manifold and testosterone is a critical factor for meiotic and postmeiotic cells and it promotes their survival and guides spermatid elongation and release (Huhtaniemi 2015). Testicular androgen signaling and action is also needed for at least the following: maintenance of spermatogonial numbers, progression through meiosis, integrity of the Sertoli cell barrier (also known as the blood-testis barrier), formation of seminiferous tubule lumen, and adhesion of spermatids and their timely release (O'Hara and Smith 2015).

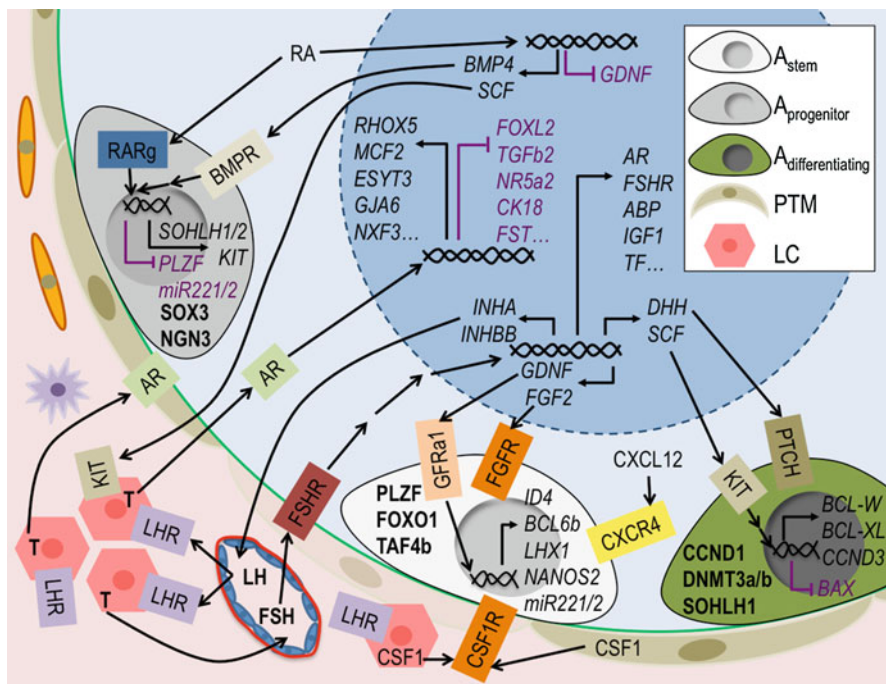
---

## Paracrine Control of Spermatogenesis

The execution of endocrine control on testicular tissue depends on the production of local factors in Sertoli and Leydig cells in response to FSH and LH binding. The paracrine signaling network is not limited only to Sertoli, Leydig, and germ cells but also includes other testicular cell populations: myoid cells, endothelial cells, macrophages, etc. The local factors produced by these cell types work in paracrine, juxtacrine, and autocrine fashion to bring a change to cellular function. There are numerous molecules in the testis that fulfill these criteria. In the following chapters we focus on a selection of them based on significance and solidity of the supporting data. The paracrine and endocrine regulation of SSPCs has been discussed earlier in the text. A schematic overview of testicular endocrine, paracrine, juxtacrine, and autocrine signaling mechanisms based mainly on research performed on rodents is provided in Fig. 4.

## Stem Cell Factor (SCF)

SCF/KIT signaling has an important role at many different stages during testis development and germ cell differentiation. It guides the migration of PGCs from the hindgut to the gonadal ridge during embryonic development, and the early



**Fig. 4** Endocrine and paracrine regulation of spermatogenesis. Pituitary-derived LH and FSH are carried to the testis by blood stream. FSH receptor (*FSHR*) is expressed on the Sertoli cell surface. FSH–FSHR interaction activates intracellular signaling that leads to expression of FSH target genes. Testosterone synthesis in testicular interstitium is stimulated by LH that binds its receptor on Leydig cell surface. Testosterone reaches its target cells by diffusion. Activation of androgen receptor (*AR*) signaling by testosterone binding results in dimerization and translocation of the receptor complex to the nucleus. *AR* signaling regulates transcription of hundreds of genes in the Sertoli cells. *RA* is produced in Sertoli cells from blood-born precursors. *RA* controls gene expression in an autocrine fashion in Sertoli cells but also affects the transcriptome of germ cells and as shown induces commitment to differentiate, for instance. Paracrine and juxtacrine factors produced by Sertoli cells bind to their receptors expressed by different subpopulations of germ cells. Sertoli cell-derived molecules are essential for SSPC self-renewal ( $A_{stem}$ ) and differentiation ( $A_{progenitor}$ ). *SCF*–*KIT* signaling is needed for survival and proliferation of  $A_{differentiating}$  spermatogonia. Peritubular myoid cells (*PTM*) and Leydig cells (*LC*) are also a vital part of the testis paracrine signaling network, and control SSPC maintenance via secretion of *CSF1*, for instance. See text for details. Inhibin from Sertoli cells and testosterone produced by Leydig cells need to be taken to the hypothalamus and pituitary by circulation in order for hypothalamus–pituitary–gonadal axis to work. The presented data is based mainly on rodent research. For the sake of clarity, meiotic and postmeiotic cells have been omitted from the figure and only a selection of molecular interactions and signaling pathways have been included. For abbreviations see *Abbreviations*

postnatal relocation of gonocytes to the basal lamina of the seminiferous tubule (McCoshen and McCallion 1975; Orth et al. 1997). The significance of *SCF*/*KIT* signaling during spermatogenesis is emphasized by sterility if either of the genes is not functional (Besmer et al. 1993). *SCF* is yet another gene whose expression is

strongly regulated in Sertoli cells by FSH in a stage-dependent manner (Hakovirta et al. 1999; Rossi et al. 1993; Yan et al. 1999). The highest steady state levels of *SCF* mRNA are recorded at stages II–VI during rat spermatogenesis (Hakovirta et al. 1999). FSH readily stimulates *SCF* expression at these stages but also in other stages (Makela et al. 2011; Yan et al. 1999). SCF is either secreted or bound to the cell membrane (Huang et al. 1992). SSPCs do not express KIT but it is strongly induced in differentiating spermatogonia alongside with DNMT3A, DNMT3B, CCND1 (cyclin D1), and SOHLH1 (Costoya et al. 2004; Barrios et al. 2012; Shirakawa et al. 2013). Expression of KIT is therefore considered a hallmark of differentiation commitment.

SCF/KIT signaling has a profound effect on differentiating spermatogonia and it promotes their survival, stimulates their proliferation, and thus keeps the differentiation process going (Feng et al. 2000; Yan et al. 2000a, b; Dolci et al. 2001). KIT is also present on cell surface of primary spermatocytes, and in a truncated form, tr-KIT, in postmeiotic germ cells (Albanesi et al. 1996; Manova et al. 1990). Besides germ cells, KIT is also expressed in Leydig cells, and SCF/KIT signaling is considered to play a paracrine regulatory role in Leydig cell proliferation and steroidogenesis (Manova et al. 1990; Yan et al. 2000c; Rothschild et al. 2003). A similar expression pattern for KIT has been observed in human testis, as well (Sandlow et al. 1996). Human spermatogonia at stages I–VI express higher level of KIT than stage VII–XII spermatogonia (Unni et al. 2009). Altered SCF/KIT signaling in human has been associated with fertility problems in a number of studies (Figueira et al. 2014).

## Retinoic Acid (RA)

The significance of retinoic acid for murine spermatogenesis is demonstrated by progressive degeneration of the seminiferous epithelium observed in RAR $\alpha$  and RAR $\gamma$  (retinoic acid receptor alpha and gamma) mice (Lohnes et al. 1993; Lufkin et al. 1993). RA is synthesized and secreted by Sertoli cells during spermatogenesis and it has a multifaceted role in the regulation of germ cell differentiation. First of all, RA promotes SSPC exit from self-renewal ability-retaining state and it can therefore be seen as a GDNF antagonistic. An illustrative example of this is the regulation of miR-221 and miR222, which target *KIT* mRNA. GDNF stimulates the expression of these miRNAs, whereas RA has the opposite effect (Yang et al. 2013b). RA is a key regulator of spermatogenic entry as deficiency of vitamin A (a dietary precursor of RA) or inhibition of RA signaling leads to complete or partial failure of sperm production due to inability of SSPCs to differentiate (Sugimoto et al. 2012). RA works in many different ways to support and ensure differentiation of spermatogonia: by stimulating expression of RA-responsive genes in Sertoli cells and germ cells, by upregulating *SCF* and downregulating *GDNF* expression in Sertoli cells, and by downregulating *PLZF* expression in SSPCs (Pellegrini et al. 2008; Dann et al. 2008). RA also induces expression of *SOHLH1* and *SOHLH2* (spermatogenesis and oogenesis specific basic

helix-loop-helix 1/2), both of which are required for spermatogonial differentiation (Barrios et al. 2012; Suzuki et al. 2012). SOHLH1 then induces *KIT* expression. *KIT* expression is also stimulated by BMP4, a RA target gene in Sertoli cells (Barrios et al. 2012; Carlomagno et al. 2010). Propensity to differentiate within the SSPC population is associated with RAR $\gamma$  expression, and those cells that express higher levels of RAR $\gamma$  also show high NGN3, SOX3, and low GFRA1 expression (Ikami et al. 2015; Raverot et al. 2005). Ability to respond to RA stimulus enabled by RAR $\gamma$  expression thus functionally divides the SSPC pool into (1) differentiation-primed RA sensitive and (2) self-renewing RA insensitive subpopulations.

Besides differentiation commitment of SSPCs, RA is also instrumental for initiation of meiosis. Expression of RA-stimulated gene *STRA8* is needed for meiotic entry of preleptotene spermatocytes (Anderson et al. 2008). In the prepubertal testis RA is actively degraded by Sertoli cells to prevent premature entry of germ cells into meiosis (Svingen and Koopman 2013). Most premeiotic germ cells are responsive to RA and therefore a similar process has to take place in the adult, and RA levels need to be kept low at all other stages except for VII–VIII when A1 spermatogonia and preleptotene spermatocytes are formed in an RA-dependent manner (Endo et al. 2015). Direct and indirect data show, however, that RA levels remain high until stage XII/I in the mouse and low levels of RA are typical of stages II–VI (Endo et al. 2015). RA is also needed by postmeiotic cells and lack of RXR $\beta$  (retinoid X receptor beta) perturbs spermiogenesis and spermiation (Kastner et al. 1996). These data show that RA is alongside with testosterone and FSH one of the key regulators of spermatogenesis. The significance of RA for human spermatogenesis is a relatively unexplored field of science. Given its crucial role in rodents, it is likely that RA is also needed for human germ cell differentiation.

## Desert Hedgehog (DHH)

Sertoli cell-derived DHH is the testis-specific member of the mammalian Hedgehog protein family. *DHH* is one of the first genes to be expressed in the testis primordium during embryonic development, but it is also expressed in the adult (Bitgood et al. 1996). DHH deficient mice are azoospermic and have obvious defects in testis histology, whereas DHH mutations in human are associated with partial or complete testicular dysgenesis syndrome (Bitgood et al. 1996; Umehara et al. 2000; Canto et al. 2004, 2005; Das et al. 2011; Castro et al. 2013; Werner et al. 2015). Maternal smoking impinges on DHH expression in utero (Fowler et al. 2008). From animal studies we know that DHH is needed for fetal Leydig cell lineage specification, fetal Hedgehog signaling and androgen production are interregulatory, Hedgehog signaling promotes germ cell survival probably via regulating SCF/*KIT* signaling, and *DHH* expression is regulated by FSH (Makela et al. 2011; Brokken et al. 2009; Szczepny et al. 2009; Li et al. 2016). FSH suppresses *DHH* expression in vitro in a latent fashion suggesting that the effect might be indirect (Makela et al. 2011).

## Activin, Inhibin, and Follistatin

Activin, inhibin, and follistatin are structurally related glycoproteins and important for testicular function. Activin and inhibin have antagonistic activating and inhibiting effects, respectively, on pituitary FSH production and release. Follistatin is an inhibin agonist in terms of its endocrine function. One or more subunits of dimeric activins and inhibins are expressed by most different cell types in the testis, which makes understanding of the paracrine function of these proteins quite challenging. Some conclusions can be drawn, however. Apart from its role in regulation of FSH production, *in vitro* and *in vivo* data suggest that activins, and especially Activin A, and follistatins (activin antagonists) play a role in testis development, SSC maintenance, spermatogonial proliferation, meiotic progress, and preservation of fertility (O'Shaughnessy 2014).

## Estrogen

As counterintuitive as it may sound, human testis synthesizes estradiol under LH control and estrogens are needed for normal testis development and spermatogenesis (Carreau et al. 2012). Inability to produce estrogens due to lack of aromatase, which converts testosterone to estradiol, results in spermiogenic arrest, immotile sperm, and male infertility (Rochira et al. 2005). Interestingly enough, long, low dose estrogen treatment regime will restore qualitatively normal spermatogenesis in hypogonadal mice (Ebling et al. 2006). Much of the effect might be explained by FSH secretion that the exogenous estrogen induces, though. This is probably the explanation for the significance of estrogen for testicular function in most cases: the effects of estrogens are indirect and therefore difficult to study, understand, and manipulate. In the human testis, aromatase and both estrogen receptors (ERA/b) are expressed by differentiating germ cells, spermatozoa, and Leydig cells (Carreau et al. 2012). Male mice lacking any of these proteins are infertile, but it is not completely clear in all cases whether it is caused by spermatogenic defects or postspemiation events, *i.e.*, epididymal sperm maturation, or by an estrogen-independent mechanism. It is known, however, that ligand-independent ERA signaling controls fluid reabsorption in the epididymis and contributes to concentration of sperm (Sinkevicius et al. 2009). Much like testosterone, estrogens seem to have a role mainly in postmeiotic phase of spermatogenesis, and it has been suggested that acrosome biogenesis is an estrogen dependent event (Cacciola et al. 2013).

---

## References

- Ahmed EA, Barten-van Rijbroek AD, Kal HB, et al. Proliferative activity *in vitro* and DNA repair indicate that adult mouse and human Sertoli cells are not terminally differentiated, quiescent cells. *Biol Reprod.* 2009;80(6):1084–91.
- Airaksinen MS, Saarma M. The GDNF family: signalling, biological functions and therapeutic value. *Nat Rev Neurosci.* 2002;3(5):383–94.

- Albanesi C, Geremia R, Giorgio M, Dolci S, Sette C, Rossi P. A cell- and developmental stage-specific promoter drives the expression of a truncated c-kit protein during mouse spermatid elongation. *Development*. 1996;122(4):1291–302.
- Allan DJ, Harmon BV, Roberts SA. Spermatogonial apoptosis has three morphologically recognizable phases and shows no circadian rhythm during normal spermatogenesis in the rat. *Cell Prolif*. 1992;25(3):241–50.
- Amann RP. The cycle of the seminiferous epithelium in humans: a need to revisit? *J Androl*. 2008;29(5):469–87.
- Anderson EL, Baltus AE, Roepers-Gajadien HL, et al. Stra8 and its inducer, retinoic acid, regulate meiotic initiation in both spermatogenesis and oogenesis in mice. *Proc Natl Acad Sci U S A*. 2008;105(39):14976–80.
- Ayhan O, Balkan M, Guven A, et al. Truncating mutations in TAF4B and ZMYND15 causing recessive azoospermia. *J Med Genet*. 2014;51(4):239–44.
- Barrios F, Filippini D, Campolo F, et al. SOHLH1 and SOHLH2 control kit expression during postnatal male germ cell development. *J Cell Sci*. 2012;125(Pt 6):1455–64.
- Benda C. Neue mittheilungen über die entwicklung der genitadrüsen und über die metamorphose der samenzellen (histogenese der spermatozoen). *Arch Anat Physiol Physiol Abt*. 1891;549–52.
- Besmer P, Manova K, Duttlinger R, et al. The kit-ligand (steel factor) and its receptor c-kit/W: pleiotropic roles in gametogenesis and melanogenesis. *Dev Suppl*. 1993;125–37.
- Bitgood MJ, Shen L, McMahon AP. Sertoli cell signaling by desert hedgehog regulates the male germline. *Curr Biol*. 1996;6(3):298–304.
- Blok LJ, Mackenbach P, Trapman J, Themmen AP, Brinkmann AO, Grootegoed JA. Follicle-stimulating hormone regulates androgen receptor mRNA in Sertoli cells. *Mol Cell Endocrinol*. 1989;63(1–2):267–71.
- Bortolussi M, Zanchetta R, Belvedere P, Colombo L. Sertoli and Leydig cell numbers and gonadotropin receptors in rat testis from birth to puberty. *Cell Tissue Res*. 1990;260(1):185–91.
- Bremner WJ, Matsumoto AM, Sussman AM, Paulsen CA. Follicle-stimulating hormone and human spermatogenesis. *J Clin Invest*. 1981;68(4):1044–52.
- Brennan J, Capel B. One tissue, two fates: molecular genetic events that underlie testis versus ovary development. *Nat Rev Genet*. 2004;5(7):509–21.
- Brokken LJ, Adamsson A, Paranko J, Toppari J. Antiandrogen exposure in utero disrupts expression of desert hedgehog and insulin-like factor 3 in the developing fetal rat testis. *Endocrinology*. 2009;150(1):445–51.
- Buaa F, Kirsh A, Sharma M, et al. Plzf is required in adult male germ cells for stem cell self-renewal. *Nat Genet*. 2004;36(6):647–52.
- Cacciola G, Chioccarelli T, Fasano S, Pierantoni R, Cobellis G. Estrogens and spermiogenesis: new insights from type 1 cannabinoid receptor knockout mice. *Int J Endocrinol*. 2013;2013:501350.
- Canto P, Soderlund D, Reyes E, Mendez JP. Mutations in the desert hedgehog (DHH) gene in patients with 46,XY complete pure gonadal dysgenesis. *J Clin Endocrinol Metab*. 2004;89(9):4480–3.
- Canto P, Vilchis F, Soderlund D, Reyes E, Mendez JP. A heterozygous mutation in the desert hedgehog gene in patients with mixed gonadal dysgenesis. *Mol Hum Reprod*. 2005;11(11):833–6.
- Carlomagno G, van Bragt MP, Korver CM, Repping S, de Rooij DG, van Pelt AM. BMP4-induced differentiation of a rat spermatogonial stem cell line causes changes in its cell adhesion properties. *Biol Reprod*. 2010;83(5):742–9.
- Carreau S, Bouraima-Lelong H, Delalande C. Estrogen, a female hormone involved in spermatogenesis. *Adv Med Sci*. 2012;57(1):31–6.
- Castro JJ, Mendez JP, Coral-Vazquez RM, et al. In vitro and molecular modeling analysis of two mutant desert hedgehog proteins associated with 46,XY gonadal dysgenesis. *DNA Cell Biol*. 2013;32(9):524–30.
- Chang C, Chen YT, Yeh SD, et al. Infertility with defective spermatogenesis and hypotestosteronemia in male mice lacking the androgen receptor in Sertoli cells. *Proc Natl Acad Sci U S A*. 2004;101(18):6876–81.

- Chemes HE, Rey RA, Nistal M, et al. Physiological androgen insensitivity of the fetal, neonatal, and early infantile testis is explained by the ontogeny of the androgen receptor expression in Sertoli cells. *J Clin Endocrinol Metab.* 2008;93(11):4408–12.
- Chen C, Ouyang W, Grigura V, et al. ERM is required for transcriptional control of the spermatogonial stem cell niche. *Nature.* 2005;436(7053):1030–4.
- Chiarini-Garcia H, Hornick JR, Griswold MD, Russell LD. Distribution of type A spermatogonia in the mouse is not random. *Biol Reprod.* 2001;65(4):1179–85.
- Chiarini-Garcia H, Raymer AM, Russell LD. Non-random distribution of spermatogonia in rats: evidence of niches in the seminiferous tubules. *Reproduction.* 2003;126(5):669–80.
- Clermont Y. Quantitative analysis of spermatogenesis of the rat: a revised model for the renewal of spermatogonia. *Am J Anat.* 1962;111:111–29.
- Clermont Y. The cycle of the seminiferous epithelium in man. *Am J Anat.* 1963;112:35–51.
- Clermont Y. Kinetics of spermatogenesis in mammals: seminiferous epithelium cycle and spermatogonial renewal. *Physiol Rev.* 1972;52(1):198–236.
- Clermont Y, Leblond CP. Differentiation and renewal of spermatogonia in the monkey, *Macacus rhesus*. *Am J Anat.* 1959;104:237–73.
- Clermont Y, Perey B. Quantitative study of the cell population of the seminiferous tubules in immature rats. *Am J Anat.* 1957;100(2):241–67.
- Clermont Y, Oko R, Hermo L. Cell biology of mammalian spermiogenesis. In: Desjardins C, Ewing LL, editors. *Cell and molecular biology of the testis*, vol. 1. New York: Oxford University Press; 1993. p. 332–76.
- Corbinau S, Lassalle B, Givélet M, et al. Spermatogonial stem cells and progenitors are refractory to reprogramming to pluripotency by the transcription factors Oct3/4, c-myc, Sox2 and Klf4. *Oncotarget.* 2017;8(6):10050–63. doi:10.18632/oncotarget.14327.
- Costoya J, Hobbs R, Barna M, et al. Essential role of plzf in maintenance of spermatogonial stem cells RID B-2718-2009. *Nat Genet.* 2004;36(6):653–9.
- Creemers LB, Meng X, den Ouden K, et al. Transplantation of germ cells from glial cell line-derived neurotrophic factor-overexpressing mice to host testes depleted of endogenous spermatogenesis by fractionated irradiation. *Biol Reprod.* 2002;66(6):1579–84.
- Dann CT, Alvarado AL, Molyneux LA, Denard BS, Garbers DL, Porteus MH. Spermatogonial stem cell self-renewal requires OCT4, a factor downregulated during retinoic acid-induced differentiation. *Stem Cells.* 2008;26(11):2928–37.
- Das DK, Sanghavi D, Gawde H, Idicula-Thomas S, Vasudevan L. Novel homozygous mutations in desert hedgehog gene in patients with 46,XY complete gonadal dysgenesis and prediction of its structural and functional implications by computational methods. *Eur J Med Genet.* 2011;54(6):e529–34.
- De Gendt K, Swinnen JV, Saunders PT, et al. A Sertoli cell-selective knockout of the androgen receptor causes spermatogenic arrest in meiosis. *Proc Natl Acad Sci U S A.* 2004;101(5):1327–32.
- De Gendt K, Verhoeven G, Amieux PS, Wilkinson MF. Genome-wide identification of AR-regulated genes translated in Sertoli cells in vivo using the RiboTag approach. *Mol Endocrinol.* 2014;28(4):575–91.
- de Mateo S, Sassone-Corsi P. Regulation of spermatogenesis by small non-coding RNAs: role of the germ granule. *Semin Cell Dev Biol.* 2014;29:84–92.
- Dierich A, Sairam MR, Monaco L, et al. Impairing follicle-stimulating hormone (FSH) signaling in vivo: targeted disruption of the FSH receptor leads to aberrant gametogenesis and hormonal imbalance. *Proc Natl Acad Sci U S A.* 1998;95(23):13612–7.
- Dolci S, Pellegrini M, Di Agostino S, Geremia R, Rossi P. Signaling through extracellular signal-regulated kinase is required for spermatogonial proliferative response to stem cell factor. *J Biol Chem.* 2001;276(43):40225–33.
- Dovere L, Fera S, Grasso M, et al. The niche-derived glial cell line-derived neurotrophic factor (GDNF) induces migration of mouse spermatogonial stem/progenitor cells. *PLoS One.* 2013;8(4):e59431.

- Dym M, Fawcett DW. The blood-testis barrier in the rat and the physiological compartmentation of the seminiferous epithelium. *Biol Reprod.* 1970;3(3):308–26.
- Dym M, Jia MC, Dirami G, et al. Expression of c-kit receptor and its autophosphorylation in immature rat type A spermatogonia. *Biol Reprod.* 1995;52(1):8–19.
- Ebling FJ, Nwagwu MO, Baines H, Myers M, Kerr JB. The hypogonadal (hpg) mouse as a model to investigate the estrogenic regulation of spermatogenesis. *Hum Fertil (Camb).* 2006;9(3):127–35.
- Eddy E, Kahri A. Cell associations and surface features in cultures of juvenile rat seminiferous tubules. *Anat Rec.* 1976;185(3):333–58.
- Ehmcke J, Schlatt S. A revised model for spermatogonial expansion in man: lessons from non-human primates. *Reproduction.* 2006;132(5):673–80.
- Ehmcke J, Simorangkir DR, Schlatt S. Identification of the starting point for spermatogenesis and characterization of the testicular stem cell in adult male rhesus monkeys. *Hum Reprod.* 2005a;20(5):1185–93.
- Ehmcke J, Luetjens CM, Schlatt S. Clonal organization of proliferating spermatogonial stem cells in adult males of two species of non-human primates, *Macaca mulatta* and *Callithrix jacchus*. *Biol Reprod.* 2005b;72(2):293–300.
- Endo T, Romer KA, Anderson EL, Baltus AE, de Rooij DG, Page DC. Periodic retinoic acid-STR A8 signaling intersects with periodic germ-cell competencies to regulate spermatogenesis. *Proc Natl Acad Sci U S A.* 2015;112(18):E2347–56.
- Falender AE, Freiman RN, Geles KG, et al. Maintenance of spermatogenesis requires TAF4b, a gonad-specific subunit of TFIID. *Genes Dev.* 2005;19(7):794–803.
- Feng LX, Ravindranath N, Dym M. Stem cell factor/c-kit up-regulates cyclin D3 and promotes cell cycle progression via the phosphoinositide 3-kinase/p70 S6 kinase pathway in spermatogonia. *J Biol Chem.* 2000;275(33):25572–6.
- Figueira MI, Cardoso HJ, Correia S, Maia CJ, Socorro S. Hormonal regulation of c-KIT receptor and its ligand: implications for human infertility? *Prog Histochem Cytochem.* 2014;49(1–3):1–19.
- Filipponi D, Hobbs RM, Ottolenghi S, et al. Repression of kit expression by plzf in germ cells. *Mol Cell Biol.* 2007;27(19):6770–81.
- Fischer S, Kohlhasse J, Bohm D, et al. Biallelic loss of function of the promyelocytic leukaemia zinc finger (PLZF) gene causes severe skeletal defects and genital hypoplasia. *J Med Genet.* 2008;45(11):731–7.
- Fok KL, Chen H, Ruan YC, Chan HC. Novel regulators of spermatogenesis. *Semin Cell Dev Biol.* 2014;29:31–42.
- Fowler PA, Cassie S, Rhind SM, et al. Maternal smoking during pregnancy specifically reduces human fetal desert hedgehog gene expression during testis development. *J Clin Endocrinol Metab.* 2008;93(2):619–26.
- Franca LR, Ogawa T, Avarbock MR, Brinster RL, Russell LD. Germ cell genotype controls cell cycle during spermatogenesis in the rat. *Biol Reprod.* 1998;59(6):1371–7.
- Franca LR, Hess RA, Dufour JM, Hofmann MC, Griswold MD. The Sertoli cell: one hundred fifty years of beauty and plasticity. *Andrology.* 2016;4(2):189–212.
- Fu Z, Tindall DJ. FOXOs, cancer and regulation of apoptosis. *Oncogene.* 2008;27(16):2312–9.
- Galetzka D, Weis E, Tralau T, Seidmann L, Haaf T. Sex-specific windows for high mRNA expression of DNA methyltransferases 1 and 3A and methyl-CpG-binding domain proteins 2 and 4 in human fetal gonads. *Mol Reprod Dev.* 2007;74(2):233–41.
- Gaspar ML, Meo T, Bourgaire P, Guenet JL, Tosi M. A single base deletion in the tfm androgen receptor gene creates a short-lived messenger RNA that directs internal translation initiation. *Proc Natl Acad Sci U S A.* 1991;88(19):8606–10.
- Goertz MJ, Wu Z, Gallardo TD, Hamra FK, Castrillon DH. Foxo1 is required in mouse spermatogonial stem cells for their maintenance and the initiation of spermatogenesis. *J Clin Invest.* 2011;121(9):3456–66.
- Gottlieb B, Beitel LK, Nadarajah A, Paliouras M, Trifiro M. The androgen receptor gene mutations database: 2012 update. *Hum Mutat.* 2012;33(5):887–94.



- Guo Y, Hai Y, Gong Y, Li Z, He Z. Characterization, isolation, and culture of mouse and human spermatogonial stem cells. *J Cell Physiol.* 2014;229(4):407–13.
- Hai Y, Hou J, Liu Y, et al. The roles and regulation of Sertoli cells in fate determinations of spermatogonial stem cells and spermatogenesis. *Semin Cell Dev Biol.* 2014;29:66–75.
- Hakovirta H, Yan W, Kaleva M, et al. Function of stem cell factor as a survival factor of spermatogonia and localization of messenger ribonucleic acid in the rat seminiferous epithelium. *Endocrinology.* 1999;140(3):1492–8.
- Hammond GL, Ruokonen A, Kontturi M, Koskela E, Vihko R. The simultaneous radioimmunoassay of seven steroids in human spermatic and peripheral venous blood. *J Clin Endocrinol Metab.* 1977;45(1):16–24.
- Hara K, Nakagawa T, Enomoto H, et al. Mouse spermatogenic stem cells continually interconvert between equipotent singly isolated and syncytial states. *Cell Stem Cell.* 2014;14(5):658–72.
- He Z, Kokkinaki M, Dym M. Signaling molecules and pathways regulating the fate of spermatogonial stem cells. *Microsc Res Tech.* 2009;72(8):586–95.
- Heckert LL, Griswold MD. Expression of follicle-stimulating hormone receptor mRNA in rat testes and Sertoli cells. *Mol Endocrinol.* 1991;5(5):670–7.
- Heckert L, Griswold MD. Expression of the FSH receptor in the testis. *Recent Prog Horm Res.* 1993;48:61–77.
- Heller CG, Clermont Y. Spermatogenesis in man: an estimate of its duration. *Science.* 1963;140(3563):184–6.
- Heller CH, Clermont Y. Kinetics of the germinal epithelium in man. *Recent Prog Horm Res.* 1964;20:545–75.
- Hobbs RM, Seandel M, Falcatori I, Rafii S, Pandolfi PP. Plzf regulates germline progenitor self-renewal by opposing mTORC1. *Cell.* 2010;142(3):468–79.
- Hobbs RM, Fagoonee S, Papa A, et al. Functional antagonism between Sall4 and plzf defines germline progenitors. *Cell Stem Cell.* 2012;10(3):284–98.
- Hobbs RM, La HM, Makela JA, Kobayashi T, Noda T, Pandolfi PP. Distinct germline progenitor subsets defined through Tsc2-mTORC1 signaling. *EMBO Rep.* 2015;16(4):467–80.
- Huang HF, Marshall GR. Failure of spermatid release under various vitamin A states – an indication of delayed spermiation. *Biol Reprod.* 1983;28(5):1163–72.
- Huang EJ, Nocka KH, Buck J, Besmer P. Differential expression and processing of two cell associated forms of the kit-ligand: KL-1 and KL-2. *Mol Biol Cell.* 1992;3(3):349–62.
- Huckins C. The morphology and kinetics of spermatogonial degeneration in normal adult rats: an analysis using a simplified classification of the germinal epithelium. *Anat Rec.* 1978;190(4):905–26.
- Huhtaniemi I. A hormonal contraceptive for men: how close are we? *Prog Brain Res.* 2010;181:273–88.
- Huhtaniemi I. A short evolutionary history of FSH-stimulated spermatogenesis. *Hormones (Athens).* 2015;14(4):468–78.
- Huhtaniemi I, Nikula H, Rannikko S. Treatment of prostatic cancer with a gonadotropin-releasing hormone agonist analog: acute and long term effects on endocrine functions of testis tissue. *J Clin Endocrinol Metab.* 1985;61(4):698–704.
- Ikami K, Tokue M, Sugimoto R, et al. Hierarchical differentiation competence in response to retinoic acid ensures stem cell maintenance during mouse spermatogenesis. *Development.* 2015;142(9):1582–92.
- Irie N, Tang WW, Azim Surani M. Germ cell specification and pluripotency in mammals: a perspective from early embryogenesis. *Reprod Med Biol.* 2014;13(4):203–15.
- Ishii K, Kanatsu-Shinohara M, Toyokuni S, Shinohara T. FGF2 mediates mouse spermatogonial stem cell self-renewal via upregulation of Etv5 and Bcl6b through MAP2K1 activation. *Development.* 2012;139(10):1734–43.
- Izadyar F, Wong J, Maki C, et al. Identification and characterization of repopulating spermatogonial stem cells from the adult human testis. *Hum Reprod.* 2011;26(6):1296–306.

- Jahnukainen K, Chrysis D, Hou M, Parvinen M, Eksborg S, Soder O. Increased apoptosis occurring during the first wave of spermatogenesis is stage-specific and primarily affects midpachytene spermatocytes in the rat testis. *Biol Reprod.* 2004;70(2):290–6.
- Jing S, Wen D, Yu Y, et al. GDNF-induced activation of the ret protein tyrosine kinase is mediated by GDNFR-alpha, a novel receptor for GDNF. *Cell.* 1996;85(7):1113–24.
- Kaipia A, Parvinen M, Shimasaki S, Ling N, Toppari J. Stage-specific cellular regulation of inhibin alpha-subunit mRNA expression in the rat seminiferous epithelium. *Mol Cell Endocrinol.* 1991;82(2–3):165–73.
- Kanatsu-Shinohara M, Ogonuki N, Inoue K, et al. Long-term proliferation in culture and germline transmission of mouse male germline stem cells RID C-1358-2010. *Biol Reprod.* 2003;69(2):612–6.
- Kanatsu-Shinohara M, Inoue K, Ogonuki N, Morimoto H, Ogura A, Shinohara T. Serum- and feeder-free culture of mouse germline stem cells. *Biol Reprod.* 2011;84(1):97–105.
- Kangasniemi M, Kaipia A, Mali P, Toppari J, Huhtaniemi I, Parvinen M. Modulation of basal and FSH-dependent cyclic AMP production in rat seminiferous tubules staged by an improved transillumination technique. *Anat Rec.* 1990;227(1):62–76.
- Kastner P, Mark M, Leid M, et al. Abnormal spermatogenesis in RXR beta mutant mice. *Genes Dev.* 1996;10(1):80–92.
- Kluin PM, Kramer MF, de Rooij DG. Proliferation of spermatogonia and Sertoli cells in maturing mice. *Anat Embryol (Berl).* 1984;169(1):73–8.
- Korhonen HM, Meikar O, Yadav RP, et al. Dicer is required for haploid male germ cell differentiation in mice. *PLoS One.* 2011;6(9):e24821.
- Kormano M. An angiographic study of the testicular vasculature in the postnatal rat. *Z Anat Entwicklungsgesch.* 1967;126(2):138–53.
- Kossack N, Meneses J, Shefi S, et al. Isolation and characterization of pluripotent human spermatogonial stem cell-derived cells. *Stem Cells.* 2009;27(1):138–49.
- Kotaja N, Kimmins S, Brancorsini S, et al. Preparation, isolation and characterization of stage-specific spermatogenic cells for cellular and molecular analysis. *Nat Methods.* 2004;1(3):249–54.
- Kubota H, Avarbock MR, Brinster RL. Spermatogonial stem cells share some, but not all, phenotypic and functional characteristics with other stem cells. *Proc Natl Acad Sci U S A.* 2003;100(11):6487–92.
- Kubota H, Avarbock M, Brinster R. Growth factors essential for self-renewal and expansion of mouse spermatogonial stem cells. *Proc Natl Acad Sci U S A.* 2004;101(47):16489–94.
- Kumar TR, Wang Y, Lu N, Matzuk MM. Follicle stimulating hormone is required for ovarian follicle maturation but not male fertility. *Nat Genet.* 1997;15(2):201–4.
- Layman LC, Porto AL, Xie J, et al. FSH beta gene mutations in a female with partial breast development and a male sibling with normal puberty and azoospermia. *J Clin Endocrinol Metab.* 2002;87(8):3702–7.
- Leblond CP, Clermont Y. Definition of the stages of the cycle of the seminiferous epithelium in the rat. *Ann N Y Acad Sci.* 1952;55(4):548–73.
- Lee J, Kanatsu-Shinohara M, Inoue K, et al. Akt mediates self-renewal division of mouse spermatogonial stem cells. *Development.* 2007;134(10):1853–9.
- Lee J, Kanatsu-Shinohara M, Morimoto H, et al. Genetic reconstruction of mouse spermatogonial stem cell self-renewal in vitro by Ras-cyclin D2 activation. *Cell Stem Cell.* 2009;5(1):76–86.
- Li X, Wang Z, Jiang Z, et al. Regulation of seminiferous tubule-associated stem Leydig cells in adult rat testes. *Proc Natl Acad Sci U S A.* 2016;113(10):2666–71.
- Lindstedt G, Nystrom E, Matthews C, Ernest I, Janson PO, Chatterjee K. Follitropin (FSH) deficiency in an infertile male due to FSHbeta gene mutation. A syndrome of normal puberty and virilization but underdeveloped testicles with azoospermia, low FSH but high lutropin and normal serum testosterone concentrations. *Clin Chem Lab Med.* 1998;36(8):663–5.
- Lohnes D, Kastner P, Dierich A, Mark M, LeMeur M, Chambon P. Function of retinoic acid receptor gamma in the mouse. *Cell.* 1993;73(4):643–58.

- Lufkin T, Lohnes D, Mark M, et al. High postnatal lethality and testis degeneration in retinoic acid receptor alpha mutant mice. *Proc Natl Acad Sci U S A*. 1993;90(15):7225–9.
- Ma X, Dong Y, Matzuk MM, Kumar TR. Targeted disruption of luteinizing hormone beta-subunit leads to hypogonadism, defects in gonadal steroidogenesis, and infertility. *Proc Natl Acad Sci U S A*. 2004;101(49):17294–9.
- Maguire SM, Tribble WA, Griswold MD. Follicle-stimulating hormone (FSH) regulates the expression of FSH receptor messenger ribonucleic acid in cultured Sertoli cells and in hypophysectomized rat testis. *Biol Reprod*. 1997;56(5):1106–11.
- Makela JA, Saario V, Bourguiba-Hachemi S, et al. Hedgehog signalling promotes germ cell survival in the rat testis. *Reproduction*. 2011;142(5):711–21.
- Makela JA, Toppari J, Rivero-Muller A, Ventela S. Reconstruction of mouse testicular cellular microenvironments in long-term seminiferous tubule culture. *PLoS One*. 2014;9(3):e90088.
- Manku G, Culty M. Mammalian gonocyte and spermatogonia differentiation: recent advances and remaining challenges. *Reproduction*. 2015;149(3):R139–57.
- Manova K, Nocka K, Besmer P, Bachvarova RF. Gonadal expression of c-kit encoded at the W locus of the mouse. *Development*. 1990;110(4):1057–69.
- Matson CK, Murphy MW, Sarver AL, Griswold MD, Bardwell VJ, Zarkower D. DMRT1 prevents female reprogramming in the postnatal mammalian testis. *Nature*. 2011;476(7358):101–4.
- Matsumoto AM, Paulsen CA, Bremner WJ. Stimulation of sperm production by human luteinizing hormone in gonadotropin-suppressed normal men. *J Clin Endocrinol Metab*. 1984;59(5):882–7.
- McCoshen JA, McCallion DJ. A study of the primordial germ cells during their migratory phase in steel mutant mice. *Experientia*. 1975;31(5):589–90.
- McKinnell C, Mitchell RT, Morris K, et al. Perinatal germ cell development and differentiation in the male marmoset (*Callithrix jacchus*): similarities with the human and differences from the rat. *Hum Reprod*. 2013;28(4):886–96.
- McLean DJ, Friel PJ, Pouchnik D, Griswold MD. Oligonucleotide microarray analysis of gene expression in follicle-stimulating hormone-treated rat Sertoli cells. *Mol Endocrinol*. 2002;16(12):2780–92.
- Meehan T, Schlatt S, O'Bryan MK, de Kretser DM, Loveland KL. Regulation of germ cell and Sertoli cell development by activin, follistatin, and FSH. *Dev Biol*. 2000;220(2):225–37.
- Meikar O, Kotaja N. Isolation of chromatoid bodies from mouse testis as a rich source of short RNAs. *Methods Mol Biol*. 2014;1173:11–25.
- Meikar O, Da Ros M, Liljenback H, Toppari J, Kotaja N. Accumulation of piRNAs in the chromatoid bodies purified by a novel isolation protocol. *Exp Cell Res*. 2010;316(9):1567–75.
- Meikar O, Vagin VV, Chalmel F, et al. An atlas of chromatoid body components. *RNA*. 2014;20(4):483–95.
- Meng X, Lindahl M, Hyvonen M, et al. Regulation of cell fate decision of undifferentiated spermatogonia by GDNF. *Science*. 2000;287(5457):1489–93.
- Mongan NP, Tadokoro-Cuccaro R, Bunch T, Hughes IA. Androgen insensitivity syndrome. *Best Pract Res Clin Endocrinol Metab*. 2015;29(4):569–80.
- Moyle WR, Armstrong DT. Stimulation of testosterone biosynthesis by luteinizing hormone in transplantable mouse Leydig cell tumors. *Steroids*. 1970;15(5):681–93.
- Muciaccia B, Boitani C, Berloco BP, et al. Novel stage classification of human spermatogenesis based on acrosome development. *Biol Reprod*. 2013;89(3):60.
- Mullaney BP, Skinner MK. Basic fibroblast growth factor (bFGF) gene expression and protein production during pubertal development of the seminiferous tubule: follicle-stimulating hormone-induced Sertoli cell bFGF expression. *Endocrinology*. 1992;131(6):2928–34.
- Nagano M, Avarbock MR, Leonida EB, Brinster CJ, Brinster RL. Culture of mouse spermatogonial stem cells. *Tissue Cell*. 1998;30(4):389–97.
- Nagano M, Patrizio P, Brinster RL. Long-term survival of human spermatogonial stem cells in mouse testes. *Fertil Steril*. 2002;78(6):1225–33.

- O'Donnell L, McLachlan RI, Wreford NG, de Kretser DM, Robertson DM. Testosterone withdrawal promotes stage-specific detachment of round spermatids from the rat seminiferous epithelium. *Biol Reprod.* 1996;55(4):895–901.
- O'Hara L, Smith LB. Androgen receptor roles in spermatogenesis and infertility. *Best Pract Res Clin Endocrinol Metab.* 2015;29(4):595–605.
- O'Shaughnessy PJ. Hormonal control of germ cell development and spermatogenesis. *Semin Cell Dev Biol.* 2014;29:55–65.
- O'Shaughnessy PJ, Monteiro A, Abel M. Testicular development in mice lacking receptors for follicle stimulating hormone and androgen. *PLoS One.* 2012;7(4):e35136.
- Oakberg EF. Duration of spermatogenesis in the mouse and timing of stages of the cycle of the seminiferous epithelium. *Am J Anat.* 1956;99(3):507–16.
- Oatley JM, Avarbock MR, Telaranta AI, Fearon DT, Brinster RL. Identifying genes important for spermatogonial stem cell self-renewal and survival. *Proc Natl Acad Sci U S A.* 2006;103(25):9524–9.
- Oatley JM, Avarbock MR, Brinster RL. Glial cell line-derived neurotrophic factor regulation of genes essential for self-renewal of mouse spermatogonial stem cells is dependent on src family kinase signaling. *J Biol Chem.* 2007;282(35):25842–51.
- Oatley JM, Oatley MJ, Avarbock MR, Tobias JW, Brinster RL. Colony stimulating factor 1 is an extrinsic stimulator of mouse spermatogonial stem cell self-renewal. *Development.* 2009;136(7):1191–9.
- Oatley MJ, Kaucher AV, Racicot KE, Oatley JM. Inhibitor of DNA binding 4 is expressed selectively by single spermatogonia in the male germline and regulates the self-renewal of spermatogonial stem cells in mice. *Biol Reprod.* 2011;85(2):347–56.
- Oduwole OO, Vydra N, Wood NE, et al. Overlapping dose responses of spermatogenic and extragonadal testosterone actions jeopardize the principle of hormonal male contraception. *FASEB J.* 2014;28(6):2566–76.
- Ohta H, Yomogida K, Dohmae K, Nishimune Y. Regulation of proliferation and differentiation in spermatogonial stem cells: the role of c-kit and its ligand SCF. *Development.* 2000;127(10):2125–31.
- Orth JM. The role of follicle-stimulating hormone in controlling Sertoli cell proliferation in testes of fetal rats. *Endocrinology.* 1984;115(4):1248–55.
- Orth JM, Gunsalus GL, Lamperti AA. Evidence from Sertoli cell-depleted rats indicates that spermatid number in adults depends on numbers of Sertoli cells produced during perinatal development. *Endocrinology.* 1988;122(3):787–94.
- Orth JM, Jester Jr WF, Qiu J. Gonocytes in testes of neonatal rats express the c-kit gene. *Mol Reprod Dev.* 1996;45(2):123–31.
- Orth JM, Qiu J, Jester Jr WF, Pilder S. Expression of the c-kit gene is critical for migration of neonatal rat gonocytes in vitro. *Biol Reprod.* 1997;57(3):676–83.
- Paronetto MP, Sette C. Role of RNA-binding proteins in mammalian spermatogenesis. *Int J Androl.* 2010;33(1):2–12.
- Parvinen M. Regulation of the seminiferous epithelium. *Endocr Rev.* 1982;3(4):404–17.
- Pellegrini M, Filippini D, Gori M, et al. ATRA and KL promote differentiation toward the meiotic program of male germ cells. *Cell Cycle.* 2008;7(24):3878–88.
- Phillip M, Arbelle JE, Segev Y, Parvari R. Male hypogonadism due to a mutation in the gene for the beta-subunit of follicle-stimulating hormone. *N Engl J Med.* 1998;338(24):1729–32.
- Phillips BT, Gassei K, Orwig KE. Spermatogonial stem cell regulation and spermatogenesis. *Philos Trans R Soc Lond Ser B Biol Sci.* 2010;365(1546):1663–78.
- Pitetti JL, Calvel P, Zimmermann C, et al. An essential role for insulin and IGF1 receptors in regulating Sertoli cell proliferation, testis size, and FSH action in mice. *Mol Endocrinol.* 2013;27(5):814–27.
- Raverot G, Weiss J, Park SY, Hurley L, Jameson JL. Sox3 expression in undifferentiated spermatogonia is required for the progression of spermatogenesis. *Dev Biol.* 2005;283(1):215–25.

- Rochira V, Granata AR, Madeo B, Zirilli L, Rossi G, Carani C. Estrogens in males: what have we learned in the last 10 years? *Asian J Androl.* 2005;7(1):3–20.
- Romero Y, Meikar O, Papaioannou MD, et al. Dicer1 depletion in male germ cells leads to infertility due to cumulative meiotic and spermiogenic defects. *PLoS One.* 2011;6(10):e25241.
- Roosen-Runge EC, Leik J. Gonocyte degeneration in the postnatal male rat. *Am J Anat.* 1968; 122(2):275–99.
- Rossi P, Dolci S, Albanesi C, Grimaldi P, Ricca R, Geremia R. Follicle-stimulating hormone induction of steel factor (SLF) mRNA in mouse Sertoli cells and stimulation of DNA synthesis in spermatogonia by soluble SLF. *Dev Biol.* 1993;155(1):68–74.
- Rotgers E, Rivero-Muller A, Nurmio M, et al. Retinoblastoma protein (RB) interacts with E2F3 to control terminal differentiation of Sertoli cells. *Cell Death Dis.* 2014;5:e1274.
- Rothschild G, Sottas CM, Kissel H, et al. A role for kit receptor signaling in Leydig cell steroidogenesis. *Biol Reprod.* 2003;69(3):925–32.
- Russell LD, Ettl RA, SinhaHikim AP, Clegg ED. Histological and histopathological evaluation of the testis. Clearwater: Cache River Press; 1990.
- Sada A, Hasegawa K, Pin PH, Saga Y. NANOS2 acts downstream of glial cell line-derived neurotrophic factor signaling to suppress differentiation of spermatogonial stem cells. *Stem Cells.* 2012;30(2):280–91.
- Saito K, O'Donnell L, McLachlan RI, Robertson DM. Spermiation failure is a major contributor to early spermatogenic suppression caused by hormone withdrawal in adult rats. *Endocrinology.* 2000;141(8):2779–85.
- Sandlow JI, Feng HL, Cohen MB, Sandra A. Expression of c-KIT and its ligand, stem cell factor, in normal and subfertile human testicular tissue. *J Androl.* 1996;17(4):403–8.
- Sasaki H, Matsui Y. Epigenetic events in mammalian germ-cell development: reprogramming and beyond. *Nat Rev Genet.* 2008;9(2):129–40.
- Schrans-Stassen BH, van de Kant HJ, de Rooij DG, van Pelt AM. Differential expression of c-kit in mouse undifferentiated and differentiating type A spermatogonia. *Endocrinology.* 1999; 140(12):5894–900.
- Sharpe RM. Regulation of spermatogenesis. In: Knobil E, Neill JD, editors. *The physiology of reproduction.* 2nd ed. New York: Raven Press; 1994. p. 1363–434.
- Sharpe RM, McKinnell C, Kivlin C, Fisher JS. Proliferation and functional maturation of Sertoli cells, and their relevance to disorders of testis function in adulthood. *Reproduction.* 2003; 125(6):769–84.
- Shinohara T, Avarbock MR, Brinster RL. Beta1- and Alpha6-integrin are surface markers on mouse spermatogonial stem cells. *Proc Natl Acad Sci U S A.* 1999;96(10):5504–9.
- Shirakawa T, Yaman-Deveci R, Tomizawa S, et al. An epigenetic switch is crucial for spermatogonia to exit the undifferentiated state toward a kit-positive identity. *Development.* 2013; 140(17):3565–76.
- Simon L, Ekman GC, Tyagi G, Hess RA, Murphy KM, Cooke PS. Common and distinct factors regulate expression of mRNA for ETV5 and GDNF, Sertoli cell proteins essential for spermatogonial stem cell maintenance. *Exp Cell Res.* 2007;313(14):3090–9.
- Simorangkir DR, Marshall GR, Ehmcke J, Schlatt S, Plant TM. Prepubertal expansion of dark and pale type A spermatogonia in the rhesus monkey (*Macaca mulatta*) results from proliferation during infantile and juvenile development in a relatively gonadotropin independent manner. *Biol Reprod.* 2005;73(6):1109–15.
- Sinkevicius KW, Laine M, Lotan TL, Woloszyn K, Richburg JH, Greene GL. Estrogen-dependent and -independent estrogen receptor-alpha signaling separately regulate male fertility. *Endocrinology.* 2009;150(6):2898–905.
- Skinner MK, Schlitz SM, Anthony CT. Regulation of Sertoli cell differentiated function: testicular transferrin and androgen-binding protein expression. *Endocrinology.* 1989;124(6):3015–24.
- Smith BE, Braun RE. Germ cell migration across Sertoli cell tight junctions. *Science.* 2012; 338(6108):798–802.

- Snyder EM, Small C, Griswold MD. Retinoic acid availability drives the asynchronous initiation of spermatogonial differentiation in the mouse. *Biol Reprod.* 2010;83(5):783–90.
- Stern H. The process of meiosis. In: Desjardins C, Ewing LL, editors. *Cell and molecular biology of the testis*, vol. 1. New York: Oxford University Press; 1993. p. 296–331.
- Suarez-Quian CA, Martinez-Garcia F, Nistal M, Regadera J. Androgen receptor distribution in adult human testis. *J Clin Endocrinol Metab.* 1999;84(1):350–8.
- Sugimoto R, Nabeshima Y, Yoshida S. Retinoic acid metabolism links the periodical differentiation of germ cells with the cycle of Sertoli cells in mouse seminiferous epithelium. *Mech Dev.* 2012;128(11–12):610–24.
- Sulliman BA, Xu D, Williams BR. The promyelocytic leukemia zinc finger protein: two decades of molecular oncology. *Front Oncol.* 2012;2:74.
- Suzuki H, Ahn HW, Chu T, et al. SOHLH1 and SOHLH2 coordinate spermatogonial differentiation. *Dev Biol.* 2012;361(2):301–12.
- Svingen T, Koopman P. Building the mammalian testis: origins, differentiation, and assembly of the component cell populations. *Genes Dev.* 2013;27(22):2409–26.
- Sylvester SR, Griswold MD. Localization of transferrin and transferrin receptors in rat testes. *Biol Reprod.* 1984;31(1):195–203.
- Szczepny A, Hogarth CA, Young J, Loveland KL. Identification of hedgehog signaling outcomes in mouse testis development using a hanging drop-culture system. *Biol Reprod.* 2009;80(2):258–63.
- Tadokoro Y, Yomogida K, Ohta H, Tohda A, Nishimune Y. Homeostatic regulation of germinal stem cell proliferation by the GDNF/FSH pathway RID C-3375-2009. *Mech Dev.* 2002;113(1):29–39.
- Takashima S, Kanatsu-Shinohara M, Tanaka T, et al. Functional differences between GDNF-dependent and FGF2-dependent mouse spermatogonial stem cell self-renewal. *Stem Cell Rep.* 2015;4(3):489–502.
- Tan KA, De Gendt K, Atanassova N, et al. The role of androgens in Sertoli cell proliferation and functional maturation: studies in mice with total or Sertoli cell-selective ablation of the androgen receptor. *Endocrinology.* 2005;146(6):2674–83.
- Tapanainen JS, Aittomaki K, Min J, Vaskivuo T, Huhtaniemi IT. Men homozygous for an inactivating mutation of the follicle-stimulating hormone (FSH) receptor gene present variable suppression of spermatogenesis and fertility. *Nat Genet.* 1997;15(2):205–6.
- Tarulli GA, Stanton PG, Lerchl A, Meachem SJ. Adult Sertoli cells are not terminally differentiated in the Djungarian hamster: effect of FSH on proliferation and junction protein organization. *Biol Reprod.* 2006;74(5):798–806.
- Tegelenbosch RA, de Rooij DG. A quantitative study of spermatogonial multiplication and stem cell renewal in the C3H/101 F1 hybrid mouse. *Mutat Res.* 1993;290(2):193–200.
- Timmons PM, Rigby PW, Poirier F. The murine seminiferous epithelial cycle is pre-figured in the Sertoli cells of the embryonic testis. *Development.* 2002;129(3):635–47.
- Toocheck C, Clister T, Shupe J, et al. Mouse spermatogenesis requires classical and nonclassical testosterone signaling. *Biol Reprod.* 2016;94(1):11.
- Toppari J, Kaleva M. Maldescendus testis. *Horm Res.* 1999;51(6):261–9.
- Toppari J, Parvinen M. In vitro differentiation of rat seminiferous tubular segments from defined stages of the epithelial cycle morphologic and immunolocalization analysis. *J Androl.* 1985;6(6):334–43.
- Toppari J, Kaleva M, Virtanen HE. Trends in the incidence of cryptorchidism and hypospadias, and methodological limitations of registry-based data. *Hum Reprod Update.* 2001;7(3):282–6.
- Treanor JJ, Goodman L, de Sauvage F, et al. Characterization of a multicomponent receptor for GDNF. *Nature.* 1996;382(6586):80–3.
- Uhlenhaut NH, Jakob S, Anlag K, et al. Somatic sex reprogramming of adult ovaries to testes by FOXL2 ablation. *Cell.* 2009;139(6):1130–42.

- Umehara F, Tate G, Itoh K, et al. A novel mutation of desert hedgehog in a patient with 46,XY partial gonadal dysgenesis accompanied by minifascicular neuropathy. *Am J Hum Genet.* 2000;67(5):1302–5.
- Unni SK, Modi DN, Pathak SG, Dhabalia JV, Bhartiya D. Stage-specific localization and expression of c-kit in the adult human testis. *J Histochem Cytochem.* 2009;57(9):861–9.
- van Alphen MM, van de Kant HJ, de Rooij DG. Repopulation of the seminiferous epithelium of the rhesus monkey after X irradiation. *Radiat Res.* 1988;113(3):487–500.
- van den Driesche S, Sharpe RM, Saunders PT, Mitchell RT. Regulation of the germ stem cell niche as the foundation for adult spermatogenesis: a role for miRNAs? *Semin Cell Dev Biol.* 2014;29:76–83.
- Ventela S, Makela JA, Kulmala J, Westermarck J, Toppari J. Identification and regulation of a stage-specific stem cell niche enriched by Nanog-positive spermatogonial stem cells in the mouse testis. *Stem Cells.* 2012;30(5):1008–20.
- Verhoeven G, Cailleau J. Follicle-stimulating hormone and androgens increase the concentration of the androgen receptor in Sertoli cells. *Endocrinology.* 1988;122(4):1541–50.
- von Brunn A. Beiträge zur Entwicklungsgeschichte der samenkörper. *Arch Mikrosk Anat.* 1876;12:528–36.
- Walker WH. Molecular mechanisms of testosterone action in spermatogenesis. *Steroids.* 2009;74(7):602–7.
- Walker WH. Non-classical actions of testosterone and spermatogenesis. *Philos Trans R Soc Lond Ser B Biol Sci.* 2010;365(1546):1557–69.
- Walker WH, Cheng J. FSH and testosterone signaling in Sertoli cells. *Reproduction.* 2005;130(1):15–28.
- Welsh M, Saunders PT, Atanassova N, Sharpe RM, Smith LB. Androgen action via testicular peritubular myoid cells is essential for male fertility. *FASEB J.* 2009;23(12):4218–30.
- Werner R, Merz H, Birnbaum W, et al. 46,XY gonadal dysgenesis due to a homozygous mutation in desert hedgehog (DHH) identified by exome sequencing. *J Clin Endocrinol Metab.* 2015;100(7):E1022–9.
- Wu X, Schmidt JA, Avarbock MR, et al. Prepubertal human spermatogonia and mouse gonocytes share conserved gene expression of germline stem cell regulatory molecules. *Proc Natl Acad Sci U S A.* 2009;106(51):21672–7.
- Yan W, Linderborg J, Suominen J, Toppari J. Stage-specific regulation of stem cell factor gene expression in the rat seminiferous epithelium. *Endocrinology.* 1999;140(3):1499–504.
- Yan W, Suominen J, Toppari J. Stem cell factor protects germ cells from apoptosis in vitro. *J Cell Sci.* 2000a;113(Pt 1):161–8.
- Yan W, Suominen J, Samson M, Jegou B, Toppari J. Involvement of bcl-2 family proteins in germ cell apoptosis during testicular development in the rat and pro-survival effect of stem cell factor on germ cells in vitro. *Mol Cell Endocrinol.* 2000b;165(1–2):115–29.
- Yan W, Kero J, Huhtaniemi I, Toppari J. Stem cell factor functions as a survival factor for mature Leydig cells and a growth factor for precursor Leydig cells after ethylene dimethane sulfonate treatment: implication of a role of the stem cell factor/c-kit system in Leydig cell development. *Dev Biol.* 2000c;227(1):169–82.
- Yang QE, Kim D, Kaucher A, Oatley MJ, Oatley JM. CXCL12-CXCR4 signaling is required for the maintenance of mouse spermatogonial stem cells. *J Cell Sci.* 2013a;126(Pt 4):1009–20.
- Yang QE, Racicot KE, Kaucher AV, Oatley MJ, Oatley JM. MicroRNAs 221 and 222 regulate the undifferentiated state in mammalian male germ cells. *Development.* 2013b;140(2):280–90.
- Yeh S, Tsai MY, Xu Q, et al. Generation and characterization of androgen receptor knockout (ARKO) mice: an in vivo model for the study of androgen functions in selective tissues. *Proc Natl Acad Sci U S A.* 2002;99(21):13498–503.
- Yeh JR, Zhang X, Nagano MC. Wnt5a is a cell-extrinsic factor that supports self-renewal of mouse spermatogonial stem cells. *J Cell Sci.* 2011;124(Pt 14):2357–66.

- Yomogida K, Yagura Y, Tadokoro Y, Nishimune Y. Dramatic expansion of germinal stem cells by ectopically expressed human glial cell line-derived neurotrophic factor in mouse Sertoli cells. *Biol Reprod.* 2003;69(4):1303–7.
- Yoshida S, Sukeno M, Nakagawa T, et al. The first round of mouse spermatogenesis is a distinctive program that lacks the self-renewing spermatogonia stage. *Development.* 2006;133(8):1495–505.
- Yoshida S, Sukeno M, Nabeshima Y. A vasculature-associated niche for undifferentiated spermatogonia in the mouse testis. *Science.* 2007;317(5845):1722–6.
- Zhang FP, Hamalainen T, Kaipia A, Pakarinen P, Huhtaniemi I. Ontogeny of luteinizing hormone receptor gene expression in the rat testis. *Endocrinology.* 1994;134(5):2206–13.
- Zhang FP, Poutanen M, Wilbertz J, Huhtaniemi I. Normal prenatal but arrested postnatal sexual development of luteinizing hormone receptor knockout (LuRKO) mice. *Mol Endocrinol.* 2001;15(1):172–83.
- Zhou Q, Nie R, Prins GS, Saunders PT, Katzenellenbogen BS, Hess RA. Localization of androgen and estrogen receptors in adult male mouse reproductive tract. *J Androl.* 2002;23(6):870–81.



S. Marchiani, L. Tamburrino, M. Muratori, and E. Baldi

## Abstract

In order to acquire progressive motility, complete maturation and compaction of chromatin, regulate their volume, and acquire molecules necessary for fertilization, spermatozoa released from the testis must transit through the epididymis, a long convoluted tubule that connects the efferent ducts to the vas deferens, where they undergo several molecular modifications. Sperm modifications occurring during transit in the three segments that compose the epididymis (caput, corpus, and cauda) are accomplished by epididymal epithelium secretions, including epididymosomes (extracellular microvesicles enriched in cholesterol and proteins), miRNA, and other macromolecules. Epididymal pH and electrolytes composition of the luminal fluid are also important for a correct sperm maturation. Epididymal secretions are regulated by a variety of factors, mostly androgens and estrogens, to create a different luminal environment in each epididymal segment supporting progressive sperm maturation and allowing maintenance of sperm viability and motility during storage in the cauda. Finally, epididymal contraction allows sperm emission at ejaculation. Overall, the role of epididymis on the development of sperm functions is essential for male reproduction, and alterations in any of its functions may lead to subfertility or infertility. Due to its importance for a successful male reproductive function, the epididymis appears to be a promising target for post-testicular male contraception.

S. Marchiani • L. Tamburrino • M. Muratori

Dipartimento di Scienze Biomediche, Sperimentali e Cliniche, Università di Firenze, Florence, Italy

E. Baldi (✉)

Dipartimento di Medicina Sperimentale e Clinica, University of Florence, Florence, Italy

e-mail: [elisabetta.baldi@unifi.it](mailto:elisabetta.baldi@unifi.it)

---

**Keywords**

 Epididymis • Sperm epididymal transit • Sperm epididymal maturation
 

---

**Contents**

Introduction .....	458
Anatomical Background .....	459
The Epididymis as a Secretory Organ .....	460
Regulation of Epididymis Secretion .....	462
Functions of Epididymis .....	464
Sperm Chromatin Compaction .....	464
Volumetric Regulation of Spermatozoa .....	465
Acquisition of Motility and Membrane Modifications .....	466
Sperm Storage .....	468
Sperm Emission .....	469
Impact of Epididymal Alterations on Male Fertility .....	469
Epididymis as the Target of Male Contraception .....	470
Conclusion .....	471
References .....	472

---

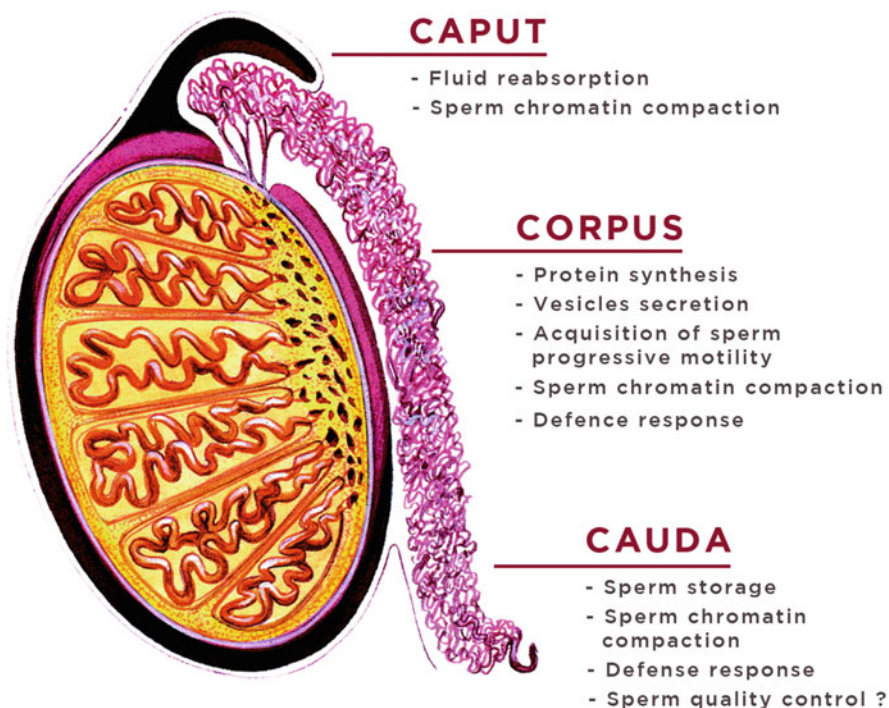
**Introduction**

Although fully differentiated into a highly specialized cell within the testis, the male gamete needs to undergo, following spermiation, several maturation events in order to become fully functional and able to fertilize the oocyte. Such events occur during transit both in the male and female genital tracts. In the former, spermatozoa complete chromatin maturation, acquire the ability to swim progressively, and come into contact with several proteins which are needed for sperm-oocyte interaction and other functions. In the female genital tract, by interacting with uterine and tubal epithelial cells and fluids, spermatozoa undergo the complex process of capacitation (De Jonge 2005), which allows development of a special type of motility (known as hyperactivation and required to penetrate oocyte vestments) and renders the spermatozoa able to respond to stimuli inducing acrosomal exocytosis and to fuse with the oocyte. In this complex series of events necessary for the reproductive function, the epididymis has a central role, accomplishing most of the post-testicular maturation events and representing the structure where spermatozoa are stored before ejaculation. In such a situation, it appears clear that any problem causing epididymal dysfunction or abnormal development of the organ may generate disturbances of male fertility. In addition, understanding the molecular basis of epididymal function is critical to the generation of novel approaches to alleviate male infertility or for the development of new methods for male contraception. It is important to underline that most of the knowledge on the functions of this complex organ derives from animal studies because of the difficulty of obtaining human epididymis and studying epididymal functions in human beings. In view of the differences in the molecular events involved in the reproductive functions in mammalian species, it cannot be excluded that part of the information collected so far is specific for a given specie and not necessarily true for humans.

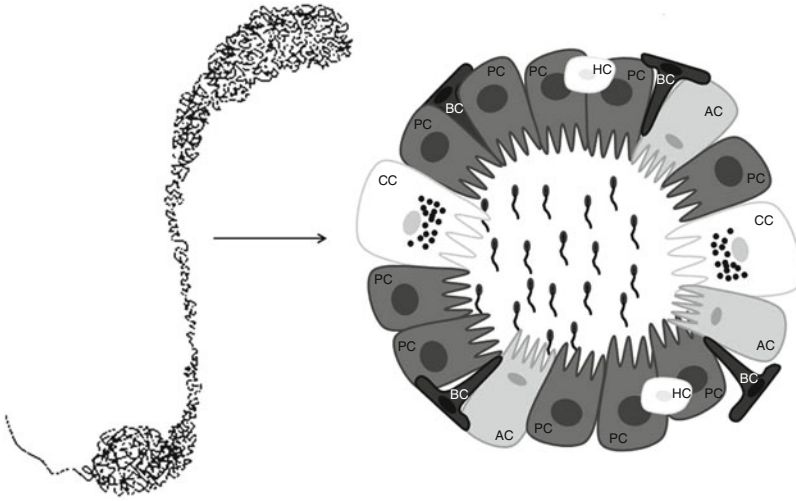
## Anatomical Background

The epididymis is located along the posterolateral surface of the testis and connects efferent ducts to vas deferens. In humans, epididymis has a total length of 6 m (Robaire and Chan 2010) and can be grossly divided into three regions: caput (head), consisting mainly of efferent ducts, corpus, (body) and cauda (tail) which evolves in the vas deferens (Fig. 1). Besides showing histological differences, each epididymal region carries out distinctive functions: the caput and corpus accomplishing, respectively, early and late sperm maturational events, and the cauda region primarily serving as a storage site for functionally mature spermatozoa. The epididymis derives from the Wolffian duct and consists, at birth, mainly of mesenchymal tissue. After birth, the epididymis undergoes considerable remodeling leading to duct elongation and convolution until reaching, at puberty, its fully differentiated state consisting of a highly tortuous tubule lined by epithelial cells (Rodriguez et al. 2002). The development of a fully differentiated epithelium is dependent not only on androgens but requires also the influence of luminal (lumicrine) factors secreted by the testis or other epididymal segments (Rodriguez et al. 2002).

The epididymal epithelium consists of several cell types, namely, principal, basal, clear, narrow, apical, and halo, which are pseudostratified and delimitate the intraluminal compartment (Fig. 2). The most represented cell type throughout the



**Fig. 1** Regions of the human epididymis: caput (including the initial segment), corpus, and cauda. The distinctive functions of each region is indicated



**Fig. 2** Representation of the different cell types present in the epithelium of the corpus epididymis. *PC* principal cell, *AC* apical cell, *CC* clear cell, *BC* basal cell, *HC* halo cell

tubule is the principal one which constitutes 80% of the epithelium and is, by far, the most studied, since it is responsible for the secretion of the bulk of proteins, ions, and organic molecules that are present in the lumen. These cells are distributed along the entire duct but show structural differences in each region, in particular, the luminal diameter increases and the cell height decreases from caput to cauda. Narrow, apical, and clear cells contain the vacuolar type  $H^+$ -ATPase (V-ATPase) which secretes protons into the lumen participating in acidification of the epididymal fluid (Pietrement et al. 2006; Kujala et al. 2007); in particular, clear cells are large and show endocytotic properties being likely responsible for clearance of proteins from the epididymal lumen. Basal cells possess thin processes that extend along the basement membrane and do not have direct access to the lumen of the duct. They express a number of antioxidant proteins and are thought to play a role in protecting from oxidative stress and other possible environmental factors that may affect sperm integrity. Finally, halo cells consist of T helper lymphocytes, cytotoxic T lymphocytes, and monocytes playing a role in immune protection of spermatozoa during epididymal transit (Serre and Robaire 1999). The epididymal epithelium is characterized by a unique set of tight junctions that forms the blood–epididymis barrier allowing an intraluminal milieu with a composition of electrolytes and macromolecules different from that of the circulating body fluids and creating an immunoprotective environment within the epididymal lumen.

## The Epididymis as a Secretory Organ

The epididymal epithelium is very active in protein synthesis and secretion. Importantly, each epididymal region presents specific patterns of gene expression and protein secretions leading to different composition of the luminal fluid in caput,

corpus, and cauda to accomplish the different maturation steps of spermatozoa. Besides androgens and other steroid hormones (see below for regulation of epididymal secretion), region-dependent gene and protein expression are under control of many paracrine and lumicrine secretions of the testis. Several epididymal luminal proteins have been identified and characterized. Many of these proteins are implicated in sperm maturation processes and are acquired by mammalian spermatozoa during epididymal transit (Cornwall 2009). In some cases, such proteins become integral membrane proteins of spermatozoa, being glycosylphosphatidylinositol (GPI) anchored (Cooper 1998).

As mentioned, most of protein secretions derive from the principal cells of the epididymal epithelium. These cells have been shown to release epididymosomes as part of a process known as apocrine secretion. Apocrine secretion consists of blebbing of the apical part of secretory cells forming vesicles that are then released in the lumen. In the male genital tract, apocrine secretion has been described also for the prostate, which secretes prostasomes. Epididymosomes are highly heterogeneous in protein content and various in sizes (from 50 to 250 nm; Sullivan 2015). They transit along the epididymis, and those reaching the caudal segment represent a mixed population of vesicles secreted in the three segments. In some species, epididymosomes have been shown on sperm surface, bound to the acrosome, where they might be involved in cholesterol exchange with the sperm membrane (Rejraji et al. 2006). Indeed, epididymosome membranes are rich in cholesterol (Sullivan and Saez 2013), and its amount increases during epididymal transit (Rejraji et al. 2006) in contrast to spermatozoa where cholesterol is reduced (see below). Analysis of the proteins associated with epididymosomes reveals protein profiles quite different from that of proteins present in the lumen. In addition, protein and lipid composition of epididymosomes is species specific and varies in the different epididymal compartments. Among proteins found in epididymosomes, some are involved in sperm–egg interaction (such as SPAM1; Kimura et al. 2009), development and maintenance of motility (such as aldose reductase; Frenette et al. 2004), and protection from oxidative stress (such as glutathione peroxidases; Drevet 2006).

Sullivan (2015) separated, by serial centrifugation steps, two distinct populations of epididymosomes characterized by different size and different protein content. One population contains the tetraspanin CD9 and other members of the tetraspanin family and preferentially binds to live spermatozoa, likely exerting a protective role against oxidative stress and other insults that may occur during transit in epididymis. The other population contains epididymal sperm binding protein 1 (ELSPBP1) which is transferred to unviable or dying spermatozoa and remains associated with them following ejaculation, likely to prevent the release of molecules with detrimental effects on viable spermatozoa. Epididymosomes contain also tRNA fragments (Sharma et al. 2016) and miRNA (Belleannée et al. 2013) although it is not clear whether these molecules are transferred to spermatozoa. Overall, epididymosomes play an essential role to produce male gametes with optimal fertilizing ability (Sullivan et al. 2005).

A summary of the most characterized proteins (luminal and within epididymosomes) having a role in sperm maturation and acquisition of fertilizing ability is provided in Table 1.

**Table 1** Proteins secreted by epididymis and associated with spermatozoa with known or proposed functions in the fertilization process

Protein name	Protein functions	References
ADAM 2, 3, 7 (a disintegrin and metalloproteinase 2, 3, 7)	Sperm–oocyte interaction	Oh et al. (2005)
Clusterin	Sperm motility and sperm aggregation	Han et al. (2012)
CRISP1 (cysteine-rich secretory protein 1)	Participates in the binding of spermatozoa to the zona pellucida	Da Ros et al. (2015)
Kinases cSrc	Sperm capacitation	Krapf et al. (2012)
GPX4, GPX5 (glutathione peroxidase 4, 5)	Protection against oxidative stress	Drevet (2006)
HE2 (human epididymis protein 2)	Antimicrobial protein	Yenugu et al. (2004)
HE5/CD52 (human epididymis protein 2/ cluster of differentiation 52)	Protection against immune attack	Kirchhoff and Hale (1996)
Lactoferrin	Immune system defense protein	Guyonnet et al. (2011)
Liprin $\alpha$ 3	Acrosome reaction	Joshi et al. (2012)
MIF (macrophage migration inhibitory factor)	Inhibition of sperm motility in the epididymis	Frenette et al. (2005)
NPC2 (Niemann–Pick disease type C2)	Cholesterol transport during sperm maturation	Kirchhoff et al. (1998)
PGDS (prostaglandin D2 synthase)	Lipophilic ligand-binding protein	Moura et al. (2006)
EPPIN	Antimicrobial protection, binding seminogelin involved in sperm motility	O'rand et al. (2004)
HE6 (human epididymal protein 6)	Regulation of fluid reabsorption	Davies et al. (2004)
SED1	Binding to zona pellucida	Raymond et al. (2010)
SPAM1 (sperm adhesion molecule 1)	Sperm–oocyte interaction	Kimura et al. (2009)
Rnase10	sperm-oocyte interaction	Krutsikh et al. (2012)

## Regulation of Epididymis Secretion

Changes in fluid composition in each segment of epididymis are the result of different expression of a wide spectrum of genes (Turner et al. 2003; Cornwall 2009). In a recent paper, Browne et al. (2016), by evaluating gene expression profiles on tissue and cultured epithelial cells derived from each segment of the human epididymis, demonstrated a different expression of genes in caput with respect to

corpus and cauda, whereas only few genes were differentially expressed in the latter segments. In particular, genes related to ion transport and those involved in the response to hormone and urogenital tract development are predominant in the caput, whereas genes related to responses to environmental insults are more represented in the corpus and cauda. A higher expression of ion transport proteins in the caput epididymis is likely involved in maintaining a low bicarbonate and acidic environment in the caput lumen favoring development of progressive motility and maturation but assuring quiescence of spermatozoa (see below) (Browne et al. 2016).

Many genes expressed in the epididymis are regulated by sex hormones (estrogens and androgens). In the epididymis, testosterone derived from the testis is converted into 5 $\alpha$ -dihydrotestosterone (DHT) (Turner 1991) by 5 $\alpha$ -reductase or into estradiol by the aromatase P450 enzyme. Androgen receptor (AR) and estrogen receptor- $\beta$  (ER $\beta$ ) are expressed at similar levels along the entire epididymis, whereas ER $\alpha$  is primarily expressed in the efferent ducts and the caput of the epididymis (Zhou et al. 2002). In the absence of androgens (such as following androgen deprivation or orchidectomy), spermatozoa become immotile, lose the ability to fertilize, and die (Dyson and Orgebin-Crist 1973) due to alterations of the secretory function of principal cells and, consequently, of the epididymal fluid composition. In addition, an apoptotic process is triggered throughout the epididymis (Fan and Robaire 1998). Re-administration of DHT results in up- and downregulation of many gene families (involved in solute transport, cell communication, cell proliferation and apoptosis, signal transduction, proteolysis, peptidolysis, and development) restoring most of the histological features of the organ (Robaire et al. 2007). Clearly, any androgen-deprived condition results also in lack of estrogens, and thus these studies could not discriminate between estrogen and androgen effects on epididymis. Generation of ER $\alpha$  KO mice (Lubahn et al. 1993) allowed to understand that several proteins that are important in fluid/ion equilibrium in the epididymis, such as solute carrier family 9 member 3 (SLC9A3), carbonic anhydrase 2 (CAR2), and two aquaporin water channels, AQP1 and AQP9 (Zhou et al. 2001; Ruz et al. 2006), are estrogen regulated. The absence of ER $\alpha$  results in lack of reabsorption of the large volume of fluid secreted by the testis leading to infertility due to lower motility and inability to fertilize of spermatozoa. On the contrary, the ER $\beta$  KO mouse is fully fertile (Krege et al. 1998). More recent studies have shown that estrogens regulate also epididymal contractility by upregulating the calcium-sensitive Ras homolog gene family, member A (RhoA)/Rho-associated protein kinase (ROCK) pathway in epididymal smooth muscle cells, increasing responsiveness of oxytocin and endothelin-1 receptors (Fibbi et al. 2009) (see also below).

Other possible mechanisms could regulate the activation of gene transcription beside androgens and estrogens. Among these, miRNAs (small noncoding RNAs that control gene expression posttranscriptionally) were shown to be implicated in the epithelium differentiation and in the regulation of sex steroid signaling in epididymis (Bjorkgren et al. 2012). In particular, miR-200a (Wu et al. 2012), miR-200c (Wang and Ruan 2010a), miR-335 (Wang and Ruan 2010b), and miR-29a (Ma et al. 2012) were demonstrated to regulate epididymal development. miRNAs display a different expression among the epididymal regions in many

species including the human (Belleannee et al. 2012; Ma et al. 2012; Nixon et al. 2015). As an example, in rats, miR-200 family members are more expressed in the caput with respect to the cauda epididymis, contributing to the distinct physiological function in sperm maturation/storage of the two segments (Chu et al. 2015). Gene transcription in the epididymis may also be regulated by DNA methylation. It has been shown that ion transportation-related, sexual reproduction-related, and spermatogenesis-related genes resulted to be methylated throughout the epididymis (Chu et al. 2015), but, intriguingly, such methylation is not related, in the mature epididymis, to a repression of gene transcription. However, it is possible that DNA methylation of such genes plays a role in the early epididymal differentiation (Chu et al. 2015).

---

## Functions of Epididymis

As mentioned, each epididymis region has specific properties and different functions in order to guarantee sperm maturation during epididymal transit and safe storage before ejaculation (Fig. 1). A spontaneous and rhythmic contraction of smooth muscle cells surrounding the epididymal ducts guarantees sperm movement through caput and corpus up to the cauda. The passage through human epididymis and consequently all the biochemical modifications underlying sperm maturation last 10–15 days (Johnson and Varner 1988). The essential processes for sperm maturation and acquisition of motility take place mostly in caput and corpus, whereas the cauda represents mainly a storage structure of mature spermatozoa. There is also evidence for a role of epididymis in sperm protection and in elimination of defective sperm cells (Fraile et al. 1996; Sutovsky et al. 2001), although the existence of an epididymal “sperm quality control” is highly debated (Cooper et al. 2002).

## Sperm Chromatin Compaction

During spermatogenesis a complex process of chromatin remodeling occurs in order to obtain a rigid sperm nucleus required for protection of sperm chromatin integrity, successful transport in the female reproductive tract, and penetration of the oocyte (Huszar et al. 1999). In particular, histones associated with sperm DNA are replaced, during spermiogenesis, first by transition proteins and later by protamines. The process of chromatin compaction is completed during epididymal transit, when redox-mediated intra- and intermolecular disulfide bridges within protamines are established resulting in a tightly compacted nucleus. This process occurs thanks to the pro-oxidative environment present in the epididymis. The efficiency of the formation of disulfide bridges depends also on the correct binding of protamines to DNA, which, in turn, is dependent on phosphorylation-dephosphorylation of protamines occurring in the testis (Marushige and Marushige 1978; Balhorn et al. 1984). The stability of the chromatin is determined by the number of –S–S– cross-links formed between thiol groups of adjacent protamine chains. Evaluation of the



number of disulfide bonds in protamines from spermatozoa coming from the different epididymal segments has shown that the number of bridges increases passing from caput to cauda (Auger and Dadoune 1993) which coincides with a greater stabilization of chromatin during epididymal transit. The entire process of chromatin compaction is of vital importance for spermatozoa, as a less compacted nucleus may be more vulnerable and can suffer from DNA damage. Since the main mission of spermatozoa is to deliver a fully intact and functioning paternal genome to the oocyte, occurrence of DNA damage can compromise the reproductive outcome both in natural and assisted reproduction (Tamburrino et al. 2012). Maintenance of equilibrium between beneficial and detrimental sperm oxidation in the epididymis relies on the many antioxidant substances present, from small metabolites to enzymes. Among them, the glutathione peroxidase (Gpx) family plays a key role, as these enzymes act as reactive oxidative species (ROS) scavengers to protect spermatozoa (Drevet 2006). For instance, although not presenting evident signs of infertility, Gpx5<sup>-/-</sup> mice are characterized by an excess in free radicals that could compromise sperm DNA integrity. Indeed Gpx5<sup>-/-</sup> mice display higher incidence of miscarriages and embryo developmental defects when they were mated with wild-type females. The targeted epididymis GPx5 knockout model brought some clear evidence that GPx5 is a true ROS scavenger protecting epididymis-transiting spermatozoa from oxidative damage (Chabory et al. 2009). Similarly, the mouse mGPx4<sup>-/-</sup> model (KO for mitochondria-associated isoform of GPx4) shows impaired sperm integrity, including structural malformations of the midpiece, a significant reduction of forward motility, and of the mitochondrial membrane potential, resulting in infertility (Noblanc et al. 2011). A reduced expression of GPx4 was found in apolipoprotein E receptor-2 (ApoER2) knockout mice, which are also infertile. ApoER2 is highly expressed in the initial segment of the epididymis and has a crucial role in sperm maturation, in particular in the acquisition and development of sperm motility, by regulating the expression of sperm GPx4 (Andersen et al. 2003).

It appears clear that if sperm nuclear compaction is not optimal (e.g., defective protamination in the testis), or if dysfunctions in epididymal secretions occur (e.g., low levels of GPx enzymes), the long periods of epididymal transit and storage may represent challenging moments when spermatozoa could be at risk of oxidative damage.

## **Volumetric Regulation of Spermatozoa**

Progressive fluid reabsorption, driven by aquaporins (see also above), allows an increase of sperm and luminal protein concentrations that facilitates interactions of the sperm surface with the secretory products of the epididymis and influences the time of sperm storage. Besides AQP9 and AQP1 (Badran and Hermo 2002; Da Silva et al. 2006), sodium transporters at the apical pole (including the sodium–hydrogen exchanger 3, sodium–glucose transporter, and sodium–nucleotide transporters (Leung et al. 2001; Zhou et al. 2001)) are involved in such a process. Another

consequence of water removal from the lumen is the increase in osmolality of the lumen fluid that reaches the highest levels in the cauda (Cooper and Yeung 2003), and that is essential to regulate sperm volume. High osmolality prevents osmotic sperm dehydration and, likely, provides a reserve of osmolytes which is useful to maintain the volume when spermatozoa enter in contact with the hypotonic seminal plasma. A spermatozoon which fails volume regulation changes its flagellar shape by coiling or angulation in order to avoid excessive stretching of the plasma membrane. Inability to maintain straight flagella and consequent infertility has been demonstrated in *c-ros* (gene encoding proto-oncogene tyrosine–protein kinase) KO mice, where a failure in pubertal differentiation of the epididymal initial segment leads to changes in expression of some proteins, including epithelial transporters. However, caudal spermatozoa from *c-ros* KO mice are able to fertilize eggs *in vitro* indicating that they maintain their ability to interact with eggs (Cooper et al. 2003).

### Acquisition of Motility and Membrane Modifications

In the caput of epididymis, spermatozoa show immature tail movements characterized by thrashing beats in wide arcs that result in little forward progression. Within the corpus the frequency of beat increases and the amplitude decreases resulting in a more progressive motility. Within the cauda most spermatozoa present a mature motility pattern. The key factors involved in this process are calcium ions ( $\text{Ca}^{2+}$ ), bicarbonate ( $\text{HCO}_3^-$ ), and cyclic adenosine monophosphate (cAMP). The calcium concentration in the epididymal fluid decreases from 0.8 mM in caput to 0.5 mM in the cauda (Jenkins et al. 1980), and also intracellular sperm calcium decreases during epididymal transit (Vijayaraghavan et al. 1989). Low intracellular calcium is required to maintain a quiescent status and avoid premature hyperactivation (Dacheux and Dacheux 2013). Although bicarbonate concentration of the luminal fluid increases from 2 to 5–7 mM from caput to cauda epididymis, it is maintained at critical concentrations to keep a low luminal pH (in the cauda pH is about 6.8 vs 6.5 in the caput) and to avoid premature activation of hyperactivated motility or capacitation, which are supposed to occur in the female genital tract, where bicarbonate concentration and pH rise up to 90 mM and 7.4, respectively (Pastor-Soler et al. 2003). In the caput, lumen acidification is maintained, thanks to bicarbonate reabsorption by principal cells and proton secretion by clear cells through the V-ATPase pump. Conversely, principal cells in the cauda secrete bicarbonate through cystic fibrosis transmembrane conductance regulator (CFTR), which induces a mild alkalization of the epididymal fluid in this region and is believed to “prime” spermatozoa before ejaculation. Bicarbonate activates an intra-sperm soluble adenylate cyclase (sAC) (Chang and Oude-Elferink 2014) involved in development and maintenance of sperm motility. cAMP generated following sAC stimulation activates a cAMP-dependent protein kinase A (PKA) that phosphorylates Ser and Thr residues on proteins that are involved in various sperm functions including motility. Several studies have demonstrated that  $\text{Ca}^{2+}$  and  $\text{HCO}_3^-$  act synergistically on sAC to stimulate motility (Wennemuth et al. 2003; Liu et al. 2012). Perturbations

in these processes result in reduced male reproductive health and consequent subfertility or infertility. Mutations of the CFTR gene are associated with a reduced sperm capacitation due to a disruption of  $\text{HCO}_3^-$ -dependent events, including increase in intracellular pH, cAMP production, and membrane hyperpolarization (Xu et al. 2007). Moreover, 60–70% of men with mutations of CFTR display congenital bilateral absence of vas deferens (CBAVD) resulting in obstructive azoospermia. Although subjects with CBAVD can father a child after percutaneous epididymal sperm aspiration, recent evidence suggests that pregnancies initiated by these men have an increased risk of miscarriages and stillbirth (Lu et al. 2014), suggesting alterations of sperm integrity likely due to low bicarbonate concentrations in the epididymis.

During epididymal sperm maturation, several membrane modifications in lipid and protein composition occur (Robaire et al. 2000; Cornwall 2009). Spermatozoa collected from cauda epididymis of mouse, rat, hamster, and ram display a 50% reduction in cholesterol levels compared with those retrieved from the caput (Rejraji et al. 2006; Hall et al. 1991; Awano et al. 1993; Parks and Hammerstedt 1985). Furthermore, most mammals, including the human, show a change in the sperm fatty acid composition (from saturated to polyunsaturated forms) during epididymal transit (Rejraji et al. 2006; Hall et al. 1991; Awano et al. 1993; Parks and Hammerstedt 1985; Nikolopoulou et al. 1985; Haidl and Opper 1997; Pyttel et al. 2014). The addition of polyunsaturated fatty acids (PUFAs), in combination with decreased levels of cholesterol during the epididymal sperm maturation, causes an increase in membrane fluidity, which is required for proper sperm motility and fertility (Hall et al. 1991; Haidl and Opper 1997, Evans and Setchell 1979; Aveldaño et al. 1992). If epididymal PUFA synthesis is perturbed, spermatozoa may lose their fertilizing ability as it occurs in mice with conditioned KO of *Dicer1* (a gene encoding an endoribonuclease involved in miRNA formation), characterized by a decrease in the synthesis of PUFAs together with an increased expression of factors involved in cholesterol synthesis in the epididymal epithelium leading to an increase of cholesterol/PUFA ratio in the sperm membrane and, consequently, to membrane instability (Björkgren et al. 2015).

Modification of sperm membrane proteins during epididymal transit is a complex event implying contact with luminal secretions and epididymosomes. First, spermatozoa lose some surface proteins through the action of different proteolytic activities of the epididymal fluid. The second important modification is the appearance of new proteins at the sperm surface. Using 2D electrophoresis gels (Belleannée et al. 2011) and mass spectrometry, many proteins have been identified as being added/removed to sperm surface during epididymal transit (see Table 1 for those having an established role in sperm functions and fertilizing ability). In particular, it has been found that during epididymal transit, about 732 proteins were acquired and 1,034 proteins lost by spermatozoa. Interestingly, in terms of the number of proteins, sperm proteome complexity rose from caput (1,536 proteins) to a maximum in the corpus (1,720) and then decreased in the cauda (1,234). Most of these proteins are common between species although their concentration is variable (Gatti et al. 2004; Dacheux et al. 2005). Only clusterin has always been found in high amounts throughout the

epididymal tract in all studied species (see review by Dacheux and Dacheux 2013). The interaction between a protein secreted by the epididymis and sperm membrane can be characterized by loose binding (potentially involved in maintaining a quiescent state in the epididymis), tight binding (potentially needed for functions in the female tract or for fertilization), or by insertion/modification of integral membrane proteins (involved in masking/unmasking of membrane proteins and sperm decapacitation). Indeed, some integral membrane proteins become detectable only in spermatozoa retrieved from the cauda epididymis or in the ejaculate. A glycosylation process is likely involved in unmasking surface proteins in mature spermatozoa. Moreover, some of the proteins which are transferred to spermatozoa are anchored by GPI to the sperm plasma membrane (Ilio and Hess 1994; Kirchhoff and Hale 1996; Ecroyd et al. 2005). The transfer of proteins to specific membrane domains of spermatozoa depends on temperature and pH (Sullivan et al. 2005). The presence of zinc in the medium, but not of calcium or magnesium, has been shown to increase the efficiency of protein transfer (Frenette et al. 2002).

As mentioned, among the proteins acquired by spermatozoa during epididymal transit, some are essential to guarantee the transit in the female genital tract and oocyte fertilization, as demonstrated by knockout (KO) studies (Table 1). Sperm adhesion molecule 1 (SPAM1), a protein with hyaluronidase activity, is likely involved in sperm penetration through the cumulus matrix. SPAM1<sup>-/-</sup> mice are fertile, but the lack of SPAM1 results in a remarkably increased accumulation of spermatozoa on the surface or outer edge of the cumulus (Kimura et al. 2009). SED1, a protein involved in cell–cell interaction, is secreted by the initial segment of the epididymis, and its KO in mice leads to a failure to regulate the epididymal fluid and an inability of sperm to bind and fertilize eggs (Raymond et al. 2010). ADAM7, a disintegrin and metalloprotease associated with epididymosomes (Oh et al. 2009), is involved in sperm motility, and KO animals show reduced fertility due to anomalies in epididymal caput structure and reduced sperm motility associated with abnormalities in tail morphology and tyrosine phosphorylation of proteins. Cysteine-rich secretory proteins (CRISP) are present on sperm surface and involved in acquisition of sperm fertilizing ability. CRISP family members can be of testicular (such as Crisp 2) or epididymal (such as Crisp1, Crisp3, and Crisp4) origin. CRISP1-deficient spermatozoa show defects in their ability to increase protein tyrosine phosphorylation during capacitation and impaired interaction with the oocyte *in vitro*. Despite this, they are fertile probably due to a compensatory mechanism by other members of the family (Da Ros et al. 2015).

## Sperm Storage

The principal role of cauda epididymis is sperm storage. The storage period varies from days to weeks depending on the sexual and mating behavior of the specie (Jones et al. 2007). As mentioned above, during the passage from testis to efferent ducts and initial region of epididymis, about 90% of water is reabsorbed (Wong and Yeung 1978; Turner 1984). Water reabsorption is essential to achieve good storage

conditions and to preserve viability of spermatozoa. Other factors involved in maintaining sperm motility and viability are androgens and scrotal temperature. A low scrotal temperature with respect to body and testis (Brooks 1973) preserves viability and motility. Conversely, an increase in the scrotal temperature of only 2 °C for 4 days decreases sperm motility and embryo viability after ART (Mieusset et al. 1991). Higher temperatures modify water, Na<sup>+</sup>, K<sup>+</sup>, and Cl<sup>-</sup> channels in the cauda epididymis (Wong and Yeung 1978) and determine the disappearance of several proteins typically present in its secretions (Bedford 1991; Regalado et al. 1993). Moreover high temperatures reduce the diameter and length of the duct in the cauda region (Foldesy and Bedford 1982) and so its storage capacity. Among mammalian species, human is the one that presents the lowest storage capacity. Sperm survival in the cauda epididymidis is influenced also by androgens. Removal or decline of androgens triggers mechanisms that lead to a malfunctioning epithelium and activate death pathways that ultimately dissolve spermatozoa (Jones 2004). Other important factors involved in sperm survival are a low oxygen content (Free et al. 1976) and absence of glucose (Annisson et al. 1963). The protective role of epididymis on spermatozoa is demonstrated by studies showing that spermatozoa from epididymis stored at 4 °C for several days after the death of the animal (Abella et al. 2015) or cryoconserved in the epididymides for up to 48 h (Takeo et al. 2014) maintained high fertilization potential.

## Sperm Emission

During the emission phase a strong contractility of the epididymis and vas deferens occurs provoking a rapid transport of spermatozoa toward more distal regions. Caput and corpus transfer spermatozoa by spontaneous, peristaltic-like contractions, whereas the cauda is characterized by a rich adrenergic innervation which coordinates the muscular contractile activity necessary for emission phase of the ejaculatory process (El-Badawi and Schenk 1967). The group of Maggi (Vignozzi et al. 2008) demonstrated that epididymal contractile activity is mediated by neuronal and nonneuronal factors and hormones. Among the latter, oxytocin and endothelin-1 are two well-characterized factors and are involved in creating an autocrine/paracrine loop which supports the autonomous peristaltic movements of the epididymis and favors sperm progression throughout the duct. Another essential factor to maintain the epididymal sensitivity to these locally produced contractile factors is estradiol, which increases RhoA/ROCK signaling (Fibbi et al. 2009), involved in regulating the myogenic tone of smooth muscle cells.

---

## Impact of Epididymal Alterations on Male Fertility

The essential role played by the epididymis in sperm maturation and development of key sperm functions suggests that alterations of epididymal functions may lead to sub- or infertility. In particular, infections and inflammations may cause tissue

damage impairing epididymal secretory function (Cooper et al. 1990). In addition, recruitment of phagocytic cells to the site of the infection leads to the release of cytokines and other inflammatory mediators and an increased generation of ROS (Azenabor et al. 2015; Lotti and Maggi 2015) affecting functions and integrity of both epididymis and transiting spermatozoa. It is estimated that infections and inflammations of the genital tract constitute about 15% of all cases of male factor infertility and epididymitis together with combined epididymo-orchitis is the major contributor. Infection/inflammation of epididymis may result from microbial invasion, genital trauma, and sterile reflux, but bacterial invasion appears to be the most prevalent (Schagdarsurengin et al. 2016). The occurrence of epididymitis leads not only to a reduction of sperm number (due to induction of apoptosis after exposure to microbes and leukocytes for long time) but also premature acrosome reaction within the epididymal lumen (due to the presence of  $\alpha$ -hemolysin and other toxins which damage the acrosome) (Schagdarsurengin et al. 2016). In addition, toxins may increase generation of ROS that alter membrane integrity, reduce motility, and produce oxidative DNA damage and DNA fragmentation in spermatozoa transiting the epididymis. Epididymal alterations may be also induced by environmental factors, in particular, endocrine disruptors can directly affect hormonal regulation of luminal secretions or induce epigenetic modifications of gene expression and, consequently, alterations in the composition of the luminal fluid.

Common abnormalities of the epididymis are cysts and spermatoceles, benign formations mainly located in the head of the organ. They are reported in one out of four men undergoing ultrasound examination. Cysts appear as anechoic avascular spherical formations and spermatoceles as slightly hypoechoic inhomogeneous abnormalities (Lotti and Maggi 2015). Their exact etiology is not clear, but they might be due to a blockage in one of the tubes that transports spermatozoa. The association between cysts or spermatocele and male infertility is doubtful, as their involvement in complete epididymal obstruction and obstructive azoospermia has never been proven. Spermatoceles are generally painless and are filled with milky or clear fluid that usually contain spermatozoa, representing, when large enough, a reservoir of viable and motile spermatozoa that can be used in assisted reproduction (Hirsh et al. 1996; Müller-Tyl et al. 1990).

---

## **Epididymis as the Target of Male Contraception**

Apart from condoms and vasectomy, contraceptive methods for men are still unavailable. An ideal method of contraception should be rapid, fully and quickly reversible as well as without side effects. Recently, researchers begun to focus their attention on a nonhormonal approach that should display high selectivity. In particular, two principal technical approaches are available to interfere with essential functions in male fertility: immunocontraception and a drug-based contraception. The identification of target proteins specifically expressed in the male reproductive tract and showing a fundamental importance for sperm functions may allow the development of highly selectively acting drugs with excellent safety profiles. The

fact that sperm maturation changes, occurring during epididymal transit, are prerequisites for a successful reproductive function highlights the epididymis and epididymal secretions as important targets for male contraception. Interfering pharmacologically or immunologically with epididymal sperm maturation process could be indeed a good prospective for developing a post-testicular contraception drug. In particular, an epididymal antigen, as candidate, would be optimal for immunocontraception since it allows inhibiting only post-testicular sperm maturation events, without affecting testicular function and so avoiding a possible effect on germ cells. Recently, some studies focused on possible epididymal targets of immunocontraception. O'rand et al. (2004), immunizing seven monkeys against recombinant eppin (an epididymal protease inhibitor involved in modulating prostate-specific antigen activity, providing antimicrobial protection and binding semenogelin, thereby inhibiting sperm motility), obtained a complete, but reversible, contraception in five animals, highlighting the role of the protein in male fertility. Immunization of rat males and females with either native or recombinant CRISP1 (see above and Table 1) produced specific antibodies in over 90% of the animals, resulting in a reversible inhibition of fertility in both sexes (Da Ros et al. 2015). Other possible epididymal candidates for immunocontraception could be  $\beta$ -defensin proteins, involved in regulation of sperm motility (Dorin and Barratt 2014). It has been demonstrated that deletions or mutations in defensin genes lead to, respectively, male sterility and subfertility (Zhou et al. 2013; Tollner et al. 2011; Björkgren et al. 2016).

It should be mentioned that an immunological approach to contraception raises several concerns such as the possibility of provoking autoimmunity and the reversibility of the infertility status. In addition a variability in both the degree and duration of response among individuals has been demonstrated. An attractive alternative would be the development of pharmacological inhibitors to target epididymal proteins. Applying a set of indication-specific criteria, putative drug targets can be efficiently identified. Such criteria include tissue-selective expression, crucial biological function in fertility, and druggable properties. Proteins have first to fulfil these criteria before a drug discovery process can be initiated. Possible targets using such approach could be epididymis-specific disintegrin and metalloproteases containing proteins (ADAMs), especially ADAM7 (see Table 1) and the G-protein-coupled receptor HE6 (Table 1).

Even though a number of novel potential drug targets are emerging, male contraception based on epididymal function is in its infancy from a clinical point of view, since delivering potential contraceptive drugs to the epididymis appears difficult because of the presence of the blood–epididymis barrier. Development of shuttle molecules able to deliver drugs through the blood–epididymis barrier as well as to target them to specific tissues/cells is under investigation.

---

## Conclusion

The epididymis is exerting an essential role in male reproductive functions, allowing poorly motile spermatozoa released from the testis to achieve the progressive motility necessary to reach the oocyte as well as to complete their chromatin

compaction, regulate their volume, and acquire competence to fertilize. Such roles are accomplished by the variegated secretory activities of the epithelium which are under regulation of sex steroid hormones and other epididymal and testicular factors and are specialized in the different segments. Finally, the epididymis guarantees the safe storage of spermatozoa and supports their emission at ejaculation. In view of such important functions, the epididymis is involved in male infertility and represents an attractive target for development of novel contraceptive strategies.

---

## References

- Abella DF, Da Costa M, Guérin Y, Dacheux JL. Fertility of undiluted ram epididymal spermatozoa stored for several days at 4°C. *Animal*. 2015;9(2):313–9.
- Andersen OM, Yeung CH, Vorum H, Wellner M, Andreassen TK, Erdmann B, Mueller EC, Herz J, Otto A, Cooper TG, Willnow TE. Essential role of the apolipoprotein E receptor-2 in sperm development. *J Biol Chem*. 2003;278(26):23989–95.
- Annisson EF, Scott TW, Waites GM. The role of glucose and acetate in the oxidative metabolism of the testis and epididymis of the ram. *Biochem J*. 1963;88:482–8.
- Auger J, Dadoune JP. Nuclear status of human sperm cells by transmission electron microscopy and image cytometry: changes in nuclear shape and chromatin texture during spermiogenesis and epididymal transit. *Biol Reprod*. 1993;49(1):166–75.
- Aveladaño MI, Rotstein NP, Vermouth NT. Lipid remodelling during epididymal maturation of rat spermatozoa. Enrichment in plasmenylcholines containing long-chain polyenoic fatty acids of the n-9 series. *Biochem J*. 1992;283(Pt 1):235–41.
- Awano M, Kawaguchi A, Mohri H. Lipid composition of hamster epididymal spermatozoa. *J Reprod Fertil*. 1993;99(2):375–83.
- Azenabor A, Ekun AO, Akinloye O. Impact of inflammation on male reproductive tract. *J Reprod Infertil*. 2015;16(3):123–9. Review.
- Badran HH, Hermo LS. Expression and regulation of aquaporins 1, 8, and 9 in the testis, efferent ducts, and epididymis of adult rats and during postnatal development. *J Androl*. 2002;23(3):358–73.
- Balhorn R, Weston S, Thomas C, Wyrobek AJ. DNA packaging in mouse spermatids. Synthesis of protamine variants and four transition proteins. *Exp Cell Res*. 1984;150(2):298–308.
- Bedford JM. Effects of elevated temperature on the epididymis and testis: experimental studies. *Adv Exp Med Biol*. 1991;286:19–32. Review.
- Belleannée C, Belghazi M, Labas V, Teixeira-Gomes AP, Gatti JL, Dacheux JL, Dacheux F. Purification and identification of sperm surface proteins and changes during epididymal maturation. *Proteomics*. 2011;11(10):1952–64.
- Belleannée C, Calvo E, Thimon V, Cyr DG, Légaré C, Garneau L, Sullivan R. Role of microRNAs in controlling gene expression in different segments of the human epididymis. *PLoS One*. 2012;7(4):e34996.
- Belleannée C, Calvo É, Caballero J, Sullivan R. Epididymosomes convey different repertoires of microRNAs throughout the bovine epididymis. *Biol Reprod*. 2013;89(2):30.
- Björkgren I, Saastamoinen L, Krutskikh A, Huhtaniemi I, Poutanen M, Sipilä P. Dicer1 ablation in the mouse epididymis causes dedifferentiation of the epithelium and imbalance in sex steroid signaling. *PLoS One*. 2012;7(6):e38457.
- Björkgren I, Gylling H, Turunen H, Huhtaniemi I, Strauss L, Poutanen M, Sipilä P. Imbalanced lipid homeostasis in the conditional Dicer1 knockout mouse epididymis causes instability of the sperm membrane. *FASEB J*. 2015;29(2):433–42.
- Björkgren I, Alvarez L, Blank N, Balbach M, Turunen H, Laajala TD, Toivanen J, Krutskikh A, Wahlberg N, Huhtaniemi I, Poutanen M, Wachten D, Sipilä P. Targeted inactivation of the



- mouse epididymal beta-defensin 41 alters sperm flagellar beat pattern and zona pellucida binding. *Mol Cell Endocrinol.* 2016;427:143–54.
- Brooks DE. Epididymal and testicular temperature in the unrestrained conscious rat. *J Reprod Fertil.* 1973;35(1):157–60.
- Browne JA, Yang R, Leir SH, Eggener SE, Harris A. Expression profiles of human epididymis epithelial cells reveal the functional diversity of caput, corpus and cauda regions. *Mol Hum Reprod.* 2016;22(2):69–82.
- Chabory E, Damon C, Lenoir A, Kauselmann G, Kern H, Zevnik B, Garrel C, Saez F, Cadet R, Henry-Berger J, Schoor M, Gottwald U, Habenicht U, Drevet JR, Vernet P. Epididymis seleno-independent glutathione peroxidase 5 maintains sperm DNA integrity in mice. *J Clin Invest.* 2009;119(7):2074–85.
- Chang JC, Oude-Elferink RP. Role of the bicarbonate-responsive soluble adenylyl cyclase in pH sensing and metabolic regulation. *Front Physiol.* 2014;5:42. Review.
- Chu C, Zheng G, Hu S, Zhang J, Xie S, Ma W, Ni M, Tang C, Zhou L, Zhou Y, Liu M, Li Y, Zhang Y. Epididymal region-specific miRNA expression and DNA methylation and their roles in controlling gene expression in rats. *PLoS One.* 2015;10(4):e0124450.
- Cooper TG. Interactions between epididymal secretions and spermatozoa. *J Reprod Fertil Suppl.* 1998;53:119–36. Review.
- Cooper TG, Yeung CH. Acquisition of volume regulatory response of sperm upon maturation in the epididymis and the role of the cytoplasmic droplet. *Microsc Res Tech.* 2003;61(1):28–38. Review.
- Cooper TG, Weidner W, Nieschlag E. The influence of inflammation of the human male genital tract on secretion of the seminal markers alpha-glucosidase, glycerophosphocholine, carnitine, fructose and citric acid. *Int J Androl.* 1990;13(5):329–36.
- Cooper TG, Yeung CH, Jones R, Orgebin-Crist MC, Robaire B. Rebuttal of a role of the epididymis in sperm quality control by phagocytosis of defective sperm. *J Cell Sci.* 2002;115(Pt 1):5–7.
- Cooper TG, Wagenfeld A, Cornwall GA, Hsia N, Chu ST, Orgebin-Crist MC, Drevet J, Vernet P, Avram C, Nieschlag E, Yeung CH. Gene and protein expression in the epididymis of infertile c-ros receptor tyrosine kinase-deficient mice. *Biol Reprod.* 2003;69(5):1750–62.
- Cornwall GA. New insights into epididymal biology and function. *Hum Reprod Update.* 2009;15(2):213–27. Review.
- Da Ros VG, Muñoz MW, Battistone MA, Brukman NG, Carvajal G, Curci L, Gómez-Ellas MD, Cohen DB, Cuasnicu PS. From the epididymis to the egg: participation of CRISP proteins in mammalian fertilization. *Asian J Androl.* 2015;17(5):711–5.
- Da Silva N, Silberstein C, Beaulieu V, Piétremont C, Van Hoek AN, Brown D, Breton S. Postnatal expression of aquaporins in epithelial cells of the rat epididymis. *Biol Reprod.* 2006;74(2):427–38.
- Dacheux JL, Dacheux F. New insights into epididymal function in relation to sperm maturation. *Reproduction.* 2013;147(2):R27–42. Review.
- Dacheux JL, Castella S, Gatti JL, Dacheux F. Epididymal cell secretory activities and the role of proteins in boar sperm maturation. *Theriogenology.* 2005;63(2):319–41. Review. Erratum in: *Theriogenology.* 2005;64(5):1244.
- Davies B, Baumann C, Kirchhoff C, Ivell R, Nubbemeyer R, Habenicht UF, Theuring F, Gottwald U. Targeted deletion of the epididymal receptor HE6 results in fluid dysregulation and male infertility. *Mol Cell Biol.* 2004;24(19):8642–8.
- De Jonge C. Biological basis for human capacitation. *Hum Reprod Update.* 2005;11(3):205–14. Review.
- Dorin JR, Barratt CL. Importance of  $\beta$ -defensins in sperm function. *Mol Hum Reprod.* 2014;20(9):821–6. Review.
- Drevet JR. The antioxidant glutathione peroxidase family and spermatozoa: a complex story. *Mol Cell Endocrinol.* 2006;250(1–2):70–9. Review.
- Dyson ALMB, Orgebin-Crist MC. Effect of hypophysectomy, castration and androgen replacement upon the fertilizing ability of rat epididymal spermatozoa. *Endocrinology.* 1973;93(2):391–402.

- Ecroyd H, Belghazi M, Dacheux JL, Gatti JL. The epididymal soluble prion protein forms a high-molecular-mass complex in association with hydrophobic proteins. *Biochem J*. 2005;392(Pt 1): 211–9.
- El-Badawi A, Schenk EA. The distribution of cholinergic and adrenergic nerves in the mammalian epididymis: a comparative histochemical study. *Am J Anat*. 1967;121(1):1–14.
- Evans RW, Setchell BP. Lipid changes in boar spermatozoa during epididymal maturation with some observations on the flow and composition of boar rete testis fluid. *J Reprod Fertil*. 1979; 57(1):189–96.
- Fan X, Robaire B. Orchidectomy induces a wave of apoptotic cell death in the epididymis. *Endocrinology*. 1998;139(4):2128–36.
- Fibbi B, Filippi S, Morelli A, Vignozzi L, Silvestrini E, Chavalmane A, De Vita G, Marini M, Gacci M, Manieri C, Vannelli GB, Maggi M. Estrogens regulate humans and rabbit epididymal contractility through the RhoA/Rho-kinase pathway. *J Sex Med*. 2009;6(8):2173–86.
- Foldesdy RG, Bedford JM. Biology of the scrotum. I. Temperature and androgen as determinants of the sperm storage capacity of the rat cauda epididymidis. *Biol Reprod*. 1982;26(4):673–82.
- Fraile B, Martin R, De Miguel MP, Arenas MI, Bethencourt FR, Peinado F, Paniagua R, Santamaria L. Light and electron microscopic immunohistochemical localization of protein gene product 9.5 and ubiquitin immunoreactivities in the human epididymis and vas deferens. *Biol Reprod*. 1996;55(2):291–7.
- Free MJ, Schlutz GA, Jaffe RA. Respiratory gas tensions in tissues and fluids of the male rat reproductive tract. *Biol Reprod*. 1976;14(4):481–8.
- Frenette G, Lessard C, Sullivan R. Selected proteins of “prostate-like particles” from epididymal cauda fluid are transferred to epididymal caput spermatozoa in bull. *Biol Reprod*. 2002; 67(1):308–13.
- Frenette G, Lessard C, Sullivan R. Polyol pathway along the bovine epididymis. *Mol Reprod Dev*. 2004;69(4):448–56.
- Frenette G, Légaré C, Saez F, Sullivan R. Macrophage migration inhibitory factor in the human epididymis and semen. *Mol Hum Reprod*. 2005;11(8):575–82.
- Gatti JL, Castella S, Dacheux F, Ecroyd H, Métayer S, Thimon V, Dacheux JL. Post-testicular sperm environment and fertility. *Anim Reprod Sci*. 2004;82–83:321–39. Review.
- Guyonnet B, Dacheux F, Dacheux JL, Gatti JL. The epididymal transcriptome and proteome provide some insights into new epididymal regulations. *J Androl*. 2011;32(6):651–64. doi:10.2164/jandrol.111.013086. Review.
- Haidl G, Opper C. Changes in lipids and membrane anisotropy in human spermatozoa during epididymal maturation. *Hum Reprod*. 1997;12(12):2720–3.
- Hall JC, Hadley J, Doman T. Correlation between changes in rat sperm membrane lipids, protein, and the membrane physical state during epididymal maturation. *J Androl*. 1991;12(1):76–87.
- Han Z, Wang Z, Cheng G, Liu B, Li P, Li J, Wang W, Yin C, Zhang W. Presence, localization, and origin of clusterin in normal human spermatozoa. *J Assist Reprod Genet*. 2012;29(8):751–7.
- Hirsh AV, Dean NL, Mohan PJ, Shaker AG, Bekir JS. Natural spermatozoa in irreversible obstructive azoospermia—reservoirs of viable spermatozoa for assisted conception. *Hum Reprod*. 1996;11(9):1919–22.
- Huszar G, Zeyneloglu HB, Vigue L. Cellular maturity and fertilising potential of sperm populations in natural and assisted reproduction. In: Gagnon C, editor. *The male gamete: from basic knowledge to clinical applications*. Illinois: Cache River Press; 1999. p. 385–96.
- Ilio KY, Hess RA. Structure and function of the ductuli efferentes: a review. *Microsc Res Tech*. 1994;29(6):432–67. Review.
- Jenkins AD, Lechene CP, Howards SS. Concentrations of seven elements in the intraluminal fluids of the rat seminiferous tubules, rete testis, and epididymis. *Biol Reprod*. 1980;23(5):981–7.
- Johnson L, Varner DD. Effect of daily spermatozoan production but not age on transit time of spermatozoa through the human epididymis. *Biol Reprod*. 1988;39(4):812–7.
- Jones R. Sperm survival versus degradation in the mammalian epididymis: a hypothesis. *Biol Reprod*. 2004;71(5):1405–11. Review.

- Jones RC, Dacheux JL, Nixon B, Ecroyd HW. Role of the epididymis in sperm competition. *Asian J Androl.* 2007;9(4):493–9. Review.
- Joshi CS, Suryawanshi AR, Khan SA, Balasinar NH, Khole VV. Liprin  $\alpha$ 3: a putative estrogen regulated acrosomal protein. *Histochem Cell Biol.* 2013;139(4):535–48.
- Kimura M, Kim E, Kang W, Yamashita M, Saigo M, Yamazaki T, Nakanishi T, Kashiwabara S, Baba T. Functional roles of mouse sperm hyaluronidases, HYAL5 and SPAM1, in fertilization. *Biol Reprod.* 2009;81(5):939–47.
- Kirchhoff C, Hale G. Cell-to-cell transfer of glycosylphosphatidylinositol-anchored membrane proteins during sperm maturation. *Mol Hum Reprod.* 1996;2(3):177–84. Review.
- Kirchhoff C. Molecular characterization of epididymal proteins. *Rev Reprod.* 1998;3(2):86–95. Review.
- Krapf D, Ruan YC, Wertheimer EV, Battistone MA, Pawlak JB, Sanjay A, Pilder SH, Cuasnicu P, Breton S, Visconti PE. cSrc is necessary for epididymal development and is incorporated into sperm during epididymal transit. *Dev Biol.* 2012;369(1):43–53.
- Krege JH, Hodgin JB, Couse JF, Enmark E, Warner M, Mahler JF, Sar M, Korach KS, Gustafsson JA, Smithies O. Generation and reproductive phenotypes of mice lacking estrogen receptor beta. *Proc Natl Acad Sci U S A.* 1998;95(26):15677–82.
- Krutsikh A, Poliandri A, Cabrera-Sharp V, Dacheux JL, Poutanen M, Huhtaniemi I. Epididymal protein Rnase10 is required for post-testicular sperm maturation and male fertility. *FASEB J.* 2012;26(10):4198–209.
- Kujala M, Hihnala S, Tienari J, Kaunisto K, Hästbacka J, Holmberg C, Kere J, Höglund P. Expression of ion transport-associated proteins in human efferent and epididymal ducts. *Reproduction.* 2007;133(4):775–84.
- Leung GP, Tse CM, Chew SB, Wong PY. Expression of multiple Na<sup>+</sup>/H<sup>+</sup> exchanger isoforms in cultured epithelial cells from rat efferent duct and cauda epididymidis. *Biol Reprod.* 2001;64(2):482–90.
- Liu Y, Wang DK, Chen LM. The physiology of bicarbonate transporters in mammalian reproduction. *Biol Reprod.* 2012;86(4):99. Review.
- Lotti F, Maggi M. Ultrasound of the male genital tract in relation to male reproductive health. *Hum Reprod Update.* 2015;21(1):56–83. doi:10.1093/humupd/dmu042. Review.
- Lu S, Cui Y, Li X, Zhang H, Liu J, Kong B, Cai F, Chen ZJ. Association of cystic fibrosis transmembrane-conductance regulator gene mutation with negative outcome of intracytoplasmic sperm injection pregnancy in cases of congenital bilateral absence of vas deferens. *Fertil Steril.* 2014;101(5):1255–60.
- Lubahn DB, Moyer JS, Golding TS, Couse JF, Korach KS, Smithies O. Alteration of reproductive function but not prenatal sexual development after insertional disruption of the mouse estrogen receptor gene. *Proc Natl Acad Sci U S A.* 1993;90(23):11162–6.
- Ma W, Xie S, Ni M, Huang X, Hu S, Liu Q, Liu A, Zhang J, Zhang Y. MicroRNA-29a inhibited epididymal epithelial cell proliferation by targeting nuclear autoantigenic sperm protein (NASP). *J Biol Chem.* 2012;287(13):10189–99.
- Marushige Y, Marushige K. Phosphorylation of sperm histone during spermiogenesis in mammals. *Biochim Biophys Acta.* 1978;518(3):440–9.
- Mieusset R, Quintana Casares PI, Sanchez-Partida LG, Sowerbutts SF, Zupp JL, Setchell BP. The effects of moderate heating of the testes and epididymides of rams by scrotal insulation on body temperature, respiratory rate, spermatozoa output and motility, and on fertility and embryonic survival in ewes inseminated with frozen semen. *Ann N Y Acad Sci.* 1991;637:445–58.
- Moura AA, Chapman DA, Koc H, Killian GJ. Proteins of the cauda epididymal fluid associated with fertility of mature dairy bulls. *J Androl.* 2006;27(4):534–41.
- Müller-Tyl E, Deutinger J, Reinthaller A, Fischl F, Riss P, Lunglmayr G. In vitro fertilization with spermatozoa from alloplastic spermatocele. *Fertil Steril.* 1990;53(4):744–6.
- Nikolopoulou M, Soucek DA, Vary JC. Changes in the lipid content of boar sperm plasma membranes during epididymal maturation. *Biochim Biophys Acta.* 1985;815(3):486–98.

- Nixon B, Stanger SJ, Mihalas BP, Reilly JN, Anderson AL, Tyagi S, Holt JE, McLaughlin EA. The microRNA signature of mouse spermatozoa is substantially modified during epididymal maturation. *Biol Reprod*. 2015;93(4):91.
- Noblañc A, Kocer A, Chabory E, Vernet P, Saez F, Cadet R, Conrad M, Drevet JR. Glutathione peroxidases at work on epididymal spermatozoa: an example of the dual effect of reactive oxygen species on mammalian male fertilizing ability. *J Androl*. 2011;32(6):641–50. Review.
- Oh J, Woo JM, Choi E, Kim T, Cho BN, Park ZY, Kim YC, Kim DH, Cho C. Molecular, biochemical, and cellular characterization of epididymal ADAMs, ADAM7 and ADAM28. *Biochem Biophys Res Commun*. 2005;331(4):1374–83.
- Oh JS, Han C, Cho C. ADAM7 is associated with epididymosomes and integrated into sperm plasma membrane. *Mol Cell*. 2009;28(5):441–6.
- O'rand MG, Widgren EE, Sivashanmugam P, Richardson RT, Hall SH, French FS, VandeVoort CA, Ramachandra SG, Ramesh V, Jagannadha RA. Reversible immunocontraception in male monkeys immunized with eppin. *Science*. 2004;306(5699):1189–90.
- Parks JE, Hammerstedt RH. Development changes occurring in the lipids of ram epididymal spermatozoa plasma membrane. *Biol Reprod*. 1985;32(3):653–68.
- Pastor-Soler N, Beaulieu V, Litvin TN, Da Silva N, Chen Y, Brown D, Buck J, Levin LR, Breton S. Bicarbonate-regulated adenylyl cyclase (sAC) is a sensor that regulates pH-dependent V-ATPase recycling. *J Biol Chem*. 2003;278(49):49523–9.
- Pietrement C, Sun-Wada GH, Silva ND, McKee M, Marshansky V, Brown D, Futai M, Breton S. Distinct expression patterns of different subunit isoforms of the V-ATPase in the rat epididymis. *Biol Reprod*. 2006;74(1):185–94.
- Pyttel S, Nimptsch A, Böttger J, Zschörnig K, Jakop U, Wegener J, Müller K, Raymond AS, Elder B, Ensslin M, Shur BD. Loss of SED1/MFG-E8 results in altered luminal physiology in the epididymis. *Mol Reprod Dev*. 2010;77(6):550–63.
- Pyttel S, Nimptsch A, Böttger J, Zschörnig K, Jakop U, Wegener J, Müller K, Paasch U, Schiller J. Changes of murine sperm phospholipid composition during epididymal maturation determined by MALDI-TOF mass spectrometry. *Theriogenology*. 2014;82:396–402.
- Raymond AS, Elder B, Ensslin M, Shur BD. Loss of SED1/MFG-E8 results in altered luminal physiology in the epididymis. *Mol Reprod Dev*. 2010;77(6):550–63.
- Regalado F, Esponda P, Nieto A. Temperature and androgens regulate the biosynthesis of secretory proteins from rabbit cauda epididymidis. *Mol Reprod Dev*. 1993;36(4):448–53.
- Rejraji H, Sion B, Prensier G, Carreras M, Motta C, Frenoux JM, Vericel E, Grizard G, Vernet P, Drevet JR. Lipid remodeling of murine epididymosomes and spermatozoa during epididymal maturation. *Biol Reprod*. 2006;74(6):1104–13. Erratum in: *Biol Reprod*. 2006;75(2):306.
- Robaire B, Chan P. What does the epididymis do and how does it do it? In: Hinton BT, editor. *Handbook of andrology*. 2nd ed. Lawrence: Allen Press; 2010. p. 10–5.
- Robaire B, Syntin P, Jervis K. The coming of age of the epididymis. In: Jegou B, editor. *Testis, epididymis and technologies in the year 2000*. New York: Springer-Verlag; 2000. p. 229–62.
- Robaire B, Seenundun S, Hamzeh M, Lamour SA. Androgenic regulation of novel genes in the epididymis. *Asian J Androl*. 2007;9(4):545–53. Review.
- Rodríguez CM, Labus JC, Hinton BT. Organic cation/carnitine transporter, OCTN2, is differentially expressed in the adult rat epididymis. *Biol Reprod* 2002;67(1):314–319.
- Ruz R, Gregory M, Smith CE, Cyr DG, Lubahn DB, Hess RA, Hermo L. Expression of aquaporins in the efferent ductules, sperm counts, and sperm motility in estrogen receptor-alpha deficient mice fed lab chow versus casein. *Mol Reprod Dev*. 2006;73(2):226–37.
- Schagdarsurengin U, Western P, Steger K, Meinhardt A. Developmental origins of male subfertility: role of infection, inflammation, and environmental factors. *Semin Immunopathol*. 2016;38(6):765–781. [Epub ahead of print] Review.
- Serre V, Robaire B. Distribution of immune cells in the epididymis of the aging Brown Norway rat is segment-specific and related to the luminal content. *Biol Reprod*. 1999;61(3):705–14.
- Sharma U, Conine CC, Shea JM, Boskovic A, Derr AG, Bing XY, Belleannee C, Kucukural A, Serra RW, Sun F, Song L, Carone BR, Ricci EP, Li XZ, Fauquier L, Moore MJ, Sullivan R,

- Mello CC, Garber M, Rando OJ. Biogenesis and function of tRNA fragments during sperm maturation and fertilization in mammals. *Science*. 2016;351(6271):391–6.
- Sullivan R. Epididymosomes: a heterogeneous population of microvesicles with multiple functions in sperm maturation and storage. *Asian J Androl*. 2015;17(5):726–9.
- Sullivan R, Saez F. Epididymosomes, prostasomes, and liposomes: their roles in mammalian male reproductive physiology. *Reproduction*. 2013;146(1):R21–35. Review.
- Sullivan R, Saez F, Girouard J, Frenette G. Role of exosomes in sperm maturation during the transit along the male reproductive tract. *Blood Cells Mol Dis*. 2005;35(1):1–10. Review.
- Sutovsky P, Moreno R, Ramalho-Santos J, Dominko T, Thompson WE, Schatten G. A putative, ubiquitin-dependent mechanism for the recognition and elimination of defective spermatozoa in the mammalian epididymis. *J Cell Sci*. 2001;114(Pt 9):1665–75.
- Takeo T, Fukumoto K, Kondo T, Haruguchi Y, Takeshita Y, Nakamuta Y, Tsuchiyama S, Yoshimoto H, Shimizu N, Li MW, Kinchen K, Vallelunga J, Lloyd KC, Nakagata N. Investigations of motility and fertilization potential in thawed cryopreserved mouse sperm from cold-stored epididymides. *Cryobiology*. 2014;68(1):12–7.
- Tamburrino L, Marchiani S, Montoya M, Elia Marino F, Natali I, Cambi M, Forti G, Baldi E, Muratori M. Mechanisms and clinical correlates of sperm DNA damage. *Asian J Androl*. 2012;14(1):24–31. Review.
- Tollner TL, Venners SA, Hollox EJ, Yudin AI, Liu X, Tang G, Xing H, Kays RJ, Lau T, Overstreet JW, Xu X, Bevins CL, Cherr GN. A common mutation in the defensin DEFB126 causes impaired sperm function and subfertility. *Sci Transl Med*. 2011;3(92):92ra65. Erratum in: *Sci Transl Med*. 2014;6(236):236er3. *Sci Transl Med*. 2011;(94):94er5.
- Turner TT. Resorption versus secretion in the rat epididymis. *J Reprod Fertil*. 1984;72(2):509–14.
- Turner TT. Spermatozoa are exposed to a complex microenvironment as they traverse the epididymis. *Ann N Y Acad Sci*. 1991;637:364–83. Review.
- Turner TT, Bomgardner D, Jacobs JP, Nguyen QA. Association of segmentation of the epididymal interstitium with segmented tubule function in rats and mice. *Reproduction*. 2003;125(6):871–8.
- Vignozzi L, Filippi S, Morelli A, Luconi M, Jannini E, Forti G, Maggi M. Regulation of epididymal contractility during semen emission, the first part of the ejaculatory process: a role for estrogen. *J Sex Med*. 2008;5(9):2010–6; Review. Erratum in: *J Sex Med*. 2008;5(10):2480.
- Vijayaraghavan S, Bhattacharyya A, Hoskins DD. Calcium uptake by bovine epididymal spermatozoa is regulated by the redox state of the mitochondrial pyridine nucleotides. *Biol Reprod*. 1989;40(4):744–51.
- Wang J, Ruan K. miR-200c affects the mRNA expression of E-cadherin by regulating the mRNA level of TCF8 during post-natal epididymal development in juvenile rats. *Acta Biochim Biophys Sin Shanghai*. 2010a;42(9):628–34.
- Wang J, Ruan K. miR-335 is involved in the rat epididymal development by targeting the mRNA of RASA1. *Biochem Biophys Res Commun*. 2010b;402(2):222–7.
- Wennemuth G, Carlson AE, Harper AJ, Babcock DF. Bicarbonate actions on flagellar and Ca<sup>2+</sup>-channel responses: initial events in sperm activation. *Development*. 2003;130(7):1317–26.
- Wong PY, Yeung CH. Absorptive and secretory functions of the perfused rat cauda epididymidis. *J Physiol*. 1978;275:13–26.
- Wu X, Zhao B, Li W, Chen Y, Liang R, Li L, Jin Y, Ruan K. MiR-200a is involved in rat epididymal development by targeting  $\beta$ -catenin mRNA. *Acta Biochim Biophys Sin Shanghai*. 2012;44(3):233–40.
- Xu WM, Shi QX, Chen WY, Zhou CX, Ni Y, Rowlands DK, Yi Liu G, Zhu H, Ma ZG, Wang XF, Chen ZH, Zhou SC, Dong HS, Zhang XH, Chung YW, Yuan YY, Yang WX, Chan HC. Cystic fibrosis transmembrane conductance regulator is vital to sperm fertilizing capacity and male fertility. *Proc Natl Acad Sci U S A*. 2007;104(23):9816–21.
- Yenugu S, Hamil KG, French FS, Hall SH. Antimicrobial actions of the human epididymis 2 (HE2) protein isoforms, HE2alpha, HE2beta1 and HE2beta2. *Reprod Biol Endocrinol*. 2004;2:61.
- Zhou Q, Clarke L, Nie R, Carnes K, Lai LW, Lien YH, Verkman A, Lubahn D, Fisher JS, Katzenellenbogen BS, Hess RA. Estrogen action and male fertility: roles of the sodium/

- hydrogen exchanger-3 and fluid reabsorption in reproductive tract function. *Proc Natl Acad Sci U S A*. 2001;98(24):14132–7.
- Zhou Q, Nie R, Prins GS, Saunders PT, Katzenellenbogen BS, Hess RA. Localization of androgen and estrogen receptors in adult male mouse reproductive tract. *J Androl*. 2002;23(6):870–81.
- Zhou YS, Webb S, Lettice L, Tardif S, Kilanowski F, Tyrrell C, Macpherson H, Semple F, Tennant P, Baker T, Hart A, Devenney P, Perry P, Davey T, Barran P, Barratt CL, Dorin JR. Partial deletion of chromosome 8  $\beta$ -defensin cluster confers sperm dysfunction and infertility in male mice. *PLoS Genet*. 2013;9(10):e1003826.

---

## **Part II**

# **Clinical Approach to the Disorders of Male Reproduction**

Francesco Lombardo,  
Francesco Pallotti, Francesco Cargnelutti, and Andrea Lenzi

---

## Abstract

Anamnesis, i.e., the medical history, and physical examination are essential in every branch of medicine, including andrology. Regardless of the reason that leads a patient to the andrological visit, the first step must be the complete and comprehensive collection of information which will serve to guide the specialist for a diagnosis and, therefore, a therapy. An accurate andrological examination includes inspection and palpation of the entire genital area. However, they may cause the patient some embarrassment and discomfort. Every moment of the visit, from the opening the conversation to the physical examination, can be hindered by shyness and modesty since the medical act invades the genital area and sexuality. Any issue about the genital area, sexually transmitted infections, and sexual life can be difficult topics for the patient to discuss. In general, men are less prepared to disclose intimate details than women, independent of their age, feel awkward when asked about them, and are worried that talking about intimate issues is not acceptable. Therefore, patients require empathy, expertise (a specialist in the sexual field, e.g., reduces wariness, when talking about sexual issues), accurate up-to-date information, positive body language (eye contact, gentle attention), and acceptance of sexual behavior.

---

## Keywords

Medical history • Physical examination

---

F. Lombardo (✉) • F. Cargnelutti  
Department of Experimental Medicine, University of Rome “La Sapienza”, Rome, Italy  
e-mail: [francesco.lombardo@uniroma1.it](mailto:francesco.lombardo@uniroma1.it)

F. Pallotti • A. Lenzi  
Department of Experimental Medicine, Laboratory of Seminology-Sperm Bank, University of Rome “La Sapienza”, Rome, Italy



## Contents

Introduction .....	482
Medical History .....	482
Doctor-Patient Relationship .....	484
Advantages of an Effective Communication .....	485
General Physical Examination .....	486
Andrological Physical Examination .....	487
Penis .....	488
Rectal Examination .....	490
Breast Exam .....	491
Most Common Pathologies in Male Reproductive Endocrinology Disorders .....	491
References .....	493

## Introduction

*Semiotics* is the branch of medicine that studies which are the symptoms (subjective) and signs (objective) of the disease and how they integrate to reach the elaboration of a diagnosis. Broadly speaking, semiotics is the study of both medical history and physical examination, possibly enriched by the findings of laboratory tests and of other instrumental diagnostic techniques. Semiotics can be divided in different branches: there is a *physical semiotics*, represented by history and physical examination; a *laboratory semiotics*, which uses blood samples, other body fluids (urine, semen, etc.), and tissue samples, to carry out various diagnostic tests; and *instrumental semiotics* (ultrasound, radiological, etc.) that focuses on the instrumental evaluation of the body.

## Medical History

Regardless of the reason that leads a patient to the andrological visit, the first step must be the complete and comprehensive collection of information which will serve to guide the specialist for the diagnosis and, therefore, the therapy. A comprehensive medical history, or anamnesis, includes the structured collection of information of diagnostic interest related to the patient's personal history (e.g., the type of childbirth and breastfeeding received, first steps, first words, age of sexual development, any pregnancies, menopause, type of work, voluptuary habits, regularity of physiological functions) and of his family.

Classical semiotics distinguishes several stages:

- *Family diseases*: it includes information related to the patient's family health (parents, grandparents, other relatives) such as any disease and the presence of recurrent disease (genetic or otherwise).
- *Physiological anamnesis*: it is the accurate description of the clinical "physiological" history of the patient, focusing on the type of childbirth and breastfeeding received, the presence of cryptorchidism, first steps, first words, age of sexual

development, type of work, habits/addictions (smoking, coffee, alcohol, recreational drugs), and regularity of physiological functions.

- *Educational/occupational anamnesis*: a complete medical history should include information regarding educational (school attendance, degree, etc.) and occupational status in order to define the patient's ability to understand medical information and to comply to the prescriptions; the occupational status may also be informative about professional exposure to pollutants and toxic substances.
- *Past medical history*: it should include all diseases and injuries in which the patient has suffered, including an indication of hospitalizations and any surgical interventions; special attention should be paid to the presence of any allergies, to drug intolerance, and to routinely taken therapy.
- *History of the present illness and chief complaint*: it consists in the careful description of symptoms in place, pushing the patient to search for medical examination.
- *Reproductive and sexual anamnesis*: a complete andrological interview should always include questions about sexual desire (Has the patient noted a reduction of sexual desire? From when? Does he associate it with particular conditions?), erectile function (especially morning erections should be investigated, because of their correlation with testosterone levels), head and testicular trauma, and sexual activity (Is the patient in a stable relationship? How many sexual intercourses in a week? Pregnancies or abortions in the medical history of the partner?) (see Table 1).

The clinician should pay a lot of attention to the patient's report of his pathologies. It is essential to guide the patient in this mnemonic process, without haste, with the formulation of general questions in a first moment and eventually asking more specific ones, until the identification of the problem. "Closed" questions should be avoided, in order to minimize the risk that the patient is misled not to refer signs and/or symptoms that may be helpful in the diagnosis process. Also, patient's perception of the physician and, thus, its degree of satisfaction and openness can vary greatly due to the doctor's behavior. For example, if during the interview, the

**Table 1** Andrological history checklist

Important things to ask in andrological history	
Cryptorchidism	<input checked="" type="checkbox"/>
Age of sexual development	<input checked="" type="checkbox"/>
Head/testicular trauma	<input checked="" type="checkbox"/>
Genital/abdominal surgery and diseases	<input checked="" type="checkbox"/>
Occupation	<input checked="" type="checkbox"/>
Exposure to toxic substances and/or pollutants	<input checked="" type="checkbox"/>
Sexual desire	<input checked="" type="checkbox"/>
Erectile function (morning erections, during intercourses, etc.)	<input checked="" type="checkbox"/>
Sexual activity	<input checked="" type="checkbox"/>

doctor is sitting and appears to be listening carefully, the patient may tend to appreciate the committed time and to perceive the visit as longer and more satisfying. Instead, if the doctor is standing, frequently checking the time at his watch, this is often interpreted negatively by the patient. The greatest risk, in fact, is the loss of the relationship between the physician and patient, to which many factors contribute, especially practicing a medicine increasingly dependent from instrumental and laboratory analysis. It allows the most accurate diagnosis and the most effective therapies, but at the cost of the time committed to explain the situation and to empathize with the patient.

---

## Doctor-Patient Relationship

The clinical interview is the most useful tool in medicine (Ha et al. 2010). Communication between physician and patient can be carried out on different levels, emphasizing the biological component (“doctor/disease”-centered medicine) or paying special attention to both the patient and his/her feelings and sufferings (patient-centered medicine). While the first level can be referred to an old concept of paternalistic medicine, taking communication to the patient level is the cornerstone on which to set the helping relationship, promoting the so-called therapeutic alliance and achieving an adequate compliance. This cannot be obtained by the anamnesis alone, intended as a “simple” structured interview. It requires listening skills and empathic attitude, so that the patient can perceive the clinician as a person not only willing to cure his disease but also interested in listening to his concerns and taking care of his needs. That is why the developing of communication skills and experience of role-playing should find a place among the training activities of every clinician. These skills involve both style and content of communication. Attentive listening skills, empathy, and use of open-ended questions are some examples. Above all, empathy is one of the most powerful ways of providing this support to reduce patients’ feelings of isolation and validating their feelings or thoughts as normal and to be expected. Miscommunication, conversely, has serious implications, as it may hinder the patients’ understanding, expectations of treatment, or involvement in treatment planning. In addition, miscommunication decreases patient satisfaction with medical care and level of trust in the treatment. In fact, patients often perceive their doctors as the most important source of psychological support. The culmination of these abilities is found in the report of bad news to patients (e.g., the presence of a testicular cancer). It requires the ability to build a strong empathic relationship, a deep understanding of patients’ perspectives and expectations, as well as the ability to select only the relevant information for each patient (Baile et al. 2006).

In summary, the clinician must focus his attention from “treating” to “caring” (from “to treat” to “to care”). When the physician “treats,” he is focused mainly on the organism, its alterations, and on the most effective treatment. In this sense, the acquired skills and knowledge are considered not only necessary items but also sufficient for a correct and responsible professional practice. Therefore, the

physician is fully authorized to visit the body, to inspect it even in its most intimate and hidden parts, with invasive and unpleasant techniques, in order to identify the pathology and eliminate it.

When the physician “cares,” instead, the subject of the relationship is moved toward the patient and his needs. Essentially, the focus is no longer on the doctor and the pathology, but centers on the patient himself, and the empathic attitude of the clinician is expressed at this different level of communication. It may be facilitated by a natural personal disposition, but can also be learned through particular communication strategies.

Communication is especially important in andrology, because every moment of the patient’s visit from opening the conversation to the physical examination can be hindered by shyness and modesty, since the medical act invades the genital area and sexuality. An effective approach to the patient will make sure that an intimate question will be mentioned and discussed and that the medical advice will be accepted. Difficult topics for the patient to discuss could include any issue about the genital area (pain, tenderness), sexually transmitted infections, or sexual life.

In general, men are less prepared to disclose intimate details than women, independently of their age, feel awkward when asked about them, and consider talking about intimate issues unacceptable. However, effective communication can allow patients to abandon their inhibitions.

In fact, doctors are not simply expected to skillfully diagnose and treat sicknesses, but also to communicate about them effectively.

To achieve and maintain a good communication, the clinician must:

- Create a good interpersonal relationship.
- Facilitate the exchange of information.
- Include patients in decision making.

Inevitably the doctor’s “bedside manner” is judged by the patient as a major indicator of his general competence. Patients reporting good communication with their doctor are more likely to be satisfied with their care and will share pertinent information for accurate diagnosis of their problems, follow advice, and show better compliance with prescribed treatments.

To summarize, to establish a correct and fruitful communication, patients require empathy, expertise (a specialist in the sexual field, e.g., reduces wariness, when talking about sexual issues), accurate up-to-date information, positive body language (eye contact, gentle attention), and acceptance of sexual behavior.

## **Advantages of an Effective Communication**

By the nature of his role, a physician is invariably in a unique position of respect and power, and effective and emphatic communication can be a source of motivation, incentive, reassurance, and support for the patient. In fact, a good doctor-patient relationship can increase job satisfaction and improve the clinician’s attitude toward

the patient and will have a positive effect that reinforces the relationship and strengthens the patients' self-confidence, motivation, and positive view of their health status, which ultimately may influence their health outcome.

There is evidence that doctors with better communication and interpersonal skills are able to detect problems earlier, can prevent medical crises and expensive intervention, and provide better support to their patients. Patient's satisfaction is higher, hand in hand with higher-quality outcomes, lower costs of care, greater patient understanding of health issues, and better adherence to the treatment process. Current practice is justifiably marked with a greater expectation of collaborative decision making, with physicians and patients equally participating to achieve the goals of the clinical relationship and the improvement of quality of life.

Since an effective communication has become the cornerstone of the doctor-patient therapeutic alliance, it is also the central component in the delivery of health care.

---

## General Physical Examination

When the preliminary interview is finished, the next step is the physical examination: general state, fat distribution, hair distribution, and volume and sensitivity of testicles, penis, breasts, and prostate (the latter by digital examination). Obviously, the examination will be targeted to specific organs according to the symptoms and the individual case.

General physical examination is the report of the findings of the visit; it includes vital signs (such as breath, posture, state of the skin and mucous membranes, pulse, blood pressure, temperature) and the systematic description of the various parts of the body (head, neck, chest, heart, abdomen, limbs, neurological status, etc.). It is advisable to focus on specific parts of the body (local physical examination, more detailed and targeted at the site of the investigated disease) only after the general examination (Kasper et al. 2015).

More specifically, for physical examination, semiotics typically recognizes four different moments: *inspection*, *palpation*, *percussion*, and *auscultation*:

- **Inspection:** inspection means to observe the patient for useful information. The clinician should collect all obtainable information "at a glance," as obvious as they may seem. Indeed, the inspection starts when the patient enters the doctor's office. At first, the physician makes notes of sex and age (most diseases are age- and gender-related), gait, and posture. In addition, the physician can determine the degree of nutrition and hydration of the patient and measure vital signs (heart rate or pulse, respiratory rate, body temperature, blood pressure). Observation can identify a particular "*facies*," that is, the facial appearance, revealing the set of color and condition of the skin, expression, etc. which may be typical of certain diseases. At the end, the physician inspects the cutaneous annexes (like nails and hair) and the general conformation of specific areas of the body, recording the presence of asymmetries, swellings, etc.

- **Palpation** indicates the evaluation with the touch of one or more regions of the body in order to recognize normal or pathological situations. It must be superficial at first and then deep. It allows to identify the nature of many masses or swelling (e.g., it may be useful to distinguish an hernia from an abscess). Specific maneuvers can be performed to evoke signs that, if present, can be very helpful for the diagnosis of specific diseases (e.g., causing pain when applying pressure at McBurney's point is a typical clinical sign of acute appendicitis).
- **Percussion** is done with the middle finger of one hand (plexor) striking on the middle finger of the other hand (pleximeter) firmly placed on the body over tissue. The aim is to produce a sound that will be specific for each body area. Sounds are basically of two types: dull sound, typical of full organs (parenchymatous organs), and resonant sound, typical of the hollow organs (when air is present). The presence of a different sound from the one expected suggests a pathological situation. The percussion is usually performed on the chest (being careful to strike only on the intercostal spaces) and abdominal area.
- **Auscultation** is performed using a stethoscope. It can distinguish the physiological noises, which are normally produced by the working organs (e.g., heartbeat), from the abnormal noises, normally not present (such as wheeze, rhonchi, stridor, crackles, etc.). Auscultation is usually performed on the chest (for examination of the heart and lungs), abdominal area, and arteries (in order to identify bruits).

In general, physical examination should always be carried out on the patient, to minimize the risk of not recognizing pathologies that could have negative repercussions on his health. Obviously, in clinical practice an andrologist also has to focus specifically on the genitourinary system.

---

## Andrological Physical Examination

It is mandatory to perform an accurate andrological examination. To blindly prescribe instrumental or laboratory testing is, in the best case, a waste of resources, time, and money. Therefore, after making a general physical examination, if possible guided by some symptoms reported in the anamnesis, the andrologist must focus on examination of the reproductive apparatus. Undoubtedly, some patients may be more reluctant to be examined, because of cultural preconceptions and personal modesty. It may cause the patient some embarrassment as well as discomfort. However, it is necessary to inform them that making the visit is essential in order to achieve correct diagnosis (Carlsen et al. 2000).

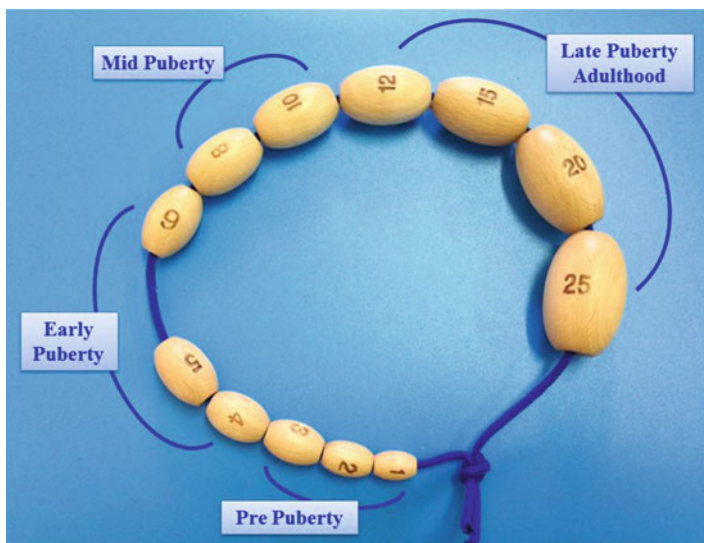
Physical examination starts by asking the patient to remove the underwear, if he has not already done so. This examination may be easier to perform if it is done with the patient standing while the physician is seated in front of him. However, it can also be performed while he lies on the examination table. At first, the entire genital area should be inspected, looking for bulges, scars, or any skin abnormalities (such as pigmented areas, ulcers, vesicles, etc.). After general inspection, it is possible to

focus on the penis and scrotum (Hafez et al. 2005; Nieschlag et al. 2009; Schill et al 2006).

## Penis

At first the glans should be inspected. If the patient is not circumcised, it should be exposed by drawing back the foreskin, so that the glans can be observed in its entirety. Occasionally retracting the foreskin from the head of the penis can be very difficult or even impossible (phimosis). Then, the opening of the urethra should be inspected. It may be debouched on the dorsal surface of the penis (a condition known as epispadias) or on the ventral surface (hypospadias). Secretions and signs of inflammation such as erythema, swelling, and tenderness are suggestive of urethritis or balanoposthitis, often caused by gonorrhea, *Chlamydia*, or *Candida*. After the inspection, palpation should be done along the shaft of the penis, looking for firm or hard areas; fibrosis (Peyronie's disease) may be recognized by the presence of plaques and penile curvature.

**Testicle:** the two testes are normally larger than 12 ml. Testicular size may be estimated by several means, of which Prader's orchidometer (Fig. 1), a set of oval beads with default volume, is probably the most used. When using Prader's orchidometer, one testis is palpated by one hand and is compared with different sizes of ellipsoids in the other hand. However, this method is very subjective and literature reports large interobserver variation. For this reason, ultrasonography is often considered important for the precise evaluation of testicular volume, obtaining



**Fig. 1** Prader's orchidometer

the three orthogonal diameters and applying ellipsoid formula for volume calculation. Testicular volume and pubic hair should be evaluated in order to define children's development. In general, the left testis lies a bit lower in the scrotum than the right. They may retract a bit up toward the inguinal canal if the room is particularly cold (cremasteric reflex). Palpation should be gentle, using the thumb and next two fingers. It is advisable to ask the patient if he experiences any pain or discomfort during the examination. Both testicles should be of comparable size and consistency (normally a pliant, soft rubbery consistency). If there appears to be a single testis, the inguinal canal should be carefully examined in search for the location of an undescended testis. Any protrusions or lumps of the testis should be thoroughly investigated for testicular cancer, especially if there is a firm, hard nodule. In this case, ultrasonography is mandatory. When the entire scrotum seems to be enlarged, hydrocele may be the cause. It is a collection of fluid surrounding the testis. Transillumination can be used to distinguish hydrocele, which allows the transmission of light, from testicular tissue. Testicular lymphatic drainage runs to the intra-abdominal lymph nodes, which are not palpable. If inguinal lymph nodes are enlarged, penis or scrotum pathologies should be suspected.

**Epididymis:** it can be palpated as a structure which lies toward the top and back of each testis. Even if it is the most common source of acute and chronic scrotal pain, there are not standardized techniques which can be used to palpate it. Epididymis may be enlarged and painful, which can be caused by inflammation, infection, or even obstruction, especially in the case of chronic inflammation. Sometimes cysts can be found, frequently located in the head portion. Although they usually do not require surgery, periodic controls are recommended because they can enlarge. A hydatid of Morgagni ("appendix testis"), a rare formation, can be palpated and can be differentiated from cysts because of their mobility, while cysts are fixed on the head of the epididymis (Di Pierdomenico et al. 2014).

**Spermatic cord:** the spermatic cord is a structure that runs from the epididymis up through the inguinal canal and is formed by vas deferens, testicular artery/vein, nerves, lymphatics, and fatty tissue. Normally these structures cannot be clearly distinguished from each other, with the exception of vas deferens, which is firmer. Dilated veins, referred to as a varicocele, will be palpable throughout the length of the cord structures as a non-tender, twisted mass, sometimes similar to a bag of worms. The Valsalva maneuver can be very useful in order to investigate the presence of varicocele. It is performed by asking the patient to breathe out against a closed airway (usually closing the mouth and pinching the nose shut while pressing out as if blowing up a balloon), for a few seconds. Increasing intra-abdominal pressure, this maneuver increases the dilatation of the veins. According to Dubin, varicocele can be classified during the physical examination in grade I (not visible, palpable only with Valsalva maneuver), grade II (not visible, palpable without Valsalva maneuver), and grade III (visible through the scrotum and palpable without Valsalva maneuver).

**Inguinal canal:** during the genital examination, the inguinal canal area should always be investigated. It begins with the inspection of the inguinal region. It may be helpful to have the patient perform a Valsalva maneuver or cough while looking at



the inguinal region. In fact, the increase of the intra-abdominal pressure forces intestines, omentum, or peritoneal fluid through any opening which may exist and makes an hernia more apparent. Placing a finger along the spermatic cord allows to distinct where it emerges from the external ring of the inguinal canal. The tip of the index finger should be placed into this narrow opening while the other hand is placed over the inguinal canal, which runs obliquely toward the patient's anterior-superior iliac crest, or on top of any appreciably swollen area. As usual, if the patient performs a Valsalva maneuver, several signs should become more evident. Hernias are generally non-tender and variable in size (from barely palpable to massive swellings). The inability to place the bulge back into the abdomen and the presence of signs of acute inflammation, such as skin edema or redness, suggest incarceration or strangulation of the contents, which both require emergency surgery. Auscultation may allow the detection of bowel sounds, which usually confirm the diagnosis of inguinal hernia.

## **Rectal Examination**

Also known as digital rectal examination (DRE), it is the most invasive procedure; therefore, the patient should be instructed by the clinician about the procedure. The patient should turn around and be instructed to rest his chest on the examination table. There are several positions where the anus is accessible, such as lying on the side, bent over the examination table, or lying on the back with knees bent and lifted. At first, separating the cheeks of the buttocks has to be done in order to look for any skin abnormalities, fissures, hemorrhoids, or other bleeding sites. After the inspection, the digital rectal exam must be performed. It can provide information about many organs, like the bulb of the penis, the urogenital diaphragm, the anorectal ring, and the prostate. The delicate aspect of this exam should always be remembered, so it is recommended to proceed slowly and to explain every step to the patient. For the same reason, putting a lot of lubricant on the gloved index finger must never be forgotten. Then, the lubricated finger should be placed against the anus, but not inserted immediately. Bearing down may help the patient relaxing the external sphincter and decreasing discomfort. The finger should be gently pushed forward until it is entirely inside the anal canal. The muscular tone is then assessed; asking the patient to try to hold on the finger with the rectum may be useful. It can be diminished or absent in nervous system diseases, while it can be increased if a fissure is present, making it very difficult to penetrate the anal sphincter. After this, the canal should be explored looking for rectal-based masses; malignant tumors usually do not move. The prostate gland can be examined anteriorly through the wall of rectum. The prostate has two lobes with a cleft between them; it is important to identify any area firmer than the others, which is suspicious for malignancy. If the prostate does not seem to move freely but is fixed to the pelvis, it is highly suspicious for direct extension of a malignancy. Pain produced by pushing on the prostate gland is suggestive of inflammation; in this case prostate is usually enlarged, but this is a very subjective finding.

## Breast Exam

It starts with the inspection of the breast, which is usually easier while the patient sits up, searching for skin or nipple dimpling/retraction, discoloration, asymmetry, or tumefactions. Palpation has to be done with the pads, applying steady pressure, at first superficial, then medium, and then deep. Especially in young males, gynecomastia is frequent. It is a breast enlargement with soft and compressible glandular tissue palpated under the areola of the nipple, usually on both breasts. It has to be differentiated by pseudogynecomastia, which is due to abundant fat tissue. Gynecomastia is often physiological (more frequently in newborns, adolescents, older men), but it is necessary to exclude several conditions as liver or kidney failure, tumors (especially testicular tumors), and medications. Milky discharge from the nipple can orient the diagnosis toward a prolactin-secreting tumor. Breast cancer is rare, but not impossible in males. It usually appears as a firm, irregular, hard to delimit mass. Following direct palpation of the breast, the axillary region should be investigated, because the axillary lymph nodes are usually the first site of spread in the setting of breast cancer. It may be helpful to have the patient lower his arm, so it is next to its side with the hand behind the head. Any abnormal nodules or lumps should be investigated, making note especially of their firmness and mobility. Axillary lymph nodes are usually not palpable; painful adenopathy with normal consistency instead suggests infections.

---

## Most Common Pathologies in Male Reproductive Endocrinology Disorders

**Hypogonadism:** male hypogonadism is a condition characterized by low production of testosterone. It may be caused by testicular failure (hypergonadotropic hypogonadism) or by hypothalamic/pituitary failure (hypogonadotropic hypogonadism). Signs and symptoms are extremely different, depending on the cause and age of its occurrence. Affected adults often complain the absence or reduction of sexual interest (libido), poor sexual function (like the inability to obtain or sustain an erection), and decreased body hair growth. Unusual growth of breasts may also be rarely seen in these subjects. Physical examination is usually normal but it can be very helpful to identify the underlying cause. Affected children have instead a delayed growth spurt in comparison to their peers, and clinical examinations in these subjects usually confirm incomplete sexual maturation (prepubertal testicular volume often associated with a small penis) (Tables 2 and 3). Eunuchoid body habitus (disproportionally long arms when compared to height), decreased body hair growth, decreased muscle mass, and gynecomastia are frequent. The degree of pubertal maturation can vary considerably with some individuals lacking any sign of puberty, whereas others may have partial pubertal features.

*Kallmann syndrome:* it is an example of hypogonadotropic hypogonadism. It is a genetic condition characterized by hypogonadism and anosmia, due to lack of GnRH (gonadotrophin-releasing hormone) normally produced by the hypothalamus.

**Table 2** Tanner stages of genitalia development (Marshall and Tanner 1970)

Tanner stages of pubertal maturation – genitalia development	
Stage 1	Preadolescent, the vellus over the pubes is no more developed than that over the abdominal wall (no pubic hair)
Stage 2	Sparse growth of long, slightly pigmented, downy hair, straight or only slightly curled, appearing in particular at the base of the penis
Stage 3	Considerably darker, coarser, and more curled hair grows, spreading sparsely over the junction of the pubes
Stage 4	Additional penis enlargement in length and largeness with development of glans, testes, and scrotum are further increased, darkening of the scrotal skin
Stage 5	Genitalia has become adult in size and shape; no other enlargement takes place after Stage 5 is reached

**Table 3** Tanner stages of pubic hair development (Marshall and Tanner 1970)

Tanner stages of pubertal maturation – pubic hair development	
Stage 1	Preadolescent: testes, scrotum, and penis are of about the same size and proportion as in early childhood
Stage 2	The scrotum and testes have enlarged, and there is a change in the consistency of the scrotal skin (>4 ml); there is also some reddening of it
Stage 3	Growth of the penis has occurred, at first mainly in length but with some increase in largeness; further growth of testes and scrotum is present
Stage 4	Hair is now adult in type, but the area covered is still considerably smaller than in most adults, no spread to the medial surface of the thighs
Stage 5	Adult in quantity and type; hair spreads to the medial surface of the thighs but not up the linea alba or elsewhere above the base

It usually manifests with delayed puberty. Many patients also exhibit a spectrum of nonhormonal features, such as midline facial defects (e.g., cleft lip and/or palate), short fingers (especially the fourth finger), deafness, eye movement abnormalities, poor balance (due to cerebellar ataxia), scoliosis (bent spine), and many others.

*Klinefelter syndrome*: it is an example of hypergonadotropic hypogonadism. It is a genetic condition in which there is at least one additional X chromosome (sometimes, also multiple Y chromosomes can exist). It causes abnormal development of the testicles, which become atrophic and nonfunctioning. For this reason, they are very small and firm, which is the most characteristic physical sign of this syndrome. The other typical features of hypogonadism are usually associated. Moreover, malformations such as hypospadias, prognathism, and radioulnar synostosis may be present.

**Cryptorchidism**: it is the absence of one or both testes from the scrotum. The testicles normally develop inside the abdomen and usually move down into the scrotum before birth. Sometimes, this does not occur. However, in most cases, the testicles descend by the child's first 3 months of life. An undescended testicle that remains outside the scrotum throughout childhood can result in abnormal testicular development. For this reason, therapy for an undescended testicle should begin

between 6 months and 2 years of age and may consist of hormonal or surgical treatment, depending on the position of the testicle. Physical exam can be very difficult and the entire inguinal canal has to be explored in order to identify the correct place. If not palpable, intra-abdominal location must be suspected and the femoral region and perineum should be investigated. In childhood, it is important to distinguish the ascending testis syndrome (a previously normal testicle can ascend and remain permanently in the inguinal canal) that requires surgery from retractile testes (prepubertal boys often have an exaggerated cremasteric reflex, and the testis may retract out of the scrotum because of cold, excitement, or physical activity, descending when relaxed and warm or by handling) that do not require any therapy.

**Testicular torsion:** it is an emergency situation in which the spermatic cord twists. As a result, blood flow is affected and the tissues in the testicle begin to suffer from ischemic damage. Testicular torsion most frequently occurs in adolescents, often involving retractile testes. Early diagnosis and treatment are necessary in order to save the testicle. Diagnosis is often clinical, in most cases confirmed by ultrasonography. Surgical treatment or manual detorsion must be performed quickly to prevent testicular damage and atrophy. Severe and acute pain is the main symptom the patient experiences; dizziness, nausea, and vomiting may also exist. Physical examination shows swelling and redness of the entire testicle, which can be limited to one side. The most characteristic aspect of the physical exam is that the painful and swollen testicle is higher than the other, because of the spermatic cord's twisting; it is usually useful to differentiate testicular torsion from other causes of acute testicular pain like orchitis. When used, ultrasonography shows lower than normal blood flow to the testes. Manual detorsion can be tried, but surgery is more often performed, allowing at the same time to untwist the spermatic cord and sew both testicles to the scrotum in order to prevent future recurrence.

---

## References

- Baile WF, Buckman R, Schapira L, Parker PA. Breaking bad news: more than just guidelines. *J Clin Oncol.* 2006;24(19):3217.
- Carlsen E, Andersen AG, Buchreitz L, Jørgensen N, Magnus O, Matulevicius V, Nerøen I, Petersen JH, Punab M, Suominen J, Zilaitiene B, Giwercman A. Inter-observer variation in the results of the clinical andrological examination including estimation of testicular size. *Int J Androl.* 2000;23(4):248–53.
- Di Pierdomenico A, Beiko D. Physical examination of the epididymis made easy: a novel, reproducible and structured approach. *Can J Urol.* 2014;21(4):7396–8.
- Ha JF, Longnecker N. Doctor-patient communication: a review. *Ochsner J.* 2010;10(1):38–43.
- Hafez ES, Hafez SD. *Atlas of clinical andrology.* Boca Raton: CRC Press; 2005.
- Kasper DL, Fauci AS, Hauser SL, Longo DL, Jameson JL, Loscalzo J. *Harrison's principles of internal medicine.* 19th ed. New York: McGraw-Hill Education; 2015.
- Marshall WA, Tanner JM. Variations in the pattern of pubertal changes in boys. *Arch Dis Child.* 1970;45(239):13–23.
- Nieschlag E, Behre HM, Nieschlag S. *Andrology: male reproductive health and dysfunction.* 3rd ed. Berlin: Springer; 2009.
- Schill WB, Comhaire FH, Hargreave TB. *Andrology for the clinician.* New York: Springer; 2006.

Uberto Pagotto, Flaminia Fanelli, and Antonio Raffaele Granata

## Abstract

Hormones are involved at several levels in the clinical approach to men affected by reproduction disorders. Impaired serum hormone levels can be the cause of impaired fertility, as is the case in hypogonadotropic hypogonadism (HH), but impaired hormone levels can also be the consequence of impaired fertility, as in men affected by hypergonadotropic hypogonadism. In this chapter the hormones involved in male fertility and their laboratory examination will be discussed.

## Keywords

Fertility • Pituitary-gonadal axis • Sexual hormones

## Contents

Introduction .....	496
Gonadotropins .....	496
GnRH Test .....	499
Total Testosterone and Free Testosterone .....	500
Human Chorionic Gonadotropin Test .....	502
Prolactin .....	503
Inhibin B .....	503
Anti-Müllerian Hormone (AMH) .....	504
Estradiol .....	504
$\beta$ -Human Chorionic Gonadotropin .....	505
The Analytical Side of Hormone Testing .....	505

U. Pagotto (✉) • F. Fanelli

Endocrinology Unit and Center for Applied Biomedical Research, Department of Medical and Surgical Sciences, University of Bologna – S. Orsola-Malpighi Hospital, Bologna, Italy  
e-mail: [uberto.pagotto@unibo.it](mailto:uberto.pagotto@unibo.it); [flaminia.fanelli@gmail.com](mailto:flaminia.fanelli@gmail.com)

A.R. Granata

Endocrinology Unit, Department of Internal Medicine, Endocrinology, Metabolism and Geriatrics, Azienda Ospedaliero Universitaria, Modena, Italy  
e-mail: [antonio\\_granata@yahoo.com](mailto:antonio_granata@yahoo.com)

Steroid Hormones .....	506
Protein Hormones .....	508
Gonadotropins .....	509
Prolactin .....	509
Inhibin B .....	510
Anti-Müllerian Hormone .....	511
References .....	511

---

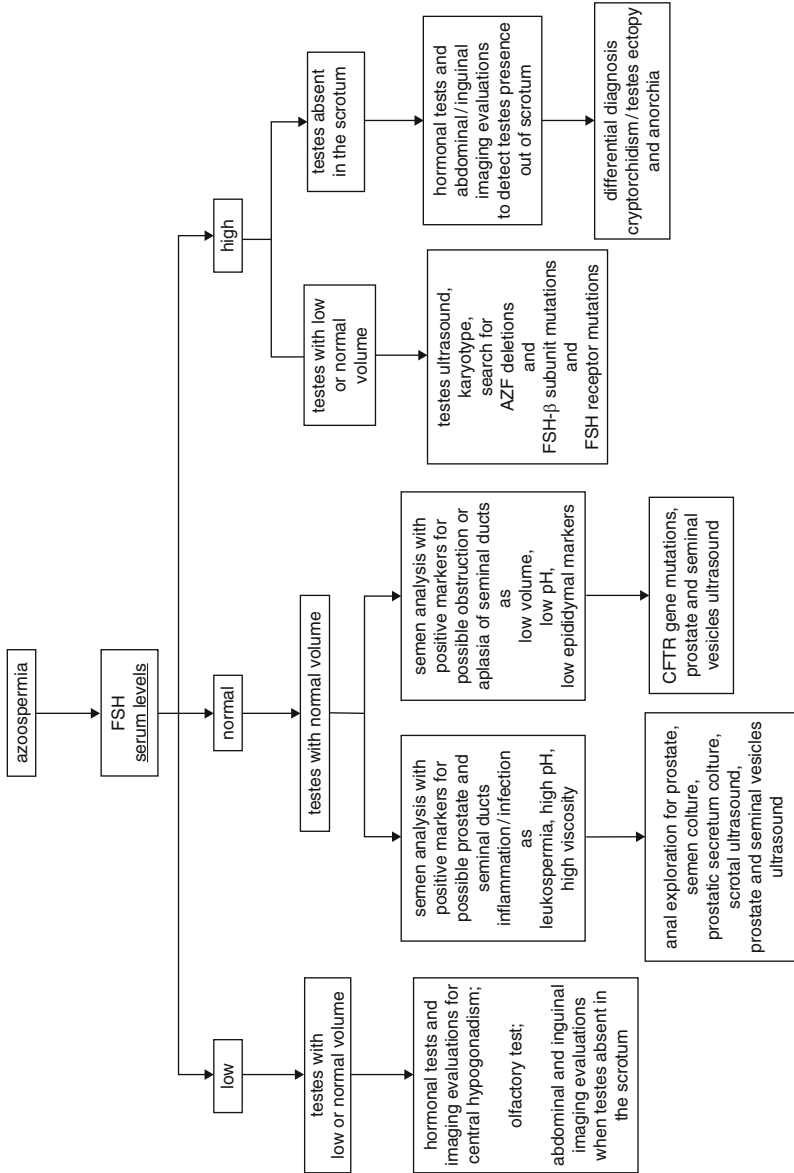
## Introduction

The disorders of male reproduction need the evaluation of both the hormones that regulate the pituitary-testicular axis and change as response to the function of this axis (Fig. 1). These assessments can be performed by measurements of basal hormone concentrations or following stimulation of hormone production (Table 1). Depending on the clinical question, most relevant tests will be performed. Therefore, the serum levels of luteinizing hormone (LH) and follicle-stimulating hormone (FSH) secreted by the hypophysis and of testosterone (T) secreted by the testes represent a first diagnostic step in search for hypogonadotropic hypogonadism (HH) or hypergonadotropic hypogonadism. When the hypothesis of a central hypogonadism is verified, a stimulation test by the administration of gonadotropin-releasing hormone (GnRH) will be performed. Other hormones may be assayed as part of a first diagnostic step, including prolactin (PRL) and estradiol, when the reproduction disorder involves low libido, and estradiol when hepatic insufficiency or gynecomastia is concomitant and still estradiol together with human chorionic gonadotropin (hCG) when a testicular tumor is suspected. Some hormone assessments can be used as the second step, such as PRL and other pituitary hormones when HH has been detected. Inhibin B measurement has a possible role in the differential diagnosis between constitutively delayed puberty and HH. An hCG stimulation test will be performed to promote T secretion, and anti-Müllerian-hormone (AMH) will be assayed to evaluate the presence of Sertoli cells (and testis tissue) in order to differentiate between cryptorchidism, ectopic testicles, and congenital anorchia. In case of precocious puberty and low gonadotropin levels, congenital adrenal hyperplasia (CAH) can be suspected; due to the high prevalence of CAH as a consequence of steroid 21-hydroxylase deficiency, steroid precursors will be assayed paying special attention to serum levels of 17OH-progesterone. Precocious puberty could also be due to constitutively activating LH receptor mutation.

---

## Gonadotropins

According to gonadotropin serum levels, hypogonadism, as sometimes referred to as low serum T levels irrespective of sperm characteristics, can be distinguished as HH and hypergonadotropic hypogonadism. The latter one is due to a compromised Leydig cell function and is also called primary hypogonadism. HH is due to a



**Fig. 1** FSH serum levels as the main parameter to refer to in the choice of the tests for an etiological diagnosis of azoospermia. *CFTR* cystic fibrosis transmembrane conductance regulator, *AZF* azoospermia factors

**Table 1** Hormonal assessments in disorders of male reproduction

Hormones and hormonal stimulation tests	Significance
FSH	High serum levels suggest impaired spermatogenesis; normal and low FSH levels are poor predictor of spermatogenesis
LH	Stimulates testosterone production by Leydig cells; high serum levels suggest primary hypogonadism and low serum levels suggest central hypogonadism
GnRH test	Performed when HH is suspected; has the aim to discriminate between hypothalamic and pituitary cause of HH
Testosterone	Levels fundamental for the diagnosis of hypogonadism; due to the good correlation between total and free T serum levels, total T usually sufficient to detect clearly normal or clearly suppressed levels. Free T may improve diagnosis at borderline total T levels or when suspecting changes in SHBG concentration (e.g., aging, obesity)
hCG test	Performed to differentiate between complete absence of testes (anorchia) and testes absent from the scrotum (i.e., cryptorchidism or ectopy of testes)
Prolactin	High serum levels can be idiopathic but are most frequently due to pituitary or sellar tumors, to neuroleptic drugs, or to stress; high serum levels can be associated with HH because of the negative effect of hyperprolactinemia on both GnRH hypothalamic production and pituitary LH and FSH release
Inhibin B	Serum levels are low in testicular dysfunction and poor spermatogenesis
Anti-Müllerian hormone	Might be a marker of Sertoli cell number, function, and/or maturation in men with actual or previous maldescended testes
Estradiol	Data on a direct role in male fertility come from very few men affected by aromatase deficiency or estrogen resistance
$\beta$ -Human chorionic gonadotropin	Is a marker of both seminoma and non-seminoma testicular cancers

Legend: *T* testosterone, *SHBG* sex hormone-binding globulin, *HH* hypogonadotropic hypogonadism, *AMH* anti-Müllerian hormone, *hCG* human chorionic gonadotropin

compromised function of the hypothalamus and/or pituitary gland and is also called central or secondary hypogonadism.

The different secretory pattern of LH and FSH has to be recognized to interpret correctly the assay results. The hypothalamic GnRH stimulates both synthesis and secretion of LH and FSH. These two hormones have a pulsatile secretion with up to 20 spikes per day in an adult male with less distinct pulsatility for FSH than LH, due to its longer half-life, which is 4–6 h as opposed to 20–40 min for LH (Santen and Bardin 1973); therefore single assessments are sufficient for FSH while multiple assays or pooling two to three samples could improve the value of LH measurements. The frequency of LH serum spikes is directly linked with GnRH secretion, with lower frequency in case of failure in GnRH secretion and higher frequency in primary hypogonadism. Simultaneous high concentrations of serum LH and T suggest androgen resistance, whereas low LH levels and high T could be found in



connection with activating LH receptor mutation leading to male-limited gonadotropin-independent precocious puberty (Ulloa-Aguirre et al. 2014).

FSH is an accurate indicator of spermatogenesis, at least when its levels are high as it is the case in primary hypogonadism in general and in patients affected by Klinefelter syndrome in particular (Nieschlag et al. 1999). However, the testicular volume can be regarded as a discriminant between Klinefelter syndrome and other primary hypogonadisms because only in the first one the testicular volume is usually lower than 6 cm<sup>3</sup> (Kamischke et al. 2003) (Fig. 1). In contrast to high FSH, normal or low FSH levels are poor predictors of spermatogenesis, with low FSH levels possibly associated with normal spermatogenesis (Andersson et al. 2004). Even if inhibin B is normally produced by Sertoli cells and has a negative role on FSH serum levels, inhibin B serum levels are low in Sertoli cell-only syndrome (Silber et al. 1995; von Eckardstein et al. 1999). When normal levels of serum FSH are concomitant with azoospermia, normal testicular volume, low sperm volume, and sperm pH lower than 7.0 suggest obstructive infertility, including cystic fibrosis (Ahmad et al. 2013; Wosnitzer et al. 2014).

---

## GnRH Test

The GnRH test has the aim to stimulate the secretion of LH and FSH from the pituitary gland. Therefore, this test is only performed when HH is detected or when serum gonadotropin levels are inappropriately normal in connection with low T serum. The increase of LH and FSH levels after GnRH administration demonstrates that the central hypogonadism has its cause at the hypothalamic rather than pituitary level.

Generally, GnRH stimulation test is performed administering a single i.v. GnRH bolus of 100 mcg (Table 2). Relative to the 0' the time when GnRH is administered, the following time-points for blood sampling can be used: -15', 0', +15', +30', +60', +90', +120' or -15', 0', +20', +60', +90' to -15', 0', 20', and 60'. However, because of the faster response of LH levels and a possibly delayed FSH increase, the most important time-points are at about +30' and +60' (Table 2). LH levels should increase sharply with a maximum increase of at least threefold between 20' and 30'. FSH levels increase more slowly and with a less sharp peak levels with a maximum 1.5–2-fold increase between 40' and 60' from the GnRH bolus (Fραιetta et al. 2013).

A single GnRH bolus may not be sufficient to stimulate LH and FSH response if the central hypogonadism has a hypothalamic cause, as if the pituitary cells secreting LH and FSH would lose their capacity to produce hormones as a consequence of the prolonged absence of GnRH stimulation. In order to achieve prolonged GnRH stimulation in the attempt to differentiate between hypothalamic and pituitary hypogonadism, several methods are suggested (Table 3): (i) GnRH 500 µg s.c. twice daily for 7–14 days, (ii) GnRH 25 ng/Kg s.c. at 90-min intervals via portable infusion pump for 7–14 days, and (iii) GnRH 5 mcg s.c. at 90–120-min intervals via portable infusion pump for 7 days followed by a GnRH i.v. bolus after

**Table 2** GnRH stimulation test (100 µg i.v. bolus): different time-points for blood collection. Luteinizing hormone increases at time-points 20' or 30'; Follicle-stimulating hormone increases at time-points 30' or 60'

Blood collection time-points							
-15'	0'	+15'		+30'	+60'	+90'	+120'
	GnRH adm						
-15'	0'	+15'	+20'	+30'	+60'	+90'	
	GnRH adm						
-15'	0'	+15'	+20'		+60'		
	GnRH adm						

Legend: *GnRH* gonadotropin-releasing hormone, *adm* administration

**Table 3** Different methods to prolong GnRH test by subcutaneous GnRH administration to differentiate between hypothalamic and pituitary hypogonadism

GnRH dose	Administration intervals	Test duration	Prolonged GnRH administration followed by GnRH i.v. bolus
500 µg	Twice daily	7 or 14 days	–
25 ng/Kg	90' intervals	7 or 14 days	–
5 µg	90' intervals	36 h or 7 days	Yes

Legend: *GnRH* gonadotropin-releasing hormone

36 h or 7 days (Fraietta et al. 2013; Partsch et al. 1985; Shargil 1987; Smals et al. 1994).

## Total Testosterone and Free Testosterone

Measurement of serum T concentration represents the key assay for the diagnosis of hypogonadism, even if low T level alone will not discriminate between HH and hypergonadotropic hypogonadism. Some comments are needed to perform and interpret the T assay correctly.

Only about 2% of circulating T is present as biologically active-free (fT) T, i.e., not bound to transport proteins. About 44% of circulating T is bound with high affinity to sex hormone-binding globulin (SHBG) and 54% is bound with low affinity to albumin and other proteins. SHBG levels can be increased (e.g., aging, estrogens, some antiepileptic drugs, hypogonadism, hepatic insufficiency, hyperthyroidism) or decreased (e.g., obesity, androgens, glucocorticoids, hyperinsulinemia, hypothyroidism) in several conditions (Bhasin 2007; Hammond 2002).

Aging is associated to some extent with reduction of serum total (tT) and fT levels, the latter showing a more pronounced reduction because of concomitantly increased SHBG levels. The age-related decrease in serum T is partially due to

concomitant health problems, but also a consequence of decreased growth hormone (GH) production; on the other hand, the increase of the ratio of free estradiol over fT seems unlikely to promote an increase of SHBG levels and a consequent decrease of fT serum levels (Kaufman and Vermeulen 2005; Wu et al. 2008).

Physical activity can influence serum T levels, with an increase in case of intense and short-lasting physical activity and a decrease in case of intense and prolonged physical activity (Schürmeyer et al. 1984; Stroud et al. 1997).

Serum T levels have a diurnal rhythm with higher concentrations in the morning, and therefore the patient should undergo blood collection between 7 and 11 am. This is important with all men, albeit the amplitude of the diurnal variation flattens somewhat beyond 40 years of age (Luboshitzky et al. 2003). Hypogonadism should be verified with at least two blood samples, because of the variability of T levels, especially around the lower end of the reference range.

When hypogonadism has been diagnosed, the patient should start T replacement treatment only after the low T serum levels have been confirmed some weeks after the first T assessment because of the possibly low T due to transient physical or psychological stresses (Tancredi et al. 2005; Vermeulen and Verdonck 1992). There is a good correlation between tT and fT serum levels; therefore, fT assay is only necessary when a concomitant pathology or the related treatment can interfere on tT levels by interfering on SHBG (Wu et al. 2008) or when tT is only marginally decreased.

T can also be assayed in saliva. Salivary T concentration is correlated with fT serum levels, but some limits have been highlighted as the interference effects caused by the leakage of blood into saliva even when samples are not visibly contaminated with blood and the finding that storage at  $-20^{\circ}\text{C}$  or  $-40^{\circ}\text{C}$  is associated with artificially lower estimates of T compared with samples frozen at  $-80^{\circ}\text{C}$  immediately after collection (Granger et al. 2004); however, recent studies suggest an increasing reliability of salivary T assay (Gao et al. 2015; Lienen et al. 2010). Several methods have been proposed in order to obtain reliable saliva samples; the very first method consisted of a dental cotton roll or a swab placed in the mouth, chewed for 30–45 s, and then placed in a tube to be centrifuged, but this method implies an overstimulation of the saliva glands and a consequent possible interference on some hormone assays as T, whose concentration has been found reduced (Granger et al. 2004) or otherwise increased but only in the first few minutes after chewing (Schultheiss 2013). According to a new method, the subject is asked to fast for at least 1 h, then the mouth is rinsed with water, and the saliva collection starts 5 min later and for 10 min into 50 cc Falcon tubes stored in crushed ice; one of the most used methods is the passive drool technique with the saliva allowed to pool on the mouth floor and then collected in a cryovial by tilting the head (Beale et al. 2016; May et al. 1978; Li et al. 2004; Pernot et al. 2014). While T assessment in saliva is possible, on the other hand and from a clinical point of view, T should be assessed on blood if blood collection is anyhow performed.

According to a consensus statement dated in 2008 (Wang et al. 2009), in adult males, tT serum levels are normal when they are above 12 nmol/L and low when below 8 nmol/L. However, T serum levels should be verified with at least two blood

samples. Serum fT levels lower than 225 pmol/L can be regarded as diagnostic for hypogonadism even if there is not a general consensus on the lower limits of normal fT serum levels (Rosner et al. 2007; Vermeulen 2005). The gold standard for fT assessment is equilibrium dialysis while the immunoassays are not accurate; fT assessment by liquid chromatography-mass spectrometry is promising but still needs full standardization; fT can be calculated by a formula from the serum levels of tT, SHBG, and albumin, and the calculated fT shows a good correlation with fT by equilibrium dialysis (see below for T assessment details) (Taieb et al. 2003; Fanelli et al. 2013; Vermeulen et al. 1999).

## Human Chorionic Gonadotropin Test

The hCG stimulation test is mainly performed when anatomical or functional absence of the testes is suspected as in the case of bilateral nonpalpable testes in the scrotum and lack of certainty to locate the testes by physical examination or imaging diagnostic procedures. The hCG test is performed to differentiate between complete absence of testes (anorchia) and their absence from the scrotum (cryptorchidism or ectopy of the testes). The hCG injection is followed by T production only when this gonadotropin can stimulate Leydig cell steroidogenesis. Therefore, hCG test is not followed by an increase of serum T in anorchia or testicular atrophy.

The hCG test can be performed according to several protocols (Table 4). One of these protocols consists in a daily i.m. injection of 1500 IU hCG for three consecutive days. Blood is collected for the measurement of T and possibly other steroids at the beginning of the test and 24 h after the third injection (Ahmed et al. 1999). Another protocol consists in a single i.m. injection of 5000 IU hCG and blood collection at the beginning of the test and after 48 or 72 or 96 h (Kolon and Miller 2001; Shima et al. 1986). When the hCG test does not produce a clear-cut result, the test can be prolonged for up to 2 weeks with 5000 IU hCG injections every 3 days (Dunkel et al. 1985).

The attempt to use hCG test to differentiate between patient with HH and patients with constitutionally delayed puberty provided inconclusive results (Martin and Martin 2005; Segal et al. 2009).

**Table 4** hCG test: different methods to perform hCG test in order to differentiate between testes completely absent and absent in the scrotum

hCG i.m. dose	Administration intervals	Blood collection time-points				
1500 IU	Once daily for 3 days	Immediately before hCG administration			96 h	
5000 IU	Only when test starts	Immediately before hCG administration	48 h	72 h	96 h	
5000 IU	Every 3 days for 10 days	Immediately before hCG administration				14th day

Legend: *hCG* human chorionic gonadotropin, *h* hours, *d* day

## Prolactin

PRL assessment should always be performed when disorders of male reproduction are associated with HH because of the negative effect of hyperprolactinemia on both GnRH hypothalamic production and pituitary LH and FSH release (Casanueva et al. 2006); hyperprolactinemia should also be suspected when low libido, erectile dysfunction, gynecomastia, and galactorrhea occur, but the latter two symptoms are rare in men. Furthermore, because 80% of prolactinomas in men are macroadenomas, they will be also associated with neurological symptoms and hypopituitarism due to mass effect (Kars et al. 2010; Oh et al. 2012).

The first blood collection for PRL should be performed with the least possible stress for the subject; differently from T, blood for PRL can be collected at any time of the day, but better at least 1 h after awakening or eating; however, when a first PRL assessment rises doubts, collection should be repeated on another day and on a multiple base, as two or three collections 15–20 min apart (Casanueva et al. 2011; Melmed et al. 2011).

Several physiological and pathological conditions can promote an increase in serum PRL levels. Therefore, these conditions should be documented or excluded, including physical exercise, sleep, stress, kidney disease, liver insufficiency, inadequately treated primary hypothyroidism, and treatment with some antipsychotic drugs (Casanueva et al. 2006; Melmed et al. 2011).

In the past some tests have been used for the diagnosis of hyperprolactinemia, including administration of TRH, L-dopa, nomifensine, domperidone, and insulin. The current and widely accepted view is that the diagnosis of hyperprolactinemia should be performed by basal PRL assessment, imaging of the pituitary gland, and excluding other causes (Casanueva et al. 2006; Melmed et al. 2011).

---

## Inhibin B

Inhibin B is a glycoprotein and a member of the transforming growth factor- $\beta$  family produced by Sertoli cells in the testicle (Illingworth et al. 1996). Serum inhibin B levels are not constant during life, showing a brief increase after birth followed by low levels up to puberty, when a progressive increase occurs concomitantly with the activation of Sertoli cell function (Crofton et al. 2002; Radicioni et al. 2005). Inhibin B shows also a circadian rhythm with higher levels in early morning (Carlsen et al. 1999).

Inhibin B exerts a negative feedback on FSH, with low inhibin B serum levels when there is testicular dysfunction and poor spermatogenesis (Pierik et al. 1998). Inhibin B serum levels are associated with FSH levels and have a positive correlation with sperm concentration and testicular volume (Pierik et al. 1998). However, there are controversial data on inhibin values as predictor for sperm retrieval by testicular sperm extraction (TESE) in men with nonobstructive azoospermia (Balleca et al. 2000; Bohring et al. 2002; Huang et al. 2012; Meachem et al. 2001; Tunc et al. 2006; Vernaev et al. 2002). Therefore, serum inhibin B assessment cannot be recommended as a routine measurement in men with nonobstructive azoospermia.

Another use of inhibin B is in the discrimination between isolated HH and delayed puberty in boys, with higher serum levels in the latter group (Coutant et al. 2010; Hero et al. 2012; McNeilly 2012). However, further evaluation is needed in order to verify if inhibin B has a significant role in the diagnosis of male delayed puberty (Wei and Crowne 2016).

When TESE is planned in men with azoospermia, serum inhibin B levels correlate with testicular histology/cytology but are not a better predictor than FSH for the presence of sperm in testes (Goulis et al. 2009; Iliadou et al. 2015).

---

## Anti-Müllerian Hormone (AMH)

AMH is a glycoprotein, a member of transforming growth factor- $\beta$  family, secreted by Sertoli cells and causing Müllerian duct regression in males in fetal life (Aksglaede et al. 2010; Baker et al. 1990; Lee et al. 1996; Misra et al. 2002). There is not a full agreement on the pattern of AMH serum levels during life. According to Aksglaede et al. (2010), AMH shows high levels during the very first months of postnatal life with highest levels at 3 months, and then the levels decline at 12 months, are almost constant until puberty, and thereafter show a further progressive decline in adult life when the levels are 3–4% compared to those during the first months of life. Other authors (Baker et al. 1990; Lee et al. 1996; Misra et al. 2002) detected increased serum AMH levels during the first year of life, highest values during late infancy and a decline during adolescence; therefore, AMH highest levels would occur after the postnatal mini-puberty (Misra et al. 2002). Despite the lack of agreement on AMH levels, its concentrations are higher in males during infancy and adolescence than in adulthood. This, together with the extreme decrease of gonadotropins and T after 3–6 months from birth and until puberty (Bergadá et al. 2006), provides AMH with a role as a marker to discriminate between anorchia and undescended testes in prepubertal boys with nonpalpable testes. Furthermore, when comparing hCG test to AMH assessment, the latter is more sensitive and similarly specific when studying prepubertal boys with unpalpable testes (Lee et al. 1997).

Moving to adulthood, serum AMH levels are correlated with spermatogenic parameters only in men with actual or previously maldescended testes. Therefore, AMH might be a marker of Sertoli cell number, function, and/or maturation in this group of men but not in all men with altered spermatogenesis (Tüttelmann et al. 2009). When TESE is planned in men with azoospermia, serum inhibin B and AMH levels correlate with testicular histology/cytology but are not better predictor than FSH for the presence of sperm in testes (Goulis et al. 2009; Iliadou et al. 2015).

---

## Estradiol

The assessment of estradiol is mandatory when male gynecomastia or breast cancer is suspected (Fentiman et al. 2006). On the contrary, data on a direct role of estradiol on male fertility come from the few men described as affected by aromatase

deficiency or by estrogen resistance (Bulun 2014; Carani et al. 1997; Lanfranco et al. 2008; Maffei et al. 2007; Smith et al. 1994). These two conditions are characterized by eunuchoid body proportions, unfused epiphyses, tall stature, osteopenia, insulin resistance, and impaired fertility due to oligoasthenospermia of variable severity (Bulun 2014; Carani et al. 1997; Lanfranco et al. 2008; Maffei et al. 2007; Smith et al. 1994). However, the causal relationship between estrogen deficiency and impaired estrogen activity on one hand and impaired fertility on the other hand still needs to be clarified (Bulun 2014; Carani et al. 1997; Smith et al. 1994).

---

## **$\beta$ -Human Chorionic Gonadotropin**

$\beta$ -hCG is a marker of both seminoma and non-seminoma testicular cancers. Therefore, the assessment of  $\beta$ -hCG serum levels, together with the assessment of  $\alpha$ -fetoprotein, will be performed when testicular cancer is suspected in a man undergoing evaluations because of infertility. Commercially available kits provide the serum value of total  $\beta$ -hCG and perform a two-site immunoenzymatic assay, measuring both intact  $\beta$ -hCG and free  $\beta$ -subunit (Rajpert-De Meyts et al. 2015).

---

## **The Analytical Side of Hormone Testing**

A large part of the routine hormone testing is performed in clinical laboratories by automated high-throughput commercial platforms arranged in modules, each dedicated to single hormone quantitation by immunoassays (IAs) with different designs. Not all the hormones required for a comprehensive evaluation of male hypogonadism are available in routine clinical laboratories. Manual kits are commercially available for most hormones not routinely assayed; however, they are mostly meant for research application. In addition, experienced laboratories perform in-house IAs.

IAs include a variety of designs in which the identification of the compound of interest (i.e., the analyte) relies upon its specific recognition by an antibody added to the reaction mixture. Early steroid radioimmunoassays (RIA) eliminated, at least partly, the matrix (e.g., serum) effects by sample purification by extraction or chromatography before assay. Later on, the procedures have been simplified in order to cope for the increasing volume of samples faced by clinical laboratories. Modern IAs, based on direct exposure of the intact sample to new generation antibodies (often monoclonal), were developed and subsequently automated to drastically reduce sample volume, operator manual work, and the overall runtime. Competitive assays, usually requiring labeled (e.g., radioactive or fluorescent) antigens, have largely, but not completely, been replaced by reagent excess immunometric assays employing non-radioactively labeled antibodies and allowing reduced reaction time.

Clinical laboratories are currently experiencing a period of important transformation prompted by the advent of liquid chromatography-tandem mass spectrometry (LC-MS/MS) technology. This innovative technique is the result of decades of

studies on the development of an efficient strategy to combine the versatile high-pressure liquid chromatography (HPLC) to the highly specific and sensitive MS. LC-MS/MS offers elevated analytical performance for small molecule quantitation (e.g., steroid hormones) and is replacing several assays in clinical laboratories not only in the endocrine field but also in neonatal screening, toxicology, and therapeutic drug monitoring. Though requiring experienced personnel and, in some cases, operator benchwork, the state of the art shows how this technique has the potential to satisfy the high throughput of large clinical laboratories, elevating the quality of the laboratory medicine and of the overall clinical efficiency. Besides, we still have to wait for further technological advancement to see the development of practicable and sensitive assays for protein detection and quantitation.

## Steroid Hormones

The routine assessment of steroid hormones has traditionally been accomplished by IAs. Most of them, including T and estradiol, are assayed by fully automated commercial kits, while a minor but relevant part of routine steroids, such as aldosterone, estrone, 17OH-progesterone, and DHEA, are assayed by manual immunoassay, often exposing the operator to radioactivity as well as additional costs of label generation and waste disposal. The quest for higher throughput led to drawbacks in terms of loss of accuracy, precision, sensitivity, and reproducibility among different laboratories and different suppliers. The major obstacles are cross-reactivity of the antibody toward structurally related compounds, very frequent within the steroid family, interference from heterogeneous matrix components, competition with hormone-binding proteins and heterophilic antibodies, and overall unpredictably affecting the final result. IA reliability for sex steroid determination in the low concentration range has largely been questioned, mostly for T in females and children and for estradiol in males and postmenopausal females (Taieb et al. 2003; Wang et al., 2004; Yang et al. 2004; Fanelli et al. 2013).

Concerns about IA reliability became louder when a viable and effective alternative technology emerged. In LC-MS/MS, the analyte is determined according to its chemical-physical features by a multistep process guaranteeing elevated specificity. HPLC allows the separation of heterogeneous compounds present in the biological sample and the identification of the analyte according to a specific retention time. Compared to GC, traditionally used in combination with MS as a technique for structure characterization and for reference methods, HPLC is more practicable and faster, overcoming the need for extensive sample pretreatment. Moreover, innovative strategies for online purification allow the reduction of the benchwork and open developments toward automation. Dealing with the complex steroid family, LC has an additional role in separating isobaric compounds (stereoisomers with identical molecular weight) which cannot be distinguished by the MS detector. Upon ionization, indeed, the analyte is selected according to the mass-to-charge ( $m/z$ ) ratio of the intact ion and of the fragment ion specifically generated, which can be seen as measures of analyte specific molecular weight and structure,



respectively. Further parameters can be used to check for specificity, such as the peak shape and the ratio between the signals obtained by two parent ion/daughter ion transitions. Isotopic dilution quantitation, based on the addition of a stable isotope (i.e., deuterium or  $^{13}\text{C}$ ) of the analyte at the beginning of the preanalytical procedure, allows for the correction of procedural losses and of matrix effects on ionization, thus ensuring precise and accurate measurements. A key advantage of LC-MS/MS relies on its multianalyte potential, allowing the generation of steroid profiles tailored on the specific clinical or laboratory needs (Fanelli et al. 2011).

Among steroids, T was the preferred target upon the advent of LC-MS/MS methods published since 10 years. High-end platforms allow the quantitation of serum T down to 1 pg/mL (3 pmol/L) on small sample volume ( $\leq 100\ \mu\text{L}$ ) with a simple set up and short runtime. The sensitivity potential prompted the development of LC-MS/MS assays dedicated to salivary T measurement (Morley et al. 2006; Macdonald et al. 2011). The use of salivary T as a substitute of cumbersome determination of free T by equilibrium dialysis was long-awaited as a valid tool in male hypogonadism diagnosis and management, because the suboptimal sensitivity and specificity of IAs hampered both the extensive evaluation and definition of reference ranges. In this frame, LC-MS/MS offers the potential to exploit saliva and to achieve a standardization of what would result in an ease, stress-free, and cost-effective diagnostic approach (Wang et al. 2008).

Estrogens still remain to be the challenging analytes. Earlier attempts were based on chemical derivatization (i.e., by pentafluorobenzyl and dansyl agents) requiring extensive sample processing and leading to reduced specificity (Wang et al. 2016). Recently, effective additives enhancing ionization (Fiers et al. 2012) and high-resolution HPLC strategies were developed (Wang et al. 2016). However, the desired sensitivity of 1 pg/mL (3 pmol/L) is still hard to obtain even with high-end platforms (Rosner et al. 2013).

A rich literature contributed to the knowledge that LC-MS/MS can provide results in agreement with GC-MS-based reference methods; notably, reference methods based on LC-MS/MS for T and other steroids were also published (Fanelli et al. 2013; Taylor et al. 2015). In parallel, the unsatisfactory IA performance led scientific societies and journals to release somewhat prematurely – and later retracted – statements and recommendations for the definitive replacement of IAs by LC-MS/MS (Handelsman and Wartofsky 2013). The originated debate between MS and IAs users ended in the wiser general agreement on the need for assays that are properly validated and monitored and whose performance fits with the intended use (i.e., biological fluid, concentration level) both in research and routine settings (Auchus 2014) – irrespective of the method used (IA or MS). Interestingly, results from the first multicenter comparison studies showed that the variability of T measurement among different LC-MS/MS methods used in research and routine settings can vary between 14% and 24% in the female range and between 8% and 15% in the male range (Büttler et al. 2015, 2016). Though such results clearly witness the superiority of the LC-MS/MS standardization level compared to IAs, improvements are still needed in the female range. The sources of variability were postulated as calibrators, internal standards, extraction procedures, and disposables (Büttler et al. 2015;

Owen and Keevil 2012). Recently, certified pure standards became available; however, matrix-based calibrators are still unavailable.

Studies on LC-MS/MS standardization for estradiol have not been performed yet, but IAs for low-level estradiol proved to have similar lack of accuracy and reproducibility (Lee et al. 2006), with within-assay imprecision up to 42.6% (Yang et al. 2004) and poor reliability in the male range (Huhtaniemi et al. 2012).

In conclusion, though LC-MS/MS will probably replace most of the current technique in clinical laboratories, it is not infallible per se and requires careful validation and monitoring. Ready to use kits will probably become the preferred choice for routine laboratories; however, lessons from IA history should be kept in mind in order to guarantee elevated analytical standardization and quality. Efforts are still required to achieve a definitive harmonization of results and the generation of widely applicable reference intervals and of diagnostic cutoff values.

Nonetheless, until those goals will be achieved, most of the current direct IAs for T measurement can provide reliable results in hypogonadal and eugonadal range. As a consequence of competition with novel LC-MS/MS, IA suppliers invested in the improvement of kit performance. Besides, IAs performance is not adequate for estradiol evaluation in males and should be performed by LC-MS/MS (Taylor et al. 2015). Whatever is the assay used in one's lab, reference ranges and clinical cutoff values should be considered as method and laboratory-specific and should be verified in the resident population.

## Protein Hormones

IAs are the predominant assays used for the measurement of large molecule or polypeptide hormones both in research and in routine clinical settings. As steroid IAs suffer from cross-reactivity among the wide number of compounds belonging to the steroid family, protein hormone measurement has to face similar problems, because they are usually accompanied by several variant forms deriving from posttranslational modification, cleavage variants, pro-hormones, degradation products, multimer combinations, and complexes. Moreover, IAs are vulnerable to interference from heterophilic antibodies in the sample that are endogenous antibodies reacting against animal antibodies or to other assay reagents.

Specificity in protein hormone determination relies on the two-site designs involving a *capture* and an *indicator* or *detection* antibody directed toward epitopes located in different part of the molecule. In the most popular assay design, the enzyme-linked immunosorbent assay (ELISA), the capture antibody is conjugated to biotin, while the detection antibody is conjugated to a streptavidin-horseradish peroxidase complex. Once the two antibodies are properly bound to the antigen, and the unreacted compounds eliminated, the biotin-streptavidin system can interact, and, in the presence of the substrate tetramethylbenzidine, the peroxidase can generate a colorimetric reaction proportional to the amount of antigen present in the sample. Most of the ELISAs use microtiter plates coated with the capture antibodies according to a sandwich immobilization design. Variants to this scheme

use magnetic particles to immobilize the two antibodies-antigen complex, while other assays use fluorimetric labels or electrochemiluminescent detection systems.

## Gonadotropins

FSH, LH, and hCG are heterodimeric glycoprotein hormones composed by a common  $\alpha$ -subunit and a  $\beta$ -subunit conferring biologic specificity. Automated assays are available in most of the clinical laboratories. The two-site IA design confers specificity among the different heterodimers, with the biotinylated capture antibody directed to the  $\alpha$ -subunit and the indicator antibody conjugated with a chemiluminescent or electrochemiluminescent label directed to the  $\beta$ -subunit.

The immobilization of the immunocomplex is obtained by streptavidin-coated particles acting on biotin, and, after the removal of unreacted compounds, the label reaction will be stimulated and the signal registered. Gonadotropins are generally measured in EDTA plasma or serum and were shown to be stable at least for 2 h at room temperature (Evans et al. 2001). Calibration is performed by international units/liter (IU/L) of International Reference Preparation of the purified hormone standards (Winters 2016).

Some monoclonal antibodies have been reported to cause improper determination of low or undetectable hormone concentration due to a polymorphism in the epitope site (Lamminen and Huhtaniemi 2001). For these reason, a second testing with a different assay is recommended in case of unexpectedly low or undetectable levels.

## Prolactin

PRL is a monomeric peptide usually determined in serum or plasma and is stable for more than 2 h at 4 °C (Evans et al. 2001). Its measurement is performed by a two-site IA designed to prevent the cross-reactivity toward related hormones, such as GH. Concentration is expressed as mU/L of the 23 KDa reference peptide purified from the pituitary.

Most of the assays shows good within-method variability, but assays from different vendors show poor reproducibility, and reference ranges are largely assay-specific. This is supposed to be caused by different immunoreactivity of antibodies toward the standard peptide as well as toward other variants of the hormone caused by posttranslational modifications. Furthermore, the main problem associated with PRL assay relies on the frequent presence of high molecular weight circulating complexes generally formed by IgG autoantibodies directed against PRL with low affinity but high capacity. In most individuals, the active monomer accounts for the 65–85% of circulating forms, while big PRL complex at 50 KDa and big-big PRL complex, also termed macroprolactin, at 150 KDa, account for <20% and <10%, respectively. In some subjects, however, the big/macroprolactin fraction is preeminent, causing false-positive results in simple tests and, due to elevated half-life of complexes, in prolactin suppression tests.

All IAs are affected by macroprolactin interference, even though to different degrees. Less affected IAs are probably those in which autoantibodies are masking the epitope site recognized by capture or detection antibodies. Current recommendations require repeating the measurement of the hormone every time an elevated result is observed, after inducing the precipitation of IgG complexes by polyethylene glycol (PEG) addition. A reduction of 40% of PRL level after PEG precipitation is considered indicative of macroprolactinemia. Though simple and reproducible, a limit to this technique is represented by the lack of normative values for active PRL following PEG treatment. Caution should be paid in order to identify a clinically relevant excess of active PRL (Fahie-Wilson and Smith 2013).

PRL determination by two-site IAs is subjected to another kind of pitfall causing false-negative results. The *hook effect* refers to a situation in which the capture antibody concentration is not in excess. It particularly affects PRL determination causing a disjointed binding with the capture and with the detector antibodies, resulting in large fraction of detection antibody forming soluble immunocomplexes that are lost with washing steps. The result obtained when such a phenomenon occurs may be normal or slightly elevated. Sample dilution can avoid this artifact and should be carried out when hyperprolactinemia is suspected (do Carmo Dias Gontijo et al. 2016).

## Inhibin B

Assay specificity is a major challenge in the measurement of this hormone. The combination between an  $\alpha$ -subunit and a  $\beta$ -subunit, either  $\beta$ B or  $\beta$ A, leads to the generation of a complex family of homo- and heterodimers including inhibins and activins. Inhibin B is a 32 KDa heterodimer composed by the  $\alpha$ -subunit and the  $\beta$ B-subunit, the latter specifically produced by Sertoli cells. Measurement can be performed in serum and in lithium-heparin plasma; stability upon repeated thawing/freezing cycles has been reported (Hillebrand et al. 2017). Quantitation is performed by a two-site ELISA requiring the recognition of both subunits, having the capture antibody directed toward the  $\beta$ B-subunit, and the biotinylated detection antibody raised against the  $\alpha$ -subunit. Once the generated immunocomplex is immobilized and unreacted antibodies and matrix residuals are washed away, the streptavidin-horseradish peroxidase complex and the substrate tetramethylbenzidine are added to the reaction mixture to generate a colorimetric signal. Early assays required additional steps, such as the oxidation of methionine in the  $\beta$ B-subunit for the proper recognition by the capture antibody, the heat/sodium dodecyl sulfate treatment to remove any catalase or binding protein interfering with oxidation, and overnight incubation for improving sensitivity, overall limiting the assay practicality and throughput, and preventing its routine clinical application (Groome et al. 1996). Novel antibodies with high specificity were recently generated that overcome the need for extensive processing (Ludlow et al. 2008); however, the available commercial kits are intended for research applications and no automated routine-suited assays have been released yet.

## Anti-Müllerian Hormone

Commercial kits for two-site sandwich ELISA are available for the determination of this homodimer for research purposes. AMH can be measured in serum and in lithium-heparin plasma. Both biological stability and assay performance contributed to the poor reproducibility of results reported in literature. Indeed, stability of this hormone became an intriguing matter of investigation: several studies reported an increase in AMH concentration in plasma or serum in suboptimal conditions of storage and transportation. Moreover, preanalytical conditions, such as sample dilution and, possibly, the antibody specificity as to the epitope localization on the molecule, were shown to cause large hormone increase and high variability. The mechanism causing such phenomena may involve AMH degradation to isoforms that are more immunoreactive or the degradation of an interfering compound mimicking AMH immunoreactivity (Rustamov et al. 2014). Such hypotheses could explain why some assays are more susceptible than others to biological instability. In particular, Beckman Coulter recognized the poor reliability of results generated by the AMH GenII kit and released a modification in the preanalytical procedure in order to improve reproducibility. In the last years, fully automated assays have been released that are being introduced in routine clinical laboratories (Deeks 2015; Demirdjian et al. 2016).

---

## References

- Ahmad A, Ahmed A, Patrizio P. Cystic fibrosis and fertility. *Curr Opin Obstet Gynecol*. 2013;25:167–72.
- Ahmed SF, Cheng A, Hughes IA. Assessment of the gonadotrophin-gonadal axis in androgen insensitivity syndrome. *Arch Dis Child*. 1999;80:324–9.
- Aksglaede L, Sørensen K, Boas M, Mouritsen A, Hagen CP, Jensen RB, Petersen JH, Linneberg A, Andersson AM, Main KM, Skakkebaek NE, Juul A. Changes in anti-Müllerian hormone (AMH) throughout the life span: a population-based study of 1027 healthy males from birth (cord blood) to the age of 69 years. *J Clin Endocrinol Metab*. 2010;95:5357–64.
- Andersson AM, Petersen JH, Jørgensen N, Jensen TK, Skakkebaek NE. Serum inhibin B and follicle-stimulating hormone levels as tools in the evaluation of infertile men: significance of adequate reference values from proven fertile men. *J Clin Endocrinol Metab*. 2004;89:2873–9.
- Auchus RJ. Steroid assays and endocrinology: best practices for basic scientists. *Endocrinology*. 2014;155:2049–51.
- Baker ML, Metcalfe SA, Hutson JM. Serum levels of müllerian inhibiting substance in boys from birth to 18 years, as determined by enzyme immunoassay. *Clin Endocrinol Metab*. 1990; 70:11–5.
- Ballesca JL, Balasch J, Calafell JM, Alvarez R, Fabregues F, de Osaba MJ, Ascaso C, Vanrell JA. Serum inhibin B determination is predictive of successful testicular sperm extraction in men with non-obstructive azoospermia. *Hum Reprod*. 2000;15:1734–8.
- Beale DJ, Jones OA, Karpe AV, Dayalan S, Oh DY, Kouremenos KA, Ahmed W, Palombo EA. A review of analytical techniques and their application in disease diagnosis in breathomics and salivaomics research. *Int J Mol Sci*. 2016 Dec 23;18. doi:10.3390/ijms18010024. pii: E24.
- Bergadá I, Milani C, Bedecarrás P, Andreone L, Ropelato MG, Gottlieb S, Bergadá C, Campo S, Rey RA. Time course of the serum gonadotropin surge, inhibins, and anti-Müllerian hormone in normal newborn males during the first month of life. *J Clin Endocrinol Metab*. 2006;91:4092–8.

- Bhasin S. Disorders of the testis and the male reproductive tract. In: Kronenberg H, Melmed S, Polonski K, Wilson JD, Larsen PR, editors. *Williams textbook of endocrinology*. 11th ed. Philadelphia: WB Saunders; 2007.
- Bohring C, Schroeder-Printzen I, Weidner W, Krause W. Serum levels of inhibin B and follicle-stimulating hormone may predict successful sperm retrieval in men with azoospermia who are undergoing testicular sperm extraction. *Fertil Steril*. 2002;78:1195–8.
- Bulun SE. Aromatase and estrogen receptor  $\alpha$  deficiency. *Fertil Steril*. 2014;101:323–9.
- Büttler RM, Martens F, Fanelli F, Pham HT, Kushnir MM, Janssen MJ, Owen L, Taylor AE, Soeborg T, Blankenstein MA, Heijboer AC. Comparison of 7 published LC-MS/MS methods for the simultaneous measurement of testosterone, androstenedione, and dehydroepiandrosterone in serum. *Clin Chem*. 2015;61:1475–83.
- Büttler RM, Martens F, Ackermans MT, Davison AS, van Herwaarden AE, Kortz L, Krabbe JG, Lentjes EG, Syme C, Webster R, Blankenstein MA, Heijboer AC. Comparison of eight routine unpublished LC-MS/MS methods for the simultaneous measurement of testosterone and androstenedione in serum. *Clin Chim Acta*. 2016;454:112–8.
- Carani C, Qin K, Simoni M, Faustini-Fustini M, Serpente S, Boyd J, Korach KS, Simpson ER. Effect of testosterone and estradiol in a man with aromatase deficiency. *N Engl J Med*. 1997;337:91–5.
- Carlsen E, Olsson C, Petersen JH, Andersson AM, Skakkebaek NE. Diurnal rhythm in serum levels of inhibin B in normal men: relation to testicular steroids and gonadotropins. *J Clin Endocrinol Metab*. 1999;84:1664–9.
- Casanueva FF, Molitch ME, Schlechte JA, Abs R, Bonert V, Bronstein MD, Brue T, Cappabianca P, Colao A, Fahlbusch R, Fideleff H, Hadani M, Kelly P, Kleinberg D, Laws E, Marek J, Scanlon M, Sobrinho LG, Wass JA, Giustina A. Guidelines of the pituitary society for the diagnosis and management of prolactinomas. *Clin Endocrinol*. 2006;65:265–73.
- Coutant R, Biette-Demeneix E, Bouvattier C, Bouhours-Nouet N, Gatelais F, Dufresne S, Rouleau S, Lahlou N. Baseline inhibin B and anti-müllerian hormone measurements for diagnosis of hypogonadotropic hypogonadism in boys with delayed puberty. *J Clin Endocrinol Metab*. 2010;95:5225–32.
- Crofton PM, Evans AE, Groome NP, Taylor MR, Holland CV, Kelnar CJ. Inhibin B in boys from birth to adulthood: relationship with age, pubertal stage, FSH and testosterone. *Clin Endocrinol*. 2002;56:215–21.
- Deeks ED. Elecsys(®) AMH assay: a review in anti-Müllerian hormone quantification and assessment of ovarian reserve. *Mol Diagn Ther*. 2015;19:245–9.
- Demirdjian G, Bord S, Lejeune C, Masica R, Rivière D, Nicouveau L, Denizot P, Marquet PY. Performance characteristics of the access AMH assay for the quantitative determination of anti-Müllerian hormone (AMH) levels on the access\* family of automated immunoassay systems. *Clin Biochem*. 2016. doi:10.1016/j.clinbiochem.2016.08.005. pii: S0009-9120(16)30184-9. [Epub ahead of print].
- do Carmo Dias Gontijo M, de Souza Vasconcellos L, Ribeiro-Oliveira Jr A. Hook effect and linear range in prolactin assays: distinct confounding entities. *Pituitary*. 2016;19:458–9.
- Dunkel L, Perheentupa J, Sorva R. Single versus repeated dose human chorionic gonadotropin stimulation in the differential diagnosis of hypogonadotropic hypogonadism. *J Clin Endocrinol Metab*. 1985;60:333–7.
- Evans MJ, Livesey JH, Ellis MJ, Yandle TG. Effect of anticoagulants and storage temperatures on stability of plasma and serum hormones. *Clin Biochem*. 2001;34:107–12.
- Fahie-Wilson M, Smith TP. Determination of prolactin: the macroprolactin problem. *Best Pract Res Clin Endocrinol Metab*. 2013;27:725–42.
- Fanelli F, Belluomo I, Di Lallo VD, Cuomo G, De Iasio R, Baccini M, Casadio E, Casetta B, Vicennati V, Gambineri A, Grossi G, Pasquali R, Pagotto U. Serum steroid profiling by isotopic dilution-liquid chromatography-mass spectrometry: comparison with current immunoassays and reference intervals in healthy adults. *Steroids*. 2011;76:244–53.

- Fanelli F, Gambineri A, Mezzullo M, Vicennati V, Pelusi C, Pasquali R, Pagotto U. Revisiting hyper- and hypo-androgenism by tandem mass spectrometry. *Rev Endocr Metab Disord*. 2013; 14:185–205.
- Fentiman IS, Fourquet A, Hortobagyi GN. Male breast cancer. *Lancet*. 2006;367:595–604.
- Fiers T, Casetta B, Bernaert B, Vandersypt E, Debock M, Kaufman JM. Development of a highly sensitive method for the quantification of estrone and estradiol in serum by liquid chromatography tandem mass spectrometry without derivatization. *J Chromatogr B Anal Technol Biomed Life Sci*. 2012;893–894:57–62.
- Fraietta R, Suslik Zylberstejn D, Esteves SD. Hypogonadotropic hypogonadism revisited. *Clinics*. 2013;68:81–8.
- Gao W, Stalder T, Kirschbaum C. Quantitative analysis of estradiol and six other steroid hormones in human saliva using a high throughput liquid chromatography-tandem mass spectrometry assay. *Talanta*. 2015;143:353–8.
- Goulis DG, Tsameti C, Iliadou PK, Polychronou P, Kantartzi PD, Tarlatzis BC, Bontis IN, Papadimas I. Serum inhibin B and anti-Müllerian hormone are not superior to follicle-stimulating hormone as predictors of the presence of sperm in testicular fine-needle aspiration in men with azoospermia. *Fertil Steril*. 2009;91:1279–84.
- Granger DA, Shirlcliff EA, Booth A, Kivlighan KT, Schwartz EB. The “trouble” with salivary testosterone. *Psychoneuroendocrinology*. 2004;29:1229–40.
- Groome NP, Illingworth PJ, O’Brien M, Pai R, Rodger FE, Mather JP, McNeilly AS. Measurement of dimeric inhibin B throughout the human menstrual cycle. *J Clin Endocrinol Metab*. 1996;81:1401.
- Hammond GL. Access of reproductive steroids to target tissues. *Obstet Gynecol Clin N Am*. 2002;29:411–23.
- Handelsman DJ, Wartofsky L. Requirement for mass spectrometry sex steroid assays in the *Journal of Clinical Endocrinology and Metabolism*. *J Clin Endocrinol Metab*. 2013;98:3971–3.
- Hero M, Tommiska J, Vaaralahti K, Laitinen EM, Sipilä I, Puhakka L, Dunkel L, Raivio T. Circulating anti-müllerian hormone levels in boys decline during early puberty and correlate with inhibin B. *Fertil Steril*. 2012;97:1242–7.
- Hillebrand JJ, Heijboer AC, Ender E. Effects of repeated freeze-thaw cycles on endocrine parameters in plasma and serum. *Ann Clin Biochem*. 2017;54:289–292. pii: 0004563216657361. [Epub ahead of print].
- Huang X, Bai Q, Yan LY, Zhang QF, Geng L, Qiao J. Combination of serum inhibin B and follicle-stimulating hormone levels can not improve the diagnostic accuracy on testicular sperm extraction outcomes in Chinese non-obstructive azoospermic men. *Chin Med J*. 2012; 125:2885–9.
- Huhtaniemi IT, Tajar A, Lee DM, O’Neill TW, Finn JD, Bartfai G, Boonen S, Casanueva FF, Giwercman A, Han TS, Kula K, Labrie F, Lean ME, Pendleton N, Punab M, Silman AJ, Vanderschueren D, Forti G, Wu FC, EMAS Group. Comparison of serum testosterone and estradiol measurements in 3174 European men using platform immunoassay and mass spectrometry; relevance for the diagnostics in aging men. *Eur J Endocrinol*. 2012;166:983–91.
- Iliadou PK, Tsameti C, Kaprara A, Papadimas I, Goulis DG. The Sertoli cell: novel clinical potentiality. *Hormones (Athens)*. 2015;14:504–14.
- Illingworth PJ, Groome NP, Byrd W, Rainey WE, McNeilly AS, Mather JP, Bremner WJ. Inhibin-B: a likely candidate for the physiologically important form of inhibin in men. *J Clin Endocrinol Metab*. 1996;81:1321–5.
- Kamischke A, Baumgardt A, Horst J, Nieschlag E. Clinical and diagnostic features of patients with suspected Klinefelter syndrome. *J Androl*. 2003;24:41–8.
- Kars M, Dekker OM, Pereira AM, Romijn JA. Update in prolactinomas. *Neth J Med*. 2010;68:104–12.
- Kaufman JM, Vermeulen A. The decline of androgen levels in elderly men and its clinical and therapeutic implications. *Endocr Rev*. 2005;26:833–76.

- Kolon TF, Miller OF. Comparison of single versus multiple dose regimens for the human chorionic gonadotropin stimulatory test. *J Urol.* 2001;166:1451–4.
- Lanfranco F, Zirilli L, Baldi M, Pignatti E, Corneli G, Ghigo E, Aimaretti G, Carani C, Rochira V. A novel mutation in the human aromatase gene: insights on the relationship among serum estradiol, longitudinal growth and bone mineral density in an adult man under estrogen replacement treatment. *Bone.* 2008;43:628–63.
- Lee MM, Donahoe PK, Hasegawa T, Silverman B, Crist GB, Best S, Hasegawa Y, Noto RA, Schoenfeld D, MacLaughlin DT. Mullerian inhibiting substance in humans: normal levels from infancy to adulthood. *J Clin Endocrinol Metab.* 1996;81:571–6.
- Lee MM, Donahoe PK, Silverman BL, Hasegawa T, Hasegawa Y, Gustafson ML, Chang YC, MacLaughlin DTN. Measurements of serum müllerian inhibiting substance in the evaluation of children with nonpalpable gonads. *Engl J Med.* 1997;336:1480–6.
- Lee JS, Ettinger B, Stanczyk FZ, Vittinghoff E, Hanes V, Cauley JA, Chandler W, Settlege J, Beattie MS, Folkerd E, Dowsett M, Grady D, Cummings SR. Comparison of methods to measure low serum estradiol levels in postmenopausal women. *J Clin Endocrinol Metab.* 2006;91:3791–7.
- Li Y, St. John MA, Zhou X. Salivary transcriptome diagnostics for oral cancer detection. *Clin. Cancer Res.* 2004;10:8442–50.
- Liening SH, Stanton SJ, Saini EK, Schultheiss OC. Salivary testosterone, cortisol, and progesterone: two-week stability, interhormone correlations, and effects of time of day, menstrual cycle, and oral contraceptive use on steroid hormone levels. *Physiol Behav.* 2010;99:8–16.
- Luboshitzky R, Shen-Orr Z, Herer P. Middle-aged men secrete less testosterone at night than young healthy men. *J Clin Endocrinol Metab.* 2003;88:3160–6.
- Ludlow H, Muttukrishna S, Hyvönen M, Groome NP. Development of a new antibody to the human inhibin/activin beta B subunit and its application to improved inhibin B ELISAs. *J Immunol Methods.* 2008;329:102–11.
- Macdonald PR, Owen LJ, Wu FC, Macdowall W, Keevil BG, NATSAL team. A liquid chromatography-tandem mass spectrometry method for salivary testosterone with adult male reference interval determination. *Clin Chem.* 2011;57:774–5.
- Maffei L, Rochira V, Zirilli L, Antunez P, Aranda C, Fabre B, Simone ML, Pignatti E, Simpson ER, Houssami S, Clyne CD, Carani C. A novel compound heterozygous mutation of the aromatase gene in an adult man: reinforced evidence on the relationship between congenital oestrogen deficiency, adiposity and the metabolic syndrome. *Clin Endocrinol.* 2007;67:218–24.
- Martin MM, Martin AL. Constitutional delayed puberty in males and hypogonadotropic hypogonadism: a reliable and cost-effective approach to differential diagnosis. *J Pediatr Endocrinol Metab.* 2005;18:909–16.
- May PRA, van Putten T, Jenden DJ, Cho AK. Test dose response in schizophrenia: chlorpromazine blood and saliva levels. *Arch Gen Psychiatry.* 1978;35:1091–7.
- McNeilly AS. Diagnostic applications for inhibin and activins. *Mol Cell Endocrinol.* 2012;359:121–5.
- Meachem SJ, Nieschlag E, Simoni M. Inhibin B in male reproduction: pathophysiology and clinical relevance. *Eur J Endocrinol.* 2001;145:561–71.
- Melmed S, Casanueva FF, Hoffman AR, Kleinberg DL, Montori VM, Schlechte JA, Wass JA. Diagnosis and treatment of hyperprolactinemia: an Endocrine Society clinical practice guideline. *J Clin Endocrinol Metab.* 2011;96:273–88.
- Misra M, MacLaughlin DT, Donahoe PK, Lee MM. Measurement of mullerian inhibiting substance facilitates management of boys with microphallus and cryptorchidism. *J Clin Endocrinol Metab.* 2002;87:3598–602.
- Morley JE, Perry 3rd HM, Patrick P, Dollbaum CM, Kells JM. Validation of salivary testosterone as a screening test for male hypogonadism. *Aging Male.* 2006;9(3):165–9.
- Nieschlag E, Simoni M, Gromoll J, Weinbauer GF. Role of FSH in the regulation of spermatogenesis: clinical aspects. *Clin Endocrinol.* 1999;51:139–46.
- Oh MC, Kunwar S, Blevins L, Aghi MK. Medical versus surgical management of prolactinomas. *Neurosurg Clin N Am.* 2012;23:669–78.
- Owen LJ, Keevil BG. Testosterone measurement by liquid chromatography tandem mass spectrometry: the importance of internal standard choice. *Ann Clin Biochem.* 2012;49:600–2.



- Partsch CJ, Hermanussen M, Sippell WG. Differentiation of male hypogonadotropic hypogonadism and constitutional delay of puberty by pulsatile administration of gonadotropin-releasing hormone. *J Clin Endocrinol Metab.* 1985;60:1196–203.
- Pemot E, Cardis E, Badie C. Usefulness of saliva samples for biomarker studies in radiation research. *Cancer Epidemiol Biomark Prev.* 2014;23:2673–80.
- Pierik FH, Vreeburg JT, Stijnen T, De Jong FH, Weber RF. Serum inhibin B as a marker of spermatogenesis. *J Clin Endocrinol Metab.* 1998;83:3110–4.
- Radicioni AF, Anzuini A, De Marco E, Nofroni I, Castracane VD, Lenzi A. Changes in serum inhibin B during normal male puberty. *Eur J Endocrinol.* 2005;152:403–9.
- Rajpert-De Meyts E, Nielsen JE, Skakkebaek NE, Almstrup K. Diagnostic markers for germ cell neoplasms: from placental-like alkaline phosphatase to micro-RNAs. *Folia Histochem Cytobiol.* 2015;53:177–88.
- Rosner W, Auchus RJ, Azziz R, Sluss PM, Raff H. Position statement: utility, limitations, and pitfalls in measuring testosterone: an Endocrine Society position statement. *J Clin Endocrinol Metab.* 2007;92:405–13.
- Rosner W, Hankinson SE, Sluss PM, Vesper HW, Wierman ME. Challenges to the measurement of estradiol: an endocrine society position statement. *J Clin Endocrinol Metab.* 2013;98:1376–87.
- Rustamov O, Smith A, Roberts SA, Yates AP, Fitzgerald C, Krishnan M, Nardo LG, Pemberton PW. The measurement of anti-Müllerian hormone: a critical appraisal. *J Clin Endocrinol Metab.* 2014;99:723–32.
- Santen RJ, Bardin CW. Episodic luteinizing hormone secretion in man. Pulse analysis, clinical interpretation, physiologic mechanisms. *J Clin Invest.* 1973;52:2617–28.
- Schultheiss OC. Effects of sugarless chewing gum as a stimulant on progesterone, cortisol, and testosterone concentrations assessed in saliva. *Int J Psychophysiol.* 2013;87:111–4.
- Schürmeyer T, Jung K, Nieschlag E. The effect of an 1100 km run on testicular, adrenal and thyroid hormones. *Int J Androl.* 1984;7:2762–82.
- Segal TY, Mehta A, Anazodo A, Hindmarsh PC, Dattani MT. Role of gonadotropin-releasing hormone and human chorionic gonadotropin stimulation tests in differentiating patients with hypogonadotropic hypogonadism from those with constitutional delay of growth and puberty. *J Clin Endocrinol Metab.* 2009;94:780–5.
- Shargil AA. Treatment of idiopathic hypogonadotropic hypogonadism in men with luteinizing hormone-releasing hormone: a comparison of treatment with daily injections and with the pulsatile infusion pump. *Fertil Steril.* 1987;47:492–501.
- Shima H, Ikoma F, Yabumoto H, Mori M, Satoh Y, Terakawa T, Fukuchi M. Gonadotropin and testosterone response in prepubertal boys with hypospadias. *J Urol.* 1986;135:539–42.
- Silber SJ, Van Steirteghem AC, Devroey P. Sertoli cell only revisited. *Hum Reprod.* 1995;10:1031–2.
- Smals AG, Hermus AR, Boers GH, Pieters GF, Benraad TJ, Kloppenborg PW. Predictive value of luteinizing hormone releasing hormone (LHRH) bolus testing before and after 36-hour pulsatile LHRH administration in the differential diagnosis of constitutional delay of puberty and male hypogonadotropic hypogonadism. *J Clin Endocrinol Metab.* 1994;78:602–8.
- Smith EP, Boyd J, Frank GR, Takahashi H, Cohen RM, Specker B, Williams TC, Lubahn DB, Korach KS. Estrogen resistance caused by a mutation in the estrogen-receptor gene in a man. *N Engl J Med.* 1994;331:1056–61.
- Stroud MA, Ritz P, Coward WA, Sawyer MB, Constantin-Teodosiu D, Greenhaff PL, Macdonald IA. Energy expenditure using isotope-labelled water (2H218O), exercise performance, skeletal muscle enzyme activities and plasma biochemical parameters in humans during 95 days of endurance exercise with inadequate energy intake. *Eur J Appl Physiol Occup Physiol.* 1997;76:243–52.
- Taieb J, Mathian B, Millot F, Patricot MC, Mathieu E, Queyrel N, Lacroix I, Somma-Delpero C, Boudou P. Testosterone measured by 10 immunoassays and by isotope-dilution gas chromatography-mass spectrometry in sera from 116 men, women, and children. *Clin Chem.* 2003;49:1381–95.

- Tancredi A, Reginster JY, Luyckx F, Legros JJ. No major month to month variation in free testosterone levels in aging males. Minor impact on the biological diagnosis of 'andropause'. *Psychoneuroendocrinology*. 2005;30:638–46.
- Taylor AE, Keevil B, Huhtaniemi IT. Mass spectrometry and immunoassay: how to measure steroid hormones today and tomorrow. *Eur J Endocrinol*. 2015;173:D1–2.
- Tunc L, Kirac M, Gurocak S, Yucel A, Kupeli B, Alkibay T, Bozkirli I. Can serum inhibin B and FSH levels, testicular histology and volume predict the outcome of testicular sperm extraction in patients with non-obstructive azoospermia? *Int Urol Nephrol*. 2006;38:629–35.
- Tüttelmann F, Dykstra N, Themmen AP, Visser JA, Nieschlag E, Simoni M. Anti-Müllerian hormone in men with normal and reduced sperm concentration and men with maldescended testes. *Fertil Steril*. 2009;91:1812–9.
- Ulloa-Aguirre A, Reiter E, Bousfield G, Dias JA, Huhtaniemi I. Constitutive activity in gonadotropin receptors. *Adv Pharmacol*. 2014;70:37–80.
- Vermeulen A. Hormonal cut-offs of partial androgen deficiency: a survey of androgen assays. *J Endocrinol Investig*. 2005;28:28–31.
- Vermeulen A, Verdonck G. Representativeness of a single point plasma testosterone level for the long term hormonal milieu in men. *J Clin Endocrinol Metab*. 1992;74:939–42.
- Vermeulen A, Verdonck L, Kaufman JM. A critical evaluation of simple methods for the estimation of free testosterone in serum. *J Clin Endocrinol Metab*. 1999;84:3666–72.
- Vernaev V, Tournaye H, Schiettecatte J, Verheyen G, Van Steirteghem A, Devroey P. Serum inhibin B cannot predict testicular sperm retrieval in patients with non-obstructive azoospermia. *Hum Reprod*. 2002;17:971–6.
- von Eckardstein S, Simoni M, Bergmann M, Weinbauer GF, Gassner P, Schepers AG, Nieschlag E. Serum inhibin B in combination with serum follicle-stimulating hormone (FSH) is a more sensitive marker than serum FSH alone for impaired spermatogenesis in men, but cannot predict the presence of sperm in testicular tissue samples. *J Clin Endocrinol Metab*. 1999;84:2496–501.
- Wang C, Catlin DH, Demers LM, Starcevic B, Swerdloff RS. Measurement of total serum testosterone in adult men: comparison of current laboratory methods versus liquid chromatography-tandem mass spectrometry. *J Clin Endocrinol Metab*. 2004;89:534–43.
- Wang C, Nieschlag E, Swerdloff R, Behre HM, Hellstrom WJ, Gooren LJ, Kaufman JM, Legros JJ, Lunenfeld B, Morales A, Morley JE, Schulman C, Thompson IM, Weidner W, Wu FC. Investigation, treatment and monitoring of late-onset hypogonadism in males: ISA, ISSAM, EAU, EAA and ASA recommendations. *Eur J Endocrinol*. 2008;159:507–14.
- Wang C, Nieschlag E, Swerdloff R, Behre HM, Hellstrom WJ, Gooren LJ, Kaufman JM, Legros JJ, Lunenfeld B, Morales A, Morley JE, Schulman C, Thompson IM, Weidner W, Wu FC. ISA, ISSAM, EAU, EAA and ASA recommendations: investigation, treatment and monitoring of late-onset hypogonadism in males. *Int J Impot Res*. 2009;21:1–8.
- Wang Q, Mesaros C, Blair IA. Ultra-high sensitivity analysis of estrogens for special populations in serum and plasma by liquid chromatography-mass spectrometry: assay considerations and suggested practices. *J Steroid Biochem Mol Biol*. 2016;162:70–9.
- Wei C, Crowne EC. Recent advances in the understanding and management of delayed puberty. *Arch Dis Child*. 2016;101:481–8.
- Winters SJ. Laboratory assessment of testicular function. In: De Groot LJ, Beck-Peccoz P, Chrousos G, Dungan K, Grossman A, Hershman JM, Koch C, McLachlan R, New M, Rebar R, Singer F, Vinik A, Weickert MO, editors. *Endotext* [Internet]. South Dartmouth: MDText.com; 2000–2016 Jan 1.
- Wosnitzer M, Goldstein M, Hardy MP. Review of azoospermia. *Spermatogenesis*. 2014;4:e28218.
- Wu FC, Tajar A, Pye SR, Silman AJ, Finn JD, O'Neill TW, Bartfai G, Casanueva F, Forti G, Giwercman A, Huhtaniemi IT, Kula K, Punab M, Boonen S, Vanderschueren D, European Male Aging Study Group. Hypothalamic-pituitary-testicular axis disruptions in older men are differentially linked to age and modifiable risk factors: the European Male Aging Study. *J Clin Endocrinol Metab*. 2008;93:2737–45.
- Yang DT, Owen WE, Ramsay CS, Xie H, Roberts WL. Performance characteristics of eight estradiol immunoassays. *Am J Clin Pathol*. 2004;122:332–7.

Csilla Krausz

---

## Abstract

Genetic factors are responsible for about 20–25% of severe male factor infertility and may affect both gametogenic and endocrine functions of the testis or may cause the congenital absence of vas deferens. Testing for chromosomal anomalies (karyotype and Y chromosome microdeletions) is performed in all patients affected by moderate or severe oligozoospermia and azoospermia, whereas mutation screening in candidate genes is indicated in specific disease conditions. All the abovementioned analyses aim at the identification of genetic factors showing a cause-effect relationship with the given phenotype, and they are part of the diagnostic work-up of infertile men. During the last 20 years, active research has been carried out in order to identify novel candidate genes and genetic risk factors for impaired sperm production. Despite efforts, the only genetic risk factor which is currently screened in selected populations is the Y-chromosome linked “gr/gr deletion.” With the recent advent of next-generation sequencing (NGS), the analysis of the entire exome has been applied also to male infertility. Although whole exome/genome data interpretation remains challenging, whole exome analysis seems to be a valid diagnostic tool for familial cases or for patients with consanguineous parents.

---

## Keywords

AZF deletions • Azoospermia • CFTR • Genetics • Male infertility • Spermatogenesis • Y chromosome

---

C. Krausz (✉)

Department of Experimental and Clinical Biomedical Sciences “Mario Serio”, University of Florence, Florence, Italy  
e-mail: [c.krausz@dfc.unifi.it](mailto:c.krausz@dfc.unifi.it)

## Contents

Introduction .....	518
Karyotype Analysis .....	519
Numerical Chromosome Anomalies .....	520
Structural Chromosome Anomalies .....	522
Y Chromosome Microdeletion Screening .....	522
Gene Mutation Screening .....	524
Congenital Hypogonadotropic Hypogonadism (cHH or Idiopathic Hypogonadotropic Hypogonadism (iHH)) .....	524
Mutation Analysis of the Androgen Receptor Gene (AR) .....	525
CFTR Mutation Screening: .....	526
Genetic Testing in Monomorphic Teratozoospermia .....	527
Future Directions in Genetic Testing .....	528
Next-Generation Sequencing (NGS) in Male Infertility .....	528
Array-Comparative Genomic Hybridization (Array-CGH) in Male Infertility .....	528
X Chromosome and Male Infertility .....	529
Conclusions .....	529
References .....	530

## Introduction

Genetic factors are responsible for about 20–25% of severe male factor infertility and may affect both gametogenic and endocrine functions of the testis or may cause the congenital absence of vas deferens. The indication for the different types of genetic tests varies according to the patient's phenotype (Table 1). For instance, karyotype and Y chromosome microdeletion analyses are performed in all patients affected by moderate or severe oligozoospermia and azoospermia. Gene mutation screening is performed when a specific disease condition is suspected: hypogonadotropic hypogonadism, partial or mild androgen insensitivity syndrome, congenital absence of vas deferens (CAVD), and monomorphic forms of teratozoospermia. All the abovementioned analyses aim at the identification of genetic factors showing a cause-effect relationship with the given phenotype, and they are part of the diagnostic work-up of infertile men. During the last 20 years, active research has been carried out in order to identify novel candidate genes and genetic risk factors for impaired sperm production. The initial candidate gene resequencing studies have been followed by genome-wide association studies (GWAS) based on SNP array and array CGH, but very few of the identified risk factors have been validated in more than one study (Krausz et al. 2015). The only genetic risk factor which is currently screened in selected populations is the Y-chromosome-linked “gr/gr deletion.” With the recent advent of next-generation sequencing (NGS), the analysis of the entire exome has been applied also to male infertility. Although whole exome/genome data interpretation remains challenging, whole exome analysis seems to be a valid diagnostic tool for familial cases or for patients with consanguineous parents. In this chapter a clinical overview will be given on the abovementioned genetic tests including their indication and interpretation with specific focus on genetic counselling.

**Table 1** Genetic tests indicated in the diagnostic work-up of men with different infertile phenotypes. Methods which are most commonly used for their detection are also shown

Genetic tests	Indication for the analysis	Method
<b>Chromosomal anomalies</b>		
Karyotype	Azoo or <10 million spzoa/ml	Cytogenetic analysis
AZF deletion screening	Azoo- or <5 million spzoa/ml	PCR plus/minus
gr/gr deletion screening	Oligozoospermia (< 20 milion spzoa/ml)	PCR plus/minus (confirmatory steps with gene dosage <sup>a</sup> and RFLP)
<b>Mutations screening</b>		
cHH candidate genes	Kallmann sdr or normosmiccHH	NGS based candidate gene panel
AndrogenReceptor (AR)	Hypoandrogenized infertile man	Sanger sequencing
<i>CFTR</i>	Congenital Absence of Vas Deferens(uni/bilateral) Idiopathic epididymal obstruction	Mutation panel (with the most frequent mutations in a given geographic area)
<i>TEX11</i> <sup>b</sup>	Azoospermia (meioticarrest)	Sanger sequencing/a-CGH
<i>DPY19L2</i>	Globozoospermia	Sanger sequencing and qPCR
<i>AURKC</i>	Macrozoospermia	Sanger Sequencing

*Sdr* syndrome, *cHH* congenital Hypogonadotrophic Hypogonadism, *NGS* next generation sequencing, *RFLP* restriction fragment length polymorphism

<sup>a</sup>Gene dosage with semiquantitative fluorescent assay (Genescan software) or qPCR

<sup>b</sup>Potentially introducible into diagnostic practice

## Karyotype Analysis

Chromosomal abnormalities may affect the number or the structure of chromosomes, and in the large majority of cases, their etiopathogenesis resides in meiotic errors. Klinefelter syndrome represents the most common karyotype abnormality in severe male factor infertility, followed by Y chromosome terminal deletions (Yq-) and structural autosomal abnormalities.

*Indication for testing* is based on the sperm count; however, in case there is a family history of recurrent abortions, malformations, or mental retardation, karyotype analysis should be requested regardless of the sperm concentration. The most widely accepted cutoff for karyotype analysis is moderate oligozoospermia (<10 million spermatozoa/ml) since in this category of patients, there is already a ten times higher incidence (4%) of mainly autosomal structural abnormalities in respect to the general population (Jungwirth et al. 2012). The more severe is the testicular phenotype, the higher is the frequency of chromosomal abnormalities

meaning that among severe oligozoospermic men (<5 million spermatozoa/ml), the frequency increases to 7–8%, whereas in non-obstructive azoospermic men, it reaches the highest values, 15–16% (Vincent et al. 2002).

## Numerical Chromosome Anomalies

### Klinefelter Syndrome (KS)

Klinefelter syndrome (47, XXY or mosaics 46, XY/47, XXY or higher-grade sex chromosomal aneuploidy, i.e., XXXY, XXXXY, etc.) is the most common sex chromosome aberration (sex chromosome aneuploidy) in humans with an incidence of 1:600 in live births and 1:300 in spontaneous abortion. The diagnosis can be made in three different age groups: (i) in fetus during prenatal genetic diagnosis, (ii) in childhood mainly for behavioral and/or learning problems, and (iii) in adulthood for infertility and/or sexual dysfunction (hypoandrogenism). The highest frequency of this syndrome is found in azoospermic men (14%) as the most typical semen phenotype is the absence of spermatozoa in the ejaculate. The clinical phenotype of androgen deficiency in KS ranges from clinically overt hypogonadism to normally virilized males. The classical symptoms include small firm testes with hyalinization of seminiferous tubules, azoospermia or extremely severe oligozoospermia/cryozoospermia, hypergonadotropic hypogonadism with or without gynecomastia, and eunuchoid proportions (for review, see Aksglaede and Juul 2013). Elevated LH and FSH levels are universal and already present in young men, whereas the decline of the testosterone level below the normal range shows high interindividual variability.

**Genetic counselling:** After diagnosis, patient must be informed about the general and reproductive health's consequences of the disease. This chromosome aberration does not only affect testicular function (androgen deficiency and infertility), but it is also associated with nonreproductive problems, dyslexia, executive dysfunction, behavioral problems and predisposition to venous insufficiency, systemic diseases such as diabetes mellitus, and autoimmune disorders. It is therefore mandatory that these patients adopt preventive measures (especially for metabolic syndrome) and that are followed up during their entire life span.

Although the fertility spectrum is rather uniform and mainly characterized by azoospermia, occasionally spermatozoa can be found in the ejaculate of some mosaic patients or of non-mosaic but younger patients (Kamischke et al. 2003). Since germ cell loss is progressive with age (Aksglaede et al. 2006), preventive cryopreservation of ejaculated or intratesticular spermatozoa has been proposed in order to preserve fertility (Plotton et al. 2015). Concerning pubertal and postpubertal adolescent males with KS, there is great debate with regard to whether they should have testicular sperm extraction (TESE) offered upon diagnosis to “preserve” future fertility. The number of prepubertal patients analyzed overall is rather small, since the diagnosis of KS is rarely made at this age. Still, the retrieval rate of mature germ

cells seems rather low, and spermatogenic stem cell (SSC) cryopreservation would appear as the only approach; however, germ cell in vitro maturation techniques are still at an experimental stage in animal models and far from guaranteeing future fertility in humans (Van Saen et al. 2012). In adults, TESE and especially microsurgical TESE (micro-TESE) followed by ICSI with an average of 50% of testicular sperm recovery rate may allow Klinefelter patients to generate their own genetic children (Fullerton et al. 2010).

Although data on ICSI babies from KS fathers are ensuring, a study based on ICSI combined with preimplantation genetic diagnosis (PGD) on 113 embryos showed that there is a significant fall in the rate of normal embryos for couples with KS in respect to controls (54% vs. 77.2%). Due to the significant increase of sex chromosomal and autosomal abnormalities in the embryos of KS patients, PGD should be considered as an appropriate preventive option (Staessen et al. 2003).

#### **46, XX Male (de La Chapelle Syndrome)**

The frequency and the health consequences of this disease are markedly different from that found in Klinefelter syndrome (Vorona et al. 2007). It is a rare disease with a prevalence of 1 in 20,000 newborn males, and in about 80% of cases, it is due to the translocation of the *SRY* gene (encoding the testis-determining factor; Sinclair et al. 1990) to the X chromosome during paternal meiosis. The cause of *SRY*-negative XX maleness remains to be elucidated (for review, see Bashamboo and McElreavey 2015; Eggers et al. 2014), and patients belonging to this category may present ambiguous genitalia. XX male is characterized by decreased body height and an increased rate of maldescended testes and gynecomastia in respect to the general population.

**Genetic counselling:** These patients may present hypoandrogenism which implies that a careful endocrine assessment and follow-up is always advised. Given that the long arm of the Y chromosome contains important genes for spermatogenesis, this disease is not compatible with residual spermatogenesis, and TESE should not be advised.

#### **47, XYY Male**

It is a relatively frequent karyotype anomaly occurring in 1:750 men. Carriers of this abnormality show a great diversity in the degree of spermatogenic impairment, ranging from severe oligozoospermia to apparent normality (Skakkebaek et al. 1973). Distortion of sex vesicle formation is probably the major cause of disturbed spermatogenesis in these men (Berthelsen et al. 1981).

**Genetic counselling:** Given the high variability of the phenotype, it is difficult to predict the reproductive consequences of this condition and to estimate the risk for aneuploidy in the embryo/fetus. Sperm FISH analysis can be useful in order to evaluate the aneuploidy rate in a given subject.

*Aneuploidies of autosomes:* Most numerical aneuploidies of autosomes are lethal. Patients affected by Down syndrome may be fertile or infertile (Zühlke et al. 1994).

## Structural Chromosome Anomalies

*Y chromosome structural anomalies detectable with karyotype analysis* include isodicentric Y chromosomes, truncated Y chromosomes, or ring Y chromosomes (Kim et al. 2012; Lange et al. 2009). After the KS, these microscopic alterations of the Y chromosome are the most frequent karyotype anomalies in azoospermic men.

**Genetic counselling:** This disease is not associated with a higher risk for hypoandrogenism or general health problems. TESE can be attempted depending on the presence/absence of the AZF regions. A careful evaluation of the proportion of 45, X cells is important because mosaicism is commonly found and represents a poor prognosis for testicular sperm retrieval.

## Autosomal Structural Anomalies

Oligozoospermic men are at the highest risk for autosomal karyotype abnormalities which include Robertsonian translocations, reciprocal translocations, paracentric inversions, and marker chromosomes. In 60% of all cases of Robertsonian translocations, a (13;14)-translocation is found. This abnormality is rarely observed in azoospermic men but is often found in oligozoospermic patients (about nine times higher in infertile men than in healthy controls) and sporadically also in normozoospermic men (Chandley et al. 1975). Pericentric inversions are 13 times higher in infertile men, and probably interfere with meiosis, leading to a reduced rate of post-meiotic sperm development.

## Genetic Counseling

The importance of the detection of these structural chromosomal anomalies is related to the increased risk of aneuploidy or unbalanced chromosomal complements in the fetus. In case of Robertsonian translocations, a special risk is represented by uniparental disomies which are generated through a mechanism called “trisomy rescue” (repairing the trisomic status) during the first division of the zygote. For chromosomes 14 (the most frequently involved chromosome) and 15, both paternal and maternal uniparental disomies are pathological and give rise to severe disease such as Angelman or Prader-Willi syndromes, despite an apparently normal or balanced karyotype. Similarly to KS sperm, FISH analysis and/or PGD should be performed to give a more accurate risk estimation of affected offspring.

In conclusion, karyotype analysis should be strongly considered in the diagnostic work-up in all oligozoospermic men with <10 million spermatozoa/ml and in all non-obstructive azoospermic men. The diagnosis of a karyotype anomaly has multiple implications: it defines the etiology of the impaired sperm production and it allows the adoption of preventive measures both for the carrier and his future offspring.

---

## Y Chromosome Microdeletion Screening

Submicroscopic deletions on the Yq are also called as *azoospermia factor* (AZF) deletions and represent the most frequently known molecular genetic cause of oligo-/azoospermia (Vogt et al. 1996).



The richness of large repeated DNA sequences (segmental duplications organized in amplicons) makes this chromosome prone to deletions and duplications. Although there are five recombination hot spots on Yq, for clinical practice we continue to refer to these three “classical” deletion intervals *AZF<sub>a</sub>*, *AZF<sub>b</sub>*, and *AZF<sub>c</sub>* (Krausz et al. 2014). Clinically relevant microdeletions remove partially or, in the large majority of cases completely, one or more of the *AZF* regions. In each *AZF* region, spermatogenesis candidate genes have been identified, which are removed *en block*; therefore, the spermatogenic function of a single *AZF* gene is still unclear. Gene-specific deletions removing a single gene, e.g., *USP9Y*, have been reported only in the *AZF<sub>a</sub>* region, and the associated phenotype suggests that this gene is a “fine tuner” of sperm production (Krausz et al. 2006; Tyler-Smith and Krausz 2009).

Since the frequency of isolated *AZF* gene deletions/mutations is extremely rare (and restricted to *USP9Y*, so far), testing for isolated gene deletions is not advised. The method used for the detection of these genetic anomalies is standardized and reported in detail in the recent EAA/EMQN guidelines (Krausz et al. 2014). Thanks to the EAA/EMQN external quality control program (<http://www.emqn.org/emqn/>), Yq testing has become more homogeneous and reliable in different routine genetic laboratories.

*Indication for testing* is based on sperm count, and it is advised in men with <5 million spermatozoa/ml. The frequency of *AZF* deletions increases with the severity of spermatogenic disturbance, and the highest percentage (8–10%) is encountered in idiopathic non-obstructive azoospermia (Lo Giacco et al. 2014a). It is worth noting that the large majority of deletion carriers in the oligozoospermic group belongs to the range of <2 million/ml, where its frequency is about 3–5%.

**Genetic counselling:** The identification of a Yq microdeletion is not only relevant for diagnostic purposes but has prognostic value as well. For example, in cases of complete *AZF<sub>a</sub>* and *AZF<sub>b</sub>* microdeletions, the chance of finding spermatozoa upon surgical testicular exploration (testicular sperm extraction, TESE) is virtually zero (Krausz et al. 2000).

In contrast, if an *AZF<sub>c</sub>* microdeleted man is azoospermic, there is still a good chance (on average 50%) that spermatozoa could be harvested upon TESE (Oates et al. 2002).

It is important to ask for an extensive karyotype analysis in order to detect 46, XY/45, X0 mosaicism which confers a poor prognostic value for TESE success (Jaruzelska et al. 2001).

*AZF* microdeletions which are compatible with sperm production (*AZF<sub>c</sub>*, or partial *AZF<sub>a</sub>*, *AZF<sub>b</sub>* deletions) will be obligatorily transmitted to all male offspring, and the extent of spermatogenic failure of each conceived son may vary substantially. However, given the strict cause-effect relationship between an *AZF<sub>c</sub>* microdeletion and severely reduced spermatogenesis, normozoospermia cannot be expected.

*gr/gr deletion of the Yq:* This deletion removes half of the *AZF<sub>c</sub>* region gene content affecting the dosage of multicopy genes with exclusive expression in the testis (Repping et al. 2003). The reduced *AZF<sub>c</sub>* gene dosage is associated with an impaired efficiency of spermatogenesis, and according to all available

meta-analyses, it confers on average a twofold increased risk for oligozoospermia (for review, see Krausz et al. EAA/EMQN).

*Indication for testing:* This is still debated among experts. The frequency in oligozoospermic patients is about 4% whereas in normozoospermic subjects is about 0.5% (Giachini et al. 2008). However, both the frequency and phenotypic expression may vary in different ethnic groups, depending on the Y chromosome background (in specific Y haplogroups, such as D2b and Q3, common in Japan and certain parts of China, the deletion is fixed and apparently does not have any negative effect on spermatogenesis). According to the EAA/EMQN guidelines, the screening should be performed in those populations for which an accurate risk estimate exists. For instance, in Italy, data based on >1000 subjects show an OR = 7.9 (95% CI (1.8–33.8) to develop oligozoospermia.

**Genetic counselling:** The deletion contributes to the etiopathogenesis of impaired sperm production since it is able to influence the spermatogenic potential of the carrier. It is therefore important that the couple should be aware that the deletion (i.e., a genetic risk factor for impaired sperm production) will be obligatorily transmitted to their male offspring and the deletion may become a complete AZFc deletion (i.e., a clear-cut causative factor for spermatogenic impairment) in the next generation) (Lu et al. 2009; Zhang et al. 2007).

---

## Gene Mutation Screening

### Congenital Hypogonadotropic Hypogonadism (cHH or Idiopathic Hypogonadotropic Hypogonadism (iHH))

cHH is a rare disease (incidence of 1:8000 males) (Boehm et al. 2015) characterized by a deficit of gonadotropins leading to different phenotypic pictures ranging from the more severe, complete form with absent puberty (frequently associated with cryptorchidism, micropenis) to the adult-onset HH. The presence or absence of anosmia/hyposmia is the basis for dividing cHH into two major clinical groups: Kallmann syndrome (with olfactory symptoms) and normosmic cHH. From a genetic point of view, such a sharp distinction seems to be inappropriate since in some cases the same gene can be involved in both clinical manifestations (e.g., *FGFR1*, *PROKR2*). cHH shows two main peculiarities: (i) it does not follow the rules of Mendelian inheritance, and in about 15% of cases, there is a digenic/oligogenic inheritance, i.e., the presence of heterozygous mutations in two or more cHH candidate genes leads to the disease (Pitteloud et al. 2007), (ii) despite its genetic origin, “reversibility” of the gonadotrophin deficiency in about 10% of patients has been described (Raivio et al. 2007; Ribeiro et al. 2007). Mutations of cHH candidate genes are potentially related also to late-onset hypogonadism, and accordingly a *GNRHR* mutation has been described in this pathological condition (Tommiska et al. 2013).

*Indication for testing* is restricted for patients with confirmed cHH after the exclusion of all secondary forms (pituitary tumors, empty sella, etc). Genetic testing

should be performed since in about 90% of these patients, azoospermia can be “cured” by the administration of gonadotrophins making possible the transmission of gene mutations either spontaneously or by assisted reproductive techniques. Genetic testing for the most frequently mutated candidate genes is available in many diagnostic genetic laboratories as a next-generation sequencing (NGS) gene panel.

**Genetic counselling:** The complexity of this disease (variable expressivity, penetrance, and inheritance fashions) makes it rather difficult to predict the exact health consequences for the descendants. Depending on the type of gene involved and on the type of mutation, i.e., whether a clear-cut cause-effect relationship is found, PGD or prenatal diagnosis may be offered to the couple. Preventive procedures are especially advised for those gene mutations which could cause serious nonreproductive and nonolfactory anomalies (renal agenesis, hearing loss, etc.). Genetic testing does not seem to help in identifying patients with higher probability of “reversal” since this condition has been described in relationship with many cHH candidate genes. This implies that all patients affected by cHH should be reassessed for recovery of the hypothalamo-pituitary-gonadal axis after a certain period of hormonal replacement therapy.

## Mutation Analysis of the Androgen Receptor Gene (AR)

This gene is situated on the X chromosome (Xq11-12), and more than 1000 gene mutations have been described so far (Gottlieb et al. 2012). The phenotypic spectrum ranges from a phenotypic female in the complete androgen insensitivity syndrome to undervirilized male phenotype in partial androgen insensitivity syndrome (PAIS) and normal male genitals but impaired sperm production in mild androgen insensitivity syndrome (MAIS) (O’Hara and Smith 2015). The AR gene contains two polymorphic sites in the N-terminal transactivation domain of the receptor: a polyglutamine tract, (CAG) $n$ , and a polyglycine tract, (GGC) $n$ , which were the subject of many publications related to male infertility (for review, see Davis-Dao et al. 2007). The large majority of papers have focused on the (CAG) $n$  length which normally ranges between 6 and 39 repeats in the general population, with a median value that varies according to the ethnicity (21–22 in White Caucasian, 19–20 in African-American, 22–23 in Asian populations). The originally described inverse relationship between CAG repeat length and the receptor transactivation led to the hypothesis that longer (CAG) $n$  repeat conferred a higher risk for infertility and cryptorchidism. However, although the meta-analysis of available data gives support for an association between increased androgen receptor CAG length and idiopathic male infertility, there are still important unanswered questions, i.e., what range of AR CAG repeat lengths predisposes to impaired sperm production and what risk of infertility is associated with each length in this range (Davis-Dao et al. 2007). Recent functional (Nenonen et al. 2010) and observational studies reporting that both a longer or a shorter CAG tract might have a negative effect on the receptor function (Davis-Dao et al. 2012; Nenonen et al. 2011) suggest that the highest transcription

seemingly occurs in the presence of an optimal number of CAG repeats, which is represented by the median CAG length encountered in the general population. We can therefore speculate that the “optimum” range may vary between the genomic and non-genomic action and also in different tissues because the effect of polyQ repeat on transactivation is cell specific, presumably due to distinct profiles of co-regulator proteins (Krausz 2012). Indeed, the role of CAG repeats in male infertility is probably more complex than it has been previously considered, and more functional and clinical studies are needed before this polymorphism can be introduced into the diagnostic setting.

*Indication for testing:* As stated above, screening for (CAG) repeat length is not advised for clinical purposes; mutation screening in infertile men should be performed only if PAIS or MAIS is suspected, i.e., in case of hypoandrogenization and a hormone profile with especially high androgen sensitivity index (ASI), calculated as the product of serum testosterone times serum luteinizing hormone, i.e., high LH in the presence of relatively high testosterone levels may suggest mild resistance. Since the frequency of mutations in the *AR* gene in unselected infertile men (including both normal and high ASI) varies between 0% and 1.7% (Ferlin et al. 2006; Rajender et al. 2007), a routine screening to all infertile men is not advised.

### **CFTR Mutation Screening:**

The *CFTR* gene encodes the cystic fibrosis transmembrane conductance regulator, a protein involved in chloride conduction across epithelial cell membranes. The *CFTR* gene is one of the most mutated genes in the human genome since more than 1000 mutations have been identified in patients affected by cystic fibrosis (CF). With the exception of the widely spread delta F508 mutation (p.Phe508del), the rest of mutations occur with a low frequency and show different geographic/ethnic distribution.

*Indication for testing:* Infertile men is restricted to congenital absence of vas deferens (CAVD), which is considered a mild form of cystic fibrosis (CF). CAVD may affect one or both vasa deferentia and is typically associated with agenesis of the seminal vesicles and epididymal malformations. CAVD is transmitted as an autosomal recessive disease (Oates and Amos 1994; Patrizio and Leonard 2000), and from a genetic point of view, two scenarios can be present: (i) a severe mutation in one allele and a mild mutation, which leaves some residual CFTR activity, in the other allele and (ii) two mild mutations in the two alleles. The 5T variant in intron 8 (IVS8-5T) is considered a “mild” mutation, and its frequency shows a five- to sixfold increase among CAVD chromosomes (Patrizio and Leonard 2000). The length of the T tract (IVS8-5T, IVS8-7T, IVS8-9T) affects the splicing efficiency of exon 9 and thus the percent of normal CFTR mRNA. The 5T tract is the less efficient, and in about 90% of CFTR mRNA, exon 9 is missing with a consequent impaired function of the Cl channel. In a small percentage of CBAVD cases, *CFTR* mutation cannot be detected and is predicted to be caused by a different yet unknown gene defect. These

patients may have unilateral renal agenesis which implies that all patients affected by CAVD should undergo an ultrasound scan of the pelvic region prior genetic testing.

**Genetic counselling:** Mutations may cause both bilateral (CBAVD) and unilateral (CAVD) agenesis of vas deferens. The former is associated with azoospermia, the later with either oligo- or normozoospermia. Since the testicular function is normal, conception of a biological child in CBAVD is possible through TESE combined with ICSI procedure. Given that the carrier frequency of *CFTR* mutations in persons with European descent is high (1:25), its screening in the female partners is mandatory. In most cases the standard screening panel, containing the 30–50 most common mutations for a given geographic area and ethnic group, may not be sufficient for detecting the two mutations in the affected male partner. If it is the case, whole gene screening is advised in the CAVD patient which should be also extended to his partner (except if the panel screening reveals already her carrier status). If mutations are detected in both partners, the risk of an offspring with CF (or mild forms of CF, depending on the type and combination of mutations) is very high, and PGD should be advised to the couple. However, precise risk estimates are difficult to be made due to different degrees of penetrance of the same genotype between different individuals (Cuppens and Cassiman 2004).

## Genetic Testing in Monomorphic Teratozoospermia

In the past few years, major advances have been obtained in the definition of the genetic background of two monomorphic forms of teratozoospermia: sperm macrocephaly and globozoospermia. Sperm macrocephaly is described as a rare condition with a <1% prevalence in the subfertile population and is characterized by large-headed and multi-flagellated spermatozoa (Nistal et al. 1977). Globozoospermia (incidence of 0.1%) is characterized by the production of round-headed acrosomeless spermatozoa that are unable to fertilize the oocyte, since no acrosome reaction can occur (for review, see Coutton et al. 2015; De Braekeleer et al. 2015). Up to now, *AURKC* gene mutations are the only known genetic causes of sperm macrocephaly. This protein is essential for correct meiotic chromosomal segregation and cytokinesis (Dieterich et al. 2007). The most frequently diagnosed mutation is a 1-bp deletion (c.144delC), and it has been reported to occur exclusively in the North African ancestry, suggesting the possibility of a founder effect (Ben Khelifa et al. 2012; Dieterich et al. 2009). In addition, few other point mutations have been reported in this gene either in compound heterozygosis with the deletion or in homozygosis. A recent report on sperm macrocephaly without mutations in the *AURKC* gene (Molinari et al. 2013) suggests that other genes are likely to be involved. Regarding globozoospermia, the most prevalent genetic defect observed in this disease is a ~200 Kb homozygous deletion of *DPY19L2* (12q14.2), first identified by a genome-wide scan analysis using a 10 K SNP array (Koscinski et al. 2011). It has been proved that *DPY19L2* deletion leads to the blockage of sperm head elongation and acrosome formation. Two further genes have been associated with

globozoospermia in humans, *SPATA16* and *PICK*, while mutation screening in other candidate genes derived from mouse KO studies did not lead to the identification of novel human candidate genes (Chianese et al. 2015).

*Indication for testing* should be restricted to complete form of globozoospermia or macrocephalia with a nearly 100% of abnormal spermatozoa. In these highly selected cases the likelihood to find mutations in the abovementioned candidate genes is high.

**Genetic counselling:** Since *AURKC* mutations are associated with an exceptionally high aneuploidy rate (especially tetraploidy), demonstrated by sperm FISH analysis, ICSI is contraindicated. In case of 100% globozoospermia due *DPY19L2* mutations, the ICSI outcome is extremely poor for at least two reasons: (i) the spermatozoa is not be able to activate the oocyte alone because of the missing PLC $\zeta$ -dependent induction of calcium increase in the oocyte and (ii) spermatozoa of *DPY19L2* homozygous-deleted patients show abnormal histone retention (compaction defect) accompanied by a high rate of DNA fragmentation leading to impaired embryo developmental potential (Yassine et al. 2015). Although artificial oocyte activation (AOA) using Ca $^{2+}$  ionophores could overcome the first defect, much care should be taken for the reported epigenetic/genetic alterations which could leave to general health problems in the future offspring.

In order to better define the globozoospermia risk in the male descendants (recessive inheritance), the female partner of male carriers of *DPY19L2* deletion/mutations should be also screened for at least the more frequently occurring *DPY19L2* deletion. A recently developed qPCR technique provides an easy and cost-effective screening (Chianese et al. 2015).

---

## Future Directions in Genetic Testing

### Next-Generation Sequencing (NGS) in Male Infertility

With the advent of NGS, whole exome analysis became feasible allowing diagnosing the genetic cause of a few familial infertility cases (Ayhan et al. 2014; Okutman et al. 2015; Ramasamy et al. 2015). In fact, this approach, although still expensive, is especially successful when it comes to consanguineous families in which a recessive transmission is suspected. It is important to note that with the current NGS platforms, the analysis of copy number variations (CNVs) remains suboptimal.

### Array-Comparative Genomic Hybridization (Array-CGH) in Male Infertility

Array-CGH is an ideal method to detect small structural rearrangements (deletions/duplications), invisible at cytogenetic analysis. Previous array-CGH studies revealed the presence of a deletion burden in the genome (especially evident in the sex chromosomes) of infertile men (Krausz et al. 2012; Lopes et al. 2013;

Tüttelmann et al. 2011). This finding suggests higher genome instability in these subjects that might have consequences not only on their fertility status but also on their general health. Although the hypothesis of a link between genomic instability (CNV burden) and higher morbidity/mortality of infertile men stimulates further research, the diagnostic use of a-CGH is limited to few selected cases (familial infertility or presence of other nonreproductive symptoms).

## X Chromosome and Male Infertility

The unexpectedly high number of X chromosome-linked genes with specific testicular expression (especially multi-copy genes which have been recently acquired on the human X chromosome during evolution) (Mueller et al. 2013) is in agreement with the higher deletion load in this chromosome in infertile men (see paragraph above). The first X chromosome-linked recurrent deletion (CNV67), specific to oligo-/azoospermia represents a potential novel diagnostic target in male infertility (Lo Giacco et al. 2014b). Recently, intragenic deletions and mutations in the *TEX11* gene (a testis-specific gene involved in meiosis) have been identified in azoospermic men (Yang et al. 2015; Yatsenko et al. 2015). It remains to be established whether all reported point mutations in *TEX11* are truly causative mutations and thus whether the frequency of damaging mutations is as high as 15% in men affected by spermatogenic arrest at the spermatocytic stage.

---

## Conclusions

In the era of in vitro fertilization, it is of utmost importance to identify the underlying genetic cause of impaired sperm production since the risk of transmitting genetic disorders to the future offspring exists. Despite progress, in about 40% of male infertility cases, the pathophysiology remains unknown and the diagnosis and/or treatment still represents a challenge. Not yet identified monogenic mutations (with clear-cut cause-effects) or polymorphisms (“genetic risk factors”) acting with other co-factors (genetic or environmental) are likely to be involved in the majority of “idiopathic” cases. From a genetic point of view, different scenarios can be envisaged in sporadic idiopathic oligo-/azoospermia: (i) the presence of a large-size effect, rare mutation with dominant negative effect, or X chromosome-linked mutations which cannot be compensated for by a wild-type allele in male; (ii) combination of rare variants in genes participating in the same biological pathway (digenic/oligogenic inheritance); and (iii) combined action of low-size effect genetic risk factors (both rare or common variants). The ideal diagnostic tool should be the development of a gene-panel based on candidate genes/mutations which are recurrently involved in infertility. However, resequencing of hundreds of spermatogenesis candidate in the past 20 years (mainly in groups of subjects with heterogeneous semen phenotypes) did not lead to the identification of recurrent gene defects. It is plausible that highly homogeneous testicular phenotypes (SCOS or Spermatogenic

arrest) represent a better target for future gene-panel-based screening since they are likely to be caused by a relatively small number of recurrent gene defects. In this regard, *TEX11* mutations are encouraging for the meiotic arrest phenotype. Taken together all the above considerations and the fact that data on the majority of genetic risk factors is highly controversial, the development of such a diagnostic gene panel remains a major challenge in the field of male infertility.

---

## References

- Aksglaede L, Juul A. Testicular function and fertility in men with Klinefelter syndrome: a review. *Eur J Endocrinol.* 2013;168:R67–76.
- Aksglaede L, Wikstrom AM, Rajpert-De ME, Dunkel L, Skakkebaek NE, Juul A. Natural history of seminiferous tubule degeneration in Klinefelter syndrome. *Hum Reprod Update.* 2006;12:39–48.
- Ayhan Ö, Balkan M, Guven A, Hazan R, Atar M, Tok A, Tolun A. Truncating mutations in TAF4B and ZMYND15 causing recessive azoospermia. *J Med Genet.* 2014;51:239–44.
- Bashamboo A, McElreavey K. Human sex-determination and disorders of sex-development (DSD). *Semin Cell Dev Biol.* 2015;45:77–83.
- Ben Khelifa M, Coutton C, Blum MGB, Abada F, Harbuz R, Zouari R, et al. Identification of a new recurrent aurora kinase C mutation in both European and African men with macrozoospermia. *Hum Reprod.* 2012;27(11):3337–46.
- Berthelsen JG, Skakkebaek N, Perboll O, et al. Electron microscopic demonstration of the extra Y chromosome in spermatocytes from human XYY males. In: Byskov AG, Peters H, editors. *Development and function of reproductive organs.* Amsterdam: *Experta Medica*; 1981. p. 328–37.
- Boehm U, Bouloux PM, Dattani MT, de Roux N, Dodé C, Dunkel L, Dwyer AA, Giacobini P, Hardelin JP, Juul A, Maghnie M, Pitteloud N, Prevot V, Raivio T, Tena-Sempere M, Quinton R, Young J. Expert consensus document: European consensus statement on congenital hypogonadotropic hypogonadism-pathogenesis, diagnosis and treatment. *Nat Rev Endocrinol.* 2015;11(9):547–64.
- Chandley AC, Edmond P, Christie S, Gowans L, Fletcher J, Frackiewicz A, Newton M. Cytogenetics and infertility in man. I. Karyotype and seminal analysis: results of a five-year survey of men attending a subfertility clinic. *Ann Hum Genet.* 1975;39:231–54.
- Chianese C, Fino MG, Riera Escamilla A, López Rodrigo O, Vinci S, Guarducci E, Daguin F, Muratori M, Tamburrino L, Lo Giacco D, Ars E, Bassas L, Costa M, Pisatauro V, Noci I, Coccia E, Provenzano A, Ruiz-Castañe E, Giglio S, Piomboni P, Krausz C. Comprehensive investigation in patients affected by sperm macrocephaly and globozoospermia. *Andrology.* 2015;3(2):203–12.
- Coutton C, Escoffier J, Martinez G, Arnoult C, Ray PF. Teratozoospermia: spotlight on the main genetic actors in the human. *Hum Reprod Update.* 2015;21(4):455–85.
- Cuppens H, Cassiman JJ. CFTR mutations and polymorphisms in male infertility. *Int J Androl.* 2004;27:251–6.
- Davis-Dao CA, Tuazon ED, Sokol RZ, Cortessis VK. Male infertility and variation in CAG repeat length in the androgen receptor gene: a meta-analysis. *J Clin Endocrinol Metab.* 2007;92:4319–2624.
- Davis-Dao C, Koh CJ, Hardy BE, Chang A, Kim SS, De Filippo R, et al. Shorter androgen receptor CAG repeat lengths associated with cryptorchidism risk among Hispanic white boys. *J Clin Endocrinol Metab.* 2012;97:E393–9.
- De Braekeleer M, Nguyen MH, Morel F, Perrin A. Genetic aspects of monomorphic teratozoospermia: a review. *J Assist Reprod Genet.* 2015;32(4):615–23.



- Dieterich K, Soto Rifo R, Faure AK, Hennebicq S, Ben Amar B, Zahi M, et al. Homozygous mutation of AURKC yields large-headed polyploid spermatozoa and causes male infertility. *Nat Genet.* 2007;39(5):661–5. Epub 2007 Apr 15.
- Dieterich K, Zouari R, Harbuz R, Vialard F, Martinez D, Bellayou H, et al. The Aurora Kinase C c.144delC mutation causes meiosis I arrest in men and is frequent in the North African population. *Hum Mol Genet.* 2009;18(7):1301–9. 16–19.
- Eggers S, Ohnesorg T, Sinclair A. Genetic regulation of mammalian gonad development. *Nat Rev Endocrinol.* 2014;10(11):673–83.
- Ferlin A, Vinanzi C, Garolla A, Selice R, et al. Male infertility and androgen receptor gene mutations: clinical features and identification of seven novel mutations. *Clin Endocrinol.* 2006;65:606–10.
- Fullerton G, Hamilton M, Maheshwari A. Should non-mosaic Klinefelter syndrome men be labelled as infertile in 2009? *Hum Reprod.* 2010;25:588–97.
- Giachini C, Laface I, Guarducci E, Balercia G, et al. Partial AZFc deletions and duplications: clinical correlates in the Italian population. *Hum Genet.* 2008;124:399–410.
- Gies I, Oates R, de Schepper J, Tournaye H. Testicular biopsy and cryopreservation for fertility preservation of pre-pubertal boys with Klinefelter syndrome: a pro/con debate. *Fertil Steril.* 2016;105:249–55.
- Gottlieb B, Beitel LK, Nadarajah A, Palioura M, Trifiro M. The androgen receptor gene mutations database (ARDB): 2012 update. *Human Mutation.* 2012;33:887–94.
- Jaruzelska J, Korcz A, Wojda A, Jedrzejczak P, Bierla J, Surmacz T, Pawelczyk L, Page DC, Kotecki M. Mosaicism for 45,X cell line may accentuate the severity of spermatogenic defects in men with AZFc deletion. *J Med Genet.* 2001;38:798–802.
- Jungwirth A, Giwercman A, Tournaye H, Diemer T, Kopa Z, Dohle G, Krausz C. European association of urology working group on male infertility. European association of urology guidelines on male infertility: the 2012 update. *Eur Urol.* 2012;62(2):324–32.
- Kamischke A, Baumgardt A, Horst J, Nieschlag E. Clinical and diagnostic features of patients with suspected Klinefelter syndrome. *J Androl.* 2003;24:41–8.
- Kim JW, Park SY, Ryu HM, et al. Molecular and clinical characteristics of 26 cases with structural Y chromosome aberrations. *Cytogenet Genome Res.* 2012;136:270–7.
- Koscinski I, Elinati E, Fossard C, Redin C, Muller J, Velez de la Calle J, et al. DPY19L2 deletion as a major cause of globozoospermia. *Am J Hum Genet.* 2011;88(3):344–50.
- Krausz C. An encore for the repeats: new insights into an old genetic variant. *J Clin Endocrinol Metab.* 2012;97:764–7.
- Krausz C, Quintana-Murci L, McElreavey K. Prognostic value of Y deletion analysis: what is the clinical prognostic value of Y chromosome microdeletion analysis? *Hum Reprod.* 2000;15:1431–4.
- Krausz C, Degl'Innocenti S, Nuti F, et al. Natural transmission of USP9Y gene mutations: a new perspective on the role of AZFa genes in male fertility. *Hum Mol Genet.* 2006;15:2673–81.
- Krausz C, Giachini C, Lo Giacco D, Daguin F, Chianese C, Ars E, et al. High resolution X chromosome-specific array-CGH detects new CNVs in infertile males. *PLoS One.* 2012;7:e44887.
- Krausz C, Hoefsloot L, Simoni M, Tüttelmann F, European Academy of Andrology, European Molecular Genetics Quality Network. EAA/EMQN best practice guidelines for molecular diagnosis of Y-chromosomal microdeletions: state-of-the-art 2013. *Andrology.* 2014;2:5–19.
- Krausz C, Escamilla AR, Chianese C. Genetics of male infertility: from research to clinic. *Reproduction.* 2015;150(5):R159–74.
- Lange J, Skaletsky H, van Daalen SK, et al. Isodicentric Y chromosomes and sex disorders as byproducts of homologous recombination that maintains palindromes. *Cell.* 2009;138:855–69.
- Lo Giacco D, Chianese C, Sánchez-Curbelo J, Bassas L, Ruiz P, Rajmil O, Sarquella J, Vives A, Ruiz-Castañe E, Oliva R, Ars E, Krausz C. Clinical relevance of Y-linked CNV screening in male infertility: new insights based on the 8-year experience of a diagnostic genetic laboratory. *Eur J Hum Genet.* 2014a;22(6):754–61.

- Lo Giacco D, Chianese C, Ars E, Ruiz-Castañé E, Forti G, Krausz C. Recurrent X chromosome-linked deletions: discovery of new genetic factors in male infertility. *J Med Genet.* 2014b;51:340–4.
- Lopes AM, Aston KI, Thompson E, Carvalho F, Gonçalves J, Huang N, et al. Human spermatogenic failure purges deleterious mutation load from the autosomes and both sex chromosomes, including the gene DMRT1. *PLoS Genet.* 2013;9:e1003349.
- Lu C, Zhang J, Li Y, Xia Y, et al. The b2/b3 subdeletion shows higher risk of spermatogenic failure and higher frequency of complete AZFc deletion than the gr/gr subdeletion in a Chinese population. *Hum Mol Genet.* 2009;18:1122–30.
- Molinari E, Mirabelli M, Raimondo S, Brussino A, Gennarelli G, Bongioanni F, et al. Sperm macrocephaly syndrome in a patient without AURKC mutations and with a history of recurrent miscarriage. *Reprod BioMed Online.* 2013;26(2):148–56.
- Mueller JL, Skaletsky H, Brown LG, Zaghul S, Rock S, Graves T, et al. Independent specialization of the human and mouse X chromosomes for the male germ line. *Nat Genet.* 2013;45:1083–7.
- Nononen H, Björk C, Skjaerpe P, Giwercmana RL, Svartberg J, et al. CAG repeat number is not inversely associated with androgen receptor activity in vitro. *Mol Hum Reprod.* 2010;16:153–7.
- Nononen HA, Giwercman A, Hallengren E, Giwercman YL. Non-linear association between androgen receptor CAG repeat length and risk of male subfertility – a meta-analysis. *Int J Androl.* 2011;34:327–32.
- Nistal M, Paniagua R, Herruzo A. Multi-tailed spermatozoa in a case with asthenospermia and teratospermia. *Virchows Arch B Cell Pathol.* 1977;26(2):111–8.
- O'Hara L, Smith LB. Androgen receptor roles in spermatogenesis and infertility. *Best Pract Res Clin Endocrinol Metab.* 2015;29:595–605.
- Oates RD, Amos JA. The genetic basis of congenital bilateral absence of the vas deferens and cystic fibrosis. *J Androl.* 1994;15:1–8.
- Oates RD, Silber S, Brown LG, Page DC. Clinical characterization of 42 oligospermic or azoospermic men with microdeletion of the AZFc region of the Y chromosome, and of 18 children conceived via ICSI. *Hum Reprod.* 2002;17:2813–24.
- Okutman O, Muller J, Baert Y, Serdarogullari M, Gultomruk M, Piton A, Rombaut C, Benkhalifa M, Teletin M, Skory V, Bakircioglu E, Goossens E, et al. Exome sequencing reveals a nonsense mutation in TEX15 causing spermatogenic failure in a Turkish family. *Hum Mol Genet.* 2015;24:5581–8.
- Patrizio P, Leonard DG. Mutations of the cystic fibrosis gene and congenital absence of the vas deferens. *Results Probl Cell Differ.* 2000;28:175–86.
- Pitteloud N, Quinton R, Pearce S, et al. Digenic mutations account for variable phenotypes in idiopathic hypogonadotropic hypogonadism. *J Clin Invest.* 2007;117:457–63.
- Plotton I, Giscard d'Estaing S, Cuzin B, et al. Preliminary results of a prospective study of testicular sperm extraction in young versus adult patients with non-mosaic 47,XXY Klinefelter syndrome. *J Clin Endocrinol Metab.* 2015;100:961–7.
- Raivio T, Falardeau J, Dwyer A, et al. Reversal of idiopathic hypogonadotropic hypogonadism. *N Engl J Med.* 2007;357:863–73.
- Rajender S, Singh L, Thangaraj K. Phenotypic heterogeneity of mutations in androgen receptor gene. *Asian J Androl.* 2007;9:147–79.
- Ramasamy R, Bakircioglu ME, Cengiz C, Karaca E, Scovell J, Jhangiani SN, Akdemir ZC, Bainbridge M, Yu Y, Huff C, Gibbs RA, Lupski JR, et al. Whole-exome sequencing identifies novel homozygous mutation in NPAS2 in family with nonobstructive azoospermia. *Fertil Steril.* 2015;104:286–91.
- Repping S, Skaletsky H, Brown L, van Daalen SK, et al. Polymorphism for a 1.6-Mb deletion of the human Y chromosome persists through balance between recurrent mutation and haploid selection. *Nat Genet.* 2003;35:247–51.
- Ribeiro RS, Vieira TC, Abucham J. Reversible Kallmann syndrome: report of the first case with a KAL1 mutation and literature review. *Eur J Endocrinol.* 2007;156:285–90.

- Sinclair AH, Berta P, Palmer MS, Hawkins JR, Griffiths BL, Smith MJ, Foster JW, Frischauf AM, Lovell-Badge R, Goodfellow PN. A gene from the human sex-determining region encodes a protein with homology to a conserved DNA-binding motif. *Nature*. 1990;346:240–4.
- Skakkebaek NE, Zeuthen E, Nielsen J, Yde H. Abnormal spermatogenesis in XYY Males: a report on 4 cases ascertained through a population study. *Fertil Steril*. 1973;24:390–5.
- Staessen C, Tournaye H, Van Assche E, Michiels A, et al. PGD in 47,XXY Klinefelter's syndrome patients. *Hum Reprod Update*. 2003;9:319–30.
- Tommiska J, Jørgensen N, Christiansen P, Juul A, Raivio T. A homozygous R262Q mutation in the gonadotropin-releasing hormone receptor presenting as reversal of hypogonadotropic hypogonadism and late-onset hypogonadism. *Clin Endocrinol*. 2013;78:316–7.
- Tüttelmann F, Simoni M, Kliesch S, Ledig S, Dworniczak B, Wieacker P, et al. Copy number variants in patients with severe oligozoospermia and Sertoli-cell-only syndrome. *PLoS One*. 2011;6:e19426.
- Tyler-Smith C, Krausz C. The will-o'-the-wisp of genetics – hunting for the azoospermia factor gene. *N Engl J Med*. 2009;360:925–7.
- Van Saen D, Gies I, De Schepper J, Tournaye H, Goossens E. Can pubertal boys with Klinefelter syndrome benefit from spermatogonial stem cell banking? *Hum Reprod*. 2012;27:323–30.
- Vincent MC, Daudin M, De MP, Massat G, et al. Cytogenetic investigations of infertile men with low sperm counts: a 25-year experience. *J Androl*. 2002;23:18–22. discussion 44–15.
- Vogt PH, Edelmann A, Kirsch S, Henegariu O, Hirschmann P, Kiesewetter F, Köhn FM, Schill WB, Farah S, Ramos C, Hartmann M, Hartschuh W, Meschede D, Behre HM, Castel A, Nieschlag E, Weidner W, Gröne HJ, Jung A, Engel W, Haidl G. Human Y chromosome azoospermia factors (AZF) mapped to different subregions in Yq11. *Hum Mol Genet*. 1996;5:933–43.
- Vorona E, Zitzmann M, Gromoll J, Schüring AN, Nieschlag E. Clinical, endocrinological, and epigenetic features of the 46, XX male syndrome, compared with 47,XXY Klinefelter patients. *J Clin Endocrinol Metab*. 2007;92(9):3458–65. Epub 2007 June 19.
- Yang F, Silber S, Leu NA, et al. TEX11 is mutated in infertile men with azoospermia and regulates genome-wide recombination rates in mouse. *EMBO Mol Med*. 2015;7:1198–210.
- Yassine S, Escoffier J, Martinez G, Coutton C, Karaouzene T, Zouari R, Ravanat JL, Metzler-Guillemain C, Lee HC, Fissore R, Hennebicq S, Ray PF, Arnoult C. Dpy19l2-deficient globozoospermic sperm display altered genome packaging and DNA damage that compromises the initiation of embryo development. *Mol Hum Reprod*. 2015;21:169–85.
- Yatsenko AN, Georgiadis AP, Röpke A, et al. X-linked TEX11 mutations, meiotic arrest, and azoospermia in infertile men. *N Engl J Med*. 2015;372:2097–107.
- Zhang F, Lu C, Li Z, Xie P, et al. Partial deletions are associated with an increased risk of complete deletion in AZFc: a new insight into the role of partial AZFc deletions in male infertility. *J Med Genet*. 2007;44:437–44.
- Zühlke C, Thies U, Braulke I, Reis A, Schirren C. Down syndrome and male fertility: PCR-derived fingerprinting, serological and andrological investigations. *Clin Genet*. 1994;46:324–6.

---

# The Semen Analysis: The Investigation of the Human Ejaculate

# 18

Lars Björndahl and Rebecka Holmberg

---

## Abstract

Assessment of human ejaculate characteristics is a cornerstone in the evaluation of male fertility and in investigations of the function of the male reproductive organs. However, to evaluate the quality of results provided by a laboratory performing semen analysis, it is important for the clinician to have a thorough understanding of the physiological and biological basis for the formation and transport of spermatozoa and the process of ejaculation, as well as an understanding of basic aspects of laboratory science related to analysis of the human ejaculate. Consideration of causes for variability that is not based on pathology is thus also important for the clinician. This chapter does not aim to be a complete laboratory handbook but to give a guide for the clinician to understand strengths and weaknesses of semen analyses. With knowledge of the principles for modern laboratory medicine integrated into basic semen analysis, the clinician has a basis for evidence-based care for the patient whether investigated for infertility or for other diseases or disorders affecting the male reproductive organs.

---

## Keywords

Semen analysis • Ejaculate • Spermatozoa • Motility • Sperm concentration • Morphology • Reliability • Quality control

## Contents

What the Ejaculate Can Tell .....	536
Aspects of Analytical Work .....	538
Pre-analytical Aspects .....	539
Analytical Aspects .....	540

---

L. Björndahl (✉) • R. Holmberg

ANOVA – Andrology, Sexual Medicine and Transgender Medicine, Karolinska University Hospital and Karolinska Institute, Stockholm, Sweden

e-mail: [lars.bjorndahl@ki.se](mailto:lars.bjorndahl@ki.se); [rebecka.holmberg.1@ki.se](mailto:rebecka.holmberg.1@ki.se)

© Springer International Publishing AG 2017

535

M. Simoni, I.T. Huhtaniemi (eds.), *Endocrinology of the Testis and Male Reproduction*, Endocrinology 1, [https://doi.org/10.1007/978-3-319-44441-3\\_18](https://doi.org/10.1007/978-3-319-44441-3_18)

Post-Analytical Aspects .....	544
Semen Analysis or Ejaculate Analysis? .....	549
What Is Ejaculate Analysis Useful for? .....	551
The Physiology of Variability in Ejaculate Analysis .....	551
Technical Variability in Ejaculate Characteristics: How Much Can We Improve? .....	552
Training of Laboratory Staff Members .....	553
Summary .....	553
References .....	554

---

## What the Ejaculate Can Tell

Laboratory investigations of the human ejaculate – commonly called semen analysis – are not always well spoken of. There are numerous publications pointing at poor predictive value of semen analysis regarding reproductive success. The background is most likely due to the special biological properties of the ejaculate causing a slow development of standard operating procedures (SOP). Reports as early as the first half of the twentieth century (Harvey and Jackson 1945) pointed to the need for standardization of semen analysis. Not until the activities promoted by the WHO, there was a development of a universal standard (World Health Organization 1987, 1992, 1999, 2010; Belsey et al. 1980), although the ability of clinical laboratories to comply with the recommendations has been questioned (Keel et al. 2002; De Jonge 2012). The techniques and procedures presented and discussed in this chapter are based on the recommendations by the WHO and published by the Special Interest Group in Andrology (SIGA) of the European Society of Human Reproduction and Embryology (ESHRE) (Barratt et al. 2011).

The investigation of the human ejaculate can provide information related to sperm production, transport in the male, basic sperm function (sperm motility and vitality), as well as give indications of active or earlier infections and inflammatory reactions influencing sperm function.

Basically, a report of semen analysis should include (see example in Fig. 1):

- Abstinence time, time to initiation of assessments, and semen volume
- Abnormal presence of clumping
- Sperm motility – at least divided into proportions of immotile, nonprogressive, and progressive (although information also on the presence of rapid progressive is useful for predicting the outcome of IVF)
- Sperm concentration and total number of spermatozoa
- Sperm vitality – at least when few sperm are motile
- Sperm morphology
- Abnormal presence of inflammatory cells (white blood cells)

Further investigations of the ejaculate can often give important information to understand abnormal sperm function and disorders in the male reproductive organs:

<b>Specialist Hospital</b> Andrology Unit Andrology Laboratory Medicine Town, PO Box 50 043 Phone: 01 - 23 456 789; E-mail: androlab@spec.hosp.xx			patient: [REDACTED] <b>Jan 18, 1990</b> partner: [REDACTED] <b>June 1, 1989</b> Refer.: Dr Johnson, GP, High Street			printdate: <b>June 14, 2016</b>		
Date:	Dec 2, 2015	May 5, 2016						
Lab ID:	2015/4287	2016/2102						
<b>PAGE 1: BASIC EJACULATE ANALYSIS</b>								
ref	Unit							
sampl tech:	m	m						(1) -
completeness:	y	y						(2) -
time to exam.:	0.30	0.30						<1.00 h.min
pH:	7.8	7.7						7.2-7.8 -
volume:	2.3	4.8						1.5-6.0 mL
Rapid progr:	18	27						>25 %
Slow progr:	33	37						>40 (3) %
Non progr:	12	15						%
Immotile:	37	21						<60 %
%Live:	59	75						>40 %
Aggregates:	2	1						0-1 a.u. (4)
Abst. days:	4	3						1-4 days
Sperm conc:	42	65						10 <sup>6</sup> /mL
<b>Sperm numb:</b>	97	312						>40 10 <sup>6</sup> /ejac
Inflam. Cells:	0.2	0.0						<1 10 <sup>6</sup> /mL
<b>MORPHOLOGY ASSESSMENT</b>								
% Ideal:	5	7						%
Head defects:	94	91						%
Neck/Midpiece:	22	24						%
Tail defect:	18	23						%
cytopl.resid:	4	5						%
Terato-index <sub>92</sub> :	1.45	1.57						<2.00 -
Immature:	1	2						<8 /100 sp
<b>BIOCHEMISTRY</b>								
α-Glukosidase:	34.5	52.0						mU/mL
α-G-amount:	79.4	249.6						>20.0 mU/mL
Zink conc.:	2.1	3.4						>1.2 mmol/L
Zinc amount:	4.8	16.3						>2.5 μmol
Fructose conc.:	23.4	28.0						>6.0 mmol/L
Fructose amount:	53.8	134.4						>13.0 μmol
Zinc/Fructose:	0.09	0.12						>0.10 -
<b>ANTISPERM ANTIBODIES</b>								
Sp w ASAB:	23	10						<40 %
localization:	tail	tail						
<b>Date</b>	<b>Lab ID</b>	<b>Comments</b>						
Dec 2, 2015	2015/4287	Increased viscosity						

Fig. 1 Example of a laboratory report sheet

**Table 1** Examples of semen analysis findings, possible causes, and further investigations to reach a diagnosis

Finding	Possible cause	Further investigation
No spermatozoa	Sertoli cell only	Testicular biopsy
	Y chromosome microdeletion	Genetic tests (blood)
	Agenesis of the Wolffian duct (congenital bilateral agenesia of the vasa deferentia – CBAVD)	Physical examination
		Ultrasound
Few spermatozoa	Y chromosome microdeletion	Genetic tests (blood)
	Hypogonadism	Hormones (blood)
	Small testicles	Physical examination
	Frequent hot baths	Patient history
Poor motility	Inflammation/infection	Physical examination
	Abnormal sequence of ejaculation/ejaculatory duct obstruction	Split ejaculate assay
		Ultrasound
No or very poor motility	Immotile cilia syndrome or other sperm tail disorders	Electron microscopy of sperm tails
	Inflammation/infection/antibody reaction?	Physical examination
		Anti-sperm anti body test
Poor morphology	Disturbed spermatogenesis	Patient history – e.g., exposure to excessive heat?
		Hormones (blood)
	Epididymal disorders (cytoplasmic residues)	Physical examination, signs of infection?

- Markers for male accessory gland secretion
  - Epididymis (e.g.,  $\alpha$ -glucosidase)
  - Prostate (e.g., zinc)
  - Seminal vesicles (e.g., fructose)

The results from the initial semen analysis seldom provide a clinical diagnosis but are often helpful to guide the further investigation of the man. Table 1 gives an overview of some typical findings, possible causes, and examples of further investigations to reach a proper diagnosis as a basis for discussions with the patient on options for treatments.

---

## Aspects of Analytical Work

The systematic way of analyzing laboratory work is to divide procedures into the three stages of pre-analytic, analytic, and post-Analytic. The first section comprises all necessary preparations before the analyses. The middle section includes

everything involved in the proper analyses. The last section includes all procedures to ensure that the correct results are delivered to the right recipients. This last phase can therefore also include help for the recipient to interpret correctly the analytic data.

## **Pre-analytical Aspects**

Since the ejaculate is completely different compared to other body fluids, a reliable result depends on the full cooperation of the patient, both concerning the actual collection of the specimen and that the information on time of sexual abstinence is truthful. Also other information, primarily concerning any period of high fever or other systemic inflammatory disease, within about 3 months before the time for ejaculate analysis, is important to get from the patient, as well as information about other diseases, drug treatment, major surgical procedures, or a habit of daily hot baths.

The generally agreed entity time of “sexual abstinence” is not entirely based on scientific evidence – it is very much a matter of consensus based on empirical experience: long abstinence time in general meaning higher ejaculate volume and more spermatozoa but larger proportion with poor or no motility and poor morphology. With short abstinence time, ejaculate volume and sperm number may be lower, but sperm motility tends to be better. From a general biological point of view, longer abstinence time is likely to mean increased number of “aged” spermatozoa likely to have started to deteriorate and therefore expressing decreasing motility and worsening physical appearance. From a strict scientific point of view, the measure “days of sexual abstinence” is a very crude gage for increased proportion of aged, deteriorating spermatozoa. It would probably be better to obtain information about the frequency of ejaculations for a period of time before the ejaculate analysis, but in clinical routine, it appears that “days of sexual abstinence” gives sufficient hints about the relative contribution of dying, senescent spermatozoa. From a basic biological point of view, there is no evidence that fertility is better if a man has few ejaculations, which has sometimes been assumed to be the case, based mainly on deduction from findings of higher sperm counts of ejaculates collected *in vitro* after longer periods of abstinence.

The most important data that is practically only available by sincere information from the man is if the collection of the ejaculate was complete. It is important that the patient understands that any information about ejaculate fractions that were not collected in the container is essential to make the correct interpretation of the data obtained. In general, a missed early fraction of the ejaculate could mean that most of the spermatozoa have not been captured. The sperm count may then show low numbers giving the wrong interpretation as pathological. Ejaculates which have been incompletely collected therefore must be interpreted with great care, but it would be wrong not to analyze even incompletely collected ejaculates at all, since completely normal findings under such conditions still give important information.



## **Patient Instructions**

Patient instructions should include explanation of the entity “time of sexual abstinence” and why it is necessary to give a truthful statement of this. Furthermore, although many men may prefer to collect the specimen at home and transport it to the laboratory, the risks with temperature drop (immobilizing spermatozoa) and delayed assessment of motility must be objectively explained. It is important that the laboratory can provide sufficiently comfortable rooms for ejaculate collection where the men can feel safe and secure. Certainly, if a man has obvious problems producing a sample at the laboratory, other alternatives must be available, including specimen collection at home and offering non-spermicidal condoms for collection during sexual intercourse, the latter especially if the act of masturbation itself is the matter of concern. Also the importance of truthful information if the specimen collection was complete or not should be explained to the patient.

## **Sample Handling Before Analysis**

Sample handling comprises a time- and temperature-controlled storage to allow sufficient liquefaction and preferably also mixing between ejaculate collection and the initiation of analyses.

A temperature during storage before analysis controlled at +37 °C is preferable. Since liquefaction is an enzymatic process, the time needed will at least partially depend on the ambient temperature. Room temperature is in general not well controlled. Therefore, a standardized temperature of +37 °C allows reliable evaluation of the liquefaction process. Furthermore, the velocity of motile spermatozoa in vitro varies with the ambient temperature. Therefore, also the assessment of sperm motility benefits from a standardized temperature of +37 °C.

The third important aspect of ejaculate preparation for analysis is the time. As mentioned above, the enzymatic process of liquefaction is time dependent. Also sperm motility assessment is highly dependent on the time elapsed after ejaculate collection – motility decreases, with high interindividual variation, with time after sample collection. For the best comparability, it is therefore recommended that motility assessments begin within 30 min after collection and that storage before is controlled at +37 °C.

To ensure best possible conditions for the ejaculate analysis, thorough mixing during pre-analytical storage is recommended. An orbital mixer can facilitate mixing and thereby both liquefaction and increased probability for obtaining a representative sampling of aliquots for ejaculate analysis.

## **Analytical Aspects**

### **Matters Related to the Laboratory Equipment**

There are aspects of the laboratory equipment that are essential to obtain reliable results. Even if some quality tools may appear more expensive to purchase, improvement of result quality as well as user-friendliness (with improved efficiency in the laboratory work) must be included when costs are evaluated.

For sperm motility, a constant temperature is important, since the sperm velocity is highly dependent on the temperature. As in the case of the pre-analytical storage, room temperature is not a standardized temperature; it is prone to vary due to season as well as heating and cooling of the room. The best temperature control is obtained using a heated microscope stage. This is often best accomplished when buying a new microscope because it can be integrated in the microscope stage. Second best, especially to supplement an already existing microscope, is an extra, temperature-controlled plate installed on the surface of the microscope stage. In any case, pre-warmed microscope slides and cover slips, and perhaps even pre-warmed pipette tips, are recommended to avoid any cooling down of the aliquot sampled for motility assessment.

For microscope work, phase contrast optics is necessary to see live, unstained spermatozoa as in assessment of sperm motility and sperm concentration (at least objective lenses 10 $\times$  and 40 $\times$  combined with oculars of 10–12.5 $\times$ ). For fixed and stained spermatozoa (morphology and vitality) ordinary bright field optics is preferable, since phase contrast optics under the required magnification (objective lens 100 $\times$  oil; oculars 10–12.5 $\times$ ) has a far too low resolution. For sperm morphology, a high-resolution objective may at the first glance appear to be too expensive. However, taking into consideration all the time and effort consumed by staff members to work with a resolution that barely exposes the details expected to be examined clearly speaks in favor the optics with highest resolution.

Common laboratory pipettes (“air displacement pipettes”) are made for fluids with viscosity similar to water. The principle is that an air volume is displaced allowing an exact volume of liquid to fill the pipette tip (by ambient air pressure). However, ejaculate viscosity is higher than that of water – although it varies a lot between different ejaculates. Using an air displacement, pipette results in a too low volume due to the flow resistance caused by the viscosity. The error is related to the viscosity of the sample. Repeated measurements of one ejaculate may be consistent with an air displacement pipette – but consistently wrong. For pipetting of exact volumes, positive displacement pipettes (sometimes also called PCR pipettes) are indispensable. In this type of pipettes, there is a plunger in the pipette tip, and the entire inside of the tip should be filled by the liquid to correspond with the required volume. Thus there is no air volume that can be expanded in case the viscosity counteracts the filling of the pipette tip. Still, only exact volumes for accurate determination of sperm concentrations require positive displacement pipettes. For all other purposes, the much less expensive air displacement pipette tips are sufficient.

Counting sperm is a quite complicated matter. The biological range of concentrations is extremely wide – also for results considered to be without signs of pathology. First, motile spermatozoa are always more difficult to count than immotile ones. It is therefore an advantage to immobilize sperm by dilution. This also reduces the difficult influence of high viscosity. On the other hand, dilution means that larger volumes need to be examined in order to assess sufficient numbers of spermatozoa. To solve this, the general recommendation is to use hemocytometers to assess the sperm concentration. These chambers have been developed to give

reliable volumes to assess. For the purpose of ejaculate analysis, those chambers having an “improved Neubauer ruling” are considered most versatile for a few standard dilutions and the wide range of possible concentrations, but any hemocytometer will have a sufficient accuracy in volume (grid areas and depth). In more shallow chambers, it can be difficult to obtain sufficient exact volume (an error of 1  $\mu\text{m}$  in placing the cover slip in a 10  $\mu\text{m}$  chamber gives a 10% error while an error of 1  $\mu\text{m}$  in a 100  $\mu\text{m}$  chamber, as in a hemocytometer, gives a 1% error). Also in samples with low sperm concentrations, shallow chambers can be too small – causing a high risk for error because of too small number of sperm assessed.

Sperm concentration does not provide the most interesting information, since this number is the function of (a) the total number of spermatozoa in the ejaculate and (b) the ejaculate volume (that is the secretions from the mainly seminal vesicles and the prostate). Therefore, the total number of spermatozoa tells us more about sperm production and sperm transport than only the sperm concentration. There is an ongoing debate whether there should be a limit between what should be considered acceptable and what should require further andrological investigations. Both to make good decisions for the individual patient and to make evidence-based advances of this matter, the methodology of investigations must be crystal clear.

### **Matters Related to How Assessments Are Performed**

A fundamental principle for reliable results of cell and particle counting is that sufficient numbers of observations are made. From the probabilities of Poisson distributions, it can be deduced that if a total of 400 observations (i.e., 400 spermatozoa) are made, there is a 95% probability that the true value is within  $\pm 10\%$ ; if only 100 observations are made, the corresponding interval is  $\pm 20\%$ .

Another basic principle is to compare replicate assessments to minimize the risk for random errors. This is not necessary for all ejaculate characteristics. Replicate assessments with comparisons are necessary for controlling sampling of diluted spermatozoa, loading and counting in hemocytometers. It is equally important to do replicate assessments with comparisons for sperm motility assessment, primarily because of the risk for poor representation by the sampled aliquots. These problems should not occur in the assessment of sperm vitality and sperm morphology.

For morphology and vitality assessments, staining is necessary. As mentioned above, phase contrast does not give sufficient details for this purpose. By staining procedures, contrasts of different structures are enhanced and can be assessed at high magnification (100 $\times$  objective lens and 10–12.5 $\times$  ocular) under oil. Different stains exist, but the Papanicolaou staining modified for sperm gives the best overall staining of all sperm structures. Replicate assessment with comparisons has not been shown to increase the quality of results. The limiting step for quality is the consistency in the use of the Tygerberg strict criteria for human sperm morphology as recommended by the WHO. This can only be controlled by internal quality control (IQC) and external quality assessment (EQA) and must be based on proper training.

For vitality, another type of staining is needed that cannot pass over the cell membrane of live cells (therefore often called supravital staining). Care must be taken to avoid older recommendations of the WHO (before the fifth edition), where

the stain itself can kill a variable proportion of the sperm. As for morphology, assessments are done under light microscope, 100× objectives (under oil) and oculars 10–12.5×.

### **Key Points in the Laboratory Investigation**

Determination of the ejaculate volume can be done by weighing the sample container already before storage during the pre-analytic phase. Provided the empty weight has been recorded, the volume (by one decimal accuracy) can be equalled to the net weight in grams.

The liquefaction is assessed by macroscopic inspection 30 min after collection. As pointed out, liquefaction is an enzymatic process. Therefore, full liquefaction should be achieved within 30 min when kept at 37 °C and preferably mixed carefully during liquefaction. A warm cabinet, if possible with an orbital mixer installed internally, is therefore strongly recommended. As part of the macroscopic inspection, annotations are made if there are abnormalities concerning odor or color. Due to the continuous loss of CO<sub>2</sub> during storage of the ejaculate in ambient atmosphere, pH will increase with time after ejaculation in most samples. A clinically important pH change is therefore only expected in cases of suspected agenesis of the Wolffian ducts (vasa deferentia). If the agenesis includes also agenesis of the seminal vesicles, the ejaculate will not have a major contribution of alkaline secretion from the seminal vesicles, and the pH will be low, usually under 7.5.

Wet preparation for motility assessments is easiest done on ordinary microscope slides with ordinary coverslips. The important point is to keep the sperm at +37 °C – preferably by a heated microscope plate. Preheated slides (and cover slips) reduce risks for variability due to cooling effects. Each assessed spermatozoon is classified into one of four classes: rapidly progressive, slowly progressive, nonprogressive, and immotile.

In the wet preparation, observations are made to decide the proper dilution (and sperm immobilization) for sperm concentration assessment. Also comments on observation of sperm clumping (aggregates- or antibody-caused agglutinates) and presence of other cells, crystals, or identifiable microorganisms are made.

Smears for morphology or vitality assessments should be done as soon as possible to avoid increasing *in vitro* artefacts to occur. Once morphology smears have dried, they should be fixed in alcohol and then stored for later staining.

Dilutions for the assessment of sperm concentration should preferably be done once the motility assessments are finished. Use of a diluent that fixes spermatozoa (and prevents overgrowth of microorganisms) makes sperm counting easier and more reliable.

Assessment of biochemical markers for the secretion from the epididymis ( $\alpha$ -glucosidase), prostate (zinc), and seminal vesicles (fructose) can provide information about the functional state of these glands, as well as indications of agenesis of the Wolffian ductal system in case of absence of spermatozoa in the ejaculate.

Presence of anti-sperm antibodies (ASABs) can be assessed with commercial kits, but they require the presence of motile sperm; thus, cytotoxic ASABs that

supposedly kill sperm cannot be detected with such techniques. The validity of these tests has been questioned, since it appears that two different methods do not necessarily give the same result.

## Post-Analytical Aspects

Once the primary results have been obtained, it is the task of the laboratory to calculate any derived parameters and check the accuracy of the entire processes by analyzing existing information from internal quality control (IQC) and external quality assessment (EQA). On this basis, the laboratory can produce a report that provides the information requested by the referring clinician. There is an international standard for medical laboratories (ISO 15189), regulating (among many other aspects of documentation of the laboratory work) how laboratory results should be reported.

### Basic Information in the Laboratory Report

The report should contain information on patient identity and date of investigation. Time of sexual abstinence before collection of the investigated ejaculate is important for interpretation of the results. Also the time from sample collection to the initiation of examination is necessary for a well-founded interpretation. Any deviation from routine (e.g., if the ejaculate was collected elsewhere and transported to the laboratory), incomplete collection, or findings deviating from the common findings, like significant odor or failing liquefaction, should be noted in the report. An example of a lab report (to be followed by free text comments for recipients with less experience in interpreting such data) is given in Fig. 1.

### Calculation and Presentation of Results

Sperm concentration is calculated from the number of assessed spermatozoa, total volume examined, and dilution. The total sperm number is calculated from sperm concentration and ejaculate volume. Ideally at least a total of 400 spermatozoa should be counted. Results are presented as integer values for million spermatozoa per mL, possibly with the exception for sperm numbers under ten million. For even lower sperm counts, the results could, for instance, be presented as 400,000 spermatozoa/ejaculate or 25,000 spermatozoa/ejaculate, to avoid using decimals that can give the wrong impression of high accuracy.

For sperm motility, the average of at least two replicate assessments are calculated: all classes of motility are calculated and presented together with the proportion of motile and progressive (rapid and slow) spermatozoa. At least 200 spermatozoa should be assessed in each replicate, in at least four different microscope fields. All motility results are presented as integer percentages (no decimals).

For sperm morphology, the commonly used characteristic is the proportion of "normal" spermatozoa. However, using the hitherto best evaluated criteria for human sperm morphology assessment (Tygerberg strict criteria), it would be better to use the term "% typical." The Tygerberg strict criteria are based on the morphological

appearance of spermatozoa which have been able to transfer to the site of fertilization. Thus, ejaculated spermatozoa that fulfil the criteria have morphology that is *typical* for spermatozoa that can reach the site of fertilization. It has been shown that not only the proportion of *typical* spermatozoa is of interest. Also the number of abnormalities that on average can be found in each abnormal spermatozoon has information about the efficacy in sperm production and possibly also about sperm functionality. The teratozoospermia index (TZI), i.e., the average number of abnormalities per abnormal spermatozoon, should therefore also be calculated and presented together with the proportion of “typical” spermatozoa and the four groups of abnormalities: head, neck/midpiece, tail, and cytoplasmic residues. At least 200 spermatozoa should be assessed. All morphology results are presented as integer percentages (no decimal places), with exception for the TZI that is presented with two decimal places.

For sperm vitality, the proportion of live sperm is calculated and presented as an integer percentage (no decimals). At least 200 spermatozoa should be assessed.

### **Internal Quality Control**

The IQC should be incorporated in the SOP including routines for replicate assessment with comparisons when appropriate to reduce risk for errors. Other forms of IQC include “monthly” means (time period depending on the number of samples processed in the laboratory) as well as internal quality rounds where all staff members involved in analytical work perform analyses of the same material (consecutive samples and archive material) in order to provide data on interindividual consistency as well as temporal consistency (including intraindividual consistency).

### **External Quality Assessment**

External quality assessment is the comparison of analysis results between different laboratories. While the IQC controls the internal variability, the EQA provides a tool to compare with other laboratories. With data from experienced “expert laboratories,” it is possible to compare with a certain level of “standard.” EQA is indispensable to determine whether a laboratory in practical work actually uses, for instance, morphological criteria in the same way as other laboratories. Also, if a laboratory wants to implement decision limits obtained in other centers (e.g., published in a scientific journal), it can only be justified if the “receiving” laboratory has evidence that their own methods and results are comparable with the laboratory from where the results originate.

### **Interpretation of Results**

To provide valid interpretation of the results for the clinician, it is essential that the laboratory provides reference ranges or other similar guidance for the interpretation. It is important that each laboratory using the reference limits suggested by the WHO recognizes that they are only valid if results are obtained with adequate techniques. As mentioned above, a basic aspect is that the limits cannot be “borrowed” unless the own laboratory uses the same techniques and by external comparisons can show that its results are comparable to those from the laboratory providing the reference limits.

The matter of providing reference ranges or reference limits for semen analysis results is quite delicate. A basic requirement is to have data both from individuals with a disorder and from individuals without the disorder. This creates a problem in semen analysis since the definition of disorder is ambiguous. Infertility is a problem of a couple, and in many couples, the exact causes are not known. It is therefore difficult to define a group of men with a defined disorder. Many known or suspected causes of male infertility are not dichotomous (with only two distinct possibilities: fertile or infertile) but with a wide range of gradually decreasing fertility. Many investigations have used the end point of pregnancy or child birth, but in doing so, many factors not depending on the man are included. In the most recent WHO manual, an ambitious attempt to establish useful limits has been made (Cooper et al. 2010; World Health Organization 2010). Data were compiled from studies published during several decades. These data give, as published in the WHO manual, the distribution of results from recent fathers. A common misunderstanding is that the presented, evidence-based distributions and percentiles automatically represent exact limits between fertile and infertile men.

Another problem related to the common misconception of WHO reference limits is that the reference limits do not take into account the substantial overlap in semen analysis results between fertile and “subfertile” men. Thus, the distribution of semen analysis data from recent fathers give an idea about variability of results among men with recent reproductive success but does not exclude that men with results within the “fertile” range may have severe andrological problems that would need clinical attention (Björndahl 2011). It has been proposed that semen analysis results are better understood with three ranges: normal, intermediate, and abnormal, where an intermediate range corresponds to the borderline zone between clearly normal results and equally clearly pathological results (Eliasson 1977, 1981; Bostofte et al. 1984; Mortimer 1985, 1994; Björndahl et al. 2016) (See also Table 2).

Another problem linked to semen analysis interpretation is the wish to find a predictive value, which has been widely accepted not to be possible when only single semen parameters are tested. This is an apparent mistake, since studies of combinations (multiparametric) of ejaculate parameters can provide highly predictive values, in contrast to mono-parametric interpretation that typically show very low predictive values for ejaculate parameters (Guzick et al. 2001; Jedrzejczak et al. 2008).

### **Absence of Spermatozoa**

Absence of spermatozoa in the ejaculate is primarily a question of how thorough the laboratory investigations have been. A minimum requirement is that a 10  $\mu$ L aliquot of a centrifugation pellet, suspended in a minute volume of supernatant, is examined under a phase contrast microscope (40 $\times$  objective lens).

In case of passage hinder, marker for epididymal secretion ( $\alpha$ -glucosidase) should be low if the passage hinder is between the epididymis and urethra. When passage hinder consists of agenesis of the Wolffian ducts, also the seminal vesicles may be missing and the marker (fructose) is reduced.

**Table 2** Consensus-based suggestions for the interpretation of human ejaculate analysis. After Barratt et al. (2011)

Characteristic	Units	Normal	Borderline	Pathological	Notes
Volume	ml	2.0–6.0	1.5–1.9	<1.5	1
Sperm concentration	10 <sup>6</sup> /ml	20–250	10–20	<10	1,2
Total sperm count	10 <sup>6</sup> /ejaculate	≥80	20–79	<20	1,2
Motility	% motile	≥60	40–59	<40	3,4
	% progressive	≥50	35–49	<35	3,4
	% rapid	≥25			3,4,5
Morphology	% typical forms	≥14	4–13	<4	6
	TZI	≤1.60	1.61–1.80	>1.80	6
Vitality (vital)	% live	≥60	40–59	<40	7

(1) 2–4 days of abstinence

(2) For sample volume 2.0–6.0-mL (“normal”)

(3) 30 min after ejaculation

(4) At 37 °C

(5) Only a normal threshold value is available

(6) Tygerberg “strict criteria,” Papanicolaou-stained smears

(7) Eosin dye exclusion at 30 min after ejaculation

Failing sperm production needs other diagnostic means, e.g., genetic testing of karyotype and microdeletions in the Y chromosome as well as a hormone panels to map possible endocrine disorders including hypogonadism.

### Poor Motility

Poor motility is traditionally often suspected to be due to infections and related inflammatory processes. High proportion of round cells, presumably white blood cells, strengthens the suspicion. Bacteriological culture of semen is, however, extremely unsuccessful. Clinical investigation is therefore of great importance: symptoms and signs from the prostate, seminal vesicles, or epididymis should increase the suspicion of an ongoing infection. Still the most successful way to diagnosis is *ex juvantibus*, that is if a treatment with antibiotics improves motility and reduces the load with round cells, then the diagnosis bacterial infection was likely correct.

As mentioned before, tests for antibodies are in general not very reliable, at least in ejaculates where many but not all spermatozoa appear to carry antibodies. Furthermore, today’s commercially available tests rely entirely on the presence of sufficient numbers (and dominant proportion) of motile spermatozoa. Therefore, such tests are not likely to give any results concerning the presence of anti-sperm antibodies (ASAB) that damage spermatozoa severely enough to hinder their motility.

Another group of patients with severely reduced sperm motility are those with ciliary defects. Most commonly known is the “immotile cilia syndrome” first described in 1975 (Afzelius et al. 1975). In these rare cases, all spermatozoa were totally immotile due to a total lack of dynein arms in sperm tails as well as in all other



cilia in the body. However, it appears that also men with less than total sperm immotility can have ciliary defects. This can be tested by comparing motility results with vitality results: if a substantial proportion of all spermatozoa can be calculated to be alive but immotile, it strengthens the suspicion that a defect in the sperm tail structure – a ciliary defect – is the cause. Only electron microscopy of sperm tails can confirm the suspicion.

### **Abnormal Morphology**

Only a few specific sperm defects have been described. Other morphology abnormalities appear more to reflect general inefficiency in spermatogenesis or other suppression of testicular function.

Globozoospermia is the term for spermatozoa with spherical heads completely lacking acrosome. Due to this lack, normal fertilization is not possible – only intracytoplasmic sperm injection (ICSI) has been tried with varying success. Possibly further activation of the injected oocyte could improve treatment success.

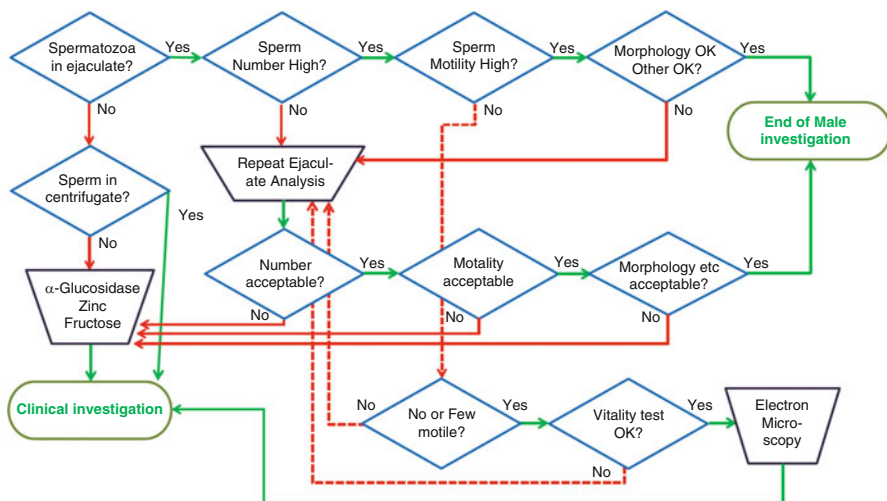
Short or stump tail syndrome is another likely genetically caused disorder. The morphological abnormality is visibly distinct, but the genetic background is not well explored, and treatment results – as judged from the scarce information available – appears to be poor.

Much more common are less specific and more general deteriorations of sperm morphology. The best indicator is the TZI where results above 2.00 (i.e., on average at least two abnormalities on all abnormal spermatozoa) that has been interpreted as a general testicular problem. Here a multiparametric interpretation is very helpful: an ejaculate with poor morphology, reduced motility, and low sperm number indicate a severe testicular problem, while other cases with only one isolated “deviation” from the “normal distribution” are much weaker indicators. It has been shown that combinations of sperm number, motility, morphology, and vitality can even provide results with significant predictive value (Guzick et al. 2001; Jedrzejczak et al. 2008).

### **Suggestions for Investigations in Men Assessed for Infertility**

Based on existing information of an increased risk for later morbidity and premature mortality among men with poor ejaculate analysis results, it would be mandatory to have an algorithm to select the patients that would benefit from further clinical investigations. Using reliable laboratory techniques, it is possible to rapidly exclude men with clearly normal results in a single semen analysis from extra laboratory investigations. This would direct laboratory resources from repeated investigations of men not needing further attention, to men that belong to the group of men with increased risk for later disease. Laboratory resources as well as clinical investigations can then be focused on men with poor semen analysis results.

In Fig. 2, a flow chart is shown as an example of how the laboratory investigations can be streamlined to optimize resources and to reduce unnecessary delays in the overall investigation.



**Fig. 2** Flow chart of streamlined ejaculate analysis

## Semen Analysis or Ejaculate Analysis?

Semen analysis is different from most other modern clinical laboratory investigations. In comparison with, for instance, blood samples, the ejaculate is not a homogenous representation of a body fluid. It could therefore be argued that it is not adequate to use a term like “semen sample.” From a semantic and biological point of view, “ejaculate” and “ejaculate analysis” would avoid leading the receiver into the false assumption that an ejaculate is comparable to, for instance, blood samples or urine samples. The ejaculate is a not a homogenous liquid. It is a sequentially expelled, heterogeneously composed combination of mainly spermatozoa and epididymal secretion, prostatic fluid, and finally seminal vesicular fluid. When the individual ejaculate fractions are collected separately, a typical pattern is normal: the bulk of spermatozoa are normally expelled in the first ejaculate fractions together with epididymal secretion and prostatic fluid, while approximately the last two-thirds of the ejaculate are completely dominated by the seminal vesicular secretion. A thorough mixture of the ejaculate is not achieved *in vivo*, only *in vitro* when the entire ejaculate is collected in one container. The entrapment of the entire ejaculate into a gel has also only been demonstrated *in vitro*. Furthermore, comparisons of spermatozoa which have mainly been in contact with one of the two main secretions of the ejaculate indicate substantial differences in the effects of these two secretions on sperm function. Prostatic fluid appears to be beneficial to sperm motility, survival, and chromatin stability, while seminal vesicular fluid mainly has negative influence on sperm. This may be due to an evolutionary remnant equivalent

to the situation in rodents where the last part of the ejaculate forms a plug that can kill spermatozoa from a second male mating the female.

For the sake of laboratory practice, a standard has developed – more for practical reasons than based on scientific evidence – to collect the entire ejaculate in one container, allowing the entrapment of the prostatic fluid and spermatozoa in the gel coming from the seminal vesicles. Then, to allow the performance of reliable laboratory investigations, the gel must be disintegrated. The seminal vesicular secretion is either expelled as a thixotropic (gel-like substance with little fluid) or it forms a coagulum at ejaculation. Then enzymes of mainly prostatic origin will, *in vitro*, break down the gel – or coagulum-forming compounds during the process called liquefaction.

It is not only that the whole ejaculate is collected in one container and that the contents are exposed to enzymatic macromolecule degradation. In addition, there is no homeostatic control of the mix of cells and the continuously changing fluid. These changes are due to a cascade of events occurring *in vitro*. During this process, there is also a loss of carbon dioxide (CO<sub>2</sub>) to the ambient environment, usually nothing but common air. Therefore, the post-ejaculatory handling of the ejaculate *in vitro* will not only increase the fluidity of the ejaculate. It will also expose spermatozoa to an increasingly alkaline environment due to the loss of CO<sub>2</sub>. Furthermore, the enzymatic degradation of large molecular compounds into a high number of smaller particles results in a huge increase in the osmotic pressure. This is likely to provoke compensatory mechanisms in the spermatozoa to reduce loss of intracellular water due to osmosis. If spermatozoa after compensation are exposed to an environment with relatively lesser osmotic pressure, a severe osmotic stress can occur, due to rapid influx of water into the spermatozoa, potentially even killing them.

Changes in the environment of the spermatozoa are dramatic, and there are also significant changes within the spermatozoa, changes that are likely to be enhanced by the influence of the immediate environment of the spermatozoa. The structural stability of the sperm chromatin changes rapidly after ejaculation. From easy decondensation of the sperm chromatin of almost all spermatozoa by withdrawal of intracellular zinc immediately after ejaculation, structural changes occur *in vitro* so that only half of the sperm exhibit this zinc-dependent ability to decondense the nuclear chromatin after 60 min storage *in vitro*. This indicates that there is a shift in the nature of the structural stability of the sperm chromatin that will change the access to the sperm DNA *in vitro*, a change that can contribute to the observed variability in assessments of so-called sperm DNA damage or sperm DNA fragmentation. All in all, the changes occurring in and around spermatozoa after ejaculation *in vitro* mean that many sperm characteristics are continuously affected by the changes in the ejaculate. To make any comparison of analysis results meaningful, it is therefore necessary to rigorously standardize at least the time and temperature between sample collection and initiation of analysis.

Besides the handling of the ejaculate itself, laboratory techniques must be chosen to minimize the risk for errors to occur also in the process of assessments, and the staff must be well educated and trained in both laboratory techniques and pre- and

post-analytic handling of semen and semen analysis results. Another basic requirement for reliable results from ejaculate analyses is that the laboratory equipment is chosen to minimize the risk for general technical errors as such but also to avoid negative influence of errors that could be caused by properties of the ejaculate that differ from other fluids deriving from the human body.

---

## What Is Ejaculate Analysis Useful for?

A common misunderstanding in the field of assisted reproductive technology (ART) is that semen analysis is only a tool in the process of choosing treatment modality. From this point of view, the matter of prediction of success or failure of ART strategies is of course valid, but there are also other situations where ejaculate analysis has an important role in clinical situations.

Reliable ejaculate analysis results are also the base for andrology investigations and follow-up of various treatments. In cases of hypogonadism with poor ejaculate quality, ejaculate analysis provides a biological marker for positive effects of the treatment. Other examples are, for instance, treatment of varicocele by, e.g., coiling, where improvement in ejaculate analysis results is a clear indication of treatment success. In the opposite direction, follow-up of sterilization by vasectomy is also an important indication for reliable ejaculate analyses.

---

## The Physiology of Variability in Ejaculate Analysis

To understand the basis for variability in semen characteristics, it is central to be aware of the huge physiological variability that can influence the semen analysis results.

In short, the number of testicular tubuli with spermatogonia active in sperm production is considered a basic determinant for sperm production. The number of functional tubuli is related to the testicular volume, indicating the importance for the clinician to correlate the total number of spermatozoa in the laboratory report to the testicular volume determined at physical examination of the patient.

There are also non-pathological causes for variation after the production of spermatozoa. Time of “sexual abstinence” – or rather frequency of ejaculation – is well known and discussed earlier in this chapter. Other factors that can vary both between men and from one ejaculate to another include the sexual arousal of the man. Extended duration of stimulation for ejaculate collection can increase both sperm number and ejaculate volume, indicating both stimulated transport of spermatozoa from the epididymis and increased secretory activity from the prostate and seminal vesicles.

In the following, major aspects of normal physiology and related pathophysiology are discussed.

The process of ejaculation is primarily under autonomic nerve control, starting with peristaltic contractions of the vasa deferentia, moving spermatozoa from the

cauda epididymis to the urethra where the mixture with primarily prostatic secretion takes place. The secretion of the prostate and the seminal vesicles is mainly stimulated during sexual arousal prior to sperm transport from the epididymis. The normal sequence of the ejaculation, where the bulk of spermatozoa is mixed with, and expelled together with the prostatic fluid, is most likely dependent on the difference in the muscular properties of the small prostatic glandules and those of the large seminal vesicles. Contraction of smooth muscle cells in the glandular walls would allow the approximately 30 small glands of the prostate to empty before the much larger seminal vesicles would empty. An early contact between spermatozoa and the zinc-rich prostatic fluid appears to be beneficial for the function of spermatozoa, allowing better motility, longer survival, and better protection of the sperm DNA *in vitro* compared to spermatozoa primarily exposed to seminal vesicular fluid. Also from a clinical point, it has been established, long before IVF was developed, that intracervical insemination using the sperm-rich fraction (which is usually the first ejaculate fractions) is more successful than using the entire ejaculate.

From a physiological point of view, the sequence of ejaculation would allow highly motile spermatozoa in prostatic fluid, expelled *in vivo* onto the cervical mucus, to enter the cervical mucus before any detrimental contact with the seminal vesicular fluid. Thus, *in vivo*, there is no evidence of highly motile sperm in the first ejaculate fractions being entrapped by the fluid from the seminal vesicles.

A problem known from urological investigations is the repeated or chronic inflammation in the region of the entrance of the ejaculatory ducts into the urethra. An ejaculatory duct obstruction (EDO) can cause poor sperm motility (Fisch et al. 2006), probably caused by abnormal contact between spermatozoa and seminal vesicular fluid because EDO hinders normal sperm passage to the urethra. Thus it is likely that under such circumstances, spermatozoa do not reach the urethra until pushed through the obstruction together with the seminal vesicular fluid. It has been shown that transurethral surgical treatment of the obstruction not only decreases pressure built up in the seminal vesicles but also may improve sperm motility.

---

## **Technical Variability in Ejaculate Characteristics: How Much Can We Improve?**

Many laboratories still perform semen analysis without complying with recommendations from WHO and scientific organizations like the European Society of Human Reproduction and Embryology (ESHRE). It has been argued that the present recommendations by the WHO should result in an unnecessarily low variability. However, to justify the use of techniques and procedures with higher risk of errors, random or systematic, it is essential that the true variability (uncertainty) of the “simpler” techniques and procedures are recognized and found acceptable. Also the cost, due to erroneous results misleading in choice of investigations and treatment modalities, should be considered for the patients and the health care.

It is a fact that outdated techniques are still in use in some centers. This means that results from such clinics are likely to be highly variable – causing poor investigations

and poor choice of treatments. Many published scientific studies claim compliance with the international recommendations, but in reality, very few conform to the essence of the techniques. This is a great concern for the development of both clinical and basic andrology. Besides directing toward a less optimal treatment – causing more couples to receive inadequate treatment and therefore producing unnecessary expenses for patients, insurance companies, or tax payers – poor clinical testing is also likely to result in missed diagnoses that could have prevented later morbidity. Furthermore, from a scientific point of view, poor quality of laboratory investigations will contaminate the entire field of andrology science. Studies based on poor laboratory quality can both imply false relations as well as cover true relations. It is therefore of great importance that scientific journals publishing studies relying on ejaculate analysis results can verify that the results have been obtained using adequate techniques. Recently, a checklist has been proposed that provides a tool for scientists planning studies and for scientific journals reviewing submitted manuscripts (Bjorndahl et al. 2016).

---

## **Training of Laboratory Staff Members**

In addition to general training as laboratory professional (technologist, biomedical analyst, or similar post-secondary training), further training specific to ejaculate analysis is necessary. Following basic training, further practice and in-house training is essential. Regular internal quality control (IQC) and participating in an external quality assessment scheme (EQA) provide materials and data for training and re-training of staff members in the individual laboratory. Any new member of the laboratory staff should have access to training material and the possibility to compare the results with results obtained by experienced analysts. Systematically done training by examining and comparing results with archive data or results of experienced colleagues has been shown to be a very efficient way to train in the andrology laboratory. This can also be done to “re-train” staff members after longer leaves of absence.

---

## **Summary**

The reliability of semen analysis results depends on a multitude of factors, including training of staff members, use of adequate equipment, and implementation of standard operating procedures focusing on best available methods possible to control. Any laboratory performing analyses in a clinical context also needs routines for ongoing internal quality control as well as for using results from external quality assessments to establish the quality of the service and enable improvements of the performance of the laboratory. In general, compliance with reliable laboratory techniques is poor, which is a problem both for clinical matters and for the development of andrology science overall.

## References

- Afzelius BA, Eliasson R, Johnsen O, Lindholmer C. Lack of dynein arms in immotile human spermatozoa. *J Cell Biol.* 1975;66:225–32.
- Barratt CL, Björndahl L, Menkveld R, Mortimer D. ESHRE special interest group for andrology basic semen analysis course: a continued focus on accuracy, quality, efficiency and clinical relevance. *Hum Reprod.* 2011;26:3207–12.
- Belsey M, Eliasson R, Gallegos AJ, Moghissi KS, Paulsen CA, Prasad AMN. Laboratory manual for the examination of human semen and semen-cervical mucus interaction. Singapore: Press Concern; 1980.
- Björndahl L. What is normal semen quality? On the use and abuse of reference limits for the interpretation of semen analysis results. *Hum Fertil (Camb).* 2011;14:179–86.
- Björndahl L, Barratt CL, Mortimer D, Jouannet P. ‘How to count sperm properly’: checklist for acceptability of studies based on human semen analysis. *Hum Reprod.* 2016;31:227–32.
- Bostofte E, Serup J, Rebbe H. Interrelations among the characteristics of human semen, and a new system for classification of male infertility. *Fertil Steril.* 1984;41:95–102.
- Cooper TG, Noonan E, von Eckardstein S, Auger J, Baker HW, Behre HM, Haugen TB, Kruger T, Wang C, Mbizvo MT, et al. World Health Organization reference values for human semen characteristics. *Hum Reprod Update.* 2010;16:231–45.
- De Jonge C. Semen analysis: looking for an upgrade in class. *Fertil Steril.* 2012;97:260–6.
- Eliasson R. Semen analysis and laboratory workup. In: Cockett ATK, Urry RL, editors. Male infertility. Workup, treatment and research. New York: Grune & Stratton; 1977. p. 169–88.
- Eliasson R. Analysis of semen. In: Burger HG, De Kretser DM, editors. The testis. New York: Raven Press; 1981. p. 381–99.
- Fisch H, Lambert SM, Goluboff ET. Management of ejaculatory duct obstruction: etiology, diagnosis, and treatment. *World J Urol.* 2006;24:604–10.
- Guzick DS, Overstreet JW, Factor-Litvak P, Brazil CK, Nakajima ST, Coutifaris C, Carson SA, Cisneros P, Steinkampf MP, Hill JA, et al. Sperm morphology, motility, and concentration in fertile and infertile men. *N Engl J Med.* 2001;345:1388–93.
- Harvey C, Jackson MH. Assessment of male fertility by semen analysis – an attempt to standardise methods. *Lancet.* 1945;2:99–104.
- Jedrzejcak P, Taszarek-Hauke G, Hauke J, Pawelczyk L, Duleba AJ. Prediction of spontaneous conception based on semen parameters. *Int J Androl.* 2008;31:499–507.
- Keel BA, Stemberge TW, Pineda G, Serafy Sr NT. Lack of standardization in performance of the semen analysis among laboratories in the United States. *Fertil Steril.* 2002;78:603–8.
- Mortimer D. The male factor in infertility. Part I: semen analysis. current problems in obstetrics, gynecology and fertility. Chicago: Year Book Medical Publishers; 1985. p. 87.
- Mortimer D. Practical laboratory andrology. Oxford: Oxford University Press; 1994.
- World Health Organization. WHO laboratory manual for the examination of human semen and semen-cervical mucus interactions. 2nd ed. Cambridge, UK: Cambridge University Press; 1987.
- World Health Organization. WHO laboratory manual for the examination of human semen and sperm-cervical mucus interactions. 3rd ed. Cambridge, UK: Cambridge University Press; 1992.
- World Health Organization. WHO laboratory manual for the examination of human semen and sperm-cervical mucus interactions. 4th ed. Cambridge, UK: Cambridge University Press; 1999.
- World Health Organization. WHO laboratory manual for the examination and processing of human semen. 5th ed. Geneva: World Health Organization; 2010.

---

# Color-Doppler Ultrasound and New Imaging Techniques in Andrological Examination

# 19

Francesco Lotti and Mario Maggi

---

## Abstract

Imaging of the male genital tract (MGT) has assumed growing importance in andrological evaluation, playing a key role in specific issues. In particular, color-Doppler ultrasound (CDUS) is widely used to assess MGT abnormalities, providing useful information on three main andrological topics: infertility, testicular malignancy, and male accessory gland infection. Scrotal CDUS is very useful in assessing (1) scrotal organs and abnormalities when physical examination is unreliable; (2) signs of testicular dysgenesis, often related to sperm abnormalities and to a higher risk of cancer, and testicular lesions suggestive of malignancy; (3) scrotal pain, signs of inflammation (including epididymo-orchitis), and andrological emergencies (including testicular torsion); (4) varicocele; and (5) congenital absence of vas deferens (along with transrectal CDUS). Transrectal CDUS is useful in detecting signs suggestive of (1) MGT obstruction, including ejaculatory duct abnormalities, prostate median cysts, or SV enlargement/emptying impairment and (2) prostate and SV inflammation. However, MGT-CDUS still suffers from a lack of standardization, which is advisable. Along with CDUS, new imaging techniques, such as contrast-enhanced ultrasound, elastography, and magnetic resonance, have been proposed for improving MGT imaging. Even if they are promising, currently, there is not enough evidence for their routine use, with the exception of some specific indications.

---

## Keywords

Scrotal and transrectal imaging/color-Doppler ultrasound • Male genital tract • Male infertility • Testicular malignancy • Male accessory glands infection/inflammation

---

F. Lotti (✉) • M. Maggi

Sexual Medicine and Andrology Unit, Department of Experimental and Clinical Biomedical Sciences, University of Florence, Florence, Italy

e-mail: [francesco.lotti@unifi.it](mailto:francesco.lotti@unifi.it); [flottimd@yahoo.it](mailto:flottimd@yahoo.it); [m.maggi@dfc.unifi.it](mailto:m.maggi@dfc.unifi.it)

© Springer International Publishing AG 2017

M. Simoni, I.T. Huhtaniemi (eds.), *Endocrinology of the Testis and Male Reproduction*, Endocrinology 1, [https://doi.org/10.1007/978-3-319-44441-3\\_19](https://doi.org/10.1007/978-3-319-44441-3_19)

555



## Contents

Introduction .....	556
Embryological Development of the Male Genital Tract .....	557
Testis and Epididymal Head .....	557
Testicular Descent .....	557
Epididymis, Vas Deferens (VD), and Seminal Vesicles (SV) .....	558
Prostate, Ureters, and Kidneys .....	558
Color-Doppler Ultrasound of the Male Genital Tract: Anatomy and Normal Patterns .....	558
Scrotal Region .....	558
Prostate-Vesicular Region .....	566
Color-Doppler Ultrasound in Pathological Conditions .....	568
Testis .....	568
Varicocele .....	588
Epididymis and Vas Deferens .....	592
Prostate .....	595
Seminal Vesicles .....	597
Specific Applications of Scrotal and Transrectal Ultrasound .....	599
Sensitivity and Specificity in Discriminating Obstructive and Non-obstructive	
Azoospermia .....	599
Testis CDUS and Surgical Sperm Retrieval in Azoospermic Subjects .....	599
Scrotal and Transrectal Ultrasound and Hormonal Treatments .....	600
Color-Doppler Ultrasound Clinical Utility and Impact on Male Reproductive Health	
Management .....	601
New Imaging Techniques for the Evaluation of Testis and Prostate Abnormalities .....	604
Contrast-Enhanced Ultrasound (CEUS) .....	604
Sonographic Elastography (SE) .....	605
Magnetic Resonance Imaging (MRI) .....	606
Conclusions .....	607
Cross-References .....	607
References .....	608

## Introduction

Imaging of the male genital tract (MGT) has progressively expanded, playing a seminal role in andrological examination. In particular, ultrasound (US), which employs high-frequency sound waves to capture live images of organs inside the body, is widely used to assess MGT abnormalities (Ammar et al. 2012; Raza and Jhaveri 2012; Lotti and Maggi 2015). Gray-scale and color-Doppler US (CDUS) can provide useful information on three main andrological topics: infertility (Lotti and Maggi 2015), testicular malignancy (Woodward et al. 2002; Isidori and Lenzi 2008), and male accessory gland infection (MAGI) (La Vignera et al. 2012a). While scrotal CDUS has been used in medicine since a long time, only recently transrectal CDUS has assumed growing importance in MGT imaging, extending the examination to the prostate, seminal vesicles (SV), and deferential ampullas (Ammar et al. 2012; Lotti et al. 2012b; Raza and Jhaveri 2012). Recently, new imaging techniques, such as contrast-enhanced ultrasound (CEUS) (Cantisani et al. 2015) and elastography (Huang and Sidhu 2012), along with magnetic resonance (MRI) (Kim et al. 2007) have been proposed for improving the imaging of MGT abnormalities.

We previously systematically analyzed (Lotti and Maggi 2015) and recapitulate in this chapter the diagnostic impact of CDUS on the MGT in relation to infertility, testicular lesions, and MAGI. The role of the new imaging techniques is also scrutinized (see below, “[New Imaging Techniques for the Evaluation of Testis and Prostate Abnormalities](#)”).

---

## Embryological Development of the Male Genital Tract

### Testis and Epididymal Head

In week 6 of embryonic life, the human primordial germ cells (PGC), of endodermal origin, migrate from the yolk sac and invade the *genital ridges*, which proliferate from the coelomic epithelium into the underlying mesenchyme, forming the primary *sex cords* (Sadler 2011). The undifferentiated gonad develops into the testis toward week 7, modulated by Y chromosome genes. *Sex cords*, compartmentalized by the developing tunica albuginea, become the *seminiferous tubules* (ST), which give the *tubuli recti* that converge in the *rete testis*. At this stage, ST consist of *spermatogonia*, derived from the PGC, and two different types of somatic cells, the *Sertoli cells*, derived from the germinal epithelium, and the *peritubular cells* (myofibroblasts), included in the *lamina propria* covering the mature ST. ST become progressively separated by mesenchyme, which gives the *interstitial Leydig cells*. The developing testis lies adjacent to the mesonephros (embryonal transitory kidney), that, toward the end of month 2, begins to regress, with glomerular disappearance. Only 15–20 tubules, the *efferent ducts*, persist, *link the rete testis*, and connect the genital gland with the mesonephric duct. The efferent ducts constitute the future epididymal head, while the mesonephric duct evolves in the epididymis and vas deferens (Christensen and Dogra 2007; Sadler 2011). The strict link between the efferent ducts (future epididymal head) and the rete testis, and the different embryological development of different epididymal parts, may explain why, when epididymal agenesis occurs, part of the epididymal head is persisting (Sadler 2011), being detectable by US (see section “[Agenesis](#)”).

### Testicular Descent

Between the month 3 of pregnancy and its end, the testes begins to descend from the lumbar region into the scrotum. Testicular descent includes two separate stages. The “transabdominal” stage (8–15 weeks of gestation) is characterized by gubernaculum testis enlargement (swelling reaction), modulated by insulin-like factor 3 (INSL3), leucine-rich repeat-containing G protein-coupled receptor 8 (LGR8) and anti-Müllerian hormone (AMH), and regression of the cranial suspensory ligament in response to testosterone (Christensen and Dogra 2007; Hutson et al. 2010, 2015; Virtanen and Toppari 2014). The “inguinoscrotal” stage (25–35 weeks of gestation)

is characterized by gubernaculum and testis migration from the inguinal region into the scrotum, mainly regulated by androgens (Christensen and Dogra 2007; Garriga et al. 2009). Shortly afterward, the vaginal process, an evagination of the peritoneum which allows the abdominal fetal testis to reach the scrotum, obliterates with formation of the tunica vaginalis (Garriga et al. 2009).

## **Epididymis, Vas Deferens (VD), and Seminal Vesicles (SV)**

The genital tracts have the same appearance in male and female embryos until week 7, consisting of two paramesonephric (Müllerian) and two mesonephric (Wolffian) ducts (Sajjad 2010). At the end of month 2 of pregnancy, androgen production by fetal testes induces regression of the Müllerian and differentiation (stabilization) of the Wolffian structures (Sajjad 2010). The prostatic utricle persists as a Müllerian remnant. The proximal Wolffian ducts give rise to the epididymis (body and tail) and the VD, while the distal part forms the deferential ampulla, SV, and ejaculatory ducts (Sajjad 2010; Sadler 2011; Shaw and Renfree 2014).

## **Prostate, Ureters, and Kidneys**

At the end of week 5 of pregnancy, the *ureteric bud* arises from the mesonephric duct and blends with the metanephric blastema to become the primitive kidney, which ascends to the lumbar region at weeks 6–7. The ureteric bud becomes the ureter, which separates from the mesonephric duct, migrates cranially and opens into the bladder (Kim et al. 2009; Sadler 2011). Any alteration occurring during ureteric bud development may affect SV or VD formation (mesonephric duct origin). Accordingly, developmental anomalies of SV and VD are often associated with renal and/or ureteral anomalies. Due to embryological origin of the aforementioned organs, multiple developmental abnormalities of the genito-urinary tract may occur in the same individual (Sadler 2011) and must be investigated carefully, US playing a key role in their assessment (see section “**Agenesis**”).

The prostate develops from the urogenital sinus, by epithelial (entodermal) buds penetrating into the adjacent mesenchyme. Then, it encloses the ejaculatory ducts, the prostatic utricle, and the urethra (Kim et al. 2009; Sadler 2011).

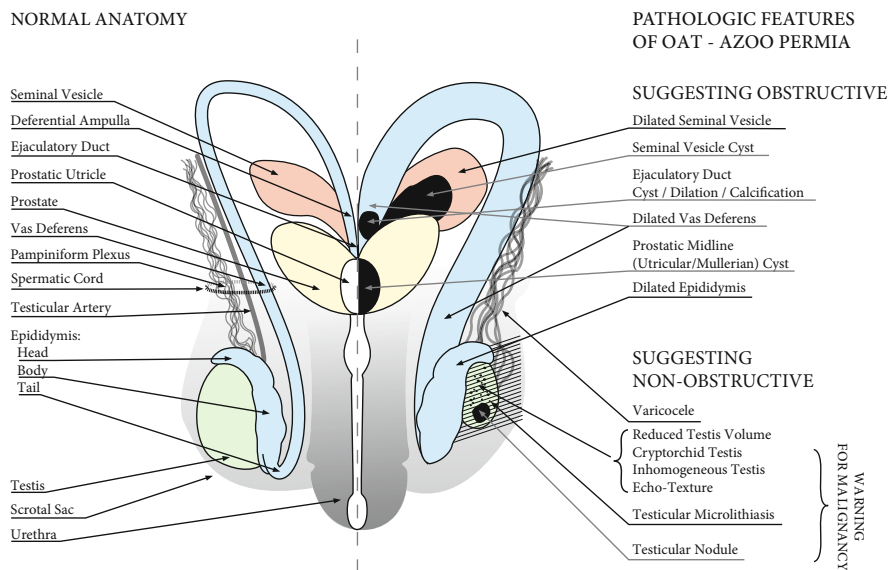
---

## **Color-Doppler Ultrasound of the Male Genital Tract: Anatomy and Normal Patterns**

### **Scrotal Region**

The testes are normally located within the scrotum (Figs. 1 and 2). This external, superficial position allows their evaluation with a high-frequency small part transducer (7–15 MHz). Testes US examination is performed with the patient laying

SCHMATIC REPRESENTATION OF THE MALE GENITAL TRACT



**Fig. 1** Schematic representation of the normal and pathologic features of the male genital tract (MGT) in relation to male reproductive health. *Right side:* normal anatomy of the MGT. *Left side:* pathologic features of the MGT suggesting obstructive or non-obstructive oligo-asthenoteratozoospermia (OAT)/azoospermia. Warning for malignancy is extensively discussed in the text (Adapted from Lotti and Maggi 2015, with permission)

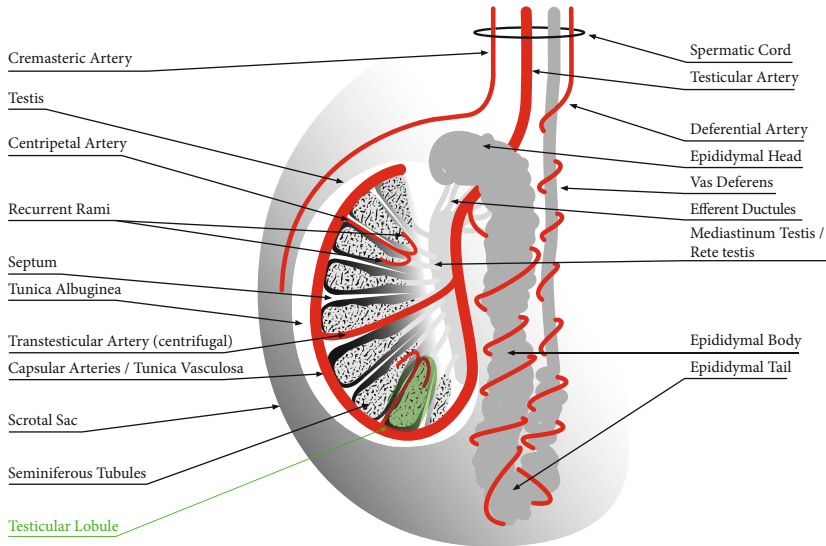
supine with the penis resting on the suprapubic region, applying abundant gel over the scrotal sac. The testes are examined in longitudinal, transverse, and oblique planes, and images are acquired in both gray-scale and color-Doppler modes, to assess testicular blood flow (Appelbaum et al. 2013; Ammar et al. 2012).

**Testis**

**Volume**

Testis volume (TV) is clinically assessed by Prader’s orchidometer (PO) (Nieschlag and Behre 2010). Although orchidometry overestimates TV as compared to US (Behre et al. 1989; Lenz et al. 1993; Diamond et al. 2000; Goede et al. 2011; Rastrelli et al. 2013), Prader-derived TV may be considered a reliable surrogate of that measured by US, easier to perform and less expensive. In fact, PO- and US-derived TV are closely related (Rastrelli et al. 2013), both in young (Goede et al. 2011) and in adult eugonadal or hypogonadal subjects (Behre et al. 1989; Lenz et al. 1993; Diamond et al. 2000; Rastrelli et al. 2013). Nevertheless, US is more accurate in TV measurement than PO (Lenz et al. 1993; Sakamoto et al. 2007a, b). In particular, US plays an important role in evaluating TV when the physical examination is unreliable, such as in the case of large hydrocele, inguinal testis, epididymal

SCHEMATIC REPRESENTATION OF THE SCROTAL ORGANS  
AND RELATED ARTERIAL SUPPLY



**Fig. 2** Schematic representation of the scrotal organs and related arterial supply. The main structures of the testis, as well as epididymis and vas deferens, are shown in *black* and *white*. One testicular lobule is highlighted in *green*. The arterial supply of the scrotal organs is shown in *red*. The structure of the testis and the normal anatomy of the scrotal arterial supply are extensively discussed in the text (section [Color-Doppler Ultrasound of the Male Genital Tract: Anatomy and Normal Patterns - Testis](#)) (Adapted from Lotti and Maggi 2015, with permission)

enlargement/fibrosis, thickened scrotal skin (Behre et al. 1989; Sakamoto et al. 2006; Nijs et al. 2007; Behre and Zitzmann 2010), or small testis, in which the epididymis is large in comparison to the total TV (Goede et al. 2011).

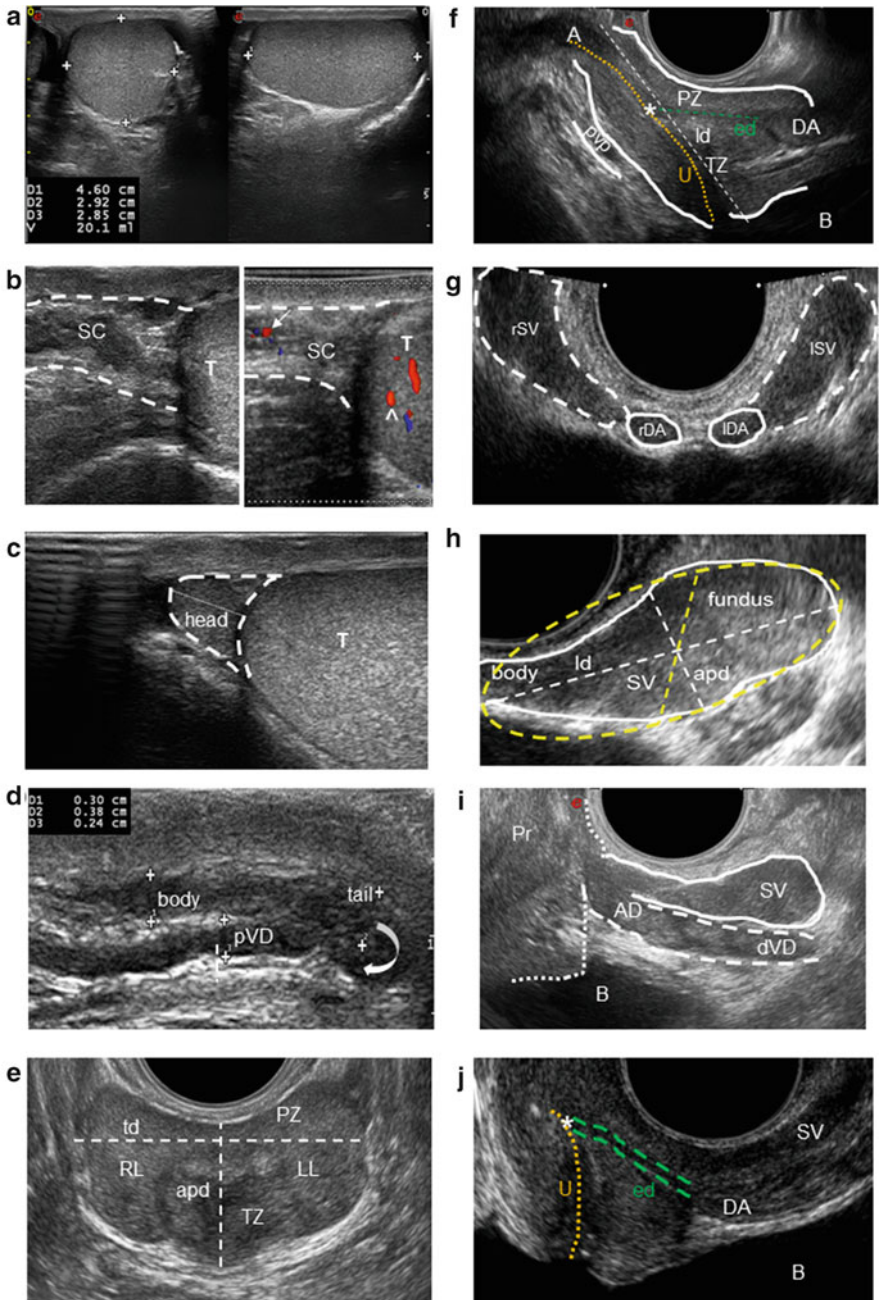
TV varies with age. Prepubertal boys have a TV  $\leq 3$  ml, whereas a TV  $> 3$  ml represents the first sign of an ongoing puberty (Palmer and Dunkel 2012). During puberty, TV increases rapidly (Goede et al. 2011), up to tenfold between 10 and 15 years, reaching the maximum volume around the age of 20 (Béres et al. 1989). Reference growth curves for orchidometry-derived TV are available (Goede et al. 2011; Joustra et al. 2015). Some studies report a decrease of TV as a function of age (Stearns et al. 1974; Baker et al. 1976), while others did not (Harman and Tsitsouras 1980; Sparrow et al. 1980; Nieschlag et al. 1982). More recent studies suggest that a mild TV decline occurs starting from the 50–60 years on (Rastrelli et al. 2013; Pilatz et al. 2013a), although a significant TV reduction has been reported only in the eighth decade of life (Handelsman and Staraj 1985; Sartorius and Nieschlag 2010). In addition, malnutrition and illnesses seem to exert independent negative effects on TV (Handelsman and Staraj 1985). Due to differences in the nature of the populations studied – including geographic area, nourishment, ethnicity, and environmental factors (Diamond 1986; Takihara et al. 1987; Bahk et al. 2010) – so far

there are no uniform TV reference values. Considering Europe, the mean PO-based TV reported in the general population is  $20.0 \pm 5.0$  ml (Jørgensen et al. 2002; Jensen et al. 2004; Nordkap et al. 2016), whereas in infertile patients, it is  $18.0 \pm 5.0$  ml (Nieschlag and Behre 2010). According to a recent study (Lotti et al. 2016a), there is a significant difference in mean TV, assessed both by Prader and US, comparing fertile and infertile subjects, TV decreasing as a function of severity of semen quality impairment.

At US, the adult testis appears as an oval-shaped organ of 30–50 mm length, 20–40 mm width, and 30 mm height (Appelbaum et al. 2013) (Fig. 3a). TV is usually calculated by applying the ellipsoid formula (length  $\times$  width  $\times$  height  $\times$  0.52), although the use of this formula is not universally accepted (Lin et al. 2009; Goede et al. 2011; Pilatz et al. 2013a). The mean difference in TV between PO and US is 4–5 ml (Carlsen et al. 2000; Sakamoto et al. 2007a, 2008a). Hence, assuming that a normal TV by PO is  $>14$ – $15$  ml (Takahara et al. 1986; Forti and Krausz 1998), the normal US-TV should be  $>10$ – $11$  ml (Lotti et al. 2012b). So far, testicular hypotrophy by US has been defined as a TV  $<12$  ml (see Condorelli et al. 2013). Although US-derived TV values for boys aged 0–6 years (Kuijper et al. 2008) and 6 months to 18 years (Goede et al. 2011; Joustra et al. 2015) are available, normative values in the general adult population are lacking. As stated before, US-assessed TV varies according to the mathematical formula applied; however, it is similar among different ethnic groups (Lenz et al. 1993; Bahk et al. 2010; Pilatz et al. 2013a; Foresta et al. 2013). In a recent study (Pilatz et al. 2013a), TV is reported in the same subjects according to different mathematical formulas. Using the ellipsoid formula, an average TV of 14 ml was found in healthy German (Pilatz et al. 2013a), Danish (Lenz et al. 1993), and Italian (Foresta et al. 2013) men. Right TV has been reported larger than the left one by some (Béres et al. 1989; Lenz et al. 1993; Pilatz et al. 2013a), but not all (Bahk et al. 2010) authors. An average TV at US in infertile men ranges from  $\sim 10$  (Lenz et al. 1994) to  $\sim 13.0 \pm 5.0$  ml (Sakamoto et al. 2007a), the latter study reporting that the mean TV measured by US was significantly lower than that measured by PO, with a mean difference of 5 ml, as previously reported (see above).

### Homogeneity and Echogenicity

The normal adult testis has a *homogeneous* fine echo-texture, made of *medium level echoes* with uniform distribution, similar to the *echogenicity* of the normal thyroid gland (Hamm and Fobbe 1995; Isidori and Lenzi 2008) (Fig. 3a). The testis is surrounded by a hyperechoic fibrous capsule, the tunica albuginea, which projects into the interior part with fibrous septa, dividing it into 200–400 lobules (Fig. 2). Each lobule contains interstitial Leydig cells and seminiferous tubules (Fig. 2), with germinal cells at different stages of maturation and somatic Sertoli cells. Seminiferous tubules account for  $\sim 85\%$  of the entire TV (Takahara et al. 1987; Forti and Krausz 1998; Kollin et al. 2006). Septa radiating from the tunica albuginea (Fig. 2) may be seen as hypoechoic linear structures crossing the testis and converging into the hilum of the testis (*mediastinum testis*; Fig. 2), which appears as an eccentric hyperechoic line or triangle in longitudinal and transversal scans, respectively.



**Fig. 3** Normal color-Doppler ultrasound (CDUS) features of the organs of the male genital tract. **a** Testis of normal volume, homogeneity, and echogenicity with ellipsoid shape. Longitudinal (*right figure*) and transversal (*left figure*) scans of the testis, with length (D1), width (D2), and height

Whereas the concept of echo-texture *homogeneity* is a relatively objective finding, that of *normal echogenicity* is more operator dependent. So far, two classifications are available for *homogeneity* (Lenz et al. 1993; Westlander et al. 2001) (Table 2). *Echogenicity* depends on the seminiferous tubules maturation and germ cell representation. Prepubertal testis is slightly more hypoechoic than the adult one, since seminiferous tubules have not developed a lumen yet. During puberty, testis echogenicity progressively increases, as a function of lumen development, up to adult level. Seminiferous tubule reduction and interstitium increase lead to a hypoechoic and/or inhomogeneous echo-texture (Béres et al. 1989; Loberant et al. 2010) (Fig. 4a, b, respectively).

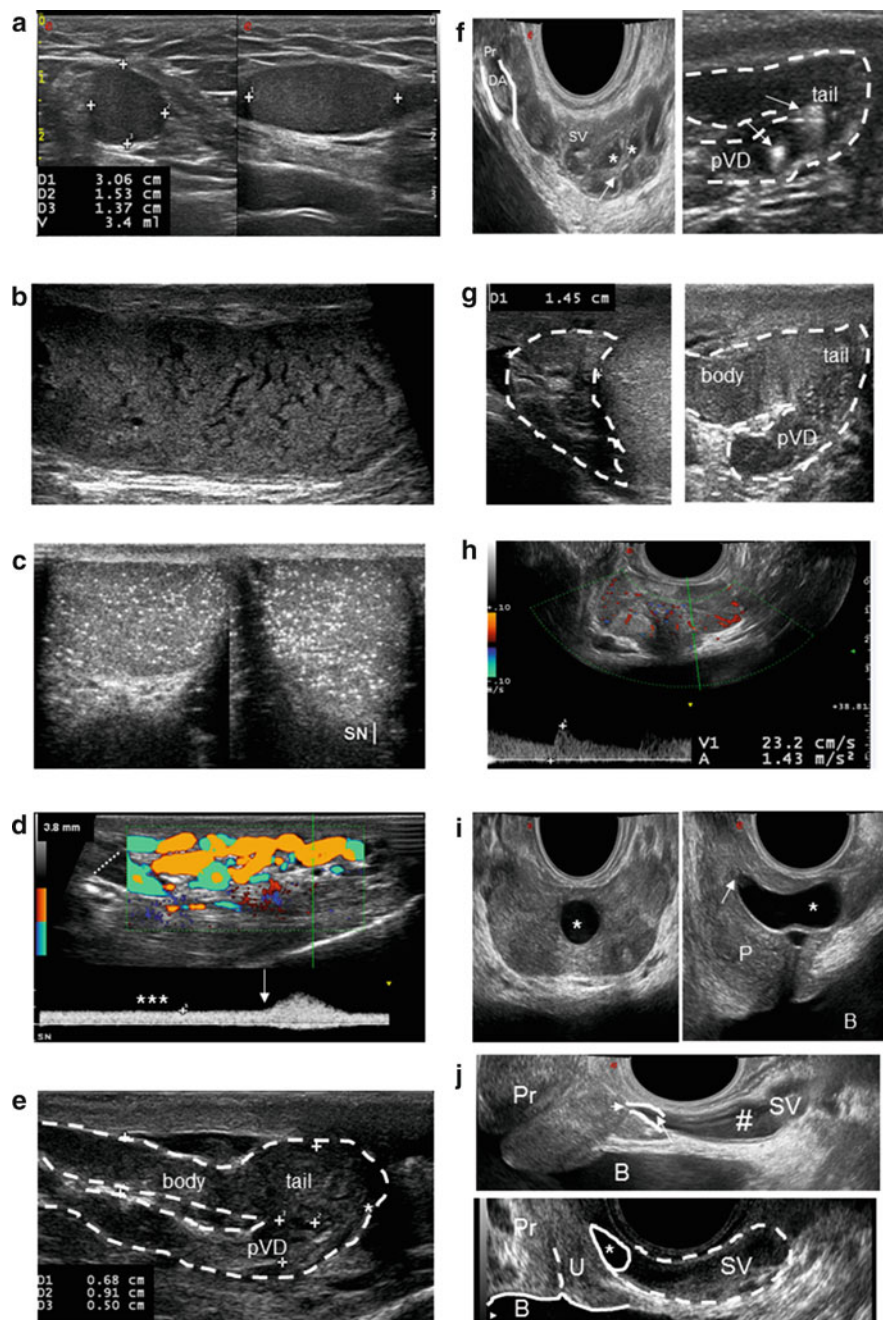
### Vascularization

Scrotal perfusion is ensured by three main arteries: the *testicular artery* (TA), which supplies the testis; the *deferential artery*, which perfuses the epididymis and vas deferens; and the *cremasteric artery*, which supplies the tissues around the testis and the scrotal wall (Horstman et al. 1991a; Isidori and Lenzi 2008) (Figs. 1 and 2).



**Fig. 3** (continued) (D3) measurements are reported. **b** *Left figure*: B-mode appearance of the spermatic cord (SC) and the upper pole of the testis (T) in longitudinal scan. Small, non-dilated venous vessels of the pampiniform plexus are difficult to differentiate from the other structures of the SC. *Right figure*: CDUS detection of the testicular artery (*arrow*) in the SC and recurrent ramus (^) of an intratesticular centripetal artery. Venous reflux at rest in the venous vessels is not detectable. **c** Normal epididymal head with triangular shape (*dashed line*) in longitudinal scan, homogeneous, with echogenicity comparable to that of the testis (T). Its length is measured from the top to the base of the triangle (*dotted line*). **d** Homogeneous epididymal body and tail and proximal vas deferens (pVD) in longitudinal scan. Their echogenicity is slightly hypoechoic compared to the testis and the epididymal head in (**c**). Their diameters are reported as *dashed lines*. *Red dashed line* indicates the end of the epididymal tail and the beginning of the pVD. The *curve arrow* indicates the epididymal-deferential handle. **e** Prostate of normal volume, homogeneity, and echogenicity in transversal scan. Peripheral and transitional zone (PZ and TZ) show a 3:1 ratio in young men. Right and left lobes (RL and LL, respectively) and periprostatic venous plexus (PVP) are indicated. Anterior-posterior and transverse diameters (“apd” and “td”, respectively) are reported. **f** Prostate of normal volume, homogeneity, and echogenicity in sagittal scan evaluated with “end fire” probe. Peripheral and transitional zone (PZ and TZ, respectively) and apex (A) are indicated, as well as bladder (B), urethra (U, *yellow dotted line*), ejaculatory duct (*green dashed line*), prostatic utricle (\*), deferential ampulla (DA), and periprostatic venous plexus (pvp). The longitudinal diameter (“ld”) is reported and represented with a *white dashed line*. **g** Right and left seminal vesicles (rSV and lSV, respectively) with typical “bow-tie” appearance and, medial to them, right and left deferential ampullas (sDA and lDA, respectively) in transversal scan. **h** Seminal vesicle (SV) assessed by “end fire” probe in sagittal scan. Fundus and body are reported, as well as longitudinal and anterior-posterior diameters (“ld” and “apd” *dashed lines*, respectively). A schematic model of SV volume calculation is reported, using the “ellipsoid/prolate spheroid ( $d_1 > d_2 = d_3$ )” (*red ellipse*) mathematical formula ( $d_1 \times d_2 \times d_3 \times 4/3 \times \pi$ ), with  $d_1 = ld$  and  $d_2 = apd$ , and  $d_3$  assumed =  $d_2$  (*red dashed line*) (According to Lotti et al. 2012a). **i** Distal vas deferens (dVD) and deferential ampulla (DA) beside a section of the seminal vesicle (SV) assessed by “end fire” probe in sagittal scan. **j** Ejaculatory duct (*double green dashed lines*) and prostatic utricle (\*) assessed by “end fire” probe in sagittal scan. Deferential ampulla (DA), a section of the seminal vesicle (SV), urethral (U) course (*dashed line*), bladder (B) and prostate (Pr) are reported





**Fig. 4** Abnormal color-Doppler ultrasound (CDUS) features of the organs of the male genital tract. **a** Testis with low volume and hypoechoic echo-texture, detected in a man with a history of cryptorchidism. **b** Testis with echo-texture inhomogeneity in sagittal scan. **c** Testicular microlithiasis with "starry

TA arises from the aorta, below the renal arteries, while the *deferential* and the *cremasteric arteries* are branches of the vesicular artery and of the inferior epigastric artery, respectively (Horstman et al. 1991a) (Fig. 2). TA enters the spermatic cord at the deep inguinal ring and reaches the upper pole of the testis (Horstman et al. 1991a) (Figs. 2 and 3b). From this point, TA penetrates the tunica albuginea in the posterior side of the testis and runs along the fibrous capsule branching the *capsular* and the *transmediastinal arteries* (Fig. 2).

The *capsular arteries* run beneath the tunica albuginea in a layer called *tunica vasculosa*, over the surface of seminiferous tubules (Schlegel and Li-Ming 1997) (Fig. 2). They supply *centripetal arteries* that enter the testicular parenchyma and flow toward the hilum (Horstman et al. 1991a) penetrating between the septa dividing the testicular lobules (Schlegel and Li-Ming 1997). As they approach the mediastinum, the *centripetal arteries* arborize into *recurrent rami* that branch back in the opposite direction, carrying blood from the mediastinum into the testis (Middleton et al. 1989; Migaletto et al. 2012) (Fig. 2).

The *transmediastinal artery* is a centrifugal artery present in about half of the men. It enters at the mediastinum and runs across the testicular parenchyma with a straight course, to form capsular branches on the opposite side (Horstman et al. 1991a; Pais et al. 2004) (Fig. 2).

### Pampiniform Plexus

Normal pampiniform plexus (Fig. 1) is scarcely assessed by physical examination as well as by gray-scale US, because it is difficult to differentiate it from the other structures of the spermatic cord (Fig. 3b). Color or power Doppler, which usually help in appreciating vascular flow, should not detect any venous reflux. In normal conditions, US detects a complex network of small vessels <2 mm (Dogra et al. 2003; Cina et al. 2006) converging into the spermatic veins. The right spermatic vein enters into the inferior vena cava with an acute angle, whereas the left one enters



**Fig. 4** (continued) sky” appearance. **d** CDUS evaluation of dilated veins of the pampiniform plexus with colored signal (*left*), showing continuous reflux at rest (\*\*\*) , increasing with Valsalva (*arrow*), identifying a severe, sonographic-defined, varicocele, according to different classifications (see Table 3). **e** Dilated and inhomogeneous epididymal body and tail and proximal vas deferens (pVD), with irregularly shaped mass (\*) in the epididymal tail region, detected in sagittal scan. **f** *Left figure*: section of a dilated deferential ampulla (DA) beside a dilated seminal vesicle (SV) with areas of endocapsulation (\*) and thick septa (*arrow*) detected by “end fire” probe in sagittal scan. *Right figure*: dilated, inhomogeneous epididymal tail and proximal vas deferens (pVD), with coarse calcifications (*arrow*). **g** *Left figure*, dilated (>12 mm), inhomogeneous, hypoechoic epididymal head; *right figure*, abrupt interruption of the proximal vas deferens (pVD) in a man with congenital bilateral absence of vas deferens. Epididymal body and tail are also visualized in sagittal scan. **h** Prostate with hyperemia end elevated arterial peak systolic velocity. **i** Midline prostatic cyst (\*) in transversal (*left*) and sagittal (*right*) scan. The prostatic utricle is indicated with an *arrow*. *P* prostate, *B* bladder. **j** *Upper figure*, ejaculatory duct dilation (*arrow*) and microcalcification (*short arrow*), and seminal vesicle cyst (#), assessed by “end fire” probe in sagittal scan. *Lower figure*, ejaculatory duct cyst (\*). *SV* seminal vesicle, *Pr* prostate, *U* urethra, *B* bladder

perpendicular into the left renal vein. For this reason, the latter is characterized by a higher blood hydrostatic pressure. When the pressure becomes excessive and/or venous valve impairment occurs, venous reflux and dilation may occur, leading to varicocele (Gat et al. 2008) (see section “[Varicocele](#)”).

### **Epididymis and Proximal Vas Deferens**

The normal epididymis is a soft organ adjacent to the testis, arbitrarily divided into three parts: head, body, and tail (Figs. 1 and 2). The head consists of 10–15 efferent ductules originating from the rete testis and converging in a single, convoluted tube in the distal portion (Fig. 2). At US, the *epididymis* is usually detected posterior and lateral with respect to the testis, with the head at the upper pole and the tail at the lower pole of the male gonad. The normal head is triangular, with isoechoic to slightly hyperechoic texture with respect to the testis (Dogra et al. 2003; Lee et al. 2008) (Fig. 3c). It is usually measured in a longitudinal scan from the top to the base of the triangle (Pezzella et al. 2013; Pilatz et al. 2013a) (Fig. 3c). The body and tail diameters are measured in a longitudinal scan considering the anterior-posterior diameters (Pezzella et al. 2013; Vicari 1999) (Fig. 3d). A head of 5–12 mm (Behre et al. 1995; Vicari 1999; Dogra et al. 2003; Lee et al. 2008; Pezzella et al. 2013; Pilatz et al. 2013a), a body of 2–4 mm (Behre et al. 1995; Dogra et al. 2003; Lee et al. 2008), and a tail of 2–6 mm (Lee et al. 2008; Dogra et al. 2003; Vicari 1999) have been proposed as normal. Blood flow is detectable by CDUS in discrete vascular spots in all tracts of the epididymis (Keener et al. 1997).

The vas deferens (VD) is a straight tense cord which runs along the spermatic cord (Figs. 1 and 2). VD absence, with or without epididymal agenesis, is often difficult to be evaluated by physical examination, and US is useful to confirm this finding. At scrotal US, the proximal VD appears as a straight duct, slightly hypoechoic compared to the epididymis, extending from the epididymal tail (Fig. 3d) toward the inguinal channel (Isidori and Lenzi 2008).

### **Prostate-Vesicular Region**

The prostate-vesicular region can be studied by transabdominal or transrectal US (TRUS) (Huang Foen Chung et al. 2004; Stravodimos et al. 2009). Although some authors revealed no significant difference between the two US to measure prostate volume (Huang Foen Chung et al. 2004), other authors reported that TRUS is more accurate in predicting adenoma volume in BPH patients (Stravodimos et al. 2009). In addition, in our opinion, TRUS has higher accuracy in detecting echo-texture and vascular parameters. Hence, in this chapter, we will focus on TRUS.

TRUS is performed using a transrectal biplanar probe (linear and convex transducer, 6.5–7.5 MHz) and/or an “end fire” probe (6.5 MHz, field of view 50–200°), with the patient placed in the left lateral decubitus, scanning the organs in transverse, longitudinal, and oblique ways (Behre et al. 1995; Older and Watson 1996; Vicari 1999; Lotti et al. 2011a, b; Lotti et al. 2012a, c).

## Prostate

The prostate is an exocrine gland, which surrounds the urethra (Fig. 1) just below the neck of the bladder. It produces prostatic fluid, an acidic secretion that makes up ~30% of the total ejaculate (Cooper 2010).

At TRUS, the normal prostate appears different according to age, with a triangular or pear shape in younger and older subjects, respectively (Older and Watson 1996; Raza and Jhaveri 2012). Its base lies at the bladder neck, at the beginning of the urethra, detectable in a longitudinal scan as a hypoechoic duct curving toward the prostatic apex. TRUS identifies a *peripheral zone (PZ)*, which extends laterally and posteriorly from the apex to the base, and a *transitional zone (TZ)*, centrally located and slightly hypoechoic (Fig. 3e). PZ and TZ show a 3:1 ratio in young men (Doble and Carter 1989; Jin et al. 2001). A *central zone* has been also described (Berger et al. 2006; Jin et al. 2001). Prostate volume (PV) is often measured using a planimetric method (Behre et al. 1995; Vicari 1999; Lotti et al. 2011a, b). It is calculated measuring three diameters (anterior-posterior and transverse in the transversal scan, longitudinal in the sagittal one; Fig. 3e, f) using the mathematical formula of the ellipsoid (Collins et al. 1995; St Sauver et al. 2006; Lotti et al. 2011a, 2013d). “TZ volume” is similarly calculated (St Sauver et al. 2006; Lotti et al. 2013d). A PV of 20–25 ml has been proposed as normal in young men (Raza and Jhaveri 2012). The normal adult prostate shows thin, densely packed, and homogeneously deployed echoes. Periprostatic venous plexus is detectable as a slightly hypoechoic system of vessels (Fig. 3e, f). Intraprostatic arteries are grouped in *central/periuethral* and *peripheral/capsular* arteries, supplying the TZ and PZ, respectively (Older and Watson 1996).

## Seminal Vesicles, Deferential Ampullas, and Ejaculatory Ducts

*Seminal vesicles (SV)* are paired and saccular structures, which lie superior and posterior to the prostate between the bladder and the rectum (Fig. 1) (Ramchandani et al. 1993; Kim and Lipshultz 1996; Kim et al. 2009). They produce an alkaline fluid contributing 50–80% of the ejaculate volume (Ramchandani et al. 1993; Kim et al. 2009).

At TRUS, SV have a typical “bow-tie” appearance in transversal scans and a tennis-racket shape in longitudinal scans (Fig. 3g, h, respectively). SV echo-texture is characterized by homogenous fine echoes and is slightly less echogenic than the prostate (Ramchandani et al. 1993; Kim and Lipshultz 1996). In relatively young subjects, SV volume is negatively associated with age (Lotti et al. 2012a) and tends to shrink after the fifth decade, showing a significant reduction in the eighth compared to the fourth decade (Terasaki et al. 1993). SV volume increases with sexual abstinence (Lotti et al. 2012a), whereas it decreases in current smokers as a function of smoking habit and of lifetime exposure to cigarette smoking (Lotti et al. 2015). SV volume is also positively affected by testosterone (Sasagawa et al. 1989, 1990), prolactin (Lotti et al. 2013a), and free triiodothyronine (fT3; Lotti et al. 2016b) levels. While most of the available studies assessed SV *diameters*, we recently proposed to calculate SV *volume* by measuring the maximum longitudinal

and anterior-posterior diameters, using the “ellipsoid/prolate spheroid” mathematical formula (Lotti et al. 2012a) (Fig. 3h). SV volume varies with ejaculation and is positively related to the ejaculate volume, but not with sperm parameters (Lotti et al. 2012a). SV emptying with ejaculation is positively related to fT3 levels (Lotti et al. 2016b), and subjects with subclinical hyperthyroidism show a higher reduction of SV longitudinal diameters after ejaculation as compared with eu- and hypothyroid men (Lotti et al. 2016b).

The *deferential ampullas* (Fig. 1) appear at TRUS as oval structures medial to the SV in transversal scans, cephalic to the prostate, or as distal VD enlargements in longitudinal scans (Fig. 3g, i, respectively). They have an echo-texture similar to that of SV.

The *ejaculatory ducts* (Fig. 1) appear at TRUS as fine and hypoechoic, with a normal caliber <2 mm. They are detectable in longitudinal scans crossing the prostate up to the urethra (Kim and Lipshultz 1996; Raza and Jhaveri 2012) (Fig. 3j).

---

## Color-Doppler Ultrasound in Pathological Conditions

### Testis

#### Volume

Low TV (Fig. 1) at Prader evaluation is associated with worse sperm parameters, including lower total sperm count (Handelsman et al. 1984; Bujan et al. 1989; Arai et al. 1998; Jørgensen et al. 2002; Sakamoto et al. 2008a), motility (Bujan et al. 1989; Arai et al. 1998; Sakamoto et al. 2008a), and normal morphology (Jørgensen et al. 2002). In addition, a low TV is related to abnormalities in sexual hormones, including low testosterone and increased gonadotropin levels (Sakamoto et al. 2008a; Rastrelli et al. 2013). Finally, TV correlates with fatherhood (Fisher et al. 2012). Accordingly, TV measured by US is positively related to total sperm count (Lenz et al. 1993, 1994; Sakamoto et al. 2008a; Cooper 2010), motility (Sakamoto et al. 2008a), normal morphology (Lenz et al. 1993), and testosterone levels and negatively to gonadotropins (Sakamoto et al. 2008a; Sakamoto and Ogawa 2009). In addition, a reduced US-TV is associated with worse nonconventional sperm parameters, including higher sperm DNA fragmentation – particularly seminal levels of PI<sup>dimmer</sup> population (Lotti et al. 2016c) and M540 bodies (Lotti et al. 2012d) – as well as higher chromatin compactness, mitochondrial membrane potential, and phosphatidylserine externalization (Condorelli et al. 2013).

On the other hand, oversize testes are considered abnormal, this finding being defined “macroorchidism” or “megalotestes” (Lachiewicz and Dawson 1994; Meschede et al. 1995). However, a clear cutoff indicative of macroorchidism, both at PO or US, is lacking. One report defined macroorchidism as a TV >95th percentile of the standard testicular curves (Lachiewicz and Dawson 1994). A TV  $\geq 4$  ml at Prader evaluation in infants and children up to 8 years old (see Lachiewicz and Dawson 1994) and a TV >25–30 ml in adults have been suggested as indicative of macroorchidism (Nielsen et al. 1982; Meschede et al. 1995). The majority of the

studies on megalotestes have been performed on men with fragile X syndrome or mental retardation, but limited reports described macroorchidism also in men with different diseases (see Lachiewicz and Dawson 1994). Slightly enlarged TV may, however, be a normal variant in adult men (Nielsen et al. 1982). In addition, any definition of abnormal enlarged testes should refer to the ethnic group, age, and anthropometric parameters (Nielsen et al. 1982). Interestingly, limited studies report that large male gonads show normal function (Cantu et al. 1976; Berkovitz et al. 1986; Meschede et al. 1995).

### Echo-Pattern Abnormalities

The main echo-pattern abnormality of the testis is *inhomogeneity* (Figs. 1 and 4a, b). So far, testicular inhomogeneity (TI) has been classified on 5-point scale by Lenz et al. (1993) and Westlander et al. (2001) (Table 2). TI is detected by US as overexpressed hypoechoic striae, giving a mottled, scratched, or netting appearance defined as “striated” (Loberant et al. 2010) (Fig. 4b), suggesting atrophy and fibrosis (Loberant et al. 2010). In fact, the hypoechoic striae mirror the thickening of the interlobular septa, deriving from a decrease in the parenchymal component of the testis and an increase of the interstitium (Loberant et al. 2010). TI builds up with age (Lenz et al. 1993), and although it is frequent in elderly men and considered normal, in young subjects, it is considered an abnormal finding and is associated with several pathological conditions (see Table 2). TI has been associated with testicular dysfunction (Lenz et al. 1993; Behre et al. 1995), abnormal sperm morphology (Lenz et al. 1993; Lotti et al. 2013), and history of cryptorchidism (Lenz et al. 1993). TI has been associated also with testis malignancy (see below and Table 1), in particular with a high risk of *carcinoma* in situ in subjects with a history of cryptorchidism (Lenz et al. 1987; Lenz 1991) or with testicular microlithiasis (Elzinga-Tinke et al. 2010). At present, US follow-up is suggested if severe TI is detected, especially if *additional risk factors* for testicular malignancy (see section “**Testicular Lesions**”) are present. Conversely, a diagnostic testicular biopsy is not recommended (Lotti and Maggi 2015). Finally, diffuse TI could be related to massive tumors or lymphoma, the latter occurring later in life (50–70 years) and hard at physical examination, usually highly vascularized at CDUS (Woodward et al. 2002; Isidori and Lenzi 2008).

### Vascularization

The detection of the testis vascular perfusion plays a key role in the differential diagnosis among testicular torsion (absent), infarction (absent or peripheral), epididymo-orchitis, or some malignant conditions (i.e., leukemia, lymphoma) (enhanced), supporting suspicions arising from clinical abnormal findings (Isidori and Lenzi 2008) (see Table 1). This is relevant, because these conditions may exert a definitive negative effect on male reproductive and general health (Tekgül et al. 2008; Sharp et al. 2013; Grabe et al. 2013; Jungwirth et al. 2016). In addition, the knowledge of testicular vascularization (see section “**Vascularization**” and Fig. 2) is relevant to perform testis surgery. In fact, *centripetal arteries* (Fig. 2) are end arteries, and their damage during testicular sperm extraction (Schlegel and

**Table 1** Male genital tract (MGT) color-Doppler ultrasound (CDUS) clinical utility and impact on male reproductive health management. The clinical utility of the parameters investigated by CDUS has been arbitrarily classified as low, moderate, and high, in relation to fertility (F) or general health (GH)

CDUS parameter	Clinical utility	Comments		Impact on male reproductive health management
		Pros	Cons	
<b>Scrotal CDUS</b>				
Testis localization	F: Low	Useful in localizing inguinal testis (see Color-Doppler Ultrasound in Pathological Conditions – Testis – Testicular findings and lesions – <b>Cryptorchidism</b> )	Physical examination often informative enough Useless in localizing intraabdominal testis (see Color-Doppler Ultrasound in Pathological Conditions – Testis – Testicular findings and lesions – <b>Cryptorchidism</b> )	Debated utility prior to planning orchiopexy No impact on management of nonpalpable testes Useful in follow-up of cryptorchid testis-related malignancy risk and contralateral testis (see Color-Doppler Ultrasound in Pathological Conditions – Testis – Testicular findings and lesions – <b>Cryptorchidism</b> )
	GH: Moderate			
Testis volume (TV)	F and GH: Low	US useful when Prader orchidometer is unreliable (large hydrocele, inguinal testis, enlarged epididymis) (see Color-Doppler Ultrasound of the Male Genital Tract: Anatomy and Normal Patterns – Testis – <b>Volume</b> )	Prader orchidometer-derived TV is strictly related to US-TV; US shows greater accuracy, but Prader orchidometer is informative enough in clinical setting (see section: Color-Doppler Ultrasound of the Male Genital Tract: Anatomy and Normal Patterns – Testis – <b>Volume</b> )	Positive correlation with sperm and hormonal parameters (see section Color-Doppler Ultrasound of the Male Genital Tract: Anatomy and Normal Patterns – Testis – <b>Volume</b> ) Poor utility in TESE decision-making Poor utility in spermatogenic arrest
Testis echotexture and calcifications	F: Moderate	Inhomogeneity suggests testicular function impairment and abnormal sperm morphology (see section “Color-Doppler Ultrasound in Pathological Conditions – Testis – <b>Echo-pattern abnormalities</b> ”)	Inhomogeneity may be found in several diseases or exposure to harmful causes, so it is not specific (see section “Color-Doppler Ultrasound in Pathological Conditions – Testis – <b>Echo-pattern abnormalities</b> ”)	US useful in follow-up for malignancy when severe inhomogeneity or microcalcifications are found, especially when other risk factors are present (see Color-Doppler Ultrasound in Pathological Conditions – Testis – <b>Testicular findings and lesions</b> )

	GH: Moderate	Severe inhomogeneity warns of malignancy (see section "Color-Doppler Ultrasound in Pathological Conditions – Testis – <a href="#">Echo-pattern abnormalities</a> ")	Associations between microcalcifications and malignancy are recently debated (see Color-Doppler Ultrasound in Pathological Conditions – Testis – Testicular findings and lesions – <a href="#">Calcifications</a> )	Biopsy debated in presence of microcalcifications (see Color-Doppler Ultrasound in Pathological Conditions – Testis – Testicular findings and lesions – <a href="#">Calcifications</a> )
		Microcalcifications warn of malignancy, suggesting US follow-up and eventually biopsy (see Color-Doppler Ultrasound in Pathological Conditions – Testis – Testicular findings and lesions – <a href="#">Calcifications</a> )	Poor utility in TESE decision-making (see section "Color-Doppler Ultrasound in Pathological Conditions – Testis – <a href="#">Echo-pattern abnormalities</a> ")	Poor utility in infertility management (see section "Color-Doppler Ultrasound in Pathological Conditions – Testis – <a href="#">Echo-pattern abnormalities</a> ")
Testicular lesions	F: Low	Detection of small and large lesions and their characteristics (extension, vascularization, echo-texture) (see Color-Doppler Ultrasound in Pathological Conditions – Testis – Testicular findings and lesions – <a href="#">Testicular lesions</a> )	Physical examination informative enough to detect large/hard lesions	Useful in follow-up of cryptorchid testis-related malignancy risk or small lesions (see Color-Doppler Ultrasound in Pathological Conditions – Testis – Testicular findings and lesions – <a href="#">Testicular lesions</a> )
	GH: Moderate/high	Useful in follow-up of cryptorchid testis-related malignancy risk or small lesions (see "Testicular Findings and Lesions")	Poor information on the biological behavior of the lesion; histology required (see Color-Doppler Ultrasound in Pathological Conditions – Testis – Testicular findings and lesions – <a href="#">Testicular lesions</a> )	Moderate utility in large/hard lesions decision-making (see Color-Doppler Ultrasound in Pathological Conditions – Testis – Testicular findings and lesions – <a href="#">Testicular lesions</a> )

*(continued)*



Table 1 (continued)

CDUS parameter	Clinical utility	Comments		Impact on male reproductive health management
		Pros	Cons	
Testicular vascularization	F: Low	Useful for torsion, infarction (reduced), orchitis/epididymitis, or some tumors (enhanced) (see section “Color-Doppler Ultrasound in Pathological Conditions – Testis – <a href="#">Vascularization</a> ”)	Not standardized for fertility assessment	Useful for torsion, infarction (reduced), orchitis or some tumors (enhanced) (see section “Color-Doppler Ultrasound in Pathological Conditions – Testis – <a href="#">Vascularization</a> ”)
	GH: High	A few reports on positive correlation with sperm parameters and retrieval in TESE (see section “Color-Doppler Ultrasound in Pathological Conditions – Testis – <a href="#">Vascularization</a> ”)		Not standardized for fertility assessment Poor utility for TESE decision-making
Varicocele	F: Moderate	US (see section “ <a href="#">Varicocele</a> ”)	Physical examination is sufficient for treatment decision	Poor utility when varicocele is palpable or visible
	GH: Low	Confirms clinical diagnosis	Treatment of subclinical varicocele disputable	Useful when physical examination is unreliable
		Confirms clinical diagnosis	Risk of complications (see section “ <a href="#">Varicocele</a> ”)	Useful in detecting recurrence/persistence after surgery (see section “ <a href="#">Varicocele</a> ”)
		Detects the type of venous reflux		
		Detects subclinical varicocele with persistent reflux		
		Avoids “false” varicocele (dilation without reflux)		
		Detects recurrence/persistence after surgery		

Epididymal diameters	F: Moderate	US shows greater accuracy compared to physical examination (see section "Epididymis, Vas Deferens (VD), and Seminal Vesicles (SV)")	Difficult to evaluate after scrotal surgery or in the presence of large varicocele	Epididymal enlargement may indicate distal obstruction in subjects with oligo/azoospermia (see Color-Doppler Ultrasound in Pathological Conditions – Epididymis and Vas Deferens – <b>Obstruction-Related Findings</b> ), eventually leading to extent US investigation to the prostate-vesicular region
	GH: Low	Enlarged epididymis suggestive of past or present inflammation or post-testicular obstruction (see Color-Doppler Ultrasound in Pathological Conditions – Epididymis and Vas Deferens)	Primary obstruction may only be suggested, but not proven, by US (see Color-Doppler Ultrasound in Pathological Conditions – Epididymis and Vas Deferens – <b>Obstruction-Related Findings</b> )	
Epididymal echo-texture	F and GH: Low	Echo-texture abnormalities may associate with past or present inflammation (see Color-Doppler Ultrasound in Pathological Conditions – Epididymis and Vas Deferens – <b>CDUS Abnormalities</b> )	Not standardized	May associate with reduced sperm count and motility (see Color-Doppler Ultrasound in Pathological Conditions – Epididymis and Vas Deferens – <b>CDUS Abnormalities</b> )
Epididymal vascularization	F: Low GH: Moderate	Hyperemia indicates Inflammation (see Color-Doppler Ultrasound in Pathological Conditions – Epididymis and Vas Deferens – <b>CDUS Abnormalities</b> ) Follow-up after medical treatment (see Color-Doppler Ultrasound in Pathological Conditions – Epididymis and Vas Deferens – <b>CDUS Abnormalities</b> )	Not standardized	Hyperemia indicates medical treatment (associated with medical history and clinical symptoms/signs)

(continued)

Table 1 (continued)

CDUS parameter	Clinical utility	Comments		Impact on male reproductive health management
		Pros	Cons	
Epididymal abnormalities	F: Moderate GH: Low	US detects abnormalities or the absence of the epididymis (see Color-Doppler Ultrasound in Pathological Conditions – Epididymis and Vas Deferens – <a href="#">Agenesis</a> )	Epididymal cysts have low utility in infertility assessment (see Color-Doppler Ultrasound in Pathological Conditions – Epididymis and Vas Deferens – <a href="#">CDUS Abnormalities</a> )	Useful in suggesting absence or downstream obstruction (see Color-Doppler Ultrasound in Pathological Conditions – Epididymis and Vas Deferens – <a href="#">Obstruction-Related Findings and Color-Doppler Ultrasound in Pathological Conditions – Epididymis and Vas Deferens – <a href="#">Agenesis</a></a> )
Vas deferens (VD)	F: High	US detects abnormalities or the absence of the proximal or distal VD (see “ <a href="#">Agenesis</a> ”)	The intermediate portion of the VD is not detectable by US	Useful in defining OA cause (see Color-Doppler Ultrasound in Pathological Conditions – Epididymis and Vas Deferens – <a href="#">Agenesis</a> and Color-Doppler Ultrasound in Pathological Conditions – Prostate – <a href="#">Ejaculatory Ducts Obstruction/Abnormalities</a> )
	GH: Moderate	VD dilation may indicate distal obstruction (see section “Epididymal Diameters”)		Positive sperm retrieval by TESE (see Color-Doppler Ultrasound in Pathological Conditions – Epididymis and Vas Deferens – <a href="#">Agenesis</a> ) VD absence suggests CFTR gene and kidneys US evaluation (see Color-Doppler Ultrasound in Pathological Conditions – Epididymis and Vas Deferens – <a href="#">Agenesis</a> )

Transrectal CDUS				
Prostate volume	F: Low	US shows greater accuracy than physical examination (see section "Prostate")	Physical examination may reveal normal, reduced, or enlarged prostate (see section "Prostate")	Not very useful in infertile male management
	GH: Moderate	Useful to assess upward growth (bladder) (see section "Prostate")	TRUS is uncomfortable	Reduced volume may suggest hypogonadism Useful in benign prostatic hyperplasia management Impact on fertility not demonstrated
Prostate echo-texture	F and GH: Low	Abnormalities suggestive of past or present inflammation (see Table 2)	Abnormal echo-texture: frequent, poorly specific	Impact on fertility not demonstrated
	F: Low	May indicate current inflammation (see Table 2)	Few available studies (see section "Prostate")	
Prostate vascular parameters	GH: Moderate	Correlation with CPPS and PLS (see Table 2)	Not standardized	
	F: Moderate/high	Large cysts may cause ejaculatory duct obstruction	No size cutoff associated with distal obstruction (see Color-Doppler Ultrasound in Pathological Conditions – Prostate – Ejaculatory Ducts Obstruction/Abnormalities)	Useful in defining OA cause (see Color-Doppler Ultrasound in Pathological Conditions – Prostate – Ejaculatory Ducts Obstruction/Abnormalities and "Prostate") Aspiration in OA subject may lead to semen parameters improvement (see Color-Doppler Ultrasound in Pathological Conditions – Prostate – Ejaculatory Ducts Obstruction/Abnormalities and "Prostate")
Ejaculatory ducts (ED)	GH: Low	US used in follow-up after cyst aspiration (see Color-Doppler Ultrasound in Pathological Conditions – Prostate – Ejaculatory Ducts Obstruction/Abnormalities)		
	F: Moderate/high	TRUS detects abnormalities (see Color-Doppler Ultrasound in Pathological Conditions – Prostate – Ejaculatory Ducts Obstruction/Abnormalities)		Useful in defining OA cause (Singh et al. 2012)
	GH: Low			ED cyst may indicate CFTR gene evaluation

(continued)

Table 1 (continued)

CDUS parameter	Clinical utility	Comments		Impact on male reproductive health management
		Pros	Cons	
Seminal vesicle (SV) agenesis	F: Moderate/high GH: Low	TRUS detects uni- or bilateral absence (see Color-Doppler Ultrasound in Pathological Conditions – <a href="#">Seminal Vesicles</a> )		SV absence suggests CFTR gene and kidneys US evaluation (see Color-Doppler Ultrasound in Pathological Conditions – <a href="#">Seminal Vesicles</a> )
Seminal vesicle volume	F: Moderate GH: Low	Dilation after ejaculation may indicate partial ED obstruction (see Color-Doppler Ultrasound in Pathological Conditions – <a href="#">Seminal Vesicles</a> )	Dilation or hypoplasia are not standardized (see Color-Doppler Ultrasound in Pathological Conditions – <a href="#">Seminal Vesicles</a> )	Dilation suggestive of partial ED obstruction, but no standardization
Seminal vesicle echo-texture	F: Low/moderate GH: Low	Abnormalities may indicate past or present inflammation or stasis (see <a href="#">Table 2</a> )	Should be evaluated after ejaculation (see “ <a href="#">Echo-Pattern Abnormalities</a> ” and “ <a href="#">Obstruction-Related Findings</a> ”)	Giant cyst may indicate genitourinary anomalies investigation (see “ <a href="#">SV Agnesis, Hypoplasia, and Cysts</a> ”)
		Giant cyst may indicate genitourinary anomalies investigation (see “ <a href="#">SV Agnesis, Hypoplasia, and Cysts</a> ”)		Abnormalities may indicate inflammation or stasis

From Lotti and Maggi (2015), with permission

The statements made are associated to numbers in brackets referring to the different sections of the manuscript  
*MGT* male genital tract, *US* ultrasound, *CDUS* color-Doppler ultrasound, *TRUS* transrectal ultrasound, *TV* testis volume, *TESE* testicular sperm extraction (including microTESE), *OA* obstructive azoospermia, *ED* ejaculatory duct, *SV* seminal vesicles, *CFTR* cystic fibrosis transmembrane conductance regulator

**Table 2** Color-Doppler ultrasound (CDUS) abnormalities of the organs of the male genital tract, clinical associations, and available cutoff discriminating normal and pathologic features

CDUS echo-pattern abnormalities	Associations	Cutoff
Testis		
Inhomogeneity	Carcinoma in situ in cryptorchid men (Lenz et al. 1987)	Abnormal pattern: grade 2–5
Lenz et al. (1993)	Testis tumor (Lenz 1991; Woodward et al. 2002; Isidori and Lenzi 2008)	
1. Very uniform pattern		
2. Slightly irregular pattern	Several pathological conditions, including hypogonadism, ischemia, orchitis, trauma, torsion, exposure to physical or chemical agents, chemo- and radiotherapy, or alcohol abuse (Loberant et al. 2010; Migaletto et al. 2012; Lotti et al. 2013b)	
3. Moderately irregular pattern or small echogenic points throughout any sectional view		
4. Very irregular pattern or bright echogenic spots (at least throughout the testis)		
5. Tumor suspected due to demarcated area	Klinefelter's syndrome: inhomogeneous testicles with spread hyper- and hypoechoic foci (Ekerhovd and Westlander 2002)	
	M540 bodies, round anucleated elements, detected by fluorocytometry in the semen, markers of apoptosis-related spermatogenesis derangement (Lotti et al. 2012d)	
Westlander et al. (2001)	Metabolic syndrome, a cluster of medical conditions which increases the risk of type 2 diabetes mellitus and cardiovascular diseases, recently recognized as a new risk factor also for fertility (Kasturi et al. 2008; Lotti et al. 2013b)	Abnormal pattern: grade 3–5
1. Homogeneous		
2. Homogeneous with some hyperechogenic foci		
3. Heterogeneous with spread hyperechogenicity		
4. Heterogeneous with both hyperechogenic and cystic (hypoechogenic) parenchyma		
5. Postoperative intratesticular lesion		
Calcifications microcalcification	TM and testicular cancer (debated) (Appelbaum et al. 2013; Richenberg and Brejt 2012)	Microcalcifications: 1–3 mm

(continued)

**Table 2** (continued)

CDUS echo-pattern abnormalities	Associations	Cutoff
Testicular microlithiasis (TM)		TM and male infertility (Yee et al. 2011)
		TM, $\geq 5$ /US scan (Richenberg and Brejt 2012)
Epididymis		
Hypoechoogenicity	Acute/subacute inflammation (Woodward et al. 2003), PI <sup>dimmer</sup> sperm DNA fragmentation (Lotti et al. 2016b), MAGI, sIL8 (Lotti et al. 2011a; Lotti and Maggi 2013)	Not reported
Hyperemia		
Hyperechogenicity		
Coarse calcifications		
Prostate		
Glandular asymmetry	MAGI (Christiansen and Purvis 1991; Vicari 1999)	Not reported; proposed 5 mm
	Fibro-sclerotic MAGI (La Vignera et al. 2011e)	
Nonhomogeneity	MAGI, CP/CPPS (Di Trapani et al. 1988; Christiansen and Purvis 1991; Behre et al. 1995; Vicari 1999)	Abnormal pattern: Grade 1–3: 1, mild; 2, moderate; 3, severe inhomogeneity (Lotti et al. 2011b, 2013d)
	Elevated sIL8 (Lotti et al. 2011a; Lotti and Maggi 2013)	
	Overweight/obesity (Lotti et al. 2011b) and MetS (Lotti et al. 2013c)	
	PLS (Lotti et al. 2013d)	
Hypoechoogenicity	Edema, acute/subacute inflammation (Doble and Carter 1989; Purvis and Christiansen 1993), hypertrophic-congestive MAGI (Vicari 1999; La Vignera et al. 2011e)	Not reported
	Elevated sIL8 (Lotti et al. 2011a; Lotti and Maggi 2013)	
	PLS (Lotti et al. 2013d)	

*(continued)*

**Table 2** (continued)

CDUS echo-pattern abnormalities	Associations	Cutoff
Hyperechogenicity	MAGI, CP/CPPS (Doble and Carter 1989; Vicari 1999)	Not reported
	Fibro-sclerotic MAGI (La Vignera et al. 2011e)	
Calcifications	MAGI,CP/CPPS (Doble and Carter 1989; Purvis and Christiansen 1993; Vicari 1999)	Macro-calcifications: > 3 mm ( )
	Elevated sIL8 (Lotti et al. 2011a; Lotti and Maggi 2013)	
	Overweight/obesity (Lotti et al. 2012b) and MetS (Lotti et al. 2013c)	
	PLS (Lotti et al. 2013d); PI <sup>brighter</sup> sperm DNA fragmentation (Lotti et al. 2016b)	
	Maintenance of CP, bacterial colonization (Meares 1974; Shoskes et al. 2007)	
	Corpora amylacea (Sfanos et al. 2009)	
Hyperemia	Tissue inflammation and clinical activity (Cho et al. 2000)	≥15 Doppler spots (Cho et al. 2000)
	PI <sup>brighter</sup> sperm DNA fragmentation (Lotti et al. 2016b)	
Arterial prostatic peak systolic velocity	Tissue inflammation and clinical activity (Lotti et al. 2011a, 2012c, 2013d; Lotti and Maggi 2013) and PLS (Lotti et al. 2013d)	Moderate-severe PLS in young men: 11 cm/s (Lotti et al. 2013)
	PI <sup>brighter</sup> sperm DNA fragmentation (Lotti et al. 2016b)	BPH: >15 cm/s (Berger et al. 2006)
Resistive index	BPH and LUTS (Berger et al. 2006; Shinbo et al. 2010)	Not reported. >0.72 (?)
Dilation of the prostatic venous plexus	MAGI and CP/CPPS (Di Trapani et al. 1988; Vicari 1999; Lotti et al. 2009)	Not well defined/not replicable
	Varicocele (Lotti et al. 2009)	>150 mm <sup>2</sup> (Di Trapani et al. 1988)
		Diameter >3 mm (Kamoi 1996)
	>4 mm (La Vignera et al. 2011e)	

(continued)



**Table 2** (continued)

CDUS echo-pattern abnormalities	Associations	Cutoff
Ejaculatory ducts (ED)		
Dilation	ED partial or complete obstruction (Engin et al. 2000; Fisch et al. 2002; Lotti et al. 2012a)	>2 mm (see Fisch et al. 2002)
Cysts	ED partial or complete obstruction (Engin et al. 2000; Fisch et al. 2002; Lotti et al. 2012a)	Not reported
Calcifications	ED partial or complete obstruction (Engin et al. 2000; Fisch et al. 2002; Lotti et al. 2012a)	Not reported
	Hemospermia (Littrup et al. 1988) and PLS (Lotti et al. 2013d)	
Seminal vesicles		
Enlargement	MAGI (Vicari 1999; La Vignera et al. 2008)	Not well defined. Proposed: APD >14–15 mm (Jarow 1993; Vicari 1999); Total volume after ejaculation >7 ml (extrapolated from Lotti et al. 2012a)
	Partial ejaculatory duct obstruction (Lotti et al. 2012a)	
Reduction	Congenitally small SV (Kim et al. 2009)	Not well defined. Proposed: APD <7 mm (Vicari 1999) LD <25 mm (Donkol 2010)
	MAGI/fibrosis (Vicari 1999)	
	T deficiency (Sasagawa et al. 1989, 1990)	
Asymmetry	MAGI (Vicari 1999; La Vignera et al. 2008)	Not reported
Wall thickening and septa	MAGI (Kim and Lipshultz 1996; Vicari 1999; Kim et al. 2009)	Not reported
	Diabetes mellitus (La Vignera et al. 2009, 2011b, c, d)	Persisting after ejaculation (Lotti et al. 2012a)
	Emptying impairment (Lotti et al. 2012a)	
Abnormal fundus/body ratio	MAGI: low or high	Low <1
	Diabetes mellitus: high (La Vignera et al. 2011b)	High >2.5 (La Vignera et al. 2011b)
Calcifications	MAGI (Vicari 1999; Lotti et al. 2011a)	Not reported
	Hemospermia and ejaculatory pain (Littrup et al. 1988; Zhao et al. 2012)	

(continued)

**Table 2** (continued)

CDUS echo-pattern abnormalities	Associations	Cutoff
Areas of endocapsulation	MAGI (Colpi et al. 1997; Vicari 1999; La Vignera et al. 2008; Lotti et al. 2011a)	Not reported
	PLS (Lotti et al. 2013d)	Prevalence reduction after ejaculation (Lotti et al. 2012a)
Inhomogeneity	Higher PRL (in the normal range) (Lotti et al. 2013a)	Not reported

From Lotti and Maggi (2015), with permission

Regarding male reproductive health, testis inhomogeneity is related to impaired sperm parameters (Lenz et al. 1993; Loberant et al. 2010). Epididymis, prostate, and SV echo-texture abnormalities have been suggested to be related to inflammation, which possible negative impact on semen quality/quantity is debated (La Vignera et al. 2011a; Rusz et al. 2012). Ejaculatory duct abnormalities may be associated with distal obstruction and painful ejaculation (Singh et al. 2012)

*TM* testicular microlithiasis, *MAGI* male accessory gland infection, *sIL-8* seminal interleukin 8, a surrogate marker of prostate and overall MGT inflammation (Penna et al. 2007; Lotti and Maggi 2013); *CP/CPPS* chronic prostatitis/chronic pelvic pain syndrome, *PLS* prostatitis-like symptoms, defined as “perineal and/or ejaculatory pain or discomfort and a National Institutes of Health-Chronic Prostatitis Symptom Index pain subdomain score  $\geq 4$ ” (Nickel et al. 2001); *MetS* metabolic syndrome, *BPH* benign prostatic hyperplasia, *LUTS* lower urinary tract symptoms, *PRL* prolactin

Li-Ming 1997; Ron-El et al. 1998) and, rarely, percutaneous fine needle sperm aspiration (Friedler et al. 1997) may lead to devascularization of one or more lobules. Testicular open or percutaneous biopsy may also lead to intratesticular or extratunical hematoma formation (Schlegel and Li-Ming 1997; Friedler et al. 1997) and to inflammatory changes affecting spermatogenesis (Schlegel and Li-Ming 1997). Interestingly, specific vascular parameters such as arterial resistivity or pulsatility index, measured both in the testicular artery or in intratesticular vessels, represent a new frontier of research in fertility evaluation, however not yet used in the clinical practice (see section “[Testis CDUS and Surgical Sperm Retrieval in Azoospermic Subjects](#)”).

### Testicular Findings and Lesions

Several abnormal CDUS testicular findings may be associated with male reproductive or general health problems (see Tables 1 and 2).

### Calcifications

Calcifications are calcium deposits within the seminiferous tubules (Richenberg and Brejt 2012). Solitary parenchymal calcifications may be due to a prior trauma, orchitis, infarction, torsion, or chemo-/radiotherapy or may be associated with testicular atrophy, maldescended testis, or, rarely, a burnt-out tumor (Mihmanli and Kantarci 2009; Raza and Jhaveri 2012; Appelbaum et al. 2013).

- *Microcalcifications* are nonshadowing bright echogenic foci measuring 1–3 mm randomly scattered throughout the testicular parenchyma.
- *Testicular microlithiasis (TM)* (Fig. 1) is defined as more than five echogenic foci in a single US image (Richenberg and Brejt 2012; Raza and Jhaveri 2012; Appelbaum et al. 2013). They can be limited, “clusters,” or diffuse (“starry sky” appearance; Fig. 4c) (Mihmanli and Kantarci 2009; Elzinga-Tinke et al. 2010). TM prevalence ranges from 0.6% to 9% (see Richenberg and Brejt 2012). However, some authors (Elzinga-Tinke et al. 2010) reported a prevalence of 43% considering less than five microcalcifications for US scan as TM. Interestingly, these authors (Elzinga-Tinke et al. 2010) reported detection of *carcinoma in situ* in ~25% of TM patients, particularly when “clusters” of TM or testicular inhomogeneity were present. Although most of previous studies reported an association between TM and testicular cancer, recent literature is debating this relationship (see Appelbaum et al. 2013 and Table 1), and a meta-analysis suggests no causal link between TM and testicular neoplasms (Richenberg and Brejt 2012). According to the European Association of Urology (EAU) guidelines (Albers et al. 2013), US follow-up of TM is recommended in subjects with *additional risk factors* for testicular malignancy (see section “**Testicular Lesions**”). Solely, the presence of TM is not considered an indication for regular scrotal US follow-up or biopsy (Albers et al. 2013). Conversely, testicular biopsy should be offered to men with TM and high-risk conditions (infertility and bilateral TM, atrophic testes, undescended testes, a history of testicular tumors, or contralateral TM) (Jungwirth et al. 2016).

The relationship between TM and infertility is under debate (Aizenstein et al. 1998; Miller and Sidhu 2002; Yee et al. 2011). In infertile men, asymptomatic TM is not considered as a risk factor for the production of antisperm antibodies (Clyne 2012; Jiang and Zhu 2013). Recent evidence supports TM as an additional feature of the “testicular dysgenesis syndrome” (see section “**Cryptorchidism**” and Fig. 1) suggesting a genetic background (Tan and Eng 2011). So far, the impact of TM in the management of male infertility is low (Table 1).

### **Orchitis**

The inflammation of the testis is defined orchitis. Primary orchitis is mainly viral (mumps orchitis), occurring in 20%–30% of infected postpubertal men (Grabe et al. 2013). In almost half of the cases, its onset follows an epididymitis (Horstman et al. 1991b; Pilatz et al. 2013b), and in this case, its etiology is mainly bacterial. Orchitis is usually characterized by diffuse testis swelling and pain (Grabe et al. 2013). At CDUS, orchitis presents with testis hypervascularization (see Table 1), diffuse enlargement, inhomogeneous, mainly hypoechoic, testicular echo-texture, and reactive hydrocele (see in Dogra et al. 2003; Isidori and Lenzi 2008; Ammar et al. 2012; Pilatz et al. 2013b). Post-orchitis testis may present with inhomogeneous echo-texture, mainly hypo- or hyperechoic, with normal or reduced vascularization and micro- or macro-calcifications (Isidori and Lenzi 2008; Ammar et al. 2012). Although chronic inflammation may result in testicular atrophy (see Grabe et al. 2013), no

atrophy occurs if an acute epididymo-orchitis is adequately treated (Pilatz et al. 2013b). However, orchitis often hesitates in sperm abnormalities (Isidori and Lenzi 2008; Ammar et al. 2012).

### Testicular Lesions

Testicular lesions (Fig. 1) can be detected by US incidentally, especially during infertility assessment or when a patient is seeking medical care for scrotum discomfort, lump or painless swelling of the testis, or dull or heavy pain, the latter reported by 10%–20% of males with testis malignancy (Isidori and Lenzi 2008). Differential diagnosis is difficult, particularly when, at US, severe inhomogeneity is detected. Testicular lesions may be small (millimetric) or large. Small hypoechoic areas, especially when not vascularized, may be related to spermatoceles, cysts, focal Leydig cell hyperplasia, fibrosis, and focal inhomogeneity due to previous pathologic conditions (Isidori and Lenzi 2008). However, they may also indicate small tumors (Isidori and Lenzi 2008). Hence, they require careful evaluation and follow-up, with periodic US examination (see Table 1), especially if *additional risk factors for malignancy* are present (i.e., infertility, bilateral TM, cryptorchidism, testicular atrophy, inhomogeneous parenchyma, history of testicular tumor, contralateral tumor, and age < 50 years (van Casteren et al. 2009; Elzinga-Tinke et al. 2010; Albers et al. 2013; Jungwirth et al. 2016). If a small nodule grows (Dohle et al. 2012), or additional risk factors for malignancy are present, testicular biopsy/surgery should be considered (Jungwirth et al. 2016). Large nodules may be either benign or malignant. CDUS is not accurate enough to define the origin of the lesion, and histology remains the only certain diagnostic tool (Woodward et al. 2002). However, CDUS may detect some specific characteristic suggestive or not of malignancy. Clinical and CDUS patterns of testicular lesions have been described in detail elsewhere (Woodward et al. 2002; Isidori and Lenzi 2008). Table 3 summarizes the CDUS characteristics of the main malignant and benign testicular lesions. In addition, new imaging techniques, such as contrast-enhanced ultrasound, elastography, and MRI, have improved the characterization of testicular lesions (Huang and Sidhu 2012) (see section “[New Imaging Techniques for the Evaluation of Testis and Prostate Abnormalities](#)”).

According to the EAU guidelines (Albers et al. 2013), scrotal US is useful to confirm the presence of a testicular mass and to explore the contralateral testis. US discloses a testicular mass with a sensitivity of ~100% (Kim et al. 2007). US detects whether a mass is intra- or extratesticular (Kim et al. 2007), its features, and differentiates among different clinical conditions (i.e., malignancy, inflammation, cysts) (Montgomery and Bloom 2011; Woodward et al. 2002). US should be performed even when a testicular malignancy is clinically evident (Shaw 2008; Albers et al. 2013). According to the EAU guidelines (Albers et al. 2013), every subject with a suspected testicular mass must undergo surgical exploration, with orchiectomy if a malignant tumor is found, or testicular biopsy with histological examination if the diagnosis is not clear. In our opinion, US is useful in detection and follow-up of small lesions or of additional risk factors for malignancy, playing an adjuvant role in the management of large/hard lesions (Table 1).

**Table 3** Main malignant and benign lesions of the testis, color-Doppler ultrasound (CDUS) characteristics, age distribution, biologic behavior, and associated abnormalities or syndromes

Main testis lesions	Age peak incidence and biologic behavior	CDUS characteristics	Associated abnormalities or syndromes
<b>Malignant</b>			
<b>Germ cell tumors (~95%)</b>			
Seminoma (35–55%)	Typical (85%): 20–40/50 years	Homogeneous, hypochoic, solid nodules of varies size; round, oval, or with polycyclic lobulated margins	Cryptorchidism
	Anaplastic (5%–10%): 20–40 years	Often high-flow, low-resistance vascular arborization	Microlithiasis
	Spermatocytic (5%–10%): 50–70 years	Rarely bilateral or in mixed germ cell tumor	
	Good prognosis		
Non-seminoma	20–30 years, aggressive	Inhomogeneous, hypochoic, solid nodules with cystic areas or calcifications within the lesion	
Embryonal cell carcinoma (20%–25%)	<4 years, benign; 20–30 years, malignant		
Teratoma (5%–10%)	10–30 years, highly malignant		
Choriocarcinoma (0.5%)	<2 years and 20–30 years, malignant		
Yolk sac tumor (<1%)	Mixed: 20–30 years, malignant		
Mixed (20%–40%)			
<b>Stromal (~5%)</b>			
Leydig cell tumor (3%)	Children and 20–50 years (90% benign, 10% malignant)	Often small, unilateral and solitary with circumferential blood flow	May secrete estrogens (30%): gynecomastia Pseudo-pubertas precox, azoospermia, erectile dysfunction, loss of libido

*(continued)*

**Table 3** (continued)

Main testis lesions	Age peak incidence and biologic behavior	CDUS characteristics	Associated abnormalities or syndromes
Sertoli cell tumor (~1%)	Children and 20–30 years (“borderline”; <20% malignant)	Hypo- or hyperechoic nodules with possible calcifications	Rarely secrete estrogens: Gynecomastia
		With dysplastic syndromes: bilateral and multifocal	Klinefelter syndrome
		Without dysplastic syndrome: unilateral and focal	Peutz-Jeghers syndrome
		Large-cell calcifying Sertoli cell tumor: diffusely heterogeneous pattern, hyperechoic, large calcifications	Testicular feminization Carney complex
Others			
Lymphoma	2% or 25% of testicular tumors in subjects with <50 or 50–70 years, respectively	Homogeneous hypoechoic diffuse testis infiltration or multifocal hypoechoic lesions of various size	
	Malignant	Parallel hypoechoic lines radiating peripherally from the mediastinum (blood vessels), high vascularization	
		8%–18% bilateral, synchronous or asynchronous	
Leukemia	Children	Unilateral or bilateral, diffuse or focal, hypo- or hyperechoic lesions with longitudinal hypoechoic striae and increased blood flow	
	Malignant, often recurs		
Metastases	50–70 years	No specific US finding	Common primary sites:
	Aggressive		Prostate
			Lung
			Bowel
			Melanoma
Kidney			
Benign	Age presentation		
Intratesticular cysts	Variable	Usually solitary, can be multiple; often near the	

(continued)

**Table 3** (continued)

Main testis lesions	Age peak incidence and biologic behavior	CDUS characteristics	Associated abnormalities or syndromes
		mediastinum; well-defined round anechoic lesions; various size	
Tunica albuginea cysts	40–60 years	Small round anechoic peripheral lesions of various size	
Dilation of the rete testis	50–70 years	Multiple micro- or macro-tubular fluid-filled structures, often near the mediastinum; no vascularization at CDUS	
Epidermoid cyst	20–40 years; benign	Variable: 1–3 cm; hyperechoic fibrous or calcified rim; sometimes “onion ring” pattern	
Dermoid cyst	Children	Similar to mature teratoma	
Global and segmental ischemia	Variable	Diffuse or focal, usually segmental, area without blood flow at CDUS in an otherwise normal testicular parenchyma	Results from torsion, epididymal-orchitis or trauma
Hematoma	Variable	Hypoechoic non vascularized lesions	Trauma
Abscess	Variable	Complex heterogeneous fluid collection, hypo/ anechoic, with irregular walls, occasionally with hypervascular margins	Usually complication of epididymitis and/or orchitis
Adrenal rest	Neonates, rarely adults	Rounded hypoechoic small eccentric solid masses, which may be bilateral or multifocal. Typically, the vessels course through the lesion is not deviated	Congenital adrenal hyperplasia
	Regression with corticosteroids		
Sarcoidosis	20–40 years	Hypoechoic, irregular or rounded masses, often unilateral	
Gummas	20–40 years	Hypoechoic nodule	Syphilis

Data are reported according to Woodward et al. (2002), Isidori and Lenzi (2008), and Coley 2007

Testicular tumors account for 4%–6% of all MGT neoplasms and 1%–2% of the male neoplasms and represent the most common malignancy in young men (15–34 years; Woodward et al. 2002). Testicular cancer is often associated with other testicular disorders, such as sperm abnormalities, male infertility, or maldescended testis. Malignancy-related sperm alterations depend on neoplasm volume and histology, general tumor effects, disease stage, previous testicular disorders, and orchiectomy (Trost and Brannigan 2012; Rives et al. 2012). Among seminal samples of oligozoospermic men cryopreserved for cancer, those from subjects with a testicular tumor show the worse basal semen quality and recovery after thawing (Degl’Innocenti et al. 2013; Hotaling et al. 2013) and motility recovery similar to that of noncancer samples (see Degl’Innocenti et al. 2013). Combined information on sperm concentration, age, and contralateral TV may predict the risk of contralateral *carcinoma* in situ in patients with unilateral testicular germ cell tumor (Rud et al. 2013).

### Cryptorchidism

The term *cryptorchidism* is derived from the Greek words *kryptos* and *orchis*, literally meaning “hidden testis.” This affection includes abnormal testis development and/or failure of its descent into the scrotal sac (see Christensen and Dogra 2007). Cryptorchidism is the most common abnormality in newborn males, affecting 1%–6% of full-term neonates and ~0.8% of infants at 1 year of age, with a higher overall incidence for preterm infants (see Christensen and Dogra 2007). It is unilateral in ~90% of patients and bilateral in the remaining ~10%. Cryptorchidism is associated with an increased risk for infertility and testicular cancer (Fig. 1), the latter showing four to sevenfold higher prevalence than in the healthy population. In ~20% of cryptorchid patients, testis malignancy occurs in the contralateral descended testis, resulting more frequent when both testes are maldescended (see Christensen and Dogra 2007). Furthermore, cryptorchidism is associated with urinary tract abnormalities, including renal agenesis or ectopia, ureteral duplication, SV agenesis or cysts, and hypospadias (see Christensen and Dogra 2007). Some authors consider maldescended testis as one manifestation of a primitive generalized defect in genitourinary embryogenesis, also advocating a common origin for cryptorchidism, defective spermatogenesis, and testicular germ cell tumor (“testicular dysgenesis syndrome”; Skakkebaek and Jørgensen 2005). On the other hand, considering that almost 80% of maldescended testes are located within the inguinal canal, and 5%–16% within the abdomen, it has been suggested that a higher temperature of these sites with respect to that of the scrotal sac may lead to a secondary degeneration of the cryptorchid testis. Regarding infertility, germ cell failure seems not to be congenital, but rather acquired, beginning approximately at the age of 4 months and progressively decreasing thereafter, finally reaching gonadal atrophy at the age of 5. Hence, early surgical correction has been advocated to prevent infertility (see Christensen and Dogra 2007). Finally, undescended testes show an increased risk for testicular torsion (Schultz and Walker 1984).

At US, the cryptorchid testis is often characterized by a reduced volume, low echogenicity (Fig. 4a), and inhomogeneity with or without macro- or



microcalcifications (Christensen and Dogra 2007; Ozden et al. 2012). The role of US in the setting of cryptorchidism and preoperative planning before orchiopexy is controversial (Christensen and Dogra 2007; Ozden et al. 2012). A recent systematic review and meta-analysis reports that US does not reliably localize nonpalpable testes or rule out an intra-abdominal testis (Tasian and Copp 2011). Hence, performing US does not change the clinical management of nonpalpable testes. However, US can reliably identify a cryptorchid testis lying below the level of the internal inguinal ring (Nijs et al. 2007). In conclusion, US plays a key role in cancer detection or in the follow-up of the cryptorchid and contralateral testes (see Table 1).

## Varicocele

Varicoceles are abnormally dilated veins of the pampiniform plexus (Figs. 1 and 4d), characterized by retrograde venous flow (Forti and Krausz 1998; Forti et al. 2003; Zini and Boman 2009). According to the aforementioned anatomical considerations (see section “Pampiniform Plexus”), varicocele is detected on the left side in ~90% of cases (Fig. 1) (Sakamoto and Ogawa 2008; Zini and Boman 2009). Varicocele is virtually absent in prepubertal boys, and its prevalence increases with age, up to ~15% in the general adult population (Forti et al. 2003; Canales et al. 2005; Cayan and Woodhouse 2007). In the clinical practice, varicocele is classified into three grades: I, palpated during Valsalva maneuver; II, palpated without Valsalva maneuver; and III, visible (Dubin and Amelar 1970). While clinically assessed grade III varicoceles are easily diagnosed, detection of milder forms depends on the investigator experience. In fact, its detection may be distorted by cremasteric contraction, previous surgery, hydroceles, or maldescended testis (see Liguori et al. 2012). Pathophysiologic mechanisms leading to varicocele development and its clinical associations have been extensively described elsewhere (see Sakamoto and Ogawa 2008; Gat et al. 2008).

Venography of the internal spermatic vein is considered the gold standard for varicocele assessment (see Geatti et al. 1991; Lee et al. 2008; Liguori et al. 2012) since it is characterized by a high technical accuracy and interobserver concordance (see Lee et al. 2008). However, venography is time-consuming, invasive, and exposes to radiations (see Liguori et al. 2012). Hence, even if it is the most accurate technique for varicocele detection and often used for comparison with all the other diagnostic approaches in research studies, venography is currently indicated in clinical practice only in selected cases (see Liguori et al. 2012). So far, the American Urology Association/American Society for Reproductive Medicine (AUA/ASRM; see Practice Committee of American Society for Reproductive Medicine 2008) and the EAU Guidelines on Male Infertility (Jungwirth et al. 2016) suggest to diagnose a varicocele by clinical examination, because “only palpable varicocele have been documented as being associated with infertility” (AUA/ASRM; see Practice Committee of American Society for Reproductive Medicine 2008). However, the diagnosis should be confirmed by CDUS (Jungwirth et al. 2016), especially when physical examination is not conclusive (AUA/ASRM; see Practice Committee of

American Society for Reproductive Medicine 2008). In particular, CDUS shows higher diagnostic accuracy than physical examination (see Lee et al. 2008), becoming precious when the latter is unreliable (Liguori et al. 2012), and it is considered the imaging modality of choice for detection and grading varicocele (Liguori et al. 2012), offering a more complete stratification of lower grades (Isidori and Lenzi 2008). In addition, CDUS may identify the so-called “false” clinical varicocele, referring to dilated vessels without venous reflux (Isidori and Lenzi 2008), and plays a key role in detecting postoperative recurrence/persistence (Lund et al. 2000; Tefekli et al. 2001; Isidori and Lenzi 2008). Compared to venography, physical examination has a 50%–70% sensitivity in varicocele detection, while CDUS 93% (see Lee et al. 2008; Zini and Boman 2009). Hence, CDUS has become the most widely accepted, as well as the most frequently used, modality for varicocele evaluation (see Lee et al. 2008). In conclusion, although physical examination remains the cornerstone of varicocele management, CDUS have a higher diagnostic accuracy (Table 1).

At CDUS, varicocele should be assessed with the patient lying down and standing. A palpable varicocele feels like a “bag of worms” and is easier to be detected in upright position. When a suspected varicocele is not clearly palpable, it should be examined, while the patient performs a Valsalva maneuver in a standing position (AUA/ASRM; see Practice Committee of American Society for Reproductive Medicine 2008). Some authors suggest evaluating the internal spermatic vein between the upper pole of the testis and the inguinal ligament, in order to assess a straight vein instead of the convoluted vessels below (Orda et al. 1987). The size and location of the varices, their number, basal intermittent or continuous reflux at CDUS, and changes during Valsalva maneuver should be considered.

The US gray-scale appearance of varicocele consists of multiple (>3), hypoechoic, serpiginous tubular structures of varying size, >2–3 mm, which could extent from the upper pole of the testis to the bottom of the scrotal sac (Dogra et al. 2003; Lee et al. 2008; Isidori and Lenzi 2008; Raheem 2013). Available CDUS classifications of varicocele severity are reported in Table 4, which attempts to harmonize the different classifications. In most of them, severe CDUS varicocele is defined by a continuous venous reflux at rest, increasing or not during Valsalva maneuver (Fig. 4d).

Most of the studies report a TV reduction in men with varicocele, with normal or slightly increased gonadotropin levels (Zini and Boman 2009; Raheem 2013). Conversely, the effect of varicocele on testosterone levels is under debate (Tanrikut et al. 2011). A recent meta-analysis showed an increase in testosterone levels after varicocele surgical correction (Li et al. 2012). Most studies, but not all, report worse sperm parameters in subjects with varicocele. However, these studies have been conducted in infertile subjects, while data in fertile men are contrasting. In addition, 75% of subjects with varicocele have normal semen parameters (see Zini and Boman 2009). The majority of the studies reported no difference in paternity comparing men with or without varicocele (see Zini and Boman 2009). The possibility of reverting infertility through varicocele treatment is under debate. According to the AUA/ASRM (see Practice Committee of American Society for Reproductive Medicine 2008), when

**Table 4** Proposed classification of varicocele according to clinical and increasing sonographic severity, by different authors

First author of classification	Varicocele clinical grade	[2] Palpable	[3] Visible
Dubin and Amelar 1970	[1] Detectable only during Valsalva		[3] Visible
	Varicocele CDUS grade		
Hirsh et al. 1980	[1] No spontaneous reflux, inducible with Valsalva	[2] Intermittent spontaneous reflux	[3] Continuous spontaneous reflux
Dhabuwala et al. 1989	[1] Reflux <2 s	[2] Reflux >2 s	[3] Spontaneous reflux increasing with Valsalva
Sarteschi et al. 1993	[1] Inguinal reflux only during Valsalva in not enlarged vessels	[2] Supra-testicular reflux only during Valsalva in small posterior varicosities	[4] Enlarged vessels in supine and standing position, with caliber not increasing with Valsalva [5] Enlarged vessels in supine and standing position, with caliber not increasing with Valsalva
Liguori et al. 2004		[3] Peri-testicular reflux only during Valsalva in enlarged vessels Visible but not dilated vessels when supine, enlarged when standing	Reflux at rest, not increasing during Valsalva Common testicular hypotrophy Reflux at rest, not increasing during Valsalva Intratesticular varices and / or testicular hypotrophy
Hoekstra and Witt 1995	[1] Dilated veins <2.5 mm without flow reversal after Valsalva	[2] Dilated veins 2.5–3.5 mm and flow reversal after Valsalva	Dilated veins >3.5 mm and flow reversal after Valsalva
Cornud et al. 1999	[1] <i>Brief</i> reflux: <1 s [2] <i>Intermediate</i> reflux <2 s, decreasing during and stopping prior to the end of Valsalva		[3] <i>Permanent</i> reflux: >2 s and with a plateau aspect throughout the abdominal strain

Oyen 2002				Diameter of the veins >3 mm increasing during Valsalva and/or in the upright position
<i>B-mode</i>				[3] Reflux at rest or during the entire Valsalva
<i>Reflux-Doppler</i>				
Isidori and Lenzi 2008	[1] Slight reflux (<2 s) during Valsalva	[2] Reflux (>2 s) during Valsalva, not continuous	[3] Supra- and peritesticular vessel dilation (>3 mm)	[5] Peritesticular vessel dilation not increasing with Valsalva, or intratesticular vessels and testicular hypotrophy
<i>B-mode</i>	[1] Dilated vessels (>2.5 mm) in inguinal region	[2] Supra-testicular vessel dilation (>3 mm)		
<i>Reflux-Doppler</i>	[1] Inguinal reflux only during Valsalva (2-3 s)	[2] Supra-testicular reflux only during Valsalva (>3 s)		[5] Peritesticular reflux at rest which increases minimally with Valsalva or dilated intratesticular veins which refill with Valsalva
Pauroso et al. 2011	[1] Reflux in the inguinal channel only during Valsalva	[2] Small varicosities with reflux only during Valsalva		[4] Enlarged vessels with venous reflux at rest not increasing during Valsalva
Iosa and Lazzarini 2013	[1] Reflux > 1 s only during Valsalva	Spontaneous, discontinuous reflux not increased [2] or increased [3] by Valsalva		[4A] Spontaneous, continuous reflux not increased by Valsalva

From Lotti and Maggi (2015), with permission

The grade severity of each classification is reported in brackets. Since the different classifications did not use the same parameter to categorize severity, a strict comparison is not applicable. Extension, size, and number of dilated veins, affected side, duration of retrograde flow during Valsalva, the presence of spontaneous retrograde flow in the upright position, volume, and echo-texture of the affected testis, and comparison with the contralateral should be reported when varicocele evaluation is performed

varicocele is detected in men with couple infertility, surgery should be considered when all of the following conditions are met: (1) varicocele is clinically palpable; (2) the couple has known infertility; (3) the female partner has normal fertility or a potentially treatable cause of infertility; and (4) the male partner shows abnormality in semen parameters or sperm function tests. Varicocele treatment for infertility is not indicated in patients with either normal semen quality or a subclinical varicocele. A recent meta-analysis reported that varicocele surgery improves sperm parameters (count, total, and progressive motility), reduces sperm DNA damage and seminal oxidative stress, and improves sperm ultramorphology (Baazeem et al. 2011). Although there is no conclusive evidence that a varicocelectomy improves spontaneous pregnancy rates, a recent Cochrane review concluded that surgical or radiological treatment in subfertile men, with a clinically manifest varicocele and poor semen quality, may be of benefit, reporting one additional pregnancy for every seven men treated (Kroese et al. 2013). In addition, some men with scrotal pain, low testosterone, non-obstructive azoospermia, or at risk for testicular dysfunction may benefit from varicocele repair (Schlegel and Goldstein 2011). However, varicocelectomy may be associated with complications, such as hydrocele, inadvertent arterial ligation, testicular atrophy, vas deference occlusion, and epididymitis (Isidori and Lenzi 2008; Iaccarino and Venetucci 2012); hence its potential benefits must be carefully considered. These considerations are even more critical when *subclinical* varicocele is considered. *Subclinical* varicocele is a radiological entity defined as venous reflux detectable by CDUS but not at physical examination. A recent Cochrane review considers its treatment disputable, the number needed to treat to benefit being 17 (Kroese et al. 2012). However, treatment of subclinical varicocele with grade III reflux according to Cornud (1999), defined as permanent reflux, regardless of the size of the veins, resulted in changes similar to those seen after repair of palpable varicocele (Cornud et al. 1999; Lee et al. 2008). In addition, grade III reflux according to Cornud (1999) was found to be palpable in 60% of cases (Cornud et al. 1999; Lee et al. 2008). Hence, detection of “permanent reflux” by CDUS (see Table 4) could be an indication for varicocele treatment when physical examination is inconclusive, although, at present, this is not evidence based.

Finally, varicocele has also been suggested as a potential cause of intrapelvic venous congestion, prostate inflammation, and, eventually, prostatitis-related premature ejaculation (Lotti et al. 2009). Accordingly, a previous study reported that varicocele surgery leads to improvement of premature ejaculation (Ahmed et al. 2014).

## Epididymis and Vas Deferens

### CDUS Abnormalities

At physical examination, tense-elastic spherical findings detected within the epididymis, mainly in the head, may represent cysts or spermatoceles. Epididymal *cysts* and *spermatoceles* are present in ~25% of men and appear at US as

anechoic avascular and slightly hypoechoic findings, respectively (Leung et al. 1984). Their clinical significance and association with male infertility has not been yet defined, since no study demonstrated their relationship with complete epididymal obstruction and obstructive azoospermia (see Singh et al. 2012). Hence, their detection by US has no impact on infertility decision-making (Table 1). Conversely, epididymal injury secondary to excision surgery, mainly performed for large and painful lesions, may lead to epididymal obstruction (see Singh et al. 2012). Hence, epididymal cyst removal is not suggested for fertility improvement (Table 1).

Epididymal US echo-texture abnormalities have been associated with acute or chronic inflammation (see Table 2; Woodward et al. 2003; Isidori and Lenzi 2008; Lotti et al. 2011a; Lotti and Maggi 2013). Acute epididymitis is characterized by a painful hemiscrotum, epididymal swelling, and fever (Grabe et al. 2013; Pilatz et al. 2013b). CDUS plays a key role in its detection, revealing epididymal hyperemia and dilation (see Table 1), mainly of the tail or both the tail and head (Pilatz et al. 2013b), along with inhomogeneous echo-texture, often hypoechoic with scattered hyperechoic foci, and reactive hydrocele with skin thickening (Horstman et al. 1991b; Woodward et al. 2003; Isidori and Lenzi 2008; Pilatz et al. 2013b). Concomitant orchitis, revealed in ~50% of men, is associated with hydrocele, testicular increase, hyperemia, and pain (Pilatz et al. 2013b). Under conservative treatment, epididymal CDUS parameters normalize (Pilatz et al. 2013b). Hence, along with clinical characteristics, CDUS may play a role in the follow-up of acute epididymitis (Table 1). Chronic epididymitis frequently affects the tail, with coarse calcifications in a dilated hypo- or hyperechoic epididymis (Fig. 4e, f). This process is characterized by US inhomogeneity, irregular profile, and hard irregularly shaped masses (Fig. 4e) or indenting the testicular parenchyma, mimicking a primary testicular mass (Woodward et al. 2003). Hydrocele and tunica albuginea thickening are commonly associated, the latter sometimes so severe as to be called “fibrous pseudotumor” (Isidori and Lenzi 2008). Epididymitis impact on male reproductive function seems to be more relevant than inflammation/infection of the prostate and/or SV (Haidl et al. 2008; see sections “CDUS Abnormalities” and “Echo-Pattern Abnormalities”). Acute epididymitis may lead to transient semen impairment, although often persistent detrimental effects are observed (see Rusz et al. 2012). Chronic epididymitis may result in reduced sperm count and motility (Haidl et al. 2008).

Regarding VD, chronic inflammation and diabetes may be associated with luminal or parietal calcifications, respectively (Kim et al. 2009) (Fig. 4f). A dilated, inhomogeneous proximal VD may be seen in patients with chronic inflammation (Fig. 4e), distal VD, or ED obstruction – often showing deferential ampulla and SV dilation/echo-texture abnormalities (Fig. 4f) – or vasectomy (see also sections “Obstruction-Related Findings” and “Ejaculatory Ducts Obstruction/Abnormalities”). Hence, according to medical history, epididymal and VD dilation is indicative of a distal obstruction (Fig. 1), suggesting the extension of the US examination to the prostate-vesicular region by transrectal ultrasound (TRUS) (Table 1).

## Obstruction-Related Findings

Primary obstruction may only be suggested, but not proven, by US (Table 1). Epididymal tail >6 mm (Vicari 1999) and head >11 (Pezzella et al. 2013) or >12 mm (Vicari 1999) have been proposed as suggestive of obstruction (Fig. 4e, g). Obstruction of the epididymal tail or of proximal VD has been demonstrated in blocked seminal tracts in subjects treated by epididymovasostomy (Matsuda et al. 1994). After vasectomy, an epididymal head >15 mm in vasectomized patients (Reddy et al. 2004) and an increment of 2 cm in epididymal head, with a higher frequency of cysts and inhomogeneity, have been reported (Jarvis and Dubbins 1989; Cho et al. 2011) (Fig. 4g). Abrupt tapering, tubular ectasia, enlargement (Fig. 1), with or without calcifications, or mass-like lesions, together with a normal VD caliber, suggest partial or complete epididymal obstruction (Moon et al. 2006). Similar findings have been described for secondary changes of the proximal VD (Donkol 2010). It has not yet been clearly demonstrated that MAGI results in complete epididymal or VD obstruction, with the exception of genital tuberculosis (Dohle 2003), which may present, at US, with enlarged hypochoic epididymis with an irregular profile, calcifications, and firm granulomatous masses (Isidori and Lenzi 2008).

## Agenesis

*Congenital uni- or bilateral agenesis of vas deferens (CUAVD and CBAVD, respectively)* (Fig. 4g) may be *partial or complete*, depending on the level of the Wolffian duct abnormality. Since VD, seminal vesicles (SV), ejaculatory ducts, and epididymis have a similar embryological origin from the Wolffian duct, VD agenesis may be associated with agenesis or abnormalities of these structures. Hence, if VD agenesis is detected at scrotal US, TRUS should be performed to extend the examination to the prostate-vesicular (Table 1). Interestingly, when VD and epididymis agenesis occurs, epididymal head is always present and detectable by US (Sadler 2011; Singh et al. 2012).

CBAVD accounts for 1%–2% of infertile men, 4%–17% of azoospermic men, and up to 25% of those with obstructive azoospermia (Singh et al. 2012). CBAVD may be isolated or associated with cystic fibrosis. Almost all men with cystic fibrosis also have CBAVD. Cystic fibrosis is common in Caucasian populations, but rare in others (see Yu et al. 2012). A recent meta-analysis reported that 78% of CBAVD subjects have at least one CFTR mutation (Yu et al. 2012), which may exhibit ethnic differences. CBAVD is associated with bilateral SV agenesis in ~50% of the patients and usually presents with normal kidneys (Schlegel et al. 1996). Almost ~20% of cases of CBAVD, ~20% of cases of unilateral SV agenesis, and ~70% of cases of unilateral SV giant cyst may present with kidney agenesis and are usually not related to CFTR gene mutations (Singh et al. 2012). Subjects with CBAVD usually show normal testes volume and function (Silber et al. 1990). Hence, CBAVD investigation by US is essential in the diagnosis of obstructive azoospermia and in its clinical decision-making, since surgical sperm retrieval is virtually always positive (see Table 1).

CUAVD is present in ~1% of men. CUAVD is associated with ipsilateral and contralateral SV agenesis in 90% and 20% of patients, respectively, and with renal

agenesis in 79% of cases (Singh et al. 2012). Subjects with CUAVD are usually fertile, but at high risk for infertility, having a single patent VD. Furthermore, those with CUAVD and contralateral SV agenesis may have contralateral deferential ampulla atresia. Hence, a subset of men with CUAVD may have abnormal semen parameters or azoospermia (Singh et al. 2012). Similar problems may be present in subjects with CUAVD and contralateral testis damage.

## Prostate

### Volume

Detection of prostate volume (PV) by TRUS is important in subjects with LUTS, while it has a low impact in the work-up of male infertility (Table 1). A reduced PV suggests hypogonadism, because prostate is an androgen-dependent gland (Behre et al. 1995; Jin et al. 2001). An increased PV is related to benign prostatic enlargement (BPE). A PV >30 ml has been suggested as indicative for initial gland enlargement (Older and Watson 1996) and >60 ml for a severe increase (Gacci et al. 2012). BPE has a continuum spectrum of TRUS abnormalities ranging from larger transitional zone to a well-defined adenoma. The typical TRUS characteristics of BPE are echo-texture inhomogeneity, occasional cysts, well- and poorly defined nodules, and calcifications, especially at the “surgical capsule” (Older and Watson 1996). Interestingly, BPE has been recently associated with overweight/obesity (Lotti et al. 2011b) and metabolic syndrome (Lotti et al. 2013c).

### CDUS Abnormalities

The impact of prostatitis on semen parameters is under debate (La Vignera et al. 2011a; Rusz et al. 2012, Lotti et al. 2013d). Accordingly, the relationship between prostate inflammation, CDUS-related abnormalities, and semen quality is controversial. Hence, the assessment of CDUS prostate abnormalities by TRUS has a low impact on male infertility management (Table 1). Conversely, several TRUS features have been considered suggestive of prostate inflammation (Table 2), and increasing evidence suggests a TRUS role in identification of dynamic CDUS findings related to prostatitis-like symptoms, such as hyperemia and higher peak systolic velocity in prostatic arteries (Fig. 4h) (Lotti et al. 2013d and Table 2). However, so far, EAU guidelines consider ultrasound as a technique with limited value in assessing chronic pelvic pain (Engeler et al. 2016).

### Ejaculatory Ducts Obstruction/Abnormalities

– *Ejaculatory ducts obstruction* (EDO) affects 1%–5% of infertile men and may be congenital or acquired (Singh et al. 2012). Congenital causes include ED atresia/stenosis, midline prostatic cysts, or ED congenital cysts (Fig. 1). Acquired causes may be secondary to infection/inflammation, calcifications, or iatrogenic (Fisch et al. 2002). Detection of bilateral EDO by TRUS is useful in defining the diagnosis of obstructive azoospermia and its clinical management, considering surgical treatments if specific abnormalities are found (see below and Table 1).



- Subjects with congenital or noninfectious causes of EDO, or with partial EDO, have better improvements in semen parameters after treatment than those with infectious causes or complete EDO (see Fisch et al. 2002; El-Assmy et al. 2012).
- TRUS findings in suspected EDO include midline prostate cysts and ED dilation, calcifications, or cysts (Fig. 4i, j). Dilated SV (anterior-posterior diameter >15 mm) and enlarged deferential ampulla (diameter >6 mm) have also been previously suggested as EDO-related findings (Fig. 1) (Jarow 1993; Engin et al. 2000; Engin 2012; Jungwirth et al. 2016). We recently proposed a new parameter related to the SV emptying capacity, “SV ejection fraction,” reporting a cutoff suggestive for complete or partial EDO (Lotti et al. 2012a). However, further studies are needed to assess the clinical relevance of this parameter.
  - *Intraprostatic cysts* can be classified as congenital or acquired, or, based on their position within the prostate, as midline, paramedian, and lateral cysts (Nghiem et al. 1990; Singh et al. 2012; Shebel et al. 2013). *Midline cysts* (Fig. 1) affect 1%–5% of men, with a higher frequency in infertile men. They may cause partial or complete EDO, with reduced sperm count or obstructive azoospermia, respectively, often associated with SV obstruction/dilation, reduced ejaculate volume, and pH (see Singh et al. 2012). At TRUS, they appear as roundish or pear-/oval-shaped anechoic formations in transversal and longitudinal scans, respectively (Fig. 4i). According to previous studies (see Nghiem et al. 1990; Singh et al. 2012; Shebel et al. 2013), two main different cystic entities have been recognized. The first, *Müllerian cyst*, is thought to arise from a regression failure of the Müllerian ducts, causing a focal saccular dilation. This cyst is located at midline or slightly lateral to midline, is large and may extend above the base of the prostate, does not communicate with the urethra or contain spermatozoa, and may be associated with various genitourinary abnormalities (see Nghiem et al. 1990; Singh et al. 2012; Shebel et al. 2013). However, it eventually may erode ED and include sperm (McDermott et al. 1995). The second, *utricular cyst*, is thought to derive from dilation of the prostatic utricle, is strictly midline, smaller than the former, and confined to the prostate; it communicates with the urethra and usually contains spermatozoa. Both midline cysts may cause EDO by deviating or compressing ED (see Nghiem et al. 1990; Singh et al. 2012; Shebel et al. 2013). However, even if detection of a midline cyst suggests EDO, conclusions concerning its functional significance cannot be drawn, and size cutoffs for complete EDO have not been reported (Table 1). Midline cyst-related EDO may be diagnosed only after TRUS-guided aspiration (Donkol 2010), which will allow cyst reduction and restore semen emission. This is of clinical relevance, since aspiration of large cysts in subjects with obstructive azoospermia may lead to semen parameter improvement (Table 1). However, after this procedure, midline cysts may enlarge and lead to EDO and azoospermia again, after variable times. In this case, TRUS should be considered to evaluate cyst recurrence (Table 1). Various complications may be associated with prostate cysts, besides infertility, such as urinary tract infection, pain, recurrent epididymitis or prostatitis, and hemospermia (Singh et al. 2012).

- *Ejaculatory duct (paramedian) cysts* (Figs. 1 and 3j) may be congenital, originating from Wolffian ducts, or acquired and may be related or not to cystic fibrosis (Singh et al. 2012). Uni- or bilateral, they may lead to obstructive azoospermia. In this case, cyst detection by TRUS is useful in clinical management (Table 1), their surgical treatment often restoring semen emission (Engin 2012).
- *Ejaculatory duct dilation* (Figs. 1 and 3j) has been defined as an ED diameter  $>2$  mm (Fisch et al. 2002; Engin et al. 2000; Engin 2012) and may be related to inflammatory distal stenosis, which is often difficult to detect (Cornud et al. 1997).
- *Ejaculatory duct calcifications* (Figs. 1 and 3j) may be associated with EDO but are not a reliable indicator of it (Jarow 1993; Fisch et al. 2002; Engin 2012). They have also been associated with hemospermia (Littrup et al. 1988) and prostatitis-like symptoms (Lotti et al. 2013d) (Table 2). Accordingly, EDO may be associated with hemospermia, prostatitis, and painful ejaculation.

In select cases, transurethral resection of ED results in marked improvement in semen parameters, and pregnancies have been achieved (Fisch et al. 2002; Donkol 2010; Engin 2012).

## Prostate Cancer

Prostate cancer is usually suspected on the basis of digito-rectal examination and/or increased PSA levels. At TRUS, prostate cancer is often seen as a hypoechoic lesion in the peripheral zone of the gland; however it can be isoechoic or hyperechoic, and it is not always anatomically well defined (Sarkar and Das 2016). Definitive diagnosis depends on histopathological verification of cancer in prostate biopsy cores or specimens from transurethral resection of the prostate or prostatectomy for benign prostatic enlargement (Mottet et al. 2016). According to EAU guidelines, gray-scale TRUS is not reliable in detecting prostate cancer (Smeenge et al. 2012). Thus, there is no evidence that US-targeted biopsies can replace systematic ones and there is not enough evidence for TRUS routine use in prostate cancer assessment (Mottet et al. 2016).

## Seminal Vesicles

### Volume

SV volume abnormalities include dilation and hypoplasia. *SV dilation* (Fig. 1) has been defined, based on SV diameters, as a SV anterior-posterior diameter  $>14$  (Vicari 1999) or 15 mm (Jarow 1993; Fisch et al. 2002; Engin et al. 2000, Engin 2012; Jungwirth et al. 2016), suggestive of EDO (Jungwirth et al. 2016). Recently, we proposed an algorithm calculating *SV volume* (Lotti et al. 2012a; see section “Seminal Vesicles, Deferential Ampullas, and Ejaculatory Ducts”). So far, a volumetric cutoff for SV dilation is lacking. However, a higher post-ejaculatory SV volume has been associated with a higher prevalence of SV abnormalities

(see sections “[Echo-Pattern Abnormalities](#),” “[Obstruction-Related Findings](#),” and “[SV Agenesis, Hypoplasia, and Cysts](#)”), a higher prostate volume and detection of a prostatic midline cyst, supposed to cause partial or complete EDO, as well as signs suggestive of upstream MGT dilation, such as higher deferential and epididymal tail diameters (Lotti et al. 2012a) (Fig. 1).

*SV hypoplasia* has been defined as a SV anterior-posterior diameter  $<5$  (Raviv et al. 2006) or  $<7$  mm (Vicari 1999) or as SV longitudinal diameter  $<25$  mm (Donkol 2010). So far, a SV volume cutoff is lacking. The term mainly refers to congenitally small SV (Kim et al. 2009), although an acquired form may be associated with testosterone deficiency (Sasagawa et al. 1989, 1990).

### **Echo-Pattern Abnormalities**

Several US features are suggestive of SV abnormalities and have been associated with inflammation or stasis (see Table 2). Their possible negative impact on semen quality/quantity is controversial (La Vignera et al. 2011a; Rusz et al. 2012). In particular, “SV areas of endocapsulation,” which should be assessed after ejaculation (Lotti et al. 2012a and Table 2), is considered a feature suggestive of EDO (Colpi et al. 1997; Jungwirth et al. 2016), however with low impact on clinical decision-making (Table 1).

### **Obstruction-Related Findings**

Enlarged SV anterior-posterior diameter has been related to partial EDO (Littrup et al. 1988; Kim and Lipshultz 1996; Colpi et al. 1997) as well as “SV areas of endocapsulation” (see section “[Echo-Pattern Abnormalities](#)”). Diagrams showing partial EDO percentage probability in function of SV anterior-posterior diameter variation have been reported (Colpi et al. 1997). Reduced “SV ejection fraction” (see section “[Ejaculatory Ducts Obstruction/Abnormalities](#)”) is suggestive of impaired SV emptying and partial EDO and is associated with higher prevalence of SV giant cysts and ED abnormalities (dilation, calcifications, or cysts) (Lotti et al. 2012a) (Fig. 1).

Reduced or absent contraction of SV during ejaculation without a clear obstructive cause has been defined as “functional SV atony” (La Vignera et al. 2011b, c, d). Signs suggestive of SV atony have been reported in subjects with type 2 diabetes mellitus with or without diabetic neuropathy (La Vignera et al. 2009, 2011b, c, d).

### **SV Agenesis, Hypoplasia, and Cysts**

SV congenital abnormalities include defect in number (agenesis, fusion), maturation (hypoplasia), and canalization (cysts) of the glands (Vohra and Morgentaler 1997). Their detection is clinically relevant, because they are often associated with abnormal development of other mesonephric/metanephric derivatives, such as the VD, ureter, and kidney (Patel et al. 2002), which should be evaluated by US (Table 1).

*Unilateral SV agenesis* arises if an insult occurs before the seventh week of gestation, when the ureteric bud arises from the mesonephric duct (Kim et al. 2009). It is often associated with ipsilateral renal agenesis (79%) or other renal abnormalities (12%) (Kim et al. 2009).

*Bilateral SV agenesis* is associated with CFTR mutations in 64%–73% of cases, with CBAVD in half of the cases and with normal kidneys (Kim et al. 2009). SV abnormalities are observed in 50% of children and 90% of adults with cystic fibrosis, the latter showing bilateral agenesis in half of cases, supporting the hypothesis of a progression of the cystic fibrosis-related abnormalities (Carter et al. 1989; Cornud et al. 1997; Rathaus et al. 2006).

*Congenital SV hypoplasia* may be isolated or associated with other congenital genitourinary anomalies (Kim et al. 2009).

*SV cysts* (Figs. 1 and 3j) are rare and may be congenital or acquired. Congenital SV cyst may be isolated or, more frequently, associated with other genitourinary anomalies. They are mainly secondary to EDO caused by development abnormalities of the distal portion of the mesonephric duct (Patel et al. 2002). They are associated with ipsilateral renal agenesis (Zinner syndrome) or dysgenesis in two-thirds of cases (King et al. 1989). Ectopic ureteral insertion into the SV, ED, VD, or prostatic urethra or VD agenesis may also be present (Kim et al. 2009). Bilateral SV cysts have been reported to occur in 44%–60% of patients with autosomal dominant polycystic kidney disease (Danaci et al. 1998). Hence, detection of SV cysts by TRUS is clinically relevant, leading to evaluate carefully the urinary tract by US (Table 1). Acquired cysts are usually unilateral and associated with inflammation-related EDO (Patel et al. 2002). Cystic SV dilatation has been associated with perineal pain (Littrup et al. 1988).

---

## Specific Applications of Scrotal and Transrectal Ultrasound

### Sensitivity and Specificity in Discriminating Obstructive and Non-obstructive Azoospermia

Du et al. (2010) reported that performing scrotal and transrectal US, at the same time assessing TV and genital tract obstruction-related findings, respectively, discriminates obstructive and non-obstructive azoospermia (OA and NOA, respectively) with 95% sensitivity and 97% specificity and may be of help in evaluating OA etiology. More recently, Abdulwahed et al. (2013) reported that scrotal US is more sensitive for OA and specific for NOA detection, while TRUS showed the opposite trend. Both imaging examinations had greater specificity than sensitivity for OA, indicating that US is better able to exclude, more than to diagnose, OA. However, US is still unlikely to replace testicular biopsy (Abdulwahed et al. 2013).

### Testis CDUS and Surgical Sperm Retrieval in Azoospermic Subjects

Sperm retrieval by testicular surgery has been reported in 50%–60% of men with NOA and in almost all with OA (Dohle et al. 2012). Among the different CDUS characteristics investigated as predictors of successful sperm retrieval by testicular biopsy in azoospermic men, testicular parameters such as TV and vascularization

have shown increasing evidence in the last few years, although still controversial and with limited clinical utility (see below).

Azoospermic men with normal FSH levels and positive sperm retrieval have higher TV compared to those with a negative harvesting (Mitchell et al. 2011). TV in OA has been reported as higher than in NOA patients (Moon et al. 2006; Du et al. 2010). Subjects with CBAVD-related OA usually have testes with normal volume and function (Silber et al. 1990; Singh et al. 2012), and sperm retrieval by testicular biopsy is virtually certain. In NOA subjects, most (Ziaee et al. 2006; Ravizzini et al. 2008; Turunc et al. 2010; Boitrelle et al. 2011), but not all (Tournaye et al. 1997; Dohle et al. 2012), studies reported higher TV in subjects with a positive sperm retrieval. TV has been reported as an independent parameter related to testicular biopsy outcome (Boitrelle et al. 2011). A total TV of 16 ml (Boitrelle et al. 2011) or a mean TV of 9.5 ml (Ziaee et al. 2006) have been proposed as a cutoff for a positive sperm retrieval. However, other authors report that TV is not a useful parameter for sperm retrieval prediction (Tournaye et al. 1997; Dohle et al. 2012). In fact, sperms can be retrieved by surgery even in men with very small testis, such as those with Klinefelter's syndrome (Dabaja and Schlegel 2013; Bryson et al. 2014). On the other hand, subjects with spermatogenic arrest, usually showing normal TV and FSH levels, are characterized by a poor surgical outlook (Hung et al. 2007). Hence, we conclude that even if US has some prognostic value in surgical sperm retrieval outcomes, it is limited, playing a limited role in the work-up of the infertile male (Table 1).

Interestingly, some vascular parameters detected by testicular CDUS have been associated with sperm quality (Herwig et al. 2007; Hillelsohn et al. 2013), suggested as useful in discriminating OA and NOA (Foresta et al. 1998; Battaglia et al. 2001; Biagiotti et al. 2002a, b; Schurich et al. 2009) or residual spermatogenic areas in NOA (Foresta et al. 1998). However, at present, they have been evaluated only for research purpose, with no impact on the clinical management of the azoospermic men (Table 1).

## Scrotal and Transrectal Ultrasound and Hormonal Treatments

The sonographic assessment of testis, prostate, and SV characteristics before the beginning and/or during hormonal treatment represents an effective tool in evaluating the response of target organs and in monitoring the appearance of suspicious findings. Baseline US-assessed TV represents one of the main determinants of gonadotropin responsiveness in subjects with hypogonadotropic hypogonadism (HH). In fact, a better response in terms of sperm output and ongoing pregnancy has been observed for basal TV >4 ml (Liu et al. 2002), although a recent meta-analysis failed to find any significant association between TV and appearance of spermatozoa in the semen upon gonadotropin therapy (Rastrelli et al. 2014). In addition, US has been performed by some authors to evaluate TV increment during hormonal treatment. GnRH (Canale et al. 1990) or gonadotropin (Main et al. 2002; Miyagawa et al. 2005) treatment in HH subjects was associated with a TV increase

up to 170%. A 12-week treatment with FSH in men with idiopathic infertility demonstrated a TV increase of 5 ml compared to baseline (Kamischke et al. 1998). Considering that among infertile (Jacobsen et al. 2000; Walsh et al. 2009) and azoospermic (Eisenberg et al. 2013) men the risk of testicular malignancy is higher, scrotal US should be performed with prevention purpose in azoospermic and/or HH subjects unresponsive to hormonal treatment. However, at present, no agreement on US testis surveillance in these subjects is available.

TRUS is a useful tool in evaluating prostate response to hormonal treatment in HH subjects under gonadotropin, GnRH, or T treatment (Canale et al. 1990; Behre et al. 1995), monitoring not only their possible effect on volume increment but also for cancer screening, along with palpation and PSA measurements (Behre et al. 1995). Also SV volume shows changes at US during hormonal supplementation of hypogonadal men with (Sasagawa et al. 1989) or without (Sasagawa et al. 1990) Klinefelter syndrome.

## Color-Doppler Ultrasound Clinical Utility and Impact on Male Reproductive Health Management

Table 1 summarizes our view on the clinical utility of MGT-CDUS evaluation on clinical decision-making (ranking from mild to high relevance) in male infertility according to the different sites and types of abnormalities. In most cases, clinical, hormonal, and seminal parameters are informative enough for the management of infertile men (Krausz 2011; Lotti et al. 2012b). However, MGT-CDUS shows a critical role in specific conditions. Table 5 offers a provisional summary of seminal, US, and hormonal correlates of some recognized causes of male infertility. MGT-CDUS, particularly TRUS, shows a key role in obstructive azoospermia (Du et al. 2010; Abdulwahed et al. 2013), leading to operational decision-making, such as TRUS-guided cyst aspiration if a large prostatic cyst is found, surgical treatment if ejaculatory duct abnormalities are observed, and testicular biopsy if CBAVD is detected (Fisch et al. 2002; Donkol 2010; Engin 2012). In particular, EAU Guidelines on Male Infertility (Jungwirth et al. 2016) consider TRUS important to detect distal obstruction. SV enlargement (anterior-posterior diameter >15 mm), and SV roundish anechoic areas are TRUS abnormalities often associated with EDO, especially when semen volume is <1.5 ml (Jungwirth et al. 2016). Prostate midline and ejaculatory duct cysts or calcifications are anomalies often associated with obstructive azoospermia (Jungwirth et al. 2016). In addition, scrotal US is helpful in finding other signs of obstruction (e.g., dilatation of rete testis, enlarged epididymis) (Jungwirth et al. 2016).

Transrectal and scrotal US are useful in detecting CBAVD or CUAVD (EAU Guidelines on Male Infertility; Jungwirth et al. 2016), suggesting more specific examinations (CFTR gene evaluation, urinary tract evaluation by US, and surgical sperm extraction) (see Forti and Krausz 1998; Lotti et al. 2012b). TRUS may detect SV cysts, usually associated with other genito-urinary abnormalities (Patel et al. 2002) and should prompt other investigations.

**Table 5** Schematic summary of seminal, ultrasound (US) and hormonal abnormalities in different etiological causes of male infertility

	Primary hypogonadism <sup>a</sup>	Secondary hypogonadism <sup>a</sup>	Complete bilateral EDO	CBAVD <sup>b</sup>	Proximal bilateral (sub) obstruction	Maturation arrest and SCOS
Semen parameters						
Sperm concentration	Oligo-/azoospermia	Oligo-/azoospermia	Azoospermia	Azoospermia	Oligo-/azoospermia	Azoospermia
Ejaculate volume <sup>c</sup>	~Reduced	~Reduced	Low	Normal Reduced if SV abnormalities	Normal	Normal
pH <sup>e</sup>	Normal/reduced	Normal/reduced	Low	Normal Reduced if SV abnormalities	Normal	Normal
US						
Testis <sup>d</sup>	Highly reduced volume, abnormal echo-texture	Slightly reduced volume; abnormal echo-texture	Normal volume and echo-texture	Normal volume and echo-texture	Normal volume and echo-texture	Maturation arrest: normal volume and echo-texture SCOS: normal/reduced volume and slight inhomogeneity
Epididymal head <sup>d</sup>	Normal length	Normal length	Normal/increased	Normal/increased	Normal/increased	Normal length
Epididymal tail <sup>d</sup>	Normal width	Normal width	Normal/increased	Normal/increased	Normal/increased	Normal width
Proximal vas deferens	Normal width	Normal width	Normal/increased	Normal/increased	Normal	Normal width
Deferential ampulla <sup>d</sup>	Normal width	Normal width	Normal/increased	Normal/increased	Normal	Normal width
Prostate volume <sup>d</sup>	Reduced	Reduced	Normal	Normal	Normal	Normal

Ejaculatory ducts <sup>d</sup>	Normal	Normal	Dilated and/or cysts and/or calcifications	Possible abnormalities	Normal	Normal
SV <sup>d</sup>	Reduced (?)	Reduced (?)	Dilated No modification with ejaculation <sup>e</sup> Present	Possible abnormalities	Normal	Normal
Kidneys	Present	Present		Usually present	Present	Present
Hormones						
T <sup>f</sup>	Low	Low	Normal	Normal	Normal	Normal
FSH <sup>f</sup>	Elevated	Normal/low	Normal	Normal	Normal	Maturation arrest: normal SCOS: normal/high
LH <sup>f</sup>	Elevated	Normal/low	Normal	Normal	Normal	Normal

The seminal, US, and hormonal parameters related to the different categories of azoospermia are defined according to Fisch et al. (2002), Isidori and Lenzi (2008), Cooper (2010), Simoni and Nieschlag (2010), and Singh et al. (2012)

*EDO* ejaculatory duct obstruction, *CBAVD* congenital bilateral absence of vas deferens, *SCOS* Sertoli-cells-only syndrome, *SV* seminal vesicles, *SVEF* seminal vesicle ejection fraction, *LH* luteinizing hormone, *FSH* follicle-stimulating hormone, *T* testosterone

<sup>a</sup>Hypogonadism is defined as impaired testis production of spermatozoa and/or testosterone  
<sup>b</sup>Abnormalities of CBAVD may be found in the congenital unilateral absence of vas deferens (CUAVD) with contralateral EDO or testis impairment. CUAVD is frequently associated with ipsilateral abnormalities/absence of epididymis, SV, and kidney

<sup>c</sup>Normal ejaculate volume and pH are defined  $\geq 1.5$  ml and 7.2 ml, respectively (WHO 2010)  
<sup>d</sup>Normal and abnormal US definition. Normal US-testicular volume is defined  $>10$ – $11$  ml (see section Color-Doppler Ultrasound of the Male Genital Tract: Anatomy and Normal Patterns - Testis - Volume). Dilated epididymal head and tail are defined when  $>12$  and 6 mm, respectively (Vicari 1999; Pezzella et al. 2013). Normal prostate volume is considered 20–25 ml (Raza and Jhaveri 2012); initial enlargement  $>30$  ml (Older and Watson 1996); low volume is defined  $<15$  ml (extrapolated from Canale et al. 1990; Sasagawa et al. 1989, 1990). Dilated deferential ampulla,  $> 6$  mm; dilated ejaculatory duct,  $> 2$  mm; dilated SV: anterior-posterior diameter after ejaculation  $>14$  (Vicari 1999) or 15 mm (Jarow 1993; Fisch et al. 2002; Engin et al. 2000, 2012; Jungwirth et al. 2016), or total SV volume after ejaculation  $> 7$  ml (extrapolated from Lotti et al. 2012a). SV hypoplasia: anterior-posterior diameter  $<5$  (Raviv et al. 2006) or 7 mm (Vicari 1999), or longitudinal diameter  $<25$  mm (Donkol 2010)

<sup>e</sup>Suggestive of impaired SV emptying: “SV ejection fraction”  $<21.6\%$  (Lotti et al. 2012a)

<sup>f</sup>Biochemical hypogonadism is defined for total testosterone levels  $<12$  nmol/L or calculated free testosterone  $<225$  pmol/L (Wang et al. 2009). Normal or elevated FSH is defined for FSH levels  $<8$  or  $\geq 8$  U/L (Andersson et al., 2004). Secondary or primary hypogonadism are defined for LH  $\leq 9.4$  or  $>9.4$  U/L, respectively (Tajar et al. 2010). Very low LH and FSH levels are defined as  $<1$ – $2$  U/L (Silveira and Latronico 2013) (From Lotti and Maggi 2015, with permission)



Scrotal US offers a greater accuracy in TV evaluation than assessment by Prader orchidometer (Lenz et al. 1993; Sakamoto et al. 2007a, b), but Prader- and US-derived TV are closely related (Goede et al. 2011; Rastrelli et al. 2013); hence TV assessed clinically is sufficient for the management of infertile men in everyday clinical practice. However, scrotal US is useful in evaluating testicular characteristics when physical examination is unreliable (Behre et al. 1989; Sakamoto et al. 2006; Behre and Zitzmann 2010), such as in the case of large hydrocele, inguinal testis, epididymal enlargement/fibrosis, small testes, and thickened scrotal skin.

Scrotal US is able to detect findings suggestive of testicular damage in non-obstructive azoospermia (Abdulwahed et al. 2013); however, it is not predictive of sperm retrieval in spermatogenic arrest-associated non-obstructive azoospermia (Hung et al. 2007).

Scrotal US is useful in assessing or monitoring signs of testicular dysgenesis (i.e., inhomogeneous testicular echo-pattern, microcalcifications, cryptorchid testis, and suspected small lesions) (Christensen and Dogra 2007; Dohle et al. 2012; Jungwirth et al. 2016) or testicular abnormalities resembling malignancy (Isidori and Lenzi 2008; Albers et al. 2013).

CDUS is useful in localizing inguinal (Nijs et al. 2007) but not intra-abdominal testes (Tasian and Copp 2011), and its role is debated in preoperative planning (Christensen and Dogra 2007; Ozden et al. 2012).

MGT-CDUS shows poor utility in surgical sperm extraction decision-making, since the latter is performed even when small testes or karyotype abnormalities are found (Dabaja and Schlegel 2013; Bryson et al. 2014).

Physical examination may be considered sufficient for diagnosis and decision-making in varicocele treatment (AUA/ASRM; see Practice Committee of American Society for Reproductive Medicine 2008); however, EAU Guidelines on Male Infertility (Jungwirth et al. 2016) report that “the diagnosis of varicocele should be confirmed by CDUS.” In particular, scrotal CDUS plays a role when physical examination is unreliable, exploring persistent reflux in clinical and subclinical varicocele, and is useful in evaluating venous reflux recurrence/persistence after surgery (see Lee et al. 2008).

---

## **New Imaging Techniques for the Evaluation of Testis and Prostate Abnormalities**

### **Contrast-Enhanced Ultrasound (CEUS)**

Nowadays, contrast-enhanced ultrasonography (CEUS) is a significant advancement in imaging, although with a still limited clinical diffusion (Piscaglia et al. 2012). CEUS involves the use of microbubble contrast agents and specialized imaging techniques to show sensitive blood flow and tissue perfusion information. It provides an effective evaluation of microvascularization, a parameter that aids characterization of lesions and depiction of tumor angiogenesis (Cantisani et al. 2015). CEUS is a safe and easily performed technique with no requirement for ionizing radiation and

no risk of nephrotoxicity. The main indication for CEUS in testicular pathology assessment is differential diagnosis of testicular lesions. Differential diagnosis between hypovascular and avascular lesions, for instance, may be difficult at CDUS assessment, especially for small lesions. CEUS is extremely effective in assessing the presence or lack of lesion perfusion (Cantisani et al. 2015). However, while CEUS is valuable to distinguish between vascularized and avascular testicular lesions, characterization of the former as benign or malignant is challenging. Only few studies are dealing with use of CEUS for characterization of testicular nodules. In most of cases, both benign and malignant tumors enhance strongly (Cantisani et al. 2015). Analysis of time-intensity curves after bolus microbubble injection may be of help. A prospective study, performed on 115 consecutive small nonpalpable lesions (<15 mm), reported that the rapidity of washin and washout was the parameter that better differentiated malignant from benign tumors, with a typical prolonged washout observed in Leydig cell tumors (Isidori et al. 2014). However, a recent multicenter study (Drudi et al. 2016), investigating 14 Leydig cell tumors and 17 seminomas, reported that Leydig cell tumors had earlier and higher enhancement compared to seminoma but washout characteristics did not differ significantly. Hence, although CEUS shows high accuracy in distinguishing vascularized and avascular testis lesions, further studies with larger series of patients are required to validate differentiation between benign and malignant tumors, particularly Leydig cell tumor and seminoma (Cantisani et al. 2015).

Other applications of CEUS in testis imaging are related to differential diagnosis of testicular torsion, areas of infarction and abscess, extent of hematomas, and hemorrhagic areas within the testis in patients with scrotal trauma (see, for review, Cantisani et al. 2015).

While there is an increasing interest in the use of CEUS in testicular pathology, its application in prostatic abnormalities seems less promising. Several studies investigated the potential of CEUS to identify prostate cancer (see Cantisani et al. 2015; Sano and Uemura 2015). Although the initial results were encouraging (Mitterberger et al. 2010), other studies did not confirm these results (Seitz et al. 2011; Taverna et al. 2011). Thus, in patients with prostate cancer or with possible recurrence after treatment, CEUS remains an interesting topic for research but cannot be recommended for routine clinical use (Cantisani et al. 2015). Other suggested uses of CEUS in prostate assessment include the study of hemodynamics in response to medical treatment in patients with BPH (Bertolotto et al. 2009), although its utility must be confirmed by further studies.

## **Sonographic Elastography (SE)**

Sonographic elastography (SE) is a method to assess the mechanical properties of a tissue, by applying stress and detecting tissue displacement using US. There are several SE techniques used in clinical practice; strain (compression) SE is the most common technique that allows real-time visualization of the elastographic map on the screen. SE outputs include a color-coded representation (qualitative assessment)

of the lesion, and a semiquantitative characterization by strain ratio, calculated as the ratio of the surrounding parenchyma to the lesions, providing a measure of lesion stiffness. A color scale from red to blue characterizes the color-coded elastograms. Red indicates the highest elastic strain (softest tissue), and blue indicates no strain (hardest tissue). Available scales have been published (Patel et al. 2012), including a 5-point scale by Itoh et al. (2006) at first used for qualitative assessment of breast and thyroid nodules.

SE has been successfully used in the evaluation of acute scrotal pathology (Patel et al. 2014; Yusuf et al. 2015). However, to date, only few retrospective (Schurich et al. 2009; Grasso et al. 2010; Aigner et al. 2012; Huang and Sidhu 2012; Patel et al. 2012) and one prospective (Goddi et al. 2012) study explored the role of SE in focal testicular lesions. In particular, only one retrospective study assessed the value of strain ratio measurements in assessing neoplastic testicular lesions (Pastore et al. 2014). A recent study (Pozza et al. 2016) evaluated prospectively the accuracy of qualitative and strain ratio SE in the differential diagnosis of 106 nonpalpable testicular lesions. The authors concluded that testicular SE may support conventional US in identifying nonneoplastic lesions when findings are controversial, but its additional benefit in clinical practice remains to be proven. In particular, SE could be helpful in differentiating nonpalpable testicular malignancies from nonneoplastic lesions in challenging cases, but it cannot be used to discriminate benign from malignant neoplasms (Pozza et al. 2016).

SE also provides additional information for detecting prostate cancer and guiding biopsies (Correas et al. 2013). SE has high sensitivity in prostate cancer detection and shows high negative predictive values, ensuring that only few cancers will be missed (Correas et al. 2013). SE should become an additional method of imaging the prostate, complementing the conventional TRUS and MRI. Currently there is not enough evidence for SE routine use (Mottet et al. 2016).

## **Magnetic Resonance Imaging (MRI)**

MRI can be useful as a problem-solving tool when traditional US findings are equivocal. MRI allows characterization of scrotal masses as intratesticular or extratesticular and can demonstrate various types of lesions and tissue, including cysts or fluid, solid masses, fat, and fibrosis, as well as inflammatory or vascular abnormalities (Kim et al. 2007; Tsili et al. 2014). Gadolinium-enhanced MRI can help differentiating a benign cystic lesion and a cystic neoplasm. In addition, it can also be used to demonstrate areas of absent or reduced testicular perfusion, such as in segmental testicular infarct (Kim et al. 2007). Finally, MRI can demonstrate an intraabdominal undescended testis, which can be difficult to detect with US, and is superior to US in differentiation between an undescended testis and testicular agenesis (Kim et al. 2007).

MRI provides a precise imaging diagnosis of SV defect, which is considered superior to the TRUS examination for the patients with CAVD (Chiang et al. 2013).

The primary indication at undergoing MRI of the prostate is the evaluation of prostate cancer after a TRUS-guided prostate biopsy has confirmed cancer, in order to determine if there is extracapsular extension (Sala et al. 2006; Hricak et al. 2007). Both the American College of Radiology (ACR) and European Society of Uroradiology (ESUR) advocate the use of multiparametric MRI in prostate imaging (Quon et al. 2015). MRI can also be used to detect and localize cancer when the PSA is persistently elevated, but routine TRUS biopsy is negative (Roethke et al. 2012). Following radical prostatectomy, patients with elevated PSA should also be examined using MRI.

---

## Conclusions

Nowadays, scrotal and transrectal imaging of the MGT have greatly helped in assessing anatomy and physiology of MGT and pathology such as male infertility, MGT lesions, and inflammation. However, MGT-CDUS still suffers from a lack of standardization and often tends to produce subjective and vague diagnoses. This is the main reason why the European Academy of Andrology promoted an ongoing multicenter study (see at <http://www.andrologyacademy.net/studies.aspx>) aimed at defining the anatomic and functional characteristic of healthy, fertile men, defined as partners of a pregnant woman in the second or third trimester of pregnancy or who fathered a child during the last year, following natural conception. Defining US parameters of a healthy and fertile cohort will be of great help in establishing criteria for its pathological counterpart. Finally, new imaging techniques, such as CEUS, elastography, and MRI, have improved the characterization of MGT lesions. However, currently, there is not enough evidence for their routine use, with the exception of some specific indications.

---

## Cross-References

- ▶ [Anamnesis and Physical Examination](#)
- ▶ [Epididymal Sperm Transport and Fertilization](#)
- ▶ [Functional Anatomy and Histology of the Testis](#)
- ▶ [Genetics of Male Infertility](#)
- ▶ [Pre-Testicular, Testicular, and Post-Testicular Causes of Male Infertility](#)
- ▶ [Testicular Steroidogenesis](#)
- ▶ [Testis Development and Descent](#)
- ▶ [Treatment of Hypogonadism](#)

## References

- Abdulwahed SR, Mohamed EE, Taha EA, Saleh MA, Abdelsalam YM, ElGanainy EO. Sensitivity and specificity of ultrasonography in predicting etiology of azoospermia. *Urology*. 2013;81:967–71.
- Aigner F, De Zordo T, Pallwein-Prettner L, Junker D, Schafer G, Pichler R, Leonhartsberger N, Pinggera G, Dogra VS, Frauscher F. Real-time sonoelastography for the evaluation of testicular lesions. *Radiology*. 2012;263:584–9.
- Aizenstein RI, DiDomenico D, Wilbur AC, O'Neil HK. Testicular microlithiasis: association with male infertility. *J Clin Ultrasound*. 1998;26:195–8.
- Albers P, Albrecht W, Algaba F, Bokemeyer C, Cohn-Cedermark G, Fizazi K, Horwich A, Laguna MP. Guidelines on testicular cancer. European Association of Urology Guidelines. In: EAU Guidelines Office. The Netherlands: Arnhem; 2013.
- American Institute of Ultrasound, Ahmed AF, Abdel-Aziz AS, Maarouf AM, Ali M, Emara AA, Gomaa A. Impact of varicocelectomy on premature ejaculation in varicocele patients. *Andrologia*. 2014 Mar 10.; Epub ahead of print.
- Ammar T, Sidhu PS, Wilkins CJ. Male infertility: the role of imaging in diagnosis and management. *Br J Radiol*. 2012;85:S59–68.
- Andersson AM, Petersen JH, Jørgensen N, Jensen TK, Skakkebaek NE. Serum inhibin B and follicle-stimulating hormone levels as tools in the evaluation of infertile men: significance of adequate reference values from proven fertile men. *J Clin Endocrinol Metab*. 2004;89:2873–9.
- Appelbaum L, Gaitini D, Dogra VS. Scrotal ultrasound in adults. *Semin Ultrasound CT MR*. 2013;34:257–73.
- Arai T, Kitahara S, Horiuchi S, Sumi S, Yoshida K. Relationship of testicular volume to semen profiles and serum hormone concentrations in infertile Japanese males. *Int J Fertil Womens Med*. 1998;43:40–7.
- Baazeem A, Belzile E, Ciampi A, Dohle G, Jarvi K, Salonia A, Weidner W, Zini A. Varicocele and male factor infertility treatment: a new meta-analysis and review of the role of varicocele repair. *Eur Urol*. 2011;60:796–808.
- Bahk JY, Jung JH, Jin LM, Min SK. Cut-off value of testes volume in young adults and correlation among testes volume, body mass index, hormonal level, and seminal profiles. *Urology*. 2010;75:1318–23.
- Baker HWG, Burger HG, de Kretser DM, Hudson B, O'Connor S, Wang C, Mirovics A, Court J, Dunlop M, Rennie GC. Changes in the pituitary-testicular system with age. *Clin Endocrinol*. 1976;5:349–72.
- Battaglia C, Giulini S, Regnani G, Madgar I, Facchinetti F, Volpe A. Intratesticular Doppler flow, seminal plasma nitrites/nitrates, and nonobstructive sperm extraction from patients with obstructive and nonobstructive azoospermia. *Fertil Steril*. 2001;75:1088–94.
- Behre HM, Nashan D, Nieschlag E. Objective measurement of testicular volume by ultrasonography: evaluation of the technique and comparison with orchidometer estimates. *Int J Androl*. 1989;12:395–403.
- Behre HM, Kliesch S, Schädel F, Nieschlag E. Clinical relevance of scrotal and transectal ultrasonography in andrological patients. *Int J Androl*. 1995;18:27–31.
- Behre HM, Zitzmann M. Imaging diagnostics. In: Nieschlag E, Behre HM, Nieschlag S, editors. *Andrology. Male reproductive health and dysfunction*, 3rd Ed. Berlin: Springer Verlag; 2010. Chapter 6, p. 101–107.
- Béres J, Papp G, Pazonyi I, Czeizel E. Testicular volume variations from 0 to 28 years of age. *Int Urol Nephrol*. 1989;21:159–67.
- Berger AP, Hominger W, Bektic J, Pelzer A, Spranger R, Bartsch G, Frauscher F. Vascular resistance in the prostate evaluated by colour Doppler ultrasonography: is benign prostatic hyperplasia a vascular disease? *BJU Int*. 2006;98(3):587–90.
- Berkovitz GD, Wilson DP, Carpenter NJ, Brown TR, Migeon CJ. Gonadal function in men with the Martin-Bell (fragile-X) syndrome. *Am J Med Genet*. 1986;23:227–39.

- Bertolotto M, Trincia E, Zappetti R, Bernich R, Savoca G, Cova MA. Effect of Tadalafil on prostate haemodynamics: preliminary evaluation with contrastenhanced US. *Radiat Med.* 2009;114:1106–14.
- Biagiotti G, Cavallini G, Modenini F, Vitali G, Gianaroli L. Spermatogenesis and spectral echo-colour Doppler traces from the main testicular artery. *BJU Int.* 2002a;90:903–8.
- Biagiotti G, Vitali G, Cavallini G. Dyspermia and testicular artery peak systolic velocity. *Arch Ital Urol Androl.* 2002b;74:243–6.
- Boitrelle F, Robin G, Marcelli F, Albert M, Leroy-Martin B, Dewailly D, Rigot JM, Mitchell V. A predictive score for testicular sperm extraction quality and surgical ICSI outcome in non-obstructive azoospermia: a retrospective study. *Hum Reprod.* 2011;26:3215–21.
- Bryson CF, Ramasamy R, Sheehan M, Palermo GD, Rosenwaks Z, Schlegel PN. Severe testicular atrophy does not affect the success of microdissection testicular sperm extraction. *J Urol.* 2014;191:175–8.
- Bujan L, Mieusset R, Mansat A, Moatti JP, Mondinat C, Pontonnier F. Testicular size in infertile men: relationship to semen characteristics and hormonal blood levels. *Br J Urol.* 1989;64:632–7.
- Canale D, Mais V, Turchi P, Andreini F, Melis GB, Menchini-Fabris GF. Ultrasound monitoring of testis and prostate maturation in hypogonadotropic hypogonadic males during gonadotropin-releasing hormone treatment. *Fertil Steril.* 1990;53:537–40.
- Canales BK, Zapzalka DM, Ercole CJ, Carey P, Haus E, Aeppli D, Pryor JL. Prevalence and effect of varicoceles in an elderly population. *Urology.* 2005;66:627–31.
- Cantisani V, Bertolotto M, Weskott HP, Romanini L, Grazhdani H, Passamonti M, Drudi FM, Malpassini F, Isidori A, Meloni FM, Calliada F, D'Ambrosio F. Growing indications for CEUS: the kidney, testis, lymph nodes, thyroid, prostate, and small bowel. *Eur J Radiol.* 2015;84:1675–84.
- Cantu JM, Scaglia HE, Medina M, Gonzalez-Diddi M, Moranto T, Moreno ME, Perez-Palacios G. Inherited congenital normofunctional testicular hyperplasia and mental deficiency. *Hum Genet.* 1976;33:23–33.
- Carlsen E, Andersen AG, Buchreitz L, Jørgensen N, Magnus O, Matulevicius V, Neramoen I, Petersen JH, Punab M, Suominen J, Zilaitiene B, Giwercman A. Inter-observer variation in the results of the clinical andrological examination including estimation of testicular size. *Int J Androl.* 2000;23:248–53.
- Carter SS, Shinohara K, Lipshultz LI. Transrectal ultrasonography in disorders of the seminal vesicles and ejaculatory ducts. *Urol Clin N Am.* 1989;16:773–90.
- Cayan S, Woodhouse CR. The treatment of adolescents presenting with a varicocele. *BJU Int.* 2007;100:744–7.
- Chiang HS, Lin YH, Wu YN, Wu CC, Liu MC, Lin CM. Advantages of magnetic resonance imaging (MRI) of the seminal vesicles and intra-abdominal vas deferens in patients with congenital absence of the vas deferens. *Urology.* 2013;82(2):345–51.
- Cho IR, Keener TS, Nghiem HV, Winter T, Krieger JN. Prostate blood flow characteristics in the chronic prostatitis/pelvic pain syndrome. *J Urol.* 2000;163:1130–3.
- Cho SH, Min SK, Lee ST. Associations of ultrasonographic features with scrotal pain after vasectomy. *Korean J Urol.* 2011;52:782–6.
- Christiansen E, Purvis K. Diagnosis of chronic abacterial prostatic vesiculitis by rectal ultrasonography in relation to symptoms and findings. *Br J Urol.* 1991;67:173–6.
- Christensen JD, Dogra VS. The undescended testis. *Semin Ultrasound CT MR.* 2007;28:307–16.
- Cina A, Minnetti M, Pirroni T, Vittoria Spampinato M, Canadè A, Oliva G, Ribatti D, Bonomo L. Sonographic quantitative evaluation of scrotal veins in healthy subjects: normative values and implications for the diagnosis of varicocele. *Eur Urol.* 2006;50:345–50.
- Clyne M. Male factor infertility: Asymptomatic testicular microlithiasis does not increase antisperm antibody production in infertile men. *Nat Rev Urol.* 2012. doi:10.1038/nrurol.2012.179. [Epub ahead of print].
- Coley BD. Sonography of pediatric scrotal swelling. *Semin Ultrasound CT MR.* 2007;28(4):297–306.

- Collins GN, Raab GM, Hehir M, King B, Garraway WM. Reproducibility and observer variability of transrectal ultrasound measurements of prostatic volume. *Ultrasound Med Biol.* 1995;21:1101–5.
- Colpi GM, Negri L, Nappi RE, China B. Is transrectal ultrasonography a reliable diagnostic approach in ejaculatory duct sub-obstruction? *Hum Reprod.* 1997;12:2186–91.
- Condorelli R, Calogero AE, La Vignera S. Relationship between Testicular Volume and Conventional or Nonconventional Sperm Parameters. *Int J Endocrinol.* 2013;2013:145792. doi:10.1155/2013/145792. Epub 2013 Sep 5.
- Cooper TG. Semen analysis. In: Nieschlag E, Behre HM, Nieschlag S, editors. *Andrology. Male reproductive health and dysfunction*, 3rd Ed. Berlin: Springer Verlag. 2010; p. 125–138.
- Cornud F, Belin X, Delafontaine D, Amar T, Hélénon O, Moreau JF. Imaging of obstructive azoospermia. *Eur Radiol.* 1997;7:1079–85.
- Cornud F, Belin X, Amar E, Delafontaine D, Hélénon O, Moreau JF. Varicocele: strategies in diagnosis and treatment. *Eur Radiol.* 1999;9:536–45.
- Correas JM, Tissier AM, Khairoune A, Khoury G, Eiss D, Hélénon O. Ultrasound elastography of the prostate: state of the art. *Diagn Interv Imaging.* 2013;94(5):551–60.
- Dabaja AA, Schlegel PN. Microdissection testicular sperm extraction: an update. *Asian J Androl.* 2013;15:35–9.
- Danaci M, Akpolat T, Baştemiz M, Sarikaya S, Akan H, Selçuk MB, Cengiz K. The prevalence of seminal vesicle cysts in autosomal dominant polycystic kidney disease. *Nephrol Dial Transplant.* 1998;13:2825–8.
- Degl'Innocenti S, Filimberti E, Magini A, Krausz C, Lombardi G, Fino MG, Rastrelli G, Maggi M, Baldi E. Semen cryopreservation for men banking for oligospermia, cancers, and other pathologies: prediction of post-thaw outcome using basal semen quality. *Fertil Steril* 10 Sep 2013. doi:10.1016/j.fertnstert.2013.08.005. [Epub ahead of print]
- Dhabuwala CB, Kumar AB, Kerkar PD, Bhutawala A, Pierce J. Patterns of Doppler recordings and its relationship to varicocele in infertile men. *Int J Androl.* 1989;12:430–8.
- Di Trapani D, Pavone C, Serretta V, Cavallo N, Costa G, Pavone-Macaluso M. Chronic prostatitis and prostatodynia: ultrasonographic alterations of the prostate, bladder neck, seminal vesicles and periprostatic venous plexus. *Eur Urol.* 1988;15:230–4.
- Diamond JM. Ethnic differences. Variation in human testis size. *Nature.* 1986;320:488–9.
- Diamond DA, Paltiel HJ, DiCanzio J, Zurakowski D, Bauer SB, Atala A, Ephraim PL, Grant R, Retik AB. Comparative assessment of pediatric testicular volume: orchidometer versus ultrasound. *J Urol.* 2000;164:1111–4.
- Doble A, Carter SS. Ultrasonographic findings in prostatitis. *Urol Clin N Am.* 1989;16:763–72.
- Dogra VS, Gottlieb RH, Oka M, Rubens DJ. Sonography of the scrotum. *Radiology.* 2003; 227:18–36.
- Dohle GR. Inflammatory-associated obstructions of the male reproductive tract. *Andrologia.* 2003;35:321–4.
- Dohle GR, Elzanaty S, van Casteren NJ. Testicular biopsy: clinical practice and interpretation. *Asian J Androl.* 2012;14:88–93.
- Donkol RH. Imaging in male-factor obstructive infertility. *World J Radiol.* 2010;2:172–9.
- Drudi FM, Valentino M, Bertolotto M, Malpassini F, Maghella F, Cantisani V, Liberatore M, De Felice C, D'Ambrosio F. CEUS time intensity curves in the differentiation between leydig cell carcinoma and seminoma: a multicenter study. *Ultraschall Med.* 2016;37(2):201–5.
- Du J, Li FH, Guo YF, Yang LM, Zheng JF, Chen B, Zhu JS, Liu Q. Differential diagnosis of azoospermia and etiologic classification of obstructive azoospermia: role of scrotal and transrectal US. *Radiology.* 2010;256:493–503.
- Dubin L, Amelar RD. Varicocele size and results of varicocelectomy in selected subfertile men with varicocele. *Fertil Steril.* 1970;21:606–9.
- Eisenberg ML, Betts P, Herder D, Lamb DJ, Lipshultz LI. Increased risk of cancer among azoospermic men. *Fertil Steril.* 2013;100:681–5.

- Ekerhovd E, Westlander G. Testicular sonography in men with Klinefelter syndrome shows irregular echogenicity and blood flow of high resistance. *J Assist Reprod Genet.* 2002;19:517–22.
- El-Assmy A, El-Tholoth H, Abouelkheir RT, Abou-El-Ghar ME. Transurethral resection of ejaculatory duct in infertile men: outcome and predictors of success. *Int Urol Nephrol.* 2012;44:1623–30.
- Elzinga-Tinke JE, Sirre ME, Looijenga LH, van Casteren N, Wildhagen MF, Dohle GR. The predictive value of testicular ultrasound abnormalities for carcinoma in situ of the testis in men at risk for testicular cancer. *Int J Androl.* 2010;33:597–603.
- Engeler D, Baranowski AP, Borovicka J, Dinis-Oliveira P, Elneil S, Hughes J, Messelink EJ, de C Williams AC, Guidelines Associates, Cottrell A, Goonewardene S. EAU guidelines on chronic pelvic pain. In: EAU Guidelines Office. The Netherlands: Arnhem; 2016.
- Engin G. Transrectal US-guided seminal vesicle aspiration in the diagnosis of partial ejaculatory duct obstruction. *Diagn Interv Radiol.* 2012;18:488–95.
- Engin G, Kadioğlu A, Orhan I, Akdöl S, Rozanes I. Transrectal US and endorectal MR imaging in partial and complete obstruction of the seminal duct system. A comparative study. *Acta Radiol.* 2000;41:288–95.
- Fisch H, Kang YM, Johnson CW, Goluboff ET. Ejaculatory duct obstruction. *Curr Opin Urol.* 2002;12:509–15.
- Fisher AD, Rastrelli G, Bandini E, Corona G, Balzi D, Melani C, Monami M, Matta V, Mannucci E, Maggi M. Metabolic and cardiovascular outcomes of fatherhood: results from a cohort of study in subjects with sexual dysfunction. *J Sex Med.* 2012;9:2785–94.
- Foresta C, Garolla A, Bettella A, Ferlin A, Rossato M, Candiani F. Doppler ultrasound of the testis in azoospermic subjects as a parameter of testicular function. *Hum Reprod.* 1998;13:3090–3.
- Foresta C, Garolla A, Frigo AC, Carraro U, Isidori AM, Lenzi A, Ferlin A. Anthropometric, penile and testis measures in post-pubertal Italian males. *J Endocrinol Investig.* 2013;36:287–92.
- Forti G, Krausz C. Clinical review 100: evaluation and treatment of the infertile couple. *J Clin Endocrinol Metab.* 1998;83:4177–88.
- Forti G, Krausz C, Cilotti A, Maggi M. Varicocele and infertility. *J Endocrinol Investig.* 2003;26:564–9.
- Friedler S, Razieli A, Strassburger D, Soffer Y, Komarovskiy D, Ron-El R. Testicular sperm retrieval by percutaneous fine needle aspiration compared with testicular sperm extraction by open biopsy in men with non-obstructive azoospermia. *Hum Reprod.* 1997;12:1448–93.
- Garriga V, Serrano A, Marin A, Medrano S, Roson N, Pruna X. US of the tunica vaginalis testis: anatomic relationships and pathologic conditions. *Radiographics.* 2009;29:2017–32.
- Gat Y, Gornish M, Heiblum M, Joshua S. Reversal of benign prostate hyperplasia by selective occlusion of impaired venous drainage in the male reproductive system: novel mechanism, new treatment. *Andrologia.* 2008;40:273–81.
- Geatti O, Gasparini D, Shapiro B. A comparison of scintigraphy, thermography, ultrasound and phlebography in grading of clinical varicocele. *J Nucl Med.* 1991;32:2092–7.
- Goddi A, Sacchi A, Magistretti G, Almolla J, Salvatore M. Real-time tissue elastography for testicular lesion assessment. *Eur Radiol.* 2012;22:721–30.
- Goede J, Hack WW, Sijstermans K, van der Voort-Doedens LM, Van der Ploeg T, Meij-de Vries A, Delemarre-van de Waal HA. Normative values for testicular volume measured by ultrasonography in a normal population from infancy to adolescence. *Horm Res Paediatr.* 2011;76:56–64.
- Grabe M, Bjerklund-Johansen TE, Botto H, Çek M, Naber KG, Pickard RS, Tenke P, Wagenlehner F, Wulft B. Guidelines on urological infections, European Association of Urology Guidelines. In: EAU Guidelines Office. The Netherlands: Arnhem; 2013.
- Grasso M, Blanco S, Raber M, Nespoli L. Elasto-sonography of the testis: preliminary experience. *Arch Ital Urol Androl.* 2010;82:160–3.
- Haidl G, Allam JP, Schuppe HC. Chronic epididymitis: impact on semen parameters and therapeutic options. *Andrologia.* 2008;40:92–6.



- Hamm B, Fobbe F. Maturation of the testis: ultrasound evaluation. *Ultrasound Med Biol*. 1995;21:143–7.
- Handelsman DJ, Staraj S. Testicular size: the effects of aging, malnutrition, and illness. *J Androl*. 1985;6:144–51.
- Handelsman DJ, Conway AJ, Boylan LM, Turtle JR. Testicular function in potential sperm donors: normal ranges and the effects of smoking and varicocele. *Int J Androl*. 1984;7:369–82.
- Harman SM, Tsitsouras PD. Reproductive hormones in aging men: I. Measurement of sex steroids, basal luteinizing hormone and Leydig cell response to human chorionic gonadotropin. *J Clin Endocrinol Metab*. 1980;51:35–40.
- Herwig R, Tosun K, Schuster A, Rehder P, Glodny B, Wildt L, Illmensee K, Pinggera GM. Tissue perfusion-controlled guided biopsies are essential for the outcome of testicular sperm extraction. *Fertil Steril*. 2007;87:1071–6.
- Hillelsohn JH, Chuang KW, Goldenberg E, Gilbert BR. Spectral Doppler sonography: a noninvasive method for predicting dyspermia. *J Ultrasound Med*. 2013;32:1427–32.
- Hirsh AV, Cameron KM, Tyler JP, Simpson J, Pryor JP. The Doppler assessment of varicoceles and internal spermatic vein reflux in infertile men. *Br J Urol*. 1980;52:50–6.
- Hoekstra T, Witt MA. The correlation of internal spermatic vein palpability with ultrasonographic diameter and reversal of venous flow. *J Urol*. 1995;153:82–4.
- Horstman WG, Middleton WD, Melson GL, Siegel BA. Color Doppler US of the scrotum. *Radiographics*. 1991a;11:941–57.
- Horstman WG, Middleton WD, Melson GL. Scrotal inflammatory disease: color Doppler US findings. *Radiology*. 1991b;179:55–9.
- Hotaling JM, Lopushnyan NA, Davenport M, Christensen H, Pagel ER, Muller CH, Walsh TJ. Raw and test-thaw semen parameters after cryopreservation among men with newly diagnosed cancer. *Fertil Steril*. 2013;99:464–9.
- Hricak H, Choyke PL, Eberhardt SC, et al. Imaging prostate cancer: a multidisciplinary perspective. *Radiology*. 2007;243(1):28–53.
- Huang DY, Sidhu PS. Focal testicular lesions: colour Doppler ultrasound, contrast-enhanced ultrasound and tissue elastography as adjuvants to the diagnosis. *Br J Radiol*. 2012;85:S41–53.
- Huang Foen Chung JW, de Vries SH, Raaijmakers R, Postma R, Bosch JL, van Mastrigt R. Prostate volume ultrasonography: the influence of transabdominal versus transrectal approach, device type and operator. *Eur Urol*. 2004;46(3):352–6.
- Hung AJ, King P, Schlegel PN. Uniform testicular maturation arrest: a unique subset of men with nonobstructive azoospermia. *J Urol*. 2007;178:608–12.
- Hutson JM, Balic A, Nation T, Southwell B. Cryptorchidism. *Semin Pediatr Surg*. 2010;19:215–24.
- Hutson JM, Li R, Southwell BR, Newgreen D, Cousinery M. Regulation of testicular descent. *Pediatr Surg Int*. 2015;31:317–25.
- Iaccarino V, Venetucci P. Interventional radiology of male varicocele: current status. *Cardiovasc Intervent Radiol*. 2012;35:1263–80.
- Iosa G, Lazzarini D. Hemodynamic classification of varicoceles in men: our experience. *J Ultrasound*. 2013;16:57–63.
- Isidori AM, Lenzi A. Scrotal CDU: morphological and functional atlas. Genova: Forum Service Editore s.r.l.; 2008.
- Isidori AM, Pozza C, Gianfrilli D, Giannetta E, Lemma A, Pofi R, Barbagallo F, Manganaro L, Martino G, Lombardo F, Cantisani V, Franco G, Lenzi A. Differential diagnosis of nonpalpable testicular lesions: qualitative and quantitative contrast-enhanced US of benign and malignant testicular tumors. *Radiology*. 2014;273(2):606–18.
- Itoh A, Ueno E, Tohno E, Kamma H, Takahashi H, Shiina T, Yamakawa M, Matsumura T. Breast disease: clinical application of US elastography for diagnosis. *Radiology*. 2006;239:341–50.
- Jacobsen R, Bostofte E, Engholm G, Hansen J, Olsen JH, Skakkebaek NE, Moller H. Risk of testicular cancer in men with abnormal semen characteristics: cohort study. *BMJ*. 2000;321:789–92.
- Jarow JP. Transrectal ultrasonography of infertile men. *Fertil Steril*. 1993;60:1035–9.

- Jarvis LJ, Dubbins PA. Changes in the epididymis after vasectomy: sonographic findings. *AJR Am J Roentgenol.* 1989;152:531–4.
- Jensen TK, Jørgensen N, Punab M, Haugen TB, Suominen J, Zilaitiene B, Horte A, Andersen AG, Carlsen E, Magnus Ø, Matulevicius V, Nermoen I, Vierula M, Keiding N, Toppari J, Skakkebaek NE. Association of in utero exposure to maternal smoking with reduced semen quality and testis size in adulthood: a cross-sectional study of 1,770 young men from the general population in five European countries. *Am J Epidemiol.* 2004;159:49–58.
- Jiang H, Zhu WJ. Testicular microlithiasis is not a risk factor for the production of antisperm antibody in infertile males. *Andrologia.* 2013;45:305–9.
- Jin B, Conway AJ, Handelsman DJ. Effects of androgen deficiency and replacement on prostatic zonal volumes. *Clin Endocrinol.* 2001;54:437–45.
- Jørgensen N, Carlsen E, Nermoen I, Punab M, Suominen J, Andersen AG, Andersson AM, Haugen TB, Horte A, Jensen TK, Magnus Ø, Petersen JH, Vierula M, Toppari J, Skakkebaek NE. East-West gradient in semen quality in the Nordic-Baltic area: a study of men from the general population in Denmark, Norway, Estonia and Finland. *Hum Reprod.* 2002;17:2199–208.
- Joustra SD, van der Plas EM, Goede J, Oostdijk W, Delemarre-van de Waal HA, Hack WW, van Buuren S, Wit JM. New reference charts for testicular volume in Dutch children and adolescents allow the calculation of standard deviation scores. *Acta Paediatr.* 2015;104(6):e271–8.
- Jungwirth A, Diemer T, Dohle GR, Kopa Z, Krausz C, Tournaye H. EAU guidelines on male infertility. In: EAU Guidelines Office. The Netherlands: Arnhem; 2016.
- Kamischke A, Behre HM, Bergmann M, Simoni M, Schäfer T, Nieschlag E. Recombinant human follicle stimulating hormone for treatment of male idiopathic infertility: a randomized, double-blind, placebo-controlled, clinical trial. *Hum Reprod.* 1998;13:596–603.
- Kamoi K. Clinical usefulness of transrectal sonography and transperineal color Doppler flow imaging in the diagnosis of intrapelvic venous congestion syndrome. *Nihon Hinyokika Gakkai Zasshi.* 1996;87:1009–17. [Article in Japanese].
- Kasturi SS, Tannir J, Brannigan RE. The metabolic syndrome and male infertility. *J Androl.* 2008;29:251–9.
- Keener TS, Winter TC, Nghiem HV, Schmiedel UP. Normal adult epididymis: evaluation with color Doppler US. *Radiology.* 1997;202:712–4.
- Kim ED, Lipshultz LI. Role of ultrasound in the assessment of male infertility. *J Clin Ultrasound.* 1996;24:437–53.
- Kim W, Rosen MA, Langer JE, et al. US-MR Imaging correlation in pathologic conditions of the scrotum. *Radiographics.* 2007;27:1239–53.
- Kim B, Kawashima A, Ryu JA, Takahashi N, Hartman RP, King Jr BF. Imaging of the seminal vesicle and vas deferens. *Radiographics.* 2009;29:1105–21.
- King BF, Hattery RR, Lieber MM, Williamson Jr B, Hartman GW, Berquist TH. Seminal vesicle imaging. *Radiographics.* 1989;9:653–76.
- Kollin C, Hesser U, Ritzen EM, Karpe B. Testicular growth from birth to two years of age, and the effect of orchidopexy at age nine months: a randomized, controlled study. *Acta Paediatr.* 2006;95:318–24.
- Krausz C. Male infertility: pathogenesis and clinical diagnosis. *Best Pract Res Clin Endocrinol Metab.* 2011;25:271–85.
- Kroese AC, de Lange NM, Collins JA, Evers JL. Varicocele surgery, new evidence. *Hum Reprod Update.* 2013;19:317.
- Kuijper EA, van Kooten J, Verbeke JI, van Rooijen M, Lambalk CB. Ultrasonographically measured testicular volumes in 0- to 6-year-old boys. *Hum Reprod.* 2008;23:792–6.
- La Vignera S. Seminal vesicles of infertile patients with male accessory gland infection: ultrasound evaluation after prolonged treatment with tadalafil, a selective phosphodiesterase-5 inhibitor. *Andrologia.* 2012. doi:10.1111/and.12027. [Epub ahead of print].
- La Vignera S, Calogero AE, Arancio A, Castiglione R, De Grande G, Vicari E. Transrectal ultrasonography in infertile patients with persistently elevated bacteriospermia. *Asian J Androl.* 2008;10:731–40.

- La Vignera S, Lanzafame F, Di Mauro M, Condorelli R, Vicari E. Spermatic and ultrasound characterization of young diabetic patients. *Arch Ital Urol Androl.* 2009;81:245–7.
- La Vignera S, Condorelli RA, Di Mauro M, D'Agata R, Vicari E, Calogero AE. Seminal vesicles and diabetic neuropathy: ultrasound evaluation. *J Androl.* 2011a;32:478–83.
- La Vignera S, Condorelli RA, Vicari E, D'Agata R, Calogero AE. Seminal vesicles and diabetic neuropathy: ultrasound evaluation in patients with couple infertility and different levels of glycaemic control. *Asian J Androl.* 2011b;13:872–6.
- La Vignera S, Vicari E, Condorelli R, D'Agata R, Calogero AE. Hypertrophic-congestive and fibro-sclerotic ultrasound variants of male accessory gland infection have different sperm output. *J Endocrinol Investig.* 2011c;34:e330–5.
- La Vignera S, Vicari E, Condorelli R, D'Agata R, Calogero AE. Ultrasound characterization of the seminal vesicles in infertile patients with type 2 diabetes mellitus. *Eur J Radiol.* 2011d;80:e64–7.
- La Vignera S, Vicari E, Condorelli RA, D'Agata R, Calogero AE. Male accessory gland infection and sperm parameters (review). *Int J Androl.* 2011e;34:e330–47.
- Lachiewicz AM, Dawson DV. Do young boys with fragile X syndrome have macroorchidism? *Pediatrics.* 1994;93:992–5.
- Lee JC, Bhatt S, Dogra VS. Imaging of the epididymis. *Ultrasound Q.* 2008;24:3–16.
- Lenz S. Cancer of the testicle diagnosed by ultrasound and the ultrasonic appearance of the contralateral testicle. *Scand J Urol Nephrol Suppl.* 1991;137:135–8.
- Lenz S, Giwercman A, Skakkebaek NE, Bruun E, Frimodt-Møller C. Ultrasound in detection of early neoplasia of the testis. *Int J Androl.* 1987;10:187–90.
- Lenz S, Giwercman A, Elsborg A, Cohr KH, Jelnes JE, Carlsen E, Skakkebaek NE. Ultrasonic testicular texture and size in 444 men from the general population: correlation to semen quality. *Eur Urol.* 1993;24:231–8.
- Lenz S, Thomsen JK, Giwercman A, Hertel NT, Hertz J, Skakkebaek NE. Ultrasonic texture and volume of testicles in infertile men. *Hum Reprod.* 1994;9:878–81.
- Leung ML, Gooding GA, Williams RD. High-resolution sonography of scrotal contents in asymptomatic subjects. *AJR Am J Roentgenol.* 1984;143:161–4.
- Li F, Yue H, Yamaguchi K, Okada K, Matsushita K, Ando M, Chiba K, Fujisawa M. Effect of surgical repair on testosterone production in infertile men with varicocele: a meta-analysis. *Int J Urol.* 2012;19:149–54.
- Liguori G, Trombetta C, Garaffa G, Bucci S, Gattuccio I, Salamè L, Belgrano E. Color Doppler ultrasound investigation of varicocele. *World J Urol.* 2004;22:378–81.
- Liguori G, Bucci S, Trombetta C, Boris B, Bertolotto M. Imaging the infertile male-1: varicocele. In: Bertolotto M, Trombetta C, editors. *Scrotal pathology. Medical radiology. Diagnostic imaging.* Berlin: Springer-Verlag; 2012. p. 261–74.
- Lin CC, Huang WJ, Chen KK. Measurement of testicular volume in smaller testes: how accurate is the conventional orchidometer? *J Androl.* 2009;30:685–9.
- Littrup PJ, Lee F, McLeary RD, Wu D, Lee A, Kumasaka GH. Transrectal US of the seminal vesicles and ejaculatory ducts: clinical correlation. *Radiology.* 1988;168:625–8.
- Liu PY, Gebiski VJ, Turner L, Conway AJ, Wishart SM, Handelsman DJ. Predicting pregnancy and spermatogenesis by survival analysis during gonadotrophin treatment of gonadotrophin-deficient infertile men. *Hum Reprod.* 2002;17:625–33.
- Loberant N, Bhatt S, McLennan GT, Dogra VS. Striated appearance of the testes. *Ultrasound Q.* 2010;26:37–44.
- Lotti F, Maggi M. Interleukin 8 and the male genital tract. *J Reprod Immunol.* 2013;100(1):54–65. Review.
- Lotti F, Maggi M. Ultrasound of the male genital tract in relation to male reproductive health. *Hum Reprod Update.* 2015;21:56–83.
- Lotti F, Corona G, Colpi GM, Filimberti E, Degli Innocenti S, Mancini M, Baldi E, Noci I, Forti G, Adorini L, Maggi M. Elevated body mass index correlates with higher seminal plasma interleukin 8 levels and ultrasonographic abnormalities of the prostate in men attending an andrology clinic for infertility. *J Endocrinol Investig.* 2011a;34:e336–42.

- Lotti F, Corona G, Mancini M, Filimberti E, Degli Innocenti S, Colpi GM, Baldi E, Noci I, Forti G, Adorini L, Maggi M. Ultrasonographic and clinical correlates of seminal plasma interleukin-8 levels in patients attending an andrology clinic for infertility. *Int J Androl.* 2011b;34:600–13.
- Lotti F, Corona G, Colpi GM, Filimberti E, Innocenti SD, Mancini M, Baldi E, Noci I, Forti G, Maggi M. Seminal vesicles ultrasound features in a cohort of infertility patients. *Hum Reprod.* 2012a;27:974–82.
- Lotti F, Corona G, Krausz C, Forti G, Maggi M. The infertile male-3: endocrinological evaluation. In: Bertolotto M, Trombetta C, editors. *Scrotal pathology. Medical radiology. Diagnostic imaging.* Berlin: Springer-Verlag; 2012b. p. 223–40.
- Lotti F, Corona G, Rastrelli G, Forti G, Jannini EA, Maggi M. Clinical correlates of erectile dysfunction and premature ejaculation in men with couple infertility. *J Sex Med.* 2012c;9:2698–707.
- Lotti F, Tamburrino L, Marchiani S, Muratori M, Corona G, Fino MG, Degli Innocenti S, Forti G, Maggi M, Baldi E. Semen apoptotic M540 body levels correlate with testis abnormalities: a study in a cohort of infertile subjects. *Hum Reprod.* 2012d;27:3393–402.
- Lotti F, Corona G, Degli Innocenti S, Filimberti E, Scognamiglio V, Vignozzi L, Forti G, Maggi M. Seminal, ultrasound and psychobiological parameters correlate with metabolic syndrome in male members of infertile couples. *Andrology.* 2013a;1:229–39.
- Lotti F, Corona G, Maseroli E, Rossi M, Silverii A, Degli Innocenti S, Rastrelli G, Forti G, Maggi M. Clinical implications of measuring prolactin levels in males of infertile couples. *Andrology.* 2013b;1:764–71.
- Lotti F, Corona G, Mondaini N, Maseroli E, Rossi M, Filimberti E, Noci I, Forti G, Maggi M. Seminal, clinical and color-Doppler ultrasound correlations of prostatitis-like symptoms in males of infertile couples. *Andrology.* 2013c;2(1):30–41.
- Lotti F, Corona G, Vignozzi V, Rossi M, Maseroli E, Cipriani S, Gacci M, Forti G, Maggi M. Metabolic syndrome and prostate abnormalities in male subjects of infertile couples. *Asian J Androl.* 2013d;16(2):295–304.
- Lotti F, Corona G, Vitale P, Maseroli E, Rossi M, Fino MG, Maggi M. Current smoking is associated with lower seminal vesicles and ejaculate volume, despite higher testosterone levels, in male subjects of infertile couples. *Hum Reprod.* 2015;30(3):590–602.
- Lotti F, Corona G, Castellini G, Maseroli E, Fino MG, Cozzolino M, Maggi M. Semen quality impairment is associated with sexual dysfunction according to its severity. *Hum Reprod.* 2016a;31(12):2668–80.
- Lotti F, Maseroli E, Fralassi N, Degli Innocenti S, Boni L, Baldi E, Maggi M. Is thyroid hormones evaluation of clinical value in the work-up of males of infertile couples? *Hum Reprod.* 2016b;31(3):518–29.
- Lotti F, Tamburrino L, Marchiani S, Maseroli E, Vitale P, Forti G, Muratori M, Maggi M, Baldi E. DNA fragmentation in two cytometric sperm populations: relationship with clinical and ultrasound characteristics of the male genital tract. *Asian J Androl.* 2016c;. [Epub ahead of print].
- Lund L, Roebuck DJ, Lee KH, Sørensen HT, Yeung CK. Clinical assessment after varicocelectomy. *Scand J Urol Nephrol.* 2000;34:119–22.
- Main KM, Schmidt IM, Toppari J, Skakkebaek NE. Early postnatal treatment of hypogonadotropic hypogonadism with recombinant human FSH and LH. *Eur J Endocrinol.* 2002;146:75–9.
- Matsuda T, Horii Y, Yoshida O. Obstructive azoospermia of unknown origin: sites of obstruction and surgical outcomes. *J Urol.* 1994;151:1543–6.
- McDermott VG, Meakem 3rd TJ, Stolpen AH, Schnall MD. Prostatic and periprostatic cysts: findings on MR imaging. *Am J Roentgenol.* 1995;164:123–7.
- Meares Jr EM. Infection stones of prostate gland. Laboratory diagnosis and clinical management. *Urology.* 1974;4:560–6.
- Meschede D, Behre HM, Nieschlag E. Endocrine and spermatological characteristics of 135 patients with bilateral megalotestis. *Andrologia.* 1995;27:207–12.
- Middleton WD, Thorne DA, Melson GL. Color Doppler ultrasound of the normal testis. *AJR Am J Roentgenol.* 1989;152:293–7.

- Migaleddu V, Virgilio G, Del Prato A, Bertolotto M. Sonographic scrotal anatomy. In: Bertolotto M, Trombetta C, editors. *Scrotal pathology. Medical radiology. Diagnostic imaging*. Berlin: Springer-Verlag; 2012. p. 41–54.
- Mihmanli I, Kantarci F. Sonography of scrotal abnormalities in adults: an update. *Diagn Interv Radiol*. 2009;15:64–73.
- Miller FN, Sidhu PS. Does testicular microlithiasis matter? A review. *Clin Radiol*. 2002;57:883–90.
- Mitchell V, Robin G, Boitrelle F, Massart P, Marchetti C, Marcelli F, Rigot JM. Correlation between testicular sperm extraction outcomes and clinical, endocrine and testicular histology parameters in 120 azoospermic men with normal serum FSH levels. *Int J Androl*. 2011;34:299–305.
- Mitterberger MJ, Aigner F, Horninger W, et al. Comparative efficiency of contrast-enhanced colour Doppler ultrasound targeted versus systematic biopsy for prostate cancer detection. *Eur Radiol*. 2010;20:2791–6.
- Miyagawa Y, Tsujimura A, Matsumiya K, Takao T, Tohda A, Koga M, Takeyama M, Fujioka H, Takada S, Koide T, Okuyama A. Outcome of gonadotropin therapy for male hypogonadotropic hypogonadism at university affiliated male infertility centers: a 30-year retrospective study. *J Urol*. 2005;173:2072–5.
- Montgomery JS, Bloom DA. The diagnosis and management of scrotal masses. *Med Clin N Am*. 2011;95:235–44.
- Moon MH, Kim SH, Cho JY, Seo JT, Chun YK. Scrotal US for evaluation of infertile men with azoospermia. *Radiology*. 2006;239:168–73.
- Mottet N et al., Guidelines on prostate cancer, European Association of Urology Guidelines, 2016.; <https://uroweb.org/guideline/prostate-cancer/>
- Nghiem HT, Kellman GM, Sandberg SA, Craig BM. Cystic lesions of the prostate. *Radiographics*. 1990;10:635–50.
- Nickel JC, Downey J, Hunter D, Clark J. Prevalence of PLS in a population based study using the National Institutes of Health chronic prostatitis symptom index. *J Urol*. 2001;165:842–5.
- Nielsen KB, Tommerup N, Dyggve HV, Schou C. Macroorchidism and fragile X in mentally retarded males. Clinical, cytogenetic, and some hormonal investigations in mentally retarded males, including two with the fragile site at Xq28, fra(X)(q28). *Hum Genet*. 1982;61:113–7.
- Nieschlag E, Behre HM. Anamnesis and physical examination. In: Nieschlag E, Behre HM, Nieschlag S, editors. *Andrology. Male reproductive health and dysfunction*, 3rd Ed. Berlin: Springer Verlag; 2010. Chapter 5, p. 93–100.
- Nieschlag E, Lammers U, Freischem CW, Langer K, Wickings EJ. Reproductive functions in young fathers and grandfathers. *Clin Endocrinol Metab*. 1982;55:676–81.
- Nijs SM, Eijsbouts SW, Madern GC, Leyman PM, Lequin MH, Hazebroek FW. Nonpalpable testes: is there a relationship between ultrasonographic and operative findings? *Pediatr Radiol*. 2007;37:374–9.
- Nordkap L, Jensen TK, Hansen ÅM, Lassen TH, Bang AK, Joensen UN, Blomberg Jensen M, Skakkebaek NE, Jørgensen N. Psychological stress and testicular function: a cross-sectional study of 1,215 Danish men. *Fertil Steril*. 2016;105:174–87.e1–2.
- Older RA, Watson LR. Ultrasound anatomy of the normal male reproductive tract. *J Clin Ultrasound*. 1996;24:389–404.
- Orda R, Sayfan J, Manor H, Witz E, Sofer Y. Diagnosis of varicocele and postoperative evaluation using inguinal ultrasonography. *Ann Surg*. 1987;206:99–101.
- Oyen RH. Scrotal ultrasound. *Eur Radiol*. 2002;12:19–34.
- Ozden E, Turgut AR, Dogra VS. Imaging the undescended testis. In: Bertolotto M, Trombetta C, editors. *Scrotal pathology. Medical radiology. Diagnostic imaging*. Berlin: Springer-Verlag; 2012. p. 301–12.
- Pais D, Fontoura P, Esperança-Pina JA. The transmediastinal arteries of the human testis: an anatomical study. *Surg Radiol Anat*. 2004;26:379–83.
- Palmert MR, Dunkel L. Clinical practice. Delayed puberty. *N Engl J Med*. 2012;366:443–53.

- Pastore AL, Palleschi G, Maceroni P, Manfredonia G, Autieri D, Cacciotti J, Sardella B, Porta N, Petrozza V, Carbone A. Correlation between semiquantitative sonoelastography and immunohistochemistry in the evaluation of testicular focal lesions. *Cancer Imaging*. 2014;14:29.
- Patel B, Gujral S, Jefferson K, Evans S, Persad R. Seminal vesicle cysts and associated anomalies. *BJU Int*. 2002;90:265–71.
- Patel K, Sellars ME, Clarke JL, Sidhu PS. Features of testicular epidermoid cysts on contrast enhanced sonography and real-time tissue elastography. *J Ultrasound Med*. 2012;31:115–22.
- Patel KV, Huang DY, Sidhu PS. Metachronous bilateral segmental testicular infarction: multiparametric ultrasound imaging with grey-scale ultrasound, Doppler ultrasound, contrast enhanced ultrasound (CEUS) and real-time tissue elastography (RTE). *J Ultrasound*. 2014;17:233–8.
- Pauroso S, Di Leo N, Fulle I, Di Segni M, Alessi S, Maggini E. Varicocele. Ultrasonographic assessment in daily clinical practice. *J Ultrasound*. 2011;14:199–204.
- Penna G, Mondaini N, Amuchastegui S, Degli Innocenti S, Carini M, Giubilei G, Fibbi B, Colli E, Maggi M, Adorini L. Seminal plasma cytokines and chemokines in prostate inflammation: interleukin 8 as a predictive biomarker in chronic prostatitis/chronic pelvic pain syndrome and benign prostatic hyperplasia. *Eur Urol*. 2007;51:524–33.
- Pezzella A, Barbonetti A, Micillo A, D'Andrea S, Necozone S, Gandini L, Lenzi A, Francavilla F, Francavilla S. Ultrasonographic determination of caput epididymis diameter is strongly predictive of obstruction in the genital tract in azoospermic men with normal serum FSH. *Andrology*. 2013;1:133–8.
- Pilatz A, Rusz A, Wagenlehner F, Weidner W, Altinkilic B. Reference values for testicular volume, epididymal head size and peak systolic velocity of the testicular artery in adult males measured by ultrasonography. *Ultraschall Med*. 2013a;34:349–54.
- Pilatz A, Wagenlehner F, Bschleipfer T, Schuppe HC, Diemer T, Linn T, Weidner W, Altinkilic B. Acute epididymitis in ultrasound: results of a prospective study with baseline and follow-up investigations in 134 patients. *Eur J Radiol*. 8 Sept 2013b. doi:10.1016/j.ejrad.2013.08.050. [Epub ahead of print].
- Piscaglia F, Nolsøe C, Dietrich CF, Cosgrove DO, Gilja OH, Bachmann Nielsen M, Albrecht T, Barozzi L, Bertolotto M, Catalano O, Claudon M, Clevert DA, Correas JM, D'Onofrio M, Drudi FM, Eydung J, Giovannini M, Hocke M, Ignee A, Jung EM, Klauser AS, Lassau N, Leen E, Mathis G, Saftoiu A, Seidel G, Sidhu PS, ter Haar G, Timmerman D, Weskott HP. The EFSUMB guidelines and recommendations on the clinical practice of contrast enhanced ultrasound (CEUS): update 2011 on non-hepatic applications. *Ultraschall Med*. 2012;33(1):33–59.
- Pozza C, Gianfrilli D, Fattorini G, et al. Diagnostic value of qualitative and strain-ratio elastography in the differential diagnosis of testicular lesions. *Andrology*. 2016;6:1193–203.
- Practice Committee of American Society for Reproductive Medicine. Report on varicocele and infertility. *Fertil Steril*. 2008;90:S247–9.
- Purvis K, Christiansen E. Infection in the male reproductive tract. Impact, diagnosis and treatment in relation to male infertility. *Int J Androl*. 1993;16:1–13.
- Quon J, Kielar AZ, Jain R, et al. Assessing the utilization of functional imaging in multiparametric prostate MRI in routine clinical practice. *Clin Radiol*. 2015;70(4):373–8.
- Raheem OA. Surgical management of adolescent varicocele: systematic review of the world literature. *Urol Ann*. 2013;5:133–9.
- Ramchandani P, Banner MP, Pollack HM. Imaging of the seminal vesicles. *Semin Roentgenol*. 1993;28:83–91.
- Rastrelli G, Corona G, Lotti F, Boddi V, Mannucci E, Maggi M. Relationship of testis size and LH levels with incidence of major adverse cardiovascular events in older men with sexual dysfunction. *J Sex Med*. 2013;10:2761–73.
- Rastrelli G, Corona G, Mannucci E, Maggi M. Factors affecting spermatogenesis upon gonadotropin-replacement therapy: a meta-analytic study. *Andrology*. 2014;2:794–808.
- Rathaus V, Werner M, Freud E, Mei-Zahav M, Mussaffi H, Blau H. Sonographic findings of the genital tract in boys with cystic fibrosis. *Pediatr Radiol*. 2006;36:162–6.

- Raviv G, Mor Y, Levron J, Shefi S, Zilberman D, Ramon J, Madgar I. Role of transrectal ultrasonography in the evaluation of azoospermic men with low-volume ejaculate. *J Ultrasound Med.* 2006;25:825–9.
- Ravizzini P, Carizza C, Abdelmassih V, Abdelmassih S, Azevedo M, Abdelmassih R. Microdissection testicular sperm extraction and IVF-ICSI outcome in nonobstructive azoospermia. *Andrologia.* 2008;40:219–26.
- Raza SA, Jhaveri KS. Imaging in male infertility. *Radiol Clin North Am.* 2012;50:1183–200.
- Reddy NM, Gerscovich EO, Jain KA, Le-Petross HT, Brock JM. Vasectomy-related changes on sonographic examination of the scrotum. *J Clin Ultrasound.* 2004;32:394–8.
- Richenberg J, Brejt N. Testicular microlithiasis: is there a need for surveillance in the absence of other risk factors? *Eur Radiol.* 2012 Nov;22:2540–6.
- Rives N, Perdrix A, Hennebicq S, Saïas-Magnan J, Melin MC, Berthaut I, Barthélémy C, Daudin M, Szerman E, Bresson JL, Brugnon F, Bujan L. The semen quality of 1158 men with testicular cancer at the time of cryopreservation: results of the French National CECOS Network. *J Androl.* 2012;33:1394–401.
- Roethke M, Anastasiadis AG, Lichy M, et al. MRI-guided prostate biopsy detects clinically significant cancer: analysis of a cohort of 100 patients after previous negative TRUS biopsy. *World J Urol.* 2012;30(2):213–8.
- Ron-El R, Strauss S, Friedler S, Strassburger D, Komarovsky D, Raziel A. Serial sonography and colour flow Doppler imaging following testicular and epididymal sperm extraction. *Hum Reprod.* 1998;13:3390–3.
- Rud CN, Daugaard G, Rajpert-De Meyts E, Skakkebaek NE, Petersen JH, Jørgensen N. Sperm concentration, testicular volume and age predict risk of carcinoma in situ in contralateral testis of men with testicular germ cell cancer. *J Urol.* 14 Jun 2013. doi:10.1016/j.juro.2013.06.023. [Epub ahead of print]
- Rusz A, Pilatz A, Wagenlehner F, Linn T, Diemer T, Schuppe HC, Lohmeyer J, Hossain H, Weidner W. Influence of urogenital infections and inflammation on semen quality and male fertility. *World J Urol.* 2012;30:23–30.
- Sadler TW. *Langman's medical embryology.* 12th ed. Philadelphia: Lippincott Williams & Wilkins; 2011.
- Sajjad Y. Development of the genital ducts and external genitalia in the early human embryo. *J Obstet Gynaecol Res.* 2010;36:929–37.
- Sakamoto H, Ogawa Y. Is varicocele associated with underlying venous abnormalities? Varicocele and the prostatic venous plexus. *J Urol.* 2008;180:1427–31.
- Sakamoto H, Ogawa Y. Does a clinical varicocele influence the relationship between testicular volume by ultrasound and testicular function in patients with infertility? *Fertil Steril.* 2009;92:1632–7.
- Sakamoto H, Saito K, Shichizyo T, Ishikawa K, Igarashi A, Yoshida H. Color Doppler ultrasonography as a routine clinical examination in male infertility. *Int J Urol.* 2006;13:1073–8.
- Sakamoto H, Saito K, Ogawa Y, Yoshida H. Testicular volume measurements using Prader orchidometer versus ultrasonography in patients with infertility. *Urology.* 2007a;69:158–62.
- Sakamoto H, Saito K, Oohta M, Inoue K, Ogawa Y, Yoshida H. Testicular volume measurement: comparison of ultrasonography, orchidometry, and water displacement. *Urology.* 2007b;69:152–7.
- Sakamoto H, Ogawa Y, Yoshida H. Relationship between testicular volume and testicular function: comparison of the Prader orchidometric and ultrasonographic measurements in patients with infertility. *Asian J Androl.* 2008;10:319–24.
- Sala E, Eberhardt SC, Akin O, et al. Endorectal MR imaging before salvage prostatectomy: tumor localization and staging. *Radiology.* 2006;238(1):176–83.
- Sano F, Uemura H. The utility and limitations of contrast-enhanced ultrasound for the diagnosis and treatment of prostate cancer. *Sensors (Basel).* 2015;15(3):4947–57.
- Sarkar S, Das S. A review of imaging methods for prostate cancer detection. *Biomed Eng Comput Biol.* 2016;7(Suppl 1):1–15.

- Sarteschi LM, Paoli R, Bianchini M, Menchini Fabris GF. Lo studio del varicocele con eco-color Doppler. *G Ital Ultrasonologia*. 1993;4:43–9.
- Sartorius GA, Nieschlag E. Paternal age and reproduction. *Hum Reprod Update*. 2010;16:65–79.
- Sasagawa I, Nakada T, Kazama T, Terada T, Katayama T. Testosterone replacement therapy and prostate/seminal vesicle volume in Klinefelter's syndrome. *Arch Androl*. 1989;22:245–9.
- Sasagawa I, Nakada T, Kazama T, Satomi S, Terada T, Katayama T. Volume change of the prostate and seminal vesicles in male hypogonadism after androgen replacement therapy. *Int Urol Nephrol*. 1990;22:279–84.
- Schlegel PN, Goldstein M. Alternate indications for varicocele repair: non-obstructive azoospermia, pain, androgen deficiency and progressive testicular dysfunction. *Fertil Steril*. 2011;96:1288–93.
- Schlegel PN, Li-Ming S. Physiological consequences of testicular sperm extraction. *Hum Reprod*. 1997;12:1688–92.
- Schlegel PN, Shin D, Goldstein M. Urogenital anomalies in men with congenital absence of the vas deferens. *J Urol*. 1996;155:1644–8.
- Schultz KE, Walker J. Testicular torsion in undescended testes. *Ann Emerg Med*. 1984;13:567–9.
- Schurich M, Aigner F, Frauscher F, Pallwein L. The role of ultrasound in assessment of male fertility. *Eur J Obstet Gynecol Reprod Biol*. 2009;144:S192–8.
- Seitz M, Gratzke C, Schlenker B, Buchner A, Karl A, Roosen A, Singer BB, Bastian PJ, Ergün S, Stief CG, Reich O, Tilki D. Contrast-enhanced transrectal ultrasound (CE-TRUS) with cadence-contrast pulse sequence (CPS) technology for the identification of prostate cancer. *Urol Oncol*. 2011;29(3):295–301.
- Sfanos KS, Wilson BA, De Marzo AM, Isaacs WB. Acute inflammatory proteins constitute the organic matrix of prostatic corpora amylacea and calculi in men with prostate cancer. *Proc Natl Acad Sci U S A*. 2009;106:3443–8.
- Sharp VJ, Kieran K, Arlen AM. Testicular torsion: diagnosis, evaluation, and management. *Am Fam Physician*. 2013;88:835–40.
- Shaw J. Diagnosis and treatment of testicular cancer. *Am Fam Physician*. 2008;77:469–74.
- Shaw G, Renfree MB. Wolffian duct development. *Sex Dev*. 2014;8(5):273–80.
- Shebel HM, Farg HM, Kolokythas O, El-Diasty T. Cysts of the lower male genitourinary tract: embryologic and anatomic considerations and differential diagnosis. *Radiographics*. 2013;33:1125–43.
- Shinbo H, Kurita Y, Takada S, Imanishi T, Otsuka A, Furuse H, Nakanishi T, Mugiya S, Ozono S. Resistive index as risk factor for acute urinary retention in patients with benign prostatic hyperplasia. *Urology*. 2010;76:1440–5.
- Shoskes DA, Lee CT, Murphy D, Kefer J, Wood HM. Incidence and significance of prostatic stones in men with chronic prostatitis/chronic pelvic pain syndrome. *Urology*. 2007;70:235–8.
- Silber SJ, Patrizio P, Asch RH. Quantitative evaluation of spermatogenesis by testicular histology in men with congenital absence of the vas deferens undergoing epididymal sperm aspiration. *Hum Reprod*. 1990;5:89–93.
- Silveira LF, Latronico AC. Approach to the patient with hypogonadotropic hypogonadism. *J Clin Endocrinol Metab*. 2013;98:1781–8.
- Simoni M, Nieschlag E. Endocrine laboratory diagnosis. In: Nieschlag E, Behre HM, Nieschlag S, editors. *Andrology*. Male reproductive health and dysfunction. 3rd ed. Berlin: Springer Verlag; 2010. p. 109–18.
- Singh R, Hamada AJ, Bukavina L, Agarwal A. Physical deformities relevant to male infertility. *Nat Rev Urol*. 2012;9:156–74.
- Skakkebaek NE, Jørgensen N. Testicular dysgenesis and fertility. *Andrologia*. 2005;37:217–8.
- Smeenge M, et al. Role of transrectal ultrasonography (TRUS) in focal therapy of prostate cancer: report from a consensus panel. *BJU Int*. 2012;110:942.
- Sparrow D, Bosse R, Rowe JW. The influence of age, alcohol consumption, and body build on gonadal function in men. *Clin Endocrinol Metab*. 1980;51:508–12.



- St Sauver JL, Jacobson DJ, Girman CJ, McGree ME, Lieber MM, et al. Correlations between longitudinal changes in transitional zone volume and measures of benign prostatic hyperplasia in a population-based cohort. *Eur Urol.* 2006;50:105–11.
- Stearns EL, MacDonnell JA, Kaufman BJ, Padua R, Lucman TS, Winter JSD, Faiman C. Declining testicular function with age. *Am J Med.* 1974;57:761–6.
- Stravodimos KG, Petrolekas A, Kapetanakis T, Vourekas S, Koritsiadis G, Adamakis I, Mitropoulos D, Constantinides C. TRUS versus transabdominal ultrasound as a predictor of enucleated adenoma weight in patients with BPH: a tool for standard preoperative work-up? *Int Urol Nephrol.* 2009;41(4):767–71.
- Tajar A, Forti G, O'Neill TW, Lee DM, Silman AJ, Finn JD, Bartfai G, Boonen S, Casanueva FF, Giwercman A, et al. Characteristics of secondary, primary, and compensated hypogonadism in aging men: evidence from the European Male Ageing Study. *J Clin Endocrinol Metab.* 2010;95:1810–8.
- Takahara H, Cosentino MJ, Sakatoku J, Cockett AT. Significance of testicular size measurement in andrology. II. Correlation of testicular size with testicular function. *J Urol.* 1987;137:416–9.
- Tan MH, Eng C. Testicular microlithiasis: recent advances in understanding and management. *Nat Rev Urol.* 2011;8:153–63.
- Tanrikut C, McQuaid JW, Goldstein M. The impact of varicocele and varicocele repair on serum testosterone. *Curr Opin Obstet Gynecol.* 2011;23:227–31.
- Tasian GE, Copp HL. Diagnostic performance of ultrasound in nonpalpable cryptorchidism: a systematic review and meta-analysis. *Pediatrics.* 2011;127:119–28.
- Taverna G, Morandi G, Seveso M, Giusti G, Benetti A, Colombo P, Minuti F, Grizzi F, Graziotti P. Colour Doppler and microbubble contrast agent ultrasonography do not improve cancer detection rate in transrectal systematic prostate biopsy sampling. *BJU Int.* 2011;108(11):1723–7.
- Tefekli A, Cayan S, Uluocak N, Poyanli A, Alp T, Kadioğlu A. Is selective internal spermatic venography necessary in detecting recurrent varicocele after surgical repair? *Eur Urol.* 2001;40:404–8.
- Tekgül S, Riedmiller H, Dogan HS, Hoebeke P, Kocvara R, Nijman R, Chr R, Stein R. Guidelines on paediatric urology, European Association of Urology Guidelines. In: EAU Guidelines Office. The Netherlands: Arnhem; 2008.
- Terasaki T, Watanabe H, Kamoi K, Naya Y. Seminal vesicle parameters at 10-year intervals measured by transrectal ultrasonography. *J Urol.* 1993;150:914–6.
- Tournaye H, Verheyen G, Nagy P, Ubaldi F, Goossens A, Silber S, Van Steirteghem AC, Devroey P. Are there any predictive factors for successful testicular sperm recovery in azoospermic patients? *Hum Reprod.* 1997;12:80–6.
- Trost LW, Brannigan RE. Oncofertility and the male cancer patient. *Curr Treat Options in Oncol.* 2012;13:146–60.
- Tsili AC, Giannakis D, Sylakos A, Ntorkou A, Sofikitis N, Argyropoulou MI. MR imaging of scrotum. *Magn Reson Imaging Clin N Am.* 2014;22(2):217–38.
- Turunc T, Gul U, Haydardedeoglu B, Bal N, Kuzgunbay B, Peskircioglu L, Ozkardes H. Conventional testicular sperm extraction combined with the microdissection technique in nonobstructive azoospermic patients: a prospective comparative study. *Fertil Steril.* 2010;94:2157–60.
- van Casteren NJ, Looijenga LH, Dohle GR. Testicular microlithiasis and carcinoma in situ overview and proposed clinical guideline. *Int J Androl.* 2009;32:279–87.
- Vicari E. Seminal leukocyte concentration and related specific reactive oxygen species production in patients with male accessory gland infections. *Hum Reprod.* 1999;14:2025–30.
- Virtanen HE, Toppari J. Embryology and physiology of testicular development and descent. *Pediatr Endocrinol Rev.* 2014;11(Suppl 2):206–13.
- Vohra S, Morgentaler A. Congenital anomalies of the vas deferens, epididymis, and seminal vesicles. *Urology.* 1997;49:313–21.
- Walsh TJ, Croughan MS, Schembri M, Chan JM, Turek PJ. Increased risk of testicular germ cell cancer among infertile men. *Arch Intern Med.* 2009;169:351–6.

- Wang C, Nieschlag E, Swerdloff R, Behre HM, Hellstrom WJ, Gooren LJ, Kaufman JM, Legros JJ, Lunenfeld B, Morales A, Morley JE, Schulman C, Thompson IM, Weidner W, Wu FC. ISA, ISSAM, EAU, EAA and ASA recommendations: investigation, treatment and monitoring of late-onset hypogonadism in males. *Int J Impot Res.* 2009;21:1–8.
- Westlander G, Ekerhovd E, Granberg S, Lycke N, Nilsson L, Werner C, Bergh C. Serial ultrasonography, hormonal profile and antisperm antibody response after testicular sperm aspiration. *Hum Reprod.* 2001;16:2621–7.
- Woodward PJ, Sohaey R, O'Donoghue MJ, Green DE. From the archives of the AFIP: tumors and tumorlike lesions of the testis: radiologic-pathologic correlation. *Radiographics.* 2002;22:189–216.
- Woodward PJ, Schwab CM, Sesterhenn IA. From the archives of the AFIP: extratesticular scrotal masses: radiologic-pathologic correlation. *Radiographics.* 2003;23:215–40.
- World Health Organization. WHO laboratory manual for the examination and processing of human semen. 5th ed. Geneva: WHO Press; 2010.
- Yee WS, Kim YS, Kim SJ, Choi JB, Kim SI, Ahn HS. Testicular microlithiasis: prevalence and clinical significance in a population referred for scrotal ultrasonography. *Korean J Urol.* 2011;52:172–7.
- Yu J, Chen Z, Ni Y, Li Z. CFTR mutations in men with congenital bilateral absence of the vas deferens (CBAVD): a systemic review and meta-analysis. *Hum Reprod.* 2012;27:25–35.
- Yusuf G, Konstantatou E, Sellars ME, Huang DY, Sidhu PS. Multiparametric sonography of testicular hematomas: features on grayscale, color Doppler, and contrast-enhanced sonography and strain elastography. *J Ultrasound Med.* 2015;34:1319–28.
- Zhao H, Luo J, Wang D, Lu J, Zhong W, Wei J, Chen W. The value of transrectal ultrasound in the diagnosis of hematospermia in a large cohort of patients. *J Androl.* 2012;33:897–903.
- Ziaee SA, Ezzatnegad M, Nowroozi M, Jamshidian H, Abdi H, Hosseini Moghaddam SM. Prediction of successful sperm retrieval in patients with nonobstructive azoospermia. *Urol J.* 2006;3:92–6.
- Zini A, Boman JM. Varicocele: red flag or red herring? *Semin Reprod Med.* 2009;27:171–8.

Ewa Rajpert-De Meyts, Kenneth M. Grigor, and Niels E. Skakkebaek

---

## Abstract

The histopathological evaluation of a testicular biopsy is a very important part of the diagnostic workup of andrological patients with azoospermia or severe oligozoospermia as well as men at risk for germ cell neoplasia in situ. The biopsy is also often the only way for infertile men to become biological fathers. In this chapter, clinical and research-related indications for open testicular biopsy in adult men are discussed. Technical issues related to the handling and processing of tissue samples as well as the use of helpful immunohistochemical markers of different cell types and maturation stages are also briefly reviewed. Typical histopathological patterns associated with azoospermia and impaired spermatogenesis in andrological patients are described in detail and illustrated. Examples of early stages of testicular cancer, germ cell neoplasia in situ, and other manifestations of testicular dysgenesis that can be encountered in a testicular biopsy are also presented. The review underlines the importance of testicular biopsy as a diagnostic tool and research resource.

---

## Keywords

Azoospermia • Impaired spermatogenesis • Germ cell neoplasia in situ • Sertoli cell-only syndrome • Spermatogenic arrest • Testis histology • Testicular dysgenesis syndrome • Microlithiasis • Immunohistochemistry

---

E. Rajpert-De Meyts (✉) • N.E. Skakkebaek  
Department of Growth and Reproduction, Rigshospitalet, University of Copenhagen and EDMaRC, Copenhagen, Denmark  
e-mail: [erm@rh.dk](mailto:erm@rh.dk); [erdemeyts@gmail.com](mailto:erdemeyts@gmail.com); [nes@rh.dk](mailto:nes@rh.dk)

K.M. Grigor  
Department of Pathology, University of Edinburgh, Edinburgh, Scotland, UK  
e-mail: [ken.grigor@blueyonder.co.uk](mailto:ken.grigor@blueyonder.co.uk)

## Contents

Introduction .....	624
Indications for Testicular Biopsy .....	625
Evaluation and Classification of Spermatogenesis .....	625
Detection of Early Stages of Germ Cell Neoplasia .....	626
Biopsy Preparation and Immunohistochemical Markers .....	627
Surgical Procedure .....	627
Tissue Processing .....	628
Immunohistochemical Markers .....	628
Histological Patterns Found in a Testicular Biopsy .....	629
Normal Testis Histology .....	629
Sertoli Cell-only Syndrome (SCOS) .....	629
Spermatogenic Arrest .....	631
Prepubertal Pattern in an Adult Man .....	631
Hypospermatogenesis .....	632
Tubular Hyalinization: Klinefelter Syndrome Pattern .....	633
Inflammatory Changes .....	634
Germ Cell Neoplasia in Situ (GCNIS) and Testicular Dysgenesis .....	635
Early Invasive Germ Cell Neoplasms .....	637
Testicular Adrenal Rest Tumor (TART) .....	638
Reporting on Testicular Biopsy .....	638
Summary and Conclusion .....	640
Cross-References .....	641
References .....	641

---

## Introduction

Testicular biopsy is an important diagnostic test in andrology, urology, and genitourinary oncology. A thorough physical examination and a comprehensive evaluation of other diagnostic tests, especially semen analysis, reproductive hormone profile, and selected genetic tests, must be scrutinized before making decisions on the biopsy. This is a surgical procedure, so it has to be undertaken sparingly and only in well-justified cases. The open biopsy, however, gives a necessary direct insight into testicular histology and is often instrumental in establishing the diagnosis. This is particularly true if germ cell maturation arrest, including early germ cell neoplasia, is suspected; no biochemical or genetic tests have been developed as yet to detect these lesions, although some inroads have been made into developing noninvasive approaches.

The great progress in endocrine and genetic testing over the decades has made it possible to avoid taking biopsies in an increasing number of patients. On the other hand, the explosive development in assisted reproductive technologies (ART) has resulted in a huge increase in testicular sperm extraction (TESE) procedures, usually performed by fine needle aspiration (FNA) in fertility clinics, where the primary aim is the retrieval of late spermatids for use in intracytoplasmic sperm injection (ICSI). FNA and TESE will not be further discussed here; this chapter focusses on the histopathological evaluation of open testicular biopsies, which give the most detailed information on the testicular histology and architecture as well as on the presence

and maturation stage of all cell types, not only germ cells but also testicular somatic cells. This chapter discusses the indications for testicular biopsy and presents typical histopathological patterns associated with male infertility. A substantial part is devoted to manifestations of testicular dysgenesis, which might be encountered in an adult patient, in particular detection and evaluation of the preinvasive testicular cancer, the so-called germ cell neoplasia in situ (GCNIS), previously known as *carcinoma in situ* (CIS) (Skakkebaek 1972).

---

## Indications for Testicular Biopsy

In the vast majority of cases, a testicular biopsy from adult men is performed for one of the following main indications:

- Evaluation and classification of spermatogenesis in infertile men with azoospermia or cryptozoospermia/oligozoospermia, including clinical workup, research projects, and clinical trials (depending on the aim of the project and ethical considerations), as well as isolation and cryopreservation of late spermatids for ART
- Detection of early preinvasive neoplastic changes

These indications are described and discussed below.

## Evaluation and Classification of Spermatogenesis

In this group of patients, usually referred to the clinics because of infertility, the main indication for a biopsy is azoospermia. The referral for biopsy has to be made after at least two semen sample examinations (with an interval of several days) have shown the absence of spermatozoa in the ejaculate. It is important to underline that “azoospermia” is a sign and not a diagnosis. In azoospermic patients the main purpose of the biopsy is to differentiate between obstructive azoospermia (OA) and nonobstructive azoospermia (NOA), the latter caused by testicular failure. NOA is most often associated with a complete lack of sperm, or only very few spermatozoa usually detectable only after centrifugation of the ejaculate (cryptozoospermia). Reproductive hormone profiles can give a strong indication as to whether the testis is functioning properly, thus helping to distinguish the two forms of azoospermia. For example, normal levels of serum gonadotropins, testosterone, and inhibin B are indicative of OA, although a normal or nearly normal hormone profile can also be found in rare cases of a late-stage spermatogenic arrest. In all cases of suspected OA, it is important to exclude vasectomy and to test for a mutation causing congenital absence of the vas deferens (e.g., in cystic fibrosis). Conversely, a high serum FSH with a very low or undetectable inhibin B level would be indicative of NOA.

Previously, patients with severe NOA phenotypes, especially those with a known genetic aberration such as Klinefelter syndrome or a complete AZFc deletion of the Y chromosome, would not be referred for testicular biopsy. However, the hormone profile might sometimes be equivocal or might not match other clinical features. In such cases, testicular biopsies are very informative and can give not only the accurate diagnosis but also prognosis for subsequent treatment.

The advent of ART and discovery of small pockets of ongoing spermatogenesis, even in men with non-mosaic Klinefelter syndrome, created a possibility of harvesting some sperm by TESE for ICSI treatment (Tournaye et al. 1996; Tüttelmann et al. 2011), especially in younger patients. It is important during TESE to reserve a small intact portion of tissue for careful histopathological evaluation of spermatogenesis and detection of other pathological changes, e.g., GCNIS (Schulze et al. 1999).

A detailed classification of spermatogenesis, which is only possible by testicular biopsy, might be required in the course of research projects and clinical trials to correctly classify a spermatogenic disorder in men with poor semen quality. Different spermatogenic disorders may lead to similar outcomes of oligozoospermia, teratozoospermia, or azoospermia. In many cases, a biopsy will be the only informative information on the underlying disorder. It is also important to establish the testicular phenotype in patients with novel genetic aberrations. Histology of the testis from infertile patients can be very variable, ranging from complete normality, e.g., in men with OA, to the complete lack of germ cells, with intermediate patterns of spermatogenic arrest at various stages of germ cell maturation. Discordant patterns between a patient's two testicles, as well as histological heterogeneity with a mixture of different patterns within a single testis, are not uncommon (Cooperberg et al. 2005). Hence it is very important always to perform bilateral biopsies. The mechanism of discordant patterns, e.g., the presence of tubules with normal spermatogenesis side by side with tubules devoid of germ cells, is not clear. Developmental disturbances are suspected if a proportion of tubules contain only Sertoli cells but no germ cells, whereas a mixture of complete spermatogenesis and atrophic tubules is suggestive of secondary impairment.

## **Detection of Early Stages of Germ Cell Neoplasia**

Men with fertility problems, including those with cryptorchidism or a history of problems with testicular descent and other genital malformations, are at increased risk of testicular germ cell cancer (Giwerzman et al. 1989; Jacobsen et al. 2000). These disorders are often associated with an impaired early development of the gonads and have been placed together within one clinical entity, the testicular dysgenesis syndrome (TDS) (Skakkebaek et al. 2001). The fetal development of the testis determines, to a large extent, its endocrine function and quality of spermatogenesis in later life. Germ cells appear to be exquisitely sensitive to the signals from somatic cells during development, and a disturbance of this cross talk will often lead to the arrest of germ cell differentiation at the fetal gonocyte stage.

Persisting gonocytes physiologically express pluripotency-related factors such as OCT3/4 (POU5F1 or NANOG). In the peripubertal period, these cells respond to endogenous hormonal stimulation resulting in an increased proliferation and transformation into GCNIS (Sonne et al. 2009) which is the precursor lesion of testicular germ cell tumors that occur in young adults, namely, seminoma or non-seminoma. This precursor lesion has been previously called carcinoma in situ (CIS), intratubular germ cell neoplasia unclassified (IGCNU), or testicular intraepithelial neoplasia (TIN); however, these terms have been replaced by germ cell neoplasia in situ (GCNIS) during a WHO expert panel consensus meeting (Ulbricht et al. 2016).

Not all infertile men should be automatically referred for testicular biopsy if they have normal sized testicles and reasonably good sperm production. At least one sign suggestive of an increased risk of neoplasia should be present. Studies have provided evidence that the risk of harboring GCNIS is especially high in men with poor semen quality in conjunction with small testicles or other signs of testicular atrophy. Microlithiasis and hyalinization can occur in atrophy and are usually manifest as “snow” or an irregular echo pattern in scrotal ultrasound examinations (Lenz et al. 1987; Elzinga-Tinke et al. 2010). Men with palpable tumors, or tumors visible on ultrasound, should not be biopsied but should be referred directly for surgical exploration during which an immediate histopathological evaluation of the tumor should be performed by frozen section.

Detecting GCNIS in the remaining contralateral testicle is also important in patients with unilateral testicular germ cell cancer in order to prevent the development and dissemination of a second cancer which might require aggressive treatment. GCNIS is detected in the contralateral testicle in approximately 2–8% of patients with clinical unilateral cancer, the range of frequency depending on the studied cohort, patient selection, and methodology (Dieckmann et al. 2011). This preinvasive lesion can be eradicated by low-dose radiation therapy (Petersen et al. 2002). Contralateral biopsies are routinely performed in some centers (Denmark, parts of Germany, Sweden, and the Netherlands), whereas in other parts of the world the procedure is not performed or is reserved for patients at increased risk (small testis volume, decreased sperm concentration, or ultrasonically detected microlithiasis) (Dieckmann et al. 2011; Rud et al. 2013).

---

## Biopsy Preparation and Immunohistochemical Markers

### Surgical Procedure

Testicular biopsies can be taken under local or general anesthesia, the latter likely to be the choice of most patients. The biopsy is considered to be a low-risk procedure, with only 2.8% minor complications reported (Bruun et al. 1987; Dieckmann et al. 2005). The skill of a urologist performing the biopsy is important, with three golden rules – the incision spot should avoid large vessels, the tissue should not be mechanically squeezed or fragmented, and the sample should be of sufficient size (Dieckmann et al. 2011). The technical issues are essential, because neglect at any

stage will impair the quality of the final specimen and might render the histopathological evaluation difficult or even impossible. A representative open biopsy should have a minimum size of  $3 \times 3 \times 3$  mm so as to include approximately 100 tubules in a cross section. In most cases a single biopsy per testis is sufficient, but if the diagnosis of GCNIS is the primary aim of the biopsy, two-site biopsies from the same testicle are often advised, especially in young patients with normal-size testicles, as the gain of diagnostic sensitivity can be up to 17% of such cases (Dieckmann et al. 2007; Ruf et al. 2015).

## Tissue Processing

The biopsy must be placed immediately in a fixative, preferably one enabling good preservation of morphological detail of the soft testis tissue, such as Bouin's fluid or similar fluids, e.g., GR fixative developed and used in Copenhagen. However, these fixatives might have the drawback of being less suitable for immunochemistry, but the availability of robust antibodies and special antigen retrieval protocols (e.g., in a standardized pressure cooker) has largely eliminated this drawback. Each biopsy should be further processed and paraffin-embedded in a pathology department or specialized histology laboratory. The tissue blocks should be cut into a large number of serial sections, divided among several slides, because the testis histology is often heterogeneous and the pattern at one end of the sample might differ from that at the other end. In addition to hematoxylin-eosin (HE) staining of the bulk of the sections, a few slides may be stained with periodic acid-Schiff (PAS) or Masson trichrome stains, which help to detect microliths and ghost tubules and enhance detection of tubule wall thickening or hyalinization. Additional sections should be cut and reserved for immunohistochemical staining.

## Immunohistochemical Markers

At least one immunohistochemical marker for GCNIS or microinvasive germ cell cancer must be included in evaluation of each testicular biopsy (van Casteren et al. 2009). In the Copenhagen center, two different GCNIS markers are used, which are placed at the beginning and the end of the glass series. The following markers, for which robust antibodies are available on the market, are recommended in daily practice: placental-like alkaline phosphatase (PLAP), pluripotency-related transcription factor OCT3/4 (POU5F1), or podoplanin (PDPN, D2-40, or M2A antigen) (Rajpert-De Meyts et al. 2015). In addition to markers of neoplastic cells, it is advisable to include an immunohistochemical marker for normal spermatogonia/early primary spermatocytes (e.g., MAGE-A4 or VASA), because this facilitates detection of single spermatogonia in cases of widespread occurrence of Sertoli cell-only (SCO) pattern or severe atrophy, for example, in specimens from men with Klinefelter syndrome. Depending on the clinical picture, additional immunohistochemical markers can be included on a case-by-case basis, to recognize the presence of somatic cells or their



maturation stage, for example, immature Sertoli cells (e.g., AMH), Leydig cells (e.g., INSL3 or CYP11A1), peritubular cells (vimentin), and inflammatory cells (e.g., CD45 for all white cells, CD3 for T cells, CD20 for B cells, CD60 for macrophages). It is important to include proper positive and negative controls.

---

## Histological Patterns Found in a Testicular Biopsy

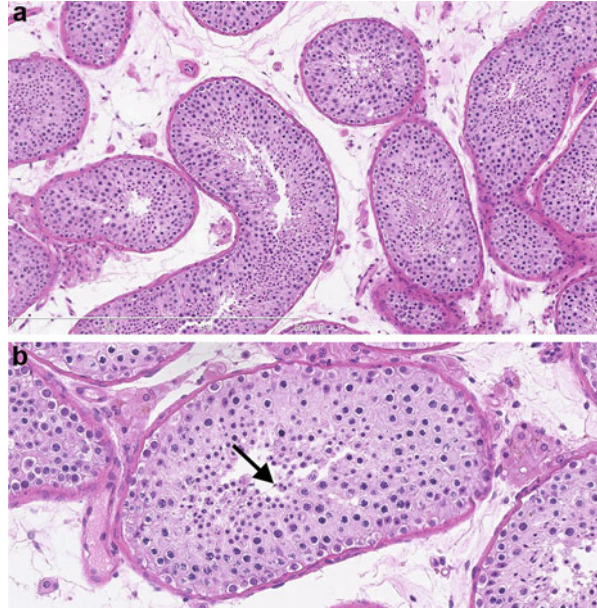
### Normal Testis Histology

Normal testis parenchyma contains two main compartments: seminiferous epithelium and the interstitial compartment. Here, only a brief list of the cellular components is given; for a detailed description, the reader should consult another chapter in this volume (► [Chap. 9, “Functional Anatomy and Histology of the Testis”](#) by Bergmann et al.). Normal seminiferous tubules in an adult man are delineated by a few layers of peritubular cells and contain a columnar layer of Sertoli cells intertwined with germ cells at different maturation stages: spermatogonia A dark and pale, which are located at the basement membrane; spermatogonia B, numerous primary spermatocytes at different meiotic stages (leptotene, zygotene, pachytene, and diplotene), few secondary spermatocytes, and a good number of small round spermatids (Sa, Sb); and late spermatids (Sc, Sd), including well-condensed mature spermatids Sd2 and residual bodies. Mature Sertoli cells contain an invaginated oval or triangular nucleus with a prominent nucleolus. A normal interstitial compartment contains blood- and lymphatic vessels and small groups of Leydig cells, distinguished by regular round nuclei and prominent cytoplasm that usually contains small lipid droplets. Reinke crystalloids are frequently observed in some of the Leydig cells. Other cell types present in the interstitial space are fibroblasts, nerve cells, macrophages, mast cells, and dendritic cells. As active spermatogenesis continues throughout the life span of a man, a general histological picture remains largely unchanged, albeit with pronounced individual heterogeneity. There is agreement that in most men there is a slow and gradual decline, with Sertoli cells morphology and Leydig cells numbers most affected, as well as increasing fibrotic changes in the interstitium (Perheentupa and Huhtaniemi 2009). However, in general, the aging process usually appears late. An example of normal testis tissue in a man in the fifth decade of his life is shown in Fig. 1.

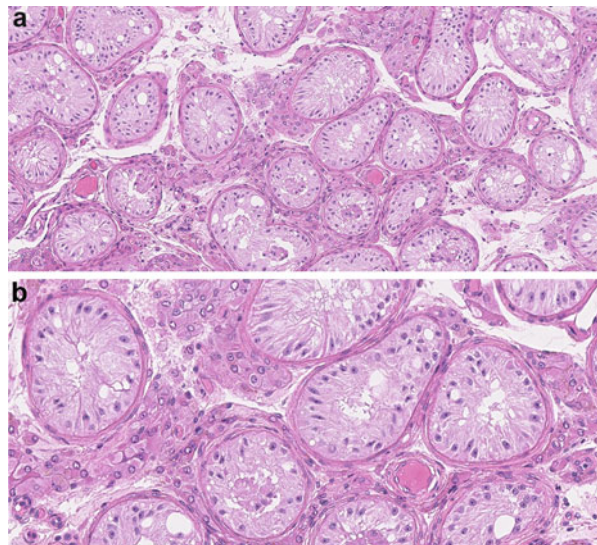
### Sertoli Cell-only Syndrome (SCOS)

This phenotype is defined as the complete absence of germ cells within tubules containing preserved Sertoli cells and is sometimes termed germinal aplasia. In some cases, this condition is considered congenital as in the XX-male syndrome. SCOS, however, might be a secondary feature caused by toxic exposure, including chemotherapy, irradiation, or prolonged androgen therapy. In biopsies from infertile men, a heterogeneous pattern is often seen with SCO tubules mixed with tubules containing germ cells, but this pattern should not be classified as SCOS (see section

**Fig. 1** Normal testis histology (a normal contralateral biopsy in a 41-year-old man with tumor in his other testis). Picture (a) shows the general architecture of the testis, with well-developed seminiferous epithelium and small groups of Leydig cells visible in the interstitial compartment. The close-up picture (b) shows a cross section of one tubule with all stages of germ cell maturation present, including a mature late spermatid with a flagellum (*arrow*)

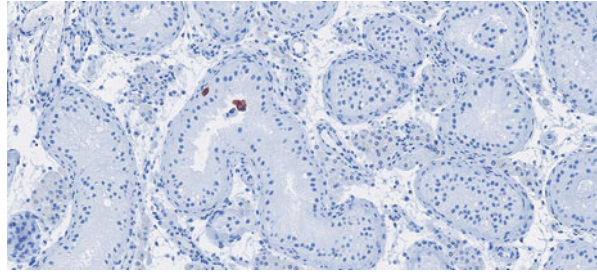


**Fig. 2** Sertoli cell-only (SCO) pattern in an infertile man with azoospermia (bilateral pattern). The hallmark of this pattern is complete absence of germ cells. Picture (a) shows an overview. Tubules contain only Sertoli cells, some with large vacuoles. The interstitial tissue shows clusters of Leydig cells. The picture (b) shows a close-up: note well-differentiated Sertoli cells



“[Hypospermatogenesis](#)”). In a typical SCOS pattern as in congenital aplasia, the seminiferous tubules have normal membranes and only slightly decreased diameter containing well-differentiated Sertoli cells as the only cell type and nuclei usually lined in a single row near the basal membrane (Fig. 2).

**Fig. 3** Careful examination of a biopsy with presumed Sertoli cell-only (SCO) pattern is needed to detect the presence of germ cells. Immunohistochemical staining for MAGE-A4 is very helpful to detect even single spermatogonia (stained *red*)



In some patients, Sertoli cells might display signs of immaturity, sometimes with small undifferentiated Sertoli cells filling the tubule (see section “[Germ Cell Neoplasia in Situ \(GCNIS\) and Testicular Dysgenesis](#)”). In secondary SCOS cases, e.g., after radiotherapy, tubular walls can be thickened and Sertoli cells might contain vacuoles or display signs of degeneration. Tubules should be assessed for the presence of germ cells, because even if very few are present, there are prospects of focal pockets of full spermatogenesis, opening the possibility for ART treatment. The use of immunohistochemistry can help to identify germ cells (Fig. 3).

## Spermatogenic Arrest

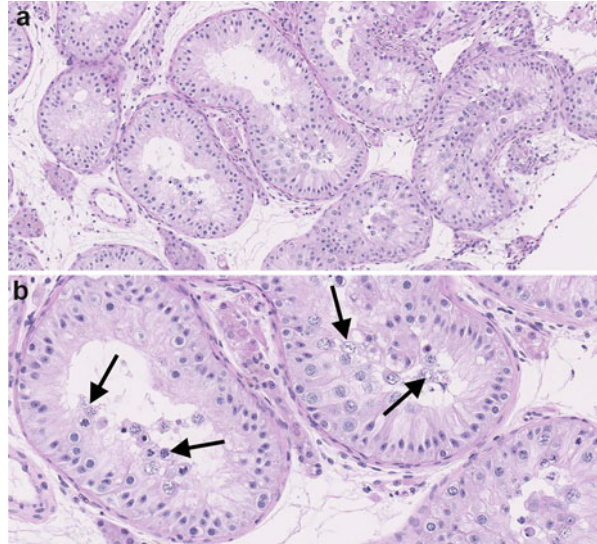
This pattern is characterized by an arrest of maturation of germ cells, which can occur at different stages. Pure patterns with uniform arrest in all tubules are relatively rare (McLachlan et al. 2007). The arrest at the stage of primary spermatocytes, or spermatocytic arrest, is the most common and is usually caused by a genetic error disrupting the process of meiosis as, e.g., in complete AZFb deletion or *TEX11* mutations. In this pattern all haploid cells, including round and late spermatids, are absent (Fig. 4). Primary spermatocytes are often abnormal, with poorly adhering chromatids sometimes visible in pachytene spermatocytes.

Apoptotic cells can also be seen in the lumen of tubules. Incomplete forms of spermatocytic arrest, with single round spermatids present, are occasionally reported. A uniform arrest at the stage of round spermatids is relatively rare. An even rarer finding is the universal arrest of maturation at the spermatogonial level. More often, a mixture of tubules showing spermatocytic arrest with tubules containing only spermatogonia and occasionally some SCO tubules can be seen, e.g., in patients with large deletions in the AZF region, suggestive of progressive depletion of germ cells.

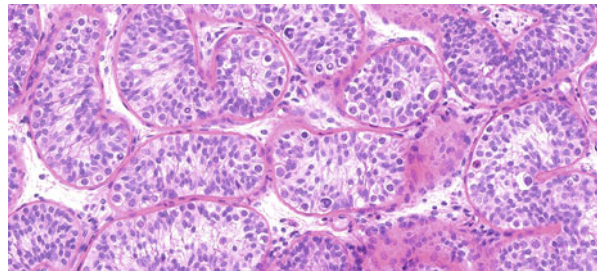
## Prepubertal Pattern in an Adult Man

An example of a reversible arrest of testicular development is the prepubertal pattern observed in biopsies from patients with hypogonadotropic hypogonadism. This is a rare finding, because these patients are usually diagnosed in childhood, but occasionally

**Fig. 4** Spermatogenic maturation arrest at the level of primary spermatocytes. No haploid cells (round or late spermatids) are visible in the biopsy (a). Picture (b) shows a higher magnification of tubules: note abnormal spermatocytes that cannot complete meiosis and degenerate (arrows)



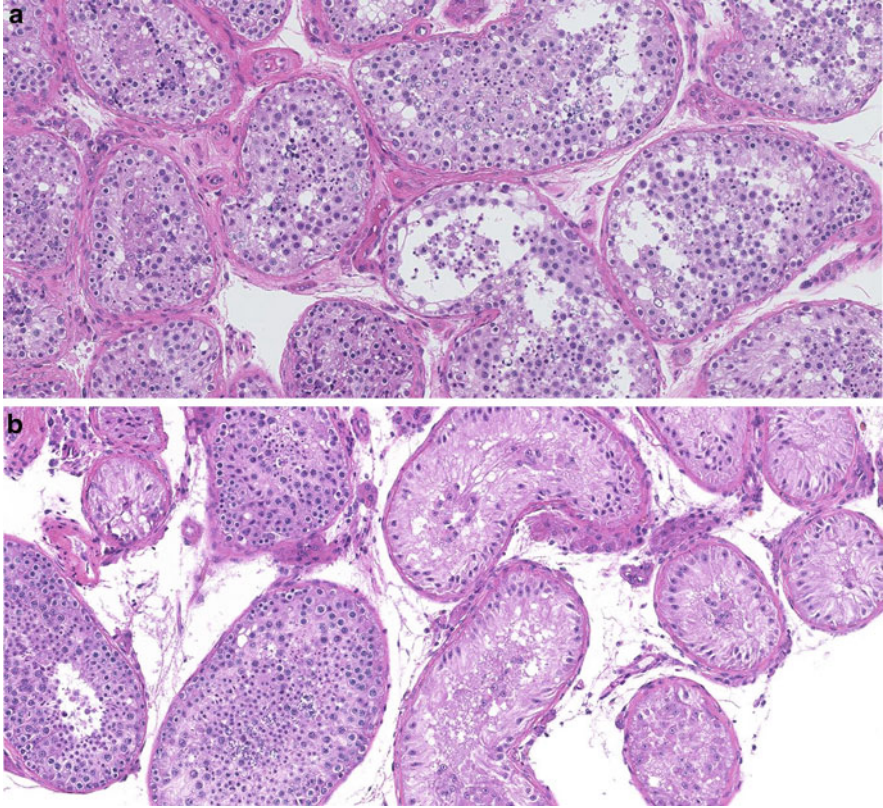
**Fig. 5** An example of a prepubertal testicular pattern in an adult patient with hypogonadotropic hypogonadism. Note undifferentiated Sertoli cells and lack of germ cell maturation beyond spermatogonia



there might be a delay of diagnosis until young adulthood. In this pattern only spermatogonia are found in the tubules and the germ cell maturation arrest is accompanied by the immature appearance of tubules with undifferentiated Sertoli cells, which are small; contain smaller, round nuclei; and are usually present in several layers. Usually, a relative paucity of Leydig cells is observed in the interstitial compartment (Fig. 5).

## Hypospermatogenesis

This is a very common pattern found in testicular biopsies of infertile men and is defined by the presence of late spermatids at least in a few tubules or a uniformly markedly decreased number of spermatids in the biopsy (McLachlan et al. 2007). Tubules with decreased spermiogenesis are often mixed with tubules having more severely impaired spermatogenesis, including SCO. The mechanism of such



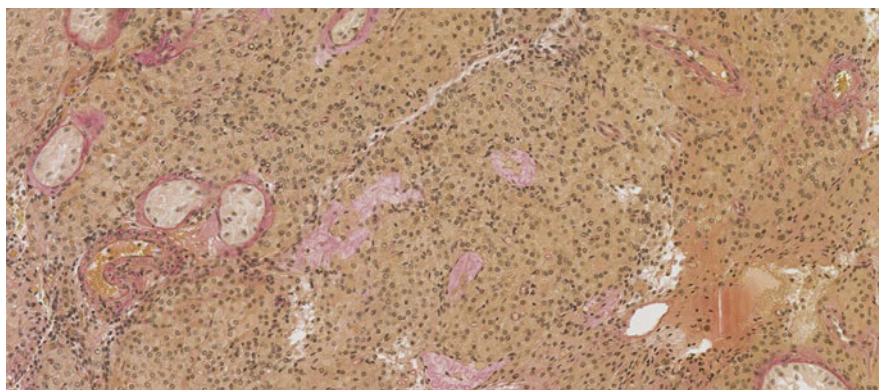
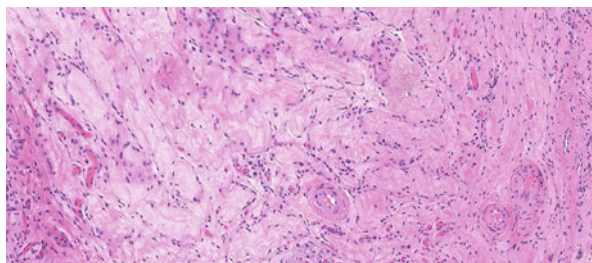
**Fig. 6** Two histological manifestations of decreased spermatogenesis (hypospermatogenesis). In the picture (a), a pattern with uniformly decreased number of late spermatids is shown. Picture (b) shows a quite common heterogeneous pattern with a mixture of tubules with normal spermatogenesis (on the left) and SCO tubules (on the right side)

discordant patterns remains poorly understood, but their presence must be kept in mind by attending clinicians, especially if ART is considered. Both uniform and heterogeneous patterns of hypospermatogenesis can be accompanied by other abnormalities, such as decreased tubule diameter, thickened tubular membranes, or the presence of abnormal germ cells with pyknotic nuclei suggestive of increased apoptosis (Fig. 6). Sertoli cells might display cytoplasmic vacuoles. In the interstitial compartment, larger clusters of Leydig cells (micronodules) are often seen.

### **Tubular Hyalinization: Klinefelter Syndrome Pattern**

In some patients with infertility, a prevalent pattern is testicular atrophy, with extensive hyalinization (sclerosis) of seminiferous tubules, sometimes extending to

**Fig. 7** Extensive hyalinization in a testicular biopsy from an infertile patient (normal 46,XY karyotype)



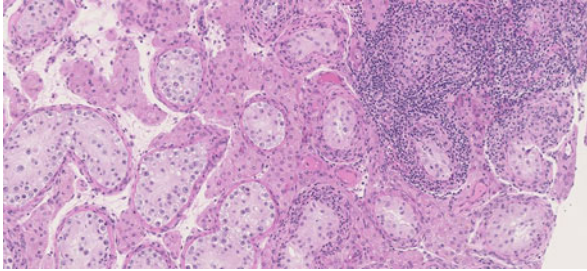
**Fig. 8** A biopsy from a patient with Klinefelter syndrome (47,XXY). Note huge nodules of Leydig cells and lack of spermatogenesis. Only a few SCO tubules are present. Completely hyalinized “ghost” tubules are stained in pale pink (trichrome stain)

all tubules (Fig. 7). The tubules are devoid of any cellular content, including Sertoli cells, but Leydig cells are usually present in the interstitial space. Such a pattern might be the end result of orchitis or ischemia.

Extensive hyalinization, with numerous ghost tubules and very large nodular aggregates of Leydig cells, is typical for testicular histology in adult patients with Klinefelter syndrome (Fig. 8). Pathognomonic for these patients, especially in younger men, is the additional presence of two morphologically different types of SCO tubules, some containing normally differentiated Sertoli cells and others filled with immature Sertoli cells, which are usually AMH-positive and can contain visible Barr bodies (Skakkebak 1969).

## Inflammatory Changes

The presence of inflammatory changes is common in testicular biopsies. These changes can accompany an infectious orchitis, but in this condition a biopsy is



**Fig. 9** Inflammatory changes in a testicular biopsy with germ cell neoplasia in situ (GCNIS), with lymphocytic infiltrates around, and within tubules with GCNIS. The GCNIS tubules contain only GCNIS cells and Sertoli cells and have no ongoing spermatogenesis

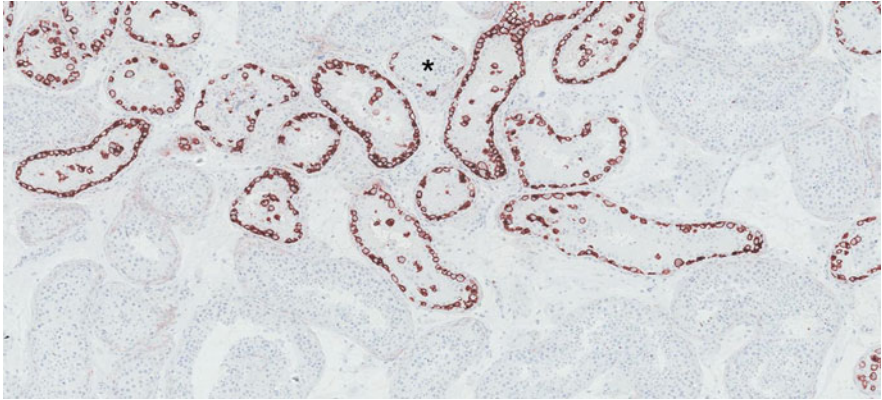
usually not taken. In some patients with chronic subclinical orchitis, degeneration of seminiferous tubules is seen. The tubules might be filled with inflammatory cells forming a granulomatous-like pattern. Complete hyalinization of seminiferous tubules can be the final result of orchitis.

In most cases, however, inflammatory changes visible in a testicular biopsy are considered to be an autoimmune reaction caused by reaction to a breached blood-testis barrier. Hence, infiltration with immune cells frequently accompanies hypospermatogenesis with partial testicular atrophy as well as GCNIS. These infiltrates are usually focal, mainly located within the interstitial space and around seminiferous tubules or tubules with GCNIS (Fig. 9). Occasionally some inflammatory cells might be visible within the tubules, the affected tubules often being partly hyalinized. The inflammatory cells are easy to distinguish in regular HE-stained sections because of their small size. The infiltrates consist of several cell types, most often T lymphocytes and macrophages, but B cells are also occasionally present, especially in specimens with GCNIS. In specialized centers, immunohistochemical analysis can help distinguish the cell subtypes (see section “[Immunohistochemical Markers](#)”).

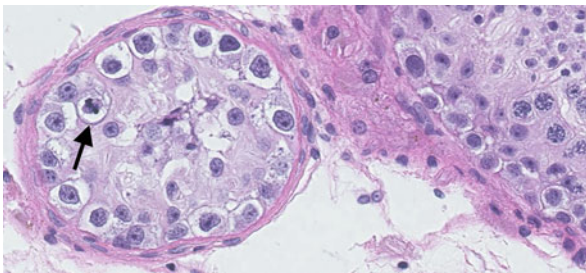
## **Germ Cell Neoplasia in Situ (GCNIS) and Testicular Dysgenesis**

GCNIS cells in a testicular biopsy from an adult man are typically located within tubules, where spermatogonia are normally situated, in a single row directly on the basal membrane, and Sertoli cells are the only other cell type present (Figs. 9, 10, and 11).

GCNIS cells are larger than spermatogonia and have large nuclei, with irregular clumps of chromatin and prominent nucleoli (Fig. 11). The tubules with GCNIS usually have significantly thickened basement membranes. Sertoli cells are usually well differentiated, but occasionally some degree of immaturity can also be seen. In some tubules, GCNIS cells can be multilayered or situated close to the lumen. Their spread might occasionally be observed inside tubules along with ongoing spermatogenesis. Invasion of the rete testis by GCNIS cells can be found in orchietomy specimens, but this will rarely be visible in a testicular biopsy.



**Fig. 10** An example of germ cell neoplasia in situ (GCNIS) in a contralateral testis biopsy from a patient with testicular cancer. The GCNIS cells are clearly visible delineated by the immunohistochemical staining for the marker D2-40/PDPN. The affected tubules show a typical pattern with only GCNIS cells and Sertoli cells present, except one tubule (*asterisk*) where there is some ongoing spermatogenesis

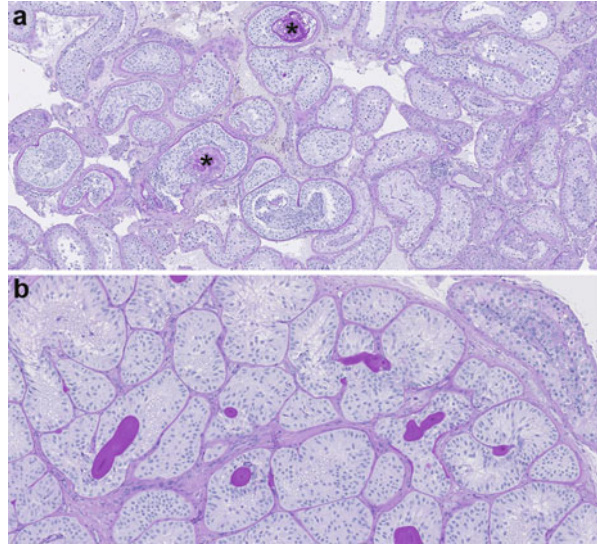


**Fig. 11** A large magnification of a tubule with GCNIS (*left*). For comparison a fragment of a tubule with preserved complete spermatogenesis is shown on the right. Note the small diameter of the tubule with GCNIS. The GCNIS cells contain large nuclei with irregular chromatin and prominent nucleoli. One mitotic figure is seen (*arrow*)

The percentage of tubules with GCNIS in a biopsy is variable from just a few tubules to 100%. Other tubules can be normal with good or decreased spermatogenesis, but signs of testicular dysgenesis are commonly found in biopsies with GCNIS. These features include poorly developed tubules, often with underdeveloped, thin tubular membranes and the presence of intratubular microcalcifications (microliths) (Fig. 12). Dysgenetic tubules usually show the SCO pattern with immature Sertoli cells. The interstitial tissue might contain clumps of morphologically heterogeneous Leydig cells. In men with severe forms of TDS, for example, in patients with hypospadias or cryptorchidism, tubules with GCNIS can sometimes display a pattern



**Fig. 12** Signs of testicular dysgenesis in biopsies from two patients. **(a)** A biopsy from a patient with a germ cell tumor. Several distorted tubules with undifferentiated Sertoli cells and large microliths (asterisks) are visible. **(b)** A biopsy from an infertile man. Note a cluster of dysgenetic tubules with poorly differentiated Sertoli cells. In the upper right corner, a tubule with an ongoing spermatogenesis is seen. In both specimens PAS staining helps to detect intensely stained microliths



resembling gonadoblastoma, with poorly differentiated Sertoli cells that are morphologically similar to ovarian granulosa cells.

Tubules with GCNIS can be accompanied by infiltrates of inflammatory cells (see section “[Inflammatory Changes](#)”). The recognition of GCNIS might be difficult in formalin-fixed biopsies but is greatly facilitated by immunohistochemical staining with one of the marker antibodies such as PLAP, OCT3/4, or D2-40 (Fig. 10: see also section on “[Immunohistochemical Markers](#)”).

## Early Invasive Germ Cell Neoplasms

In some biopsies with GCNIS, signs of early invasive transformation can occasionally be seen. This can be manifest by the presence of GCNIS-like cells in the interstitial compartment, which is usually described as microinvasive germ cell tumor. Detection of the microinvasion is greatly facilitated by immunohistochemical staining for tumor markers, such as PLAP or OCT3/4. In rare cases, most often in specimens with widespread GCNIS pattern, an intratubular growth of a tumor can be seen. Intratubular tumor growth is manifest as aggregates of tumor cells, either resembling seminoma or embryonal carcinoma. Such tubules usually do not contain any normal spermatogenic cells and can be distended by tumor cells.

In extremely rare cases, intratubular growth of spermatogonia-resembling cells might be seen. Such a pattern is considered to be an early preinvasive form of spermatocytic tumor, previously termed spermatocytic seminoma, a neoplasm which is unrelated to GCNIS (Ulbright et al. 2016). Spermatocytic tumor is diagnosed usually in men that are somewhat older (mean age around 50) than those usually referred to infertility clinics.

For differential diagnosis of all these early tumor types, immunohistochemical staining is very helpful. D2–40/PDPN (podoplanin) is positive in GCNIS and intratubular seminoma but not in embryonal carcinoma. Both GCNIS-derived tumor types are positive for OCT3/4. Early spermatocytic tumor is always negative for OCT3/4 but expresses spermatogonial markers, e.g., MAGE-A4, which is negative in seminoma and non-seminoma but can stain a subset of GCNIS cells (Rajpert-De Meyts et al. 2015).

## Testicular Adrenal Rest Tumor (TART)

TART is a benign growth and a part of the testicular phenotype in patients with congenital adrenal hyperplasia (CAH). CAH is usually diagnosed in early childhood, and only in milder forms will a testicular mass be the first clinical sign in an adult patient. A biopsy is rarely performed in patients with tumorlike masses, so this is a rare finding. TART usually regresses after dexamethasone treatment, and only rare cases require testis-sparing surgical resection. TART cells resemble Leydig cells (LC) morphologically and functionally and sometimes can be confused with Leydig cell tumors. TART cells express markers of adrenal steroidogenesis, e.g., CYP11B1, CYP21A2, and ACTH receptor/melanocortin 2 receptor (MC2R). INSL3, which is highly positive in normal and neoplastic Leydig cells, is not expressed in TART, thus helping in the differential diagnosis (Lottrup et al. 2015).

---

## Reporting on Testicular Biopsy

The stained sections should be assessed preferably by two evaluators experienced in testicular histology and recognition of early neoplastic changes. The evaluator's report on each biopsy ought to include a detailed assessment of spermatogenesis, including spermiogenesis. It is very important to look carefully for late spermatids and report on their presence, even if only a few can be seen, because this is a primary predictor of successful TESE. Likewise, the presence of even a few spermatogonia among SCO tubules should be noted, because this can give a clue as to what causes could be considered in the differential diagnosis. Heterogeneous patterns should preferably be assessed with some kind of scoring system to account for the relative occurrence of all stages of germ cell maturation from spermatogonia to late spermatids. The Copenhagen center has developed a four-digit testicular biopsy diagnosis code, which grades spermatogenesis in a semiquantitative manner (Table 1). The commonly used Johnsen's score is no longer recommended, because it does not take into account heterogeneous patterns (McLachlan et al. 2007).

A good histopathological report ought also to comment on the status of Leydig cells (e.g., hyperplasia or the presence of large micronodules), Sertoli cells (e.g., do these cells show signs of immaturity), peritubular cells, and tubular membranes (hyalinization), as well the presence of other pathological changes, such as inflammatory cells, microliths, ghost tubules, or any neoplastic cells (see examples in

**Table 1** Testicular biopsy diagnosis code based on the system used in the Copenhagen center (updated and modified from McLachlan et al. 2007). *SCO* sertoli cell-only pattern, *TDS* testicular dysgenesis syndrome, *GCNIS (CIS)* germ cell neoplasia in situ (carcinoma in situ), *GDB* gonadoblastoma, *TART* testicular adrenal rest tumor

<i>First digit</i> General pattern	<i>Second digit</i> Most prevalent pattern	<i>Third digit</i> Next important component	<i>Fourth digit</i> Other abnormalities
<b>1 Adult testis</b> (no neoplasia)	1. Homogeneous pattern, normal spermatogenesis 2. Homogeneous pattern, reduced spermatid number 3. Homogeneous pattern, spermatocytic arrest 4. Homogeneous pattern, only spermatogonia (and Sertoli cells) 5. Homogeneous pattern, SCO 6. Heterogeneous pattern, predominantly 1 or 2 7. Heterogeneous pattern, predominantly 3 8. Heterogeneous pattern, predominantly 4 9. Heterogeneous pattern, predominantly 5 <b>0</b> Other	1. Normal spermatogenesis 2. Reduced spermatid number 3. Spermatocytic arrest 4. Only spermatogonia (and Sertoli cells) 5. SCO 6. Hyalinized tubules 7. Undifferentiated tubules 8. TDS features (undifferentiated Sertoli cells, distorted tubules, microliths) 9. Klinefelter phenotype (two types of tubules + Leydig cell nodules) <b>0</b> Other	1. Lymphocytic infiltration 2. Fibrosis 3. Leydig cell clusters (micronodules) 4. Leydig aplasia (or strongly reduced number) 5. Hyaline bodies (microliths) or other TDS features 6. Granuloma (or 1 + 6) 7. 1 + 3 or 1 + 6 8. 3 + 5 or 1 + 3 + 5 9. Undifferentiated tubules <b>0</b> No abnormalities
<b>2 Prepubertal/fetal pattern</b> (no neoplasia)	1. Homogeneous pattern, normal numbers of spermatogonia/gonocytes 2. Homogeneous pattern, reduced numbers of spermatogonia/gonocytes 3. Heterogeneous pattern, sporadic germ cells 4. Homogeneous pattern, no germ cells 5. Ovarian tissue or ovary-like structures 6. Streak gonad 7. Ovotestis <b>0</b> Other	1. Only infantile spermatogonia 2. Spermatocytes present 3. Elongated spermatids in single tubules 4. Pubertal pattern (primary spermatocytes present) 5. Oocytes or primary follicles present 6. 1 + 5 or 2 + 5 (in ovotestis) 7. Hyalinized tubules 8. Gonocytes (PLAP+) present 9. Klinefelter phenotype (two types tubules + Leydig cell nodules) <b>0</b> Other	1. Lymphocytic infiltration 2. Fibrosis 3. Leydig hyperplasia (micronodules) 4. Leydig aplasia (or strongly reduced number) 5. Hyaline bodies (microliths) 6. Granuloma 7. 1 + 3 8. 3 + 5 9. Other <b>0</b> No other abnormalities

(continued)

**Table 1** (continued)

<i>First digit</i> General pattern	<i>Second digit</i> Most prevalent pattern	<i>Third digit</i> Next important component	<i>Fourth digit</i> Other abnormalities
<b>3 GCNIS (CIS), GDB, or other preinvasive neoplasias</b>	1. Adult pattern, only GCNIS and Sertoli cells 2. Adult pattern, GCNIS, and spermatogenesis 3. Adult pattern, 1 + 2 4. GCNIS, prepubertal pattern 5. GDB (gonadoblastoma) 6. GCNIS and GDB 7. TART 8. Leydig cell adenoma 9. Other	1. No invasion 2. Microinvasion into interstitial tissue 3. Invasion into rete testis 4. Atrophic tissue present 5. Only undifferentiated tumor cells outside the tubules 6. Undifferentiated tubules (Sertoli cells) 7. Hyalinized tubules 8. Necrosis 9. Ovarian-like structures <b>0</b> Other	1. Lymphocytic infiltration 2. Fibrosis 3. Leydig hyperplasia (micronodules) 4. Leydig aplasia (or strongly reduced nr) 5. Hyaline bodies (microliths) or other TDS features 6. Granuloma 7. 1 + 3 8. 3 + 5 9. Other <b>0</b> No other abnormalities

Other tissue types *B* Connective tissue, *E-S* Epididymis (spermatozoa visible), *E-0* Epididymis (no spermatozoa visible), *F* Fat tissue

Table 1). The presence or absence of GCNIS and/or microinvasive spread of early tumor cells should always be noted in a non-ambiguous manner. It should be noted which marker antibodies were used to support the diagnosis of neoplasia. A separate report should be prepared for each biopsy (left and right sided) in the cases of bilateral biopsies. Experienced evaluators should also give some advice to the attending physician, for example, if the pattern is consistent with Klinefelter syndrome or hypogonadotropic hypogonadism.

## Summary and Conclusion

Testicular biopsy is a very important diagnostic and research tool. The indications have changed over the years because a lot of information can be deduced from the semen analysis, hormone profiles, and constantly improving genetic tests. However, similar reproductive parameters, e.g., azoospermia and increased LH/testosterone ratio, can be the outcome of completely different testicular disorders. Hence the biopsy remains indispensable for detailed classification of spermatogenesis, description of maturation level of germ cells, as well as prediction of recovery of late spermatids in azoospermic patients. The histological patterns may worsen with age in some conditions, such as Klinefelter syndrome, or mixed atrophy, but in most pathologies the influence of age is unknown. Histopathological analysis is also

crucial for detection of additional pathological features such as inflammatory changes, signs of testicular dysgenesis, and early detection of preinvasive neoplastic changes. In view of the common presence of heterogeneous and discordant histological patterns, bilateral biopsy and the use of immunohistochemical markers are recommended.

---

## Cross-References

► [Functional Anatomy and Histology of the Testis](#)

---

## References

- Bruun E, Frimodt-Møller C, Giwercman A, Lenz S, Skakkebaek NE. Testicular biopsy as an outpatient procedure in screening for carcinoma-in-situ: complications and the patient's acceptance. *Int J Androl.* 1987;10(1):199–202.
- Cooperberg MR, Chi T, Jad A, Cha I, Turek PJ. Variability in testis biopsy interpretation: implications for male infertility care in the era of intracytoplasmic sperm injection. *Fertil Steril.* 2005;84(3):672–7.
- Dieckmann KP, Heinemann V, Frey U, Pichlmeier U. German Testicular Cancer Study Group. How harmful is contralateral testicular biopsy? An analysis of serial imaging studies and a prospective evaluation of surgical complications. *Eur Urol.* 2005;48(4):662–72.
- Dieckmann KP, Kulejewski M, Pichlmeier U, Loy V. Diagnosis of contralateral testicular intraepithelial neoplasia (TIN) in patients with testicular germ cell cancer: systematic two-site biopsies are more sensitive than a single random biopsy. *Eur Urol.* 2007;51(1):175–83.
- Dieckmann KP, Kulejewski M, Heinemann V, Loy V. Testicular biopsy for early cancer detection—objectives, technique and controversies. *Int J Androl.* 2011;34(4 Pt 2):e7–13.
- Elzinga-Tinke JE, Sirre ME, Looijenga LH, van Casteren N, Wildhagen MF, Dohle GR. The predictive value of testicular ultrasound abnormalities for carcinoma in situ of the testis in men at risk for testicular cancer. *Int J Androl.* 2010;33(4):597–603.
- Giwercman A, Bruun E, Frimodt-Møller C, Skakkebaek NE. Prevalence of carcinoma in situ and other histopathological abnormalities in testes of men with a history of cryptorchidism. *J Urol.* 1989;142(4):998–1001.
- Jacobsen R, Bostofte E, Engholm G, Hansen J, Olsen JH, Skakkebaek NE, Møller H. Risk of testicular cancer in men with abnormal semen characteristics: cohort study. *BMJ.* 2000;321(7264):789–92.
- Lenz S, Giwercman A, Skakkebaek NE, Bruun E, Frimodt-Møller C. Ultrasound in detection of early neoplasia of the testis. *Int J Androl.* 1987;10(1):187–90.
- Lottrup G, Nielsen JE, Skakkebaek NE, Juul A, Rajpert-De Meyts E. Abundance of DLK1, differential expression of CYP11B1, CYP21A2 and MC2R, and lack of INSL3 distinguish testicular adrenal rest tumours from Leydig cell tumours. *Eur J Endocrinol.* 2015;172(4):491–9. PMID: 25609776.
- McLachlan RI, Rajpert-De Meyts E, Hoei-Hansen CE, de Kretser DM, Skakkebaek NE. Histological evaluation of the human testis—approaches to optimizing the clinical value of the assessment: mini review. *Hum Reprod.* 2007;22(1):2–16.
- Perheentupa A, Huhtaniemi I. Aging of the human ovary and testis. *Mol Cell Endocrinol.* 2009;299(1):2–13.
- Petersen PM, Giwercman A, Daugaard G, Rørth M, Petersen JH, Skakkebaek NE, Hansen SW, von der Maase H. Effect of graded testicular doses of radiotherapy in patients treated for carcinoma-in-situ in the testis. *J Clin Oncol.* 2002;20(6):1537–43.

- Rajpert-De Meyts E, Nielsen JE, Skakkebaek NE, Almstrup K. Diagnostic markers for germ cell neoplasms: from placental-like alkaline phosphatase to micro-RNAs. *Folia Histochem Cytobiol.* 2015;53(3):177–88.
- Rud CN, Daugaard G, Rajpert-De Meyts E, Skakkebaek NE, Petersen JH, Jørgensen N. Sperm concentration, testicular volume and age predict risk of carcinoma in situ in contralateral testis of men with testicular germ cell cancer. *J Urol.* 2013;190(6):2074–80.
- Ruf CG, Gnoss A, Hartmann M, Matthies C, Anheuser P, Loy V, Pichlmeier U, Dieckmann KP. Contralateral biopsies in patients with testicular germ cell tumours: patterns of care in Germany and recent data regarding prevalence and treatment of testicular intra-epithelial neoplasia. *Andrology.* 2015;3(1):92–8.
- Schulze W, Thoms F, Knuth UA. Testicular sperm extraction: comprehensive analysis with simultaneously performed histology in 1418 biopsies from 766 subfertile men. *Hum Reprod.* 1999;14(Suppl 1):82–96.
- Skakkebaek NE. Two types of tubules containing only Sertoli cells in adults with Klinefelter's syndrome. *Nature.* 1969;223(5206):643–5.
- Skakkebaek NE. Possible carcinoma-in-situ of the testis. *Lancet.* 1972;2(7776):516–7.
- Skakkebaek NE, Rajpert-De Meyts E, Main KM. Testicular dysgenesis syndrome: an increasingly common developmental disorder with environmental aspects. *Hum Reprod.* 2001;16(5):972–8.
- Sonne SB, Almstrup K, Dalgaard M, Juncker AS, Edsgard D, Ruban L, Harrison NJ, Schwager C, Abdollahi A, Huber PE, Brunak S, Gjerdrum LM, Moore HD, Andrews PW, Skakkebaek NE, Rajpert-De Meyts E, Leffers H. Analysis of gene expression profiles of microdissected cell populations indicates that testicular carcinoma in situ is an arrested gonocyte. *Cancer Res.* 2009;69(12):5241–50.
- Tournaye H, Liu J, Nagy PZ, Camus M, Goossens A, Silber S, Van Steirteghem AC, Devroey P. Correlation between testicular histology and outcome after intracytoplasmic sperm injection using testicular spermatozoa. *Hum Reprod.* 1996;11(1):127–32.
- Tüttelmann F, Werny F, Cooper TG, Kliesch S, Simoni M, Nieschlag E. Clinical experience with azoospermia: aetiology and chances for spermatozoa detection upon biopsy. *Int J Androl.* 2011;34(4):291–8.
- Ulbricht TM, Amin MB, Balzer B, Berney DM, Epstein JI, Guo C, Idrees MT, Looijenga LHJ, Paner G, Rajpert-De Meyts E, Skakkebaek NE, Tickoo SK, Yilmaz A, Oosterhuis JW. Germ cell tumours. In: Moch H, Humphrey PA, Reuter VE, Ulbricht TM, editors. WHO classification of tumours of the urinary system and male genital organs. 4th ed. Lyon: IARC Press; 2016. p. 189–226.
- van Casteren NJ, de Jong J, Stoop H, Steyerberg EW, de Bekker-Grob EW, Dohle GR, Oosterhuis JW, Looijenga LH. Evaluation of testicular biopsies for carcinoma in situ: immunohistochemistry is mandatory. *Int J Androl.* 2009;32(6):666–74.

## Further Reading

- Jezek D, editor. Atlas on the human testis. Normal morphology and pathology. London: Springer; 2013.
- Moch H, Humphrey PA, Reuter VE, Ulbricht TM, editors. WHO classification of tumours of the urinary system and male genital organs. 4th ed. Lyon: IARC Press; 2016.
- Rajpert-De Meyts E, McGlynn KA, Okamoto K, Jewett MA, Bokemeyer C. Testicular germ cell tumours. *Lancet.* 2016; 387(10,029):1762–1774.
- Skakkebaek NE, Rajpert-De Meyts E, Buck Louis GM, Toppari J, Andersson AM, Eisenberg ML, Jensen TK, Jørgensen N, Swan SH, Sapra KJ, Ziebe S, Priskorn L, Juul A. Male reproductive disorders and fertility trends: influences of environment and genetic susceptibility. *Physiol Rev.* 2016; 96(1):55–97. Review. PMID: [26582516](https://pubmed.ncbi.nlm.nih.gov/26582516/).

---

**Part III**

**Disorders of Sexual Development and Male  
Hypogonadism**

George A. Kanakis and Dimitrios G. Goulis

## Abstract

Male hypogonadism (HG) is the functional incompetence of the male gonads to produce male sex hormones and to carry out spermatogenesis. The definition of HG relies on the measurement of serum total testosterone (tT) concentrations. A recent consensus has proposed tT concentrations of about 12 nmol/L (346 ng/dL) as the lower limit of normal and 8 nmol/L (231 ng/dL) as the unequivocally low value that deserves replacement therapy. For tT values between these limits, calculation of free T (fT) may be helpful.

The most common classification is based on the topographic localization of the cause of HG at different levels of the hypothalamic-pituitary-testicular (HPT) axis. Accordingly, the cause of HG may be of hypothalamic, pituitary, or testicular origin. HG of hypothalamic or pituitary origin is referred to as “secondary,” “central,” or *hypogonadotropic* HG, whereas HG induced by testicular disorders is referred to as “primary” or *hypergonadotropic*. Certain disorders may impair the whole HPT axis and result in *combined* HG. Moreover, HG may be classified depending on the testicular compartment being affected, as *selective*, affecting either Leydig cell function or spermatogenesis, or *total*, affecting both. Alternatively, HG is classified according to the age at onset, as the clinical sequelae of HG can be variable in different ages. HG at *early fetal life* usually results in disorders of sex development, whereas onset at the *end of fetal life* results in mild disorders, as maldescended testes and micropenis. HG in *childhood* may remain undetected, until delayed puberty is suspected with persistence of sexual infantilism and appearance of eunuchoidal proportions. HG in *adulthood* may also be insidious, since nonspecific symptoms usually precede sexual symptoms.

G.A. Kanakis (✉) • D.G. Goulis

Unit of Reproductive Endocrinology, First Department of Obstetrics and Gynaecology, Medical School, Aristotle University of Thessaloniki, Thessaloniki, Greece

e-mail: [geokan@endo.gr](mailto:geokan@endo.gr); [dgg@auth.gr](mailto:dgg@auth.gr); [dimitrios.goulis@gmail.com](mailto:dimitrios.goulis@gmail.com); [dimitrios.goulis@otenet.gr](mailto:dimitrios.goulis@otenet.gr)



Finally, *late-onset* HG (LOH) observed among several aging men is characterized by partial T deficiency and gradual onset.

The prevalence of HG in the community is variable, as the studies that contain such data have used different age ranges or T thresholds, and is estimated to be around 6–12% among 30–70-year-old men, with a progressive increase with age. The majority of cases concerns LOH, whereas overt HG due to organic disorders is much less common. The incidence of congenital hypogonadotropic HG is 1:10,000, while that of Klinefelter syndrome, the most common chromosomal abnormality in humans, is 1 in 650 newborn males.

### Keywords

Hypogonadism • Hypogonadism, hypergonadotropic • Hypogonadism, hypogonadotropic • Hypogonadism, classification • Hypogonadism, epidemiology • Hypogonadism, etiology

### Contents

Introduction .....	646
Classification .....	648
The International Classification of Diseases (ICD-10) .....	648
Classification by Localization/Cause .....	648
Classification by Testicular Function Affected .....	656
Total Testicular Failure .....	656
Selective Testicular Failure .....	657
Classification of HG by Age of Onset .....	658
Fetal-Onset Hypogonadism .....	660
Postnatal-Onset HG .....	660
Puberty-Onset HG .....	661
Adulthood-Onset HG .....	661
Late-Onset HG .....	661
Epidemiology .....	661
Summary .....	664
Cross-References .....	665
References .....	665

### Introduction

The term “male hypogonadism” has been traditionally used to describe the clinical syndrome caused by insufficient androgen secretion by the testis and is defined by low serum testosterone (T) concentrations. This point of view is still adopted by Wikipedia which defines hypogonadism (HG) as “a medical term which describes a diminished functional activity of the gonads that may result in diminished sex hormone biosynthesis.” However, such a definition focuses on Leydig cell function, without taking under consideration spermatogenesis. The need for a broader definition that describes the incompetence of both testicular functions (e.g., sex steroid production and spermatogenesis) has been stressed by pioneers in the field like

Albright and Hellinga (Hellinga 1957) and has been adopted by modern dictionaries. Consequently, HG is defined in Oxford Dictionary as a “reduction or absence of hormone secretion or other physiological activity of the gonads,” while Merriam-Webster moves a step further by specifying HG as the “functional incompetence of the gonads with subnormal or impaired production of hormones and germ cells.”

In any case, defining HG remains a field of debate, since it grossly relies on hormone measurements with no universal threshold values to have been adopted. Considering total T (tT) as the principal biomarker that reflects sex steroid secretion by the testes, different medical associations have proposed various T thresholds for diagnosing HG; the American Association of Clinical Endocrinologists (AAACE) suggests that a threshold of 7 nmol/L (200 ng/dL) should be used (Petak et al. 2002), while the Endocrine Society (ES) suggests 10.4 nmol/L (300 ng/dL) (Bhasin et al. 2010). The latter threshold stands for 2.5 standard deviations below the mean for healthy young men and has been associated with erectile dysfunction. Recently, the International Society of Andrology (ISA), the International Society for the Study of the Aging Male (ISSAM), and the European Association of Urology (EAU) stated a consensus and proposed 12 nmol/L (346 ng/dL) as the lower limit that does not require substitution and 8 nmol/L (231 ng/dL) as the unequivocally low value that deserves replacement therapy. This approach allows a gray zone between 8 and 12 nmol/L, within which a measurement/calculation of free T (fT) below 180 pmol/L and the presence of clinical symptoms are required to set the diagnosis (Nieschlag et al. 2005).

A second pitfall in the diagnosis of HG is the age at onset as the clinical sequelae are completely different in different phases of a man's life. Thus, onset at early fetal life usually results in disorders of sex development, whereas onset at the end of fetal life results in maldescended testes, micropenis, and hypospadias. On the contrary, onset at childhood, before the onset of puberty, may remain unobserved, as this age is associated with quiescence in gonadal function, and the diagnosis of HG is usually missed until delayed puberty is suspected. Diagnosis of HG in adults can also be cumbersome as nonspecific symptoms are usually evident before sexual symptoms that may alert the patient and the physician arise. Finally, some aging men may present an entity known as late-onset hypogonadism (LOH), which is characterized by mild T deficiency and insidious symptoms, often surpassed as manifestations of senescence (Rey et al. 2013).

In the first section of this chapter, the main contemporary classification schemes of HG will be analyzed, including the International Classification of Diseases (ICD-10) tool. Primarily, the topographic localization of the cause of HG at different levels of the hypothalamic-pituitary-testicular (HPT) axis is described, as this classification refers to causality and is more tangible. Furthermore, a classification is attempted based on the testicular function being affected (T secretion, spermatogenesis, or both); finally, HG is classified according to the age of onset as this kind of information changes dramatically the clinical picture. The second section refers to the epidemiology of HG both in general and regarding its specific forms. Data have been retrieved from large cross-sectional and longitudinal studies as well as registries by Andrology centers.

## Classification

### The International Classification of Diseases (ICD-10)

Classification of male HG is useful not only for educational purposes, but it is also of clinical importance, as it may guide therapeutical options. The International Classification of Diseases (ICD), the standard classification tool introduced by the World Health Organization (WHO), is organized on a mixed “localization and cause” basis. In the most recent version (ICD-10), disorders associated with HG are scattered among three large groups:

- Endocrine, nutritional, and metabolic diseases, preceded by letter “E” and subgrouped between codes E20 and E35 as “disorders of other endocrine glands,”
- Diseases of the genitourinary system, preceded by letter “N” and subgrouped between codes N40 and N51 as “diseases of male genital organs.”
- Congenital malformations, deformations, and chromosomal abnormalities, preceded by letter “Q” and subgrouped between codes Q50 and Q56 as “congenital malformations of genital organs” and Q90 and Q99 as “chromosomal abnormalities, not elsewhere classified.”

Though this classification may be practical for epidemiology and health management purposes, its value for scientific evaluation is limited due to being too imprecise (Tüttelmann and Nieschlag 2010). For example, all the types of pituitary HG are classified under the same code (E23), whereas 5-alpha-reductase deficiency is classified under testicular hypofunction (E29.1), though it represents a disorder of T action at the target tissues (Table 1).

### Classification by Localization/Cause

The most common classification scheme used by modern textbooks in Andrology is based on the topographic localization of the cause of HG at different levels of the HPT axis. According to current knowledge, the pulsatile release of the gonadotropin-releasing hormone (GnRH) from the hypothalamus stimulates the release of the luteinizing hormone (LH) and follicle-stimulating hormone (FSH) from the pituitary. LH stimulates Leydig cells to produce T, whereas FSH acts on Sertoli cells promoting thereby indirectly spermatogenesis. Circulating T, in turn, regulates gonadotropin production by exerting an inhibitory effect (negative feedback) at the level of the hypothalamus and pituitary gland (Matsumoto and Bremner 2011).

According to this classification, the cause of HG may be hypothalamic, pituitary, or testicular. Hypothalamic and pituitary HG are usually referred to under the term “secondary,” “central,” or *hypogonadotropic* HG, since the pathogenesis of such disorders relies on the impaired gonadotropin signal at the testis, which results in a

**Table 1** Codes associated with male hypogonadism in the most recent version of the International Classification of Diseases (ICD-10)

<b>Endocrine, nutritional, and metabolic diseases</b>	
E22.1	Hyperprolactinaemia
E23.0	Hypopituitarism
	Fertile eunuch syndrome
	Hypogonadotropic hypogonadism
	Isolated deficiency of gonadotropin
	Kallmann syndrome
	Panhypopituitarism
E23.3	Hypothalamic dysfunction, not elsewhere classified
E29	Testicular dysfunction
E29.1	Testicular hypofunction
	5-Alpha-reductase deficiency (with male pseudohermaphroditism)
	Defective biosynthesis of testicular androgen NOS
E30.0	Delayed puberty
	Constitutional delay of puberty
E34.5	Androgen resistance syndrome
	Male pseudohermaphroditism with androgen resistance
	Peripheral hormonal receptor disorder
	Reifenstein syndrome
	Testicular feminization (syndrome)
E89.5	Post-procedural testicular hypofunction
<b>Diseases of the genitourinary system</b>	
N44	Torsion of testis
N45	Orchitis and epididymitis
N46	Male infertility
N48.4	Impotence of organic origin
N50.0	Atrophy of testis
N62	Hypertrophy of the breast – gynecomastia
<b>Congenital malformations and chromosomal abnormalities</b>	
Q53	Undescended testicle
Q54	Hypospadias
Q55	Other congenital malformations of male genital organs
Q55.0	Absence and aplasia of testis
Q55.1	Hypoplasia of testis and scrotum
Q55.5	Congenital absence and aplasia of penis
Q56	Indeterminate sex and pseudohermaphroditism
Q56.0	Hermaphroditism, not elsewhere classified, ovotestis
Q56.1	Male pseudohermaphroditism, not elsewhere classified
Q98	Other sex chromosome abnormalities, male phenotype, NOS
Q98.0	Klinefelter syndrome karyotype 47,XXY

*(continued)*

**Table 1** (continued)

Q98.1	Klinefelter syndrome, male with more than two X chromosomes
Q98.2	Klinefelter syndrome, male with 46,XX karyotype
Q98.5	Karyotype 47,XYY
Q98.6	Male with structurally abnormal sex chromosome
Q98.7	Male with sex chromosome mosaicism
<b>Various</b>	
I86.1	Scrotal varices – varicocele

secondary testicular failure. On the contrary, HG that is based on disorders at the testicular level is referred as *hypergonadotropic* or “primary,” since testicular failure is accompanied by impaired feedback at the hypothalamic-pituitary level, resulting in excessive release of gonadotropins. Notably, certain disorders may impair both the hypothalamic-pituitary axis and the testis concomitantly and result in a state of *combined* HG. Although target organ resistance to sex steroids is not a result of frank gonadal failure, the clinical outcome is analogous to that of androgen deprivation; therefore, many authors include such disorders in this classification scheme as a post-testicular component of HG (Tüttelmann and Nieschlag 2010).

### Hypothalamic and Pituitary Hypogonadism

Disorders resulting in secondary hypogonadism (sHG) can be divided into congenital/developmental and acquired (Table 2). Disorders of pituitary development may affect multiple hormones or selectively impair gonadotropin secretion. When sHG is associated with partial or complete loss of olfaction and other developmental abnormalities, it is referred as Kallmann syndrome or anosmic hypogonadotropic HG as opposed to normosmic hypogonadotropic HG. Normosmic sHG has been traditionally referred to as idiopathic, as it was the case until recently, when the genetic basis of many disorders included in this group was elucidated (Stamou et al. 2016). Occasionally, sHG may be observed in the setting of complex genetic syndromes, such as Laurence-Moon-Biedl and Prader-Willi syndrome (syndromic sHG).

By far, the most common type of sHG is constitutional delay of puberty (CDP), which should be considered as a normal variant rather than a true disorder. The onset of puberty is delayed due to delayed activation of the GnRH pulse generator and is followed by a prolongation in the tempo of sexual maturation, which, however, is completed normally. CDP is usually accompanied by a synchronous delay in growth, and a positive family history is present in most of cases.

Acquired sHG may be the result of organic lesions lying in the sellar region, like pituitary or hypothalamic tumors as well as infiltrative diseases, such as acquired hemochromatosis (e.g., due to iron overload by transfusions), Langerhans cell histiocytosis, lymphocytic hypophysitis, and sarcoidosis. Similarly, traumatic brain injuries and vascular abnormalities (e.g., internal carotid aneurysm, pituitary

**Table 2** Etiological classification of secondary hypogonadism. Diseases marked with asterisk (\*) may cause combined primary and secondary hypogonadism**Congenital or developmental disorders**

Congenital pituitary deficiency  
 Multiple hormone deficiencies  
 Normosmic hypogonadotropic hypogonadism  
 Kallmann syndrome  
 Isolated LH or FSH deficiency  
 Congenital adrenal hyperplasia\*  
 Complex genetic syndromes  
 Laurence-Moon-Biedl syndrome  
 Prader-Willi syndrome  
 CHARGE<sup>a</sup> syndrome

Constitutional delay of puberty

Hemochromatosis\*

**Acquired disorders***Localized disorders*

Pituitary or hypothalamic tumor  
 Granulomatous or infiltrative disease  
 Traumatic brain injury  
 Vascular compromise  
 Iatrogenic  
 Surgical hypophysectomy  
 Pituitary/cranial irradiation

Drug administration/abuse  
 GnRH agonists or antagonists  
 Androgenic anabolic steroids  
 Opiates

Hyperprolactinemia  
 Drug-induced  
 Prolactinoma

*Systemic disorders*

Acute and critical illness\*  
 Chronic systemic illness\*  
 Malignancy, systemic autoimmune diseases, HIV  
 Chronic organ failure\*  
 Liver failure  
 Renal failure  
 Heart failure  
 Eating disorders  
 Starvation, malnutrition  
 Morbid obesity  
 Endurance exercise  
 Iron overload from blood transfusions ( $\beta$ -thalassemia)\*

Aging\*

<sup>a</sup>CHARGE: coloboma of the eye, heart defects, atresia of the choanae, retardation of growth and/or development, genital and/or urinary defects (hypogonadism), ear anomalies and/or deafness

apoplexy) may result in impaired gonadotropin secretion, which is commonly accompanied by deficiencies in other pituitary hormones. Analogous catastrophic lesions of the pituitary gland may be observed as a result of neurosurgical procedures or cranial irradiation. Cumulative doses of 35–40 Gy results in sHG with high frequency, which is usually settled gradually and may affect as much as 80% of patients in a decade after irradiation (Darzy and Shalet 2005).

Administration of drugs that abruptly the HPT axis, either on therapeutic purpose or as part of their adverse effects, is a common cause of sHG. GnRH agonists or antagonists are used as androgen deprivation therapy of hormone-sensitive prostate cancer and impair gonadotropin secretion by downregulating GnRH receptor expression or by directly blocking the receptor's activity, respectively. Exogenous administration of androgens or progestins may diminish endogenous androgen production by suppressing the HPT axis as a result of augmented feedback at the level of the hypothalamus and the pituitary, a property that offers the theoretical basis for use of such compounds in male hormonal contraception trials (Kanakis and Goulis 2015). Similarly, abuse of androgenic anabolic steroids suppresses the HPT axis and may result in frank HG, if steroids with weak androgen potency are used (Rogol 2010). Finally, several drugs, especially those used in mental disorders, may affect the HPT axis by elevating prolactin, which disrupts GnRH pulsatility.

In many cases of acquired sHG, an organic cause may not be found, implying the presence of a functional disorder. Excessive physical and psychological stress may disrupt the reproductive axis, as part of a generalized attempt of the body to reduce energy consumption (reproduction is considered as an energy-consuming function). Thus, reproductive dysfunction is a common sequel of starvation or malnutrition as well as intensive exercise. Similarly, acute and chronic systemic illnesses like malignancies and chronic organ failure (liver, renal, heart failure) are usually accompanied by sHG. On the other hand, caloric overload may also result in sHG which is frequently observed in morbidly obese men. In such case, excessive adipose tissue secretes hormones like leptin and inflammatory cytokines (e.g., tumor necrosis factor- $\alpha$ , interleukin-1b), which blunt GnRH and LH secretion (Matsumoto and Bremner 2011).

### **Testicular Hypogonadism**

Similarly to sHG, testicular or else primary HG (pHG) may come as a result of congenital or acquired disorders (Table 3). Several sex or autosomal chromosome aneuploidies result in gonadal dysgenesis, which varies from complete to extremely mild, depending on the type of aneuploidy. The most frequent type of sex chromosomes aneuploidy is Klinefelter syndrome (XXY karyotype) and its variants, which is characterized by the presence of mild testicular dysgenesis with normal fetal virilization. Nevertheless, the number of germ cells is already reduced from the neonatal period, and a marked reduction is observed during puberty due to increased apoptosis. Leydig cell function may remain normal until early pubertal stages or even later; however, LH is usually elevated, indicating a compensated Leydig cell dysfunction, which is not uncommon to end up in overt HG later in life (Lanfranco et al. 2004). Similarly, trisomy 21 (Down syndrome), though an autosomal aneuploidy, is often accompanied by germ cell degeneration and compensated Leydig cell dysfunction.

**Table 3** Etiological classification of primary hypogonadism. Diseases marked with asterisk (\*) may cause combined primary and secondary hypogonadism**Congenital or developmental disorders**

## Chromosomal abnormalities

- Klinefelter syndrome (XXY) and variants
- 46,XX and 46,XY disorders of sexual differentiation
- Down syndrome

## Noonan syndrome

## (Un)-maldescended testes

## Bilateral congenital anorchia

## Testosterone biosynthetic enzyme defects

## LH receptor mutations

## Myotonic dystrophy

**Acquired disorders***Localized disorders*

## Bilateral surgical castration or trauma

## Orchitis

## Varicocele

## Drugs

- Spironolactone
- Ketoconazole
- Alcohol
- Chemotherapy agents

## Ionizing radiation

*Systemic disorders*

## Chronic systemic illness\*

## Chronic organ failure\*

## Spinal cord injury

## Vasculitis (polyarteritis)

## Sickle cell disease

Iron overload from blood transfusions ( $\beta$ -thalassemia)\*

## Aging\*

Cryptorchidism is a condition often characterized by impaired spermatogenesis and occasionally by low androgen secretion. The increased temperature of the abdominal cavity relatively to the scrotum is believed to have detrimental effects on testicular function. However, testicular maldescent should be considered as the result of other disorders rather than a clinical entity on its own. Thus, it may reflect a primary testicular disorder, sHG, or even anatomical defects of the inguinal canal. Noonan syndrome is an autosomal dominant genetic disorder associated with cryptorchidism that is characterized by short stature and unusual facial features resembling those of females with Turner syndrome. However, the syndrome results by mutations in genes in the Ras-MAPK signaling pathway, whereas the karyotype is normal. Bilateral cryptorchidism is a challenging condition that should be distinguished from congenital anorchia. In such case, the phenotype and imaging may not be helpful; assessment of anti-Müllerian hormone (AMH), insulin-like 3 protein (INSL-3), and detection of T after stimulation with human Chorionic Gonadotropin (hCG) might be warranted in order to confirm the presence of testicular tissue.



Rarely, pHG is the result of defects in enzymes that carry out T biosynthesis in Leydig cells. Defects have been detected at 17,20-lyase/17 $\alpha$ -hydroxylase, 17 $\beta$ -HSD/17-ketoreductase, and 3 $\beta$ -HSD, which block steroidogenesis at different levels and result in the accumulation of steroid precursors above the block, some of which have weak androgen activity. The phenotype in these disorders ranges from “complete” females to phenotypic males with hypospadias, gynecomastia, and pHG, depending on the enzyme’s activity. Leydig cell impairment may also result by rare mutations of the LH receptor, which evokes Leydig cell hypoplasia or even aplasia. The phenotype is usually that of female or ambiguous external genitalia with persistent sexual infantilism. The biochemical profile is that of hypergonadotropic HG, however, with normal FSH concentrations in the majority of the cases.

In acquired causes of primary HG, involvement of both testicles is usually mandatory in order HG to evolve. Testicular trauma or torsion may result in testicular atrophy through vascular compromise. Similarly, surgical treatment of inguinal hernias or orchiopexy may disrupt testicular blood flow. Varicocele is a distention of the pampiniform plexus that surrounds the seminal duct and has been associated mainly with dyspermia and less frequently with abnormal androgen production (Paduch and Skoog 2004). Its detrimental effects are attributed to the elevation of local temperature and oxidative stress due to increased blood flow. Finally, local infections like bacterial or viral orchitis may directly affect testicular parenchyma and also disrupt primarily spermatogenesis instead of hormone production.

Oncologic patients comprise a special group of patients as their gonadal function maybe compromised by both their disease as well as the therapeutic regimens used to treat them. Leydig cells prove to be more resistant than germ cells to either chemotherapy or radiotherapy; therefore, isolated arrest of spermatogenesis is more common than androgen insufficiency (Jahnukainen et al. 2011). Different chemotherapeutic agents can have variable effects on different germ cell populations. In general, spermatogonial stem cells are relatively resistant, allowing the regeneration of the spermatogenic epithelium. Moreover, certain drugs, such as spironolactone and ketoconazole, may disrupt enzymes of steroidogenesis, resulting in androgen deprivation (Matsumoto and Bremner 2011).

### **Combined Hypogonadism**

The classification of HG in primary and secondary is not always straightforward as there are disorders that may impair both the hypothalamic-pituitary axis and the testis concomitantly and provoke a combined pattern of HG with inappropriately low gonadotropins, which, however, do not respond adequately to exogenous gonadotropin secretion.

Specific congenital diseases have components on both the pituitary and the testes and are characterized by combined HG. Congenital adrenal hypoplasia is such a disorder characterized by adrenal insufficiency associated with developmental defects in the pituitary as well as the gonads. It presents in two forms: the X-linked form caused by mutations of DAX1, a transcription factor that is essential for the normal development of the pituitary-gonadal and adrenal axes, and an autosomal recessive form caused by mutations of SF-1. Moreover, congenital

adrenal hyperplasia and 21 $\alpha$ -hydroxylase deficiency in particular can provoke combined HG due to the suppression of the HPT axis by the increased concentrations of adrenal androgens on one hand, and the emergence of adrenal rests on the testicles, which disrupt testicular function on the other.

Any chronic illness may affect the whole HPT axis through the secretion of inflammatory cytokines and augmentation of oxidative stress that target the gonadotroph cells as well as the spermatogenic epithelium and Leydig cells. Similarly, systematic infiltrative disease, like hemochromatosis or amyloidosis, may affect both the pituitary and the testes with the first showing a predilection for central HG and the latter for primary HG. Sickle cell disease is another systematic disorder that affects organs by occluding microvasculature and evoking micro-infarcts, a kind of lesion which may be observed at both the pituitary and the testes (Matsumoto and Bremner 2011). The association between diabetes mellitus (DM) and HG is also complex affecting the entire HPT axis. Especially in type 2 DM, the predominant type of HG is that of secondary HG since insulin resistance has been demonstrated to affect principally the hypothalamus.

A particular type of combined HG that has triggered many scientific debates is the HG observed among aging males. Advanced age has been demonstrated to predict HG independently of other chronic comorbidities and use of certain medications associated with aging. This decline in the function of the HPT axis is thought to be part of a general neuroendocrine decline associated with senescence, also affecting the thyroid, growth hormone, and/or insulin-like growth factor. Nevertheless, many older men with elevated LH in the context of low-normal T and blunted responses of Leydig cells to gonadotropin stimulation (compensated HG) have also been reported, implying the coexistence of a primary gonadal dysfunction component.

### **Androgen Resistance**

The effects of androgens take place after their attachment to the androgen receptor (AR), a cytoplasmic protein that moves to the nucleus after ligand binding and connects to specific loci on DNA (androgen response elements, ARE), regulating the expression of several genes. Disorders characterized by insensitivity to the actions of androgens may be induced by mutations of the AR and, though they are characterized by high concentrations of circulating T and LH, their clinical features resemble those of HPT hypofunction. There is a poor correlation between AR genotype and the clinical phenotype, which may range from that of an otherwise normal woman with reduced sexual hair, absent uterus (due to normal AMH action in utero), and primary amenorrhea (complete androgen insensitivity syndrome, CAIS) to an otherwise normal man with gynecomastia and dyspermia (minimal androgen insensitivity syndrome, MAIS), depending on the AR integrity. In between lies partial androgen insensitivity syndrome (PAIS), which is characterized by ambiguous genitalia, undervirilization of various severity, and spermatogenesis impairment, also known as Reifenstein syndrome (Hughes et al. 2012).

A specific disorder of AR dysfunction is Kennedy's disease or spinal and bulbar muscular atrophy (SBMA), an adult-onset neurodegenerative disease of motor neurons associated with MAIS. In such patients, the AR defect lies on the number

of CAG repeats in the first exon of the AR gene, which is markedly expanded. MAIS is explained as the size of this region correlates inversely with the functional status of the AR, whereas neurological complications are induced by the intracellular aggregation of the mutant AR in the neurons (Rajender et al. 2007).

Another condition characterized by normal function of HPT axis, however, with impaired action of androgens to target organs is caused by defects of 5 $\alpha$ -reductase, the enzyme that converts T to dihydrotestosterone (DHT), a compound considered as the active metabolite of T as it has nearly 2.5–10 times more potent androgen activity. Patients with this disorder are born with markedly ambiguous external genitalia and are usually raised as females. Interestingly, in puberty androgen production increases, leading to partial virilization and adoption of a male gender role in some individuals or in certain ethnic environments (Kolesinska et al. 2014).

The vast majority of cases of acquired resistance to androgens are associated with the administration of drugs that inhibit binding to the AR. Such drugs are AR antagonists, like flutamide and bicalutamide, used as androgen deprivation therapy in prostate cancer. Analogous adverse effects may emerge by the use of mineralocorticoid antagonist spironolactone due to cross-binding with AR. Other drugs with potent anti-androgenic properties are 5 $\alpha$ -reductase inhibitors, such as finasteride and cyproterone acetate, which block the conversion of T to DHT. Celiac disease is among the rare pathologic entities that may result in androgen resistance. It is not uncommon in such patients to diagnose HG with high to high-normal concentrations of serum T accompanied by high LH concentrations, indicative of androgen resistance. Similar findings have been reported in HG associated with X-linked adrenoleukodystrophy (Kaltsas et al. 2000).

## Classification by Testicular Function Affected

A classification of HG that may stand as ancillary to that based on the localization of the disorder is based on the testicular compartment being affected. According to this scheme, testicular failure can be selective (STF), affecting either Leydig cell function or spermatogenesis, or total (TTF), affecting both functions. However, due to the fact that spermatogenesis is a highly androgen-dependent function, T deficiency is literally always accompanied by defects in spermatogenesis. Leydig cell function is largely reflected by serum T concentrations, whereas sperm analysis is the surrogate marker for the assessment of spermatogenesis, assisted by serum concentrations of AMH and inhibin B, as markers of Sertoli cell function.

## Total Testicular Failure

This is usually the case in central or combined HG (congenital or acquired), since impaired gonadotropin action disrupts concomitantly all testicular cell populations. LH deficiency, on one hand, results in failure of Leydig cell differentiation and T secretion, depending on the age of HG onset. FSH deficiency, on the other hand,

mainly affects Sertoli cell function and the early stages of spermatogenesis. Therefore, disorders that impair both FSH and LH secretion are characterized by concomitant dysfunction of both testicular compartments and TTF.

In addition, TTF can be observed in severe primary testicular developmental defects that impair the function of the organ as a whole. Various forms of gonadal dysgenesis normally lead to TTF, and the clinical phenotype is characterized by variable severity of undervirilization of the external genitalia as well as cryptorchidism (signs of Leydig cell dysfunction), accompanied by persistence of Müllerian derivatives (sign of Sertoli cell dysfunction), depending on the severity of the abnormality. Thus, complete gonadal dysgenesis results in streak gonads that do not secrete hormones at all, resulting in female external and internal genitalia, which ends up in sexual infantilism. On the other extreme lies Klinefelter syndrome, which is characterized by mild testicular dysgenesis, which does not affect fetal virilization and may maintain decent Leydig cell function; however, defects in spermatogenesis are already evident from early stages. Eventually, some men may stay undiagnosed until interviewed for seeking fertility.

### Selective Testicular Failure

In rare cases of central HG, genetic deficiency of only one gonadotropin may be present, affecting selectively the correspondent testicular compartment. Isolated LH $\beta$  subunit deficiency results in defective Leydig cell differentiation and T secretion (Valdes-Socin et al. 2004), which is secondarily affecting the seminiferous epithelium, causing spermatogenic arrest at meiotic entry. The initial report of this condition as “fertile eunuch syndrome” by Pasqualini probably referred to less severe mutations that allow a minimal LH- $\beta$  activity on spermatogenesis (Pasqualini and Bur 1955). Despite the lack of Leydig cell stimulation by LH, fetal virilization is at least partial as the development of genitalia during the crucial first trimester is promoted by placental hCG. On the other hand, lack of FSH $\beta$  subunit results in a frank isolated impairment of spermatogenesis, with low Sertoli cell number, affecting spermatogenesis at early stages, whereas androgen concentrations remain normal with high LH after puberty (Huhtaniemi 2002).

A particular condition of acquired testicular failure of central etiology is exogenous administration of potent androgens, such as T, which suppresses the HPT axis, while maintaining at the same time normal androgen-related functions. The result of such therapies or anabolic abuse is the near total disruption of spermatogenesis with nullification of endogenous T production, which is, however, masked by the actions of the administered androgen (Rogol 2010). This principle has been employed for the development of various regimens of male hormonal contraception. Similarly, a testicular or adrenal tumor that secretes vast amounts of androgens may suppress spermatogenesis without causing clinically apparent androgenopenia. On the other hand, tumors secreting hCG evoke an exaggerated rise of endogenous T due to hyperstimulation of Leydig cells by hCG, which, in turn, suppresses the HPT axis and, eventually, spermatogenesis without concomitant androgen deprivation.

A number of causes of isolated spermatogenic failure of testicular origin are attributed to genetic defects. The best studied forms of such disorder are Yq micro-deletions which affect three regions of the long arm of the Y chromosome. These regions are AZF-a, deletions of which are associated with azoospermia and Sertoli cell-only histology, AZF-b, associated with azoospermia and histology of spermatogenic arrest at the spermatocyte stage, and AZF-c, the most common and less severe of the three forms, which presents with severe oligozoospermia or azoospermia and hypospermatogenesis at histology. Occasionally, deletions in both the AZF-b and the AZF-c region exist, and in such case an extension panel of primers is warranted to assess if both deletions are complete or partial (Krausz et al. 2014). Similar isolated defects of spermatogenesis are present in men that carry chromosomal aneuploidies or translocations (e.g., Robertsonian translocations). In such individuals, chromosomal rearrangement leads to balanced cells, where no excess or deficit of genetic material is present and no health problems ensue for the carrier. However, imbalanced gametes may be produced, which are usually cleaved before becoming mature, resulting in reduced sperm counts (Scriven et al. 2001). In rare cases, inactivating mutations of the FSH receptor have been reported with variable presentation, which ranges from severe oligozoospermia to normal sperm concentrations with abnormal sperm morphology, implying that male fertility is less strictly dependent on normal FSH action (Tapanainen et al. 1998).

Most conditions that insult the testes result initially in isolated disruption of spermatogenesis as the seminiferous epithelium in general seems to be more sensitive in physical and pharmacological insults compared to Leydig cells. Consequently, cryptorchidism, varicocele, and other thermal distress of the testis usually result in isolated dyspermia. Even an acute febrile illness may result in a temporal decrease of sperm counts. This is the case also for local infections as well as the impact of environmental toxins and ionizing radiation and chemotherapy. However, this impact is “dose-dependent,” since extensive lesions or high doses of toxic agents usually can affect both compartments, as explained above. Irradiation doses, >24 Gy for instance, usually induce permanent germ cell depletion and may affect Leydig cell function (Dohle 2010). Nevertheless, it has to be stressed that in many men with spermatogenesis impairment, an apparent cause cannot be isolated, and these cases are classified as idiopathic. Different etiologies that may result in isolated spermatogenic failure are summarized in Table 4.

### **Classification of HG by Age of Onset**

As it is implied in many of the aforementioned disorders, the time of onset of gonadal failure may sometimes be more important for the clinical presentation of HG than the localization of the cause *per se*. An explanation for this fact may be retrieved by a brief description of the stages of the ontogenesis of the male genitalia and the development of male sexual characteristics.

**Table 4** Causes of isolated failure of spermatogenesis

<b>Hypothalamic-pituitary dysfunction</b>
Isolated FSH deficiency, FSH- $\beta$ mutations
Exogenous testosterone administration
Androgenic anabolic steroids abuse
Adrenal or testicular androgen-secreting tumors
hCG-secreting tumors
<b>Testicular dysfunction</b>
<i>Congenital/developmental disorders</i>
Y chromosome micro-deletions
Chromosomal translocations
Cryptorchidism
FSH receptor mutations
<i>Acquired disorders</i>
Varicocele
Orchitis
Thermal trauma – acute febrile illness
Environmental toxins
Ionizing radiation
Chemotherapy agents
Idiopathic azoospermia or oligozoospermia

Regardless of the karyotype of an individual, male gonadal sex is determined by the presence or absence of the SRY gene, which is normally located at the short arm of the Y chromosome. The secretion of AMH by the Sertoli cells that reside only in the male gonad triggers the regression of Müllerian ducts and their derivatives (fallopian tubes, uterus, and the upper third of the vagina). Leydig cells, initially driven by placental hCG and later by fetal LH, secrete T and INSL-3, which are responsible for the stabilization of the Wolffian tube derivatives (seminiferous ducts), the virilization of the external genitalia and the descent of the testicles in the scrotum.

In neonates, the HPT axis is activated temporarily from the first week of life and may remain active for 3–6 months after birth as a result of elimination of the maternal high estrogen milieu at birth, a period also known as “mini puberty” (Cohn et al. 1993). Interestingly, elevated T cannot induce meiosis and promote spermatogenesis at this stage, most probably due to the lack of AR expression on Sertoli cells. Later in infancy and childhood, a long period of quiescence ensues while androgen production is negligible; Sertoli cells, however, remain active and secrete AMH, preparing the testis for the forthcoming awakening at puberty. In puberty, the HPT axis is reactivated increasing T secretion from the testes, an event which coincides with AR expression on Sertoli cells and triggers the first wave of spermatogenesis. T soon thereafter reaches adult concentrations, inducing sexual maturation and achievement of adult body proportions.

## Fetal-Onset Hypogonadism

HG during the first trimester of fetal life, the period of organogenesis and sexual differentiation, results in a variable clinical picture, which depends grossly on the level of the defect, the testicular compartment affected, and the degree of HG. Central HG, even in the setting of multiple pituitary hormone deficiency, does not result in ambiguous genitalia, as Leydig cell function is still driven by placental hCG and secrete T, whereas at this early stage, Sertoli cells retain their ability to secrete AMH independently of FSH action. However, the size of the penis is significantly smaller than normal (micropenis), as is the size of the testes, which are maldescended, found usually in the inguinal canal. Similarly, HG of any localization (primary, central, or combined) which takes place in the second half of gestation, after virilization of the genitalia has already occurred, typically results in maldescended testes and micropenis.

On the other hand, in total primary testicular failure (e.g., in complete gonadal dysgenesis), absence of Sertoli cells and subsequent lack of AMH secretion result in persistence of Müllerian duct derivatives, whereas absence of Leydig cells and lack of T stimulation result in abdominal cryptorchidism and development of external genitalia in a female pattern. In case of a congenital disorder that selectively affects the Leydig cell (e.g., LH/hCG receptor mutations or defects in testicular steroidogenesis), androgen insufficiency may result in ambiguous external genitalia and cryptorchidism. Nevertheless, Müllerian ducts fully regress as a result of normal AMH secretion by Sertoli cells. On the contrary, in the persistent Müllerian duct syndrome (PMDS), deficient AMH production results in the persistence of the uterus and fallopian tubes in an otherwise normally virilized man.

## Postnatal-Onset HG

Central HG of postnatal onset and before puberty results in low gonadotropins and T, without perceivable effects on a boy's clinical phenotype. The interval between 3 and 6 months of life offers a critical window for the diagnosis of central HG as it is the only period of childhood associated with normally elevated gonadotropin concentrations (Cohn et al. 1993). Thereafter, basal gonadotropins and T are normally undetectable, and HG may remain unapparent and undiagnosed until the expected onset of puberty. In case of multiple pituitary hormone deficiency, the diagnosis is usually suspected by the defects in the growth, thyroid, and adrenal axes; otherwise, GnRH and hCG stimulation tests are needed in order to prove the integrity of the HPT axis. Similarly, the diagnosis of primary HG may be missed in childhood as gonadotropin concentrations are in the normal for age range until puberty when they usually start to elevate. In such case, the persistently low concentrations of serum AMH, which normally continue to rise in childhood, may be helpful for the diagnosis.

## Puberty-Onset HG

HG that is established before puberty and onward is evident by the absence or the arrest of pubertal development: genitalia remain infantile; secondary sex characteristics, such as androgen-dependent hair growth and deepening of voice, do not develop. In addition, eunuchoid body habitus (arm span exceeding the standing height with female fat distribution) is apparent. Depending on the level of the HPT axis affected, the hormonal findings are those of hypo- or hypergonadotropic HG.

## Adulthood-Onset HG

When HG occurs in adulthood, after sexual and skeletal maturation have been concluded, no changes in the body proportions are expected. In addition, penis size and voice pitch cannot change once they have reached mature status. However, there is loss of androgen-dependent hair and symptoms of sexual dysfunction, such as decreased libido and impotence. These specific symptoms may be preceded by a more indolent clinical picture consisting of fatigue, loss of bone and muscle mass, and defects in hemopoiesis. Testicular size in secondary HG is usually reduced due to total testicular impairment, whereas in primary HG it largely reflects the degree of dysfunction of the seminiferous epithelium.

## Late-Onset HG

Compared to the overt HG diagnosed in middle-aged men, a mild form of HG, which is characterized by partial testicular failure and gradual onset, is observed among several aging men. Although the preponderance of this condition rises among the older men, it is not ubiquitous and not as abrupt as menopause in women; therefore, the term “andropause” is misleading. Due to its indolent nature and the coexistence of other comorbidities that confuse the clinical picture, there has been substantial debate if LOH represents an entity that should be actively sought and treated. Recent consensus suggests that frankly reduced T concentrations in older men should be replenished if accompanied by definitive symptoms of androgen insufficiency provided that no contraindications exist (Bhasin et al. 2010). The various clinical pictures according to the age of presentation are summarized in Table 5.

---

## Epidemiology

The overall prevalence of HG in the community is variable, as the studies that contain such data have used different age ranges and different T thresholds. Moreover, several studies require the presence of related symptoms in addition to low T



**Table 5** Clinical manifestations of hypogonadism according to the age of onset

<b>Fetal-onset hypogonadism</b>
“Normal” female genitalia (46,XY)
Ambiguous genitalia (46,XY DSD)
Developmental disorders of male genitalia
Microphallus
Hypospadias
Bifid scrotum
Cryptorchidism
<b>Peripubertal-onset hypogonadism</b>
Delayed puberty
Infantile genitalia
Small testes
Unejaculation (lack of spermarche)
Lack of male hair pattern growth, no acne
High-pitched voice
Gynecomastia
Eunuchoidism
Disproportionately long arms and legs relative to standing height
Poorly developed muscle mass
Unspecific symptoms
Reduced motivation and initiative
Diminished strength and physical performance
Reduced peak bone mass
<b>Adulthood-onset hypogonadism</b>
Testicular shrinking
Reduced nighttime or morning spontaneous erections
Lack of sexual interest or desire (libido)
Loss of male hair (axillary and pubic hair) – reduced shaving frequency
Fine facial skin wrinkles (perioral and periorbital)
Gynecomastia
Increased body fat or body mass index
Unexplained reduction in prostate size or PSA levels
Mild normocytic, normochromic anemia (normal female range)
Unejaculation, severe oligozoospermia, or azoospermia
Unspecific symptoms
Decreased energy, vitality
Cognitive decline – drowsiness
Low bone mineral density (osteopenia or osteoporosis)
Hot flushes, sweats

concentrations in order to establish the diagnosis of HG. Grossly, the prevalence of symptomatic HG in the age range between 30 and 70 years is estimated to be around 6% to 12%, with a progressive increase with age (Martinez-Jabaloyas 2013). As it is obvious from the definition of HG, its prevalence in a given population depends grossly on the T threshold used for diagnosis. In a recent study in Italy, the prevalence of HG was estimated to be 7, 12.5, and 22%, when a T threshold of

8, 10, and 12 nmol/L was used, respectively (Boddi et al. 2014). The European Male Ageing Study (EMAS) group reported a prevalence of “biochemical” HG as high as 23.3% in middle-aged and elderly men (40–79 years old), considering tT concentrations of less than 11 nmol/L and fT concentrations of less than 220 pmol/L as abnormal. However this percentage was substantially reduced to 2.1% regarding symptomatic HG, defined as the presence of at least three sexual symptoms (loss of morning erections, low sexual desire, and erectile dysfunction) in conjunction with low T concentrations (Wu et al. 2010). This finding is similar to the prevalence of symptomatic HG reported in the Boston Area Community Health (BACH) Survey (5.6%) (McKinlay and Link 2007), whereas the prevalence of biochemical HG in Asia (defined as tT <11 nmol/L) ranges from 18.2% to 19.1% (Ho et al. 2011).

The fact that T concentrations are declining with age has been demonstrated in a number of cross-sectional and longitudinal studies; the mean T values at age 75 years are about two thirds of those at 25 (Vermeulen 1991), and an annual decline of 0.5–2% or 3.2 ng/dL in T concentrations has been estimated. Consequently, in the Massachusetts Male Aging Study (MMAS), the prevalence of biochemical HG has been shown to increase among the elderly, rising from 12 to 20, to 30, and up to 50% of men in their 50s, 60s, 70s, and 80s, respectively (Gray et al. 1991). Similarly, in the EMAS the prevalence of symptomatic HG was 0.1% for men 40–49 years of age compared to 5.1% for those 70–79 years (Wu et al. 2010). Interestingly, the rate of decline in serum T as estimated in longitudinal studies is higher than that in cross-sectional studies, as gonadal function may be compromised by the deterioration of the general health of the participants during their follow-up.

The percentage of patients with HG among men who seek consultation by a center with expertise in Andrology is also round 10%, as shown by data extracted from the database established in Münster, Germany which comprise about 13,000 patients (Androbase<sup>®</sup>, Tüttelmann and Nieschlag 2010). However, frequency of otherwise rare disorders, such as Klinefelter syndrome, hypogonadotropic HG, and primary HG of unknown etiology, is 2.6, 1.6, and 2.3%, respectively, substantially elevated compared to LOH (2.2%). This controversy reflects, on one hand, the expected referral center bias, but on the other hand implies that many of men that present HG in the community may stay without specialized medical care or even without treatment at all. This has also been demonstrated in a recent report, where only 5% of candidates were receiving treatment ([http://www.fda.gov/fdac/departs/196\\_upd.htm](http://www.fda.gov/fdac/departs/196_upd.htm)).

In fact, apart from cases of LOH, overt hypogonadotropic HG, either congenital or acquired, is quite rare. The incidence of congenital hypogonadotropic HG in males is estimated to be 1:10,000. Approximately 60% of cases are associated with olfactory disorders (Kallmann syndrome), whereas the rest 40% are not (normosmic sHG). Mutations of KAL1 gene (X-linked Kallmann syndrome) are involved in about 10% of sporadic cases, whereas this figure rises to 50% in cases with familial distribution. Mutations of fibroblast growth factor receptor 1 (FGFR1), responsible for autosomal dominant Kallmann syndrome, have been identified in about 15% of cases with Kallmann syndrome. Regarding acquired disorders, the gonadotropes seem to be quite sensitive to various insults, and the gonadal axis is often disrupted by lesion of the sellar region, such as traumatic brain lesions, inflammatory diseases,

or sellar tumors reaching a frequency of 80% (Lenzi et al. 2009). It should be stressed, however, that neither basal T concentrations nor clinical symptoms are specific enough to precisely distinguish hypogonadotropic HG from LOH (Seftel 2006).

The incidence of Klinefelter syndrome, the most common chromosomal abnormality in humans, has been demonstrated to be 1 in 650 males in newborn screening studies. Nevertheless, only 25% of these cases may be diagnosed throughout their lifetime due to the mild phenotype. The so-called variants of Klinefelter, 48,XXXY tetrasomy, and 49,XXXXY pentasomy are far less common with an estimated incidence of 1:18,000 to 1:100,000 male births (Lanfranco et al. 2004; Visoosak and Graham 2006). Similarly, bilateral congenital anorchia affects one in 20,000 46, XY males, whereas cryptorchidism despite being more common (2–5% of full-term newborn males) does not usually result in overt hypogonadism (Barthold and Gonzalez 2003).

---

## Summary

- The term “male HG” is describing the functional incompetence of the male gonads both to produce male sex hormones and to carry out spermatogenesis.
- Defining HG is based on tT serum concentrations. A tT of 12 nmol/L (346 ng/dL) is largely accepted as the lower limit of normal, whereas 8 nmol/L (231 ng/dL) as the unequivocally low value that deserves replacement therapy. For intermediate tT values, measurement or calculation of fT and the presence of clinical symptoms are required to set the diagnosis.
- Classification of male HG is of clinical importance, as it may guide therapeutical options. The most widely adopted classification scheme is based on the topographic localization of the cause of HG at different levels of the HPT axis and divides HG in primary (hypergonadotropic) and secondary (hypogonadotropic) whether the etiology is of testicular or hypothalamic-pituitary origin, respectively. However, this pattern of gonadotropin secretion is not always apparent, since in certain cases, as in prepubertal boys, the elevation of gonadotropins in primary HG is an exception due to the quiescence of the HPT axis. In addition, the distinction of testicular failure into selective and total is meaningful in cases of isolated spermatogenesis impairment, as Leydig dysfunction is literally always accompanied by defects in spermatogenesis.
- The prevalence of HG in the community is variable, as the studies that contain such data have used different age ranges or T thresholds. In general, it is estimated to be around 6–12% among 30–70-year-old men, with a progressive increase with age. The majority of cases concerns LOH, whereas overt HG due to organic disorders is much less common.
- The proportion of “classic” HG is substantially elevated in specialized centers due to referral center bias as well as the reluctance of men in the community to seek medical advice for HG.

---

## Cross-References

- ▶ [Anabolic and Metabolic Effects of Testosterone and Other Androgens: Direct Effects and Role of Testosterone Metabolic Products](#)
- ▶ [Androgen Receptor](#)
- ▶ [Androgen Resistance](#)
- ▶ [Clinical Manifestation and Diagnosis of Androgen Deficiency](#)
- ▶ [Delayed Puberty](#)
- ▶ [Gonadotropins](#)
- ▶ [Hypogonadism in Systemic Diseases](#)
- ▶ [Late-Onset Hypogonadism](#)
- ▶ [Primary and Secondary Hypogonadism](#)
- ▶ [Testicular Steroidogenesis](#)
- ▶ [Treatment of Hypogonadism](#)

---

## References

- Barthold JS, Gonzalez R. The epidemiology of congenital cryptorchidism, testicular ascent and orchiopexy. *J Urol.* 2003;170(6 Pt 1):2396.
- Bhasin S, Cunningham GR, Hayes FJ, Matsumoto AM, Snyder PJ, Swerdloff RS, Montori VM. Testosterone therapy in men with androgen deficiency syndromes: an Endocrine Society clinical practice guideline. *J Clin Endocrinol Metab.* 2010;95(6):2536.
- Boddi V, Barbaro V, McNieven P, Maggi M, Rotella CM. Present and future association between obesity and hypogonadism in Italian males. *Arch Ital Urol Androl.* 2014;86(1):26.
- Cohn L, Feller AG, Draper MW, Rudman IW, Rudman D. Carpal tunnel syndrome and gynaecomastia during growth hormone treatment of elderly men with low circulating IGF-I concentrations. *Clin Endocrinol.* 1993;39(4):417.
- Darzy KH, Shalet SM. Hypopituitarism as a consequence of brain tumours and radiotherapy. *Pituitary.* 2005;8(3–4):203.
- Dohle GR. Male infertility in cancer patients: review of the literature. *Int J Urol.* 2010;17(4):327.
- Gray A, Feldman HA, McKinlay JB, Longcope C. Age, disease, and changing sex hormone levels in middle-aged men: results of the Massachusetts Male Aging Study. *J Clin Endocrinol Metab.* 1991;73(5):1016.
- Hellings G. Classification of male hypogonadism. *Acta Endocrinol Suppl (Copenh).* 1957;24 (Suppl 31):148.
- Ho CC, Singam P, Hong GE, Zainuddin ZM. Male sexual dysfunction in Asia. *Asian J Androl.* 2011;13(4):537.
- Hughes IA, Davies JD, Bunch TI, Pasterski V, Mastroyannopoulou K, MacDougall J. Androgen insensitivity syndrome. *Lancet.* 2012;380(9851):1419.
- Huhtaniemi IT. LH and FSH receptor mutations and their effects on puberty. *Horm Res.* 2002;57 (Suppl 2):35.
- Jahnukainen K, Ehmeke J, Hou M, Schlatt S. Testicular function and fertility preservation in male cancer patients. *Best Pract Res Clin Endocrinol Metab.* 2011;25(2):287–302.
- Kaltsas G, Kanakis G, Moser H. Adrenal insufficiency due to X-linked adrenoleukodystrophy. In: De Groot LJ, Beck-Peccoz P, Chrousos G, et al., editors. *Endotext.* South Dartmouth: MDText.com, Inc.; 2000.
- Kanakis GA, Goulis DG. Male contraception: a clinically-oriented review. *Hormones (Athens).* 2015;14(4):598.

- Kolesinska Z, Ahmed SF, Niedziela M, Bryce J, Molinska-Glura M, Rodie M, Jiang J, Sinnott RO, Hughes IA, Darendeliler F, Hiort O, van der Zwan Y, Cools M, Guran T, Holterhus PM, Bertelloni S, Lisa L, Arlt W, Krone N, Ellaithi M, Balsamo A, Mazen I, Nordenstrom A, Lachlan K, Alkhwari M, Chatelain P, Weintrob N. Changes over time in sex assignment for disorders of sex development. *Pediatrics*. 2014;134(3):e710.
- Krausz C, Hoefsloot L, Simoni M, Tüttelmann F. EAA/EMQN best practice guidelines for molecular diagnosis of Y-chromosomal microdeletions: state-of-the-art 2013. *Andrology*. 2014;2(1):5.
- Lanfranco F, Kamischke A, Zitzmann M, Nieschlag E. Klinefelter's syndrome. *Lancet*. 2004;364(9430):273.
- Lenzi A, Balercia G, Bellastella A, Colao A, Fabbri A, Foresta C, Galdiero M, Gandini L, Krausz C, Lombardi G, Lombardo F, Maggi M, Radicioni A, Selice R, Sinisi AA, Forti G. Epidemiology, diagnosis, and treatment of male hypogonadotropic hypogonadism. *J Endocrinol Investig*. 2009;32(11):934.
- Martinez-Jabaloyas JM. Hypogonadism. Global epidemiology and transversal relationships. *Arch Esp Urol*. 2013;66(7):632.
- Matsumoto A, Bremner W. Male hypogonadism. In: Melmed S, Polonsky K, Larsen P, Kronenberg H, editors. *Williams textbook of endocrinology*. Philadelphia: Saunders; 2011. p. 709–55.
- McKinlay JB, Link CL. Measuring the urologic iceberg: design and implementation of the Boston Area Community Health (BACH) Survey. *Eur Urol*. 2007;52(2):389.
- Nieschlag E, Swerdloff R, Behre HM, Gooren LJ, Kaufman JM, Legros JJ, Lunenfeld B, Morley JE, Schulman C, Wang C, Weidner W, Wu FC. Investigation, treatment and monitoring of late-onset hypogonadism in males: ISA, ISSAM, and EAU recommendations. *Int J Androl*. 2005;28(3):125.
- Paduch DA, Skoog SJ. Diagnosis, evaluation and treatment of adolescent varicocele. *Scientific-WorldJournal*. 2004;4(Suppl 1):263–7.
- Pasqualini RQ, Bur G. Hypoandrogenic syndrome with spermatogenesis. *Fertil Steril*. 1955;6:2.
- Petak SM, Nankin HR, Spark RF, Swerdloff RS, Rodriguez-Rigau LJ. American Association of Clinical Endocrinologists Medical Guidelines for clinical practice for the evaluation and treatment of hypogonadism in adult male patients – 2002 update. *Endocr Pract*. 2002;8(6):440.
- Rajender S, Singh L, Thangaraj K. Phenotypic heterogeneity of mutations in androgen receptor gene. *Asian J Androl*. 2007;9(2):147.
- Rey RA, Grinspon RP, Gottlieb S, Pasqualini T, Knoblovits P, Aszpis S, Pacenza N, Stewart Usher J, Bergada I, Campo SM. Male hypogonadism: an extended classification based on a developmental, endocrine physiology-based approach. *Andrology*. 2013;1(1):3.
- Rogol AD. Drugs of abuse and the adolescent athlete. *Ital J Pediatr*. 2010;36:1.
- Scriven PN, Flinter FA, Braude PR, Ogilvie CM. Robertsonian translocations – reproductive risks and indications for preimplantation genetic diagnosis. *Hum Reprod*. 2001;16(11):2267.
- Seftel AD. Male hypogonadism. Part I: epidemiology of hypogonadism. *Int J Impot Res*. 2006;18(2):115.
- Stamou MI, Cox KH, Crowley Jr WF. Discovering genes essential to the hypothalamic regulation of human reproduction using a human disease model: adjusting to life in the “-omics” era. *Endocr Rev*. 2016;2016(1):4.
- Tapanainen JS, Vaskivuo T, Aittomaki K, Huhtaniemi IT. Inactivating FSH receptor mutations and gonadal dysfunction. *Mol Cell Endocrinol*. 1998;145(1–2):129.
- Tüttelmann F, Nieschlag E. Classification of andrological disorders. In: Nieschlag E, Behre H, Nieschlag S, editors. *Andrology*. Berlin, Heidelberg: Springer Verlag; 2010. p. 87–92.
- Valdes-Socin H, Salvi R, Daly AF, Gaillard RC, Quatresooz P, Tebeu PM, Pralong FP, Beckers A. Hypogonadism in a patient with a mutation in the luteinizing hormone beta-subunit gene. *N Engl J Med*. 2004;351(25):2619.
- Vermeulen A. Clinical review 24: androgens in the aging male. *J Clin Endocrinol Metab*. 1991;73(2):221.

- Visoosak J, Graham Jr JM. Klinefelter syndrome and other sex chromosomal aneuploidies. *Orphanet J Rare Dis.* 2006;1:1.
- Wu FC, Tajar A, Beynon JM, Pye SR, Silman AJ, Finn JD, O'Neill TW, Bartfai G, Casanueva FF, Forti G, Giwercman A, Han TS, Kula K, Lean ME, Pendleton N, Punab M, Boonen S, Vanderschueren D, Labrie F, Huhtaniemi IT. Identification of late-onset hypogonadism in middle-aged and elderly men. *N Engl J Med.* 2010;363(2):123.

Agnieszka Swiecicka and Frederick Wu

## Abstract

Male hypogonadism is defined as a clinical syndrome resulting from failure of the testes to produce physiological levels of testosterone and normal number of spermatozoa, due to disruption of one or more levels of the hypothalamic-pituitary-testicular axis.

The clinical and biochemical features of male hypogonadism vary according to the period of life when the gonadal failure begins and the level at which the disruption of hypothalamic-pituitary-testicular axis occurs. Whereas the fetal and prepubertal onset of androgen deficiency typically do not pose diagnostic difficulties, the identification of so-called adult- or late onset hypogonadism remains challenging. Low specificity of symptoms that are further confounded by comorbidities and aging, as well as relative inaccuracy of the assays deployed to measure testosterone level are the major factors hampering the precise diagnosis in ageing male without classical hypothalamic-pituitary-gonadal axis pathology.

## Keywords

Androgen deficiency • Hypogonadism • Testosterone

## Contents

Introduction .....	670
Clinical Manifestations of Androgen Deficiency .....	670
Fetal Androgen Deficiency .....	670
Prepubertal Androgen Deficiency .....	670

A. Swiecicka (✉) • F. Wu

Andrology Research Unit, Faculty of Biology, Medicine and Health, The University of Manchester, Manchester, UK

e-mail: [agnieszka.swiecicka@manchester.ac.uk](mailto:agnieszka.swiecicka@manchester.ac.uk); [a.swiecicka@nhs.net](mailto:a.swiecicka@nhs.net); [frederick.wu@man.ac.uk](mailto:frederick.wu@man.ac.uk); [frederick.wu@manchester.ac.uk](mailto:frederick.wu@manchester.ac.uk)

---

Adult Androgen Deficiency .....	672
History and Physical Examination .....	673
Diagnosis of Androgen Deficiency .....	674
Biochemical Evaluation .....	674
Diagnostic Threshold .....	680
Case Finding .....	682
Summary .....	683
References .....	683

---

## Introduction

Male hypogonadism is defined as a clinical syndrome resulting from failure of the testes to produce physiological levels of testosterone and normal number of spermatozoa, due to disruption of one or more levels of the hypothalamic-pituitary-testicular axis (Bhasin et al. 2010). The diagnosis of hypogonadism can often be very challenging as it requires not only the presence of unequivocally low testosterone but also clinical signs and symptoms that are often nonspecific and influenced by the individual's age, health status, severity, and duration of androgen deficiency.

Furthermore, the clinical presentation is crucially influenced by the age of onset of androgen deficiency.

---

## Clinical Manifestations of Androgen Deficiency

### Fetal Androgen Deficiency

Androgen receptor mutations, steroidogenic enzyme defects, gonadal dysgenesis, and Leydig cell aplasia/hypoplasia, causing fetal onset male hypogonadism in the first trimester, present at birth with female or ambiguous external genitalia. If androgen deficiency occurs in the second or third trimester (e.g., pituitary dysfunction, testicular regression syndrome, LH receptor mutation), these phenotypically male individuals may present with microphallus, pseudovaginal perineoscrotal hypospadias, bifid scrotum, and cryptorchidism of varying severity (Table 1).

### Prepubertal Androgen Deficiency

Prepubertal onset of testosterone deficiency results in eunuchoidism and delayed puberty. These individuals present with underdeveloped genitalia and scrotum (lack of pigmentation and rugal folds). Pubic (and axillary) hair is thin and sparse and lacks typical male pattern distribution with no extension to thighs and umbilical area but confined to the mons pubis only (female escutcheon). The testes are small, typically less than 4 ml in volume.



**Table 1** Clinical manifestations of hypogonadism

Onset of hypogonadism	Signs and symptoms		
Fetal	Ambiguous or female genitalia		
	Microphallus		
	Cryptorchidism		
	Bifid scrotum		
	Pseudovaginal perineoscrotal hypospadias		
Prepubertal	Delayed puberty		
	Gynaecomastia		
	Infantile genitalia/small testes		
	Eunuchoidism with its typical body proportions		
	Lack of/reduced hair growth in androgen-dependent areas		
	Reduced muscle mass, strength and physical performance		
	Low energy levels		
	<b>Physical</b>	<b>Sexual</b>	<b>Behavioral</b>
Adult	Gynaecomastia	Low libido	Reduced motivation
	Reduced hair growth in androgen-dependent areas	Reduced spontaneous and morning erections	Reduced initiative
	Low energy levels	Infertility (oligo- or azoospermia)	Low mood
	Osteoporosis/osteopenia, height loss, history of fragility fracture		Poor concentration and memory
	Hot sweats and flushes		
	Incomplete sexual development/ small testes		
	Small prostate and low PSA levels		
	Nonspecific symptoms		
	Reduced muscle mass, strength, and physical performance		
	Low energy level		
	Increased total body fat and BMI		
	Normocytic normochromic anemia		

Eunuchoidal body proportions (arm span exceeds height by 5 cm; pubic to floor length exceeds crown to pubic length by >5 cm) develop as a result of failure of long bone epiphyses to close. This is a consequence of lack of pubertal increase in testosterone level and its aromatization to estradiol, through which the process of epiphyseal fusion is mediated. Bone mineral density is often low for age and, if androgen deficiency is not diagnosed and treated in timely fashion, may result in osteoporosis and increased risk of fractures in adulthood. Hypogonadal features further include poorly developed muscle mass (and strength), female pattern

distribution of body fat, especially in the hips, as well as gynecomastia. Failure of secondary sexual development is often associated with psychological problems in adolescence. As adults, these individuals report decreased libido and reduction or lack of spontaneous, including early morning, erections. Impaired seminal fluid production (small prostate and seminal vesicles) and spermatogenesis result in sub- or infertility.

## Adult Androgen Deficiency

Prepubertal onset hypogonadism may not uncommonly present in adulthood. The diagnosis of hypogonadism in these cases is relatively easy to establish due to the incomplete or lack of secondary sexual characteristics.

In adulthood, testosterone is required to maintain the established secondary sexual characteristics, sexual function, fertility, and musculoskeletal health. The signs and symptoms of adult or postpubertal onset hypogonadism can be subtle and variable. Some adult sexual features such as genital proportions and voice do not regress, and symptoms often have low specificity for androgen deficiency, overlapping with many other conditions. Both duration and severity of androgen deficiency as well as comorbidities can significantly modify the clinical picture making the diagnosis of hypogonadism challenging.

Most adults with androgen deficiency will experience sexual dysfunction, namely, low libido, decreased frequency of spontaneous or stimulated erections, or erectile dysfunction. In the case of severe (and often longstanding) hypogonadism, secondary sexual characteristics regress, e.g., decreased hair in androgen-dependent areas (resulting in reduced shaving frequency). Many men will also have breast enlargement. Reduction in size of the testes will occur, although not to prepubertal proportions. There is an associated impairment in spermatogenesis leading to oligo- or azoospermia. Some cases of hypogonadism may present for investigations of infertility.

Testosterone, acting via its metabolite estradiol, is one of the factors responsible for maintenance of bone health in adulthood. Hypogonadism results in increased bone resorption, leading to reduced bone mass and strength, as evidenced by a presence of osteopenia or osteoporosis on bone mineral density scan (DEXA, dual-energy x-ray absorptiometry). Some men with longstanding hypogonadism may present with osteoporosis, fragility fracture, or height loss associated with vertebral compression fracture(s). Reduction in muscle mass and strength result in decreased physical performance/stamina and fatigue. Mood disturbance is common with a wide spectrum of symptoms, from dysthymia to severe depression. In addition, many individuals will complain of poor concentration and motivation.

Only a relatively small proportion of men assessed for androgen deficiency will present with a classic (and pathological) hypogonadism. The majority of men undergoing evaluation will only report nonspecific symptoms, which could equally be associated with other morbidities or aging itself, which, in the absence of clear causal endocrine pathology, is termed functional hypogonadism.

A substantial proportion of men will complain of sexual (25–35%) and physical (5–21%) symptoms in the absence of biochemical evidence of testosterone deficiency (Tajar et al. 2010). Similarly, only 20.2% of community-dwelling men aged over 50 years who completed the Boston Area Community Health Survey (BACH) and reported symptoms of androgen deficiency actually had low total testosterone level (Araujo et al. 2007). Conversely, among those who were found to have low total testosterone, only 20.1% had low libido and 29% reported erectile dysfunction. This clearly demonstrates the low predictive value of subjective symptoms of androgen deficiency for identifying low testosterone levels.

A number of population-based studies of community-dwelling middle-aged and elderly men identified sexual symptoms such as diminished libido, frequency of morning erections, erectile dysfunction, and their clustering, to be most specific indicators of androgen deficiency (Hall et al. 2008; Wu et al. 2010; Zitzmann et al. 2006).

The presence of the three mentioned sexual symptoms and low testosterone termed adult or late-onset hypogonadism affects 2% of adult community-dwelling men (Wu et al. 2010). The prevalence increases to 5.6% if additional subjective physical symptoms, such as lethargy or low mood, are considered (Araujo et al. 2007). This is in sharp contrast to the prevalence of androgen deficiency based on biochemical criteria only [total testosterone below 2.5th centile for young men (<10.4 nmol/L)] with 20% of men above the age of 50 and 50% of men aged 80 considered hypogonadal, regardless of associated symptoms (Harman et al. 2001). Yet, those men have higher-than-average frequency of depression, type 2 diabetes, and poor physical performance (Ding et al. 2006; Joshi et al. 2010; Schaap et al. 2005). It is important to acknowledge that their mortality is twofold higher than men with normal testosterone level yet much lower than that of men who present with symptomatic androgen deficiency (Pye et al. 2014).

---

## History and Physical Examination

The clinical evaluation of a male with suspected hypogonadism is an important step in the diagnostic pathway which not only points to the likelihood of androgen deficiency but also provides important information on potential causes of hypogonadism. Laboratory evaluation is essential to confirm the initial clinical findings.

The history taking should be focused on eliciting the symptoms suggestive of hypogonadism as well as the less specific symptoms. It is important to know that patients with longstanding hypogonadism are often not aware that they have symptoms which they regard as their normal state. Specific enquiry about the various symptoms in Table 1 should therefore be carried out.

In addition, men should be asked about history of genital abnormalities at birth, cryptorchidism, the onset of puberty and any history (including family) of delayed puberty, and endocrine disorders.

Careful examination focused on the clinical features presented above should be undertaken in all cases of suspected androgen deficiency.

General examination can reveal eunuchoid body habitus with female distribution of body fat and hair in androgen-dependent areas. High-pitched unbroken voice is a feature of prepubertal onset hypogonadism. Greater ratio of arm span to height is a result of continued long bone growth due to lack of epiphyseal closure.

Visual disturbances are not uncommon in men with hypogonadism secondary to pituitary lesion, and bitemporal hemianopsia due to optic chiasm compression may be found on examination. Similarly, accompanying midline field defects (cleft palate, anosmia) typically indicate an underlying genetic cause of hypogonadotropic hypogonadism. Anosmia or hyposmia can be objectively tested with the use of commercially available olfactory test kits like the Smell Identification Test, the Brief Smell Identification Test, or the squeeze-bottle odor threshold test kit (Doty et al. 1984, 1996). Gynecomastia is bilateral and usually symmetrical. Careful examination is essential to distinguish true gynecomastia from pseudogynecomastia, which represents a subareolar accumulation of adipose tissue and is often encountered in obese individuals (Braunstein 2007).

Genital examination is essential and can provide important information on the cause and the onset of androgen deficiency. It is typically performed in the lying and standing position. Careful inspection may reveal not only congenital abnormalities (ambiguous genitalia, bifid scrotum, hypospadias) but also features of absent (Tanner stage I) or arrested postnatal genital development (Tanner stage II–IV).

Normal adult testicle measures 2–4 cm in width and 3–5 cm in length, with a typical volume of 12–19 ml, assessed by Prader orchidometer (Kim et al. 2007). Testes smaller than 4 ml usually indicate prepubertal onset hypogonadism, e.g., congenital hypogonadotropic hypogonadism and Klinefelter syndrome. In addition to size, testes should be palpated for consistency (firm in the case of Klinefelter syndrome due to fibrotic changes) and presence of any masses.

---

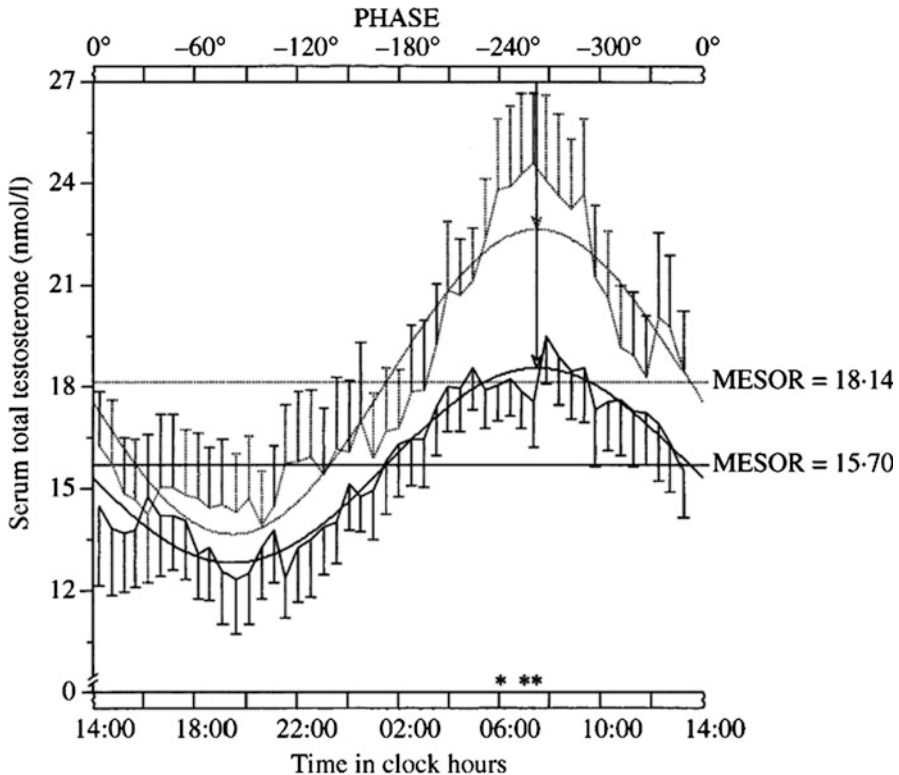
## Diagnosis of Androgen Deficiency

### Biochemical Evaluation

In every case of clinically suspected hypogonadism, biochemical confirmation is required to confirm the diagnosis. Serum measurement of total testosterone is the initial diagnostic test to identify the true cases of hypogonadism (Bhasin et al. 2010). Biochemical diagnosis of hypogonadism, however, is fraught with difficulties and challenges due to biological and assay issues.

### Testosterone Variability

Circulating testosterone levels display both circadian and ultradian rhythm with peak concentration at 8 am and gradual decrease during the day, reaching trough levels approximately 12 h later. These can be as much as 30–35% lower than the early morning values (Brambilla et al. 2009). This phenomenon is preserved, though



**Fig. 1** Cosinor-derived circadian rhythmometry (CHRONOLAB) for serum total testosterone in young (dotted lines) and elderly (solid lines) men. The arrows (dotted = young; solid = elderly) indicate the time of acrophase. PHASE represents the time in degrees  $360^\circ = 24$  h) (Reprinted from Diver et al. 2003. Copyright (2003) Copyright Wiley&Sons)

slightly attenuated, in healthy older men in whom the difference in peak and trough total testosterone level is approximately 10% (Fig. 1 (Diver et al. 2003)).

With this in mind, for diagnostic purposes, early morning measurement of testosterone level, on at least two occasions, and ideally before 10 am, is advocated.

It is also recommended to perform blood sampling for testosterone measurement in a fasted state as a decrease in serum testosterone level by as much as 47% was observed in response to glucose load in healthy eugonadal men (Caronia et al. 2013).

In addition, day-to-day variability of testosterone level within an individual can significantly impact the diagnostic process. In a population-based cohort, greater short-term (1–3 days) rather than long-term (3–6 months) intraindividual variability in testosterone level was observed (Brambilla et al. 2007). The magnitude of those differences was significant enough to conclude that a single measurement was not sufficient to confidently characterize one's testosterone level and repeated one or two measurements are warranted to ascertain the diagnosis.

## Measurement of Total Testosterone

### Radioimmunoassay

First measurements of total testosterone were performed in 1960s by radioimmunoassay (RIA), which required organic solvent extraction and chromatographic purification of a serum sample in order to increase sensitivity and specificity of testosterone measurement. Development of automated platform analysis by immunoassay eliminated the need for extraction and chromatography at the expense of accuracy and consistency of measurement especially at low testosterone concentrations, e.g., hypogonadal prepubertal males and females.

The poor standardization and performance of these now ubiquitous platform immunoassays have raised serious concerns regarding the accuracy and interlaboratory variations of testosterone measurements (Rosner and Vesper 2010). This lack of assay precision and poor repeatability, particularly at low concentration, increases the risk of misclassification in diagnosis of androgen deficiency. Nonetheless, a high-quality immunoassay, which has undergone a rigorous standardization procedure, is able to reliably detect all testosterone concentrations in males and should be considered an acceptable tool to measure testosterone levels in eugonadal and hypogonadal men (Taylor et al. 2015).

### Liquid Chromatography-Tandem Mass Spectroscopy

Due to the problems associated with immunoassay measurement of testosterone, many laboratories have turned to using liquid chromatography-tandem mass spectroscopy (LC-MS). LC-MS, used only as a reference method in the past, has increasingly become the recommended testosterone measurement as it provides highly accurate and more consistent results, particularly at a low concentration. Steroid hormones are extracted from the serum samples and separated by liquid chromatography; subsequently total testosterone level is determined by atmospheric pressure ionization mass spectrometry (Licea-Perez et al. 2008; Shiraishi et al. 2008). This initially labor-intensive and complex process has gradually become semiautomated and at present is the preferred method of testosterone measurement (Kushnir et al. 2011; Stanczyk and Clarke 2010), although the issues surrounding the standardization process, as in the case of immunoassays, pertain.

Facing those problems, the Endocrine Society together with the Centers for Disease Control and Prevention has called for a harmonization of testosterone assays across laboratories and published a set of recommendations in order to achieve highly accurate testosterone testing (Rosner and Vesper 2010).

Since then, a Hormone Standardization Program (CDC HoSt) has been introduced, and a number of laboratories in the United States have joined the scheme and use standardized methods including centrally approved calibrators. This has resulted in significant reduction in among-laboratory variability of testosterone LC-MS assays, and further improvements with immunoassays are anticipated (Vesper et al. 2014).

### The Role of SHBG in Testosterone Measurement

Circulating testosterone is bound to sex hormone-binding globulin (SHBG, 30–40%), albumin (54–68%), and corticosteroid-binding globulin (CBG, 4%) with only a small unbound fraction (2–5%), so-called free testosterone, which is thought to be the biologically active moiety at the target tissues. “Bioavailable” testosterone comprises the unbound free fraction together with the albumin- and CBG-bound components which can dissociate and be theoretically available to some target tissues. Conversely, testosterone binds to SHBG with high affinity, and according to the “free hormone hypothesis,” only free unbound hormones are biologically active in target tissues. This hypothesis, though widely accepted in clinical practice, to date has not been proven experimentally. In addition, there is some evidence that testosterone bound to SHBG can be internalized into the cells by endocytosis through megalin protein (Hammes et al. 2005), thus suggesting the possibility of a direct biological action of protein-bound testosterone. However, in practice, most would accept and apply the concepts of the “free hormone hypothesis.” Thus, alterations in SHBG level not only affect the total measurable testosterone levels but also influence biological action in the opposite direction.

Although free testosterone is thought to be responsible for the biological actions of androgen, in line with “free hormone hypothesis,” its role in the diagnosis of hypogonadism and specific reference range has not been well established. As indicated in the previous paragraph, a number of international societies suggest calculating or measuring free testosterone in men whose total testosterone level is close to the lower limit of normal (8–12 nmol/L), in order to better assess the physiologically active free or bioavailable fraction, and/or in the presence of conditions affecting SHBG concentration (Wang et al. 2008).

In conditions associated with lower SHBG concentration such as obesity, type 2 diabetes, nephrotic syndrome, or hypothyroidism, lower levels of total testosterone might be associated with normal value of free or bioavailable testosterone. In contrast, men with low-normal testosterone and conditions known to increase SHBG, such as liver cirrhosis, hyperthyroidism, estrogen excess, anticonvulsant use, or even aging process per se, may have considerably lower levels of free testosterone (Table 2). When total testosterone is in the unequivocally low (<6 nmol/L) range, SHBG (and free T) measurement is unlikely to be contributory.

**Table 2** Conditions associated with alterations in SHBG level

Increased SHBG level	Decreased SHBG level
Aging	Obesity
Estrogens	Glucocorticosteroids, progestins, androgenic steroids
Hyperthyroidism	Hypothyroidism
HIV infection	Type 2 diabetes mellitus
Hepatic dysfunction	Acromegaly
Anticonvulsants	Nephrotic syndrome

## Measurement of Free Testosterone

### Equilibrium Dialysis and Ultrafiltration

Equilibrium dialysis and ultrafiltration are considered gold standard and reference methods in measuring free testosterone. The principles of measuring free hormone fraction applied in this methodology are the same as in the case of thyroid hormones.

Serum sample, with addition of radiolabeled testosterone of known concentration, is placed under standardized conditions, reflecting the *in vivo* environment, in contact with buffering solution through a membrane which allows a passage of free testosterone but not its binding proteins. As testosterone in the serum dissociates from its binding proteins, equilibrium on both sides of the membrane is reached. The subsequent measurement of free fraction can be done either directly (immunoassay/LC-MS) or indirectly, taking into account the percentage of radiolabeled testosterone which equilibrated. This method of measuring free testosterone is labor intensive, expensive, and sensitive to contamination, which can significantly alter the result. Moreover, the accuracy largely depends on the assay used for estimation of total testosterone. Even though equilibrium dialysis is considered the preferred method of measuring free testosterone, its availability at present is mostly restricted to research laboratories.

A close alternative to equilibrium dialysis is ultrafiltration where serum is centrifuged through a membrane allowing only a passage of free testosterone and other low molecular weight particles. The amount of free testosterone in the ultrafiltrate can be measured directly and indirectly, as described in the previous paragraph. Again, this method is not fault-free, and the interaction of certain serum proteins with the membrane might lead to falsely elevated free testosterone values in the ultrafiltrate.

### Calculated Free Testosterone

When directly measured free testosterone is not available or possible, calculation of free testosterone is a simple, rapid, and widely practiced indirect method of estimating free testosterone value. The algorithms are based on either law-of-mass action (equilibrium-binding equations) or empirical equations and assume binding of each SHBG dimer to two testosterone molecules with similar affinity. The calculation requires measurement of total testosterone, SHBG, and albumin and the use of the equilibrium dissociation constants ( $K_d$ ) for the binding of testosterone to SHBG and albumin, respectively. A number of formulae have been used to date (Nanjee and Wheeler 1985; Sartorius et al. 2009; Södergård et al. 1982; Vermeulen et al. 1971), but the Vermeulen formula is currently the most widely used (Vermeulen et al. 1971). Whereas variability in albumin level has minimal effect on the results of calculated free testosterone, and frequently a constant albumin concentration of 43 g/L is used in place of a measured albumin value, SHBG variability is a significant determinant of calculated free testosterone level, and the use of standardized SHBG assay is essential in ensuring accuracy of the results. A study aiming at validation of the calculation formulae against testosterone measurement by equilibrium dialysis,



considered the gold standard for determining free testosterone concentration *in vivo*, revealed that the most commonly used equilibrium-binding formulae consistently overestimate free testosterone values (Ly et al. 2010). The validity of equilibrium-binding theory has further been questioned after the new evidence emerged, describing the binding of testosterone to SHBG as a dynamic multi-step process whereby binding of testosterone to SHBG is not a single homogenous reaction but rather a series of interrelated stoichiological processes (Zakharov et al. 2015). The binding of testosterone to one of the monomers of the SHBG affects the interaction of testosterone with the unoccupied second binding site on the SHBG dimer. Because of the multiple equilibria, dynamic and allosteric nature of these processes, testosterone's binding to SHBG cannot be described as a simple linear equation of ligand binding equilibrium. Accordingly, new mathematical model for calculation of free testosterone has been introduced but is yet to be validated in larger populations and the clinical arena.

### Salivary Testosterone

Over the past 20 years, there has been an increased interest in using saliva samples for estimating free hormone level. Salivary testosterone reflects the free fraction of the hormone which passively diffuses through the salivary glands. Due to the resemblance of this process to naturally occurring diffusion of free fraction of testosterone across membranes of the target cells, with losses due to metabolic conversion and receptor binding, salivary testosterone has been thought to better reflect the biologically active testosterone concentration (Vining and McGinley 1987). It appears to correlate well with serum free and bioavailable testosterone level. Similarly, as with serum testosterone, the precision of salivary testosterone measurement is significantly affected by the type of testosterone assay used (Goncharov et al. 2009; Morley et al. 2006).

Salivary immunoassays do share the same pitfalls as the serum immunoassays for free testosterone, predominantly lacking sensitivity and accuracy. More precise results have been achieved with liquid chromatography-mass spectrometry, which is currently the preferred method. However, the methodology of sample collection still requires standardization as the accuracy is often significantly affected by the method of collection (stimulated salivation vs. passive drooling), blood contamination (teeth brushing before the collection), and sample handling pre-analysis (Fiers et al. 2014). Nonetheless, salivary testosterone measurement by LC-MS is emerging as an attractive, noninvasive, and sensitive method of testosterone measurement (Keevil et al. 2017; Clifton et al. 2016).

### Bioavailable Testosterone

Non-SHBG-bound testosterone (bioavailable fraction) might be measured by precipitation of SHBG-bound testosterone with ammonium sulfate. Known amount of radiolabeled testosterone is added to the tested sample before the SHBG-bound testosterone is precipitated and subsequently separated from the sample. Knowing the concentration of total testosterone as well as the percentage of radiolabeled testosterone in the sample allows for calculation of the bioavailable fraction. Despite

the fact the bioavailable testosterone appears to correlate well with free testosterone measurement, the overall utility of measuring bioavailable testosterone has been questioned and, at present, its role remains unclear (Rosner et al. 2007).

## Diagnostic Threshold

Whereas the current methods allow for an increasingly precise measurement of testosterone, the threshold level below which symptoms of androgen deficiency and adverse health outcomes occur and testosterone administration improves outcomes remains largely controversial. It has been demonstrated that testosterone threshold differs for various symptoms of androgen deficiency from 8.7 to 12 nmol/L (250–348 ng/dL) (Bhasin et al. 2011; Salameh et al. 2010; Wu et al. 2010; Zitzmann et al. 2006); however, for most symptoms, testosterone value of less than 10.4 nmol/L (300 ng/dL) was associated with greater likelihood of symptoms (Shores et al. 2009; Srinivas-Shankar et al. 2010). Total testosterone of 8 nmol/L (220 ng/dL) or less is considered diagnostic of hypogonadism, particularly if the clinical presentation has been confounded by other factors such as comorbidities or age. In men whose total testosterone is between 8 and 12 nmol/L, the joint consensus statement from the International Society of Andrology, the International Society for the Study of Aging Male, the European Association of Urology, the European Academy of Andrology, and American Society of Andrology recommends calculating or measuring free testosterone by equilibrium dialysis (Wang et al. 2008). More recently, the distribution of total testosterone concentrations in four epidemiological studies that included men from different geographic regions of the United States and Europe was compared in order to generate harmonized reference range. The normal range (2.5th–97.5th percentile) in nonobese predominantly Caucasian men aged 19–39 years was found to be 9.2–31.8 nmol/L (264–916 ng/dL) (Thomas et al. 2017). Several large epidemiological studies have suggested a lower limit of reference range for calculated free testosterone to be between 160 and 243 pmol/L (46–70 pg/ml) (Bhasin et al. 2011; Salameh et al. 2010) which is higher than the values 121–156 pmol/L (35–45 pg/ml) obtained by equilibrium dialysis (Salameh et al. 2010, Mayo Medical Laboratories). The lack of well-established reference range for free testosterone does reflect to some extent the wide heterogeneity of results between laboratories. Even though experts in the field advocate estimation of free testosterone in the case of equivocal total testosterone level, the exact role of free testosterone fraction in the diagnosis of hypogonadism has not been well established. More recent data from large community-based cohort study suggest that men whose free testosterone is low ( $<220$  pmol/L), in the presence of low-normal total testosterone, display clinical features compatible with androgen deficiency as oppose to men whose total testosterone is low-normal but free testosterone is  $\geq 220$  pmol/L (Antonio et al. 2016). The latter biochemical picture, typical for obesity, did not appear to correlate with more specific sexual and physical symptoms of androgen deficiency. These findings largely support the suggestion that free testosterone might be a more important determinant of gonadal status in men with low-normal total

testosterone levels or in states where alterations in SHBG concentration are observed.

In clinical practice, testosterone levels, obtained from a hospital or commercial laboratory, are typically interpreted in the context of the laboratory-specific reference range. These normative ranges, usually based on small population samples of young men, display a considerable variability between different assays. Moreover, the normative values for older men are frequently not known. Therefore, harmonization of testosterone assays is of great importance in the ongoing process to generate population-based reference ranges for total and free testosterone in men, which will ultimately lead to the development of rational criteria for diagnosing androgen deficiency.

### **Gonadotrophins**

Knowledge of LH and FSH value in conjunction with testosterone is essential for the pathophysiological diagnosis of androgen deficiency and distinguishing primary from secondary hypogonadism (Bhasin et al. 2010). Men with primary hypogonadism have elevated LH and FSH in the presence of low testosterone level, as a result of blunted negative feedback suppression of gonadotrophin secretion by testosterone and inhibin B. Conversely, in men with secondary hypogonadism, the gonadotrophin levels are low or inappropriately normal reflecting the pituitary and/or hypothalamic defect. There are cases when mixed picture of primary and secondary hypogonadism might be present (e.g., hemochromatosis, certain medication use) but typically one of the patterns is more evident than the other. In rare situations, men will present with low testosterone and atypical gonadotrophin pattern such as elevated FSH and normal or low LH, suggestive of gonadotrophin-secreting pituitary tumor. High levels of biologically inactive alpha-subunit are found in male sera in such cases. Distinguishing primary from secondary hypogonadism is of critical importance and determines subsequent steps in clinical and biochemical evaluation as well as guide management (e.g., maximizing fertility potential in secondary but not primary hypogonadism).

Men who were found to suffer from secondary (hypogonadotropic) hypogonadism require a comprehensive biochemical assessment of the pituitary function to exclude excessive or impaired secretion of the remaining pituitary hormones. Ferritin levels should be measured to rule out hemochromatosis. The role of routine pituitary imaging in isolated hypogonadotropic hypogonadism remains largely unclear. More often than not, magnetic resonance imaging of the pituitary and hypothalamus is performed, driven by a fear of missing potentially treatable pituitary pathology. It has been demonstrated that in men with secondary hypogonadism with no hyperprolactinemia, other hormonal deficiencies, or features of sellar compression, the risk of detecting clinically significant pituitary lesion is equal to that of general population (Hirsch et al. 2015). It has been suggested that the diagnostic yield could be increased if the imaging was performed in men whose total testosterone is  $<5.2$  nmol/L ( $<150$  pg/dl), and other hormonal abnormalities as well as symptoms of tumor mass effect were present (Citron et al. 1996). The cost-effectiveness of such approach has not been evaluated to date.

Men presenting with primary hypogonadism should be referred for karyotype testing, especially when the testicular volume is less than 6 ml, in order to exclude underlying Klinefelter syndrome. While very low testicular volume is highly suggestive of 47XXY, men with Klinefelter mosaicism might have larger testicular volume. In men presenting with or having concerns about fertility, a repeated (within 1 week) semen analysis is suggested to confirm oligo- or azoospermia accompanying androgen deficiency.

The assessment of bone mineral density with DEXA is indicated in men with hypogonadism of any etiology and history of low-trauma or fragility fracture (Watts et al. 2012).

---

## Case Finding

Population-based screening for hypogonadism does not fall under the WHO principles of screening framework and as such is not recommended (Strong et al. 2005; Bhasin et al. 2010). The main limitations are related to uncertainties surrounding case definition and the significance of the androgen deficiency as a morbidity. Moreover, there is insufficient data on the natural history of (untreated) hypogonadism, although its impact on mortality has been described previously (Araujo et al. 2011; Laughlin et al. 2008; Pye et al. 2014). Similarly, the risks and benefits of testosterone therapy in asymptomatic men remain unclear. For those reasons, population screening is not recommended at present.

However, clinician could consider case detection by measuring total testosterone in patients who are at high risk of androgen deficiency and who may benefit from replacement therapy. These include men with moderate to severe chronic obstructive airways disease, HIV-associated muscle wasting, osteoporosis, end-stage renal failure on dialysis, or type 2 diabetes mellitus with obesity. The more detailed list of conditions is included in Table 3. Nonetheless, the efficacy data is largely lacking, and therefore an individualized approach with careful consideration is recommended in those cases.

**Table 3** List of conditions associated with increased risk of hypogonadism where measurement of testosterone is suggested

Type 2 diabetes with obesity
Osteoporosis
Moderate to severe chronic obstructive airways disease
HIV-associated muscle wasting
End-stage renal failure on dialysis
Treatment with medication that affects testosterone production or metabolism (opioids, glucocorticoids, 5-alpha reductase inhibitors)
History of sellar mass
History of cranial or total body irradiation
History of cytotoxic medication use

## Summary

The clinical and biochemical features of male hypogonadism vary according to the period of life when the gonadal failure begins and the level at which the disruption of hypothalamic-pituitary-testicular axis occurs. Whereas the fetal and prepubertal onset of androgen deficiency does not pose particular diagnostic difficulties, the identification of so-called adult or late-onset hypogonadism remains challenging. Low specificity of symptoms that are further confounded by comorbidities and aging and relative inaccuracy of the assays deployed to measure testosterone level are the major factors hampering the precise diagnosis in aging male without classical hypothalamic-pituitary-gonadal axis pathology. The diagnostic difficulties further affect the patient selection for interventional therapy and that subsequently translates into inconsistent efficacy results of testosterone replacement trials. Imprecise testosterone testing and poor quality standardization process have been identified as a key modifiable factors affecting the diagnosis of hypogonadism, and until testosterone level can be accurately correlated with levels of androgenicity, the diagnosis of (nonclassic) hypogonadism will remain one of the biggest challenges in endocrine practice.

---

## References

- Antonio L, Wu FCW, O'Neill TW, Pye SR, Ahern TB, Laurent MR, . . . , Vanderschueren D. Low free testosterone is associated with hypogonadal signs and symptoms in men with normal total testosterone. *J Clin Endocrinol Metab.* 2007. doi:10.1210/jc.2015-4106.
- Araujo AB, Esche GR, Kupelian V, O'Donnell AB, Travison TG, Williams RE, . . . , McKinlay JB. Prevalence of symptomatic androgen deficiency in men. *J Clin Endocrinol Metab.* 2007;92(11):4241–7. doi:10.1210/jc.2007-1245.
- Araujo AB, Dixon JM, Suarez EA, Murad MH, Guey LT, Wittert GA. Clinical review: endogenous testosterone and mortality in men: a systematic review and meta-analysis. *J Clin Endocrinol Metab.* 2011;96(10):3007–19. doi:10.1210/jc.2011-1137.
- Bhasin S, Cunningham GR, Hayes FJ, Matsumoto AM, Snyder PJ, Swerdloff RS, Montori VM. Testosterone therapy in men with androgen deficiency syndromes: an Endocrine Society clinical practice guideline. *J Clin Endocrinol Metab.* 2010;95(6):2536–59. doi:10.1210/jc.2009-2354.
- Bhasin S, Pencina M, Jasuja GK, Travison TG, Coviello A, Orwoll E, . . . , Vasani RS. Reference ranges for testosterone in men generated using liquid chromatography tandem mass spectrometry in a community-based sample of healthy nonobese young men in the Framingham Heart Study and applied to three geographically distinct cohorts. *J Clin Endocrinol Metab.* 2011;96(8):2430–9. doi:10.1210/jc.2010-3012.
- Brambilla DJ, O'Donnell AB, Matsumoto AM, McKinlay JB. Intraindividual variation in levels of serum testosterone and other reproductive and adrenal hormones in men. *Clin Endocrinol.* 2007;67(6):853–62. doi:10.1111/j.1365-2265.2007.02976.x.
- Brambilla DJ, Matsumoto AM, Araujo AB, McKinlay JB. The effect of diurnal variation on clinical measurement of serum testosterone and other sex hormone levels in men. *J Clin Endocrinol Metab.* 2009;94(3):907–13. doi:10.1210/jc.2008-1902.
- Braunstein GD. Clinical practice. Gynecomastia. *N Engl J Med.* 2007;357(12):1229–37. doi:10.1056/NEJMc070677.

- Caronia LM, Dwyer AA, Hayden D, Amati F, Pitteloud N, Hayes FJ. Abrupt decrease in serum testosterone levels after an oral glucose load in men: implications for screening for hypogonadism. *Clin Endocrinol*. 2013;78(2):291–6. doi:10.1111/j.1365-2265.2012.04486.x.
- Citron JT, Ettinger B, Rubinoff H, Ettinger VM, Minkoff J, Hom F, . . . , Alloo R. Prevalence of hypothalamic-pituitary imaging abnormalities in impotent men with secondary hypogonadism. *J Urol*. 1996;155(2):529–33. Retrieved from <http://www.ncbi.nlm.nih.gov/pubmed/8558653>
- Clifton S, Macdowall W, Copas A, Tanton C, Keevil B, Lee D, . . . , Wu F. Salivary testosterone levels and health status in a general population: findings from the third National Survey of Sexual Attitudes and Lifestyles (Natsal-3). *J Clin Endocrinol Metab*. 2016. doi:10.1210/jc.2016-1669.
- Ding EL, Song Y, Malik VS, Liu S. Sex differences of endogenous sex hormones and risk of type 2 diabetes: a systematic review and meta-analysis. *JAMA*. 2006;295(11):1288–99. doi:10.1001/jama.295.11.1288.
- Diver MJ, Intiaz KE, Ahmad AM, Vora JP, Fraser WD. Diurnal rhythms of serum total, free and bioavailable testosterone and of SHBG in middle-aged men compared with those in young men. *Clin Endocrinol*. 2003;58(6):710–7.
- Doty RL, Shaman P, Dann M. Development of the University of Pennsylvania smell identification test: a standardized microencapsulated test of olfactory function. *Physiol Behav*. 1984;32:489–502.
- Doty RL, Marcus A, Lee WW. The development of the 12-item Cross-Cultural Smell Identification Test (CC-SIT), based upon items from the University of Pennsylvania Smell Identification Test (UPSIT), is described. In, 1996;106(3):353–6.
- Fiers T, Delanghe J, T'Sjoen G, Van Caenegem E, Wierckx K, Kaufman J-M. A critical evaluation of salivary testosterone as a method for the assessment of serum testosterone. *Steroids*. 2014;86:5–9. doi:10.1016/j.steroids.2014.04.013.
- Goncharov N, Katsya G, Dobracheva A, Nizhnik A, Kolesnikova G, Herbst V, Westermann J. Diagnostic significance of free salivary testosterone measurement using a direct luminescence immunoassay in healthy men and in patients with disorders of androgenic status. *Aging Male*. 2009. Retrieved from <http://www.tandfonline.com/doi/abs/10.1080/13685530600713060?journalCode=itam20>
- Hall SA, Esche GR, Araujo AB, Travison TG, Clark RV, Williams RE, McKinlay JB. Correlates of low testosterone and symptomatic androgen deficiency in a population-based sample. *J Clin Endocrinol Metab*. 2008;93(10):3870–7. doi:10.1210/jc.2008-0021.
- Hammes A, Andreassen TK, Spoelgen R, Raila J, Hubner N, Schulz H, . . . , Willnow TE. Role of endocytosis in cellular uptake of sex steroids. *Cell*. 2005;122(5):751–62. doi:10.1016/j.cell.2005.06.032.
- Harman SM, Metter EJ, Tobin JD, Pearson J, Blackman MR. Longitudinal effects of aging on serum total and free testosterone levels in healthy men. Baltimore Longitudinal Study of Aging. *J Clin Endocrinol Metab*. 2001;86(2):724–31. doi:10.1210/jcem.86.2.7219.
- Hirsch D, Benbassat C, Toledano Y, S'chigol I, Tsvetov G, Shraga-Slutzky I, . . . , Shimon I. Pituitary imaging findings in male patients with hypogonadotrophic hypogonadism. *Pituitary*. 2015;18(4):494–9. doi:10.1007/s11102-014-0601-x.
- Joshi D, van Schoor NM, de Ronde W, Schaap LA, Comijs HC, Beekman ATF, Lips P. Low free testosterone levels are associated with prevalence and incidence of depressive symptoms in older men. *Clin Endocrinol*. 2010;72(2):232–40. doi:10.1111/j.1365-2265.2009.03641.x.
- Keevil BG et al. Distribution of salivary testosterone in men and women in a British general population-based sample: the third national survey of sexual attitudes and lifestyles (Natsal-3). *Journal of the Endocrine Society*. 2017;1(1):14–25. doi:10.1210/js.2016-1029.
- Kim W, Rosen MA, Langer JE, Banner MP, Siegelman ES, Ramchandani P. US MR imaging correlation in pathologic conditions of the scrotum. *Radiographics: Rev Publ Radiol Soc N Am, Inc*. 2007;27(5):1239–53. doi:10.1148/rg.275065172.

- Kushnir MM, Rockwood AL, Roberts WL, Yue B, Bergquist J, Meikle AW. Liquid chromatography tandem mass spectrometry for analysis of steroids in clinical laboratories. *Clin Biochem*. 2011;44(1):77–88. doi:10.1016/j.clinbiochem.2010.07.008.
- Laughlin GA, Barrett-Connor E, Bergstrom J. Low serum testosterone and mortality in older men. *J Clin Endocrinol Metab*. 2008;93(1):68–75. doi:10.1210/jc.2007-1792.
- Licea-Perez H, Wang S, Szapacs ME, Yang E. Development of a highly sensitive and selective UPLC/MS/MS method for the simultaneous determination of testosterone and 5 $\alpha$ -dihydrotestosterone in human serum to support testosterone replacement therapy for hypogonadism. *Steroids*. 2008;73(6):601–10. doi:10.1016/j.steroids.2008.01.018.
- Ly LP, Sartorius G, Hull L, Leung A, Swerdloff RS, Wang C, Handelsman DJ. Accuracy of calculated free testosterone formulae in men. *Clin Endocrinol*. 2010;73(3):382–8. doi:10.1111/j.1365-2265.2010.03804.x.
- Morley JE, Perry HM, Patrick P, Dollbaum CM, Kells JM. Validation of salivary testosterone as a screening test for male hypogonadism. *Aging Male: Off J Int Soc Study Aging Male*. 2006;9(3):165–9. doi:10.1080/13685530600907993.
- Nanjee MN, Wheeler MJ. Plasma free testosterone – is an index sufficient? *Ann Clin Biochem*. 1985;22(Pt 4):387–90.
- Pye SR, Huhtaniemi IT, Finn JD, Lee DM, O'Neill TW, Tajar A, . . . , Wu FCW. Late-onset hypogonadism and mortality in aging men. *J Clin Endocrinol Metab*. 2014;99(4):1357–66. doi:10.1210/jc.2013-2052.
- Rosner W, Vesper H. Toward excellence in testosterone testing: a consensus statement. *J Clin Endocrinol Metab*. 2010;95(10):4542–8. doi:10.1210/jc.2010-1314.
- Rosner W, Auchus RJ, Azziz R, Sluss PM, Raff H. Position statement: utility, limitations, and pitfalls in measuring testosterone: an Endocrine Society position statement. *J Clin Endocrinol Metab*. 2007;92(2):405–13. doi:10.1210/jc.2006-1864.
- Salameh WA, Redor-Goldman MM, Clarke NJ, Reitz RE, Caulfield MP. Validation of a total testosterone assay using high-turbulence liquid chromatography tandem mass spectrometry: total and free testosterone reference ranges. *Steroids*. 2010;75(2):169–75. doi:10.1016/j.steroids.2009.11.004.
- Sartorius G, Ly LP, Sikaris K, McLachlan R, Handelsman DJ. Predictive accuracy and sources of variability in calculated free testosterone estimates. *Ann Clin Biochem*. 2009;46(Pt 2):137–43.
- Schaap LA, Pluijms SMF, Smit JH, van Schoor NM, Visser M, Gooren LJJ, Lips P. The association of sex hormone levels with poor mobility, low muscle strength and incidence of falls among older men and women. *Clin Endocrinol*. 2005;63(2):152–60. doi:10.1111/j.1365-2265.2005.02315.x.
- Shiraishi S, Lee PWN, Leung A, Goh VHH, Swerdloff RS, Wang C. Simultaneous measurement of serum testosterone and dihydrotestosterone by liquid chromatography-tandem mass spectrometry. *Clin Chem*. 2008;54(11):1855–63. doi:10.1373/clinchem.2008.103846.
- Shores MM, Kivlahan DR, Sadak TI, Li EJ, Matsumoto AM. A randomized, double-blind, placebo-controlled study of testosterone treatment in hypogonadal older men with subthreshold depression (dysthymia or minor depression). *J Clin Psychiatry*. 2009;70(7):1009–16. Retrieved from <http://www.ncbi.nlm.nih.gov/pubmed/19653976>
- Södergård R, Bäckström T, Shanbhag V, Carstensen H. Calculation of free and bound fractions of testosterone and estradiol-17 beta to human plasma proteins at body temperature. *J Steroid Biochem*. 1982;16(6):801–10.
- Srinivas-Shankar U, Roberts SA, Connolly MJ, O'Connell MDL, Adams JE, Oldham JA, Wu FCW. Effects of testosterone on muscle strength, physical function, body composition, and quality of life in intermediate-frail and frail elderly men: a randomized, double-blind, placebo-controlled study. *J Clin Endocrinol Metab*. 2010;95(2):639–50. doi:10.1210/jc.2009-1251.
- Stanczyk FZ, Clarke NJ. Advantages and challenges of mass spectrometry assays for steroid hormones. *J Steroid Biochem Mol Biol*. 2010;121(3–5):491–5. doi:10.1016/j.jsbmb.2010.05.001.

- Strong K, Wald N, Miller A, Alwan A. Current concepts in screening for noncommunicable disease: World Health Organization Consultation Group Report on methodology of noncommunicable disease screening. *J Med Screen*. 2005;12(1):12–9. doi:10.1258/0969141053279086.
- Tajar A, Forti G, O'Neill TW, Lee DM, Silman AJ, Finn JD, . . . , Wu FCW. Characteristics of secondary, primary, and compensated hypogonadism in aging men: evidence from the European Male Ageing Study. *J Clin Endocrinol Metab*. 2010;95(4):1810–8. doi:10.1210/jc.2009-1796.
- Taylor AE, Keevil B, Huhtaniemi IT. Mass spectrometry and immunoassay: how to measure steroid hormones today and tomorrow. *Eur J Endocrinol*. 2015;173(2):D1–12. doi:10.1530/EJE-15-0338.
- Thomas G, Travison, Hubert W. Vesper, Eric Orwoll, Frederick Wu, Jean Marc Kaufman, Ying Wang, Bruno Lapauw, Tom Fiers, Alvin M. Matsumoto, Shalender Bhasin; Harmonized reference ranges for circulating testosterone levels in men of four cohort studies in the United States and Europe. *J Clin Endocrinol Metab*. 2017;102(4):1161–1173. doi:10.1210/jc.2016-2935.
- Vermeulen A, Stoica T, Verdonck L. The apparent free testosterone concentration, an index of androgenicity. *J Clin Endocrinol Metab*. 1971;33(5):759–67. doi:10.1210/jcem-33-5-759.
- Vesper HW, Botelho JC, Wang Y. Challenges and improvements in testosterone and estradiol testing. *Asian J Androl*. 2014;16(2):178–84. doi:10.4103/1008-682X.122338.
- Vining RF, McGinley RA. The measurement of hormones in saliva: possibilities and pitfalls. *J Steroid Biochem*. 1987;27(1–3):81–94. Retrieved from <http://www.ncbi.nlm.nih.gov/pubmed/3320544>
- Wang C, Nieschlag E, Swerdloff R, Behre HM, Hellstrom WJ, Gooren LJ, . . . , Wu FCW. Investigation, treatment and monitoring of late-onset hypogonadism in males: ISA, ISSAM, EAU, EAA and ASA recommendations. *Eur J Endocrinol/Eur Fed Endoc Soc*. 2008;159(5):507–14. doi:10.1530/EJE-08-0601.
- Watts NB, Adler RA, Bilezikian JP, Drake MT, Eastell R, Orwoll ES, Finkelstein JS. Osteoporosis in men: an Endocrine Society clinical practice guideline. *J Clin Endocrinol Metab*. 2012;97(6):1802–22. doi:10.1210/jc.2011-3045.
- Wu FCW, Tajar A, Beynon JM, Pye SR, Silman AJ, Finn JD, . . . , Huhtaniemi IT. Identification of late-onset hypogonadism in middle-aged and elderly men. *N Engl J Med*. 2010;363(2):123–35. doi:10.1056/NEJMoa0911101.
- Zakharov MN, Bhasin S, Travison TG, Xue R, Ulloor J, Vasani RS, . . . , Jasuja R. A multi-step, dynamic allosteric model of testosterone's binding to sex hormone binding globulin. *Mol Cell Endocrinol*. 2015;399:190–200. doi:10.1016/j.mce.2014.09.001.
- Zitzmann M, Faber S, Nieschlag E. Association of specific symptoms and metabolic risks with serum testosterone in older men. *J Clin Endocrinol Metab*. 2006;91(11):4335–43. doi:10.1210/jc.2006-0401.



Daniele Santi and Giovanni Corona

---

## Abstract

Male hypogonadism is a clinical condition caused by a partial or total breakdown of the cross communication among the hypothalamus, pituitary, and testis. It is generally divided into primary hypogonadism, caused by an abnormality of the testis function, and secondary hypogonadism, due to a pituitary or hypothalamic dysfunction. In primary hypogonadism, the testis is dysfunctional and fails to release sex steroids and sperm, despite strong stimulation by the pituitary (hypergonadotropic hypogonadism), whereas in secondary hypogonadism the testis is normal, but inadequately stimulated by gonadotropins (hypogonadotropic hypogonadism).

Despite taxonomy classification, the clinical features of male hypogonadism depend upon the age of onset, the severity of testosterone (T) deficiency, and whether there is an impairment only in terms of sperm production or also in T production.

In this chapter, the pathogenesis and clinical characteristics of both primary and secondary hypogonadism, along with their main underlying causes, will be evaluated and discussed in detail.

---

## Keywords

Primary Hypogonadism • Secondary Hypogonadism • Klinefelter Syndrome: Kallmann Syndrome

---

D. Santi (✉)

Unit of Endocrinology, Department of Biomedical, Metabolic and Neural Sciences, University of Modena and Reggio Emilia, Modena, Italy  
e-mail: [santi.daniele@gmail.com](mailto:santi.daniele@gmail.com)

G. Corona

Endocrinology Unit, Medical Department, Azienda USL Bologna Maggiore-Bellaria Hospital, Bologna, Italy  
e-mail: [jocorona@libero.it](mailto:jocorona@libero.it)

## Contents

Introduction .....	688
Classification .....	688
Clinical Manifestations .....	702
Secondary Hypogonadism .....	704
Congenital or Developmental Disorders .....	704
Acquired Forms .....	711
Primary Hypogonadism .....	721
Congenital or Developmental Disorders .....	722
Acquired Causes of Primary Hypogonadism .....	732
Androgen Resistance/Decreased Testosterone Bioactivity .....	736
References .....	737

## Introduction

Male hypogonadism is a clinical condition characterized by the impairment of testicular production of both sex steroids and sperm, classically due to a partial or total breakdown of the cross communication between and/or within the hypothalamus, pituitary, and testis. The term, however, is rarely used to identify abnormalities in sperm production, while it is often applied to describe testosterone (T) deficiency (Lenzi et al. 2009).

The measurement of T and gonadotropins allows clinicians to evaluate the androgenic state and the classification of hypogonadism in the majority of cases. It is important, however, to recognize that the definition of hypogonadism, especially in adulthood, remains a matter of debate. T evaluation is still mostly based on the use of commercially available immunoassays which have several pitfalls and inter-assay differences (Rosner et al. 2007; Radicioni et al. 2013). Similar problems have been reported for gonadotropin measurements (Radicioni et al. 2013) (for more information, see specific ► [Chap. 16, “Hormonal Laboratory Examination”](#)).

Despite the aforementioned problems, according to the most commonly used classification (see also ► [Chap. 21, “Classification and Epidemiology of Hypogonadism”](#)), male hypogonadism may be caused by primary disorders of the testis (primary hypogonadism) or be a consequence of hypothalamic-pituitary diseases (secondary hypogonadism). In this chapter, characteristics of both primary and secondary hypogonadism along with their main underlying causes will be evaluated and discussed in details. The treatment for hypogonadism will be extensively reviewed elsewhere (see ► [Chap. 31, “Treatment of Hypogonadism”](#)).

## Classification

According to what has been previously reported, male hypogonadism is generally divided into primary hypogonadism (pHG), if caused by an abnormality of the testes, and secondary hypogonadism (sHG), if due to a pituitary or hypothalamic dysfunction (Tables 1, 2, and 3). In pHG, testes are dysfunctional and fail to release sex

**Table 1** Classification of hypogonadism

<b>Secondary hypogonadism</b>		
<i>Congenital or developmental disorders</i>		
Effect	Common causes	Uncommon causes
<b>Decreased testosterone production</b>	<i>Constitutional delay of puberty</i> <i>Hemochromatosis<sup>a</sup></i>	<i>Combined hormone pituitary deficiency</i> <i>Idiopathic hypogonadotropic hypogonadism (IHH) with variants (see also Table 2):</i> Normosmic IHH Kallmann syndrome Isolated LH $\beta$ gene mutations Non-Kallmann syndromic forms
<b>Isolated impairment of sperm production or action</b>		<i>Congenital adrenal hyperplasia</i> 21-hydroxylase deficiency 11 $\beta$ -hydroxylase deficiency <i>Isolated FSH<math>\beta</math> gene mutations</i>
<i>Acquired disorders</i>		
<b>Decreased testosterone production</b>	<i>Localized problems</i>	
	<i>Drug induced</i> Estrogens Testosterone or androgenic-anabolic steroids Progestogens (including cyproterone acetate) Hyperlactinemia-induced drugs (see also Table 3) Opiates GnRH agonist or antagonist	<i>Hypopituitarism</i> <i>Traumatic brain injury</i> <i>Pituitary adenomas</i> <i>Hypothalamic tumors</i> Germinomas and other germ tumors Gliomas Astrocytomas Craniopharyngiomas Meningioma Metastases <i>Pituitary stalk diseases</i> <i>Iatrogenic</i> Surgical hypophysectomy Pituitary or cranial irradiation <i>Inflammatory and infection diseases</i> Lymphocytic hypophysitis Pituitary infections Granulomatous lesions Sarcoidosis Wegener's granulomatosis Other granulomatosis Encephalitis <i>Langerhans' histiocytosis</i>
	<i>Systemic diseases with hypothalamus/pituitary localization</i>	
	<i>Chronic systemic diseases<sup>a</sup></i> Metabolic diseases (Metabolic syndrome, Obesity, Type 2 diabetes mellitus) HIV infection Chronic organ failure Chronic kidney diseases (CKD)	<i>Spinal cord injury</i> <i>Transfusion-related iron overload (<math>\beta</math>-thalassemia)</i>

(continued)

**Table 1** (continued)

	Chronic obstructive pulmonary disease (COPD) Chronic liver diseases Chronic heart failure Malignancy <i>Glucocorticoid excess (Cushing syndrome)<sup>a</sup></i> <i>Eating disorders<sup>a</sup></i> Starvation, malnutrition Morbid obesity <i>Endurance exercise</i> <i>Acute a critical illness</i> <i>Aging<sup>a</sup></i>	
<b>Isolated impairment of sperm production or action</b>	<i>Drug induced</i> Testosterone or androgenic-anabolic steroids <i>Malignancy<sup>a</sup></i> Hodking diseases Testicular cancer	<i>Androgen or hCG-secreating tumors</i>
<b>Primary hypogonadism</b>		
<b>Congenital or developmental disorders</b>		
	<i>Common causes</i>	<i>Uncommon causes</i>
<b>Decreased testosterone production</b>	<i>Klinefelter syndrome</i>	<i>Rare chromosomal abnormalities</i> <i>XX male syndrome</i> <i>47 XYY syndrome</i> <i>48 XXYY syndrome</i> <i>Defects of testosterone biosynthesis:</i> STAR/20–22 desmolase 3 $\beta$ -HSD 17 $\alpha$ -HSD/17–20 lyase 17 $\beta$ -HSD <i>CAH (testicular adrenal rest tumors)</i> <i>Disorders of sex development (gonadal dysgenesis)</i> <i>LHCGR gene mutations (non capisco queta?)</i> <i>Myotonic dystrophy (including type I and II)</i> <i>Uncorrected cryptorchidism (including INSL3 and LGR8 mutations)</i> <i>Bilateral congenital anorchia</i> <i>Sickle cell disease</i> <i>Noonan syndrome</i> <i>Down syndrome</i> <i>Autosomal translocations</i> <i>Adrenoleukodystrophy</i>

(continued)

**Table 1** (continued)

<b>Isolated impairment of sperm production or action</b>	<i>Uncorrected cryptorchidism (including INSL3 and LGR8 mutations) Y chromosome microdeletions Varicocele</i>	<i>Myotonic dystrophy (including type I and II) Sertoli-cell only syndrome Primary ciliardyschinesia Down syndrome FSH receptor gene mutations/polymorphism Autosomal translocations</i>
<b>Acquired disorders</b>		
<b>Decreased testosterone production</b>	<p><i>Localized problems</i></p> <p><i>Bilateral surgical castration or trauma</i></p> <p><i>Drug induced</i></p> <ul style="list-style-type: none"> <li>Chemotherapy agents</li> <li>Alkylating agents</li> <li>Methotrexate</li> <li>Inhibitors of testosterone synthesis</li> <li>Ketoconazole</li> <li>Aminoglutethimide</li> <li>Mitotane</li> <li>Metyrapon</li> </ul> <p><i>Testicular irradiation</i></p>	<p><i>Orchitis (including mumps)</i></p> <p><i>Autoimmune testicular failure</i></p>
	<i>Systemic diseases with testis localization</i>	
	<p><i>Chronic systemic diseases<sup>a</sup></i></p> <p><i>Chronic organ failure<sup>a</sup></i></p> <p><i>Glucocorticoid excess (Cushing syndrome)<sup>a</sup></i></p> <p><i>Aging<sup>a</sup></i></p>	<p><i>Malignancy</i></p> <ul style="list-style-type: none"> <li>Lymphoma</li> <li>Testicular cancer</li> </ul> <p><i>Spinal cord injury</i></p> <p><i>Vasculitis</i></p> <p><i>Infiltrative diseases (amyloidosis leukemia)</i></p>
<b>Isolated impairment of sperm production or action</b>	<p><i>Orchitis</i></p> <p><i>Testicular irradiation</i></p> <p><i>Chemotherapy agents</i></p> <p><i>Malignancy</i></p> <ul style="list-style-type: none"> <li>Lymphoma</li> <li>Testicular cancer</li> </ul> <p><i>Idiopathic</i></p>	<p><i>Environmental toxins</i></p> <p><i>Spinal cord injury</i></p>
<b>Androgen resistance /decreased testosterone bioactivity</b>		
<b>Congenital or developmental disorders</b>		
	<i>Common causes</i>	<p><i>Uncommon causes</i></p> <p><i>Aromatase deficiency</i></p> <p><i>Kennedy diseases (spinal and bulbar muscular atrophy)and other extensions of CAG repeats</i></p> <p><i>Partial or complete androgen insensitivity</i></p> <p><i>5α reductase type II deficiency</i></p>

(continued)

**Table 1** (continued)

<i>Acquired disorders</i>	
	<i>Drug induced AR blockage</i>
	Steroidal antiandrogen
	Cyproterone acetate
	Spironolactone
	Non-steroidal antiandrogen
	Flutamide
	Bicalutamide
	Nilutamide
	<i>Drug-induced 5<math>\alpha</math> reductase activity blockade</i>
	Finasteride
	Dutasteride
	<i>Drug-induced ER blockade</i>
	Clomiphene
	Tamoxifen
	Raloxifene
	<i>Drug-induced aromatase activity blockade</i>
	Letrozole
	Anastrozole
	Exemestane
	<i>Increased Sex Hormone Binding Protein</i>
	Drug induced (antiepileptic, estrogen, thyroid hormones)
	Hyperthyroidism
	Liver diseases
	Aging
	<i>Celiac disease</i>

<sup>a</sup>Indicate the form which recognize both primary and secondary hypogonadism

steroids and/or sperm, although the pituitary gland stimulates strongly their function (hypergonadotropic hypogonadism), whereas in secondary hypogonadism, the testis is normal, but inadequately stimulated by gonadotropins (hypogonadotropic hypogonadism). More recently, a compensated form of hypogonadism has also been reported, characterized by normal T serum levels and elevated luteinizing hormone (LH) production, although its role as a new pathological entity remains obscure (Giannetta et al. 2012; Corona et al. 2014a). A hypogonadism-like syndrome can also be the result of a reduced sensitivity/insensitivity to T and its metabolites, such as dihydrotestosterone (DHT) and estrogens. Similarly, reduced bioavailability of T could be a consequence of an increase in its carrier protein, i.e., the sex hormone-binding globulin (SHBG) (Table 1).

Whereas the development of hypogonadism before puberty represents an uncommon disease, ranging from 1:500 for Klinefelter syndrome to 1:100,000 for complete androgen insensitivity syndrome, adulthood hypogonadism is much more common (Corona et al. 2012a, b). By applying only biochemical criteria, the prevalence of adulthood hypogonadism or late-onset hypogonadism (LOH) has been reported to be up to 15% in the general population (Buvat et al. 2013). However, by using the

**Table 2** Gene involved in the pathogenesis of hypogonadotropic hypogonadism

Gene	Known biological activity	Inheritance	CHH phenotypes			Overlapping syndromes										
			KS	CHH	CHH reversal	CPHD	CPHD + SOD	WS	CHARGE	HS	SHEM	D-WS	MGS	PEPNS	GHS	
<b>ANOS1 (KAL1)</b> <b>(anosmin-1)</b> <i>(OMIM 300836)</i>	Extracellular matrix protein modulating FGFR1 and integrin signaling. Guidance molecule for GnRH neuronal migration and survival	X-linked recessive	X	-	X	-	-	-	-	-	-	-	-	-	-	-
<b>FEZF1</b> <b>(FEZ family zinc finger 1)</b> <i>(OMIM 613301)</i>	Zinc finger-containing transcriptional repressor regulating the development of forebrain and neocortex. GnRH neuronal migration and survival	Autosomal recessive	X	-	X	-	-	-	-	-	-	-	-	-	-	-
<b>HESX1</b> <b>(homeobox gene expressed in ES cells 1)</b> <i>(OMIM 601802)</i>	Transcription repressor for homeodomain-containing genes. Also involved in combined pituitary hormone deficiency and septo-optic dysplasia	Autosomal recessive/dominant	X	-	-	X	X	X	-	-	-	-	-	-	-	-

(continued)

**Table 2** (continued)

Gene	Known biological activity	Inheritance	CHH phenotypes				Overlapping syndromes										
			KS	CHH	CHH reversal	CPHD	CPHD + SOD	WS	CHARGE	HS	SHFM	D-WS	MGS	PEPNS	GHS		
<b>IL17RD (SEF interleukin 17 receptor D)</b> (OMIM 606807)	Negative regulator and interactant of FGFR1	Autosomal dominant	X	-	-	-	-	-	-	-	-	-	-	-	-	-	-
<b>SEMA3A (semaphorin-3A)</b> (OMIM 603961)	Guidance molecule for GnRH neuronal migration and axonal pathfinding.	Autosomal dominant	X	-	-	-	-	-	-	-	-	-	-	-	-	-	-
<b>SOX10 (SRY-related HMG-box gene 10)</b> (OMIM 602148)	Related to testis-determining transcription factor SRY. Regulates neural crest development. Also involved in Waardenburg-Shah syndrome	Autosomal dominant	X	-	-	-	-	-	-	X	-	-	-	-	-	-	-
<b>DMXL2 (Rabconnectin-3c)</b> (OMIM 612186)	Synaptic protein involved in stimulation and homeostasis of GnRH neurons and gonadotrophs. Also mutated in polyendocrine-polyneuropathy syndrome	Autosomal recessive	-	X	-	-	-	-	-	-	-	-	-	-	x	-	-











<b>FGF8</b> <b>(fibroblast growth factor 8)</b> <i>(OMIM 600483)</i>	Ligand for FGFR1. Essential morphogen for development of forebrain, olfactory GnRH system, skeletal structure and heart	Autosomal dominant	X	X	-	-	-	-	-	-	-	-	-	-	-	-	-	-	-	-	
<b>FGF17</b> <b>(fibroblast growth factor 17)</b> <i>(OMIM 603725)</i>	Similar to FGF8 as a ligand for FGFR1, but more in patterning the dorsal frontal cortex	ND	X	X	-	-	-	-	-	-	-	-	-	-	-	-	-	-	-	-	X
<b>FGFR1</b> <b>(fibroblast growth factor receptor 1)</b> <i>(OMIM 136350)</i>	Receptor tyrosine kinase essential for development of forebrain, craniofacial niche, and stimulation and secretion of GnRH neurons and gonadotrophs	Autosomal dominant	X	X	X	X	-	-	-	-	-	-	-	-	-	-	-	-	-	-	X
<b>HS6ST1</b> <b>(heparan-sulphate 6O-sulphotransferase 1)</b> <i>(OMIM 604846)</i>	Catalyzes the transfer of sulphate to position 6 of the N-sulfolucosamine residue of heparan sulphate, essential for FGFR1 signaling activity	Autosomal dominant	X	X	X	-	-	-	-	-	-	-	-	-	-	-	-	-	-	-	-

(continued)

**Table 2** (continued)

Gene	Known biological activity	Inheritance	CHH phenotypes			Overlapping syndromes											
			K.S	CHH	CHH reversal	CPHD	CPHD + SOD	WS	CHARGE	HS	SHFM	D-WS	MGS	PEPNS	GHS		
<b>NSMF</b> (nasal embryonic luteinizing hormone-releasing hormone factor; NELF) (OMIM 608137)	Guidance molecule for olfactory axon projections required for the axonophilic migration of GnRH neurons	ND	X	X	X	-	-	-	-	-	-	-	-	-	-	-	-
<b>PROK2</b> (prokinectin 2) (OMIM 607002)	Secreted by the hypothalamic neurons of suprachiasmatic nucleus that regulate circadian clock. Chemoattractant for subventricular zone neuronal progenitors. Involved in olfactory bulb morphogenesis and the migration and stimulation of GnRH neurons	Autosomal recessive/dominant	X	X	-	-	-	-	-	-	-	-	-	-	-	-	-
<b>PROKR2</b> (prokinectin receptor-2; GPR73L 1) (OMIM 607123)	G-protein-coupled receptor for PROK2. Regulates the formation of olfactory bulb, GnRH neuron and reproductive organs	Autosomal recessive/dominant	X	X	X	X	-	-	-	-	-	-	-	-	X	-	-

<b>SEMA7A</b> <b>(semaphorin 7A)</b> <i>(OMIM 607961)</i>	Membrane-anchored guidance molecule of the semaphorin family. Enhances axon outgrowth and interacts with integrin receptors	ND	X	X	-	-	-	-	-	-	-	-	-	-	-	-	-
<b>WDR11</b> <b>(WD repeat protein II)</b> <i>(OMIM 606417)</i>	Member of the WD repeat-containing protein family. Expressed in the forebrain and HPG axis	Autosomal dominant	X	X	-	X	-	-	-	-	-	-	-	-	-	-	-

*LH* luteinizing hormone, *FSH* follicle-stimulating hormone, *CHH* congenital hypogonadotropic hypogonadism, *CHARGE* coloboma, heart defects, atresia of choanae, retardation of growth and/or development, genital and/or urinary defects, and ear anomalies or deafness, *CPHD* combined pituitary hormone deficiency, *CTO* contributes to oligogenicity, *DWS* Dandy-Walker syndrome, *GHS* Gordon Holmes syndrome, *HS* Hartsfield syndrome, *KS* Kallmann syndrome, *MGS* Morning Glory syndrome, *OMIM* Online Mendelian Inheritance in Man, *PEPNS* polycystic deficiencies and polyneuropathies, *SHEM* split-hand/foot malformation, *SOD* septo-optic dysplasia, *WS* Waardenburg syndrome, *ND* not determined, *HYPG* hypothalamic pituitary gonadal

**Table 3** Drugs associated with hyperprolactinemia

<b>I. Antipsychotics and other dopamine receptor blockers</b> (including antiemetic)
Phenothiazines (chlorpromazine, mesoridazine, thioridazine, fluphenazine, perphenazine, trifluoperazine)
Butyrophenones (haloperidol, pimozide, fluspirilene, penfluridol, risperidone)
Benzamides (sulpiride, amisulpride, levosulpiride, cisapride, metoclopramide)
Thioxanthenes (chlorprothixene, thiothixene)
<b>II. Dopamine synthesis inhibitors: <math>\alpha</math>-Metildopa</b>
<b>III. Catecholamine depletors: Reserpine</b>
<b>IV. Antidepressants</b>
Selective serotonergic reuptake inhibitor (SSRI; citalopram, paroxetine, sertraline, fluoxetine, fluvoxamine, escitalopram)
Serotonergic-noradrenergic reuptake inhibitor (SNRI)/ atypical antidepressants (venlafaxine, trazodone, mirtazapine, bupropion)
Tricyclic (chlorimipramine, amitriptyline)
<b>V. Opiates</b>
<b>VI. H<sub>2</sub> antagonist</b>
Cimetidine
Ranitidine
<b>VII. Calcium channel blockers: verapamil</b>
<b>VIII. Hormones</b>
Estrogens
Antiandrogens
<b>IX. Anticonvulsivants: Phenytoin</b>

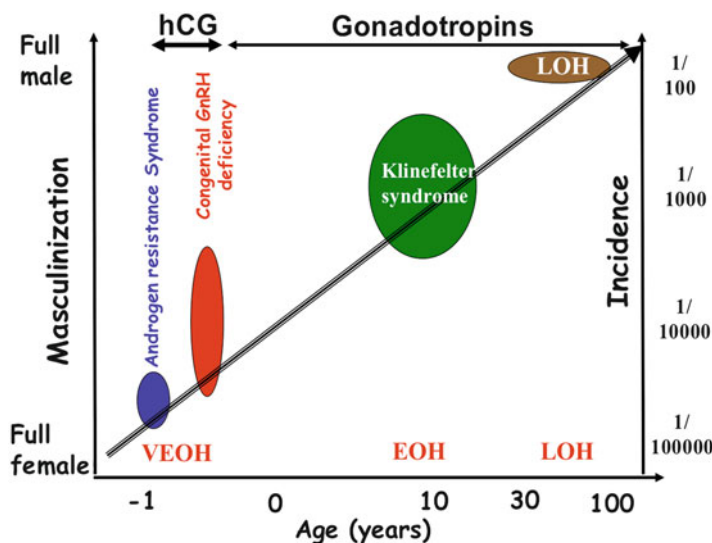
European Male Aging Study (EMAS) strict criteria (combination of reduced T levels <11 nM and sexual symptoms), the prevalence of LOH is much lower, i.e., 2.1% (Wu et al. 2010). However, subjects complaining of sexual dysfunction represent a population overloaded with LOH, with a prevalence of 5–6 times higher than that reported in the general population (Corona et al. 2013a).

For more detailed information on hypogonadism classification, refer to the ► [Chap. 21, “Classification and Epidemiology of Hypogonadism.”](#)

## Clinical Manifestations

Signs and symptoms of hypogonadism are quite similar despite taxonomy classification, whereas they are more often influenced by the age of onset of hypogonadism (Fig. 1) (Morelli et al. 2007). Essentially, the clinical features of male hypogonadism depend upon the age of onset, severity of T deficiency, and whether there is a decrease in one or both of the two major functions of the testes: sperm production and T production (for more information, see ► [Chap. 22, “Clinical Manifestation and Diagnosis of Androgen Deficiency”](#)).





**Fig. 1** Phenotypes of hypogonadism, reported according to age of onset. Hypogonadism incidence in the general population is also shown. Size of ellipsis reflects on abscissa, age range of onset, and on ordinates, incidence (right, log. Scale) and phenotype (left, arbitrary masculinization unit) (Adapted from Morelli 2007). VEOH very early-onset hypogonadism, EOH early-onset hypogonadism, AOH adult-onset hypogonadism, LOH late-onset hypogonadism. Examples of diseases inducing hypogonadism are reported at the top of each ellipsis: CAIS complete androgen insensitivity syndrome; reduction of testosterone (T) formation, deficiency of 17-hydroxylase or 3 $\beta$  hydroxysteroid dehydrogenase type 2; GPR54-, mutations of G-protein-coupled receptor 54 gene; GnRHR-, mutations of GnRH receptor gene

When androgen deficiency is manifest very early, as in fetal life, symptoms can be dramatic, spanning from an almost complete female phenotype (complete androgen insensitivity or enzymatic defects blocking androgen synthesis) to various defects in virilization (micropenis, hypospadias, cryptorchidism). In the case of pre- or peripubertal hypogonadism, a delay in the onset of puberty is generally present, with an overall eunuchoidal phenotype (Corona et al. 2013a, 2015). Eunuchoid proportions include a lower body segment (floor to pubis) that is at least 2 cm longer than the upper body segment (pubis to crown), an arm span more than 5 cm longer than height, and an upper to lower segment ratio  $< 0.92$  (Biaison-Lauber 2010). These signs are generally associated with small testes (usually less than 2 mL) and prostate, difficulty gaining muscle mass, lack of a beard, failure of the voice to deepen, and gynecomastia. The latter condition reflects different pathogenetic mechanisms according to HG etiology. In pHG, the increase of LH results in enhanced Leydig cell stimulation with inhibition of the 17,20-lyase and 17-hydroxylase activities leading to an increased aromatization of T to E2 (Braunstein 2007). On the contrary, in sHG, the impairment of LH causes a reduction of both T and E2 associated with aromatization of estrogen precursors produced by the adrenal gland (Braunstein 2007).

The final result is an estrogen/androgen imbalance causing gynecomastia (for more details, refer to the specific ► [Chap. 29, “Gynecomastia”](#)). Finally, LOH occurs when hypogonadism develops after puberty and especially with aging. In this setting, symptoms are relatively mild, insidious, and difficult to recognize (for more details, see ► [Chap. 30, “Late-Onset Hypogonadism”](#)).

---

## Secondary Hypogonadism

Secondary hypogonadism (sHG) is a clinical condition caused by insufficient secretion of pituitary gonadotropins: LH and follicle-stimulating hormone (FSH). The impaired pituitary action affects the normal testicular endocrine function during both pre- and postnatal periods and fertility after the age of puberty. sHG can be either congenital or acquired and might result in isolated gonadotropin deficiency or be combined with other pituitary hormone defects (Boehm et al. 2015).

Constitutional delay of puberty (CDOP) is a physiological variant of normal puberty characterized by a slow growth rate, resulting in a delay in the timing of pubertal development. CDOP justifies 65% of all cases of delayed puberty, representing the most common cause of delayed puberty and can be considered a transient sHG (Table 1). Conversely, permanent sHG due to isolated hypogonadotropic hypogonadism (IHH) or hypothalamic-pituitary dysfunctions, which initially are often clinically indistinguishable from CDOP, accounts for fewer than 10% of cases of delayed puberty. Finally, functional sHG due to systemic illness or medications involves 20%, whereas pHG or androgen resistance 5% of cases (Palmert and Dunkel 2012) (see below and Table 1).

## Congenital or Developmental Disorders

### Combined Pituitary Hormone Deficiency (CPHD)

The pituitary gland produces and secretes six different hormones. Clinical and animal models have documented that some transcription factors, including homeobox gene expressed in ES cells 1 (HESX1), homeobox protein prophet of PIT-1 (PROP1), POU domain, class 1, transcription factor 1 (POU1F1), LIM/homeobox proteins LHX3 and LHX4 (LHX3, LHX4), paired-like homeodomain transcription factors 1 and 2 (PITX1, PITX2), sex-determining region Y (SRY)-box 2 and SRY-box 3 (SOX2 and SOX3), are essential for its development. The expression pattern of these transcription factors dictates the phenotype that results when the gene encoding the relevant transcription factor is mutated.

PROP1 encodes a transcription factor critical for the development of most lineages of the anterior pituitary cells (Flück et al. 1998). PROP1 mutations are the most common cause of CPHD. In this case, deficiencies include thyroid-stimulating hormone (TSH), prolactin (PRL), LH, and FSH. The spectrum of gonadotropin deficiency ranges from genital abnormalities at birth to lack of puberty and from spontaneous pubertal development initiation with subsequent arrest to

infertility. Usually, individuals with PROP1 mutations exhibit normal adrenocorticotrophic hormone (ACTH) concentrations in early life, but often demonstrate an evolving cortisol deficiency with increasing age (Larson et al. 2015).

Septo-optic dysplasia (SOD) (OMIM 182230) represents a rare disease, with a reported prevalence of 6.3–10.9:100,000, characterized by at least one of the following clinical features: midline forebrain defects, optic nerve hypoplasia, and hypopituitarism (Dattani et al. 1998). Only 30% of affected patients manifest all signs, whereas the most common characteristics are hypopituitarism (62%) and absence of septum pellucidum (60%). The condition is equally prevalent in both sexes, and endocrine dysfunction ranges from isolated growth hormone (GH) deficiency to evolving CPHD. Gonadotropin secretion may be retained in the face of other pituitary hormone deficiencies. Mutations in HESX1 gene have been associated with SOD; however, their overall frequency is low, suggesting that mutations in other known or unknown genes and environmental factors may contribute to this complex disorder (Larson et al. 2015).

*LHX3* and *LHX4* genes encode transcription factors critical for the development of Rathke's pouch, and their mutations are rare causes of CPHD. Heterozygous mutations in *LHX4* can cause CPHD with a structurally abnormal pituitary gland, sella turcica, and cerebellum in some cases (Castinetti et al. 2008). Gonadotropin deficiency or complete CPHD are more common in the presence of mutations in *LHX3* (Bhangoo et al. 2006).

*SOX3* on the X chromosome encodes a transcription factor whose sequence variants, deletions, and duplications are possible causes of CPHD, along with other central nervous system morphological anomalies (OMIM 300123) (Laumonnier et al. 2002).

## Isolated Hypogonadotropic Hypogonadism (IHH)

### Epidemiology

IHH or congenital isolated sHG (CsHG) (OMIM 147950) is a rare clinically heterogeneous condition with a complex and still largely unknown pathogenesis characterized by isolated gonadotropin deficiency of varying degrees with otherwise normal pituitary function (Miraoui et al. 2013). The disease has a clearly male predominance with an incidence of 1:8000 males and 1:40,000 females. It can be associated with either a normal or defective sense of smell, which identifies normosmic CsHG or Kallmann syndrome (KAS), respectively. In addition, it can present solely as congenital GnRH deficiency or be associated with other developmental anomalies such as cleft lip or palate, dental agenesis, ear anomalies, congenital hearing impairment, renal agenesis, bimanual synkinesis, or skeletal anomalies. Understanding of the molecular genetics of CsHG and KAS has advanced tremendously in the past 20 years, since the first gene associated with KAS (*KALI* or *ANOS1*) was identified by a positional cloning strategy in 1991 (Table 2). More than 31 different putative loci for this disorder have been detected, 17 of which are also associated with KAS. The identified genes and their presumed biological activities and inheritance patterns are summarized in Table 2. Interestingly, although these

genes may be implicated in the etiology of approximately 50% of CsHG, the mutations in each of the genes account for less than 10% of such cases. Moreover, the majority of the underlying mechanisms have yet to be fully characterized (Bonomi et al. 2012).

### Pathology

GnRH neurons are unusual neuroendocrine cells, originating outside the olfactory placode and then migrating into the brain during embryonic development. Once arrived in the hypothalamus, GnRH neurons lose their axonal guides and remain in the brain parenchyma. At birth, GnRH neurons have reached their final destination in the hypothalamus and many of them project to the median eminence, where they release GnRH into the hypophyseal portal plexus, which, in turn, regulates the pituitary secretion of LH and FSH (Boehm et al. 2015). Overall, according to a recent consensus (Boehm et al. 2015), the neuroendocrine abnormalities underlying CsHG can be divided into two main groups (Table 2):

1. Developmental abnormalities affecting the hypothalamic location of GnRH neurons
2. Molecular abnormalities of the gonadotrope cascade

The latter division, however, is not mutually exclusive because the associated events are often interdependent and multiple signal pathways cross communicate with one another.

CsHG is genetically heterogeneous, with several inheritance modes, such as X chromosome-linked recessive, autosomal recessive, and dominant, representing both sporadic and familial cases (Table 2) (Boehm et al. 2015).

Although it is generally assumed that CsHG is caused by irreversible GnRH deficiency, thus requiring lifelong hormone therapy, several clinical reports have emphasized that a small group of these subjects, including those with known gene mutations, can experience reversal of the hypogonadal state (Raivio et al. 2007). These observations suggest a positive effect of androgens in the reactivation of GnRH neurons. Accordingly, *in vitro* studies on human GnRH-secreting neuroblasts showed a positive synergy between androgens and leptin on the regulatory mechanisms required for reproductive and sexual fitness (Morelli et al. 2009). Hence, based on *in vivo* and *in vitro* studies, it can be hypothesized that increasing T levels may stimulate hypothalamic-pituitary neural circuits leading to spontaneous resumption of pulsatile GnRH secretion, the *primum movens* of sexual maturation.

### Clinical Features

Based on clinical features, three main categories of patients can be identified (Tables 1 and 2):

1. Isolated CsHG with normal olfaction
2. Isolated CsHG with impaired olfaction (Kallmann syndrome)
3. Non-Kallmann syndromic forms

Kallmann syndrome accounts for about 60% of CsHG, whereas the remaining 40% have normosmic CsHG as non-Kallmann syndromic forms are very rare conditions (Bonomi et al. 2012).

### Isolated CsHG

Patients with isolated CsHG are commonly diagnosed in late adolescence or early adulthood due to delayed puberty. Any signs of eunuchoidal properties along with either anosmia or hyposmia should confirm the diagnosis of KAS. Similarly, bimannual synkinesia and renal agenesis are other important clinical clues suggesting KAS. In particular, the phenotype of KAS caused by *KAL-1* gene mutations is more severe and less variable than that of known gene defects, including synkinesia in 80% of cases and unilateral renal agenesis in 30% of cases (Pitteloud et al. 2002). Micropenis (from 5% to 10%) and cryptorchidism (30% of cases) can be present in isolated Kallmann and non-Kallmann forms but are not exclusive signs of CsHG. In some men with CsHG, the impairment of LH secretion predominates over that of FSH, allowing some germ cell maturation and spermatogenesis. The latter condition is also called isolated LH deficiency or the “fertile eunuch syndrome” (Pitteloud et al. 2001).

Among isolated CsHG, particular cases refer to the rare mutations in LH and FSH  $\beta$ -subunits or specific polymorphisms in their genes. Only few cases of inactivating LH and FSH  $\beta$ -subunits have been reported. The five men described so far carrying LH  $\beta$ -subunit mutations have a very similar phenotype, with normal masculinization at birth, demonstrating that human chorionic gonadotropin (hCG) can overcome LH deficiency for fetal male gender differentiation (Weiss et al. 1992; Valdes-Socin et al. 2004; Lofrano-Porto et al. 2007; Achard et al. 2009). However, all men presented with an absence of spontaneous puberty, confirming the crucial importance of pituitary LH for normal pubertal development and acquisition of secondary sexual characteristics. Quite interestingly, the most recently described case showed near-normal testis size and qualitatively and quantitatively normal spermatogenesis (Achard et al. 2009). Four different polymorphisms have been described in the LH  $\beta$ -subunit gene; however, their role in male infertility is still conflicting (Huhtaniemi 2006; Salvi and Pralong 2010).

A total of three men with an inactivating FSH  $\beta$ -subunit gene mutation have been reported. In contrast to isolated LH deficiency in males, they showed quite a different phenotype. Two of them presented with primary infertility, normal androgenization, and normal serum levels of T (Layman et al. 1997; Lindstedt et al. 1998). Conversely, the third affected male presented at age 18 years with delayed puberty and had small testes (Phillip et al. 1998). Interestingly, his laboratory workup disclosed a relatively high serum LH of 24.5 IU/l, low T levels, and undetectable FSH. In this case, the hyporesponsiveness of the Leydig cells to LH has been supposed to be a result of the lack of a local factor, the production of which is FSH dependent (Phillip et al. 1998). This hypothesis was confirmed by analyzing the effect in males of *FSH*  $\beta$  gene polymorphism. Several common single nucleotide polymorphisms (SNPs) exist in the human FSH receptor gene. The analysis of the effect of SNP in the *FSH*  $\beta$  gene ( $-211G > T$ , rs10835638) in a total of 1213 German men attending an

infertility clinic confirmed that this SNP was associated with lower FSH levels ( $-0.51$  U/l, T-allele), bi-testicular volume ( $-3.2$  ml), and sperm count as well as with higher LH levels ( $0.28$  U/l) (Tuttelmann et al. 2012).

Besides the signs and symptoms of isolated CsHG, the presence of growth retardation, adrenal failure, obesity, neurological disorders, or malformations can lead to an early suspicion of non-Kallmann syndromic forms. Among them, the most important are CPHD (see above), SOD (see above), CHARGE syndrome, adrenal hypoplasia congenita with HH, Waardenburg syndrome, Bardet-Biedl syndrome, Gordon Holmes syndrome, Morning Glory syndrome, Hartsfield syndrome, and Dandy-Walker syndrome.

#### CHARGE Syndrome (OMIM 214800)

CHARGE syndrome is a rare congenital disease although it represents the leading cause of congenital deaf blindness. The acronym CHARGE was coined in 1981 to describe a cluster of features identified in a number of children:

- C – Coloboma of the eye, central nervous system anomalies
- H – Heart defects
- A – Atresia of the choanae
- R – Retardation of growth and/or development
- G – Genital and/or urinary defects (hypogonadism)
- E – Ear anomalies and/or deafness

The most common genital conditions associated with CHARGE syndrome include cryptorchidism and hypospadias. In addition, CsHG is frequently associated with this condition (Boehm et al. 2015). Genetic testing for CHARGE syndrome involves the chromodomain helicase DNA-binding protein 7 (CHD-7) gene (Table 2); however, only 60% of those clinically diagnosed with CHARGE syndrome have a positive genetic test (Zentner et al. 2010).

#### Congenital Adrenal Hypoplasia (OMIM 300200)

Congenital adrenal hypoplasia (AHC) is the classic X-linked clinical presentation including primary adrenal insufficiency (PAI), which manifests during the first 2 months of life in approximately 40% of affected boys, or more insidiously throughout childhood (Hay et al. 1981). In addition, CsHG is also present with delayed puberty due to the presence of combined hypothalamic and pituitary defects. Although milder forms and later onset of PAI have been reported, generally the adrenal problems precede the reproductive impairment, and it is rare for young adults to present with impaired puberty without some history or undiagnosed features of PAI (Suntharalingham et al. 2015). However, some cases of delayed puberty with a further diagnosis of subclinical PAI have also been reported (Mantovani et al. 2002). Conversely, to date, a diagnosis of X-linked AHC has never been made in men investigated for male factor infertility alone. Dosage-sensitive sex reversal-congenital adrenal hypoplasia with a critical region on the X chromosome 1 (DAX-1), officially known as NR0B1, is a transcription factor

belonging to the nuclear receptor superfamily and considered to be involved in the pathogenesis of AHC. DAX-1 is expressed in the adrenal gland and reproductive axis during fetal development and in adult life, and mutations in its gene are associated with the development of AHC (Suntharalingham et al. 2015).

#### Waardenburg Syndrome (OMIM 193510)

Waardenburg syndrome is a rare genetic disorder (1:50,000), showing a variable phenotype ranging from varying degrees of deafness, minor defects in structures arising from the neural crest, to pigmentation anomalies. About 1 in 30 students in schools for the deaf have Waardenburg syndrome. Since SRY-related HMG-box gene 10 (SOX10) has been involved in the pathogenesis, CSHG has also been described as a possible feature of the syndrome (Izumi et al. 2015).

#### Bardet-Biedl Syndrome (OMIM 209900)

Bardet-Biedl syndrome is a human genetic disorder, caused by alteration in 14 different genes (BBS genes) in which obesity, retinitis pigmentosa, polydactyly, hypogonadism, and renal failure are generally present together (Beales et al. 1999). Historically, mental retardation has been considered a principal symptom but is no more regarded as such. Genes affected are known or suspected to play critical roles in the cell cilia involved in cell movement (Scheidecker et al. 2014).

Bardet-Biedl syndrome has a prevalence of 1:140,000 to 1:160,000 newborns. It is more frequent on the island of Newfoundland (off the east coast of Canada), where it affects an estimated 1:17,000 newborns and in the Bedouin population of Kuwait, affecting about 1:13,500 newborns (Beales et al. 1999). CSHG is a frequent feature of males who are usually also infertile.

#### Gordon Holmes Syndrome (OMIM 212840)

Gordon Holmes syndrome is characterized by neurodegenerative disorders, such as cognitive decline, dementia, and variable movement disorders (i.e., ataxia and chorea). This neurologic phenotype is often associated with CSHG. This disease shows an autosomal recessive inheritance with a typical adult-onset development. Genes involved in the pathogenesis of the syndrome include ring finger protein 216 (RNF216), OTU domain-containing protein 4 (OTUD4), and patatin-like phospholipase domain-containing protein 6 (PNPLA6), which is implicated in cell surface metabolism and is probably important for GnRH cell migration (Seminara et al. 2002).

#### Morning Glory Syndrome (OMIM 120430)

Morning Glory syndrome is an optic neuropathy, which is usually characterized by a congenital optic disc malformation similar to the morning glory flower. Although it is generally unilateral, it could reduce the visual acuity. This congenital anomaly causes the development of transsphenoidal basal encephalocele outpouching of the meninges, the optic chiasm, and the hypothalamus. Children with the syndrome usually show dysmorphic features, such as wide head, flat nose, hypertelorism, and a midline notch in the upper lip often associated with CSHG (Lee and Traboulsi 2008).

### Hartsfield Syndrome (OMIM 615465)

Hartsfield syndrome is a heterogeneous, rare, and unique association of holoprosencephaly (HPE) and ectrodactyly, with or without cleft lip and palate. In particular, subjects with Hartsfield syndrome show developmental defects of variable severity, ranging from one mildly affected individual with isolated CsHG, central diabetes insipidus, mild mental retardation, and no facial dysmorphism to patients showing multiple congenital anomalies such as cleft lip and palate, malformed ears, or hypo- or hypertelorism. Recently, dominant or recessive fibroblast growth factor receptor 1 (FGFR1) mutations responsible for this condition have been postulated (Simonis et al. 2013).

### Dandy-Walker Syndrome (OMIM 220200)

Dandy-Walker syndrome is a rare (1:30,000 live births) congenital human brain malformation characterized by complete absence of the cerebellar vermis and an enlargement of the IV ventricle. Symptoms include slower motor development and progressive enlargement of the skull. In addition, due to increased intracranial pressure, more severe neurological problems such as irritability, vomiting, and convulsions as well as signs of cerebellar dysfunction can occur in older children (Guibaud et al. 2012). Association with hypo-anosmia and CsHG has been reported since fibroblast growth factor 17 (FGF17) gene seems to be involved in the pathogenesis of the syndrome.

### Diagnosis

In the presence of the clinical feature of delayed puberty, the detection of reduced levels of T along with very low or low to normal gonadotropin levels can confirm the clinical suspicion of CsHG. One exception to this rule is the very rare case of mutations of the LH- and FSH-specific  $\beta$ -subunit genes, in which the mutated hormone may be undetectable, whereas the concentration of the other gonadotropin is high. GnRH tests in these patients do not add further information to basal hormonal evaluation and clinical features, depending on the severity of the gonadotropin deficiency (Grinspon et al. 2010). Other pituitary hormone deficiencies must be ruled out. In the same way, magnetic resonance imaging (MRI) of the pituitary region is advisable to rule out tumors and infiltrative or malformative disorders affecting the hypothalamic-pituitary region. Moreover, olfactory tests are advisable in order to exclude KAS. Nutritional status and the amount of physical activity must be carefully assessed since eating disorders and excessive physical activity are well-known causes of delayed puberty and sHG in teenagers (Sedlmeyer and Palmert 2002). Similarly, in the presence of clinical or biological signs of nutrient deficiency, the patient should be thoroughly investigated for a pauci symptomatic general condition such as celiac disease. Finally, it must be recognized that juvenile hemochromatosis could represent another often unrecognized cause of isolated sHG and delayed puberty (Cundy et al. 1993).

When systemic causes of sHG are ruled out, in the presence of adolescents with delayed puberty, the most likely diagnosis is constitutional delayed puberty, which should be considered as one extreme of the normal spectrum of pubertal timing.



Its diagnosis is essentially based on the elimination of other potential causes and the observation of progressive androgenization over time.

### **Hemochromatosis (OMIM 235200)**

Hemochromatosis is a common (1:200–400 Caucasians of Northern European descent) autosomal recessive disorder characterized by inappropriately high gastrointestinal iron absorption from the diet. The genetic defect causes an insufficient hepatic production of hepcidin, involved in the iron-exporter protein, leading to an extraordinary iron overload and deposition in parenchymal cells, resulting in cellular damage and organ dysfunction. Diabetes mellitus and hepatic cirrhosis are the usual complications of hemochromatosis. sHG has been reported in more than 50% of subjects with hemochromatosis. Other pituitary axes are generally normal in pituitary insufficiency due to hemochromatosis, indicating an affinity of iron for gonadotropic cells (Feder et al. 1996).

### **Alteration of Steroidogenesis: Congenital Adrenal Hyperplasia (CAH)**

Steroidogenesis is a complex enzymatic process that, starting from cholesterol, produces steroids. This process takes place in both adrenal and gonadal glands and errors in this process could lead to both primary and secondary hypogonadism (Miller and Auchus 2011).

### **21-Hydroxylase or 11 $\beta$ -Hydroxylase Deficiency (OMIM 201910)**

Severe deficiency of 21-hydroxylases or 11 $\beta$ -hydroxylases represents a life-threatening condition at birth due to adrenal insufficiency. Conversely, milder defects in enzyme activity, if not adequately recognized and treated, result in excessive secretion of adrenal androgens that, peripherally converted to T, can suppress gonadotropin secretion leading to infertility. Despite adequate treatment, however, subjects with CAH often show impaired sperm production and infertility due to inadequate glucocorticoid treatment of testicular damage as a consequence of adrenal rest tumors (see below) (Reisch et al. 2009).

## **Acquired Forms**

Several clinical conditions primarily affecting the hypothalamic-pituitary region of the central nervous system as well as several drugs and systemic diseases can cause the development of acquired sHG. The major causes of acquired sHG are listed in Table 1.

### **Hypopituitarism**

Several destructive or infiltrative disorders affecting the hypothalamic-pituitary region can lead to hypopituitarism. The prevalence of hypopituitarism has been estimated to be 1:2200 showing the deficiency of one or more pituitary hormones. Pituitary adenomas and hypothalamic tumors and their treatment account for about 90% of cases. Less frequently, other clinical conditions such as cranial

radiation, granulomatous or infiltrative diseases, infection, and vascular problems are detected. Clinical signs and symptoms reflect the age of onset. Indeed, the development of hypopituitarism in prepubertal boys results with delayed puberty and eunuchoidism, whereas in adulthood the symptoms can be more vague and difficult to recognize. Tumor mass effects such as headache, visual disturbances, and less commonly rhinorrhea, cranial nerve palsies, and epilepsy can also be present along with clinical syndromes related to pituitary hormone excesses. Finally, a rare acute destructive process leading to a rapid development of hypopituitarism (e.g., pituitary apoplexy or traumatic brain injury) might result in secondary adrenal insufficiency (Higham et al. 2016).

### **Hypothalamic-Pituitary Masses**

Pituitary adenomas are a heterogeneous group of tumors arising from the pituitary gland, historically classified according to size into microadenomas (dimension  $<1$  cm) and macroadenomas (dimension  $\geq 1$  cm). In addition, considering their *in vivo* hormonal activity, pituitary adenomas are further classified as functional or nonfunctional. Ezzat et al. (2004) reported an estimated prevalence of pituitary adenoma across all postmortem studies of 14.4% compared with 22.5% in radiography studies using a meta-analytic approach. The 25–41% of tumor specimens showed PRL-producing cells, whereas tumors producing other anterior pituitary hormones were significantly less common. sHG is often associated with hyperfunctioning pituitary adenomas, such as in the case of GH (acromegaly), ACTH (Cushing syndrome), or PRL hypersecretion (Ezzat et al. 2004). Nonfunctional pituitary macroadenoma can lead to a gradual progressive loss of anterior pituitary function, whereas a more specific syndromic pattern is related to secreting pituitary adenomas.

The association between PRL-secreting adenomas, low libido, and sHG in men is a common finding (Rastrelli et al. 2015). In fact, PRL acutely increases the turnover of dopamine (DA) in several brain areas partially involved in the regulation of sexual behavior (i.e., the nigrostriatal and the mesolimbic tracts) and of PRL secretion (i.e., the tuberoinfundibular tract, TIDA). In particular, in the TIDA, chronic hyperprolactinemia results in an increase in DA secretion leading to suppression of GnRH, low LH, and T; however, a direct effect of increased PRL on sexual desire has also been hypothesized. In fact, PRL receptors are expressed in the diencephalic incertohypothalamic dopaminergic system (IHDA), representing the most important area for the control of motivational and consummatory aspects of sexual behavior. In IHDA, in contrast to other areas, PRL inhibits, or does not increase, DA activity, supporting a direct, negative effect of PRL on sexual motivation (Corona et al. 2013b, 2016a, b). Despite what has been reported for low libido, the relationship between hyperprolactinemia and ED is more conflicting. In fact, the latter relationship seems to be more related to PRL-induced hypogonadism rather than to a direct effect of elevated PRL levels. Similar considerations can be drawn for hyperprolactinemia-associated infertility (Rastrelli et al. 2016).

The association between GH or ACTH excess and hypogonadism has yet to be elucidated. In fact, it is still unclear whether hypogonadism is due to the excess of

GH-IGF-1 and ACTH-cortisol or to the compression by the GH- and ACTH-producing tumor of the neighboring gonadotropin cells (Corona et al. 2016a, b). Unfortunately, no data on the long-term outcome of testicular function after correction of GH or ACTH excess are available. In a recently published retrospective analysis on 57 acromegalic patients, hypogonadism (total T < 12 nmol/l) was present in more than 60% (Lotti et al. 2015). Interestingly, however, less than 25% of the latter patients were receiving T therapy.

### Hypothalamic Masses

Suprasellar masses in children are generally represented by craniopharyngiomas, chiasmatic/hypothalamic low-grade gliomas, germinomas, and lesions attributable to a Langerhans cell histiocytosis (Allen 2000).

Craniopharyngioma is the most frequent form and is a brain tumor derived from pituitary gland embryonic tissue. It generally affects children or adults over 50 years, irrespective of gender (Muller 2014).

The 5% of childhood central nervous system (CNS) tumors is represented by diencephalic gliomas, especially under the age of 5 years. Essentially, diencephalic gliomas may be grouped into two clinical categories: optic pathway/hypothalamus gliomas (OPG), which arise primarily from a slower-growing juvenile pilocytic astrocytoma, and thalamic gliomas, which arise primarily from a fibrillary astrocytoma which can become clinically and histologically more aggressive (Ho et al. 2015). In both cases, multiple endocrine deficits may be present at diagnosis due largely to the location of these tumors. If the tumors are favorably localized, the therapy of choice is complete resection, with care taken to preserve optical and hypothalamic functions. In patients with unfavorable tumor localization (frequently for diencephalic lesions), the recommended therapy is a limited hypothalamus-sparing surgical strategy followed by local irradiation. Both the tumor itself and the consequence of surgery could lead to serious and quality of life-compromising sequelae such as hypothalamic obesity, psychopathological symptoms, and/or cognitive problems (Allen 2000; Muller 2014).

Baseline and yearly follow-up endocrine evaluations are recommended for patients with diencephalic tumors. The long-term endocrine modifications depend on the type of surgical approach and the total radiation dose delivered (see below).

### Head Trauma

Traumatic brain injury (TBI) represents one of the most common causes of death and disabilities worldwide (Mazaux and Richer 1998). Pituitary hormone deficiency could be a consequence of TBI (Molitch et al. 2011). In general, the endocrine abnormalities depend on the level of lesions and on the severity of trauma (Schneider et al. 2007).

In 2007, Schneider et al. (2007) reported data regarding the prevalence of hypopituitarism after TBI based on a review of 19 studies including 1137 patients. The pooled prevalence of post-TBI hypopituitarism was 27.5% (95% confidence interval [CI], 22.8–28.9%), with a higher prevalence in patients with severe

compared to those with mild or moderate TBI. Pituitary defections after TBI could be both transient and progressively impaired.

The overall prevalence of sHG in subjects with TBI ranges from less than 2% to more than 30% (Hohl et al. 2009). This wide range reflects the absence of accepted criteria clarifying in whom and when pituitary evaluation is advisable in subjects with TBI. Accordingly, some of the changes of the acute phase, especially hypogonadism and hyperprolactinemia, are not specific to TBI and might reflect an adaptive response to the accidents and critical illness. The ideal approach would be to test any subjects who have a relevant TBI, but this is not possible due to the huge number of cases. Based on the current suggestions (Lorenzo et al. 2005), the ideal TBI patients to test are:

- Patients with initial Glasgow Coma Scale (GCS) of 13 or less or with GCS between 13 and 15 with abnormalities on brain images
- Patients who remain under observation for at least 24 h
- Patients with intracranial hemorrhagic lesions
- Patients who develop acute hypogonadism manifestations immediately after TBI
- Patients with current hypogonadism signs or symptoms typical of hypogonadism

Arbitrarily patients with severe dysautonomia or in a vegetative state are excluded from the suggestion due to a limited risk/benefit ratio in these subjects. In general, the time factor is particularly important, considering that the abnormalities seen in the acute phase can recover spontaneously after several months. Hence, according to current evidence, it seems to be reasonable to evaluate patients with TBI at least 1 year after the injury (Lorenzo et al. 2005). Early evaluation should be performed if clinically suggested.

### **Radiotherapy**

External cranial radiotherapy is used for a variety of brain tumors and hematological malignancies and could lead to several degrees of neuroendocrine abnormalities. These adverse effects generally occur when the hypothalamic-pituitary axis lies within the radiation field, since these tissues show specific selective radiosensitivity, especially in regard to the GH axis. On the other hand, gonadotropin deficiency is infrequent after a radiation dose less than 40 Gy. However, the incidence increases when higher radiation schemes are used or when pituitary tumors are irradiated. In contrast, lower doses of irradiation may, paradoxically, result in early or precocious puberty due to the disinhibition of cortical influences on the hypothalamus (Darzy and Shalet 2009).

### **Inflammatory and Infectious Diseases**

Inflammatory and infectious diseases rarely affect the pituitary gland with neurological or endocrine symptoms (hypopituitarism) as the result of a mass effect mechanism or as a consequence of hyperprolactinemia secondary to stalk compression. The first appearance of these conditions is a radiological pituitary mass, which should be considered in the differential diagnosis of sellar lesions (Carpinteri et al. 2009).

*Lymphocytic hypophysitis* is a clinical condition characterized by focal or diffuse inflammatory infiltration of the pituitary gland, leading to a progressive gland destruction. According to the pituitary inflammatory tissue involvement, three different conditions can be identified: lymphocytic adeno-hypophysitis (LAH), lymphocytic infundibulo-neurohypophysitis (LINH), and lymphocytic pan-hypophysitis (LPH). Although there is still some debate, an autoimmune pathogenesis has been suggested (Carpinteri et al. 2009).

Endocrine symptoms are present in 66–97% of cases, ranging from partial to total hypopituitarism (Carpinteri et al. 2009). Interestingly, impaired secretion of ACTH seems to be the earliest and most frequent alteration, and it is present in about 65% of cases. TSH and/or gonadotropin deficiencies are less frequent and usually misdiagnosed, whereas data on the effects on the GH/IGF-1 axis are inconclusive. Total hypopituitarism can occur when the inflammatory process induces pituitary tissue destruction, whereas hyperprolactinemia affects approximately one-third of patients (20–38%). Finally, diabetes insipidus is present in about 14–20% of the cases with a higher prevalence when the neurohypophysis is involved (Beressi et al. 1999).

Pituitary abscess is a rare, yet potentially life-threatening disease. Only a few hundred cases have been reported. Culture examination identifies pathogens in only half of the cases, and the most common pathogens are Gram-positive bacteria. Available data show that about 30–50% of patients have anterior pituitary hormone deficiencies or central DI at onset. Growth hormone deficiency (GHD) appears to be the most frequent endocrinological abnormality, followed by gonadotropin, TSH, and ACTH deficiencies (Zhu et al. 2014). In addition, Dalan et al. found that anterior panhypopituitarism was present in 60% of patients, central DI in 28%, and hyperprolactinemia in 15% (Dalan and Leow 2008).

Only sporadic cases of fungal infections, although not only in immunodeficient patients, have been reported in the literature. The most common fungal infections include aspergillosis and coccidioidomycosis. The former belongs to the group of mycotic diseases of paranasal sinuses, which can rarely extend to the skull base regions and to the pituitary, simulating a pituitary tumor. Another rare fungal infection that can simulate a pituitary adenoma is coccidioidomycosis, usually determining an acute onset with unilateral ophthalmoplegia (Moore et al. 2016). In specific cases, endocrine dysfunctions may be found.

Tuberculosis is a relatively common disease in developing countries, but tubercular infections in the central nervous system (CNS) are not frequent and account for 0.15–4% of all cases. Anterior pituitary dysfunction features, including hypopituitarism with hyperprolactinemia as well as DI, are often present. However, headache with visual disturbances represent the most common and the earliest symptoms noted in affected individuals (Husain et al. 2008).

### **Granulomatous Lesions**

Sarcoidosis is a chronic multisystemic disease of unknown etiology, in which immune granulomas develop in the organs involved. The hypothalamus and pituitary are the glands most commonly affected. In a personal series, Bihan et al. (2007)

found that among hormonal deficiencies, hypogonadism was the most frequent, followed by DI. Hyperprolactinemia also occurs commonly as the result of a loss of dopaminergic inhibition reported by 3–32% of the patients.

### **Wegener's Granulomatosis (WG) (OMIM 608710)**

Wegener's granulomatosis is a systemic vasculitis characterized by necrotizing granulomatous of small vessels. The etiology of this disorder is unknown, but it is closely associated with anti-neutrophil cytoplasmic antibodies (ANCA). Pituitary involvement in WG is rare, accounting for less than 1% of affected subjects. DI is the most common endocrine abnormality observed (50% of cases). Hyperprolactinemia is also frequent in the case of stalk disruption, whereas one-third of subjects with pituitary involvement had both anterior and posterior pituitary deficiencies including panhypopituitarism. Conversely, only a minority of the cases present with only anterior pituitary functional abnormalities (Jagiello et al. 2004).

Further pituitary granulomatous involvement has been described in isolated case reports as associated with other systemic diseases such as Crohn's disease, Takayasu's disease, and Cogan's syndrome (Carpinteri et al. 2009).

### **Langerhans Cell Histiocytosis**

Langerhans cell histiocytosis (LCH) (OMIM 604856) is a rare disease characterized by aberrant proliferation of specific dendritic cells, called Langerhans cells, belonging to the monocyte-macrophage system. LCH is more often encountered in children, with a peak age range of 1–3 years and an incidence of 3–5 cases per million per year. Adulthood onset of the disease is even rarer, with an estimated prevalence of 1–2 cases per million. Infiltration of the hypothalamic-pituitary axis has been reported in 5–50% of autopsy patients with LCH. Diabetes insipidus (DI) is the most common endocrine abnormality, reported in 15–50% of patients, whereas anterior pituitary dysfunction has been reported in only 5–20% of affected patients (Kurtulmus et al. 2015).

GHD is the most frequent anterior pituitary hormone deficiency (up to 42% of cases), whereas gonadotropin deficiency is the second most common alteration, generally associated with DI. Hypogonadism usually develops with a median latency of 7 years from the diagnosis of DI and 9 years after the initial diagnosis of LCH. Similar to other LCH-induced anterior pituitary hormone deficiencies, gonadotropin deficiency is considered to be permanent, although occasionally spontaneous recovery has been reported (Makras et al. 2005). Isolated ACTH or TSH deficiency is quite rarely reported (1–3%). However, since ACTH deficiency is a potentially life-threatening situation, it has been suggested to evaluate the pituitary function routinely in all LCH patients with evidence of pituitary involvement.

### **Systemic Diseases with Hypothalamic-Pituitary Localization**

Several acute and chronic illnesses might interfere with the hypothalamic-pituitary-testis axis leading to the development of primary or, more frequently, secondary hypogonadism. The reduction of T in unfavorable situations might represent a protective mechanism, turning off T-dependent functions (such as reproduction

and/or physical and sexual activity) that are not desirable when the physical condition is ailing (Turner and Wass 1997). Similar adaptive mechanisms have been previously described for other hormonal axes (Bartalena et al. 1998). Hence, it is not completely known whether reduced T levels in these situations might play a direct pathogenetic role or whether low T represents only adaptive mechanisms. In the following section, some of these conditions will be analyzed in more detail. For more information, see also the specific ► [Chap. 27, “Hypogonadism in Systemic Diseases.”](#)

### Metabolic Diseases

Several observational studies have documented a close association between sHG and metabolic diseases including obesity, metabolic syndrome (MetS) and type 2 diabetes mellitus (T2DM) (Corona et al. 2014b, c, d, 2016b, c). Meta-analyses of available data showed that subjects with MetS or T2DM have significantly reduced T levels (about 3 nmol/l lower) (Corona et al. 2011a, b; Brand et al. 2014). Interestingly, it has been reported that not only established T2DM but also preclinical forms of altered glucose metabolism can significantly affect T production and impair pituitary function (Corona et al. 2013a, b). The specific pathogenetic mechanisms linking LOH with insulin resistance, MetS and T2DM, appear to be complex and not completely understood. Obesity is characterized by a relative abundance of estrogens since P450 aromatase is highly expressed by fat tissue. The increased amount of estrogen levels might, in turn, have a negative effect on both the hypothalamus and the pituitary, leading to decreased LH secretion. Accordingly, the use of the aromatase inhibitor letrozole can restore T levels and increase LH levels in severely obese hypogonadal men (Corona et al. 2015). In addition, it has been reported that body weight loss, obtained either through lifestyle or bariatric intervention, is associated with a fall in estrogen levels and with a rise in gonadotropins and T. Hence, it is plausible that the positive effect of weight loss on hypothalamic-pituitary-testis axis could be mediated by an estrogen-dependent negative feedback, most probably acting through inhibition of kisspeptin or Kiss-1. However, the link between obesity and reproductive axis disorders can be sustained by other fat-associated factors, such as leptin, ghrelin, and adiponectin (Kelly and Jones 2015). Accordingly, in subjects with T2DM, chronic hyperglycemia decreased GnRH pulsatility, without a significant change in pituitary sensitivity to GnRH or in testis sensitivity to human chorionic gonadotropin (Costanzo et al. 2014). In addition, it has been recently observed that in an animal model of MetS, obtained by feeding rabbits a high fat diet for 12 weeks, increased visceral fat and the overall MetS condition was associated with hypothalamic inflammation and derangement in the neuron network controlling GnRH release, including the expression of Kiss-1 receptor (Morelli et al. 2014). Hence, it is possible that peripheral metabolic derangements, such as those clustered in the MetS construct, signal to the hypothalamus via increased local inflammation and via a glucose-centered downregulation of the neuronal network controlling GnRH release. On the other hand, it has been reported that knockout mice lacking the neural insulin receptor show a hypogonadotropic hypogonadism with abnormal pituitary response to GnRH, showing that the stimulation of insulin receptors in the

central nervous system plays a physiologic role in the regulation of male reproductive endocrine function (Bruning et al. 2000).

### **HIV-1 Infection**

Hypogonadism is a frequent complication of HIV-1 infection, especially in subjects with wasting syndrome. The prevalence of LOH in HIV-1 ranges from 13% to 17% in the general HIV population and up to 20% in those with a wasting condition. Accordingly, Rochira et al. (2011) in a large cross-sectional, observational study involving a consecutive series of 1325 HIV male outpatients (mean age  $45.6 \pm 7.2$  years old) previously reported that HIV-infected men showed a premature decline of serum T, closely associated with inappropriately low/normal LH and increased visceral fat. The mechanisms underlying the association between sHG and HIV infection remain, however, incompletely understood, including both hypothalamic-pituitary and testicular defects. Although wasting syndrome has considerably decreased in the era of antiretroviral therapy, chronic involuntary weight loss still remains a serious problem. In addition to inadequate intake, malabsorption, and diarrhea, many subjects experience anorexia and weight loss without an identifiable cause (Cotter and Powderly 2011). All these factors might contribute to the observed sHG in HIV infection.

### **Chronic Kidney Diseases (CKD)**

All conditions associated with impaired renal function, and in particular end-stage renal diseases (ESRD), are frequently associated with male hypogonadism. The pathogenetic mechanisms underlying this process are complex and not fully understood. In particular, accelerated aging (uremia-associated oxidative stress), malnutrition, and other endocrine-associated conditions such as T2DM and hyperprolactinemia, chronic inflammation, vascular disease, hypertension, acute severe illness, and different classes of drugs used in these conditions can all contribute to the development of CKD-associated hypogonadism, acting both at central and peripheral levels (Iglesias et al. 2012). Despite this evidence, however, it is still unknown whether hypogonadism in humans has any effect on progression to ESRD.

### **Chronic Obstructive Pulmonary Disease (COPD) (OMIM 606963)**

COPD represents another chronic condition frequently associated with male hypogonadism, with a prevalence ranging from 22% to 69%. Several factors including aging, obesity, systemic inflammation, chronic disease itself, hypoxemia, hypercapnia, and administration of glucocorticoids can mutually interact in determining reduced T levels with low/normal LH (Balasubramanian and Naing 2012). Similar to what has been reported for ESRD, it is unclear whether T therapy can improve outcomes in COPD or can delay its progression.

### **Chronic Liver Diseases**

Hepatic insufficiency is usually associated with pHG in mild to moderate forms and with sHG in severe to end-stage liver diseases. SHBG levels progressively increase



with the severity of the problem, and free T evaluation is mandatory to assess T deficiency adequately (Kaymakoglu et al. 1995). Sperm production is commonly impaired in subjects with an advanced disease, and sperm motility is reduced. In addition, pulsatility of GnRH and pituitary response to GnRH stimulation are reduced in subjects with hepatic cirrhosis contributing to the development of sHG (Zietz et al. 2003). Finally, spironolactone, commonly used to treat edema and ascites, might contribute to the symptoms of androgen deficiency due to its androgen receptor (AR) antagonist properties.

### Chronic Heart Failure

Chronic heart failure (HF) is associated with biochemical hypogonadism in 25–30% of cases. As in men with other chronic organ failures, the pathogenetic mechanisms are complex and multifactorial including wasting, a pro-inflammatory state, medication use, chronic stress, or other comorbid illnesses. Interestingly, meta-analysis of four randomized clinical trials including subjects with HF indicated that T therapy significantly increased exercise capacity (Toma et al. 2012). However, it should be recognized that it is still unknown whether T supplementation can improve more important outcomes including mortality and morbidity in subjects with HF.

### Other Systemic Illnesses

*β-Thalassemia Major (OMIM 613985):* is the most important cause of secondary or acquired hemochromatosis with adoption of an intensive transfusion regimen to maintain adequate levels of hemoglobins. Chronic blood transfusions in these patients cause clinical manifestations similar to those that occur in hereditary hemochromatosis (Cao and Moi 2000).

*Spinal Cord Injury:* sHG, and more rarely pHG, frequently occurs in men with tetraplegia or paraplegia secondary to spinal cord injury. Several associated conditions including trauma per se, use of medications affecting gonadotropin and/or T production (opiates, glucocorticoids, central nervous system-acting drugs), nutritional problems, and chronic stress can contribute to the development of HG in these subjects. However, as previously reported for HF and other systemic illnesses, the benefits of T therapy in these subjects are not clear (Gaspar et al. 2014).

*Malignancy:* Primary or secondary hypogonadism is present in 40–60% of men with advanced cancers. Low T serum levels are associated with systemic inflammation, weight loss, increased symptom burden, and decreased survival in male patients with cancer. However, as previously reported, it is not clear whether T treatment might improve quality of life and survival rate in these subjects (Dev 2014). Quite interestingly, some malignancies (testicular cancer and Hodgkin's diseases), which occur in men of reproductive age are characterized by impaired sperm production, which manifests even before chemo- or radiotherapy. The reasons of such an association have not been completely clarified and are reviewed elsewhere (see ► Chap. 31, "Treatment of Hypogonadism").

## Drugs

Several types of drugs might affect the hypothalamic-pituitary axis leading to the development of sHG. Several drugs blocking dopaminergic (antipsychotic and antiemetic) or increasing serotonergic (antidepressants) transmission can cause hyperprolactinemia and sHG (Table 3). In addition, other important medications associated with the development of sHG include anabolic steroids and opiates whose effects will be analyzed in detail in the following section.

### Anabolic Steroids

Anabolic androgenic steroids (AASs) are drugs structurally related to the cyclic steroid rings system, with similar effects to T. AASs constitute a wide group of drugs used in competitive athletics, but also in recreational sports and by body builders. The global lifetime prevalence of AASs abuse is 6.4% for males and 1.6% for women. The administration of AASs exerts a suppressive effect on the hypothalamic-pituitary system resulting in suppression of LH and FSH leading in turn to a decrease in T and sperm production also defined as anabolic steroid-induced hypogonadism. Currently, there are no available investigations of the effects of high-dose AASs on testicular function. Thus, contraceptive trials are useful to understand their effects, demonstrating that a 6–24-month span provides sperm and T recovery in AAS abusers, although it has to be kept in mind that doses used for doping far exceed those used for male contraception, and therefore even longer periods may be anticipated (Nieschlag and Vorona 2015). In a large US urology department, 1.6% of 6033 patients seeking medical care for hypogonadism suffered from AAS-induced hypogonadism. The majority of these patients were seeking medical care for hypogonadism-related symptoms, whereas only one-quarter requested consultation for infertility (Coward et al. 2013).

### Opiates

Opiates are among the most prescribed analgesic drugs but present several side effects including nausea, itching, constipation, and hypogonadism. Despite its high frequency, opiate-induced hypogonadism in males is usually ignored by pain physicians and rarely considered for treatment. Strong inhibition of androgen production quickly follows the onset of sustained-action opioid use, whether the opioids are administered orally, transdermally, or intrathecally. Several hypotheses have been advanced to explain hypogonadism due to opiates. First of all, an opiate-induced inhibition of gonadotropin release has been documented although an inhibitory action is also exerted in the gonads. Opioid receptors have been described in the pituitary as well as in the gonads, and opiates have been found to upregulate their own receptors. Another mechanism involves T metabolism. Both in vitro and in vivo studies have shown that opiates can increase the activity of  $5\alpha$ -reductase activity and PRL release. A direct effect of pain on the HPG axis cannot be excluded (Coward et al. 2013).

## Functional Forms

*Eating disorders* and anorexia nervosa (AN) in particular are well-known causes of sHG in young women. Decreased energy availability in AN is believed to cause hypothalamic amenorrhea. Women with AN often show impaired LH pulsatility that resembles what is observed in prepubertal or early pubertal girls, with very low-amplitude LH pulses or a sleep-entrained pattern of LH pulsatility (Boyar et al. 1974). This condition is less frequently observed but also reported in boys with AN.

*Endurance exercise*, high-intensity endurance training, especially when combined with relative calorie deprivation, is frequently associated with the development of sHG. The exact physiological mechanism inducing the reduction of T is currently unclear but is postulated to be a dysfunction (or perhaps a readjustment) within the hypothalamic-pituitary-testicular regulatory axis as a consequence of intense stress and calorie deprivation (Hackney 2008).

## Aging

Along with the gradual decline of many other physiological functions, in the male there is an age-related decline of testicular function and T production (Buvat et al. 2013). The reasons for this phenomenon have not been completely clarified, but considering the anabolic proprieties of T, its role in the development of frailty and in ameliorating this condition has attracted considerable attention (O'Connell and Wu 2014). Similarly, age-dependent reduction of T has been considered to be involved in the development of other aging symptoms including fatigue, depression, reduced libido, and sexual dysfunction (Buvat et al. 2013). Finally, a possible role in explaining the life expectancy gender gap has been also suggested (Araujo et al. 2011; Ruige et al. 2011). However, it should be recognized that the EMAS study documented that obesity and associated morbidity, irrespective of age, appears to be associated with hypothalamic/pituitary dysregulation leading to the development of sHG. Conversely, the same study showed that age still played an independent role in the reduction of T levels in patients with primary or compensated hypogonadism. Hence, the key message arising from the EMAS is that the hypothalamic/pituitary dysfunction associated with obesity and associated morbidities in aging men considered to have sHG may potentially be reversible with weight loss or with the improvement of the underlying disease (Tajar et al. 2010). Conversely, age plays an independent role in the pathogenesis of age-related pHG. For more information on age-related hypogonadism, see the specific ► [Chap. 30, "Late-Onset Hypogonadism."](#)

---

## Primary Hypogonadism

Primary hypogonadism (pHG) (hypergonadotropic hypogonadism) defines a clinical condition where the testes are primarily affected with consequently low T production, impairment of spermatogenesis, and an increase of gonadotropin serum levels. pHG can be classified considering its etiopathogenesis.

## Congenital or Developmental Disorders

### Klinefelter Syndrome

#### Etiology

Klinefelter syndrome (KS) represents the most common genetic form of pHG, occurring in 1:500–700 new born males, representing a group of chromosomal disorders in which there is at least one extra X chromosome, added to the male karyotype, 46,XY. KS generally shows 47,XXY karyotype, although mosaicism 46,XY/47,XXY is frequently seen (Lanfranco et al. 2004). More rarely, other chromosome aneuploidies, such as 48,XXXY and 49,XXXXY, (1: 50,000 and 1: 100,000 males born, respectively) are detected. Usually, a direct relationship between the number of additional sex chromosomes and the severity of KS phenotype is observed. Rarely, patients with 47,XXY karyotype show mosaic genotype in testicular tissue, whereas patients with normal karyotype could show KS genotype only at sperm level (Linden et al. 1995).

#### Pathophysiology

The extra X chromosome in 47,XXY could result from both meiotic nondisjunction and nondisjunction in the developing zygote. The likelihood of X chromosome nondisjunction increases with advancing maternal age. Generally, in about 66% of KS cases, nondisjunction derives from maternal meiosis, whereas about 33% derive from paternal spermatogenesis (Visoosak and Graham 2006). Several studies speculated about the pathophysiology of comorbidities in KS men. The parental origin of the additional X chromosome may affect the clinical picture of KS men (Zitzmann et al. 2015). Moreover, the X chromosome contains genes of the apoptotic cascade, glucose metabolism, and inflammation, suggesting that a transcriptional dysregulation of such genes could be responsible for the clinical phenotype and increased morbidities and mortality (see below) (Gravholt et al. 2011; Zitzmann et al. 2015).

As a consequence of the genetic alteration, however, there is a rapid and progressive degeneration of germ cells, which are present at birth. Simultaneously, Leydig cells become hyperplastic. The degree of androgen deficiency depends on the number and residual function of Leydig cells (Aksglaede and Juul 2013).

#### Clinical Manifestation

In 1942, Harry Klinefelter published a report of nine men with features such as testicular dysgenesis, elevated gonadotropins, microorchidism, eunuchoidism, azoospermia, and gynecomastia. This clinical condition remained idiopathic until 1959 when Jacobs et al. recognized that KS was a chromosomal disorder in which an extra X chromosome results in the karyotype of 47,XXY (Jacobs and Strong 1959). Today, it is well known that clinical KS manifestations vary in affected individuals and depend on the extra X chromosome.

Before puberty, only a few physical anomalies can be recognized, such as cryptorchidism, slightly reduced testicular volume, long-leggedness, learning

difficulties, and limitation in verbal expressiveness. After puberty, small testicular size is the consistent physical feature in KS men, with a mean volume around 1–3 mL. Furthermore, other clinical features typical for hypogonadal men could be present also in KS men, such as tall stature, eunuchoidism, gynecomastia, sparse body hair, osteoporosis, varicosis of the legs, T2DM, MetS, deficits in verbal abilities, decreased auditory memory and processing, and language deficits (see below) (Bojesen et al. 2006; Visootsak and Graham 2006; Basaria 2014). The skeletal proportions begin to develop at the time of puberty, although the arm span rarely exceeds total body height. KS is characterized by legs longer than the trunk, with a lower segment longer than the upper segment. Moreover, KS is characterized by infertility, caused by tubular damage (Basaria 2014). However, some KS men could have spermatogenesis at puberty, even if germ cells are progressively lost over time (Wikstrom and Dunkel 2011). Accordingly, only few cases of spontaneous pregnancy have been reported, although generally in mosaic cases (Bakircioglu et al. 2011).

The degree of virilization reflects the circulating levels of T, which are usually normal at puberty. However, similarly to what has been observed for fertility, a precocious age-dependent reduction of T is reported with a high prevalence of hypogonadism detected in adulthood (Forti et al. 2010; Corona et al. 2010).

## Diagnosis

Diagnosis of KS is suspected when clinical signs and symptoms are present. However, considering the lack of pathognomonic phenotype, KS is often diagnosed in adulthood, during evaluation for primary infertility.

Biochemical evaluation shows low T serum levels in 80% of cases, even if precocious age-dependent reduction has been observed. E2 serum levels could be higher than the normal range, but generally KS shows a higher E2/T ratio. Gonadotropin serum levels are markedly above normal levels.

Cytogenetic analysis remains the gold standard approach to obtain a definite KS diagnosis. An early KS diagnosis provides several benefits, although the real difficulty remains the identification of target groups to subject to prenatal screening. The main advantage of early diagnosis is the prevention of KS complications. Early KS detection is also important to start T replacement therapy, as soon as patients need it, preventing long-term complications of hypogonadism. Finally, early diagnosis offers the opportunity to undergo new fertilization techniques, such as testicular sperm extraction (TESE) and micro-TESE or cryopreservation of testicular tissue.

Recently, Tüttelmann et al. (2014) demonstrated that testicular T production per se is not impaired in KS men. On the contrary, intratesticular T levels are increased compared to karyotypically normal men, without heightened SHBG activity (Tüttelmann et al. 2014). As a confirmation, Belli et al. (2016) demonstrated that the ability of Leydig cells to produce T is conserved after intramuscular injection of 5,000 IU of hCG (Belli et al. 2016). These results lead us to speculate that a reduced vascularization could be involved in an impaired release of T in the bloodstream.

## Other Chromosome Abnormalities

### 46, XX Male Syndrome (OMIM 400045)

XX maleness is a rare syndrome, affecting about 1 in 20,000–25,000 males. XX males are characterized by different clinical features, from ambiguous genitalia or partially to fully mature male genitalia, associated with complete or incomplete masculinization (Hughes 2008). This discrepancy seems to be due to the presence of genetic information specific to Y-chromosome on one of two X-chromosomes. In 90% of cases, this is the result of a DNA translocation from Y to X chromosome during prenatal meiosis of the sex-determining region Y (SRY). SRY is the gene responsible for differentiating initially indifferent gonad into testis (Fechner et al. 1993). Moreover, the azoospermic factor (AZF) region of Y-chromosome is lost during translocation, and 46,XX males are infertile.

About 10% of XX males lack the SRY gene. In these cases, a pathogenetic hypothesis involves an impaired expression of a putative gene, named “Z,” expressed in the XX gonad, which represses the testis-determining pathway, thus allowing an ovary to develop. In addition, other genes including FGF and WNT4 signaling pathways are suspected of being involved (Hughes 2008).

Up to now, 250 46,XX men are described in the literature, although only karyotype analysis differentiates these patients from KS men. Generally, 46,XX men show lower stature than KS men.

### 47,XYY Syndrome

Men with 47,XYY karyotype are phenotypically normal with only tall stature and larger teeth than the general population. Contrary to KS men, these patients show normal fertility and intelligence quotient (Hughes 2008).

### 48,XXYY Syndrome

Since the first description in 1960, also 48, XXYY syndrome has been considered as a KS variant (Balsera et al. 2013). KS and XXYY syndrome affect one per 17,000 males born and show several similar characteristics, such as tall stature, gynecomastia, sparse body hair, hypergonadotropic hypogonadism, small testes, and infertility. However, this syndrome shows more frequently facial dimorphism, congenital malformations, and lower intelligence quotient, with frequent and severe behavioral and psychiatric problems, including attention deficit hyperactivity disorder, autism spectrum disorders, and mood and tic disorders (Linden et al. 1995).

## Y-Chromosome Microdeletions

Microdeletions in the male-specific region on the long arm of the Y chromosome (MSY) are the most common genetic cause of male infertility after KS (Krausz et al. 2014). This region contains genes essential for spermatogenesis, and three discrete, AZFa, AZFb, and AZFc, regions are originally characterized in the MSY region (Krausz et al. 2014). New model of deletions have recently been discovered, through

the improvement in molecular characterization techniques. Currently, AZFb and AZFc overlap is proposed, as a result of three different deletions patterns (Simoni et al. 1999).

Azoospermic patients have more microdeletions than those with oligozoospermia. The degree of impaired fertility depends on the deletion breadth since larger ones result in complete tubular atrophy, with only Sertoli cells visible at biopsy, representing the Sertoli cell-only syndrome (SCOS). Sertoli cell-only syndrome is a clinical condition in which a complete absence of germ cells is demonstrated in testicular tissues, with a final result of male infertility (Stouffs et al. 2009). Although the etiology of this syndrome often remains unknown, Y-chromosome microdeletions remain the main cause (Stouffs et al. 2016). The clinical manifestation of Y-chromosome microdeletions depends on the genetic region deleted, and complete AZFa deletions always result in SCOS and azoospermia. On the other hand, complete deletions of AZFb and AZFbc could be characterized by a histological picture of SCOS or spermatogenetic arrest, resulting in azoospermia. Hence, the diagnosis of a complete deletion of the AZFa AZFb or AZFbc regions implies the virtual impossibility to retrieve testicular spermatozoa at TESE. In conclusion, partial deletions of the AZFc region are associated with a variable clinical and histological phenotype (Krausz et al. 2014). In particular, in these cases, there is an approximately 50% chance of retrieving spermatozoa from TESE.

Considering biochemical features, generally T and LH are in the normal range, even if FSH increases because of decreased production of inhibin B and loss of negative feedback (Krausz et al. 2014).

## Alteration of Steroidogenesis

### Congenital Lipoid Adrenal Hyperplasia (OMIM 201710)

Congenital lipoid adrenal hyperplasia is the most severe genetic disorder of steroidogenesis, characterized by several mutations in the *steroidogenic acute regulatory protein (StAR)* gene, involved in the first step of the complex enzymatic steroidogenic process (Bose et al. 1996). StAR is rapidly transcribed under ACTH and LH stimulus, allowing the use of cholesterol as a substrate for steroidogenesis (Arakane et al. 1997; Stocco et al. 2005). The lack of StAR transcription causes lipoid CAH, characterized by a significant reduction in several steroids. This partial reduction in steroidogenesis leads to a compensatory rise of both ACTH and LH, increasing the intracellular cAMP concentration, the uptake of cholesterol and leading to mitochondrial and cellular damage and loss of steroidogenic capacity. In this condition, Leydig cells are lost early on during gestation, and the 46,XY fetus is unable to produce T. Hence, lipoid CAH is characterized by female external genitalia and blind vaginal pouch at birth, although Müllerian duct derivatives are not developed (Bose et al. 1996; Miller and Auchus 2011). In addition, this condition represents a life-threatening condition at birth due to the associated adrenal insufficiency. A similar phenotype is observed in the presence of gene mutations in gene of the cholesterol side-chain cleavage enzyme (*CYP11A1*), converting cholesterol to pregnenolone.

Non-classic lipid CAH is characterized by mutations that lead to the retention of about 20–25% of normal StAR activity (Bose et al. 1996). These patients generally experience mild symptoms of adrenal insufficiency, having 46,XY karyotype, and normal-appearing external genitalia. Moreover, they could show hypergonadotropic hypogonadism (Miller and Auchus 2011).

### **3 $\beta$ -Hydroxysteroid Dehydrogenase (3 $\beta$ -HSD) (OMIM 201810)**

3 $\beta$ -Hydroxysteroid dehydrogenase catalyzes the conversion from 3 $\beta$ -hydroxyl to 3-keto group during steroidogenesis. It is implied in the progesterone, 17-hydroxyprogesterone, and T synthesis. The 3 $\beta$ -HSD deficiency is a rare condition in which steroidogenesis is altered and male subjects are able to produce androgens only by peripheral conversion of adrenal and testicular DHEA, although this is not enough to obtain a complete male genital development. Typically hypogonadism, small phallus, and hypospadias are present in this condition (Bongiovanni 1962; Miller and Auchus 2011).

### **17 $\alpha$ -Hydroxylase/17,20-Lyase (OMIM 202110)**

P450c17 catalyzes both 17  $\alpha$ -Hydroxylase and 17,20-lyase during the steroidogenic cascade. 17,20-Lyase is mainly important for sex steroid production, and mutations on P450c17 gene lead to 17  $\alpha$ -hydroxylase/17,20-lyase deficiency. This mutation is clinically characterized by the reduction of cortisol levels, sodium retention, hypertension, hypokalemia, and lack of both adrenal and gonadal sex steroids. Affected men show absent or incomplete development of external genitalia and a disorder of sex development (Biglieri et al. 1966; Miller and Auchus 2011).

### **17 $\beta$ -Hydroxysteroid Dehydrogenase (OMIM 300438)**

17 $\beta$ -Hydroxysteroid dehydrogenase (17 $\beta$ -HSD) catalyzes multiple reactions in the steroidogenic process, and three isoenzymes have been discovered so far (Labrie et al. 1997). 17 $\beta$ -HSD type 3 (17 $\beta$ -HSD3) catalyzes the conversion from androstenedione to T. Thus, male children with 17 $\beta$ -HSD3 deficiency show a disorder of sexual development (DSD), with hypogonadism, hypospadias, micropenis, and inguinal or intra-abdominal testes (Moghrabi et al. 1998; Miller and Auchus 2011).

### **Disorder of Sexual Development (DSD)**

DSD refers to different clinical conditions characterized by the atypical development of gonads, external genitalia, and secondary sexual characteristics. In 2008, Hughes et al. (Hughes 2008) proposed a new DSD classification, starting from the karyotype analysis. Three main categories have been recognized: sexual chromosome DSD, 46, XX DSD, and 46,XY DSD. Overall, DSD is clinically characterized by the presence of ambiguous external genitalia at birth, posing difficulties in the gender definition. However, each condition is clinically characterized by pathognomonic characteristics.

Gonadal dysgenesis is an alteration in the gonadal differentiation and represents one of the most frequent DSD. This disease is characterized by 46,XY/45,X0 or 46,



XX/46,XY mosaicisms. Clinically, gonadal dysgenesis could show incomplete virilization, ambiguous genitalia at birth, asymmetric testis development, bilateral streak gonads, or unilateral streak gonad. Generally, the phenotype is different between genders. Male newborns with gonadal dysgenesis show cryptorchidism, testicular dysgenesis, hypospadias, and presence of Müllerian derivatives (intersex genitalia, with uterus, vagina, and oviduct almost always present and testis at intra-abdominal position). Histologically, the disease is generally characterized by the lack of Sertoli and germ cells, with the presence of only stromal tissue. On the other hand, female newborns have variable degrees of virilization and clinical characteristics typical of Turner syndrome. However, both males and females show low stature and elevated risk of germinal cells cancer. This condition is generally due to mutation in WT1, SF1, SRY, SOX9, or DHH genes (Hughes 2008).

The diagnosis of pure gonadal dysgenesis can be done only through laparoscopy and gonadal biopsy. In this case, biochemical evaluation shows elevated LH and FSH serum levels with low estrogens. Similarly in mixed gonadal dysgenesis, elevated gonadotropins and low T serum levels are found.

### **Mutations in Gonadotropin Receptors**

LH and FSH act on testicular cells, binding specific receptors, which are members of the family of G-protein-coupled transmembrane receptors (Huhtaniemi and Alevizaki 2006). Mutations on the gonadotropin receptors could be activating or inactivating, and they may or may not cause alterations in gene function or structure of the encoded protein (for more details, see specific ► [Chap. 4, “Gonadotropin Receptors”](#)).

#### **LH Receptor Mutation**

Loss of function mutations on the LH receptor (LHR), or LH/hCG receptor (LHCGR), are associated with severe phenotypes (Themmen and Huhtaniemi 2000). Nonsense mutations and frameshift-inducing base insertions or deletions cause premature truncations of the LH receptor protein and loss of its function. These mutations cause a rare autosomal recessive disease called Leydig cells hypoplasia syndrome, with an estimated incidence of 1:1000,000 newborns (Huhtaniemi and Alevizaki 2006). In this clinical condition, although present, mutated LHCGR is not able to respond to LH (Huhtaniemi and Alevizaki 2006). In 1976, the case of a 35-year-old 46,XY woman, with high LH levels, normal FSH, and extremely low T serum levels was first described (Berthezene et al. 1976). The subject had female external genitalia but two abdominal testes with epididymides and vasa deferentia and absence of Müllerian structures (i.e., uterus, Fallopian tubes, and upper vagina). At the testicular histological evaluation, seminiferous tubules were found, without Leydig cells (Berthezene et al. 1976). Starting from this first case, several cases have been described in which the clinical phenotype depends on the type of inactivating mutation on LHCGR and on the extent of intrauterine T secretion. The severe clinical form of Leydig cell agenesis is characterized by 46,XY karyotype, low T, normal FSH levels, high LH levels, lack of responsiveness to LH or hCG stimulation, absent development of secondary male

(or female) sex characteristics, and lack of breast development. This is the main clinical characteristic that differentiates this condition from androgen insensitivity due to inactivating mutations in the androgen receptor gene. On the other hand, the milder form could display a broader array of phenotypic expression with micropenis, severe hypospadias, and disorder of sex differentiation and virilization (Huhtaniemi and Alevizaki 2006).

### **FSH Receptor Mutation**

Inactivating mutation on the FSH receptor (*FSHR*) gene leads to small testes and impaired spermatogenesis (Simoni et al. 1997). However, few mutations have thus far been identified, suggesting that the consequent phenotype is less clear than the effects of *LHCGR* mutations and therefore escape clinicians' attention.

Five males were identified in Finnish families with a *FSHR* mutation. These men were normally masculinized with normal circulating T, normal or slightly elevated LH, moderately elevated FSH, and slightly to severely reduced testicular volume. Two of the men had fathered, although all men had abnormal semen parameters ranging from severe oligozoospermia to normal sperm concentration (Tapanainen et al. 1997). This suggests that FSH contributes to testicular size and normal spermatogenesis.

*FSHR* gene polymorphisms affect male fertility, even if no increased incidence of hypogonadism is observed. Two polymorphisms are widely studied in the literature: a polymorphism in the *FSHB* promoter ( $-211G > T$ , rs10835638), which influences serum FSH levels, and a polymorphism in the FSH receptor gene (*FSHR*; 2039A > G, rs6166), which is associated with receptor sensitivity more in women than in men. The role of FSH receptor gene polymorphisms in female fertility is widely demonstrated in the literature, showing a relationship between polymorphisms and receptor sensitivity. The same effect is demonstrated also in males. Recently, a combined effect of *FSHB* and FSH receptor gene polymorphisms on male fertility was proposed (Simoni et al. 1997; Tüttelmann et al. 2012; Casarini et al. 2014, 2015).

Some decades ago, an activating mutation in the *FSHR* gene was discovered in a hypophysectomized man for a pituitary tumor, with undetectable serum gonadotropin levels, normal testis volume, and normal semen parameters. In this report, the activating mutation sustains spermatogenesis in the absence of gonadotropins (Gromoll et al. 1996). Another case was reported in a man with a mutation N431I in the *FSHR* gene, although the clinical picture remains quite different (Casas-Gonzalez et al. 2012).

### **Myotonic Dystrophy (OMIM 160900, 602,668)**

Myotonic dystrophy is the most common adult form of muscular dystrophy, affecting about 1:8000 individuals and characterized by progressive muscle mass wasting, cataracts, heart conduction defects, endocrine changes, and myotonia. Two main forms of myotonic dystrophy both displaying an autosomal-dominant pattern of inheritance have been described (Dalton et al. 1993). Myotonic dystrophy type 1 (DM1), also called Steinert disease, presents as a severe congenital form or a

milder adult-onset form. Conversely, myotonic dystrophy type 2 (DM2) (called proximal myotonic myopathy (PROMM)) is rarer and phenotypically milder than DM1. In males, low T serum levels, elevated FSH serum levels, oligozoospermia, and infertility characterize T2DM. Unlike DM1, this form typically affects the third decade of life, without congenital defects.

The diagnosis of both DM1 and DM2 is confirmed by muscle biopsy, searching the mutation on the CNBP (ZNF9) gene (Dalton et al. 1993). T replacement therapy can be beneficial in males with hypogonadism associated with specific symptoms.

### **Congenital Anorchia (OMIM 273250)**

The term anorchia refers to the absence of one (unilateral) or both testes (bilateral). The bilateral form affects around 1:20,000 males, whereas the unilateral form is four times more frequent. The absence of testes could be congenital, as a result of mutations of specific genes (such as SRY), or acquired, as a consequence of intrauterine infections, trauma, tumors, severe inflammation, surgical accidents, or testicular torsion (Pirgon and Dundar 2012).

Frequently, congenital anorchia seems to derive from heterozygous partial loss of function mutations in steroidogenic factor 1 (SF1) gene. This condition is usually called “vanishing testis syndrome” in which micropenis is associated with testicular agenesis (Vinci et al. 2004; Philibert et al. 2007). On the other hand, the most frequent acquired anorchia seems to be the consequence of intrauterine torsion.

The clinical phenotype of men with bilateral anorchia depends on the time in which the disease acts. In fact, if during prenatal life testes produced T, the patient shows male external genitalia and Wolffian ducts. On the other hand, if the anorchia is a consequence of a genetic disturbance, and the testes were not able to produce T during fetal life, the patient shows female external genitalia, absence of both Müllerian ducts, and Wolffian derivatives. Moreover, if androgen replacement therapy is not initiated, the typical eunuchoid phenotype develops. In bilateral anorchia, FSH and LH serum levels are highly elevated, rising to castrate levels at puberty. Moreover, AMH is undetectable and T does not rise after hCG stimulation.

With unilateral anorchia, the intact testis is able to produce androgens and disorders of sexual differentiation do not occur. In this case, hypogonadism is rare.

### **Cryptorchidism**

Cryptorchidism represents the lack at birth of one or both testes in the scrotum. It affects about 1% of infants, representing the most common birth defect of male genitalia (Wood and Elder 2009). However, the real underlying mechanism remains unknown, reflecting the intricate mechanisms regulating testicular development and descent (Mathers et al. 2009). Both endocrine factors and environmental exposures have been proposed. To this purpose, mutations in the gene for insulin-like factor (INSL)-3 and its receptor and mutation in the AR gene have been proposed to explain a minority of cases of cryptorchidism (El Houate et al. 2007; Ferlin et al. 2007). However, the role of other genetic alterations, such as mutations on leucine-rich repeat-containing G-protein-coupled receptor (LGR)-8 gene, still remains unclear (El Houate et al. 2007; Ferlin et al. 2007).

If not treated, cryptorchidism could lead to testicular aplasia and consequently PHG and infertility. Even if treated early and successfully, cryptorchidism is expected to have long-term consequences, such as reduced fertility and testicular cancer (Fawzy et al. 2015).

Cryptorchidism is fully evaluated in ► [Chap. 8, “Testis Development and Descent.”](#)

### **Varicocele**

Varicocele is the dilation of the veins of the pampiniform plexus, which is found in 15% of all men (Agarwal et al. 2007). This pathophysiological condition could adversely affect testicular function, leading to testicular discomfort, testicular atrophy, and various degrees of infertility, from oligozoospermia to complete azoospermia (Dabaja and Goldstein 2016). Varicocele could also affect testicular T production, leading to hypogonadism in some cases (Hayden and Tanrikut 2016). The negative effect of varicocele is related to increased testicular temperature, leading to detrimental effects on spermatogenesis, impaired Sertoli cell function, abnormal testicular protein metabolism, and decreased testicular Leydig cell production of T (Rajfer et al. 1987). However, the majority of men with varicocele are asymptomatic and fertile. See more information in ► [Chap. 37, “Varicocele.”](#)

### **Sickle Cell Disease (SCD) (OMIM 603903)**

Sickle cell disease (SCD) is a hereditary hemoglobinopathy characterized by abnormal hemoglobin production, hemolytic anemia, and intermittent occlusion of small vessels, leading to tissue ischemia. Two single point mutations in the beta-globulin gene result in SCD. SCD is the most common genetic hematologic disease in the USA with an estimated prevalence in 1 of 72,000 people.

SCD is associated with hypogonadism in up to 24% of cases, although doubts remain about its etiology (Smith-Whitley 2014). Two studies suggested a primary testicular failure as the etiology (Abbasi et al. 1976; Osegbe and Akinyanju 1987), whereas four studies suggested hypothalamic-pituitary dysfunction (Dada and Nduka 1980; el-Hazmi et al. 1992; Modebe and Ezeh 1995; Tadesse et al. 2012). Multiple theories on hypogonadism etiology have been proposed, such as zinc deficiency (Prasad 1984) and vaso-occlusion of testicular vessels (Parshad et al. 1994). However, long-term chronic therapies, such as hydroxyurea and transfusions, seem to be the primary cause of SCD-related infertility. In particular, hydroxyurea impacts rapidly dividing cells, such as spermatogenetic cells, and it could be related to oligozoospermia, azoospermia, decreased motility, and increased morphologic abnormalities in sperms. In spite of the known association between SCD and hypogonadism, sexual maturation is usually normal (Smith-Whitley 2014).

### **Noonan Syndrome (OMIM 163950, 610,733)**

Noonan syndrome (NS) is a genetic disorder which affects 1:1000–2000 live births, characterized by several congenital abnormalities including heart disease, short stature, a broad and webbed neck, sternal deformity, variable degree of developmental delay, cryptorchidism, increased bleeding tendency, and characteristic facial

features that evolve with age. NS is caused by mutations in the RAS/mitogen-activated protein kinase (MAPK) pathway, which is essential for cell cycle differentiation, growth, and senescence. In men, NS is frequently associated with cryptorchidism, delayed puberty, and pHG (Turner 2014).

### **Down Syndrome or Trisomy 21 (OMIM 190685)**

Down syndrome is the most common genetic condition affecting 1:700–800 infants. In more than 90% of cases, Down syndrome (DS) is a consequence of an extra chromosome 21. Rarely, (less than 2%) mosaic forms are present. Males with DS usually show pHG mainly characterized by impairment in sperm production although T deficiency can also be present (Desai 1997).

## **Other Rare Conditions**

### **Autosomal Translocations**

Gonosomal and autosomal translocations are chromosomal aberrations involving a sex chromosome and autosomes, respectively. These variations affect site-specific loss or gain of genetic material and possible translocation patterns can be complex (Stouffs et al. 2009). These chromosomal translocations involve regulatory genes for spermatogenesis, generally contributing significantly to primary infertility and hypogonadism. In the literature, several studies describe different translocations that could explain rare cases of hypogonadism and infertility (Hughes et al. 1993; Bruford et al. 1997; Zollino et al. 2003; Shimizu et al. 2008; Szvetko et al. 2012).

### **Adrenoleukodystrophy (ALD) (OMIM 300100)**

Adrenoleukodystrophy is a metabolic storage disease in which a defect in a specific enzyme results in the accumulation of very long-chain fatty acid (VLCFA) lipids in tissues of the body. As a result, protein (ALDP) is missing with following alteration in the transportation of the VLCFA from the cell into the peroxisome. The ALDP gene is located on the X-chromosome and referred to as the ABCD1 gene. The incidence of ALD has been estimated to be 1:17,000 newborns (Engelen et al. 2014). This defect affects all cells, apart from red blood cells in which peroxisomes are not present. However, for unclear reasons, the brain, spinal cord, testis, and the adrenal glands are the most affected tissues. ALD patients although asymptomatic at birth, progressively manifest neurological alterations and adrenal insufficiency. In addition, pHG can often be present (Engelen et al. 2014).

### **Sertoli Cell-only Syndrome (OMIM 400042)**

Men usually have normal androgenization and LH levels and selective increase in FSH levels. The condition could be the consequence of Y microdeletions, but in the majority of cases the underlying etiology is unknown (Krausz et al. 2014). For more information, see ► [Chap. 31, “Treatment of Hypogonadism”](#).

**Primary Ciliary Dyskinesia (Immotile Cilia Syndrome) (OMIM 244400)**

Primary ciliary dyskinesia is a rare autosomal recessive disorder due to mutations in genes encoding for dynein chains, which are essential for cilia and sperm flagellum motility. Patients carrying these mutations show recurrent respiratory infections and infertility (Krausz et al. 2014). For more information, see ► [Chap. 31, “Treatment of Hypogonadism”](#).

**Acquired Causes of Primary Hypogonadism****Testicular Trauma and Torsion**

Testes are predisposed to trauma due to their external position. However, few studies have documented the effect of scrotal trauma on testicular function and size. A prospective evaluation of ten men who had suffered blunt scrotal trauma showed a consequent testicular atrophy only in 50% of cases. Scrotal ultrasonography is highly sensitive in the diagnosis of testicular rupture after trauma, allowing the decision for the optimal surgical treatment needed (Cross et al. 1999).

Testicular torsion results in the interruption of testicular perfusion and ischemia, leading to loss of the testis in 40–60% of cases (Williamson 1977). Generally, the unaffected contralateral testis maintains normal function, although unilateral torsion could be followed by impaired seminal analysis in about 39–50% of cases and normal hormonal levels (Bartsch et al. 1980; Thomas et al. 1984).

**Infectious Diseases**

Orchitis represents the inflammation of the testis that, generally, is associated with an inflammation of the epididymis. The most frequent form is viral orchitis, in which several etiologies are recognized: mumps virus, Coxsackie virus, lymphocytic choriomeningitis virus, Marburg virus, group B arbovirus, dengue virus, and varicella zoster virus.

The inflammation of the testis could be also a consequence of other inflammations, such as nephritis, prostatitis, vesiculitis, and epididymitis, caused by bacteria.

**Mumps Orchitis**

Mumps is a moderately to highly contagious infection restricted to human beings, affecting parotid glands and associated with orchitis in 15–30% cases. Mumps orchitis is generally restricted to adolescents or young adults, and its incidence is rare before 10 and after 50 years of age (Beard et al. 1977). Generally, orchitis manifests 3–10 days after the onset of mumps, although intervals of up to 6 weeks have been reported (Manson 1990).

A painful testicular enlargement characterizes orchitis, which generally affects seminiferous tubules with severe peri-ductal interstitial edema, congestion, separation of the seminiferous tubules, and a profuse perivascular lymphocytic infiltration (Ternavasio-de la Vega et al. 2010). The involvement of seminiferous tubules could lead to testicular atrophy in 30% of cases. Since the process is often of a patchy nature, the inflammation may resolve and not be followed by later atrophic change.

However, when the inflammatory process is extensive and intense, the increased temperature and intratesticular pressure lead to necrosis and atrophy of germinal epithelium with consequent hypogonadism and interruption of spermatogenesis (Manson 1990).

Mumps orchitis shows a clinical course that ranges from mild testicular discomfort and swelling to abrupt onset of severe inflammatory testicular response, generally characterized by pain, increased testicular volume, prostration, fever, and headache (Ternavasio-de la Vega et al. 2010). This clinical situation usually progresses for 2–3 days and resolves within 1–2 weeks after the defervescence phase (Manson 1990).

Biochemical evaluation shows an increased high-sensitive C-reactive protein plasma level and erythrocyte sedimentation rate. Moreover, in about 75% of cases, a reduction in T and inhibin B serum levels is found, accompanied by low or normal gonadotropin levels (Table 4) (Ternavasio-de la Vega et al. 2010).

The treatment of mumps orchitis includes bed rest, elevation of the scrotum, local cooling, and nonsteroidal anti-inflammatory drugs. Interferon- $\alpha$  administration could be a useful tool to prevent testicular atrophy. Antibiotics should be used only when a bacterial etiology cannot be excluded (Ruther et al. 1995; Yenyol et al. 2000).

## Drugs

### Chemotherapy

Alkylating chemotherapeutic agents, such as cyclophosphamide and procarbazine, have the worst gonadal toxic effect, with final harm related to the cumulative dose used. Alkylating agents, especially when used at high doses, show prolonged azoospermia in about 90% of men (Simon et al. 2005). On the other hand, 50% of men treated with platinum compounds show prolonged azoospermia. The germinal epithelium of seminiferous tubules is the most vulnerable tissue, whereas Leydig cells are more resistant. Postpubertal testes seem to be the most susceptible to chemotherapeutic damage, and suppression of spermatogenesis occurs as early as 2 weeks after the start of the treatment. Azoospermia might be seen within 8–12 weeks. Sometimes, together with the reduction of fertility, chemotherapeutic drugs lead to a reduction in T serum levels (DeBaun 2014; Dev 2014).

The recovery of spermatogenesis depends on the viability of stem cells and spermatogonia and could be evident within 12 weeks after the end of the treatment (de Pedro et al. 2015). Moreover, chemotherapy appears to lower healthy sperm counts in cancer survivors, but after an adequate time off therapy, small studies suggest DNA integrity of sperm is reestablished similar to age-matched controls. The amount of time from therapy has not been adequately quantified. For men, semen cryopreservation is the preferred method of fertility preservation.

### Inhibitors of Testosterone Synthesis

*Ketoconazole* is an antifungal drug orally administered with a broad spectrum, used for the treatment of Cushing disease, inhibiting also testicular steroidogenesis,

**Table 4** Biochemical criteria for the definition of male hypogonadism proposed by the different international societies in the field

	Year	Total testosterone			Free testosterone		Timing of blood sampling	Conditions of blood sampling
		nmol/L	ng/ml	ng/dl	pmol/L	pg/ml		
AACE	2002	7	<2.00	<200	Not provided		Morning	–
EAA, ISA, ISSAM	2008	Mild <12 Severe <8	<3.50 <2.31	<350 <231		65	7:00–11:00 am	–
EAU, ASA, ISSM	2010	<10.4	<3.00	<300	<310	90	Morning	–
Endocrine Society	2013	Mild <12 Severe <8	<2.00	<200	<225	65	8:00 am – 12:00 pm	Fasting
ISSM								
Canadian guidelines	2015	Laboratory normal ranges <sup>a</sup>	Laboratory normal ranges <sup>a</sup>	Laboratory normal ranges <sup>a</sup>	Laboratory normal ranges <sup>a</sup>		7:00–11:00 am	–
ISSAM	2015	<12	<3.5	<350	<225	65	7:00–11:00 am	–
EAU	2015	Laboratory normal ranges <sup>a</sup>	Laboratory normal ranges <sup>a</sup>	Laboratory normal ranges <sup>a</sup>	Laboratory normal ranges <sup>a</sup>		Before 11:00 am	Fasting

See reference Petak et al. (2002), Wang et al. (2008), Bhasin et al. (2010), Buvat et al. (2013), Dhole et al. (2015), Lunenfeld et al. (2015), and Morales et al. (2015)

EAA European Academy of Andrology, ISA International Society of Andrology, ISSAM International Society for the Study of the Aging Male, EAU European Association of Urology, ASA American Society of Andrology, ISSM International Society for Sexual Medicine, ES Endocrine Society, ACE American Association of Clinical Endocrinologists

<sup>a</sup>Performed by well-validated methods



leading to a pHG (Pont et al. 1982; Schurmeyer and Nieschlag 1984). In vitro studies demonstrated with mouse Leydig cells a direct reversible inhibition of T biosynthesis by ketoconazole.

Several other drugs can affect steroidogenesis and in turn T production (Table 1). Among them, the most commonly used is represented by mitotane, the gold standard medical treatment for metastatic, inoperable, or recurrent adrenocortical carcinoma. It is generally used in those patients who have persistent disease despite surgical resection, those who are not surgical candidates, or those who have metastatic disease. Mitotane alters steroidogenesis, through a direct suppression of the adrenal cortex. Typically, male patients undergoing mitotane therapy show a picture of hypogonadism, with a decreased free androgen index due to significantly increased SHBG levels that cannot be compensated for by upregulated T production as documented by increased total T and LH levels (Sparagana 1987; Chortis et al. 2013; Gentilin et al. 2014). However, other patients can show also normal LH. In fact, in vitro studies documented that mitotane acts at the pituitary level where it reduces gonadotroph cells' viability, induces apoptosis, and modifies cell cycle phase (Gentilin et al. 2014).

### **Testicular Radiation**

Radiotherapy for cancer could lead to testicular damage, the degree of which depends on the treatment field, total dose, and fractionation schedule (Simon et al. 2005). The testicular cell population responds differently to radiation, and Leydig cells are more resistant to the damage than germinal cells (Markovina et al. 2014). Generally, young adolescent men treated with radiotherapy for cancer show normal progression during puberty with normal hormone levels, although spermatogenesis is often impaired. Radiation up to 30 Gy shows preservation of normal Leydig cell function, whereas a testicular radiation with doses >30 Gy is associated with Leydig cell dysfunction. Similarly, the toxicity on germ cells is dose related and depends on fractionation with radiation delivered in a single dose having less effect than fractionated regimens, considering that azoospermia generally occurs when more than 1.5 Gy is used (Lee and Shin 2013). Return to pretreatment levels usually occurs in 10–24 months, with longer periods required for recovery after higher doses.

### **Autoimmune Testicular Failure**

Autoimmunity negatively influences testicular function throughout the presence of steroidogenic enzymes autoantibodies, such as autoantibodies to steroid-producing cells, to steroid 17  $\alpha$ -hydroxylase, and to side chain cleavage enzyme. Only limited information is known about the predictive role of testis autoimmunity in males. This association is studied in patients with autoimmune polyglandular syndrome and, generally, Addison disease. Both autoantibodies against steroid-producing cells and against the side chain cleavage enzyme seem to cause infertility in men also with Addison disease (Meloni et al. 2012). However, although the presence of steroidogenic enzyme autoantibodies is widely evaluated in men with Addison disease, the gonadal status of these patients was not systematically assessed. Recently, it was demonstrated in a large cohort of subjects with Addison disease that autoantibodies

against steroidogenic enzymes were not related to hypergonadotropic hypogonadism. Thus, it seems that these autoantibodies are not markers of testicular autoimmune disease, and the testis can be considered as an immune-privileged site (Dalla Costa et al. 2014). Two hypotheses have been produced to explain the resistance of testicular tissue against autoimmunity. First, the blood-testis barrier protects the testis against autoantibodies. Second, peritubular cells and Sertoli cells produce immunosuppressive factors, such as transforming growth factor- $\beta$ , granulocyte-macrophage colony-stimulating factor, pro-opiomelanocortin,  $\beta$ -endorphin, meta-enkephalin, and insulin-like growth factors.

While little is known about the relationship between autoimmunity and gonadal status, much evidence is available on the correlation between autoimmunity and fertility, and the presence of sperm-bound immunoglobulin could lead to a sperm quality reduction (Gilbert et al. 1989). However, these autoantibodies do not cause DNA fragmentation (Krause et al. 2009). Antisperm antibodies have this negative effect on male fertility, considering that they are related to (i) sperm autoimmunization, leading to agglutination and impaired cervical penetration; (ii) immunoglobulin isotype, leading to complement-related sperm injury through the female genital tract; and (iii) antigenic specificity of autoantibodies, leading to interference with gamete interactions (Bozhedomov et al. 2014).

### Systemic Diseases

As already mentioned, several chronic diseases including metabolic problems, HIV infection, chronic kidney, and pulmonary diseases can often be associated with male hypogonadism. The underlying pathogenetic factors are complex and not yet completely understood. All these conditions can affect T production acting both at central and peripheral levels determining the development of secondary, primary, or more often, mixed hypogonadism.

---

## Androgen Resistance/Decreased Testosterone Bioactivity

Androgen resistance or decreased bioactivity can be the consequence of rare congenital disorders affecting AR action (e.g., Morris syndrome) or the main enzymes involved in T conversion to DHT (5 $\alpha$ -reductase type 2 deficiency) or to estrogens (aromatase deficiency). Similarly, several drugs can affect androgen metabolism and action resulting in a reduction of androgen bioactivity (Table 1). Finally, men with celiac disease might experience symptoms of androgen deficiency related to the associated malnutrition. However, in these subjects also a reduction in DHT levels has been described. 5 $\alpha$ -Reductase is present in the gut, and its loss in men with active celiac sprue can explain, at least partially, the observed reduction in DHT levels (Farthing et al. 1983). Further analysis of these problems is beyond the aim of the present chapter. For more information, see the specific ► [Chaps. 25, “Androgen Resistance,”](#) and ► [26, “Estrogen Deficiency in Men.”](#)

## References

- Abbasi AA, et al. Gonadal function abnormalities in sickle cell anemia. Studies in adult male patients. *Ann Intern Med.* 1976;85(5):601–5.
- Achard C, Courtillot C, Lahuna O, Meduri G, Soufir JC, Liere P, Bachelot A, Benyounes H, Schumacher M, Kuttenn F, Touraine P, Misrahi M. Normal spermatogenesis in a man with mutant luteinizing hormone. *N Engl J Med.* 2009;361(19):1856–63.
- Agarwal A, Deepinder F, Cocuzza M, Agarwal R, Short RA, Sabanegh E, Marmar JL. Efficacy of varicocelectomy in improving semen parameters: new meta-analytical approach. *Urology.* 2007;70(3):532–8.
- Aksglaede L, Juul A. Testicular function and fertility in men with Klinefelter syndrome: a review. *Eur J Endocrinol.* 2013;168(4):R67–76.
- Allen JC. Initial management of children with hypothalamic and thalamic tumors and the modifying role of neurofibromatosis-1. *Pediatr Neurosurg.* 2000;32(3):154–62.
- Arakane F, King SR, Du Y, Kallen CB, Walsh LP, Watari H, Stocco DM, Strauss 3rd JF. Phosphorylation of steroidogenic acute regulatory protein (StAR) modulates its steroidogenic activity. *J Biol Chem.* 1997;272(51):32656–62.
- Araujo AB, Dixon JM, Suarez EA, Murad MH, Guey LT, Wittert GA. Clinical review: Endogenous testosterone and mortality in men: a systematic review and meta-analysis. *J Clin Endocrinol Metab.* 2011;96(10):3007–19.
- Bakircioglu ME, Ulug U, Erden HF, Tosun S, Bayram A, Ciray N, Bahceci M. Klinefelter syndrome: does it confer a bad prognosis in treatment of nonobstructive azoospermia? *Fertil Steril.* 2011;95(5):1696–9.
- Balasubramanian V, Naing S. Hypogonadism in chronic obstructive pulmonary disease: incidence and effects. *Curr Opin Pulm Med.* 2012;18(2):112–7.
- Balsera AM, Estevez MN, Beltran EB, Sanchez-Giralt P, Garcia LG, Moreno TH, Garcia de Caceres M, Carbonell Perez JM, Gomez EG, Rodriguez-Lopez R. Distinct mechanism of formation of the 48, XXYY karyotype. *Mol Cytogenet.* 2013;6(1):25.
- Bartalena L, Bogazzi F, Brogioni S, Grasso L, Martino E. Role of cytokines in the pathogenesis of the euthyroid sick syndrome. *Eur J Endocrinol.* 1998;138(6):603–14.
- Bartsch G, Frank S, Marberger H, Mikuz G. Testicular torsion: late results with special regard to fertility and endocrine function. *J Urol.* 1980;124(3):375–8.
- Basaria S. Male hypogonadism. *Lancet.* 2014;383(9924):1250–63.
- Beales PL, Elcioglu N, Woolf AS, Parker D, Flinter FA. New criteria for improved diagnosis of Bardet-Biedl syndrome: results of a population survey. *J Med Genet.* 1999;36(6):437–46.
- Beard CM, Benson Jr RC, Kelalis PP, Elveback LR, Kurland LT. The incidence and outcome of mumps orchitis in Rochester, Minnesota, 1935 to 1974. *Mayo Clin Proc.* 1977;52(1):3–7.
- Belli S, Santi D, Leoni E, Dall’Olio E, Fanelli F, Mezzullo M, Pelusi C, Roli L, Tagliavini S, Trenti T, Granata ARM, Pagotto U, Pasquali R, Rochira V, Carani C, Simoni M. Human chorionic gonadotropin stimulation gives evidence of differences in testicular steroidogenesis in Klinefelter syndrome, as assessed by liquid chromatography–tandem mass spectrometry. *European Journal of Endocrinology.* 2016;174:1–11.
- Beressi N, Beressi JP, Cohen R, Modigliani E. Lymphocytic hypophysitis. A review of 145 cases. *Ann Med Interne (Paris).* 1999;150(4):327–41.
- Berthezene F, Forest MG, Grimaud JA, Claustrat B, Mormex R. Leydig-cell agenesis: a cause of male pseudohermaphroditism. *N Engl J Med.* 1976;295(18):969–72.
- Bhangoo APS, Hunter CS, Savage JJ, Anhalt H, Pavlakis S, Walvoord EC, Ten S, Rhodes SJ. A novel LHX3 mutation presenting as combined pituitary hormonal deficiency. *J. Clin. Endocr. Metab.* 2006;91:747–53.
- Bhasin S, Cunningham GR, Hayes FJ, Matsumoto AM, Snyder PJ, Swerdloff RS, Montori VM. Testosterone therapy in men with androgen deficiency syndromes: an Endocrine Society clinical practice guideline. *J Clin Endocrinol Metab.* 2010;95(6):2536–59.

- Biason-Lauber A. Control of sex development. *Best Pract Res Clin Endocrinol Metab.* 2010;24(2):163–86.
- Biglieri EG, Herron MA, Brust N. 17-hydroxylation deficiency in man. *J Clin Invest.* 1966;45(12):1946–54.
- Bihan H, Christozova V, Dumas JL, Jomaa R, Valeyre D, Tazi A, Reach G, Krivitzky A, Cohen R. Sarcoidosis: clinical, hormonal, and magnetic resonance imaging (MRI) manifestations of hypothalamic-pituitary disease in 9 patients and review of the literature. *Medicine (Baltimore).* 2007;86(5):259–68.
- Boehm U, Bouloux PM, Dattani MT, de Roux N, Dode C, Dunkel L, Dwyer AA, Giacobini P, Hardelin JP, Juul A, Maghnie M, Pitteloud N, Prevot V, Raivio T, Tena-Sempere M, Quinton R, Young J. Expert consensus document: European Consensus Statement on congenital hypogonadotropic hypogonadism—pathogenesis, diagnosis and treatment. *Nat Rev Endocrinol.* 2015;11(9):547–64.
- Bojesen A, Kristensen K, Birkebaek NH, Fedder J, Mosekilde L, Bennett P, Laurberg P, Frystyk J, Flyvbjerg A, Christiansen JS, Gravholt CH. The metabolic syndrome is frequent in Klinefelter’s syndrome and is associated with abdominal obesity and hypogonadism. *Diabetes Care.* 2006;29(7):1591–8.
- Bongiovanni AM. The adrenogenital syndrome with deficiency of 3 beta-hydroxysteroid dehydrogenase. *J Clin Invest.* 1962;41:2086–92.
- Bonomi M, Libri DV, Guizzardi F, Guarducci E, Maiolo E, Pignatti E, Asci R, Persani L. New understandings of the genetic basis of isolated idiopathic central hypogonadism. *Asian J Androl.* 2012;14(1):49–56.
- Bose HS, Sugawara T, Strauss 3rd JF, Miller WL. The pathophysiology and genetics of congenital lipoid adrenal hyperplasia. *N Engl J Med.* 1996;335(25):1870–8.
- Boyar RM, Katz J, Finkelstein JW, Kapen S, Weiner H, Weitzman ED, Hellman L. Anorexia nervosa. Immaturity of the 24-hour luteinizing hormone secretory pattern. *N Engl J Med.* 1974;291(17):861–5.
- Bozhedomov VA, Lipatova NA, Rokhlikov IM, Alexeev RA, Ushakova IV, Sukhikh GT. Male fertility and varicocele: role of immune factors. *Andrology.* 2014;2(1):51–8.
- Brand JS, Rovers MM, Yeap BB, Schneider HJ, Tuomainen TP, Haring R, Corona G, Onat A, Maggio M, Bouchard C, Tong PC, Chen RY, Akishita M, Gietema JA, Gannage-Yared MH, Unden AL, Hautanen A, Goncharov NP, Kumanov P, Chubb SA, Almeida OP, Wittchen HU, Klotzsch J, Wallaschofski H, Volzke H, Kauhanen J, Salonen JT, Ferrucci L, van der Schouw YT. Testosterone, sex hormone-binding globulin and the metabolic syndrome in men: an individual participant data meta-analysis of observational studies. *PLoS One.* 2014;9(7):e100409.
- Braunstein GD. Clinical practice. Gynecomastia. *N Engl J Med.* 2007;357(12):1229–37.
- Bruford EA, Riise R, Teague PW, Porter K, Thomson KL, Moore AT, Jay M, Warburg M, Schinzel A, Tommerup N, Tornqvist K, Rosenberg T, Patton M, Mansfield DC, Wright AF. Linkage mapping in 29 Bardet-Biedl syndrome families confirms loci in chromosomal regions 11q13, 15q22.3-q23, and 16q21. *Genomics.* 1997;41(1):93–9.
- Bruning JC, Gautam D, Burks DJ, Gillette J, Schubert M, Orban PC, Klein R, Krone W, Muller-Wieland D, Kahn CR. Role of brain insulin receptor in control of body weight and reproduction. *Science.* 2000;289(5487):2122–5.
- Buvat J, Maggi M, Guay A, Torres LO. Testosterone deficiency in men: systematic review and standard operating procedures for diagnosis and treatment. *J Sex Med.* 2013;10(1):245–84.
- Cao A, Moi P. Genetic modifying factors in beta-thalassemia. *Clin. Chem. Lab. Med.* 2000;38:123–32.
- Carpinteri R, Patelli I, Casanueva FF, Giustina A. Pituitary tumours: inflammatory and granulomatous expansive lesions of the pituitary. *Best Pract Res Clin Endocrinol Metab.* 2009;23(5):639–50.
- Casarini L, Moriondo V, Marino M, Adversì F, Capodanno F, Grisolia C, La Marca A, La Sala GB, Simoni M. FSHR polymorphism p.N680S mediates different responses to FSH in vitro. *Mol Cell Endocrinol.* 2014;393(1–2):83–91.

- Casarini L, Santi D, Marino M. Impact of gene polymorphisms of gonadotropins and their receptors on human reproductive success. *Reproduction*. 2015;150(6):R175–84.
- Casas-Gonzalez P, Scaglia HE, Perez-Solis MA, Durand G, Scaglia J, Zarinan T, Dias JA, Reiter E, Ulloa-Aguirre A. Normal testicular function without detectable follicle-stimulating hormone. A novel mutation in the follicle-stimulating hormone receptor gene leading to apparent constitutive activity and impaired agonist-induced desensitization and internalization. *Mol Cell Endocrinol*. 2012;364(1–2):71–82.
- Castinetti F, Saveanu A, Reynaud R, Quentien MH, Buffin A, Brauner R, Kaffel N, Albarel F, Guedj AM, El Kholy M, Amin M, Enjalbert A, Barlier A, Brue T. A novel dysfunctional LHX4 mutation with high phenotypical variability in patients with hypopituitarism. *J. Clin. Endocr. Metab*. 2008;93:2790–9.
- Chortis V, Taylor AE, Schneider P, Tomlinson JW, Hughes BA, O'Neil DM, Libe R, Allolio B, Bertagna X, Bertherat J, Beuschlein F, Fassnacht M, Karavitaki N, Mannelli M, Mantero F, Opocher G, Porfiri E, Quinkler M, Sherlock M, Terzolo M, Nightingale P, Shackleton CH, Stewart PM, Hahner S, Arlt W. Mitotane therapy in adrenocortical cancer induces CYP3A4 and inhibits 5 $\alpha$ -reductase, explaining the need for personalized glucocorticoid and androgen replacement. *J Clin Endocrinol Metab*. 2013;98(1):161–71.
- Corona G, Petrone L, Paggi F, Lotti F, Boddi V, Fisher A, Vignozzi L, Balercia G, Sforza A, Forti G, Mannucci E, Maggi M. Sexual dysfunction in subjects with Klinefelter's syndrome. *Int J Androl*. 2010;33(4):574–80.
- Corona G, Monami M, Rastrelli G, Aversa A, Sforza A, Lenzi A, Forti G, Mannucci E, Maggi M. Type 2 diabetes mellitus and testosterone: a meta-analysis study. *Int J Androl*. 2011a;34(6 Pt 1):528–40.
- Corona G, Monami M, Rastrelli G, Aversa A, Tishova Y, Saad F, Lenzi A, Forti G, Mannucci E, Maggi M. Testosterone and metabolic syndrome: a meta-analysis study. *J Sex Med*. 2011b;8(1):272–83.
- Corona G, Rastrelli G, Vignozzi L, Maggi M. Emerging medication for the treatment of male hypogonadism. *Expert Opin Emerg Drugs*. 2012a;17(2):239–59.
- Corona G, Rastrelli G, Vignozzi L, Mannucci E, Maggi M. How to recognize late-onset hypogonadism in men with sexual dysfunction. *Asian J Androl*. 2012b;14(2):251–9.
- Corona G, Rastrelli G, Maggi M. Diagnosis and treatment of late-onset hypogonadism: systematic review and meta-analysis of TRT outcomes. *Best Pract Res Clin Endocrinol Metab*. 2013a;27(4):557–79.
- Corona G, Rastrelli G, Ricca V, Jannini EA, Vignozzi L, Monami M, Sforza A, Forti G, Mannucci E, Maggi M. Risk factors associated with primary and secondary reduced libido in male patients with sexual dysfunction. *J Sex Med*. 2013b;10(4):1074–89.
- Corona G, Rastrelli G, Silverii A, Monami M, Sforza A, Forti G, Mannucci E, Maggi M. The identification of prediabetes condition with ARIC algorithm predicts long-term CV events in patients with erectile dysfunction. *J Sex Med*. 2013c;10(4):1114–23.
- Corona G, Maseroli E, Rastrelli G, Sforza A, Forti G, Mannucci E, Maggi M. Characteristics of compensated hypogonadism in patients with sexual dysfunction. *J Sex Med*. 2014a;11(7):1823–34.
- Corona G, Maseroli E, Maggi M. Injectable testosterone undecanoate for the treatment of hypogonadism. *Expert Opin Pharmacother*. 2014b;15(13):1903–26.
- Corona G, Giorda CB, Cucinotta D, Guida P, Nada E. Sexual dysfunction at the onset of type 2 diabetes: the interplay of depression, hormonal and cardiovascular factors. *J Sex Med*. 2014c;11(8):2065–73.
- Corona G, Rastrelli G, Filippi S, Vignozzi L, Mannucci E, Maggi M. Erectile dysfunction and central obesity: an Italian perspective. *Asian J Androl*. 2014d;16(4):581–91.
- Corona G, Vignozzi L, Sforza A, Mannucci E, Maggi M. Obesity and late-onset hypogonadism. *Mol Cell Endocrinol*. 2015;418(Pt 2):120–33.
- Corona G, Isidori AM, Aversa A, Burnett AL, Maggi M. Endocrinologic control of men's sexual desire and arousal/erection. *J Sex Med*. 2016a;13(3):317–37.

- Corona G, Giagulli VA, Maseroli E, Vignozzi L, Aversa A, Zitzmann M, Saad F, Mannucci E, Maggi M. Therapy of endocrine disease: testosterone supplementation and body composition: results from a meta-analysis study. *Eur J Endocrinol*. 2016b;174(3):R99–R116.
- Corona G, Maseroli E, Rastrelli G, Francomano D, Aversa A, Hackett G, Ferri S, Sforza A, Maggi M. Is late-onset hypogonadotropic hypogonadism a specific age-dependent disease, or merely an epiphenomenon caused by accumulating disease-burden? Focusing on metabolic diseases. *Minerva: Endocrinol*; 2016c.
- Costanzo PR, Suarez SM, Scaglia HE, Zylbersztein C, Litwak LE, Knoblovits P. Evaluation of the hypothalamic-pituitary-gonadal axis in eugonadal men with type 2 diabetes mellitus. *Andrology*. 2014;2(1):117–24.
- Cotter AG, Powderly WG. Endocrine complications of human immunodeficiency virus infection: hypogonadism, bone disease and tenofovir-related toxicity. *Best Pract Res Clin Endocrinol Metab*. 2011;25(3):501–15.
- Coward RM, Rajanahally S, Kovac JR, Smith RP, Pastuszak AW, Lipshultz LI. Anabolic steroid induced hypogonadism in young men. *J Urol*. 2013;190(6):2200–5.
- Cross JJ, Berman LH, Elliott PG, Irving S. Scrotal trauma: a cause of testicular atrophy. *Clin Radiol*. 1999;54(5):317–20.
- Cundy T, Butler J, Bomford A, Williams R. Reversibility of hypogonadotropic hypogonadism associated with genetic haemochromatosis. *Clin Endocrinol (Oxf)*. 1993;38(6):617–20.
- Dabaja AA, Goldstein M. When is a varicocele repair indicated: the dilemma of hypogonadism and erectile dysfunction? *Asian J Androl*. 2016;18(2):213–6.
- Dada OA, Nduka EU. Endocrine function and haemoglobinopathies: relation between the sickle cell gene and circulating plasma levels of testosterone, luteinising hormone (LH) and follicle stimulating hormone (FSH) in adult males. *Clin Chim Acta*. 1980;105(2):269–73.
- Dalan R, Leow MK. Pituitary abscess: our experience with a case and a review of the literature. *Pituitary*. 2008;11(3):299–306.
- Dalla Costa M, Bonanni G, Masiero S, Faggian D, Chen S, Furmaniak J, Rees Smith B, Perniola R, Radetti G, Garelli S, Chiarelli S, Albergoni MP, Plebani M, Betterle C. Gonadal function in males with autoimmune Addison's disease and autoantibodies to steroidogenic enzymes. *Clin Exp Immunol*. 2014;176(3):373–9.
- Dalton JC, Ranum LPW, Day JW. Myotonic dystrophy type 2. In: Pagon RA, Adam MP, Ardinger HH, et al., editors. *GeneReviews(R)*. Seattle WA: University of Washington, Seattle; 1993.
- Darzy KH, Shalet SM. Hypopituitarism following Radiotherapy Revisited. *Endocr Dev*. 2009;15:1–24.
- Dattani MT, Martinez-Barbera JP, Thomas PQ, Brickman JM, Gupta R, Mårtensson IL, Toresson H, Fox M, Wales JK, Hindmarsh PC, Krauss S, Beddington RS, Robinson IC. Mutations in the homeobox gene HESX1/Hesx1 associated with septo-optic dysplasia in human and mouse. *Nat Genet*. 1998;19(2):125–33.
- DeBaun MR. Hydroxyurea therapy contributes to infertility in adult men with sickle cell disease: a review. *Expert Rev Hematol*. 2014;7(6):767–73.
- de Pedro M, Otero B, Martin B. Fertility preservation and breast cancer: a review. *Ecancermedicinescience*. 2015;9:503.
- Desai SS. Down syndrome: a review of the literature. *Oral Surg Oral Med Oral Pathol Oral Radiol Endod*. 1997;84(3):279–85.
- Dev R. The assessment and management of cancer cachexia: hypogonadism and hypermetabolism among supportive and palliative care patients. *Curr Opin Support Palliat Care*. 2014;8(3): 279–85.
- Dohle GR, Arver S, Bettocchi C, Jones TH, Kliesch S, Punab M. Male hypogonadism. *European Association of Urology guidelines*. 2015. <https://uroweb.org/guideline/malehypogonadism/>
- el-Hazmi MA, Bahakim HM, al-Fawaz I. Endocrine functions in sickle cell anaemia patients. *J Trop Pediatr*. 1992;38(6):307–13.
- El Houate B, Rouba H, Sibai H, Barakat A, Chafik A, el Chadli B, Imken L, Bogatcheva NV, Feng S, Agoulnik AI, McElreavey K. Novel mutations involving the INSL3 gene associated with cryptorchidism. *J Urol*. 2007;177(5):1947–51.

- Engelen M, Kemp S, Poll-The BT. X-linked adrenoleukodystrophy: pathogenesis and treatment. *Curr Neurol Neurosci Rep.* 2014;14(10):486.
- Ezzat S, Asa SL, Couldwell WT, Barr CE, Dodge WE, Vance ML, McCutcheon IE. The prevalence of pituitary adenomas: a systematic review. *Cancer.* 2004;101(3):613–9.
- Farthing MJ, Rees LH, Edwards CR, Dawson AM. Male gonadal function in coeliac disease: 2. Sex hormones. *Gut.* 1983;24(2):127–35.
- Fawzy F, Hussein A, Eid MM, El Kashash AM, Salem HK. Cryptorchidism and Fertility. *Clin Med Insights Reprod Health.* 2015;9:39–43.
- Fechner PY, Marcantonio SM, Jaswaney V, Stetten G, Goodfellow PN, Migeon CJ, Smith KD, Berkovitz GD, Amrhein JA, Bard PA, et al. The role of the sex-determining region Y gene in the etiology of 46,XX maleness. *J Clin Endocrinol Metab.* 1993;76(3):690–5.
- Feder JN, Gnirke A, Thomas W, Tsuchihashi Z, Ruddy DA, Basava A, Dormishian F, Domingo Jr R, Ellis MC, Fullan A, Hinton LM, Jones NL, Kimmel BE, Kronmal GS, Lauer P, Lee VK, Loeb DB, Mapa FA, McClelland E, Meyer NC, Mintier GA, Moeller N, Moore T, Morikang E, Prass CE, Quintana L, Starnes SM, Schatzman RC, Brunke KJ, Drayna DT, Risch NJ, Bacon BR, Wolff RK. A novel MHC class I-like gene is mutated in patients with hereditary haemochromatosis. *Nat Genet.* 1996;13(4):399–408.
- Ferlin A, Zuccarello D, Garolla A, Selice R, Foresta C. Hormonal and genetic control of testicular descent. *Reprod Biomed Online.* 2007;15(6):659–65.
- Flück C, Deladoey J, Rutishauser K, Eblé A, Marti U, Wu W, Mullis PE. Phenotypic variability in familial combined pituitary hormone deficiency caused by a PROP1 gene mutation resulting in the substitution of Arg- > Cys at codon 120 (R120C). *J Clin Endocrinol Metab.* 1998;83(10):3727–374.
- Forti G, Corona G, Vignozzi L, Krausz C, Maggi M. Klinefelter's syndrome: a clinical and therapeutical update. *Sex Dev.* 2010;4(4–5):249–58.
- Gaspar AP, Brandao CM, Lazaretti-Castro M. Bone mass and hormone analysis in patients with spinal cord injury: evidence for a gonadal axis disruption. *J Clin Endocrinol Metab.* 2014;99(12):4649–55.
- Gentilin E, Mole D, Gagliano T, Minoia M, Ambrosio MR, Degli Uberti EC, Zatelli MC. Inhibitory effects of mitotane on viability and secretory activity in mouse gonadotroph cell lines. *Reprod Toxicol.* 2014;45:71–6.
- Giannetta E, Gianfrilli D, Barbagallo F, Isidori AM, Lenzi A. Subclinical male hypogonadism. *Best Pract Res Clin Endocrinol Metab.* 2012;26(4):539–50.
- Gilbert BR, Witkin SS, Goldstein M. Correlation of sperm-bound immunoglobulins with impaired semen analysis in infertile men with varicoceles. *Fertil Steril.* 1989;52(3):469–73.
- Gravholt CH, Jensen AS, Host C, Bojesen A. Body composition, metabolic syndrome and type 2 diabetes in Klinefelter syndrome. *Acta Paediatr.* 2011;100(6):871–7.
- Grinson RP, Ropelato MG, Gottlieb S, Keselman A, Martinez A, Ballerini MG, Domené HM, Rey RA. Basal follicle-stimulating hormone and peak gonadotropin levels after gonadotropin-releasing hormone infusion show high diagnostic accuracy in boys with suspicion of hypogonadotropic hypogonadism. *J Clin Endocrinol Metab.* 2010;95(6):2811–8.
- Gromoll J, Simoni M, Nieschlag E. An activating mutation of the follicle-stimulating hormone receptor autonomously sustains spermatogenesis in a hypophysectomized man. *J Clin Endocrinol Metab.* 1996;81(4):1367–70.
- Guibaud L, Larroque A, Ville D, Sanlaville D, Till M, Gaucherand P, Pracros JP, des Portes V. Prenatal diagnosis of 'isolated' Dandy-Walker malformation: imaging findings and prenatal counselling. *Prenat Diagn.* 2012;32(2):185–93.
- Hackney AC. Effects of endurance exercise on the reproductive system of men: the "exercise-hypogonadal male condition". *J Endocrinol Invest.* 2008;31(10):932–8.
- Hay ID, Smail PJ, Forsyth CC. Familial cytomegalic adrenocortical hypoplasia: an X-linked syndrome of pubertal failure. *Arch Dis Child.* 1981;56(9):715–21.
- Hayden RP, Tanrikut C. Testosterone and Varicocele. *Urol Clin North Am.* 2016;43(2):223–32.
- Higham CE, Johannsson G, Shalet SM. Hypopituitarism. *Lancet.* 2016;388(10058):2403–15.

- Ho CY, Mobley BC, Gordish-Dressman H, VandenBussche CJ, Mason GE, Bornhorst M, Esbenshade AJ, Tehrani M, Orr BA, LaFrance DR, Devaney JM, Meltzer BW, Hofherr SE, Burger PC, Packer RJ, Rodriguez FJ. A clinicopathologic study of diencephalic pediatric low-grade gliomas with BRAF V600 mutation. *Acta Neuropathol.* 2015;130(4):575–85.
- Hohl A, Mazzucco TL, Coral MH, Schwarzbald M, Walz R. Hypogonadism after traumatic brain injury. *Arq Bras Endocrinol Metabol.* 2009;53(8):908–14.
- Hughes IA. Disorders of sex development: a new definition and classification. *Best Pract Res Clin Endocrinol Metab.* 2008;22(1):119–34.
- Hughes PJ, Edwards JM, Ridler MA, Lane RJ. A balanced autosomal translocation (3;9) associated with primary hypogonadism and dorsal spine stenosis. *Clin Genet.* 1993;43(1):44–5.
- Huhtaniemi I. Mutations along the pituitary-gonadal axis affecting sexual maturation: novel information from transgenic and knockout mice. *Mol Cell Endocrinol.* 2006;254-255:84–90.
- Huhtaniemi I, Alevizaki M. Gonadotrophin resistance. *Best Pract Res Clin Endocrinol Metab.* 2006;20(4):561–76.
- Husain N, Husain M, Rao P. Pituitary tuberculosis mimicking idiopathic granulomatous hypophysitis. *Pituitary.* 2008;11(3):313–5.
- Iglesias P, Carrero JJ, Diez JJ. Gonadal dysfunction in men with chronic kidney disease: clinical features, prognostic implications and therapeutic options. *J Nephrol.* 2012;25(1):31–42.
- Izumi Y, Musha I, Suzuki E, Iso M, Jinno T, Horikawa R, Amemiya S, Ogata T, Fukami M, Ohtake A. Hypogonadotropic hypogonadism in a female patient previously diagnosed as having waardenburg syndrome due to a sox10 mutation. *Endocrine.* 2015;49(2):553–6.
- Jacobs PA, Strong JA. A case of human intersexuality having a possible XXY sex-determining mechanism. *Nature.* 1959;183(4657):302–3.
- Jagiello P, Gencik M, Arning L, Wieczorek S, Kunstmann E, Csernok E, Gross WL, Epplen JT. New genomic region for Wegener's granulomatosis as revealed by an extended association screen with 202 apoptosis-related genes. *Hum Genet.* 2004;114(5):468–77.
- Kaymakoglu S, Okten A, Cakaloglu Y, Boztas G, Besisik F, Tascioglu C, Yalcin S. Hypogonadism is not related to the etiology of liver cirrhosis. *J Gastroenterol.* 1995;30(6):745–50.
- Kelly DM, Jones TH. Testosterone and obesity. *Obes Rev.* 2015;16(7):581–606.
- Krause I, Anaya JM, Fraser A, Barzilai O, Ram M, Abad V, Arango A, Garcia J, Shoenfeld Y. Anti-infectious antibodies and autoimmune-associated autoantibodies in patients with type I diabetes mellitus and their close family members. *Ann N Y Acad Sci.* 2009;1173:633–9.
- Krausz CG, Carrell DT. Advances in understanding the genetics underlying male infertility and evolving diagnostic and treatment options. *Andrology.* 2014;2(3):302–3.
- Krausz C, Hoefsloot L, Simoni M, Tuttmann F. EAA/EMQN best practice guidelines for molecular diagnosis of Y-chromosomal microdeletions: state-of-the-art 2013. *Andrology.* 2014;2(1):5–19.
- Kurtulmus N, Mert M, Tanakol R, Yarman S. The pituitary gland in patients with Langerhans cell histiocytosis: a clinical and radiological evaluation. *Endocrine.* 2015;48(3):949–56.
- Labrie F, Luu-The V, Lin SX, Labrie C, Simard J, Breton R, Belanger A. The key role of 17 beta-hydroxysteroid dehydrogenases in sex steroid biology. *Steroids.* 1997;62(1):148–58.
- Lanfranco F, Kamischke A, Zitzmann M, Nieschlag E. Klinefelter's syndrome. *Lancet.* 2004;364(9430):273–83.
- Larson A, Nokoff NJ, Meeks NJ. Genetic causes of pituitary hormone deficiencies. *Discov Med.* 2015;19(104):175–83.
- Laumonnier F, Ronce N, Hamel BCJ, Thomas P, Lespinasse J, Raynaud M, Paringaux C, van Bokhoven H, Kalscheuer V, Fryns J-P, Chelly J, Moraine C, Briault S. Transcription factor SOX3 is involved in X-linked mental retardation with growth hormone deficiency. *Am. J. Hum. Genet.* 2002;71:1450–5.
- Layman LC, Lee EJ, Peak DB, Namnoum AB, Vu KV, van Lingen BL, Gray MR, McDonough PG, Reindollar RH, Jameson JL. Delayed puberty and hypogonadism caused by mutations in the follicle-stimulating hormone beta-subunit gene. *N Engl J Med.* 1997;337:607–11.



- Lee SH, Shin CH. Reduced male fertility in childhood cancer survivors. *Ann Pediatr Endocrinol Metab.* 2013;18(4):168–72.
- Lee BJ, Traboulsi EI. Update on the morning glory disc anomaly. *Ophthalmic Genet.* 2008;29(2):47–52.
- Lenzi A, Balercia G, Bellastella A, Colao A, Fabbri A, Foresta C, Galdiero M, Gandini L, Krausz C, Lombardi G, Lombardo F, Maggi M, Radicioni A, Selice R, Sinisi AA, Forti G. Epidemiology, diagnosis, and treatment of male hypogonadotropic hypogonadism. *J Endocrinol Invest.* 2009;32(11):934–8.
- Linden MG, Bender BG, Robinson A. Sex chromosome tetrasomy and pentasomy. *Pediatrics.* 1995;96(4 Pt 1):672–82.
- Lindstedt G, Nystrom E, Matthews C, Ernest I, Janson PO, Chatterjee VK. Follitropin (FSH) deficiency in an infertile male due to FSHbeta gene mutation. A syndrome of normal puberty and virilization but underdeveloped testicles with azoospermia, low FSH but high lutropin and normal serum testosterone concentrations. *Clin Chem Lab Med.* 1998;36:663–5.
- Lofrano-Porto A, Barra GB, Giacomini LA, Nascimento PP, Latronico AC, Casulari LA, da Rocha Neves Fde A. Luteinizing hormone beta mutation and hypogonadism in men and women. *N Engl J Med.* 2007;357:897–904.
- Lorenzo M, Peino R, Castro AI, Lage M, Popovic V, Dieguez C, Casanueva FF. Hypopituitarism and growth hormone deficiency in adult subjects after traumatic brain injury: who and when to test. *Pituitary.* 2005;8(3–4):233–7.
- Lotti F, Rochira V, Pivonello R, Santi D, Galdiero M, Maseroli E, Balestrieri A, Faustini-Fustini M, Peri A, Sforza A, Colao A, Maggi M, Corona G. Erectile Dysfunction is Common among Men with Acromegaly and is Associated with Morbidities Related to the Disease. *J Sex Med.* 2015;12(5):1184–93.
- Lunenfeld B, Mskhalaya G, Zitzmann M, Arver S, Kalinchenko S, Tishova Y, Morgentaler A. Recommendations on the diagnosis, treatment and monitoring of hypogonadism in men. *Aging Male.* 2015;18(1):5–15.
- Makras P, Papadogias D, Kontogeorgos G, Piaditis G, Kaltsas GA. Spontaneous gonadotrophin deficiency recovery in an adult patient with Langerhans cell histiocytosis (LCH). *Pituitary.* 2005;8(2):169–74.
- Manson AL. Mumps orchitis. *Urology.* 1990;36(4):355–8.
- Mantovani G, Ozisik B, Achermann JC, Romoli R, Borretta G, Persani L, Spada A, Jameson JL, Beck-Peccoz P. Hypogonadotropic hypogonadism as a presenting feature of late-onset X-linked adrenal hypoplasia congenita. *J Clin Endocrinol Metab.* 2002;87(1):44–8.
- Markovina S, Weschenfelder DC, Gay H, McCandless A, Carey B, DeWees T, Knutson N, Michalski J. Low incidence of new biochemical hypogonadism after intensity modulated radiation therapy for prostate cancer. *Pract Radiat Oncol.* 2014;4(6):430–6.
- Mathers MJ, Sperling H, Rubben H, Roth S. The undescended testis: diagnosis, treatment and long-term consequences. *Dtsch Arztebl Int.* 2009;106(33):527–32.
- Mazaux JM, Richer E. Rehabilitation after traumatic brain injury in adults. *Disabil Rehabil.* 1998;20(12):435–47.
- Meloni A, Willcox N, Meager A, Atzeni M, Wolff AS, Husebye ES, Furcas M, Rosatelli MC, Cao A, Congia M. Autoimmune polyendocrine syndrome type 1: an extensive longitudinal study in Sardinian patients. *J Clin Endocrinol Metab.* 2012;97(4):1114–24.
- Miller WL, Auchus RJ. The molecular biology, biochemistry, and physiology of human steroidogenesis and its disorders. *Endocr Rev.* 2011;32(1):81–151.
- Miraoui H, Dwyer AA, Sykiotis GP, Plummer L, Chung W, Feng B, Beenken A, Clarke J, Pers TH, Dworzynski P, Keefe K, Niedziela M, Raivio T, Crowley Jr WF, Seminara SB, Quinton R, Hughes VA, Kumanov P, Young J, Yialamas MA, Hall JE, Van Vliet G, Chanoine JP, Rubenstein J, Mohammadi M, Tsai PS, Sidis Y, Lage K, Pitteloud N. Mutations in FGF17, IL17RD, DUSP6, SPRY4, and FLRT3 are identified in individuals with congenital hypogonadotropic hypogonadism. *Am J Hum Genet.* 2013;92(5):725–43.

- Modebe O, Ezeh UO. Effect of age on testicular function in adult males with sickle cell anemia. *Fertil Steril*. 1995;63(4):907–12.
- Moghrabi N, Hughes IA, Dunaif A, Andersson S. Deleterious missense mutations and silent polymorphism in the human 17 $\beta$ -hydroxysteroid dehydrogenase 3 gene (HSD17B3). *J Clin Endocrinol Metab*. 1998;83(8):2855–60.
- Molitch ME, Clemmons DR, Malozowski S, Merriam GR, Vance ML. Evaluation and treatment of adult growth hormone deficiency: an Endocrine Society clinical practice guideline. *J Clin Endocrinol Metab*. 2011;96(6):1587–609.
- Moore LA, Erstine EM, Prayson RA. Pituitary aspergillus infection. *J Clin Neurosci*. 2016;29:178–80.
- Morales A, Bebb RA, Manjoo P, Assimakopoulos P, Axler J, Collier C, Elliott S, Goldenberg L, Gottesman I, Grober ED, Guyatt GH, Holmes DT, Lee JC. Diagnosis and management of testosterone deficiency syndrome in men: clinical practice guideline. *CMAJ*. 2015;187(18): 1369–77.
- Morelli A, Corona G, Filippi S, Ambrosini S, Forti G, Vignozzi L, Maggi M. Which patients with sexual dysfunction are suitable for testosterone replacement therapy? *J Endocrinol Invest*. 2007;30(10):880–8.
- Morelli A, Fibbi B, Marini M, Silvestrini E, De Vita G, Chavalmane AK, Vignozzi L, Filippi S, Forti G, Vannelli GB, Maggi M. Dihydrotestosterone and leptin regulate gonadotropin-releasing hormone (GnRH) expression and secretion in human GnRH-secreting neuroblasts. *J Sex Med*. 2009;6(2):397–407.
- Morelli A, Sarchielli E, Comeglio P, Filippi S, Vignozzi L, Marini M, Rastrelli G, Maneschi E, Cellai I, Persani L, Adorini L, Vannelli GB, Maggi M. Metabolic syndrome induces inflammation and impairs gonadotropin-releasing hormone neurons in the preoptic area of the hypothalamus in rabbits. *Mol Cell Endocrinol*. 2014;382(1):107–19.
- Muller HL. Craniopharyngioma. *Endocr Rev*. 2014;35(3):513–43.
- Nieschlag E, Vorona E. MECHANISMS IN ENDOCRINOLOGY: Medical consequences of doping with anabolic androgenic steroids: effects on reproductive functions. *Eur J Endocrinol*. 2015;173(2):R47–58.
- O'Connell MD, Wu FC. Androgen effects on skeletal muscle: implications for the development and management of frailty. *Asian J Androl*. 2014;16(2):203–12.
- Osegbe DN, Akinyanju OO. Testicular dysfunction in men with sickle cell disease. *Postgrad Med J*. 1987;63(736):95–8.
- Palmert MR, Dunkel L. Clinical practice. Delayed puberty. *N Engl J Med*. 2012;366(5):443–53.
- Petak SM, Nankin HR, Spark RF, Swerdloff RS, Rodriguez-Rigau LJ. American Association of Clinical Endocrinologists Medical Guidelines for clinical practice for the evaluation and treatment of hypogonadism in adult male patients–2002 update. *Endocr Pract*. 2002;8(6):440–56.
- Philibert P, Zenaty D, Lin L, Soskin S, Audran F, Leger J, Achermann JC, Sultan C. Mutational analysis of steroidogenic factor 1 (NR5a1) in 24 boys with bilateral anorchia: a French collaborative study. *Hum Reprod*. 2007;22(12):3255–61.
- Phillip M, Arbelle JE, Segev Y, Parvari R. Male hypogonadism due to a mutation in the gene for the beta-subunit of follicle-stimulating hormone. *N Engl J Med*. 1998;338(24):1729–32.
- Pirgon O, Dunder BN. Vanishing testes: a literature review. *J Clin Res Pediatr Endocrinol*. 2012;4(3):116–20.
- Pitteloud N, Boepple PA, DeCruz S, Valkenburgh SB, Crowley Jr WF, Hayes FJ. The fertile eunuch variant of idiopathic hypogonadotropic hypogonadism: spontaneous reversal associated with a homozygous mutation in the gonadotropin-releasing hormone receptor. *J Clin Endocrinol Metab*. 2001;86(6):2470–5.
- Pitteloud N, Hayes FJ, Boepple PA, DeCruz S, Seminara SB, MacLaughlin DT, Crowley Jr WF. The role of prior pubertal development, biochemical markers of testicular maturation, and genetics in elucidating the phenotypic heterogeneity of idiopathic hypogonadotropic hypogonadism. *J Clin Endocrinol Metab*. 2002;87(1):152–60.
- Pont A, Williams PL, Azhar S, Reitz RE, Bochra C, Smith ER, Stevens DA. Ketoconazole blocks testosterone synthesis. *Arch Intern Med*. 1982;142(12):2137–40.

- Prasad AS. Zinc deficiency in sickle cell disease. *Prog Clin Biol Res.* 1984;165:49–58.
- Radicioni A, Lenzi A, Spaziani M, Anzuini A, Ruga G, Papi G, Raimondo M, Foresta C. A multicenter evaluation of immunoassays for follicle-stimulating hormone, luteinizing hormone and testosterone: concordance, imprecision and reference values. *J Endocrinol Invest.* 2013; 36(9):739–44.
- Raivio T, Falardeau J, Dwyer A, Quinton R, Hayes FJ, Hughes VA, Cole LW, Pearce SH, Lee H, Boepple P, Crowley Jr WF, Pitteloud N. Reversal of idiopathic hypogonadotropic hypogonadism. *N Engl J Med.* 2007;357(9):863–73.
- Rajfer J, Turner TT, Rivera F, Howards SS, Sikka SC. Inhibition of testicular testosterone biosynthesis following experimental varicocele in rats. *Biol Reprod.* 1987;36(4):933–7.
- Rastrelli G, Corona G, Maggi M. The role of prolactin in andrology: what is new? *Rev Endocr Metab Disord.* 2015;16(3):233–48.
- Rastrelli G, Corona G, Tarocchi M, Mannucci E, Maggi M. How to define hypogonadism? Results from a population of men consulting for sexual dysfunction. *J Endocrinol Invest.* 2016;39(4): 473–84.
- Reisch N, Flade L, Scherr M, Rottenkolber M, Pedrosa Gil F, Bidlingmaier M, Wolff H, Schwarz HP, Quinkler M, Beuschlein F, Reincke M. High prevalence of reduced fecundity in men with congenital adrenal hyperplasia. *J Clin Endocrinol Metab.* 2009;94(5):1665–70.
- Rochira V, Zirilli L, Orlando G, Santi D, Brigante G, Diazzi C, Carli F, Carani C, Guaraldi G. Premature decline of serum total testosterone in HIV-infected men in the HAART-era. *PLoS One.* 2011;6(12):e28512.
- Rosner W, Auchus RJ, Azziz R, Sluss PM, Raff H. Position statement: Utility, limitations, and pitfalls in measuring testosterone: an Endocrine Society position statement. *J Clin Endocrinol Metab.* 2007;92(2):405–13.
- Ruige JB, Mahmoud AM, De Bacquer D, Kaufman JM. Endogenous testosterone and cardiovascular disease in healthy men: a meta-analysis. *Heart.* 2011;97(11):870–5.
- Ruther U, Stolz S, Rohl E, Nunnensiek C, Rassweiler J, Dorr U, Jipp P. Successful interferon-alpha 2 a therapy for a patient with acute mumps orchitis. *Eur Urol.* 1995;27(2):174–6.
- Salvi R, Pralong FP. Molecular characterization and phenotypic expression of mutations in genes for gonadotropins and their receptors in humans. *Front Horm Res.* 2010;39:1–12.
- Scheidecker S, Etard C, Pierce NW, Geoffroy V, Schaefer E, Muller J, Chennen K, Flori E, Pelletier V, Poch O, Marion V, Stoetzel C, Strähle U, Nachury MV, Dollfus H. Exome sequencing of Bardet-Biedl syndrome patient identifies a null mutation in the BBSome subunit BBIP1 (BBS18). *J Med Genet.* 2014;51(2):132–6.
- Schneider HJ, Kreitschmann-Andermahr I, Ghigo E, Stalla GK, Agha A. Hypothalamopituitary dysfunction following traumatic brain injury and aneurysmal subarachnoid hemorrhage: a systematic review. *JAMA.* 2007;298(12):1429–38.
- Schurmeyer T, Nieschlag E. Effect of ketoconazole and other imidazole fungicides on testosterone biosynthesis. *Acta Endocrinol (Copenh).* 1984;105(2):275–80.
- Sedlmeyer IL, Palmert MR. Delayed puberty: analysis of a large case series from an academic center. *J Clin Endocrinol Metab.* 2002;87(4):1613–20.
- Seminara SB, Acierno Jr JS, Abdulwahid NA, Crowley Jr WF, Margolin DH. Hypogonadotropic hypogonadism and cerebellar ataxia: detailed phenotypic characterization of a large, extended kindred. *J Clin Endocrinol Metab.* 2002;87(4):1607–12.
- Shimizu R, Mitsui N, Mori Y, Cho S, Yamamori S, Osawa M, Ohashi H. Cryptic 17q22 deletion in a boy with a t(10;17)(p15.3;q22) translocation, multiple synostosis syndrome 1, and hypogonadotropic hypogonadism. *Am J Med Genet A.* 2008;146A(11):1458–61.
- Simon B, Lee SJ, Partridge AH, Runowicz CD. Preserving fertility after cancer. *CA Cancer J Clin.* 2005;55(4):211–28. quiz 263–214.
- Simoni M, Gromoll J, Nieschlag E. The follicle-stimulating hormone receptor: biochemistry, molecular biology, physiology, and pathophysiology. *Endocr Rev.* 1997;18(6):739–73.
- Simoni M, Bakker E, Eurlings MC, Matthijs G, Moro E, Muller CR, Vogt PH. Laboratory guidelines for molecular diagnosis of Y-chromosomal microdeletions. *Int J Androl.* 1999; 22(5):292–9.

- Simonis N, Migeotte I, Lambert N, Perazzolo C, de Silva DC, Dimitrov B, Heinrichs C, Janssens S, Kerr B, Mortier G, Van Vliet G, Lepage P, Casimir G, Abramowicz M, Smits G, Vilain C. FGFR1 mutations cause Hartsfield syndrome, the unique association of holoprosencephaly and ectrodactyly. *J Med Genet.* 2013;50(9):585–92.
- Smith-Whitley K. Reproductive issues in sickle cell disease. *Blood.* 2014;124(24):3538–43.
- Sparagana M. Primary hypogonadism associated with o,p' DDD (mitotane) therapy. *J Toxicol Clin Toxicol.* 1987;25(6):463–72.
- Stocco DM, Wang X, Jo Y, Manna PR. Multiple signaling pathways regulating steroidogenesis and steroidogenic acute regulatory protein expression: more complicated than we thought. *Mol Endocrinol.* 2005;19(11):2647–59.
- Stouffs K, Tournaye H, Liebaers I, Lissens W. Male infertility and the involvement of the X chromosome. *Hum Reprod Update.* 2009;15(6):623–37.
- Stouffs K, Gheldof A, Tournaye H, Vandermaelen D, Bonduelle M, Lissens W, Seneca S. Sertoli Cell-Only Syndrome: Behind the Genetic Scenes. *Biomed Res Int.* 2016;2016:6191307.
- Suntharalingham JP, Buonocore F, Duncan AJ, Achermann JC. DAX-1 (NR0B1) and steroidogenic factor-1 (SF-1, NR5A1) in human disease. *Best Pract Res Clin Endocrinol Metab.* 2015;29(4):607–19.
- Szvetko A, Martin N, Joy C, Hayward A, Watson B, Cary A, Withers S. Detection of chromosome x;18 breakpoints and translocation of the xq22.3;18q23 regions resulting in variable fertility phenotypes. *Case Rep Genet.* 2012;2012:681747.
- Taddesse A, Woldie IL, Khana P, Swerdlow PS, Chu JW, Abrams J, Abou-Samra AB. Hypogonadism in patients with sickle cell disease: central or peripheral? *Acta Haematol.* 2012;128(2):65–8.
- Tajar A, Forti G, O'Neill TW, Lee DM, Silman AJ, Finn JD, Bartfai G, Boonen S, Casanueva FF, Giwercman A, Han TS, Kula K, Labrie F, Lean ME, Pendleton N, Punab M, Vanderschueren D, Huhtaniemi IT, Wu FC. Characteristics of secondary, primary, and compensated hypogonadism in aging men: evidence from the European Male Ageing Study. *J Clin Endocrinol Metab.* 2010;95(4):1810–8.
- Tapanainen JS, Aittomaki K, Min J, Vaskivuo T, Huhtaniemi IT. Men homozygous for an inactivating mutation of the follicle-stimulating hormone (FSH) receptor gene present variable suppression of spermatogenesis and fertility. *Nat Genet.* 1997;15(2):205–6.
- Ternavasio-de la Vega HG, Boronat M, Ojeda A, Garcia-Delgado Y, Angel-Moreno A, Carranza-Rodriguez C, Bellini R, Frances A, Novoa FJ, Perez-Arellano JL. Mumps orchitis in the post-vaccine era (1967-2009): a single-center series of 67 patients and review of clinical outcome and trends. *Medicine (Baltimore).* 2010;89(2):96–116.
- Themmen APN, Huhtaniemi IT. Mutations of gonadotropins and gonadotropin receptors: elucidating the physiology and pathophysiology of pituitary-gonadal function. *Endocr Rev.* 2000;21(5):551–83.
- Thomas WE, Cooper MJ, Crane GA, Lee G, Williamson RC. Testicular exocrine malfunction after torsion. *Lancet.* 1984;2(8416):1357–60.
- Toma M, McAlister FA, Coglianesi EE, Vidi V, Vasaiwala S, Bakal JA, Armstrong PW, Ezekowitz JA. Testosterone supplementation in heart failure: a meta-analysis. *Circ Heart Fail.* 2012;5(3):315–21.
- Turner AM. Noonan syndrome. *J Paediatr Child Health.* 2014;50(10):E14–20.
- Turner HE, Wass JA. Gonadal function in men with chronic illness. *Clin Endocrinol (Oxf).* 1997;47(4):379–403.
- Tuttelmann F, Laan M, Grigороva M, Punab M, Sober S, Gromoll J. Combined effects of the variants FSHB -211G > T and FSHR 2039A > G on male reproductive parameters. *J Clin Endocrinol Metab.* 2012;97(10):3639–47.
- Tuttelmann F, Damm OS, Luetjens CM, Baldi M, Zitzmann M, Kliesch S, Nieschlag E, Gromoll J, Wistuba J, Simoni M. Intratesticular testosterone is increased in men with Klinefelter syndrome and may not be released into the bloodstream owing to altered testicular vascularization- a preliminary report. *Andrology.* 2014;2(2):275–81.

- Valdes-Socin H, Salvi R, Daly AF, Gaillard RC, Quatresooz P, Tebeu PM, Pralong FP, Beckers A. Hypogonadism in a patient with a mutation in the luteinizing hormone beta-subunit gene. *N Engl J Med*. 2004;351:2619–25.
- Vinci G, Anjot MN, Trivin C, Lottmann H, Brauner R, McElreavey K. An analysis of the genetic factors involved in testicular descent in a cohort of 14 male patients with anorchia. *J Clin Endocrinol Metab*. 2004;89(12):6282–5.
- Visootsak J, Graham Jr JM. Klinefelter syndrome and other sex chromosomal aneuploidies. *Orphanet J Rare Dis*. 2006;1:42.
- Wang C, Nieschlag E, Swerdloff R, Behre HM, Hellstrom WJ, Gooren LJ, Kaufman JM, Legros JJ, Lunenfeld B, Morales A, Morley JE, Schulman C, Thompson IM, Weidner W, Wu FC. Investigation, treatment and monitoring of late-onset hypogonadism in males: ISA, ISSAM, EAU, EAA and ASA recommendations. *Eur J Endocrinol*. 2008;159(5):507–14.
- Weiss J, Axelrod L, Whitcomb RW, Harris PE, Crowley WF, Jameson JL. Hypogonadism caused by a single amino acid substitution in the beta subunit of luteinizing hormone. *N Engl J Med*. 1992;326:179–83.
- Wikstrom AM, Dunkel L. Klinefelter syndrome. *Best Pract Res Clin Endocrinol Metab*. 2011; 25(2):239–50.
- Williamson RC. Death in the scrotum: testicular torsion. *N Engl J Med*. 1977;296(6):338.
- Wood HM, Elder JS. Cryptorchidism and testicular cancer: separating fact from fiction. *J Urol*. 2009;181(2):452–61.
- Wu FC, Tajar A, Beynon JM, Pye SR, Silman AJ, Finn JD, O'Neill TW, Bartfai G, Casanueva FF, Forti G, Giwercman A, Han TS, Kula K, Lean ME, Pendleton N, Punab M, Boonen S, Vanderschueren D, Labrie F, Huhtaniemi IT. Identification of late-onset hypogonadism in middle-aged and elderly men. *N Engl J Med*. 2010;363(2):123–35.
- Yeniyol CO, Sorguc S, Minareci S, Ayder AR. Role of interferon-alpha-2B in prevention of testicular atrophy with unilateral mumps orchitis. *Urology*. 2000;55(6):931–3.
- Zentner GE, Layman WS, Martin DM, Scacheri PC. Molecular and phenotypic aspects of CHD7 mutation in CHARGE syndrome. *Am J Med Genet A*. 2010;152A(3):674–86.
- Zhu H, Gu XM, Hong J, Shen FX. Successful treatment of pituitary abscess with intravenous antibiotics: a case report and literature review. *Genet Mol Res*. 2014;13(4):10523–8.
- Zietz B, Lock G, Plach B, Drobnik W, Grossmann J, Scholmerich J, Straub RH. Dysfunction of the hypothalamic-pituitary-glandular axes and relation to Child-Pugh classification in male patients with alcoholic and virus-related cirrhosis. *Eur J Gastroenterol Hepatol*. 2003;15(5):495–501.
- Zitzmann M, Bongers R, Werler S, Bogdanova N, Wistuba J, Kliesch S, Gromoll J, Tuttmann F. Gene expression patterns in relation to the clinical phenotype in Klinefelter syndrome. *J Clin Endocrinol Metab*. 2015;100(3):E518–23.
- Zollino M, Colosimo C, Zuffardi O, Rossi E, Tosolini A, Walsh CA, Neri G. Cryptic t(1;12)(q44;p13.3) translocation in a previously described syndrome with polymicrogyria, segregating as an apparently X-linked trait. *Am J Med Genet A*. 2003;117A(1):65–71.

Nanna Kolby, Alexander S. Busch, and Anders Juul

### Abstract

Delayed puberty can be a source of great concern and anxiety, although it usually is caused by a self-limiting variant of the normal physiological timing named constitutional delay of growth and puberty (CDGP). Delayed puberty can, however, also be the first presentation of a permanent condition or a symptom of an underlying disease.

The diagnosis delayed puberty is made if there are no signs of puberty at an age corresponding to 2 SD above the population mean age at pubertal onset, often translated into 14 years in boys. Delayed puberty among boys is a frequent presentation in pediatrics. The underlying reasons for the large variation in the age at pubertal onset are not fully established; however, nutritional status and socioeconomic and environmental factors are known to be influencing, and a significant amount of influencing genetic factors have also been identified.

The challenges of diagnostic evaluation today remain in distinguishing the benign CDGP from underlying pathological causes such as hypogonadotropic hypogonadism (HH) and hypergonadotropic hypogonadism. Several techniques have been investigated for this purpose and are reviewed in this chapter; however, no single test is yet optimal in discriminating especially CDGP from HH.

Management of the delayed puberty depends on the etiology. For boys with CDGP an observational period will often reveal imminent puberty. If puberty is not progressing spontaneously, sex steroid replacement is effective in stimulating the development of secondary sexual characteristics.

---

N. Kolby (✉) • A.S. Busch • A. Juul

Department of Growth and Reproduction, Rigshospitalet, University of Copenhagen, Copenhagen Ø, Denmark

International Research and Research Training Centre in Endocrine Disruption of Male Reproduction and Child Health (EDMaRC), Rigshospitalet, University of Copenhagen, Copenhagen Ø, Denmark

e-mail: [nanna.kolby.01@regionh.dk](mailto:nanna.kolby.01@regionh.dk); [Anders.Juul@regionh.dk](mailto:Anders.Juul@regionh.dk)

Several therapy options exist for treatment of delayed puberty in boys with hypogonadism, which are reviewed in this chapter, including sex steroid replacement.

The long-term consequences of delayed puberty are both physical (e.g., reduced fertility and decreased bone mineral density) and psychological (e.g., low self-esteem) and underline the importance of careful clinical assessment of the patients.

### Keywords

Delayed puberty • Pubertas tarda • Constitutional delay of growth and puberty • Hypothalamic-pituitary-gonadal axis • Pubertal onset • Sex steroid replacement

### Abbreviations

ALL	Acute lymphoblastic leukemia
AMH	Anti-Müllerian hormone
AR	Androgen receptor
CDGP	Constitutional delay of growth and puberty
CHH	Congenital hypogonadotropic hypogonadism
CNS	Central nervous system
DHT	Dihydrotestosterone
FHH	Functional hypogonadotropic hypogonadism
FSH	Follicle-stimulating hormone
GH	Growth hormone
GnRH	Gonadotropin-releasing hormone
GWAS	Genome-wide association studies
hCG	Human chorionic gonadotropin
HH	Hypogonadotropic hypogonadism
HPG-axis	Hypothalamic-pituitary-gonadal axis
IGF-I	Insulin-like growth factor-I
IHH	Isolated/idiopathic hypogonadotropic hypogonadism
INSL3	Insulin-like factor 3
KS	Kallmann syndrome
LH	Luteinizing hormone
MPHD	Multiple pituitary hormone deficiency
SHBG	Sex hormone-binding globulin

### Contents

Introduction .....	751
Normal Variations in Pubertal Timing .....	751
The Hypothalamic-Pituitary-Gonadal (HPG) Hormone Axis .....	752
Physiological Hallmarks .....	753
Pubertal Delay .....	755
Phenotypes .....	755
Etiologies .....	757
Hypogonadotropic Hypogonadism (HH) .....	757
Hypergonadotropic Hypogonadism .....	758

Diagnostic Evaluation .....	759
Medical History .....	759
Clinical Examination .....	760
Laboratory Tests .....	760
Bone Age Examination .....	761
Endocrine Evaluation .....	762
Imaging .....	765
Genetic Testing .....	765
Long-Term Consequences of Delayed Puberty .....	765
Management .....	767
Constitutional Delay of Growth and Puberty (CDGP) .....	767
Hypogonadotropic Hypogonadism (HH) .....	768
Summary .....	769
References .....	770

---

## Introduction

Puberty is an important developmental period of life, which results in the transition from childhood to adulthood. The physiological changes in puberty ultimately lead to the attainment of adult reproductive capacity. Timing of pubertal onset exhibits a large variation in humans and the precise cause of this is not fully understood, but nutritional conditions, socioeconomic factors, environmental factors, and genetic factors play a role. Puberty does not only include prominent physiological changes but also encompasses psychological, intellectual, emotional, and sociocultural changes. Disturbed puberty may affect the future fertility of the patients and may have major influence on short- and long-term psychosocial wellbeing.

The initial clinical manifestation of puberty in boys is increase in testicular size. If there is no sign of puberty at an expected age, or if the progression stops once puberty is initiated, puberty is described as delayed. The most common cause of delayed puberty is a benign form called constitutional delay of growth and puberty (CDGP), where puberty will spontaneously occur although with a marked delay. However, more severe disorders may present with the first sign being delayed puberty, stressing the requirement for a proper diagnostic evaluation to rule out such underlying disorders. Recent investigations of the genetic background for delayed puberty have led to identification of several involved genes and a better understanding of the physiology of puberty, yet further investigations are still needed.

---

## Normal Variations in Pubertal Timing

Onset of puberty, marked by testicular enlargement in boys, approximates a Gaussian distribution, and the physiological age at pubertal onset is defined as being within two SD from the mean. The average age at pubertal onset varies between populations



and approximates 11.6 years in Danish population. The variation ( $\pm 2$  SD) around the average age at onset is usually translated to 9–14 years being the age span during which 95% of boys of European ancestry enter puberty. American studies have established a racial disparity within pubertal development that shows Afro-American boys as well as boys of Hispanic ancestry enter puberty slightly earlier than Caucasian American boys. The timing of pubertal onset is not fully understood, but based on twin studies it is estimated that genetic factors account for more than half of the phenotypic variation of pubertal timing. Genome-wide association studies (GWAS) have mapped more than a hundred genetic loci that are associated with pubertal timing. The majority of these GWAS analyses are based on data from adult women who were asked to retrospectively recall their age at menarche, and thus not directly transferable to boys. However, studies point to a largely shared genetic etiology of pubertal timing between girls and boys. To date GWAS can still only explain a limited proportion of the postulated share of this heritable trait (Day et al. 2015a).

---

## The Hypothalamic-Pituitary-Gonadal (HPG) Hormone Axis

Puberty depends on an intact hypothalamic-pituitary-gonadal (HPG) axis, where gonadotropin-releasing hormone (GnRH) from the hypothalamus reaches the anterior pituitary via the portal circulation. Here it stimulates the gonadotropic cells that constitute approximately 10% of the anterior pituitary cell population. The subsequent pituitary secretion of pituitary gonadotropins is released to the systemic circulation and has unique target cells in the gonads. The HPG-axis is regulated and activated by a complex interaction of central factors such as the neuron system of kisspeptin, neurokinin B, and dynorphin A (KNDy) in the arcuate nucleus that exerts inhibitory as well as excitatory effects on the release of GnRH.

After initial transient activation of the HPG-axis in utero, the axis is active for a brief period during the newborn's first 2–4 months, a phenomenon called mini-puberty. The HPG-axis is then silenced after the minipuberty and remains in a quiescent state during childhood. Reactivation of the HPG-axis about a decade after heralds pubertal onset. This occurs when the hypothalamic GnRH pulse generator for unknown reasons gradually starts again. This happens at the same time as levels of circulating makorin RING-finger protein 3 (MKRN3) are declining. It has therefore been proposed that MKRN3 suppresses the HPG-axis, and it is suggested as the brake responsible for the quiescent period during childhood. Recently, it has been evidenced that paternally inherited deleterious mutations in *MKRN3* “releases the brake” and results in central precocious puberty (Abreu et al. 2013).

The gonadotropins luteinizing hormone (LH) and follicle-stimulating hormone (FSH) are secreted in a pulsatile fashion with a complex diurnal variation. At the onset of puberty, FSH and LH levels are exclusively secreted in pulses at night, and frequently very low (or even undetectable) in blood samples drawn during daytime. As puberty progresses the pulsatility is extended to the daytime period and clearly detected in blood samples during daytime.

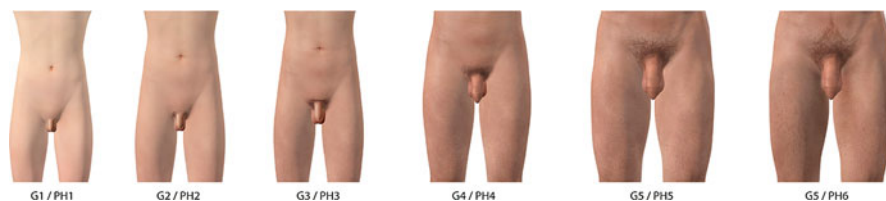In males, the primary target organs of FSH and LH are the testes. With the onset of puberty, LH stimulates the interstitial Leydig cells to produce testosterone which is present at very high intratesticular concentrations (50–100 times higher than in peripheral circulation), and secreted to the circulation. Circulating testosterone also displays diurnal variations, and at the onset of puberty testosterone increases during night only and cannot be detected in circulation in daytime. For this of reason, subtle signs of androgen actions (genital growth and pubic hair) are frequently seen in young adolescents, even when daytime testosterone levels are undetectable. The testicular Leydig cells also produce insulin-like factor 3 (INSL3) that appear to be important for the testicular descent and which may be regulated differently compared to testosterone (Bay et al. 2011). In pre- and postnatal life FSH stimulates the immature Sertoli cell pool and spermatogonia in the seminiferous tubules. The prepubertal Sertoli cells produce the glycoprotein inhibin B, which is a marker of the Sertoli cell pool (number of Sertoli cells). After puberty inhibin B appears to be secreted as a joint product of the Sertoli cell and spermatogonia. Serum inhibin B concentrations therefore are a useful clinical parameter which reflects Sertoli cell function and spermatogenesis. AMH is also secreted from the prepubertal undifferentiated Sertoli cells at very high concentrations and decline with the onset of puberty. The combined actions of high intratesticular testosterone and Sertoli cell activity induce spermatogenesis and ultimately lead to sperm production (Andersson et al. 1998; Andersson et al. 1997).

---

## Physiological Hallmarks

The pubertal changes follow a well-defined sequence, which was first described by the British professor James Tanner in 1970 (Marshall and Tanner 1970). This has led to a classification system of “Tanner-stages” which is based on a visual grading of pubertal stages that is widely used by pediatricians and endocrinologists all over the world. In boys, the first detectable sign of pubertal onset is the enlargement of the testes which is noted following testicular palpation and use of an orchidometer. When using an orchidometer in the clinic, pubertal onset is for practical reasons often defined as  $\geq 4$  ml, which in addition to penile growth is consistent with a genital stage 2 according to Tanner. The increase of testicular size is primarily due to the FSH-induced growth of the seminiferous tubules. Simultaneously, LH stimulates Leydig cells to produce testosterone that acts directly as well as after conversion to dihydrotestosterone (DHT) on the androgen receptor (AR) in external and internal genital organs. Thus, stimulation of AR induces visible signs of virilization (growth of penis and scrotum, change in texture and reddening of scrotal skin, and pubic hair development), which is reflected in the five male genital stages G1–5. Pubic hair development is also categorized in Tanner stages and usually parallels genital stages. The adult sixth pubic hair stage (PH6) is characterized by hair growth upwards along the raphe towards the umbilicus (Fig. 1).

However, pubic hair may also result from an adrenal production of androgens. The maturation of the adrenal gland (adrenarche) is independent of the HPG-axis



**Fig. 1** Genital (G1–G5) and pubic hair (PH1–6) stages in males according to Tanner. In males PH6 denotes pubic hair growth along raphe towards the umbilicus (Copyright Claus Lunau A/S and Rigshospitalet, Copenhagen)

**Table 1** Ages at physiological pubertal hallmarks

Age at	Age (years)	Reference
Testicular volume > 3 ml	11.7 (9.6–13.7) <sup>a</sup>	(Sorensen et al. 2010)
Genital stage 2	11.6 (9.4–13.8) <sup>a</sup>	(Sorensen et al. 2010)
Onset of pubertal growth	11.8 (NA)	(Aksglaede et al. 2008)
Pubic hair stage 2	12.4 (9.5–15.3) <sup>a</sup>	(Sorensen et al. 2010)
Peak height velocity	13.9 (NA)	(Mieritz et al. 2015)
Spermarche	13.8 (12.1–15.7) <sup>b</sup>	(Nielsen et al. 1986)
Voice break	14.0 (13.9–14.6) <sup>c</sup>	(Juul et al. 2007)

NA not available

Modified with permission (Tinggaard et al. 2012)

<sup>a</sup>95% prediction interval

<sup>b</sup>Range

<sup>c</sup>Confidence interval

and early presence of isolated pubic hair without testicular enlargement or other signs of virilization (e.g., increased penile size) may therefore represent premature adrenarche and thus should not be considered a valid sign of “true” pubertal onset.

The growth spurt, which is another pubertal phenomenon, is on average initiated 1 year after pubertal onset in boys. This is later than for girls, where the growth spurt is an early pubertal event. Other prominent physiological changes during puberty in boys include acne, body odor, greasy hair, growth of body and facial hair, enlargement of larynx causing voice break, and first emission of sperm (involuntary night ejaculation and voluntary ejaculation following masturbation). In addition, mood changes commonly accompany the physical changes occurring during the pubertal transition. The final attainment of adult reproductive capacity and sperm production is an important physiological hallmark (Table 1). Half of all boys develop physiological gynecomastia during the pubertal transition (usually at G3–G4), which lasts 6–12 months followed by spontaneous regression in the majority of boys. Physiological gynecomastia is considered a normal self-limiting variation, which is most likely due to a local imbalance in testosterone and estradiol in favor of estradiol at the level of the breast. Also the GH-IGF-I axis has been implicated in the development of gynecomastia.

## Pubertal Delay

Puberty is defined as delayed if there are no signs of pubertal onset at an age corresponding to or later than 2 SD above the mean age of the normal population, which corresponds to the age of approximately 14 years in boys. In pediatrics, pubertal delay is a more common presentation in boys than girls, and it mostly represents CDGP, which is an extreme variant of the normal physiological spectrum. The patients often have a family history of “late bloomers” and are likely to spontaneously enter puberty at some point. As the differential diagnoses may represent pathologic causes, including hypogonadotropic hypogonadism, CDGP is a diagnosis of exclusion.

## Phenotypes

Most boys that present with delayed puberty have a BMI in the lower part of the normal range and are characterized as being lean (small skinny boys). However, a subset of boys with CDGP may present as overweight or obese. The latter group may represent a different etiology of CDGP; however, this has not been clarified. Since the pubertal growth spurt has not occurred yet in boys with CDGP, they are usually shorter than their age-matched peers and many patients and parents are often unnecessarily concerned about final adult height. Despite the fact that CDGP is associated with short stature and decreased growth velocity, the attained adult height is often close to their target height with or without treatment (Fig. 2).

Patients with HH may on the other hand show impaired infancy growth due to lack of sex steroids in minipuberty but are often growing normally in childhood and may end up with slightly increased final height. This is due to the malfunction of the HPG-axis resulting in lack of sex steroids, which are needed for the epiphyseal fusion. Without sex steroid replacement the long bones will continue to grow and the patients will often develop characteristic physical habitus with eunuchoid body proportion, i.e., an upper-to-lower ratio less than 0.9 and arm span  $\geq 5$  cm longer than standing height. Other possible physical characteristic of HH are uni- or bilateral cryptorchidism and/or microphallus.

Midline defects such as cleft palate, anosmia, congenital heart disease, digital anomalies, renal agenesis, colorblindness, and deafness may be caused by congenital syndromes which include IHH, and should be brought to attention, as they could reveal an underlying genetic etiology.

Because puberty is a sensitive time of life, where social and psychological self-awareness develop, deviations in timing can have significant impact on short- and long-term psychosocial wellbeing. This further stresses the need to make a proper evaluation when a boy presents with delayed puberty.



## Etiologies

There can be numerous reasons for delayed puberty. The most common in males is CDGP, which is a normal variation in timing rather than an abnormal condition. CDGP occurs more often in boys than girls. The causes of CDGP are not fully understood, but there is a strong genetic basis, frequently including a family history with delayed puberty.

Although CDGP is a temporary condition rather than a medical disorder, it is, as mentioned above, a diagnosis of exclusion. The more severe differential diagnoses to CDGP include hypergonadotropic hypogonadism (e.g., sex chromosome disorders (47,XXY/46,XY) and anorchia) and hypogonadotropic hypogonadism (HH) (e.g., genetic and organic causes).

Biochemical tests are challenged in differentiating between isolated HH and CDGP, and better methods are in high demand. In both conditions it generally applies, that the HPG-axis is inactive, which results in low serum levels of FSH, LH, and testosterone.

Hypergonadotropic hypogonadism is caused by primary gonadal dysfunction, and therefore also termed primary hypogonadism, resulting in low testosterone, while FSH and LH are elevated due to feedback mechanisms (Table 2).

## Hypogonadotropic Hypogonadism (HH)

HH is characterized by absent gonadotropins and subsequently lack of testicular testosterone production. The deficiency of gonadotropins may be caused by errors at the hypothalamic and/or the pituitary level.

Tumors, hemochromatosis, and infiltrative diseases affecting the central nervous system (CNS) are known to cause HH. Likewise can sequelae from intracranial surgery or brain radiation lead to deficiency of gonadotropin-releasing hormone (GnRH) and/or pituitary gonadotropins FSH and LH. HH may occur as an isolated entity but is frequently part of a multiple pituitary hormone deficiency (MPHD) when there is an organic background.

In addition, a number of genetic abnormalities and single gene mutations have been identified in patients with isolated HH as well as in patients with MPHD.

The condition is often divided into congenital hypogonadotropic hypogonadism (CHH) and acquired functional hypogonadotropic hypogonadism (FHH) on the basis of different etiologies.

## Congenital Hypogonadotropic Hypogonadism (CHH)

The classical form of CHH is termed “Kallmann syndrome,” and is due to a mutation in the gene *ANOS1* (formerly known as *KALI*) which leads to an abnormal embryonic migration of the GnRH-synthesizing neurons. *ANOS1* codes for the protein anosmin-1, which has a permissive role in olfactory bulb development, GnRH-neuronal migration, and axonal growth, and mutations in *ANOS1* therefore not only cause GnRH-deficiencies but also anosmia (loss of the ability to smell).

However, mutations in *FGFR1*, *PROK2*, and *PROKR2*, which are likewise involved in migration of GnRH-synthesizing neurons around the olfactory bulb, are also responsible for some Kallmann syndrome cases, though sometimes leading to IHH with normosmia or hyposmia. Kallmann syndrome is seen in 1 out of 10,000 men, and it affects men four times more than women. Accompanying clinical features to Kallmann syndrome may include renal agenesis, color blindness, deafness, digital anomalies, synkinesia, and cleft palate.

Investigations of the genetics in patients with CHH have led to better understanding of the complicated GnRH-pulse regulation, and other genetic mutation in genes that regulate the GnRH-signals and secretion have been identified, including *TAC3*, *TAC3R*, and *KISS1*. These genes encode peptides that in addition to dynorphin A often are referred to as KNDy. KNDy are involved in a complicated interaction that brakes and promote the secretion of GnRH.

Mutations in genes coding for transcriptions factors involved in pituitary development have also been identified, e.g., *SOX2*, *SOX3*, *PROPI*, *LHX3* and *LHX4*. Mutation in any of them will cause normosmic IHH or combined pituitary hormone deficiency. The list of single gene mutations identified continues to grow, including genes involved in any part of the HPG-axis, such as LH, FSH, and GnRHR.

### **Functional Hypogonadotropic Hypogonadism (FHH)**

Any severe systemic or chronic illness commonly results in delayed maturing of the HPG-axis and the condition is called FHH. The condition depends on the primary illness and can be reversible if this disease is treated. Excessive exercise and/or eating disorders like anorexia nervosa (orthorexia) also impair hypothalamic GnRH secretion resulting in FHH.

### **Hypergonadotropic Hypogonadism**

Hypergonadotropic hypogonadism (primary hypogonadism) may be congenital or acquired.

Primary hypogonadism due to severe bilateral cryptorchidism or anorchia (vanishing testes) are well-known etiologies. Sex chromosome anomalies like Klinefelter syndrome (47,XXY) is the most common cause of hypergonadotropic hypogonadism affecting 1–2 out of 1000 newborn boys, and also rare conditions like SRY-positive 46XX-male syndrome or 45X/46XY gonadal dysgenesis are known to cause primary testicular failure. These patients experience a severe atrophy of seminiferous tubules, which is accompanied by a sudden decline in circulating inhibin B and an increase in FSH during puberty. Puberty usually starts at the expected time, but often displays insufficient virilization or progress slowly. The destruction of the seminiferous tubules leads to persistently small testicular volumes (often between 1–3 ml in adulthood).

Other etiologies behind primary gonadal dysfunction include testicular trauma. Finally, improved survival rates of childhood cancers have resulted in more cancer survivors who may suffer from hypergonadotropic hypogonadism with testosterone

**Table 2** Causes of delayed puberty (Data extracted from (Lawaetz et al. 2015) with permission)

	Frequency (%)	Examples	
<b>Constitutional delay in growth and puberty/CDGP</b>	<b>62.5</b>	Extreme end of normal puberty, often family history of CDGP	Quiescent HPG-axis ↓FSH, ↓LH, ↓testosterone
<b>Hypogonadotropic hypogonadism/HH</b>	<b>36.8</b>		
Isolated hypogonadotropic hypogonadism/IHH	4.7	Due to hypothalamic or pituitary failure/damage, for instance, chemo- or radiotherapy, tumor or other infiltrative diseases of the CNS, congenital abnormalities, Kallmann syndrome, and others	↓FSH, ↓LH, ↓testosterone
Functional hypogonadotropic hypogonadism/FHH	32.1	Due to primary chronic or systemic illness, excessive exercise or malnutrition. Examples include asthma, chronic renal failure, inflammatory bowel disease, celiac disease, anorexia nervosa	Delayed maturing of the HPG-axis ↓FSH, ↓LH, ↓testosterone
<b>Hypergonadotropic hypogonadism</b>	<b>0.7</b>	Lack of testes (anorchia), gonadal dysfunction due to chemo- or radiotherapy, bilateral cryptorchidism, trauma to testis, sex chromosomal anomalies like (45X/46XY) or Klinefelter syndrome (47XXY)	↑FSH, ↑LH, ↓testosterone

deficiency as well as oligozoospermia or azoospermia due to testicular radiation or alkylating chemotherapy (Kenney et al. 2012) (Table 2).

## Diagnostic Evaluation

Diagnostic evaluation includes a comprehensive medical history and a careful assessment when a boy has not entered puberty at the age of 14 years, or if progression of puberty has stopped. The assessment should always start by searching for early pubertal signs, i.e., testicular enlargement, which could be unnoticed to the patient. Such positive findings of initiated puberty should lead to reassurance and avoidance of unnecessary investigations.

## Medical History

A family history of “late bloomers” is often seen in CDGP, and it is important to include and focus on parents (and if any siblings) pubertal timing. Family members with delayed puberty that spontaneously entered puberty strongly suggest CDGP. Any chronic condition (like asthma) and/or medication (e.g., glucocorticoids) should



be recorded. Previous illness that can cause damage to the HPG-axis, including oncological treatments, intracranial surgery, or radiation should be noted. This also includes focus on previous gonadal damage (cryptorchidism, gonadal radiation, or gonadotoxic chemotherapy). Likewise questioning on previous possible testicular events like trauma or orchitis is important.

## Clinical Examination

Auxological measurements are important in the clinical examination, including height, weight, and calculated BMI. Longitudinal height assessment will reveal the typical growth pattern with a marked growth deceleration immediately prior to pubertal onset (the preadolescent “dip”). Frequently, parents to a boy who present with CDGP report that “he has almost not grown for a year.”

Inspection of the genitals and palpation of testicular volume by orchidometry.

The Tanner classification system is commonly used when evaluating the pubertal stage, but the system does not perceive if progression of puberty stops. Pubertal arrest, or slow pubertal progression, is an important recognition since it is more likely to be pathological than just constitutional delay. By using developed pubertal stage line diagrams that transform the Tanner stages into more continuous puberty SD scores such recognitions can be visualized. These diagrams assign delayed puberty in a boy when his genital stage is  $< -2$  SD for age, instead of the traditionally diagnostic definition of delayed puberty as genital stage 1 at age  $\geq 14$  years. When implemented, the stage line diagram allows the clinician to assess the onset of puberty and furthermore, it allows evaluation of the pubertal progression at any time during pubertal development (Fig. 3).

Neurological symptoms of any form prompt an exploration of the visual fields. Hyposmia or anosmia advocates for genetic investigation for Kallmann syndrome and sense of smell can be explored with sniffin’ sticks. Other dysmorphic features such as cleft palate, deafness, or color blindness could indicate genetic causes and should also be in focus during the clinical examination.

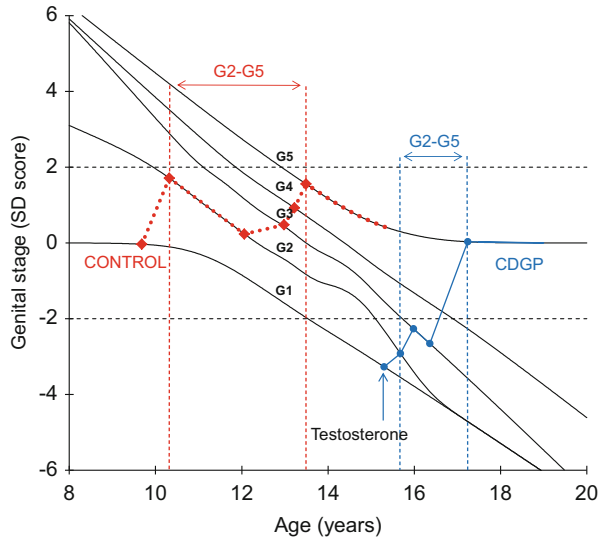
## Laboratory Tests

Baseline hormonal levels of FSH, LH, testosterone, and sex hormone-binding globulin (SHBG) can be used to point to the underlying cause of the delayed puberty. Low levels of gonadotropins combined with low levels of testosterone indicate a nonactive HPG-axis and can be caused by HH (including FHH) or by delayed activation of the HPG-axis as seen in CDGP.

Elevated levels of gonadotropins and low or undetectable levels of testosterone, i.e., hypergonadotropic hypogonadism, indicate gonadal dysfunction and fit any history of possible damage to the testes. Karyotyping for genetic mutations should be considered in such cases.

A variety of additional blood tests can be obtained to assess the disturbed puberty. Virtually any chronic diseases can influence pubertal onset, however of special

**Fig. 3** Stage line diagram built on data from Danish boys with normal pubertal development (Lawaetz et al. 2015). Examples show a healthy boy with normal pubertal onset and progression (*red squares and dashed line*) in comparison to a boy with CDGP (*blue circle and solid line*), who shows markedly delayed pubertal onset ( $-3$  SD), but rapidly progression through puberty when treated with testosterone



interest should be thyroid diseases and inflammatory bowel diseases as they tend to be the most frequent underlying conditions (Sedlmeyer and Palmert 2002).

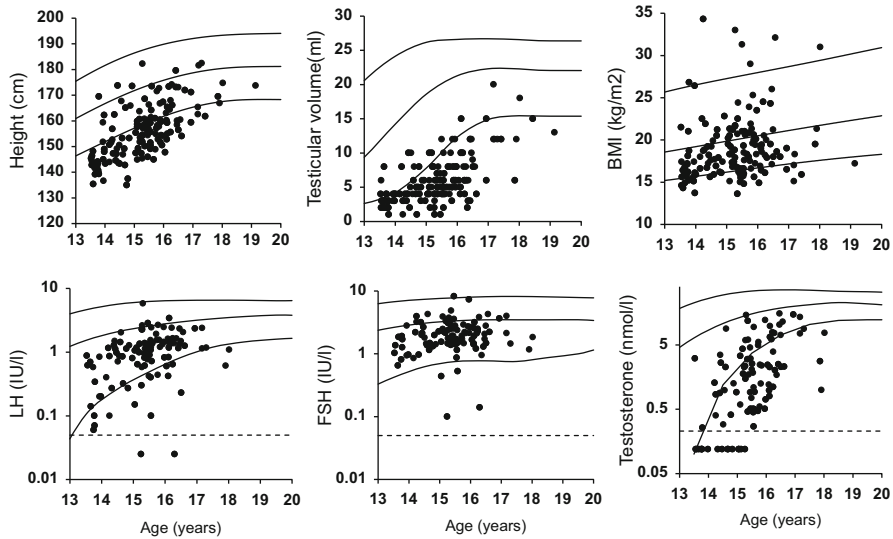
The production of insulin-like growth factor-I (IGF-I) is stimulated by growth hormone (GH) and synthesized in the liver, but in a state of malnutrition the production of IGF-I is inhibited due to acquired GH resistance. Measurement of IGF-I is relevant to evaluate possible GH deficiency but is also influenced by sex steroids and nutritional status. Serum IGF-I will usually be below the age-related normal ranges in boys with pubertal delay but appear appropriate for bone age. It is important to follow up on a subnormal IGF-I ( $< -2$  SD for age) and make sure that it increases in to the normal range during spontaneous or testosterone-induced puberty. Otherwise, pituitary testing should be performed to rule out GH deficiency.

More severe conditions such as renal and liver diseases and oncological diseases such as acute lymphoblastic leukemia (ALL) and Hodgkin's should also be considered, when no other cause is found.

The biochemical evaluation can therefore include a broad range of blood tests at least including FSH, LH, testosterone, SHBG, estradiol, inhibin B, AMH, full blood count, inflammatory markers, prolactin, IGF-I, TSH, T3, T4, Vitamin D, PTH, creatinine, sodium, potassium, calcium, phosphate, albumin, ALT, AST, ALP, and bilirubin (Fig. 4).

## Bone Age Examination

An x-ray of the left hand and wrist can establish the bone age, which does not always match the biological age. The bone age is useful for predicting final height, which can be of great importance to the patient, especially if he presents with short stature.



**Fig. 4** Baseline auxological and biochemical observations in a large cohort of 178 boys with CDGP. *Upper panels* illustrate height, testicular volume, and body mass index (*BMI*) according to chronological age and age-related references. Heights were subnormal for age in the majority of patients, whereas *BMI* were low-normal or subnormal for age. Note that a small subset of CDGP boys present with average height and high *BMI* (formerly described as “*Syndroma adiposogenitalis*”). *Lower panels* illustrate baseline LH, FSH, and testosterone serum concentrations in boys with CDGP according to age and age-related reference ranges (Lawaetz et al. 2015). Note the logarithmic Y axes. Dotted lines represent detection limits (*dL*) of the ultrasensitive hormone assays. Values below *dL* are assigned a value of *dL*/2

Bone age can be read by automated techniques, which allow a more precise and standardized interpretation. Retarded bone age is common but not diagnostic for CDGP, and may also occur in HH, growth hormone deficiency, chronic diseases, and hypothyroidism.

## Endocrine Evaluation

Basal hormone levels easily differentiate hypergonadotropic hypogonadism from HH and CDGP. However, the resemblance of the gonadotropin levels between the two latter makes it diagnostically challenging to separate them. FSH and LH are low in CDGP due to a still immature HPG-axis, whereas FSH and LH are low in IHH because of an upstream impediment. Accurate diagnosis is of importance, since prognosis, clinical counseling, and management vary between CDGP and HH.

Even though many attempts have been made in order to develop a discriminatory test to distinguish CDGP from HH at an early age, the final diagnosis is based on the presence or absence of pubertal development by 18 years of age. The investigated tests include measurement of basal FSH, LH, testosterone, estradiol, SHBG,

inhibin B, AMH and INSL3, GnRH stimulation tests, GnRH analog stimulation tests, and human chorionic gonadotropin (hCG) stimulation tests. No test has yet shown 100% diagnostic accuracy and validation of the more promising test is still needed.

### **Inhibin B Measurement**

One attempt to help establish prognosis to whether a boy will enter puberty spontaneously is to measure inhibin B. Inhibin B reflects spermatogenesis and the number and activity of the Sertoli cells in the testes. The proliferation of the Sertoli cells is FSH-dependent and begins prenatally and again during the neonatal phase. After this phase it is quiescent until the gonadotropin levels surge during early puberty. Boys with impaired hypothalamic GnRH secretion, such as in IHH and Kallmann syndrome, should theoretically not have had any activity prenatally and in the neonatal phase and thus should have lower levels of inhibin B than prepubertal boys with intact HPG-axes. The inhibin B analysis seems to withhold a promising potential, being a simple single test, but further comparative studies are needed to verify the discriminatory value.

### **AMH Measurement**

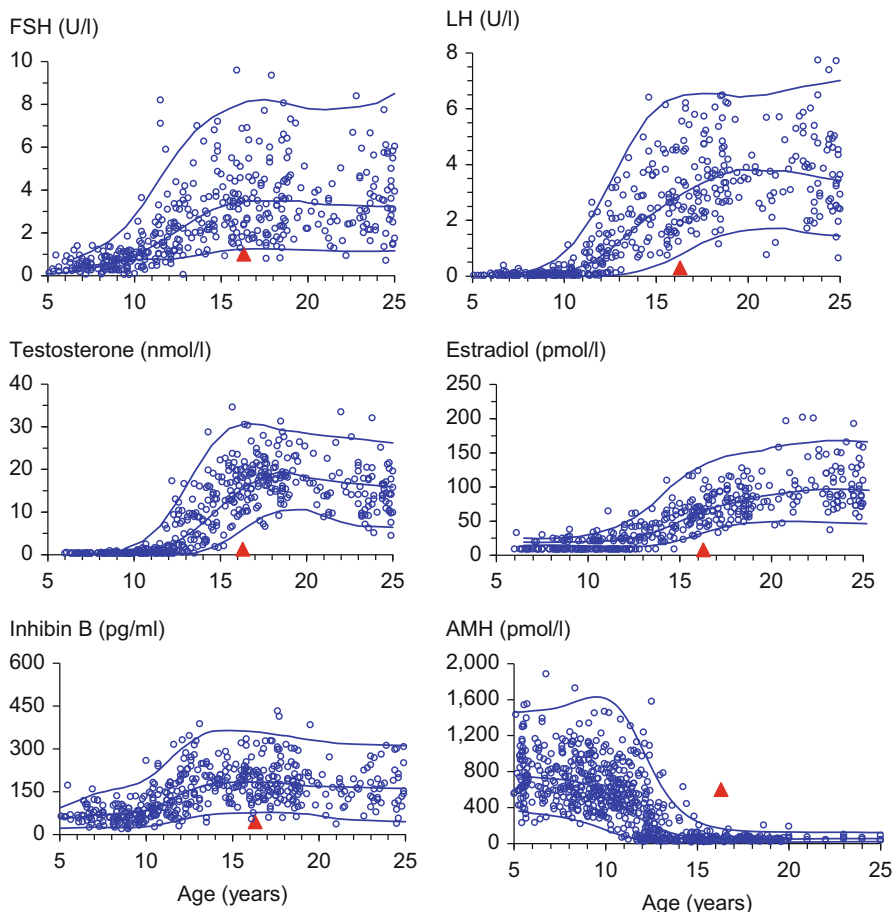
Another potential marker is AMH, which is expressed in the Sertoli cells. AMH causes the irreversible regression of the Müllerian ducts during the male embryogenesis and thus prevents the differentiation of the uterus and fallopian tubes. The embryogenic AMH is independent of the HPG-axis; however, during the neonatal period FSH stimulates the AMH production. Testosterone exerts negative feedback on AMH. When the intratesticular levels of testosterone rises during puberty, the Sertoli cells differentiate and start to express AR, subsequently AMH decreases. Circulating levels of AMH in addition to low pubertal stage and high age could therefore be an indicator of a nonfunctioning HPG-axis; however, it cannot stand alone in discriminating between CDGP and HH (Rohayem et al. 2015).

### **INSL3 Measurement**

INSL3 is a product of the Leydig cell and reflects the Leydig cells differentiation and secretory activity. The asset of this marker is that it shows minimal diurnal fluctuations in healthy boys and measurement have been scrutinized. Preliminary results have nevertheless been disappointing in differentiating CDGP from IHH (Rohayem et al. 2015) (Fig. 5).

### **GnRH Stimulation Test**

The GnRH stimulation test is the gold standard for evaluating precocious puberty, as it allows the clinician to evaluate if the HPG-axis is activated in spite of low basal FSH and LH levels. However, the test cannot make the diagnosis of CDGP with certainty, since results are overlapping boys with IHH (Dunkel et al. 1985). In this test GnRH is injected, and stimulated levels of FSH and LH are measured before and 30 min after injection. Several studies have tried to establish a cutoff value to distinguish CDGP from IHH; however, the results of the two groups have been



**Fig. 5** An illustrative example of basal reproductive hormones in a 16.3-year-old boy with CDGP (G1, Tvol 2–3 ml) (red triangles) is shown in relation to reference ranges based on healthy boys (blue dots, lines represent mean  $\pm$  2SD) (Akslae et al. 2010)

overlapping in different studies, and the test results therefore only remains presumptive in making a diagnosis. Furthermore, drawbacks of the test are its high cost and its invasive nature that requires several venipunctures.

Many modifications of the conventional GnRH stimulation test have been investigated to optimize the differential potential, but do not appear to be superior to a standard test.

### hCG Stimulation Test

The test is based on the fact that hCG stimulates LH receptors on the testicular Leydig cells to produce testosterone. This production requires an earlier priming of the Leydig cell by gonadotropins. To differentiate between CDGP and IHH, it is hypothesized that the lifelong lack of gonadotropins in IHH would render the

testicular Leydig cells immature and unable to produce sufficient testosterone upon hCG stimulation; however, concerns have been made for this technique. The best results of this test have been seen for the longest test protocols and the test requires several injections and venipunctures. Furthermore, hCG treatment for patients with cryptorchidism have been suspected to cause germ cell inflammation and apoptosis, which obviously should lead to careful considerations about its application in diagnostic purpose (Harrington and Palmert 2012; Dunkel et al. 1997).

Although many efforts have been made, as of today still no test has proven optimal in distinguishing physiological delay and gonadotropin deficiency. Further research is needed to validate the tests that show most potential.

## Imaging

In IHH, brain MRI should be applied if GnRH deficiency is diagnosed to rule out intracranial abnormalities (tumors or other space occupying lesions), and to visualize inner ear and olfactory structures. In primary hypogonadism, abdominal MRI can be used to identify intra-abdominal testes, but laparoscopy is often needed when diagnosing anorchia.

## Genetic Testing

In primary hypogonadism, karyotyping may be useful if Klinefelter is suspected. In boys with CDGP several genetic variations (SNPs) have been identified to be associated with delayed puberty, but these are not clinically relevant at present. Patients with CDGP often reveal a family history of delayed puberty and therefore thought to have a strong genetic basis; however, it has not been possible to identify responsible genes.

In CHH and Kallmann syndrome many causative mutations in single genes have been identified. Importantly, mutations in more than one gene (oligogenic inheritance) are frequently observed. Altogether these mutations explain 30–40% of the cases (Bianco and Kaiser 2009). As the list of identified mutations and genes expands, the understanding of the physiological causes of the diseases extends. Routine genetic testing for diagnostic purpose may not have direct clinical implications for the individual patient and his management at present but is obviously important for genetic counseling (Table 3).

---

## Long-Term Consequences of Delayed Puberty

Little is known about the long-term consequences of delayed puberty. Since the boys with delayed puberty usually are healthy in other respects, their connections to the clinicians are often ended once puberty is initiated. However, in 1990 Finkelstein et al. found that men with a history of delayed puberty had increased risk of impaired

**Table 3** Diagnostic evaluation

<b>History</b>	Family history of pubertal onset
	Use of medication
	Growth charts
	General health; chronic/systemic diseases
	Gonadal impairment
	Exercise
	Nutrition
	Psychosocial wellbeing
<b>Clinical examination</b>	Palpation of testes
	Pubertal staging
	Weight, height, BMI
	Dysmorphic features
	Visual fields
	Sense of smell
<b>Laboratory test</b>	Full blood count, inflammatory markers, FSH, LH, SHBG, testosterone, prolactin, IGF-I, TSH, T3, T4, vitamin D, PTH, creatinine, sodium, potassium, calcium, phosphate, albumin, ALT, AST, ALP, bilirubin
<b>Imaging</b>	Bone age, MRI, laparoscopy
<b>Endocrine tests</b>	GnRH stimulation test, 36 h–GnRH stimulation test, GnRHa stimulation test, hCG stimulation test, insl3 measurement, inhibin B measurement, AMH measurement
<b>Genetic testing</b>	Karyotyping for specific congenital syndromes, identifying genes critical for development of the HPG-axis

bone mass and osteopenia compared to a control group of men who had undergone normal puberty. This is explained by the impact of sex steroids on the growth and development of the bones.

Self-reported delayed puberty has recently been associated with decreased semen quality and a 9% reduction in testosterone (Jensen et al. 2016). Patients with HH will have a high risk of infertility but can be treated with gonadotropins to induce spermatogenesis. If untreated, testosterone deficiency itself is associated to not only erectile dysfunction and decreased libido but also gynecomastia, decreased muscle mass, and central obesity. Self-reported late puberty has also been associated to asthma, eczema, irritable bowel disease, and poor overall health (Day et al. 2015b).

Height is often a sensitive subject since the patients are often shorter than their classmates at first presentation to the physician. However, most boys who spontaneously enter puberty end up at their target heights (or slightly below). Reassurance and realistic estimates of final height can save the patient from a lot of worry.

Other physiological effects are not established considering delayed puberty with no underlying disease.

Delayed puberty can also have great impact on psychosocial wellbeing. Poor self-esteem, extreme body concerns, social isolation, depression, and anxiety are all

associated with delayed puberty, and stress the importance of acknowledging, listening, and reassuring patients with delayed puberty that seek professional care.

---

## Management

Medical induction or progression of puberty may alleviate if the patient's psychosocial wellbeing is affected by the delay and is recommendable in situations where the patient is diagnosed with hypogonadotropic hypogonadism. The goals of treatment are to increase growth velocity, induce age-appropriate sexual maturation, and improve psychosocial wellbeing without compromising final height.

In many cases of CDGP, puberty is imminent, and the patients will often settle for reassurance and a watchful waiting strategy including a short and specified observation period. In all cases, decision of appropriate choice of treatment should be individualized to the underlying diagnosis and the patient's age, physical appearance, and mental state. Moreover, decisions regarding therapy should always be done in consultation with the patient to achieve the best possible results.

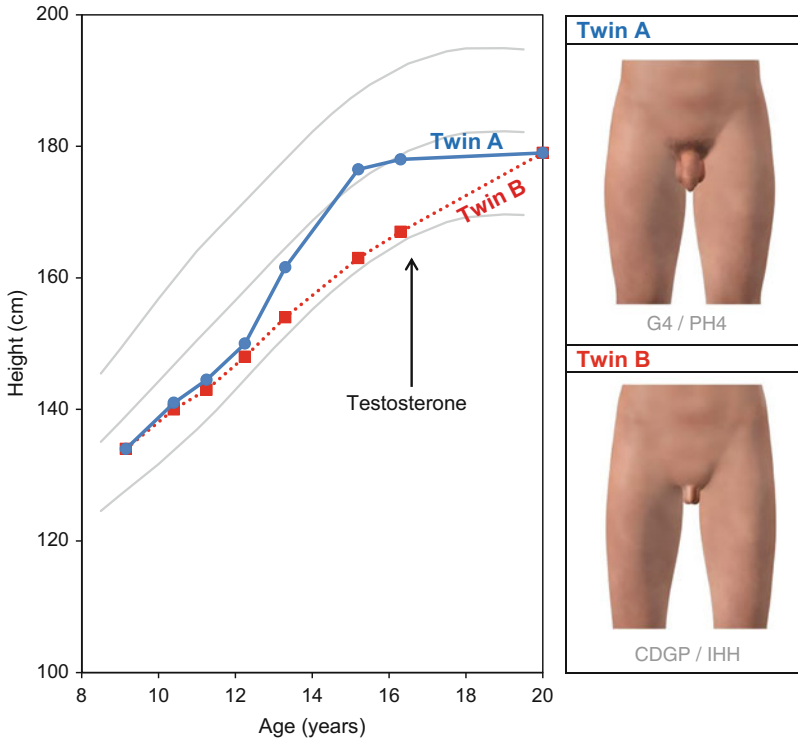
## Constitutional Delay of Growth and Puberty (CDGP)

The most commonly applied modality is to administer short course of low-dose testosterone to increase height velocity and induce virilization. Testosterone replacement can be in form of intramuscular depot injections, oral testosterone, and transdermal gels. Monthly intramuscular injections and transdermal gels are the most commonly used treatment options. Equally effective is daily oral testosterone undecanoate capsules; however, hepatic first-pass metabolism and variability in absorption can lead to irregular serum testosterone levels.

Starting dosage is determined by route of administration, most frequently used are intramuscular injections of approximately 50 mg testosterone enanthate every 4 week, gradually increasing over time depending on the individual boy's age and appearance. After 3–6 months of therapy, reassessment is often reasonable to reveal pubertal onset in the form of increasing levels of FSH, LH, and an increase in testicular volume. Fertility and testicular growth are obviously not induced by exogenous testosterone replacement and findings of such indicate spontaneous puberty (Fig. 6).

*Experimental treatments:* Aromatase inhibitors have been considered for growth therapy due to their ability to increase final height by prolonging the epiphyseal fusion. Adverse effects such as impaired development of trabecular bone and vertebral deformities have been described, thus making prepubertal growth treatment inadvisable (Hero 2016). GH treatment has also been suggested in CDGP, but data on final height are discouraging, and GH is not recommended in short statured boys with constitutional delay.





**Fig. 6** Growth charts on two identical twins presenting at 16 years of age; Twin A showing a normal pubertal development and growth spurt according to age. By contrast his identical twin (Twin B) presents completely prepubertal and his growth chart does not show any pubertal increase in height. He was diagnosed with anorchia (vanishing testes) following baseline hormone evaluation, hCG test, MRI, and laparoscopy. Testosterone treatment was initiated and increased until adult levels were reached. His final height was similar to his twin, but he had more eunuchoid body proportions, less body hair, and slight less virilized, and his face appeared younger despite 5 years of testosterone therapy (Copyright Claus Lunau A/S and Rigshospitalet, Copenhagen)

## Hypogonadotropic Hypogonadism (HH)

Patients with HH require testosterone treatment to induce and to maintain secondary sexual characteristics in adult life. The dosage should be slowly increased during puberty to mimic the physiological slowly increasing endogenous testosterone secretion over a 3–4 year period until adult levels are reached. Inexplicable reversals of idiopathic hypogonadotropic hypogonadism after sex steroid replacement have been described in 10% of IHH patients (Raivio et al. 2007) and should be closely observed.

Exogenous testosterone treatment is sufficient to induce growth and development of secondary sexual characteristics; however, the patients' lifelong lack of gonadotropins leads to equally missing testicular growth, and fertility is usually only possible by the use of more extensive treatment modalities like GnRH pulsatile

subcutaneous pump or gonadotropins (FSH and hCG). Unfortunately, treatment with gonadotropins is not only expensive but also cumbersome. To stimulate the development of the seminiferous tubules and thus inducing testicular development, intramuscular hCG injections twice weekly are needed. hCG as monotherapy can be sufficient to induce spermatogenesis especially in acquired HH, but if no sperm is present after 3–6 months of therapy, the treatment can be combined with recombinant FSH (Boehm et al. 2015). In severe CHH with small testes, FSH priming for 4 months prior to hCG stimulation has been suggested to improve outcome.

*Experimental treatments:* Treatment with FSH and hCG in infancy during mini-puberty or during puberty to induce puberty seems the most logical way of treating CHH, and the few existing studies present successful outcomes. However, standard protocols for optimal dosing strategies and outcomes are not currently available.

Promising future treatment options might exist in kisspeptin and neurokinin B analogs. This form of treatment is still in development and thus not yet applicable; however, more trials are needed to establish their merits as medications, and treatment will probably be limited to specialized use (Prague and Dhillon 2015).

---

## Summary

Puberty is a sensitive and important time of life where physiological changes lead to the transition of a child to a fertile adult. The timing of pubertal onset varies widely in humans, and the precise reason for this is not completely understood; however, nutritional status, socioeconomic factors, and environmental factors alongside genetic factors influence.

Puberty is delayed if testicular size is below 3 ml by the age of 14 years. Most often it is due to an extreme timing in the physiological spectrum and the condition is called CDGP. A well-defined sequence of physiological developments during puberty has been established. The first sign is testicular growth induced when FSH stimulates the Sertoli cells in the seminiferous tubules to induce spermatogenesis. This happens after the reemergence of the HPG-axis. Growth spurt is another pubertal event that concerns many patients as those with CDGP often are shorter than their age-matched peers.

There is often a family history of “late bloomers” among patients with CDGP indicating a strong genetic basis. More severe diagnoses such as hypergonadotropic hypogonadism and hypogonadotropic hypogonadism can also be the etiology behind delayed puberty. The latter is difficult to distinguish from CDGP, and although many attempts have been made, no endocrine test has shown superiority in doing so.

When evaluating the delayed puberty, it is important to search for any early pubertal signs, which could be unnoticed by the patient. In most cases a brief observation period can reveal the imminent puberty. However, CDGP is a diagnosis of exclusion, and a comprehensive medical history, thorough clinical examination, a range of laboratory tests, and evaluation of bone age should always be included. Long-term consequences of delayed puberty are not only psychological in the form

of depression, anxiety, and low self-esteem but also include physical sequelae such as decreased bone density and lower semen quality. Moreover, asthma, eczema, and poor overall health have been associated to delayed puberty.

Short-course testosterone replacement therapy can be administered to induce age-appropriate virilization, increase growth velocity, and improve psychosocial wellbeing. Such treatment will often lead to pubertal induction in males with CDGP.

---

## References

- Abreu AP, et al. Central precocious puberty caused by mutations in the imprinted gene MKRN3. *N Engl J Med.* 2013;368(26):2467–75.
- Akslglaede L, et al. Forty years trends in timing of pubertal growth spurt in 157,000 Danish school children. *PLoS One.* 2008;3(7):e2728.
- Akslglaede L, et al. Changes in anti-Mullerian hormone (AMH) throughout the life span: a population-based study of 1027 healthy males from birth (cord blood) to the age of 69 years. *J Clin Endocrinol Metab.* 2010; 95(12):5357–64.
- Andersson AM, et al. Serum inhibin B in healthy pubertal and adolescent boys: relation to age, stage of puberty, and follicle-stimulating hormone, luteinizing hormone, testosterone, and estradiol levels. *J Clin Endocrinol Metab.* 1997;82(12):3976–81.
- Andersson AM, et al. Longitudinal reproductive hormone profiles in infants: peak of inhibin B levels in infant boys exceeds levels in adult men. *J Clin Endocrinol Metab.* 1998;83(2):675–81.
- Bay K, et al. Testicular descent: INSL3, testosterone, genes and the intrauterine milieu. *Nat Rev Urol.* 2011;8(4):187–96.
- Bianco SD, Kaiser UB. The genetic and molecular basis of idiopathic hypogonadotropic hypogonadism. *Nat Rev Endocrinol.* 2009;5(10):569–76.
- Boehm U, et al. Expert consensus document: European Consensus Statement on congenital hypogonadotropic hypogonadism – pathogenesis, diagnosis and treatment. *Nat Rev Endocrinol.* 2015;11(9):547–64.
- Day FR, Perry JR, Ong KK. Genetic regulation of puberty timing in humans. *Neuroendocrinology.* 2015a;102(4):247–55.
- Day FR, et al. Puberty timing associated with diabetes, cardiovascular disease and also diverse health outcomes in men and women: the UK Biobank study. *Sci Rep.* 2015b;5:11208.
- Dunkel L, et al. Gonadotropin-releasing hormone test and human chorionic gonadotropin test in the diagnosis of gonadotropin deficiency in prepubertal boys. *J Pediatr.* 1985;107(3):388–92.
- Dunkel L, et al. Germ cell apoptosis after treatment of cryptorchidism with human chorionic gonadotropin is associated with impaired reproductive function in the adult. *J Clin Invest.* 1997;100(9):2341–6.
- Harrington J, Palmert MR. Clinical review: distinguishing constitutional delay of growth and puberty from isolated hypogonadotropic hypogonadism: critical appraisal of available diagnostic tests. *J Clin Endocrinol Metab.* 2012;97(9):3056–67.
- Hero M. Aromatase inhibitors in the treatment of short stature. *Endocr Dev.* 2016;30:130–40.
- Jensen TK, et al. Self-reported onset of puberty and subsequent semen quality and reproductive hormones in healthy young men. *Hum Reprod.* 2016;31(8):1886–94.
- Juul A, et al. Age at voice break in Danish boys: effects of pre-pubertal body mass index and secular trend. *Int J Androl.* 2007;30(6):537–42.
- Kenney LB, et al. Male reproductive health after childhood, adolescent, and young adult cancers: a report from the Children’s Oncology Group. *J Clin Oncol.* 2012;30(27):3408–16.
- Lawaetz JG, et al. Evaluation of 451 Danish boys with delayed puberty: diagnostic use of a new puberty nomogram and effects of oral testosterone therapy. *J Clin Endocrinol Metab.* 2015; 100(4):1376–85.

- Marshall WA, Tanner JM. Variations in the pattern of pubertal changes in boys. *Arch Dis Child*. 1970;239(45):13–25.
- Mieritz MG, et al. A longitudinal study of growth, sex steroids, and IGF-1 in boys with physiological gynecomastia. *J Clin Endocrinol Metab*. 2015;100(10):3752–9.
- Nielsen CT, et al. Onset of the release of spermatozoa (spermarche) in boys in relation to age, testicular growth, pubic hair, and height. *J Clin Endocrinol Metab*. 1986;62(3):532–5.
- Prague JK, Dhillon WS. Potential clinical use of kisspeptin. *Neuroendocrinology*. 2015;102(3):238–45.
- Raivio T, et al. Reversal of idiopathic hypogonadotropic hypogonadism. *N Engl J Med*. 2007;357(9):863–73.
- Rohayem J, et al. Inhibin B, AMH, but not INSL3, IGF1 or DHEAS support differentiation between constitutional delay of growth and puberty and hypogonadotropic hypogonadism. *Andrology*. 2015;3(5):882–7.
- Sedlmeyer IL, Palmert MR. Delayed puberty: analysis of a large case series from an academic center. *J Clin Endocrinol Metab*. 2002;87(4):1613–20.
- Sorensen K, et al. Recent changes in pubertal timing in healthy Danish boys: associations with body mass index. *J Clin Endocrinol Metab*. 2010;95(1):263–70.
- Tinggaard J, et al. The physiology and timing of male puberty. *Curr Opin Endocrinol Diabetes Obes*. 2012;19(3):197–203.

Jarmo Jääskeläinen

## Abstract

Androgen insensitivity arises from target tissue resistance to androgens. Androgen insensitivity syndrome (AIS) is the most common specific etiology of 46,XY disorder of sex development. It is a result of the failure of androgens to act via the androgen receptor. The phenotype is variable, from female phenotype in complete AIS to male phenotype with gynecomastia or infertility in minimal AIS, depending on the residual androgen receptor activity.

More than 400 different androgen receptor mutations have been reported and they have been identified in all eight exons of the gene. The treatment consists of counseling, psychosocial support, endocrine therapy, and surgery. Both hormonal substitution and timing of surgery are still controversial.

## Keywords

Androgen • Insensitivity • Resistance • Testis • Disorder of sexual development • Gonadal tumor

## Contents

Role of Androgens in the Sex Determination and Development .....	774
Androgen Insensitivity Syndrome Is a Hormone Resistance State .....	775
Historical Aspects .....	776
The Androgen Receptor .....	776
Androgen Receptor Gene Mutations in AIS .....	778
<i>AR</i> Polymorphisms and Androgen Resistance .....	779
<i>AR</i> Mutation Negative AIS .....	780
Studying Androgen Receptor Function In Vitro .....	781

J. Jääskeläinen (✉)

Institute of Clinical Medicine, Department of Pediatrics, Kuopio University Hospital and University of Eastern Finland, Kuopio, Finland

e-mail: [jarmo.jaaskelainen@kuh.fi](mailto:jarmo.jaaskelainen@kuh.fi)

Clinical Presentation of AIS .....	782
Complete Androgen Insensitivity Syndrome (CAIS) .....	782
Partial Androgen Insensitivity Syndrome (PAIS) .....	783
Diagnosis .....	783
Differential Diagnosis .....	784
Endocrine Profile in AIS .....	785
Treatment .....	785
Surgery .....	787
Hormone Replacement, Fertility, and Bone Mineral Density .....	788
Summary .....	790
Cross-References .....	790
References .....	790

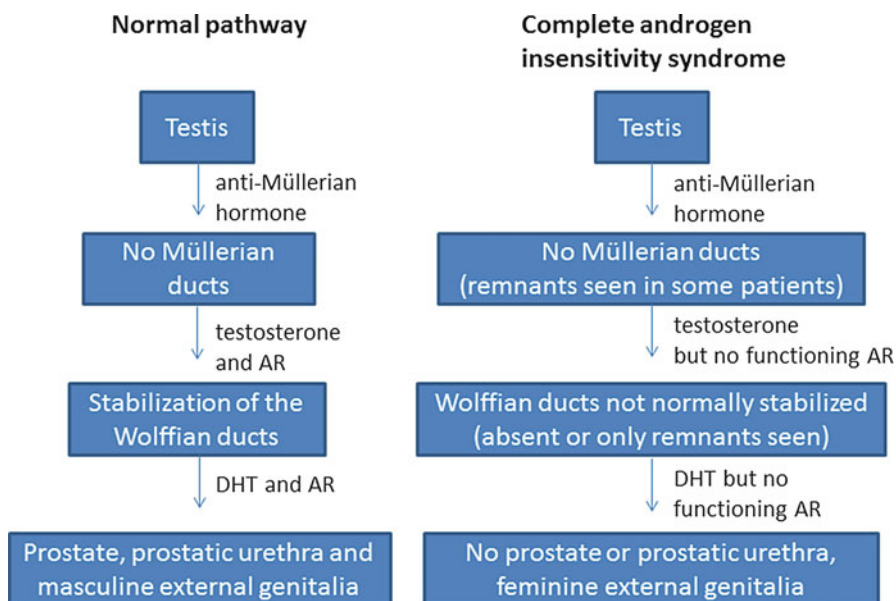
---

## Role of Androgens in the Sex Determination and Development

Androgen insensitivity syndrome (AIS) arises from target tissue resistance to androgen action. The clinical manifestations of androgen resistance vary from external genitalia that are completely female to degrees of partial masculinization. These syndromes are the most common identifiable cause of male undermasculinization, representing approximately half of all 46,XY patients with a disorder of sex development (DSD; Thyen et al. 2006).

After development of the testis which is not androgen dependent, the events of male sex differentiation involve two pathways, one inhibitory and one stimulatory (Fig. 1). The principal function of the inhibitory pathway is to cause regression of the Müllerian ducts and thus to repress the development of female internal genitalia (fallopian tubes, uterus, and upper third of the vagina). This process occurs between 6 and 8 weeks' gestation, mediated by anti-Müllerian hormone (Josso et al. 1991). The stimulatory events of male sex differentiation require high levels of androgens and a functional androgen receptor. Testosterone is critical in stabilizing the Wolffian duct system to prevent its involution and to induce differentiation into the epididymides, vasa deferentia, and seminal vesicles. Stabilization of the Wolffian ducts occurs between 9 and 13 weeks' gestation, when testosterone is secreted from the testes mostly under the control of placental chorionic gonadotropin. Dihydrotestosterone (DHT) cannot be involved in this process, as the 5 $\alpha$ -reductase enzyme which converts testosterone into DHT is not yet expressed in these tissues (Wilson et al. 1993). On the contrary, 5 $\alpha$ -reductase is expressed already at this stage of development in the prostate, prostatic urethra, and external genital primordia, and their development is DHT dependent (Imperato-McGinley et al. 1992).

Testicular descent is another critical event in male sex differentiation. This occurs in two morphologically distinct phases which are under different hormonal control from the testis (Hutson et al. 2015). During the first phase, insulin-like hormone 3 (INSL3) from the Leydig cells anchors the testis near the future inguinal canal by stimulating the gubernaculum to swell (Hutson et al. 2015; Nef and Parada 1999). In the second, inguinoscrotal phase, the gubernaculum bulges out of the inguinal region



**Fig. 1** Sexual differentiation after testicular development in normal 46,XY male and in 46,XY female with complete androgen insensitivity syndrome (CAIS)

to create the future inguinal ring and then migrates to the scrotum enabling the intraperitoneal testis to leave the abdomen while still remaining inside an extension of the peritoneum. The final event after the gubernaculum and testis reach the scrotum is closure of the proximal processus vaginalis in the human, thereby preventing inguinal hernia and/or hydrocele (Hutson et al. 2015). Androgens clearly control the inguinoscrotal phase, but the exact mechanism is not clear. In the past, it was assumed that androgens act directly on the gubernaculum, but more recent data indicate that AR does not appear in the gubernaculum during the critical inguinoscrotal phase of testicular descent (Nation et al. 2011).

## Androgen Insensitivity Syndrome Is a Hormone Resistance State

Hormone resistance is diagnosed when circulating concentrations of serum hormones are high but there is little or no clinical effect. Resistance to androgens, testosterone and its  $5\alpha$ -reduced product dihydrotestosterone (DHT), leads to androgen insensitivity syndrome (AIS). Classically, the disorder is due to a mutation in the X-linked androgen receptor which is essential for androgen action (Ahmed et al. 2000a).

AIS is the most common specific cause for 46,XY undermasculinization, but the estimates of its prevalence have varied widely, depending on the method of

ascertainment. Jagiello and Atwell estimated the prevalence of complete AIS (CAIS) as 1:62,400 males based on the prevalence of inguinal hernia in phenotypic females in London and accepting the fact that 1 in 5 patients with this syndrome do not present with an inguinal or labial swelling (Jagiello and Atwell 1962). Later, a group in Denmark reported a higher prevalence for AIS, 1:20,400 males, calculated from the number of primarily diagnosed cases with the disorder (Bangsbøll et al. 1992). In a Dutch study, which included only cases with a proven molecular diagnosis of AIS, the incidence was 1:99,000 males (Boehmer et al. 2001).

---

## Historical Aspects

There were numerous isolated case reports of individuals with probable AIS already during the 1800s and early 1900s, but Dieffenbach was the first to note the hereditary pattern of the syndrome (Dieffenbach 1912). In 1937, Pettersson and Bonnier concluded that the affected persons are genetic males. However, it was the comprehensive report of Morris in 1953, which clearly defined the androgen insensitivity syndrome (then known as testicular feminization syndrome). He recognized that this syndrome is a specific, inherited disorder, and it is the most common cause of 46,XY disorder or sex development (DSD, called then male pseudohermaphroditism). In this review of 82 AIS cases Morris specified the characteristic features of the syndrome: female habitus, breast development, and other secondary sex characteristics, absent or scanty axillary and pubic hair, female external genitalia, absence of internal female genitalia, and bilateral undescended testes with the production of estrogen and androgen. Lawson Wilkins noticed in 1950 that the pathophysiology of AIS was resistance to androgens as his affected 46,XY patient failed to show any signs of virilization in response to testosterone. In the 1960s Southern showed normal testosterone levels in affected individuals (Southern 1961), and in the 1970s the etiology of AIS became feasible at the cellular level when androgen-binding assays in genital skin fibroblasts were established (Keenan et al. 1975). The breakthrough in the understanding of the molecular pathogenesis took place in 1988 when the human AR complementary DNA was cloned (Chang et al. 1988; Lubahn et al. 1988), and already in the same year the first AR mutation associated with CAIS was reported (Brown et al. 1988).

---

## The Androgen Receptor

The androgen receptor (AR) is an intracellular transcription factor that belongs to the steroid/nuclear receptor superfamily (Evans 1988). Four of these receptors, the androgen receptor, glucocorticoid receptor, mineralocorticoid receptor, and progesterone receptor, are closely related and even have an ability to activate gene transcription via the same hormone response element. AR interacts directly with its target genes as a hormone-receptor complex and regulates their transcription.



The human *AR* gene has been localized to chromosome Xq11-12. The *AR* gene is about 90 kb long, but only about 2750 nucleotides code for an AR protein of 919 amino acid residues. The AR protein migrates during SDS-PAGE as 110 kD and 112 kD proteins, the latter representing the phosphorylated form of the AR protein (Brown et al. 1989; Chang et al. 1988; Lubahn et al. 1988). The gene is divided into eight exons, and the first exon includes two homopolymeric amino acid, polyglutamine and polyglycine, repeats which are polymorphic in length (Andrew et al. 1997; Lumbroso et al. 1999).

Like all nuclear receptors, the AR protein consists of four major functional domains: a variable N-terminal transactivation domain (NTD, encoded by exon 1), a highly conserved DNA-binding domain (DBD, encoded by exons 2 and 3), hinge region or bipartite nuclear localization signal (encoded by exons 3 and 4), and a conserved C-terminal ligand-binding domain (LBD, encoded by exons 4 to 8). In addition to their principal functions, these major domains embody subsidiary functions affecting receptor dimerization, nuclear localization, and transcriptional regulation (Brinkmann 2001). After binding of an androgen molecule to the LBD, AR rapidly translocates to the nucleus, where it directly interacts with DNA as a homodimer, at androgen response elements (ARE) found in the regulatory regions of target genes. This complex can thenceforth recruit coactivators through the ligand-dependent transactivation function (AF-2) located in the LBD and hence control transcription of specific genes. Through this mechanism, androgens such as testosterone and DHT regulate a wide range of physiological androgenic and anabolic responses, most notably male sexual differentiation and maturation including the development, growth, and maintenance of the normal prostate. The ligand structure itself determines the number of interactions it can make with the AR LBD. For example, a potent synthetic androgen tetrahydrogestrinone establishes more van der Waals contacts with the receptor than the natural androgens testosterone and DHT, whereas the geometry of the atoms forming electrostatic interactions at both extremities of the steroid nucleus seems mainly responsible for the higher affinity measured experimentally for DHT over testosterone (Pereira de Jésus-Tran et al. 2006).

In the AR N-terminal domain there are motifs that form, in part, the interface for the interaction of NTD with the LBD. These motifs interact with different regions of the LBD to stabilize the hormone-receptor complex (He et al. 2000). There also seems to be a putative interface between the AR DBD and LBD. Some LBD mutations which decrease DNA binding leave ligand binding unaffected, as well as some DBD-residing mutations which lower the ligand binding do not affect the DNA-binding affinity. Therefore it has been proposed that certain AR residues are involved in allosteric communications between the AR-DBD and AR-LBD (Helsen et al. 2012).

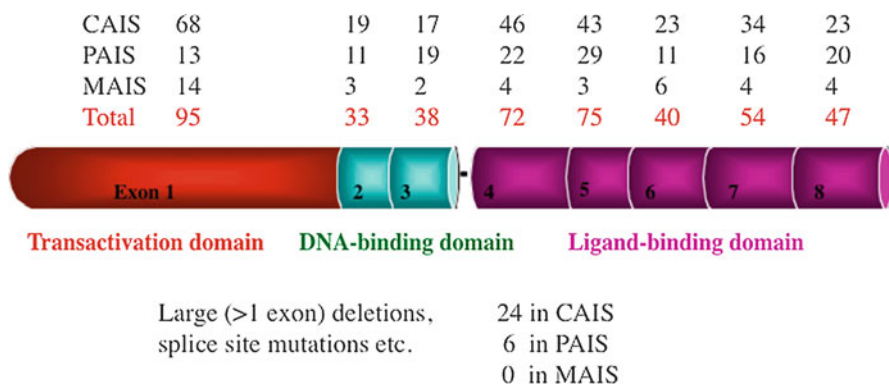
Androgen receptor is expressed in various human tissues, and AR defects have been recognized also in conditions other than AIS, such as the X-linked motor neuron disorder known as Kennedy's disease and prostate cancer.

## Androgen Receptor Gene Mutations in AIS

The rates of detected mutations in AIS have varied depending on phenotype, family history, and screening method (Ahmed et al. 2000a; Melo et al. 2003). In the largest reported Cambridge cohort, an *AR* mutation was found in 83% of the cases with CAIS. On the other hand, in PAIS, the mutation detection rate was only 28% (Ahmed et al. 2000a). In a small Brazilian study on 32 AIS patients from 20 families, the strict selection criteria, which included also family history suggestive of X-linked inheritance in prepubertal subjects and the presence of gynecomastia in postpubertal subjects, resulted in the identification of mutations in 100% of subjects with CAIS and 73% of families with PAIS (Melo et al. 2003). Thus suggestive X-linked inheritance strongly increases the likelihood of detecting an *AR* mutation also in PAIS, but in the remaining cases the etiology still remains largely unclear.

More than 400 different mutations in AIS have been reported in the androgen receptor mutations database (last updated in 2012; Gottlieb et al. 2012). Almost two thirds are missense mutations (Jääskeläinen 2012). About a quarter are nonsense point mutations, small deletions, or insertions leading to a premature stop codon. Intron splice site mutations and large deletions spanning several exons cover less than 10% of all the reported mutations. Most detected mutations have been identified in patients with CAIS (Fig. 2, Jääskeläinen 2012).

More than half of all *AR* mutations are located in the LBD, and a majority of these are missense mutations (Gottlieb et al. 2012). These mutations include the amino acid residues that line the AR ligand-binding pocket. Other clusters are located at the activation function 2, a regulatory surface cleft termed binding function 3, and a region that tethers the C-terminal tail of the receptor (Estébanez-Perpiñá et al. 2007; Tahiri et al. 2001). The mechanisms by which the LBD mutants disrupt AR signaling are not only diminished ligand binding but include also disturbed interaction with the



**Fig. 2** Distribution and number of different androgen receptor *AR* gene mutations in different forms of AIS. *CAIS* complete AIS, *PAIS* partial AIS, *MAIS* mild AIS

cofactors, transactivation domain, or DNA-binding domain (Ghali et al. 2003; Helsen et al. 2012; Jääskeläinen et al. 2006; Thompson et al. 2001).

The proportion of detected and reported mutations in the N-terminal transactivation domain (encoded by exon 1) has increased recently, and the past very low detection rates most likely reflect challenges in sequencing this GC-rich exon. Indeed, in a recent report on patients with CAIS, the mutation rate in exon 1 was already somewhat higher (27%) than previously reported (Philibert et al. 2010). Most exon 1 mutations lead to a premature stop codon (associated with CAIS) and less than a third are missense mutations, mostly associated with PAIS or MAIS (Jääskeläinen 2012).

About 15% of all detected AR mutations lie within the DBD encoded by exons 2 and 3, and only a few mutations in AR hinge region (codons 628–669, between DBD and LBD) have been reported (Jääskeläinen 2012).

Not all AR mutations are inherited: 30% of all detected mutations are de novo mutations, and there is evidence that every third de novo mutation may have occurred at a postzygotic stage leading to a somatic mutation (Hiort et al. 1998).

The phenotype may vary with identical genotypes. The androgen receptor mutations database includes about 50 cases where an identical AR mutation is associated with significant phenotypic diversity. Identical mutations have been associated with different PAIS phenotypes even in the same kindred, and siblings with the same AR mutation have been assigned a different sex of rearing (Batch et al. 1993). Phenotypic variability may be due to somatic mosaicism (Holterhus et al. 1997) or to variable expression of other genes necessary for androgen biosynthesis and metabolism (such as 5 $\alpha$ -reductase) (Boehmer et al. 2001).

## AR Polymorphisms and Androgen Resistance

There are two polymorphic trinucleotide repeat segments in the AR NH<sub>2</sub>-terminal domain of the receptor, (CAG)<sub>n</sub> encoding a polyglutamine and (GGN)<sub>n</sub> encoding a polyglycine repeat segment, respectively (Lubahn et al. 1988; Chang et al. 1988). The length of CAG repeats varies from nine to 36 in normal population (Andrew et al. 1997). When this region is  $\geq 38$  repeats in length, it may lead to reduced virilization, defective spermatogenesis, and spinal bulbar muscular atrophy (SBMA), known also as Kennedy's disease (La Spada et al. 1991).

Downstream of the CAG<sub>n</sub> repeat polymorphism is located the GGN repeat region, represented by (GGT)<sub>3</sub>GGG(GGT)<sub>2</sub>(GGC)<sub>n</sub> with n varying from 10 to 35. In AIS, these two polymorphisms may modulate the phenotypic expression of a given AR mutant in affected individuals (Werner et al. 2006; Rajender et al. 2008). Furthermore, AR CAG repeat length may contribute to the causation of androgen-related genital abnormalities with multifactorial etiology, including hypospadias (Huang et al. 2015; Lim et al. 2001). When within the normal length range neither (CAG)<sub>n</sub> nor (GGN)<sub>n</sub> are single causative factors for AIS, but they have been

associated with male infertility or serum testosterone concentrations. In 1994, Chamberlain et al. reported that AR function is reduced in vitro by increasing the length of CAG repeat. More recently, a Swedish study showed also a nonlinear association: median CAG lengths (22–23 repeats) resulted in higher AR-mediated transcription than longer and shorter repeats (Nenonen et al. 2011).

Numerous reports on *AR* CAG repeats and infertility have been published thereafter, and the results are divergent. The strongest evidence on the association of CAG repeat length with infertility comes from three meta-analyses (Davis-Dao et al. 2007; Nenonen et al. 2010; Pan et al. 2016). The first meta-analysis included a case group with infertility as measured by semen parameters and a control group of known or presumed fertile men, and measurement of CAG repeat lengths among cases and controls (Davis-Dao et al. 2007). In this meta-analysis, infertile men were shown to have 0.19 repeat longer CAG stretches than fertile men, and a similar pattern was found in the most recent meta-analysis (Pan et al. 2016). However, Nenonen et al. found in 2010 that  $CAG < 22$  and  $CAG > 23$  had 20% increased odds ratio of infertility compared with carriers of the median lengths (22–23 CAG repeats). These results suggest that an alternative model to a linear one for the genotype–phenotype association in relation to *AR* CAG<sub>n</sub> is likely, as lengths close to the median confine lowest risk of infertility.

*AR* CAG repeats have also been associated with serum testosterone concentrations in some studies. In a multinational prospective study on aging European men the *AR* CAG repeat length correlated significantly with serum testosterone and estradiol, and the phenotypic effects of long CAG repeats were merely due to increased estrogen than suppressed androgen activity (Huhtaniemi et al. 2009).

The functional effect of the GGN polymorphism on the AR function remains unclear as there are discrepancies between in vitro studies in various cell cultures (Brockschmidt et al. 2007; Lundin et al. 2007). The association of *AR* GGN with male infertility and testosterone production is also unclear (Akinloye et al. 2009). Some studies have found no association, but in a study on healthy adolescent Swedish men GGN repeat length  $< 23$  was associated with lower semen volume when compared to a longer repeat length (Lundin et al. 2006).

## **AR Mutation Negative AIS**

No other genetically proven mechanism than the mutated *AR* has been shown for AIS. Theoretically such a mechanism could be a coactivator defect. New et al. reported two sisters who were resistant to several steroids, including androgens (New et al. 2001). Also, one subject with CAIS has been reported, in whom the transmission of the activation signal from the AF1 region was disrupted but no mutation was found in the AR gene suggesting that a coactivator interacting with this region was lacking in this patient (Adachi et al. 2000). However, no proven molecular defect in any coactivator has been found in any AIS patient. Next generation sequencing should therefore be considered for an AIS patient with no detected mutation in the *AR*.

One interesting observation is that an *AR* mutation is very unlikely in a patient with a PAIS-like phenotype having a low birth weight (Lek et al. 2014). This combination may reveal a novel genetic etiology for PAIS.

## Studying Androgen Receptor Function In Vitro

The effect of the identified mutation on androgen receptor-dependent transactivation is the most used AR functional assay. The AR expressing plasmid (either normal or mutated) is transfected into a mammalian cell line (which itself does not express AR) together with a hormone response element in construct with a suitable reporter vector. The transfected cells are then incubated with the ligand, and thereafter the reporter activity is assayed.

Another functional assay is studying interaction between the AR amino- and carboxylterminal domains (N/C interaction assay based on reporter gene activation in a mammalian two-hybrid assay; He et al. 2000). Following hormone binding, helix 12 in the ligand-binding domain (LDB) undergoes conformational changes and seals the LBD. Thereby, a binding groove on the surface of the LBD is formed, called activation function 2 (AF2), which is a binding site for coactivators harboring LxxLL or FxxLF motifs. This AF2 also shows a strong inter- and intramolecular interaction with the FQNLF motif of the N-terminal domain (NTD). The N/C interaction appears to further stabilize helix 12 and bound androgen (He et al. 2006). Missense mutations found in the AR-LBD that reveal near-normal androgen-binding kinetics may display disrupted N/C-interaction, and the decreased N/C-interaction has been shown to mirror the degree of AIS (Jääskeläinen et al. 2006).

Missense mutations in the DBD may lead to a complete disruption of AR binding to AREs associated with CAIS or only to an altered affinity and selectivity of AR–androgen response element interactions associated with PAIS or MAIS. The reduced or absent DNA binding can be demonstrated by electrophoretic mobility-shift assays (EMSAs) or by fluorescence recovery following photobleaching (FRAP) experiments, comparing cells transfected with green fluorescent protein-tagged mutant and wild-type AR (Farla et al. 2004).

Studies of androgen binding in cultured genital skin fibroblasts have been utilized for the diagnosis of AIS for many years and elucidated the cause of AIS at the cellular level in many cases. A 2–3 mm genital skin biopsy intended for androgen receptor studies can be taken under local anesthetic from the labia which contains preferential expression of androgen receptor. Alternatively, skin from the prepuce or labioscrotal folds can be obtained at the time of surgery. After culturing an adequate number of cells, which takes a minimum of 6–8 weeks, the cells are incubated with a radiolabelled androgen (like DHT or mibolerone) in the presence or absence of an excess of the nonradiolabeled ligand. Several parameters (maximal ligand-binding capacity, ligand dissociation constant, thermolability) can then be measured (Griffin et al. 1976).

## Clinical Presentation of AIS

### Complete Androgen Insensitivity Syndrome (CAIS)

Complete androgen insensitivity syndrome (CAIS) is the classical manifestation of AIS. By definition, there are no visible clinical signs of androgen action and the subjects with CAIS are born with normal female external genitalia, though the clitoris, labia minora, and labia majora may be underdeveloped. If prenatal examinations are performed, CAIS can be suspected already prenatally, when the karyotype (46,XY) of the fetus does not match with the female phenotypic sex. The birth size of CAIS patients is on average the same as that of healthy male infants, suggesting that factors on the Y chromosome rather than exposure to prenatal androgens explain the sex dimorphism (Miles et al. 2010). After birth, most subjects (up to 76%) are diagnosed early when inguinal hernias or inguinal or labial swellings in an apparently female infant are discovered to contain testes (Viner et al. 1997). All in all, inguinal hernias have been reported to be present in 90% of patients with CAIS, and in most cases hernias are bilateral (Viner et al. 1997). Estimates of the incidence of AIS in female infants with hernias have ranged from 1–2%, suggesting that any girl with an inguinal hernia should have a karyotype performed or CAIS otherwise excluded (Jagiello and Atwell 1962; Pergament and Heimler 1973). Girls with CAIS have a shorter vaginal length than healthy girls, and in ultrasonography no ovaries, fallopian tubes, or uterus can be seen (Hurme et al. 2009). In some patients, however, rudimentary segments of the Müllerian ducts are present (Nichols et al. 2009). Wolffian duct differentiation is testosterone dependent, and these patients should lack vasa deferentia, epididymides, seminal vesicles, and ejaculatory ducts. However, some phenotypic CAIS patients have Wolffian ducts, explained by minor residual activity of the mutant AR which is capable of responding to high local testosterone concentrations during early development (Hannema et al. 2004). Testicular descent occurs to some extent in individuals with AIS, and the testes can be located anywhere along the pathway from the lower abdomen to the scrotum. Many subjects with CAIS are not suspected of having the diagnosis until the onset of puberty, when breast development is normal (due to abundant conversion of androgens to estrogens by P450 aromatase), but pubic and axillary hair development is not, and menarche, initially considered late, never occurs. Some affected individuals develop normal female sexual hair at puberty, and even more CAIS patients have some fine, silky pubic hair (Tanner 2), developing under the influence of factors other than AR action (Boehmer et al. 2001; Wisniewski et al. 2000). If not diagnosed by this time, CAIS can first present after puberty as a gonadal tumor (Manuel et al. 1976). The physical appearance is generally feminine, and affected individuals have mostly a feminine body image and sexual orientation (Wisniewski et al. 2000). However, some recent reports indicate that less feminine gender roles and “not exclusively androphile sexual orientation” are more common in CAIS than previously thought (Brunner et al. 2016). Adult height is between healthy males and females (Varrela et al. 1984; Zachmann et al. 1986). The enlarged adult stature in the

syndrome is thought to be mainly due to the effect of the growth-controlling region on the long arm of the Y chromosome, but genome-wide association studies have identified several other loci that affect adult height (Lango Allen et al. 2010).

## Partial Androgen Insensitivity Syndrome (PAIS)

The partial androgen insensitivity syndrome (PAIS) includes a broad spectrum of male undermasculinization. In the most severe form of PAIS, the external genitalia are nearly normal female, except for clitoromegaly and/or posterior labial fusion. At the other extreme, the genitalia may be morphologically normal male, though small, or there may be simple coronal hypospadias or a prominent midline raphe of the scrotum (Ahmed et al. 2000a).

Subjects with the mildest phenotypic form of AIS, also called minimal AIS (MAIS), are born with normal male external genitalia. At puberty, MAIS takes two phenotypic forms. In one, spermatogenesis and fertility are impaired; in the other, spermatogenesis is normal or sufficient to preserve fertility. In both, gynecomastia, high-pitched voice, sparse sex hair, and erectile dysfunction may be noted (Migeon et al. 1984; Pinsky et al. 1989).

---

## Diagnosis

The diagnosis of AIS is based on clinical findings, endocrine evaluation, and family history. The diagnostic criteria for AIS include:

1. 46,XY karyotype
2. Presence of testes with histology showing testicular differentiation
3. Normal testosterone production and metabolism
4. Absence of Müllerian ducts (remnants may be present in some individuals)
5. Undermasculinized external genitalia

Additional criteria for CAIS include:

6. Normal female external genitalia
7. Spontaneous feminization (but no menses) at puberty before gonadectomy with no virilization despite normal or high male levels of testosterone

Strict criteria for AIS include also an identified mutation in the AR gene; this is relevant especially in the case of PAIS (Mongan et al. 2015; Viner et al. 1997; Zachmann et al. 1986).

A complete diagnostic evaluation thus includes karyotype analysis, pelvic ultrasonography, basal and human chorionic gonadotropin (hCG) stimulated serum testosterone, DHT, and androstenedione, as well as basal and gonadotropin releasing-hormone (GnRH) stimulated serum luteinizing (LH) and follicle-stimulating

hormone (FSH) concentrations. Gonadal biopsy is valuable in the differential diagnosis; gonads of a patient with AIS usually show normal testicular differentiation, unlike the situation in gonadal dysgenesis.

Mutational analysis by automated sequencing is the best tool to confirm the diagnosis.

A genital skin fibroblast culture is useful when mutational analysis remains negative. Fibroblasts can be used to identify genomic mutations that disrupt normal RNA splicing, to quantify androgen binding, AR expression, and expression of androgen-dependent gene expression patterns (Holterhus et al. 2007).

An androgen sensitivity test was described on the basis of the response of serum levels of sex hormone-binding globulin (SHBG) following intake of stanozolol, which is a synthetic anabolic steroid. In healthy individuals, serum levels of SHBG decline to about 50% during 5–8 days of treatment with stanozolol (Sinnecker et al. 1997). Due to peripheral androgen resistance, this response is diminished in AIS. However, the drug is not generally available, and the test is proposed only in patients older than 1 year with an unclear disorder of androgen action (Werner et al. 2010).

---

## Differential Diagnosis

The differential diagnosis for AIS includes several conditions leading to impaired androgen production and metabolism. CAIS is a relatively clear entity, and it only rarely leads to diagnostic problems if the initial diagnostic investigations are adequate. On the contrary, PAIS is a clinically heterogeneous disorder and presents a more complicated diagnostic problem.

Defects in steroid biosynthesis and metabolism can cause male undermasculinization. In 17 $\beta$ -hydroxysteroid dehydrogenase type 3 deficiency, the final step in testosterone biosynthesis (from androstenedione to testosterone) is impaired, but the ratio of testosterone to androstenedione is not always discriminative, and the phenotype of these children might be indistinguishable from those with PAIS (Lee et al. 2007). In 5 $\alpha$ -reductase deficiency the peripheral conversion of testosterone to DHT is impaired (Andersson et al. 1991; Saez et al. 1971), but the ratio of DHT to testosterone is variable in this condition (Hiort et al. 1996). Finally, most 46,XY individuals with *NR5A1* loss-of-function mutations have evidence for gonadal dysgenesis, but some infants with heterozygous *NR5A1* mutations present with normal testosterone and DHT levels at infancy, and thus PAIS may be indistinguishable (Coutant et al. 2007).

Androgen biosynthesis is deficient in three other rare conditions: 3- $\beta$ -hydroxysteroid dehydrogenase, P450c17 (17 $\alpha$ -hydroxylase), and steroidogenic acute regulatory protein (StAR) deficiencies, which may also be associated with deficient cortisol biosynthesis (Lin et al. 1995; Rhéaume et al. 1991; Yanase et al. 1991). Leydig cell hypoplasia due to inactivating LH receptor mutations and congenital gonadotropin deficiency are other rare specific causes for deficient



testosterone production (Kremer et al. 1995). If gonadal histology is not available, disorders of gonadal differentiation must also be included in the differential diagnostics (Werner et al. 2010).

---

## Endocrine Profile in AIS

In a 46,XY individual with AIS, testicular differentiation occurs normally, and immature germ cells are present in the testes at birth and during childhood. However, there is a progressive decline of germ cell numbers with increasing age, and in adulthood, no germ cells are present in the testes of affected adults with severe AIS (Hannema et al. 2006).

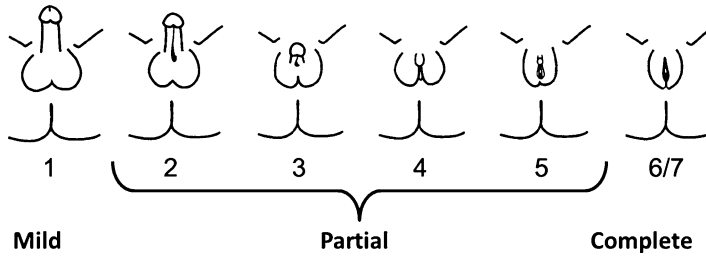
Generally, children and postpubertal (nongonadectomized) patients with AIS have normal or high basal and hCG-stimulated serum testosterone and DHT, as well as high LH concentrations (Ahmed et al. 1999), suitable with a hormone-resistant state. Serum FSH concentrations are generally normal (Melo et al. 2003). In PAIS patients, the physiologic postnatal surge of LH and testosterone during the first three postnatal months is either normal or exaggerated. However, in patients with CAIS, basal testosterone and both basal- and GnRH-induced serum LH concentrations can be markedly low in infancy, and retained testosterone biosynthesis can only be detected by monitoring the testosterone response to hCG (Bouvattier et al. 2002).

Estrogen production mainly by the testes, and to a lesser extent by aromatization of androstenedione and testosterone in peripheral tissues, is increased in individuals with AIS to about twice that of normal males due to increased LH stimulation of Leydig cells. Plasma or urinary levels of estrogens are at the upper limit of normal or elevated compared with those in normal males. SHBG levels are comparable to those in normal females reflecting peripheral androgen resistance (Tremblay et al. 1972; Quigley et al. 1995) whereas serum anti-Müllerian hormone and inhibin B levels are within or above the normal male reference range, suggesting uninhibited Sertoli cell function (Hellmann et al. 2012).

---

## Treatment

Nowadays management of DSD, including androgen insensitivity syndrome, is largely discussed and debated; these issues include especially early gender assignment and surgery before the informed consent by the patient. In AIS, gender assignment may be delayed at least until a final diagnosis has been reached and thus a reliable prognosis can be made, and irreversible and not urgent procedures should be delayed until an informed consent can be obtained. The diagnostic and management procedures should be performed by a multidisciplinary team including key members from endocrinology (pediatric or adult), urology, gynecology, and



**Fig. 3** A classification of severity of androgen insensitivity syndrome based on the external genitalia phenotype (modified from Quigley et al. 1995)

psychology. Additional members of the team may include specialists in clinical genetics, medical ethics, and social services (Hiort et al. 2014; Hughes et al. 2012).

The initial management is generally focused on counseling and gender assignment. After this, management addresses discussing functional issues like timing of gonadectomy to prevent tumor formation in testes, hormone replacement or supplementation at the appropriate time in life, surgery as appropriate for individuals raised as male or female, treatment of gynecomastia in men, and psychological support for the patient and family.

Generally, in CAIS, the sex of rearing is uniformly female, as is the phenotype. In PAIS, the phenotype of the newborn can vary from an apparent female with a slightly enlarged clitoris to a male with a mild penile hypospadias and/or well-masculinized though small external genitalia. Between these extremes are all grades of frank external genital ambiguity that require delicate decision making in order to choose a sex of rearing. In the past, the possibility of future potential fertility was not a consideration in gender assignment. However, development of intracytoplasmic sperm injection for in vitro fertilization using rare spermatozoa obtained by testis biopsy suggests that a PAIS man with azoospermia is potentially fertile with treatment (Tordjman et al. 2014). Therefore, nowadays male sex assignment is generally favored in PAIS as in other 46,XY DSD. In practice, the sex chosen depends not only on anatomical or prognostic but also on cultural considerations.

There are two grading schemes for clinical classification, which may be used in the assessment of the newborn. Quigley et al. developed a phenotypic classification for AIS, which is based on the Prader classification for congenital adrenal hyperplasia. In this system, the genital phenotype of an individual with AIS is graded 1–7 in order of increasing severity of androgen resistance and thus increasingly more female phenotype (Fig. 3, Quigley et al. 1995). In this classification, grades 1–3 refer to more male phenotype and grades 4–7 to female phenotype. Grade 4 refers to individuals with ambiguous phenotype, with severely limited masculinization evidenced by phallic structure that is intermediate between a clitoris and a penis, and labioscrotal folds with or without rugation and posterior fusion. Ahmed et al. presented another scoring system for the external genitalia (Table 1, Ahmed et al. 2000). The external masculinization score (EMS) is based on the scrotal fusion, penile size, location of the urethral meatus, and the location of the gonads.

**Table 1** External masculinization score (EMS; Ahmed et al. 2000b). An EMS sum score less than 11 indicates a multidisciplinary approach and a thorough endocrine evaluation

External masculinization score			
Feature	Score for yes	Score for yes, right	Score for yes, left
Scrotal fusion	3	-	-
Penile size not small	3	-	-
Normal urethral meatus	3	-	-
Glandular urethral meatus	2	-	-
Penile urethral meatus	1	-	-
Scrotal gonad	-	1.5	1.5
Inguinal gonad	-	1	1
Abdominal gonad	-	0.5	0.5
Absent gonad	-	0	0

## Surgery

### Gonadectomy and Gonadal Neoplasia in AIS

The risk of gonadal neoplasia (most commonly type II germ cell tumors, including seminoma) is increased in AIS, but the malignancy rates vary in different studies (Cools et al. 2006). The general consensus is that the testes should be removed at some stage in the case of female sex of rearing. The main controversy has been the timing of gonadectomy. Currently, the accepted practice is to leave the testes in place until after puberty has been completed (Hughes et al. 2006; Patel et al. 2016). True gonadal neoplasia is rare until after puberty (Manuel et al. 1976). Though carcinoma in situ and gonadoblastoma have been detected at variable rates in adolescent CAIS females, the youngest case with seminoma was a 14-year-old girl (Hurt et al. 1989). If gonads are not removed, spontaneous development of female secondary characteristics at puberty occurs satisfactorily. Furthermore, prepubertal low serum concentrations of estrogens may be important for higher central nervous system centers involved in the development of sexual identity and for bone mineralization (Collaer and Hines 1995; Soule et al. 1995).

The estimates of overall risk of gonadal malignancies in AIS have varied from 5.5% to 14% (Cools et al. 2006; Deans et al. 2012), and the risk may be higher in PAIS than in CAIS (Cools et al. 2006). The risk of neoplasia seems to increase by age (Manuel et al. 1976). However, some patients want to defer gonadectomy further, and an increasing number of women are opting to retain their gonads indefinitely (Deans et al. 2012). The retained gonads can be followed by magnetic resonance (MR) imaging (Nakhal et al. 2013) or by ultrasonography (Patel et al. 2016). MR imaging is accurate in the detection of testicular changes, including paratesticular cysts and Sertoli cell adenomas (which are usually benign). However, neither technique can depict premalignant changes like carcinoma in situ; therefore, the standard of care for patients with CAIS should still remain gonadectomy after puberty (Nakhal et al. 2013). If gonads are not visualized, laparoscopic gonadopexy and gonadal biopsy have also been suggested (Patel et al. 2016). Neoplastic lesions

of carcinoma in situ (CIS) and gonadoblastoma express consistently octamer-binding transcription factor (OCT 3/4). If OCT 3/4 is positive, gonadectomy is recommended (Patel et al. 2016).

In PAIS with female sex of rearing, the gonads are generally removed before puberty to avoid further virilization, whereas in male sex of rearing gonads are (if possible) retained.

### **Surgery of the External Genitalia**

In CAIS, the external genitalia are unambiguously female and no early surgery is necessary. The vagina is short in this condition, but surgical vaginal elongation is not indicated in most cases. Vaginal elongation can either be achieved digitally or by using dilators, and when this is done, most women are capable of normal intercourse (Boehmer et al. 2001). When a vaginoplasty procedure is required, the laparoscopic Vecchiotti procedure is becoming more widely available and appears to be a suitable surgical option based on a recent detailed review of the literature (Mongan et al. 2014).

In PAIS, questions regarding treatment are related to the hormonal stimulation of the genital tubercle to attempt to increase its size and the timing of hypospadias reconstruction, which is often complex and multistage in this group. Naturally, undescended testes should be operated as in other cases of cryptorchidism. Unfortunately, boys with PAIS have a poorer clinical long-term outcome than other boys with 46,XY DSD. They require more hypospadias operations and present more often with adult gynecomastia (Lucas-Herald et al. 2016).

## **Hormone Replacement, Fertility, and Bone Mineral Density**

### **Fertility and Endocrine Treatment in Female Sex of Rearing**

Clearly, in the absence of a uterus, a female patient with CAIS (or severe PAIS), is destined to be infertile. If gonads are remained in place, estrogen treatment at puberty is usually not indicated as the feminization occurs spontaneously due to excess testosterone being aromatized. If gonads are removed before the onset of puberty, pubertal induction with either transdermal natural estrogen or starting with ethinylestradiol is indicated (Mongan et al. 2015). It is generally considered that progesterone substitution is not needed in the absence of uterus. Some adult women with CAIS prefer to take supplementary testosterone after gonadectomy, because they report an improvement in wellbeing. This is not a standard therapy, and the mechanism of this therapy in the absence of functional AR is not clear. Apart from aromatization, nongenomic effects of androgens or their potential effects as neurosteroids have been suggested (Mongan et al. 2014).

### **Fertility and Endocrine Treatment in Male Sex of Rearing**

In PAIS patients with male sex of rearing, testes show both qualitative and quantitative disturbances of spermatogenesis, and generally patients with PAIS, including

those with even mild forms of PAIS, are considered infertile. However, several recent reports show that in nongonadectomized PAIS patients with male sex of rearing, fertility is sometimes restored. As expected, mutations associated with restored fertility show only partial loss of function when examined *in vitro* (Giwerzman et al. 2000; Chu et al. 2002).

Androgen therapy has been used to treat microphallus at infancy, but the response of treatment is variable. In a male PAIS infant, 25 mg testosterone administered by intramuscular injection every 4 weeks for up to three injections has been commonly used to treat undermasculinization of the external genitalia. An adequate response is an increase in stretched penile length into the normal range (Burnstein et al. 1979). In many cases of PAIS, it is possible to overcome the functional defects of certain mutant androgen receptors by pharmacotherapy with appropriate androgens. Some AR missense mutations express androgen binding and/or transactivation defects that are conditional on being exposed to a particular type of androgen (Pinsky et al. 1984; Kaufman et al. 1990). For example, a 46,XY patient with an AR missense mutation M807T has been reported (Ong et al. 1999). This patient was born with severely undermasculinized external genitalia. *In vitro* assays showed that AR transactivation could be restored with DHT but not with testosterone. Accordingly, *in vivo* no response in penile size was observed after treatment with testosterone, but local treatment with DHT gel led to a significant increase in penile length. Thus, *in vitro* functional assays can help to identify the subset of patients with ambiguous genitalia who could respond well to androgen therapy, providing them an option to be reared in accordance with their chromosomal sex. It is anticipated that knowledge of the AR LBD crystal structure will result in the development of a new generation of androgen-like compounds which modulate AR function in a more specific manner.

High-dose prolonged testosterone therapy has also resulted in marked progression of the masculinization in pubertal and adult male patients with PAIS, and there is one case report on improvement in sperm count and restoring fertility with intracytoplasmic microinjection (Tordjman et al. 2014).

### **Bone Mineral Density**

The role of androgens in skeletal maturation and bone mineralization is not as clear as that of estrogens. All published reports show that adult CAIS patients have bone mineral densities (BMD) somewhat lower than healthy female subjects (Bertelloni et al. 1998; Marcus et al. 2000; Muñoz-Torres et al. 1995; Sobel et al. 2006; Soule et al. 1995). Bone mineral densities are lower in healthy female subjects already before gonadectomy, and when adequately substituted with estrogens, the patients show moderate deficits in BMD, averaging close to  $-1$  SDS from normative means. The severe (BMD  $< -2$  SDS) osteopenia in some females may reflect a component of inadequate estrogen replacement rather than androgen lack alone (Marcus et al. 2000). All in all, it seems that androgens have a role in bone mineralization independent from estrogens.

## Summary

Androgen insensitivity syndrome (AIS) is characterized by undermasculinization of individuals with a 46,XY karyotype. The typical findings include impaired spermatogenesis with otherwise normal testes, absent or rudimentary Müllerian structures, evidence of normal or increased synthesis of testosterone and its normal conversion to dihydrotestosterone, and normal or increased luteinizing hormone (LH) production. Androgen receptor gene is the only gene in which the mutations are known to cause AIS.

The phenotypic spectrum of AIS is linked with the residual activity of the androgen receptor and into three main phenotypic categories: complete AIS (CAIS; female external genitalia), partial AIS (PAIS; variable undermasculinization at birth and masculinization at puberty), and minimal or mild AIS (MAIS; gynecomastia and/or infertility in a phenotypic male).

Whereas a mutation in the androgen receptor gene can be found in >90% of the patients complete AIS, partial AIS is a diagnostic challenge as mutation detection remains negative in most individuals.

To prevent testicular malignancy, treatment of CAIS includes removal of the testes after puberty when feminization is complete and estrogen replacement therapy thereafter. Treatment of PAIS depends on sex of rearing, and the long-term prognosis is poorer than in other 46,XY disorders of sex development. Androgen pharmacotherapy may improve masculinization in PAIS at infancy, and high doses of testosterone or dihydrotestosterone may improve masculinization at puberty, and in some cases it has restored fertility.

---

## Cross-References

- ▶ [Anabolic and Metabolic Effects of Testosterone and Other Androgens: Direct Effects and Role of Testosterone Metabolic Products](#)
- ▶ [Androgen Receptor](#)
- ▶ [Endocrinology of the Fetal Testis](#)
- ▶ [Sex Determination](#)
- ▶ [Male Sexual Differentiation](#)
- ▶ [Testicular Steroidogenesis](#)
- ▶ [Testis Development and Descent](#)

---

## References

- Adachi M, Takayanagi R, Tomura A, Imasaki K, Kato S, Goto K, Yanase T, Ikuyama S, Nawata H. Androgen-insensitivity syndrome as a possible coactivator disease. *N Engl J Med.* 2000;343:856–62.
- Ahmed SF, Cheng A, Hughes IA. Assessment of the gonadotropin-gonadal axis in androgen insensitivity syndrome. *Arch Dis Child.* 1999;80:324–9.

- Ahmed SF, Cheng A, Dovey L, Hawkins JR, Martin H, Rowland J, Shimura N, Tait AD, Hughes IA. Phenotypic features, androgen receptor binding, and mutational analysis in 278 clinical cases reported as androgen insensitivity syndrome. *J Clin Endocrinol Metab.* 2000a;85:658–65.
- Ahmed SF, Khwaja O, Hughes IA. The role of a clinical score in the assessment of ambiguous genitalia. *BJU Int.* 2000b;85:120–4.
- Akinloye O, Gromoll J, Nieschlag E, Simoni M. Androgen receptor gene CAG and GGN polymorphisms in infertile Nigerian men. *J Endocrinol Investig.* 2009;32:797–804.
- Andersson S, Berman DM, Jenkins EP, Russell DW. Deletion of steroid 5 $\alpha$ -reductase 2 gene in male pseudohermaphroditism. *Nature.* 1991;354:159–61.
- Andrew SE, Goldberg YP, Hayden MR. Rethinking genotype and phenotype correlations in polyglutamine expansion disorders. *Hum Mol Genet.* 1997;6:2005–10.
- Bangsboell S, Qvist I, Lebech PE, Lewinsky M. Testicular feminization syndrome and associated gonadal tumours in Denmark. *Acta Obstet Gynecol Scand.* 1992;71:63–6.
- Batch JA, Davies HR, Evans BA, Hughes IA, Patterson MN. Phenotypic variation and detection of carrier status in the partial androgen insensitivity syndrome. *Arch Dis Child.* 1993;68:453–7.
- Bertelloni S, Baroncelli GI, Federico G, Cappa M, Lala R, Saggese G. Altered bone mineral density in patients with complete androgen insensitivity syndrome. *Horm Res.* 1998;50:309–14.
- Boehmer AL, Brinkmann AO, Nijman RM, Verleun-Mooijman MC, de Ruiter P, Niermeijer MF, Drop SL. Genotype versus phenotype in families with androgen insensitivity syndrome. *J Clin Endocrinol Metab.* 2001;86:4151–60.
- Bouvattier C, Carel JC, Leconte C, David A, Sultan C, Bertrand AM, Morel Y, Chaussain JL. Postnatal changes of T, LH, and FSH in 46,XY infants with mutations in the AR gene. *J Clin Endocrinol Metab.* 2002;87:29–32.
- Brinkmann AO. Molecular basis of androgen insensitivity. *Mol Cell Endocrinol.* 2001;179:105–9.
- Brockschmidt FF, Nothen MM, Hillmer AM. The two most common alleles of the coding GGN repeat in the androgen receptor gene cause differences in protein function. *J Mol Endocrinol.* 2007;39:1–8.
- Brown TR, Lubahn DB, Wilson EM, Joseph DR, French FS, Migeon CJ. Deletion of the steroid-binding domain of the human androgen receptor gene in one family with complete androgen insensitivity syndrome: evidence for further genetic heterogeneity of this syndrome. *Proc Natl Acad Sci USA.* 1988;85:8151–5.
- Brown CJ, Goss SJ, Lubahn DB, Joseph DR, Wilson EM, French FS, Willard HF. Androgen receptor locus on human X chromosome: regional localization to Xq11-12 and description of a DNA polymorphism. *Am J Hum Genet.* 1989;44:264–9.
- Brunner F, Fliegner M, Krupp K, Rall K, Brucker S, Richter-Appelt H. Gender role, gender identity and sexual orientation in CAIS (“XY-women”) compared with subfertile and infertile 46,XX woman. *J Sex Res.* 2016;53:109–24.
- Burnstein S, Grumbach MM, Kaplan S. Early determination of androgen responsiveness is important in the management of microphallus. *Lancet.* 1979;2:983–6.
- Chamberlain NL, Driver ED, Miesfeld RL. The length and location of CAG trinucleotide repeats in the androgen receptor N-terminal domain affect transactivation function. *Nucleic Acids Res.* 1994;22:3181–6.
- Chang C, Kokontis J, Liao S. Molecular cloning of human and rat complementary DNA encoding androgen receptors. *Science.* 1988;240:324–6.
- Chu J, Zhang R, Zhao Z, Zou W, Han Y, Qi Q, Zhang H, Wang JC, Tao S, Liu X, Luo Z. Male fertility is compatible with an Arg840Cys substitution in the AR in a large Chinese family affected with divergent phenotypes of AR insensitivity syndrome. *J Clin Endocrinol Metab.* 2002;87:347–51.
- Collaer ML, Hines M. Human behavioural sex differences: a role for gonadal hormones during early development. *Psych Bull.* 1995;118:55–107.
- Cools M, Drop SL, Wolffenbuttel KP, Oosterhuis JW, Looijenga LH. Germ cell tumors in the intersex gonad: old paths, new directions, moving frontiers. *Endocr Rev.* 2006;27:468–84.

- Coutant R, Mallet D, Lahlou N, Bouhours-Nouet N, Guichet A, Coupriis L, Croue A, Morel Y. Heterozygous mutation of steroidogenic factor-1 in 46,XY subjects may mimic partial androgen insensitivity syndrome. *J Clin Endocrinol Metab.* 2007;92:2868–73.
- Davis-Dao CA, Tuazon ED, Sokol RZ, Cortessis VK. Male infertility and variation in CAG repeat length in the androgen receptor gene: a meta-analysis. *J Clin Endocrinol Metab.* 2007;92:4319–26.
- Deans R, Creighton SM, Liao LM, Conway GS. Timing of gonadectomy in adult women with complete androgen insensitivity syndrome (CAIS): patient preferences and clinical evidence. *Clin Endocrinol.* 2012;76:894–8.
- Dieffenbach H. *Familiärer hermaphroditismus*. Inaugural dissertation. Stuttgart. 1912.
- Estébanez-Perpiñá E, Arnold LA, Nguyen P, Rodrigues ED, Mar E, Bateman R, Pallai P, Shokat KM, Baxter JD, Guy RK, Webb P, Fletterick RJ. A surface on the androgen receptor that allosterically regulates coactivators binding. *Proc Natl Acad Sci USA.* 2007;10:16074–9.
- Evans RM. The steroid and thyroid hormone receptor superfamily. *Science.* 1988;240:889–95.
- Farla P, Hersmus R, Geverts B, Mari PO, Nigg AL, Dubbink HJ, Trapman J, Houtsmuller AB. The androgen receptor ligand-binding domain stabilizes DNA binding in living cells. *J Struct Biol.* 2004;147:50–61.
- Ghali SA, Gottlieb B, Lumbroso R, Beitel LK, Elhaji Y, Wu J, Pinsky L, Trifiro MA. The use of androgen receptor amino/carboxyl-terminal interaction assays to investigate androgen receptor gene mutations in subjects with varying degrees of androgen insensitivity. *J Clin Endocrinol Metab.* 2003;88:2185–93.
- Giwercman A, Kledal T, Schwartz M, Giwercman YL, Leffers H, Zazzi H, Wedell A, Skakkebaek NE. Preserved male fertility despite decreased androgen sensitivity caused by a mutation in the ligand-binding domain of the androgen receptor. *J Clin Endocrinol Metab.* 2000;85:2253–9.
- Gottlieb B, Beitel LK, Nadarajah A, Palioura M, Trifiro M. The androgen receptor gene mutations database (ARDB): 2012 update. *Hum Mutat.* 2012;33:887–94.
- Griffin JE, Punyashthiti K, Wilson JD. Dihydrotestosterone binding by cultured human fibroblasts. Comparison of cells from control subjects and from patients with hereditary male pseudohermaphroditism due to androgen resistance. *J Clin Invest.* 1976;57:1342–51.
- Hannema SE, Scott IS, Hodapp J, Martin H, Coleman N, Schwabe JW, Hughes IA. Residual activity of mutant androgen receptors explains wolffian duct development in the complete androgen insensitivity syndrome. *J Clin Endocrinol Metab.* 2004;89:5815–22.
- Hannema SE, Scott IS, Rajpert-De Meyts E, Skakkebaek NE, Coleman N, Hughes IA. Testicular development in the complete androgen insensitivity syndrome. *J Pathol.* 2006;208:518–27.
- He B, Kempainen JA, Wilson EM. FXXLF and WXXLF sequences mediate the NH<sub>2</sub>-terminal interaction with the ligand binding domain of the androgen receptor. *J Biol Chem.* 2000;275:22986–94.
- He B, Gampe Jr RT, Hnat AT, Faggart JL, Minges JT, French FS, Wilson EM. Probing the functional link between androgen receptor coactivator and ligand-binding sites in prostate cancer and androgen insensitivity. *J Biol Chem.* 2006;281:6648–63.
- Hellmann P, Christiansen P, Johannsen TH, Main KM, Duno M, Juul A. Male patients with partial androgen insensitivity syndrome: a longitudinal follow-up of growth, reproductive hormones and the development of gynaecomastia. *Arch Dis Child.* 2012;97:403–9.
- Helsen C, Dubois V, Verfaillie A, Young J, Trekels M, Vancaerenbroeck R, De Maeyer M, Claessens F. Evidence for DNA-binding domain–ligand-binding domain communications in the androgen receptor. *Mol Cell Biol.* 2012;32:3033–43.
- Hiort O, Willenbring H, Albers N, Hecker W, Engert J, Dibbelt L, Sinnecker GH. Molecular genetic analysis and human chorionic gonadotropin stimulation tests in the diagnosis of prepubertal patients with partial 5 alpha-reductase deficiency. *Eur J Ped.* 1996;155:445–51.
- Hiort O, Sinnecker GH, Holterhus PM, Nitsche EM, Kruse K. Inherited and de novo androgen receptor gene mutations: investigation of single-case families. *J Pediatr.* 1998;132:939–43.
- Hiort O, Birnbaum W, Marshall L, Wunsch L, Werner R, Schröder T, Döhnert U, Holterhus PM. Management of disorders of sex development. *Nat Rev Endocrinol.* 2014;10:520–9.



- Holterhus PM, Brüggewirht HT, Hiort O, Kleinkauf-Houcken A, Kruse K, Sinnecker GH, Brinkmann AO. Mosaicism due to a somatic mutation of the androgen receptor gene determines phenotype in androgen insensitivity syndrome. *J Clin Endocrinol Metab.* 1997;82:3584–9.
- Holterhus PM, Deppe U, Werner R, Richter-Unruh A, Bebermeier JH, Wünsch L, Kregel S, Schweikert HU, Demeter J, Riepe F, Hiort O, Brooks JD. Intrinsic androgen-dependent gene expression patterns revealed by comparison of genital fibroblasts from normal males and individuals with complete and partial androgen insensitivity syndrome. *BMC Genomics.* 2007;8:376.
- Huang G, Shan W, Zeng L, Huang L. Androgen receptor gene CAG repeat polymorphism and risk of isolated hypospadias: results from a meta-analysis. *Genet Mol Res.* 2015;6(14):1580–8.
- Hughes IA, Houk C, Ahmed SF, Lee PA, Lawson Wilkins Pediatric Endocrine Society/European Society for Paediatric Endocrinology Consensus Group. Consensus statement on management of intersex disorders. *J Pediatr Urol.* 2006;2:148–62.
- Hughes IA, Davies JD, Bunch TI, Pasterski V, Mastroyannopoulou K, MacDougall J. Androgen insensitivity syndrome. *Lancet.* 2012;380:1419–28.
- Huhtaniemi IT, Pye SR, Limer KL, Thomson W, O'Neill TW, Platt H, Payne D, John SL, Jiang M, Boonen S, Borghs H, Vanderschueren D, Adams JE, Ward KA, Bartfai G, Casanueva F, Finn JD, Forti G, Giwercman A, Han TS, Kula K, Lean ME, Pendleton N, Punab M, Silman AJ, Wu FC, European Male Ageing Study Group. Increased estrogen rather than decreased androgen action is associated with longer androgen receptor CAG repeats. *J Clin Endocrinol Metab.* 2009;94:277–84.
- Hurme T, Lahdes-Vasama T, Mäkela E, Iber T, Toppari J. Clinical findings in prepubertal girls with inguinal hernia with special reference to the diagnosis of androgen insensitivity syndrome. *Scand J Urol Nephrol.* 2009;43:42–6.
- Hurt WG, Bodurtha JN, McCall JB, Ali MM. Seminoma in pubertal patient with androgen insensitivity syndrome. *Am J Obstet Gynecol.* 1989;161:530–1.
- Hutson JM, Li R, Southwell BR, Newgreen D, Cousinery M. Regulation of testicular descent. *Pediatr Surg Int.* 2015;31:317–25.
- Imperato-McGinley J, Sanchez RS, Spencer JR, Yee B, Vaughan ED. Comparison of the effects of the 5 $\alpha$ -reductase inhibitor finasteride and the antiandrogen flutamide on prostate and genital differentiation: dose-response studies. *Endocrinology.* 1992;131:1149–56.
- Jääskeläinen J. Molecular biology of androgen insensitivity. *Mol Cell Endocrinol.* 2012;16(352):4–12.
- Jääskeläinen J, Deeb A, Schwabe JW, Mongan NP, Martin H, Hughes IA. Human androgen receptor gene ligand-binding-domain mutations leading to disrupted interaction between the N- and C-terminal domains. *J Mol Endocrinol.* 2006;36:361–8.
- Jagiello G, Atwell J. Prevalence of testicular feminization. *Lancet.* 1962;279:329.
- Josso N, Boussin L, Knebelmann B, Nihoul-Fékété C, Picard JY. Anti-Müllerian hormone and intersex states. *Trends Endocrinol Metab.* 1991;2:227–33.
- Kaufman M, Pinsky L, Gottlieb B, Schweitzer M, Brezezinski A, von Westarp C, Ginsberg J. Androgen receptor defects in patients with minimal and partial androgen resistance classified according to a model of androgen-receptor complex energy states. *Horm Res.* 1990;33:87–94.
- Keenan BS, Meyer WJ, Hadjian AJ, Migeon CJ. Androgen receptor in human skin fibroblasts. Characterization of a specific 17 $\beta$ -hydroxy-5 $\alpha$ -androstano-3-one-protein complex in cell sonicates and nuclei. *Steroids.* 1975;25:535–52.
- Kremer H, Kraaij R, Toledo SP, Post M, Fridman JB, Hayashida CY, van Reen M, et al. Male pseudohermaphroditism due to a homozygous missense mutation of the luteinizing hormone receptor. *Nature Genet.* 1995;9:160–4.
- La Spada AR, Wilson EM, Lubahn DB, Harding AE, Fischbeck KH. Androgen receptor gene mutations in X-linked spinal and bulbar muscular atrophy. *Nature.* 1991;352:77–9.
- Lango Allen H, Estrada K, Lettre G, Berndt SI, Weedon MN, Rivadeneira F, et al. Hundreds of variants clustered in genomic loci and biological pathways affect human height. *Nature.* 2010;467:832–8.

- Lee YS, Kirk JM, Stanhope RG, Johnston DI, Harland S, Auchus RJ, Andersson S, Hughes IA. Phenotypic variability in 17 $\beta$ -hydroxysteroid dehydrogenase-3 deficiency and diagnostic pitfalls. *Clin Endocrinol*. 2007;67:20–8.
- Lek N, Miles H, Bunch T, Pilfold-Wilkie V, Tadokoro-Cuccaro R, Davies J, Ong KK, Hughes IA. Low frequency of androgen receptor gene mutations in 46 XY DSD, and fetal growth restriction. *Arch Dis Child*. 2014;99:358–61.
- Lim HN, Nixon RM, Chen H, Hughes IA, Hawkins JR. Evidence that longer androgen receptor polyglutamine repeats are a causal factor for genital abnormalities. *J Clin Endocrinol Metab*. 2001;86:3207–10.
- Lin D, Sugawara T, Strauss 3rd JF, Clark BJ, Stocco DM, Saenger P, Rogol A, Miller WL. Role of steroidogenic acute regulatory protein in adrenal and gonadal steroidogenesis. *Science*. 1995;267:1828–31.
- Lubahn DB, Joseph DR, Sullivan PM, Willard HF, French FS, Wilson EM. Cloning of human androgen receptor complementary DNA and localization to the X-chromosome. *Science*. 1988;240:327–30.
- Lucas-Herald A, Bertelloni S, Juul A, Bryce J, Jiang J, Rodie M, et al. The long term outcome of boys with partial androgen insensitivity syndrome and a mutation in the androgen receptor gene. *J Clin Endocrinol Metab*. 2016;101(11):3959–67. [Epub ahead of print].
- Lumbroso R, Beitel LK, Vasiliou DM, Trifiro MA, Pinsky L. Codon-usage variants in the polymorphic (GGN)<sub>n</sub> trinucleotide repeat of the human androgen receptor gene. *Hum Genet*. 1999;101:43–6.
- Lundin KB, Giwercman YL, Rylander L, Hagmar L, Giwercman A. Androgen receptor gene GGN repeat length and reproductive characteristics in young Swedish men. *Eur J Endocrinol*. 2006;155:347–54.
- Lundin KB, Giwercman A, Dizeyi N, Giwercman Y. Functional in vitro characterisation of the androgen receptor GGN polymorphism. *Mol Cell Endocrinol*. 2007;264:184–7.
- Manuel M, Katayama KP, Jones Jr HW. The age of occurrence of gonadal tumors in intersex patients with a Y chromosome. *Br Med J*. 1976;288:1419–20.
- Marcus R, Leary D, Schneider DL, Shane E, Favus M, Quigley CA. The contribution of testosterone to skeletal development and maintenance: lessons from the androgen insensitivity syndrome. *J Clin Endocrinol Metab*. 2000;85:1032–7.
- Melo KF, Mendonca BB, Billerbeck AE, Costa EM, Inácio M, Silva FA, Leal AM, Latronico AC, Arnhold IJ. Clinical, hormonal, behavioral, and genetic characteristics of androgen insensitivity syndrome in a Brazilian cohort: five novel mutations in the androgen receptor gene. *J Clin Endocrinol Metab*. 2003;88:3241–50.
- Migeon CJ, Brown TR, Lanes R, Palacios A, Amrhein JA, Schoen EJ. A clinical syndrome of mild androgen insensitivity. *J Clin Endocrinol Metab*. 1984;59:672–8.
- Miles HL, Gidlöf S, Nordenström A, Ong KK, Hughes IA. The role of androgens in fetal growth: observational study in two genetic models of disordered androgen signalling. *Arch Dis Child Fetal Neonatal Ed*. 2010;95(6):F435–8.
- Mongan NP, Tadokoro-Cuccaro R, Bunch T, Hughes IA. Androgen insensitivity syndrome. *Best Pract Res Clin Endocrinol Metab*. 2015;29:569–80.
- Morris JM. The syndrome of testicular feminization in male pseudohermafroditas. *Am J Obstet Gynecol*. 1953;65:1192–211.
- Muñoz-Torres M, Jódar E, Quesada M, Escobar-Jiménez F. Bone mass in androgen-insensitivity syndrome: response to hormonal replacement therapy. *Calcif Tissue Int*. 1995;57:94–6.
- Nakhil RS, Hall-Craggs M, Freeman A, Kirkham A, Conway GS, Arora R, Woodhouse CR, Wood DN, Creighton SM. Evaluation of retained testes in adolescent girls and women with complete androgen insensitivity syndrome. *Radiology*. 2013;268:153–60.
- Nation TR, Buraundi S, Balic A, Farmer PJ, Newgreen D, Southwell BR, Hutson JM. The effect of flutamide on expression of androgen and estrogen receptors in the gubernaculum and surrounding structures during testicular descent. *J Pediatr Surg*. 2011;46:2358–62.
- Nef S, Parada LF. Cryptorchidism in mice mutant for *Insl3*. *Nat Genet*. 1999;22:295–9.

- Nenonen H, Bjork C, Skjaerpe PA, Giwercman A, Rylander L, Svartberg J, Giwercman YL. CAG repeat number is not inversely associated with androgen receptor activity in vitro. *Mol Hum Reprod.* 2010;16:153–7.
- Nenonen HA, Giwercman A, Hallengren E, Giwercman YL. Non-linear association between androgen receptor CAG repeat length and risk of male subfertility - a meta-analysis. *Int J Androl.* 2011;34:327–32.
- New MI, Nimkam S, Brandon DD, Cunningham-Rundles S, Wilson RC, Newfield RS, Vandermeulen J, Barron N, Russo C, Loriaux DL, O'Malley B. Resistance to multiple steroids in two sisters. *J Steroid Biochem Mol Biol.* 2001;76:161–6.
- Nichols JL, Bieber EJ, Gell JS. Case of sisters with complete androgen insensitivity syndrome and discordant Mullerian remnants. *Fertil Steril.* 2009;91(932):e15–8.
- Ong YC, Wong HB, Adaikan G, Yong EL. Directed pharmacological therapy of ambiguous genitalia due to an androgen receptor gene mutation. *Lancet.* 1999;354:1444–5.
- Pan B, Li R, Chen Y, Tang Q, Wu W, Chen L, Lu C, Pan F, Ding H, Xia Y, Hu L, Chen D, Sha J, Wang X. Genetic association between androgen receptor gene CAG repeat length polymorphism and male infertility: a meta-analysis. *Medicine (Baltimore).* 2016;95:e2878.
- Patel V, Casey RK, Gomez-Lobo V. Timing of gonadectomy in patients with complete androgen insensitivity syndrome-current recommendations and future directions. *J Pediatr Adolesc Gynecol.* 2016;29:320–5.
- Pereira de Jésus-Tran K, Côté PL, Cantin L, Blanchet J, Labrie F, Breton R. Comparison of crystal structures of human androgen receptor ligand-binding domain complexed with various agonists reveals molecular determinants responsible for binding affinity. *Protein Sci.* 2006;15:987–99.
- Pergament E, Heimler A, Shah P. Testicular feminisation and inguinal hernia. *Lancet.* 1973;2:740–1.
- Pettersson G, Bonnier G. Inherited sex-mosaic in man. *Hereditas.* 1937;23:49–69.
- Philibert P, Audran F, Pienkowski C, Morange I, Kohler B, Flori E, Heinrich C, Dacou-Voutetakis C, Joseph MG, Guedj AM, Journel H, Hecart-Bruna AC, Khotchali I, Ten S, Bouchard P, Paris F, Sultan C. Complete androgen insensitivity syndrome is frequently due to premature stop codons in exon 1 of the androgen receptor gene: an international collaborative report of 13 new mutations. *Fertil Steril.* 2010;94:472–6.
- Pinsky L, Kaufman M, Killinger DW, Burko B, Shatz D, Volpé R. Human minimal androgen insensitivity with normal dihydrotestosterone-binding capacity in cultured genital skin fibroblasts: evidence for an androgen-selective qualitative abnormality of the receptor. *Am J Hum Genet.* 1984;36:965–78.
- Pinsky L, Kaufman K, Killinger DW. Impaired spermatogenesis is not an obligate expression of receptor-defective androgen resistance. *Am J Med Genet.* 1989;32:100–4.
- Quigley CA, De Bellis A, Marschke KB, el-Awady MK, Wilson EM, French FS. Androgen receptor defects: historical, clinical, and molecular perspectives. *Endocr Rev.* 1995;16:271–321.
- Rajender S, Rajani V, Gupta NJ, Chakravarty B, Singh L, Thangaraj K. No association of androgen receptor GGN repeat length polymorphism with infertility in Indian men. *J Androl.* 2008;27:785–9.
- Réaume E, Lachance Y, Zhao HF, Breton N, Dumont M, de Launoit Y, Trudel C, Luu-The V, Simard J, Labrie F. Structure and expression of a ne complementary DNA encoding the almost exclusive 3beta-hydroxysteroid dehydrogenase/delta5-delta4-isomerase in human adrenal and gonads. *Mol Endocrinol.* 1991;5:1147–57.
- Saez JM, De Peretti E, Morera AM, David M, Bertrand J. Familial male pseudohermaphroditism with gynaecomastia due to testicular 17-ketosteroid reductase defect. 1. Studies in vivo. *J Clin Endocrinol Metab.* 1971;32:604–10.
- Sinnecker GH, Hiort O, Nitsche EM, Holterhus PM, Kruse K. Functional assessment and clinical classification of androgen sensitivity in patients with mutations of the androgen receptor gene German Collaborative Intersex Study Group. *Eur J Ped.* 1997;156:7–14.

- Sobel V, Schwartz B, Zhu YS, Cordero JJ, Imperato-McGinley J. Bone mineral density in the complete androgen insensitivity and 5 $\alpha$ -reductase-2 deficiency syndromes. *J Clin Endocrinol Metab.* 2006;91(8):3017–23.
- Soule SG, Conway G, Prelevic GM, Prentice M, Ginsburg J, Jacobs HS. Osteopenia as a feature of the androgen insensitivity syndrome. *Clin Endocrinol.* 1995;43:671–5.
- Southern AL. The syndrome of testicular feminization: a report of three cases with chromatographic analysis of the urinary neutral 17-ketosteroids. *Ann Intern Med.* 1961;55:925–31.
- Tahiri B, Auzou G, Nicolas JC, Sultan C, Lupu B. Participation of critical residues from the extreme C-terminal end of the human androgen receptor in the ligand binding function. *Biochemistry.* 2001;40:8431–7.
- Thompson J, Saatcioglu F, Jänne OA, Palvimo JJ. Disrupted amino- and carboxyl-terminal interactions of the androgen receptor are linked to androgen insensitivity. *Mol Endocrinol.* 2001;15:923–35.
- Thyen U, Lanz K, Holterhus PM, Hiort O. Epidemiology and initial management of ambiguous genitalia at birth in Germany. *Horm Res.* 2006;66:195–203.
- Tordjman KM, Yaron M, Berkovitz A, Botchan A, Sultan C, Lumbroso S. Fertility after high-dose testosterone and intracytoplasmic sperm injection in a patient with androgen insensitivity syndrome with a previously unreported androgen receptor mutation. *Andrologia.* 2014;46:703–6.
- Tremblay RR, Foley Jr TP, Corvol P, Park IJ, Kowarski A, Blizzard RM, Jones Jr HW, Migeon CJ. Plasma concentration of testosterone, dihydrotestosterone, testosterone-oestradiol binding globulin, and pituitary gonadotrophins in the syndrome of male pseudo-hermaphroditism with testicular feminization. *Acta Endocrinol.* 1972;70:331–41.
- Varela J, Alvesalo L, Vinkka H. Body size and shape in 46, XY females with complete testicular feminization. *Ann Hum Biol.* 1984;11:291–301.
- Viner RM, Teoh Y, Williams DM, Patterson MN, Hughes IA. Androgen insensitivity syndrome: a survey of diagnostic procedures and management in the UK. *Arch Dis Child.* 1997;77:305–9.
- Werner R, Holterhus PM, Binder G, Schwarz HP, Morlot M, Struve D, Marschke C, Hiort O. The A645D mutation in the hinge region of the human androgen receptor (AR) gene modulates AR activity, depending on the context of the polymorphic glutamine and glycine repeats. *J Clin Endocrinol Metab.* 2006;91:3515–20.
- Werner R, Grotsch H, Hiort O. 46,XY disorders of sex development – the undermasculinised male with disorders of androgen action. *Best Pract Res Clin Endocrinol Metab.* 2010;24:263–77.
- Wilkins L. Heterosexual development. In: Thomas CC, editor. *The diagnosis and treatment of endocrine disorders in childhood and adolescence.* Springfield, IL; 1950. p. 256–79.
- Wilson JD, Griffin JE, Russell DW. Steroid 5 $\alpha$ -reductase deficiency. *Endocr Rev.* 1993;14:577–93.
- Wisniewski AB, Migeon CJ, Meyer-Bahlburg HF, Gearhart JP, Berkovitz GD, Brown TR, Money J. Complete androgen insensitivity syndrome: long-term medical, surgical, and psychosexual outcome. *J Clin Endocrinol Metab.* 2000;85:2664–9.
- Yanase T, Simpson ER, Waterman MR. 17 $\alpha$ -hydroxylase/17,20-lyase deficiency: from clinical investigation to molecular definition. *Endocr Rev.* 1991;12:91–108.
- Zachmann M, Prader A, Sobel EH, Crigler Jr JF, Ritzén EM, Atarés M, Ferrandez A. Pubertal growth in patients with androgen insensitivity: indirect evidence for the importance of estrogens in pubertal growth of girls. *J Pediatr.* 1986;108:694–7.

Vincenzo Rochira and Cesare Carani

---

## Abstract

Congenital estrogen deficiency in men is a rare disorder that remains overlooked and undermanaged till adulthood. Similarly, other genetic diseases causing congenital hypogonadism are rare and indirectly lead to estrogen deficiency during infancy and puberty if not recognized and treated. Apart from congenital, genetic forms, estrogen deficiency may occur as a consequence of hypogonadism and reduced androgen production. Several lines of evidence support the idea that estrogen deficiency may be detrimental for several male physiological functions, especially in aging. Among them, bone loss, osteoporosis, increase of fat depots, and sexual function may depend to a various degree from estrogen deficiency. At present, however, nosological data on estrogen deficiency in men are lacking. This chapter describes the pathogenesis and clinical manifestations related to estrogen deficiency and provides clinical advice on how to diagnose and treat both congenital and acquired forms of estrogen deficiency.

---

## Keywords

Estrogen deficiency • Aromatase deficiency • Estrogen resistance • Male hypogonadism • Male osteoporosis • Estrogens in men

---

V. Rochira (✉)

Department of Biomedical, Metabolic and Neural Sciences, University of Modena and Reggio Emilia, Azienda Ospedaliero-Universitaria di Modena, Ospedale Civile di Baggiovara, Modena, Italy

e-mail: [vincenzo.rochira@unimore.it](mailto:vincenzo.rochira@unimore.it)

C. Carani

Department of Biomedical, Metabolic and Neural Sciences, University of Modena and Reggio Emilia, Modena, Italy

e-mail: [cesare.carani@unimore.it](mailto:cesare.carani@unimore.it)

## Abbreviations

ADT	Androgen deprivation therapy
BMD	Bone mineral density
DEXA	Dual energy X-ray absorptiometry
ED	Estrogen deficiency
ER	Estrogen receptor
FSH	Follicle-stimulating hormone
GnRH	Gonadotropin releasing hormone
IGF-1	Insulin-like growth factor 1
IIH	Isolated hypogonadotropic hypogonadism
LC-MS/MS	Liquid chromatography-tandem mass spectrometry
LH	Luteinizing hormone
PORD	P450 oxidoreductase deficiency
T	Testosterone

## Contents

Introduction .....	798
Physiology of Estrogens in Men .....	799
Estrogen Synthesis and Action .....	799
Role of Estrogens in Men .....	801
Pathophysiology of Estrogen Deficiency .....	801
Animal Models of Estrogen Deficiency .....	804
Human Estrogen Deficiency .....	806
Clinical Aspects of Estrogen Deficiency in Men .....	807
Congenital, Genetic Estrogen Deficiency .....	807
Acquired Estrogen Deficiency .....	815
Conclusions .....	820
Key Points .....	820
Summary .....	821
Cross-References .....	821
References .....	821

## Introduction

Estrogen deficiency in men is still a poorly understood clinical entity. Genetic forms of estrogen deficiency are rare (Rochira and Carani 2009) and data on relative estrogen deficiency due to testosterone deficiency and the consequent fall of serum estrogens below the normal range are scanty (Trabado et al. 2011; Finkelstein et al. 2013; Giton et al. 2015). Furthermore, no nosological data on estrogen deficiency are available. In clinical practice, relative estrogen deficiency due to male hypogonadism is common, especially if compared to the genetic forms. Probably, not all hypogonadal men develop estrogen deficiency, the presence and severity of which depend from the degree of testosterone deficiency as well as from the individual production rate of estrogens. However, the real prevalence of relative estrogen deficiency is still not known. Since several years ago, estrogens in men were considered relatively unimportant and their physiological role has been

progressively disclosed only in recent years (Simpson and Santen 2015). For a comprehensive review on the milestones concerning the knowledge of estrogen role in men see (Rochira et al. 2005).

At present there is strong evidence that estrogens exert their pleiotropic actions on several tissues in men (Rochira et al. 2012) (see also ► Chap. 11, “Anabolic and Metabolic Effects of Testosterone and Other Androgens: Direct Effects and Role of Testosterone Metabolic Products” for details). In particular, the role of estrogens is crucial for the skeleton (Rochira et al. 2015; Almeida et al. 2017) and for male reproduction (Rochira et al. 2005, 2016) as well as for other important physiological functions (Rochira et al. 2012).

For these reasons, estrogen deficiency in men is receiving increasing interest in the last years (Finkelstein et al. 2013, 2016; Taylor et al. 2016).

---

## Physiology of Estrogens in Men

### Estrogen Synthesis and Action

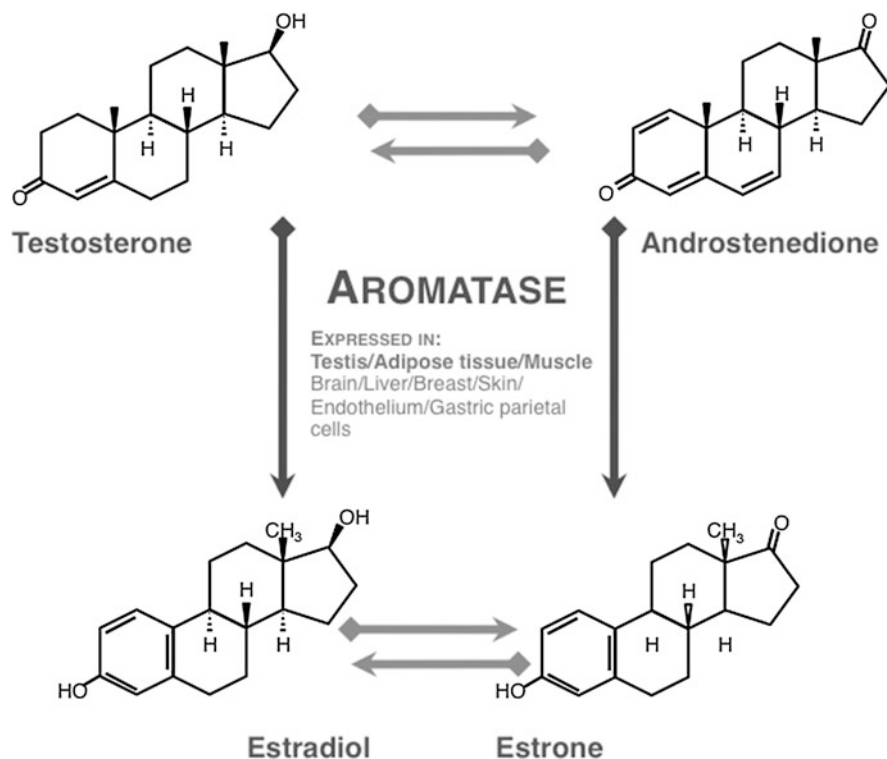
Estrogens in men derive from the conversion of androgen thanks to the action of the enzymatic complex known as aromatase, which is responsible for the aromatization of the androgen A-ring (Simpson et al. 1999; Miller and Auchus 2011; Rochira et al. 2016) (see also ► Chap. 10, “Testicular Steroidogenesis” for further details) (Fig. 1).

As other steroidogenetic enzymes, aromatase belongs to the large family of cytochrome P450 oxidases, each sharing a conserved heme-binding domain and differing for a variable substrate-binding domain (Harada 1988). Aromatase is encoded by the *CYP19A1* gene, which consists of ten exons (Harada 1988; Harada et al. 1990). The translated coding region belongs to exons 2–9 that are not tissue specific, whereas the noncoding exon 1 differs among various tissues. The presence of different exons 1 explains how the expression of aromatase is regulated in a tissue-specific fashion (Harada et al. 1990, 1993; Simpson et al. 1997). Accordingly, the *CYP19A1* gene includes multiple tissue-specific promoters, which allows the aromatase transcript to be tissue-specifically spliced from the multiple alternative exons available for exon 1 (Harada et al. 1990, 1993; Simpson et al. 1997).

The primary transcript is spliced into various transcripts in a tissue-specific fashion as a result of tissue-specific promoters (Harada 1988; Simpson et al. 1997). Finally, the mature protein includes the sequences encoded by exons 2–10 (Simpson et al. 1994, 1997).

The main sources of estrogen in men are the testes, the liver, and the adipose tissue (Gruber et al. 2002; Barakat et al. 2016), including in particular the tissues that express the aromatase enzyme and are able to locally produce estrogens (e.g. testis, adipose tissue, brain, including the hypothalamus, bone, muscle, breast, liver) (Simpson et al. 1999; Gruber et al. 2002; Barakat et al. 2016).

Estrogen action occurs through binding to specific receptors belonging to the nuclear receptors superfamily (Gruber et al. 2002; Heldring et al. 2007). Estrogen



**Fig. 1** Estrogen biosynthesis in men and main tissues expressing the aromatase enzyme

receptors are ligand-inducible transcription factors, which regulate the expression of target genes after hormone binding (Heldring et al. 2007). Two different types of intranuclear estrogen receptors (ERs) have been characterized insofar: the ER-alpha ( $ER\alpha$ ) and the ER-beta ( $ER\beta$ ) (Heldring et al. 2007). Furthermore, even a non-genomic pathway rapidly transduces estrogen signaling by involving a plasma-membrane interaction of the ER (Heldring et al. 2007; Hammes and Levin 2011). This action is mediated by GPR30, a cell-surface G protein-coupled receptor that does not act through a transcriptional mechanism (Hammes and Levin 2011). GPR30, in fact, is localized to the plasma membrane, in particular it seems that a monomeric portion of the  $ER\alpha$  is translocated from the nucleus to the plasma membrane (Hammes and Levin 2011).

ERs are widely expressed both in reproductive and nonreproductive tissues in both men and women (Drummond and Fuller 2010; Eyster 2016). In men, ERs are expressed within the testis and through all the reproductive tract including the prostate (Rochira et al. 2016) as well as in the heart and the cardiovascular system, brain, liver, bone, kidney, and adipose tissue (Gruber et al. 2002; Drummond and Fuller 2010; Eyster 2016).



## Role of Estrogens in Men

Estrogens in men exert their direct action on several tissues and organs (Rochira et al. 2005, 2012, 2015, 2016; Table 2).

Estrogens inhibits gonadotropin secretion both at hypothalamic and pituitary level in men (Hayes et al. 2000; Raven et al. 2006; Rochira et al. 2006; Finkelstein et al. 2013) and are able to regulate male reproductive hormones; thus they ultimately regulate male reproductive function (Rochira et al. 2016; Table 2). Estrogens play also a role in the control of spermatogenesis and sperm maturation, even though the level of evidence on this estrogenic action is higher in rodents than in humans (Rochira et al. 2005, 2016; Table 2). Furthermore, estrogens are also able to influence male sexual behavior by having a positive role on sexual motivation and sexual desire (Carani et al. 1999, 2005; Rochira et al. 2005, 2012, 2016; Finkelstein et al. 2013; Table 2).

The main role of estrogens in men is within the bone tissue (Rochira et al. 2015). Estrogens, in fact, have a role both on bone maturation in peripubertal boys and in the maintenance of bone mass in adult men (Rochira et al. 2000, 2006, 2012; Vanderschueren et al. 2014; Almeida et al. 2017). At puberty, estrogen are necessary for rapid elongation of long bones followed by epiphyseal closure and growth arrest, thus allowing the attainment of harmonic skeletal proportions (between the upper and lower skeletal segments) (Zirilli et al. 2008), and the achievement of peak bone mass (Rochira et al. 2001, 2015; Table 2). Once the peak bone mass has been reached, estrogens are the main sex steroids responsible for the maintenance of bone mineral density (BMD) in men (Rochira et al. 2000, 2001, 2015; Vanderschueren et al. 2014; Almeida et al. 2017); thus, they are crucial for preventing bone loss (Finkelstein et al. 2016; Table 2).

Finally, estrogens have metabolic and vascular effects since they may positively modulate insulin sensitivity (Rochira et al. 2007) and circulating lipids (especially HDL cholesterol) (Carani et al. 1997) and be able to control fat distribution, especially at the abdominal site (Maffei et al. 2007; Finkelstein et al. 2013; Table 2). Furthermore, the lack of estrogens, but not of androgens, is involved in the appearance of vasomotor symptoms in men with severe sex steroids deficiency (Taylor et al. 2016).

---

## Pathophysiology of Estrogen Deficiency

In men estrogen deficiency may result from the alteration of estrogen synthesis due to the genetic defect of the enzymes involved in estrogen synthesis or to an acquired reduction of the substrate (androgens) available for aromatization in men with low circulating testosterone (hypogonadism) (Rochira and Carani 2009; Trabado et al. 2011; Giton et al. 2015; Table 1, Fig. 2). Alternatively, the congenital loss-of-function of the ERs might represent a further condition of congenital loss of estrogen action (Smith et al. 1994, 2008; Table 1, Fig. 2).

**Table 1** Classification of estrogen deficiency in men

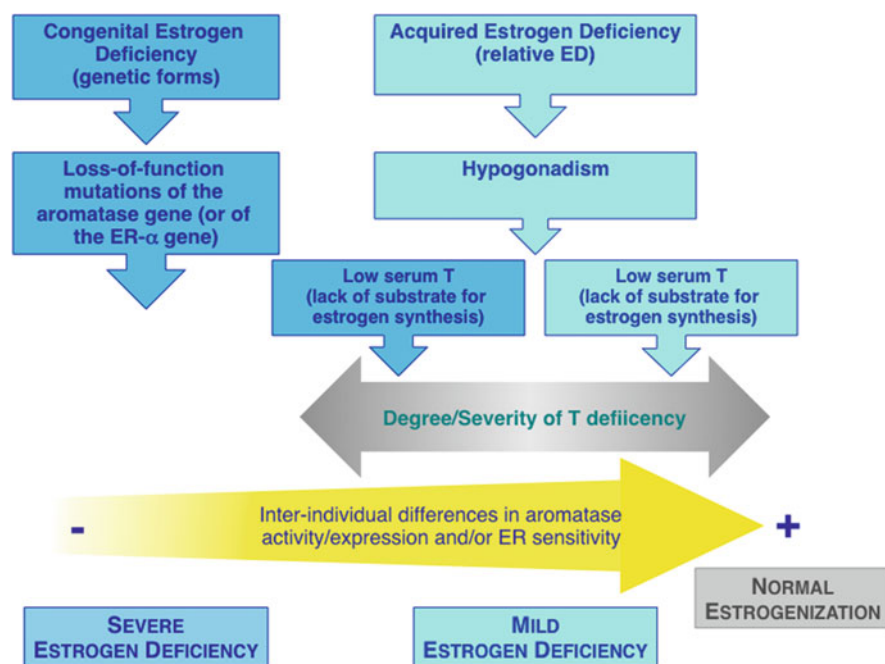
Disease development	Type of ED	Onset of clinical signs and symptoms	Grade of ED	Pathogenesis
Congenital (genetic)	Primary	Prepubertal	Severe	Genetic
Acquired	Secondary to hypogonadism (relative ED)	During adulthood	Mild	Secondary to hypogonadism <i>Drug induced</i>
Estrogen deficiency in men				
Disease	Prevalence	Grade	Causes	
Prepubertal onset				
<b><i>Congenital (genetic forms)</i></b>				
<i>Primary (classic) congenital estrogen deficiency</i>			<i>Altered estrogenic pathways</i>	
Aromatase deficiency	Very rare	Severe	Loss-of-function mutations of the aromatase ( <i>CYP19A1</i> ) gene	
Estrogen resistance (one case described)	Extremely rare	Severe	Loss-of-function mutations of the estrogen receptor $\alpha$ gene	
<i>Secondary congenital estrogen deficiency (relative estrogen deficiency)</i>			<i>Altered estrogenic pathways</i>	
17 $\alpha$ -hydroxylase deficiency	Very rare	Mild to severe	Loss-of-function mutations of the <i>CYP17A1</i> gene	
17,20-lyase deficiency	Very rare	Mild to severe	Loss-of-function mutations of the <i>CYP17A1</i> gene	
P450 Oxydoreductase Deficiency (PORD)	Very rare	Mild to severe	Loss-of-function mutations of the <i>PORD</i> gene	
<i>Isolated hypogonadotropic hypogonadism</i>	Rare	Mild to severe	All genetic causes of IIH	
<b><i>Acquired</i></b>				
Unrecognized hypogonadism due to other diseases	Rare	Mild	Hypothalamic-pituitary diseases resulting in hypogonadism, severe primary hypogonadism (e.g., anorchia congenita)	
Adult onset				
<b><i>Acquired</i></b>				
Severe untreated hypogonadism	Rare to relatively frequent	Mild	Hypothalamic-pituitary diseases resulting in hypogonadism, severe primary hypogonadism; late-onset hypogonadism	

*(continued)*

**Table 1** (continued)

Iatrogenic (pharmacologically induced or surgical)	Common (pharmacologically induced rare (surgical castration))	Mild to severe	Chemical castration; androgen deprivation therapy (ADT) for prostate cancer; therapy with aromatase inhibitors (e.g. breast cancer)
---	--	----------------	---

*ED* estrogen deficiency, *PORD* P450 oxidoreductase deficiency, *IIIH* isolated hypogonadotropic hypogonadism, *ADT* androgen deprivation therapy



**Fig. 2** Pathophysiological mechanisms of estrogen deficiency in men. *ED* estrogen deficiency, *ER* estrogen receptor, *T* testosterone

Since 1994, several cases of estrogen deficiency due to genetic defects of the ER $\alpha$  or of the aromatase enzyme have been described in literature (Smith et al. 1994, 2008; Rochira et al. 2002b; Zirilli et al. 2008). Furthermore, several lines of knockout mice lacking estrogen action were generated, and several studies focused on the role of estrogens in males by investigating the effects of the inhibition of estrogen synthesis in both rodents (Seralini and Moslemi 2001) and humans (de Ronde and de Jong 2011).

Thanks to the similarity between human and animal models of estrogen deficiency (Table 2), the comparison of the effects of estrogen deprivation in men with congenital estrogen deficiency with those of animal models permitted to better

**Table 2** Features of estrogen deficiency in animal models and in men with congenital and acquired estrogen deficiency

Estrogen actions	Animal models of ED	Human congenital ED	Human acquired mild ED
<b>Bone</b>			
Reduced BMD	+++	+++	+++
Delayed epiphyseal fusion	n.a.		
Eunuchoid skeletal proportions	n.a.	+++	+
<b>Reproductive function</b>			
Impaired spermatogenesis	+++	+/-	n.a.
Impaired sexual behavior	+++	++ (impaired sexual desire)	+/- (impaired sexual desire)
Inhibition of gonadotropin secretion	+++	+++	+++
<b>Glucose and lipid metabolism</b>			
Insulin resistance	+++	+++	++ (?)
Impaired serum lipids	+++	+++	++
<b>Adipose tissue</b>			
Body fat accumulation	+++	+++	+++

*BMD* bone mineral density, *ED* estrogen deficiency, *n.a.* not applicable

clarify the clinical phenotype of estrogen deficiency, the role of estrogens in males, and species-specific estrogen actions (Faustini-Fustini et al. 1999; Grumbach and Auchus 1999; Rochira et al. 2002; Simpson et al. 2005; Jones et al. 2006; Simpson and Jones 2006).

## Animal Models of Estrogen Deficiency

At the beginning, estrogen deficiency was studied in mice treated with aromatase inhibitors at dosages able to suppress quite completely estrogen production and secretion (Seralini and Moslemi 2001). These experiments investigated the effects in mice of aromatase inhibitors administered at birth or at different life periods. Once biotechnological advances made possible the genetic modification of genes involved in estrogen action, the effects of estrogen deprivation were investigated in genetically modified mouse models of estrogen deficiency.

### Mice Knockout Models of Estrogen Deficiency

Several lines of mouse models lacking estrogen activity have been generated by the means of inactivation of genes encoding for estrogen receptors or involved in the synthesis of estrogens (i.e., aromatase) (Couse and Korach 1999; Hamilton et al. 2014). Four models of knockout mice are currently available: (i) the knockout of the ER $\alpha$  that generated the  $\alpha$ ERKO mice with nonfunctioning ER $\alpha$  (Lubahn et al. 1993); (ii) the knockout of the estrogen receptor beta ER $\beta$  that produced the  $\beta$ ERKO mice

**Table 3** Features that characterize the phenotype of the different knockout mice lacking estrogen action

<b>Infertility</b>	$\alpha$ ERKO, $\alpha\beta$ ERKO, ArKO
<b>Impaired sexual behavior</b>	$\alpha$ ERKO, $\alpha\beta$ ERKO, ArKO
<b>Increased circulating gonadotropins</b>	$\alpha$ ERKO, $\alpha\beta$ ERKO, ArKO
<b>Increased circulating testosterone</b>	$\alpha$ ERKO
<b>Increased circulating estrogens</b>	$\alpha$ ERKO, $\alpha\beta$ ERKO,
<b>Undetectable circulating estrogens</b>	ArKO
<b>Increased adiposity</b>	ArKO
<b>Metabolic alterations</b> (insulin resistance, altered glucose tolerance, alteration of circulating lipids)	$\alpha$ ERKO, $\alpha\beta$ ERKO, ArKO
<b>Impaired BMD</b> (loss of bone mass)	$\alpha$ ERKO, $\alpha\beta$ ERKO, ArKO

with nonfunctioning ER $\beta$  (Krege et al. 1998); (iii) the knockout of both ER $\alpha$  and ER $\beta$  resulting in the  $\alpha\beta$ ERKO mice characterized by the lack of activity of both ERs (Ogawa et al. 2000); and finally (iv) the knockout of the aromatase (*CYP19A1*) gene that lead to the creation of ArKO mice, which are characterized by the lack of both circulating and locally produced estrogens (Fisher et al. 1998; Couse and Korach 1999). These models of knockout mice provided valuable information on the effects of the complete suppression of estrogen action ( $\alpha\beta$ ERKO and ArKO mice) as well as on the loss of action of each estrogen receptor ( $\alpha$ ERKO and  $\beta$ ERKO mice) in males (Couse and Korach 1999; Simpson and Jones 2006). In particular, the phenotype (Table 3) arising by inactivating estrogen pathways of action in male mice allowed to better clarifying several physiological role of estrogens in rodents (Couse and Korach 1999; Simpson and Jones 2006). Furthermore, the comparison among different mouse models permitted to characterize the way in which either or both isoforms of the receptor are involved in any given action of estrogens (Heldring et al. 2007). As expected, the phenotype of male mice models leading to estrogen deficiency varies on the basis of the type of knockout (Couse and Korach 1999; Simpson et al. 2005; Table 3).

The phenotype of estrogen-deficient mouse models is similar in  $\alpha$ ERKO and ArKO male mice (Table 3), both these two mice models display altered spermatogenesis, reduced fertility, impaired sexual behavior, reduced bone mineral density, progressive increase of adiposity, and abnormal hormone serum concentrations (Rissman et al. 1997; Couse and Korach 1999; Simpson et al. 2005; Simpson and Jones 2006; Hamilton et al. 2014; Table 3). Normal to increased serum luteinizing hormone (LH) and elevated testosterone characterize the hormonal pattern of male  $\alpha$ ERKO,  $\alpha\beta$ ERKO, and ArKO mice; serum estradiol is increased in both  $\alpha$ ERKO and  $\alpha\beta$ ERKO mice (Hamilton et al. 2014) while is undetectable in ArKO mice (Fisher et al. 1998; Couse and Korach 1999; Table 3). The increase of gonadotropins is due to the lack of inhibitory feedback exerted by estrogen on the pituitary and

hypothalamus. As a consequence, the increase of LH leads to the rise of testosterone production by the testis (Couse and Korach 1999). Vice versa the negative effects of estrogen deficiency on spermatogenesis are mainly due to the lack of estrogen action (Rochira et al. 2016).

The phenotype of male  $\beta$ ERKO mice is very close to that of wild type without particular alterations of the reproductive function and of the skeleton (Krege et al. 1998; Couse and Korach 1999; Hamilton et al. 2014).

Recently, also a knockout model of mice lacking a functioning GPR30 estrogen receptor (a transmembrane nonnuclear receptor) has become available showing a phenotype characterized by insulin resistance and altered lipid metabolism (Sharma et al. 2013).

These experimental models highlighted the role of ER $\alpha$  in mediating estrogen actions on male bone (Vanderschueren et al. 2014) and reproduction (spermatogenesis and male sexual behavior),  $\alpha$ ERKO adult mice being completely infertile (Rochira et al. 2005, 2016). The hormonal pattern of these mouse models of estrogen deficiency disclosed the major role of estrogens on gonadotropin feedback (Rochira et al. 2012, 2016; Table 2). Besides, models of male estrogen-deficient mice (both genetically and pharmacologically determined) are of concern since they are very close to that of humans with estrogen deficiency; this allows to extend several pathophysiological aspects to humans (Jones et al. 2006; Simpson and Jones 2006; Table 2).

### Pharmacologically Induced Mouse Models of Estrogen Deficiency

The pharmacological blockade of estrogen synthesis by means of the administration of aromatase inhibitors is able to induce the same effects seen in ArKO mice in terms of bone loss (Vanderschueren et al. 1997; Eshet et al. 2004), development of infertility (Turner et al. 2000), impaired male sexual behavior (Bonsall et al. 1992; Vagell and McGinnis 1997), and hormonal pattern (Bhatnagar et al. 1992). This kind of experiment predicted about 10 years earlier several concepts on the role of estrogens in males that were subsequently revealed once estrogen deficient knockout mice were generated.

### Human Estrogen Deficiency

Estrogen deficiency in men could be considered a novel nosological entity that belongs to and overlaps with several forms of male hypogonadism. At present, no specific classification of estrogen deficiency has been proposed. The disease is classified among hypogonadism or among the disorders of steroidogenesis, but a systematic clinical overview is lacking (Buvat et al. 2013; Rey et al. 2013; Huhtaniemi 2014; Dean et al. 2015). In an attempt to provide a classification of estrogen deficiency in men, the following aspects should be considered: (i) the onset of the disease (congenital/acquired); (ii) if estrogen deficiency is primarily due to alterations of estrogen pathways (primary estrogen deficiency) or if is secondary to

hypogonadism (relative estrogen deficiency); (iii) the onset of clinical manifestation; (iv) the severity of estrogen deficiency; and (v) the pathogenesis (Table 1).

### **Pathogenesis and Classification**

Primary, classic estrogen deficiency in men is due to genetic forms that are characterized by the complete blockade of estrogen synthesis or of estrogen action (ER blockade) and lead to severe congenital estrogen deficiency without androgen insufficiency (Rochira and Carani 2009; Table 1, Fig. 2). Congenital estrogen deficiency is already present at birth without evident clinical manifestations and develops from infancy to puberty becoming completely manifest in young adults (Rochira and Carani 2009; Table 1, Fig. 2).

Secondary congenital forms of estrogen deficiency are due to genetic diseases causing androgen deficiency, which leads to relative estrogen deficiency due to reduced androgen substrate available for being transformed into estrogens (Figs. 1 and 2). In all these cases, estrogen deficiency is less severe but of clinical relevance (Table 1).

Otherwise acquired estrogen deficiency may develop at any time even though it is more frequent during adulthood (acquired hypogonadism in infancy is rare and is mainly due to hypothalamic pituitary surgery) as a consequence of hypogonadism (relative estrogen deficiency) (Trabado et al. 2011; Giton et al. 2015). In these cases, the severity of estrogen deficiency depends on that of hypogonadism (Rochira et al. 2006; Trabado et al. 2011; Giton et al. 2015; Decaroli and Rochira 2016; Table 1, Fig. 2).

---

## **Clinical Aspects of Estrogen Deficiency in Men**

### **Congenital, Genetic Estrogen Deficiency**

#### **Pathogenesis**

##### **Primary Congenital Estrogen Deficiency**

Congenital estrogen deficiency is a very rare disease listed in Orphanet. ([http://www.orpha.net/consor/cgi-bin/Disease\\_Search.php?lng=EN&data\\_id=8670&Disease\\_Disease\\_Search\\_diseaseGroup=estrogen-deficiency&Disease\\_Disease\\_Search\\_diseaseType=Pat&Disease\(s\)/group%20of%20diseases=Aromatase-deficiency&title=Aromatase-deficiency&search=Disease\\_Search\\_Simple](http://www.orpha.net/consor/cgi-bin/Disease_Search.php?lng=EN&data_id=8670&Disease_Disease_Search_diseaseGroup=estrogen-deficiency&Disease_Disease_Search_diseaseType=Pat&Disease(s)/group%20of%20diseases=Aromatase-deficiency&title=Aromatase-deficiency&search=Disease_Search_Simple)).

The inheritance is autosomal recessive both in case of estrogen resistance and aromatase mutations (Rochira et al. 2002; Rochira and Carani 2009).

Notwithstanding the old view considering estrogen deficiency of the fetus not compatible with life (Grumbach and Auchus 1999; Zirilli et al. 2008), several cases of men with congenital estrogen deficiency have been progressively described and contributed to really establish the role of estrogens in men throughout the whole lifetime (Rochira and Carani 2009). While only one man with estrogen resistance

due to a loss-of-function mutation of the gene encoding for the ER $\alpha$  is known (Smith et al. 1994, 2008), at present 14 cases of aromatase deficiency have been described in literature (Morishima et al. 1995; Carani et al. 1997; Bilezikian et al. 1998; Deladoey et al. 1999; Rochira et al. 2000; Herrmann et al. 2002, 2005; Pura et al. 2003; Bouillon et al. 2004; Mittre Herve et al. 2004; Maffei et al. 2004, 2007; Lanfranco et al. 2008; Zirilli et al. 2008; Rochira and Carani 2009; Baykan et al. 2013; Pignatti et al. 2013; Chen et al. 2015; Miedlich et al. 2016; Table 1).

Estrogen deficiency due to aromatase deficiency is the consequence of inactivating mutation of the *CYP19A1* gene encoding for the transcript of the aromatase enzyme. Several mutations have been identified and in all patients these mutations lead to a nonfunctioning aromatase protein or do not allow the transcription of the protein, which in this case is absent (Rochira and Carani 2009; Baykan et al. 2013; Pignatti et al. 2013).

### Secondary Congenital Estrogen Deficiency

All the genetic diseases causing severe androgen deficiency since birth induce relative estrogen deficiency. Thus, all the diseases due to genetic alterations of steroidogenic enzymes that result in very low circulating androgens as well all genetic diseases directly causing isolated hypogonadotropic hypogonadism might be considered as forms of congenital estrogen deficiency. Furthermore, also congenital primary hypogonadism (e.g., congenital anorchia) should be listed among congenital causes of relative estrogen deficiency (Buvat et al. 2013; Dean et al. 2015). For a comprehensive review on the classification of male hypogonadism, see the following articles deficiency (Buvat et al. 2013; Huhtaniemi 2014; Dean et al. 2015).

Different from primary congenital estrogen deficiency (which is often overlooked and undermanaged until adulthood), these diseases manifest early at birth and during infancy (ambiguous genitalia) or at puberty (e.g., isolated hypogonadotropic hypogonadism and congenital anorchia); thus the starting of adequate androgen replacement therapy at puberty avoids the appearance of most of the clinical features of congenital estrogen deficiency. If untreated or if the treatment is delayed, some clinical features like eunuchoid appearance may develop and be present in adulthood (Zirilli et al. 2008).

### Clinical Phenotype

The clinical phenotype of patients with estrogen resistance is very close to that of aromatase deficiency, except for the levels of circulating hormones and the absent response to estrogen treatment in the former (Rochira et al. 2002; Bulun 2014).

The signs and symptoms of congenital estrogen deficiency are listed in Table 4 according to the time of onset of the disease.

### Clinical Features in Infancy and Puberty

As the production of sex steroids is substantially silenced during infancy (Bay et al. 2004), the signs and symptoms of congenital estrogen deficiency become evident only at puberty and in young adults. Furthermore, the diagnosis is often overlooked



**Table 4** Clinical features of estrogen deficiency in men according to the age of onset of the disease

<b>Prepubertal estrogen deficiency</b>
Delayed bone age during late adolescence
Unfused epiphyses in young male adults
Continuing linear growth during adulthood
Lack of pubertal spurt
Lack of growth arrest during late puberty
Tall stature
Eunuchoid skeletal proportions
Failure in reaching peak bone mass (osteopenia/osteoporosis)
Elevated gonadotropins
Undetectable estradiol (aromatase deficiency)
Elevated estradiol (estrogen resistance)
<i>Not always present:</i>
Genu valgum
Scoliosis
Cryptorchidism
<i>Secondary to congenital or acquired hypogonadism:</i>
Abnormalities of external genitalia
Delayed puberty
<b>Postpubertal estrogen deficiency</b>
Osteoporosis/osteopenia
Diffuse bone pain
Reduction of sexual desire
Early-onset metabolic syndrome
Fat redistribution and accumulation (abdominal adiposity)
Dyslipidemia
Acanthosis nigricans
Nonalcoholic fatty liver disease
<i>Acquired (relative estrogen deficiency)</i>
Signs and symptoms of hypogonadism

for a variable period and is usually reached during adulthood (mean age of described cases is about 30 years) (Rochira and Carani 2009).

During infancy, the disease could be suspected only if the anamnestic information regarding mother's virilization during the last trimester of pregnancy is available or in case of affected relatives (Faustini-Fustini et al. 1999; Grumbach and Auchus 1999; Rochira and Carani 2009). History of mother's virilization during pregnancy is mandatory to prompt prenatal diagnosis by means of amniocentesis (Rochira and Carani 2009; Bulun 2014; Morel et al. 2016).

At puberty, clinical evidence for the disease remains, however, difficult to unmask due to the fact that the course of the disease is characterized by few symptoms (Rochira and Carani 2009). The most evident sign of the disease at puberty seems to be the lack of pubertal growth spurt with the height continuing

to increase linearly as in children (Lee and Witchel 1997; Faustini-Fustini et al. 1999; Grumbach and Auchus 1999; Rochira et al. 2001; Table 4). Accordingly, the pubertal growth spurt seems to be completely lacking in aromatase deficiency (Lee and Witchel 1997; Faustini-Fustini et al. 1999; Grumbach and Auchus 1999; Rochira et al. 2001). In confirmation of this, pubertal spurt was absent before starting the estradiol replacement treatment at the age of 17 (Bouillon et al. 2004) in the child with early diagnosis (Deladoey et al. 1999).

In clinical practice, however, the lack of pubertal growth spurt can be easily overlooked, since it is a very difficult sign to spot in a growing boy unless a clinician keeps the height constantly monitored on the growth chart. If we additionally consider the interindividual differences in the onset and progression of the pubertal process, aromatase deficiency appears unlikely to be suspected at puberty. Furthermore, the other two associated signs (eunuchoid body proportions of the skeleton and delayed bone maturation) that are slowly developing at that time are also very difficult to detect at an early stage of the disease. For all these reasons, estrogen deficiency is not diagnosed at puberty as well as in young adults, while it is more likely to be detected in adulthood (Rochira and Carani 2009). At present, only one case was diagnosed at birth thanks to the already available diagnosis in a relative (Deladoey et al. 1999; Bouillon et al. 2004).

In case of secondary congenital estrogen deficiency, the main clinical features are related to androgen deficiency ranging from hypogonadism at birth to overt ambiguous genitalia in case of defects of the steroidogenesis (Fluck and Pandey 2014; Auchus 2017). In case of congenital isolated hypogonadotropic hypogonadism usually the delay of the onset of puberty prompts further clinical investigations and allows reaching the diagnosis in pubertal boys (Bonomi et al. 2012).

### Clinical Features in Adulthood

Signs and symptoms of congenital estrogen deficiency remain challenging also in adulthood (Rochira and Carani 2009). Patient's stature does not stop but continues to grow at such a small rate that it does not become evident as a pathological condition. As a consequence, also the eunuchoid body proportions develop very slowly and are not easily recognized as a clinical problem. The occasional finding of unfused epiphyses at X-ray examinations in an adult man may prompt the diagnosis (Rochira and Carani 2009).

For all these reasons, the congenital estrogen deficiency remains largely undiagnosed until adulthood and its diagnosis delayed even during adulthood when signs and symptoms become more evident but are not recognized (Rochira and Carani 2009).

The hormonal phenotype of patients with estrogen resistance is characterized by elevated serum levels of estradiol, luteinizing hormone (LH), follicle-stimulating hormone (FSH), and normal serum testosterone (Smith et al. 1994, 2008; Rochira et al. 2002). Vice versa, the hormonal phenotype of aromatase-deficient men is characterized by undetectable serum estradiol, elevated gonadotropins, especially FSH, and by variable serum testosterone, ranging from values slightly below the

lower end of the normal range to values slightly above the upper limit of the normal range, but being normal in most of the cases (Rochira and Carani 2009).

The clinical phenotype of aromatase-deficient men may show interindividual differences (Rochira et al. 2002), but the following clinical features are always present in adults: tall stature, diffuse bone pain, continuing, linear growth in adulthood (if untreated), delayed bone maturation and unfused epiphyses, eunuchoid proportions of skeletal segments, genu valgum, tendency to fat abdominal accumulation, osteopenia, or osteoporosis (Rochira et al. 2002; Zirilli et al. 2008; Rochira and Carani 2009). Interindividual differences in the presentation of the disease in adulthood involve the following signs and symptoms: metabolic alterations (insulin resistance, *acanthosis nigricans*, metabolic syndrome, nonalcoholic fatty liver, dyslipidemia), reduced fertility (oligozoospermia), macroorchidism, and scoliosis (Rochira and Carani 2009).

Nothing is known about the clinical phenotype of partial aromatase deficiency in men since no cases have been described. In female, partial aromatase deficiency leads of a very mild phenotype (Lin et al. 2007; Pepe et al. 2007; Gagliardi et al. 2014).

When congenital estrogen deficiency is secondary to hypogonadism, defects of external genitalia and delayed puberty are present (Table 4).

## Diagnosis

The diagnosis of primary, congenital estrogen deficiency in men is challenging and is almost always suspected in adulthood. The presence of affected relatives and/or of a history of mother's progressive, transient virilization during the last trimester (that spontaneously resolves after delivery) may prompt earlier the diagnosis (Morishima et al. 1995; Grumbach and Auchus 1999; Rochira and Carani 2009; Bulun 2014). Mother's virilization is characterized by severe hirsutism due to the androgen precursors that accumulate as a consequence of the blockade of placental aromatase and pass into mother's blood circulation (Morishima et al. 1995; Faustini-Fustini et al. 1999; Grumbach and Auchus 1999). Conversely, the disease is rarely overlooked in females since it is easy to diagnose at birth or at puberty thanks to the presence of ambiguous genitalia and primary amenorrhea, respectively (Belgorosky et al. 2009).

The main aspects that should be checked at interview and physical examination for the diagnosis of congenital estrogen deficiency are listed in Table 5.

In particular, the presence of relatives with congenital estrogen deficiency and the consanguinity of parents could orient toward a genetic disease (Rochira and Carani 2009). Physical examination should focus on patient's height (compared to the patient's target) and further, unexpected increase in height during adulthood, the presence/absence of the growth spurt (if past data are available), and on the skeletal proportions (Rochira and Carani 2009; Table 5). Usually, pubertal development progresses in a normal fashion and virilization is normal, while the testes are rarely enlarged (normal in most of the cases) or undescended (Rochira and Carani 2009; Rochira et al. 2016; Table 5).

**Table 5** Clinical aspects to be considered during the visit for the diagnosis of congenital estrogen deficiency

<b>Specific issues to address during the clinical interview</b>
<b>Information from relatives</b>
Parents' consanguinity
Parents' height for the estimation of target stature
Maternal virilization during pregnancy
History of ambiguous genitalia and/or delayed puberty in sisters
<b>Patient's information</b>
Weight and length at birth
Estimate of his target height
Patient's early growth
Patient's pubertal development
History of cryptorchidism
Presence of offspring
Patient's sexual behavior (sexual identity, sexual orientation, sexual activity)
<b>Specific issues to address during the physical examination</b>
<b>Anthropometric parameters</b>
Height
Weight
BMI
Upper and lower skeleton segments lengths
Lower segment of the skeleton length
Arm span length
Waist and hip circumferences
<b>Other clinical examinations</b>
Degree of virilization
Testicular volume
Testes localization
Penis size
Blood pressure
Check for skeletal deformations (e.g. scoliosis or <i>genu valgum</i> )
Check for surrogates of insulin resistance ( <i>acanthosis nigricans</i> and skin tags)
<b>Clinical examinations</b>
<b>Hormonal assessment</b>
Serum estradiol
Serum testosterone
Serum LH
Serum FSH
Other serum androgens (not mandatory)
IGF-1, SHBG
<b>Biochemical analyses</b>
Serum fasting glucose and insulin
Serum lipids
Liver function

(continued)

**Table 5** (continued)

Markers of bone turnover (useful for monitoring therapy)
Sperm analysis
<b>Radiological examinations</b>
X-ray film of hand and wrist
BMD measurement by DEXA at lumbar and femoral site
X-ray film of the spine in case of back pain
Liver ultrasonography
<b>Genetic analysis</b>
Aromatase or ER $\alpha$ gene sequencing (depending on clinical data)

*LH* luteinizing hormone, *FSH* follicle-stimulating hormone

Among hormonal examinations, the measurements of serum gonadotropins, estradiol, and testosterone are mandatory, while adrenal androgens are not strictly necessary (Table 5; Rochira and Carani 2009).

The diagnosis should exclude other congenital, genetic diseases that cause severe hypogonadism and/or abnormal steroidogenesis (Table 1; Rochira and Carani 2009). The finding of very low serum testosterone in the presence of low (but not undetectable serum estradiol) allows differentiating congenital estrogen deficiency from these forms (Table 5; Rochira and Carani 2009). Furthermore, these conditions are associated to various degrees of undervirilized genitalia, which are not present in congenital estrogen deficiency (Rochira and Carani 2009; Fluck and Pandey 2014; Auchus 2017; Table 4). Among congenital primary estrogen deficiency, high versus undetectable serum estradiol helps differentiating estrogen resistance from aromatase deficiency (Table 4; Rochira and Carani 2009). For this reason, the hormonal examinations together with the estimation of bone age should be considered as the first step in the diagnosis of congenital estrogen deficiency (Rochira and Carani 2009; Table 5).

Other biochemical analyses should be addressed to obtain information on the metabolic alterations and bone health status when the clinical suspicion of primary congenital estrogen deficiency is confirmed by hormonal analyses and bone age (Table 5). Accordingly, some comorbidities such as insulin resistance, dyslipidemia, abdominal obesity, fatty liver disease, and metabolic syndrome are often associated with the congenital lack of estrogen action and require specific diagnostic approaches (Rochira et al. 2002; Maffei et al. 2004, 2007; Herrmann et al. 2005; Rochira et al. 2007; Zirilli et al. 2008; Table 5).

Even in adulthood, the strength of evidence of a diagnosis based solely on clinical data (signs, symptoms, hormonal and radiological outcomes) (Table 4) is poor due to the rarity of the disease. The limits of estradiol assay in clinical practice complicate the diagnostic issue (see paragraph below for further details). Thus, the genetic analysis is strongly suggested in order to further substantiate the clinical suspect (Table 5). Accordingly, sequencing of the aromatase gene proved effective in revealing gene defects (point mutations and/or base pair deletions) in all the patients with aromatase deficiency described so far (Smith et al. 1994, 2008; Morishima et al. 1995;

Carani et al. 1997; Bilezikian et al. 1998; Deladoey et al. 1999; Rochira et al. 2000; Herrmann et al. 2002; Pura et al. 2003; Bouillon et al. 2004; Maffei et al. 2004; Mitre Herve et al. 2004; Herrmann et al. 2005; Lanfranco et al. 2008; Zirilli et al. 2008; Rochira and Carani 2009; Baykan et al. 2013; Pignatti et al. 2013; Chen et al. 2015; Miedlich et al. 2016).

The genetic analysis is useful to solve possible doubts raised by unclear clinical pattern or by the limits of estradiol assays (which are not accurate within the male range) (Table 5). Furthermore, the genetic analysis is mandatory to differentiate congenital estrogen deficiency from other forms of rare genetic alterations of steroidogenesis that share both estrogen deficiency and some clinical features (Rochira and Carani 2009; Tables 1 and 4).

Fertility should be investigated by means of sperm analysis, while a detailed sexual interview should investigate sexual health (Carani et al. 1999, 2005; Rochira and Carani 2009; Table 5).

Bone status should be studied by means of dual energy X-ray absorptiometry (DEXA) and markers of bone turnover at baseline; this work-up allows the subsequent monitoring of the efficacy of the treatment on bone (Rochira et al. 2000, 2007, 2015; Zirilli et al. 2009; Table 5).

Finally, it should be remarked that also the pituitary function, especially growth hormone secretion, may be impaired in men with congenital estrogen deficiency (Rochira et al. 2002, 2010; Table 5).

In daily clinical practice, however, the likelihood to visit a patient with clinical features suggestive for congenital estrogen deficiency is very low, and it is highly probable that most endocrinologists will never see a patient with congenital estrogen deficiency during their career due to the rarity of these diseases (Rochira and Carani 2009).

## Therapy

Treatment of congenital estrogen deficiency is based on the administration of estrogens and is effective only in men with aromatase deficiency (Carani et al. 1997; Bilezikian et al. 1998; Rochira and Carani 2009) while does not have any effect in men with estrogen resistance (Smith et al. 1994).

In adult aromatase-deficient men high starting dose of estrogens (e.g., 25–50 µg of estradiol per day) are needed for a short period (about 6–9 months) soon after the disease has been diagnosed in order to quickly complete bone maturation, fuse epiphyses, reach growth arrest and final height and induce peak bone mass (Carani et al. 1997; Bilezikian et al. 1998; Rochira et al. 2000; Balestrieri et al. 2001; Rochira and Carani 2009). This dosage is effective in obtaining serum levels of estradiol ranging from the upper limit of the normal range and values that are slightly above the upper limit of the normal range (Rochira et al. 2000, 2001; Balestrieri et al. 2001). Once the epiphyses close and the vertical growth cease, the dosage should be reduced (about to 25 µg of estradiol per day) to reach more physiological levels of circulating estradiol (Balestrieri et al. 2001; Rochira and Carani 2009). This dosage should be considered for lifelong replacement therapy in order to ensure bone mass maintenance

and a healthy metabolic status (glucose, lipid, and liver metabolism) (Balestrieri et al. 2001; Rochira and Carani 2009). In adulthood, however, estrogen treatment is ineffective in restoring normal skeletal proportions and in improving sperm count and quality and has poor effect on fat redistribution (Rochira and Carani 2009).

If the disease is diagnosed before puberty, as desirable, estrogen treatment should be started at a very low dosage starting from the onset of puberty, and the dosage should be titrated by increasing the amount of exogenous estrogens according to the progression of puberty (Bouillon et al. 2004; Rochira and Carani 2009). This treatment is able to mimic the physiological changes in circulating estrogens occurring throughout puberty and to avoid the delay of bone maturation and the development of unbalanced skeletal proportions and to reach normal peak bone mass (Bouillon et al. 2004; Zirilli et al. 2008).

The estrogen formulation of choice for replacement therapy may change according to the physician's attitude and experience (all are effective), but the administration of estradiol should be preferred since it is measurable in serum and allows monitoring changes in circulating estradiol levels obtained after dose adjustments (Rochira et al. 2000), the latter being not possible with other formulations (e.g., conjugated estrogens) (Balestrieri et al. 2001; Rochira and Carani 2009). As far as safety is concerned, no adverse effects have been reported in aromatase-deficient men treated with estrogen replacement treatment (Rochira and Carani 2009).

As estrogen treatment has positive effects on bone mass in these men, they should be supplemented with calcium and vitamin D in order to better support the anabolic effects of estrogens on bone (Rochira and Carani 2009).

Adequate follow-up should be addressed to verify the completion of bone maturation (by X-ray films of hand and wrist), to ensure optimal estrogen dosage (by monitoring hormonal analyses, especially serum LH, FSH and estradiol), to monitor bone mass (by DEXA), and to check glucose and lipid metabolism (by monitoring metabolic parameters), especially if they were altered at baseline (Rochira and Carani 2009).

Estrogen treatment of the unique patient with estrogen deficiency was ineffective in improving bone mineral density, bone maturation, and other clinical features of the disease (Smith et al. 1994). Theoretically, the further increase of circulating estrogens might be a possible strategy to overcome the blockade of the ER in cases of partial estrogen resistance, the latter, however, have never been described.

## Acquired Estrogen Deficiency

Acquired estrogen deficiency in men usually occurs during adulthood as a consequence of mild to severe hypogonadism independently from the cause of testosterone deficiency (Table 1, Fig. 2). Acquired forms of estrogen deficiency rarely develop in infancy or at puberty, in these cases they are mainly due to pituitary disorders or surgery (e.g., craniopharyngioma) or primary (hypergonadotropic) hypogonadism (Table 1).

Estrogen deficiency occurring during adulthood is always the consequence of reduced circulating estrogens secondary to impaired secretion of androgens (Fig. 2); thus, they should be considered as conditions of relative estrogen deficiency (Trabado et al. 2011; Giton et al. 2015; Table 1, Fig. 2).

### Pathogenesis of Acquired Estrogen Deficiency

The most common condition causing relative estrogen deficiency seems to be aging, since serum estradiol decreases in parallel with testosterone with advancing age (Decaroli and Rochira 2016), as documented by several longitudinal studies in older men (Feldman et al. 2002; Wu et al. 2010; Huhtaniemi et al. 2012). Other main diseases that are strictly related to adult-onset testosterone deficiency are poor general health and obesity (Wu et al. 2010; Huhtaniemi 2014; Corona et al. 2015, 2016; Decaroli and Rochira 2016).

### Diseases Causing Hypogonadism and Relative Estrogen Deficiency

All acquired hypothalamic-pituitary diseases and testicular disorders causing hypogonadism might cause concomitant estrogen deficiency (Buvat et al. 2013; Huhtaniemi 2014; Dean et al. 2015). Furthermore, all the other clinical conditions that are associated to hypogonadism should be considered (Buvat et al. 2013; Huhtaniemi 2014; Dean et al. 2015). For a comprehensive review on the classification of male hypogonadism, see the following articles deficiency (Buvat et al. 2013; Huhtaniemi 2014; Dean et al. 2015).

### Iatrogenic Estrogen Deficiency

Estrogen deficiency might also be the consequence of therapies that are able to reduce both circulating androgens and estrogens or estrogens alone.

Androgen deprivation therapy for prostate cancer results in profound fall of serum testosterone and estrogens (Guise et al. 2007; Freedland et al. 2009). Both surgical and chemical castration are able to suppress circulating sex steroids of more than 90% with respect to baseline levels (Nishii et al. 2012). Thus, severe hypogonadism results from the administration of gonadotropin releasing hormone (GnRH) agonists and antagonists as well as from surgical castration (orchiectomy) (Guise et al. 2007; Freedland et al. 2009). Independently from the type of androgen deprivation therapy, estrogen deficiency is always severe consisting with serum estradiol levels below 5 pg/mL (Nishii et al. 2012) and is responsible for bone loss, osteoporosis, and a dramatic increase of fracture risk (Shahinian et al. 2005). In these patients, estrogen deficiency leads also to lipid alterations (Freedland et al. 2009) and hot flashes (Freedland et al. 2009), the latter being mainly due to estrogen deficiency rather than to low serum testosterone (Taylor et al. 2016).

Treatment of male breast cancer includes the use of aromatase inhibitors that are effective in reducing serum estradiol but are not able to completely suppress estrogens and to induce severe estrogen deficiency (Kuba et al. 2016). Accordingly, serum estradiol in men with breast cancer treated with aromatase inhibitors is reduced to values slightly below the normal male range (Kuba et al. 2016). Even



in these patients, pharmacologically induced estrogen deficiency increases the risk of osteoporosis and of osteoporotic fractures (Saad et al. 2008).

Aromatase inhibitors are also used to increase adult height in boys with idiopathic short stature, precocious puberty, and constitutional delay of puberty (de Ronde and de Jong 2011). The strategy to increase final height is based on the induction of estrogen deficiency in order to delay epiphyseal closure and extend the period of growth (Wit et al. 2011), but this therapeutic approach might be dangerous in terms of bone health since bone deformities have been described to develop in these young patients (Hero et al. 2010).

### Clinical Significance of Relative Estrogen Deficiency

Estrogen deficiency becomes harmful for male health only when serum estradiol falls significantly (Mellstrom et al. 2008; Finkelstein et al. 2013; Rochira et al. 2015). In particular, detrimental effects of estrogen deficiency on bone develop only when serum estradiol falls below a threshold that has been settled around 20 pg/mL (Mellstrom et al. 2008; Rochira et al. 2015) and the same seems to happen for other male physiological functions such as sexual behavior and tendency to fat mass increase (Finkelstein et al. 2013). Thus, in the presence of low serum testosterone, some health problems appear and/or worsen only when also relative estrogen deficiency is present (Decaroli and Rochira 2016).

Several studies demonstrated that not only bone health but also male sexual behavior, fat redistribution, and accumulation as well as glucose and lipid metabolism depend on estrogen deficiency (Rochira et al. 2016). How deep should hypogonadism be, in terms of low serum testosterone, to induce clinically relevant estrogen deficiency is difficult to define due also to the probable existence of interindividual differences in aromatase activity and expression and/or ERs sensitivity (Fig. 2; Rochira et al. 2006, 2015; Vottero et al. 2006). It is clear that hypogonadal men who are protected by higher circulating estrogens might be at lower risk of developing signs and symptoms specifically related to estrogen deficiency (e.g., bone loss and osteoporosis) (Rochira et al. 2006; Aguirre et al. 2015). At present, however, this is a poorly investigated issue. Only two studies speak in favor of the existence of interindividual differences in aromatase function that may exacerbate or protect from estrogen deficiency depending on decreased or increased interindividual aromatase function (Fig. 2). The first one postulates that different aromatase activity may lead to different estrogenization starting from a given serum testosterone (Vottero et al. 2006); the second shows that high aromatase activity exerts protective effect on bone loss in hypogonadal men (Aguirre et al. 2015). Further clinical data come from studies focusing on the relationship between the severity of hypogonadism and that of estrogen deficiency, another important issue in determining the degree of hypoestrogenism (Fig. 2). Hence, the study of serum estradiol in hypogonadal men with or without testosterone replacement therapy indicates that severe estrogen deficiency (<10 pg/mL) is constantly present in untreated hypogonadal men with severe hypogonadism (serum testosterone below 50 ng/dL) (Trabado et al. 2011). Furthermore, adult men with untreated isolated hypogonadotropic hypogonadism have severe estrogen deficiency, but residual very

low circulating estrogens remain detectable by liquid chromatography-tandem mass spectrometry (LC-MS/MS), while in men with untreated panhypopituitarism estrogen deficiency is associated with undetectable serum estrogens due to concomitant absence of androgens not of testicular origin (Giton et al. 2015).

The knowledge of relative estrogen deficiency in adult men remains still poor, and further researches are needed. At present the best evidence comes from the group of Joel S. Finkelstein who designed an experimental placebo-controlled study on healthy men who underwent pharmacologically induced hypogonadism by means of goserelin acetate administration. The addition of various doses of testosterone allowed obtaining five different groups of patients differing in serum testosterone. Further administration of aromatase inhibitors allowed obtaining various degree of estrogen deficiency and to unravel the role of both sex steroids (androgens and estrogen) on several male functions (Finkelstein et al. 2013, 2016; Taylor et al. 2016). This experimental setting demonstrated that sexual function needs both estrogens and androgens to be fully normal that visceral and subcutaneous fat accumulation is prompted by estrogen deficiency (Finkelstein et al. 2016) and that bone loss (Finkelstein et al. 2016) and vasomotor symptoms (Taylor et al. 2016) are mainly due to estrogen deficiency.

### Relative Estrogen Deficiency: Clinical Aspects

As relative estrogen deficiency is always a consequence of hypogonadism (with the exception of estrogen deficiency induced by aromatase inhibitors), the prevailing clinical features are those of hypogonadism (Buvat et al. 2013; Huhtaniemi 2014; Dean et al. 2015). However, among signs and symptoms of hypogonadism (i.e., reduced muscle strength, fatigue, impaired well-being, reduced energy and motivation, mood disturbances, reduced sexual desire, impaired sexual function, hot flashes, bone loss, fat accumulation) (Buvat et al. 2013; Huhtaniemi 2014; Dean et al. 2015), unraveling those mainly ascribable to estrogen deficiency remains challenging. Bone loss, osteoporosis/osteopenia, hot flashes, fat accumulation, and redistribution depend mainly on estrogen deficiency (Finkelstein et al. 2013, 2016; Taylor et al. 2016). Other clinical manifestations such as alterations of sexual desire and function probably are the consequence of both estrogen and androgen deficiency.

### To Measure or Not Estrogens in Men? The Clinical Dilemma

The diagnosis of relative estrogen deficiency is usually made within the context of the clinical work-up programmed to diagnose hypogonadism. With this in view, the diagnosis of relative estrogen deficiency should be considered as the refining of the diagnosis of hypogonadism. The diagnosis of relative estrogen deficiency is mainly based on the finding of serum estradiol below the normal male range. However, serum estradiol is not always assayed in men in the *real life* of clinical practice, either in case of suspected or of already documented hypogonadism. Current guidelines or expert committee opinions on the clinical management of hypogonadism, in fact, do not recommend the measurement of circulating estrogens within the clinical work-up for the diagnosis and follow-up of male hypogonadism (Petak et al. 2002;

Wang et al. 2009; Bhasin et al. 2010; Buvat et al. 2013; Huhtaniemi 2014; Dean et al. 2015).

Theoretically, the measurement of serum estradiol is needed in order to establish if a man with hypogonadism has concomitant relative estrogen deficiency or not and/or if replacement androgen treatment ensures normal estrogenization. The information on the presence of estrogen deficiency is useful to stratify patients risks related to hypoestrogenism (e.g., osteoporosis) (Rochira et al. 2006; Aguirre et al. 2015) and to orient about the need of further clinical examinations (e.g., DEXA). In clinical practice, however, the measurement of estradiol in men raises more doubts than answers due to pitfalls related to the measurement of estradiol in the low male normal range (Santen et al. 2015). At present only the American Association Clinical Endocrinologists suggests that androgen treatment of hypogonadal men should keep also estrogens within the male physiological range but does not provide advice on how to approach this matter from a clinical point of view (Petak et al. 2002).

Outside the context of congenital, genetic forms of estrogen deficiency, the main problem concerning estrogen deficiency lies in the poor accuracy of commercially available assays when measuring circulating estrogens within the low male range (Handelsman et al. 2014; Taylor et al. 2015). Accordingly, commercially available kits, which remain the most used method for assaying estrogens in the clinic, are not reliable in men due to their poor accuracy, insufficient sensitivity, and lack of reproducibility (Rosner et al. 2013; Demers et al. 2015). Furthermore, immunoassays provide less reproducible results compared to LC-MS/MS (Handelsman et al. 2014). Vice versa LC-MS/MS is a valuable method for measuring even very low amounts of circulating estrogens, but it is mainly used for research purposes (Huhtaniemi et al. 2012; Rosner et al. 2013). At present, the gold standard LC-MS/MS is becoming more and more available in the clinical setting (Simoni et al. 2012; Santen et al. 2015.; Simpson and Santen 2015), but at the moment, it is rarely used in clinical laboratories (Santen et al. 2015; Simpson and Santen 2015). Besides, how to interpret the results obtained by LC-MS/MS in the absence of standardized reference male ranges remains challenging (Demers et al. 2015; Santen et al. 2015; Simpson and Santen 2015). Serum estradiol levels obtained by LC-MS/MS in men, in fact, remain not validated for clinical use (Demers et al. 2015). In addition, the validation of estrogen measurement by LC-MS/MS is not so easy due to technical issues with sex steroids. Thus, the measurement of serum estrogens in men is considered unessential in clinical practice at the moment (Demers et al. 2015).

In any case, clinical laboratories offer estrogen measurement for males in the daily *real life*, independently from the type of method used and clinicians ask for estrogen measurement. Notwithstanding the poor accuracy and the advice of guidelines and experts, clinicians probably consider the measurement of serum estrogens to be of some use for their practice. Even though imprecise the information on circulating estrogens could be useful to have an idea on patient's estrogen status, on the risks related to estrogen deficiency, and on the effect of testosterone treatment on serum estrogens. Because immunoassays tend to overestimate low serum estradiol

levels, they fail in detecting all patients with relative estrogen deficiency, but when a value of serum estradiol below the normal range is obtained, the diagnosis of estrogen deficiency is more reliable. Furthermore, considering that commercially available immunoassay are more accurate for detecting elevated estradiol levels in men (Huhtaniemi et al. 2012), serum estradiol measurement may be useful to avoid overtreatment in hypogonadal men under testosterone replacement therapy.

---

## Conclusions

While the role of estrogens in men and the harmful potential of estrogen deficiency are well known, the necessity to investigate estrogen deficiency from a clinical point of view, outside the context of rare congenital, genetic forms remains to be determined. Furthermore, the information on the presence/absence of estrogen deficiency is of little help for the patient, since the only therapeutic strategy available is that of using testosterone (or other aromatizable androgens). Accordingly, estrogen therapy in men with hypogonadism increases estrogen levels but inhibits gonadotropins and further decreases endogenous testosterone production.

Information on male estrogen status will potentially be useful in the future if developed new drugs are able to selectively stimulate aromatase, increase endogenous estrogens, and help in balancing estradiol end testosterone.

At present, adjunctive information on the levels of circulating estrogens and of estrogen to testosterone ratio is of relevance for setting patient's risk of developing features strictly related to estrogen deficiency (e.g., osteoporosis) as well as to monitor the effects of testosterone on estrogens during the follow-up of hypogonadal men under testosterone replacement therapy (Matsumoto 2013).

Finally, some unresolved issues still remain. Among them, we do not know the impact of estrogen deficiency in boys before infancy. Even though circulating serum sex steroids are very low during infancy, low amounts of both androgens and estrogens may be detected by using ultrasensitive assays (Bay et al. 2004), the role of which remains to be determined. Thus, the need of estrogen treatment of a child with documented congenital estrogen deficiency is unknown. Besides, the contribution of estrogen deficiency on morbidity and mortality in men needs to be determined since the studies that consider androgens and estrogens separately are scanty (Jankowska et al. 2009; Tivesten et al. 2009; Hsu et al. 2016).

---

## Key Points

Estrogen deficiency in men is a heterogeneous clinical condition.

A systematic classification of estrogen deficiency is lacking.

Congenital estrogen deficiency is an overlooked and undermanaged, rare disease.

Relative estrogen deficiency is common among hypogonadal men.

Poor accuracy of serum estrogen assays undermines the clinical approach to estrogen deficiency in adult men.

## Summary

Genetic estrogen deficiency in men is rare while relative estrogen deficiency due to male hypogonadism is a common clinical condition. In clinical practice, however, estrogen deficiency is poorly considered due to its rarity (genetic forms) or to the fact that physicians focus their attention mainly on hypogonadism, the primary disease, in the case of relative estrogen deficiency. For these reasons, the promotion of the know-how concerning the physiological and pathological role of estrogens and their insufficiency in men is important to improve, among clinicians, the awareness on this pathological condition.

---

## Cross-References

- ▶ [Anabolic and Metabolic Effects of Testosterone and Other Androgens: Direct Effects and Role of Testosterone Metabolic Products](#)
- ▶ [Gonadotropins](#)
- ▶ [Late-Onset Hypogonadism](#)
- ▶ [Testicular Steroidogenesis](#)

---

## References

- Aguirre LE, Colleluori G, Fowler KE, Jan IZ, Villareal K, Qualls C, Robbins D, Villareal DT, Armamento-Villareal R. High aromatase activity in hypogonadal men is associated with higher spine bone mineral density, increased truncal fat and reduced lean mass. *Eur J Endocrinol.* 2015;173(2):167–74.
- Almeida M, Laurent MR, Dubois V, Claessens F, O'Brien CA, Bouillon R, Vanderschueren D, Manolagas SC. Estrogens and androgens in skeletal physiology and pathophysiology. *Physiol Rev.* 2017;97(1):135–87.
- Auchus RJ. Steroid 17-hydroxylase and 17,20-lyase deficiencies, genetic and pharmacologic. *J Steroid Biochem Mol Biol.* 2017;165(Pt A):71–8.
- Balestrieri A, Faustini-Fustini M, Rochira V, Carani C. Clinical implications and management of oestrogen deficiency in the male. *Clin Endocrinol.* 2001;54(4):431–2.
- Barakat R, Oakley O, Kim H, Jin J, Ko CJ. Extra-gonadal sites of estrogen biosynthesis and function. *BMB Rep.* 2016;49(9):488–96.
- Bay K, Andersson AM, Skakkebaek NE. Estradiol levels in prepubertal boys and girls – analytical challenges. *Int J Androl.* 2004;27(5):266–73.
- Baykan EK, Erdogan M, Ozen S, Darcan S, Saygili LF. Aromatase deficiency, a rare syndrome: case report. *J Clin Res Pediatr Endocrinol.* 2013;5(2):129–32.
- Belgorosky A, Guercio G, Pepe C, Saraco N, Rivarola MA. Genetic and clinical spectrum of aromatase deficiency in infancy, childhood and adolescence. *Horm Res.* 2009;72(6):321–30.
- Bhasin S, Cunningham GR, Hayes FJ, Matsumoto AM, Snyder PJ, Swerdloff RS, Montori VM. Testosterone therapy in men with androgen deficiency syndromes: an Endocrine Society clinical practice guideline. *J Clin Endocrinol Metab.* 2010;95(6):2536–59.
- Bhatnagar AS, Muller P, Schenkel L, Trunet PF, Beh I, Schieweck K. Inhibition of estrogen biosynthesis and its consequences on gonadotrophin secretion in the male. *J Steroid Biochem Mol Biol.* 1992;41(3–8):437–43.

- Bilezikian JP, Morishima A, Bell J, Grumbach MM. Increased bone mass as a result of estrogen therapy in a man with aromatase deficiency. *N Engl J Med.* 1998;339(9):599–603.
- Bonomi M, Libri DV, Guizzardi F, Guarducci E, Maiolo E, Pignatti E, Asci R, Persani L. New understandings of the genetic basis of isolated idiopathic central hypogonadism. *Asian J Androl.* 2012;14(1):49–56.
- Bonsall RW, Clancy AN, Michael RP. Effects of the nonsteroidal aromatase inhibitor, Fadrozole, on sexual behavior in male rats. *Horm Behav.* 1992;26(2):240–54.
- Bouillon R, Bex M, Vanderschueren D, Boonen S. Estrogens are essential for male pubertal periosteal bone expansion. *J Clin Endocrinol Metab.* 2004;89(12):6025–9.
- Bulun SE. Aromatase and estrogen receptor alpha deficiency. *Fertil Steril.* 2014;101(2):323–9.
- Buvat J, Maggi M, Guay A, Torres LO. Testosterone deficiency in men: systematic review and standard operating procedures for diagnosis and treatment. *J Sex Med.* 2013;10(1):245–84.
- Carani C, Qin K, Simoni M, Faustini-Fustini M, Serpente S, Boyd J, Korach KS, Simpson ER. Effect of testosterone and estradiol in a man with aromatase deficiency. *N Engl J Med.* 1997;337(2):91–5.
- Carani C, Rochira V, Faustini-Fustini M, Balestrieri A, Granata AR. Role of oestrogen in male sexual behaviour: insights from the natural model of aromatase deficiency. *Clin Endocrinol.* 1999;51(4):517–24.
- Carani C, Granata AR, Rochira V, Caffagni G, Aranda C, Antunez P, Maffei LE. Sex steroids and sexual desire in a man with a novel mutation of aromatase gene and hypogonadism. *Psychoneuroendocrinology.* 2005;30(5):413–7.
- Chen Z, Wang O, Nie M, Elison K, Zhou D, Li M, Jiang Y, Xia W, Meng X, Chen S, Xing X. Aromatase deficiency in a Chinese adult man caused by novel compound heterozygous CYP19A1 mutations: effects of estrogen replacement therapy on the bone, lipid, liver and glucose metabolism. *Mol Cell Endocrinol.* 2015;399:32–42.
- Corona G, Vignozzi L, Sforza A, Mannucci E, Maggi M. Obesity and late-onset hypogonadism. *Mol Cell Endocrinol.* 2015;418(Pt 2):120–33.
- Corona G, Maseroli E, Rastrelli G, Francomano D, Aversa A, Hackett GI, Ferri S, Sforza A, Maggi M. Is late-onset hypogonadotropic hypogonadism a specific age-dependent disease, or merely an epiphenomenon caused by accumulating disease-burden? *Minerva Endocrinol.* 2016;41(2):196–210.
- Couse JF, Korach KS. Estrogen receptor null mice: what have we learned and where will they lead us? *Endocr Rev.* 1999;20(3):358–417.
- Dean JD, McMahon CG, Guay AT, Morgentaler A, Althof SE, Becher EF, Bivalacqua TJ, Burnett AL, Buvat J, El Meliegy A, Hellstrom WJ, Jannini EA, Maggi M, McCullough A, Torres LO, Zitzmann M. The International Society for sexual medicine's process of care for the assessment and management of testosterone deficiency in adult men. *J Sex Med.* 2015;12(8):1660–86.
- Decaroli MC, Rochira V. Aging and sex hormones in males. *Virulence.* 2016;1–26. DOI: 10.1080/21505594.2016.1259053
- Deladoey J, Fluck C, Bex M, Yoshimura N, Harada N, Mullis PE. Aromatase deficiency caused by a novel P450arom gene mutation: impact of absent estrogen production on serum gonadotropin concentration in a boy. *J Clin Endocrinol Metab.* 1999;84(11):4050–4.
- Demers LM, Hankinson SE, Haymond S, Key T, Rosner W, Santen RJ, Stanczyk FZ, Vesper HW, Ziegler RG. Measuring estrogen exposure and metabolism: workshop recommendations on clinical issues. *J Clin Endocrinol Metab.* 2015;100(6):2165–70.
- Drummond AE, Fuller PJ. The importance of ERbeta signalling in the ovary. *J Endocrinol.* 2010;205(1):15–23.
- Eshet R, Maor G, Ben Ari T, Ben Eliezer M, Gat-Yablonski G, Phillip M. The aromatase inhibitor letrozole increases epiphyseal growth plate height and tibial length in peripubertal male mice. *J Endocrinol.* 2004;182(1):165–72.
- Eyster KM. The estrogen receptors: an overview from different perspectives. *Methods Mol Biol.* 2016;1366:1–10.

- Faustini-Fustini M, Rochira V, Carani C. Oestrogen deficiency in men: where are we today? *Eur J Endocrinol.* 1999;140(2):111–29.
- Feldman HA, Longcope C, Derby CA, Johannes CB, Araujo AB, Coviello AD, Bremner WJ, McKinlay JB. Age trends in the level of serum testosterone and other hormones in middle-aged men: longitudinal results from the Massachusetts male aging study. *J Clin Endocrinol Metab.* 2002;87(2):589–98.
- Finkelstein JS, Yu EW, Burnett-Bowie SA. Gonadal steroids and body composition, strength, and sexual function in men. *N Engl J Med.* 2013;369(25):2457.
- Finkelstein JS, Lee H, Leder BZ, Burnett-Bowie SA, Goldstein DW, Hahn CW, Hirsch SC, Linker A, Perros N, Servais AB, Taylor AP, Webb ML, Youngner JM, Yu EW. Gonadal steroid-dependent effects on bone turnover and bone mineral density in men. *J Clin Invest.* 2016;126(3):1114–25.
- Fisher CR, Graves KH, Parlow AF, Simpson ER. Characterization of mice deficient in aromatase (ArKO) because of targeted disruption of the *cyp19* gene. *Proc Natl Acad Sci U S A.* 1998;95(12):6965–70.
- Fluck CE, Pandey AV. Steroidogenesis of the testis – new genes and pathways. *Ann Endocrinol (Paris).* 2014;75(2):40–7.
- Freedland SJ, Eastham J, Shore N. Androgen deprivation therapy and estrogen deficiency induced adverse effects in the treatment of prostate cancer. *Prostate Cancer Prostatic Dis.* 2009;12(4):333–8.
- Gagliardi L, Scott HS, Feng J, Torpy DJ. A case of Aromatase deficiency due to a novel CYP19A1 mutation. *BMC Endocr Disord.* 2014;14:16.
- Giton F, Trabado S, Maione L, Sarfati J, Le Bouc Y, Brailly-Tabard S, Fiet J, Young J. Sex steroids, precursors, and metabolite deficiencies in men with isolated hypogonadotropic hypogonadism and panhypopituitarism: a GCMS-based comparative study. *J Clin Endocrinol Metab.* 2015;100(2):E292–6.
- Gruber CJ, Tschugguel W, Schneeberger C, Huber JC. Production and actions of estrogens. *N Engl J Med.* 2002;346(5):340–52.
- Grumbach MM, Auchus RJ. Estrogen: consequences and implications of human mutations in synthesis and action. *J Clin Endocrinol Metab.* 1999;84(12):4677–94.
- Guise TA, Oefelein MG, Eastham JA, Cookson MS, Higano CS, Smith MR. Estrogenic side effects of androgen deprivation therapy. *Rev Urol.* 2007;9(4):163–80.
- Hamilton KJ, Arao Y, Korach KS. Estrogen hormone physiology: reproductive findings from estrogen receptor mutant mice. *Reprod Biol.* 2014;14(1):3–8.
- Hammes SR, Levin ER. Minireview: recent advances in extranuclear steroid receptor actions. *Endocrinology.* 2011;152(12):4489–95.
- Handelsman DJ, Newman JD, Jimenez M, McLachlan R, Sartorius G, Jones GR. Performance of direct estradiol immunoassays with human male serum samples. *Clin Chem.* 2014;60(3):510–7.
- Harada N. Cloning of a complete cDNA encoding human aromatase: immunochemical identification and sequence analysis. *Biochem Biophys Res Commun.* 1988;156(2):725–32.
- Harada N, Yamada K, Saito K, Kibe N, Dohmae S, Takagi Y. Structural characterization of the human estrogen synthetase (aromatase) gene. *Biochem Biophys Res Commun.* 1990;166(1):365–72.
- Harada N, Utsumi T, Takagi Y. Tissue-specific expression of the human aromatase cytochrome P-450 gene by alternative use of multiple exons 1 and promoters, and switching of tissue-specific exons 1 in carcinogenesis. *Proc Natl Acad Sci U S A.* 1993;90(23):11312–6.
- Hayes FJ, Seminara SB, Decruz S, Boepple PA, Crowley Jr WF. Aromatase inhibition in the human male reveals a hypothalamic site of estrogen feedback. *J Clin Endocrinol Metab.* 2000;85(9):3027–35.
- Heldring N, Pike A, Andersson S, Matthews J, Cheng G, Hartman J, Tujague M, Strom A, Treuter E, Warner M, Gustafsson JA. Estrogen receptors: how do they signal and what are their targets. *Physiol Rev.* 2007;87(3):905–31.

- Hero M, Toivainen-Salo S, Wickman S, Makitie O, Dunkel L. Vertebral morphology in aromatase inhibitor-treated males with idiopathic short stature or constitutional delay of puberty. *J Bone Miner Res.* 2010;25(7):1536–43.
- Herrmann BL, Saller B, Janssen OE, Gocke P, Bockisch A, Sperling H, Mann K, Broecker M. Impact of estrogen replacement therapy in a male with congenital aromatase deficiency caused by a novel mutation in the CYP19 gene. *J Clin Endocrinol Metab.* 2002;87(12):5476–84.
- Herrmann BL, Janssen OE, Hahn S, Broecker-Preuss M, Mann K. Effects of estrogen replacement therapy on bone and glucose metabolism in a male with congenital aromatase deficiency. *Horm Metab Res.* 2005;37(3):178–83.
- Hsu B, Cumming RG, Naganathan V, Blyth FM, Le Couteur DG, Hirani V, Waite LM, Seibel MJ, Handelsman DJ. Temporal changes in androgens and estrogens are associated with all-cause and cause-specific mortality in older men. *J Clin Endocrinol Metab.* 2016;101(5):2201–10.
- Huhtaniemi I. Late-onset hypogonadism: current concepts and controversies of pathogenesis, diagnosis and treatment. *Asian J Androl.* 2014;16(2):192–202.
- Huhtaniemi IT, Tajar A, Lee DM, O'Neill TW, Finn JD, Bartfai G, Boonen S, Casanueva FF, Giwercman A, Han TS, Kula K, Labrie F, Lean ME, Pendleton N, Punab M, Silman AJ, Vanderschueren D, Forti G, Wu FC. Comparison of serum testosterone and estradiol measurements in 3174 European men using platform immunoassay and mass spectrometry; relevance for the diagnostics in aging men. *Eur J Endocrinol.* 2012;166(6):983–91.
- Jankowska EA, Rozyntryt P, Ponikowska B, Hartmann O, Kustrzycka-Kratochwil D, Reczuch K, Nowak J, Borodulin-Nadzieja L, Polonski L, Banasiak W, Poole-Wilson PA, Anker SD, Ponikowski P. Circulating estradiol and mortality in men with systolic chronic heart failure. *JAMA.* 2009;301(18):1892–901.
- Jones ME, Boon WC, Proietto J, Simpson ER. Of mice and men: the evolving phenotype of aromatase deficiency. *Trends Endocrinol Metab.* 2006;17(2):55–64.
- Krege JH, Hodgin JB, Couse JF, Enmark E, Warner M, Mahler JF, Sar M, Korach KS, Gustafsson JA, Smithies O. Generation and reproductive phenotypes of mice lacking estrogen receptor beta. *Proc Natl Acad Sci U S A.* 1998;95(26):15677–82.
- Kuba S, Ishida M, Oikawa M, Nakamura Y, Yamanouchi K, Tokunaga E, Taguchi K, Esaki T, Eguchi S, Ohno S. Aromatase inhibitors with or without luteinizing hormone-releasing hormone agonist for metastatic male breast cancer: report of four cases and review of the literature. *Breast Cancer.* 2016;23(6):945–9.
- Lanfranco F, Zirilli L, Baldi M, Pignatti E, Corneli G, Ghigo E, Aimaretti G, Carani C, Rochira V. A novel mutation in the human aromatase gene: insights on the relationship among serum estradiol, longitudinal growth and bone mineral density in an adult man under estrogen replacement treatment. *Bone.* 2008;43(3):628–35.
- Lee PA, Witchel SF. The influence of estrogen on growth. *Curr Opin Pediatr.* 1997;9(4):431–6.
- Lin L, Ercan O, Raza J, Burren CP, Creighton SM, Auchus RJ, Dattani MT, Achermann JC. Variable phenotypes associated with aromatase (CYP19) insufficiency in humans. *J Clin Endocrinol Metab.* 2007;92(3):982–90.
- Lubahn DB, Moyer JS, Golding TS, Couse JF, Korach KS, Smithies O. Alteration of reproductive function but not prenatal sexual development after insertional disruption of the mouse estrogen receptor gene. *Proc Natl Acad Sci U S A.* 1993;90(23):11162–6.
- Maffei L, Murata Y, Rochira V, Tubert G, Aranda C, Vazquez M, Clyne CD, Davis S, Simpson ER, Carani C. Dysmetabolic syndrome in a man with a novel mutation of the aromatase gene: effects of testosterone, alendronate, and estradiol treatment. *J Clin Endocrinol Metab.* 2004;89(1):61–70.
- Maffei L, Rochira V, Zirilli L, Antunez P, Aranda C, Fabre B, Simone ML, Pignatti E, Simpson ER, Houssami S, Clyne CD, Carani C. A novel compound heterozygous mutation of the aromatase gene in an adult man: reinforced evidence on the relationship between congenital oestrogen deficiency, adiposity and the metabolic syndrome. *Clin Endocrinol.* 2007;67(2):218–24.
- Matsumoto AM. Reproductive endocrinology: estrogens – not just female hormones. *Nat Rev Endocrinol.* 2013;9(12):693–4.



- Mellstrom D, Vandenput L, Mallmin H, Holmberg AH, Lorentzon M, Oden A, Johansson H, Orwoll ES, Labrie F, Karlsson MK, Ljunggren O, Ohlsson C. Older men with low serum estradiol and high serum SHBG have an increased risk of fractures. *J Bone Miner Res.* 2008; 23(10):1552–60.
- Miedlich SU, Karamooz N, Hammes SR. Aromatase deficiency in a male patient – case report and review of the literature. *Bone.* 2016;93:181–6.
- Miller WL, Auchus RJ. The molecular biology, biochemistry, and physiology of human steroidogenesis and its disorders. *Endocr Rev.* 2011;32(1):81–151.
- Mittre Herve MH, Kottler ML, Pura M. Human gene mutations. Gene symbol: CYP19. Disease: aromatase deficiency. *Hum Genet.* 2004;114(2):224.
- Morel Y, Roucher F, Plotton I, Goursaud C, Tardy V, Mallet D. Evolution of steroids during pregnancy: maternal, placental and fetal synthesis. *Ann Endocrinol (Paris).* 2016;77(2):82–9.
- Morishima A, Grumbach MM, Simpson ER, Fisher C, Qin K. Aromatase deficiency in male and female siblings caused by a novel mutation and the physiological role of estrogens. *J Clin Endocrinol Metab.* 1995;80(12):3689–98.
- Nishii M, Nomura M, Sekine Y, Koike H, Matsui H, Shibata Y, Ito K, Oyama T, Suzuki K. Luteinizing hormone (LH)-releasing hormone agonist reduces serum adrenal androgen levels in prostate cancer patients: implications for the effect of LH on the adrenal glands. *J Androl.* 2012;33(6):1233–8.
- Ogawa S, Chester AE, Hewitt SC, Walker VR, Gustafsson JA, Smithies O, Korach KS, Pfaff DW. Abolition of male sexual behaviors in mice lacking estrogen receptors alpha and beta (alpha beta ERKO). *Proc Natl Acad Sci U S A.* 2000;97(26):14737–41.
- Pepe CM, Saraco NI, Baquedano MS, Guercio G, Vaiani E, Marino R, Pandey AV, Fluck CE, Rivarola MA, Belgorosky A. The cytochrome P450 aromatase lacking exon 5 is associated with a phenotype of nonclassic aromatase deficiency and is also present in normal human steroidogenic tissues. *Clin Endocrinol.* 2007;67(5):698–705.
- Petak SM, Nankin HR, Spark RF, Swerdloff RS, Rodriguez-Rigau LJ. American Association of Clinical Endocrinologists Medical Guidelines for clinical practice for the evaluation and treatment of hypogonadism in adult male patients – 2002 update. *Endocr Pract.* 2002;8(6):440–56.
- Pignatti EU, Kursad, Kartal E, Ajlouni K, Khawaja N, Carani C, Marino M, Simoni M, Vighi E, Rochira V. Complete aromatase deficiency in four adult men: detection of a novel mutation and two known mutations in the *CYP19A1* gene. *Endocr Abstr.* 2013;32(32):P640.
- Pura M, Mittre H, Carreau S, Kottler ML. Clinical findings in an adult man with a novel mutation in the aromatase gene. Abstract Book of the 85th Annual Meeting of the Endocrine Society; 2003. Philadelphia: Endocrine Society.
- Raven G, de Jong FH, Kaufman JM, de Ronde W. In men, peripheral estradiol levels directly reflect the action of estrogens at the hypothalamo-pituitary level to inhibit gonadotropin secretion. *J Clin Endocrinol Metab.* 2006;91(9):3324–8.
- Rey RA, Grinspon RP, Gottlieb S, Pasqualini T, Knoblovits P, Aszpis S, Pacenza N, Stewart Usher J, Bergada I, Campo SM. Male hypogonadism: an extended classification based on a developmental, endocrine physiology-based approach. *Andrology.* 2013;1(1):3–16.
- Rissman EF, Wersinger SR, Taylor JA, Lubahn DB. Estrogen receptor function as revealed by knockout studies: neuroendocrine and behavioral aspects. *Horm Behav.* 1997;31(3):232–43.
- Rochira V, Carani C. Aromatase deficiency in men: a clinical perspective. *Nat Rev Endocrinol.* 2009;5(10):559–68.
- Rochira V, Faustini-Fustini M, Balestrieri A, Carani C. Estrogen replacement therapy in a man with congenital aromatase deficiency: effects of different doses of transdermal estradiol on bone mineral density and hormonal parameters. *J Clin Endocrinol Metab.* 2000;85(5):1841–5.
- Rochira V, Balestrieri A, Faustini-Fustini M, Carani C. Role of estrogen on bone in the human male: insights from the natural models of congenital estrogen deficiency. *Mol Cell Endocrinol.* 2001;178(1–2):215–20.

- Rochira V, Balestrieri A, Faustini-Fustini M, Borgato S, Beck-Peccoz P, Carani C. Pituitary function in a man with congenital aromatase deficiency: effect of different doses of transdermal E2 on basal and stimulated pituitary hormones. *J Clin Endocrinol Metab.* 2002a;87(6):2857–62.
- Rochira V, Balestrieri A, Madeo B, Spaggiari A, Carani C. Congenital estrogen deficiency in men: a new syndrome with different phenotypes; clinical and therapeutic implications in men. *Mol Cell Endocrinol.* 2002b;193(1–2):19–28.
- Rochira V, Granata AR, Madeo B, Zirilli L, Rossi G, Carani C. Estrogens in males: what have we learned in the last 10 years? *Asian J Androl.* 2005;7(1):3–20.
- Rochira V, Balestrieri A, Madeo B, Zirilli L, Granata AR, Carani C. Osteoporosis and male age-related hypogonadism: role of sex steroids on bone (patho)physiology. *Eur J Endocrinol.* 2006a;154(2):175–85.
- Rochira V, Zirilli L, Genazzani AD, Balestrieri A, Aranda C, Fabre B, Antunez P, Diazzi C, Carani C, Maffei L. Hypothalamic-pituitary-gonadal axis in two men with aromatase deficiency: evidence that circulating estrogens are required at the hypothalamic level for the integrity of gonadotropin negative feedback. *Eur J Endocrinol.* 2006b;155(4):513–22.
- Rochira V, Madeo B, Zirilli L, Caffagni G, Maffei L, Carani C. Oestradiol replacement treatment and glucose homeostasis in two men with congenital aromatase deficiency: evidence for a role of oestradiol and sex steroids imbalance on insulin sensitivity in men. *Diabet Med.* 2007a;24(12):1491–5.
- Rochira V, Zirilli L, Madeo B, Aranda C, Caffagni G, Fabre B, Montangero VE, Roldan EJ, Maffei L, Carani C. Skeletal effects of long-term estrogen and testosterone replacement treatment in a man with congenital aromatase deficiency: evidences of a priming effect of estrogen for sex steroids action on bone. *Bone.* 2007b;40(6):1662–8.
- Rochira V, Zirilli L, Maffei L, Premrou V, Aranda C, Baldi M, Ghigo E, Aimaretti G, Carani C, Lanfranco F. Tall stature without growth hormone: four male patients with aromatase deficiency. *J Clin Endocrinol Metab.* 2010;95(4):1626–33.
- Rochira V, Santi D, Carani C. Pathophysiology of estrogen action in men. In: Behre ENHM, editor. *Testosterone action, deficiency, substitution.* Cambridge, UK: Cambridge University Press; 2012.
- Rochira V, Kara E, Carani C. The endocrine role of estrogens on human male skeleton. *Int J Endocrinol.* 2015;2015:165215.
- Rochira V, Madeo B, Diazzi C, Zirilli L, Santi D, Carani C. Estrogens and male reproduction. In: De Groot LJ, Chrousos G, Dungan K, Feingold KR, Grossman A, Hershman JM, Koch C, Korbonits M, McLachlan R, New M, Purnell J, Rebar R, Singer F, Vinik A, editors. *Endotext.* South Dartmouth: MDText.com; 2016.
- de Ronde W, de Jong FH. Aromatase inhibitors in men: effects and therapeutic options. *Reprod Biol Endocrinol.* 2011;9:93.
- Rosner W, Hankinson SE, Sluss PM, Vesper HW, Wierman ME. Challenges to the measurement of estradiol: an endocrine society position statement. *J Clin Endocrinol Metab.* 2013;98(4):1376–87.
- Saad F, Adachi JD, Brown JP, Canning LA, Gelmon KA, Josse RG, Pritchard KI. Cancer treatment-induced bone loss in breast and prostate cancer. *J Clin Oncol.* 2008;26(33):5465–76.
- Santen RJ, Demers LM, Ziegler RG. Workshop on measuring estrogen exposure and metabolism: summary of the presentations. *Steroids.* 2015;99(Pt A):1–7.
- Seralini G, Moslemi S. Aromatase inhibitors: past, present and future. *Mol Cell Endocrinol.* 2001;178(1–2):117–31.
- Shahinian VB, Kuo YF, Freeman JL, Goodwin JS. Risk of fracture after androgen deprivation for prostate cancer. *N Engl J Med.* 2005;352(2):154–64.
- Sharma G, Hu C, Brigman JL, Zhu G, Hathaway HJ, Prossnitz ER. GPER deficiency in male mice results in insulin resistance, dyslipidemia, and a proinflammatory state. *Endocrinology.* 2013;154(11):4136–45.
- Simoni M, Fanelli F, Roli L, Pagotto U. Methodology for measuring testosterone, dihydrotestosterone and sex hormone-binding globulin in a clinical setting. In: Behre ENHM, editor.

- Testosterone action, deficiency, substitution. Cambridge, UK: Cambridge University Press; 2012. p. 60–86.
- Simpson ER, Jones ME. Of mice and men: the many guises of estrogens. *Ernst Schering Found Symp Proc.* 2006;1:45–67.
- Simpson E, Santen RJ. Celebrating 75 years of oestradiol. *J Mol Endocrinol.* 2015;55(3):T1–20.
- Simpson ER, Mahendroo MS, Means GD, Kilgore MW, Hinshelwood MM, Graham-Lorence S, Amareh B, Ito Y, Fisher CR, Michael MD, et al. Aromatase cytochrome P450, the enzyme responsible for estrogen biosynthesis. *Endocr Rev.* 1994;15(3):342–55.
- Simpson ER, Michael MD, Agarwal VR, Hinshelwood MM, Bulun SE, Zhao Y. Cytochromes P450 11: expression of the CYP19 (aromatase) gene: an unusual case of alternative promoter usage. *FASEB J.* 1997;11(1):29–36.
- Simpson E, Rubin G, Clyne C, Robertson K, O'Donnell L, Davis S, Jones M. Local estrogen biosynthesis in males and females. *Endocr Relat Cancer.* 1999;6(2):131–7.
- Simpson ER, Misso M, Hewitt KN, Hill RA, Boon WC, Jones ME, Kovacic A, Zhou J, Clyne CD. Estrogen – the good, the bad, and the unexpected. *Endocr Rev.* 2005;26(3):322–30.
- Smith EP, Boyd J, Frank GR, Takahashi H, Cohen RM, Specker B, Williams TC, Lubahn DB, Korach KS. Estrogen resistance caused by a mutation in the estrogen-receptor gene in a man. *N Engl J Med.* 1994;331(16):1056–61.
- Smith EP, Specker B, Bachrach BE, Kimbro KS, Li XJ, Young MF, Fedarko NS, Abuzzahab MJ, Frank GR, Cohen RM, Lubahn DB, Korach KS. Impact on bone of an estrogen receptor-alpha gene loss of function mutation. *J Clin Endocrinol Metab.* 2008;93(8):3088–96.
- Taylor AE, Keevil B, Huhtaniemi IT. Mass spectrometry and immunoassay: how to measure steroid hormones today and tomorrow. *Eur J Endocrinol.* 2015;173(2):D1–12.
- Taylor AP, Lee H, Webb ML, Joffe H, Finkelstein JS. Effects of testosterone and estradiol deficiency on vasomotor symptoms in hypogonadal men. *J Clin Endocrinol Metab.* 2016; 101(9):3479–86.
- Tivesten A, Vandenput L, Labrie F, Karlsson MK, Ljunggren O, Mellstrom D, Ohlsson C. Low serum testosterone and estradiol predict mortality in elderly men. *J Clin Endocrinol Metab.* 2009;94(7):2482–8.
- Trabado S, Maione L, Salenave S, Baron S, Galland F, Bry-Gauillard H, Guiochon-Mantel A, Chanson P, Pitteloud N, Sinisi AA, Brailly-Tabard S, Young J. Estradiol levels in men with congenital hypogonadotropic hypogonadism and the effects of different modalities of hormonal treatment. *Fertil Steril.* 2011;95(7):2324–9. 2329 e2321–2323.
- Turner KJ, Morley M, Atanassova N, Swanston ID, Sharpe RM. Effect of chronic administration of an aromatase inhibitor to adult male rats on pituitary and testicular function and fertility. *J Endocrinol.* 2000;164(2):225–38.
- Vagell ME, McGinnis MY. The role of aromatization in the restoration of male rat reproductive behavior. *J Neuroendocrinol.* 1997;9(6):415–21.
- Vanderschueren D, van Herck E, Nijs J, Ederveen AG, De Coster R, Bouillon R. Aromatase inhibition impairs skeletal modeling and decreases bone mineral density in growing male rats. *Endocrinology.* 1997;138(6):2301–7.
- Vanderschueren D, Laurent MR, Claessens F, Gielen E, Lagerquist MK, Vandenput L, Borjesson AE, Ohlsson C. Sex steroid actions in male bone. *Endocr Rev.* 2014;35(6):906–60.
- Vottero A, Rochira V, Capelletti M, Viani I, Zirilli L, Neri TM, Carani C, Bernasconi S, Ghizzoni L. Aromatase is differentially expressed in peripheral blood leukocytes from children, and adult female and male subjects. *Eur J Endocrinol.* 2006;154(3):425–31.
- Wang C, Nieschlag E, Swerdloff R, Behre HM, Hellstrom WJ, Gooren LJ, Kaufman JM, Legros JJ, Lunenfeld B, Morales A, Morley JE, Schulman C, Thompson IM, Weidner W, Wu FC. Investigation, treatment, and monitoring of late-onset hypogonadism in males: ISA, ISSAM, EAU, EAA, and ASA recommendations. *J Androl.* 2009;30(1):1–9.
- Wit JM, Hero M, Nunez SB. Aromatase inhibitors in pediatrics. *Nat Rev Endocrinol.* 2011;8(3): 135–47.

- Wu FC, Tajar A, Beynon JM, Pye SR, Silman AJ, Finn JD, O'Neill TW, Bartfai G, Casanueva FF, Forti G, Giwercman A, Han TS, Kula K, Lean ME, Pendleton N, Punab M, Boonen S, Vanderschueren D, Labrie F, Huhtaniemi IT. Identification of late-onset hypogonadism in middle-aged and elderly men. *N Engl J Med.* 2010;363(2):123–35.
- Zirilli L, Rochira V, Diazzi C, Caffagni G, Carani C. Human models of aromatase deficiency. *J Steroid Biochem Mol Biol.* 2008;109(3–5):212–8.
- Zirilli L, Maffei L, Meunier PJ, Chavassieux P, Carani C, Rochira V. The effects of long-term raloxifene and estradiol treatments on bone in a patient with congenital aromatase deficiency. *Bone.* 2009;45(5):827–32.

Vincenzo Rochira

---

## Abstract

Serum testosterone is often lower than normal in patients with acute or chronic systemic diseases. The underlying mechanisms involved in the reduced testosterone secretion depend on the type of systemic disease; thus, many pathogenetic mechanisms might be involved. These mechanisms involve the hypothalamus and the pituitary (secondary hypogonadism), the testis (primary hypogonadism), or both. The resulting low-serum testosterone could be reversible or not depending on the pathogenetic mechanism. Furthermore, the relationships between hypogonadism and the systemic disease are complex since these two clinical conditions may interact with each other in a bidirectional interplay. How to interpret low-serum testosterone in systemic diseases is not easy and univocal. Biochemical hypogonadism should be differentiated into overt clinical hypogonadism and functional hypogonadism, and testosterone treatment should be offered taking into account the primary systemic disease and the possible beneficial or harmful effect on it, as well as the presence of signs and symptoms of hypogonadism. In this chapter the main systemic illnesses associated with hypogonadism will be discussed together with their underlying pathogenetic mechanisms, clinical significance, relevance, and clinical and practical implications.

---

## Keywords

Androgen deficiency • Health status • Frailty • Multimorbidity • Systemic illness • Hypogonadism • Chronic disease • Testosterone deficiency

---

V. Rochira (✉)

Department of Biomedical, Metabolic and Neural Sciences, University of Modena and Reggio Emilia, Azienda Ospedaliero-Universitaria di Modena, Ospedale Civile di Baggiovara, Modena, Italy

e-mail: [vincenzo.rochira@unimore.it](mailto:vincenzo.rochira@unimore.it)

### Abbreviations

AIDS	Acquired ImmunoDeficiency Syndrome
BMD	Bone mineral density
BMI	Body mass index
COPD	Chronic obstructive pulmonary disease
FEV1	Forced expiratory volume in 1 second
FSH	Follicle-stimulating hormone
GnRH	Gonadotropin-releasing hormone
HAART	Highly active antiretroviral therapy
hCG	Human chorionic gonadotropin
HIV	Human immunodeficiency virus
HPG	Hypothalamic-pituitary-gonadal
LC-MS/MS	Liquid chromatography-tandem mass spectrometry
LH	Luteinizing hormone
MRI	Magnetic resonance imaging
NAFLD	Nonalcoholic fatty liver disease
OSAS	Obstructive sleep apnea syndrome
SHBG	Sex hormone-binding globulin
T2DM	Type 2 diabetes mellitus

### Contents

Introduction .....	831
Which Came First, the Systemic Disease or Testosterone Deficiency? .....	832
Male Hypogonadism and Systemic Illness: Acute Versus Chronic Diseases .....	833
Acute Illnesses .....	833
Chronic Illness .....	837
Respiratory Diseases .....	839
Chronic Obstructive Pulmonary Disease (COPD) .....	839
Other Respiratory Diseases .....	842
Chronic Kidney Disease .....	843
Clinical Implications .....	844
Liver Diseases .....	845
Nonalcoholic Fatty Liver Disease (NAFLD) .....	845
Chronic Viral Hepatitis .....	846
Alcoholism .....	847
Liver Cirrhosis .....	848
Iron Overload .....	850
Hereditary Hemochromatosis .....	850
Thalassemia .....	852
Endocrine, Metabolic Diseases .....	854
Overweight, Obesity, the Metabolic Syndrome, and Type 2 Diabetes Mellitus .....	854
Other Endocrine Diseases .....	857
Cardiovascular Disease .....	857
Hypertension .....	857
Heart Failure .....	858
Testosterone Treatment and Cardiovascular Disease .....	858

Infectious Diseases .....	859
HIV Infection .....	859
Drugs and/or Treatments Causing Hypogonadism .....	863
Conclusions .....	863
Summary .....	864
Cross-References .....	865
References .....	865

---

## Introduction

Large cohort studies have demonstrated that testosterone deficiency in men is associated with several alterations of biochemical and hormonal parameters, with various types of pathological correlates, but also with a variety of clinical conditions (acute illness, infectious diseases, and chronic diseases involving pulmonary, kidney, heart function, etc.), especially in aging men (Decaroli and Rochira 2016). Among them various systemic diseases are particularly related to hypogonadism (Karagiannis and Harsoulis 2005; Kalyani et al. 2007; Sartorius and Handelsman 2012). To what extent systemic illnesses cause genuine hypogonadism, or vice versa, the finding of low-serum testosterone (biochemical hypogonadism) that represents an epiphenomenon of the primary systemic disease (Corona et al. 2016a) remains to be ascertained in most of the cases. The cause-effect relationship between systemic disease and hypogonadism, in fact, is fully understood only for some clinical conditions but remains doubtful for several others. For this reason the management of low-serum testosterone within the clinical context of a preexisting systemic disease is challenging and may change according to the type of primary systemic disease (Buvat et al. 2013; Huhtaniemi 2014; Decaroli and Rochira 2016; Corona et al. 2016a).

This chapter deals with the relationships between systemic diseases and hypogonadism in men. Systemic diseases might impact on testosterone secretion by acting at different levels on the hypothalamic-pituitary gonadal (HPG) axis (i.e., the hypothalamic-pituitary unit, the testis, or both) as well as by inducing different changes depending on the underlying pathogenetic mechanism. It should also be noticed that the mechanisms implicated in the genesis of hypogonadism might be multiple and that all the levels of the HPG axis may be involved. Furthermore, hypogonadism linked to systemic disease may or may not be reversible, depending on the type of the disease and the functional or organic origin of the hypogonadism.

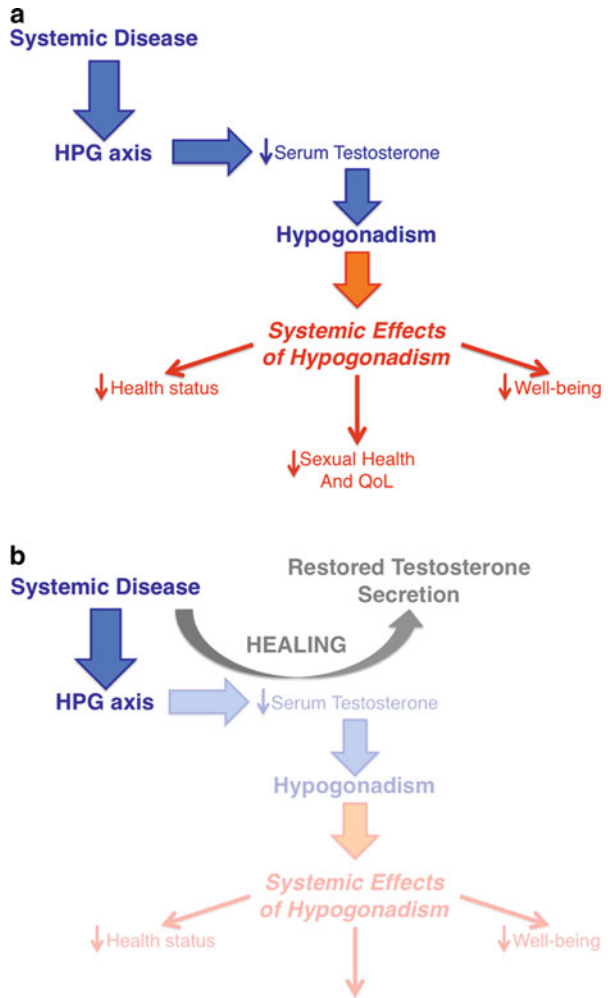
Finally, hypogonadism could be underestimated in terms of overlooked and/or delayed diagnosis in patients with systemic diseases, thus resulting in clinical undermanagement. The undermanagement might also depend on the fact that physicians focus their attention mainly on the primary, systemic disease, especially when the latter has serious consequences on patients' health status and prognosis, leaving hypogonadism in the background. This has important consequences on patient's clinical condition and well-being.

### Which Came First, the Systemic Disease or Testosterone Deficiency?

As the cause-effect relationship existing between the systemic disease and testosterone deficiency might be doubtful and differ according to the underlying systemic disease, it is difficult also to establish, in clinical practice, if hypogonadism was a preexisting condition or subsequent to the onset of the systemic disease. There are many possibilities depending on the type of the systemic disease and its effects on the HPG axis. The cause-effect relationship could be unidirectional and in this case hypogonadism is a direct consequence of the underlying systemic disease (Fig. 1a).

Hypogonadism secondary to iron overload (i.e., thalassemia and hemochromatosis), for example, is directly due to iron deposition within endocrine glands as a

**Fig. 1** Different types of relationships linking the systemic disease with hypogonadism. The cause-effect relationship may be disclosed by well-documented pathogenetic mechanisms (a) or by the demonstration of restored normal testosterone secretion after the successful treatment of the systemic disease (b). HPG hypothalamic-pituitary gonadal





consequence of the primary systemic disease. In other cases, it is possible to verify that the systemic disease precedes the occurrence of hypogonadism a posteriori, since androgen deficiency disappears completely or in part after successful treatment of the systemic disease (Fig. 1b). This is the case of acute illnesses for which serum testosterone remains lower than normal until the disease resolves and of chronic diseases for which the successful treatment results in the reversion of hypogonadism, such as chronic liver and renal insufficiency after organ transplantation.

A third possibility is that the two diseases interact with each other in a bidirectional fashion. Hence, the systemic disease influences the level of circulating testosterone, but also hypogonadism has negative effects on the primary disease. With this in view, to establish with certainty which of the two diseases had preceded the development of the second one is challenging. The establishment of such kind of vicious circle contributes to further deteriorate the patient's health status and to worsen both of the two diseases. Thus, clinical management of these patients is complex, and physicians should focus on the management of both diseases.

---

## Male Hypogonadism and Systemic Illness: Acute Versus Chronic Diseases

### Acute Illnesses

Acute critical illness induces a decrease of serum testosterone that persists until the acute phase resolves. Acute renal failure, for example, is accompanied by the decrease of serum testosterone together with unchanged gonadotropin that is consistent with secondary hypogonadism. These changes are transient and reverted by the recovery of normal renal function (Levitan et al. 1984). This kind of hypogonadism is completely reversible at the condition that a healthy status is reached after the resolution of the primary disease (Woolf et al. 1985; Travison et al. 2008). This condition does not depend on the nature of the disease and/or the organ or tissue involved (Woolf et al. 1985; Christeff et al. 1988; Luppá et al. 1991; Dong et al. 1992; Fourrier et al. 1994) but is mainly related to the severity of overall clinical condition of the patient (Vogel et al. 1985; Luppá et al. 1991; Spratt et al. 1993; Dimopoulou et al. 2004). Accordingly, acute respiratory disease (Spratt et al. 1993), burns (Lephart et al. 1987), starvation (Baker 1998; Schorr and Miller 2017), acute, severe brain diseases (Dimopoulou et al. 2005; Dimopoulou and Tsagarakis 2005), and sepsis (Luppá et al. 1991; Fourrier et al. 1994) all share the same final mechanism resulting in secondary hypogonadism.

The mechanism through which a severe, acute clinical condition leads to hypogonadism in men involves the hypothalamus and a downgrade of the setup point of the HPG axis (Table 1, Fig. 3). This adaptive response to illness operates in order to sparing energy of unhealthy patients in the presence of a concomitant condition of poor health status (Handelsman 2011), similarly to what happens in anorexia nervosa (Schorr and Miller 2017) or low T3 syndrome (Warner and Beckett 2010)

**Table 1** Pathogenesis of hypogonadism according to the type of systemic disease. In the last column an attempt to grading of the strength of evidence concerning the pathogenetic mechanism involved in hypogonadism in the specific systemic disease is provided: from 1 (weakest evidence) to 5 (strongest evidence)

Tissue/organ	Disease	Type of hypogonadism <sup>a</sup>	Pathogenetic mechanism involved in the development of hypogonadism	Grade of evidence (0–5)
<b>Respiratory diseases</b>	<b>COPD</b>	<i>Primary</i>	Direct effects of hypoxemia on T secretion	2
		<i>Secondary</i>	Effect of systemic inflammation on the HPG axis	3
		<i>Secondary</i>	Glucocorticoid inhibitory effects on the HPG axis	4
		<i>Secondary</i>	Poor health status	3
	<b>Sarcoidosis</b>	<i>Secondary</i>	Direct hypothalamic or pituitary injury due to the localization of neurosarcoidosis at this level	5
		<i>Secondary</i>	Glucocorticoid inhibitory effects on the HPG axis	4
	<b>OSAS</b>	<i>Primary</i>	Direct effects of hypoxemia on T secretion (functional, reversible dysfunction of Leydig cells)	2
		<i>Secondary</i>	Sleep interruption by OSAS and reduced LH secretion	3
<b>Chronic kidney disease</b>	<b>Chronic kidney disease</b>	<i>Primary</i>	Functional, reversible dysfunction of Leydig cells	4
		<i>Secondary</i>	Reduced pituitary LH secretion	2
		<i>Primary</i>	LH insensitivity	1
<b>Liver diseases</b>	<b>NAFLD</b>	<i>Secondary</i>	Pathogenetic mechanisms identical to that of obesity and the metabolic syndrome	4
	<b>Chronic viral hepatitis</b>	–	Altered synthesis and production of SHBG	4
		<i>Secondary</i>	Increased aromatization and circulating estrogens	3

(continued)

**Table 1** (continued)

Tissue/organ	Disease	Type of hypogonadism <sup>a</sup>	Pathogenetic mechanism involved in the development of hypogonadism	Grade of evidence (0–5)
			resulting in LH suppression	
	<i>Alcoholism</i>	<i>Primary</i>	Functional, reversible dysfunction of Leydig cells	3
	<i>Cirrhosis</i>	–	Altered synthesis and production of SHBG	3
		<i>Primary</i>	Prolonged, nonreversible dysfunction of Leydig cells in alcoholic cirrhosis	2
		<i>Secondary</i>	Increased aromatization and circulating estrogens resulting in LH suppression	4
<b>Iron overload</b>	<i>Hereditary Hemochromatosis</i>	<i>Secondary<sup>b</sup></i>	Iron deposition within the pituitary	5
		<i>Primary<sup>b</sup></i>	Iron deposition within the testes	5
	<i>Thalassemia</i>	<i>Secondary<sup>b</sup></i>	Iron deposition within the pituitary	5
		<i>Primary<sup>b</sup></i>	Iron deposition within the testes	5
<b>Endocrine and metabolic diseases</b>	<i>Overweight obesity, metabolic syndrome, and T2DM</i>	<i>Secondary</i>	Increased aromatization and circulating estrogens resulting in LH inhibition	4
		–	Altered synthesis and production of SHBG	4
		<i>Secondary</i>	Increased serum leptin and enhanced inhibitory effect on HPG axis	4
		<i>Secondary</i>	Sleep interruption by OSAS and reduced LH secretion	3
		<i>Primary</i>	Direct effects of OSAS-related hypoxemia (functional, reversible dysfunction of Leydig cells)	2
<b>Infectious diseases</b>	<i>Orchitis</i>	<i>Primary<sup>c</sup></i>	Reversible or nonreversible damage of Leydig cells	5

(continued)

**Table 1** (continued)

Tissue/organ	Disease	Type of hypogonadism <sup>a</sup>	Pathogenetic mechanism involved in the development of hypogonadism	Grade of evidence (0–5)
	<b>AIDS</b>	<i>Primary</i>	Testicular opportunistic infections causing reversible or nonreversible damage of Leydig cells	4
		<i>Secondary</i>	Poor health status related to severe opportunistic infections and relative action on the HPG axis	4
	<b>HIV infection</b>	<i>Secondary</i>	Direct effect of viral infection of the pituitary	2
		<i>Secondary</i>	Effect of HAART treatments on the hypothalamic-pituitary function	2
		<i>Secondary</i>	HIV-related lipodystrophy and visceral fat effect on estrogen-dependent LH inhibition	4
		<i>Secondary</i>	Opiates effect on HPG axis in the subgroups of abusers	5
		<i>Secondary</i>	HIV-related multimorbidity, frailty, and poor health status central, inhibitory effects on the HPG axis	4
		–	Altered synthesis and production of SHBG	3
		<i>Primary</i>	Infective localization within the testis causing Leydig cell dysfunction	2

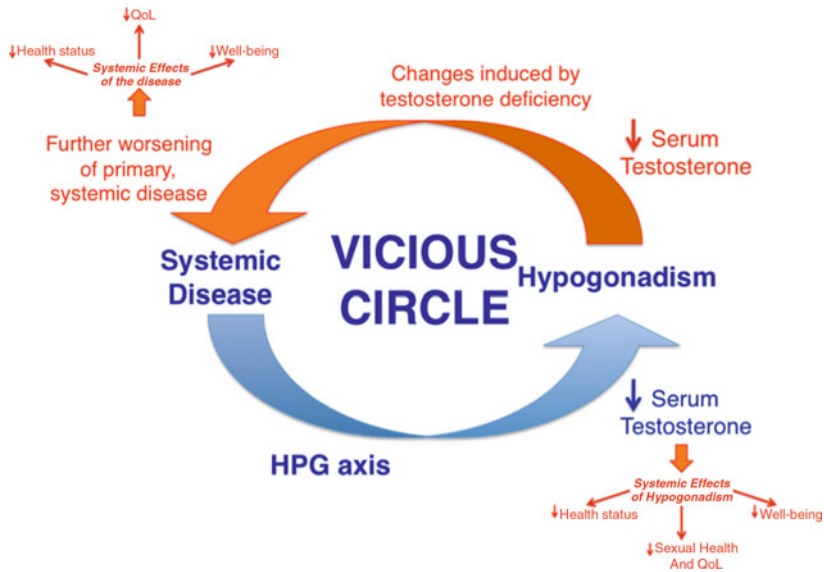
*COPD* chronic obstructive pulmonary disease, *T* testosterone, *OSAS* obstructive sleep apnea syndrome, *LH* luteinizing hormone, *n.a.* not applicable, *SHBG* sex hormone-binding globulin, *T2DM* type 2 diabetes mellitus, *AIDS* acquired immunodeficiency syndrome, *HIV* human immunodeficiency virus

<sup>a</sup>*Primary hypogonadism* or hypergonadotropic hypogonadism, *secondary hypogonadism* or hypogonadotropic hypogonadism

<sup>b</sup>Possible mixed form characterized by coexistence of both primary and secondary hypogonadism

<sup>c</sup>Caused by several infective agents (parotitis syphilis, others)

(Fig. 3). Accordingly, the lowering of testosterone means less of vigor, reduced physical activity and energy expenditure, low cardiovascular rate, as well as lessened reproductive behavior; in this manner the organism is preserved from engaging

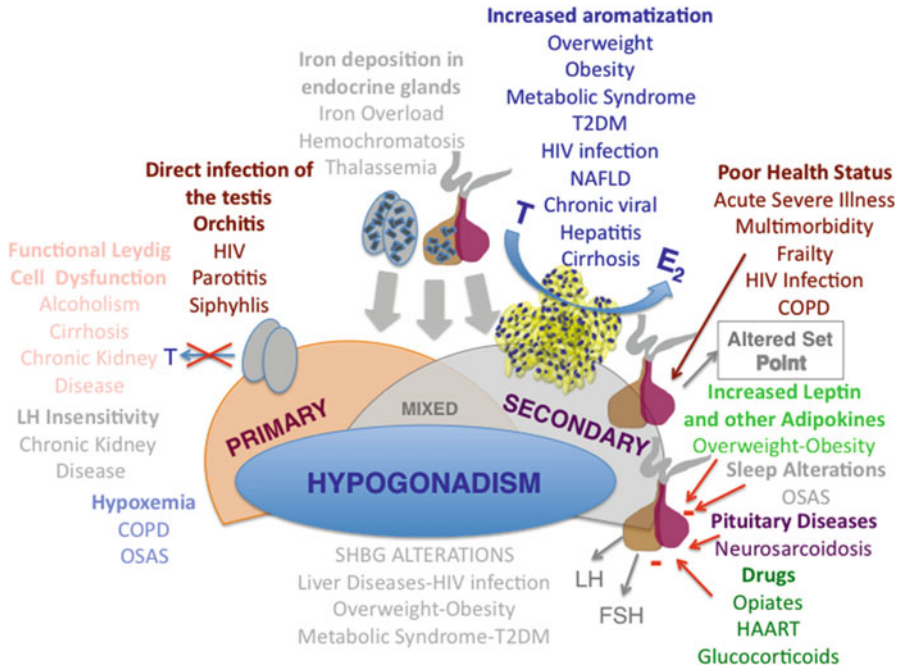


**Fig. 2** Bidirectional interplay between the primary, systemic disease, and hypogonadism: the vicious circle. *HPG* hypothalamic-pituitary gonadal

behavioral activities that might increase risks in the sick patient. Thus, in unhealthy states the downgrading of the HPG axis confers an advantage for the patient and the species in terms of sparing energy and preventing fatherhood, respectively (Corona et al. 2014a).

## Chronic Illness

Chronic illness shares the same adaptive mechanism of acute condition and induces secondary hypogonadism according to the disease as well as the number of comorbidities (Turner and Wass 1997; Isidori and Lenzi 2005; Travison et al. 2007, 2008; Rochira and Guaraldi 2014; Corona et al. 2014a, 2016a; Rochira et al. 2015; Decaroli and Rochira 2016 (Table 1, Fig. 3). Outside the context of very poor health status, chronic illness may act at the hypothalamic-pituitary level or on the testis or both, and many different mechanisms and modalities could be involved (Figs. 1, 2, and 3, Table 1), according to the pathogenesis of the underlying systemic disease (Turner and Wass 1997; Corona et al. 2014a, 2016a; Decaroli and Rochira 2016). Thus unhealthy men tend to have lower serum testosterone than age-matched healthy controls (Mohr et al. 2005; Wu et al. 2008) in the presence of normal or reduced luteinizing hormone (LH), which is consistent with secondary hypogonadotropic hypogonadism (Tajar et al. 2010; Decaroli and Rochira 2016). The hypogonadotropic hypogonadism that develops



**Fig. 3** Pathogenetic mechanisms involved in hypogonadism related to systemic diseases. *T* testosterone, *E<sub>2</sub>* estradiol, *T2DM* type 2 diabetes mellitus, *NAFLD* nonalcoholic fatty liver disease, *LH* luteinizing hormone, *FSH* follicle-stimulating hormone, *HIV* human immunodeficiency virus, *HAART* highly active antiretroviral therapy, *OSAS* obstructive sleep apnea syndrome, *COPD* chronic obstructive pulmonary disease, *SHBG* sex hormone-binding globulin

in the context of multimorbidity should be mainly considered as functional hypogonadism and for this reason may also be temporary (Wu et al. 2008; Corona et al. 2016a) (Table 1, Fig. 3).

Furthermore, serum testosterone reduction is associated to frailty in men (Travison et al. 2010, 2011; O'Connell et al. 2011; Rochira et al. 2015; Decaroli and Rochira 2016). The degree of frailty results from the sum of the patient's disabilities, physical performance, and aging; in addition it depends also on the presence of one or more comorbidities (multimorbidity) (Morley et al. 2005; Mitnitski et al. 2017). Frailty is strongly associated with hypogonadism in men, but on the other side also low-serum testosterone probably is involved in worsening the severity of the patient's frailty, since it has a negative impact on muscles (sarcopenia) (Basualto-Alarcon et al. 2014), energy and vigor, and physical performance (Zitzmann and Nieschlag 2003; Di Luigi et al. 2012; Decaroli and Rochira 2016), thus contributing to the establishment of a vicious circle (Fig. 2).

**The Practical Clinical Corner: Hypogonadism in Acute and Chronic Illnesses**

- The diagnosis of hypogonadism in men with acute illness or multimorbidity and frailty is challenging and should be made with caution.
- Documented biochemical hypogonadism (low-serum testosterone) is not sufficient for the diagnosis.
- Consider retesting patients after removal/resolution of acute disease, improvement of chronic illness, or reduction of multimorbidity in order to better substantiate the diagnosis of hypogonadism.
- Consider treating first the primary disease before considering testosterone therapy.

Main Refs (Bhasin et al. 2010; Buvat et al. 2010; Huhtaniemi 2014; Isidori et al. 2015; Corona et al. 2016a).

---

**Respiratory Diseases****Chronic Obstructive Pulmonary Disease (COPD)**

Hypogonadism is common in men with COPD (Laghi et al. 2005a; Mousavi et al. 2012). According to different settings, the prevalence of hypogonadism in men with COPD varies from 22% to 69% (Kamischke et al. 1998; Van Vliet et al. 2005; Laghi et al. 2005a; Mousavi et al. 2012), the difference among studies depending on age, the criteria and analytical methods used for defining biochemical hypogonadism, and race (Balasubramanian and Naing 2012). Some authors, however, suggest that the prevalence of hypogonadism is not significantly different in COPD if compared to that observed in age-matched controls since the high prevalence of hypogonadism found in COPD derives mainly from studies enrolling older men who commonly have low testosterone even outside the context of COPD (Laghi et al. 2005a, b).

In COPD, secondary hypogonadism with low gonadotropins is more frequent (75%) than primary hypogonadism (25%) (Laghi et al. 2005a; Svartberg 2010; Balasubramanian and Naing 2012; Mousavi et al. 2012). Study populations such as the Tromsø and the Health in Men Study demonstrated that a reduced pulmonary function is associated to lower total and free serum testosterone due to hypothalamic-pituitary dysfunction (Mulligan et al. 2006; Svartberg et al. 2007). However, increased LH and follicle-stimulating hormone (FSH) in the presence of reduced serum testosterone have also been observed in patients with COPD compared to controls (Van Vliet et al. 2005).

The pathogenesis of hypogonadism in COPD is multifactorial (Balasubramanian and Naing 2012) (Fig. 3). In patients with COPD, the following coexistent factors contribute to the development of hypogonadism (Balasubramanian and Naing 2012): hypoxemia (Semple et al. 1980; Gosney 1987), systemic inflammation

(Karadag et al. 2009), glucocorticoid use (Kamischke et al. 1998), and being a patient with a chronic illness (Isidori and Lenzi 2005; Wu et al. 2008, 2010) (Table 1, Fig. 3). Small testes due to loss of Leydig cells have been documented in men with COPD at autopsy (Gosney 1987). Chronic hypoxia is associated with smaller testes and a possible inhibitory effect of hypoxia on gonadotropins secretion by the pituitary has been hypothesized (Gosney 1987) (Table 1, Fig. 3). Glucocorticoids used in COPD seem to further worsen hypogonadism (Kamischke et al. 1998) (Table 1, Fig. 3). Furthermore, the real impact of glucocorticoids and hypoxemia on low testosterone has not been confirmed by other studies, suggesting that hypogonadism in these patients does not differ from late-onset hypogonadism in the general population (Laghi 2005; Van Vliet et al. 2005; Laghi et al. 2005a, b). At present, distinguishing the pathogenetic role of COPD per se from that of single risk factors (smoking, aging, chronic illness, hypoxemia, and glucocorticoid therapy) remains, however, challenging (Balasubramanian and Naing 2012).

The severity of COPD seems to correlate with the prevalence of hypogonadism (Makarevich 2003; Mousavi et al. 2012). Several studies, in fact, found an association between lower circulating testosterone and the severity of COPD as measured in terms of forced expiratory volume in 1 s ( $FEV_1$ ) (Svartberg et al. 2007; Mousavi et al. 2012), hypoxemia, and hypercapnia (Karadag et al. 2009). Besides, COPD exacerbation is associated with further decrease of serum testosterone, the worsening of hypogonadism being reversible in the case of COPD improvement (Akbas et al. 2010; Corbo et al. 2014), but this observation has not been confirmed in other studies (Laghi 2005; Van Vliet et al. 2005; Laghi et al. 2005a, b).

In COPD, however, the occurrence of hypogonadism might contribute to worsen COPD (e.g., depressed mood, decreased energy, muscular weakness, physical performance, osteoporosis, risk of falls, and general well-being) with a relevant effect on the patient's quality of life (Balasubramanian and Naing 2012). Hypogonadism is known to induce or worsen (if already present) sarcopenia (Basualto-Alarcon et al. 2014), and the latter is very common in patients with COPD (Morley et al. 2005; Corsonello et al. 2011). Low testosterone rather than pulmonary function associates with quadriceps weakness (Van Vliet et al. 2005). Other than sarcopenia, even osteoporosis, another common comorbidity in COPD, may be in part due to low circulating androgens (Biskobing 2002).

### **Clinical Implications**

Testosterone treatment has the potential to be useful in reinforcing muscle mass and strength and improving respiratory mechanical dynamics in men with COPD (Laghi et al. 2005a, b). This aspect might be of clinical relevance in these patients since the integrity of muscle masses might help in supporting breathing (i.e., accessory muscles) and concurs to a better physical performance that may improve resistance to training during rehabilitation programs. It has been observed that testosterone treatment improves muscle mass and strength in men with COPD and concomitant hypogonadism (Casaburi et al. 2004). Furthermore, testosterone therapy could have



beneficial effects on sexuality and quality of life but does not modify pulmonary function (Svartberg et al. 2004a). Thus, testosterone could improve muscle mass, sexual function, and could counteract bone loss. However, there is no specific indication in the treatment of COPD at present (Svartberg 2010), and placebo-controlled trials are still required since only few studies have investigated the effects of exogenous testosterone in COPD (Bhasin et al. 2010). Besides, preliminary data on patients requiring corticosteroids for various chronic illness suggests a possible beneficial effect of testosterone treatment on glucocorticoid-induced side effects, especially muscle mass and quality of life (Reid et al. 1996; Crawford et al. 2003). As a matter of fact, there is no clear indication, at present, to treat patients with COPD and low-serum testosterone since evidence on a beneficial effect on COPD is still lacking (Laghi 2005). Furthermore, testosterone treatment may result in side effects that should be avoided in COPD, such as increased hematocrit (Laghi 2005). Thus, caution is needed in starting testosterone therapy in hypogonadal patients with COPD, and the decision should be targeted on the basis of the severity of hypogonadism and the need to correct signs and symptoms specific of hypogonadism. In other words, testosterone therapy should be administered having in mind the improvement of hypogonadism, in terms of sexual function, prevention of bone loss, increase of lean body mass, well-being, and quality of life (QoL), as the main goal, leaving the possible beneficial effects on COPD in the background (Laghi 2005; Van Vliet et al. 2005). At present, guidelines and expert opinions on testosterone treatment do not recommend using exogenous testosterone in COPD to increase exercise capacity, but it should be considered if both biochemical hypogonadism and signs/symptoms of low testosterone are documented (Bhasin et al. 2010; Buvat et al. 2013; Isidori et al. 2015). Further placebo-controlled, large clinical trials are required to ascertain if testosterone treatment could improve symptoms related to COPD and have beneficial effects in hypogonadal patients with COPD.

#### **The Practical Clinical Corner: Hypogonadism in COPD**

- Check for hypogonadism, especially in men with a more severe COPD.
- Wait for diagnosis in the case of COPD exacerbations; retest the patients after remission of exacerbation.
- Consider potential benefits of testosterone therapy on sarcopenia, sexual function, and prevention of bone loss only in patients with signs and symptoms of androgen deficiency and documented biochemical hypogonadism.
- Do not treat COPD-related impairment physical performance in the absence of well-documented hypogonadism.

Main Refs (Akbas et al. 2010; Bhasin et al. 2010; Isidori et al. 2015).

## Other Respiratory Diseases

### Sarcoidosis

Male hypogonadism is common in patients with sarcoidosis, especially in those with concomitant hypothalamic-pituitary localization of the disease (neurosarcoidosis) who have hypogonadotropic hypogonadism (Bullmann et al. 2000). Accordingly, hypopituitarism is highly prevalent in patients with neurosarcoidosis (Anthony et al. 2016; Pekic and Popovic 2017), the hypothalamus and/or the pituitary being elective locations of neurosarcoidosis (Langrand et al. 2012). In all these cases, secondary hypogonadism is due to direct damage of the hypothalamic-pituitary unit (Schneider et al. 2007; Higham et al. 2016) (Table 1, Fig. 3). Furthermore, a possible contribution of both the presence of a chronic illness and the use of glucocorticoids to the development of hypogonadism in these patients cannot be completely ruled out (Spruit et al. 2007) (Table 1, Fig. 3).

### Obstructive Sleep Apnea Syndrome (OSAS)

OSAS is associated with male hypogonadism and mechanical treatment of OSAS might restore, at least in part, circulating testosterone levels (Fig. 1b), thus suggesting a putative pathogenetic role of hypoxemia on androgen deficiency (Grunstein et al. 1989) (Table 1, Fig. 3). OSAS, however, occurs mainly in obese patients (Liu et al. 2007), and obesity and the metabolic syndrome are well-known causes of male hypogonadism (Corona et al. 2011a, b, 2015) (see the paragraph below on “Overweight, Obesity, the Metabolic Syndrome, and Type 2 Diabetes Mellitus” for further details) (Table 1, Fig. 3).

On the other hand, testosterone treatment could worsen both breathing and OSAS (Sandblom et al. 1983; Matsumoto et al. 1985; Schneider et al. 1986), especially when used at high dosages and in older men (Liu et al. 2003, 2007). For this reason, guidelines on testosterone treatment of male hypogonadism recommend against testosterone treatment of hypogonadal men with untreated OSAS (Petak et al. 2002; Bhasin et al. 2010; Buvat et al. 2013; Huhtaniemi 2014; Isidori et al. 2015).

#### The Practical Clinical Corner: Hypogonadism in Sarcoidosis

- Consider treating neurosarcoidosis before starting testosterone replacement therapy.
- Consider that usually hypogonadotropic hypogonadism is severe, patients are relatively young, and neurosarcoidosis improvement or remission does not always revert hypogonadism.
- Start testosterone therapy if sarcoidosis does not relapse, consider gonadotropins if the patient asks for paternity (young patients).

(continued)

### The Practical Clinical Corner: Hypogonadism in OSAS

- The presence of untreated OSAS is a contraindication to testosterone treatment.
- The diagnosis of hypogonadism should be revised after OSAS treatment.
- Consider weight loss in patients with obesity (see paragraph below for further details).

Main Refs (Petak et al. 2002; Bhasin et al. 2010; Langrand et al. 2012; Buvat et al. 2013; Huhtaniemi 2014; Isidori et al. 2015).

---

## Chronic Kidney Disease

Renal failure could affect the HPG axis by acting both at central and peripheral level (Johansen 2004; Bao and Johansen 2015). Even mild renal insufficiency might moderately flatten the function of the HPG axis (Guevara et al. 1969; Johansen 2004; Karagiannis and Harsoulis 2005; Bao and Johansen 2015). Accordingly, biochemical hypogonadism is present in about a half of patients with chronic kidney disease (Albaaj et al. 2006).

The pathogenesis of hypogonadism in men with chronic kidney disease involves several mechanisms, and a combination of both primary and secondary hypogonadism concurs to lower serum testosterone in these patients (Johansen 2004) (Table 1, Fig. 3). Alterations of the LH secretion by the pituitary have been shown, which are consistent with decreased LH secretion per each single LH burst in the presence of normal pulsatility (Veldhuis et al. 1993). Whether or not this defect is in the hypothalamic gonadotropin-releasing hormone (GnRH) secretion or in the pituitary response to GnRH remains, however, to be ascertained (Veldhuis et al. 1993). The negative feedback remains normally functioning in uremic patients as demonstrated by normal response to clomiphene citrate administration (Lim and Fang 1976) (Table 1, Fig. 3).

The finding of increased serum LH in the presence of low-serum testosterone speaks in favor of testicular damage, but the lack of Leydig cell hyperplasia at histological level suggests a functional defect (Table 1, Fig. 3), which is further corroborated by the fact that testicular Leydig cell function is usually recovered after renal transplantation (Lim and Fang 1975, 1976) (Fig. 2). Besides, short-term human chorionic gonadotropin (hCG) administration to men with chronic kidney disease results in a blunted serum testosterone response, but long-term hCG exposure leads to normal testosterone secretion, thus suggesting that the function of the testes is no longer compromised (Stewart-Bentley et al. 1974; Dunkel et al. 1997). LH insensitivity of Leydig cells has been also documented, suggesting testicular involvement (Dunkel et al. 1997) (Table 1, Fig. 3).

Even though metabolic testosterone clearance was hypothesized to be increased in patients with chronic kidney disease (Handelsman and Dong 1993), recent studies did not show any difference between healthy men and men with chronic kidney disease (Singh et al. 2001). Furthermore, also the LH clearance could be reduced in patients with chronic kidney disease, but this hypothesis needs further evidence (Handelsman and Dong 1993).

## Clinical Implications

In patients who need dialysis androgen deficiency is very common (Handelsman and Staraj 1985; Albaaj et al. 2006). Successful renal transplantation is able to restore normal function of the testes in most of the cases (Samojlik et al. 1992; Saha et al. 2002; Akbari et al. 2003; Yadav et al. 2008), while starting dialysis usually does not significantly modify hormonal secretion of androgens (Karagiannis and Harsoulis 2005).

As far as testosterone treatment of men with chronic kidney disease is concerned, controlled studies are scanty and are based not only on exogenous testosterone but also other anabolic steroids such as nandrolone (Ballal et al. 1991; Johansen et al. 1999). Androgen treatment could counteract undernutrition, especially in terms of lean body mass (Johansen et al. 1999); however, there is no sufficient evidence to support this approach in the clinical setting (Bhasin et al. 2010).

What is known is that the presence of chronic kidney disease does not alter the metabolism and the pharmacokinetics of testosterone; thus, testosterone treatment does not require dose adjustments in these patients (Singh et al. 2001).

Testosterone promotes erythropoiesis (Rochira et al. 2009), and testosterone replacement therapy increases hematocrit in men with hypogonadism (Bachman et al. 2014). For this reason testosterone therapy has been traditionally employed for the treatment of chronic anemia in patients with chronic kidney disease (Ballal et al. 1991; Teruel et al. 1996). However, erythropoietin administration for renal anemia is now preferred in daily clinical practice to androgens, testosterone treatment only being of historical interest.

### The Practical Clinical Corner: Hypogonadism in Chronic Kidney Disease

- Testosterone treatment of men with chronic kidney disease should be considered for the treatment of symptoms of hypogonadism.
- In the case of treatment, the reduced renal function does not alter testosterone pharmacokinetics.
- Treatment with testosterone to increase exercise capacity should be avoided in end-stage renal disease.
- The recovery of normal renal function (e.g., renal transplantation) is able to restore a normal function of the testis.

Main Refs (Singh et al. 2001; Yadav et al. 2008; Bhasin et al. 2010; Isidori et al. 2015).

## Liver Diseases

The prevalence of male hypogonadism in patients with liver diseases is unknown, but the finding of low-serum testosterone as well as of signs and symptoms of testosterone deficiency are common in these patients (Handelsman et al. 1995; Sinclair et al. 2015). Sex hormone changes in men with liver diseases are often functional since they are completely reverted by liver transplantation or recovery of normal liver function (Sinclair et al. 2015) (Table 1, Fig. 3). Liver diseases may influence the amount of circulating sex steroids. The mechanism by which liver diseases cause alterations of serum testosterone is mainly based on changes in circulating sex hormone-binding globulins (SHBG) (Fig. 3). All the different types of liver diseases, in fact, share this pathophysiological mechanism, independently from the type of the disease.

### Nonalcoholic Fatty Liver Disease (NAFLD)

NAFLD is associated with hypogonadism in men (Mintziori et al. 2017). Patients with NAFLD, in fact, may have low-serum testosterone concentrations (Mintziori et al. 2017). Accordingly, serum testosterone and SHBG are significantly lower in men with NAFLD compared to healthy men (Li et al. 2015). Besides, low-serum testosterone remains associated with NAFLD in data analyses even after correcting for serum insulin and visceral adipose tissue (Kim et al. 2012). In other studies, patients with NAFLD had normal total testosterone, but serum estradiol and calculated free testosterone were lower compared to weight-matched controls (Tian et al. 2012).

Hepatic steatosis is strictly related to the metabolic syndrome and could be considered a clinical manifestation of this common disease (Volzke et al. 2010). The fat content within the liver is, in fact, directly related to visceral fat (Eguchi et al. 2006). For this reason hypogonadism in NAFLD should be considered within the context of obesity and the metabolic syndrome, which are associated to high prevalence of hypogonadism (see below the paragraph on “[Overweight, Obesity, the Metabolic Syndrome, and Type 2 Diabetes Mellitus](#)” for further details) (Table 1, Fig. 3). In men with hepatic steatosis, the fat within the liver is associated with low-serum testosterone and the latter is inversely related to steatosis within the liver (Volzke et al. 2010). Accordingly, the relationship between serum testosterone and fatty liver is bidirectional since testosterone influences also the development or the regression of NAFLD (Seo et al. 2015). Several data suggest a possible role of testosterone deficiency in the pathogenesis of NAFLD (Hazlehurst and Tomlinson 2013).

### Clinical Implications

Testosterone administration is able to reduce the amount of fat stored within the liver (Hoyos et al. 2012); however, the best strategy to improve both NAFLD and hypogonadism is lifestyle change (Corona et al. 2013a).

**The Practical Clinical Corner: Hypogonadism in NAFLD**

- Consider weight loss in patients with obesity in order to revert both NAFLD and hypogonadism (see paragraph below “Overweight, Obesity, the Metabolic Syndrome, and Diabetes” for further details).
- Testosterone administration could improve NAFLD, especially if coupled with lifestyle changes.

Main Refs (Hazlehurst and Tomlinson [2013](#); Corona et al. [2013a](#)).

**Chronic Viral Hepatitis**

In men with chronic hepatitis due to virus C infection, SHBG is increased in those with a higher degree of liver fibrosis compared to patients with less severe hepatitis; furthermore SHBG directly correlates with the severity of liver fibrosis (Nguyen et al. [2006](#); Safarinejad et al. [2010](#)) (Table 1, Fig. 3). In the presence of low-serum testosterone, gonadotropins are usually normal or slightly reduced accounting for hypogonadotropic hypogonadism (Safarinejad et al. [2010](#); Sinclair et al. [2015](#)) (Table 1, Fig. 3). Furthermore, an increased production rate of estradiol due to enhanced aromatization of testosterone within the liver could be another contributing factor explaining hypogonadotropic hypogonadism in these patients (Safarinejad et al. [2010](#)) (Table 1, Fig. 3). However, not all the studies found increased serum estradiol in men with hepatitis C (Nguyen et al. [2006](#)).

Total serum testosterone resulted also to be lower in men with chronic hepatitis C compared to healthy men (Hofny et al. [2011](#)). Furthermore, even serum estradiol appeared to be higher in men with chronic hepatitis C compared to healthy men, suggesting that a possible increase in testosterone aromatization could induce secondary hypogonadism thanks to enhanced negative feedback on both the hypothalamus and the pituitary (Santen [1981](#); Finkelstein et al. [1991a, b](#); Hayes et al. [2000](#); Rochira et al. [2006, 2012, 2016](#)). Estradiol levels are significantly increased in male patients with hepatitis B and were associated with the severity of liver disease (Mao et al. [2013](#)).

The pathogenesis of hypogonadism in patients with chronic hepatitis B infection is similar to that occurring in hepatitis C, even though elevated serum LH has been found in patients with low-serum testosterone, suggesting primary hypogonadism due to testicular dysfunction (Serin et al. [2013](#)).

**Clinical Implications**

As hypogonadism occurs mainly in men with a more severe chronic liver diseases, clinical examinations for the diagnosis of hypogonadism should be performed especially in men with advanced (in terms of liver fibrosis) chronic hepatitis due to virus C (Safarinejad et al. [2010](#)) or B and the presence of one or more symptoms that may be related to testosterone deficiency (Buvat et al. [2013](#); Huhtaniemi [2014](#);

Isidori et al. 2015; Decaroli and Rochira 2016; Corona et al. 2016a). The clinical workup should include SHBG measurement in order to calculate free testosterone (<http://www.issam.ch/freetesto.htm>) to avoid missing the diagnosis of hypogonadism (Vermeulen et al. 1996, 1999; Ly et al. 2010). It is important to remark that commercially available kits for the measurement of free serum testosterone are unreliable and inaccurate and should not be used (Rosner et al. 2007; Rosner and Vesper 2010).

Treatment with interferon alpha 2b usually does not modify (Piazza et al. 1997; Sinclair et al. 2015) or slightly decreases (Kraus et al. 2005) serum testosterone, SHBG, and free testosterone in patients with chronic hepatitis C. Anyway, even when a slight decrease of total testosterone occurs, interferon alpha 2b does not decrease serum-free testosterone below the lowest concentration of the normal range in these patients (Barreca et al. 1993; Nguyen et al. 2006).

At present, the effects of sofosbuvir, a novel effective drug useful for the treatment of chronic hepatitis C, on serum testosterone are not known, but its efficacy in reverting chronic hepatitis suggests a possible beneficial effect also on male hypogonadism, when present at baseline.

#### **The Practical Clinical Corner: Hypogonadism in Chronic Viral Hepatitis**

- Consider calculating serum-free testosterone using total testosterone and SHBG.
- Treatments with interferon do not improve testosterone secretion.
- No data is available on the new drug for virus C hepatitis (Sofosbuvir).
- Testosterone administration could increase the risk of hepatocellular carcinoma.

Main Refs (Safarinejad et al. 2010; Decaroli and Rochira 2016).

## **Alcoholism**

Alcohol seems to act both on the testis and on the hypothalamus and pituitary (Van Thiel et al. 1974) (Table 1, Fig. 3). In animal models, alcohol is able to induce testicular atrophy and primary hypogonadism (Van Thiel et al. 1975), as in patients suffering from alcoholism who show increased concentrations of serum luteinizing hormone (LH) (Van Thiel et al. 1974) (Table 1, Fig. 3). Vice versa also a reduction of pulsatile secretion of serum LH by the hypothalamic-pituitary unit has been documented (Van Thiel et al. 1974; Bannister et al. 1986; Frias et al. 2002) (Table 1, Fig. 3). Alcohol intake alone is able to increase SHBG and consequently to reduce the circulating concentration of free testosterone (Iturriaga et al. 1999). Thus, patients who abuse of alcohol may develop testosterone deficiency even in the absence of liver disease that is usually reversible, especially if patients have not yet developed cirrhosis (Ruusa et al. 1997; Frias et al. 2002).

### The Practical Clinical Corner: Hypogonadism in Alcoholism

- Consider calculating serum-free testosterone using total testosterone and SHBG (<http://www.issam.ch/freetesto.htm>).
- Consider treating alcohol abuse as the first main clinical intervention.

Main Refs (Frias et al. 2002).

## Liver Cirrhosis

Signs and symptoms of hypogonadism are common in men with liver cirrhosis, occurring in about 90% of them (Sinclair et al. 2015). Among them, altered body hair distribution, gynecomastia, reduction of testicular volume, muscle wasting, impaired sexual function, anemia, and fatigue may be related to low-serum testosterone (Sinclair et al. 2015).

In patients with cirrhosis, hypogonadism may be due to several factors. Primary hypogonadism due to testicular alcohol-induced damage has been documented (Ruusa et al. 1997) (Table 1, Fig. 3).

Secondary, hypogonadotropic hypogonadism, however, is the most prevalent pattern in men with alcoholic cirrhosis (Distiller et al. 1976) or with cirrhosis due to viral hepatitis (Zietz et al. 2003; Sinclair et al. 2015) (Table 1, Fig. 3).

Estrogens are usually increased in men with cirrhosis (Bahnsen et al. 1981; Cavanaugh et al. 1990; Kaymakoglu et al. 1995; Zietz et al. 2003; Bandyopadhyay et al. 2009; Sinclair et al. 2015), even though normal in some studies (Green et al. 1976). Most of the studies on estrogens in men with cirrhosis are, however, old and may suffer from methodological bias concerning the measurement of estrogens in men. Accordingly, commercially available kits have poor accuracy and sensitivity, and old kits used in the past were also more imprecise than those used today. At present no study has investigated circulating estrogens in men with cirrhosis using liquid chromatography-tandem mass spectrometry (LC-MS/MS), which is the gold standard method for measuring estrogens in men (Rochira et al. 2012, 2016). Anyway, studies showing high estradiol levels in cirrhotic patients are numerous, and commercially available methods fail in detecting estrogen deficiency in men, while they are more reliable in showing high estradiol levels (see ► Chap. 26, “Estrogen Deficiency in Men” for further details) (Rochira et al. 2012, 2016). Besides, the common observation of signs of hyperestrogenism (i.e., gynecomastia) in these patients further support the finding of elevated serum estrogens (Sinclair et al. 2015). The increase of circulating estrogens seems to be due to increased peripheral conversion of androgens into estrogens and may be enhanced by increased arteriovenous shunts enabling liver estrogen metabolism (Gordon et al. 1975). Secondary hypogonadism is due to the inhibitory effects of estrogens on the hypothalamus and the pituitary (Santen 1981; Finkelstein et al. 1991a, b; Hayes et al. 2000; Rochira et al. 2006, 2012, 2016) (Table 1, Fig. 3).



Besides, SHBG is increased in men with cirrhosis (Maruyama et al. 1991; Zietz et al. 2003), despite the expected reduction of protein synthesis in the liver (Sinclair et al. 2015). Increased SHBG further contributes to lowering the free, unbound fraction of serum testosterone (Table 1, Fig. 3).

### Clinical Implications

When approaching hypogonadism in men with liver cirrhosis, the measurements of SHBG and estradiol are mandatory, bearing in mind that the results of them are hard to interpret in practice.

Few uncontrolled trials on the effects of exogenous testosterone in men with liver cirrhosis are available demonstrating an improvement of gynecomastia when present (Rambaldi and Gluud 2006; Sinclair et al. 2015). Again, as for other systemic diseases, testosterone treatment should be offered to patients with signs and symptoms of androgen deficiency and a concomitant diagnosis of biochemical hypogonadism, thus avoiding to administer testosterone to patients with liver cirrhosis for resolving symptoms specifically related to liver dysfunction. Testosterone formulations that do not pass through the liver should be preferred (i.e., injectable and transdermal).

When offering testosterone to cirrhotic patients, it should be remarked that higher serum testosterone had been associated to the development of hepatocellular carcinoma (Tanaka et al. 2000), and this might also concern aromatase inhibitors.

At present there is no clinical trial on the use of aromatase inhibitors in men with cirrhosis. They have the potential to counteract hyperestrogenism and increase endogenous testosterone concentrations (Hayes et al. 2000; de Boer et al. 2005; Loves et al. 2008; Rochira et al. 2016).

The recovery of normal liver function after liver transplantation is able to completely reverse hypogonadism in about 6 months and to restore normal serum levels of testosterone, estradiol, SHBG, and gonadotropins, independently of the viral or alcoholic origin of the disease (Guechot et al. 1994; Madersbacher et al. 1994).

#### The Practical Clinical Corner: Hypogonadism in Liver Cirrhosis

- Consider calculating serum-free testosterone using total testosterone and SHBG (<http://www.issam.ch/freetesto.htm>).
- Treatments with testosterone should be considered for the treatment of hypogonadism and not of cirrhosis.
- Testosterone administration could increase the risk of hepatocellular carcinoma.
- Liver transplantation might revert hypogonadism.

Main Refs (Madersbacher et al. 1994; Tanaka et al. 2000; Sinclair et al. 2015).

## Iron Overload

Diseases causing iron overload can affect several endocrine functions. The pathogenetic mechanism involves the deposition of iron in excess within the endocrine tissues (Table 1, Fig. 3). Endocrine glands together with liver (Ernst et al. 1997) and heart (Rund and Rachmilewitz 2005) are more susceptible than other tissues (Housman et al. 1989) to iron deposition, thus explaining the high prevalence of endocrine diseases in patients with iron overload (Housman et al. 1989; Rund and Rachmilewitz 2005). Iron overload causes iron deposition within the tissue and then leads to tissue injury through oxidative and inflammatory reactions (Rund and Rachmilewitz 2005). Tissue damage results ultimately into cell and organ dysfunction.

Hypogonadism in men with iron overload is one of the most common endocrine dysfunctions and is mainly due to iron deposition within the testis (Miaux et al. 1995) and/or the pituitary (Wood et al. 2010; Noetzli et al. 2012) (Table 1, Fig. 3). In the case of hypogonadotropic hypogonadism due to hypothalamic-pituitary dysfunction, hypogonadism is strictly associated with the amount of iron within the pituitary as measured by magnetic resonance imaging (MRI) (Wood et al. 2010; Noetzli et al. 2012).

## Hereditary Hemochromatosis

In men with hereditary hemochromatosis, hypogonadism is common, but its real prevalence is not known (Pelusi et al. 2016). In a recent study, 6.8% of men with hemochromatosis had hypogonadotropic hypogonadism (McDermott and Walsh 2005). Several other studies found a greater prevalence ranging from 10% to 100% (Pelusi et al. 2016). It is possible that older studies were associated almost always to male hypogonadism (40–100%) since they involved patients with a more severe iron overload, due to the lack of available chelating agents, (Tournaire et al. 1974; Charbonnel et al. 1981; McNeil et al. 1983; Kley et al. 1985). On the contrary, more recent studies on patients treated with proper iron chelators show a lower prevalence due to the better clinical conditions of patients resulting from early diagnosis and available treatments (McDermott and Walsh 2005; Pelusi et al. 2016).

In general, hypogonadotropic hypogonadism is more frequent than primary hypogonadism, since testosterone secretion in response to hCG administration is usually conserved in these patients (Siminoski et al. 1990), while the basal and stimulated gonadotropin secretion is reduced (Altman et al. 1980; Charbonnel et al. 1981; Duranteau et al. 1993) (Table 1, Fig. 3). It is not clear, however, if hypothalamic dysfunction (Piperno et al. 1992) dominates in importance over that of the pituitary gland in these patients (Duranteau et al. 1993; Pelusi et al. 2016). The alteration of gonadotropin secretion is most often involved, especially in cases of uncontrolled hemochromatosis, the testis being normal or smaller than normal due to the lack of gonadotropin stimulation (Pelusi et al. 2016). It is likely that both the hypothalamus and the pituitary are concomitantly involved in the genesis of hypogonadism (Siminoski et al. 1990) (Table 1, Fig. 3).

This issue becomes more complex if we consider that even primary hypogonadism may develop in these patients due to iron deposition within the testes (Kelly et al. 1984; Miaux et al. 1995; Pelusi et al. 2016). With this in mind, also mixed forms could be present with both the pituitary and the testis more or less involved (McNeil et al. 1983; Bhansali et al. 1992) depending on the prevailing site of iron deposition (i.e., the pituitary or the testis) (Miaux et al. 1995; Cox and Kelly 1998) (Table 1, Fig. 3).

The impact of the different genetic types of hemochromatosis on the prevalence of hypogonadism is not known, and some authors suggest that more severe forms (e.g., type 2) are more prone to develop hypogonadism and other comorbidities (Pietrangelo 2010; Pelusi et al. 2016).

Early reduction of iron overload by specific treatments (e.g., iron chelation and/or venesection) results in the recovery of pituitary function. Thus the prompt onset of hemochromatosis therapy is usually able to restore normal testosterone secretion (Kelly et al. 1984; Gama et al. 1995; Hamer et al. 2001; Pelusi et al. 2016). However, the recovery of normal HPG function seems to occur mainly in youngest patients (<40 years) (Cundy et al. 1993). In patients with advanced disease, liver cirrhosis further contributes to the development of hypogonadism in these patients.

### Clinical Implications

MRI allows identifying preclinical pituitary iron deposition, a strategy that could be useful to prevent the development of hypogonadism by improving iron chelation in patients with normal functioning of the HPG axis (Wood et al. 2010). The height of the pituitary measured at MRI, in fact, is a good parameter to predict pituitary dysfunction and hypogonadism. The latter, in fact, is almost constantly present in patients with a pituitary less than 4.2 mm in height (Argyropoulou et al. 2001).

Testosterone treatment of patients with hemochromatosis and hypogonadism has beneficial effect on sexual function, well-being (Kley et al. 1992), and bone mineral density (Diamond et al. 1991). Cardiac morbidity should be considered prior to starting testosterone treatment since the latter might be harmful in patients with severe heart failure (Bhasin et al. 2010; Buvat et al. 2013; Isidori et al. 2015) due to iron deposition in the heart (Gulati et al. 2014).

#### The Practical Clinical Corner: Hypogonadism in Hereditary Hemochromatosis

- Adult men with hemochromatosis should be periodically screened for hypogonadism.
- Consider testosterone treatment in patients with documented biochemical hypogonadism and signs or symptoms of androgen deficiency.
- Testosterone administration could be beneficial also for preventing bone loss, a frequent morbidity associated with hemochromatosis.
- Avoid testosterone treatment in case of concomitant, uncontrolled heart failure.

Main Refs (Bhasin et al. 2010; Pietrangelo 2010; Buvat et al. 2013; Isidori et al. 2015; Pelusi et al. 2016).

## Thalassemia

Iron overload in patients with thalassemia major causes iron deposition in various tissues, among them the pituitary (Berkovitch et al. 2000; Mousa et al. 2016) and the testis (Rund and Rachmilewitz 2005) (Table 1, Fig. 3). Iron overload starts since infancy and hypopituitarism as well as hypogonadism might develop before puberty in about 50% of cases (Albu et al. 2014) leading to problems in entering puberty. The remaining 20% of cases develop hypogonadism during adulthood (Albu et al. 2014). Thus only 30% of adult patients with thalassemia do not have hypogonadism (Albu et al. 2014). Accordingly, hypogonadism is the most frequent endocrinopathy in men with thalassemia (Fung et al. 2006; Perera et al. 2010; Thuret et al. 2010) and its prevalence increases with advancing age (Rund and Rachmilewitz 2005; Thuret et al. 2010).

Secondary, hypogonadotropic hypogonadism (Berkovitch et al. 2000; Chern et al. 2003; Skordis et al. 2006) is more frequent than primary hypogonadism (Soliman et al. 2005; Perera et al. 2010) and mixed forms are common (Table 1, Fig. 3). Accordingly, a half of thalassemic patients with hypogonadotropic hypogonadism (documented low LH and testosterone) do not respond to human chorionic gonadotropin (hCG) since testosterone and testis volume do not respond to the treatment, suggesting the presence of damage both at pituitary and testicular level (Soliman et al. 2005). Iron deposition within the testis of thalassemic patients has been clearly documented in autopsy studies (Canale et al. 1974). FSH and LH levels are expected to be high (hypergonadotropic hypogonadism) in thalassemic patients with primary hypogonadism due to testicular atrophy, the presence of iron deposition in the pituitary leading to inappropriate gonadotropin secretion in mixed forms of hypogonadism involving both the pituitary and the testes (Rund and Rachmilewitz 2005) (Table 1, Fig. 3). Besides, when compared to patients with sickle cell anemia, thalassemic men show a significantly higher prevalence of gonadal dysfunction and hypogonadism notwithstanding the same transfusion regimen (Fung et al. 2006).

Higher iron overload and lower hemoglobin values are associated with the occurrence of hypogonadism (Albu et al. 2014). Similarly, the delayed onset of chelation treatment as well as undertreatment could more easily result in comorbidities and hypogonadism (Albu et al. 2014). Accordingly, children who are promptly treated with iron chelation are less prone to develop hypogonadism and delayed puberty (Bronspiegel-Weintrob et al. 1990).

It should be remarked that most of the studies on hypogonadism in thalassemia derive from prepubertal or pubertal young boys (Chern et al. 2003), and only few studies have involved adult men (Skordis et al. 2006; Safarinejad 2008; Perera et al. 2010; Poggi et al. 2016).

## Clinical Implications

The prepubertal onset of male hypogonadism is easy to recognize due to delayed puberty and the lack of development and/or progress of primary and secondary sexual characteristics at the time of puberty (Dwyer et al. 2015). The disease is more difficult to diagnose in adults, even though the high prevalence of hypogonadism in these patients is translated into practice in periodic controls of the HPG axis.

Of course, prepubertal and adult onset hypogonadism require differentiated approaches in terms of replacement treatment and follow-up.

MRI could be a useful tool for the early detection of pituitary iron overload (Mousa et al. 2016).

Intensive chelating strategies, such as combination therapy, are able to block iron overload and to obtain iron load normalization; this clinical result is able to reverse male hypogonadism in about a half of patients with hypogonadism, especially in young patients (Farmaki et al. 2010). Furthermore, early starting of iron chelation therapy avoids the development of endocrinopathies and hypogonadism (Bronspiegel-Weintrob et al. 1990; Shalitin et al. 2005; Albu et al. 2014). Therefore, early endocrinological evaluation and adequate control of the hematological disease could be essential in order to reduce the prevalence of hypogonadism at any age (Shalitin et al. 2005). For these reasons the approach to the disease should be multidisciplinary and should involve both the endocrinologist and the clinicians who manage thalassemic patients (e.g., hematologist, internist, pediatrician).

Testosterone replacement therapy is mandatory in patients with thalassemia (Rund and Rachmilewitz 2005), the dosage being titrated considering both the patient's age and the expected level of circulating testosterone as well as the pubertal stage in adolescents (Dwyer et al. 2015). The target of replacement therapy should be the restoration of normal serum testosterone according to patients' age and the benefits on bone mass (Anapliotou et al. 1995) in order to correct for a concomitant cause of osteopenia/osteoporosis (Voskaridou and Terpos 2004; Rund and Rachmilewitz 2005).

#### **The Practical Clinical Corner: Hypogonadism in Thalassemia**

- Boys and adult men with thalassemia should be periodically screened for hypogonadism.
- Testosterone treatment is mandatory in patients with documented biochemical hypogonadism and signs or symptoms of androgen deficiency, especially at pubertal age.
- Testosterone administration is needed both for bone maturation (boys) and mineralization (boys and adult men).
- Consider bone health and sexual function as main end points in the follow-up.
- Consider the desire of paternity and the need to shift to gonadotropin therapy.
- Mixed forms (primary and secondary hypogonadism) might not respond completely to gonadotropin administration.
- Avoid testosterone treatment in case of concomitant, uncontrolled heart failure.

Main Refs (Anapliotou et al. 1995; Voskaridou and Terpos 2004; Rund and Rachmilewitz 2005; Bhasin et al. 2010; Buvat et al. 2013; Dwyer et al. 2015; Isidori et al. 2015).

## Endocrine, Metabolic Diseases

### Overweight, Obesity, the Metabolic Syndrome, and Type 2 Diabetes Mellitus

In men, overweight and obesity are strictly correlated to the occurrence of the metabolic syndrome and type 2 diabetes mellitus (T2DM). All these three clinical conditions are also associated to male hypogonadism (Taylor et al. 2015). In addition, these three clinical conditions interact with each other through various mechanisms with the result that they exacerbate each other as in a vicious circle (Lamm et al. 2016) (Fig. 2).

The first observation that a higher body mass index (BMI) and chronic disease are associated with low-serum total and free testosterone comes from the Massachusetts Male Aging Study (Mohr et al. 2005), and this finding has been replicated by several other studies. Accordingly, serum testosterone is significantly reduced in obese men compared to healthy controls (Zumoff et al. 1990; Corona et al. 2011a, 2015; Taylor et al. 2015; Lamm et al. 2016). Besides, lifestyle and body weight impact significantly on gonadal function in men (Travison et al. 2007).

The prevalence of biochemical hypogonadism in obese men is around 40–50% (Mulligan et al. 2006; Hofstra et al. 2008; Ippertiel et al. 2013) with some studies showing higher percentages (58%) (Hofstra et al. 2008). The Health in Men Study demonstrated that 52.4% of obese men have serum testosterone below 300 ng/dL (Mulligan et al. 2006). The prevalence of patients with low total serum testosterone usually increases if also free serum testosterone is considered, for example in men with T2DM the prevalence of hypogonadism was 43% considering only total testosterone and raised to 57% when also free testosterone was taken into account (Grossmann et al. 2008). It seems that the prevalence of hypogonadism increases according to the degree of obesity, especially of its visceral component (Ippertiel et al. 2013).

According to different studies, the prevalence of hypogonadism among men with T2DM varies from 43% (Grossmann et al. 2008; Dhindsa et al. 2010; Dandona and Dhindsa 2011) to up to 50% (Taylor et al. 2015). Similar percentages are found in men with the metabolic syndrome. It has been estimated that the metabolic status related to overweight, obesity, and/or T2DM may increase the probability of having hypogonadism (Dhindsa et al. 2004; Corona et al. 2011b, 2016a; Rastrelli et al. 2015). In middle-aged men the presence of metabolic syndrome increases the risk of developing hypogonadism 2.6-fold during a subsequent follow-up of 11 years (Laaksonen et al. 2004). Similar percentages of reduction in serum testosterone occur in patients with T2DM (Corona et al. 2011c). Furthermore, T2DM is independently associated with hypogonadism (Corona et al. 2011c), and T2DM alone seems to increase the risk of developing hypogonadism, since the prevalence of hypogonadism in obese men was greater in those with than without T2DM (Dhindsa et al. 2010). On average patients with the metabolic syndrome have serum testosterone that is 85 ng/dL lower than in healthy controls (Corona et al. 2011b).

The interplay between obesity, metabolic syndrome, and T2DM, on one hand, and low-serum testosterone, on the other hand, is bidirectional since low testosterone is the

most significant predictor of the increase in visceral fat (Tsai et al. 2000). Thus, androgen deficiency predispose to the development of both the metabolic syndrome and T2DM (Lamm et al. 2016) and contributes to weight and visceral fat increase (Corona et al. 2011a, b, 2015). Accordingly, low-serum testosterone contributes to increase visceral fat in hypogonadal men (Corona et al. 2011a, 2015; Lamm et al. 2016).

The pathogenesis of hypogonadism in overweight, obese men with or without the metabolic syndrome and/or T2DM is complex due to this bidirectional interplay that complicates the cause-effect relationship (Fig. 2).

The most accredited mechanism involved in the pathogenesis of hypogonadism in obesity is the increased aromatization within the adipose tissue resulting in increased circulating estrogens (Schneider et al. 1979; Rochira and Guaraldi 2014; Decaroli and Rochira 2016) (Table 1, Fig. 3). Estrogens act on the hypothalamus and the pituitary as potent inhibitors of gonadotropin secretion in men (Santen 1981; Finkelstein et al. 1991a, b; Hayes et al. 2000; Rochira et al. 2006, 2012, 2016). Hence, the reduction of LH does not permit to increase testosterone secretion by Leydig cells leaving circulating testosterone unbalanced. The administration of letrozole, a potent aromatase inhibitor, to hypogonadal men with severe obesity resulted in a significant increase of both serum LH and testosterone and in a significant decrease of serum estradiol (Loves et al. 2008), thus further confirming the underlying pathogenetic mechanism.

Another mechanism involved in the pathogenesis of low-serum testosterone in obese men involves the reduction of SHBG due to insulin-dependent suppression of liver SHBG production. Low-serum SHBG leads to the reduction of both total and free testosterone (Vermeulen et al. 1996, 1999), the latter being available for aromatization (Taylor et al. 2015) (Table 1, Fig. 3).

Leptin, which is increased in obese men, may further contribute to gonadotropins inhibition in obese men (Isidori et al. 1999) (Table 1, Fig. 3). Several other cytokines, named adipokines (such as adiponectin, interleukin-6, tumor necrosis factor alpha etc.) are released by the adipose tissue, especially visceral fat, and are able to inhibit the hypothalamic GnRH secretion (Fig. 3) (Mah and Wittert 2010; Tchernof and Despres 2013; Martin 2014; Lamm et al. 2016). In addition, OSAS, a very common morbidity associated to overweight and obesity, is involved in lowering serum testosterone since sleep interruption and fragmentation cause a reduction of nocturnal production of LH by the pituitary (Luboshitzky et al. 2002) (Table 1, Fig. 3).

### Clinical Implications

Due to the bidirectional interplay, it is difficult in front of a patient with low-serum testosterone and obesity to comprehend with certainty which of the two clinical conditions occurred first. Secondly, it is difficult to establish whether or not the finding of low-serum testosterone (biochemical hypogonadism) in obese men is clinically relevant and requires to be treated and what is the most appropriate therapy (Huhtaniemi 2014; Decaroli and Rochira 2016). Theoretically, what the physician should do is to attempt to treat both (hypogonadism and the metabolic disease) possibly by using one single therapeutic option (Bhasin et al. 2010; Buvat et al. 2013; Huhtaniemi 2014; Isidori et al. 2015; Corona et al. 2016a).

Weight loss improves serum testosterone and reverts completely or in part hypogonadism, independently of the type of clinical intervention employed (i.e., diet, exercise, bariatric surgery) (Corona et al. 2013a). Accordingly, weight loss obtained thanks to lifestyle intervention (Kaukua et al. 2003; Armamento-Villareal et al. 2016) or bariatric surgery (Ippertiel et al. 2013) both improve or revert hypogonadism. A recent meta-analysis has further confirmed these results providing also evidence that the greater the weight loss, the greater is the increase of serum testosterone (Corona et al. 2013a).

Vice versa also testosterone replacement therapy may reduce body fat mass, waist circumference, and increase muscle mass and could be considered as an adjuvant treatment modality for counteracting obesity in hypogonadal obese men (Saad et al. 2013; Yassin and Doros 2013) with or without T2DM (Corona et al. 2011c; Haider et al. 2014). Besides, testosterone therapy is effective not only in reducing body fat and increasing lean body mass in men with low-serum testosterone (<346 ng/dL) but also in improving fasting serum glucose, insulin resistance, and circulating lipids, as shown by a recent meta-analysis (Corona et al. 2016b). When combined with lifestyle changes, testosterone treatment results in a better outcome in men with low-serum testosterone (Corona et al. 2015). Another possible strategy includes the use of aromatase inhibitors to increase endogenous secretion of testosterone (de Boer et al. 2005).

#### **The Practical Clinical Corner: Hypogonadism in Overweight, Obesity, Metabolic Syndrome, and T2DM**

- All obese patients with or without metabolic syndrome or T2DM should be periodically screened for hypogonadism in the presence of hypogonadal signs and symptoms.
- Apart from gonadotropins and testosterone, SHBG and estradiol should also be a part of the endocrine workup.
- Lifestyle modifications (diet plus exercise) have beneficial effects on weight loss and increase serum testosterone.
- Testosterone treatment should be considered together with lifestyle modifications in patients with documented biochemical hypogonadism and signs or symptoms of androgen deficiency (reduced sexual function and virilization, loss of vigor).
- Bariatric surgery when indicated for the treatment of severe obesity results in the increase of serum testosterone.
- Consider avoiding testosterone treatment in case of concomitant, uncontrolled heart failure or in the presence of a very poor health status.

Main Refs (Buvat et al. 2013; Ippertiel et al. 2013; Corona et al. 2013a, 2016a, b; Huhtaniemi 2014; Isidori et al. 2015; Decaroli and Rochira 2016).



---

## Other Endocrine Diseases

All the pathological events affecting the hypothalamus and the pituitary have the potential to cause directly secondary hypogonadism (Schneider et al. 2007; Anthony et al. 2016; Higham et al. 2016; Pekic and Popovic 2017) (Table 1, Fig. 3).

Hypercortisolism and congenital adrenal hyperplasia might affect testosterone synthesis by acting on the steroid metabolic pathway by inhibiting enzyme function (Turner and Wass 1997).

Altered thyroid function causes reduced (hypothyroidism) or increased (hyperthyroidism) synthesis of SHBG resulting in slight, transitory changes of serum testosterone (Jaya Kumar et al. 1990).

---

## Cardiovascular Disease

Hypogonadism is common in men with cardiovascular disease. The relationship between hypogonadism and cardiovascular disease is bidirectional (Fig. 2) since cardiovascular disease might induce hypogonadism and low-serum testosterone worsens cardiovascular function and increases the risks of cardiovascular disease (Corona et al. 2011a).

Low-serum testosterone has been associated with increased cardiovascular risk (Araujo et al. 2011; Corona et al. 2011a, d), and men with coronary artery disease often display low-serum testosterone (Kloner et al. 2016).

At present, there is no consensus on the predictive value of low-serum testosterone on cardiovascular death (Wu 2012) since there are studies supporting a putative role of androgen deficiency on cardiovascular mortality (Barrett-Connor and Khaw 1988), while other studies do not find any relationship (Araujo et al. 2007). Hence, the relationships between cardiovascular disease and hypogonadism remain complex, and it is difficult to ascertain whether or not low-serum testosterone is only an epiphenomenon related to illness and merely represents a biomarker of poor health status (Shores and Matsumoto 2014; Decaroli and Rochira 2016).

## Hypertension

Several observational studies found an association between hypertension and low-serum testosterone (Khaw and Barrett-Connor 1988; Hughes et al. 1989). However, it is difficult to unmask the real cause-effect relationship between these two clinical conditions since several other confounding factors could contribute to androgen deficiency in men with hypertension. Among them, the most important are the use of antihypertensive drugs (e.g., spironolactone, atenolol) that may lower

testosterone secretion (Suzuki et al. 1988) and the high prevalence of metabolic disease (obesity, T2DM, metabolic syndrome) in men with hypertension, as clearly shown in population studies (Barrett-Connor and Khaw 1988; Svartberg et al. 2004b).

## Heart Failure

The relationships between hypogonadism and heart failure remain contradictory (Malkin et al. 2010). On one hand, several trials suggest that testosterone treatment may improve cardiac performance (Malkin et al. 2006), while it is contraindicated in severe heart failure (Bhasin et al. 2010).

## Testosterone Treatment and Cardiovascular Disease

Some trials on testosterone therapy reported an increased incidence of cardiovascular events (Basaria et al. 2010; Vigen et al. 2013; Finkle et al. 2014; Kloner et al. 2016). For this reason, the Food and Drug Administration provided an alert (<https://www.fda.gov/Drugs/DrugSafety/ucm436259.htm>) in 2014 suggesting caution in prescribing testosterone. The subsequent publication of four meta-analysis showed no clear association between testosterone replacement treatment and cardiovascular events (Calof et al. 2005; Haddad et al. 2007; Fernandez-Balsells et al. 2010; Corona et al. 2014b). At present, in fact, only one meta-analytic study found an association between testosterone therapy and cardiovascular events (Xu et al. 2013). Besides, the other study that found an increased incidence of major cardiovascular events included among older participants immobile patients in poor health status due to multimorbidity and a positive history of previous major cardiovascular events who received high dose exogenous testosterone (Basaria et al. 2010). In another study suggesting exogenous testosterone as harmful, the reasons for testosterone treatment were not known suggesting that not all patients were truly hypogonadic (Finkle et al. 2014). It should be considered that men suffering from systemic diseases present with a poor health status more often than men without chronic illnesses and that this condition could negatively impact on serum testosterone (Corona et al. 2014a; Rochira et al. 2015; Decaroli and Rochira 2016). With this in view, the general health status of the patient should be always considered before starting testosterone therapy in order to identify patients for whom testosterone may be harmful. Older men, sick patients, and patients with congestive heart failure should be carefully considered before prescribing testosterone, the latter should be offered after a comprehensive evaluation of potential benefits and risks (Bhasin et al. 2010; Malkin et al. 2010; Isidori et al. 2015; Decaroli and Rochira 2016; Gencer and Mach 2016). Severe, uncontrolled heart failure is considered a contraindication to testosterone treatment (Calof et al. 2005; Bhasin et al. 2010; Isidori et al. 2015). Recently, the volume of non-calcified coronary plaques increased after one year of testosterone

treatment compared to placebo group in older men with hypogonadism, the clinical significance of this finding needing further investigations especially in terms of related major cardiovascular events (Budoff et al. 2017).

#### **The Practical Clinical Corner: Hypogonadism in Cardiovascular Diseases**

- Serum testosterone should not be assayed soon after a cardiovascular event.
- Patients should be informed about the potential risks of testosterone.
- Consider risk/benefits of testosterone treatment.
- Avoid testosterone treatment in patients with severe uncontrolled heart failure.
- The follow-up for increased hematocrit during testosterone treatment should be stricter.
- Avoid the use of exogenous testosterone for treating cardiac dysfunction.

Main Refs (Bhasin et al. 2010; Malkin et al. 2010; Isidori et al. 2015; Gencer and Mach 2016).

---

## **Infectious Diseases**

Hypogonadism might be the consequences of infectious diseases. Apart acute viral or bacterial infections that might localize within the testes, several chronic infective diseases are associated to low-serum testosterone and male hypogonadism.

Acute viral or bacterial infections that cause orchitis could lead to irreversible damage of the testis such as in the case of parotitis (Davis et al. 2010) and syphilis (Mackenzie et al. 2011) or may cause transient hypogonadism such as in the case of infection of the testis by trichomonas vaginalis (Lloyd et al. 2003).

Chronic infections that may lead to hypogonadism are viral hepatitis (see above the chapter on liver diseases) and human immunodeficiency virus (HIV) infection.

### **HIV Infection**

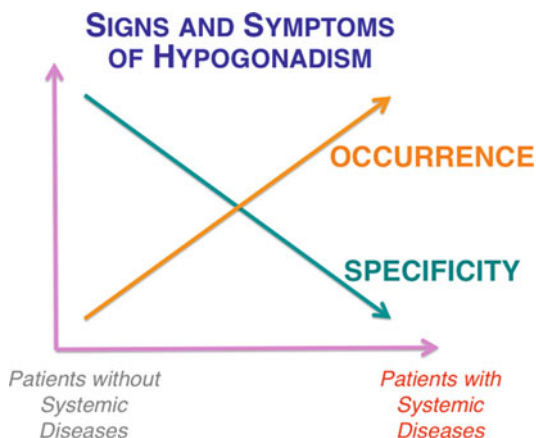
In men with HIV infection, the prevalence of hypogonadism is around 25%, varying from 13% to 40%, according to different studies (Rochira and Guaraldi 2014). This difference depends on different factors. The studies performed before the development of the highly active antiretroviral therapy (HAART) shows higher rate of incidence and prevalence among patients with HIV, due to the fact that they almost constantly developed the acquired immunodeficiency syndrome (AIDS) (Zirilli et al. 2008). Patients with overt AIDS were exposed to multiple opportunistic infections, which often localized to the reproductive tract (Raffi et al. 1991), including the testis (Salehian et al. 1999). Furthermore, AIDS was associated with very poor health

status, a condition that is associated with low-serum testosterone (see also the paragraph above “[Male Hypogonadism and Systemic Illnesses: Acute Versus Chronic Diseases](#)” for Further Details) (Rochira and Guaraldi 2014). Other possible confounding factors were related to the methods used in the past for testosterone measurement as well as to the lack of criteria to define hypogonadism (Rochira and Guaraldi 2014).

The prevalence of hypogonadism among HIV-infected men decreased during the HAART era (Zirilli et al. 2008) but remains still of significance if compared to what happens in non-HIV-infected men. At present, the prevalence is around 25% on average (Rochira and Guaraldi 2014), and this prevalence has been calculated on the results of studies with larger samples and using accurate methods for diagnosing hypogonadism (Rochira et al. 2011; Monroe et al. 2012, 2014; Sunchatawirul et al. 2012; Blick 2013). This prevalence is of clinical relevance, especially if the youngest age of patients living with the HIV is considered (Rochira and Guaraldi 2014). Accordingly, hypogonadism in HIV is characterized by a premature decline of serum testosterone (Rochira et al. 2011) resulting in values of serum testosterone levels of middle-aged men (40–50 years) similar to those of older men (>65 years) (Rochira et al. 2011; Rochira and Guaraldi 2014).

The pathogenesis of low-serum testosterone in men with HIV infection is multifactorial, even though some mechanisms play a more important role than others (Table 1, Fig. 3). This issue is complicated by the fact that several classic risk factors of hypogonadism do not result not, or are poorly associated with, serum testosterone in HIV-infected men, probably as a consequence of the strong role exerted by HIV per se (Rochira et al. 2011; Rochira and Guaraldi 2014). Hypogonadotropic hypogonadism (secondary hypogonadism) is more frequent than primary hypogonadism (Rochira et al. 2011). Secondary hypogonadism may be due to (i) viral infection of the pituitary, (ii) the direct inhibitory action on the hypothalamus-pituitary unit of HAART drugs, (iii) the indirect effect on the pituitary on adipose tissue redistribution due to HAART (the most accredited mechanism), (iv) the use of opiates in the subgroups of HIV-infected men who are drug abusers, and finally (v) the poor health status due to multimorbidity and frailty in these patients (Rochira and Guaraldi 2014) (Table 1, Fig. 3). At present, evidence exists supporting a role for visceral fat, increased aromatization, and estrogen inhibitory effects on the HPG axis (Rochira et al. 2011) and a role of multimorbidity, frailty, and poorer health status in the genesis of hypogonadism (Rochira et al. 2015), since all these factors resulted strongly inversely related to serum testosterone (Table 1, Fig. 3). The observation of a high prevalence of growth hormone deficiency in adult men with HIV further supports a possible inhibitory role of visceral fat on the hypothalamic-pituitary function (Zirilli et al. 2008, 2012; Brigante et al. 2014; Diazzi et al. 2017). Finally, SHBG is often increased in patients with HIV infection, and this might further contribute to the development of low-serum-free testosterone (Moreno-Perez et al. 2010) (Table 1, Fig. 3). Primary hypogonadism is less frequent (about 14% of all hypogonadal HIV-infected men) and seems to be associated with a poor control of HIV infection (Rochira et al. 2011; Rochira and Guaraldi 2014) (Table 1, Fig. 3).

**Fig. 4** Changes in the frequency of signs and symptoms of hypogonadism and in their specificity in patients with acute or chronic systemic diseases



### Clinical Implications

In high-income countries, the incidence and prevalence of overt AIDS dropped thanks to the introduction of HAART, the hypogonadism related to AIDS remaining a major problem only in low-income countries with limited access to HAART treatments.

The finding of low-serum testosterone in HIV-infected men treated with HAART is not sufficient to make a clinical diagnosis of hypogonadism since the possibility that is a functional, transient condition related to poor health status should be considered (Rochira and Guaraldi 2014). The diagnosis of hypogonadism is challenging in clinical practice due to the fact that sign and symptoms become less specific for hypogonadism in men with HIV (Rochira and Guaraldi 2014), similarly to what happens for other chronic, systemic diseases (Decaroli and Rochira 2016) (Fig. 4). Accordingly, some classic correlates of hypogonadism such as osteopenia, osteoporosis, sexual dysfunction, body composition changes, and mood disturbances are less related to the gonadal status (Rochira et al. 2011; Rochira and Guaraldi 2014). In particular, bone mineral density (BMD) is not different when HIV-infected men with or without serum testosterone below 300 ng/dL are compared, since bone loss and osteoporosis are more prevalent in HIV-infected than in healthy men (Rochira et al. 2011; Santi et al. 2016). Accordingly, sexual dysfunction is highly prevalent in men with HIV (Zona et al. 2012; Santi et al. 2014) due to several factors such as psychological concerns and lipodystrophy-related alterations of body image perception (Luzi et al. 2009), fear of HIV transmission, and stigma (Santi et al. 2014). Again, the presence of several HIV-specific factors influencing sexual dysfunction masks the role of classical risk factors (Guaraldi et al. 2012) and leads to no difference in terms of serum testosterone when patients are grouped according to the presence or absence of erectile dysfunction (Rochira et al. 2011). Thus signs and symptoms due to hypogonadism or HIV infection may overlap with each other (Rochira and Guaraldi 2014) (Fig. 4).

As SHBG is frequently increased in HIV-infected men (Moreno-Perez et al. 2010; Monroe et al. 2014), its measurement should be included in the clinical workup for the diagnosis of hypogonadism in men with HIV in order to avoid missing patients with low free serum testosterone (Bhasin et al. 2010; Rochira and Guaraldi 2014). SHBG, in fact, allows measuring calculated free testosterone (<http://www.issam.ch/freetesto.htm>) and avoid under esteem of hypogonadism (Vermeulen et al. 1996, 1999; Ly et al. 2010). On the other hand, commercially available kits for the measurement of free serum testosterone have a very poor diagnostic value (Rosner et al. 2007; Rosner and Vesper 2010).

In clinical practice, the possible coexistence of chronic viral hepatitis should be considered as an additional risk factor for having hypogonadism (Rochira and Guaraldi 2014).

Testosterone replacement treatment is recommended in HIV-infected men with hypogonadism by several guidelines (Bhasin et al. 2010) or expert panels (Isidori et al. 2015), but the main randomized controlled trails in this population have evaluated the effects of exogenous testosterone on lean body mass in patients with AIDS-related wasting syndrome independently of patients' testosterone values at baseline; in addition supraphysiological doses of exogenous testosterone were used. As a consequence, the results of these trials are not directly applicable to the hypogonadal HIV-infected patients treated with HAART (Rochira and Guaraldi 2014).

#### **The Practical Clinical Corner: Hypogonadism in HIV-Infected Men**

- Adult HIV-infected men should be periodically screened for hypogonadism in the presence of hypogonadal symptoms.
- Apart from gonadotropins and testosterone, SHBG, estradiol, and calculated free testosterone (<http://www.issam.ch/freetesto.htm>) should also be part of the endocrine workup.
- A wait and see approach characterized by the periodical monitoring of serum testosterone could be a good option in case of slightly low or borderline serum testosterone values or in case of low testosterone and lack of signs and symptoms of hypogonadism.
- Testosterone treatment should be considered in patients with documented biochemical hypogonadism and signs or symptoms of androgen deficiency (reduced sexual function and virilization, loss of vigor), especially when young and in an otherwise good health status.
- Consider treating hypogonadism as a whole without using testosterone only for changing body composition.
- The use of supraphysiological doses of testosterone should be avoided, especially in sick patients or for long-term schedules of treatment.
- Consider avoiding testosterone treatment in case of a very poor health status due to HIV-related multimorbidity.

Main Refs (Bhasin et al. 2010; Buvat et al. 2013; Rochira and Guaraldi 2014; Isidori et al. 2015).

**Table 2** Medications potentially lowering serum testosterone

Glucocorticoids
Antihypertensive drugs
<i>Spironolactone</i>
<i>Atenolol</i>
Endocrine agents
<i>GnRH analogues</i>
<i>Anabolics steroids</i>
<i>5 alpha-reductase inhibitors</i>
Adrenal enzymatic suppressors
<i>Ketoconazole</i>
<i>Mitotane</i>
<i>Metyrapone</i>
Opiates
Drugs increasing prolactin
Antipsychotics
Chemotherapy for malignancies
Radiotherapy for malignancies

---

## Drugs and/or Treatments Causing Hypogonadism

Several drugs used for the treatment of systemic diseases could cause hypogonadism, and the mechanisms involved depend on the type of drug (Table 2). Other surgical or radiotherapeutic treatments involving the HPG axis (the hypothalamus-pituitary or the testes) could cause hypogonadism.

---

## Conclusions

The issue concerning how to correctly diagnose hypogonadism in men (Buvat et al. 2013; Corona et al. 2013b; Huhtaniemi 2014; Decaroli and Rochira 2016) becomes of great clinical relevance in men with systemic disease (Huhtaniemi 2014; Rochira and Guaraldi 2014; Corona et al. 2016a). First of all, the finding of biochemical hypogonadism (i.e., serum testosterone below the normal range) depends on the threshold used for its definition. This threshold changes according to the cutoff provided by the guideline taken into consideration (Petak et al. 2002; Bhasin et al. 2010; Decaroli and Rochira 2016). Secondly, the finding of biochemical hypogonadism is not sufficient alone for the diagnosis of hypogonadism in these patients since the coexistence of low-serum testosterone with main signs and symptoms of hypogonadism is needed (Corona et al. 2012, 2013b, 2016a; Buvat et al. 2013; Huhtaniemi 2014; Decaroli and Rochira 2016). In addition, reference ranges for circulating testosterone apply in a different way to different decades of age and harmonized reference ranges could be useful in clinical practice to better categorize

patients as having or not hypogonadism (Travison et al. 2017). The main practical problem concerning the clinical diagnosis of hypogonadism in men with systemic disease lies in the fact that there is overlap between the symptoms of hypogonadism with those of the systemic disease (as for loss of vigor and vitality, depression, fatigue, sexual dysfunction, bone loss, cognitive symptoms) (Petak et al. 2002; Buvat et al. 2013; Corona et al. 2013b; Huhtaniemi 2014; Decaroli and Rochira 2016) (Fig. 4). Besides, also the severity of androgen deficiency in terms of low-serum testosterone does matter, especially to decide upon the need of testosterone replacement treatment (Buvat et al. 2013; Huhtaniemi 2014; Decaroli and Rochira 2016). The identification of (i) patients who may benefit from testosterone treatment and (ii) patients for whom exogenous testosterone might potentially be harmful is important in clinical practice in order to lead decision-making. The presence of another major, systemic disease is a confounding factor that could lead to misdiagnosis or to unnecessary therapies. In general, testosterone treatment should be considered aimed at treating clinical hypogonadism and should not be taken into account for improving specific symptoms of the systemic disease (Buvat et al. 2013; Huhtaniemi 2014; Decaroli and Rochira 2016). In particular, physicians should avoid overtreatment and should consider possible beneficial effects on symptoms of hypogonadism (improvement of sexual function, body composition, well-being). Today, however, the patients' demand of androgenic compounds to improve quality of life, sexual function, and body image is increasing in western countries even among older men; in parallel the use of testosterone products is also growing (Handelsman 2011; Bhasin 2016). Hence, the finding of biochemical hypogonadism in older men who have a good probability to have at least one chronic disease represents a frequent, current event for the endocrinologist and the probability that the patient will ask for testosterone therapy during the visit is extremely high. This poses several unresolved issues due to the fact that evidence-based information on this issue is still lacking. Further information is needed to optimize the management of hypogonadism within the clinical context of systemic disease and aging. The challenge for the near future will be to improve our knowledge on the beneficial or harmful effects of testosterone treatment according to the underlying systemic disease in order to individualize and tailor treatment strategies.

---

## Summary

Gonadal function is often compromised in chronic or acute systemic disease. Clinical management of androgen deficiency depends on the type of systemic disease and its severity as well as on patients' health condition. The restoration of a normal gonadal function should be the goal, bearing in mind that in some particular circumstances, a reduced gonadal function might be an adaptive mechanism for sparing energy or that the treatment employed for restoring normal circulating androgens might be harmful.



---

## Cross-References

- ▶ [Classification and Epidemiology of Hypogonadism](#)
- ▶ [Clinical Manifestation and Diagnosis of Androgen Deficiency](#)
- ▶ [Estrogen Deficiency in Men](#)
- ▶ [Hormonal Laboratory Examination](#)
- ▶ [Late-Onset Hypogonadism](#)
- ▶ [Primary and Secondary Hypogonadism](#)
- ▶ [Treatment of Hypogonadism](#)

---

## References

- Akbari F, Alavi M, Esteghamati A, Mehraei A, Djaladat H, Zohrevand R, Pourmand G. Effect of renal transplantation on sperm quality and sex hormone levels. *BJU Int.* 2003;92(3):281–3.
- Akbas T, Karakurt S, Unluguzel G, Celikel T, Akalin S. The endocrinologic changes in critically ill chronic obstructive pulmonary disease patients. *COPD.* 2010;7(4):240–7.
- Albaaj F, Sivalingham M, Haynes P, McKinnon G, Foley RN, Waldek S, O'Donoghue DJ, Kalra PA. Prevalence of hypogonadism in male patients with renal failure. *Postgrad Med J.* 2006;82(972):693–6.
- Albu A, Barbu CG, Antonie L, Vladareanu F, Fica S. Risk factors associated with hypogonadism in beta-thalassemia major patients: predictors for a frequent complication of a rare disease. *Postgrad Med.* 2014;126(5):121–7.
- Altman JJ, Zygelman M, Roger M, Fiet J, Passa P. The GnRH test in idiopathic hemochromatosis. *J Endocrinol Invest.* 1980;3(3):223–7.
- Anapliotou ML, Kastanias IT, Psara P, Evangelou EA, Liparaki M, Dimitriou P. The contribution of hypogonadism to the development of osteoporosis in thalassaemia major: new therapeutic approaches. *Clin Endocrinol (Oxf).* 1995;42(3):279–87.
- Anthony J, Esper GJ, Ioachimescu A. Hypothalamic-pituitary sarcoidosis with vision loss and hypopituitarism: case series and literature review. *Pituitary.* 2016;19(1):19–29.
- Araujo AB, Dixon JM, Suarez EA, Murad MH, Guey LT, Wittert GA. Clinical review: endogenous testosterone and mortality in men: a systematic review and meta-analysis. *J Clin Endocrinol Metab.* 2011;96(10):3007–19.
- Araujo AB, Kupelian V, Page ST, Handelsman DJ, Bremner WJ, McKinlay JB. Sex steroids and all-cause and cause-specific mortality in men. *Arch Intern Med.* 2007;167(12):1252–60.
- Argyropoulou MI, Kiortsis DN, Metafratzi Z, Bitsis S, Tsatoulis A, Efremidis SC. Pituitary gland height evaluated by MR in patients with beta-thalassemia major: a marker of pituitary gland function. *Neuroradiology.* 2001;43(12):1056–8.
- Armamento-Villareal R, Aguirre LE, Qualls C, Villareal DT. Effect of lifestyle intervention on the hormonal profile of frail, obese older men. *J Nutr Health Aging.* 2016;20(3):334–40.
- Bachman E, Travison TG, Basaria S, Davda MN, Guo W, Li M, Connor Westfall J, Bae H, Gordeuk V, Bhasin S. Testosterone induces erythrocytosis via increased erythropoietin and suppressed hepcidin: evidence for a new erythropoietin/hemoglobin set point. *J Gerontol A Biol Sci Med Sci.* 2014;69(6):725–35.
- Bahnsen M, Gluud C, Johnsen SG, Bennett P, Svenstrup S, Micic S, Dietrichson O, Svendsen LB, Brodthagen UA. Pituitary-testicular function in patients with alcoholic cirrhosis of the liver. *Eur J Clin Invest.* 1981;11(6):473–9.
- Baker HW. Reproductive effects of nontesticular illness. *Endocrinol Metab Clin North Am.* 1998;27(4):831–50.

- Balasubramanian V, Naing S. Hypogonadism in chronic obstructive pulmonary disease: incidence and effects. *Curr Opin Pulm Med*. 2012;18(2):112–7.
- Ballal SH, Domoto DT, Polack DC, Marciulonis P, Martin KJ. Androgens potentiate the effects of erythropoietin in the treatment of anemia of end-stage renal disease. *Am J Kidney Dis*. 1991; 17(1):29–33.
- Bandyopadhyay SK, Moulick A, Saha M, Dutta A, Bandyopadhyay R, Basu AK. A study on endocrine dysfunction in adult males with liver cirrhosis. *J Indian Med Assoc*. 2009;107(12): 866. 868–869.
- Bannister P, Handley T, Chapman C, Losowsky MS. Hypogonadism in chronic liver disease: impaired release of luteinising hormone. *Br Med J (Clin Res Ed)*. 1986;293(6556):1191–3.
- Bao Y, Johansen KL. Diagnosis and treatment of low testosterone among patients with end-stage renal disease. *Semin Dial*. 2015;28(3):259–65.
- Barreca T, Picciotto A, Franceschini R, Varagona G, Garibaldi A, Valle F, Cataldi A, D'Agostino S, Rolandi E. Sex hormones and sex hormone-binding globulin in males with chronic viral hepatitis during recombinant interferon-alpha 2b therapy. *J Interferon Res*. 1993;13(3):209–11.
- Barrett-Connor E, Khaw KT. Endogenous sex hormones and cardiovascular disease in men. A prospective population-based study. *Circulation*. 1988;78(3):539–45.
- Basaria S, Coviello AD, Travison TG, Storer TW, Farwell WR, Jette AM, Eder R, Tennstedt S, Ulloor J, Zhang A, Choong K, Lakshman KM, Mazer NA, Micek R, Krasnoff J, Elmi A, Knapp PE, Brooks B, Appleman E, Aggarwal S, Bhasin G, Hede-Brierley L, Bhatia A, Collins L, LeBrasseur N, Fiore LD, Bhasin S. Adverse events associated with testosterone administration. *N Engl J Med*. 2010;363(2):109–22.
- Basualto-Alarcon C, Varela D, Duran J, Maass R, Estrada M. Sarcopenia and androgens: a link between pathology and treatment. *Front Endocrinol (Lausanne)*. 2014;5:217.
- Berkovitch M, Bistrizter T, Milone SD, Perlman K, Kucharczyk W, Olivieri NF. Iron deposition in the anterior pituitary in homozygous beta-thalassemia: MRI evaluation and correlation with gonadal function. *J Pediatr Endocrinol Metab*. 2000;13(2):179–84.
- Bhansali A, Banerjee PK, Dash S, Radotra B, Dash RJ. Pituitary and testicular involvement in primary haemochromatosis. A case report. *J Assoc Physicians India*. 1992;40(11):757–9.
- Bhasin S. A perspective on the evolving landscape in male reproductive medicine. *J Clin Endocrinol Metab*. 2016;101(3):827–36.
- Bhasin S, Cunningham GR, Hayes FJ, Matsumoto AM, Snyder PJ, Swerdloff RS, Montori VM. Testosterone therapy in men with androgen deficiency syndromes: an Endocrine Society clinical practice guideline. *J Clin Endocrinol Metab*. 2010;95(6):2536–59.
- Biskobing DM. COPD and osteoporosis. *Chest*. 2002;121(2):609–20.
- Blick G. Optimal diagnostic measures and thresholds for hypogonadism in men with HIV/AIDS: comparison between 2 transdermal testosterone replacement therapy gels. *Postgrad Med*. 2013;125(2):30–9.
- Brigante G, Diazi C, Ansaloni A, Zirilli L, Orlando G, Guaraldi G, Rochira V. Gender differences in GH response to GHRH+ARG in lipodystrophic patients with HIV: a key role for body fat distribution. *Eur J Endocrinol*. 2014;170(5):685–96.
- Bronspiegel-Weintrob N, Olivieri NF, Tyler B, Andrews DF, Freedman MH, Holland FJ. Effect of age at the start of iron chelation therapy on gonadal function in beta-thalassemia major. *N Engl J Med*. 1990;323(11):713–9.
- Budoff MJ, Ellenberg SS, Lewis CE, Mohler ER 3rd, Wenger NK, Bhasin S, Barrett-Connor E, Swerdloff RS, Stephens-Shields A, Cauley JA, Crandall JP, Cunningham GR, Ensrud KE, Gill TM, Matsumoto AM, Molitch ME, Nakanishi R, Nezarat N, Matsumoto S, Hou X, Basaria S, Diem SJ, Wang C, Cifelli D, Snyder PJ. Testosterone treatment and coronary artery plaque volume in older men with low testosterone. *JAMA*. 2017;317(7): 708–16.

- Bullmann C, Faust M, Hoffmann A, Heppner C, Jockenhovel F, Muller-Wieland D, Krone W. Five cases with central diabetes insipidus and hypogonadism as first presentation of neurosarcooidosis. *Eur J Endocrinol.* 2000;142(4):365–72.
- Buvat J, Maggi M, Gooren L, Guay AT, Kaufman J, Morgentaler A, Schulman C, Tan HM, Torres LO, Yassin A, Zitzmann M. Endocrine aspects of male sexual dysfunctions. *J Sex Med.* 2010; 7(4 Pt 2):1627–56.
- Buvat J, Maggi M, Guay A, Torres LO. Testosterone deficiency in men: systematic review and standard operating procedures for diagnosis and treatment. *J Sex Med.* 2013;10(1):245–84.
- Calof OM, Singh AB, Lee ML, Kenny AM, Urban RJ, Tenover JL, Bhasin S. Adverse events associated with testosterone replacement in middle-aged and older men: a meta-analysis of randomized, placebo-controlled trials. *J Gerontol A Biol Sci Med Sci.* 2005;60(11):1451–7.
- Canale VC, Steinherz P, New M, Erlandson M. Endocrine function in thalassemia major. *Ann N Y Acad Sci.* 1974;232(0):333–45.
- Casaburi R, Bhasin S, Cosentino L, Porszasz J, Somfay A, Lewis MI, Fournier M, Storer TW. Effects of testosterone and resistance training in men with chronic obstructive pulmonary disease. *Am J Respir Crit Care Med.* 2004;170(8):870–8.
- Cavanaugh J, Niewoehner CB, Nuttall FQ. Gynecomastia and cirrhosis of the liver. *Arch Intern Med.* 1990;150(3):563–5.
- Charbonnel B, Chupin M, Le Grand A, Guillon J. Pituitary function in idiopathic haemochromatosis: hormonal study in 36 male patients. *Acta Endocrinol.* 1981;98(2):178–83.
- Chern JP, Lin KH, Tsai WY, Wang SC, Lu MY, Lin DT, Lin KS, Lo SH. Hypogonadotropic hypogonadism and hematologic phenotype in patients with transfusion-dependent beta-thalassemia. *J Pediatr Hematol Oncol.* 2003;25(11):880–4.
- Christeff N, Benassayag C, Carli-Vielle C, Carli A, Nunez EA. Elevated oestrogen and reduced testosterone levels in the serum of male septic shock patients. *J Steroid Biochem.* 1988; 29(4):435–40.
- Corbo GM, Di Marco Bernardino A, Mancini A, Inchingolo R, Smargiassi A, Raimondo S, Valente S. Serum level of testosterone, dihydrotestosterone and IGF-1 during an acute exacerbation of COPD and their relationships with inflammatory and prognostic indices: a pilot study. *Minerva Med.* 2014;105(4):289–94.
- Corona G, Giagulli VA, Maseroli E, Vignozzi L, Aversa A, Zitzmann M, Saad F, Mannucci E, Maggi M. Therapy of endocrine disease: testosterone supplementation and body composition: results from a meta-analysis study. *Eur J Endocrinol.* 2016b;174(3):R99–116.
- Corona G, Maseroli E, Rastrelli G, Francomano D, Aversa A, Hackett GI, Ferri S, Sforza A, Maggi M. Is late-onset hypogonadotropic hypogonadism a specific age-dependent disease, or merely an epiphenomenon caused by accumulating disease-burden? *Minerva Endocrinol.* 2016a;41(2):196–210.
- Corona G, Maseroli E, Rastrelli G, Isidori AM, Sforza A, Mannucci E, Maggi M. Cardiovascular risk associated with testosterone-boosting medications: a systematic review and meta-analysis. *Expert Opin Drug Saf.* 2014b;13(10):1327–51.
- Corona G, Monami M, Rastrelli G, Aversa A, Sforza A, Lenzi A, Forti G, Mannucci E, Maggi M. Type 2 diabetes mellitus and testosterone: a meta-analysis study. *Int J Androl.* 2011a; 34(6 Pt 1):528–40.
- Corona G, Monami M, Rastrelli G, Aversa A, Tishova Y, Saad F, Lenzi A, Forti G, Mannucci E, Maggi M. Testosterone and metabolic syndrome: a meta-analysis study. *J Sex Med.* 2011c; 8(1):272–83.
- Corona G, Rastrelli G, Maggi M. Diagnosis and treatment of late-onset hypogonadism: systematic review and meta-analysis of TRT outcomes. *Best Pract Res Clin Endocrinol Metab.* 2013b; 27(4):557–79.
- Corona G, Rastrelli G, Maseroli E, Fralassi N, Sforza A, Forti G, Mannucci E, Maggi M. Low testosterone syndrome protects subjects with high cardiovascular risk burden from major adverse cardiovascular events. *Andrology.* 2014a;2(5):741–7.

- Corona G, Rastrelli G, Monami M, Guay A, Buvat J, Sforza A, Forti G, Mannucci E, Maggi M. Hypogonadism as a risk factor for cardiovascular mortality in men: a meta-analytic study. *Eur J Endocrinol.* 2011d;165(5):687–701.
- Corona G, Rastrelli G, Monami M, Saad F, Luconi M, Lucchese M, Facchiano E, Sforza A, Forti G, Mannucci E, Maggi M. Body weight loss reverts obesity-associated hypogonadotropic hypogonadism: a systematic review and meta-analysis. *Eur J Endocrinol.* 2013a;168(6):829–43.
- Corona G, Rastrelli G, Vignozzi L, Mannucci E, Maggi M. Testosterone, cardiovascular disease and the metabolic syndrome. *Best Pract Res Clin Endocrinol Metab.* 2011b;25(2):337–53.
- Corona G, Rastrelli G, Vignozzi L, Mannucci E, Maggi M. How to recognize late-onset hypogonadism in men with sexual dysfunction. *Asian J Androl.* 2012;14(2):251–9.
- Corona G, Vignozzi L, Sforza A, Mannucci E, Maggi M. Obesity and late-onset hypogonadism. *Mol Cell Endocrinol.* 2015;418(Pt 2):120–33.
- Corsonello A, Antonelli Incalzi R, Pistelli R, Pedone C, Bustacchini S, Lattanzio F. Comorbidities of chronic obstructive pulmonary disease. *Curr Opin Pulm Med.* 2011;17(Suppl 1):S21–8.
- Cox TM, Kelly AL. Haemochromatosis: an inherited metal and toxicity syndrome. *Curr Opin Genet Dev.* 1998;8(3):274–81.
- Crawford BA, Liu PY, Kean MT, Bleasel JF, Handelsman DJ. Randomized placebo-controlled trial of androgen effects on muscle and bone in men requiring long-term systemic glucocorticoid treatment. *J Clin Endocrinol Metab.* 2003;88(7):3167–76.
- Cundy T, Butler J, Bomford A, Williams R. Reversibility of hypogonadotropic hypogonadism associated with genetic haemochromatosis. *Clin Endocrinol (Oxf).* 1993;38(6):617–20.
- Dandona P, Dhindsa S. Update: hypogonadotropic hypogonadism in type 2 diabetes and obesity. *J Clin Endocrinol Metab.* 2011;96(9):2643–51.
- Davis NF, McGuire BB, Mahon JA, Smyth AE, O'Malley KJ, Fitzpatrick JM. The increasing incidence of mumps orchitis: a comprehensive review. *BJU Int.* 2010;105(8):1060–5.
- de Boer H, Verschoor L, Ruinemans-Koerts J, Jansen M. Letrozole normalizes serum testosterone in severely obese men with hypogonadotropic hypogonadism. *Diabetes Obes Metab.* 2005;7(3):211–5.
- Decaroli MC, Rochira V. Aging and sex hormones in males. *Virulence.* 2016;1–26.
- Dhindsa S, Miller MG, McWhirter CL, Mager DE, Ghanim H, Chaudhuri A, Dandona P. Testosterone concentrations in diabetic and nondiabetic obese men. *Diabetes Care.* 2010;33(6):1186–92.
- Dhindsa S, Prabhakar S, Sethi M, Bandyopadhyay A, Chaudhuri A, Dandona P. Frequent occurrence of hypogonadotropic hypogonadism in type 2 diabetes. *J Clin Endocrinol Metab.* 2004;89(11):5462–8.
- Di Luigi L, Romanelli F, Sgro P, Lenzi A. Andrological aspects of physical exercise and sport medicine. *Endocrine.* 2012;42(2):278–84.
- Diamond T, Stiel D, Posen S. Effects of testosterone and venesection on spinal and peripheral bone mineral in six hypogonadal men with hemochromatosis. *J Bone Miner Res.* 1991;6(1):39–43.
- Diazzi C, Brigante G, Ferrannini G, Ansaloni A, Zirilli L, De Santis MC, Zona S, Guaraldi G, Rochira V. Pituitary growth hormone (GH) secretion is partially rescued in HIV-infected patients with GH deficiency (GHD) compared to hypopituitary patients. *Endocrine.* 2017;55(3):885–98.
- Dimopoulou I, Kouyialis AT, Orfanos S, Armaganidis A, Tzanela M, Thalassinou N, Tsagarakis S. Endocrine alterations in critically ill patients with stroke during the early recovery period. *Neurocrit Care.* 2005;3(3):224–9.
- Dimopoulou I, Tsagarakis S. Hypothalamic-pituitary dysfunction in critically ill patients with traumatic and nontraumatic brain injury. *Intensive Care Med.* 2005;31(8):1020–8.
- Dimopoulou I, Tsagarakis S, Theodorakopoulou M, Douka E, Zervou M, Kouyialis AT, Thalassinou N, Roussos C. Endocrine abnormalities in critical care patients with moderate-to-severe head trauma: incidence, pattern and predisposing factors. *Intensive Care Med.* 2004;30(6):1051–7.
- Distiller LA, Sagel J, Dubowitz B, Kay G, Carr PJ, Katz M, Kew MC. Pituitary-gonadal function in men with alcoholic cirrhosis of the liver. *Horm Metab Res.* 1976;8(6):461–5.

- Dong Q, Hawker F, McWilliam D, Bangah M, Burger H, Handelsman DJ. Circulating immunoreactive inhibin and testosterone levels in men with critical illness. *Clin Endocrinol (Oxf)*. 1992;36(4):399–404.
- Dunkel L, Raivio T, Laine J, Holmberg C. Circulating luteinizing hormone receptor inhibitor(s) in boys with chronic renal failure. *Kidney Int*. 1997;51(3):777–84.
- Duranteau L, Chanson P, Blumberg-Tick J, Thomas G, Brailly S, Lubetzki J, Schaison G, Bouchard P. Non-responsiveness of serum gonadotropins and testosterone to pulsatile GnRH in hemochromatosis suggesting a pituitary defect. *Acta Endocrinol*. 1993;128(4):351–4.
- Dwyer AA, Phan-Hug F, Hauschild M, Elowe-Gruau E, Pitteloud N. Transition in endocrinology: hypogonadism in adolescence. *Eur J Endocrinol*. 2015;173(1):R15–24.
- Eguchi Y, Eguchi T, Mizuta T, Ide Y, Yasutake T, Iwakiri R, Hisatomi A, Ozaki I, Yamamoto K, Kitajima Y, Kawaguchi Y, Kuroki S, Ono N. Visceral fat accumulation and insulin resistance are important factors in nonalcoholic fatty liver disease. *J Gastroenterol*. 2006;41(5):462–9.
- Ernst O, Sergeant G, Bonvarlet P, Canva-Delcambre V, Paris JC, L'Hermine C. Hepatic iron overload: diagnosis and quantification with MR imaging. *AJR Am J Roentgenol*. 1997;168(5):1205–8.
- Farmaki K, Tzoumari I, Pappa C, Chouliaras G, Berdoukas V. Normalisation of total body iron load with very intensive combined chelation reverses cardiac and endocrine complications of thalassaemia major. *Br J Haematol*. 2010;148(3):466–75.
- Fernandez-Balsells MM, Murad MH, Lane M, Lampropoulos JF, Albuquerque F, Mullan RJ, Agrwal N, Elamin MB, Gallegos-Orozco JF, Wang AT, Erwin PJ, Bhasin S, Montori VM. Clinical review 1: adverse effects of testosterone therapy in adult men: a systematic review and meta-analysis. *J Clin Endocrinol Metab*. 2010;95(6):2560–75.
- Finkelstein JS, O'Dea LS, Whitcomb RW, Crowley Jr WF. Sex steroid control of gonadotropin secretion in the human male. II. Effects of estradiol administration in normal and gonadotropin-releasing hormone-deficient men. *J Clin Endocrinol Metab*. 1991b;73(3):621–8.
- Finkelstein JS, Whitcomb RW, O'Dea LS, Longcope C, Schoenfeld DA, Crowley Jr WF. Sex steroid control of gonadotropin secretion in the human male. I. Effects of testosterone administration in normal and gonadotropin-releasing hormone-deficient men. *J Clin Endocrinol Metab*. 1991a;73(3):609–20.
- Finkle WD, Greenland S, Ridgeway GK, Adams JL, Frasco MA, Cook MB, Fraumeni Jr JF, Hoover RN. Increased risk of non-fatal myocardial infarction following testosterone therapy prescription in men. *PLoS One*. 2014;9(1):e85805.
- Fourrier F, Jallot A, Leclerc L, Jourdain M, Racadot A, Chagnon JL, Rime A, Chopin C. Sex steroid hormones in circulatory shock, sepsis syndrome, and septic shock. *Circ Shock*. 1994;43(4):171–8.
- Frias J, Torres JM, Miranda MT, Ruiz E, Ortega E. Effects of acute alcohol intoxication on pituitary-gonadal axis hormones, pituitary-adrenal axis hormones, beta-endorphin and prolactin in human adults of both sexes. *Alcohol Alcohol*. 2002;37(2):169–73.
- Fung EB, Harmatz PR, Lee PD, Milet M, Bellevue R, Jeng MR, Kalinyak KA, Hudes M, Bhatia S, Vichinsky EP. Increased prevalence of iron-overload associated endocrinopathy in thalassaemia versus sickle-cell disease. *Br J Haematol*. 2006;135(4):574–82.
- Gama R, Smith MJ, Wright J, Marks V. Hypopituitarism in primary haemochromatosis; recovery after iron depletion. *Postgrad Med J*. 1995;71(835):297–8.
- Gencer B, Mach F. Testosterone: a hormone preventing cardiovascular disease or a therapy increasing cardiovascular events? *Eur Heart J*. 2016;37(48):3569–75.
- Gordon GG, Olivo J, Rafil F, Southren AL. Conversion of androgens to estrogens in cirrhosis of the liver. *J Clin Endocrinol Metab*. 1975;40(6):1018–26.
- Gosney JR. Atrophy of Leydig cells in the testes of men with longstanding chronic bronchitis and emphysema. *Thorax*. 1987;42(8):615–9.
- Green JR, Mowat NA, Fisher RA, Anderson DC. Plasma oestrogens in men with chronic liver disease. *Gut*. 1976;17(6):426–30.

- Grossmann M, Thomas MC, Panagiotopoulos S, Sharpe K, Macisaac RJ, Clarke S, Zajac JD, Jerums G. Low testosterone levels are common and associated with insulin resistance in men with diabetes. *J Clin Endocrinol Metab.* 2008;93(5):1834–40.
- Grunstein RR, Handelsman DJ, Lawrence SJ, Blackwell C, Caterson ID, Sullivan CE. Neuroendocrine dysfunction in sleep apnea: reversal by continuous positive airways pressure therapy. *J Clin Endocrinol Metab.* 1989;68(2):352–8.
- Guaraldi G, Beggi M, Zona S, Luzi K, Orlando G, Carli F, Ligabue G, Rochira V, Rossi R, Modena MG, Bouloux P. Erectile dysfunction is not a mirror of endothelial dysfunction in HIV-infected patients. *J Sex Med.* 2012;9(4):1114–21.
- Guechot J, Chazouilleres O, Loria A, Hannoun L, Balladur P, Parc R, Giboudeau J, Poupon R. Effect of liver transplantation on sex-hormone disorders in male patients with alcohol-induced or post-viral hepatitis advanced liver disease. *J Hepatol.* 1994;20(3):426–30.
- Guevara A, Vidt D, Hallberg MC, Zorn EM, Pohlman C, Wieland RG. Serum gonadotropin and testosterone levels in uremic males undergoing intermittent dialysis. *Metabolism.* 1969;18(12):1062–6.
- Gulati V, Harikrishnan P, Palaniswamy C, Aronow WS, Jain D, Frishman WH. Cardiac involvement in hemochromatosis. *Cardiol Rev.* 2014;22(2):56–68.
- Haddad RM, Kennedy CC, Caples SM, Tracz MJ, Bolona ER, Sideras K, Uraga MV, Erwin PJ, Montori VM. Testosterone and cardiovascular risk in men: a systematic review and meta-analysis of randomized placebo-controlled trials. *Mayo Clin Proc.* 2007;82(1):29–39.
- Haider A, Saad F, Doros G, Gooren L. Hypogonadal obese men with and without diabetes mellitus type 2 lose weight and show improvement in cardiovascular risk factors when treated with testosterone: an observational study. *Obes Res Clin Pract.* 2014;8(4):e339–49.
- Hamer OW, Gnad M, Scholmerich J, Palitzsch KD. Successful treatment of erectile dysfunction and infertility by venesection in a patient with primary haemochromatosis. *Eur J Gastroenterol Hepatol.* 2001;13(8):985–8.
- Handelsman DJ. An old emperor finds new clothing: rejuvenation in our time. *Asian J Androl.* 2011;13(1):125–9.
- Handelsman DJ, Dong Q. Hypothalamo-pituitary gonadal axis in chronic renal failure. *Endocrinol Metab Clin North Am.* 1993;22(1):145–61.
- Handelsman DJ, Staraj S. Testicular size: the effects of aging, malnutrition, and illness. *J Androl.* 1985;6(3):144–51.
- Handelsman DJ, Strasser S, McDonald JA, Conway AJ, McCaughan GW. Hypothalamic-pituitary-testicular function in end-stage non-alcoholic liver disease before and after liver transplantation. *Clin Endocrinol (Oxf).* 1995;43(3):331–7.
- Hayes FJ, Seminara SB, Decruz S, Boepple PA, Crowley Jr WF. Aromatase inhibition in the human male reveals a hypothalamic site of estrogen feedback. *J Clin Endocrinol Metab.* 2000;85(9):3027–35.
- Hazlehurst JM, Tomlinson JW. Non-alcoholic fatty liver disease in common endocrine disorders. *Eur J Endocrinol.* 2013;169(2):R27–37.
- Higham CE, Johannsson G, Shalet SM. Hypopituitarism. *Lancet.* 2016;388(10058):2403–15.
- Hofny ER, Ali ME, Taha EA, Nafeh HM, Sayed DS, Abdel-Azeem HG, Abdou EF, Kamal GM, Mostafa T. Semen and hormonal parameters in men with chronic hepatitis C infection. *Fertil Steril.* 2011;95(8):2557–9.
- Hofstra J, Loves S, van Wageningen B, Ruinemans-Koerts J, Jansen I, de Boer H. High prevalence of hypogonadotropic hypogonadism in men referred for obesity treatment. *Neth J Med.* 2008;66(3):103–9.
- Housman JF, Chezmar JL, Nelson RC. Magnetic resonance imaging in hemochromatosis: extrahepatic iron deposition. *Gastrointest Radiol.* 1989;14(1):59–60.
- Hoyos CM, Yee BJ, Phillips CL, Machan EA, Grunstein RR, Liu PY. Body compositional and cardiometabolic effects of testosterone therapy in obese men with severe obstructive sleep apnoea: a randomised placebo-controlled trial. *Eur J Endocrinol.* 2012;167(4):531–41.

- Hughes GS, Mathur RS, Margolius HS. Sex steroid hormones are altered in essential hypertension. *J Hypertens*. 1989;7(3):181–7.
- Huhtaniemi I. Late-onset hypogonadism: current concepts and controversies of pathogenesis, diagnosis and treatment. *Asian J Androl*. 2014;16(2):192–202.
- Ippertiel V, Lepot A, Gruson D, Jamart J, Alexopoulou O, Maiter D, Thissen J-P. Hypogonadotropic hypogonadism among a population of obese men: prevalence, risk factors and reversibility after weight loss induced by bariatric surgery. *e-SPEN J*. 2013;8(2):e37–43.
- Isidori AM, Balercia G, Calogero AE, Corona G, Ferlin A, Francavilla S, Santi D, Maggi M. Outcomes of androgen replacement therapy in adult male hypogonadism: recommendations from the Italian society of endocrinology. *J Endocrinol Invest*. 2015;38(1):103–12.
- Isidori AM, Caprio M, Strollo F, Moretti C, Frajese G, Isidori A, Fabbri A. Leptin and androgens in male obesity: evidence for leptin contribution to reduced androgen levels. *J Clin Endocrinol Metab*. 1999;84(10):3673–80.
- Isidori AM, Lenzi A. Risk factors for androgen decline in older males: lifestyle, chronic diseases and drugs. *J Endocrinol Invest*. 2005;28(Suppl 3):14–22.
- Iturriaga H, Lioi X, Valladares L. Sex hormone-binding globulin in non-cirrhotic alcoholic patients during early withdrawal and after longer abstinence. *Alcohol Alcohol*. 1999;34(6):903–9.
- Jaya Kumar B, Khurana ML, Ammini AC, Karmarkar MG, Ahuja MM. Reproductive endocrine functions in men with primary hypothyroidism: effect of thyroxine replacement. *Horm Res*. 1990;34(5–6):215–8.
- Johansen KL. Testosterone metabolism and replacement therapy in patients with end-stage renal disease. *Semin Dial*. 2004;17(3):202–8.
- Johansen KL, Mulligan K, Schambelan M. Anabolic effects of nandrolone decanoate in patients receiving dialysis: a randomized controlled trial. *JAMA*. 1999;281(14):1275–81.
- Kalyani RR, Gavini S, Dobs AS. Male hypogonadism in systemic disease. *Endocrinol Metab Clin North Am*. 2007;36(2):333–48.
- Kamischke A, Kemper DE, Castel MA, Luthke M, Rolf C, Behre HM, Magnussen H, Nieschlag E. Testosterone levels in men with chronic obstructive pulmonary disease with or without glucocorticoid therapy. *Eur Respir J*. 1998;11(1):41–5.
- Karadag F, Ozcan H, Karul AB, Yilmaz M, Cildag O. Sex hormone alterations and systemic inflammation in chronic obstructive pulmonary disease. *Int J Clin Pract*. 2009;63(2):275–81.
- Karagiannis A, Harsoulis F. Gonadal dysfunction in systemic diseases. *Eur J Endocrinol*. 2005;152(4):501–13.
- Kaukua J, Pekkarinen T, Sane T, Mustajoki P. Sex hormones and sexual function in obese men losing weight. *Obes Res*. 2003;11(6):689–94.
- Kaymakoglu S, Okten A, Cakaloglu Y, Boztas G, Besisik F, Tascioglu C, Yalcin S. Hypogonadism is not related to the etiology of liver cirrhosis. *J Gastroenterol*. 1995;30(6):745–50.
- Kelly TM, Edwards CQ, Meikle AW, Kushner JP. Hypogonadism in hemochromatosis: reversal with iron depletion. *Ann Intern Med*. 1984;101(5):629–32.
- Khaw KT, Barrett-Connor E. Blood pressure and endogenous testosterone in men: an inverse relationship. *J Hypertens*. 1988;6(4):329–32.
- Kim S, Kwon H, Park JH, Cho B, Kim D, Oh SW, Lee CM, Choi HC. A low level of serum total testosterone is independently associated with nonalcoholic fatty liver disease. *BMC Gastroenterol*. 2012;12:69.
- Kley HK, Stremmel W, Kley JB, Schlaghecke R. Testosterone treatment of men with idiopathic hemochromatosis. *Clin Investig*. 1992;70(7):566–72.
- Kley HK, Stremmel W, Niederau C, Hehrmann R, Shams O, Strohmeyer G, Kruskemper HL. Androgen and estrogen response to adrenal and gonadal stimulation in idiopathic hemochromatosis: evidence for decreased estrogen formation. *Hepatology*. 1985;5(2):251–6.
- Kloner RA, Carson 3rd C, Dobs A, Kopecky S, Mohler 3rd ER. Testosterone and cardiovascular disease. *J Am Coll Cardiol*. 2016;67(5):545–57.

- Kraus MR, Schafer A, Bentink T, Scheurlen M, Weissbrich B, Al-Taie O, Seufert J. Sexual dysfunction in males with chronic hepatitis C and antiviral therapy: interferon-induced functional androgen deficiency or depression? *J Endocrinol*. 2005;185(2):345–52.
- Laaksonen DE, Niskanen L, Punnonen K, Nyyssonen K, Tuomainen TP, Valkonen VP, Salonen R, Salonen JT. Testosterone and sex hormone-binding globulin predict the metabolic syndrome and diabetes in middle-aged men. *Diabetes Care*. 2004;27(5):1036–41.
- Laghi F. Low testosterone in chronic obstructive pulmonary disease. *Am J Respir Crit Care Med*. 2005;172(9):1069–70.
- Laghi F, Antonescu-Turcu A, Collins E, Segal J, Tobin DE, Jubran A, Tobin MJ. Hypogonadism in men with chronic obstructive pulmonary disease: prevalence and quality of life. *Am J Respir Crit Care Med*. 2005a;171(7):728–33.
- Laghi F, Langbein WE, Antonescu-Turcu A, Jubran A, Bammert C, Tobin MJ. Respiratory and skeletal muscles in hypogonadal men with chronic obstructive pulmonary disease. *Am J Respir Crit Care Med*. 2005b;171(6):598–605.
- Lamm S, Chidakel A, Bansal R. Obesity and Hypogonadism. *Urol Clin North Am*. 2016;43(2):239–45.
- Langrand C, Bihan H, Raverot G, Varron L, Androdias G, Borson-Chazot F, Brue T, Cathebras P, Pinede L, Muller G, Broussolle C, Cotton F, Valeyre D, Seve P. Hypothalamo-pituitary sarcoidosis: a multicenter study of 24 patients. *QJM*. 2012;105(10):981–95.
- Lephart ED, Baxter CR, Parker Jr CR. Effect of burn trauma on adrenal and testicular steroid hormone production. *J Clin Endocrinol Metab*. 1987;64(4):842–8.
- Leviton D, Moser SA, Goldstein DA, Kletzky OA, Lobo RA, Massry SG. Disturbances in the hypothalamic-pituitary-gonadal axis in male patients with acute renal failure. *Am J Nephrol*. 1984;4(2):99–106.
- Li Y, Liu L, Wang B, Chen D, Wang J. Nonalcoholic fatty liver disease and alteration in semen quality and reproductive hormones. *Eur J Gastroenterol Hepatol*. 2015;27(9):1069–73.
- Lim VS, Fang VS. Gonadal dysfunction in uremic men. A study of the hypothalamo-pituitary-testicular axis before and after renal transplantation. *Am J Med*. 1975;58(5):655–62.
- Lim VS, Fang VS. Restoration of plasma testosterone levels in uremic men with clomiphene citrate. *J Clin Endocrinol Metab*. 1976;43(6):1370–7.
- Liu PY, Caterson ID, Grunstein RR, Handelsman DJ. Androgens, obesity, and sleep-disordered breathing in men. *Endocrinol Metab Clin North Am*. 2007;36(2):349–63.
- Liu PY, Yee B, Wishart SM, Jimenez M, Jung DG, Grunstein RR, Handelsman DJ. The short-term effects of high-dose testosterone on sleep, breathing, and function in older men. *J Clin Endocrinol Metab*. 2003;88(8):3605–13.
- Lloyd G, Case JR, De Frias D, Brannigan RE. *Trichomonas vaginalis* orchitis with associated severe oligoastheno-teratospermia and hypogonadism. *J Urol*. 2003;170(3):924.
- Loves S, Ruinemans-Koerts J, de Boer H. Letrozole once a week normalizes serum testosterone in obesity-related male hypogonadism. *Eur J Endocrinol*. 2008;158(5):741–7.
- Luboshitzky R, Aviv A, Hefetz A, Herer P, Shen-Orr Z, Lavie L, Lavie P. Decreased pituitary-gonadal secretion in men with obstructive sleep apnea. *J Clin Endocrinol Metab*. 2002;87(7):3394–8.
- Luppa P, Munker R, Nagel D, Weber M, Engelhardt D. Serum androgens in intensive-care patients: correlations with clinical findings. *Clin Endocrinol (Oxf)*. 1991;34(4):305–10.
- Luzi K, Guaraldi G, Murri R, De Paola M, Orlando G, Squillace N, Esposito R, Rochira V, Zirilli L, Martinez E. Body image is a major determinant of sexual dysfunction in stable HIV-infected women. *Antivir Ther*. 2009;14(1):85–92.
- Ly LP, Sartorius G, Hull L, Leung A, Swerdloff RS, Wang C, Handelsman DJ. Accuracy of calculated free testosterone formulae in men. *Clin Endocrinol (Oxf)*. 2010;73(3):382–8.
- Mackenzie H, Mahmalji W, Raza A. The gamma and the gonad: syphilitic orchitis, a rare presentation of testicular swelling. *Int J STD AIDS*. 2011;22(9):531–3.
- Madersbacher S, Grunberger T, Maier U. Andrological status before and after liver transplantation. *J Urol*. 1994;151(5):1251–4.



- Mah PM, Wittert GA. Obesity and testicular function. *Mol Cell Endocrinol.* 2010;316(2):180–6.
- Makarevich AE. Disorders of sex hormone status in patients with chronic obstructive pulmonary disease. *Wiad Lek.* 2003;56(3–4):140–6.
- Malkin CJ, Channer KS, Jones TH. Testosterone and heart failure. *Curr Opin Endocrinol Diabetes Obes.* 2010;17(3):262–8.
- Malkin CJ, Pugh PJ, West JN, van Beek EJ, Jones TH, Channer KS. Testosterone therapy in men with moderate severity heart failure: a double-blind randomized placebo controlled trial. *Eur Heart J.* 2006;27(1):57–64.
- Mao WL, Shi XP, Lou YF, Ye B, Lu YQ. The association between circulating oestradiol levels and severity of liver disease in males with hepatitis B virus infection. *Liver Int.* 2013;33(8):1211–7.
- Martin LJ. Implications of adiponectin in linking metabolism to testicular function. *Endocrine.* 2014;46(1):16–28.
- Maruyama Y, Adachi Y, Aoki N, Suzuki Y, Shinohara H, Yamamoto T. Mechanism of feminization in male patients with non-alcoholic liver cirrhosis: role of sex hormone-binding globulin. *Gastroenterol Jpn.* 1991;26(4):435–9.
- Matsumoto AM, Sandblom RE, Schoene RB, Lee KA, Giblin EC, Pierson DJ, Bremner WJ. Testosterone replacement in hypogonadal men: effects on obstructive sleep apnoea, respiratory drives, and sleep. *Clin Endocrinol (Oxf).* 1985;22(6):713–21.
- McDermott JH, Walsh CH. Hypogonadism in hereditary hemochromatosis. *J Clin Endocrinol Metab.* 2005;90(4):2451–5.
- McNeil LW, McKee Jr LC, Lorber D, Rabin D. The endocrine manifestations of hemochromatosis. *Am J Med Sci.* 1983;285(3):7–13.
- Miaux Y, Daurelle P, Zagdanski AM, Passa P, Bourrier P, Frija J. MRI in haemochromatosis: pituitary versus testicular iron deposition in five patients with hypogonadism. *Eur Radiol.* 1995;5(2):165–71.
- Mintziori G, Poulakos P, Tsameti C, Goulis DG. Hypogonadism and non-alcoholic fatty liver disease. *Minerva Endocrinol.* 2017;42(2):145–50.
- Mitnitski AB, Rutenberg AD, Farrell S, Rockwood K (2017) Aging, frailty and complex networks. *Biogerontology.* doi:10.1007/s10522-017-9684-x. [Epub ahead of print].
- Mohr BA, Guay AT, O'Donnell AB, McKinlay JB. Normal, bound and nonbound testosterone levels in normally ageing men: results from the Massachusetts Male Ageing Study. *Clin Endocrinol (Oxf).* 2005;62(1):64–73.
- Monroe AK, Dobs AS, Cofrancesco Jr J, Brown TT. Testosterone and abnormal glucose metabolism in an inner-city cohort. *J Mens Health.* 2012;9(3):154–9.
- Monroe AK, Dobs AS, Paella FJ, Kingsley LA, Witt MD, Brown TT. Morning free and total testosterone in HIV-infected men: implications for the assessment of hypogonadism. *AIDS Res Ther.* 2014;11(1):6.
- Moreno-Perez O, Escoin C, Serna-Candel C, Portilla J, Boix V, Alfayate R, Gonzalez-Sanchez V, Mauri M, Sanchez-Paya J, Pico A. The determination of total testosterone and free testosterone (RIA) are not applicable to the evaluation of gonadal function in HIV-infected males. *J Sex Med.* 2010;7(8):2873–83.
- Morley JE, Kim MJ, Haren MT, Kevorkian R, Banks WA. Frailty and the aging male. *Aging Male.* 2005;8(3–4):135–40.
- Mousa AA, Ghonem M, el Elhadidy HM, Azmy E, Elbackry M, Elbaiomy AA, Elzehery RR, Shaker GA, Saleh O. Iron overload detection using pituitary and hepatic MRI in thalassemic patients having short stature and hypogonadism. *Endocr Res.* 2016;41(2):81–8.
- Mousavi SA, Kouchari MR, Samdani-Fard SH, Gilvae ZN, Arabi M. Relationship between serum levels of testosterone and the severity of chronic obstructive pulmonary disease. *Tanaffos.* 2012;11(3):32–5.
- Mulligan T, Frick MF, Zuraw QC, Stenhagen A, McWhirter C. Prevalence of hypogonadism in males aged at least 45 years: the HIM study. *Int J Clin Pract.* 2006;60(7):762–9.

- Nguyen HV, Mollison LC, Taylor TW, Chubb SA, Yeap BB. Chronic hepatitis C infection and sex hormone levels: effect of disease severity and recombinant interferon-alpha therapy. *Intern Med J.* 2006;36(6):362–6.
- Noetzi LJ, Panigrahy A, Mittelman SD, Hyderi A, Dongelyan A, Coates TD, Wood JC. Pituitary iron and volume predict hypogonadism in transfusional iron overload. *Am J Hematol.* 2012; 87(2):167–71.
- O'Connell MD, Ravindrarajah R, Tajar A, Wu FC. Low testosterone in ageing men: a modifiable risk factor for frailty? *Trends Endocrinol Metab.* 2011;22(12):491–8.
- Pekic S, Popovic V. Diagnosis of endocrine disease: expanding the cause of hypopituitarism. *Eur J Endocrinol.* 2017;176:R269–82.
- Pelusi C, Gasparini DI, Bianchi N, Pasquali R. Endocrine dysfunction in hereditary hemochromatosis. *J Endocrinol Invest.* 2016;39(8):837–47.
- Perera NJ, Lau NS, Mathews S, Waite C, Ho PJ, Caterson ID. Overview of endocrinopathies associated with beta-thalassaemia major. *Intern Med J.* 2010;40(10):689–96.
- Petak SM, Nankin HR, Spark RF, Swerdloff RS, Rodriguez-Rigau LJ. American Association of clinical endocrinologists medical guidelines for clinical practice for the evaluation and treatment of hypogonadism in adult male patients—2002 update. *Endocr Pract.* 2002;8(6):440–56.
- Piazza M, Tosone G, Borgia G, Orlando R, Fenzi G, Vitale M, Bloise A, Mariano A, Macchia V. Long-term interferon-alpha therapy does not affect sex hormones in males with chronic hepatitis C. *J Interferon Cytokine Res.* 1997;17(9):525–9.
- Pietrangelo A. Hereditary hemochromatosis: pathogenesis, diagnosis, and treatment. *Gastroenterology.* 2010;139(2):393–408. 408 e391-392.
- Piperno A, Rivolta MR, D'Alba R, Fargion S, Rovelli F, Ghezzi A, Micheli M, Fiorelli G. Preclinical hypogonadism in genetic hemochromatosis in the early stage of the disease: evidence of hypothalamic dysfunction. *J Endocrinol Invest.* 1992;15(6):423–8.
- Poggi M, Sorrentino F, Pugliese P, Smacchia MP, Daniele C, Equitani F, Terlizzi F, Guitarrini MR, Monti S, Maffei L, Losardo A, Pasin M, Toscano V. Longitudinal changes of endocrine and bone disease in adults with beta-thalassemia major receiving different iron chelators over 5 years. *Ann Hematol.* 2016;95(5):757–63.
- Raffi F, Brisseau JM, Planchon B, Remi JP, Barrier JH, Grolleau JY. Endocrine function in 98 HIV-infected patients: a prospective study. *AIDS.* 1991;5(6):729–33.
- Rambaldi A, Gluud C. Anabolic-androgenic steroids for alcoholic liver disease. *Cochrane Database Syst Rev.* 2006;4:CD003045.
- Rastrelli G, Carter EL, Ahern T, Finn JD, Antonio L, O'Neill TW, Bartfai G, Casanueva FF, Forti G, Keevil B, Maggi M, Giwercman A, Han TS, Huhtaniemi IT, Kula K, Lean ME, Pendleton N, Punab M, Vanderschueren D, Wu FC. Development of and recovery from secondary hypogonadism in aging men: prospective results from the EMAS. *J Clin Endocrinol Metab.* 2015; 100(8):3172–82.
- Reid IR, Wattie DJ, Evans MC, Stapleton JP. Testosterone therapy in glucocorticoid-treated men. *Arch Intern Med.* 1996;156(11):1173–7.
- Rochira V, Diazzi C, Santi D, Brigante G, Ansaloni A, Decaroli MC, De Vincentis S, Stentarelli C, Zona S, Guaraldi G. Low testosterone is associated with poor health status in men with human immunodeficiency virus infection: a retrospective study. *Andrology.* 2015;3(2):298–308.
- Rochira V, Guaraldi G. Hypogonadism in the HIV-infected man. *Endocrinol Metab Clin North Am.* 2014;43(3):709–30.
- Rochira V, Madeo B, Diazzi C, Zirilli L, Daniele S, Carani C (2016) Estrogens and male reproduction. In: LJ De Groot, Chrousos G, Dungan K, Feingold KR, Grossman A, Hershman JM, Koch C, Korbonits M, McLachlan R, New M, Purnell J, Rebar R, Singer F, Vinik A(eds). *Endotext* [Internet] South Dartmouth MA, MDText.com, Inc. <https://www.ncbi.nlm.nih.gov/books/NBK278933>, PMID: 25905171
- Rochira V, Santi D, Carani C. Pathophysiology of estrogen action in men. In: Nieschlag E, Behre HM, editors. *Testosterone Action, Deficiency, Substitution.* Cambridge, UK: Cambridge University Press; 2012.

- Rochira V, Zirilli L, Genazzani AD, Balestrieri A, Aranda C, Fabre B, Antunez P, Diazzi C, Carani C, Maffei L. Hypothalamic-pituitary-gonadal axis in two men with aromatase deficiency: evidence that circulating estrogens are required at the hypothalamic level for the integrity of gonadotropin negative feedback. *Eur J Endocrinol.* 2006;155(4):513–22.
- Rochira V, Zirilli L, Madeo B, Maffei L, Carani C. Testosterone action on erythropoiesis does not require its aromatization to estrogen: insights from the testosterone and estrogen treatment of two aromatase-deficient men. *J Steroid Biochem Mol Biol.* 2009;113(3–5):189–94.
- Rochira V, Zirilli L, Orlando G, Santi D, Brigante G, Diazzi C, Carli F, Carani C, Guaraldi G. Premature decline of serum total testosterone in HIV-infected men in the HAART-era. *PLoS One.* 2011;6(12):e28512.
- Rosner W, Auchus RJ, Azziz R, Sluss PM, Raff H. Position statement: utility, limitations, and pitfalls in measuring testosterone: an endocrine society position statement. *J Clin Endocrinol Metab.* 2007;92(2):405–13.
- Rosner W, Vesper H. Toward excellence in testosterone testing: a consensus statement. *J Clin Endocrinol Metab.* 2010;95(10):4542–8.
- Rund D, Rachmilewitz E. Beta-thalassemia. *N Engl J Med.* 2005;353(11):1135–46.
- Ruusa J, Bergman B, Sundell ML. Sex hormones during alcohol withdrawal: a longitudinal study of 29 male alcoholics during detoxification. *Alcohol Alcohol.* 1997;32(5):591–7.
- Saad F, Haider A, Doros G, Traish A. Long-term treatment of hypogonadal men with testosterone produces substantial and sustained weight loss. *Obesity (Silver Spring).* 2013;21(10):1975–81.
- Safarinejad MR. Evaluation of semen quality, endocrine profile and hypothalamus-pituitary-testis axis in male patients with homozygous beta-thalassemia major. *J Urol.* 2008;179(6):2327–32.
- Safarinejad MR, Kolahi AA, Irvani S. Evaluation of semen variables, sperm chromosomal abnormalities and reproductive endocrine profile in patients with chronic hepatitis C. *BJU Int.* 2010;105(1):79–86.
- Saha MT, Saha HH, Niskanen LK, Salmela KT, Pasternack AI. Time course of serum prolactin and sex hormones following successful renal transplantation. *Nephron.* 2002;92(3):735–7.
- Salehian B, Jacobson D, Swerdloff RS, Grafe MR, Sinha-Hikim I, McCutchan JA. Testicular pathologic changes and the pituitary-testicular axis during human immunodeficiency virus infection. *Endocr Pract.* 1999;5(1):1–9.
- Samojlik E, Kirschner MA, Ribot S, Szmaj E. Changes in the hypothalamic-pituitary-gonadal axis in men after cadaver kidney transplantation and cyclosporine therapy. *J Androl.* 1992;13(4):332–6.
- Sandblom RE, Matsumoto AM, Schoene RB, Lee KA, Giblin EC, Bremner WJ, Pierson DJ. Obstructive sleep apnea syndrome induced by testosterone administration. *N Engl J Med.* 1983;308(9):508–10.
- Santen RJ. Feedback control of luteinizing hormone and follicle-stimulating hormone secretion by testosterone and estradiol in men: physiological and clinical implications. *Clin Biochem.* 1981;14(5):243–51.
- Santi D, Brigante G, Zona S, Guaraldi G, Rochira V. Male sexual dysfunction and HIV – a clinical perspective. *Nat Rev Urol.* 2014;11(2):99–109.
- Santi D, Madeo B, Carli F, Zona S, Brigante G, Vescini F, Guaraldi G, Rochira V. Serum total estradiol, but not testosterone is associated with reduced bone mineral density (BMD) in HIV-infected men: a cross-sectional, observational study. *Osteoporos Int.* 2016;27(3):1103–14.
- Sartorius GA, Handelsman DJ. Testicular dysfunction in systemic diseases. In: Nieschlag E, Behre HM, Nieschlag S, editors. *Andrology.* Berlin/Heidelberg: Springer; 2012. p. 339–64.
- Schneider BK, Pickett CK, Zwillich CW, Weil JV, McDermott MT, Santen RJ, Varano LA, White DP. Influence of testosterone on breathing during sleep. *J Appl Physiol (1985).* 1986;61(2):618–23.
- Schneider G, Kirschner MA, Berkowitz R, Ertel NH. Increased estrogen production in obese men. *J Clin Endocrinol Metab.* 1979;48(4):633–8.

- Schneider HJ, Aimaretti G, Kreitschmann-Andermahr I, Stalla GK, Ghigo E. Hypopituitarism. *Lancet*. 2007;369(9571):1461–70.
- Schorr M, Miller KK. The endocrine manifestations of anorexia nervosa: mechanisms and management. *Nat Rev Endocrinol*. 2017;13(3):174–86.
- Semple PD, Beastall GH, Watson WS, Hume R. Serum testosterone depression associated with hypoxia in respiratory failure. *Clin Sci (Lond)*. 1980;58(1):105–6.
- Seo NK, Koo HS, Haam JH, Kim HY, Kim MJ, Park KC, Park KS, Kim YS. Prediction of prevalent but not incident non-alcoholic fatty liver disease by levels of serum testosterone. *J Gastroenterol Hepatol*. 2015;30(7):1211–6.
- Serin A, Akarsu M, Akpınar H, Simsek I. Changes of some hormones levels in patients with hepatitis B virus-related chronic liver disease. *Gastroenterology Res*. 2013;6(4):134–8.
- Shalitin S, Carmi D, Weintrob N, Phillip M, Miskin H, Kornreich L, Zilber R, Yaniv I, Tamary H. Serum ferritin level as a predictor of impaired growth and puberty in thalassemia major patients. *Eur J Haematol*. 2005;74(2):93–100.
- Shores MM, Matsumoto AM. Testosterone, aging and survival: biomarker or deficiency. *Curr Opin Endocrinol Diabetes Obes*. 2014;21(3):209–16.
- Siminoski K, D'Costa M, Walfish PG. Hypogonadotropic hypogonadism in idiopathic hemochromatosis: evidence for combined hypothalamic and pituitary involvement. *J Endocrinol Invest*. 1990;13(10):849–53.
- Sinclair M, Grossmann M, Gow PJ, Angus PW. Testosterone in men with advanced liver disease: abnormalities and implications. *J Gastroenterol Hepatol*. 2015;30(2):244–51.
- Singh AB, Norris K, Modi N, Sinha-Hikim I, Shen R, Davidson T, Bhasin S. Pharmacokinetics of a transdermal testosterone system in men with end stage renal disease receiving maintenance hemodialysis and healthy hypogonadal men. *J Clin Endocrinol Metab*. 2001;86(6):2437–45.
- Skordis N, Michaelidou M, Savva SC, Ioannou Y, Rousounides A, Kleanthous M, Skordos G, Christou S. The impact of genotype on endocrine complications in thalassaemia major. *Eur J Haematol*. 2006;77(2):150–6.
- Soliman AT, Nasr I, Thabet A, Rizk MM, El Matary W. Human chorionic gonadotropin therapy in adolescent boys with constitutional delayed puberty vs those with beta-thalassemia major. *Metabolism*. 2005;54(1):15–23.
- Spratt DI, Cox P, Orav J, Moloney J, Bigos T. Reproductive axis suppression in acute illness is related to disease severity. *J Clin Endocrinol Metab*. 1993;76(6):1548–54.
- Spruit MA, Thomeer MJ, Gosselink R, Wuyts WA, Van Herck E, Bouillon R, Demedts MG, Decramer M. Hypogonadism in male outpatients with sarcoidosis. *Respir Med*. 2007;101(12):2502–10.
- Stewart-Bentley M, Gans D, Horton R. Regulation of gonadal function in uremia. *Metabolism*. 1974;23(11):1065–72.
- Sunchatawirul K, Tantiwongse K, Chathaisong P, Thongyen S, Chumpathat N, Manosuthi W. Hypogonadism among HIV-infected men in Thailand. *Int J STD AIDS*. 2012;23(12):876–81.
- Suzuki H, Tominaga T, Kumagai H, Saruta T. Effects of first-line antihypertensive agents on sexual function and sex hormones. *J Hypertens Suppl*. 1988;6(4):S649–51.
- Svartberg J. Androgens and chronic obstructive pulmonary disease. *Curr Opin Endocrinol Diabetes Obes*. 2010;17(3):257–61.
- Svartberg J, Aasebo U, Hjalmarson A, Sundsfjord J, Jorde R. Testosterone treatment improves body composition and sexual function in men with COPD, in a 6-month randomized controlled trial. *Respir Med*. 2004a;98(9):906–13.
- Svartberg J, Schirmer H, Medbo A, Melbye H, Aasebo U. Reduced pulmonary function is associated with lower levels of endogenous total and free testosterone. The Tromso study. *Eur J Epidemiol*. 2007;22(2):107–12.
- Svartberg J, von Muhlen D, Schirmer H, Barrett-Connor E, Sundsfjord J, Jorde R. Association of endogenous testosterone with blood pressure and left ventricular mass in men. The Tromso Study. *Eur J Endocrinol*. 2004b;150(1):65–71.

- Tajar A, Forti G, O'Neill TW, Lee DM, Silman AJ, Finn JD, Bartfai G, Boonen S, Casanueva FF, Giwercman A, Han TS, Kula K, Labrie F, Lean ME, Pendleton N, Punab M, Vanderschueren D, Huhtaniemi IT, Wu FC. Characteristics of secondary, primary, and compensated hypogonadism in aging men: evidence from the European Male Ageing Study. *J Clin Endocrinol Metab.* 2010;95(4):1810–8.
- Tanaka K, Sakai H, Hashizume M, Hirohata T. Serum testosterone: estradiol ratio and the development of hepatocellular carcinoma among male cirrhotic patients. *Cancer Res.* 2000;60(18):5106–10.
- Taylor SR, Meadowcroft LM, Williamson B. Prevalence, pathophysiology, and management of androgen deficiency in men with metabolic syndrome, type 2 diabetes mellitus, or both. *Pharmacotherapy.* 2015;35(8):780–92.
- Tchernof A, Despres JP. Pathophysiology of human visceral obesity: an update. *Physiol Rev.* 2013;93(1): 359–404.
- Tuerel JL, Marcen R, Navarro-Antolin J, Aguilera A, Fernandez-Juarez G, Ortuno J. Androgen versus erythropoietin for the treatment of anemia in hemodialyzed patients: a prospective study. *J Am Soc Nephrol.* 1996;7(1):140–4.
- Thuret I, Pondarre C, Loundou A, Steschenko D, Girot R, Bachir D, Rose C, Barlogis V, Donadieu J, de Montalembert M, Hagege I, Pegourie B, Berger C, Micheau M, Bernaudin F, Leblanc T, Lutz L, Galacteros F, Simeoni MC, Badens C. Complications and treatment of patients with beta-thalassemia in France: results of the National Registry. *Haematologica.* 2010;95(5):724–9.
- Tian GX, Sun Y, Pang CJ, Tan AH, Gao Y, Zhang HY, Yang XB, Li ZX, Mo ZN. Oestradiol is a protective factor for non-alcoholic fatty liver disease in healthy men. *Obes Rev.* 2012; 13(4):381–7.
- Tournaire J, Fevre M, Mazenod B, Ponsin G. Effects of clomiphene citrate and synthetic LHRH on serum luteinizing hormone (LH) in men with idiopathic hemochromatosis. *J Clin Endocrinol Metab.* 1974;38(6):1122–4.
- Travison TG, Araujo AB, Kupelian V, O'Donnell AB, McKinlay JB. The relative contributions of aging, health, and lifestyle factors to serum testosterone decline in men. *J Clin Endocrinol Metab.* 2007;92(2):549–55.
- Travison TG, Nguyen AH, Naganathan V, Stanaway FF, Blyth FM, Cumming RG, Le Couteur DG, Sambrook PN, Handelsman DJ. Changes in reproductive hormone concentrations predict the prevalence and progression of the frailty syndrome in older men: the concord health and ageing in men project. *J Clin Endocrinol Metab.* 2011;96(8):2464–74.
- Travison TG, Shackelton R, Araujo AB, Hall SA, Williams RE, Clark RV, O'Donnell AB, McKinlay JB. The natural history of symptomatic androgen deficiency in men: onset, progression, and spontaneous remission. *J Am Geriatr Soc.* 2008;56(5):831–9.
- Travison TG, Shackelton R, Araujo AB, Morley JE, Williams RE, Clark RV, McKinlay JB. Frailty, serum androgens, and the CAG repeat polymorphism: results from the Massachusetts Male Ageing Study. *J Clin Endocrinol Metab.* 2010;95(6):2746–54.
- Travison TG, Vesper HW, Orwoll E, Wu F, Kaufman JM, Wang Y, Lapauw B, Fiers T, Matsumoto AM, Bhasin S. Harmonized reference ranges for circulating testosterone levels in men of four cohort studies in the United States and Europe. *J Clin Endocrinol Metab.* 2011;102(4):1161–73.
- Tsai EC, Boyko EJ, Leonetti DL, Fujimoto WY. Low serum testosterone level as a predictor of increased visceral fat in Japanese-American men. *Int J Obes Relat Metab Disord.* 2000; 24(4):485–91.
- Turner HE, Wass JA. Gonadal function in men with chronic illness. *Clin Endocrinol (Oxf).* 1997; 47(4):379–403.
- Van Thiel DH, Gavalier JS, Lester R, Goodman MD. Alcohol-induced testicular atrophy. An experimental model for hypogonadism occurring in chronic alcoholic men. *Gastroenterology.* 1975;69(2):326–32.
- Van Thiel DH, Lester R, Sherins RJ. Hypogonadism in alcoholic liver disease: evidence for a double defect. *Gastroenterology.* 1974;67(6):1188–99.

- Van Vliet M, Spruit MA, Verleden G, Kasran A, Van Herck E, Pitta F, Bouillon R, Decramer M. Hypogonadism, quadriceps weakness, and exercise intolerance in chronic obstructive pulmonary disease. *Am J Respir Crit Care Med.* 2005;172(9):1105–11.
- Veldhuis JD, Wilkowski MJ, Zwart AD, Urban RJ, Lizzaralde G, Iranmanesh A, Bolton WK. Evidence for attenuation of hypothalamic gonadotropin-releasing hormone (GnRH) impulse strength with preservation of GnRH pulse frequency in men with chronic renal failure. *J Clin Endocrinol Metab.* 1993;76(3):648–54.
- Vermeulen A, Kaufman JM, Giagulli VA. Influence of some biological indexes on sex hormone-binding globulin and androgen levels in aging or obese males. *J Clin Endocrinol Metab.* 1996;81(5):1821–6.
- Vermeulen A, Verdonck L, Kaufman JM. A critical evaluation of simple methods for the estimation of free testosterone in serum. *J Clin Endocrinol Metab.* 1999;84(10):3666–72.
- Vigen R, O'Donnell CI, Baron AE, Grunwald GK, Maddox TM, Bradley SM, Barqawi A, Woning G, Wierman ME, Plomondon ME, Rumsfeld JS, Ho PM. Association of testosterone therapy with mortality, myocardial infarction, and stroke in men with low testosterone levels. *JAMA.* 2013;310(17):1829–36.
- Vogel AV, Peake GT, Rada RT. Pituitary-testicular axis dysfunction in burned men. *J Clin Endocrinol Metab.* 1985;60(4):658–65.
- Volzke H, Aumann N, Krebs A, Nauck M, Steveling A, Lerch MM, Rosskopf D, Wallaschofski H. Hepatic steatosis is associated with low serum testosterone and high serum DHEAS levels in men. *Int J Androl.* 2010;33(1):45–53.
- Voskaridou E, Terpos E. New insights into the pathophysiology and management of osteoporosis in patients with beta thalassaemia. *Br J Haematol.* 2004;127(2):127–39.
- Warner MH, Beckett GJ. Mechanisms behind the non-thyroidal illness syndrome: an update. *J Endocrinol.* 2010;205(1):1–13.
- Wood JC, Noetzel L, Hyderi A, Joukar M, Coates T, Mittelman S. Predicting pituitary iron and endocrine dysfunction. *Ann N Y Acad Sci.* 2010;1202:123–8.
- Woolf PD, Hamill RW, McDonald JV, Lee LA, Kelly M. Transient hypogonadotropic hypogonadism caused by critical illness. *J Clin Endocrinol Metab.* 1985;60(3):444–50.
- Wu FC. Caveat emptor: does testosterone treatment reduce mortality in men? *J Clin Endocrinol Metab.* 2012;97(6):1884–6.
- Wu FC, Tajar A, Beynon JM, Pye SR, Silman AJ, Finn JD, O'Neill TW, Bartfai G, Casanueva FF, Forti G, Giwercman A, Han TS, Kula K, Lean ME, Pendleton N, Punab M, Boonen S, Vanderschueren D, Labrie F, Huhtaniemi IT. Identification of late-onset hypogonadism in middle-aged and elderly men. *N Engl J Med.* 2010;363(2):123–35.
- Wu FC, Tajar A, Pye SR, Silman AJ, Finn JD, O'Neill TW, Bartfai G, Casanueva F, Forti G, Giwercman A, Huhtaniemi IT, Kula K, Punab M, Boonen S, Vanderschueren D. Hypothalamic-pituitary-testicular axis disruptions in older men are differentially linked to age and modifiable risk factors: the European Male Aging Study. *J Clin Endocrinol Metab.* 2008;93(7):2737–45.
- Xu L, Freeman G, Cowling BJ, Schooling CM. Testosterone therapy and cardiovascular events among men: a systematic review and meta-analysis of placebo-controlled randomized trials. *BMC Med.* 2013;11:108.
- Yadav R, Mehta SN, Kumar A, Guleria S, Seenu V, Tiwari SC. A prospective analysis of testicular androgenic function in recipients of a renal allograft. *Int Urol Nephrol.* 2008;40(2):397–403.
- Yassin A, Doros G. Testosterone therapy in hypogonadal men results in sustained and clinically meaningful weight loss. *Clin Obes.* 2013;3(3–4):73–83.
- Zietz B, Lock G, Plach B, Drobnik W, Grossmann J, Scholmerich J, Straub RH. Dysfunction of the hypothalamic-pituitary-glandular axes and relation to Child-Pugh classification in male patients with alcoholic and virus-related cirrhosis. *Eur J Gastroenterol Hepatol.* 2003;15(5):495–501.
- Zirilli L, Orlando G, Carli F, Madeo B, Cocchi S, Diazzi C, Carani C, Guaraldi G, Rochira V. GH response to GHRH plus arginine is impaired in lipotrophic women with human immunodeficiency virus compared with controls. *Eur J Endocrinol.* 2012;166(3):415–24.

- Zirilli L, Orlando G, Diazzi C, Squillace N, Carani C, Guaraldi G, Rochira V. Hypopituitarism and HIV-infection: a new comorbidity in the HAART era? *J Endocrinol Invest.* 2008;31 (Suppl 9):33–8.
- Zitzmann M, Nieschlag E. Effects of androgen replacement on metabolism and physical performances in male hypogonadism. *J Endocrinol Invest.* 2003;26(9):886–92.
- Zona S, Guaraldi G, Luzi K, Beggi M, Santi D, Stentarelli C, Madeo B, Rochira V. Erectile dysfunction is more common in young to middle-aged HIV-infected men than in HIV-uninfected men. *J Sex Med.* 2012;9(7):1923–30.
- Zumoff B, Strain GW, Miller LK, Rosner W, Senie R, Seres DS, Rosenfeld RS. Plasma free and non-sex-hormone-binding-globulin-bound testosterone are decreased in obese men in proportion to their degree of obesity. *J Clin Endocrinol Metab.* 1990;71(4):929–31.

Aleksander Giwercman

## Abstract

An increasing proportion of young male cancer patients are cured, why the issue of quality of life (QoL) of survivors plays an important role. Several studies have shown that, among young subjects treated for malignant disease, well preserved reproductive function represents one of the most important aspects of the QoL. In this chapter, the current evidence as well as gaps of knowledge regarding the impact of cancer and cancer treatment on testicular function – including fertility, androgen production and health of the offspring – are summarized. Also recommendations for preservation of fertility prior to cancer therapy as well as clinical management of reproductive issues in male cancer survivors, are given.

## Keywords

Cancer • Cancer treatment • Spermatogenesis • Fertility • Leydig cell function

## Contents

Introduction .....	882
The Impact of Cancer and Cancer Treatment on Male Fertility .....	882
Impact of Disease Per Se .....	883
Surgical Treatment .....	884
Radiation Therapy .....	885
Chemotherapy .....	886
The Impact of Cancer and Cancer Treatment on Testosterone Production .....	889
Impact of Cancer Disease .....	889
Impact of Cancer Treatment .....	890

A. Giwercman (✉)

Translational Medicine, Lund University, Malmö, Sweden

Molecular Reproductive Medicine, Department of Translational Medicine, Lund University, Malmö, Sweden

e-mail: [aleksander.giwercman@med.lu.se](mailto:aleksander.giwercman@med.lu.se)



Biomarkers of Post-Treatment Recovery of Testicular Function .....	891
Management Before Cancer Treatment .....	892
Management After Cancer Treatment .....	894
Fertility .....	894
Androgen Deficiency .....	894
Cancer, Cancer Treatment and Health of the Offspring .....	895
References .....	895

---

## Introduction

To date, due to improved diagnostic as well as therapeutic procedures physicians are more likely to be confronted with young cancer survivors. This is true for e.g. those treated for childhood cancer, testicular malignancy or lymphomas. Furthermore, as the age at first parenthood is gradually increasing, the demand of preservation of reproductive function has been extended to men at more advanced age, and may be relevant for a proportion of patients treated for common malignancies as colon or prostate cancer.

Both cancer per se, but also different modalities of oncological treatment, can be harmful to male reproductive function. In this context, so far, most attention has been given to impairment of fertility in young cancer survivors (Giwercman and Petersen 2000). However, there is a growing body of evidence, that those patients are at increased risk of developing both primary and secondary hypogonadism (Greenfield et al. 2007; Fung et al. 2015; Romerius et al. 2009; Oldenburg 2015) and sexual dysfunction (Eberhard et al. 2009).

Testicular damage can be due to testicular disease, surgery of the gonads or radiation therapy directed to the testes and adjacent tissues, as well as systemic chemotherapy. Secondary hypogonadism can be induced by surgery or radiotherapy of tumors in the central nervous system, foremost in the pituitary region. In addition, testosterone levels naturally decrease with age, and men being eugonadal in early adulthood can develop androgen deficiency in more advanced age (Harman et al. 2001; Tajar et al. 2010).

This chapter focuses on direct and indirect impact of most common cancer treatments on testicular function leading to impairment of:

- (a) Fertility
- (b) Sex hormone production

---

## The Impact of Cancer and Cancer Treatment on Male Fertility

Male fertility can be negatively affected by cancer disease per se and/or by its treatment, the pathogenesis including impairment of function at some of following levels:

- (a) Pre-testicular – pituitary/hypothalamic
- (b) Testicular
- (c) Post-testicular – ejaculatory/dtdtag

**Table 1** Clinical and laboratory characteristics, causes and level of damage in relation to cancer treatment related impairment of male reproductive function

Level of damage	Cause	Clinical/laboratory characteristics
Hypothalamic/pituitary	Surgery in hypothalamic/pituitary region	Low levels of FSH/LH
	Cranial irradiation	Untreated – low testosterone and ejaculate volume Often azoospermia
Testes	Due to cancer (e.g. testicular)	High levels of FSH/LH
	Surgery – total or partial orchidectomy	Untreated – low testosterone and ejaculate volume
	Radiation <sup>a</sup> (directly on the testes or as “scattered irradiation”)	Often oligozoospermia or azoospermia
	Chemotherapy <sup>a</sup>	
Ejaculatory process	Surgery in pelvic area	Normal hormone levels
	Radiation	Often anejaculation or aspermia (e.g., due to retrograde ejaculation) Can be associated with erectile dysfunction

<sup>a</sup>For a list of impact of different cancer treatments on fertility – see Table 2

The most common causes and clinical as well as laboratory features are listed in Table 1.

## Impact of Disease Per Se

This effect is most pronounced in men with testicular germ cell cancer (TGCC). Patients with TGCC have poor sperm production

- Either due to the fact that the disease is localized in the testis, or
- Because of aetiological and pathological links between development of TGCC and development of gonadal dysfunction (Skakkebaek et al. 2001). This should be seen in view of the young age of TGCC patients (often below 40 years) and the very good prognosis of survival (up to 98%).

A large proportion of patients with TGCC has oligozoospermia; approximately 50% having – before any treatment has been given – sperm concentration below 10–15 mill/mL (Petersen et al. 1998) as compared to median levels in the general population of about 50–100 mill/ml (Petersen et al. 1999a; Shoshany et al. 2016). Sperm production in men with unilateral TGCC is even more impaired than it could be explained by the fact that one testis harbours a tumour. The assumption of poor spermatogenesis as the cause of poor semen quality is supported by the observations of increased follicle-stimulating hormone (FSH) levels and low Inhibin B levels in men with TGCC as compared to healthy men (Petersen et al. 1998). The effect of

**Table 2** How can cancer treatment affect male fertility

Azoospermia – no sperms in the ejaculate
Oligozoospermia – reduced sperm concentration/number
Impairment of sperm motility/morphology
Anejaculation/retrograde ejaculation
Impairment of sperm DNA integrity
Other functional defects

tumour-produced hCG on sperm production is not clear but no significant difference between patients with and without increased serum hCG levels was reported (van Casteren et al. 2010). Likewise there is no obvious correlation between stage of the disease and sperm production. There is no doubt that patients with TGCC have impaired spermatogenesis and that this effect is not due to a general cancer effect but specifically associated with gonadal malignancy (Petersen et al. 1998) (Table 1).

Approximately 10% of the patients with TGCC have a history of testicular maldescent. Thus it seems likely that pre-existing dysfunction of spermatogenesis due to common aetiological factors of spermatogenic dysfunction and TGCC are contributing causes of the poor sperm production in these men. This hypothesis is supported by histological studies which have shown severe abnormalities in about 25% of the biopsies from the contralateral testis in men who were orchidectomized for unilateral TGCC. Eight per cent had no sperm production, 16% showed varying degrees of spermatogenic impairment and 5% had Germ Cell Neoplasia in Situ (GCNIS) (Berthelsen and Skakkebaek 1983). Furthermore, it has been hypothesized that TGCC, poor semen quality, Leydig cell dysfunction, testicular maldescent and hypospadias are part of the so called Testicular Dysgenesis Syndrome (TDS), caused by early fetal exposure to environmental and/or lifestyle related factors combined with genetically determined susceptibility to the adverse effects of these exposures (Skakkebaek et al. 2001). The data considering pre-treatment semen quality in men with other cancer diagnoses are somewhat conflicting. Some studies reported that men with Hodgkin's disease and sarcomas have sperm counts comparable to or only slightly lower than age matched healthy donors (Paoli et al. 2016; Caponecchia et al. 2016). However, a recent report based on semen samples almost 4,500 cancer patients indicated that even men with leukemias, lymphomas, sarcomas and brain tumours do have significantly decreased sperm counts as well as impairment of sperm motility and morphology (Auger et al. 2016).

## Surgical Treatment

Semen quality expressed by sperm concentration and total sperm count per ejaculate is apparently poorer after orchidectomy as compared to the pre-orchidectomy level (Petersen et al. 1999b). Moreover, a proportion of the men with sperm in the ejaculate before orchidectomy become azoospermic after orchidectomy and azoospermia is observed in more than 10% of the men (Petersen et al. 1999b). These observations are supported by histological investigations showing that 8% of the

patients did not produce sperm in the contralateral testis and by hormone investigations showing increased FSH and decreased inhibin B levels after orchidectomy as compared to pre-orchidectomy levels (Petersen et al. 1998). In patients treated with orchidectomy alone for stage I testicular cancer some compensatory improvement of semen quality seems to occur during the first 2 years after surgery, with some deterioration during subsequent years (Hansen et al. 1990). Thus it appears that semen quality decreases after orchidectomy and later some compensatory increase is seen due to elevated FSH levels.

Also other types of surgical treatment may have a negative impact on fertility of cancer survivors:

- Pelvic surgery in men with TGCC (retroperitoneal lymph node dissection), rectal or prostate cancer may, due to damage of nerve fibers lead to disturbed ejaculation and/or erectile dysfunction;
- Gonadotropin deficiency and, due to that, disturbed sperm production may be caused by impairment of hypothalamic/pituitary function.

The most common complications following ‘classical’ RPLND are anejaculation and retrograde ejaculation. During the last 10–15 years the frequency of these complications has been reduced from more than 75% to less than 33% by changing from radical RPLND to modified (right or left) RPLND with no effect on the relapse rate (Petersen et al. 1998). More specific methods have been developed in selected groups of patients. Nerve-sparing techniques are possible in 20% of the patients depending on extent and localization of disease. Only 15% of these patients had ejaculatory dysfunction after such specific treatment (Coogan et al. 1996). However, the complications after surgery may depend on the experience of the surgeons.

## Radiation Therapy

The effects of single-dose irradiation on spermatogenesis in normal men are well known. Irreversible azoospermia may result when the testicular dose exceeds 6–8 Gy (Rowley et al. 1974).

Total body irradiation – as given prior to bone marrow transplantation – or direct testicular irradiation, applied in some boys with acute lymphoblastic leukemia –also implies permanent azoospermia.

Men with TGCC are treated with radiotherapy given in fractionated schedules, which is known to be more toxic to the germ cells than the bio-equivalent dose given as a single dose. Moreover, the patients may be more vulnerable to the harmful effects of irradiation because they already have poor spermatogenic function before irradiation and persistent azoospermia may be induced in some patients at lower dose levels. Patients treated with infradiaphragmatic irradiation will receive scattered irradiation (approximately 0.5 Gy) on the residual testis despite a gonadal shield. This treatment was shown to cause an initial decline in sperm concentration, which returned to pre-treatment levels 2–5 years after therapy (Romerius et al. 2011).

However, although at group level the mean sperm counts, following radiotherapy, return to post-orchidectomy level, it cannot be excluded that some subjects may develop permanent or long-term azoospermia. Adjuvant abdominal radiotherapy, with an estimated testicular dose of  $<0.5$  Gy, was shown to induce a transient increase in the proportion of sperms with DNA strand breaks, normalizing within 3–5 years (Stahl et al. 2006). Also in childhood cancer survivors (CCS) the percentage of spermatozoa with DNA strand breaks was increased following extra-gonadal irradiation (Romerius et al. 2010).

Irradiation of the prostate bed in patients with prostate cancer results in a pronounced dose into the testicles. The calculated projected doses into the testicles made on a standard series of 40 fractions of external-beam radiotherapy were 196 cGy ( $\pm 145$  cGy). In this patient group direct irradiation (15–35 cGy) causes oligozoospermia; doses between 35 cGy and 50 cGy cause reversible azoospermia. The nadir of sperm count occurs 4–6 months after the end of treatment, and 10–18 months are required for complete recovery. However, doses more than 120 cGy are associated with a reduced risk of recovery of spermatogenesis. Cumulative doses of fractionated radiotherapy more than 250 cGy generally result in prolonged and likely permanent azoospermia.

The effects of brachytherapy given as treatment of prostate cancer, with irradiation doses received by the testes usually being less than 20 cGy, seems to be less harmful to fertility than external radiotherapy (Tran et al. 2015).

## Chemotherapy

Gonadotoxicity caused by chemotherapy is due to the fact that it targets rapidly proliferating cells. The effect of chemotherapy on gonadal function is dependent on the type of treatment as well as the dose given. Table 3 gives an overview of risk of azoospermia in relation to different types of cytotoxic treatments. Generally, the harmful effect on spermatogenesis is most pronounced in alkylating drugs and cisplatin.

Most data are available for treatment of TGCC, since this is the most common type of cancer in young males and the treatment is relatively standardized.

TGCC patients treated with one to two cycles of chemotherapy exhibit no or only slight decrease in sperm concentration, 6 months post treatment with following return to the same level as prior to cytotoxic treatment. The risk of developing long term or persisting azoospermia following this treatment is considered to be close to zero. On the other hand, three to four cycles of cisplatin-based chemotherapy induce gonadal dysfunction with azoospermia in significant proportion of TGCC patients and a simultaneous rise in FSH levels is seen in most of them. Recovery of spermatogenesis is seen in most patients during the 2–5 years after chemotherapy (Eberhard et al. 2004). After this follow-up period approximately 8% of TGCC men remain azoospermic, this proportion being as high as 65% in those who have received a cumulative dose of cisplatin at  $600 \text{ mg/m}^2$  or more (Petersen et al. 1994; Isaksson et al. 2014). Possibly there is a genetic variability explaining the intra-individual sensitivity observed.

**Table 3** Risk of azoospermia in relation to different types and doses of cancer treatment (Adapted from Puscheck et al. 2004)

Agent	Cumulative dose	Azoospermia	Additive effect with other cytotoxic drugs	Comments
<i>Radiation</i>				
Testes	2,5 Gy/ 0,6 Gy	Permanent/ temporary	Yes	Fractionated treatment worse than single dose
Total body	8 Gy single/ 12 Gy fractionated	Permanent	Yes	
<i>Chemotherapy</i>				
Cyclophosphamide	19 g/m <sup>2</sup>	Yes		
Chlorambucil	1,4 g/m <sup>2</sup>	Yes		
Cisplatin	500 mg/m <sup>2</sup>	Yes		
Procarbazine	4 g/m <sup>2</sup>	Yes		
Carboplatin	>2 g/m <sup>2</sup>	Likely		
Nitrosoureas				
Busulfan	>600 mg/kg	Likely		
Ifosfamide	>30 g/m <sup>2</sup>	Likely	+ cyclophosphamide	
Camustine	1 g/m <sup>2</sup>	Likely		
Lomustine	500 mg/m <sup>2</sup>	Likely		
Nitrogen mustard		Unknown		Used with other highly gonadotoxic agents
Malphalan		Unknown		Same
Aktinomycin D		Unknown		Same
Doxorubicin	770 mg/m <sup>2</sup>	Yes	Yes	Azoospermia in combination with other cytotoxics
Cytosine arabinoside	1 g/m <sup>2</sup>	Temporary oligozoospermia	Yes	Azoospermia in combination with other cytotoxics
Vinblastine	50 g/m <sup>2</sup>	Temporary oligozoospermia	Yes	Azoospermia in combination with other cytotoxics
Vinkristin	8 g/m <sup>2</sup>	Temporary oligozoospermia	Yes	Azoospermia in combination with other cytotoxics. Less toxic than vinblastine

(continued)

**Table 3** (continued)

Agent	Cumulative dose	Azoospermia	Additive effect with other cytotoxic drugs	Comments
Pacliatxel		Unknown		
Docetaxel		Unknown		
Gemcitabine		Unknown		
Trastuzumab		Unknown		
Irinotecan		Unknown		
Oxaliplatin		Unknown		

Among the childhood cancer survivors (CCS) approximately 20% present with azoospermia, this risk being approximately 15% in those treated with chemotherapy only and 33% in patients who had received a combination of chemotherapy and radiotherapy (Romerius et al. 2011).

Of the CCS who had received potentially sterilizing doses of cisplatin/alkylating agents (Table 3), but no radiotherapy, the proportion of men with azoospermia is as high 80% but 5% only if cisplatin/alkylating agents were given in doses below the anticipated threshold doses.

In both patient groups mentioned above, chemotherapy was not shown to affect sperm DNA integrity negatively (Stahl et al. 2006; Romerius et al. 2010).

The drug and dose dependency in relation to gonadotoxic effects of cytotoxic drugs and the trend toward developing less toxic treatment strategies is clearly demonstrated by the evolution in therapy of Hodgkin's Lymphoma (HL). Until the late 1970s MOPP (Mustargen, Oncovin, Procarbazine, Prednisone) was the cornerstone of HL treatment, this regimen implying long-term azoospermia in 70–80% of patients. However, introduction of ABVD (Adriamycin, Bleomycin, Vinblastine, Dacarbazine) reduced this side effect to almost zero, without worsening the survival prognosis (Viviani et al. 1985). However, in more advanced cases of HL, the standard ABVD treatment is substituted by mixed regimens as BEACOPP (Bleomacin, Etoposide, Adriamycin, Cyclophosphamide, Oncovin Procarbazine, Prednisone), COPP/ABVD, OPP/ABVD or MOPP. Patients given six or more cycles of these treatments were found to have permanent absence of sperm in the seminal fluid, while following a low number of cycles (<6), spermatogenesis recovered after 3–5 years but semen quality was highly impaired (Paoli et al. 2016).

Modern cancer therapy includes use of biological or targeted therapies that often involve small molecule inhibitors or monoclonal antibodies. Studies of the effects of these agents on male reproductive system have been limited (Meistrich 2013).

Imatinib, a tyrosine kinase inhibitor has been most studied for its action on the male reproductive system. In humans, men on treatment with imatinib do produce normal pregnancies and offspring although there may be some effects on spermatogenesis. One study reported a decline in sperm count to less than  $1 \times 10^6/\text{mL}$  whereas another study reported normal sperm counts. Low sperm count, and

increased inhibin B/FSH ratio, also indicative of spermatogenic failure, has been observed following imatinib treatment during puberty.

Use of rapamycin (sirolimus) – mTOR inhibitor – as cancer treatment in humans have been shown to imply elevated FSH, indicating spermatogenic dysfunction; sperm counts on one patient did show oligozoospermia, reversed within 6 months of cessation of treatment (Meistrich 2013).

Chronic treatment of adult male cancer patients with interferon-alpha did not affect sperm counts (Meistrich 2013).

In general, data in patients obtained so far with most of biological targeted therapies are compatible with the men being either naturally fertile or having some sperm for use to achieve pregnancies by assisted reproductive techniques. However, most targeted therapies are new, and newer targets and therapies are constantly under development but have not been evaluated in humans for reproductive effects.

---

## The Impact of Cancer and Cancer Treatment on Testosterone Production

Generally, the impact of cancer and cancer therapy on Leydig cell function has received less attention than the fertility issues. However, long-term follow-up studies of young cancer survivors have shown that those men are at increased risk of adverse cardiovascular events as well as metabolic disease (Haugnes et al. 2007, 2008, 2010), which might be linked to androgen deficiency.

### Impact of Cancer Disease

According to the TDS hypothesis (Skakkebaek et al. 2001; Sharpe and Skakkebaek 2008), the abnormal fetal germ cell development leading to TGCC is linked to a Sertoli and Leydig cell insufficiency. For that reason, it is obvious to expect the TGCC patients being more prone to testosterone deficiency.

In accordance with this anticipation, it was found that Leydig cell response to hCG stimulation is significantly lower in men unilaterally orchidectomised due to TGCC, as compared to those in whom one testis was removed due to torsion or trauma (Willemse et al. 1983). The few studies dealing with pre-orchidectomy hormonal levels in TGCC men have failed to find any increase in LH and/or decrease in testosterone T levels in hCG-negative patients (Petersen et al. 1999b). However, in 33% of these men the LH/testosterone ratio was reported to be outside the 97.5 percentile before orchidectomy suggesting subtle disturbances of the pituitary-Leydig cell axis already present at the time of diagnosis (Bandak et al. 2011).

For other cancer categories – relatively rare tumors in the pituitary gland, hypothalamus or their vicinity may, through their expansive growth, have a negative impact on gonadotropin secretion and, thereby, lead to testosterone deficiency (Littley et al. 1989).



## Impact of Cancer Treatment

Orchidectomy is standard treatment in men diagnosed with TGCC. This procedure was reported to imply no immediate decline in testosterone levels. However, a significant increase in LH concentration indicates a reduction in Leydig cell capacity (Petersen et al. 1999a). Accordingly, long-term follow-up of TGCC men has shown – as compared to controls – doubling in the prevalence of hypogonadism in patients treated with surgery only (Nord et al. 2003).

It seems that the risk of androgen deficiency increases with the intensity of the treatment, almost 30% of 10 years survivors given chemotherapy in doses above the standard treatment present with increased LH and/or subnormal testosterone levels (Nord et al. 2003).

It also appears that some of the men given standard dose chemotherapy or retroperitoneal irradiation may develop hypogonadism 6–12 months post-treatment, subsequently the endocrine parameters being normalized. However, in the long run, even those men are at increased risk of testosterone deficiency (Eberhard et al. 2008).

The risk of hypogonadism was found to be 1.5 times higher in TGCC survivors above 45 years as compared to those in younger age group. This finding may be explained by the age-related deterioration of Leydig cell function (Nord et al. 2003).

Even CCS have a significant increased risk of hypogonadism defined as decreased testosterone and/or high LH, this hormonal aberration found in approximately 25% of them who reach early adulthood. It corresponds to five to seven times increased odds ratio for this adverse treatment outcome, as compared to age matched healthy controls (Romerius et al. 2009).

Hypophysectomy and testicular irradiation (e.g. as part of leukemia treatment or total body irradiation prior to bone marrow transplantation) are obvious reasons for secondary and primary hypogonadism, respectively. However, even other types of treatment were found to increase the risk of testosterone deficiency (Romerius et al. 2009):

- Hypogonadism was seen in 20% of CCS following brain surgery (not close to the pituitary), whereas this effect was not seen in those receiving cranial irradiation. Furthermore, CCS treated with surgery alone (other than brain surgery) had no increased risk of developing hypogonadism.
- Increased odds ratio for hypogonadism was also seen in those treated with chemotherapy, alone or in combination with (non-testicular) radiation therapy. Interestingly, although this risk increase was most pronounced in those men who have received alkylating drugs, usually considered as being most gonadotoxic, the adverse effect of chemotherapy was observed even for other types of treatment regimens.

In men the life time risk of rectal cancer (RC) is about 2% and more than 60% of these men are expected to become cured. Preoperative radiotherapy is frequently applied in those men and although the testes, usually, are outside the target radiation volume, they can be exposed to scattered irradiation and, in some cases with a very

low cancer, be directly exposed. The available data indicate approximately three times increased risk of subnormal testosterone levels in RC patients given irradiation as compared to those treated with surgery only (Buchli et al. 2011, 2015).

Another, relatively large group of young cancer survivors, in whom the issue of Leydig cell dysfunction may become a clinical problem, are those with hematological malignancies.

Following a non myeloablative bone marrow transplantation, sustained severe damage to the Leydig cells was seen. This effect was seen as significant increase in LH levels median LH pre-transplant, 5.4 IU/L; median LH post-transplant, 9.6 IU/L) and reduced Leydig cell reserve, as evident from a diminished testosterone/LH ratio (2.6 pre-transplant vs. 1.6 post-transplant) (Kyriacou et al. 2003). Even cytotoxic treatment only was found to be deleterious to Leydig cell function in lymphoma patients. Thus, 25% of men treated with COPP-regimen had elevated levels of LH and in as many as 90% the GnRH-stimulated LH response was increased (Bramswig et al. 1990).

Similarly to what is the case for the impact of chemotherapy on spermatogenesis, the treatment regimens not including alkylating drugs and/or irradiation seem less deleterious to testosterone production (Romerius et al. 2009).

---

## **Biomarkers of Post-Treatment Recovery of Testicular Function**

Several studies have shown that for many cancer survivors the issue of preservation of ability to achieve parenthood is one of the major life quality issues. A significant proportion of these patients are also worried about possible negative impact of cancer treatment on their fertility. Therefore, there is a demand for reliable markers which may give an estimate of current status and predict recovery of sperm production. In the daily clinical practice the first question to ask is whether there are spermatozoa in the ejaculate or not. Presence of the gametes – even if their number is low – allows the use of techniques of assisted reproduction as e.g. standard in vitro fertilization (IVF) or intracytoplasmic sperm injection (ICSI). However, it should be kept in mind that even in cases of azoospermia, in some cases, spermatozoa for ICSI can be retrieved by means of testicular sperm extraction.

Using the lower normal range for serum levels of Inhibin B, in CCS, the positive predictive value (PPV) for prediction of azoospermia was 66% and the corresponding NPV was 98%. For the upper normal level of FSH the corresponding figures were 50% for PPV and 99% for NPV. For total testicular size of 24 mL the PPV was 61% and the NPV of 92% (Romerius et al. 2011).

In men treated for TGCC, when similar cut off level for Inhibin B was used for serum samples obtained 6 months post-treatment, the PPV for prediction of long term (>36 months) azoospermia was 35% whereas the NPV was 100% (Isaksson et al. 2014).

In summary, although both FSH and Inhibin B have some value in relation to predicting presence/absence of spermatozoa in the ejaculate, in the clinical situation these biomarkers are not sufficiently reliable to substitute standard semen analysis.

As concerns identification of those men who are candidates for androgen replacement therapy, the diagnosis should be based on standard criteria, including presence of clinical symptoms of hypogonadism and levels of testosterone, SHBG and LH in fasting blood samples obtained in the morning (before 10 am).

Interestingly, in TGCC men, microlithiasis in the contralateral testis, as detected with ultrasound, was found to be associated with four to five times increased risk of testosterone deficiency (Eberhard et al. 2008). This phenomenon may be explained by previous reports on link between TDS and TM (Holm et al. 2003; Hoei-Hansen et al. 2005).

---

## Management Before Cancer Treatment

It is generally accepted that men with malignant disease and potential wish of future fatherhood should be offered cryopreservation of semen before cytotoxic treatment, radiotherapy or surgery which might have an impact on their fertility (Fig. 1).

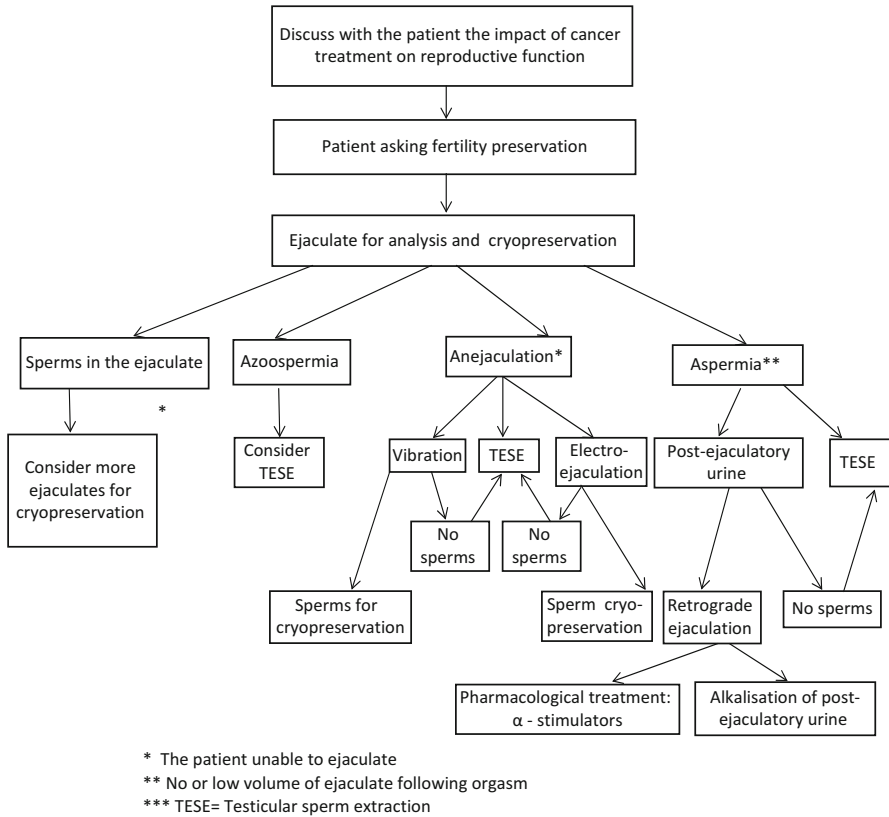
Since the available data indicate that sperm concentration drops significantly after orchidectomy, patients with TGCC should be offered cryopreservation before the tumour-bearing testis is removed (Petersen et al. 1999b). Patient referred for cryopreservation should be offered andrological counselling regarding his subsequent fertility potential. He should be given a realistic picture of his future fertility potential – both with and without use of assisted reproduction techniques. Serum samples for measurement of testosterone, LH, sex hormone binding globulin, oestradiol, FSH and – if available – Inhibin B should also be taken since this information will facilitate post-treatment monitoring of gonadal function in these patients.

By use of ICSI even ejaculates with very few sperm can be used for fertilization. Therefore, even men with very poor semen quality should be offered cryopreservation if some motile sperm are present.

The question of safety of preserving spermatozoa obtained after the initiation of cytotoxic treatment is, due to potential risk of chemotherapy-induced genetic aberration, still unresolved. For the same reason, most centres recommend avoiding pregnancy at least 6–12 months after completion of radio- or chemotherapy (Meistrich 1993).

An ethical question is whether sperm cryopreservation should be offered to terminally ill cancer patients with a very short life expectancy. The legislation regarding options for using spermatozoa from deceased persons differs from country to country and should be taken into consideration when developing local guidelines for the sperm storage.

It should be kept in mind that sperm cryopreservation should even be considered in boys who have not yet reached the full pubertal development. In a group of 86 boys aged 12.2–17.9 years, 76 (88%) had spermatozoa in their ejaculate and in 71 (83%) motile spermatozoa suitable for cryopreservation were found. Of the 86 boys, 74 produced a semen sample by masturbation, whereas semen samples were obtained from 12 patients by penile vibration or electroejaculation. The



**Fig. 1** Flow chart visualizing the clinical handling of men referred for fertility preservation prior to cancer treatment (Adapted from Brannigan 2007), \*The patient unable to ejaculate, \*\*No or low volume of ejaculate following orgasm, \*\*\*TESE Testicular sperm extraction

youngest patient with an ejaculate containing motile spermatozoa was 12.2 years old, and the smallest testicular volumes in boys associated with motile spermatozoa in the ejaculate were 6–7 mL. It was, therefore, concluded that regardless of their age, adolescent boys with testicular volumes of more than 5 mL should be offered semen banking prior to gonadotoxic treatment or other procedures that could potentially damage future fertility (Hagenas et al. 2010).

Cryopreservation of testicular tissue from pre-pubertal boys represents a medical as well as ethical challenge. Attempts to in vivo and in vitro maturation of pre-pubertal human testicular tissue are ongoing and despite such procedure cannot yet be offered as a clinical routine, it has been suggested that storage of testicular tissue should be offered to boys prior to cancer treatment implying a high risk of sterility (Jahnukainen and Stukenborg 2012).

For technical aspects, please, see ► Chap. 42, “Cryopreservation of Spermatozoa” by Gandini et al.

## Management After Cancer Treatment

### Fertility

Male patients who have been treated for cancer and have a potential wish of fatherhood and/or at increased risk of developing hypogonadism should be offered andrological counselling. Men who become azoospermic after chemotherapy may regain sperm production even more than 2 years after treatment. When assessing the fertility potential of these men, pretreatment and post-treatment hormone and seminal values, and knowledge about the treatment given are important pieces of information. Other possible andrological abnormalities which may influence sperm output should not be overlooked.

The decision regarding use of techniques of assisted reproduction should be based on the prediction of timing and probability of recovery of spermatogenesis, which should be based on information on pre-treatment reproductive function combined with details of type and dose of treatment given. Also the age and fertility of the female partner needs to be considered. Such considerations should also be made regarding use of fresh versus cryopreserved spermatozoa.

The timing of the assisted reproduction should take into consideration the disease specific risk of the recurrence of the malignant disease.

### Androgen Deficiency

Men treated for cancer in childhood or adulthood should, as a part of follow-up, be offered investigation aiming to disclose any signs of androgen deficiency. In childhood cancer survivors it should be done after completion of puberty. In case of malignancy in adulthood, 6–12 months after completing cancer treatment, if not hypogonadism is expected immediately after the therapy has been given (e.g. following bilateral orchidectomy or hypophysectomy and/or radiotherapy to the testes or the pituitary gland). The symptoms of male hypogonadism, which are rather unspecific, can develop slowly and gradually. Therefore they may be overseen by the patient as well as by a doctor not specifically focusing on the possibility of androgen deficiency.

Knowing the pretreatment hormone values may be of great help in detecting a drop in testosterone level, which may be of importance since even men with androgen concentrations above the lower level of reference interval may show clinical signs of hypogonadism. However, in TGCC patients, Leydig cell dysfunction following irradiation or three to four cycles of cisplatin based chemotherapy, appearing shortly after completion of the cancer treatment, may be temporary (Eberhard et al. 2008). Therefore, in these patients one should be slightly hesitating with initiating androgen replacement therapy or, an off treatment re-testing, should be done 2 years after completion of the cancer therapy.

Diagnosis of androgen deficiency in adult patients previously treated for cancer is based on traditional criteria of male hypogonadism. If the patient has no clear

**Table 4** Summary of andrological procedures to be offered to cancer patients

Procedure	Before treatment	6–12 months post-treatment	Long term follow up
Andrological counselling	X	X	X <sup>a</sup>
Semen analysis	X		X <sup>a</sup>
Cryopreservation	X		X <sup>a</sup>
Hormonal evaluation	X	X	X <sup>a</sup>

<sup>a</sup>If the patient has complaints of infertility or symptoms/biochemical signs of hypogonadism

symptoms of hypogonadism and testosterone levels are in the lower end of the normal range and/or LH is in the upper normal range, a re-investigation should be offered in 1–5 years, and even longer follow-up should be considered.

Pre-pubertal boys should be carefully followed for signs of delayed puberty.

Andrological procedures to be offered to male cancer patients, before and after the treatment, are summarised in Table 4.

---

## Cancer, Cancer Treatment and Health of the Offspring

A significant proportion of men treated for cancer express a worry for the negative consequences of cancer treatment on the health of their offspring. In a large Danish-Swedish register study of more than 1.8 million newborns, the risk of congenital malformations was marginally increased (from 3.2% to 3.8%) in children born one or more years after their father was diagnosed with cancer. Although no treatment data were available, finding of same risk increase in children of men diagnosed with skin cancer – a disease most often treated with surgery only – might indicate that the increase in malformation risk is rather associated with cancer per se rather than with its treatment (Stahl et al. 2011).

---

## References

- Auger J, Sermondade N, Eustache F. Semen quality of 4480 young cancer and systemic disease patients: baseline data and clinical considerations. *Basic Clin Androl.* 2016;26:3.
- Bandak M, Aksglaede L, Juul A, Rorth M, Daugaard G. The pituitary-Leydig cell axis before and after orchiectomy in patients with stage I testicular cancer. *Eur J Cancer.* 2011;47(17):2585–91.
- Berthelsen JG, Skakkebaek NE. Gonadal function in men with testis cancer. *Fertil Steril.* 1983;39(1):68–75.
- Bramswig JH, Heimes U, Heiermann E, Schlegel W, Nieschlag E, Schellong G. The effects of different cumulative doses of chemotherapy on testicular function. Results in 75 patients treated for Hodgkin's disease during childhood or adolescence. *Cancer.* 1990;65(6):1298–302.
- Brannigan RE. Fertility preservation in adult male cancer patients. *Cancer Treat Res.* 2007;138:28–49.

- Buchli C, Martling A, Arver S, Holm T. Testicular function after radiotherapy for rectal cancer – a review. *J Sex Med.* 2011;8(11):3220–6.
- Buchli C, Tapper J, Bottai M, Holm T, Arver S, Blomqvist L, et al. Testosterone and body composition in men after treatment for rectal cancer. *J Sex Med.* 2015;12(3):774–82.
- Caponecchia L, Cimino G, Sacchetto R, Fiori C, Sebastianelli A, Salacone P, et al. Do malignant diseases affect semen quality? Sperm parameters of men with cancers. *Andrologia.* 2016; 48(3):333–40.
- Coogan CL, Hejase MJ, Wahle GR, Foster RS, Rowland RG, Bihrl R, et al. Nerve sparing post-chemotherapy retroperitoneal lymph node dissection for advanced testicular cancer. *J Urol.* 1996;156(5):1656–8.
- Eberhard J, Stahl O, Giwercman Y, Cwikiel M, Cavallin-Stahl E, Lundin KB, et al. Impact of therapy and androgen receptor polymorphism on sperm concentration in men treated for testicular germ cell cancer: a longitudinal study. *Hum Reprod.* 2004;19(6):1418–25.
- Eberhard J, Stahl O, Cwikiel M, Cavallin-Stahl E, Giwercman Y, Salmonson EC, et al. Risk factors for post-treatment hypogonadism in testicular cancer patients. *Eur J Endocrinol.* 2008;158(4): 561–70.
- Eberhard J, Stahl O, Cohn-Cedermark G, Cavallin-Stahl E, Giwercman Y, Rylander L, et al. Sexual function in men treated for testicular cancer. *J Sex Med.* 2009;6(7):1979–89.
- Fung C, Fossa SD, Williams A, Travis LB. Long-term morbidity of testicular cancer treatment. *Urol Clin North Am.* 2015;42(3):393–408.
- Giwercman A, Petersen PM. Cancer and male infertility. *Baillieres Best Pract Res Clin Endocrinol Metab.* 2000;14(3):453–71.
- Greenfield DM, Walters SJ, Coleman RE, Hancock BW, Eastell R, Davies HA, et al. Prevalence and consequences of androgen deficiency in young male cancer survivors in a controlled cross-sectional study. *J Clin Endocrinol Metab.* 2007;92(9):3476–82.
- Hagenas I, Jorgensen N, Reznitzer C, Sommer P, Holm M, Schmiegelow K, et al. Clinical and biochemical correlates of successful semen collection for cryopreservation from 12-18-year-old patients: a single-center study of 86 adolescents. *Hum Reprod.* 2010;25(8):2031–8.
- Hansen PV, Trykker H, Svennekjaer IL, Hvolby J. Long-term recovery of spermatogenesis after radiotherapy in patients with testicular cancer. *Radiother Oncol.* 1990;18(2):117–25.
- Harman SM, Metter EJ, Tobin JD, Pearson J, Blackman MR. Longitudinal effects of aging on serum total and free testosterone levels in healthy men. *Baltimore Longitudinal Study of Aging.* *J Clin Endocrinol Metab.* 2001;86(2):724–31.
- Haugnes HS, Aass N, Fossa SD, Dahl O, Klepp O, Wist EA, et al. Components of the metabolic syndrome in long-term survivors of testicular cancer. *Ann Oncol.* 2007;18(2):241–8.
- Haugnes HS, Aass N, Fossa SD, Dahl O, Klepp O, Wist EA, et al. Predicted cardiovascular mortality and reported cardiovascular morbidity in testicular cancer survivors. *J Cancer Surviv.* 2008;2(3):128–37.
- Haugnes HS, Wethal T, Aass N, Dahl O, Klepp O, Langberg CW, et al. Cardiovascular risk factors and morbidity in long-term survivors of testicular cancer: a 20-year follow-up study. *J Clin Oncol.* 2010;28(30):4649–57.
- Hoei-Hansen CE, Sommer P, Meyts ER, Skakkebaek NE. A rare diagnosis: testicular dysgenesis with carcinoma in situ detected in a patient with ultrasonic microlithiasis. *Asian J Androl.* 2005;7(4):445–7.
- Holm M, Hoei-Hansen CE, Rajpert-De Meyts E, Skakkebaek NE. Increased risk of carcinoma in situ in patients with testicular germ cell cancer with ultrasonic microlithiasis in the contralateral testicle. *J Urol.* 2003;170(4 Pt 1):1163–7.
- Isaksson S, Eberhard J, Stahl O, Cavallin-Stahl E, Cohn-Cedermark G, Arver S, et al. Inhibin B concentration is predictive for long-term azoospermia in men treated for testicular cancer. *Andrology.* 2014;2(2):252–8.
- Jahnukainen K, Stukenborg JB. Clinical review: present and future prospects of male fertility preservation for children and adolescents. *J Clin Endocrinol Metab.* 2012;97(12):4341–51.

- Kyriacou C, Kottaridis PD, Eliahoo J, McKeag N, Bomford J, McGarrigle HH, et al. Germ cell damage and Leydig cell insufficiency in recipients of nonmyeloablative transplantation for haematological malignancies. *Bone Marrow Transplant.* 2003;31(1):45–50.
- Little MD, Shalet SM, Beardwell CG, Ahmed SR, Applegate G, Sutton ML. Hypopituitarism following external radiotherapy for pituitary tumours in adults. *Q J Med.* 1989;70(262):145–60.
- Meistrich ML. Potential genetic risks of using semen collected during chemotherapy. *Hum Reprod.* 1993;8(1):8–10.
- Meistrich ML. Effects of chemotherapy and radiotherapy on spermatogenesis in humans. *Fertil Steril.* 2013;100(5):1180–6.
- Nord C, Bjoro T, Ellingsen D, Mykletun A, Dahl O, Klepp O, et al. Gonadal hormones in long-term survivors 10 years after treatment for unilateral testicular cancer. *Eur Urol.* 2003;44(3):322–8.
- Oldenburg J. Hypogonadism and fertility issues following primary treatment for testicular cancer. *Urol Oncol.* 2015;33(9):407–12.
- Paoli D, Rizzo F, Fiore G, Pallotti F, Pulsoni A, Annechini G, et al. Spermatogenesis in Hodgkin's lymphoma patients: a retrospective study of semen quality before and after different chemotherapy regimens. *Hum Reprod.* 2016;31(2):263–72.
- Petersen PM, Hansen SW, Giwercman A, Rorth M, Skakkebaek NE. Dose-dependent impairment of testicular function in patients treated with cisplatin-based chemotherapy for germ cell cancer. *Ann Oncol.* 1994;5(4):355–8.
- Petersen PM, Giwercman A, Skakkebaek NE, Rorth M. Gonadal function in men with testicular cancer. *Semin Oncol.* 1998;25(2):224–33.
- Petersen PM, Skakkebaek NE, Vistisen K, Rorth M, Giwercman A. Semen quality and reproductive hormones before orchiectomy in men with testicular cancer. *J Clin Oncol.* 1999a;17(3):941–7.
- Petersen PM, Skakkebaek NE, Rorth M, Giwercman A. Semen quality and reproductive hormones before and after orchiectomy in men with testicular cancer. *J Urol.* 1999b;161(3):822–6.
- Puscheck E, Philip PA, Jeyendran RS. Male fertility preservation and cancer treatment. *Cancer Treat Rev.* 2004;30(2):173–80.
- Romerius P, Stahl O, Moell C, Relander T, Cavallin-Stahl E, Wiebe T, et al. Hypogonadism risk in men treated for childhood cancer. *J Clin Endocrinol Metab.* 2009;94(11):4180–6.
- Romerius P, Stahl O, Moell C, Relander T, Cavallin-Stahl E, Gustafsson H, et al. Sperm DNA integrity in men treated for childhood cancer. *Clin Cancer Res.* 2010;16(15):3843–50.
- Romerius P, Stahl O, Moell C, Relander T, Cavallin-Stahl E, Wiebe T, et al. High risk of azoospermia in men treated for childhood cancer. *Int J Androl.* 2011;34(1):69–76.
- Rowley MJ, Leach DR, Warner GA, Heller CG. Effect of graded doses of ionizing radiation on the human testis. *Radiat Res.* 1974;59(3):665–78.
- Sharpe RM, Skakkebaek NE. Testicular dysgenesis syndrome: mechanistic insights and potential new downstream effects. *Fertil Steril.* 2008;89(Suppl 2):e33–8.
- Shoshany O, Shtabholtz Y, Schreter E, Yakimov M, Pinkas H, Stein A, et al. Predictors of spermatogenesis in radical orchiectomy specimen and potential implications for patients with testicular cancer. *Fertil Steril.* 2016;106:70–4.
- Skakkebaek NE, Rajpert-De Meyts E, Main KM. Testicular dysgenesis syndrome: an increasingly common developmental disorder with environmental aspects. *Hum Reprod.* 2001;16(5):972–8.
- Stahl O, Eberhard J, Jepson K, Spano M, Cwikel M, Cavallin-Stahl E, et al. Sperm DNA integrity in testicular cancer patients. *Hum Reprod.* 2006;21(12):3199–205.
- Stahl O, Boyd HA, Giwercman A, Lindholm M, Jensen A, Kjaer SK, et al. Risk of birth abnormalities in the offspring of men with a history of cancer: a cohort study using Danish and Swedish national registries. *J Natl Cancer Inst.* 2011;103(5):398–406.
- Tajar A, Forti G, O'Neill TW, Lee DM, Silman AJ, Finn JD, et al. Characteristics of secondary, primary, and compensated hypogonadism in aging men: evidence from the European Male Ageing Study. *J Clin Endocrinol Metab.* 2010;95(4):1810–8.
- Tran S, Boissier R, Perrin J, Karsenty G, Lechevallier E. Review of the different treatments and management for prostate cancer and fertility. *Urology.* 2015;86(5):936–41.



- van Casteren NJ, Boellaard WP, Romijn JC, Dohle GR. Gonadal dysfunction in male cancer patients before cytotoxic treatment. *Int J Androl.* 2010;33(1):73–9.
- Viviani S, Santoro A, Ragni G, Bonfante V, Bestetti O, Bonadonna G. Gonadal toxicity after combination chemotherapy for Hodgkin's disease. Comparative results of MOPP vs ABVD. *Eur J Cancer Clin Oncol.* 1985;21(5):601–5.
- Willemsse PH, Sleijfer DT, Sluiter WJ, Schraffordt Koops H, Doorenbos H. Altered Leydig cell function in patients with testicular cancer: evidence for bilateral testicular defect. *Acta Endocrinol.* 1983;102(4):616–24.

Marco Zavattaro, Giovanna Motta, Stefano Allasia, and  
Fabio Lanfranco

---

## Abstract

Gynecomastia – the enlargement of male breast tissue in men – is a relatively common finding, frequently observed in newborns, adolescents, and old men. Physiological gynecomastia, occurring in almost 25% of cases, is benign and self-limited; on the other hand, several conditions and drugs may induce proliferation of male breast tissue. True gynecomastia is a common feature often related to estrogen excess and/or androgen deficiency as a consequence of different endocrine disorders. Nonendocrine illnesses, including liver failure and chronic kidney disease, are another cause of gynecomastia, which should be considered. Due to the diversity of possibly etiologies, including neoplasm, performing a careful history and physical examination is imperative. Once gynecomastia has been diagnosed, treatment of the underlying cause is warranted. If no underlying cause is discovered, then close observation is appropriate. If gynecomastia is severe, however, medical therapy can be attempted and if ineffective, glandular tissue can be removed surgically.

---

## Keywords

Gynecomastia • Male breast enlargement • Testosterone • Estradiol • Hyperprolactinemia • Hypogonadism

---

M. Zavattaro

Department of Translational Medicine, Division of Endocrinology,  
University of Eastern Piedmont, Novara, Italy  
e-mail: [marco.zavattaro@med.uniupo.it](mailto:marco.zavattaro@med.uniupo.it)

G. Motta • S. Allasia • F. Lanfranco (✉)

Department of Medical Sciences, Division of Endocrinology, Diabetology and Metabolism,  
University of Torino, Torino, Italy  
e-mail: [giovanna.motta83@gmail.com](mailto:giovanna.motta83@gmail.com); [stefano.allasia@alice.it](mailto:stefano.allasia@alice.it); [fabio.lanfranco@unito.it](mailto:fabio.lanfranco@unito.it)

## Contents

Introduction .....	900
Physiologic Gynecomastia .....	902
Neonatal Gynecomastia .....	902
Pubertal Gynecomastia .....	903
Aging Gynecomastia .....	904
Pathologic Gynecomastia .....	904
Androgen Deficiency .....	904
Hyperprolactinemia .....	906
Absolute Estrogen Excess .....	906
Estrogen-Secreting Tumors .....	907
Nonestrogen-Secreting Tumors .....	908
Thyroid Disorders .....	908
Obesity .....	908
Leptin .....	909
Growth Hormone and IGF-I Excess .....	909
Familial Gynecomastia .....	909
Other Conditions .....	909
Pharmacological Gynecomastia .....	910
Antiandrogens .....	911
Exogenous Estrogen .....	911
Phytoestrogens .....	911
Recreational Drug Use .....	911
Drug Abuse in Sports .....	912
Idiopathic Gynecomastia .....	912
Patient Evaluation .....	912
Treatment .....	914
Medical Treatment .....	914
Surgical Treatment .....	915
Gynecomastia in Prostate Cancer .....	916
Summary .....	917
Cross-References .....	917
References .....	917

## Introduction

Gynecomastia is the benign enlargement of the male breast caused by proliferation of glandular tissue (Braunstein 2007; Johnson et al. 2011; Narula and Carlson 2014). It is the most common breast alteration in males, occurring more frequently during infancy, puberty, and old age (Sansone et al. 2017): prevalence rates are 60–90% in newborns, 50–60% in adolescents, and 24–65% in men between 50 and 69 years (Johnson et al. 2011; Cuhaci et al. 2014).

On inspection, it is difficult to distinguish gynecomastia from increased adipose tissue deposition within the breast in the absence of glandular proliferation (pseudogynecomastia or lipomastia), which is commonly present in obese men and boys. Detection of glandular breast tissue requires a careful physical examination feeling a firm, rubbery, finely lobular mobile disc of tissue that extends concentrically from under the nipple and areola. Initially, gynecomastia of relatively recent and rapid

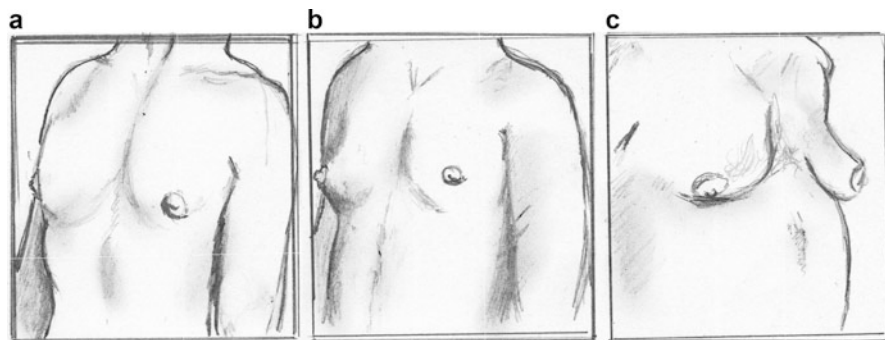
onset may be painful and associated with tenderness. With time, glandular tissue is replaced by fibrous tissue and tenderness resolves, although palpable tissue remains. In contrast, pseudogynecomastia is soft, nondiscrete, and irregularly lobular, similar to subcutaneous fat in the abdomen.

Gynecomastia is usually present bilaterally but may be asymmetric in size. If palpable breast tissue is present unilaterally, the major concern is male breast cancer. Breast cancer is usually rock-hard and indurated, eccentrically located from the nipple and areola, and fixed to underlying tissue. It may be associated with skin dimpling with retraction of hair follicles, nipple retraction, nipple bleeding or discharge, or axillary lymphadenopathy (Gomez-Raposo et al. 2010).

Histologically, three different patterns of gynecomastia have been identified: florid (showing high numbers of budding ducts), fibrous (minimal ductal proliferation), and intermediate (overlapping of both previous patterns) (Bannayan and Hajdu 1972).

Clinically, there are many classifications for gynecomastia. Simon et al. (1973) proposed a practical classification based on the amount of tissue to be removed in cases of surgery and took into consideration not only the size of the breast but also the amount of redundant skin (Fig. 1). Considering the degree of lipodystrophy and skin excess, Rohrich et al. in 2003 proposed a classification identifying four different subtypes: grade I, with minimal hypertrophy without ptosis (<250 g of breast tissue); grade II, with moderate hypertrophy without ptosis (250–500 g of breast tissue); grade III, with severe hypertrophy and moderate ptosis (>500 g of breast tissue); and grade IV, with severe hypertrophy and severe ptosis (>500 g of breast tissue) (Rohrich et al. 2003). Based on its consistency, gynecomastia has been subdivided by Fodor into true (predominantly glandular hypertrophy), pseudo (predominantly adipose tissue), and mixed (combination of both) types (Fodor 1989).

The primary hormones that regulate breast tissue development are estrogens, which stimulate the growth and differentiation of breast epithelium to form ducts,



**Fig. 1** Simon classification of gynecomastia. (a) Class I: minor breast enlargement with no skin redundancy; (b) Class II: moderate breast enlargement with no (IIa) or minor (IIb) skin redundancy; (c) Class III: marked breast enlargement with major skin redundancy (resembles the female breast)

and progesterone, which controls acinar development and the formation of glandular buds. Androgens inhibit the growth and differentiation of breast tissue. Growth hormone (GH), insulin-like growth factor-I (IGF-I), insulin, thyroid hormone, and cortisol play permissive roles in breast development. In fact, although estrogens and progestogens are vital to mammary growth, they are ineffective in the absence of anterior pituitary hormones (Swerdloff and Ng 2015).

Prolactin is another anterior pituitary hormone integral to breast development. Prolactin is not only secreted by the pituitary gland but may be produced in normal mammary tissue epithelial cells and breast tumors. It stimulates epithelial cell proliferation only in the presence of estrogen and enhances lobulo-alveolar differentiation only with concomitant progesterone (Swerdloff and Ng 2015). Prolactin stimulates differentiated breast acinar cells to produce milk, but high progesterone levels inhibit lactogenesis. Therefore, milk production requires a reduction in high progesterone levels in the presence of high prolactin levels, as occurs in the first few days after delivery. Milk production (galactorrhea) is rarely seen in men with hyperprolactinemia and gynecomastia, because progesterone levels are not usually high enough for breast acinar development to occur, and they do not decline in the presence of high prolactin levels to stimulate lactogenesis.

Gynecomastia develops in clinical situations in which the levels or activity of estrogens is relatively high in comparison with androgens (i.e., high estrogen-to-androgen ratio). This hormonal milieu may result from high estrogen or low androgen concentrations or activity. Androgen deficiency is a major cause of gynecomastia. However, the differential diagnosis of other causes of gynecomastia should be considered in patients who present with breast enlargement with or without tenderness.

The classification of gynecomastia according to different etiologies is reported in Table 1.

---

## Physiologic Gynecomastia

Gynecomastia can occur normally during three phases of life: shortly after birth, during puberty, and during older age.

### Neonatal Gynecomastia

Neonatal gynecomastia occurs in 60% to 90% of neonatal boys as a result of transplacental transfer of maternal estrogens, leading to a transient and self-limited imbalance in estradiol (E2)-to-testosterone (T) ratio (Sloand 1998). It can persist for several weeks after birth and can cause mild breast discharge called “witch’s milk” (Swerdloff and Ng 2015). Spontaneous resolution of this phenomenon commonly occurs; further investigation is advised should symptoms persist for more than 1 year (Dickson 2012).

**Table 1** Etiological classification of gynecomastia

<b>Physiologic gynecomastia</b>
1. Neonatal gynecomastia
2. Pubertal gynecomastia
3. Aging gynecomastia
<b>Pathologic gynecomastia</b>
1. Androgen deficiency: <ul style="list-style-type: none"> <li>• Hypogonadism (either primitive or secondary)</li> <li>• Androgen resistance: Reifenstein's syndrome, Kennedy syndrome</li> </ul>
2. Estrogen excess: <ul style="list-style-type: none"> <li>• Absolute estrogen excess:           <ul style="list-style-type: none"> <li>– Exposure to exogenous estrogen or estrogen receptor agonists</li> <li>– Reduced estrogen clearance</li> <li>– Increase aromatization of estrogen precursors (including administration of testosterone and other aromatizable androgens)</li> </ul> </li> <li>• Estrogen secreting tumors: Adrenal tumors, Leydig cell tumors, Sertoli cell tumors, Granulosa cell tumors</li> <li>• Nonestrogen secreting tumors: Germ cell testicular tumors (Embryonal carcinoma, Yolk sac carcinoma, Choriocarcinoma, Teratoma), Large-cell lung carcinoma, Gastric carcinoma, Renal cell carcinoma, Hepatocarcinomas (adults) and Hepatoblastomas (children)</li> </ul>
3. Hyperprolactinemia: <ul style="list-style-type: none"> <li>• Pituitary adenomas</li> <li>• Neoplasm of sellar/parasellar region (i.e., craniopharyngiomas)</li> <li>• Drugs</li> </ul>
4. Endocrine diseases: <ul style="list-style-type: none"> <li>• Thyroid disorders: hypothyroidism, hyperthyroidism</li> <li>• Obesity</li> <li>• Growth hormone and IGF-I excess</li> </ul>
5. Chronic diseases: <ul style="list-style-type: none"> <li>• Malnourishment (refeeding gynecomastia)</li> <li>• End-stage chronic kidney disease and dialysis</li> <li>• Type 1 diabetes mellitus on insulin therapy</li> <li>• Tuberculosis on antituberculosis medication</li> <li>• HIV/AIDS on HAART</li> <li>• Chronic liver disease/hepatic cirrhosis</li> </ul>
6. Familial gynecomastia
<b>Idiopathic gynecomastia</b>
<b>Pharmacological gynecomastia (Table 2)</b>

*HIV* human immunodeficiency virus, *AIDS* acquired immunodeficiency syndrome, *HAART* highly active antiretroviral treatment

## Pubertal Gynecomastia

A rapid increase in E<sub>2</sub>, occurring before a similar increase in T, causes an elevated E<sub>2</sub>-to-T ratio and could be responsible for physiological gynecomastia at the start of puberty. Breast enlargement greater than 0.5 cm in diameter, which is often tender, initially occurs in 50% to 60% of boys by 14 years of age. Although it is mostly bilateral, it is often asymmetrical and can occur unilaterally.

The breast enlargement usually resolves spontaneously in 2–3 years, when the E2-to-T ratio is restored (Dickson 2012; Swerdloff and Ng 2015). Psychological or sexual issues are among the chief complaints, although pain may be frequent. Reassurance and follow-up are the treatment of choice; however, patients might require pharmacological or surgical treatment to ease their psychosocial burden.

Rarely, boys may develop severe pubertal gynecomastia (female size breast development, Tanner stage III through V) that persists to adulthood (persistent pubertal macromastia). This disorder is not associated with specific hormonal or receptor abnormalities and remains idiopathic.

## Aging Gynecomastia

Gynecomastia occurs in 24–65% of men between 50 and 69 years (Johnson et al. 2011; Cuhaci et al. 2014). Although the exact mechanisms by which this can occur have not been fully elucidated, evidence suggests that it may result from increased peripheral aromatase activity secondary to the increase in total body fat, coupled with mild hypogonadism associated with aging (Swerdloff and Ng 2015). Interestingly, not only does total body fat increase with age, but there may be an increase in aromatase activity in the adipose tissue already present, increasing circulating estrogens even further. Sex hormone binding globulin (SHBG) increases with age in men. Since SHBG binds estrogen with lesser affinity than testosterone, the bioavailable estradiol to bioavailable testosterone ratio may increase in the obese older male (Swerdloff and Ng 2015). Moreover, gynecomastia is a common symptom of many clinical conditions occurring in the elderly. Lastly, elderly patients may take multiple medications associated with gynecomastia (Table 2).

---

## Pathologic Gynecomastia

Pathologic gynecomastia may result from excessive estrogen levels or action or from androgen deficiency or resistance/insensitivity. In some conditions, both estrogen excess and androgen deficiency contribute to proliferation of glandular breast tissue (Table 1) (Braunstein 2007; Johnson et al. 2011; Narula and Carlson 2014).

## Androgen Deficiency

In all circumstances of increased E2-to-T ratio, and therefore in almost all forms of male hypogonadism, the altered hormonal homeostasis contributes to the genesis of gynecomastia (Rokutanda et al. 2008). In fact, gynecomastia might help identifying individuals with T deficiency. Primary male hypogonadism is characterized by decreased T production, increased luteinizing hormone (LH) production to stimulate Leydig cells, and elevated aromatization of T to E2; in secondary male hypogonadisms, low levels of T are subsequent to reduced LH secretion, despite normal

**Table 2** Pharmacological causes of gynecomastia and mechanism of action

<b>1. Estrogen-like or binding to estrogen receptor</b>	<ul style="list-style-type: none"> <li>● Estrogen vaginal cream</li> <li>● Estrogen-containing embalming cream</li> <li>● Delousing powder</li> <li>● Digitalis</li> <li>● Phytoestrogens</li> <li>● Clomiphene</li> <li>● Marijuana</li> </ul>
<b>2. Stimulate estrogen synthesis</b>	<ul style="list-style-type: none"> <li>● Gonadotropins</li> <li>● Growth Hormone</li> </ul>
<b>3. Supply aromatizable estrogen precursors</b>	<ul style="list-style-type: none"> <li>● Exogenous androgen</li> <li>● Androgen precursors (i.e., Androstenedione and DHEA)</li> <li>● Anabolic androgenic steroids (doping)</li> </ul>
<b>4. Direct Testicular Damage</b>	<ul style="list-style-type: none"> <li>● Ethanol</li> <li>● Busulfan</li> <li>● Vincristine</li> <li>● Nitrosourea</li> </ul>
<b>5. Block testosterone synthesis</b>	<ul style="list-style-type: none"> <li>● GnRH agonists and antagonists</li> <li>● Ketoconazole</li> <li>● Spironolactone</li> <li>● Metronidazole</li> <li>● Etomidate</li> <li>● Opioids</li> </ul>
<b>6. Block androgen action</b>	<ul style="list-style-type: none"> <li>● Flutamide, Bicalutamide</li> <li>● Finasteride</li> <li>● Cyproterone, Zanoterone</li> <li>● Cimetidine, Ranitidine</li> <li>● Spironolactone</li> </ul>
<b>7. Displace estrogen from SHBG</b>	<ul style="list-style-type: none"> <li>● Spironolactone</li> <li>● Ethanol</li> </ul>
<b>8. Unknown mechanism</b>	<ul style="list-style-type: none"> <li>● HAART</li> <li>● Calcium channel blockers (nifedipine, verapamil)</li> <li>● Amiodarone</li> <li>● Antidepressants (Tricyclic, SSRI)</li> <li>● Amphetamines</li> <li>● Penicillamine</li> <li>● Sulindac</li> <li>● Phenytoin</li> <li>● Omeprazole</li> <li>● Theophylline</li> </ul>

DHEA: dehydroepiandrosterone; SHBG: sex hormone-binding globulin; HAART: highly active antiretroviral treatment; SSRI: selective serotonin reuptake inhibitors.

production of adrenal estrogen precursors (Bembo and Carlson 2004). Therefore, in both conditions, serum E2-to-T ratio is increased. In hypogonadal men, T replacement therapy is usually able to reduce breast tenderness and size (Narula and Carlson 2014; Sansone et al. 2017) as administration of exogenous androgens is able to restore the balance in sexual hormones ratio.



Klinefelter syndrome (KS) is the most common chromosomal anomaly associated with hypogonadism, although frequently overlooked (Lanfranco et al. 2004). Prevalence of gynecomastia in men affected by KS is up to 70%, and unfortunately, in this population the risk of developing breast cancer is significantly increased (Brinton 2011); consequently, an adequate breast examination is of utmost importance in these patients.

The *androgen resistance syndromes*, including complete and partial testicular feminization (e.g., Reifenstein's syndrome), are characterized by gynecomastia and varying degrees of pseudohermaphroditism. Kennedy syndrome, a neurodegenerative disease, is also associated with decreased effective testosterone due to a defective androgen receptor (Swerdluff and Ng 2015). Gynecomastia in these diseases is the combination of decreased androgen responsiveness at the breast level and increased estrogen levels as a result of elevated androgen precursors of estradiol and estrone. As such, androgens are not recognized by the peripheral tissues including the breast and pituitary. Androgen resistance at the pituitary results in elevated serum LH levels and increased circulating testosterone. The increased serum testosterone is then aromatized peripherally, promoting gynecomastia. Thus, gynecomastia is the result of increased estradiol levels that arise due to unopposed androgen unresponsiveness (Swerdluff and Ng 2015).

## Hyperprolactinemia

Hyperprolactinemia could be involved in the pathogenesis of gynecomastia as a cause of secondary hypogonadism. However, prolactin receptors have been found in male breast tissue (Ferreira et al. 2008), and they might be co-expressed and cross-regulated with growth hormone and progesterone receptors. Activation of progesterone receptors is often linked to reduced expression of androgen receptors, hampering the androgen-mediated inhibition on breast tissue growth observed in condition of normal hormonal homeostasis. Consequently, besides male hypogonadism, hyperprolactinemia might induce gynecomastia through a completely different pathway: elevated levels of prolactin might stimulate breast tissue growth as a result of excessive progesterone receptor activation, and reduced availability of androgen receptors (Bravo et al. 2015).

## Absolute Estrogen Excess

Since the development of breast tissue in males occurs in an analogous manner to that in females, the same hormones that affect female breast tissue can cause gynecomastia. The testes secrete only a small fraction of estrogens in circulation (i.e., 15% of estradiol and 5% of estrone); the remainder of estrogens in males is derived from the extraglandular aromatization of testosterone and androstenedione to estradiol and estrone (Mathur and Braunstein 1997). Thus, any cause of estrogen excess from overproduction to peripheral aromatization of androgens can initiate the cascade to breast development. However, the most common causes of absolute

estrogen excess include exposure to exogenous estrogens (e.g., diethylstilbestrol treatment of prostate cancer, contact with an estrogen-containing cream or cosmetic, accidental occupational exposure to estrogens, ingestion of estrogen-containing nutritional supplements or excessive amounts of phytoestrogens) and exposure to estrogen receptor (ER) agonists such as marijuana smoke or digitoxin. Moreover, reduced clearance, increased aromatization, and direct estrogen secretion from tumors must be taken into account (Narula and Carlson 2014). Uncommonly, administration of testosterone or other aromatizable androgens, usually to prepubertal boys or men with long-standing severe androgen deficiency, induces or worsens gynecomastia by initially causing relatively higher estradiol than testosterone levels.

## Estrogen-Secreting Tumors

Estrogen-secreting tumors include adrenal tumors, Leydig cell tumors, Sertoli cell tumors, and granulosa cell tumors.

Feminizing adrenal tumors are rare neoplasms, featuring gynecomastia as the most common clinical manifestation in adults following increased adrenal production of estrogens (Chentli et al. 2015). Weight loss, signs, and symptoms of Cushing syndrome or mineralocorticoid excess and the presence of an abdominal mass in the presence of gynecomastia suggest the presence of an adrenal tumor.

Gynecomastia might also be the first clinical sign of a testicular cancer, the most common neoplasm in young adults (Stevenson and Lowrance 2015). Estrogen-secreting Leydig or Sertoli tumors are usually small and benign. Leydig cell tumors constitute 1%–3% of all testis tumors. Usually, they occur in men between the ages of 20 and 60, although up to 25% of them occur prepubertally. In prepubertal cases, isosexual precocity, rapid somatic growth, and increased bone age with elevated serum testosterone levels are the presenting features. In adults, elevated estrogen levels coupled with a palpable testicular mass and gynecomastia suggest a testicular tumor. Noteworthy, some lesions are impalpable and thus only detectable on ultrasound (Swerdloff and Ng 2015).

Sertoli cell tumors comprise less than 1% of all testicular tumors and occur at all ages, but one third have occurred in patients less than 13 years, usually in boys under 6 months of age. Although they arise in young boys, they usually do not produce endocrine effects in children. Again, the majority is benign, but up to 10% are malignant. Gynecomastia occurs in one third of cases of Sertoli cell tumors, presumably due to increased estrogen production (Swerdloff and Ng 2015). Feminizing Sertoli tumors (in particular the large cell calcifying variety) may occur in association with autosomal dominant disorders such as Peutz-Jeghers syndrome (multiple intestinal polyps and mucocutaneous pigmented macules) or the Carney complex (cardiac or cutaneous myxomas, pigmented skin lesions, and endocrinopathy, including functioning endocrine tumors of the adrenal and testis).

Granulosa cell tumors, occurring very rarely in the testes, can also overproduce estrogen. In fact, only 11 cases have been reported with gynecomastia as a presenting feature in half of them (Swerdloff and Ng 2015).

Testicular pain or enlargement should be evaluated during physical examination for all patients with gynecomastia.

## Nonestrogen-Secreting Tumors

Besides feminizing adrenal tumors and nongermline cell testicular cancers, different neoplasms can induce gynecomastia via increased production of human chorionic gonadotropin (hCG), including germ cell testicular tumors, large-cell lung carcinoma, gastric carcinoma, renal cell carcinoma, or hepatic carcinomas in adults and hepatoblastomas in boys.

Germ cell tumors are the most common cancer in males between the ages of 15 and 35. They are divided into seminomatous and nonseminomatous subtypes and include embryonal carcinoma, yolk sac carcinoma, choriocarcinoma, and teratomas. Elevated alpha fetoprotein (AFP) and  $\beta$ -hCG function as reliable markers in some tumors. As a result of the increased hCG, acting analogously to LH to stimulate the Leydig cell LH receptor, testicular estrogen production is increased, which, in turn, can cause gynecomastia. Although germ cell tumors generally arise in the testes, they can also originate extra-gonadally, specifically in the mediastinum (Swerdlow and Ng 2015).

## Thyroid Disorders

Gynecomastia during thyrotoxicosis has been reported for more than 60 years and has occasionally been described as the first symptom of hyperthyroidism (Sansone et al. 2017).

Effects of thyroid hormones on the hypothalamic–pituitary–gonadal axis have been described in literature (Jannini et al. 1995): hypothyroid men have reduced T secretion and often develop hyperprolactinemia, whereas hyperthyroidism is associated with increased E2, SHBG, and T concentrations. Elevated SHBG leads to low free T concentrations associated to increased E2 concentrations: therefore, this leads to a status of hormonal imbalance, resulting in gynecomastia among other symptoms. Moreover, LH levels are often elevated in men with hyperthyroidism, which stimulates relatively more estradiol than testosterone secretion by Leydig cells of the testes.

In both hypothyroidism and hyperthyroidism, gynecomastia is commonly resolved after euthyroid state restoration.

## Obesity

Aromatization of T to E2 occurs in the adipose tissue and, as previously discussed, is the main source of E2 in men.

The role of aromatase in the pathogenesis of gynecomastia has been extensively studied (Mathur and Braunstein 1997). In obese people, both increased expression and activity of aromatase can be involved in the development of gynecomastia. It is

also worth remembering that aging does increase aromatase activity (Braunstein 1999; Braunstein 2007), resulting in a further increased prevalence of gynecomastia in aging, obese men.

## Leptin

Research on leptin has steadily increased in the last decades: although traditionally associated with energy expenditure and satiety, leptin seems to be involved in many pathophysiological processes. The effect of leptin on the hypothalamic–pituitary–gonadal axis has been clearly identified: patients with defective leptin signaling are affected by delayed puberty and some degree of infertility, and investigation on treatment with recombinant leptin has shown promising results (Farooqi and O’Rahilly 2014). Recent studies have demonstrated that both increase in total leptin levels and polymorphisms in its receptor (Eren et al. 2014) can be involved in the pathogenesis of gynecomastia: accelerated estrogen metabolism and increased expression of aromatase have been identified as possible gynecomastia-inducing factors (Habib et al. 2015).

## Growth Hormone and IGF-I Excess

Enlargement of mammary glands following exogenous GH administration has been observed two decades ago in primates (Ng et al. 1997): in humans, a role of the GH-IGF-I axis on the pathogenesis of gynecomastia has been speculated, and the synergistic role of estrogens, which induce expression of IGF-I receptors on breast tissue, seems to prove that.

Gynecomastia is common in patients treated with GH, and cases of acromegaly manifesting with gynecomastia as its first symptom are reported.

## Familial Gynecomastia

Familial gynecomastia, an autosomal dominant or X-linked genetic disorder caused by constitutive activation of the *CYP19A1* (aromatase) gene that results in increased peripheral conversion of androgen to estrogen, is a very rare cause of gynecomastia that manifests as prepubertal gynecomastia persisting into adulthood (Matsumoto and Bremner 2016).

## Other Conditions

Gynecomastia has been observed after resumption of a normal diet following long periods of malnourishment (*refeeding gynecomastia*). In both starvation and severe

chronic illness that is commonly associated with anorexia and weight loss, central gonadotropin-releasing hormone (GnRH) production and concomitant gonadotropin and T secretion are markedly suppressed, in the face of normal concentrations of E2: the resulting impairment in the E2-to-T ratio is, as already reported, the main factor involved in the pathogenesis of gynecomastia. With refeeding or restitution of appetite and weight gain, there is activation of the hypothalamic–pituitary–testicular axis and restoration of gonadal function, similar to what occurs during puberty, resulting in transiently higher levels of estrogen relative to androgen levels and inducing gynecomastia. Refeeding gynecomastia can occur in stage 5 chronic kidney disease with the initiation of hemodialysis, in type 1 diabetes mellitus with insulin therapy, in tuberculosis with antituberculosis medications, and in human immunodeficiency virus (HIV) infection or acquired immunodeficiency syndrome (AIDS) with highly active antiretroviral treatment (HAART). As mentioned, these chronic disorders also cause androgen deficiency that may contribute to the pathogenesis of gynecomastia (Matsumoto and Bremner 2016).

Gynecomastia is a common sign of chronic liver disease, since T levels are frequently low (Sinclair et al. 2015); in advanced liver disease, increased SHBG levels reduce the bioavailable quota of T, contributing to the pathogenesis of gynecomastia. In hepatic cirrhosis, there is reduced catabolism of  $\Delta 4$ -androstenedione, resulting in increased peripheral conversion of  $\Delta 4$ -androstenedione to estrone and increased circulating estrogen levels.

Testicular damage from chronic kidney disease results in impaired T secretion (Iglesias et al. 2012), which can present as gynecomastia. Dialysis does not affect gynecomastia, which occasionally regresses idiopathically.

---

## Pharmacological Gynecomastia

Around 20% of gynecomastia is caused by medications or exogenous chemicals (Bowman et al. 2012). Some drugs may increase estrogen effect by several mechanisms: (1) they possess intrinsic estrogen-like properties, (2) they increase endogenous estrogen production, or (3) they supply an excess of an estrogen precursor (e.g., testosterone or androstenedione), which can be aromatized to estrogen.

Antipsychotics, corticosteroids, spironolactone, antiretrovirals, statins, proton pump inhibitors, and opioids are just a few of the many contributors to the development of gynecomastia (Bowman et al. 2012).

Drugs that induce gynecomastia by known mechanisms are listed in Table 2.

The mechanisms of gynecomastia associated with a number of drugs are not entirely clear, and these cases are usually classified as idiopathic. Such drugs include HAART, calcium channel blockers (e.g., nifedipine, verapamil), amiodarone, antidepressants (selective serotonin reuptake inhibitors, tricyclic antidepressants), alcohol, amphetamines, penicillamine, sulindac, phenytoin, omeprazole, and theophylline

(Braunstein 2007; Johnson et al. 2011; Bowman et al. 2012; Narula and Carlson 2014).

## Antiandrogens

Antiandrogens, binding to the androgen receptors, inhibit the action of T and dihydrotestosterone on breast glandular tissue and hamper the negative feedback of the hypothalamic–pituitary–gonadal axis. Therefore, antiandrogens lead to an increase in T levels; aromatization of T to E2 increases the E2-to-T ratio.

Similarly, GnRH analogues have reportedly been associated with gynecomastia, although with a smaller incidence.

## Exogenous Estrogen

Accidental exposure to estrogen has been observed in subjects using topical creams for baldness or in those eating foods from estrogen-treated animals (Sansone et al. 2017).

## Phytoestrogens

Phytoestrogens are estrogens not produced by the endocrine system, but obtained through dietary intake or taken as medications and interacting with the estrogen receptor.

Soy products and digoxin are both commonly used phytoestrogens, which have been linked to gynecomastia in mice: it seems likely that their similarity with endogenous estrogens exerts some effects of excess E2, although there is still uncertainty in regard to the degree of feminization in humans (Sansone et al. 2017).

Phytoestrogens are ubiquitous: lavender and tea tree oil are used for cosmetics and in some foods; hops are used as flavoring and stability agent in beer; phthalates and herbicides have gained media exposure as endocrine disruptors in recent years and are still used in most countries for industrial and agricultural needs.

## Recreational Drug Use

Recreational drug use has been occasionally associated with increased risk of gynecomastia (Sansone et al. 2017). Although the exact mechanisms are still unclear, the presence of plant estrogens has been considered as a possible trigger for marijuana-related gynecomastia. Furthermore, opioids reduce T, follicle-stimulating hormone (FSH), and LH; this effect is likely to be caused by inhibitory effects on both the hypothalamic–pituitary–gonadal axis and the testicular production of T.

---

## Drug Abuse in Sports

Medication use and abuse (i.e., doping) are the most common cause of gynecomastia in adults. Anabolic androgenic steroids (AAS) are perhaps the most used performance-enhancing drugs (Di Luigi et al. 2012; Nieschlag and Vorona 2015). Although prohibited by the World Anti-Doping Agency (WADA), AAS are very often abused by athletes and nonathletes, as they can provide a boost to performance and/or to muscle development. Gynecomastia and acne are common side effects of AAS abuse, mainly resulting from increased E2 concentration following peripheral AAS aromatization (Basaria 2010). Negative feedback in the regulation of the hypothalamic–pituitary–gonadal axis resulting from the continuous administration of AAS might also cause gynecomastia, erectile dysfunction, and infertility due to hypogonadism.

Gynecomastia can also be the result of conjoined abuse of AAS and GH (Birzniece 2015). hCG is another commonly abused drug, able to induce gynecomastia on its own.

---

## Idiopathic Gynecomastia

In a number of cases of adult-onset gynecomastia, the cause remains idiopathic. Most of these cases are probably caused by increased aromatization of androgens to estrogens associated with increased peripheral adiposity, enhanced breast production of estrogens, enhanced sensitivity to estrogens, or some combination of these factors (Matsumoto and Bremner 2016).

---

## Patient Evaluation

Most gynecomastia is asymptomatic and of mild degree but can be appreciated on a properly performed physical examination.

The degree of gynecomastia can be estimated on a semiquantitative basis using the Tanner grading system for breast development:

- I: Prepubertal,
- II: Breast bud stage,
- III/IV: Advanced stage of development,
- V: Mature breast of an adult female.

Mild, asymptomatic gynecomastia found incidentally on examination and in isolation does not warrant evaluation. However, breast enlargement that is recent and rapid in onset, large (>5 cm in obese men, <2 cm in lean men), symptomatic (i.e., associated with breast pain, tenderness, or galactorrhea), asymmetric, or suspicious for malignancy (eccentrically located, rock-hard, fixed, or overlying or underlying tissues, or associated with bloody nipple discharge or lymphadenopathy) should trigger further evaluation (Matsumoto and Bremner 2016).

A careful history, including medication history, and physical examination usually identify potential predisposing conditions or medications causing gynecomastia that in older men may be multifactorial (Braunstein 2007; Johnson et al. 2011; Narula and Carlson 2014). Clinical evaluation should focus on evidence of androgen deficiency; assessment of prescription and over-the-counter medications, substance abuse, herbal or nutritional supplement intake, cosmetic use, and usual dietary intake; symptoms and signs of systemic illness (e.g., hepatic or renal disease), malignancy or endocrine disorders (e.g., thyroid, GH, cortisol excess); and history of recent recovery from malnutrition, severe weight loss, or chronic illness.

Physical examination must not be restricted to the pectoral area. A thorough testicular exam is essential. Bilaterally small testes imply testicular failure, while asymmetric testes or a testicular mass suggest the possibility of neoplasm.

If gynecomastia is mild and nonprogressive or if adolescent gynecomastia is a very likely diagnosis, the initial laboratory evaluation comprises serum testosterone, estradiol, LH, and FSH levels. In less straightforward cases, the basic laboratory workup should include also thyroid-stimulating hormone (TSH), SHBG, prolactin,  $\beta$ -hCG, and liver and renal function tests.

An elevated  $\beta$ -hCG or a markedly elevated serum estradiol suggests neoplasm and a testicular ultrasound is warranted to identify a testicular tumor, keeping in mind, however, that other nontesticular tumors can also secrete hCG. A low testosterone level, with an elevated LH and normal to high estrogen level, indicates primary hypogonadism. If the history suggests Klinefelter syndrome, then a karyotype should be performed for definitive diagnosis. Low testosterone, low LH, and normal estradiol levels imply secondary hypogonadism, and hypothalamic or pituitary causes should be sought. If testosterone, LH, and estradiol levels are all elevated, then the diagnosis of androgen resistance should be entertained (Swerdlloff and Ng 2015).

Breast enlargement suspicious for malignancy should be evaluated by mammography and biopsy (Matsumoto and Bremner 2016). Mammography (MMG) is the primary imaging method used when there is any suspicion of cancer. It accurately distinguishes between malignant and benign male breast diseases and can differentiate true gynecomastia from a mass that requires tissue sampling to exclude malignancy, reducing the need for biopsies (Cuhaci et al. 2014). The sensitivity and specificity of MMG for benign and malignant breast conditions is greater than 90%, but its positive predictive value for malignancies is low (55%), because of the low prevalence of malignancy in patients presenting with gynecomastia (Johnson and Murad 2009). In cases of pseudogynecomastia, breast tissue is filled with radiolucent adipose tissue. Breast ultrasonography is widely used in the diagnosis of gynecomastia cases and is more comfortable for male patients.

Scrotal ultrasonography and abdominal computerized tomography can also be used. However, when there is no history or physical examination suggestive of an underlying pathological cause, these tests are not recommended in clinical practice, since they are unlikely to be useful in the absence of suspicious pathology (Johnson and Murad 2009). If necessary, pituitary magnetic resonance imaging is recommended (Cuhaci et al. 2014).



## Treatment

Pubertal gynecomastia usually resolves spontaneously without treatment in 2–3 years and by age 17 in about 90% of cases. In adults, spontaneous regression of symptoms (breast pain and tenderness, nipple sensitivity) associated with inflammatory glandular proliferation usually occurs within 6 months, after which progressive stromal fibrosis causes more or less permanent palpable breast tissue and only partial regression of gynecomastia by 1 year.

Treatment of the underlying endocrinologic or systemic disease that has caused gynecomastia is mandatory. Testicular tumors, such as Leydig cell, Sertoli cell, or granulosa cell tumors, should be surgically removed. In addition to surgery, germ cell tumors are further managed with chemotherapy involving cisplatin, bleomycin, and either vinblastine or etoposide (Swerdlhoff and Ng 2015).

Should underlying thyrotoxicosis, renal, or hepatic failure be discovered, appropriate therapy should be initiated. Medications that cause gynecomastia should also be discontinued whenever possible based on their role in management of the underlying condition. The improvement should be apparent within a month after discontinuation of the culprit drug.

If no pathologic abnormality is detected, then reassurance and periodic follow-up are recommended at 3- or 6-month intervals until gynecomastia regresses or stabilizes, after which a breast exam can be performed yearly (Cuhaci et al. 2014; Swerdlhoff and Ng 2015).

## Medical Treatment

If gynecomastia is severe, does not resolve, and does not have a treatable underlying cause, some medical therapies may be attempted. There are three classes of medical treatment for gynecomastia: androgens (testosterone, dihydrotestosterone, danazol), antiestrogens (clomiphene citrate, tamoxifen), and aromatase inhibitors (letrozole and anastrozole).

Testosterone replacement therapy in androgen-deficient men may result in partial regression of gynecomastia, especially if breast enlargement is of recent onset. Unfortunately, testosterone treatment may actually produce the side effect of gynecomastia by being aromatized to estradiol. Thus, although testosterone is used to treat hypogonadism, its use to specifically counteract gynecomastia is limited (Swerdlhoff and Ng 2015).

A gel formulation of dihydrotestosterone, a nonaromatizable androgen, is used to treat gynecomastia in some countries.

Danazol, a weak androgen that inhibits gonadotropin secretion, resulting in decreased serum testosterone levels, has been studied in a prospective placebo-controlled trial, whereby gynecomastia resolved in 23% of the patients, as opposed to 12% of the patients on placebo (Jones et al. 1990). The dose used for gynecomastia is 200 mg orally twice daily. Unfortunately, undesirable side effects including edema, acne, and cramps have limited its use.

Investigators have reported a 64% response rate with 100 mg/day of clomiphene citrate, a weak estrogen, and moderate antiestrogen (Swerdlhoff and Ng 2015). Lower doses of clomiphene have shown varied results, indicating that higher doses may need to be administered, if clomiphene is to be attempted.

ER antagonists (tamoxifen, 10 to 20 mg daily, or raloxifene, 60 mg daily) are effective in treating pubertal and adult gynecomastia and preventing gynecomastia induced by androgen deprivation therapy. Although complete breast regression may not be achieved and a chance of recurrence exists with therapy, tamoxifen, due to relatively lower side effect profile, may be a more reasonable choice when compared to the other therapies (Swerdlhoff and Ng 2015).

For unclear reasons, aromatase inhibitors (e.g., anastrozole) are not effective.

Gynecomastia of recent onset, during the initial phase of ductal proliferation, periductal inflammation and edema, and subareolar fat accumulation, is usually responsive to medical therapy (e.g., androgen replacement in hypogonadal men, ER antagonist therapy).

With long-standing gynecomastia (>1 year), there is progressive stromal fibrosis of the breast that is not responsive to medical treatment. In these cases, surgical reduction mammoplasty may be necessary (Matsumoto and Bremner 2016).

## Surgical Treatment

When medical therapy is ineffective, particularly in cases of longstanding gynecomastia, when the breast enlargement is severe, painful, socially embarrassing, or disfiguring, or when there is suspicion of malignancy of breast, then surgical therapy is appropriate. On the other hand, surgical treatment should be postponed in pubertal gynecomastia, preferably until after completion of puberty, so as to minimize the chance of recurrent gynecomastia after surgery.

The aim of surgery is to achieve a normal appearance of the masculine thorax with the smallest possible scar. The surgical technique used depends on the degree of gynecomastia and the distribution and proportion of the different breast components (fat, parenchyma, and looseness of the skin envelope). Minimally invasive methods aim to achieve a high level of patient satisfaction with few complications. These methods include surgical excision via Webster's (skin incision below the areolar edge), puncture or zigzag (semicircular incision along the junction of the skin and the lower half of the areola), or endoscopic methods (Fagerlund et al. 2015). The surgical excisions are easy to perform, leave inconspicuous scars, and are usually associated with a low complication rate. A newer method, using radiofrequency-assisted liposuction (RFAL) to remove both fat and glandular tissue, has been proposed (Fagerlund et al. 2015); in spite of the minimal scarring and satisfactory results, sometimes a direct incision might be needed in the event that the glandular tissue is too hard and resistant to the RFAL.

Ultrasound guided excision using an 8-gauge Mammotome biopsy system is another described minimally invasive technique, effective especially for glandular

gynecomastia. Levels of satisfaction have been high and complications rare (Fagerlund et al. 2015).

Glandular tissue can also be removed by endoscopic mastectomy with an ultrasonic scalpel, with good clinical and aesthetic effects, and a low complication rate (Fagerlund et al. 2015).

Histological analysis of the gynecomastia tissue is recommended because unexpected findings such as spindle-cell hemangioendothelioma and papilloma occur in 3% of cases (Johnson and Murad 2009).

Complications of surgery may include contour irregularity, hematoma/seroma, numbness of the nipple and areolar areas, the shedding of tissue due to loss of blood supply, breast asymmetry, nipple necrosis, or flattening and hypertrophic or broad scars (Cuhaci et al. 2014). It is important to note that results are cosmetically unsatisfactory in 50% of patients (Bembo and Carlson 2004).

---

## Gynecomastia in Prostate Cancer

Because androgen deprivation is one of the commonly used treatment modalities for advanced prostate cancer, its possible role in the development of gynecomastia is of particular concern to clinicians. Up to 80% of patients receiving nonsteroidal antiandrogen therapy may develop gynecomastia, usually 6–9 months after hormonal treatment (Swerdloff and Ng 2015). The prevalence in males treated with antiandrogen monotherapy is high because drugs are used at high doses (e.g., 150 mg/day bicalutamide), whereas the prevalence is only 15% in males receiving antiandrogen and GnRH analog combination therapy, where the bicalutamide dose is 50 mg/day. In these patients, the effectiveness of medical treatment and irradiation (RT) is limited when gynecomastia occurs. The aim of the treatment is therefore to prevent breast development with antiestrogens or RT.

Tamoxifen has been proven to be effective in prostate cancer patients receiving high-dose bicalutamide. Tamoxifen must be continued throughout the antiandrogen therapy, since its effects do not persist after it has been discontinued. Current data suggest tamoxifen 10–20 mg per day is the optimum dose required for prophylaxis of gynecomastia in patients with prostate cancer receiving androgen deprivation therapy. Anastrozole also reduced antiandrogen-related gynecomastia, but was less effective than tamoxifen.

In several studies, prophylactic RT was found to be effective in preventing gynecomastia and mastodynia in patients with prostate cancer (Bembo and Carlson 2004; Carlson 2011). However, although the high radiation doses may improve pain, they are less effective in reducing the volume of the tissue. Nevertheless, concomitant therapy with tamoxifen may be more effective than prophylactic RT alone in patients receiving a high dose (150 mg/day) of bicalutamide alone after radical prostatectomy (Carlson 2011). However, it must be noted that tamoxifen can modulate the effects of antiandrogen therapy.

## Summary

Gynecomastia is defined clinically as generalized enlargement of male breast tissue, with the presence of a rubbery or firm mass extending concentrically and symmetrically from the nipple, accompanied by histopathologically benign proliferation of glandular male breast tissue. A related condition, pseudogynecomastia or lipomastia, manifests as fat deposition without glandular proliferation and occurs most frequently in obese men.

Physiological gynecomastia, occurring in almost 25% of cases, is benign and self-limited; on the other hand, several conditions and drugs may induce proliferation of male breast tissue. True gynecomastia is a common feature often related to estrogen excess and/or androgen deficiency as a consequence of different endocrine disorders. Nonendocrine illnesses, including liver failure and chronic kidney disease, are another cause of gynecomastia, which should be considered. Because gynecomastia causes anxiety, psychosocial discomfort, and a fear of breast cancer, patients seek medical attention and require diagnostic evaluation. Due to the diversity of etiologies, including neoplasm, performing a careful history and physical examination is imperative. Once gynecomastia has been diagnosed, treatment of the underlying cause is warranted. If no underlying cause is discovered, then close observation is appropriate. If gynecomastia is severe, however, medical therapy can be attempted, and if ineffective, glandular tissue can be removed surgically.

---

## Cross-References

- ▶ [Androgen Resistance](#)
- ▶ [Clinical Manifestation and Diagnosis of Androgen Deficiency](#)
- ▶ [Delayed Puberty](#)
- ▶ [Hypogonadism in Systemic Diseases](#)
- ▶ [Late-Onset Hypogonadism](#)
- ▶ [Primary and Secondary Hypogonadism](#)
- ▶ [Use, Misuse, and Abuse of Androgens](#)

---

## References

- Bannayan GA, Hajdu SI. Gynecomastia: clinicopathologic study of 351 cases. *Am J Clin Pathol.* 1972;57:431–7.
- Basaria S. Androgen abuse in athletes: detection and consequences. *J Clin Endocrinol Metab.* 2010;95(4):1533–43.
- Bembo SA, Carlson HE. Gynecomastia: its features, and when and how to treat it. *Cleve Clin J Med.* 2004;71(6):511–7.
- Birzniece V. Doping in sport: effects, harm and misconceptions. *Intern Med J.* 2015;45(3):239–48.
- Bowman JD, Kim H, Bustamante JJ. Drug-induced gynecomastia. *Pharmacotherapy.* 2012;32(12):1123–40.

- Braunstein GD. Aromatase and gynecomastia. *Endocr Relat Cancer*. 1999;6(2):315–24.
- Braunstein GD. Clinical practice. Gynecomastia. *N Engl J Med*. 2007;357(12):1229–37.
- Bravo ML, Pinto MP, Gonzalez I, Oliva B, Kato S, Cuello MA, Lange CA, Owen GI. Progesterone regulation of tissue factor depends on MEK1/2 activation and requires the proline-rich site on progesterone receptor. *Endocrine*. 2015;48(1):309–20.
- Brinton LA. Breast cancer risk among patients with Klinefelter syndrome. *Acta Paediatr*. 2011;100(6):814–8.
- Carlson HE. Approach to the patient with gynecomastia. *J Clin Endocrinol Metab*. 2011;96:15–21.
- Chentli F, Bekkaye I, Azzoug S. Feminizing adrenocortical tumors: literature review. *Indian J Endocrinol Metab*. 2015;19(3):332–9.
- Cuhaci N, Polat SB, Evranos B, Ersoy R, Cakir B. Gynecomastia: clinical evaluation and management. *Indian J Endocrinol Metab*. 2014;18(2):150–8.
- Di Luigi L, Romanelli F, Sgro P, Lenzi A. Andrological aspects of physical exercise and sport medicine. *Endocrine*. 2012;42(2):278–84.
- Dickson G. Gynecomastia. *Am Fam Physician*. 2012;85(7):716–22.
- Eren E, Edgunlu T, Korkmaz HA, Cakir ED, Demir K, Cetin ES, Celik SK. Genetic variants of estrogen beta and leptin receptors may cause gynecomastia in adolescent. *Gene*. 2014;541(2):101–6.
- Fagerlund A, Lewin R, Rufolo G, Elander A, Santanelli di Pompeo F, Selvaggi G. Gynecomastia: a systematic review. *J Plast Surg Hand Surg*. 2015;49(6):311–8.
- Farooqi IS, O'Rahilly S. 20 Years of leptin: human disorders of leptin action. *J Endocrinol*. 2014;223(1):T63–70.
- Ferreira M, Mesquita M, Quaresma M, Andre S. Prolactin receptor expression in gynecomastia and male breast carcinoma. *Histopathology*. 2008;53(1):56–61.
- Fodor PB. Breast cancer in a patient with gynecomastia. *Plast Reconstr Surg*. 1989;84:976–9.
- Gómez-Raposo C, Zambrana Tévar F, Sereno Moyano M, López Gómez M, Casado E. Male breast cancer. *Cancer Treat Rev*. 2010;36(6):451–7.
- Habib CN, Al-Abd AM, Tolba MF, Khalifa AE, Khedr A, Mosli HA, Abdel-Naim AB. Leptin influences estrogen metabolism and accelerates prostate cell proliferation. *Life Sci*. 2015;121(C):10–5.
- Iglesias P, Carrero JJ, Diez JJ. Gonadal dysfunction in men with chronic kidney disease: clinical features, prognostic implications and therapeutic options. *J Nephrol*. 2012;25(1):31–42.
- Jannini EA, Ulisse S, D'Armiento M. Thyroid hormone and male gonadal function. *Endocr Rev*. 1995;16(4):443–59.
- Johnson RE, Murad MH. Gynecomastia: pathophysiology, evaluation, and management. *Mayo Clin Proc*. 2009;84:1010–5.
- Johnson RE, Kermott CA, Murad MH. Gynecomastia—evaluation and current treatment options. *Ther Clin Risk Manag*. 2011;7:145–8.
- Jones DJ, Holt SD, Surtees P, Davison DJ, Coptcoat MJ. A comparison of danazol and placebo in the treatment of adult idiopathic gynecomastia: results of a prospective study in 55 patients. *Ann R Coll Surg Engl*. 1990;72:296–8.
- Lanfranco F, Kamischke A, Zitzmann M, Nieschlag E. Klinefelter's syndrome. *Lancet*. 2004;364(9430):273–83.
- Mathur R, Braunstein GD. Gynecomastia: pathomechanisms and treatment strategies. *Horm Res*. 1997;48(3):95–102.
- Matsumoto AM, Bremner WJ. Testicular disorders. In: *Williams Textbook of Endocrinology – 13th Edition*, S. Melmed, K.S. Polonsky, P. Reed Larsen, H.M. Kronenberg, Eds., Elsevier, Philadelphia; 2016: 1219–1233.
- Narula HS, Carlson HE. Gynecomastia—pathophysiology, diagnosis and treatment. *Nat Rev Endocrinol*. 2014;10(11):684–498.
- Ng ST, Zhou J, Adesanya OO, Wang J, LeRoith D, Bondy CA. Growth hormone treatment induces mammary gland hyperplasia in aging primates. *Nat Med*. 1997;3(10):1141–4.

- Nieschlag E, Vorona E. Mechanisms in endocrinology: medical consequences of doping with anabolic androgenic steroids: effects on reproductive functions. *Eur J Endocrinol*. 2015;173(2):R47–58.
- Rohrich RJ, Ha RY, Kenkel JM, Adams Jr WP. Classification and management of gynecomastia: defining the role of ultrasound-assisted liposuction. *Plast Reconstr Surg*. 2003;111:909–23.
- Rokutanda N, Iwasaki T, Odawara H, Nagaoka R, Miyazaki W, Takeshita A, Koibuchi Y, Horiguchi J, Shimokawa N, Iino Y, Morishita Y, Koibuchi N. Augmentation of estrogen receptor-mediated transcription by steroid and xenobiotic receptor. *Endocrine*. 2008;33(3):305–16.
- Sansone A, Romanelli F, Sansone M, Lenzi A, Di Luigi L. Gynecomastia and hormones. *Endocrine*. 2017;55(1):37–44.
- Simon BE, Hoffman S, Kahn S. Classification and surgical correction for gynecomastia. *Plast Reconstr Surg*. 1973;51:48.
- Sinclair M, Grossmann M, Gow PJ, Angus PW. Testosterone in men with advanced liver disease: abnormalities and implications. *J Gastroenterol Hepatol*. 2015;30(2):244–51.
- Sloand E. Pediatric and adolescent breast health. *Lippincotts Prim Care Pract*. 1998;2(2):170–5.
- Stevenson SM, Lowrance WT. Epidemiology and diagnosis of testis cancer. *Urol Clin N Am*. 2015;42(3):269–75.
- Swerdloff RS, Ng JCM. Gynecomastia: etiology, diagnosis, and treatment. In: De Groot LJ, Chrousos G, Dungan K, Feingold KR, Grossman A, Hershman JM, Koch C, Korbonits M, McLachlan R, New M, Purnell J, Rebar R, Singer F, Vinik A, editors. *Endotext* [Internet]. South Dartmouth: MDText.com, Inc.; 2015. 2000-. Available from <http://www.ncbi.nlm.nih.gov/books/NBK279105/>

Giulia Rastrelli and Gianni Forti

---

## Abstract

Testosterone (T) levels progressively declines with aging. Symptoms of androgen deficiency are not specific and often overlap with those related to aging. Hence, it is difficult to identify and define late-onset hypogonadism (LOH). The definition of LOH and its clinical significance is a matter of debate as well as the strategies of treating this condition. During the last years, the data produced by the European Male Ageing Study (EMAS) greatly helped in advancing the knowledge on LOH.

In the European general population, LOH has been defined as the presence of low T associated with three sexual symptoms. Thus defined, LOH specifically identifies a condition characterized by the classical features of androgen deficiency. However, according to the EMAS data, LOH is not a homogeneous condition. In fact, a moderate and a severe form, respectively characterized by moderate (8–11 nmol/L) or severe (<8 nmol/L) low T levels, can be identified. Severe LOH is more strongly associated with symptoms and signs of androgen deficiency, thus probably representing a more genuine form of LOH. In European general population, T levels are lower as BMI increases and, accordingly, prevalence of LOH is significantly higher in obese men. In the EMAS study, LOH has been associated also with an increased all-cause and CV mortality and, also in this

---

G. Rastrelli

Sexual Medicine and Andrology Unit, Department of Experimental and Clinical Biomedical Sciences, University of Florence, Florence, Italy

e-mail: [giulia.rastrelli@gmail.com](mailto:giulia.rastrelli@gmail.com)

G. Forti (✉)

Endocrinology Unit, Department of Experimental and Clinical Biomedical Sciences, University of Florence, Florence, Italy

e-mail: [gianni.forti@unifi.it](mailto:gianni.forti@unifi.it)

case, severe LOH exhibits the strongest relationship. The evidence that, similarly to LOH, also sexual symptoms and total T < 8 nmol/L are associated, independently of each other, with an increased mortality complicates the interpretation of the clinical significance of LOH. In fact, at present, it is not clear whether LOH should be considered a pathologic condition, with consequences for well-being and quality of life as well as for general and CV health, or whether it is an epiphenomenon of poor health, representing a marker of frailty, rather than a causing condition. Pending long-term, adequately powered, and designed RCTs, it is unclear whether TRT is useful and beneficial in subjects with LOH and the treatment should be undertaken after comparing possible risks and benefits in each patient and monitoring the onset of side effects, according to the available guidelines.

### Keywords

Testosterone • Sexual symptoms • Late-onset hypogonadism • Age • Obesity • Comorbidities • Mortality

### Contents

Introduction .....	922
Late-Onset Hypogonadism: Definition and Epidemiology .....	924
Risk Factors for T Decline .....	927
Evidence from Epidemiological Studies .....	927
Mechanisms Involved in the Glycometabolic Metabolism Derangements-Induced Hypogonadism .....	929
Evidence for Remission from Obesity-Related Secondary Hypogonadism .....	931
Testosterone and Sexual Behavior: Preclinical Data .....	931
Clinical Significance of LOH: Sexual Symptoms .....	933
Low Testosterone and Mortality .....	936
Summary .....	937
References .....	938

### Introduction

The growing interest in preventive interventions and continuous research in the pharmacological field have led to a meaningful progression in management of chronic illnesses, which in turn extends human life expectancy. The life expectancy of men at birth in Europe has increased from 68 years in 1990 to 73 years in 2013 (WHO <http://apps.who.int/gho/data/view.main.690?lang=en>). This imposes the problem of managing an aging male population for both the treatment of chronic illnesses and maintenance or improvement in quality of life. Testosterone (T) is a hormone with a wide range of functions in male. During fetal life and puberty, T is the major hormone responsible for induction of the male phenotype; during adulthood, it maintains male characteristics and preserves muscle mass, thus inducing physical strength and endurance; it is involved in mood modulation and cognitive



performance; and it has a stimulatory effect on all phases of the sexual response, including desire, arousal, erection, orgasm, and ejaculation. These functions make T a possible candidate for being involved in maintenance and improvement of quality of life in aging men.

Several epidemiological cross-sectional studies on the general population have evaluated the age trends in sex hormone levels in men (Wu et al. 2008; Feldman et al. 2002; Harman et al. 2001; Morley et al. 1997; Shi et al. 2013). Similar to studies conducted in the USA and Australia (Feldman et al. 2002; Harman et al. 2001; Morley et al. 1997; Shi et al. 2013), data from the European Male Ageing Study (EMAS), a population-based study involving more than 3,000 men, aged 40–79 years, randomly selected from general population of eight European countries, show that total T declines with age (Wu et al. 2008). After the age of 40 years, sex hormone binding globulin (SHBG) progressively increases thus leading to an age-dependent reduction in free T (the proportion of T unbound to SHBG) that is more pronounced than that observed for total T (Wu et al. 2008). However, the decline in T levels is modest, being 0.4% and 1.3% yearly for total and free T, respectively. The limited extent of T fall can be at least partially explained by the increase in luteinizing hormone (LH) levels that is observed during aging. Aging induces several modifications of testicular histology, including the reduction in Leydig cells amount (Liao et al. 1993; Deslypere and Vermeulen 1984) and functional studies, using positron emission tomography, have shown that, after the age of 65 years, testicular uptake of (Dohle et al. 2015) F-fluorodeoxyglucose slightly declines (Well et al. 2007). Conversely, histology characteristics of the pituitary in aging men were not different from those of younger ones (Sano et al. 1993) and also the secretion of LH after gonadotropin-releasing hormone (GnRH) infusion did not differ in younger and older men (Mulligan et al. 1999). These observations suggest that testicular steroidogenic activity is progressively and negatively affected by age but this process is accompanied by a hypothalamic-pituitary response that is not blunted by age and the increase in LH levels, consequent to T reduction, is able to compensate, although not invariably, the testis failure. The hypothalamic-pituitary-testis (HPT) axis feedback mechanism is often sufficiently efficient to maintain T levels within the normal range, whereas a fall below the lower limit is relatively uncommon. Besides aging and independently from it, other factors can affect T levels and, among them, probably the most important role is played by obesity. In the EMAS population, T levels decline according to the classes of BMI with a fall that is more pronounced than that associated with ageing (Wu et al. 2008). In contrast with the aging process, the reduction in T in overweight and obese men is not associated with an increase in LH (Wu et al. 2008). This pattern, that is consistent with the definition of secondary hypogonadism (Tajar et al. 2010), suggests an impairment of hypothalamus and/or pituitary. The clinical relevance of low T levels in adult males is still unknown and several research efforts have been made during the last decades for understanding whether or not low T levels in adult and older men require medical care and/or treatment.

## Late-Onset Hypogonadism: Definition and Epidemiology

The term late-onset hypogonadism (LOH) refers to the status of androgen deficiency, which develops in adulthood. Its definition is still strongly debated and, consequently, its prevalence is inconsistently reported. Formerly, it was identified according to a biochemical criterion and the normal range for T values in adult and aging men was assimilated to that of healthy young men. Based on this biochemical definition, the prevalence of LOH in general population was estimated by different population-based studies. In the Baltimore Longitudinal Study on Aging (BLSA), involving men older than 20 years, the overall prevalence of hypogonadism, as defined by total T < 11.3 nmol/L, was about 15%, with a rate of about 20%, 30%, and 50% among men over 60, 70, and 80 years, respectively (Harman et al. 2001). Later data from the Massachusetts Male Ageing Study (MMAS), recruiting more than 1700 men aged 40–70 years, showed a similar prevalence of low T, with 14% of the population having total T lower than 10.4 nmol/L (Araujo et al. 2007). A higher frequency of total T < 10.4 nmol/L was reported in the Boston Area Community Health (BACH) Survey. In this study, involving more than 2,300 men aged 30–70 years, low T was found in 24% of the population that, differently from that included in the MMAS and BLSA studies, was composed of White, Black, and Hispanic men in similar rates (Araujo et al. 2007). In the European population observed in the EMAS, the prevalence of T below 10.5 nmol/L was 16% (Tajar et al. 2010), aligning with US studies enrolling a population with similar characteristics (Harman et al. 2001; Araujo et al. 2007). However, it has become apparent that the diagnosis of LOH only according to a biochemical criterion is not satisfactory. In fact, the normal range for T is still derived from levels found in healthy young men and age-specific values have not yet been defined. Based on the aforementioned data from the general population, healthy older men could have lower T levels than younger ones, but this biochemical finding is not invariably associated with disturbances. In addition, it is still not clear which threshold value for T is associated with increased probability of reporting androgen deficiency symptoms and signs. In fact, several symptoms and signs have been associated with low circulating T levels (Table 1), but they are not specific to androgen deficiency, being highly prevalent in adult men also when T levels are within the normal range (Wu et al. 2010; Rastrelli et al. 2015). For these reasons, it is now believed that LOH should be diagnosed when both low T levels and clinical features suggestive of androgen deficiency are found. This aspect is now recognized by most of the guidelines for management of LOH (Wang et al. 2009; Bhasin et al. 2010; Dohle et al. 2015). The guidelines recognize the necessity of both biochemical and clinical criteria for diagnosis of LOH, but they do not agree on the threshold of T to be used. In addition, they do not univocally and precisely indicate which clinical features should be regarded consequent to hypoandrogenism. The International Society of Andrology (ISA), the International Society for the Study of Aging Male (ISSAM), the European Association of Urology (EAU), the European Academy of Andrology (EAA), and the American Society of Andrology (ASA) recommend to consider the diagnosis of LOH when total T is below 8 nmol/L or within 8 and

**Table 1** Symptoms and signs of hypogonadism reported by the guidelines of the International Society of Andrology (ISA), International Society for the Study of Aging Male (ISSAM), European Association of Urology (EAU), European Academy of Andrology (EAA), American Society of Andrology (ASA) (Wang et al. 2009), the Endocrine Society (Bhasin et al. 2010), and the EAU (Dohle et al. 2015). According to the guidelines, testosterone levels should be assessed in subjects with these symptoms and signs and diagnosis of late onset hypogonadism should be done if total and/or free testosterone is low

	ISA, ISSAM, EAU, EAA, and ASA (Wang et al. 2009)	Endocrine Society (Bhasin et al. 2010)	EAU (Dohle et al. 2015)
<b>Symptoms</b>			
<b>Sexual</b>	Low libido Erectile dysfunction	Reduced sexual desire <sup>a</sup> Reduced sexual activity <sup>a</sup> Decreased spontaneous morning erections <sup>a</sup>	Reduced sexual desire Reduced sexual activity Erectile dysfunction Fewer and diminished nocturnal erections
<b>Psychological</b>	Decreased vitality Depressed mood	Decreased energy Decreased motivation Decreased initiative Decreased self-confidence Depressed mood Feeling sad or blue Dysthymia Poor concentration and memory	Fatigue Changes in mood Anger
<b>Other</b>		Sleep disturbance Increased sleepiness Hot flushes, sweats <sup>a</sup> Breast discomfort <sup>a</sup>	Sleep disturbances Hot flushes
<b>Signs</b>			
<b>Primary and secondary sexual characteristics</b>		Gynecomastia <sup>a</sup> Testis hypotrophy <sup>a</sup> Infertility <sup>a</sup> Oligo-azoospermia <sup>a</sup> Reduced body hair and frequency of shaving <sup>a</sup>	Gynecomastia Small testes Male-factor infertility Decreased body hair
<b>Bone</b>	Decreased bone mineral density Osteoporosis	Height loss <sup>a</sup> Low trauma fracture <sup>a</sup> Low bone mineral density <sup>a</sup>	Low trauma fractures Decrease in bone mineral density (osteoporosis)

(continued)

**Table 1** (continued)

	ISA, ISSAM, EAU, EAA, and ASA (Wang et al. 2009)	Endocrine Society (Bhasin et al. 2010)	EAU (Dohle et al. 2015)
<b>Muscle mass</b>	Decreased muscle mass Decreased muscle strength	Reduced muscle bulk and strength Diminished physical or work performance	Decrease in lean body mass and muscle strength
<b>Fat mass</b>	Increased body fat	Increased body fat	Visceral obesity
<b>Other</b>		Mild anemia	Metabolic syndrome Insulin resistance and type 2 diabetes mellitus Diminished cognitive function

<sup>a</sup>The Endocrine Society reports these symptoms and signs as the most specific to androgen deficiency

12 nmol/L and free T is below 225 pmol/L (Wang et al. 2009). Similar thresholds are recommended by the EAU guidelines which, however, suggest the threshold of 243 pmol/L for free T (Dohle et al. 2015). The Endocrine Society indicates for total T a threshold between 9.8 and 10.4 nmol/L and for free T between 170 and 310 pmol/L when measured in qualified laboratories (Bhasin et al. 2010). The three guidelines agree on the necessity of repeating the measurement of T, since in 30–50% of subjects a mild reduction in circulating T is not confirmed by a second assessment (Brambilla et al. 2007; Swerdloff et al. 2000). Furthermore, when repeatedly measured during 24 h, T has been found below the lower limit of the normal range in several measurements even in healthy young men (Swerdloff et al. 2000). In addition, since serum T levels exhibit a circadian rhythm, with a peak in the morning (Swerdloff et al. 2000; Bremner et al. 1983), it is recommended to measure T on samples obtained before 11 am.

Based on different thresholds of T and different clinical features studied in general population, several definitions of LOH have been provided. According to the MMAS, LOH is defined for total T < 7 nmol/L or total T within 7 and 14 nmol/L with free T < 310 pmol/L in presence of at least three symptoms and signs of androgen deficiency (Araujo et al. 2004). Using this definition, a mean prevalence of 6% was found in a population of more than 1000 men (Araujo et al. 2004). A similar prevalence was also observed in a population of 1475 men involved in the BACH study, where LOH was defined for total and free T below 10.4 nmol/L and 170 pmol/L, respectively, with at least one clinical feature deemed as specific, such as low libido, ED, or osteoporosis, or two or more features with lower specificity, including sleep disturbances, depressed mood, lethargy, or low physical performance (Araujo et al. 2007). More recently, in the EMAS population, a systematic and analytical approach was used for producing a definition of LOH (Wu et al. 2010). Starting from a large set of possible candidate symptoms of hypogonadism, only

nine (three sexual, three physical, and three psychological) demonstrated an association with low T, being both total and free T significantly lower in symptomatic than asymptomatic men. Among these symptoms, only sexual ones [erectile dysfunction (ED), decreased sexual thoughts and decreased morning erections] and one of the physical ones (limited physical vigor) demonstrated a nonlinear threshold relationship with total and free T, thus indicating values below which the prevalence of the symptom steeply increases. These thresholds are different for each symptom, ranging from 13 to 8 nmol/L of total T and from 280 to 160 pmol/L of free T, thus confirming that different functional thresholds exist for various androgen-dependent conditions (Zitzmann et al. 2006; Bhasin et al. 2005; Gray et al. 2005). In this study, it has been also demonstrated that sexual symptoms, but not physical or psychological ones, cluster with low T levels (total T < 8 nmol/L or total T < 11 nmol/L and free T < 220 pmol/L) as a syndromic aggregate. Based on these data, LOH is defined as the simultaneous presence of total T < 11 nmol/L and free T < 220 pmol/L with at least three sexual symptoms (Wu et al. 2010). According to the EMAS parsimonious clinical and biochemical diagnostic criteria, the overall LOH prevalence was 2.1% (Wu et al. 2010), i.e. lower than that reported in the MMAS (Araujo et al. 2004) and BACH survey (Araujo et al. 2007). In the EMAS population, the prevalence of LOH increased with age, being 0.1%, 0.6%, 3.2%, and 5.1% in men aged 40–49, 50–59, 60–69, and 70–79 years, respectively. The specificity of the cluster of sexual symptoms, more than the presence of a single symptom, has been also recognized in a population of almost 5000 subjects seeking medical care for sexual dysfunction, which showed that both total and free T have a higher accuracy in detecting men with two or three sexual symptoms than those reporting only one of them (Rastrelli et al. 2016). In this population of symptomatic men, LOH, as defined for total T < 10.4 nmol/L or free T < 225 pmol/L and at least two sexual symptoms, has a prevalence of 4.8% (Rastrelli et al. 2016).

---

## Risk Factors for T Decline

### Evidence from Epidemiological Studies

Besides aging, testicular function is negatively affected by several different risk factors. In the EMAS population, the presence of at least one chronic illness was associated with hypogonadism (Tajar et al. 2010). Several chronic diseases associated with low T levels (Table 2) should be investigated and treated, as, according to the ISA/ISSAM/EAU/EAA/ASA, the Endocrine Society, and the EAU guidelines (Wang et al. 2009; Bhasin et al. 2010; Dohle et al. 2015) limited information is available on the effects and risks of T replacement therapy (TRT) in these conditions. Mechanisms leading to hypogonadism in chronic diseases are not fully understood. Cytokines are deemed as the most probable mediators of HPT axis impairment. In particular, several data show that tumor necrosis factor- $\alpha$  (TNF- $\alpha$ ), that is increased in several systemic diseases, can impair testis responsiveness to gonadotropins (van der Poll et al. 1993; Hong et al. 2004). In addition, TNF- $\alpha$  together with other

**Table 2** Chronic diseases and conditions for whom the guidelines recommend the assessment of testosterone levels, known the high prevalence of hypogonadism associated with these disorders

ISA, ISSAM, EAU, EAA, and ASA (Wang et al. 2009)	Endocrine Society (Bhasin et al. 2010)	EAU (Dohle et al. 2015)
	Sellar mass <sup>a</sup> Radiation to the sellar region Other diseases of the sellar region	Pituitary mass Radiation involving the sellar region Other diseases in the hypothalamic and sellar region
	Treatment with medications that affect testosterone production or metabolism, (e.g., glucocorticoids and opioids) <sup>a</sup>	Treatment with medications that cause suppression of testosterone levels (e.g., corticosteroids and opiates)
	Infertility	Infertility
HIV-related diseases	HIV-associated weight loss <sup>a</sup>	HIV infection with sarcopenia
Renal-related diseases	End-stage renal disease Maintenance hemodialysis	End-stage renal disease receiving hemodialysis
Chronic obstructive lung disease	Moderate to severe chronic obstructive lung disease	Moderate to severe chronic obstructive lung disease
Inflammatory arthritis		
Hemochromatosis		
	Osteoporosis Low-trauma fracture <sup>a</sup>	Osteoporosis Low-trauma fractures
Diabetes mellitus	Type 2 diabetes mellitus	Type 2 diabetes mellitus
Obesity		Obesity
Metabolic syndrome		Metabolic syndrome

<sup>a</sup>For these conditions, the Endocrine Society recommends assessment of testosterone levels even in absence of androgen deficiency symptoms

ISA International Society of Andrology, ISSAM International Society for the Study of Aging Male, EAU European Association of Urology, EAA European Academy of Andrology, ASA American Society of Andrology

cytokines, such as IL-6 and IL-8, can induce a deregulation in GnRH-gonadotropin secretion (Morelli et al. 2014).

Metabolic syndrome (MetS) is a diagnostic category defined by the concomitant presence of several derangements, such as central obesity, dyslipidemia, hyperglycemia, and hypertension, conferring a higher risk for developing metabolic and cardiovascular diseases. Several cross-sectional observations have shown that MetS is associated with low T levels, and, in particular, a meta-analysis of cross-sectional studies found that total T is about 3 nmol/L lower in men with MetS than in those without (Corona et al. 2011a). In the Kuopio Ischemic Heart Disease Risk Factor Study, a prospective population-based study involving almost 700 Finnish middle-aged men followed-up for 11 years, the presence of MetS in eugonadal subjects at baseline or the development of MetS during follow-up predicted the decrease of total T below 11 nmol/L (Laaksonen et al. 2005). Among the MetS components, glucose and waist circumference, as well as insulin, were risk factor for

the decline in T levels (Laaksonen et al. 2005). The predictive effect of hyperglycemia and central obesity has also been confirmed in a large population of men seeking medical care for sexual dysfunction (Corona et al. 2011b, 2012a). The inverse association between T and hyperglycemia is well known. Cross-sectional studies have shown that hypogonadism is significantly more prevalent in men with type 2 diabetes mellitus (T2DM) (Ding et al. 2006; Corona et al. 2008a, . 2009a) and the role of T2DM as a risk factor for decreasing T levels has been documented in prospective studies on general population (Laaksonen et al. 2005; Corona et al. 2009a; Derby et al. 2006; Rodriguez et al. 2007).

Obesity, and in particular central obesity, is an important risk factor for hypogonadism. Data from longitudinal studies have shown that overweight and obesity are associated with a significant decline in T levels (Tajar et al. 2010; Derby et al. 2006; Camacho et al. 2013). In the EMAS (Wu et al. 2008), T levels in obese men were respectively of 5 nmol/L and 55 pmol/L lower than normal-weight men. Contrary to what happens in the age-related T decline, low T associated with obesity is not accompanied by high LH levels (Wu et al. 2008). This biochemical feature is consistent with the definition of secondary hypogonadism, which is characterized by a reduction in T levels that is not accompanied by an appropriate compensatory increase in LH. Secondary hypogonadism is the most frequent form of hypogonadism both in the general population (Tajar et al. 2010) and in patients attending an Outpatient Clinic for sexual dysfunction (Corona et al. 2014a). In the longitudinal assessment of the EMAS cohort, its incidence was 6.3% during 4.3 years of follow-up, corresponding to a yearly rate of 1.6% (Rastrelli et al. 2015). The development of secondary hypogonadism was predicted by weight gain, baseline body mass index (BMI) above 30 kg/m<sup>2</sup>, and baseline waist circumference above 94 cm (Rastrelli et al. 2015), thus confirming the important role of obesity as a risk factor for hypogonadism.

## **Mechanisms Involved in the Glycometabolic Metabolism Derangements-Induced Hypogonadism**

### **Glucose Metabolism**

Hyperinsulinemia is one of the metabolic derangements linking hyperglycemia and T2DM with hypogonadism. GnRH neurons express insulin receptors (Salvi et al. 2005) and selective neuronal knockout mice for these receptors show an increased body mass and hypogonadotropic hypogonadism (Bruning et al. 2000), thus suggesting a role of insulin in regulating HPT axis. Accordingly, in mice, the use of increasing doses of insulin for performing a hyperinsulinemic clamp led to an increase in circulating LH levels (Burcelin et al. 2003). In addition, *in vitro* insulin treatment of GnRH neurons induces a dose-dependent secretion of GnRH (Gamba and Pralong 2006). However, besides hyperinsulinemia, hyperglycemia itself can play a direct downregulating role on HPT axis function. In an animal model of MetS induced by a high fat diet, hyperglycemia was associated with lower T and gonadotropins and with an increased hypothalamic expression of GLUT4, one of the

membrane glucose transporters (Morelli et al. 2014). Hypothalamic GLUT4 transcription is, in turn, associated with lower T and gonadotropins as well as with higher expression of hypothalamic markers of inflammation (Morelli et al. 2014). The effect of hyperglycemia in the hypothalamus seems to be mediated, directly or indirectly, by Kiss1 neuron activity. In rats with diabetes induced by streptozotocin (a model of type 1 diabetes), both basal and postgonadectomy hypothalamic transcription of Kiss1 and serum LH levels are blunted (Castellano et al. 2006). Administration of kisspeptin to these diabetic rats can increase LH levels to those observed in the control group and, in the nongonadectomized animals, also T levels are restored (Castellano et al. 2006).

### **Adipokines and Cytokines**

Several mechanisms have been proposed for explaining the causative role of visceral obesity for hypogonadism. The insulin resistance that is associated with increased visceral fat and that, as aforementioned, has a detrimental role on the HPT axis represents one of them. Visceral fat can contribute to the pathogenesis of secondary hypogonadism also through the production of a large amount of adipokines and cytokines. One of the most studied is leptin, an adipokine whose circulating levels parallels the fat mass amount and mirrors the nutritional status, being higher after a meal (Yannakoulia et al. 2003; Boden et al. 1996). Leptin is involved in several functions, including insulin sensitization, regulation of the balance hunger-satiety, and regulation of HPT axis (Margetic et al. 2002; Garcia-Galiano et al. 2014). In animal models of genetic leptin deficiency, a secondary hypogonadism with lack of puberty is found (Farooqi, 2002). However, in obese men, leptin levels are low, rather than high, because a leptin resistance occurs (van Rossum et al. 2003; Banks 2001; Oswal and Yeo 2009). GnRH neurons do not express receptors for leptin and its action on them is mediated by other neurons, part of their regulatory network, such as Kiss1 neurons secreting kisspeptin (Smith et al. 2006), a molecule that, interacting with its receptor (GPR54) on the hypothalamus, stimulates the secretion of GnRH. Visceral obesity is also associated with increased circulating levels of TNF- $\alpha$  as well as IL-6 and IL-8. These inflammatory cytokines are putative mediators of hypothalamic derangements leading to secondary hypogonadism. In an animal model of MetS induced by a high fat diet, secondary hypogonadism was part of the phenotypical characteristics (Morelli et al. 2014). The hypothalamus of the rabbits showed molecular features of inflammation, including a hyper-expression of IL-6, IL-8, and COX2 as well as a macrophage infiltrate (Morelli et al. 2014). The expression of these inflammatory markers negatively correlated with circulating gonadotropins (Morelli et al. 2014). Furthermore, circulating TNF- $\alpha$  levels were increased and treatment with infliximab, an anti-TNF- $\alpha$  monoclonal antibody unable to cross the brain-blood barrier, prevented the development of the hypothalamic inflammatory infiltrate (Morelli et al. 2014).

### **Estrogens**

A further pathogenetic hypothesis for the obesity-related secondary hypogonadism is the hyper-expression of aromatase due to the expansion of the adipose tissue. This



would lead to increased circulating levels of estrogens, able to downregulate the HPT axis by the negative feedback on GnRH neuron activity. In line with this hypothesis, treating severely obese hypogonadal men with low dose of letrozole restored LH and T levels (Loves et al. 2008). Other observations disagree with this hypothesis, in fact both diabetic (Dhindsa et al. 2011) and nondiabetic (Tajar et al. 2010) obese men in comparison with normal weight controls, showed lower, rather than higher, estradiol levels, positively associated with T, but not BMI.

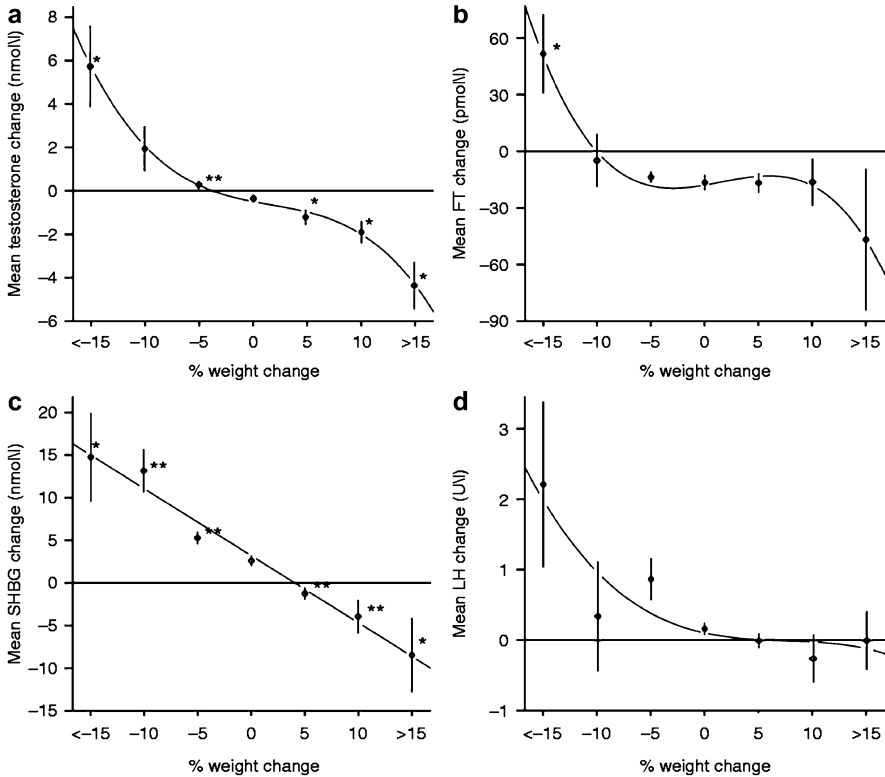
### **Evidence for Remission from Obesity-Related Secondary Hypogonadism**

Whatever the mechanism involved, obesity induces a derangement at hypothalamic-pituitary level, with a downregulation of the HPT axis. This is evident from the data obtained by the longitudinal observation of the EMAS cohort (Fig. 1; Camacho et al. 2013). In the European general population, increasing weight is associated with a decrease in total T without a compensatory increase in LH levels, which remain unchanged. On the other hand, weight loss is associated with an increase in total T that is accompanied by an increase in LH, thus suggesting a recovery of hypothalamic-pituitary function. Therefore, these data suggest that hypogonadism, in particular secondary hypogonadism, can remit. Accordingly, in the MMAS, a relevant rate of remission from LOH was observed. In fact, among 70 men meeting the definition of LOH, according to the MMAS criteria (low T levels with relevant symptoms; see above), 39 did not show the clinical characteristics of LOH at following evaluations, accounting for a remission rate of 55% (Travison et al. 2008). Of the remissions observed, approximately two-thirds were ascribable to an increase in T levels (above 14 nmol/L), whereas the remaining were due to the improvement of symptoms (Travison et al. 2008). The remission from hypogonadism was considered also in the EMAS population, where, during a follow-up of 4.3 years, 43% of men meeting the biochemical criteria for secondary hypogonadism (total < 10.5 nmol/L and LH < 9.4 UL) increased their total T level above 10.5 nmol/L (Rastrelli et al. 2015). Younger subjects, non-obese and those with a higher level of education more probably recovered from secondary hypogonadism. However, in these subjects, the normalization of gonadal status did not correspond to an improvement in symptoms associated with androgen deficiency (Rastrelli et al. 2015).

### **Testosterone and Sexual Behavior: Preclinical Data**

T is widely involved in modulating sexual behavior and function at both central and peripheral level.

*Sexual desire* is a feeling that leads animals to act behaviors that favor the opportunity to obtain sexual rewards (Pfaus 2009). The physiology of sexual desire is complex and still not completely understood. Several neurocircuitries are involved



**Fig. 1** Mean changes during 4.4 years of follow-up in total testosterone (Panel **a**), free testosterone (*FT*, Panel **b**), sex hormone binding globulin (*SHBG*, Panel **c**) and luteinizing hormone (*LH*, Panel **d**) in 2395 men involved in the European Male Ageing Study. The change in hormone levels is reported according to percentage of weight change during the follow-up. The cohort was stratified, according to increasing levels of weight gain or loss, into seven separate groups: loss of >15%, loss of 10–15%, loss of 5–10%, within 5%, gain of 5–10%, gain of 10–15%, and gain of >15% (This figure is reproduced from Camacho et al. (2013) in accordance to figure reproduction policy of the European Journal of Endocrinology)

with different neurotransmitters providing facilitating or inhibiting stimuli. Although different physiologic and pathologic conditions can affect sexual desire, the role of hormones is well established by animal models and human studies. Several brain areas, known to be involved in sexual behavior and response to sexual stimuli, such as amygdala, nucleus accumbens, medial preoptic area, paraventricular nucleus of the hypothalamus, and periaqueductal gray matter, express the androgen receptor (Rochira et al. 2003; Bancroft 2005) and the administration of T in the mediobasal hypothalamus is able to restore sexual behaviors in castrated male rats (Christensen and Clemens 1974; Smith et al. 1977). Consistently, male rats that have multiple ejaculations and reach the sexual satiation have a decreased expression of the androgen receptor in specific areas of the hypothalamus, such as the medial preoptic area and the nucleus accumbens (Fernandez-Guasti et al. 2003).

*Erectile function* is largely affected by the androgenic milieu. T is involved in development and maintenance of penile structures, in particular trabecular smooth muscle cells, and it is important for the neurosignaling at penile level, being the activity of the postganglionic parasympathetic neurons T-dependent (Isidori et al. 2014; Corona and Maggi, 2010). Furthermore, T can induce the expression of endothelial and neuronal nitric oxide (NO) synthases (e-NOS and n-NOS) and phosphodiesterase type 5 (PDE5) and downregulate the activity of Ras homolog gene family member/Rho-associated kinase (RhoA/ROCK) pathway, a calcium sensitizing mechanism acting within the penile smooth muscle cells (Isidori et al. 2014; Corona and Maggi 2010). Hence, T is involved in facilitating both the beginning (e-NOS, n-NOS, and RhoA/ROCK) and the end (PDE5) of the erectile mechanisms.

*Ejaculation* is the result of a reflex that arises from genital and/or brain stimulation. The spinal ejaculatory generator at the T12-L2 level of the spinal cord coordinates sexual stimuli (Corona et al. 2012b). Super-spinal nuclei, including the medial preoptic area, bed nucleus of the stria terminalis, median amygdala, and posterior thalamus, control the spinal ejaculatory generator (Corona et al. 2012b). The signal deriving from the information integrated by the spinal ejaculatory generator is transported by the sympathetic, parasympathetic, and motor nervous outflow leading to ejaculation (Corona et al. 2012b). These nervous impulses lead to the secretion of seminal fluid from the accessory glands of male genital tract (parasympathetic signaling), the contraction of epididymis, vas deferens, seminal vesicles and prostate (sympathetic signaling), and the rhythmic contractions of the pelvic floor muscles (motor signaling) (Corona et al. 2012b). These events lead to the expulsion of seminal fluid through the urethra and usually temporarily coincide with the orgasm. T is involved in this mechanism at several levels. The central nuclei that modulate the reflex express the androgen receptor (Corona et al. 2012b) and also the muscles of the pelvic floor are known to be androgen dependent (Corona et al. 2012b). Furthermore, the contractility of the genital tract is under the control of the NO-PDE5 system, which as aforementioned is regulated by T. Finally, the accessory glands produce the seminal bolus in a T-dependent fashion.

## **Clinical Significance of LOH: Sexual Symptoms**

The role of T in sexual function agrees with the epidemiological data of sexual symptoms as the most specific ones to low T levels (Wu et al. 2008).

In a population of more than 3700 subjects seeking medical care for sexual dysfunction, reduced sexual desire was reported by more than 40% of patients with total T below 12 nmol/L and there was a significant positive association between the severity of the symptom and the extent of T deficiency (Corona et al. 2013). The androgen-dependency of sexual desire was confirmed also in the European general population where both total and free T were associated with frequency of sexual thoughts (Wu et al. 2010; O'Connor et al. 2011). Low levels of total and free T were associated with the complaint of reduced sexual desire with a

steep increase of the prevalence of the symptom when total and free T fell below 8 nmol/L and 160 pmol/L, respectively (Wu et al. 2010).

In the EMAS population, a relationship between impairment of erectile function and free T levels was also found, although the magnitude of the effect was quite modest (O'Connor et al. 2011). However, the impact of T decline in prevalence of ED becomes more pronounced when total and free T drop below 8.5 nmol/L and 280 pmol/L, respectively (Wu et al. 2010), thus suggesting that the effect of T on erectile function occurs at relatively low concentrations above which a plateau is reached. The relatively modest association of ED with T was also apparent in a sample of almost 5000 patients consulting for sexual dysfunction. In fact, in this population with a high percentage of subjects with total T below 10.4 nmol/L (19.6%) or ED (72.2%), an association of ED with androgens was present only when considering severe ED, whereas milder complaints were T-independent (Rastrelli et al. 2016). The reason for a mild association between low T levels and ED, despite the importance of the hormone in the physiology of erection (see before), is probably due to the fact that T acts both on mechanisms that make erection start and finish. Accordingly, low T has a quite modest net impact on erection (Isidori et al. 2014; Corona and Maggi 2010). Since erection is mainly a vascular phenomenon, another possible explanation for the weak association between ED and T deficiency is that in ED patients with a predominant arteriopathic component, the vascular impairment masks the specific effect of T (Corona et al. 2008b).

Androgen deficient men shows ejaculatory difficulties with complaints ranging from longer ejaculatory times to anejaculation (Corona et al. 2011c). Moreover, also orgasmic capability has been associated with both total and free T levels in the EMAS population (Corona et al. 2010a).

Although T levels can affect sexual function, a wide range of different conditions can cause sexual disorders, as mirrored by their high prevalence in men with T within the normal range (Wu et al. 2010; Rastrelli et al. 2015; Rastrelli et al. 2016). By now, it is well known that ED is one of the possible manifestations of cardiovascular diseases (Corona et al. 2009a) and diabetes (Lue et al. 2000). Accordingly, in the EMAS population, a history of cardiovascular disease or T2DM, as well as obesity and smoking habits, was independent predisposing factors for ED (Corona et al. 2010a; Han et al. 2011). Beyond organic diseases, ED can occur also in subjects with psychiatric conditions (Corona et al. 2010a, 2012c), such as depression (Corona et al. 2010a; Bandini et al. 2010) and it can derive also from relational problems within the couple (Corona et al. 2010a; Boddi et al. 2012). Similarly, reduced sexual desire and ejaculatory or orgasmic impairment are multifactorial and can be caused by hormonal derangements other than low T, such as hyperprolactinemia and hypothyroidism (Corona et al. 2011c, 2012b, 2013;), psychiatric disorders and their pharmacological treatments (Corona et al. 2009b, 2013) as well as relational issues (Corona et al. 2013). Furthermore, all sexual disorders are affected by aging (Corona et al. 2010a) and their age-related increase in prevalence confounds the relationship with low T. Similar to sexual symptoms, physical, and psychological ones possibly related to low T levels increase their prevalence with aging. However,

sexual symptoms, more than physical and psychological ones, seem to be specifically related to low T levels, as demonstrated in a longitudinal evaluation on the EMAS population, which showed that the development of hypogonadism was associated with the new occurrence or worsening of sexual but not physical and psychological symptoms (Rastrelli et al. 2015). The greater specificity of sexual symptoms to low T has been confirmed in a recent randomized clinical trial involving 800 older hypogonadal men (Snyder et al. 2016). In this study, that is the first of the seven studies planned to determine whether testosterone replacement therapy (TRT) is beneficial in elderly men (Snyder et al. 2014), TRT provided for 12 months, as compared with placebo, significantly improved sexual symptoms, with a little or no results on physical and psychological outcomes (Snyder et al. 2016). For this reason using, as aforementioned, a definition of LOH taking into account not only T levels but also the presence of symptoms confers a greater specificity. In fact, the comparison of the extent of the association between low T or LOH (EMAS definition, see before) with putative androgen dependent symptoms and signs showed that both conditions are associated with impairment in physical performance, bone mineral density, hemoglobin, metabolic and anthropometric parameters, feelings of well-being, and quality of life, but the strength of the association is greater for LOH than for low T (Tajar et al. 2012). A further improvement in specificity of the definition is produced by reducing the threshold of T in the definition of low. In fact, when comparing men with three sexual symptoms with T levels moderately (total T 8–11 nmol/L) or severely (total T < 8 nmol/L) reduced, the impairment in perception of well-being, physical performance, bone mineral density, and hemoglobin, although present in both the categories, was more pronounced in severe LOH. Furthermore, a relationship with metabolic outcomes including glycaemia, insulinemia, and HOMA-IR was apparent only in the severe category (Antonio et al. 2016).

Recent evidence from the EMAS study has underlined the importance of free T in the diagnosis of LOH. Free T is associated with symptoms of androgen deficiency (Wu et al. 2010; Antonio et al. 2016), as well as with reduction of lean mass and bone mineral density (Antonio et al. 2016) even when total T is within the normal range (Antonio et al. 2016). On the other hand, subjects with low total T and normal free T were not characterized by symptoms and signs of androgen deficiency (Antonio et al. 2016), thus suggesting that free T is a more specific marker of androgen deficiency.

Available data suggest that T is involved in several physiologic functions and its decline can be a possible cause of the impairment in these functions. However, not only T levels can affect sexual, physical, psychological and metabolic function, especially in ageing men in whom different risk factors intertwine in complex pathogenic mechanisms. Recognizing low T as a possible cause is important because TRT can improve sexual symptoms, body composition, and metabolic profile, as shown by meta-analyses of randomized clinical trials (Corona et al. 2016) which must be confirmed in specifically designed studies. For this reason, it is pivotal to recognize appropriately men whose clinical picture is likely to be related to androgen deficiency. For this purpose, a good specificity is retained by the simultaneous

presence of sexual symptoms and severely reduced total T. When a milder reduction or normal total T is found, free T can provide useful and specific information for recognizing subjects with LOH.

## Low Testosterone and Mortality

The meta-analysis of the available longitudinal studies has shown that low T is associated with all-cause and cardiovascular (CV) mortality (Araujo et al. 2011; Corona et al. 2011d). In apparent contrast with these data, low T does not predict the occurrence of CV events (Corona et al. 2011d, e). However, when a CV event occurs, in subjects with low T levels it is more often lethal (Corona et al. 2010b, 2011d). In a longitudinal study on the EMAS population, subjects with LOH (low T levels and three sexual symptoms together) were at higher risk for CV and all-cause death, even after adjusting for other risk factors, such as age, smoking habits, and BMI (Pye et al. 2014). When dividing LOH into moderate or severe, according to T levels  $<8$  nmol/L or  $8\text{--}11$  nmol/L, both of them were associated with increased mortality, but severe LOH showed a stronger association (Pye et al. 2014). In the same study, the role of low T and sexual symptoms as predictors of all-cause and CV mortality was considered apart (Pye et al. 2014). Sexual symptoms demonstrated to be per se associated with increased mortality, whereas severe low T levels ( $<8$  nmol/L), but not moderate ( $8\text{--}11$  nmol/L), predicted significantly increased mortality. The pathiopathologic significance of these data is uncertain and several explanations can be provided. T has a role in regulation of vasomotion and hemostasis and it is an anti-inflammatory factor (Corona et al. 2011e). All these mechanisms are involved in the balance between protection and formation of atherosclerotic plaques. Therefore, the decline in T could compromise this balance leading to an acceleration of the atherosclerotic process. Accordingly, in animal models, TRT demonstrated to restrain the fat storage in the arterial wall and to limit the restenosis postangioplasty (Nettlehip et al. 2007; Tharp et al. 2009). Based on this evidence, a direct role of low T in inducing CV mortality can be hypothesized. The effect of low T could be also indirect, possibly mediated by obesity, insulin resistance, and related metabolic derangements that can be induced by low T (Corona et al. 2011a, 2011f). However, either a direct or an indirect effect of T would assume that not only CV mortality but also events would be associated with hypogonadism and even the associated all-cause mortality is not likely to be the consequence of androgen deficiency. Another possible hypothesis is that hypogonadism is an epiphenomenon of pre-existing diseases and a marker of poor health that are per se associated with an increased mortality. In subjects with poor health, low T can take on a further, different meaning. In fact, in subjects with sexual dysfunction, low T is associated with incidence of CV events in normal-weight subjects, but not in overweight ones, and in obese men, it even represents a protective factor (Corona et al. 2011g). Similarly, in subjects with sexual dysfunction at high CV risk, such as those with a

history of a previous event, low T shows a protective role toward the occurrence of a new CV event (Corona et al. 2014b). These data suggest that low T can be regarded as a mechanism for protecting men with ill-health conditions from wasting energies on unnecessary functions, such as sexuality and fertility. Switching-off these physiologic activities can decrease the energy expense in favor of other essential functions with a mechanism that is analog to the low triiodothyronine syndrome.

Understanding the physiopathologic meaning of the androgen deficiency-related mortality is pivotal because if T has an effect, either direct or indirect, TRT would be beneficial. Conversely, if low T is a compensatory protective mechanism in frail men, TRT would be dangerous.

---

## Summary

The definition and clinical significance of LOH is matter of debate as well as the opportunity of treating this condition. In fact, symptoms and signs commonly associated with low T levels are not specific and overlap with clinical features typical of the physiological processes of aging. During the last years, a large amount of data have been produced by the EMAS study which showed that, in the European general population, low T associated with three sexual symptoms specifically identifies a condition of symptomatic androgen deficiency that is characterized by a higher risk of impaired physical vigor, low bone mineral density and hemoglobin, reduced feeling of well-being and quality of life, and impaired metabolic parameters (Tajar et al. 2012). However, according to the EMAS data, LOH is a condition characterized by different degrees of severity according to T levels that can be moderately (8–11 nmol/L) or severely (<8 nmol/L) reduced (Tajar et al. 2012). LOH with severely reduced T levels is more strongly associated with symptoms and signs of androgen deficiency as well as with impaired glycometabolic parameters. Hence, severe LOH probably represents a more genuine form of androgen deficiency. In the EMAS study, LOH has been associated also with an increased all-cause and CV mortality and, also in this case, severe LOH exhibits the strongest relationship (Pye et al. 2014). The evidence that, similarly to LOH, also sexual symptoms and total T <8 nmol/L are associated, independently of each other, with an increased mortality complicates the interpretation of the clinical significance of these data. In fact, at present, it is not clear whether LOH should be considered a pathologic condition, with consequences for well-being and quality of life as well as for general and CV health, or whether it is an epiphenomenon of poor-health, representing a marker of frailty, rather than a causing condition. Pending long-term, adequately powered, and designed RCTs, it is unclear whether TRT is useful and beneficial in subjects with LOH and the treatment should be undertaken after comparing possible risks and benefits in each patient and monitoring the onset of side effects, according to the available guidelines (Wang et al. 2009; Bhasin et al. 2010; Dohle et al. 2015).

## References

- Antonio L, Wu FC, O'Neill TW, Pye SR, Ahern TB, Laurent MR, Huhtaniemi IT, Lean ME, Keevil BG, Rastrelli G, Forti G, Bartfai G, Casanueva FF, Kula K, Punab M, Giwercman A, Claessens F, Decallonne B, Vanderschueren D, EMAS Study Groupdagger. Low free testosterone is associated with hypogonadal signs and symptoms in men with normal total testosterone. *J Clin Endocrinol Metab.* 2016;101:2647–57.
- Araujo AB, O'Donnell AB, Brambilla DJ, Simpson WB, Longcope C, Matsumoto AM, McKinlay JB. Prevalence and incidence of androgen deficiency in middle-aged and older men: estimates from the Massachusetts Male Aging Study. *J Clin Endocrinol Metab.* 2004;89:5920–6.
- Araujo AB, Esche GR, Kupelian V, O'Donnell AB, Travison TG, Williams RE, Clark RV, McKinlay JB. Prevalence of symptomatic androgen deficiency in men. *J Clin Endocrinol Metab.* 2007;92:4241–7.
- Araujo AB, Dixon JM, Suarez EA, Murad MH, Guey LT, Wittert GA. Clinical review: endogenous testosterone and mortality in men: a systematic review and meta-analysis. *J Clin Endocrinol Metab.* 2011;96:3007–119.
- Bancroft J. The endocrinology of sexual arousal. *J Endocrinol.* 2005;186:411–27.
- Bandini E, Fisher AD, Corona G, Ricca V, Monami M, Boddi V, Balzi D, Melani C, Forti G, Mannucci E, Maggi M. Severe depressive symptoms and cardiovascular risk in subjects with erectile dysfunction. *J Sex Med.* 2010;7:3477–86.
- Banks WA. Leptin transport across the blood-brain barrier: implications for the cause and treatment of obesity. *Curr Pharm Des.* 2001;7:125–33.
- Bhasin S, Woodhouse L, Casaburi R, Singh AB, Mac RP, Lee M, Yarasheski KE, Sinha-Hikim I, Dzekov C, Dzekov J, Magliano L, Storer TW. Older men are as responsive as young men to the anabolic effects of graded doses of testosterone on the skeletal muscle. *J Clin Endocrinol Metab.* 2005;90:678–88.
- Bhasin S, Cunningham GR, Hayes FJ, Matsumoto AM, Snyder PJ, Swerdloff RS, Montori VM, Task Force, Endocrine Society. Testosterone therapy in men with androgen deficiency syndromes: an Endocrine Society clinical practice guideline. *J Clin Endocrinol Metab.* 2010;95:2536–59.
- Boddi V, Corona G, Fisher AD, Mannucci E, Ricca V, Sforza A, Forti G, Maggi M. “It takes two to tango”: the relational domain in a cohort of subjects with erectile dysfunction (ED). *J Sex Med.* 2012;9:3126–36.
- Boden G, Chen X, Mozzoli M, Ryan I. Effect of fasting on serum leptin in normal human subjects. *J Clin Endocrinol Metab.* 1996;81:3419–23.
- Brambilla DJ, O'Donnell AB, Matsumoto AM, McKinlay JB. Intraindividual variation in levels of serum testosterone and other reproductive and adrenal hormones in men. *Clin Endocrinol.* 2007;67:853–62.
- Bremner WJ, Vitiello MV, Prinz PN. Loss of circadian rhythmicity in blood testosterone levels with aging in normal men. *J Clin Endocrinol Metab.* 1983;56:1278–81.
- Bruning JC, Gautam D, Burks DJ, Gillette J, Schubert M, Orban PC, Klein R, Krone W, Muller-Wieland D, Kahn CR. Role of brain insulin receptor in control of body weight and reproduction. *Science.* 2000;289:2122–5.
- Burcelin R, Thorens B, Glauser M, Gaillard RC, Pralong FP. Gonadotropin-releasing hormone secretion from hypothalamic neurons: stimulation by insulin and potentiation by leptin. *Endocrinology.* 2003;144:4484–91.
- Camacho EM, Huhtaniemi IT, O'Neill TW, Finn JD, Pye SR, Lee DM, Tajar A, Bartfai G, Boonen S, Casanueva FF, Forti G, Giwercman A, Han TS, Kula K, Keevil B, Lean ME, Pendleton N, Punab M, Vanderschueren D, Wu FC, EMAS Group. Age-associated changes in hypothalamic-pituitary-testicular function in middle-aged and older men are modified by weight change and lifestyle factors: longitudinal results from the European male ageing study. *Eur J Endocrinol.* 2013;168:445–55.



- Castellano JM, Navarro VM, Fernández- Fernández R, Roa J, Vigo E, Pineda R, Dieguez C, Aguilar E, Pinilla L, Tena-Sempere M. Expression of hypothalamic KiSS-1 system and rescue of defective gonadotropic responses by kisspeptin in streptozotocin-induced diabetic male rats. *Diabetes*. 2006;55:2602–10.
- Christensen LW, Clemens LG. Intrahypothalamic implants of testosterone or estradiol and resumption of masculine sexual behavior in long-term castrated male rats. *Endocrinology*. 1974;95:984–90.
- Corona G, Forti G, Maggi M. Why can patients with erectile dysfunction be considered lucky? The association with testosterone deficiency and metabolic syndrome. *Aging Male*. 2008a;11:193–9.
- Corona G, Fagioli G, Mannucci E, Romeo A, Rossi M, Lotti F, Sforza A, Morittu S, Chiarini V, Casella G, Di Pasquale G, Bandini E, Forti G, Maggi M. Penile doppler ultrasound in patients with erectile dysfunction (ED): role of peak systolic velocity measured in the flaccid state in predicting arteriogenic ED and silent coronary artery disease. *J Sex Med*. 2008b;5:2623–34.
- Corona G, Mannucci E, Forti G, Maggi M. Hypogonadism, ED, metabolic syndrome and obesity: a pathological link supporting cardiovascular diseases. *Int J Androl*. 2009a;32:587–98.
- Corona G, Ricca V, Bandini E, Mannucci E, Lotti F, Boddi V, Rastrelli G, Sforza A, Faravelli C, Forti G, Maggi M. Selective serotonin reuptake inhibitor-induced sexual dysfunction. *J Sex Med*. 2009b;6:1259–69.
- Corona G, Maggi M. The role of testosterone in erectile dysfunction. *Nat Rev Urol*. 2010;7:46–56.
- Corona G, Lee DM, Forti G, O'Connor DB, Maggi M, O'Neill TW, Pendleton N, Bartfai G, Boonen S, Casanueva FF, Finn JD, Giwercman A, Han TS, Huhtaniemi IT, Kula K, Lean ME, Punab M, Silman AJ, Vanderschueren D, Wu FC, EMAS Study Group. Age-related changes in general and sexual health in middle-aged and older men: results from the European Male Ageing Study (EMAS). *J Sex Med*. 2010a;7:1362–80.
- Corona G, Monami M, Boddi V, Cameron-Smith M, Fisher AD, de Vita G, Melani C, Balzi D, Sforza A, Forti G, Mannucci E, Maggi M. Low testosterone is associated with an increased risk of MACE lethality in subjects with erectile dysfunction. *J Sex Med*. 2010b;7:1557–64.
- Corona G, Monami M, Rastrelli G, Aversa A, Sforza A, Lenzi A, Forti G, Mannucci E, Maggi M. Type 2 diabetes mellitus and testosterone: a meta-analysis study. *Int J Androl*. 2011a;34:528–40.
- Corona G, Rastrelli G, Morelli A, Vignozzi L, Mannucci E, Maggi M. Hypogonadism and metabolic syndrome. *J Endocrinol Investig*. 2011b;34:557–67.
- Corona G, Monami M, Rastrelli G, Aversa A, Tishova Y, Saad F, Lenzi A, Forti G, Mannucci E, Maggi M. Testosterone and metabolic syndrome: a meta-analysis study. *J Sex Med*. 2011c;8:272–83.
- Corona G, Jannini EA, Lotti F, Boddi V, De Vita G, Forti G, Lenzi A, Mannucci E, Maggi M. Premature and delayed ejaculation: two ends of a single continuum influenced by hormonal milieu. *Int J Androl*. 2011d;34:41–8.
- Corona G, Rastrelli G, Monami M, Guay A, Buvat J, Sforza A, Forti G, Mannucci E, Maggi M. Hypogonadism as a risk factor for cardiovascular mortality in men: a meta-analytic study. *Eur J Endocrinol*. 2011e;165:687–701.
- Corona G, Rastrelli G, Vignozzi L, Mannucci E, Maggi M. Testosterone, cardiovascular disease and the metabolic syndrome. *Best Pract Res Clin Endocrinol Metab*. 2011f;25:337–53.
- Corona G, Rastrelli G, Monami M, Melani C, Balzi D, Sforza A, Forti G, Mannucci E, Maggi M. Body mass index regulates hypogonadism-associated CV risk: results from a cohort of subjects with erectile dysfunction. *J Sex Med*. 2011g;8:2098–105.
- Corona G, Rastrelli G, Balercia G, Lotti F, Sforza A, Monami M, Forti G, Mannucci E, Maggi M. Hormonal association and sexual dysfunction in patients with impaired fasting glucose: a cross-sectional and longitudinal study. *J Sex Med*. 2012a;9:1669–80.
- Corona G, Jannini EA, Vignozzi L, Rastrelli G, Maggi M. The hormonal control of ejaculation. *Nat Rev Urol*. 2012b;9:508–19.
- Corona G, Ricca V, Bandini E, Rastrelli G, Casale H, Jannini EA, Sforza A, Forti G, Mannucci E, Maggi M. SIEDY scale 3, a new instrument to detect psychological component in subjects with erectile dysfunction. *J Sex Med*. 2012c;9:2017–26.

- Corona G, Rastrelli G, Ricca V, Jannini EA, Vignozzi L, Monami M, Sforza A, Forti G, Mannucci E, Maggi M. Risk factors associated with primary and secondary reduced libido in male patients with sexual dysfunction. *J Sex Med.* 2013;10:1074–89.
- Corona G, Maseroli E, Rastrelli G, Sforza A, Forti G, Mannucci E, Maggi M. Characteristics of compensated hypogonadism in patients with sexual dysfunction. *J Sex Med.* 2014a;11:1823–34.
- Corona G, Rastrelli G, Maseroli E, Fralassi N, Sforza A, Forti G, Mannucci E, Maggi M. Low testosterone syndrome protects subjects with high cardiovascular risk burden from major adverse cardiovascular events. *Andrology.* 2014b;2:741–7.
- Corona G, Giagulli VA, Maseroli E, Vignozzi L, Aversa A, Zitzmann M, Saad F, Mannucci E, Maggi M. Testosterone supplementation and body composition: results from a meta-analysis study. *Eur J Endocrinol.* 2016;174:R99–R116.
- Derby CA, Zilber S, Brambilla D, Morales KH, McKinlay JB. Body mass index, waist circumference and waist to hip ratio and change in sex steroid hormones: the Massachusetts male ageing study. *Clin Endocrinol.* 2006;65:125–31.
- Deslypere JP, Vermeulen A. Leydig cell function in normal men: effect of age, lifestyle, residence, diet and activity. *J Clin Endocrinol Metab.* 1984;59:955–62.
- Dhindsa S, Furlanetto R, Vora M, Ghanim H, Chaudhuri A, Dandona P. Low estradiol concentrations in men with subnormal testosterone concentrations and type 2 diabetes. *Diabetes Care.* 2011;34:1854–9.
- Ding EL, Song Y, Malik VS, Liu S. Sex differences of endogenous sex hormones and risk of type 2 diabetes: a systematic review and meta-analysis. *JAMA.* 2006;295:1288–99.
- Dohle GR, Arver S, Bettocchi C, Jones TH, Kliesch S, Punab M. Guidelines on male hypogonadism. Amhem: European Association of Urology; 2015. Available: <http://uroweb.org/wp-content/uploads/EAU-Guidelines-Male-Hypogonadism-2015.pdf>
- Farooqi IS. Leptin and the onset of puberty: insights from rodent and human genetics. *Semin Reprod Med.* 2002;20:139–44.
- Feldman HA, Longcope C, Derby CA, Johannes CB, Araujo AB, Coviello AD, Bremner WJ, McKinlay JB. Age trends in the level of serum testosterone and other hormones in middle-aged men: longitudinal results from the Massachusetts male aging study. *J Clin Endocrinol Metab.* 2002;87:589–98.
- Fernandez-Guasti A, Swaab D, Rodríguez-Manzo G. Sexual behavior reduces hypothalamic androgen receptor immunoreactivity. *Psychoneuroendocrinology.* 2003;28:501–12.
- Gamba M, Pralong FP. Control of GnRH neuronal activity by metabolic factors: the role of leptin and insulin. *Mol Cell Endocrinol.* 2006;254–255:133–9.
- García-Galiano D, Allen SJ, Elias CF. Role of the adipocyte-derived hormone leptin in reproductive control. *Horm Mol Biol Clin Invest.* 2014;19:141–9.
- Gray PB, Singh AB, Woodhouse LJ, Storer TW, Casaburi R, Dzekov J, Dzekov C, Sinha-Hikim I, Bhasin S. Dose-dependent effects of testosterone on sexual function, mood, and visuospatial cognition in older men. *J Clin Endocrinol Metab.* 2005;90:3838–46.
- Han TS, Tajar A, O'Neill TW, Jiang M, Bartfai G, Boonen S, Casanueva F, Finn JD, Forti G, Giwercman A, Huhtaniemi IT, Kula K, Pendleton N, Punab M, Silman AJ, Vanderschueren D, Lean ME, Wu FC, EMAS group. Impaired quality of life and sexual function in overweight and obese men: the European Male Ageing Study. *Eur J Endocrinol.* 2011;164:1003–11.
- Harman SM, Metter EJ, Tobin JD, Pearson J, Blackman MR. Longitudinal effects of aging on serum total and free testosterone levels in healthy men. Baltimore longitudinal study of aging. *J Clin Endocrinol Metab.* 2001;86:724–31.
- Hong CY, Park JH, Ahn RS, Im SY, Choi HS, Soh J, Mellon SH, Lee K. Molecular mechanism of suppression of testicular steroidogenesis by proinflammatory cytokine tumor necrosis factor alpha. *Mol Cell Biol.* 2004;24:2593–604.
- Isidori AM, Buvat J, Corona G, Goldstein I, Jannini EA, Lenzi A, Porst H, Salonia A, Traish AM, Maggi M. A critical analysis of the role of testosterone in erectile function: from pathophysiology to treatment—a systematic review. *Eur Urol.* 2014;65:99–112.

- Laaksonen DE, Niskanen L, Punnonen K, Nyyssönen K, Tuomainen TP, Valkonen VP, Salonen JT. The metabolic syndrome and smoking in relation to hypogonadism in middle-aged men: a prospective cohort study. *J Clin Endocrinol Metab.* 2005;90:712–9.
- Liao C, Reaven E, Azhar S. Age-related decline in the steroidogenic capacity of isolated rat Leydig cells: a defect in cholesterol mobilization and processing. *J Steroid Biochem Mol Biol.* 1993;46:39–47.
- Loves S, Ruinemans-Koerts J, de Boer H. Letrozole once a week normalizes serum testosterone in obesity-related male hypogonadism. *Eur J Endocrinol.* 2008;158:741–7.
- Lue TF, Brant WO, Shindel A, Bella AJ. Sexual dysfunction in diabetes. In: De Groot LJ, Beck-Peccoz P, Chrousos G, Dungan K, Grossman A, Hershman JM, Koch C, McLachlan R, New M, Rebar R, Singer F, Vinik A, Weickert MO, editors. *Endotext* [Internet]. South Dartmouth: MDText.com, Inc.; 2000–2013.
- Margetic S, Gazzola C, Pegg GG, Hill RA. Leptin: a review of its peripheral actions and interactions. *Int J Obes Relat Metab Disord.* 2002;26:1407–33.
- Morelli A, Sarchielli E, Comeglio P, Filippi S, Vignozzi L, Marini M, Rastrelli G, Maneschi E, Cellai I, Persani L, Adorini L, Vannelli GB, Maggi M. Metabolic syndrome induces inflammation and impairs gonadotropin-releasing hormone neurons in the preoptic area of the hypothalamus in rabbits. *Mol Cell Endocrinol.* 2014;382:107–19.
- Morley JE, Kaiser FE, Perry 3rd HM, Patrick P, Morley PM, Stauber PM, Vellas B, Baumgartner RN, Garry PJ. Longitudinal changes in testosterone, luteinizing hormone, and follicle-stimulating hormone in healthy older men. *Metabolism.* 1997;46:410–3.
- Mulligan T, Iranmanesh A, Kerzner R, Demers LW, Veldhuis JD. Two-week pulsatile gonadotropin releasing hormone infusion unmasks dual (hypothalamic and Leydig cell) defects in the healthy aging male gonadotropic axis. *Eur J Endocrinol.* 1999;141:257–66.
- Nettleship JE, Jones TH, Channer KS, Jones RD. Physiological testosterone replacement therapy attenuates fatty streak formation and improves high-density lipoprotein cholesterol in the Tfm mouse: an effect that is independent of the classic androgen receptor. *Circulation.* 2007;116:2427–34.
- O'Connor DB, Lee DM, Corona G, Forti G, Tajar A, O'Neill TW, Pendleton N, Bartfai G, Boonen S, Casanueva FF, Finn JD, Giwercman A, Han TS, Huhtaniemi IT, Kula K, Labrie F, Lean ME, Punab M, Silman AJ, Vanderschueren D, Wu FC, European Male Ageing Study Group. The relationships between sex hormones and sexual function in middle-aged and older European men. *J Clin Endocrinol Metab.* 2011;96:E1577–87.
- Oswal A, Yeo G. Leptin and the control of body weight: a review of its diverse central targets, signaling mechanisms, and role in the pathogenesis of obesity. *Obesity (Silver Spring).* 2009;18:221–9.
- Pfaus JG. Pathways of sexual desire. *J Sex Med.* 2009;6:1506–33.
- Pye SR, Huhtaniemi IT, Finn JD, Lee DM, O'Neill TW, Tajar A, Bartfai G, Boonen S, Casanueva FF, Forti G, Giwercman A, Han TS, Kula K, Lean ME, Pendleton N, Punab M, Rutter MK, Vanderschueren D, Wu FC, EMAS Study Group. Late-onset hypogonadism and mortality in aging men. *J Clin Endocrinol Metab.* 2014;99:1357–66.
- Rastrelli G, Carter EL, Ahern T, Finn JD, Antonio L, O'Neill TW, Bartfai G, Casanueva FF, Forti G, Keevil B, Maggi M, Giwercman A, Han TS, Huhtaniemi IT, Kula K, Lean ME, Pendleton N, Punab M, Vanderschueren D, Wu FC, EMAS Study Group. Development of and recovery from secondary hypogonadism in aging men: prospective results from the EMAS. *J Clin Endocrinol Metab.* 2015;100:3172–82.
- Rastrelli G, Corona G, Tarocchi M, Mannucci E, Maggi M. How to define hypogonadism? Results from a population of men consulting for sexual dysfunction. *J Endocrinol Investig.* 2016;39:473–84.
- Rochira V, Zirilli L, Madeo B, Balestrieri A, Granata AR, Carani C. Sex steroids and sexual desire mechanism. *J Endocrinol Investig.* 2003;26:29–36.
- Rodriguez A, Muller DC, Metter EJ, Maggio M, Harman SM, Blackman MR, Andres R. Aging, androgens, and the metabolic syndrome in a longitudinal study of aging. *J Clin Endocrinol Metab.* 2007;92:3568–72.

- Salvi R, Castillo E, Viroil MJ, Glauser M, Rey JP, Gaillard RC, Vollenweider P, Pralong FP. GnRH-expressing neurons immortalized conditionally are activated by insulin: implication of the MAP kinase pathway. *Endocrinology*. 2005;147:816–26.
- Sano T, Kovacs KT, Scheithauer BW, Young Jr WF. Aging and the human pituitary gland. *Mayo Clin Proc*. 1993;68:971–7.
- Shi Z, Araujo AB, Martin S, O'Loughlin P, Wittert GA. Longitudinal changes in testosterone over five years in community-dwelling men. *J Clin Endocrinol Metab*. 2013;98:3289–97.
- Smith ER, Damassa DA, Davidson JM. Plasma testosterone and sexual behavior following intracerebral implantation of testosterone propionate in the castrated male rat. *Horm Behav*. 1977;8:77–87.
- Smith JT, Acohido BV, Clifton DK, Steiner RA. KiSS-1 neurones are direct targets for leptin in the ob/ob mouse. *J Neuroendocrinol*. 2006;18:298–303.
- Snyder PJ, Ellenberg SS, Cunningham GR, Matsumoto AM, Bhasin S, Barrett-Connor E, Gill TM, Farrar JT, Cella D, Rosen RC, Resnick SM, Swerdloff RS, Cauley JA, Cifelli D, Fluharty L, Pahor M, Ensrud KE, Lewis CE, Molitch ME, Crandall JP, Wang C, Budoff MJ, Wenger NK, Mohler 3rd ER, Bild DE, Cook NL, Keaveny TM, Kopperdahl DL, Lee D, Schwartz AV, Storer TW, Ershler WB, Roy CN, Raffel LJ, Romashkan S, Hadley E. The testosterone trials: seven coordinated trials of testosterone treatment in elderly men. *Clin Trials*. 2014;11:362–75.
- Snyder PJ, Bhasin S, Cunningham GR, Matsumoto AM, Stephens-Shields AJ, Cauley JA, Gill TM, Barrett-Connor E, Swerdloff RS, Wang C, Ensrud KE, Lewis CE, Farrar JT, Cella D, Rosen RC, Pahor M, Crandall JP, Molitch ME, Cifelli D, Dougar D, Fluharty L, Resnick SM, Storer TW, Anton S, Basaria S, Diem SJ, Hou X, Mohler 3rd ER, Parsons JK, Wenger NK, Zeldow B, Landis JR, Ellenberg SS. Testosterone trials investigators: effects of testosterone treatment in older men. *N Engl J Med*. 2016;374(7):611–24.
- Swerdloff RS, Wang C, Cunningham G, Dobs A, Iranmanesh A, Matsumoto AM, Snyder PJ, Weber T, Longstreth J, Berman N. Long-term pharmacokinetics of transdermal testosterone gel in hypogonadal men. *J Clin Endocrinol Metab*. 2000;85:4500–10.
- Tajar A, Forti G, O'Neill TW, Lee DM, Silman AJ, Finn JD, Bartfai G, Boonen S, Casanueva FF, Giwercman A, Han TS, Kula K, Labrie F, Lean ME, Pendleton N, Punab M, Vanderschueren D, Huhtaniemi IT, Wu FC, EMAS Group. Characteristics of secondary, primary, and compensated hypogonadism in aging men: evidence from the European Male Ageing Study. *J Clin Endocrinol Metab*. 2010;95:1810–8.
- Tajar A, Huhtaniemi IT, O'Neill TW, Finn JD, Pye SR, Lee DM, Bartfai G, Boonen S, Casanueva FF, Forti G, Giwercman A, Han TS, Kula K, Labrie F, Lean ME, Pendleton N, Punab M, Vanderschueren D, Wu FC, EMAS Group. Characteristics of androgen deficiency in late-onset hypogonadism: results from the European Male Ageing Study (EMAS). *J Clin Endocrinol Metab*. 2012;97:1508–16.
- Tharp DL, Masseur I, Ivey J, Ganjam VK, Bowles DK. Endogenous testosterone attenuates neointima formation after moderate coronary balloon injury in male swine. *Cardiovasc Res*. 2009;82:152–60.
- Travison TG, Shackelton R, Araujo AB, Hall SA, Williams RE, Clark RV, O'Donnell AB, McKinlay JB. The natural history of symptomatic androgen deficiency in men: onset, progression, and spontaneous remission. *J Am Geriatr Soc*. 2008;56:831–9.
- van der Poll T, Romijn JA, Endert E, Sauerwein HP. Effects of tumor necrosis factor on the hypothalamic-pituitary-testicular axis in healthy men. *Metabolism*. 1993;42:303–7.
- van Rossum CT, Hoebee B, van Baak MA, Mars M, Saris WH, Seidell JC. Genetic variation in the leptin receptor gene, leptin, and weight gain in young Dutch adults. *Obes Res*. 2003;11:377–86.
- Wang C, Nieschlag E, Swerdloff R, Behre HM, Hellstrom WJ, Gooren LJ, Kaufman JM, Legros JJ, Lunenfeld B, Morales A, Morley JE, Schulman C, Thompson IM, Weidner W, Wu FC, International Society of Andrology (ISA), International Society for the Study of Aging Male (ISSAM), European Association of Urology (EAU), European Academy of Andrology (EAA), American Society of Andrology (ASA). Investigation, treatment, and monitoring of late-onset

- hypogonadism in males: ISA, ISSAM, EAU, EAA, and ASA recommendations. *J Androl.* 2009;30:1–9.
- Well D, Yang H, Houseni M, Iruvuri S, Alzeair S, Sansovini M, Wintering N, Alavi A, Torigian DA. Age-related structural and metabolic changes in the pelvic reproductive end organs. *Semin Nucl Med.* 2007;37:173–84.
- Wu FC, Tajar A, Pye SR, Silman AJ, Finn JD, O'Neill TW, Bartfai G, Casanueva F, Forti G, Giwercman A, Huhtaniemi IT, Kula K, Punab M, Boonen S, Vanderschueren D, European Male Aging Study Group. Hypothalamic-pituitary-testicular axis disruptions in older men are differentially linked to age and modifiable risk factors: the European Male Aging Study. *J Clin Endocrinol Metab.* 2008;93:2737–45.
- Wu FC, Tajar A, Beynon JM, Pye SR, Silman AJ, Finn JD, O'Neill TW, Bartfai G, Casanueva FF, Forti G, Giwercman A, Han TS, Kula K, Lean ME, Pendleton N, Punab M, Boonen S, Vanderschueren D, Labrie F, EMAS Group. Identification of late-onset hypogonadism in middle-aged and elderly men. *N Engl J Med.* 2010;363:123–35.
- Yannakoulia M, Yiannakouris N, Bluher S, Matalas AL, Klimis-Zacas D, Mantzoros CS. Body fat mass and macronutrient intake in relation to circulating soluble leptin receptor, free leptin index, adiponectin, and resistin concentrations in healthy humans. *J Clin Endocrinol Metab.* 2003;88:1730–6.
- Zitzmann M, Faber S, Nieschlag E. Association of specific symptoms and metabolic risks with serum testosterone in older men. *J Clin Endocrinol Metab.* 2006;91:4335–43.

Giulia Rastrelli and Mario Maggi

## Abstract

Hypogonadism is a frequent condition, in particular during adult age. Whereas no doubts exist on the opportunity of treating patients with hypogonadism deriving from definite conditions affecting the hypothalamic-pituitary-testicular axis, more concerns are present for treatment of men with age-related testosterone (T) decline, the so-called late-onset hypogonadism (LOH). Several options are available for treating hypogonadism, and the choice should be done according to rationale, indications, and expected outcomes, taking also into account the advantages and disadvantages associated with each molecule and preparation. Although GnRH and gonadotropins are the cornerstone of therapy in secondary hypogonadism (sHG) men requiring fertility, few data are present on their use in LOH. Testosterone replacement therapy (TRT) is the most studied therapy in this particular and controversial condition. Randomized clinical trials (RCTs) on TRT are few and short lasting. However, there is substantial consistence on the efficacy of TRT in improving sexual function, increasing lean mass, and decreasing fat mass. The results are more controversial on the effectiveness of TRT in improving glycolipid profile and mood. Concerning bone mineral density, the evidence is scarce and those concerning fractures are nonexistent. An intense debate is ongoing on the putative risk of cardiovascular (CV) events associated with TRT. Pending results from RCTs specifically designed for assessing this outcome, available evidence reassures on CV safety of TRT, but caution should be used in older and frail men.

G. Rastrelli • M. Maggi (✉)

Sexual Medicine and Andrology Unit, Department of Experimental and Clinical Biomedical Sciences, University of Florence, Florence, Italy

e-mail: [giulia.rastrelli@gmail.com](mailto:giulia.rastrelli@gmail.com); [mario.maggi@unifi.it](mailto:mario.maggi@unifi.it)

© Springer International Publishing AG 2017

M. Simoni, I.T. Huhtaniemi (eds.), *Endocrinology of the Testis and Male Reproduction*, Endocrinology 1, [https://doi.org/10.1007/978-3-319-44441-3\\_32](https://doi.org/10.1007/978-3-319-44441-3_32)

945

---

**Keywords**

 Hypogonadism • Treatment • Testosterone • Gonadotropins • GnRH
 

---

**Contents**

Treatment of Hypogonadism .....	946
Who Should Be Treated? .....	946
Which Are the Available Strategies? .....	948
Pharmacological Therapies .....	948
Non-pharmacological Therapy .....	957
How to Follow Patients Undergoing Therapy for Hypogonadism? .....	958
What Are the Objectives of Therapy? .....	959
Fertility .....	960
Sexual Function .....	961
Physical Strength and Body Composition .....	963
Metabolic Parameters .....	965
Bone Health .....	967
Mood .....	968
Cardiovascular Health .....	968
Summary .....	970
References .....	971

---

**Treatment of Hypogonadism**

Treatment of testosterone (T) deficiency (male hypogonadism) is based, as many hormonal deficiencies, on the concept of correcting and/or replacing the specific deficiency. According to this rationale, treatment of hypogonadism could be considered a straightforward issue. However, the decision of starting a therapy for hypogonadism is far from being simple. In fact, several considerations should be taken into account during each step of the decision-making process. The main questions that should be answered are reported in Table 1 and will be discussed in the following paragraphs.

---

**Who Should Be Treated?**

This question, apparently simple to be answered, is the core of an intense debate. Male hypogonadism can be caused by different pathological processes extensively reported in a dedicated chapter (Part III, ► [Chap. 23, “Primary and Secondary Hypogonadism”](#)). Briefly, the possible causes of hypogonadism can derive from a damage of the testis itself (primary hypogonadism) or from a derangement in the hypothalamic-pituitary axis controlling testicular function (secondary hypogonadism (sHG)). Although there is no doubt that adult men with “classic” hypogonadism, due to an organic or functional disease leading to impairment of testicular or hypothalamic-pituitary function, deserve therapy, the treatment of the so-called late-onset hypogonadism (LOH) is more debated. A detailed description of the

**Table 1** Steps of the decision-making in endocrine therapy of hypogonadism

<b>Step 1</b>	<b>Who should be treated?</b>	<ol style="list-style-type: none"> <li>1. All subjects with a well-defined pathology leading to primary or secondary hypogonadism (see also ► Chap. 23, “Primary and Secondary Hypogonadism,” Part III)</li> <li>2. Consider treatment for subjects with LOH (see also ► Chap. 30, “Late-Onset Hypogonadism,” Part III)</li> </ol>									
<b>Step 2</b>	<b>Which are the available medications?</b>	<table border="0"> <tr> <td>           Pharmacological therapies           <ol style="list-style-type: none"> <li>1. GnRH</li> <li>2. Gonadotropins</li> <li>3. Testosterone</li> <li>4. Antiestrogens</li> </ol> </td> <td style="font-size: 3em; vertical-align: middle; padding: 0 10px;">}</td> <td style="vertical-align: middle;">see Table 2 for details</td> </tr> <tr> <td colspan="3">Non-pharmacological therapy</td> </tr> <tr> <td colspan="3">5. Weight loss</td> </tr> </table>	Pharmacological therapies <ol style="list-style-type: none"> <li>1. GnRH</li> <li>2. Gonadotropins</li> <li>3. Testosterone</li> <li>4. Antiestrogens</li> </ol>	}	see Table 2 for details	Non-pharmacological therapy			5. Weight loss		
Pharmacological therapies <ol style="list-style-type: none"> <li>1. GnRH</li> <li>2. Gonadotropins</li> <li>3. Testosterone</li> <li>4. Antiestrogens</li> </ol>	}	see Table 2 for details									
Non-pharmacological therapy											
5. Weight loss											
<b>Step 3</b>	<b>How to follow patients undergoing therapy for hypogonadism?</b>	<ol style="list-style-type: none"> <li>1. First, visit after 3–6 months from the beginning of therapy</li> <li>2. Assessment of symptoms and signs of hypogonadism</li> <li>3. Evaluation of possible side effects: hematocrit, DRE, and PSA</li> <li>4. Measurement of T levels</li> </ol>									
<b>Step 4</b>	<b>Which are the objectives of therapy?</b>	<ol style="list-style-type: none"> <li>1. Fertility (only GnRH and gonadotropins in secondary hypogonadism)</li> <li>2. Sexual function</li> <li>3. Physical strength and body composition</li> <li>4. Metabolic parameters</li> <li>5. Bone health</li> <li>6. Mood</li> </ol>									

*LOH* late-onset hypogonadism, *DRE* digital rectal examination, *PSA* prostate-specific antigen, *T* testosterone, *GnRH* gonadotropin-releasing hormone

clinical significance of LOH, as well as the areas of uncertainty concerning the opportunity of treating this condition, is reported elsewhere in the present manual (Part III, ► Chap. 30, “Late-Onset Hypogonadism”). It is generally accepted that the treatment of “classical” forms of hypogonadism provides improvement in clinical features and well-being; however, specific RCT demonstrating these improvements has never been published. On the other hand, the risk-benefit ratio of treating LOH is still under debate. Recently, the Food and Drug Administration (FDA) expressed concerns on the increasing prescriptions of T medications for men not diagnosed with hypogonadism from a “classical” etiology (<http://www.fda.gov/Drugs/DrugSafety/ucm436259.htm>). Major concerns are related to the publication of a number of studies pointing out a possible increase in cardiovascular (CV) events in aging men undergoing testosterone replacement therapy (TRT) (vide infra). While demanding that long-term, adequately powered RCTs were conducted, the FDA recommends caution when deciding on treatment of hypogonadism in aging men.



## Which Are the Available Strategies?

### Pharmacological Therapies

#### Gonadotropin-Releasing Hormone (GnRH)

GnRH therapy represents, at present, the most physiological, orthotropic approach for treating hypogonadism arising from any GnRH deficiency, i.e., isolated or in combination with other hypothalamic hormone deficiencies. When administered in a pulsatile fashion, it stimulates pituitary to release luteinizing hormone (LH) and follicle-stimulating hormone (FSH). This allows testicular growth, inducing and maintaining pubertal development, as well as spermatogenesis (Corona et al. 2015). However, its use is limited to patients with secondary hypogonadism with an intact pituitary function (Rastrelli et al. 2014). Furthermore, it cannot be used in subjects carrying mutations in the GnRH receptor, which represents 3.5–16% of the sporadic cases and up to 40% of familial cases of congenital, normosmic sHG (Bianco and Kaiser 2009). GnRH must be administered in a pulsatile fashion (Table 2), with the aim of mimicking the activity of hypothalamic pulse generator (Rastrelli et al. 2014; 2016a; Maggi and Buvat 2013). Accordingly, GnRH is delivered by pumps, which administer intravenously or subcutaneously 100–400 ng/kg of GnRH every 90–120 min (Table 2). LH, FSH, and T must be monitored for dose titration (Corona et al. 2015). The inconvenience of the administration of GnRH, together with the availability of gonadotropin therapy, as compared to which, so far, GnRH did not show any advantage in clinical outcomes (Rastrelli et al. 2014; Buchter et al. 1998; Liu et al. 1988a, b; Oppermann et al. 1987) makes the use of GnRH quite limited for clinical practice. However, GnRH therapy has been recently chosen by experts in the field of congenital sHG as the reference therapy in a RCT evaluating the role of pretreatment with FSH in inducing testicular maturation in prepubertal congenital sHG patients (Dwyer et al. 2013). This suggests that GnRH therapy, although rarely used, cannot still be regarded as a historical therapy. GnRH therapy is associated with rare adverse events, mainly represented by inflammation and/or infection at the insertion site and development of antibodies vs. GnRH (Table 2).

### Gonadotropins

#### hCG or LH

This therapy is based on the use of compounds that, by activating the LH/hCG receptor, can stimulate steroidogenesis in Leydig cells, thus leading to T secretion, resulting in increased concentrations both within the testis and in the bloodstream. Human chorionic gonadotropin (hCG) and human recombinant LH (r-hLH) bind to the LH/hCG receptor, and their pharmacokinetic characteristics make them available for therapy (Table 2). hCG is usually extracted from urine of pregnant women (u-hCG); however, also recombinant hCG (r-hCG) is available, although it is not approved for the use in men (Liu et al. 2003). u-hCG is administered by intramuscular or subcutaneous injections two or three times a week, with a cumulative

**Table 2** Preparations for pharmacological therapy of hypogonadism

Compound	Trade name	Standard adult dosage	Advantages	Disadvantages
<b>GnRH</b>	Lutrelif <sup>®</sup> Factrel <sup>®</sup> Lutrepulse <sup>®</sup>	100–400 ng/kg every 90–120 min	Induction of testicular maturation Induction of spermatogenesis Reduction of time to fertility achievement after TRT	Inconvenient to administer
<b>Gonadotropins</b>	<i>hCG or LH:</i> Novarel <sup>®</sup> Chorex <sup>®</sup> Gonic <sup>®</sup> Choron <sup>®</sup> Chorigon <sup>®</sup> Pregnyl <sup>®</sup> Gonasi <sup>®</sup> Prophasi <sup>®</sup> Ovidrel <sup>®</sup> Ovitrelle <sup>®</sup>	1,000–2,000 UI twice to thrice weekly	Induction of testicular maturation Induction of spermatogenesis Reduction of time to fertility achievement after TRT	Inconvenient to administer Expensive
	<i>hMG, hpMG or rhFSH:</i> Meropur <sup>®</sup> Menogon <sup>®</sup> Pergoveris <sup>®</sup> Puregon <sup>®</sup> Gonal-f <sup>®</sup>	75–150 UI thrice weekly		
<b>Testosterone</b>				
<b>Injectable</b>				
<b>Short acting</b>				
T enanthate	Testoviron Depot <sup>®</sup> Delatestyl <sup>®</sup> Testoenant <sup>®</sup>	250 mg i.m. every 2–3 weeks	Injections every month Cheap Wide experience	Wide T plasma level fluctuations Erythrocytosis
T cypionate	Depo- testosterone inj <sup>®</sup>	200 mg i.m. every 2–3 weeks		
T propionate	Testovis <sup>®</sup>	100 mg i.m. every 2 days	Cheap	Frequent administration
<b>Long acting</b>				
T undecanoate	Nebido <sup>®</sup> Aveed <sup>®</sup>	1,000 mg every 12 weeks 750 mg every 12 weeks	Long lasting Stable T plasma levels	Pain at injection site Dosage modifications are not prompt

(continued)

**Table 2** (continued)

Compound	Trade name	Standard adult dosage	Advantages	Disadvantages
<b>Oral</b>				
T undecanoate	Andriol <sup>®</sup> Andriol Testocaps <sup>®</sup>	120–240 mg daily fractionated into three administrations	Easy to take Non-toxic Promptly modifiable dosage Wide clinical experience	Daily administration Unpredictable absorption Wide T plasma level fluctuation
<b>Transdermal</b>				
Patches	<i>Not scrotal:</i> Androderm <sup>®</sup> Andropatch <sup>®</sup> Testopatch <sup>®</sup> <i>Scrotal:</i> Testoderm <sup>®</sup>	5–10 mg for daily	Easy to take Resemble circadian rhythm Stable T plasma levels Promptly modifiable dosage	Itching and contact dermatitis (~50%) Expensive
Gel 1%	Androgel <sup>®</sup> Testogel <sup>®</sup> Testim <sup>®</sup> Fortigel <sup>®</sup>	5 g daily	Easy to take Resemble circadian rhythm	Expensive Skin irritation (more rare than patches)
Gel 1.62%	Androgel <sup>®</sup> 1.62 (available only in the USA)	1.25–5 g daily	Stable T plasma levels Promptly modifiable dosage	Daily administration Possible transfer with contact (except underarm solution)
Gel 2%	Testostop <sup>®</sup> Tostrex <sup>®</sup> Axiron <sup>®</sup>	2.5 g daily or 60–120 mg daily per underarm solution		
<b>Pellet</b>	Testopel <sup>®</sup> Testo implant <sup>®</sup>	800–1,200 mg/kg every 6 months	Long acting	Invasive and inconvenient to apply Risk of extrusion and infection
<b>Buccal</b>	Striant <sup>®</sup>	30 mg twice a day	Stable T plasma levels	Possible oral irritation Administration twice a day Unpleasant taste

(continued)

**Table 2** (continued)

Compound	Trade name	Standard adult dosage	Advantages	Disadvantages
<b>Antiestrogens (SERMs)</b>				
Clomiphene	Clomid <sup>®</sup>	25–50 mg daily	Easy to take Induction of spermatogenesis Suggested for idiopathic infertility	Limited risk of venous thromboembolism Required intact hypothalamus-pituitary-testicular axis No approved for use in male (off-label use)
Enclomiphene	Valodex <sup>®</sup> Androxal <sup>®</sup>	12.5–25 mg daily		
Tamoxifen	Kessar <sup>®</sup> Nolvadex <sup>®</sup> Nomafen <sup>®</sup>	10–20 mg daily		
Toremifene	Fareston <sup>®</sup>	80 mg daily		
Raloxifene	Evista <sup>®</sup> Optruma <sup>®</sup>	60 mg daily		

*GnRH* gonadotropin-releasing hormone, *TRT* testosterone replacement therapy, *hCG* human chorionic gonadotropin, *LH* luteinizing hormone, *hMG* human menopausal gonadotropin, *hpMG* highly purified menotropin, *hrFSH* human recombinant follicle-stimulating hormone, *T* testosterone

weekly dose ranging 1250–5000 IU (Table 2). The use of r-hLH in males is still limited and its dosage is not standardized. In a study involving six men with postpubertal-acquired sHG, r-hLH (900 IU daily) increased T levels, but, most probably because of its shorter half-life, it was not able to restore them up to those of healthy adult males, whereas u-hCG 1500 UI twice a week was effective (Young et al. 2000). u-hCG has the advantage of a longer half-life than r-hLH, which allows a frequency of administration two or three times a week. However, the use of u-hCG, like other human-derivative proteins, carries the theoretical risk of prion diseases. r-hLH or r-hCG excludes the possibility of prion diseases. However, their cost is greater and the shorter half-life of r-hLH requires daily administrations. This makes recombinant preparations less attractive option than u-hCG. Hence, u-hCG is still the most widely used option in men with sHG, also because, at present, there is no evidence of improvement in clinical outcomes obtained with recombinant preparations as compared with the one extracted from pregnancy urine.

### FSH in Association with hCG/LH

FSH therapy is often combined with u-hCG/r-hLH (Table 2). In fact, whereas treatment of most hypogonadal symptoms and signs can benefit only from restoration of T levels by u-hCG/r-hLH injections, induction or recovery of fertility often requires a combined u-hCG/r-hLH and FSH therapy (Rastrelli et al. 2014). At present, sHG is one of the few causes of infertility for which a nonempirical treatment is possible. Considering that spermatogenesis and fertility can be restored only with u-hCG/r-hLH, in particular in postpubertal sHG, according to the experience and opinion of experts in the field, u-hCG/r-hLH monotherapy for 6 months is indicated (Anawalt 2013; Dwyer et al. 2015). If sperm concentration remains below

10 million/mL after 4–6 months of monotherapy, subcutaneous or intramuscular FSH should be added (Anawalt 2013), starting from a dosage of 75 IU every other day that can be doubled if sperm concentration remains below 20 million/mL (Anawalt 2013). Combined gonadotropin therapy can also be used for induction of pubertal development in sHG boys (Rastrelli et al. 2016a). In these boys with delayed puberty, a slow and progressive increase in T levels – mimicking the physiological rise, which happens during pubertal transition – is necessary for inducing male secondary sexual characteristics. The increase in T levels can be obtained with the use of u-hCG which, by stimulating Leydig cells, can increase steroidogenesis. At variance from the administration of the final product – i.e., T therapy – u-hCG can increase testis volume. Since low testis volume in boys with delayed puberty is psychologically distressing, u-hCG therapy can improve this issue. Even more importantly, u-hCG itself can induce spermatogenesis (Rastrelli et al. 2014). The coadministration of FSH in nonresponders can improve the results on testis growth and spermatogenesis, and it is often required in patients with low testis volume whose pubertal developments stopped at an early stage (Dwyer et al. 2015).

### **FSH Pretreatment**

Preliminary evidence suggests the usefulness of another therapeutic scheme: pretreatment with FSH before starting a GnRH or u-hCG (Raivio et al. 2007). A RCT comparing the effectiveness of GnRH alone or after a pretreatment of 4 months with FSH in congenital hypogonadotropic hypogonadal boys showed increased testis volume and proliferation of Sertoli and germ cells in the pretreated arm (Dwyer et al. 2013). Accordingly, all the pretreated patients achieved sperm in ejaculate. Even though more evidence is needed, pretreatment with FSH seems to be an effective therapeutic option for inducing fertility in prepubertal boys with sHG.

### **FSH Preparations**

Different preparations containing FSH are available (Table 2). Human menopausal gonadotropin (hMG) is extracted from urine of postmenopausal women, and it has been widely used for therapy in both men and women because of its cost-effectiveness. However, due to its biological origin, hMG does not contain only FSH, and a certain fraction of the product binds to LH/hCG receptors. This led to the introduction of highly purified FSH (hpFSH) and recombinant human FSH (r-hFSH), with increasingly lower contents of compounds with LH activity but also higher costs. These selective compounds are specifically designed for women, because mimicking the menstrual cycle needs of a precise and selective LH and FSH activity at specific time points. However, in men, the selectivity of the stimulation is not required, and so far, no study demonstrated a superiority of the most expensive preparation upon the cheaper ones (Rastrelli et al. 2014). FSH binds its receptors on Sertoli cells, thus improving their support activity on germ cell differentiation and finally leading to testis growth, improved spermatogenesis, and fertility.

### Clinical Use

The use of FSH, pivotal for inducing fertility and pubertal development in patients with sHG, is not necessary in men not requiring fertility and in those with LOH. Conversely, hCG can be theoretically used in LOH, as an alternative to TRT, even though the less convenient administration of hCG should be kept in mind. Few studies evaluated the usefulness of hCG in LOH, and the results obtained with respect of different outcomes are reported in the dedicated section of the present chapter.

Gonadotropin therapy is well tolerated and side effects are rarely reported. Among them, gynecomastia is the most frequent, followed by allergic reactions and development of antibodies vs. the compounds limiting the pharmacologic activity (Corona et al. 2015).

### Testosterone

TRT is the most widespread therapy for hypogonadism, due to the greater convenience of the administration; the limited costs, as compared with GnRH and gonadotropin therapy; and the greater amount of available data on its outcomes. A number of different preparations of T have been developed for overcoming the pharmacokinetic disadvantages of native T (Table 2). In fact, native T either administered per os or parenterally is well absorbed, but rapidly inactivated by liver metabolism, and, therefore, it is not useful for therapy purpose. Bioavailability and pharmacokinetics of T have been improved by different chemical modifications: (i) the alkylation at the 17 $\alpha$  position prevents liver metabolism, but it causes hepatotoxicity, so that these preparations are almost abandoned, (ii) the alkylation at 1 position and the esterification of the 17 $\beta$ -hydroxyl group prevent liver metabolism without affecting liver function, and (iii) esterification at 17 $\beta$  position with carboxyl groups lends the property for intramuscular administration, but it does not provide a half-life longer than the native T, and a prolonged effect relies only on the delayed release from depot injections.

### Oral Preparations

T undecanoate (TU), with the substitution of undecanoic acid in 17 $\beta$  of T, is the only available preparation for oral administration (Table 2). It is absorbed in the bowel by the lymphatic vessels and then conducted in the systemic bloodstream bypassing the portal stream and thus the liver metabolism. The absorption through the lymphatic vessels requires a high content of lipid in the intestinal bolus. Hence, oral TU should be taken during meals with at least 20 mg of fat. Blood clearance for TU is high, and a daily covering with adequate concentrations is achieved if TU is administered at least three times a day (Table 2). However, this administration produces irregular T concentrations during the day. Oral TU has the advantages of self-administration, flexibility of dosage, and rapid elimination when interrupted (Table 2). This makes oral TU potentially useful for use in prepubertal boys and in older men. According to the clinical necessities, TU can be administered in dosage 20–40 mg daily (beginning pubertal development) to 120–240 mg daily (replacement of adult hormone levels) (Table 2).

### Transbuccal Preparations

This is a quite new preparation made by a muco-adhesive buccal patch containing T that is applied to the upper gum twice a day (Table 2). The absorption through the oral mucosa avoids the portal bloodstream and the liver metabolism. The use of patches of 30 mg twice daily achieved serum T levels in the eugonadal range in otherwise hypogonadal men (Wang et al. 2004), without any difference from those obtained with an equivalent dose T gels (Dobs et al. 2004). Rare and transient adverse effects were reported, mainly due to minor local conditions (Wang et al. 2004).

### Transdermal Preparations

This category includes T patches and T gels. Available T patches can be applied on scrotal or non-scrotal skin (Table 2). Available scrotal patches have a surface of 20, 40, or 60 cm<sup>2</sup>, containing 5, 10, and 15 mg of T, respectively, of whom, approximately one-third is delivered (Hadgraft and Lane 2015). Daily application in hypogonadal patients is able to restore T levels up to the eugonadal range, with serum T concentrations dependent on patch size and dosage (Hadgraft and Lane 2015). Non-scrotal patches contain T, glycerin, and enhancers for penetration. They are available in different sizes, with a T content that is proportional to the patch area (Hadgraft and Lane 2015). Patches should be applied once a day at bedtime for resembling the physiologic circadian rhythm of T with a peak serum concentration in the morning (Table 2). Dosage can be modulated by using one or two patches at a time. Different sites of application have been tried (Meikle et al. 1996) with the most convenient pharmacokinetics shown when patches were applied at the back, thigh, upper arm, and abdomen (Meikle et al. 1996).

For both scrotal and non-scrotal patches, local reactions, annoying enough to discontinue treatment, have been frequently reported, and they are the most important limitation to this form of therapy (Table 2).

Alternative preparations for transdermal use are represented by gels containing T. They have been first introduced in 2000 in the USA. They consist of a hydroalcoholic gel containing T with concentration ranging from 1% to 2%. T gels should be applied once daily in the morning, for mimicking circadian T rhythm, on the intact and dry skin of shoulders, upper arms, and abdomen (Table 2). Residuals should be removed for avoiding the possible transfer of gel to other people (Table 2). Swimming or bathing should be avoided in the hours following the application. The starting dose for gels is 5 or 2.5 g, for 1% and 2% gels, respectively, which allows the delivery of 5 mg daily, considering an average absorption of 10% (Table 2). The dosage might be titrated, according to plasma T levels, since skin absorption can vary considerably in each subject. Once the gel is absorbed, a reservoir of T forms in the stratum corneum of the skin, and T is delivered from there to the bloodstream during the following 24 h. Adverse events, mainly local reactions, are reported less frequently than with T patches, and T gels can be considered overall a well-tolerated medication. The concern of possible accidental transfer of gel led to the introduction of a 2% T solution that can be applied underarm (Table 2). Similar to T gels, it is an alcoholic solution with a daily administration, but it differs for the way of application that is through a metered dose applicator rather than hands. The underarm 2% T solution demonstrated to restore T

levels up to the normal range in hypogonadal men (Wang et al. 2011). A starting dose of 60 mg (30 mg/axilla) is recommended, and dose titration should be done according to serum T measurement. According to recently published data, T measurement for monitoring should be performed 8–16 h after the last application for minimizing inconsistency between T obtained from a single blood draw and mean T concentration during the day (Muram and Ni 2016). An alternative solution introduced for decreasing the risk of transfer is the 1.62% gels (Table 2). This formulation, available only in the USA, allows the application of a lower quantity of gel than the 1% preparations, thus reducing the residual that could be potentially transferred. Although these gels demonstrated to restore serum T levels up to the eugonadal range and to be well tolerated (Kaufman et al. 2011, 2012; Miller et al. 2011), the objective of limiting transfer is not achieved, since it has been shown that the risk remains significant for at least 12 h from the application (Stahlman et al. 2012a, b, c).

### **Injectable Preparation**

These preparations include 17 $\beta$ -hydroxyl esters dissolved in oily solutions. They can be classified according to their half-life into short and long acting (Table 2). Short-acting preparations include T propionate, T cypionate, and T enanthate. T propionate requires multiple administrations per week, usually 50–100 mg two or three times a week, and this very short half-life remarkably limits its routine use (Table 2). T cypionate and enanthate have relatively longer half-lives, which allows administration of 200–250 mg every 2–3 weeks, making these preparations more convenient (Table 2). Each of these preparations is characterized by a rapid and steep increase in serum T that often achieves supraphysiologic levels. However, T levels are not sustained for a long time and progressively and quickly decline to the hypogonadal range often before the following scheduled injection (Table 2). This “up-and-down” phenomenon has consequences both on symptoms and on safety. In fact, patients often perceive the fluctuation in T levels as a bothersome alternation of agitation and/or euphoria and reappearance of hypogonadal symptoms. Even more importantly, the supraphysiologic peak of serum T can overstimulate the bone marrow with consequent polycythemia, a potentially dangerous side effect, associated with incident stroke (Table 2). Despite these drawbacks, T cypionate and enanthate are still largely used worldwide for their limited costs and long pharmacovigilance.

The most recently introduced injectable preparation is a long-acting one (Table 2). It contains TU dissolved in castor oil, and both the presence of undecanoic acid in the molecule and the oil solution contribute to the longer half-life. The recommended administration requires a loading dose provided by injection of the first 4-mL vial containing 1,000 mg followed by a second one after 6 weeks and thereafter each 12 weeks (Table 2). TU is also available in 3-ml vials containing 750 mg that should be administered once at the initiation of therapy, at 4 weeks, and then every 10 weeks. TU is usually injected in the buttock where a reservoir develops into the muscle and from which TU is gradually and slowly released. This controlled and slow release avoids the wide fluctuation of T concentration in blood that is the most severe disadvantage of the short-acting injectable forms, and serum T levels after TU injection are maintained within the normal range and constant during the



entire period between the injections (Table 2). Consistently, the up-and-down symptoms are not reported in patients treated with this preparation. The long action of injectable TU, which is a desirable characteristic for the aforementioned reasons, can be sometimes a disadvantage because, when discontinuation is needed, a complete washout from this preparation takes up to 3 months. Among the side effects specific for this preparation, as for other injectable preparations, pain at the site of injection and the risk of fat embolism should be mentioned.

### **Pellet Preparation**

Pellets of T are small bars made by crystals of T. They must be introduced subcutaneously with a microsurgery intervention, including incision, implantation, and suture. For this reason, their use requires specialized personnel. Usually, four pellets containing 200 mg of T are implanted. After subcutaneous introduction, pellets are slowly eroded with delivery of T into bloodstream for 4–7 months. At present, T pellets are the most long-lasting preparation for TRT and this represents their strength. However, the required procedure for insertion, as well as side effects, such as infection or extrusion, is an important limitation for their therapeutic use (Table 2).

## **Antiestrogens**

### **Rationale for Use in Hypogonadism**

The negative feedback of T on the hypothalamus-pituitary is mediated by the estrogen receptors (ERs). For this reason, in sHG men with anatomically intact hypothalamus-pituitary structures, the increase of endogenous T levels can be obtained by the inhibition of ER signaling. A selective inhibition of ERs on hypothalamus-pituitary nuclei can be achieved by using selective ER modulators (SERMs). These molecules have been developed for having agonistic or antagonistic effect on ERs in different tissues. Besides hypothalamus-pituitary, SERMs have an ER antagonistic effect on the breast, whereas an agonistic effect is shown on the bone, liver, male genital tract, and venous system.

### **Different SERMs**

The progenitor of this pharmacological class, derivative of triphenylethylene, is clomiphene citrate, which is made for 62% by the trans-isomer (enclomiphene) and the remaining part by the cis-isomer (zuclomiphene). Enclomiphene is characterized by an entirely antagonistic effect and a shorter half-life (10.5 h), whereas zuclomiphene maintains both the agonistic and antagonistic effects and has a longer half-life (Corona et al. 2015). Among the first-generation SERMs, derivative of triphenylethylene and tamoxifen should also be mentioned. Tamoxifen is characterized by a similar pharmacodynamics of clomiphene, but in addition, an agonistic effect on the G protein-coupled receptor 30 (GPR30) has been shown (Comeglio et al. 2014). GPR30 is an ER expressed on cellular and intracellular membranes of several tissues in male genitourinary tract, including the bladder, prostate, testis, and corpora cavernosa (Comeglio et al. 2014), and its activation has been suggested as a possible pro-inflammatory mechanism in benign prostate hyperplasia (Comeglio

et al. 2014). Second- and third-generation molecules (raloxifene and bazedoxifene) have been later developed, but their use to date is limited to osteoporosis in females.

### Effect on Gonadal Axis

SERMs, administered orally, by antagonizing hypothalamus-pituitary ERs, increase gonadotropin levels, and, in turn, this corresponds to an increase in serum total T and sperm output (Corona et al. 2015). An increase in sex hormone-binding globulin (SHBG) levels, due to the agonistic effect of SERMs on the liver, resulting in unchanged free T, was not consistently reported (Corona et al. 2015). Only few studies have been conducted for evaluating the use of SERMs in men with hypogonadism, and they mainly used clomiphene with variable doses (25 or 50 mg, daily to thrice a week) (Corona et al. 2015). Tamoxifen 10 or 20 mg has been mostly studied in men with idiopathic oligozoospermia, and it demonstrated to improve sperm concentration, besides T and gonadotropin levels (Chua et al. 2013). More recently, a preparation containing only the enclomiphene isomer, rather than the mixture of the trans- and cis-isomers, has been developed for increasing the LH-dependent secretion on T in hypogonadal men. The rationale for this drug is to reduce the exposition to the ER agonist actions of the cis-isomer (zuclomiphene) which, given its longer half-life, achieves high serum concentrations during long-term clomiphene therapy (Helo et al. 2016). In sHG patients, either obese or non-obese, enclomiphene 12.5–25 mg daily, as compared with TRT, demonstrated an increase of total T levels similarly or more than T gel, with a concomitant increase in LH, FSH, and sperm count that, as expected, is not associated with TRT (Kaminetsky et al. 2013; Kim et al. 2016).

Further studies on the use of SERMs in sHG men are necessary for evaluating their advantages as compared with conventional therapies. Furthermore, the specific patients that can benefit the most from this treatment should be defined. However, SERMs seem to be promising options for treatment of hypogonadism. In fact, they carry the advantage of the oral administration and are well tolerated. Their agonistic effect on venous vessels causes the most serious of the adverse events, that, is venous thromboembolic disease, whose absolute risk, however, is relatively small (Kaminetsky et al. 2013; Kim et al. 2016; Riggs and Hartmann 2003; Smith et al. 2010, 2011).

## Non-pharmacological Therapy

### Weight Loss

The close relationship between body weight and serum T is well known, and ► [Chap. 30, “Late-Onset Hypogonadism”](#) in Part III of the present manual describes this topic in detail. The derangement in hypothalamus-pituitary-testicular function occurring in obese men is functional rather than organic, and, consequently, it is potentially reversible through the withdrawal of the pathogenic stimulus. Accordingly, weight loss is associated with an increase in T levels (Rastrelli et al. 2015; Corona et al. 2013). The consequences on T levels have been studied for both

low-calorie diet and bariatric surgery. A recent meta-analysis summarizing the results of the available studies shows that, whatever obtained, weight loss is associated with a significant increase in total and free T, as well as SHBG, and with a recovery of gonadotropins (Corona et al. 2013). The increase in total T is more pronounced after bariatric surgery intervention, which is associated with an increase of more than 10 nmol/L of total T [10.2 (6.6–13.8)], than in low-calorie diet [2.1 (1.0–3.2)] (Corona et al. 2013). According to this meta-analysis, the recovery in total T is greater in men with more severe obesity at baseline and in those experiencing a greater weight loss, whereas older age and diabetes mellitus limit the recovery of endogenous T levels (Corona et al. 2013). Whereas weight loss, either obtained with low-calorie diet or bariatric surgery, has demonstrated to improve metabolic outcomes and sexual function (Tuomilehto et al. 2001; Gupta et al. 2011), the contribution of weight loss-related increase of T levels to the recovery mechanisms has never been specifically investigated.

---

## How to Follow Patients Undergoing Therapy for Hypogonadism?

When starting TRT, it is recommended to perform the first follow-up visit after 3–6 months and then once yearly (Wang et al. n.d.; Bhasin et al. 2010; Dohle et al. 2015). During follow-up visits, symptoms and signs of androgen deficiency should be assessed as well as serum T levels, with the aim of achieving the middle of the eugonadal range (Wang et al. n.d.; Bhasin et al. 2010; Dohle et al. 2015). Furthermore, the onset of side effects should be ruled out. The main side effects during TRT are polycythemia, due to the anabolic effect of T on bone marrow erythropoiesis and acceleration of prostate cancer growth. For monitoring polycythemia onset, hematocrit must be evaluated and therapy interrupted if it increases up to 52–54% (Wang et al. n.d.; Bhasin et al. 2010; Dohle et al. 2015). In polycythemic patients, phlebotomy could be considered for decreasing hematocrit, and evaluation for comorbid sleep apnea syndrome or other causes of secondary polycythemia should be ruled out and adequately treated (Wang et al., n.d.; Bhasin et al. 2010; Dohle et al. 2015). When normal values are achieved, TRT can be started again with a lower dosage (Bhasin et al. 2010). The presence or development of prostate cancer must be evaluated by performing digital rectal examination (DRE) and measuring prostate-specific antigen (PSA) (Wang et al. n.d.; Bhasin et al. 2010; Dohle et al. 2015). It should be born in mind that PSA levels physiologically increase during the first months of therapy, as a trophic effect of T on prostate. However, when eugonadism is restored, PSA achieves a plateau and further elevations are suspected (Rastrelli et al. 2013). Further evaluations, including transrectal prostate ultrasound, prostate biopsy, and urological consultation, should be performed when a prostate nodule is detected by DRE or when an increase in PSA of more than 0.4 ng/mL from the PSA measured after 6 months of therapy or more than 1.4 ng/mL during any 12 months period is found (Bhasin et al. 2010).

Specific recommendations for monitoring GnRH or gonadotropin therapy are not available. Following the same scheme of follow-up visits of TRT is reasonable, and,

even though the increase in serum T levels in patients treated with GnRH or gonadotropin is limited by the testicular functional potential, hematocrit and PSA could be considered useful parameters for monitoring side effect onset. Similar remarks can be made for SERMs whose safety in hypogonadal men has been recently evaluated in a small cohort without finding any significant increase in PSA or hematocrit during a mean follow-up of almost 1 year (Chandrapal et al. 2016).

---

## What Are the Objectives of Therapy?

When starting a treatment for hypogonadism, it is important to consider whether the patient wishes to become fertile in a short-term period. In fact, whereas GnRH and gonadotropin therapy as well as SERMs can improve spermatogenesis thus favoring fertility, TRT has a neutral or even detrimental effect on it. To date, TRT is not indicated in men wishing fertility, even though its long-term consequences on fertility are still debated. This topic is particularly relevant for boys with sHG who start a treatment several years before planning a pregnancy. In these patients, the most convenient therapy is represented by T preparations, which are characterized by a lower cost and by a simpler administration, making them more sustainable for long-term therapy. However, a study conducted in Australia on 75 gonadotropin-deficient men showed that the use of TRT before attempting conception negatively affected the outcome, in terms of speed of attainment of spermatogenesis and conception (Liu et al. 2009). In apparent contrast, a meta-analysis of the studies considering the improvement of spermatogenesis during gonadotropin replacement therapy in azoospermic men with sHG has shown that the rate of patients who achieved spermatogenesis and the concentration of spermatozoa in semen were not significantly different in men with or without a previous TRT (Rastrelli et al. 2014). After the publication of this meta-analysis, two other studies failed to find a detrimental effect of a previous TRT on fertility outcomes (Liu et al. 2016; Mao et al. 2015). Although studies specifically designed for answering this question are needed, present data reassure on the opportunity of TRT for long-term therapy, even in younger patients.

Among hypogonadal men, only those with a hypothalamic-pituitary disorder (sHG) can be treated with GnRH, gonadotropins, or SERMs for restoring or improving fertility. In fact, men with a primary testicular injury cannot benefit from GnRH or gonadotropin therapy, and TRT is the only therapeutic option. Hence, when evaluating patients for hypogonadism, only serum T measurement is not sufficient but also serum gonadotropins and needed, because they allow classifying the condition into primary or secondary hypogonadism, with important practical implications.

All treatments for hypogonadism have the common outcome of increasing serum T levels. Irrespective of the therapy used, this allows to treat androgen deficiency symptoms and to maintain androgen-dependent functions. Clinical results have been investigated in several studies. The highest degree of evidence on therapy efficacy is

provided by RCTs. It should be noted that in the field of hypogonadism therapy, RCTs are relatively few, involving small samples and for short follow-ups. A great advance on knowledge, at least in part overcoming the problem of sample size, is provided by meta-analyses. However, for some outcomes, RCTs are not at all available, and observational longitudinal studies represent the highest level of evidence. The following paragraphs summarize the evidence available on outcomes of therapy for hypogonadism. Since the scientific literature is mostly focusing on TRT, and specifically on advantages and disadvantages of TRT in LOH, the following sections will be mainly concentrated on this topic.

## Fertility

As mentioned above, for obtaining fertility in sHG men, it is mandatory to treat with GnRH, gonadotropins, or SERMs. Studies on fertility outcomes upon these treatments are few, and, in particular, RCTs are lacking. This is most probably due to ethical concerns deriving from the use of placebo and the lack of alternative established therapies to which GnRH, gonadotropins, or SERMs could be compared. Furthermore, congenital sHG, which is a pure model for studying the efficacy of GnRH or gonadotropin treatments, is a rare condition which makes the recruitment of subjects for a well-powered study extremely challenging.

## GnRH or Gonadotropin Therapy

Several longitudinal studies exist, and a meta-analysis has been recently performed on the use of GnRH and gonadotropin therapy in azoospermic men with secondary hypogonadism (Rastrelli et al. 2014). According to this meta-analysis, 75% of patients obtained the appearance of spermatozoa in semen after treatment with GnRH, with a mean sperm concentration of 4.3 million/mL achieved (Rastrelli et al. 2014). Similar results were obtained in men undergoing gonadotropin therapy with a slightly higher sperm concentration achieved, i.e., 5.9 million/mL (Rastrelli et al. 2014). In subjects undergoing gonadotropin replacement, the use of combined therapy with FSH and hCG resulted in significantly better results than the use of hCG only (Rastrelli et al. 2014). Furthermore, studies recruiting both patients with pre- and postpubertal-onset hypogonadism found significantly better results than studies involving only prepubertal hypogonadal subjects, thus suggesting that postpubertal hypogonadism is more responsive to gonadotropin therapy (Rastrelli et al. 2014). As previously mentioned, previous TRT did not negatively affect the results, and no differences were obtained when recombinant, purified, or urinary derived FSH were used (Rastrelli et al. 2014). In addition, patients with sHG derived from either hypothalamic or pituitary conditions had similar success after gonadotropin therapy. Data derived from studies on GnRH were available only for comparison of results in pre- and postpubertal-onset hypogonadism, and they substantially confirmed the findings of gonadotropin therapy (Rastrelli et al. 2014).

## SERM Therapy

Concerning SERMs, the change in sperm parameters has been evaluated in few observational studies in hypogonadal men (Corona et al. 2015). A RCT comparing enclomiphene with T gel and placebo in obese hypogonadal men with normal sperm count has been recently published (Kim et al. 2016). In this study, enclomiphene demonstrated an increase in T levels up to the normal range maintaining a normal sperm concentration, whereas T gel was associated with T levels in the normal range but a significant decrease in sperm count and placebo with T in the hypogonadal range with a nonsignificant slight decline in sperm count (Kim et al. 2016). RCTs on the efficacy of SERMs in improving semen parameters and/or fertility in hypogonadal infertile men are not available. The improvement in fertility upon SERMs has been studied with a RCT designed only for idiopathic infertile men. The results of these RCTs have been reviewed in three meta-analyses during the last 20 years. The earliest ones (Kamischke and Nieschlag 1999; Vandekerckhove et al. 2000) failed to find a significant effect of different antiestrogens on pregnancy rate, whereas the most recent and updated meta-analysis (Chua et al. 2013) shows that SERMs can improve sperm concentration and motility as well as pregnancy rate.

## Sexual Function

### The Role of Endogenous T

T is involved in regulating sexual function at several levels. Discrete brain areas, important for the sexual behavior and for the response to sexual stimuli – such as the amygdala, nucleus accumbens, medial preoptic area, paraventricular nucleus of the hypothalamus, and periaqueductal gray matter – express the androgen receptor (Rochira et al. 2003). Penile erection, the physical counterpart of arousal, is a neurovascular process highly affected by androgen milieu (Isidori et al. 2014). T induces, preserves, and maintains smooth muscle cells of corpora cavernosa and nerves involved in neuro-signaling leading to erection (Isidori et al. 2014). In addition, it modulates the expression of enzymes involved in both relaxation (endothelial and neuronal nitric oxide synthases and Ras homologue gene family member/Rho-associated kinase) and contraction (phosphodiesterase type 5) of cavernosal smooth muscle cells, thus facilitating erection but also allowing its termination (Isidori et al. 2014). Even ejaculation is largely affected by T (Corona et al. 2012). Ejaculation is the result of a reflex arising from genital and/or brain stimulation which leads to the rhythmic contractility of pelvic muscles and muscles of the genital tract which results in emission of semen bolus (Corona et al. 2012). Supraspinal nuclei that modulate the reflex (medial preoptic area, bed nucleus of the stria terminalis, median amygdala, and posterior thalamus) as well as perineal and genital tract muscles are androgen dependent (Corona et al. 2012). Hence, it is not surprising that sexual dysfunction is frequently reported by subjects with low T. Similar to all the symptoms that can be associated with hypogonadism, sexual symptoms are frequent also in subjects with T levels within the eugonadal range, and their prevalence increases as a function of aging. Nonetheless, they are considered the

most specific symptoms for defining LOH, and according to the EMAS study, they are among the minimum criteria for its diagnosis (Wu et al. 2010).

### **Efficacy of TRT**

Several studies evaluated the efficacy of T preparations for improving sexual dysfunctions with conflicting results. A recent meta-analysis of the available RCTs, taking into account overall 1,930 subjects for a mean follow-up of 27 weeks, demonstrated that T therapy significantly improved erectile function, sexual desire, and orgasmic function (Corona et al. 2014a; Fig. 1). Interestingly, when analyzing separately studies involving eugonadal or hypogonadal men, T therapy was effective in improving sexual outcomes only in hypogonadal men, with progressively better results as a function of T deficiency at baseline. After the publication of this meta-analysis, the efficacy of TRT in improving sexual function has been further confirmed by two additional RCTs. The former RCT, involving almost 600 hypogonadal men >18 years, randomly assigned patients to receive placebo or T gel 2% underarm for 16 weeks (Brock et al. 2016). The latter RCT, involving almost 800 older hypogonadal men (>65 years old), randomly assigned to receive T gel 1% or placebo for 1 year (Snyder et al. 2016). Recently, a systematic review of RCTs on the use of TRT on several outcomes, including the improvement in sexual symptoms, concluded for no evidence from RCTs for beneficial effects of TRT on sexual symptoms (Huo et al. 2016). However, it must be noticed that the authors did not employ the meta-analytic method, and the evaluation appears largely qualitative. In conclusion, evidence so far suggest that, although long-term studies involving large samples are still advocated, available data support a role of TRT in improving sexual symptoms.

### **Efficacy of GnRH or Gonadotropin Therapy**

Data on the improvement of sexual symptoms in men with LOH treated with GnRH are lacking, whereas few studies evaluated the role of hCG. In a study evaluating the administration of hCG 3,000 IU every 2 weeks, for a mean of 8 months, to 21 patients aged more than 50 years, a significant improvement in androgen deficiency symptoms, as derived from the Aging Male Scale (AMS) questionnaire, has been found. However, no improvement in erectile dysfunction, as assessed by the International Index of Erectile Function (IIEF), was reported (Tsuji-mura et al. 2005). In a more recent study, comparing 6-month treatment with hCG (2,000 IU twice a week) to TRT in 50 men with LOH (median age 50 years), no difference in improvement of sexual function was found between hCG and TRT (La Vignera et al. 2016).

### **Efficacy of SERMs**

The role of SERMs on sexual function in hypogonadal men has been scarcely investigated (Corona et al. 2015). The only RCT (Guay et al. 1995), involving 17 patients with SHG and erectile dysfunction, comparing clomiphene 50 mg three times a week with placebo for 2 months with a crossover design failed to show an

improvement in erection, either self-assessed by questionnaires or evaluated by the nocturnal penile tumescence and rigidity testing. Whereas clomiphene was not associated with the improvement of erectile function, one of the symptoms deemed to be most specific to low T results from RCTs demonstrated its effectiveness in preventing and treating gynecomastia and mastodynia in men with profound hypogonadism induced by androgen deprivation therapy for prostate cancer (Saltzstein et al. 2005; Perdonà et al. 2005; Bedognetti et al. 2010).

## Physical Strength and Body Composition

### The Role of Endogenous T

Hypogonadism is associated with change in body composition, with a decrease in lean mass, and with an increase in fat mass. This has been recently confirmed in a sample of more than 400 young and middle-aged healthy volunteers in whom a profound hypogonadotropic hypogonadism was experimentally induced by a GnRH analogue (Finkelstein et al. 2013). In these men, hypogonadism was associated with a reduction in lean mass and leg-press strength, as well as an increase in total fat mass (Finkelstein et al. 2013). These alterations were fully restored by the administration of exogenous T, which can be converted to usual metabolites (i.e., estrogens and dihydrotestosterone) (Finkelstein et al. 2013). Feeling of reduced energy and physical strength is a common complaint in hypogonadal patients, but it is a frequent finding also in aging men and in those with chronic illnesses, including obesity. These conditions are, in turn, frequently associated with low T levels, and this complex, bidirectional, physio-pathological network makes it challenging to understand whether decreased physical vigor is a real consequence of low T, possibly improved with restoration of normal T levels, or just an etiological determinant of hypogonadism.

### Efficacy of TRT

A recent meta-analysis of the available RCTs on the efficacy of T therapy in modifying body composition takes into account more than 5,000 men, with a mean age of 62 years and a mean follow-up of 8.7 months (Corona et al. 2016; Fig. 1). It demonstrated that actively treated men, as compared with placebo, have a significantly reduced fat mass (Fig. 1), with a significantly greater effect obtained in hypogonadal men, and an increased lean mass (Fig. 1), with a similar effect in eugonadal and hypogonadal subjects (Corona et al. 2016). However, the increase in lean mass is not accompanied by an improvement in physical performance, as shown by another meta-analysis, which found a small effect with a trend toward significance only for improvement in dominant knee extension and handgrip (Isidori et al. 2005; Fig. 1). However, the studies considered in the meta-analysis were few, involving less than 300 subjects with a mean follow-up of 9 months. It is possible that the power was not adequate to detect differences between placebo and T or also



# Studies	# Subjects	Follow-up (weeks)	Age (years)	Effect size
16	234	N/A	18-46	Success rate
48	897	N/A	18-38	Success rate
11	1091	6-48	20-75	Difference in means
11	826	4-52	21-72	Difference in means
10	700	6-52	20-75	Difference in means
11	715	12-168	52-77	Standardized diff in means
10	1000	12-168	52-71	Standardized diff in means
5	203	12-144	59-73	Standardized diff in means
4	94	12-48	67-76	Standardized diff in means
4	191	12-144	59-73	Standardized diff in means
5	253	12-144	68-77	Standardized diff in means
7	409	12-48	52-69	Difference in means
6	397	12-52	52-69	Difference in means
15	784	12-168	33-71	Difference in means
12	631	12-168	33-71	Difference in means
7	833	12-48	44-64	Standardized diff in means
6	649	12-48	44-64	Difference in means
5	178	12-144	36-71	Standardized diff in means
6	322	36-144	41-73	Standardized diff in means
7	355	6-12	>18	MH odds ratio

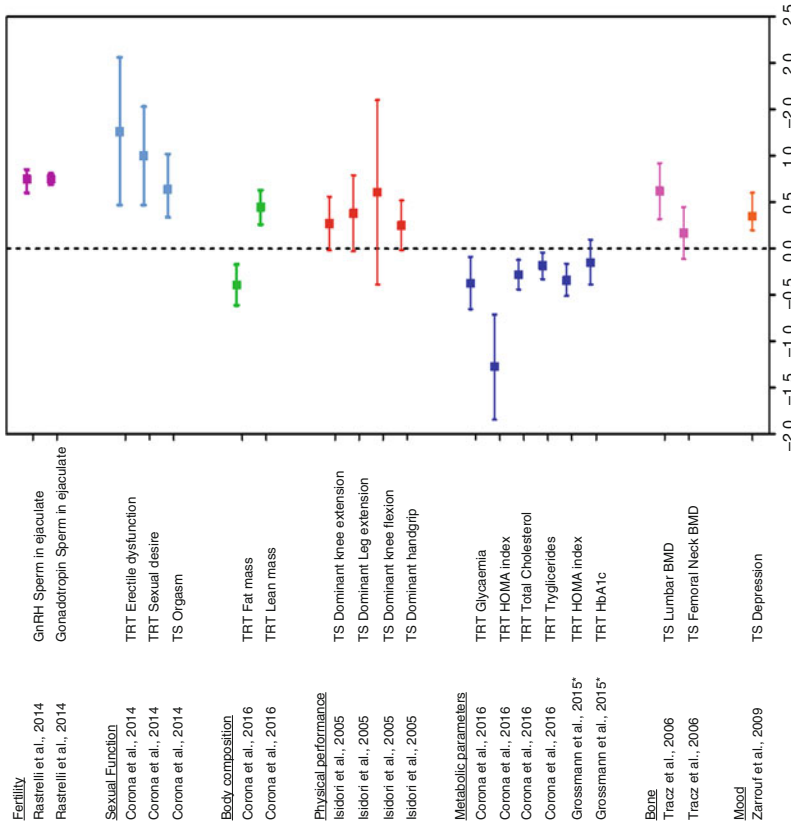


Fig. 1 (continued)

that the effect on physical performance test requires longer therapy to be apparent. After the publication of this meta-analysis, other RCTs assessing the efficacy of TRT in improving physical performance and muscle strength have been published (Travison et al. 2011; Kenny et al. 2010; Sheffield-Moore et al. 2011; Hildreth et al. 2013), again with conflicting results. Also for these studies, the short-term follow-up is a concern. Furthermore, they all considered populations of elderly and/or frail men. Despite these disappointing results on objective evaluations of physical performance, data on subjective perception of improvement of physical endurance and strength, assessed both in longitudinal observational studies (Zitzmann et al. 2013; Rastrelli et al. 2016b) and RCTs (Snyder et al. 2016), demonstrated that it may be ameliorated by TRT.

### **Efficacy of GnRH or Gonadotropin Therapy**

Concerning GnRH and physical strength and body composition, no studies are available. A randomized clinical trial, involving 40 patients with LOH treated with hCG 5,000 IU twice weekly for 3 months, demonstrated that hCG significantly improved lean mass, with a reduction in fat mass, without any change in physical functioning (Liu et al. 2002). In another RCT, hCG administered for 6 months produced improvement in body composition without significant differences from TRT (La Vignera et al. 2016).

### **Efficacy of SERMs**

Although few observational studies evaluated the body composition during therapy with SERMs in hypogonadal men producing nearly neutral results (Corona et al. 2015), data on this outcome are too scanty for drawing conclusions.

## **Metabolic Parameters**

### **The Role of Endogenous T**

Effect of TRT on changing metabolic parameters is closely related to the previous topic (change in body composition). As mentioned above, low T is associated with



**Fig. 1** Summary of the results of the most recent meta-analyses published on the effect of therapy for hypogonadism on different outcomes. When available, data deriving from studies on hypogonadal men were reported. Direct comparisons can be done only when the same effect size was used in different meta-analyses. Standardized difference in means is reported as Hedges *g*. Hedges *g* is commonly interpreted as follows: values around 0.2 represent a small effect size, values around 0.5 represent a medium effect size, and values around 0.8 represent a large effect size. \*This meta-analysis included studies conducted on hypogonadal men with metabolic syndrome or diabetes mellitus. *GnRH* gonadotropin-releasing hormone, *TRT* testosterone replacement therapy (results obtained from studies enrolling hypogonadal men), *TS* testosterone supplementation (results obtained from studies enrolling eugonadal or mixed eu- and hypogonadal men), *HOMA* homeostasis model assessment, *HbA1c* glycated hemoglobin, *BMD* bone mineral density, *MH* Mantel-Haenszel

an increase in fat mass and a decrease in lean mass. Besides these quantitative changes, T is also involved in qualitative changes of metabolism. Important information on this topic has been provided by studies on androgen receptor knockout (ARKO) mice. ARKO mice develop obesity, with shift from a brown to a white adipose tissue phenotype (Yanase et al. 2008). Furthermore, ARKO mice develop hypertriglyceridemia, as well as skeletal muscle and liver steatosis (Yeh et al. 2002). These conditions stem for a status of insulin resistance. Accordingly, an insulin-sensitizing role for T has been confirmed by *in vivo* studies. In a rabbit model of metabolic syndrome, induced by a high-fat diet, hypogonadotropic hypogonadism is one of the phenotypical features. In this model, pre-adipocytes prepared from visceral adipose tissue showed a downregulation of genes involved in adipogenesis and an impairment in triglyceride synthesis, glucose uptake, AKT phosphorylation, and GLUT4 membrane translocation (Maneschi et al. 2012, 2013), all conditions consistent with an insulin resistance. In pre-adipocytes deriving from rabbits fed with a high-fat diet and co-treated with T therapy, these derangements were prevented, thus showing that T can play a role in adipocyte commitment and function (Maneschi et al. 2012).

### **Efficacy of TRT**

The effectiveness of TRT in improving metabolic outcomes has been evaluated by RCTs, whose results have been pooled in a recent meta-analysis (Corona et al. 2016). In hypogonadal subjects, TRT is associated with a significant, although modest, improvement in fasting glycemia and insulin sensitivity, as assessed by the HOMA index (Corona et al. 2016; Fig. 1). When considering only hypogonadal patients, TRT was also able to reduce total cholesterol and triglycerides (Corona et al. 2016; Fig. 1). A different and almost contemporary meta-analysis evaluated the effect of TRT, lasting from 3 to 12 months, on metabolic parameters in men with metabolic syndrome and diabetes mellitus (Grossmann et al. 2015; Fig. 1). In this meta-analysis, involving overall more than 800 men aged 44–64 years, only a small decrease in HOMA index was found with no effect on glycated hemoglobin (Grossmann et al. 2015; Fig. 1). These data overall denote that a considerable degree of uncertainty on this topic still exists. According to present data, TRT on glycolipid metabolism has a small effect, if any. However, it should be noted that the RCTs on the topic have been conducted for a short follow-up, mostly less than 1 year, and it is conceivable that modifications in metabolic functions take longer time to make their results evident. However, pending further studies, at present there is not enough evidence to advice TRT as a treatment for metabolic derangements in hypogonadal men.

### **Efficacy of GnRH or Gonadotropin Therapy**

Few data are available on the effect of hCG on metabolic parameters and none on GnRH therapy. In a RCT the use of hCG 5,000 IU twice a week in men with LOH was associated with a significant decrease in both total and LDL cholesterol and triglycerides, without any change in HDL cholesterol and HOMA index (Liu et al.

2002, 2003). In a recent RCT, hCG 200 IU twice a week produced similar results to TRT, improving lipid profile and markers of insulin sensitivity (La Vignera et al. 2016).

### **Efficacy of SERMs**

The change in metabolic parameters upon SERMs has been reported in few longitudinal studies with conflicting results on glucose and lipid profile (Corona et al. 2015), but no RCT so far have evaluated this outcome.

## **Bone Health**

### **The Role of Endogenous T**

T is involved in maintenance of bone tissue. Although for long time it has been assumed that its action was completely mediated by the aromatization to estradiol, there is now evidence also of a direct role of T (Meier et al. 2008; LeBlanc et al. 2009). Whatever the mechanism, hypogonadism is among the most important risk factors for decreased bone mineral density (Tajar et al. 2012) and fractures (Tran et al. 2015; Drake et al. 2012) in men.

### **Efficacy of TRT**

The RCTs conducted so far assessing the efficacy of TRT in improving bone mineral density are few and with a maximum follow-up of 36 months. Two meta-analyses (Isidori et al. 2005; Tracz et al. 2006) of the RCTs have consistently found a modest increase in bone mineral density at lumbar spine and no change at femoral neck (Fig. 1); data further confirmed in a following RCT (Kenny et al. 2010). Unfortunately, so far, no study evaluated the effect of TRT in reducing bone fractures; hence T is still not approved for treatment and prevention of osteoporosis (MacLean et al. 2008).

### **Efficacy of SERMs**

SERMs, in particular raloxifene, are an approved second-line drugs for treatment of osteoporosis, and they have been mostly studied in women. Bone parameters in hypogonadal men treated with SERMs have been assessed in few longitudinal studies (Moskovic et al. 2012; Kacker et al. 2014) with mixed results. Few RCTs have been conducted. These showed that raloxifene (60 mg daily; Smith et al. 2004) or toremifene (80 mg daily; Smith et al. 2010, 2011, 2013) improves bone mineral density and bone turnover and decreases the risk of fractures in men with prostate cancer and hypogonadism induced by androgen deprivation therapy.

### **Efficacy of GnRH or Gonadotropin Therapy**

No data on the effect of GnRH or gonadotropin therapy on bone mineral density or fractures are available.

## Mood

### The Role of Endogenous T

Data linking T levels and mood are quite inconsistent. There is evidence that T is significantly lower in depressed than in nondepressed men (Burriss et al. 1992; Baischer et al. 1995; Osran et al. 1993; Seidman and Walsh 1999; Sachar et al. 1973). In addition, a high prevalence of hypogonadism is found among patients with a drug-resistant depression (Delhez et al. 2003; Yesavage et al. 1985). Furthermore, basal and GnRH-stimulated gonadotropin levels are blunted in depressed men (Brambilla et al. 1990; Uden et al. 1988; Amsterdam et al. 1981). However, in epidemiological studies on general population, the association between T levels and depressive symptoms is weak or absent (Rastrelli et al. 2015; Wu et al. 2010; Delhez et al. 2003).

### Efficacy of TRT

The several RCTs that have been conducted for assessing the efficacy of T therapy in improving depressive symptoms have provided conflicting results. However, it is not clear whether the inconsistency is due to a minimal or null effect of T therapy or, otherwise, it is ascribable to differences in populations analyzed that were hypo- or eugonadal, dysthymic or with major depression, treated only with T or using also other antidepressants. A meta-analysis of seven RCTs has shown a significant T-induced decrease in depressive symptom that was confirmed in studies enrolling hypogonadal men (Fig. 1), but not in those enrolling eugonadal ones (Zarrouf et al. 2009). However, in following RCTs using TRT alone or as an augmentation therapy in drug-resistant depressive men, this positive effect on mood was not confirmed (Snyder et al. 2016; Pope et al. 2010).

### Efficacy of GnRH, Gonadotropins, or SERMs

No data on the effect of GnRH, gonadotropin, or SERM therapy on mood are available.

## Cardiovascular Health

### The Role of Endogenous T

The association between T and cardiovascular (CV) diseases (CVD) is extremely controversial and is the center of an intense debate. Epidemiological studies drew different conclusions (Corona et al. 2011a), but the meta-analysis of their results showed that low serum T levels are not associated with incidence of CV events (Corona et al. 2011b); however, they are significantly associated with increased CV mortality (Corona et al. 2011b; Araujo et al. 2011). Accordingly, in a population of subjects with erectile dysfunction, T levels in the overt hypogonadal range were associated with CV lethality. In other words, low T is not a risk factor for forthcoming CV events, but when a CV event occurs, it is more often fatal in men with low serum T. The biological meaning of this phenomenon is not clear, and it should also

be considered that the knowledge in this field could be affected by a citation bias, i.e., more often studies reporting negative or neutral results on a T-dependent CV risk are cited (Zhao and Schooling 2015). A direct effect of T level on lethality from CV events can be hypothesized based on the role of T in regulation of vasomotion and hemostasis or as an anti-inflammatory factor (Corona et al. 2011a). However, the role of low T could be mediated by associated conditions leading to CV mortality, such as obesity and insulin resistance with its related metabolic derangements. Another possibility is that low T is a just a marker of frailty or poor health conditions. Besides its role as a marker, low T in frail men has been hypothesized to be a protective mechanism, for switching off unnecessary functions, such as fertility and sexuality, and shifting energy toward vital functions (Pesonen et al. 2016). Accordingly, in subjects with sexual dysfunction, low T is associated with an increased incidence of CV events in normal weight men, whereas it represents a protective factor in obese ones (Corona et al. 2011c). Similarly, in the same cohort, subjects with a history of previous CV events and low T are less prone to the occurrence of a new CV event than the eugonadal counterpart (Corona et al. 2014b). Understanding the pathogenetic link between low T and CVD is of pivotal relevance. In fact, if a direct or indirect causative role of TRT on CVD is demonstrated, TRT could be beneficial, whereas if low T represents a resilient, protective mechanism against CVD, TRT would be even detrimental. RCTs specifically designed for evaluating the effect of TRT on development of CV event morbidity or mortality is still lacking.

### **TRT Safety on CV Health**

Three meta-analyses have been conducted summarizing the CV safety data extracted from RCTs designed for the assessment of the efficacy of TRT on different outcomes, other than CV events. Two of them (Fernandez-Balsells et al. 2010; Corona et al. 2014c), including the most recent and updated one (Corona et al. 2014c), found no significant relationship between TRT and CV events, whereas another one (Xu et al. 2013) showed a higher incidence of CV events in men treated with TRT. The meta-analysis that concludes for a significant CV risk associated with TRT (Xu et al. 2013) considered as CV events, not only the major adverse CV events (MACE), but a broad spectrum of composite endpoints, including peripheral edema and self-reported syncope, thus leading to an overestimation of the risk. On the other hand, the meta-analyses showing no significant association (Fernandez-Balsells et al. 2010; Corona et al. 2014c) did not use a temporal threshold as an exclusion criterion, thus allowing for the inclusion of studies with a duration not sufficient to detect CV events. Accordingly, the most recent meta-analytic survey (Albert and Morley 2016) did not find any significant association between TRT and CV events, although in a sub-analysis of data an increased risk was reported in subjects older than 65 years, especially in the first year of supplementation. It is important to note that all the aforementioned meta-analyses consider studies not designed for assessing CV outcomes. This can lead to an underestimation of the incidence of MACE due to an underpowered study population. On the other hand, these studies can be affected by a misclassification of MACEs, which do not undergo a formal adjudication by an ad hoc committee. This can possibly provide an underestimation, but more probably, it

is associated with an overestimation of the risk, as happened in a quite recent RCT (Basaria et al. 2010) where events such as peripheral edema or elevation of blood pressure are included among the CV events.

In the last few years, the topic of the relationship between TRT and CV outcomes has been the primary aim of large observational studies with a retrospective design, which produced mixed results. Among them, two found an increased CV risk in subjects treated with T (Vigen et al. 2013; Finkle et al. 2014), whereas the most recent one (Wallis et al. 2016) found a significantly lower mortality and incidence of CV events in men undergoing TRT. However, an important bias common to all these studies is that information on TRT is obtained by databases reporting prescriptions and their filling, but no biological data are available for confirming the actual use of TRT.

Overall, the data on TRT and CV events are scanty and of not adequate quality for drawing conclusions on this important topic. Pending further studies specifically designed and powered for the assessment of this outcome, the FDA recommended caution in prescribing medications containing T in aging men (Corona and Maggi 2015; <http://www.fda.gov/Drugs/DrugSafety/ucm436259.htm>), whereas the European Medicines Agency expressed a more reassuring judgment, concluding that, so far, there is not consistent evidence of an increased risk of heart problems with T medicines ([http://www.ema.europa.eu/ema/index.jsp?curl=pages/medicines/human/referrals/Testosterone-containing\\_medicines/human\\_referral\\_prac\\_000037.jsp&mid=WC0b01ac05805c516f](http://www.ema.europa.eu/ema/index.jsp?curl=pages/medicines/human/referrals/Testosterone-containing_medicines/human_referral_prac_000037.jsp&mid=WC0b01ac05805c516f)). We therefore suggest offering TRT only in subjects with proven T deficiency and exerting caution in those with underlying health conditions.

---

## Summary

Hypogonadism is a frequent condition, in particular during adulthood (Part III, ► Chap. 30, “Late-Onset Hypogonadism”). Whereas no doubts exist on the opportunity of treating patients with hypogonadism deriving from definite conditions affecting hypothalamic-pituitary-testicular axis, more concerns are present for treatment of men with age-related T decline, the so-called LOH. Several options, either pharmacological or not pharmacological, are available for treating hypogonadism, and the choice should be done according to rationale, indications, and expected outcomes, taking also into account advantages and disadvantages associated with each molecule, preparation, or strategy.

Although GnRH and gonadotropins are the cornerstone of therapy in sHG men requiring fertility, few data are present on their use in LOH. Data are scanty also for the use of SERMs for treatment of hypogonadism. Weight loss represents the most physiological treatment for increasing T levels in obese men, and strategies for losing weight should be encouraged as the first-line treatment in these men. However, there is no evidence that the improvement in metabolic and sexual outcomes is due to recovering in T levels, rather than weight loss per se. TRT is the most often employed therapy in this particular and controversial condition. RCTs on TRT are few and short lasting. However, there is substantial consistence on the efficacy of

TRT in improving sexual function, increasing lean mass, and decreasing fat mass. More controversial results are present for the effectiveness of TRT in improving glycolipid profile and mood. Concerning bone mineral density, the evidence is scarce, and those concerning fractures are absent. An intense debate is ongoing on the putative risk of CV events associated with TRT. Pending results from RCTs specifically designed for assessing this outcome, available evidence reassures on CV safety of TRT, but caution should be used in older and frail men.

---

## References

- Albert SG, Morley JE. Testosterone therapy, association with age, initiation and mode of therapy with cardiovascular events: a systematic review. *Clin Endocrinol (Oxf)*. 2016;85(3):436–43.
- Amsterdam JD, Winokur A, Caroff S, Snyder P. Gonadotropin release after administration of GnRH in depressed patients and healthy volunteers. *J Affect Disord*. 1981;3:367–80.
- Anawalt BD. Approach to male infertility and induction of spermatogenesis. *J Clin Endocrinol Metab*. 2013;98:3532–42.
- Araujo AB, Dixon JM, Suarez EA, Murad MH, Guey LT, Wittert GA. Clinical review: Endogenous testosterone and mortality in men: a systematic review and meta-analysis. *J Clin Endocrinol Metab*. 2011;96:3007–19.
- Baischer W, Koinig G, Hartmann B, Huber J, Langer G. Hypothalamic-pituitary-gonadal axis in depressed premenopausal women: Elevated blood testosterone concentrations compared to normal controls. *Psychoneuroendocrinology*. 1995;20:553–9.
- Basaria S, Coviello AD, Travison TG, Storer TW, Farwell WR, Jette AM, Eder R, Tennstedt S, Ulloor J, Zhang A, Choong K, Lakshman KM, Mazer NA, Miciek R, Krasnoff J, Elmi A, Knapp PE, Brooks B, Appleman E, Aggarwal S, Bhasin G, Hede-Brierley L, Bhatia A, Collins L, LeBrasseur N, Fiore LD, Bhasin S. Adverse events associated with testosterone administration. *N Engl J Med*. 2010;363:109–22.
- Bedognetti D, Rubagotti A, Conti G, Francesca F, De Cobelli O, Canclini L, Gallucci M, Aragona F, Di Tonno P, Cortellini P, Martorana G, Lapini A, Boccardo F. An open, randomised, multicentre, phase 3 trial comparing the efficacy of two tamoxifen schedules in preventing gynaecomastia induced by bicalutamide monotherapy in prostate cancer patients. *Eur Urol*. 2010;57:238–45.
- Bhasin S, Cunningham GR, Hayes FJ, Matsumoto AM, Snyder PJ, Swerdloff RS, Montori VM, Task Force, Endocrine Society. Testosterone therapy in men with androgen deficiency syndromes: an Endocrine Society clinical practice guideline. *J Clin Endocrinol Metab*. 2010;95:2536–59.
- Bianco SD, Kaiser UB. The genetic and molecular basis of idiopathic hypogonadotropic hypogonadism. *Nat Rev Endocrinol*. 2009;5:569–76.
- Brambilla F, Maggioni M, Ferrari E, Scarone S, Catalano M. Tonic and dynamic gonadotropin secretion in depressive and normothymic phases of affective disorders. *Psychiatry Res*. 1990;32:229–39.
- Brock G, Heiselman D, Maggi M, Kim SW, Rodríguez Vallejo JM, Behre HM, McGettigan J, Dowsett SA, Hayes RP, Knorr J, Ni X, Kinchen K. Effect of Testosterone Solution 2% on Testosterone Concentration, Sex Drive and Energy in Hypogonadal Men: Results of a Placebo Controlled Study. *J Urol*. 2016;195:699–705.
- Buchter D, Behre HM, Kliesch S, Nieschlag E. Pulsatile GnRH or human chorionic gonadotropin/human menopausal gonadotropin as effective treatment for men with hypogonadotropic hypogonadism: a review of 42 cases. *Eur J Endocrinol*. 1998;139:298–303.
- Burris AS, Banks SM, Carter CS, Davidson JM, Sherins RJ. A long-term, prospective study of the physiology and behavioral effects of hormone replacement in untreated hypogonadal men. *J Androl*. 1992;13:297–304.



- Chandrapal JC, Nielson S, Patel DP, Zhang C, Presson AP, Brant WO, Myers JB, Hotaling JM. Characterising the safety of clomiphene citrate in male patients through prostate-specific antigen, haematocrit, and testosterone levels. *BJU Int.* 2016;118(6):994–1000.
- Chua ME, Escusa KG, Luna S, Tapia LC, Dofitas B, Morales M. Revisiting oestrogen antagonists (clomiphene or tamoxifen) as medical empiric therapy for idiopathic male infertility: a meta-analysis. *Andrology.* 2013;1:749–57.
- Comeglio P, Morelli A, Cellai I, Vignozzi L, Sarchielli E, Filippi S, Maneschi E, Corcetto F, Corno C, Gacci M, Vannelli GB, Maggi M. Opposite effects of tamoxifen on metabolic syndrome-induced bladder and prostate alterations: a role for GPR30/GPER? *Prostate.* 2014;74:10–28.
- Corona G, Maggi M. Perspective: regulatory agencies' changes to testosterone product labeling. *J Sex Med.* 2015;12:1690–3.
- Corona G, Rastrelli G, Vignozzi L, Mannucci E, Maggi M. Testosterone, cardiovascular disease and the metabolic syndrome. *Best Pract Res Clin Endocrinol Metab.* 2011a;2:337–53.
- Corona G, Rastrelli G, Monami M, Guay A, Buvat J, Sforza A, Forti G, Mannucci E, Maggi M. Hypogonadism as a risk factor for cardiovascular mortality in men: a meta-analytic study. *Eur J Endocrinol.* 2011b;165:687–701.
- Corona G, Rastrelli G, Monami M, Melani C, Balzi D, Sforza A, Forti G, Mannucci E, Maggi M. Body mass index regulates hypogonadism-associated CV risk: results from a cohort of subjects with erectile dysfunction. *J Sex Med.* 2011c;8:2098–105.
- Corona G, Jannini EA, Vignozzi L, Rastrelli G, Maggi M. The hormonal control of ejaculation. *Nat Rev Urol.* 2012;9:508–19.
- Corona G, Rastrelli G, Monami M, Saad F, Luconi M, Lucchese M, Facchiano E, Sforza A, Forti G, Mannucci E, Maggi M. Body weight loss reverts obesity-associated hypogonadotropic hypogonadism: a systematic review and meta-analysis. *Eur J Endocrinol.* 2013;168:829–43.
- Corona G, Isidori AM, Buvat J, Aversa A, Rastrelli G, Hackett G, Rochira V, Sforza A, Lenzi A, Mannucci E, Maggi M. Testosterone supplementation and sexual function: a meta-analysis study. *J Sex Med.* 2014a;11:1577–92.
- Corona G, Rastrelli G, Maseroli E, Fralassi N, Sforza A, Forti G, Mannucci E, Maggi M. Low testosterone syndrome protects subjects with high cardiovascular risk burden from major adverse cardiovascular events. *Andrology.* 2014b;2:741–7.
- Corona G, Maseroli E, Rastrelli G, Isidori AM, Sforza A, Mannucci E, Maggi M. Cardiovascular risk associated with testosterone-boosting medications: a systematic review and meta-analysis. *Expert Opin Drug Saf.* 2014c;13:1327–51.
- Corona G, Rastrelli G, Maggi M. The pharmacotherapy of male hypogonadism besides androgens. *Expert Opin Pharmacother.* 2015;16:369–87.
- Corona G, Giagulli VA, Maseroli E, Vignozzi L, Aversa A, Zitzmann M, Saad F, Mannucci E, Maggi M. Testosterone supplementation and body composition: results from a meta-analysis study. *Eur J Endocrinol.* 2016;174:R99–116.
- Delhez M, Hansenne M, Legros JJ. Andropause and psychopathology: Minor symptoms rather than pathological ones. *Psychoneuroendocrinology.* 2003;28:863–74.
- Dobs AS, Matsumoto AM, Wang C, Kipnes MS. Short-term pharmacokinetic comparison of a novel testosterone buccal system and a testosterone gel in testosterone deficient men. *Curr Med Res Opin.* 2004;20:729–38.
- Dohle GR, Arver S, Bettocchi C, Jones TH, Kliesch S, Punab M. Guidelines on male hypogonadism. Arnhem: European Association of Urology; 2015. Available: <http://uroweb.org/wp-content/uploads/EAU-Guidelines-Male-Hypogonadism-2015.pdf>.
- Drake MT, Murad MH, Mauck KF, Lane MA, Undavalli C, Elraiyah T, Stuart LM, Prasad C, Shahrour A, Mullan RJ, Hazem A, Erwin PJ, Montori VM. Clinical review. Risk factors for low bone mass-related fractures in men: a systematic review and meta-analysis. *J Clin Endocrinol Metab.* 2012;97:1861–70.
- Dwyer AA, Sykiotis GP, Hayes FJ, Boepple PA, Lee H, Loughlin KR, Dym M, Sluss PM, Crowley Jr WF, Pitteloud N. Trial of recombinant follicle-stimulating hormone pretreatment for GnRH-

- induced fertility in patients with congenital hypogonadotropic hypogonadism. *J Clin Endocrinol Metab.* 2013;98:E1790–5.
- Dwyer AA, Raivio T, Pitteloud N. Gonadotrophin replacement for induction of fertility in hypogonadal men. *Best Pract Res Clin Endocrinol Metab.* 2015;29:91–103.
- Fernandez-Balsells MM, Murad MH, Lane M, Lampropoulos JF, Albuquerque F, Mullan RJ, Agrwal N, Elamin MB, Gallegos-Orozco JF, Wang AT, Erwin PJ, Bhasin S, Montori VM. Clinical review 1: adverse effects of testosterone therapy in adult men: a systematic review and meta-analysis. *J Clin Endocrinol Metab.* 2010;95:2560–75.
- Finkelstein JS, Yu EW, Burnett-Bowie SA. Gonadal steroids and body composition, strength, and sexual function in men. *N Engl J Med.* 2013;369:2457.
- Finkle WD, Greenland S, Ridgeway GK, Adams JL, Frasco MA, Cook MB, Fraumeni Jr JF, Hoover RN. Increased risk of non-fatal myocardial infarction following testosterone therapy prescription in men. *PLoS ONE.* 2014;9:e85805.
- Grossmann M, Hoermann R, Wittert G, Yeap BB. Effects of testosterone treatment on glucose metabolism and symptoms in men with type 2 diabetes and the metabolic syndrome: a systematic review and meta-analysis of randomized controlled clinical trials. *Clin Endocrinol (Oxf).* 2015;83:344–51.
- Guay AT, Bansal S, Heatley GJ. Effect of raising endogenous testosterone levels in impotent men with secondary hypogonadism: double blind placebo controlled trial with clomiphene citrate. *J Clin Endocrinol Metab.* 1995;80:3546–52.
- Gupta BP, Murad MH, Clifton MM, Prokop L, Nehra A, Kopecky SL. The effect of lifestyle modification and cardiovascular risk factor reduction on erectile dysfunction: a systematic review and meta-analysis. *Arch Intern Med.* 2011;171:1797–803.
- Hadgraft J, Lane ME. Transdermal delivery of testosterone. *Eur J Pharm Biopharm.* 2015;92:42–8.
- Helo S, Mahon J, Ellen J, Wiehle R, Fontenot G, Hsu K, Feustel P, Welliver C, McCullough A. Serum levels of enclomiphene and zuclomiphene in men with hypogonadism on long-term clomiphene citrate treatment. *BJU Int.* 2016. doi:10.1111/bju.13625. [Epub ahead of print].
- Hildreth K, Barry DW, Moreau KL, Vande Griend J, Meacham RB, Nakamura T, Wolfe P, Kohrt WM, Ruscini JM, Kittelson J, Cress ME, Ballard R, Schwartz RS. Effects of testosterone and progressive resistance exercise in healthy, highly functioning older men with low-normal testosterone levels. *J Clin Endocrinol Metab.* 2013;98:1891–900.
- Huo S, Scialli AR, McGarvey S, Hill E, Tüger Timur B, Hogenmiller A, Hirsch AI, Fugh-Berman A. Treatment of men for “low testosterone”: a systematic review.
- Isidori AM, Giannetta E, Greco EA, Gianfrilli D, Bonifacio V, Isidori A, Lenzi A, Fabbri A. Effects of testosterone on body composition, bone metabolism and serum lipid profile in middle-aged men: a meta-analysis. *Clin Endocrinol (Oxf).* 2005;63:280–93.
- Isidori AM, Buvat J, Corona G, Goldstein I, Jannini EA, Lenzi A, Porst H, Salonia A, Traish AM, Maggi M. A critical analysis of the role of testosterone in erectile function: from pathophysiology to treatment—a systematic review. *Eur Urol.* 2014;65:99–112.
- Kacker R, Connors W, Zade J, Morgentaler A. Bone mineral density and response to treatment in men younger than 50 years with testosterone deficiency and sexual dysfunction or infertility. *J Urol.* 2014;191:1072–6.
- Kaminetsky J, Werner M, Fontenot G, Wiehle RD. Oral enclomiphene citrate stimulates the endogenous production of testosterone and sperm counts in men with low testosterone: comparison with testosterone gel. *J Sex Med.* 2013;10:1628–35.
- Kamischke A, Nieschlag E. Analysis of medical treatment of male infertility. *Hum Reprod.* 1999;14 (Suppl 1):1–23.
- Kaufman JM, Miller MG, Garwin JL, Fitzpatrick S, McWhirter C, Brennan JJ. Efficacy and safety study of 1.62% testosterone gel for the treatment of hypogonadal men. *J Sex Med.* 2011;8:2079–89.
- Kaufman JM, Miller MG, Fitzpatrick S, McWhirter C, Brennan JJ. One-year efficacy and safety study of a 1.62% testosterone gel in hypogonadal men: results of a 182-day open-label extension of a 6-month double-blind study. *J Sex Med.* 2012;9:1149–61.

- Kenny AM, Kleppinger A, Annis K, Rathier M, Browner B, Judge JO, McGee D. Effects of transdermal testosterone on bone and muscle in older men with low bioavailable testosterone levels, low bone mass, and physical frailty. *J Am Geriatr Soc.* 2010;58:1134–43.
- Kim ED, McCullough A, Kaminetsky J. Oral enclomiphene citrate raises testosterone and preserves sperm counts in obese hypogonadal men, unlike topical testosterone: restoration instead of replacement. *BJU Int.* 2016;117:677–85.
- La Vignera S, Condorelli RA, Cimino L, Russo GI, Morgia G, Calogero AE. Late-onset hypogonadism: the advantages of treatment with human chorionic gonadotropin rather than testosterone. *Aging Male.* 2016;19:34–9.
- LeBlanc ES, Nielson CM, Marshall LM, Lapidus JA, Barrett-Connor E, Ensrud KE, Hoffman AR, Laughlin G, Ohlsson C, Orwoll ES. The effects of serum testosterone, estradiol, and sex hormone binding globulin levels on fracture risk in older men. *J Clin Endocrinol Metab.* 2009;94:3337–46.
- Liu L, Banks SM, Barnes KM, Sherins RJ. Two-year comparison of testicular responses to pulsatile gonadotropin-releasing hormone and exogenous gonadotropins from the inception of therapy in men with isolated hypogonadotropic hypogonadism. *J Clin Endocrinol Metab.* 1988a;67:1140–5.
- Liu L, Chaudhari N, Corle D, Sherins RJ. Comparison of pulsatile subcutaneous gonadotropin-releasing hormone and exogenous gonadotropins in the treatment of men with isolated hypogonadotropic hypogonadism. *Fertil Steril.* 1988b;49:302–8.
- Liu PY, Wishart SM, Handelsman DJ. A double-blind, placebo-controlled, randomized clinical trial of recombinant human chorionic gonadotropin on muscle strength and physical function and activity in older men with partial age-related androgen deficiency. *J Clin Endocrinol Metab.* 2002;87:3125–35.
- Liu PY, Wishart SM, Celermajer DS, Jimenez M, Pierro ID, Conway AJ, Handelsman DJ. Do reproductive hormones modify insulin sensitivity and metabolism in older men? A randomized, placebo-controlled clinical trial of recombinant human chorionic gonadotropin. *Eur J Endocrinol.* 2003;148:55–66.
- Liu PY, Baker HW, Jayadev V, Zacharin M, Conway AJ, Handelsman DJ. Induction of spermatogenesis and fertility during gonadotropin treatment of gonadotropin-deficient infertile men: predictors of fertility outcome. *J Clin Endocrinol Metab.* 2009;94:801–8.
- Liu Z, Mao J, Wu X, Xu H, Wang X, Huang B, Zheng J, Nie M, Zhang H. Efficacy and outcome predictors of gonadotropin treatment for male congenital hypogonadotropic hypogonadism: a retrospective study of 223 patients. *Medicine (Baltimore).* 2016;95:e2867.
- MacLean C, Newberry S, Maglione M, McMahon M, Ranganath V, Suttrop M, Mojica W, Timmer M, Alexander A, McNamara M, Desai SB, Zhou A, Chen S, Carter J, Tringale C, Valentine D, Johnsen B, Grossman J. Systematic review: comparative effectiveness of treatments to prevent fractures in men and women with low bone density or osteoporosis. *Ann Intern Med.* 2008;148:197–213.
- Maggi M, Buvat J. Standard operating procedures: pubertas tarda/delayed puberty—male. *J Sex Med.* 2013;10:285–93.
- Maneschi E, Morelli A, Filippi S, Cellai I, Comeglio P, Mazzanti B, Mello T, Calcagno A, Sarchielli E, Vignozzi L, Saad F, Vettor R, Vannelli GB, Maggi M. Testosterone treatment improve metabolic syndrome-induced adipose tissue derangements. *J Endocrinol.* 2012;215:347–62.
- Maneschi E, Vignozzi L, Morelli A, Mello T, Filippi S, Cellai I, Comeglio P, Sarchielli E, Calcagno A, Mazzanti B, Vettor R, Vannelli GB, Adorini L, Maggi M. FXR activation normalizes insulin sensitivity in visceral preadipocytes of a rabbit model of MetS. *J Endocrinol.* 2013;218:215–31.
- Mao J, Xu H, Wang X, Huang B, Liu Z, Zhen J, Nie M, Min L, Wu X. Congenital combined pituitary hormone deficiency patients have better responses to gonadotrophin-induced spermatogenesis than idiopathic hypogonadotropic hypogonadism patients. *Hum Reprod.* 2015;30:2031–7.

- Meier C, Nguyen TV, Handelsman DJ, Schindler C, Kushnir MM, Rockwood AL, Meikle AW, Center JR, Eisman JA, Seibel MJ. Endogenous sex hormones and incident fracture risk in older men. *Arch Intern Med.* 2008;168:47–54.
- Meikle AW, Arver S, Dobs AS, Sanders SW, Rajaram L, Mazer NA. Pharmacokinetics and metabolism of a permeation-enhanced testosterone transdermal system in hypogonadal men: influence of application site – a clinical research center study. *J Clin. Endocrinol. Metab.* 1996;81:1832–40.
- Miller J, Britto M, Fitzpatrick S, McWhirter C, Testino SA, Brennan JJ, Zumbrunnen TL. Pharmacokinetics and relative bioavailability of absorbed testosterone after administration of a 1.62% testosterone gel to different application sites in men with hypogonadism. *Endocr Pract.* 2011;17:574–83.
- Moskovic DJ, Katz DJ, Akhavan A, Park K, Mulhall JP. Clomiphene citrate is safe and effective for long-term management of hypogonadism. *BJU Int.* 2012;110:1524–8.
- Muram D, Ni X. Utility of a single serum testosterone measurement to determine response to topical testosterone replacement in hypogonadal men. *Curr Med Res Opin.* 2016;32:263–9.
- Oppermann D, Happ J, Mayr WR. Stimulation of spermatogenesis and biological paternity by intranasal (low dose) gonadotropin-releasing hormone (GnRH) in a male with Kallmann's syndrome: intraindividual comparison of GnRH and gonadotropins for stimulation of spermatogenesis. *J Clin Endocrinol Metab.* 1987;65:1060–6.
- Osran H, Reist C, Chen CC, Lifrak ET, Chic-DeMet A, Parker LN. Adrenal androgens and cortisol in major depression. *Am J Psychiatry.* 1993;150:806–9.
- Perdonà S, Autorino R, De Placido S, D'Armiendo M, Gallo A, Damiano R, Pingitore D, Gallo L, De Sio M, Bianco AR, Di Lorenzo G. Efficacy of tamoxifen and radiotherapy for prevention and treatment of gynecomastia and breast pain caused by bicalutamide in prostate cancer: a randomised controlled trial. *Lancet Oncol.* 2005;6:295–300.
- Pesonen E, Pussinen P, Huhtaniemi I. Adaptation to acute coronary syndrome-induced stress with lowering of testosterone: a possible survival factor. *Eur J Endocrinol.* 2016;174:481–9.
- Pope Jr HG, Amiaz R, Brennan BP, Orr G, Weiser M, Kelly JF, Kanayama G, Siegel A, Hudson JI, Seidman SN. Parallel-group placebo-controlled trial of testosterone gel in men with major depressive disorder displaying an incomplete response to standard antidepressant treatment. *J Clin Psychopharmacol.* 2010;30:126–34.
- Raivio T, Wikström AM, Dunkel L. Treatment of gonadotropin-deficient boys with recombinant human FSH: long-term observation and outcome. *Eur J Endocrinol.* 2007;156:105–11.
- Rastrelli G, Corona G, Vignozzi L, Maseroli E, Silverii A, Monami M, Mannucci E, Forti G, Maggi M. Serum PSA as a predictor of testosterone deficiency. *J Sex Med.* 2013;10:2518–28.
- Rastrelli G, Corona G, Mannucci E, Maggi M. Factors affecting spermatogenesis upon gonadotropin-replacement therapy: a meta-analytic study. *Andrology.* 2014;2:794–808.
- Rastrelli G, Carter EL, Ahern T, Finn JD, Antonio L, O'Neill TW, Bartfai G, Casanueva FF, Forti G, Keevil B, Maggi M, Giwercman A, Han TS, Huhtaniemi IT, Kula K, Lean ME, Pendleton N, Punab M, Vanderschueren D, Wu FC, EMAS Study Group. Development of and recovery from secondary hypogonadism in aging men: prospective results from the EMAS. *J Clin Endocrinol Metab.* 2015;100:3172–82.
- Rastrelli G, Vignozzi L, Maggi M. Different medications for hypogonadotropic hypogonadism. *Endocr Dev.* 2016a;30:60–78.
- Rastrelli G, Giovannini L, Calogero AE, Gianfrilli D, Serra E, Pizzocaro A, Giagulli VA, Motta G, Vancieri G, Sperandio A, Andò S, Selice R, Luca G, Cocchiara F, Canale D, Maggi M. Predictors and clinical consequences of starting androgen therapy in men with low testosterone: results from the SIAMO-NOI registry. *J Endocrinol Invest.* 2016b;39:695–708.
- Riggs BL, Hartmann LC. Selective estrogen-receptor modulators – mechanisms of action and application to clinical practice. *N Engl J Med.* 2003;348:618–29.
- Rochira V, Zirilli L, Madeo B, Balestrieri A, Granata AR, Carani C. Sex steroids and sexual desire mechanism. *J Endocrinol Invest.* 2003;26:29–36.

- Sachar EJ, Halpern F, Rosenfeld RS, Galligher TF, Hellman L. Plasma and urinary testosterone levels in depressed men. *Arch Gen Psychiatry*. 1973;28:15–8.
- Saltzstein D, Sieber P, Morris T, Gallo J. Prevention and management of bicalutamide-induced gynecomastia and breast pain: randomized endocrinologic and clinical studies with tamoxifen and anastrozole. *Prostate Cancer Prostatic Dis*. 2005;8:75–83.
- Seidman SN, Walsh BT. Testosterone and depression in aging men. *Am J Geriatr Psychiatry*. 1999;7:18–33.
- Sheffield-Moore M, Dillon EL, Casperson SL, Gilkison CR, Paddon-Jones D, Durham WJ, Grady JJ, Urban RJ. A randomized pilot study of monthly cycled testosterone replacement or continuous testosterone replacement versus placebo in older men. *J Clin Endocrinol Metab*. 2011;96:E1831–7.
- Smith MR, Fallon MA, Lee H, Finkelstein JS. Raloxifene to prevent gonadotropin-releasing hormone agonist-induced bone loss in men with prostate cancer: a randomized controlled trial. *J Clin Endocrinol Metab*. 2004;89:3841–6.
- Smith MR, Morton RA, Barnette KG, Sieber PR, Malkowicz SB, Rodriguez D, Hancock ML, Steiner MS. Toremifene to reduce fracture risk in men receiving androgen deprivation therapy for prostate cancer. *J Urol*. 2010;184:1316–21.
- Smith MR, Malkowicz SB, Brawer MK, Hancock ML, Morton RA, Steiner MS. Toremifene decreases vertebral fractures in men younger than 80 years receiving androgen deprivation therapy for prostate cancer. *J Urol*. 2011;186:2239–44.
- Smith MR, Morton RA, Barnette KG, Sieber PR, Malkowicz SB, Rodriguez D, Hancock ML, Steiner MS. Toremifene to reduce fracture risk in men receiving androgen deprivation therapy for prostate cancer. *J Urol*. 2013;189(1 Suppl):S45–50.
- Snyder PJ, Bhasin S, Cunningham GR, Matsumoto AM, Stephens-Shields AJ, Cauley JA, Gill TM, Barrett-Connor E, Swerdloff RS, Wang C, Ensrud KE, Lewis CE, Farrar JT, Cella D, Rosen RC, Pahor M, Crandall JP, Molitch ME, Cifelli D, Dougar D, Fluharty L, Resnick SM, Storer TW, Anton S, Basaria S, Diem SJ, Hou X, Mohler 3rd ER, Parsons JK, Wenger NK, Zeldow B, Landis JR, Ellenberg SS, Testosterone Trials Investigators, Snyder PJ, Barrett-Connor E, Bhasin S, Cauley JA, Cella D, Crandall JP, Cunningham G, Ellenberg SS, Ensrud KE, Farrar JT, Gill TM, Lewis CE, Matsumoto AM, Molitch ME, Pahor M, Resnick S, Rosen RC, Swerdloff RS, Ellenberg SS, Hou X, Stephens-Shields A, Landis JR, Zeldow B, Cen L, Moore RH, Cifelli D, Dougar D, Fluharty L, Gallagher L, Ballard S, Chai T, Dattilo J, Brown T, Smith S, Chicchi F, Kasner SE, Lewis CE, Messe SR, Mohler 3rd ER, Crandall JP, Tabatabaie V, Epstein E, Barzel U, Trandafirescu G, Cunningham GR, Cordero E, Marino P, Bhasin S, Basaria S, Eder R, Appleman E, Halley KA, Molitch M, Toft D, Wallia A, Larsen D, Massaro E, Adelman D, Lewis CE, Shikany J, Kolettis P, Johnson P, Pike MN, Joffrion II, Swerdloff R, Wang C, Han X, Ashai J, Barrett-Connor E, Herbst K, Hofflich H, Parsons J, Kamantigue N, Carrion-Peterson ML, Reno G, Claravall L, Smith J, Pahor NK, Nayfield S, Anton SD, Manini T, Dahm P, Marsiske M, Sandesara B, Lewis M, Black ML, Knaggs J, Marena W, Lu JC, Ensrud KE, Diem SJ, Fink H, Warlick C, Potter S, Welch L, Van Covering P, Jacobson KL, Miller L, Cauley J, Horwitz MJ, Greenspan SL, Jaffe TM, Prebehalla L, Bonk JT, Rush JL, Matsumoto AM, Gilchrist J, Winter K, Wojtowicz M, Gill TM, deRekeneire N, Kashaf S, Katz L, Mojibian H, McGloin J, Wu K, Martinez D, Shepard D. Effects of testosterone treatment in older men. *N Engl J Med*. 2016;374:611–24.
- Stahlman J, Britto M, Fitzpatrick S, McWhirter C, Testino SA, Brennan JJ, Zumbrunnen TL. Serum testosterone levels in non-dosed females after secondary exposure to 1.62% testosterone gel: effects of clothing barrier on testosterone absorption. *Curr Med Res Opin*. 2012a;28:291–301.
- Stahlman J, Britto M, Fitzpatrick S, McWhirter C, Testino SA, Brennan JJ, Zumbrunnen TL. Effect of application site, clothing barrier, and application site washing on testosterone transfer with a 1.62% testosterone gel. *Curr Med Res Opin*. 2012b;28:281–90.
- Stahlman J, Britto M, Fitzpatrick S, McWhirter C, Testino SA, Brennan JJ, Zumbrunnen TL. Effects of skin washing on systemic absorption of testosterone in hypogonadal males after administration of 1.62% testosterone gel. *Curr Med Res Opin*. 2012c;28:271–9.

- Tajar A, Huhtaniemi IT, O'Neill TW, Finn JD, Pye SR, Lee DM, Bartfai G, Boonen S, Casanueva FF, Forti G, Giwercman A, Han TS, Kula K, Labrie F, Lean ME, Pendleton N, Punab M, Vanderschueren D, Wu FC. EMAS Group. Characteristics of androgen deficiency in late-onset hypogonadism: results from the European Male Aging Study (EMAS). *J Clin Endocrinol Metab.* 2012;97:1508–16.
- Tracz MJ, Sideras K, Boloña ER, Haddad RM, Kennedy CC, Uruga MV, Caples SM, Erwin PJ, Montori VM. Testosterone use in men and its effects on bone health. A systematic review and meta-analysis of randomized placebo-controlled trials. *J Clin Endocrinol Metab.* 2006;91:2011–6.
- Tran TS, Center JR, Seibel MJ, Eisman JA, Kushnir MM, Rockwood AL, Nguyen TV. Relationship between Serum Testosterone and Fracture Risk in Men: A Comparison of RIA and LC-MS/MS. *Clin Chem.* 2015;61:1182–90.
- Travison TG, Basaria S, Storer TW, Jette AM, Miciek R, Farwell WR, Choong K, Lakshman K, Mazer NA, Coviello AD, Knapp PE, Ulloor J, Zhang A, Brooks B, Nguyen AH, Eder R, LeBrasseur N, Elmi A, Appleman E, Hede-Brierley L, Bhasin G, Bhatia A, Lazzari A, Davis S, Ni P, Collins L, Bhasin S. Clinical meaningfulness of the changes in muscle performance and physical function associated with testosterone administration in older men with mobility limitation. *J Gerontol A Biol Sci Med Sci.* 2011;66:1090–9.
- Tsujimura A, Matsumiya K, Takao T, Miyagawa Y, Takada S, Koga M, Iwasa A, Takeyama M, Okuyama A. Treatment with human chorionic gonadotropin for PADAM: a preliminary report. *Aging Male.* 2005;8:175–9.
- Tuomilehto J, Lindström J, Eriksson JG, Valle TT, Hämäläinen H, Ilanne-Parikka P, Keinänen-Kiukaanniemi S, Laakso M, Louheranta A, Rastas M, Salminen V, Uusitupa M, Finnish Diabetes Prevention Study Group. Prevention of type 2 diabetes mellitus by changes in lifestyle among subjects with impaired glucose tolerance. *N Engl J Med.* 2001;344:1343–50.
- Uden F, Ljunggren JG, Beck-Friis J, Kjellman BF, Wetterberg L. Hypothalamic-pituitary-gonadal axis in major depressive disorders. *Acta Psychiatr Scand.* 1988;78:138–46.
- Vandekerckhove P, Lilford R, Vail A, Hughes E. Clomiphene or tamoxifen for idiopathic oligo/asthenospermia. *Cochrane Database Syst Rev.* 2000;2:CD000151.
- Vigen R, O'Donnell CI, Barón AE, Grunwald GK, Maddox TM, Bradley SM, Barqawi A, Woning G, Wierman ME, Plomondon ME, Rumsfeld JS, Ho PM. Association of testosterone therapy with mortality, myocardial infarction, and stroke in men with low testosterone levels. *JAMA.* 2013;310:1829–36.
- Wallis CJ, Lo K, Lee Y, Krakowsky Y, Garbens A, Satkunasingam R, Herschorn S, Kodama RT, Cheung P, Narod SA, Nam RK. Survival and cardiovascular events in men treated with testosterone replacement therapy: an intention-to-treat observational cohort study. *Lancet Diabetes Endocrinol.* 2016;4:498–506.
- Wang C, Swerdloff R, Kipnes M, Matsumoto AM, Dobs AS, Cunningham G, Katznelson L, Weber TJ, Friedman TC, Snyder P, Levine HL. New testosterone buccal system (Striant) delivers physiological testosterone levels: pharmacokinetics study in hypogonadal men. *J Clin Endocrinol Metab.* 2004;89:3821–9.
- Wang C, Nieschlag E, Swerdloff R, Behre HM, Hellstrom WJ, Gooren LJ, Kaufman JM, Legros JJ, Lunenfeld B, Morales A, Morley JE, Schulman C, Thompson IM, Weidner W, Wu FC, International Society of Andrology (ISA), International Society for the Study of Aging Male (ISSAM), European Association of Urology (EAU), European Academy of Andrology (EAA), American Society of Andrology (ASA). Investigation, treatment, and monitoring of late-onset hypogonadism in males: ISA, ISSAM, EAU, EAA, and ASA recommendations. *J Androl.* 2009;30:1–9.
- Wang C, Ilani N, Arver S, McLachlan RI, Soulis T, Watkinson A. Efficacy and safety of the 2% formulation of testosterone topical solution applied to the axillae in androgen-deficient men. *Clin Endocrinol (Oxf).* 2011;75:836–43.
- Wu FC, Tajar A, Beynon JM, Pye SR, Silman AJ, Finn JD, O'Neill TW, Bartfai G, Casanueva FF, Forti G, Giwercman A, Han TS, Kula K, Lean ME, Pendleton N, Punab M, Boonen S,

- Vanderschueren D, Labrie F. EMAS Group. Identification of late-onset hypogonadism in middle-aged and elderly men. *N Engl J Med.* 2010;363:123–35.
- Xu L, Freeman G, Cowling BJ, Schooling CM. Testosterone therapy and cardiovascular events among men: a systematic review and meta-analysis of placebo-controlled randomized trials. *BMC Med.* 2013;11:108.
- Yanase T, Fan W, Kyoya K, Min L, Takayanagi R, Kato S, Nawata H. Androgens and metabolic syndrome: lessons from androgen receptor knock out (ARKO) mice. *J Steroid Biochem Mol Biol.* 2008;109:254–7.
- Yeh S, Tsai MY, Xu Q, Mu XM, Lardy H, Huang KE, Lin H, Yeh SD, Altuwaijri S, Zhou X, Xing L, Boyce BF, Hung MC, Zhang S, Gan L, Chang C. Generation and characterization of androgen receptor knockout (ARKO) mice: an in vivo model for the study of androgen functions in selective tissues. *Proc Natl Acad Sci U S A.* 2002;99:13498–503.
- Yesavage JA, Davidson J, Widrow L, Berger PA. Plasma testosterone levels, depression, sexuality and age. *Biol Psychiatry.* 1985;20:199–228.
- Young J, Couzinet B, Chanson P, Brailly S, Loumaye E, Schaison G. Effects of human recombinant luteinizing hormone and follicle-stimulating hormone in patients with acquired hypogonadotropic hypogonadism: study of Sertoli and Leydig cell secretions and interactions. *J Clin Endocrinol Metab.* 2000;85:3239–44.
- Zarrouf FA, Artz S, Griffith J, Sirbu C, Kommor M. Testosterone and depression: Systematic review and meta-analysis. *J Psychiatr Pract.* 2009;15:289–305.
- Zhao J, Schooling CM. Promotion of "Low T" and citation bias in testosterone studies. *Int J Cardiol.* 2015;184:510–1.
- Zitzmann M, Mattern A, Hanisch J, Gooren L, Jones H, Maggi M. IPASS: a study on the tolerability and effectiveness of injectable testosterone undecanoate for the treatment of male hypogonadism in a worldwide sample of 1,438 men. *J Sex Med.* 2013;10:579–88.

---

## **Part IV**

# **Male Infertility**



Fotios Dimitriadis, George Adonakis, Apostolos Kaponis, Charalampos Mamoulakis, Atsushi Takenaka, and Nikolaos Sofikitis

---

## Abstract

Infertility is both a private and a social health problem that can be observed in 12–15% of all sexually active couples. The male factor can be diagnosed in 50% of these cases either alone or in combination with a female component. The causes of male infertility can be identified as factors acting at pre-testicular, testicular or post-testicular level. However, despite advancements, predominantly in the genetics of fertility, etiological factors of male infertility cannot be identified in approximately 50% of the cases, classified as idiopathic infertility. On the other hand, the majority of the causes leading to male infertility can be treated or prevented. Thus a full understanding of these conditions is crucial in order to allow the clinical andrologist not simply to retrieve sperm for assisted reproductive techniques purposes, but also to optimize the male's fertility potential in order to offer the couple the possibility of a spontaneous conception. This chapter offers the clinical andrologist a wide overview of pre-testicular, testicular, and post-testicular causes of male infertility.

---

F. Dimitriadis

Department of Urology, School of Medicine, Aristotle University, Thessaloniki, Greece  
e-mail: [helabio@yahoo.gr](mailto:helabio@yahoo.gr)

G. Adonakis • A. Kaponis

Department of Ob/Gyn, School of Medicine, Patras University, Patras, Greece

C. Mamoulakis

Department of Urology, School of Medicine, University of Crete, Heraklion, Crete, Greece

A. Takenaka

Department of Urology, School of Medicine, Tottori University, Yonago, Japan

N. Sofikitis (✉)

Department of Urology, School of Medicine, Ioannina University, Ioannina, Greece  
e-mail: [akrosnin@hotmail.com](mailto:akrosnin@hotmail.com)

## Keywords

Male infertility • Pre-testicular causes • Testicular causes • Post-testicular causes • Hypogonadotropic hypogonadism • Pituitary diseases • Varicocele • Cryptorchidism • Idiopathic infertility • Sertoli cell only syndrome • Klinefelter's syndrome • Y chromosome microdeletions

## Contents

Pre-Testicular Causes of Male Infertility .....	982
Hypogonadotropic Hypogonadism .....	982
Pituitary Diseases .....	984
Coital Disorders .....	985
Testicular Causes of Male Infertility .....	985
Varicocele .....	985
Cryptorchidism .....	986
Noonan Syndrome .....	988
Vanishing Testis Syndrome .....	989
Myotonic Dystrophy .....	990
46,XX Testicular Disorders of sex Development .....	990
47,XYY Syndrome .....	991
Klinefelter's Syndrome .....	992
Y Chromosome Microdeletions .....	992
Sertoli Cell-Only Syndrome (Germ Cell Aplasia) .....	994
Gonadotoxins .....	995
Systemic Diseases .....	996
Testis Injury .....	1000
Idiopathic Infertility .....	1001
Post-Testicular Causes of Male Infertility .....	1001
Male Reproductive Tract Obstruction .....	1002
Disorders of Sperm Function or Sperm Motility .....	1007
Disorders of Coitus .....	1009
References .....	1010

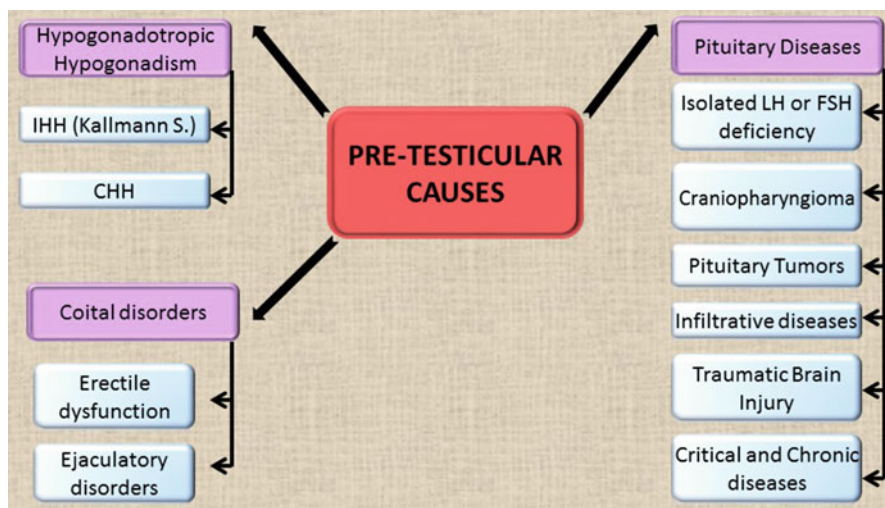
## Pre-Testicular Causes of Male Infertility

### Hypogonadotropic Hypogonadism

Hypogonadotropic hypogonadism is defined by deficient secretion of gonadotropins (FSH and LH). Testosterone secretion by testicular Leydig cells is impaired if LH and FSH stimulation is absent, and spermatogenesis is compromised. The major diagnostic categories include *isolated hypogonadotropic hypogonadism (IHH)* and *pituitary disease* (Fig. 1).

### Isolated Hypogonadotropic Hypogonadism

Isolated hypothalamic GnRH secretion deficiency results in the classic form of IHH (Kallmann syndrome). The syndrome is associated with KAL-1 gene mutations and



**Fig. 1** Pre-testicular causes of male infertility. *IHH* isolated hypogonadotropic hypogonadism, *CHH* congenital hypogonadotropic hypogonadism, *LH* luteinizing hormone, *FSH* follicle-stimulating hormone

follows a sex-linked pattern of inheritance with an incidence of 1 in 10,000 males (Bhagavath et al. 2006). IHH can also follow an autosomal dominant or recessive pattern of inheritance. However, most cases of normosmic Kallmann syndrome are sporadic (Sokol 2009). An IHH variant (adult-onset or acquired IHH) appears with impotence and/or oligospermia (Nachtigall et al. 1997).

### **Congenital Hypogonadotropic Hypogonadism (CHH)**

CHH is a very rare genetic disorder that results from deficient secretion or action of GnRH presenting as absent puberty and infertility (Krausz 2011). It is heterogeneous and clinical presentation relates to the degree of GnRH deficiency. Patients present with prepubertal testes (testicular volume < 4 mL) in adolescence or early adulthood (Georgopoulos et al. 2009). Severer forms present with cryptorchidism/micropenis at birth and complete absence of pubertal development later. Milder forms show some degree of testicular development (testicular volume > 4 mL). Anosmia may be present in about 50% of cases (Kallmann syndrome). The majority of CHH cases are sporadic, but in about a third of the cases, a familial inheritance pattern is evident (Huhtaniemi and Alevizaki 2007), including autosomal dominant, recessive, X-linked, or oligogenic forms (Sykiotis et al. 2010a). More than 20 associated loci have been detected to date acting alone or in synergy. Nevertheless, only about 35–40% of cases are currently accounted for by mutations in the identified genes. X-linked form with *KAL-1* gene mutations shows the worst response to treatment and genetic counseling should be offered (Sykiotis et al. 2010b). Targeted mutation screening in affected offspring and neonatal hormonal profiling could facilitate early diagnosis (Dwyer et al. 2015).

## Pituitary Diseases

### Isolated LH or FSH Deficiency

Isolated LH deficiency (fertile eunuch syndrome) is a rare disorder characterized by normal FSH secretion that stimulates spermatogenesis but inadequate testosterone production by testicular Leydig cells leading to impaired virilization (Ma et al. 2004). Isolated FSH deficiency is extremely rare. Patients are normally virilized given a normal LH/testosterone axis.

### Craniopharyngioma

Craniopharyngioma derives from Rathke's pouch remnants and usually grows slowly. It is a benign tumor often invading sella turcica leading to suppression of pituitary hormone secretion and optic chiasm compression. Patients present with pituitary hormonal dysfunction headaches, visual disturbances, impaired spermatogenesis, and impotence (Sokol 2009).

### Pituitary Tumors

Prolactin-producing tumors (prolactinomas) are the commonest tumors of the pituitary gland. Gonadotropin secretion is disturbed by pituitary compression and patients often present with impotence. Growth hormone and adrenocorticotrophic hormone-secreting tumors present with gigantism or acromegaly and Cushing syndrome, respectively. FSH-producing tumors manifest with gradual visual impairment, oligospermia, and impotence. Non-prolactin-producing tumors may result in modest prolactin elevation due to disruption of neurogenic pathways that attenuate dopamine release into portal circulation of the pituitary gland. They also interfere with LH/FSH secretion due gonadotropic cell compression (Sokol 2009).

### Infiltrative Diseases

These include histiocytosis X, amyloidosis, sarcoidosis, and infectious granulomatous diseases (Melmed 2008). Diseases that cause increased circulating iron levels (sickle cell anemia, thalassemia, and hemochromatosis) may also present with HH due to iron deposition in the pituitary gland.

### Traumatic Brain Injury

Skull base trauma can lead to decreased pituitary hormone secretion. Head trauma may be minor and have occurred as far as some decades before the diagnosis of hypopituitarism. This fact leads the physician to neglect or underestimate the importance of head trauma in the etiology of HH. Greater decrease of FSH versus LH secretion is reported in the majority of the cases of post-traumatic hypopituitarism. Pituitary ischemia (necrosis) can be a long-term but not a permanent, irreversible complication of head trauma (Sokol 2009).

### Critical and Chronic Diseases

Critical illnesses such as severe burns, myocardial infarction, and acquired immune deficiency syndrome (AIDS) suppress the hypothalamic–pituitary axis. Hormonal

suppression level is related to disease severity. Chronic diseases suppress the axis but also the testes directly. Obesity, metabolic syndrome, and diabetes mellitus may affect the production of testosterone (Ding et al. 2006).

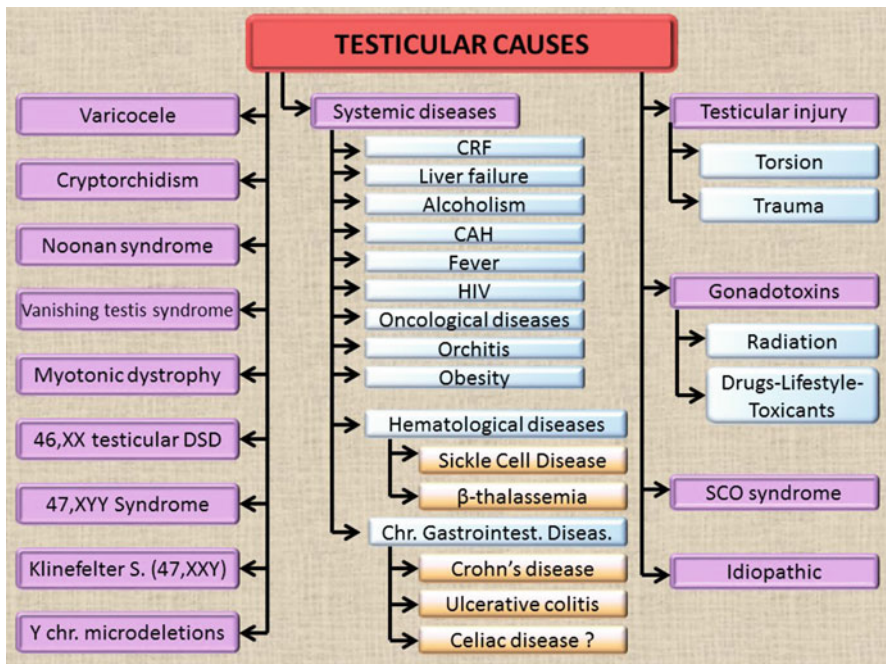
### Coital Disorders

Sexual dysfunction including erectile and ejaculatory disorders represents rare causes of male infertility and they will be discussed later in this session.

## Testicular Causes of Male Infertility

### Varicocele

Varicocele represents a vascular abnormality of the venous drainage system of the testes. The abnormally dilated veins may concern either the pampiniform or the cremasterium plexus. Varicocele has been considered as a cause responsible for the infertile phenotype in 35% or 81% of men with infertility problems or men with secondary infertility, respectively (Clarke 1966; Gorelick and Goldstein 1993) (Fig. 2).



**Fig. 2** Testicular causes of male infertility. *46,XX testicular DSD* 46,XX testicular disorders of sex development, *SCO Sertoli cell-only syndrome*, *CRF* chronic renal failure, *CAH* congenital adrenal hyperplasia, *HIV* human immunodeficiency virus

Increases in testicular temperature, deficiency of the hypothalamic–pituitary–testicular axis, abnormal flow of adrenal or renal metabolites down the left spermatic vein, testicular hypoxia, testicular metabolic defects, and cadmium accumulation in testicular venous blood are theories that have been suggested to explain the damaging effect of left varicocele on the left testis (Sofikitis et al. 1992b, 1993a; Hendin et al. 1999; Benoff et al. 2004; Khera and Lipshultz 2008; Pasqualotto et al. 2008; Dimitriadis et al. 2009; Smit et al. 2010). It should be emphasized that left varicocele has a deleterious consequence on the contralateral testicular function (Sofikitis et al. 1993b, 2014; Ozturk et al. 2001).

Clinical examination with Valsalva maneuver, Doppler ultrasonography, and thermography is important for the diagnosis of varicocele.

For varicocele repair, several techniques have been employed (Goldstein et al. 1992; Sofikitis et al. 1994; Hirsch et al. 1998; Matthews et al. 1998; Giannakis et al. 2004; Cayan et al. 2009; Baazeem et al. 2011; Giagulli and Carbone 2011), but the gold standard approach appears to be the microsurgical subinguinal varicocelectomy because this approach allows identification of the testicular arteries, identification and preservation of the lymphatics of the spermatic cord, and ligation of both the pampiniform plexus-internal spermatic vein venous plexus system and the cremasterium plexus-external spermatic vein venous plexus system.

## Cryptorchidism

Cryptorchidism is the commonest congenital abnormality of male genitalia with an incidence of nearly 1% at the end of infancy (Jungwirth et al. 2016). Normal descent of the testes (DT) represents a complex multistage procedure that involves several anatomical elements, genes, and hormonal and environmental factors, but its purpose and the exact etiology of cryptorchidism remain unknown (Hutson et al. 2010; Mamoulakis et al. 2015). Hormonal deficiencies are uncommon causes despite the fact that DT presupposes a normally functioning hypothalamic–pituitary–gonadal axis (Toppari and Kaleva 1999). Several factors acting in utero, such as environmental or maternal lifestyle factors, might interfere with normal DT as well (Bay et al. 2011). Genetic factors have also been implicated in the etiology under certain conditions by gene–environment interactions, and there is evidence that at least some cases have a genetic basis (Massart and Saggese 2009; Hutson et al. 2010; Jensen et al. 2010). Several known genetic factors have been investigated in many studies concluding that these are responsible for a small proportion of cryptorchid cases (Bay et al. 2011) and that novel candidate genes warrant testing (Mamoulakis et al. 2013a, b, 2014).

Cryptorchidism, hypospadias, testicular cancer, and poor semen quality are nowadays considered symptoms of a sole underlying entity, the testicular dysgenesis syndrome (TDS), which is the result of gonadal development disruption in utero by adverse environmental effects possibly acting on a susceptible genetic background (Skakkebaek et al. 2001). TDS manifestation varies with the severity of testicular dysgenesis. Based on epidemiological data, a hypothesis warranting further testing

has been set forth, according to which relatively lower hCG levels at early (8th–9th week) or late gestational stage (26th week) are manifested as cryptorchidism or hypospadias, respectively (Mamoulakis et al. 2002).

A biphasic model has been proposed to explain normal DT in the human (Hutson 1985). According to this model, the first phase of DT, from its initial position near the kidney to the internal inguinal ring (transabdominal DT, TDT), is regulated by a non-androgenic hormone/factor, and it is accomplished during the first trimester of the gestation. The second phase of DT, from the internal inguinal ring to the scrotum (inguinoscrotal DT, ISDT), is regulated by androgens, and it is accomplished during the third trimester of the gestation (Backhouse 1982; Heyns 1982). Caudal gubernacular enlargement (gubernacular swelling reaction) caused by rapid cell proliferation with increase in glycosaminoglycans/hyaluronic acid (Backhouse 1982; Heyns et al. 1986, 1990) is closely associated with TDT (Hutson et al. 1997). Insulin-like 3 (INSL3), a hormone produced by Leydig cells, has been shown in animal models to govern TDT by controlling gubernacular differentiation through its receptor (LGR8) (Kumagai et al. 2002). Many studies have investigated the possibility that human INSL3 gene alterations are implicated etiologically in DT impairment with the vast majority failing to indicate such an association (Mamoulakis et al. 2014). The cumulative incidence of INSL3 gene mutations in cryptorchidism is relative low (1.6–2.2%), without a definite evidence of a causal role for most of them; on the other hand, INSL3 mutations undoubtedly represent the first description of specific genetic alterations related to DT impairment in the human (Mamoulakis et al. 2015). The potential role of the LGR8 gene alterations in cryptorchidism has been investigated as well showing a modest cumulative frequency of mutations (2.9%) (Mamoulakis et al. 2015). Most studies have focused on T222P, a missense mutation that reduces LGR8 expression on cell surface membrane potentially leading to cryptorchidism. This hypothesis is supported by mutation screening studies in Italy but has not been confirmed in other countries leading to the notion that cryptorchid phenotype may be dependent on genetic and/or environmental background. Based on these results, it has been concluded that INSL3/LGR8 gene mutations are rare causes of cryptorchidism (Mamoulakis et al. 2015). ISDT is governed by androgens but the exact mode of their action is unclear (Hutson et al. 2013). They possibly act indirectly rather than directly on the gubernaculum, through the genitofemoral nerve. Their action results in calcitonin gene-related peptide (CGRP) release by the nerve, a neurotransmitter acting as second messenger of androgenic stimulation on the gubernaculum to promote ISDT (Hutson et al. 2013; Mamoulakis et al. 2015).

The clinical significance of cryptorchidism is underlined by a close association with testicular cancer and infertility. Cryptorchidism is the only well-established risk factor of testicular cancer (UK Testicular Cancer Study Group 1994a, b). The higher the testis position, the higher the relative risk, which is up to 50 times that of the general population. Cryptorchidism is also an important etiologic factor of impaired male fertility. Azoospermia is seen in around 0.5% of the general population (Hadziselimovic and Herzog 2001), in around 13% of unilaterally cryptorchid patients regardless if they are treated or not but it affects almost 100% of untreated

bilaterally cryptorchid patients, while up to 70% of untreated unilaterally cryptorchid patients are azoospermic or oligozoospermic (Hadziselimovic 2002). Paternity rates are reduced significantly in males with a history of bilateral cryptorchidism (61.5–65.3%) in contrast to those with a history of unilateral cryptorchidism (89.7%) compared to the general population (93.2–94.6%), while paternity rates of males having only one testis for whatever reason are similar to those of men with treated cryptorchidism or normal controls (Lee and Coughlin 2002). Preoperative testicular location and small testicular size at orchidopexy in males with a history of unilateral cryptorchidism are not major determinants of fertility (Lee et al. 2000). The exact pathogenesis of reduced fertility in cryptorchidism is not fully clarified. Some of the potential mechanisms include malformations of the epididymis, reduced numbers of spermatogonia containing tubules/spermatogonia per tubule, mild concurrent hypogonadism, sperm antibodies' formation, damage of the contralateral testis, and increased apoptosis of germ cells (Mamoulakis et al. 2004, 2012). Based on the EAU guidelines, the following evidence summary/recommendations apply for the management of cryptorchidism (Tekgül et al. 2016): Treatment should start early in life to rescue spermatogenic potential and reduce future testicular cancer risk. The later the intervention, the higher the fertility impairment/testicular malignancy risk. The treatment of choice is surgical placement of the testis in the scrotum, usually by either inguinal or laparoscopic approach for palpable testes or non-palpable testes, respectively. Retractable testes necessitate close follow-up until puberty without any medical or surgical treatment. Orchidopexy is strongly recommended prior to 12 months and by 18 months at the latest. In cases that both testes are non-palpable, male neonates should be investigated for potential disorders of sex development (DSD). If there is no DSD evidence, laparoscopy is preferred due to high specificity/sensitivity in intra-abdominal testes detection and the possibility for concurrent treatment. Two types of medical treatment exist (hCG and GnRH) that stimulate the hypothalamic–pituitary–gonadal axis, increasing therefore testosterone production. However, the value of hormonal treatment is controversial; adjuvant/neoadjuvant medical treatment is not routinely recommended and each case must be evaluated individually. Medical treatment is recommended in bilaterally cryptorchid cases. For unilaterally cryptorchid cases at postpubertal age and beyond, testis removal should be discussed due to the theoretical risk of malignancy in the future.

## Noonan Syndrome

Noonan syndrome (NS) is a disorder of variable expression affecting multiple systems, inherited by the autosomal dominant mode, with an estimated prevalence of 1 in 1000–2500 (Mendez and Opitz 1985). The diagnosis is principally based on clinical observation of cardinal features, including developmental delay, short stature, typical facies changing considerably with age, posteriorly rotated ears with fleshy helices, wide-spaced eyes with blue or blue-green irises, thick eyelids and



epicanthus, webbed neck, peculiar chest, low-set nipples, heart defect, lymphatic dysplasias, defects of coagulation, and uni- or bilateral cryptorchidism generally present in up to 80% of the cases and in 94% of those bearing PTPN11 mutations in particular (Allanson and Roberts 2001). Deficient spermatogenesis may be related to cryptorchidism, but an intrinsic gonadal defect attributed to a primary Sertoli cell dysfunction cannot be ruled out (Allanson and Roberts 2001; Roberts et al. 2013). The genes involved in NS encode proteins integral to the RAS–MAPK pathway with mutations usually enhancing signal flow (Schubbert et al. 2007; Roberts et al. 2013). NS is identified using molecular genetic testing that may detect mutations in PTPN11 (50%), SOS1 ( $\approx$ 13%), RAF1 (3–17%), KRAS ( $<$ 5%), or other genes (NRAS, BRAF, and MAP2K1;  $<$ 1%). Mutations appear *de novo* but an affected parent is found in up to 75% of families. A number of Noonan-like syndromes should be distinguished, especially those with greatest overlap such as Turner syndrome, cardiofaciocutaneous syndrome, Costello syndrome, and Aarskog syndrome (Allanson and Roberts 2001; Roberts et al. 2013). Guidelines for the management of NS have been recently developed (Allanson 2007; van der Burg 2007; Romano et al. 2010).

## Vanishing Testis Syndrome

Testicular regression or vanishing testis syndrome (VTS) is attributed to a subsequent disappearance/atrophy in utero of an initially normal testis (Hegarty et al. 2007). VTS is seen in  $<$ 5% of cryptorchid cases (Spires et al. 2000), accounting for 35–60% of those with non-palpable testis that consist a 10–20% of cryptorchid cases (Elder 1994; Rozanski et al. 1996; Koyama et al. 1997; Cendron et al. 1998; Storm et al. 2007). VTS is commoner than testicular agenesis (Merry et al. 1997) with a prevalence of around 1/1250 males (Grady et al. 1998). VTS is considered to result from thrombosis, torsion, or endocrinopathy, with more recent studies favoring the theory of vascular accident/antenatal torsion (Wright 1986; Bar-Maor et al. 1993; Rozanski et al. 1996; Papparella et al. 1999). It has also been sporadically associated with genetic abnormalities like Yq11 microdeletions and persistent Müllerian duct syndrome (Calogero et al. 2001).

VTS presents more commonly as a unilateral entity or, far less frequently, bilaterally with complete or partial testicular tissue absence and normal external genitalia. The phenotype is usually masculine, but although uncommon, it may vary from normal male with non-palpable testis unilaterally to female (Josso and Briard 1980), probably depending on the intrauterine event extent/timing in relation to sexual development. These 46, XY patients lack detectable testicular structures and Müllerian duct system (Coulam 1979; Naffah 1989; Selby 1992). Viable germ cells/seminiferous tubules are present in 0–16% of excised testicular remnants (Smith et al. 1991; Rozanski et al. 1996; Merry et al. 1997; Cendron et al. 1998; Spires et al. 2000; Van Savage 2001; Emir et al. 2007; Storm et al. 2007). Presence of germ cells might indicate a germ cell-derived cancer risk. Nevertheless, no association with

germ cell tumors has been reported (Pirgon and Dundar 2012). Optimal management remains therefore controversial. Routine removal of testicular remnants is suggested to prevent future malignancy, while this notion has been disputed by others (Plotzker et al. 1992; Cendron et al. 1998; Van Savage 2001).

## Myotonic Dystrophy

Myotonic dystrophy (dystrophia myotonica, DM) is an autosomal dominant multi-system disorder with two major types: type 1 (DM1) or Steinert disease (Bird 1993–2016 [updated 2015 Oct 22]) and type 2 (DM2) or proximal myotonic myopathy (Dalton et al. 1993–2016. 2006 Sep 21 [updated 2013 Jul 3]). The prevalence is approximately 1/8000 (Dalton et al. 1993–2016. 2006 Sep 21 [updated 2013 Jul 3]). The proportions of DM1 and DM2 cases are not known. DM1 is caused by expansion to 50–5000 copies of a CTG trinucleotide repeat sequence, an unstable motif found in the 3' untranslated region (normally containing 5–34 copies) of the dystrophia myotonica protein kinase (DMPK) gene (Brook et al. 1992; Mahadevan et al. 1992; Bird 1993–2016 [updated 2015 Oct 22]). DM2 is caused by a CCTG expansion of a complex repeat motif [(TG)<sub>n</sub>(TCTG)<sub>n</sub>(CCTG)<sub>n</sub>] contained in intron 1 of the cellular nucleic acid-binding protein (CNBP) gene. The overall normal CCTG repeat tract ranges from 11–26 CCTG repeats, while pathogenic alleles show a mean of ~5000 CCTG repeats (Liquori et al. 2001, 2003). DM1 affects the skeletal/smooth muscles, central nervous system, heart, eye, and endocrine system. Three somewhat overlapping phenotypes are seen: mild, classic, and congenital. DM2 presents with myotonia (90%) rarely causing severe symptoms, muscle dysfunction (82%), cataracts (36–78%), primary testicular failure (29–65%), diabetes mellitus (25–75%), and cardiac conduction defects (19%).

Reproductive abnormalities are a well-recognized finding in both types. Progressive testicular atrophy is a prominent feature occurring in about 80% and up to 60% of DM1 and DM2 cases, respectively. Histological abnormalities include complete hyalinization, atrophy, fibrosis of the seminiferous tubules, and reduced sperm numbers (Sarkar et al. 2004). Oligospermia/azoospermia is reported in about 73% of patients with DM1 (Klesert et al. 1997). The most prominent physical manifestation of gonadal failure is small testes. Testosterone is usually low but LH is high in about half of the cases (Sagel et al. 1975). Seminiferous tubule failure may be seen (rise in FSH with normal testosterone). No therapy exists for seminiferous tubule failure. Symptomatic patients with low testosterone require replacement therapy.

## 46,XX Testicular Disorders of sex Development

The prevalence of nonsyndromic 46,XX testicular DSD is around 1/20,000 males. Algorithms have been developed for evaluation/diagnosis (Barseghyan et al. 2015). The diagnosis is suspected by clinical and/or laboratory findings (Délot and Vilain 1993–2016. 2003 Oct 30 [updated 2015 May 7]). External genitalia are masculine

with both testes present but range from typical to ambiguous (penoscrotal hypospadias) without evidence of Müllerian structures' presence. Laboratory findings include a 46,XX karyotype, hypergonadotropic hypogonadism secondary to testis failure (Perez-Palacios et al. 1981), and azoospermia. Testis biopsy shows decreased size and number of seminiferous tubules, peritubular fibrosis, germ cell absence, and Leydig cell hyperplasia (Délot and Vilain 1993–2016. 2003 Oct 30 [updated 2015 May 7]). The diagnosis is established in an individual with the clinical features, a 46,XX karyotype and evidence of presence of either SRY (SRY-positive 46,XX testicular DSD) or copy number variants/rearrangements in/around SOX9 (SOX9-related 46,XX testicular DSD) or SOX3 (SOX3-related 46,XX testicular DSD); the last two are collectively referred as SRY-negative 46,XX testicular DSD.

About 15% of patients with 46,XX testicular DSD are born with ambiguous genitalia: typically penoscrotal hypospadias with or without chordee (Zenteno-Ruiz et al. 2001). The majority is SRY negative (Fechner et al. 1993; McElreavey et al. 1993; Boucekkine et al. 1994). About 85% of patients with 46,XX testicular DSD present with normal pubic hair/penile size, small testes, gynecomastia, and azoospermia after puberty (Zenteno-Ruiz et al. 2001). The vast majority of them are SRY positive (McElreavey et al. 1993). The testes are usually soft but may become firmer in time. A minority presents with cryptorchidism and/or anterior hypospadias (Boucekkine et al. 1994). Management is similar to that for other causes of testosterone deficiency.

## 47,XYY Syndrome

It is the commonest sex chromosome anomaly following Klinefelter's syndrome (Hook and Hamerton 1977; Gekas et al. 2001; Rives et al. 2005a), occurring in around 1/1000 males born alive (Morel et al. 1999; Rives et al. 2005a). Non-mosaic form results from paternal nondisjunction at second meiosis, leading to passage of an extra Y chromosome to the offspring (Wong et al. 2008; El-Dahtory and Elsheikha 2009). Passage following parental nondisjunction after postzygotic mitosis results in mosaic (46,XY/47,XYY) (Moretti et al. 2008; El-Dahtory and Elsheikha 2009). Patients often present delayed speech, learning disabilities, and behavioral problems, but the majority is diagnosed late due to indistinguishable phenotypical characteristics from 46,XY individuals (Stochholm et al. 2010).

Sperm counts range from normal to azoospermia (Faed et al. 1976; Lim et al. 1999; Egozcue et al. 2000; Rives et al. 2005a; Abdel-Razic et al. 2012; Kim et al. 2013). Fertility may be impaired (Speed et al. 1991; Blanco et al. 1997; Chevret et al. 1997; Morel et al. 1999; Gonzalez-Merino et al. 2007), but many are fertile (Rives et al. 2005a; Moretti et al. 2008; Wong et al. 2008; El-Dahtory and Elsheikha 2009). Overall, 47,XYY negatively affects sperm count and maturation (Kim et al. 2013). Pregnancy can spontaneously be achieved, but in vitro fertilization/intracytoplasmic sperm injection is often required and genetic counseling is recommended (Gonzalez-Merino et al. 2007).

## Klinefelter's Syndrome

Klinefelter's syndrome (47,XXY) is the most common sex chromosome abnormality (Davila Garza and Patrizio 2013) and the most common genetic reason for azoospermia: approximately 14% of azoospermic cases (Turek 2008). The 47,XXY genotype is found in 90% of Klinefelter's men, whereas 10% are mosaic, with a combination of 47,XXY/46,XY chromosomes.

While newborns with Klinefelter's syndrome demonstrate no significant dysmorphism, typically, as adult men they have small firm testicles, gynecomastia, and azoospermia (Turek 2008). However, the phenotype varies from a normally virilized man to one with signs of androgen deficiency, including delayed sexual maturation, scant body hair, female hair distribution, as well as long arms and legs.

The testes are less than 3.5 cm, and the histologic pattern reveals degeneration of the seminiferous tubules, progressive hyalinization, fibrosis (Turek 2008), and hyperplasia of Leydig cells. Leydig cell secretory function is impaired leading to a reduced capacity for testosterone synthesis (Wang et al. 1975). Thus 63–85% of men have low testosterone levels (Groth et al. 2013).

Approximately 8% of Klinefelter's syndrome men have sperm in the ejaculate, whereas the rest are azoospermic (Oates 2012). Thus, paternity with this syndrome is rare but more likely in the mosaic or to hidden mosaicism with 46,XY cells in the gonads (Wieacker 2006). In patients with azoospermia, the therapeutic approach should include TESE (or micro-TESE) since spermatozoa can be found in about 30% of cases (Tournaye et al. 1996; Kamischke et al. 2003) especially if biopsy is done at younger age. Therefore, even if Klinefelter's syndrome men in their early twenties may not desire immediate conception, a preventive testicular or ejaculated sperm recovery and cryopreservation of the recovered spermatozoa should be a correct way to preserve their future fertility. ICSI after testicular sperm extraction offer a potential fertility to non-mosaic Klinefelter's syndrome patients.

Men with Klinefelter's syndrome require a close follow-up (possibly every year). Androgen replacement therapy should be start after the appearance of fertility problems and when testosterone level is in the range of hypoandrogenism.

## Y Chromosome Microdeletions

The human Y chromosome is one of the smallest chromosomes in humans (approximately 60 mega base pairs), containing many of the genes crucial for the development of the male gonads and the spermatogenesis (Tilford et al. 2001; Navarro-Costa 2012). In fact, the long arm of the Y chromosome contains three partially overlapping but discrete regions that regulate spermatogenesis (Vogt et al. 1996). The loss of one of these regions, indicated as AZF (azoospermia factor)a, AZFb (P5/proximal P1), AZFc (b2/b4), and AZFbc (with two variants differing in the proximal breakpoint: P5/distal P1 and P4/distal P1), can lead to infertility (Skaletsky

et al. 2003). These deletions are thought to occur between the palindromic and direct repeats (Repping et al. 2002).

The incidence of AZF deletions is 15–20% in idiopathic azoospermic men and 7–10% in idiopathic severe oligozoospermic men (Kraus et al. 2005). Y chromosome microdeletions are extremely rare in infertile men with sperm concentration more than 5 million/ml. AZFc deletions are most common (65–70%) (Simoni et al. 2008), followed by Y microdeletions of the AZFb and AZFb + c or AZFa + b + c regions (25–30%). AZFa region microdeletions are rare (5%) (Massart et al. 2012).

Infertile men with Y chromosome microdeletions generally have no apparent symptoms and present severely disturbed spermatogenesis. Testicular histopathology varies from complete or focal SCO syndrome to spermatogenic arrest or hypospertogenesis (Simoni et al. 2008). However, microdeletions are not found in normozoospermic men suggesting a direct relationship between Y deletions and spermatogenic failure (Krausz et al. 2003). Azoospermic men present the highest frequency of Y microdeletions (8–12%), followed by oligozoospermic (3–7%) men (Simoni et al. 1997). Complete deletion of the AZFa region leads to SCO syndrome, while complete deletion of the AZFb region causes spermatogenic arrest. On the other hand, men carrying complete AZFc deletions have severe oligozoospermia in about 50% of cases, and in azoospermic carriers, successful TESE seems possible in about half of them (Mulhall et al. 1997; Brandell et al. 1998; Kamp et al. 2001; Zhou-Cun et al. 2006; Jungwirth et al. 2016). Complete AZF deletions are not associated with higher risk for cryptorchidism or testicular cancer (Krausz and Degl'Innocenti 2006). In most cases, the son will have the same microdeletion as his father (Krausz et al. 2014) or occasionally the son may have a larger one (Stuppia et al. 1998).

Recently, new “partial deletions” of AZFc region have been reported (Repping et al. 2003) deleting approximately half of the gene content of AZFc region (including two DAZ copies and one CDY1 copy). Among them, gr/gr partial deletion is believed to cause spermatogenic impairment especially oligozoospermia (Repping et al. 2003; Giachini et al. 2005; Giachini et al. 2008; Visser et al. 2009). This type of deletion arises by homologous recombination and has been extensively examined in large groups of men worldwide conferring a 2.5–8-fold increased risk for oligozoospermia (Giachini et al. 2008; Visser et al. 2009; Navarro-Costa et al. 2010; Stouffs et al. 2011; Krausz et al. 2014).

Other microdeletions in the AZFc region most commonly reported in the literature are encompassing copies of the DAZ gene (previously known as SPGY), which is believed to be integrally associated with spermatogenesis (Saxena et al. 2000). DAZ protein is cytoplasmic, and its expression is limited to the male germ line regulating gametogenesis and protein translation during spermatogenesis. DAZ is detected only in humans and old-world primates. The rest of the mammals possess an autosomal homologue (DAZL) which in mice is located on chromosome 17. The corresponding human autosomal homologue is also present and located on chromosome 3p24 (Dorfman et al. 1999). DAZL is required for the fertility of male and female mice since homozygous knockout DAZL mice of both sexes are infertile (Saunders et al. 2003).

## Sertoli Cell-Only Syndrome (Germ Cell Aplasia)

Sertoli cell-only (SCO) syndrome also known as germ cell aplasia, rather than a diagnosis, represents a histopathologic phenotype (Del Castillo et al. 1947). Nieschlag et al. reported that about 30% of their infertile patients presented focal or complete SCO syndrome, and in 8% of them, SCO syndrome was bilateral (Nieschlag et al. 2010). Complete germ cell aplasia is characterized by spermatid tubules, with decreased diameter, totally devoid of germ cells and containing only Sertoli cells. The interstitial tissue, as well as the basement membranes and the Sertoli cells, is normal with the later ones presenting an increased apoptotic index (Kim et al. 2007). The patients representing this histologic pattern are always infertile. However, more often the SCO syndrome is focal with varying percentage of tubules containing germ cells. In these tubules spermatogenesis is often in both quantitatively and qualitatively limited (hypospermatogenesis) (Nieschlag et al. 2010). In these later cases, germ cells such as elongated spermatids may be found in the biopsy which are suitable for intracytoplasmic sperm injection (ICSI). The SCO syndrome is one common cause of nonobstructive azoospermia (NOA) (Nieschlag et al. 2010).

SCO syndrome can be due to lack of migration of the primordial germ cells from the yolk sac into the future gonads or due to their succumb in the spermatid epithelium after their migration. The molecular mechanisms leading to completion of spermatogenesis are still under investigation. Common reasons of complete loss of germ cells are antineoplastic treatment such as chemotherapy or radiation, mumps orchitis, maldescended testes, androgen resistance (Nieschlag et al. 2010; Walsh and Smith 2013), and chromosomal abnormalities, especially Y chromosome micro-deletions (Foresta et al. 1998). The testicular volume is usually reduced or in the lower normal range (Nieschlag et al. 2010). The histology of Sertoli cells represents normal but with an increased apoptotic index (Kim et al. 2007). In the interstitial tissue, Leydig cells are usually not affected so that patients have usually normal testosterone levels and infertility is the only reason to seek medical consultation (Nieschlag et al. 2010); only few patients have hypoandrogenism requiring treatment. On the other hand, FSH is usually elevated (Bergmann et al. 1994). Inhibin B correlates negatively with the degree of testicular failure, improving the diagnostic sensitivity, but it cannot predict with high diagnostic accuracy the presence or absence of foci of advanced spermatogenesis (von Eckardstein et al. 1999).

The diagnosis of SCO syndrome requires testicular biopsy. However, in certain SCO syndrome patients, the testicular biopsy was positive for sperm retrieval by microsurgical testicular sperm extraction (micro-TESE) (Schulze et al. 1999) suggesting a marked discordance of spermatogenic phenotype pattern between both testes that can be detected in about 28% of patients (McLachlan et al. 2007).

At the moment, there is no treatment for the spermatogenic failure of complete SCO syndrome patients that leads to improvement of spermatogenesis. Micro-TESE should therefore be planned as both a diagnostic and therapeutic procedure (Sabanegh and Agarwal 2012).

## Gonadotoxins

### Effects of Radiation

The testis represents high sensitivity to radiation. Radiation has its most potent effect upon spermatogonia, especially upon spermatogonia type B (Beretta 2015). Spermatoocytes, on the other hand, are less sensitive and spermatids are rather radio-resistant. The likeliness of infertility after radiation depends mainly on the dose to the testes but also on the shielding and fractionation (multiple doses) (Meistrich and Beck 1990). A temporary reduction in sperm count occurs after a radiation dose of 0.15 Gy, while single exposures above 2 Gy may cause azoospermia (Rowley et al. 1974). Higher doses cause delay in recovery of sperm output, which is proportional to dose and beyond 4Gy the spermatogenic damage is persistent for up to 5 years or may produce irreversible damage, consistent with spermatogonial eradication. Fractionation has a more favorable effect in terms of side effects but causes more damage to sperm than a larger, single radiation dose (Beretta 2015). Leydig cells are less sensitive to the effects of radiation, with damage occurring at 30 Gy in mature males and 20 Gy in prepubescent males.

High-frequency electromagnetic radiation (from 300 kHz to 300 MHz) is non-ionizing radiation transmitted by cellular phones, among other devices or related to occupational exposure such as in employees working with thermal plastic sealing, physiotherapy, and military radar equipment. Early studies showed that the apparent effect of high-frequency electromagnetic radiation on semen quality may be due to the heating effect associated with the radiation. Cell phone usage has been associated with decreased sperm progressive motility, decreased sperm viability, increased levels of reactive oxygen species, decreased sperm counts, and increased abnormal sperm morphology (Kilgallon and Simmons 2005; Agarwal et al. 2008).

### Effects of Drugs, Lifestyle, and Toxicants

A variety of prescription drugs can impair fertility by direct toxic effect on germ cells or interfere with the reproductive axis. Ketoconazole and spironolactone disrupt testicular steroidogenesis and lower serum testosterone levels. Cimetidine acts as an androgen antagonist (Turek 2008). Antihypertensive agents decrease sperm motility and interfere with the ability of spermatozoa to penetrate and fertilize the ova. In addition antihypertensive agents cause decreased libido and/ or sexual dysfunction. Antibiotics including erythromycin, nitrofurantoin, gentamycin, and tetracycline demonstrate direct gonadotoxicity or adversely affect sperm function. Sulfasalazine, a medicine used for the treatment of ulcerative colitis, is linked with reversible impairment of basic sperm parameters (Toth 1979). Cancer chemotherapy has been considered to eradicate rapidly dividing cells leading to undesirable cytotoxic effect on normal tissues such as the spermatogenic epithelium especially the differentiating spermatogonia (Turek 2008). Cyclophosphamide, chlorambucil, and nitrogen mustard are examples of alkylating agents with severe gonadotoxic effects (Turek 2008). Exogenous androgens suppress gonadotropins, thus acting against fertility at a

pre-testicular level. The overall effect is suppression of sperm production. Recreational drugs have also demonstrated gonadotoxic effect. They are thought to disrupt hormone secretion at more than one level of the reproductive axis.

Tobacco smoking has been linked with an enhanced frequency of sperm cell aneuploidies (Harkonen et al. 1999). Moreover, tobacco smoking may cause decreased sperm concentration, forward motility, morphology, and viability (Vine 1996), as well as declines in sperm penetration ability (Sofikitis et al. 1995; Joesbury et al. 1998).

Pesticides include a vast and heterogeneous group of chemical compounds designed to produce deleterious effects on living organisms. The most well-established example of occupational adverse effects on male reproduction is nematocide dibromochloropropane (DBCP). Its deleterious action is likely to be mediated through an estrogen-like activity (Turek 2008). Several other pesticides in current use, such as chloroprene, para-tertiary butyl acid, and 2,4-dichlorophenoxyacetic acid (Lerda and Rizzi 1991), are also suspected for reproductive toxicity (Bonde and Toppari 2010).

Other gonadotoxic compounds which may affect the male reproductive health mainly due to occupational exposure include inorganic lead, cadmium, mercury, manganese, and organic solvents (Lee and Dixon 1975; Lauwerys et al. 1985; McGregor and Mason 1990; Vanhoorne et al. 1994; Kolstad et al. 1999; Bonde 2006).

## Systemic Diseases

### Chronic Renal Failure

Chronic renal failure (CRF) affects hypothalamic–pituitary–gonadal axis both centrally and peripherally. Uremia has been shown to be linked with reduced fertility potential, decreased sexual activity and libido, and gynecomastia (Turek 2008). In addition, CRF causes direct testicular effects; often testicular atrophy (Handelsman et al. 1995) with manifestations suggesting both endocrine and exocrine testicular dysfunction (Mastrogiacomo et al. 1984; Prem et al. 1996).

The underlying mechanism of hypogonadism in CRF is still eluding and likely multifactorial. Testosterone levels are usually diminished and associated with elevated FSH and LH levels (Turek 2008). In 25% of patients suffering from CRF, serum prolactin levels are raised (Kheradmand and Javadneia 2003; Turek 2008). In addition, it is probable that the estrogen excess which has been described in patients with CRF may have a detrimental effect on testicular steroid biosynthesis (Mahmoud and Comhaire 2006).

Hemodialysis may improve sperm motility (Kheradmand and Javadneia 2003). However, the only effective treatment is renal transplantation (Prem et al. 1996). Subfertile CRF men with untreatable severely impaired semen quality may participate in assisted reproductive technology trials (Bonde and Toppari 2010).



## Liver Failure

Liver diseases, particularly liver cirrhosis, cause reproductive dysfunction regardless of the reason for cirrhosis (i.e., hepatitis or excessive alcohol intake). Liver failure is associated with loss of libido, sexual dysfunction and reduced fertility and secondary sexual characteristics, as well as testicular atrophy, and gynecomastia (Sartorius and Handelsman 2010).

The pathogenesis of hypogonadism in liver cirrhosis is not fully elucidated and may include various contributing factors. It has been recorded an augmented conversion of androgens to estrogens by aromatases that produce excess of serum estradiol (Kaymakoglu et al. 1995; Baker 1998). Testosterone levels are low, while sex hormone-binding globulin is elevated, further reducing the bioavailable testosterone level. Gonadotropins are elevated or may remain unchanged (Luppa et al. 2006). The severity of the liver disease determines the deterioration of the reproductive functions.

Liver transplantation can normalize the hypothalamic–pituitary–testicular hormone axis and gonadal tissue function in the majority of the cases (Handelsman et al. 1995).

## Hematological Diseases

### Sickle Cell Disease

Men with sickle cell disease display eunuchoid skeletal proportions, reduced testicular volume, decreased muscle mass, and decreased hair (Landefeld et al. 1983; el-Hazmi et al. 1992). Sickle cell anemia can cause hypogonadism and spermatogenic failure as a result of thromboses and multiple microinfarcts, both in the hypothalamus and in the testes.

In a significant proportion of patients with sickle cell disease, serum testosterone levels are low, and gonadotropin levels are variable (Walsh and Smith 2013).

### $\beta$ -Thalassemia

Patients with  $\beta$ -thalassemia undergo regular transfusions that produce iron overload leading to decreased gonadotropin levels and subsequent hypogonadotropic hypogonadism with impaired semen parameters (Safarinejad 2008). However, if fully sexually matured, 45% of  $\beta$ -thalassemic subjects will have normal sperm count and motility (De Sanctis et al. 1989).

Prepubertal onset of iron chelation therapy may potentially reverse fertility-related complications in  $\beta$ -thalassemic patients (Bronspiegel-Weintrob et al. 1990; Farmaki et al. 2010).

## Alcoholism

While small amounts of alcohol intake seem to have no negative effect on male fertility (Bonde and Toppari 2010), acute excessive alcohol intake causes sharp drop of peripheral testosterone levels and should be taken into consideration when

counseling men with pregnancy plans (Bonde and Toppari 2010). Excessive alcohol intake interferes with the endocrine system and causes systemic pathologies in organs that can compromise fertility such as the gonads and the liver (Mahmoud and Comhaire 2006). Chronic alcoholism disturbs the peripheral hormonal metabolism (Bonde and Toppari 2010). It has been shown experimentally that blood testosterone concentrations decrease within hours after ingesting a sufficient amount of alcohol to produce hangover (Bonde and Toppari 2010). Likewise, in chronic alcoholism, the levels of testosterone are low (Bonde and Toppari 2010). Other manifestations of chronic alcoholism include reduced libido, sexual dysfunction, gynecomastia, testicular atrophy, and reduced sperm count and thus reduced fertility (Bonde and Toppari 2010), and furthermore on a nearly daily basis of alcohol abuse, these effects are more prominent. The elevated LH levels suggest that high ethanol concentration in peripheral blood may exert direct toxic effect on the testis (Pajarinen and Karhunen 1994, Pajarinen et al. 1997). Moreover, in chronic alcoholism the serum concentrations of estrogens are usually increased due to the increased conversion of androgens to estrogens in the liver and fat cells (Bonde and Toppari 2010).

Chronic alcoholism is also linked with extensive suppression of the hypothalamic–pituitary–gonadal axis suggesting a detrimental effect of alcohol at pre-testicular level as well (Salonen et al. 1992).

### **Congenital Adrenal Hyperplasia**

Congenital adrenal hyperplasia (CAH) includes various autosomal recessive pathologies caused by gene mutation coding enzymes involved in the biochemical steps of steroidogenesis (Warrell 2005). Any alteration in the production of sex steroids may adversely interfere with the primary or secondary male sex characteristics (Milunsky and Milunsky 2010). If it is not treated adequately, CAH may be accompanied by infertility, reduced testes volume, decreased sperm counts even up to azoospermia, and decreased gonadotropic levels (Winters 1999). Adequate restoration of glucocorticoids and mineralocorticoids levels normalizes spermatogenesis (Winters 1999).

### **Chronic Gastrointestinal Diseases**

Chronic inflammatory bowel diseases (i.e., ulcerative colitis and Crohn's disease) are often linked with impaired fertility and a delayed puberty. The underlying mechanisms may involve a combined effect of chronic inflammation factors such as fever, undernutrition, and cytokines (i.e., as TNF $\alpha$ ) which frequently impair spermatogenesis (Farthing and Dawson 1983).

Celiac disease has controversial effect on male fertility. Some investigators associate celiac disease with delayed puberty, subfertility, and reduced sperm parameters (Bona et al. 2002), while others do not find any major influence of untreated celiac disease on male reproductive health (Lohi et al. 2009).

### **Fever**

Fever may affect sperm parameters (Carlsen et al. 2003). The adverse effect of the fever depends on the duration of the elevated temperature (Carlsen et al. 2003).

Other studies associated fever with sperm DNA damage (Evenson et al. 2000). However, these effects appear to be temporary.

### **Human Immunodeficiency Virus (HIV) Infection**

The prevalence of hypogonadism in patients with HIV infection under antiretroviral therapy ranges from 20% to 25% (Rietschel et al. 2000; Crum et al. 2005). Primary hypogonadism in HIV-infected men could be caused by malignancies or testicular atrophy due to opportunistic infections (Baker 1998; Umamathy et al. 2001). Secondary hypogonadism is more commonly associated with fertility problems in HIV-positive patients. The popular use of anabolic steroids in these patients is another cause of hypogonadism (Pena et al. 2003). In addition, cytokine release may affect the reproductive axis in HIV patients (Mylonakis et al. 2001). Interleukin-1 interferes with gonadotropin release and LH binding to Leydig cells leading to decreased testosterone levels (Mylonakis et al. 2001). It has been reported that serum hormone-binding globulin increases as the disease progresses in HIV/AIDS syndrome resulting in decreased bioavailable testosterone (Poretsky et al. 1995).

When assisted reproductive techniques are required to overcome fertility issues in HIV-infected hypogonadal men, it is necessary to separate accurately the spermatozoa from the leukocytes during semen laboratory manipulation since the HIV virus is transferred by leukocytes and not by spermatozoa (Sauer 2005).

### **Oncological Diseases**

Neoplasms in general can severely compromise spermatogenesis (Costabile and Spevak 1998). Although nowadays an increasing proportion of cancer patients will survive their disease due to the improvements in cancer therapy, cancer therapy itself may have detrimental and sometimes irreversible impact on the individual's fertility. Particular malignancies such as Hodgkin disease have gonadotoxic effects even before administration of treatment due to endocrinopathies, germ cell genetic abnormalities, and cytokine production interfering deleteriously to both the seminiferous tubules and the interstitial testicular tissue (Rueffer et al. 2001). Other mechanisms leading to decreased spermatogenesis include destruction of the surrounding tissue by the neoplasm, alterations in the local testicular blood flow with intrascrotal temperature elevation, and local production of hCG and other paracrine agents. Pelvic radiation treatment may cause permanent spermatogenic arrest and azoospermia (Rowley et al. 1974), and therefore appropriate protection of the gonads during treatment is crucial (Mahmoud and Comhaire 2006). Chemotherapy can cause irreversible damage especially when alkylating agent-based regimens are employed (Colpi et al. 2004). Therefore, multiple semen samples should be cryopreserved prior to radiotherapy or chemotherapy in all cases when fertility is desired (Meistrich 1993). If the patient cannot ejaculate (i.e., pediatric patients), the use of a vibrator may be attempted. However, due to practical issues, testicular tissue recovery and freezing may be more feasible in these cases. Freezing spermatozoa or their precursors gives the probability to these patients to father their own biological children.

## Orchitis

Epididymo-orchitis is commonly caused by bacterial infections of the testicular tissue (Turek 2008). Viral infections and more frequently infectious parotitis (mumps), coxsackie, or herpes are also seen (Mahmoud and Comhaire 2006). Mumps orchitis in postpubertal men is a common complication of infectious parotitis affecting approximately 20–30% of cases. The pathogenic mechanism leading to compromised fertility is not fully elucidated. Most probably the testicular inflammation and the subsequent edema increase the intratesticular pressure leading to testicular atrophy (Bartak 1973). In cases of azoospermia, testicular sperm extraction is indicated even with high concentrations of FSH and LH (Masuda et al. 2011).

## Obesity

Fertility status in men is also linked to alimentary factors (Pusch 1996). It has been shown that overweight in the male is independently contributing up to 50% higher rate of fertility problems in comparison with non-obese men (Pauli et al. 2008). Obesity associated infertility is mainly linked with increased estradiol to androgen ratio due to enhanced androgen to estrogen conversion in the adipose tissue (Mahmoud and Comhaire 2006) with suppressing effects on pituitary gonadotropin secretion (FSH and LH) affecting negatively spermatogenesis (Schlegel 2012). Other mechanisms include increased leptin production in the adipose tissue with detrimental effect on the sperm functionality (Hofny et al. 2010) and hyperinsulinemia which is related to inhibition of spermatogenesis, damage in sperm DNA, and subsequent reduction in fertility (Agbaje et al. 2007).

## Testis Injury

### Testicular Torsion

Testicular torsion is an urgent medical condition threatening the viability of the testis. Prompt surgical approach may rescue the torsed testis but infertility remains one of the main potential sequela (Bartsch et al. 1980). The “normal” non-torsed contralateral testis may also present histologic alterations (Turek 2008).

The principal pathophysiologic mechanism in testicular torsion is ischemia–reperfusion (IR) injury which probably involves the production of reactive oxygen species (Anim et al. 2005). Reactive oxygen species cause DNA damage, germ cell necrosis/apoptosis in both testes, and loss of spermatogenesis (Prillaman and Turner 1997; Turner et al. 1997; Lysiak et al. 2001). This loss of spermatogenesis may be attributed to germ cell-specific apoptosis.

So far experimental data from animal models offer some interesting new modalities to overcome the detrimental effect of IR injury to the testis. Among them the use of sivelestat, a neutrophil elastase inhibitor, has been found to reduce the oxidative stress and partially prevent the testicular damage both in the ischemic and in the contralateral testis (Tsounapi et al. 2011). Likewise, cromakalim, a KATP channel opener, shows a beneficial effect against IR-induced testicular damage (Tsounapi

et al. 2012). Moreover, ischemic post-conditioning, a surgical maneuver including rapid intermittent suspensions of blood supply in the early stage of reperfusion, may also protect both testes after unilateral testicular ischemia and reperfusion (Shimizu et al. 2011).

### Trauma

The testis represents an immunologically privileged site in the body, and because of this peculiar immunological status, trauma to the testis can raise a nonphysiological immune response potentially leading to infertility. In contrast, minor scrotal injuries are common but usually without any impact to fertility (Mahmoud and Comhaire 2006). The effect of testicular injury on semen characteristics is highly variable and depends on the extent and the type of the testicular trauma (Rowe et al. 2000).

### Idiopathic Infertility

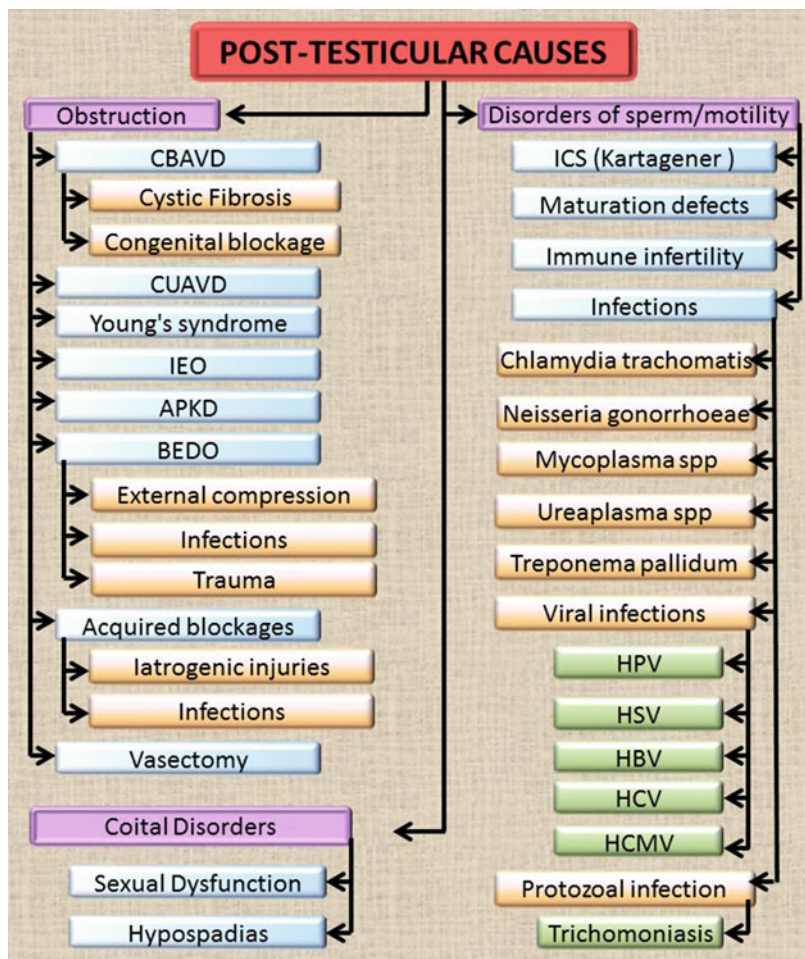
Idiopathic infertility is characterized by oligospermia and/or asthenospermia and/or teratospermia with no observable cause and applies approximately for the 30% of infertile men (Nieschlag 1997). Infective agents such as chlamydia trachomatis and adenovirus infections have been associated with idiopathic oligoasthenoteratospermia (iOAT) (Eggert-Kruse et al. 1997). On the other hand, noninflammatory functional alterations of male accessory glands appear to play a more important role in some cases of iOAT. For example, low prostatic secretory function (Carpino et al. 1994), diminished epididymal neutral  $\alpha$ -glycosidase, or modification of epididymal methylation of spermatogenesis-related genes may also be involved in some cases of iOAT (Ariel et al. 1995). Gene mutations in the X chromosome (Turek 2008), subtle hormonal alterations and molecular variants of LH are some other possible explanations of human iOAT cases (Ramanujam et al. 2000). Moreover, environmental pollutants and lifestyle characteristics may also deteriorate semen quality. The consequences of decreased physical activity, obesity, alcohol, tobacco use, psychological stress, and cellular phone usage on male infertility have been investigated, but further well-designed placebo-controlled trials are necessary in order to extrapolate solid conclusions (Walsh and Smith 2013).

Due to the absence of obvious causality in the cases of iOAT, the therapeutic approach involves the employment of empiric medical treatment or assisted reproductive techniques (Siddiq and Sigman 2002).

---

### Post-Testicular Causes of Male Infertility

The post-testicular causes of infertility include obstruction or stricture of the ductal system of the male reproductive tract (Fig. 3). In contrast with testicular disorders, post-testicular abnormalities are commonly treatable. Thus, restoration of fertility potential may be possible.



**Fig. 3** Post-testicular causes of male infertility. *CBAVD* congenital bilateral absence of the vas deferens, *CUAVD* congenital unilateral absence of vas deferens, *IEO* idiopathic epididymal obstruction, *APKD* adult polycystic kidney disease, *BEDO* bilateral ejaculatory duct obstruction, *ICS* immotile cilia syndrome, *HPV* human papillomavirus, *HSV* herpes simplex virus, *HBV* hepatitis B virus, *HCV* hepatitis C virus, *HCMV* human cytomegalovirus

## Male Reproductive Tract Obstruction

A certain number of infertile men have normal spermatogenic epithelium, and it is the lumen of the male genital tract that does not allow the spermatozoa to reach the external urethral orifice.

### Congenital Bilateral Absence of the VD (CBAVD)

Cystic fibrosis (CF): CF affects approximately 1 in 2000 newborns. Progressive pancreatic insufficiency and bronchopulmonary disease are common clinical

manifestations (Welsh et al. 1995). It is an autosomal recessive disease commonly found in Caucasians.  $\Delta F508$  is a major gene mutation in the encoding area of CF transmembrane regulator (CFTR) that can be identified in over 75% of patients with CF. Infertility due to obstructive azoospermia is very common (Kaplan et al. 1968; Heaton and Pryor 1990). Clinical features of the disease include azoospermia, acidic (pH < 7.2) ejaculate of decreased volume (<2 mL), as well as decreased seminal plasma levels of epididymal and seminal vesicle markers.

Pancreatic insufficiency, bronchopulmonary disease, and malformations of the genital tract in CF are consequences of mutations in the CF transmembrane conductance regulator (CFTR) gene (Kerem and Kerem 1996). Sperm obtained from men with both CFTR mutations and CBAVD were linked with increased risk of miscarriage and stillbirth after ICSI as compared with men without either CFTR mutations or CBAVD (Lu et al. 2014). Decreased motility and fertilizing capacity in spermatozoa obtained from elderly men with CFTR mutations (Diao et al. 2013) and downregulation of CFTR protein in testicular samples were observed (Xu et al. 2011). Thus an additional role for CFTR (to that related to CF disease) was indicated.

Genetic links between CF and CAVD have been established due to the increased frequency of the p.Phe508del mutation described in CAVD patients (Anguiano et al. 1992). The p.Arg117His, p.Phe508del, and T5 allele have been proposed to be the commonest CFTR mutations in Caucasians with CAVD phenotype (Chillon et al. 1995; De Braekeleer and Ferec 1996). New mutations for CF are continuously discovered. Four novel mutations of the *CFTR* gene are discovered (Yang et al. 2015). The gene mutation spectrum of CFTR varies markedly among populations (mutations in Indian CAVD males are different from those observed in Caucasians) (Sharma et al. 2014).

**Congenital blockage:** CBAVD is a genital tract pathology, genetically related to CF but with a distinct clinical pattern. A certain number of patients present a history of chronic sinusitis, nonprogressive bronchitis, and pneumonia in infancy but their main complaint as adults is infertility (Augarten et al. 1994; Casals et al. 1995). The semen parameters are similar as in men with CF disease (Oates and Amos 1994). VD aplasia is accompanied by epididymal tail aplasia and several anatomical or functional abnormalities of the SV (Mercier et al. 1995) (Table 1).

### **Congenital Unilateral Absence of VD (CUAVD)**

Unilateral VD obstruction is compatible with natural fertility. Therefore, CUAVD is believed to remain in the most cases undiagnosed. CUAVD is attributable to defective organogenesis of the Wolffian duct system. Renal agenesis is a common clinical feature as well. Also, bilateral or unilateral vasal hypoplasia or unilateral absence of the VD may cause obstructive azoospermia. It was found that a high percentage of men with CUAVD demonstrated abnormalities in the contralateral ejaculatory ducts or seminal vesicles as well (Raviv et al. 2006). CUAVD is associated also with CFTR mutations (Mickle et al. 1995).

**Table 1** Cystic fibrosis gene (CFTR) mutations in men with various disorders of the seminal ducts and seminal vesicles. *CBAVD* congenital bilateral absence of the vas deferens, *CUAVD* congenital unilateral absence of vas deferens

Author	Patients	% of (+) mutation
<b>CBAVD</b>		
(Dumur et al. 1990)	17	20.6
(Anguiano et al. 1992)	25	38
(Osborne et al. 1993)	26	38
(Augarten et al. 1994)	47	38
(Culard et al. 1994)	12	66
(Oates and Amos 1994)	49	82
(Chillon et al. 1995)	102	78
(Costes et al. 1995)	45	89
(Jarvi et al. 1995)	25	80
(Le Lannou et al. 1995)	26	77
(Mercier et al. 1995)	67	66
(Rave-Harel et al. 1995)	40	48
(Silber et al. 1995)	52	70
(Zielenski et al. 1995)	70	79
(Dork et al. 1997)	101	84
(Attardo et al. 2001)	34	71
(Wang et al. 2002)	92	67
(Anzai et al. 2003)	19	58
(Grangeia et al. 2005)	31	58
(Radpour et al. 2006)	106	80
(Chiang et al. 2009)	63	57
(Bareil et al. 2007)	217	68
(Giuliani et al. 2010)	23	60
(Sachdeva et al. 2011)	35	100
<b>CUAVD</b>		
(Jarvi et al. 1995)	2	50
(Mickle et al. 1995)	21	38
(Dork et al. 1997)	4	75
(Grangeia et al. 2005)	4	75
<b>Ejaculatory duct obstruction</b>		
(Meschede et al. 1997)	7	86
<b>Seminal vesicles anomalies</b>		
(Meschede et al. 1997)	16	13
<b>Young's syndrome</b>		
(Hirsh et al. 1993)	7	29
(Le Lannou et al. 1995)	12	0



### **Young's Syndrome**

Young's syndrome is a pathophysiology presented with obstructive azoospermia chronic sinopulmonary infections and bronchiectasis. Young's syndrome may represent genetic variations of Kartagener syndrome (Ichioka et al. 2006) or CFTR gene mutations (Goeminne and Dupont 2010). Genetic testing is required in these patients.

Young's syndrome may cause a bilateral epididymal obstruction leading to azoospermia. The obstruction is the result of the presence of an amorphous mass within the epididymal lumen (Handelsman et al. 1984). The pathophysiology may involve abnormal mucus quality or abnormal ciliary function. Patients may report sino-bronchial symptoms from early childhood on, and they can develop bronchiectasis over time. The surgical reconstruction is technically feasible but with poor outcomes (Hendry et al. 1993).

### **Idiopathic Epididymal Obstruction**

Epididymal obstruction (EO) is the most frequent cause of OA affecting 30–67% of men with azoospermia (Dohle et al. 2005). Idiopathic EO is a relatively uncommon pathology found in men with no other apparent health problems. Recent evidence is linking this condition to CF. The causes of EO may be infection-related, iatrogenic, trauma-related, vasectomy-related, and idiopathic (Chan et al. 2005, 2008). In a study, of 134 consecutive men with azoospermia, idiopathic EO was detected in two-thirds of the cases in which blocked reproductive duct was suspected (Peng et al. 2012). On the other hand, Chan et al. (2008) reported that the incidence of idiopathic EO in his study was only 3%. EO is assumed to take place when the pressure within the epididymal lumen surpasses the integrity of the delicate epididymal tubule leading to sperm extravasation with consequent EO (Peng et al. 2012).

### **Polycystic Kidney Disease**

Adult polycystic kidney disease (APKD) is a hereditary systemic disorder, affecting multiple organs. Patients with APKD usually have no fertility problems, though various studies have documented male infertility in these patients (Peces and Venegas 2005; Shefi et al. 2009). The most commonly reported semen aberration in these patients is asthenozoospermia (Torra et al. 2008) due to structural defects at spermatozoa tail and abnormal polycystins. The dilation of the SV noted in men with APKD usually is the result of the distal obstruction.

### **Ejaculatory Duct Obstruction**

Common reasons for a bilateral ejaculatory duct obstruction (BEDO) include external compression from neoplasms or cysts, infectious disorders, or traumas. Constitutional BEDO is another distinct cause of male infertility and results from CFTR gene variations (Meschede et al. 1997). Clinical features of men with BEDO are azoospermia, small semen volume, dilated SV, normal secondary sex characteristics, normal testicular volume, and normal hormonal profiles. A transrectal ultrasound may be performed to confirm the diagnosis (Hopps et al. 2002).

## Acquired Blockages

### Iatrogenic Injuries: Groin Surgery

A variety of surgical procedures in the inguinal, pelvic, and scrotal areas such as herniorrhaphy, appendectomy, renal transplant, and hydrocelectomy may cause vasal injury and postsurgical obstruction up to 25% of the cases (Steigman et al. 1999; Ridgway et al. 2002).

A common reason of non-vasal obstruction is accidental injury during surgery for hernia repair which more commonly takes place when the hernia repair is performed during infancy (59%). However, it may occur after any inguinal surgery when the spermatic cord is manipulated (Matsuda et al. 1992). Postoperative inflammatory response caused by the mesh may entrap and obstruct the inguinal VD. Patients with the history of bilateral hernia reconstruction had a slightly raised risk for infertility (<1%) (Hallen et al. 2012). Surgical repair is feasible in many cases of iatrogenic injury of the vas either in the level of the inguinal canal or in the scrotum.

### Infections

Infection may cause OA in 8–46% of men undergoing vasal surgery in various large series (Berardinucci et al. 1998; Chan et al. 2005; Schiff et al. 2005). Common pathogens associated with epididymitis include chlamydia, gonorrhea, brucellosis, trichomonas, mycoplasma, ureaplasma, adenovirus, coliforms bacteria, and enterovirus. Epididymitis can cause an intense inflammatory reaction, leading to secondary scarring and obstruction of the epididymis. Typically, the volume of the semen is normal. Tuberculosis may be associated with nodular and enlarged vas deference, and when tuberculosis involves the SV, the volume of the ejaculate may be reduced (Baker and Sabanegh 2013). A feasible option for postinfectious obstruction of the epididymis is scrotal exploration with microsurgical reconstruction. However in the case of tuberculosis, the extensive scarring at multiple levels of the male reproductive tract gives poor outcomes (Baker and Sabanegh 2013). Prevention of this terminal obstructive status based on early treatment and resolution of the inflammation gives more successful results in the reappearance of spermatozoa in the ejaculate (Paick et al. 2000).

### Vasectomy for Male Contraception and Demand of Vasovasostomy

Vasectomy has different prevalence among countries due to religious and cultural reasons, and it is the most common cause of vas deference obstruction performed as a contraceptive measure (Costabile and Spevak 2001). The restoration of fertility after a vasectomy relies upon vasectomy reversal through microscopic reconstruction of the vas deference. Vasal, epididymal, or testicular sperm retrieval and ART can be performed in couples whose male partner has a bilateral vasectomy and a concomitant female factor is present (Baker and Sabanegh 2013). The option of sperm retrieval during the surgery and the subsequent cryopreservation should be recommended to the couples (Baker and Sabanegh 2013).

## Disorders of Sperm Function or Sperm Motility

### Immotile Cilia Syndrome/Primary Ciliary Dyskinesia Syndrome

Immotile cilia syndrome (ICS) or primary ciliary dyskinesia (PCD) is an autosomal recessive disease. Pathological features include impaired ciliary motion and abnormal mucociliary clearance. *DNAI1* and *DNAH5* are the two genes which are directly implicated in PCD. *DNAI1* and *DNAH5* are encoding components that constitute the outer dynein arm complex (Guichard et al. 2001; Bush and Ferkol 2006; Hornef et al. 2006). The reported frequency is 1 per 26,000–40,000 live births. Kartagener was the first to describe a syndrome characterized by situs inversus, bronchiectasis, and chronic sinusitis known as Kartagener syndrome (Kartagener 1933). Patients with this Kartagener syndrome have defects in the ciliary defects at ultrastructural level. In subsequent studies it was noticed that the cilia rather than immotile presented a disorganized and uncoordinated motion, and therefore the term immotile cilia syndrome was changed to primary ciliary dyskinesia syndrome. The term PCD describes the genetic defect differentiating it from other acquired defects (Carson et al. 1985).

Seminal analysis in primary CDS demonstrates a normal number of viable but immotile spermatozoa. Spermatozoa of patients with PCD have usually decreased motion to varying degrees or are even completely motionless with defective morphology. ICSI represents currently the only therapeutic approach to this condition but with poorer outcomes (Abu-Musa et al. 1999) maybe due to higher incidence of aneuploid sperm, related to primary cilia abnormalities (Rives et al. 2005b). These abnormalities may also enhance the risk of genetic defects in the offspring, and the genetic evaluation of the spermatozoa is highly suggested prior to ICSI procedures (Abu-Musa et al. 1999).

### Maturation Defects

Maturation process of spermatozoa demands their interaction with proteins that are synthesized and secreted by the epididymis (Toshimori 1998). Posttranslational changes of existing sperm proteins are crucial for the spermatozoon to acquire its fertilizing potential. Phosphorylation and glycosylation are common posttranslational changes that sperm proteins undergo during their passage through the epididymis resulting in modifications in protein function resulting to the development of mature spermatozoa (Cornwall 2014).

Reactive oxygen species (ROS) play a key role in the physiology of the sperm function. Normal quantitative profiles of ROS are involved in the initiation and development of several sperm functions including sperm hyperactivation, sperm capacitation, and acrosome reaction (de Lamirande and Gagnon 1995; Griveau et al. 1995). On the other hand, an overproduction of ROS leads in oxidative damage of sperm membrane lipids, sperm proteins, and sperm DNA (Alvarez and Storey 1984; Aitken 1995) resulting in decreased motility, damaged acrosomal membranes, and thus inability of the spermatozoon to fertilize the oocyte.

Poor sperm and decreased motility have been associated with mutations in the mitochondrial DNA (Ruiz-Pesini et al. 2000). Mitochondrial DNA is exclusively inherited by the oocyte, and therefore there is an interesting probability that some types of male infertility are transmitted only through the mother (Danan et al. 1999; Rovio et al. 2001; Dacheux and Dacheux 2014).

### Immunologic Infertility

The term immune infertility refers to spontaneously occurring antibodies which bind to antigens of the spermatozoa impairing the interaction between sperm and oocyte. The expression of antisperm antibodies is associated with certain HLA classes (Omu et al. 1999) suggesting that immune infertility constitutes an autoimmune disorder. Abnormalities in the development of the formation of the blood–testis barrier may result in the formation antisperm antibodies (Bohring and Krause 2003). Antisperm antibodies are observed in men with testicular tissue injury (i.e., testicular torsion, surgery, or trauma). Other common reasons include infections and obstruction of sperm transport, for example, in men after vasectomy or in men diagnosed with CF or congenital agenesis of VD. In all these later conditions, the immune equilibrium within the testis may be altered (Sotolongo 1982; Vazquez-Levin et al. 1994).

The diagnostic approach is based mainly on mixed antiglobulin reaction test and immunobead binding test that are used for detection of antisperm antibodies. A cutoff value of 50% of motile spermatozoa carrying antisperm antibodies has been regarded significant in the clinical practice (Vazquez-Levin et al. 2014). Antisperm antibodies may affect sperm motility and viability, sperm–oocyte interaction, early embryonic development, embryonic capacity for implantation, and fetal development (Ohl and Naz 1995; Chiu and Chamley 2004). Antisperm antibodies also affect sperm capacitation process, spermatozoal ability to undergo the acrosomal reaction and to bind to and penetrate the zona pellucida of the female gamete (Shibahara et al. 1996; Nakagawa et al. 2004).

Currently, there is no standardized therapeutic option, and the actual clinical meaning of antisperm antibodies in infertile men is still debatable (Silva et al. 2008). However, a significant increase in pregnancy rates was found among anti-sperm antibody-positive men receiving prednisolone for more than 3 months compared to placebo group (Hendry et al. 1990). In addition assisted reproductive technologies are the treatment of choice for male infertility associated with anti-sperm antibodies. Other systemic medications that have been proposed include immunosuppressive agents (azathioprine or intravenous cyclophosphamide) and intravenous immunoglobulin (Silva et al. 2008).

### Infections

Bacterial pathogens in seminal plasma can reduce sperm motility, induce apoptosis or necrosis, alter sperm morphology, and thus affect directly sperm quality (Villegas et al. 2005; Isaiah et al. 2011; Rybar et al. 2012). Major bacterial sexually transmitted disease organisms affecting semen include *Chlamydia trachomatis*, *Neisseria gonorrhoeae*, *Mycoplasma* spp., *Ureaplasma* spp., and *Treponema pallidum*. Other pathogens include protozoal infections mainly *Trichomonas vaginalis* and

viral infections such as *human papillomavirus*, *herpes simplex virus*, *hepatitis B and C viruses*, and *human cytomegalovirus* (Dejucq and Jegou 2001; Kalichman et al. 2008). Antiviral and antiretroviral therapies may also induce testicular damage with deleterious effects on sperm quality (Lorusso et al. 2010).

## Disorders of Coitus

### Sexual Dysfunction

Erectile dysfunction, rather than infertility cause, represents a factor making conception very difficult. For the majority of men, erectile dysfunction is a greater problem than infertility. The enormous success of phosphodiesterase type 5 inhibitors in the modern industrial world and the plethora of aphrodisiac potions around the world suggest that for most men, the desire for erections is a more immediate and pressing concern than maximizing their fecundity. Furthermore, erectile dysfunction may lead to psychological distress, feeling of sexual failure, and lower self-esteem (Wibowo et al. 2016).

Ejaculation disorders could be the result of:

- Functional blockages such as functional obstruction of the SV, spinal cord injury, or sympathetic nerve injury
- Pharmacologic (drugs causing retrograde ejaculation)

Ejaculatory duct obstruction (EDO) has been originally diagnosed in men with azoospermia with complete ductal obstruction, but a larger number of patients have oligoasthenospermia; the latter is characteristic of partial EDO. Functional EDO is a form of ejaculatory dysfunction with a similar presentation but without physical blockage (Walsh and Turek 2006).

Spinal cord injury (SCI) patients and patients after retroperitoneal lymphadenectomy experience ejaculation problems especially when the sympathetic centers which regulate the ejaculation (T9–T11 and L2–L3) are damaged (Chehense et al. 2013). Sympathectomy including bilateral removal of the T12–L2 paravertebral sympathetic ganglia is commonly associated with impaired ejaculation (Courty and Franchebois 1952; Rose 1953). In men with SCI, spermatozoa can be collected by electroejaculation using a rectal probe or can be surgically retrieved from the epididymis or the testis (Brackett et al. 2010). Acetylcholinesterase inhibitors, prostigmin, physostigmine, and midodrine, an  $\alpha 1$ -adrenergic receptor agonist, have been used to increase the rate of ejaculation in men suffering from SCI combined with penile vibratory stimulation (Soler et al. 2008).

Premature ejaculation as defined by the International Society for Sexual Medicine may be lifelong or acquired (Serefoglu et al. 2014). Treatment with tricyclic antidepressants or serotonergic uptake inhibitors combined with sexual counseling can be very effective (Turek 2008). Delayed ejaculation and anejaculation are more common as men age and have multiplex organic and psychogenic reasons. They have a significant impact on couple's sexual fulfillment resulting in infertility (Lue 2016).

Treatment of men with delayed ejaculation or anejaculation should be cause specific, including patient/couple psychoeducation and/or psychosexual therapy, pharmacotherapy, or integrated treatment. Retrograde ejaculation or anejaculation due to surgical procedures on the retroperitoneum, bladder, or pelvis may also cause infertility (Turek 2008). Ejaculation disorders may also be the result of medications such as antihypertensives especially  $\alpha$ -blockers and thiazides, as well as antipsychotic drugs and antidepressants (Turek 2008).

## Hypospadias

Hypospadias affects 0.3–0.7% of newborns (Giwercman and Giwercman 2000). The European Surveillance of Congenital Anomalies demonstrates a trend in raising incidence of hypospadias over a period of 10 years (Loane et al. 2011). The association between reduced semen quality and hypospadias is well documented. The most likely explanation is that fathers (with reduced semen quality) and their sons (with hypospadias) share the same susceptibility genes that govern their reproductive function (Skakkebaek et al. 2001; Asklund et al. 2007).

---

## References

- Abdel-Razic MM, Abdel-Hamid IA, ElSobky ES. Nonmosaic 47,XYY syndrome presenting with male infertility: case series. *Andrologia*. 2012;44(3):200–4.
- Abu-Musa A, Hannoun A, Khabbaz A, Devroey P. Failure of fertilization after intracytoplasmic sperm injection in a patient with Kartagener's syndrome and totally immotile spermatozoa: case report. *Hum Reprod*. 1999;14(10):2517–8.
- Agarwal A, Deepinder F, Sharma RK, Ranga G, Li J. Effect of cell phone usage on semen analysis in men attending infertility clinic: an observational study. *Fertil Steril*. 2008;89(1):124–8.
- Agbaje IM, Rogers DA, McVicar CM, McClure N, Atkinson AB, Mallidis C, Lewis SE. Insulin dependant diabetes mellitus: implications for male reproductive function. *Hum Reprod*. 2007; 22(7):1871–7.
- Aitken RJ. Free radicals, lipid peroxidation and sperm function. *Reprod Fertil Dev*. 1995; 7(4):659–68.
- Allanson JE. Noonan syndrome. *Am J Med Genet C Semin Med Genet*. 2007;145C(3):274–9.
- Allanson JE, Roberts AE. Noonan syndrome. In: Pagon RA, Adam MP, Ardinger HH, et al., editors. *GeneReviews*<sup>®</sup> [Internet]. Seattle: University of Washington; 2001.
- Alvarez JG, Storey BT. Assessment of cell damage caused by spontaneous lipid peroxidation in rabbit spermatozoa. *Biol Reprod*. 1984;30(2):323–31.
- Anguiano A, Oates RD, Amos JA, Dean M, Gerrard B, Stewart C, Maher TA, White MB, Milunsky A. Congenital bilateral absence of the vas deferens. A primarily genital form of cystic fibrosis. *JAMA*. 1992;267(13):1794–7.
- Anim JT, Kehinde EO, Prasad A, Varghese R. Morphological responses of the rabbit testis to ischemic/reperfusion injury due to torsion. *Urol Int*. 2005;75(3):258–63.
- Anzai C, Morokawa N, Okada H, Kamidono S, Eto Y, Yoshimura K. CFTR gene mutations in Japanese individuals with congenital bilateral absence of the vas deferens. *J Cyst Fibros*. 2003; 2(1):14–8.
- Ariel M, Robinson E, McCarrey JR, Cedar H. Gamete-specific methylation correlates with imprinting of the murine Xist gene. *Nat Genet*. 1995;9(3):312–5.
- Asklund C, Jorgensen N, Skakkebaek NE, Jensen TK. Increased frequency of reproductive health problems among fathers of boys with hypospadias. *Hum Reprod*. 2007;22(10):2639–46.

- Attardo T, Vicari E, Mollica F, Grazioso C, Burrello N, Garofalo MR, Lizzio MN, Garigali G, Cannizzaro M, Ruvolo G, D'Agata R, Calogero AE. Genetic, andrological and clinical characteristics of patients with congenital bilateral absence of the vas deferens. *Int J Androl.* 2001; 24(2):73–9.
- Augarten A, Yahav Y, Kerem BS, Halle D, Laufer J, Szeinberg A, Dor J, Mashiach S, Gazit E, Madgar I. Congenital bilateral absence of vas deferens in the absence of cystic fibrosis. *Lancet.* 1994;344(8935):1473–4.
- Baazeem A, Belzile E, Ciampi A, Dohle G, Jarvi K, Salonia A, Weidner W, Zini A. Varicocele and male factor infertility treatment: a new meta-analysis and review of the role of varicocele repair. *Eur Urol.* 2011;60(4):796–808.
- Backhouse KM. Embryology of testicular descent and maldescent. *Urol Clin North Am.* 1982;9:315–25.
- Baker HW. Reproductive effects of nontesticular illness. *Endocrinol Metab Clin North Am.* 1998;27(4):831–50.
- Baker K, Sabanegh Jr E. Obstructive azoospermia: reconstructive techniques and results. *Clinics (Sao Paulo).* 2013;68 Suppl 1:61–73.
- Bar-Maor JA, Groisman G, Lam M. Antenatal torsion of the testes, a cause of vanishing testis syndrome. *Pediatr Surg Int.* 1993;8:236–8.
- Bareil C, Guittard C, Altieri JP, Templin C, Claustres M, des Georges M. Comprehensive and rapid genotyping of mutations and haplotypes in congenital bilateral absence of the vas deferens and other cystic fibrosis transmembrane conductance regulator-related disorders. *J Mol Diagn.* 2007;9(5):582–8.
- Barseghyan H, Delot E, Vilain E. New genomic technologies: an aid for diagnosis of disorders of sex development. *Horm Metab Res.* 2015;47(5):312–20.
- Bartak V. Sperm count, morphology and motility after unilateral mumps orchitis. *J Reprod Fertil.* 1973;32(3):491–4.
- Bartsch G, Frank S, Marberger H, Mikuz G. Testicular torsion: late results with special regard to fertility and endocrine function. *J Urol.* 1980;124(3):375–8.
- Bay K, Main KM, Toppari J, Skakkebaek NE. Testicular descent: INSL3, testosterone, genes and the intrauterine milieu. *Nat Rev Urol.* 2011;8(4):187–96.
- Benoff SH, Millan C, Hurley IR, Napolitano B, Marmar JL. Bilateral increased apoptosis and bilateral accumulation of cadmium in infertile men with left varicocele. *Hum Reprod.* 2004; 19(3):616–27.
- Berardinucci D, Zini A, Jarvi K. Outcome of microsurgical reconstruction in men with suspected epididymal obstruction. *J Urol.* 1998;159(3):831–4.
- Beretta G. Iatrogenic infertility. In: Cavallini G, Beretta G, editors. *Clinical management of male infertility.* New York/Dordrecht/London: Springer; 2015. p. 145–51.
- Bergmann M, Behre HM, Nieschlag E. Serum FSH and testicular morphology in male infertility. *Clin Endocrinol (Oxf).* 1994;40(1):133–6.
- Bhagavath B, Podolsky RH, Ozata M, Bolu E, Bick DP, Kulharya A, Sherins RJ, Layman LC. Clinical and molecular characterization of a large sample of patients with hypogonadotropic hypogonadism. *Fertil Steril.* 2006;85(3):706–13.
- Bird TD. Myotonic dystrophy type 1. In: Pagon RA, Adam MP, Ardinger HH, et al, editors. *GeneReviews*<sup>®</sup> [Internet]. Seattle: University of Washington; 1993–2016 [updated 2015 Oct 22].
- Blanco J, Rubio C, Simon C, Egozcue J, Vidal F. Increased incidence of disomic sperm nuclei in a 47,YYY male assessed by fluorescent in situ hybridization (FISH). *Hum Genet.* 1997; 99(3):413–6.
- Bohring C, Krause W. Immune infertility: towards a better understanding of sperm (auto)-immunity. The value of proteomic analysis. *Hum Reprod.* 2003;18(5):915–24.
- Bona G, Marinello D, Oderda G. Mechanisms of abnormal puberty in coeliac disease. *Horm Res.* 2002;57 Suppl 2:63–5.
- Bonde JP. Effects of lifestyle and toxicants. In: Schill WB, Comhaire FH, Hargreave TB, editors. *Andrology for the clinician.* Berlin/Heidelberg/New York: Springer; 2006. p. 348–57.

- Bonde JP, Toppari J. Prevention of male infertility: environmental and systemic disease effects on male fertility. In: Björndahl L, Giwercman A, Tournaye H, Weidner W, editors. *Clinical andrology EAU/ESAU course guidelines*. New York: Informa Healthcare; 2010. p. 164–75.
- Boucekkine C, Toublanc JE, Abbas N, Chaabouni S, Ouahid S, Semrouni M, Jaubert F, Toublanc M, McElreavey K, Vilain E, et al. Clinical and anatomical spectrum in XX sex reversed patients. Relationship to the presence of Y specific DNA-sequences. *Clin Endocrinol (Oxf)*. 1994; 40(6):733–42.
- Brackett NL, Lynne CM, Ibrahim E, Ohl DA, Sonksen J. Treatment of infertility in men with spinal cord injury. *Nat Rev Urol*. 2010;7(3):162–72.
- Brandell RA, Mielnik A, Liotta D, Ye Z, Veeck LL, Palermo GD, Schlegel PN. AZFb deletions predict the absence of spermatozoa with testicular sperm extraction: preliminary report of a prognostic genetic test. *Hum Reprod*. 1998;13(10):2812–5.
- Bronspiegel-Weintrob N, Oliver NF, Tyler B, Andrews DF, Freedman MH, Holland FJ. Effect of age at the start of iron chelation therapy on gonadal function in beta-thalassemia major. *N Engl J Med*. 1990;323:713–9.
- Brook JD, McCurrach ME, Harley HG, Buckler AJ, Church D, Aburatani H, Hunter K, Stanton VP, Thirion JP, Hudson T, et al. Molecular basis of myotonic dystrophy: expansion of a trinucleotide (CTG) repeat at the 3' end of a transcript encoding a protein kinase family member. *Cell*. 1992;68(4):799–808.
- Bush A, Ferkol T. Movement: the emerging genetics of primary ciliary dyskinesia. *Am J Respir Crit Care Med*. 2006;174(2):109–10.
- Calogero AE, Garofalo MR, Barone N, De Palma A, Vicari E, Romeo R, Tumino S, D'Agata R. Spontaneous regression over time of the germinal epithelium in a Y chromosome-microdeleted patient: case report. *Hum Reprod*. 2001;16(9):1845–8.
- Carlsen E, Andersson AM, Petersen JH, Skakkebaek NE. History of febrile illness and variation in semen quality. *Hum Reprod*. 2003;18(10):2089–92.
- Carpino A, Sisci D, Aquila S, Salerno M, Siciliano L, Sessa M, Ando S. Adnexal gland secretion markers in unexplained asthenozoospermia. *Arch Androl*. 1994;32(1):37–43.
- Carson JL, Collier AM, Hu SS. Acquired ciliary defects in nasal epithelium of children with acute viral upper respiratory infections. *N Engl J Med*. 1985;312(8):463–8.
- Casals T, Bassas L, Ruiz-Romero J, Chillón M, Gimenez J, Ramos MD, Tapia G, Narvaez H, Nunes V, Estivill X. Extensive analysis of 40 infertile patients with congenital absence of the vas deferens: in 50% of cases only one CFTR allele could be detected. *Hum Genet*. 1995;95(2): 205–11.
- Cayan S, Shavakhov S, Kadioglu A. Treatment of palpable varicocele in infertile men: a meta-analysis to define the best technique. *J Androl*. 2009;30(1):33–40.
- Cendron M, Schned AR, Ellsworth PI. Histological evaluation of the testicular nubbin in the vanishing testis syndrome. *J Urol*. 1998;160(3 Pt 2):1161–2; discussion 1163.
- Chan PT, Brandell RA, Goldstein M. Prospective analysis of outcomes after microsurgical intussusception vasoepididymostomy. *BJU Int*. 2005;96(4):598–601.
- Chan PT, Lee R, Li PS. Six years of experience with microsurgical longitudinal intussusception vasoepididymostomy (LIVE): a prospective analysis [abstract]. *J Urol*. 2008;179(suppl):591.
- Chehensse C, Bahrami S, Denys P, Clement P, Bernabe J, Giuliano F. The spinal control of ejaculation revisited: a systematic review and meta-analysis of anejaculation in spinal cord injured patients. *Hum Reprod Update*. 2013;19(5):507–26.
- Chevret E, Rousseaux S, Monteil M, Usson Y, Cozzi J, Pelletier R, Sele B. Meiotic behaviour of sex chromosomes investigated by three-colour FISH on 35,142 sperm nuclei from two 47,XXY males. *Hum Genet*. 1997;99(3):407–12.
- Chiang HS, Lu JF, Liu CH, Wu YN, Wu CC. CFTR (TG)m(T)n polymorphism in patients with CBAVD in a population expressing low incidence of cystic fibrosis. *Clin Genet*. 2009;76(3): 282–6.



- Chillon M, Casals T, Mercier B, Bassas L, Lissens W, Silber S, Romey MC, Ruiz-Romero J, Verlingue C, Claustres M, et al. Mutations in the cystic fibrosis gene in patients with congenital absence of the vas deferens. *N Engl J Med*. 1995;332(22):1475–80.
- Chiu WW, Chamley LW. Clinical associations and mechanisms of action of antisperm antibodies. *Fertil Steril*. 2004;82(3):529–35.
- Clarke BG. Incidence of varicocele in normal men and among men of different ages. *JAMA*. 1966;198(10):1121–2.
- Colpi GM, Contalbi GF, Nerva F, Sagone P, Piediferro G. Testicular function following chemo-radiotherapy. *Eur J Obstet Gynecol Reprod Biol*. 2004;113 Suppl 1:S2–6.
- Cornwall GA. Role of posttranslational protein modifications in epididymal sperm maturation and extracellular quality control. In: Sutovsky P, editor. *Posttranslational protein modifications in the reproductive system*, *Advances in experimental medicine and biology*. New York: Springer; 2014. p. 159–80.
- Costabile RA, Spevak M. Cancer and male factor infertility. *Oncology (Williston Park)*. 1998;12(4):557–62, 565; discussion 566–58, 570.
- Costabile RA, Spevak M. Characterization of patients presenting with male factor infertility in an equal access, no cost medical system. *Urology*. 2001;58(6):1021–24.
- Costes B, Girodon E, Ghanem N, Flori E, Jardin A, Soufir JC, Goossens M. Frequent occurrence of the CFTR intron 8 (TG)n 5T allele in men with congenital bilateral absence of the vas deferens. *Eur J Hum Genet*. 1995;3(5):285–93.
- Coulam CB. Testicular regression syndrome. *Obstet Gynecol*. 1979;53(1):44–9.
- Courty A, Franchebois P. [The genital disturbances in arteritis]. *Presse Med*. 1952;60(65):1379–81.
- Crum NF, Furtek KJ, Olson PE, Amling CL, Wallace MR. A review of hypogonadism and erectile dysfunction among HIV-infected men during the pre- and post-HAART eras: diagnosis, pathogenesis, and management. *AIDS Patient Care STDS*. 2005;19(10):655–71.
- Cularud JF, Desgeorges M, Costa P, Laussel M, Razakatzara G, Navratil H, Demaille J, Claustres M. Analysis of the whole CFTR coding regions and splice junctions in azoospermic men with congenital bilateral aplasia of epididymis or vas deferens. *Hum Genet*. 1994;93(4):467–70.
- Dacheux JL, Dacheux F. New insights into epididymal function in relation to sperm maturation. *Reproduction*. 2014;147(2):R27–42.
- Dalton JC, Ranum LPW, Day JW. Myotonic dystrophy type 2. In: Pagon RA, Adam MP, Ardinger HH, et al, editors. *GeneReviews*<sup>®</sup>. Seattle: University of Washington; 1993–2016. 2006 Sep 21 [updated 2013 Jul 3].
- Danan C, Sternberg D, Van Steirteghem A, Cazeneuve C, Duquesnoy P, Besmond C, Goossens M, Lissens W, Amselem S. Evaluation of parental mitochondrial inheritance in neonates born after intracytoplasmic sperm injection. *Am J Hum Genet*. 1999;65(2):463–73.
- Davila Garza SA, Patrizio P. Reproductive outcomes in patients with male infertility because of Klinefelter's syndrome, Kartagener's syndrome, round-head sperm, dysplasia fibrous sheath, and 'stump' tail sperm: an updated literature review. *Curr Opin Obstet Gynecol*. 2013;25(3):229–46.
- De Braekeleer M, Ferec C. Mutations in the cystic fibrosis gene in men with congenital bilateral absence of the vas deferens. *Mol Hum Reprod*. 1996;2(9):669–77.
- de Lamirande E, Gagnon C. Capacitation-associated production of superoxide anion by human spermatozoa. *Free Radic Biol Med*. 1995;18(3):487–495.
- De Sanctis V, Katz M, Wonke B. Semen parameters in patients with homozygous  $\beta$ -thalassemia. *Infertility*. 1989;12:167–74.
- Dejuqc N, Jegou B. Viruses in the mammalian male genital tract and their effects on the reproductive system. *Microbiol Mol Biol Rev*. 2001;65(2):208–31; first and second pages, table of contents.
- Del Castillo EB, Trabucco A, FA DEIB. Syndrome produced by absence of the germinal epithelium without impairment of the Sertoli or Leydig cells. *J Clin Endocrinol Metab*. 1947;7(7):493–502.

- Délot EC, Vilain EJ. Nonsyndromic 46,XX testicular disorders of sex development. In: Pagon RA, Adam MP, Ardinger HH, et al., editors. *GeneReviews*<sup>®</sup>. Seattle: University of Washington; 1993–2016. 2003 Oct 30 [updated 2015 May 7].
- Diao R, Fok KL, Zhao L, Chen H, Tang H, Chen J, Zheng A, Zhang X, Gui Y, Chan HC, Cai Z. Decreased expression of cystic fibrosis transmembrane conductance regulator impairs sperm quality in aged men. *Reproduction*. 2013;146(6):637–45.
- Dimitriadis F, Giannakis D, Pardalidis N, Tsoukanelis K, Kanakas N, Saito M, Watanabe T, Miyagawa I, Tsounapi P, Sofikitis N. Effects of primary testicular damage on sperm DNA oxidative status and embryonic and foetal development. *Andrologia*. 2009;41(5):282–96.
- Ding EL, Song Y, Malik VS, Liu S. Sex differences of endogenous sex hormones and risk of type 2 diabetes: a systematic review and meta-analysis. *JAMA*. 2006;295(11):1288–99.
- Dohle GR, Colpi GM, Hargreave TB, Papp GK, Jungwirth A, Weidner W. EAU guidelines on male infertility. *Eur Urol*. 2005;48(5):703–11.
- Dorfman DM, Genest DR, Reijo Pera RA. Human DAZL1 encodes a candidate fertility factor in women that localizes to the prenatal and postnatal germ cells. *Hum Reprod*. 1999;14(10):2531–6.
- Dork T, Dworniczak B, Aulehla-Scholz C, Wieczorek D, Bohm I, Mayerova A, Seydewitz HH, Nieschlag E, Meschede D, Horst J, Pander HJ, Sperling H, Ratjen F, Passarge E, Schmidtke J, Stuhmann M. Distinct spectrum of CFTR gene mutations in congenital absence of vas deferens. *Hum Genet*. 1997;100(3–4):365–77.
- Dumur V, Gervais R, Rigot JM, Lafitte JJ, Manouvrier S, Biserte J, Mazeman E, Roussel P. Abnormal distribution of CF delta F508 allele in azoospermic men with congenital aplasia of epididymis and vas deferens. *Lancet*. 1990;336(8713):512.
- Dwyer AA, Raivio T, Pitteloud N. Gonadotrophin replacement for induction of fertility in hypogonadal men. *Best Pract Res Clin Endocrinol Metab*. 2015;29(1):91–103.
- Eggert-Kruse W, Rohr G, Demirakca T, Rusu R, Naher H, Petzoldt D, Runnebaum B. Chlamydial serology in 1303 asymptomatic subfertile couples. *Hum Reprod*. 1997;12(7):1464–75.
- Egozcue S, Blanco J, Vendrell JM, Garcia F, Veiga A, Aran B, Barri PN, Vidal F, Egozcue J. Human male infertility: chromosome anomalies, meiotic disorders, abnormal spermatozoa and recurrent abortion. *Hum Reprod Update*. 2000;6(1):93–105.
- El-Dahtory F, Elsheikha HM. Male infertility related to an aberrant karyotype, 47,XYY: four case reports. *Cases J*. 2009;2(1):28.
- el-Hazmi MA, Bahakim HM, al-Fawaz I. Endocrine functions in sickle cell anaemia patients. *J Trop Pediatr*. 1992;38(6):307–13.
- Elder JS. Laparoscopy for impalpable testes: significance of the patent processus vaginalis. *J Urol*. 1994;152(2 Pt 2):776–8.
- Emir H, Ayik B, Elicevik M, Buyukunal C, Danismend N, Dervisoglu S, Soylet Y. Histological evaluation of the testicular nubbins in patients with nonpalpable testis: assessment of etiology and surgical approach. *Pediatr Surg Int*. 2007;23(1):41–4.
- Evenson DP, Jost LK, Corzett M, Balhorn R. Characteristics of human sperm chromatin structure following an episode of influenza and high fever: a case study. *J Androl*. 2000;21(5):739–46.
- Faed M, Robertson J, MacIntosh WG, Grieve J. Spermatogenesis in an infertile XYY man. *Hum Genet*. 1976;33(3):341–7.
- Farmaki K, Tzoumari I, Pappa C, Chouliaras G, Berdoukas V. Normalisation of total body iron load with very intensive combined chelation reverses cardiac and endocrine complications of thalassaemia major. *Br J Haematol*. 2010;148(3):466–75.
- Farthing MJ, Dawson AM. Impaired semen quality in Crohn's disease – drugs, ill health, or undernutrition? *Scand J Gastroenterol*. 1983;18(1):57–60.
- Fechner PY, Marcantonio SM, Jaswaney V, Stetten G, Goodfellow PN, Migeon CJ, Smith KD, Berkovitz GD, Amrhein JA, Bard PA, et al. The role of the sex-determining region Y gene in the etiology of 46,XX maleness. *J Clin Endocrinol Metab*. 1993;76(3):690–5.

- Foresta C, Ferlin A, Garolla A, Moro E, Pistorello M, Barbaux S, Rossato M. High frequency of well-defined Y-chromosome deletions in idiopathic Sertoli cell-only syndrome. *Hum Reprod.* 1998;13(2):302–7.
- Gekas J, Thepot F, Turleau C, Siffroi JP, Dadoune JP, Briault S, Rio M, Bourouillou G, Carre-Pigeon F, Wasels R, Benzacken B. Chromosomal factors of infertility in candidate couples for ICSI: an equal risk of constitutional aberrations in women and men. *Hum Reprod.* 2001;16(1):82–90.
- Georgopoulos NA, Koika V, Varnavas P, Efthymiadou A, Marioli DJ, Mantagos S, Chrysis D. Can Kallmann syndrome be occasionally diagnosed during childhood? Genetic diagnosis in a child with associated renal agenesis and mirror movements. *Asian J Androl.* 2009;11(4):521–3.
- Giachini C, Guarducci E, Longepied G, Degl'Innocenti S, Becherini L, Forti G, Mitchell MJ, Krausz C. The gr/gr deletion(s): a new genetic test in male infertility? *J Med Genet.* 2005;42(6):497–502.
- Giachini C, Laface I, Guarducci E, Balercia G, Forti G, Krausz C. Partial AZFc deletions and duplications: clinical correlates in the Italian population. *Hum Genet.* 2008;124(4):399–410.
- Giagulli VA, Carbone MD. Varicocele correction for infertility: which patients to treat? *Int J Androl.* 2011;34(3):236–41.
- Giannakis D, Baltogiannis D, Tsoukanelis K, Loutradis D, Miyagawa I, Makrydimas G, Kanakas N, Sofikitis N. Role of testicular tissue telomerase assay for the prediction of the presence of testicular spermatozoa in azoospermic men with varicoceles, pre- and post-varicocelectomy. *Andrologia.* 2004;36(3):111–22.
- Giuliani R, Antonucci I, Torrente I, Grammatico P, Palka G, Stupia L. Identification of the second CFTR mutation in patients with congenital bilateral absence of vas deferens undergoing ART protocols. *Asian J Androl.* 2010;12(6):819–26.
- Giwercman A, Giwercman YL. Epidemiology of male reproductive disorders. In: De Groot LJ, Beck-Peccoz P, Chrousos G, et al., editors. *Endotext.* South Dartmouth: MDText.com; 2000.
- Goeminne PC, Dupont LJ. The sinusitis-infertility syndrome: Young's saint, old devil. *Eur Respir J.* 2010;35(3):698.
- Goldstein M, Gilbert BR, Dicker AP, Dwosh J, Gnecco C. Microsurgical inguinal varicocelectomy with delivery of the testis: an artery and lymphatic sparing technique. *J Urol.* 1992;148(6):1808–11.
- Gonzalez-Merino E, Hans C, Abramowicz M, Englert Y, Emiliani S. Aneuploidy study in sperm and preimplantation embryos from nonmosaic 47,XYY men. *Fertil Steril.* 2007;88(3):600–6.
- Gorelick JJ, Goldstein M. Loss of fertility in men with varicocele. *Fertil Steril.* 1993;59(3):613–6.
- Grady RW, Mitchell ME, Carr MC. Laparoscopic and histologic evaluation of the inguinal vanishing testis. *Urology.* 1998;52(5):866–9.
- Grangeia A, Carvalho F, Fernandes S, Silva J, Sousa M, Barros A. A novel missense mutation P1290S at exon-20 of the CFTR gene in a Portuguese patient with congenital bilateral absence of the vas deferens. *Fertil Steril.* 2005;83(2):448–51.
- Griveau JF, Renard P, Le Lannou D. Superoxide anion production by human spermatozoa as a part of the ionophore-induced acrosome reaction process. *Int J Androl.* 1995;18(2):67–74.
- Groth KA, Skakkebaek A, Host C, Gravholt CH, Bojesen A. Clinical review: Klinefelter syndrome – a clinical update. *J Clin Endocrinol Metab.* 2013;98(1):20–30.
- Guichard C, Harricane MC, Lafitte JJ, Godard P, Zaegel M, Tack V, Lalau G, Bouvagnet P. Axonemal dynein intermediate-chain gene (DNAI1) mutations result in situs inversus and primary ciliary dyskinesia (Kartagener syndrome). *Am J Hum Genet.* 2001;68(4):1030–5.
- Hadziselimovic F. Cryptorchidism, its impact on male fertility. *Eur Urol.* 2002;41(2):121–3.
- Hadziselimovic F, Herzog B. Importance of early postnatal germ cell maturation for fertility of cryptorchid males. *Horm Res.* 2001;55(1):6–10.
- Hallen M, Wester Dahl J, Nordin P, Gunnarsson U, Sandblom G. Mesh hernia repair and male infertility: a retrospective register study. *Surgery.* 2012;151(1):94–8.

- Handelsman DJ, Conway AJ, Boylan LM, Turtle JR. Young's syndrome. Obstructive azoospermia and chronic sinopulmonary infections. *N Engl J Med.* 1984;310(1):3–9.
- Handelsman DJ, Strasser S, McDonald JA, Conway AJ, McCaughan GW. Hypothalamic-pituitary-testicular function in end-stage non-alcoholic liver disease before and after liver transplantation. *Clin Endocrinol (Oxf).* 1995;43(3):331–7.
- Harkonen K, Viitanen T, Larsen SB, Bonde JP, Lahdetie J. Aneuploidy in sperm and exposure to fungicides and lifestyle factors. ASCLEPIOS. A European Concerted Action on Occupational Hazards to Male Reproductive Capability. *Environ Mol Mutagen.* 1999;34(1):39–46.
- Heaton ND, Pryor JP. Vasa aplasia and cystic fibrosis. *Br J Urol.* 1990;66(5):538–40.
- Hegarty PK, Mushtaq I, Sebire NJ. Natural history of testicular regression syndrome and consequences for clinical management. *J Pediatr Urol.* 2007;3(3):206–8.
- Hendin BN, Kolettis PN, Sharma RK, Thomas AJ, Jr., Agarwal A. Varicocele is associated with elevated spermatozoal reactive oxygen species production and diminished seminal plasma antioxidant capacity. *J Urol.* 1999;161(6):1831–4.
- Hendry WF, A'Hern RP, Cole PJ. Was Young's syndrome caused by exposure to mercury in childhood? *BMJ.* 1993;307(6919):1579–82.
- Hendry WF, Hughes L, Scammell G, Pryor JP, Hargreave TB. Comparison of prednisolone and placebo in subfertile men with antibodies to spermatozoa. *Lancet.* 1990;335(8681):85–8.
- Heyns CF. The gubernaculum during testicular descent and maldescent. *Urol Clin N Am.* 1982;9:315–25.
- Heyns CF, Human HJ, De Klerk DP. Hyperplasia and hypertrophy of the gubernaculum during testicular descent in the fetus. *J Urol.* 1986;135(5):1043–7.
- Heyns CF, Human HJ, Werely CJ, De Klerk DP. The glycosaminoglycans of the gubernaculum during testicular descent in the fetus. *J Urol.* 1990;143(3):612–7.
- Hirsch IH, Abdel-Meguid TA, Gomella LG. Postsurgical outcomes assessment following varicocele ligation: laparoscopic versus subinguinal approach. *Urology.* 1998;51(5):810–5.
- Hirsh A, Williams C, Williamson B. Young's syndrome and cystic fibrosis mutation delta F508. *Lancet.* 1993;342(8863):118.
- Hofny ER, Ali ME, Abdel-Hafez HZ, Kamal Eel D, Mohamed EE, Abd El-Azeem HG, Mostafa T. Semen parameters and hormonal profile in obese fertile and infertile males. *Fertil Steril.* 2010;94(2):581–4.
- Hook EB, Hamerton JL. The frequency of chromosome abnormalities detected in consecutive newborn studies- differences between studies- results by sex and by severity of phenotypic involvement. In: Hook EB, Porter IH, editors. *Population cytogenetics.* New York: Academic; 1977. p. 63–79.
- Hopps CV, Goldstein M, Schlegel PN. The diagnosis and treatment of the azoospermic patient in the age of intracytoplasmic sperm injection. *Urol Clin North Am.* 2002;29(4):895–911.
- Hornef N, Olbrich H, Horvath J, Zariwala MA, Fliegauf M, Loges NT, Wildhaber J, Noone PG, Kennedy M, Antonarakis SE, Blouin JL, Bartoloni L, Nusslein T, Ahrens P, Griese M, Kuhl H, Sudbrak R, Knowles MR, Reinhardt R, Omran H. DNAH5 mutations are a common cause of primary ciliary dyskinesia with outer dynein arm defects. *Am J Respir Crit Care Med.* 2006;174(2):120–6.
- Huhtaniemi I, Alevizaki M. Mutations along the hypothalamic-pituitary-gonadal axis affecting male reproduction. *Reprod Biomed Online.* 2007;15(6):622–32.
- Hutson JM. A biphasic model for the hormonal control of testicular descent. *Lancet.* 1985;2(8452):419–21.
- Hutson JM, Balic A, Nation T, Southwell B. Cryptorchidism. *Semin Pediatr Surg.* 2010;19(3):215–24.
- Hutson JM, Hasthorpe S, Heyns CF. Anatomical and functional aspects of testicular descent and cryptorchidism. *Endocr Rev.* 1997;18(2):259–80.
- Hutson JM, Southwell BR, Li R, Lie G, Ismail K, Harisis G, Chen N. The regulation of testicular descent and the effects of cryptorchidism. *Endocr Rev.* 2013;34(5):725–52.

- Ichioka K, Kohei N, Okubo K, Nishiyama H, Terai A. Obstructive azoospermia associated with chronic sinopulmonary infection and situs inversus totalis. *Urology*. 2006;68(1):204 e205–207.
- Isaiah IN, Nche BT, Nwagu IG, Nnanna, II. Current studies on bacterospermia the leading cause of male infertility: a protege and potential threat towards mans extinction. *N Am J Med Sci*. 2011; 3(12):562–4.
- Jarvi K, Zielenski J, Wilschanski M, Durie P, Buckspan M, Tullis E, Markiewicz D, Tsui LC. Cystic fibrosis transmembrane conductance regulator and obstructive azoospermia. *Lancet*. 1995; 345(8964):1578.
- Jensen MS, Toft G, Thulstrup AM, Henriksen TB, Olsen J, Christensen K, Bonde JP. Cryptorchidism concordance in monozygotic and dizygotic twin brothers, full brothers, and half-brothers. *Fertil Steril*. 2010;93(1):124–9.
- Joesbury KA, Edirisinghe WR, Phillips MR, Yovich JL. Evidence that male smoking affects the likelihood of a pregnancy following IVF treatment: application of the modified cumulative embryo score. *Hum Reprod*. 1998;13(6):1506–13.
- Josso N, Briard ML. Embryonic testicular regression syndrome: variable phenotypic expression in siblings. *J Pediatr*. 1980;97(2):200–4.
- Jungwirth A, Giwercman A, Tournaye H, Diemer T, Kopa Z, Dohle G, Krausz C, European Association of Urology Working Group on Male I. European Association of Urology guidelines on Male Infertility: the 2012 update. *Eur Urol*. 2016;62(2):324–32.
- Kalichman SC, Di Berto G, Eaton L. Human immunodeficiency virus viral load in blood plasma and semen: review and implications of empirical findings. *Sex Transm Dis*. 2008;35(1):55–60.
- Kamischke A, Baumgardt A, Horst J, Nieschlag E. Clinical and diagnostic features of patients with suspected Klinefelter syndrome. *J Androl*. 2003;24(1):41–8.
- Kamp C, Huellen K, Fernandes S, Sousa M, Schlegel PN, Mielnik A, Kleiman S, Yavetz H, Krause W, Kupker W, Johannisson R, Schulze W, Weidner W, Barros A, Vogt PH. High deletion frequency of the complete AZFa sequence in men with Sertoli-cell-only syndrome. *Mol Hum Reprod*. 2001;7(10):987–94.
- Kaplan E, Shwachman H, Perlmutter AD, Rule A, Khaw KT, Holsclaw DS. Reproductive failure in males with cystic fibrosis. *N Engl J Med*. 1968;279(2):65–9.
- Kartagener M. Zur pathogene der bronkiektasein:bronkiektasein bei situs viscerum inversus. *Beitr Klin Tuberk*. 1933;82:489.
- Kaymakoglu S, Okten A, Cakaloglu Y, Boztas G, Besisik F, Tascioglu C, Yalcin S. Hypogonadism is not related to the etiology of liver cirrhosis. *J Gastroenterol*. 1995;30(6):745–50.
- Kerem B, Kerem E. The molecular basis for disease variability in cystic fibrosis. *Eur J Hum Genet*. 1996;4(2):65–73.
- Khera M, Lipshultz LI. Evolving approach to the varicocele. *Urol Clin North Am*. 2008;35(2): 183–9, viii.
- Kheradmand AR, Javadneia AH. Efficacy of hemodialysis and renal transplantation on reproductive function in men with end stage renal disease. *Transplant Proc*. 2003;35(7):2718–9.
- Kilgallon SJ, Simmons LW. Image content influences men's semen quality. *Biol Lett*. 2005;1(3): 253–5.
- Kim IW, Khadilkar AC, Ko EY, Sabanegh ES, Jr. 47,XYY Syndrome and Male Infertility. *Rev Urol*. 2013;15(4):188–96.
- Kim SK, Yoon YD, Park YS, Seo JT, Kim JH. Involvement of the Fas-Fas ligand system and active caspase-3 in abnormal apoptosis in human testes with maturation arrest and Sertoli cell-only syndrome. *Fertil Steril*. 2007;87(3):547–53.
- Klesert TR, Otten AD, Bird TD, Tapscott SJ. Trinucleotide repeat expansion at the myotonic dystrophy locus reduces expression of DMAHP. *Nat Genet*. 1997;16(4):402–6.
- Kolstad HA, Bisanti L, Roeleveld N, Bonde JP, Joffe M. Time to pregnancy for men occupationally exposed to styrene in several European reinforced plastics companies. *Asclepius. Scand J Work Environ Health*. 1999;25 Suppl 1:66–9; discussion 68–76.

- Koyama T, Nonomura K, Ameda K, Kakizaki H, Matsugase Y, Shinno Y, Kanno T, Yamashita T, Murakumo M, Koyanagi T. Laparoscopic evaluation and the management of the nonpalpable testis. *Diagn Ther Endosc.* 1997;4(2):69–74.
- Kraus MR, Schafer A, Bentink T, Scheurlen M, Weissbrich B, Al-Taie O, Seufert J. Sexual dysfunction in males with chronic hepatitis C and antiviral therapy: interferon-induced functional androgen deficiency or depression? *J Endocrinol.* 2005;185(2):345–52.
- Krausz C. Male infertility: pathogenesis and clinical diagnosis. *Best Pract Res Clin Endocrinol Metab.* 2011;25(2):271–85.
- Krausz C, Degl'Innocenti S. Y chromosome and male infertility: update, 2006. *Front Biosci.* 2006;11:3049–61.
- Krausz C, Forti G, McElreavey K. The Y chromosome and male fertility and infertility. *Int J Androl.* 2003;26(2):70–5.
- Krausz C, Hoefsloot L, Simoni M, Tuttelmann F. EAA/EMQN best practice guidelines for molecular diagnosis of Y-chromosomal microdeletions: state-of-the-art 2013. *Andrology.* 2014;2(1):5–19.
- Kumagai J, Hsu SY, Matsumi H, Roh JS, Fu P, Wade JD, Bathgate RA, Hsueh AJ. INSL3/Leydig insulin-like peptide activates the LGR8 receptor important in testis descent. *J Biol Chem.* 2002;277(35):31283–6.
- Landefeld CS, Schambelan M, Kaplan SL, Embury SH. Clomiphene-responsive hypogonadism in sickle cell anemia. *Ann Intern Med.* 1983;99(4):480–3.
- Lauwerys R, Roels H, Genet P, Toussaint G, Bouckaert A, De Cooman S. Fertility of male workers exposed to mercury vapor or to manganese dust: a questionnaire study. *Am J Ind Med.* 1985;7(2):171–6.
- Le Lannou D, Jezequel P, Blayau M, Dorval I, Lemoine P, Dabadie A, Roussey M, Le Marec B, Legall JY. Obstructive azoospermia with agenesis of vas deferens or with bronchiectasia (Young's syndrome): a genetic approach. *Hum Reprod.* 1995;10(2):338–41.
- Lee IP, Dixon RL. Effects of mercury on spermatogenesis studied by velocity sedimentation cell separation and serial mating. *J Pharmacol Exp Ther.* 1975;194(1):171–81.
- Lee PA, Coughlin MT. The single testis: paternity after presentation as unilateral cryptorchidism. *J Urol.* 2002;168(4 Pt 2):1680–2; discussion 1682–3.
- Lee PA, Coughlin MT, Bellinger MF. Paternity and hormone levels after unilateral cryptorchidism: association with pretreatment testicular location. *J Urol.* 2000;164(5):1697–701.
- Lerda D, Rizzi R. Study of reproductive function in persons occupationally exposed to 2,4-dichlorophenoxyacetic acid (2,4-D). *Mutat Res.* 1991;262(1):47–50.
- Lim AS, Fong Y, Yu SL. Analysis of the sex chromosome constitution of sperm in men with a 47, XYY mosaic karyotype by fluorescence in situ hybridization. *Fertil Steril.* 1999;72(1):121–3.
- Liquori CL, Ikeda Y, Weatherspoon M, Ricker K, Schoser BG, Dalton JC, Day JW, Ranum LP. Myotonic dystrophy type 2: human founder haplotype and evolutionary conservation of the repeat tract. *Am J Hum Genet.* 2003;73(4):849–62.
- Liquori CL, Ricker K, Moseley ML, Jacobsen JF, Kress W, Naylor SL, Day JW, Ranum LP. Myotonic dystrophy type 2 caused by a CCTG expansion in intron 1 of ZNF9. *Science.* 2001;293(5531):864–7.
- Loane M, Dolk H, Kelly A, Teljeur C, Greenlees R, Densem J. Paper 4: EUROCAT statistical monitoring: identification and investigation of ten year trends of congenital anomalies in Europe. *Birth Defects Res A Clin Mol Teratol.* 2011;91 Suppl 1:S31–43.
- Lohi S, Lohi O, Vierula M, Maki M, Toppari J. Coeliac disease autoantibodies in seminal plasma from cases with screen-detected coeliac disease. *Scand J Gastroenterol.* 2009;44(4):509–11.
- Lorusso F, Palmisano M, Chironna M, Vacca M, Masciandaro P, Bassi E, Selvaggi Luigi L, Depalo R. Impact of chronic viral diseases on semen parameters. *Andrologia.* 2010;42(2):121–6.
- Lu S, Cui Y, Li X, Zhang H, Liu J, Kong B, Cai F, Chen ZJ. Association of cystic fibrosis transmembrane-conductance regulator gene mutation with negative outcome of intracytoplasmic sperm injection pregnancy in cases of congenital bilateral absence of vas deferens. *Fertil Steril.* 2014;101(5):1255–60.

- Lue TF. Physiology of penile erection and pathophysiology of erectile dysfunction. In: Wein AJ, Kavoussi LR, Partin AW, Peters CA, editors. *Campbell-Walsh urology*. vol. 1. Philadelphia: Elsevier; 2016. p. 612–42.
- Luppa PB, Thaler M, Schulte-Frohlinde E, Schreiegg A, Huber U, Metzger J. Unchanged androgen-binding properties of sex hormone-binding globulin in male patients with liver cirrhosis. *Clin Chem Lab Med*. 2006;44(8):967–73.
- Lysiak JJ, Turner SD, Nguyen QA, Singbartl K, Ley K, Turner TT. Essential role of neutrophils in germ cell-specific apoptosis following ischemia/reperfusion injury of the mouse testis. *Biol Reprod*. 2001;65(3):718–25.
- Ma X, Dong Y, Matzuk MM, Kumar TR. Targeted disruption of luteinizing hormone beta-subunit leads to hypogonadism, defects in gonadal steroidogenesis, and infertility. *Proc Natl Acad Sci U S A*. 2004;101(49):17294–9.
- Mahadevan M, Tsilifidis C, Sabourin L, Shutler G, Amemiya C, Jansen G, Neville C, Narang M, Barcelo J, O'Hoy K, et al. Myotonic dystrophy mutation: an unstable CTG repeat in the 3' untranslated region of the gene. *Science*. 1992;255(5049):1253–5.
- Mahmoud A, Comhaire F. Systemic causes of male infertility. In: Schill WB, Comhaire FH, Hargreave TB, editors. *Andrology for the clinician*. Berlin/Heidelberg/New York: Springer; 2006. p. 57–62.
- Mamoulakis C, Antypas S, Sofras F, Takenaka A, Sofikitis N. Testicular Descent. *Hormones (Athens)*. 2015;14(4):515–30.
- Mamoulakis C, Demetriadis D, Antypas S, Sofikitis N. Seasonality of cryptorchidism and hypopadias in Greece: epidemiological relationships. *J Androl*. 2002;March/April(Suppl):37.
- Mamoulakis C, Georgiou I, Dimitriadis F, Tsounapi P, Giannakis I, Chatzikyriakidou A, Antypas S, Sofras F, Takenaka A, Sofikitis N. Genetic analysis of the human Insulin-like 3 gene: absence of mutations in a Greek paediatric cohort with testicular maldescent. *Andrologia*. 2014;46(9):986–96.
- Mamoulakis C, Georgiou I, Dimitriadis F, Tsounapi P, Koukos S, Antypas S, Tzortzakakis D, Sofras F, Takenaka A, Sofikitis N. Screening for Y chromosome microdeletions in childhood: lack of evidence for a direct association with testicular maldescent. *Andrologia*. 2013a;45(6):409–16.
- Mamoulakis C, Kaponis A, Georgiou J, Giannakis D, Antypas S, Tsambalas S, Giannakopoulos X, Miyagawa I, Sofikitis N. Mammalian testicular descent and maldescent; implications in fertility potential. In: Colpi GM, editor. *Male infertility today*. vol. 4. Milan: Italian Andrological Society; 2004. p. 63–137.
- Mamoulakis C, Sofikitis N, Tsounapi P, Vlachopoulou E, Chatzikyriakidou A, Antypas S, Tzortzakakis D, Sofras F, Takenaka A, Georgiou I. The (TAAAA)n polymorphism of sex hormone-binding globulin gene is not associated with testicular maldescent. *Andrologia*. 2013b;45(1):40–5.
- Mamoulakis C, Tzortzakakis D, Sofras F. Cryptorchidism. In: Sakellaris G, editor. *Essentials in pediatric urology*. India: Research Signpost; 2012.
- Massart A, Lissens W, Tournaye H, Stouffs K. Genetic causes of spermatogenic failure. *Asian J Androl*. 2012;14(1):40–8.
- Massart F, Saggese G. Sex steroidal targets & genetic susceptibility to idiopathic cryptorchidism. *Pediatr Endocrinol Rev*. 2009;6(4):481–90.
- Mastrogiacomo I, De Besi L, Zucchetta P, Serafini E, Gasparotto ML, Marchini P, Pisani E, Dean P, Chini M. Effect of hyperprolactinemia and age on the hypogonadism of uremic men on hemodialysis. *Arch Androl*. 1984;12(2–3):235–42.
- Masuda H, Inamoto T, Azuma H, Katsuoka Y, Tawara F. [Successful testicular sperm extraction in an azoospermic man with postpubertal mumps orchitis]. *Hinyokika Kiyo*. 2011;57(9):529–30.
- Matsuda T, Horii Y, Yoshida O. Unilateral obstruction of the vas deferens caused by childhood inguinal herniorrhaphy in male infertility patients. *Fertil Steril*. 1992;58(3):609–13.
- Matthews GJ, Matthews ED, Goldstein M. Induction of spermatogenesis and achievement of pregnancy after microsurgical varicocelectomy in men with azoospermia and severe oligoasthenospermia. *Fertil Steril*. 1998;70(1):71–5.

- McElreavey K, Vilain E, Abbas N, Herskowitz I, Fellous M. A regulatory cascade hypothesis for mammalian sex determination: SRY represses a negative regulator of male development. *Proc Natl Acad Sci U S A*. 1993;90(8):3368–72.
- McGregor AJ, Mason HJ. Chronic occupational lead exposure and testicular endocrine function. *Hum Exp Toxicol*. 1990;9(6):371–6.
- McLachlan RI, Rajpert-De Meyts E, Hoei-Hansen CE, de Kretser DM, Skakkebaek NE. Histological evaluation of the human testis – approaches to optimizing the clinical value of the assessment: mini review. *Hum Reprod*. 2007;22(1):2–16.
- Meistrich ML. Potential genetic risks of using semen collected during chemotherapy. *Hum Reprod*. 1993;8(1):8–10.
- Meistrich ML, M.E. vB. Radiation sensitivity of the human testis. *Adv Radiat Biol*. 1990;14:227–68.
- Melmed S. Update in pituitary disease. *J Clin Endocrinol Metab*. 2008;93(2):331–8.
- Mendez HM, Opitz JM. Noonan syndrome: a review. *Am J Med Genet*. 1985;21(3):493–506.
- Mercier B, Verlingue C, Lissens W, Silber SJ, Novelli G, Bonduelle M, Audrezet MP, Ferec C. Is congenital bilateral absence of vas deferens a primary form of cystic fibrosis? Analyses of the CFTR gene in 67 patients. *Am J Hum Genet*. 1995;56(1):272–7.
- Merry C, Sweeney B, Puri P. The vanishing testis: anatomical and histological findings. *Eur Urol*. 1997;31(1):65–7.
- Meschede D, Dworniczak B, Behre HM, Kliesch S, Claustres M, Nieschlag E, Horst J. CFTR gene mutations in men with bilateral ejaculatory-duct obstruction and anomalies of the seminal vesicles. *Am J Hum Genet*. 1997;61(5):1200–2.
- Mickle J, Milunsky A, Amos JA, Oates RD. Congenital unilateral absence of the vas deferens: a heterogeneous disorder with two distinct subpopulations based upon aetiology and mutational status of the cystic fibrosis gene. *Hum Reprod*. 1995;10(7):1728–35.
- Milunsky A, Milunsky J. Genetic disorders and the fetus: diagnosis, prevention and treatment. Chichester: Wiley; 2010.
- Morel F, Roux C, Bresson JL. Sex chromosome aneuploidies in sperm of 47,XYY men. *Arch Androl*. 1999;43(1):27–36.
- Moretti E, Federico MG, Giannerini V, Collodel G. Sperm ultrastructure and meiotic segregation in a group of patients with chronic hepatitis B and C. *Andrologia*. 2008;40(5):286–91.
- Mulhall JP, Reijo R, Alagappan R, Brown L, Page D, Carson R, Oates RD. Azoospermic men with deletion of the DAZ gene cluster are capable of completing spermatogenesis: fertilization, normal embryonic development and pregnancy occur when retrieved testicular spermatozoa are used for intracytoplasmic sperm injection. *Hum Reprod*. 1997;12(3):503–8.
- Mylonakis E, Koutkia P, Grinspoon S. Diagnosis and treatment of androgen deficiency in human immunodeficiency virus-infected men and women. *Clin Infect Dis*. 2001;33(6):857–64.
- Nachtigall LB, Boepple PA, Pralong FP, Crowley WF, Jr. Adult-onset idiopathic hypogonadotropic hypogonadism – a treatable form of male infertility. *N Engl J Med*. 1997;336(6):410–5.
- Naffah J. [Familial testicular regression syndrome]. *Bull Acad Natl Med*. 1989;173(6):709–14; discussion 705–714.
- Nakagawa K, Yamano S, Kamada M, Maegawa M, Tokumura A, Irahara M, Saito H. Sperm-immobilizing antibodies suppress an increase in the plasma membrane fluidity of human spermatozoa. *Fertil Steril*. 2004;82 Suppl 3:1054–8.
- Navarro-Costa P. Sex, rebellion and decadence: the scandalous evolutionary history of the human Y chromosome. *Biochim Biophys Acta*. 2012;1822(12):1851–63.
- Navarro-Costa P, Goncalves J, Plancha CE. The AZFc region of the Y chromosome: at the crossroads between genetic diversity and male infertility. *Hum Reprod Update*. 2010;16(5):525–42.
- Nieschlag E. Andrology at the end of the twentieth century: from spermatology to male reproductive health. Inaugural Address at the VIth International Congress of Andrology, Salzburg, 25 May 1997. *Int J Androl*. 1997;20(3):129–31.



- Nieschlag E, Behre HM, Wieacker P, Meschede D, Kamischke A, Kliesch S. Disorders at the testicular level. In: Nieschlag E, Behre HM, Nieschlag S, editors. *Andrology. Male reproductive health and dysfunction*. Berlin/Heidelberg: Springer; 2010. p. 193–238.
- Oates RD. The natural history of endocrine function and spermatogenesis in Klinefelter syndrome: what the data show. *Fertil Steril*. 2012;98(2):266–73.
- Oates RD, Amos JA. The genetic basis of congenital bilateral absence of the vas deferens and cystic fibrosis. *J Androl*. 1994;15(1):1–8.
- Ohl DA, Naz RK. Infertility due to antisperm antibodies. *Urology*. 1995;46(4):591–602.
- Omu AE, al-Qattan F, Ismail AA, al-Taher S, al-Busiri N. Relationship between unexplained infertility and human leukocyte antigens and expression of circulating autogeneic and allogeneic antisperm antibodies. *Clin Exp Obstet Gynecol*. 1999;26(3–4):199–202.
- Osborne LR, Lynch M, Middleton PG, Alton EW, Geddes DM, Pryor JP, Hodson ME, Santis GK. Nasal epithelial ion transport and genetic analysis of infertile men with congenital bilateral absence of the vas deferens. *Hum Mol Genet*. 1993;2(10):1605–9.
- Ozturk H, Tander B, Aydin A, Okumus Z, Cetinkursun S. The effects of chemical sympathectomy on testicular injury in varicocele. *BJU Int*. 2001;87(3):232–4.
- Paick J, Kim SH, Kim SW. Ejaculatory duct obstruction in infertile men. *BJU Int*. 2000;85(6):720–4.
- Pajarinen J, Laippala P, Penttila A, Karhunen PJ. Incidence of disorders of spermatogenesis in middle aged finnish men, 1981–91: two necropsy series. *BMJ*. 1997;314(7073):13–8.
- Pajarinen JT, Karhunen PJ. Spermatogenic arrest and ‘Sertoli cell-only’ syndrome – common alcohol-induced disorders of the human testis. *Int J Androl*. 1994;17(6):292–9.
- Papparella A, Zamparelli M, Cobellis G, Amici G, Saggiomo G, Parmeggiani P, Fioretti GP. Laparoscopy for nonpalpable testis: is inguinal exploration always necessary when the cord structures exit the inguinal ring? *Pediatr Endosu Innov Tech*. 1999;3:29–33.
- Pasqualotto FF, Sundaram A, Sharma RK, Borges E, Jr., Pasqualotto EB, Agarwal A. Semen quality and oxidative stress scores in fertile and infertile patients with varicocele. *Fertil Steril*. 2008;89(3):602–7.
- Pauli EM, Legro RS, Demers LM, Kunselman AR, Dodson WC, Lee PA. Diminished paternity and gonadal function with increasing obesity in men. *Fertil Steril*. 2008;90(2):346–51.
- Peces R, Venegas JL. [Seminal vesicle cysts and infertility in autosomal dominant polycystic kidney disease]. *Nefrologia*. 2005;25(1):78–80.
- Pena JE, Thornton MH, Jr., Sauer MV. Reversible azoospermia: anabolic steroids may profoundly affect human immunodeficiency virus-seropositive men undergoing assisted reproduction. *Obstet Gynecol*. 2003;101(5 Pt 2):1073–5.
- Peng J, Yuan Y, Cui W, Zhang Z, Gao B, Song W, Xin Z. Causes of suspected epididymal obstruction in Chinese men. *Urology*. 2012;80(6):1258–61.
- Perez-Palacios G, Medina M, Ullao-Aguirre A, Chavez BA, Villareal G, Dutrem MT, Cahill LT, Wachtel S. Gonadotropin dynamics in XX males. *J Clin Endocrinol Metab*. 1981;53(2):254–7.
- Pirgon O, Dundar BN. Vanishing testes: a literature review. *J Clin Res Pediatr Endocrinol*. 2012;4(3):116–20.
- Plotzker ED, Rushton HG, Belman AB, Skoog SJ. Laparoscopy for nonpalpable testes in childhood: is inguinal exploration also necessary when vas and vessels exit the inguinal ring? *J Urol*. 1992;148(2 Pt 2):635–7; discussion 638.
- Poretzky L, Can S, Zumoff B. Testicular dysfunction in human immunodeficiency virus-infected men. *Metabolism*. 1995;44(7):946–53.
- Prem AR, Punekar SV, Kalpana M, Kelkar AR, Acharya VN. Male reproductive function in uraemia: efficacy of haemodialysis and renal transplantation. *Br J Urol*. 1996;78(4):635–8.
- Prillaman HM, Turner TT. Rescue of testicular function after acute experimental torsion. *J Urol*. 1997;157(1):340–5.
- Pusch H. [Environmental factors on male fertility]. *Fortschr Med*. 1996;114(14):172–4.

- Radpour R, Gourabi H, Gilani MA, Dizaj AV, Rezaee M, Mollamohamadi S. Two novel missense and one novel nonsense CFTR mutations in Iranian males with congenital bilateral absence of the vas deferens. *Mol Hum Reprod.* 2006;12(11):717–21.
- Ramanujam LN, Liao WX, Roy AC, Ng SC. Association of molecular variants of luteinizing hormone with male infertility. *Hum Reprod.* 2000;15(4):925–8.
- Rave-Harel N, Madgar I, Goshen R, Nissim-Rafinia M, Ziadni A, Rahat A, Chiba O, Kalman YM, Brautbar C, Levinson D, et al. CFTR haplotype analysis reveals genetic heterogeneity in the etiology of congenital bilateral aplasia of the vas deferens. *Am J Hum Genet.* 1995;56(6):1359–66.
- Raviv G, Mor Y, Levron J, Shefi S, Zilberman D, Ramon J, Madgar I. Role of transrectal ultrasonography in the evaluation of azoospermic men with low-volume ejaculate. *J Ultrasound Med.* 2006;25(7):825–9.
- Repping S, Skaletsky H, Brown L, van Daalen SK, Korver CM, Pyntikova T, Kuroda-Kawaguchi T, de Vries JW, Oates RD, Silber S, van der Veen F, Page DC, Rozen S. Polymorphism for a 1.6-Mb deletion of the human Y chromosome persists through balance between recurrent mutation and haploid selection. *Nat Genet.* 2003;35(3):247–51.
- Repping S, Skaletsky H, Lange J, Silber S, Van Der Veen F, Oates RD, Page DC, Rozen S. Recombination between palindromes P5 and P1 on the human Y chromosome causes massive deletions and spermatogenic failure. *Am J Hum Genet.* 2002;71(4):906–22.
- Ridgway PF, Shah J, Darzi AW. Male genital tract injuries after contemporary inguinal hernia repair. *BJU Int.* 2002;90(3):272–6.
- Rietschel P, Corcoran C, Stanley T, Basgoz N, Klibanski A, Grinspoon S. Prevalence of hypogonadism among men with weight loss related to human immunodeficiency virus infection who were receiving highly active antiretroviral therapy. *Clin Infect Dis.* 2000;31(5):1240–4.
- Rives N, Milazzo JP, Miraux L, North MO, Sibert L, Mace B. From spermatocytes to spermatozoa in an infertile XYY male. *Int J Androl.* 2005a;28(5):304–10.
- Rives N, Mousset-Simeon N, Mazurier S, Mace B. Primary flagellar abnormality is associated with an increased rate of spermatozoa aneuploidy. *J Androl.* 2005b;26(1):61–9.
- Roberts AE, Allanson JE, Tartaglia M, Gelb BD. Noonan syndrome. *Lancet.* 2013;381(9863):333–42.
- Romano AA, Allanson JE, Dahlgren J, Gelb BD, Hall B, Pierpont ME, Roberts AE, Robinson W, Takemoto CM, Noonan JA. Noonan syndrome: clinical features, diagnosis, and management guidelines. *Pediatrics.* 2010;126(4):746–59.
- Rose SS. An investigation into sterility after lumbar ganglionectomy. *Br Med J.* 1953;1:247–50.
- Rovio AT, Marchington DR, Donat S, Schuppe HC, Abel J, Fritsche E, Elliott DJ, Laippala P, Ahola AL, McNay D, Harrison RF, Hughes B, Barrett T, Bailey DM, Mehmet D, Jequier AM, Hargreave TB, Kao SH, Cummins JM, Barton DE, Cooke HJ, Wei YH, Wichmann L, Poulton J, Jacobs HT. Mutations at the mitochondrial DNA polymerase (POLG) locus associated with male infertility. *Nat Genet.* 2001;29(3):261–2.
- Rowe PJ, Comhaire FH, Hargreave TB, Mahmoud AMA. WHO manual for the standardized investigation, diagnosis and management of the infertile male. Cambridge: Cambridge University Press; 2000.
- Rowley MJ, Leach DR, Warner GA, Heller CG. Effect of graded doses of ionizing radiation on the human testis. *Radiat Res.* 1974;59(3):665–78.
- Rozanski TA, Wojno KJ, Bloom DA. The remnant orchiectomy. *J Urol.* 1996;155(2):712–13; discussion 714.
- Rueffer U, Breuer K, Josting A, Lathan B, Sieber M, Manzke O, Grotenhermen FJ, Tesch H, Bredenfeld H, Koch P, Nisters-Backes H, Wolf J, Engert A, Diehl V. Male gonadal dysfunction in patients with Hodgkin's disease prior to treatment. *Ann Oncol.* 2001;12(9):1307–11.
- Ruiz-Pesini E, Lapena AC, Diez-Sanchez C, Perez-Martos A, Montoya J, Alvarez E, Diaz M, Urries A, Montoro L, Lopez-Perez MJ, Enriquez JA. Human mtDNA haplogroups associated with high or reduced spermatozoa motility. *Am J Hum Genet.* 2000;67(3):682–96.

- Rybar R, Prinosislova P, Kopecka V, Hlavicova J, Veznik Z, Zajicova A, Rubes J. The effect of bacterial contamination of semen on sperm chromatin integrity and standard semen parameters in men from infertile couples. *Andrologia*. 2012;44 Suppl 1:410–8.
- Sabaneh EJ, Agarwal IA. Male infertility. In: Wein AJ, editor. *CAMPBELL-WALSH urology*. vol. 1. Philadelphia: Saunders, an imprint of Elsevier; 2012. p. 616–47.
- Sachdeva K, Saxena R, Majumdar A, Chadha S, Verma IC. Mutation studies in the CFTR gene in Asian Indian subjects with congenital bilateral absence of vas deferens: report of two novel mutations and four novel variants. *Genet Test Mol Biomarkers*. 2011;15(5):307–12.
- Safarinejad MR. Evaluation of semen quality, endocrine profile and hypothalamus-pituitary-testis axis in male patients with homozygous beta-thalassemia major. *J Urol*. 2008;179(6):2327–32.
- Sagel J, Distiller LA, Morley JE, Isaacs H, Kay G, Van Der Walt A. Myotonia dystrophica: studies on gonadal function using luteinizing hormone-releasing hormone (LRH). *J Clin Endocrinol Metab*. 1975;40(6):1110–3.
- Salonen I, Pakarinen P, Huhtaniemi I. Effect of chronic ethanol diet on expression of gonadotropin genes in the male rat. *J Pharmacol Exp Ther*. 1992;260(2):463–7.
- Sarkar PS, Paul S, Han J, Reddy S. Six5 is required for spermatogenic cell survival and spermiogenesis. *Hum Mol Genet*. 2004;13(14):1421–31.
- Sartorius GA, Handelsman DJ. Testicular dysfunction in systemic diseases. In: Nieschlag E, Behre HM, Nieschlag S, editors. *Andrology. Male reproductive health and dysfunction*. Berlin/Heidelberg: Springer; 2010. p. 339–64.
- Sauer MV. Sperm washing techniques address the fertility needs of HIV-seropositive men: a clinical review. *Reprod Biomed Online*. 2005;10(1):135–40.
- Saunders PT, Turner JM, Ruggiu M, Taggart M, Burgoyne PS, Elliott D, Cooke HJ. Absence of mDazl produces a final block on germ cell development at meiosis. *Reproduction*. 2003;126(5):589–97.
- Saxena R, de Vries JW, Repping S, Alagappan RK, Skaletsky H, Brown LG, Ma P, Chen E, Hoovers JM, Page DC. Four DAZ genes in two clusters found in the AZFc region of the human Y chromosome. *Genomics*. 2000;67(3):256–67.
- Schiff J, Chan P, Li PS, Finkelberg S, Goldstein M. Outcome and late failures compared in 4 techniques of microsurgical vasoepididymostomy in 153 consecutive men. *J Urol*. 2005;174(2):651–5; quiz 801.
- Schlegel PN. Aromatase inhibitors for male infertility. *Fertil Steril*. 2012;98(6):1359–62.
- Schubert S, Shannon K, Bollag G. Hyperactive Ras in developmental disorders and cancer. *Nat Rev Cancer*. 2007;7(4):295–308.
- Schulze W, Thoms F, Knuth UA. Testicular sperm extraction: comprehensive analysis with simultaneously performed histology in 1418 biopsies from 766 subfertile men. *Hum Reprod*. 1999;14 Suppl 1:82–96.
- Selby DM. Sexual maldevelopment syndromes. In: Stocker JT, Dehner L, editors. *Pediatric pathology*. Philadelphia: JB Lippincott; 1992. p. 117–59.
- Serefoglu EC, McMahon CG, Waldinger MD, Althof SE, Shindel A, Adaikan G, Becher EF, Dean J, Giuliano F, Hellstrom WJ, Giraldi A, Glina S, Incrocci L, Jannini E, McCabe M, Parish S, Rowland D, Segraves RT, Sharlip I, Torres LO. An evidence-based unified definition of lifelong and acquired premature ejaculation: report of the second International Society for Sexual Medicine Ad Hoc Committee for the Definition of Premature Ejaculation. *J Sex Med*. 2014;11(6):1423–41.
- Sharma H, Mavuduru RS, Singh SK, Prasad R. Heterogeneous spectrum of mutations in CFTR gene from Indian patients with congenital absence of the vas deferens and their association with cystic fibrosis genetic modifiers. *Mol Hum Reprod*. 2014;20(9):827–35.
- Shefi S, Levron J, Nadu A, Raviv G. Male infertility associated with adult dominant polycystic kidney disease: a case series. *Arch Gynecol Obstet*. 2009;280(3):457–60.
- Shibahara H, Shigetani M, Inoue M, Hasegawa A, Koyama K, Alexander NJ, Isojima S. Diversity of the blocking effects of antisperm antibodies on fertilization in human and mouse. *Hum Reprod*. 1996;11(12):2595–9.

- Shimizu S, Saito M, Dimitriadis F, Kinoshita Y, Shomori K, Satoh I, Satoh K. Protective effect of ischaemic post-conditioning on ipsilateral and contralateral testes after unilateral testicular ischaemia-reperfusion injury. *Int J Androl.* 2011;34(3):268–75.
- Siddiq FM, Sigman M. A new look at the medical management of infertility. *Urol Clin North Am.* 2002;29(4):949–63.
- Silber SJ, Van Steirteghem AC, Devroey P. Sertoli cell only revisited. *Hum Reprod.* 1995;10(5):1031–32.
- Silva CA, Borba E, Cocuzza M, Carvalho J, Bonfá E. Autoimmune orchitis. In: Shoenfeld YCC, Gershwin ME, editors. *Diagnostic criteria in autoimmune diseases.* California: Springer Science; 2008. p. 281–4.
- Simoni M, Gromoll J, Dworniczak B, Rolf C, Abshagen K, Kamischke A, Carani C, Meschede D, Behre HM, Horst J, Nieschlag E. Screening for deletions of the Y chromosome involving the DAZ (Deleted in AZoospermia) gene in azoospermia and severe oligozoospermia. *Fertil Steril.* 1997;67(3):542–7.
- Simoni M, Tuttelmann F, Gromoll J, Nieschlag E. Clinical consequences of microdeletions of the Y chromosome: the extended Munster experience. *Reprod Biomed Online.* 2008;16(2):289–303.
- Skakkebaek NE, Rajpert-De Meyts E, Main KM. Testicular dysgenesis syndrome: an increasingly common developmental disorder with environmental aspects. *Hum Reprod.* 2001;16(5):972–8.
- Skaletsky H, Kuroda-Kawaguchi T, Minx PJ, Cordum HS, Hillier L, Brown LG, Repping S, Pyntikova T, Ali J, Bieri T, Chinwalla A, Delehaunty A, Delehaunty K, Du H, Fewell G, Fulton L, Fulton R, Graves T, Hou SF, Latrielle P, Leonard S, Mardis E, Maupin R, McPherson J, Miner T, Nash W, Nguyen C, Ozersky P, Pepin K, Rock S, Rohlfling T, Scott K, Schultz B, Strong C, Tin-Wollam A, Yang SP, Waterston RH, Wilson RK, Rozen S, Page DC. The male-specific region of the human Y chromosome is a mosaic of discrete sequence classes. *Nature.* 2003;423(6942):825–37.
- Smit M, Romijn JC, Wildhagen MF, Veldhoven JL, Weber RF, Dohle GR. Decreased sperm DNA fragmentation after surgical varicocelectomy is associated with increased pregnancy rate. *J Urol.* 2010;183(1):270–4.
- Smith NM, Byard RW, Bourne AJ. Testicular regression syndrome – a pathological study of 77 cases. *Histopathology.* 1991;19(3):269–72.
- Sofikitis N, Dritsas K, Miyagawa I, Koutselinis A. Anatomical characteristics of the left testicular venous system in man. *Arch Androl.* 1993a;30(2):79–85.
- Sofikitis N, Miyagawa I. Experimental models for the study of varicocele: a selected review. *Jpn J Fertil Steril.* 1993b;38(1):168–77.
- Sofikitis N, Miyagawa I, Dimitriadis D, Zavos P, Sikka S, Hellstrom W. Effects of smoking on testicular function, semen quality and sperm fertilizing capacity. *J Urol.* 1995;154(3):1030–4.
- Sofikitis N, Miyagawa I, Zavos PM. Re: should the testicular artery be preserved at varicocelectomy? *J Urol.* 1994;151(5):1355.
- Sofikitis N, Miyagawa I, Zavos PM, Inaga S, Iino A, Toda T, Harada T, Mio Y, Terakawa N. Acrosin profiles of human spermatozoa recovered from the new Sperm Prep II filtration column. *Tohoku J Exp Med.* 1992a;166(4):451–7.
- Sofikitis N, Stavrou S, Skouros S, Dimitriadis F, Tsounapi P, Takenaka A. Mysteries, Facts, and Fiction in Varicocele Pathophysiology and Treatment. *EUROPEAN UROLOGY SUPPLEMENT S.* 2014;13:89–99.
- Sofikitis N, Takahashi C, Nakamura I, Hirakawa S, Miyagawa I. Surgical repair of secondary right varicocele in rats with primary left varicocele: effects on fertility, testicular temperature, spermatogenesis, and sperm maturation. *Arch Androl.* 1992b;28(1):43–52.
- Sokol RZ. Endocrinology of male infertility: evaluation and treatment. *Semin Reprod Med.* 2009;27(2):149–58.
- Soler JM, Prevaire JG, Plante P, Denys P, Chartier-Kastler E. Midodrine improves orgasm in spinal cord-injured men: the effects of autonomic stimulation. *J Sex Med.* 2008;5(12):2935–41.
- Sotolongo JR, Jr. Immunological effects of vasectomy. *J Urol.* 1982;127(6):1063–6.

- Speed RM, Faed MJ, Batstone PJ, Baxby K, Barnetson W. Persistence of two Y chromosomes through meiotic prophase and metaphase I in an XYY man. *Hum Genet.* 1991;87(4):416–20.
- Spires SE, Woolums CS, Pulito AR, Spires SM. Testicular regression syndrome: a clinical and pathologic study of 11 cases. *Arch Pathol Lab Med.* 2000;124(5):694–8.
- Steigman CK, Sotelo-Avila C, Weber TR. The incidence of spermatic cord structures in inguinal hernia sacs from male children. *Am J Surg Pathol.* 1999;23(8):880–5.
- Stochholm K, Juul S, Gravholt CH. Diagnosis and mortality in 47,XYY persons: a registry study. *Orphanet J Rare Dis.* 2010;5:15.
- Storm D, Redden T, Aguiar M, Wilkerson M, Jordan G, Sumfest J. Histologic evaluation of the testicular remnant associated with the vanishing testes syndrome: is surgical management necessary? *Urology.* 2007;70(6):1204–6.
- Stouffs K, Lissens W, Tournaye H, Haentjens P. What about gr/gr deletions and male infertility? Systematic review and meta-analysis. *Hum Reprod Update.* 2011;17(2):197–209.
- Stuppia L, Gatta V, Calabrese G, Guanciali Franchi P, Morizio E, Bombieri C, Mingarelli R, Sforza V, Frajese G, Tenaglia R, Palka G. A quarter of men with idiopathic oligo-azoospermia display chromosomal abnormalities and microdeletions of different types in interval 6 of Yq11. *Hum Genet.* 1998;102(5):566–70.
- Sykiotis GP, Hoang XH, Avbelj M, Hayes FJ, Thambundit A, Dwyer A, Au M, Plummer L, Crowley WF, Jr., Pitteloud N. Congenital idiopathic hypogonadotropic hypogonadism: evidence of defects in the hypothalamus, pituitary, and testes. *J Clin Endocrinol Metab.* 2010a;95(6):3019–27.
- Sykiotis GP, Plummer L, Hughes VA, Au M, Durrani S, Nayak-Young S, Dwyer AA, Quinton R, Hall JE, Gusella JF, Seminara SB, Crowley WF, Jr., Pitteloud N. Oligogenic basis of isolated gonadotropin-releasing hormone deficiency. *Proc Natl Acad Sci U S A.* 2010b;107(34):15140–4.
- Tekgül S, Dogan HS, Erdem E, Hoebeke P, Kocvara R, Nijman JM, Radmayr C, Silay MS, Stein R, Undre S. EAU guidelines on paediatric urology. 31th EAU Annual Congress, Munich; 2016.
- Tilford CA, Kuroda-Kawaguchi T, Skaletsky H, Rozen S, Brown LG, Rosenberg M, McPherson JD, Wylie K, Sekhon M, Kucaba TA, Waterston RH, Page DC. A physical map of the human Y chromosome. *Nature.* 2001;409(6822):943–5.
- Toppari J, Kaleva M. Malescendus testis. *Horm Res.* 1999;51(6):261–9.
- Torra R, Sarquella J, Calabia J, Marti J, Ars E, Fernandez-Llana P, Ballarin J. Prevalence of cysts in seminal tract and abnormal semen parameters in patients with autosomal dominant polycystic kidney disease. *Clin J Am Soc Nephrol.* 2008;3(3):790–3.
- Toshimori K. Maturation of mammalian spermatozoa: modifications of the acrosome and plasma membrane leading to fertilization. *Cell Tissue Res.* 1998;293(2):177–87.
- Toth A. Male infertility due to sulphasalazine. *Lancet.* 1979;2(8148):904.
- Tournaye H, Liu J, Nagy PZ, Camus M, Goossens A, Silber S, Van Steirteghem AC, Devroey P. Correlation between testicular histology and outcome after intracytoplasmic sperm injection using testicular spermatozoa. *Hum Reprod.* 1996;11(1):127–32.
- Tsounapi P, Saito M, Dimitriadis F, Kitatani K, Kinoshita Y, Shomori K, Takenaka A, Satoh K. The role of K ATP channels on ischemia-reperfusion injury in the rat testis. *Life Sci.* 2012;90(17–18):649–56.
- Tsounapi P, Saito M, Dimitriadis F, Shimizu S, Kinoshita Y, Shomori K, Satoh I, Satoh K. Protective effect of sivelestat, a neutrophil elastase inhibitor, on ipsilateral and contralateral testes after unilateral testicular ischaemia-reperfusion injury in rats. *BJU Int.* 2011;107(2):329–36.
- Turek PJ. Male infertility. In: Tanagho EA, McAninch JW, editors. *Smith's general urology.* New York: McGraw-Hill; 2008. p. 684–716.
- Turner TT, Tung KS, Tomomasa H, Wilson LW. Acute testicular ischemia results in germ cell-specific apoptosis in the rat. *Biol Reprod.* 1997;57(6):1267–74.

- UK\_Testicular\_Cancer\_Study\_Group. Aetiology of testicular cancer: association with congenital abnormalities, age at puberty, infertility, and exercise. United Kingdom Testicular Cancer Study Group. *BMJ*. 1994a;308(6941):1393–9.
- UK\_Testicular\_Cancer\_Study\_Group. Social, behavioural and medical factors in the aetiology of testicular cancer: results from the UK study. UK Testicular Cancer Study Group. *Br J Cancer*. 1994b;70(3):513–20.
- Umapathy E, Simbini T, Chipata T, Mbizvo M. Sperm characteristics and accessory sex gland functions in HIV-infected men. *Arch Androl*. 2001;46(2):153–8.
- van der Burgt I. Noonan syndrome. *Orphanet J Rare Dis*. 2007;2:4.
- Van Savage JG. Avoidance of inguinal incision in laparoscopically confirmed vanishing testis syndrome. *J Urol*. 2001;166(4):1421–4.
- Vanhooorne M, Comhaire F, De Bacquer D. Epidemiological study of the effects of carbon disulfide on male sexuality and reproduction. *Arch Environ Health*. 1994;49(4):273–8.
- Vazquez-Levin MH, Kupchik GS, Torres Y, Chaparro CA, Shtainer A, Bonforte RJ, Nagler HM. Cystic fibrosis and congenital agenesis of the vas deferens, antisperm antibodies and CF-genotype. *J Reprod Immunol*. 1994;27(3):199–212.
- Vazquez-Levin MH, Marin-Briggiler CI, Veaute C. Antisperm antibodies: invaluable tools toward the identification of sperm proteins involved in fertilization. *Am J Reprod Immunol*. 2014;72(2):206–18.
- Villegas J, Schulz M, Soto L, Sanchez R. Bacteria induce expression of apoptosis in human spermatozoa. *Apoptosis*. 2005;10(1):105–10.
- Vine MF. Smoking and male reproduction: a review. *Int J Androl*. 1996;19(6):323–37.
- Visser L, Westerveld GH, Korver CM, van Daalen SK, Hovingh SE, Rozen S, van der Veen F, Repping S. Y chromosome gr/gr deletions are a risk factor for low semen quality. *Hum Reprod*. 2009;24(10):2667–73.
- Vogt PH, Edelmann A, Kirsch S, Henegariu O, Hirschmann P, Kiesewetter F, Kohn FM, Schill WB, Farah S, Ramos C, Hartmann M, Hartschuh W, Meschede D, Behre HM, Castel A, Nieschlag E, Weidner W, Grone HJ, Jung A, Engel W, Haidl G. Human Y chromosome azoospermia factors (AZF) mapped to different subregions in Yq11. *Hum Mol Genet*. 1996;5(7):933–43.
- von Eckardstein S, Simoni M, Bergmann M, Weinbauer GF, Gassner P, Schepers AG, Nieschlag E. Serum inhibin B in combination with serum follicle-stimulating hormone (FSH) is a more sensitive marker than serum FSH alone for impaired spermatogenesis in men, but cannot predict the presence of sperm in testicular tissue samples. *J Clin Endocrinol Metab*. 1999;84(7):2496–501.
- Walsh TJ, Smith JF. Male infertility. In: McAninch JW, Lue TF, editors. *Smith & Tanagho's general urology*. New York: McGraw-Hill; 2013. p. 687–719.
- Walsh TJ, Turek PJ. Partial ejaculatory duct obstruction: new approaches to diagnosis and treatment. *Contemp Urol*. 2006;18:48.
- Wang C, Baker HW, Burger HG, De Kretser DM, Hudson B. Hormonal studies in Klinefelter's syndrome. *Clin Endocrinol (Oxf)*. 1975;4(4):399–411.
- Wang Z, Milunsky J, Yamin M, Maher T, Oates R, Milunsky A. Analysis by mass spectrometry of 100 cystic fibrosis gene mutations in 92 patients with congenital bilateral absence of the vas deferens. *Hum Reprod*. 2002;17(8):2066–72.
- Warrell DA. *Oxford textbook of medicine*: sections 18–33. Oxford: Oxford University Press; 2005.
- Welsh MJ, Tsui LC, Boat TF, Beaudet AL. Cystic fibrosis. In: Striver CL, Beaudet AL, Sly D, Valle D, editors. *The metabolic and molecular bases of inherited disease*. New York: McGraw-Hill; 1995. p. 3799–876.
- Wibowo E, Johnson TW, Wassersug RJ. Infertility, impotence, and emasculation – psychosocial contexts for abandoning reproduction. *Asian J Androl*. 2016;18(3):403–8.
- Wieacker P. Mechanisms of dysfunction and pathology. Disorders of prenatal sexual development. In: Schill WB, Comhaire FH, Hargreave TB, editors. *Andrology for the clinician*. Berlin/Heidelberg/New York: Springer; 2006. p. 305–13.

- Winters S. Male hypogonadism. In: Melmed S, editor. Male reproductive function. Norwell: Kluwer; 1999. p. 119–38.
- Wong EC, Ferguson KA, Chow V, Ma S. Sperm aneuploidy and meiotic sex chromosome configurations in an infertile XYY male. *Hum Reprod.* 2008;23(2):374–8.
- Wright JE. The atrophic testicular remnant. *Pediatr Surg Int.* 1986;1:229–31.
- Xu WM, Chen J, Chen H, Diao RY, Fok KL, Dong JD, Sun TT, Chen WY, Yu MK, Zhang XH, Tsang LL, Lau A, Shi QX, Shi QH, Huang PB, Chan HC. Defective CFTR-dependent CREB activation results in impaired spermatogenesis and azoospermia. *PLoS One.* 2011;6(5):e19120.
- Yang X, Sun Q, Yuan P, Liang H, Wu X, Lai L, Zhang Y. Novel mutations and polymorphisms in the CFTR gene associated with three subtypes of congenital absence of vas deferens. *Fertil Steril.* 2015;104(5):1268–75 e1261–1262.
- Zenteno-Ruiz JC, Kofman-Alfaro S, Mendez JP. 46,XX sex reversal. *Arch Med Res.* 2001;32(6):559–66.
- Zhou-Cun A, Yang Y, Zhang SZ, Zhang W, Lin L. Chromosomal abnormality and Y chromosome microdeletion in Chinese patients with azoospermia or severe oligozoospermia. *Yi Chuan Xue Bao.* 2006;33(2):111–6.
- Zielenski J, Patrizio P, Corey M, Handelin B, Markiewicz D, Asch R, Tsui LC. CFTR gene variant for patients with congenital absence of vas deferens. *Am J Hum Genet.* 1995;57(4):958–60.

Frank Tüttelmann and Albrecht Röpke

---

## Abstract

Male infertility may be caused by genetic defects that increase in prevalence when spermatogenesis is severely impaired. Thus, especially infertile men with severe oligozoospermia or azoospermia should be investigated by cytogenetic and molecular genetic analysis. Structural chromosomal aberrations (e.g., balanced translocations) are found significantly more frequently in oligo- and azoospermic men and numerical chromosomal aberrations of the sex chromosomes, especially Klinefelter syndrome (karyotype 47,XXY), are common among azoospermic men. Screening for Y-chromosomal AZF (“AZoospermia Factor”) deletions is warranted in all men with severe oligo- or azoospermia. Infertile men with obstructive azoospermia should be evaluated for mutations in the Cystic Fibrosis Transmembrane conductance Regulator (*CFTR*) gene. Detecting chromosomal aberrations, AZF deletions, and *CFTR* mutations has important prognostic value for the subsequent work-up and especially for genetic counseling about risk for offspring. Patients with Congenital Hypogonadotropic Hypogonadism (CHH), other syndromic forms of male infertility, or infertile men with rare monomorphic defects of spermatozoa should be carefully investigated for the underlying genetic cause. In the near future, men with severe spermatogenic failure may be evaluated by targeted sequencing of a panel of genes.

---

## Keywords

Male infertility • Chromosomal aberrations • Sex chromosomes • Klinefelter syndrome • AZF deletions • CBAVD • *CFTR* • Congenital hypogonadotropic hypogonadism • Kallmann syndrome

---

F. Tüttelmann (✉) • A. Röpke

Institute of Human Genetics, University of Münster, Münster, Germany

e-mail: [frank.tuettelmann@ukmuenster.de](mailto:frank.tuettelmann@ukmuenster.de); [albrecht.roepke@ukmuenster.de](mailto:albrecht.roepke@ukmuenster.de)

© Springer International Publishing AG 2017

M. Simoni, I.T. Huttaniemi (eds.), *Endocrinology of the Testis and Male Reproduction*,  
Endocrinology 1, [https://doi.org/10.1007/978-3-319-44441-3\\_34](https://doi.org/10.1007/978-3-319-44441-3_34)

1029



## Contents

Introduction .....	1030
Chromosomal Aberrations .....	1032
Klinefelter Syndrome .....	1033
XX-Male Syndrome .....	1035
YYY Syndrome .....	1036
Y-chromosomal Deletions .....	1037
Classical AZF Deletions .....	1037
Partial AZF Deletions .....	1039
Structural Aberrations of the Y Chromosome Including Complex AZF Deletions .....	1040
Other Submicroscopic Chromosomal Aberrations .....	1040
Single-Gene Defects .....	1041
Congenital Absence of the Vas Deference (CBAVD) .....	1041
Hypogonadotropic Hypogonadism .....	1042
Disorders of Androgen Action .....	1045
Specific Defects of Spermatozoa .....	1046
Single-Gene Defects in Isolated Severe Spermatogenic Failure .....	1046
Genetic Syndromes Associated with Male Infertility .....	1047
Outlook .....	1047
Summary .....	1048
Cross-References .....	1049
References .....	1049

## Introduction

Male infertility (and hypogonadism) may be caused by a genetic defect, which should be investigated by cytogenetic or molecular genetic analysis. The two most severe clinical phenotypes in infertile males, which are identifiable by semen analysis, are oligo-(astheno-terato-)zoospermia (OAT) and azoospermia. While OAT describes reduced sperm number, altered morphology, and reduced motility, azoospermia is defined as the absence of spermatozoa in the ejaculate. Azoospermia is identified in ~15% of infertile men and can be classified into obstructive azoospermia (OA) and nonobstructive azoospermia (NOA). OA is mainly caused by the physical blockage of the male excurrent ductal system and affected patients display normal gonadotropin and androgen levels, and normal spermatogenesis, because neither the endocrine system nor spermatogenesis is affected. OAT and NOA, which comprise the majority of azoospermic men (>80%), are frequent symptoms of primary testicular failure with elevated LH, FSH levels, and small testes and rarely of secondary testicular failure (Congenital Hypogonadotropic Hypogonadism (CHH)) with decreased LH and FSH and small testes. In contrast to OA, which may be caused by urogenital infections or mutations in the *CFTR* gene, the etiology of OAT and NOA remains largely unclear.

Currently, a specific genetic cause can be demonstrated in only about 4% of unselected infertile men, while this rate increases to about 20% in patients presenting with azoospermia (Table 1). Among the best known and most frequent genetic causes of male infertility are structural and numerical chromosomal

**Table 1** Genetic causes identified by routine analyses (patients of the Centre of Reproductive Medicine and Andrology, Münster)

Genetic diagnosis	Unselected patients (N = 12,945)	Azoospermic patients (N = 1446)
<b>Chromosomal aberrations</b>	<b>2.8%</b>	<b>15.0%</b>
Klinefelter Syndrome (47,XXY)	2.6%	13.7%
XX-Male (46,XX)	0.1%	0.6%
Translocations	0.1%	0.3%
Others	<0.1%	0.3%
<b>CBAVD incl. cystic fibrosis</b>	<b>0.5%</b>	<b>3.1%</b>
<b>Congenital hypogonadotropic Hypogonadism incl. Kallmann syndrome</b>	<b>0.7%</b>	<b>0.9%</b>
<b>Y-chromosomal AZF deletions</b>	<b>0.3%</b>	<b>1.6%</b>
<b>Total</b>	<b>4.3%</b>	<b>20.6%</b>

aberrations (e.g., Klinefelter syndrome), microdeletions of the AZF (“AZoospermia Factor”) regions on the long arm of the Y chromosome, and mutations of the *CFTR* gene. Any of these causes can be identified by well-established genetic tests and form the widely applied clinical routine analyses. In addition, several genes involved in the migration and function of GnRH neurons have been discovered that can be mutated in patients with CHH with or without anosmia. Other genetic causes of male infertility comprise disorders of androgen action, genetic syndromes including infertility as a symptom, and specific defects of sperm morphology and function. Furthermore, mutations and polymorphisms of various genes have been found to be associated with unspecific spermatogenic failure/male infertility, but none of these have been introduced into the clinical workup of the infertile male so far.

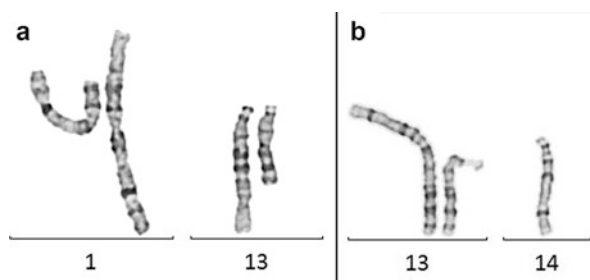
Overall, genetic causes increase in prevalence in men with lower sperm counts, i.e., increasingly severe spermatogenic failure. Therefore, the main indications for genetic testing in male infertility are severe oligozoospermia and azoospermia found in routine semen analysis. While an evidence-based cut-off for sperm counts justifying genetic tests does not exist, for clinical routine a threshold of a total sperm count below 10–15 million seems adequate. In cases of CHH and specific sperm defects, mutation screening of the associated genes is indicated.

Many forms of male infertility due to severe oligozoospermia or even azoospermia can be overcome by in vitro fertilization (IVF) combined with intracytoplasmic sperm injection (ICSI). Even though the detection of a genetic alteration will in most cases not substantially change the treatment, the clinical value lies in (1) establishing a definitive causal diagnosis, (2) the prognostic value comprising chances of testicular biopsy and pregnancy, and (3) assessing the risks for the offspring in case of successful treatment. Expert genetic counseling should accompany every (positive) genetic test.

## Chromosomal Aberrations

Numerical and structural chromosomal aberrations (translocations [Fig. 1], inversions, deletions, duplications, etc.) can be discovered by conventional cytogenetic analysis (e.g., Giemsa/Trypsin staining on metaphases derived from peripheral blood lymphocytes), molecular cytogenetic methods (e.g., fluorescence *in situ* hybridization [FISH], or comparative genomic hybridization [CGH]). Overall, the prevalence of chromosomal aberrations in infertile men is around 10–15 times higher compared with the general population and ranges between 2% and 16% with an increasing frequency of abnormalities of the autosomes with decreasing sperm count. In contrast, sex chromosome abnormalities – most importantly Klinefelter syndrome (described separately below) – constitute the majority of pathological findings in men with azoospermia. The causative role of autosomal aberrations in relation to the men's infertility can usually not be established in an individual case, but there is growing evidence that the abnormal chromosome(s) leads to disturbances of meiosis and thereby to oligo- or azoospermia. Structural aberrations of the Y chromosome are often associated with large or complex AZF deletions and are addressed in a specific paragraph below.

In the majority of cases, the infertile patient is an otherwise healthy male (aside from syndromic cases, see below) and the chromosomal anomaly does not imply any other risks for the man himself. However, men carrying, e.g., a translocation have a markedly increased risk to induce a pregnancy (e.g., by ICSI) ending in miscarriage/stillbirth or fathering a child with varying degrees of mental and/or physical retardation in case of an unbalanced karyotype in the offspring. Therefore, chromosomal analysis is indicated in every infertile man with (severe) oligo- or azoospermia. At least in case of an abnormal karyotype, accompanying genetic counseling should be offered which will include discussion of specific risks, the possibility of preimplantation and prenatal genetic diagnostics, and – for certain aberrations – the probability of other family members being carriers of the same aberration.




**Fig. 1** Examples of a balanced translocation between chromosomes 1 and 13, karyotype 46,XY,t(1;13) (a) and the most common Robertsonian translocation involving chromosomes 13 and 14, karyotype 45,XY,der(13;14)(q10;q10) (b)

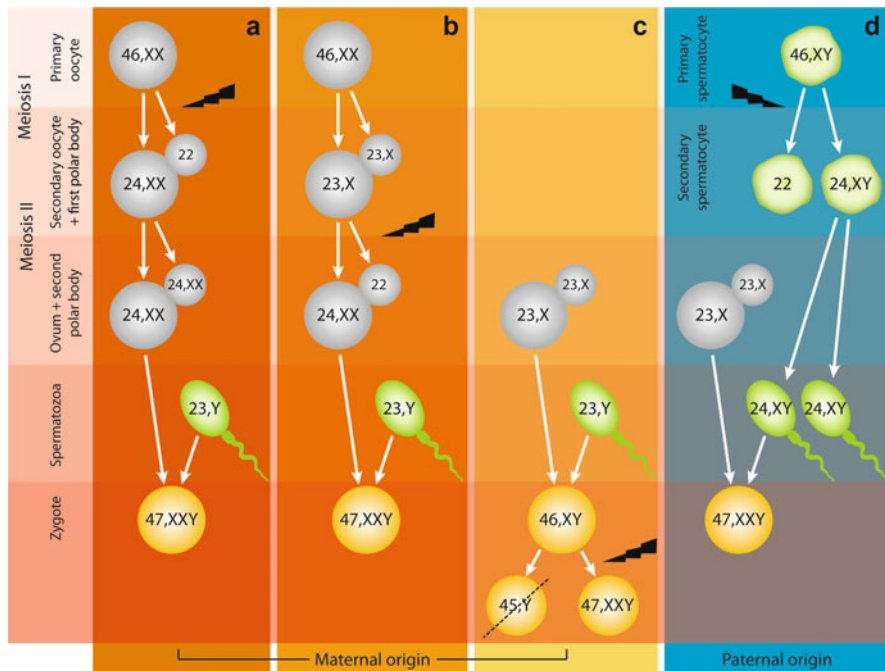
## Klinefelter Syndrome

Harry F. Klinefelter was the first to describe men with a syndrome comprising “gynecomastia, aspermatogenesis without Leydigism, and increased excretion of follicle stimulating hormone” in 1942. The cause for the syndrome was later found in 1959 by Patricia Jacobs as a supernumerary X chromosome resulting in the karyotype 47,XXY (Fig. 2).

Klinefelter syndrome (KS) is established as the most common chromosome aneuploidy with a prevalence of about 1–2 per 1000 men. About 80–90% of KS men bear the “original” karyotype of 47,XXY, while the remaining exhibit (in decreasing frequency) varying mosaicism (e.g., 47,XXY/46,XY) and carry additional sex chromosomes (48,XXX; 48,XXYY; 49,XXXXY) or structurally abnormal X chromosomes. The numerical chromosome aberration in KS men arises from nondisjunction either during the meiotic divisions occurring in gametogenesis of the parents or in postzygotic mitotic cell divisions during early embryogenesis (Fig. 3). Contrary to autosomal trisomies in which paternal nondisjunctions overall account for only about 10% of all cases, in KS the supernumerary X-chromosome is of paternal origin in about 50% of patients.



**Fig. 2** Typical 47,XXY karyogram of a man with Klinefelter syndrome



**Fig. 3** Different parental origins of KS by nondisjunction (depicted by flash) in maternal meiosis I (a), maternal meiosis II (b), during one of the first postzygotic divisions (c), and paternal meiosis I (d) (Tüttelmann and Gromoll 2010)

Men with KS are common among infertile patients: the prevalence increases from around 3% in unselected to around 15% in azoospermic patients making KS the most frequent genetic cause of azoospermia. Affected men may be identified by the leading clinical features of reduced testicular volume (usually <6 ml bi-testicular volume), azoospermia (only very rarely KS patients have some few sperm in their ejaculate), and markedly increased gonadotropin levels (luteinizing hormone (LH) and follicle stimulating hormone (FSH)). In addition, patients may have low serum testosterone concentrations (<12 nmol/l) and varying symptoms of hypogonadism (e.g., undervirilized body constitution and/or gynecomastia). However, although KS is regularly associated with infertility due to azoospermia and hypergonadotropic hypogonadism, the clinical picture of KS patients may range from severe signs of androgen deficiency, or even a lack of spontaneous puberty, to normally virilized males that only consult because of their infertility. This variability is most likely explaining why supposedly only 10% of KS men are diagnosed until puberty and only ~25% during their lifetime. In contrast to previous thinking, KS patient's intelligence lies within the normal range, but on average 10 IQ points lower than in age-matched men.

The vast majority of KS patients is infertile due to azoospermia, even if case reports of spontaneous conceptions have been published. However, with the

introduction of ICSI, Klinefelter men have a chance to become fathers. Recent studies report high success rates of around 50% to yield spermatozoa for ICSI by performing a testicular biopsy and testicular sperm extraction (TESE). The best results can be achieved with special microsurgical techniques locating focal spermatogenesis (mTESE). Some authors report a decreasing success rate with increasing age, and previous testosterone substitution may have a negative effect. Therefore, the possibility of testicular biopsy/TESE and cryopreservation of tissue should be discussed upon first diagnosis of KS even without current wish for conception. According to the published TESE procedures and ICSI cycles, the pregnancy and live birth rates seem to be comparable to ICSI because of other indications. The outcome of children of KS fathers is overall reassuring without a significantly increased risk of chromosomal aberrations or birth defects.

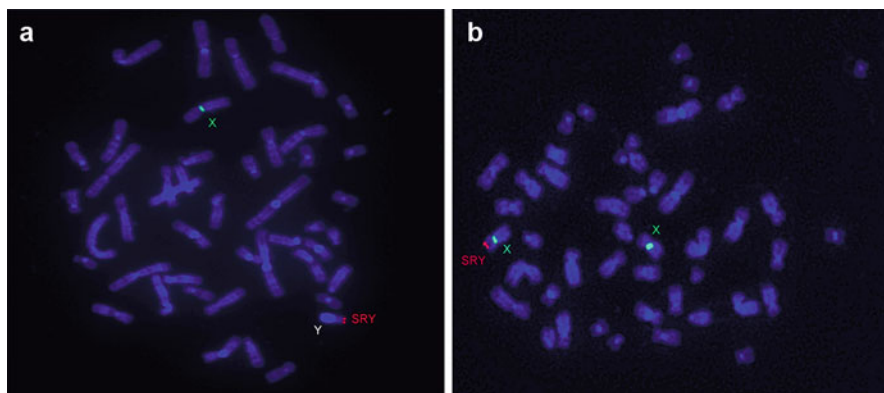
The important question of how spermatogenesis is generally disturbed in KS and how it may still work in some testicular foci was long a topic of debate. While first the rare completion of meiosis of 47,XXY spermatogonia was postulated based on indirect clues, more recent analyses showed that all meiotic spermatocytes in KS men were euploid 46,XY. Thus, some spermatogonia in KS patients may have never carried a supernumerary X chromosome or may have lost their supernumerary X chromosome during fetal, neonatal, or pubertal development. Independent of the mechanism, some spermatogonia seem to contain a normal set of chromosomes (46,XY) and these are able to proceed through meiosis, establishing a testicular (tissue-specific) mosaicism. What role a disturbed testicular environment involving somatic 47,XXY Sertoli and Leydig cells plays in the disturbed spermatogenesis remains to be elucidated.

---

## XX-Male Syndrome

The XX-male syndrome is characterized by the combination of male external genitalia, testicular differentiation of the gonads, and a 46,XX karyotype by conventional cytogenetic analysis. This sex-chromosome aneuploidy is much rarer than KS with a prevalence of 1:9000 to 1:20,000. In about 80% of XX-males, material of the Y chromosome is usually translocated to an X chromosome (Fig. 4). Translocation of a DNA segment that contains the testis-determining gene (*SRY* = Sex Determining Region Y) from the Y to the X chromosome takes place during paternal meiosis. The presence of the *SRY* gene is sufficient to cause the initially indifferent gonad to develop into a testis. This X;Y translocation cannot be detected using standard karyotyping. Thus, molecular cytogenetic analysis using a specific probe for the *SRY* locus should be carried out in all cases of XX males. The breakpoints and consecutively the size and content of the translocation seem to influence the severity of the phenotype. There are very few reports on Y;autosomal translocations including the *SRY* gene leading to XX males.

XX-males are often clinically compared with KS and, indeed, most *SRY*-positive XX-males are quite similar to KS patients concerning the hallmarks of small testes, azoospermia, and hypergonadotropic hypogonadism. However, 46,XX males



**Fig. 4** Fluorescence in situ hybridization highlighting the X-centromere (*green*) and the *SRY*-locus (*red*). (a) Normal constellation with one X chromosome and *SRY* on the Y chromosome. (b) XX-male with translocation of *SRY* to one of the X chromosomes.

present with significantly shorter stature than KS patients and also shorter-than-average stature compared with healthy men. The mean height is comparable with females, which is in line with the recent view that the number and constitution of sex-chromosomes (most importantly copies of the *SHOX* gene) largely determines final height. The incidence of cryptorchidism is significantly higher than that in KS and about every second XX-male develops gynecomastia. XX-males seem to have normal intelligence; however, exact data are lacking. The testicular histology of postpubertal *SRY*-positive XX-males shows atrophy and hyalinization of the seminiferous tubules devoid of germ cells and no chance for testicular sperm extraction.

In *SRY*-negative XX-males (about 20% of XX-males), mutations of *SOX9* and *RSPO1* have been described to be causing the syndrome. However, mutations in these genes are very rare and, thus, other candidate genes are likely responsible for the sex reversal. Overall, the mechanism underlying the majority of *SRY*-negative XX cases currently remains unclear. *SRY*-negative XX-males are generally even less virilized than *SRY*-positive ones and often show additional malformations of the genital organs such as bifid scrotum or hypospadias.

## XYY Syndrome

Most 47,XYY males have no health problems distinct from those of normal 46,XY males. Usually the finding is incidental, occurring when karyotyping has been undertaken for unrelated issues, but may be also a finding during workup for infertility. The prevalence among unselected newborns is reported to be around 1:1000.

Men with 47,XYY syndrome exhibit serum testosterone and gonadotropin levels as well as testicular volumes comparable to those of normal healthy men. Most men with 47,XYY-syndrome also have normal fertility. Onset of puberty may be delayed and adult height is in excess of the male population mean. The intelligence quotient

lies within the normal range, but men score an average of 10 points less than age-matched peers. Behavioral problems are more common in 47,XYY males. However, in contrast to outdated views, aggressive or violent behavior is exceptional.

Most 47,XYY men do not need any specific therapy and men who achieve fatherhood can expect chromosomally normal offspring probably with the same likelihood as normal men.

---

## Y-chromosomal Deletions

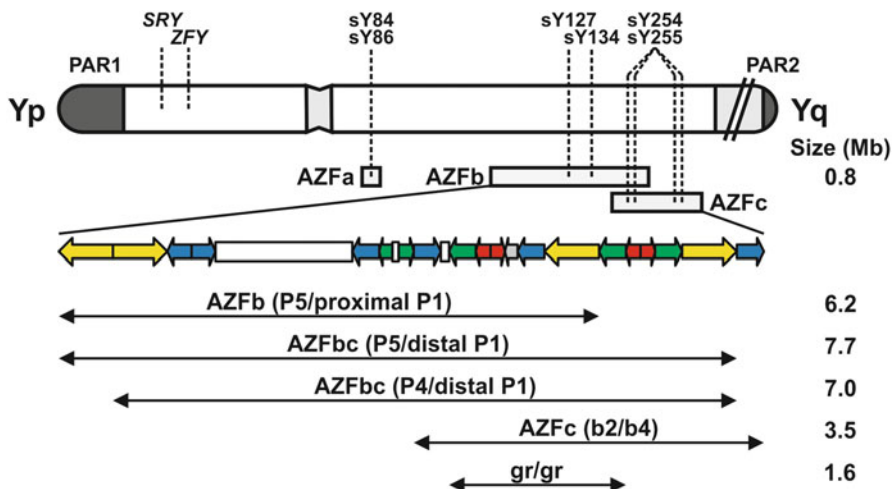
The long arm of the Y chromosome contains three partially overlapping but discrete regions that are essential for normal spermatogenesis. The loss (deletion) of any of these submicroscopic regions, designated as Y-chromosomal AZF (“AZoospermia Factor”) microdeletions, regularly leads to infertility due to severe oligo- or azoospermia. The prevalence of AZF deletions lies between 5% and 10% in azoospermic men and between 2% and 5% in men with severe oligozoospermia (<5 million/ml sperm concentration). It is well established that microdeletions of the Y chromosome occur in infertile men but not in control men, although the frequency differs remarkably between countries, possibly depending on the selection criteria of the patients and on the ethnic background. Thus, patients with nonobstructive azoospermia or severe oligozoospermia should be investigated for the presence of AZF deletions, which represent one of the few, well-recognized genetic causes of spermatogenetic failure resulting in male infertility (Krausz et al. 2014). The molecular diagnosis of Y-chromosomal microdeletions is relatively easy, justifying its popularity, which now makes it one of the most frequently performed diagnostic tests in molecular genetics (see ► Chap. 17, “Genetic Analysis in Male Infertility”).

---

## Classical AZF Deletions

The portion of the male-specific region of the Y chromosome (MSY) affected by deletions was completely sequenced in 2003, allowing the molecular mechanism of microdeletions to be identified as homologous recombination between identical retroviral or palindromic sequences. The breakpoints of deletions are well characterized and five main microdeletion patterns have been identified, named AZFa, AZFb (P5-proximal P1), AZFbc (with two variants differing in the proximal breakpoint: P5/distal P1 and P4/distal P1), and AZFc (b2/b4) (Fig. 5). The vast majority of clinically recognized deletions (over 80%) comprise the AZFc region. The AZFb and AZFc regions are partially overlapping and together comprise 24 genes, most of which are present in multiple copies for a total of 46 copies. The complete deletion of AZFb removes 6.2 Mb (including 32 copies of genes and noncoding transcription units) and results from homologous recombination between the palindromes P5/proximal P1. The AZFc region includes 12 genes and transcription units, each present in a variable number of copies making a total of 32 copies.





**Fig. 5** Schematic representation of the Y chromosome and the current microdeletion model. Repetitive sequences (color coded palindromes) explain the origin of deletions in the AZFbc region by homologous recombination between identical sequences. The location of the STS primers suggested by the present guidelines is indicated by *dashed lines*

The classical complete deletion of AZFc (b2/b4 deletion) removes 3.5 Mb, corresponding to 21 copies of genes and transcription units. Combined AZFb and AZFc deletions occur by two major mechanisms involving homologous recombination between P5/distal P1 (7.7 Mb and 42 copies removed) or between P4/distal P1 (7.0 Mb, 38 copies removed). Interestingly, it currently remains unclear if any single gene of the respective regions or the deletions by itself (as a microdeletion syndrome) are responsible for the infertility.

Clinically, patients carrying an AZF deletion present with severely disturbed spermatogenesis; testicular endocrine function may or may not be present as in other cases of spermatogenetic failure. In azoospermic men, the presence of a complete deletion of AZFa seems to be associated with uniform germ cell aplasia (complete Sertoli-cell-only syndrome, SCOS), while a histological picture of SCOS or spermatogenic arrest seems common in men carrying complete AZFb or AZFbc deletions. However, in exceptional cases, complete AZFb-deletions seem compatible with finding, albeit very few, spermatozoa. Overall, the chances for successful sperm retrieval in carriers of complete AZFa as well as AZFb and AZFbc deletions have still to be considered “virtually zero.” In contrast, men carrying complete AZFc deletions may have a milder phenotype with about 50% having severe oligozoospermia – though mostly cryptozoospermia with very few sperm in the ejaculate, rarely sperm concentration of up to 1 million/ml and only hardly ever higher sperm counts. Repeated semen analysis might be useful in such patients, since spermatozoa may occasionally appear in the ejaculate and be used for ICSI. The other half of AZFc deleted men has azoospermia with a varying histological picture ranging from complete or focal SCOS to spermatogenic arrest or mixed atrophy with

qualitatively intact but quantitatively severely reduced spermatogenesis. In general, TESE is possible in patients with AZFc deletions with a probability to recover sperm of about 50%. A progressive deterioration of spermatogenesis in adult patients with AZFc deletions has been proposed but never demonstrated.

There are no clinical parameters beyond azoospermia or severe oligozoospermia which can be used to predict the presence of a microdeletion of the Y chromosome and, accordingly, all men with very low sperm counts or azoospermia should be screened for AZF deletions. A positive result of the analysis provides a causal explanation for the patient's disturbed spermatogenesis. Beyond this, the test also has prognostic value, as TESE may be possible in about 50% of men with AZFc deletion and every son of such a patient will carry the paternal Y chromosomal microdeletion and thereby inherit the disturbed fertility. Hence, genetic counseling is indicated for all carriers of Y chromosomal microdeletions.

The diagnosis of microdeletions is usually performed by PCR amplification of selected regions of the long arm of the Y chromosome. Lack of amplification suggests the presence of a microdeletion which, however, must be confirmed by a separate PCR based on different primers ("extension analysis"). Laboratory guidelines issued on behalf of the European Academy of Andrology (EAA) and the European Molecular Genetics Quality Network (EMQN) are available (Krausz et al. 2014). It is estimated that the proposed basic protocol for routine microdeletion screening is sufficient to detect over 95% of clinically relevant deletions, although very rare exceptions of partial deletions within the above-mentioned regions might occur. These partial deletions, however, are of unclear pathogenic significance and their characterization is still experimental. An external quality assessment scheme is currently offered jointly by the EAA and the EMQN ([www.emqn.org](http://www.emqn.org)).

---

## Partial AZF Deletions

Smaller deletions removing only part of the AZFc region have also been identified. These comprise the so-called gr/gr, b1/b3, b2/3 deletions, and others. These partial deletions arise by the same mechanism as classical, complete AZF deletions (homologous recombination) and have been extensively studied in large groups of men in different countries. Some of these partial AZF deletions have only been associated with infertility on a specific Y background (haplogroup) common, e.g., in Asia. In contrast, the gr/gr deletion, named after the fluorescent probes ("green" and "red") used when first described, is significantly associated with infertility, especially oligozoospermia, in many populations. However, in specific Y haplogroups (such as D2b, Q3, and Q1) common in Japan and certain areas of China, the deletion is fixed and apparently does not have negative effects on spermatogenesis. Overall, gr/gr deletions are found in about 7% of infertile men but also in 4% of the controls with normal sperm counts. Several meta-analyses have reported significant odd's ratios, reporting on average 2–2.5 fold increased risks of reduced sperm output/infertility. Thus, gr/gr deletions represent a significant risk factor for male infertility, but its clinical significance is still a matter of debate, because carriers may exhibit highly variable phenotypes ranging from

azoo- to normozoospermia. Concerns have been raised that a gr/gr (partial AZFc) deletion may expand to a complete AZFc deletion in the next generation and gr/gr deletions have also been reported as risk factor for testicular cancer. Currently, however, no general agreement to advise routine testing has been reached.

---


## Structural Aberrations of the Y Chromosome Including Complex AZF Deletions

Larger and/or complex Y chromosomal deletions can be caused by structural Y-chromosomal rearrangements (Fig. 6). These are usually detected by cytogenetic and molecular cytogenetic analyses (see above), but may also be detected upon AZF deletion screening. A deletion of the whole AZF region (comprising AZFa, b, and c) is possible in case of a derivative Y chromosome consisting of two short arms leading to an isochromosome Yp. Comparably, a deletion of AZFb and AZFc can be caused by an isodicentric Y chromosome. Likewise, ring chromosomes may cause loss of larger parts of the Y chromosome. Furthermore, complex AZF deletions may indicate an unbalanced translocation between the Y chromosome and other chromosomes. All of these larger rearrangements have more severe implications for the offspring than the classical AZF deletions. For example, translocations between Y chromosome/autosome lead to a high risk for unbalanced chromosomal aberrations and larger structural aberrations of the Y chromosome increase the risk for mosaicism of cells with or without monosomy of the X chromosome in the offspring (45, X/46,XY). The latter may cause a broad spectrum of gonadal dysgenesis and ambiguous external genitalia, i.e., disorders of sexual development (DSD).

---

## Other Submicroscopic Chromosomal Aberrations

Since the advent of genome-wide technologies (array-Comparative Genomic Hybridization, array-CGH) to identify submicroscopic deletions and duplication, these are analyzed on a large scale in many diseases and are termed Copy Number Variants (CNVs). It immediately became clear that CNVs add to the variation in our



**Fig. 6** Examples of structural Y chromosomal aberrations detected in infertile males: Two differently sized Y ring chromosomes (a, b) and an isodicentric chromosome Yp that is accompanied by a deletion of AZFbc (c)

genome and the majority has probably no relevance for disease. However, many novel microdeletion syndromes, many of which are associated with mental retardation and malformations, have now been described.

While the submicroscopic Y-chromosomal deletions in the AZF region described above have been analyzed in infertile men routinely for many years, other microdeletions (and -duplications) are currently only studied in research settings. To date, only few genome-wide studies have been conducted in infertile men (Tüttelmann et al. 2011) and some others have focused specifically on the X-chromosome (Lo Giacco et al. 2014). Probably the most important and consistent finding of these studies is an increased “burden” of microdeletions in infertile (oligo- or azoospermic) compared with fertile (or normozoospermic) men, i.e., infertile men carry significantly more microdeletions than controls. In conjunction with the notion that infertile men also seem to carry more nucleotide variations (SNPs) than controls, this may allude to an association between infertility and an increased genome instability. Nevertheless, to date no specific CNV has been identified (and replicated in an independent study) that explains spermatogenic failure in carriers. Thus, no testing for any CNV can currently be advised to be tested in clinical routine. In contrast, high-resolution detection of CNVs in a research setting may help identify novel genes in which mutations (deletions as well as point mutations) lead to male infertility, for which the gene *TEX11* is a recent example (see below).

---

## Single-Gene Defects

Mutations of some (few) genes have been well established as causes for specific diseases associated with male infertility. However, the large majority of infertile men does not fall into this category and causative mutations in men with isolated spermatogenic failure have long been sought for.

---

## Congenital Absence of the Vas Deferens (CBAVD)

Patients with obstructive azoospermia are candidates for genetic testing of mutations of the Cystic Fibrosis Transmembrane conductance Regulator (*CFTR*) gene. Homozygous or compound heterozygous mutations of this gene are well known to cause autosomal-recessive cystic fibrosis (CF) which comprises severe lung and pancreas problems as leading symptoms. Nearly all men with full clinical CF are also affected by Congenital Absence of the Vas Deferens (CBAVD) and, thus, exhibit obstructive azoospermia and are infertile. However, CBAVD can also occur independently of full CF and is one form of the so-called CF-related disorders. Aside from the effects on other organs (lung, pancreas, etc.), the disruption of *CFTR* protein function leads to a congenital malformation of the Wolffian ducts, which are the precursors of the vas deferens, epididymis, and seminal vesicles during fetal development. Therefore, hypo- or aplasia of the epididymis or seminal vesicles can accompany the absence of the vas deferens.

Both CF and isolated CBAVD are caused by an overlapping but also distinct spectrum of *CFTR* mutations which is highly dependent on the ethnic origin of the patient. CF is regularly caused by two mutations completely abolishing or severely impairing *CFTR* protein function, with a deletion of 3 bp in exon 10, leading to the loss of the amino acid phenylalanine (F508del) being the most common mutation in nearly all populations. In contrast, isolated CBAVD is mostly caused by a combination of one severe and a second milder *CFTR* mutation that only partially disturbs *CFTR* protein function (e.g., most commonly F508del/R117H).

In contrast to men with Y-chromosomal microdeletions, patients with CBAVD exhibit distinct clinical features: azoospermia in conjunction with decreased seminal volume, pH, and markers of epididymis ( $\alpha$ -glucosidase) and seminal vesicles (fructose) in the presence of normal LH, FSH, and testosterone and normal testicular volume. In the majority of men with CBAVD, normal spermatogenesis will be found upon testicular biopsy with histological evaluation/TESE, which also confirms the diagnosis of obstructive azoospermia, and thus these men have a high chance to conceive a child by ICSI. However, the risk for the child having CF is increased in comparison with the general population and can be estimated depending on the *CFTR* carrier status of the female partner because CF is inherited in an autosomal recessive manner. The carrier rate (heterozygote frequency) may be as high as 5% in the Caucasian population. Hence, *CFTR* mutational analysis is usually not only indicated in the men with CBAVD but also his partner before testicular biopsy/TESE and IVF therapy. Current recommendations include a two-step approach to genetic testing of suspected CBAVD cases: first, frequent mutations are analyzed (usually by a commercial kit) and afterwards full sequence analysis is performed if only one or no mutations were found. Depending on the extent of analytic technologies used, the detection rate of two mutated *CFTR* alleles in men with CBAVD has been reported to be around 80% and in about an additional 10% only one mutated allele can be identified (Ratbi et al. 2007). *CFTR* mutations have also been described in men with unilateral absence of the vas deference (CUAVD) and in patients with oligo-/azoospermia without clinical features of obstruction, but the published data are not consistent.

Very recently, mutations of the X-linked gene *ADGRG2* have been described to also cause CBAVD (Patat et al. 2016). Truncating mutations of *ADGRG2* were identified in about 15% of men with CBAVD in whom *CFTR* analysis was negative. Although this is currently the only study on this gene, sequence analysis of *ADGRG2* will very likely be embedded in the routine genetic analyses of men with CBAVD soon, because it will allow for appropriate genetic counseling with regard to the X-linked transmission of the molecular defect.

---

## Hypogonadotropic Hypogonadism

Congenital Hypogonadotropic Hypogonadism (CHH, also “Idiopathic” or “Isolated” HH (IHH)) is characterized by low gonadotropin levels leading to a lack of sex steroid production and consequently no or incomplete pubertal development and anovulation in females/no spermatogenesis in males. Circulating LH and FSH levels

are either undetectable or very low, resulting from a defect in the normal pulsatile secretion pattern of GnRH from the hypothalamus or impaired GnRH action. Clinically, CHH can present in conjunction with many other symptoms including cleft lip and/or palate, dental agenesis, renal agenesis, digit malformations, and synkinesia. A distinctive feature is a normal sense of smell (in about 40% of cases) or an impaired sense of smell (anosmia, in about 60% of cases), the latter being the hallmark of Kallmann syndrome.

The primary anatomic defect of Kallmann syndrome, identified in 1989, is the agenesis of the bulbous olfactorius with associated failure of the GnRH neurons to migrate from the olfactory epithelium to the hypothalamus. The first gene identified to be responsible for this phenotype was denominated *KAL1* (the official gene symbol is *ANOS1*) that encodes the extracellular matrix protein anosmin 1. Successively, many more genes were found to be associated with CHH with or without anosmia (Table 2), such as the GnRH receptor gene (*GNRHR*), the fibroblast growth factor receptor 1 gene (*FGFR1*) (involved in the formation of the olfactory bulb and responsible for the autosomal dominant form of the Kallmann syndrome), the KISS1 receptor gene (*KISS1R*, formerly G protein-coupled receptor 54, *GPR54*), the prokineticin 2 gene (*PROK2*) and its receptor (*PROKR2*), and the fibroblast growth factor 8 gene (*FGF8*). Mutations of *GNRHR*, *GNRH1*, *KISS1R*, *TAC3*, and *TACR3* genes are found in CHH patients without anosmia, while mutations of *KAL1*, *PROK2*, and *PROKR2* are usually associated with reduction of the sense of smell suggesting a role for these genes in olfactory bulb formation. All other currently known genes (*FGFR1*, *CHD7*, *FGF8*, *NSMF*, *WDR11*, *HS6ST1*, and *SEMA3A*) are variably associated with impaired sense of smell.

Mutations of the above-mentioned genes have been described in several families and show variable penetrance, with cases of full clinical CHH, but also isolated anosmia or only delayed puberty within the same family. Interestingly, mutations of the *FGF8* gene have been found also in cases of acquired (adult-onset) hypogonadotropic hypogonadism. The growing family of genes involved in GnRH neuron migration and function and the expanding phenotypic expression of mutations thereof suggest that the distinction between Kallmann syndrome, isolated anosmia, normosmic CHH, delayed puberty, and acquired HH is probably arbitrary. Indeed, these clinical pictures are often present in various combinations within families carrying the same mutation. In addition, it has been shown that CHH and Kallmann syndrome can spontaneously revert in about 10% of patients upon discontinuation of treatment.

The search for mutations of the genes associated with CHH (with or without anosmia) requires direct gene sequencing. Initially, to keep time and resources low, it was tried to limit the number of genes to be screened by careful definition of the full spectrum of clinical symptoms, identification of the familial cases, and definition of the pattern of inheritance (autosomal-dominant, autosomal-recessive, or X-linked). However, with the advent of next-generation sequencing (NGS) technology, targeted sequencing of a panel of all potential genes is now the more cost-efficient laboratory approach. Still, the clinical evaluation needs to go hand in hand with the genetic analyses, because often several variants are identified that would otherwise be

**Table 2** Selected genes mutated in Congenital hypogonadotropic hypogonadism and Kallmann syndrome

Acronym	Name	Location	OMIM	Function
<i>KALI</i> ( <i>ANOS1</i> )	Kallmann syndrome 1 sequence (anosmin 1)	Xp22.32	300836	Neural cell adhesion and axonal migration
<i>FGFR1</i>	Fibroblast growth factor receptor 1	8p11.2-p11.1	136350	Binds both acidic and basic fibroblast growth factors
<i>PROKR2</i>	Prokineticin receptor 2	20p12.3	607123	G protein-coupled receptor for prokineticins
<i>PROK2</i>	Prokineticin 2	3p13	607002	Chemoattractant for neuronal precursor cells in the olfactory bulb
<i>CHD7</i>	Chromodomain helicase DNA binding protein 7	8q12.2	608892	Expressed in undifferentiated neuroepithelium and in mesenchyme of neural crest origin
<i>FGF8</i>	Fibroblast growth factor 8	10q24	600483	Member of the fibroblast growth factor (FGF) family involved in organogenesis
<i>GNRHR</i>	Gonadotropin-releasing hormone receptor	4q21.2	138850	Receptor for the gonadotropin releasing hormone
<i>GNRH1</i>	Gonadotropin-releasing hormone 1	8p21.2	152760	Ligand for gonadotropin releasing hormone receptor
<i>KISS1R</i> ( <i>GPR54</i> )	KISS1 receptor (G protein-coupled receptor 54)	19p13.3	604161	Receptor for Kiss-1: stimulation of GnRH secretion
<i>KISS1</i>	KiSS-1 metastasis-suppressor (metastin)	1q32	603286	Ligand of KISS1R: stimulation of GnRH secretion
<i>NSMF</i> ( <i>NELF</i> )	NMDA receptor synaptonuclear signaling and neuronal migration factor (nasal embryonic LHRH factor)	9q34.3	608137	Guidance molecule for olfactory axon projections
<i>TAC3</i>	Tachykinin 3 (Neurokinin B)	12q13-q21	162330	Probably involved in hypothalamic GnRH release
<i>TACR3</i>	Tachykinin 3 (Neurokinin B) receptor	4q25	162332	
<i>WDR11</i>	WD repeat-containing protein 11	10q26.12	606417	Putative function in olfactory GnRH neurons
<i>HS6ST1</i>	Heparan sulfate 6-O-Sulfotransferase 1	2q14.3	604846	Regulates neural branching in concert with other genes (e.g. <i>KALI</i> )
<i>SEMA3A</i>	Semaphorin 3A	7q21.11	603961	Putative function in neuronal migration

difficult to interpret concerning their pathogenicity. Comprehensive sequencing of larger numbers of the above-mentioned genes (and not stopping when one mutation of one gene was identified) has led to the notion that CHH is in a not small fraction of cases caused by more than one mutation of one gene, i.e., establishing a oligogenic causes of the disease. Overall, causal mutations are still only found in about 40% of cases although more than 20 genes have now been identified to be associated with CHH (Vezzoli et al. 2016). Thus, numerous others so far unidentified genes or other mechanisms (e.g., epigenetic regulation) remain to be described in the pathogenesis of CHH.

Aside from “isolated” CHH, several syndromes are associated with hypogonadotropic hypogonadism. Examples are Prader-Willi syndrome (caused by a loss of paternal 15q11.2), combined pituitary hormone deficiency (caused by mutations of *PROPI*, *HESX1*, or *LHX3*), obesity syndromes (caused by mutation of *PCSK1*, *LEP*, or *LEPR*), Bardet-Biedl syndrome (caused by mutations in at least 16 genes), and X-linked adrenal hypoplasia congenital (caused by mutation of *DAX1*). Because of their additional, usually severe symptoms, these syndromes are usually diagnosed much earlier than isolated CHH and warrant the specific genetic analyses.

---

## Disorders of Androgen Action

Mutations in the X-linked Androgen Receptor (*AR*) gene cause a wide spectrum of androgen insensitivity syndromes (AIS). Depending on the functional impact on the receptor, mutations may lead to complete androgen insensitivity (CAIS) with a female phenotype in karyotypic males, partial forms (PAIS) in patients with ambiguous genitalia, or mild forms (MAIS) in men with hypospadias, gynecomastia, and spermatogenic impairment. However, mutations in the *AR* gene seem to be a rare cause of isolated male infertility as only few cases have been described although rather large sequencing studies have been performed. Therefore, *AR* gene sequencing is currently not warranted in isolated male infertility, but only in patients with additional symptoms, e.g., severe hypospadias.

The *AR* gene contains a CAG-repeat in exon 1 encoding a polyglutamine stretch in the AR protein. If expanded to or above 38 CAG-repeats, this expansion causes X-linked recessive Spinal and Bulbar Muscular Atrophy (SBMA, also known as Kennedy’s disease). SBMA occurs only in males and is characterized by a gradually progressive neuromuscular disorder in which degeneration of lower motor neurons results in muscle weakness, muscle atrophy, and fasciculations. Affected individuals additionally often show gynecomastia, testicular atrophy, and reduced fertility as a result of mild androgen insensitivity.

According to in vitro as well as a number of clinical studies, the CAG-repeat in the *AR* gene also modulates the activity of the receptor protein in the normal range (9–34 repeats, median ~21/22 repeats in the European population and significantly different, e.g., in Africans [shorter] and Asians [longer]). Overall, longer CAG-repeats encode a less active androgen receptor, i.e., the same amount of



circulating testosterone will have less effect. Therefore, determining the specific length of the *AR*-CAG-repeat in hypogonadal men receiving testosterone substitution may help titrate the individual dosage in a pharmacogenetic approach (Zitzmann 2009). In addition, men with symptoms of hypogonadism and borderline testosterone serum levels may be eligible for testosterone treatment if they carry a long *AR*-CAG-repeat (leading to a less active receptor).

Many studies have sought for an association between the *AR*-CAG-repeat length and male infertility. However, although meta-analysis has shown a significant difference between CAG-repeat length of infertile patients and controls, this difference comes down to about one half CAG-repeat between these two groups, which has no clinical implication at all (Davis-Dao et al. 2007). Thus, the analysis of the *AR*-CAG-repeat in infertile men is not warranted.

---

## Specific Defects of Spermatozoa

Monomorphic sperm defects are rare but will be caused in the large majority by genetic defects. The two distinctive forms of morphological defects in which some genetic causes have been identified so far relate to the correct formation of the acrosome and the construction of the sperm tail. Globozoospermia is characterized by round headed spermatozoa lacking the acrosome. This rare form of teratozoospermia can be caused by mutations in the *SPATA16* or *DPY19L2* genes (both described as autosomal-recessive disorders) and probably many other so far unknown genetic defects.

Primary Ciliary Dyskinesia (PCD) is caused by abnormal ciliary structure and function resulting in highly variable symptoms like situs abnormalities (situs inversus), chronic otosinopulmonary disease, and also abnormal sperm motility. While “full” PCD is a severe, multiorgan disease often comprising male infertility due to reduced or absent sperm motility, milder forms may cause isolated sperm motility defects. PCD is a highly heterogeneous disease and can be caused by mutations in *DNAH5*, *DNAH11*, *CCDC39*, *DNAI1*, *CCDC40*, *CCDC103*, *SPAG1*, *ZMYND10*, *ARMC4*, *CCDC151*, *DNAI2*, *RSPH1*, *CCDC114*, *RSPH4A*, *DNAAF1*, *DNAAF2*, and *LRRC6*. PCD is invariably inherited in an autosomal-recessive manner. So far, only the minority of PCD genes have been analyzed in isolated male infertility due to immotility of spermatozoa and, thus, the role of mutations in these genes in infertile men remains to be elucidated.

---

## Single-Gene Defects in Isolated Severe Spermatogenic Failure

Over the last few years, many genes have been reported to be mutated in men with severely impaired sperm production exhibiting severe oligozoospermia, cryptozoospermia, or azoospermia without symptoms of obstruction (NOA). However, most of these genes have so far not been replicated in independent studies and their role currently remains unclear. Exceptions are *NR5A1* and *DMRT1* which are

involved in gonadal development and in which mutations have been known for a longer time to cause gonadal dysgenesis and disorders of sexual development (DSD). Milder (missense) mutations in these two genes have now also been described in men with isolated spermatogenic failure, i.e., NOA or severe oligozoospermia. Mutations in the *TEX11* have very recently been identified as first common X-linked cause of meiotic arrest (a specific form of NOA) in about 15% of men with this phenotype (Yatsenko et al. 2015).

---

## Genetic Syndromes Associated with Male Infertility

Many complex genetic (syndromic) diseases are associated with some form of male infertility. These diseases, of which some are summarized in Table 3, are usually diagnosed early in life. If fertility evaluation is required, the preexisting diagnosis needs to be taken into account to prevent unnecessary examinations. Hemochromatosis and Myotonic Dystrophy Type 1 are mentioned specifically as both are rather common genetic diseases also causing male infertility.

Autosomal-recessive hemochromatosis is caused by mutations in the *HFE* gene and characterized by inappropriately high absorption of iron by the gastrointestinal mucosa leading to excessive storage of iron in the liver, skin, pancreas, heart, joints, and testes. Untreated individuals may exhibit progressive increase in skin pigmentation, diabetes mellitus, congestive heart failure, and/or arrhythmias, arthritis, and hypogonadism including testosterone deficiency and oligo-/azoospermia.

Autosomal-dominant myotonic dystrophy type 1 is caused by an expansion of a CTG-repeat at the 3'-end of the *DMPK* gene. Myotonic dystrophy is a multisystem disorder that affects skeletal and smooth muscle as well as the eye, heart, endocrine system, and central nervous system. The clinical findings span a continuum from mild to severe and include male infertility due to testicular atrophy and oligo-/azoospermia.

---

## Outlook

For many years, single candidate genes have been evaluated with the goal of identifying causal mutations for spermatogenic failure and usually genotyping SNPs or direct sequencing has been used. However, most of these approaches were not very successful most probably because (1) “male infertility” as well as “spermatogenic failure” is genetically highly heterogeneous and (2) selection of patient groups is often not stringent. Conversely, novel genetic technologies now allow unbiased approaches to decipher the underlying causes for specific forms of male infertility. These technologies comprise genome-wide association studies (GWAS), array-CGH, and whole-exome or even genome sequencing. These novel methodologies easily outperform the previous candidate gene approaches, which is illustrated by an increasing number of recent publications identifying genetic defects causing spermatogenic failure, of which some examples have been mentioned

**Table 3** Selection of rare complex genetic syndromes that can include male infertility as symptom

Syndrome	OMIM	Symptoms	Gene
Aarskog-Scott syndrome	305400	Hypertelorism, short stature, clinodactyly, <b>cryptorchidism</b>	<i>FGD1</i>
Noonan syndrome	163950	Short stature, epicanthus, ptosis, heart defects, mental retardation, <b>cryptorchidism</b>	<i>PTPN11</i> , <i>KRAS</i> , <i>RAF1</i> , <i>NRAS</i> , etc.
LEOPARD syndrome	151100	Acronym for: lentigines, EKG abnormalities, hypertelorism, obstructive cardiomyopathy, pulmonic stenosis, abnormalities of genitalia ( <b>hypospadias</b> , <b>cryptorchidism</b> ), retardation of growth, deafness	
Autoimmune polyendocrinopathy syndrome type I	240300	Adrenale insufficiency, hypoparathyroidism, diabetes, candida infections, <b>hypogonadism</b>	<i>AIRE</i>
Popliteal pterygium syndrome	119500	Cleft lip/palate, popliteal pterygium, <b>bifid scrotum</b> , <b>cryptorchidism</b> , <b>testicular atrophy</b>	<i>IRF6</i>
Werner syndrome	277700	Short stature, cataracts, premature aging, <b>hypogonadism</b>	<i>RECQL2</i>
Rothmund-Thomson syndrome	268400	Cataracts, poikiloderma, short stature, <b>cryptorchidism</b>	<i>RECQL4</i>
Ataxia-telangiectasia	208900	Short stature, telangiectasia, cerebellar ataxia, lymphoma, <b>hypogonadism</b> , <b>spermatogenic impairment</b>	<i>ATM</i>
Progressive external ophthalmoplegia with mitochondrial DNA deletions-1	157640	Ptosis, hearing loss, muscle weakness, ataxia, <b>testicular atrophy</b>	<i>POLG</i>
Gordon-Holmes syndrome	212840	Cerebellar ataxia, <b>hypogonadotropic hypogonadism</b>	<i>RNF216</i>

above. In the near future, these novel technologies will greatly increase the fraction of infertile men with a specific genetic diagnosis.

## Summary

Depending on the clinical findings, the infertile male patient needs genetic evaluation: Karyotype analysis should be performed in patients with oligo- or azoospermia to rule out structural chromosomal abnormalities and Klinefelter syndrome. Severe oligozoospermia and azoospermia indicate Y chromosome microdeletion screening. Men with obstructive azoospermia need careful analysis of the *CFTR*-gene. Mutation screening should be performed in patients with CHH and other syndromic forms

of male infertility. In the near future, men with severe spermatogenic failure (firstly NOA) may be evaluated by targeted sequencing of a panel of genes. All positive genetic analyses should be accompanied by expert genetic counseling.

---

## Cross-References

- ▶ [Genetic Analysis in Male Infertility](#)
- ▶ [Pre-Testicular, Testicular, and Post-Testicular Causes of Male Infertility](#)
- ▶ [Sex Determination](#)
- ▶ [Male Sexual Differentiation](#)
- ▶ [The Semen Analysis: The Investigation of the Human Ejaculate](#)

---

## References

- Davis-Dao CA, Tuazon ED, Sokol RZ, Cortessis VK. Male infertility and variation in CAG repeat length in the androgen receptor gene: a meta-analysis. *J Clin Endocrinol Metab.* 2007;92:4319–26.
- Krausz C, Hoefsloot L, Simoni M, Tüttelmann F. EAA/EMQN best practice guidelines for molecular diagnosis of Y-chromosomal microdeletions: state-of-the-art 2013. *Andrology.* 2014;2:5–19.
- Lo Giacco D, Chianese C, Ars E, Ruiz-Castañé E, Forti G, Krausz C. Recurrent X chromosome-linked deletions: discovery of new genetic factors in male infertility. *J Med Genet.* 2014;51:340–4.
- Online Mendelian Inheritance in Man (OMIM). <http://omim.org/>
- GeneReviews. Pagon RA, Adam MP, Ardinger HH, et al., editors. Seattle (WA): University of Washington, Seattle; 1993–2016. <https://www.ncbi.nlm.nih.gov/books/NBK1122/>
- Patat O, Pagin A, Siegfried A, Mitchell V, Chassaing N, Faguer S, Monteil L, Gaston V, Bujan L, Courtade-Saïdi M, Marcelli F, Lalau G, Rigot JM, Mieuisset R, Bieth E. Truncating mutations in the adhesion G protein-coupled receptor G2 gene ADGRG2 cause an X-linked congenital bilateral absence of vas deferens. *Am J Hum Genet.* 2016;99:437–42.
- Ratbi I, Legendre M, Niel F, Martin J, Soufir JC, Izard V, Costes B, Costa C, Goossens M, Girodon E. Detection of cystic fibrosis transmembrane conductance regulator (CFTR) gene rearrangements enriches the mutation spectrum in congenital bilateral absence of the vas deferens and impacts on genetic counselling. *Hum Reprod.* 2007;22:1285–91.
- Tüttelmann F, Gromoll J. Novel genetic aspects of Klinefelter's syndrome. *Mol Hum Reprod.* 2010;16:386–95.
- Tüttelmann F, Simoni M, Kliesch S, Ledig S, Dworniczak B, Wieacker P, Röpke A. Copy number variants in patients with severe oligozoospermia and Sertoli-cell-only syndrome. *PLoS One.* 2011;6:e19426.
- Vezzoli V, Duminou P, Bassi I, Guizzardi F, Persani L, Bonomi M. The complex genetic basis of congenital hypogonadotropic hypogonadism. *Minerva Endocrinol.* 2016;41:223–39.
- Yatsenko AN, Georgiadis AP, Röpke A, Berman AJ, Jaffé T, Olszewska M, Westernströer B, Sanfilippo J, Kurpisz M, Rajkovic A, Yatsenko SA, Kliesch S, Schlatt S, Tüttelmann F. X-linked TEX11 mutations, meiotic arrest, and azoospermia in infertile men. *N Engl J Med.* 2015;372:2097–107.
- Zitzmann M. Pharmacogenetics of testosterone replacement therapy. *Pharmacogenomics.* 2009;10:1341–9.

Qian Jiang and Daishu Han

---

## Abstract

Microbial infections and immunological disorders in the male genital system are among the etiological factors of male infertility. The male genital tracts, particularly the testis and epididymis, possess special immunoregulatory mechanisms to protect sperm from immune attacks. However, microbial infections, chemical toxins, and physical trauma may disrupt the immune homeostasis in the male genital tracts and induce local inflammation or autoimmune responses, thereby perturbing fertility. Inflammation in the male genital system is characterized by leukocyte infiltration, increased levels of pro-inflammatory cytokines, and impairment of tissue function. Autoimmune responses to male germ cell antigens may lead to a chronic inflammation in the testis and the generation of antisperm antibodies that impair sperm function. Understanding the mechanisms underlying infectious and immunological infertility can aid in the development of preventive and therapeutic approaches for the disease. This chapter describes the major microbial infections and immunological disorders in the male genital system, as well as their detrimental effects on male fertility.

---

## Keywords

Male infertility • Infection • Inflammation • Antisperm antibody

## Contents

Introduction .....	1052
Microbial Infections in the Male Genital System .....	1054
Bacterial Infection .....	1054
Viral Infection .....	1055

---

Q. Jiang • D. Han (✉)

Department of Cell Biology, Institute of Basic Medical Sciences, Chinese Academy of Medical Sciences, School of Basic Medicine, Peking Union Medical College, Beijing, China  
e-mail: [dshan@ibms.pumc.edu.cn](mailto:dshan@ibms.pumc.edu.cn)

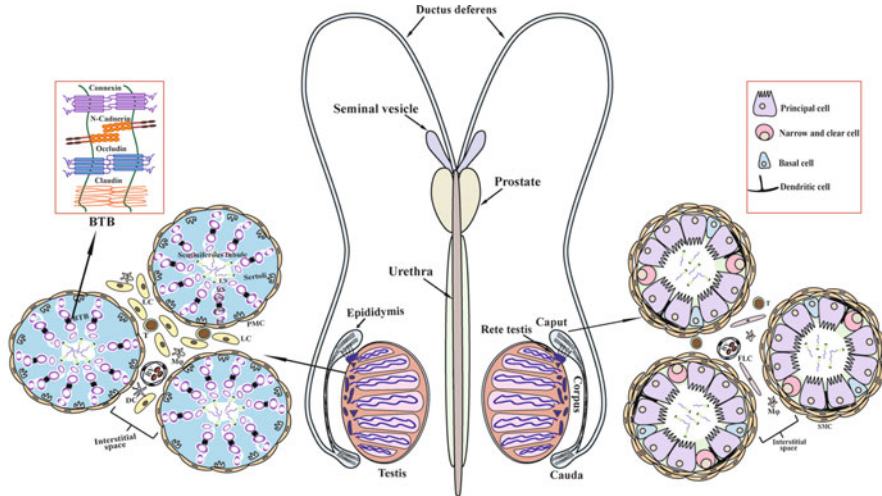
Protozoan Infection .....	1057
Immunological Components in the Testis .....	1058
Immune Privilege in the Testis .....	1058
Testicular Innate Immune System .....	1059
Orchitis and Male Infertility .....	1061
Immunity in the Epididymis .....	1061
Immunoregulation in the Epididymis .....	1062
Epididymitis .....	1063
Prostatitis .....	1063
Urethritis .....	1064
Autoimmunity in Male Infertility .....	1064
Autoimmune Orchitis .....	1064
Antisperm Antibodies in Infertility .....	1065
Conclusions .....	1066
References .....	1067

---

## Introduction

Human infertility, which is defined as the failure of pregnancy within 1 year of unprotected coitus, affects approximately 15% of couples of reproductive age worldwide. Male factors contribute up to 45% of infertility cases. Various conditions, such as congenital malformations, environmental factors, genetic aberrations, endocrinological disorders, and immunological disorders, may lead to male infertility. Immune responses to microbial infections and endogenous stimuli in the genital system (Fig. 1) can cause local inflammation, including orchitis, epididymitis, prostatitis, urethritis, and autoimmune reaction to male germ cells. Immunological disorders are responsible for about 10% of male infertility in developed countries (Bachir and Jarvi 2014). Notably, the incidence of immunological infertility can be considerably higher in developing countries where medical care and environmental conditions are poor. Inflammation in different organs of the male genital system can be induced by the infections of numerous microbial pathogens types and the regulation of local immune responses. This chapter will summarize the microbial infections and immunoregulation in the male genital system, and their associations with male infertility.

A large spectrum of microorganisms, including bacteria, viruses, and protozoa, may cause inflammation of the male genital system, thereby impairing male fertility. The World Health Organization has estimated that the microbial infections in the male genital system represent about 3% of men globally (AbouZahr and Vaughan 2000). Deleterious impacts of immunological disorders in different sites of the male genital system on male fertility can be greatly varied. Among inflammatory diseases in the male genital system, epididymitis and orchitis may severely impair fertility because the involved organs are critical sites for normal spermatogenesis and sperm function. Moreover, the epithelia of the epididymis and testis are not regenerative and can be permanently damaged by inflammatory conditions. Epididymitis is more common than orchitis. Most orchitis cases occur with epididymitis and are diagnosed as epididymo-orchitis, whereas isolated orchitis is rare. These phenomena are



**Fig. 1** Schematic of the topography of the male genital system (*middle panel*) and histological structures of the testis (*left panel*) and the epididymis (*right panel*). The male genital system is mainly composed of the testis and the epididymis, two reproductive glands where sperm are produced and matured, respectively. The testis is histologically composed of two distinct compartments: seminiferous tubules and interstitial spaces. The seminiferous tubules are surrounded by peritubular myoid cells (PMCs) and lined by the seminiferous epithelium containing columnar Sertoli cells that embrace different stages of germ cells, including spermatogonia (Sg), primary spermatocytes (PSc), secondary spermatocytes (SSc), round spermatids (RS), and elongating spermatids (ES). The blood-testis barrier (BTB), which is located between PSc and SSc, is found by various junctions of two adjacent Sertoli cells. The interstitial spaces in the testis contain Leydig cells (LC) and certain immune cells, including mainly macrophages (M $\phi$ ), as well as minor T lymphocytes, and dendritic cells (DCs). Blood vessels (BV) are distributed in the interstitial spaces. The epididymis is divided into three segments, including caput, corpus, and cauda. The caput epididymis is connected with the testis by the rete testis. The epididymis comprises a single coiled epididymal tubule and the interstitial spaces. The epididymal tubule is surrounded by a layer of smooth muscle cells (SMC) and lined by a pseudostratified epithelium that is composed of principal cells, narrow cells, clear cells, and basal cells. Certain DCs locate in the basal regions of the epididymal epithelium. The epididymal interstitial spaces contain BV, M $\phi$ , T cells, and certain fibroblast-like cells (FLC). The cauda epididymis is connected by the ductus deferens and followed by the urethra. The seminal vesicles and prostates attach to the ductus deferens and produce nutritional fluid to help sperm movement and contribute the volume of the ejaculate

caused by different immunoregulation and infectious pathways in the two organs. Noninfectious inflammation in the testis and epididymis can also be caused by chemical toxins and physical trauma, which frequently lead to chronic inflammation and are usually associated with male infertility (Haidl et al. 2008; Schuppe et al. 2008). Autoimmune responses to germ cell antigens may cause autoimmune orchitis and the generation of antisperm antibodies. Although autoimmune orchitis is rare in human beings, antisperm antibodies are highly associated with male infertility.

Other male genital tract sites, such as the prostate and the urethra, can be infected by microorganisms, thereby resulting in prostatitis and urethritis. Although

inflammatory conditions in these sites unlikely impair spermatogenesis, the conditions may affect semen parameters and damage genital tract structure, thereby perturbing male fertility. The inflammatory conditions in these sites and their deleterious effects on male fertility will also be mentioned in this chapter.

---

## Microbial Infections in the Male Genital System

Numerous microbial pathogens can infect the male genital system and perturb organ functions, thus impairing male fertility. Microbial infections are organ dependent in the genital system. Ascending bacterial infections predominantly infect the urethra, epididymis, and prostate, but the testis is mostly infected by viruses arriving from the circulation pathway. These organs are generally susceptible to infectious attacks. Microbial infections may perturb organ functions and sperm parameters by inducing local inflammation and the direct noxious effects to sperms.

### Bacterial Infection

Bacterial species that infect the male genital system and their relevance to male infertility vary according to age distribution. Sexually transmitted bacteria, mainly *Chlamydia trachomatis* and *Neisseria gonorrhoeae*, predominantly infect the genital system of men younger than 35 years old, whereas enteric *E. coli* is usually implicated in older men.

*C. trachomatis* represents the most common sexually transmitted bacterial infection worldwide. Although *C. trachomatis* infection may lead to female infertility because of inflammatory tubal obstruction, the influence of the infection on male infertility is debated. Guidelines for screening male infertility from *C. trachomatis* infection are not available. However, *C. trachomatis* infection evidently causes urethritis, epididymitis, epididymo-orchitis, and prostatitis, which are supposed to impair male fertility (Cunningham and Beagley 2008). In addition, *C. trachomatis* may directly induce sperm apoptosis, thus altering sperm parameters. *C. trachomatis* infection reduces sperm concentration, mobility, and viability. *C. trachomatis* infection has been observed in 4.3% of infertile men compared with 1.4% of fertile men. Notably, approximately 50% of *C. trachomatis* infections do not result in any symptom. The silent *C. trachomatis* infection can be sexually transmitted to the partner, mostly from male to female. Therefore, when discussing the detrimental effect of *C. trachomatis* infection on male fertility, transmission to their female partners should also be considered.

Along with *C. trachomatis*, *N. gonorrhoeae* represents another prevalent sexually transmitted bacterial pathogen (Domes et al. 2012). *N. gonorrhoeae* predominantly infects the female cervix or male urethra and results in cervicitis or urethritis. Approximately half of individuals infected by *N. gonorrhoeae* do not show symptomatic inflammation. Similarly to *C. trachomatis* infection, the transmission of



*N. gonorrhoeae* more frequently occurs from male to female. *N. gonorrhoeae* infection in men usually causes urethritis and occasionally leads to epididymo-orchitis. These conditions may result in urethral structure damage or obstruction, thereby reducing male fertility. *N. gonorrhoeae* infection is more relevant in male infertility than *C. trachomatis* infection. However, *N. gonorrhoeae* infection is poorly studied with respect to male infertility despite several reports showing its deleterious effect on fertility (Ochsendorf 2008). *N. gonorrhoeae* infection does not induce protective immune responses because of the antigenic variation of bacterial surface molecules and the active suppression of the adaptive immune responses by pathogens. *N. gonorrhoeae* infection induces innate immune responses in host cells through the activation of toll-like receptor 2 (TLR2) and TLR4. However, *N. gonorrhoeae* inhibits adaptive immune responses through the interaction with host antigen-presenting cells. Moreover, *N. gonorrhoeae* induces IL-10 production and Th1 cell response, thus suppressing adaptive immunity (Liu et al. 2014). Further understanding of the mechanism by which *N. gonorrhoeae* suppresses immune responses may provide novel clues for developing therapeutic approaches against *N. gonorrhoeae* infection.

In addition to *C. trachomatis* and *N. gonorrhoeae*, several other sexually transmitted bacteria are able to infect the genital tract and perturb fertility. *Mycoplasma genitalium* and *Mycoplasma hominis* colonize the male genital tract without showing any symptom. These *Mycoplasma* species are associated with female genital pathogenesis (Gdoura et al. 2008). Asymptomatic colonization of *Mycoplasma* in male genital tract is speculated to impair fertility through the transmission of pathogens to female partners. *Ureaplasma urealyticum* is frequently isolated from the genital tract of infertile men and may result in urethritis. However, the harmful effects of *U. urealyticum* on male fertility remain unclear.

## Viral Infection

Viral infections of the male genital system is of considerable concern not only because of their detrimental effects on tissue functions and male fertility but also the possibilities of pathogen transmission to sexual partners and fetus (Dejuqc and Jegou 2001). Various viruses are able to infect the male genital tract and semen in humans and seriously impair fertility.

The mumps virus (MuV) is the most well-known virus that causes male infertility. MuV infection leads to orchitis in up to 40% of pubertal and postpubertal men, thus impairing androgen production and male fertility. Approximately 50% of patients with mumps orchitis eventually develop testicular atrophy because of the deposition of collagen within the interstitium. MuV orchitis may result in transient or permanent infertility because of germ cell degeneration. However, MuV does not directly damage germ cells in vitro. Several indirect effects may be involved in the MuV-impaired fertility: (1) the most common hypothesis is that the high fever of patients may change testicular temperature, which leads to germ cell death,

(2) decrease in testosterone synthesis in mumps orchitis patients should impair germ cell development, and (3) pro-inflammatory cytokine production by Leydig and Sertoli cells in response to MuV infection may impair testicular functions (Wu et al. 2016). The mechanisms underlying the MuV-caused infertility deserve further investigation because of a global resurgence of mumps orchitis recently (Davis et al. 2010). Notably, MuV can replicate in the testis, and IFN treatment reduces the testicular damage by MuV orchitis (Ku et al. 1999). MuV replication and innate anti-MuV responses in testicular cells are worth clarifying.

Human immunodeficiency virus (HIV) infection significantly affects male fertility. Endocrine and testicular dysfunctions are observed in men infected with HIV-1. Acquired immune deficiency syndrome (AIDS) patients often suffer from orchitis, endocrine disorder, oligozoospermia, or azoospermia depending on the stage of the disease (Poretsky et al. 1995). The first study on the testis histology in AIDS patients found interstitial inflammation in 53% of cases and a high incidence of “Sertoli cell only” symptom (Chabon et al. 1987). The reduced testosterone level is common in AIDS patients, probably resulting from leukocyte infiltrations and decreased Leydig cell numbers. HIV may also indirectly impair testosterone synthesis via the perturbation of the hypothalamic-pituitary-gonad axis because HIV infection reduces the hypothalamic gonadotropin-releasing hormone that is indirectly necessary for testosterone production. Moreover, certain HIV-induced pro-inflammatory cytokines are able to suppress testosterone synthesis. HIV may also directly impair testicular function because the virus can invade into the testis. HIV is speculated to invade into the testis via the migration of lymphocytes and macrophages carrying virus. Notably, HIV-1 DNA has been detected in male germ cells of the AIDS patients (Muciaccia et al. 1998). The mechanism by which HIV infects germ cells remains unclear because CD4 receptor has yet to be detected on the germ cell surface. HIV infection in male germ cells suggests that these cells are possible hidden viral reservoirs because they are isolated by the blood-testis-barrier (BTB) that restricts the access of antiviral antibodies and therapeutic drugs. Intercourse is one of the major HIV transmission pathways, and semen is the main vector of transmission. HIV can reside in semen as free virions, sperm-associated virions, and virion-carrying leukocytes. The presence of HIV in semen also suggests that HIV may replicate in the genital tract. An increase in the semen/blood ratios of several pro-inflammatory cytokines and chemokines, such as IL-1 $\beta$ , IL-6, and MCP-1, in HIV-infected men indicates that innate immune responses occur in the genital tract, which should be induced by local HIV infection. The mechanisms underlying HIV-induced innate immune responses in the genital tract should be investigated further.

Herpes simplex viruses (HSV), including HSV-1 and HSV-2, are the most common viruses in humans. Although two types of HSV have been detected in semen, only HSV-2 causes genital herpes, whereas HSV-1 predominantly causes oral sores. HSV DNA can be detected in human spermatozoa. The association between the presence of HSV in the semen and male infertility is debated. HSV DNA has been detected in the semen of fertile and infertile men without significant difference. However, HSV-1 inoculation in mice irreversibly damages

spermatogenesis (Malolina et al. 2014), and an accumulation of HSV-1 thymidine kinase in the spermatids of transgenic rats results in male infertility because of spermatogenic disruption (Cai et al. 2009). Notably, evidence that HSV infection impairs spermatogenesis in men is missing. These observations suggest that different responses to HSV-1 infection should be induced in the human and murine testes, and the underlying mechanisms are worth clarification.

The effects of hepatitis B virus (HBV) and hepatitis C virus (HCV) infections on male fertility have been investigated (Bachir and Jarvi 2014). HBV and HCV may impair male fertility via various mechanisms. HBV and HCV have been detected in the testis of infected men, suggesting that viruses may induce testicular immune response and perturb spermatogenesis. HBV or HCV infections also impair sperm motility, morphology, and counts. Sperm exposed to HBV or HCV suffer from oxidative stress. Therefore, HBV and HCV infections in men can impair sperm quality at multiple levels. Screening tests for HBV and HCV in infertile men can aid in further understanding the associations between HBV/HCV infections and male infertility.

## Protozoan Infection

Protozoan infection of the male genital system is relatively rare compared with bacteria and viruses. The presence of several species of parasites in the male genital tract and their effects on male fertility have been recently reviewed (Nourollahpour Shiadeh et al. 2016). *Trichomonas vaginalis* is the most common sexually transmitted parasite (McClelland 2008). The pathogenesis of *T. vaginalis* infection has been investigated in female vaginal epithelium. The parasite induces the expression of pro-inflammatory cytokines that promote leukocyte infiltration. The effect of *T. vaginalis* infection on the male genital system is largely unknown because most of the infections in males are asymptomatic. Only a minority of *T. vaginalis* infections in men can be diagnosed and treated. Therefore, *T. vaginalis* infection may persist and lead to male infertility. In men with symptomatic infections, *T. vaginalis* is able to induce epididymo-orchitis, prostatitis, and urethritis. *T. vaginalis* has been detected more often in infertile men than fertile controls. The production of pro-inflammatory cytokines from *T. vaginalis* infection may impair male fertility. Screening of *T. vaginalis* in infertile men can aid in elucidating the effect of the parasite on male fertility.

*Toxoplasma gondii* is a globally widespread intracellular protozoan parasite that infects animals and humans (Dubey and Jones 2008). *T. gondii* infection impairs testicular function and male fertility. Experimentally acute *T. gondii* infection in rodents results in *T. gondii* tachyzoite invasion into the testis and induces germ cell apoptosis. However, evidence that *T. gondii* infects the human testis is missing. Although several reports showed the association between *T. gondii* infection and impairment of male infertility, the underlying mechanisms remain to be clarified.

## Immunological Components in the Testis

The mammalian testis requires a special immune microenvironment that is composed of immunoprivileged status and local innate defense system (Zhao et al. 2014). The testicular immune environment must be tightly controlled to maintain homeostasis, which is essential for testicular functions. The immune homeostasis in the testis can be disrupted under certain pathological conditions, thereby resulting in orchitis to impair male fertility. Understanding the mechanisms underlying testicular immune privilege and the innate defense system not only provides novel clues to develop therapeutic approaches for immunological disorders in the testis but also may benefit the protection of grafted organs from immune rejection and the induction of tissue-specific defense against microbial infections.

### Immune Privilege in the Testis

Testicular structure, local active immunosuppression, and systemic immune tolerance to autoantigens are cooperatively involved in the maintenance of the testicular immunoprivileged environment (Li et al. 2012). Mammalian testis histologically comprises two functional compartments, namely, the seminiferous tubules and the interstitial spaces (Fig. 1, left). The BTB is formed by adjacent Sertoli cells near the basal lamina of the seminiferous tubules. The barrier functions in maintaining testicular immune privilege by separating the late stages of developing germ cells within the seminiferous tubules from immune components in the interstitial spaces. However, the BTB could not be fully responsible for testicular immune privilege because the interstitial space also displays immunoprivileged properties.

Most studies on the mechanisms underlying the testicular immune privilege have focused on the local immunosuppressive milieu. Several endocrine and paracrine networks comprise the immunosuppressive environment within the testis. Testosterone produced by Leydig cells plays a critical role in normal spermatogenesis and extra-testicular androgen target organs. Notably, testosterone inhibits immune responses to grafts in the testis and favors immunoprivileged status. Testosterone administration inhibits the induction of experimental autoimmune orchitis (EAO) in rats. EAO is an autoimmune orchitis model that can be induced by immunizing rodent animals with testicular antigens (Naito et al. 2012). Testosterone should not directly act on immune cells as these cells do not express its receptor. Mechanisms by which testosterone inhibits testicular immune responses remain therefore to be clarified. Testicular cells produce various anti-inflammatory cytokines. Transforming growth factor  $\beta$  (TGF- $\beta$ ) is produced by Sertoli and Leydig cells. TGF- $\beta$  inhibits immune responses and prolongs the survival of islet grafts in the testis. Activin, a homologue of TGF- $\beta$ , is produced by Sertoli cells and inhibits testicular immune responses (de Kretser et al. 1999). IL-10 is a well-defined anti-inflammatory cytokines. IL-10 is produced by testicular macrophages and inhibits EAO induction (Winnall et al. 2011). The cooperation of these immunosuppressive molecules is important in maintaining testicular immunoprivileged status.

Several immune-negative regulatory systems contribute to the immunoprivileged status in the testis. The Fas/Fas ligand (Fas/FasL) and programmed death receptor-1/programmed death ligand-1 (PD-1/PD-L1) systems are two critical immune tolerance mechanisms through the induction of lymphocyte apoptosis (Green and Ferguson 2001; Keir et al. 2008). An early study showed that FasL is expressed in Sertoli cells and performs a critical function in maintaining the testicular immunoprivileged status (Bellgrau et al. 1995). This concept has been debated because FasL is expressed in male germ cells but not in Sertoli cells (D'Alessio et al. 2001). The function of FasL located on the germ cells remains elusive. PD-L1 is also expressed in male germ cells and contributes to testicular immune privilege (Cheng et al. 2009). Three receptor tyrosine kinases, Tyro3, Axl, and Mer (TAM), as well as their common ligand growth arrest-specific gene 6 (Gas6), inhibit innate immune responses (Lemke and Rothlin 2008). The TAM/Gas6 system plays important role in regulating immune privilege in various organs, including the testis, eye, and brain (Deng et al. 2016). TAM receptors are expressed in Sertoli and Leydig cells, whereas Gas6 is exclusively expressed in Leydig cells. The TAM/Gas6 system promotes phagocytic removal of apoptotic germ cells by Sertoli cells (Xiong et al. 2008). The timely removal of apoptotic germ cells by Sertoli cells prevents endogenous inflammation because damaged male germ cells induce pro-inflammatory cytokine production in Sertoli cells (Zhang et al. 2013b). Moreover, TAM/Gas6 signaling inhibits pattern recognition receptor (PRR)-initiated innate immune responses in Sertoli and Leydig cells (Shang et al. 2011). In accordance with these previous observations, TAM knockout male mice progressively develop autoimmune orchitis (Sun et al. 2010; Zhang et al. 2013a). These studies have demonstrated that the TAM/Gas6 system inhibits the testicular immune responses via different mechanisms.

Although systemic immune tolerance to male germ cell antigens is believed to regulate testicular immune privilege, only a limited number of studies have investigated the function of systemic immune tolerance in maintaining the immunoprivileged status in the testis. Using the EAO model, a recent study showed that Axl and Mer receptors function in regulating systemic immune tolerance to germ cell antigens, as mice lacking Axl and Mer are susceptible to EAO induction (Li et al. 2015). In contrast, TLR2 and TLR4 mediate autoimmune orchitis development because TLR2 and TLR4 knockout mice are resistant to EAO induction (Liu et al. 2015). Notably, TLR2 is critical in mediating the production of autoantibodies against male germ cells. These studies confirmed that systemic immunoregulatory mechanisms are involved in the regulation of testicular immune privilege. Further understanding of the mechanisms underlying testicular immune privilege can aid in the development of preventive and therapeutic approaches for autoimmune orchitis.

## **Testicular Innate Immune System**

Despite being an immunoprivileged organ, the testis can be infected by various microbial pathogens. The local innate immune system functions in testicular defense against microbial infections. Most types of immune cells reside in the testicular

interstitial spaces and function in counteracting microbial infections via circulating blood. In particular, macrophages are the majority of immune cells in the testis and represent about 80% of total testicular leukocytes under physiological conditions. Macrophages are believed to comprise the first line of testicular defense against invading microbes. Macrophages, together with dendritic cells (DCs), are professional antigen-presenting and potent innate immune cells. However, macrophages in the testis display immunosuppressive phenotypes by producing anti-inflammatory cytokines, which favor the testicular immunoprivileged status (Kern et al. 1995). Therefore, whether the testicular macrophages perform critical functions in the immune defense against microbial infections is in question. Other types of immune cells, including DCs, T lymphocytes, mast cells, and natural killer cells, can also be found as a minor number in the interstitial spaces of the testis under physiological conditions. Immune cell numbers are significantly increased under inflammatory conditions and are involved in testicular pathogenesis (Perez et al. 2013).

The testis is composed of various tissue-specific cells, including Leydig, Sertoli, and germ cells (Fig. 1, left panel). A growing body of evidence shows that these testicular cells are well equipped with an innate immune machinery and participate in the innate testicular defense against microbial infections (Zhao et al. 2014). Innate antiviral responses in rat testicular cells were reported about two decades ago (Dejucq et al. 1995). Notably, human Leydig cells exhibit relatively weak antiviral responses in comparison to their rat counterparts, which may explain why certain virus types induce orchitis in human but natural viral orchitis is absent in murine animals. Testicular cells abundantly express a large panel of PRRs, which initiate innate immune responses in the testis (Chen et al. 2016). PRRs constitute a large family of receptors that can be activated by conserved pathogen-associated molecular patterns. PRR activation initiates innate immune response and subsequently regulates adaptive immunity against microbial pathogens (Iwasaki and Medzhitov 2015). Several subfamilies of PRRs, including TLRs, retinoic acid-inducible gene I (RIG-I)-like receptors (RLRs), and cytosolic DNA sensors, have been well characterized (Kumar et al. 2011). Expression and function of TLRs in mouse Sertoli cells were first established, suggesting that Sertoli cells are involved in the testicular innate immune defense against microbial infections. Moreover, mouse Leydig cells constitutively express several TLRs. TLR activation in Leydig cells induces pro-inflammatory cytokine expression and inhibits testosterone synthesis, suggesting that the innate immune responses in testicular cells may impair testicular function (Shang et al. 2011). RLRs contain two functional members, RIG-I and melanoma differentiation-associated protein 5 (MDA5), which recognize viral double-stranded RNA. RIG-I and MDA5 are expressed in mouse Leydig cells and initiate innate antiviral response by inducing the expression of type 1 interferons and antiviral proteins (Zhu et al. 2013). A cytosolic DNA sensor p204 is also expressed in mouse Leydig cells and initiates innate antiviral response to viral DNA stimulation (Zhu et al. 2014). Notably, the activation of RIG-I and MDA5 inhibits testosterone synthesis in Leydig cells, whereas p204 signaling does not perturb

testosterone synthesis. Therefore, the initiation of DNA sensor signaling should be an ideal strategy for inducing testicular antiviral response without impairing testicular function.

## Orchitis and Male Infertility

Sperm production and testosterone synthesis are two key functions of the testis. An immunological homeostasis in the testis is essential for retaining testicular functions. Disruption of the testicular immune homeostasis may result in orchitis, thereby impairing male fertility. Orchitis is predominantly caused by systemic viral infection, ascending bacterial infection, and noninfectious inflammatory stimuli (Schuppe et al. 2008). Retrograde pathogens from the ascending genital tract, including mostly bacteria such as *C. trachomatis* and *E. coli*, usually induce epididymo-orchitis and epididymitis. The isolated orchitis is usually caused by the dissemination of viruses via circulating blood after systemic viral infection. Various noninfectious stimuli, including physical trauma, vasectomy, neoplasia, and autoimmunity, may induce orchitis. Whereas infectious orchitis frequently manifests acute inflammation, non-infectious etiological factors usually cause chronic orchitis. Notably, certain chronic orchitis conditions are asymptomatic. Therefore, the incidence of orchitis in the general male population is underestimated.

Acute orchitis may impair spermatogenesis and testosterone synthesis via various mechanisms. Inflammation-increased pro-inflammatory cytokines, such as TNF- $\alpha$ , IL-6, and IL-1 $\alpha$ , inhibit steroidogenesis in Leydig cells. The high levels of TNF- $\alpha$  and IL-6 directly induce the apoptosis of germ cells. In addition, these cytokines also impair the integrity and function of the BTB, which may lead to autoimmune responses. Given that chronic orchitis is asymptomatic in certain cases, the detrimental effects of chronic orchitis on testicular functions and male fertility remain to be clarified further.

---

## Immunity in the Epididymis

After spermatogenesis is completed in the testis, spermatozoa move into the epididymis for maturation and storage for more than 2 weeks. A tight epididymal immune environment is required for the immune tolerance to spermatozoa and local defense against microbial infections (Guiton et al. 2013). The mechanism underlying the epididymal immunoregulation vary from that in the testis. In fact, epididymitis occurs more frequently in comparison with orchitis. The epididymal structure and local immunoregulation maintain an immune homeostasis in the epididymis, and breakdown of this homeostasis leads to epididymitis, which impairs sperm quality and male fertility.

## Immunoregulation in the Epididymis

The epididymis includes a convoluted epididymal tubule and the interstitial spaces. Morphologically and functionally, the epididymis is divided into three segments, including caput, corpus, and cauda (Fig. 1, right panel). The epididymal tubule is lined by a pseudostratified epithelium that is mainly composed of principal cells and minor basal, narrow, and clear cells, which are surrounded by a peritubular layer of smooth muscle cells. The antigen-presenting cells, including macrophages and DCs, are present in the epididymis. Epididymal macrophages predominantly reside in the interstitial spaces and peritubular regions. A dense network of DCs has been identified in murine epididymis (Da Silva et al. 2011). DCs mainly locate in the basal regions of the epididymal epithelium and extend their processes toward the epididymal lumen. These findings challenge a traditional view that considers the epididymis as an organ that lacks antigen-presenting cells and indicate that the epididymis is active in maintaining immune tolerance to sperm. A few lymphocytes are observed in the interstitium and epithelium of the epididymis (Flickinger et al. 1997). Although immune cells are found in all segments of the epididymis, these cells are more dense and active in the caput epididymis in comparison to the corpus and cauda epididymides. The different distributions of immune cells in the epididymis suggest segment-specific immunological surveillance. The immune responses in the caput epididymis are particularly interesting because the responses may limit the transmission of retrograde pathogens into the testis.

The epididymis has been considered as an immunoprivileged site because it immunologically tolerates sperm. However, epididymis epithelial barrier, which is formed by apical tight junctions between two adjacent principal cells, is not as effective as the BTB. Therefore, the epididymis is more susceptible to inflammatory and autoimmune induction than the testis. Activin A is abundantly expressed in the caput epididymis and inhibits immune response to sperm antigens (Winnall et al. 2013). A large number of defensins, which are short peptides with potent antimicrobial activities, are expressed along the length of the epididymis and participate in epididymal defense against microbial infections (Dorin and Barratt 2014). The epididymal epithelial cells (EECs) express most PRRs, which initiate innate immune responses in EECs. TLR2 and TLR4 initiate innate immune responses to *Staphylococcus aureus* infection in the EECs. TLR4 and TLR5 cooperatively mediate innate immune responses to uropathogenic *E. coli* infection in mouse EECs (Cheng et al. 2016). Viral RNA and DNA analogs induce innate antiviral responses in mouse EECs through the activation of RNA and DNA sensors (Zhu et al. 2015). Given that the epididymal tubule is a single convoluted duct that reaches up to 3 m long in humans and shows segmental differences in immunological events, fine tuning of immunoregulation in the epididymis remains unclear. The mechanisms underlying immune tolerance to sperm antigens and the local innate defense system require further investigation.



## Epididymitis

Epididymitis is the most common intrascrotal inflammation in urological outpatients. Acute epididymitis is mainly caused by retrograde bacterial infections via the ascending urogenital tract. *C. trachomatis*, *N. gonorrhoeae*, and urogenital *E. coli* are major pathogens that induce epididymitis. Chronic epididymitis is usually caused by noninfectious stimuli, such as physical trauma, vasectomy, tumor, vasculitis, and autoimmune involvements. Epididymitis occurs more often than orchitis, and certain cases manifest as epididymo-orchitis. However, the detrimental effects of epididymitis on male fertility have not been extensively studied. The isolated epididymitis generally does not cause male infertility. However, the epididymitis usually impairs sperm parameters and temporarily perturbs sperm quality in most patients (Haidl et al. 2008). Epididymitis can lead to decreased sperm count, impaired motility, or altered sperm morphology. Severe oligozoospermia has been reported in certain cases, which may be caused by a testicular dysfunction because an epididymal infection can be spread to the testis. The detrimental effects of the epididymitis on male fertility are worth further investigation. In this context, animal models of experimental epididymitis have provided valuable insights into pathogenesis.

Bacterial epididymitis of murine animals can be induced by clinically relevant pathogens mimicking the ascending route of retrograde infections. Experimental epididymitis has been used in investigating the pathogenesis and treatments of the disease. Similar to clinical observations in patients, animal epididymitis results in reddening, swelling, and enlargement of the epididymis. Evident leukocyte infiltrations have been observed in the interstitium of experimental epididymitis in rats (Ludwig et al. 2002). Infiltrated leukocytes are mainly lymphocytes and polymorphonuclear neutrophils. In agreement with observations in patients, experimental epididymitis in animals may also affect the testis to elicit epididymo-orchitis, thereby resulting in leukocyte infiltration, loss of germ cells, tubular atrophy, and interstitial fibrosis, in the testis. Notably, bacteria and viruses can induce innate immune responses in EECs, suggesting that these epididymal cells are involved in inflammatory response in the epididymis (Cheng et al. 2016; Zhu et al. 2015). The functions of epididymal tissue-specific cells in the pathogenesis of epididymitis remain to be clarified.

---

## Prostatitis

Prostatitis is inflammation of the prostate gland. The effect of prostatitis on male fertility has been investigated by examining sperm parameters, and the conclusions are largely controversial. An early study in 1991 reported that sperm count, motility, and morphology are not significantly changed in prostatitis patients (Weidner et al. 1991). However, another study in the same year found that sperm concentration and motility are significantly reduced and sperm morphology is altered in the prostatitis

group (Christiansen et al. 1991). Later studies frequently showed the reduction in sperm motility and abnormal morphology in prostatitis patients. In contrast, sperm counts are not apparently different between patients and healthy controls. The discrepant results may be due to different diagnostic criteria and stages of prostatitis. In general, patients with symptomatic chronic prostatitis and pelvic pain syndrome likely present abnormal sperm parameters, whereas asymptomatic prostatitis does not affect sperm parameters. An association between prostatitis and male infertility remains to be clarified. The establishment of accurate diagnostic markers for prostatitis should be helpful in clarifying this issue.

---

## Urethritis

The urethra is a tract through which mature sperm temporarily pass during ejaculation. Although urethritis is frequently caused by sexually transmitted pathogens, impairment of sperm quality is unlikely because sperm is not stored in the urethral environment. However, microbial pathogens may spread from the urethra to the epididymis and testis, thereby leading to epididymitis and epididymo-orchitis, which can impair fertility (Ness et al. 1997). Moreover, chronic urethritis may lead to urethral obstruction, thus resulting in a decrease in ejaculatory volume and impairment of fertility.

---

## Autoimmunity in Male Infertility

The first wave of spermatogenesis is completed in puberty, a long time after the establishment of immune self-tolerance during fetal and neonatal periods. Therefore, most male germ cells produce autoantigens that are strangers to the immune system. These autoantigens are immunologically tolerated in the genital tract under physiological conditions. However, this tolerance can be disrupted under certain pathological conditions, thereby inducing autoimmune responses against germ cell antigens and leading to autoimmune orchitis and antisperm antibody production, which are important etiological factors of male infertility.

## Autoimmune Orchitis

Although the mammalian testis is a remarkable immunoprivileged organ, the testicular immunoprivileged status can be disrupted under certain pathological conditions, such as physical trauma, microbial infections, cryptorchidism, and tumors, thus evoking autoimmune response to germ cell antigens and resulting in autoimmune orchitis (Jacobo et al. 2011). Autoimmune orchitis is characterized by local immune cell recruitment, which is associated with germ cell apoptosis and subsequent male infertility. Autoimmune orchitis is classified into primary isolated autoimmune

orchitis and secondary autoimmune orchitis together with systemic autoimmune diseases, such as systemic lupus erythematosus and chronic rheumatoid arthritis.

The pathomechanisms of autoimmune orchitis have been extensively investigated by using EAO models in rodent animals (Naito et al. 2012). Multiple mechanisms are involved in the pathogenesis of EAO. During EAO progress, circulating macrophages markedly infiltrate into the testis. These macrophages produce a large spectrum of pro-inflammatory cytokines, including TNF- $\alpha$ , IL-6, and IL- $\beta$ . High levels of these cytokines impair testicular functions. Notably, the pro-inflammatory cytokines are produced not only by immune cells but also by tissue-specific cells. PRR-mediated innate immune responses in testicular cells to endogenous and microbial stimuli produce pro-inflammatory cytokines and chemokines. Considering that the tissue-specific cells first encounter invading pathogens and produce immunoregulatory cytokines, the functions of testicular cell-produced cytokines in the pathogenesis of autoimmune orchitis require future research.

### **Antisperm Antibodies in Infertility**

Although sperm is normally protected from the immune responses in the testis and epididymis, antisperm antibodies (ASAs) can be generated in men under specific pathological conditions. In certain instances, a woman's cervical mucus may also develop ASAs to her partner's sperm when the body becomes sensitive to sperm. ASAs have been considered to cause infertility in around 10–30% of infertile couples (Restrepo and Cardona-Maya 2013). A variety of pathological conditions are associated with ASA generation. High levels of ASAs are frequently detected in patients with history of testicular torsion, testicular carcinoma, and vasectomy, as well as infectious orchitis and epididymitis. These conditions can result in tissue damage, thus releasing autoantigens to interact with systemic immune components. ASAs bind to spermatic surface antigens, thereby leading to sperm agglutination, interfering with sperm motility, and inhibiting capacitation and fertilization. Moreover, ASAs may induce spermatic apoptosis and increase phagocytosis of apoptotic sperm by phagocytes.

Sperm antigens are composed of a set of proteins that are distributed in different segments from the head to tail. Several of these antigens include acrosin in the acrosome and heat shock proteins on the surface of the sperm tail. Depending on the sites where ASAs bind, sperm can be affected in different ways. When ASAs bind to the antigens on the tail, sperm may be immobilized or accumulated. ASAs against the antigens of the sperm head interfere with binding between the sperm and the egg, thereby disturbing fertilization. Notably, ASA production, either in the male or female, is not an absolute cause of infertility. ASAs can be found in some men and women with normal fertility. The detrimental effects of ASAs on fertility are graduated, that is, the higher level of ASAs, the lower chance of pregnancy. The mechanisms by which ASAs perturb fertility must require further investigation to establish accurate treatment for each infertile couple caused by ASAs.

ASAs are produced by immune cells after stimulation by antigens on the outer sperm membranes. Sperm antigens induce antibody formation upon meeting immune components in the blood. Under physiological conditions in men, sperm antigens and blood are separated by the BTB to prevent immunologic stimulation. However, when the BTB is broken by certain physical, chemical, or biological attacks, sperm antigens may be released into blood circulation and come in contact with immune cells, thereby stimulating immune cells to produce antisperm antibodies. In the female body, sperm cells are totally foreign invaders and such would normally induce immune responses. However, although exposed to billions of sperm cells during her lifetime, few women develop ASAs. The mechanisms underlying the immunoprotective environment in females are poorly understood. The structure of the vagina has been speculated to provide a physical barricade to protect the sperm from immunologic attack, and semen supposedly contains immunoinhibitory molecules. The precise mechanisms by which sperm escapes from immune responses in the female body remain unclear.

---

## Conclusions

Immunological disorders in the genital system, which can be caused by microbial infections and noninfectious insults, are frequently associated with male infertility or subfertility. Further understanding of the pathomechanisms underlying the microbial infections and inflammation in the genital system is urgently needed for the development of diagnostic and therapeutic approaches for immunological infertility. Several issues should be prioritized in future research. (1) Detection of seminal microorganisms in infertile men does not reflect an infection and inflammation in the genital tract because of potential contamination. New convincing diagnostic approaches for inflammation in the genital system are important in determining immunological infertility. The levels of seminal pro-inflammatory cytokines should be additional criteria for determining inflammation in the male genital tract. (2) Given that the tissue-specific cells of the male genital system express PRRs, the functions of PRR-mediated innate immune responses in local defense against microbial infections remain to be clarified. (3) Major testicular cells significantly produce pro-inflammatory cytokines in response to infections. The roles of testicular cell-produced cytokines in inducing local inflammation are worth further investigation. (4) Abundant FasL is presented on spermatozoa surfaces; whether it functions for escaping from immune attacks in the male and female bodies is an interesting issue. (5) The testis is sensitive to numerous systemic inflammatory diseases. The mechanisms by which the systemic inflammation affects testicular functions should be clarified in future research. Further investigation on these issues will provide novel insights into the mechanisms underlying the immunoprotection and immunopathogenesis in the male genital system.

**Acknowledgments** This work was supported by the National Natural Science Foundation of China (Grant Nos. 31261160491, 31371518) and Major State Basic Research Project of China (Grant Nos. 2015CB943001, 2016YFA0101001).

## References

- AbouZahr C, Vaughan JP. Assessing the burden of sexual and reproductive ill-health: questions regarding the use of disability-adjusted life years. *Bull World Health Organ.* 2000;78:655–66.
- Bachir BG, Jarvi K. Infectious, inflammatory, and immunologic conditions resulting in male infertility. *Urol Clin North Am.* 2014;41:67–81.
- Bellgrau D, Gold D, Selawry H, Moore J, Franzusoff A, Duke RC. A role for CD95 ligand in preventing graft rejection. *Nature.* 1995;377:630–2.
- Cai LY, Kato T, Nakayama M, Susa T, Murakami S, Izumi S, Kato Y. HSV type 1 thymidine kinase protein accumulation in round spermatids induces male infertility by spermatogenesis disruption and apoptotic loss of germ cells. *Reprod Toxicol.* 2009;27:14–21.
- Chabon AB, Stenger RJ, Grabstald H. Histopathology of testis in acquired immune deficiency syndrome. *Urology.* 1987;29:658–63.
- Chen Q, Deng T, Han D. Testicular immunoregulation and spermatogenesis. *Semin Cell Dev Biol.* 2016. doi:10.1016/j.semcdb.2016.01.019.
- Cheng X, Dai H, Wan N, Moore Y, Vankayalapati R, Dai Z. Interaction of programmed death-1 and programmed death-1 ligand-1 contributes to testicular immune privilege. *Transplantation.* 2009;87:1778–86.
- Cheng L, Chen Q, Zhu W, Wu H, Wang Q, Shi L, Zhao X, Han D. Toll-like receptors 4 and 5 cooperatively initiate the innate immune responses to uropathogenic *Escherichia coli* infection in mouse epididymal epithelial cells. *Biol Reprod.* 2016;94:58.
- Christiansen E, Tollefsrud A, Purvis K. Sperm quality in men with chronic abacterial prostatovesiculitis verified by rectal ultrasonography. *Urology.* 1991;38:545–9.
- Cunningham KA, Beagley KW. Male genital tract chlamydial infection: implications for pathology and infertility. *Biol Reprod.* 2008;79:180–9.
- D'Alessio A, Riccioli A, Lauretti P, Padula F, Muciaccia B, De Cesaris P, Filippini A, Nagata S, Ziparo E. Testicular FasL is expressed by sperm cells. *Proc Natl Acad Sci U S A.* 2001;98:3316–21.
- Da Silva N, Cortez-Retamozo V, Reinecker HC, Wildgruber M, Hill E, Brown D, Swirski FK, Pittet MJ, Breton S. A dense network of dendritic cells populates the murine epididymis. *Reproduction.* 2011;141:653–63.
- Davis NF, McGuire BB, Mahon JA, Smyth AE, O'Malley KJ, Fitzpatrick JM. The increasing incidence of mumps orchitis: a comprehensive review. *BJU Int.* 2010;105:1060–5.
- de Kretser DM, Hedger MP, Phillips DJ. Activin A and follistatin: their role in the acute phase reaction and inflammation. *J Endocrinol.* 1999;161:195–8.
- Dejucq N, Jegou B. Viruses in the mammalian male genital tract and their effects on the reproductive system. *Microbiol Molecular Biol Rev.* 2001;65:208–31.
- Dejucq N, Dugast I, Ruffault A, van der Meide PH, Jegou B. Interferon-alpha and -gamma expression in the rat testis. *Endocrinology.* 1995;136:4925–31.
- Deng T, Chen Q, Han D. The roles of TAM receptor tyrosine kinases in the mammalian testis and immunoprivileged sites. *Front Biosci.* 2016;21:316–27.
- Domes T, Lo KC, Grober ED, Mullen JB, Mazzulli T, Jarvi K. The utility and cost of Chlamydia trachomatis and Neisseria gonorrhoeae screening of a male infertility population. *Fertil Steril.* 2012;97:299–305.
- Dorin JR, Barratt CL. Importance of beta-defensins in sperm function. *Mol Hum Reprod.* 2014;20:821–6.
- Dubey JP, Jones JL. *Toxoplasma gondii* infection in humans and animals in the United States. *Int J Parasitol.* 2008;38:1257–78.
- Flickinger CJ, Bush LA, Howards SS, Herr JC. Distribution of leukocytes in the epithelium and interstitium of four regions of the Lewis rat epididymis. *Anat Rec.* 1997;248:380–90.
- Gdoura R, Kchaou W, Ammar-Keskes L, Chakroun N, Sellemi A, Znazen A, Rebai T, Hammami A. Assessment of Chlamydia trachomatis, Ureaplasma urealyticum, Ureaplasma parvum, Mycoplasma hominis, and Mycoplasma genitalium in semen and first void urine specimens of asymptomatic male partners of infertile couples. *J Androl.* 2008;29:198–206.

- Green DR, Ferguson TA. The role of Fas ligand in immune privilege. *Nat Rev Mol Cell Biol.* 2001;2:917–24.
- Guiton R, Henry-Berger J, Drevet JR. The immunobiology of the mammalian epididymis: the black box is now open! *Basic Clin Androl.* 2013;23:8.
- Haidl G, Allam JP, Schuppe HC. Chronic epididymitis: impact on semen parameters and therapeutic options. *Andrologia.* 2008;40:92–6.
- Iwasaki A, Medzhitov R. Control of adaptive immunity by the innate immune system. *Nat Immunol.* 2015;16:343–53.
- Jacobo P, Guazzone VA, Theas MS, Lustig L. Testicular autoimmunity. *Autoimmun Rev.* 2011;10:201–4.
- Keir ME, Butte MJ, Freeman GJ, Sharpe AH. PD-1 and its ligands in tolerance and immunity. *Annu Rev Immunol.* 2008;26:677–704.
- Kern S, Robertson SA, Mau VJ, Maddocks S. Cytokine secretion by macrophages in the rat testis. *Biol Reprod.* 1995;53:1407–16.
- Ku JH, Kim YH, Jeon YS, Lee NK. The preventive effect of systemic treatment with interferon-alpha2B for infertility from mumps orchitis. *BJU Int.* 1999;84:839–42.
- Kumar H, Kawai T, Akira S. Pathogen recognition by the innate immune system. *Int Rev Immunol.* 2011;30:16–34.
- Lenke G, Rothlin CV. Immunobiology of the TAM receptors. *Nat Rev Immunol.* 2008;8:327–36.
- Li N, Wang T, Han D. Structural, cellular and molecular aspects of immune privilege in the testis. *Front Immunol.* 2012;3:152.
- Li N, Liu Z, Zhang Y, Chen Q, Liu P, Cheng CY, Lee WM, Chen Y, Han D. Mice lacking Axl and Mer tyrosine kinase receptors are susceptible to experimental autoimmune orchitis induction. *Immunol Cell Biol.* 2015;93:311–20.
- Liu Y, Liu W, Russell MW. Suppression of host adaptive immune responses by *Neisseria gonorrhoeae*: role of interleukin 10 and type 1 regulatory T cells. *Mucosal Immunol.* 2014;7:165–76.
- Liu Z, Zhao S, Chen Q, Yan K, Liu P, Li N, Cheng CY, Lee WM, Han D. Roles of Toll-like receptors 2 and 4 in mediating experimental autoimmune orchitis induction in mice. *Biol Reprod.* 2015;92:63.
- Ludwig M, Johannes S, Bergmann M, Failing K, Schiefer HG, Weidner W. Experimental *Escherichia coli* epididymitis in rats: a model to assess the outcome of antibiotic treatment. *BJU Int.* 2002;90:933–8.
- Malolina EA, Kulibin AY, Naumenko VA, Gushchina EA, Zavalishina LE, Kushch AA. Herpes simplex virus inoculation in murine rete testis results in irreversible testicular damage. *Int J Exp Pathol.* 2014;95:120–30.
- McClelland RS. *Trichomonas vaginalis* infection: can we afford to do nothing? *J Infect Dis.* 2008;197:487–9.
- Muciaccia B, Uccini S, Filippini A, Ziparo E, Paraire F, Baroni CD, Stefanini M. Presence and cellular distribution of HIV in the testes of seropositive subjects: an evaluation by in situ PCR hybridization. *FASEB J.* 1998;12:151–63.
- Naito M, Terayama H, Hirai S, Qu N, Lustig L, Itoh M. Experimental autoimmune orchitis as a model of immunological male infertility. *Med Mol Morphol.* 2012;45:185–9.
- Ness RB, Markovic N, Carlson CL, Coughlin MT. Do men become infertile after having sexually transmitted urethritis? An epidemiologic examination. *Fertil Steril.* 1997;68:205–13.
- Nourollahpour Shideh M, Niyayati M, Fallahi S, Rostami A. Human parasitic protozoan infection to infertility: a systematic review. *Parasitol Res.* 2016;115:469–77.
- Ochsendorf FR. Sexually transmitted infections: impact on male fertility. *Andrologia.* 2008;40:72–5.
- Perez CV, Theas MS, Jacobo PV, Jarazo-Dietrich S, Guazzone VA, Lustig L. Dual role of immune cells in the testis: Protective or pathogenic for germ cells? *Spermatogenesis.* 2013;3:e23870.
- Poretzky L, Can S, Zumoff B. Testicular dysfunction in human immunodeficiency virus-infected men. *Metab Clin Exp.* 1995;44:946–53.

- Restrepo B, Cardona-Maya W. Antisperm antibodies and fertility association. *Actas Urol Esp.* 2013;37:571–8.
- Schuppe HC, Meinhardt A, Allam JP, Bergmann M, Weidner W, Haidl G. Chronic orchitis: a neglected cause of male infertility? *Andrologia.* 2008;40:84–91.
- Shang T, Zhang X, Wang T, Sun B, Deng T, Han D. Toll-like receptor-initiated testicular innate immune responses in mouse Leydig cells. *Endocrinology.* 2011;152:2827–36.
- Sun B, Qi N, Shang T, Wu H, Deng T, Han D. Sertoli cell-initiated testicular innate immune response through toll-like receptor-3 activation is negatively regulated by Tyro3, Axl, and mer receptors. *Endocrinology.* 2010;151:2886–97.
- Weidner W, Jantos C, Schiefer HG, Haidl G, Friedrich HJ. Semen parameters in men with and without proven chronic prostatitis. *Arch Androl.* 1991;26:173–83.
- Winnall WR, Muir JA, Hedger MP. Rat resident testicular macrophages have an alternatively activated phenotype and constitutively produce interleukin-10 in vitro. *J Leukoc Biol.* 2011;90:133–43.
- Winnall WR, Wu H, Sarraj MA, Rogers PA, de Kretser DM, Girling JE, Hedger MP. Expression patterns of activin, inhibin and follistatin variants in the adult male mouse reproductive tract suggest important roles in the epididymis and vas deferens. *Reprod Fertil Dev.* 2013;25:570–80.
- Wu H, Shi L, Wang Q, Cheng L, Zhao X, Chen Q, Jiang Q, Feng M, Li Q, Han D. Mumps virus-induced innate immune responses in mouse Sertoli and Leydig cells. *Sci Rep.* 2016;6:19507.
- Xiong W, Chen Y, Wang H, Wang H, Wu H, Lu Q, Han D. Gas6 and the Tyro 3 receptor tyrosine kinase subfamily regulate the phagocytic function of Sertoli cells. *Reproduction.* 2008;135:77–87.
- Zhang Y, Li N, Chen Q, Yan K, Liu Z, Zhang X, Liu P, Chen Y, Han D. Breakdown of immune homeostasis in the testis of mice lacking Tyro3, Axl and Mer receptor tyrosine kinases. *Immunol Cell Biol.* 2013a;91:416–26.
- Zhang X, Wang T, Deng T, Xiong W, Lui P, Li N, Chen Y, Han D. Damaged spermatogenic cells induce inflammatory gene expression in mouse Sertoli cells through the activation of Toll-like receptors 2 and 4. *Mol Cell Endocrinol.* 2013b;365:162–73.
- Zhao S, Zhu W, Xue S, Han D. Testicular defense systems: immune privilege and innate immunity. *Cell Mol Immunol.* 2014;11:428–37.
- Zhu W, Chen Q, Yan K, Liu Z, Li N, Zhang X, Yu L, Chen Y, Han D. RIG-I-like receptors mediate innate antiviral response in mouse testis. *Mol Endocrinol.* 2013;27:1455–67.
- Zhu W, Liu P, Yu L, Chen Q, Liu Z, Yan K, Lee WM, Cheng CY, Han D. p204-initiated innate antiviral response in mouse Leydig cells. *Biol Reprod.* 2014;91:8.
- Zhu W, Zhao S, Liu Z, Cheng L, Wang Q, Yan K, Chen Q, Wu H, Han D. Pattern recognition receptor-initiated innate antiviral responses in mouse epididymal epithelial cells. *J Immunol.* 2015;194:4825–35.

Andrea M. Isidori, Andrea Sansone, and Daniele Gianfrilli

---

## Abstract

Treatment of male infertility has become one of the hottest topics of research in endocrinology and andrology. A significant proportion of the causes of male infertility can now be treated: obstructive azoospermia, infections, and, to a certain extent, varicocele are known factors for sub- or infertility which can be improved through various types of treatment. Hormone therapy has been used for hypogonadotropic hypogonadism (HH), whether congenital or acquired. In these patients, exogenous hCG, LH, and FSH are given to induce fertility and stimulate testicular steroidogenesis.

The administration of exogenous gonadotropins can restore spermatogenesis, albeit not to normal levels, in most cases of HH-associated azoospermia, but recent evidence suggests that other conditions involving reduced germ cell output might also benefit. In some cases of idiopathic oligoasthenoteratozoospermia (OAT), gonadotropin administration improved sperm quality and parameters, although the changes were of uncertain clinical significance. More convincing evidence has emerged on the effect of FSH administration on nonconventional sperm parameters, including chromatin condensation and DNA fragmentation, suggesting a possible adjuvant use in assisted reproduction techniques (ART). Areas of active research include the identification of the best or individualized doses and regimens to administer gonadotropins. Recent advances in genome research have also paved the way for new approaches to the hormonal treatment of idiopathic OAT. Polymorphisms in the FSH receptor have been investigated as a contributing pathogenic factor but also as a predictor of response to treatment. Genetic variants might explain why not all men respond in the same way to gonadotropin administration. There is no rationale for the use of hormone

---

A.M. Isidori (✉) • A. Sansone • D. Gianfrilli

Department of Experimental Medicine, Section of Medical Pathophysiology, Food Science and Endocrinology, Sapienza University of Rome, Rome, Italy  
e-mail: [andrea.isidori@uniroma1.it](mailto:andrea.isidori@uniroma1.it)



treatment in men with elevated gonadotropins, and such treatment is mostly unsuccessful.

Other drugs acting on hormonal homeostasis have also been used to treat male infertility, including aromatase inhibitors and antiestrogens. The evidence for their use is far from definitive, although some possible factors predictive of a positive response have been identified. Tailored therapy, genetic profiling, and new drugs with slower absorption rates have shown promising results, and recent evidence suggests that hormone therapy may also benefit men with oligozoospermia and normal concentrations of FSH and LH.

### Keywords

Gonadotropins • Hormonal treatment • Oligoasthenoteratozoospermia • Idiopathic oligoasthenoteratozoospermia • Hypogonadotropic hypogonadism • Sperm quality

## Contents

Introduction .....	1072
The History of Hormone Therapy of Male Infertility .....	1073
State of the Art: Evidence for Treatment .....	1075
Beyond Gonadotropins .....	1079
What Is Next .....	1080
The Quest for a Longer Half-Life .....	1080
New Drugs for Old Ideas .....	1081
New Ideas for Older Drugs .....	1082
Genetic Profiling and Tailored Treatment .....	1083
References .....	1086

## Introduction

Almost 15% of all couples trying to conceive are affected by infertility. In almost half of these cases male infertility is the sole or a contributing factor, causing significant distress to the couple. Male infertility is traditionally investigated by evaluation of semen analysis: the discovery of any impairment in sperm volume, motility, or morphology is usually followed by an endocrine investigation to assess whether the infertility might be a consequence of an endocrine disease. The most common cause is the idiopathic failure of spermatogenesis. In some cases medical treatment is feasible, and based on this distinction, the management of male infertility has been divided into “rational” and “empiric” treatment (Isidori et al. 2006).

Rational treatment of infertility is based on its etiology. Administration of exogenous gonadotropins often restores spermatogenesis in men with hypogonadotropic hypogonadism (HH), a condition in which azoospermia is due to lacking or insufficient production of FSH and LH. Based on its effectiveness in most HH men, gonadotropin administration has been hypothesized as a possible treatment for oligozoospermic men. The results have been inconsistent, but some studies have

suggested that adjustment of the “standard” dosage (150 IU every other day) might produce better results.

Hormone therapy of male infertility is a burning but controversial area of research. The introduction of ART has dramatically changed the approach to male infertility, as pregnancy is achievable even where fertility is severely impaired thanks to in vitro fertilization (IVF) and intracytoplasmic sperm injection (ICSI). The quest for “best-quality sperm” has recently rekindled interest in hormone therapy prior to ART. Would treatment to improve semen parameters provide a better outcome in terms of pregnancy rate? Would hormone therapy be helpful in men with normal gonadotropin levels?

FSH exerts its effects by binding to a specific receptor located on the surface of Sertoli cells. Over the last 20 years, numerous researchers have investigated how polymorphisms in this receptor or in the FSH  $\beta$ -subunit genes (respectively, *FSHR* and *FSHB*) might be involved in muting response to both exogenous and endogenous gonadotropins. It is now clear that genetic polymorphisms could explain different responses to therapy in infertile men undergoing the same treatment schedule and might similarly provide a rationale for different baseline conditions. Genetic profiling might therefore have a leading role in suggesting whether and how patients should be treated: it is evident that the same treatment schedule might successfully induce spermatogenesis in some men but fail in others with different genetic polymorphisms.

It is also important to remember that the ultimate aim of any treatment for male infertility is an increase in confirmed pregnancies and, ultimately, in live births. Even when semen parameters improve, pregnancy might still be problematic: any clinician investigating and treating male infertility should suggest that the female partner also undergoes a thorough evaluation. Failing to identify any causes of diminished female fertility, that frequently coexist alongside male factor infertility, wastes all efforts to improve sperm quality.

In this chapter, we aim to assess the efficacy of hormone therapy on male infertility, discussing administration schedules and the evidence in favor of or against each treatment.

---

## The History of Hormone Therapy of Male Infertility

Treatment with gonadotropins is now taken for granted, but it is the result of many years of research and development. The role of the hypothalamic-pituitary-gonadal (HPG) axis in infertility has been postulated since the early twentieth century. In 1910 Crowe observed gonadal atrophy in dogs following pituitary ablation, and in 1912 Aschner observed similar features in patients suffering from brain or pituitary tumors. These findings paved the way for new research, as between 1926 and 1930 the first studies on implanted pituitary glands proved that *something* in the implant induced the rapid development of sexual puberty in animals. In 1930 Zondek

hypothesized that two pituitary hormones, which he identified in the blood and urine of postmenopausal women and called *Prolan A* and *Prolan B*, were involved in sexual development and in the rhythm of ovarian function (Zondek 1930). His findings were confirmed the following year by Fevold et al., and the two hormones gained their current names of follicle-stimulating hormone (FSH) and luteinizing hormone (LH) (Fevold et al. 1931). Zondek also identified a gonad-stimulating substance in the serum and urine of pregnant women: this human chorionic gonadotropin (hCG) was launched on the market in 1932.

Following Zondek's findings, gonadotropins extracted from swine pituitary glands were introduced into clinical practice. In the same period, Cole and Hart discovered another hormone that induced ovulation and follicular growth in laboratory studies and could be extracted from the blood of pregnant mares (Cole and Hart 1930). This pregnant mare serum gonadotropin (PMSG) was also used in humans, although clinical trials showed inconsistent results in women. The two-step protocol, involving PMSG and hCG, restored menstrual flow in women with amenorrhea.

In the following decade, preparations with swine and sheep gonadotropins became available and could be used as substitutes for PMSG. However, it was soon noticed that the long-term effects of these products were unreliable, as the response became increasingly weaker following each administration. Zondek hypothesized that the culprit was an "antihormone," although we know today that what he described was in fact the formation of antibodies to animal gonadotropins.

Gonadotropins extracted from human pituitaries (human pituitary gonadotropin, hPG) were first obtained in the late 1950s, but the availability of human glands was insufficient for the multitude of patients requiring treatment (the latter was probably a fortunate limitation as hPG has been implicated in cases of Creutzfeldt-Jakob disease). Human menopausal gonadotropin (hMG), a mixture of several gonadotropins, was obtained in 1949 via a lengthy but simple procedure. This preparation, also known as menotropin, became the treatment of choice for amenorrhoeic hypogonadal women from the early 1960s; however, the preparations were impure, having both LH-like and FSH-like effects and therefore were far from perfect.

In the early 1970s, the demand for more tailored treatments resulted in a renewed interest in gonadotropin research. Sadly, the quest to obtain pure gonadotropin preparations using newly developed methods proved too expensive or too cumbersome. However, Eshkol and Lunenfeld (1967) succeeded in obtaining purified gonadotropins by combining old and new methods: FSH and LH were separated by filtering urinary hMG preparations through a column with polyclonal anti-LH antibodies, once again demonstrating that a safe treatment was feasible. The same path was trodden during the following decade when highly purified urinary FSH was produced using progressively more complex processes.

The demand for gonadotropins rose steeply over the years, outstripping the capacity of the few centers involved in urine collection and extraction for medical purposes. There were few (just 600) urine donors, and they were known personally by the collectors. To meet the increased demand, over 600,000 donors were needed – a 1,000-fold increase. The increased number of required donors highlighted the

shortcomings of the procedure: poor quality control, risk of cross contamination, and lack of donor traceability were just a few of the issues.

Luckily, what was once considered impossible has been made reality by recent advances in genetic engineering. Recombinant FSH, hCG, and LH have been mass produced *in vitro* in laboratories since 1988 and are now used worldwide. Genetic engineering has also enabled researchers to identify changes in the molecular structure of both FSH and its receptor and to devise new drugs which might open the way to the treatment of all forms of male infertility (Lunenfeld 2004).

---

## State of the Art: Evidence for Treatment

Male infertility is traditionally grouped into four main categories: idiopathic, obstructive, primary, and secondary (Trussell 2013). Obstructive infertility benefits from surgical correction of the obstruction, although microsurgical retrieval of spermatozoa from the gonads is a more viable option; in any case, hormone therapy is not recommended. Similarly, primary infertility resulting from testicular failure does not usually benefit from hormone administration. In selected cases, pregnancy might be achieved through ART, although no definite hormonal marker of retrieval success has been identified.

The effects of gonadotropin administration in severe testicular diseases have been investigated in experimental trials. Most forms of secondary and some forms of idiopathic infertility might be resolved by administering suitable drugs (Nieschlag and Lenzi 2013). Given their role in spermatogenesis, gonadotropins have often been in the spotlight as a possible treatment for infertile men; however, based on current evidence, hypothesizing that “one treatment might fit all” is clearly a mistake. Gonadotropin administration is not a panacea for male infertility: all patients should undergo meticulous evaluation by a specialist to establish the most suitable treatment.

**Hypogonadotropic hypogonadism.** Administration of exogenous gonadotropins (in any form) has restored spermatogenesis in men with HH. As discussed elsewhere in this book, HH is a rare form of secondary hypogonadism accounting for about 1–2% of all cases of male infertility (Trussell 2013) in which insufficient release of LH and FSH from the pituitary results in clinical azoospermia. However, the combination of increasing age of fatherhood, prescription drug use, substance abuse, and poor lifestyle habits results in an incidence of mild subclinical hypogonadotropic hypogonadism far higher than previously thought, especially in middle-aged obese men (Isidori et al. 1999, 2005, 2008; Isidori and Lenzi 2005). In cases of hypothalamic dysfunction (e.g., Kallmann syndrome), treatment with 5–20 µg GnRH administered subcutaneously, intranasally, or intravenously every 2 h (Kumar 2013) is theoretically feasible. This regimen would make subcutaneous administration through an infusion pump the only viable choice; however, it is rarely used, as it would be both cumbersome and expensive (Han and Bouloux 2010).

Gonadotropin administration is useful in restoring spermatogenesis in hypogonadotropic men with azoospermia (Matsumoto et al. 1986) and has been the

standard of treatment for such men in the last decades. Besides the obvious implications for compliance, administration of exogenous gonadotropins is also preferred in cases of pituitary dysfunction due to their efficacy (Dwyer et al. 2015). Treatment with LH or hCG is mandatory in men with HH and should be started before administering FSH to provide the intratesticular testosterone (T) concentration required for spermatogenesis (Page 2011; Huhtaniemi 2015). hCG alone can sometimes induce spermatogenesis, particularly in men on the mild end of the phenotypic spectrum or with acquired HH. hCG is an analog of pituitary LH produced by the syncytiotrophoblast of the human placenta. For commercial use, it can be obtained from urinary samples from pregnant women or via recombinant DNA engineering. hCG is the treatment of choice because of its longer half-life and lower cost, but recombinant LH is also a viable treatment. Urinary LH is available in the form of menotropin mixed with urinary FSH. Compared to early menotropin treatment, which dates back to 1961 (Lunenfeld 2004), the more recent preparations are vastly superior in terms of safety, efficacy, and performance (Practice Committee of American Society for Reproductive Medicine 2008). hCG has now largely replaced hMG in the treatment of infertility. In the future, the currently off-label recombinant LH could become an option.

Treatment with urinary FSH has proven effective for all its intended uses in men and women alike. Highly purified urinary FSH addresses all the safety issues of previous forms of urinary gonadotropins and is therefore a viable treatment for ovarian stimulation in women and for induction of spermatogenesis in men. Since its introduction, recombinant FSH has become another treatment of choice, based on its efficacy, lack of LH-like activity, and safety. Studies comparing recombinant and urinary gonadotropins in men trying to achieve spermatogenesis did not find any treatment to be superior (Liu et al. 1999; Sinisi et al. 2010).

Since the first trials, most clinical studies have used the same treatment schedule. Varying dosages of hCG (or similar preparations, including recombinant LH), usually 1,500–2,500 IU twice a week, are administered subcutaneously for at least 3 months (Sinisi et al. 2010). Serum testosterone and semen analysis should then be evaluated, as in some cases spermatogenesis is achieved with hCG treatment only. This is most commonly seen in secondary HH, in subjects who have been previously exposed to some FSH, necessary for the first spermatogenic wave. If serum testosterone and testicular volume are increased following administration of hCG and no spermatozoa are found in the semen, FSH should be introduced. Treatment usually consists of 150 IU of FSH (highly purified urinary derivatives or recombinant) on alternate days while continuing hCG administration. Semen analysis should be performed after at least 3 months of treatment and every 3 months for up to 1 year until spermatogenesis is achieved. Median times for the development of sperm in the ejaculate are in the range of 9–12 months for the combined treatment (Dwyer et al. 2015).

Up to 80% of men undergoing treatment with hCG alone or hCG + FSH recover spermatogenesis, but some patients fail to respond. Identification of possible predictors of clinical response is consequently an area of intense research. A pretreatment testicular volume <4 ml is suggestive of a lack of response (Dwyer et al. 2015),

consistently with the observation that response is for the most part (>90%) dependent on the enlargement of seminal tubules (Russell et al. 1990), although stromal and vascular expansion are also observed after treatment with gonadotropins. Patients with postpubertal HH usually respond better than those with congenital HH (Rastrelli et al. 2014), perhaps as the result of their larger pretreatment testicular volume.

Cryptorchidism is an important prognostic factor for infertility in the general population. Gonocyte survival is severely impaired if testicular descent does not occur in the first year of life, resulting in diminished long-term fertility. Given the higher incidence of cryptorchidism in children with congenital HH, orchidopexy should be performed as soon as possible to reduce the risk of persistent damage to germ and Sertoli cells. However, despite the possible benefits of orchidopexy, surgical procedures in infants can be technically challenging. The treatment with hCG as an alternative to surgical treatment (Dwyer et al. 2015) has been questioned, since studies linked an increased apoptosis of spermatogonia (Dunkel et al. 1997; Cortes et al. 2000) to hCG administration. A recent meta-analysis has doubted the efficacy of hCG and LHRH in boys with cryptorchidism, suggesting that their administration cannot be recommended given the low success rates and unknown long-term effects on fertility (Bu et al. 2016).

Evaluation of the effect of previous androgen treatment has produced contrasting results. Despite previous reports (Anawalt 2013; Liu et al. 2009), a recent meta-analysis found neither detrimental nor positive effects of previous testosterone administration on the outcomes of gonadotropin replacement therapy (Rastrelli et al. 2014).

If administration of gonadotropins fails to induce spermatogenesis and an increased testicular volume after 1 year of an adequately performed stimulation regimen, continuing the treatment is normally useless, although in rare circumstances spermatozoa have been observed after 2 years of combined therapy. Men who do achieve spermatogenesis after a first cycle of treatment are more likely to respond to a second cycle (Liu et al. 2009).

Patients undergoing treatment require careful monitoring for both safety and assessment of prognosis. A marked increase in testicular volume (sum of left and right testis volume >20 ml after treatment) is a good marker of positive response (Liu et al. 2009). Evaluation of serum markers – notably inhibin B and anti-Müllerian hormone (AMH) – helps assess both the efficacy of the treatment and its prognosis. As a result of their low testosterone concentration and small Sertoli cell population, inhibin B is extremely low in pretreatment HH men, while AMH is remarkably high. Inhibin B levels usually plateau after 2 months of treatment (Dwyer et al. 2015), and their increase (>60 pg/ml) while undergoing treatment is a good marker of Sertoli cell proliferation, suggesting that the treatment is effective.

The most common side effect of hCG administration is gynecomastia, a usually benign condition which can have serious psychological consequences. It occurs in up to one third of treated subjects and is frequently mistaken for breast cancer, causing the patient significant worry. To reduce the burden of treatment, it is often suggested that patients should undergo semen cryopreservation once the treatment

has induced spermatogenesis. If the couple wishes to achieve a second pregnancy shortly after the first, hCG administration may be continued for as long as desired before administration of exogenous FSH (or derivatives).

Congenital HH has traditionally been considered a lifelong disorder, treatable via steroid or gonadotropin administration but not curable. However, since 1975 several cases of reversible HH have been reported, with results ranging from spontaneous LH secretion to restoration of fertility following cessation of treatment. The rate of HH reversibility seems to be higher than previously thought, as recent reports (Dwyer et al. 2016) suggest that 10–15% of the affected subjects might revert to eugonadism. Reversibility may be the result of intermittent exposure to exogenous sex steroids, resulting in androgen-driven upregulation of the genes involved in regulating GnRH secretion. This phenomenon may be transient, and therefore the reversal might not last for very long. To date, no markers predicting the length of reversal have been identified.

**Normogonadotropic OAT.** The crucial role of FSH in spermatogenesis has been clearly elucidated in cases of HH. However, only a small minority of infertile patients present with similar conditions, whereas the vast majority have normal or normal-high concentrations of endogenous gonadotropins. In most of these subjects, infertility is characterized by abnormal conventional sperm parameters (concentration, motility, or morphology) which might result in impaired ability to conceive. In OAT, all these parameters are subnormal, and in most circumstances, no definite cause can be identified. Idiopathic OAT is the most prevalent finding in male infertility and is currently a major area of research in reproductive medicine. Several treatments have been proposed, with varying results. Based on the assumption that exogenous gonadotropins might induce spermatogenesis in HH men, FSH administration has been considered as a possible treatment. To date, there is no consensus on the hypothetical correct dosage or whether recombinant or highly purified FSH should be favored. In the first experimental trials, 50 men with severe infertility were administered FSH 150 IU on alternate days, and despite the lack of significant improvements in sperm parameters, there was an increased pregnancy rate in the treated couples (Acosta et al. 1991; Acosta et al. 1992). Treatment protocols in subsequent studies range from 75 IU on alternate days to 150 IU daily, while treatment duration is usually between 30 and 90 days. Several studies, including a systematic review (Isidori et al. 2006), reported significantly higher sperm count but conflicting results in sperm motility, morphology, or viability (Paradisi et al. 2014). A recent study found beneficial effects on morphology and forward motility using higher doses of FSH (200–300 IU on alternate days) and after a prolonged treatment (>5 months), preferentially in subjects with normal or low-normal inhibin B levels (Ding et al. 2015).

Improvements in nonconventional sperm parameters, including DNA fragmentation and ultrastructural features, have been described in subjects undergoing treatment with recombinant human FSH (Kamischke et al. 1998; Colacurci et al. 2012) and suggest a rationale for the improved pregnancy rate in treated couples (Valenti et al. 2013). The vast heterogeneity of the treatment posology, dosage, and duration in these studies is a key issue, as extensively described in recent

meta-analyses investigating FSH administration in male idiopathic infertility (Attia et al. 2013; Santi et al. 2015).

As previously stated, even in the absence of large changes in conventional sperm parameters, FSH administration might improve pregnancy rates, and as such its clinical applications obviously extend to ART. There is evidence of its role in DNA repair mechanisms, and recombinant or urinary FSH could therefore be a useful adjuvant treatment for men with idiopathic infertility (Ramasamy et al. 2012). Future research should investigate clinical predictors of response to exogenous FSH administration so as to administer gonadotropins only to those who actually require treatment. Besides the obvious consideration that gonadotropin administration does not seem to be indicated in patients with high baseline FSH levels, some authors have also suggested that pretreatment spermatid count might help identify candidate patients (Garolla et al. 2014). Genetic factors have also been considered, and recent research has shown that polymorphisms in the *FSHR* gene might reduce the benefits of exogenous FSH administration on DNA fragmentation (Simoni et al. 2016).

---

## Beyond Gonadotropins

Although gonadotropins are the mainstay of treatment for male infertility, several other drugs have been used with varying degrees of safety, efficacy, and reliability.

**Dopamine receptor agonists.** Hyperprolactinemia is the most common disease of the hypothalamic-pituitary axis and a relatively common finding in men with sexual symptoms. Erectile dysfunction and hypoactive sexual desire are in fact often caused by a form of hypogonadotropic hypogonadism secondary to elevated prolactin (PRL) (Luciano 1999). Physiologic, iatrogenic, and pathologic factors are all involved in its pathogenesis. PRL-secreting pituitary adenomas (*prolactinomas*) are the most common cause of organic hyperprolactinemia (Ciccarelli et al. 2005): if elevated PRL levels are confirmed after retesting and after ruling out any other possible cause of hyperprolactinemia, magnetic resonance imaging should be performed.

Treatment for pituitary adenomas is either surgical or medical. Indications for surgery include visual disorders, growth of the tumor, and unremitting headache (Freda et al. 2011). In most cases, medical treatment with dopamine receptor agonists is a viable choice in terms of compliance and efficacy: cabergoline (0.125–1.0 mg twice a week) is the preferred agent, based on its ease of use and its efficacy in normalizing PRL levels and shrinking adenomas (Ramasamy et al. 2012). Bromocriptine, although less expensive, has a higher risk of side effects and a shorter half-life (Ramasamy et al. 2012). Treatment with dopamine receptor agonists usually restores spermatogenesis by normalizing gonadotropins and testosterone, although it might take 3–6 months to observe significant improvements; furthermore, some patients do not respond to this treatment and might require administration of exogenous gonadotropins to achieve normal spermatogenesis (Trussell 2013).



**Antiestrogens.** Clomiphene and tamoxifen have been extensively used for off-label treatment of idiopathic OAT for more than 50 years. Treatment usually consists of tamoxifen 20 mg/day or clomiphene 50 mg/day. Both drugs block estrogen receptors in the hypothalamus and the pituitary, indirectly increasing FSH and LH secretion via stimulation of GnRH release (Chua et al. 2013) and theoretically resulting in increased spermatogenesis and testosterone production. There are conflicting reports of the efficacy of these treatments. Some studies found improvements in both LH/FSH and sperm concentration (Micic and Dotlic 1985; Mellinger and Thompson 1966; Check et al. 1989), but more recent papers failed to confirm these results (Roth et al. 2013; Willets et al. 2013). Systematic reviews also failed to find any evidence in favor of antiestrogens (Vandekerckhove et al. 1996; Kamischke and Nieschlag 1999). However, a more recent meta-analysis (Chua et al. 2013) suggested that antiestrogens might have beneficial effects on sperm concentration and motility.

The side effects of these treatments, including cardiovascular events, are widely recognized (Wibowo et al. 2016; Chandrapal et al. 2016) and should be discussed with the patient before starting treatment. Reports of deep vein thrombosis in men undergoing treatment with tamoxifen are anecdotal but raise further safety concerns. As noted above both clomiphene and tamoxifen are used off-label, and therefore signed informed consent is mandatory in many countries before starting treatment.

**Aromatase inhibitors.** Aromatase inhibitors (AIs) block the conversion of testosterone to estradiol, therefore inhibiting the negative feedback exerted by estrogens on the HPG axis (Kumar 2013). AIs are a rational indication for the treatment of male subfertility (Schlegel 2012), and different studies have investigated the effects of several drugs, most notably anastrozole 1 mg/day or letrozole 2.5 mg/day. However, no significant improvement in sperm parameters has been observed (Raman and Schlegel 2002; Pavlovich et al. 2001). As aromatase is expressed in adipose tissue, it has been hypothesized that obese patients might have a more marked response (Roth et al. 2008). AIs are used off-label, and informed consent is required before their administration.

The issue of safety has been addressed in several studies, mostly in regard to bone health and metabolism, cardiovascular effects, and cognition (de Ronde and de Jong 2011). Although the results suggest a lack of significant side effects in older men, there are no clear indications in adolescents or young men. Considering their side effects and dubious efficacy, AIs should not be used to treat subfertility until there is more solid evidence (Anawalt 2013; Garg and Kumar 2015).

---

## What Is Next

### The Quest for a Longer Half-Life

Many patients undergoing gonadotropin treatment to achieve spermatogenesis complain about the injection frequency. Research in the last two decades has therefore attempted to identify drugs with a longer half-life to facilitate administration and increase patient compliance.

The  $\beta$ -subunit of endogenous FSH has two N-linked glycosylation sites which allow FSH to exist as a number of isoforms with different isoelectric points based on the number of sialic acid residues. Sialic acid content is the main determinant of half-life – the greater the content, the higher the acidity and the longer the isoform’s biological half-life. However, isoforms with a lower sialic acid content have greater biological activity. Commercial preparations with recombinant FSH essentially contain only exact copies of the same isoform, whereas human FSH and, therefore, commercial preparations with highly purified urinary FSH are a mixture of different isoforms (Gordon 2002). The concentrations of the different isoforms change over time, as, remarkably, also occurs during the menstrual cycle: different glycosylation patterns of the FSH molecules might thus have physiologic relevance (Andersen et al. 2004). Despite the increased half-life, these isoforms are still likely to require several injections a week to induce and maintain spermatogenesis. Future research might help clarify the role and the optimum administration schedule of a “tailored” treatment.

Corifollitropin alfa is a hybrid molecule designed in 1992 by adding the carboxyl terminal peptide (CTP) of hCG  $\beta$ -subunit to the FSH molecule (Fares et al. 1992) and thus increasing the half-life. The genetically engineered chimeric gene is then transfected to Chinese hamster ovary cells, as with current recombinant preparations. Corifollitropin alfa has no LH-like action and interacts with the FSH receptor only, theoretically providing a similar efficacy to FSH but with fewer injections (Patil 2014). It is currently used to treat female infertility in both ART and non-ART cycles. However, its efficacy and safety profile have not been fully investigated in men. Results from a trial investigating its effects on testicular volume and sperm count in men with HH have yet to be published.

Several other treatments are currently being investigated, including low molecular weight gonadotropins which might permit oral administration (Patil 2014). These new drugs seem promising, although the trials required to evaluate their safety and efficacy could take many years.

## New Drugs for Old Ideas

A “biosimilar” drug is an almost identical copy of another biological product whose patent has expired and is manufactured using recombinant DNA technology by transfecting prokaryotic and eukaryotic cell lines. The patent for recombinant FSH expired in 2012, and there have been intensive efforts to find a biosimilar replacement. Two new FSH-biosimilars were recently approved by the European Medicines Agency (Santi and Simoni 2014).

Biosimilar drugs are non-inferior to the original compounds but are not free from side effects. For the two FSH-biosimilars, not only the potential anti-drug antibody response but also the degree of glycosylation might differ, depending on the cell lines used, while the extraction and purification steps could change the biological activity and the safety and efficacy profile. Although FSH-biosimilars have not yet been studied as treatments for male infertility, they are still indicated for male

hypogonadism despite the lack of clinical experience. However, they should not be offered as a first-line treatment until more evidence of their safety, efficacy, and cost/benefit ratio is available (Santi and Simoni 2014).

## New Ideas for Older Drugs

**Different treatment schedules.** Spermatogenic capacity is strictly dependent on the seminiferous tubules, and therefore factors promoting tubule development have been postulated as a way of improving fertility outcomes. One of the key issues in exogenous gonadotropin administration is the treatment schedule, as there is little evidence for the adequacy of the usual regimen. Considering the half-life of bioactive FSH, some authors have suggested that current dosing regimens might be too low (Kamischke et al. 1998). It is possible, although there is still little evidence, that high doses of FSH (300 IU on alternate days or higher or more frequent doses) might be beneficial, whereas lower doses, including the “standard” treatment with 150 IU every other day, might not improve conventional and nonconventional sperm parameters in patients with idiopathic OAT. Prolonged treatment with high-dose FSH resulted in increased sperm count and pregnancy rates compared to placebo (Paradisi et al. 2014; Ding et al. 2015), but there is still no evidence that this treatment might be more efficacious than the standard regimen.

Some studies have suggested an “inverted” approach to gonadotropin administration in selected patients, providing unopposed treatment with FSH alone before administering hCG. This therapy aims to stimulate testicular growth and development before introducing hCG and has shown promising results in patients with congenital HH and in several forms of prepubertal hypogonadism (Dwyer et al. 2015). Unopposed treatment with FSH for up to 4 months before switching to either combined treatment or GnRH administration was effective in congenital HH men, with better results than both standard therapies (Dwyer et al. 2015). However, larger studies are required to fully assess the efficacy of treatment and possible predictors of outcome. As noted above, continuing treatment for more than a year despite no improvements in spermatogenesis or testicular volume is not advisable.

**Gonadotropin block and replace for severe testicular diseases.** In cases of severe testicular failure, an interesting approach based on the desensitization of the FSH receptor has been suggested. Increased FSH levels – which are frequently observed in men with severe testicular diseases – downregulate the FSH receptor (Foresta et al. 2004). In an experimental study in men with severe oligozoospermia, a GnRH agonist was administered to suppress FSH receptor expression before starting treatment with human FSH and hCG, and after 3 months significant improvements in sperm concentration and motility were observed (Foresta et al. 2009). The pregnancy rate was higher in treated subjects than controls, although the difference was not statistically significant. This therapy improved spermatogenesis in the described population, but whether this treatment might be useful in different conditions is still unproven.

**Hormonal treatment in Klinefelter syndrome.** Klinefelter syndrome (KS) is the most common sex chromosome abnormality, in most cases resulting from a meiotic nondisjunction event leading to a 47,XXY karyotype. It is largely underdiagnosed: despite its estimated prevalence of 1 in 660 newborns (Aksglaede et al. 2013), less than 25% of patients are diagnosed. Almost all KS patients are azoospermic, and in fact 11% of azoospermic men and 3% of infertile men have a 47, XXY karyotype.

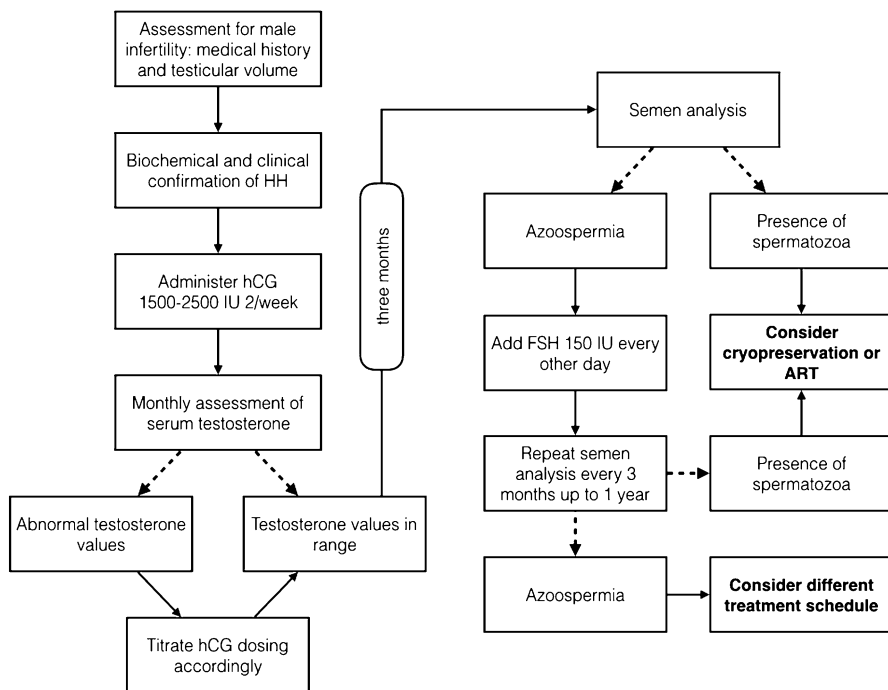
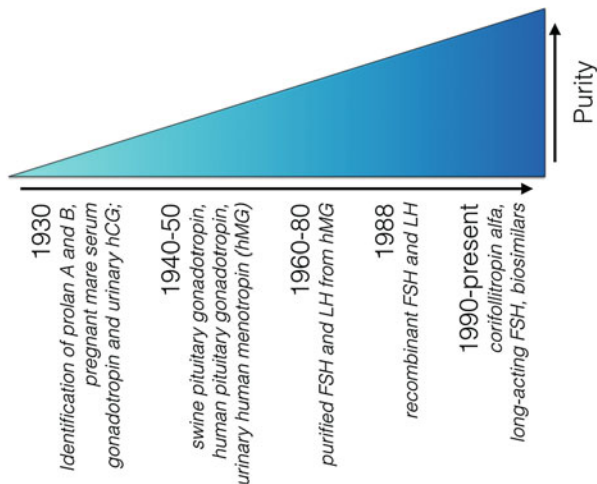
The introduction of ART has dramatically changed the approach to fertility in KS. As discussed by some of the most influential researchers on KS, testicular sperm extraction (TESE)-ICSI yields similar results in KS as in normal karyotype men with nonobstructive azoospermia (Nieschlag et al. 2016). Based on results in azoospermic non-KS men, some researchers have suggested treatment with hCG, AI, or antiestrogens as a means of improving ART outcomes (Schiff et al. 2005; Ramasamy et al. 2009). Sperm retrieval with micro-TESE was more successful in patients whose testosterone had been significantly increased by hormone therapy. Despite these promising results, the supposed positive effects of hormone treatment on fertility in KS are not yet clear: not only are the reports of improved sperm retrieval scarce and lacking in evidence, but the issues of previous androgen treatment and of predictive markers of successful micro-TESE are still unresolved (Nieschlag et al. 2016).

**Other nonobstructive azoospermia.** In a case report, administering FSH 150 IU three times a week restored spermatogenesis in a previously azoospermic, 32-year-old normogonadotropic man with a Y chromosome microdeletion (Selman et al. 2004). Despite the small amount of spermatozoa in the ejaculate, pregnancy was achieved using ART. In a subsequent study, gonadotropin treatment restored spermatogenesis in 49 normogonadotropic azoospermic men with spermatogenic maturation arrest, resulting in three pregnancies in the couples involved (Selman et al. 2006). More recently, rhFSH 75–150 IU twice a week was given to azoospermic patients with maturation arrest after unsuccessful micro-TESE: spermatozoa were found in 5 of the 26 treated patients (Kobori et al. 2015). It is still unknown if nonresponse to treatment is a consequence of genetic alterations in the *FSHR* gene: in fact, spermatogenesis is severely impaired but still present in men with inactivating mutations of the FSH receptor (Huhtaniemi 2015).

## Genetic Profiling and Tailored Treatment

The molecular mechanisms of FSH are still largely unknown, but there is solid evidence that spermatogenesis is severely impaired when its action is disrupted (Simoni et al. 2002). To fully understand the mechanisms of action of FSH in human fertility, it is a good idea to take a step back and focus on the interaction between the FSH molecule and its receptor. The genetics of male infertility might depend on single-base mutations in the nucleotide chain involved in the synthesis of both the FSH molecule and the FSH receptor. Evidence of the impact of genetic polymorphisms has long been controversial and contradictory, and only recently

**Fig. 1** The evolution of gonadotropins for the treatment of infertility



**Fig. 2** Flowchart suggesting the rational approach to gonadotropin treatment of HH infertile males

**Table 1** Take-home messages on the hormone therapy of male infertility

- 
- Exogenous gonadotropins have been used since the first half of the twentieth century to induce ovulation; more recently they have been considered a treatment option for some forms of male hypogonadism with low-to-normal gonadotropin levels
    - Currently available treatments include human chorionic gonadotropin (hCG), highly purified urinary LH and FSH, and recombinant FSH and LH. Other compounds have also been studied but have not been approved for treatment of male infertility

---

  - Impairments in spermatogenesis resulting from hypogonadotropic hypogonadism (HH) are usually restored by adequate administration of exogenous gonadotropins
    - The first semen evaluation should be performed after a further 3 months of treatment with hCG monotherapy following normalization of T (hCG 1,500–2,500 IU twice a week or greater if needed to normalize T levels). If spermatogenesis has not been achieved, 150 IU of FSH (either highly purified urinary derivatives or recombinant) should be administered on alternate days while continuing hCG treatment
    - At least 3 months of treatment is required before assessing its effects; however, it might take up to 12 months for spermatozoa to be observed
    - Different regimens with daily FSH or up to 300 IU on alternate days are under investigation

---

  - Idiopathic OAT might be treatable with exogenous FSH. No definitive evidence as to the dosage or treatment duration has been obtained. Despite the lack of improvement in conventional sperm parameters, pregnancy rates might be increased in treated couples through effects on nonconventional parameters (chromatin condensation and DNA fragmentation)
    - Improving sperm quality through hormone therapy might increase the success rate of assisted reproduction techniques

---

  - Aromatase inhibitors and antiestrogens have been used off-label to treat male infertility. Given their possible side effects and off-label use, they should be limited to selected cases where increased aromatization is suspected and only administered after informed consent
  - Infertility secondary to prolactinoma can be treated with dopamine receptor agonists, which are relatively safe and effective

---

  - Experimental findings suggest that increasing the FSH dosage might have a better effect on spermatogenesis; similarly, it has been suggested that unopposed treatment with FSH alone before administering hCG might increase treatment efficacy in severe testicular diseases. There are few reports of successful hormone therapy in Klinefelter syndrome and other hypergonadotropic forms of nonobstructive azoospermia

---

  - Genetic polymorphisms might impair the production of endogenous FSH or the effects of both endogenous and exogenous gonadotropins on their receptors. In patients with severe spermatogenic impairment and low or inappropriately normal FSH plasma levels, response to treatment might be influenced by these polymorphisms

---

  - Hormonal treatment of male infertility should take the pharmacogenomics into account

---

have the various theories been unified and “resolved” by a more cohesive interpretation (Simoni and Casarini 2014).

Mutations of the FSH receptor gene (*FSHR*) are incredibly rare (Gromoll et al. 1996), but polymorphisms of a single nucleotide are far more common. Within a given gene, the incidence of single nucleotide polymorphisms (SNPs) ranges from 15% to 50% in the general population. SNPs do not have pronounced effects on gene function but can change or regulate endocrine feedback systems and hormone action.

Their role in male infertility has been studied extensively in recent years. Polymorphisms in the *FSHB* gene promoter can lead to reduced FSH serum levels, while reduced receptor function is a consequence of specific SNPs involving the *FSHR* gene. The *FSHR* SNP only manifests when serum FSH levels are kept low by the *FSHB* SNP (Tuttelmann et al. 2012). Men with homozygous variants for both SNPs probably have low basal levels of FSH and reduced receptor function, two conditions which would in turn inhibit physiologic stimulation of spermatogenesis (Selice et al. 2011). Subjects with *FSHB* SNP, and supposedly even those with both SNPs, are more likely to respond to exogenous FSH administration (Ferlin et al. 2011). Genetic profiling could identify patients with severe spermatogenic impairment and low or inappropriately normal FSH plasma levels, providing a new approach to the treatment of some forms of male infertility (Figs. 1 and 2 and Table 1).

---

## References

- Acosta AA, Oehninger S, Ertunc H, Philput C. Possible role of pure human follicle-stimulating hormone in the treatment of severe male-factor infertility by assisted reproduction: preliminary report. *Fertil Steril*. 1991;55(6):1150–6.
- Acosta AA, Khalifa E, Oehninger S. Pure human follicle stimulating hormone has a role in the treatment of severe male infertility by assisted reproduction: Norfolk's total experience. *Hum Reprod*. 1992;7(8):1067–72.
- Aksglaede L, Link K, Giwercman A, Jorgensen N, Skakkebaek NE, Juul A. 47,XXY Klinefelter syndrome: clinical characteristics and age-specific recommendations for medical management. *Am J Med Genet C: Semin Med Genet*. 2013;163C(1):55–63. doi:10.1002/ajmg.c.31349.
- Anawalt BD. Approach to male infertility and induction of spermatogenesis. *J Clin Endocrinol Metab*. 2013;98(9):3532–42. doi:10.1210/jc.2012-2400.
- Andersen CY, Westergaard LG, van Wely M. FSH isoform composition of commercial gonadotrophin preparations: a neglected aspect? *Reprod BioMed Online*. 2004;9(2):231–6.
- Attia AM, Abou-Setta AM, Al-Inany HG. Gonadotrophins for idiopathic male factor subfertility. *Cochrane Database Syst Rev*. 2013;8:CD005071. doi:10.1002/14651858.CD005071.pub4.
- Bu Q, Pan Z, Jiang S, Wang A, Cheng H. The effectiveness of hCG and LHRH in Boys with Cryptorchidism: a meta-analysis of randomized controlled trials. *Horm Metab Res*. 2016; 48(5):318–24. doi:10.1055/s-0042-104059.
- Chandrapal JC, Nielson S, Patel DP, Zhang C, Presson AP, Brant WO, et al. Characterizing the safety of clomiphene citrate in male patients through PSA, hematocrit, and testosterone levels. *BJU Int*. 2016. doi:10.1111/bju.13546.
- Check JH, Chase JS, Nowroozi K, Wu CH, Adelson HG. Empirical therapy of the male with clomiphene in couples with unexplained infertility. *Int J Fertil*. 1989;34(2):120–2.
- Chua ME, Escusa KG, Luna S, Tapia LC, Dofitas B, Morales M. Revisiting oestrogen antagonists (clomiphene or tamoxifen) as medical empiric therapy for idiopathic male infertility: a meta-analysis. *Andrology*. 2013;1(5):749–57. doi:10.1111/j.2047-2927.2013.00107.x.
- Ciccarelli A, Guerra E, De Rosa M, Milone F, Zarrilli S, Lombardi G, et al. PRL secreting adenomas in male patients. *Pituitary*. 2005;8(1):39–42. doi:10.1007/s11102-005-5084-3.
- Colacurci N, Monti MG, Fornaro F, Izzo G, Izzo P, Trotta C, et al. Recombinant human FSH reduces sperm DNA fragmentation in men with idiopathic oligoasthenoteratozoospermia. *J Androl*. 2012;33(4):588–93. doi:10.2164/jandrol.111.013326.

- Cole HH, Hart GH. The potency of blood serum of mares in progressive stages of pregnancy in affecting the sexual maturity of the immature rat. *Am J Phys.* 1930;93:57.
- Cortes D, Thorup J, Visfeldt J. Hormonal treatment may harm the germ cells in 1 to 3-year-old boys with cryptorchidism. *J Urol.* 2000;163:1290–2. doi:10.1016/S0022-5347(05)67763-4.
- de Ronde W, de Jong FH. Aromatase inhibitors in men: effects and therapeutic options. *Reprod Biol Endocrinol.* 2011;9:93. doi:10.1186/1477-7827-9-93.
- Ding YM, Zhang XJ, Li JP, Chen SS, Zhang RT, Tan WL, Shi XJ. Treatment of idiopathic oligozoospermia with recombinant human follicle-stimulating hormone: a prospective, randomized, double-blind, placebo-controlled clinical study in Chinese population. *Clin Endocrinol.* 2015;83(6):866–71. doi:10.1111/cen.12770.
- Dunkel L, Taskinen S, Hovatta O, Tilly JL, Wikström S. Germ cell apoptosis after treatment of cryptorchidism with human chorionic gonadotropin is associated with impaired reproductive function in the adult. *J Clin Invest.* 1997;100:2341–6. doi:10.1172/JCI119773.
- Dwyer AA, Raivio T, Pitteloud N. Gonadotrophin replacement for induction of fertility in hypogonadal men. *Best Pract Res Clin Endocrinol Metab.* 2015;29(1):91–103. doi:10.1016/j.beem.2014.10.005.
- Dwyer AA, Raivio T, Pitteloud N. Management of endocrine disease: reversible hypogonadotropic hypogonadism. *Eur J Endocrinol.* 2016;174(6):R267–74. doi:10.1530/EJE-15-1033.
- Eshkol A, Lunenfeld B. Purification and separation of follicle stimulating hormone (FSH) and luteinizing hormone (LH) from human menopausal gonadotrophin (HMG) Part III. *Acta Endocrinol.* 1967;54:919.
- Fares FA, Suganuma N, Nishimori K, LaPolt PS, Hsueh AJ, Boime I. Design of a long-acting follitropin agonist by fusing the C-terminal sequence of the chorionic gonadotropin beta subunit to the follitropin beta subunit. *Proc Natl Acad Sci U S A.* 1992;89(10):4304–8.
- Ferlin A, Vinanzi C, Selice R, Garolla A, Frigo AC, Foresta C. Toward a pharmacogenetic approach to male infertility: polymorphism of follicle-stimulating hormone beta-subunit promoter. *Fertil Steril.* 2011;96(6):1344–9 e2. doi:10.1016/j.fertnstert.2011.09.034.
- Fevold SL, Hisaw FL, Leonard SL. The gonad-stimulating and the luteinizing hormones of the anterior lobe of the hypophysis. *Am J Phys.* 1931;97:291–301.
- Foresta C, Bettella A, Spolaore D, Merico M, Rossato M, Ferlin A. Suppression of the high endogenous levels of plasma FSH in infertile men are associated with improved Sertoli cell function as reflected by elevated levels of plasma inhibin B. *Hum Reprod.* 2004;19(6):1431–7. doi:10.1093/humrep/deh255.
- Foresta C, Selice R, Moretti A, Pati MA, Carraro M, Engl B, et al. Gonadotropin administration after gonadotropin-releasing-hormone agonist: a therapeutic option in severe testiculopathies. *Fertil Steril.* 2009;92(4):1326–32. doi:10.1016/j.fertnstert.2008.07.1766.
- Freda PU, Beckers AM, Katznelson L, Molitch ME, Montori VM, Post KD, et al. Pituitary incidentaloma: an endocrine society clinical practice guideline. *J Clin Endocrinol Metab.* 2011;96(4):894–904. doi:10.1210/jc.2010-1048.
- Garg H, Kumar R. Empirical drug therapy for idiopathic male infertility: what is the new evidence? *Urology.* 2015;86(6):1065–75. doi:10.1016/j.urology.2015.07.030.
- Garolla A, Selice R, Engl B, Bertoldo A, Menegazzo M, Finos L, et al. Spermatid count as a predictor of response to FSH therapy. *Reprod BioMed Online.* 2014;29(1):102–12. doi:10.1016/j.rbmo.2014.02.014.
- Gordon K. New developments in gonadotrophin pharmacology. *Reprod BioMed Online.* 2002; 5(3):259–64.
- Gromoll J, Simoni M, Nieschlag E. An activating mutation of the follicle-stimulating hormone receptor autonomously sustains spermatogenesis in a hypophysectomized man. *J Clin Endocrinol Metab.* 1996;81(4):1367–70. doi:10.1210/jcem.81.4.8636335.
- Han TS, Bouloux PM. What is the optimal therapy for young males with hypogonadotropic hypogonadism? *Clin Endocrinol.* 2010;72(6):731–7. doi:10.1111/j.1365-2265.2009.03746.x.



- Huhtaniemi I. A short evolutionary history of FSH-stimulated spermatogenesis. *Horm (Athens)*. 2015;14(4):468–78. doi:10.14310/horm.2002.1632.
- Isidori AM, Caprio M, Strollo F, Moretti C, Frajese G, Isidori A, Fabbri A. Leptin and androgens in male obesity: evidence for leptin contribution to reduced androgen levels. *J Clin Endocrinol Metab*. 1999;84(10):3673–80.
- Isidori AM, Lenzi A. Risk factors for androgen decline in older males: lifestyle, chronic diseases and drugs. *J Endocrinol Invest*. 2005;28(3 Suppl):14–22.
- Isidori AM, Giannetta E, Pozza C, Bonifacio V, Isidori A. Androgens, cardiovascular disease and osteoporosis. *J Endocrinol Invest*. 2005;28(10 Suppl):73–9.
- Isidori AM, Giannetta E, Lenzi A. Male hypogonadism. *Pituitary*. 2008;11(2):171–80.
- Isidori AM, Pozza C, Gianfrilli D, Isidori A. Medical treatment to improve sperm quality. *Reprod BioMed Online*. 2006;12(6):704–14.
- Kamischke A, Nieschlag E. Analysis of medical treatment of male infertility. *Hum Reprod*. 1999;14(Suppl 1):1–23.
- Kamischke A, Behre HM, Bergmann M, Simoni M, Schafer T, Nieschlag E. Recombinant human follicle stimulating hormone for treatment of male idiopathic infertility: a randomized, double-blind, placebo-controlled, clinical trial. *Hum Reprod*. 1998;13(3):596–603.
- Kobori Y, Suzuki K, Iwahata T, Shin T, Sato R, Nishio K, et al. Induction of spermatogenesis by rhFSH for azoospermia due to spermatogenic dysfunction with maturation arrest: five case series. *Syst Biol Reprod Med*. 2015;61(3):168–70. doi:10.3109/19396368.2015.1024897.
- Kumar R. Medical management of non-obstructive azoospermia. *Clin (Sao Paulo)*. 2013;68(Suppl 1):75–9.
- Liu PY, Turner L, Rushford D, McDonald J, Baker HW, Conway AJ, et al. Efficacy and safety of recombinant human follicle stimulating hormone (Gonal-F) with urinary human chorionic gonadotrophin for induction of spermatogenesis and fertility in gonadotrophin-deficient men. *Hum Reprod*. 1999;14(6):1540–5.
- Liu PY, Baker HW, Jayadev V, Zacharin M, Conway AJ, Handelsman DJ. Induction of spermatogenesis and fertility during gonadotropin treatment of gonadotropin-deficient infertile men: predictors of fertility outcome. *J Clin Endocrinol Metab*. 2009;94(3):801–8. doi:10.1210/jc.2008-1648.
- Luciano AA. Clinical presentation of hyperprolactinemia. *J Reprod Med*. 1999;44(Suppl 12):1085–90.
- Lunenfeld B. Historical perspectives in gonadotrophin therapy. *Hum Reprod Update*. 2004;10(6):453–67. doi:10.1093/humupd/dmh044.
- Matsumoto AM, Karpas AE, Bremner WJ. Chronic human chorionic gonadotropin administration in normal men: evidence that follicle-stimulating hormone is necessary for the maintenance of quantitatively normal spermatogenesis in man. *J Clin Endocrinol Metab*. 1986;62(6):1184–92. doi:10.1210/jcem-62-6-1184.
- Mellinger RC, Thompson RJ. The effect of clomiphene citrate in male infertility. *Fertil Steril*. 1966;17(1):94–103.
- Micic S, Dotlic R. Evaluation of sperm parameters in clinical trial with clomiphene citrate of oligospermic men. *J Urol*. 1985;133(2):221.
- Nieschlag E, Lenzi A. The conventional management of male infertility. *Int J Gynaecol Obstet*. 2013;123(Suppl 2):S31–5. doi:10.1016/j.ijgo.2013.09.001.
- Nieschlag E, Ferlin A, Gravholt CH, Gromoll J, Kohler B, Lejeune H, et al. The Klinefelter syndrome: current management and research challenges. *Andrology*. 2016;4(3):545–9. doi:10.1111/andr.12208.
- Page ST. Physiologic role and regulation of intratesticular sex steroids. *Curr Opin Endocrinol Diabetes Obes*. 2011;18(3):217–23. doi:10.1097/MED.0b013e328345d50e.
- Paradisi R, Natali F, Fabbri R, Battaglia C, Seracchioli R, Venturoli S. Evidence for a stimulatory role of high doses of recombinant human follicle-stimulating hormone in the treatment of male-factor infertility. *Andrologia*. 2014;46(9):1067–72. doi:10.1111/and.12194.

- Patil M. Gonadotrophins: the future. *J Hum Reprod Sci.* 2014;7(4):236–48. doi:10.4103/0974-1208.147490.
- Pavlovich CP, King P, Goldstein M, Schlegel PN. Evidence of a treatable endocrinopathy in infertile men. *J Urol.* 2001;165(3):837–41.
- Practice Committee of American Society for Reproductive Medicine BA. Gonadotropin preparations: past, present, and future perspectives. *Fertil Steril.* 2008;90(Suppl 5):S13–20. doi:10.1016/j.fertnstert.2008.08.031.
- Raman JD, Schlegel PN. Aromatase inhibitors for male infertility. *J Urol.* 2002;167(2 Pt 1):624–9.
- Ramasamy R, Ricci JA, Palermo GD, Gosden LV, Rosenwaks Z, Schlegel PN. Successful fertility treatment for Klinefelter's syndrome. *J Urol.* 2009;182(3):1108–13. doi:10.1016/j.juro.2009.05.019.
- Ramasamy R, Stahl PJ, Schlegel PN. Medical therapy for spermatogenic failure. *Asian J Androl.* 2012;14(1):57–60. doi:10.1038/aja.2011.63.
- Rastrelli G, Corona G, Mannucci E, Maggi M. Factors affecting spermatogenesis upon gonadotropin-replacement therapy: a meta-analytic study. *Andrology.* 2014;2(6):794–808. doi:10.1111/andr.262.
- Roth MY, Amory JK, Page ST. Treatment of male infertility secondary to morbid obesity. *Nat Clin Pract Endocrinol Metab.* 2008;4(7):415–9. doi:10.1038/ncpendmet0844.
- Roth LW, Ryan AR, Meacham RB. Clomiphene citrate in the management of male infertility. *Semin Reprod Med.* 2013;31(4):245–50. doi:10.1055/s-0033-1345271.
- Russell LD, Ren HP, Sinha Hikim I, Schulze W, Sinha Hikim AP. A comparative study in twelve mammalian species of volume densities, volumes, and numerical densities of selected testis components, emphasizing those related to the Sertoli cell. *Am J Anat.* 1990;188(1):21–30. doi:10.1002/aja.1001880104.
- Santi D, Simoni M. Biosimilar recombinant follicle stimulating hormones in infertility treatment. *Expert Opin Biol Ther.* 2014;14(10):1399–409. doi:10.1517/14712598.2014.925872.
- Santi D, Granata AR, Simoni M. FSH treatment of male idiopathic infertility improves pregnancy rate: a meta-analysis. *Endocr Connect.* 2015;4(3):R46–58. doi:10.1530/EC-15-0050.
- Schiff JD, Palermo GD, Veeck LL, Goldstein M, Rosenwaks Z, Schlegel PN. Success of testicular sperm extraction [corrected] and intracytoplasmic sperm injection in men with Klinefelter syndrome. *J Clin Endocrinol Metab.* 2005;90(11):6263–7. doi:10.1210/jc.2004-2322.
- Schlegel PN. Aromatase inhibitors for male infertility. *Fertil Steril.* 2012;98(6):1359–62. doi:10.1016/j.fertnstert.2012.10.023.
- Selice R, Garolla A, Pengo M, Caretta N, Ferlin A, Foresta C. The response to FSH treatment in oligozoospermic men depends on FSH receptor gene polymorphisms. *Int J Androl.* 2011;34(4):306–12. doi:10.1111/j.1365-2605.2010.01086.x.
- Selman HA, Cipollone G, Stuppia L, De Santo M, Sterzik K, El-Danasouri I. Gonadotropin treatment of an azoospermic patient with a Y-chromosome microdeletion. *Fertil Steril.* 2004;82(1):218–9. doi:10.1016/j.fertnstert.2003.11.055.
- Selman H, De Santo M, Sterzik K, Cipollone G, Aragona C, El-Danasouri I. Rescue of spermatogenesis arrest in azoospermic men after long-term gonadotropin treatment. *Fertil Steril.* 2006;86(2):466–8. doi:10.1016/j.fertnstert.2005.12.055.
- Simoni M, Casarini L. Mechanisms in endocrinology: genetics of FSH action: a 2014-and-beyond view. *Eur J Endocrinol.* 2014;170(3):R91–107. doi:10.1530/EJE-13-0624.
- Simoni M, Nieschlag E, Gromoll J. Isoforms and single nucleotide polymorphisms of the FSH receptor gene: implications for human reproduction. *Hum Reprod Update.* 2002;8(5):413–21.
- Simoni M, Santi D, Negri L, Hoffmann I, Muratori M, Baldi E, et al. Treatment with human, recombinant FSH improves sperm DNA fragmentation in idiopathic infertile men depending on the FSH receptor polymorphism p.N680S: a pharmacogenetic study. *Hum Reprod.* 2016. doi:10.1093/humrep/dew167.
- Sinisi AA, Esposito D, Bellastella G, Maione L, Palumbo V, Gandini L, et al. Efficacy of recombinant human follicle stimulating hormone at low doses in inducing spermatogenesis

- and fertility in hypogonadotropic hypogonadism. *J Endocrinol Investig.* 2010;33(9):618–23. doi:10.3275/7022. 1007/BF03346659.
- Trussell JC. Male reproductive endocrinology: when to replace gonadotropins. *Semin Reprod Med.* 2013;31(4):237–44. doi:10.1055/s-0033-1345270.
- Tuttelmann F, Laan M, Grigorova M, Punab M, Sober S, Gromoll J. Combined effects of the variants FSHB -211G > T and FSHR 2039A > G on male reproductive parameters. *J Clin Endocrinol Metab.* 2012;97(10):3639–47. doi:10.1210/jc.2012-1761.
- Valenti D, La Vignera S, Condorelli RA, Rago R, Barone N, Vicari E, et al. Follicle-stimulating hormone treatment in normogonadotropic infertile men. *Nat Rev Urol.* 2013;10(1):55–62. doi:10.1038/nrurol.2012.234.
- Vandekerckhove P, Lilford R, Vail A, Hughes E. WITHDRAWN: clomiphene or tamoxifen for idiopathic oligo/asthenospermia. *Cochrane Database Syst Rev.* 1996;4:CD000151. doi:10.1002/14651858.CD000151.
- Wibowo E, Pollock PA, Hollis N, Wassersug RJ. Tamoxifen in men: a review of adverse events. *Andrology.* 2016. doi:10.1111/andr.12197.
- Willems AE, Corbo JM, Brown JN. Clomiphene for the treatment of male infertility. *Reprod Sci.* 2013;20(7):739–44. doi:10.1177/1933719112466304.
- Zondek B. Ueber die Hormone des Hypophysenvorderlappens. *Klin Wochenschr.* 1930;9:245–8.

Aldo E. Calogero, Rosita A. Condorelli, and Sandro La Vignera

## Abstract

A nonhormonal medical treatment can be used in patients with male infertility. When the cause has not been identified, the treatment is defined empirical and the empirical nonhormonal medical treatment involves the use of anti-inflammatory, fibrinolytic and antioxidant compounds, oligo-elements, and vitamin supplementation. This empirical therapy is prescribed to patients with idiopathic or non-curable oligo-astheno-teratozoospermia and for selected normozoospermic infertile patients. The treatment is defined rational if the pathogenic mechanism can be solved or the cause be ameliorated through the use of specific treatment. This includes antibiotics, anti-inflammatory drugs, and/or antioxidants required for infection, inflammation, and/or increased oxidative stress. Combined therapies can contribute to the improvement of sperm quality.

## Keywords

Male infertility • Nonhormonal treatment • Sperm parameters

## Contents

Introduction .....	1092
Rational Treatment .....	1092
Antibiotic Treatment .....	1093
Quinolones .....	1093
Trimethoprim .....	1093

A.E. Calogero (✉) • R.A. Condorelli • S. La Vignera  
Department of Clinical and Experimental Medicine, University of Catania, Catania, Italy  
e-mail: [acaloger@unict.it](mailto:acaloger@unict.it); [rositacondorelli@email.it](mailto:rositacondorelli@email.it); [sandrolavignera@unict.it](mailto:sandrolavignera@unict.it)

Tetracyclines .....	1094
Macrolides .....	1094
β-Lactam Antibiotics .....	1094
Eradication Rate .....	1095
Antibiotics and Sperm Toxicity .....	1095
Critical Summary on the Antibiotic Treatment .....	1096
Empirical Treatment .....	1096
Anti-inflammatory Treatment .....	1098
Nonsteroidal Anti-inflammatory Drugs .....	1098
Antioxidants .....	1099
Summary .....	1107
References .....	1107

---

## Introduction

The nonhormonal medical treatment has a relevant role in male infertility. Indeed, it may act on spermatozoa and/or it may improve the environment where spermatozoa are produced and mature to ameliorate sperm parameters and to improve fertility. The nonhormonal treatment may be classified as rational and empirical treatment.

---

## Rational Treatment

A rational treatment is prescribed when the cause of infertility has been identified and it is curable. This treatment is based on drugs that can eradicate the etiological agent responsible of the disease. In case of urogenital tract infections, the rational treatment for infertility is based on the use of specific antibiotics, following identification of the microorganisms by microbiological investigation and the relative antibiogram.

In culture of diluted seminal plasma, the microbial forms show the growth of more than  $10^3$  pathogenic bacteria or more than  $10^4$  nonpathogenic bacteria per ml. The etiological agents of sexually transmitted diseases (*Chlamydia trachomatis*, *Ureaplasma urealyticum*, *Treponema pallidum*, *Neisseria gonorrhoeae*, etc.) and some Gram-negative bacteria (Enterobacteriaceae such as *Escherichia coli*, Klebsiella species, Proteus, Serratia, Pseudomonas species, etc.) are recognized as “certain pathogens” of the prostate (category II according to the National Institutes of Health classification). On the other hand, some microorganisms occasionally detectable in the urogenital tract, are considered as “nonpathogenic,” “likely pathogens,” “occasional pathogens” (Gram-positive germs, such as *Enterococcus spp.*, *Staphylococcus aureus*, obligate anaerobes) or “possible pathogens” (coagulase-negative germs, such as *Staphylococcus haemolyticus*, *Staphylococcus epidermidis*, mycoplasmas) (La Vignera et al. 2014). Recently, elevated frequency of HPV infection has arose in patients with infertility (La Vignera et al. 2015). HPV is a viral form and therefore it does not respond to antibiotic treatment.

## Antibiotic Treatment

Targeted therapy is recommended and the choice of the antibiotic should be based on the nature of the microorganism identified and the results of the relative antibiogram. Several classes of antibiotics may be used (Grabe et al. 2013; Rees et al. 2015), but the most frequently used families of antimicrobial drugs for the treatment of the microbial forms are fluoroquinolones, macrolides, and tetracyclines (Magri et al. 2011; Perletti et al. 2013).

### Quinolones

Quinolones (ciprofloxacin, levofloxacin, ofloxacin, norfloxacin, pefloxacin, enoxacin, fleroxacin, lomefloxacin, and other new ones) are considered a first-line therapy. Although there are differences in peak serum concentrations and  $\beta$ -elimination half-life, this class of antibiotics has a favorable pharmacokinetic profile and excellent oral bioavailability (greater than 95%). As suggested by high volumes of distribution and low binding to serum proteins, their penetration into many body tissues and fluids is advantageous. They have an excellent ability to penetrate into the prostate and good activity against typical and atypical pathogens.

Oral bioavailability of quinolones has been shown to be good in sick as well as healthy subjects but is reduced by co-administration with magnesium- and aluminum-containing acids, sucralfate (which contains aluminum), or ferrous sulfate (Wolfson and Hooper 1991). They are associated with phototoxicity, CNS adverse events (variable among the different agents), and tendonitis.

Quinolones more frequently used in the clinical practice are ciprofloxacin and levofloxacin. Ciprofloxacin is absorbed primarily in the duodenum and jejunum, and according to some studies it is cleared by transepithelial elimination into the bowel lumen as well as by the renal route. Levofloxacin seems to offer advantages over ciprofloxacin for bacterial eradication rates and clinical improvement in patients with chronic prostatitis (Zhang et al. 2012), whereas another study of similar sample size and design did not show significant differences (Bundrick et al. 2003).

Dose and duration should be sufficient to eradicate the infection, for example, ciprofloxacin 500 mg (once or twice/day), levofloxacin 500 mg (once/daily) for 20–28 days. The treatment should be given for 4–6 weeks after initial diagnosis (Grabe et al. 2013). It may be split into two cycles of 10–14 days, separated by an interval of 1–2 weeks to reduce the adverse effects with a better compliance and eradication.

### Trimethoprim

Trimethoprim is a second-line therapy. This antibiotic is rapidly absorbed from the gastrointestinal tract and widely distributed into body tissues and fluids, including

seminal fluid and prostatic tissue. It is eliminated by glomerular filtration and tubular secretion in urine; only small amounts are excreted in feces by biliary elimination. Trimethoprim is active against many relevant pathogens, but has no activity against *Pseudomonas*, some enterococci, and some enterobacteriaceae. Monitoring is unnecessary.

Dose and duration should be sufficient to eradicate the infection, for example, 200 mg once or twice/day for 28 days. The treatment may be split into two cycles of 10–14 days, separated by an interval of 1–2 weeks.

## Tetracyclines

Tetracyclines are a second-line therapy. They are readily absorbed and bound by plasma proteins, concentrated by the liver in the bile and excreted in the urine and feces at high concentrations in a biologically active form. Tetracyclines are contraindicated in renal and liver failure and have a good activity against *Chlamydia trachomatis* and mycoplasmas. These show unreliable activity against coagulase-negative staphylococci, *Escherichia coli*, other enterobacteriaceae, and enterococci and no activity against *Pseudomonas aeruginosa*. They are associated with risk of skin sensitization.

Dose and duration should be sufficient to eradicate the infection. Doxycycline is administered at the dose of 100 mg once or twice/day for 28 days. The treatment may be split into two cycles of 10–14 days, separated by an interval of 1–2 weeks.

## Macrolides

Macrolides are used for selected indications, based on the microbiological findings. They have a good prostate penetration and are effective against *Chlamydia trachomatis* and Gram-positive bacteria, but they have an unreliable activity against Gram-negative bacteria. Minor side effects of macrolide administration include nausea, vomiting, diarrhea, and ringing or buzzing in the ears (tinnitus). Serious side effects, including allergic reaction and cholestatic hepatitis (inflammation and congestion of bile ducts in the liver), are generally associated only with the use of erythromycin.

Dose and duration should be sufficient to eradicate the infection. Azithromycin is prescribed at the dose of 1 g once/day for 7–10 days.

## β-Lactam Antibiotics

β-Lactam antibiotics (penicillin derivatives, cephalosporins, monobactams, carbapenems) have a limited use in male infertility. They can be used in male urogenital quinolone-resistant infections, such as acute prostatitis caused by

extended-spectrum  $\beta$ -lactamase-producing bacteria, which seems to be sensitive to imipenem, ceftioxin, and amoxicillin/clavulanic acid (Oh et al. 2013).

Other uses of  $\beta$ -lactam antibiotics include management of *Neisseria gonorrhoeae* infections. It is the second most commonly reported sexually transmitted bacterial infection in the United States, after *Chlamydia trachomatis*, and the prevalence of this infection has increased in recent decades. The 2015 Centers for Disease Control and Prevention guidelines recommend dual therapy with intramuscular ceftriaxone and oral azithromycin as first-line treatment, but there is a high level of resistance to this type of treatment (Lancaster et al. 2015).

The recommended dose for uncomplicated gonococcal urethral infections is a single dose of ceftriaxone, 250 mg intramuscularly, and either azithromycin (1 g orally) or doxycycline (100 mg orally twice/day) for 7 days.

## Eradication Rate

A number of studies have compared the microbiological eradication rate between the different antibiotics (Table 1). Higher eradication rates (>90%) have been reported with azithromycin and levofloxacin either prescribed alone, in combination, or sequentially, depending upon the infection site (urethral, prostatic, or both) in patients with chronic bacterial prostatitis by *Chlamydia trachomatis* infection (Magri et al. 2010) (Table 1).

## Antibiotics and Sperm Toxicity

The antibiotic treatment is essential to preserve or restore normal sperm parameters in urogenital infections, but some of them have a spermiotoxic effect. Data on both testicular and sperm toxicity for some antibiotics have been shown in rats or mice, but randomized clinical trials do not show these effects directly in humans. The toxicity has been shown for ciprofloxacin and pefloxacin (Abd-Allah et al. 2000), ofloxacin (El-Harouny et al. 2010), lomefloxacin (Singh et al. 2003), tetracyclines (Farombi et al. 2008), cefonicid and other cephalosporins (Manson et al. 1987), and norfloxacin in quails (Singh et al. 2013).

**Table 1** Main antibiotics used in clinical practice and their eradication rates

Antibiotic	Eradication rate	References
Ciprofloxacin	40–77%	Bundrick et al. 2003; Skerk et al. 2003
Levofloxacin	75%	Bundrick et al. 2003
Azithromycin	80%	Skerk et al. 2002, 2003, 2004
Doxycycline	77%	Skerk et al. 2004
Clarithromycin	80%	Skerk et al. 2002
Azithromycin + ciprofloxacin	62–77%	Magri et al. 2011



## Critical Summary on the Antibiotic Treatment

Antibiotic treatment is prescribed only in microbial forms to eradicate the etiopathogenic noxa and to improve the microenvironment where spermatozoa mature. The most commonly used antibiotics in the clinical practice of male infertility are quinolones (ciprofloxacin and levofloxacin). Their sperm toxicity has not been shown in humans.

---

## Empirical Treatment

Patients with idiopathic oligo-astheno-teratozoospermia (OAT), with OAT due to a noncurable disease and in normozoospermic infertile patients without identifiable risk factors for infertility, often undergo to empirical nonhormonal medical treatment because, sometime, a slight improvement of the sperm parameters enable them to impregnate their partners. Inflammation and/or increased oxidative stress are two conditions that interfere with the reproductive function. They often coexist and can be treated with an empirical treatment. However, studies that clearly show the effectiveness of this treatment are scanty. Anti-inflammatory, fibrinolytic, and antioxidant compounds, oligo-elements, and vitamin supplementation are used as empirical treatment. The male partners of infertile couples undergoing assisted reproduction techniques (ART) are often prescribed antioxidants, but further studies are required to clarify the role of these compounds (Showell et al. 2014).

The urogenital inflammatory forms are characterized by leukocytospermia (seminal fluid leukocyte concentration  $>10^6/\text{ml}$ ) and/or overproduction of reactive oxygen species (ROS). An increased number of leukocytes in the seminal fluid may persist even after antibiotic treatment of the urogenital microbial forms in some patients with complicated infection of the male accessory glands, such as prostatovesiculo-epididymitis (PVE). In addition to leukocytospermia (WHO 2010), these patients have often abnormal conventional sperm parameters (concentration, motility, and morphology) (Yanushpolsky et al. 1996) and other signs of inflammation. Seminal leukocytes are predominantly polymorphonuclear leukocytes (neutrophils), but histochemistry, the technique used for their identification (based on the presence of peroxidase in granulocytes) does not detect other types of leukocytes. Other markers of inflammation are represented by some cytokines (IL-1, IL-2, IL-6, IL-8, IL-18,  $\alpha\text{TNF}$   $\gamma\text{INF}$ ) (La Vignera et al. 2013). In these patients, therefore, anti-inflammatory treatment is indicated. This may be done using nonsteroidal anti-inflammatory drugs (NSAIDs) (Lackner et al. 2006) that can be administered simultaneously to or after the antibiotic therapy (Vicari et al. 2001), or using nutraceutical compounds with anti-inflammatory and fibrinolytic properties.

Oxidative stress damages spermatozoa by increasing the production of ROS, byproducts of aerobic life, that exceeds the natural scavenger ability of spermatozoa and of the seminal fluid. ROS play a physiological, useful role on sperm function. Indeed, spermatozoa produce a small amount of ROS in their earliest stages of development (Agarwal et al. 2004) that play a physiological role in sperm chromatin

condensation and in the balance between apoptosis and proliferation of spermatogonia (Fisher and Aitken 1997). In mature spermatozoa, ROS are necessary for the capacitation process and the acrosome reaction. They are involved in mitochondrial sheath stability and sperm motility. Spermatozoa with abnormal morphology, mainly those immature, with cytoplasmic residues, and reduced fertile potential produce higher amount of ROS than spermatozoa with normal morphology (Gomez et al. 1996; Aitken 1999). In fertile men, ROS production and the total antioxidant capacity remain in balance (Jung and Seo 2014). Infections, autoimmune disorders, chronic disease, advanced age, alcohol consumption, cigarette smoking, stress, and obesity alter this balance and increase the oxidative stress (Agarwal et al. 2014).

The seminal plasma contains natural antioxidants, such as vitamins C and E, superoxide dismutase (SOD), glutathione, uric acid, and the polyamine spermine that acts as a free radical scavenger (Opuwari and Henkel 2016). Mature spermatozoa are particularly susceptible to oxidative stress because of the high concentration of unsaturated lipids in the plasma membrane and the relative paucity of oxyradical scavenger enzyme, due to the virtual absence of cytoplasm. Superoxide anion radical ( $O_2^-$ ) is the main ROS produced by spermatozoa, which generates hydrogen peroxide spontaneously or following SOD activity. The pathways that contribute to ROS production are the NADPH oxidase system at level of cell plasma membrane and the NADH oxidoreductase at the mitochondria level (Lanzafame et al. 2009).

Infections and/or inflammation of the urogenital tract that increase the number of seminal leukocytes and their activation causes ROS overproduction because leukocytes physiologically produce up to 1000 times more ROS than spermatozoa. This ROS production plays an important role in the cellular defense mechanism against infections and inflammation, but concomitantly it damages spermatozoa. Varicocele, long sexual abstinence, or exposure to environmental factors increases also the number of leukocytes in the seminal plasma (Walczak-Jedrzejowska et al. 2013; Lahdetie 1995; Thonneau et al. 1998; Slowikowska-Hilczer 2006; De Celis 1996; Agarwal et al. 2009).

In the seminal plasma, a target of ROS action is the polyunsaturated fatty acids of the sperm plasma membrane that leads to lipid peroxidation, measurable as malondialdehyde (MDA) and as loss of sperm motility (Opuwari and Henkel 2016). ROS overproduction alters biofunctional sperm parameters with single- and double-strand DNA breaks, an increased DNA protein cross-linking (La Vignera et al. 2013), and mitochondrial DNA damage (Opuwari et al. 2016). Spermatozoa with fragmented DNA show a deterioration of conventional parameters such as sperm count, morphology, motility, and fertilization rate (Lanzafame et al. 2009; Opuwari and Henkel 2016).

Antioxidants are advantageous because they are widely available and relatively inexpensive when compared to other molecules used for fertility treatment. Furthermore, there is no evidence of adverse events and they seem to be effective in improving sperm parameters and in increasing couple's chance of having a live birth. Indeed, an updated review, including 48 randomized controlled trials, has compared the effects of combined antioxidant with placebo, no treatment, or another antioxidant in 4179 subfertile men. Four randomized controlled trials suggest that

antioxidants improve live birth rates in couples attending fertility clinics and increase the pregnancy rate, though with a low quality evidence. These findings support the administration of molecules with antioxidant properties in patients with oxidative stress-induced sperm damage (Showell et al. 2014).

---

## Anti-inflammatory Treatment

### Nonsteroidal Anti-inflammatory Drugs

#### Salicylates

Salicylates include diflunisal and salsalates. There are no available data on the last two categories. Mesalazine has a negative effect on fertility. Indeed, sperm concentration and motility, percentage of spermatozoa with normal form, seminal fluid volume, and total motile sperm count increase after mesalazine discontinuation (Shin et al. 2014), and patients with irritable bowel disease require treatment cessation to achieve fertility. Sulfasalazine administration to mice results in decreased sperm count and motility (Sharma and Kalla 1994). The administration of salicylate (650 mg four times a day) significantly decreased sperm motility after 3 days of treatment in four patients. This detrimental effect does not seem to be due to necrozoospermia (Porat-Soldin and Soldin 1992).

#### Profens

Few data are available on profens. A study showed that ibuprofen might cause a significant alteration of sperm parameters and chromatin/DNA integrity in mice. These deleterious effects are dose-dependent and are observed in early and late stages of drug administration (Roodbari et al. 2015). On the other hand, Vargas and colleagues showed that a reproductive damage induced by continuous or intermittent hypoxia is partially ameliorated by the simultaneous treatment with ibuprofen (Vargas et al. 2011).

#### Cox-2 Inhibitors

The data are contrasting for this class of NSAIDs. Sperm motility and morphology improved and seminal fluid leukocyte concentration decreased in patients with amicrobial leukocytospermia undergoing ART who were treated with rofecoxib (Gambera et al. 2007). Similar data have been reported in patients who were given valdecoxib (Lackner et al. 2006). The dosage used in these studies was 25 mg/day for rofecoxib (for 30 days) or 20 mg/day for valdecoxib (for 2 weeks). According to some authors, sperm parameters (with the exception of morphology) improved in patients with chronic pelvic pain syndrome treated with a combination of  $\alpha$ -blockers and coxibs (Byun et al. 2012). These findings suggest that coxibs may be prescribed in infertile patients with leukocytospermia, but only prospective, nonrandomized studies may support this conclusion. On the other hand, studies in mice and turkeys showed a negative effect of coxibs on sperm parameters (Kennedy et al. 2003; Duffy and VandeVoort 2011). More data are needed to further evaluate this therapeutic use.

### **Sulfonanilides**

Sulfonanilides include the relatively COX-2 selective nimesulide. The administration of nimesulide (100 mg twice/day for three cycles of 10 days each) to 30 patients with abacterial prostatitis ameliorated the dysuric symptoms and improved inflammatory signs at the transrectal ultrasound prostate evaluation. A significant decrease in the number of abnormal forms has been observed, but no statistically significant changes on sperm count and motility occurred (Canale et al. 1993). Another study showed that nimesulide does not seem to be spermatotoxic in prepubertal rats at normal therapeutic doses (Ugochukwu et al. 2011).

### **Steroidal Anti-inflammatory Drugs**

Glucocorticoids are employed for the treatment of infertility when antisperm antibodies (ASA) are found. Recent studies have investigated the effects of ASA and the correlation between ASA and sperm parameter abnormalities, but inconsistent results have been reported. A meta-analysis showed a significant negative effect of ASA on sperm parameters: indeed, sperm concentration and total motility were lower in ASA-positive patients compared to ASA-negative patients and sperm liquefaction time was longer in ASA-positive patients (Cui et al. 2015). A recent study showed that prednisone (25 mg once/day for 30 days) significantly improved sperm parameters in a selected population of idiopathic oligozoospermic patients with urogenital inflammations (Milardi et al. 2017).

An immune-suppressive treatment has been found poorly effective; hence, other therapeutic strategies have been proposed such as ART (intrauterine insemination and in vitro fertilization) and laboratory techniques (sperm washing, immunomagnetic sperm separation, proteolytic enzyme treatment, and use of immunobeads) (Naz 2004).

### **Critical Summary on Anti-Inflammatory Drugs**

Anti-inflammatory treatment can be prescribed in urogenital inflammation characterized by an increased number of seminal fluid leukocytes. Overall, NSAIDs could be considered for the treatment of the acute forms of male accessory gland inflammation for symptoms relief and they should not be given for chronic usage (if not strict required) in patients with infertility. Glucocorticoids are used to turn off the immune response in the presence of ASA. Additional studies are needed to explore the possibility of positive effects of coxibs in patients with “idiopathic” leukocytospermia.

### **Antioxidants**

The protective antioxidant system comprehends enzymatic factors (superoxide dismutase (SOD), catalase and glutathione peroxidase, GPX), nonenzymatic factors and low molecular weight compounds (glutathione, *N*-acetyl-cysteine (NAC), vitamins A, E, and C, coenzyme Q10 (CoQ10), carnitines, myo-inositol (MYO), lycopene, astaxanthin, *Serenoa repens*, etc.), and micronutrients (selenium, zinc, copper) which interact with each other to ensure an optimal protection against the oxidative stress. A deficiency of one of them may result in a decrease

of total plasma antioxidant capacity (Walczak-Jedrzejowska et al. 2013). The more commonly used antioxidants are discussed below, whereas others with scantier supportive studies are listed in Table 1.

### Glutathione

Glutathione is a sulfur-containing tripeptide present in both a reduced (GSH) and an oxidated (GSSG) state. GSH participates in preserving the intracellular milieu in a reduced state and, in addition, it is an electron donor to GPX. GSH displays its antioxidant activity by the reconstruction of thiol groups ( $-SH$ ) in proteins and preventing cell membrane from lipid oxidation (Walczak-Jedrzejowska et al. 2013).

GSH levels are maintained through two metabolic pathways: one is the de novo synthesis from Cys, Glu, and Gly that is catalyzed by the  $\gamma$ -glutamyl-cysteine synthetase ( $\gamma$ GCS) and glutathione synthetase; and the other is recycling by glutathione reductase, using NADPH as an electron donor. Glutathione is pumped out when it is oxidized or forms conjugates with cytotoxic compounds, including xenobiotical chemicals. Plasma glutathione is hydrolyzed the  $\gamma$ -glutamini-transpeptidase ( $\gamma$ GT), localized at the cellular surface as a membrane protein, into its consisting aminoacids that are then taken up by the specific transporter and reused by cells (Fujii et al. 2003).

In animals, GSH therapy affects positively sperm quality. It increases sperm motility and fertilization in bulls with asthenozoospermia due to varicocele and in rabbits with dysspermia caused by cryptorchidism (Tripodi et al. 2003).

In human seminal plasma, glutathione decrease causes motility disorder due to spermatozoon midpiece instability (Lenzi et al. 1994). In some andrological diseases, particularly during inflammation, some authors suggest that its supplementation plays a therapeutic role. A placebo-controlled, double-blind, and cross-over trial including 20 infertile patients with unilateral varicocele or inflammation of the urogenital tract showed that glutathione administration leads to a significant improvement of sperm motility (forward and kinetic parameters) and morphology (Lenzi et al. 1993). Varicocele and urogenital inflammation are two conditions in which ROS and other toxic compound production plays a pathogenetic role. Their effects on spermatozoa can be partially reversed in case of not too severe structural cell membrane damage (Lenzi et al. 1994), suggesting a protective role of GSH on cell membrane lipid components (Opuwari and Henkel 2016).

Glutathione is given at the dosage of 600 mg/day intramuscularly for 2–3 months. However, this route of administration lowers the compliance, hence GSH is hardly used for the treatment of male infertility.

### N-Acetyl-Cysteine

NAC, a glutathione precursor effective in metal chelation, seems to improve sperm motility and to prevent sperm DNA oxidative damage (Walczak-Jedrzejowska et al. 2013). In an animal model, it improves sperm parameters and seminal vesicles weight, after treatment with  $As_2O_3$  (Silva et al. 2016). In humans, it improves seminal fluid volume and viscosity increasing sperm motility (Ciftci et al. 2009). In women with polycystic ovary syndrome, NAC (administered at the doses of

1500 mg/day) is a viable alternative to metformin because it improves oocyte and embryo quality (Cheraghi et al. 2016). A double-blind, placebo controlled, randomized study showed a significant positive correlation between NAC seminal plasma concentrations and sperm parameters. Indeed, NAC alone or in addition to selenium significantly improved all sperm parameters. These data support a possible use of this compound for the treatment of human infertility (Safarinejad and Safarinejad 2009).

NAC is commercialized in combination with other antioxidants. The oral dosage more frequently used is 600 mg/day and its administration is suggested for at least 3 months.

### **Vitamin C (Ascorbic Acid)**

Vitamin C has a powerful antioxidant action mostly when peroxyradicals are in the aqueous phase (Doba et al. 1985; Frei et al. 1989). It has a 10-fold higher concentration in the seminal plasma than in the serum (Jacob et al. 1992). Vitamin C acts as an antioxidant when the concentration is lower than 1000  $\mu\text{mol/l}$ . In contrast, at higher concentrations, it is a pro-oxidant agent (Wayner et al. 1986; Lanzafame et al. 2009). An intake of 1 g/day provides a 2.2-fold increase in plasma ascorbic acid concentrations (Wen et al. 1997). In mice, at a concentration equivalent to the human therapeutic dose (10 mg/Kg), it is able to decrease malondialdehyde (MDA) concentration (the product of the lipid peroxidation) and it increases sperm count and the percentage of normally shaped spermatozoa (Mishra and Acharya 2004).

In humans, seminal ascorbic acid concentration correlates positively with the percentage of morphologically normal spermatozoa (Thiele et al. 1995) and negatively with DNA fragmentation index (Song et al. 2006). Accordingly, vitamin C (1 g/day) increases sperm concentration, total sperm count, and motility (Eskenazi et al. 2005). A double blind, placebo-controlled clinical trial has shown that vitamin C, after varicocelectomy, increases significantly sperm motility and morphology versus placebo (Cyrus et al. 2015). These above-mentioned findings could support the therapeutic use of vitamin C in selected infertile men. The majority of the studies investigating the effect of vitamin C administration on sperm quality refer to this oral administration (Dawson et al. 1992; Levine et al. 1996). In a randomized, placebo-controlled, double-blind study the administration of high dosage of vitamin C and E did not improve sperm parameters or 24 h sperm survival rate (Rolf et al. 1999). Furthermore, two prospective randomized trials showed that the pregnancy rate did not change significantly after vitamin C treatment compared to the treatment with mesterolone or clomiphene citrate (Hargreave et al. 1984; Abel et al. 1982).

The duration of the treatment has not yet been established, indeed according to some authors, an improvement in sperm parameters was evident after 1 month of treatment (Dawson et al. 1992), but longer periods of treatment are also reported (Levine et al. 1996).

### **Vitamin E**

Vitamin E ( $\alpha$ -tocopherol) is a fat-soluble organic compound mainly localized in cell membranes. Vitamin E defends cell membrane by oxidative stress-induced damage, avoids lipid peroxidation, and captures free hydroxyl radicals and superoxide

(Walczak-Jedrzejowska et al. 2013). In the seminal plasma, the concentration of vitamin E significantly increases after its administration at the dosage of 300 and 1200 mg/day for 3 weeks (Moilanen and Hovatta 1995). Efforts have been made to ascertain the efficacy of vitamin E supplementation on sperm parameters (Kessopoulou et al. 1995). The  $\alpha$ -tocopherol concentration within spermatozoa correlates significantly with the percentage of motile spermatozoa, but it is independent of the total  $\alpha$ -tocopherol concentration in the seminal plasma (Thérond et al. 1996). The enhancement of sperm motility correlates with a decreased sperm production of MDA (Suleiman et al. 1996). A double-blind placebo-controlled trial showed an improved sperm function *in vitro* after 600 mg daily administration of vitamin E for 3 months. Furthermore, the administration improved sperm motility and the sperm capability to bind the hamster oocyte in the hamster egg-penetration test (Kessopoulou et al. 1995). In other studies, lower doses (200 or 300 mg/day) have been used (Giovenco et al. 1987; Moilanen et al. 1993; Geva et al. 1996). However, in a randomized, placebo-controlled, double-blind study, administration of high-dosage of vitamins C and E has shown no significant changes on sperm parameters or 24 h sperm survival rate (Rolf et al. 1999).

A placebo-controlled double-blind study reported an improvement of sperm motility in patients with oligo-astheno-teratozoospermia after vitamin E oral supplementation (Suleiman et al. 1996), and a prospective randomized trial showed that this improvement is greater in combination with clomiphene citrate (ElSheikh et al. 2015). The same conclusions can be made for the pregnancy rate (Ghanem et al. 2010). Furthermore, in the course of the 6-month treatment period, 21% of patients belonging to the treated group achieved pregnancy (Suleiman et al. 1996). Seminal plasma MDA decrease seems to correlate with the success rate of pregnancy. In a prospective study, 15 normozoospermic men with low fertilization rates in previous ART cycles were treated with 200 mg/day of vitamin E for 3 months. The pre-treatment high MDA concentration normalized and the fertilization rate per cycle significantly improved after 1 month of treatment (Geva et al. 1996). In addition, dietary habit plays a role in sperm quality with a positive correlation between vitamin E dietary intake and progressive and total motility (Eskenazi et al. 2005). This finding suggests that vitamin E may have a positive effect on sperm quality and in increasing the pregnancy rate. Therefore, vitamin E could be a therapeutic choice for the treatment of male infertility.

### **Coenzyme Q<sub>10</sub>**

CoQ<sub>10</sub> is the only lipid-soluble antioxidant synthesized endogenously. In the Q-cycle, it is present in three redox states: ubiquinone (CoQ<sub>10</sub>-oxidized), ubiquinol (CoQ<sub>10</sub>H<sub>2</sub>-reduced), and semiquinone (partially reduced, as radical). The reduced form, with higher antioxidant activity, represents approximately 90% of the total CoQ<sub>10</sub>. It inhibits protein and DNA oxidation and lipid peroxidation. CoQ<sub>10</sub> plays a role also in mitochondrial function where it regulates the electron transport in the respiratory chain. It receives electrons from complex I and II and passing them to complex III and transfers protons from fatty acids to the matrix. CoQ<sub>10</sub> also regulates the permeability transition pore opening and nutrition uptake through the

voltage-dependent anion channel (VDAC) of the outer mitochondrial membrane (GvozdjÁková et al. 2015).

Many clinical studies showed the effectiveness of ubiquinone on male fertility. In fact, it has been shown to improve sperm parameters (concentration, motility, and morphology) in patients with idiopathic OAT (Balercia et al. 2009; Safarinejad 2009), with positive effects on the pregnancy rate (Safarinejad 2012). A randomized placebo-controlled study showed a protective effect against the oxidative stress increasing sperm concentration, improving sperm morphology, and increasing catalase and SOD levels, after 3 months of treatment (Nadjarzadeh et al. 2014). The same authors had previously conducted a randomized, double-blind, placebo-controlled trial showing that CoQ<sub>10</sub> had no effects on sperm concentration, morphology, and motility but only on the levels of oxidative stress (Nadjarzadeh et al. 2011). In addition, CoQ<sub>10</sub> treatment improves sperm parameters and antioxidant status in infertile men with varicocele (GvozdjÁková et al. 2015).

In conclusion, a systematic review and meta-analysis have shown that there is no evidence that CoQ<sub>10</sub> increases live birth and pregnancy rate, but the treatment seems to improve all sperm parameters (Lafuente et al. 2013).

Different therapeutic schemes have been reported in literature. The lower dosage used is 90 mg/day for a minimum of 3 months to a maximum of 9 months, but the improvement of sperm parameters has been obtained also by higher dosages (e.g., 100 mg/day for three months, 200 mg for 6 months). The highest dosage reported is 300 mg twice a day for 12 months (GvozdjÁková et al. 2015).

Ubiquinol has a stronger antioxidant effects compared to ubiquinone. It seems to be able to regenerate other antioxidants such as vitamin E and vitamin C. CoQ<sub>10</sub> testicular biosynthesis is very active and high levels of ubiquinol in sperm (Mancini et al. 1998) strongly correlate with sperm count, motility, and morphology (Mancini et al. 1998). Its concentration directly correlates with sperm motility (GvozdjÁková et al. 2015). Ubiquinol is given orally at a dosage of 150 to 200 mg daily, for at least 4 months.

Finally, Carnitine-ubiquinol combination showed a beneficial effect on sperm mitochondrial function of infertile men. It may be due to their uptake by VDAC of the outer mitochondrial membrane, along with the activity of carnitine palmitoyl-transferase I (CPTI) in outer mitochondrial membrane. However, further studies are required to support this hypothesis (GvozdjÁková et al. 2015).

## Carnitine

Currently, carnitine is the molecule with antioxidant activity that has the greatest agreement in literature, especially in its forms L-carnitine and L-acetylcarnitine.

L-Carnitine is a high-polar, water-soluble quaternary amine. Human can synthesize it, but the most used L-carnitine is of exogenous origin. It acts as an essential cofactor for the transport of long chain fatty acids within the mitochondrial matrix to allow the oxidative processes and to participate in the cellular energy production (Agarwal and Said 2004; Ng et al. 2004). L-Acetyl-carnitine is synthesized by acetyl-L-carnitine transferase, the enzyme that modulates the intracellular and mitochondrial concentration of coenzyme A (CoA) and acetyl-CoA (Lenzi et al. 1992;



Vicari et al. 2001). It seems that the high concentrations of carnitine in the male reproductive tract, particularly in the epididymis, correlate with a role in energy metabolism and sperm maturation (Lenzi et al. 1992; Vicari et al. 2001). Some studies have shown a decrease of L-carnitine in the seminal fluid of patients with epididymitis (Bornman et al. 1989; Cooper et al. 1990); thus, carnitine concentration in the ejaculate has been regarded as a marker of epididymal function.

Inflammatory processes cause oxidative stress because they increase ROS production from leukocytes and/or spermatozoa. Accordingly, the antioxidant properties of carnitine have been studied in patients with male accessory gland inflammation. Prostatitis-vesiculitis-epididymitis (PVE) is a disease with the highest level of oxidative stress and some studies have shown the best effect is obtained administering antibiotics first followed by anti-inflammatory drug and subsequently by L-carnitine. The co-administration of antimicrobial agents and antioxidants is less effective, while treatment with L-carnitine alone has no effect (Vicari et al. 2001; Vicari et al. 2002).

The data in the literature show a statistically significant improvement of sperm progressive motility in patients with OAT treated with L-carnitine or acetyl-L-carnitine at the dose of 3 g/day (Moncada et al. 1992; Costa et al. 1994; Vitali et al. 1995) for some months. Moreover, treatment with acetyl-L-carnitine increases sperm motility and viability in asymptomatic infertile patients with ROS overproduction and ultrasonographic evidence of PVE who already received antimicrobial therapy (Vicari and Calogero 2001). There is no evidence of statistical significant variation of marker of epididymal function, such as  $\alpha$ -glycosidase concentration and of sperm membrane lipid peroxidation (Lenzi et al. 2003). Treatment with L-carnitine (2 g/day) and acetyl-L-carnitine (500 mg twice a day) is effective in improving sperm quality in infertile patients (Lenzi et al. 2004; De Rosa et al. 2005) and it improves the total oxyradical scavenging capacity of the seminal fluid (Balercia et al. 2005). In a placebo-controlled randomized trial, the combined treatment with L-carnitine (2 g/day) and acetyl-L-carnitine (1 g/day) seems to be a valid option in patients with OAT because it can improve sperm motility and pregnancy rate (Li et al. 2005). Interestingly, the addition of L-carnitine in samples to be cryopreservation improves significantly sperm quality (Banihani et al. 2014). All these data show the beneficial effects of carnitine on sperm parameters. It can be a potential therapeutic option for the treatment of male infertility.

The best therapeutic scheme is represented by the co-administration of at least 2 g/daily of L-carnitine and at least 1 g/daily of acetyl-L-carnitine for at least 3 months.

### **Myo-inositol**

Inositol is a component of the vitamin B complex. MYO, the most biologically important form in nature, is a precursor of second messengers and it is involved in several signal transduction mechanisms in the cell membrane such as the expression of proteins essential for embryogenetic development and for sperm chemiotaxis and sperm motility. It regulates seminal plasma osmolarity and volume. Furthermore, inositols are involved in sperm capacitation and acrosome reaction.

Oral supplementation with MYO seems to improve sperm parameters (Calogero et al. 2015; Gulino et al. 2016) and the *in vitro* exposure to MYO increases sperm motility and the number of spermatozoa retrieved by swim-up in both normozoospermic men and in patients with abnormal sperm parameters. This suggests an improvement of sperm mitochondrial function in patients with OAT (Condorelli et al. 2011; Condorelli et al. 2012). On this basis, the therapeutic use of MYO has been considered both *in vivo* and *in vitro* assisted reproductive techniques. A prospective two-center, randomized trial has demonstrated that *in vitro* treatment of spermatozoa with myo-inositol seems to improve the fertilization rate and embryo quality on day 3 in ICSI cycles (Rubino et al. 2015). In particular, a double-blind, randomized, placebo-controlled study showed that patients with idiopathic infertility, treated for 3 months with MYO (2 g twice daily), had a significant increase of sperm concentration, total count, progressive motility, and acrosome-reacted spermatozoa. In addition, MYO rebalances LH, FSH, and inhibin-B concentrations (Calogero et al. 2015).

The most frequently reported supplementation strategy consists of a daily oral dose of 4 g (plus 400 µg of folic acid), for at least 2 months.

### **Astaxanthin**

Astaxanthin is a natural occurring xanthophyll. A randomized, double-blind, and placebo-controlled study showed that a supplementation with 16 mg daily of astaxanthin in 30 infertile patients resulted in higher sperm linear velocity, better capacity of binding the oocyte in the hamster penetration test, and higher total and per cycle pregnancy rates compared to the placebo group (Comhaire et al. 2005). In a model of obese rats, administration of vitamin A, E, and astaxanthin was associated with better viability, motility, and morphology of spermatozoa obtained from the tail of the epididymis and with a significantly higher number of spermatogonium and Sertoli cells at the histological evaluation (Mortazavi et al. 2014). This finding led to the hypothesis that low sperm quality of obese men may be improved by the administration of this cocktail of antioxidants. However, additional studies on greater numbers of patients are needed to confirm if human sperm parameters may benefit from astaxanthin administration. Astaxanthin is administered in combined therapies at a daily dose of 16 mg. The duration of the treatment is not defined; in the mentioned study, astaxanthin was administered for 3 months (Comhaire et al. 2005). No further controlled studies have been published since 2005.

### **Combined Therapies**

The synergic effect of some component with different antioxidant properties has been studied. In a randomized trial, the daily administration of vitamin E (400 mg) and selenium (225 µg) for 3 months resulted in a significant decrease in MDA concentrations and an improvement of sperm motility (Makker et al. 2009). In mice, the co-administration of vitamin C (10 mg/kg) and vitamin E (100 mg/kg) led to a decrease of testicular MDA content, along with increased sperm count and decreased percentage of spermatozoa with abnormal form (Mishra and Acharya 2004). According to Greco and colleagues, the daily administration of vitamin C (1 g)

and vitamin E (1 g) for 2 months significantly decreased the percentage of human DNA-fragmented spermatozoa (Greco et al. 2005a). The co-administration of vitamin C and vitamin E seems to improve clinical pregnancy and implantation rates compared to the group of patients receiving placebo (Greco et al. 2005b). A decrease of seminal plasma ascorbate concentration is associated with a decreased fertilization rate, while a higher consumption of  $\alpha$ -tocopheryl acetate in the diet seems to increase seminal vitamin E concentration and its oxidative stability after cryopreservation. In rabbits, a high amount of dietary vitamin E (50 vs. 200 mg/kg diet) significantly increased the level of vitamin E in the seminal fluid and the sperm oxidative stability after storage at 5 °C for 24 h (Castellini et al. 2000).

The combination of ascorbic acid with high vitamin E levels increases vitamin E levels in semen and the semen oxidative stability, whereas both parameters were reduced with lower vitamin E levels. Hence, their combination significantly improves the viability and kinetics of spermatozoa with an increased fertility rate (Castellini et al. 2000). These evidences sustain the role of the co-administration of vitamin E and C for the improvement of sperm quality in idiopathic male infertility.

The use of oral antioxidants (NAC or vitamins A plus E) and essential fatty acids in 27 infertile male increases sperm count and decreases ROS and 8-hydroxydeoxyguanine concentration in oligozoospermic patients. Moreover, the treatment improved the acrosome reaction rate and the proportion of PUFA in phospholipids and sperm membrane (Comhaire et al. 2000). In addition, a 26-week-long daily administration of selenium (200  $\mu$ g) and NAC (600 mg) in 468 infertile men with idiopathic asthenozoospermia resulted in an improvement of all sperm parameters. Furthermore, a positive relationship between seminal plasma concentration of NAC and selenium and sperm parameters has been found (Safarinejad and Safarinejad 2009). A prospective open-label study has shown that carnitine in association with fructose, citric acid selenium, CoQ<sub>10</sub>, zinc, ascorbic acid, cyanocobalamin, and folic acid seems to improve sperm quality (Busetto et al. 2012).

Other commercialized and currently used antioxidants are shown in Table 2.

### Critical Summary on Antioxidants

Antioxidants can ameliorate sperm damage caused by oxidative stress. The therapeutic use of coenzyme Q10, carnitine, and myo-inositol is supported by placebo-controlled double-blind randomized trials and meta-analysis (for Coenzyme Q10).

**Table 2** Other antioxidants

Aminoacids	Arginin, Taurin, Ornitin, Citrullin
Vitamins	Vitamins of group B complex, niacin (vitamin PP), pantothenic acid, folic acid
Omega-3 fatty acids	Docosanoid acid (DHA), eicosanoid acid (EPA)
Others	Magnesium, flavonoid, <i>Curcuma longa</i> , <i>Camellia sinensis</i> , <i>UrticaDioica</i> , <i>Lepidiummeyeriiwalp.</i> , <i>Muirapuama</i> ( <i>PtychopetalumolacoidesBenth</i> ), <i>Ginkgo biloba</i> , <i>Scutellariabaicalensis</i> , <i>Georgi radix</i> , <i>PinusMassoniana</i> , <i>Curcubita maxima</i> , <i>Aesculushippocastanum</i> , <i>Crocus sativus</i> , <i>Epilobium</i> ( <i>Angustifolium</i> and <i>Parviflorum</i> ), <i>Citrus bergamia</i> , <i>Ortosiphon</i> , etc.

They are among those most commonly used with a good compliance with the exception of glutathione. The administration of NAC is also suggested by placebo-controlled double-blind randomized trial, but it is commercialized in combination with other antioxidant. Further studies are needed to evaluate the efficacy of the other listed antioxidants on male fertility.

---

## Summary

Potential treatments used in male infertility include the prescription of nonhormonal compounds, such as antibiotics, anti-inflammatory drugs, and antioxidants. They are chosen on the basis of the etiopathogenetic mechanism involved in the disease. Antibiotics are prescribed when a urogenital infection is identified. The most used antibiotics in the clinical practice are quinolones (ciprofloxacin, levofloxacin, etc.), tetracyclines, macrolides, trimethoprim, and  $\beta$ -lactam antibiotics (penicillin derivatives, cephalosporins, monobactams, carbapenems). Anti-inflammatory drugs should be given when leukocytospermia and/or inflammatory sign and/or symptoms are present. Finally, antioxidants may be used to protect spermatozoa from oxidative stress overproduction that occurs in many clinical inflammatory conditions. This class includes a vast array of molecules that may be prescribed alone or in combination. The use of these compounds allows a customized therapeutic strategy.

---

## References

- Abd-Allah AR, Aly HA, Moustafa AM, Abdel-Aziz AA, Hamada FM. Adverse testicular effects of some quinolone members in rats. *Pharmacol Res.* 2000;41(2):211.
- Abel BJ, Carswell G, Elton R, Hargreave TB, Kyle K, Orr S, Rogers A, Baxby K, Yates A. Randomised trial of clomiphene citrate treatment and vitamin C for male infertility. *Br J Urol.* 1982;54:780.
- Agarwal A, Said TM. Carnitines and male infertility. *Reprod BioMed Online.* 2004;8(4):376.
- Agarwal A, Nallella KP, Allamaneni SS, Said TM. Role of antioxidants in treatment of male infertility: an overview of the literature. *Reprod BioMed Online.* 2004;8:616.
- Agarwal A, Sharma RK, Desai NR, Prabakaran S, Tavares A, Sabanegh E. Role of oxidative stress in pathogenesis of varicocele and infertility. *Urology.* 2009;73:461.
- Agarwal A, Virk G, Ong C, du Plessis SS. Effect of oxidative stress on male reproduction. *World J Mens Health.* 2014;32:1.
- Aitken RJ. The Amoroso Lecture. The human spermatozoon—a cell in crisis? *J Reprod Fertil.* 1999;115:1.
- Balercia G, Regoli F, Armeni T, Koverech A, Mantero F, Boscaro M. Placebo-controlled double-blind randomized trial on the use of L-carnitine, L-acetylcarnitine, or combined L-carnitine and L-acetylcarnitine in men with idiopathic asthenozoospermia. *Fertil Steril.* 2005;84(3):662.
- Balercia G, Buldreghini E, Vignini A, Tiano L, Paggi F, Amoroso S, Ricciardo-Lamonica G, Boscaro M, Lenzi A, Littarru G. Coenzyme Q10 treatment in infertile men with idiopathic asthenozoospermia: a placebo-controlled, double-blind randomized trial. *Fertil Steril.* 2009; 91(5):1785.
- Banihani S, Agarwal A, Sharma R, Bayachou M. Cryoprotective effect of l-carnitine on motility, vitality and DNA oxidation of human spermatozoa. *Andrologia.* 2014;46(6):637.

- Bormman MS, du Toit D, Otto B, Müller II, Hurter P, du Plessis DJ. Seminal carnitine, epididymal function and spermatozoal motility. *S Afr Med J*. 1989;75(1):20.
- Bundrick W, Heron SP, Ray P, et al. Levofloxacin versus ciprofloxacin in the treatment of chronic bacterial prostatitis: a randomized double-blind multicenter study. *Urology*. 2003;62:537.
- Busetto GM, Koverech A, Messano M, Antonini G, De Berardinis E, Gentile V. Prospective open-label study on the efficacy and tolerability of a combination of nutritional supplements in primary infertile patients with idiopathic asthenozoospermia. *Arch Ital Urol Androl*. 2012;84:137.
- Byun JS, Yoon TK, Rhee HW, Kim JH, Shin JS, Kim HS, Bak CW. Chronic pelvic pain syndrome and semen quality of Korean men in their fourth decade. *J Androl*. 2012;33(5):876.
- Calogero AE, Gullo G, La Vignera S, Condorelli RA, Vaiarelli A. Myoinositol improves sperm parameters and serum reproductive hormones in patients with idiopathic infertility: a prospective double-blind randomized placebo-controlled study. *Andrology*. 2015;3(3):491.
- Canale D, Scaricabarozzi I, Giorgi P, Turchi P, Ducci M, Menchini-Fabris GF. Use of a novel non-steroidal anti-inflammatory drug, nimesulide, in the treatment of abacterial prostatovesiculitis. *Andrologia*. 1993;25(3):163.
- Castellini C, Lattaioli P, Bernardini M, Dal Bosco A. Effect of dietary alpha-tocopheryl acetate and ascorbic acid on rabbit semen stored at 5 degrees C. *Theriogenology*. 2000;54(4):523.
- Cheraghi E, Mehranjani MS, Shariatzadeh MA, Esfahani MH, Ebrahimi Z. N-Acetylcysteine improves oocyte and embryo quality in polycystic ovary syndrome patients undergoing intracytoplasmic sperm injection: an alternative to metformin. *Reprod Fertil Dev*. 2016; 28(6):723.
- Ciftci H, Verit A, Savas M, Yeni E, Erel O. Effects of N-acetylcysteine on semen parameters and oxidative/antioxidant status. *Urology*. 2009;74(1):73.
- Comhaire FH, Christophe AB, Zalata AA, Dhooge WS, Mahmoud AM, Depuydt CE. The effects of combined conventional treatment, oral antioxidants and essential fatty acids on sperm biology in subfertile men. *Prostaglandins Leukot Essent Fat Acids*. 2000;63(3):159.
- Comhaire FH, El Garem Y, Mahmoud A, Eertmans F, Schoonjans F. Combined conventional/ antioxidant "Astaxanthin" treatment for male infertility: a double blind, randomized trial. *Asian J Androl*. 2005;7(3):257.
- Condorelli RA, La Vignera S, Di Bari F, Unfer V, Calogero AE. Effects of myoinositol on sperm mitochondrial function in-vitro. *Eur Rev Med Pharmacol Sci*. 2011;15(2):129.
- Condorelli RA, La Vignera S, Bellanca S, Vicari E, Calogero AE. Myoinositol: does it improve sperm mitochondrial function and sperm motility? *Urology*. 2012;79(6):1290.
- Cooper TG, Weidner W, Nieschlag E. The influence of inflammation of the human male genital tract on secretion of the seminal markers alpha-glucosidase, glycerophosphocholine, carnitine, fructose and citric acid. *Int J Androl*. 1990;13(5):329.
- Costa M, Canale D, Filicori M, D'Iddio S, Lenzi A. L-carnitine in idiopathic asthenozoospermia: a multicenter study. Italian Study Group on Carnitine and Male Infertility. *Andrologia*. 1994;26(3):155.
- Cui D, Han G, Shang Y, Liu C, Xia L, Li L, Yi S. Antisperm antibodies in infertile men and their effect on semen parameters: a systematic review and meta-analysis. *Clin Chim Acta*. 2015;444:29.
- Cyrus A, Kabir A, Goodarzi D, Moghimi M. The effect of adjuvant vitamin C after varicocele surgery on sperm quality and quantity in infertile men: a double blind placebo controlled clinical trial. *Int Braz J Urol*. 2015;41:230.
- Dawson EB, Harris WA, Teter MC, Powell LC. Effect of ascorbic acid supplementation on the sperm quality of smokers. *Fertil Steril*. 1992;58(5):1034.
- De Celis R, Pedron-nuevo N, Feria-velasco A. Toxicology of male reproduction in animals and humans. *Arch Androl*. 1996;37:201.
- De Rosa M, Boggia B, Amalfi B, Zarrilli S, Vita A, Colao A, Lombardi G. Correlation between seminal carnitine and functional spermatozoal characteristics in men with semen dysfunction of various origins. *Drugs R D*. 2005;6(1):1.

- Doba T, Burton GW, Ingold KU. Antioxidant and co-antioxidant activity of vitamin C. The effect of vitamin C, either alone or in the presence of vitamin E or a water-soluble vitamin E analogue, upon the peroxidation of aqueous multilamellar phospholipid liposomes. *Biochim Biophys Acta*. 1985;835(2):298.
- Duffy DM, VandeVoort CA. Maturation and fertilization of nonhuman primate oocytes are compromised by oral administration of a cyclooxygenase-2 inhibitor. *Fertil Steril*. 2011; 95(4):1256.
- El-Harouny MA, Zalata AA, Naser ME, Abo El-Atta HM, El-Shawaf IM, Mostafa T. Long-term ofloxacin testicular toxicity: an experimental study. *Andrologia*. 2010;42(2):92.
- ElSheikh MG, Hosny MB, Elshenoufy A, Elghamrawi H, Fayad A, Abdelrahman S. Combination of vitamin E and clomiphene citrate in treating patients with idiopathic oligoasthenozoospermia: a prospective randomized trial. *Andrology*. 2015;3:864–7.
- Eskenazi B, Kidd SA, Marks AR, Slotter E, Block G, Wyrobek AJ. Antioxidant intake is associated with semen quality in healthy men. *Hum Reprod*. 2005;20(4):1006.
- Farombi EO, Ugwuezumba MC, Ezenwadu TT, Oyeyemi MO, Ekor M. Tetracycline-induced reproductive toxicity in male rats: effects of vitamin C and N-acetylcysteine. *Exp Toxicol Pathol*. 2008;60(1):77.
- Fisher HM, Aitken RJ. Comparative analysis of the ability of precursor germ cells and epididymal spermatozoa to generate reactive oxygen metabolites. *J Exp Zool*. 1997;277:390.
- Frei B, England L, Ames BN. Ascorbate is an outstanding antioxidant in human blood plasma. *Proc Natl AcadSci USA*. 1989;86(16):6377.
- Fujii J, Iuchi Y, Matsuki S, Ishii T. Cooperative function of antioxidant and redox systems against oxidative stress in male reproductive tissues. *Asian J Androl*. 2003;5(3):231.
- Gambera L, Serafini F, Morgante G, Focarelli R, De Leo V, Piomboni P. Sperm quality and pregnancy rate after COX-2 inhibitor therapy of infertile males with abacterial leukocytospermia. *Hum Reprod*. 2007;22(4):1047.
- Geva E, Bartoov B, Zabludovsky N, Lessing JB, Lerner-Geva L, Amit A. The effect of antioxidant treatment on human spermatozoa and fertilization rate in an in vitro fertilization program. *Fertil Steril*. 1996;66(3):430.
- Ghanem H, Shaer O, El-Segini A. Combination clomiphene citrate and antioxidant therapy for idiopathic male infertility: a randomized controlled trial. *Fertil Steril*. 2010;93:2232.
- Giovenco P, Amodei M, Barbieri C, Fasani R, Carosi M, Dondero F. Effects of kallikrein on the male reproductive system and its use in the treatment of idiopathic oligozoospermia with impaired motility. *Andrologia*. 1987;19:238.
- Gomez E, Buckingham DW, Brindle J, Lanzafame F, Irvine DS, Aitken RJ. Development of an image analysis system to monitor the retention of residual cytoplasm by human spermatozoa: correlation with biochemical markers of the cytoplasmic space, oxidative stress, and sperm function. *J Androl*. 1996;17:276.
- Grabe M, Bjerklund-Johansen TE, Botto H et al. Guidelines on urological infections. *Eur Assoc Urol*; 2013. Available at: [http://uroweb.org/wp-content/uploads/18\\_Urological-infections\\_LR.pdf](http://uroweb.org/wp-content/uploads/18_Urological-infections_LR.pdf).
- Greco E, Iacobelli M, Rienzi L, Ubaldi F, Ferrero S, Tesarik J. Reduction of the incidence of sperm DNA fragmentation by oral antioxidant treatment. *J Androl*. 2005a;26(3):349.
- Greco E, Romano S, Iacobelli M, Ferrero S, Baroni E, Minasi MG, Ubaldi F, Rienzi L, Tesarik J. ICSI in cases of sperm DNA damage: beneficial effect of oral antioxidant treatment. *Hum Reprod*. 2005b;20(9):2590.
- Gulino FA, Leonardi E, Marilli I, Musmeci G, Vitale SG, Leanza V, Palumbo MA. Effect of treatment with myo-inositol on semen parameters of patients undergoing an IVF cycle: in vivo study. *Gynecol Endocrinol*. 2016;32(1):65.
- Gvozdjaková A, Kucharská J, Dubravický J, Mojto V, Singh RB. Coenzyme Q10,  $\alpha$ -tocopherol, and oxidative stress could be important metabolic biomarkers of male infertility. *Dis Markers*. 2015; 827941.

- Hargreave TB, Kyle KF, Baxby K, Rogers AC, Scott R, Tolley DA, Abel BJ, Orr PS, Elton RA. Randomised trial of mesterolone versus vitamin C for male infertility. Scottish Infertility Group. *Br J Urol*. 1984;56:740–4.
- Jacob RA, Pinalto FS, Agee RE. Cellular ascorbate depletion in healthy men. *J Nutr*. 1992; 122(5):1111.
- Jung JH, Seo JT. Empirical medical therapy in idiopathic male infertility: Promise or panacea? *Clin Exp Reprod Med*. 2014;41(3):108.
- Kennedy JH, Korn N, Thurston RJ. Prostaglandin levels in seminal plasma and sperm extracts of the domestic turkey, and the effects of cyclooxygenase inhibitors on sperm mobility. *Reprod Biol Endocrinol*. 2003;1:74.
- Kessopoulou E, Powers HJ, Sharma KK, Pearson MJ, Russel JM, Cooke D, Barrat CL. A double-blind randomized placebo cross-over controlled trial using the antioxidant vitamin E to treat reactive oxygen species associated male infertility. *Fertil Steril*. 1995;64(4):825.
- La Vignera S, Condorelli RA, Vicari E, Tumino D, Morgia G, Favilla V, Cimino S, Calogero AE. Markers of semen inflammation: supplementary semen analysis? *J Reprod Immunol*. 2013;100(1):2.
- La Vignera S, Condorelli RA, Vicari E, Salmeri M, Morgia G, Favilla V, Cimino S, Calogero AE. Microbiological investigation in male infertility: a practical overview. *J Med Microbiol*. 2014;63:1.
- La Vignera S, Vicari E, Condorelli RA, Franchina C, Scalia G, Morgia G, Perino A, Schillaci R, Calogero AE. Prevalence of human papilloma virus infection in patients with male accessory gland infection. *Reprod BioMed Online*. 2015;30(4):385.
- Lackner JE, Herwig R, Schmidbauer J, Schatzl G, Kratzik C, Marberger M. Correlation of leukocytospermia with clinical infection and the positive effect of antiinflammatory treatment on semen quality. *Fertil Steril*. 2006;86(3):601.
- Lafuente R, González-Comadrán M, Solà I, López G, Brassesco M, Carreras R, Checa MA. Coenzyme Q10 and male infertility: a meta-analysis. *J Assist Reprod Genet*. 2013;30:1147.
- Lahdetie J. Occupation- and exposure-related studies on human sperm. *J Occup Environ Med*. 1995;37:922.
- Lancaster JW, Mahoney MV, Mandal S, Lawrence KR. Update on Treatment Options for Gonococcal Infections. *Pharmacotherapy*. 2015;35(9):856.
- Lanzafame FM, La Vignera S, Vicari E, Calogero AE. Oxidative stress and medical antioxidant treatment in male infertility. *Reprod BioMed Online*. 2009;19(5):638.
- Lenzi A, Lombardo F, Gandini L, Dondero F. Metabolism and action of L-carnitine: its possible role in sperm tail function. *Arch Ital Urol Nefrol Androl*. 1992;64(2):187.
- Lenzi A, Culasso F, Gandini L, Lombardo F, Dondero F. Placebo-controlled, double-blind, cross-over trial of glutathione therapy in male infertility. *Hum Reprod*. 1993;8(10):1657.
- Lenzi A, Picardo M, Gandini L, Lombardzo F, Terminali O, Passi S, Dondero F. Glutathione treatment of dyspermia: effect on the lipoperoxidation process. *Hum Reprod*. 1994;9(11):2044.
- Lenzi A, Lombardo F, Sgrò P, Salacone P, Caponecchia L, Dondero F, Gandini L. Use of carnitine therapy in selected cases of male factor infertility: a double-blind crossover trial. *Fertil Steril*. 2003;79(2):292.
- Lenzi A, Sgrò P, Salacone P, Paoli D, Gilio B, Lombardo F, Santulli M, Agarwal A, Gandini L. A placebo-controlled double-blind randomized trial of the use of combined L-carnitine and L-acetyl-carnitine treatment in men with asthenozoospermia. *Fertil Steril*. 2004;81(6):1578.
- Levine M, Conry-Cantilena C, Wang Y, Welch RW, Washko PW, Dhariwal KR, Park JB, Lazarev A, Graumlich JF, King J, Cantilena LR. Vitamin C pharmacokinetics in healthy volunteers: evidence for a recommended dietary allowance. *Proc Natl Acad Sci USA*. 1996;93(8):3704.
- Li Z, Chen GW, Shang XJ, Bai WJ, Han YF, Chen B, Teng XM, Meng FH, Zhang B, Chen DN, Liu JH, Zheng XM, Cao XR, Liu Y, Zhu XB, Wang YX. A controlled randomized trial of the use of combined L-carnitine and acetyl-L-carnitine treatment in men with oligoasthenozoospermia. *Zhonghua Nan KeXue*. 2005;11:761–4.

- Magri V, Marras E, Skerk V, et al. Eradication of *Chlamydia trachomatis* parallels symptom regression in chronic bacterial prostatitis patients treated with a fluoroquinolone-macrolide combination. *Andrologia*. 2010;42:366.
- Magri V, Montanari E, Skerk V, et al. Fluoroquinolone-macrolide combination therapy for chronic bacterial prostatitis: retrospective analysis of pathogen eradication rates, inflammatory findings and sexual dysfunction. *Asian J Androl*. 2011;13:819.
- Makker K, Agarwal A, Sharma R. Oxidative stress & male infertility. *Indian J Med Res*. 2009; 129(4):357.
- Mancini A, Conte G, Milardi D, de Marinis L, Littarru GP. Relationship between sperm cell ubiquinone and seminal parameters in subjects with and without varicocele. *Andrologia*. 1998;30(1):1.
- Manson JM, Zolna LE, Kang YJ, Johnson CM. Effects of cefonicid and other cephalosporin antibiotics on male sexual development in rats. *Antimicrob Agents Chemother*. 1987;31(7):991.
- Milardi D, Luca G, Grande G, Ghezzi M, Caretta N, Brusco G, De Filipo G, Marana R, Pontecorvi A, Calafiore R, Foresta C, Garolla A. Prednisone treatment in infertile patients with oligozoospermia and accessory gland inflammatory alterations *Andrology*. 2017;5(2):268.
- Mishra M, Acharya UR. Protective action of vitamins on the spermatogenesis in lead-treated Swiss mice. *J Trace Elem Med Biol*. 2004;18(2):173.
- Moilanen J, Hovatta O. Excretion of alpha-tocopherol into human seminal plasma after oral administration. *Andrologia*. 1995;27(3):133.
- Moilanen J, Hovatta O, Lindroth L. Vitamin E levels in seminal plasma can be elevated by oral administration of vitamin E in infertile men. *Int J Androl*. 1993;16(2):165.
- Moncada ML, Vicari E, Cimino C, Calogero AE, Mongioi A, D'Agata R. Effect of acetylcarnitine treatment in oligoasthenospermic patients. *Acta Eur Fertil*. 1992;23(5):221.
- Mortazavi M, Salehi I, Alizadeh Z, Vahabian M, Roushandeh AM. Protective effects of antioxidants on sperm parameters and seminiferous tubules epithelium in high fat-fed rats. *J Reprod Infertil*. 2014;15(1):22.
- Nadjarzadeh A, Sadeghi MR, Amirjannati N, Vafa MR, Motevalian SA, Ohari MR, Akhondi MA, Yavari P, Shidfar F. Coenzyme Q10 improves seminal oxidative defense but does not affect on semen parameters in idiopathic oligoasthenozoospermia: a randomized double-blind, placebo controlled trial. *J Endocrinol Investig*. 2011;34:224–8.
- Nadjarzadeh A, Shidfar F, Amirjannati N, Vafa MR, Motevalian SA, Gohari MR, NazeriKakhki SA, Akhondi MM, Sadeghi MR. Effect of Coenzyme Q10 supplementation on antioxidant enzymes activity and oxidative stress of seminal plasma: a double-blind randomized clinical trial. *Andrologia*. 2014;46:177–83.
- Naz RK. Modalities for treatment of antisperm antibody mediated infertility: novel perspectives. *Am J Reprod Immunol*. 2004;51(5):390.
- Ng CM, Blackman MR, Wang C, Swerdloff RS. The role of carnitine in the male reproductive system. *Ann N Y Acad Sci*. 2004;1033:177.
- Oh MM, Chae JY, Kim JW, Kim JW, Yoon CY, Park MG, Moon du G. Positive culture for extended-spectrum  $\beta$ -lactamase during acute prostatitis after prostate biopsy is a risk factor for progression to chronic prostatitis. *Urology*. 2013;81(6):1209.
- Opuwari CS, Henkel RR. An update on oxidative damage to spermatozoa and oocytes. *Biomed Res Int*. 2016;2016(9540142).
- Perletti G, Marras E, Wagenlehner FM, Magri V. Antimicrobial therapy for chronic bacterial prostatitis *Cochrane Database Syst Rev*. 2013;(8) CD009071.
- Porat-Soldin O, Soldin SJ. Preliminary studies on the in vitro and in vivo effect of salicylate on sperm motility. *Ther Drug Monit*. 1992;14(5):366.
- Rees J, Abrahams M, Doble A, Cooper A. Prostatitis Expert Reference Group (PERG). Diagnosis and treatment of chronic bacterial prostatitis and chronic prostatitis/chronic pelvic pain syndrome: a consensus guideline. *BJU Int*. 2015;116(4):509–25.
- Rolf C, Cooper TG, Yeung CH, Nieschlag E. Antioxidant treatment of patients with asthenozoospermia or moderate oligoasthenospermia with high-dose vitamin C and vitamin E: a randomized, placebo-controlled, double-blind study. *Hum Reprod*. 1999;14:1028–33.



- Roodbari F, Abedi N, Talebi AR. Early and late effects of Ibuprofen on mouse sperm parameters, chromatin condensation, and DNA integrity in mice. *Iran J Reprod Med.* 2015;13(11):703.
- Rubino P, Palini S, Chigioni S, Carlomagno G, Quagliarello A, De Stefani S, Baglioni A, Bulletti C. Improving fertilization rate in ICSI cycles by adding myoinositol to the semen preparation procedures: a prospective, bicentric, randomized trial on sibling oocytes. *J Assist Reprod Genet.* 2015;32:387–94.
- Safarinejad MR. Efficacy of coenzyme Q10 on semen parameters, sperm function and reproductive hormones in infertile men. *J Urol.* 2009;182(1):237.
- Safarinejad MR. The effect of coenzyme Q10 supplementation on partner pregnancy rate in infertile men with idiopathic oligoasthenoatozoospermia: an open-label prospective study. *Int Urol Nephrol.* 2012;44(3):689.
- Safarinejad MR, Safarinejad S. Efficacy of selenium and/or N-acetyl-cysteine for improving semen parameters in infertile men: a double-blind, placebo controlled, randomized study. *J Urol.* 2009;181(2):741–51.
- Sharma RK, Kalla NR. Spermatozoal abnormalities and male infertility in the rat following sulfasalazine treatment. *Int J Fertil Menopausal Stud.* 1994;39(6):347.
- Shin T, Kobori Y, Suzuki K, Iwahata T, Yagi H, Soh S, Arai G, Okada H. Inflammatory bowel disease in subfertile men and the effect of mesalazine on fertility. *Syst Biol Reprod Med.* 2014;60(6):373.
- Showell MG, Mackenzie-Proctor R, Brown J, Yazdani A, Stankiewicz MT, Hart RJ. Antioxidants for male subfertility. *Cochrane Database Syst Rev.* 2014; (12). CD007411.
- da Silva RF, dos Santos Borges C, Villela P, Villela S, Missassi G, Kiguti LRA, Pupo AS, Barbosa FJ, Anselmo-Franci JA, De Grava Kempinas W. The Coadministration of N-acetylcysteine ameliorates the effects of arsenic trioxide on the male mouse genital system. *Oxid Med Cell Longev.* 2016; 4257498.
- Singh AC, Kumar M, Jha AM. Genotoxicity of lomefloxacin—an antibacterial drug in somatic and germ cells of Swiss albino mice in vivo. *Mutat Res.* 2003;535(1):35.
- Singh RP, Sastry KV, Dubey PK, Agrawal R, Singh R, Pandey NK, Mohan J. Norfloxacin drug induces reproductive toxicity and alters androgen receptor gene expression in testes and cloacal gland of male Japanese quail (*Coturnix japonica*). *Environ Toxicol Chem.* 2013;32(9):2134.
- Skerk V, Scheonwald S, Krhen I, et al. Comparative analysis of azithromycin and clarithromycin efficacy and tolerability in the treatment of chronic prostatitis caused by *Chlamydia trachomatis*. *J Chemother.* 2002;14:384.
- Skerk V, Schönwald S, Krhen I, Banaszak A, Begovac J, Strugar J, Strapac Z, Vrsalovic R, Vukovic J, Tomas M. Comparative analysis of azithromycin and ciprofloxacin in the treatment of chronic prostatitis caused by *Chlamydia trachomatis*. *Int J Antimicrob Agents.* 2003;21:457.
- Skerk V, Krhen I, Lisi M, Krhen I, Lisić M, Begovac J, Roglić S, Skerk V, Stemak SL, Banaszak A, Strugar-Suica J, Vuković J. Comparative randomized pilot study of azithromycin and doxycycline efficacy in the treatment of prostate infection caused by *Chlamydia trachomatis*. *Int J Antimicrob Agents.* 2004;24:188.
- Slowikowska-Hilczek J. Xenobiotics with estrogen or antiandrogen action – disruptors of the male reproductive system. *CEJM.* 2006;3:205.
- Song GJ, Norkus EP, Lewis V. Relationship between seminal ascorbic acid and sperm DNA integrity in infertile men. *Int J Androl.* 2006;29(6):569.
- Suleiman SA, Ali ME, Zaki ZM, el-Malik EM, Nasr MA. Lipid peroxidation and human sperm motility: protective role of vitamin E. *J Androl.* 1996;17(5):530.
- Thérond P, Auger J, Legrand A, Jouannet P. Alpha-Tocopherol in human spermatozoa and seminal plasma: relationships with motility, antioxidant enzymes and leukocytes. *Mol Hum Reprod.* 1996;2(10):739.
- Thiele JJ, Friesleben HJ, Fuchs J, Ochsendorf FR. Ascorbic acid and urate in human seminal plasma: determination and interrelationships with chemiluminescence in washed semen. *Hum Reprod.* 1995;10(1):110.

- Thonneau P, Bujan L, Multigner L, Mieusset R. Occupational heat exposure and male fertility: a review. *Hum Reprod.* 1998;13:2122.
- Tripodi L, Tripodi A, Mammì C, Pullé C, Cremonesi F. Pharmacological action and therapeutic effects of glutathione on hypokinetic spermatozoa for enzymatic-dependent pathologies and correlated genetic aspects. *Clin Exp Obstet Gynecol.* 2003;30(2-3):130.
- Ugochukwu AP, Ebere OO, Okwuoma A. Effects of nimesulide on testicular functions in prepubertal albino rats. *J Basic Clin Physiol Pharmacol.* 2011;22(4):137.
- Vargas A, Bustos-Obregón E, Hartley R. Effects of hypoxia on epididymal sperm parameters and protective role of ibuprofen and melatonin. *Biol Res.* 2011;44(2):161.
- Vicari E, Calogero AE. Effects of treatment with carnitines in infertile patients with prostatovesiculo-epididymitis. *Hum Reprod.* 2001;16(11):2338.
- Vicari E, Rubino C, De Palma A, Longo G, Lauretta M, Consoli S, Arancio A. Antioxidant therapeutic efficiency after the use of carnitine in infertile patients with bacterial or non-bacterial prostatovesiculo-epididymitis. *Arch Ital Urol Androl.* 2001;73(1):15.
- Vicari E, La Vignera S, Calogero AE. Antioxidant treatment with carnitines is effective in infertile patients with prostatovesiculoepididymitis and elevated seminal leukocyte concentrations after treatment with nonsteroidal anti-inflammatory compounds. *Fertil Steril.* 2002;78(6):1203.
- Vitali G, Parente R, Melotti C. Carnitine supplementation in human idiopathic asthenospermia: clinical results. *Drugs Exp Clin Res.* 1995;21(4):157.
- Walczak-Jedrzejowska R, Wolski JK, Slowikowska-Hilczzer J. The role of oxidative stress and antioxidants in male fertility. *Cent European J Urol.* 2013;66(1):60.
- Wayner DD, Burton GW, Ingold KU. The antioxidant efficiency of vitamin C is concentration-dependent. *Biochim Biophys Acta.* 1986;884(1):119.
- Wen Y, Cooke T, Feely J. The effect of pharmacological supplementation with vitamin C on low-density lipoprotein oxidation. *Br J Clin Pharmacol.* 1997;44(1):94.
- Wolfson JS, Hooper DC. Pharmacokinetics of quinolones: newer aspects. *Eur J Clin Microbiol Infect Dis.* 1991;10(4):267.
- World Health Organization. WHO Laboratory Manual for the Examination and Processing of Human Semen. 5th ed. Geneva: World Health Organization; 2010.
- Yanushpolsky EH, Politch JA, Hill JA, Anderson DJ. Is leukocytospermia clinically relevant? *Fertil Steril.* 1996;66(5):822.
- Zhang ZC, Jin FS, Liu DM, Shen ZJ, Sun YH, Guo YL. Safety and efficacy of levofloxacin versus ciprofloxacin for the treatment of chronic bacterial prostatitis in Chinese patients. *Asian J Androl.* 2012;14:870.

M. W. Ragab and S. Kliesch

---

## Abstract

Varicocele is defined as a palpable dilated, elongated, and tortuous pampiniform plexus of veins draining the testis. The prevalence of varicocele is high with about 20% of men and increased in patients with primary infertility to 35%. The evidence-based recommendations for management of varicocele are under constant modification. There is no consensus for management of infertile men presenting with varicocele. This can be explained by absence of clear diagnostic criteria for varicocele that requires treatment, emerging of different varicocelectomy techniques with different outcomes, and the complex nature of couple infertility. This chapter aims to provide a concise review of epidemiology, pathophysiology, and diagnosis of varicocele. It focuses on fertility and endocrine disturbances associated with the condition, in addition to outlining the updated best practice in management of infertile varicocele patients with brief description of all management modalities. The role of varicocele repair in azoospermia, adolescents, and candidates for assisted reproductive techniques are also highlighted besides etiology and management of recurrent varicocele.

---

M.W. Ragab

Department of Clinical and Surgical Andrology, Center of Reproductive Medicine and Andrology, University Hospital, Münster, Germany

Department of Andrology, Faculty of Medicine, Cairo University, Cairo, Egypt

e-mail: [m.w.ragab@kasralainy.edu.eg](mailto:m.w.ragab@kasralainy.edu.eg); [dr.wa2el@gmail.com](mailto:dr.wa2el@gmail.com)

S. Kliesch (✉)

Department of Clinical and Surgical Andrology, Center of Reproductive Medicine and Andrology, University Hospital, Münster, Germany

WHO Collaborating Center, EAA Training Center, Münster, Germany

e-mail: [sabine.kliesch@ukmuenster.de](mailto:sabine.kliesch@ukmuenster.de)

### Keywords

Male infertility • Symptomatic varicocele • Varicocele • Varicocele treatment • Varicocelectomy • Adolescent varicocele • Varicocele and assisted reproduction • Varicocele and azoospermia

### Contents

Introduction .....	1116
Epidemiology .....	1117
Venous Drainage of Testis and the Etiology of Varicocele .....	1117
Pathophysiology of Testicular Damage by Varicocele .....	1118
Venous Hypertension and Testicular Ischemia .....	1118
Reactive Oxygen Species and Oxidative Stress .....	1118
Hyperthermia .....	1119
Sertoli Cell Dysfunction and Impairment of Blood Testicular Barrier (BTB) .....	1119
Endocrine Dysfunction .....	1119
Immune Infertility .....	1120
Epididymal Dysfunction .....	1120
Diagnosis of Varicocele .....	1121
Clinical Examination .....	1121
Imaging of the Varicocele .....	1122
Investigations .....	1123
Treatment Modalities for Varicocele .....	1125
Conservative and Symptomatic Treatment .....	1125
Medical Therapy .....	1125
Interventional Therapy .....	1126
Summary .....	1137
Cross-References .....	1138
References .....	1138

### Introduction

Varicocele is a palpable dilated, elongated, and tortuous pampiniform plexus of veins that drain the testis. It has been related to different pathologic conditions as male factor infertility, scrotal pain, decreased ipsilateral testicular volume, and testosterone deficiency.

As early as 1550, Ambroise Paré termed peritesticular “tumor of veins dilated and woven” as *Circocele* (Hirsh and Pryor 1984). Thomas B. Curling replaced the term *Circocele* by *Varicocele* in 1843 (Noske and Weidner 1999). One of the earliest historical studies that demonstrated fertility improvement after varicocele repair was published in 1955 by Tulloch, who reported restoration of spermatogenesis and spontaneous pregnancy after varicocelectomy in infertile male with azoospermia (Tulloch 1955). Later on, thousands of studies, review articles, and meta-analyses demonstrated variable degrees of associations between male infertility and varicocele. A few studies denied any role of varicocele repair in management of male infertility. Recent guidelines advocate varicocele repair in managing of male infertility under certain conditions. The evidence-based recommendations for

varicocele repair in management of male infertility are under constant modification. There is no consensus approach for management of infertile men presenting with varicocele. This can be explained by absence of clear diagnostic criteria for varicocele that requires treatment, emerging of different varicocelectomy techniques with different outcomes, and the complex nature of couple infertility.

---

## Epidemiology

Varicocele is a common anatomical abnormality. It presents in approximately 20% of the normal adult male population (Beretta 2015; Hamada et al. 2016a). The prevalence of palpable varicocele in male patients presenting with primary infertility is 35% (Gorelick and Goldstein 1993). In a large multicenter study that involved 34 World Health Organization (WHO) collaborating centers in 24 countries, it was found in couples presenting with infertility that varicocele is present in 25.4% of men with abnormal semen parameters and only in 11.7% of men with normal semen parameters (World Health Organization 1992).

The prevalence of varicocele peaks in the peripubertal age. Before the age of 10 years, the prevalence of varicocele is 0.92%, it increases to 7.8% at the age between 11 and 14 years reaching up to 14.1% at the age between 15 and 19 years (Akabay et al. 2000). The higher prevalence of varicocele (42%) in elderly population suggests a progressive nature of varicocele (Canales et al. 2005). Lower body mass index is associated with increased prevalence of varicocele (Nielsen et al. 2006). The prevalence of varicocele is higher when a first degree family member has the condition (Raman et al. 2005). Palpable varicocele is more common on the left side (Dubin and Amelar 1977). Venographic studies suggest that varicocele affects both sides in up to 84% of cases (Gat et al. 2005b). Isolated or predominant rapidly progressive right-sided varicocele is rare and may denote situs inversus or retroperitoneal/renal mass (Parker and Hicks 1975; Wilms et al. 1988). Clinical recommendations include sonographic examination of the kidneys and the retroperitoneum, if varicocele has been verified, especially if a right-sided varicocele is documented.

---

## Venous Drainage of Testis and the Etiology of Varicocele

Pampiniform plexus of veins that drains the testis can be divided into three groups: anterior, middle, and posterior. The anterior group converges to form a lesser number of veins termed internal spermatic veins through their course in the inguinal canal, and they accompany the internal spermatic artery in the pelvis and coalesce to form a single internal spermatic vein. The right internal spermatic vein drains into inferior vena cava while the left internal spermatic vein drains into the under surface of left renal vein. The middle group of pampiniform plexus of veins forms the vasal vein that runs along with vas deferens and drains into the internal iliac vein. Posterior group drains into the external pudendal vein and external spermatic (cremasteric)

vein. The latter drains into the inferior epigastric vein or the great saphenous vein which drains to the external iliac vein. External spermatic and vasal veins are smaller collaterals in the venous drainage system of the testis and there is no cross communication between the right and left venous systems at scrotal, inguinal, and pelvic levels (Wishahi 1992; Liguori et al. 2012). Higher cross communications between left and right internal spermatic veins are documented (Halpern et al. 2016). The unique venous drainage of left and right testes explain increased prevalence of left varicocele due to increased intravenous pressure that causes dilation and tortuosity. Left spermatic vein has a longer course and drains into the left renal vein by a right angle while the right spermatic vein drain into the inferior vena cava which has a lower hydrostatic pressure. The left renal vein is compressed between superior mesenteric artery and aorta to form what is so-called nutcracker phenomenon (Chait et al. 1971).

---

## Pathophysiology of Testicular Damage by Varicocele

The relation between varicocele and male infertility is not considered as cause-effect relationship, as 80% of men with varicocele are fertile (Sylora and Pryor 1994).

In contrast, the prevalence of varicocele is higher in infertile population (Gorelick and Goldstein 1993). In infertile men with varicocele lower total sperm count, decreased motility, higher abnormal morphology in semen analysis, and reduced ipsilateral testicular volumes are described. Semen parameters may further decrease with higher grade of varicocele (World Health Organization 1992; Agarwal et al. 2016). Several mechanisms may explain varicocele-associated testicular damage.

## Venous Hypertension and Testicular Ischemia

Increased hydrostatic pressure in internal spermatic vein is transmitted to the intratesticular veins. This high pressure can impend intratesticular arterial inflow when it exceeds the pressure in arterial microcirculation (Gat et al. 2005b; Gandhi et al. 2016). Refluxing blood to the testis contains high concentrations of catecholamines. These catecholamines are produced from left suprarenal gland, released to left renal vein, and reached the intratesticular circulation through incompetent valves of internal spermatic vein (Comhaire and Vermeulen 1974). The exposure of testicular arterioles to catecholamines for long duration is associated with vasoconstriction and irreversible endothelial hyperplasia that leads to reduction of testicular arterial perfusion (Comhaire et al. 1983; Pasqualotto et al. 2011).

## Reactive Oxygen Species and Oxidative Stress

Reactive oxygen species (ROS) are produced as by-products during some intracellular reactions and are capable of inducing cellular damage. Sperm ROS play

important physiological role in acrosome reaction and capacitation during oocyte fertilization (Griveau and Le Lannou 1997). ROS are normally neutralized by different types of antioxidants. Oxidative stress is a pathologic condition that refers to an imbalance due to increased ROS and decreased total antioxidant capacity (TAC) (Ray et al. 2012). Varicocele induces oxidative stress in the testis by increasing ROS production and decreasing TAC. Oxidative stress is associated with increased sperm DNA damage, lipid peroxidation of sperm cell membrane, and apoptosis of germ cells (Saleh et al. 2003; Agarwal et al. 2006; Mostafa et al. 2016). High levels of DNA fragmentation is not only associated with low probability of achieving natural pregnancy, but also with reduced success rates of assisted reproductive techniques (Evenson and Wixon 2006).

## Hyperthermia

The optimal temperature for spermatogenesis is 2.5–4 °C lower than core temperature. Several mechanisms maintain the relative lower temperature of the testis, including the counter current exchange mechanism: the temperature of arterial inflow to the testis is reduced by the relatively cooler venous outflow along their common course (Dahl and Herrick 1959). Varicocele disrupts this mechanism and elevates testicular temperature (Björndahl et al. 2010). Scrotal hyperthermia is associated with increased germ cell apoptosis and impairment of spermatogenesis (Shiraishi et al. 2010).

## Sertoli Cell Dysfunction and Impairment of Blood Testicular Barrier (BTB)

Surgically induced varicocele in rats is associated with increased proinflammatory cytokines along with deregulation of Claudin-11. Deregulation of this tight junction protein in Sertoli cells alters the permeability of BTB (Oh et al. 2016). One of the increased proinflammatory cytokines is interleukin-6 that inhibits transferrin production. Transferrin is an iron transport protein which plays a pivotal role in iron transportation to the developing spermatogenic cells (Pasqualotto et al. 2011).

## Endocrine Dysfunction

More than 95% of serum testosterone is produced by Leydig cells in the testis, which is mainly regulated by pituitary LH. Intratesticular testosterone plays an important role in spermatogenesis. Intratesticular testosterone is more than 80-fold higher than serum levels, which is maintained by androgen binding protein (ABP) secreted by Sertoli cells (Weinbauer et al. 2010).

Recent studies suggest that varicocele leads to impairment of Leydig and Sertoli cell function with decrease in serum and intratesticular testosterone levels. Several

controlled studies showed that varicocele groups have significantly lower serum testosterone level than control groups but remained mostly in the normal range of testosterone levels for eugonadal men (Hayden and Tanrikut 2016). In a meta-analysis that involved 814 patients from nine studies, varicocele repair was found to increase total testosterone by a mean of 97.5 ng/dL (3.38 nmol/L) (Li et al. 2012b). Patients were included in these studies mainly for fertility causes, resulting in sampling bias. In a large cross-sectional multicenter study that involved 7035 young men with a median age of 19 years from six European countries, varicocele was found in 1102 (15.7%) of the study population. The varicocele subgroup showed higher serum levels of FSH, LH, and lower levels of inhibin B. No significant differences in serum total or free testosterone were found (Damsgaard et al. 2016). Elevation of LH can be considered as compensatory mechanism for Leydig cell dysfunction to stimulate synthesis of testosterone. In another study, the duration of varicocele was found to negatively influence testosterone production (Ando et al. 1984).

Histological and histochemical examination of Leydig cells in varicocele patients showed Leydig cell hyperplasia, vacuolization of the cytoplasm, and decreased number of cells expressing testosterone. Leydig cell hyperplasia can be considered a compensatory mechanism for their dysfunction (Sirvent et al. 1990). Varicocele patients with lower sperm counts display excessive FSH and LH responses to GnRH infusion denoting altered integrity of hypothalamic-pituitary-testicular (HPG) axis (Hudson et al. 1981). Leydig cells show blunted testosterone production response after stimulation by human chorionic gonadotropin (hCG) in varicocele patients (Scholler et al. 1984). Varicocele inhibits multiple enzymes involved in testosterone biosynthesis (Ando et al. 1983; Hayden and Tanrikut 2016). Furthermore, a controlled study showed that sperm androgen receptor expression is significantly decreased in infertile men with varicocele (Zalata et al. 2013).

## Immune Infertility

Despite the early suggestion of a probable association between varicocele and anti-sperm antibodies (ASA) formation, recent studies doubt the association between varicocele mediated infertility and ASA (Marconi and Weidner 2017).

## Epididymal Dysfunction

The epididymis is also drained by the pampiniform plexus of veins and may be affected by the presence of varicocele. Sperm maturation in terms of chromatin condensation, motility and fertilizing capacity occurs in the epididymis. Seminal neutral  $\alpha$ -glucosidase is produced exclusively from the epididymis and it is considered as a marker for obstruction or epididymal dysfunction. In patients with varicocele, lower seminal levels of neutral  $\alpha$ -glucosidase, impaired sperm chromatin condensation, and lower scores in tests of sperm membrane integrity suggest impaired epididymal function (Vivas-Acevedo et al. 2014).

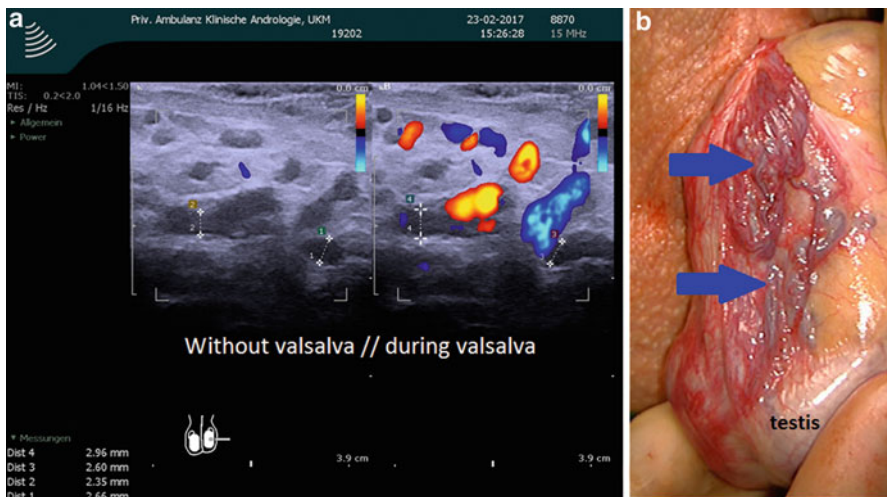


## Diagnosis of Varicocele

The diagnosis of varicocele is mainly a clinical diagnosis. Clinical examination alone may be inconclusive in case of suspected recurrence of varicocele after varicocele repair, low grade varicocele, presence of other cord swelling e.g., inguinal hernia or cord lipoma, or after previous inguinal operation; as well as in morbidly obese patients. The diagnosis should be further confirmed by color Doppler/Duplex ultrasonography and the increase of the diameter of veins in addition to reflux with Valsalva maneuver should be documented (Fig. 1) (Pilatz et al. 2011).

## Clinical Examination

Assessment of a patient presenting with varicocele should include a careful medical and reproductive history. The classical presentations of varicocele include infertility, scrotal pain, decreased testicular volume or scrotal swelling. Other causes of male infertility should be assessed and managed. Exclusion of female factor infertility is an essential step in evaluation of varicocele patients presenting with infertility. The classical scrotal pain is characterized by being dull aching or throbbing pain and exacerbate by prolonged standing. Varicocele has gradual onset and slow progression. Rapidly developing varicocele may denote abdomino-pelvic mass obstructing venous return.



**Fig. 1** (a) Color-duplex ultrasonography picture of a left-sided varicocele prior to (*left part of the picture*) and after Valsalva maneuver with increase of vein diameter from 2.66 and 2.35 mm to 2.60 and 2.96 mm, respectively. Reflux is prominent in the dilated veins. Clinically grade II varicocele was clinically also documented (CDU with linear probe, 15 MHz, B&K Medical ProFocus). (b) (*right*) shows an intraoperative picture of a grade II left-sided varicocele (*blue arrows mark dilated veins*) (Department of Clinical and Surgical Andrology, CeRA, Münster, Germany)

Clinical examination should be performed in warm room with warm hands to avoid cremasteric muscle contraction. Examination should be done with the patient in standing and recumbent positions. Varicocele grading is classified as follows in accordance with WHO criteria:

Grade I: Veins are only palpable during Valsalva maneuver

Grade II: Dilated veins are palpable without performing Valsalva maneuver

Grade III: Pampiniform plexus of veins is markedly dilated. Dilated veins are visible under scrotal skin, even without Valsalva maneuver

Subclinical varicocele cannot be detected clinically. They can only be detected by Doppler/Duplex ultrasonography, thermography or venography (Dubin and Amelar 1970).

## Imaging of the Varicocele

### Ultrasonography

The standard investigation nowadays is the Color-coded Duplex Ultrasonography (CDU) that replaced simple Doppler examination in clinical practice. CDU allows not only confirmation of the presence of venous reflux by colored blood stream in combination with the Doppler signal, but also accurate measurement of the diameter of pampiniform veins and testicular size in sonography. The measurement in sonography should be performed distant from the color-coded duplex signal or with a separate picture, as the veins could be overestimated in size when color-coded (Fig. 1).

Gat et al. found that Doppler ultrasonography was able to diagnose left varicocele in 250 patient out of 251 diagnosed by venography and right varicocele in only 189 patient out of 210 diagnosed by venography, which confirm the validity of Doppler ultrasonography in diagnosis of varicocele (Gat et al. 2004).

Cutoff value of vein diameter is a point of controversy. Chiou et al. recommended using a cutoff value of 3 mm and reported a specificity of 90% and a sensitivity of 50% in diagnosis of varicocele compared to clinical examination (Chiou et al. 1997). Pilatz et al. recommended a cutoff point of 2.45 mm at rest and 2.95 mm during Valsalva maneuver while the patient in supine position. The sensitivity of this cutoff was 84% and specificity was 81% at rest and 84% for both with Valsalva maneuver, for diagnosis of clinical varicocele (Pilatz et al. 2011).

Ultrasonography assessment of varicocele should include maximum diameter and duration of reflux in veins in rest and with Valsalva maneuver as well as testicular volume. The presence of any condition that is relevant to infertility should be reported, e.g., testicular heterogeneity and testicular or epididymal masses or cysts. These conditions are rather associated with infertility and discovered accidentally during varicocele work-up.

According to the recommendations of the European Association of Urology (EAU), the clinical diagnosis of varicocele should be confirmed by color duplex ultrasonography. American Urological Association (AUA) and American Society of

Reproductive Medicine (ASRM) recommend the use of ultrasonography only when clinical diagnosis is inconclusive (Roque and Esteves 2016).

In addition to diagnose of the veins, sonography of the kidneys should accomplish ultrasonographic diagnostic procedure, especially if right-sided varicoceles are documented.

### **Venography**

Venography is an invasive technique which is not commonly used. Usually it is performed as a diagnostic step in percutaneous embolization of varicocele. It is the most sensitive technique for detecting reflux of blood to the pampiniform plexus. It allows also the detection of cross-communications between left and right internal spermatic veins at the retroperitoneal level which may contribute to recurrence of highly ligated varicocele (Halpern et al. 2016).

### **Thermography**

Thermographies are designed to detect elevation of scrotal temperature in the presence of varicocele which elevates testicular temperature. Thermographies are classified into: Contact thermographies, noncontact telethermographies, and digital thermographies (Kulis et al. 2012; Hamada et al. 2016b).

This technique has high sensitivity (97%) but low specificity (9%). This rapid and relatively cheaper diagnostic tool is not commonly used due to its low specificity and absence of clear cutoffs for varicocele diagnosis (Trum et al. 1996).

In summary, CDDU is a fast and accurate diagnostic tool which is recommended for routine evaluation of patients presenting with varicocele.

## **Investigations**

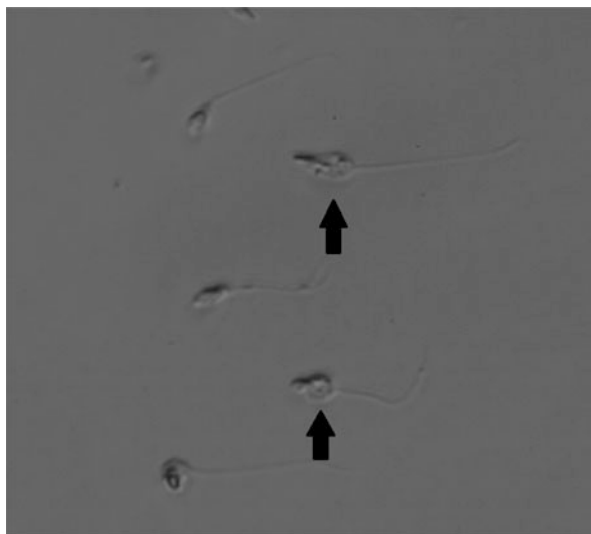
### **Laboratory Diagnosis**

#### **Conventional Semen Analysis**

At least two semen analyses according to WHO recommendations after 2–7 days of abstinence are required for proper assessment of male fertility (World Health Organization 2010). Abnormal seminal parameters are frequently associated with the presence of varicocele. In 1965, Macleod described an abnormal common pattern in seminal analyses of varicocele patients. This pattern involved increased number of tapered sperm head deformity and immature spermatogenic cells and it was termed “stress pattern” (MacLeod 1965). This pattern was found to be associated with abnormal testicular function and not pathognomonic for varicocele. The use of peroxidase-test to exclude seminal leukocytosis is recommended when the seminal fluid includes high number of round cells, as immature spermatogenic cells and leukocytes are round cells and share similar morphological criteria.

Varicocele is associated with retention of cytoplasmic droplet as a mid-piece defect of the sperm (Fig. 2) (Zini et al. 2000).

**Fig. 2** Sperms with residual cytoplasmic droplet (*black arrows*), denoting incomplete sperm maturation (Department of Clinical and Surgical Andrology, Center of Reproductive Medicine and Andrology, Muenster)



In a recent meta-analysis of 10 studies that involved 1232 men (783 with varicocele and 449 controls), Agarwal et al. evaluated the effect of varicocele on semen parameters based on the 2010 WHO laboratory manual for the examination and processing of human semen. Infertile men with varicocele were found to have lower mean sperm concentration than normal fertile men by  $44.48 \times 10^6$  /mL, reduced mean total motility by 26.67%, and higher abnormal forms by a mean of 19.68% (Agarwal et al. 2016).

### **Sperm Function Tests, Seminal Reactive Oxygen Species (ROS), and Total Antioxidant Capacity (TAC)**

Sperm function tests are reserved for academic and scientific uses only. Zona pellucida binding, sperm penetration assay, and hypo-osmotic swelling tests show lower levels in varicocele patients – denoting impaired fertilization capacity in varicocele patients (Vigil et al. 1994; Vivas-Acevedo et al. 2014).

Seminal TAC assessment by the enhanced chemiluminescence technique shows significantly lower levels in varicocele patients. Measurement of seminal ROS in varicocele patients by chemiluminescence revealed significantly higher levels than normal controls (Agarwal et al. 2006; Mostafa et al. 2009). However, these tests are not performed in routine clinical practice.

### **DNA Fragmentation Index**

Evaluation of DNA fragmentation index (DFI) is recommended in cases of varicocele associated with repeated in-vitro fertilization (IVF) failure or recurrent early abortion (Robinson et al. 2012; Osman et al. 2015). Patients with varicocele have significantly higher sperm DNA fragmentation index by mean difference of 9.84% than controls (Wang et al. 2012). Ni et al. reported in a controlled study, a significant

increase in pregnancy rate associated with improvement of DFI after microsurgical varicocelectomy (Ni et al. 2014).

Higher post-varicocelectomy DFI values are associated with failure of achieving pregnancy spontaneously or with assisted reproductive techniques (Smit et al. 2013).

### **Hormonal Analysis**

Measurement of serum total and calculated free testosterone, FSH, and LH is relevant for complete evaluation of varicocele. Elevation of FSH indicates established damage of the spermatogenic epithelium. Elevated LH and low serum testosterone suggest Leydig cell dysfunction. Lower serum levels of inhibin B suggest Sertoli cell dysfunction in varicocele patients (Goulis et al. 2011). But as inhibin B inversely correlates with FSH levels it does not offer additional value for clinical evaluation of the infertile patient and should not be used routinely.

---

## **Treatment Modalities for Varicocele**

### **Conservative and Symptomatic Treatment**

Scrotal suspenders, analgesics, and limitation of physical activity are the main conservative measures in management of symptomatic varicocele. Conservative measures were the main principle for varicocele management in the early twentieth century due to high surgical complications. Scrotal suspender and moderate sexual intercourse were the main strategies to overcome scrotal pain associated with varicocele (Noske and Weidner 1999). Conservative measures were found to be effective in management of varicocele associated scrotal pain in only 0.04% of a single study population (Yaman et al. 2000). Nieschlag et al. found in a prospective randomized study no significant improvement in pregnancy rates after interventional treatment of varicocele in comparison with regular counseling. Spontaneous pregnancy was achieved in 25.4% of counseling group during one year of regular follow-up (Nieschlag et al. 1998).

Conservative management of varicocele is recommended when there is no clear indication for varicocelectomy along with regular follow up by semen analysis and hormonal profile for early detection of deterioration in testicular functions.

### **Medical Therapy**

Empirical medications are prescribed broadly in andrological practice despite absence of solid scientific evidence in management of male infertility or scrotal pain. A randomized placebo controlled study of 40 patients presenting with painful varicocele showed significant improvement of pain in the group treated with micronized purified flavonoid fraction in comparison with placebo group (Soylemez et al. 2012). Small controlled and uncontrolled clinical trials showed significant short-term improvement in semen parameters of infertile varicocele patients with

empirical treatment by gonadotrophins as FSH or selective estrogen receptor modulator as clomiphene citrate or antioxidants as Coenzyme Q10 or anti-inflammatory drugs that reduce ROS formation or combinations of pentoxifylline, zinc, and folic acid (Garg and Kumar 2016). However, a drop to baseline parameters was observed in most of these studies after therapy cessation.

Using medical treatment as adjuvant therapy in combination with varicocelectomy gained practical popularity in the past few years for the aim of maximizing the outcome after varicocelectomy. In studies that compare improvement of seminal parameters after varicocelectomy alone or in adjuvant with antioxidants and vitamins, higher improvement was reported after varicocelectomy with adjuvant therapy. In four arms randomized controlled trial (RCT), Azizollahi et al. found significant improvement of sperm count, motility, and morphology with combined therapy of zinc and folic acid after varicocelectomy in comparison with varicocele alone or with the use of folic acid or zinc alone after varicocelectomy (Azizollahi et al. 2013). Commonly prescribed adjuvant therapies include: clomiphene citrate, L-carinitine, antioxidants, multivitamins, and zinc.

These few data are not valid enough for recommending the use of empirical medications in routine practice, and larger randomized placebo-controlled studies are required along with evaluation of natural pregnancy and live birth rates as ultimate goal for these medications.

## **Interventional Therapy**

### **Indications and Predictive Factors for Varicocele Repair**

#### **Male Infertility**

Recommendations and guidelines for management of varicocele in infertile males have changed several times through the last few years. The presence of varicocele is not an indication per se for varicocele treatment in infertile males. Proper assessment of the infertile couple, exclusion of other causes of infertility, and ensuring proper intercourse timing in relation to female ovulation is mandatory before the decision to treat a varicocele.

Cochrane database of systematic reviews is a major source for systematic reviews that influence evidence-based clinical practice worldwide. In 2004, Cochrane database review of eight RCTs indicated no improvement in pregnancy rate with varicocele repair in subfertile males (Evers and Collins 2004). This review was criticized by many urologists/andrologists for inclusion of men with subclinical varicocele and patients with normal semen parameters (Ficarra et al. 2006). A meta-analysis of five (not all randomized) studies, that excluded subclinical varicocele and patients with normal semen parameters, showed significant increase in pregnancy rate after varicocelectomy (Marmar et al. 2007). In 2012, Cochrane database review of ten RCTs published between 1993 and 2011 (including data from one abstract!) showed low-quality evidence favoring varicocele repair: one natural pregnancy occurs for every 17 varicocele repairs. Subgroup analysis

**Table 1** Summary of guidelines for fertility indications of varicocele repair

Organization	Guidelines
EAU guidelines on male infertility – updated in 2016 (available at: <a href="http://uroweb.org/guideline/male-infertility">http://uroweb.org/guideline/male-infertility</a> )	<ol style="list-style-type: none"> <li>1. Varicocele repair is recommended in infertile males with clinical varicocele, oligozoospermia, and otherwise couple unexplained infertility</li> <li>2. Varicocele repair is not recommended in infertile males who have normal seminal parameters or subclinical varicocele</li> </ol>
ASRM committee opinion – updated in 2014 (Practice Committee of the American Society for Reproductive Medicine and the Society for Male Reproduction and Urology 2014)	<ul style="list-style-type: none"> <li>• Varicocele repair should be considered when most or all of the following criteria are present: <ol style="list-style-type: none"> <li>1. Clinically palpable varicocele</li> <li>2. Abnormal semen parameters</li> <li>3. Known couple infertility</li> <li>4. Female partner has normal fertility or a potentially treatable infertility cause, and time to conception is not a concern</li> </ol> </li> <li>• Varicocele repair is not recommended in patients with normal semen parameters, isolated teratozoospermia, and subclinical varicocele, or when there is a female factor indicating the use of assisted reproductive techniques</li> <li>• Adult patients with palpable varicocele and abnormal semen parameters with no current attempts for conception shall be offered varicocele repair to preserve future fertility</li> </ul>

*ASRM* American society of reproductive medicine, *EAU* European association of urology

of studies, that excluded subclinical varicocele and patients with normal semen parameters, showed an effect size by 2.39 (odds ratio) for treatment in 505 patients included in RCT: one natural pregnancy for every seven varicocele repairs in idiopathic infertile couples (Kroese et al. 2012).

Patient counseling before operation should include the fact that the available evidence for achieving natural pregnancy after varicocele repair is rather suggestive than conclusive. Regardless of the fact that about 65% of patients had significant improvement of seminal parameters after varicocele repair (Schlesinger et al. 1994), improvement of seminal parameters is not essentially correlated with achievement of natural pregnancy (Nieschlag et al. 1998).

Table 1 summarizes EAU and ASRM guidelines for fertility indications of varicocele treatment.

Proper patient selection is the key for surgical success. Several studies were performed to assess predictors of improvement of semen parameters and pregnancy rate after varicocele repair.

Age is inversely related to improvement of semen parameters after varicocele repair. Longer duration of infertility predicts lower pregnancy rate after the operation. The repair of higher varicocele grade is directly associated with better improvement of semen parameters. Preoperative total motile count (TMC)  $\geq 5$  millions/mL

**Table 2** Potentially predictive factors for the outcome of varicocele repair

Positive predictive factors	Negative predictive factors
• Moderate oligo $\pm$ asthenozoospermia	• Normal semen parameters
• TMC $\geq$ 5 million/mL	• Subclinical varicocele
• Higher clinical grade of varicocele	• Elevated FSH
• Vein diameter $>$ 3 mm (by ultrasonography)	• History of cryptorchidism
• Reversal of blood flow (by ultrasonography)	• Genetic abnormality, e.g., AZFc microdeletion
• Bilateral repair of bilateral varicocele	• Absolute teratozoospermia
• Higher baseline DNA fragmentation	• Presence of female factor infertility

TMC total motile count, FSH follicle stimulating hormone, AZFc Azoospermia factor C

predicts higher improvement rates in sperm count and pregnancy rate after the operation. Lower baseline preoperative FSH and higher testosterone level predict improvement of semen parameters of oligozoospermia patients after varicocele repair (Kondo et al. 2009; Vivas-Acevedo et al. 2010; Choi and Kim 2013; Samplaski and Jarvi 2016). Bilateral repair of left large varicocele, i.e. grade II or III, and right small varicocele, i.e. grade I, is associated with higher improvement in semen parameters and pregnancy rate than unilateral repair of left varicocele alone (Scherr and Goldstein 1999). In contrast, Hsiao et al. found no significant difference in the outcome of varicocele repair in different age groups (Hsiao et al. 2011). Elevation of FSH reflects damage to spermatogenic epithelium. The role of FSH is not proven yet as a predictive factor for the outcome of varicocele repair by a randomized controlled study (Nieschlag et al. 2010). Table 2 shows potentially predictive factors for the outcome of varicocele repair.

### Scrotal Pain

The decision of varicocele repair should be preceded by exclusion of other causes of chronic orchialgia, e.g., chronic epididymitis, lower urinary tract symptoms due to distal ureteral stone or chronic prostatitis, irritable bowel syndrome, and referred pain, e.g., due to ureteric stones. Varicocele patients who present with chronic scrotal pain as surgical complications that appeared after inguinal hernia repair should not offered surgery option as the most probable cause is nerve entrapment injury or present with orchialgia after vasectomy as it is usually due to chronic congestive epididymitis or sperm granuloma.

Conservative measures should be offered before the decision for varicocele repair. Higher varicocele grade, classical pain characteristics, and long duration of testicular pain ( $>$ 3 months) were found to be a good predictor for pain resolution after varicocele repair (Shridharani et al. 2012).

Subinguinal varicocelectomy approach is preferred over laparoscopic repair as ligation of external spermatic vein is possible, which is essential for surgical success (Karademir et al. 2005).

In a review and meta-analysis by Schlegel and Goldstein, varicocele repair was found to resolve testicular pain in up to 76% of patients (Schlegel and Goldstein 2011).



### Varicocele During Adolescence

The widely used, but not evidence-based proven, varicocele repair indications are reduction of ipsilateral testicular volume and disturbance of semen parameters if semen samples are obtainable. The reduction of ipsilateral testicular volume by more than 20% is associated with abnormalities in semen parameters in up to 59% of affected adolescents (Diamond et al. 2007).

The idea for surgical intervention is to protect against the deleterious effect of varicocele for future fertility. Catch-up growth of testicular volume after varicocele repair occurs in about 80% of operated adolescents (Messina et al. 2006; Li et al. 2012a). However, a cohort study observed a spontaneous normalization of previously abnormal semen parameters in up to 47% of adolescents (Chu et al. 2016) without any intervention. Spontaneous normalization of testicular size occurs in about 50% of adolescent patients with varicocele affecting testicular volume (Czeloth et al. 2013).

The presence of grade II or III varicocele is not an indication by itself for varicocelectomy (Diamond et al. 2011). Regular follow-up by clinical examination and ultrasonography to measure testicular volume disproportion and regular semen analysis every 6 months should be done for at least one year to observe improvement or deterioration of testicular volume and/or semen parameters. However, reduction testicular volume per se is only a cosmetic abnormality. In the absence of evident disturbance of semen parameters or scrotal pain, conservative measures are recommended. The available evidence is not enough for supporting repair of adolescent varicocele as a prophylactic measure to prevent future infertility.

Çayan et al. reported in a controlled study significantly improved semen parameters, higher paternity rates, and shorter time to pregnancy after microsurgical varicocelectomy during adolescence compared to a conservatively managed group. This is the first study to show evidence for a positive outcome favoring varicocele repair in adolescents to improve fertility later in life (Çayan et al. 2017).

Table 3 shows the indications for varicocele repair in children and adolescence according to EAU and ASRM guidelines.

### Varicocele and Nonobstructive Azoospermia (NOA)

As early as 1955, Tulloch reported a case of a 27-year-old infertile male with azoospermia, who showed significant improvement after varicocelectomy operation; in few months sperms appeared in the ejaculate and within 9 months natural conception of wife occurred (Tulloch 1955). The emergence of intracytoplasmic sperm injection (ICSI) with the use of sperms derived from testicular sperm extraction (TESE) minimized the role of varicocele repair in managing of patients with NOA associated with varicocele. The aim of varicocele repair in men with NOA is to alleviate the negative effects of varicocele on the testis to improve the spermatogenic activity, either with subsequent appearance of spermatozoa in the ejaculate to achieve unassisted conception or achieve conception with assisted reproductive techniques. Furthermore, varicocele repair prior to TESE aims to increase the chances for successful sperm retrieval.

**Table 3** Indications for varicocele repair in children and adolescents according to EAU and ASRM

Organization	Guidelines
EAU guidelines on pediatric urology – updated in 2016 (available at: <a href="http://uroweb.org/guideline/paediatric-urology">http://uroweb.org/guideline/paediatric-urology</a> )	<p>Varicocele repair is recommended in the following conditions:</p> <ol style="list-style-type: none"> <li>1. Ipsilateral reduction of testicular volume by &gt;2 mL or 20% compared to the ipsilateral testis</li> <li>2. Presence of other testicular condition that affects fertility</li> <li>3. Palpable bilateral varicocele</li> <li>4. Abnormal semen parameters (in older adolescents)</li> <li>5. Varicocele associated with scrotal pain</li> </ol>
EAU guidelines on male infertility (available at: <a href="http://uroweb.org/guideline/male-infertility">http://uroweb.org/guideline/male-infertility</a> )	<ol style="list-style-type: none"> <li>1. In adolescent varicocele, there is a significant risk of overtreatment. Most adolescents with varicocele have no problem achieving pregnancy later in life</li> <li>2. Varicocele repair is recommended in case of growth deterioration of ipsilateral testis by documented serial clinical examinations and in case of impaired semen parameters</li> </ol>
ASRM committee opinion – updated in 2014 (Practice Committee of the American Society for Reproductive Medicine and the Society for Male Reproduction and Urology 2014)	<ol style="list-style-type: none"> <li>1. Varicocele repair is recommended in adolescents with evident reduced ipsilateral testicular volume</li> <li>2. Annual follow-up with measurement of testicular volume and/or semen analyses for early detection of testicular damage.</li> </ol> <p>Varicocele repair should be offered on detection of testicular or semen abnormalities</p>

*ASRM* American society of reproductive medicine, *EAU* European association of urology

Several recent meta-analyses reported considerable positive outcome after repairing of clinically palpable varicocele in men with NOA. Weedin et al. reported appearance of motile sperms in the ejaculate in 91 out of 233 patients (39.1%) and occurrence of 14 natural pregnancies after varicocele repair (Weedin et al. 2010). In another meta-analysis by Schlegel and Goldstein, sperms appeared in the ejaculate of 119 patients out of total 327 patients (36%) after varicocele repair, and 18 out of 317 (6%) reported spontaneous pregnancy (Schlegel and Goldstein 2011). Similarly, Esteves et al. found that about 44% of varicocele patients with NOA had sperms in the ejaculate after varicocele repair. They reported spontaneous pregnancy was 13.6%. Furthermore, sperm retrieval rate (SRR) was found to be higher by 2.65 folds after varicocele repair (Esteves et al. 2016).

Testicular histopathology predicts the outcome of varicocele repair in NOA patients. Patients with Sertoli cell only (SCO) and maturation arrest have worse prognosis, compared to patients with late maturation arrest or hypospermatogenesis (Weedin et al. 2010). Patients with Y-chromosome microdeletions do not benefit from varicocele repair (Dada et al. 2007).

There is a growing evidence that supports varicocele repair in NOA patients. Young-aged NOA patients with high-grade palpable varicocele (grade II or III), with normal-sized testes, and having no evidence of obstructive or genetic abnormalities should be offered the option of varicocele repair. Appearance of spermatozoa in the ejaculate after repair should be followed by immediate cryopreservation, due to the possibility of relapsing of azoospermia (Gat et al. 2005a).

### **Testosterone Deficiency and Symptoms of Hypogonadism**

One of the earliest studies that described improvement of testosterone levels after varicocele repair was published by Comhaire and Vermeulen in 1975, when they reported normalization of testosterone levels after varicocele repair in 10 patients with low preoperative testosterone levels (Comhaire and Vermeulen 1975). Many subsequent studies reported similar results. Most of them were nonrandomized, noncontrolled, retrospective, or involved small population. Varicocele repair in all studies was performed for infertility or pain resulting in a biased population sample that does not represent all varicocele patients with low testosterone. Long-term follow up was not performed in any of these studies.

A meta-analysis of nine studies showed significant improvement of testosterone levels by 97.48 ng/dL (3.38 nmol/L) after varicocele repair (Li et al. 2012b). In a prospective study in infertile men, Zohdy et al. reported significant improvement of international index of erectile functions (IIEF-5) scores – denoting improvement of sexual functions, along with normalization of testosterone levels in hypogonadal subpopulation (Zohdy et al. 2011). In a recent review, Dabaja and Goldstein recommended varicocele treatment for patients with hypogonadism even in the absence of infertility (Dabaja and Goldstein 2016).

According to the available literature, varicocele is considered a risk factor for low testosterone level. However, the available scientific evidence is too low to consider varicocele treatment as a prophylactic measure or as a treatment option for hypogonadism.

### **Role of Varicocele Treatment in the era of Assisted Reproductive Techniques (ART)**

After the first successful in-vitro fertilization (IVF) trial in 1977 and intracytoplasmic sperm injection (ICSI) in 1992, assisted reproductive techniques became gradually the preferred method in managing male factor infertility due to its rapid outcome and considerable success rate. The role of varicocele treatment decreased further after Cochrane review in 2004 which indicated no benefit for varicocele repair in male factor infertility. The Cochrane review 2012 evaluated the increased evidence that supports the role of varicocele treatment in managing male factor infertility and influenced also the EAU male infertility guidelines. The grade of recommendation for varicocele repair in infertile men with palpable varicocele and oligozoospermia raised from grade of recommendation B in 2012 to grade of recommendation A representing the highest level based on high quality evidence in 2013 and in the following updates till 2016.

Varicocele repair may decrease the need for ART in managing male factor infertility in well-selected constellations. Furthermore, it optimizes the reproductive potential and enhances the outcome of ART (McIntyre et al. 2012). Kirby et al. used pregnancy rates and live birth rates as an outcome measure in a meta-analysis to evaluate the effect of previous varicocele repair on the outcome of ART in patients with clinically palpable varicocele and azoospermia or oligozoospermia. There was statistically significant difference favoring varicocele repair in patients with clinical varicocele and azoospermia or oligozoospermia in terms of improving pregnancy rates and live birth rates in couples undergoing ART trials (Kirby et al. 2016). Varicocele repair improves DNA fragmentation index (DFI) which was found to be one of the causes of early miscarriage (Tesarik et al. 2004). However, improved DFI explains only the improvement of IVF success rates with lower DFI. Live birth rates after ICSI are not affected by levels of DFI according to a recent meta-analysis (Osman et al. 2015).

### **Interventional Varicocele Repair**

The aim of varicocele repair is to eliminate the venous reflux to the testis, while persevering arterial supply and lymphatic drainage to reduce complications. Feasibility, rate of recurrence, rate of complications, and cost/effectiveness are the most important factors for the overall effectiveness of treatment modalities. Deterioration of lymph drainage during the operation is associated with hydrocele formation. Missing of a tributary of internal spermatic vein or dilated external spermatic vein is associated with recurrence or persistence of the varicocele. Arterial supply of the testis consists of internal and external spermatic arteries and vasal artery. Extensive injury to the arterial supply is complicated by testicular atrophy. Ligation of testicular artery will not be always associated with testicular atrophy (Salem and Mostafa 2009; Kang et al. 2013). In contrast, Chan et al. concluded that testicular atrophy occurs in 5% after accidental injury of spermatic artery. Preservation of external spermatic artery may reduce the incidence but does not prevent this complication. The same study reported lower pregnancy rates after accidental injury of internal spermatic artery during microsurgical varicocelectomy in comparison with varicocelectomy with internal spermatic artery sparing (Chan et al. 2005). Intratesticular testosterone level is lower after varicocelectomy with internal spermatic artery ligation in comparison with artery sparing varicocelectomy as demonstrated by an animal model study (Zheng et al. 2008). Intratesticular testosterone plays an important role as a local regulator of spermatogenesis.

Commonly used interventional modalities for varicocele intervention comprise different approaches:

Surgical approaches include:

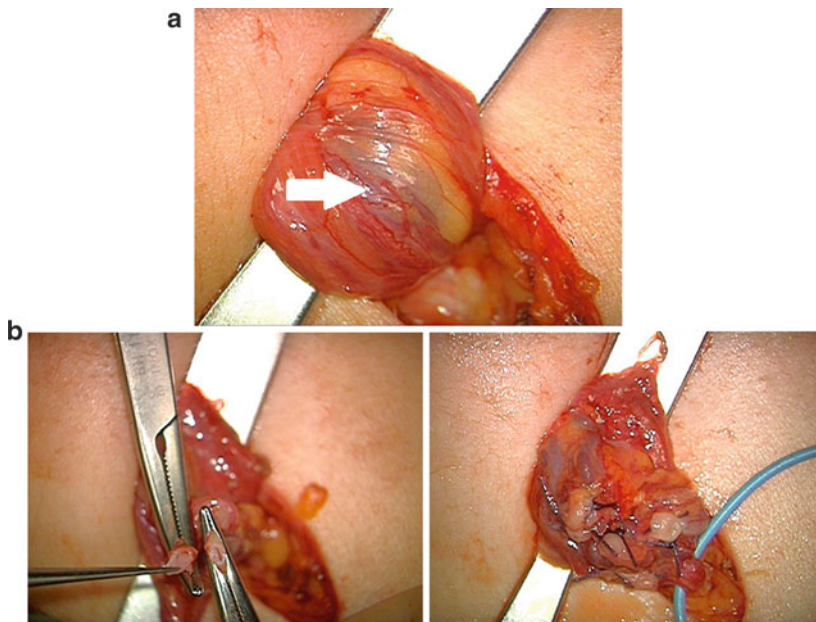
- Microsurgical subinguinal varicocele surgery
- Inguinal varicocele surgery
- Retroperitoneal varicocele surgery
- Laparoscopic varicocele surgery
- Antegrade or reterograde sclerotherapy
- Retrograde embolization

### Microsurgical Subinguinal Varicocelectomy

Microsurgical subinguinal varicocele surgery involves approaching the spermatic cord via 2–3 cm subinguinal incision, nontraumatic exposure of the spermatic cord at the external inguinal ring and using a surgical microscope to identify and preserve internal spermatic artery and lymph vessels. In addition, identification and ligation of all veins including small ones is mandatory and possible due to magnification (Fig. 3a, b).

Based on the current evidence, microsurgical varicocelectomy is the optimal and most effective technique for varicocele repair (Al-Kandari et al. 2007; Ding et al. 2012; Wang et al. 2015) with lowest complication rates. Performing the operation by a subinguinal approach allows identification and ligation of external spermatic veins and avoids external oblique aponeurosis dissection. Therefore, it is associated with less postoperative pain. Ilioinguinal nerve remains intact with this approach. Drawbacks of this approach include the complexity of internal spermatic veins around the internal spermatic artery. This complexity is higher by three times than at the inguinal level (Hopps et al. 2003).

This technique was outlined by Marmar et al. (1985). Only minimal modifications were introduced to the original technique. Marmar et al. combined this technique



**Fig. 3** (a) Intraoperative exposure of the spermatic cord at the external inguinal ring under a surgical microscope after a small inguinal incision of the skin (2–3 cm) and separation of the subcutaneous adipose tissue. The dilated veins are visible beneath adipose tissue (arrow). (b) (left) and (right) Intraoperative microscopic picture after separation of a vein, followed by ligation. Ligated veins, intact lymph vessels, and artery (with blue vessel loop marked). (Department of Clinical and Surgical Andrology, CeRA, Münster, Germany)

with injection of sclerosing material to obliterate small veins, which is not done routinely in the current practice.

When identification of testicular artery by optical magnification is difficult, it is recommended to use local spraying of the vasodilator papaverine hydrochloride to induce arterial contractions of internal spermatic artery or to use of intraoperative sterile Duplex sonography or Doppler probe to identify arterial pulsations. Shibata et al. suggested a novel technique that involves using of intraoperative indocyanine green angiography with infrared fluorescence module integrated into a surgical microscope which is commonly used in neurosurgical operations for easy identification of internal spermatic artery (Shibata et al. 2016).

Generally, microsurgical varicocelectomy had the highest rates of improvement of semen parameters and highest pregnancy rates according to a meta-analysis that included 35 RCTs and observational studies comparing different modalities for management of clinical varicocele (Wang et al. 2015). EAU guidelines for male infertility recommend microsurgical varicocelectomy for varicocele repair in adults and adolescents (Roque and Esteves 2016).

Table 4 summarizes varicocele interventions, their risk for recurrence, and possible complications. Most techniques can be applied on an outpatient service.

Recurrence rate of nonmicrosurgical subinguinal varicocelectomy is high (11.3%) when compared with recurrence rate of the microsurgical technique (0–1.4%). The rate of hydrocele formation is higher (8.7%) without magnification and with microscopic magnification decreases to 0.3–1.2%. The incidence of other complications as hematoma formation and postoperative infection varies between different operators and surgical settings (Jungwirth et al. 2001; Abdel-Maguid and Othman 2010). The use of loupe magnification is not as effective as microscopic magnification in identifying small veins especially those adherent to the preserved internal spermatic artery, and hence carries higher risk of recurrence (Zhang et al. 2014). Some andrologists favor testicular delivery through the inguinal incision to access and ligate small collateral veins and gubernacular vein. A prospective randomized controlled study found no significant reduction in recurrence rate with this maneuver. In addition, this study reported significant improvement of semen parameters but with no significant improvement in pregnancy rates (Hou et al. 2015).

### **Inguinal Varicocelectomy (Modified Ivanissevich Technique)**

The original technique described by Ivanissevich in 1918 involved approaching internal spermatic vein via suprainguinal approach (Ivanissevich 1960; Gonzalez 2014). Bernardi modified the original approach of this technique to inguinal approach (Chiba and Fujisawa 2016). The advantage of this approach over subinguinal approach is the presence of lower number of veins at inguinal level, which makes identification and preservation of testicular artery easier. Furthermore, dilated external spermatic veins can be identified and ligated through this approach. Subinguinal and inguinal microsurgical varicocelectomy are considered the standard

**Table 4** Summary of varicocele interventions, possible complications and possibility of performing the interventions in outpatient settings

Technique of intervention	Recurrence of VC	Hydrocele formation	Other complications	Outpatient therapy
Micosurgical subinguinal varicocelectomy	0–1.4%	0.3–1.2%	–	Yes
Micosurgical inguinal varicocelectomy	0.6%		Pain	(Yes) / No
Non-microsurgical subinguinal varicocelectomy	11.3%	8.7%	Ligation of artery and lymph vessels	Yes
Inguinal varicocelectomy (modified Ivanissevich)	1.3–13.3%	7.3–13%	Ligation of artery and lymph vessels, pain, injury of N. ilioinguinalis	No
Retroperitoneal varicocelectomy (Palomo)	9.3–14.9%	8.2%	Ligation of artery and lymph vessels	No
Laparoscopic varicocelectomy	4.3%	2.8%	Bowel adhesion, organ perforation	No
Antegrade sclerotherapy (Tauber)	9%	nd	Testicular X-ray exposure	Yes
Retrograde embolization or sclerotherapy	12.7%	nd	X-ray exposure	Yes

*nd* not determined

techniques in the contemporary practice. The major disadvantages of the inguinal technique in contrast with subinguinal approach is higher postoperative pain due to dissection of external oblique aponeurosis and the possibility of injuring the ilioinguinal nerve which leads to chronic groin pain.

The incidence of hydrocele formation with the conventional technique is 13%. Hydrocele formation with microsurgical inguinal approach is uncommon (Al-Kandari et al. 2007). Higher rate of recurrence is observed without microscopic magnification (1.3–13.3%) in comparison with reported low recurrence rate (0.6%) by microsurgical technique (Ivanissevich 1960; Goldstein et al. 1992; Rotker and Sigman 2016).

### **Retroperitoneal Varicocelectomy (Modified Palomo Technique)**

The original technique which was described by Palomo in 1949 involves retroperitoneal ligation of internal spermatic artery, vein, and lymphatics. It was modified later on to involve ligation of internal spermatic vein only (Gonzalez 2014).

Currently, this technique is not commonly used. The external spermatic vein is not accessible and is not ligated with this technique which increases the recurrence rate. The incidence of recurrence with this technique is 9.3% (Rotker and Sigman 2016).

### **Laparoscopic Varicocelectomy**

Laparoscopic approach resembles the retroperitoneal approach but with smaller incisions and optical magnifications. In addition to the same drawbacks of retroperitoneal approach, this technique carries the risk of air embolism, injury of abdominal organs, port-site hernias, and bowel adhesion (Chiba and Fujisawa 2016). Depending on artery-sparing and lymph-sparing approaches, hydrocele formation as complication may vary. This technique is associated with high recurrence rates and it is not recommend for routine management of varicocele.

### **Antegrade Sclerotherapy**

This so-called minimally invasive technique is performed through high scrotal approach, followed by cannulation of the most dilated internal spermatic vein and injection of contrast medium and radiological imaging to confirm proper cannulation of pampiniform plexus. Then sclerosant agent is injected slowly while the patient performs Valsalva maneuver. Sclerosant agent diffuses through communicated meshwork of pampiniform plexus and obliterates these veins. The rate of recurrence with this technique is 9% according to the early data (Tauber and Johnsen 1993). However, a recent review by Crestani et al. reported in an uncontrolled study a lower recurrence rate (5%), improvement of semen parameters and a pregnancy rate of 31% within 12 months of follow up after the operation (Crestani et al. 2016). Generally, this technique is associated with unnecessary radiological exposure and associated with high recurrence rates with large varicocele.

### **Percutaneous Retrograde Embolization or Sclerotherapy**

Percutaneous embolization allows occlusion of the internal spermatic vein via transjugular or transfemoral venous catheter under radiological guidance. Embolic agents are either solid or liquid. Solid agents include vascular plugs, balloons, and coils. Liquid agents include sodium tetradecylsulfate and adhesive polymers. The main advantage of this technique is that it can be done in outpatient settings under local anesthesia. The main drawbacks include unnecessary exposure to radiation and the possibility of occurrence of major complications as injury of femoral artery and obstruction of renal vein by a migrated coil. Agent-specific complications include venous perforation by solid agents and venous inflammation or entrapment of the catheter by liquid embolic agents. This technique shows high success rate in management of recurrent varicocele after surgical repair (Jargiello et al. 2015; Halpern et al. 2016).

### **Recurrent Varicocele**

Recurrence is the most common complication of varicocele repair. Microsurgical subinguinal varicocelectomy has the lowest recurrence rate according to the current evidence. Open inguinal or subinguinal approaches without microscopic



magnification are associated with increased chances of missing small internal spermatic veins. Ligation of external spermatic (cremasteric) veins is not feasible with retroperitoneal and laparoscopic approaches. Recurrence through these veins may happen. Whether the dilation of external spermatic veins after varicocelectomy should be considered a recurrence or it is just increased outflow after ligation of internal spermatic venous group is a point of debate. Jargiello et al. found in 33 patients with recurrent varicocele that the recurrence occurred in 31 patients (93%) through incompetent internal spermatic veins. In the remaining two patients, venography did not show any incompetent veins draining directly into inferior vena cava or iliac veins, suggesting alternative venous pathways (Jargiello et al. 2015).

Longer follow-up after the operation is associated with detection of new cases of recurrent varicocele. Patients with lower body mass index are more susceptible for recurrence after varicocele repair (Gorur et al. 2015). The diagnosis of recurrent varicocele is difficult, and color-coded Duplex ultrasonography is recommended when recurrence is suspected (Rotker and Sigman 2016).

Patients presenting with recurrent varicocele after inguinal, retroperitoneal, or laparoscopic approach should be offered microsurgical subinguinal varicocelectomy after considering semen and hormonal parameters, fertility status of the partner, and exclusion of other causes of infertility and/or scrotal pain. Recurrent varicocele after subinguinal varicocelectomy is difficult to manage by subinguinal microsurgical approach due to the presence of postoperative fibrosis and disturbed normal anatomy of internal spermatic artery after the first operation. In all cases, the risk of arterial injury (which is to be assumed after non-microsurgical approaches) and subsequent testicular atrophy in redo surgeries should be weighed against the expected benefit from the operation. In such conditions, retrograde embolization should be considered as alternative. The use of assisted reproductive techniques to achieve pregnancy should be considered in every case presenting with recurrent varicocele and infertility.

---

## Summary

Dilation, elongation, and tortuosity of the pampiniform plexus of veins draining the testis is defined as varicocele. The prevalence of varicocele in patients with primary infertility is 35% compared to the male population with about 20% prevalence. Varicocele may negatively affect spermatogenesis, maturation, and functional quality of spermatozoa by several mechanisms. Moreover, it may be associated with gently lowered testosterone production. The diagnosis of varicocele is clinical and should be confirmed by Color-coded Duplex ultrasonography. The decision of varicocele repair for fertility reasons should be discussed with the couple after at least one year of failed trials for achieving conception, presence of clinical relevant varicocele, two semen analyses showing subnormal parameters, only moderately elevated FSH serum levels, and exclusion of other causes of infertility and female partner factors. Surgical repair of clinical varicocele in adolescents should not be regularly offered as evidence- when fertility protection is the target- is still low.

Reduced ipsilateral testicular volume and impaired spermatogenesis after end of pubertal development may favor intervention in selected cases. Pain is a trigger for treatment mainly combined with grade III varicoceles. Selected patients with azoospermia and varicocele may benefit from varicocele treatment under certain conditions. Varicocele treatment may reduce the need for ART in the management of male factor infertility in selected patients, and on the other hand, it may improve pregnancy rates and live births by ART in varicocele patients with subnormal semen parameters. There is not sufficient evidence for recommending varicocele repair for testosterone deficiency or as preventive treatment to avoid adolescent or adult progressive testicular failure. The main indications for varicocele treatment remain idiopathic male and couple infertility and/or scrotal pain.

If treatment is intended, subinguinal microsurgical varicocele surgery with artery and lymph vessels sparing (and without testicular delivery) is the method of choice with lowest recurrence and complication rates accompanied by the highest rate of improvement of fertility outcomes.

---

## Cross-References

- ▶ [Anamnesis and Physical Examination](#)
- ▶ [Assisted Reproduction for Male Infertility](#)
- ▶ [Color-Doppler Ultrasound and New Imaging Techniques in Andrological Examination](#)
- ▶ [Functional Anatomy and Histology of the Testis](#)

---

## References

- Abdel-Maguid AF, Othman I. Microsurgical and nonmagnified subinguinal varicocelectomy for infertile men: a comparative study. *Fertil Steril.* 2010;94(7):2600–3. doi:[10.1016/j.fertnstert.2010.03.063](#).
- Agarwal A, Prabakaran S, Allamaneni SS. Relationship between oxidative stress, varicocele and infertility: a meta-analysis. *Reprod Biomed Online.* 2006;12(5):630–3.
- Agarwal A, Sharma R, Harlev A, Esteves SC. Effect of varicocele on semen characteristics according to the new 2010 World Health Organization criteria: a systematic review and meta-analysis. *Asian J Androl.* 2016;18(2):163–70. doi:[10.4103/1008-682X.172638](#).
- Akbay E, Cayan S, Doruk E, Duce MN, Bozlu M. The prevalence of varicocele and varicocele-related testicular atrophy in Turkish children and adolescents. *BJU Int.* 2000;86(4):490–3.
- Al-Kandari AM, Shabaan H, Ibrahim HM, Elshebiny YH, Shokeir AA. Comparison of outcomes of different varicocelectomy techniques: open inguinal, laparoscopic, and subinguinal microscopic varicocelectomy: a randomized clinical trial. *Urology.* 2007;69(3):417–20. doi:[10.1016/j.urology.2007.01.057](#).
- Ando S, Giacchetto C, Colpi G, Beraldi E, Panno ML, Lombardi A, Sposato G. Physiopathologic aspects of Leydig cell function in varicocele patients. *J Androl.* 1984;5(3):163–70.
- Ando S, Giacchetto C, Colpi G, Panno ML, Beraldi E, Lombardi A, Sposato G. Plasma levels of 17-OH-progesterone and testosterone in patients with varicoceles. *Acta Endocrinol.* 1983;102(3):463–9.

- Azizollahi G, Azizollahi S, Babaei H, Kianinejad M, Baneshi MR, Nematollahi-mahani SN. Effects of supplement therapy on sperm parameters, protamine content and acrosomal integrity of varicocelectomized subjects. *J Assist Reprod Genet.* 2013;30(4):593–9. doi:[10.1007/s10815-013-9961-9](https://doi.org/10.1007/s10815-013-9961-9).
- Beretta G (2015) Varicocele and Infertility. In: Cavallini G, Beretta G (eds) *Clinical Management of Male Infertility*. Springer International Publishing, Cham, pp 55–61. doi:[10.1007/978-3-319-08503-6\\_7](https://doi.org/10.1007/978-3-319-08503-6_7).
- Björndahl L, Giwercman A, Tournaye H, Weidner W. *Clinical andrology: EAU/ESAU course guidelines*. CRC Press; 2010. doi:[10.3109/9781841847474-14](https://doi.org/10.3109/9781841847474-14).
- Canales BK, Zapzalka DM, Ercole CJ, Carey P, Haus E, Aeppli D, Pryor JL. Prevalence and effect of varicoceles in an elderly population. *Urology.* 2005;66(3):627–31. doi:[10.1016/j.urology.2005.03.062](https://doi.org/10.1016/j.urology.2005.03.062).
- Çayan S, Şahin S, Akbay E. Comparison of paternity rates and time to conception between adolescents with varicocele who underwent microsurgical varicocele repair or had observation only: a single institute experience with 408 cases. *J Urol.* 2017. doi:[10.1016/j.juro.2017.01.066](https://doi.org/10.1016/j.juro.2017.01.066).
- Chait A, Matasar KW, Fabian CE, Mellins HZ. Vascular impressions on the ureters. *Am J Roentgenol Radium Therapy, Nucl Med.* 1971;111(4):729–49.
- Chan PT, Wright EJ, Goldstein M. Incidence and postoperative outcomes of accidental ligation of the testicular artery during microsurgical varicocelectomy. *J Urol.* 2005;173(2):482–4. doi:[10.1097/01.ju.0000148942.61914.2e](https://doi.org/10.1097/01.ju.0000148942.61914.2e).
- Chiba K, Fujisawa M. Clinical outcomes of varicocele repair in infertile men: a review. *World J Mens Health.* 2016;34(2):101–9. doi:[10.5534/wjmh.2016.34.2.101](https://doi.org/10.5534/wjmh.2016.34.2.101).
- Chiou RK, Anderson JC, Wobig RK, Rosinsky DE, Matamoros Jr A, Chen WS, Taylor RJ. Color Doppler ultrasound criteria to diagnose varicoceles: correlation of a new scoring system with physical examination. *Urology.* 1997;50(6):953–6. doi:[10.1016/S0090-4295\(97\)00452-4](https://doi.org/10.1016/S0090-4295(97)00452-4).
- Choi WS, Kim SW. Current issues in varicocele management: a review. *World J Mens Health.* 2013;31(1):12–20. doi:[10.5534/wjmh.2013.31.1.12](https://doi.org/10.5534/wjmh.2013.31.1.12).
- Chu DI, Zderic SA, Shukla AR, Srinivasan AK, Tasian GE, Weiss DA, Long CJ, Canning DA, Kolon TF. The natural history of semen parameters in untreated asymptomatic adolescent varicocele patients: a retrospective cohort study. *J Pediatr Urol.* 2016. doi:[10.1016/j.jpuro.2016.09.008](https://doi.org/10.1016/j.jpuro.2016.09.008).
- Comhaire F, Simons M, Kunnen M, Vermeulen L. Testicular arterial perfusion in varicocele: the role of rapid sequence scintigraphy with technetium in varicocele evaluation. *J Urol.* 1983;130(5):923–6.
- Comhaire F, Vermeulen A. Varicocele sterility: cortisol and catecholamines. *Fertil Steril.* 1974;25(1):88–95.
- Comhaire F, Vermeulen A. Plasma testosterone in patients with varicocele and sexual inadequacy. *J Clin Endocrinol Metab.* 1975;40(5):824–9. doi:[10.1210/jcem-40-5-824](https://doi.org/10.1210/jcem-40-5-824).
- Crestani A, Giannarini G, Calandriello M, Rossanese M, Mancini M, Novara G, Ficarra V. Antegrade scrotal sclerotherapy of internal spermatic veins for varicocele treatment: technique, complications, and results. *Asian J Androl.* 2016;18(2):292–5. doi:[10.4103/1008-682X.171658](https://doi.org/10.4103/1008-682X.171658).
- Czeloth K, Kalble T, Kliesch S. Varicocele in adolescents. *Der Urologe Ausg A.* 2013;52(1):48–53. doi:[10.1007/s00120-012-3080-6](https://doi.org/10.1007/s00120-012-3080-6).
- Dabaja AA, Goldstein M. When is a varicocele repair indicated: the dilemma of hypogonadism and erectile dysfunction? *Asian J Androl.* 2016;18(2):213–6. doi:[10.4103/1008-682X.169560](https://doi.org/10.4103/1008-682X.169560).
- Dada R, Kumar R, Shamsi MB, Sidhu T, Mitra A, Singh S, Kumar R, Sharma RS, Gupta SK, Gupta NP. Azoospermia factor deletions in varicocele cases with severe oligozoospermia. *Indian J Med Sci.* 2007;61(9):505–10.
- Dahl EV, Herrick JF. A vascular mechanism for maintaining testicular temperature by counter-current exchange. *Surg Gynecol Obstet.* 1959;108(6):697–705.
- Damsgaard J, Joensen UN, Carlsen E, Erenpreiss J, Blomberg Jensen M, Matulevicius V, Zilaitiene B, Olesen IA, Perheentupa A, Punab M, Salzbrunn A, Toppari J, Virtanen HE, Juul A, Skakkebaek NE, Jorgensen N. Varicocele is associated with impaired semen quality

- and reproductive hormone levels: a study of 7035 healthy young men from six European countries. *Eur Urol.* 2016;70(6):1019–29. doi:[10.1016/j.eururo.2016.06.044](https://doi.org/10.1016/j.eururo.2016.06.044).
- Diamond DA, Gargollo PC, Caldafone AA. Current management principles for adolescent varicocele. *Fertil Steril.* 2011;96(6):1294–8. doi:[10.1016/j.fertnstert.2011.10.034](https://doi.org/10.1016/j.fertnstert.2011.10.034).
- Diamond DA, Zurakowski D, Bauer SB, Borer JG, Peters CA, Cilento Jr BG, Paltiel HJ, Rosoklija I, Retik AB. Relationship of varicocele grade and testicular hypotrophy to semen parameters in adolescents. *J Urol.* 2007;178(4 Pt 2):1584–8. doi:[10.1016/j.juro.2007.03.169](https://doi.org/10.1016/j.juro.2007.03.169).
- Ding H, Tian J, Du W, Zhang L, Wang H, Wang Z. Open non-microsurgical, laparoscopic or open microsurgical varicocelectomy for male infertility: a meta-analysis of randomized controlled trials. *BJU Int.* 2012;110(10):1536–42. doi:[10.1111/j.1464-410X.2012.11093.x](https://doi.org/10.1111/j.1464-410X.2012.11093.x).
- Dubin L, Amelar RD. Varicocele size and results of varicocelectomy in selected subfertile men with varicocele. *Fertil Steril.* 1970;21(8):606–9.
- Dubin L, Amelar RD. Varicocelectomy: 986 cases in a twelve-year study. *Urology.* 1977;10(5):446–9.
- Esteves SC, Miyaoka R, Roque M, Agarwal A. Outcome of varicocele repair in men with nonobstructive azoospermia: systematic review and meta-analysis. *Asian J Androl.* 2016;18(2):246–53. doi:[10.4103/1008-682X.169562](https://doi.org/10.4103/1008-682X.169562).
- Evenson DP, Wixon R. Clinical aspects of sperm DNA fragmentation detection and male infertility. *Theriogenology.* 2006;65(5):979–91. doi:[10.1016/j.theriogenology.2005.09.011](https://doi.org/10.1016/j.theriogenology.2005.09.011).
- Evers JL, Collins JA. Surgery or embolisation for varicocele in subfertile men. *Cochrane Database Syst Rev.* 2004;3:CD000479. doi:[10.1002/14651858.CD000479.pub2](https://doi.org/10.1002/14651858.CD000479.pub2).
- Ficarra V, Cerruto MA, Liguori G, Mazzoni G, Minucci S, Tracia A, Gentile V. Treatment of varicocele in subfertile men: the Cochrane review – a contrary opinion. *Eur Urol.* 2006;49(2):258–63. doi:[10.1016/j.eururo.2005.11.023](https://doi.org/10.1016/j.eururo.2005.11.023).
- Gandhi J, Dagur G, Sheynkin YR, Smith NL, Khan SA. Testicular compartment syndrome: an overview of pathophysiology, etiology, evaluation, and management. *Transl Androl Urol.* 2016;5(6):927–34. doi:[10.21037/tau.2016.11.05](https://doi.org/10.21037/tau.2016.11.05).
- Garg H, Kumar R. An update on the role of medical treatment including antioxidant therapy in varicocele. *Asian J Androl.* 2016;18(2):222–8. doi:[10.4103/1008-682X.171657](https://doi.org/10.4103/1008-682X.171657).
- Gat Y, Bachar GN, Everaert K, Levinger U, Gornish M. Induction of spermatogenesis in azoospermic men after internal spermatic vein embolization for the treatment of varicocele. *Hum Reprod.* 2005a;20(4):1013–7. doi:[10.1093/humrep/deh706](https://doi.org/10.1093/humrep/deh706).
- Gat Y, Bachar GN, Zukerman Z, Belenky A, Gornish M. Varicocele: a bilateral disease. *Fertil Steril.* 2004;81(2):424–9. doi:[10.1016/j.fertnstert.2003.08.010](https://doi.org/10.1016/j.fertnstert.2003.08.010).
- Gat Y, Zukerman Z, Chakraborty J, Gornish M. Varicocele, hypoxia and male infertility: fluid mechanics analysis of the impaired testicular venous drainage system. *Hum Reprod.* 2005b;20(9):2614–9. doi:[10.1093/humrep/dei089](https://doi.org/10.1093/humrep/dei089).
- Goldstein M, Gilbert BR, Dicker AP, Dwosh J, Gnecco C. Microsurgical inguinal varicocelectomy with delivery of the testis: an artery and lymphatic sparing technique. *J Urol.* 1992;148(6):1808–11.
- Gonzalez R. Proposal for describing procedures to correct varicocele: a new terminology. *Front Pediatr.* 2014;2:47. doi:[10.3389/fped.2014.00047](https://doi.org/10.3389/fped.2014.00047).
- Gorelick JJ, Goldstein M. Loss of fertility in men with varicocele. *Fertil Steril.* 1993;59(3):613–6.
- Gorur S, Candan Y, Helli A, Akcin S, Cekirge SD, Kaya YS, Cekic C, Kiper AN. Low body mass index might be a predisposing factor for varicocele recurrence: a prospective study. *Andrologia.* 2015;47(4):448–54. doi:[10.1111/and.12287](https://doi.org/10.1111/and.12287).
- Goulis D, Mintziori G, Koliakos N, Hatzichristou D, Papadimas I, Hatzimouratidis K, Goulis DG. Inhibin B and anti-mullerian hormone in spermatic vein of subfertile men with varicocele. *Reprod Sci.* 2011;18(6):551–5. doi:[10.1177/1933719110393024](https://doi.org/10.1177/1933719110393024).
- Griveau JF, Le Lannou D. Reactive oxygen species and human spermatozoa: physiology and pathology. *Int J Androl.* 1997;20(2):61–9.
- Halpern J, Mittal S, Pereira K, Bhatia S, Ramasamy R. Percutaneous embolization of varicocele: technique, indications, relative contraindications, and complications. *Asian J Androl.* 2016;18(2):234–8. doi:[10.4103/1008-682X.169985](https://doi.org/10.4103/1008-682X.169985).

- Hamada A, Esteves SC, Agarwal A (2016a) Definitions and epidemiology. In: *Varicocele and male infertility: current concepts, controversies and consensus*, Springer International Publishing, Cham, pp 1–3. doi:[10.1007/978-3-319-24936-0\\_1](https://doi.org/10.1007/978-3-319-24936-0_1)
- Hamada A, Esteves SC, Agarwal A (2016b) Varicocele classification. In: *Varicocele and male infertility: current concepts, controversies and consensus*, Springer International Publishing, Cham, pp 37–43. doi:[10.1007/978-3-319-24936-0\\_4](https://doi.org/10.1007/978-3-319-24936-0_4)
- Hayden RP, Tanrikut C. Testosterone and varicocele. *Urol Clin North Am.* 2016;43(2):223–32. doi:[10.1016/j.ucl.2016.01.009](https://doi.org/10.1016/j.ucl.2016.01.009).
- Hirsh A, Pryor JP (1984) Are there different types of varicocele? In: Glezerman M, Jecht EW (eds) *Varicocele and male infertility II*. Springer Berlin/Heidelberg, pp 49–52. doi:[10.1007/978-3-642-69435-6\\_7](https://doi.org/10.1007/978-3-642-69435-6_7)
- Hopps CV, Lemer ML, Schlegel PN, Goldstein M. Intraoperative varicocele anatomy: a microscopic study of the inguinal versus subinguinal approach. *J Urol.* 2003;170(6 Pt 1):2366–70. doi:[10.1097/01.ju.0000097400.67715.f8](https://doi.org/10.1097/01.ju.0000097400.67715.f8).
- Hou Y, Zhang Y, Zhang Y, Huo W, Li H. Comparison between microsurgical subinguinal varicolectomy with and without testicular delivery for infertile men: is testicular delivery an unnecessary procedure. *Urol J.* 2015;12(4):2261–6.
- Hsiao W, Rosoff JS, Pale JR, Greenwood EA, Goldstein M. Older age is associated with similar improvements in semen parameters and testosterone after subinguinal microsurgical varicolectomy. *J Urol.* 2011;185(2):620–5. doi:[10.1016/j.juro.2010.09.114](https://doi.org/10.1016/j.juro.2010.09.114).
- Hudson RW, Crawford VA, McKay DE. The gonadotropin response of men with varicoceles to a four-hour infusion of gonadotropin-releasing hormone. *Fertil Steril.* 1981;36(5):633–7.
- Ivanisovich O. Left varicocele due to reflux; experience with 4,470 operative cases in forty-two years. *J Int Coll Surg.* 1960;34:742–55.
- Jargiello T, Drelich-Zbroja A, Falkowski A, Sojka M, Pyra K, Szczerbo-Trojanowska M. Endovascular transcatheter embolization of recurrent postsurgical varicocele: anatomic reasons for surgical failure. *Acta Radiol.* 2015;56(1):63–9. doi:[10.1177/0284185113519624](https://doi.org/10.1177/0284185113519624).
- Jungwirth A, Gogus C, Hauser G, Gomahr A, Schmeller N, Aulitzky W, Frick J. Clinical outcome of microsurgical subinguinal varicolectomy in infertile men. *Andrologia.* 2001;33(2):71–4.
- Kang DH, Lee JY, Chung JH, Jo JK, Lee SH, Ham WS, Cho KS, Lee KS, Kim TH, Lee SW. Laparoendoscopic single site varicocele ligation: comparison of testicular artery and lymphatic preservation versus complete testicular vessel ligation. *J Urol.* 2013;189(1):243–9. doi:[10.1016/j.juro.2012.09.024](https://doi.org/10.1016/j.juro.2012.09.024).
- Karademir K, Senkul T, Baykal K, Ates F, Iseri C, Erden D. Evaluation of the role of varicolectomy including external spermatic vein ligation in patients with scrotal pain. *Int J Urol.* 2005;12(5):484–8. doi:[10.1111/j.1442-2042.2005.01063.x](https://doi.org/10.1111/j.1442-2042.2005.01063.x).
- Kirby EW, Wiener LE, Rajanahally S, Crowell K, Coward RM. Undergoing varicocele repair before assisted reproduction improves pregnancy rate and live birth rate in azoospermic and oligospermic men with a varicocele: a systematic review and meta-analysis. *Fertil Steril.* 2016;106(6):1338–43. doi:[10.1016/j.fertnstert.2016.07.1093](https://doi.org/10.1016/j.fertnstert.2016.07.1093).
- Kondo Y, Ishikawa T, Yamaguchi K, Fujisawa M. Predictors of improved seminal characteristics by varicocele repair. *Andrologia.* 2009;41(1):20–3. doi:[10.1111/j.1439-0272.2008.00882.x](https://doi.org/10.1111/j.1439-0272.2008.00882.x).
- Kroese AC, de Lange NM, Collins J, Evers JL. Surgery or embolization for varicoceles in subfertile men. *Cochrane Database Syst Rev.* 2012;10:CD000479. doi:[10.1002/14651858.CD000479.pub5](https://doi.org/10.1002/14651858.CD000479.pub5).
- Kulis T, Kolaric D, Karlovic K, Knezevic M, Antonini S, Kastelan Z. Scrotal infrared digital thermography in assessment of varicocele – pilot study to assess diagnostic criteria. *Andrologia.* 2012;44(Suppl 1):780–5. doi:[10.1111/j.1439-0272.2011.01265.x](https://doi.org/10.1111/j.1439-0272.2011.01265.x).
- Li F, Chiba K, Yamaguchi K, Okada K, Matsushita K, Ando M, Yue H, Fujisawa M. Effect of varicolectomy on testicular volume in children and adolescents: a meta-analysis. *Urology.* 2012a;79(6):1340–5. doi:[10.1016/j.urology.2012.02.022](https://doi.org/10.1016/j.urology.2012.02.022).
- Li F, Yue H, Yamaguchi K, Okada K, Matsushita K, Ando M, Chiba K, Fujisawa M. Effect of surgical repair on testosterone production in infertile men with varicocele: a meta-analysis. *Int J Urol.* 2012b;19(2):149–54. doi:[10.1111/j.1442-2042.2011.02890.x](https://doi.org/10.1111/j.1442-2042.2011.02890.x).

- Liguori G, Ollandini G, Napoli R, Mazzon G, Petrovic M, Trombetta C (2012) Anatomy of the scrotum. In: Bertolotto M, Trombetta C (eds) *Scrotal pathology*. Springer, Berlin/Heidelberg, pp. 27–34. doi:[10.1007/174\\_2011\\_170](https://doi.org/10.1007/174_2011_170)
- MacLeod J. Seminal cytology in the presence of varicocele. *Fertil Steril*. 1965;16(6):735–57.
- Marconi M, Weidner W (2017) Site and risk factors of antisperm antibodies production in the male population. In: Krause WKH, Naz RK (eds) *Immune infertility: impact of immune reactions on human fertility*. Springer International Publishing, Cham, pp. 133–147. doi:[10.1007/978-3-319-40788-3\\_8](https://doi.org/10.1007/978-3-319-40788-3_8)
- Marmar JL, Agarwal A, Prabakaran S, Agarwal R, Short RA, Benoff S, Thomas Jr AJ. Reassessing the value of varicocelectomy as a treatment for male subfertility with a new meta-analysis. *Fertil Steril*. 2007;88(3):639–48. doi:[10.1016/j.fertnstert.2006.12.008](https://doi.org/10.1016/j.fertnstert.2006.12.008).
- Marmar JL, DeBenedictis TJ, Praiss D. The management of varicoceles by microdissection of the spermatic cord at the external inguinal ring. *Fertil Steril*. 1985;43(4):583–8.
- McIntyre M, Hsieh TC, Lipshultz L. Varicocele repair in the era of modern assisted reproductive techniques. *Curr Opin Urol*. 2012;22(6):517–20. doi:[10.1097/MOU.0b013e328358e191](https://doi.org/10.1097/MOU.0b013e328358e191).
- Messina M, Zagordo L, Di Maggio G, Molinaro F, Abate V, Nardi N. Testicular hypotrophy in varicocele: pre and postoperative echographic follow-up in the pediatric age. *Minerva Urol Nefrol = Ital J Urol Nephrol*. 2006;58(3):151–5.
- Mostafa T, Anis T, Imam H, El-Nashar AR, Osman IA. Seminal reactive oxygen species-antioxidant relationship in fertile males with and without varicocele. *Andrologia*. 2009;41(2):125–9. doi:[10.1111/j.1439-0272.2008.00900.x](https://doi.org/10.1111/j.1439-0272.2008.00900.x).
- Mostafa T, Rashed LA, Nabil NI, Osman I, Mostafa R, Farag M. Seminal miRNA relationship with apoptotic markers and oxidative stress in infertile men with varicocele. *Biomed Res Int*. 2016;2016:4302754. doi:[10.1155/2016/4302754](https://doi.org/10.1155/2016/4302754).
- Ni K, Steger K, Yang H, Wang H, Hu K, Chen B. Sperm protamine mRNA ratio and DNA fragmentation index represent reliable clinical biomarkers for men with varicocele after microsurgical varicocele ligation. *J Urol*. 2014;192(1):170–6. doi:[10.1016/j.juro.2014.02.046](https://doi.org/10.1016/j.juro.2014.02.046).
- Nielsen ME, Zderic S, Freedland SJ, Jarow JP. Insight on pathogenesis of varicoceles: relationship of varicocele and body mass index. *Urology*. 2006;68(2):392–6. doi:[10.1016/j.urology.2006.02.005](https://doi.org/10.1016/j.urology.2006.02.005).
- Nieschlag E, Behre HM, Wieacker P, Meschede D, Kamischke A, Kliesch S (2010) Disorders at the testicular level. In: Nieschlag E, Behre HM, Nieschlag S (eds) *Andrology: male reproductive health and dysfunction*. Springer, Berlin/Heidelberg, pp. 193–238. doi:[10.1007/978-3-540-78355-8\\_13](https://doi.org/10.1007/978-3-540-78355-8_13)
- Nieschlag E, Hertle L, Fishedick A, Abshagen K, Behre HM. Update on treatment of varicocele: counselling as effective as occlusion of the vena spermatica. *Hum Reprod*. 1998;13(8):2147–50.
- Noske HD, Weidner W. Varicocele: a historical perspective. *World J Urol*. 1999;17(3):151–7.
- Oh YS, Jo NH, Park JK, Gye MC. Changes in inflammatory cytokines accompany deregulation of claudin-11, resulting in inter-septoli tight junctions in varicocele rat testes. *J Urol*. 2016;196(4):1303–12. doi:[10.1016/j.juro.2016.05.004](https://doi.org/10.1016/j.juro.2016.05.004).
- Osman A, Alsomait H, Seshadri S, El-Toukhy T, Khalaf Y. The effect of sperm DNA fragmentation on live birth rate after IVF or ICSI: a systematic review and meta-analysis. *Reprod Biomed Online*. 2015;30(2):120–7. doi:[10.1016/j.rbmo.2014.10.018](https://doi.org/10.1016/j.rbmo.2014.10.018).
- Parker DA, Hicks T. Varicocele and renal tumor on right side. *Urology*. 1975;5(4):530–2.
- Pasqualotto FF, Borges E, Roth F, Lara LV, Pasqualotto EB (2011) Varicocele: to fix or not to fix. In: Sabanegh ES (ed) *Male infertility: problems and solutions*. Humana Press, Totowa, pp 65–79. doi:[10.1007/978-1-60761-193-6\\_8](https://doi.org/10.1007/978-1-60761-193-6_8)
- Pilatz A, Altinkilic B, Kohler E, Marconi M, Weidner W. Color Doppler ultrasound imaging in varicoceles: is the venous diameter sufficient for predicting clinical and subclinical varicocele? *World J Urol*. 2011;29(5):645–50. doi:[10.1007/s00345-011-0701-4](https://doi.org/10.1007/s00345-011-0701-4).
- Practice Committee of the American Society for Reproductive Medicine and the Society for Male Reproduction and Urology. Report on varicocele and infertility: a committee opinion. *Fertil Steril*. 2014;102(6):1556–60. doi:[10.1016/j.fertnstert.2014.10.007](https://doi.org/10.1016/j.fertnstert.2014.10.007).

- Raman JD, Walmsley K, Goldstein M. Inheritance of varicoceles. *Urology*. 2005;65(6):1186–9. doi:[10.1016/j.urology.2004.12.057](https://doi.org/10.1016/j.urology.2004.12.057).
- Ray PD, Huang B-W, Tsuji Y. Reactive oxygen species (ROS) homeostasis and redox regulation in cellular signaling. *Cell Signal*. 2012;24(5):981–90. doi:[10.1016/j.cellsig.2012.01.008](https://doi.org/10.1016/j.cellsig.2012.01.008).
- Robinson L, Gallos ID, Conner SJ, Rajkhowa M, Miller D, Lewis S, Kirkman-Brown J, Coomarasamy A. The effect of sperm DNA fragmentation on miscarriage rates: a systematic review and meta-analysis. *Hum Reprod*. 2012;27(10):2908–17. doi:[10.1093/humrep/des261](https://doi.org/10.1093/humrep/des261).
- Roque M, Esteves SC. A systematic review of clinical practice guidelines and best practice statements for the diagnosis and management of varicocele in children and adolescents. *Asian J Androl*. 2016;18(2):262–8. doi:[10.4103/1008-682X.169559](https://doi.org/10.4103/1008-682X.169559).
- Rotker K, Sigman M. Recurrent varicocele. *Asian J Androl*. 2016;18(2):229–33. doi:[10.4103/1008-682X.171578](https://doi.org/10.4103/1008-682X.171578).
- Saleh RA, Agarwal A, Sharma RK, Said TM, Sikka SC, Thomas Jr AJ. Evaluation of nuclear DNA damage in spermatozoa from infertile men with varicocele. *Fertil Steril*. 2003;80(6):1431–6.
- Salem HK, Mostafa T. Preserved testicular artery at varicocele repair. *Andrologia*. 2009;41(4):241–5. doi:[10.1111/j.1439-0272.2009.00926.x](https://doi.org/10.1111/j.1439-0272.2009.00926.x).
- Samplaski MK, Jarvi KA. Prognostic factors for a favorable outcome after varicocele repair in adolescents and adults. *Asian J Androl*. 2016;18(2):217–21. doi:[10.4103/1008-682X.169558](https://doi.org/10.4103/1008-682X.169558).
- Scherr D, Goldstein M. Comparison of bilateral versus unilateral varicocelectomy in men with palpable bilateral varicoceles. *J Urol*. 1999;162(1):85–8. doi:[10.1097/00005392-199907000-00021](https://doi.org/10.1097/00005392-199907000-00021).
- Schlegel PN, Goldstein M. Alternate indications for varicocele repair: non-obstructive azoospermia, pain, androgen deficiency and progressive testicular dysfunction. *Fertil Steril*. 2011;96(6):1288–93. doi:[10.1016/j.fertnstert.2011.10.033](https://doi.org/10.1016/j.fertnstert.2011.10.033).
- Schlesinger MH, Willets IF, Nagler HM. Treatment outcome after varicocelectomy: a critical analysis. *Urol Clin North Am*. 1994;21(3):517–29.
- Scholler R, Nahoul K, Castanier M, Rotman J, Salat-Baroux J. Testicular secretion of conjugated and unconjugated steroids in normal adults and in patients with varicocele: baseline levels and time-course response to hCG administration. *J Steroid Biochem*. 1984;20(1):203–15.
- Shibata Y, Kurihara S, Arai S, Kato H, Suzuki T, Miyazawa Y, Koike H, Ito K, Nakamura T, Suzuki K. Efficacy of indocyanine green angiography on microsurgical subinguinal varicocelectomy. *J Investig Surg*. 2016;1–5. doi:[10.1080/08941939.2016.1236855](https://doi.org/10.1080/08941939.2016.1236855).
- Shiraishi K, Takihara H, Matsuyama H. Elevated scrotal temperature, but not varicocele grade, reflects testicular oxidative stress-mediated apoptosis. *World J Urol*. 2010;28(3):359–64. doi:[10.1007/s00345-009-0462-5](https://doi.org/10.1007/s00345-009-0462-5).
- Shridharani A, Lockwood G, Sandlow J. Varicocelectomy in the treatment of testicular pain: a review. *Curr Opin Urol*. 2012;22(6):499–506. doi:[10.1097/MOU.0b013e328358f69f](https://doi.org/10.1097/MOU.0b013e328358f69f).
- Sirvent JJ, Bernat R, Navarro MA, Rodriguez Tolra J, Guspi R, Bosch R. Leydig cell in idiopathic varicocele. *Eur Urol*. 1990;17(3):257–61.
- Smit M, Romijn JC, Wildhagen MF, Veldhoven JL, Weber RF, Dohle GR. Decreased sperm DNA fragmentation after surgical varicocelectomy is associated with increased pregnancy rate. *J Urol*. 2013;189(1 Suppl):S146–50. doi:[10.1016/j.juro.2012.11.024](https://doi.org/10.1016/j.juro.2012.11.024).
- Soylemez H, Kilic S, Atar M, Penbegul N, Sancaktutar AA, Bozkurt Y. Effects of micronised purified flavonoid fraction on pain, semen analysis and scrotal color Doppler parameters in patients with painful varicocele; results of a randomized placebo-controlled study. *Int Urol Nephrol*. 2012;44(2):401–8. doi:[10.1007/s11255-011-0038-3](https://doi.org/10.1007/s11255-011-0038-3).
- Sylora JA, Pryor JL. Varicocele. *Curr Ther Endocrinol Metab*. 1994;5:309–14.
- Tauber R, Johnsen N. Antegrade scrotal sclerotherapy for treatment of testicular varicocele: technique and late results. *Der Urologe Ausg A*. 1993;32(4):320–6.
- Tesarik J, Greco E, Mendoza C. Late, but not early, paternal effect on human embryo development is related to sperm DNA fragmentation. *Hum Reprod*. 2004;19(3):611–5. doi:[10.1093/humrep/deh127](https://doi.org/10.1093/humrep/deh127).

- Trum JW, Gubler FM, Laan R, van der Veen F. The value of palpation, varicoscreen contact thermography and colour Doppler ultrasound in the diagnosis of varicocele. *Hum Reprod.* 1996;11(6):1232–5.
- Tulloch WS. Varicocele in subfertility; results of treatment. *Br Med J.* 1955;2(4935):356–8.
- Vigil P, Wohler C, Bustos-Obregon E, Comhaire F, Morales P. Assessment of sperm function in fertile and infertile men. *Andrologia.* 1994;26(2):55–60.
- Vivas-Acevedo G, Lozano-Hernandez R, Camejo MI. Varicocele decreases epididymal neutral alpha-glucosidase and is associated with alteration of nuclear DNA and plasma membrane in spermatozoa. *BJU Int.* 2014;113(4):642–9. doi:[10.1111/bju.12523](https://doi.org/10.1111/bju.12523).
- Vivas-Acevedo G, Lozano JR, Camejo MI. Effect of varicocele grade and age on seminal parameters. *Urol Int.* 2010;85(2):194–9. doi:[10.1159/000314226](https://doi.org/10.1159/000314226).
- Wang J, Xia SJ, Liu ZH, Tao L, Ge JF, Xu CM, Qiu JX. Inguinal and subinguinal micro-varicocelectomy, the optimal surgical management of varicocele: a meta-analysis. *Asian J Androl.* 2015;17(1):74–80. doi:[10.4103/1008-682X.136443](https://doi.org/10.4103/1008-682X.136443).
- Wang Y-J, Zhang R-Q, Lin Y-J, Zhang R-G, Zhang W-L. Relationship between varicocele and sperm DNA damage and the effect of varicocele repair: a meta-analysis. *Reprod Biomed Online.* 2012;25(3):307–14. doi:[10.1016/j.rbmo.2012.05.002](https://doi.org/10.1016/j.rbmo.2012.05.002).
- Weedin JW, Khera M, Lipshultz LI. Varicocele repair in patients with nonobstructive azoospermia: a meta-analysis. *J Urol.* 2010;183(6):2309–15. doi:[10.1016/j.juro.2010.02.012](https://doi.org/10.1016/j.juro.2010.02.012).
- Weinbauer GF, Luetjens CM, Simoni M, Nieschlag E (2010) Physiology of testicular function. In: Nieschlag E, Behre HM, Nieschlag S (eds) *Andrology: male reproductive health and dysfunction*. Springer Berlin/Heidelberg, pp 11–59. doi:[10.1007/978-3-540-78355-8\\_2](https://doi.org/10.1007/978-3-540-78355-8_2).
- Wilms G, Oyen R, Casselman J, Peene P, Steeno O, Baert AL. Solitary or predominantly right-sided varicocele: a possible sign of situs inversus. *Urol Radiol.* 1988;9(4):243–6.
- Wishahi MM. Anatomy of the spermatic venous plexus (pampiniform plexus) in men with and without varicocele: intraoperative venographic study. *J Urol.* 1992;147(5):1285–9.
- World Health Organization. The influence of varicocele on parameters of fertility in a large group of men presenting to infertility clinics. *Fertil Steril.* 1992;57(6):1289–93. doi:[10.1016/S0015-0282\(16\)55089-4](https://doi.org/10.1016/S0015-0282(16)55089-4).
- World Health Organization. WHO laboratory manual for the examination and processing of human semen. 5th ed. Geneva: World Health Organization; 2010.
- Yaman O, Ozdiler E, Anafarta K, Gogus O. Effect of microsurgical subinguinal varicocele ligation to treat pain. *Urology.* 2000;55(1):107–8.
- Zalata AA, Mokhtar N, Badawy Ael N, Othman G, Alghobary M, Mostafa T. Androgen receptor expression relationship with semen variables in infertile men with varicocele. *J Urol.* 2013;189(6):2243–7. doi:[10.1016/j.juro.2012.11.112](https://doi.org/10.1016/j.juro.2012.11.112).
- Zhang H, Liu XP, Yang XJ, Huang WT, Ruan XX, Xiao HJ, Li LY, Gao X, Zhang Y. Loupe-assisted versus microscopic varicocelectomy: is there an intraoperative anatomic difference? *Asian J Androl.* 2014;16(1):112–4. doi:[10.4103/1008-682X.122189](https://doi.org/10.4103/1008-682X.122189).
- Zheng YQ, Zhang XB, Zhou JQ, Cheng F, Rao T, Yao Y. The effects of artery-ligating and artery-preserving varicocelectomy on the ipsilateral testes in rats. *Urology.* 2008;72(5):1179–84. doi:[10.1016/j.urology.2008.03.035](https://doi.org/10.1016/j.urology.2008.03.035).
- Zini A, Defreitas G, Freeman M, Hechter S, Jarvi K. Varicocele is associated with abnormal retention of cytoplasmic droplets by human spermatozoa. *Fertil Steril.* 2000;74(3):461–4.
- Zohdy W, Ghazi S, Arafa M. Impact of varicocelectomy on gonadal and erectile functions in men with hypogonadism and infertility. *J Sex Med.* 2011;8(3):885–93. doi:[10.1111/j.1743-6109.2010.01974.x](https://doi.org/10.1111/j.1743-6109.2010.01974.x).



Biljana Popovic-Todorovic and Herman Tournaye

**Abstract**

Male factor is the main cause of infertility in about 20% of infertile couples and contribute to 50% of all cases. Only a limited number of causes of male infertility are potentially treatable and the majority of male infertility is idiopathic. Meta-analyses have shown that empirical medical treatments for unexplained male infertility are merely of unproven benefit. The last decades have witnessed expansion of assisted reproduction techniques (ART) both in terms of advanced technology used and its availability. Intrauterine insemination (IUI) may be considered as a first-line treatment in a couple in which the female partner has a normal fertility status and at least  $1 \times 10^6$  progressively motile spermatozoa are recovered after sperm preparation. If no pregnancy is achieved after 3–6 IUI cycles of IUI, IVF can be proposed. When less than  $0.5 \times 10^6$  progressively motile spermatozoa are obtained after seminal fluid processing or sperm are recovered surgically from the testis or epididymis, intracytoplasmic sperm injection (ICSI) should be performed. Although the outcome of no other ART has ever been scrutinized as much before, no large-scale “macroproblems” have as yet been observed after ICSI. ICSI-candidates should be rigorously screened before embarking on treatment and thoroughly informed of the limitations of our knowledge on the hereditary aspects of male infertility and the safety aspects of ART. The vast expansion of especially ICSI treatments demands for global guidelines and inclusion policies for both IVF and ICSI procedures. There is an urgency for improved sperm selection methods and in particular clinical applicability of sperm DNA fragmentation assessment. The medical infertility society should strive towards using the best technology that is available to treat patients in most effective, evidence-based and efficient patient-friendly way.

---

B. Popovic-Todorovic (✉) • H. Tournaye  
Centre for Reproductive Medicine, UZ Brussel, Brussel, Belgium  
e-mail: [drbiba@yahoo.com](mailto:drbiba@yahoo.com)

---

**Keywords**

 Male infertility • Assisted reproduction • IUI • IVF • ICSI
 

---

**Contents**

Introduction .....	1146
Which ART Should Be Used to Circumvent Male Factor Infertility? .....	1147
Intrauterine Insemination (IUI) .....	1149
Sperm Preparation for IUI .....	1149
Single or Double Insemination .....	1150
Immobilization After IUI .....	1151
Effect of Paternal Age .....	1152
In Vitro Fertilization (IVF) and Intracytoplasmic Sperm Injection (ICSI) .....	1154
Absolute Indications for ICSI in Male Factor Infertility .....	1155
Azoospermia and ICSI .....	1158
ICSI with Spermatids .....	1160
Outcomes After ICSI .....	1161
The Use of Surgically Retrieved Sperm in Assisted Reproduction .....	1162
Cost-Effectiveness of IUI Vs. IVF Vs. ICSI .....	1164
Shifting Paradigms .....	1166
Conclusion .....	1167
References .....	1167

---

**Introduction**

Infertility affects 15% of couples in their reproductive age. Male factor is the main cause of infertility in about 20% of infertile couples and contributes to 50% of all cases (Agarwal et al. 2015). The diagnosis is based on the semen analysis, which is the best proxy for testicular exocrine function.

Unfortunately, only a limited number of causes of male infertility are potentially treatable and the majority of male infertility is idiopathic meaning that the patient has unexplained abnormalities in the sperm parameters (Tournaye et al. 2016a). Men with idiopathic infertility are prone to receive a number of empirical therapies. Meta-analyses have shown that empirical medical treatments for unexplained male infertility are of unproven benefit (Tournaye et al. 2016a).

In the era of evidence-based medicine applying pharmacological regimens without either the pathophysiological basis or any scientific proof of benefit is, to say the least, controversial.

The incidence of male factor as the only cause of infertility is not high; it is usually combined with the female factor and approach and choice of treatment is determined with respect to both. Ideally, each factor contributing to infertility should be identified and treated. In reality, many causes of infertility can be surpassed by assisted reproduction techniques, both in men and women.

The last decades have witnessed expansion of assisted-reproduction techniques (ART) both in terms of advanced technology used and its availability. Lacking the proof of usefulness of empirical therapies and keeping in mind the pressure of the

infertile couple to achieve a healthy pregnancy in the shortest amount of time, clinicians tend to turn more and more to ART.

ART aims at increasing the probability of fertilization by bringing the spermatozoa closer to (or even within) the oocyte(s), overcoming numerical and/or functional deficits of the male gametes. Intrauterine insemination (IUI) and in vitro fertilization (IVF) are the most popular techniques for treating male-factor infertility. In the latter, the rate of fertilization is enhanced by microinjecting one single spermatozoon directly into the oocyte's cytoplasm, i.e., ICSI (intracytoplasmic sperm injection). ICSI allows the successful use of ejaculated, epididymal, or testicular spermatozoa to obtain fertilization in vitro.

## Which ART Should Be Used to Circumvent Male Factor Infertility?

WHO has defined reference values to classify semen parameters compatible with fertility. Normal reference values according to the WHO criteria from 2010 (Table 1) encompass a volume of  $>1.5$  ml, a concentration of more than  $15 \times 10^6$ /ml, a total sperm count  $>39 \times 10^6$ , motility of  $>40\%$ , and a normal morphology of  $>4\%$  (Cooper et al. 2010). These reference values were assessed in a population of almost 2,000 men worldwide who had fathered a child or impregnated their partner, with the condition that the time to pregnancy was less than 1 year. Different forms of male infertility are classified on the basis of descriptive nomenclature given by WHO: hypospermia when the volume of ejaculate is  $<1.5$  ml, oligozoospermia when the concentration is below  $15 \times 10^6$ /ml, asthenozoospermia when the fast progressive motility and slow progressive motility are less than 32%, and teratozoospermia when there are less than 4% of morphologically normal sperm in the ejaculate (World Health Organization 2010).

Table 2 shows the distribution of sperm abnormalities in 4,457 men who underwent diagnostic semen analysis in Brussels, Belgium, including abnormalities infrequently observed (unpublished) (Tournaye et al. 2016b).

However, the predictive value of these reference values and this WHO classification of semen analysis remains poor for both prognosis and treatment choice, including ART (Tournaye et al. 2016b). Before embarking on any ART, the female

**Table 1** WHO 2010 reference values for normal fertility

Semen volume	1.5 mL
Sperm concentration	$15 \times 10^6$ /mL
Total sperm concentration	$39 \times 10^6$ spermatozoa per ejaculate
Total motility	40%
Progressive motility	32% <sup>a</sup>
Vitality	58%
Normal morphology	4%

Values are lower reference limits of fifth centiles

<sup>a</sup>Grade A (fast progressive motility  $>25$   $\mu$ m/s) + grade B (slow progressive motility 5–25  $\mu$ m/s)

**Table 2** Distribution of semen abnormalities (Tournaye et al. 2016b)

	Number of men
<b>Number of spermatozoa (n = 4457)</b>	
<39 × 10 <sup>6</sup> spermatozoa	1098 (24.6%)
Azoospermia	436 (9.8%)
<b>Oligozoospermia</b>	
Extreme (>0 but <0.1 million)	129 (2.9%)
Severe (≥0.1 million but <1.0 million)	89 (2.0%)
Mild (≥1.0 million but <5.0 million)	125 (2.8%)
<b>Motility (n = 4021<sup>b</sup>)</b>	
<32% motility <sup>a,c</sup>	1447 (36.0%)
Immotile sperm	27 (0.6%)
Necrozoospermia	10 (0.2%)
<b>Morphology (n = 4021<sup>b</sup>)</b>	
<4% normal morphology <sup>a</sup>	2251 (56.0%)
Teratozoospermia (0% normal)	201 (5.0%)
Complete globozoospermia	3 (<0.1%)
Complete macrocephaly	1 (<0.1%)

Data from the Centre for Reproductive Medicine, Brussels, Belgium, in the period 2013–15 (unpublished)

<sup>a</sup>Lower reference limit of fifth centile in the WHO 2009 reference values

<sup>b</sup>Excludes azoospermic men

<sup>c</sup>Progressive motility, grade A (fast progressive motility >25 μm/s) + grade B (slow progressive motility 5–25 μm/s)

fertility status has to be carefully assessed, the patients have to be informed on the prognosis of treatment taking into account both partners, and only then can the appropriate treatment be implemented.

In addition to that, semen analysis results have no value in predicting pregnancy after IUI (van Weert et al. 2005a).

Total motile sperm count (TMC) is the mostly used variable in deciding what kind of ART treatment should be offered to a couple. TMC is the total number of spermatozoa in the ejaculate or prepared sample (volume × concentration) multiplied by the percentage of progressive motile spermatozoa (Ayala et al. 1996). Morphology of the sperm is not taken into account as this variable has no effect on the pregnancy rates after IUI and as such should not be a reason for advancing to IVF straight away (Deveneau et al. 2014).

TMC can be assessed before (prewash) and after (postwash) sperm preparation. If the native, unprocessed semen sample has at least a TMC of 1–3 × 10<sup>6</sup>, corresponding to mild to moderate oligoasthenoteratozoospermia (OAT), IUI can be proposed as a first-line approach when at least 0.8 × 10<sup>6</sup> motile sperm can be recovered after preparation which will not always be the case in this subgroup. Van der Weert et al. showed in a meta-analysis including 16 studies that a postwash value between 0.8 × 10<sup>6</sup> and 5 × 10<sup>6</sup> has a prognostic value in couples who had IUI (van Weert et al. 2004). The postwash TMC probably has the best predictive value

because it reflects both sperm concentration and motility as well as the effects of sperm processing (van Weert et al. 2005a).

---

## Intrauterine Insemination (IUI)

Intrauterine insemination is a technique which is used to increase the number of motile sperm that are morphologically normal at the site of fertilization by injecting a small volume of prepared semen transcervically into the uterine cavity at the expected time of ovulation. The rationale behind this procedure is to bypass the cervix and to bring the semen closer to the oocyte released into the fallopian tube.

IUI was performed already before the twentieth century (Ombelet and Van Robays 2015), but prior to the introduction of IVF and sperm preparation techniques, the ejaculate was not prepared and was as such inseminated causing uterine cramps and increasing the risk of infections (Cohlen 2014).

IUI is a simple technique but a heated debate is ongoing regarding its prognosis, cost-effectiveness, and time to achieve pregnancy (Kim et al. 2015). Compared to IVF with or without ICSI, there is good evidence, albeit not based on live birth rates, that IUI is a cost-effective treatment option that should be initiated before more invasive and expensive treatment alternatives are offered (Bensdorp et al. 2007). Although there are no studies available in the literature demonstrating increased live birth rates after IUI in male-factor infertility, six randomized controlled trials (RCTs) showed a significant increase in pregnancy rates after IUI compared with timed intercourse in cases of male-factor infertility (Bensdorp et al. 2007). When used for unexplained infertility, ovarian superovulation coupled with IUI will increase the pregnancy rate, but level 1 evidence does not show this to be true when ovarian superovulation coupled with IUI is applied for male-factor infertility (Bensdorp et al. 2007; van Weert et al. 2005b; Cohlen et al. 1998). However, timing by either detecting the onset of the LH surge or administering hCG or rec-hCG is beneficial (level 1 evidence) (Zreik et al. 1999). Both timing methods are of similar value (Cantineau et al. 2010), but hCG injection has to be performed when the dominant follicle(s) reach(es) a mean diameter of 16–18 mm and is followed by insemination 36–42 h later. When a spontaneous LH peak is detected in serum, insemination has to be scheduled 24 h later, and when detected in urine, 18 h afterwards.

## Sperm Preparation for IUI

While good evidence is available that at least 1 million motile spermatozoa have to be inseminated at IUI (Bensdorp et al. 2007), limited evidence is available on how to prepare semen for IUI.

Sperm prior to IUI has to be processed in order to allow the most motile sperm population with intact functional and genetic properties of normal morphology and minimal DNA damage to be used for insemination. Seminal plasma contains decapacitation factors that need to be removed for complete capacitation of the

spermatozoa. Capacitation is an essential process for both fertilizations in vivo and in vitro. Semen preparation also removes debris, prostaglandins, and white blood cells and at the same time reduces the number of immotile and morphologically abnormal sperm cells from the suspension. Three sperm preparation techniques are used in laboratories worldwide for capacitation: simple dilution and washing, swim-up technique, and density gradient centrifugation, all being described in detail in the Laboratory Manual for the Examination and Processing of Human Semen of the World Health Organization (World Health Organization 2010). The comparison of the three methods has been the subject of extensive research. Density gradient has been shown to be superior to the swim-up and wash technique as it increased the number of morphologically normal spermatozoa with rapid progressive motility and normal DNA integrity (Boomsma et al. 2007), i.e., it yields the highest recovery rates. However, when a meta-analysis was performed, no semen preparation technique appeared superior with regards to pregnancy rates when compared to others that are also in common use (Boomsma et al. 2007).

Whether exogenous agents used to promote sperm motility, sperm capacitation and the acrosome reaction can improve the chances for conception after IUI for male-factor infertility also remains inconclusive. Addition to sperm wash used for intrauterine insemination of platelet-activating factor (PAF), a signaling phospholipid known to be involved in the regulation of sperm-fertilizing potential does not result in a significantly higher pregnancy rate (Baka et al. 2009). This disputed the findings of the two previous studies (Roudebush et al. 2004; Grigoriou et al. 2005).

## Single or Double Insemination

There is also an ongoing controversy whether a second insemination per cycle increases the chances for conception. The rationale for the use of double IUI is that the cumulative number of motile spermatozoa inseminated in double IUI cycles is higher than that in single IUI cycles. Having in mind that the clinical pregnancy rate in IUI cycles is correlated with the number of motile spermatozoa inseminated (Wainer et al. 2004), this may be important for couples dealing with male-factor infertility. In these couples, the number of spermatozoa inseminated is often lower than in couples with unexplained or other causes of infertility. Therefore, as the result of double IUI, more motile spermatozoa are delivered at the site of fertilization in each treatment cycle, which in turn may increase pregnancy rates. In addition, double IUI prolongs the presence of spermatozoa in the female genital tract, hence a better overlap with the “ovulation window,” and this might also contribute to the increase in the success rate of IUI per cycle. The timing of insemination is very important for the success of IUI (Ghanem et al. 2011) because follicle rupture may occur over a long time interval. With double IUI, a longer interval after hCG administration in ovarian stimulation/IUI cycles of living spermatozoa is achieved, which may eventually result in a higher fertilization rate (Testart and Frydman 1982).

When combining the conclusions of six RCTs in a meta-analysis with regards to male-factor cases, a double insemination strategy appears to be of some of benefit.

However, this is based upon one large RCT with extremely high pregnancy rates per cycle and its conclusion is contradictory to those from the five other RCTs, obviously casting some doubt on the final recommendation (Cantineau et al. 2003). In a more recent meta-analysis a similar conclusion was reached, with the reflection that double IUI might be beneficial in couples with male infertility but more high-quality RCTs are needed before any clinical recommendation can be given (Zavos et al. 2013).

## Immobilization After IUI

Sperm migration and its survival in the female genital tract has been subject of a number of early studies. Spermatozoa may reach the site of fertilization (i.e., the Fallopian tube) within 2–10 min (Settlage et al. 1973; Kissler et al. 2004), suggesting that sperm movement is independent of the position of the woman directly after intrauterine insemination.

In 2000, Saleh et al. reported that if a woman remained in a supine position for 10 min after intrauterine insemination, the pregnancy rates increased significantly compared with immediate mobilization (13% vs. 4% per cycle) (Saleh et al. 2000). Although it was a RCT, there were quite a few methodological issues such as a small and unbalanced sample size, 40 couples vs. 55 couples without a well-defined pregnancy outcome (Saleh et al. 2000).

To assess the effectiveness of immobilization after intrauterine insemination, a large multicenter randomized clinical trial ( $n = 391$ ) was carried out by Custers et al., who showed a significantly higher ongoing pregnancy rate per couple in the immobilization group than in the control group: 27% versus 18% relative risk 1.5, 95% confidence interval (CI) 1.1–2.2 (Custers et al. 2009). Live birth rates were 27% in the immobilization group and 17% in the control group: relative risk 1.6, 95% CI 1.1–2.4 (Custers et al. 2009).

The same group took it a step further and followed all the couples in the 3-year period after randomization and pregnancies and treatments were recorded (Scholten et al. 2014). The primary outcome was an ongoing pregnancy during the 3 years after the initial trial. In this time period, there were 143 ongoing pregnancies in the immobilization group ( $n = 199$  couples) and 112 ongoing pregnancies in the immediate mobilization group ( $n = 192$ ). The ongoing pregnancy rates were 72% and 58%, respectively (relative risk 1.2, 95% CI 1.1–1.4). The persistent significant difference in ongoing pregnancy rates underpins the importance of immobilization after IUI (Scholten et al. 2014).

Immobilization is cheap and easily done, and as such it has been incorporated as a standard procedure in intrauterine insemination treatment worldwide.

This could change in the future since the results of a prospective randomized trial reported recently showed no beneficial effect of immobilization after intrauterine insemination on pregnancy rates (van Rijswijk et al. 2016). The trial included 479 patients diagnosed with idiopathic or mild male subfertility and an indication for IUI treated with 1934 cycles. Randomization was stratified for the diagnosis of

idiopathic or mild male subfertility. The primary outcome was the cumulative ongoing pregnancy rate per couple which was not significantly different between the two groups; in total, 76 ongoing pregnancies (32.2%) were accomplished after 15 min of immobilization versus 98 ongoing pregnancies (40.3%) after immediate mobilization [OR 0.70 (95% CI 0.483–1.022), *p*-value 0.065] (van Rijswijk et al. 2016). However, since the latter was a preliminary report, the current recommendation remains.

---

## Effect of Paternal Age

The age of the first time parenthood has increased in the last decades in the developed world. The effect of increased maternal age has been intensively studied as it negatively affects the oocyte quality, increasing the aneuploidy rate in the embryo, and lowers the pregnancy rates (Beguería et al. 2014a). In contrast to the extensive investigation of the relationship between maternal age and the success of ART, studies examining the effect of paternal age on ART outcomes are few; the results are conflicting and there is still no consensus of the effect of paternal age on reproductive outcome (Beguería et al. 2014a).

It has been shown that advanced paternal age is associated with reduced semen volume as well as, reduced sperm count, motility, and morphology (Kidd et al. 2016; Bahadur et al. 2016b; Eskenazi et al. 2003). Recent studies have also reported that male aging can directly damage sperm DNA (Moskovtsev et al. 2006), increase sperm DNA methylation (Jenkins et al. 2013), and cause sperm damage through the production of excessive reactive oxygen species (Cocuzza et al. 2008).

For spontaneous conception, advanced paternal age has no profound effect whenever the female partner is young, but time to pregnancy is reported to be longer when compared to younger men (Ford et al. 2000; Hassan and Killick 2003). However, when the female partner is also of advanced age, there seems to be synergistic adverse effect of paternal age, as reported in a large, retrospective, multicenter study (de la Rochebrochard and Thonneau 2003). According to retrospective cohort studies, most pregnancies achieved with IUI in women under 37 years of age will occur during the first three to four treatment cycles (Aboulghar et al. 2001; Morshedi et al. 2003).

Retrospective data suggest that the synergistic effect described for spontaneous conception may also exist in IUI, i.e., no age effect when older men and a young female partner employ IUI but reduced reproductive success when the female partner is older (Brzechffa and Buyalos 1997).

In the context of natural conception and conception via intrauterine insemination (IUI), advanced paternal age has been associated with lower pregnancy rates and increased rates of spontaneous abortion (independent of maternal age) (Mathieu et al. 1995). Also after IUI, an association between paternal age and elevated incidence of pregnancy loss has been shown by two large studies (Bellver et al. 2008; Belloc et al. 2014) supporting the notion that paternal age affects sperm genomic integrity in a



way that it affects late embryonic development. Although the sample size of the latter study is large, i.e., more than 17,000 cycles were analyzed, the study did not properly control for confounding factors and hence the conclusions need to be interpreted with a certain degree of caution (Belloc et al. 2014).

In IVF and oocyte donation programs, a significant decrease in late blastocyst development has been seen in those cycles using spermatozoa of older men (Robertshaw et al. 2014). In a retrospective cohort study of almost 5,000 oocyte donation cycles, Begueria et al. have shown that although paternal age is associated with a decrease in semen quality it does not affect either pregnancy or live birth rates in ICSI cycles when the oocytes come from donors <36 years old (Begueria et al. 2014b).

No significant relationship between paternal age and IVF or ICSI pregnancy rates has been observed in a recent meta-analysis of ten IVF and or /ICSI studies on ART pregnancy (Dain et al. 2011). It may be postulated that in IUI population, the sperm parameters are relatively homogenous while in the IVF/ICSI patients the heterogeneity of sperm parameters is so pronounced that the effect of age might be masked by these marked differences.

The current evidence on paternal age involves mostly retrospective data. In the meta-analysis by Dain et al., it is important to note that the only prospective trial regarding this issue showed increased odds of not having a pregnancy and not having a successful live birth with each additional year of paternal age, after adjusting for maternal age and additional confounders (Klonoff-Cohen and Natarajan 2004).

Further limitation of the studies is the poorly described group of advanced paternal age (>50 years). In a large Dutch retrospective cohort study looking at a 13-year period and 7051 first IVF/ICSI cycles, paternal age did not affect ongoing pregnancy rate at 8 weeks' gestation (Meijerink et al. 2016). In addition, there was neither paternal aging effect found on the best embryo quality available for transfer nor on the biochemical pregnancy rate (Meijerink et al. 2016). When subgroup analyses were performed for IVF, ICSI, and ICSI with nonejaculated spermatozoa, similar results were found (Meijerink et al. 2016). This study involved 636 men >45 years and 244 men equal or above >50 years.

In another recent publication by the Chinese group, analysis of 2627 ICSI cycles, after adjusting for female age, paternal age negatively influenced the number of high-quality embryos while it had no effect on the pregnancy outcome (Wu et al. 2016).

The decreasing quality of spermatozoa with age (Sharma et al. 2015) makes the need to use ICSI to achieve fertilization in the older group more evident. Poor sperm chromatin condensation resulting in increased DNA damage might have long-term effects not observed at the time of fertilization and early pregnancy.

In conclusion, although substantial research has been conducted the effect of paternal age on reproduction remains controversial. More studies focusing on paternal aging influences on neonatal health and genetic disorders related to male infertility are needed.

## **In Vitro Fertilization (IVF) and Intracytoplasmic Sperm Injection (ICSI)**

When the TMC is too low to perform IUI (post processing TMC below 1 million) or when the couple does not achieve pregnancy after 3–4 IUIs in couples with moderate male factor subfertility with at least 1 million motile sperm after semen preparation, the next treatment option is IVF.

IVF was introduced to overcome tubal factor infertility and subsequently also used as a treatment option for male subfertility without adequate randomized trials. In 2000, Goverde et al. showed that IVF was less cost effective compared with IUI with or without mild ovarian stimulation in couples with unexplained and male subfertility (Goverde et al. 2000). However, the IVF success rate was rather low in this study. In the meantime, the debate on the cost-effectiveness of IUI vs. IVF continues and will be discussed below.

There are two main issues regarding IVF for male infertility, namely fertilization failure and the place of conventional IVF versus that of ICSI.

The prevalence of complete fertilization failure after conventional IVF is reported to be as high as 50% (Coates et al. 1992). In a study of IVF vs. ICSI on sibling oocytes in couples where the male partner had a semen sample of poor morphology, oocytes were inseminated with  $5 \times 10^4$  motile spermatozoa per ml (Payne et al. 1994). The overall fertilization rate of ICSI and IVF oocytes differed significantly, 76% versus 15%, and the incidence of total fertilization failure in the IVF group was 61% (Payne et al. 1994).

Complete fertilization failure is an unwanted event both for the reason of cycle failure but also due to the negative, distressing, psychological impact on the couple. Forty percentage of couples abandon IVF after a single cycle (Verberg et al. 2008). This study revealed that among the most common cause was the physical and psychological burden of the treatment and accounted for 35% of dropout (Verberg et al. 2008).

The causes of total fertilization failure during standard IVF are related to either oocyte, sperm, or laboratory factors; this is also true for ICSI cycles in which complete fertilization failure occurs in less than 3% of started cycles (Liu et al. 1995).

The cut-off values for sperm characteristics compatible with fertilization after conventional IVF are ill defined, mostly experience-based and/or center-specific. Motile progressive count ranging from as low as 0.2 million motile progressive spermatozoa (Payne et al. 1994) through 0.5 million progressive motile spermatozoa (Verheyen et al. 1999) to 1 million (Kastrop et al. 1999) have been proposed as the lower limits for conventional IVF (Table 2). High insemination concentration has been also studied in order to increase the fertilization rates, particularly in cases of failed fertilization (Kastrop et al. 1999). The insemination concentration was elevated if the semen characteristics showed poor morphology in one or more previous semen analyses and/or poor motility on the oocyte retrieval (Kastrop et al. 1999).

Occasionally, a combination of morphology and motile count is analyzed. Plachot et al. suggested that at least 0.5 million normal, progressively motile sperm per ml

must be present in the ejaculate in order to recommend conventional IVF (Plachot et al. 2002).

Contemporary strategies for deciding between IVF and ICSI are either formulated using these experience-based, preset cut-off values or are created with the assumption that ICSI is the more robust insemination technique. A meta-analysis focusing only on border-line oligoasthenoteratozoospermia concluded that whether fertilization occurs or not during standard IVF is highly dependent on the numbers of motile spermatozoa used for insemination (Tournaye et al. 2002). Subanalysis of three RCTs in which a high insemination concentration was used could not show any significant benefit of ICSI over IVF. Although the current evidence is limited, the result of this meta-analysis calls for caution when promoting ICSI for moderate male factor infertility (Tournaye et al. 2002; Hotaling et al. 2011; van derWesterlaken et al. 2005).

Split IVF-ICSI cycle, in which sibling oocytes are either inseminated conventionally or microinjected is an optional treatment strategy in moderate male factor infertility (Hotaling et al. 2011). Although there is still inconclusive evidence on the role of this tactic, a split IVF-ICSI approach may prevent complete fertilization failure in one out of four cycles where conventional IVF is applied for moderate male factor infertility and where even a high insemination concentration is applied (Kihaila et al. 2003; Nagy et al. 1995).

No other treatment has caused a revolution in treatment of male infertility as did the introduction of intracytoplasmic sperm injection (ICSI) in 1992 (Palermo et al. 1992). Almost two and a half decades later it is by far the most used infertility treatment for both male and nonmale infertility (Evers 2016).

Despite the fact that ICSI has been put forth as the most robust technique for achieving fertilization in an IVF program, the aim of reproductive medicine and the specialists that practice it should always be to use the simplest and least expensive procedure with the greatest long-term chance of healthy children. It must be kept in mind that the unnecessary use of ICSI is time consuming and costly. Indeed, 5–10% of oocytes are damaged after rupture of the oolemma. The risks of disturbing the spindle during introduction of the pipette (Asada et al. 1995; Blake et al. 2000; Dumoulin et al. 2001), the possible asynchronized decondensation of sperm chromosomes (Terada et al. 2000), the reduced capacity for blastocyst formation in vitro particularly in cases of poor sperm motility and morphology (Griffiths et al. 2000; Miller and Smith 2001) should also be taken into account.

---

## **Absolute Indications for ICSI in Male Factor Infertility**

Although there is no good clinical evidence available, there are well accepted, absolute indications for ICSI: use of surgically retrieved testicular and epididymal sperm, use of immotile, yet viable, ejaculated spermatozoa, e.g., in flagellar dyskinesia and immotile cilia syndromes, and when using round-headed spermatozoa (globozoospermia) (Table 3). In addition, some authors believe that the presence of significant levels of antisperm antibodies is an indication to always perform ICSI (Lahteenmaki et al. 1995) despite a recent meta-analysis concluding that there is no

**Table 3** Indications for IUI, IVF, ICSI

<b>IUI</b>
TMC postprocessing $>1 \times 10^6$
<b>IVF</b>
Cutoff values ill-defined, experience-based or center specific
TMC postprocessing $0.2 \times 10^6$ , $0.5 \times 10^6$ , $1 \times 10^6$
<b>ICSI – absolute indications</b>
• Previous fertilization failure with IVF
• Surgically retrieved testicular or epididymal sperm
• Globozoospermia
• Teratozoospermia
• Absolute asthenozoospermia (immotile but viable sperm)

benefit of ICSI over IVF in cases of antisperm antibody-mediated male factor infertility (Zini et al. 2011). For cryopreserved sperm from cancer patients, no prospective comparative studies pitting the use of IVF versus ICSI are available in the literature. However, based on retrospective case series, it may be prudent that for most of these patients, given the poor quality of cryopreserved sperm, the postthaw sperm damage that may occur and the limited numbers of spermatozoa available, ICSI should be the method of choice when assisted reproduction is indicated (Kelleher et al. 2001; Tournaye et al. 2004; Hourvitz et al. 2008).

Absolute asthenozoospermia, i.e., 100% immotile spermatozoa in the ejaculate, is reported at a frequency of 0.6% in men attending a fertility department (Tournaye 1999). It is extremely important to determine the underlying etiology, e.g., primary ciliary dyskinesia (all spermatozoa are immotile but viable) or necrozoospermia (all spermatozoa are immotile and dead as may occur in partial obstruction of the vas or ejaculatory ducts). In the former category, electron microscopy is the gold standard to diagnose specific sperm defects (Mobberley 2010). Correction should be carried out when possible (e.g., transurethral resection of the ejaculatory ducts in partial ejaculatory duct obstruction) (Xu et al. 2011).

Injection of uncharacterized immotile sperm makes fertilization after ICSI unpredictable and decreases both fertilization and pregnancy rates (Tournaye 1999). When no motile spermatozoa are found in the ejaculate, the patient should produce a second ejaculate. In most patients, the second semen sample often contains a few motile spermatozoa for use with ICSI. In patients with absolute asthenozoospermia, even after extensive processing of the semen specimen(s), different strategies can be applied to improve ICSI outcome. Immotile but vital spermatozoa may be selected by a hypoosmotic swelling test (HOS test). Since the HOS test depends, in part, on the integrity of the sperm tail membrane, it is not very useful when there are anatomical or functional sperm-tail and flagellar defects (Tournaye 1998). Apart from the HOS test, additional corrective measures can be tried, such as exposure of the sperm to pentoxifylline, application of laser-assisted immotile sperm (LAISS) selection, or the use of a birefringence-polscope (Hotaling et al. 2011). If only dead sperm are present in repeated ejaculates (necrozoospermia),

viable spermatozoa may be recovered from a testicular biopsy and lead to normal fertilization and pregnancies after ICSI (De Vos et al. 2003).

Globozoospermia is an uncommon cause of male sterility, affecting <0.1% of all patients suffering from male infertility (Tournaye et al. 2016b) and is characterized by the complete absence of the acrosomal vesicle, i.e., acrosomal aplasia or agenesis, hence the synonym round-headed sperm (Zini et al. 2011). Globozoospermia is the morphological end result of disturbed spermiogenesis, and, recently, genetic etiologies have been described (Souza Setti et al. 2010; Huszar et al. 2007). Various case reports have detailed the birth of ICSI-conceived offspring using round-headed acrosome-less spermatozoa, but in consecutive case series, the results after ICSI are poor and unpredictable, even when artificial oocyte activation with calcium-ionophore is applied (Tournaye 2010).

Apart from globozoospermia and structural abnormalities involving the midpiece or sperm tail, as mentioned above, the impact of teratozoospermia on the outcome after ICSI remains limited. Minor structural defects may be diverse and not present in all spermatozoa. Hence, functional spermatozoa will likely be injected in at least a portion of the oocyte pool and create a variable number of morphologically good-quality embryos and healthy offspring. But again, the prevalence of absolute teratozoospermia, i.e., 0% normal morphology affecting all spermatozoa is only 5% in men attending a fertility clinic (Tournaye et al. 2016b). A meta-analysis of studies focusing on teratozoospermia concluded that no decrease in the probability of conception is observed after ICSI using sperm from men with isolated teratozoospermia (Chansel-Debordeaux et al. 2015). However, when only embryos resulting from ICSI using morphologically abnormal spermatozoa are transferred, implantation rates are lower (Van Peperstraten et al. 2008).

Loss of DNA integrity may also have an impact on ICSI outcome although its impact on ART outcome remains controversial (Schulte et al. 2010).

Unfortunately, there are no real-time methods available to discard spermatozoa with ultrastructural tail deficiencies, DNA damage or chromosomal instability. Yet, novel methods to improve selection of spermatozoa for ICSI have been introduced. In the technique of intracytoplasmic morphologically selected sperm injection (IMSI), spermatozoa are selected by high-power magnification (about 6000 $\times$ ). Based on the few studies available in the literature, a recent, albeit premature, meta-analysis concluded that IMSI may significantly improve implantation and pregnancy rates while also reducing miscarriage rates after ICSI (Setti et al. 2014). This meta-analysis did not take into account indications for ICSI and only a single RCT and two nonrandomized studies were included.

Leandri et al. performed a properly designed RCT in 255 couples attempting their first assisted-reproductive technology (ART) attempt for male infertility (motile sperm count <1  $\times 10^6$  after sperm selection but at least 3  $\times 10^6$  spermatozoa per ejaculate to allow a detailed analysis of sperm characteristics) to compare the clinical outcomes of IMSI and ICSI and to evaluate the influence of sperm characteristics on these outcomes (Leandri et al. 2013). IMSI did not provide any significant improvement in the clinical outcomes compared with ICSI neither for implantation (24% vs. 23%), nor clinical pregnancy (31% vs. 33%), nor live birth rates (27% vs. 30%).

Moreover, the results of IMSI were similar to the ICSI ones whatever the degree of sperm DNA fragmentation, nuclear immaturity, and sperm morphology (Leandri et al. 2013). These results show that IMSI instead of ICSI has no advantage in the first ART attempts. However, this does not rule out IMSI completely and more randomized trials must be performed especially regarding patients carrying severe teratozoospermia or high sperm DNA fragmentation levels or having previous ICSI failures (Leandri et al. 2013).

Finally, a technique that depends on binding of spermatozoa to solid-state hyaluronate has been introduced in an effort to select mature spermatozoa with lower levels of chromosomal instability for use in conjunction with ICSI (Kalsi et al. 2011). Since the bound mature spermatozoa have to be “harvested” from a Petri dish coated with solid-state hyaluronate, this selection method has been named “PICSI.” Unfortunately, to date, no data from RCTs are available in order to evaluate the benefit from this novel method.

---

## Azoospermia and ICSI

Male infertility treatment has been revolutionized twice: the first time by the introduction of intracytoplasmic sperm injection (ICSI) in 1992 (Palermo et al. 1992) and the second time when ICSI allowed spermatozoa retrieved from the testis to fertilize an oocyte leading to viable embryos and healthy pregnancies (Schoysman et al. 1993). In patients with nonobstructive azoospermia (NOA), the first pregnancy was achieved in 1995 (Devroey et al. 1995).

In patients with obstructive azoospermia (OA) in whom surgical correction is not possible or has failed, spermatozoa may be recovered from either the epididymis or the testis. Different surgical techniques including microsurgical epididymal sperm aspiration (MESA), percutaneous epididymal sperm aspiration (PESA), testicular sperm extraction (TESE), testicular sperm aspiration (TESA), and fine-needle aspiration of the testis (FNA) have all been described (Donoso et al. 2007).

A Cochrane meta-analysis on surgical sperm retrieval techniques concludes that there is insufficient evidence to recommend any specific sperm retrieval technique and that the least invasive technique should be used (Tournaye 2010).

Aspiration methods are usually simple and less invasive and can be repeatedly performed under local anaesthesia. In men with normal spermatogenesis, e.g., men with an irreparable vasectomy or postinfectious obstruction, or men with congenital absence of the vas deferens (CBAVD), motile spermatozoa can be harvested from either the epididymis or the testis.

When epididymal sperm are to be obtained, motile fractions must be recovered, i.e., spermatozoa with very low levels of DNA damage, so as to not jeopardize the success rate of the coincident ICSI cycle (Ramos et al. 2002). When ICSI and sperm retrieval for azoospermia was first introduced due to the high success rates with testicular sperm, it was assumed that with ICSI sperm origin was irrelevant (Devroey et al. 1996). This was assumed despite many studies prior to the ICSI era which have

revealed the importance of sperm transition from the testis to epididymis (Bedford 1963; Bedford et al. 1973; Silber et al. 1990).

In the era of ICSI, the early publications have shown that when motile spermatozoa were used, no differences in fertilization rate or live birth rates were observed between epididymal and testicular sperm used for ICSI, but epididymal spermatozoa can more easily be cryopreserved (Nagy et al. 1997). Van Wely et al., in a study of couples with obstructive azoospermia, have shown that the use of epididymal spermatozoa resulted in significantly higher live birth rate than did the use of testis spermatozoa (van Wely et al. 2015). The authors postulate based on their observations that although perfectly capable of fertilizing oocytes via ICSI testicular sperm apparently do not support optimal embryo development as well as epididymal sperm do. This may be because epididymal sperm maturation contributes to proper embryo development for a number of reasons which need to be studied: the contribution of paternal RNAs to early embryo development, effects on the mitotic spindle of the resulting embryo, or disulfide bonding or ultrastructural changes already described in the literature. Indeed, the same group has previously shown that embryos generated via TESE-ICSI had high levels of chaotic chromosomal aneuploidies (Silber et al. 2003).

There are no differences in outcome after ICSI with fresh or with frozen-thawed epididymal spermatozoa (Tournaye et al. 1999).

Therefore, when cryopreservation is required, PESA is the method of choice, followed by TESE whenever PESA fails. When cryopreservation is not required, then FNA can be performed, being a minimally invasive “no-scar” technique (Donoso et al. 2007).

For men suffering from nonobstructive azoospermia in need of ICSI, TESE is the best choice to recover sperm as it provides the highest sperm recovery rate. Although technically more demanding, there is potential benefit in a microsurgically-guided technique, i.e., micro-TESE. Retrieval rates in nonobstructive azoospermic patients are between 40% and 50%. However, they vary between reports because of patient selection, reallocation of successful patients, or inclusion of patients with hypospermatogenesis and patients with slightly elevated FSH levels with no confirmatory histologic diagnosis available. Even in men persistently azoospermic after cancer treatment, including ablative chemotherapy, testicular spermatozoa may be recovered for ICSI (Carpi et al. 2009). Lastly, in adult azoospermic 47,XXY Klinefelter patients, spermatozoa can be recovered for ICSI (Vermaeve et al. 2006).

Currently, surgical techniques are reaching a plateau in terms of sperm retrieval rates, with varying success rates according to the specific diagnosis or selection of the patients. Sperm can be retrieved in virtually all cases of obstructive azoospermia (OA), but only in 40–50% of nonobstructive azoospermia (NOA) cases when no preliminary selection of patients on basis of histopathology has been performed (Tournaye et al. 1997a). Based on poorly controlled retrospective case series, a microscope-guided sperm retrieval, i.e., micro-TESE, may increase the retrieval rate from an average of 40% to an average of 50% (Deruyver et al. 2014).

Compared to men with obstructive azoospermia, men with nonobstructive azoospermia have lower fertilization and clinical pregnancy rates (Vermaeve et al. 2003).

Hence, the contribution of the ART laboratory has become increasingly important, specifically in developing methods to enhance the retrieval of spermatozoa from the tissue, to avoid sperm damage, and to improve the selection of good quality sperm for ICSI.

In men with nonobstructive azoospermia, there is controversy on the timing of TESE relative to the cycle of ICSI (Vloeberghs et al. 2015). Since not all cryopreserved TESE samples will yield spermatozoa for ICSI after thawing, a study by our group showed that following thawing there will be no sperm available for injection in 27.5% of NOA ICSI cycles and subsequent back-up fresh TESE procedure was performed on the day of oocyte retrieval (Vloeberghs et al. 2015).

Recovering sperm by TESE the day before oocyte aspiration must also be avoided because testicular sperm may accumulate DNA damage overnight and should thus be injected without delay (Tournaye et al. 1997b). If couples accept ICSI with donor sperm as a back-up, then TESE can be scheduled the day of oocyte aspiration. Alternatively, unfertilized oocytes can now be safely cryopreserved for ICSI using donor sperm at a later stage (Vernaev et al. 2003).

## ICSI with Spermatids

The most mature stage of the male gamete at the end of spermiogenesis is the elongated spermatid. After spermiation, spermatozoa are released into the tubular lumen. These spermatozoa become functional during the passage through the epididymis. The recovery of fully elongated spermatids or spermatozoa fails in approximately 50% of NOA men (1.114) meaning that their only hope would be the use of more immature germ cells for ICSI. Spermatids are the earliest cells in the male germ cell lineage with a haploid number of chromosomes.

Following the reports of results in animals (Ogura et al. 1994; Sofikitis et al. 1994), several groups have described the use of round (Tesarik et al. 1995) or elongated spermatids, retrieved from either the ejaculate or to treat men with NOA when no testicular spermatozoa could be retrieved (Fishel et al. 1995). Either intact round spermatids (ROSI) (Tesarik et al. 1995), round spermatid nuclei (ROSNI) (Hannay 1995), or elongated spermatids (ELSI) (Sousa et al. 2002) are injected into the oocyte. Although ELSI, ROSI, and ROSNI were introduced 20 years ago, the number of reported pregnancies has remained limited. The latest series of 14 children born after ROSI has been reported by a Japanese group (Tanaka et al. 2015).

There are two issues regarding the spermatid injection which have prevented their increased use.

One is the identification of spermatids within a heterogeneous population of round cells that have been obtained from either testicular tissue or the ejaculate. Elongating or elongated spermatids are easy to recognize but the identification of round spermatids is more difficult. Misidentification can lead to the injection of round cells that are not round spermatids which could explain low success rates of ROSI (Vloeberghs et al. 2013). Staining procedures have only diagnostic value and cannot be used in clinical practice (Angelopoulos et al. 1997). The use of phase



contrast optics on an inverted microscope is a simple and reliable method of round spermatid identification (Verheyen et al. 1998). One must also be aware that maturation arrest at the level of round spermatids is a rare event. Schulze et al. identified late maturation arrest, i.e., round spermatid arrest in only 7 out of 1418 stained biopsies from 766 azoospermic men which is 0.9% (Schulze et al. 1999). In our center's experience, round spermatids are found in patients who also had more mature stages of sperm development (Verheyen et al. 1998), concluding that only a limited number of patients have maturation arrest at the level of round spermatids.

The second issue in addition to low pregnancy rates is the questionable safety of ICSI with immature haploid cell due to the possibility of genetic and epigenetic risks to the offspring. Genomic imprinting primarily occurs during gametogenesis and may be incomplete or defective in immature gametes or in gametes that have matured under abnormal conditions, e.g., in an in vitro culture (Tesarik et al. 1998).

Preimplantation genetic diagnosis (PGD) has been proposed to increase both the implantation rate and safety of ROSI. Data of preimplantation genetic diagnosis (PGD) performed on embryos derived by ROSI by Bekhalifa et al. indicated that the failure of ROSI to produce pregnancy and live births occurs at both the prezygotic and postzygotic stages and is primarily caused by aneuploidy (Benkhalifa et al. 2004). Although Benkhalifa et al. did not report any increases in chromosomal or other genetic abnormalities in the rare pregnancies that occurred, they concluded that ROSI should not be used in ART program (Benkhalifa et al. 2004).

---

## Outcomes After ICSI

In order to provide ICSI candidate couples a more accurate prognosis, they should be preferentially informed about cumulative live birth rates. Unfortunately, there are only a few studies with cumulative live birth rates as an outcome measure. About 80% of couples in whom the female partner is younger than 37 years of age will achieve childbirth within four cycles (Tournaye et al. 2016b). However, in women over 40 years old, this figure decreases to 35% and over 42 years the live birth rate does even not exceed 10% (Tournaye et al. 2016b).

Although ART has been a treatment modality for treating infertility for 37 years, there are concerns on the association of ART procedures and risk of congenital malformations. A systematic review and meta-analysis on 45 cohort studies including 92,671 ART infants compared to 3,870,760 spontaneously conceived infants suggest a 32% increased risk of birth defects in children born following ART. The risk increases slightly when singleton births are examined separately (36%) and when the studies are restricted to studies examining major birth defects only (42%) (Hansen et al. 2013). The limitations of this and the later meta-analysis (Qin et al. 2015) are namely heterogeneity of the studies and the fact that the data has been collected over a long time period in a field that is moving extremely quickly.

The underlying mechanisms involved in the association between ART and congenital malformations are uncertain and further research is needed. There are biologically plausible reasons for CM risks: on one hand, factors associated with

ART procedures and on the other hand, infertility itself with the advanced age of infertile couples as well as the cause of infertility itself may increase the risk of CM. This is supported by elevated risk of CM in subfertile couples who conceived spontaneously (Davies et al. 2012). Furthermore, there is a possibility that the pregnancies following ART procedures are more closely monitored than the spontaneous ones which might account for high incidence of CM (Hansen et al. 2002).

From its introduction, ICSI has generated much controversy concerning its safety, mainly because of concerns about potential damage to the cytoskeleton and meiotic spindle from the process itself, deleterious modifications that may occur in genomic imprinting and because of worries about the transmission of genetic risks carried by candidate patients (Bonduelle et al. 1998; Wennerholm et al. 2000).

There are two meta-analyses that address the question whether birth defects are more common in ICSI compared to IVF infants (Lie et al. 2005; Wen et al. 2012) and both suggest no significant differences in risk between the two techniques. Moreover, because of the greater scrutiny to which ICSI children are subjected, any difference between ICSI, IVF, and spontaneous conception may not be noteworthy. However, the mean sex-chromosome aneuploidy rate after ICSI (0.8%) is significantly higher than in the general population (0.2%) (Silber et al. 2003). Neither obstetric outcome of ICSI pregnancies nor child development of ICSI offspring was different from conventional IVF and not influenced by sperm origin or quality (Bettio et al. 2008; Palermo et al. 1999).

---

## The Use of Surgically Retrieved Sperm in Assisted Reproduction

In patients with obstructive azoospermia, the spermatogenesis is mostly not affected and the treatment prognosis is good. Obstruction can be acquired (vasectomy, infection, or trauma) or congenital, the most common is CBAVD which is linked to the mutations in the cystic fibrosis transmembrane-conductance regulator gene. The current evidence states that the surgical retrieval is highly successful in men with OA regardless of the cause of obstruction and high live birth rates (average of 34%) are achieved (Esteves et al. 2013). Neonatal data are also reassuring: Woldringh et al. have shown in a follow-up study of 378 children born after ICSI with epididymal sperm that ICSI with epididymal sperm does not lead to more stillbirths or congenital malformations in comparison to IVF and ICSI with ejaculated sperm (Woldringh et al. 2011). A study by our group on neonatal outcome of 724 children born after ICSI using nonejaculated sperm showed no differences between children from fathers with NOA and OA (Belva et al. 2011). The overall major malformation rate and incidence of karyotype anomalies were comparable between the non-ejaculated and the ejaculated sperm groups (OR 1.4; 95% CI 0.9–2.2) (Belva et al. 2011). The risk of major anomalies in live borns does not depend on the origin of the sperm, which is in accordance with other groups (Wennerholm 2000; Ludwig and Katalinic 2003; Fedder et al. 2007).

Men with NOA have dysfunctional testes resulting from a number of conditions: genetic and chromosomal abnormalities, postinfectious diseases, trauma, endocrine

disorders, idiopathic causes, and vast majority of them have irreparable testicular failure. NOA patients undergoing TESE should be counselled that not only are the sperm recovery rates limited but also that the fertilization, implantation, and conception rates are decreased compared to men with normal spermatogenesis. Sperm retrieval rates after TESE range from 16.5% to 80% (Donoso et al. 2007). The differences in the retrieval rates arise from the inconsistencies in the selection of patients, e.g., inclusion of patients with hypospermatogenesis or patients without proper histopathologic diagnosis could lead to inclusion of patients with misdiagnosed obstructive azoospermia resulting in overestimated retrieval rates (Vloeberghs et al. 2015; Osmanagaoglu et al. 2003).

There is scarce information on cumulative delivery rates using testicular sperm in NOA. The crude cumulative delivery rates after three ICSI cycles was 17% in the first report by our group (Tournaye et al. 1997b) which increased to 34% after three cycles and to only 37% after six cycles in the latest publication by our group (Vloeberghs et al. 2015). Improvement in the ART laboratory as well as inclusion of frozen embryo transfers may account for the differences. In a 15-year follow-up study, Vloeberghs et al. observed a clinical pregnancy rate per cycle of 21.7% and a live birth delivery rate per cycle of 20.6% in an unselected cohort of consecutive NOA patients. The important information provided by Vloeberghs et al. is that almost four out of ten (37%) NOA couples who undergo ICSI treatment will have a delivery (Vloeberghs et al. 2015). However, before undergoing TESE, unselected candidate NOA patients should be counseled that only one out of seven men (13.4%) will eventually father his genetically own child (Vloeberghs et al. 2015).

Although the use of cryopreserved testicular sperm for ICSI has several advantages, the data concerning the outcomes of IVF-ICSI procedures using frozen-thawed testicular sperm are still controversial. A meta-analysis showed a significantly lower implantation rate when frozen-thawed sperm had been used compared with fresh sperm (relative risk, RR 1.75; 95% CI: 1.10–2.80); however, no differences were observed in fertilization and ongoing pregnancy rates (Nicopoullos et al. 2004). Our group has shown that despite the increased risk of not finding sperm suitable for injection, the outcome of ICSI cycles using frozen-thawed testicular sperm is not inferior to cycles with fresh testicular sperm (Verheyen et al. 2004).

A recent Danish population-based cohort study which included all Danish children born after ICSI with epididymal or testicular sperm showed that singletons as well as twins born after ICSI with epididymal or testicular sperm have similar perinatal/neonatal outcomes and similar congenital malformation rates compared with children born after IVF and ICSI with ejaculated sperm (Fedder et al. 2013).

Given the limited numbers of children being evaluated and the doubts about the validity of data from many reports because of potential bias, e.g., background risk factors, comparison with fertile controls, overscrutinizing of ICSI pregnancies, further follow-up is certainly recommended and both IVF or ICSI candidate parents should be informed about the uncertainties concerning the safety of these techniques in regards to their future offspring. Besides, candidate patients need genetic testing prior to ICSI not only for pure diagnostic reasons but also to prevent transmission of genetic traits associated to their infertility problem.

## Cost-Effectiveness of IUI Vs. IVF Vs. ICSI

The main issues to compare cost-effectiveness are the methodological flaws in IUI studies. These studies are prone to a substantial risk of bias, due to the comparative trials not being properly controlled, minimal information on allocation concealment and randomization, small sample sizes, no reporting of live-birth rates, and follow-up periods being variable and inadequate (Pandian et al. 2012; Veltman-Verhulst et al. 2016). Furthermore, only a few studies have reported adverse effects of IUI, such as multiple pregnancies and ovarian hyperstimulationsyndrome (OHSS) (Pandian et al. 2012; Veltman-Verhulst et al. 2016).

The most recent reports support the effectiveness of IUI (Bensdorp et al. 2015; Tjon-Kon-Fat et al. 2015) in couples with unexplained infertility. Without any significant difference in efficacy, the IVF strategies were significantly more expensive when compared with stimulated IUI. When compared with IVF in a managed natural cycle (MNC), IUI with controlled ovarian hyperstimulation (IUI-COH) was the dominant strategy.

The cost-effectiveness of IUI and IVF in relation to sperm count has also been analyzed. VanVoorhis et al. suggested that an average total motile sperm count of 10 million may be a useful threshold value for decisions regarding the treatment of a couple with IUI or IVF or 0.8 M motile count postwash (Van Voorhis et al. 2001).

The cost-effectiveness of IUI over IVF is confirmed when treatment occurs with a total motile sperm count (TMSC) of more than 3 million (Moolenaar et al. 2015), thereby highlighting the need for more motile sperm for effectiveness of IUI. A computer-simulated cohort of subfertile women aged 30 years with a partner was analyzed with a prewash TMSC of 0–10 million. Three treatments were evaluated: IUI with and without controlled ovarian stimulation, IVF, and ICSI. Main outcome was expected live birth; secondary outcomes were cost per couple and the incremental cost-effectiveness ratio. The choice of IVF over IUI with ovarian stimulation and ICSI over IVF depends on the willingness to pay for an extra live birth. If only cost per live birth is considered for each treatment, above a prewash TMSC of 3 million, IUI is less costly than IVF and, below a prewash, TMSC of 3 million ICSI is less costly. Effectiveness needs to be confirmed in a large randomized controlled trial (Moolenaar et al. 2015). Applying a “consecutive ejaculation” may overcome the sperm threshold (Bahadur et al. 2016a).

The added costs necessary to achieve one additional healthy child in the IVF-Single Embryo Transfer group compared with stimulated IUI were 43,375 euros (Tjon-Kon-Fat et al. 2015).

Multiple births have been the major reason pitched against IUI but there is no evidence for this in Cochrane reviews (Pandian et al. 2012; Veltman-Verhulst et al. 2016). This prejudice is based on historical practices involving irresponsible ovulation induction which led to multifollicular growth during IUI treatments (Dickey et al. 2005). Adequate cycle monitoring has reduced the absolute rate of multiple pregnancies to 0.3% after monofollicular growth and 2.8% after multifollicular growth (van Rumste et al. 2008). The risk of multiple pregnancies is estimated to increase by 6, 14, and 10% with respect to the number of follicles, two, three, and

four, respectively (van Rumste et al. 2008). Bifollicular growth in IUI cycle increases the chance of achieving an IUI pregnancy by 3.4-fold compared to unifollicular cycles (van Rumste et al. 2008). In the Netherlands, more multiple pregnancies result from IVF than of IUI treatment.

Keeping in mind the rising risks of multiple pregnancies with the rising number of follicles, when more than two follicles of 14 mm are present on the day of ovulation trigger, the treatment can be withheld or follicular reduction may be performed.

Adequate and responsible cycle monitoring provides IUI stronger basis for first line treatment.

The advent of ICSI has changed infertility treatment forever in a number of ways, which are not necessarily always evidence based and adequately substantiated (Evers 2016).

The introduction of intracytoplasmic sperm injection (ICSI) has been responsible as now for over two million babies worldwide and has been instrumental in helping men with suboptimal gametes to achieve their reproductive dream (Palermo et al. 2014). Intracytoplasmic sperm injection is principally a procedure to optimize fertilization rates. In addition, ICSI offers diagnostic benefits by stripping oocytes of surrounding granulosa cells in preparation for ICSI, and information about egg quality is gained, which can affect treatment decisions downstream.

ICSI has replaced all prior assisted-fertilization techniques because it has the ability to successfully bypass any effect of antisperm antibodies, to deal with sperm acrosome dysfunction, and to override sperm kinetic defects (Palermo et al. 2012). ICSI is hardly impacted by the immaturity of the male gamete such as those generated from the epididymis and the testicle often characterized by an incomplete flagellum and peculiar cell membrane.

These successes achieved across the arrays of dysfunctional spermatozoa has allowed to push the boundaries of the application of the sperm injection technique towards the most extreme aspect of male infertility even when only few spermatozoa can be identified as often encountered in cryptozoospermia, virtual azoospermia, or when surgical specimens are used in absolute azoospermia (Ron-El et al. 1997).

A powerful tool in the hands of medical world dealing with infertility, ICSI use has exploded (Evers 2016). Among fresh IVF cycles in USA, ICSI use increased from 36.4% in 1996 to 76.2% in 2012, with the largest relative increase among cycles without male-factor infertility (Boulet et al. 2015).

By 2013, the number of IVF cycles per year has increased from 90,000 in 2000 to 150,000 in 2010 (Kawwass et al. 2013). Similar trend has been seen in Europe; in 2011, 138,592 IVF cycles and 298,918 ICSI cycles were reported by 1064 clinics from 33 countries (European IVF-Monitoring Consortium (EIM) et al. 2016).

In the United Kingdom, diagnosis of unexplained infertility has tripled from 6204 to 19,522 cycles (Kamphuis et al. 2014), while severe male infertility cases have increased by 290% from 6771 to 19,643 from 2000 to 2011 (Kamphuis et al. 2014). The dramatic increase in the diagnosis of unexplained infertility could be explained by the increasing female childbearing age and ovarian senescence in these older women presenting as unexplained subfertility (Maheshwari et al. 2008).

This tremendous increase in diagnosis of male infertility has to be seriously addressed since only severe male infertility can justify the use of IVF/ICSI procedures.

The definition of abnormal semen parameters and therefore the primary indication for ICSI changed over the last decades. The World Health Organization criteria were revised in 1999 and again in 2010 (World Health Organization 2010) resulting in increasingly strict criteria and fewer abnormal semen analyses which should, in turn, decrease the incidence of male infertility. There is need for standardization of laboratories since not all have adequate ISO-15189 standards, and therefore the results of semen analysis cannot be properly compared. None of these increases can be explained scientifically nor by evidence-based medicine. In addition, the higher incidence of severe male infertility could be at least partially explained by increase in the reporting.

Are we overtreating our patients? A broad estimate states that more than 50% of couples are undergoing an unnecessary IVF treatment (Maheshwari et al. 2008; Romundstad et al. 2015). The high availability of advanced medical techniques which are used as strategy for reducing patient's time to family completion are largely responsible for these statistics. It has to be kept in mind that the population seeking infertility treatment is aging and the pressures are high to achieve pregnancy in the shortest period of time.

In addition, the most recent Cochrane review on the use of assisted reproduction for male subfertility evaluated the effectiveness and safety of different fertility treatments (expectant management, timed intercourse (TI), IUI, IVF, and ICSI) for couples whose subfertility appears to be due to abnormal sperm parameters (Cissen et al. 2016). The authors found insufficient evidence to determine whether there was any difference in safety and effectiveness between different treatments for male subfertility, advocating for more research (Cissen et al. 2016).

Contradictorily, on one hand, we have witnessed major improvements in technology and on the other hand, these have not been adequately followed by high-quality research leading to vague conclusions of meta-analysis and reviews by authorities in research, depriving the practitioners with clear-cut treatment recommendations.

---

## Shifting Paradigms

The introduction of intracytoplasmic sperm injection (ICSI) has been responsible as now for over two million babies worldwide and has been instrumental in helping men with suboptimal gametes to achieve their reproductive dream.

There are definitely shifting paradigms as to the most cost-effective treatment strategy for infertile couples. In recent years, the pregnancy rates are raising with IVF/ICSI treatment while at the same time the pregnancy rates remain unchanged over the years with IUI.

For IUI to succeed, there has to be a drive to optimize the outcome but there have not been major changes since its introduction in 1962 (Cohen 1962). Couples

generally prefer to continue with IUI even after three unsuccessful attempts since they perceive it as a much less stressful treatment.

---

## Conclusion

In the last decades, assisted-reproductive technologies for treating male infertility have been on a very fast developing track. The constant drive for improvement, the increased availability of ART procedures, and shifting paradigms have resulted in explosion of mostly ICSI treatments.

Is it time to pause and reassess? There is a need to develop global guidelines and inclusion policies for IVF and ICSI procedures. There is urgency for improved sperm selection methods, and in particularly clinical applicability of sperm DNA fragmentation is long overdue.

The medical infertility community should strive towards using the high technology that is available to treat patients in most effective and efficient patient-friendly way. Clinical decisions should be based on critical appraisal of literature and new treatment modalities should be used only when sufficient evidence allows it.

---

## References

- Aboulghar M, Mansour R, Serour G, Abdrazek A, Amin Y, Rhodes C. Controlled ovarian hyperstimulation and intrauterine insemination for treatment of unexplained infertility should be limited to a maximum of three trials. *Fertil Steril*. 2001;75:88–91.
- Agarwal A, Mulgund A, Hamada A, Chyatte MR. A unique view on male infertility around the globe. *Reprod Biol Endocrinol*. 1st ed. BioMed Central. 2015;13(1):37.
- Angelopoulos T, Krey L, McCullough A, Adler A, Grifo JA. A simple and objective approach to identifying human round spermatids. *Hum Reprod*. 1997;12(10):2208–16.
- Asada Y, Baka SG, Hodgen GD, Lanzendorf SE. Evaluation of the meiotic spindle apparatus in oocytes undergoing intracytoplasmic sperm injection. *Fertil Steril*. 1995;64(2):376–81.
- Ayala C, Steinberger E, Smith DP. The influence of semen analysis parameters on the fertility potential of infertile couples. *J Androl*. 1996;17(6):718–25.
- Bahadur G, Almossawi O, Zeirideen Zaid R, Ilahibuccus A, Al-Habib A, Muneer A, et al. Semen characteristics in consecutive ejaculates with short abstinence in subfertile males. *Reprod Biomed Online*. 2016a;32(3):323–8.
- Bahadur G, Homburg R, Muneer A, Racich P, Alangaden T, Al-Habib A, et al. First line fertility treatment strategies regarding IUI and IVF require clinical evidence. *Hum Reprod*. 2016b;31(6):1141–6.
- Baka S, Grigoriou O, Hassiakos D, Konidaris S, Papadias K, Makrakis E. Treatment of sperm with platelet-activating factor does not improve intrauterine insemination outcome in unselected cases of mild male factor infertility: a prospective double-blind randomized crossover study. *Urology*. 2009;74(5):1025–8.
- Bedford JM. Changes in the electrophoretic properties of rabbit spermatozoa during passage through the epididymis. *Nature*. 1963;200:1178–80.
- Bedford JM, Calvin H, Cooper GW. The maturation of spermatozoa in the human epididymis. *J Reprod Fertil Suppl*. 1973;18:199–213.

- Beguería R, García D, Obradors A, Poisot F, Vassena R, Vernaev V. Paternal age and assisted reproductive outcomes in ICSI donor oocytes: is there an effect of older fathers? *Hum Reprod.* 2014a;29(10):2114–22.
- Beguería R, García D, Obradors A, Poisot F, Vassena R, Vernaev V. Paternal age and assisted reproductive outcomes in ICSI donor oocytes: is there an effect of older fathers? *Hum Reprod.* 2014b;29(10):2114–22.
- Belloc S, Hazout A, Zini A, Merviel P, Cabry R, Chahine H, et al. How to overcome male infertility after 40: influence of paternal age on fertility. *Maturitas.* 2014;78(1):22–9.
- Bellver J, Garrido N, Remohí J, Pellicer A, Meseguer M. Influence of paternal age on assisted reproduction outcome. *Reprod BioMed Online.* 2008;17(5):595–604.
- Belva F, De Schrijver F, Tournaye H, Liebaers I, Devroey P, Haentjens P, et al. Neonatal outcome of 724 children born after ICSI using non-ejaculated sperm. *Hum Reprod.* 2011;26(7):1752–8.
- Benkhalifa M, Kahraman S, Bircicik A, Serteyl S, Domez E, Kumtepe Y, et al. Cytogenetic abnormalities and the failure of development after round spermatid injections. *Fertil Steril.* 2004;81(5):1283–8.
- Bensdorp AJ, Cohlen BJ, Heineman MJ, Vandekerckhove P. Intra-uterine insemination for male subfertility. Bensdorp A, editor. *Cochrane Database Syst Rev.* Chichester: Wiley. 2007;(4):CD000360.
- Bensdorp AJ, Tjon-Kon-Fat RI, Bossuyt PMM, Koks CAM, Oosterhuis GJE, Hoek A, et al. Prevention of multiple pregnancies in couples with unexplained or mild male subfertility: randomised controlled trial of in vitro fertilisation with single embryo transfer or in vitro fertilisation in modified natural cycle compared with intrauterine insemination with controlled ovarian hyperstimulation. *BMJ.* 2015;350:g7771.
- Bettio D, Venci A, Levi Setti P. Chromosomal abnormalities in miscarriages after different assisted reproduction procedures. *Placenta.* 2008;29(Suppl B):126–8.
- Blake M, Garrisi J, Tomkin G, Cohen J. Sperm deposition site during ICSI affects fertilization and development. *Fertil Steril.* 2000;73(1):31–7.
- Bonduelle M, Wilikens A, Buysse A, Van Assche E, Devroey P, Van Steirteghem AC, Liebaers I. A follow-up study of children born after intracytoplasmic sperm injection (ICSI) with epididymal and testicular spermatozoa and after replacement of cryopreserved embryos obtained after ICSI. *Hum Reprod.* 1998;13(Suppl 1):196–207.
- Boomsma CM, Heineman MJ, Cohlen BJ, Farquhar C. Semen preparation techniques for intra-uterine insemination. Boomsma CM, editor. *Cochrane Database Syst Rev.* Chichester: Wiley. 2007;(4):CD004507.
- Boulet SL, Mehta A, Kissin DM, Warner L, Kawwass JF, Jamieson DJ. Trends in use of and reproductive outcomes associated with intracytoplasmic sperm injection. *JAMA.* 2015;313(3):255–63.
- Brzechffa P, Buyalos R. Female and male partner age and menotrophin requirements influence pregnancy rates with human menopausal gonadotrophin therapy in combination with intrauterine insemination. *Hum Reprod.* 1997;12:29–33.
- Cantineau AE, Heineman MJ, Cohlen BJ. Single versus double intrauterine insemination (IUI) in stimulated cycles for subfertile couples. Cantineau AE, editor. *Cochrane Database Syst Rev.* Chichester: Wiley. 2003;(1):CD003854.
- Cantineau AE, Janssen MJ, Cohlen BJ. Synchronised approach for intrauterine insemination in subfertile couples. Janssen MJ, editor. *Cochrane Database Syst Rev.* Chichester: Wiley. 2010;(4):CD006942.
- Carpi A, Sabanegh E, Mechanick J. Controversies in the management of nonobstructive azoospermia. *Fertil Steril.* 2009;91(4):963–70.
- Chansel-Debordeaux L, Dandieu S, Bechoua S, Jimenez C. Reproductive outcome in globozoospermic men: update and prospects. *Andrology.* 2015;3(6):1022–34.
- Cissen M, Bensdorp A, Cohlen BJ, Repping S, de Bruin JP, van Wely M. Assisted reproductive technologies for male subfertility. Cissen M, editor. *Cochrane Database Syst Rev.* Chichester: Wiley. 2016;2:CD000360.



- Coates TE, Check JH, Choe J, Nowroozi K, Lurie D, Callan C. An evaluation of couples with failure of fertilization in vitro. *Hum Reprod.* 1992;7:978–81.
- Cocuzza M, Athayde KS, Agarwal A, Sharma R, Pagani R, Lucon AM, et al. Age-related increase of reactive oxygen species in neat semen in healthy fertile men. *Urology.* 2008;71(3):490–4.
- Cohen M. Intrauterine insemination. *Int J Fertil.* 1962;7:235–40.
- Cohlen B. In: Ombelet W, editor. *Intra uterine insemination: evidence based guidelines for daily practice.* Boca Raton: CRC Press; 2014.
- Cohlen BJ, te Velde ER, van Kooij RJ, Looman CW, Habbema JD. Controlled ovarian hyperstimulation and intrauterine insemination for treating male subfertility: a controlled study. *Hum Reprod.* 1998;13:1553–8.
- Cooper TG, Noonan E, von Eckardstein S, et al. World Health Organization reference values for human semen characteristics. *Hum Reprod Update.* 2010;16(3):231–45.
- Custers IM, Flierman PA, Maas P, Cox T, Van Dessel TJHM, Gerards MH, et al. Immobilisation versus immediate mobilisation after intrauterine insemination: randomised controlled trial. *BMJ.* 2009;339:b4080.
- Dain L, Auslander R, Dimfeld M. The effect of paternal age on assisted reproduction outcome. *Fertil Steril.* 2011;95(1):1–8.
- Davies MJ, Moore VM, Willson KJ, Van Essen P, Priest K, Scott H, et al. Reproductive technologies and the risk of birth defects. *N Engl J Med.* 2012;366(19):1803–13.
- de la Rochebrochard E, Thonneau P. Paternal age  $\geq 40$  years: an important risk factor for infertility. *Am J Obstet Gynecol.* 2003;189:901–15.
- De Vos A, Van De Velde H, Joris H, Verheyen G, Devroey P, Van Steirteghem A. Influence of individual sperm morphology on fertilization, embryo morphology, and pregnancy outcome of intracytoplasmic sperm injection. *Fertil Steril.* 2003;79:42–8.
- Deruyver Y, Vanderschueren D, Van der Aa F. Outcome of microdissection TESE compared with conventional TESE in non-obstructive azoospermia: a systematic review. *Andrology.* 2014;2(1):20–4.
- Deveneau NE, Sinno O, Krause M, Eastwood D, Sandlow JI, Robb P, et al. Impact of sperm morphology on the likelihood of pregnancy after intrauterine insemination. *Fertil Steril.* 2014;102(6):1584–90. e2.
- Devroey P, Liu J, Nagy Z, Goossens A, Tournaye H, Camus M, et al. Pregnancies after testicular sperm extraction and intracytoplasmic sperm injection in non-obstructive azoospermia. *Hum Reprod.* 1995;10(6):1457–60.
- Devroey P, Nagy P, Tournaye H, Liu J, Silber S, Van Steirteghem A. Outcome of intracytoplasmic sperm injection with testicular spermatozoa in obstructive and non-obstructive azoospermia. *Hum Reprod.* 1996;11(5):1015–8.
- Dickey RP, Taylor SN, Lu PY, Sartor BM, Rye PH, Pyrzak R. Risk factors for high-order multiple pregnancy and multiple birth after controlled ovarian hyperstimulation: results of 4,062 intrauterine insemination cycles. *Fertil Steril.* 2005;83(3):671–83.
- Donoso P, Tournaye H, Devroey P. Which is the best sperm retrieval technique for non-obstructive azoospermia? A systematic review. *Hum Reprod Update.* 2007;13(6):539–49.
- Dumoulin JM, Coonen E, Bras M, Bergers-Janssen JM, Ignoul-Vanvuchelen RC, van Wissen LC, et al. Embryo development and chromosomal anomalies after ICSI: effect of the injection procedure. *Hum Reprod.* 2001;16(2):306–12.
- Eskenazi B, Wyrobek AJ, Slotter E, Kidd SA, Moore L, Young S, et al. The association of age and semen quality in healthy men. *Hum Reprod.* 2003;18(2):447–54.
- Esteves SC, Lee W, Benjamin DJ, Seol B, Verza S, Agarwal A. Reproductive potential of men with obstructive azoospermia undergoing percutaneous sperm retrieval and intracytoplasmic sperm injection according to the cause of obstruction. *J Urol.* 2013;189(1):232–7.
- European IVF-Monitoring Consortium (EIM), European Society of Human Reproduction and Embryology (ESHRE), Kupka MS, D’Hooghe T, Ferraretti AP, de Mouzon J, et al. Assisted reproductive technology in Europe, 2011: results generated from European registers by ESHRE. *Hum Reprod.* 2016;31(2):233–48.

- Evers JLHH. Santa Claus in the fertility clinic. *Hum Reprod.* 2016;31(7):1381–2.
- Fedder J, Gabrielsen A, Humaidan P, Erb K, Ernst E, Loft A. Malformation rate and sex ratio in 412 children conceived with epididymal or testicular sperm. *Hum Reprod.* 2007;22(4):1080–5.
- Fedder J, Loft A, Parner ET, Rasmussen S, Pinborg A. Neonatal outcome and congenital malformations in children born after ICSI with testicular or epididymal sperm: a controlled national cohort study. *Hum Reprod.* 2013;28(1):230–40.
- Fishel S, Green S, Bishop M, Thornton S, Hunter A, Flemiry S, et al. Pregnancy after intracytoplasmic injection of spermatid. *Lancet.* 1995;345(8965):1641–2.
- Ford WCL, North K, Taylor H, Farrow A, Hull MGR, Golding J. Increasing paternal age is associated with delayed conception in a large population of fertile couples: evidence for declining fecundity in older men. *Hum Reprod.* 2000;15:1703–8.
- Ghanem ME, Bakre NI, Emam MA, Al Boghdady LA, Helal AS, Elmetwally AG, et al. The effects of timing of intrauterine insemination in relation to ovulation and the number of inseminations on cycle pregnancy rate in common infertility etiologies. *Hum Reprod.* 2011;26(3):576–83.
- Goverde AJ, McDonnell J, Vermeiden JP, Schats R, Rutten FF, Schoemaker J. Intrauterine insemination or in-vitro fertilisation in idiopathic subfertility and male subfertility: a randomised trial and cost-effectiveness analysis. *Lancet.* 2000;355(9197):13–8.
- Griffiths TA, Murdoch AP, Herbert M. Embryonic development in vitro is compromised by the ICSI procedure. *Hum Reprod.* 2000;15(7):1592–6.
- Grigoriou O, Makrakis E, Konidaris S, Hassiakos D, Papadias K, Baka S, et al. Effect of sperm treatment with exogenous platelet-activating factor on the outcome of intrauterine insemination. *Fertil Steril.* 2005;83(3):618–21.
- Hannay T. New Japanese IVF method finally made available in Japan. *Nat Med.* 1995;1(4):289–90.
- Hansen M, Kurinczuk JJ, Bower C, Webb S. The risk of major birth defects after intracytoplasmic sperm injection and in vitro fertilization. *N Engl J Med.* 2002;346(10):725–30.
- Hansen M, Kurinczuk JJ, Milne E, de Klerk N, Bower C. Assisted reproductive technology and birth defects: a systematic review and meta-analysis. *Hum Reprod Update.* 2013;19(4):330–53.
- Hassan MA, Killick SR. Effect of male age on fertility: evidence for the decline in male fertility with increasing age. *Fertil Steril.* 2003;79(Suppl 3):1520–7.
- Hotaling JM, Smith JF, Rosen M, Muller CH, Walsh TJ. The relationship between isolated teratozoospermia and clinical pregnancy after in vitro fertilization with or without intracytoplasmic sperm injection: a systematic review and meta-analysis. *Fertil Steril.* 2011;95(3):1141–5.
- Hourvitz A, Goldschlag DE, Davis OK, Gosden LV, Palermo GD, Rosenwaks Z. Intracytoplasmic sperm injection (ICSI) using cryopreserved sperm from men with malignant neoplasm yields high pregnancy rates. *Fertil Steril.* 2008;90:557–63.
- Huszar G, Jakab A, Sakkas D, Ozenci CC, Cayli S, Delpiano E, Ozkavukcu S. Fertility testing and ICSI sperm selection by hyaluronic acid binding: clinical and genetic aspects. *Reprod BioMed Online.* 2007;14:650–63.
- Jenkins TG, Aston KI, Cairns BR, Carrell DT. Paternal aging and associated intraindividual alterations of global sperm 5-methylcytosine and 5-hydroxymethylcytosine levels. *Fertil Steril.* 2013;100(4):945–51.
- Kalsi J, Thum MY, Muneer A, Pryor J, Abdullah H, Minhas S. Analysis of the outcome of intracytoplasmic sperm injection using fresh or frozen sperm. *BJU Int.* 2011;107(7):1124–8.
- Kamphuis EI, Bhattacharya S, van der Veen F, Mol BWJ, Templeton A, Evidence Based IVF Group. Are we overusing IVF? *BMJ.* 2014;348:g252.
- Kastrop PM, Weima SM, Van Kooij RJ, Velde Te ER. Comparison between intracytoplasmic sperm injection and in-vitro fertilization (IVF) with high insemination concentration after total fertilization failure in a previous IVF attempt. *Hum Reprod.* 1999;14(1):65–9.
- Kawwass JF, Monsour M, Crawford S, Kissin DM, Session DR, Kulkarni AD, et al. Trends and outcomes for donor oocyte cycles in the United States, 2000–2010. *JAMA.* 2013;310(22):2426–34.

- Kelleher S, Wishart SM, Liu PY, Turner L, Di Pierro I, Conway AJ, Handelsman DJ. Long-term outcomes of elective human sperm cryostorage. *Hum Reprod.* 2001;16:2632–9.
- Kidd SA, Eskenazi B, Wyrobek AJ. Effects of male age on semen quality and fertility: a review of the literature. *Fertil Steril.* 2001;75(2):237–48.
- Kihaille PE, Misumi J, Hirotsuru K, Kumasako Y, Kisanga RE, Utsunomiya T. Comparison of sibling oocyte outcomes after intracytoplasmic sperm injection and in vitro fertilization in severe teratozoospermic patients in the first cycle. *Int J Androl.* 2003;26(1):57–62.
- Kim D, Child T, Farquhar C. Intrauterine insemination: a UK survey on the adherence to NICE clinical guidelines by fertility clinics. *BMJ Open.* 2015;5(5):e007588.
- Kissler S, Siebzehnuebl E, Kohl J, Mueller A, Hamscho N, Gaetje R, et al. Uterine contractility and directed sperm transport assessed by hysterosalpingoscintigraphy (HSSG) and intrauterine pressure (IUP) measurement. *Acta Obstet Gynecol Scand.* 2004;83(4):369–74.
- Klonoff-Cohen HS, Natarajan L. The effect of advancing paternal age on pregnancy and live birth rates in couples undergoing in vitro fertilization or gamete intrafallopian transfer. *Am J Obstet Gynecol.* 2004;191(2):507–14.
- Lahteenmaki A, Reima I, Hovatta O. Treatment of severe male immunological infertility by intracytoplasmic sperm injection. *Hum Reprod.* 1995;10:2824–8.
- Leandri RD, Gachet A, Pfeffer J, Celebi C, Rives N, Carre-Pigeon F, et al. Is intracytoplasmic morphologically selected sperm injection (IMSI) beneficial in the first ART cycle? A multicentric randomized controlled trial. *Andrology.* 2013;1(5):692–7.
- Lie RT, Lyngstadaas A, Ørstavik KH, Bakketeig LS, Jacobsen G, Tanbo T. Birth defects in children conceived by ICSI compared with children conceived by other IVF-methods: a meta-analysis. *Int J Epidemiol.* 2005;34(3):696–701.
- Liu J, Nagy Z, Joris H, Tournaye H, Smits J, Camus M, et al. Analysis of 76 total fertilization failure cycles out of 2732 intracytoplasmic sperm injection cycles. *Hum Reprod.* 1995;10(10):2630–6.
- Ludwig M, Katalinic A. Pregnancy course and health of children born after ICSI depending on parameters of male factor infertility. *Hum Reprod.* 2003;18(2):351–7.
- Maheshwari A, Hamilton M, Bhattacharya S. Effect of female age on the diagnostic categories of infertility. *Hum Reprod.* 2008;23(3):538–42.
- Mathieu C, Ecochard R, Bied V, Lornage J, Czyba JC. Cumulative conception rate following intrauterine artificial insemination with husband's spermatozoa: influence of husband's age. *Hum Reprod.* 1995;10(5):1090–7.
- Meijerink AM, Ramos L, Fleischer K, Veltman JA, Hendriks JC, Braat DD. Influence of paternal age on ongoing pregnancy rate at eight weeks' gestation in assisted reproduction. *Reprod Biomed Online.* 2016;32(1):96–103.
- Miller JE, Smith TT. The effect of intracytoplasmic sperm injection and semen parameters on blastocyst development in vitro. *Hum Reprod.* 2001;16(5):918–24.
- Mobberley MA. Electron microscopy in the investigation of asthenozoospermia. *Br J Biomed Sci.* 2010;67(2):92–100.
- Moolenaar LM, Cissen M, de Bruin JP, Hompes PGA, Repping S, van der Veen F, et al. Cost-effectiveness of assisted conception for male subfertility. *Reprod Biomed Online.* 2015;30(6):659–66.
- Morshedi M, Duran HE, Taylor S, Oehninger S. Efficacy and pregnancy outcome of two methods of semen preparation for intrauterine insemination: a prospective randomized study. *Fertil Steril.* 2003;79(Suppl 3):1625–32.
- Moskovtsev SI, Willis J, Mullen JBM. Age-related decline in sperm deoxyribonucleic acid integrity in patients evaluated for male infertility. *Fertil Steril.* 2006;85(2):496–9.
- Nagy ZP, Verheyen G, Liu J, Joris H, Janssenswillen C, Wisanto A, et al. Results of 55 intracytoplasmic sperm injection cycles in the treatment of male-immunological infertility. *Hum Reprod.* 1995;10(7):1775–80.
- Nagy ZP, Verheyen G, Tournaye H, Devroey P, Van Steirteghem AC. An improved treatment procedure for testicular biopsy specimens offers more efficient sperm recovery: case series. *Fertil Steril.* 1997;68(2):376–9.

- Nicopoulos JDM, Gilling-Smith C, Almeida PA, Norman-Taylor J, Grace I, Ramsay JWA. Use of surgical sperm retrieval in azoospermic men: a meta-analysis. *Fertil Steril*. 2004;82(3):691–701.
- Ogura A, Matsuda J, Yanagimachi R. Birth of normal young after electrofusion of mouse oocytes with round spermatids. *Proc Natl Acad Sci USA*. 1994;91(16):7460–2.
- Ombelet W, Van Robays J. Artificial insemination history: hurdles and milestones. *Facts Views Vis Obgyn*. 2015;7(2):137–43.
- Osmanagaoglu K, Vermaeue V, Kolibianakis E, Tournaye H, Camus M, Van Steirteghem A, et al. Cumulative delivery rates after ICSI treatment cycles with freshly retrieved testicular sperm: a 7-year follow-up study. *Hum Reprod*. 2003;18(9):1836–40.
- Palermo G, Joris H, Devroey P, Van Steirteghem AC. Pregnancies after intracytoplasmic injection of single spermatozoon into an oocyte. *Lancet*. 1992;340(8810):17–8.
- Palermo G, Schlegel PN, Hariprasad JJ, Ergün B, Mielnik A, Zaninovic N, Veeck LL, Rosenwaks Z. Fertilization and pregnancy outcome with intracytoplasmic sperm injection for azoospermic men. *Hum Reprod*. 1999;14:741–8.
- Palermo GD, Neri QV, Monahan D, Kocent J, Rosenwaks Z. Development and current applications of assisted fertilization. *Fertil Steril*. 2012;97(2):248–59.
- Palermo GD, Neri QV, Schlegel PN, Rosenwaks Z. Intracytoplasmic sperm injection (ICSI) in extreme cases of male infertility. *PLoS One*. 2014;9(12):e113671.
- Pandian Z, Gibreel A, Bhattacharya S. In vitro fertilisation for unexplained subfertility. Pandian Z, editor. *Cochrane Database Syst Rev*. Chichester: Wiley. 2012;(4):CD003357.
- Payne D, Flaherty SP, Jeffrey R, Warnes GM, Matthews CD. Successful treatment of severe male factor infertility in 100 consecutive cycles using intracytoplasmic sperm injection. *Hum Reprod*. 1994;9(11):2051–7.
- Plachot M, Belaisch-Allart J, Mayenga J-M, Chouraqui A, Tesquier L, Serkine AM. Outcome of conventional IVF and ICSI on sibling oocytes in mild male factor infertility. *Hum Reprod*. 2002;17(2):362–9.
- Qin J, Sheng X, Wang H, Liang D, Tan H, Xia J. Assisted reproductive technology and risk of congenital malformations: a meta-analysis based on cohort studies. *Arch Gynecol Obstet*. 2015;292(4):777–98.
- Ramos L, Kleingeld P, Meuleman E, van Kooy R, Kremer J, Braat D, et al. Assessment of DNA fragmentation of spermatozoa that were surgically retrieved from men with obstructive azoospermia. *Fertil Steril*. 2002;77(2):233–7.
- Robertshaw I, Khoury J, Abdallah ME, Warikoo P, Hofmann GE. The effect of paternal age on outcome in assisted reproductive technology using the ovum donation model. *Reprod Sci*. 2014;21(5):590–3.
- Romundstad LB, Opdahl S, Pinborg A. Which treatment option for couples with unexplained or mild male subfertility? *BMJ*. 2015;350:g7843.
- Ron-El R, Strassburger D, Friedler S, Komarowski D, Bern O, Soffer Y, et al. Extended sperm preparation: an alternative to testicular sperm extraction in non-obstructive azoospermia. *Hum Reprod*. 1997;12(6):1222–6.
- Roudebush WE, Toledo AA, Kort HI, Mitchell-Leef D, Elsner CW, Massey JB. Platelet-activating factor significantly enhances intrauterine insemination pregnancy rates in non-male factor infertility. *Fertil Steril*. 2004;82(1):52–6.
- Saleh A, Tan SL, Biljan MM, Tulandi T. A randomized study of the effect of 10 minutes of bed rest after intrauterine insemination. *Fertil Steril*. 2000;74(3):509–11.
- Scholten I, Custers IM, Moolenaar LM, Flierman PA, Cox T, Gianotten J, et al. Long-term follow up of couples initially randomized between immobilization and immediate mobilization subsequent to IUI. *Reprod Biomed*. 2014;29(1):125–30.
- Schoysman R, Vanderzwalmen P, Nijs M, Segal-Bertin G, van de Casseye M. Successful fertilization by testicular spermatozoa in an in-vitro fertilization programme. *Hum Reprod*. 1993;8(8):1339–40.
- Schulte RT, Ohl DA, Sigman M, Smith GD. Sperm DNA damage in male infertility: etiologies, assays, and outcomes. *J Assist Reprod Genet*. 2010;27(1):3–12.

- Schulze W, Thoms F, Knuth UA. Testicular sperm extraction: comprehensive analysis with simultaneously performed histology in 1418 biopsies from 766 subfertile men. *Hum Reprod.* 1999;14(Suppl 1):82–96.
- Setti AS, Braga DPAF, Figueira RCS, Iaconelli A, Borges E. Intracytoplasmic morphologically selected sperm injection results in improved clinical outcomes in couples with previous ICSI failures or male factor infertility: a meta-analysis. *Eur J Obstet Gynecol Reprod Biol.* 2014;183:96–103.
- Settlage DS, Motoshima M, Tredway DR. Sperm transport from the external cervical os to the fallopian tubes in women: a time and quantitation study. *Fertil Steril.* 1973;24(9):655–61.
- Sharma R, Agarwal A, Rohra VK, Assidi M, Abu-Elmagd M, Turki RF. Effects of increased paternal age on sperm quality, reproductive outcome and associated epigenetic risks to offspring. *Reprod Biol Endocrinol.* 4 ed. BioMed Central. 2015;13(1):35.
- Silber SJ, Ord T, Balmaceda J, Patrizio P, Asch RH. Congenital absence of the vas deferens. The fertilizing capacity of human epididymal sperm. *N Engl J Med.* 1990;323(26):1788–92.
- Silber S, Escudero T, Lenahan K, Abdelhadi I, Kilani Z, Munné S. Chromosomal abnormalities in embryos derived from testicular sperm extraction. *Fertil Steril.* 2003;79(1):30–8.
- Sofikitis NV, Miyagawa I, Agapitos E, Pasyianos P, Toda T, Hellstrom WJ, et al. Reproductive capacity of the nucleus of the male gamete after completion of meiosis. *J Assist Reprod Genet.* 1994;11(7):335–41.
- Sousa M, Cremades N, Silva J, Oliveira C, Ferraz L, Teixeira da Silva J, et al. Predictive value of testicular histology in secretory azoospermic subgroups and clinical outcome after microinjection of fresh and frozen-thawed sperm and spermatids. *Hum Reprod.* 2002;17(7):1800–1810.
- Souza Setti A, Ferreira RC, Paes de Almeida Ferreira Braga D, de Cassia Savio Figueira R, Iaconelli Jr A, Borges Jr E. Intracytoplasmic sperm injection outcome versus intracytoplasmic morphologically selected sperm injection outcome: a meta-analysis. *Reprod BioMed Online.* 2010;21:450–5.
- Tanaka A, Nagayoshi M, Takemoto Y, Tanaka I, Kusunoki H, Watanabe S, et al. Fourteen babies born after round spermatid injection into human oocytes. *Proc Natl Acad Sci USA.* 2015; 112(47):14629–34.
- Terada Y, Luetjens CM, Sutovsky P, Schatten G. Atypical decondensation of the sperm nucleus, delayed replication of the male genome, and sex chromosome positioning following intracytoplasmic human sperm injection (ICSI) into golden hamster eggs: does ICSI itself introduce chromosomal anomalies? *Fertil Steril.* 2000;74(3):454–60.
- Tesarik J, Mendoza C, Testart J. Viable embryos from injection of round spermatids into oocytes. *N Engl J Med.* 1995;333(8):525.
- Tesarik J, Greco E, Mendoza C. ROSI, instructions for use: 1997 update. Round spermatid injection. *Hum Reprod.* 1998;13(3):519–23.
- Testart J, Frydman R. Minimum time lapse between luteinizing hormone surge or human chorionic gonadotropin administration and follicular rupture. *Fertil Steril.* 1982;37(1):50–3.
- Tjon-Kon-Fat RI, Tjon Kon Fat AJ, Bossuyt PMM, Koks C, Oosterhuis GJE, Hoek A, et al. Is IVF-served two different ways-more cost-effective than IUI with controlled ovarian hyperstimulation? *Hum Reprod.* 2015;30(10):2331–9.
- Tournaye H. Sperm parameters, globozoospermia, necrozoospermia and ICSI outcome. In: Filicori M, editor. *Treatment of infertility: the new frontiers.* Princeton: Communications media for education; 1998. p. 259–68.
- Tournaye H. Clinical aspects of ICSI with immotile sperm. In: Hamamah S, Olivennes F, Mieuisset R, Frydman R, editors. *Male sterility and motility disorders.* New York: Springer; 1999. p. 135–40.
- Tournaye H. Update on surgical sperm recovery – the European view. *Hum Fertil (Camb).* 2010;13:242–6.
- Tournaye H, Verheyen G, Nagy P, Ubaldi F, Goossens A, Silber S, et al. Are there any predictive factors for successful testicular sperm recovery in azoospermic patients? *Hum Reprod.* 1997a; 12(1):80–6.

- Tournaye H, Verheyen G, Nagy P, Ubaldi F, Goossens A, Silber S, et al. Are there any predictive factors for successful testicular sperm recovery in azoospermic patients? *Hum Reprod.* 1997b;12(1):80–6.
- Tournaye H, Merdad T, Silber S, Joris H, Verheyen G, Devroey P, et al. No differences in outcome after intracytoplasmic sperm injection with fresh or with frozen-thawed epididymal spermatozoa. *Hum Reprod.* 1999;14(1):90–5.
- Tournaye H, Verheyen G, Albano C, Camus M, Van Landuyt L, Devroey P, Van Steirteghem A. Intracytoplasmic sperm injection versus in vitro fertilization: a randomized controlled trial and a meta-analysis of the literature. *Fertil Steril.* 2002;78:1030–7.
- Tournaye H, Goossens E, Verheyen G, Frederickx V, De Block G, Devroey P, Van Steirteghem A. Preserving the reproductive potential of men and boys with cancer: current concepts and future prospects. *Hum Reprod Update.* 2004;10:525–32.
- Tournaye H, Krausz C, Oates RD. Concepts in diagnosis and therapy for male reproductive impairment. *Lancet Diabetes Endocrinol.* 2016a;S2213–8587(16):30043–2.
- Tournaye H, Krausz C, Oates RD. Novel concepts in the aetiology of male reproductive impairment. *Lancet Diabetes Endocrinol.* 2016b;S2213–8587(16):30040–7.
- van der Westerlaken L, Helmerhorst F, Dieben S, Naaktgeboren N. Intracytoplasmic sperm injection as a treatment for unexplained total fertilization failure or low fertilization after conventional in vitro fertilization. *Fertil Steril.* 2005;83:612–7.
- Van Peperstraten A, Proctor ML, Johnson NP, Philipson G. Techniques for surgical retrieval of sperm prior to intra-cytoplasmic sperm injection (ICSI) for azoospermia. *Cochrane Database Syst Rev.* 2008;16:CD002807.
- van Rijswijk J, Caanen M, Ammi Y, Mijatovic V, Vergouw C, Lambalk C, Schats R. Should patients be immobilised after intrauterine insemination? A randomised controlled comparison between 15 min of immobilisation and direct mobilisation. *Hum Reprod.* 2016;(suppl 1):i69.
- van Rumste MME, Custers IM, van der Veen F, van Wely M, Evers JLH, Mol BWJ. The influence of the number of follicles on pregnancy rates in intrauterine insemination with ovarian stimulation: a meta-analysis. *Hum Reprod Update.* 2008;14(6):563–70.
- Van Voorhis BJ, Barnett M, Sparks AE, Syrop CH, Rosenthal G, Dawson J. Effect of the total motile sperm count on the efficacy and cost-effectiveness of intrauterine insemination and in vitro fertilization. *Fertil Steril.* 2001;75(4):661–8.
- van Weert J-M, Repping S, Van Voorhis BJ, van der Veen F, Bossuyt PMM, Mol BWJ. Performance of the postwash total motile sperm count as a predictor of pregnancy at the time of intrauterine insemination: a meta-analysis. *Fertil Steril.* 2004;82(3):612–20.
- van Weert J-M, Repping S, van der Steeg JW, Steures P, van der Veen F, Mol BWJ. IUI in male subfertility: are we able to select the proper patients? *Reprod BioMed Online.* 2005a;11(5):624–31.
- van Weert JM, Repping S, van der Steeg JW, Steures P, van der Veen F, Mol BW. IUI in male subfertility: are we able to select the proper patients? *Reprod BioMed Online.* 2005b;11:624–31.
- van Wely M, Barbey N, Meissner A, Repping S, Silber SJ. Live birth rates after MESA or TESE in men with obstructive azoospermia: is there a difference? *Hum Reprod.* 2015;30(4):761–6.
- Veltman-Verhulst SM, Hughes E, Ayeleke RO, Cohlen BJ. Intra-uterine insemination for unexplained subfertility. Veltman-Verhulst SM, editor. *Cochrane Database Syst Rev.* Chichester: Wiley. 2016;2:CD001838.
- Verberg MFG, Eijkemans MJC, Heijnen EMEW, Broekmans FJ, de Klerk C, Fauser BCJM, et al. Why do couples drop-out from IVF treatment? A prospective cohort study. *Hum Reprod.* 2008;23(9):2050–5.
- Verheyen G, Crabbé E, Joris H, Van Steirteghem A. Simple and reliable identification of the human round spermatid by inverted phase-contrast microscopy. *Hum Reprod.* 1998;13(6):1570–7.
- Verheyen G, Tournaye H, Staessen C, De Vos A, Vandervorst M, Van Steirteghem A. Controlled comparison of conventional in-vitro fertilization and intracytoplasmic sperm injection in patients with asthenozoospermia. *Hum Reprod.* 1999;14(9):2313–9.

- Verheyen G, Vernaev V, Van Landuyt L, Tournaye H, Devroey P, Van Steirteghem A. Should diagnostic testicular sperm retrieval followed by cryopreservation for later ICSI be the procedure of choice for all patients with non-obstructive azoospermia? *Hum Reprod.* 2004;19(12):2822–30.
- Vernaev V, Tournaye H, Osmanagaoglu K, Verheyen G, Van Steirteghem A, Devroey P. Intracytoplasmic sperm injection with testicular spermatozoa is less successful in men with nonobstructive azoospermia than in men with obstructive azoospermia. *Fertil Steril.* 2003;79(3):529–33.
- Vernaev V, Verheyen G, Goossens A, Van Steirteghem A, Devroey P, Tournaye H. How successful is repeat testicular sperm extraction in patients with azoospermia? *Hum Reprod.* 2006;21(6):1551–4.
- Vloeberghs V, Verheyen G, Tournaye H. Intracytoplasmic spermatid injection and in vitro maturation: fact or fiction? *Clinics (Sao Paulo).* 2013;68(Suppl 1):151–6.
- Vloeberghs V, Verheyen G, Haentjens P, Goossens A, Polyzos NP, Tournaye H. How successful is TESE-ICSI in couples with non-obstructive azoospermia? *Hum Reprod.* 2015;30(8):1790–6.
- Wainer R, Albert M, Dorion A, Bailly M, Bergère M, Lombroso R, et al. Influence of the number of motile spermatozoa inseminated and of their morphology on the success of intrauterine insemination. *Hum Reprod.* 2004;19(9):2060–5.
- Wen J, Jiang J, Ding C, Dai J, Liu Y, Xia Y, et al. Birth defects in children conceived by in vitro fertilization and intracytoplasmic sperm injection: a meta-analysis. *Fertil Steril.* 2012;97(6):1331–7. e1–4.
- Wennerholm WB. Cryopreservation of embryos and oocytes: obstetric outcome and health in children. *Hum Reprod.* 2000;15(Suppl 5):18–25.
- Wennerholm UB, Bergh C, Hamberger L, Westlander G, Wikland M, Wood M. Obstetric outcome of pregnancies following ICSI, classified according to sperm origin and quality. *Hum Reprod.* 2000;15:1189–94.
- Woldringh GH, Horvers M, Janssen AJWM, Reuser JJCM, de Groot SAF, Steiner K, et al. Follow-up of children born after ICSI with epididymal spermatozoa. *Hum Reprod.* 2011;26(7):1759–67.
- World Health Organization. Laboratory manual for the examination of human semen and semen-cervical mucus interaction. 5th ed. New York: Cambridge University Press; 2010. p. 287.
- WuY, KangX, ZhengH, LiuH, HuangQ, LiuJ. Effect of paternal age on reproductive outcomes of intracytoplasmic sperm injection. Drevet JR, editor. *PLoS One.* Public Library of Science. 2016;11(2):e0149867.
- Xu B, Niu X, Wang Z, Li P, Qin C, Li J, et al. Novel methods for the diagnosis and treatment of ejaculatory duct obstruction. *BJU Int.* 2011;108(2):263–6.
- Zavos A, Daponte A, Garas A, Verykoui C, Papanikolaou E, Anifandis G, et al. Double versus single homologous intrauterine insemination for male factor infertility: a systematic review and meta-analysis. *Asian J Androl.* 2013;15(4):533–8.
- Zini A, Jamal W, Cowan L, Al-Hathal N. Is sperm DNA damage associated with IVF embryo quality? A systematic review. *J Assist Reprod Genet.* 2011;28(5):391–7.
- Zreik TG, García-Velasco JA, Habboosh MS, Olive DL, Arici A. Prospective, randomized, crossover study to evaluate the benefit of human chorionic gonadotropin-timed versus urinary luteinizing hormone-timed intrauterine inseminations in clomiphene citrate-stimulated treatment cycles. *Fertil Steril.* 1999;71(6):1070–4.

Davide Oreggia, Eugenio Ventimiglia, and Andrea Salonia

---

## Abstract

In the scenario of medically assisted reproduction, sperm retrieval techniques (SRTs) represent a concrete possibility to find, freeze, and use spermatozoa in men with a diagnosis of azoospermia. Therefore, many infertile couples because of a severe male factor can achieve a biological offspring.

Nowadays the surgical overview in this field has a number of available techniques according to the causal and baseline condition. These stretch from the percutaneous approach to the latest and more sophisticated microsurgical dissection techniques aimed at increasing surgical specificity and eventually the sperm retrieval rate in individuals with nonobstructive azoospermia. In this context, the careful and complete diagnostic classification of every patient (obstructive vs. nonobstructive azoospermia) is essential in the choice of the surgical approach (percutaneous vs. open) and the anatomical site of acquisition (epididymis vs. testis), as well as in the prediction of the sperm retrieval successful rate.

Although can be considered day-surgery procedures, SRTs are clearly not free from potential sequelae and complications; therefore, it is clinically relevant to have an appropriate surgical indication, a thorough information of the patient and a meticulous perioperative management.

---

## Keywords

Azoospermia • MESA • Sperm retrieval • TESE

---

D. Oreggia • E. Ventimiglia • A. Salonia (✉)  
University Vita-Salute San Raffaele, Milan, Italy

Division of Experimental Oncology/Unit of Urology, URI-Urological Research Institute, IRCCS  
Ospedale San Raffaele, Milan, Italy  
e-mail: [salonia.andrea@hsr.it](mailto:salonia.andrea@hsr.it)



## Contents

Introduction .....	1178
Patient Management Before Surgery .....	1179
Surgical Techniques .....	1181
Percutaneous Sperm Retrieval Methods .....	1182
Conventional Open Sperm Retrieval Methods .....	1184
Microsurgical Sperm Retrieval Methods .....	1185
Anesthesiological Aspects .....	1186
Sperm Retrieval Rates .....	1189
Patient Management After Surgery .....	1192
Complications .....	1192
References .....	1194

## Introduction

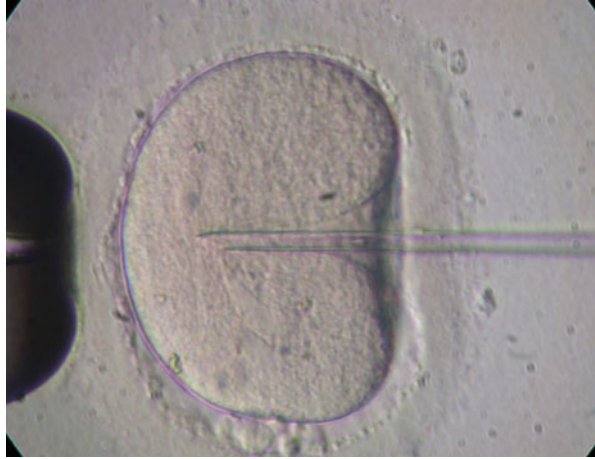
The desire of a biological offspring in couples with azoospermic male partners encouraged the achievement of unbelievable goals within the last decades (Esteves et al. 2013a, b). Temple-Smith et al. described in 1985 the first pregnancy resulting from in vitro fertilization (IVF) using spermatozoa retrieved by microepididymal sperm aspiration (MESA) even though fertilization rate was low (Temple-Smith et al. 1985; Gorgy et al. 1998). In 1992, Palermo et al. introduced the intracytoplasmic sperm injection (ICSI) as a promising assisted reproductive technique (ART) addressed to women for whom standard in vitro fertilization (IVF) or subzonal insemination (SUZI) of oocytes failed (Palermo et al. 1992; Silber et al. 1994).

In ICSI, a single spermatozoon is injected centrally into the cytoplasm of the oocyte using a fine sharp-tipped glass pipette. In the hands of skilled biologists with expertise in the field of embryology, the procedure consists of two essential components that are completed within 2–4 min per oocyte. Firstly, a selected sperm is stunned by one of several commonly used techniques such as rubbing the tail with the injection pipette or abruptly aspirating the sperm into the pipette. The sperm is aspirated from the tail first into the injection pipette and positioned at 3 o'clock near the oocyte. A suction pipette stabilizes the oocyte with the polar body at either the 6 o'clock or 12 o'clock position as the pipette is inserted. Secondly, the cytoplasm is drawn up into the pipette to ensure the cytoplasmic membrane is broken, thus allowing successful insertion of the sperm. The pipette is subsequently withdrawn from the egg (Van Rumste et al. 2003) (Fig. 1).

In case of conventional IVF, one oocyte is instead inseminated with approximately 50,000 spermatozoa (Van Rumste et al. 2003).

Several studies showed that ICSI resulted in a significantly higher fertilization rate when compared to standard IVF (Esteves et al. 2013a, b; Silber et al. 1994), and it has supplanted *de facto* all prior assisted fertilization techniques. ICSI has been responsible as for now for the birth of over two million babies worldwide and provided the possibility for men with impaired spermatozoa to achieve their biological fatherhood dream (Van Rumste et al. 2003).

**Fig. 1** In intracytoplasmic sperm injection (ICSI), a single spermatozoon is injected centrally into the cytoplasm of the oocyte using a fine sharp-tipped glass pipette



The possibility to extend ICSI to men with azoospermia was achieved in 1994 when Craft and Shrivastav first described a percutaneous approach to retrieve sperm from the epididymis (PESA) (Craft and Shrivastav 1994); thereafter, Lewin et al. showed sperm retrieval from testis using a fine needle (TESA) in 1996 (Lewin et al. 1996). The study by Janzen et al. (2000) published in 2000 can be considered a further cornerstone in this context. Until then, several works reported lower pregnancy rates in IVF/ICSI using cryopreserved epididymal sperm as compared with freshly retrieved sperm. Jansen decided to directly evaluate only couples who underwent IVF/ICSI for the first time, comparing those who used cryopreserved spermatozoa with those who used freshly retrieved epididymal sperm. A possible explanation for the lower pregnancy rates achieved in previous studies was in fact the inclusion of couples who had already failed an IVF/ICSI. The study found out similar fertilization and pregnancy rates in the two groups legitimizing the use of cryopreserved spermatozoa. The advantages of this method were consequently the solution of logistic real-life problems related to the use of fresh sperm and the possibility to store in abundance high-quality sperm retrieved from a single procedure for all future attempts at IVF/ICSI. In the rare case of nonviable sperm available after thawing, a fresh retrieval would obviously be necessary (Janzen et al. 2000).

---

## Patient Management Before Surgery

Although azoospermia is classically divided into obstructive (OA) and non-obstructive (NOA) (Tournaye et al. 2016a; EAU Guidelines on Male Infertility 2016) and this categorization is often used to determine the probability of retrieval, limited data available allow us to adequately counsel couples on the success rate of sperm retrieval (Bromage et al. 2007). Obstructive azoospermia and NOA can be, indeed, confidently diagnosed only with testicular histology, where OA is associated with normal spermatogenesis and NOA with different degrees of impaired

spermatogenesis up to the complete absence of germ line cells (Bromage et al. 2007; Donoso et al. 2007). Nevertheless, in clinical practice, testicular biopsy is rarely performed prior to sperm retrieval because it is an invasive procedure that may cause damage to the testis, and the cost implication is similar to that of a negative TESE (Bromage et al. 2007). Therefore, excluding cases in which an obstructive cause is clear (e.g., previous vasectomy), much caution is necessary during the counseling when a presumed diagnosis of OA or NOA is made without histology, and it is based on the presence or absence of clinical features associated to obstruction (Bromage et al. 2007). Accepting that the terms OA and NOA cannot be properly used before the histological exam (Donoso et al. 2007), many authors focused on the possibility of using clinical data (e.g., physical exam, hormones levels, ultrasound findings) in order to predict the origin of azoospermia and, as a consequence, the eventual success of sperm retrieval (Bromage et al. 2007; Donoso et al. 2007; Carpi et al. 2009).

The typical clinical setting for men with OA includes normal testicular palpation, normal ultrasound findings, normal serum follicle-stimulating hormone (FSH) and inhibin levels; apart from this, a reduced volume of seminal plasma and a lower pH are also possible clinical findings. FSH, in particular, reflects testicular volume and germ cell content, that are, by definition, not impaired in patients with OA (Bromage et al. 2007; Donoso et al. 2007; Ramasamy et al. 2009a). Enlarged and hardened epididymal segments or missing vasa deferentia, such as in the congenital bilateral absence of the vas deferens (CBAVD), are furthermore considered pathognomonic features of OA (EAU Guidelines on Male Infertility 2016). Although epididymal distension has been commonly associated with obstruction, and, therefore, with a high success sperm retrieval rate (Esteves et al. 2013b), an interesting study by Bromage et al. (2007) showed that only 71% of patients analyzed with a clinical epididymal distention had successful sperm retrieval. Therefore, in clinical practice, epididymal distention is a poor clinical sign of obstruction and can be misleading (Bromage et al. 2007). In any event, it is important to identify the etiology of azoospermia in obstructive cases, not only for the high success in retrieval rate, but mainly to identify patients (e.g., those with CBAVD) that would be suitable primarily for surgical reconstruction from those who, conversely, can/must be directly addressed to a sperm retrieval techniques (SRT) (EAU Guidelines on Male Infertility 2016; Wosnitzer et al. 2014; Miyamoto et al. 2015; Tournaye et al. 2016b).

As said, FSH concentration has been shown to be inversely proportional to the spermatogonial population (EAU Guidelines on Male Infertility 2016; Ramasamy et al. 2009a; Wosnitzer et al. 2014; Miyamoto et al. 2015; Tournaye et al. 2016b). Vice versa, inhibin B has been found to be decreased in patients with azoospermia (namely, NOA) and elevated FSH levels, and it has been postulated that the decrease of the former hormone is responsible for the rise of the latter (Bromage et al. 2007). Along with increased FSH levels, decreased testicular volume is usually associated with maturation arrest and testicular failure (Bromage et al. 2007). It is not surprising therefore that reduced testicular long axis testicular ( $\leq 4.6$  cm), reduced testicular volume ( $< 5$  mL), loss of testicular resilience on palpation, abnormal ultrasound

patterns, increased FSH ( $\geq 7.6$  IU/L), and reduced inhibin B levels have been typically associated with NOA and with a poorer sperm retrieval success rate (Carpi et al. 2009). Several reports reviewed the retrieval success as a function of testicular volume and serum FSH. In particular sperm retrieval success rate is generally considered poor in male with FSH  $> 20$  IU/L or in patients with bi-testicular volume  $< 8$  mL and FSH  $> 10$  IU/L (EAU Guidelines on Male Infertility 2016; Carpi et al. 2009). According to the European Association of Urology (EAU) guidelines, however, high FSH levels and reduced testicular volume do not exclude patients from sperm retrieval procedures (EAU Guidelines on Male Infertility 2016). Different studies show indeed good retrieval rates in patients with high FSH level and small testicles (e.g., 26 IU/L and 5 mL, respectively) (Carpi et al. 2002, 2009; Ramasamy et al. 2009a; Tsujimura et al. 2004; Devroey et al. 1995). For instance, Schiff et al. reported a sperm retrieval rate of 72% per TESE attempt in a cohort of 42 men with Klinefelter syndrome and a mean FSH level of 33.2 IU/L (Schiff et al. 2005). At the same time, normal FSH level and testicular volume can be found in patients with complete maturation arrest and a negative surgical sperm retrieval (Carpi et al. 2009; Tsujimura et al. 2004; Martin-du-Pan and Bischof 1995; Saccà et al. 2016).

While in oncologic urology nomograms have become valuable for the assessment of patients information, we still lack similar sets of data in the field of male infertility. In this context, all the candidate markers for spermatogenesis have proven imperfect (Ramasamy et al. 2009a). In particular, to predict successful sperm retrieval at TESE, Ezeh et al. (1999) evaluated several parameters such as age, body mass index, different hormone levels, testicular volume, and Johnsen score of testicular biopsy histology. The latter score ranges from 1 to 10, where seminiferous tubules without any cells score as 1 and seminiferous tubules with  $\geq 5$  spermatozoa score as 10. Overall, testicular histology confirmed to be the best (and effective) predictor of either a successful or unsuccessful sperm retrieval at TESE (Carpi et al. 2009; Tournaye et al. 2016b; Saccà et al. 2016; Caroppo et al. 2017).

---

## Surgical Techniques

Sperm retrieval techniques can be divided according to the anatomical site of acquisition (epididymis vs. testis) and to the type of surgical approach (percutaneous vs. open). Moreover, open surgery can be divided into a conventional approach and microsurgical techniques (Table 1).

In almost all OA cases, spermatozoa can be retrieved from the epididymis or the testicles, irrespectively of the technique used or the cause of obstruction. Conversely, men with NOA have no treatment option other than attempting testicular sperm retrieval (conventional TESE or micro-TESE) (EAU Guidelines on Male Infertility 2016; Tournaye et al. 2016b; Saccà et al. 2016; Ramasamy et al. 2005). Despite the technique used, sperm retrieval methods share common goals such as the acquisition of an adequate number of sperm (for immediate use and/or cryopreservation), the retrieval of the highest quality sperm, and the reduction of damage to the

**Table 1** Sperm retrieval techniques and their indications

Technique		Acronym	Indications
Percutaneous techniques	Percutaneous epididymal sperm aspiration	PESA	OA cases only
	Testicular sperm aspiration	TESA/ TEFNA	Failed PESA in OA CAVD cases Favorable testicular histopathology <sup>a</sup> in NOA cases Previous successful TESA/ TEFNA attempt in NOA cases
Conventional open techniques	Open epididymal fine-needle aspiration		OA cases only
	Testicular sperm extraction	TESE	Failed PESA and TESA in OA NOA cases
Microsurgical techniques	Microsurgical epididymal sperm aspiration	MESA	OA cases only
	Microsurgical testicular sperm extraction	Micro- TESE	NOA cases

OA obstructive azoospermia, TEFNA testicular fine-needle aspiration, NOA nonobstructive azoospermia, CAVD congenital absence of the vas deferens

<sup>a</sup>Hypospermatogenesis

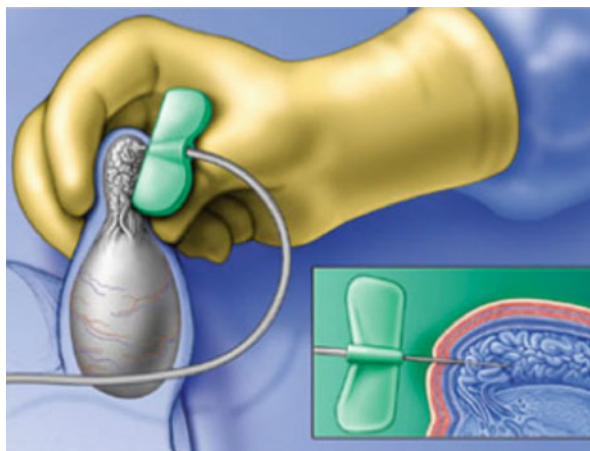
reproductive tract, in order to preserve testicular function and the option of future retrieval attempts (Esteves et al. 2013a; EAU Guidelines on Male Infertility 2016; Donoso et al. 2007; Ramasamy et al. 2005).

Before analyzing the specific techniques, it is compulsory to remember some common general aspects for SRTs. In clinical terms, aspirin and/or nonsteroidal drugs (FANS) should be avoided for at least 1 week before surgery in order to reduce the risk of bleeding during or after the procedure. Anticoagulant agents should also be discontinued during the perioperative period. As for all surgical procedures, all patients must sign a proper informed consent prior to surgery (Esteves et al. 2013a; EAU Guidelines on Male Infertility 2016). Scrotal shaving is required for open techniques, while it is optional for the percutaneous approach. Either local or loco-regional anesthesia is generally performed with or without intravenous sedation (see the separate section below). Once in the operating room, the patient should be positioned on the operating table in a supine position and skin should be cleaned from mid-abdomen to mid-thigh using a povidone-iodine or similar solution.

## Percutaneous Sperm Retrieval Methods

As mentioned before, percutaneous approaches can be used both for the epididymis and the testis, with either diagnostic or therapeutic intent. These techniques share the use of a needle that is blindly insert through the skin in order to obtain sperm. Fresh sperm retrieved can be used for ICSI or cryopreserved. These techniques are

**Fig. 2** Percutaneous Epididymal Sperm Aspiration (PESA). A needle (generally 26 G) attached to a tuberculin syringe is blindly inserted through the skin into the epididymis itself



generally performed under local anesthesia alone or in association with intravenous sedation (Carpi et al. 2002). Percutaneous epididymal sperm aspiration (PESA) is recommended only in obstructive OA cases, where epididymal fluid collected can contain sperm (Esteves 2015; Jensen et al. 2016). In testicular sperm aspiration (TESA), the seminiferous tubules and their contents are removed; thus, this technique can be offered to OA cases but also for selected NOA patients (Esteves et al. 2013b; EAU Guidelines on Male Infertility 2016).

### **Percutaneous Epididymal Sperm Aspiration (PESA)**

This approach was first described by Craft and Shrivastav (1994). The epididymis is stabilized between the index finger, thumb, and forefinger. A needle (generally 26 G) attached to a tuberculin syringe is blindly inserted through the skin into the epididymis itself (Fig. 2). A negative pressure is created by pulling the syringe plunger and the needle is gently moved in and out inside the epididymis until the fluid is aspirated into a tube containing sperm medium. If needed, PESA can be repeated at a different site (EAU Guidelines on Male Infertility 2016; Jensen et al. 2016). Poor-quality senescent sperm are often retrieved from the caudal portion of epididymis; therefore, PESA is generally first performed from the corpus and then, if necessary, repeated from the caput in the same operative session (Esteves et al. 2013b).

### **Testicular Sperm Aspiration (TESA) and Testicular Fine-Needle Aspiration (TEFNA)**

Both of these techniques involve the insertion of a needle through the scrotal skin into the testis. A 20/22 gauge needle is generally used for TESA, while a finer 18/19-gauge needle is used for TEFNA. The needle attached to a syringe is usually insert at the anteromedial or anterolateral portion of the superior testicular pole in an oblique angle towards the medium and lower poles. These areas are least likely to contain major branches of the testicular artery running superficially underneath tunica albuginea. After insertion, a negative pressure is created by pulling the syringe

plunger and the needle is gently moved in and out in the testis to disrupt seminiferous tubules and to sample different areas. The procedure can be safely performed under local anesthesia, causing less damage to subtunical blood vessels than unilocular or multilocular open procedures. The use of ultrasound-guided testicular sperm aspiration for visualization of the major vessels, to avoid postaspiration subtunical testicular bleeding, has not gained widespread acceptance (EAU Guidelines on Male Infertility 2016; Donoso et al. 2007; Jensen et al. 2016; Lewin et al. 1999). If insufficient or no sperm is obtained, TESA (and/or TESE) can be performed in the contralateral testis (Esteves et al. 2013b; EAU Guidelines on Male Infertility 2016; Donoso et al. 2007; Lewin et al. 1999).

## **Conventional Open Sperm Retrieval Methods**

Conventional open sperm retrieval techniques can be used for both epididymal and testicular sperm collection. To approach either the epididymis or the testis, a cut in the scrotum layers is performed. The exteriorization of the whole testis out of the scrotum is optional and the procedure can be carried out just using a “window” technique. Local anesthesia with or without intravenous sedation or epidural anesthesia is performed. Like in percutaneous approach, open epididymal aspiration is typical of OA, while testicular sperm retrieval can be used both for OA and selected NOA cases (Esteves et al. 2013b; EAU Guidelines on Male Infertility 2016; Sacca et al. 2016).

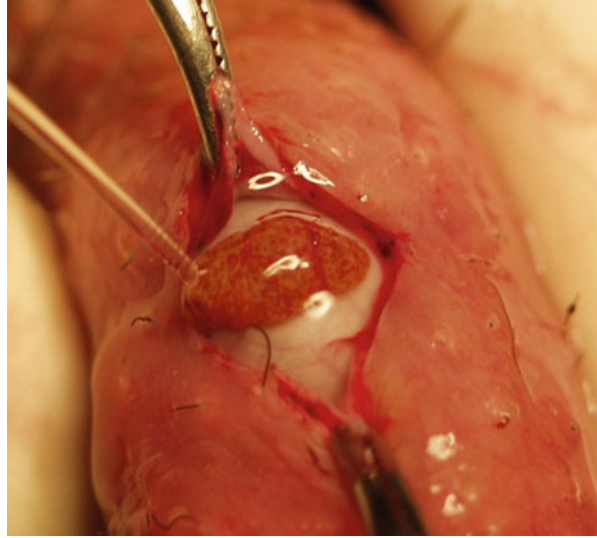
### **Open Epididymal Fine-Needle Aspiration**

This technique requires few instruments and material but is not validated in large series of patients. Epididymis is exposed and directly punctured, but not opened, and the fluid is collected with a 26 G needle. The fluid that continues to flow out of the punctured tubule must be aspirated, too. Different locations of the epididymis can be used in the same session in order to collect a sufficient number of spermatozoa (Esteves et al. 2013b).


### **Testicular Sperm Extraction (TESE)**

Described for the first time in 1995 (Devroey et al. 1995), conventional TESE is a standard open surgical biopsy technique performed without the use of microscope. A 2-cm transverse incision is made on the anterior scrotal skin, dartos, and tunica vaginalis. A 1-cm incision is made in the albuginea and a gentle pressure on the testis is applied in order to aid the extrusion of testicular parenchyma (Fig. 3). With sharp scissor, a 5 × 5 mm fragment of parenchyma is collected and placed in sperm culture media. This procedure can be repeated and other specimen can be collected from the same incision. Other cuts into the tunica albuginea can indeed be performed in order to obtain specimen from the upper, the middle, and the lower testicular poles. Albuginea is then sutured with a running suture. With increased numbers of incisions, as well as bilateral procedure, chances increase in retrieving sperm, especially in NOA, but the exact number of incision needed is still under debate (Esteves et al.

**Fig. 3** Testicular Sperm Extraction (*TESE*). A 2-cm transverse incision is made on the anterior scrotal skin, dartos and tunica vaginalis. A 1-cm incision is made in the albuginea and a gentle pressure on the testis is applied in order to aid the extrusion of testicular parenchyma (Picture courtesy by Prof. Giorgio Franco, Rome, Italy)



**Fig. 4** Multibiopsy Testicular Sperm Extraction. With increased numbers of incisions, as well as bilateral procedure, chances increase in retrieving sperm, especially in NOA, but the exact number of incision needed is still under debate



2013b; EAU Guidelines on Male Infertility 2016; Saccà et al. 2016; Ramasamy et al. 2005; Fasouliotis et al. 2002; Turek et al. 1999) (Fig. 4).

## Microsurgical Sperm Retrieval Methods

Microsurgical SRTs are open surgical techniques involving a microscope for optical magnification. This group includes sperm acquisition methods applied for epididymal and testicular retrievals. The first types are indicated for OA cases, whereas the second to the most severe NOA cases. The use of optical magnification allows the surgeon to better and more specifically identify larger and potentially more sperm-rich tubules in order to increase the success rate of sperm retrieval. This group includes Microsurgical Epididymal Sperm Aspiration (MESA) and Microsurgical



Testicular Sperm Extraction (micro-TESE) (Esteves et al. 2013b; EAU Guidelines on Male Infertility 2016; Shin and Turek 2013). Unlike conventional open surgical methods, these techniques require the exteriorization of the whole testis from the scrotum during the procedure. Either local anesthesia and intravenous sedation are generally performed.

### **Microsurgical Epididymal Sperm Aspiration (MESA)**

The goal of the technique, first described by Temple-Smith et al. (1985), is to identify and aspirate sperm-rich, red blood cell-free fluid that can be used for fresh sperm injection with ICSI or cryopreservation. A 2- to 3-cm transversal scrotal incision is usually made. Both dartos and tunica vaginalis are also opened, and the testis is delivered out of the scrotum. Epididymal tunica is incised and an enlarged tubule is selected and opened with sharp microsurgical scissors. The fluid that flows out is immediately aspirated with a silicone tube attached to a tuberculin syringe and placed into a dedicated sperm medium. If needed, MESA can be repeated in different points of the epididymis, with the same direction cauda-caput described for the percutaneous approach; likewise, it can be performed on the contralateral epididymis until an adequate number of motile sperm is eventually retrieved. Both TESA and TESE can be performed during the same operation if required (Esteves et al. 2013b; EAU Guidelines on Male Infertility 2016; Shin and Turek 2013).

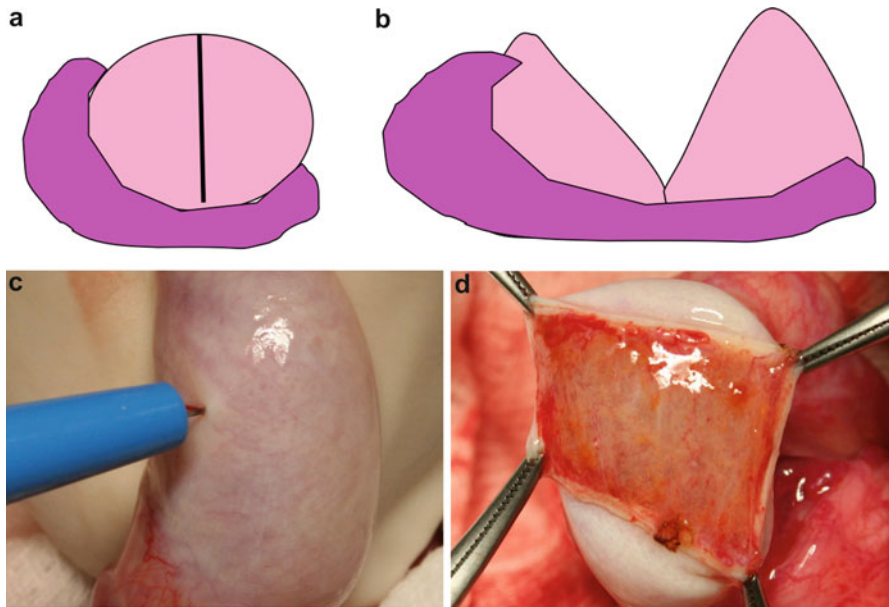
### **Microsurgical Testicular Sperm Extraction (Microdissection TESE)**

First described by Schlegel (1999), micro-TESE is the successful combination of testicular sperm extraction with the assistance of an operating microscope. As described for MESA, a 2- to 3-cm incision of scrotum skin, dartos, and tunica vaginalis is performed and the testis is delivered out. Tunica albuginea is analyzed with the microscope at  $\times 12$ – $\times 18$  magnification (up to  $\times 32$ ) and a single, large, mid-portion near-circumferential incision is made in an avascular area to preserve arteriolar branches and limiting parenchymal damage (Shin and Turek 2013; Schlegel 1999) (Fig. 5). The testicular parenchyma is then exposed and analyzed until larger tubules are found; in this regard, tubules of larger diameter more likely contain germ cells and normal sperm production (Fig. 6). These tubules are isolated and excised with microsurgical forceps. If no larger tubules are found, random specimens are taken. Each sample is immediately analyzed in the laboratory and, if no spermatozoa are identified, more samples from the same testis and/or from the contralateral side are taken (Esteves et al. 2013b; EAU Guidelines on Male Infertility 2016; Ramasamy et al. 2005; Shin and Turek 2013; Schlegel 1999).

---

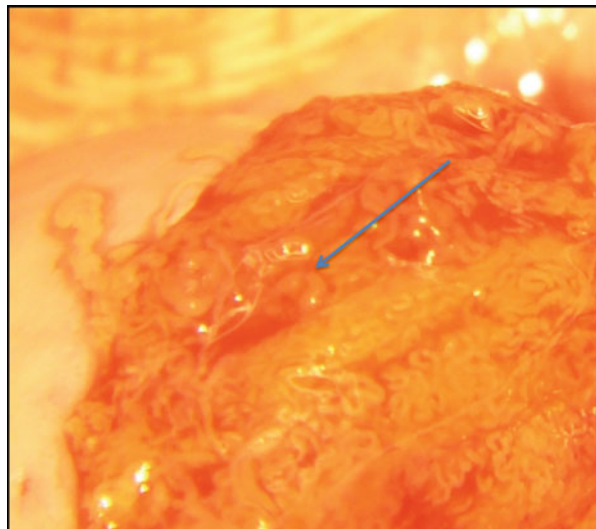
## **Anesthesiological Aspects**

Sperm retrieval approaches are generally considered day-surgery procedures. The discharge of the patient a few hours after surgery entails several anesthesiological aspects in order to combine the right control of perioperative pain with the reduction of postoperative side effect that anesthesia itself may cause.



**Fig. 5** (a–d) Microsurgical Testicular Sperm Extraction (microdissection TESE). Tunica albuginea is analyzed with the microscope at  $\times 12$ – $\times 18$  magnification (up to  $\times 32$ ) and a single, large, mid-portion near-circumferential incision is made in an avascular area to preserve arteriolar branches and limiting parenchymal damage

**Fig. 6** Microsurgical Testicular Sperm Extraction (microdissection TESE). The testicular parenchyma is then exposed and analyzed until larger tubules are found in this regard, tubules of larger diameter more likely contain germ cells and normal sperm production (Picture courtesy by Prof. Giorgio Franco, Rome, Italy)



As far as concern the anatomical aspect, it is possible to obtain a good control of pain just using local or loco-regional anesthesia. On the other side, a condition of general anxiety is frequently generated by the procedure itself, considering the delicate part of the male body involved and the high expectations in patients undergoing this kind of surgery (Esteves et al. 2013a). Overall, if general anesthesia can achieve a good management of anxiety, N<sub>2</sub>O and halogenated agents used to perform this type of anesthesia can cause unpleasant postoperative side effects such as nausea and vomiting, two of the main fears of patients. This aspect is associated with the inability to discharge patients a few hours after the surgical procedure. Therefore, the use of propofol (2,6 diisopropylphenol) can reduce postoperative complaints due to its antiemetic effects. Moreover, propofol causes gentle awakening and patients refer a feeling of well-being and clear mental state (Esteves et al. 2013a; Shin and Turek 2013). Although performed with propofol, general anesthesia implicates by itself a longer recovery time when compared with the simpler intravenous sedation. This last option can benefit from the satisfying effects of propofol, too. The combination of local anesthesia and intravenous sedation can offers the benefits of a good pain control given from local anesthetics with comfort, anxiety control, and minimal side effects given from intravenous sedation with propofol (Esteves et al. 2013a).

Current scientific literature scarcely analyzed the role of anesthesia techniques during SRTs procedures (Esteves et al. 2013a). In 1998, Gorgy et al. analyzed 37 men submitted to PESA and/or TESA (Gorgy et al. 1998). The procedures were performed with local anesthesia obtained with 10 mL of 1% lidocaine injected along the sides of the vas deferens near to the external inguinal rings (spermatic cord block). Of 37 procedures, 29 patients felt no pain or discomfort, six experienced moderate but tolerable pain, and two actually required intravenous sedation to obtain a good analgesia. Focusing on anxiety, 24 patients felt relaxed, while 13 felt anxious. Therefore, local anesthesia was adequate for a large proportion of patients undergoing PESA and/or TESA, but more than a third of patients could have benefited from co-administration of loco-regional anesthesia and intravenous sedation (Gorgy et al. 1998).

Similarly, Nudell et al. focused on 26 patients undergoing MESA (Nudell et al. 1998). Of all, 38% of patients tolerated the procedure only with local anesthesia (5–8 mL of 1% lidocaine); conversely, the remaining 62% of subjects required a low-dose of intravenous sedation in addition to local lidocaine. The percentage of men requiring intravenous sedation raised up to 75% considering men who underwent a bilateral procedure (Nudell et al. 1998).

If pain control and anxiety reduction are evident features concerning anesthesia, a recent study by Ali Jorsaraei et al. analyzed the effects of general and local anesthesia on the quality of sperm retrieved (Ali Jorsaraei et al. 2016). The authors compared several parameters of retrieved spermatozoa within different hours after testicle biopsy in patients who underwent either general or local anesthesia. General anesthesia was premedicated with fentanyl and midazolam, then induced and maintained with propofol, while local anesthesia was achieved with 10 mL of 2% plain lidocaine injected into a testicular cord. In particular, the study analyzed sperm

concentration, motility, and morphology immediately after processing, 1 and 2 h later. No statistically significant differences were found between the two groups; therefore, the authors concluded that the type of anesthesia did not impact over the quality of retrieved sperm (Ali Jorsaraei et al. 2016).

---

## Sperm Retrieval Rates

Obstructive azoospermia is considered one of the most favorable prognostic conditions for male infertility since spermatogenesis is not disrupted, unlike in NOA patients (Esteves et al. 2013b). Success rates in OA, regardless the technique used, range from 90% to 100% (Esteves et al. 2013a; EAU Guidelines on Male Infertility 2016; Donoso et al. 2007; Saccà et al. 2016; Shin and Turek 2013; Amer et al. 2000; Okada et al. 2002). A study by Esteves et al. in 2013 reported a cumulative success retrieval rate of 97.3% and the result did not differ among CBAVD, vasectomy, and postinfection groups (Esteves et al. 2013b). Epididymal sperm retrievals alone (e.g., PESA) were successful in 78.0% of the cases, and subsequent attempts at testicular retrieval (e.g., TESA) were successful in the vast majority of failed retrievals from the epididymis (Esteves et al. 2013b). More in details, published results indicated that PESA was sufficient for sperm retrieval in CBAVD cases and TESA was required in about a third of the cases in the other etiology groups, thus suggesting that the damage of epididymis can be severe in cases of vasectomy and in post-infection disease (Esteves et al. 2013b). Overall, the complication rate for percutaneous techniques amounted to 5.5% and, albeit of minimal morbidity, occurred more often in patients undergoing TESA compared with those undergoing PESA (Esteves et al. 2013a). Therefore, percutaneous methods could be suggested as preferable approaches in OA cases, in particular PESA over TESA (Esteves et al. 2013a; Shin and Turek 2013). Nevertheless, also microsurgical methods share with percutaneous techniques a very high success rate in OA cases (EAU Guidelines on Male Infertility 2016; Shin and Turek 2013). Therefore, the choice of sperm retrieval by either percutaneous or open surgery from either the testis or epididymis should be based upon local preferences and expertise since there is no evidence that site or method of sperm retrieval affects outcome of ICSI for patients with OA (EAU Guidelines on Male Infertility 2016; Shin and Turek 2013).

As far as concerns NOA, the overall successful retrieval rate (SRR), according to different studies, ranges from 30% to 50% when all etiologies are considered (i.e., cryptorchidism, orchitis, genetic abnormalities and variants, radio/chemotherapy gonadal toxicity, and idiopathic infertility) (EAU Guidelines on Male Infertility 2016; Tournaye et al. 2016b; Shin and Turek 2013; Takeda et al. 2017; Mascarenhas et al. 2016). Recently, Cissen et al. (2016) reported the findings of a retrospective nationwide cohort study with data from 1,371 TESE procedures collected between June 2007 and June 2015 in two fertility centers. The authors developed a prediction model, built after multivariate logistic regression analysis, which demonstrated that higher levels of serum testosterone and lower levels of FSH and LH were predictive for successful sperm retrieval. Diagnosis of idiopathic NOA and the presence of an

Azoospermia Factor (AZF) c gene deletion were predictive for unsuccessful sperm retrieval (Cissen et al. 2016).

As a whole, the role of FSH and inhibin B levels as predictors of SRR has been already discussed. FSH is classically considered as a marker of testicular reserve, reflecting the global spermatogenic function. The large retrospective study by Ramasamy et al. (2009a) demonstrated that chances for sperm retrieval are common for NOA men with elevated FSH than for those with lower FSH; therefore, hormonal levels are not predictive of SRR in the real-life setting (Deruyver et al. 2014). A recent meta-analysis investigated inhibin B as a noninvasive marker of active spermatogenesis; in this context, inhibin B proved as the most predictive biomarker of presence of spermatozoa, because of its high level of specificity and sensibility, although its predictive capacity was not enough to be considered as the sole independent marker of spermatogenesis. Therefore, it is still not possible to predict the SRR in NOA patients on the basis of simple noninvasive parameters (EAU Guidelines on Male Infertility 2016; Carpi et al. 2009; Saccà et al. 2016; Shin and Turek 2013; Cissen et al. 2016). As a consequence, testicular histology remains the strongest predictor of positive SRR (Saccà et al. 2016; Caroppo et al. 2017), even if testicular biopsy is not performed any longer in clinical practice before a surgical sperm retrieval approach. Retrieval rates show a significant decrease along with the decline in terms of quality of testicular histopathology; moreover, a strong positive correlation between the presence of Johnsen score  $\geq 8$  tubules and spermatozoa retrieval has been clearly demonstrated (Saccà et al. 2016; Abdel Raheem et al. 2013). Thereof, SRR are approximately 85% in men with hypospermatogenesis, but only 6–25% in unfortunate patterns as germinal aplasia (Esteves et al. 2011).

The efficacy of SRR in NOA varies depending on the method of sperm collection (EAU Guidelines on Male Infertility 2016; Shin and Turek 2013; Esteves et al. 2011). TESA retrieval rates range from 10% to 30% except in favorable cases of previous successful TESA or testicular histopathology showing hypospermatogenesis. In those cases, TESA SRR rise up from 70% to 100% (Abdel Raheem et al. 2013). A meta-analysis by Donoso et al. in 2007 reported that SRR for conventional-TESE (c-TESE) was 49.5% (95% CI 49.0–49.9) (Donoso et al. 2007). Moreover, c-TESE with multiple biopsies resulted in higher SRR than TEFNA (a variation of TESA) especially in cases of Sertoli-cell-only (SCOS) and maturation arrest (Donoso et al. 2007; Abdel Raheem et al. 2013). Also c-TESE with multiple biopsies has a significantly higher SRR when compared with a single c-TESE (mainly in MA and SCOS), although the most appropriate number of samples still remains controversial (EAU Guidelines on Male Infertility 2016; Donoso et al. 2007; Saccà et al. 2016; Shin and Turek 2013; Abdel Raheem et al. 2013). The success rate for micro-TESE has been reported to range between 35% and 77%; therefore, the current evidence suggests that micro-TESE performs better than either c-TESE or TESA, especially in poor histological findings (e.g., SCOS) (Esteves et al. 2013b; EAU Guidelines on Male Infertility 2016; Saccà et al. 2016; Esteves 2015; Shin and Turek 2013; Schlegel 1999; Deruyver et al. 2014; Franco et al. 2016). This aspect can be explained considering the possibility, during micro-TESE,

to identify larger tubules containing active foci of spermatogenesis thanks to the optical magnification (Donoso et al. 2007; Shin and Turek 2013; Schlegel 1999; Franco et al. 2016). Moreover, the smaller amount of tissue removed as opposed to conventional TESE (50- to 70-fold less) facilitates sperm processing and results in higher SRR (Ramasamy et al. 2005; Esteves et al. 2011).

A systematic review and meta-analysis by Bernie et al. analyzed 15 studies to investigate the relative differences in outcomes of TESA, conventional TESE, and micro-TESE (Bernie et al. 2015). This work confirmed that SRR was higher in micro-TESE when compared with c-TESE (absolute increase 17%), and c-TESE was better than TESA (absolute increase 28%). Moreover, the authors underlined that many men analyzed undergoing micro-TESE had failed a previous TESA or c-TESE, suggesting that if all men treated were naïve to a previous procedure, the difference between micro-TESE and c-TESE might be even more pronounced (Bernie et al. 2015).

Until recently c-TESE represented the first line option to retrieve spermatozoa in NOA men for ICSI purposes (Saccà et al. 2016; Shin and Turek 2013; Deruyver et al. 2014). To date many centers have replaced this technique with micro-TESE due to the great advantage coming from the optical magnification (Saccà et al. 2016; Shin and Turek 2013; Schlegel 1999; Franco et al. 2016; Bernie et al. 2015). In the literature, at least four studies (Okada et al. 2002; Tsujimura et al. 2002; Ramasamy et al. 2005; Ghalayini et al. 2011) directly compared SRRs between c-TESE and micro-TESE, according to the histopathology findings. In patients with SCOS, micro-TESE emerged to be superior to c-TESE (SRRs 22.5–41% and 6.3–29%, respectively). Indeed, contrary to expectation, SCOS could be associated with patchy spermatogenesis and the optical magnification may help to identify the zones where spermatozoa are produced (Deruyver et al. 2014). Conversely, in men with maturation arrest the four studies did not show a significant difference between surgical techniques. Finally, only Ramasamy et al. (2005) showed a significant difference in favor of micro-TESE for men with hypospermatogenesis.

Another interesting aspect that must be considered as preoperative factor for SRR is genetic testing. Testicular sperm can be found, for example, in approximately 70% of men with AZFc deletion, while the chance in men with complete AZFa or AZFb deletion is poor. Current EAU guidelines outline that in men with AZFa and AZFb microdeletions, the likelihood of sperm retrieval is virtually zero and therefore TESE procedures are not indicated (EAU Guidelines on Male Infertility 2016). In patients with Klinefelter syndrome, a positive sperm retrieval has been documented in approximately 50%, with pregnancy rates by ICSI ranging from 30% to 50%. However, it is currently under investigation whether retrieval during early adulthood improves sperm retrieval rate in men with Klinefelter syndrome (Plotton et al. 2015; Rohayem et al. 2015; Gies et al. 2016).

Moreover medical therapy (e.g., aromatase inhibitors, clomiphene, or human chorionic gonadotropin) prior to micro-TESE in Klinefelter syndrome has been reported to be associated with an enhanced success rates of sperm retrieval in those men who respond to medication by increasing serum testosterone to more than 100 ng/dL from baseline (Esteves et al. 2011; Ramasamy et al. 2009b).

## Patient Management After Surgery

As mentioned in connection with the anesthesiological aspects, sperm retrieval techniques are considered day-surgery procedures. Therefore, patients are generally discharged 2–3 h after surgery. Physical examination to identify scrotal hematoma is recommended prior to discharge and 24 h later. Patients can neither leave the hospital alone nor drive if general anesthesia or intravenous sedation has been administered. Antibiotics are not generally prescribed while analgesics are useful for 3–5 days. Bed rest and local ice pack are recommended for 48 h. Sports activities, heavy lifting, and sexual intercourse must be avoided for 4 weeks. It is clinically relevant to inform patients that scrotal swelling and ecchymosis at the wound site are normal; conversely, fever, persistent pain or swelling, bleeding, or excessive fluid leakage from the wound must be reported to the surgeon (Esteves et al. 2013a, 2011).

---

## Complications

The incidence of complications, including persistent pain, swelling, infection, hydrocele, and hematoma, ranges from 0% to 70% depending mainly on the surgical technique that has been used (Esteves et al. 2011, 2013a; EAU Guidelines on Male Infertility 2016; Shin and Turek 2013). Ultrasound is considered the first line diagnostic imaging technique in case of complications (Esteves et al. 2013a). Of all, haematoma, fibrosis, and testicular atrophy are considered as the three main sequelae (Donoso et al. 2007). In this context, an ultrasound assessment performed 3 months after TESE may identify intratesticular hematoma in up to 80% patients, followed generally by spontaneous resolution without compromising testicular function (Esteves et al. 2013a; Donoso et al. 2007). Several studies documented a lower incidence of hemorrhagic complication following micro-TESE compared with the conventional technique (Esteves et al. 2013a; Donoso et al. 2007; Ramasamy et al. 2005; Amer et al. 2000; Okada et al. 2002).

As discussed, micro-TESE was developed as a solution to the problem of improving sperm recovery with excision of a limited amount of tissue (Ramasamy et al. 2005). The use of an operating microscope allows, at the same time, the identification and preservation of subtunical vessels (Esteves et al. 2013a); indeed, in humans the testicular artery enters the testis posterior beneath the epididymis at the mid-pole, to continue inferiorly to the lower pole and then it courses superiorly along the anterior surface, where it gives rise to branches that supply the parenchyma. As a consequence, multiple site testicular biopsy during TESE can interrupt these branches causing damage to the tissue together with pressure atrophy from intratesticular swelling and hematoma due to the nonflexible characteristics of tunica albuginea (Silber et al. 1994; Donoso et al. 2007; Ramasamy et al. 2005). Optical magnification with intraoperative microscope during micro-TESE allows the vessel to be preserved reducing the damage risk (Esteves et al. 2011, 2013a; Donoso et al. 2007; Shin and Turek 2013; Schlegel 1999). For this reason, Ramasamy et al. analyzed structural and functional changes in testis after c-TESE versus

micro-TESE (Ramasamy et al. 2005). Structural changes, in particular, were evaluated with ultrasound. The authors considered diffuse heterogeneity of the testicular paranchyma or focal hypoechoic lesions seen with ultrasound as expression of hematoma and/or inflammation and, consequently, considered an acute change. Vice versa, both calcifications and linear hyperechoic foci have been considered suggestive of resolution of inflammation and scar formation (Ramasamy et al. 2005). Overall, despite the large transverse incision in the tunica albuginea that is performed during micro-TESE, fewer acute and chronic changes were seen during the follow-up when compared to conventional TESE (Ramasamy et al. 2005). Those findings confirmed previous results reported by other authors (Ramasamy et al. 2005; Amer et al. 2000; Okada et al. 2002).

Although multiple controlled observational studies have compared TEFNA and TESE, only few of them detailed complications and complications rates (Donoso et al. 2007). Harrington et al., for instance, reported intratesticular bleeding in 29% of individuals who underwent TESE as compared with only 7% of patients after TEFNA (Harrington et al. 1996). Similarly, Friedler et al. confirmed a greater incidence of haematoma in patients after TESE as compared with those submitted to TEFNA (Friedler et al. 1997). Conversely, Khadra et al., in 2003, reported no hemorrhagic complications for both TEFNA and TESE in a series of 84 patients (Khadra et al. 2003).

Focusing on the percutaneous technique, quite a common complication is fibrosis. In men after PESA, for example, complications are usually of minimal morbidity, although fibrosis at the aspiration site is often seen (Esteves et al. 2011). Likewise, open technique can lead to the development of scar tissue, as demonstrated in different studies with ultrasonographic findings. Only few studies compared the risk of fibrotic outcomes after c-TESE and micro-TESE (Donoso et al. 2007). In particular, Amer et al. (2000) observed fibrosis in 30% of cases 6 months after c-TESE as compared with 3.3% of cases of fibrotic derangement after micro-TESE. Similar findings arise from the study by Okada et al. (2002), who reported a 23% of fibrosis of the testis parenchyma after c-TESE versus a virtual 0% in men undergoing micro-TESE.

The last and most severe complication we consider is testicular atrophy. Postoperative vascular damage, indeed, can conduce to a decrease in Leydig cells that can lead to reduction of testosterone production with serious long-term consequences (hypogonadism including osteoporosis, increased insulin resistance, depression, etc.) (Donoso et al. 2007). Therefore, many authors recommend the determination of hormone levels (e.g., total and free testosterone, FSH, LH, and estradiol) before and 6 months after any open testicular intervention (Esteves et al. 2013a). Large-volume conventional TESE, in particular, may be associated with transient or, rarely, permanent reduction of serum testosterone levels due to the loss of parenchymal vascularization associated with excessive removal of testicular tissue (Esteves et al. 2013a; Carpi et al. 2009; Ramasamy et al. 2005). Quoting again the study by Ramasamy et al., the authors, as said, analyzed structural and functional changes in c-TESE compared to micro-TESE. Functional changes were identified analyzing testosterone levels preoperatively and at 3, 6, 12, and 18 months after surgery. The



study demonstrated a reduction of testosterone both in the c-TESE and micro-TESE group at 3- and 6-month assessments. The initial decrease was nevertheless followed by a return to presurgical values of testosterone levels (85% c-TESE and 95% micro-TESE, respectively) 18 months after surgery, with no difference between the two groups ( $p < 0.01$ ) (Ramasamy et al. 2005).

---

## References

- Abdel Raheem A, Garaffa G, Rushwan N, De Luca F, Zacharakis E, Abdel Raheem T, Freeman A, Serhal P, Harper JC, Ralph D. Testicular histopathology as a predictor of a positive sperm retrieval in men with non-obstructive azoospermia. *BJU Int.* 2013;111:492–9.
- Ali Jorsaraei SG, Shafi H, Alereza H, Esmailzadeh S, Delavar MA, Saeed A, Fasihiyan M, Golsorkhtabamiri M. Azoospermia and testicular biopsy before intra-cytoplasmic sperm injection: does the type of anesthesia make a difference? *J Nat Sci Biol Med.* 2016;7:89–92.
- Amer M, Ateyah A, Hany R, Zohdy W. Prospective comparative study between microsurgical and conventional testicular sperm extraction in non-obstructive azoospermia: follow-up by serial ultrasound examinations. *Hum Reprod.* 2000;15:653–6.
- Bernie AM, Mata DA, Ramasamy R, Schlegel PN. Comparison of microdissection testicular sperm extraction, conventional testicular sperm extraction, and testicular sperm aspiration for non-obstructive azoospermia: a systematic review and meta-analysis. *Fertil Steril.* 2015;104:1099–103.e1-3.
- Bromage SJ, Falconer DA, Lieberman BA, Sangar V, Payne SR. Sperm retrieval rates in subgroups of primary azoospermic males. *Eur Urol.* 2007;51(2):534–9.
- Caroppo E, Colpi EM, Gazzano G, Vaccaluzzo L, Scropo FI, D'Amato G, Colpi GM. Testicular histology may predict the successful sperm retrieval in patients with non-obstructive azoospermia undergoing conventional TESE: a diagnostic accuracy study. *J Assist Reprod Genet.* 2017;34:149–54.
- Carpi A, Fabris GF, Chiechi A, Nardini V, Romani R, Di Coscio G. Spermatogenesis in azoospermic, formerly cryptorchid men. Use of needle aspiration techniques. *Acta Cytol.* 2002;46:848–54.
- Carpi A, Sabanegh E, Mechanick J. Controversies in the management of nonobstructive azoospermia. *Fertil Steril.* 2009;91:963–70.
- Cissen M, Meijerink AM, D'Hauwers KW, Meissner A, van der Weide N, Mochtar MH, de Melker AA, Ramos L, Repping S, Braat DD, Fleischer K, van Wely M. Prediction model for obtaining spermatozoa with testicular sperm extraction in men with non-obstructive azoospermia. *Hum Reprod.* 2016;31:1934–41.
- Craft I, Shrivastav P. Treatment of male infertility. *Lancet.* 1994;344(8916):191–2.
- Deruyver Y, Vanderschueren D, Van der Aa F. Outcome of microdissection TESE compared with conventional TESE in non-obstructive azoospermia: a systematic review. *Andrology.* 2014;2:20–4.
- Devroey P, Liu J, Nagy Z, Goossens A, Tournaye H, Camus M, Van Steirteghem A, Silber S. Pregnancies after testicular sperm extraction and intracytoplasmic sperm injection in non-obstructive azoospermia. *Hum Reprod.* 1995;10:1457–60.
- Donoso P, Tournaye H, Devroey P. Which is the best sperm retrieval technique for non-obstructive azoospermia? A systematic review. *Hum Reprod Update.* 2007;13:539–49.
- EAU Guidelines on Male Infertility. 2016. <https://uroweb.org/wp-content/uploads/EAU-Guidelines-Male-Infertility-2016.pdf>
- Esteves SC. Percutaneous epididymal sperm aspiration as a method for sperm retrieval in men with obstructive azoospermia seeking fertility: operative and laboratory aspects. *Int Braz J Urol.* 2015;41:817.

- Esteves SC, Miyaoka R, Agarwal A. Sperm retrieval techniques for assisted reproduction. *Int Braz J Urol.* 2011;37:570–83.
- Esteves SC, Miyaoka R, Orosz JE, Agarwal A. An update on sperm retrieval techniques for azoospermic males. *Clinics.* 2013a;68(Suppl 1):99–110.
- Esteves SC, Lee W, Benjamin DJ, Seol B, Verza Jr S, Agarwal A. Reproductive potential of men with obstructive azoospermia undergoing percutaneous sperm retrieval and intracytoplasmic sperm injection according to the cause of obstruction. *J Urol.* 2013b;189:232–7.
- Ezeh UI, Taub NA, Moore HD, Cooke ID. Establishment of predictive variables associated with testicular sperm retrieval in men with non-obstructive azoospermia. *Hum Reprod.* 1999;14:1005–12.
- Fasouliotis SJ, Safran A, Porat-Katz A, Simon A, Laufer N, Lewin A. A high predictive value of the first testicular fine needle aspiration in patients with non-obstructive azoospermia for sperm recovery at the subsequent attempt. *Hum Reprod.* 2002;17:139–42.
- Franco G, Scarselli F, Casciani V, De Nunzio C, Dente D, Leonardo C, Greco PF, Greco A, Minasi MG, Greco E. A novel stepwise micro-TESE approach in non obstructive azoospermia. *BMC Urol.* 2016;16:20.
- Friedler S, Raziell A, Strassburger D, Soffer Y, Komarovskiy D, Ron-El R. Testicular sperm retrieval by percutaneous fine needle sperm aspiration compared with testicular sperm extraction by open biopsy in men with non-obstructive azoospermia. *Hum Reprod.* 1997;12:1488–93.
- Ghalayini IF, Al-Ghazo MA, Hani OB, Al-Azab R, Bani-Hani I, Zayed F, Haddad Y. Clinical comparison of conventional testicular sperm extraction and microdissection techniques for non-obstructive azoospermia. *J Clin Med Res.* 2011;3:124–31.
- Gies I, Oates R, De Schepper J, Tournaye H. Testicular biopsy and cryopreservation for fertility preservation of prepubertal boys with Klinefelter syndrome: a pro/con debate. *Fertil Steril.* 2016;105:249–55.
- Gorgy A, Meniru GI, Naumann N, Beski S, Bates S, Craft IL. The efficacy of local anaesthesia for percutaneous epididymal sperm aspiration and testicular sperm aspiration. *Hum Reprod.* 1998;13:646–50.
- Harrington TG, Schauer D, Gilbert BR. Percutaneous testis biopsy: an alternative to open testicular biopsy in the evaluation of the subfertile man. *J Urol.* 1996;156:1647–51.
- Janzen N, Goldstein M, Schlegel PN, Palermo GD, Rosenwaks Z, Hariprashad J. Use of electively cryopreserved microsurgically aspirated epididymal sperm with IVF and intracytoplasmic sperm injection for obstructive azoospermia. *Fertil Steril.* 2000;74:696–701.
- Jensen CF, Ohl DA, Hiner MR, Fode M, Shah T, Smith GD, Sonksen J. Multiple needle-pass percutaneous testicular sperm aspiration as first-line treatment in azoospermic men. *Andrology.* 2016;4:257–62.
- Khadra AA, Abdulhadi I, Ghunain S, Kilani Z. Efficiency of percutaneous testicular sperm aspiration as a mode of sperm collection for intracytoplasmic sperm injection in nonobstructive azoospermia. *J Urol.* 2003;169:603–5.
- Lewin A, Weiss DB, Friedler S, Ben-Shachar I, Porat-Katz A, Meirow D, Schenker JG, Safran A. Delivery following intracytoplasmic injection of mature sperm cells recovered by testicular fine needle aspiration in a case of hypergonadotropic azoospermia due to maturation arrest. *Hum Reprod.* 1996;11:769–71.
- Lewin A, Reubinoff B, Porat-Katz A, Weiss D, Eisenberg V, Arbel R, Bar-el H, Safran A. Testicular fine needle aspiration: the alternative method for sperm retrieval in non-obstructive azoospermia. *Hum Reprod.* 1999;14:1785–90.
- Martin-du-Pan RC, Bischof P. Increased follicle stimulating hormone in infertile men. Is increased plasma FSH always due to damaged germinal epithelium? *Hum Reprod.* 1995;10:1940–5.
- Mascarenhas M, Thomas S, Kamath MS, Ramalingam R, Kongari AM, Yuvarani S, Srivastava VM, George K. Prevalence of chromosomal abnormalities and Y chromosome microdeletion among men with severe semen abnormalities and its correlation with successful sperm retrieval. *J Hum Reprod Sci.* 2016;9:187–93.
- Miyamoto T, Minase G, Okabe K, Ueda H, Sengoku K. Male infertility and its genetic causes. *J Obstet Gynaecol Res.* 2015;41:1501–5.

- Nudell DM, Conaghan J, Pedersen RA, Givens CR, Schriock ED, Turek PJ. The mini-micro-epididymal sperm aspiration for sperm retrieval: a study of urological outcomes. *Hum Reprod.* 1998;13:1260–5.
- Okada H, Dobashi M, Yamazaki T, Hara I, Fujisawa M, Arakawa S, Kamidono S. Conventional versus microdissection testicular sperm extraction for nonobstructive azoospermia. *J Urol.* 2002;168:1063–7.
- Palermo G, Joris H, Devroey P, Van Steirteghem AC. Pregnancies after intracytoplasmic injection of single spermatozoon into an oocyte. *Lancet.* 1992;340(8810):17–8.
- Plotton I, Giscard d'Estaing S, Cuzin B, Brosse A, Benchaib M, Lornage J, Ecochard R, Dijoud F, Lejeune H, FERTIPRESERVE group. Preliminary results of a prospective study of testicular sperm extraction in young versus adult patients with nonmosaic 47,XXY Klinefelter syndrome. *J Clin Endocrinol Metab.* 2015;100(3):961–7.
- Ramasamy R, Yagan N, Schlegel PN. Structural and functional changes to the testis after conventional versus microdissection testicular sperm extraction. *Urology.* 2005;65:1190–4.
- Ramasamy R, Lin K, Gosden LV, Rosenwaks Z, Palermo GD, Schlegel PN. High serum FSH levels in men with nonobstructive azoospermia does not affect success of microdissection testicular sperm extraction. *Fertil Steril.* 2009a;92:590–3.
- Ramasamy R, Ricci JA, Palermo GD, Gosden LV, Rosenwaks Z, Schlegel PN. Successful fertility treatment for Klinefelter's syndrome. *J Urol.* 2009b;182:1108–13.
- Rohayem J, Fricke R, Czeloth K, Mallidis C, Wistuba J, Krallmann C, Zitzmann M, Kliesch S. Age and markers of Leydig cell function, but not of Sertoli cell function predict the success of sperm retrieval in adolescents and adults with Klinefelter's syndrome. *Andrology.* 2015;3:868–75.
- Saccà A, Pastore AL, Roscigno M, Naspro R, Pellucchi F, Fuschi A, Maruccia S, Territo A, Pisano F, Zanga L, Capitano E, Carbone A, Fusi F, Chinaglia D, Da Pozzo LF. Conventional testicular sperm extraction (TESE) and non-obstructive azoospermia: is there still a chance in the era of microdissection TESE? Results from a single non-academic community hospital. *Andrology.* 2016;4:425–9.
- Schiff JD, Palermo GD, Veeck LL, Goldstein M, Rosenwaks Z, Schlegel PN. Success of testicular sperm extraction [corrected] and intracytoplasmic sperm injection in men with Klinefelter syndrome. *J Clin Endocrinol Metab.* 2005;90:6263–7.
- Schlegel PN. Testicular sperm extraction: microdissection improves sperm yield with minimal tissue excision. *Hum Reprod.* 1999;14:131–5.
- Shin DH, Turek PJ. Sperm retrieval techniques. *Nat Rev Urol.* 2013;10:723–30.
- Silber SJ, Nagy ZP, Liu J, Godoy H, Devroey P, Van Steirteghem AC. Conventional *in-vitro* fertilization versus intracytoplasmic sperm injection for patients requiring microsurgical sperm aspiration. *Hum Reprod.* 1994;9:1705–9.
- Takeda T, Iwatsuki S, Hamakawa T, Mizuno K, Kamiya H, Umemoto Y, Kubota H, Kubota Y, Sasaki S, Yasui T. Chromosomal anomalies and sperm retrieval outcomes of patients with non-obstructive azoospermia: a case series. *Andrology.* 2017. doi:10.1111/andr.12338. [Epub ahead of print].
- Temple-Smith PD, Southwick GJ, Yates CA, Trounson AO, de Kretser DM. Human pregnancy by *in vitro* fertilization (IVF) using sperm aspirated from the epididymis. *J In Vitro Fert Embryo Transf.* 1985;2:119–22.
- Tournaye H, Krausz C, Oates RD. Novel concepts in the aetiology of male reproductive impairment. *Lancet Diabetes Endocrinol.* 2016a. doi:10.1016/S2213-8587(16)30040-7. pii: S2213-8587(16)30040-7.
- Tournaye H, Krausz C, Oates RD. Concepts in diagnosis and therapy for male reproductive impairment. *Lancet Diabetes Endocrinol.* 2016b. doi:10.1016/S2213-8587(16)30043-2. pii: S2213-8587(16)30043-2.
- Tsujimura A, Matsumiya K, Miyagawa Y, Tohda A, Miura H, Nishimura K, Koga M, Takeyama M, Fujioka H, Okuyama A. Conventional multiple or microdissection testicular sperm extraction: a comparative study. *Hum Reprod.* 2002;17:2924–9.

- Tsujimura A, Matsumiya K, Miyagawa Y, Takao T, Fujita K, Koga M, Takeyama M, Fujioka H, Okuyama A. Prediction of successful outcome of microdissection testicular sperm extraction in men with idiopathic nonobstructive azoospermia. *J Urol*. 2004;172:1944–7.
- Turek PJ, Givens CR, Schriock ED, Meng MV, Pedersen RA, Conaghan J. Testis sperm extraction and intracytoplasmic sperm injection guided by prior fine-needle aspiration mapping in patients with nonobstructive azoospermia. *Fertil Steril*. 1999;71:552–7.
- Van Rumste MM, Evers JL, Farguhar CM. Intra-cytoplasmic sperm injection versus conventional techniques for oocyte insemination during *in vitro* fertilization in patients with non-male subfertility. *Cochrane Database Syst Rev*. 2003;2:CD001301.
- Wosnitzer M, Goldstein M, Hardy MP. Review of azoospermia. *Spermatogenesis*. 2014;4:e28218.

Giulia Gava, Renato Seracchioli, and Maria Cristina Meriggiola

## Abstract

In adult gender dysphoric natal males, where full development of male secondary sexual characteristics has already taken place, the goal of cross-sex hormonal therapy is the suppression of testosterone secretion to achieve regression of male characteristics and the development of feminine secondary sexual characteristics. For this reason, in transwomen an almost complete suppression of endogenous androgen production and action with combined administration of estrogens is required. The aim of therapy is to maintain hormone levels within the normal physiological range for the individual's desired gender. Practice guidelines describe eligibility for puberty suppression in adolescents that have met the criteria for gender dysphoria and that have experienced at least Tanner stage 2 puberty. In these subjects if dysphoria persists, cross-hormonal therapy is generally started after 16 years of age.

## Keywords

(MeSH terms): antiandrogens • Gender dysphoria • Testosterone suppression

## Contents

Introduction .....	1200
Aims and Outcomes of Cross Sex Hormonal Therapy in Adult Gender Dysphoric Natal Males .....	1200
Therapy with Antiandrogens in Adolescent Gender Dysphoric Natal Males: Suppression of Puberty .....	1201

G. Gava • R. Seracchioli • M.C. Meriggiola (✉)  
Gynecology and Physiopathology of Human Reproduction, S. Orsola-Malpighi Hospital,  
Department of Medical and Surgical Science, University of Bologna, Bologna, Italy  
e-mail: [giulia.gava@studio.unibo.it](mailto:giulia.gava@studio.unibo.it); [renato.seracchioli@aosp.bo.it](mailto:renato.seracchioli@aosp.bo.it); [cristina.meriggiola@unibo.it](mailto:cristina.meriggiola@unibo.it)

Antiandrogen Therapy for the Treatment of Gender Dysphoric Natal Males .....	1202
Cyproterone Acetate .....	1202
GnRH Agonists .....	1204
Other Antiandrogens .....	1205
Summary .....	1206
References .....	1207

---

## Introduction

Therapy with antiandrogens has three main fields of application: they can be used for the treatment of metastatic prostate cancer, in natal male with gender dysphoria (GD) and in subjects with sexual deviation disorders, or paraphilias.

---

## Aims and Outcomes of Cross Sex Hormonal Therapy in Adult Gender Dysphoric Natal Males

According to the Diagnostic and Statistical Manual of Mental Disorders, Fifth Edition (DSM-V 2013), GD is the distress that may accompany the experience of a significant incongruence between the experienced/expressed gender and the assigned gender. GD's most extreme expression is trans-sexualism. Adult natal males diagnosed with GD are also referred to as transwomen or male-to-female (MtF).

Current diagnosis and care of gender dysphoric adults is performed according to the Standard of Care provided by the World Professional Association for Transgender Health (WPATH) (Coleman et al. 2011), Endocrine Society guidelines (Hembree et al. 2009), Good Practice Guidelines by The Royal College of Psychiatrists (Rcpsych 2013) and the DSM-V.

In adult gender dysphoric natal males, where development of male secondary sexual characteristics have been fully established, the goal of cross-sex hormonal therapy (CHT) is the suppression of testosterone secretion in order to achieve regression of male characteristics and the development of feminine secondary sexual characteristics (Hembree et al. 2009).

The final aim of medical and, when requested, surgical therapy in these subjects is to improve the well-being and quality of life; it has been reported that hormonal treatment used to suppress the endogenous gonadal hormones and to induce the secondary sex characteristics of the new sex, is one of the most important predictors for higher quality of life in these subjects (Murad et al. 2010).

For this reason, in transwomen an almost complete suppression of endogenous androgens production and action with antiandrogens administration combined to estrogens is required to achieve elimination of sexual hair, induction of breast formation and female fat distribution. The aim of therapy is to maintain hormone levels within the normal physiological range for the individual's desired gender.

Estrogens can be administered using various routes (oral, transdermal as gel or patches and intramuscular). The transdermal route is considered to be the safest option guaranteeing a slow and prolonged release and obtaining more stable systemic blood hormone levels. Patches are sometimes problematic in transwomen causing skin reactions or adhesion problems, making gel preparations a better option for these people. Unlike oral administration, transdermal estrogens do not have a significant first pass hepatic metabolism reaching the liver via the portal circulation in small quantities. This peculiar metabolism leads to a more favorable lipidic, inflammatory and coagulative profile. For this reason, the transdermal route represents the safest route in transwomen over 40 years of age, smokers, and those with liver disease or diabetes mellitus.

Initial changes induced by CHT include decreased libido and reduction of skin oiliness and acne, redistribution of fat mass with an increase in subcutaneous fat, and a decrease in lean body mass and muscle strength (Hembree et al. 2009).

Adult male pattern body hair becomes thinner and lighter and may eventually diminish. Initial reduction of body hair may occur within 4 months of treatment but hair density on cheeks and the upper abdomen reduces more slowly and progressively. Adult male beard growth is often resistant to hormonal treatment and usually requires hair removal treatment for additional cosmetic benefits.

Elimination of previous androgen effects on the skeleton is obviously not possible: the greater height, the size and shape of hands, feet, jaws, pelvis and development of laryngeal prominence cannot be pharmacologically altered (Hembree et al. 2009).

After sex-reassignment surgery (SRS), anti-androgen therapy can be stopped and continued only in those few subjects that continue to have male pattern of hair growth (Gooren 2011). After gonadectomy, to prevent hypogonadism and to maintain female phenotypic characteristics and to avoid symptoms of sex hormone deficiency, estrogen administration should be continued for the longer term.

Because of the potential increased risks with age, the continuation of CHT requires dose and route adjustments and it is important to monitor elderly transwomen commencing or continuing estrogens continuously (Gooren 2011). Up to now it's not clear if there is an age at which CHT should be discontinued in older transwomen. Long-term follow-up data have documented a greater cardiovascular morbidity and mortality in transwomen taking oral estrogens as opposed to transdermal or percutaneous estrogens and for this reason elderly transwomen should be switched to transdermal administration (Ettner 2013).

---

## **Therapy with Antiandrogens in Adolescent Gender Dysphoric Natal Males: Suppression of Puberty**

Eligibility criteria for hormonal therapy in adolescents with GD require assessment of GD according to the DSM-V criteria and the evaluation of the overall psychological functioning of the individual performed by trained mental health professionals (DSM-V); they should also provide the adolescent and their families with

information about pros and cons of treatments and evaluate the presence of adequate psychological and social support (Fisher et al. 2014). Puberty suppression and CHT in adolescents is performed according to the Dutch experience (De Vries and Cohen-Kettenis 2012) and the Endocrine Society Guidelines. The development of secondary sexual characteristics typically induces distress in adolescents with GD leading to psychological diseases as depression, suicidal tendencies, substance abuse and high-risk sexual behavior (Hembree et al. 2009). For these reasons pubertal suppression in adolescents with diagnosis of GD allows confirmation of the diagnosis and the extension of the diagnostic phase avoiding the development of male sexual secondary characteristics (Fisher et al. 2014). Puberty suppression is usually accompanied by psychological benefits and it allows subsequent CHT to achieve more satisfactory outcomes with a reduced need for medical and surgical interventions.

Available practice guidelines suggest starting suppression of puberty only after Tanner stage II or III of puberty (Hembree et al. 2009). Suppression of pubertal progression is performed using monthly or three monthly GnRH analogs depot formulations (Schagen et al. 2016). During GnRH analogues therapy monitoring is mandatory to prevent growth and bone density impairment. Puberty suppression is fully reversible and the stop of GnRH analogs allows the pubertal maturation to continue in whom the diagnosis has not been confirmed. In case of confirmation of GD, practice guidelines suggest to start CHT after 16 years of age as it is the age of legal adulthood in many countries. Induction of puberty is similar to hypogonadal females through gradual increments of estradiol which should be regulated according to clinical response (Hembree et al. 2009).

Puberty suppression and CHT in adolescents with GD should always be performed in specialized centers by trained personal that should also provide young subjects and their families with information about various related issues such as fertility consequences and long-term effects.

---

## **Antiandrogen Therapy for the Treatment of Gender Dysphoric Natal Males**

CHT in adult gender dysphoric natal males is performed according to the Endocrine Society practice guidelines published in 2009 (Hembree et al. 2009) and to the WPATH standards of care that were updated in 2011 (Coleman et al. 2011).

The following are the main preparations used as antiandrogens in the treatment of individuals with GD.

### **Cyproterone Acetate**

Cyproterone acetate (CPA) is an anti-androgenic progestin, and it is the most widely used anti-androgen outside the USA, where it is not available. It is a progestational steroid that acts both by competitive androgen antagonism at the level of target tissues and by exerting a negative feedback on the hypothalamic receptors, thereby



suppressing gonadotrophin release and inhibiting androgen synthesis. It also has some residual estrogenic activity. CPA is also reported to have glucocorticoid activity that may lead to weight gain. The recommended dose of CPA for subjects with GD is 50–100 mg/day (Hembree et al. 2009), but even lower doses may effectively induce a profound suppression of gonadotrophins due to its accumulation in the subcutaneous tissue. Following oral administration, CPA is quickly and completely absorbed. The absolute bioavailability of CPA is almost complete. Excretion occurs via the bile (70%) and urine (30%). CPA is almost exclusively bound to plasma albumin and it does not bind to SHBG (sex hormone binding globulin). About 3.5–4% of total drug levels circulate unbound. Because protein binding is non-specific, changes in SHBG levels do not affect the pharmacokinetics of CPA. CPA is reported to be well tolerated, but its estrogenic activity has been associated with a risk of deep venous and arterial thromboses. In transwomen with a history of thromboembolic disorders or severe diabetes with vascular changes, the risk-benefit ratio must be considered carefully in each individual case before CHT is prescribed. Venous thromboembolism (VTE) is a serious complication in transwomen treated with CHT, and the type of estrogen, dose, and administration route have been reported to affect the VTE risk therefore the contribution of progestin to this risk should not be overlooked. Higher incidence of VTE in subjects treated with ethinyl estradiol or conjugated equine estrogens compounds compared to estradiol valerate or estradiol have been reported (Ott et al. 2010). Other studies have also suggested that the transdermal route may be safer than the oral route. It has been reported that treatment with CPA only, or with transdermal or oral estradiol, produces little effect on hemostatic variables, whereas oral ethinyl estradiol treatment resulted in a significant change in hemostatic variables (Toorians et al. 2003).

Although direct hepatic toxicity, including jaundice, hepatitis and hepatic failure has been occasionally fatal in older men with prostatic cancer treated with 200–300 mg/day cyproterone acetate, these adverse effects have not been reported in the GD population (Savidou et al. 2006). Toxicity is dose-related and usually develops several months after treatment has begun. Liver function tests should be performed pre-treatment and whenever any symptoms or signs suggesting hepatotoxicity occur. In addition, cases of dose-dependent sedative effects have been reported. CPA has been associated with an increased risk of depression particularly in the initial stages of therapy (Seal et al. 2012).

CPA causes inhibition of spermatogenesis: the sperm count and the volume of ejaculate is reduced, and azoospermia may occur as early as 8 weeks after initial administration. Reversible atrophy of the seminiferous tubules and spermatogenesis usually revert to its previous state about three to 5 months after therapy cessation (Merigiola et al. 1997).

Cases of hormone-dependent tumors have been described, such as prolactinomas and meningiomas, in MtF transgenders (Gazzeri et al. 2007; Mueller and Gooren 2008; Wengel et al. 2016). CPA has been associated with a higher risk of meningioma and eight cases of meningioma have been reported after hormonal treatment with estrogens plus cyproterone acetate (Wengel et al. 2016). An 11.4% increased risk of meningioma (95% CI 4.3–30.8) has been described in a retrospective cohort

study of mainly female users (70%) who used a dose of 25 mg or higher for at least 1 year (Gil et al. 2011). Another case–control study showed a significantly increased risk in male subjects using high doses of CPA (>50 mg daily) (OR 6.30; 95% CI 1.37–28.94) (Cea-Soriano et al. 2012). Meningiomas seem to be hormone-sensitive tumors and evidences are given by their higher prevalence in women than in men, their epidemiological association with breast cancer and the worsening of symptoms during periods of relative progesterone excess, such as pregnancy (Blankenstein et al. 2000). The expression of progesterone receptors in human meningiomas is already well known. Meningiomas are slow growing benign tumors and it is possible that the binding to progesterone receptors can modulate tumor growth rather than tumor initiation (Wigertz et al. 2008).

In transwomen diagnosed with meningioma, after stopping CPA, follow-up may be sufficient in some cases, however neurosurgery may be necessary in others. Immunohistochemical analysis of the hormonal receptor status in these subjects is fundamental as the decision to continue CHT should be carefully evaluated on a case- by- case basis.

Twenty percent of transwomen using estrogens may have increased prolactin levels (Knezevich et al. 2012). It should be borne in mind that CPA is also associated with an increase of prolactin levels when used alone or in combination with estrogens. Up to now seven cases of prolactinomas have been reported in literature after CHT: two transwomen receiving normal doses of estrogens for an extended period and five cases in transwomen who self-medicated with supra-physiological doses of estrogens (Bunck et al. 2009; Cunha et al. 2015).

## GnRH Agonists

GnRH agonists induce profound suppression of testicular testosterone production through inhibition of gonadotrophin secretion. They can be administrated in long-acting intramuscular monthly or three monthly injections. During the first 10 days of treatment, GnRH agonists binding to the GnRH receptors increase luteinizing hormone (LH) and follicle-stimulating hormone (FSH) production. Paradoxically, chronic treatment leads to a cessation in pituitary secretion of LH and FSH through a desensitization of gonadotrophic cells of the pituitary gland to endogenous GnRH. The fall in pituitary LH and FSH secretion leads to the decrease of secretion from the testes in males (Wilson et al. 2007). GnRH agonists are derived from native GnRH by substituting a D-amino acid the native L-amino acid at position six of the native decapeptide. This substitution makes the agonist resistant to degradation by endopeptidases, increasing the half-life and resulting in prolonged receptor occupancy.

GnRH analogues require a parenteral administration and recommended dosages in transgender population are: Leuprolide acetate 3.75 mg monthly or 11.25 mg every 3 months, or Triptorelin 3.75 mg monthly or 11.25 mg every 3 months or Goserelin acetate 3.6 mg monthly or 10.8 mg every 3 months. During CHT the administration of GnRH analogues is accompanied by estrogens use in order to obtain female secondary sexual characteristics. The concomitant administration of

estrogens reduces the side effects of GnRH analogues described in the urologic literature such as hot flushes, sexual dysfunction, irritability, fatigue, headache, depression, changes in skin texture and hair distribution, loss of muscle mass, osteopenia, muscle and joint pain and metabolic syndrome, due to hormonal deprivation. Recently a direct comparison of 1 year of treatment with CPA plus estradiol versus leuprolide plus estradiol has been performed: the suppression of gonadotrophins and androgens was similar in the two groups however the cyproterone group showed significantly increased prolactin levels and a reduction in HDL cholesterol while in leuprolide group HDL cholesterol increased. (Gava et al. 2016) This study showed that administration of either CPA or leuprolide in combination with transdermal estradiol for 1 year is both safe and effective. The reduced risk of hyperprolactinaemia and the increase in HDL-cholesterol in the leuprolide group compared to CPA group should be investigated in longer studies. Considering the similarity in effectiveness in the suppression of androgen production and action, the possible side effects on hepatic function and mood associated with CPA and the unavailability of CPA in certain areas (U.S.), the use of GnRH analogues could be considered as the preferred option in transwomen (Gava et al. 2016).

In fact GnRH analogues are increasingly prescribed in natal males with GD although their cost may often prohibit their long-term use in this population particularly in those areas where the drug is not funded by the local health system.

## Other Antiandrogens

In countries where CPA is not available or in transwomen who cannot afford GnRH analogs, spironolactone and other antiandrogens such as flutamide, finasteride and dutasteride can be suggested as second choice option.

Spironolactone is a weak inhibitor of testosterone synthesis which blocks the androgen receptor; the inhibition of  $17\alpha$ -hydroxylase inhibits testosterone synthesis but can also result in an increase of progesterone through inhibition of the same enzyme; it is also an aldosterone antagonist in the distal renal tubules. It inhibits  $5\alpha$ -reductase activity (Moore et al. 2003; Tangpricha et al. 2003). Its solubility in water is very poor and for this reason its absorption after oral administration is variable. It should be avoided in subjects with renal insufficiency or when combined with potassium supplements and other potassium-sparing medications because it may cause hyperkalemia. In the literature spironolactone use has been linked to an increased risk of upper gastrointestinal bleeding (Gulmez et al. 2008). It has estrogen receptor agonistic action gaining additional estrogenic effects. In the transpopulation spironolactone has been associated with a higher need for breast augmentation when compared to other antiandrogens or GnRH agonists, and this may result in poorer breast outcome consequent to the excessive estrogenic action similar to that in self medicated subjects with inappropriate doses of estrogens (Seal et al. 2012). The recommended dose of spironolactone is 100–200 mg/day in the GD population (Hembree et al. 2009).

Other potential options are finasteride, dutasteride or flutamide, which are non-steroidal antiandrogens. Their use in the GD population is not recommended.

Finasteride blocks one of the two  $5\alpha$ -reductase isoenzymes (type II) inhibiting the conversion of testosterone to dihydrotestosterone (DHT) leading to a reduction in serum and tissue DHT. The routine use of finasteride is not recommended in GD individuals because the blocking of only one of the two  $5\alpha$ -reductase isoenzymes leads to only minor anti-androgenic effects. Finasteride is usually administered at a dose of 5 mg/day (Dahl et al. 2006).

Dutasteride blocks both  $5\alpha$ -reductase isoenzymes (type I and II) and is used at the dose of 0.5 mg/day, but there is little evidence of its efficacy in this population (Dahl et al. 2006).

Flutamide is a competitive inhibitor of androgen binding to the androgen receptor. It blocks only androgen peripheral action causing a rebound increase of gonadotrophin levels and thereby of serum testosterone levels. At higher doses, it can cause severe liver toxicity which, however, is relatively uncommon but can be severe or fatal. For this reason hepatic function must be closely monitored during administration. Flutamide has a half-life of about 5 h and is almost completely excreted in the urine. Relatively frequent side effects are diarrhea, nausea, and vomiting. If used, the dosage should be 750 mg/day however its use is not recommended in the GD population (Spack 2013; Hembree et al. 2009).

---

## Summary

Therapy with antiandrogens and estrogens in adults with gender dysphoria should be customized and its ultimate goal must be the improvement in the well-being and quality of life.

After sex-reassignment surgery anti-androgen therapy can be stopped but estrogen administration should be continued for longer term to prevent hypogonadism, in order to maintain female phenotypic characteristics and to avoid symptoms of sex hormone deficiency. Because of the increase in cardiovascular risks with age, continuation of estrogen administration requires dose and route adjustments.

Adolescents with diagnosis of gender dysphoria that have experienced at least Tanner stage II puberty can be eligible for puberty suppression therapy that is usually performed with GnRH analogs administration. In these subjects if dysphoria persists, cross-hormonal therapy with increasing doses of estrogens is generally started after 16 years of age.

Currently used antiandrogens are cyproterone acetate, GnRH analogs and other antiandrogens such as spironolactone, flutamide, finasteride and dutasteride that can be suggested as second choice option (Table 1).

Cyproterone acetate is widely used outside the USA, where it is not available. The recommended dose is 50–100 mg/day, even if lower doses may be effective thanks to its accumulation in the subcutaneous fatty tissue. Side effects are usually dose-dependent and include: weight gain, hepatotoxicity, sedative effects, increased risk of meningioma and depression.

**Table 1** Antiandrogen therapy in transwomen: most commonly used formulations and doses

Agent	Route	Recommended dosage	Notes
Cyproterone acetate	Oral	50–100 mg/day	Not available in USA
			Possible dose dependent side effects: weight gain, hepatotoxicity, sedative effects, increased risk of meningioma and depression
			Lower doses with reduced side effects may be effective thanks to its accumulation in subcutaneous tissue
GnRH analogues	Parenteral	Leuprolide acetate 3.75 mg monthly or 11.25 mg every 3 months	High cost if not funded by the local health system
		Triptorelin 3.75 mg monthly or 11.25 mg every 3 months	Side effects described in the urologic literature are reduced by simultaneous administration of estrogens
		Goserelin acetate 3.6 mg monthly or 10.8 mg every 3 months	
Spironolactone	Oral	100–200 mg/day	Second choice antiandrogen
			Highly variable absorption
			Possible hyperkalemia
			Increased risk of upper gastrointestinal bleeding
Finasteride	Oral	2.5–5 mg/die	Second choice antiandrogen
		Dutasteride 0.5 mg/die	Limited efficacy
Flutamide	Oral	750 mg/die	Second choice antiandrogen
			Risk of liver toxicity

GnRH agonists can be used in long-acting monthly or three monthly injections. The concomitant administration of estrogens reduces the side effects of GnRH analogues described mainly in the urologic literature due to hormonal deprivation. For this reason GnRH analogues are increasingly prescribed though their cost often prohibits their use in this population.

Antiandrogens plus estrogens therapy should be performed according to practice guidelines and it can be considered safe if periodic monitoring and long-term check-ups are made.

## References

American Psychiatric Association. Diagnostic and statistical manual of mental disorders. 5th ed. Arlington: American Psychiatric Association; 2013. Available from: [dsm.psychiatryonline.org](http://dsm.psychiatryonline.org). Accessed 1 June 2016.

- Blankenstein MA, Verheijen FM, Jacobs JM, et al. Occurrence, regulation, and significance of progesterone receptors in human meningioma. *Steroids*. 2000;65:795–800.
- Bunck MC, Debono M, Giltay EJ, et al. Autonomous prolactin secretion in two male-to-female transgender patients using conventional oestrogen dosages. *BMJ Case Rep*. 2009;2009:bcr02.
- Cea-Soriano L, Blenk T, Wallander M-A, et al. Hormonal therapies and meningioma: is there a link? *Cancer Epidemiol*. 2012;36:198–205.
- Coleman E, Bockting W, Botzer M, et al. Standards of care for the health of transsexual transgender, and gender-nonconforming people, version 7. *Int J Transgenderism*. 2011;13:165–232.
- Cunha FS, Domenice S, Câmara VL, et al. Diagnosis of prolactinoma in two male-to-female transsexual subjects following high-dose cross-sex hormone therapy. *Andrologia*. 2015;47(6):680–4.
- Dahl M, Feldman JL, Goldberg J, et al. Endocrine therapy for transgender adults in British Columbia: suggested guidelines. Vancouver: Transgender Health Program; 2006. Available from: <http://transhealth.vch.ca/>. Accessed 1 June 2016.
- De Vries AL, Cohen-Kettenis PT. Clinical management of gender dysphoria in children and adolescents: the Dutch approach. *J Homosex*. 2012;59:301–20.
- Ettner R. Care of the elderly transgender patient. *Curr Opin Endocrinol Diabetes Obes*. 2013;20(6):580–4.
- Fisher AD, Ristori J, Bandini E, et al. Medical treatment in gender dysphoric adolescents endorsed by SIAMS-SIESIEDP- ONIG. *J Endocrinol Investig*. 2014;37:675–87.
- Gava G, Cerpolini S, Martelli V, et al. Cyproterone acetate vs leuprolide acetate in combination with transdermal oestradiol in transwomen: a comparison of safety and effectiveness. *Clin Endocrinol*. 2016;85(2):239–46.
- Gazzeri R, Galarza M, Gazzeri G. Growth of a meningioma in a transsexual patient after estrogen-progestin therapy. *N Engl J Med*. 2007;357:2411–2.
- Gil M, Oliva B, Timoner J, et al. Risk of meningioma among users of high doses of cyproterone acetate as compared with the general population: evidence from a population-based cohort study. *Br J Clin Pharmacol*. 2011;72:965–8.
- Gooren LJ. Clinical practice. Care of transsexual persons. *N Engl J Med*. 2011;364:1251–7.
- Gulmez SE, Lassen AT, Aalykke C, et al. Spironolactone use and the risk of upper gastrointestinal bleeding: a population-based case-control study. *Br J Clin Pharmacol*. 2008;66:294–9.
- Hembree WC, Cohen-Kettenis P, Delemarre-van de Waal HA, et al. Endocrine treatment of transsexual persons: an endocrine society clinical practice guideline. *J Clin Endocrinol Metab*. 2009;94:3132–54.
- Knezevich EL, Viereck LK, Drincic AT. Medical management of adult transsexual persons. *Pharmacotherapy*. 2012;32:54–66.
- Meriggiola MC, Bremner WJ, Costantino A, et al. An oral regimen of cyproterone acetate and testosterone undecanoate for spermatogenic suppression in men. *Fertil Steril*. 1997;68(5):844–50.
- Moore E, Wisniewski A, Dobs A. Endocrine treatment of transsexual people: a review of treatment regimens, outcomes, and adverse effects. *J Clin Endocrinol Metab*. 2003;88:3467–73.
- Mueller A, Gooren L. Hormone-related tumors in transsexuals receiving treatment with cross-sex hormones. *Eur J Endocrinol*. 2008;159:197–202.
- Murad MH, Elamin MB, Garcia MZ, et al. Hormonal therapy and sex reassignment: a systematic review and meta-analysis of quality of life and psychosocial outcomes. *Clin Endocrinol (Oxford)*. 2010;72:214–31.
- Ott J, Kaufmann U, Bentz EK, et al. Incidence of thrombophilia and venous thrombosis in transsexuals under cross-sex hormone therapy. *Fertil Steril*. 2010;93:1267–72.
- Royal College of Psychiatrists. Good practice guidelines or the assessment and treatment of adults with gender dysphoria. Royal College of Psychiatrists, 2013. Available from: <http://www.rpsych.ac.uk/usefulresources/publications/collegereports/cr/cr181.aspx>. Accessed 18 June 2016.

- Savidou I, Deutsch M, Soutati AS, et al. Hepatotoxicity induced by cyproterone acetate: a report of three cases. *World J Gastroenterol*. 2006;12:7551–5.
- Schagen SE, Cohen-Kettenis PT, Delemarre-van de Waal HA, et al. Efficacy and safety of gonadotropin-releasing hormone agonist treatment to suppress puberty in gender dysphoric adolescents. *J Sex Med*. 2016;13(7):1125–32.
- Seal LJ, Franklin S, Richards C, et al. Predictive markers for mastectomy and a comparison of side effect profiles in transwomen taking various hormonal regimens. *J Clin Endocrinol Metab*. 2012;97:4422–8.
- Spack NP. Management of transgenderism. *JAMA*. 2013;309:478–84.
- Tangpricha V, Ducharme SH, Barber TW, et al. Endocrinologic treatment of gender identity disorders. *Endocr Pract*. 2003;9:12–21.
- Ter Wengel PV, Martin E, Gooren L, et al. Meningiomas in three male-to-female transgender subjects using oestrogens/progestogens and review of the literature. *Andrologia*. 2016. doi:10.1111/and.12550. [Epub ahead of print].
- Toorians AW, Thomasse MC, Zweegman S, et al. Venous thrombosis and changes of hemostatic variables during cross-sex hormone treatment in transsexual people. *J Clin Endocrinol Metab*. 2003;88(12):5723–9.
- Wigertz A, Lonn S, Hall P, et al. Reproductive factors and risk of meningioma and glioma. *Cancer Epidemiol Biomark Prev*. 2008;17:2663–70.
- Wilson AC, Meethal SV, Bowen RL, et al. Leuprolide acetate: a drug of diverse clinical applications. *Expert Opin Investig Drugs*. 2007;16:1851–63.

---

## **Part V**

# **Miscellaneous Aspects**



Bradley D. Anawalt and Stephanie T. Page

## Abstract

About 25% of couples worldwide use vasectomy or condoms for contraception. Vasectomy should be considered irreversible, and condoms are often used incorrectly (leading to high failure rates) and may decrease sexual pleasure. These are the only available effective male-based contraceptives, and the high usage of these methods despite the above drawbacks indicates that there is a need for novel forms of male contraception. The novel male contraceptives furthest along in development are male hormonal contraceptives. In efficacy trials, male hormonal contraceptives have failure rates of <5% – rates that are superior to male condoms and compare favorably to female hormonal contraceptives. A long-acting injectable formulation of testosterone plus a progestin is most likely to be the first commercially available male hormonal contraceptive. In clinical trials, such long-acting formulations have been demonstrated to be safe, effective, and reversible. The most common side effects are acne, gain, and modest suppression of serum high density lipoprotein concentrations. There have been some concerns about possible adverse mood effects, too. The most promising nonhormonal contraceptive is reversible inhibition of sperm under guidance (more widely known as RISUG). RISUG involves the injection of a solution of styrene maleic anhydride into the vasa deferentia where the solution solidifies into a plug. RISUG is reversible; the plug can be dissolved with a vaginal injection of sodium bicarbonate. Other potential nonhormonal male contraceptives include gamendazole, molecular inhibitors of an epididymal protease inhibitor (Eppin), and inhibitors of testis-specific aldehyde dehydrogenase. The development of novel hormonal and nonhormonal male contraceptives would be useful for men and for heterosexual couples who would like additional options for family planning.

B.D. Anawalt (✉) • S.T. Page

Department of Medicine- Metabolism, Endocrinology and Nutrition, University of Washington, Seattle, WA, USA

e-mail: [banawalt@medicine.washington.edu](mailto:banawalt@medicine.washington.edu); [page@uw.edu](mailto:page@uw.edu)

© Springer International Publishing AG 2017

M. Simoni, I.T. Huhtaniemi (eds.), *Endocrinology of the Testis and Male Reproduction*, Endocrinology 1, [https://doi.org/10.1007/978-3-319-44441-3\\_43](https://doi.org/10.1007/978-3-319-44441-3_43)

1213

---

**Keywords**

 Male hormonal contraception • Male contraception • Vasectomy • Condoms
 

---

**Contents**

Introduction .....	1214
Mechanisms .....	1214
Available Male Contraceptives .....	1215
Vasectomy and Condoms .....	1215
Vasectomy .....	1215
Condoms .....	1215
Experimental Male Contraceptives .....	1216
Hormonal Male Contraceptives .....	1216
Nonhormonal Contraceptives .....	1228
Summary and Conclusions About Male Contraceptives .....	1229
References .....	1229

---

**Introduction**

Male contraception has made little progress since the development of the condom in the eighteenth century (Youssef 1993) and vasectomy in the late nineteenth century (Drake et al. 1999). About 25% of women and their sexual partners use one of these male methods of contraception in the United States and worldwide (Daniels et al. 2015; Darroch 2013).

The high rate of use of vasectomy and condoms highlights the global demand for male methods of contraception. Demand for male contraceptive methods is driven by many factors including intolerance of female contraceptives in stable couple relationships and the desire of many men to participate meaningfully in family planning and have control over their reproduction. Because vasectomy is not easily reversible and condoms have a high failure rate, there is a need for novel male contraceptives. In this chapter, we review the effectiveness of currently available male methods and investigational methods at various stages of development. Withdrawal, a male-based contraceptive method, has a failure rate of 18% in the first year of use and is not reviewed in this chapter (Kost et al. 2008). As a framework for considering the effectiveness of available and potential male contraceptives, it is useful to consider the effectiveness of existing female contraceptives. The estimated failure rate in the first year of typical use with female oral and injectable contraceptives is 7–9% (Kost et al. 2008). The estimated typical failure rate for intrauterine devices is <1% (Trussell 2011).

---

**Mechanisms**

Current and potential male-based contraceptives can be categorized by mechanism: (1) suppression of spermatogenesis, (2) inactivation of sperm motility or disruption of the capacity to bind and fertilize the egg, and (3) blockade of the transport path from the testes to the vagina.

## Available Male Contraceptives

### Vasectomy and Condoms

#### Mechanism of Action

The two available methods of male contraception are vasectomy and condoms, and both act by blockade to the transport path from the testes to the vagina.

#### Vasectomy

Vasectomy is a safe, cost-effective, and effective contraceptive. It is used as the contraceptive in 2–3% of married couples worldwide (Population Reference Bureau 2008; Pile and Barone 2009). There are regional differences in the use of vasectomy with the highest use in Bhutan and New Zealand (40% and 20%, respectively). Female sterilization is far more commonly used for contraception worldwide than vasectomy. In the United States, 17% of women between 15–44 years have had tubal sterilization, but only 6% rely on male sterilization (vasectomy) for contraception (Mosher and Jones 2010) even though vasectomy is less expensive and causes less morbidity.

Vasectomy may be performed under local anesthesia as an outpatient surgery in 10–15 min (Li et al. 2014). The “no-scalpel” technique was developed decades ago in China (Huber 1989), and it has become the standard procedure for vasectomy. With this technique, the vasa deferentia are surgically cut with scissors through a small scrotal incision. The ends of the transected vasa are usually occluded by one of several techniques (e.g., ligation, cautery or fascial interposition) (Shih et al. 2011). The failure rate of vasectomy plus successful occlusion is <1% with virtually all patients rendered azoospermic within 3–4 months (Li et al. 2014; Shih et al. 2011; Sharlip et al. 2012). The complication rate is low and is limited to postoperative pain that usually remits within a few days and rare incision site infections or hematoma (Li et al. 2014; Shih et al. 2011; Sharlip et al. 2012). Up to 15% of all men experience significant chronic testicular pain after vasectomy (McMahon et al. 1992), but the 2012 American Urological Vasectomy Guidelines quote a prevalence of 1–2% of chronic pain severe enough to affect quality of life (Sharlip et al. 2012).

Vasectomy should be reserved for men who do not desire future fertility and should be considered a form of male sterilization. It can be reversed, but it is costly, not broadly available globally, and requires reanastomosis by a skilled surgeon. Vasovasotomy (to reverse a vasectomy) restores fertility in most men and results in pregnancy rates of up to 75% of couples (Herrel et al. 2015).

#### Condoms

With perfect use of condoms, pregnancy rates are 1–2% per year (Zhao et al. 2014), but the pregnancy rates with typical use are closer to 15–20% in the first year of use in fertile young couples using condoms as a sole contraceptive (Kost et al. 2008;

Fu et al. 1999; Steiner et al. 2003). Condoms with spermicide (nonoxynol-9) are no more effective and may cause local irritation to the female partner (World Health Organization 2002). The high failure rates are due primarily to inconsistent or incorrect use, but breakage or slippage occurs in up to 6% of episodes of condom use (D'Anna et al. 2012). There are few adverse effects of condoms, although many men and women feel that condoms decrease sexual pleasure (Martinez et al. 2006; Newby et al. 2013). Most condoms are made of latex, and some men and women develop latex allergies (Levy et al. 1998). For men and women who have latex allergies, polyurethane condoms are available, but they are less effective than latex condoms (Steiner et al. 2003; Gallo et al. 2006). An important noncontraceptive benefit of condoms is that they effectively prevent most sexually transmitted diseases including human immunodeficiency viral infections (Batár and Sivin 2010; Giannou et al. 2016).

---

## Experimental Male Contraceptives

### Hormonal Male Contraceptives

#### Mechanism of Action

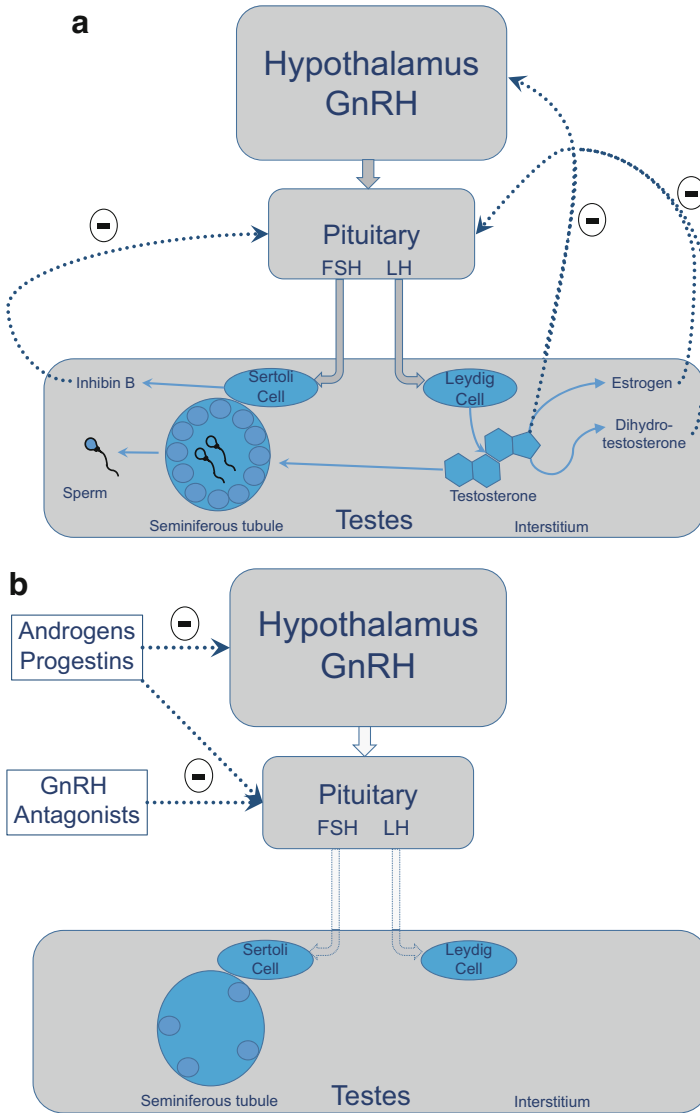
Male hormonal contraceptives act by inhibition of pituitary secretion of gonadotropins into the circulation, thereby removing the stimulus for endogenous testicular steroidogenesis and spermatogenesis (Fig. 1a and b). Profound suppression of gonadotropins and intratesticular testosterone results in a block in spermatogonial differentiation from pale type A spermatogonia to type B spermatogonia (McLachlan et al. 2002). Spermatogonia that have already differentiated into type B spermatogonia may complete the maturation process over the next 7–8 weeks (O'Donnell et al. 2011). Thus, complete effectiveness of male hormonal contraceptives is delayed by 6–12 weeks from the time of initial administration.

Because of suppression of testicular steroidogenesis, all forms of male hormonal contraception contain an androgen (to avoid inducing hypogonadism). Lack of or an inadequate dosage of an androgen in a male hormonal contraceptive results in hot flashes, decreased libido and sexual function, loss of bone density, and lean body mass. Testosterone alone and combinations of testosterone plus progestins and/or gonadotropin-releasing hormone antagonists have been studied as potential male hormonal contraceptives, and six efficacy studies have been published (Table 1). Novel compounds with androgenic and androgenic-progestogenic properties are being developed as potential male hormonal contraceptives.

### Testosterone-Alone Efficacy Studies

#### Short-Acting Injectable Testosterone-Alone Studies

Two World Health Organization (WHO) studies published in the 1990s proved the concept that androgen-based male hormonal contraceptives are effective and safe.



**Fig. 1** Panel (a) depicts the normal male hypothalamic-pituitary-gonadal axis. The hypothalamus produces gonadotropin-releasing hormone (*GnRH*) that stimulates the pituitary to produce and secrete follicle stimulating hormone (*FSH*) and luteinizing hormone (*LH*). *FSH* stimulates the Sertoli cells which foster spermatogenesis. *FSH* also stimulates inhibin B production from Sertoli cells; inhibin B suppresses *FSH* secretion by negative feedback. *LH* stimulates Leydig cells to make testosterone, estradiol, and dihydrotestosterone (*DHT*). These sex steroids inhibit *FSH* and *LH* secretion from the pituitary; estradiol is the most potent inhibitor of *LH* secretion. Panel (b) depicts the mechanisms of suppression of the normal male hypothalamic-pituitary-gonadal axis by current potential male hormonal contraceptives. Androgens and progestins suppress *FSH* and *LH* secretion

The first WHO testosterone-alone study enrolled 271 men from 10 centers in China, Australia, Europe, and the United States (World Health Organization Task Force on Methods for the Regulation of Male Fertility 1990). The men were healthy, and each was in a stable sexual relationship with a woman who was  $\leq 35$  years old and had regular menses. The men were administered 200 mg of intramuscular testosterone enanthate weekly for 6 months. After this 6-month suppression phase, the 157 men (58%) who became azoospermic were enrolled in a 12-month efficacy phase with continuation of weekly testosterone injections. During the efficacy phase, the men and their female partners did not use any other form of contraception. Only one pregnancy occurred among the 119 couples who completed the efficacy phase. The pregnancy rate of 0.8 per 100 person-years compares favorably with oral female contraceptives (Kubba et al. 2000). This initial WHO study demonstrated that an androgen-based regimen that suppressed spermatogenesis to azoospermia provides effective contraception.

The second international testosterone-alone WHO study was designed to evaluate the contraceptive effects of suppression to near-azoospermia (World Health Organization Task Force on Methods for the Regulation of Male Fertility 1996). In this nine-country study, 399 healthy, young men (123 from Asian and 276 from non-Asian countries) in stable heterosexual relationships were recruited. Eighty-six percent of the men had proven fertility prior to the study, and 77% had conceived children with their partners (with whom they had enrolled in the study). Of the men (89%) who completed the 6-month suppression phase of intramuscular testosterone enanthate (200 mg weekly), 98% suppressed to the target threshold ( $\leq 3$  million spermatozoa/mL). The combined pregnancy rate for the men whose sperm concentration suppressed to 0 to 3 million/mL was 1.4 per 100 person-years. The combined pregnancy rate for men whose sperm concentration suppressed to 0 to 1 million/mL was 0.7 per 100 person-years. Based on this study, the benchmark for potential male hormonal contraceptive studies has been the percentage of men whose sperm concentration suppresses to  $\leq 1$  million/mL (Nieschlag 2007).

### Longer-Acting Formulations of Testosterone-Alone Efficacy Studies

The WHO trials demonstrated that a supraphysiological dosage of testosterone (Anderson and Wu 1996) provides effective contraception for  $>95\%$  of healthy young men. However, these studies used testosterone enanthate, a formulation that must be administered every 1–2 weeks, and the dosage of testosterone was about twice the usual replacement therapy for male hypogonadism. It is unlikely that many men would be willing to use a contraceptive that requires 2–4 injections each month,



**Fig. 1** (continued) directly at the pituitary and indirectly by inhibiting hypothalamic secretion of GnRH. GnRH antagonists inhibit pituitary secretion of FSH and LH. When LH concentrations are suppressed, Leydig cell production of sex steroids is inhibited. When FSH concentrations are suppressed, Sertoli cell function is inhibited. The combined effects of suppression of FSH and LH result in decreased spermatogenesis (decreased sperm and sperm precursors)

**Table 1** Summary of testosterone-based male hormonal contraceptive efficacy trials

Trial	Regimen	Eligibility criteria for efficacy phase	Duration of efficacy phase	Efficacy based on entry into efficacy phase	Overall efficacy	Reference
First WHO trial	Testosterone enanthate 200 mg im weekly	0 million sperm/mL after 6 month-suppression phase	12 months	~1 per 100 person-years	NA	World Health Organization Task Force on Methods for the Regulation of Male Fertility <a href="#">1990</a>
Second WHO trial	Testosterone enanthate 200 mg im weekly	<3 million sperm/mL after 6 month-suppression phase	12 months	~2 per 100 person-years	~5 per 100 person-years	World Health Organization Task Force on Methods for the Regulation of Male Fertility <a href="#">1996</a>
First Chinese trial	Testosterone undecanoate 1000 mg followed by 500 mg monthly	<3 million sperm/mL after 6 month-suppression phase	12 months	<1 per 100 person-years	~5 per 100 person-years	Gu et al. <a href="#">2003</a>
Second Chinese trial	Testosterone undecanoate 1000 mg followed by 500 mg monthly	≤1 million sperm/mL after 6 month-suppression phase	24 months	~1 per 100 person-years	~6 per 100 person-years	Gu et al. <a href="#">2009</a>
Australian Trial	Testosterone pellets every 4 months plus depot medroxypro-gesterone every 3 months	<1 million sperm/mL after 6 month-suppression phase	12 months	0 per 100 person-years	<4 per 100 person-years	Turner et al. <a href="#">2003</a>
Third WHO trial	Testosterone undecanoate plus norethisterone every 8 weeks	≤1 million sperm/mL after 6 month-suppression phase	12 months	~2 per 100 person-years	NA	Behre et al. <a href="#">2016</a>

and there have been concerns about the long-term safety of using high dosages of androgen in normal men.

Two longer-acting formulations of testosterone have been studied as potential male hormonal contraceptives. The most promising testosterone formulation for use in male hormonal contraceptives is testosterone undecanoate (in sterile tea or sesame oil). Intramuscular testosterone undecanoate has been approved for use in most countries in the world. This formulation of testosterone maintains serum testosterone concentrations in the normal range when injected at intervals of up to 12 weeks (Fennell et al. 2010).

Two studies in China have demonstrated that intramuscular testosterone undecanoate is an effective hormonal contraceptive. In the first study (Gu et al. 2003), 308 men in stable heterosexual relationships were enrolled in a 6-month suppression phase (1000 mg initial dosage of intramuscular testosterone undecanoate followed by 500 mg monthly). Of the original cohort, 97% men had sperm concentrations suppress to  $<3$  million/mL during this phase, and these 296 men (and their partners) were enrolled in an additional 6-month efficacy phase (without use of other contraception). There was only 1 pregnancy in the 280 Chinese couples who completed the efficacy phase. Based on these promising results, a follow-up study (Gu et al. 2009) was conducted with 1045 young, healthy Chinese men in stable heterosexual relationships. The same regimen of intramuscular testosterone undecanoate was used (1000 mg initial dosage followed by 500 mg monthly) in a suppression phase of up to 6 months. Men whose sperm concentrations suppressed to severe oligozoospermia (sperm concentration  $\leq 1$  million/mL) and their partners were eligible to enroll in a 24-month efficacy phase. Of the original cohort, 893 couples completed the suppression phase and 95.2% of the male subjects had sperm concentrations that suppressed to severe oligozoospermia and enrolled in the efficacy phase. There were nine pregnancies during the efficacy phase with a cumulative pregnancy rate of 1.1 per 100 men for 2 years (0.55 per 100 person-years).

Using a long-acting injectable testosterone formulation, the Chinese studies confirmed the efficacy findings of the WHO shorter-acting testosterone-alone trials. The findings of the Chinese studies highlighted another finding that was noted in the original WHO trials (Handelsman et al. 1995): Asian men appeared to be significantly more likely to suppress to azoospermia than non-Asian men. In the Chinese and the WHO testosterone-alone trials, 90% or more of non-Asian men suppressed to azoospermia whereas only 70% of non-Asian men suppressed to azoospermia in the WHO testosterone-alone trials. Thus, a testosterone-alone male hormone contraceptive would be very effective in Asian countries, but it might be less effective in other areas of the world.

### **Testosterone Plus Progestin Combinations**

Progestogenic compounds suppress gonadotropin secretion, and several combinations of testosterone plus a progestin have been studied as potential male hormonal contraceptives (Meriggiola et al. 1996; Anawalt et al. 1999; Bebb et al. 1996; Gui et al. 2004; Anderson et al. 2002; Brady et al. 2006; Anawalt et al. 2000; Mommers



et al. 2008; Kinniburgh et al. 2001; Kinniburgh et al. 2002; Meriggiola et al. 2005; Kamischke et al. 2002; Gu et al. 2004; Page et al. 2006). In general, these studies have demonstrated more rapid and complete suppression of spermatogenesis with the addition of a progestin to testosterone (Liu et al. 2008). The addition of a progestin also appears to allow for a lower, more physiological dosage of testosterone than used in the WHO testosterone-alone trials without decreasing effectiveness of suppression. The lower dosage of testosterone may reduce androgenic side effects such as acne.

Although many testosterone-progestin regimens have been studied as potential male hormonal contraceptives, there have not been head-to-head comparative-effectiveness trials. In general, the testosterone-progestin regimens have been associated with weight gain and suppression of serum high density lipoprotein cholesterol concentrations. The androgenicity of the various progestins that have been studied is highly variable, and it is likely that novel, less androgenic progestins under development might be associated with less suppression of serum high density lipoprotein cholesterol.

### **Efficacy Trials of Testosterone Plus a Progestin**

There have been two efficacy studies of testosterone plus a progestin. In an Australian study, 55 married men were administered testosterone pellet implants every 4 months plus intramuscular depot medroxyprogesterone acetate (at a conventional dosage used for female contraception) every 3 months (Turner et al. 2003). The primary endpoint of the study was pregnancy. All male subjects entered a “suppression” phase of 6 months of testosterone pellets plus depot medroxyprogesterone. Couples used a barrier method of contraception during the suppression phase. For entry into the efficacy phase of the study, the male subjects were required to have two consecutive monthly seminal fluid samples with sperm concentrations of <1 million/mL after the suppression phase, and their wives had to have negative pregnancy tests. Two couples were excluded from the efficacy phase due to inadequate spermatogenic suppression in two men. In the 12-month efficacy phase, there were no pregnancies in the 53 enrolled couples.

Preliminary studies demonstrated that intramuscular testosterone undecanoate plus intramuscular norethisterone enanthate (a progestin with androgenic and progestogenic properties) injected every 8 weeks induced azoospermia or severe oligozoospermia in 100% of men ( $n = 20$ ) (Meriggiola et al. 2005). Based on these data, the WHO and CONRAD (a nonprofit organization based in the United States and funded by philanthropists) sponsored an efficacy study of injectable testosterone undecanoate and norethisterone enanthate (Behre et al. 2016). Eligible couples at 10 centers in Europe, South America, Asia, and Australia were entered a suppression phase of up to 26 weeks. During the suppression phase, the men received injections of testosterone undecanoate and norethisterone enanthate every 8 weeks. A couple was eligible to transition into the 56-week efficacy phase when the man had two consecutive semen samples with sperm concentrations  $\leq 1$  million/mL. During the efficacy phase, the couples used no other form of contraception. The Pearl index was calculated as 2.18 per 100 person-years, but the

true efficacy of this regimen is difficult to accurately assess because the study was stopped early in 2011. The study was terminated early based on the recommendations of an external safety review committee because of concern of adverse events (principally mood changes and depression). Adverse effects in this study included site injection, myalgias, emotional disorders, increased libido, and acne. More than 90% of the adverse effects related to emotional disorders occurred at one center, and all adverse effects on mood at this center were rated as "mild." The majority of the reports of injection site pain, myalgias, and increased libido also occurred at this same center. There was one suicide during the efficacy phase that was judged by the investigators to be unrelated to the study medications. There was also one case of depression (judged to be probably related to the study medications) and one attempted acetaminophen overdose (judged to be possibly related). Although this study confirmed previous findings that testosterone-based male hormonal contraceptives are very effective, this study raised concerns about the potential adverse effect of progestin-containing regimens on mood, a finding that requires further study.

### **Testosterone Plus Gonadotropin-Releasing Hormone Antagonists**

Although testosterone-alone and testosterone-progestin clinical trials have demonstrated that the majority of men have significant suppression of spermatogenesis with these regimens, 5–20% of men continue to produce sperm above the threshold of highly effective contraception (severe oligozoospermia). One postulated hypothesis to explain this nonuniform suppression has been that testosterone alone or current testosterone-progestin combinations do not suppress circulating gonadotropins enough in all men to achieve uniformly effective contraception.

Gonadotropin-releasing hormone (GnRH) antagonists suppress circulating gonadotropin concentrations within hours of administration, and it is plausible that the addition of a GnRH antagonist to androgen-based male hormonal contraceptive regimens would potentiate suppression of circulating gonadotropins and spermatogenesis.

There have been no efficacy trials of male hormonal contraceptive regimens that include a GnRH antagonist, but studies of an androgen plus short-acting GnRH antagonists have generally not demonstrated superior suppression of spermatogenesis. One study demonstrated that the combination of weekly injections of testosterone enanthate plus the daily injections of the short-acting GnRH antagonist Nal-Glu demonstrated no significant difference in the incidence of azoospermia compared to testosterone enanthate alone (Bagatell et al. 1993). A study using a suppression phase of testosterone enanthate plus Nal-Glu for 12 weeks followed by a maintenance phase of testosterone enanthate alone for another 20 weeks induced persistent azoospermia in 8/15 subjects and persistent suppression to sperm concentration less than 3 million/mL in 13/15 subjects (Swerdloff et al. 1998). The investigators did not report on suppression to severe oligozoospermia. Of note, a single study of another short-acting GnRH antagonist, cetrorelix, plus 19-nortestosterone (a nonaromatizable testosterone derivative) induced azoospermia by 12 weeks in 6/6 men (Behre et al. 2001).

A longer-acting GnRH antagonist, acyline, suppresses serum testosterone to concentrations associated with castration for 15 days after a single injection (Herbst et al. 2004). A study of testosterone plus depot medroxyprogesterone with or without acyline showed similar rates of suppression to severe oligozoospermia after 24 weeks of treatment (19/21 vs. 14/17). Overall, the addition of a short or longer-acting GnRH antagonist has not significantly improved the rate of suppression to severe oligozoospermia in studies of androgen-based male hormonal contraceptives.

### **Studies Including Daily Oral and Transdermal Formulations of Testosterone**

The route of delivery of testosterone affects its pharmacokinetics, side effects, and acceptability. Based on experience with female hormonal contraceptives, it is clinically useful to have multiple formulations and possible routes of administration. Although a long-acting injectable testosterone-based male hormonal contraceptive is the most likely candidate for a first commercially available product, other routes of administration have been investigated and should be further developed.

#### **Oral Formulations**

The “male pill” has been regarded by many as the ultimate goal of male hormonal contraception, but there is no oral formulation of testosterone or androgen that can be taken once daily and safely maintain eugonadism. An exploratory study of oral testosterone plus a progestin for 16 weeks did not cause enough spermatogenic suppression for effective contraception. Only 1/8 men suppressed to azoospermia while taking oral testosterone undecanoate (80 mg twice daily) plus cyproterone acetate (12.5 mg daily) (Merigiola et al. 1997). However, the study might have been too short (16 weeks) to assess full suppressive effects on spermatogenesis, and it did not report the incidence of severe oligozoospermia. Further studies of a “male pill” are awaiting development of an oral androgen that can be taken once daily.

#### **Transdermal Formulations**

Transdermal testosterone patch systems and gels are available for treatment of hypogonadism. These testosterone formulations are self-applied daily and are preferred by many men who are fearful of injectable formulations. Testosterone patches and gels have been studied as potential components of an androgen-based male hormonal contraceptive. Early studies indicated that testosterone patches plus a progestin were ineffective in suppressing spermatogenesis, with less than 50% of men suppressing to severe oligozoospermia (Buchter et al. 1999; Gonzalo et al. 2002; Hair et al. 2001), and a high percentage of men developed rash or other problems related to the testosterone patches (Hair et al. 2001). The lack of uniform spermatogenic suppression in these studies likely was due to lower serum testosterone concentrations during the treatment phase (Buchter et al. 1999; Hair et al. 2001). Some studies have demonstrated that transdermal testosterone plus oral, transdermal, or injectable progestin effectively suppress spermatogenesis (Soufir et al. 2011; Ilani et al. 2012). A descriptive study of transdermal testosterone plus oral medroxyprogesterone acetate demonstrated that the majority of men suppressed to severe

oligozoospermia on this regimen (Soufir et al. 2011). In addition, this regimen provided effective contraception for 25 couples who used it for up to 11 months as their sole contraceptive. This descriptive study, which was completed in the 1980s and published in 2011, was not designed as a true efficacy trial, but it provided early evidence of the potential effectiveness of a transdermal testosterone plus oral progestin male contraceptive regimen. In another study, testosterone gel plus nesterone gel induced severe oligozoospermia in 59/67 subjects (88%) with no or minimal adverse local reaction to the gels (Ilani et al. 2012). A combination gel of testosterone plus nesterone is under development, and a phase 2 efficacy study (sponsored by the National Institute of Health) of this combination is expected to be initiated soon. Because nesterone has little androgenic effect, a testosterone-nesterone gel might cause less suppression of serum high density lipoprotein concentrations than previously studied male hormonal contraceptive regimens. Finally, the combination of daily testosterone gel plus depot medroxyprogesterone injected every 3 months suppressed 90% (19/21) men to severe oligozoospermia (Page et al. 2006).

### **Testosterone Implants (Pellets)**

Testosterone subdermal implants were developed in the 1930s. These testosterone pellet implants provide nearly stable testosterone concentrations for 4–6 months, and they are used for treatment of male hypogonadism. Testosterone implants have been used in combination with progestin in several studies (Anderson et al. 2002; Kinniburgh et al. 2002; Turner et al. 2003; Brady et al. 2004) and achieved severe oligozoospermia in >90% of the subjects studied. As described in the testosterone-progestin efficacy section, the combination of testosterone pellets and depot medroxyprogesterone was highly efficacious in a 1-year contraceptive study (Turner et al. 2003). Although testosterone pellets are well tolerated and effective, implantation of these pellets is a minor surgical procedure that requires some training to perform. There is also a small risk of self-extrusion of these pellets (Kelleher et al. 2004). Finally, testosterone pellets have been largely replaced by long-acting injectable testosterone undecanoate for the treatment of male hypogonadism and as a component of a testosterone-based male hormonal contraceptive. These two long-acting testosterone formulations are clinically and pharmacodynamically similar, but the majority of men (>90%) preferred injectable testosterone undecanoate over implantable testosterone pellets (Fennell et al. 2010).

### **Adverse Effects of Male Hormonal Contraceptives**

In general, the adverse effects of testosterone-based male hormonal contraceptives have been modest. The most common side effects have been acne and weight gain (2–4 kg). Most studies of male hormonal contraceptives have also demonstrated a decline in serum high density cholesterol concentrations. In the only placebo-controlled trial of a potential male hormonal contraceptive, 9% of men in the active treatment groups discontinued due to an adverse event compared to 6% in the placebo group after 44 weeks of etonogestrel implants plus intramuscular

testosterone undecanoate versus placebo implants and injections (Mommers et al. 2008). Acne, body weight increase, libido change (the majority reported increased libido), mood changes, and night sweats occurred more commonly in the active treatment groups compared to placebo.

There has been no evidence to suggest that male hormonal contraceptives increase the risk of gynecomastia, prostate disease, or cardiovascular events, but the studies have been done in healthy men who are young or middle-aged (18–50 years). The clinical trials have only been 1 to 2.5 years, and they have not been designed to identify cardiovascular, thrombotic, or prostatic events. Concerns about the safety of long-term administration of androgens and progestins remain a major barrier for the successful development of a marketable male hormonal contraceptive.

An integrated analysis of several male hormonal contraceptives demonstrated that the suppressive effects on spermatogenesis are fully reversible (Liu et al. 2006). Sperm concentrations return to normal generally within 6–12 months after cessation of an androgen-based contraceptive regimen with longer times to recovery (up to 2 years) with longer-acting formulations.

### **Potential Acceptability of Male Hormonal Contraceptives**

There is some question whether men would use a male hormonal contraceptive. A survey of almost 2000 men in Scotland, South Africa, and China in the late 1990s indicated that the majority of men would welcome the possibility of a male hormonal contraceptive pill (Martin et al. 2000). A more recent multinational survey confirmed significant interest in a hypothetical hormonal contraceptive in a broad range of cultures and ethnic groups (Heinemann et al. 2005a, b). Surveys of men involved in male hormonal contraceptive trials using gels or injectable formulations have demonstrated that the majority of participants were satisfied with the hormonal contraceptive and would recommend it to other men if it were commercially available (Roth et al. 2014; Amory et al. 2007; Meriggiola et al. 2006; Ringheim 1995; Zhang et al. 2006; Sjogren and Gottlieb 2001). Although these questionnaires of men who participated in clinical trials might not reflect the general population, they indicate that a significant percentage of men would be interested in a safe, effective, and reversible male hormonal contraceptive. In addition, in one survey of nearly 2000 women in Scotland, China, and South Africa, the majority of women in a stable relationship with a male sexual partner indicated that they would trust their partner to use a male hormonal contraceptive and welcomed sharing the responsibility of contraception with their male partners (Martin et al. 2000). Thus, many men and women would be enthusiastic about the development and use of male hormonal contraceptives.

### **Hypotheses on Nonuniform Suppression of Spermatogenesis**

A number of hypotheses have been posited to explain why 5–20% of men fail to suppress to severe oligozoospermia. First, incomplete suppression of circulating gonadotropins might permit persistent spermatogenesis in some men. Although

analyses of multiple male hormonal contraceptives have failed to demonstrate significant differences in serum FSH or LH concentrations in men who suppress to severe *oligozoospermia* vs. those who do not (Liu et al. 2008; McLachlan et al. 2004), these analyses are not definitively conclusive because serum gonadotropins suppress to or below the lower limit of quantification with even the best modern assays. Thus, there might be small, but significant, differences in suppression of serum gonadotropin concentrations in those men who suppress to severe oligozoospermia and those who do not. In addition, there might be differential responsivity (e.g., due to differential expression of coactivators or receptor polymorphisms) to circulating gonadotropins such that very low concentrations of gonadotropins maintain spermatogenesis more in some men than others. Another hypothesis is that persistent, gonadotropin-independent testicular steroidogenesis is sufficient to maintain spermatogenesis in some men even when circulating gonadotropin concentrations are markedly suppressed (Page et al. 2008; Oduwole et al. 2014). Intratesticular testosterone concentrations suppressed from normal levels (60–100-fold higher than normal serum testosterone concentrations), but were still comparable to normal or slightly supranormal serum concentrations even when circulating gonadotropins are suppressed to the lower limit of detectability (Roth et al. 2013; Page et al. 2007). Further studies must be done in humans to determine whether there is a threshold intratesticular testosterone concentration necessary to maintain some degree of spermatogenesis.

## **Novel Candidates for Hormonal Contraceptives**

### **Novel Synthetic Androgens**

There has been much progress in understanding the physiological effects of androgens in the past two decades, and this has led to significant progress in the development of synthetic androgens that might be useful for male hormonal contraception. In men, testosterone is  $5\alpha$ -reduced to dihydrotestosterone and aromatized to estradiol. Conversion to dihydrotestosterone is very high in the prostate where  $5\alpha$ -reductase type 2 is highly expressed, and this potent androgen stimulates prostate growth (Bartsch et al. 1990). Aromatase is highly expressed in bone, fat, and the brain, and estradiol has been demonstrated to be important for normal bone health, body composition, and sexual function in men (Finkelstein et al. 2013). Both enzymes are also expressed in the testes, but the specific roles of dihydrotestosterone and estradiol in testicular function remains to be elucidated.

Two synthetic androgens are being investigated as potentially promising candidates for male hormonal contraception. A derivative of 19-nortestosterone,  $7\alpha$ -methyl-19-nortestosterone (MeNT), is resistant to  $5\alpha$ -reductase inhibition but is aromatized to an estrogen that binds human estrogen receptors and has estrogenic activity in nonhuman animal models (LaMorte et al. 1994; Beri et al. 1998). In an initial 1-year study of implantable MeNT, 8/11 of men developed severe oligozoospermia with four implants (von Eckardstein et al. 2003). Subsequent studies of MeNT plus a progestin demonstrated that there was a design flaw in

the implants that prevented sustained and adequate release of MeNT and have stalled future investigation of MeNT in a male contraceptive regimen (Nieschlag et al. 2013). Prototypes of revamped MeNT implants are being manufactured for future studies; it will likely be studied in combination with a long-acting progestin to ensure uniform suppression of spermatogenesis.

Dimethandrolone undecanoate is another 19-nortestosterone derivative that has androgenic and progestogenic properties. Like MeNT, dimethandrolone undecanoate and its active metabolite, dimethandrolone, are not 5 $\alpha$ -reduced (Attardi et al. 2010). Unlike MeNT, they also might not be aromatizable and therefore might not confer the favorable benefits of estrogen on male physiology (Attardi et al. 2008), but a study in rats demonstrated that administration of dimethandrolone was associated with favorable changes in body composition and maintenance of bone mineral density (Attardi et al. 2011). Early human studies of dimethandrolone undecanoate indicate that it appears to be safe when administered orally and that it significantly suppresses circulating gonadotropin and testosterone concentrations (Surampudi et al. 2014). Dimethandrolone undecanoate is a promising candidate for a single-compound male contraceptive pill.

### **Inhibitors of Testosterone Synthesis**

Because it is possible that LH-independent testicular androgen production is sufficient to maintain spermatogenesis in some men treated with regimens that suppress serum concentrations, an inhibitor of intratesticular testosterone production might be an effective adjunct in a male hormonal contraceptive. One study has demonstrated that the addition of an inhibitor of testosterone synthesis decreases intratesticular testosterone concentrations significantly more than a GnRH antagonist alone (Roth et al. 2013). However, currently available inhibitors of testosterone production such as ketoconazole and abiraterone also inhibit production of cortisol and may cause mineralocorticoid excess in many men and potentially glucocorticoid deficiency in some men (Vasaitis et al. 2011). Inhibitors with more specific inhibition of testosterone production are under development for treatment of prostate cancer, and such drugs could be useful for male hormonal contraception.

### **Conclusions About Male Hormonal Contraception**

A long-acting injectable formulation is likely to be the first male hormonal contraceptive to become commercially available. The contraceptive trials using long-acting hormonal contraceptives have established that such regimens are safe and effective. The major challenges for producing a commercial male hormonal contraceptive are the lack of a single delivery system (e.g., a single long-acting injectable, gel, or pill with an androgen plus a progestin), a persistent skepticism about the efficacy of a product that permits persistent, albeit markedly suppressed spermatogenesis, and concerns about whether single men or couples would use a male hormonal contraceptive. These challenges coupled with heightened regulatory requirements for demonstration of safety have resulted in low levels of investment by pharmaceutical companies during the past decade. There has continued to be

financial support from the National Institute of Health, however, and this investment has been essential for continued further research and development.

---

## Nonhormonal Contraceptives

The most promising novel mechanical (barrier) method as an alternative to the condom or vasectomy is reversible inhibition of sperm under guidance (more commonly known by its acronym, RISUG). This method involves the injection of a solution of styrene maleic anhydride into the vasa deferentia (Lohiya et al. 2014). Styrene maleic anhydride, a clear polymer, forms a plug and nearly completely occludes the vasa. It induces infertility by preventing sperm from being ejaculated and causing deleterious morphological aberrations in the spermatozoa that manage to pass around the occlusive plug. A phase III study demonstrated that 25/25 subjects became azoospermic within 4 months after RISUG administration (Chaki et al. 2003). The majority (84%) became azoospermic within 2 months after RISUG administration. RISUG is reversible; the RISUG plug can be extruded into the urethra by the injection of a sodium bicarbonate solution proximally into the vas deferens. An extended phase III clinical trial has been conducted, but the results have not been published.

There are a number of nonhormonal male contraceptives that have been considered as potential candidates for drug development, but none of them have been tested in men. The most promising candidates include gamendazole, molecular inhibitors of an epididymal protease inhibitor (Eppin) and inhibitors of testis-specific aldehyde dehydrogenase. Gamendazole is a nonsteroidal molecule that has anti-spermatogenesis activity and is small enough to pass through the blood-testis barrier (Tash et al. 2008a, b). A single dose of gamendazole rendered 7/7 male rats infertile, but only 4/7 recovered fertility (Tash et al. 2008b). Lower dosages are being investigated for possible testing in men. Eppin, a seminal fluid protein, has a number of physiological functions including regulating the activation of sperm motility and preventing proteolysis of spermatozoa in the female reproductive tract (O'Rand et al. 2016). Immunization against Eppin caused reversible infertility in 7/9 male monkeys (O'Rand et al. 2004), and there is work being done to develop small molecular inhibitors of Eppin (O'Rand et al. 2016).

Based on the observation that the active metabolite of vitamin A, retinoic acid, is essential for spermatogenesis, investigators have been developing specific inhibitors of testicular retinoic acid biosynthesis. Oral administration of WIN 18446 reduces intratesticular retinoic acid biosynthesis by inhibiting testicular aldehyde dehydrogenase and spermatogenesis in rabbits (Amory et al. 2011). WIN 18846 has also been shown to induce reversible spermatogenic suppression in men (Heller et al. 1961). Because WIN18846 is a nonspecific inhibitor of aldehyde dehydrogenase, it causes nausea and vomiting when taken with alcohol. A more specific inhibitor of the testis-specific aldehyde dehydrogenase (ALDH1A2) could result in reversible male contraceptive without significant extratesticular effects. Such inhibitors are under development.



## Summary and Conclusions About Male Contraceptives

There are a number of potential male contraceptives on the horizon. Androgen-based contraceptives are the most highly developed and studied novel forms of male birth control, and it is likely that a male hormonal contraceptive will be the first new male contraceptive available commercially. However, some nonhormonal compounds hold promise as male contraceptives or as adjunctive compounds with a hormonal contraceptive. A novel male contraceptive would be a welcome addition for men who would like to control their reproductive fate and for heterosexual couples who would like additional options for determining the timing and number of children in their families.

---

## References

- Amory JK, Page ST, Anawalt BD, Matsumoto AM, Bremner WJ. Acceptability of a combination testosterone gel and depomedroxyprogesterone acetate male contraceptive regimen. *Contraception*. 2007;75:218–23.
- Amory JK, Muller CH, Shimshoni AJ, Isoherranen N, Paik J, Moreb JS, et al. Suppression of spermatogenesis by bisdichloroacetyldiamines is mediated by inhibition of testicular retinoic acid biosynthesis. *J Androl*. 2011;32:111–9.
- Anawalt BD, Bebb RA, Bremner WJ, Matsumoto AM. A lower dosage levonorgestrel and testosterone combination effectively suppresses spermatogenesis and circulating gonadotropin levels with fewer metabolic effects than higher dosage combinations. *J Androl*. 1999;20:407–14.
- Anawalt BD, Herbst KL, Matsumoto AM, Mulders TM, Coelingh-Bennink HJ, Bremner WJ. Desogestrel plus testosterone effectively suppresses spermatogenesis but also causes modest weight gain and high-density lipoprotein suppression. *Fertil Steril*. 2000;74:707–14.
- Anderson R, Wu FCW. Comparison between testosterone enanthate-induced azoosperm and oligozoospermia in a male contraceptive study. II. Pharmacokinetics and pharmacodynamics of once weekly administration of testosterone enanthate. *J Clin Endocrinol Metab*. 1996;81:896–901.
- Anderson RA, Kinniburgh D, Baird DT. Suppression of spermatogenesis by etonogestrel implants with depot testosterone: potential for long-acting male contraception. *J Clin Endocrinol Metab*. 2002;87:3640–9.
- Attardi BJ, Pham TC, Radler LC, Burgenson J, Hild SA, Reel JR. Dimethandrolone (7alpha,11beta-dimethyl-19-nortestosterone) and 11betamethyl-19-nortestosterone are not converted to aromatic A-ring products in the presence of recombinant human aromatase. *J Steroid Biochem Mol Biol*. 2008;110:214–22.
- Attardi BJ, Hild SA, Koduri S, Pham T, Pessaint L, Engbring J, et al. The potent synthetic androgens, dimethandrolone (7alpha,11beta-dimethyl-19-nortestosterone) and 11beta-methyl-19-nortestosterone, do not require 5alphareduction to exert their maximal androgenic effects. *J Steroid Biochem Mol Biol*. 2010;122:212–8.
- Attardi BJ, Marck BT, Matsumoto AM, Koduri S, Hild SA. Long-term effects of dimethandrolone 17beta-undecanoate and 11beta-methyl-19-17beta-dodecylcarbonate on body composition, bone mineral density, serum gonadotropins, and androgenic/anabolic activity in castrated male rats. *J Androl*. 2011;32:183–92.
- Bagatell CJ, Matsumoto AM, Christensen RB, Rivier JE, Bremner WJ. Comparison of a gonadotropin releasing-hormone antagonist plus testosterone (T) versus T alone as potential male contraceptive regimens. *J Clin Endocrinol Metab*. 1993;77:427–32.

- Bartsch W, Klein H, Schiemann U, Bauer HW, Voigt KD. Enzymes of androgen formation and degradation in the human prostate. *Ann N Y Acad Sci.* 1990;595:53–66.
- Batár I, Sivin I. State-of-the-art of non-hormonal methods of contraception: I. Mechanical barrier contraception. *Eur J Contracept Reprod Health Care.* 2010;15(2):67–88.
- Bebb RA, Anawalt BD, Christensen RB, Paulsen CA, Bremner WJ, Matsumoto AM. Combined administration of levonorgestrel and testosterone induces more rapid and effective suppression of spermatogenesis than testosterone alone: a promising male contraceptive approach. *J Clin Endocrinol Metab.* 1996;81:757–62.
- Behre HM, Kliesch S, Lemcke B, von Eckardstein S, Nieschlag E. Suppression of spermatogenesis to azoospermia by combined administration of GnRH antagonist and 19-nortestosterone cannot be maintained by this non-aromatizable androgen alone. *Hum Reprod.* 2001;16:2570–7.
- Behre HM, Zitzmann M, Anderson RA, Handelsman DJ, Lestari SW, McLachlan RI, et al. Efficacy and safety of an injectable combination hormonal contraceptive for men. *J Clin Endocrinol Metab.* 2016. in press.
- Beri R, Kumar N, Savage T, Benalcazar L, Sundaram K. Estrogenic and progestational activity of 7alpha-methyl-19-nortestosterone, a synthetic androgen. *J Steroid Biochem Mol Biol.* 1998;67:275–83.
- Brady BM, Walton M, Hollow N, Kicman AT, Baird DT, Anderson RA. Depot testosterone with etonogestrel implants result in induction of azoospermia in all men for long-term contraception. *Hum Reprod.* 2004;19:2658–67.
- Brady BM, Amory JK, Perheentupa A, Zitzmann M, Hay CJ, Apter D, et al. A multicentre study investigating subcutaneous etonogestrel implants with injectable testosterone decanoate as a potential long-acting male contraceptive. *Hum Reprod.* 2006;21:285–94.
- Buchter D, von Eckardstein S, von Eckardstein A, Kamischke A, Simoni M, Behre HM, et al. Clinical trial of transdermal testosterone and oral levonorgestrel for male contraception. *J Clin Endocrinol Metab.* 1999;84:1244–9.
- Chaki SP1, Das HC, Misro MM. A short-term evaluation of semen and accessory sex gland function in phase III trial subjects receiving intravasal contraceptive RISUG. *Contraception.* 2003;67(1):73–8.
- Daniels K, Daugherty J, Jones J, Mosher W. Current contraceptive use and variation by selected characteristics among women aged 15–44: United States, 2011–2013. *Natl Health Stat Report.* 2015;86:1–14.
- D'Anna LH, Korosteleva O, Warner L, Douglas J, Paul S, Metcalf C, et al. Factors associated with condom use problems during vaginal sex with main and nonmain partners. *Sex Transm Dis.* 2012;39:687–9.
- Darroch JE. Trends in contraceptive use. *Contraception.* 2013;8:259–63.
- Drake MJ, Mills IW, Cranston D. On the chequered history of vasectomy. *BJU Int.* 1999;84:475–81.
- von Eckardstein S, Noe G, Brache V, Nieschlag E, Croxatto H, Alvarez F, et al. A clinical trial of 7 alpha-methyl-19-nortestosterone implants for possible use as a long-acting contraceptive for men. *J Clin Endocrinol Metab.* 2003;88:5232–9.
- Fennell C, Sartorius G, Ly LP, Turner L, Liu PY, Conway AJ, Handelsman DJ. Randomized crossover clinical trial of injectable vs. implantable depot testosterone for maintenance of testosterone replacement therapy in androgen deficient men. *Clin Endocrinol (Oxf).* 2010;73:102–9.
- Finkelstein JS, Lee H, Burnett-Bowie SA, Pallais JC, Yu EW, Borges LF, Leder BZ. Gonadal steroids and body composition, strength, and sexual function in men. *N Engl J Med.* 2013;369:1011–22.
- Fu H, Darroch JE, Haas T, Ranjit N. Contraceptive failure rates: new estimates from the 1995 National Survey of Family Growth. *Fam Plan Perspect.* 1999;31:56–84.
- Gallo MF, Grimes DA, Lopez LM, Schulz KF. Nonlatex versus latex male condoms for contraception. *Cochrane Database Syst Rev.* 2006:CD003550.
- Giannou FK, Tsiara CG, Nikolopoulos GK, Talias M, Benetou V, Kantzanou M, et al. Condom effectiveness in reducing heterosexual HIV transmission: a systematic review and meta-analysis

- of studies on HIV serodiscordant couples. *Expert Rev Pharmacoecon Outcomes Res.* 2016;16:489–99.
- Gonzalo IT, Swerdloff RS, Nelson AL, Clevenger B, Garcia R, Berman N, Wang C. Levonorgestrel implants (Norplant II) for male contraception clinical trials: combination with transdermal and injectable testosterone. *J Clin Endocrinol Metab.* 2002;87:3562–72.
- Gu YQ, Wang XH, Xu D, Peng L, Cheng LF, Huang MK, et al. A multicenter contraceptive efficacy study of injectable testosterone undecanoate in healthy Chinese men. *J Clin Endocrinol Metab.* 2003;88:562–8.
- Gu YQ, Tong JS, Ma DZ, Wang XH, Yuan D, Tang WH, et al. Male hormonal contraception: effects of injections of testosterone undecanoate and depot medroxyprogesterone acetate at eight-week intervals in Chinese men. *J Clin Endocrinol Metab.* 2004;89:2254–62.
- Gu Y, Liang X, Wu W, Liu M, Song S, Cheng L, et al. Multicenter contraceptive efficacy trial of injectable testosterone undecanoate in Chinese men. *J Clin Endocrinol Metab.* 2009;94:1910–5.
- Gui YL, He CH, Amory JK, Bremner WJ, Zheng EX, Yang J, et al. Male hormonal contraception: suppression of spermatogenesis by injectable testosterone undecanoate alone or with levonorgestrel implants in Chinese men. *J Androl.* 2004;25:720–7.
- Hair WM, Kitteridge K, O'Connor DB, Wu FC. A novel male contraceptive pill-patch combination: oral desogestrel and transdermal testosterone in the suppression of spermatogenesis in normal men. *J Clin Endocrinol Metab.* 2001;86:5201–9.
- Handelsman DJ, Farley TM, Peregoudov A, Waites GM. Factors in nonuniform suppression of azoospermia by testosterone enanthate in normal men. World Health Organization Task Force on methods for the regulation of male fertility. *Fertil Steril.* 1995;63:125–33.
- Heinemann K, Saad F, Wiesemes M, White S, Heinemann LA. Attitudes toward male fertility control: results of a multinational survey on four continents. *Hum Reprod.* 2005a;20:549–56.
- Heinemann K, Saad F, Wiesemes M, Heinemann LA. Expectations toward a novel male fertility control method and potential user types: results of a multinational survey. *J Androl.* 2005b;26:155–62.
- Heller CG, Moore DJ, Paulsen CA. Suppression of spermatogenesis and chronic toxicity in men by a new series of bis(dichloroacetyl) diamines. *Toxicol Appl Pharmacol.* 1961;3:1–11.
- Herbst KL, Coviello AD, Page S, Amory JK, Anawalt BD, Bremner WJ. A single dose of the potent gonadotropin-releasing hormone antagonist acyline suppresses gonadotropins and testosterone for 2 weeks in healthy young men. *J Clin Endocrinol Metab.* 2004;89:5959–65.
- Herrel LA, Goodman M, Goldstein M, Hsiao W. Outcomes of microsurgical vasovasostomy for vasectomy reversal: a meta-analysis and systematic review. *Urology.* 2015;85:819–25.
- Huber D. No-scalpel vasectomy: the transfer of a refined surgical technique from China to other countries. *Adv Contracept.* 1989;5:217–8.
- Ilani N, Roth MY, Amory JK, Swerdloff RS, Dart C, Page ST, et al. A new combination of testosterone and nesterone transdermal gels for male hormonal contraception. *J Clin Endocrinol Metab.* 2012;97:3476–86.
- Kamischke A, Heuermann T, Kruger K, von Eckardstein S, Schellschmidt I, Rubig A, et al. An effective hormonal male contraceptive using testosterone undecanoate with oral or injectable norethisterone preparations. *J Clin Endocrinol Metab.* 2002;87:530–9.
- Kelleher S, Howe C, Conway AJ, Handelsman DJ. Testosterone release rate and duration of action of testosterone pellet implants. *Clin Endocrinol.* 2004;60:420–8.
- Kinniburgh D, Anderson RA, Baird DT. Suppression of spermatogenesis with desogestrel and testosterone pellets is not enhanced by addition of finasteride. *J Androl.* 2001;22:88–95.
- Kinniburgh D, Zhu H, Cheng L, Kicman AT, Baird DT, Anderson RA. Oral desogestrel with testosterone pellets induces consistent suppression of spermatogenesis to azoospermia in both Caucasian and Chinese men. *Hum Reprod.* 2002;17:1490–501.
- Kost K, Singh S, Vaughan B, Trussell J, Bankole A. Estimates of contraceptive failure from the 2002 National Survey of Family Growth. *Contraception.* 2008;77:10–21.
- Kubba A, Guillebaud J, Anderson R, MacGregor E. Contraception. *Lancet.* 2000;356:1913–9.

- LaMorte A, Kumar N, Bardin CW, Sundaram K. Aromatization of 7 $\alpha$ -methyl-19-nortestosterone by human placental microsomes in vitro. *J Steroid Biochem Mol Biol.* 1994;48:297–304.
- Levy DA, Khouader S, Leynadier F. Allergy to latex condoms. *Allergy.* 1998;53:110–2.
- Li L, Shao J, Wang X. Percutaneous no-scalpel vasectomy via one puncture in China. *Urol J.* 2014;11:1452–6.
- Liu PY, Swerdloff RS, Christenson PD, Handelsman DJ, Wang C. Rate, extent, and modifiers of spermatogenic recovery after hormonal male contraception: an integrated analysis. *Lancet.* 2006;367(9520):1412–20.
- Liu PY, Swerdloff RS, Anawalt BD, Anderson RA, Bremner WJ, Elliesen J, et al. Determinants of the rate and extent of spermatogenic suppression during hormonal male contraception: an integrated analysis. *J Clin Endocrinol Metab.* 2008;93:1774–83.
- Lohiya NK, Alam I, Hussain M, Khan SR, Ansari AS. RISUG: an intravasal injectable male contraceptive. *Indian J Med Res.* 2014;140(Suppl):S63–72. Review.
- Martin CW, Anderson RA, Cheng L, Ho PC, van der Spuy Z, Smith KB, et al. Potential impact of hormonal male contraception: cross-cultural implications for development of novel preparations. *Hum Reprod.* 2000;15:637–45.
- Martinez GM, Chandra A, Abma JC, Jones J, Mosher WD. Fertility, contraception, and fatherhood: data on men and women from cycle 6 (2002) of the 2002 National Survey of Family Growth. *Vital Health Stat 23.* 2006;26:1–142.
- McLachlan RI, O'Donnell L, Stanton PG, Balourdos G, Frydenberg M, de Kretser DM, et al. Effects of testosterone plus medroxyprogesterone acetate on semen quality, reproductive hormones, and germ cell populations in normal young men. *J Clin Endocrinol Metab.* 2002;87:546–56.
- McLachlan RI, Robertson DM, Pruyers E, Ugoni A, Matsumoto AM, Anawalt BD, Bremner WJ, Meriggiola C. Relationship between serum gonadotropins and spermatogenic suppression in men undergoing steroidal contraceptive treatment. *J Clin Endocrinol Metab.* 2004;89:142–9.
- McMahon AJ, Buckley J, Taylor A, Lloyd SN, Deane RF, Kirk D. Chronic testicular pain following vasectomy. *Br J Urol.* 1992;69:188–91.
- Meriggiola MC, Bremner WJ, Paulsen CA, Valdiserri A, Incorvaia L, Motta R, et al. A combined regimen of cyproterone acetate and testosterone enanthate as a potentially highly effective male contraceptive. *J Clin Endocrinol Metab.* 1996;81:3018–23.
- Meriggiola MC, Bremner WJ, Costantino A, Pavani A, Capelli M, Flamigni C. An oral regimen of cyproterone acetate and testosterone undecanoate for spermatogenic suppression in men. *Fertil Steril.* 1997;68:844–50.
- Meriggiola MC, Costantino A, Saad F, D'Emidio L, Morselli Labate AM, Bertaccini A, et al. Norethisterone enanthate plus testosterone undecanoate for male contraception: effects of various injection intervals on spermatogenesis, reproductive hormones, testis, and prostate. *J Clin Endocrinol Metab.* 2005;90:2005–14.
- Meriggiola MC, Cerpolini S, Bremner WJ, Mbizvo MT, Vogelsong KM, Martorana G, et al. Acceptability of an injectable male contraceptive regimen of norethisterone enanthate and testosterone undecanoate for men. *Hum Reprod.* 2006;21:2033–40.
- Mommers E, Kersemaekers WM, Elliesen J, Kepers M, Apter D, Behre HM, et al. Male hormonal contraception: a double-blind, placebo-controlled study. *J Clin Endocrinol Metab.* 2008;93:2572–80.
- Mosher WD, Jones J. Use of contraception in the United States: 1982–2008. *Vital Health Stat.* 2010;23:23.
- Newby KV, Brown KE, French DP, Wallace LM. Which outcome expectancies are important in determining young adults' intentions to use condoms with casual sexual partners? A cross-sectional study. *BMC Public Health.* 2013;13:133–41.
- Nieschlag E. 10th Summit Meeting consensus: recommendations for regulatory approval for hormonal male contraception. October 22–23, 2006. *Contraception.* 2007;75:166–7.

- Nieschlag E, Kumar N, Sitruk-Ware R. 7 $\alpha$ -methyl-19-nortestosterone (MENTR): the population council's contribution to research on male contraception and treatment of hypogonadism. *Contraception*. 2013;87:288–95.
- O'Donnell L, Nicholls PK, O'Bryan MK, McLachlan RI, Stanton PG. Spermiation: the process of sperm release. *Spermatogenesis*. 2011;1:14–35.
- Oduwole OO, Vydra N, Wood NE, Samanta L, Owen L, Keevil B, Donaldson M, Naresh K, Huhtaniemi IT. Overlapping dose responses of spermatogenic and extragonadal testosterone actions jeopardize the principle of hormonal male contraception. *FASEB J*. 2014;28:2566–76.
- O'Rand MG, Widgren EE, Sivashanmugam P, Richardson RT, Hall SH, French FS, et al. Reversible immunocontraception in male monkeys immunized with eppin. *Science*. 2004;306:1189–90.
- O'Rand MG, Silva EJ, Hamil KG. Non-hormonal male contraception: a review and development of an Eppin based contraceptive. *Pharmacol Ther*. 2016;157:105–11.
- Page ST, Amory JK, Anawalt BD, Irwig MS, Brockenbrough AT, Matsumoto AM, Bremner WJ. Testosterone gel combined with depomedroxyprogesterone acetate is an effective male hormonal contraceptive regimen and is not enhanced by the addition of a GnRH antagonist. *J Clin Endocrinol Metab*. 2006;91:4374–80.
- Page ST, Kalhorn TF, Bremner WJ, Anawalt BD, Matsumoto AM, Amory JK. Intratesticular androgens and spermatogenesis during severe gonadotropin suppression induced by male hormonal contraceptive treatment. *J Androl*. 2007;28:734–41.
- Page ST, Amory JK, Bremner WJ. Advances in male contraception. *Endocr Rev*. 2008;29:465–93.
- Pile JM, Barone MA. Demographics of vasectomy – USA and international. *Urol Clin North Am*. 2009;36:295–305.
- Population Reference Bureau. Family planning worldwide 2008 data sheet. 2008. New York City, New York. [www.prb.org/pdf08/fpds08.pdf](http://www.prb.org/pdf08/fpds08.pdf).
- Ringheim K. Evidence for the acceptability of an injectable hormonal method for men. *Fam Plan Perspect*. 1995;27:123–8.
- Roth MY, Nya-Ngatchou JJ, Lin K, Page ST, Anawalt BD, Matsumoto AM, et al. Androgen synthesis in the gonadotropin-suppressed human testes can be markedly suppressed by ketocozazole. *J Clin Endocrinol Metab*. 2013;98:1198–206.
- Roth MY, Shih G, Ilani N, Wang C, Page ST, Bremner WJ, Swerdloff RS, Sitruk-Ware R, Blithe DL, Amory JK. Acceptability of a transdermal gel-based male hormonal contraceptive in a randomized controlled trial. *Contraception*. 2014;90:407–12.
- Sharlip ID, Belker AM, Honig S, Labrecque M, Marmar JL, Ross LS, et al. Vasectomy: AUA guideline. *J Urol*. 2012;188:2482–91.
- Shih G, Turok DK, Parker WJ. Vasectomy: the other (better) form of sterilization. *Contraception*. 2011;83:310–5.
- Sjogren B, Gottlieb C. Testosterone for male contraception during one year: attitudes, well-being and quality of sex life. *Contraception*. 2001;64:59–65.
- Soufiri JC, Meduri G, Ziyat A. Spermatogenic inhibition in men taking a combination of oral medroxyprogesterone acetate and percutaneous testosterone as a male contraceptive method. *Hum Reprod*. 2011;26:1708–14.
- Steiner MJ, Dominik R, Rountree RW, Nanda K, Dorflinger LJ. Contraceptive effectiveness of a polyurethane condom and a latex condom: a randomized controlled trial. *Obstet Gynecol*. 2003;101:539–47.
- Surampudi P, Page ST, Swerdloff RS, Nya-Ngatchou JJ, Liu PY, Amory JK, et al. Single, escalating dose pharmacokinetics, safety and food effects of a new oral androgen dimethandrolone undecanoate in man: a prototype oral male hormonal contraceptive. *Andrology*. 2014;2:579–87.
- Swerdloff RS, Bagatell CJ, Wang C, Anawalt BD, Berman N, Steiner B, et al. Suppression of spermatogenesis in man induced by Nal-Glu gonadotropin releasing hormone antagonist and testosterone enanthate (TE) is maintained by TE alone. *J Clin Endocrinol Metab*. 1998;88:4659–67.

- Tash JS, Chakrasali R, Jakkraj SR, Hughes J, Smith SK, Hornbaker K, et al. Gamendazole, an orally active indazole carboxylic acid male contraceptive agent, targets HSP90AB1 and EEF1A1, and stimulates IIIa transcription in rat Sertoli cells. *Biol Reprod.* 2008a;78:1139–52.
- Tash JS, Attardi B, Hild SA, Chakrasali R, Jakkraj SR, Georg GI. A novel potent indazole carboxylic acid derivative blocks spermatogenesis and is contraceptive in rats after a single oral dose. *Biol Reprod.* 2008b;78:1127–38.
- Trussell J. Contraceptive failure in the United States. *Contraception.* 2011;83:397–404.
- Turner L, Conway AJ, Jimenez M, Liu PY, Forbes E, McLachlan RI, et al. Contraceptive efficacy of a depot progestin and androgen combination in men. *J Clin Endocrinol Metab.* 2003;88:4659–67.
- Vasaitis TS, Bruno RD, Njar VC. CYP17 inhibitors for prostate cancer therapy. *J Steroid Biochem Mol Biol.* 2011;125(1–2):23–31.
- World Health Organization. WHO/CONRAD technical consultation on nonoxynol-9, World Health Organization, Geneva, 9–10 October 2001: summary report. *Reprod Health Matters.* 2002;10:175–81.
- World Health Organization Task Force on Methods for the Regulation of Male Fertility. Contraceptive efficacy of testosterone-induced azoospermia in normal men. *Lancet.* 1990;336:955–9.
- World Health Organization Task Force on Methods for the Regulation of Male Fertility. Contraceptive efficacy of testosterone-induced azoospermia and oligozoospermia in normal men. *Fertil Steril.* 1996;65:821–9.
- Youssef H. The history of the condom. *J R Soc Med.* 1993;86:226–8.
- Zhang L, Shah IH, Liu Y, Vogelsong KM. The acceptability of an injectable, once-a-month male contraceptive in China. *Contraception.* 2006;73:548–53.
- Zhao R, Wu JQ1, Li YY, Zhou Y, Ji HL, Li YR. Efficacy of a combined contraceptive regimen consisting of condoms and emergency contraception pills. *BMC Public Health.* 2014;14:354–63.

Loredana Gandini, Francesco Pallotti, Donatella Paoli, and  
Andrea Lenzi

---

## Abstract

Cryopreservation is a technique that keeps the cells and tissues in a vital state, using cryogenic temperatures ( $-196\text{ }^{\circ}\text{C}$ ). Despite the first experiments of sperm preservation with snow dating back to the eighteenth century, it was only the discovery of the protective role of glycerol against freezing damage in the twentieth century and the use of liquid nitrogen that started the era of modern cryobiology. The use of cryoprotectants and adequate cryopreservation methods (rapid or slow freezing procedures) allow to prevent freezing damage and maintain the cells in a state of “suspended animation” which will preserve for a long time. Sperm Bank is a medical facility characterized by two purposes: to preserve the patient’s fertility and to access to assisted reproduction techniques (ART). There are many indications (neoplasms, autoimmune diseases, urological pathologies) but, as a general rule, semen or testicular tissue cryopreservation must always be executed before any therapy, which may interfere with either spermatogenesis and genome integrity or ejaculation mechanisms. Also, it is possible to cryopreserve a patient’s semen to facilitate access to ART. The activities of a Sperm Bank are strictly regulated by the current EU legislation. This involves quality standards, structural and personnel requirements, archive, traceability, storage, and distribution of human tissues and cells. These rules consist in the adoption by the various Member States of Directive 2004/23/EC and following (2006/17/EC and 2006/86/EC) issued by the European Parliament.

---

Loredana Gandini: deceased.

L. Gandini • F. Pallotti • D. Paoli (✉) • A. Lenzi

Department of Experimental Medicine, Laboratory of Seminology-Sperm Bank, University of Rome “La Sapienza”, Rome, Italy

e-mail: [francesco.pallotti@uniroma1.it](mailto:francesco.pallotti@uniroma1.it); [donatella.paoli@uniroma1.it](mailto:donatella.paoli@uniroma1.it); [andrea.lenzi@uniroma1.it](mailto:andrea.lenzi@uniroma1.it)

## Keywords

Spermatozoa • Cryopreservation • Testicular cancer • Hodgkin lymphoma • Sperm bank • ART

## Contents

Introduction .....	1236
Indications to Cryopreservation .....	1238
Neoplasia .....	1238
Autoimmune Diseases .....	1240
Urological Pathologies .....	1240
Vasectomy .....	1241
Spinal Cord Injury .....	1241
Patients Undergoing ART .....	1241
Severe Alterations of Spermatogenesis .....	1242
Psychological Implications .....	1243
Legal Aspects .....	1243
Rules to Perform Sperm Cryopreservation .....	1245
Materials .....	1246
Cryopreservation Methods .....	1247
Patient Identification Pathway .....	1248
Archive .....	1249
Summary .....	1249
References .....	1250

## Introduction

The first experiment of sperm preservation with snow was attempted by Lazzaro Spallanzani in 1776. Then, Paolo Mantegazza at the end of the nineteenth century had the first idea of a sperm bank dedicated to the military that went to war to ensure them a future fertility. The modern era of cryobiology begins when Jean Rostand discovered the protective role of glycerol against the freezing damage with the experiments on frog sperm in 1946 and Polge on bull sperm in 1949 (Rostand 1946; Polge et al. 1949). Not long after in 1953 Bunge and Sherman report initial success in terms of pregnancies (Bunge and Sherman 1953). Finally, the use of liquid nitrogen has allowed the realization of structures dedicated to cryopreservation, defined Sperm banks that have rapidly spread in many countries (Sherman 1963).

Cryopreservation is a technique that keeps the cells and tissues in a vital state, using cryogenic temperatures ( $-196\text{ }^{\circ}\text{C}$ ). However, cell exposure to such temperatures causes damage over the controlling mechanisms of molecular activities. All life processes take place due to biochemical modifications that take place through molecular movements in a water environment. If cellular and extracellular water is turned into ice to block these movements, and if the same biological system can be turned back to room temperature without causing cellular damage, then it is possible to create a state of “suspended animation” which will preserve the cells for a long time. To achieve this, it is necessary to carry out specific procedures in order to



prevent the cells exposed to low temperatures from suffering irreversible damage and cellular death. In fact, the cooling process induces severe alterations to biological systems, causing reduction of the enzymatic activity and of the transport mechanisms, as well as modification of the membrane structure with transmembrane loss of ions. Further temperature reduction below 0°C causes the water in the extracellular environment to freeze, increasing the concentration of the solutes. This generates osmotic pressure, causing solvent to flow through the plasma membrane, from inside to outside the cell. This extracellular need for water leads to a reduction in cell volume and then to dehydration, a process that is essential to protect cells from the formation of intracellular ice, which can cause them to die. However, this intense dehydration process can reach a point of no return (at approximately 40% of the original cell volume), at which the cell suffers permanent damage.

If ice crystals form inside a cell, osmotic pressure does not change and cells do not suffer volume modifications. However, when thawing takes place, ice crystals cause mechanical damage to subcellular organelles and to plasma membrane.

Cryoprotectant media containing low molecular weight compounds that modify the cell environment are used to obviate these problems. By replacing the water content, they keep the extracellular environment in the liquid phase even when the temperature drops below the freezing point. These substances have been defined as “any additive which can be provided to cells before freezing and yields a higher postthaw survival than can be obtained in its absence”. There are two classes of cryoprotectants, which differ according to their ability to cross cell membranes. Some, such as glycerol and dimethyl sulfoxide (DMSO), penetrate into the cell, others, such as polyvinylpyrrolidone (PVP) and sucrose, remain in the extracellular environment. Their use is mainly related to the type of cell that is to be protected. The effectiveness of these substances also depends on how long the cryoprotectant and the cells interact. This temporal window is called “conditioning” and represents the time required to cryoprotectant to interact with cells. In particular, in andrology the ability to freeze spermatozoa or testicular tissue is based upon the use of a cryopreservation medium, consisting of substances which have the purpose of preserving spermatozoa from dehydration and from an increase of saline concentration, to protect from thermal shock, to safeguard the functional and structural integrity of the cell membrane, and to optimize the osmolarity of the extracellular fluids. Cryopreservation is performed in nitrogen vapor using two methods that provide either a slow or a rapid freezing. The first method employs automatic equipment that lead the cells gradually from room temperature to that of cryopreservation with controlled speed. The second method, which is more commonly used for sperm cryopreservation, allows a rapid freezing and does not require sophisticated equipment. The thawing phase must allow the cells to recover the normal biological activities, limiting as much as possible rapid temperature differences. Therefore, it is necessary to slowly extract the biological material from liquid nitrogen and allow to reach thermal equilibrium between cellular material and external environment. Cell survival after freezing and thawing depends largely on the ability to minimize the formation of crystals of intracellular and extracellular ice using appropriate methodologies. Thanks to their cellular structure and to the action

of glycerol, human spermatozoa can tolerate a wide range of temperature changes; in fact, the high fluidity of the membrane due to the polyunsaturated fatty acids of the lipid bilayer and the very low amount of cytoplasm (with the consequent low water content, approximately 50%) allows them to survive to the damage caused by a rapid initial cooling (freezing shock).

---

## Indications to Cryopreservation

Cryopreservation of semen is a powerful tool for patients who undergo medical or surgical treatment that can potentially induce sterility, while the cryopreservation of testicular tissue offers patients suffering from azoospermia (obstructive or non-obstructive), the only chance to gain access to assisted reproduction techniques (ART) and a possible fertility. Therefore, a Sperm Bank is a medical facility characterized by two purposes, namely to preserve the patient's fertility and access to ART. In the first case, the cryopreserved semen will not necessarily be used. This happens to any patient recovering fertility at the end of antineoplastic treatments. Otherwise, if the patient does not recover fertility, he can access ART even many years after cryopreservation. In the second case, the cryopreserved sample, either liquid or tissue, will allow the use of partner's spermatozoa at the time of oocyte retrieval. Cryopreservation in "Sperm Banks" may be "homologous", if the cryopreserved semen belongs to the same subject who will use the sperm, or "heterologous" if a donor deposits the sperm which will then be used by a couple unrelated to the donor himself.

The main indications for cryopreservation of homologous semen and testicular tissue are described in the following paragraphs.

## Neoplasia

The most frequently represented tumors in patients cryopreserving their sperm are the cancers that affect males in fertile age, which are, in particular, testicular tumors and lymphomas (Hodgkin and non-Hodgkin) (Gandini et al. 2003).

Testicular germ cell tumors (TGCT) represent 1–2% of male cancers and about 4–10% of all genito-urinary tract cancers. The mean incidence in male population is currently increasing, reaching 3–4 cases/year/100,000 persons, with significant geographical differences. The peak of incidence is located in northern Europe and New Zealand, up to three or four times higher than in the global population. Strangely, differences in epidemiological trends can be found even in a geographically limited area such as Scandinavian countries, despite their proximity and social similarities. In fact, Denmark has a risk of TGCT five times higher than Finland, with Sweden having an intermediate risk. In the last 20 years, improvements in antineoplastic treatments (chemotherapy and/or radiotherapy combined with surgical techniques) allowed a significant improvement in the prognosis and survival of these patients. Currently, about 90% of these early cancers diagnosed can be cured. In fact,

several cellular characteristics such as their origin from germ cells (which are radio- and chemosensitive) and a predictable pattern of diffusion make these tumors more susceptible to cancer treatment. Moreover, the onset is often in young people who usually do not have other diseases and can tolerate more aggressive treatments. TGCT can be treated in the first instance with radical orchiectomy, radical retroperitoneal lymph node dissection, and if necessary chemo- or radiotherapy chosen according to the histological type.

The most widely used chemotherapy regimen is PEB, consisting of etoposide, bleomycin, and cisplatin. These treatments can cause serious alterations in spermatogenesis with possible transient or permanent azoospermia and sperm chromatin structure. In particular, PEB protocol cytotoxic activity works by breaking individual DNA strands and blocking the cell cycle at the S–G 2 phase.

Seminomas are generally treated with radiation therapy at the lumbar-aortic lymph node stations. Radiotherapy prevents cells from replicating and causes death by ionization of DNA molecules directly, by the excitation of DNA atoms, or indirectly, as a result of interaction of radiation with non-DNA molecules which release secondary electrons, inducing ionization of the genetic material (Gandini et al. 2006).

Lymphoma is a malignant disease of the lymphoid tissue (T and B lymphocytes and their precursors). Lymphomas are the third most common cancer worldwide, which constitutes 5% of malignant cancers and the fifth leading cause of cancer death. Hodgkin lymphoma (LH) represents about 30% of all malignant lymphomas and its incidence is increasing. The incidence is bimodal, and it is higher in young people aged between 20 and 30 years and in older with over 70 years of age. Non-Hodgkin lymphomas (NHL) represent approximately 70% of all lymphomas and have the peak incidence between 45 and 60 years (although their onset can be at any age). For these conditions, a multidrug regimen is indicated and it is diversified according to the clinical stage.

The ABVD protocol, introduced in the mid-1970s, soon became the standard of care for the treatment of HL. The BEACOPP protocol was introduced by the German Hodgkin Study Group (GHSG); it has different active substances and a substantial increase in dose-density compared with ABVD. The BEACOPP protocol improves the control of neoplasia at the cost of greater toxicity than ABVD or hybrid protocols and can induce acute hematological and nonhematological toxicity, secondary tumors, and infertility (Paoli et al. 2016).

These drugs are active on the cellular cycle with genotoxic effects. Thus, patients are always recommended to postpone any attempt of pregnancy of at least 2 years.

Cancer patients in fertile age, despite having to deal with a serious problem, will find in cryopreservation of semen not only the hope of a future fertility but also a psychological support to deal with the various stages of treatment protocols (Dohle 2010). Advances in antineoplastic therapy and increasingly sophisticated assisted reproduction techniques (ART) opened new reproductive possibilities for the infertile male, and cryopreservation of semen is also needed in cases of severely altered seminal fluids that would have had no chance to fertilize before the introduction of ICSI, that is, the intracytoplasmic injection of sperm into the oocyte (Mortimer 2004). Given the importance of reproductive issues in these patients, which very

often are young, and without children, it is imperative for oncologists and hematologists to recommend this possibility and for the health management institutions of each country to ensure such option as quickly and efficiently as possible. It is, therefore, mandatory to inform cancer patients of this possibility in case of therapies that may affect irreversibly the fertilizing capacity and to perform the cryopreservation before the start of any therapy. Unfortunately, at present this goal is quite far from being reached as it is estimated that many patients are still excluded or not informed for the deposit of the semen.

In case of testicular neoplasms, the correct timing for cryopreservation is before orchiectomy or between the surgical procedure itself and the start of chemo- or radiotherapy.

Therefore, the optimal approach consists of offering the patient the possibility to perform the cryopreservation at both moments, especially in cases where the testicle not involved by the neoplasm shows clinical signs of suffering, in order to minimize the risk of cryopreservation of a sample of poor quality. As a general rule, in any case, in all cancers, degenerative or autoimmune diseases, semen cryopreservation must always be executed before any therapy which may interfere with spermatogenesis and with the integrity of the genome.

## **Autoimmune Diseases**

Immunosuppressive agents are frequently used in inflammatory and autoimmune diseases, as well as in transplantation. In Europe, autoimmune diseases are the third cause of morbidity and mortality, following cancer and cardiovascular disease. Moreover, about 300,000 people undergo transplantation and are currently subjected to immunosuppressive therapy. Since the majority of these therapies are prescribed to people in fertile age, some concerns have risen about the deleterious effects of these drugs on fertility and pregnancy outcome. Concerns about male fertility focus on the evidence of negative impact on spermatogenesis and possible teratogenic effects. Several drugs, such as methotrexate, cyclosporine, leflunomide, mitoxantrone, and mTOR inhibitors (sirolimus, everolimus, temsirolimus), have been described to interfere with spermatogenesis. However, there are many other drugs, as well as new biological therapies (monoclonal antibodies such as rituximab, abatacept, tocilizumab, and others), whose effect on male fertility are still insufficiently investigated. Therefore, it is recommended to perform sperm cryopreservation before the administration of these substances (Leroy et al. 2015).

## **Urological Pathologies**

Radical prostatectomy for prostate cancer involves removal of the prostate and seminal vesicles with subsequent anastomosis of the bladder with urethral stump. The surgery is usually preceded by the removal of lymph nodes draining from the prostate gland.

In case of benign prostatic hypertrophy, a transurethral resection of the prostate is performed using a technique, which allows to remove the central part of the prostate without harming its capsule.

Frequently, these interventions can cause retrograde ejaculation, that is, the passage of sperm towards the bladder at the time of ejaculation, rather than the outside as normal. However, even in these conditions, a preemptive cryopreservation can obviate any “*impotentia generandi*” that these patients face (Hugosson et al. 2011).

## Vasectomy

Vasectomy is an invasive contraceptive method. At present it is rarely used, mostly because its results are irreversible in most cases. Although the couple may decide to make the final choice on its procreative capacity, various circumstances (death of a child or partner, separation from partner, renewed desire for fatherhood) may lead to reconsideration of the decision, resulting in a recanalization attempt. Cryopreservation in these cases may allow the possibility of fertility in case the intervention of recanalization does not bring the expected results.

## Spinal Cord Injury

A group of patients definitely less represented and, at times, neglected, is the one with spinal cord injury and subsequent loss of ejaculatory capacity. Posttraumatic or postsurgical spinal cord injury (as well as other systemic neuropathies such as multiple sclerosis and diabetic neuropathy) may be associated with infertility. The most important cause is the neurological damage of the seminal tract that causes the failure of semen emission (anejaculation) or the passage of semen into the bladder (retrograde ejaculation). Anejaculation can be treated applying genital vibrostimulation at the level of the dorsal and ventral surface of the glans and of the penoscrotal area. In the case of failure, the other option is a rectal electroejaculation. This technique, however, requires general anesthesia in 25% of cases, in particular, in patients with preserved sensitivity and/or incomplete injuries. Therefore, the complexity of these techniques requires properly trained medical and paramedical personnel and it is particularly expensive. For these reasons, the cryopreservation of semen can offer patients the advantage of not having to repeat these treatments several times and to use the frozen sperm in ART (Chen et al. 2005).

## Patients Undergoing ART

Cryopreservation of semen allows to have available the sperm of the partner with certainty at the time of oocyte collection in cases where patients have psychological difficulties to collect the ejaculate or, for various reasons cannot be present on the

day of insemination. Ever since the techniques of artificial fertilization were introduced, ICSI in particular, the approach to infertility and its prognosis have profoundly changed. In fact, in the pre-ICSI era, severe male factor infertility (azoospermia or severe oligoastheno-teratozoospermia) had a poor reproductive prognosis. A true revolution in this field took place when ICSI was combined with the surgical removal of testicular or epididymal sperm. Testicular biopsy, the last diagnostic level of excretory or secretory azoospermia, in addition to fitting into an ART program, must always be combined with cryopreservation of testicular tissue. This will allow the patient to avoid a second biopsy in the case of assisted reproduction.

### **Severe Alterations of Spermatogenesis**

Patients with severely impaired spermatogenesis, either idiopathic or secondary (trauma or testicular torsion, hypogonadism, etc.), represent a further indication for cryopreservation. It is important to point out that patients with severe oligoastheno-teratozoospermia (OAT) may undergo alterations in semen quality caused by the underlying disease process.

In addition, it is possible to observe, in the same patient, changes in seminal parameters that are well documented in the literature, albeit difficult to predict. The variation in these patients may eventually lead to azoospermia, which may be transient in some cases, but may make it impossible to perform a cycle of ART. In both transient azoospermia and/or severe OAT, cryopreservation of sperm may rescue ICSI cycles and prevent unnecessary testicular biopsy. In other cases, the deterioration of semen quality may become permanent, due to the underlying disease. On this basis, the indication of cryopreserving the semen will offer the patient a chance of future fertility.

In case of azoospermia (obstructive or nonobstructive), it is possible to the search for spermatozoa in biopsy of testicular parenchyma. TESE (Testicular Sperm Extraction) consists of a small incision of the tunica albuginea through which several fragments of testicular pulp can be collected. Another procedure, called MicroTESE, implies, after the opening and exposure of the testis, the collection of individual tubules that at the observation through the operating microscope show a larger diameter. The MicroTESE procedure seems to be significantly more effective than TESE in terms of recovery rate of spermatozoa in patients with nonobstructive azoospermia. Moreover, there are also other sampling methods, distinguished by the location of recovery (testicular or posttesticular) and by the type of access ("open" or percutaneous): PESA (percutaneous aspiration from epididymis), MESA (microsurgical epididymal sperm aspiration), and TESA (testicular sperm aspiration). These techniques, combined with ART, have provided the possibility of fertility in cases of obstructive or non-obstructive azoospermia. In fact, in recent years, the use of cryopreserved testicular spermatozoa in assisted reproduction techniques, such as ICSI, has changed the rational of testicular biopsy that is no longer used as a purely diagnostic tool, but also as a therapeutic procedure of

infertility. In particular, over the last 15 years, these techniques have allowed to deny the Klinefelter-sterility combination. Various studies have reported numerous pregnancies through TESE/ICSI with delivery of healthy children without chromosomal abnormalities (Madureira et al. 2014).

---

## Psychological Implications

During the period of the diagnosis and before the beginning of any cancer treatment, patients may undergo significant distress. The overwhelming psychological burden of the disease, the fear of both short- and long-term consequences of chemo and radiotherapy will almost certainly impact negatively on the patient's life. In these circumstances, the oncologist plays a key role. It is imperative to provide the patient with a considerable amount of information (ranging from proposed treatments and complications to fertility implications). With particular regards to fertility issues, patients are avid to obtain information regarding sperm banking, including fertility status after treatments, how to access to assisted reproduction and the likely good health of children conceived from frozen sperm. Some men may refuse sperm banking out of fear that it may delay cancer treatment; others have been reported to worry about the risk of abnormalities for offspring born from cryopreserved semen. It is obvious that it is the oncologist who has the task to inform the patient and to clarify what is really going to happen and to alleviate misconceptions and prejudices about cryopreservation.

However, some clinicians may underestimate the psychological benefits of banking. Other factors known to influence the patient's decision about sperm banking are age, marital status, family member preferences, and prejudices.

After cryopreservation and cancer treatment, successful pregnancies have been reported even after long time storage of preserved semen (Feldschuh et al. 2005; Clarke et al. 2006). Frozen sperm can be used in assisted reproduction, as discussed in the previous section; however, the number of patients accessing banked semen for this purpose has been reported to be lower than expected. This may be in part due to natural recovery from nonpermanent gonadal toxicity of some treatments and in part to patient's specific concerns about assisted reproduction. Also it is possible that many patients refuse to continue the fertility follow-up for psychological burden (reluctance and fear to know about fertility, development of sexual/ejaculatory disorders) or even for practical reasons (travel time, separate appointments for oncology/andrology follow-up, loss of daily payment) (Pacey and Eiser 2011).

---

## Legal Aspects

Currently, the activities of the Sperm Bank are strictly regulated by current legislation in the individual EU countries. They consist in the transposition by the various Member States of Directive 2004/23/EC and following (2006/17/EC and

2006/86/EC) issued by the European Parliament and the Council on “standards of quality and safety for the donation, procurement, testing, processing, preservation, storage and distribution of human tissues and cells.” Essentially, these legislative acts govern the use of human tissues and cells for human applications including, evidently, the reproductive cells. In particular, the European Directive focuses on the following points:

*Accreditation and authorization* – Each Member State shall designate a Competent Authority (or authorities) that will verify the requirements of the Tissue Bank.

*Structure and personnel* – A Sperm or Tissue Bank must meet specific structural and functional criteria, strictly regulated by specific legislation and guidelines. A “cryobiology” or “cryogenic” room is a structure built and designed for the cryopreservation of biological material at low temperatures using appropriate cryogenic fluids (liquid nitrogen). The preservation of reproductive cells, since it is aimed for clinical use, has to ensure maximum efficiency and functionality. The premises must be suitable and dedicated, with appropriate characteristics and specific instruments to the functions and activities carried out, and in compliance with the safety regulations. The staff must be qualified and dedicated, with specific training regarding the preservation of biological material.

*Traceability and coding* – personnel (and authorities if it is the case) must be able to retrace tissues and cells in every phase from procurement to distribution (or disposal). In fact, the tissue bank shall ensure that all tissues and cells procured, processed, stored, or distributed can be traced from the donor to the recipient and vice versa. This traceability shall also apply to all relevant data relating to products and materials coming into contact with these tissues and cells. It is necessary to assign a unique code and to label each donation and each product associated with it.

*Biological tests* – Since hepatitis B and C viruses, as well as HIV, can be transmitted through the liquid nitrogen in which the semen samples are cryopreserved, it is necessary that the patient undergoes laboratory investigations to exclude the presence of such viruses to prevent the transmission from one sample to another (Bielanski 2012). Thus, no more than 3 months before the cryopreservation of semen are to be executed:

- Anti-HIV-1,2 Ab
- HBsAg
- Anti-HBc Ab
- Anti-HCV Ab

Moreover, even if not explicitly requested by the European Directive, it is advisable to conduct laboratory investigation for Cytomegalovirus (IgG and IgM) and, in case of IgM positivity, the evaluation of its nucleic acid (NAT). In fact, several papers published in recent years clearly demonstrated the possibility of infection between cryopreserved samples infected from the virus (Bresson et al. 2003).



*Quality management* – Each Sperm Bank shall take all necessary measures to ensure a quality system based on the principles of good practice that includes at least the following documentation:

Standard operating procedures

Guidelines

Training and reference manuals

Reporting forms

Donor records

Information on the final destination of tissues or cells

*Register* – Tissue establishments shall keep a record of their activities, including the types and quantities of tissues and/or cells procured, tested, preserved, processed, stored, and distributed.

*Distribution* – Sperm Bank shall ensure the quality of tissues and cells during distribution and have the responsibility of granting compliance to the requirements defined by the European directives. In particular, the release of gametes must follow specific guidelines which discipline the relationship between Sperm Bank and ART centers depending on the gametes owner's request to make the ART.

---

## Rules to Perform Sperm Cryopreservation

**Abstinence** – It is advantageous to observe a period of sexual abstinence from 3 to 5 days. This may be ignored for clinical reasons in cases of emergency relating to the beginning of antineoplastic treatments or surgery.

**Collection** – For legal reasons, the collection of the semen sample must take place at the Sperm Bank. The patient is given a sterile container, marked with his name and surname or with an identification code, in which he must collect the semen sample by masturbation.

**Informed consents** – The patient must fill in and sign an informed consent form that will regulate its relationship with the Sperm Bank, according to current regulations in each Member State of the European Community.

The cryopreserved semen sample can be distributed only to the person who produced it, upon presentation of valid identification documents.

The relationship between Bank and patient is defined by several informed consents concerning:

- Cryopreservation (one for each semen cryopreserved)
- Renewal of cryopreservation
- Disposal of the sample
- Withdrawal of the entire sample
- Withdrawal of one or more straws

If the patient is a minor, the informed consent must also be signed by the holder of the parental authority.

## Materials


All materials used must be specific for cryogenics (Fig. 1).

*Straws* – High security heat-sealable straws must be used. Straws currently sold on the market with these characteristics are of 0.3 ml and 0.5 ml of volume.

Straws have to be sealed and free of external contamination, for this reason it is mandatory to use connectors that allow to fill the straws preventing immersion in the seminal fluid and heat sealer for the closure.

*Cryoprotectant media* – Almost all media contain glycerol, to protect against thermal shock; sugars, which provide the sperm with energy and optimize osmolarity and hydrogen ion concentration; egg yolk, which improves the fluidity of the cytoplasmic membrane, provides structural and functional protection and, through its lipoprotein content, safeguards sperm integrity; and antibiotics, to protect against any microorganisms that might be present.

*Dewar* – The cryobiology dewars have great importance, that is, those devices capable of retaining biological material under controlled temperature conditions. There are various types of cryobiology dewar and the choice must be made according to the characteristics of the biological sample to be cryopreserved, the number of cryopreservation, the characteristics of cryogenic room, and



**Fig. 1** Materials used for sperm cryopreservation. (a) 0.3 and 0.5 ml straws, (b) straw junctions, (c) vacuum pump, (d) heat sealer, and (e) visotube

nitrogen supply plant. The number of dewars must be adequate to the structural features of the room. In case of presence of an automatic liquid nitrogen filling system, type and number of the dewar must be specific to the technical characteristics of the distribution line.

The storage of the biological material must simultaneously allow protection (both of the sample and of the operators) and traceability of the sample. Nitrogen level detection and temperature registration systems must be present and operational for of each cryogenic container. Device maintenance and control must follow the specifications of the maintenance plan provided in the user manual.

---

## Cryopreservation Methods

Rapid freezing was first proposed by Sherman (1963). It does not require automatic equipment. The most common technique is vertical freezing, carried out in cryogenic dewar of a suitable size. Semen samples are diluted with cryoprotectant medium and left to equilibrate at 37 °C for 10 min. The suspension is aspirated with a vacuum pump into 300- or 500- $\mu$ L straws. The straws are sealed and placed in nitrogen vapor for 8 min and then immersed in liquid nitrogen at  $-196$  °C. Nitrogen vapor contains a thermal gradient depending on the distance from the surface of the liquid nitrogen and the volume of underlying liquid. The straws are placed 15–20 cm above the nitrogen level and are then slowly lowered to reach the surface before being raised once more. This gives a fast freezing rate (approximately 20 °C/min). Following this phase, the straws are plunged into liquid nitrogen.

Slow freezing was proposed by Behrman and Sawada (1966). It uses automatic equipment that takes cells from room temperature to the storage temperature at a controlled rate. The sample is first diluted with cryoprotectant and then taken from room temperature to 5 °C at a rate of 0.5–1 °C/min. The temperature is then lowered to  $-80$  °C at 1–10 °C/min, and finally the sample is plunged into liquid nitrogen. However, this method can cause ice crystals to form if the freezing rate is too fast or too slow. In both of these methods, the cells are exposed to cryoprotectant before freezing to protect them from cooling damage. This stage is called conditioning. The efficacy of cryoprotectant is a function of how long the cryoprotectant and the cells have to interact and the temperature at which this exposure takes place. For this reason, cryoprotectant medium is added drop by drop and mixed gently to avoid osmotic stress and the mixture is incubated at 37 °C for 10–15 min to allow the cells and medium to equilibrate. Another important point is that the thawing techniques must enable the cells to recover their normal biological activities, minimizing fast temperature changes as much as possible. For this reason, the straws are extracted very slowly to enable a thermal equilibrium between the cells and the external environment to be reached. Different protocols can be used: (1) straws are kept at room temperature for 10 min and then incubated at 37 °C for 10 min; (2) straws are

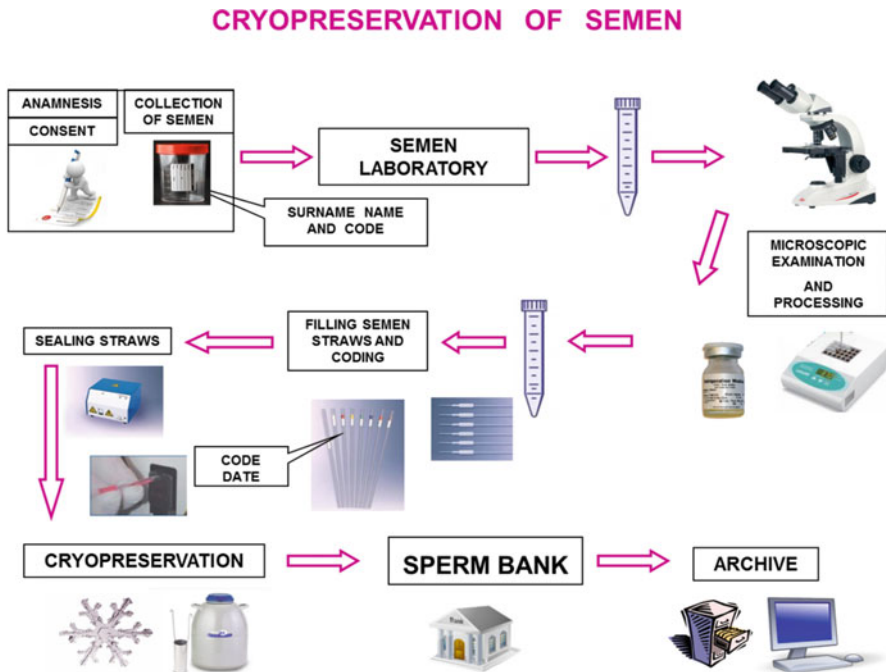
placed in a thermostatic bath at 37 °C for 10 min; (3) straws are thawed at room temperature (22 °C) for 15 min.

## Patient Identification Pathway

The Sperm Bank must carry out appropriate procedures to ensure the constant traceability of the sample, which must always be identified with a clearly legible and indelible unique code in order to avoid an exchange between samples (Fig. 2). Traceability is performed by marking with code:

- Sterile sample container
- Sterile tube
- Straws
- Visotube

Access to the area dedicated to the Bank must be restricted to authorized personnel only.



**Fig. 2** Sperm cryopreservation processing pathway

---

## Archive

Every Sperm Bank must be equipped with an archive, which must maintain indefinitely all data related to patients who underwent semen cryopreservation, even if it has been eliminated or withdrawn in its entirety. Archive access must be restricted to authorized personnel only.

The following data must be stored:

- Patient identification
- Documentation proving why cryopreservation was performed
- Laboratory analysis for infectious viruses
- Informed consent(s)
- Cryoprotectant buffer, expiry date, and batch
- Straw type, expiry date, and batch
- Number of frozen straws and their location
- Number of straws withdrawn
- Outcome of the ART
- Number of straws eliminated
- Outcome of the natural fertility
- Death certificate (if any)

---

## Summary

Semen or testicular tissue cryopreservation is the mainstay for fertility preservation in patients undergoing any surgical or medical therapy with a predictable harmful effect on the reproductive function. There are many indications (neoplasms, autoimmune diseases, urological pathologies, vasectomy, spinal cord injury) but, as a general rule, cryopreservation must always be performed before any therapy, especially if they interfere with either spermatogenesis and genome integrity or ejaculation mechanisms. Also, it is possible to cryopreserve a patient's semen in case of severe alterations of spermatogenesis and/or to facilitate access to ART.

Before the collection, but within 3 months, laboratory investigations must be performed to exclude the presence of several viruses to prevent the transmission from one sample to another (HBV, HCV, CMV, HIV)

A patient must be informed to observe, if possible, a period of sexual abstinence from 3 to 5 days and to collect the sample at the Sperm Bank to ensure the unique identification of the patient's semen. Finally, the patient must fill in and sign an informed consent form, to regulate his relationship with the Sperm Bank.

Cryopreservation and utilization of gametes, as well as the activities of a Sperm Bank, are strictly regulated by both European and National laws and regulations.

## References

- Behrman SJ, Sawada Y. Heterologous and homologous insemination with human semen frozen and stored in a liquid-nitrogen refrigerator. *Fertil Steril.* 1966;17:457–66.
- Bielanski A. A review of the risk of contamination of semen and embryos during cryopreservation and measures to limit cross-contamination during banking to prevent disease transmission in ET practices. *Theriogenology.* 2012;77(3):467–82.
- Bresson JL, Clavequin MC, Mazeron MC, Mengelle C, Scieux C, Segondy M, Houhou N, Fédération Française des CECOS. Risk of cytomegalovirus transmission by cryopreserved semen: a study of 635 semen samples from 231 donors. *Hum Reprod.* 2003;18(9):1881–6.
- Bunge RG, Sherman JK. Fertilizing capacity of frozen human spermatozoa. *Nature.* 1953;172(4382):767–8.
- Chen SU, Shieh JY, Wang YH, Lu T, Ho HN, Yang YS. Successful pregnancy achieved by intracytoplasmic sperm injection using cryopreserved electroejaculate sperm in a couple both with spinal cord injury: a case report. *Arch Phys Med Rehabil.* 2005;86(9):1884–6.
- Clarke GN, Liu DY, Baker HW. Recovery of human sperm motility and ability to interact with the human zona pellucida after more than 28 years of storage in liquid nitrogen. *Fertil Steril.* 2006;86(3):721–2.
- Dohle GR. Male infertility in cancer patients: review of the literature. *Int J Urol.* 2010;17(4):327–31.
- Feldschuh J, Brassel J, Durso N, Levine A. Successful sperm storage for 28 years. *Fertil Steril.* 2005 Oct;84(4):1017.
- Gandini L, Lombardo F, Salacone P, Paoli D, Anselmo AP, Culasso F, Dondero F, Lenzi A. Testicular cancer and Hodgkin's disease: evaluation of semen quality. *Hum Reprod.* 2003;18(4):796.
- Gandini L, Sgrò P, Lombardo F, Paoli D, Culasso F, Toselli L, Tsamatropoulos P, Lenzi A. Effect of chemo- or radiotherapy on sperm parameters of testicular cancer patients. *Hum Reprod.* 2006;21(11):2882–9.
- Hugosson J, Stranne J, Carlsson SV. Radical retropubic prostatectomy: a review of outcomes and side-effects. *Acta Oncol.* 2011;50(Suppl 1):92–7.
- Leroy C, Rigot JM, Leroy M, Decanter C, Le Mapihan K, Parent AS, Le Guillou AC, Yakoub-Agha I, Dharancy S, Noel C, Vantuyghem MC. Immunosuppressive drugs and fertility. *Orphanet J Rare Dis.* 2015;21:10–136.
- Madureira C, Cunha M, Sousa M, Neto AP, Pinho MJ, Viana P, Gonçalves A, Silva J, Teixeira da Silva J, Oliveira C, Ferraz L, Dória S, Carvalho F, Barros A. Treatment by testicular sperm extraction and intracytoplasmic sperm injection of 65 azoospermic patients with non-mosaic Klinefelter syndrome with birth of 17 healthy children. *Andrology.* 2014;2(4):623–31.
- Mortimer D. Cryopreservation and assisted human conception. *Reprod BioMed Online.* 2004;9:134.
- Pacey AA, Eiser C. Banking sperm is only the first of many decisions for men: what healthcare professionals and men need to know. *Hum Fertil (Camb).* 2011;14(4):208–17.
- Paoli D, Rizzo F, Fiore G, Pallotti F, Pulsoni A, Annechini G, Lombardo F, Lenzi A, Gandini L. Spermatogenesis in Hodgkin's lymphoma patients: a retrospective study of semen quality before and after different chemotherapy regimens. *Hum Reprod.* 2016;31(2):263–72.
- Polge C, Smith AU, Parkes AS. Revival of spermatozoa after vitrification and dehydration at low temperatures. *Nature.* 1949;164(4172):666.
- Rostand J. Glycerine et resistance du sperm aux basses temperature. *CR Acad Sci Paris.* 1946;222:1524.
- Sherman JK. Improved methods of preservation of human spermatozoa by freezing and freeze-drying. *Fertil Steril.* 1963;14:49–64.

David J. Handelsman

## Abstract

Androgens are potent pharmacological drugs requiring legal prescription for valid medical indications but are also misused for invalid or unproven off-label medical reasons as well as used illicitly as a form of drug abuse. Understanding these distinctions and applications requires a knowledge of androgen physiology, pharmacology, and toxicology which is discussed in historical as well as present clinical practice terms. The present epidemic of testosterone misuse mainly involves using testosterone as an antiaging and/or sexual dysfunction tonic for middle-aged or older men for which the efficacy and safety are unproven, and there is concern that such treatment may be unsafe. Androgen abuse originated during the Cold War as an epidemic among elite athletes as ergogenic agents but in the 1980s transitioned to become an endemic in most communities with sufficient affluence to support an illicit drug industry geared toward body sculpting of hypermasculine body image for occupational or recreational reasons.

## Keywords

Abuse • Androgen • Andropause • Drug abuse • Hypogonadism • Misuse • Testosterone • Use

## Contents

Introduction .....	1252
Historical Background .....	1252
Use .....	1255
Testosterone Replacement Therapy .....	1255
Pharmacological Androgen Treatment .....	1262

D.J. Handelsman (✉)

ANZAC Research Institute, University of Sydney, Sydney, Australia

Andrology Department, Concord Hospital, Sydney, Australia

e-mail: [djh@anzac.edu.au](mailto:djh@anzac.edu.au)

© Her Majesty the Queen in Right of Australia 2017

M. Simoni, I.T. Huhtaniemi (eds.), *Endocrinology of the Testis and Male Reproduction*,  
Endocrinology 1, [https://doi.org/10.1007/978-3-319-44441-3\\_44](https://doi.org/10.1007/978-3-319-44441-3_44)

1251

---

Misuse .....	1263
Aging and Testosterone Misuse .....	1266
Trends in Testosterone Prescribing .....	1269
Harm from Testosterone Misuse .....	1272
Abuse .....	1273
Historical .....	1273
Androgen Abuse in Sport .....	1273
Androgen Abuse in the Community .....	1275
Androgen Abuse Regimes and Consequences .....	1277
References .....	1278

---

## Introduction

Androgens are potent pharmacological drugs requiring legal prescription for valid medical indications but are also misused for invalid medical reasons as well as used illicitly as a form of drug abuse. Following its discovery and first clinical use in the mid-1930s, the medical use of testosterone proliferated in the post-WWII decades, and it remains one of the oldest marketed drugs still in regular therapeutic use. Yet despite decades of clinical use, the sole unequivocal indication for the use of testosterone, in hormone replacement therapy in pathological disorders of the reproductive system, remains clouded by various wider claims asserting unproven and/or unlikely benefits, mostly the unrecognized reincarnation of wishful thinking about rejuvenation. Here we address appropriate indications for testosterone use as well as the misuse of testosterone, defined as prescribing without valid clinical indications, and abuse of testosterone and related synthetic androgens (androgen abuse), defined as the non-prescription abuse of androgens without regard to medical indications, such as by athletes, bodybuilders, and others for recreational, cosmetic, or occupational reasons (Table 1).

---

## Historical Background

Testosterone is the principal molecule responsible for the striking gender dichotomy between masculine and feminine physical features and behaviors which have been widely appreciated throughout human history without understanding the precise molecular basis for the obvious distinctions. Understanding the use, misuse, and abuse of androgens requires not only an understanding of androgen physiology and pharmacology but also historical perspective to avoid blind repetition of history and its numerous misadventures and dead ends. Testosterone was first fully characterized as the principal mammalian male sex steroid of testicular origin in 1935 (David et al. 1935) followed rapidly by its first clinical use (1937) (Hamilton 1937) and a 1939 Nobel Prize for the discovery. Yet androgens had an ancient prehistory that long pre-dates the birth of modern androgen pharmacology in the 1930s.



**Table 1** Classification and definition of use, misuse, and abuse of androgens

	Therapeutic status	Application
Use	Physiological replacement therapy	Pathological hypogonadism
	Pharmacological androgen treatment	Non-gonadal disease Functional low testosterone states
Misuse	Invalid indication	Misinformation (infertility, erectile dysfunction in the absence of pathological hypogonadism, “andropause,” “LowT,” “late-onset hypogonadism”)
Abuse	No medical indications	Elite sport performance
		Image enhancement and body building for cosmetic, recreation, occupational reasons

The pivotal role of the testis as the source of virility and fertility was known since antiquity. Castration of men and animals was practiced since ancient times to generate obedient slaves or harem guardians, as punishment for sexual misdemeanor, religious self-mutilation as well as to render domesticated animals more docile. The Chinese eunuch system, a tradition dating from the imperial period, persisted into the turn of the twentieth century (Nieschlag and Nieschlag 2014) as did the European practice of castrating boys to preserve their high-pitched voices combined with adult large lung capacity for opera singing (Jenkins 1998). Furthermore, since ancient times, building on vague perceptions of the testis' functions together with the unwelcome decline of virility with age, the desire for rejuvenation has fostered attempts to revive youthfulness and virility by manipulation of the testes aiming to restore its governing impact on youthful bodily function. Outbursts of rejuvenation fads have erupted whenever there was sufficient affluence to afford the indulgence in health hobbies like life extension. Prominent episodes included the sixteenth-century expeditions of Juan Ponce de Leon to the Caribbean in a search for the fabled Fountain of Youth and other imagined schemes for life extension (Haber 2004). But undoubtedly the greatest flowering of rejuvenation quackery occurred at the turn of the twentieth century with the development of organotherapy, a rejuvenation fad associated with the names of Brown-Sequard, Steinach, and Voronoff (Miller and Fulmer 2007). Organotherapy had garnered experimental credence in the late nineteenth century when Berthold demonstrated experimentally the androgen dependence of male secondary sexual characteristics restoring the castration-induced changes in rooster's capons by implanting testes into the abdominal cavity (Miller and Fulmer 2007). These experiments provided concrete scientific evidence that was foreshadowed by John Hunter's eighteenth-century wide-ranging imaginative experiments with testicular transplantation in fowl but which were only indirectly recorded (Medvei 1982). Hunter and Berthold's suggestive positive findings lifted the previously negative evidence linking aging with the decline of virility to give organotherapy a more substantial scientific basis for wishful thinking about rejuvenation. Organotherapy gained mainstream attention after its first proponent, Charles Edouard Brown-Sequard, a genuine pioneer of experimental endocrinology during

his working life, claimed at a post-retirement meeting that self-injection of crude extracts of animal testes restored his vitality, virility, and intellectual capacity for prolonged periods. This was derided by his contemporary peers as fantasy (Anonymous 1889) and has subsequently been proven to be a placebo effect because his well-documented aqueous extraction procedure obtained only trivial amounts of hydrophobic testosterone (Cussons et al. 2002). Nevertheless, treatment by the Brown-Sequard's organotherapy was enormously popular among the affluent turn of the century European and North American public offering the façade of scientific respectability to the wishful dreaming about rejuvenation by administering extracts of testes (Borell 1976a). Subsequently, the Austrian surgeon Steinach promoted vas ligation as an alternative rejuvenation procedure, reportedly performed in Vienna on 100 university professors including Freud and the Nobel Prize winning Irish writer WB Yeats (Sengoopta 2003; Wyndham 2003). A third alternative was developed by Serge Voronoff grating testis slices from various nonhuman animals onto the capsule of the human testis (Voronoff 1925; Hamilton 1986). These popular mass delusions only subsided in the 1930s with the coincidence of the Great Depression, which removed the disposable cash that fueled frivolous pursuits, as well as the scientific discovery of testosterone as the principal male hormone of the testis.

After initial misidentification of androsterone in 1931 as the principal male sex steroid, in 1935 testosterone was finally purified from bull testis and named by Ernst Laqueur's research group in Amsterdam working with the Dutch company Organon (David et al. 1935). Later that year in the same journal, the purification of testosterone from human urine was confirmed by Adolph Butenandt from the German company Schering (Butenandt and Hanisch 1935), and again independently Leopold Ruzicka from the Swiss company CIBA reported the complete synthesis of testosterone (Ruzicka and Wettstein 1935), providing decisive confirmation of testosterone's structure and function. Curiously, the 1939 Nobel Prize for Chemistry was awarded jointly to Butenandt and Ruzicka but excluding Lacquer. Arising in the shadow of World War II, this anomaly probably arose from Hitler's banning of Germans taking up Nobel Prizes (after the 1935 Nobel Peace Prize award to a German pacifist), so the Nobel Committees may have avoided having a Dutch Jew sharing a prize with German scientists.

Although there was a flurry of clinical research published in early endocrinology journals within the few years between the first clinical use of testosterone (Hamilton 1937) and the major impact of World War II, most pharmaceutical developments of testosterone were deferred until after the hiatus of the war. The immediate postwar decades, the Golden Age of Steroid Pharmacology, produced the successful pharmaceutical development of synthetic glucocorticoids and oral contraceptives. However a third major quest, for the development of a non-virilizing androgen ("anabolic steroid") suitable for use in women and children, based on dissociating the virilizing from the anabolic effects of androgens failed comprehensively (Handelsman 2011a). This failure is now understood in terms of the later discovery of a singular androgen receptor together with the flawed interpretations of non-specific whole animal

androgen bioassays then employed to screen for supposedly distinct anabolic and virilizing androgen effects. For clarity the more accurate and clearer term “androgen” is used exclusively for both endogenous and synthetic androgens including references to chemicals misleadingly named elsewhere as “anabolic steroids” or “anabolic-androgenic steroids,” which confuse by continuing to make an obsolete distinction where there is no difference (Handelsman 2011a).

---

## Use

### Testosterone Replacement Therapy

The rationale for testosterone replacement therapy is derived broadly from the modern concept of medicine which rests upon the pathological basis of disease. More specifically, from the inherent justification to replace physiological functions which the impact of disease(s) render the body unable to provide. Broadly, in medicine this justification extends to natural hormones just as it does to artificial prostheses, mechanical devices, and organ or tissue transplants, although the medical consequences of each specific replacement modality require scrutiny. The sole unequivocal therapeutic indication for testosterone is as replacement therapy for men with pathological disorders of the reproductive system. These disorders prevent testosterone synthesis being able to meet the supply required for physiological function of androgen-sensitive organs and tissues. These defects in the capacity to secrete testosterone may be due to either testicular damage, which disrupts Leydig cell testosterone synthesis and secretion, or hypothalamo-pituitary disorders, which limit pituitary LH secretion, the principal drive to Leydig cell testosterone production. For androgen replacement therapy, testosterone is used exclusively as, among the wide range of endogenous and synthetic androgens or pro-androgens, it alone displays the full spectrum of androgen effects. The full spectrum of androgen effects include not only testosterone acting in its own right on androgen receptors but also its metabolism to active metabolites often as a local modulating mechanism within androgen target tissues. The ramifications of testosterone's action via its metabolites include amplification through conversion by 5 $\alpha$ -reductase enzymes to the more potent, pure androgen dihydrotestosterone (DHT), most evident in the prostate and skin but also present in other tissues such as the liver, kidney, pancreas, and brain. Another ramification of testosterone action is its diversification by local conversion to the sole potent estrogen, estradiol, via the enzyme aromatase, most strikingly in the brain and bone but also in fat and skin. Hence, pure synthetic androgens which lack effects mediated via estrogen receptors and/or local tissue amplification mediated by 5 $\alpha$  reduction cannot provide the full spectrum of effects that testosterone provides for androgen replacement.

The major features of testosterone as a therapeutic drug are its short duration of action and minimal oral bioactivity, due to avid first-pass hepatic metabolism. For

testosterone replacement therapy, these limitations have to be overcome by creation of long-acting depot or non-oral routes of administration. The first was injectable testosterone products formed by testosterone esterified with lipophilic, long-chain fatty acids formulated in a vegetable oil vehicle (Junkman 1957). These injectable vegetable oil depot products remained the most widely used forms of testosterone delivery for decades until the development in the late 1980s of alternative non-oral routes of administration, mainly transdermal patches and gels delivering unesterified testosterone.

The goal of testosterone replacement therapy is to reproduce physiological levels of testosterone in blood and tissues to maintain the full spectrum of androgen effects comparable with eugonadal men. This objective implies a goal of recapitulating the lifetime safety and efficacy of endogenous testosterone production. Hence, the doses of testosterone used clinically for replacement therapy are intended to most closely simulate the patterns of circulating testosterone in eugonadal men. Exogenous administration of testosterone is constrained by the available pharmaceutical formulations, currently consisting of injectable, implantable, transdermal, and oral products. While all these can provide sustained testosterone delivery over prolonged periods, product-specific limitations exist such as (a) the excessive fluctuations in circulating testosterone levels and corresponding symptom relief and mood with injectable or oral products, (b) the need for frequent application for daily transdermal or oral products, and (c) the risk of unintended topical transfer of transdermal gels or solutions to other persons (e.g. women, children) in intimate contact with the user. Other generic limitations include the inability to replicate momentary, circadian, and diurnal rhythms, though these limitations have no known detrimental clinical impact.

Appropriate use of testosterone replacement therapy requires an accurate diagnosis of pathological hypogonadism. Hypogonadism is a clinical diagnosis, with a pathological basis and confirmed by hormone assays. The clinical diagnosis relies on history and physical examination to identify underlying disorders of the testis, pituitary, or hypothalamus that justify the need for lifelong testosterone replacement therapy. Additionally, in men with hypothalamic or pituitary diseases, gonadotrophin replacement therapy may be required for induction of puberty, spermatogenesis, and fertility to overcome pathological gonadotrophin deficiency (Dwyer et al. 2015; Liu et al. 2009). Confirmation of a presumptive diagnosis of pathological hypogonadism, together with an assessment of the degree of androgen deficiency, requires a comprehensive evaluation of reproductive hormone status by measurement of serum testosterone, LH, and FSH on at least two separate days, with at least one in the morning. Usually measurement of serum sex hormone-binding globulin (SHBG) may be useful to explain an apparently isolated low serum testosterone concentration, frequently observed in obese men. Serum LH and FSH consistently in the mid to normal range are a useful indicator of adequate tissue androgen exposure, as serum LH is an effective and useful but often overlooked androgen sensor, noting that pulsatile LH secretion requires multiple serum sampling to ensure sound interpretation. This interpretation is quite analogous to the use of normal serum TSH as a thyroid hormone sensor for interpreting unusual thyroid function test other than in overt central hypothyroidism. Men with structural hypothalamo-pituitary disorders (e.g. pituitary tumors and/or their treatment) usually exhibit low or

undetectable serum LH and FSH. In selective cases other tests may help establish the clinical diagnosis and/or provide a baseline for follow-up (Table 4).

The above definition of hypogonadism differs from US (Bhasin et al. 2006, 2010) and European (Wang et al. 2009; Nieschlag et al. 2005) clinical guidelines and other societies and single-issue associations (Lunenfeld et al. 2015) that followed them, which have stretched the boundaries of the term “hypogonadism.” Whereas hypogonadism was long recognized as referring to intrinsic pathological disorders of the reproductive system, this permissive redefinition substitutes a vague and open-ended description of a bewildering array of symptoms, a loose conjunction of virtually any non-specific clinical signs or symptoms coupled with a low serum testosterone, yet disregarding the underlying disease(s) that cause the clinical and biochemical features. In effect, that approach abolishes the fundamental distinction between pathological hypogonadism and functional causes of a low circulating testosterone. The latter comprise a wide variety of miscellaneous clinical states associated with low circulating testosterone concentrations but without specific reproductive system pathology. These represent an adaptive hypothalamic response to systemic illness and/or its treatment, the consequence of which may be beneficial, neutral, or detrimental. Hence in these situations, the use of testosterone treatment needs rigorous evidence of safety and efficacy to create a justified indication for testosterone therapy. Unlike pathological hypogonadism where testosterone treatment is aimed to restore the testosterone supply which is lacking due to disease, it is not justified to simply rectify low circulating testosterone concentrations arising from a normal adaptive response of the reproductive system to systemic illness without evidence that it is safe and effective to do so.

Testosterone treatment of men with non-specific symptoms may improve symptoms or tolerance for minor disabilities regardless of androgen status, similar to the effects of an antidepressant or mood-elevating substances. This reflects the generic effects of testosterone, regardless of androgen status, to produce pleasurable mood and sensations consistent with its long-known psychoactive, mood-elevating effects (Kanayama et al. 2007; Amiaz and Seidman 2008). These led in 1948 to testosterone being patented as an antidepressant prior to the modern antidepressant era (Altschule and Tillotson 1948), and in more recent times it has had modest efficacy shown as an adjuvant antidepressant (Shores et al. 2009; Pope et al. 2010) with hypomania as an overdose side effect (Kanayama et al. 2010). Even the most permissive guidelines recommend against population screening for androgen deficiency (Bhasin et al. 2010). Open-ended testosterone prescribing guidelines that blur the distinction between pathological hypogonadism and functional states associated with low circulating testosterone are open to disease mongering and have led to the massive increases in unwarranted testosterone prescribing as a generic antiaging tonic to counter sexual dysfunction and/or decreased energy, vitality, or virility (Table 2).

### **Diagnosis of Hypogonadism**

Defining a pathological basis for the diagnosis of hypogonadism requires a thorough reproductive and general medical history as well as a physical examination (Handelsman 2015a). The history aims to evaluate potential reproductive

**Table 2** Clinical features of history and physical examination for the clinical diagnosis of pathological hypogonadism

	Interpretation
<b>History</b>	
<i>Reproductive</i>	
Around birth	Prematurity, testis maldescent, torsion, inguinal hernia, and surgery
Around puberty	Timing, tempo, and completeness of puberty relative to peers and family Olfactory function
Adult life	Marital and fertility status, infertility Sexual function, sexually transmitted infections Reproductive toxins at work or recreation
<i>General</i>	Depression Headache and/or visual field disturbance (pituitary tumor)
<b>Physical examination</b>	
<i>Reproductive</i>	Testis volume (orchidometry) and consistency Scrotal development, hypospadias, cryptorchidism and orchiopexy, penile plaque, epididymal cysts, defects in vas deferens, varicocele Androgenization, habitus (eunuchoidal), body hair distribution, voice pitch, musculature, acne, gynecomastia
<i>General</i>	Visual field Leg pulses and reflexes Digital rectal examination prostate (older men)

pathologies which manifest around the times of birth (prematurity, testis maldescent, torsion, inguinal hernia surgery), puberty (timing, tempo and completeness of puberty relative to peers and family, olfactory function), and in adult life (marital and fertility status, sexual function, infertility, sexually transmitted infections, reproductive toxins in work and hobbies, depression, headache and/or visual disturbance suggestive of pituitary tumor) and notably the timing and severity of recent onset of non-specific symptoms (well-being, energy and/or vitality, lethargy, fatigue) with any contributory causes. The history is critical for defining the lead symptom of men with pathological hypogonadism. This is the most consistent, characteristic, or recognizable complaint related to testosterone deficiency for that individual. This is important for the follow-up of testosterone-treated men because the lead symptom occurs reproducibly at a characteristic blood testosterone threshold for that individual, although the actual symptom(s) and blood testosterone threshold differ between individuals (Kelleher et al. 2004).

The physical examination is also critical in providing objective evidence which may be decisive for the diagnosis of pathological hypogonadism. The single most informative feature of the physical examination is evaluating the testis, the most accessible internal organ of the body, which should be palpated to determine testis volume (by orchidometry) and consistency (atrophic soft or normal consistency). Other important features of the physical examination include other genital features (scrotal development, penile plaques, hypospadias, cryptorchidism, epididymal

**Table 3** Tests to confirm the clinical diagnosis of pathological hypogonadism

	Application and interpretation
<b>Hormone assays</b>	
<i>Routine</i>	
Serum testosterone	At least two samples on different days, at least one morning
Serum LH and FSH	Always with serum testosterone for interpretation of primary versus secondary hypogonadism
Serum SHBG	Always with serum testosterone or at least to explain low serum testosterone
<i>Selective</i>	
Serum prolactin	
Serum TSH and thyroxine, IGF-I, cortisol, and ACTH	To evaluate nonreproductive pituitary function and/or exclude panhypopituitarism
Serum glycoprotein $\alpha$ -subunit	For diagnosis of a nonfunctional chromophobe pituitary tumor
Serum DHT, estradiol, DHEAS, 17 hydroxyprogesterone	Rarely required for diagnosis of steroidogenic tumors or defects
GnRH or hCG stimulation tests	Very rarely required as current baseline hormone assays are usually as diagnostic as stimulation test
Serum inhibin B and AMH	To evaluate spermatogenesis
<b>Other tests</b>	
<i>Routine</i>	
Hemoglobin	To evaluate mild anemia at start and as baseline to detect polycythemia during treatment
Bone density	Useful long-term, integrated measure of adequate tissue (bone) androgen status especially during follow-up
Serum PSA	For men over 50 years, initial check to exclude pre-existing prostate cancer and as baseline for follow-up
<i>Selective</i>	
Genetics	Karyotype (Klinefelter's syndrome), Y chromosome microdeletions and AZF (infertility)
Iron studies (transferrin saturation, HFE C282Y genotype)	To diagnose hemochromatosis
Semen analysis	To evaluate sperm output for male fertility evaluation
Hypothalamo-pituitary imaging	CT or MRI scan to visualize a pituitary tumor, hypothalamic infiltrate, or pituitary stalk section or discontinuity

cysts, vas defects, varicocele), androgenization (eunuchoidal or normal physiognomy, body hair distribution, voice pitch, musculature, acne, gynecomastia) as well as general features (visual fields, peripheral leg pulses and reflexes) and digital rectal examination of the prostate in older men.

Confirmation of the diagnosis of hypogonadism requires laboratory hormone assays and other tests (Table 3). Serum testosterone measurements should always be

accompanied by serum LH, FSH, and SHBG which are required for interpretation of circulating testosterone.

Calculation of so-called “free” or “bioavailable” testosterone have no meaningful or validated role in diagnosis of hypogonadism. The speculative free hormone hypothesis, based on outmoded 1970s pharmacology theory of drug interactions attributed to mutual displacement of protein binding, postulates that the small moiety (1–2%) of circulating testosterone not bound to any circulating protein (or a variant which extends to testosterone loosely bound to albumin and other low-affinity binding proteins) is the most “biologically active” fraction of circulating testosterone for its greater accessibility to tissues compared with tightly bound steroid (Ekins 1990; Edwards and Ekins 1988; Mendel 1989). Yet this theory cannot explain why unbound hormones would be more rather less biologically active as they are also equally more accessible to sites of degradation than bound hormones. Despite the misconceived theory, measurement of so-called “free” testosterone by dialysis-based methods is feasible but laborious so not widely used. Instead, widely used calculations based mostly on equilibrium binding equations (Sodergard, Vermeulen) have proved inaccurate relative to lab measurements due to their reliance on influential assumptions (Ly et al. 2010). Yet, being easy to calculate, these inaccurate calculations are widely but uncritically used. Furthermore, by its formulaic dependence on two age-sensitive variables, such calculated “free” testosterone is a deterministic (inverse) function of age. Hence, introducing such a calculated variable, a masked surrogate for “age,” confuses rather than clarifies uncertain clinical evaluation of older men. There is so far no sound evidence that such calculations provide clinically meaningful information beyond accurately measured serum testosterone. Hence if recourse is sought to such derived measures of testosterone when androgen status is clinically uncertain, this is precisely when the use of invalid estimates are least reliable and therefore can not contribute to sound clinical decision making.

Testosterone is available in injectable and oral testosterone esters formulations as well as implantable and transdermal forms of unesterified testosterone. The injectable and implantable products form long-term depots with duration of action of 2 or 12 weeks for injectable products and 6 months for implants, which are often most convenient for younger men to reduce the compliance burden. The transdermal and oral products require at least daily administration and are more suited for older men where the quick onset and offset of treatment effects may be advantageous. Adequate testosterone replacement therapy is usually achievable with any product with the choice of modality aiming for optimal patient convenience, which is the key to long-term compliance for lifelong treatment. Product-specific limitations include pain, bleeding or infection with parenteral products, pulmonary oil micro-embolization with intramuscular oil-based injections, inadvertent topical transfer of testosterone to women or children in intimate contact with users of transdermal gels or solutions, application site skin irritation from transdermal patches, and gastrointestinal side effects from oral testosterone ester capsules.



As the underlying causes of pathological hypogonadism are essentially irreversible, testosterone replacement therapy is inevitably to be lifelong. Long-term follow-up aims to rectify symptoms and signs of androgen deficiency as well as to maintain continuity of adequate testosterone treatment. Clinical appraisal of the adequacy of testosterone replacement therapy starts with reviewing whether the lead symptom is sufficiently ameliorated. This can be reinforced by objective criteria such as, in the short term, by trough serum testosterone concentrations which should be in the low-normal eugonadal range and, in the longer term, by rectifying deficits in bone density. Evaluating serum testosterone concentrations should always consider concurrent serum SHBG as well as LH and FSH. Unusually high or low SHBG may explain corresponding variations in serum testosterone concentrations. Similarly, incomplete suppression of serum LH and FSH in men with primary (hypergonadotrophic) hypogonadism suggests inadequate testosterone dosage. Serial bone density measurement at 1–2 year intervals can provide a time-integrated measure of net androgen exposure whereby more normal levels are consistent with adequate testosterone dosage, whereas failure to improve low bone density may indicate suboptimal testosterone dosage (Aminorroaya et al. 2005).

The justification for testosterone replacement therapy for men with pathological hypogonadism does not require formal proof of efficacy, and safety and few studies have evaluated the outcomes of well-defined testosterone replacement therapy (Snyder et al. 2000). The low prevalence of pathological hypogonadism together with the even lower frequency of new diagnoses has meant that many studies over recent decades, notably registration studies of new testosterone products, have been filled with a large but usually undefined proportion of men with “andropause” for whom neither the same justification for testosterone treatment extends nor are their necessary safety and efficacy outcomes well defined.

A glaring failure in the proper application of testosterone use for replacement therapy is the severe underdiagnosis of the most frequent form of pathological hypogonadism, Klinefelter’s syndrome (KS, 47XXY), the most frequent genetic disorder of male reproduction and single most common cause of hypogonadism, occurs in ~1:650 male births (152 per 100,000) in all populations surveyed (Handelsman 2007; Groth et al. 2013). Yet European registry data shows that, despite characteristic, virtually pathognomonic, firm small testes (<4 ml) and a near normal life expectancy (Bojesen et al. 2004), lifetime diagnosis of KS is only ~40 per 100,000 in the UK (Bojesen et al. 2003) and in Denmark (Swerdlow et al. 2005). This discrepancy shows that the large majority (~75%) of cases go through life undiagnosed thereby missing out on simple, affordable, and effective testosterone treatment. The high rate of missed diagnosis is due to men mostly going through life without ever undergoing a medical examination of their genitalia, which would not miss the diagnostic tiny testes. Conversely, if men underwent even a single postpubertal genital examination, more like their female age peers, it is likely that improved rate of diagnosis would be achieved. Genetic screening at birth is technically feasible but requires evidence to prove its medical cost-effectiveness (Herlihy and McLachlan 2015; Table 4).

**Table 4** Differences between androgen replacement and pharmacological androgen treatment

	Androgen replacement therapy	Pharmacological androgen treatment
Androgen	Testosterone	Any androgen
Dose	Limited	Unlimited
	Pharmacokinetics	Pharmacodynamics
Evaluation	Intrinsic appeal to lifetime safety and efficacy of eugonadal men	Empirical evaluation of efficacy, safety, and cost-effectiveness as for any non-hormonal drug
Objective, goal, or expectation	Mortality – unlikely	Modify natural history of underlying disease
	Morbidity – bone, muscle, QoL	
Indications	Androgen deficiency due pathological hypogonadism (hypothalamic, pituitary, or testicular disease)	Non-gonadal disorders
		Chronic disease, catabolic states, and aging associated with functional low testosterone
		Hormonal male contraception

## Pharmacological Androgen Treatment

Pharmacological androgen treatment is the clinical use of androgens, usually synthetic androgens modeled on testosterone but with distinctive structural, functional, and pharmacological differences, as xenobiotic drugs aiming to influence the natural history and morbidities due to a wide variety of systemic illnesses (Handelsman 2011b). Synthetic androgens include chemical classes with distinctive pharmacological features including 17 $\alpha$ -alkylated androgens, 1-methyl androgens, and nonsteroidal androgens. In general, the desirable pharmacological features include oral bioavailability (considered desirable for marketing of drugs) and tissue selectivity (a modern reframing of the requirement for a pure, non-virilizing androgen).

Pharmacological androgen treatment mainly aims to exploit the prominent pharmacological features of androgens, notably their myotrophic effects to increase muscle mass and strength, but in other setting for increasing hemoglobin, bone mass, hepatic C1 esterase inhibitor concentrations or suppressing endogenous gonadal function (shrinking endometriosis, hormonal male contraception) (Handelsman 2011b). In many clinical settings, pharmacological androgen therapy is now an affordable, cost-effective second-line option as an alternative to more expensive and/or less available, specific mechanism-based treatments such as bisphosphonates for osteoporosis (Kilbourne et al. 2007) and erythropoietin and its analogs for renal anemia (Nakhoul and Simon 2016), GnRH analogs for endometriosis (Jee et al. 2009), and recombinant C1 esterase inhibitor for hereditary angioedema (Sabharwal and Craig 2015; Table 5).

**Table 5** Examples of pharmacological androgen treatment and their status

Target tissue	Clinical indication	Status
Spermatogenesis	Hormonal male contraception	Proven in principle, no product
	Male infertility	Disproven
Hemoglobin	Renal or marrow failure	Proven (second line)
Bone	Osteoporosis	Proven (second line)
	Steroid-induced bone loss	Proven (second line)
Muscle	HIV wasting/cachexia	Proven
	Genetic myopathy	Disproven
Psychosexual	Sexual dysfunction	Disproven (eugonadal men)
Mood	Depression, quality of life	Proven (mild)
Antiestrogen	Breast cancer (advanced)	Proven (last resort)
	Endometriosis	Proven (second line)
Hepatic	Hereditary angioedema (C1 esterase deficiency)	Proven (second line)

## Misuse

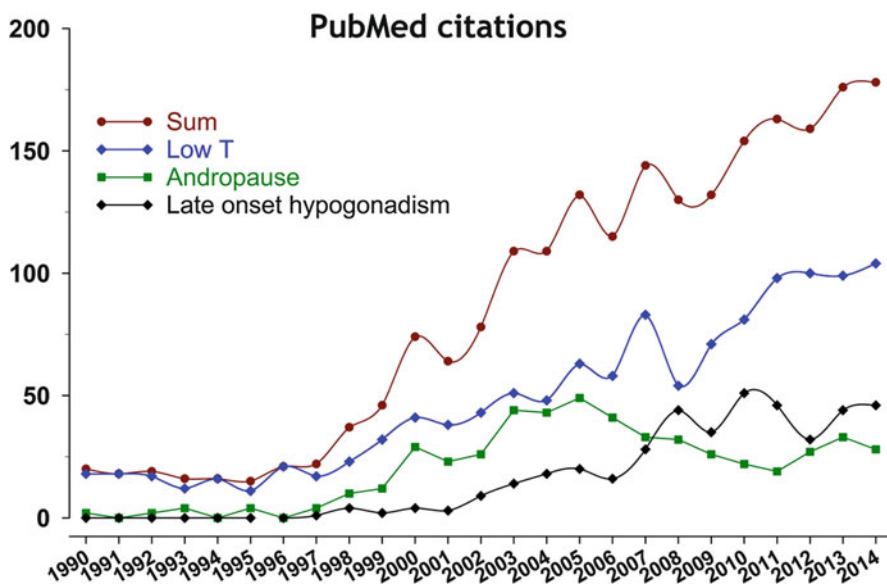
Androgen misuse involves the prescription of testosterone for invalid, unproven, or harmful (counterproductive) indications. For example, an egregious misuse of testosterone is its use for treating male infertility, where misguided use can only be detrimental to spermatogenesis. Yet, remarkably, 30% of practicing urologists report recommending such treatment (Ko et al. 2012), known as an iatrogenic cause of male infertility (Samplaski et al. 2014; Kolettis et al. 2015) and cause for regret among individuals who used androgens while unaware of this risk (Kovac et al. 2015). Other misuses of testosterone include its use in the absence of proven androgen deficiency for sexual dysfunction or as a tonic for age-related non-specific symptoms (e.g. reduced energy, vitality, easy fatigue). Androgens such as testosterone are highly susceptible to wishful marketing and promotion and, although the exact boundary between valid and unproven indications can be subjective, extremes involving mass marketing and promotion without reliable evidence of efficacy and safety are often clear.

In direct continuity with the prehistory of androgen pharmacology, the major current misuse of testosterone is its extravagant promotion as an unproven but popular antiaging tonic both for the loss of energy or vitality as well as sexual dysfunction. By modern standards, the social marketing of androgen misuse requires a form of branding to legitimize testosterone prescriptions in the absence of proven indications or evidence of efficacy and safety for off-label prescribing. For this purpose, inventing an attractive and popular terminology has attracted significant efforts with the espousal of terms such as “male menopause,” “climacteric,” “andropause,” “viropause,” “(partial) androgen deficiency in the aging male ((P)

ADAM),” “LowT,” and the most recent, upmarket makeover to create greater medical gravitas, “late-onset hypogonadism.” The motivation for this drive is apparent from the known prevalence of androgen deficiency due to pathological hypogonadism (~0.5% of men (Handelsman 2010)) compared with the estimated prevalence of “andropause” as up to 40% (Mulligan et al. 2006), or more usually claimed in the range 10–25% (Araujo et al. 2004; Orwoll et al. 2006; Haring et al. 2010), and even the most modest estimates of 2–3% (Wu et al. 2010) representing major (5- to 100-fold) increases in potential market size over pathological hypogonadism.

In contrast to pathological hypogonadism where, due to reproductive system disorders, the testis is unable to meet the usual physiological demands for androgen secretion, the newly minted conditions under the elastic redefinition of the term “hypogonadism” or “androgen/testosterone deficiency” have in common solely some reduction in circulating testosterone which represents an adaptive response, mediated by the hypothalamus, dictating a downturn in endogenous testosterone production. Whether this adaptive response is beneficial, neutral, or harmful cannot be assumed, and testosterone treatment requires direct clinical evidence from well-designed (randomization, placebo controls) clinical trials of testosterone to be convincing.

The epitome of rejuvenation folly is depicted in Lucas Cranach’s sixteenth-century fantasy landscape of the Fountain of Youth, the legendary spring waters that restore youthfulness, portraying wizened old crones entering a bathing pool to emerge as nubile youthful figures. Curiously, the painter’s imagination considered it sufficient to rekindle flagging male virility for the object of libidinal interest to be rejuvenated, without needing to revitalize the male body. The latter aspiration, however, gained greater attention in the most florid historical outburst of rejuvenation quackery originating over the turn of the twentieth century reaching an apogee over its first three decades before its abrupt extinction. Serious but self-deluded doctors announced to great public acclaim various fanciful schemes starting with Brown-Sequard’s injections of nonhuman testis extracts (Borell 1976a, b) and soon joined by Steinach’s “autoplastic” procedure (unilateral vasectomy) (Sengoopta 2003; Wyndham 2003) and Voronoff’s testis grafts (stitching nonhuman testis slices onto the human testicular capsule) (Voronoff 1925; Hamilton 1986; Kahn 2005). With the earnest self-belief of pioneers proclaiming scientific triumphs, these doctors dutifully published their methods to allow for replication by others reflecting motivation of integrity rather than hunger for limelight or enrichment. However, decades later, once the testosterone content of testes could be measured, it was easily calculated or shown directly (Cussons et al. 2002) that Brown-Sequard’s *aqueous* extract could yield no hydrophobic constituents such as testosterone. Like much good science, this realization came too late to derail the flashy transit of hollow fashion. Consequently, Brown-Sequard’s, as well as the associated millenarian fads, were simply placebos, mass delusions flourishing among a credulous public in thrall to the hubris of early medical science with its new temptation of scientific rejuvenation. Instinctively, contemporary medical journals deplored Brown-Sequard’s



**Fig. 1** PubMed citations for variations on the term “andropause”

claims as “... recalling ... with an incredulous smile....the wild imagings of medieval philosophers in search of an *elixir vitae* ...,” disdaining his discovery as a “Pentacle<sup>1</sup> of Rejuvenescence” (Anonymous 1889, 1890). Presciently anticipating the placebo effects of expectation, the critic recorded that the dramatic effects claimed in public displays could not be replicated in hospitalized patients unaware of the expected effects (Anonymous 1890). Nevertheless, the promise of revitalization ensured enormous popularity for rejuvenation quackery (Borell 1976a, b) until its abrupt eclipse in the 1930s. Ultimately, thoughtful, scholarly skepticism is never a match for turbocharged optimism in the public arena, noting that doctors remain members of the community and vulnerable to popular fashion and expectation. The sudden demise of rejuvenation quackery in the mid-1930s was due to the coincidence of the birth of modern androgen pharmacology built on the discovery of testosterone coinciding with the Depression, which removed discretionary spending on frivolous health pursuits. Yet, hope never springs eternal more than when it comes to rejuvenation. Rather than vanishing without a trace, the underlying rejuvenation fantasies simply went into decades-long hibernation to reemerge as the “andropause” phenomenon around the turn of the following century, an ironic recurrence of centennial madness (Fig. 1).

<sup>1</sup>An ancient magical talisman consisting of a five-pointed star believed to summon energy.

## Aging and Testosterone Misuse

The desire to prevent or reverse aging is the prime motivation for modern testosterone misuse. This health hobby fetishizes testosterone as an elixir of youthful vigor to rekindle sexual function and vitality in aging men and women. This inherent medicalizing of aging whereby treatment is directed at a diffuse, poorly defined entity of “aging” stands in contrast to medical treatments for specific diseases that accumulate during aging. The modern medical (re)incarnation of hormonal rejuvenation, with a scientific fixation on testosterone, is distinctive from other traditional lineage of quasi-medical rejuvenation follies such as the Asian medicinal use of exotic animal body parts or the Western counterpart of overpriced placebos of the health food supplement industry.

The modern scientific rationale for testosterone treatment to rejuvenate older men is based on considering male aging as analogous to either menopause or pathological hypogonadism. The former is a false analogy as menopause has a unique natural history featuring relatively abrupt and complete cessation of ovarian estrogen secretion in mid-adult life. This differs entirely from all other human hormonal systems which decline gradually, modestly, and inconsistently during aging, resulting from the impact of comorbidities of aging rather than growing old itself. This dichotomy provided a firm basis for empirically testing the value of estrogen replacement for the postmenopausal state of uniform, complete estrogen deficiency. Decades of wide and enthusiastic promotion of estrogens for menopause had occurred for not only for relief of estrogen deficiency symptoms but also for expanded claims of objective health benefits such as prevention of cardiovascular disease, based on over-interpreted observational studies that compared healthier, wealthier estrogen-using women with those not using estrogens (Grodstein et al. 2000). Nevertheless, the first randomized placebo-controlled clinical trial (Rossouw et al. 2002) refuted such expectations and led to an 80% decline in estrogen use (Santen et al. 2010). For all other age-related declines in pituitary hormonal axes, there is no convincing evidence of medical benefit, and notably less enthusiasm, for correcting the modest age-related changes in thyroid, adrenal, or growth hormone secretion, which compares starkly with the popularity of testosterone for both older men and women.

The other analogy, with pathological hypogonadism, is based on the superficial resemblance of non-specific symptoms of aging but which are equally apparent in not only virtually every other hormonal deficiency states but also most chronic non-gonadal diseases. This “andropause hypothesis” was so poorly substantiated that the authoritative 2004 US Institute of Medicine’s review (Liverman and Blazer 2004) concluded that a large-scale prospective study of testosterone for older men, comparable in scale and scope to the Women’s Health Initiative for estrogen replacement in menopause, was not warranted due to the paucity of evidence for efficacy. As a result, the NIH funded a series of short-term testosterone trials to establish efficacy. In 2016, the first reported, improved sexual function in men over 65 years treated with testosterone (Snyder et al. 2016). That study involved 790 men over 65 years of age, mostly obese, hypertensive ex-smokers (i.e., men with “andropause” but not pathological hypogonadism), recruited from over 2 million

mail-outs resulting in over 50,000 telephone interviews, who were treated with testosterone or placebo gel daily for 12 months. There was only a modest increase in sexual function (about one-third of an increase over baseline activity), which waned during the study period, but no significant increase in physical activity or vitality, compared with placebo. The beneficial effect on sexual function was, according to the study authors, less consistent or robust than the effects of PDE5 inhibitors and, according to the accompanying editorial (Orwoll 2016), insufficient clinically to warrant starting such treatment at all. This underwhelming result does not materially change the unfavorable balance of evidence for testosterone treatment for functional causes of a low serum testosterone in the absence of pathological hypogonadism.

The most ambitious and best organized attempt to define “andropause” resulting in the lowest and most credible prevalence estimate of 2–3% has been from the EMAS study (Wu et al. 2010). The EMAS is a high-quality large, multicenter cohort study involving over 3300 men drawn from population-based sources in 8 European cities. In a cross-sectional observational study, the investigators correlated a diverse array of non-specific physical and mental symptoms with a single blood testosterone measurement. There was no relationship between any physical or psychological features and blood testosterone concentrations using a wide array of physical and questionnaire measures. With focus on three sexual symptoms (erectile dysfunction, frequency of morning erections, or sexual thoughts) there was a weak but significant correlation with blood testosterone concentrations characterized by high rates of false positive (25–50%) and negatives (40–50%), but no positive or negative predictive values were reported. For each sexual symptom, regression on blood testosterone levels produced shallow breakpoints at testosterone concentrations of 8.0 and 11 nmol/L with the only consistent relationship was between all three sexual symptoms and a blood testosterone concentration threshold of <8 nmol/L. Yet, the proposed “definition” required all three sexual symptoms plus the higher (<11 nmol/L) blood testosterone threshold. Crucially, all these weak associations were nullified by adjustment for age, obesity, and coexisting illnesses indicating their relationships are due to confounding by those underlying factors, rather than any authentic independent and direct relationships between sexual symptoms and blood testosterone levels. A practical implication of these features is that, among older men without known pituitary or testicular pathology, reduced blood testosterone is due to, and a biomarker for, their obesity, cardiovascular disease, and/or coexisting illnesses. Hence an objective of rectifying any reduced blood testosterone, if warranted, should be directed toward ameliorating the underlying causes rather than administration of testosterone. Surprisingly, the opposite conclusion was drawn by the authors and accompanying editorial claiming this constituted a valid diagnosis of “andropause” (Bremner 2010). Although men with classical pathological hypogonadism have highly reproducible blood testosterone thresholds for their distinctive individual symptoms of androgen deficiency (Kelleher et al. 2004; Zitzmann et al. 2006), neither the thresholds nor the specific symptoms are consistent between individuals (Kelleher et al. 2004). Hence, grouping individuals with unequivocal organic androgen deficiency according to symptoms pools individuals with a wide range of

testosterone thresholds, which then become blurred losing focus on the underlying relationship (Zitzmann et al. 2006). When the symptom aggregation is undertaken for men without pathological hypogonadism, the abundance of “noise” from non-specific symptoms due to comorbidities of aging intrudes to further attenuate any potential relationships.

Other limitations of this study include:

- (i) The post hoc definition of the triad of sexual symptoms violating the analysis that assume pre-specified relationships.
- (ii) The unidirectional assumption that sexual symptoms must be caused by reduced blood testosterone levels is equally flawed in that not only is observational data unable to ascribe causality but there is growing evidence that sexual activity maintains blood testosterone concentration (Jannini et al. 1999; Carosa et al. 2004; Spitzer et al. 2012; Hsu et al. 2015).
- (iii) The reliance on a single rather than at least two blood testosterone measurements (Travison et al. 2008), the recommendation of all clinical guidelines (Bhasin et al. 2010; Wang et al. 2009; Conway et al. 2000) due to biological and analytical variability of blood testosterone measurements including regression to the mean.
- (iv) Reliance on an inaccurate formula to calculate “free” testosterone (Ly et al. 2010; Ly and Handelsman 2005; Sartorius et al. 2009), a variable with an unearned and dubious claim as a superior measure of testosterone action but which by its formula is a masked but deterministic (inverse) function of age.

The flawed assumptions, interpretations, and slides in meaning undermine the credibility of the purported definition of “andropause” (Handelsman 2011c), an invention the FDA concluded in 2014 was not a genuine medical disorder, let alone warranted testosterone treatment (Food and Drug Administration (FDA) Center for Drug Evaluation and Research 2014). Independent research casts further doubt on the validity of the entity known as “andropause.” Two major, complementary meta-analyses examined in comprehensive detail the evidence basis for the diagnosis and treatment of “andropause” (Huo et al. 2016; Millar et al. 2016). Both concluded in refuting the concept, from the clinical basis of the entity (Millar et al. 2016) as well as testosterone treatment for it (Huo et al. 2016). More broadly, the EMAS purported definition of “andropause” together with the permissive professional society guidelines purporting to abolish the fundamental distinction between pathological hypogonadism and functional states associated with low circulating testosterone levels have contributed the scientific rationale of defining age-related “hypogonadism.” Other enthusiasts together with single-issue clinics and ad hoc societies with industry support and, in North America, direct-to-consumer-marketing have enthusiastically adopted such legitimization to foster the epidemic-like, unjustified increase in testosterone prescribing especially since 2000. The challenge remains whether it is possible to break free from the seemingly irresistible pull into a familiar downward spiral, to learn from the history of rejuvenation rather than blindly repeating it.

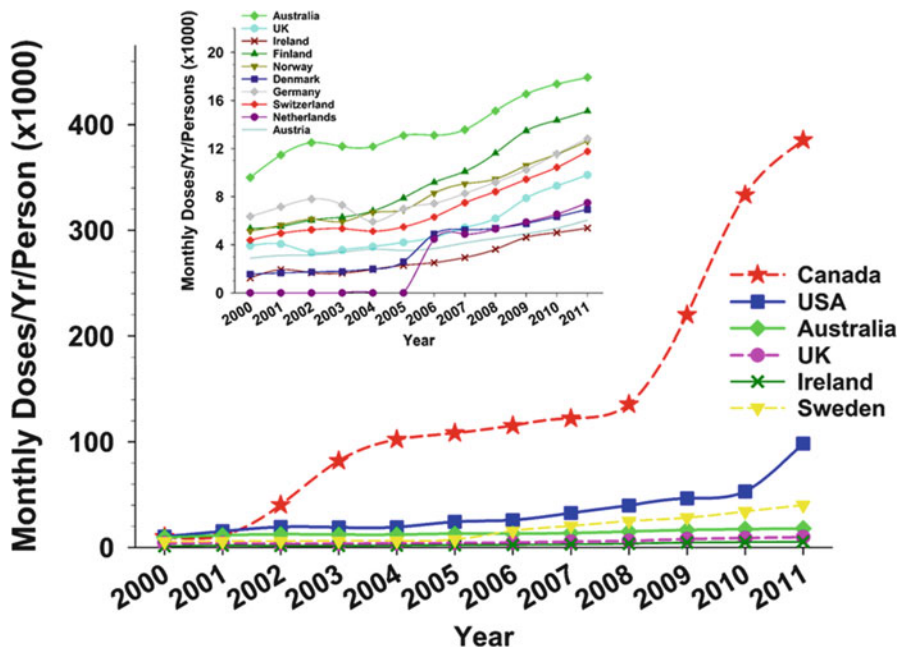


## Trends in Testosterone Prescribing

The most visible manifestation of the disease mongering of testosterone has been that, despite no new proven indications for testosterone treatment, there has been a remarkable growth of testosterone prescribing spanning the start of the twenty-first century, a century after the peak of the rejuvenation quackery era. Based on testosterone sales data, testosterone prescribing has increased 100-fold from \$18 million in the late 1980s (Bhasin et al. 2003) to \$1.8 billion over three decades (Handelsman 2013). Most probably the epidemic of testosterone prescribing is for age-related comorbidities including sexual dysfunction and/or reduced vigor, energy, and vitality (Jasuja et al. 2015; Handelsman 2015b). This increase is most prominent in North America with more modest but parallel changes in virtually all other regional markets (Handelsman 2012, 2013), an “andropause” bandwagon that has undoubtedly left the station propelled by direct-to-public drug advertising and permissive prescribing guidelines by professional scientific societies.

Patterns of testosterone prescribing have been studied in countries where reliable data is available from prospective national or regional single-payer health scheme, private or national public health insurance, or comprehensive health system databases (reviewed in Gabrielsen et al. 2016). Studies reveal a large and progressive increase in testosterone prescribing across a wide range of countries over more than a decade. Data has been deduced from regions or countries such as Australia (Handelsman 2004, 2012), Canada (Hall et al. 2014), the UK (Gan et al. 2013; Layton et al. 2014) and Switzerland (Nigro and Christ-Crain 2012) that operate centralized health schemes. Other more selective data has been derived from private health insurance databases (Baillargeon et al. 2013) or the Veteran Administration medical system (Jasuja et al. 2015; Walsh et al. 2015). However, data from large-scale non-monopoly systems may underestimate prescribing outside the dominant system, and, similarly, data based on private health insurance databases is subject to access bias based on socioeconomic status; neither has any well-defined population base. The Australian national pharmaceutical benefits scheme database demonstrates striking (but medically inexplicable) differences between states (Handelsman 2004) with progressively increasing use of more costly, newer products (Handelsman 2012). Transient, partially effective impact of regulatory curbs on unproven testosterone prescribing has been demonstrated in Australia (Handelsman 2004, 2012) and Canada (Piszczek et al. 2014).

An international pharmacoepidemiological study of testosterone prescribing (Fig. 2) showed that for every region and for 37 of 41 countries, there was a major and progressive increase in per capita testosterone usage over the first decade of this century (Handelsman 2013). This was based on wholesale testosterone sales data converted into product-specific usage (per person per month) (Handelsman 2004, 2012) and assuming a steady state between purchase, prescribing, and clinical use of testosterone products according to their approved regimens. The increases in North America over only the 11 years studied were striking with a 40-fold increases in Canada and tenfold increase in the USA. Other estimates from the USA (Baillargeon et al. 2013), the VA system (Jasuja et al. 2015; Walsh et al. 2015), and the Canadian



**Fig. 2** Global testosterone usage in monthly doses per capita for different countries incorporating all marketed testosterone products into total usage per person. Main figure for countries with higher usage and inset for countries with lower testosterone usage. Note the 20-fold lower scale on inset (From Handelsman 2013)

province (Hall et al. 2014) display markedly lesser increases over comparable periods. Such lesser estimates of increased testosterone prescribing garnered from selective source populations relative to the general community indicate that much greater increases in testosterone usage occur outside those selective populations.

There was a striking acceleration in testosterone prescribing in the second half of the study decade. This reflects the impact of permissive US (Bhasin et al. 2006) and European-based (Nieschlag et al. 2005) prescribing guidelines originally published in 2005–2006 and republished virtually unchanged 4 years later (Bhasin et al. 2010; Wang et al. 2009). These guidelines redefined the term “hypogonadism,” long understood as a pathological disorder that interferes with gonadal function, by eliminating the fundamental distinction between pathological hypogonadism and functional states with a low circulating testosterone. This elastic redefinition of the basis for valid testosterone replacement therapy created a loose collection of virtually any signs or symptoms coupled with a low serum testosterone but, crucially, without reference to the underlying reproductive or general disease(s) that cause such clinical features. These lax guidelines led many other societies, single-issue associations, and clinics as well as individual enthusiasts to

espouse that expanded, open-ended definition of “hypogonadism” as a license to prescribe testosterone without reference to organic, classical, or pathological hypogonadism. These expanded, permissive guidelines were highly influential with the European-based recommendations appearing as a paper in seven different peer-review journals. They were highly cited and widely understood as a de facto endorsement of testosterone prescribing for “andropause” (Braun 2013). Not surprisingly, these permissive guidelines were eagerly adopted by pharmaceutical industry leading to heavy marketing with both bold and subtle promotion aiming to influence key opinion leaders to foster off-label usage of testosterone products, effectively bypassing the need for high-quality evidence from randomized placebo-controlled clinical trials for off-label indications (Liverman and Blazer 2004). Under this influence, the ensuing medical literature over the last two decades has increasingly failed to differentiate between on-label and off-label indications for testosterone use. This created a highly influential, subsidized drive to marketing which produced the epidemic upsurge in testosterone prescribing over the first decade of this century. This de facto bypass of the usual regulatory controls regarding the promotion of testosterone for off-label usage was criticized by the FDA in its March 2015 website statement of post-marketing safety information (Food and Drug Administration (FDA) Center for Drug Evaluation and Research 2015) which stated that

Testosterone is FDA-approved as replacement therapy only for men who have low testosterone levels due to disorders of the testicles, pituitary gland, or brain that cause a condition called hypogonadism. Examples of these disorders include failure of the testicles to produce testosterone because of genetic problems, or damage from chemotherapy or infection. However, FDA has become aware that testosterone is being used extensively in attempts to relieve symptoms in men who have low testosterone for no apparent reason other than aging. The benefits and safety of this use have not been established.

An additional feature of this pharmacoepidemiological analysis was the increasing proportion of usage represented by transdermal compared with depot products. This increase was greater than that for total usage and represents a surrogate measure of prescribing targeted to older men. Daily use testosterone products are more convenient and safer for older men as short duration of action allows for rapid cessation with a new diagnosis of prostate cancer; by contrast, younger men, facing a lifetime of treatment, prefer long-acting depot injectables which facilitate maintaining continuity and convenience for lifelong treatment (Handelsman 2010).

In concert, both the permissive guidelines and the increasing proportion of transdermal products indicate that the dramatic increases in testosterone prescribing over the first decade of the century are primarily directed toward off-label treatment for older men. Together with direct-to-consumer advertising in North America, they are responsible for the epidemic-like increase in testosterone prescribing over the first decade of this century, in historical continuity with, and at the centenary anniversary of, the rejuvenation quackery era of a century ago.

## Harm from Testosterone Misuse

The potential public health consequences of the present epidemic of testosterone prescribing may be reflected in the incidence and prevalence of cardiovascular and prostate diseases when considered before and during the epidemic testosterone prescribing. The ongoing large-scale uncontrolled social experiment of dramatic increases in testosterone usage in middle-aged and older men may lead to measurable changes in common androgen-sensitive disorders of men's health detectable from surveillance of cardiovascular event or prostate cancer disease or death rates.

The potential adverse effects of testosterone use in older men without pathological hypogonadism were highlighted by the premature termination of a well-designed clinical trial of testosterone in frail, elderly men (Basaria et al. 2010). Nevertheless, previous longer and higher dose studies produced no similar excess cardiovascular harms (Handelsman 2011c), although the bias in underreporting of cardiovascular harm in industry-sponsored studies may lead to risk underestimation (Xu et al. 2013). Multiple meta-analyses of the same limited collection of small clinical trial have produced conflicting interpretations, although the odds ratios are consistently greater than 1.0 consistent with a small increased risk of cardiovascular events from testosterone treatment of older men without pathological hypogonadism (Xu et al. 2013; Borst et al. 2014; Corona et al. 2014; Ruige et al. 2011). On the background of age-specific cardiovascular mortality declining in many countries from its peak in the 1970s (Tunstall-Pedoe et al. 1999; Laatikainen et al. 2005; Taylor et al. 2006; Ford et al. 2007; Allender et al. 2008), the superimposition of potential testosterone-induced cardiovascular harm from the recent epidemic of testosterone prescribing for older men warrants critical surveillance of population cardiovascular morbidity and mortality rates. In the interim, testosterone prescribing for men without pathological hypogonadism should be confined to well-designed clinical trials geared to determining the efficacy and safety of testosterone prescribing for functional states, such as "andropause," associated with low circulating testosterone levels.

The other public health concern is whether increased testosterone prescribing will increase prostate hyperplasia/hypertrophy or cancer. While postpubertal exposure to adult male circulating testosterone concentrations is required for full development of the prostate and the development of late life prostate diseases such as benign prostatic hyperplasia/hypertrophy and prostate cancer, meta-analyses of observational studies suggest negligible risk that either endogenous or exogenous testosterone exposure predicts subsequent prostate cancer. Pooling prospective observational studies of circulating concentrations of testosterone or other androgens and pro-androgens show no consistent relationship with risk of subsequent prostate cancer (Roddam et al. 2008; Boyle et al. 2016). Similarly, pooling available randomized, placebo-controlled clinical trials of exogenous testosterone also showed no measurable risk of subsequent prostate cancer although only for up to 3 years follow-up (Cui et al. 2014). Further population surveillance of prostate diseases is warranted to detect any impact of the recent epidemic of testosterone prescribing.

## Abuse

### Historical

Androgen abuse<sup>2</sup> is defined as the use of androgens for nonmedical purposes and notably improved muscular size, strength, and power with the goal of either superior performance in elite sports or a hypermasculine bodybuilding image. It represents an epidemic originating during the early years of the Cold War that subsequently became an established endemic variant of drug abuse in the community. Originally it was confined to drug cheating within elite power sports but in the decades following the end of the Cold War, it became established as an endemic drug abuse subculture of recreational abusers seeking cosmetic body sculpting effects often to cartoonish lengths.

### Androgen Abuse in Sport

Androgen abuse originated as an epidemic among elite competitive athletes in the post-World War II decades. It developed as a facet of Cold War ideological rivalry in which sport was a stage upon which the opposing sociopolitical systems could compete in symbolic rather than military terms, using athletes on the field of sport as a surrogate for soldiers on the field of battle. Emerging during the late 1950s, elite athletes of eastern European countries were using androgens to achieve supremacy over their Western political rivals (Handelsman and Heather 2008; Hoffman et al. 2009). This culminated in the East German systematic national doping programs disclosed after the fall of the Berlin Wall (Franke and Berendonk 1997), and comparable national programs of other Eastern bloc countries remain undisclosed. This has only been exceeded by the revelation in 2016 of the Russian national doping programs which descends to new depths of organized cheating. Ultimately, androgen doping was enthusiastically but surreptitiously adopted by individual elite athletes and coaches from competing nations, reaching epidemic proportions notably in power sports where the gains in muscle mass and strength were most advantageous and especially conspicuous among female athletes whose circulating testosterone remains at all ages comparable with prepubertal males (Franke and Berendonk 1997).

Epidemic androgen abuse in elite sport coincided, and was fostered by, the flourishing of the golden age of steroid pharmacology. This was the period of the postwar decades during which synthetic glucocorticoids and hormonal contraceptives were developed into highly successful commercial products that still occupy a

---

<sup>2</sup>The term androgen abuse is used exclusively herein when referring to abuse of testosterone and/or its synthetic analog derivatives. This is more accurate terminology for steroids which are still often misnamed as “anabolic steroids” or “androgenic-anabolic steroids” elsewhere. For more detailed explanation see Handelsman (2011a).

major share of the established pharmaceutical market. However, during that epoch the third major quest in pharmaceutical steroid development and the efforts to develop a pure anabolic steroid devoid of virilizing androgen properties, such that it could be used freely in women and children, failed comprehensively. Nevertheless, that failed quest left legacies including thousands of never-marketed synthetic androgens recorded in expired patent databases. These now form an abundant resource for the flourishing illicit trade in synthetic androgens as designer or nutraceutical androgens. The illicit marketing of androgens has grown exponentially over recent decades with the availability of low cost, competitive chemical manufacturing plants, mainly in China, using the vast echo chamber of the Internet as a free, ubiquitous marketing tool for illicit sales of androgens. These may be sold illicitly as androgens or included as undeclared components of health food supplements which, as foods, bypass drug regulation.

Androgen abuse remains the most potent and prevalent form of sports doping detected (Handelsman 2015c). For example, among the nearly 270,000 anti-doping tests conducted worldwide by WADA approved anti-doping laboratories in 2013, almost 6000 (2.2%) were positive tests (adverse analytical findings) with the majority (57%) being hormones, of which >99% were androgens. Within sports, both direct androgen abuse (administration of androgens) and indirect androgen abuse (administration of non-androgenic drugs to increase endogenous testosterone) are now readily detectable with mass spectrometry-based anti-doping urine tests. Yet, the ongoing temptation of fame and fortune coupled with the undoubted effectiveness of androgen abuse especially for power sports continues to entice cheating via renewed approaches aiming to exploit androgens. These require ongoing vigilance and inventiveness in anti-doping science and targeting coaches as well as athletes in order to build resilience and deterrence against doping in order to maintain fairness in elite sport.

During the postwar decades, thousands of synthetic androgens were invented based on the steroidal structures of the natural androgens, testosterone, and DHT (Kicman 2008). The vast majority were 17- $\alpha$  alkylated, a substituent that rendered androgens more potent and orally active but suffered from hepatotoxicity, a class-specific adverse effect not shared by endogenous androgens or other types of synthetic androgens such as 1-methyl or nonsteroidal androgens. By modern drug regulatory standards, the 17- $\alpha$ -alkylated androgens would not have been registered due to their hepatotoxicity; however, by grandfathering, a diminishing number still remain on the pharmaceutical market. Only a tiny minority of these synthetic androgens outlined in the pharmaceutical patent literature of the 1950s–1970s were ever marketed. Many more, never-marketed androgens were described, and a small number underwent evaluation in research laboratories with no or only preliminary clinical studies. These provide a goldmine for development of apparently novel, designer androgens which initially cannot be detected by urine mass spectrometry-based anti-doping tests, which require prior knowledge of the chemical structure of the synthetic androgens and its metabolites.

Due to their hepatotoxicity, most marketed synthetic 17- $\alpha$ -alkylated androgens have been progressively eliminated from the market (Handelsman 2011b). Yet the

ergogenic advantages of androgens for power sports and their efficacy for body sculpting fostered the continuing availability of well-known alkylated androgens such as stanozolol, methandienone, and oxandrolone via the Internet for illicit use (Geyer et al. 2004; Thevis et al. 2011; Cordaro et al. 2011; Abbate et al. 2014; Krug et al. 2014; Rahnema et al. 2015). However, in sports all marketed androgens were readily identified by mass spectrometry-based doping detection methods (Kicman 2008) making such androgen doping highly likely to be detected by anti-doping tests. Consequently various alternative strategies were adopted to continue exploiting androgen doping without detection by other means. One approach has been to utilize never-marketed synthetic androgens identified from the old patent literature but whose structures remained undisclosed, whereas mass spectrometry-based urine detection tests required a known structure (Handelsman and Heather 2008; Abbate et al. 2014; Kazlauskas 2010). The first such designer androgen identified in an athlete's urine was norbolethone, a 17- $\alpha$ -alkylated androgen originally synthesized in 1960 but never marketed (Catlin et al. 2002). Soon after, tetrahydrogestrinone (THG), a previously unknown androgen produced illicitly by a one-step chemical reduction of a marketed alkylated progestin (gestrinone), was identified structurally (Catlin et al. 2004) and then as a potent androgen by an *in vitro* androgen bioassay (Death et al. 2004). Subsequently, desoxymethyltestosterone (Madol), another never-marketed androgen patented in 1960s, was identified (Sekera et al. 2005). A recent review notes at least six designer androgens available over the Internet (Rahnema et al. 2015). Nevertheless once identified, these designer androgens have never again been detected in regular doping tests reflecting effective deterrence.

The first nonsteroidal androgen invented was reported in 1998 (Dalton et al. 1998) leading to a new class of structurally diverse AR agonists ("SARM") with the overall goal of tissue selectivity, reviving the older attempts to dissociate virilizing from anabolic effects of androgens (Mohler et al. 2009). This aims to replicate the serendipitous but largely unexplained tissue selectivity of selective estrogen receptor modulators (SERM). So far no nonsteroidal androgens are yet approved for clinical use (Bhasin and Jasuja 2009; Dobs et al. 2013; Dalton et al. 2013), and their use in sport was prohibited in 2008. Yet, characteristically, potentially ergogenic drugs in pre-marketing development become available illicitly over the Internet for doping or bodybuilding, in breach of law, patents, and doping codes. For example, Andarine (S-4), widely advertised on the Internet (Kohler et al. 2010), has been identified in urine samples from athletes (Grata et al. 2011; Starcevic et al. 2013). Given the limited clinical trial data available (Dobs et al. 2013), the full safety profile of nonsteroidal androgens, even at conventional let alone doping doses, remains little understood.

## Androgen Abuse in the Community

In contrast to the well-known impact of androgen abuse as ergogenic drug cheating in sport, the challenge of androgen abuse in the community among recreational

abusers is only slowly being recognized and effective approaches to combat this new form of drug abuse remain to be developed.

Toward the end of the Cold War among countries with sustainable illicit drug subculture networks, androgen abuse spread from elite power sports to the larger market of recreational users for cosmetic effects. By the 1990s this had transformed an epidemic focused on elite power sports into a new, endemic dimension of illicit urban drug consumption easily grafted onto body-beautiful and image enhancement subcultures. During the preceding decade, this progression was propelled by entrepreneurial drug dealers fostering an underground folklore, epitomized by the infamous *Underground Steroid Handbook* of the early 1980s and culminating in the present situation where the majority of current androgen abusers now aim to achieve cosmetic goals such as bodybuilding and/or image sculpting for recreational or occupational reasons rather than doping in elite sports (Parkinson and Evans 2006; Ip et al. 2011). An important prospective stratified random sampling study provides evidence that, among US adolescents, the prevalence of androgen abuse peaked at the turn of the twenty-first century and has been declining since (Fig. 1).

Over recent decades the epidemic of androgen abuse has spread and settled into becoming an endemic in countries like Australia with sufficient affluence to sustain an illicit underground drug market. Few studies in Australia and elsewhere have systematically studied this relatively recent and growing form of drug abuse. A monumental meta-analysis of 271 studies involving 2.8 million participants showed that men were the predominant users (6.4% vs. 1.6% in females) with the prevalence of androgen abuse highest among recreational sports (18.4%), well ahead of athletes (13.4%), prisoners (12.4%), drug users (8.0%), and high school students (2.3%) compared with the general nonathlete community (1.0%) (Sagoe et al. 2014). Androgen abuse is a well-known practice among a minority of men in security-related occupations (military, police, security, club doormen) where sculpting a fearsome, hypermasculine body image may be a prevailing esthetic or a professional advantage. Using the captive population of secondary schools, the prevalence of androgen abuse among Australian male secondary students have remained at 2–3% for over the last two decades (Dunn and White 2011; Handelsman and Gupta 1997), whereas the prevalence in the general population is reportedly <1%, though the latter is probably an underestimate of the present usage as it is based on a self-report from a 2007 household survey (Dunn 2010). Given the higher incidence of violence (Lundholm et al. 2015), criminality (Klotz et al. 2006; Lundholm et al. 2010), and psychiatric disorders (Kanayama et al. 2008, 2009; Hall et al. 2005) as well as a wide variety of medical problems (Pope et al. 2014) including habituation or dependence (Kanayama et al. 2009), excess cardiovascular risk and premature death (Thiblin et al. 2000, 2015; Darke et al. 2014), mood, behavioral and cognitive disorders including aggressive, irresponsible or violent behavior possibly related to neurotoxicity (Kanayama et al. 2013) associated with androgen abuse, the growing prevalence of androgen abuse among youth is a public health concern.



## Androgen Abuse Regimes and Consequences

Characteristically, androgen abuse typically involves massive doses, many times beyond those employable in medicine, with the folklore encouraging “cycling” regimes comprising “stacking” of multiple androgens in pyramidal (“pyramiding”) escalating and then de-escalating doses over a 6–12 weeks periods. These drug use periods are separated by drug-free periods purportedly to recover sensitivity and/or minimize side effects that follow from receptor downregulation and desensitization due to sustained exposure to huge supraphysiologic androgen doses. Alternatively some professional bodybuilders may simply use continuous high-dose androgens for prolonged periods without drug-free intervals.

The androgen regimens typically combine multiple different androgens, although sometimes they are the same drugs with different trade names. These include not only marketed synthetic androgens but also extend to an increasing number of never-marketed androgens, so-called designer or nutraceutical androgens, that are found in unregulated, over-the-counter, and Internet-marketed food supplements, which often do not identify steroids on the label but are promoted as purportedly legal bodybuilding alternatives to androgens (Abbate et al. 2014; Akram et al. 2011). Abused androgens are obtained mainly from illicit sources, notably purchase over the Internet or locally supply from smuggled imports sold by illicit drug suppliers often related to criminal gangs. Only minimal supply of androgens for abuse arises by way of valid medical prescriptions, usually then from well-meaning doctors who succumb to manipulation for prescribing on demand and/or the occasional androgen-abusing doctor. These abuse patterns with alternating supraphysiological and deficient androgen states lead to fluctuating sexual dysfunction (reduced libido and sexual activity, erectile dysfunction) and poor general well-being (lethargy, reduced muscular power, depressed mood, emotional lability). These features reinforce the desire to continue abusing androgens resulting in habituation (Kanayama et al. 2009) as well as deeper, more prolonged suppression of endogenous testicular function which further retards ultimate recovery.

Among the medical consequences of androgen abuse, hypogonadism due to negative steroidal (androgenic) feedback effects on the hypothalamus is the most consistent and an almost universal endocrine consequence (Nieschlag and Vorona 2015). The usually profound suppression of testicular endocrine (steroidogenesis) and exocrine (spermatogenesis) functions with supraphysiologic doses of exogenous androgens leads to impaired spermatogenesis with testicular atrophy and reduced sperm output causing male subfertility or infertility. When exogenous androgen abuse is stopped after hypothalamic suppression is established, androgen deficiency symptoms experienced vary between individuals (Kelleher et al. 2004) but often include lethargy, loss of vitality and/or easy fatigue, and sexual dysfunction. In concert, these symptoms plus the loss of acquired muscle mass and strength, often a major objective of the androgen abuse, lead to a cycle of habituation and dependence which discourage cessation. Nevertheless, based on the reversible

mechanisms of steroidal negative feedback on the hypothalamus, it is generally believed, and supported by limited anecdotal information (Nieschlag and Vorona 2015; de Souza and Hallak 2011; Rahnema et al. 2014), that such hypothalamic suppression of male reproductive function may ultimately be reversible after cessation of the androgen abuse. However, the extent and time course of such reversibility have not been studied systematically.

Other adverse medical consequences of androgen abuse are reviewed in detail elsewhere (Pope et al. 2014; Nieschlag and Vorona 2015). The massive androgen doses and use of hepatotoxic 17- $\alpha$ -alkylated androgens in androgen abuse represent the major differences from the adverse effects of androgen misuse. Prominent adverse effects of androgen abuse include habituation and dependence (Kanayama et al. 2010) and neuropsychiatric and psychological (Kanayama et al. 2008), cardiovascular (Vanberg and Atar 2010), hepatic (Ishak and Zimmerman 1987; Turani et al. 1983), and a variety of musculoskeletal, connective tissue and metabolic disorders.

---

## References

- Abbate V, Kicman AT, Evans-Brown M, McVeigh J, Cowan DA, Wilson C, et al. Anabolic steroids detected in bodybuilding dietary supplements – a significant risk to public health. *Drug Test Anal.* 2014;7:609.
- Akram ON, Bursill C, Desai R, Heather AK, Kazlauskas R, Handelsman DJ, et al. Evaluation of androgenic activity of nutraceutical-derived steroids using mammalian and yeast in vitro androgen bioassays. *Anal Chem.* 2011;83:2065–74.
- Allender S, Scarborough P, O’Flaherty M, Capewell S. Patterns of coronary heart disease mortality over the 20th century in England and Wales: possible plateaus in the rate of decline. *BMC Public Health.* 2008;8:148.
- Altschule MD, Tillotson KJ. The use of testosterone in the treatment of depressions. *N Engl J Med.* 1948;239:1036–8.
- Amiaz R, Seidman SN. Testosterone and depression in men. *Curr Opin Endocrinol Diabetes Obes.* 2008;15:278–83.
- Aminorroaya A, Kelleher S, Conway AJ, Ly LP, Handelsman DJ. Adequacy of androgen replacement influences bone density response to testosterone in androgen-deficient men. *Eur J Endocrinol.* 2005;152:881–6.
- Anonymous. The pentacle of rejuvenescence. *Br Med J.* 1889;1:1416.
- Anonymous. Dr Brown-Sequard’s “Elixir of Life”. *Lancet.* 1890;135:57–8.
- Araujo AB, O’Donnell AB, Brambilla DJ, Simpson WB, Longcope C, Matsumoto AM, et al. Prevalence and incidence of androgen deficiency in middle-aged and older men: estimates from the Massachusetts male aging study. *J Clin Endocrinol Metab.* 2004;89:5920–6.
- Baillargeon J, Urban RJ, Ottenbacher KJ, Pierson KS, Goodwin JS. Trends in androgen prescribing in the United States, 2001 to 2011. *JAMA Intern Med.* 2013;173:1465–6.
- Basaria S, Coviello AD, Travison TG, Storer TW, Farwell WR, Jette AM, et al. Adverse events associated with testosterone administration. *N Engl J Med.* 2010;363:109–22.
- Bhasin S, Jasuja R. Selective androgen receptor modulators as function promoting therapies. *Curr Opin Clin Nutr Metab Care.* 2009;12:232–40.
- Bhasin S, Singh AB, Mac RP, Carter B, Lee MI, Cunningham GR. Managing the risks of prostate disease during testosterone replacement therapy in older men: recommendations for a standardized monitoring plan. *J Androl.* 2003;24:299–311.

- Bhasin S, Cunningham GR, Hayes FJ, Matsumoto AM, Snyder PJ, Swerdloff RS, et al. Testosterone therapy in adult men with androgen deficiency syndromes: an endocrine society clinical practice guideline. *J Clin Endocrinol Metab.* 2006;91:1995–2010.
- Bhasin S, Cunningham GR, Hayes FJ, Matsumoto AM, Snyder PJ, Swerdloff RS, et al. Testosterone therapy in men with androgen deficiency syndromes: an Endocrine Society clinical practice guideline. *J Clin Endocrinol Metab.* 2010;95:2536–59.
- Bojesen A, Juul S, Gravholt CH. Prenatal and postnatal prevalence of Klinefelter syndrome: a national registry study. *J Clin Endocrinol Metab.* 2003;88:622–6.
- Bojesen A, Juul S, Birkebaek N, Gravholt CH. Increased mortality in Klinefelter syndrome. *J Clin Endocrinol Metab.* 2004;89:3830–4.
- Borell M. Brown-Sequard's organotherapy and its appearance in America at the end of the nineteenth century. *Bull Hist Med.* 1976a;50:309–20.
- Borell M. Organotherapy, British physiology, and discovery of the internal secretions. *J Hist Biol.* 1976b;9:235–68.
- Borst SE, Shuster JJ, Zou B, Ye F, Jia H, Wokhlu A, et al. Cardiovascular risks and elevation of serum DHT vary by route of testosterone administration: a systematic review and meta-analysis. *BMC Med.* 2014;12:211.
- Boyle P, Koechlin A, Bota M, d'Onofrio A, Zaridze DG, Perrin P, et al. Endogenous and exogenous testosterone and the risk of prostate cancer and increased prostate specific antigen (PSA): a meta-analysis. *BJU Int.* 2016;118:731.
- Braun SR. Promoting “Low T”: a medical writer's perspective. *JAMA Intern Med.* 2013;173:1458–60.
- Bremner WJ. Testosterone deficiency and replacement in older men. *N Engl J Med.* 2010;363:189–91.
- Butenandt A, Hanisch G. Über die Umwandlung des Dehydroandrosterons in Androstenol-(17)-one-(3) (Testosterone); Umweg zur darstellung des testosterons aus Cholesterolin (vorlaufmitteilung). *Z Physiol Chem.* 1935;237:89–97.
- Carosa E, Martini P, Brandetti F, Di Stasi SM, Lombardo F, Lenzi A, et al. Type V phosphodiesterase inhibitor treatments for erectile dysfunction increase testosterone levels. *Clin Endocrinol.* 2004;61:382–6.
- Catlin DH, Ahrens BD, Kucherova Y. Detection of norbolethone, an anabolic steroid never marketed, in athletes' urine. *Rapid Commun Mass Spectrom.* 2002;16:1273–5.
- Catlin DH, Sekera MH, Ahrens BD, Starcevic B, Chang YC, Hatton CK. Tetrahydrogestrinone: discovery, synthesis, and detection. *Rapid Commun Mass Spectrom.* 2004;18:1245–9.
- Conway AJ, Handelsman DJ, Lording DW, Stuckey B, Zajac JD. Use, misuse and abuse of androgens: the Endocrine Society of Australia consensus guidelines for androgen prescribing. *Med J Aust.* 2000;172:220–4.
- Cordaro FG, Lombardo S, Cosentino M. Selling androgenic anabolic steroids by the pound: identification and analysis of popular websites on the Internet. *Scand J Med Sci Sports.* 2011;21:e247–59.
- Corona G, Maseroli E, Rastrelli G, Isidori AM, Sforza A, Mannucci E, et al. Cardiovascular risk associated with testosterone-boosting medications: a systematic review and meta-analysis. *Expert Opin Drug Saf.* 2014;13:1327–51.
- Cui Y, Zong H, Yan H, Zhang Y. The effect of testosterone replacement therapy on prostate cancer: a systematic review and meta-analysis. *Prostate Cancer Prostatic Dis.* 2014;17:132–43.
- Cussons AJ, Bhagat CI, Fletcher SJ, Walsh JP. Brown-Sequard revisited: a lesson from history on the placebo effect of androgen treatment. *Med J Aust.* 2002;177:678–9.
- Dalton JT, Mukherjee A, Zhu Z, Kirkovsky L, Miller DD. Discovery of nonsteroidal androgens. *Biochem Biophys Res Commun.* 1998;244:1–4.
- Dalton JT, Taylor RP, Mohler ML, Steiner MS. Selective androgen receptor modulators for the prevention and treatment of muscle wasting associated with cancer. *Curr Opin Support Palliat Care.* 2013;7:345–51.

- Darke S, Torok M, Duflou J. Sudden or unnatural deaths involving anabolic-androgenic steroids. *J Forensic Sci.* 2014;59:1025–8.
- David K, Dingemans E, Freud J, Laqueur E. Über krystallinisches männliches Hormon aus Hoden (Testosteron), wirksamer als aus Ham oder aus Cholestrin bereitetes Androsteron. *Hoppe Seylers Zeitschrift Physiol Chemie.* 1935;233:281–2.
- de Souza GL, Hallak J. Anabolic steroids and male infertility: a comprehensive review. *BJU Int.* 2011;108:1860–5.
- Death AK, McGrath KC, Kazlauskas R, Handelsman DJ. Tetrahydrogestrinone is a potent androgen and progestin. *J Clin Endocrinol Metab.* 2004;89:2498–500.
- Dobs AS, Boccia RV, Croot CC, Gabrail NY, Dalton JT, Hancock ML, et al. Effects of enobosarm on muscle wasting and physical function in patients with cancer: a double-blind, randomised controlled phase 2 trial. *Lancet Oncol.* 2013;14:335–45.
- Dunn M. The non-medical use of steroids in Australia: results from a general population survey. *Aust N Z J Public Health.* 2010;34:531–2.
- Dunn M, White V. The epidemiology of anabolic-androgenic steroid use among Australian secondary school students. *J Sci Med Sport.* 2011;14:10–4.
- Dwyer AA, Raivio T, Pitteloud N. Gonadotrophin replacement for induction of fertility in hypogonadal men. *Best Pract Res Clin Endocrinol Metab.* 2015;29:91–103.
- Edwards P, Ekins R. The “Pardridge” hypotheses relating to the role of hormone binding proteins in hormone delivery: a critique. *Steroids.* 1988;52:367–8.
- Ekins R. Measurement of free hormones in blood. *Endocr Rev.* 1990;11:5–46.
- Food and Drug Administration (FDA) Center for Drug Evaluation and Research. Minutes of the Joint Meeting of the Bone, Reproductive and Urologic Drugs Advisory Committee and the Drug Safety and Risk Management advisory committee, 2014. 2014. Available from: <http://www.fda.gov/downloads/AdvisoryCommittees/CommitteesMeetingMaterials/Drugs/ReproductiveHealthDrugsAdvisoryCommittee/UCM418144.pdf>.
- Food and Drug Administration (FDA) Center for Drug Evaluation and Research. FDA Drug Safety Communication: FDA cautions about using testosterone products for low testosterone due to aging; requires labeling change to inform of possible increased risk of heart attack and stroke with use. 2015. Available from: <http://www.fda.gov/Drugs/DrugSafety/ucm436259.htm>.
- Ford ES, Ajani UA, Croft JB, Critchley JA, Labarthe DR, Kottke TE, et al. Explaining the decrease in U.S. deaths from coronary disease, 1980–2000. *N Engl J Med.* 2007;356:2388–98.
- Franke WW, Berendonk B. Hormonal doping and androgenization of athletes: a secret program of the German Democratic Republic government. *Clin Chem.* 1997;43:1262–79.
- Gabrielsen JS, Najari BB, Alukal JP, Eisenberg ML. Trends in testosterone prescription and public health concerns. *Urol Clin North Am.* 2016;43:261–71.
- Gan EH, Pattman S, HSP S, Quinton R. A UK epidemic of testosterone prescribing, 2001–2010. *Clin Endocrinol.* 2013;79:564–70.
- Geyer H, Parr MK, Mareck U, Reinhart U, Schrader Y, Schanzer W. Analysis of non-hormonal nutritional supplements for anabolic-androgenic steroids – results of an international study. *Int J Sports Med.* 2004;25:124–9.
- Grata E, Perrenoud L, Saugy M, Baume N. SARM-S4 and metabolites detection in sports drug testing: a case report. *Forensic Sci Int.* 2011;213:104–8.
- Grodstein F, Manson JE, Colditz GA, Willett WC, Speizer FE, Stampfer MJ. A prospective, observational study of postmenopausal hormone therapy and primary prevention of cardiovascular disease. *Ann Intern Med.* 2000;133:933–41.
- Groth KA, Skakkebaek A, Host C, Gravholt CH, Bojesen A. Clinical review: Klinefelter syndrome – a clinical update. *J Clin Endocrinol Metab.* 2013;98:20–30.
- Haber C. Life extension and history: the continual search for the fountain of youth. *J Gerontol A Biol Sci Med Sci.* 2004;59:B515–22.
- Hall RC, Hall RC, Chapman MJ. Psychiatric complications of anabolic steroid abuse. *Psychosomatics.* 2005;46:285–90.

- Hall SA, Ranganathan G, Tinsley LJ, Lund JL, Kupelian V, Wittert GA, et al. Population-based patterns of prescription androgen use, 1976–2008. *Pharmacoepidemiol Drug Saf.* 2014;23:498–506.
- Hamilton JB. Treatment of sexual underdevelopment with synthetic male hormone substance. *Endocrinology.* 1937;21:649–54.
- Hamilton D. *The monkey gland affair.* London: Chatto & Windus; 1986. p. 155.
- Handelsman DJ. Trends and regional differences in testosterone prescribing in Australia, 1991–2001. *Med J Aust.* 2004;181:419–22.
- Handelsman DJ. Update in andrology. *J Clin Endocrinol Metab.* 2007;92:4505–11.
- Handelsman DJ. Androgen physiology, pharmacology and abuse. In: DeGroot LJ, Jameson JL, editors. *Endocrinology.* 6th ed. Philadelphia: Elsevier Saunders; 2010. p. 2469–98.
- Handelsman DJ. Commentary: androgens and “anabolic steroids”: the one-headed Janus. *Endocrinology.* 2011a;152:1752–4.
- Handelsman DJ. Androgen therapy in non-gonadal disease. In: Nieschlag E, Behre HM, editors. *Testosterone: action, deficiency and substitution.* 4th ed. Cambridge: Cambridge University Press; 2011b. p. 372–407.
- Handelsman DJ. An old emperor finds new clothing: rejuvenation in our time. *Asian J Androl.* 2011c;13:125–9.
- Handelsman DJ. Pharmacoepidemiology of testosterone prescribing in Australia, 1992–2010. *Med J Aust.* 2012;196:642–5.
- Handelsman DJ. Global trends in testosterone prescribing, 2000–2011: expanding the spectrum of prescription drug misuse. *Med J Aust.* 2013;199:548–51.
- Handelsman DJ. Androgen physiology, pharmacology and abuse. In: DeGroot LJ, Jameson JL, editors. *Endocrinology.* 7th ed. Philadelphia: Elsevier Saunders; 2015a. p. 2368–93.
- Handelsman DJ. Irrational exuberance in testosterone prescribing: when will the bubble burst? *Med Care.* 2015b;53:743–5.
- Handelsman DJ. Performance enhancing hormones in sports doping. In: DeGroot LJ, Jameson JL, editors. *Endocrinology.* 7th ed. Philadelphia: Elsevier Saunders; 2015c. p. 441–54.
- Handelsman DJ, Gupta L. Prevalence and risk factors for anabolic-androgenic steroid abuse in Australian secondary school students. *Int J Androl.* 1997;20:159–64.
- Handelsman DJ, Heather A. Androgen abuse in sports. *Asian J Androl.* 2008;10:403–15.
- Haring R, Ittermann T, Volzke H, Krebs A, Zygumt M, Felix SB, et al. Prevalence, incidence and risk factors of testosterone deficiency in a population-based cohort of men: results from the study of health in Pomerania. *Aging Male.* 2010;13:247–57.
- Herlihy AS, McLachlan RI. Screening for Klinefelter syndrome. *Curr Opin Endocrinol Diabetes Obes.* 2015;22:224–9.
- Hoffman JR, Kraemer WJ, Bhasin S, Storer T, Ratamess NA, Haff GG, et al. Position stand on androgen and human growth hormone use. *J Strength Cond Res/National Strength Cond Assoc.* 2009;23:S1–S59.
- Hsu B, Cumming RG, Blyth FM, Naganathan V, Le Couteur DG, Seibel MJ, et al. The longitudinal relationship of sexual function and androgen status in older men: the Concord Health and Ageing in Men Project. *J Clin Endocrinol Metab.* 2015;100:1350–8.
- Huo S, Scialli AR, McGarvey S, Hill E, Tugertimur B, Hogenmiller A, et al. Treatment of men for “Low Testosterone”: a systematic review. *PLoS One.* 2016;11:e0162480.
- Ip EJ, Barnett MJ, Tenerowicz MJ, Perry PJ. The anabolic 500 survey: characteristics of male users versus nonusers of anabolic-androgenic steroids for strength training. *Pharmacotherapy.* 2011;31:757–66.
- Ishak KG, Zimmerman HJ. Hepatotoxic effects of the anabolic-androgenic steroids. *Semin Liver Dis.* 1987;7:230–6.
- Jannini EA, Screponi E, Carosa E, Pepe M, Lo Giudice F, Trimarchi F, et al. Lack of sexual activity from erectile dysfunction is associated with a reversible reduction in serum testosterone. *Int J Androl.* 1999;22:385–92.

- Jasuja GK, Bhasin S, Reisman JI, Berlowitz DR, Rose AJ. Ascertainment of testosterone prescribing practices in the VA. *Med Care*. 2015;53:746–52.
- Jee BC, Lee JY, Suh CS, Kim SH, Choi YM, Moon SY. Impact of GnRH agonist treatment on recurrence of ovarian endometriomas after conservative laparoscopic surgery. *Fertil Steril*. 2009;91:40–5.
- Jenkins JS. The voice of the castrato. *Lancet*. 1998;351:1877–80.
- Junkman K. Long-acting steroids in reproduction. *Recent Prog Horm Res*. 1957;13:380–419.
- Kahn A. Regaining lost youth: the controversial and colorful beginnings of hormone replacement therapy in aging. *J Gerontol A Biol Sci Med Sci*. 2005;60:142–7.
- Kanayama G, Amiaz R, Seidman S, Pope Jr HG. Testosterone supplementation for depressed men: current research and suggested treatment guidelines. *Exp Clin Psychopharmacol*. 2007;15:529–38.
- Kanayama G, Hudson JI, Pope Jr HG. Long-term psychiatric and medical consequences of anabolic-androgenic steroid abuse: a looming public health concern? *Drug Alcohol Depend*. 2008;98:1–12.
- Kanayama G, Brower KJ, Wood RI, Hudson JI, Pope Jr HG. Anabolic-androgenic steroid dependence: an emerging disorder. *Addiction*. 2009;104:1966–78.
- Kanayama G, Hudson JI, Pope Jr HG. Illicit anabolic-androgenic steroid use. *Horm Behav*. 2010;58:111–21.
- Kanayama G, Kean J, Hudson JI, Pope Jr HG. Cognitive deficits in long-term anabolic-androgenic steroid users. *Drug Alcohol Depend*. 2013;130:208–14.
- Kazlauskas R. Designer steroids. *Handb Exp Pharmacol* 2010;195:155–85.
- Kelleher S, Conway AJ, Handelsman DJ. Blood testosterone threshold for androgen deficiency symptoms. *J Clin Endocrinol Metab*. 2004;89:3813–7.
- Kicman AT. Pharmacology of anabolic steroids. *Br J Pharmacol*. 2008;154:502–21.
- Kilbourne EJ, Moore WJ, Freedman LP, Nagpal S. Selective androgen receptor modulators for frailty and osteoporosis. *Curr Opin Investig Drugs*. 2007;8:821–9.
- Klotz F, Garle M, Granath F, Thiblin I. Criminality among individuals testing positive for the presence of anabolic androgenic steroids. *Arch Gen Psychiatry*. 2006;63:1274–9.
- Ko EY, Siddiqi K, Brannigan RE, Sabanegh Jr ES. Empirical medical therapy for idiopathic male infertility: a survey of the American Urological Association. *J Urol*. 2012;187:973–8.
- Kohler M, Thomas A, Geyer H, Petrou M, Schanzer W, Thevis M. Confiscated black market products and nutritional supplements with non-approved ingredients analyzed in the Cologne Doping Control Laboratory 2009. *Drug Test Anal*. 2010;2:533–7.
- Kolettis PN, Purcell ML, Parker W, Poston T, Nangia AK. Medical testosterone: an iatrogenic cause of male infertility and a growing problem. *Urology*. 2015;85:1068–72.
- Kovac JR, Scovell J, Ramasamy R, Rajanahally S, Coward RM, Smith RP, et al. Men regret anabolic steroid use due to a lack of comprehension regarding the consequences on future fertility. *Andrologia*. 2015;47:872–8.
- Krug O, Thomas A, Walpurgis K, Piper T, Sigmund G, Schanzer W, et al. Identification of black market products and potential doping agents in Germany 2010–2013. *Eur J Clin Pharmacol*. 2014;70:1303–11.
- Laatikainen T, Critchley J, Vartiainen E, Salomaa V, Ketonen M, Capewell S. Explaining the decline in coronary heart disease mortality in Finland between 1982 and 1997. *Am J Epidemiol*. 2005;162:764–73.
- Layton JB, Li D, Meier CR, Sharpless J, Sturmer T, Jick SS, et al. Testosterone lab testing and initiation in the United Kingdom and the United States, 2000–2011. *J Clin Endocrinol Metab*. 2014;99:835–842.
- Liu PY, Baker HW, Jayadev V, Zacharin M, Conway AJ, Handelsman DJ. Induction of spermatogenesis and fertility during gonadotropin treatment of gonadotropin-deficient infertile men: predictors of fertility outcome. *J Clin Endocrinol Metab*. 2009;94:801–8.
- Liverman CT, Blazer DG (Eds). *Testosterone and aging: clinical research directions*. Washington, DC: Institute of Medicine: The National Academies Press; 2004.

- Lundholm L, Kall K, Wallin S, Thiblin I. Use of anabolic androgenic steroids in substance abusers arrested for crime. *Drug Alcohol Depend.* 2010;111:222–6.
- Lundholm L, Frisell T, Lichtenstein P, Langstrom N. Anabolic androgenic steroids and violent offending: confounding by polysubstance abuse among 10,365 general population men. *Addiction.* 2015;110:100–8.
- Lunenfeld B, Mskhalaya G, Zitzmann M, Arver S, Kalinchenko S, Tishova Y, et al. Recommendations on the diagnosis, treatment and monitoring of hypogonadism in men. *Aging Male.* 2015;18:5–15.
- Ly LP, Handelsman DJ. Empirical estimation of free testosterone from testosterone and sex hormone-binding globulin immunoassays. *Eur J Endocrinol.* 2005;152:471–8.
- Ly LP, Sartorius G, Hull L, Leung A, Swerdloff RS, Wang C, et al. Accuracy of calculated free testosterone formulae in men. *Clin Endocrinol.* 2010;73:382–8.
- Medvei VC. A history of endocrinology. Lancaster: MTP Press; 1982.
- Mendel CM. The free hormone hypothesis: a physiologically based mathematical model. *Endocr Rev.* 1989;10:232–74.
- Millar AC, Lau AN, Tomlinson G, Kraguljac A, Simel DL, Detsky AS, et al. Predicting low testosterone in aging men: a systematic review. *CMAJ.* 2016;188:E321–30.
- Miller NL, Fulmer BR. Injection, ligation and transplantation: the search for the glandular fountain of youth. *J Urol.* 2007;177:2000–5.
- Mohler ML, Bohl CE, Jones A, Coss CC, Narayanan R, He Y, et al. Nonsteroidal selective androgen receptor modulators (SARMs): dissociating the anabolic and androgenic activities of the androgen receptor for therapeutic benefit. *J Med Chem.* 2009;52:3597–617.
- Mulligan T, Frick MF, Zuraw QC, Stenhagen A, McWhirter C. Prevalence of hypogonadism in males aged at least 45 years: the HIM study. *Int J Clin Pract.* 2006;60:762–9.
- Nakhoul G, Simon JF. Anemia of chronic kidney disease: treat it, but not too aggressively. *Cleve Clin J Med.* 2016;83:613–24.
- Nieschlag E, Nieschlag S. Testosterone deficiency: a historical perspective. *Asian J Androl.* 2014;16:161–8.
- Nieschlag E, Vorona E. mechanisms in endocrinology: medical consequences of doping with anabolic androgenic steroids: effects on reproductive functions. *Eur J Endocrinol.* 2015;173:R47–58.
- Nieschlag E, Swerdloff R, Behre HM, Gooren LJ, Kaufman JM, Legros JJ, et al. Investigation, treatment and monitoring of late-onset hypogonadism in males: ISA, ISSAM, and EAU recommendations. *Int J Androl.* 2005;28:125–7.
- Nigro N, Christ-Crain M. Testosterone treatment in the aging male: myth or reality? *Swiss Med Wkly.* 2012;142:w13539.
- Orwoll ES. Establishing a framework – does testosterone supplementation help older men? *N Engl J Med.* 2016;374:682–3.
- Orwoll E, Lambert LC, Marshall LM, Phipps K, Blank J, Barrett-Connor E, et al. Testosterone and estradiol among older men. *J Clin Endocrinol Metab.* 2006;91:1336–44.
- Parkinson AB, Evans NA. Anabolic androgenic steroids: a survey of 500 users. *Med Sci Sports Exerc.* 2006;38:644–51.
- Piszczek J, Mamdani M, Antoniou T, Juurlink DN, Gomes T. The impact of drug reimbursement policy on rates of testosterone replacement therapy among older men. *PLoS One.* 2014;9:e98003.
- Pope Jr HG, Amiaz R, Brennan BP, Orr G, Weiser M, Kelly JF, et al. Parallel-group placebo-controlled trial of testosterone gel in men with major depressive disorder displaying an incomplete response to standard antidepressant treatment. *J Clin Psychopharmacol.* 2010;30:126–34.
- Pope Jr HG, Wood RI, Rogol A, Nyberg F, Bowers L, Bhasin S. Adverse health consequences of performance-enhancing drugs: an Endocrine Society scientific statement. *Endocr Rev.* 2014;35:341–75.
- Rahnema CD, Lipshultz LI, Crosnoe LE, Kovac JR, Kim ED. Anabolic steroid-induced hypogonadism: diagnosis and treatment. *Fertil Steril.* 2014;101:1271–9.

- Rahnema CD, Crosnoe LE, Kim ED. Designer steroids – over-the-counter supplements and their androgenic component: review of an increasing problem. *Andrology*. 2015;3:150.
- Roddam AW, Allen NE, Appleby P, Key TJ. Endogenous sex hormones and prostate cancer: a collaborative analysis of 18 prospective studies. *J Natl Cancer Inst*. 2008;100:170–83.
- Rossouw JE, Anderson GL, Prentice RL, LaCroix AZ, Kooperberg C, Stefanick ML, et al. Risks and benefits of estrogen plus progestin in healthy postmenopausal women: principal results from the Women's Health Initiative randomized controlled trial. *JAMA*. 2002;288:321–33.
- Ruige JB, Mahmoud AM, De Bacquer D, Kaufman JM. Endogenous testosterone and cardiovascular disease in healthy men: a meta-analysis. *Heart*. 2011;97:870–5.
- Ruzicka L, Wettstein A. Über die krystallische Herstellung des Testikelhormons, Testosteron (androst-3-on-17-ol). *Helv Chim Acta*. 1935;18:1264–75.
- Sabharwal G, Craig T. Recombinant human C1 esterase inhibitor for the treatment of hereditary angioedema due to C1 inhibitor deficiency (C1-INH-HAE). *Expert Rev Clin Immunol*. 2015;11:319–27.
- Sagoe D, Molde H, Andreassen CS, Torsheim T, Pallesen S. The global epidemiology of anabolic-androgenic steroid use: a meta-analysis and meta-regression analysis. *Ann Epidemiol*. 2014;24:383–98.
- Samplaski MK, Loai Y, Wong K, Lo KC, Grober ED, Jarvi KA. Testosterone use in the male infertility population: prescribing patterns and effects on semen and hormonal parameters. *Fertil Steril*. 2014;101:64–9.
- Santen RJ, Allred DC, Ardoin SP, Archer DF, Boyd N, Braunstein GD, et al. Postmenopausal hormone therapy: an Endocrine Society scientific statement. *J Clin Endocrinol Metab*. 2010;95:s1–s66.
- Sartorius G, Ly LP, Sikaris K, McLachlan R, Handelsman DJ. Predictive accuracy and sources of variability in calculated free testosterone estimates. *Ann Clin Biochem*. 2009;46:137–43.
- Sequera MH, Ahrens BD, Chang YC, Starcevic B, Georgakopoulos C, Catlin DH. Another designer steroid: discovery, synthesis, and detection of 'madol' in urine. *Rapid Commun Mass Spectrom*. 2005;19:781–4.
- Sengoopta C. 'Dr Steinach coming to make old young!': sex glands, vasectomy and the quest for rejuvenation in the roaring twenties. *Endeavour*. 2003;27:122–6.
- Shores MM, Kivlahan DR, Sadak TI, Li EJ, Matsumoto AM. A randomized, double-blind, placebo-controlled study of testosterone treatment in hypogonadal older men with subthreshold depression (dysthymia or minor depression). *J Clin Psychiatry*. 2009;70:1009–16.
- Snyder PJ, Peachey H, Berlin JA, Hannoush P, Haddad G, Dlewati A, et al. Effects of testosterone replacement in hypogonadal men. *J Clin Endocrinol Metab*. 2000;85:2670–7.
- Snyder PJ, Bhasin S, Cunningham GR, Matsumoto AM, Stephens-Shields AJ, Cauley JA, et al. Effects of testosterone treatment in older men. *N Engl J Med*. 2016;374:611–24.
- Spitzer M, Basaria S, Travison TG, Davda MN, Paley A, Cohen B, et al. Effect of testosterone replacement on response to sildenafil citrate in men with erectile dysfunction: a parallel, randomized trial. *Ann Intern Med*. 2012;157:681–91.
- Starcevic B, Ahrens BD, Butch AW. Detection of the selective androgen receptor modulator S-4 (Andarine) in a doping control sample. *Drug Test Anal*. 2013;5:377–9.
- Swerdlow AJ, Higgins CD, Schoemaker MJ, Wright AF, Jacobs PA. Mortality in patients with Klinefelter syndrome in Britain: a cohort study. *J Clin Endocrinol Metab*. 2005;90:6516–22.
- Taylor R, Dobson A, Mirzaei M. Contribution of changes in risk factors to the decline of coronary heart disease mortality in Australia over three decades. *Eur J Cardiovasc Prev Rehabil*. 2006;13:760–8.
- Thevis M, Geyer H, Thomas A, Schanzer W. Trafficking of drug candidates relevant for sports drug testing: detection of non-approved therapeutics categorized as anabolic and gene doping agents in products distributed via the Internet. *Drug Test Anal*. 2011;3:331–6.
- Thiblin I, Lindquist O, Rajs J. Cause and manner of death among users of anabolic androgenic steroids. *J Forensic Sci*. 2000;45:16–23.



- Thiblin I, Garmo H, Garle M, Holmberg L, Byberg L, Michaelsson K, et al. Anabolic steroids and cardiovascular risk: a national population-based cohort study. *Drug Alcohol Depend.* 2015;152:87–92.
- Travison TG, Shackelton R, Araujo AB, Hall SA, Williams RE, Clark RV, et al. The natural history of symptomatic androgen deficiency in men: onset, progression, and spontaneous remission. *J Am Geriatr Soc.* 2008;56:831–9.
- Tunstall-Pedoe H, Kuulasmaa K, Mahonen M, Tolonen H, Ruokokoski E, Amouyel P. Contribution of trends in survival and coronary-event rates to changes in coronary heart disease mortality: 10-year results from 37 WHO MONICA project populations. Monitoring trends and determinants in cardiovascular disease. *Lancet.* 1999;353:1547–57.
- Turani H, Levi J, Zevin D, Kessler E. Hepatic lesions in patients on anabolic androgenic therapy. *Isr J Med Sci.* 1983;19:332–7.
- Vanberg P, Atar D. Androgenic anabolic steroid abuse and the cardiovascular system. *Handb Exp Pharmacol.* 2010;195:411–57.
- Voronoff S. Rejuvenation by grafting. London: George Allen & Unwin Ltd; 1925.
- Walsh TJ, Shores MM, Fox AE, Moore KP, Forsberg CW, Kinsey CE, et al. Recent trends in testosterone testing, low testosterone levels, and testosterone treatment among Veterans. *Andrology.* 2015;3:287–92.
- Wang C, Nieschlag E, Swerdloff R, Behre HM, Hellstrom WJ, Gooren LJ, et al. Investigation, treatment, and monitoring of late-onset hypogonadism in males: ISA, ISSAM, EAU, EAA, and ASA recommendations. *J Androl.* 2009;30:1–9.
- Wu FC, Tajar A, Beynon JM, Pye SR, Silman AJ, Finn JD, et al. Identification of late-onset hypogonadism in middle-aged and elderly men. *N Engl J Med.* 2010;363:123–35.
- Wyndham D. Verse-making and lovemaking – W. B. Yeats’ “strange second puberty”: Norman Haire and the Steinach rejuvenation operation. *J Hist Behav Sci.* 2003;39:25–50.
- Xu L, Freeman G, Cowling BJ, Schooling CM. Testosterone therapy and cardiovascular events among men: a systematic review and meta-analysis of placebo-controlled randomized trials. *BMC Med.* 2013;11:108.
- Zitzmann M, Faber S, Nieschlag E. Association of specific symptoms and metabolic risks with serum testosterone in older men. *J Clin Endocrinol Metab.* 2006;91:4335–43.

Jane Fisher and Karin Hammarberg

## Abstract

Investigations of the psychological and social aspects of reproductive life events, have, until quite recently, focused predominantly on women. Research has now considered in more detail the psychological aspects of desire for children, avoiding pregnancy when it is not wanted, achieving pregnancy when it is sought, and experiences of infertility among men. The research evidence has been generated predominantly in high- and upper-middle income countries; there is less evidence about these experiences among men living in low- and lower-middle income nations.

Men aspire to parenthood as much as women do but they have less knowledge about fertility and the factors that affect it than women do. The gap between ideal biological and ideal social age for parenthood appears to be widening, increasing the risk of involuntary childlessness or having fewer children than planned. Male factors either alone or in combination with female factors contribute to 50% of infertility. Up to 12% of men experience fertility difficulties, with the highest rates being in countries of Africa and Central and Eastern Europe.

Male factor infertility remains stigmatized, with pejorative associations with compromised masculinity. Notions that men are unaffected or unperturbed by infertility are false and reflect outdated and unhelpful gender stereotypes. While mental disorders are no more prevalent than in the general community, infertility-specific anxiety is common among men being investigated for fertility difficulties or whose partners are receiving fertility treatment.

In general, men prefer to receive psychologically informed care from the infertility treatment team to specialist psychological care. Referral to a mental health professional is recommended for the subgroups of men who have not

---

J. Fisher (✉) • K. Hammarberg  
Jean Hailes Research Unit, School of Public Health and Preventive Medicine, Monash University,  
Melbourne, VIC, Australia  
e-mail: [jane.fisher@monash.edu](mailto:jane.fisher@monash.edu); [karin.hammarberg@monash.edu](mailto:karin.hammarberg@monash.edu)

disclosed infertility to anyone apart from their spouse; appraise being infertile as hopeless or overwhelming or who are considering the use of donor sperm. Preprocedure counseling is also recommended for men considering vasectomy about its permanence and the limited potential for reversal. It is also recommended that infertility counselors are trained in the skills to manage intense psychological distress and interventions to enhance couple communication.

### Keywords

Psychological and social aspects • Infertility • Assisted reproduction • Fatherhood • Fathering

### Contents

Fatherhood: Attitudes, Intentions, and Aspirations Among Men .....	1289
Fatherhood Aspirations Among Men Who Are Gay .....	1290
Prevalence of Infertility .....	1290
Causes of Infertility Among Men .....	1291
Age and Health-Related Behaviors that Influence Fertility .....	1291
Fatherhood Aspirations Among Men Who Are Experiencing Fertility Difficulties .....	1293
Psychological Reactions to a Diagnosis of Infertility .....	1294
Understandings of Men's Experiences of Infertility in Low and Middle Income Countries .....	1297
Investigations in Which Cause of Infertility Was Considered .....	1299
Psychological Factors Associated with Infertility Distress in Men .....	1301
Consequences of Infertility for Intimate Partner Relationship and Sexual Functioning . .	1302
Psychological Aspects of Men's Experiences of Infertility Treatment .....	1303
Needs for Social and Professional Support .....	1306
Long-Term Psychosocial Aspects of Infertility and Fertility Treatment .....	1308
Summary and Implications .....	1309
References .....	1312

The desire to have a child is influenced by many aspects of a person's characteristics and circumstances, including their age, marital status, whether or not they already have children, culture and traditions, experiences within their family of origin, religious beliefs, and the degree of reproductive autonomy and access to contraception in a particular setting (Hadley and Hanley 2011). In most high-income nations the average ages at which men father children and at which women first give birth have risen rapidly in the last three decades, and there has been an overall decrease in the total fertility rate and average family size (Kessler et al. 2013). Using data from the 2006–2010 National Survey of Family Growth (NSFG), Kessler et al. (2013) investigated 6168 American men aged 15–44 years who had not fathered a child. They found that most childless men want a child someday, but by the age of 45 more than 1 in 7 remain childless.

Investigations of the psychological and social aspects of reproductive life events, including having a child, or being unable to conceive or be a partner in a pregnancy, have, until quite recently, focused predominantly on women. Research has now considered in more detail the psychological aspects of desire for children, avoiding pregnancy when it is not wanted, achieving pregnancy

when it is sought, and experiences of infertility among men. Overall, the available evidence has been generated from secondary analyses of national data, quantitative paper-based and online self-report surveys, structured telephone interviews, and qualitative investigations using interviews and small group discussions. Some research has been designed specifically to investigate men and some has investigated men as members of couples or as fathers. The research evidence has been generated predominantly in high- and upper-middle income countries; there is less evidence about these experiences among men living in low- and lower-middle income nations.

---

### **Fatherhood: Attitudes, Intentions, and Aspirations Among Men**

There are relatively few population-based investigations of the aspirations, expectations, and desires to have children among men. In a survey of Australian undergraduate, single, childless, male psychology students who had indicated that they wanted to father a child at some point in the future, it was found that most wanted to do this when aged in their late 20s or early 30s and that they preferred this to happen within a married, rather than a nonmarried but stable, relationship and when a permanent job and dependable income had been secured (Thompson and Lee 2011). In follow-up in-depth interviews with a subgroup of these men, having children (in general two or three) was described by most as being fundamental to lifetime contentment and fulfillment. Some acknowledged that realizing the circumstances essential to being able to contemplate parenthood might narrow the life window in which this goal was possible (Thompson and Lee 2011).

Almost all (86%) of a group of 500 biologically childless men aged 20–45 years in Canada wanted to have a child, 6.3% were trying actively to conceive (Roberts et al. 2011). Most (88%) wanted to have a child in the future, with proportions expressing this wish declining with age. Like the younger Australian men in Thompson et al.'s studies, the Canadian men identified financial security as an important precondition, but also the partner's desire for children and "suitability" as a potential co-parent. Men who were aged over 35 years were significantly less likely than younger men (20–24 years) to regard financial security as a precondition for fatherhood, and more likely to acknowledge that they were experiencing a "biological clock," suggesting more adaptation to the reality that there are rarely perfect circumstances in which to have a child as they aged.

In community-based surveys in Germany (Stöbel-Richter et al. 2005) and England (Langdridge et al. 2005) desire for children among childless women and men aged at least 30 was equal and linked to wishes to create new life, form a household, and experience love and was lowered by financial concerns.

Nevertheless, the most common reason for women in high-income nations to be childless by their mid-thirties is their difficulty in finding a man who is willing to commit to partnership and parenthood (Holton et al. 2011) and few women wish to become intentional single parents by using donor sperm. Puur et al. (2008) investigated men aged 20–44 years in eight European countries using data from the

Population Policy Acceptance Study. Using a standardized measure of gender role attitudes they found that men with egalitarian attitudes had higher fertility aspirations than those with traditional attitudes. The authors conclude that while women's participation rates in higher education and income-generating work have increased dramatically, there have been "few signs" of men increasing responsibilities for the work of caregiving and management of household tasks. This has led to "incoherence in levels of gender equity" with more having been achieved in the public than the private life sphere and that fertility has declined as a consequence.

### **Fatherhood Aspirations Among Men Who Are Gay**

There is a small literature describing aspirations for fatherhood and intentions to become a parent among gay men. In Italy, a small proportion (10%) of gay men have children, most born in prior heterosexual relationships. Baiocco and Laghi (2013) compared the parenting intentions and aspirations among 930 childless heterosexual and homosexual people, including 199 gay men. Fewer gay (51.8%) than heterosexual men (81.0%) wanted to have children and even fewer, 30.2%, compared to 73.1% described an intention to become a parent. In America, Riskind and Patterson (2010) analyzed data from the 2002 National Survey of Family Growth of 12,571 people (103 gay men) to investigate the observed population pattern that fewer people in same sex relationships became parents. Findings were very similar to the Italian study, including that desires and intentions to become a parent were lower among homosexual than heterosexual men and lesbian women. In both studies, however, a substantial proportion did want to become parents, and Riskind and Patterson (2010) noted that valuing of parenthood was the same among heterosexual and homosexual participants. Baiocco and Laghi (2013) interpreted their findings as reflecting the contextual barriers of lack of access to surrogacy or adoption for men in same sex partnerships.

### **Prevalence of Infertility**

Definitions of infertility vary in terms of whether the condition is identified by self-report, based on a personal history of reproductive events, or a formal medical diagnosis. Infertility is now generally defined as the inability to conceive after 12 months of sexual intercourse without contraception. It is estimated to affect 15% of couples worldwide. The Men in Australia Telephone Survey involved standardized computer-assisted interviews with a randomly selected, age-stratified, national sample. In total 5990 men aged from 40 to more than 70 years participated. Overall, 12.2% of the participants had never fathered a child, among them 7.6% who were "involuntarily infertile." Among the childless men 34% still wished or once wished to be a father. However, because population-based data about prevalence of infertility among men are not available for most nations and most data about infertility are generated through investigations of women who are seeking to

conceive, precise global prevalence data of male infertility are unavailable. In general, it is agreed that 20–30% of couple infertility is solely attributable to male factors, and male factors in combination with female factors explain up to a further 20%, meaning that they contribute to 50% of infertility overall. Agarwal et al. (2015) used these fractions to calculate male infertility rates by region on the basis of reported prevalence of infertility among women and concluded that from 2.5% to 12% of men are infertile and that the highest rates are in Africa and Central and Eastern Europe.

## Causes of Infertility Among Men

Infertility is regarded as a heterogeneous group of health problems, influenced by diverse risk factors. The most common cause is impaired semen quality in terms of concentration, morphology, or motility of sperm. Other causes are obstruction azoospermia, mostly attributable to vasectomy, disorders of intercourse or ejaculation, sperm antibodies, and hormonal deficiencies (McLachlan et al. 2005). Infectious causes appear to be less common in male than female factor infertility, but parasitic infections (including schistosomiasis, which damages the male genital tract) have been implicated in some countries (Kols and Nguyen 1997). Diagnosis requires medical investigations.

## Age and Health-Related Behaviors that Influence Fertility

There is growing recognition that individual characteristics, health-related behaviors, and circumstances influence fertility.

### Age

The consequences of chronological age for female fertility, including increased time to pregnancy (TTP) and higher rates of chromosomal abnormalities associated with reduced chance of conception and increased risk of spontaneous abortion, from the mid-30s are well established (Schmidt et al. 2012). Fertility among men also declines with age, with increasing proportions of morphologically abnormal sperm and higher mutation rates in genetic material carried within the sperm of older compared to younger men. While conceptions can occur between a man in his 50s and a younger woman, in general infertility rates increase among men from the late 30s (Kessler et al. 2013). Hassan and Killick (2003) investigated TTP among more than 2000 women receiving antenatal care at a teaching hospital in Hull, England. They found a fivefold increase in time to pregnancy associated with men being older than 45 years compared to men aged less than 25 years and that those aged more than 45 years were 4.6 times more likely to have a TTP of at least 1 year. In a recent review of the evidence about the impact of paternal age on the health and development of offspring, Lawson and Fletcher (2014) found that when maternal age is controlled, rates of stillbirth are higher when the father is aged over 40 years and

increase further when he is over 50 years. While overall rates are low, they also found that there are increased risks of autism spectrum disorders, bipolar affective disorders, and schizophrenia among the offspring of older than younger fathers.

### **High Body Mass Index**

Worse sperm quality, reduced erectile function, and alterations in libido, which together reduce fertility, have been found among men with a high rather than average body mass index. Analyzing data from the Longitudinal Investigation of Fertility and the Environment (LIFE) Study of 501 couples attempting to conceive in Texas and Michigan, USA, Eisenberg et al. (2014) found a linear reduction in ejaculate volume with increasing body mass and waist circumference ( $P < 0.01$ ) and a negative linear association between total sperm count and waist circumference ( $P < 0.01$ ). In a systematic review of 30 studies, reporting pooled data of about 115,158 participants, Campbell et al. (2015) found that men who were obese had higher odds of infertility (OR = 1.66, 95% CI 1.53–1.79) and a reduced rate of live births per cycle of treatment with assisted reproduction technology (ART) (OR = 0.65, 95% CI 0.44–0.97).

### **Occupational and Environmental Exposures**

The LIFE study data were also used to investigate the associations among occupational exposures, general health, and semen quality (Eisenberg et al. 2015). Semen samples were collected at home for next day analysis and were available for 456 men. Heavy manual work was associated with lower total sperm count. In terms of general health, men with hypertension had significantly lower sperm morphology scores than men whose blood pressure was in the normal range. Overall, there was a negative association between number of medications and sperm count. Cigarette smoking and exposure to potentially harmful occupational and environmental toxicants are also associated with adverse reproductive outcomes (Hruska et al. 2000). In some low-income countries, unsafe work, including occupational exposures to heavy metals, biological metabolites, pesticides and heat, may also contribute to infertility (Inhorn and Buss 1994; Kols and Nguyen 1997).

### **Knowledge About Fertility**

One of the factors associated with the later age of childbearing is men's overestimation of the duration of potential fertility. Daniluk and Koert (2013) surveyed 599 men aged 20–50 years who were childless, but presumed to be fertile. They used a male version of a fertility knowledge survey that had been developed and tested among women. While participants' self-rated confidence in their knowledge about fertility was high, fewer than 50% were able to answer more than 4 of 20 specific questions about fertility correctly. Their knowledge of fertility was lower than among women. Hammarberg et al. (2013) surveyed 462 Australians aged 18–45 years who wanted to have a child or another child in the future using structured telephone interviews. Overall 80% of male respondents believed that female fertility begins to decline at 35 and 51% that it does not begin to decline until over the age of 40 years or that age is irrelevant to fertility. More than half thought that male fertility

begins to decline at 50 years or is irrelevant to fertility. Significantly higher proportions of men believed that male obesity (25%) and smoking (15%) have no influence on fertility than women (13% and 7%). More than one in three did not know or had inaccurate knowledge about the time in the menstrual cycle when women are most likely to conceive.

### **Mental Health**

There have been substantial investigations in recent decades into whether semen quality at a population level is changing in response to factors other than chronological age. Psychological stress, long thought to be a factor contributing to unexplained infertility among women, has been investigated in a more limited way among men. Most commonly semen samples from men in couples seeking fertility treatments have been investigated. There have not been comprehensive surveys of samples representative of men in the general population. Gollenberg et al. (2010) assessed experiences of major adverse life events in the prior 3 months (the period of spermatogenesis) and standard parameters of semen quality among 744 fertile men who with their pregnant partners were participants in the Study for Future Families conducted in five major US cities. They found that those reporting two or more recent events were twice as likely to have sperm classified as below normal standard international criteria for concentration, motility, and morphology than those who reported fewer than two such events, including when alcohol, tobacco, and illegal substance abuse were controlled for in analyses. These authors propose an endocrine pathway with increased stress hormones leading to reduction in essential precursors for sperm production. Li et al. (2011) reviewed 57 cross-sectional studies with a total participant pool of almost 30,000 men from 26 nations, which had investigated associations between psychological, social, or behavioral factors and semen parameters. Meta-analyses of the impact of age, body mass index, smoking, alcohol, and coffee consumption and self-reported psychological stress were conducted. They concluded that although there might be interactions among them, higher age, smoking, alcohol consumption, and psychological stress were all risk factors for poorer semen quality and therefore for male fertility.

### **Cancer and Cancer Therapies**

One of the most clearly established risks to fertility is cancers, some of which have a direct impact on reproductive organs and cytotoxic chemotherapies or radiotherapy for cancer treatment (Pacey 2007).

### **Fatherhood Aspirations Among Men Who Are Experiencing Fertility Difficulties**

Stereotypically women are presumed to desire children and therefore to experience grief when the life goal of motherhood is unrealized, but men, having more diverse life opportunities, have been described as being “disappointed but not devastated” by being unable to have a child (Greil et al. 2010). Investigations of



desire for fatherhood among men diagnosed as infertile or whose partners are infertile or who have unexplained infertility as a couple indicate that this is an oversimplification.

Hadley and Hanley (2011) used individual semistructured interviews to investigate aspirations for fatherhood in a convenience sample of 10 employed men aged between 33 and more than 60 years who were not biological fathers. Four were single and two were stepfathers. They identified a spectrum which ranged from no interest in or desire to have a child to a visceral yearning for children

*P9: But I've never had any . . . never felt broody in my life*

*P5: I really do want my own children . . . I wanted that more than I wanted a marriage . . .*

*P5: I felt the pain of it, emotionally there was a real gut feeling that, you know, arghh . . . that I'm not the father of my own children.*

*P2: . . . grieving for those that were never born . . . which is a paradox.*

(Hadley and Hanley 2011).

While some participants described career, financial, and leisure time benefits to being childless, most (8 of 10) described having experienced depression associated to some degree with being childless. Their childless state contributed also to experiences of social exclusion, in particular from the activities and family lives of their peers.

Edelmann et al. (1994) conducted a postal survey of emotional distress among 205 couples belonging to the National Association for the Childless in the United Kingdom in which the male partner was infertile. Levels of distress were higher than in the general community and similar among men and women, suggesting that men do not experience infertility as merely “disappointing.” Dyer et al. (2008) found among 50 couples attending public infertility treatment clinics in South Africa that men and women desired children with similar intensity.

Longer-term attitudes towards parenthood were surveyed among 112 Australian men who had been diagnosed as infertile 5 years earlier (Fisher et al. 2010). Of these participants, 84% reported that they desired parenthood as much as their partner did; fewer than half agreed that it would be more disappointing for a woman than a man not to have a child. In the Netherlands among 108 infertile couples who had not become parents, on average 8.6 years after treatment initiation, men were less likely than women to “think often” about having children, but they were equally likely (86%) still to want a child and to identify happiness as the main motive to seek parenthood (van Balen and Trimbos-Kemper 1995).

## **Psychological Reactions to a Diagnosis of Infertility**

A relatively small group of studies has focused on the psychological consequences and emotional needs experienced by men of being diagnosed as infertile or being a member of an infertile couple. A number of dimensions of psychological functioning after diagnosis have been investigated including the consequences for mood, identity, self-esteem, and quality of life. Some also examined interactions between mood

and personality variously conceptualized as coping style, capacity for emotional self-regulation, tendency to appraise situations as stressful, and locus of control. Most studies have used self-report questionnaires including both standardized psychometric measures and study-specific questions.

### **Investigations in Which Cause of Infertility Was Not Considered**

Prospective (Beaurepaire et al. 1994; Edelmann and Connolly 2000; Anderson et al. 2003; Zorn et al. 2007) and cross-sectional (Peterson et al. 2006; Klemetti et al. 2010; Wichman et al. 2011) studies have assessed psychological functioning in men at diagnosis or immediately before commencing ART treatment. In broad terms, these sought to elucidate the nature of psychological distress: whether there were differences in psychological symptoms, most commonly depression and anxiety or quality of life between men and women, whether rates of clinically significant symptoms exceeded population prevalence, and whether risk factors for, or correlates of, mental health problems could be identified. Most compared data from consecutively recruited cohorts of men, women, or members of couples attending clinical services and some also made comparisons with published population norms. While this group of studies included people affected by fertility difficulties, none reported psychological outcomes by cause of infertility.

All the studies which compared men and women analyzed data presuming that the groups were independent of each other and none controlled for clustering effects within couples which can alter effect sizes. Nevertheless, a consistent pattern emerged. At initiation of infertility treatment 113 Australian men had significantly lower mean depression and anxiety scores than women (Beaurepaire et al. 1994) and Edelmann and Connolly (2000) found a similar pattern among 246 couples in England. Anderson et al. (2003) found among 113 Scottish couples that 1.8% of men and 2.7% of women ( $p = 0.02$ ) scored in the clinical range on a self-report depression scale and 9% of men and 26% of women ( $p < 0.001$ ) on a scale of anxiety symptoms. In the United States, Wichman et al. (2011) found among 162 couples that fewer men than women reported at least mild depression and anxiety ( $p < 0.01$ ). These studies demonstrate that rates of clinically significant mental health problems among infertile men are no higher than in the general population.

Anxiety appeared to be specific to the infertility situation rather than generalized. Wichman et al. (2011) found that infertility-specific distress was prevalent in both sexes: 51.3% of men and 66% of women ( $p < 0.001$ ). Peterson et al. (2006) used a fertility difficulties instrument to assess “infertility stress” and found scores among 506 men were significantly lower than among 520 women prior to initiation of treatment in North America. Anderson et al. (2003) found with a study-specific measure that men had lower levels than women of “infertility-related concerns” about life satisfaction, sexuality, self-esteem, and social participation, but 25% of men reported compromised life satisfaction. In Sweden, reactions to infertility were investigated among 91 couples prior to initiation of treatment. Men were less likely than women to think about infertility, find it difficult to separate infertility from the rest of life, and feel like a failure because of infertility. However, in other ways, for example, feeling guilty and finding that having a child was a major focus of life and

that difficulty in conceiving a child was more difficult to bear than had been imagined, there were no differences between men and women (Hjelmstedt et al. 1999). Edelmann and Connolly (2000) concluded that claims that men have fewer adverse reactions to infertility than their partners reflect stereotypes about desires for parenthood and that while some responses might be gender-specific, both men and women have heightened psychological needs in response to this unanticipated adverse life event.

One major population survey (Klemetti et al. 2010) investigated whether among 2291 randomly selected 30–44 year old Finnish people those who had experienced infertility had more severe or persistent mental health problems than those who had not. The 99 (9%) of men who reported infertility had the same rates of psychiatric illness and of psychological symptoms as among men in the general population. Childless men who had experienced infertility had significantly lower subjectively appraised quality of life than men who were childless but had not experienced infertility, attributed to degree of choice about this reproductive outcome. Beaurepaire et al. (1994) reported that more men at treatment initiation had “clinically elevated” anxiety scores indicating “situational distress” than population norms but fewer had depressive symptoms (4% vs. 10%,  $p = 0.03$ ). Similarly Glover et al. (1994) assessed 109 “male subfertility clinic attenders” before and immediately following the first specialist consultation. They found that high anticipatory anxiety and self-blame for infertility diminished but that depressive feelings increased, perhaps related to their lowered personal estimates of pregnancy likelihood. Dyer et al. (2009) compared responses to a standardized measure of psychological symptoms among 120 men attending an infertility clinic and 120 attending an antenatal clinic as a partner in pregnancy in South Africa. On average, while scores were in the normal range, men attending the infertility clinic had significantly higher scores on scales of global distress than others. This was interpreted as reflecting a reaction to their situations and not an indicator of underlying pathologies.

Conrad and Schilling (Conrad et al. 2001) compared capacity to communicate emotions (alexithymia) among 84 men diagnosed as infertile and 96 who were presumed to be fertile. They found that men who were infertile were significantly less likely to discuss emotions (for example, “I do not like to talk with others about their feelings, I prefer talking about their daily activities”), which was interpreted as reflecting stigma related to the diagnosis and a defensive or self-protective psychological function.

In Slovenia, links between psychological factors and semen quality were assessed among 1076 men having infertility investigations (Zorn et al. 2007). It was found that 19.9% scored in the clinical range on an anxiety scale but only 1.8% had indicated that they were possibly depressed. Higher rates of cigarette smoking, alcohol use, and sexual difficulties were found among men with anxiety scores in the clinical range. Edelmann and Connolly (2000) reported that infertile men’s scores on anxiety and general psychological distress measures were on average indistinguishable from or lower than those of men in the general population. Holter et al. (2007) reported that 166 Swedish men were in “generally good psychological

health” with no differences from population norms. Overall there appears to be consistent evidence that there is low prevalence of clinically significant psychological symptoms compared to community norms among men who are experiencing infertility apart from acute and situation-specific anxiety. Chachamovich et al. (2010) conducted a systematic review of 14 studies investigating quality of life “in infertility” of which nine compared men and women in infertile couples. They described these as “infertile men” but did not provide supporting evidence for this assertion. They found that women in this situation had consistently lower quality of life than men did, but that men had specific impairments in quality of life related to self-regard.

In qualitative studies using in-depth interviews Hinton and Miller (2013) explored men’s experiences of reproductive health care in the context of changes in the social roles of men as fathers and partners of mothers. They identified a disparity between expectations that men be involved and invested in reproductive life, but that fertility services have not been designed to understand or address men’s needs. Expression of emotions can be experienced by men as indicating “deficiency or weakness” and services can marginalize men and position them as observers rather than directly affected parties with gender-specific needs.

## **Understandings of Men’s Experiences of Infertility in Low and Middle Income Countries**

Most men of reproductive age live in the world’s low- and middle-income countries (LAMIC). Many LAMIC have a public policy focus on population control and less recognition of the needs of, or service provision for, people with fertility difficulties (Inhorn and Patrizio 2015). Inhorn (2009) argues that “in addition to the right to control fertility, reproductive rights must encompass the right to facilitate fertility when [it] is threatened,” but warns (Inhorn 2007) that in Muslim communities religious beliefs make infertility assessment and treatment particularly difficult for men because masturbation is proscribed. Procreation is highly valued in many of these settings and infertility contributes to substantial suffering including: loss of security of marital relationships, social stigma, and ostracization. Limited understanding of reproduction means that women are frequently held responsible for infertility and bear the social costs when conception does not occur and children are not born (Fisher 2009). Umeora et al. (2008) found that of 138 consultations by women in Southeast Nigeria for infertility only 63% of their husbands were ultimately prepared to attend the clinic and of these 17.5% were “very reluctant” and required much persuasion to undergo seminal fluid evaluation and 12.6% refused. Most (71%) believed that they could not be responsible for infertility and others were concerned that the sample could be used for witchcraft (34.6%) or rituals (19.2%).

In a major investigation of the sociocultural consequences of infertility, 312 women in Rwanda presenting with failure to conceive, 254 of their partners and fertile comparison groups of similar size were surveyed; and focus group

discussions (which included 20 men) were conducted (Dhont et al. 2010, 2011). Stigmatization, chronic suffering, and misattribution of characteristics (e.g., being accused of witchcraft or bringing bad luck) were widespread. While men in the focus groups described the loss associated with lack of continuity of the family, and that a life without children was less fulfilling, few agreed with the stereotype that masculinity was confirmed by fathering a child. Male and female focus group participants were surprised to learn about male factor infertility, having believed that it was always attributable to women. While participants suggested that men would generally separate from a woman who had not had a child, few thought that women would leave a male partner who was infertile. In general, understanding of causes of infertility was low and many had sought assistance from traditional healers. Men were more likely to have sought treatment in the formal medical sector if they had a higher income, were married, and had been infertile for at least 5 years (Dhont et al. 2010). Similarly in Zimbabwe Folkvord et al. (2005) investigated 311 men identified as infertile at a family planning clinic. Most (70%) “felt uncomfortable about being infertile” with a third reporting symptoms of at least mild depression and sleeping difficulties. Many reported interpersonal difficulties, with tension in their relationships with their partners and wider family. Superstitious beliefs about fertility difficulties, for example, that their wives’ “wombs were tired and turned against the sperm,” were common, and 80% had consulted traditional healers before attending the clinic. Nieuwenhuis et al. (2009) drew similar conclusions from in-depth interviews with seven infertile men in Nigeria but found that in addition to beliefs about “powers of darkness or Jujū” or being cursed by God, “immorality” was widely regarded as causing infertility. Moyo and Muhwati (2013) reached similar conclusions from focus group discussions with community members and interviews with key informant religious leaders and traditional healers in Zimbabwe. Male infertility was attributed to “supra-human causes” and as reflecting angry ancestors and punishment from God. In Nigeria 600 adults were asked about causes of infertility and while most perceived it as a disease, 92% attributed it to paranormal causes, fewer than a third suggested that sexually transmitted infections might contribute (Iliyasu et al. 2013). Few in Folkvord et al.’s study (2005) were prepared to consider the use of donor gametes because of beliefs that ancestral lines would be damaged by “alien sperm.” Sperm donation within the family was more acceptable.

Dyer et al. undertook a qualitative study with 27 men attending a public access fertility clinic in South Africa for the first time and found that they had limited reproductive health knowledge and attributed infertility to a “dirty womb,” ancestral disapproval, or witchcraft invoked by a jealous person (Dyer et al. 2004).

A study of 192 infertile couples in China found that lower income, poorer marital relationship, greater desire to have a child, and having a wife who believed that infertility could be caused by the male partner were significantly associated with poorer mental health among men (Lau et al. 2008). A study in India comparing infertile women ( $n = 44$ ) and men ( $n = 36$ ) found that men were more satisfied with their marital relationship and less worried about infertility than women (Barani Ganth et al. 2013).

## Investigations in Which Cause of Infertility Was Considered

### Male Factor Infertility

Another group of studies used comparable methods but made comparisons between groups of men and of couples classified on the basis of cause of infertility.

Nachtigall et al. (1992) investigated, using snowball sampling and in-depth interviews with 36 volunteer couples undergoing infertility treatment in America, whether emotional response varied by sex-specific diagnosis. They found that men with male factor infertility experienced more “negative emotional responses,” including a sense of loss, stigma, and reduced self-esteem than men whose partners were infertile or were in couples in which fertility difficulties were unexplained. They concluded that men’s responses to infertility approximated those of women only if it is attributable to a male factor.

Data from the Copenhagen Multi-Centre Psychosocial Infertility (COMPI) research program revealed no differences between men’s scores on measures of infertility distress and psychological well-being at initiation of treatment by whether infertility was attributable to male, female, mixed, or unexplained causes (Peronace et al. 2007). Lee et al. (2001) used the same classification for 138 couples presenting for treatment in Taiwan. They assessed psychological functioning with a Chinese infertility distress measure and found no differences in men’s self-esteem or guilt between groups. Holter et al. (2007) also found no differences between men’s psychological well-being scores by cause of infertility among 200 men in Sweden. Dhillon et al. (2000) in Canada compared groups of men who were partners of currently pregnant women and presumed to be fertile, infertile with oligoasthenospermia, or in a couple with unexplained infertility. There were no differences in mean scores on measures of depression, anxiety, anger, or self-esteem between these groups. However, on a measure of life events which assesses the impact of current stressful events on mood, men whose partners were pregnant had significantly higher psychological distress than either of the infertile groups but all were in the moderate range reflecting “typical levels of family stress.” Smith and Walsh (Smith et al. 2009) surveyed 357 men who were attending clinics as members of couples who were infertile, among them 12% were experiencing infertility attributable to a male factors; and in 41% it was either unexplained or attributable to both male and female factors. Data were collected in a study-specific questionnaire assessing personal, social, marital, and sexual impacts. When other potential explanatory factors were controlled, men with male factor infertility had significantly lower sexual enjoyment, felt less sexually attractive, had more “sexual failure” (Sexual Impact), and had a greater sense of being personally defective and of missing a crucial life experience (Personal Impact) than men in couples experiencing infertility not related to a male factor.

### Men as Members of Infertile Couples

In Poland, Drosdzol and Skrzypulex (2009) compared psychological functioning in 188 men and 206 women in couples aged 20–45 years who attended an infertility clinic with data from 190 couples of similar age with at least one child in which the woman was attending a general gynecology clinic. Men in infertile couples had

significantly higher levels than fertile men of symptoms of depression. More infertile than fertile men had at least mild clinically significant symptoms but in most it was mild to moderate and in none was it severe. Tuzer et al. (2010) assessed 60 couples with primary infertility who had experienced at least 3 years of fertility treatment in Turkey. On average, women in infertile couples in both these studies had higher symptom scores than men, but the differences were not significant. Anxiety related to treatment procedures increased among men, but not women, interpreted as desensitization associated with repeated exposure to intrusive treatments in women (Tüzer et al. 2010).

### **Infertility Related to Treatments for Cancer**

There have been quite extensive investigations of the psychological and social consequences of fertility difficulties related to cancer experienced during childhood or the reproductive years, synthesized in systematic and narrative reviews (Tschudin and Bitzer 2009; Carpentier and Fortenberry 2010).

People in this circumstance experience the complex psychological demands of adjustment to a potentially life-limiting condition, which might require treatments with the potential side effect of loss of fertility, including removal of malignant tissues, and adjuvant treatments to prevent recurrence. Tschudin and Bitzer reviewed 24 studies, which had used interviews or surveys to assess the psychological aspects of fertility preservation among men and women in the context of cancer (Tschudin and Bitzer 2009). They identified the contrasting psychological processes of fear, loss, and despondency that might accompany cancer and of joy and optimism that are associated with fertility and suggested that fertility preservation could be experienced as providing hope in an otherwise bleak situation. However, they also found that while clinicians were in general in favor of sperm banking for all men experiencing cancer, some oncology specialists lacked either personal knowledge of the techniques, relationships with clinicians specialized in fertility preservation, or access to services to offer it and were hesitant to raise the topic in consultations. In general, patient perspectives were that they wanted to preserve future fertility but did not want it to involve delays in initiating cancer treatment.

Goossens et al. reviewed 27 papers reporting investigations of fertility-related information needs and preferences and experiences of clinical consultations from the perspectives of people who had experienced cancer and health care providers (Goossens et al. 2014). People with cancer, in particular those who are young, do not yet have children, or who have plans for further children want fertility-related information, but there is great variation in the proportion (0–85%) who receive it. Younger patients were more likely than those who were older to report unmet information needs. Barriers to the provision of such information identified by health care providers included: prioritization of survival over other concerns and self-appraised lack of knowledge and skills about fertility preservation. Similar conclusions had been reached by Quinn et al. in their review of 29 papers about fertility decision-making in the context of pediatric cancers (Quinn et al. 2011). They found consistent evidence that adolescents experiencing cancer want to participate in fertility decision-making and do not want decisions made in their interests by either treating clinicians or their parents.

Crawshaw elaborated these findings in a narrative review of the fertility preservation needs of adolescents and young adults experiencing cancer (Crawshaw 2013). She concluded that “professional gate-keeping” related to inadequate knowledge or perceptions that patients are too young, or too sick, or have too limited a prognosis, or that risk of damage to fertility is low, or unease in discussing sexual or reproductive matters can lead clinicians not to provide information or invite discussion with young people in this predicament or their families. Fertility preservation was more likely to be discussed with people who were childless, graduates, Caucasian, and heterosexual than others. Parents too can feel awkward about discussing fertility preservation with young men, in particular as collection of semen requires masturbation.

As survival rates following testicular cancer are generally high and life expectancy is not necessarily reduced, Carpentier and Fortenberry argued there are needs to consider long-term as well as the immediate- and medium-term impacts of survivorship among adolescents and young men (Carpentier and Fortenberry 2010). In their review of 37 studies they found that the mental health, including self-esteem, of men who were in committed romantic relationships at point of diagnosis was protected. However, men who were single were especially vulnerable to subsequent lasting anxiety about sexual functioning and fear that disclosure of having experienced cancer would limit future intimate partnerships. Although some studies reported that there was little evidence that sexual interest, functioning, and pleasure changed after treatment for testicular cancer, others reported that anxiety about sexual performance began during treatment and was enduring.

Overall, conclusions were that providing clinical care in this situation is especially difficult because it involves not only the transfer of information about cancer and cancer treatments but also about future fertility, each with ethical complexities (Tschudin and Bitzer 2009). It requires sustained emotional support and consideration of existential meanings all bound by the time constraints of commencement of oncology treatment. Crawshaw highlights the importance of taking a life course approach, which incorporates awareness that from the point of cancer diagnosis onwards, future hopes, aspirations, and expectations both in the immediate and longer term are altered (Crawshaw 2013). She concludes that consideration of fertility, including fertility preservation, is intrinsic to comprehensive cancer care and should be included routinely as a best practice. Crawshaw (2013) argues in a subsequent review that men might be more effectively engaged in care if health care providers enquire into their social circumstances and their hopes and self-perceived capacity to be fathers in the future.

---

## **Psychological Factors Associated with Infertility Distress in Men**

Some investigations sought to identify whether personality characteristics or attitudes governed adjustment to infertility. Band et al. (1998) used measures of perceived stress and coping styles to assess men with male factor infertility attending a clinic in England. More severe depressive and anxious symptoms were associated



with an avoidant coping style – a “tendency to appraise situations as stressful” and failure to seek social support.

With similar aims, Beaurepaire et al. (1994) reported that in general men had a more internal locus of control, reflecting a greater sense of agency over events, and less self-blame and guilt about infertility than women did. Their locus of control was comparable to community norms. Peterson et al. (2006) also found differences between the sexes, with men using “distancing” or making light of the situation, “self-controlling,” or keeping feelings about infertility contained and not permitting them to govern daily life and “planful problem-solving” or seeking information and solutions more commonly than women did. Men and women used “seeking social support” or talking to friends and professionals at the same level. Among both men and women using a problem-solving approach and seeking social support were associated with lower levels of “infertility stress.” Anderson et al. (2003) used a structured study-specific questionnaire to assess “concerns” and found that men were less likely than women to experience self-blame and reduced self-esteem and to avoid seeing friends. In Sweden, Hjelmstedt et al. (1999) found that significantly more men than women had not confided in anyone about their infertility problem. In contrast to other findings, in this study men who had an information-seeking adaptive style were more distressed than those who tended to avoid information. This was interpreted as reflecting the inherent frustrations of being in a situation which is poorly understood and in which assured treatments are not available.

Jordan and Revenson (1999) undertook a meta-analysis of six cross-sectional studies published between 1966 and 1995 which had examined coping strategies after infertility diagnosis using standardized measures in men and women. They concluded that overall there were more similarities than differences in the eight assessed strategies. However, men used less social support seeking, avoidance, and positive reappraisal of the situation than women did. Wischmann and Thorn (2013) concluded that while overall the emotional impact of infertility is experienced similarly by men and women, the style of communicating distress is likely to differ. In the face of loss, including of fertility and potentially of having children, men stereotypically focus on restoration and with seeking active and practical solutions to the problem and do not express sadness and despair openly. These strategies are similar to those used in response to other life stresses.

### **Consequences of Infertility for Intimate Partner Relationship and Sexual Functioning**

Some investigations sought to elucidate the consequences of infertility for the quality of relationship between intimate partners. Most focused on the sexual and fewer on the emotional and communicative aspects of the relationship and in general comparisons on the basis of whether infertility was attributable to male or female factors were not drawn (Hunt and McHale 2007).

In Germany (Müller et al. 1999), current and prediagnosis recollections of frequency of intercourse and sexual satisfaction were assessed in 68 consecutively

recruited men with male factor infertility. Frequency of intercourse was lower among those with relationships (and awareness of infertility) of longer duration, but overall there were high levels of current sexual satisfaction. Using the same measures, Ramezanzadeh et al. (2006) investigated 200 men who were recruited consecutively while attending an infertility service in Iran. Although there were generally high levels of sexual satisfaction 41.5% reported at least some reduction in desire and 52.5% in satisfaction since diagnosis. Neither age nor cause of infertility was related to sexual satisfaction, but it was negatively related ( $p < 0.01$ ) to duration of interval since diagnosis. In the study by Smith et al. (2009) men with male factor or in couples with unexplained infertility had lower levels of sexual quality of life, assessed as enjoyment, sense of attractiveness to intimate partner and intrusiveness of thoughts about fertility problems and wanting a child during intercourse. Tüzer et al. (2010) in Turkey found that fewer men (20%) than women (44%) said that sexual interest had decreased since diagnosis. Men with male factor infertility had higher scores on a measure of expression of affection for the intimate partner than women, interpreted as indicating that men in this situation feel the need to give their partners compensatory affection. In the Australian long-term follow-up study (Fisher et al. 2010; Hammarberg et al. 2010) 25% regarded infertility as having had a generally negative effect on the relationship with their intimate partner and 32% that sexual satisfaction had been diminished.

The baseline and 12-month follow-up phase of the Danish COMPI study (Schmidt et al. 2005) assessed “marital benefit” or the extent to which childlessness had strengthened the relationship among those who had not experienced a pregnancy. At baseline about 50% of the 1081 male respondents (significantly fewer ( $p < 0.002$ ) than among female respondents) agreed that childlessness had marital benefits. Men who used active coping (expressing feelings, seeking advice), could make meaning of the experience, and did not keep infertility secret, had higher marital benefits. The finding that infertility can strengthen the marital relationship is supported by the finding that among 202 couples in Sweden who were followed-up 20 years after undergoing infertility treatment, only three had separated (Sydsjö et al. 2011). Hjelmstedt et al. (1999) found that among men the experience of infertility was associated with a sense of injustice and increased concern about partner wellbeing, but also that it had led to enhanced personal maturity and a closer marital relationship.

## **Psychological Aspects of Men’s Experiences of Infertility Treatment**

A systematic review of research about patients’ perspectives on fertility care (Dancet et al. 2010a) found that very few studies (3/51) had focused specifically on men’s experiences. The main findings were not disaggregated to distinguish men’s accounts, but it was argued that the relevant dimensions applied to all infertility treatment consumers and included: access to services; respect for values, choices, and needs; continuity and coordination of care; appropriate information and education; physical comfort; support to reduce anxiety; and involvement of the partner.

They concluded that there was a dearth of evidence about men's perceptions of care, in particular invasive procedures. In broad terms, the available research has focused on satisfaction with technical and procedural aspects of care and perceptions of quality of emotional care.

Using data contributed by more than 4000 men aged 15–44 years to Cycle 6 of the National Survey of Family Growth in America Anderson et al. (2009) found that 7.5% of those who were sexually experienced had consulted a clinical service for help with having a baby. Among them 18.1% reported clinician diagnosed infertility related to a male factor. Hotaling et al. (2012) analyzed a subset of these data, pertaining to the 2161 who were aged over 30 years, and found that helpseeking was strongly associated with indicators of advantage: private health insurance, suggesting that in this setting the needs of men who cannot afford these services are not addressed or understood.

Pook et al. (2002) assessed psychological distress using their Infertility Distress Scale in 113 German men attending for “infertility workup” and followed-up 60 men 4 months later. They concluded that initiating treatment was associated with a decline in distress, but only among men attending for first consultations and not for those with longstanding fertility difficulties. In a subsequent study using the same measure (Pook and Krause 2005) with men who had repeat infertility assessment visits at least 6 months apart, these authors found that distress increased across this interval in men who had been in prolonged treatment or who had experienced treatment failure. Peronace et al. (2007) followed 256 men who had been assessed prior to treatment initiation in Denmark up after 12 months of unsuccessful treatment. Regardless of cause of infertility, distress increased significantly when treatment was unsuccessful. Twelve month follow-up COMPI data (1934 participants, 909 men from five clinics) found generally high satisfaction with both technical and psychosocial aspects of care, and no differences among men and women, but satisfaction was highest among those who had conceived (Schmidt et al. 2003b). In contrast, study-specific Australian data about perception of quality of infertility-related health care among 112 men diagnosed as infertile 5 years earlier revealed high satisfaction with medical and nursing care irrespective of whether treatment had resulted in fatherhood (Hammarberg et al. 2010).

In the Netherlands Dancet et al. (2010b) used open-ended questions in face-to-face interviews to explore 17 men's experiences of testicular biopsy and in telephone interviews with a further 15 men to appraise satisfaction with care. They concluded that in addition to technical skill, high quality care was characterized by friendly empathic staff attitudes; treatment stage-specific oral and written information; and privacy, including access to a waiting space separate from one used by pregnant couples, and staff support during procedures. Also in the Netherlands (van Empel et al. 2010) focus groups were used to develop a questionnaire about clinical services which was then completed by 286 women and 280 men from 369 couples at 13 clinics. Clinic strengths were respect, autonomy, and partner involvement, but most commonly identified weaknesses were lack of emotional support and continuity of care.

In resource-constrained countries where specialist medical services might be unavailable or only accessible to a small relatively advantaged fraction of the population, there have been few investigations of men's experiences of assistance for fertility difficulties. Moyo and Muhwati (2013) found that whether or not medical services were accessed, men would be likely to consult a traditional or faith-based healer who would prescribe rituals or "powders, decoctions, infusions, inhalations, fumigation (using mbanda) and scarification," or recommend religious solutions to address the underlying causes and restore fertility.

In addition to prayer, the infertile man is given either holy water with a stone inside (munyengetero) or a mixture of raw eggs and sterilized milk. These have an impact of improving the quality and quantity of sperms.

In Northern Nigeria Iliyasu et al. (2013) found in a community-based survey that, while there was general awareness of ART, acceptance was low and reflected the stigma associated with infertility. Men who were highly educated, from non-Muslim religious backgrounds, and childless, were more likely than others to regard it as acceptable.

### **Consideration of Donor Insemination**

One alternative for family formation to be considered by couples experiencing infertility attributable to a male factor that cannot be treated with intracytoplasmic sperm injection, or vasectomy is irreversible, or where there is a wish not to pass on a heritable condition, is the use of donated sperm to conceive (Wischmann and Thorn 2013). Eisenberg et al. (2010) ascertained views about use of donated sperm or eggs among 377 couples at their first visit to an infertility clinic in California. Respondents held significantly more negative views about gametes from the opposite than their own sex, but both men and women held the opinion that use of donor sperm was more likely to have negative consequences for the intimate partner relationship than donor eggs.

Indekeu et al. (2012) compared emotional wellbeing and intentions to disclose among men in couples being treated with intrauterine insemination using their own ( $n = 151$ ) or donated ( $n = 46$ ) sperm in Belgium. Men in couples using donor sperm had lower self-regard and more guilt than men using autologous sperm, but overall well-being did not differ. There was lower intention of disclosing mode of conception to potential future children among donor than autologous sperm users. In a subsequent study, repeat home interviews with seven couples who had conceived with donor sperm were used to investigate their adaptation to parenthood prospectively. During pregnancy the psychological significance of the donor was prominent in their reflections, with men expressing uncertainty about position as a nonbiological parent, and the meaning of this for future family relationships. This was interpreted as reflecting in part the local cultural and jurisdictional priority afforded to genetic over social relationships. Once the baby was born, it was observed consistently that these concerns diminished as emotional attachments between father and baby grew.

Wischmann and Thorn (2013) conclude that male factor infertility remains stigmatized, with pejorative associations with compromised masculinity and that

the notion that men are unaffected or unperturbed by infertility is false, and reflects outdated and unhelpful gender stereotypes.

## **Needs for Social and Professional Support**

In this situation, there have been research efforts to understand men's perceptions of their needs for informal and formal support during investigations for infertility, adjustment to diagnosis, and treatment.

### **Informal Social Support**

Some investigated the extent to which men affected by infertility confided in and sought additional support from family members and friends. A Swedish study (Hjelmstedt et al. 1999) found for men that common sources of support were friends (38%) and their own mothers (27%) and fathers (23%), but a large group had not confided in anyone other than their spouse. In Italy, Agostini et al. (2011) conducted a cohort study of 83 couples from treatment initiation to 1 month after embryo transfer and investigated perceived social support. At all time points men were found to have less social support and to have been less likely to discuss infertility and treatment with others than women. In Taiwan, in-depth interviews with 30 men diagnosed as infertile revealed the tension between need for support and preserving "face." In general, shame about the diagnosis constrained disclosure to anyone apart from their wives (Lee and Chu 2001).

Malik and Coulson (2008) investigated the extent to which the Internet was used as a resource for information and emotional support, postulating that availability, accessibility, and anonymity would make it especially acceptable to men. They undertook a thematic analysis of 728 messages posted by men on an online infertility support group message board. They concluded that men experience "emotional anguish" as a result of infertility but that this needed to be suppressed in order to protect their partners and that online support groups which do not involve face-to-face encounters may be particularly useful locations for men to confide in others.

Using interviews with couples who had experienced ART treatment without conceiving a child, Throsby and Gill (2004) concluded that in addition to the intense mixed emotions of grief which include, anger, envy, sadness, and regret which were described by men and women, there were gender-specific reactions among men. These included that there was both personal and social questioning of virility and sexual adequacy. When fertility was disclosed to colleagues or friends, the usual presumption was that it was attributable to a female factor. Men reported workplace banter which involved jocular offers to assist.

### **Formal Support from Infertility Clinicians and Mental Health Professionals**

In broad terms, two approaches have been taken to investigating needs for information and emotional support from professionals: preferences about and satisfaction with routine clinical care, and uptake of specialist mental health care.

In America Brucker and McKenry (2004) developed a study-specific measure assessing how well needs for information and emotional support had been met by medical and nursing staff among 120 members of an infertility support group (47 men). For men, but not women, higher perceived support from health care professionals was associated with lower levels of stress and anxiety but not depression. Hammarberg et al's (2010) survey assessed preferred sources of infertility-related information and emotional support. Like the group in Glover et al's (1994) study, primary preference was for information to be provided in face-to-face discussions with clinic staff. The most helpful and valued sources of support were their partners and clinic staff and the least preferred were friends and support groups. Mikkelsen et al. (2013) surveyed 210 men in Denmark about their experiences of clinical care and learnt that most (63%) experienced the treating clinician as communicating predominantly with their female partner, even more (72%) said they were not given information about the psychological aspects of infertility for men.

In France, Laffont and Edelmann (1994) surveyed 218 people (101 men) who were undergoing treatment with a study-specific questionnaire about perceived and desired support. Most men had told their parents and friends about participating in infertility treatment and 58% had discussed treatment outcomes with a doctor. Overall 66% thought that psychological services including individual (66%), couple (61%), and group (44%) counseling should be available in particular after a failed cycle. However, fewer men (10%) than women (21%) ( $p < 0.05$ ) had actually talked to a psychologist suggesting that there are significant barriers to uptake of such services.

Schmidt et al. (2003a) investigated consumer opinions at the outset of treatment about the needs for "patient-centered" or routine empathic supportive care and psychological care provided by a mental health practitioner in 2250 (1081 men) COMPI participants. While most identified communication of test results and discussion of treatment options as important, fewer men than women wanted these in writing. Both men and women valued patient-centered care, including explicit concern for emotional well-being. They wanted this within routine care rather than being referred to information and support services for childless people or being given written information about mental health. Only 8.9% of men indicated that they would attend a course about childlessness, 7.5% a psychologist, 5.7% a sex therapist, and 4.1% a support group.

Boivin et al. (1999) investigated barriers to use of counseling services in a group being treated for infertility (49 men) in England. For both men and women the spouse was the most common source of support (57.1%) and counselors (6.1%) and self-help groups (2.0%) the least. The main factors preventing seeing a counselor were having sufficient support available from other people, financial costs, practical difficulties, and awkwardness. The authors concluded that information about emotional factors should be made available through other media including written information and documentaries.

Wischmann et al. (2009) used local measures to assess life satisfaction, desire for a child, personality, and psychological symptoms among 564 German couples at first infertility clinic visit. Overall 34% actually participated in formal psychological

counseling. Participation was most strongly predicted by distress at baseline in the female partner, but compared to those who did not participate; men who attended counseling had lower sexual satisfaction and lower quality of intimate partner relationship at treatment initiation.

In contrast, Furman et al. (2010) assessed 284 men with low incomes receiving government-funded infertility treatment in Chile. In this service, at no cost to the individual, couple and group counseling is offered to all patients, who can self-refer. Group counseling is a limited series of four sessions with a mixed didactic and interactive format. Overall 143 took up at least one form of counseling, most commonly attending groups as a couple; 43% of couples with male factor, but 23% with female factor infertility attended all sessions. While the high uptake might have been attributable to cultural factors the investigators considered that access to psychological services within the clinic and orientation-to-treatment sessions which emphasize the value of counseling for all patients were critical. Groups were rated as “highly useful” in increasing social connection and enhanced the relationship between partners.

Petok (2015) outlines the lack of resources specific to the needs of men experiencing infertility (only 1 of 251 online support groups for example was specific to men in America). He argues that men’s emotional responses to infertility and infertility treatment require adaptation to the communication styles and emotional literacy that characterizes men, rather than a presumption that men should adapt to the existing approaches which have emerged in response to the experiences and needs of women.

More recent evidence indicates that improvements in care reflecting these findings are emerging. (Huppelschoten et al. 2013) surveyed 1620 Dutch women and their partners being treated for infertility about their experiences of care. There were no differences in scores on the Patient-Centeredness Questionnaire-Infertility among women and men and men rated perceived staff competence and respect for patient’s values higher than women did.

## **Long-Term Psychosocial Aspects of Infertility and Fertility Treatment**

The long-term psychosocial sequelae of infertility for men have been reported in three investigations. Throsby and Gill (2004) undertook discourse analysis of in-depth interviews with 41 people (13 men, all interviewed within couples) who had elected to cease treatment in England. All were interviewed at least 2 years after last IVF treatment. They identified that while women’s disclosures about infertility tended to attract support, men were more likely to have been subjected to banter and thoughtless comments, in particular about sexual technique and potency and especially in the workplace, which had constrained support seeking. Infertility treatments were regarded with ambivalence both as valuable technologies which had great potential to bring scientific assistance to a “natural” problem but also as uncomfortable and intrusive and as reducing men’s capacity for agency, because apart from providing semen they were generally excluded from active treatment. The inability

to father a child had engendered feelings of humiliation and inadequacy and men had felt obliged to set aside their emotional needs in order to “be strong for her.”

Sherrod (2006) conducted in-depth interviews with 10 men aged at least 50 years who had not become biological fathers, six because of male factor infertility. She found that these participants had avoided disclosure or revelation of emotional distress to protect their own dignity, their partners from further suffering, and their relationships and concluded that this had impeded the development of a satisfying life without children.

The Australian long-term follow-up study (Fisher et al. 2010; Hammarberg et al. 2010) assessed current life satisfaction, physical health, and emotional well-being. Most participants (96%) had pursued infertility treatment and 87% were fathers. There were no differences in general satisfaction with life and they were in good physical health. However, when other factors were controlled men who had not become fathers had significantly worse mental health than those who were fathers, interpreted as reflecting a state of chronic sorrow or grief among those for whom parenthood had been a desired life goal.

Martins et al. (2016) have recently published a systematic review of the 12 available prospective investigations of men’s psychological responses to infertility and medically assisted reproductive treatments that had not led to pregnancy or biological parenthood. They found consistent evidence of a deterioration in mental health in the first year following diagnosis and that the quality of the relationship with the intimate partner was crucial. Risk was increased if a man’s partner experienced depression and anxiety and catastrophized or used avoidant coping. Mutual support between partners and from others, access to high quality information, and capacity to communicate clearly about infertility were protective.

## Summary and Implications

While there is a smaller quantum of research about the experiences of men, than women affected by infertility, there is now a considerable body of evidence which elucidates some of the psychological and social aspects of infertility for men (Greil et al. 2010). The research has been undertaken in diverse settings, most, but not only, in high and upper-middle income nations, used varied designs, sampling, and recruitment strategies and data sources, but there is coherence and considerable consistency in findings. We acknowledge that in surveying the English-language literature and including only studies with an identified focus on men that relevant studies might have been overlooked. We also acknowledge that this review does not elucidate the experiences of people who do not “define their [in]ability to have a child as a problem” (Greil et al. 2010).

There is recent evidence of increased equity in exploring, understanding, and addressing the needs of men experiencing or affected by infertility, but overall the evidence reflects social norms and stereotypes about the importance of child bearing and rearing for women, which coupled with the focus of ART treatment on women’s bodies have reduced visibility and awareness of men’s experiences of infertility.



Overall, however, the data indicate that independent of their partner's wishes, fertile and infertile men want to father children and experience fatherhood and they experience grief when this life goal is unrealized, which can become an enduring sadness if fertility treatment is unsuccessful. They also suggest that there is a disjunction between putative popular beliefs about the conflation of virility and fertility and individual men's experiences of these as separate aspects of their lives. In low income settings, these are worsened by lack of accessible services and limited knowledge of reproduction, including of risks to fertility.

It appears that infertility-specific anxiety is elevated in men at initiation of diagnostic investigations, confirmation of diagnosis, and during treatment, but that overall prevalence of clinically significant symptoms of depression and anxiety is not higher than in the general population. Men might be more able than women to compartmentalize infertility-specific anxiety and to continue to participate in their professional and wider social lives without being preoccupied or disabled by it. They might also suspend their emotional needs in service of their partner's increased requirements for support. However, distress worsens if treatment is unsuccessful, in particular after a year. Assertions that lack of articulation of specific emotional needs indicates that these are not being experienced are inaccurate. There is consistent recent evidence that men do experience distress, and benefit from and want empathy, encouragement, and high quality information. There is some evidence that men who are socially isolated, have an avoidant style, and appraise stressful events as overwhelming are particularly vulnerable to more severe anxiety

In general, it appears that men feel most comfortable confiding their increased needs in their partners and are less comfortable discussing them with other people. However, this strategy can be less effective if their partners are themselves in a heightened state of vulnerability and are seeking to receive rather than provide support. Information about causes of infertility and treatment options and outcomes is sought from infertility practitioners with a preference for oral rather than written communication. With the exception of those attending the infertility service in Chile (Furman et al. 2010) men prefer to receive relevant emotional support from infertility clinicians within routine care rather than from mental health professionals, self-help support groups, or friends. Nevertheless, structured facilitated psycho-educational groups which are didactic, but permit informal sharing of experiences, might be beneficial. The exception appears to be the support needed to assist men to disclose the use of donor sperm, in particular in settings in which semen is donated anonymously and children will not ever have access to identifying information about the donor.

### **Implications for Clinical Practice**

These findings suggest that comprehensive clinical care within infertility services is of particular importance to the protection of emotional well-being among men affected by infertility. As men appear to be more likely to confide in and want information and emotional support from infertility clinicians, than from friends or mental health professionals, explicit assessment of the emotional well-being of men

at initial assessment and during treatment, especially prolonged or unsuccessful, might be beneficial (Glover et al. 1994; Brucker and Mckenry 2004; Hammarberg et al. 2010). Spontaneous disclosure of emotional needs and explicit support seeking appear to be uncommon. Some investigators propose that systematic assessment of mental health using psychometric questionnaires within assessment and treatment protocols would assist detection of psychological symptoms, but acceptability and feasibility have not been established (Brucker and Mckenry 2004). As Mikkelsen et al. (2013) argue people seeking infertility care want “a more open and balanced dialogue about infertility treatment and the role of the male partner,” and men experiencing infertility “want health professionals to view them on equal terms with their partner.” Improved clinical communication skills are required. If clinicians are willing, then explicit enquiry using the statement then question method can be an effective clinical tool (e.g., I have met many men experiencing infertility and they often feel. . . sad, worried, embarrassed, lonely, etc; followed by the enquiry: Have you had any feelings of this kind or I would be interested to hear how you are feeling). A first-line response in which empathic responses are coupled with exploration of who has been disclosed to; what alternative sources of support might be considered; and specific encouragement to pursue these has the potential to reduce social isolation and anxiety.

Referral to a mental health professional might assist the subgroup of men who have not disclosed their situation to anyone apart from their spouse and appraise the situation as catastrophic, hopeless, or overwhelming. It is also suggested that consultation with a mental health professional should be mandatory prior to use of donor sperm (Eisenberg et al. 2010). Sharma et al. (2013) emphasize the need for preprocedure counseling for men considering vasectomy about its permanence and the limited potential for reversal. In addition, Martins et al. (2016) recommend training in the skills to manage intense psychological distress and couple communication enhancement interventions in routine counseling.

### **Implications for Policy**

The implications for policy include for structural changes. Thompson and Lee (2011) argue that postponed parenthood, much attributable to men’s resistance to commit to partnership and parenthood, has been identified as a significant driver of the trends towards smaller families and underachieved fertility aspirations. Programs and policies which facilitate the establishment of important “preconditions” for parenthood, including access to and security of employment and equitable access to part-time employment for men and women, would support individuals to achieve their reproductive aspirations.

There is a clear need for public education about fertility, fertility protection, and medically assisted conception targeted appropriately to school students, young people, and people planning reproductive lives to avert the causes of infertility related to personal characteristics and circumstances (Hammarberg et al. 2013)

Petok (2015) argue that the stigma, shame, and embarrassment that accompany experiences of infertility among men might be countered by public campaigns that include “high-visibility individuals willing to speak about the problem” and that full

participation in care, including counseling or education programs, not just the provision of semen samples, should be promoted in clinic policies.

### **Implications for Future Research**

While there is an emerging body of evidence focused on the psychological and social aspects of infertility for men, significant knowledge gaps remain (Sherrod 2006; Greil et al. 2010). Culley et al. (2013) call for a “reframing of the research agenda on men and assisted reproduction.”

As most studies recruited participants from clinical services, little is known about men who do not seek treatment. Among those who do pursue treatment the factors that influence persistence with and decisions to discontinue treatment are unknown. The psychological aspects of treatment including experiences of invasive procedures or of witnessing their partners undergoing procedures have not been described. The factors governing decisions either to become a parent through adoption or to live without children among men in couples who elect not to pursue infertility treatment are also unknown. Subfertile men’s reactions when spontaneous conception occurs unexpectedly have not been studied. There is some evidence about women’s experiences of pregnancy and early parenthood after assisted conception but none about men’s reactions to and needs during these experiences. The needs of men who experience fatherhood through surrogacy or co-parenting are not well understood.

Few of the studies reported whether male-specific cut-off scores were used to identify the prevalence of clinically significant psychological conditions in particular anxiety and depression. However, comparisons with test norms indicate that apart from situation-specific anxiety, prevalence appears to be the same in men affected by infertility as in the general population. In order to understand men’s needs more fully, other relevant dimensions of psychological functioning including experiences of grief and shame warrant systematic investigation.

Trials of comprehensive psychologically informed approaches to care for men are not yet available and are an essential next step.

There is a marked disparity in the availability of evidence about men’s experiences of infertility and fertility treatment between high-income countries and the low and lower-middle income countries in which most men of reproductive age live, which constitutes a serious knowledge gap.

These complex human experiences and their implications require multiple method, interdisciplinary research that includes men of all levels of education, ethnicity, and literacy, including health literacy.

---

## **References**

- Agarwal A, Mulgund A, Hamada A, Chyatte MR. A unique view on male infertility around the globe. *Reprod Biol Endocrinol.* 2015;13:37.
- Agostini F, Monti F, De Pascalis L, Paterlini M, Battista de Sala G, Blickstein I. Psychosocial support for infertile couples during assisted reproductive technology treatment. *Fertil Steril.* 2011;95(2):707–10.

- Anderson KM, Sharpe M, Rattray A, Irvine DS. Distress and concerns in couples referred to a specialist infertility clinic. *J Psychosom Res.* 2003;54:353–5.
- Anderson JE, Farr SL, Jamieson DJ, Warner L, Macaluso M. Infertility services reported by men in the United States: national survey data. *Fertil Steril.* 2009;91(6):2466–70.
- Baiocco R, Laghi F. Sexual orientation and the desires and intentions to become parents. *J Fam Stud.* 2013;19(1):90–8.
- Band DA, Edelman RJ, Avery S, Brinsden PR. Correlates of psychological distress in relation to male infertility. *Br J Health Psychol.* 1998;3:245–56.
- Barani Ganth D, Thiyagarajan S, Nigesh K. Role of infertility, emotional intelligence and resilience on marital satisfaction among Indian couples. *Int J Appl Psychol.* 2013;3(3):31–7.
- Beaurepaire J, Jones M, Thiering P, Saunders D, Tennant C. Psychosocial adjustment to infertility and its treatment: male and female responses at different stages of IVF/ET treatment. *J Psychosom Res.* 1994;38(3):229–40.
- Boivin J, Scanlan L, Walker SM. Why are infertile couples not using psychosocial counselling? *Hum Reprod.* 1999;14(5):1384–91.
- Brucker PS, Mckenry PC. Support from health care providers and the psychological adjustment of individuals experiencing infertility. *J Obstet Gynecol Neonatal Nurs.* 2004;33(5):597–603.
- Campbell JM, Lane M, Owens JA, Bakos HW. Paternal obesity negatively affects male fertility and assisted reproduction outcomes: a systematic review and meta-analysis. *Reprod Biomed Online.* 2015;31(5):593–604.
- Carpentier MY, Fortenberry JD. Romantic and sexual relationships, body image, and fertility in adolescent and young adult testicular cancer survivors: a review of the literature. *J Adolesc Health.* 2010;47(2):115–25.
- Chachamovich JR, Chachamovich E, Ezer H, Fleck MP, Knauth D, Passos EP. Investigating quality of life and health-related quality of life in infertility: a systematic review. *J Psychosom Obstet Gynecol.* 2010;31(2):101–10.
- Conrad R, Schilling G, Langenbuch M, Haidl G, Liedtke R. Alexithymia in male infertility. *Hum Reprod.* 2001;16(3):587–92.
- Crawshaw M. Psychosocial oncofertility issues faced by adolescents and young adults over their lifetime: a review of the research. *Hum Fertil.* 2013;16(1):59–63.
- Culley L, Hudson N, Lohan M. Where are all the men? The marginalization of men in social scientific research on infertility. *Reprod Biomed Online.* 2013;27(3):225–35.
- Dancet EAF, Nelen WLDM, Sermeus W, De Leeuw L, Kremer JAM, D’Hooghe T. The patients’ perspective on fertility care: a systematic review. *Hum Reprod Update.* 2010a. doi:10.1093/humupd/dmq004.
- Dancet EAF, Spiessens C, Blocquiaux L, Sermeus W, Vanderschuerem S, D’Hooghe TM. Testicular biopsy before ART: the patients’ perspective on the quality of care. *Hum Reprod.* 2010b;25(12):3072–82.
- Daniluk JC, Koert E. The other side of the fertility coin: a comparison of childless men’s and women’s knowledge of fertility and assisted reproductive technology. *Fertil Steril.* 2013;99(3):839–46.
- Dhillon R, Cumming CE, Cumming DC. Psychological well-being and coping patterns in infertile men. *Fertil Steril.* 2000;74(4):702–6.
- Dhont M, Luchters S, Ombelet W, Vyankandondera J, Gasarabwe A, van de Wijgert J, Temmerman M. Gender differences and factors associated with treatment-seeking behaviour for infertility in Rwanda. *Hum Reprod.* 2010;25(8):2024–30.
- Dhont N, van de Wijgert J, Coene G, Gasarabwe A, Temmerman M. Mama and papa nothing: living with infertility among an urban population in Kigali, Rwanda. *Hum Reprod.* 2011;26(3):623–9.
- Drosdzol A, Skrzypulex V. Depression and anxiety among Polish infertile couples – and evaluative prevalence study. *J Psychosom Obstet Gynecol.* 2009;30(1):11–20.
- Dyer SJ, Abrahams N, Mokoena NE, van der Spuy ZM. You are a man because you have children: experiences, reproductive health knowledge and treatment seeking behaviour among men suffering from couple infertility in South Africa. *Hum Reprod.* 2004;19(4):960–7.

- Dyer S, Mokoena N, Maritz J, van der Spuy Z. Motives for parenthood among couples attending a level 3 infertility clinic in the public health sector in South Africa. *Hum Reprod.* 2008;23(2): 353–7.
- Dyer S, Lombard C, Van der Spuy Z. Psychological distress among men suffering from couple infertility in South Africa: a quantitative assessment. *Hum Reprod.* 2009;24(11):2821–6.
- Edelmann RJ, Connolly KJ. Gender differences in response to infertility and infertility investigation: real or illusory. *Br J Health Psychol.* 2000;5:365–75.
- Edelmann RJ, Humphry M, Owens DJ. The meaning of parenthood and couples' reactions to male infertility. *Br J Med Psychol.* 1994;67:291–9.
- Eisenberg ML, Smith JF, Millstein SG, Walsh TJ, Breyer BN, Katz PP. Perceived negative consequences of donor gametes from male and female members of infertile couples. *Fertil Steril.* 2010;94(3):921–6.
- Eisenberg ML, Kim S, Chen Z, Sundaram R, Schisterman EF, Buck Louis GM. The relationship between male BMI and waist circumference on semen quality: data from the LIFE study. *Hum Reprod.* 2014;29(2):193–200.
- Eisenberg ML, Chen Z, Ye A, Buck Louis GM. Relationship between physical occupational exposures and health on semen quality: data from the Longitudinal Investigation of Fertility and the Environment (LIFE) Study. *Fertil Steril.* 2015;103(5):1271–7.
- Fisher J. Infertility and assisted reproduction. Mental health aspects of women's reproductive health. A global review of the literature. Geneva: WHO; 2009.
- Fisher JRW, Hammarberg K, Baker HWG. Long term health, wellbeing, life satisfaction and attitudes to parenthood in men diagnosed as infertile: challenges to gender stereotypes and implications for practice. *Fertility and Sterility.* 2010;94(2):574–80.
- Folkvord S, Odegaard OA, Sundby J. Male infertility in Zimbabwe. *Patient Educ Couns.* 2005;59:239–43.
- Furman I, Parra L, Fuentes A, Devoto L. Men's participation in psychologic counseling services offered during in vitro fertilization. *Fertil Steril.* 2010;94(4):1460–4.
- Glover L, Gannon K, Sherr L, Abel PD. Psychological distress before and immediately after attendance at a male sub-fertility clinic. *J R Soc Med.* 1994;87(8):448–9.
- Gollenberg AL, Liu F, Brazil C, Drobnis E, Gizick D, Overstreet JW, Redmon JB, Asparks A, Wang C, Swan SH. Semen quality in fertile men in relation to psychosocial stress. *Fertil Steril.* 2010;93(4):1104–11.
- Goossens J, Delbaere I, Van Lancker A I, Beeckman D, Verhaeghe S, Van Hecke A. Cancer patients' and professional caregivers' needs, preferences and factors associated with receiving and providing fertility-related information: a mixed-methods systematic review. *Int J Nurs Stud.* 2014;51(2):300–19.
- Greil A, Slauson-Blevins K, McQuillan J. The experience of infertility: a review of recent literature. *Sociol Health Illn.* 2010;32(1):140–62.
- Hadley R, Hanley T. Involuntarily childless men and the desire for fatherhood. *J Reprod Infant Psychol.* 2011;29(1):56–68.
- Hammarberg K, Baker HWG, Fisher J. Men's experiences of infertility and infertility treatment 5 years after diagnosis of male factor infertility: a retrospective cohort study. *Hum Reprod.* 2010;25(11):2815–20.
- Hammarberg K, Setter T, Norman RJ, Holden CA, Michelmores J, Johnson L. Knowledge about factors that influence fertility among Australians of reproductive age: a population-based survey. *Fertil Steril.* 2013;99(2):502–7.
- Hassan MAM, Killick SR. Effect of male age on fertility: evidence for the decline in male fertility with increasing age. *Fertil Steril.* 2003;79 Suppl 3:1520–7.
- Hinton L, Miller T. Mapping men's anticipations and experiences in the reproductive realm: (in) fertility journeys. *Reprod Biomed Online.* 2013;27(3):244–52.
- Hjelmstedt A, Andersson L, Skoog-Svanberg A, Bergh T, Boivin J, Collins A. Gender differences in psychological reactions to infertility among couples seeking IVF- and ICSI-treatment. *Acta Obstet Gynecol Scand.* 1999;78:42–8.

- Holter H, Anderheim L, Bergh C, Möller A. The psychological influence of gender infertility diagnoses among men about to start IVF or ICSI treatment using their own sperm. *Hum Reprod.* 2007;22(9):2559–65.
- Holton S, Fisher J, Rowe H. To have or not to have? Australian women's childbearing desires, expectations and outcomes. *J Popul Res.* 2011;28(4):353–79.
- Hotaling JM, Davenport MT, Eisenberg ML, VanDenEeden SK, Walsh TJ. Men who seek infertility care may not represent the general U.S. population: data from the National Survey of Family Growth. *Urology.* 2012;79(1):123–7.
- Hruska KS, Futrth PA, Seifer DB, Sharara FI, Flaws JA. Environmental factors and infertility. *Clin Obstet Gynecol.* 2000;43(4):821–9.
- Hunt N, McHale S. Psychosocial aspects of andrologic disease. *Endocrinol Metab Clin North Am.* 2007;36(2):521–31.
- Huppelschoten AG, van Duijnhoven NT, van Bommel PF, Kremer JA, Nelen WL. Do infertile women and their partners have equal experiences with fertility care? *Fertil Steril.* 2013;99(3):832–8.
- Iliyasu Z, Galadanci HS, Abubakar IS, Bashir FM, Salihu HM, Aliyu MH. Perception of infertility and acceptability of assisted reproduction technology in northern Nigeria. *Niger J Med.* 2013;22(4):341–7.
- Indekeu A, D'Hooghe T, De Sutter P, Demyttenaere K, Vanderschot B, Welkenhuysen M, Rober P, Colpin H. Parenthood motives, well-being and disclosure among men from couples ready to start treatment with intrauterine insemination using their own sperm or donor sperm. *Hum Reprod.* 2012;27(1):159–66.
- Inhorn M, Buss K. Ethnography, epidemiology and infertility in Egypt. *Social Science and Medicine.* 1994;39(5):671–86.
- Inhorn MC. Masturbation, semen collection and men's IVF experiences: anxieties in the Muslim world. *Body Soc.* 2007;13(3):37–53.
- Inhorn MC. Right to assisted reproductive technology: overcoming infertility in low-resource countries. *Int J Gynecol Obstet.* 2009;106(2):172–4.
- Inhorn MC, Patrizio P. Infertility around the globe: new thinking on gender, reproductive technologies and global movements in the 21st century. *Hum Reprod Update.* 2015;21(4):411–26.
- Jordan C, Revenson TA. Gender differences in coping with infertility: a meta-analysis. *J Behav Med.* 1999;22(4):341–58.
- Kessler LM, Craig BM, Saigal C, Quinn GP. Starting a family: characteristics associated with men's reproductive preferences. *Am J Mens Health.* 2013;7(3):198–205.
- Klemetti R, Raitanen J, Sihvo S, Saarni S, Koponen P. Infertility, mental disorders and well-being: a nationwide survey. *Acta Obstet Gynecol Scand.* 2010;89(5):677–82.
- Kols A, Nguyen T. Infertility in developing countries. *Reproductive Health Outlook.* 1997;15(3):1–14.
- Laffont I, Edelmann RJ. Perceived support and counselling needs in relation to in vitro fertilization. *J Psychosom Obstet Gynecol.* 1994;15:183–8.
- Langdridge D, Sheeran P, Connolly K. Understanding the reasons for parenthood. *J Reprod Infant Psychol.* 2005;23(2):121–33.
- Lau J, Wang Q, Cheng Y, Kim J, Yang X, Yi Tsui H. Infertility-related perceptions and responses and their associations with quality of life among rural Chinese infertile couples. *J Sex Marital Ther.* 2008;34(3):248–67.
- Lawson G, Fletcher R. Delayed fatherhood. *J Fam Plann Reprod Health Care.* 2014;40(4):283–8.
- Lee TY, Chu TY. The Chinese experience of male infertility. *West J Nurs Res.* 2001;23(7):714–25.
- Lee T-Y, Sun G-H, Chao S-C. The effect of an infertility diagnosis on the distress, marital and sexual satisfaction between husbands and wives in Taiwan. *Hum Reprod.* 2001;16(8):1762–7.
- Li Y, Lin H, Li Y, Cao J. Association between socio-psycho-behavioral factors and male semen quality: a systematic review and meta-analyses. *Fertil Steril.* 2011;95(1):116–23.
- Malik S, Coulson N. The male experience of infertility: a thematic analysis of an online infertility support group bulletin board. *J Reprod Infant Psychol.* 2008;26(1):18–30.

- Martins MV, Basto-Pereira M, Pedro J, Peterson B, Almeida V, Schmidt L, Costa ME. Male psychological adaptation to unsuccessful medically assisted reproduction treatments: a systematic review. *Hum Reprod Update*. 2016;22(4):466–78.
- McLachlan RI, Yazdani A, Kovacs G, Howlett D. Management of the infertile couple. *Australian Family Physician*. 2005;34(3):111–17.
- Mikkelsen AT, Madsen SA, Humaidan P. Psychological aspects of male fertility treatment. *J Adv Nurs*. 2013;69(9):1977–86.
- Moyo S, Muhwati I. Socio-cultural perspectives on causes and intervention strategies of male infertility: a case study of Mhondoro-Ngezi, Zimbabwe. *Afr J Reprod Health*. 2013;17(2):89–101.
- Müller MJ, Schilling G, Haidl G. Sexual satisfaction in male infertility. *Arch Androl*. 1999;42:137–43.
- Nachtigall RD, Becker G, Wozny M. The effect of gender-specific diagnosis on men's and women's response to infertility. *Fertil Steril*. 1992;57(1):113–21.
- Nieuwenhuis SL, Odukogbe AT, Theobald S, Liu X. The impact of infertility on infertile men and women in Ibadan, Oyo State, Nigeria: a qualitative study. *Afr J Reprod Health*. 2009;13(3):85–98.
- Pacey AA. Fertility issues in survivors from adolescent cancers. *Cancer Treat Rev*. 2007;33(7):646–55.
- Peronace LA, Boivin J, Schmidt L. Patterns of suffering and social interactions in infertile men: 12 months after unsuccessful treatment. *J Psychosom Obstet Gynecol*. 2007;28(2):105–14.
- Peterson BD, Newton CR, Rosen KH, Skaggs GE. Gender differences in how men and women who are referred to IVF cope with infertility stress. *Hum Reprod*. 2006;21(9):2443–9.
- Petok WD. Infertility counseling (or the lack thereof) of the forgotten male partner. *Fertil Steril*. 2015;104(2):260–6.
- Pook M, Krause W. The impact of treatment experiences on the course of infertility distress in male patients. *Hum Reprod*. 2005;20(3):825–8.
- Pook M, Krause W, Drescher S. Distress of infertile males after fertility workup: a longitudinal study. *J Psychosom Res*. 2002;53(6):1147–52.
- Puur A, Oláh LS, Tazi-Preve MI, Dorbritz J. Men's childbearing desires and views of the male role in Europe at the dawn of the 21st century. *Demogr Res*. 2008;19(56):1883–912.
- Quinn GP, Murphy D, Knapp C, Stearsman DK, Bradley-Klug KL, Sawczyn K, Clayman ML. Who decides? Decision making and fertility preservation in teens with cancer: a review of the literature. *J Adolesc Health*. 2011;49(4):337–46.
- Ramezanzadeh F, Aghssa MM, Jafarabadi M, Zayeri F. Alterations of sexual desire and satisfaction in male partners of infertile couples. *Fertil Steril*. 2006;85(1):139–43.
- Riskind RG, Patterson CJ. Parenting intentions and desires among childless lesbian, gay, and heterosexual individuals. *J Fam Psychol*. 2010;24(1):78–81.
- Roberts E, Metcalfe A, Jack M, Tough SC. Factors that influence the childbearing intentions of Canadian men. *Hum Reprod*. 2011;25(5):1202–8.
- Schmidt L, Holstein BE, Boivin J, Sangren H, Tjørnhøj-Thomsen T, Blaabjerg J, Hald F, Nyboe Andersen A, Rasmussen PE. Patients' attitudes to medical and psychosocial aspects of care in fertility clinics: findings from the Copenhagen Multi-centre Psychosocial Infertility (COMPI) research programme. *Hum Reprod*. 2003a;18(3):628–37.
- Schmidt L, Holstein BE, Boivin J, Tjørnhøj-Thomsen T, Blaabjerg J, Hald F, Rasmussen PE, Nyboe Andersen A. High ratings of satisfaction with fertility treatment are common: findings from the Copenhagen Multi-centre Psychosocial Infertility (COMPI) research programme. *Hum Reprod*. 2003b;18(12):2638–46.
- Schmidt L, Holstein B, Christensen U, Boivin J. Does infertility cause marital benefit? An epidemiological study of 2250 women and men in fertility treatment. *Patient Educ Couns*. 2005;59:244–51.
- Schmidt L, Sobotka T, Bentzen JG, Nyboe Andersen A. Demographic and medical consequences of the postponement of parenthood. *Hum Reprod Update*. 2012;18(1):29–43.

- Sharma V, Le BV, Sheth KR, Zargaroff S, Dupree JM, Cashy J, Brannigan RE. Vasectomy demographics and postvasectomy desire for future children: results from a contemporary national survey. *Fertil Steril*. 2013;99(7):1880–5.
- Sherrod RA. Male infertility: the element of disguise. *J Psychosoc Nurs Ment Health Serv*. 2006;44(10):30–7.
- Smith J f, Walsh TJ, Shindel AW, Turek PJ, Wing H, Pasch L, Katz PP. Sexual, marital and social impact of a man's perceived infertility diagnosis. *J Sex Med*. 2009;6:2505–15.
- Stöbel-Richter Y, Beutel ME, Finck C, Brähler E. The 'wish to have a child', childlessness and infertility in Germany. *Hum Reprod*. 2005;20(10):2850–7.
- Sydsjö G, Svanberg AS, Lampic C, Jablonowska B. Relationships in IVF couples 20 years after treatment. *Hum Reprod*. 2011;26(7):1836–42.
- Thompson R, Lee C. Sooner or later? Young Australian men's perspectives on timing of parenthood. *J Health Psychol*. 2011;16(5):807–18.
- Throsby K, Gill R. "It's different for men" Masculinity and IVF. *Men Masculinities*. 2004;6(4):330–48.
- Tschudin S, Bitzer J. Psychological aspects of fertility preservation in men and women affected by cancer and other life-threatening diseases. *Hum Reprod Update*. 2009;15(5):587–97.
- Tüzer V, Tuncel A, Göka S, Dogan Balut S, Yüksel F, Atan A, Göka E. Marital adjustment and emotional symptoms in infertile couples: gender differences. *Turk J Med Sci*. 2010;40(2):229–37.
- Umeora OU, Ejikeme BN, Sunday-Adeoye I, Umeora MC. Sociocultural impediments to male factor infertility evaluation in rural South-east Nigeria. *J Obstet Gynaecol*. 2008;28(3):323–6.
- van Balen F, Trimbos-Kemper TCM. Involuntary childless couples: their desire to have children and their motives. *J Psychosom Obstet Gynecol*. 1995;16:137–44.
- van Empel I, Nelen W, Tepe E, van Laarhoven E, Veerhaak C, Kremer JAM. Weaknesses, strengths and needs in fertility care according to patients. *Hum Reprod*. 2010;25(1):142–9.
- Wichman C, Ehlers S, Wichman S, Weaver A, Coddington C. Comparison of multiple psychological distress measures between men and women preparing for in vitro fertilization. *Fertil Steril*. 2011;95(2):717–21.
- Wischnann T, Thorn P. (Male) infertility: what does it mean to men? New evidence from quantitative and qualitative studies. *Reprod Biomed Online*. 2013;27(3):236–43.
- Wischnann T, Scherg H, Strowitski T, Verres R. Psychosocial characteristics of women and men attending infertility counselling. *Hum Reprod*. 2009;24(2):378–85.
- Zorn B, Auger J, Velikonja V, Kolbezen M, Meden-Vrtovec H. Psychological factors in male partners of infertile couples: relationship with semen quality and early miscarriage. *Int J Androl*. 2007;31:557–64.



Maurizio Mori

---

## Abstract

The author provides a brief explanation of what ethics is, distinguishing between *common sense ethics* and *critical ethics*. Historically sexuality has always been strictly connected with reproduction, and this connection shedded many issues were. Now that we are able to split sexuality from reproduction, any analysis of the various issues concerning sexual disorders has to consider that the reproductive decision (that of bringing a new offspring into the world) springs from *an existential choice*, even if the process may have to resort to medical assistance and involve some *clinical choice* as well. An adequate analysis of sexual disorders issues from the point of view of a critical ethics needs a demarcation criterion between what is *medical* (or *clinical*) and what is *non-medical* (existential or pertaining to ethics in general). This distinction is crucial because sexuality is a mixture of various aspects and two are of the utmost importance:

- (a) sexuality as (mere) mating for reproductive aims;
- (b) sexuality as acting for the self-realization of the person.

The so-called *sexual and reproductive rights* are the new cultural creation elaborated in order to promote and protect such a distinction, even if they are strongly opposed by part of common sense ethics and some religious fractions (notably the official teaching of the Roman Catholic Church).

This means that we have to acknowledge that our age is one of rapid transition and that there are two opposite ethical paradigms. According to the traditional “Hippocratical paradigm” together with some religious perspectives it is morally

---

M. Mori (✉)

Università di Torino, Consulta di Bioetica Onlus, Turin, Italy

e-mail: [maurizio.mori@unito.it](mailto:maurizio.mori@unito.it)

wrong to split sexuality from reproduction, any technology in the field is to be rejected and sexual rights are nonsensical or wicked. According to the newer ethical paradigm reproductive technologies are wellcome since they can favor people's wellbeing and self-realization. Therefore, ICSI as well as other forms of assisted reproduction are morally permitted. Moreover, since in most social systems parenthood depends on social criteria (responsability for the child, and not "genetic or blood" criteria), from the point of view of critical ethics, that donor insemination as well as surrogacy are to me permitted.

Other issues concerning sexual issues are examined such as erectile disfunctions, homosexuality, transexuality, intersexuality, sexuality of the disabled people, sexuality of the prisoners and chemical castration.

The conclusion is that from a critical ethics' point of view the new treatments of sexual disorders that has been examined are morally valuable and supported by good reasons, even though the author is aware that they are open to questions and should be debated.

### Keywords

Ethics, concept of • Ethics, different levels of • Professional Ethics, concept of • Medicine, demarcation criterion • Illness, as dynamic disorder • Illness, as existential condition • Sexuality, as mating • Sexuality, as relational self-realization • Marriage, traditional notion • Sexual health • Sexual rights • Sexual right, of citizens and disabled, and of prisoners • ICSI • Homosexuality • Transexuality • Intersexuality • Pregnancy for others (surrogacy) • Donor insemination • Erectile dysfunction • Chemical castration • Embryo, respect due to

### Contents

What We Are Speaking about when Ethics Is Involved .....	1321
Ethical Issues of Human Reproduction .....	1323
General Problems on Human Reproductions and the Demarcation Criterion between What it Is "Medical" and "Nonmedical" .....	1324
Application of the New Criterion of Demarcation to Reproductive Field: Two Different Notions of "Sexuality" .....	1327
Disorders Connected to Reproductive Sexuality .....	1328
Male Infertility and Assisted Reproduction .....	1328
ICSI and two Different Moral Paradigms on Assisted Reproduction .....	1329
Medical Objection to ICSI which Are Relevant from a Moral Point of View .....	1332
Donor Insemination .....	1334
Notes on the Issue of the Moral Duties toward the Embryo .....	1338
Conditions Connected to Sexuality as Self-Realization .....	1340
Erectile Dysfunction .....	1340
Homosexuality, Transexuality, and Intersexuality .....	1341
Disabled People and Sexuality .....	1344
Prisons and Chemical Castration (Neutering) .....	1346
A Short Conclusion .....	1348
References .....	1348

## What We Are Speaking about when Ethics Is Involved

Ethics (as well as its derivatives) is a trendy word used in many different meanings and sometimes quite peculiar ones. It is important to make clear what we mean with such a term before we enter in the details of the specific issues concerning male reproductive disorders. In a very general sense, “ethics” is the *ethos* or the spirit of an age: ethics is part of the culture of a society or a community as manifested in its beliefs and aspirations in a certain period. From this point of view, it is important to acknowledge that only in the last decades, doctors begun to recognize that men may have various reproductive disorders apart from impotence and that such disorders raise real ethical issues. Until recent times, reproductive disorders appeared to be a problem reserved only to women. In this sense, ethics is making a significant improvement, and this is mainly due to careful scientific observation: science has provided us with new knowledge showing that similar troubles are involving males and females alike. This aspect is leading to a more egalitarian attitude among humans, which is one of the major moral progresses in the field. The fact that this book examines these problems is a piece of evidence of such a moral change as well as a contribution to it.

“Ethics” can be used synonymously to “morals” to indicate that a specific social institution exists devoted to promote spontaneous and convinced motivation to comply with some norms and to endorse some values that are socially beneficial. Humans are social beings and live in communities included in larger societies. Social life needs reciprocal nonaggression as well as coordination of behavior in order to reach an adequate level of peace and individual flourishing. Our life is much calmer and more relaxed if we know that our neighbour will not endanger our life, and we are better off if he/she is ready to cooperate in activities that require the help of others to be realized or at least are greatly facilitated by such a help.

*Law* is the special institution establishing *rules* that enforce people not be aggressive toward other people and that state what has to be done in order to reach social coordination: people need to know what will be the others’ conduct to adjust one’s own behavior to the circumstances. Law provides such rules and forces people to abide under threat of sanctions which are explicitly stated.

*Ethics* or *morality* is another special institution that establishes rules and values that are accepted voluntarily, and for this reason, normally the correspondent conduct follows spontaneously. In this sense, ethics is similar to a language which is the special institution establishing the rules for our verbal communication: both institutions are learned by imitation and complied with as if they were “natural,” i.e., something that is given and beyond human capacities. In fact one is astonished that others speak different languages or that they make mistakes of their own, as they are surprised that there are various folkways or are hurt by moral mistakes. As a language is a powerful set of linguistic rules for transmitting information of all sorts, a morality is a powerful code of deeply interiorized rules devoted to permit immediate and prompt social coordination. For this reason, ethics is so crucial in social life.

As any important social structure, *ethics* or *morality* may present different levels of analysis as well. In the case of “law,” it is usual to distinguish, for instance, among different branches as civil law, criminal law, etc., with language among different kinds as ordinary language or technical language, etc.; in the case of ethics, the same word can have different meanings that should be carefully distinguished.

At the basic level, *ethics* indicates the *folkways* or the set of *received opinions* that form the so-called *commonsense morality*, i.e., the norms and values that are widespread in society and strongly internalized so to be spontaneously obeyed. Commonsense morality is analogous with our ordinary language that we use in our daily life spontaneously and without knowing why it is used in such a way: we have learned it from our environment, and we simply use it unreflexibly. Our ordinary language is never “pure” but always laden with some “accent” (even if normally the speaker does not realize it) or local expressions. Similarly, our folkways may present biases depending on beliefs or taboos widespread in the community. In a sense, the opening remark concerning the new acknowledgment that males may have reproductive troubles is a point of commonsense morality: it was hardly imaginable a few decades ago, and it is still rooted in the most conservative factions of our societies.

Commonsense morality guarantees and enables people in the group with certain moral norms and values to coordinate their social life. In this sense, folkways are the basis of a society looked in its static part (as a picture). However, we know that nothing is fixed and that social life is in a perennial state of change. This means that moral rules and values have to adjust to the new situations, if they want to perform their functions in an appropriate way. One reason to revise moral rules and values is that often they may depend on obsolete or even false beliefs about the machinery of the world or of the bodies. This is quite clear in the field of sexuality, which until a few decades ago was covered by a sort of mystery. Another reason is that historical circumstances change, and correspondent modifications are to be introduced if the specific institution has to work out its function: in winter it is appropriate to wear heavy clothes in order to maintain one’s health and well-being, but in summer to reach the same target, one has to do the opposite and wear light clothing. If social conditions change, morality has to adapt, if social coordinations are to be guaranteed successfully.

In the past the pace of social change was quite slow, and about a century ago, an Italian sociologist could remark:

if an ancient Greek or a Roman would resurrect now, I think that his brain would understand almost nothing of our modern world, but his heart would still beat in tune with many other hearts. . . . Ideas change quite quickly, while in many years and in many centuries, sentiments have undergone but a slow transformation. . . . The central sentiments regulating the morals of human existence are more or less the same as they always had been: nowadays a man behaves in his affective life more or less as his ancient ancestors behaved long ago. (Sighele 1899)

In the last decades, the situation has changed significantly, especially in the field of human sexuality. We should not be too optimistic, since deep down many peoples’ atavistic feelings still remain well and alive. However, in the richer part of the world,

there is an awareness that we have to renew some of the norms and values regulating our social life. Courts and parliaments are involved in a process of updating the laws, some of which are more advanced than folkways, while in other cases, they appear obsolete if not reactionary. As far as morality is concerned, such a process of renewal is propelled by two factors. On one hand there is the emergence of the codes of *professional ethics* formed by the set of norms and values that are stated by the members of a profession. A professional ethics is more refined than commonsense ethics (folkways), because it is stated after some reflection: in the practice of a profession, some quandaries emerge more often than in normal life, and the codes of ethics are developed in order to prescribe specific rules and values to prevent conflicts and to contribute to group identity.

On the other hand we have to acknowledge [or realize] that professional ethics can be a stimulus to improve commonsense morality, but this may not be enough. In most cases the basic intuitions of professional ethics come from commonsense morality, and this may be questioned. To accomplish this further task there is a third level of *ethics*, which is called *critical ethics*, which is the result of reflection on the received opinions in order to see whether or not they are rationally justified, i.e., that are supported by good reasons. Critical ethics is the branch that emerges from commonsense ethics when a moral agent starts to think on the reason supporting a given solution. Normally this occurs in quandaries, when the agent has to choose between two courses of action and she/he asks why to prefer the one to the other. This process brings to question the received customs that up to then have been accepted in an automatic way, by tradition. It is impossible to control each single received opinion, and this is the reason for which “a culture” (including religious and customary traditions) is so influential on each of us. It is the background that shapes our form of life, and we can control and possibly revise only some fraction of it.

Something similar occurs with a language: one can modify only a fraction of one’s mother tongue, as it occurs when one learns a technical language (for instance, becomes a doctor or a lawyer) that becomes so familiar to him that starts to influence his way of speaking. Analogously it may happen with morality: having faced a deep quandary, a moral agent can become aware of the values directing one’s choice and abide by them consciously. This marks a sort of new (moral) birth, which is typical of *critical ethics*: after such a clarification, the person not only promptly follows the moral values she/he sees but also knows why it is proper to do it, i.e., she/he knows that they are the right values and why they are to be applied in the circumstances.

In the following pages, the word *ethics* is used to indicate *critical ethics*, and I’ll try to apply as far as I can norms and values that are rationally justified, or at least I’ll do my best in providing a justification for any step of my ethical arguments.

---

## Ethical Issues of Human Reproduction

If we look at the ethical problems of human reproduction from a critical point of view, the first thing we have to do is to clarify the peculiar nature of the issues that we have to face and how to classify them. In order to do so, we have to consider how

these issues have been considered in the Hippocratic tradition, which is so important in Western culture and in medicine.

### **General Problems on Human Reproductions and the Demarcation Criterion between What it Is “Medical” and “Nonmedical”**

In the traditional medical ethics (Hippocratic), human reproduction is so strictly connected to sexuality and to its management that the whole process is reduced on *reproduction* so that sexuality is practically equivalent to mating and hardly exists as an independent and specific reality. As it has always been written over the centuries, the primary goal of sexuality is reproduction (or “procreation” as theologians say), and this means that human sexual activity is reduced to mating analogously to what happens with other mammals. In this sense, the so-called *reproductive disorders* of a human adult attracted medical attention and have been cured in view of restoring the possibility of mating so to make possible a new birth. This is in line with the medical (conceptual) paradigm underlying Hippocratic ethics, which was so influential in the Western culture to be unconsciously included in most of current practice. This conceptual paradigm states a demarcation line between *medical* and *non-medical* issues, i.e., problems which can be considered as *clinical* and problems that cannot be included in the clinics but are to be considered as *social, artistic, economic*, etc.

It is clear that the field of medicine is limited to a part of the world and that medicine claims neither to relieve from any kind of suffering nor to offer salvation from any evil. However, it is more difficult to assert a clear-cut of demarcation line between what belongs to medicine and what is outside medicine. To do so we can start with the old Latin dictum stating that the task of medicine is *sanare infirmos et sedare dolorem*: heal the sick and relieve pain. A first problem with this dictum is that it appears to individuate *two* tasks and not just a *one*, and the second – *sedare dolorem* – is quite large and can include almost everything.

A way of clearing the difficulty is to note that the primary goal of medicine is *sanare infirmos* and that the first duty of doctors is to heal the patient and oppose pathologies. This means that medicine is about *infirmos* in the sense that it has to do with people who are sick and affected by some pathology. Usually such a condition is also painful, and therefore a doctor has also the task of *sedare dolorem*, i.e., relieve the pain *produced by the illness*. The last clause is crucial, because it specifies the demarcation line between the medical and nonmedical. There is a lot of pain in the world, but medicine is not committed to relieve any pain but only a specific class of pain. Poverty is a source of enormous suffering, but it is a *social* problem, and it is *not a medical one*. Analogously, one can say that being ugly or deformed is often another source of intense pain, which is not a medical problem, but an aesthetic one. But in this case, we see that the situation is more complicated and that the demarcation line is not so straight and clear-cut. We are inclined to say that *some* ugly traits can be treated clinically, and it is important

to try to understand which ones and why. So far we have stated that the *sedare dolore* is subordinated to the *sanare infirmos*, and therefore that it is limited to the relief of pain brought about by a pathology or by a therapy and does not include any pain such as, for example, those produced by poverty or other existential condition.

Now, we have to make clear that a pathology, an illness, is to be understood as a deviation from the normal process that prevents or interferes the working of the self-preservative finalism of the organism. A human being is an organized whole aiming to one's own self-preservation and maintainance of the species. In this sense a body is coming to existence with a specific finalism tending to self-preservation. A pathology is what prevents or makes difficult the working of the finalism. In order to maintain its life, the body has a *vis medicatrix naturae*, nature's healing force, that permits to overcome some troubles. However, sometimes it is not enough, and then a therapeutic intervention is required, which is the specific task of medicine. It is interesting to remark that in Greek, *therapein* means "to help": a therapy is a help to the body and to the *vis medicatrix naturae* to restore the natural functionality of the body. In this sense, for the traditional paradigm medicine's aim is neither to enhance nature nor to overcome the limits set by nature nor to try to substitute or modify the self-preservative finalism of the body. The Hippocratic physician is an assistant of nature who tries to increase the power of the *vis medicatrix naturae*, but he/she is not interested to change nature's finalism: a task which is outside the goals of medicine (as presented by the traditional paradigm).

It is true that going beyond nature's limits set by life's intrinsic finalism can bring about utilities and relieve a lot of human pain. But here we go back to the issue that medicine is not the universal remedy against any pain, but only to pain produced by pathologies understood as deviations from the intrinsic finalism of life. In this sense, being ugly or beautiful as well as being tall or short is a *biological state or condition* which can raise an aesthetic or a social problem, not a medical one. Of course if a noticeable nose is also obstructing the respiratory function, medicine can correct such a trouble and at the same time also change the shape of the nose and overcome the aesthetic problem. Thus there are occasions when aesthetics and functionality go together and are synergistic. But they are in principle different and must be kept distinct.

I am aware that the paradigm that I try to outline is an ideal and that it has a lot of problems and some notable exceptions as psychiatry. However, one can say that exceptions must be considered in a special category which does not modify the general frame or paradigm. In this sense, it is still plausible to remark that medicine is concerned with situations of *illness* or *pathology* as dynamic disorders that prevent or block the finalism. This remark is crucial to come to what are the two fundamental distinctions in the field:

- (a) The distinction between *illness* as dynamic disorder of the organism and *biological state* as a specific vital condition of the organism. For example, it is an illness to have a gangrenous arm, but it is a biological state not to have an arm

(being born without it or having lost it). The first situation raises a *medical* or *clinical* problem, while the other raises problems as well which are socially important but are *nonmedical*.

- (b) The other basic distinction is between *illness* (as above defined) and *basic existential state* which is that specific *biological state consisting in the coming into the world* or of *being born* in a given condition. In fact, to choose or to decide that a new being has to enter or not to enter into the world is an *existential* or a *moral* question which has many social features, but it is not in itself a *medical* or *clinical* question even if it may have some kinds of medical implications. The first one is that, for instance, a pathology could prevent the instantiation of a basic existential state, i.e., the coming into the world of a new being whose birth would be morally chosen. In this case, a *medical* or *therapeutic* intervention is required to favor such a choice.

Briefly speaking, choosing or deciding that someone comes (or does not come) into the world is an existential choice and not a medical one. It belongs to general ethics (for this I call it “existential choice”), and not to medical ethics which has nothing to say on whether it is good to be born instead of not coming into the world (and at which conditions it could possibly be): *medical ethics* is about issues raising *within* an actual life and does to consider possible future lives.

However, it is an issue of *medical ethics* whether or not to contribute in some way to the existential choice of a person willing that someone enters or does not enter into the world. There are two basic situations: (1) one wants that another one comes into the world, but a pathology prevents it, and medicine is asked to promote such a choice by overcoming the obstacle, or (2) one does not want that another come into the world, and medicine is asked to promote such a choice by preventing births. In this sense, medical ethics is somehow *involved* in the issue which is *existential* or *metaphysical*, and its involvement is increasing: in the past medicine’s ability to favor or not to favor, such a choice was very limited, but now it has a role, and it is important to state whether cooperation is permitted or not, within which limits and for which purpose.

Not only is this relevant for the issues concerning basic existential state but is it even more significant for the resulting *biological state* which continues after birth and which can be more or less pleasant or present positive or negative qualities. Once again, this situation raises *social* or psychological questions but not *medical* ones unless such a person is affected by some clear pathology. Here it is fundamental to stress that pathologies are dynamic disorders of the organism which may endanger life or become chronic, and they are to be distinguished from disabilities, deformities, and other defects. For instance, being affected by Tay-Sachs syndrome or cystic fibrosis is a medical issue, but not to have a hand or being ugly is not in itself a medical problem, but a social one. It is a kind of disadvantage more similar to living in a state of poverty or of physical handicap.

However, medicine can now be somewhat involved because the distinction is not clear-cut: the quality of life of some kinds of biological state can be improved by means of medical interventions, and this creates new problems.



## Application of the New Criterion of Demarcation to Reproductive Field: Two Different Notions of “Sexuality”

The distinctions we have drawn allow us to provide some interesting remarks when they are applied to the reproductive field in general and in particular to the human male. The main point is that if medicine is no longer limited to *sanare infirmos*, i.e., to restore the self-conservative finalism, then the old distinction between different meanings of “sexuality” has to be considered in new light. Since ancient times it was well known that sexuality has various functions (or meanings) and can be directed toward different goals: specifically, either toward reproduction or toward a pleasant creative self-realization, i.e., the situation in which a person perceives to be committed in activities satisfying one’s deep plans and giving meaning to life. These two goals were usually so strictly tied to appear intrinsically connected, i.e., that they *ought not to be separated*. In this sense, reproduction and pleasant self-realization had to go always together, and reproduction was the primary meaning of marriage, the social institution devoted to regulate sexuality and guarantee perpetuation of the species. Accordingly in the Hippocratic tradition, medicine was devoted to find out therapies in order to restore sexuality devoted to reproduction. This is the time-honored received opinion included in our commonsense morality.

However, in the last century, we gained the ability to split sexuality from reproduction, showing that such a relation is not at all *intrinsic* but is *extrinsic*: as a matter of fact, we *can* separate sexuality from reproduction so that we can have sex without children and children without sex as well. This means that we have to distinguish two different kinds of sexuality:

- (i) *Sexuality as (mere) mating* which is devoted primarily or solely to reproduction and from which new offspring can derive
- (ii) *Sexuality as relational self-realization* which is devoted to create new forms of personal commitments without any reproductive goal, which could be included as a part of one’s plan of life (and not as a result of mere mating)

It is interesting to note that such a distinction was mainly brought about by medicine and that it raises basic problems concerning the goals of medicine itself and its specific field of action. Medicine has to reestablish the criterion of demarcation about what is properly *medical* and what is *not medical* but simply raising other social issues. And this is to be done on ethical bases, since it is clear that from a *biological* point of view, the connection between the two kinds of sexuality is *extrinsic*, and we *can* split it. The problem is if from an *ethical* (or *moral*) point of view, we *may* do it or even *ought to* do it. This is the question that for about a century has torn many people and has been at the center of medical ethics as well as of a large social debate which is not yet over.

Possibly this traditional concept of naturalistic conception of sexuality is near to its end. The new concepts of *sexual health* and *sexual rights* (as claims to have a self-realizing sexual life) are a piece of evidence that the distinction drawn is widely

spread at least in critical ethics as well as at the top in the agenda of WHO and other international institutions. But social change is not immediate (like to switch on and off the light), and we have to realize that the received (Hippocratic) opinion still maintains its influence on many quarters of society and of medicine. For instance, the Roman Catholic Church at least in theory still forbids and condemns contraception in principle. Other religions concur as well on the point, and some survivals of this conceptual frame become clear about the concept of *sexual disorders* which are those concerning sexuality as mating. On the other hand, in our society a great number of sexual disorders are about sexuality as relational self-realization, which are now included in the medical field, while they were outside it according to the Hippocratic paradigm. This means that the demarcation line has changed and that medicine has enlarged its field. Some problems which in the past were mere *social* problems are now proper *medical problems*. This is a great leap, whose consequences are explored in examining the list of the issues that are now normally treated.

---

## Disorders Connected to Reproductive Sexuality

Having distinguished two different kinds of *sexuality*, we are now examining the various issues concerning each. We start with problems connected to some sort of reproductive failure which up to a few years ago were the *only* issues treated as medical problems. Our analysis will be developed according to the central distinction between commonsense ethics and critical ethics in the sense that we will present both what is the opinion received from the tradition and spread in society and the position which can be held on the basis of critical ethics.

### Male Infertility and Assisted Reproduction

One of the main reproductive disorders is infertility, which is the inability to produce live offsprings. In the past, infertility was usually ascribed only to the woman, but now we know that also the man can cooperate to create such a situation since sometimes he is unable to produce the adequate number of spermatozoa required for fertilization. Oligozoospermia and azoospermia are the most common forms of male infertility.

Donor insemination is a way used to overcome male infertility, and I shall examine some of the issues concerning such a practice soon. For reasons that will become clear, it is preferable to start considering another more recent technique which people can resort to: the so-called ICSI, acronym for “intracytoplasmic sperm injection,” i.e., the practice of injecting one sperm into one oocyte so to get a new embryo to transfer into the woman’s womb. ICSI became available in 1992 and since then is one of the most widespread practices to treat male infertility. It is enough that a man produces a few sperm to enable him to fertilize an oocyte.

## ICSI and two Different Moral Paradigms on Assisted Reproduction

From a critical ethics viewpoint, ICSI appears to be positive since it opens up the possibility of having children. A positive aspect of the practice is that both gametes come from the couple and there are no issues concerning the genetic part: difficulties that may be involved in donor insemination. In this sense ICSI is a very useful and simple case to be studied to examine the problems involved in the practice. Secular ethicists strongly support assisted reproduction in general, and some Christian churches concur in saying that the technique is morally good on the basis of an argument in the following line: God provided man of reason and wanted him to use it to overcome the troubles of life and increase human self-realization. Reason applied in the reproductive field led to the new techniques, which are positive gifts since they allow people to have desired children. In this sense, assisted reproduction is considered in a favorable way, and the problem is to state adequate rulings in order to get the maximum and avoid possible harms.

However, other religions are against assisted reproduction, and in this they can count on the approval of that large part of commonsense ethics which is conservative and abhors any change: as Reverend Sydney Smith (1771–1845) said “there are always a set of worthy and moderately-gifted men who bawl out death and ruin upon every valuable change which the varying aspect of human affairs absolutely and imperiously requires.” This common sensical negative attitude is peculiarly strong when modifications are about human reproduction, a field that for long time was mysterious and winded up by false knowledge, and where feelings are so intense and deeply rooted that sometimes opposition becomes vehement. But intensity of a feeling is by itself neither an evidence of its correctness nor a reason for its justification: people may have deep and intense feelings against racial and sexual equality, but any form of discrimination is morally wrong. Only rational justified feelings can count as moral, and therefore we can dismiss commonsensical received opinions.

Some religions, however, present reasons for their opposition to the new technique, and it is interesting to examine those put forward by the Roman Catholic Church, which is possibly the most important institution constrastring ICSI as well as other forms of assisted reproduction. As it is stated in a specific official statement issued in 2008, one reason depends on the fact that “indeed ICSI takes place “outside the bodies of the couple through actions of third parties whose competence and technical activity determine the success of the procedure. Such fertilization entrusts the life and identity of the embryo into the power of doctors and biologists and establishes the domination of technology over the origin and destiny of the human person. Such a relationship of domination is in itself contrary to the dignity and equality that must be common to parents and children. Conception in vitro is the result of the technical action which presides over fertilization. Such fertilization is neither in fact achieved nor positively willed as the expression and fruit of a specific act of the conjugal union” (Congregation for the Doctrine of the Faith, *Dignitatis Personae*, 2008, n. 17).

This passage may lead people to the conclusion that the main reason against ICSI has to do with the more general opposition to the intrusion of techniques in human reproduction and life, which seems to be justified by the urgent need to prevent the excesses of technology. However, if it would be the need to constrain technology the reason that justifies such an opposition, then it would be an *extrinsic* reason that could be modified or replaced. For instance, the same result could be accomplished by some adequate rulings. This means that – properly speaking – that reason (the need to constrain technology) is a complementary remark, that may get stronger a view that is already asserted on other grounds. The real justification of the Roman Catholic position is that “Just as in general with in vitro fertilization, of which it is a variety, ICSI is intrinsically illicit: it causes a complete separation between procreation and the conjugal act.” This is an *intrinsic* reason connected with the very nature of the practice and not on its possible (and contingent) consequences. In this sense ICSI is ethically wrong because it violates the moral principle of *the inseparability of the unitive and procreative meaning of sexual intercourse*.

It is this principle that justifies the Catholic prohibition of the new technique. It is important to be aware of this point because if an ethical principle is involved, then the Catholic view can claim to be supported by a rational justification. Therefore, it is not simply a variation of commonsense ethics based on received opinions transmitted by traditional emotions. We have to evaluate this perspective on the basis of its assumption, and to do so, we have to deepen the perspective and see the role of the principle for the doctrine of marriage and to examine some implications stemming from it. To the point the following passage seems to be enlightening: “The Church’s teaching on marriage and human procreation affirms the “inseparable connection, willed by God and unable to be broken by man on his own initiative, between the two meanings of the conjugal act: the unitive meaning and the procreative meaning. Indeed, by its intimate structure, the conjugal act, while most closely uniting husband and wife, capacitates them for the generation of new lives, according to laws inscribed in the very being of man and of woman.” This principle, which is based upon the nature of marriage and the intimate connection of the goods of marriage, has well-known consequences on the level of responsible fatherhood and motherhood. “By safeguarding both these essential aspects, the unitive and the procreative, the conjugal act preserves in its fullness the sense of true mutual love and its ordination toward man’s exalted vocation to parenthood.” The same doctrine concerning the link between the meanings of the conjugal act and between the goods of marriage throws light on the moral problem of homologous artificial fertilization, since “it is never permitted to separate these different aspects to such a degree as positively to exclude either the procreative intention or the conjugal relation.” Contraception deliberately deprives the conjugal act of its openness to procreation and in this way brings about a voluntary dissociation of the ends of marriage. Homologous artificial fertilization, in seeking a procreation which is not the fruit of a specific act of conjugal union, objectively effects an analogous separation between the goods and the meanings of marriage. Thus, *fertilization is licitly sought when it is the result of a* “conjugal act which is per se suitable for the generation of children to which marriage is ordered by its nature and by which the spouses become

one flesh” (Congregation for the Doctrine of the Faith, Instruction *Donum Vitae*, 1987, II. B, 4.a).

The long quotation makes clear that the inseparability principle has a central place in the general view of marriage as a divine institution and that it is included in a worldview that from an internal point of view is consistent. In this sense specific practical solutions can be justified within the accepted paradigm. Of course, it is possible to criticize such solutions by rejecting the whole paradigm and by appealing to an external point of view with different criteria of rationality. But to do it is not an intellectual challenge, but something equivalent to a victory of a political election or of a military action: it is analogous to the occupation of a territory (be it physical or intellectual) which has nothing to do with rational arguments.

A very interesting aspect of the question is that the paradigm implicit in the Catholic view is quite close to and consistent with the Hippocratic tradition and its demarcation line between medical and nonmedical. Here we see that the Catholic perspective is not simply “religious” in the sense of being dependent on a mere faith, because it is claimed that such a faith is grounded in a long-standing and honored rational tradition. It is this general paradigm inherited from the Greek culture that is at stake. As a matter of fact, it is a controversial issue whether assisted reproduction is “therapeutic” or not in the strict sense of the word, i.e., whether it is really a help to the living process of transmission of life or it is a substitution of it that allows human control of the process (as the Congregation for the Doctrine of the Faith stresses in the quoted passages). It goes without saying that this new control of the reproductive process on one hand blurs the distinction between what is medical and not medical and on the other one at the same time marks the distinction between the two senses of sexuality that we have distinguished. If sexuality is not any longer intrinsically connected with reproduction, then it can be detached and freed from such an aspect and become an independent field to be explored in its own terms.

It is crucial to see which sort of reasons we can give pro or con the inseparability principle. We are well aware that they cannot be definitive or striking down the opposite view, because cultural paradigms are incommensurable, i.e. cannot be compared. However, it is important to present some of these reasons and see the limits within which they can be held. The first reason in favor of the Roman Catholic Paradigm is general and is about the nature of marriage. As we have seen, for the Catholic doctrine marriage is a divine and natural institution, and on this ground, the Catholic teaching affirms the “inseparable connection, willed by God and unable to be broken by man on his own initiative, between the two meanings of the conjugal act: the unitive meaning and the procreative meaning. Indeed, by its intimate structure, the conjugal act, while most closely uniting husband and wife, capacitates them for the generation of new lives, according to laws inscribed in the very being of man and of woman.” This view presupposes a very specific concept of God and of the order of nature, i.e., metaphysical assumptions which are controversial and are shared neither by many other religions nor by the secular perspectives. Within a given paradigm and seen from its internal point of view, such assumptions may be “rational,” but they cannot be brought to the public arena, where only scientific and

secular reasons are apt to be considered. In this sense, that view may be held as a *private* opinion but cannot claim to be valid at the *public* level.

The second reason is more specific and is about one practical consequence deriving from the Catholic conception of marriage. The inseparability principle forbids not only the ICSI and the other forms of assisted reproduction but also contraception. As stated above, “contraception deliberately deprives the conjugal act of its openness to procreation and in this way brings about a voluntary dissociation of the ends of marriage. Homologous artificial fertilization, in seeking a procreation which is not the fruit of a specific act of conjugal union, objectively effects an analogous separation between the goods and the meanings of marriage.” This clear statement forces us to a choice: either contraception is a *medical* practice as well as homologous-assisted fertilization and the inseparability principle is to be rejected or the inseparability principle is morally valid and contraception is a *nonmedical* practice as well as other forms of assisted reproduction. It is clear that this choice has more general consequences on the demarcation line between the medical and nonmedical and states the Gestalt switch between the two different paradigms.

Since contraception is a well-established *medical* practice, we can say to have a good reason for rejecting the inseparability principle and to support the new medical paradigm. In this sense, at least in principle, ICSI and other forms of assisted reproduction are morally welcome on the basis of a critical ethics. As already mentioned, the new practice opens up the horizons of human reproduction, and this increases the possibilities of self-realization of both prospective parents and the future newborn. If there are no principled objection to the ICSI as a therapy to overcome reproductive failures, there may be practical objections concerning the application of the ICSI which are morally relevant. This train of argument has to be examined with due attention.

### **Medical Objection to ICSI which Are Relevant from a Moral Point of View**

Some people claim that ICSI is not yet a reliable technique because its effects on future children are not precisely known, and it is possible that they are exposed to an increased risk of birth defects. Medical objections to ICSI point to these sorts of troubles to conclude that the practice is ethically unacceptable and ought to be abandoned (at least until more reliable results are available). Objections of this sort are certainly relevant to the moral debate on the issue: if the technique is not safe enough and it could possibly produce damages to the future child, this fact has to be taken into account and carefully evaluated from a moral point of view. A basic moral principle enjoins to do what is good, and assisted reproduction is a morally good practice if it does the good of the people involved in it, including the child. If the ICSI is a source of troubles for the newborn, it is morally wrong.

Before being focused on the ICSI, this kind of criticism was used against IVF in general since assisted reproduction was available in 1978. After four decades of experience and about 5 million infants born through various forms of assisted

reproduction, this criticism appears to be specious and somewhat arbitrary, at least *prima facie*. If such techniques were to be really risky or involved a visible and palpable danger, people would have perceived it by now and would have ceased to resort to it. The fast development of these techniques and the growing demand for them seem to confirm that the risk is not significant enough as to lead to the conclusion that assisted reproduction is to be abandoned and banned: if the possibility of any harm would be perceived, people would prevent from resorting to it.

Nevertheless, it is true that sometimes assisted reproduction ends up in problematic births, and these events seem to support the idea that such practices are risky and dangerous. The issue has to be dug out and two preliminary remarks are to be considered. The first is that any birth is risky to some degree because unfortunately not every birth is perfect. Also sexually conceived birth (SCB) involves some risk and that this basis has to be taken as the criterion of comparison to say that assisted reproduction technology (ART) birth is riskier than SCB. Scientific research done since the 1980s shows that SCB involves the following risks: about 3% of malformations at birth, plus about 3% of mental retardation, to which one should add another 1% of infants with Mendelian disorders and another 1% of chromosomal disorder (this latter may increase up to 10% depending on the age of the mother). Roughly speaking, about 7% of all infants resulting from SCB have birth defects upon coming into the world (at least in societies with an infant mortality rate of less than 1%). Therefore, we can assume that about 7% is the basic criterion of comparison for the two forms of reproduction, and some further adjustment can be required (as maternal age and other factors).

The second preliminary remark is that many studies have been done on the issue, and some of them have instilled doubts. Also the report of the Italian Commission for the so-called “Fertility Day” in 2015 stated that the effects of assisted reproduction “on the health [of newborns] are in part unknown” and listed 18 possible complications such as congenital anomalies, neurologic or cognitive deficiencies, etc. (Ministero della Salute 2015). It is true that some studies are alarming, but we have also to keep in mind that the authoritative meta-analysis of the epidemiological studies done by Wen et al. in 2012 found that out a list of 925 studies examined, only 56 (6.05%) have been judged worthy of being considered. All the others have been discarded because of various defects like poor or inadequate designs, false data, etc. This is to say that great attention has to be reserved to the analysis of empirical data reported on the issue: only reliable and serious studies are worthy to be considered.

Looking with the due attention to the best available knowledge, we can report that an important and detailed study by Davies et al. (2012) compared an Australian cohort of 6163 IVF/ICSI infants born from 1986 to 2002, of which 1407 were ICSI, with SCB infants, and reached the conclusion that “the increased risk of birth defects associated with IVF was no longer significant after adjustment for parental factors.” This means that IVF is not more dangerous than SCB, if due distinctions are considered – such as the fact that many IVF pregnancies involve twins or triplets which may cause birth defects and other problems. In this sense, Davies reports that the general adjusted risk is 1.28%, i.e., significantly higher than 1.0% (the basic “natural” risk). However, among singleton IVF newborns from fresh embryos, the

adjusted risk is 1.06, showing that IVF as such entails no increased overall risk for birth defects (Davies et al. 2012).

Davies' report also compared IVF and ICSI infants and concluded that "the risk of birth defects associated with ICSI remained increased after multivariate adjustment, although the possibility of residual confounding cannot be excluded." This conclusion was immediately amplified by the media all over the world and still serves as the base of many critics who say that ICSI is a serious danger for the newborn. Many ICSI parents were worried and many physicians had doubts about it. This is not the place to enter into a detailed analysis of such a conclusion, but it is important to say that this conclusion depends on the observation that among singleton newborns after ICSI with fresh embryos, the adjusted risk rose up to 1.55%, i.e., 0.55% above the 1.0% threshold. This is a statistically significant increase, and Davies reported it correctly (mentioning the possibility of residual confounding). But in general terms, the number of ICSI infants with birth defects would only increase a few units. Moreover, that conclusion is criticized by Pinborg et al. (2012) on the ground of a recent study of a larger cohort of Swedish infants. This new study is based on 15,570 IVF/ICSI infants born between 2001 and 2007, of which 9372 were born after ICSI. This new data appears to be more reliable than that deriving from the Australian cohort where most children were born when the ICSI was just beginning. In contrast to Davis' conclusion, Pinborg's result is that "the adjusted risk of birth defects for the ICSI vs. IVF cohort (2001–2007)" is 0.90%, i.e., lower than the basic "natural risk." This thesis is also confirmed by Wen et al. (2012), who remarked at the end of their meta-analysis that "there is no risk difference between children conceived by IVF and/or ICSI." Finally, in a more recent study concerning newborns in the Nordic countries over the last two decades, Henningsen et al. (2015) register that the number of multiple births decreased with time as well as perinatal deaths and low birth weight. In brief, *ART-conceived children are better off than those who are conceived naturally.*

The aforementioned data seems to be the best that has been made available as of yet, and the situation it describes is not as discouraging as critics point out. Therefore, ICSI can be a viable solution to male reproductive disorders. It is ethically positive since it favors self-realization of everyone.

## Donor Insemination

The analysis we have done has shown that from the point of view of critical ethics, ICSI can be a valuable therapy for male infertility. We are now in a more adequate position to examine the morality of donor insemination, which has two other important problems to be considered: the issue of parenthood and that of the embryo.

### What Is Parenthood? Genetic Vs. Social Criteria

A great advantage of the ICSI is that in it, the genetic endowment is internal to the couple, and therefore there are no controversies on parenthood. For this reason I preferred to examine the issue before donor insemination where part of the gametes



is external to the couple, and this would raise a further problem stemming from the fact that parenthood is depending from genetic connection to the child. According to a widespread received opinion, the parental relationship is constituted by “blood connection.” This means that donor insemination is morally and legally problematic because it violates one of the basic tenets of the family.

We have to distinguish the moral level from the legal one and also keep in mind that different legal systems have suggested different solutions. Here I cannot enter into the details of these various proposals advanced in different countries, but some ideas can be useful to distinguish the general perspectives and orientate our thinking. The first point is to make clear that among humans, *parenthood* is primarily a *legal concept*: father is who the law states he is, as mother is who the law states she is. However, articles of law are not stated by chance but are informed to some criterion and are giving voice to it. Our problem is to grasp the criterion which is underneath the letter (formulation) of the various single articles of the positive law of different countries. Let’s consider the question: is it the *genetic relation itself* that constitutes legal parenthood or is it the *social responsibility for the child* that constitutes such a legal relation, and the genetic connection is (only) evidence of an act concerning the child which the man ought to be responsible of?

The answer to this question brings us to distinguish two different criteria of parenthood: the *social criterion* for which fatherhood is created any time the law ascribes to a man the responsibility for the child, regardless of any genetic connection even if it can be a reason for ascription of parental responsibility; and the *genetic criterion* for which fatherhood constitutes any time a biological connection between a child and an adult is discovered, as if such a relation would be immediate and by itself binding.

As soon as we distinguish the two criteria, we can see that most of Western legislations presuppose the social criterion. Because they do it, they can envisage and do envisage adoption as a form of parenthood: in adoption we know that there is no genetic relation between the father and the child, and it would be impossible if the genetic criterion had been accepted. It is true that adoption is a special kind of parenthood and that normally parenthood presupposes genetic relationship. But even in these normal cases, it is not the genetic relation that per se creates parenthood, but the genetic relation is simply a sign showing that what the man did had some consequences [the birth of a child] which he has to be responsible for, since it is this responsibility for the child that creates parenthood.

In the past the distinction between social and genetic criteria hardly appeared because marriage was the great *social* institution in charge of controlling how human life ought to be correctly transmitted to the next generation. In this perspective, children are born within and from marriage, and those born outside marriage are not acknowledged. Adultery is a most heinous crime just because it can bring to the light the distinction between the two criteria and conjugal fidelity a most valuable virtue because it guarantees the equivalence of the two.

In the last decades, the situation has radically changed. Marriage is no longer so important for the transmission of life, and the decision to bring a child into the world may be independent of marriage. In these new historical conditions, it is not easy to

establish who is the father, and we have to be careful. In “normal” cases father is the man who did some acts whose consequences end up in the birth of a new child whom he ought to be responsible for: to do those acts is equivalent to decide to bring a new being into the world, and therefore the responsibility for the child is ascribed to him.

However, in some cases it may occur that a man wants to bring a new being into the world and decides to do so, but for the most different reasons, he may be physically unable to do so. Therefore, he decides to ask someone else to help him in the venture by donating the required gametes. If the donor accepts the request, then a new child is born, and the situation is the following: the newborn has a genetic relationship with the donor who accepted to cooperate with the man who decided to bring the child into the world, did most of the acts to such an effect, and in this sense is responsible for that birth, even if he has no genetic connection with the child. If in this case we ask who is the father, the answer is that the father is the man who is accountable for such a birth and has to assume legal responsibility for the child he decided to bring into the world.

This shows that fatherhood is a social concept sanctioned by the law. The donor is not at all “father” in any sense, because he does not have the responsibility for such a birth but simply has provided some cooperation. In order to avoid confusion, I would recommend not to say that the donor is the “genetic father” opposed to the “legal or social father,” because adjectives modify in part the noun but do not cancel the evocative force hidden in it. I would say, instead, that the donor is the “genetic ancestor” of the child, because such an expression would make clear that he has no responsibility and cannot be involved in parental roles.

Conclusion: from a critical ethics’ point of view donor insemination is a valuable solution to male infertility troubles. This result, however, does not solve all the problems raised by the practice and many remain open. For instance, still unclear is the answer to the *psychological* problems about whether or not revealing the identity of the sperm donor to the new person: when to do it, who has to do it, for which reasons, etc. There may be *medical* reasons connected to protect the newborn’s health, or *social* reasons dependent on the opportunity of maintaining transparent relations. Other issues may raise from the sperm donor’s point of view, and again others at legal levels.

I am well aware of these further problems and I have no pretence to give a definite answer to them all. I tried to provide some ethical indications: once we have clearer ideas at this level, we can also face the other aspects of the question.

### **Pregnancy for Others (or Surrogacy)**

IVF makes it possible that also women can donate their gametes or provide gestation for another woman. The result is a new medical practice in which women can be involved in two ways:

- (a) A woman can donate both her gametes for the creation of the embryo and the pregnancy required to bring it [him/her?] to birth.
- (b) A woman can donate only the pregnancy of an embryo created with gametes of others.

One problem of this practice is how to call it. In English the term used to indicate it is “surrogacy,” which is adequate as it is rather neutral. However, its translation in other languages (mainly neo-Latin) is problematic because “surrogate” means “of second choice” and has a negative tone. For this reason, one adequate name for such a practice can be “pregnancy for others,” meaning that a woman provides the service of bringing to birth a newborn for other people. This term has no negative connotation and appears not to be evaluative. It has also the advantage of making clear that the main moral problems to be examined are the following:

1. Whether such a service is morally permissible or not.
2. Granted that the practice is permitted, at which conditions it is.

One way to test our reflective intuitions about the practice is to compare it with time-honored wet nursing, which was the help provided by a woman who had milk to another woman, the mother, who was without milk or did not want to breastfeed in order to make possible that the newborn will survive and grow up. Without such a help, the newborn would have died in a short time, which is practically equivalent to saying that it had never come into the world. Wet nursing was a help provided *after birth*, while pregnancy for others is a help provided *before birth* to make it possible that a newborn can come into the world. If it is positive that a new person comes into existence and continues to live, then both practices are *prima facie* morally good.

The clause “*prima facie*” is to be considered, because it signals that such practices are good at first sight or *ceteris paribus*, i.e., other things being equal, but sometimes in specific circumstances, other things *are not* equal, and therefore to a more careful inspection, the action may be morally wrong. So the analogy with wet nurses shows only that in itself, surrogacy is not morally wrong, but in some circumstances, it may be morally reprehensible. Here I cannot examine all the various circumstances, but one point appears to be clear: when pregnancy for others is completed for merely altruistic reasons and without financial compensation, the practice is judged morally good and also commendable. This means that circulation of money is the disruptive element, which may justify the negative judgment.

On this issue one remark is due: in the past wet nurses were usually rather well paid and had a remarkable place in the family, while nowadays surrogate women have to disappear immediately, and many claim that they are poorly compensated and grossly exploited. This is not the place to consider all these details, but it is enough for us to observe that the issue of “exploitation” (without any gender discrimination) belongs to the ethics of economics and labor, and it should be considered under that class. We can acknowledge that there are problems, and serious ones, because people are always ready to take advantage of others. This, however, is a more general problem of social justice which has little to do with the ethical evaluation of the specific issue concerning whether or not surrogacy is *prima facie* morally good. It is important to note that I am saying “*prima facie* morally good”, where *prima facie* means “at a first sight” or “at a first consideration” assuming that there may be “a second one” (that could be heavier). Other issues remain open in the matter, as the social and legal questions connected to the

relationship with the child. Ethics is focused on justice and beneficence and evaluate human actions and their consequences from this viewpoint. Empirical data are to be acquired in order to establish if the new practice meets the ethical criteria. But of course we need at least a “*prima facie* evaluation” to start the new practice and see how it can work. This holds also for other new situations, such as lesbians having children through donor insemination or gays having them through surrogacy. In this latter case one crucial point is about reciprocal relationship between the surrogate and the newborn: it is not clear if the *psychological* bond with the child is stronger or more intense in the case of surrogacy or in that of wet-nursing. More experience seems to be needed before we can take a final stand and give a definitive *moral* evaluation.

A final point is to be considered. If our analysis is correct, then pregnancy for others is *prima facie* morally permissible, and this holds for everyone independently of one’s sexual orientation. It may be that surrogacy will become a practice analogous to wet nursing, even if we’ll have to consider the influence of possible new knowledge concerning the pre-natal development of the child. This new control on reproduction will bring to the fore the difference between *bringing someone into the world* (pregnancy) and *raising him* (education) and the issue of who is fitted to do it or more fitted to accomplish the specific task. Up to now the two functions have been unified but it could be that in the future it is good for the child (as well as for the women involved) that the two functions will be distinct. Problems of this sort are so far too complex to be considered here and in any case they would require a specific study. However, it was opportune to mention them because they may become prominent in the future.

## Notes on the Issue of the Moral Duties toward the Embryo

This is an immense issue, and here I can say only very little in order to orient the mind in the proper direction. As we have seen, in the Hippocratic tradition, medicine is “assistance to nature’s goals of the human body” which are self-maintenance of the individual and of the species. Sexuality is primarily devoted to preserve the species, and medicine as therapy has to be helpful in the transmission of human life from one generation to the other. In this sense, any action against reproductive teleology was seen as worse than action against single individuals, because they endangered the species. In this sense all the so-called “sexual deviations” were punished most severely. In the last decades, the Western culture entered in a sort of “new world” in which sexuality is regulated by a new paradigm, and it is difficult for us to understand the deep sense of repugnance for any action classified as “against nature” and why such violations were even more heinous than violence against people.

In this respect, one crucial change is found in the fact that in the West, sexuality among consenting adults has finished to be considered a “private affair” which is relevant only for the involved individuals. In this sense sexuality has become a matter of private taste and has lost its public dimension. In the past, sexuality was “public” in the sense of serving that non-private function which is the permanence of

the group. For this reason, anything connected with reproduction appeared to be more precious than any individual (or private) matter. Other aspects reinforced this attitude, such as the fact that the reproductive functions were circumvented by an aura of mystery that supported the view that reproduction was a holy or sacred field.

This more general perspective was translated in institutional terms into the idea that marriage was the great institution in charge of the transmission of human life. Any violation of marital bonds was considered a serious crime, even more serious than private violence. This view is compatible with Hippocratism that acknowledges the natural teleology of the reproductive functions and aims at “therapy” which is the aid provided to any life’s process in troubles. But of course, Hippocratism is very much against any action aiming at interfering or at preventing the natural finalism. In this sense, the recent slogan “Abortion is not Health Care” grasps a Hippocratic intuition and is in line with Hippocratism.

Within this paradigm the whole process of life’s transmission is rigorously protected, and the question “When does human life begin?” becomes meaningless: if any interference with the process is strictly forbidden, there is no reason to distinguish a part from another. It is interesting to note that according to the Roman Catholic Church, the techniques of artificial human procreation are to be evaluated in reference to two fundamental values: (i) “the life of the human being called into existence and (ii) the special nature of the transmission of human life in marriage” (Congregation for the Doctrine of the Faith. (1987) *Instruction Donum Vitae* on respect for human life at its origins and for the dignity of procreation, Intro., 4). According to my view, this second value (“the special nature of the transmission of human life in marriage”) is enough to guarantee a general protection to the whole reproductive process, apart from any distinction of stages in prenatal life. As a matter of fact, the Roman Catholic Church never states when “human life begins” which nowadays is equivalent to state when a “human person” is there. In the Catholic paradigm, this latter issue is a philosophical one, and it is explicitly asserted that “the Magisterium has not expressly committed itself to an affirmation of a philosophical nature, but it constantly reaffirms the moral condemnation of any kind of procured abortion” (Ibid. I, 1). This shows that the Catholic prohibition of abortion is independent of the problem of whether or not it is a form of “killing a person” and goes back to a form of Hippocratic perspective.

This is an interesting result because most Roman Catholics think that the real value at stake is the first one, i.e., that concerning “the life of the human being called into existence.” On the contrary, this value is not relevant at all because no answer is provided to the question (when does a person begin?) that is at the basis of such a value. I am well aware that a huge controversy opens up at this point and that I cannot here discuss the details. I can only say that the first value as well as its basic question (when does a person begin?) becomes meaningful only in a social and cultural context where the value of marriage has already faded away. In order to defend the same prohibition in the new cultural context, a new argument had to be presented. Here is the source of the idea that any destruction of embryonic life is already a form of homicide. There is no scientific or rational support for such a thesis, but it appears persuasive to many people already accustomed to the traditional

prohibition and willing to reaffirm it. These few remarks are suggested as a basis of a new rethinking of the issue concerning the value of the human embryo.

---

## Conditions Connected to Sexuality as Self-Realization

So far we have examined the problems connected to sexuality as mating, which are connected to reproduction and have always been in the center of medical attention, whose goal was to help mating. Now that the ability to split sexuality from reproduction has tremendously increased, we can turn to other problems of sexuality as creative self-realization and to its problems. This part is new and had hardly any tradition in the past.

### Erectile Dysfunction

According to a standard medical definition, impotence is the inability to achieve or maintain an erection long enough to engage in sexual intercourse. There are several causes for such a dysfunction which form a part of the clinical workup. From the point of view of a critical ethics, we want to understand which are the reasons that justify such clinical interventions.

A lot of attention was devoted to erectile dysfunction as a cause of infertility, when sexual intercourse was the only way to have children. However, thanks to assisted reproduction, this problem can now be overcome, and a man can have children even if impotent. This means that nowadays erectile dysfunction has to be treated mainly in order to allow a man's self-realization and couple's strengthening. It is well known that sexuality can be a strong resource for bringing a couple together: if the partners undertake sexuality by autonomous choice, this is ethically positive because it increases human welfare and self-realization. Moreover, impotency is a source of depression as well as of a sense of frustration, and the possibility of overcoming such a condition is a most beneficent action. Only people supporting old taboos can think that effective treatment of erectile dysfunction is evil and perverted. There are no reasons at all to limit therapies against erectile dysfunctions in order to extend as much as possible the chances to entertain sexuality as self-realization (splitted from reproduction). This is one of the main arguments in favor of sexual rights, which are valid claims to have the opportunity to enjoy "sexual health" understood as the ability to start and to continue sexual activities between consenting partners when the subjects choose to do it.

In this sense the advent of the *sildenafil citrate* known under the brand name *Viagra* is certainly an outstanding achievement of medical research. Approved by the FDA on March 27, 1998, the drug obtained immediate success on the market: an evidence that it accomplished a real positive revolution in the field of sexuality. Before the advent of *Viagra* and similar drugs, men had to resort only to herbs and other ineffective treatment: the result was that the problem was concealed. As soon as an effective treatment was available, the problem emerged and became public, and

we now know that according to a study published in 2007 in the US, “52% of men aged 40–70 experienced some degree of erectile dysfunction (ED), while 10% experienced complete erectile dysfunction.” This shows the social dimension of the treatment and its beneficiality.

Two problems are to be mentioned. The first is whether it is ethical to treat erectile dysfunction in people affected by sexually transmitted diseases (serious and potentially fatal) who can then participate in unsafe sex or whether it is more prudent to deny any treatment in order to prevent the risk. The question is important but in a sense obsolete, because in the last two decades, Viagra was sold mainly throughout Internet, and it is hardly possible to deny the treatment to any person. In any case it must be clear that respect for persons requires that the request of a competent adult patient ought to be complied with, unless there are clear medical contraindications. It is up to the treated person to be responsible and engage in safe sex.

The other problem has a wider social dimension, having to do with aging. We know that age is the most important factor causing erectile dysfunction. If for young people erectile dysfunction can be correctly classified as a disease, some think that such a condition is normal for the old people, and no treatment is due. In one sense it is a normal deficiency of a non-vital function, and for this reason it should be quietly accepted as it is accepted that an 80-year-old man runs slower than a 20-year-old one. Trying to overcome these limits – so the argument runs – is not a therapy but a form of enhancing which is (and should be) outside medicine.

However, once we have abandoned the Hippocratic paradigm, the difference between therapy and enhancement is fuzzy, and in any case, there are no reasons against enhancing sexual capacities. Old people have a right to enjoy sexual life as a form of self-realization, at least as long as they are alert of their choice, are consenting, and are responsible. If this is true, then nursing homes have to be equipped for the new opportunity: this means that they have to provide enough privacy and that their pharmacies should dispense such drugs.

## **Homosexuality, Transexuality, and Intersexuality**

Under this big?? Categories are listed in three different topics because they raise similar moral problems. For the sake of brevity, I take homosexuality as the heading issue, and once the situation is cleared with it, the others will follow in the same line. Homosexuality is here taken as a general class including both gay men, lesbians, and bisexual people: all together represent about 15–20% of the whole population.

If we approach homosexuality from the point of view of critical ethics (as we should), we have to realize that the issue raises no special moral problems, if not that possible treatment of their sexual and reproductive problems deserve some attention and care in order to avoid prejudices, stigma, or other negative attitudes which still prevail in our societies. One consequence of this analysis is that if any person has the right to become a parent, this should apply irrespective of one’s own physical limitations (infertility, aging, etc.) including his/her own sexual orientation. This

means that from the point of view of critical ethics, homosexuals may become parents throughout donor insemination and/or surrogacy.

Some historical remarks can be useful to clarify the issue of homosexuality, since the change of attitude in the field represents one of the major change in morality, if not the most important one, that occurred in the last centuries. It was extremely fast, and for this reason, it may be useful to outline some recent history. Just to have an idea of this rapidity, we can consider that in January 1986 President Bill Clinton signed the Doma (Defense of Marriage Act), a federal law stating that in the USA marriage was only a between a man and a woman. That law was a sort of Maginot Line drawn in defense of heterosexual marriage when arguments against homosexuality appeared to be very weak. A research of the National Opinion Research Center (University of Chicago), performed in 1988, reported that 74.9% of the Americans thought that sex between two people of the same gender was always wrong, and this in a sense was in favor of the Doma. However, only 10 years later, in 1998, that percentage had fallen to 54.6%, and 15 years later (26 of June 2013) the Supreme Court decided that equality of all citizens against the law requires that marriage is not limited to heterosexuals. In about a quarter of a century, the Doma-line disappeared, making it clear that at least in the American society the attitude toward homosexuality had changed.

This result is of course the consequence of many factors, and a main one is the new approach to sexuality that took place in our age. For centuries sexuality was considered primarily as mating, and homosexuality was classified as a sin and a crime, and transsexuality and intersexuality hardly were acknowledged, if not included in the category of "monster." Starting from the end of nineteenth century up to almost three quarters of the twentieth century, homosexuality was considered a psychiatric disorder or a state of immaturity (as Sigmund Freud thought), which had to be cured. In the 1960s the spread of the pill made it possible to split sexuality from reproduction, and in the early 1970s, homosexuality began to be considered by psychiatrists as a "normal state of a minority, something like to be left-handed."

The great leap occurred in 1973 when the American Psychiatric Association decided that homosexuality should not to be classified as a sort of mental illness, and therefore should not be enlisted in the DSM III, the reference book referring all pathologies. Many controversies had been raised for such a decision, and some critics said that it was more "political" than "scientific," and some still say it, since cultural survivals tend to resist for some times. A piece of evidence in favor of that decision is the fact that it was immediately confirmed several times in the following years not only by the same APA but also by the American Psychological Association as well as by many other scientific societies around the world. Of course such a fast change is not easily accepted, and expressions of hostility (to say the least) are still spread in many Western societies, not to speak in other countries (where homosexuality is still a crime punished by death!).

What is wrong in the traditional approach is that the most important point to be considered is not physiology (that sometimes is not clear, as we shall see shortly), but sexual orientation. As stated by the American Psychological Association, sexual orientation is "an enduring pattern of emotional, romantic, and/or sexual attractions



to men, women, or both sexes. Sexual orientation also refers to a person's sense of identity based on those attractions, related behaviors, and membership in a community of others who share those attractions." In this sense sexual orientation can be directed in different directions. "There is no consensus among scientists about the exact reasons that an individual develops" one's own sexual orientation. Even though a lot of research has been done, "no findings have emerged that permit scientists to conclude that sexual orientation is determined by any particular factor or factors. Many think that nature and nurture both play complex roles; *most people experience little or no sense of choice about their sexual orientation*" (my italics).

This last remark is crucial and peculiarly important, because one's sexual orientation is not a frivolous preference but is something profound for one's own existence. To say that homosexuality is "abnormal" or "intrinsically disordered" as some organizations keep saying sounds as a lack of respect, if not offensive. Such expressions are the products of some cultural survivals of sexuality as mating for reproductive reasons, and they stem out of a prejudice that excludes the other dimensions of sexual orientation. We know that prejudices as well as cultural survivals or relicts are hard to be eradicated, but they have no rational legitimacy. From the point of view of critical ethics, we can conclude that the new attention toward homosexuality is a step forward of a civilization which is more respectful of these minorities.

In this sense, as asserted earlier on, there are no peculiar moral problem with homosexuality. Patients with the most different sexual orientations requiring treatment for some sexual illness have to be treated as any other patient, paying more attention to possible problems arising from belonging to a minority normalcy. Possibly, further work has to be done in order to realize a more complete change at social level. This is because sexual orientation is not a characteristic of an isolated individual, but it is "defined in terms of relationships with others. People express their sexual orientation through behaviors with others, including such simple acts as holding hands or kissing. Thus, sexual orientation is closely tied to the intimate personal relationship that meet deeply felt needs for love, attachment, and intimacy. [. . . It] is not merely a personal characteristic within an individual. Rather, one's sexual orientation defines the group of people in which one is likely to find the satisfying and fulfilling romantic relationships that are an essential component of personal identity for many people."

This means that we have to operate in such a way that our society can acquire a more flexible style and be more tolerant toward this sort of minority. This is a very important task, because if from a critical ethics point of view, equality of all persons is sovereign, the folkways of many countries (even Western) are still imbued of hostility and prejudice against homosexuals. For instance, only in December 2016 being the first in the world, Malta banned the so-called "reparative therapy" aimed to change, repress, or eliminate a person's sexual orientation.

A new social atmosphere concerning sexual orientation is of the utmost importance because it will favor the liberation of other minorities such as the transexuals. Much cooperation is needed to reach this goal, and medicine has a significant role therein, because, for instance, the "DSM not only determines how mental disorders

are defined and diagnosed, it impacts on how people see themselves and others.” For this reason in the last edition of DSM-5 (2013), transexuality is no more classified as “gender identity disorders” but as “gender dysphoria” (a kind of distress), to make clear that “gender nonconformity is not in itself a mental disorder.”

Transexual people experience a gender identity that is not coherent with, or is divergent with, the sex assigned to them. Most of the transexuals do want to keep their body and still continue to identify themselves with a different gender, while some transexuals desire to transit to the opposite sex, and they seek medical assistance such as sex surgery and hormone therapy in order to align their body with the sex or gender they identify with.

From the critical ethics viewpoint, this assistance is welcome because medicine is a serving profession promoting people’s welfare and their well-being. Any effort should be done to prevent and avoid stigma that still covers the issue. Prejudice is so thick that transexuality is often kept secret, and it is difficult to have precise data about the number of transexuals. Estimates are quite different and range from 1:200 (0.5%) to 1:50.000 (0.002%), and a reasonable one is about 1:5.000 (0.02%); this group raises problems which are rather delicate and complex – each case deserves peculiar attention and has to be evaluated with the greatest care. This is the strategy to reach the goal of a critical ethics, which is to make it possible that sexuality as self-realization can be fully enjoyed by any transexual.

The last case of this category to be considered is intersexuality, which is the condition of people that “do not fit the typical definition for male or female bodies.” They are about 1:4.000 (0.025%) and at birth have no clear genitalia: therefore their sexual characters have to be assigned through medical assistance. One ethical problem depends on the fact that most legislations in the world require that the sex of the newborn is declared immediately at birth. This compels a quick decision which might be disrespectful of the future identity of the new person. Many troubles and suffering have been caused by such immediate decisions, often made out of parents’ urgent need to reach what appears to be a socially accepted solution. Instead of looking for the child’s future self-realization, the decision is often informed to old prejudices and obsolete knowledge. It is ethically commendable the 2013 German law allowing parents not to decide their child’s sex at birth. This will permit to have time to understand better which is the sexual orientation of the child and then to decide the sort of treatment that suits best to the person.

## **Disabled People and Sexuality**

“Disability” is for sure an umbrella term indicating various sorts of impairments, limitations, and restrictions which can concern bodily functions and/or body structures so to limit mobility, communication, learning, and other aspects of individual life. Disability is not in itself a medical problem, even if a stroke can be the cause of subsequent disability which is an existential condition influenced by the interaction between the characteristics of a person’s body and the requirements of one’s society. In Western societies, aging results in disabilities, even if usually we think of

a disabled as someone who has some deficiencies concerning one's movement or intellectual abilities or some bodily deformities so that he/she encounters more difficulties in performing an action or a task. The number of disabled people in this sense is estimated to be about 650 million.

It is another positive leap of our society that in the last decade, new attention has been devoted to the problems of disabled people. A sign of it is the Convention on the Rights of Persons with Disabilities adopted on December 13, 2006, by the United Nations General Assembly. It was opened for signature on March 3, 2007, and went into force on May 2008 after the 20th state ratified it. It was one of the most quickly ratified of all the international human right treaties, and on December 2016, the Convention has been ratified by about 150 states, including European Union, but not the USA. As for the USA, the reason is that the Senate did not reach the required quorum for political divisions; while the Vatican did not sign it because, as declared by Archbishop Celestino Migliore, the Convention includes "terms and phrases regarding family planning services, regulation of fertility and marriage in article 23, as well as the word 'gender,' [...] and most importantly, regarding article 25 on health, and specifically the reference to sexual and reproductive health [...] We oppose[d] the inclusion of such a phrase in this article, because in some countries reproductive health services include abortion" ([http://www.catholicnewsagency.com/news/vatican\\_reemphasizes\\_opposition\\_to\\_u.n.\\_document\\_promoting\\_abortion\\_of\\_babies\\_with\\_disabilities/](http://www.catholicnewsagency.com/news/vatican_reemphasizes_opposition_to_u.n._document_promoting_abortion_of_babies_with_disabilities/)).

This is not the place to discuss if such a reading of the Convention is adequate or not and if indeed it envisages abortion. For us it is enough to say that it is an important document in favor of the rights of disabled people responding to some basic requirements of a critical ethics, in particular those stressing that "persons with disabilities have the right to the enjoyment of the highest attainable standard of health [...] and] to health services that are gender-sensitive" and that States Parties shall provide them "with the same range, quality and standard of free or affordable health care and programmes as provided to other persons, including the area of sexual and reproductive health and population-based public health programmes." It is doubtful whether or not these words imply the access to abortion, but in any case, it is clear that Art. 25 stresses the importance of "sexual health."

This is against the cultural background that permeates most of our received opinion on the issue of disabled people's sexuality. The idea that sex is connected primarily with reproduction (sexuality as mating) conjoined with the idea that some disabilities restrict the disabled from having children leads to the conclusion that disabled people do not have any sexual life. In our culture, people with disabilities are perceived and prospected as eternal children needing help and care. In this sense they are seen as asexual, and as we do with children, often we relate with them according to the well-known policy: "don't ask don't tell." In this way we often marginalize them and even do not imagine that disabled people can have sex and enjoy sex.

Having realized how important sexuality as self-realization is for people, we have to develop a new attitude toward sexuality of people with disabilities. Medicine can provide a great contribution not only to promote a new culture open to this

perspective but also to enact effective treatments for the welfare of the disabled people. Medicine is a serving profession and ought to do it, because self-realization of people with disabilities is too important to be subordinated to old prejudices. This holds also with possible parenthood, because disabled people are not to be discriminated in any sense, and their desires for children are to be considered on the par with analogous desires of any other persons. As alluded earlier to, the pressing problem is about the criteria of parenthood, a topic which has to be examined separately.

### **Prisons and Chemical Castration (Neutering)**

The last remark regarding sexuality as self-realization is about what medicine can do with people that are in prison because they breached the law. Modern principles of criminal law state that the goal of imprisonment is neither retaliation nor retribution of pain, but it is prevention of crime's repetition and possibly rehabilitation and education of the criminal. To that end a person is put to jail, and the punishment consists in deprivation of freedom. Infliction of further pain is unnecessary and morally wrong. It would be wrong, for instance, to keep prisoners in starvation or to give them food of poor quality or again to lodge them in cold/hot conditions. Such a treatment is not proper punishment, but would be a form of cruelty, because deprivation of freedom in itself is already very painful. A number of scholars even think that such a restriction is so painful that also life imprisonment is indeed cruel. For this reason prisons should be humane locations, having enough space for adequate physical exercises and other normal comforts of modern life: magazines and books, as well as television, etc., associated with adequate food and shelter. We know very well that unfortunately the real situation of the world is quite different and that traditional ideas concerning retaliation are still strong enough, and often prisoners live in inhumane conditions. However, from the point of view of critical ethics, we should look for the best and be able to set an ideal to be approached in due time.

Granted that a person is punished by restricting his/her freedom of movement and no further infliction of pain is justified, the prisoner may claim that as it is morally wrong to deprive him/her of good food, it is equally wrong to deprive him/her of the exercise one's sexuality in both forms that above we have distinguished. First, a prisoner may claim to have sexual life in order to have children (sexuality as mating) even if he/she is in prison. In a few cases, some courts gave an answer by suggesting recourse to assisted reproduction, and children are born accordingly. Evaluations of such solutions would be too complex and require specific studies. Here we can only say that the question is to be examined in the light of general criteria for responsible parenthood, an issue which should receive more attention as we tried to remark.

Second, a prisoner may claim to have sexual life in prison for one's own self-realization. Often people in jail are young individuals with strong sexual drives, and their claim cannot be easily dismissed. Once again, this is a new issue, which raises lots of problems even connected with security. Sexual life requires intimacy as well as privacy, and these characteristics may be used to put security at risk. However, the

problem is there and will have to be considered: possibly new architectural structures will have to be envisioned. In this process medicine is not a first actor that is directly involved, but doctors will have to provide knowledge to make society alert of the problem and treatment to cure possible impairments if they will occur.

A quite special problem is that of people who are in prison because of sexual abuse: a class including notably pedophiles and rapists. This sort of crimes outrage public opinion, and they appear so heinous and revolting to raise strong and sometimes violent reactions as well as callings for the most severe punishments. As a matter of fact, many legislations envisage severe punishment for it. However, for historical reasons connected to sex taboos, most of these crimes remain secret, and according to the US Department of Justice, only 30% of all types of sexual assaults are reported (including those where children are victims). This means that our knowledge of the questions involved is quite limited, and therefore our remarks are incomplete and provisional.

Apart from public protests and commonsense opinions, some of these cases raise serious problems because it is doubtful whether rapists and pedophiles are “free” enough to say that their actions are “voluntary.” Some scholars think that they act under the pressure of an overwhelming urge which is out of control. What they do is certainly wicked, and they have to be prevented from repeating it. But these cases are dilemmatic, because they appear analogous to kleptomania, the irresistible urge to steal (usually something which is unnecessary and of little value). In our affluent societies, kleptomania does not appear so heinous, and most legislations do not punish kleptomaniacs, but acknowledge that it is a psychological or psychiatric disorder to be treated. However, in the past they had been severely oppressed, and some scholars hold that something analogous now occurs with rapists and pedophiles. In this sense, they say that it is wrong to punish them and that they deserve forms of medical treatment as well. The so-called “chemical castration” appears to be a welcome solution. It is a treatment targeted to drug delivery that reduces the testosterone levels and therefore the sexual drive of potential sex abusers. Moreover, it has the advantage of being non-invasive and reversible: for this many think it is an adequate solution. So a psychiatrist dispensing Lupron says that “it reduces the sex drive and mitigates deviant desires; while the feelings remain, they’re less obsessive.” For this reason, the patients “prefer shots of medication to feeling uninvited urges and, in their own words, “living in a dark place.”

This train of thinking appears convincing to many people, and in fact some countries have changed their legislation to include chemical castration: Argentina, Australia, Estonia, Israel, Moldova, New Zealand, Poland, and Russia as well as some states of the USA adopted it, and others such as India and Indonesia are going to have new laws. However, it is not clear how this treatment is to be administered. One reason is that it is not even clear that such a treatment works and is effective. Moreover, if chemical castration is mandatory, it would be at least equivalent to surgical castration and would result to be a violation of human rights because it inflicts a permanent amputation of the body. In a sense it would be similar to the cutting of the hand of a thief, which is a barbaric practice. Forced chemical castration could be even worse than surgical castration, since it may have permanent

undesirable side effects of the health of sex offender: Amnesty International declared that forced chemical castration is an “inhuman treatment.”

On the other hand, if chemical castration is an option that the sex offender may ask to have a reduction of his punishment, then one can say that such a choice is not itself “free,” but it is adopted for strategic reasons to diminish the length of imprisonment. Moreover, questions remain concerning its real effectiveness. As we hinted above, our knowledge of the problem is incomplete, and many scholars doubt that it is effective. They observe that there are many kinds of sex offenders, and it is doubtful that one and the same practice is apt to solve all the problems. Possibly chemical castration may be properly administrated in some specific and extreme uncoercible case, but we have to be very careful not to generalize. As it is wrong to think that every thief is affected by kleptomania, so it would be wrong to say that chemical castration is the universal solution for any sex offense. We need to get more adequate knowledge before taking a stand: this is a case in which critical ethics faces an unescapable dilemma which might be solved by new and more detailed medical information.

---

## A Short Conclusion

Not all the problems concerning our topic have been examined, and the analysis of those I have considered may not be complete: the goal of this analysis was neither completeness nor any definitive statement, but only to provide some hints for further reflection. Ethics is not flattened on the received opinions of our own cultural tradition but requires critical thinking informed to the best knowledge available and adequate values which are to be kept together in a coherent frame. This is neither an easy job, and to do it is to adopt a critical ethics, whose internal coherence may lead us to enter into new ways and to reach unforeseen conclusions. In this essay I presented some results deriving from the point of view of a critical ethicist: I am aware that some of my theses diverge from some received and commonsense opinions, but I claim that I have given the reasons for holding them. If an opponent wants to criticize one of them, he/she has to show that it relies on weak or invalid reasons. Any criticism in this direction is welcome, because analysis of reasons is the only way we have to reach more solid ethical conclusions. In this sense critical ethics is similar to science, and science is open to revise its own result. This is what I tried to convey in this contribution.

---

## References

- Congregation for the Doctrine of the Faith. Instruction *Donum Vitae* on respect for human life at its origins and for the dignity of procreation (22 February 1987). AAS. 1987;(1988):70–102. [http://www.vatican.va/roman\\_curia/congregations/cfaith/documents/rc\\_con\\_cfaith\\_doc\\_19870222\\_respect-for-human-life\\_en.html](http://www.vatican.va/roman_curia/congregations/cfaith/documents/rc_con_cfaith_doc_19870222_respect-for-human-life_en.html)

- Congregation for the Doctrine of the Faith. Instruction *Dignitas Personae* on certain bioethical questions (8 September 2008). AAS. 2008;100:858–87. [http://www.vatican.va/roman\\_curia/congregations/](http://www.vatican.va/roman_curia/congregations/)
- Davies MJ, Moore VM, Willson KJ, Van Essen P, Priest K, Scott H. Reproductive technologies and the risk of birth defects. *New England J Med.* 2012;366:1803–13.
- Henningsen AA, Gissler M, Skjaerven R, Bergh C, Tiitinen A, Romundstad LB, Wennerholm UB, Lidegaard O, Nyboe Andersen A, Forman JL, Pinborg A. Trends in perinatal health after assisted reproduction: a Nordic study from the CoNARTaS group. *Hum Reprod.* 2015;30:710–6.
- Ministero della Salute. Tavolo consultivo in materia di tutela e conoscenza della fertilità e prevenzione delle cause di infertilità. Contributo per il Piano Nazionale per la Fertilità, Roma, 27 maggio 2015. [http://www.salute.gov.it/imgs/C\\_17\\_pubblicazioni\\_2367\\_allegato.pdf](http://www.salute.gov.it/imgs/C_17_pubblicazioni_2367_allegato.pdf).
- Pinborg A, Loft A, Aaris Henningsen A-K, Ziebe S. Does assisted reproductive treatment increase the risk of birth defects in the offspring? *Acta Obstet Gynecol Scand.* 2012;91:1245–6.
- Scipio Sighele. *Idee e problemi d'un positivista*. Milano: Remo Sandron; 1899 (2nd edition 1907).
- Wen J, Jie J, Chenyue D, Juncheng D, Yao L, Yankai X, Jiayin L, Zhibin H. Birth defects in children conceived by in vitro fertilization and intracytoplasmic sperm injection: a meta-analysis. *Fertil Steril.* 2012;97:1331–7.

# Index

## A

- Activin, 444
- Adipokines, 930
- Adrenal, 4-binding protein (AD4BP), 176
- Adrenal-gonadal primordium (AGP), 247
- Adrenal hyperplasia, 248
- $\alpha$ -adrenergic receptor blocking agents, 17
- Adreno-gonadal primordium (AGP), 170, 174, 178
- Adriamycin, Bleomycin, Vinblastine, Dacarbazine (ABVD) protocol, 888, 1239
- Adult androgen deficiency, 672–673
- Adult polycystic kidney disease (APKD), 1005
- Age, 923, 924, 934
- Aging gynecomastia, 904
- Air displacement pipettes, 541
- Alcoholism, 847–848
- Alpha fetoprotein (AFP), 908
- 5 alpha reductase, 388
- Anabolic androgenic steroids (AAS), 912
- Anabolic steroids, 354, 368
- Androgen(s), 344, 346, 347, 349, 354–357, 374, 1252
  - abuse, 1273–1278
  - AIS (*see* Androgen insensitivity syndrome (AIS))
  - aspect of, 367
  - classification and definition, 1253
  - CYP17A1, 359
  - effects on bone, 376–379
  - HSD3B2, 359
  - HSD17B3, 360
  - levels throughout lifespan, 376
  - misuse, 1262–1272
  - pharmacological treatment, 1262
  - post-translational effect of, 368
  - replacement vs. pharmacological androgen treatment, 1262
  - resistance, 655
  - role of, 774
  - SRD5A2, 360–361
  - StAR and CYP11A1, 358
  - treatment and status, 1263
  - use, 1255–1262
- Androgen binding protein (ABP), 1119
- Androgen deficiency, 849, 855, 894–895
  - bioavailable testosterone, 680
  - clinical manifestations, 670–673
  - gonadotrophins, 681–682
  - history and physical examination, 673–674
  - measurement of free testosterone, 678–679
  - measurement of total testosterone, 676–677
  - salivary testosterone, 679
  - testosterone variability, 674–675
- Androgen insensitivity syndrome (AIS), 774
  - androgen receptor, 776–781
  - complete androgen insensitivity syndrome, 782–783
  - diagnosis of, 783–784
  - differential diagnosis, 784–785
  - endocrine profile, 785
  - historical aspects, 776
  - hormone replacement, fertility and bone mineral density, 788–789
  - partial androgen insensitivity syndrome, 783
  - treatment, 785–788
- Androgen receptor (AR), 255, 323, 326, 354, 463
  - coregulators, 405–407
  - enhancer RNA, 407
  - gene, 525
  - gene protein, 396–399
  - nongenomic, 402
  - post-translational modifications, 407–409
  - target genes, 402–403
  - transcription factors, 404



- Androgen receptor (AR) (*cont.*)  
 transcription, mediated regulations, 400
- Androgen response elements (AREs), 400, 401
- Androstenedione, 253, 254, 258
- Antegrade sclerotherapy, 1136
- Anti-androgens, 911, 1201–1202  
 cyproterone acetate, 1202–1204  
 GnRH agonists, 1204  
 spironolactone, 1205–1206
- Antiestrogens, 1080
- Anti-Müllerian hormone (AMH), 188,  
 260–261, 504, 511
- Anti-sperm antibody(ies), 543, 1053,  
 1065–1066
- Anxiety, 1295
- Apocrine secretion, 461
- Aromatase, 374, 376, 378, 381, 384,  
 385, 388  
 deficiency, 808, 810, 811, 813, 814  
 inhibitors, 1080
- Array-comparative genomic hybridization  
 (array-CGH), 528
- Assisted reproduction, 1292, 1309.  
*See also* Intrauterine insemination;  
 In-vitro fertilization (IVF)  
 aims, 1147  
 total mobile sperm count, 1148
- Assisted reproduction technology (ART), 551,  
 1131–1132, 1333
- Autosomal structural anomalies, 522
- Azoospermia, 625, 630, 1158
- Azoospermia factor (AZF), deletions  
 classical, 1037–1039  
 partial, 1039–1040  
 structural aberrations, Y chromosome, 1040
- B**
- BEACOPP protocol, 1239
- Beta-catenin ( $\beta$ -catenin/CTNNB1), 183, 196
- 17 $\beta$ -hydroxysteroid dehydrogenase, 256
- 3 $\beta$ -hydroxysteroid dehydrogenase type,  
 2 (3 $\beta$ -HSD2), 256
- $\beta$ -thalassemia, 997
- Bilateral ejaculatory duct obstruction  
 (BEDO), 1005
- Bioavailable testosterone, 680
- Biomarkers, 891–892
- Biosimilar drugs, 1081
- Bipotential gonad, 274–275
- Blepharophimosis/ptosis/epicanthus inversus  
 syndrome (BPES), 196
- Blood testicular barrier (BTB), 1119
- C**
- Calcifications, 581
- Campomelic dysplasia (CD), 192
- Capacitation, 1150
- Carcinoma in situ (CIS), 625, 627
- CBAVD. *See* Congenital absence of the vas  
 deference (CBAVD)
- Cbp/p300-interacting transactivator, with  
 Glu/Asp-rich carboxy-terminal  
 domain 2 (CITED2), 178
- Celiac disease, 656
- CFTR mutation screening, 526–527
- CFTR. *See* Cystic fibrosis transmembrane  
 conductance regulator (CFTR)
- Chemotactic gradient, 171
- Childhood cancer survivors (CCS), 888,  
 890, 891
- Chorionic gonadotropin hormone (CG), 73,  
 77, 80–83
- Chromatin  
 androgen-induced change, 400  
 immunoprecipitation (ChIP), 400  
 looping, 407  
 remodeling, 405
- Chromobox 2 (CBX2), 178–180
- Chromosomal aberrations, 1032–1033  
 Klinefelter syndrome, 1033–1035  
 structural aberrations, 1040  
 submicroscopic chromosomal aberrations,  
 1040–1041  
 XX-male syndrome, 1035–1036  
 XYY syndrome, 1036–1037
- Chromosomal sex determination  
 evolutionarily conserved aspects, 187–188  
 in mammals (XX/XY system), 185  
 mechanisms, 184–187  
 role, 183–184
- Chronic disease, 837–839
- Chronic hypoxia, 840
- Chronic obstructive pulmonary disease  
 (COPD), 839–841
- Chronic renal failure (CRF), 996
- Chronic viral hepatitis, 846–847
- Classification, hypogonadism  
 age of onset, 658–662  
 localization/cause, 648–656  
 testicular function, 656–658
- Clomiphene, 1080
- Color-coded duplex ultrasonography  
 (CDU), 1122
- Color-Doppler ultrasound  
 clinical utility, 601–604  
 in pathological conditions, 568

- prostate-vesicular region, 566–568  
 scrotal region, 558
- Comorbidities, LOH. *See* Late onset hypogonadism (LOH)
- Complementary sex determiner (Csd), 187
- Condoms, 1215
- Congenital absence of the vas deference (CBAVD), 1041–1042
- Congenital adrenal hyperplasia (CAH), 998
- Congenital adrenal hypoplasia, 654
- Congenital bilateral absence of vas deferens (CBAVD), 467, 1002–1003
- Congenital hypogonadotropic hypogonadism (CHH), 524, 983, 1031, 1042–1045
- Congenital unilateral absence of VD (CUAVD), 1003
- Constitutional delay of growth and puberty (CDGP), 751, 767–768
- Constitutional delay of puberty (CDP), 650
- Contraception, 470
- Contrast enhanced ultrasonography (CEUS), 604–605
- Conventional semen analysis, 1123
- Coregulators, AR, 400
- Corifollitropin alfa, 1081
- Corticotropin releasing factor (CRH), 260
- Craniopharyngioma, 984
- Critical and chronic diseases, 984–985
- Critical ethics, 1323
- Cross-sex hormonal therapy (CHT), 1200, 1201
- Cryopreservation  
 ART patients, 1241–1242  
 autoimmune diseases, 1240  
 description, 1236  
 legal aspects, 1243–1245  
 materials, 1246–1247  
 methods, 1247–1248  
 neoplasia, 1238–1240  
 processing pathway, 1249  
 psychological implications, 1243  
 rules for, 1245  
 spermatogenesis, 1242  
 spinal cord injury, 1241  
 urological pathologies, 1240–1241  
 vasectomy, 1241
- Cryptorchidism, 288–294, 587, 653, 986–988, 1077
- CYP17A1, 348, 349, 359–361
- Cyproterone acetate, 1202
- Cysteine-rich secretory proteins (CRISP), 468
- Cystic fibrosis transmembrane conductance regulator (CFTR), 466, 1041, 1042
- Cytokines, 930
- D**
- Dehydroepiandrosterone (DHEAS), 247
- Delayed puberty, 751, 755, 756  
 causes, 759  
 etiology, 757  
 long-term consequences of, 765–767, 769  
 medical history, 759
- Denys–Drash syndromes, 174
- Desert hedgehog (DHH), 222, 258, 280, 443
- Digital rectal examination (DRE), 958
- 5 $\alpha$ -dihydrotestosterone (DHT), 401
- Dihydrotestosterone (DHT), 253, 344, 349–352, 374, 914  
 and androgen receptor, 354–356  
 non-classical actions of, 356–357  
 and physiologic precursors, 353–354
- Dimethandrolone undecanoate, 1227
- Diplotene primary spermatocytes, 330
- Disorder of sex development (DSD), 258, 273, 303, 774, 776, 785, 788
- DM domain proteins, 180
- DNA adenine methyltransferase identification (DamID), 180
- DNA-binding domain (DBD), 397, 399
- DNA fragmentation index (DFI), 1124, 1132
- Donor insemination, 1334
- Dopamine, 17
- Dopamine receptor agonists, 1079
- Doublesex (dsx), 187
- Doublesex-and MAB-3-related transcription factor, 1 (DMRT1), 186, 230–231, 233
- Down syndrome, 652
- Ductuli efferentes (testis), 336
- E**
- Echo-pattern abnormality of the testis, 569
- Ectoplasmic specializations, 325
- Ejaculate, 536. *See also* Semen analysis
- Ejaculatory duct (paramedian), cysts, 597
- Ejaculatory duct obstruction (EDO), 552, 595, 1005, 1009
- Emotional distress, 1294
- Empty spiracles homeobox 2 (EMX2), 177, 181–182
- Endocrine dysfunction, 1119
- Endogenous T  
 cardiovascular health, 968, 969  
 metabolic parameters, 965, 966  
 mood, 968  
 physical strength and body composition, 963  
 sexual function, 961

- Endothelial cells, 223–224  
 E negative feedback effect, 16  
 Enhancer RNA (eRNA), 407  
 Environmental and maternity factors, sex determination  
   diet, 200–201  
   external factors, 202–203  
   menstrual cycle, 201  
   pre-conception environment (pH), 197–199  
   sex hormones, 201–202  
 Epidemiology, hypogonadism, 661  
 Epidermal growth factor receptor (EGFR), 182  
 Epididymal dysfunction, 1120  
 Epididymal obstruction (EO), 1005  
 Epididymal sperm binding protein 1, 461  
 Epididymis  
   anatomy, 459  
   functions of, 464  
   male contraception, 470  
   proteins secreted by, 462  
   secretion regulation, 462  
   as secretory organ, 460–461  
   spermatozoa, 466  
   sperm storage, 468  
 Epididymosomes, 461  
 Epithelial-to-mesenchymal transition (EMT), 171, 173  
 Eppin, 1228  
 Equilibrium dialysis, 678  
 Erectile dysfunction (ED), 1341  
 Estradiol, 374, 376, 385, 387, 504, 906, 913  
 Estrogen(s), 444, 930  
   male fetus importance, 258  
   resistance, 807, 808, 810, 813, 814  
   signaling, 227, 229–230  
 Estrogen deficiency, 798  
   acquired, 815–820  
   animal models of, 804–806  
   clinical aspects of, 807–815  
   congenital, genetic, 807  
   human, 806–807  
   pathophysiology, 801–804  
 Estrogen receptor- $\beta$  (ER $\beta$ ), 15, 463  
 Estrogens in men, 798  
   physiology of, 799–801  
   role of, 801  
 Ethics, 1321  
   common sense morality, 1322  
   critical ethics, 1323  
   human reproduction, issues of, 1323–1328  
   medical ethics, 1324, 1326, 1327  
   professional ethics, 1323  
 Eunuchoidism, 670  
 External quality assessment, 544, 545  
 Extracellular signal-regulated kinases (ERK), 39, 43, 50  
**F**  
 Familial gynecomastia, 909  
 Fatherhood, 1289–1290, 1293–1294  
 Feedback and feedforward regulation  
   importance, 264–265  
 Feminizing adrenal tumors, 907  
 Fertile eunuch syndrome, 657  
 Fertility  
   impaired, 505  
   male, 504  
 Fetal androgen deficiency, 670  
 Fetal cortex, 256  
 Fetal steroidogenesis, 250–255  
 Fetal testis  
   adrenal cortex, 256–257  
   adrenal steroid, 256  
   androgen roles, 255–256  
   control of endocrine, 263–264  
   development of environmental endocrine disruption, 265–266  
   paracrine and endocrine acting hormones and growth factors, 258–263  
   steroidogenesis, 250  
*Fgf9*, 221  
 FGFR2 nuclear receptor, 277  
 Fibroblast(s), 320  
 Fibroblast growth factor (FGF), 277  
 Fibroblast growth factor 9 (FGF9), 193, 277  
 Fibrous pseudotumor, 593  
 Follicle-stimulating hormone (FSH), 73, 76, 77, 81, 85, 88, 91, 96, 100, 102, 106, 437–438  
   di/oligomerization, 141  
   gene and protein structure, 131  
   inperivascular endothelium, 130  
   ligand-receptor binding, 132  
   promoter, 129  
   signal transduction, 136  
   structure, 124  
   therapy, 951  
 Follistatin, 444  
 Forkhead box A1 (FOXA1), 404–405  
 Forkhead box L2 (FOXL2), 196, 228–231  
 Frailty, 838, 860  
 Frasier syndrome, 191  
 Free hormone hypothesis, 677

**G**

- GABA<sub>A</sub> receptor, 17
- Galactorrhea, 902
- Gamendazole, 1228
- GATA binding protein 4 (GATA4), 171–174, 194
- Gender dysphoria
- anti-androgens (*see* Anti-androgens)
  - description, 1200
  - diagnosis and care, 1200
- Gene mutation screening, 524–528
- Genetic counselling, 525
- Genetic profiling and tailored treatment, 1083–1086
- Genital ridge, 170, 218, 221, 226
- Genital ridge formation and specification factors
- Cbp/p300-interacting transactivator, with Glu/Asp-rich carboxy-terminal domain 2 (CITED2), 178
  - chromobox 2 (CBX2), 178
  - empty spiracles homeobox 2 (EMX2), 181
  - GATA binding protein 4 (GATA4), 171
  - insulin-like growth factor, 1 receptor (IGF1R), 177
  - insulin receptor (INSR), 177–178
  - LIM homeobox protein 9 (LHX9), 180
  - milk fat globule-EGF factor 8 protein (MFGE8), 182
  - nuclear receptor subfamily 5, group A, member 1 (NR5A1), 176–177
  - odd-skipped related 1 (OSR1), 175–176
  - pre B cell leukemia transcription factor1 (Pbx1), 180
  - roof plate-specific spondin (RSPO1), 183
  - sine oculis-related homeobox 1 (SIX), 176
  - Wilm's Tumor 1 (WT1), 174–175
  - wingless-type MMTV integration site family 4 (WNT4), 183
- Germ cell(s), 224–227, 328
- development, 422
  - differentiation, 434–436
  - post-meiotic, 433
  - primordial, 424
  - and Sertoli cells, 429
- Germ cell neoplasia in situ (GCNIS), 625, 627, 635–638
- Germ-line stem cell (GSC), 417
- Glial cell-derived neurotrophic factor (GDNF), 421, 432, 442
- Globozoospermia, 1155, 1157
- Glucocorticoid receptor (GC-R), 20
- Glucocorticoids, 840
- Glucose metabolism, 929–930
- Glutamate, 17
- Glutathione peroxidase, 465
- Glycoprotein hormone (GPH), 73, 93, 96, 98
- Glycoproteins, 73, 83, 86, 96, 99
- Gonadal function, 73
- Gonadal steroid regulation, 14
- Gonadal tumor, 782
- Gonadotoxins, 994–996
- Gonadotrophin receptors (GnRs)
- clinical diagnostics, 148
  - di/oligomerization, 140–142
  - FSHR and LHCGR, 124–128
  - functions, 128–130
  - intracellular fluorescent protein tags, 150
  - ligand-receptor binding, 132–136
  - ligand-specific signal transduction, 127–136
  - localization, 149
  - mutational analysis, 148
  - post-endocytotic trafficking and signaling, 138–140
  - quantification of arrestins, 150
  - receptor mutations, 133–145
  - single-nucleotide polymorphisms, 142–145
  - structure of human gene and proteins, 130–132
  - transgenic models, 150–153
- Gonadotropin(s), 496–499, 509, 1074, 1225
- administration, 1075
  - biological effects, 101–103
  - biosynthesis of, 87–93
  - demand, 1074
  - hypogonadotropic hypogonadism, 1075
  - ormogonadotropic OAT, 1078
  - pharmacokinetics, 98–101
  - processing, 96–97
  - secretion, 97–98
  - structural abnormalities, 104–106
  - structural features, 75–87
  - subunit assembly, 93–96
- Gonadotropin inhibitory hormone (GnIH), 18
- Gonadotropin-releasing hormone (GnRH), 4, 36
- agonists, 1204–1205
  - antagonists, 1222
  - development and migration, 6
  - GnRH-secreting neurons, 6–9
  - gonadotropin inhibitory hormone, 18–19
  - information theoretic approaches, 55–56
  - isoforms, 5
  - Kisspeptin control, 11–13
  - Kisspeptin neurons, 13
  - KNDy neurons, 13–14
  - neurotransmitters and neuropeptides, 17–18

- Gonadotropin-releasing hormone (GnRH)  
 (*cont.*)  
 pulsatile, 49–55  
 receptor(s), 15, 36  
 extra pituitary, 44–47  
 signaling and gonadotropin secretion, 37  
 trafficking, compartmentalization and desensitization, 42–44  
 signaling and gene expression, 39–42  
 steroid regulation, 14–17  
 test, 499–500
- Gonadotropin therapy  
 fertility, 960  
 metabolic parameters, 966  
 physical strength and body composition, 965  
 sexual function, 962
- Gonads, 218–220, 227, 235. *See also* Ovary; Testis
- Gonad specification  
 bipotential gonadal primordium origin, 194–195  
 genital ridge formation and specification factors (*see* Genital ridge formation and specification factors)
- G-protein coupled receptor (GPCR), 18, 261
- G-proteins, 40, 45
- Granulosa cell(s), 227, 228  
 DMRT1 and FOXL2 levels, 227  
 gonads development, 220  
 Sertoli cells transdifferentiation, 229
- Granulosa cell tumors, 907
- gr/gr deletion, 518
- Growth arrest and DNA damage 45 (GADD45), 191–192
- Gynecomastia  
 aging, 904–905  
 causes, 900  
 classification, 901  
 idiopathic, 912  
 neonatal, 902  
 pathologic, 905–910  
 patient evaluation, 912–913  
 patterns of, 901  
 pharmacological, 910–912  
 in prostate cancer, 916  
 pubertal, 904  
 treatment, 914–916
- H**
- Halo cells, 460
- Haplodiploidy sex determination, 187
- Health status, 859–860
- Heart failure, 858
- Heat shock proteins (HSP), 401
- Hedgehogs, 280
- Hepatic steatosis, 845
- Hereditary hemochromatosis hypogonadism, 850–851
- High body mass index, 1292
- Highly active antiretroviral therapy (HAART), 859
- Hodgkin lymphoma, 1239
- Hormonal analysis, 1125
- Hormonal treatment in Klinefelter syndrome, 1083
- Hormone testing, 505–511
- Human, 424, 426, 428, 433, 435, 442
- β-Human chorionic gonadotropin, 505
- Human chorionic gonadotropin (hCG), 948
- Human chorionic gonadotropin (hCG) test, 502
- Human menopausal gonadotropin (hMG), 952, 1074
- Hyperprolactinemia, 906, 1079
- Hypertension, 857–858
- Hyperthermia, 1119
- Hypogonadism, 670, 882, 890, 894, 904, 913, 1257, 1259  
 and acute illness, 833–837  
 adulthood-onset, 661  
 alcoholism, 847–848  
 cardiovascular diseases, 857–859  
 and chronic illnesses, 837–839  
 chronic kidney disease, 843–844  
 chronic viral hepatitis, 846–847  
 clinical diagnosis, 1259  
 clinical features, 1258  
 COPD, 839–841  
 definition, 646  
 drugs causing, 863  
 endocrine and metabolic diseases, 854–857  
 epidemiology, 661–664  
 etiology, 651–653, 657  
 fetal-onset, 660  
 HIV infection, 859–863  
 hypothalamic and pituitary, 650–652  
 International Classification of Diseases (ICD-10), 648, 649  
 iron overload, 850–851  
 late-onset, 661  
 liver cirrhosis, 848–849  
 non-alcoholic fatty liver disease, 845–846  
 OSAS, 842–843  
 pathogenesis, 834–836  
 postnatal-onset, 660  
 puberty-onset, 661

- sarcoidosis, 842  
 testicular, 652–654 (*see also* Androgen deficiency)
- Hypogonadism treatment, 946  
 antiestrogens, 956  
 GnRH therapy, 948  
 gonadotropins, 948  
 outcomes, 959  
 testosterone, 953
- Hypogonadotropic hypogonadism, 648, 663, 837, 846, 848, 850, 852, 982–983, 1075–1078
- Hypospadias, 1010
- Hypothalamic-pituitary-gonadal (HPG) axis, 752–753, 832–833
- I**
- Idiopathic epididymal obstruction, 1005
- Idiopathic infertility, 1001
- Idiopathic oligoasthenoteratospermia (iOAT), 1001, 1078–1079
- Imatinib, 888
- Immotile cilia syndrome (ICS), 547, 1007
- Immune infertility, 1120
- Immunohistochemistry, 631
- Impaired spermatogenesis, 632
- Infection  
 bacterial, 1054  
 protozoan, 1057  
 viral, 1055
- Infertility  
 age and health-related behaviours, 1291–1293  
 anxiety, 1295  
 cancer treatment, 1300–1301  
 causes, 1291  
 male factor, 1299  
 prevalence, 1290  
 psychological factors, 1301–1312  
 psychological reactions for diagnosis, 1294
- Infertility men's experiences in low and middle income countries, 1297–1298
- Inflammation, 1052, 1053, 1066
- Inhibin, 444
- Inhibin B, 503, 510
- Inhibins and activins, 261
- Inhibitor of testosterone synthesis, 1227
- Insensitivity, androgen. *See* Androgen insensitivity syndrome (AIS)
- INSL3. *See* Insulin-like peptide 3 (INSL3)
- Insulin-like 3 (INSL3), 282, 284
- Insulin-like growth factor 1 (IGF1), 259
- Insulin-like growth factor 1 receptor (IGF1R), 177
- Insulin-like peptide 3 (INSL3), 262–263
- Insulin receptor (INSR), 177
- Internal quality control, 544, 545
- Intracytoplasmic sperm injection (ICSI), 891, 892, 1178–1179
- Intracytoplasmic morphologically selected sperm injection (IMSI), 1157
- Intra-cytoplasmic sperm injection (ICSI), 1328  
 advantage of, 1334  
 azoospermia, 1158–1161  
 cost-effectiveness, 1164  
 indications, 1155–1158  
 and IVF, 1154  
 medical objection to, 1332–1334  
 moral paradigms on assisted reproduction, 1329–1332  
 outcomes after, 1161–1162
- Intraprostatic cysts, 596
- Intratesticular testosterone (ITT), 438
- Intrauterine insemination, 1305  
 cost-effectiveness, 1164  
 description, 1149  
 immobilization after, 1151–1152  
 single/double, 1150–1151  
 sperm preparation, 1149–1150
- In-vitro fertilization (IVF)  
 cost-effectiveness, 1164–1166  
 indications, 1156  
 and intra-cytoplasmic sperm injection, 1153–1155  
 and oocyte donation programs, 1153
- Iron overload  
 hereditary hemochromatosis, 850–851  
 thalassemia, 852–853
- Isolated hypogonadotropic hypogonadism (IHH), 982–983
- K**
- Kallmann syndrome (KAS), 650, 705, 707, 710, 1043, 1044
- Karyotype analysis, 519
- Ki-67 expression, 330
- Kisspeptin  
 central control, 11  
 neurons, 13
- KIT, 434, 440
- Klinefelter syndrome (KS), 190, 520–521, 626, 906, 991–992, 1033, 1083  
 aetiology, 722  
 clinical manifestation, 722

- Klinefelter syndrome (KS) (*cont.*)  
  diagnosis, 723  
  pathophysiology, 722  
KNDy neurons, 14
- L**  
Lamina propria, 322  
Laparoscopic varicocelectomy, 1136  
Late onset hypogonadism (LOH), 647  
  adipokines and cytokines, 930  
  definition and epidemiology, 924–927  
  epidemiological studies, evidence, 927–929  
  estrogens, 930–931  
  glucose metabolism, 929  
  low testosterone and mortality, 936–937  
  obesity-related secondary hypogonadism, 931  
  sexual behavior, 931  
  sexual symptoms, 933–936  
Law, 1321, 1330, 1335, 1342, 1344  
Leptin, 18, 855  
Leydig cell(s), 224–225, 275, 282–283, 319,  
  654, 1119, 1120, 1125  
Leydig cell tumors, 907  
Ligand-binding domain (LBD), 397, 399  
LIM homeobox protein 9 (LHX9), 178, 180  
Lipocalin-type Ptgds (L-Ptgds), 194  
Liquefaction, 550  
Liquid chromatography-tandem mass  
  spectroscopy (LC-MS), 676  
Luteinizing hormone (LH), 73, 76, 80, 82, 85,  
  88, 91, 95, 97, 98, 100, 102, 104,  
  106, 436, 438–440  
Luteinizing hormone (LH)/chorionic  
  gonadotrophin (CG) receptor  
  (LHCGR)  
  di/oligomerization, 141  
  gene and protein structure, 131  
  ligand-receptor binding, 132  
  physiological function, 130  
  promoter, 129  
  signal transduction, 136  
  structure, 124, 132  
  in uterus, 130
- M**  
Macroheterogeneity, 84, 85  
Macroorchidism, 568  
Magnetic resonance imaging (MRI), 606–607  
Male abnormal-3 (mab-3), 187  
Male accessory gland infection/inflammation  
  (MAGI), 556, 594
- Male  
  aging, 375  
  breast (*see* Gynecomastia)  
  breast enlargement, 900  
  hypogonadism, 798, 806, 808, 816, 818  
  osteoporosis, 811, 816, 818  
Male contraception  
  condoms, 1215–1216  
  vasectomy, 1215  
Male fertility, cancer treatment  
  chemotherapy, 886–889  
  impact of disease, 883–884  
  radiation therapy, 885  
  surgical treatment, 884–885  
Male genital tract  
  color-Doppler ultrasound, 558  
  epididymis, vas deferens and seminal  
    vesicles, 558  
  prostate, ureters and kidneys, 558  
  testicular descent, 557  
  testis and epididymal head, 557  
Male hormonal contraception  
  adverse effects, 1224  
  mechanism of action, 1216  
  oral testosterone, 1223  
  potential acceptability, 1225  
  synthetic androgens, 1226  
  testosterone-alone efficacy studies,  
    1216–1220  
  testosterone plus gonadotropin-releasing  
    hormone antagonists, 1222–1223  
  testosterone plus progestin, 1220–1222  
  testosterone subdermal implants, 1224  
  transdermal testosterone patch systems,  
    1223–1224  
Male infertility, 587, 593, 595, 601, 1030, 1146,  
  1157, 1158  
  alcoholism, 997–998  
  autoimmunity, 1064–1066  
  bacterial infection, 1054–1055  
  CAH, 998  
  chromosomal aberrations  
    (*see* Chromosomal aberrations)  
  chronic gastrointestinal diseases, 998  
  chronic renal failure, 996  
  classification, 1147  
  cryptorchidism, 986  
  fever, 998–999  
  genetic causes, 1030  
  gonadotoxins, 995  
  hematological diseases, 997  
  human immunodeficiency virus  
    infection, 999

- hypogonadotropic hypogonadism, 982
- hypospadias, 1010
- idiopathic infertility, 1001
- immotile cilia syndrome/primary ciliary dyskinesia syndrome, 1007
- immunologic infertility, 1008
- Klinefelter's syndrome, 992
- liver failure, 997
- male reproductive tract obstruction, 1002–1006
- maturation defects, 1007–1008
- myotonic dystrophy, 990
- non-hormonal medical treatment (see Non-hormonal medical treatment, male infertility)
- Noonan syndrome, 988–989
- obesity, 1000
- oncological diseases, 999
- orchitis, 1000, 1061
- pituitary diseases, 984–985
- prostatitis, 1063
- protozoan infection, 1057
- SCO, 994
- sexual dysfunction, 1009–1010
- single-gene defects, 1041–1048
- testicular torsion, 1000–1001
- trauma, 1001
- urethritis, 1064
- vanishing testis syndrome, 989
- varicocele, 985
- viral infection, 1055–1057
- 46, XX testicular disorders of sex development, 990–991
- 47, XYY syndrome, 991
- Y-chromosomal deletions, 1037–1040
- Y chromosome microdeletions, 992–993
- Male reproductive disorders, ethical aspects, 1338–1340
  - donor insemination, 1334
  - erectile dysfunction, 1340–1341
  - ICSI, 1329
  - male infertility and assisted reproduction, 1328
- Male sexual determination
  - DMRT1, role of, 231
  - estrogen signaling, 227
  - foxl2, role of, 228
  - germ cell differentiation, 225
  - granulosa-to-Sertoli cell mechanisms, 229, 233
  - Leydig cell, 224
  - Sertoli cells, 220–221
  - sexual differentiation, 227
  - SOX9, role of, 232
  - testis cords (see Testis cords)
  - testis development and function, 218–220
- Mammalian ovarian sex determination genes
  - forkhead box L2 (Foxl2), 196
  - nuclear receptor subfamily 0, group B, member 1 (Nr0b1/Dax1), 196–197
  - wingless-type MMTV integration site family 4 (WNT4), 195–196
- Mammalian testicular sex determination genes
  - fibroblast growth factor 9 (Fgf9), 193
  - prostaglandin D2 synthase (Ptgds), 194
  - sex determining region of chromosome Y (Sry), 190
  - sex determining region of chromosome Y (Sry)-box 9 (Sox9), 192
  - zinc finger protein, multitype 2 (Zfp2/Fog2), 194
- Mammography (MMG), 913
- Medical ethics, 1324, 1326
- Medical history, 482–484
- Megalotestes, 568
- Meiosis, 329, 331
- Mental health, 1293
- Metabolic syndrome, 854–856
- 7 $\alpha$ -methyl-19-nortestosterone (MeNT), 1226
- Microheterogeneity, 84, 87
- Microolithiasis, 627
- Microsurgical epididymal sperm aspiration (MESA), 1186
- Microsurgical subinguinal varicocelectomy, 1133
- Microsurgical testicular sperm extraction, 1186
- MicroTESE, 1242
- Milk fat globule-EGF factor 8 protein (MFGE8), 182–183
- Minimal androgen insensitivity syndrome (MAIS), 655
- miRNAs, 463
- Mitogen-activated protein kinase (MAP3K4), 191–192
- Mitogen-activated protein kinase (MAPK), 39, 43
- Modified Ivanissevich technique, 1134
- Modified Palomo technique, 1135
- Morphology, sperm, 542
- Mortality, 936
- Motility, 540, 543, 547
- Multimorbidity, 838, 860
- Mustargen, Oncovin, Procarbazine, Prednisone (MOPP), 888
- Myotonic dystrophy, 990



**N**

- Natriuretic peptides, 262
- Neonatal gynecomastia, 902
- Neuropeptide Y (NPY), 18
- Neurotransmitters, 17
- Neurotrophin, 280
- Next generation sequencing (NGS), male infertility, 528
- N-methyl-D-aspartate (NMDA), receptors, 17
- Non-alcoholic fatty liver disease (NAFLD), 845–846
- Non-Hodgkin lymphoma, 1239
- Non-hormonal contraceptives, 1228
- Non-hormonal medical treatment, male infertility
  - antibiotics and sperm toxicity, 1095
  - antioxidants, 1099–1107
  - $\beta$ -lactam antibiotics, 1094–1095
  - empirical treatment, 1096–1098
  - eradication rate, 1095
  - macrolides, 1094
  - non-steroidal anti-inflammatory drugs, 1098–1099
  - quinolones, 1093
  - rational treatment, 1092
  - steroidal anti-inflammatory drugs, 1099
  - tetracyclines, 1094
  - trimethoprim, 1093–1094
- Non-obstructive azoospermia (NOA), 1129
- Noonan syndrome (NS), 653, 988
- Norepinephrine, 17
- N-terminal-activating domain (NTD), 397–399
- Nuclear factor of activated T cells (NFAT), 50–57
- Nuclear receptor subfamily 5, group A, member 1 (NR5A1), 176
- Nursery cells. *See* Sertoli cells

**O**

- Obesity, 929, 931
- Obstructive sleep apnea syndrome (OSAS), 842–843
- Odd-skipped related, 1 (OSR1), 175
- Oligoasthenoatozoospermia, 1242
- Oligozoospermia, 1226
- Open epididymal fine-needle aspiration, 1184
- Opioids, 17
- Orchitis, 582, 999–1000
- Ovary, 220, 227, 230–231
- Overweight and obesity, 854–856
- Oxidative stress, 1119

**P**

- Pachytene spermatocytes, 435
- Parenthood, 1334–1336
- Paternal age, 1152–1153
- Pathologic gynecomastia
  - absolute estrogen excess, 906–907
  - androgen deficiency, 904–906
  - estrogen-secreting tumors, 907
  - familial gynecomastia, 909
  - growth hormone and IGF-I excess, 909
  - hyperprolactinemia, 906
  - leptin, 909
  - non-estrogen-secreting tumors, 908
  - obesity, 908
  - thyroid disorders, 908
- PCR-pipettes, 541
- Percutaneous epididymal sperm aspiration (PESA), 1183
- Peri-renal position, 255
- Peritubular cells (PTC), 322
- Peritubular myoid (PTM) cells, 223, 422, 438
- Peutz–Jeghers syndrome, 907
- Phospholipase C, 37
- Phosphorylation, 179
- Physical examination
  - andrological, 487
  - auscultation, 487
  - inspection, 486
  - palpation, 487
  - percussion, 487
- Phytoestrogens, 911
- Pioneer factor, 404
- Pituitary adenyllyl cyclase activating polypeptide (PACAP), 261
- Pituitary tumors, 984
- Platelet-derived growth factors (PDGFs), 280
- Platelet-derived growth factor A (PDGF-A), 259
- Polycystic kidney disease, 1005
- Positive predictive value (PPV), 891
- Post-translational modifications (PTMs), 407
- Pre B cell leukemia transcription factor1 (Pbx1), 177, 180–181
- Preimplantation genetic diagnosis (PGD), 1161
- Prepubertal androgen deficiency, 670–672
- Primary hypogonadism, 731
  - alteration of steroidogenesis, 725
  - autoimmune testicular failure, 735
  - congenital anorchia, 729
  - cryptorchidism, 729
  - disorder of sexual development, 726
  - Down syndrome, 731
  - drugs, 733

- gonadotropin receptors, mutations in, 727  
infectious diseases, 732  
Klinefelter syndrome, 722  
myotonic dystrophy, 728  
Noonan syndrome, 730  
sickle-cell disease, 730  
systemic diseases, 736  
testicular radiation, 735  
testicular trauma and torsion, 732  
varicocele, 730  
46, XX male syndrome, 724  
48, XXYY syndrome, 724  
47, XYY syndrome, 724  
Y-chromosome microdeletions, 724  
Primordial germ cells (PGCs), 225–226  
Problem-solving approach, 1302  
Professional ethics, 1323  
Progesterone receptors, 906  
Prolactin, 503, 509  
Promyelocytic leukemia zinc finger (PLZF), 432  
Prostaglandin(s), 259  
Prostaglandin D2 (PGD2), 277–278  
Prostaglandin D2 synthase (Ptgds), 194  
Prostate cancer, 597  
Prostate specific antigen (PSA), 958  
Protamine 1 mRNA expression, 332  
Protein hormones, 508–511  
Psychological and social aspects, 1288, 1309, 1312  
Pubertal gynecomastia, 904  
Pubertal onset, 751, 755, 760, 761, 767, 769
- R**  
Radiation therapy, 885–886  
Radiofrequency-assisted liposuction (RFAL), 915  
Radioimmunoassay, 676  
Randomized controlled trial (RCT), 1126  
Rapamycin, 889  
Rapid freezing, 1247  
Reactive oxygen species (ROS), 1118, 1124  
Recreational drug use, 911  
Rectal cancer (RC), 890  
Recurrent varicocele, 1136  
Refeeding gynecomastia, 909  
Relaxin family peptide receptor 2 (RXFP2), 262, 264  
Reliability of semen analysis, 553  
Reproductive disorders, 1324  
Reproductive function, 73, 91
- Resistance, AIS. *See* Androgen insensitivity syndrome (AIS)  
Rete testis, 321, 336  
Retinoic acid (RA), 281, 442–443  
Reversible inhibition of sperm under guidance, 1228  
Roof plate-specific spondin (RSPO1), 183
- S**  
Salivary testosterone, 679  
Sarcoidosis, 842  
Scrotal and transrectal imaging. *See* Color-Doppler ultrasound  
Scrotum, 314  
Secondary hypogonadism (sHG), 704, 882  
combined pituitary hormone deficiency, 704  
congenital adrenal hyperplasia, 711  
drugs, 720  
functional forms, 721  
hemochromatosis, 711  
hypopituitarism, 711  
hypothalamus pituitary localization, systemic diseases, 716  
isolated hypogonadotropic hypogonadism, 705  
SED1, 468  
Selective estrogen receptor modulators (SERMS), 957  
fertility, 961  
metabolic parameters, 967  
physical strength and body composition, 965  
sexual function, 962  
Semen analysis, 536  
analytical aspects, 540–544  
description, 549–551  
examples, 538  
flow chart, 549  
physiological variability, 551–552  
post-analytical aspects, 544–548  
pre-analytical aspects, 539–540  
problems, 546  
technical variability, 552  
uses, 551  
Seminiferous tubules, 323  
Sertoli cell(s), 178, 193, 194, 197, 218–220, 229, 276–278, 324, 327, 429–430  
dysfunction, 1119  
tumors, 907  
Sertoli cell only syndrome (SCOS), 629–631, 993–994  
Sex chromosomes, 185–187, 1032, 1033

- Sex determination, 228, 233, 235, 248
- Sex determining region of chromosome Y (Sry), 185, 186, 190–192, 221, 276, 277
- Sex determining region of chromosome Y (Sry)-box 9 (Sox9), 188, 192–193
- Sex hormone, 374, 376, 379, 385, 387
- Sex hormone binding globulin (SHBG), 401, 500, 677, 904, 1203
- Sex steroid replacement, 755, 768
- Sexual health, 1327
- Sexuality
- and disabled people, 1344–1346
  - donor insemination, 1334–1338
  - erectile dysfunction, 1341
  - homosexuality, transsexuality and intersexuality, 1341–1344
  - ICSI, 1329–1334
  - male infertility and assisted reproduction, 1328
  - as mating, 1327
  - prisons and chemical castration, 1346–1348
  - as relational self-realization, 1327
  - sexual rights, 1327
- Sexually conceived birth (SBC), 1333
- Sexual rights, 1327
- Sexual symptoms, 927, 933
- Sickle cell disease, 655, 997
- Sine oculis-related homeobox 1 (SIX1), 176
- Sine oculis-related homeobox 4 (SIX4), 176
- Single-nucleotide polymorphisms (SNPs), 142
- Slow freezing, 1247
- Sonographic elastography (SE), 605–606
- SOX9, 248, 276, 278
- and DMRT1 expression mechanisms, 233
  - expression regulation, 221
  - FOXL2 repression, 229–231
  - role in testis and ovary, 232
- Sperm adhesion molecule 1 (SPAM1), 468
- Spermatids, 331–333, 1160
- Spermatocytes, 470
- Spermatocytes, 329–331
- Spermatogenesis, 326, 328, 334, 335, 659, 1242
- endocrine control, 436–440
  - meiotic phase, 435
  - mitotic phase, 434
  - paracrine control, 440–444
  - spermiogenic phase, 436
- Spermatogenic arrest, 631
- Spermatogonia, 329
- Spermatogonial stem cells (SSCs), 430–434
- Spermatozoa, 333, 1237, 1238, 1242
- absence of, 546
  - changes in environment, 550
  - fixed and stained, 541
  - globozoospermia, 548
  - motile, 541
- Sperm Bank, 1238, 1243, 1245, 1248
- Sperm chromatin compaction, 464–465
- Sperm concentration, 541, 544
- Sperm DNA fragmentation, 550
- Sperm function tests, 1124
- Spermiation, 333–334
- Spermiogenesis, 331
- Sperm parameters, 1092, 1095, 1097, 1098, 1100, 1102, 1103, 1105, 1106
- Sperm quality, 1073, 1085
- Sperm retrieval techniques (SRTs)
- anesthesiological aspects, 1186–1189
  - complications, 1192–1194
  - conventional open methods, 1184–1185
  - microsurgical, 1185–1186
  - patient management after surgery, 1192
  - patient management before surgery, 1179–1181
  - PESA, 1183
  - retrieval rates, 1189–1191
  - testicular fine-needle aspiration, 1183
  - testicular sperm aspiration, 1183
- Spinal cord injury, 1009, 1241
- Spironolactone, 1205
- Spontaneous conception, 1152
- SRD5A1, 348, 352, 353, 357, 361, 364, 368
- Stem cell factor (SCF), 440–442
- Steroid hormone(s), 506
- Steroid hormone receptor (SR), 396, 398
- Steroid receptor coactivators (SRC) 1, 400, 402
- Steroids
- adrenal hormone action, 256
  - 21 hydroxylase, 257
  - 17 $\alpha$ -hydroxylated, 256
  - sulfatase, 258
  - sulfotransferase (SULT2A1), 256
- Styrene maleic anhydride, 1228
- SUMOylation, 408–409
- Supravital staining, 542
- Surgically retrieved sperm in assisted reproduction, 1162–1163
- Surrogacy, 1336–1338
- Synthetic androgens, 1226–1227
- Systemic illness, 860
- T**
- Tamoxifen, 915, 956, 1080
- Tay–Sachs syndrome, 1326
- Teratozoospermia, 527
- Teratozoospermia index (TZI), 545

- Testicular cancer, 1238  
 Testicular dysgenesis syndrome (TDS), 265, 325, 626, 986  
 Testicular fine-needle aspiration (TEFNA), 1183  
 Testicular function, cancer treatments  
   male fertility, 882–889  
   management, 892–895  
   post-treatment recovery, biomarkers of, 891  
   testosterone production, 889–891  
 Testicular germ cell cancer (TGCC), 883, 885, 886, 889, 892, 894  
 Testicular ischemia, 1118  
 Testicular malignancy, 569, 582, 583  
 Testicular microlithiasis, 582  
 Testicular sperm aspiration (TESA), 1183  
 Testicular sperm extraction (TESE), 1184  
 Testis, 403, 774, 786. *See also* Testis cords;  
   Testis differentiation  
     androgen production, 282  
     bipotential gonad, 274  
     external appearance, 317  
     germ cell commitment, 280–282  
     germ cells, 328  
     histology, 318  
     interstitial compartment, 318  
     interstitium, role of, 279–280  
     lamina propria, 322  
     peritubular cells, 322  
     Sertoli cell commitment, 276  
     Sertoli cells, 324  
     spermatogenesis, 328  
     testis cord formation, 278–279  
     undescended testis (*see* Undescended testis)  
 Testis cords  
   desert hedgehog (DHH), 222  
   development, 223–224  
   homozygous mutants, 224  
   Sertoli cells, 218, 219, 222  
   Wilms' tumor suppressor 1, 222–223  
 Testis differentiation, 221, 231  
 Testis histology, 629  
 Testosterone, 374, 376, 385, 388, 389, 436, 438, 500–502, 904, 906, 913, 914, 922, 1252  
   action of T, DHT and androgen receptor, 354–356  
   biochemistry of T, DHT and physiologic precursors, 353  
   deficiency, 832–833  
   genetic defects, 364–365  
   injectable preparation, 955  
   low testosterone and mortality, 936  
   misuse, 1272  
   non-classical actions of T/DHT, 356  
   oral preparations, 953  
   pellet preparation, 956  
   and sexual behavior, 931–933  
   subdermal implants, 1224  
   suppression, 1200, 1204  
   T decline, risk factors for, 927–931  
   T metabolism/inactivation, 357  
   transbuccal preparations, 954  
   transdermal preparations, 954, 955  
 Testosterone replacement therapy (TRT), 856, 1255  
   cardiovascular health, 969, 970  
   metabolic parameters, 966  
   mood, 968  
   physical strength and body composition, 963  
   sexual function, 962  
 Testicular dysgenesis syndrome (TDS), 884, 889, 892  
 Tetraspannin CD9, 461  
 Thalassemia, 852–853  
 Three amino acid loop extension (TALE), 180  
 Time to pregnancy, 1291  
 Total antioxidant capacity (TAC), 1119, 1124  
 Total motile sperm count (TMC), 1148  
 Transcription  
   androgen receptor collaboration, 404–405  
   androgen receptor-mediated regulation, 400–402  
   factor (TF), 275, 277, 280, 281, 396  
   gene, 402  
 Transcription factor 21 (Tcf21), 175  
 Transdermal testosterone patch systems, 1223  
 Transdifferentiation  
   DMRT1, role of, 231–232  
   estrogen signaling, 227–228  
   FOXL2, role of, 228–229  
   granulosa to Sertoli cell mechanisms, 229–231, 233–234  
   sexual, 227  
   SOX9, role of, 232–233  
 Transforming growth factor-beta (TGF- $\beta$ ), 188  
 Traumatic brain injury, 984  
 Tubuli recti, 335, 336  
 Turner syndrome, 190  
 Tygerberg strict criteria, 544  
 Type 2 diabetes mellitus, 854–856
- U**  
 Ultrafiltration, 678  
 Undescended testis  
   classification, 284–285

- Undescended testis (*cont.*)
- complications of cryptorchidism, 288
  - complications of surgery, 300
  - definition, 283
  - diagnosis, 286–288
  - differential diagnosis, 285–286
  - epidemiology, 286
  - etiology, 283–284
  - follow up, 300
  - indications for surgical treatment, 294
  - laparoscopic two stage Fowler Stephens orchidopexy, 299–300
  - medical therapy, 301–302
  - open two stage orchidopexy, 299
  - orchiectomy, 300
  - standard open single stage orchidopexy, 295–299
  - timing of surgical treatment, 294–295
- V**
- Vanishing testis syndrome (VTS), 989–990
- Varicoceles, 588, 985–986
- antegrade sclerotherapy, 1136
  - clinical examination, 1121
  - conservative and symptomatic treatment, 1125
  - definition, 1116
  - during adolescence, 1129
  - evidence-based recommendations, 1116
  - historical studies, 1116
  - inguinal varicocelectomy, 1134
  - laboratory diagnosis, 1123
  - laparoscopic varicocelectomy, 1136
  - male infertility, 1126
  - medical therapy, 1125
  - microsurgical subinguinal varicocele surgery, 1133
  - and NOA, 1129
  - pathophysiology of testicular damage, 1118
  - percutaneous retrograde embolization/sclerotherapy, 1136
  - prevalence of, 1117
  - recurrent varicocele, 1136
  - retroperitoneal varicocelectomy, 1135
  - role of varicocele treatment, ART, 1131
  - scrotal pain, 1128
  - testosterone deficiency and symptoms of hypogonadism, 1131
  - thermography, 1123
  - ultrasonography, 1122
  - venography, 1123
  - venous drainage of testis and etiology, 1117
- Vascular endothelial growth factor (VEGF), 259, 279
- Vasectomy, 1006, 1215, 1241
- Venous hypertension, 1118
- Venous thromboembolism (VTE), 1203
- W**
- Weight loss, 958
- Wilm's tumor 1 (WT1), 174
- Wilms tumor-aniridia-genital anomalies-retardation (WAGR), 174
- Wilms' tumor suppressor, 1 (WT1), 222
- WIN18846, 1228
- Wingless-type MMTV integration site family 4 (WNT4), 183, 195
- Witch's milk, 902
- WT1-KTS isoforms, 174, 175, 191
- X**
- X chromosome and male infertility, 529
- 46, XX male (de la Chapelle syndrome), 521
- XX/XY system, 185
- 47, XYY male, 521
- Y**
- Y chromosome microdeletion screening, 522–524
- Y chromosome structural anomalies detectable with Karyotype analysis, 522
- Young's syndrome, 1003–1005
- Z**
- Zinc finger protein, multitype 2 (Zfp2/Fog2), 194–195
- Zygotene primary spermatocytes, 330
- ZZ/ZW system, 185