

---

# Excimer Laser Ablation in Keratoconus Treatment: Sequential High Definition Wavefront-Guided PRK After CXL

# 26

Mohamed Shafik Shaheen and Ahmed Shalaby

---

## 26.1 Introduction

Laser refractive surgery in patients with such irregular corneas has long been contraindicated because of the risk of postoperative progression of the disease process. However, numerous studies claim the safety of surface ablation in suspected keratoconus or in “forme fruste keratoconus” as in photorefractive keratectomy (PRK). In patients with mild to moderate keratoconus, combined PRK and collagen cross-linking has been proven to be a safe and effective alternative to correct minor refractive error, stabilizing the remaining stromal bed and avoiding progression of ectatic disease [1, 2].

Kanellopoulos and Binder (2007) proposed a two-step procedure with corneal CXL and topography-guided PRK after a 1-year interval. They studied the effect of this two-step approach on keratoconus progression and concluded that

there was significant clinical improvement and apparent stability for more than a year compared to the untreated mate eye that continued to progress over the same period [3].

Kanellopoulos and Asimellis also described the ATHENS protocol of simultaneous topography-guided PRK with same-day collagen CXL [4]. Kanellopoulos found superior results of this protocol compared to sequential CXL with later PRK after 6 months in his study that included 325 eyes with progressive keratoconus [5].

Thus, combination of laser surface ablation and CXL provides a potential treatment for keratoconus.

---

## 26.2 Higher Order Aberrations and Keratoconus

Keratoconus causes a reduction in the optical quality of the eye as a result of corneal distortion, corneal scarring, and higher order aberrations. The correction of these optical aberrations would significantly improve the visual performance of keratoconic eyes. However, the first step would be to measure the optical flaws in keratoconus accurately, which in itself presents a challenge. In keratoconus, corneal thinning causes marked shape changes which create large amounts of higher order optical aberrations, which differ significantly from the aberrations found in normal eyes [6].

Increased negative vertical coma, the major aberrometric finding in keratoconus, is caused by

---

M. Shafik Shaheen, M.D., Ph.D. (✉)  
Department of Ophthalmology, University of  
Alexandria, Egypt, P.O. Box 27, Ibrahimia,  
Alexandria 21321, Egypt  
e-mail: [m.shafik@link.net](mailto:m.shafik@link.net)

A. Shalaby, M.D.  
Department of Ophthalmology, University  
of Alexandria Main Hospitals, Alexandria, Egypt  
e-mail: [dr\\_ahmadshalaby@yahoo.com](mailto:dr_ahmadshalaby@yahoo.com)

the relatively slower wavefront in the inferior part of the cornea; the relatively advanced wavefront in the superior part of the cornea is also an indicator of infero-superior asymmetry [7].

Measurement of the wavefront error of the eye provides an accurate method to assess the optical properties of the eye beyond sphere and cylinder, evaluate therapy (e.g., refractive surgery) designed to improve the optical properties of the eye, and provide the necessary information to design optical prescriptions for the eye to minimize all refractive errors.

Modern high-definition aberrometers that were introduced to the ophthalmic armamentarium could read the aberrations of such irregular corneas and generate a dependable ablation profile out of them for precise correction [8].

---

### 26.3 Wavefront vs. Topography-Guided Ablation

Attempts to treat irregular cornea by laser vision correction (LVC) started early by the work of Fernandez et al. (2000). They used a kind of primitive topography-guided ablation profile (contoured ablation pattern=Custom CAP) to treat irregular cornea cases including stable keratoconic patients. The results were disappointing, as the authors mentioned in their work, due to: The variability of refractive condition (sphere, cylinder, and irregular astigmatism) made it difficult to predict the precise spherical or regular cylindrical component that will remain, the ablation profile which was a primitive topo-guided one did not provide good tackling for the cause-effect relationship, the calculation and positioning of the laser beam lacked by that time the precision to address such irregularity with no compensation for cyclotorsion and no compensation for pupil centroid shift [9].

The use of wavefront-guided laser technology for the management of aberrated corneas has been shown to effectively reduce HOAs in corneas with residual refractive errors post keratorefractive surgeries [10]. Wavefront-guided technology has also shown efficacy in addressing irregularities in pathologic corneas once their

biomechanical weakening has been addressed through the application of CXL [1]. However, limitations of wavefront-guided procedures have been described, mainly related to the technical limitations of aberrometers in measuring ocular aberrations [11].

After the introduction of the high-definition aberrometers, irregular astigmatism accompanying highly aberrated corneas could be handled [8, 10]. Modern aberrometers that were introduced to the ophthalmic armamentarium could read the aberrations of the irregular cornea and generate a dependable and reliable ablation profile out of them. Few years ago, a newer version of high-definition Hartmann-Shack aberrometer (iDesign system<sup>®</sup>) was introduced to the field of refractive surgery by Abbott Inc. with reports about their abilities to read and treat precisely the highly aberrated corneas [8].

---

### 26.4 Sequential vs. Simultaneous Treatment

The simultaneous approach is thought to be too invasive (two techniques at the same sitting), does not address emmetropia due to the prolonged flattening effect of CXL with uncontrolled refractive outcome [12].

Besides, the sequential protocol is, in fact, making use of the stable cornea provided by previous CXL. This stable corneal surface provides, in turn, a stable refractive surface (even still irregular) from which we can calculate a reliable and dependable ablation profile to correct the irregularity and avoid refractive surprises and changes that can potentially occur with the use of the simultaneous approach [8].

---

### 26.5 Wavefront-Guided PRK After CXL

We recommend Sequential wavefront-guided PRK using the ablation profile generated by the high-definition Hartmann-Shack aberrometer (iDesign system<sup>®</sup>, Abbott, USA) in cross-linked stable keratoconic eyes after at least 12 months of

the cross-linking according to the data of a pilot study published recently by our team [8]. It is also recommended to have the cross-linking done by an epithelium-off approach to guarantee maximum corneal tissue compactness and stiffness before ablating a thin part of it.

The following selection criteria are recommended:

- Stage I, II keratoconus cases according to Amsler-Krumeich classification [13].
- Stable keratoconus after corneal collagen cross-linking as defined by stability of subjective refraction ( $\pm 0.5$  diopters (D) change in spherical equivalent) in three consecutive monthly visits after 1 year of corneal CXL together with keratometric stability (no increase of the cone apex keratometry of  $\geq 0.75$  D) in the last 6 months of follow-up [14].
- Manifest refraction spherical equivalent  $\leq 6$  D.
- Corneal thickness at the thinnest location  $\geq 400$   $\mu\text{m}$ .
- Clear cornea in the pupillary area.

---

## 26.6 Preoperative and Postoperative Examination

Preoperative ophthalmic examination should include manifest and cycloplegic refraction, UDVA and CDVA testing, pupil diameter measurement under mesopic conditions using the Colvard pupillometer (Oasis, Glendora, CA, USA), slit lamp anterior segment examination, corneal topography, and anterior segment imaging using the Pentacam-HR system (Oculus Inc., Wetzlar, Germany) or similar Scheimpflug imaging device, ocular aberrometry (iDesign aberrometer, Abbott Medical Optics, AMO, Santa Ana, CA), applanation tonometry, and funduscopy. With the Pentacam topography system, the following topographic and pachymetric parameters were recorded and evaluated: flattest and steepest keratometric readings (K1 and K2), maximum keratometry (K-max), corneal asphericity ( $Q$ ) for an 8-mm diameter, central corneal thickness (CCT), minimum corneal thickness (MCT), maximum anterior corneal elevation

(AE) for an 8-mm diameter, index of surface variation (ISV), index of vertical asymmetry (IVA), keratoconus index (KI), center keratoconus index (CKI), index of height asymmetry (IHA), index of height decentration (IHD), and minimal radius of curvature ( $R_{\text{min}}$ ).

With the high-resolution aberrometer, the following parameters are recorded and evaluated for a 6-mm pupil: total root mean square (RMS), HOAs RMS, primary coma RMS ( $Z_3^{\pm 1}$ ), trefoil RMS ( $Z_3^{\pm 3}$ ), and the Zernike term corresponding to the primary spherical aberration ( $Z_4^0$ ).

Postoperatively, patients should be examined the third day after surgery and at 1 week postoperatively to assess the status of the corneal epithelial healing and if a complete epithelialization is present, the therapeutic contact lens fitted has to be removed. Afterward, patients should be examined at 1, 3, 6, and 12 months after surgery. UDVA and CDVA testing, manifest refraction, corneal topography, ocular aberrometry, and biomicroscopic examination are performed in these four visits. In all postoperative visits, the level of corneal haze has to be evaluated on a scale from 0 to 4 (0=clear cornea, 1=mild haze, 2=moderate haze, 3=severe haze, and 4=reticular haze obstructing iris details) [5].

---

## 26.7 Surgical Procedure

All surgical procedures are performed under topical anesthesia (benoxinate hydrochloride 0.4% Sterile Ophthalmic Solution). In all cases, the corneal epithelium is removed using the 9.0-mm Amoils brush (Innovative Excimer Solutions, Inc., Toronto, Canada) and the laser ablation is then applied. A WFG-PRK laser treatment is applied using the VISX Star S4IR excimer laser (Abbott Medical Optics, Santa Ana, California) and an ablation profile generated according to the measurements obtained with the iDesign system. An adjustment to the profile is applied as needed to reduce the maximum ablation depth to a maximum of 15% of the corneal thickness at the thinnest location, reducing only the sphere component without changing the cylinder. The sphere adjustment is limited to 2.50 D, which is the maximum adjustment allowed by the manufacturer.

After laser ablation, a 6-mm cellulose disc soaked in Mitomycin C (MMC) 0.02 % solution is applied over the ablated tissue for 20 s followed by irrigation with 30 mL of chilled balanced salt solution. A bandage contact lens is then fitted, remaining in place until full reepithelialization. The postoperative treatment regimen consists of Topical Antibiotics/Corticosteroids, e.g., moxifloxacin hydrochloride 0.5 % (Vigamox, Alcon Laboratories) applied four times daily up to 2 weeks after complete reepithelialization, a combination of tobramycin 3 mg/mL with dexamethasone 1 mg/mL (Tobradex, Alcon Laboratories, UK) applied four times daily until complete reepithelialization and then gradual tapering over 2 weeks, preservative-free tear substitutes applied every 2 h for 2 weeks (e.g., Refresh plus, Allergan, Inc, USA), and oral analgesic nonsteroidal anti-inflammatory drug applied three times daily for 3 days (Catafast, Novartis, Switzerland).

### 26.8 Clinical Results

A study by Shafik Shaheen et al. was done on 34 eyes with stage I and II keratoconus meeting the above-mentioned criteria who had previous CXL at least 1 year before treatment to demonstrate the effect of this wavefront-guided laser surface correction on visual, refractive, corneal morphology, and aberrometric data (Recently published: Shafik Shaheen M, Bardan AS, Pinero D, Ezzeldin H, El-Kateb M, Helaly H, Khalifa M.

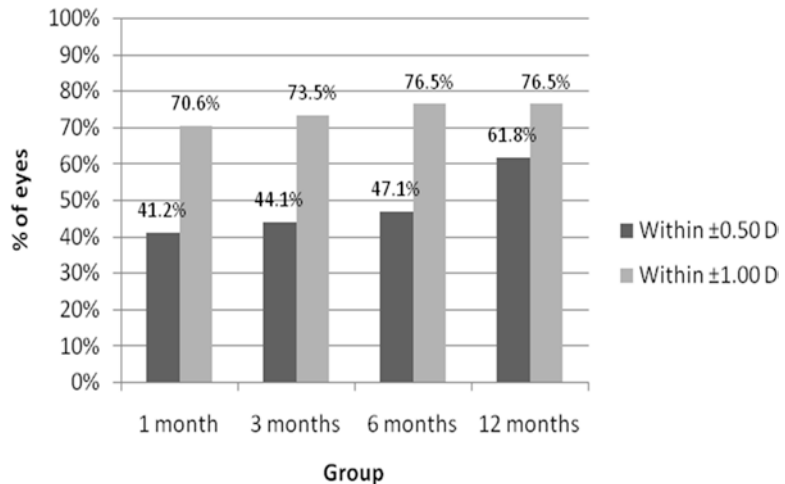
Wave Front-Guided Photorefractive Keratectomy Using a High-Resolution Aberrometer After Corneal Collagen Cross-Linking in Keratoconus. *Cornea* 2016;35(7):946–953).

It demonstrated a statistically significant improvement in the mean logMAR UDVA from  $0.93 \pm 0.33$  (mean  $\pm$  SD) preoperatively to  $0.14 \pm 0.11$  (mean  $\pm$  SD) at the last follow-up visit and the mean logMAR CDVA has been improved from  $0.28 \pm 0.24$  (mean  $\pm$  SD) preoperatively to  $0.05 \pm 0.06$  (mean  $\pm$  SD) at the last follow-up visit; ( $p$ -value  $< 0.001$ ) for both. The mean MRSE has been reduced from  $-3.22$  preoperatively to  $-0.68$  at the 12th month postoperatively. The magnitude of reduction is shown in Fig. 26.1. The study demonstrates a high safety and efficacy indices at the last follow-up visit. Efficacy index was  $1.58 \pm 1.11$  (mean  $\pm$  SD),  $p < 0.001$ , safety index was  $1.96 \pm 1.52$  ( $p < 0.001$ ) proving safety and efficacy regarding VA improvement.

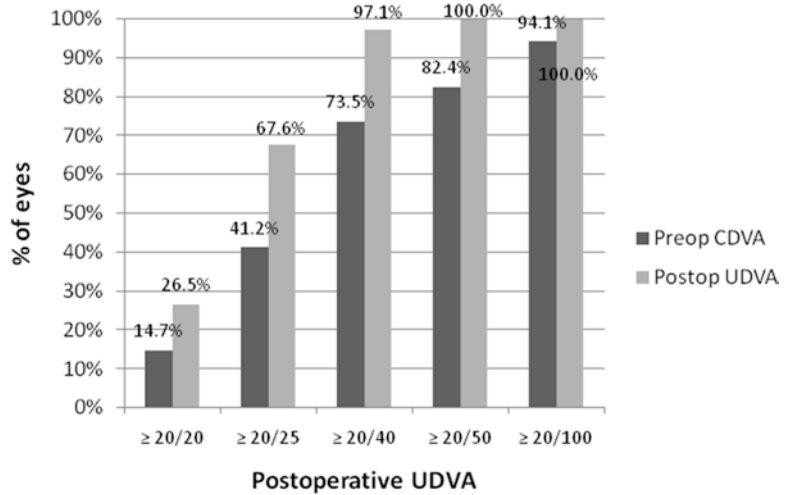
About the predictability of the procedure, at the sixth month postoperatively, 76.5 % of eyes had a manifest refraction within  $\pm 1.00$  D of emmetropia, 47.1 % were within  $\pm 0.50$  D. At the last follow-up visit 62 % of the cases reached within  $\pm 0.50$  D. Summary is shown in Fig. 26.1.

As shown in Fig. 26.2, 97.1 % of the study subjects reached  $\geq 20/40$  UDVA at the last follow-up visit compared to 73.5 % only reaching CDVA of  $\geq 20/40$  preoperatively. Hundred percent reached  $\geq 20/50$  UDVA at the last follow-up visit at 1 year postoperatively.

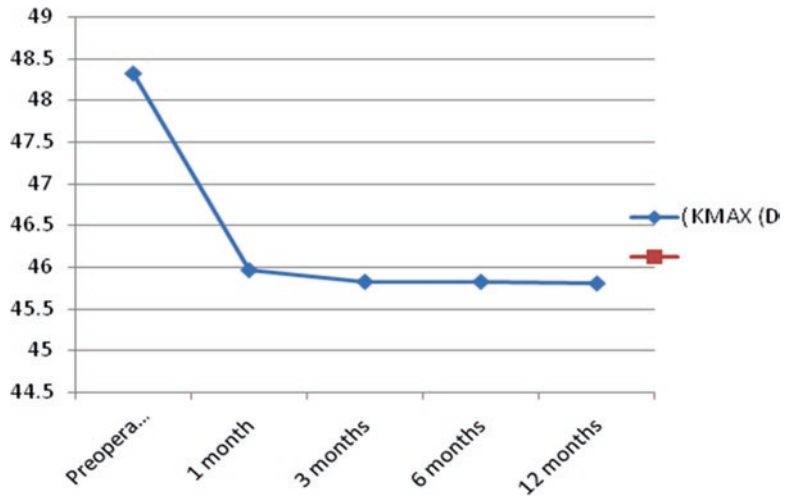
**Fig. 26.1** Summary of the predictability outcomes after surgery in the analyzed sample



**Fig. 26.2** Comparison of the distribution of the postoperative UDVA (after 1 year) and the preoperative CDVA outcomes



**Fig. 26.3** Stability of the maximum keratometry (K-MAX) over the postoperative follow-up

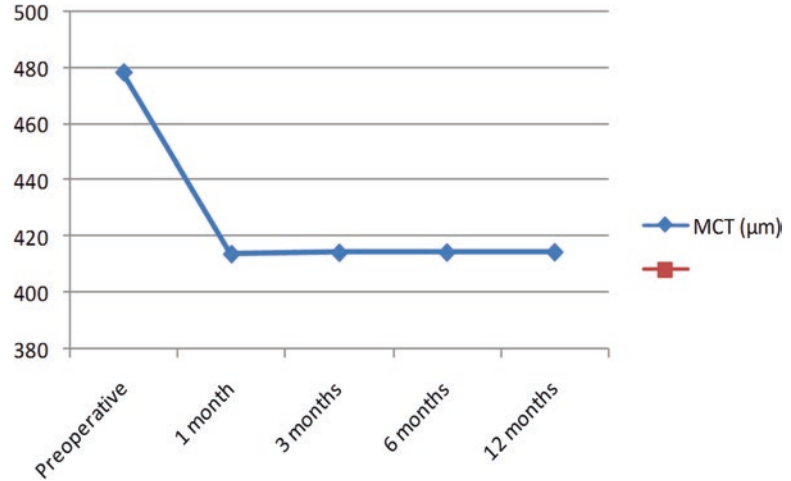


The study demonstrated many changes in the corneal morphology. First of all the reduction of the maximum K reading from a mean of 48.32 D preoperatively to a mean of about 45.8 D at month 3 which remained in the same range over the first year postoperatively as shown in Fig. 26.3. Mean Q-value has decreased from -0.44 to -0.26. Central corneal thickness has decreased from  $491.12 \pm 39.19 \mu\text{m}$  (mean  $\pm$  SD) preoperatively to  $429.56 \pm 61.81 \mu\text{m}$  at the last follow-up visit. Minimal corneal thickness decreased from  $478.32 \mu\text{m}$  (mean) preoperatively to about  $414 \mu\text{m}$  (mean) which remained stable over the period of follow-up as shown in Fig. 26.4. All the results are statistically significant ( $p < 0.001$ ).

About the corneal indices, the results showed decrease in the values of the eight Pentacam indices studied. The reduction in IVA, IHA, IHD, and CKI was not statistically significant. While the reduction in ISV,  $R_{\text{min}}$ , and KI was statistically significant. The study showed also stability of the indices through the period of follow-up.

There was a statistically significant reduction in the higher order aberrations in general demonstrated by the significant reduction of total RMS;  $p$ -value  $< 0.001$ , and the RMS HOA; ( $p = 0.003$ ), and reduction of coma ( $p = 0.001$ ) and trefoil ( $p < 0.001$ ). The primary coma RMS has decreased from  $0.60 \pm 0.59 \mu\text{m}$  (mean  $\pm$  SD) preoperatively to  $0.37 \pm 0.37 \mu\text{m}$  at the last fol-

**Fig. 26.4** Stability of the minimal corneal thickness (MCT) over the postoperative follow-up



low-up visit ( $p=0.001$ ). Mean Trefoil RMS has decreased from  $0.35 \mu\text{m}$  preoperatively to  $0.21 \mu\text{m}$  at the last follow-up visit.

Astigmatic analysis was done by vector analysis (Alpins method) for better understanding and presentation of astigmatic correction. Targeted induced astigmatic correction (TIA) was  $2.79 \pm 1.82$  (mean  $\pm$  SD), while the real change achieved at the last follow-up visit (SIA) was  $2.36 \pm 1.72$  (mean  $\pm$  SD) and this showed a magnitude of error (ME) of  $0.43 \pm 0.86$  (mean  $\pm$  SD) which is the difference between SIA and TIA (positive number means undercorrection). The correction index (CI) was evaluated and found to be  $0.88 \pm 0.29$  (mean  $\pm$  SD) which means slight undercorrection. This is described in detail in Table 26.1.

The following vectors were determined and evaluated: targeted induced astigmatism (TIA) as the vector of intended change in cylinder for each treatment, surgically induced astigmatism (SIA) as the vector of the real change achieved, and difference vector (DV) as the additional astigmatic change that would enable the initial surgery to achieve its intended target. Additionally, the following parameters derived from the relationship between these vectors were calculated and analyzed in each postoperative visit:

- Magnitude of error (ME): the arithmetic difference between the magnitudes of the SIA and TIA. Positive: undercorrection; negative: overcorrection.

- Angle of error (AE): the angle described by the vectors of the achieved correction (SIA) and the intended correction (TIA): Negative: achieved correction is clockwise to its intended axis. Positive: achieved correction is counterclockwise to its intended axis
- Correction index (CI): The ratio of the SIA to the TIA; what the surgery actually induced versus what the surgery was meant to induce. The CI is preferably 1; it is greater than 1 if an overcorrection occurs and less than 1 if there is an undercorrection.

### Case Example 1

A 25-year-old female patient. Wavefront-guided PRK was performed 2 years after corneal collagen cross-linking. Table 26.2 represents the preoperative clinical data, Pentacam and iDesign wavefront measurements compared to the findings at the final postoperative follow-up visit (12 months postop).

In this case there is a noticeable reduction in the total RMS value by (52%), RMS HOA by (51.4%), Coma reduction by (58.9%), trefoil reduction by (40.2%). This improvement was reflected on the patient's visual outcome (log-MAR CDVA was improved from +0.50 to 0.00). Figures 26.5, 26.6, 26.7, 26.8, and 26.9 show the pre- and postoperative investigations and the ablation profile of this patient.

**Table 26.1** Summary of the parameters derived from the vector analysis of ocular astigmatic changes at the end of the follow-up in the analyzed sample (Alpins method)

Vector parameters	Mean (SD)
	Median (range)
TIA (D)	2.79 (1.82) 3.00 (0.00 to 7.00)
SIA (D)	2.36 (1.72) 2.39 (0.00 to 7.95)
DV (D)	1.06 (0.92) 0.75 (0.00 to 3.25)
ME	0.43 (0.86) 0.28 (2.58 to -0.95)
CI	0.88 (0.29) 0.83 (0.26 to 1.61)
AE (°)	2.57 (15.43) 2.34 (48.76 to -44.86)

TIA targeted intended astigmatism, SIA surgically induced astigmatism, DV difference vector, ME magnitude of error, AE angle of error, CI correction index, SD standard deviation

**Table 26.2** Summary of preoperative and postoperative data of case 1

Preoperative data		Final postoperative data
UDVA (logMAR)	+1.30	+0.10
CDVA (logMAR)	+0.50	0.00
Refraction	+0.75 - 4.00 × 110	-0.25 - 1.00 × 155
Pentacam corneal data		
Thinnest location	422 μm	374 μm
ISV	67	51
IVA	0.83	0.49
KI	1.19	1.17
CKI	1.03	1.05
R <sub>min</sub>	6.78	6.98
IHA	9.8	15.3
IHD	0.061	0.057
iDesign data at 5 mm WFD		
RMS total	3.65 μm	1.75 μm
RMS HOA	2.72 μm	1.32 μm
Coma	1.16574	0.47882
Trefoil	0.67390	0.40287
Spherical aberrations	-0.00306	-0.21724

**Case Example 2**

A 30-year-old female patient. Wavefront-guided PRK was performed 3 years after corneal collagen cross-linking. Table 26.3 represents the preoperative clinical data, Pentacam and iDesign wavefront measurements compared to the findings at the final postoperative follow-up visit (12 months postop).

In this case there is a noticeable reduction in the total RMS value by (67.6%), RMS HOA by (24.6%), Coma reduction by (28.8%). This improvement was reflected on the patient’s visual outcome (logMAR UDVA was improved from +0.70 to 0.00). Figures 26.10, 26.11, 26.12, 26.13, and 26.14 show the pre- and postoperative investigations and the ablation profile of this patient.

**26.9 Discussion**

Keratoconus has a great impact on the visual performance which in turn affects the patient’s quality of life owing to the highly aberrated irregular cornea that lead to image quality degradation. Retinal image quality is degraded by scatter, diffraction, and wavefront aberrations (better known as wavefront errors) [15].

In the modern era, a great breakthrough in the management of keratoconus was achieved by introducing the corneal collagen cross-linking that halts the disease progression and makes the cornea stiffer and more stable. Moreover, advances in laser vision correction changed the way of thinking and added a lot of options to the armamentarium of irregular cornea management [16–19].

Attempts to implement surface ablation to treat early to moderate keratoconus have evolved in the era of CXL. Some authors preferred the simultaneous approach [1, 2, 5] (same day PRK + CXL) while others preferred the sequential PRK after CXL [3, 8].

In his work, Kanellopoulos advised using topography-guided ablation to treat early and moderate keratoconus with simultaneous same day CXL. He stated that he was not able to use

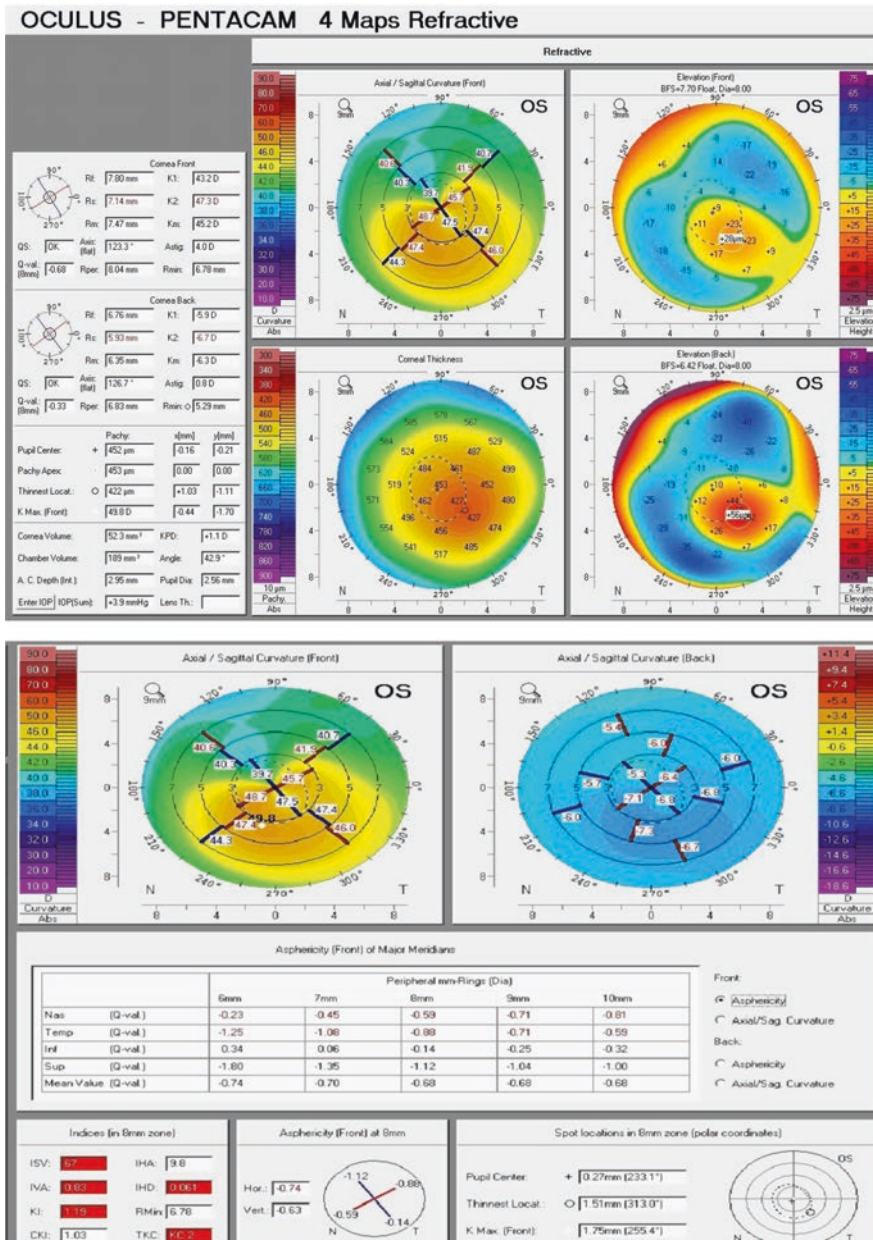
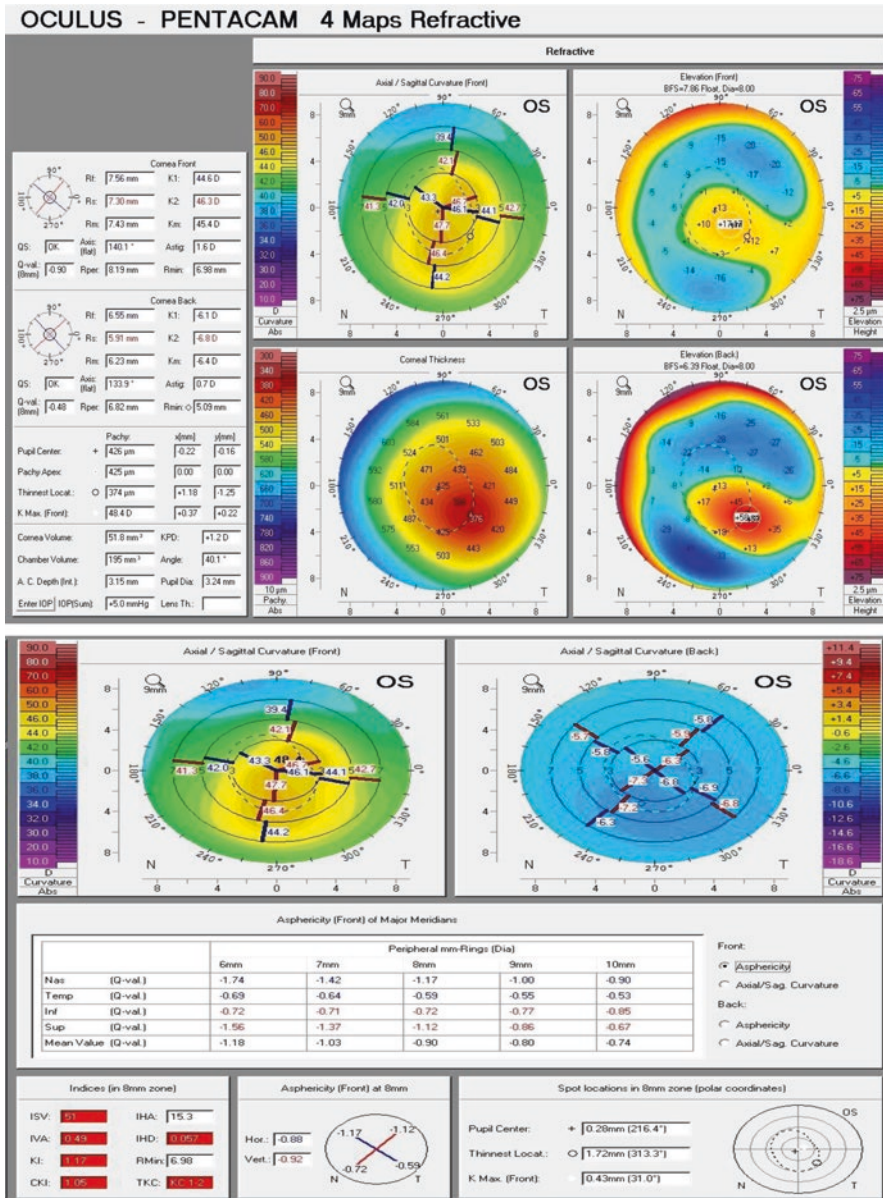


Fig. 26.5 Preoperative Pentacam of case 1

a wavefront-guided ablation profile because the highly irregular keratoconic eyes were beyond the limits of wavefront measuring devices making topo-guided approach more efficient in such cases. He also claimed superior results of the simultaneous over the sequential technique for three reasons: the combination reduces the patient’s time away from work, performing

both procedures at the same time with topography-guided PRK first appeared to minimize the potential superficial stromal scarring resulting from PRK, and when topography-guided PRK is performed after the CXL procedure, some of the cross-linked anterior cornea is removed, minimizing the potential benefit of CXL [5].





**Fig. 26.6** Postoperative (final follow-up visit) Pentacam of case 1

Innovations in ablation profiles, excimer laser technology, and diagnostic equipments have allowed surgeons not only to correct LOAs but also to minimize HOAs, increasing the levels of postoperative efficacy, predictability, and visual quality [20]. Even so, the management of significantly irregular corneas remains as a challenge for refractive surgeons.

The use of wavefront-guided laser technology for the management of aberrated corneas has been shown to effectively reduce HOAs in corneas with residual refractive errors post keratorefractive surgeries [10, 21]. Wavefront-guided technology has also shown efficacy in addressing irregularities in pathologic corneas once their biomechanical weakening has been addressed

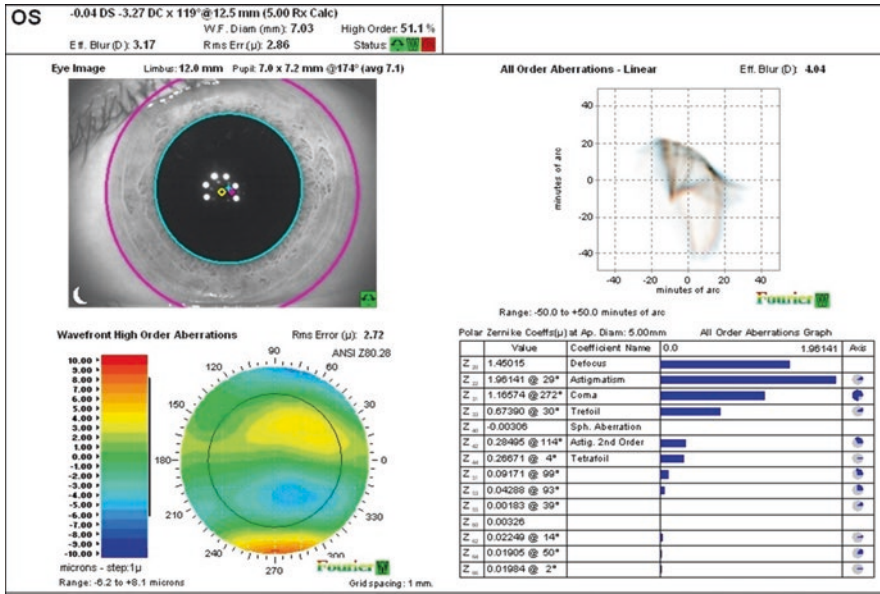


Fig. 26.7 Preoperative wavefront map of case 1

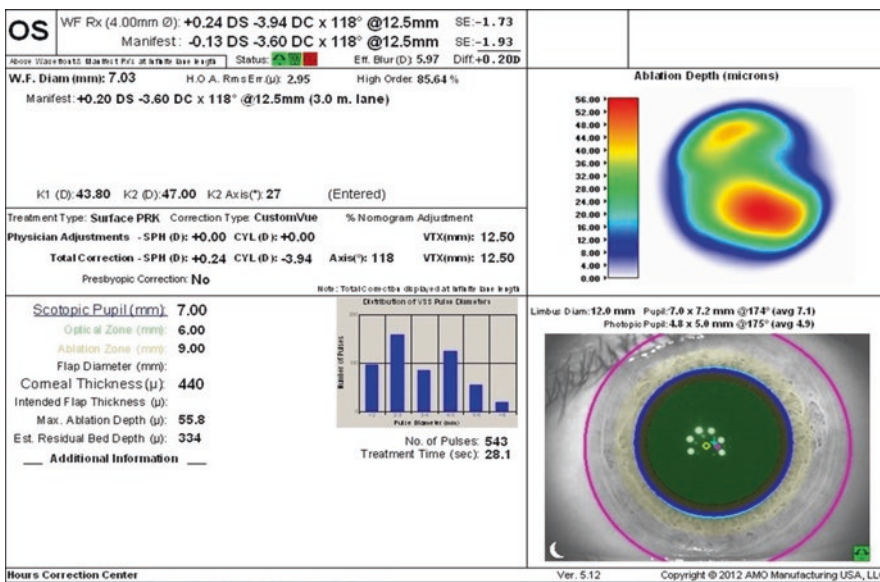


Fig. 26.8 Ablation profile generated by iDesign® for case 1

through the application of CXL [22]. However, limitations of wavefront-guided procedures have been described, mainly related to the technical limitations of aberrometers in measuring ocular aberrations [11].

Recently after the introduction of the high-definition aberrometers, irregular astigmatism

accompanying highly aberrated corneas could be handled [8, 10]. Modern aberrometers that were introduced to the ophthalmic armamentarium could read the aberrations of the irregular cornea and generate a dependable and reliable ablation profile out of them. Few years ago, a newer version of high-definition Hartmann-Shack aberrometer

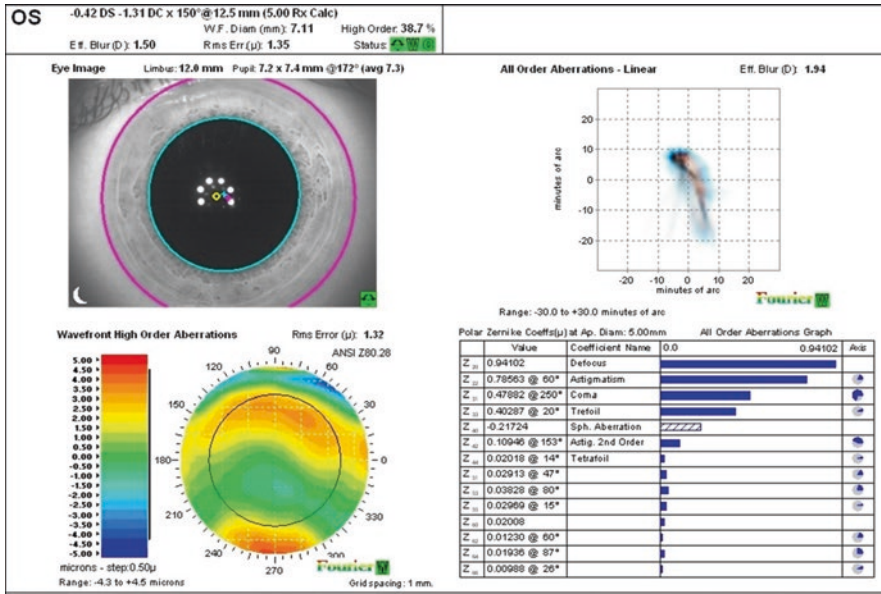


Fig. 26.9 Postoperative (final) wavefront map of case 1

Table 26.3 Summary of preoperative and postoperative data of case 2

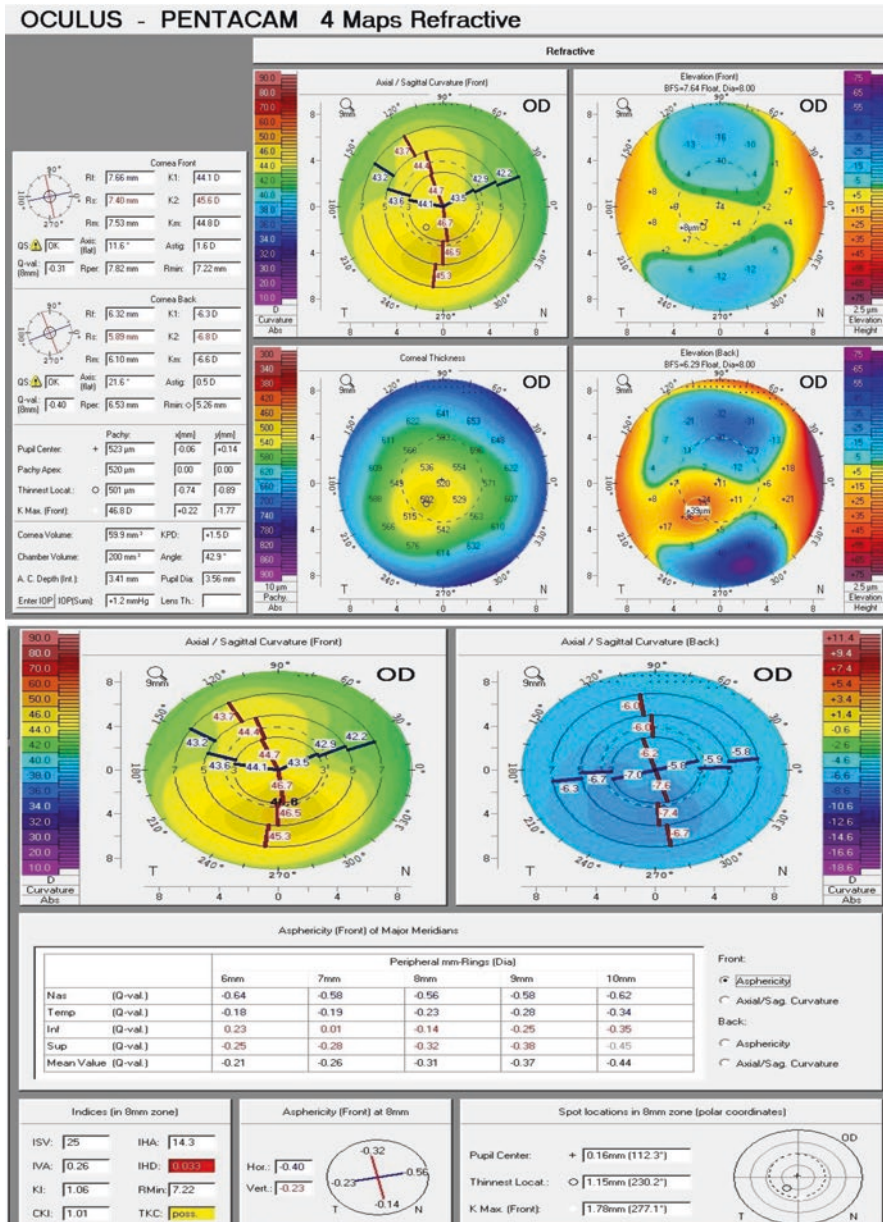
Preoperative data		Final postoperative data
UDVA (logMAR)	+0.70	0.00
CDVA (logMAR)	+0.10	0.00
Refraction	-2.75 -0.50 × 180	0.00 -0.25 × 80
Pentacam corneal data		
Thinnest location	501 μm	468 μm
ISV	25	21
IVA	0.26	0.26
KI	1.06	1.04
CKI	1.01	1.00
R <sub>min</sub>	7.22	7.52
IHA	14.3	22.1
IHD	0.033	0.032
iDesign data at 5 mm WFD		
RMS total	2.72 μm	0.88 μm
RMS HOA	0.69 μm	0.52 μm
Coma	0.23022	0.16375
Trefoil	0.07142	0.16481
Spherical aberrations	-0.01702	-0.08772

(iDesign system®) was introduced to the field of refractive surgery with reports about their abilities to read and treat precisely the highly aberrated corneas [8].

Our point of view in performing the sequential approach to treat keratoconic eyes after stabilizing them with CXL is due to the potential disadvantages of the simultaneous approach. The simultaneous approach is thought to be too invasive (two techniques at the same sitting) and does not address emmetropia due to the prolonged flattening effect of CXL with uncontrolled refractive outcome [12, 23].

The previously explained points were behind the philosophy of choosing the sequential wavefront-guided PRK after stabilizing the cornea with CXL.

Our study (under publication) demonstrated clearly in a statistically proved number of eyes (n=34) the safety and efficacy of a sequential high-definition aberrometer-guided PRK in providing a satisfactory visual outcome for the patients. The mean efficacy index (ratio of the postoperative UDVA to the preoperative CDVA)



**Fig. 26.10** Preoperative Pentacam of case 2

calculated after 1 year of follow-up was  $1.58 \pm 1.11$  (mean  $\pm$  SD);  $p$ -value  $< 0.001$ . Whereas the safety index (ratio of the postoperative CDVA to the preoperative CDVA) calculated after 1 year of follow-up was  $1.96 \pm 1.52$  (mean  $\pm$  SD);  $p$ -value  $< 0.001$ .

At the last follow-up visit, the preoperative logMAR UDVA of  $0.93 \pm 0.33$  (mean  $\pm$  SD) has been

improved to  $0.14 \pm 0.11$  postoperatively;  $p$ -value  $< 0.001$ , and logMAR CDVA has been improved from  $0.28 \pm 0.24$  preoperatively to  $0.05 \pm 0.06$  (mean  $\pm$  SD) postoperatively;  $p$ -value  $< 0.001$ . Results also showed reduction in MRSE from  $-3.22 \pm 1.32$  D (mean  $\pm$  SD) preoperatively to  $-0.68 \pm 0.64$  D at the last follow-up visit. About the predictability of the procedure, at the sixth month

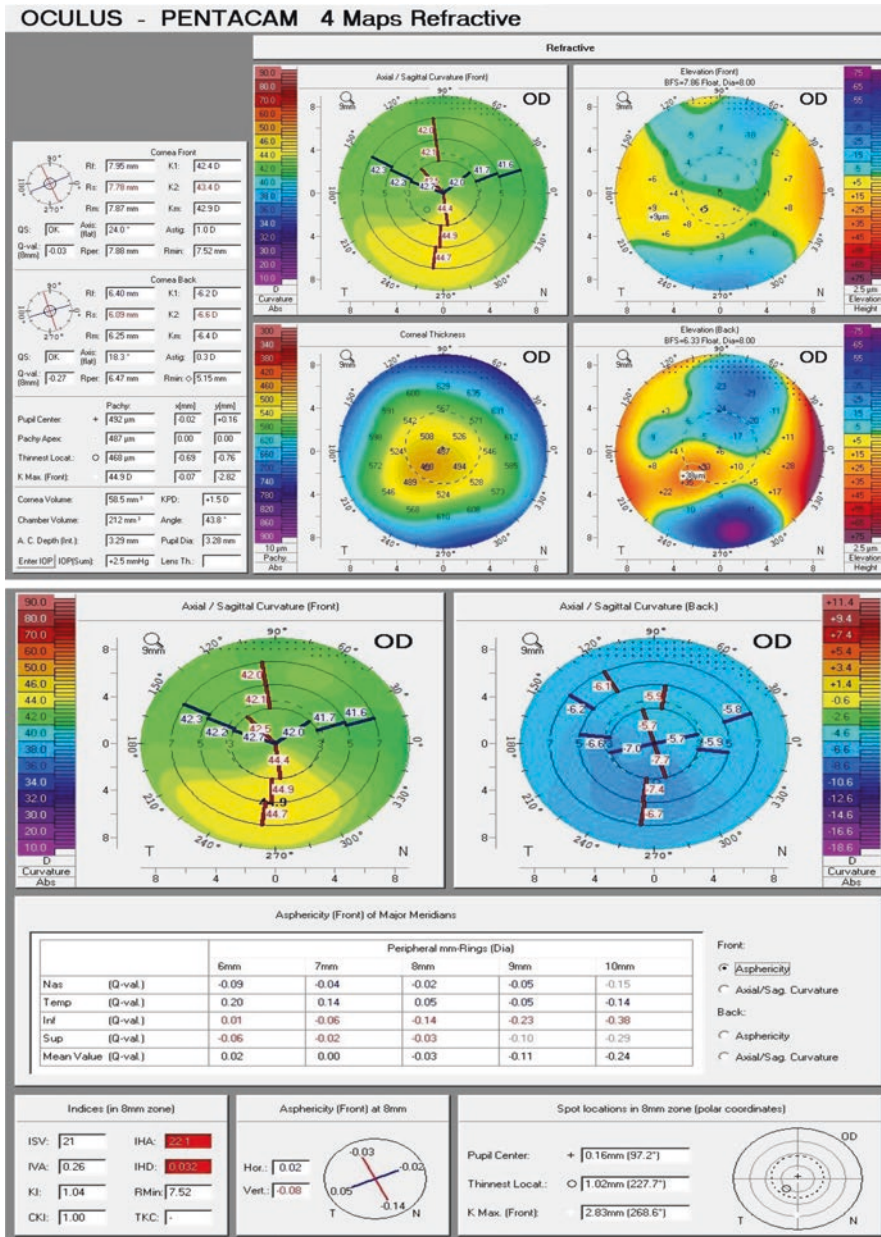


Fig. 26.11 Postoperative (final follow-up visit) Pentacam of case 2

postop, 76.5% of eyes had a manifest refraction within  $\pm 1.00$  D of emmetropia, 47.1% were within  $\pm 0.50$  D. At the last follow-up visit 62% of the cases reached within  $\pm 0.50$  D. A total of 97.1% of our patients reached  $\geq 20/40$  UDVA at the last follow-up compared to 73.5% only reaching CDVA of  $\geq 20/40$  preoperatively. Hundred percent of our patients reached  $\geq 20/50$  UDVA at the final follow-

up. A total of 44.1% of our patients gained two or more lines in the CDVA at month 12.

Our work also demonstrated a statistically significant reduction in the maximum keratometric reading from  $48.32 \pm 4.25$  (mean  $\pm$  SD) preoperatively to  $45.81 \pm 3.45$  at the last follow-up visit. There was insignificant change in its value over the follow-up period.

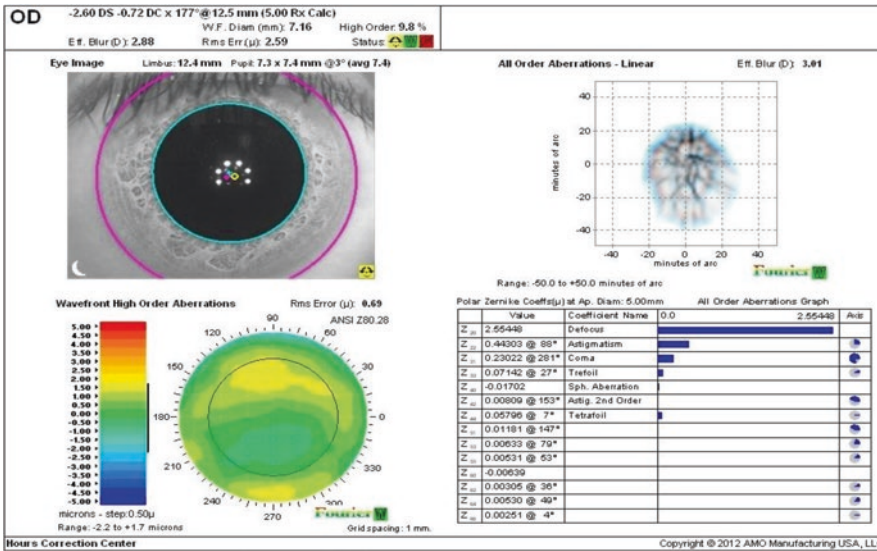


Fig. 26.12 Preoperative wavefront of case 2

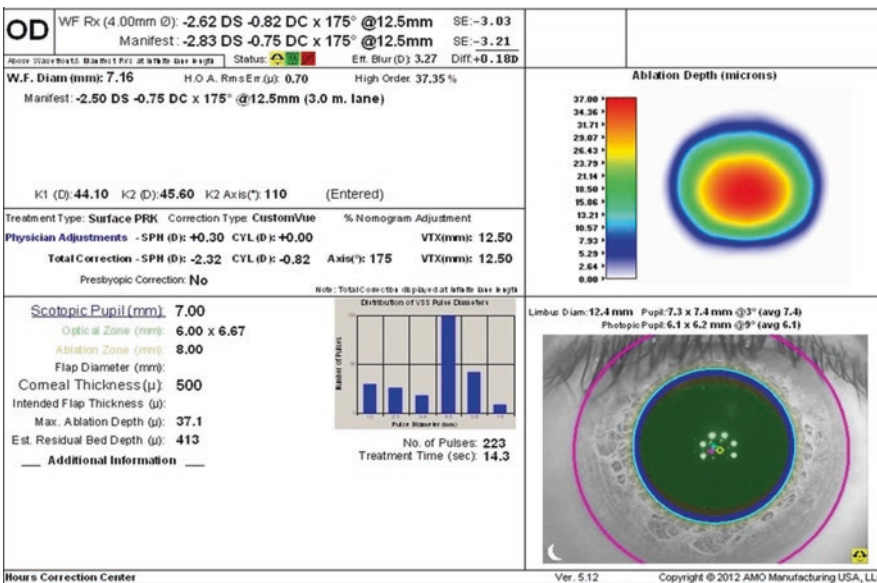


Fig. 26.13 Ablation profile generated by iDesign® for case 2

The mean starting central corneal thickness of the studied group was  $491.12 \pm 39.19 \mu\text{m}$  (mean  $\pm$  SD) at the thinnest location that was reduced to  $429.56 \pm 61.81 \mu\text{m}$  at the last follow-up visit. It decreased as a result of excimer laser ablation and then remained stable through the follow-up period. The mean intended ablation depth for our patients was  $54.53 \pm 11.44 \mu\text{m}$

(mean  $\pm$  SD). The ablation depth percentage calculated as (max. ablation depth in  $\mu\text{m}$ /corneal thinnest location thickness in  $\mu\text{m}$ ) presented a mean of 11.4% and a SD of 3.2%. To some extent this exceeds the ablation depth in most of other reviewed studies. Many authors used a maximum ablation depth of 50  $\mu\text{m}$ , this value was chosen arbitrarily by the authors based on

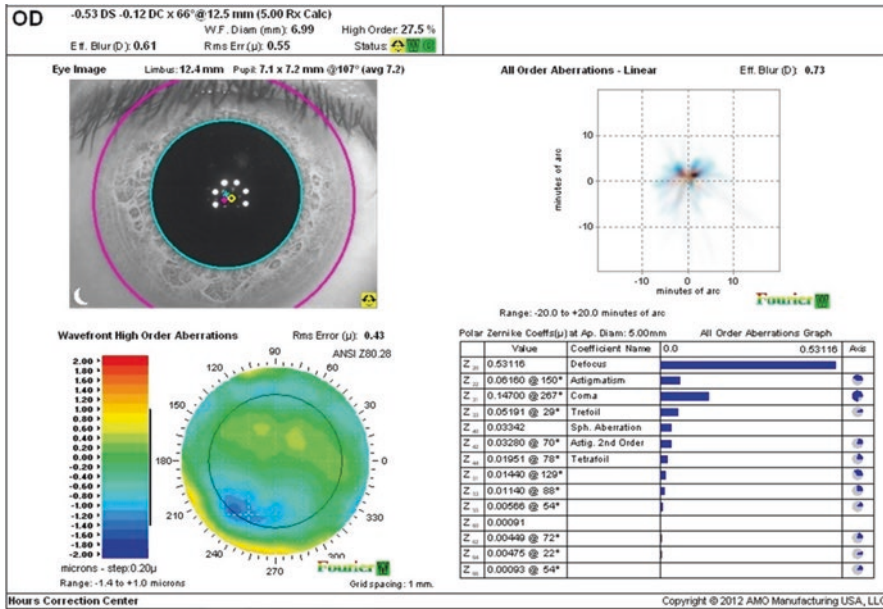


Fig. 26.14 Postoperative (final) wavefront of case 2

their own experience [5]. In our work, the maximum intended ablation depth did not exceed 15% of the corneal thinnest location thickness and the results showed stability of the cornea over the follow-up period (1 year).

There was a statistically significant reduction in the higher order aberrations in general demonstrated by the significant reduction of total RMS  $p$ -value <0.001 and the RMS HOA  $p$ -value 0.003, and reduction of coma, trefoil with  $p$ -value 0.001, <0.001, respectively. It is to be mentioned that the reduction of HOA in these eyes is considered number one reason behind the postoperative improvement in both UDVA and CDVA. From our point of view, this is a real addressing to what was named “Cause–Effect relationship” in Tamayo work [9].

In our study, vector analysis of ocular astigmatic changes was done (Alpins method) for better understanding and presentation of astigmatic correction. Targeted induced astigmatic correction (TIA) was  $2.79 \pm 1.82$  (mean  $\pm$  SD), while the real change achieved at the last follow-up visit (SIA) was  $2.36 \pm 1.72$  (mean  $\pm$  SD) and this showed a magnitude of error (ME) of  $0.43 \pm 0.86$  (mean  $\pm$  SD) which is the difference between SIA and TIA (positive number means undercorrec-

tion). The correction index (CI) was evaluated and found to be  $0.88 \pm 0.29$  (mean  $\pm$  SD) which means slight undercorrection.

There was insignificant corneal haze in the whole sample, six eyes had mild haze (grade 1) on the scale used and this was present from the start after CXL. The apparently insignificant postoperative haze could be attributed to the use of MMC in all of the cases after finalizing the laser ablation procedure.

The corneal indices were included in our study in an attempt to study the impact of corneal ablation by iDesign-guided profile on improving the corneal irregularities in these eyes; we noted reduction in values of the corneal indices. The reduction in IVA, IHA, IHD, and CKI was not statistically significant. While the reduction in ISV,  $R_{min}$ , and KI was statistically significant. The study shows also stability of the indices through the follow-up period. By studying these values, it is to be noted that the improvement of visual performance in these patients was achieved without increasing their corneal irregularities. On the contrary, all corneal regularity indices demonstrated a trend toward a more regular cornea although it was not statistically significant in some of the studied indices.

Our study demonstrates that wavefront-guided PRK treatment seems to be safe and effective to restore the visual function in aberrated stable keratoconic eyes. By this technique we provide a better management of the cause–effect relationship. In other words, we are treating the higher order aberrations that are responsible for image quality degradation. At the same time, we are correcting the lower order refractive errors that affect negatively the visual performance of those patients, the precisely positioned excimer laser beam using a platform that compensates for cyclotorsion and pupil centroid shift ensures targeting the exact irregularities in the corneal surface that degrade the image.

Besides, the sequential protocol that we suggest is, in fact, making use of the stable cornea provided by previous CXL. This stable corneal surface provides, in turn, a stable refractive surface (even still irregular) from which we can calculate a reliable and dependable ablation profile to correct the irregularity and avoid refractive surprises and changes that can potentially occur with the use of the simultaneous approach.

We strongly believe that the proposed protocol could be a very good modality to provide a useful glasses-independent vision for selected keratoconic eyes after CXL.

Of course, in the dilemma of keratoconus, the treating surgeon cannot promise perfection but at least can deliver to his patient, by the proposed protocol, a useful good vision using the patient's own cornea without the need for keratoplasty modalities with all their known complications.

---

## 26.10 Conclusions

High-definition aberrometers are able to read highly aberrated corneas (such as in stable keratoconus) and generate out of them a reliable ablation profile which can be used to reduce refractive error / HOAs in such eyes and provide better quality of vision for those patients.

Wavefront-guided ablation profile seems to be a good option to address visual rehabilitation in stable keratoconic eyes.

Sequential PRK for keratoconic eyes after doing corneal CXL seems to be a good option as

it can address precisely the visual rehabilitation and refractive error correction in selected cases after having the maximum effect of CXL.

The proposed protocol could be a good tool to provide a useful glasses-independent vision for selected keratoconic eyes using their own cornea without the need for any type of keratoplasty.

**Compliance with Ethical Requirements** Mohamed Shafik Shaheen and Ahmed Shalaby declare that they have no conflict of interest.

All procedures followed were in accordance with the ethical standards of the responsible committee on human experimentation (institutional and national and with the Helsinki Declaration of 1975, as revised in 2000. Informed consent was obtained from all patients for being included in the study.

No animal studies were performed by the authors for this chapter.

*Financial disclosure:* The studies by the authors included in this chapter were supported in part by an unrestricted educational grant from Abbott Medical Optics Inc.

---

## References

1. Kymionis GD, Portaliou DM, Kounis GA, Limnopoulou AN, Kontadakis GA, Grentzelos MA. Simultaneous topography-guided photorefractive keratectomy followed by corneal collagen cross-linking for keratoconus. *Am J Ophthalmol.* 2011;152(5):748–55.
2. Krueger RR, Kanellopoulos AJ. Stability of simultaneous topography-guided photorefractive keratectomy and riboflavin/UVA cross-linking for progressive keratoconus: case reports. *J Refract Surg.* 2010;26(10):S827–32.
3. Kanellopoulos AJ, Binder PS. Collagen cross-linking (CCL) with sequential topography-guided PRK: a temporizing alternative for keratoconus to penetrating keratoplasty. *Cornea.* 2007;26(7):891–5.
4. Kanellopoulos AJ, Asimellis G. Keratoconus management: long-term stability of topography-guided normalization combined with high-fluence CXL stabilization (the Athens Protocol). *J Refract Surg.* 2014;30(2):88–93.
5. Kanellopoulos AJ. Comparison of sequential vs same-day simultaneous collagen cross-linking and topography-guided PRK for treatment of keratoconus. *J Refract Surg.* 2009;25(9):S812.
6. Weed K, Macewen C, McGhee C. The Dundee University Scottish Keratoconus Study II: a prospective study of optical and surgical correction. *Ophthalmic Physiol Opt.* 2007;27(6):561–7.
7. Bühren J, Kühne C, Kohnen T. Defining subclinical keratoconus using corneal first-surface higher-order aberrations. *Am J Ophthalmol.* 2007;143(3):381–9.e2.



8. Shafik Shaheen M, El-Kateb M, Hafez TA, Piñero DP, Khalifa MA. Wavefront-guided laser treatment using a high-resolution aberrometer to measure irregular corneas: a pilot study. *J Refract Surg.* 2015;31(6):411–8.
9. Fernandez GET, Serrano MG. Early clinical experience using custom excimer laser ablations to treat irregular astigmatism. *J Cataract Refract Surg.* 2000;26(10):1442–50.
10. Alió JL, Piñero DP, Puche ABP. Corneal wavefront-guided photorefractive keratectomy in patients with irregular corneas after corneal refractive surgery. *J Cataract Refract Surg.* 2008;34(10):1727–35.
11. López-Miguel A, Maldonado MJ, Belzunce A, Barrio-Barrio J, Coco-Martín MB, Nieto JC. Precision of a commercial Hartmann-Shack aberrometer: limits of total wavefront laser vision correction. *Am J Ophthalmol.* 2012;154(5):799–807.e5.
12. Koller T, Pajic B, Vinciguerra P, Seiler T. Flattening of the cornea after collagen crosslinking for keratoconus. *J Cataract Refract Surg.* 2011;37(8):1488–92.
13. Alió JL, Shabayek MH. Corneal higher order aberrations: a method to grade keratoconus. *J Refract Surg.* 2006;22(6):539.
14. Chelala E, El Rami H, Dirani A, Fadlallah A, Fakhoury O, Warrak E. Photorefractive keratectomy in patients with mild to moderate stable keratoconus: a five-year prospective follow-up study. *Clin Ophthalmol.* 2013;7:1923.
15. Applegate RA, Marsack JD, Ramos R, Sarver EJ. Interaction between aberrations to improve or reduce visual performance. *J Cataract Refract Surg.* 2003;29(8):1487–95.
16. Wollensak G, Spoerl E, Seiler T. Riboflavin/ultraviolet-A-induced collagen cross-linking for the treatment of keratoconus. *Am J Ophthalmol.* 2003;135(5):620–7.
17. Wollensak G. Cross-linking treatment of progressive keratoconus: new hope. *Curr Opin Ophthalmol.* 2006;17(4):356–60.
18. Koller T, Seiler T. Therapeutic cross-linking of the cornea using riboflavin/UVA. *Klin Monbl Augenheilkd.* 2007;224(9):700–6.
19. Koller T, Mrochen M, Seiler T. Complication and failure rates after corneal cross-linking. *J Cataract Refract Surg.* 2009;35(8):1358–62.
20. Schallhorn SC, Tanzer DJ, Kaupp SE, Brown M, Malady SE. Comparison of night driving performance after wavefront-guided and conventional LASIK for moderate myopia. *Ophthalmology.* 2009;116(4):702–9.
21. Kanellopoulos AJ, Pe LH. Wavefront-guided enhancements using the wavelight excimer laser in symptomatic eyes previously treated with LASIK. *J Refract Surg.* 2006;22(4):345–9.
22. Kymionis GD, Kontadakis GA, Kounis GA, Portaliou DM, Karavitaki AE, Magarakis M, et al. Simultaneous topography-guided PRK followed by corneal collagen cross-linking for keratoconus. *J Refract Surg.* 2009;25(9):S807–11.
23. Mazzotta C, Caporossi T, Denaro R, Bovone C, Sparano C, Paradiso A, et al. Morphological and functional correlations in riboflavin/UVA corneal collagen cross-linking for keratoconus. *Acta Ophthalmol.* 2012;90(3):259–65.