

Michela Maffi and Mario Lima

8.1 Introduction

Congenital esophageal stenosis (CES) is a rare entity with an estimated incidence of 1:25,000–50,000 live births [1]. This anomaly was first reported in 1936 by Frey and Duschl who described the case of a dead 19-year-old girl with a suspected diagnosis of achalasia. The necropsy revealed cartilage in the cardia [2]. At the beginning of the past century, all the esophageal stenoses diagnosed in newborn were considered congenital so that Sir Arthur Keith in a report of 1910 did not differentiate between esophageal stenosis and atresia [3]. CES was also described as a further type of esophageal atresia (EA) and included in Gross classification as type F [4].

8.2 Classification

The most used classification of CES has been proposed by Nihoul-Fèkètè et al. in 1987 [5]. This classification delineates three forms of CES:

1. Tracheobronchial remnant
2. Segmental fibromuscular hypertrophy
3. Membranous web

M. Maffi (✉) • M. Lima
Pediatric Surgery, S. Orsola-Malpighi Hospital,
Bologna University, Via Massarenti 11, 40138
Bologna, Italy
e-mail: michela.maffi@libero.it; mario.lima@unibo.it

8.2.1 Tracheobronchial Remnant

The embryological origin of the cartilaginous ring is to be found in the separation of the primitive esophagus and respiratory diverticulum, which is performed by the tracheoesophageal septum, formed by the proliferation of cells starting from the lateral crests of the primitive foregut. It may happen that, with the consequent cranial lengthening of the esophagus and the respiratory tree, mesenchymal cells belonging to the respiratory diverticulum can remain embedded in the esophageal wall. These ectopic tissue remnants are typically represented by seromucinous respiratory glands, respiratory epithelium, and cartilaginous tissue. Stenosis results from extrinsic compression by the ectopic tissue, as well as from inextensibility caused by the structure of the cartilaginous tissue. Heterotopic tissue of the tracheobronchial origin is most frequently seen in the distal esophagus, particularly in the lower third with a preference to the cardia level.

8.2.2 Segmental Fibromuscular Hypertrophy

This form is characterized by subepithelial proliferation of the smooth muscle and fibrosis. The embryologic origin of the esophageal stricture has to be found in developmental defects incurred within the first 10 weeks of gestation. The primitive gut separates from the trachea for the formation

of a tracheoesophageal septum to approximately the 36th day of development. After 4 weeks, the muscular and submucosal layers are well represented. Subsequently, between the seventh and the eighth week of gestational life, there is a process of rapid proliferation of epithelial cells that leads to an almost complete closure of the primitive esophagus lumen except for small vacuolated areas that remain in the context of obliterated lumen. These areas, at the end of the 10th week of gestational age, give rise to a process of channeling which leads to the reformation of a tubular cavity. The primitive fetal esophageal epithelium is composed of ciliated cells that are being replaced, at about the 4th month, by stratified squamous epithelium. The fibromuscular stenosis is mainly located in the middle third and in the proximal part of the lower third of the esophagus.

8.2.3 Mucosal Web

The development of this web is similar to that of the diaphragm which can be located in any other intestinal tract. These membranes are in fact strictly related to defects of recanalization of the previously obliterated lumen which occurred during the 10th week of gestation. Histologically these diaphragms are composed only by mucosa and submucosa.

8.3 Associated Anomalies

CES can be associated with other congenital anomalies in 17–33% of cases [6]. The most reported association is with esophageal atresia and/or tracheobronchial fistula whose frequency ranges from 3 to 14% [1]. Other anomalies include chromosomal anomalies, cardiac anomalies, intestinal atresia, anorectal malformation, and trisomy 21 [1, 3].

8.4 Symptoms

The clinical feature of the complete esophageal web appears at birth, and it is the same for esophageal atresia, characterized by drooling, cough-

ing, and regurgitation. The inability to place a nasogastric tube in the stomach confirms the diagnosis. However if the diaphragm is incomplete or broken, or in case of fibromuscular stenosis or cartilaginous ectopic tissue, the clinical onset occurs later in life, usually when solid foods are introduced in the diet. In the literature, it is reported that the onset of symptoms can occur in a wide range of age, from 1 day old to 57 years of age, but it usually takes place during the first year of life, with dysphagia, vomiting during meals, regurgitation of undigested food, insufficient growth, and relapsing pneumonia due to aspiration.

8.5 Diagnosis

The diagnosis of esophageal stenosis is not particularly difficult and is done with a *barium esophagogram* performed on the indication of the clinical feature (Fig. 8.1). Less simple and certainly more important for a correct surgical therapy is the differential diagnosis that must be made between the various forms of esophageal stenosis; among these, achalasia and peptic strictures may also be included.

The radiologic appearance is morphologically similar in all cases of esophageal stenosis: an important esophageal dilation followed by a threadlike narrowing. The site of the stricture can be useful to reach a first differential diagnosis. It has been seen how the three different forms of congenital cause have different favorite localizations.

The ectopic cartilaginous tissue is found in more than 90% of cases in the lower third of the esophagus and especially near the cardia; fibromuscular stenosis is more frequently found between the middle and the lower third with a predilection for the proximal part of the latter; in achalasia instead, by definition, the stenotic portion is always located in the cardia.

A first rough differentiation between the three types of CES can be made by examining the patient. Symptoms caused by tracheobronchial remnants and fibromuscular stenosis are typical in early infancy, while those caused by achalasia

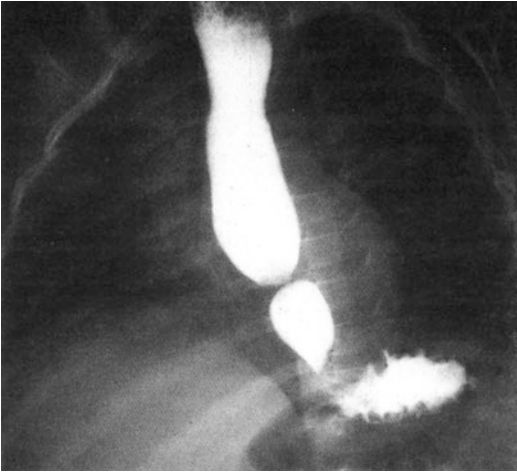


Fig. 8.1 Congenital stenosis of the distal third of the esophagus

usually occur later in school age; also peptic stricture typically affects older children. When radiographic examination is not able to identify the diagnosis, an *endoscopic study* can highlight the main characteristics of the lesion. The direct vision of the section affected by a peptic stricture will show an inflamed area also above the stenosis; the endoscopic images, associated with medical history and evaluation of symptoms, lead to the correct diagnosis. Regarding other types of stenosis, correct diagnosis can be made in the course of endoscopic examination, based on the ease or otherwise to overcome the restricted portion by the endoscope.

In case of achalasia, the cardia can be passed by the endoscope, forcing it kindly, and a mild dilation can be obtained, albeit only temporarily. In the presence of fibromuscular stenosis, the endoscope cannot exceed the stenotic tract that can be dilated with special probes. In ectopic cartilaginous ring, the direct vision does not allow the differential diagnosis, but the attempt to dilate the narrow tract is usually unsuccessful, and this causes the operator to desist. In case of cardia localization of fibromuscular stenosis, differential diagnosis with achalasia becomes more difficult and in some cases impossible even after endoscopy. Even if most of the patients' endoscopic examination can lead to diagnosis, further information can be obtained with a manometric

examination. Also the outcome of dilations can be used as a diagnostic criterion: in case of achalasia, improvement will only be transitional, while it will be present and often progressive in case of congenital stenosis sensitive to expansion.

Endoscopic ultrasonography (EUS) is a useful tool in differential diagnosis between the three types of congenital stenosis. In particular, EUS is able to evidence the presence of cartilage which is difficult to be seen with CT scan or MRI. EUS is available for pediatric patients from 2001, and recently, a 3D miniprobe has been used to obtain multiplanar and oblique views of the stenosis [7–9].

8.5.1 Therapy

The first-line treatment of CES is dilation. It can be performed with hydrostatic balloon probe or with Savary-Gilliard bougie. There is no strong evidence on which is the better technique, and the choice depends on the expertise of each center. Jones et al. reported advantages of balloon dilation because of radial and localized force applied by the balloon, rather than axial shearing force applied on stenosis by the bougie [10]. On the other hand, Romeo et al. reported a higher risk of perforation with balloon dilation affirming that bouginage seems safer [9]. An endoscopic check after dilation is mandatory, and in case of deep mucosal laceration, an esophagogram is recommended.

Whatever the technique chosen, the dilations are usually performed every 15 days until reaching a stable esophageal caliber. The subsequent dilations are established on the basis of clinics, age, and results obtained on each patient.

Some authors reported success in endoscopic electrocauterization or partial resection of mucosal web added to dilations [11, 12].

Fibromuscular stenosis and mucosal web usually respond successfully to dilations, while in case of cartilaginous remnant or dilation failure, it is necessary to undergo surgery (Fig. 8.2).

In these cases, the treatment of choice is the resection of the stenotic tract followed by end-to-end anastomosis (Fig. 8.3) and eventual fundoplication if the stenosis is closed to gastroesophageal

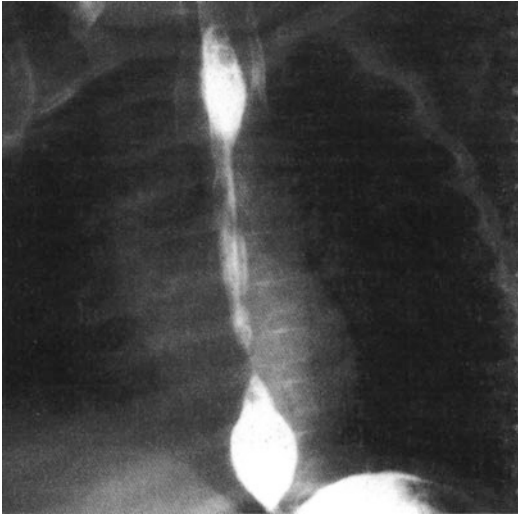


Fig. 8.2 Barium esophagogram after six dilations. The patient continued to complain of severe dysphagia

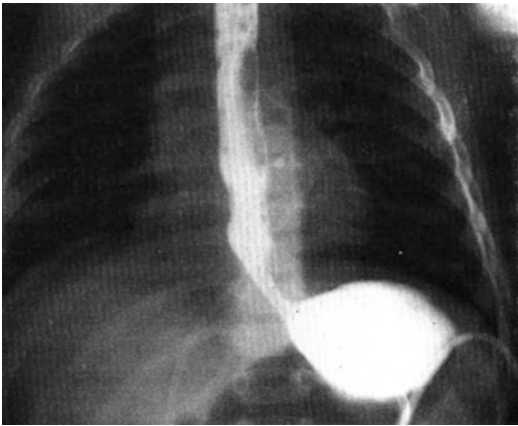


Fig. 8.3 The previous case after resection of the stenotic tract and end-to-end anastomosis

junction [2, 13]. The stricture can be identified externally by palpation or with the use of a catheter placed preoperatively. Maeda and Saito reported two patients affected by tracheobronchial remnant treated with circular extramucosal myectomy at the stenotic level followed by suture of the esophageal wall. This technique allows extirpation of the cartilage and muscular disarrangement avoiding lumen opening [14, 15].

8.6 Complications and Outcome

The most serious complication is surely the esophageal perforation whose reported incidence varies widely (from 10 to 44%) [9]. The treatment in these cases is initially conservative with fasting, nasogastric tube, and parenteral nutrition. In severe cases, segmental replacement of the esophagus may be necessary [13].

Despite various therapeutic options that could obtain a resolution of the stricture from a morphological point of view, a substantial proportion of patients (approximately 30–60%) continues to complain of dysphagia [7]. This suggests that these patients should be followed up for a long time.

References

1. McCann F, Michaud L, Aspirot A, Levesque D, Gottrand F, Faure C (2015) Congenital esophageal stenosis associated with esophageal atresia. *Dis Esophagus* 28(3):211–215
2. Rebelo PG, Ormonde JV, Ormonde Filho JB (2013) Congenital esophageal stenosis owing to tracheobronchial remnants. *Rev Paul Pediatr* 31(3):406–410
3. Appignani A (1993) Stenosi esofagee congenite. In: Dòmini R, Lima M (eds) *Chirurgia delle malformazioni digestive*. Piccin, Bologna
4. van Poll D, van der Zee DC (2012) Thoracoscopic treatment of congenital esophageal stenosis in combination with H-type tracheoesophageal fistula. *J Pediatr Surg* 47(8):1611–1613
5. Nihoul-Fèkète C, De Backer A, Lortat-Jacob S et al (1987) Congenital esophageal stenosis: a review of 20 cases. *Pediatr Surg Int* 2:86–92
6. Vasudevan SA, Kerendi F, Lee H, Ricketts RR (2002) Management of congenital esophageal stenosis. *J Pediatr Surg* 37(7):1024–1026
7. Michaud L, Coutenier F, Podevin G et al (2013) Characteristics and management of congenital esophageal stenosis: findings from a multicenter study. *Orphanet J Rare Dis* 8:186
8. Bocus P, Realdon S, Eloubeidi MA, Diamantis G, Betalli P, Gamba P, Zanon GF, Battaglia G (2011) High-frequency miniprobe and 3-dimensional EUS for preoperative evaluation of the etiology of congenital esophageal stenosis in children (with video). *Gastrointest Endosc* 74(1):204–207
9. Romeo E, Foschia F, de Angelis P et al (2011) Endoscopic management of congenital esophageal stenosis. *J Pediatr Surg* 46(5):838–841

10. Jones DW, Kunisaki SM, Teitelbaum DH, Spigland NA, Coran AG (2010) Congenital esophageal stenosis: the differential diagnosis and management. *Pediatr Surg Int* 26(5):547–551
11. Chao HC, Chen SY, Kong MS (2008) Successful treatment of congenital esophageal web by endoscopic electrocauterization and balloon dilatation. *J Pediatr Surg* 43(1):e13–e15
12. Takamizawa S, Tsugawa C, Mouri N, Satoh S, Kanegawa K, Nishijima E, Muraji T (2002) Congenital esophageal stenosis: therapeutic strategy based on etiology. *J Pediatr Surg* 37(2):197–201
13. Amae S, Nio M, Kamiyama T, Ishii T, Yoshida S, Hayashi Y, Ohi R (2003) Clinical characteristics and management of congenital esophageal stenosis: a report on 14 cases. *J Pediatr Surg* 38(4):565–570
14. Maeda K, Hisamatsu C, Hasegawa T, Tanaka H, Okita Y (2004) Circular myectomy for the treatment of congenital esophageal stenosis owing to tracheobronchial remnant. *J Pediatr Surg* 39(12):1765–1768
15. Saito T, Ise K, Kawahara Y, Yamashita M, Shimizu H, Suzuki H, Gotoh M (2008) Congenital esophageal stenosis because of tracheobronchial remnant and treated by circular myectomy: a case report. *J Pediatr Surg* 43(3):583–585