

Clinical Oral Medicine and Pathology

Second Edition

Jean M. Bruch
Nathaniel S. Treister

 Springer

Clinical Oral Medicine and Pathology

Jean M. Bruch • Nathaniel S. Treister

Clinical Oral Medicine and Pathology

 Springer

Jean M. Bruch
Massachusetts Eye & Ear Infirmary
Harvard Medical School
Boston, MA, USA

Nathaniel S. Treister
Brigham & Women's Hospital
Dana-Farber Cancer Institute
Harvard School of Dental Medicine
Boston, MA, USA

ISBN 978-3-319-29765-1 ISBN 978-3-319-29767-5 (eBook)
DOI 10.1007/978-3-319-29767-5

Library of Congress Control Number: 2016938530

© Springer International Publishing Switzerland 2017

This work is subject to copyright. All rights are reserved by the Publisher, whether the whole or part of the material is concerned, specifically the rights of translation, reprinting, reuse of illustrations, recitation, broadcasting, reproduction on microfilms or in any other physical way, and transmission or information storage and retrieval, electronic adaptation, computer software, or by similar or dissimilar methodology now known or hereafter developed.

The use of general descriptive names, registered names, trademarks, service marks, etc. in this publication does not imply, even in the absence of a specific statement, that such names are exempt from the relevant protective laws and regulations and therefore free for general use.

The publisher, the authors and the editors are safe to assume that the advice and information in this book are believed to be true and accurate at the date of publication. Neither the publisher nor the authors or the editors give a warranty, express or implied, with respect to the material contained herein or for any errors or omissions that may have been made.

Printed on acid-free paper

This Springer imprint is published by Springer Nature
The registered company is Springer International Publishing AG Switzerland

Preface to the Second Edition

What is *oral medicine*? Broadly speaking, it is the field of medicine that encompasses the diagnosis and management of diseases affecting the oral cavity. Many conditions produce oral signs and symptoms, and yet the oral cavity is an unfamiliar zone for many clinicians. Physicians generally receive little formal training in dental and oral medicine and tend to view the oral cavity as a place reserved for their “dental” colleagues. Likewise, dentists are experts in the diagnosis and management of diseases related to the teeth and periodontium; however, the proportion of dental education dedicated to the “non-dental” part of the oral cavity often falls short. For these reasons, it is not at all uncommon for a patient to visit 5–10 doctors before receiving a correct diagnosis and appropriate treatment plan, often months to years following the onset of symptoms. It was from this landscape that this book was designed and written.

Given the wide range of clinical presentations, patients with oral complaints may seek out or be referred to a variety of health-care providers, including primary care physicians, dentists, otolaryngologists, oral surgeons, dermatologists, neurologists, psychiatrists, and rheumatologists. Many of these oral conditions can be recognized and managed without the need for additional specialty referral. In this thoroughly revised and updated second edition, we have attempted to provide a rational, concise, and yet comprehensive approach to the practice of oral medicine for all clinicians who are likely to encounter diseases of the oral cavity in their daily practice. In addition to including a new chapter entitled “Oral Sequelae of Cancer and Cancer Therapy,” the summary boxes throughout the book have been updated and improved for fast and effective clinical reference. We have included specific guidelines on diagnosis, management, and follow-up for all included oral medicine conditions. Our intent was to create a clinically relevant and accessible resource for health-care professionals, truly bridging the worlds of dentistry and medicine.

Jean M. Bruch
Nathaniel S. Treister

Boston, MA, USA

Acknowledgments

We would like to thank Eric Stoopler, Mark Lerman, Ross Kerr, Andres Pinto, Juan Yepes, Vidya Sankar, Raj Lalla, Kevin Emerick, Francisco Marty, and Dena Fischer for their critical and constructive comments on the text. We are indebted to Mark Lerman, Andres Pinto, Sook-Bin Woo, Stephen Sonis, Ross Kerr, Mark Schubert, and Scott De Rossi for their generous contributions of clinical images. We are particularly grateful to our administrative and clinical coworkers and professional colleagues for their continued dedication and drive toward excellence in patient care. We extend our gratitude to our mentors and colleagues who have provided invaluable insight, guidance, and inspiration and to our students, residents, and fellows for their continuous enthusiasm for knowledge and growth. Most importantly, we cannot forget our patients and their families, many of whom we will never forget, for putting their trust in our care. And last, but not least, we extend a very warm thanks to our loving families for their unconditional support of our professional and academic pursuits.

Jean M. Bruch
Nathaniel S. Treister

Boston, MA, USA

About the Authors

Jean M. Bruch, D.M.D., M.D. Dr. Bruch earned her D.M.D. from Harvard School of Dental Medicine in 1989 and M.D. from Harvard Medical School in 1991. She subsequently completed surgical residency training programs in oral and maxillofacial surgery at Massachusetts General Hospital and otolaryngology at Massachusetts Eye and Ear Infirmary as well as a fellowship in laryngology. She currently practices otolaryngology at Massachusetts Eye and Ear Infirmary with special interest in laryngology, salivary gland disorders, and oral diseases. She is currently an Assistant Professor of Otolaryngology at Harvard Medical School and spends time teaching medical students and otolaryngology residents.

Nathaniel S. Treister, D.M.D., D.M.Sc. Dr. Treister earned his D.M.D. from the University of Pennsylvania School of Dental Medicine in 2000. He subsequently completed his oral medicine residency and oral biology training at Harvard School of Dental Medicine. He is board certified in oral medicine and practices at Brigham and Women's Hospital and Dana-Farber Cancer Institute with special interest in oral mucosal diseases, salivary gland diseases, and oral complications in cancer patients. He is the Chief of the Division of Oral Medicine and Dentistry at Brigham and Women's Hospital and Dana-Farber Cancer Institute and an Associate Professor of Oral Medicine in the Department of Oral Medicine, Infection and Immunity at Harvard School of Dental Medicine.

Contents

1	Normal Anatomy	1
	Introduction.....	1
	Surface Landmarks	1
	Oral Mucosa.....	1
	Tongue.....	4
	Floor of Mouth.....	6
	Palate.....	7
	Dentition	7
	Temporomandibular Joint	9
	Innervation	10
	Jaws and Teeth	10
	Tongue.....	11
	Muscles of Mastication and Facial Muscles	12
	Salivary Glands	12
	Lymphatics.....	15
	Sources.....	16
2	Variants of Normal and Common Benign Conditions	17
	Introduction.....	17
	Physiologic Pigmentation	17
	Fordyce Granules	19
	Gingival Grafts.....	20
	Lingual Tonsil	20
	Fissured Tongue	21
	Geographic Tongue	22
	Median Rhomboid Glossitis	23
	Fibroma.....	24
	Inflammatory Papillary Hyperplasia	25
	Tori and Exostoses	27
	Ankyloglossia and Prominent Frenula.....	29
	Sources.....	30
3	Diagnostic Tests and Studies	31
	Introduction.....	31
	Examination	31
	Culture Techniques	33
	Bacterial Cultures.....	33
	Fungal Cultures	33

Viral Cultures	33
Blood Tests.....	34
Radiographic Studies	34
Plain Films	34
Computed Tomography.....	34
Magnetic Resonance Imaging.....	35
Other Imaging Studies	35
Cytology.....	35
Tissue Biopsy	37
Adjuvant Tests.....	41
Sources	43
4 White Lesions	45
Introduction.....	45
Leukoedema.....	45
Linea Alba	47
Cheek Biting	48
Hairy Tongue.....	49
Oral Hairy Leukoplakia	50
Nicotinic Stomatitis	51
White Sponge Nevus.....	52
Chemical Burn	52
Exfoliative Cheilitis	53
Sources	55
5 Immune-Mediated and Allergic Conditions	57
Introduction.....	57
Angioedema	57
Orofacial Granulomatosis	59
Traumatic Ulcerative Granuloma.....	60
Apthous Stomatitis.....	61
Behcet Disease	64
Erythema Multiforme.....	64
Oral Lichen Planus.....	69
Mucous Membrane Pemphigoid	73
Pemphigus Vulgaris.....	75
Other Autoimmune Vesiculobullous Diseases	76
Paraneoplastic Pemphigus	76
Epidermolysis Bullosa Acquisita	76
Linear IgA Disease	77
Sources	77
6 Pigmented Lesions	79
Introduction.....	79
Melanotic Lesions	79
Melanotic Macule	79
Pigmented Nevus	81
Mucosal Melanoma.....	82
Inflammatory Pigmentation	82

Endocrine-Related Pigmentation	83
Drug-Induced Pigmentation	84
Nonmelanotic Pigmentation.....	86
Amalgam Tattoo.....	86
Heavy Metals	86
Hemochromatosis	87
Vascular Lesions	88
Varix.....	88
Hemangioma.....	89
Pyogenic Granuloma.....	90
Kaposi Sarcoma	91
Other	92
Sources.....	93
7 Oral Infections.....	95
Introduction.....	95
Bacterial Infections	95
Odontogenic Infections.....	96
Parotitis	106
Fungal Infections	108
Oral Candidiasis.....	108
Deep Fungal Infections	111
Viral Infections.....	111
Herpes Simplex Virus	111
Varicella Zoster Virus.....	114
Cytomegalovirus	115
Epstein-Barr Virus.....	116
Human Papilloma Virus	117
Enterovirus	119
Sources.....	120
8 Salivary Gland Disease	121
Introduction.....	121
Mucus Extravasation and Retention Phenomena.....	121
Mucocele.....	121
Ranula	123
Mucus Retention Cyst.....	124
Sialadenitis.....	125
Sialolithiasis	125
Necrotizing Sialometaplasia	127
Sialadenosis (Sialosis)	128
Xerostomia.....	128
Sjögren Syndrome.....	129
Iatrogenic	130
Neoplasia.....	131
Benign Tumors.....	132
Malignant Tumors.....	132
Sources.....	133

9 Oral Cancer	135
Introduction.....	135
Epidemiology	135
Risk Factors	136
Tobacco	136
Alcohol.....	136
Sun Exposure	136
Betel	136
Viral.....	137
Immunosuppression	137
Nutrition.....	137
Sanguinaria	137
Other	137
High-Risk Sites	137
Tongue.....	137
Lip	138
Floor of Mouth.....	139
Signs and Symptoms.....	139
Squamous Cell Carcinoma.....	139
Verrucous Carcinoma.....	140
Histopathology	141
Terminology and Definitions	141
Biopsy Considerations	142
Potentially Malignant Lesions	142
Actinic Cheilitis (Sailor’s Lip; Solar Cheilitis).....	143
Leukoplakia.....	143
Proliferative Verrucous Leukoplakia.....	144
Tobacco Pouch Keratosis	144
Oral Submucous Fibrosis.....	145
Erythroplakia.....	146
Oral Lichen Planus.....	146
Cancer Staging	147
Treatment	148
Sources.....	150
10 Orofacial Pain Conditions	153
Introduction.....	153
Odontogenic Pain.....	155
Myofascial and Temporomandibular Joint Pain.....	156
History and Examination	156
Treatment	157
Atypical Facial Pain	159
Trigeminal Neuralgia	159
Burning Mouth Syndrome	161
Sources.....	162

11 Oral Manifestations of Systemic Disease	163
Introduction.....	163
Immune-Mediated Diseases.....	163
Systemic Lupus Erythematosus	163
Chronic Cutaneous Lupus Erythematosus	165
Progressive Systemic Sclerosis	165
IgG4 Disease.....	166
Gastrointestinal Disorders.....	167
Inflammatory Bowel Disease	167
Gardner Syndrome	169
Peutz-Jeghers Syndrome	170
Granulomatous Diseases.....	170
Wegener Granulomatosis	170
Sarcoidosis	171
Orofacial Granulomatosis	172
Human Immunodeficiency Virus	172
Hematologic Disorders	174
Anemia.....	174
Thrombocytopenia	175
Cyclic Neutropenia	176
Malignancy	176
Lymphomas.....	176
Leukemias	177
Metastatic Solid Tumors	177
Cowden Syndrome.....	178
Jaundice.....	179
Sources	180
12 Oral Sequelae of Cancer Therapy	181
Introduction.....	181
Principles of Dental Screening and Basic Oral Care	181
Principles of Dental Screening.....	181
Basic Oral Care	182
Surgery	182
Functional Deficits	182
Neurologic Deficits	183
Cosmetic Deficits	183
Chemotherapy	183
General Considerations	183
Bleeding	184
Infection	184
Pain	184
Dysguesia and Dysphagia	185
Targeted Therapy.....	185
Mammalian Target of Rapamycin Inhibitors	185
Multi-Targeted Tyrosine Kinase Inhibitors	185
Antiresorptive Therapies	186
Radiation Therapy.....	189

General Considerations	189
Mucositis.....	189
Xerostomia.....	190
Dysguesia, Trismus, Dental Caries	190
Osteoradionecrosis	190
Dysphagia	191
Allogeneic Hematopoietic Cell Transplantation.....	191
Acute Graft-Versus-Host Disease	191
Chronic Graft-Versus-Host Disease.....	192
Secondary Malignancy.....	193
Pediatric Oncology Considerations.....	194
Summary	195
Sources.....	196
13 Prescribing Guidelines for Commonly Used Medications	197
Inflammatory Conditions	197
Topical Immunomodulatory Agents.....	197
Systemic Immunomodulatory Agents.....	198
Infectious Conditions	199
Antibacterial Agents.....	199
Antiviral Agents	200
Antifungal Agents	200
Salivary Gland Hypofunction	200
Sialogogues.....	200
Fluoride	200
Pain Conditions.....	201
Nonsteroidal Anti-inflammatory Agents.....	201
Anticonvulsants.....	201
Tricyclic Antidepressants.....	201
Topical Analgesics	202
Index.....	203

Introduction

The oral cavity sits at the opening of the digestive tract, bounded by the lips anteriorly and the oropharynx posteriorly, and is supported structurally by the maxillary (upper jaw) and mandibular (lower jaw) bone structures (Fig. 1.1). The vermilion zone serves as the transition area between the moist oral mucosa and the skin of the face. The oral structures are adapted to serve a variety of functions, including maintenance of a protective barrier, mastication, and initiation of digestion, special taste sensation, speech and swallowing, immunologic defense, and provision of salivary lubricants and buffers.

Surface Landmarks

The oral cavity can be subdivided broadly into three areas consisting of the vestibule, oral cavity proper, and oropharynx (Fig. 1.2). The *vestibule* is defined as the space between the lips or cheeks laterally and the dentition medially. The *oral cavity proper* lies inside the dental arches and is bounded posteriorly by the anterior pillar of the fauces, or *palatoglossal arch*. The *oropharynx* lies posterior to the palatoglossal arch, and includes the posterior one-third of the tongue, palatine tonsils, soft palate, and visible posterior wall (Fig. 1.3). The palatine tonsils sit in an

alcove between the anterior (*palatoglossal*) and posterior (*palatopharyngeal*) arches, or *pillars*, and frequently exhibit surface pits or depressions called *crypts* (Fig. 1.4).

The *retromolar trigone* is a roughly triangular area behind the mandibular molars representing the posterior aspect of the vestibule (Fig. 1.5). Adjacent to this is the *pterygomandibular raphe*, which indicates the junction between the buccinator and superior constrictor muscles, and is used as a landmark for administration of intraoral local anesthesia. The *parotid papilla*, which houses the opening of Stenson duct of the parotid gland, is located in the buccal vestibule opposite the maxillary second molar (Fig. 1.6).

The *labial frenula* are folds of mucosa in the midline maxillary and mandibular labial vestibules that anchor the lips to the alveolar mucosa or gingiva (Figs. 1.7 and 1.8). These can be quite prominent in some cases and even affect tooth eruption.

Oral Mucosa

The oral mucosa lines the oral cavity and serves a variety of functions, including protection, sensation, and secretion, and is histologically adapted to the unique environment inside the mouth. Oral mucosa lacks the appendages seen in skin, although sebaceous glands can be found in the upper lip and buccal mucosa in approximately

Fig. 1.1 Anatomy of the lips. Note small melanotic macule on the vermillion of the left upper lip near the border as well as physiologic pigmentation of upper lip

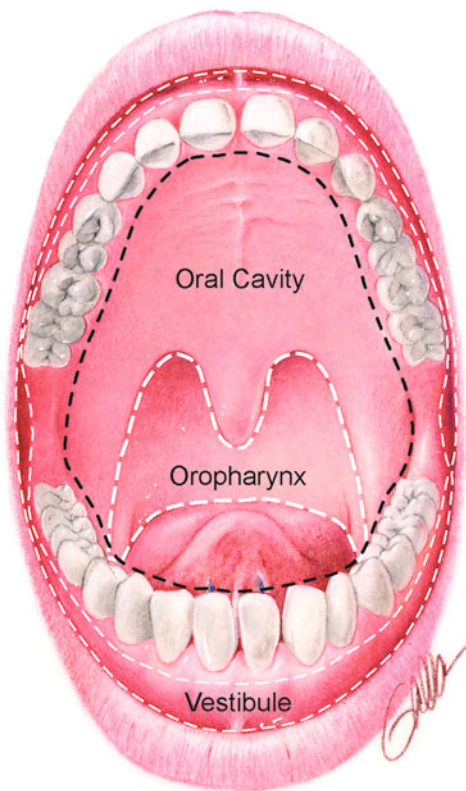
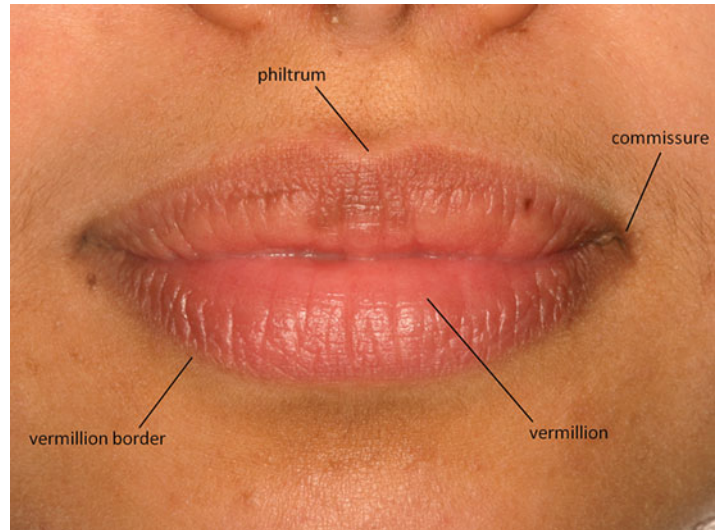


Fig. 1.2 Major areas of oral cavity: oral cavity proper, oropharynx, and vestibule. The vestibule is referred to as *buccal* posteriorly and *labial* anteriorly where it contacts the cheek and lip, respectively

75% of adults (see Chap. 2). Subepithelial minor salivary glands, responsible for a component of overall saliva production, are found throughout the oral cavity, with highest concentrations in the palate and lower lip. Aggregates of lymphoid tissue can be visualized on the posterior aspect of the tongue, however, the largest collection of lymphoid tissue, known as *Waldeyer ring*, is located posteriorly within the oropharynx. This consists of the palatine, lingual, and adenoid (pharyngeal) tonsils, and virtually encircles the entrance to the oropharynx. Small nodules of accessory tonsil tissue can be observed on the posterior wall of the oropharynx and may become enlarged with inflammation or infection and mistaken for a suspicious mass. Normal pits and depressions in tonsil tissue (*tonsillar crypts*) may become plugged with keratin or other debris and form cysts which appear yellow to white in color (Figs. 1.4 and 1.9).

The majority of the oral cavity is lined by soft, moist, pliable, nonkeratinized mucosa which is loosely attached to underlying tissues and exhibits some mobility. This consists of a stratified squamous epithelium which continually renews itself by division of progenitor cells in the deeper basal layer (Fig. 1.10). New cells show progressive maturation as they migrate to

Fig. 1.3 Posterior oral cavity/oropharynx. The anterior pillar (*palatoglossal arch*) marks the posterior boundary of the oral cavity proper. The palatine tonsils, which are located in the tonsillar fossae, are not visible in this photo. *Asterisk* marks posterior oropharyngeal wall

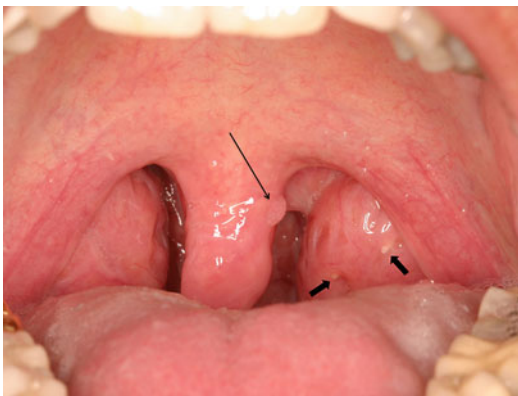
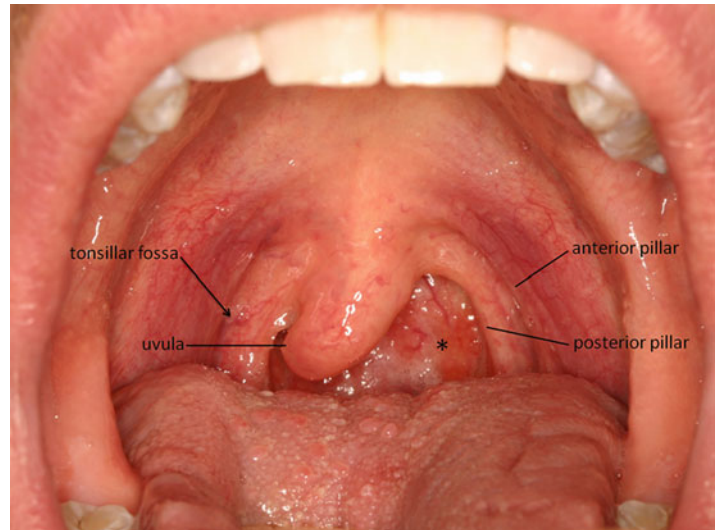


Fig. 1.4 Oropharynx showing large palatine tonsils with prominent crypts. Note debris visible within crypts on the left (*short arrows*) as well as a papilloma at the left base of uvula (*long arrow*)

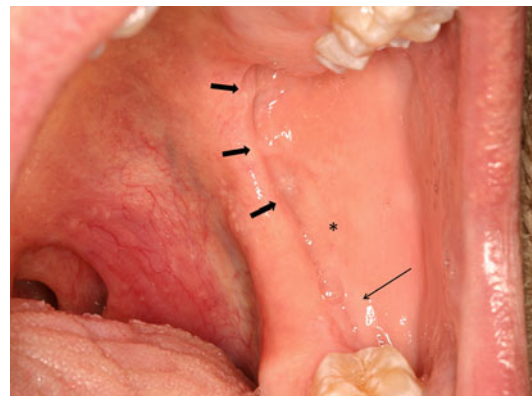


Fig. 1.5 Posterior oral cavity showing left retromolar trigone (*long arrow*) and pterygomandibular raphe (*short arrows*). Local anesthetic for a mandibular nerve block is injected lateral to the raphe, piercing the buccinator muscle (*asterisk*)

the surface layers, which are subsequently shed. Areas of the mouth that receive a greater degree of masticatory stress, namely the hard palate, tongue dorsum, and gingiva, are lined with keratinized mucosa, giving more protection against friction and abrasion. This tissue is more firmly attached to the underlying periosteum, which prevents damage from shearing forces.

The *mucogingival junction*, where the mobile mucosa lining the vestibule and floor of mouth

joins the tightly adherent *gingiva* of the dental alveolus, should be easily visible in the healthy state. The gingiva appears paler pink due to decreased visibility of underlying blood vessels through the relatively opaque keratin layer. The *gingival margin* should be well-defined with a slightly rolled appearance and pointed interdental papillae. Healthy tissue will exhibit stippling, representing collagen fibers attaching the gingiva to the underlying periosteum (Figs. 1.7, 1.8, and 1.11).

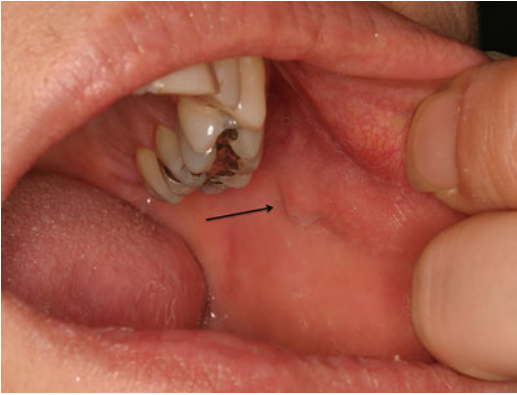


Fig. 1.6 Left maxillary buccal vestibule. Note parotid papilla with drop of saliva at opening of Stenson duct (*arrow*). Amalgam restorations are present in the maxillary posterior teeth

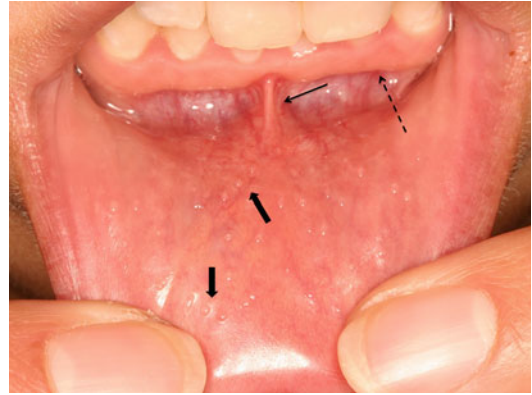


Fig. 1.8 Mandibular labial vestibule. Note frenulum (*long solid arrow*) and secretions from minor salivary glands in the lower lip (*short solid arrows*). The mucogingival junction represents the transition from thin nonkeratinized alveolar mucosa to the thicker keratinized attached gingiva and is quite prominent in this photo (*broken arrow*)

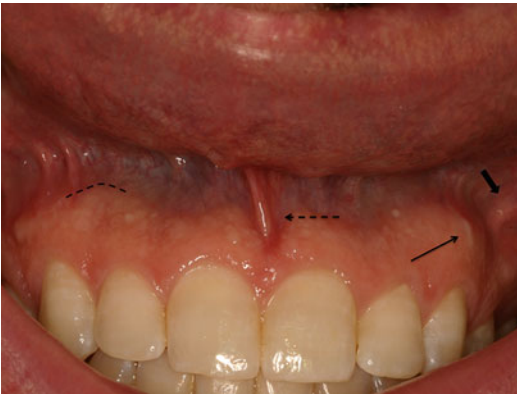

Fig. 1.7 Maxillary labial vestibule showing frenulum (*broken arrow*). Note bulge over root of canine tooth (canine eminence; *long solid arrow*) and adjacent depression (canine fossa; *short solid arrow*). A portion of the mucogingival junction is marked with a broken line on the right. Sebaceous glands are visible on the inner aspect of the upper lip

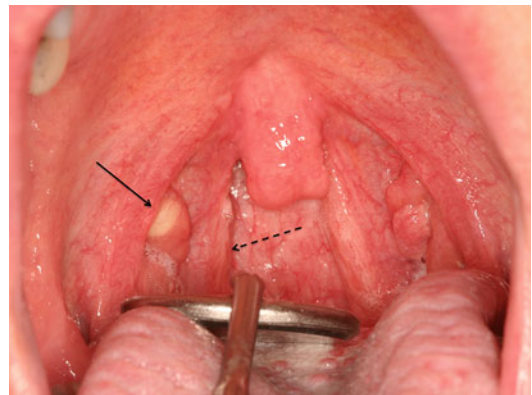


Fig. 1.9 Lobulated tonsils with lymphoepithelial cyst evident in the superior right tonsillar pole (*long solid arrow*). Note blunted and slightly bifid tip of uvula. Posterior pillar is marked with a *broken arrow*

Tongue

The tongue is divided into the *oral tongue* (anterior two-thirds) and *tongue base* (posterior third) by the *circumvallate papillae*, which form a v-shaped border anterior to the *foramen cecum* (Fig. 1.12). The foramen cecum is a shallow depression which exists as a developmental remnant of the thyroglossal duct. The oral tongue can be subdivided into four surface areas: tip,

lateral (sides), dorsum (top), and ventral (undersurface).

Embryologically, the mucosa lining the anterior portion of the tongue arises from the first branchial arch, and carries with it the trigeminal nerve. The mucosa of the tongue base arises from the third arch and is innervated by the glossopharyngeal nerve. The intrinsic muscles of the tongue are derived from the occipital somites, and are supplied by the hypoglossal nerve. Lingual tonsil tissue is frequently seen on the surface of the

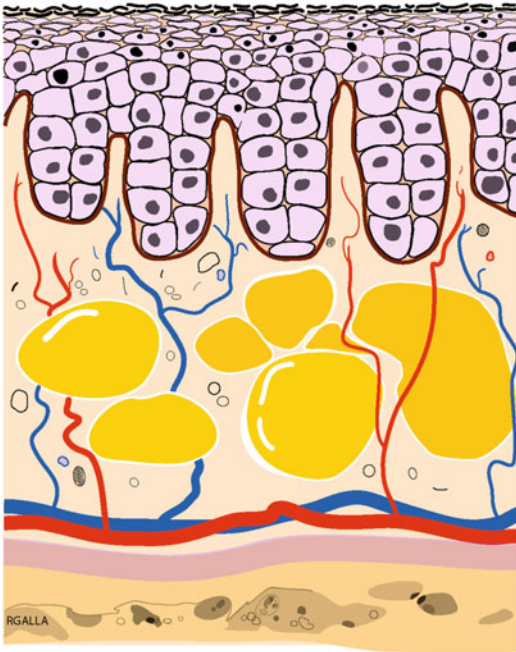


Fig. 1.10 Normal stratified squamous epithelium. The basal cells are cuboidal and abut the basement membrane. The shape becomes more flattened (*squamoid*) as the cells mature and move toward the surface. Irregularly shaped spinous, or prickle cells are present in the intermediate layers. Surface keratin is also present in this diagram. The connective tissue layer below the basement membrane contains blood vessels, lymphatics, fatty tissue, fibrous and elastic tissues, bone, and muscle

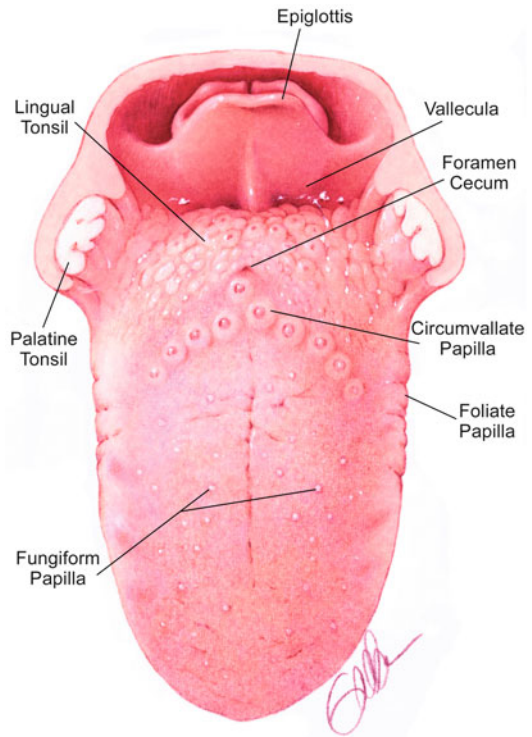


Fig. 1.12 Tongue dorsum showing major surface landmarks (Janfaza (2001) with permission; Lippincott Williams & Wilkins)

tongue posterior to the circumvallate papillae and lining the *vallecula*, which is a valley-like depression separating the tongue base from the epiglottis. Mucus glands are present posteriorly, and open into the crypts of the lingual tonsil.

The epithelium lining the tongue dorsum is specialized to withstand masticatory trauma as well as receive taste sensation. The dorsum has an irregular, bumpy, surface due to the presence of *papillae*. Although some taste receptors (*taste buds*) can be found in the soft palate and pharynx, the majority are located within the lingual papillae. Numerous small, hair-like, keratinized, *filiform papillae* cover the anterior surface of the tongue dorsum. While these do not contain taste receptors, the projections provide an abrasive surface that helps break down food against the hard palate during mastication. They are interspersed with fewer numbers of larger, smooth,

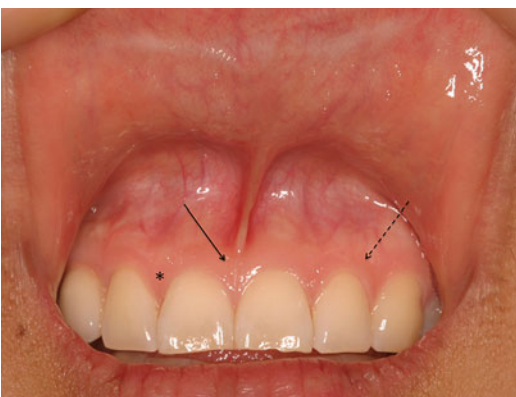

Fig. 1.11 Maxillary labial vestibule showing healthy appearing soft tissues with gingival stippling (*solid arrow*), rolled gingival margin (*broken arrow*), and sharp interdental papillae (*asterisk*). Note wear on incisal edges of maxillary central incisors

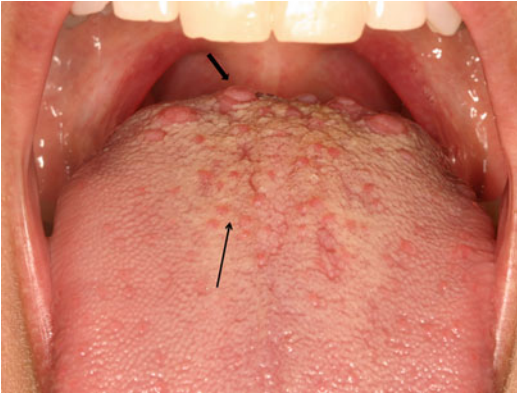

Fig. 1.13 Tongue dorsum showing contrast of fungiform papillae (*long arrow*) against background of lighter colored filiform papillae. Note row of circumvallate papillae (*short arrow*) posteriorly

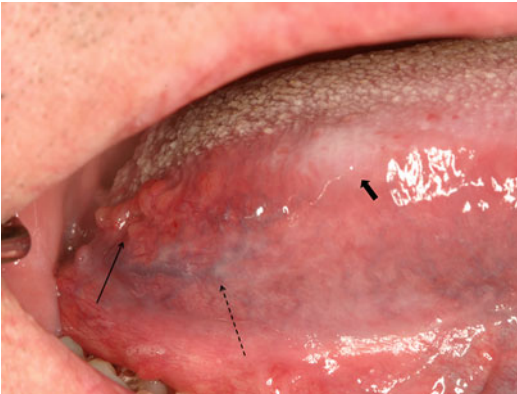

Fig. 1.14 Foliate papillae (*long solid arrow*). Also note prominent submucosal veins (*broken arrow*) and frictional hyperkeratosis (*short solid arrow*)

and more rounded nonkeratinized *fungiform papillae*, with taste buds located on their superior surface. The fungiform papillae frequently appear deeper red in hue compared to the filiform papillae, as the color of the underlying vascular core is transmitted prominently through the epithelium (Fig. 1.13). *Foliate papillae* are ridge-like structures on the posterolateral aspect of the tongue containing taste buds. These can be mistaken for abnormal tissue as they vary greatly in size and appearance, and can be virtually absent in some patients (Fig. 1.14). The *circumvallate papillae* are large round structures on the posterior tongue dorsum which also house taste buds.

These are often not appreciated on exam unless the tongue is protruded, and because of their prominence are sometimes mistaken for pathology (Fig. 1.13).

Floor of Mouth

The lateral and ventral surfaces of the tongue, as well as the floor of mouth, are lined by thin, smooth, nonkeratinized mucosa that is somewhat translucent (Fig. 1.15). Veins along the ventral surface of the tongue are easily visualized through the mucosa, often appearing quite prominent. A fringed fold of mucosa, called the *plica fimbriata*, sits lateral to the midline on each side and frequently contains tissue tags that can be mistaken for pathology. The sublingual salivary glands are located in the anterolateral floor of mouth and may be observed as a bulging mass in this area, whereas the submandibular glands are located further posteriorly and deep to the mylohyoid muscle. Both glands can be palpated using bimanual technique, with one hand positioned submandibularly. The main sublingual duct joins the submandibular (*Wharton*) duct to empty into the oral cavity at the sublingual papilla near the base of the lingual frenulum. Additional tiny ducts open from the sublingual gland directly into the overlying mucosa.

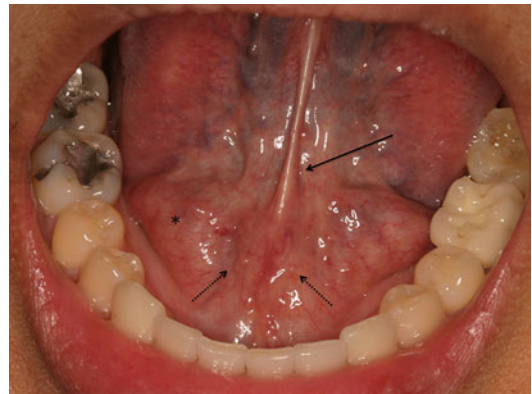


Fig. 1.15 Floor of mouth. Note frenulum (*solid arrow*), submandibular duct orifices (*broken arrows*), and visible prominence of sublingual gland under the mucosa (*asterisk*)

Palate

The palate forms the roof of the oral cavity and is divided into the *hard palate* anteriorly and the *soft palate* posteriorly (Figs. 1.16 and 1.17). The mucoperiosteum of the hard palate is tightly bound and immobile, which explains why dental injections into this area are especially painful. The midline *incisive papilla* anteriorly indicates the opening of the incisive canal, which transmits the sensory nasopalatine nerves to the anterior hard palate. A midline raphe can be visualized, representing embryologic fusion of the palatal shelves. Anteriorly positioned lateral folds of firm keratinized mucosa, known as *palatal rugae*, assist in mastication. At the midline posterior aspect of the hard palate, the palatine fovea can be seen as small pits, formed by coalescence of mucous gland ducts. The greater palatine neurovascular bundle exits its bony foramen under the mucosa opposite the maxillary second molar, innervating the posterior

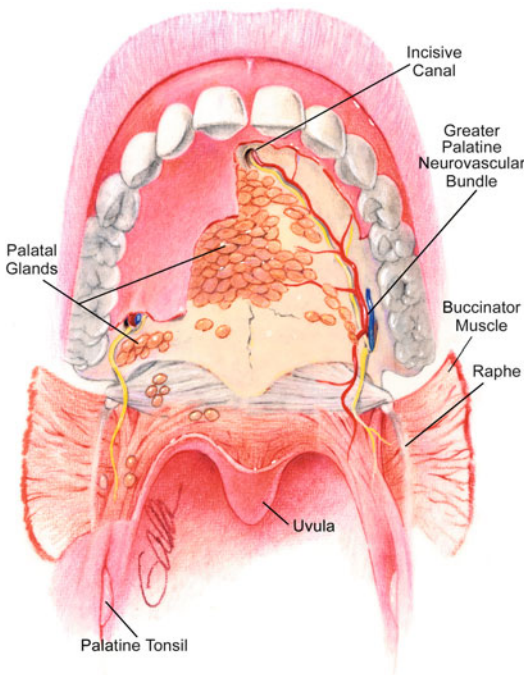


Fig. 1.16 Palate with cutaway view showing submucosal glands, musculature, and neurovascular bundles exiting the incisive and greater palatine foramina

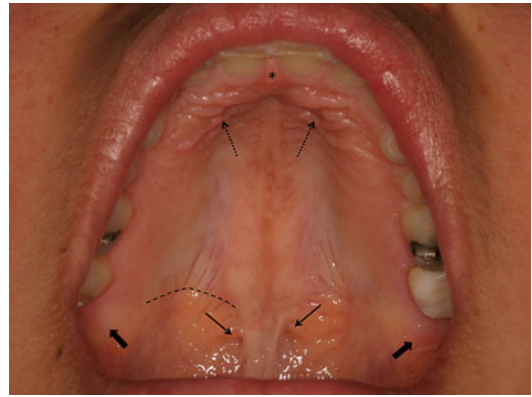


Fig. 1.17 Palate. Note junction of hard and soft palate (dotted line), maxillary tuberosities (thick solid arrows), palatine fovea (thin solid arrows), rugae (broken arrows), and incisive papilla (asterisk). The midline raphe is clearly evident

hard palate. The *maxillary tuberosity* can be palpated posterior and lateral to this behind the last molar, as the broad posterior extent of the maxilla.

Dentition

The tooth containing portion of the oral cavity is divided into maxillary and mandibular *dental arches* (Fig. 1.18). These are each further divided in half by the midline into *quadrants*. The teeth sit within the raised, *alveolar* (tooth bearing) *bone* of the dental arches. The adult, or secondary, dentition consists of 32 teeth, with 3 molars, 2 premolars (“bicuspid”), 1 canine (“eye tooth” or “cuspid”), and 2 incisors per quadrant. Molars and premolars are referred to as posterior teeth; canine and incisors are anterior. The pediatric or primary dentition contains a total of 20 teeth, with 2 molars, 1 canine, and 2 incisors per quadrant. The premolars erupt into the space occupied by the primary molars, and the permanent molars erupt posterior to this as the jaws and dental arches elongate with growth.

There are a variety of numbering systems used to identify each tooth. The most widely accepted method numbers the teeth from “1” to “32”, beginning with the upper right third molar (tooth #1) and proceeding clockwise across the upper

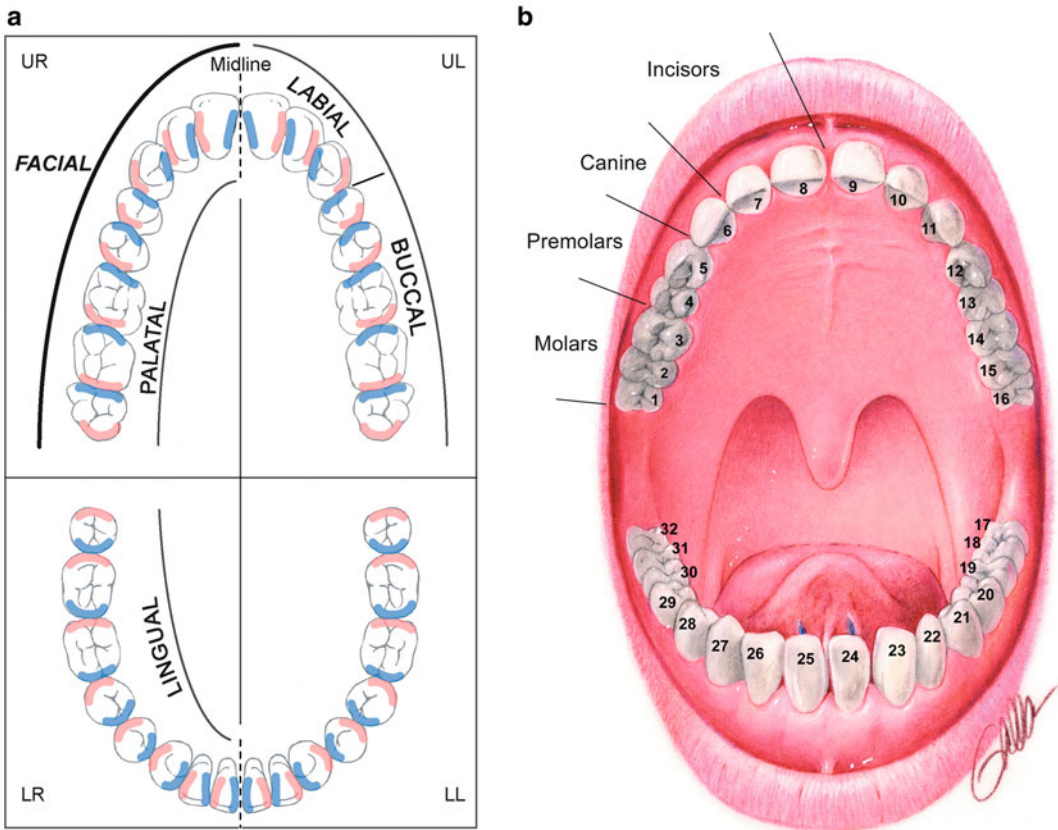


Fig. 1.18 Adult dentition. (a) Maxillary and mandibular dental arches. The four quadrants are referred to as upper right (UR), upper left (UL), lower left (LL), and lower right (LR). Mesial tooth surfaces are indicated in blue; distal in pink. The maxillary and mandibular dental midlines are marked with a broken line. The lingual, palatal, and

facial (which includes buccal and labial) surfaces are also indicated. (b) Commonly used numbering system for teeth, beginning with tooth #1 in the upper right quadrant and proceeding around the arches in a clockwise fashion. Each quadrant contains three molars, two premolars, one canine, and two incisors

then lower arches, ending with the lower right third molar (tooth #32).

Each tooth consists anatomically of a *root* and *crown*, with the crown being the portion visible above the gingival margin (Fig. 1.19). The bulk of the tooth is made up of a calcified substance known as *dentin*, with an outer surface layer of harder *enamel* covering the crown and a softer material called *cementum* lining the root surface. The hollow inner core of the tooth, or *pulp chamber*, contains the *pulp*, a soft jelly-like material composed of nerve endings and blood vessels entering through the tip (*apex*) of the root via the *apical foramen*.

The clinically visible junction of crown and root is called the *cementoenamel junction*, and is generally protected by the free upper edge of the gingival margin in the healthy state. Gingival recession may occur, with exposure of the softer root surface and concomitant increased risk of root surface caries, abrasion, or sensitivity. The tooth is anchored to the bony socket by collagen fibers attaching the root to cementum (*periodontal ligament*), which can be weakened or destroyed by periodontal disease.

The crown of every tooth has five surfaces, and each one is specifically named. The biting surface of a posterior tooth is referred to as the *occlusal*

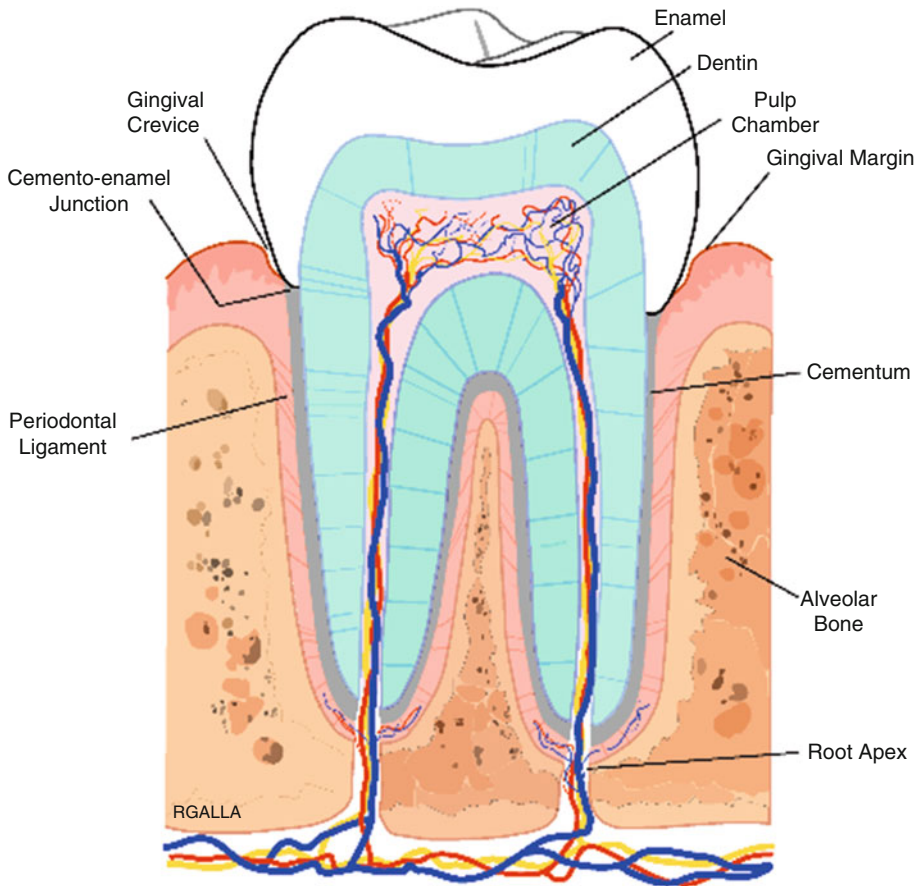


Fig. 1.19 Anatomy of a tooth. The cemento-enamel junction represents the anatomic junction of the root and crown; this is also referred to as the “neck” or cervical area of the tooth. The apical foramen, which opens at the

tip of each root, transmits the neurovascular bundle (Reprinted with permission from Janfaza (2001); Lippincott Williams & Wilkins)

surface. The more tapered biting, or incising, surface of an anterior tooth is called the *incisal edge*. The outer, or lateral, surface of a posterior tooth adjacent to the cheek is referred to as *buccal*. The same surface of an anterior tooth adjacent to the lip is *labial*. Alternatively, any buccal or labial surface may also be referred to as the *facial* surface. The inner, or medial, surface of a lower tooth abutting the tongue is *lingual*, and the same surface of an upper tooth facing the palate is *palatal*. The contacting surfaces of adjacent teeth are called *interproximal*; with the posteriorly oriented surface (i.e., away from midline) being *distal*, and the more anteriorly oriented surface (toward midline) being *mesial*.

Temporomandibular Joint

The temporomandibular joint (TMJ), where the football-shaped *condylar process* of the mandible articulates with the glenoid fossa of the temporal bone, is a synovial joint, and is located immediately anterior to the external auditory canal (Fig. 1.20). A roughly biconcave fibrocartilage disk (*meniscus*) is positioned within the joint space, dividing it into upper and lower cavities and allowing both hinge and gliding movements. The joint is enclosed by a fibrous capsule, and surrounding ligaments limit excessive joint movement. Dislocation of the jaw occurs when

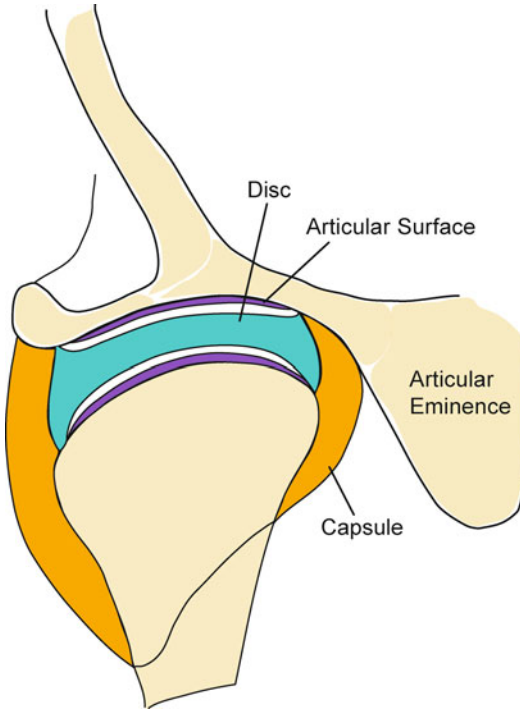


Fig. 1.20 Temporomandibular joint. Note how the mandibular condyle seats into the concave glenoid fossa of the temporal bone posterior to the articular eminence. The joint space is separated into superior and inferior spaces by the articular disk. In cases of internal derangement of the TMJ, the disk may be displaced anteriorly

the mandibular condyle advances anterior to the *articular eminence*.

The initial 10–15 mm of mouth opening occurs by hinge-like *rotation* of the condyle against the articular disk in the inferior joint space without movement of the disk itself or movement in the upper joint space. With wider mouth opening, the superior surface of the disk then glides anteriorly downward along the articular eminence, carrying the condyle forward. This second type of movement is referred to as *translation*. This sequence is then reversed with jaw closure.

Internal derangement of the joint can occur with destruction, detachment, or malpositioning of the disk, resulting in displacement or dislocation of the disk (usually anteriorly, in front of the condyle). In patients with this problem, a “click” may be present upon mouth opening as the condyle moves forward during translation and spontaneously recaptures the disk. This is referred to as *reduction* of the disk, and a *reciprocal click* may

be noted with closure as the condyle again moves posterior to the disk. In a situation where reduction does not occur, the disk can become jammed anterior to the condyle and limit the degree of mouth opening; in severe cases this can result in a *closed lock* with limitation of mouth opening.

Innervation

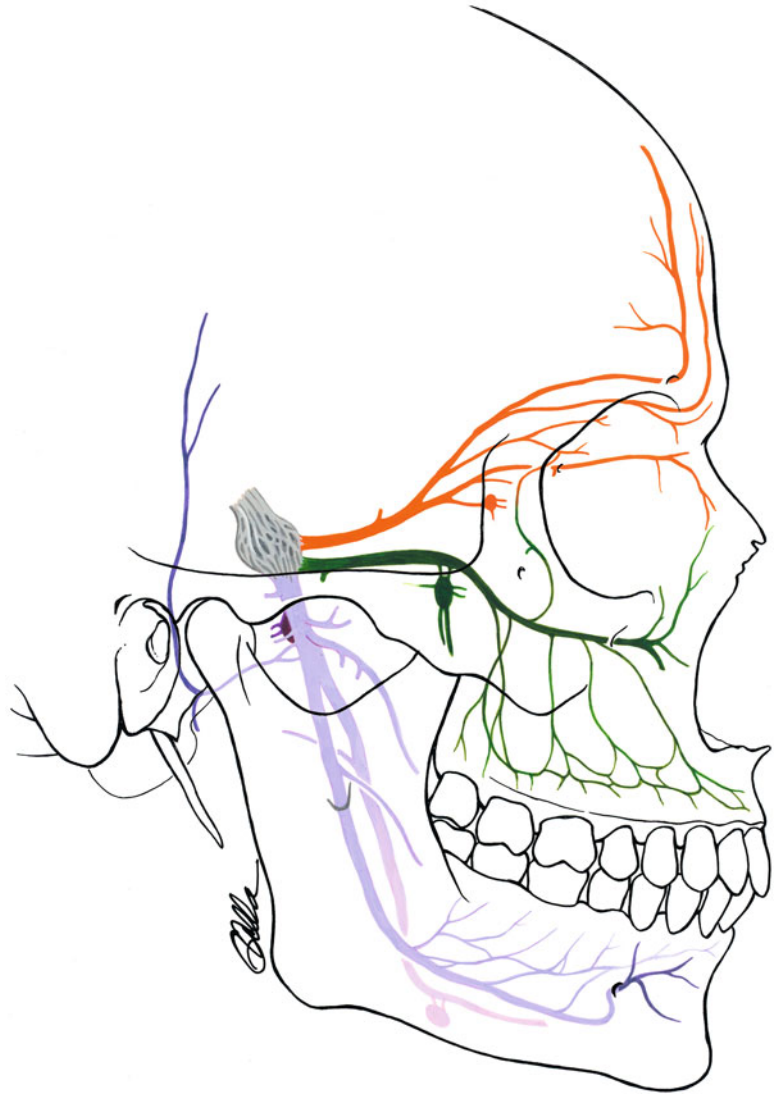
Jaws and Teeth

As first branchial arch derivatives, the maxilla and mandible are supplied by the trigeminal nerve (CN 5), which is predominantly sensory (Fig. 1.21; Table 1.1). The trigeminal (*semilunar* or *Gasserian*) ganglion is located in the floor of the middle cranial fossa and gives rise to three large nerve trunks. The *ophthalmic division* (V1) travels to the eye via the superior orbital fissure. The *maxillary division* (V2) passes through the foramen rotundum into the pterygopalatine fossa, where it receives sensory input from the maxillary alveolar bone, upper teeth, hard palate, and mucosa via the *superior alveolar nerves*, *nasopalatine nerve*, and *greater palatine nerve*. The *mandibular division* (V3) exits the skull base through the foramen ovale, passes through the infratemporal fossa, and provides sensory innervation to the lower jaw via the *inferior alveolar nerve* (IAN), *buccal nerve*, and *lingual nerve*. The IAN is encased within the bone of the mandible below the roots of the posterior mandibular teeth and is subject to injury during third molar (wisdom tooth) extraction. The *mental nerve*, which is a terminal branch of the IAN, exits the bone in the region of the premolar teeth, and can be injured by procedures in this area.

Tongue

The *lingual nerve* branches off the mandibular division of the trigeminal nerve near the inner ramus of the mandible and supplies general sensation (pain, touch, and temperature) to the mucosa of the tongue anterior to the circumvallate papillae, floor of mouth, and mandibular anterior lingual gingiva. This nerve can be injured during third molar extraction or procedures

Fig. 1.21 Trigeminal nerve showing the three divisions: V1 (*orange*), V2 (*green*), and V3 (*lavender*) (Reprinted with permission from Janfaza (2001); Lippincott Williams & Wilkins)



involving the floor of mouth such as removal of a submandibular duct stone. The tongue base receives sensory input via the glossopharyngeal nerve (CN 9), except for a small area posteriorly supplied by CN10. Motor innervation to the intrinsic tongue muscles is supplied by the hypoglossal nerve (CN 12). Taste buds are present in highest concentration at the base of the circumvallate papillae, and to a lesser extent around the fungiform papillae. There may also be scattered taste receptors on the foliate papillae and throughout the mucosa of the soft palate and epiglottis. Special sensory taste fibers travel through the chorda tympani branch of the facial nerve (CN 7) to join the lingual nerve, providing taste

sensation to the anterior two-thirds of the tongue. Special taste fibers to the posterior tongue travel with the glossopharyngeal nerve.

Muscles of Mastication and Facial Muscles

The primary muscles of mastication include the *masseter*, *temporalis*, *lateral (external) pterygoid*, and *medial (internal) pterygoid* (Fig. 1.22). The lateral pterygoid functions in mouth opening and mandibular protrusion, whereas the other muscles act mainly to close the mouth. These muscles are innervated by motor branches of the trigeminal

Table 1.1 Cranial nerves

Number	Name	Function(s)
I	Olfactory	Sense of smell
II	Optic	Vision
III	Oculomotor	Eye movement (except that mediated by lateral rectus and superior oblique muscles)
IV	Trochlear	Eye movement (mediated by superior oblique muscle)
V	Trigeminal	Oral/facial sensation (except taste); muscles of mastication
VI	Abducens	Eye movement (mediated by lateral rectus muscle)
VII	Facial	Facial sensation and taste (anterior tongue); muscles of facial expression and stapedius; secretomotor innervation to salivary glands (except parotid)
VIII	Vestibulocochlear	Hearing and balance
IX	Glossopharyngeal	Sensation and movement of pharynx; sensation and taste to posterior tongue; secretomotor innervation to parotid gland
X	Vagus	Main sensory and motor innervation to larynx and pharynx; taste sensation from epiglottis; parasympathetic supply to thoracic and abdominal viscera
XI	Spinal accessory	Trapezius and sternocleidomastoid muscles
XII	Hypoglossal	Tongue movement

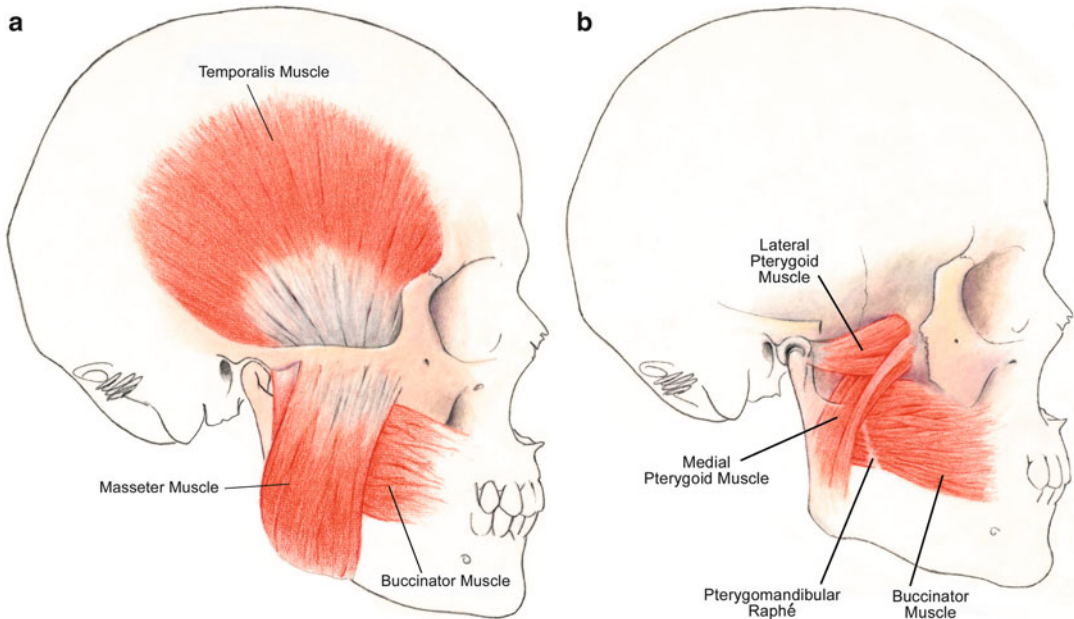


Fig. 1.22 Muscles of mastication. **(a)** The masseter originates from the maxillary zygomatic process/arch and inserts onto the lower aspect of the lateral mandibular ramus and angle. The temporalis arises from the temporal fossa of the lateral skull and inserts onto the coronoid process and ascending ramus of the mandible. Note buccinator muscle extending forward from underneath the masseter. **(b)** The lateral pterygoid arises from the ptery-

goid plate of the sphenoid bone and inserts onto the TMJ capsule and mandibular condyle. The medial pterygoid originates more medially on the pterygoid plate and inserts onto the medial surface of the mandibular ramus. In this diagram, the mandibular ramus is rendered partially transparent to visualize the muscle insertion. Note the origin of the buccinator muscle from the posterior mandible/maxilla and pterygomandibular raphe

nerve, which arise from the mandibular division (V3). It is important to remember that other muscles, such as the strap muscles of the neck, affect mandibular position and function. Effective mastication also requires adequate function of muscles controlling the tongue, lips, and cheeks.

The muscles of facial expression, or mimetic muscles, insert into the dermis of the skin and control movement around the scalp, orbit, ear, mouth, nose, and neck. They are all innervated by the facial nerve (CN 7). The *orbicularis oris muscle* forms the major sphincter of the lips, allowing complex movement in this area. The *buccinator muscle* makes up the bulk of the cheek and joins

the superior pharyngeal constrictor muscle in the posterior oral cavity at the pterygomandibular raphe. Facial nerve paralysis, such as Bell's palsy, may result in flaccidity of the buccinator muscle, with decreased ability to control food in the vestibule or problems with cheek biting.

Salivary Glands

There are three sets of paired major salivary glands: sublingual, submandibular, and parotid (Figs. 1.23 and 1.24). The *sublingual gland* is the smallest, and rests on the mylohyoid muscle in the

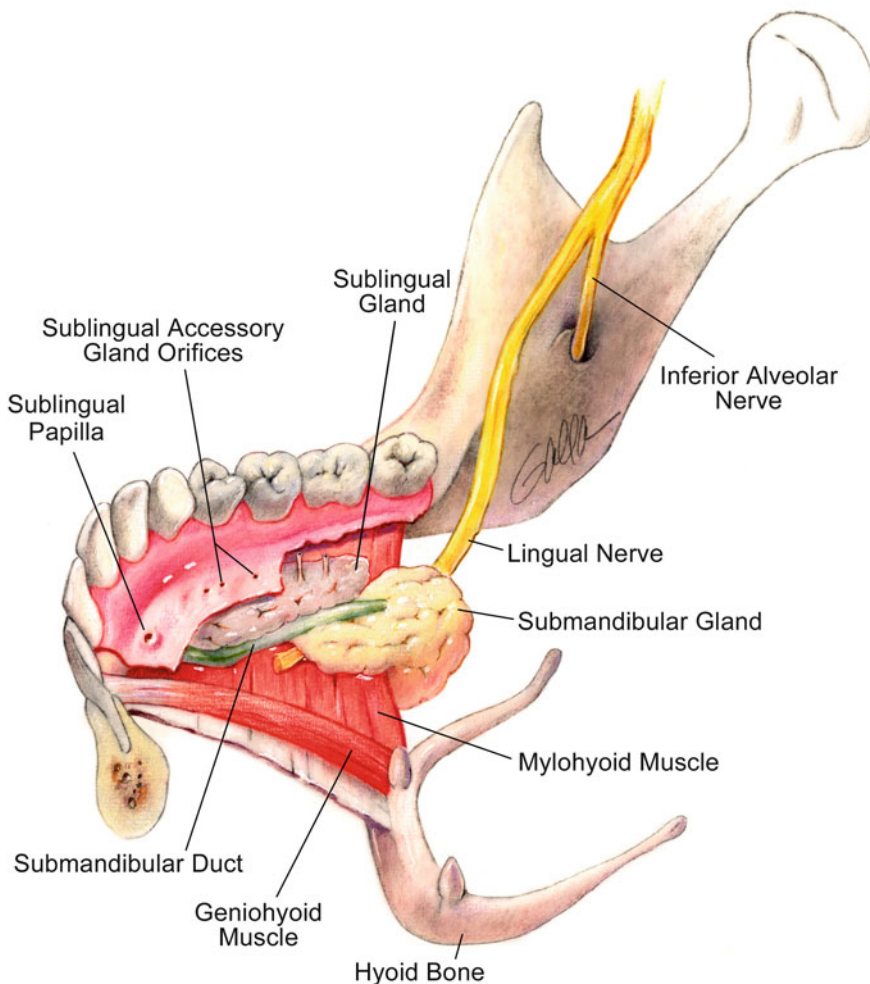


Fig. 1.23 Sublingual and submandibular salivary glands. The inferior alveolar nerve branches from the main trunk of V3 to enter the mandible on the medial surface of the ramus and travels forward within the bone to innervate the mandibular teeth; the small bump of bone illustrated adja-

cent to the foramen is called the *lingula*. The lingual nerve crosses from lateral to medial in the floor of mouth and passes underneath the submandibular duct prior to entering the tongue

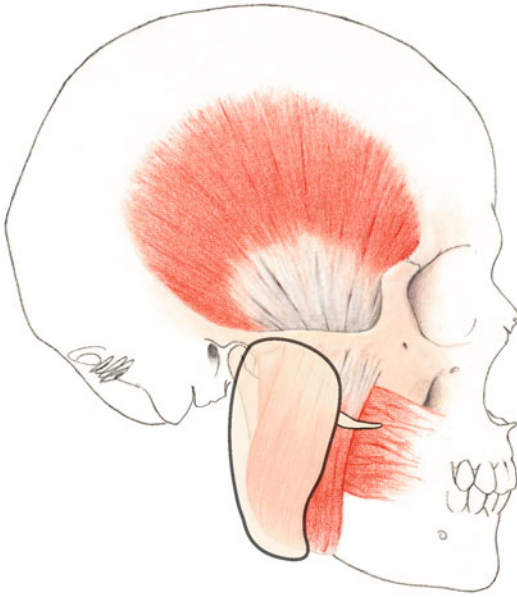

Fig. 1.24 Parotid gland schematically outlined overlying masseter muscle. The tail extends inferiorly below the angle of the mandible. The duct travels over the anterior edge of the masseter muscle and then pierces the buccinator muscle to enter the oral cavity

anterolateral floor of mouth immediately under the mucosa. The secretions of this gland are primarily mucinous, and are therefore more viscous than saliva produced by the parotid and submandibular glands. The *submandibular gland* is larger and occupies the submandibular triangle with extension of the gland over the posterior border of the mylohyoid muscle into the floor of mouth. The secretions from this gland are mixed seromucinous, with viscosity intermediate between those of the sublingual and parotid glands.

The *parotid gland* is the largest of the three major salivary glands and is located in front of the ear (preauricular region), with extension to the posterior belly of the digastric muscle inferiorly and the masseter muscle anteriorly (Fig. 1.24). The “tail” of the gland extends posteriorly under the earlobe to the sternocleidomastoid muscle (SCM). The gland is divided into superficial and deep lobes by the plane of the facial nerve (CN 7), with extension of the deep lobe to the parapharyngeal space medially. Tumors of the deep lobe may result in visible bulging within the oral cavity in the region of the

tonsil, and may present as the first sign of pathology. Lymph nodes are present within the parenchyma of the parotid gland, mainly in the superficial lobe, due to incorporation of lymphoid tissue into the gland during fetal development. These may present clinically as masses secondary to reactive or neoplastic processes. The parotid gland produces serous saliva, which is thin and watery compared to secretions from the other salivary glands.

There are hundreds of subepithelial *minor salivary glands* present throughout the oral cavity (except for the gingiva and anterior hard palate), with a high density notable on the soft palate and posterolateral hard palate. Secretions from these glands are purely mucinous and represent a very small proportion of total salivary flow.

Innervation to the salivary glands is supplied by the autonomic nervous system, with both sympathetic and parasympathetic components. The parasympathetic system regulates fluid and electrolyte secretion, while the sympathetic system governs protein synthesis and secretion. The parotid gland receives parasympathetic secretomotor fibers from the glossopharyngeal nerve (CN 9), which synapse in the otic ganglion and then travel with the auriculotemporal branch of V3. Parasympathetic fibers to the submandibular and sublingual glands travel with the facial nerve (CN 7) and chorda tympani to synapse in the submandibular ganglion prior to joining the lingual nerve. Sympathetic innervation to all of these glands is supplied from the superior cervical ganglion via the external carotid artery.

Lymphatics

Knowledge of lymphatic drainage pathways from the oral cavity and neck is important with respect to spread of infection and cancer (Fig. 1.25). The lymphatic system provides a mechanism to redirect tissue fluid back into the circulation, passing through a series of lymph node “filters” along the way that functions in immune surveillance.

Superficial cervical lymph nodes lie along the external and anterior jugular veins, superficial to the SCM muscle, receiving drainage from the skin of the scalp, face, neck, and ear. *Submental*

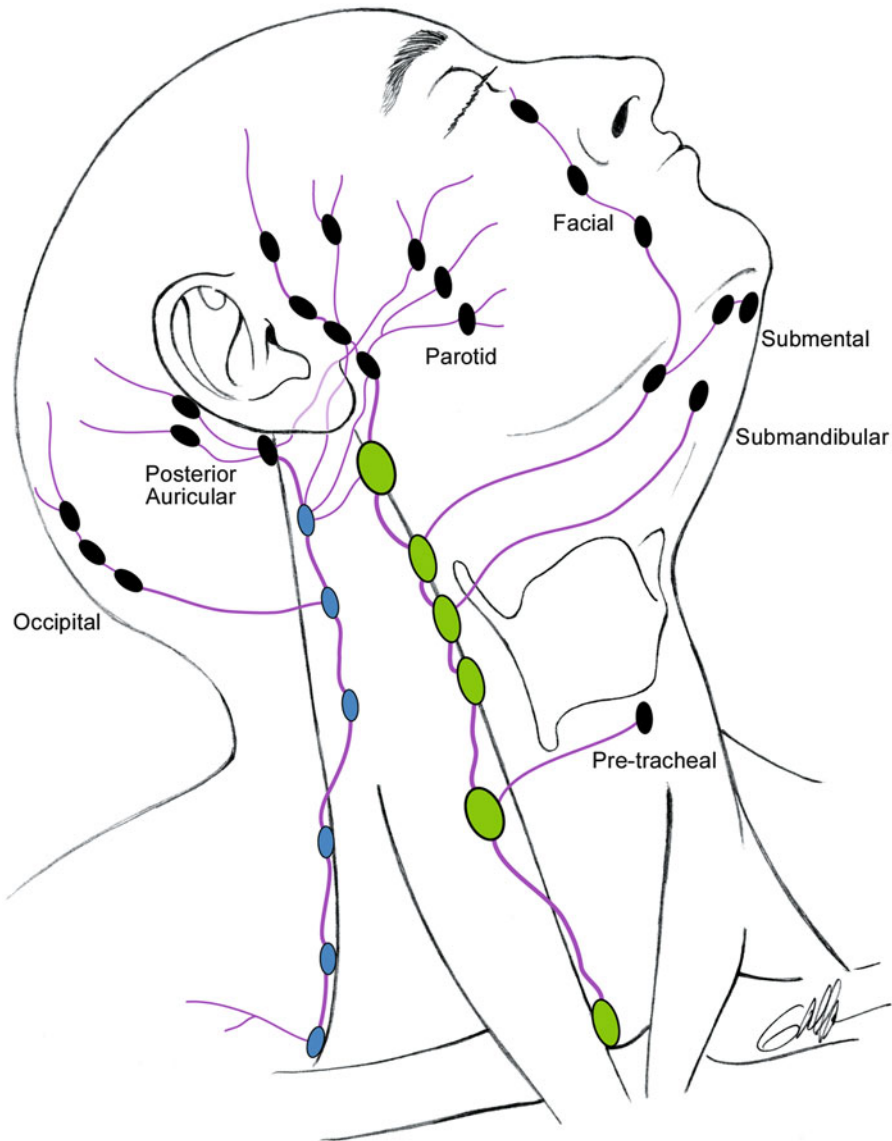


Fig. 1.25 Lymph nodes of the neck. The deep cervical chain is illustrated in *green*, which courses deep to the SCM at the level of the carotid sheath. The superficial cervical chain, which lies above the SCM, is illustrated in *blue*

nodes drain the chin, inner aspect of the lower lip, lower incisor teeth and gingiva, and tip of tongue. The submental nodes drain into *submandibular nodes*, which also receive drainage from the skin of the anterior face, anterior nasal cavity, anterior two-thirds of the tongue, and majority of dentition, gingiva, and hard palate.

The *deep cervical chain* of lymph nodes lies along the carotid sheath around the internal jugular vein extending from the base of skull into the root

of the neck. These nodes are extremely important, as they ultimately receive all lymphatic drainage from the head and neck region. The *jugulodigastric node* drains the oropharynx, including tongue base, soft palate, and tonsils, and can be palpated just behind the angle of the mandible.

Drainage from tissues is generally to *ipsilateral* (same side) nodes, but can cross over to the *contralateral* (opposite) side, particularly with midline structures. This is of particular concern

in the case of the tongue, which has a very rich lymphatic supply. Progression of disease, such as inflammation, infection, or cancer, through the chain of cervical lymph nodes often occurs in predictable sequence. However, this is not always the case, as can be seen in patients with oral cancer which has spread to the neck and “skips over” certain groups of nodes.

Sources

- Clemente C. *Anatomy: a regional atlas of the human body*. 6th ed. Baltimore: Lippincott Williams & Wilkins; 2010.
- Janfaza P. *Surgical anatomy of the head and neck*. Hagerstown: Lippincott Williams & Wilkins; 2001.
- Jung HS, Akita K, Kim JY. Spacing patterns on tongue surface-gustatory papilla. *Int J Dev Biol*. 2004;48:157–61.
- Kraus B, Jordan R, Abrams L. *A study of the masticatory system: dental anatomy and occlusion*. Baltimore: Lippincott Williams & Wilkins; 1984.
- Netter F. *Atlas of human anatomy*. 6th ed. Philadelphia: Saunders; 2014.
- Patil MS, Patil SB, Acharya AB. Palatine rugae and their significance in clinical dentistry: a review of the literature. *J Am Dent Assoc*. 2008;139:1471–8.
- Pernkopf E. *Atlas of topographical and applied human anatomy, Head and neck, vol. 1*. 2nd ed. Munich: Urban and Schwarzenberg; 1980.
- Schünke M, Ross LM, Schulte E, Lamperti ED, Schumacher U, Voll M. *Thieme atlas of anatomy: head and neuroanatomy*. Stuttgart: Georg Thieme; 2007.
- Squier CA, Kremer MJ. Biology of oral mucosa and esophagus. *J Natl Cancer Inst Monogr*. 2001;29:7–15.

Introduction

Fundamental to diagnosing oral pathologic conditions is the ability to recognize the spectrum of clinical findings that represents variation of normal within the population. The range of such variation is wide and findings can be very subtle or notably prominent. Some are purely developmental, while others have a clear inflammatory or traumatic etiology. These conditions, in large part, do not require therapy unless specifically noted in the text.

Physiologic Pigmentation

Melanocytes are a normal component of the basal cell layer of the oral epithelium. They cause varying degrees of mucosal pigmentation, ranging from light brown to black, due to the production of melanin. *Physiologic pigmentation* is observed

much more frequently in darker skinned individuals, however, even those with very fair complexions may demonstrate characteristic findings. Focal, freckle-like *melanotic macules* are very common (Fig. 2.1; see Chap. 6). The keratinized mucosa, in particular the gingiva, is most commonly affected (Fig. 2.2). Pigmentation is due to deposition of melanin into the connective tissue without an increase in the number or size of melanocytes and lesions are therefore flat. This may become more pronounced in areas of chronic trauma or inflammation, such as along the occlusal bite line of the buccal mucosa (Fig. 2.3).

In most cases, the diagnosis can be made clinically but occasionally a biopsy is warranted to rule out melanoma; particularly if any changes are noted in size, shape, or degree of pigmentation, or if a flat lesion becomes raised. Intraoral melanoma, however, is exceedingly rare, representing less than 1% of all melanomas. Other causes of pigmentation, including both intrinsic and extrinsic etiologies, are discussed in Chap. 6.

Fig. 2.1 Melanotic macule of the lower lip with *dark brown* pigmentation and sharply defined borders. The lips are slightly chapped

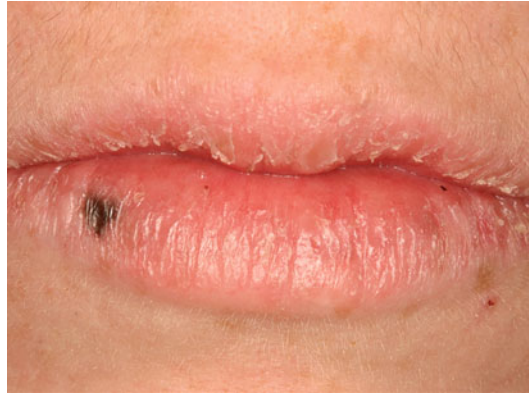





Fig. 2.2 Physiologic pigmentation in an African-American child. The interdental papillae are affected to a variable degree; the nonkeratinized mucosa is entirely unaffected

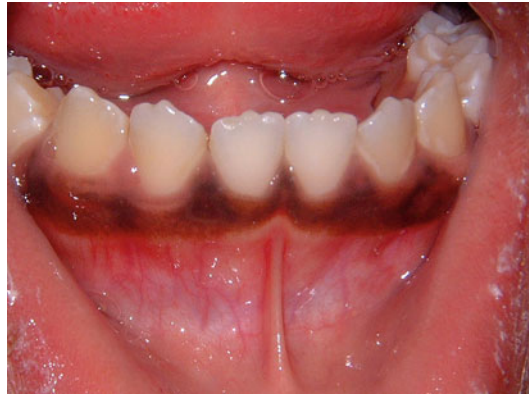
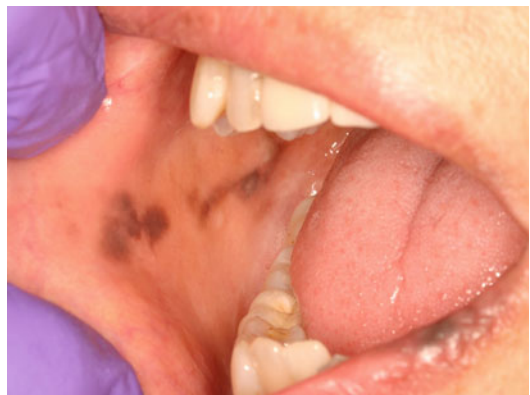
Fig. 2.3 Postinflammatory pigmentation of the right buccal mucosa secondary to chronic cheek biting



Physiologic Pigmentation

	DIAGNOSTIC TESTS	None.
	BIOPSY	No, with rare exception.
	TREATMENT	None.
	FOLLOW-UP	Annual.

Fordyce Granules

Sebaceous glands, which are a normal feature of facial skin, can often be identified within the buccal mucosa due to the anatomic proximity of skin to the oral mucosa in this area. These are less commonly noted on the lip or the labial mucosa

(Figs. 2.4 and 2.5). Fordyce granules appear white to yellow in color, are generally present in clusters, may be slightly raised, and are asymptomatic. Sebaceous glands in the oral mucosa are nonfunctional. Occasionally patients become aware of their presence by detecting the raised surfaces with their tongue, or during self-examination with a mirror.

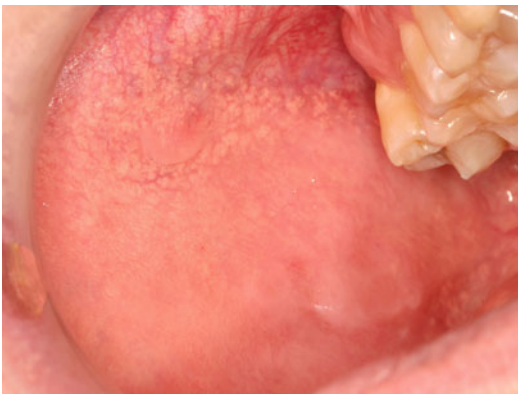





Fig. 2.4 Prominent Fordyce granules in the right buccal mucosa

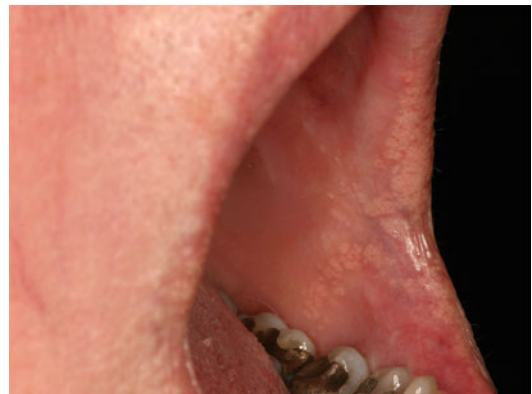

Fig. 2.5 Dense concentration of Fordyce granules in the left buccal mucosa

Fordyce Granules

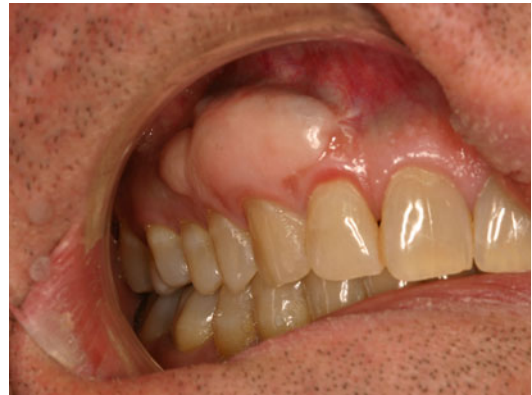	DIAGNOSTIC TESTS	None; clinical appearance is usually classic and sufficient for diagnosis.
	BIOPSY	No.
	TREATMENT	None.
	FOLLOW-UP	None.

Gingival Grafts





In cases of severe gingival recession, gingival grafting may be performed as a periodontal surgical procedure to restore the attached soft tissue, reduce root-surface sensitivity, and prevent further tissue loss. The donor tissue, which is harvested from the patient's palate as an auto-

graft, has a distinct appearance that is typically raised and more pale than the adjacent gingiva. Grafts are generally easily recognized, very sharply defined, and should not be mistaken for pathology (Fig. 2.6). If there is any doubt, the patient should be able to provide suitable history regarding whether such a procedure was performed.

Fig. 2.6 Free gingival graft covering a prominent exostosis in an area of previous gingival recession. Note the thicker, more clearly defined keratinized mucosa compared to the adjacent nonkeratinized tissue



Gingival Grafts

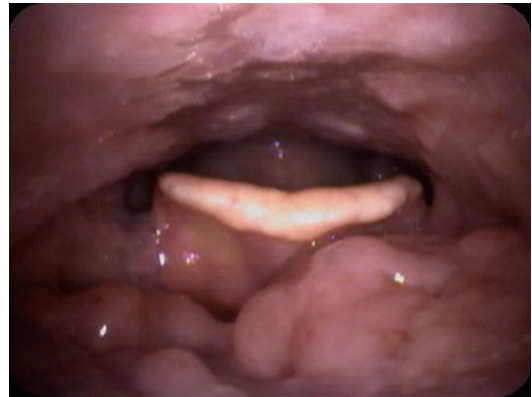	DIAGNOSTIC TESTS	None.
	BIOPSY	No.
	TREATMENT	None.
	FOLLOW-UP	None.

Lingual Tonsil





Lymphoid tissue is often found along the posterior lateral tongue, forming part of *Waldeyer ring*. The clinical presentation ranges from imperceptible to strikingly prominent. Lingual tonsils appear as exophytic mucosal colored masses that may exhibit folds and crypts as seen

in the palatine tonsils (Fig. 2.7). As with any lymphoid tissue, these can become enlarged and tender secondary to inflammation. It is generally under these circumstances that patients or physicians become aware of their presence. Unilateral or asymmetrically enlarged tissue should be considered for biopsy to rule out other pathology such as lymphoma or squamous cell carcinoma.

Fig. 2.7 Endoscopic examination demonstrating lingual tonsil tissue, asymmetrically enlarged on the patient's left side (lower right side of picture)



Lingual Tonsil

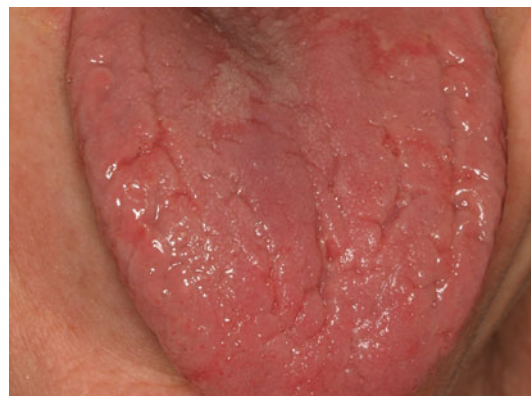	<p>DIAGNOSTIC TESTS</p>	<p>None.</p>
	<p>BIOPSY</p>	<p>No, unless unilateral, asymmetric, or otherwise suspicious in appearance.</p>
	<p>TREATMENT</p>	<p>None.</p>
	<p>FOLLOW-UP</p>	<p>None.</p>

Fissured Tongue





There is remarkable variation in the appearance of the tongue throughout the population. One common finding is the presence of fissures and grooves along the dorsal surface. These can range from shallow appearing cracks to deep, penetrating fissures

(Fig. 2.8). These features may be associated with geographic tongue (see below) and may rarely predispose to recurrent candidiasis (see Chap. 7). Most patients are universally asymptomatic; however, it is not uncommon for a patient to examine his or her tongue and become aware of fissuring following the onset of otherwise unrelated symptoms, such as burning mouth syndrome (see Chap. 10).

Fig. 2.8 Fissured tongue with extensive grooves and fissures over the entire dorsal surface



Fissured Tongue

	DIAGNOSTIC TESTS	None.
	BIOPSY	No.
	TREATMENT	None.
	FOLLOW-UP	None.

Geographic Tongue

Also referred to as *benign migratory glossitis*, geographic tongue is a common inflammatory condition of the tongue. Other oral mucosal sites can be affected less frequently, in which case the condition is called *stomatitis erythema migrans* or *ectopic geographic tongue*. Geographic tongue is usually evident in early childhood and rarely causes symptoms. The lesions demonstrate a wide variety of clinical patterns, ranging from irregularly shaped erythematous macules with surrounding elevated white borders to patchy areas of depapillation and smooth glossy mucosa (Figs. 2.9, 2.10, 2.11, and 2.12). These features can give the tongue a map-like appearance, thus the descriptive term “geographic.” In an affected individual, the

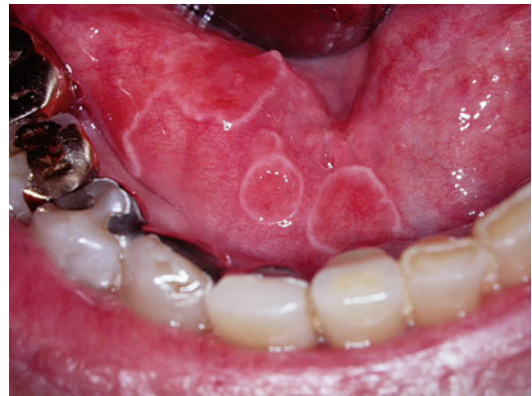

Fig. 2.10 Benign migratory glossitis of the ventral tongue and floor of mouth. As this region of the tongue does not normally contain papillae, only the white rimmed borders are noted

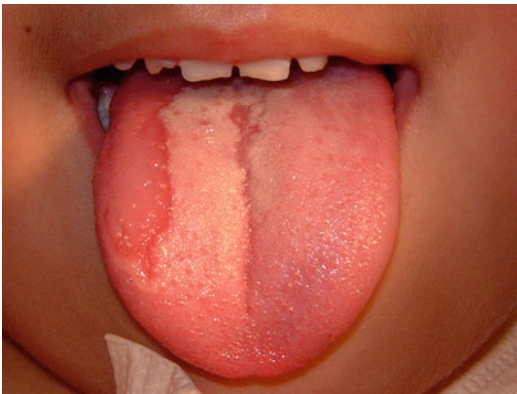

Fig.2.9 Benign migratory glossitis in a child. There is a very well-defined area of depapillation on the right side of the tongue dorsum, while the rest of the surface is unaffected

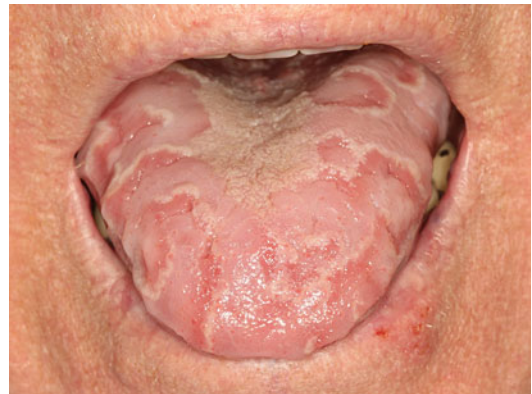

Fig.2.11 Extensive benign migratory glossitis affecting the entire tongue dorsum with prominent areas of depapillation surrounded by white rimmed borders

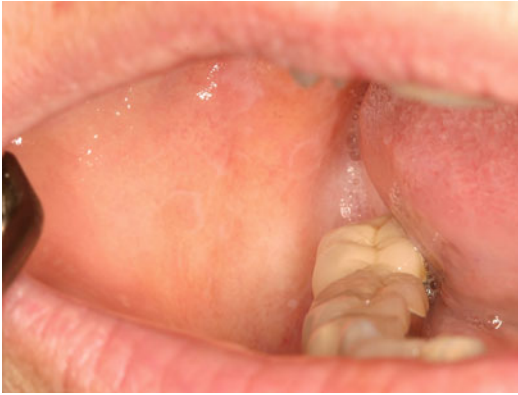





Fig. 2.12 Stomatitis erythema migrans showing subtle circular lesions with white borders of the right buccal mucosa and concurrent changes consistent with benign migratory glossitis

presentation can change on a daily basis and therefore appear “migratory.” Although the clinical presentation can be striking, there are few if any other conditions that mimic geographic tongue (including oral lichen planus, erythematous candidiasis, and leukoplakia); with a good history and examination, lesions rarely warrant biopsy.

Although rare, patients may describe sensitivity of the tongue to otherwise normally tolerated food and beverages. This may or may not correlate with the extent of lesions noted clinically. Management with topical therapies may be effective in such cases. Other causes of tongue sensitivity must be considered as well, such as candidiasis or immune-mediated conditions, especially when there is recent or abrupt onset of symptoms.

Geographic Tongue

	DIAGNOSTIC TESTS	None; diagnosis is based on clinical appearance.
	BIOPSY	No, except very atypical presentations.
	TREATMENT	None in most cases. When symptomatic, rinses containing topical dexamethasone or diphenhydramine may be effective in reducing symptoms. Be sure to consider other causes of tongue discomfort, such as <i>burning mouth syndrome</i> (see Chap. 10).
	FOLLOW-UP	None.

Median Rhomboid Glossitis

This is a poorly understood condition that affects the tongue dorsum. It is characterized by a chronic, atrophic, erythematous, depapillated patch in the posterior midline of the tongue dorsum typically measuring between 0.25 and 2.0 cm in diameter (Fig. 2.13). While there is great variation in clinical presentation among patients, the size and quality of the lesion do not tend to change significantly over time in a given individual.

While many cases are never symptomatic, mild discomfort may develop specifically in the area of atrophic change. Symptoms tend to wax

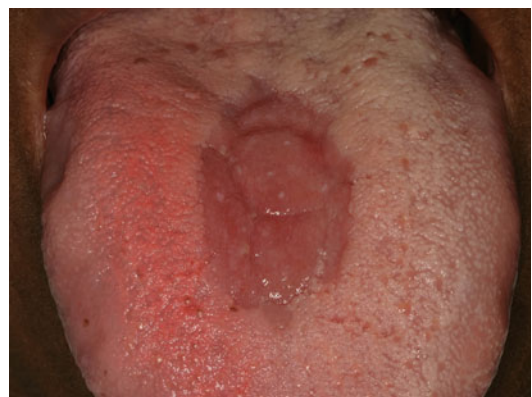





Fig. 2.13 Median rhomboid glossitis with a well-defined depapillated patch in the posterior midline of the tongue dorsum with normal surrounding tissue

and wane, rarely persisting. Because tissue biopsy often demonstrates superficial candidal colonization and an inflammatory infiltrate in the underlying connective tissue, there is some thought that median rhomboid glossitis is mediated by chronic candidal colonization. The tissue may be particularly susceptible to recurrent fungal infection due to the reduced thickness of the epithelium. Therefore, when a patient develops

symptoms of tongue discomfort in the presence of median rhomboid glossitis, first-line treatment consists of topical or systemic antifungal therapy. If symptoms persist following an appropriate course of antifungal therapy, topical corticosteroid therapy should be instituted. If this is ineffective and all other potential etiologies have been excluded, then symptoms may be managed as a neuropathic pain disorder (see Chap. 10).

Median Rhomboid Glossitis

	DIAGNOSTIC TESTS	None routinely. A positive fungal culture or cytological smear may or may not represent a true infection (see Chap. 3). This may be clinically useful to determine baseline status prior to initiating antifungal therapy.
	BIOPSY	No, except for atypical presentations.
	TREATMENT	None in most cases. When symptomatic, initial therapy should consist of a 1-week course of either clotrimazole troches or fluconazole. Be sure to consider other causes of tongue discomfort, such as <i>geographic tongue</i> or <i>burning mouth syndrome</i> . If there is no improvement following 1 week of antifungal therapy, treatment with high potency topical corticosteroid gels (fluocinonide 0.05 % or clobetasol 0.05 %), two to three times daily, should be initiated. If this is also ineffective, consider treating as a neuropathic condition (see Chap. 10).
	FOLLOW-UP	None if asymptomatic, otherwise patients should be re-evaluated after 1 week of antifungal therapy.

Fibroma

Fibromas are probably the most commonly encountered oral soft tissue lesions. Frequently used terms include *irritation fibroma* and *traumatic fibroma*, indicating the underlying reactive etiology. These are initiated by trauma, typically a bite injury (that the patient may not recall) or secondary to friction from the sharp edge of a tooth or dental restoration. Fibromas present clinically as round or ovoid, firm, exophytic, smooth-surfaced masses that are the same color as, or slightly lighter than, the surrounding mucosa (Fig. 2.14). Lesions range in size from several millimeters to 1.0 cm in diameter (Fig. 2.15). Larger lesions are

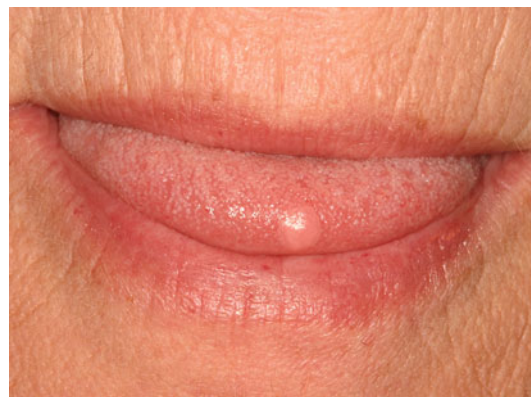

Fig. 2.14 Fibroma of the anterior tongue tip secondary to bite trauma. The lesion is well-defined and has a smooth, raised surface in comparison to the adjacent tissue; it is firm and nontender

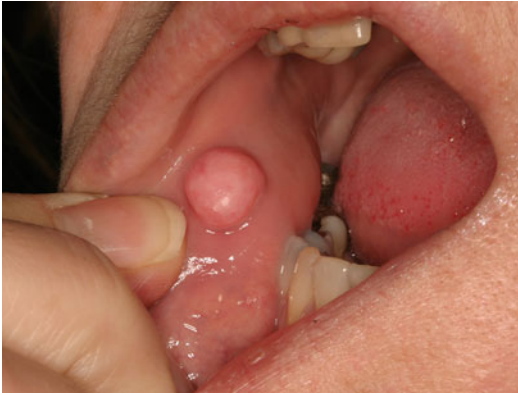

Fig. 2.15 Large fibroma of the right buccal mucosa. The surface mucosa is thicker in appearance than the surrounding tissue

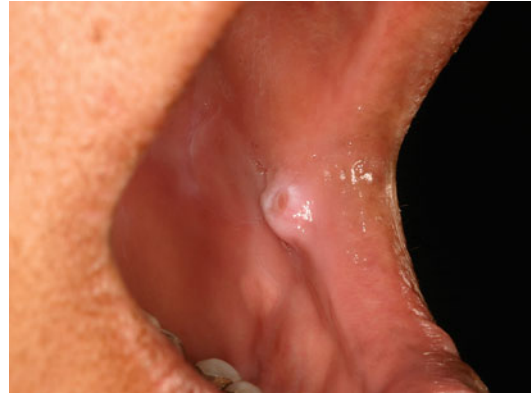

Fig. 2.16 Fibroma of the left buccal mucosa with focal ulceration secondary to repetitive bite injury





exceedingly rare and biopsy should be considered in such cases to rule out a neoplasm. As these are often caused by bite trauma, the most commonly involved areas are along the bite plane of the buccal mucosa and lateral tongue, although the lower labial mucosa and tongue dorsum can also be affected. There are no specific risk factors other than a history of minor trauma.

Fibromas are generally asymptomatic and do not require treatment unless they are particularly bothersome to the patient. Depending on the size and location, lesions may simply be an annoyance

or they may become quite uncomfortable due to repetitive trauma. Lesions may progressively enlarge with recurrent injury, thereby compounding the clinical situation. In such cases the surface mucosa often becomes ulcerated, characterized by a yellowish white pseudomembrane (Fig. 2.16).

Treatment is surgical excision, after which lesions rarely recur. Histopathological examination demonstrates a dense collection of fibrous tissue with normal surface epithelium. Fibromas have no malignant potential; however, they should be excised and submitted for histopathological analysis if the clinical diagnosis is uncertain.

Fibroma

	DIAGNOSTIC TESTS	None.
	BIOPSY	Only if the appearance is suspicious.
	TREATMENT	None if asymptomatic; otherwise surgical excision.
	FOLLOW-UP	None.

Inflammatory Papillary Hyperplasia

This is a benign reactive condition that develops on denture-bearing mucosa. This includes the maxillary and mandibular alveolar mucosa, the

hard palate, and the vestibular mucosa. Inflammatory papillary hyperplasia can affect a very limited area of mucosa or be quite extensive, in some cases involving the entire hard palate. A focal lesion with a distinct wrinkled or folded appearance is often termed *epulis fissuratum*, and

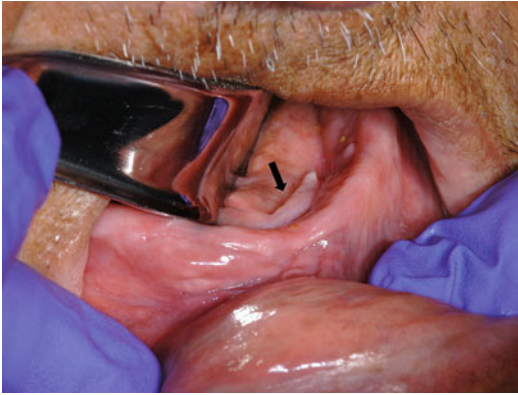


Fig. 2.17 Fibrous hyperplasia (*epulis fissuratum*) of the mandibular mucosa (*arrow*) secondary to a poorly fitting denture

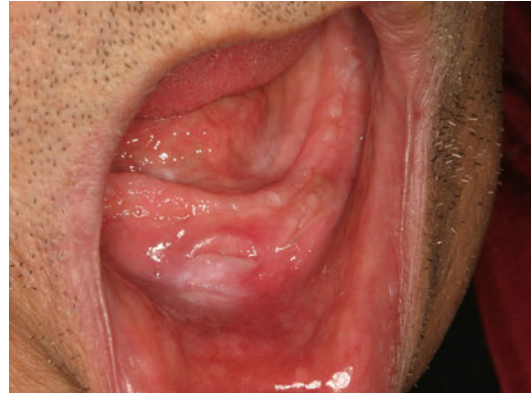

Fig. 2.19 Epulis fissuratum of the mandibular alveolar mucosa due to a poorly fitting denture

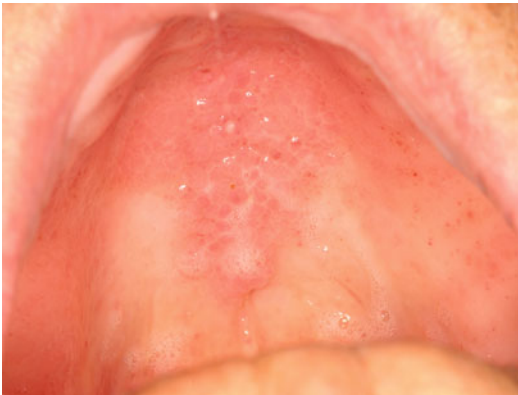

Fig. 2.18 Inflammatory papillary hyperplasia in a patient with a full upper denture. A punch biopsy was obtained to rule out malignancy. As the lesion was asymptomatic and the denture was otherwise comfortable, no further treatment was necessary

is most commonly encountered in the anterior buccal vestibule at the edge of a denture flange (Fig. 2.17). Lesions are characterized by pebbly, papillary changes that are variably associated with tissue hyperplasia, and verrucous-like changes that can be quite notable (Fig. 2.18). This condition is rarely symptomatic, however, patients are typically aware of its presence.

Depending on the location and extent of tissue hyperplasia, lesions may be susceptible to secondary trauma or interfere with prosthesis fit and function (Fig. 2.19).

The etiology of inflammatory papillary hyperplasia is poorly understood. It is thought that chronic irritation due to a loose or poorly fitting denture, or inadequate denture hygiene (with candida colonizing the denture material), contributes to localized inflammatory-mediated reactive changes in the mucosa. As lesions may mimic other pathologic conditions, including *proliferative verrucous leukoplakia* and *squamous cell carcinoma* (see Chap. 9), biopsy may be necessary to rule out dysplasia or malignancy. Histopathological findings include benign papillary acanthosis (increased epithelial thickness) that is commonly associated with a chronic inflammatory infiltrate in the underlying connective tissue.





The first step in treatment is careful evaluation of the prosthesis. The extension of the denture borders into the vestibule as well as the overall stability should be examined closely by an appropriate specialist (i.e., general dentist or prosthodontist). Recommendation should be made to soak the prosthesis overnight in an over-the-counter denture disinfectant solution

or prescription chlorhexidine gluconate 0.12%. Another simple and inexpensive option for non-metal containing prostheses is use of a 1:10 dilution of sodium hypochlorite, or common household bleach. Even in the absence of obvious oral fungal infection, a 1–2 week course of fluconazole 100 mg once daily, in addition to daily denture hygiene, is reasonable empiric therapy. During this time, the prosthesis should be left out of the mouth as much as possible to avoid exacerbation of the lesion. Surgical excision is indicated for lesions that fail to respond to conservative therapy and are bothersome or interfere with function (Fig. 2.20).

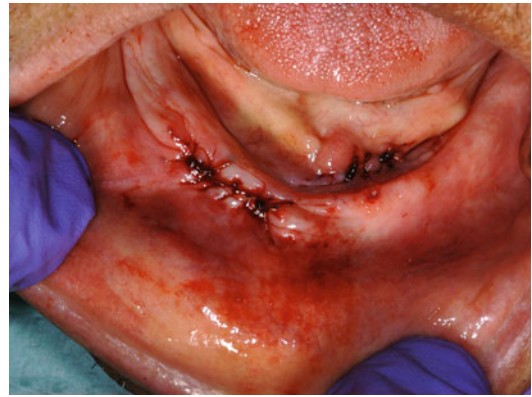

Fig. 2.20 Areas of fibrous tissue shown in Fig. 2.17 were excised and submitted for histopathology in preparation for fabricating a new set of complete dentures

Inflammatory Papillary Hyperplasia

	DIAGNOSTIC TESTS	None.
	BIOPSY	Yes, to rule out malignancy if the clinical appearance is suspicious.
	TREATMENT	Prosthesis should be evaluated for fit, stability, and hygiene and adjusted or otherwise managed appropriately. Hyperplastic tissue can be surgically excised or laser ablated if bothersome or otherwise symptomatic.
	FOLLOW-UP	None. Patients should be instructed to maintain good denture hygiene and return to their dentist for regular follow-up.

Tori and Exostoses

These are benign, developmental bony growths that are commonly observed in the oral cavity. Tori are more common and are specific to the midline hard palate and anterolateral lingual mandible. Similar lesions involving the buccal aspect of the maxilla or mandible are called exostoses. These areas are covered by keratinized or nonkeratinized mucosa, depending on the anatomic location, and can be mistaken for mucosal growths. Changes are not typically evident until the second decade, and while highly variable, growth is generally very slow throughout life. Even when lesions become quite extensive, patients may be unaware of their presence due to the gradual incremental growth pattern over decades.

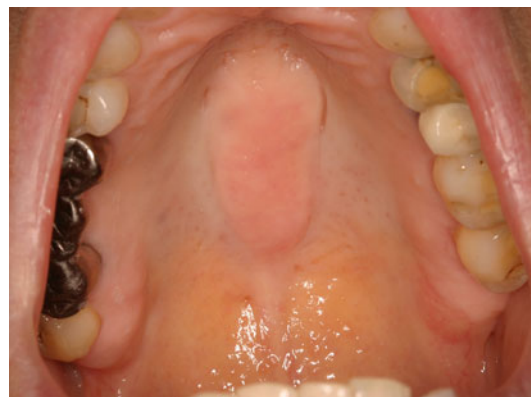

Fig. 2.21 Maxillary torus with smooth surface and well-defined borders in the midline of the hard palate

Maxillary tori occur in the midline of the hard palate and range from barely discernable dome-shaped smooth swellings to large multi-lobulated masses (Figs. 2.21, 2.22, and 2.23).

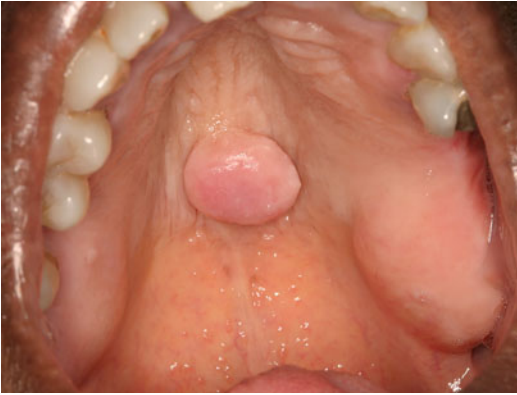


Fig. 2.22 Maxillary torus with a stalk-like attachment to the underlying palatal bone

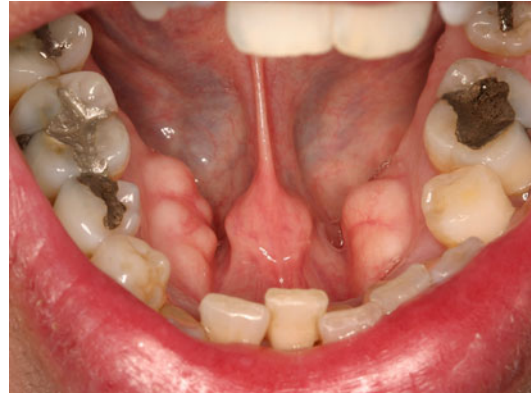

Fig. 2.24 Mandibular tori in the premolar region with multiple lobules

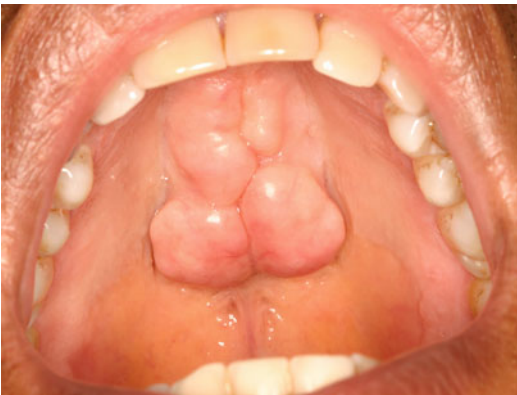

Fig. 2.23 Multilobulated maxillary torus showing slight asymmetry

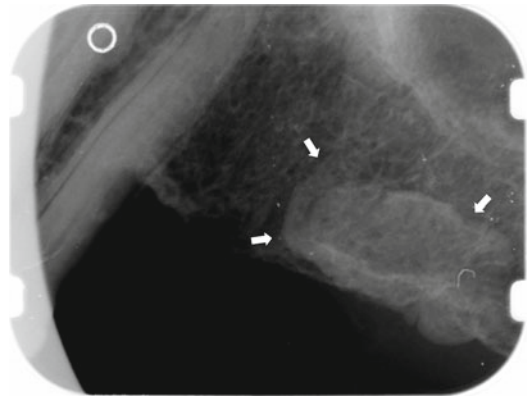






Fig. 2.25 Radiographic appearance of a maxillary torus as a well-defined radiopacity (outlined by *arrows*)

Mandibular tori develop most commonly along the lingual aspect of the mandible inferior to the premolars bilaterally. Mandibular tori also exhibit a wide range of presentations; however, lesions usually demonstrate 2–3 well-defined smooth lobules (Fig. 2.24). Exostoses appear clinically identical to mandibular tori on the buccal surface of the mandible or maxilla (Fig. 2.26). These can grow to be quite large yet rarely have any discernable effect on the external facial appearance. On intraoral periapical

dental radiographs, the involved areas appear as dense radiopacities within the maxilla and mandible (Fig. 2.25).

Tori and exostoses generally do not require any treatment. The covering mucosa may occasionally become irritated or ulcerated from trauma, and is managed symptomatically. Tori can be surgically removed in some situations may if denture fabrication is required in order to maximize retention of the prosthesis and minimize the risk of pressure-induced trauma.

Tori and Exostoses

	DIAGNOSTIC TESTS	None.
	BIOPSY	No.
	TREATMENT	None.
	FOLLOW-UP	None.

Ankyloglossia and Prominent Frenula

Abnormal prominence of *frenula* (tissue attachments of the anterior tongue and labial mucosa), can result in a variety of complications. In the case of the *lingual frenulum*, this can lead to problems with infant feeding and speech development, and is referred to *ankyloglossia* or “tongue tie.” Localized periodontal recession on

the lingual aspect of the central incisors can also occur. A prominent *labial mandibular frenulum* can similarly affect the facial aspect of the same teeth. High insertion of the *maxillary frenulum* onto the gingiva may lead to formation of a gap, or *diastema*, between the central incisors (Fig. 2.26). These conditions are typically identified in young children by their dentist or pediatrician. If indicated, treatment is simple surgical repositioning or excision.

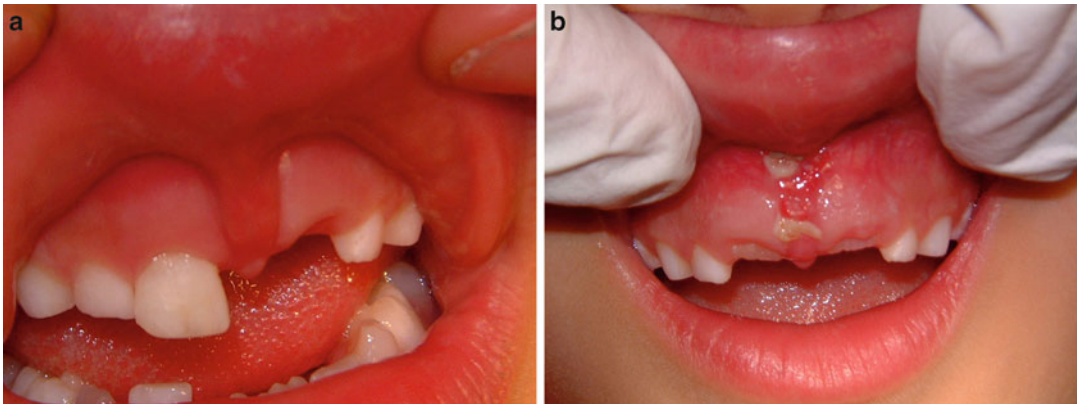






Fig. 2.26 Thick maxillary frenulum in a 5-year-old before (a) and after (b) surgical repositioning

Ankyloglossia and Prominent Frenula

	DIAGNOSTIC TESTS	None.
	BIOPSY	No.
	TREATMENT	Refer for surgical evaluation.
	FOLLOW-UP	None.

Sources

- Antoniades DZ, Belazi M, Papanayiotou P. Concurrence of torus palatines with palatal and buccal exostoses: case report and review of the literature. *Oral Surg Oral Med Oral Pathol Oral Radiol Endod.* 1998;85:552–7.
- Assimakopoulos D, Patrikakos C, Fotika C, et al. Benign migratory glossitis or geographic tongue: an enigmatic oral lesion. *Am J Med.* 2002;15:751–5.
- Canaan TJ, Meehan SC. Variations of structure and appearance of the oral mucosa. *Dent Clin N Am.* 2005;49:1–14.
- Carter LC. Median rhomboid glossitis: review of a puzzling entity. *Compendium.* 1990;11(446):448–51.
- Cicek Y, Ertas U. The normal and pathological pigmentation of oral mucous membrane: a review. *J Contemp Dent Pract.* 2003;15:76–86.
- Jainkittivong A, Langlais R. Geographic tongue: clinical characteristics of 188 cases. *J Contemp Dent Pract.* 2005;6:123–35.
- Rogers RS, Bruce AJ. The tongue in clinical diagnosis. *J Eur Acad Dermatol Venereol.* 2004;18:254–9.
- Segal LM, Stephenson R, Dawes M, et al. Prevalence, diagnosis, and treatment of ankyloglossia: methodologic review. *Can Fam Physician.* 2007;53:1027–33.
- Thwaites MS, Jeter TE, Ajagbe O. Inflammatory papillary hyperplasia: review of literature and case report involving a 10-year-old child. *Quintessence Int.* 1990;21(2):133–8.

Introduction

When evaluating an oral medicine patient, obtaining a comprehensive yet targeted medical history and history of present illness is critical to generating a differential diagnosis. Key elements include: (a) medical conditions and comorbidities for which the patient is being treated; (b) medications and allergies; (c) whether this represents an initial or recurrent episode; (d) timing of oral symptoms and precipitating factors; (e) symptoms or lesions involving other areas of the body; (f) pain score if relevant; (g) whether the condition is improving, remaining stable, or getting worse; and (h) any treatments that have already been provided and their effectiveness. Throughout the following chapters, specific aspects of the history that are directly relevant to a particular condition or group of conditions are emphasized.

Diagnostic tests and studies often provide additional information necessary to arrive at the correct diagnosis. In many cases, negative findings are just as revealing as positive findings. The most important considerations are when, why, and how to order certain studies, how to interpret the results, and what to do with the information obtained. Throughout the following chapters, indicated studies are listed for each condition, and suggestions are made regarding interpretation of results within a specific clinical context.

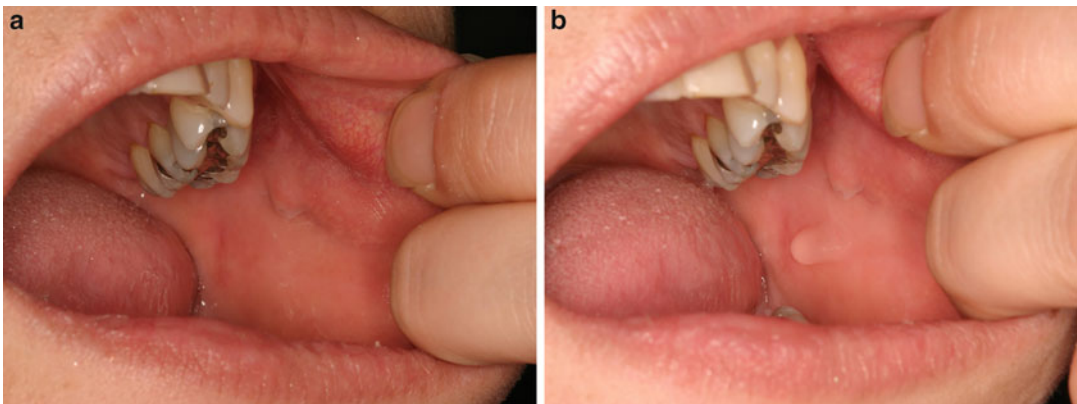
Examination

The physical examination begins extraorally with visual inspection for evidence of extraoral lesions (e.g., erythema, rash, and pigmentation), asymmetry, and swelling. The head and neck should be carefully palpated for swelling, tenderness, and lymphadenopathy. The muscles of mastication (particularly the masseter and temporalis muscles) and the temporomandibular joint should be palpated for function and tenderness (see Chap. 10); any asymmetries, deviations, or limitations in mouth opening should be noted. A cranial nerve examination should be performed to evaluate for neuromuscular and neurosensory deficits. If the patient reports any specific non-oral issues or findings these should also be investigated.

The entire oral cavity and oropharynx must be examined, regardless of the patient's chief complaint. A good light source is paramount. Any abnormalities of the soft tissue should be noted with respect to size, extent, thickness, texture, color, consistency, and tenderness (Table 3.1). The amount and consistency of saliva is observed, and the salivary gland duct orifices are evaluated for patency and flow (Fig. 3.1a, b). The dentition should be inspected for obvious *caries* (decay), fractured or missing restorations, excessive periodontal recession and bone loss (characterized by excessive root surface exposure), percussion

Table 3.1 Terms commonly used to describe oral lesions

Atrophy	Loss of tissue, typically due to thinning of cell layers; often associated with erythema
Bulla	A fluid-filled blister >0.5 cm in diameter
Ecchymosis	A macular area of submucosal hemorrhage (bruise) appearing as a well-defined area of erythema or purplish-blue pigmentation
Endophytic	A lesion that appears to be growing inward toward the underlying tissues
Erosion	Loss or thinning of superficial epithelial layers not extending through the full thickness of epithelium, typically secondary to inflammation
Erythema	Redness of the mucosa often due to a combination of inflammation, increased vascularity, and epithelial atrophy
Exophytic	A lesion that appears to be growing outward from the mucosa
Fixed	A lesion that is nonmobile and firmly attached to the underlying structures
Hematoma	A tumor-like collection of blood in the submucosa presenting as a well-defined raised lesion that is red, purple, or black
Indurated	Hard and firm upon palpation in tissue that would normally be soft
Leukoplakia	A white lesion that does not rub away and that cannot be defined by any obvious clinical entity; requires further evaluation to rule out potential malignancy
Macule	A well-defined flat lesion with color or texture changes
Mobile	A movable lesion that does not appear to be connected to underlying structures
Nodule	A solid mass visible or palpable within or underneath the mucosa
Papillary	A lesion with multiple finger-like projections
Papule	A well-defined elevated lesion <0.5 cm in diameter
Pedunculated	An exophytic lesion that is attached to the mucosa by a thinner stalk
Petechia	A small, punctate area of submucosal hemorrhage
Plaque	A well-defined elevated lesion >0.5 cm in diameter on skin or mucosal surface
Pustule	A small, well-defined accumulation of pus, usually located superficially
Sessile	An exophytic lesion that is firmly attached to the mucosa by a broad base
Ulcer	Loss of epithelium, typically presenting with a yellow or whitish-gray pseudomembrane
Vegetation	An exophytic lesion with multiple papillary or nodular areas of outgrowth
Verrucous	Papillary and deeply folded epithelial changes that can appear wart-like
Vesicle	A fluid-filled blister <0.5 cm in diameter

**Fig. 3.1** Expression of serous saliva from the parotid gland duct orifice. (a) Saliva is seen as it begins to flow from Stenson's duct. (b) Expressed saliva flowing inferiorly toward the buccal vestibule

sensitivity, mobility, and adjacent soft tissue swelling and/or purulent discharge (see Chap. 7). Removable prostheses should be evaluated for fit, comfort, and overall appearance and hygiene.

Culture Techniques

Microbial culturing is utilized to confirm (or rule out) the presence of an infection, to identify specific pathogens, and to determine antimicrobial susceptibilities. Understanding when to culture, which sampling technique to use, which culture techniques to request from the diagnostic laboratory, and how to properly submit the specimen are all critical to ensure that the culture yields useful diagnostic information.

Bacterial Cultures

There are relatively few indications for obtaining bacterial cultures of the oral cavity, which is colonized in normal health by more than 300 species of commensal bacteria. Cultures are not routinely submitted in cases of uncomplicated dental infection or suppurative bacterial parotitis unless there is poor clinical response to rational empiric antibiotic therapy. Cultures should be submitted following drainage of abscesses and in cases of suspected streptococcal pharyngitis. Both aerobic and anaerobic cultures should be collected by swabbing or aspirating the purulent material directly; culture and sensitivity testing should be requested. There are no generalized indications for surveillance mucosal swabbing.

Fungal Cultures

Similarly, fungal cultures of the oral cavity are not routinely obtained. *Candida albicans*, the most common fungal pathogen of the oral cavity, is a frequent component of normal oral flora. A positive culture, in the absence of obvious signs of fungal infection (see Chap. 7), is therefore not typically a useful or meaningful piece of information. Occasionally, a culture with antifungal

susceptibilities may be indicated after a failed trial of empiric antifungal therapy in the presence of clinical signs of fungal infection.

Viral Cultures

In contrast to bacterial and fungal cultures, viral cultures are often a key diagnostic test when painful oral mucosal or lip ulcers are present. Specific viral culture transport medium must be used and the specimen must be immediately transported to the laboratory, or kept on ice when on-site facilities are not available. Lesions are lightly swabbed with the sterile cotton tip which is then placed tip down into the medium and sealed (Fig. 3.2). Herpes simplex virus (HSV) and Varicella zoster virus are both readily cultured from ulcerative lesions; although false negatives are common, particularly with resolving infections. Negative results require careful interpretation as the sample may have been inadequate or nonvital if there was a delay in transport/processing time, and reculturing should always be considered when there is continued clinical suspicion. DFA, or direct fluorescence antibody test, is a very rapid HSV test that requires a specific kit from the laboratory and is useful when an immediate (same day) diagnosis is required. Polymerase chain reaction (PCR) is an extremely sensitive assay with tests available for most of the human herpes viruses. Herpesvirus PCR can be positive in the absence of clinical lesions due to

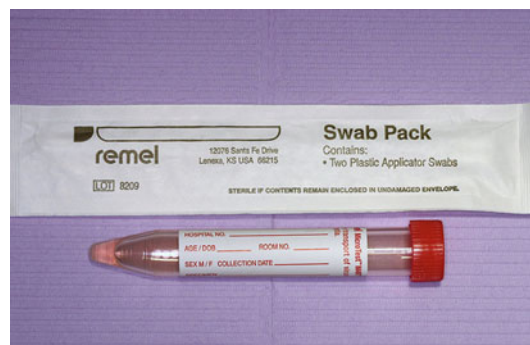

Fig. 3.2 Viral culture kit. Viral cultures can only be submitted in specific viral culture medium and must be kept on ice and processed in a timely manner

asymptomatic viral shedding, thus caution should be used in interpreting positive results.

Cytomegalovirus (CMV), a rare cause of oral ulcers in immunocompromised patients, cannot be cultured from the surface exudate of ulcers as the virus resides deep in endothelial tissues. If CMV infection is suspected, an incisional biopsy of ulcerated tissue should be obtained and submitted for histopathology and viral isolation.

Blood Tests

Analysis of the blood and serum is an important component of the diagnostic workup of certain oral medicine conditions. Routinely ordered tests include complete blood count with white blood cell differential; iron, folic acid, and vitamin B₁₂ levels; ANA, RF, SS-A, and SS-B levels; and antigen-specific antibody titers. Certain systemic medications used to treat oral medicine conditions also require blood test monitoring for toxicity. Throughout the following chapters specific tests and their interpretation will be highlighted in the context of relevant medical conditions.

Radiographic Studies

Radiographic studies are utilized to image bony or mineralized lesions, determine the extent of soft tissue lesions, image the salivary glands, and evaluate lymph nodes. Imaging studies should be reserved for clinical situations where the information obtained will contribute to diagnosis, guide management, or facilitate evaluation of response to therapy.

Plain Films

Intraoral and extraoral plain film radiography provides a safe and cost-effective means of imaging the hard tissues of the maxilla and mandible. In most cases these images are acquired and interpreted at a clinical oral health facility rather than a hospital. Bitewing radiographs are useful for visualizing interproximal caries and assessing

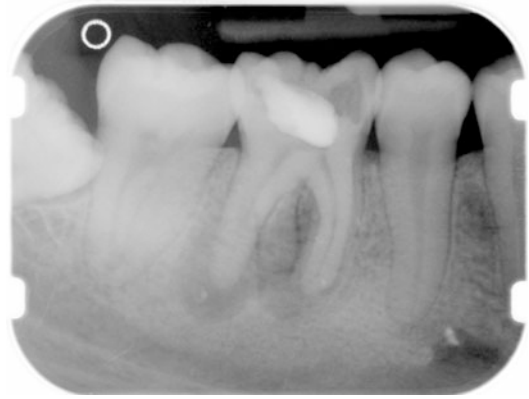


Fig. 3.3 Intraoral periapical radiograph. This technique is optimal for evaluating the periapical region of teeth. In this case, dental caries have infected the pulp of the right mandibular first molar resulting in periapical radiolucencies

alveolar bone height levels. Periapical radiographs are excellent for identifying periapical radiolucencies, which may be a sign of odontogenic infection (Fig. 3.3). Panoramic tomography provides a complete image of the mandible and maxilla and is useful in evaluating expansile bony lesions, the temporomandibular joints, fractures, and other pathology not visualized on intraoral films. It can also be used as a method for imaging the dentition when the patient is not able to open widely due to trismus, which may preclude traditional intraoral radiographic techniques (Fig. 3.4). Occlusal films may identify palatal and mandibular or sublingual lesions (Fig. 3.5). Lateral cephalometric films are used primarily for evaluation of orthodontic and orthognathic conditions.

Computed Tomography

Computed tomography (CT) provides high-resolution three-dimensional imaging of the hard and soft tissues of the head and neck. Given the increased cost and greater radiation exposure compared to plain films, CT should be ordered only when clinically warranted. CT can be particularly useful in determining the extent of a lesion prior to surgery, evaluating salivary gland pathology, assessing the status of cervical lymph nodes in cases of known or suspected malignancy.

Fig. 3.4 Panoramic radiograph. This technique provides a complete image of the mandible and lower maxilla

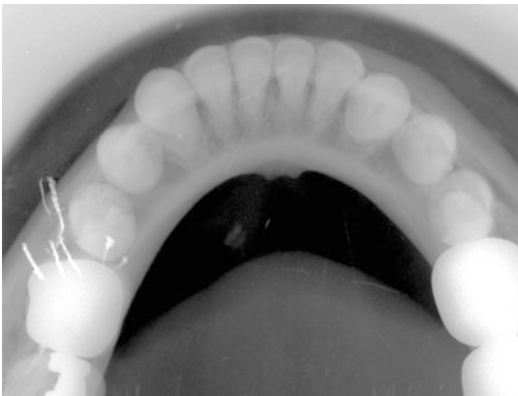
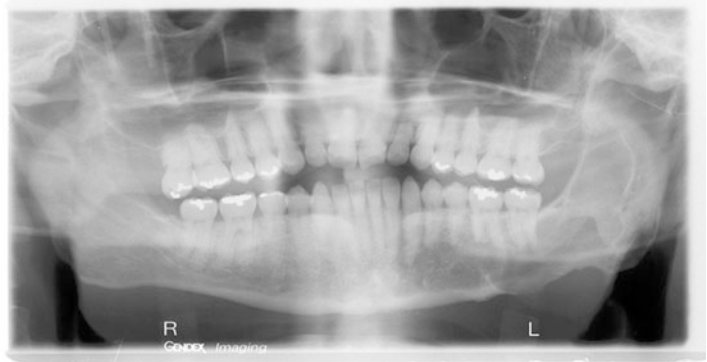
Fig. 3.5 Mandibular occlusal radiograph demonstrating presence of a salivary gland stone in the submandibular duct

nancy, and evaluating deep neck space infections (Figs. 3.6 and 3.7). The need for an intravenous contrast agent should be determined in conjunction with the radiologist. Cone beam, or helical, CT for head and neck imaging allows for high-resolution images with significantly decreased radiation exposure compared to traditional CT.

Magnetic Resonance Imaging

While CT can be useful for soft tissue imaging, magnetic resonance imaging (MRI) offers much higher resolution and provides greater ability to differentiate between different types of tissues. In addition MRI does not use ionizing radiation. Utilization of MRI in the context of clinical oral medicine is primarily indicated for evaluation of suspicious salivary gland or other soft tissue

lesions (Fig. 3.8). Despite an extensive body of literature, MRI has limited utility in the evaluation and diagnosis of patients with temporomandibular disorders. Overall, the clinical utility of MRI in oral medicine conditions is limited.

Other Imaging Studies

There are a number of additional imaging modalities that are not routinely used in the diagnosis of common oral medicine conditions. These include *positron emission tomography* (PET) scanning, which is used for diagnosis and surveillance of certain malignancies (Fig. 3.9); *ultrasonography*, which can be utilized for imaging of the salivary glands, thyroid, and cervical lymph nodes; *sialography*, in which a radiopaque medium is injected into the salivary ducts to identify obstructive and degenerative changes (Fig. 3.10); and *scintigraphy*, which can be used to assess salivary gland function via radioisotope uptake.

Intraoral photography can be very useful for documenting mucosal lesions and evaluating changes over time (Fig. 3.11). This requires a specially equipped camera with proper illumination and focus adjustment, typically including a macro lens and ring flash attachment (Fig. 3.12).

Cytology

Cytology specimens are quickly interpreted, and sampling is minimally invasive compared to traditional biopsy (Fig. 3.13). Interpretation requires

Fig. 3.6 Maxillofacial CT demonstrating extensive lytic changes in the right mandible secondary to osteoradionecrosis. High-resolution CT imaging can delineate the location and extent of bone and soft tissue lesions more precisely than plain radiographs

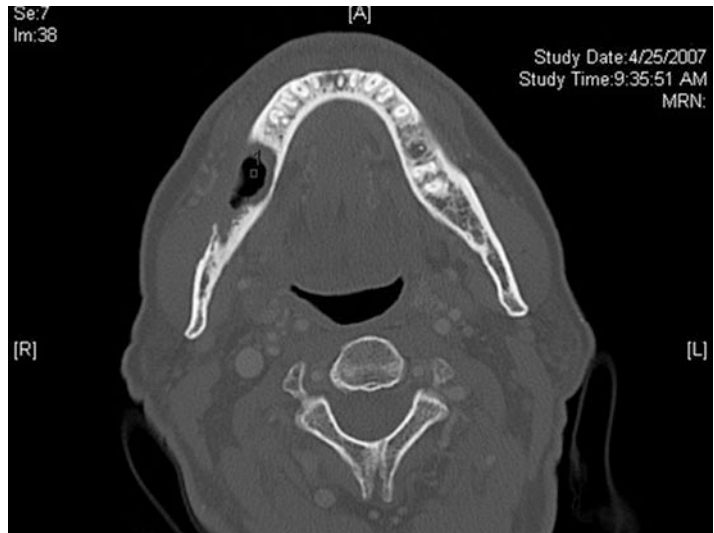

Fig. 3.7 Maxillofacial CT showing a condylar fracture

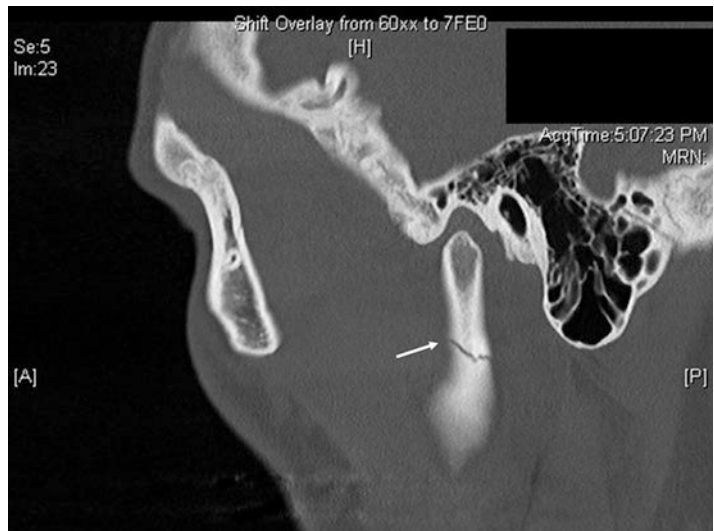
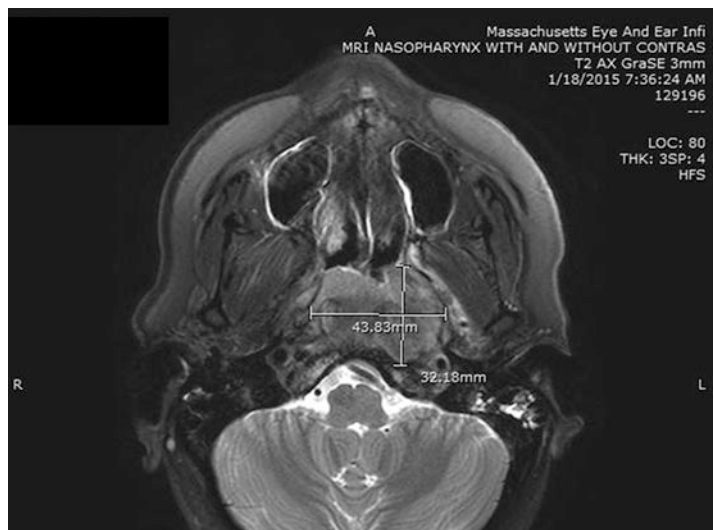
Fig. 3.8 Maxillofacial MRI demonstrating a large soft tissue mass at the level of the maxillary sinuses



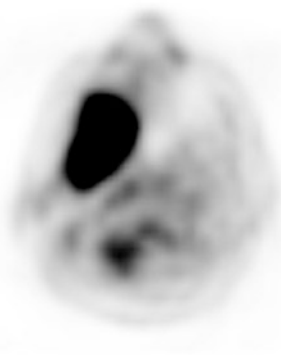


Fig. 3.9 PET scan demonstrating focal uptake in the right maxilla in a patient with recurrent non-Hodgkin lymphoma with intraoral soft tissue involvement. Diagnosis was confirmed with tissue biopsy

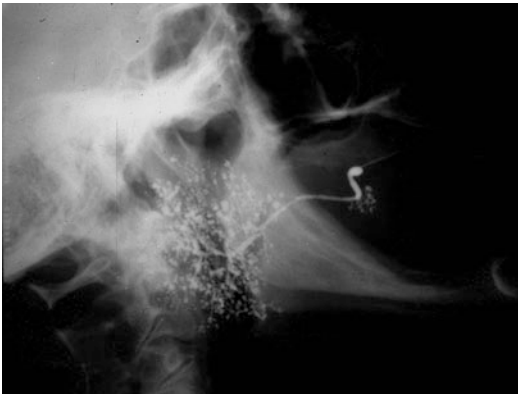

Fig. 3.10 Sialogram in a patient with Sjögren syndrome (see Chap. 8) demonstrating sialectasia secondary to chronic sialadenitis and fibrosis

an experienced cytologist, but can provide information about both infectious and noninfectious conditions of the oral cavity. Lesions suspicious for *Candida* are scraped with the intent of obtaining cellular material, and smeared on a glass slide. The slide is then treated with potassium hydroxide, lactophenol blue, or other dye (or fixed and stained with Periodic Acid-Schiff), and analyzed under the light microscope for the presence of characteristic fungal organisms (Fig. 3.14). Cytologic smears for HSV may reveal features pathognomonic for viral infec-

tion, such as multinucleated giant cells and “ballooning” cytoplasm (Fig. 3.15). Viral cytology is especially useful when culture results are inconclusive.

Enlarged lymph nodes, salivary gland masses, intrabony radiolucencies, and vascular appearing lesions may be initially evaluated using a fine needle aspiration biopsy technique. This procedure must be performed by an experienced clinician and the specimen interpreted by an experienced cytologist, who should ideally be present at the time of the procedure (Fig. 3.16).

Tissue Biopsy

Tissue biopsy is the gold standard for definitive diagnosis of soft and hard tissue lesions. An *incisional* biopsy evaluates a small representative sample, whereas an *excisional* biopsy indicates removal and evaluation of the entire lesion. Biopsies may be submitted in formalin for routine histopathology or in saline or Michel’s medium for direct immunofluorescence and other advanced studies (including tissue culture) that require non-fixed tissue. Immunohistochemical studies can be performed on both formalin fixed and fresh tissue samples and may be useful for determining or refining the diagnosis. The pathology laboratory should be consulted in advance when there are any questions as to how a specimen should be submitted, as some diagnostic studies require fresh, unfixed tissue.

The procedure in most cases is straightforward and often takes no more than 5 or 10 min to perform. Following informed consent, a small amount of local anesthetic is injected, a 4.0-mm skin punch is rotated into the full thickness of the mucosa, and the specimen is grasped with tissue forceps and incised at its deepest point with scissors or scalpel (Figs. 3.17 and 3.18). In areas where the tissue is closely attached to underlying bone (e.g., hard palate and gingiva), a simple wedge biopsy with a scalpel is generally easier than using a skin

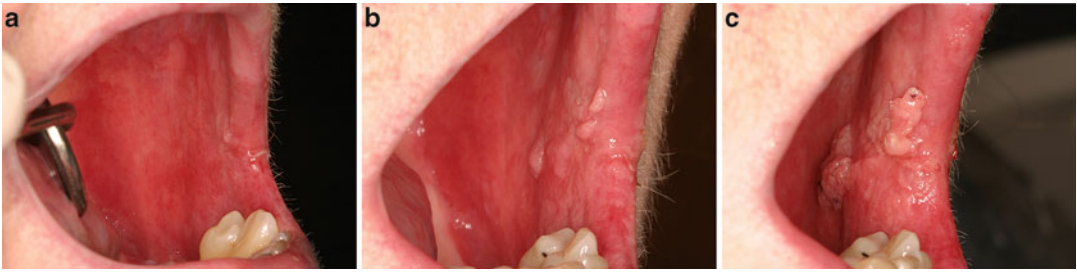

Fig. 3.11 Series of intraoral photographs of the left buccal mucosa in a patient with chronic graft-versus-host disease (cGVHD; see Chap. 11). (a) At initial presentation the patient reported intraoral sensitivity consistent with a long-standing history of oral cGVHD and was treated accordingly. (b) At 2-month follow-up multiple papillary

growths were noted and biopsy was scheduled 2 weeks later. (c) The patient returned 2 months after initial presentation, at which time the lesions had increased in size and biopsy confirmed invasive squamous cell carcinoma (see Chap. 9)



Fig. 3.12 Digital SLR camera equipped for intraoral photography with macro lens and ring flash

punch. Small, well-defined lesions may be excised fully (Fig. 3.19). Placement of simple interrupted resorbable sutures or application of silver nitrate is generally effective to control bleeding (Fig. 3.20). Pain following biopsy is typically mild and rarely requires postoperative prescription pain medication.

There are several important points to consider when performing a biopsy. If the lesion is nonhomogeneous, more than one area within the lesion should be sampled because early malignancies can present only focally in a field of dysplastic changes (Fig. 3.21). If the differential diagnosis includes a vesiculobullous disorder, the biopsy site should be perilesional, specifically avoiding any area of ulceration (Fig. 3.22). As ulcers lack epithelial layers, direct immunofluorescence testing cannot be adequately performed on specimens taken from such areas. All specimens should be carefully mapped and oriented. Regardless of the presumed clinical diagnosis, any tissue that is excised should be submitted for

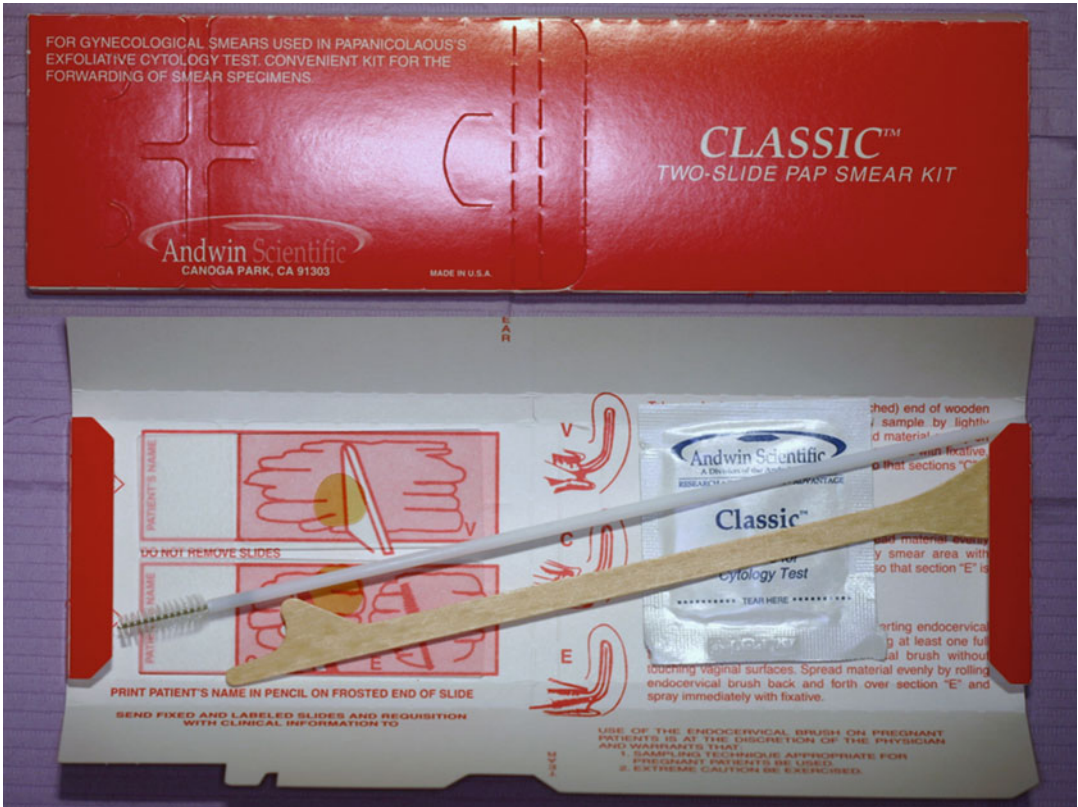

Fig. 3.13 Exfoliative cytology kit including glass slides, alcohol packet, wood spatula, and brush

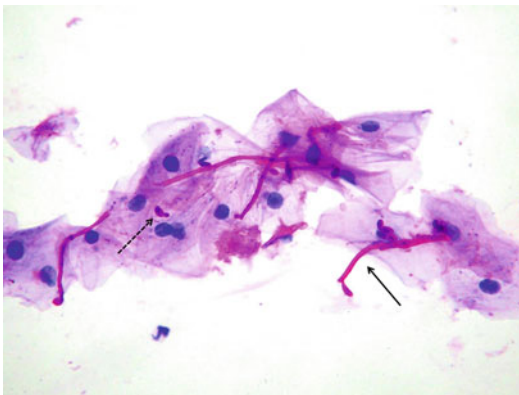


Fig. 3.14 Oral cytology specimen of a suspected fungal infection demonstrating *Candida* hyphae (linear organisms; *solid arrow*) and conidia (ovoid budding organisms; *broken arrow*). Photomicrograph courtesy of Mark Lerman, D.M.D., Boston, MA

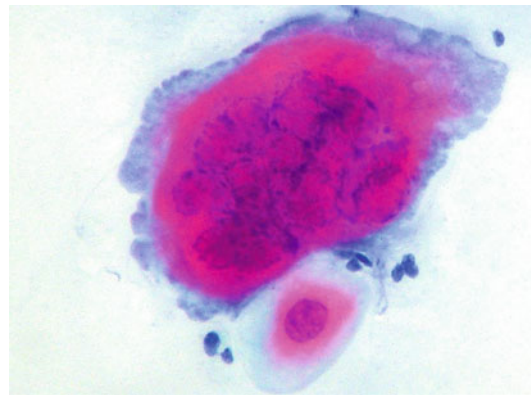


Fig. 3.15 Oral cytology specimen of a suspected herpes simplex virus infection demonstrating classic viral cytopathic changes in the cell above the normal keratinocyte. Photomicrograph courtesy of Mark Lerman, D.M.D., Boston, MA

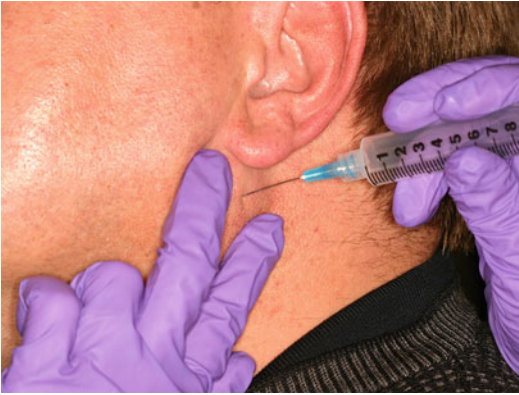

Fig. 3.16 Fine needle aspiration of an enlarged cervical lymph node. Photograph courtesy of Sook-Bin Woo, D.M.D., M.M.Sc., Boston, MA

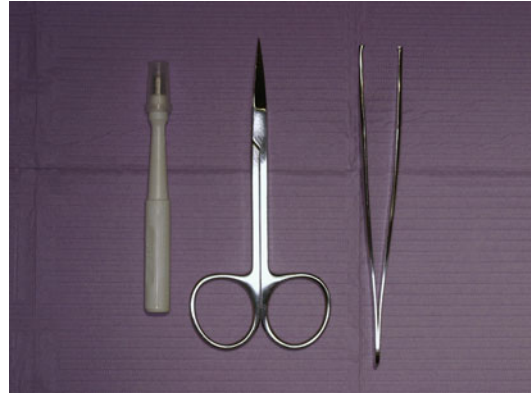

Fig. 3.17 Oral punch biopsy armamentarium that includes a 4.0-mm disposable punch, tissue forceps, and surgical scissors

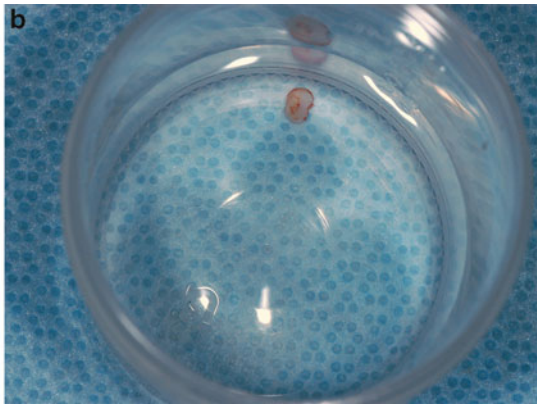
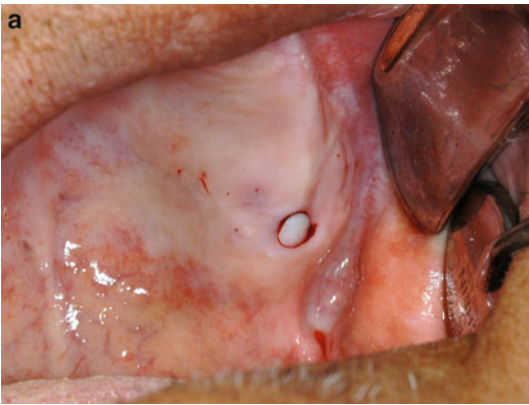


Fig. 3.18 Punch biopsy of an area of leukoplakia on the hard palate. (a) After rotation of the punch down to periosteum, prior to excision with forceps and scissors. (b) Excised surgical specimen placed in formalin

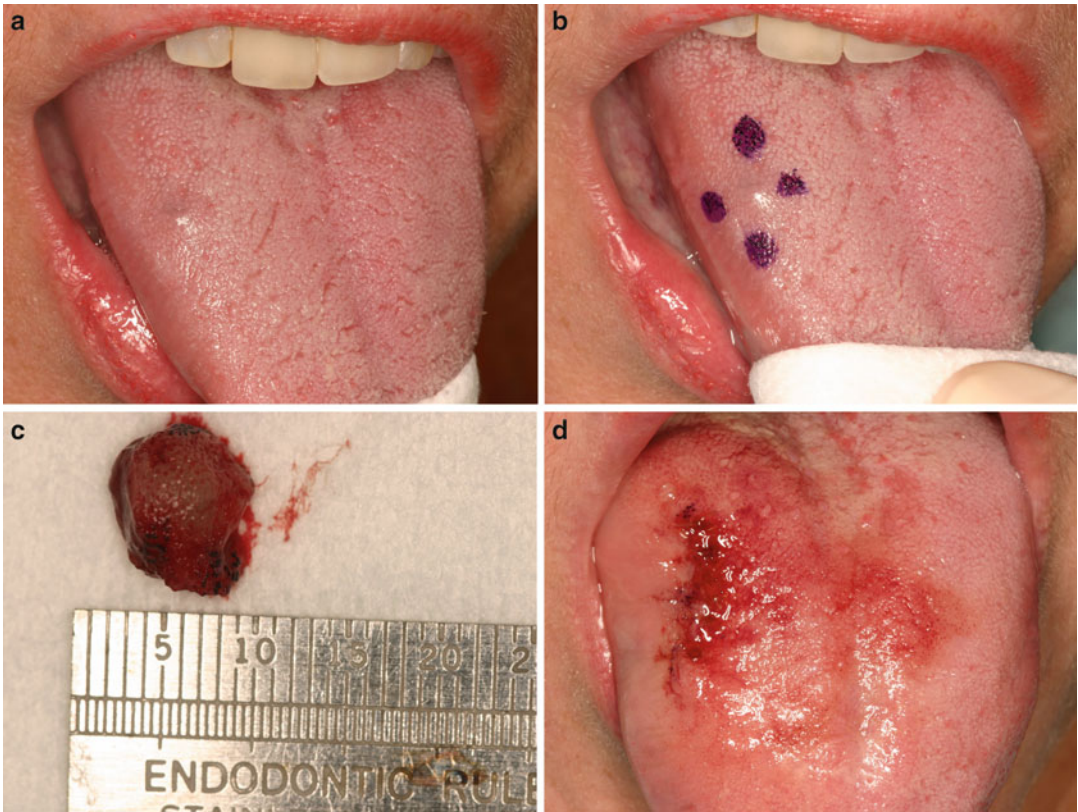


Fig. 3.19 (a) Excisional biopsy of a recurrent benign tongue neoplasm (spindle cell tumor). (b) Outline of excision marked with surgical pen to ensure adequate margins. (c) Gross pathology of excised specimen. (d) Postoperative sutured excision site

histopathological analysis. It is generally preferable to send specimens to a pathology laboratory with a board-certified oral pathologist on staff or general pathologist with special training in oral pathology.

Adjuvant Tests

A number of commercially available adjuvant diagnostic tests and devices for the screening of premalignant and malignant lesions are available. These include brush cytology (OralCDx Brush Biopsy, CDx Laboratories, Suffren, NY), tolu-

idine blue vital tissue staining, tissue reflectance (ViziLite Plus, Zila Pharmaceuticals, Phoenix, AZ, and MicroLux DL, AdDent, Danbury, CT), and tissue fluorescence (VELscope, LED Dental Inc., Vancouver, Canada). There is considerable debate in the head and neck oncology, oral medicine, and oral pathology professional communities as to the value of these tests and devices, given that their utility in aiding in the detection of oral cancer has yet to be definitively demonstrated. Of the above tests, toluidine blue may be useful in long-term surveillance of high-risk patients specifically as a tool to identify sites for biopsy.

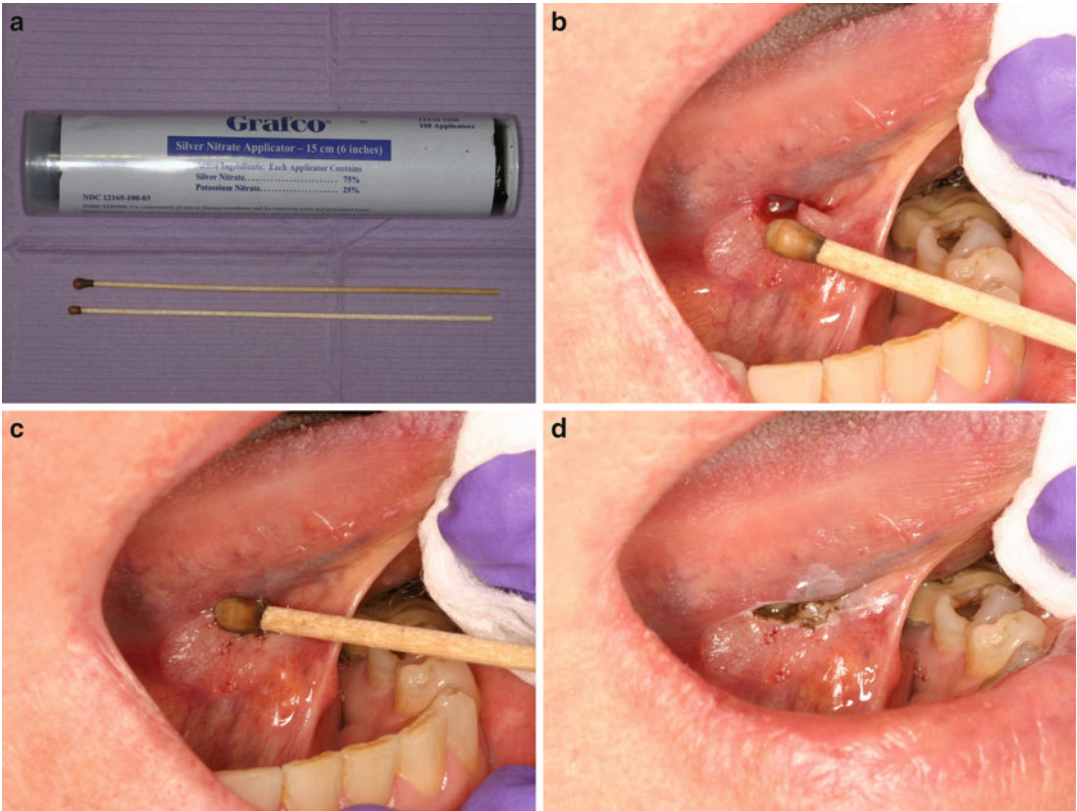


Fig. 3.20 Use of silver nitrate following a punch biopsy. (a) Silver nitrate sticks. (b) Prior to application. (c) The stick is quickly rotated and removed. (d) Biopsy site following application. The gray discoloration will gradually fade

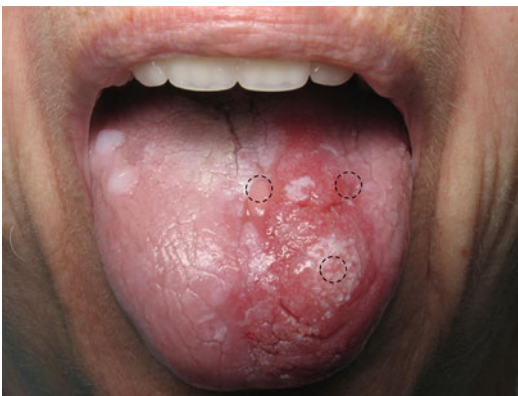

Fig. 3.21 Selection of multiple biopsy sites in a patient with a large area of erythroleukoplakia (see Chap. 9) to ensure adequate sampling

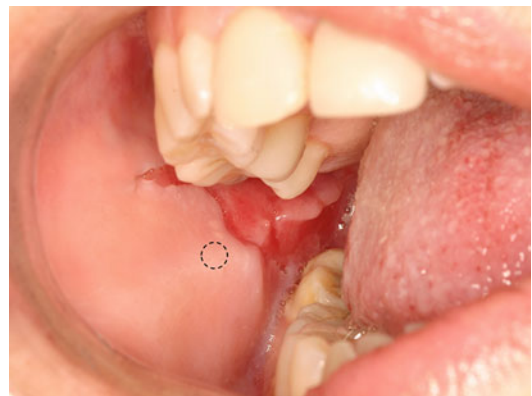


Fig. 3.22 Perilesional biopsy in a patient with an ulcerative lesion undergoing evaluation for autoimmune vesiculobullous disease. The biopsy specimen was divided into equal fragments and submitted for both routine histopathology and direct immunofluorescence

Sources

- Jordan RC, Daniels TE, Greenspan JS, et al. Advanced diagnostic methods in oral and maxillofacial pathology. Part 1: molecular methods. *Oral Surg Oral Med Oral Pathol Oral Radiol Endod.* 2001;92:650–69.
- Jordan RC, Daniels TE, Greenspan JS, et al. Advanced diagnostic methods in oral and maxillofacial pathology. Part 2: immunohistochemical and immunofluorescent methods. *Oral Surg Oral Med Oral Pathol Oral Radiol Endod.* 2002;93:56–74.
- Lingen MW, Kalmar JR, et al. Critical evaluation of diagnostic aids for the detection of oral cancer. *Oral Oncol.* 2008;44:10–22.
- Orel S, Sterrett G, Whitaker D. *Fine needle aspiration cytology.* 4th ed. China: Elsevier; 2005.
- Patton LL, Epstein JB, Kerr AR. Adjunctive techniques for oral cancer examination and lesion diagnosis: a systematic review of the literature. *J Am Dent Assoc.* 2008;139:896–905.
- Shintaku W, Enciso R, Broussard J, Clark GT. Diagnostic imaging for chronic orofacial pain, maxillofacial osseous and soft tissue pathology and temporomandibular disorders. *J Calif Dent Assoc.* 2006;34:633–44.

Introduction

The oral mucosa is normally semitranslucent, allowing the color of underlying tissues such as fat, blood vessels, or melanin pigment to show through to a variable degree. This is affected by the thickness of the overlying tissue as well as the amount of surface keratin, concentration of submucosal fat or other substance, and density of the tissue capillary bed. For this reason, the thin nonkeratinized mucosa lining the vestibule and floor of mouth normally appears darker red than the thicker pale pink keratinized gingiva. Likewise, the vermilion zone of the lip appears red secondary to an abundant subepithelial capillary blood supply.

Inflammatory conditions frequently result in increased redness (*erythema*) due to thinning of the mucosa and/or increased underlying vascularity. Lesions most commonly appear white secondary to increased thickness of the epithelium, or to a lesser extent, decreased vascularity (Fig. 4.1). Thickening of the epithelium can be caused by epithelial hypertrophy or hyperplasia, edema, and increased production of surface keratin (*hyperkeratosis*). Thickening specifically in the spinous, or prickle, layer of the epithelium is

referred to as *acanthosis*. Collapsed bullae or ulcerative lesions covered with a surface layer of fibrin may also appear white. Mechanical friction or other irritants to the mucosal lining can stimulate keratin production as a protective response. Some white lesions can be identified and treated on clinical grounds alone, whereas others require additional testing and/or biopsy for definitive diagnosis.

Leukoedema

This is a common entity that presents as a generalized opacification or gray-white to milky opalescence of the buccal mucosa bilaterally (Fig. 4.2). It may appear filmy or wrinkled and cannot be rubbed off. The color becomes less evident or disappears entirely when the mucosa is stretched. It is usually noted as an incidental finding on exam and is asymptomatic; biopsy is not indicated. The etiology is not clearly established, however, there may be a hereditary component. This condition is more frequently seen in patients of African-American descent. Histologically, the tissue exhibits intracellular edema in the spinous cell layer of the epithelium. This is a benign condition, and no treatment is required.

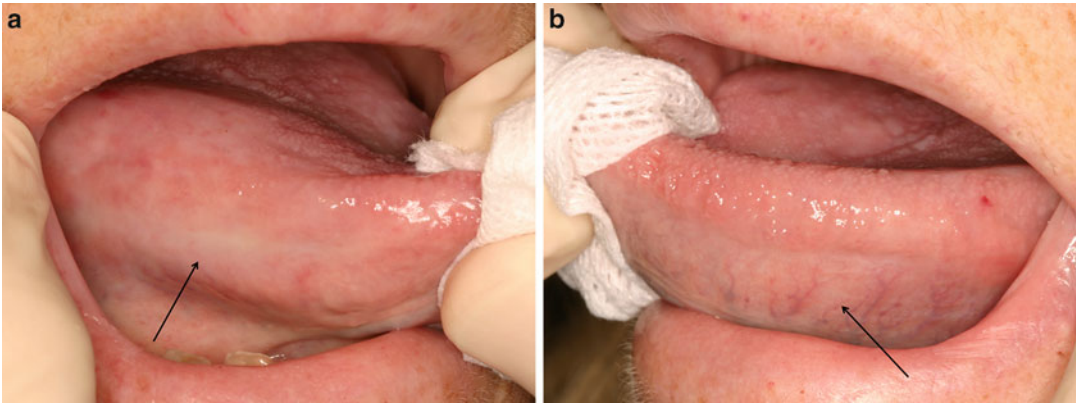


Fig. 4.1 Appearance of the ventrolateral tongue in a patient following radiation therapy. The *right* side (a), which was in the field of radiation, appears pale white with obliteration of vasculature. On the *left* side (b), which was not radiated, normal appearing vessels are easily visualized. Also note small petechia secondary to bite trauma

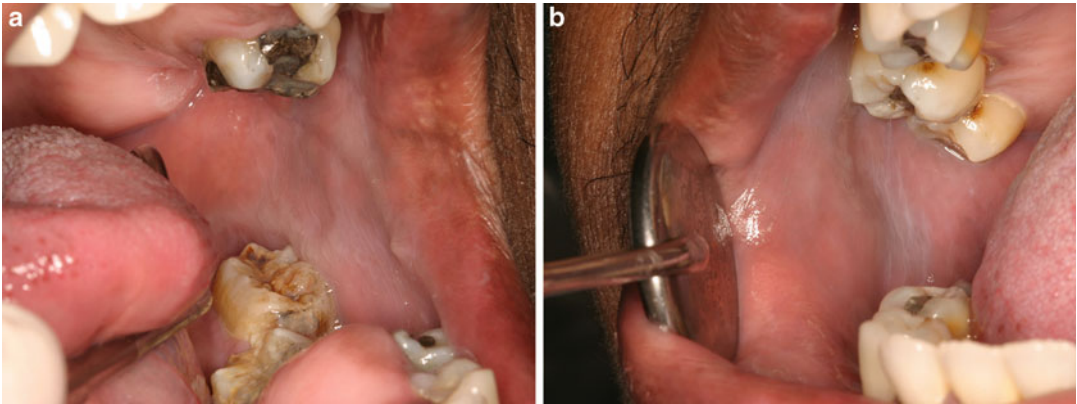






Fig. 4.2 Leukoedema of the (a) left buccal mucosa and (b) right buccal mucosa. The *white* changes disappear upon stretching of the tissue with a dental mirror

Leukoedema

	<p>DIAGNOSTIC TESTS</p>	<p>Stretching of the tissue with resulting diminished white color is diagnostic; no further testing is required.</p>
	<p>BIOPSY</p>	<p>No.</p>
	<p>TREATMENT</p>	<p>None.</p>
	<p>FOLLOW-UP</p>	<p>None.</p>

Linea Alba

Literally meaning “white line,” this is a focal hyperkeratosis resulting from chronic frictional trauma of the tissues rubbing against the adjacent teeth. It is most commonly seen as a horizontal white streak along the buccal mucosa at the level of the occlusal plane bilaterally and conforms to

the configuration of the teeth in that area (Fig. 4.3). Frictional hyperkeratosis can also be seen focally in other commonly traumatized areas such as edentulous alveolar ridge spaces (Fig. 4.4), lips (Fig. 4.5), and lateral aspect of the tongue. This may be confused with lichen planus, which is a white lesion commonly occurring on the buccal mucosa (see Chap. 5).

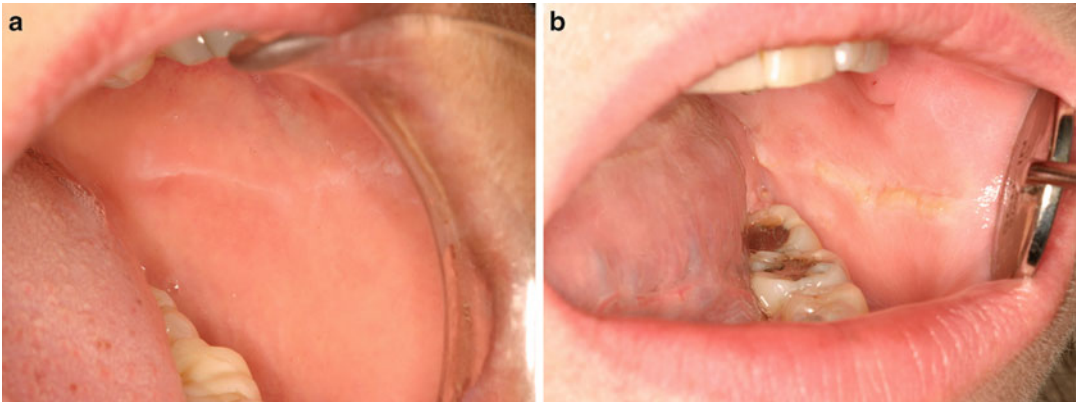


Fig. 4.3 Linea alba. (a) Fine, distinct linea alba of the left buccal mucosa. (b) Linea alba with a wide, shaggy appearance due to bite injury

Fig. 4.4 Benign alveolar ridge keratosis. Frictional hyperkeratosis is common in edentulous areas

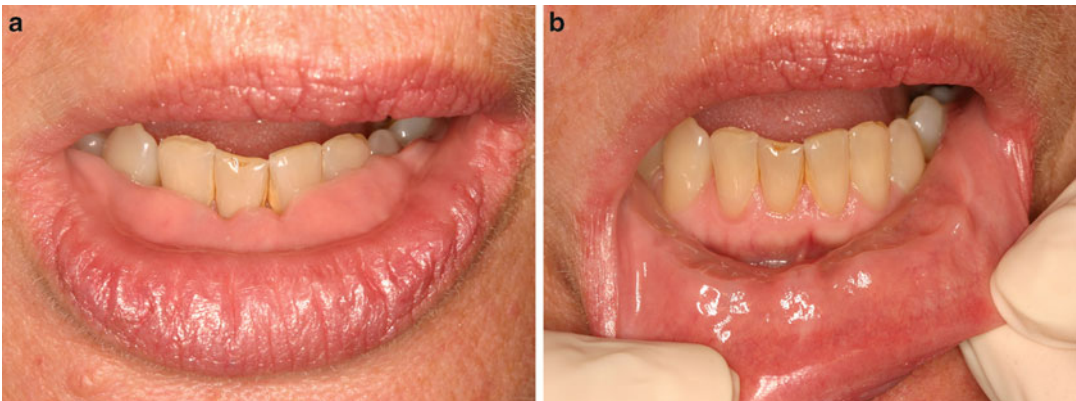
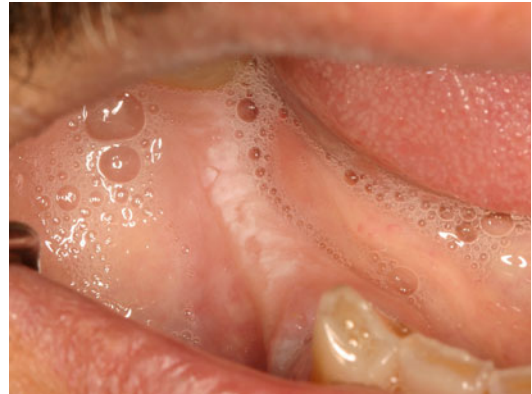





Fig. 4.5 Hyperplastic tissue of the (a) lower labial mucosa related to parafunctional activity, (b) with lower lip retracted

Linea Alba

	DIAGNOSTIC TESTS	None; diagnosis is based on clinical features.
	BIOPSY	No, unless the appearance is atypical or diagnosis is uncertain.
	TREATMENT	None.
	FOLLOW-UP	None.

Cheek Biting

Hyperkeratosis from frictional trauma may be quite pronounced in cases of chronic cheek or lip biting or chewing (*morsicatio buccarum*, *morsicatio labiorum*). Lesions can appear ragged or frayed, with areas of ulceration or redness (Figs. 4.6, 4.7, and 4.8). Chronic chewing lesions of the tongue (*morsicatio linguarum*) can resemble *oral hairy leukoplakia*. Patients may or may not be aware of the habit and lesions are almost universally asymptomatic. Other than educating the patient as to the underlying cause, no treatment is necessary. There are no long-term consequences of this benign condition.

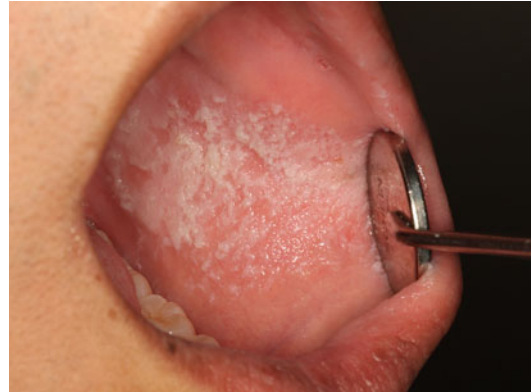

Fig. 4.7 Chronic bite trauma to the left buccal mucosa

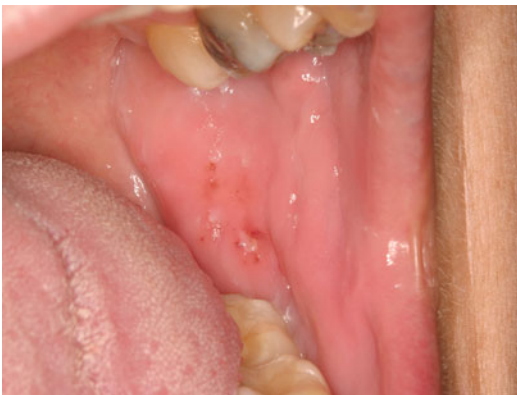





Fig. 4.6 Acute bite injury to the left buccal mucosa

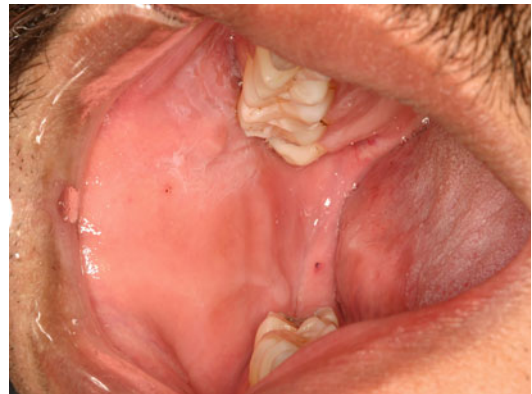

Fig. 4.8 Chronic bite injury to the right buccal mucosa. Parafunctional habits resulted in white lesions above the occlusal plane that could easily be mistaken for leukoplakia

Cheek Biting

	DIAGNOSTIC TESTS	None, as diagnosis is based on history and clinical appearance.
	BIOPSY	No.
	TREATMENT	None.
	FOLLOW-UP	None.

Hairy Tongue

Hairy tongue, or *lingua villosa*, is an entirely benign condition that can have a striking presentation. Elongation of the filiform papillae occurs secondary to decreased desquamation of the keratin layer causing a white coating on the tongue dorsum, usually posteriorly (Fig. 4.9). The surface coating can become quite matted and hair-like, with gagging or sensation of irritation in some patients if the papillae become extremely long. Oral burning may be noted in cases of superimposed *candidiasis* (see Chap. 7). Trapping of chromogenic organisms and debris and staining from coffee or tobacco can cause a range of color variations from black to green (Fig. 4.10). The etiology is unclear, but has been linked to the use of antibiotics and antimicrobial mouthrinses. It is also seen with dehydration, xerostomia (Fig. 4.11), poor nutrition, and a soft or minimally abrasive diet. Treatment is generally not

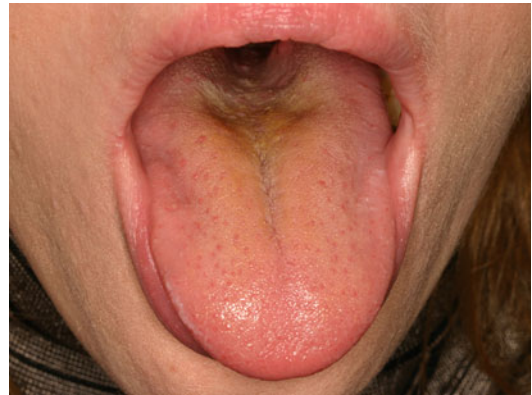

Fig. 4.10 Hairy tongue with yellowish orange pigmentation

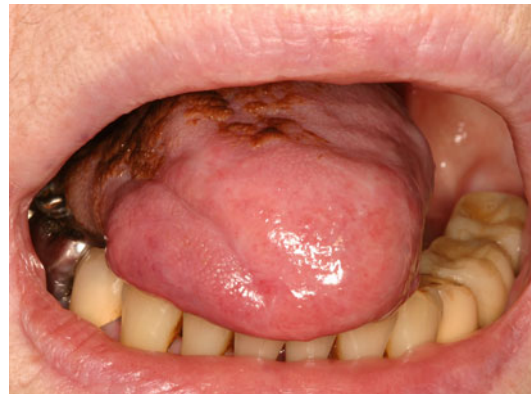





Fig. 4.11 Brown hairy tongue in a patient with chronic atrophic glossitis following head and neck radiation therapy. Only the papillated regions of the tongue are affected

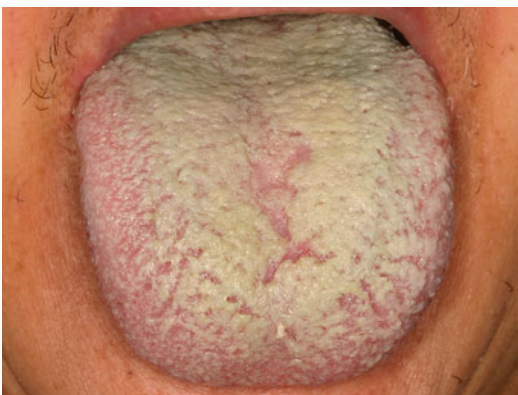

Fig. 4.9 Hairy tongue in a patient restricted to a soft diet

necessary, and elimination of any contributing factors typically results in complete resolution. If lesions persist and are bothersome to the patient, gentle brushing or scraping of the tongue is recommended.

Hairy Tongue

	DIAGNOSTIC TESTS	None; diagnosis is based on clinical appearance and medical history.
	BIOPSY	No.
	TREATMENT	Encourage well-balanced diet and smoking cessation. Gentle cleansing of the tongue can be helpful.
	FOLLOW-UP	None.

Oral Hairy Leukoplakia

This is a benign, well-demarcated, generally asymptomatic white lesion of the ventrolateral tongue seen in HIV infected or immunosuppressed individuals. It can appear flat or raised, is

often thick and corrugated, and frequently exhibits its vertical ridge-like striations (Figs. 4.12 and 4.13). The lesions cannot be rubbed off, distinguishing the condition from *pseudomembranous candidiasis* (see Chap. 7). The etiology is associated with Epstein-Barr virus infection and does not exhibit any malignant potential.

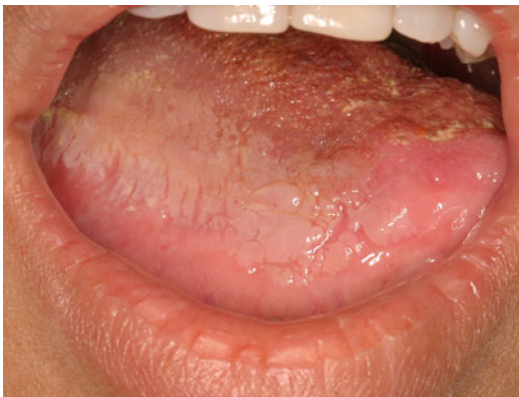





Fig. 4.12 Oral hairy leukoplakia of the right lateral tongue with diffuse white corrugated plaques

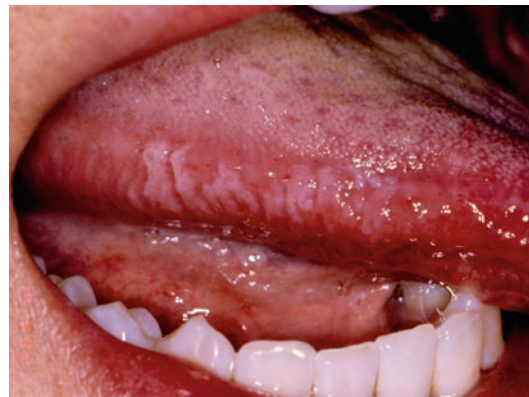

Fig. 4.13 Oral hairy leukoplakia of the right lateral tongue with focal linear white plaques

Oral Hairy Leukoplakia

	DIAGNOSTIC TESTS	None; diagnosis is usually established clinically in the context of HIV disease. Immune or HIV status should be ascertained if unknown.
	BIOPSY	May be indicated to distinguish from <i>hyperplastic candidiasis</i> (see Chap. 7) or <i>leukoplakia</i> (see Chap. 9).
	TREATMENT	None.
	FOLLOW-UP	Observation.

Nicotinic Stomatitis

Direct irritation of the palatal mucosa from hot tobacco smoke can lead to inflammatory changes which are initially erythematous, then become white secondary to progressive epithelial hyperplasia and hyperkeratosis. The palate exhibits a cracked or wrinkled appearance, with punctate red dots representing inflammation and squamous metaplasia of minor salivary gland duct orifices (Figs. 4.14 and 4.15). This is commonly referred to as “smoker’s palate”. Any mucosa covered by a denture will be spared if the prosthesis is typically worn while smoking.

The clinical appearance is usually diagnostic and biopsy is not necessary unless there are associated areas of ulceration or focal *erythroplakia* (see Chap. 9). This lesion is reversible with smoking cessation. Although this is not considered a precancerous condition, its presence directly correlates with the intensity of smoking and is usually a marker of heavy tobacco use. Observation is therefore recommended in conjunction with careful screening of the entire oral cavity.

Other white lesions related to tobacco are discussed in Chap. 9, including *leukoplakia* and *tobacco pouch keratosis*.

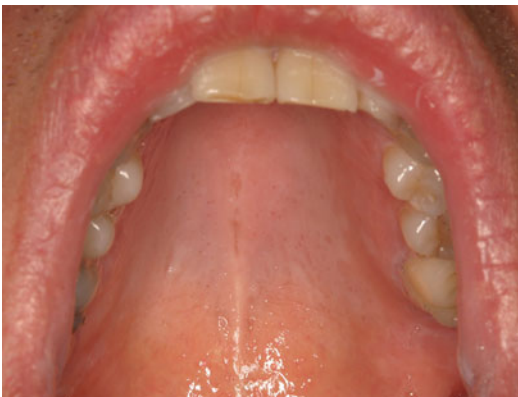





Fig. 4.14 Mild smoker’s palate showing excessive keratinization of the hard palate and focally inflamed minor salivary gland duct orifices

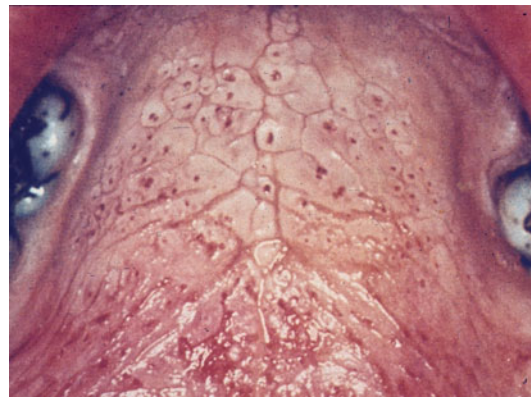

Fig. 4.15 Severe smoker’s palate showing heavy keratinization and intensely inflamed duct orifices. Photograph courtesy of Ellen Eisenberg, D.M.D., Farmington, CT

Nicotinic Stomatitis





	DIAGNOSTIC TESTS	None; diagnosis is based on clinical appearance.
	BIOPSY	No, unless lesions exhibit worrisome changes over time or persist after smoking is discontinued.
	TREATMENT	Smoking cessation.
	FOLLOW-UP	Observation.

White Sponge Nevus

This is an exceedingly rare lesion, inherited as an autosomal dominant trait, which usually presents in childhood or adolescence without gender predilection. Genetic analysis has pinpointed the defect to genes encoding mucosal keratin (keratin 4 and 13). It appears as a thick corrugated or folded white

plaque with a spongy texture affecting the buccal mucosa bilaterally and is generally asymptomatic. The clinical appearance and family history are so distinctive that biopsy is not necessary. It can appear less frequently in other areas of the oral cavity as well as the esophagus, genitalia, and rectum, in which case biopsy may be indicated. This is a benign condition and no treatment is required.

White Sponge Nevus

	DIAGNOSTIC TESTS	None; diagnosis is made based on clinical appearance.
	BIOPSY	No, unless appearance is not classic.
	TREATMENT	None.
	FOLLOW-UP	None.

Chemical Burn

A number of chemicals and medications can be extremely caustic to the oral mucosa if they come in direct contact. Inappropriate topical use of certain medications by the patient, such as aspirin tablets or powder held against the tissue, can result in significant trauma, causing coagulation necrosis and sloughing of the epithelium. Iatrogenic injuries can also be caused by agents such as sodium hypochlorite (a disinfectant used for root canal irrigation), formocresol, silver nitrate, and acid etching solutions used during dental treatment. The initial lesion is usually white and leathery or wrinkled in

appearance and generally very painful. If contact with the caustic substance was brief, which is usually the case, healing without scar or other complications should occur within 10–14 days and palliative treatment with topical agents can be used. If more severe injury occurs, with surface desquamation and presence of deeper tissue necrosis, then treatment with antibiotics and debridement may be required. Over the counter alcohol-containing mouthrinses and other topical dentrifices may cause superficial chemical burns, including hydrogen peroxide in concentrations greater than 3% (Fig. 4.16). These are almost always painless and can be “peeled” away revealing normal appearing underlying mucosa.

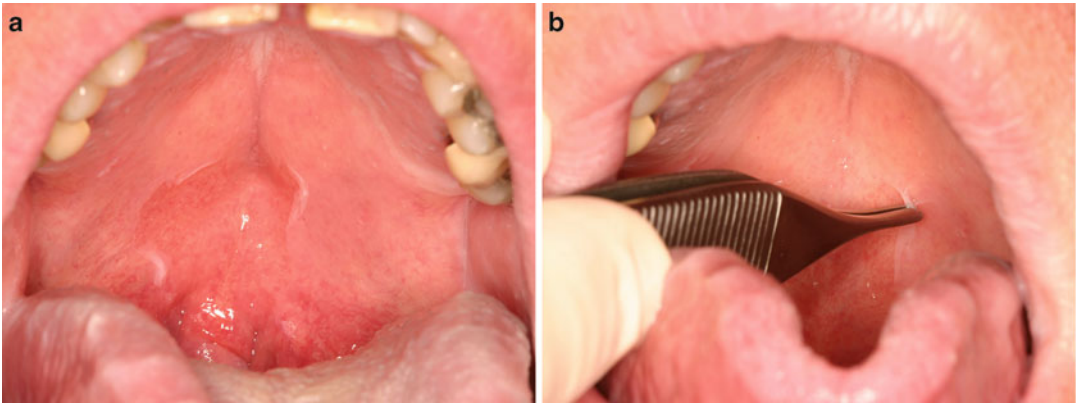






Fig. 4.16 Superficial chemical injury from use of an alcohol-containing mouthwash. **(a)** The palatal mucosa has a filmy appearance with areas of tissue slough. **(b)** The superficial necrotic layer can be painlessly removed with tissue forceps. Photograph courtesy of Sook-Bin Woo, D.M.D., M.M.Sc., Boston, MA

Chemical Burn

	DIAGNOSTIC TESTS	None; diagnosis is based on history and clinical appearance.
	BIOPSY	No.
	TREATMENT	Palliative treatment with analgesics. Severe injuries may require antibiotics or tissue debridement.
	FOLLOW-UP	As needed until condition is resolved.

Exfoliative Cheilitis

This is an unusual chronic condition of the lips characterized by crusting and peeling of the superficial epithelium, often associated with discomfort or burning. In most cases the entire upper and lower lips are involved, and there may be associated erythema and swelling (Fig. 4.17).

The cause is believed to be related to repetitive lip irritation, such as chronic lip licking or picking, as well as other factitious or maladaptive behaviors. There may be an association with stress or depression in some patients. There is rarely an infectious component, but secondary infection with candida should be considered if features consistent with *angular cheilitis* (see Chap. 7) are present.

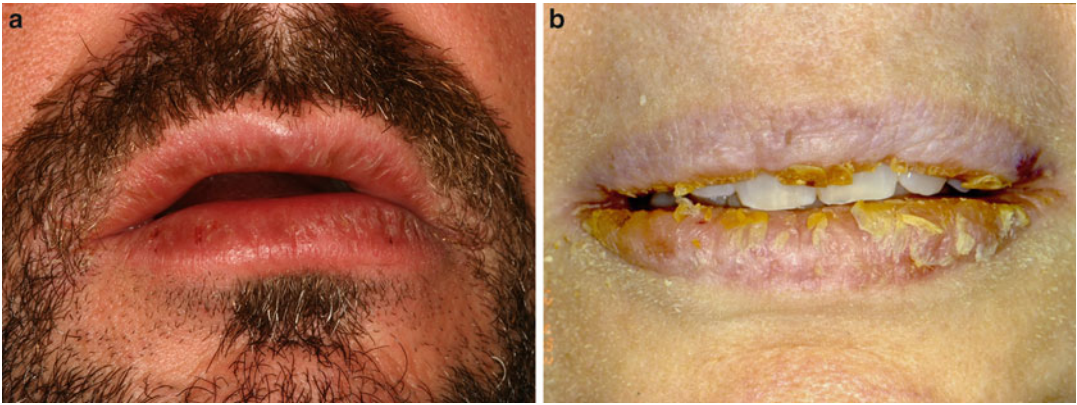


Fig. 4.17 Exfoliative cheilitis. (a) Mild case with crusting and peeling of the lips. (b) More severe case with extensive peeling and flaking

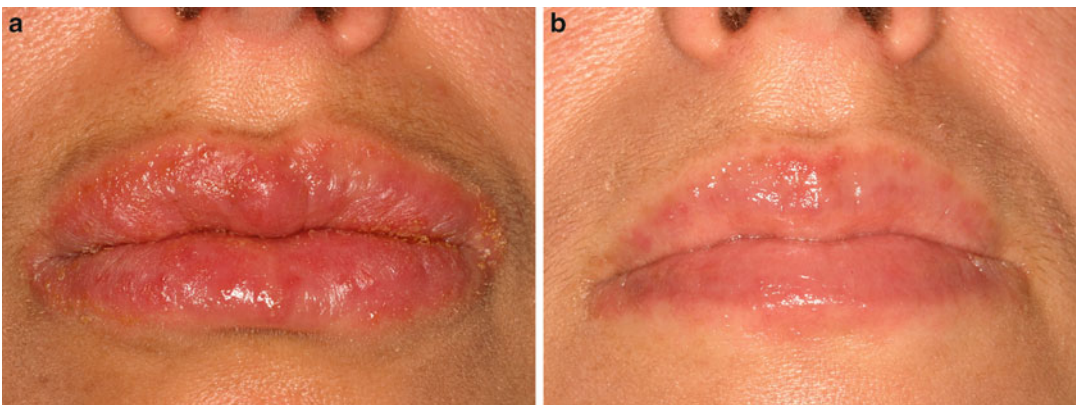






Fig. 4.18 Exfoliative cheilitis presenting with (a) swollen, erythematous lips with superficial crusting; (b) following several weeks of therapy with topical tacrolimus

Exfoliative Cheilitis

	DIAGNOSTIC TESTS	None; diagnosis is based on clinical appearance and history.
	BIOPSY	No.
	TREATMENT	Patient education regarding discontinuation of potentially causative habits or behaviors, such as lip licking. Use of topical petrolatum jelly usually results in resolution; tacrolimus 0.1 % ointment once or twice daily may be effective in refractory cases (Fig. 4.18).
	FOLLOW-UP	As needed while condition is active.

Sources

- Almazrooa SA, Woo SB, et al. Characterization and management of exfoliative cheilitis: a single-center experience. *Oral Surg Oral Med Oral Pathol Oral Radiol.* 2013;116:e485–9.
- Chi AC, Lambert PR, Pan Y, et al. Is alveolar ridge keratosis a true leukoplakia?: a clinicopathologic comparison of 2,153 lesions. *J Am Dent Assoc.* 2007;138:641–51.
- Komatsu TL, Rivero ERC, et al. Epstein-Barr virus in oral hairy leukoplakia scrapes: identification by PCR. *Braz Oral Res.* 2005;19:317–21.
- Martelli H, Pereira SM, Rocha TM, et al. White sponge nevus: report of a three-generation family. *Oral Surg Oral Med Oral Pathol Oral Radiol Endod.* 2007;103:43–7.
- Natarajan E, Woo SB. Benign alveolar ridge keratosis (oral lichen simplex chronicus): a distinct clinicopathologic entity. *J Am Acad Dermatol.* 2008;58:151–7.
- Taybos G. Oral changes associated with tobacco use. *Am J Med Sci.* 2003;326:179–82.
- Woo SB, Lin D. Morsicatio mucosae oris: a chronic oral frictional keratosis, not a leukoplakia. *J Oral Maxillofac Surg.* 2009;67:140–6.

Introduction

A wide variety of immune-mediated conditions can affect the orofacial region. Some present in a limited fashion related to a localized immune response, such as contact hypersensitivity, while others represent more widespread systemic disease with distinct oral manifestations, such as the group of autoimmune vesiculobullous disorders. The underlying pathobiological mechanisms are also quite varied and involve components of the innate and acquired immune systems. Some of these are very well characterized while others are not.

Determining the correct diagnosis is critical, as management strategies can vary considerably from one entity to the next. In some situations additional medical specialty consultation may be indicated, such as dermatology, ophthalmology, or otolaryngology. Oral lesions may precede the appearance of findings in other areas of the body or may represent the sole manifestation of the disease. This chapter is devoted to conditions in which oral findings are a primary feature. Systemic conditions that variably present with oral findings or complications are discussed in Chap. 11.

When evaluating a patient with a suspected immune-mediated or allergic oral disease that requires a tissue diagnosis, it is important to obtain a biopsy prior to initiating any topical or systemic immunosuppressive therapies, as these

may mask characteristic or defining histopathological features. Since many of these conditions are chronic and require treatment with long-term topical and or systemic therapies, all patients should be followed on a regular basis. Detailed prescribing guidelines for the most commonly used medications are provided in Chap. 12.

Angioedema

This condition is characterized by rapid localized swelling of the skin or mucosa and underlying connective tissue. While angioedema can occur anywhere in the body, it most commonly presents in the head and neck region. The lips and tongue are most frequently affected; however, the floor of mouth and other areas of the face can also be involved. With involvement of the pharynx and larynx, patients may develop wheezing, voice change, and difficulty in breathing; in severe cases this can progress to potentially fatal airway obstruction. The lower gastrointestinal tract can also be affected, resulting in abdominal pain and diarrhea. Episodes typically develop within minutes to a few hours and resolve within 2–3 days, although changes can persist for as long as 1 week. Affected areas are characterized by painless, non-pitting edema with adjacent uninvolved tissues exhibiting a normal appearance (Fig. 5.1). Swollen tissues may be secondarily traumatized, but this is not a primary feature of the condition.

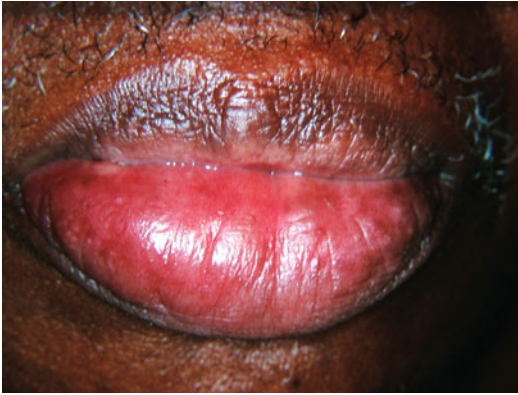





Fig. 5.1 Angioedema of the lower lip associated with ACE inhibitor use. The upper lip and facial skin are unaffected. Photograph courtesy of Andres Pinto, D.M.D., M.P.H., Philadelphia, PA

Angioedema occurs in hereditary and acquired forms. Hereditary cases typically present within the first or second decade of life and are caused by a deficiency in C1-esterase inhibitor, which is inherited in an autosomal dominant fashion. This results in uncontrolled activation of the complement cascade, causing tissue edema through mechanisms of vasodilation and increased vascular permeability. A rare form of acquired C1-esterase deficiency is believed to be autoimmune in nature and in some cases may be associated with an underlying lymphoproliferative disorder. Nonhereditary angioedema may be medication-induced, allergic, or idiopathic. The idiopathic variety is the most common of all

types, affecting approximately 40% of patients with angioedema. The majority of medication-induced cases are caused by ACE inhibitors and these typically present within the first few weeks of therapy, although some may occur years later. ACE inhibitors decrease the production of angiotensin II, a potent vasoconstrictor that is involved in the inactivation of bradykinin. Allergic cases are related to IgE-mediated mast cell degranulation with release of histamine, and symptoms typically develop within an hour of exposure. Common allergic triggers include nonsteroidal anti-inflammatory agents, opiates, other antihypertensive agents, contrast dyes, and foods (e.g., nuts, eggs, and shellfish). In some cases, stress and trauma have been implicated as triggers.

Oral lesions are usually self-limiting and resolve within 2–3 days. Patients with upper airway symptoms, including wheezing, gasping, or voice changes, should be evaluated emergently, as airway obstruction results in a significant risk of death in this condition. Patients with angioedema that is not obviously associated with an ACE inhibitor should be referred to an allergist or immunologist for comprehensive evaluation. Prophylactic therapies in patients with recurrent episodes include use of antihistamines (diphenhydramine, ranitidine); androgens (danazol, stanozolol), which directly increase levels of C1-esterase inhibitor; hemostatic agents (aminocaproic acid, tranexamic acid), which act through inhibition of plasmin; and glucocorticosteroids.

Angioedema

	DIAGNOSTIC TESTS	Referral to a specialist to further characterize the disorder and identify risk factors. Allergy and immunology work-up is generally indicated.
	BIOPSY	Not required in most cases.
	TREATMENT	Androgens, hemostatic agents, antihistamines, and glucocorticosteroids can be effective prophylactic therapies.
	FOLLOW-UP	Patients should be followed as needed to assess response to treatment.

Orofacial Granulomatosis

Orofacial granulomatosis (OFG) is a rare disorder characterized by chronic recurrent painless swelling of the oral mucosa, lips, and perioral tissues (Fig. 5.2). The etiology is poorly understood, but in some cases can be attributed to hypersensitivity to certain foods or additives. The condition typically presents during early adulthood, and while generally asymptomatic, the disfiguring changes can have significant psychosocial consequences. Lesions are characterized by diffuse swelling, oftentimes with associated erythema, folded or fissured mucosal changes (“cobblestoning”), and focal areas of ulceration (Fig. 5.3). While the lips and perioral region are most frequently affected, any part of the mouth or face can be involved. OFG presenting with both fissured tongue and facial nerve paralysis is referred to as *Melkersson-Rosenthal syndrome*.

The diagnosis of OFG is made based on biopsy of affected tissue. Histopathology demonstrates granulomatous inflammation and edema. A carefully recorded food diary may be helpful in

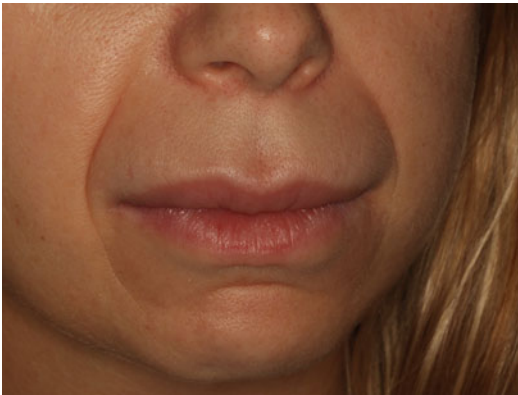

Fig. 5.2 Orofacial granulomatosis with prominent enlargement of the upper lip and characteristic vertical creases

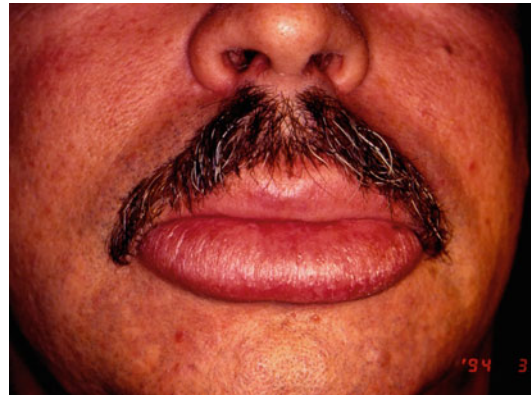





Fig. 5.3 Orofacial granulomatosis with painless swelling and fissuring of the lower lip. Photograph courtesy of Sook-Bin Woo, D.M.D., M.M.Sc., Boston, MA

identifying potential causative agents, but most cases are idiopathic. *Inflammatory bowel disease* (i.e., Crohn disease and ulcerative colitis) and sarcoidosis must also be considered, as each of these can present with similar clinical features (see Chap. 11).

Effective treatment of OFG can be challenging. Any suspected food triggers should be strictly eliminated from the diet. Episodes will generally respond to a short course of high-dose prednisone, which can be very effective in controlling lesions in the short-term; however, this is not an appropriate treatment strategy for long-term management. Other medications that can be used include dapsone, hydroxychloroquine, sulfasalazine, minocycline, azathioprine, thalidomide, and anti-tumor necrosis factor (TNF-alpha) biological agents. For cases refractory to systemic therapies, intralesional corticosteroid therapy can be very effective with or without concurrent systemic therapy. Intralesional steroid therapy must be administered regularly over an extended time period, even weekly, to maintain clinical control.

Orofacial Granulomatosis

	DIAGNOSTIC TESTS	None specific for this condition. Evaluate for sarcoidosis and inflammatory bowel disease. Consider allergy patch testing.
	BIOPSY	Yes.
	TREATMENT	Initial therapy consists of systemic and/or intralesional corticosteroid therapy. Preventive therapies include dapsone, hydroxychloroquine, minocycline, sulfasalazine, azathioprine, thalidomide, and anti-TNF- α biological agents.
	FOLLOW-UP	Patients should be followed regularly because even those receiving prophylactic therapy frequently develop breakthrough lesions.

Traumatic Ulcerative Granuloma

Traumatic ulcerative granuloma (TUG), sometimes also referred to as *traumatic ulcerative granuloma with stromal eosinophilia* (TUGSE), is a painful intraoral inflammatory lesion that is initiated by some type of traumatic event, most frequently a bite injury.

While the majority of traumatic injuries heal uneventfully in the oral cavity, TUGs transform into chronic, deep, and penetrating ulcerations that can be extremely painful and disabling (Fig. 5.4). The borders of the lesion may appear thickened and indurated with hyperkeratosis and striations, representing an attempt by the surrounding tissue to heal (Fig. 5.5). This lesion can be easily mistaken for oral cancer clinically. There are no known risk factors, and these can be

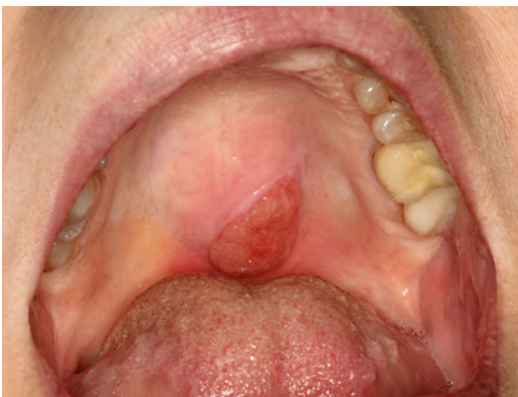

Fig. 5.4 Traumatic ulcerative granuloma of the hard palate

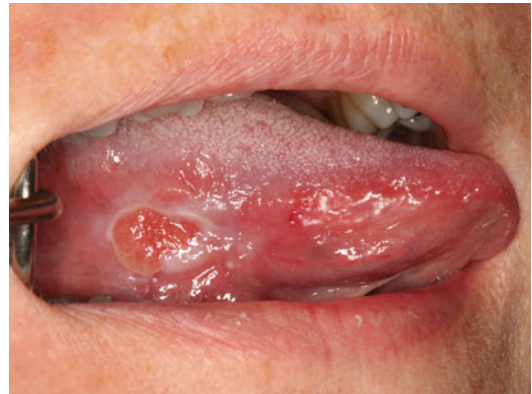

Fig. 5.5 Exophytic traumatic ulcerative granuloma of the right posterior lateral tongue with well-defined white borders

seen in any age group. The most common location for TUG is the posterior lateral tongue but lesions can also be seen on the buccal and labial mucosa and soft palate. Once established, TUGs rarely resolve without intervention.





Diagnosis requires an incisional biopsy, which should be taken from the ulcer margin to avoid obtaining necrotic tissue from the center of the lesion. Histopathology demonstrates ulceration with a dense infiltrate of acute and chronic inflammatory cells, often including numerous eosinophils that penetrate into the underlying skeletal muscle.

TUGs rarely heal spontaneously, and are typically present for several weeks before patients seek evaluation. Any obvious parafunctional habits or other factors contributing to persistent irritation, such as a fractured dental restoration,

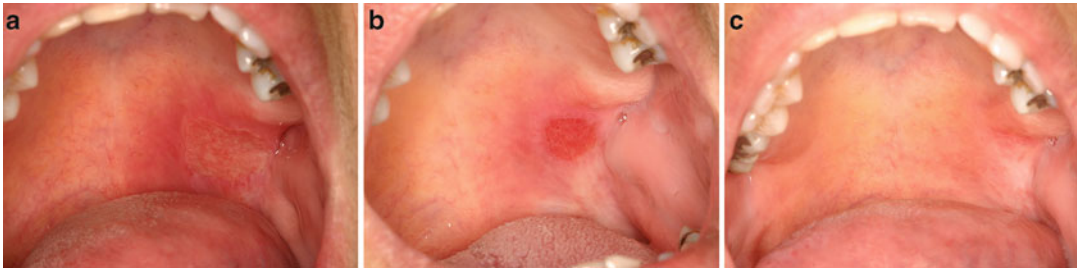

Fig. 5.6 Traumatic ulcerative granuloma of the left soft palate with extensive surrounding erythema. (a) This patient complained of severe odynophagia and referred pain to the ear. (b) Lesion 2 weeks, and (c) 4 weeks following combined intralesional and topical corticosteroid therapy

Traumatic Ulcerative Granuloma

	DIAGNOSTIC TESTS	None; consider viral culture to rule out herpes simplex virus (HSV).
	BIOPSY	Yes, specifically to rule out other pathology including squamous cell carcinoma.
	TREATMENT	Topical and intralesional corticosteroid therapy.
	FOLLOW-UP	None following healing.

should be addressed and corrected if possible. Once the diagnosis is made, the most effective first-line therapy is intralesional corticosteroid injection (Fig. 5.6). This often requires multiple sequential injections on a weekly basis; at least three to four treatments should be provided before determining the lesion to be nonresponsive. A high-potency topical corticosteroid gel, such as fluocinonide 0.05 % or clobetasol 0.05 % should also be prescribed and applied three to four times daily. Nonresponsive lesions can be treated with a 7–10-day course of high-dose prednisone. If still refractory, lesions should be considered for surgical excision; in some cases the inflammation is so deep and established that tissue debridement and primary wound closure is required.

Aphthous Stomatitis

Recurrent aphthous stomatitis (RAS) is the most common painful oral mucosal disease, affecting approximately 20% of the population. Also

referred to as *aphthous ulcers*, or the more commonly used lay term *canker sores*, RAS presents with a wide spectrum of severity ranging from a minor nuisance to a disabling condition. Characteristic oral ulcerations initially present in the first or second decade of life, making this one of the few immune-mediated oral inflammatory conditions seen in both children and adults. While the frequency of episodes often diminishes sharply during the third decade, patients are always at risk for developing recurrent lesions. Rarely, for reasons that are not understood, the frequency and severity of RAS can increase later in life.

Lesions appear clinically as nonspecific shallow round or oval ulcerations covered by a grayish-white fibrin pseudomembrane that is surrounded by a sharply defined erythematous halo (Fig. 5.7). Aphthous ulcers most commonly present as solitary lesions limited to the *nonkeratinized mucosa*, although exceptions exist and are discussed below. Ulcers may be preceded within hours by a tingling or burning sensation, allowing most patients to sense when they will develop a lesion. Once

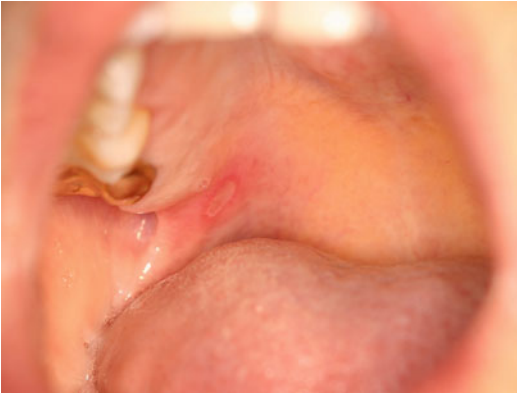

Fig. 5.7 Minor aphthous ulcer on the right soft palate with characteristic erythematous halo

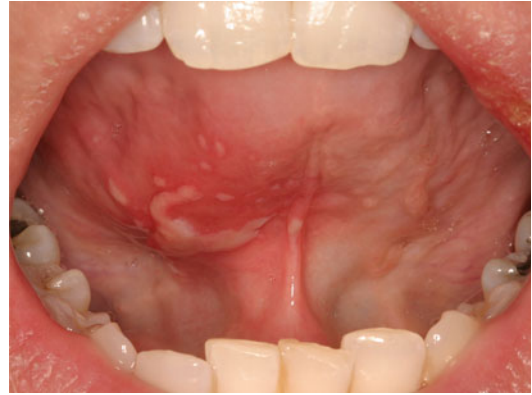

Fig. 5.8 Herpetiform aphthous ulcers of the ventral tongue. There is a central zone of coalescing ulceration with multiple crop-like smaller surrounding lesions

formed, ulcers typically last 7–10 days (with the first 3–4 days generally being the most symptomatic), and heal without complications.

The defining feature of RAS is pain. While lesions can be uncomfortable at rest, it is during function, such as speaking and eating, that symptoms are most intense. Like most painful oral inflammatory conditions, the location of lesions influences the severity of symptoms. Ulcers on the tongue can make speaking and chewing uncomfortable, while ulcers on the soft palate or in the esophagus can cause swallowing to be acutely painful. Ingestion of acidic foods and beverages can also be particularly uncomfortable.

There are four distinct clinical presentations: *minor*, *herpetiform*, *major* and *complex/severe aphthous ulcers*. By far the most common, *minor aphthous* ulcers are less than 0.5 cm in diameter and follow the classic clinical pattern described above. An uncommon variant, *herpetiform aphthous ulcers* present as multiple small ulcerations that erupt in crops and subsequently coalesce to form an irregularly shaped lesion that mimics (but is unrelated to) those caused by HSV (Fig. 5.8; see Chap. 7). Although individual herpetiform aphthous lesions are less well-defined and typically smaller in size than minor RAS lesions, the overall appearance is identical; these also typically heal within 7–10 days. *Major aphthous ulcers* are larger than 1.0 cm in diameter

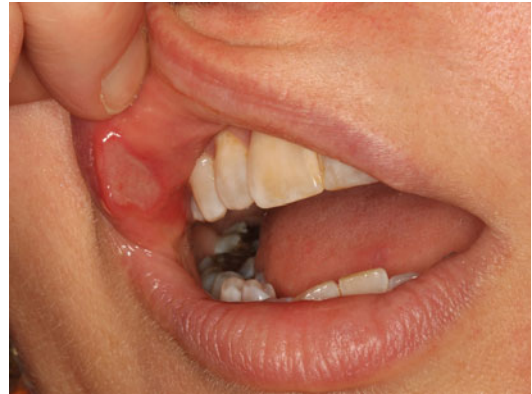

Fig. 5.9 Major aphthous ulcer of the right upper labial mucosa

and occur far less frequently than minor lesions. These are deeper, more penetrating ulcers that can be intensely painful even at rest (Figs. 5.9 and 5.10). Major ulcers can last for weeks or months and may result in scar formation with resolution. *Complex* or *severe aphthous stomatitis* is a clinical entity in which an affected individual is almost never without ulcers, resulting in debilitating chronic pain that can lead to weight loss, malnutrition, and considerable morbidity. Patients often suffer from multiple ulcers at any given time with new lesions developing as existing ones heal. The keratinized mucosa may also

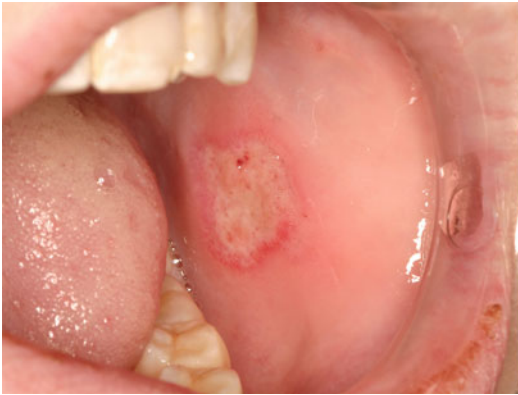

Fig. 5.10 Trauma-induced major aphthous ulcer of the left buccal mucosa. The patient accidentally bit both cheeks and subsequently developed bilateral major aphthae 2 days later. A focal area of petechiae shows where the bite injury initially occurred

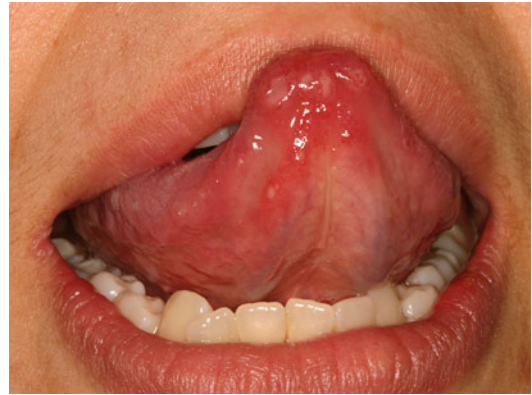

Fig. 5.12 Multiple minor aphthous ulcers of the tongue in a patient with severe recurrent aphthous stomatitis

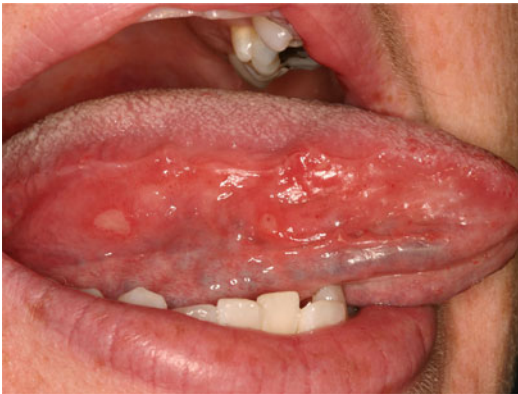

Fig. 5.11 Patient with severe recurrent aphthous ulcers with two minor ulcers of the right lateral tongue in addition to multiple other lesions throughout the oral cavity

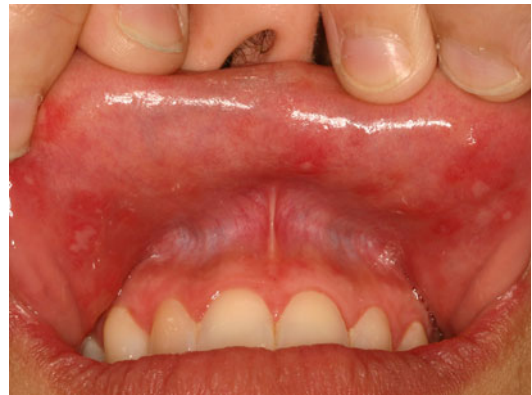

Fig. 5.13 Severe recurrent aphthous stomatitis with extensive ulcers of the upper labial mucosa

be affected in these patients (Figs. 5.11, 5.12, 5.13, and 5.14).

The etiology of RAS is poorly understood. Histopathology demonstrates nonspecific ulceration with a dense infiltration of acute and chronic inflammatory cells. T-cells predominate and there are high local levels of the proinflammatory cytokine TNF- α . Lesions are not contagious and are not caused by HSV. Precipitating factors in some patients include stress, trauma, hormonal fluctuations, and certain foods and drinks. A number of conditions and diseases can present

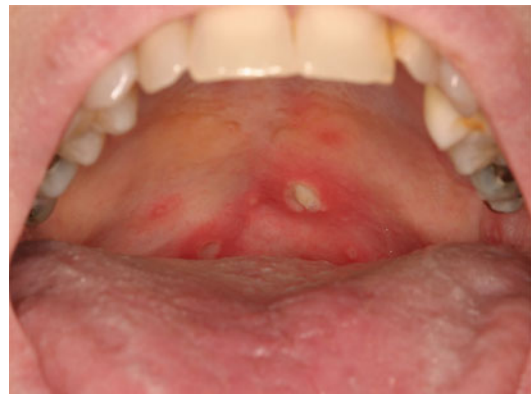

Fig. 5.14 Multiple soft palatal ulcers in a patient with severe recurrent aphthous stomatitis. Due to the location of the lesions, all oral activities were very painful

with RAS, including deficiencies in folic acid, vitamin B₁₂, and iron, inflammatory bowel disease (see Chap. 11), celiac disease, Behcet disease, and HIV disease. For reasons not well understood, patients with HIV disease can develop severe recurrent *major* ulcers that are often larger than 1.0 cm in diameter (Fig. 5.15; see Chap. 11).

Depending on the severity and frequency of outbreaks, management strategies range from simple palliative measures to systemic preventive

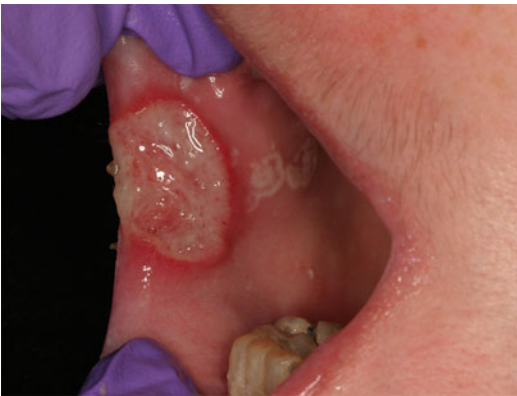





Fig. 5.15 Major aphthous ulcer of the anterior right buccal mucosa and commissure in a patient with advanced AIDS. Pseudomembranous candidiasis is also seen more posteriorly, although the two lesions are not specifically related (see Chap. 7)

therapies. The vast majority of patients with RAS never requires any specific therapy and simply lives with occasional oral discomfort. Isolated painful episodes can be treated with over-the-counter products such as mucoadhesive agents and topical anesthetics.

Application of high-potency corticosteroid gels can significantly reduce sensitivity and may reduce healing time. *Major* lesions require intensive topical corticosteroid therapy (e.g., 3–4 times/day) and may benefit from intralesional corticosteroid injection (Fig. 5.16). For topical treatment of multiple or poorly accessible lesions, a corticosteroid rinse (e.g., dexamethasone 0.1 mg/mL) can be much easier to apply than a gel.

Patients with *severe* RAS often require management with systemic medications. Acute or persistent ulcers are highly responsive to short courses of corticosteroids. Several agents can be effective in long-term prevention, including pentoxifylline, colchicine, thalidomide, and azathioprine. Topical corticosteroid rinses (at least daily) should also be included as part of any preventive approach. Patients responding favorably to treatment may cease developing ulcers altogether, or may experience lesions less frequently and of less severity. Even in patients with well-controlled disease, occasional short pulses of systemic corticosteroids may be necessary to control breakthrough episodes.

Aphthous Stomatitis

	DIAGNOSTIC TESTS	Consider evaluation of iron, B12, and folate levels.
	BIOPSY	No.
	TREATMENT	For occasional episodes: topical methylcellulose combined with benzocaine, viscous lidocaine, and high potency topical corticosteroids. For acute management of severe outbreaks: high-dose prednisone for 7–10 days. For prevention: pentoxifylline, followed by addition of colchicine if adequate response is not achieved (must give up to 2-3 months to evaluate response). Other effective agents include azathioprine and thalidomide.
	FOLLOW-UP	All patients with <i>major</i> and <i>severe</i> RAS should be followed closely.

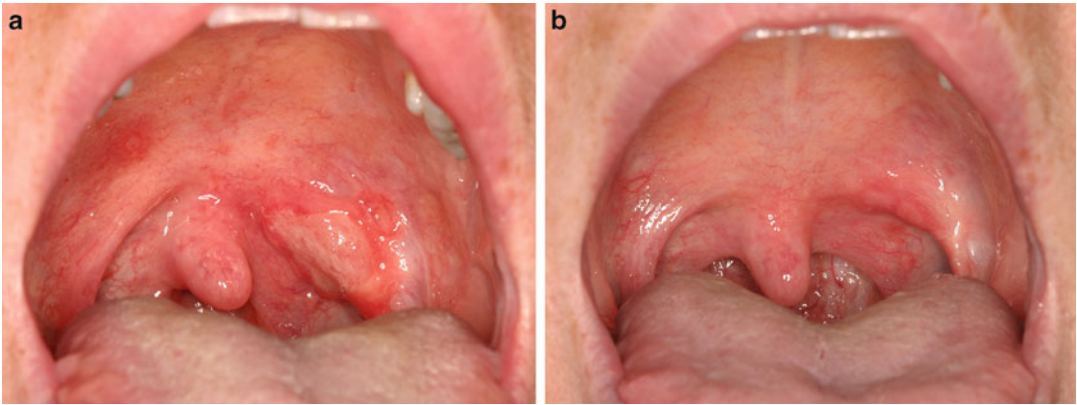


Fig. 5.16 Treatment of major aphthous ulcers with intralesional corticosteroid therapy. (a) Large, painful ulceration of the soft palate. (b) Same lesion 2 weeks following intralesional therapy

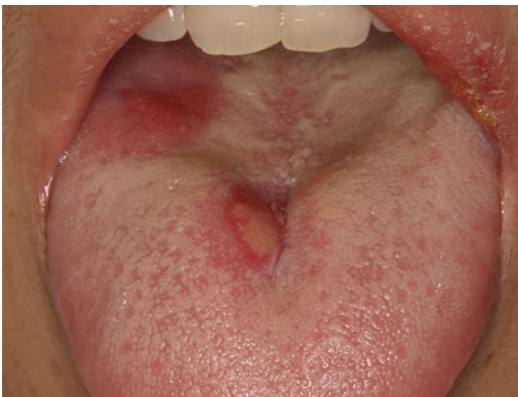

Fig. 5.17 Ulcerations of the tongue dorsum in a patient with Behcet disease. The patient also had painful genital ulcerations

Behcet Disease

Behcet disease is a systemic disease with RAS as one of its defining features (Fig. 5.17). These include aphthous ulcers of the oral and anogenital mucosae, uveitis, inflammatory skin lesions, and other systemic findings such as arthritis, vasculitis, and CNS symptoms. Behcet disease is genetically determined and seen more frequently in individuals from the Middle East and Far East. Systemic therapy is indicated in those with sufficiently severe clinical disease. In addition to the treatments for RAS discussed above, the use of anti-TNF- α biological agents, such as infliximab and etanercept, has demonstrated significant efficacy in patients with Behcet disease.

Erythema Multiforme

Erythema multiforme (EM) is an acute, self-limiting mucocutaneous hypersensitivity reaction that presents with a wide range of clinical severity and appearance. Prodromal symptoms, including fever, malaise, and sore throat, are common and occur anywhere from days to 1–2 weeks prior to onset of lesions. EM can be divided into *minor* and *major* forms; *EM minor* is limited to skin, and *EM major* involves either the skin with at least one mucosal site or a single mucosal site with extensive involvement. *Stevens-Johnson syndrome* is a more severe manifestation of EM major in which there is extensive multisite involvement. Males are affected slightly more than females, with most patients presenting during their second or third decades of life. Recurrences are common.

Approximately 50% of cases of EM are associated with either medications or recent infection. The most commonly implicated medications include sulfonamides, nonsteroidal anti-inflammatory agents, and anticonvulsants. A proportion of cases are associated with either HSV or *mycoplasma* infection. In the case of HSV, EM most commonly occurs following outbreak of oral or genital herpetic lesions (see Chap. 7), but activation during subclinical shedding can also occur. Approximately 50% of cases are idiopathic with no obvious cause.

Behcet Disease





	DIAGNOSTIC TESTS	Skin pathergy test in which the skin is penetrated with a sterile 20 to 22-gauge needle and evaluated 48 h later for an erythematous papule >2 mm.
	BIOPSY	Not required in most cases.
	TREATMENT	Similar to treatment for RAS, including anti-TNF- α biological agents. Referral to an ophthalmologist for evaluation and management of ocular involvement.
	FOLLOW-UP	All patients should be followed regularly.

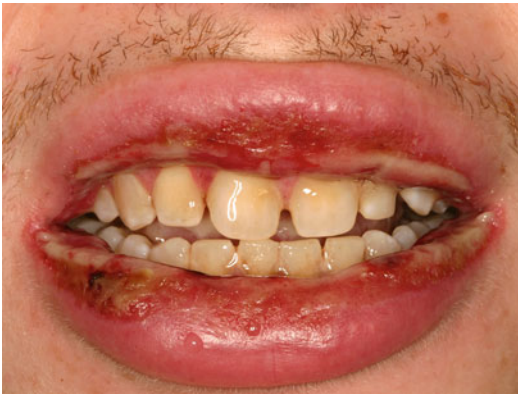

Fig. 5.18 Ulceration and crusting of the lips in a patient with erythema multiforme

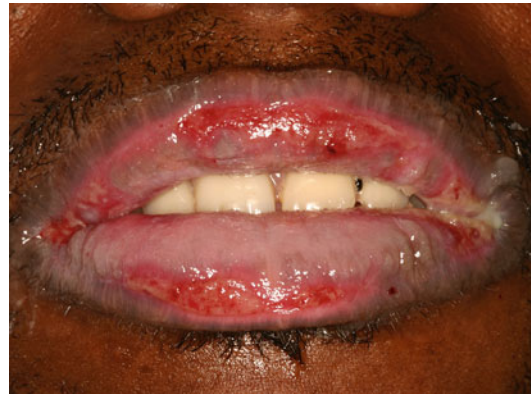

Fig. 5.19 Extensive ulceration of the lips in a patient with Stevens-Johnson syndrome. The patient had oral, ophthalmic, and genital ulcerations as well as skin lesions

Although not always present, the most consistent oral findings are crusting and ulceration of the lips (Figs. 5.18, 5.19, and 5.20). Intraorally, lesions are characterized by nonspecific irregular ulcerations ranging from millimeters to centimeters in diameter with prominent surrounding erythema (Figs. 5.21 and 5.22). The keratinized mucosa is generally spared, and lesions tend to occur toward the anterior aspect of the oral cavity. The genital and ophthalmic mucosa can also be affected. Skin lesions have a classic “targetoid” appearance (Fig. 5.23). Oral lesions develop over several days and can become intensely painful, resulting in inability to eat or speak (Fig. 5.24). The condition is self-limiting, lasting

anywhere from 2 to 4 weeks, and ulcerations heal without scarring.

Diagnosis of oral EM is primarily clinical, although viral culture should be obtained and biopsy considered if the clinical presentation is atypical. A perilesional biopsy should be submitted for both histopathology and direct immunofluorescence (DIF). Characteristic findings include a high-density T-cell infiltrate with prominent necrosis of the basal cell layer, subepithelial or intraepithelial blistering, and eosinophils. DIF studies are nonspecific but are helpful in ruling out other conditions such as *pemphigus* and *pemphigoid* (see below). When present, characteristic lip crusting and sparing of the keratinized mucosa

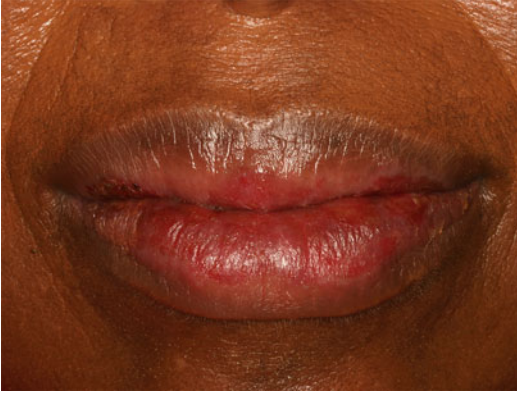

Fig. 5.20 Erythema and slight crusting of the lips in a patient with erythema multiforme. The patient had skin as well as oral lesions

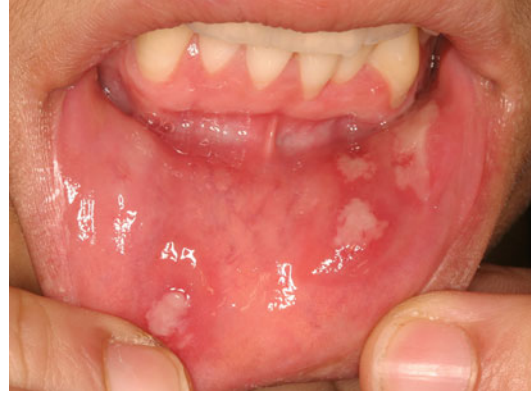

Fig. 5.22 Intraoral erythema multiforme in a patient with concurrent targetoid skin lesions. Although aphthous-like, the borders of the lesions are irregular and ragged in appearance

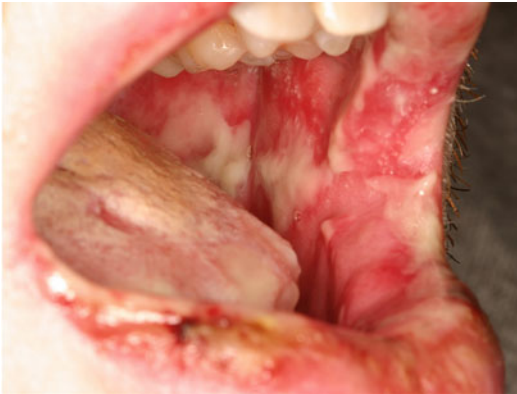

Fig. 5.21 Extensive intraoral lesions in a patient with erythema multiforme. The ulcers are irregular with extensive surrounding erythema. Given the severity of findings, this should be considered erythema multiforme *major* despite lesions being restricted to a single anatomic site

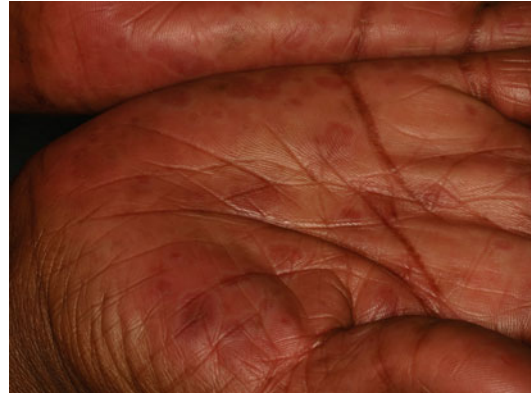

Fig. 5.23 Target lesions on the palms of the patient depicted in Fig. 5.20

easily distinguishes EM from primary HSV. When target lesions are also present, the diagnosis is very straightforward.

Treatment should be initiated as early as possible. The use of systemic corticosteroids in EM is controversial but is generally prescribed for patients with extensive oral involvement, and is given for 7–10 days without taper. Topical





steroid rinses, three to four times daily, are also useful. Topical anesthetics (e.g., magic mouthwash) can help control symptoms, but many patients require opioid analgesics. Patients must be instructed to maintain adequate hydration and nutrition. For patients with a history of recurrent herpes labialis, acyclovir therapy may prevent future recurrences.

Fig. 5.24 The patient in Fig. 5.21 was in so much pain that he was not able to speak or eat

I CANT TALK DUE TO PAIN

Doc. I came to you in APRIL/MAY 2006 w/ Stomatitis in the Gums THROAT AND LIPS AND ~~WAS~~ A HUGE fever. TODAY I'm BACK w/ THE Same thing which is caused by STRESS AND ~~BEING~~ being sick last week. I think I may HAD 2 VISITS w/ you, the first when you gave me GUMS & PAINKILLERS and 2nd a follow up. Today. The stuff is DEEP in my Throat, lips and under my Tongue ITS ALSO on my Tongue aswell. THES ALL STARTED LAST ~~FRIDAY~~ FRI - I STARTED TO put ointment on it but it didnt do anything. its kept growing - on Tues I went to the ER in Cambridge to get pain killers I.V. fluids and Anti Biotics - BUT IT HAS Done little to reduce this pain and growth. Right now im unable to drink / eat with at times tens of pain killers which I ran out of, and ~~can~~ cant sleep at all. Should I go to the ER after I see you?

Erythema Multiforme

	DIAGNOSTIC TESTS	Viral culture to rule out HSV.
	BIOPSY	Only if the clinical picture is not consistent with EM. Specimens should be perilesional and submitted for both routine histopathology and DIF to rule out autoimmune vesiculobullous disorders.
	TREATMENT	Systemic and topical corticosteroids for severe cases; topical corticosteroids alone for milder cases. Pain management and nutritional support.
	FOLLOW-UP	Patients should be reevaluated 1 week after initiating therapy. For patients with a history of recurrent HSV and recurrent EM, long-term prophylaxis with acyclovir or valacyclovir should be initiated.

Oral Lichen Planus

Lichen planus is a chronic mucocutaneous T-cell mediated inflammatory condition that affects nearly 1% of the adult population. Oral lesions are common and in many cases present as the only site of involvement. Although the extent and severity of lesions may fluctuate over time, the condition tends to be persistent once established. Women are affected slightly more than men, with most patients diagnosed during their fourth through seventh decades of life. Since lichen planus can affect the skin as well as other mucosal sites including the larynx and genitalia, patients should be specifically questioned regarding extraoral symptoms.

Oral lichen planus (OLP) most likely represents a heterogeneous group of hypersensitivity reactions exhibiting indistinguishable clinical and histopathological features. If a specific causative agent, typically a medication, is identified, the condition may be referred to as a *lichenoid hypersensitivity reaction*. Numerous medications have been associated with OLP including antihypertensive and nonsteroidal anti-inflammatory agents. Discontinuation of the suspected trigger may be effective, although cross-sensitivity with other medications is common and lesions may persist. Amalgam dental restorations (silver fillings) and cinnamon-flavored products have been associated with localized *contact lichenoid hypersensitivity*

reactions. These lesions appear clinically identical to OLP, occur at the site of contact with the offending agent, and generally resolve following removal of the causative agent (Fig. 5.25). The majority of cases of OLP are idiopathic with no obvious cause.

Patients may complain of symptoms, which are highly variable, but often consist of oral sensitivity to toothpaste, acidic substances, alcohol, carbonated beverages, spicy or salty foods, and abrasive foods. Many patients with OLP may be unaware of their condition due to complete lack of symptoms.

There are three distinct clinical presentations of OLP, any of which may be observed in an affected individual at a given time: *reticular*, *erythematous*, and *erosive*. *Reticular* lesions, also known as *Wickham striae*, appear as lacey white mucosal changes due to a distinct pattern of hyperkeratosis. This is a classic defining feature of OLP that is also seen in skin lesions (Figs. 5.26, 5.27, and 5.28). A less common variation of the reticular form includes *plaque-like* changes (Fig. 5.29), which may be difficult to differentiate from true leukoplakia (see Chap. 9). *Erythematous* lesions, which are often intimately associated with reticular changes, are due to thinning or atrophy of the epithelium with inflammation of the underlying connective tissue (Fig. 5.30). *Erosive/Ulcerative OLP* is the most severe form, and is almost always associated with

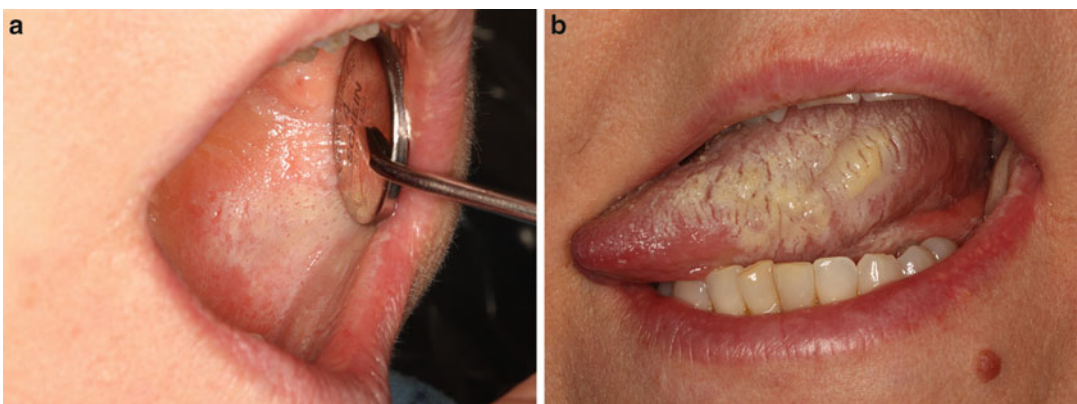


Fig. 5.25 Contact lichenoid hypersensitivity reaction to cinnamon-containing chewing gum, primarily affecting the buccal (a) and lingual (b) mucosae due to direct,

repeated contacts. There was complete resolution of lesions after the patient changed to a different flavor gum

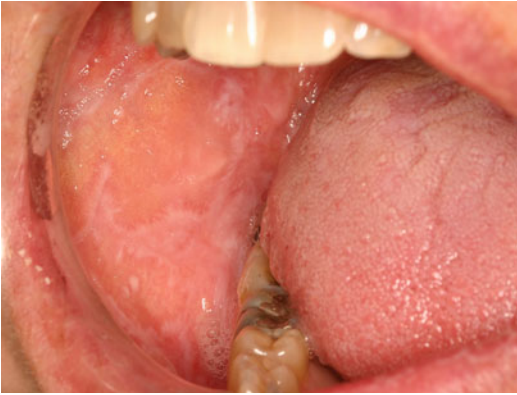

Fig. 5.26 Oral lichen planus of the right buccal mucosa exhibiting a fine reticular pattern and minimal erythema

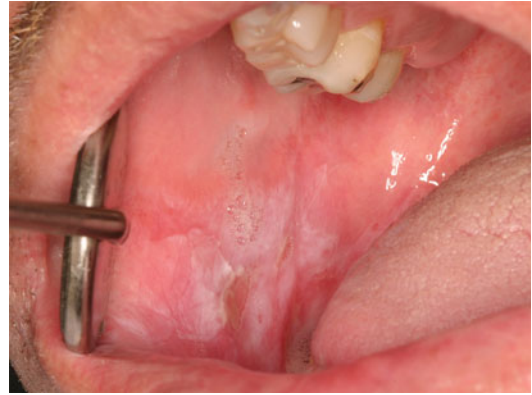

Fig. 5.29 Plaque-like oral lichen planus of the right buccal mucosa. While some areas of reticulation can be seen, these lesions are characterized by white plaques that can easily be mistaken for leukoplakia. There are also focal areas of ulceration

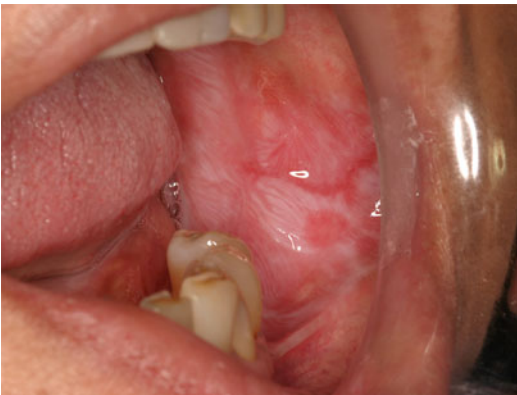

Fig. 5.27 Oral lichen planus of the left buccal mucosa with prominent linear reticulation and erythema

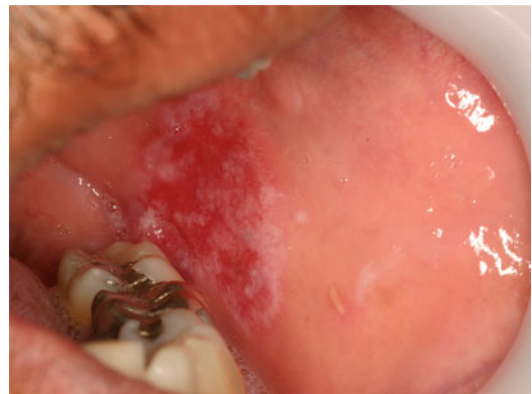

Fig. 5.30 Oral lichen planus of the left buccal mucosa with reticulation and severe erythema

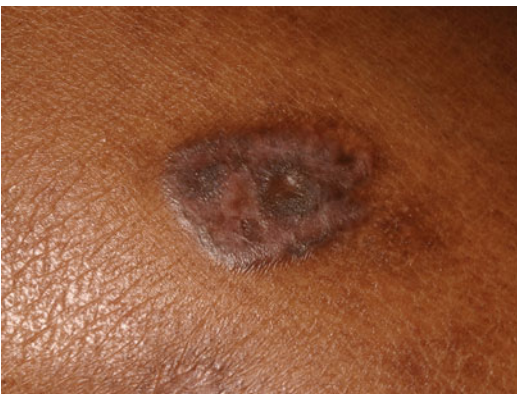

Fig. 5.28 Lichen planus of the skin in an African-American patient with concurrent oral lesions. The same characteristic reticulation seen in the mouth can be seen on the skin

reticular and erythematous changes (Figs. 5.31, 5.32, and 5.33). Patients with extensive ulcerative lesions tend to have more severe symptoms than those with purely reticular changes, although even patients with apparently “mild” clinical disease may experience significant morbidity.

Any intraoral site can be affected, with the most common being the buccal mucosa and lateral tongue; these lesions are almost always present bilaterally. The gingiva and alveolar mucosa are also frequently affected (Figs. 5.34, 5.35, and 5.36); if this represents the only site of involvement, and erythema and/or ulceration are present, the clinical condition is called *desqua-*

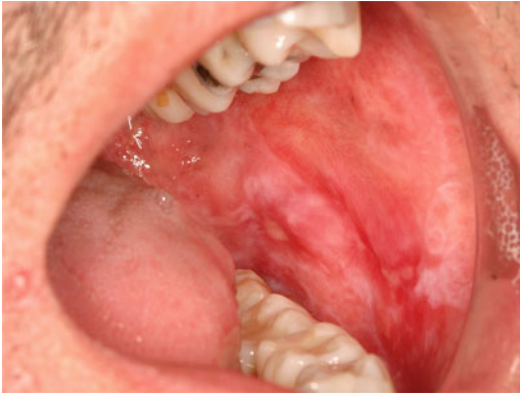

Fig. 5.31 Oral lichen planus of the left buccal mucosa with reticulation, erythema, and focal ulcerations

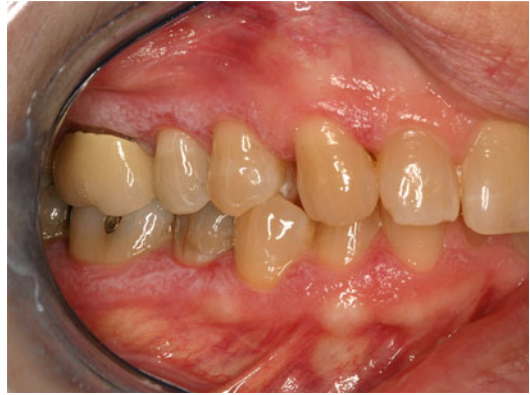


Fig. 5.34 Oral lichen planus with prominent reticulation restricted to the gingiva

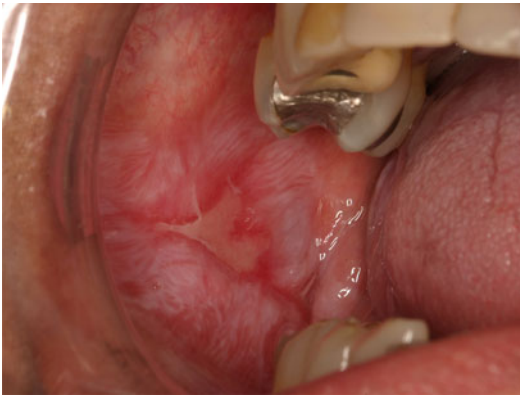

Fig. 5.32 Oral lichen planus of the right buccal mucosa with prominent reticulation, erythema, and central ulceration

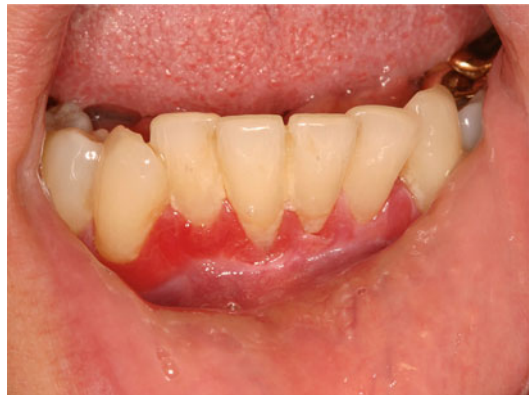

Fig. 5.35 Oral lichen planus presenting with only desquamative gingivitis. Without classic reticulation, biopsy is needed for diagnosis

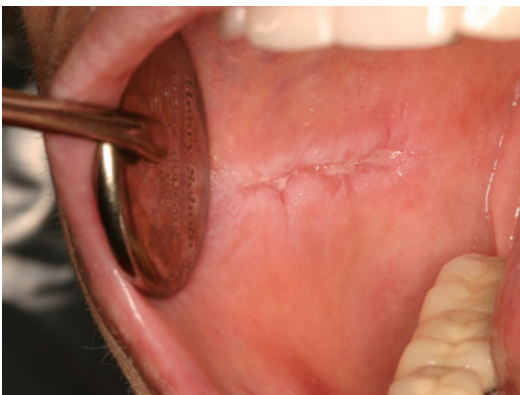

Fig. 5.33 Oral lichen planus of the right buccal mucosa with focal linear ulceration

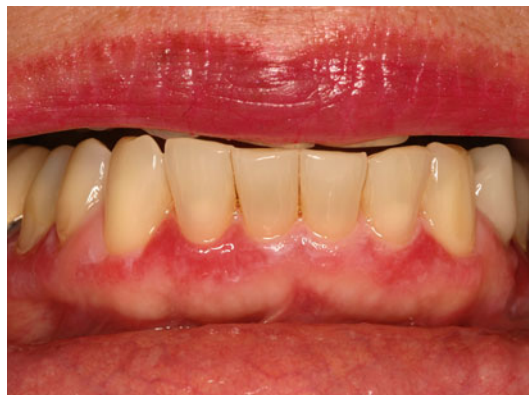

Fig. 5.36 Oral lichen planus with erythema and reticulation of the anterior mandibular gingiva

mative gingivitis. Fifty percent of cases of desquamative gingivitis ultimately prove to be *mucous membrane pemphigoid (MMP)*, 25% are OLP, and the remaining 25% are composed of other vesiculobullous disorders including *pemphigus vulgaris* and *linear IgA disease* (see below). The extent and severity of lesions can fluctuate over time and are often exacerbated during periods of illness and stress.

In patients presenting with classic appearing reticulated lesions, the diagnosis can typically be made by clinical examination alone. In cases when the diagnosis is not evident, a biopsy should be obtained avoiding ulcerative areas due to lack of intact epithelium. In the case of desquamative gingivitis, the specimen should be submitted for both routine histopathology as well as DIF. Histopathological features of reticulated lesions include hyperkeratosis, a “saw-toothed” appearance of the epithelial rete ridges, and the presence of band-like lymphocytic (primarily T-cell) infiltrate in the connective tissue just below the basement membrane with associated basal cell degeneration. There are no blood tests that help with the diagnosis of OLP.

Treatment should be dictated by the severity of symptoms rather than clinical appearance. Patients with asymptomatic OLP do not require treatment. In symptomatic cases the mainstay of therapy is high-potency topical corticosteroids. Limited lesions can be treated with a topical gel, while more extensive or difficult-to-reach areas are most effectively treated with a rinse. Patients





with desquamative gingivitis can benefit from custom fabricated trays to apply the medication.

In refractory cases, topical tacrolimus can be applied in addition to corticosteroids. This is commercially available as an ointment, but can be formulated as a solution by a compounding pharmacy.

In cases where topical therapy is inadequate, a short course of high-dose prednisone can be effective for severe flares. Some cases of OLP may require long-term use of systemic steroid-sparing agents to maintain adequate disease control. Nonsteroidal systemic therapies include hydroxychloroquine, azathioprine, cyclosporine, tacrolimus, and thalidomide, and in severe refractory cases, extracorporeal photopheresis can be considered. Due to the lack of adequate controlled trials of systemic agents for OLP, there is little evidence to recommend the use of one therapy over another. Once the disease is under good control, attempts should be made to taper any systemic agents to the lowest effective dose possible while maximizing the effects of topical treatment.

The most serious complication of OLP is malignant transformation to squamous cell carcinoma (see Chap. 9). It is estimated that approximately 1% of cases of OLP ultimately develop oral squamous cell carcinoma. The epidemiology and risk factors are poorly characterized, but it is generally thought that the more severe or refractory cases represent the highest risk. For this reason, any suspicious changes should be biopsied and all patients with OLP should be examined at least annually.

Oral Lichen Planus

	DIAGNOSTIC TESTS	None.
	BIOPSY	Only when clinical presentation is not classic (reticular) in appearance.
	TREATMENT	Topical corticosteroids and topical tacrolimus are the mainstay of therapy. When necessary, systemic agents should be considered. For severe refractory cases consider extracorporeal photopheresis or anti-TNF- α biological therapy.
	FOLLOW-UP	Patients should be followed carefully to evaluate response to therapy. Stable or asymptomatic cases should be followed annually; assess carefully for signs of malignancy.

Mucous Membrane Pemphigoid

While there are several variants of pemphigoid, MMP most commonly affects the oral mucosa. MMP is an autoimmune vesiculobullous blistering disease characterized by autoreactive antibodies that target the hemidesmosomal complex of the epithelial basement membrane, resulting in subepithelial tissue separation. This disease most frequently presents during the fifth to seventh decades of life and affects women at nearly twice the rate of men. Aside from pain, one of the greatest complications of MMP is scarring, which can lead to blindness in the setting of ocular lesions. When disease manifestations are limited to the oral mucosa, scarring is relatively rare. All patients should be questioned about extraoral symptoms including involvement of the throat, nose, eyes, and genitals, as these may be sites of undiagnosed disease.

Any oral mucosal site can be affected. Intact blisters may be observed, however, these generally rupture quickly and leave irregularly shaped ulcerations (Fig. 5.37). Many patients present only with desquamative gingivitis (Fig. 5.38). Diagnosis of MMP relies on perilesional biopsy submitted for both histopathology and DIF studies. Histopathology demonstrates clear subepithelial clefting (Fig. 5.39). DIF shows distinct deposition of IgG and complement at the basement membrane (Fig. 5.40). Indirect immunofluorescence results are variable.

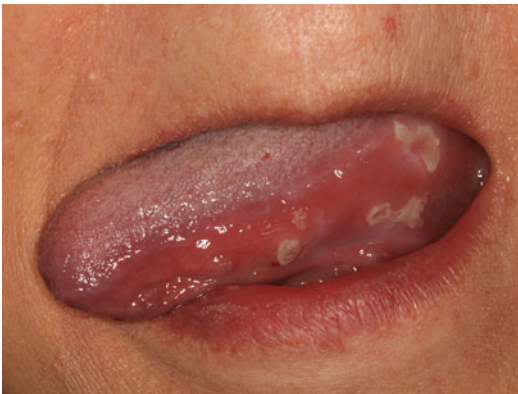

Fig. 5.37 Mucous membrane pemphigoid with nonspecific ulceration of the ventrolateral tongue

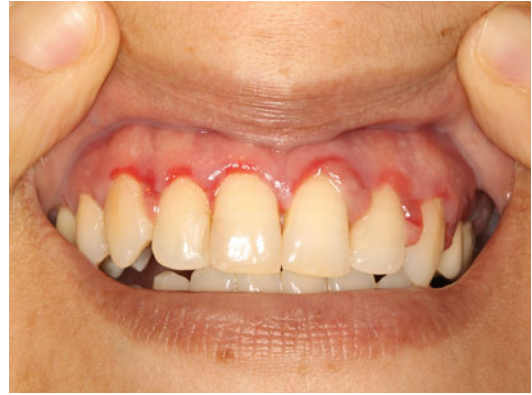

Fig. 5.38 Mucous membrane pemphigoid presenting as desquamative gingivitis. The gingiva is erythematous with focal areas of ulceration

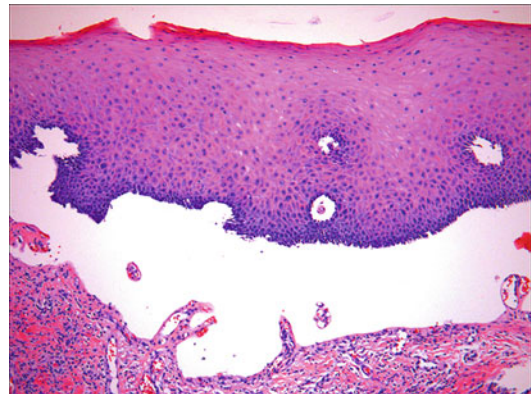


Fig. 5.39 Mucous membrane pemphigoid histopathology (H&E stain) demonstrating a clear subepithelial separation at the basement membrane. Photomicrograph courtesy of Mark Lerman, D.M.D., Boston, MA

If lesions are not limited to the oral mucosa, systemic therapy with corticosteroids and steroid-sparing agents is generally indicated. Purely oral cases of MMP should be treated based on symptoms and generally respond well to topical corticosteroids or tacrolimus. Desquamative gingivitis is most effectively treated with custom trays containing high-potency corticosteroid gels (Fig. 5.41).

Fig. 5.40 Mucous membrane pemphigoid (direct immunofluorescence) showing a prominent band of reactivity along the basement membrane. Photomicrograph courtesy of Stephen Sonis, D.M.D., D.M.Sc., Boston, MA

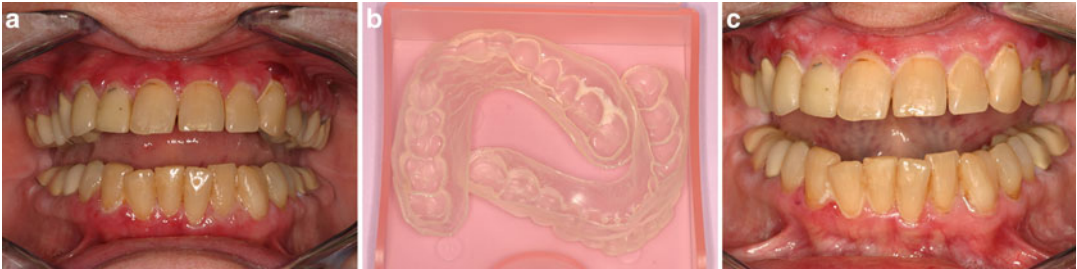
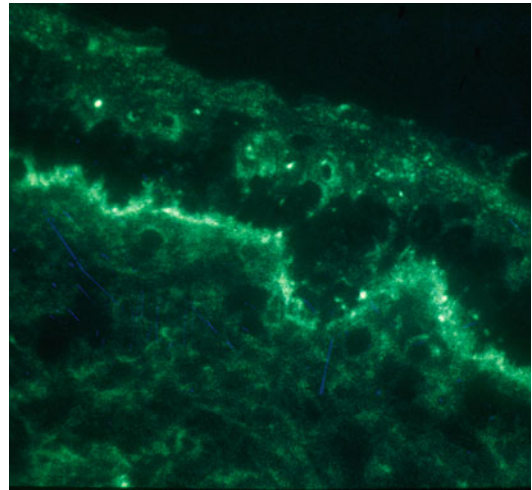






Fig. 5.41 Soft trays for localized intensive application of topical therapy for desquamative gingivitis. (a) Patient with extensive desquamative gingivitis due to mucous membrane pemphigoid. (b) Soft trays were made and the

patient was instructed to treat with fluocinonide gel 0.05 % daily. (c) After 1 month of therapy with almost complete resolution of all signs and symptoms

Mucous Membrane Pemphigoid

	DIAGNOSTIC TESTS	None.
	BIOPSY	Yes; the specimen should be obtained from a perilesional area and submitted for both routine histopathology and DIF.
	TREATMENT	Topical corticosteroids (first-line) or tacrolimus (second-line) as the mainstay of therapy. Systemic agents if refractory: prednisone, mycophenolate mofetil, azathioprine, dapsone, cyclosporine, and tacrolimus. For severe refractory cases consider rituximab, intravenous immunoglobulin (IVIg), and extracorporeal photopheresis.
	FOLLOW-UP	Patients should be followed carefully while evaluating response to therapy. Patients with stable disease should be followed at least annually.

Pemphigus Vulgaris

The term “pemphigus” encompasses a group of autoimmune vesiculobullous blistering diseases, the most common of which is *pemphigus vulgaris*. This is a potentially severe disease, but it is no longer the life-threatening condition it was prior to the introduction of corticosteroids. Circulating IgG autoantibodies target the desmosomal complex, specifically binding the surface glycoproteins desmoglein 1 and 3, resulting in intraepithelial splitting. Females are affected slightly more frequently than males, with most patients presenting during the fourth to sixth decades of life. Patients of Mediterranean and Ashkenazi Jewish descent are affected at a higher rate. The skin is almost always involved; however, the appearance of oral lesions usually precedes cutaneous manifestations. Other mucosal sites, such as the nasal and anogenital regions, may be affected.

Oral lesions appear as well-demarcated, irregular erythematous erosions, and ulcerations that can become quite large and very painful (Figs. 5.42 and 5.43). Commonly affected oral sites are the buccal mucosa, palate, and gingiva. Intact bullae are rarely observed. A *positive Nikolsky sign* is a nonspecific feature in which a blister may be induced by rubbing unaffected skin or mucosa; this may be seen in pemphigus vulgaris but also in MMP or various other conditions. As any other mucosal site can be affected, patients should be questioned regarding extraoral symptoms and referred to an appropriate specialist as necessary. Without intervention, lesions tend to persist for weeks to months, often continuing to grow in size.

Diagnosis requires a perilesional tissue biopsy submitted for both histopathology and DIF studies. Histopathological findings include intraepithelial separation, typically just above the basal cell layer, and *acantholysis*, or separation of the epithelial cells from each other (Fig. 5.44). DIF demonstrates a classic intercellular binding pattern of IgG (Fig. 5.45). Indirect immunofluores-

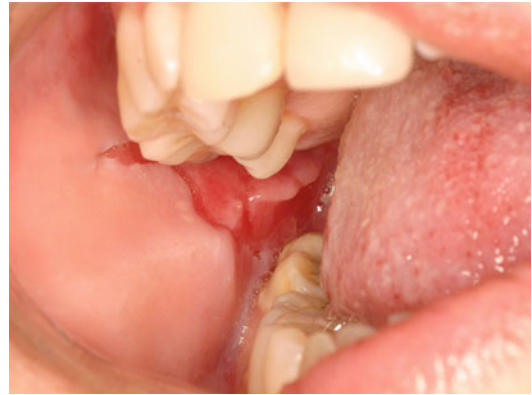

Fig. 5.42 Pemphigus vulgaris with well-defined ulceration and normal appearing surrounding tissues

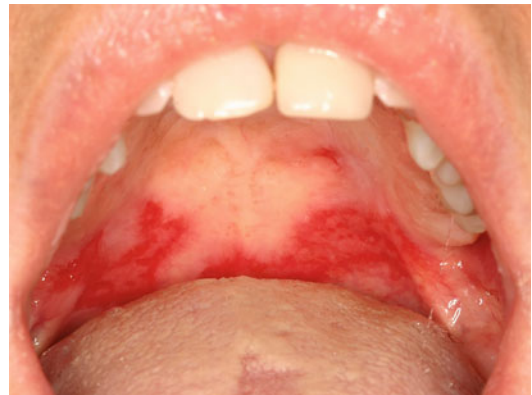

Fig. 5.43 Palatal lesions in a patient with pemphigus vulgaris

cence (IIF) studies are typically positive for antibodies against desmosomal glycoproteins.

Management of pemphigus vulgaris invariably requires systemic therapy. Corticosteroids and steroid-sparing immunomodulatory agents (azathioprine, cyclosporine, tacrolimus, and mycophenolate mofetil) are the mainstays of treatment. Breakthrough lesions are common, in which case topical corticosteroids play an important role. Refractory cases of pemphigus vulgaris may be controlled with intravenous immunoglobulin therapy, rituximab, and extracorporeal photopheresis.

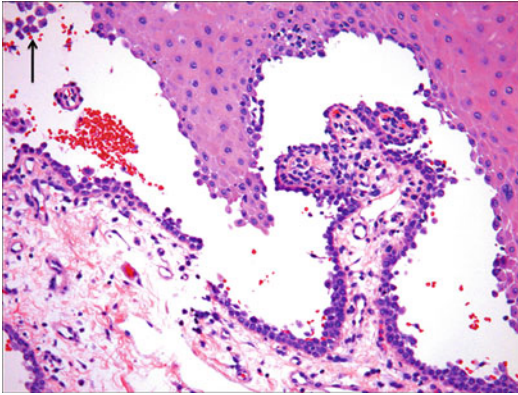


Fig. 5.44 Pemphigus vulgaris histopathology (H&E stain) demonstrating suprabasilar separation of cells and individual acantholytic (Tzanck) cells within the cleft (black arrow). Photomicrograph courtesy of Mark Lerman, D.M.D., Boston, MA

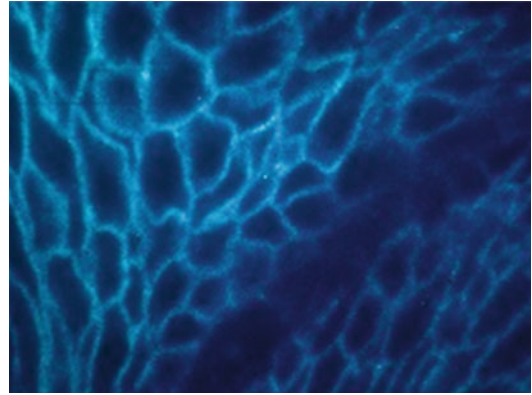






Fig. 5.45 Pemphigus vulgaris (direct immunofluorescence) showing prominent reactivity between keratinocytes throughout the epithelium. Photomicrograph courtesy of Stephen Sonis, D.M.D., D.M.Sc., Boston, MA

Pemphigus Vulgaris

	DIAGNOSTIC TESTS	IIF is generally positive.
	BIOPSY	Yes; the specimen should be obtained from a perilesional area and submitted for both routine histopathology and DIF.
	TREATMENT	Topical corticosteroids, or if ineffective, topical tacrolimus for oral lesions. Systemic agents include prednisone, mycophenolate mofetil, azathioprine, dapsone, cyclosporine, and tacrolimus. For severe refractory cases consider rituximab, IVIG, and extracorporeal photopheresis.
	FOLLOW-UP	Patients should be followed carefully while evaluating response to therapy. Patients with stable disease should be followed at least annually.

Other Autoimmune Vesiculobullous Diseases

Paraneoplastic Pemphigus

A very rare but important variant of pemphigus vulgaris seen exclusively in patients with underlying neoplasia is termed *paraneoplastic pemphigus*, also referred to as *paraneoplastic autoimmune multiorgan syndrome*. This condition has been associated with non-Hodgkin lymphoma, chronic lymphocytic leukemia, sarcomas, thymomas, and Castleman disease. Circulating autoantibodies are produced that target desmosomes and hemidesmo-

somes, resulting in potentially severe skin and mucosal lesions. Diagnosis and management of the underlying neoplasm are essential and generally results in resolution of the mucocutaneous disease.

Epidermolysis Bullosa Acquisita

Epidermolysis bullosa is a rare chronic autoimmune subepidermal vesiculobullous disorder that affects the skin and mucosa. Onset is very early in life, however, severity varies greatly such that milder forms of the disease are often not identified for many years. Autoantibodies target mul-

tipple hemidesmosomal antigens, in particular components of type VII collagen, resulting in blister formation secondary to minor amounts of trauma. Diagnosis requires histopathology as well as direct and indirect immunofluorescence studies. Management includes corticosteroids, dapsone, azathioprine, mycophenolate mofetil, rituximab, and intravenous immunoglobulin. Oral lesions may be responsive to intensive topical corticosteroid therapy.

Linear IgA Disease

Linear IgA disease, also known as *Linear IgA bullous dermatosis*, is an autoimmune subepidermal vesiculobullous disorder characterized by deposition of IgA at the basement membrane zone. Numerous autoantibodies and target antigens have been identified. Linear IgA disease affects both children and adults; in children the course is often self-limiting while drug-related cases are more common in older adults. Oral lesions are common and clinically identical to those seen in MMP. Diagnosis requires perilesional biopsy for both histopathology and immunofluorescence studies. Management includes prednisone, dapsone, sulfapyridine, and colchicine. Intensive intraoral topical therapy as described above can be very effective.

Sources

- Ayangco L, Rogers RS. Oral manifestations of erythema multi-forme. *Dermatol Clin*. 2003;21:195–205.
- Challacombe SJ, Setterfield J, Shirlaw P, et al. Immunodiagnosis of pemphigus and mucous membrane pemphigoid. *Acta Odontol Scand*. 2001;59:226–34.
- Dagistan S, Goregen M, Miloglu O, et al. Oral pemphigus vulgaris: a case report with review of the literature. *J Oral Sci*. 2008;50:359–62.
- Eguia del Valle A, Aguirre Urizar JM, Martinez Sahuquillo A. Oral manifestations caused by the linear IgA disease. *Med Oral*. 2004;9:39–44.
- Escudier M, Bagan J, Number SC, VII. Behçet's disease (Adamantiades syndrome). *Oral Dis*. 2006;12:78–84.
- Grave B, McCullough M, Wiesenfeld D. Orofacial granulomatosis: a 20-year review. *Oral Dis*. 2009;15:46–51.
- Hirshberg A, Amariglio N, Akrish S, et al. Traumatic ulcerative granuloma with stromal eosinophilia: a reactive lesion of the oral mucosa. *Am J Clin Pathol*. 2006;126:522–9.
- Kanerva M, Moilanen K, Virolainen S, et al. Melkersson-Rosenthal syndrome. *Otolaryngol Head Neck Surg*. 2008;138:246–51.
- Mignogna MD, Fortuna G, Leuci S, et al. Nikolsky's sign on the gingival mucosa: a clinical tool for oral health practitioners. *J Periodontol*. 2008;79:2241–6.
- Radfar L, Wild RC, Suresh L. A comparative treatment study of topical tacrolimus and clobetasol in oral lichen planus. *Oral Surg Oral Med Oral Pathol Oral Radiol Endod*. 2008;105:187–93.
- Scully C. Aphthous ulceration. *N Engl J Med*. 2006;355:165–72.
- Scully C, Carrozzo M. Oral mucosal disease: lichen planus. *Br J Oral Maxillofac Surg*. 2008;46:15–21.
- Scully C, Lo ML. Oral mucosal diseases: mucous membrane pemphigoid. *Br J Oral Maxillofac Surg*. 2008;46:358–66.
- Scully C, Porter S. Oral mucosal disease: recurrent aphthous stomatitis. *Br J Oral Maxillofac Surg*. 2008;46:198–206.
- Termino VM, Peebles RS. The spectrum and treatment of angioedema. *Am J Med*. 2008;12:282–6.
- Tilakaratne WM, Freysdottir J, Fortune F. Orofacial granulomatosis: review on aetiology and pathogenesis. *J Oral Pathol Med*. 2008;37:191–5.
- Woodley DT, Remington J, Chen M. Autoimmunity to type VII collagen: epidermolysis bullosa acquisita. *Clin Rev Allergy Immunol*. 2007;33:78–84.
- Yancey KB, Egan CA. Pemphigoid: clinical, histological, immunopathologic, and therapeutic considerations. *JAMA*. 2000;19:350–6.
- Zhu X, Zhang B. Paraneoplastic pemphigus. *J Dermatol*. 2007;34:503–11.

Introduction

Unusual or abnormal coloration of the oral mucosa can arise from a variety of exogenous (extrinsic) or endogenous (intrinsic) sources. Extrinsic pigmentation occurs following exposure to foreign agents such as medication or heavy metals. Intrinsic pigmentation is most frequently related to an increased presence of melanin, which is produced by melanocytes in the basal layer of the epithelium. Melanocytes are derived from neural crest tissue and migrate to the epithelium during development.

Pigmentation may be present in a generalized fashion throughout the oral cavity or as an isolated (focal) lesion. Generalized pigmentation can represent either a normal (physiologic) response (see Chap. 2) or manifestation of a pathologic process. In general, the intensity of color depends on the amount and location of melanin within the tissue. Lesions in close proximity to the surface appear brown or black, while deeper deposits appear blue. Nonmelanotic lesions may also appear pigmented. For example, bilirubin may impart a yellow color to the mucosa in patients with jaundice (see Chap. 11) and vascular lesions may appear red or blue. Rarely intrinsic pigmentation of bone (e.g. due to medications) can make the overlying mucosa appear pigmented.

Melanotic Lesions

Melanotic Macule

This is common, benign, asymptomatic flat (macular) lesion with well-demarcated borders, and brownish black or bluish color that is usually no larger than 1–2 mm in diameter (Figs. 6.1 and 6.2). The lower lip vermillion is affected most frequently, followed by the gingiva, buccal mucosa, and hard palate. Melanotic macules are characterized histologically by increased melanin production without an increase in the number of melanocytes (Fig. 6.3). This common lesion represents the oral counterpart to a skin freckle. Biopsy should be obtained when lesions demonstrate atypical features including growth and/or change in clinical characteristics.

Multiple mucocutaneous melanocytic macules can be observed in the rare autosomal dominant disorder, Peutz-Jeghers syndrome. In this condition, lesions occur most commonly in the perioral region; however, freckling may also be noted on the face, extremities, and oral mucosa. This syndrome is also associated with intestinal polyps which have a variable potential for malignant transformation, as well as intussusception of the bowel.

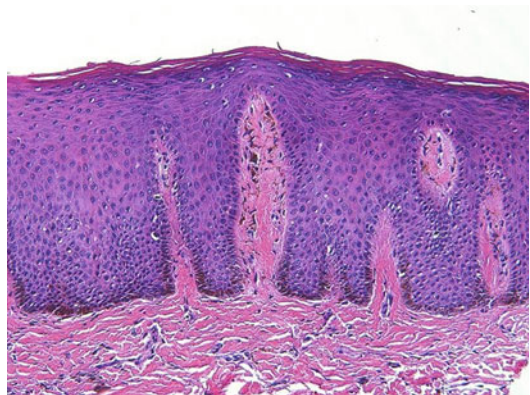
Fig.6.1 Melanotic macule of the lower left lip. Pigmentation is light brown and the borders are well-defined

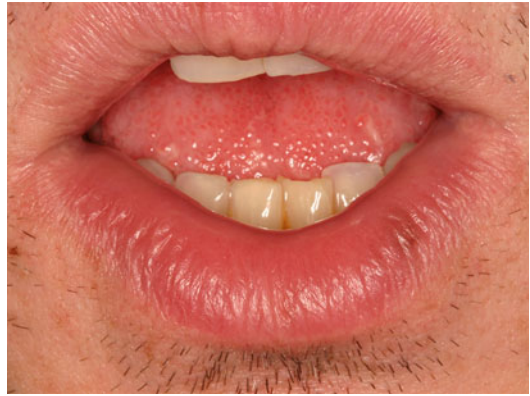





Fig. 6.2 Melanotic macule of the anterior mandibular gingiva

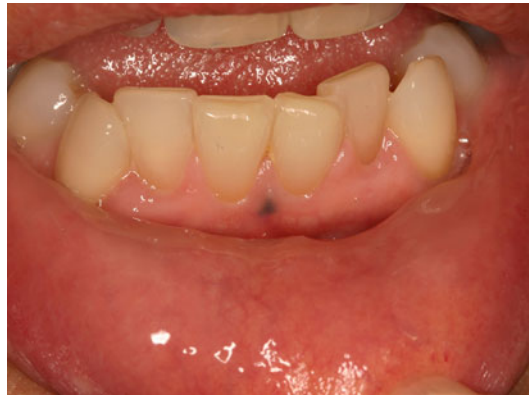

Fig. 6.3 Histopathology of a melanotic macule demonstrating a normal appearing basal cell layer with localized melanin deposition. Photomicrograph courtesy of Mark Lerman, D.M.D., Boston, MA



Melanotic Macule

	DIAGNOSTIC TESTS	None.
	BIOPSY	No, unless the appearance is unusual or has changed.
	TREATMENT	None.
	FOLLOW-UP	Annual examination.

Pigmented Nevus

Nevi, sometimes referred to as “moles,” are seen commonly on the skin, and less frequently can occur in the oral cavity. Pigmented nevi may appear clinically similar to melanotic macules; however, histological examination shows an increased number of melanocytes (occurring in nests or theques) in the basal epithelial layers or

underlying connective tissue. Lesions can present as either flat or raised, and vary in color from brown to blue (Figs. 6.4 and 6.5). Nevi are classified as junctional, compound, intramucosal, and blue based on the location of the melanocytes within the tissue. There is some question of malignant potential, however, this has not been clearly demonstrated. Biopsy is generally performed to rule out melanoma.

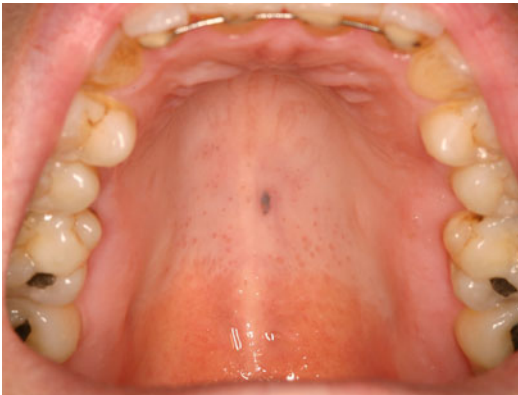





Fig. 6.4 Bluish-gray nevus of the hard palate. Clinically, the lesion was slightly raised

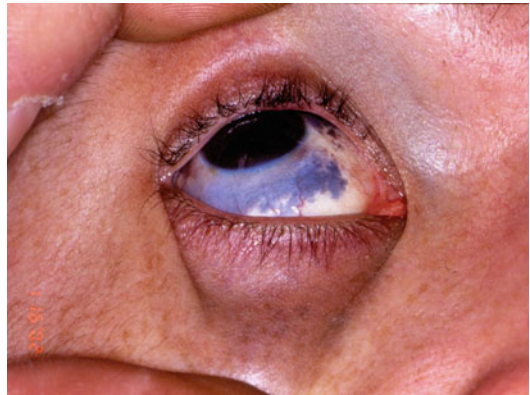

Fig. 6.5 Nevus of Ota showing striking orofacial pigmentation of the sclera. This condition is associated with increased melanin in and around the eyes

Pigmented Nevus

	DIAGNOSTIC TESTS	None.
	BIOPSY	Yes.
	TREATMENT	None.
	FOLLOW-UP	Annual; observe for any changes in size, color, or overall appearance.





Mucosal Melanoma

Malignant melanoma of the oral mucosa is exceedingly rare, accounting for less than 1% of all melanomas, however, it tends to be more aggressive and carries a more ominous prognosis than cutaneous melanoma. Unlike the cutaneous form where sun exposure is known to be etiologic, no risk factors have been identified for intraoral lesions. It also presents in an older age group, with an average age at diagnosis greater than 50 years. The palate and maxillary gingiva are the most frequently affected intraoral sites. Irregular or jagged appearing borders, change in color, rapid growth, pain, ulceration, and bleeding should arouse suspicion (Fig. 6.6). Unfortunately, most lesions are asymptomatic and may go unnoticed for a long period of time before diagnosis. Some lesions may be nonpigmented (appearing white, pink, or red), which further confounds the diagnosis.

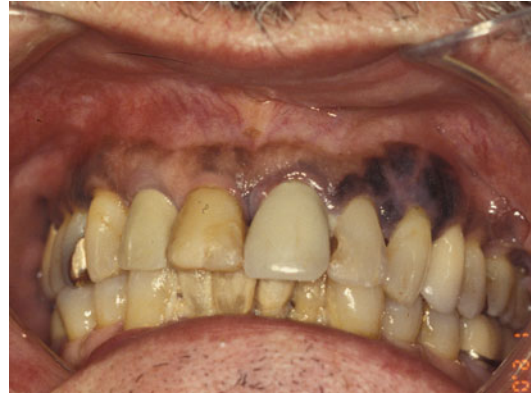

Fig. 6.6 Malignant melanoma of the left maxillary gingiva with focal, dark brown expansile area of pigmentation. Photograph courtesy of Sook-Bin Woo, D.M.D., M.M.Sc., Boston, MA

Mucosal Melanoma

	DIAGNOSTIC TESTS	None. But diagnosis of intraoral melanoma should prompt referral to a dermatologist for comprehensive skin examination.
	BIOPSY	Yes.
	TREATMENT	Wide surgical excision; possible adjunctive chemotherapy.
	FOLLOW-UP	Close follow-up for recurrence and metastasis.

Inflammatory Pigmentation

Melanin is often released by melanocytes and deposited into the surrounding tissue in response to chronic irritation or inflammation. In general, this tends to occur more often in individuals with a darker baseline skin type. Smoker's melanosis is seen in heavy smokers, and is probably caused by melanocyte stimulation secondary to heat or chemical compounds in the tobacco. Lesions are typically asymptomatic and are not

considered premalignant; they appear brown in color, diffuse, and flat. They occur commonly on the labial gingiva and buccal mucosa and may regress with smoking cessation (Fig. 6.7). Inflammatory pigmentation can also be seen in association with immune-mediated inflammatory conditions (such as lichen planus; see Chap. 5), periodontal disease, and gingivitis (Figs. 6.8 and 6.9). Post-inflammatory pigmentation may be permanent or may fade and resolve with time.

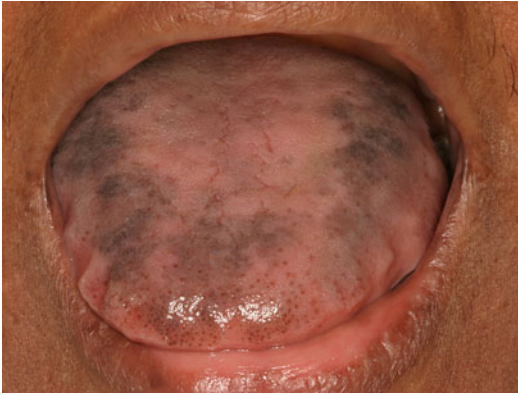





Fig. 6.7 Diffuse macular pigmentation of the tongue dorsum in an African American with a heavy smoking history

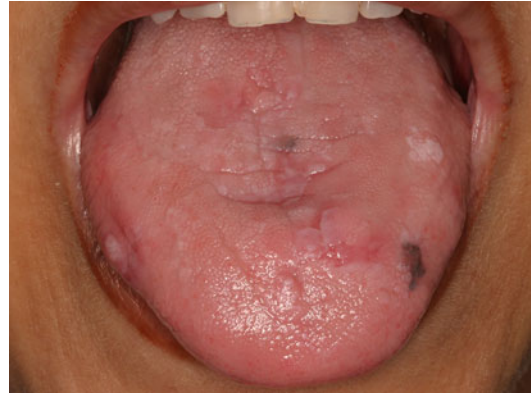

Fig. 6.8 Post-inflammatory pigmentation of the tongue dorsum in a patient with chronic graft-versus-host disease (see Chap. 11). There are chronic inflammatory changes consisting of depapillation, reticulation, and erythema, as well as two focal areas of dark brown pigmentation

Inflammatory Pigmentation

	DIAGNOSTIC TESTS	None.
	BIOPSY	No.
	TREATMENT	None.
	FOLLOW-UP	None.

Endocrine-Related Pigmentation

Certain endocrine conditions can result in oral pigmentation. In Addison disease (primary adrenocortical insufficiency), overproduction of adrenocorticotrophic hormone from the pituitary gland causes an increase in circulating melanocyte-stimulating hormone with subsequent stimulation of melanin production. The

skin takes on a bronze coloration and diffuse brown patches may be seen intraorally. Similar findings can be seen in Cushing syndrome, which involves excess production of adrenal corticosteroids. Female sex hormones may also affect pigmentation through the same pathway, with similar changes noted during and after pregnancy as well as in individuals taking oral contraceptives (Fig. 6.10).

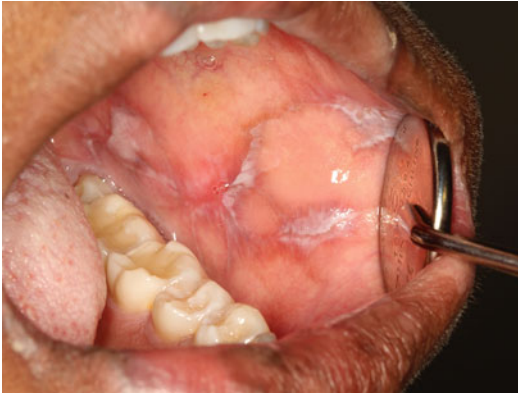






Fig. 6.9 Post-inflammatory pigmentation of the right buccal mucosa in a patient with active oral chronic graft-versus-host disease

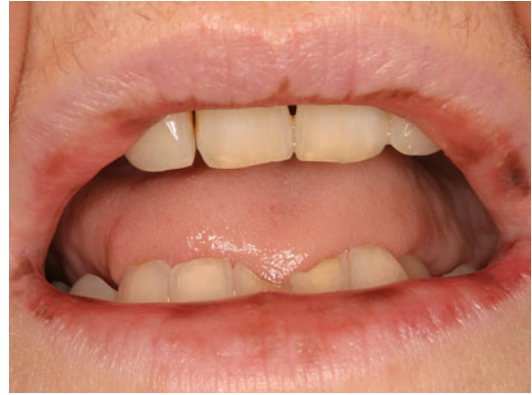

Fig. 6.10 Diffuse pigmentation of the lips in a female, most likely related to use of oral contraceptives

Endocrine-Related Pigmentation

	DIAGNOSTIC TESTS	None; work-up for endocrine disease as clinically indicated.
	BIOPSY	No.
	TREATMENT	None.
	FOLLOW-UP	None.

Drug-Induced Pigmentation

Pigmentation can be caused by a variety of medications, including antimalarials, antibiotics, oral contraceptives, chemotherapeutic agents, and antipsychotics (Table 6.1). The specific mechanism varies with the agent in question; it may involve an increase in melanin production or deposition of the drug or metabolite into the tissues (Figs. 6.11 and 6.12).

Table 6.1 Medications associated with oral pigmentation

Antimalarials
Quinacrine, chloroquine, hydroxychloroquine, quinine
Antibiotics
Tetracycline, minocycline
Antifungals
Ketoconazole
Oral contraceptives
Antipsychotics
Chlorpromazine (phenothiazines)
Antiarrhythmics
Quinidine, amiodarone
Chemotherapeutic agents
Busulfan, bleomycin, cyclophosphamide, doxorubicin, 5-fluorouracil
Other
Zidovudine (AZT), clofazamine, carotene, chlorhexidine

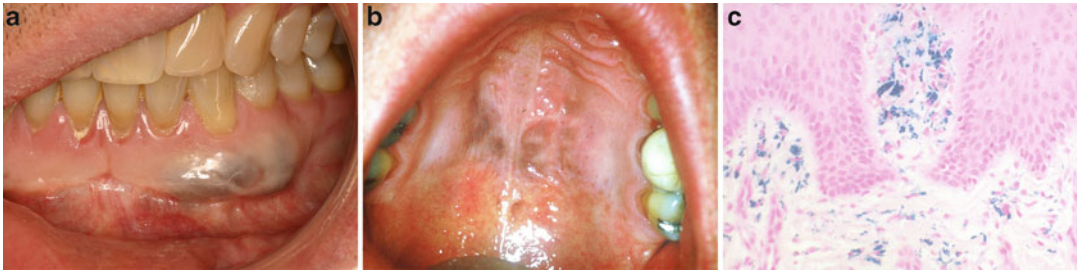
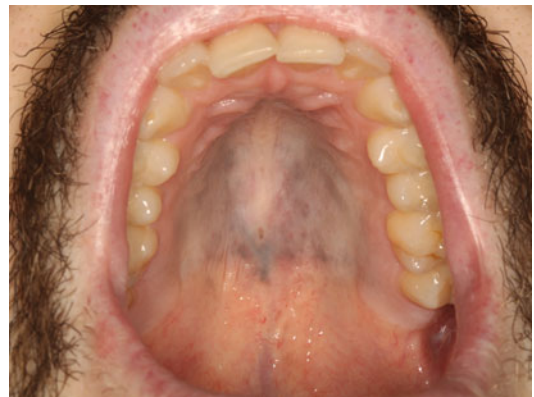
Fig. 6.11 Minocycline-induced oral pigmentation. (a) Focal dark gray pigmentation following gingival graft placement. (b) Diffuse brown pigmentation of the hard and soft palate. (c) Photomicrograph of biopsy specimen

demonstrating pigment deposition in the lamina propria (Prussian blue stain). Reprinted from Treister et al. (2004), with permission from Elsevier

Fig. 6.12 Diffuse pigmentation of the palate related to imatinib therapy



Nonmelanotic Pigmentation

Amalgam Tattoo

The amalgam tattoo (focal argyrosis) is the most common example of extrinsic pigmentation, caused by deposition of silver-containing amalgam restoration material into the surrounding mucosa during placement of a filling or dental extraction. These are asymptomatic, blue–gray in color, and most often seen on the gingiva and alveolar mucosa (Figs. 6.13 and 6.14). Diagnosis is made clinically, with biopsy reserved only for lesions that appear unusual. Biopsy shows amalgam particles within the tissue; these may also be

evident radiographically. Tattooing can also be seen from graphite (pencil lead, Fig. 6.15) as well as other substances (Figs. 6.16 and 6.17).

Heavy Metals

Nonmelanotic pigmentation can be seen in cases of significant heavy metal exposure. Deposition of lead, mercury, platinum, arsenic, and bismuth occurs in a band-like distribution along the gingival margin where capillary permeability to the metals is enhanced, particularly in the presence of inflammation. These changes are not reversible with treatment of the underlying problem.

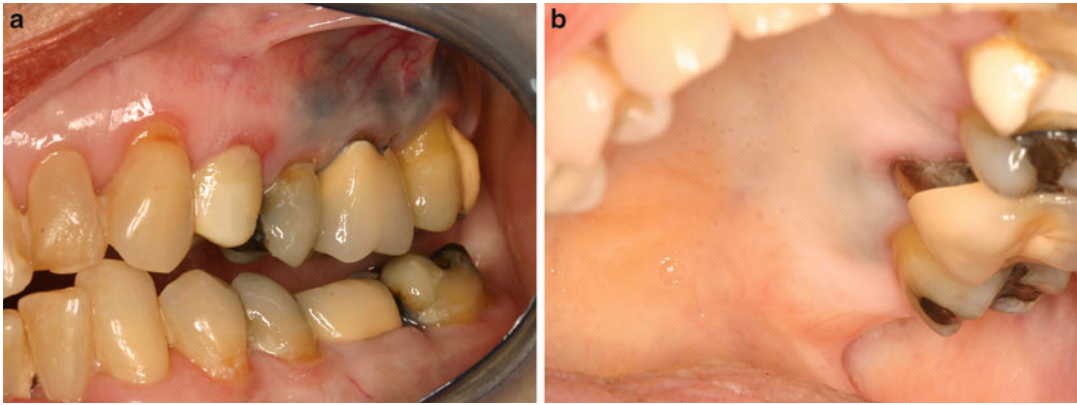


Fig. 6.13 Amalgam tattoo (a) left buccal gingiva and alveolar mucosa, and (b) palate, with grayish-blue diffuse pigmentation

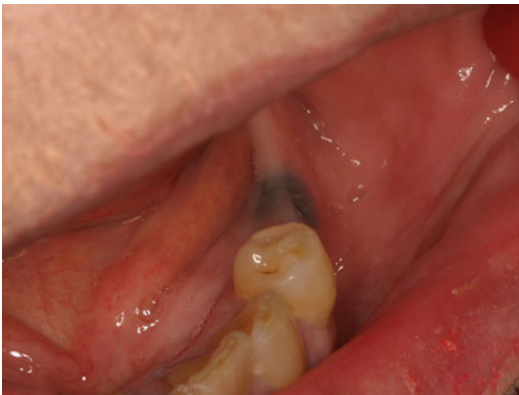

Fig. 6.14 Amalgam tattoo of the mandibular left alveolar ridge with focal gray pigmentation

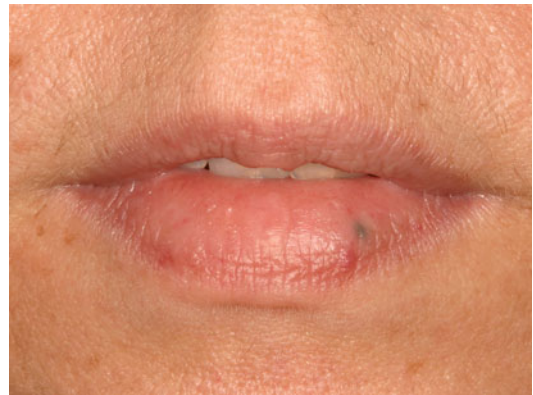

Fig. 6.15 Graphite tattoo of the right lower lip from a previous injury with a pencil tip

Heavy Metals





	DIAGNOSTIC TESTS	None.
	BIOPSY	No.
	TREATMENT	Treat underlying medical issue; no specific treatment for oral lesions.
	FOLLOW-UP	None.

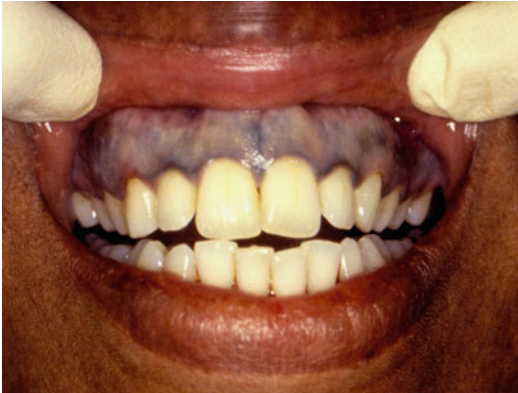

Fig. 6.16 Cosmetic ritualistic tattooing of the maxillary gingiva and alveolar mucosa in an African patient. Photograph courtesy of Sook-Bin Woo, D.M.D., M.M.Sc., Boston, MA

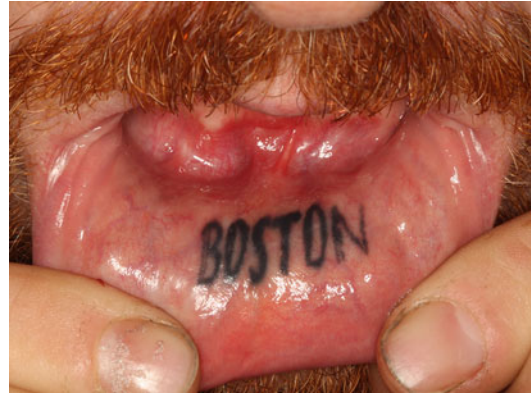


Fig. 6.17 Amateur tattoo of the lower labial mucosa

Hemochromatosis

This is an inherited condition of systemic iron overload characterized by increased absorption of dietary iron in the gut with deposition into body tissues. Accumulation of iron in the form of ferritin and hemosiderin eventually results in skin bronzing and organ failure including cirrhosis, diabetes, and cardiac dysfunction. Oral pigmentation can be seen in approximately 15–20% of patients, with the presence of diffuse brown to gray macules.

Vascular Lesions

Vascular lesions appear pigmented due to hemoglobin in blood, which may be contained in underlying vessels or extravasated into the

surrounding tissue. Oxygenated blood in the arterial system generally appears brighter red, whereas deoxygenated blood in the venous system is more bluish-purple. The color is also affected significantly by the depth of the lesion and thickness of overlying epithelium and connective tissue.

Varix

Varicosities are dilated or distended veins that are seen fairly common in the oral cavity, most often on the ventrolateral surface of the tongue and floor of mouth. Although observed in all age groups, they are much more common in older patients. Lesions are usually superficial and painless with a classic blue to purple color and will transiently empty blood (blanch) when manually compressed

Hemochromatosis





	DIAGNOSTIC TESTS	None.
	BIOPSY	No.
	TREATMENT	None.
	FOLLOW-UP	None.

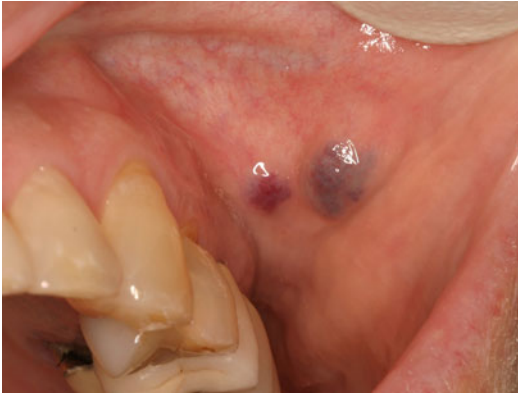

Fig. 6.18 Varix of the left maxillary vestibule

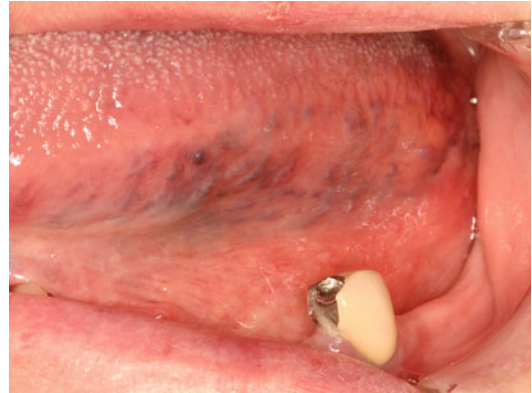

Fig. 6.20 Prominent varicosities of the ventral tongue

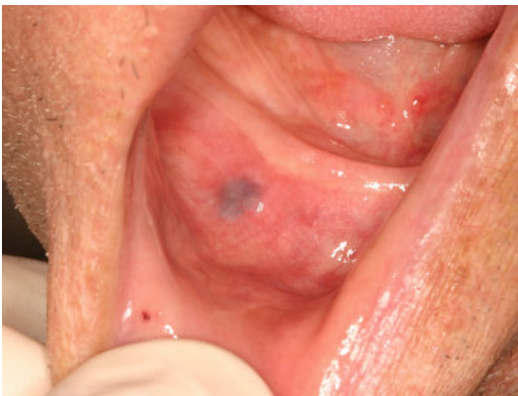

Fig. 6.19 Varix of the anterior mandibular vestibule

(Figs. 6.18, 6.19, and 6.20). Occasionally small calcifications (phleboliths) form within the varix secondary to venous stasis. These may be palpable as firm nodules and do not need to be removed unless bothersome to the patient. Varicosities also occur on the lower lip, where removal may be indicated for cosmetic reasons or bleeding; otherwise treatment is not required.

Hemangioma

Hemangiomas and vascular malformations are benign lesions that can be seen in the oral cavity.

Varix

	<p>DIAGNOSTIC TESTS</p>	<p>None; clinical appearance is classic.</p>
	<p>BIOPSY</p>	<p>No.</p>
	<p>TREATMENT</p>	<p>None unless symptomatic or cosmetically bothersome.</p>
	<p>FOLLOW-UP</p>	<p>None.</p>

Hemangiomas represent a rapid proliferation of vascular endothelium arising in infancy that tends to regress (involute) with the growth of the child. These are therefore typically evident at a very young age. Vascular malformations exhibit a more normal-appearing endothelium histologically with associated dilated or ectatic vessels. They grow proportionately with the growth of the individual without involution and are classified

according to the type of vessels contained within the lesion (arterial, venous, capillary, and lymphatic). Clinically, both types of lesions blanch with pressure and occur most commonly on the tongue, where they can range from flat to multinodular and generally appear bluish-red in color (Figs. 6.21 and 6.22). Symptomatic or cosmetically bothersome lesions can be removed.





Fig. 6.21 Vascular malformation of the hard and soft palate

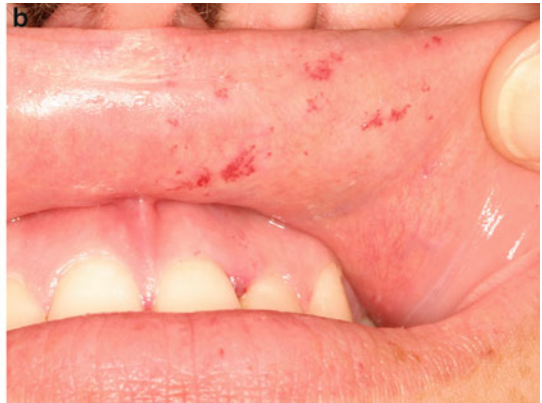
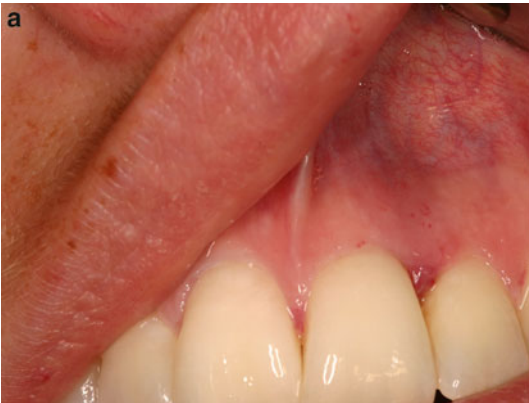
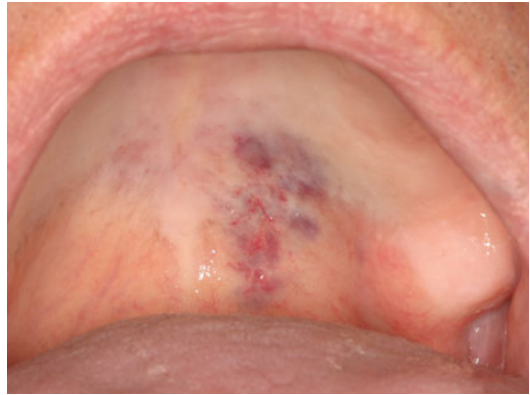Fig. 6.22 Multifocal vascular lesions with spontaneous gingival bleeding and left-sided epistaxis in a patient with hereditary hemorrhagic telangiectasia. (a) The lesion on

the tip of the interdental papilla between the central and lateral incisors is pronounced. (b) Petechial lesions can also be seen in the alveolar and labial mucosa

Hemangioma

	DIAGNOSTIC TESTS	None.
	BIOPSY	No.
	TREATMENT	None in most cases; treatment with surgery, sclerotherapy, embolization, or laser ablation if symptomatic.
	FOLLOW-UP	None.

Pyogenic Granuloma

This inflammatory lesion presents as a focal mass of benign reactive granulation tissue in response to local injury or irritation, such as from dental calculus or bite trauma. These lesions are seen most commonly on the gingiva near the interdental papilla and occur more frequently in women, often during pregnancy. They are well-defined exophytic growths that are usually bright red in color, often ulcerated, and bleed easily (Figs. 6.23, 6.24, and 6.25). Treatment is via simple excision, although gingival lesions tend to recur.

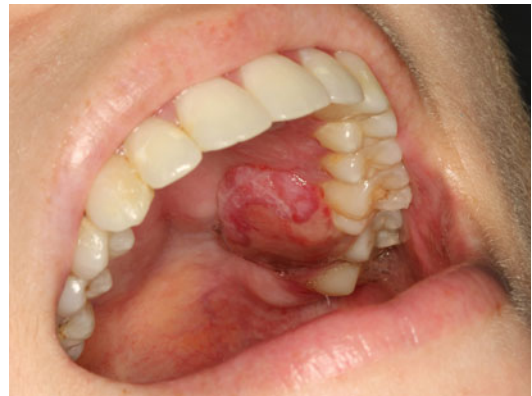

Fig. 6.24 Pyogenic granuloma of the palatal mucosa with focal ulceration

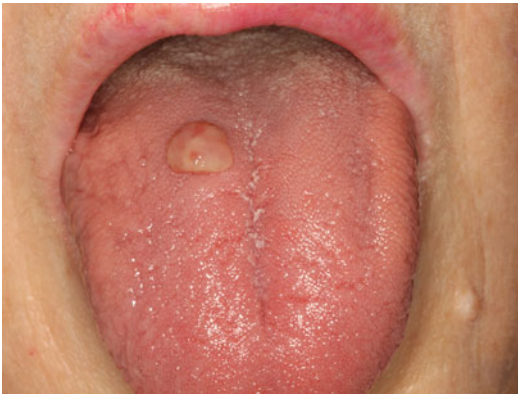





Fig. 6.23 Pyogenic granuloma of the tongue dorsum

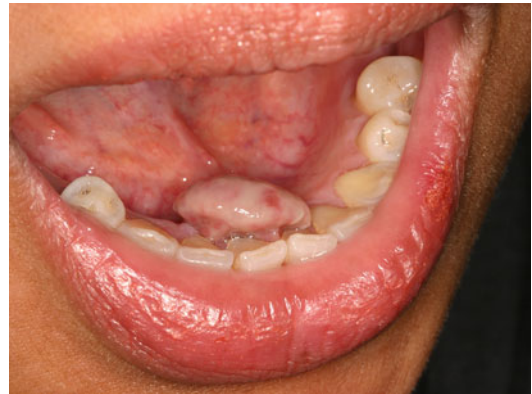

Fig. 6.25 Large pyogenic granuloma of the lingual mandibular gingiva in a pregnant woman

Pyogenic Granuloma

	DIAGNOSTIC TESTS	None.
	BIOPSY	Yes.
	TREATMENT	Excision.
	FOLLOW-UP	As needed if lesion recurs.

Kaposi Sarcoma





Kaposi sarcoma is a vascular malignancy found almost exclusively in HIV-positive individuals, however, can also be seen in other chronically immunosuppressed patients such as following organ transplantation. It has been associated with human herpes virus (HHV-8), and is seen as a marker of AIDS progression. Lesions are often multifocal and can be quite aggressive, involving the skin, lungs, gastrointestinal tract, and other organ systems. The oral cavity is frequently involved, with lesions occurring most often on the palate. The appearance ranges from flat and plaque-like to nodular with varying red, blue, and purple coloration (Fig. 6.26). KS lesions do not blanch with pressure, distinguishing them from hemangiomas. Treatment may be required for large or exophytic lesions if there is symptomatic bleeding or ulceration. Treatment options consist

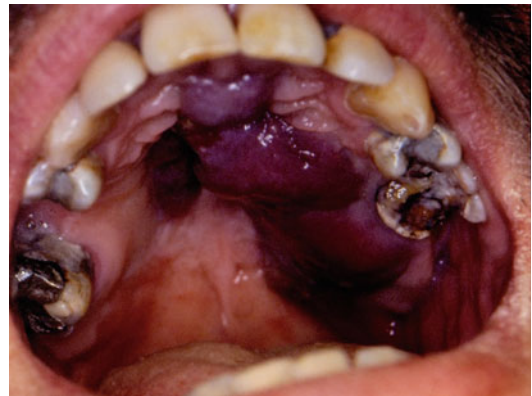

Fig. 6.26 Kaposi sarcoma of the palate in an HIV-positive patient. Photograph courtesy of Sook-Bin Woo, D.M.D., M.M.Sc., Boston, MA

of surgical excision, local injection with sclerosing or chemotherapeutic agents, or radiotherapy. Systemic chemotherapy is reserved for advanced cutaneous or disseminated disease.

Kaposi Sarcoma

	DIAGNOSTIC TESTS	Evaluation and assessment regarding underlying immune status.
	BIOPSY	Yes.
	TREATMENT	Treatment of oral lesions if symptomatic.
	FOLLOW-UP	Close follow-up to monitor lesions and progression of underlying disease.

Other

Other vascular lesions, such as hematomas, ecchymoses, and petechiae, may occur in the oral cavity as a result of minor local trauma. Lesions appear red, blue, purple, or black in color and do not blanch secondary to the presence of extravasated blood in the tissues (Figs. 6.27, 6.28, 6.29, 6.30, 6.31, and 6.32). They often arise in the setting of systemic blood dyscrasias but can also be seen in otherwise healthy individuals. Small dilated vessels, or telangiectasias, may be seen particularly following radiation therapy. These also occur in association with the inherited condition hereditary hemorrhagic telangiectasia (Osler-Weber-Rendu syndrome), which is characterized by bleeding from lesions in the nasal cavity and gastrointestinal tract.

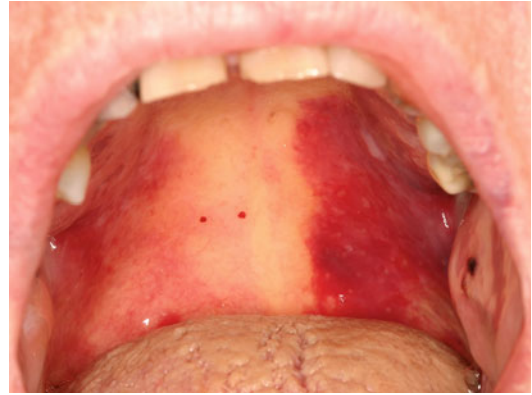

Fig. 6.29 Extensive palatal ecchymoses in a patient with profound thrombocytopenia resulting from minor trauma

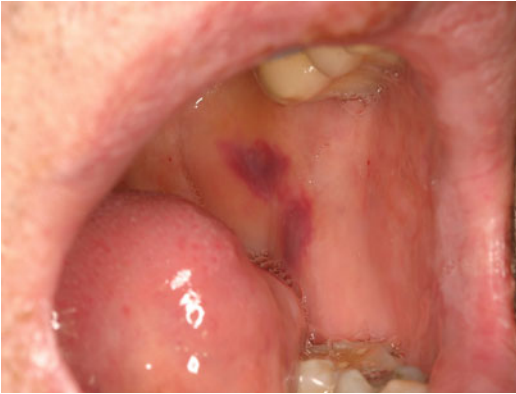

Fig. 6.27 Ecchymoses of the posterior buccal mucosa in a patient taking warfarin for anticoagulation. The lesions are clearly in the pattern of a bite injury

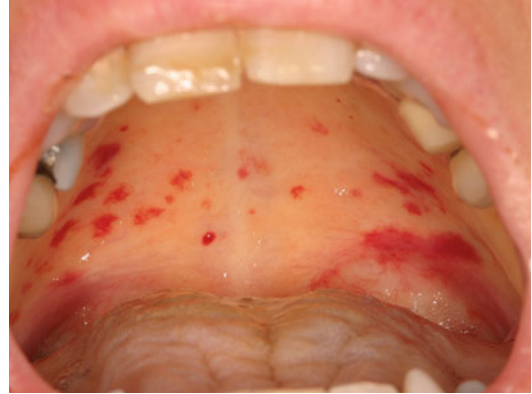

Fig. 6.30 Palatal petechiae and ecchymoses in a profoundly thrombocytopenic patient with acute leukemia

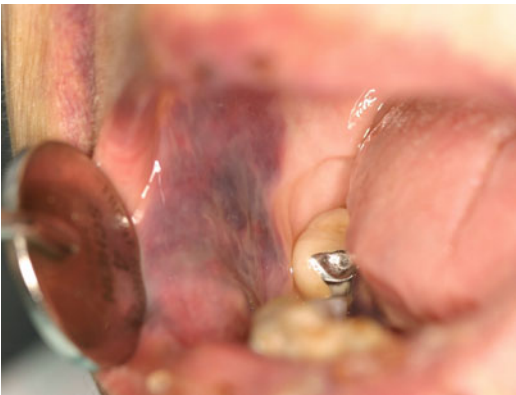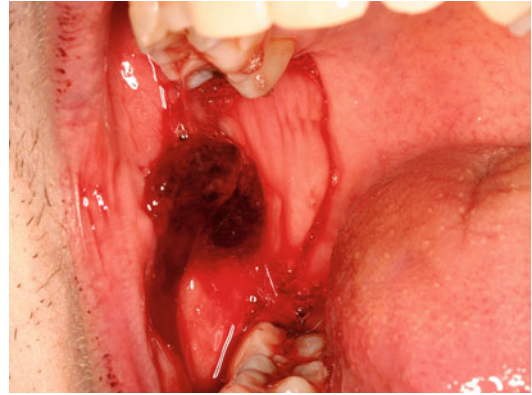


Fig. 6.28 Large ecchymosis of the right buccal mucosa in a heavily anticoagulated patient following a fall

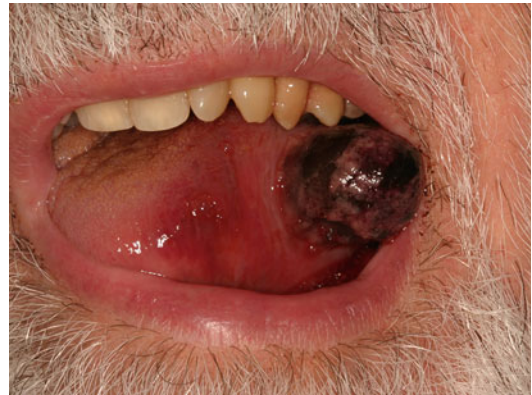





Fig. 6.31 Large hematoma of the lateral tongue in a thrombocytopenic patient with advanced multiple myeloma. Reprinted from Mawardi et al. (2009), with permission from Elsevier

Fig. 6.32 Excessive clot formation (*liver clot*) and persistent bleeding following a 4.0-mm punch biopsy in a patient with a previously undiagnosed coagulopathy. Placement of a single suture effectively closed the wound and controlled bleeding



Other

	DIAGNOSTIC TESTS	Attempt to identify source of trauma. Laboratory testing and work-up for underlying bleeding disorder/coagulopathy as indicated.
	BIOPSY	No.
	TREATMENT	None.
	FOLLOW-UP	None.

Sources

- Dereure O. Drug induced skin pigmentation. Epidemiology, diagnosis, and treatment. *Am J Clin Dermatol.* 2001;2:253–62.
- Femiano F, Lanza A, Buonaiuto C, et al. Oral malignant melanoma: a review of the literature. *J Oral Pathol Med.* 2008;37:383–8.
- Giardiello FM, Trimbath JD. Peutz-Jeghers syndrome and management recommendations. *Clin Gastroenterol Hepatol.* 2006;4:408–15.
- Gorsky M, Epstein JB. A case series of acquired immunodeficiency syndrome patients with initial neoplastic diagnoses of intraoral Kaposi's sarcoma. *Oral Surg Oral Med Oral Pathol Oral Radiol Endod.* 2000;90:612–7.
- Jafarzadeh H, Sanatkhan M, Mohtasham N. Oral pyogenic granuloma: a review. *J Oral Sci.* 2006;48:167–75.
- Lerman MA, Karimbux N, Guze KA, et al. Pigmentation of the hard palate. *Oral Surg Oral Med Oral Pathol Oral Radiol Endod.* 2009;107:8–12.
- Treister NS, Magalnick D, Woo SB. Oral mucosal pigmentation secondary to minocycline therapy: report of two cases and a review of the literature. *Oral Surg Oral Med Oral Pathol Oral Radial Endod.* 2004;97:718–25.
- Mawardi H, Cutler C, Treister N. Medical management update: non-Hodgkin lymphoma. *Oral Surg Oral Med Oral Pathol Oral Radiol Endod.* 2009;107:e19–33.
- Werner JA, Dunne A, Folz BJ, et al. Current concepts in the classification, diagnosis and treatment of hemangiomas and vascular malformations of the head and neck. *Eur Arch Otorhinolaryngol.* 2001;258:141–9.

Introduction

Bacterial, fungal, and viral infections are frequently encountered in the oral cavity. The immune system, protective components in saliva, and mucosal integrity are all key elements that work in concert to prevent the development of infection. When any of these are compromised, the resulting imbalance increases the potential for commensal, latent, or invading organisms to cause disease. Behavioral factors, including diet, nutrition, hydration, and oral hygiene, also have a significant influence on an individual's risk. Medications play an important role: immunosuppressive and immunomodulatory agents alter immune function, broad spectrum antibiotics affect the ecological balance of the oral flora, and xerogenic agents impact on the composition and flow of saliva.

There is no single feature characterizing infection in the mouth; findings range from painful swelling to mucosal ulceration to painless papules. The clinical appearance may be similar to that of noninfectious conditions. Therefore, careful history taking and examination, identification of risk factors, and appropriate utilization

and interpretation of diagnostic tests (see Chap.3) are critical. The clinical presentation of some infections may be altered in the *immunocompromised* patient: the anatomic distribution of lesions can be quite different, typical signs of infection may be diminished or absent, and standard doses of therapeutic medications may be ineffective. Failure to diagnose and initiate appropriate therapy in these patients can result in needless pain and suffering as well as progression to systemic infection.

Bacterial Infections

Oral bacterial infections are most commonly of dental origin and can progress to abscess formation with potentially significant complications if left untreated. In an otherwise healthy individual, it is exceedingly rare for a nonodontogenic bacterial infection to develop within the oral cavity. Infection rarely occurs following oral surgical procedures (such as tooth extraction and soft tissue biopsy) or minor trauma. Infection of the salivary glands is uncommon and mucosal infection outside of the periodontium (e.g., other than gingivitis and periodonti-

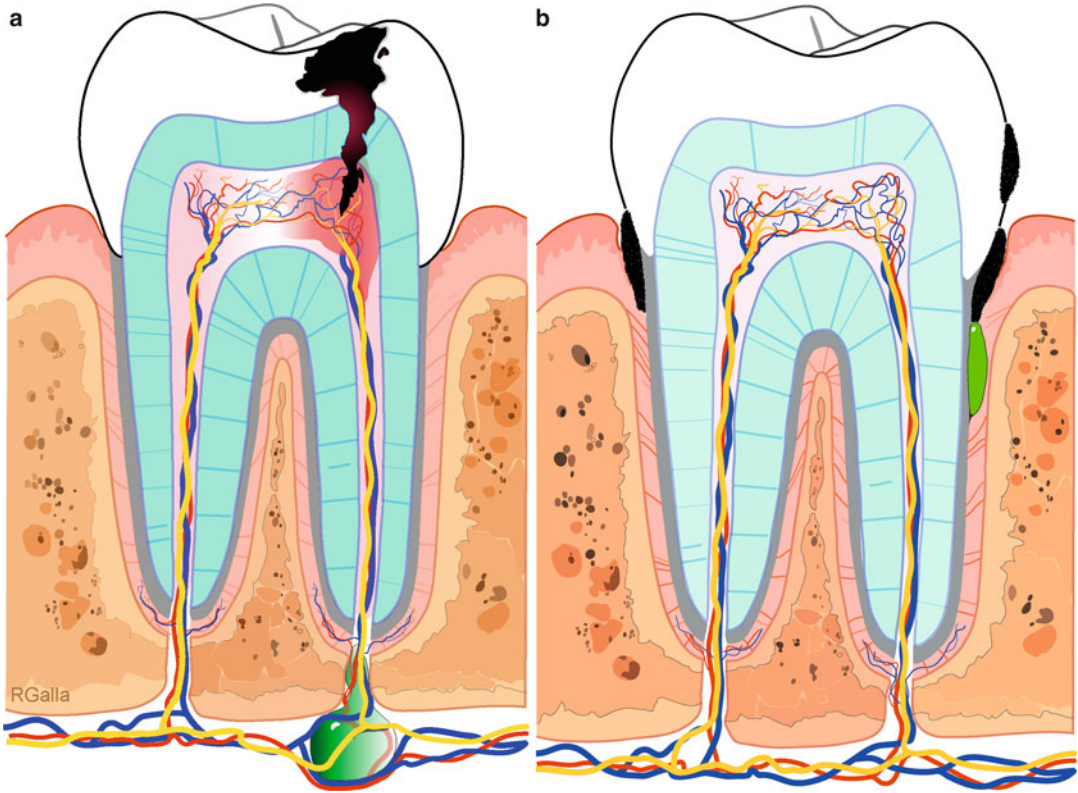


Fig. 7.1 Odontogenic infection. (a) Caries is seen extending through the calcified enamel and dentin of the crown with pulpal involvement. A periapical abscess has formed at a root apex (illustrated in *green*) representing extension of necrotic material from the pulp chamber into the alveolar bone through the apical foramen. (b) Accumulation of

calculus on the crown and root surface (subgingival and supragingival; illustrated in *black*) with deepening of the gingival crevice and formation of a periodontal pocket. Note also how a periodontal abscess (illustrated in *green*) may form in this situation

tis) is generally only encountered in those who are immunosuppressed.

Odontogenic Infections

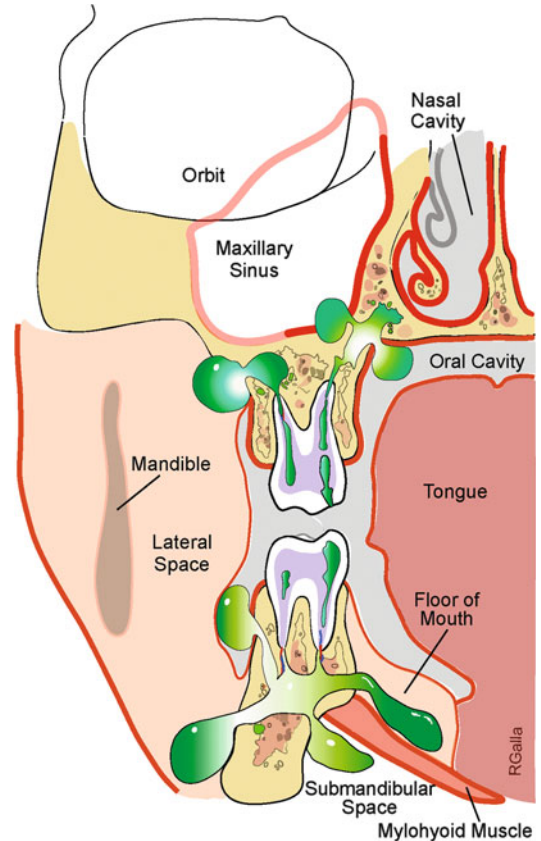
Odontogenic infections can be broadly classified as either *endodontal*, which are characterized by infection of the dental pulp initiated by dental caries; or *periodontal*, which are characterized by infection of the tooth's supporting structures initiated by accumulation of plaque and calculus (Fig. 7.1). In both cases, the primary risk factors

include inadequate oral hygiene with dental plaque accumulation. While the reasons are not entirely clear, many patients with high caries rates often have minimal periodontal disease, whereas patients with advanced periodontal disease often have few caries.

Dental Caries

Caries are caused by the metabolism of sugar in dental plaque by *Streptococcus mutans*, resulting in the production of acid and subsequent demineralization of the protective enamel layer. The destructive process advances inward toward

Fig. 7.2 Potential pathways of spread of odontogenic infection illustrated on a coronal diagram. Infection (illustrated in *green*) takes the path of least resistance and can emerge from the alveolar bone into the vestibule, floor of mouth, submandibular space, maxillary sinus, nasal cavity, palate, and lateral muscular space surrounding the mandibular ramus



the pulp, and in the absence of treatment, results in pulpal necrosis and potential abscess formation (Fig. 7.2). Infected material drains from the pulp chamber through the apical foramen into surrounding bone, causing abscess formation at the root apex (*periapical abscess*; Fig. 7.3). From there infection can spread to other parts of the oral cavity, face, or neck and lead to potentially life-threatening soft tissue infections such as Ludwig angina, deep neck abscess, necrotizing fasciitis, and mediastinitis (Figs. 7.4, 7.5, and 7.6). Infection in molars can result in *trismus* (limitation of mouth opening) due to inflamma-

tion of the adjacent masticatory muscles (Fig. 7.7).

Decay can form on any tooth surface, but frequently affects the occlusal surfaces of posterior teeth due to the presence of anatomic pits and fissures. The interproximal surfaces are also commonly affected because plaque can be difficult to remove from these areas. The facial surfaces near the gingival margin and exposed root surfaces are particularly susceptible because they are covered with cementum, which is much softer than enamel. Early lesions may show areas of decalcification on the enamel, and are character-

Fig. 7.3 Left facial swelling associated with a decayed and abscessed mandibular molar

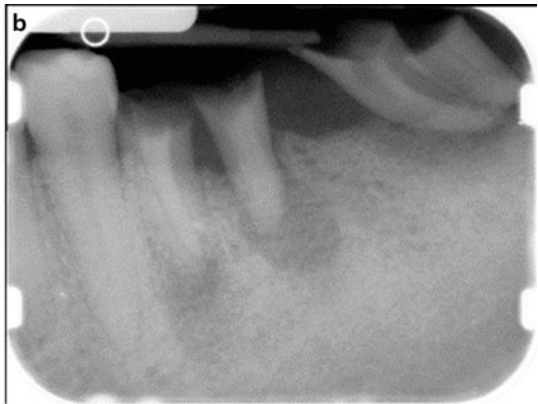
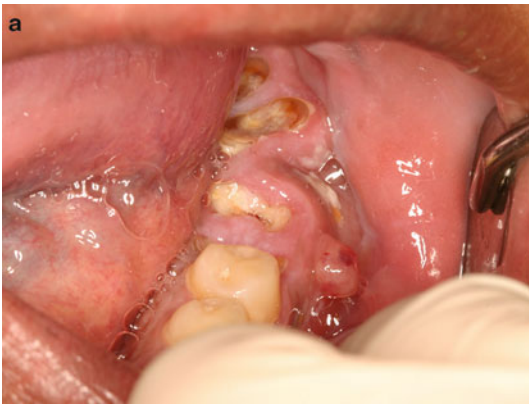
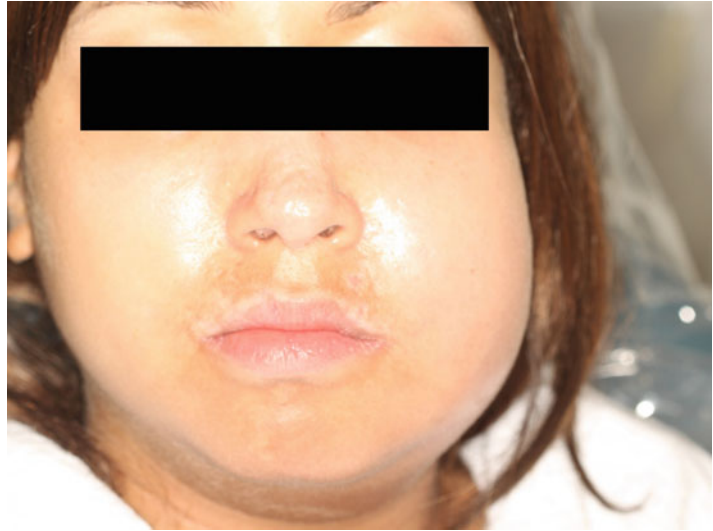Fig. 7.4 Left mandibular gingival swelling due to a draining abscess (a) associated with the remaining decayed and broken down molar roots. (b) Periapical

radiograph demonstrating periapical radiolucencies associated with the remaining root tips

ized by white spots that may collapse under the pressure of a dental instrument (Fig. 7.8). More advanced lesions demonstrate obvious cavitation with brownish-black discoloration (Figs. 7.9 and 7.10). Entire sections of the tooth may fracture and exposure of the pulp chamber may be evident (Fig. 7.11).

Intraoral dental radiographs are used to diagnose caries, which appear as distinct areas of radiolucency within the tooth structure

(Fig. 7.12). These can also demonstrate the presence of a *periapical radiolucency*, indicative of pulpal pathology (Figs. 7.4, 7.5, and 7.6). Computed tomography (CT) may be indicated if extensive soft tissue swelling is present and there is concern for progression of infection into the deep spaces of the neck (Fig. 7.13). When dental infection is suspected, the patient should be referred to a dentist or other oral health care specialist for further evaluation.

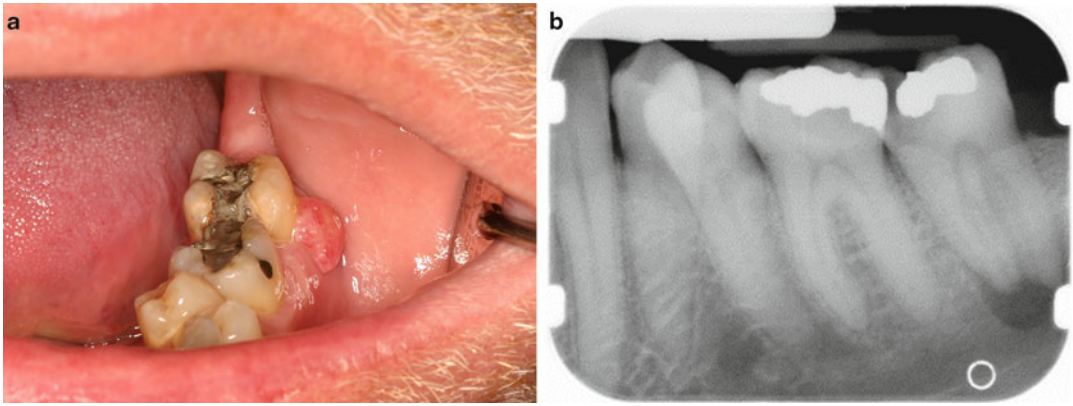


Fig. 7.5 Left mandibular gingival swelling (a) associated with abscessed second molar with a fractured amalgam restoration with underlying recurrent caries. (b) Periapical radiograph showing dental caries extending into the pulp with well-defined periapical radiolucency

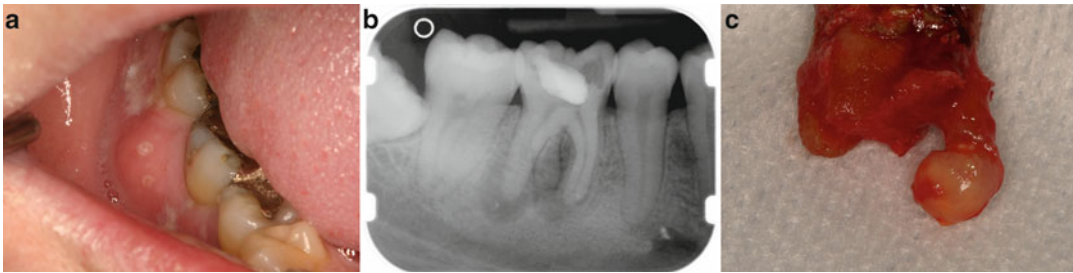


Fig. 7.6 Periapical pathology. (a) Abscessed mandibular first molar with adjacent gingival swelling. (b) Periapical radiograph (not the same patient) showing caries extending into the pulp chamber and periapical radiolucencies. (c) Extracted molar with attached periapical lesion; histopathological evaluation is required to differentiate between a *granuloma* versus *radicular cyst*

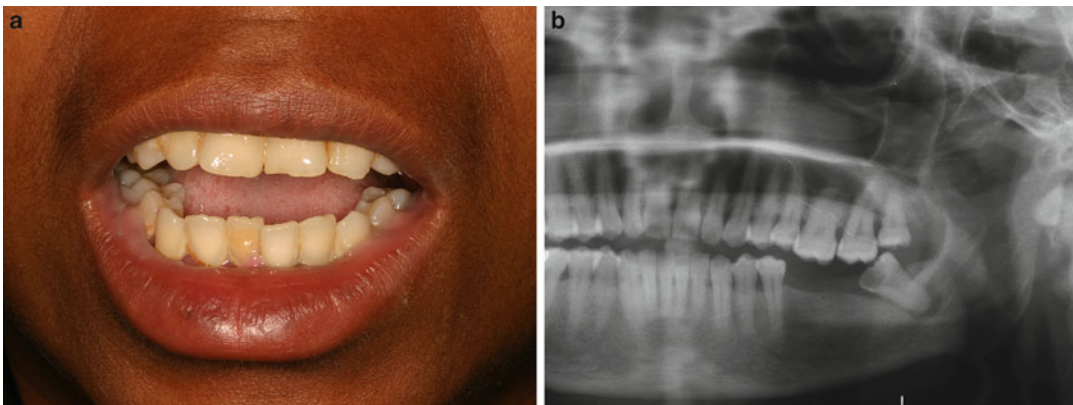


Fig. 7.7 Severe trismus in a patient with an abscessed third molar. (a) This is the widest opening that the patient is able to achieve. (b) Panoramic radiograph showing the mandibular left third molar with extensive caries and large periapical radiolucency

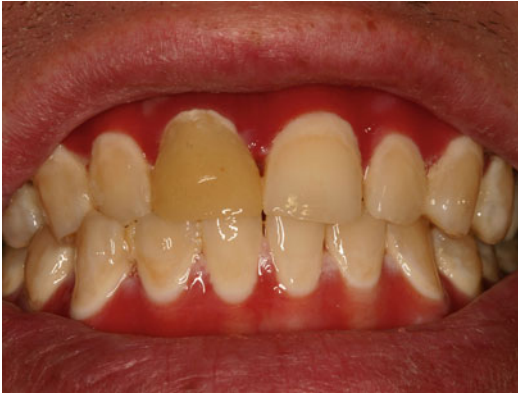

Fig. 7.8 Generalized decalcification or “white spots” along the cervical margins. Caries are most likely already present in many of these areas. The right maxillary central incisor is restored with a temporary crown made of an acrylic material

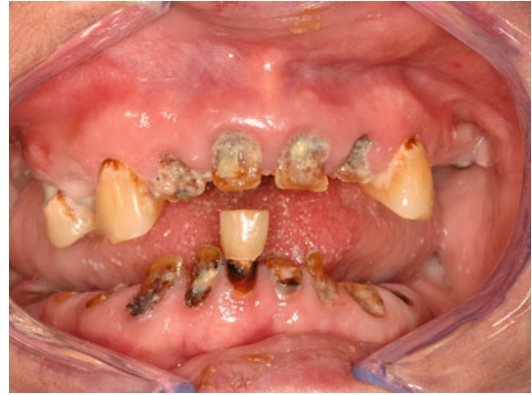

Fig. 7.11 Rampant decay in a patient several years after completion of radiation therapy for head and neck cancer. Numerous teeth are fractured at the cervical margin and the pulp chambers are exposed

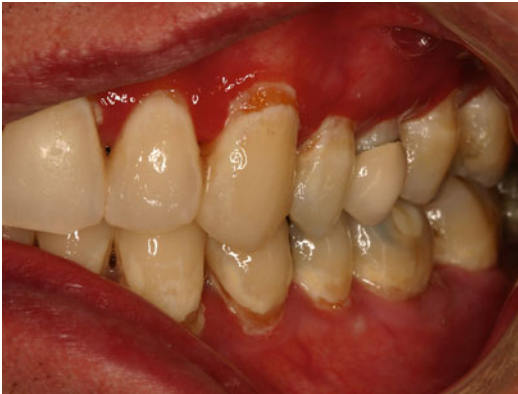

Fig. 7.9 Generalized cervical caries with loss of enamel and brown discoloration. This pattern of dental caries is often seen in patients with salivary gland hypofunction

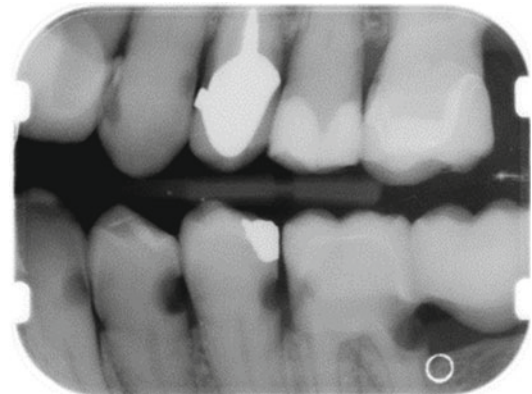


Fig. 7.12 Bitewing radiograph demonstrating interproximal decay on the root surfaces of the posterior maxillary teeth. The areas of decay appear as rounded radiolucent lesions

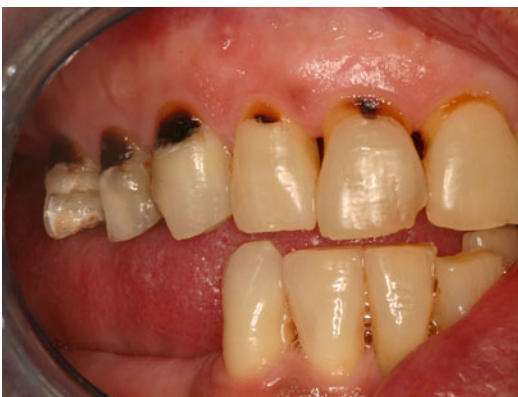

Fig. 7.10 Dark brown cervical caries. Dental caries that are longstanding or “arrested” tend to become darker in appearance over time

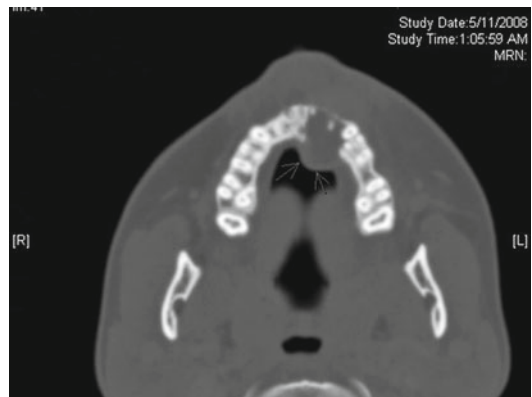

Fig. 7.13 Axial CT scan demonstrating a large abscess associated with the maxillary left lateral incisor with destruction of palatal bone and extensive soft tissue swelling

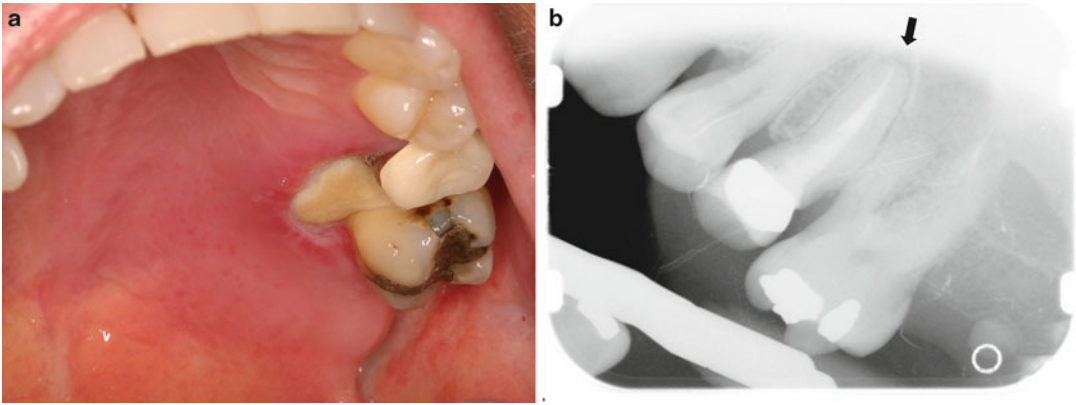


Fig. 7.14 Abscessed premolar in a patient with advanced refractory acute myelogenous leukemia. (a) Secondary neutropenic ulceration of the palate due to spread of infection.





(b) Periapical radiograph showing adequate-appearing endodontic fill with a small periapical radiolucency (arrow)

As long as the pulp chamber has not been breached, caries can be mechanically removed and the tooth can be restored with a variety of dental materials. With pulpal involvement, endodontic therapy (*root canal therapy*) or extraction of the tooth is required. Endodontic treatment involves removal of neurovascular tissue from the pulp chamber and replacement with an inert material such as gutta-percha. In cases of localized intraoral swelling, incision and drainage may also be necessary in conjunction with definitive treatment of the tooth.

The only significant medical risk factor for the development of dental caries is reduced salivary function (see Chap. 8). In patients with profound neutropenia, previously latent or subclinical periapical infections can become acutely active with soft tissue swelling or localized gingival and mucosal necrosis (Fig. 7.14). Antibiotics should be given in these situations, as well as in cases of significant soft tissue swelling. Otherwise, the decision to prescribe antibiotics will depend on the individual clinical situation.

The mainstays of caries prevention involve attention to diet, maintenance of oral hygiene, and use of fluoride. Overall consumption of carbohydrate and frequency of exposure are both important. For example, an individual who ingests snacks or sugary beverages frequently throughout the day is at higher risk for caries than someone who eats only three meals per day and drinks water. Brushing with a soft toothbrush and fluoride toothpaste for 2 min at least twice daily (ideally after every meal) removes dental plaque accumulation and significantly reduces the risk of dental caries. Daily use of dental floss removes plaque from the interproximal regions, which are otherwise difficult areas to clean. Systemic fluoride, usually obtained through fluoridated water, is important during tooth development in children because it incorporates into the developing tooth structure and renders it less susceptible to attack from caries. Prescription topical fluoride preparations are typically reserved for individuals considered to be at high risk for caries.

Dental Caries

	DIAGNOSTIC TESTS	Clinical exam and intraoral radiographs.
	BIOPSY	No.
	TREATMENT	Mechanical removal of decayed tooth structure and restoration of tooth integrity. Endodontic therapy or extraction of tooth is indicated when the pulp is infected. Consider antibiotics depending on clinical presentation, in which case penicillin-group or clindamycin for 7–10 days is generally effective.
	FOLLOW-UP	Patients with dental caries should be seen by a dentist regularly following treatment of all active caries to monitor for new or recurrent lesions. High risk patients and those with rampant caries should be prescribed sodium fluoride gel 5,000 parts-per-million which can be applied by toothbrush or in soft custom-fabricated dental trays.

Periodontal Disease

Periodontal disease is caused by the accumulation of plaque and *calculus* (calcified dental plaque also referred to as *tartar*), that leads to chronic inflammation of the adjacent gingiva, periodontal attachment structures, and alveolar bone. Periodontal “pockets” form between the tooth and gingival soft tissues as the infected material migrates apically. As the pockets become deeper and more inflamed, it becomes more difficult to adequately clean these areas. Heavy smoking also contributes to inflammation of the periodontium. Signs of periodontal disease include plaque and calculus accumulation, gingival recession or bleeding, periodontal pocketing, root exposure, and tooth mobility (Figs. 7.15, 7.16, and 7.17). Advanced periodontal disease is often associated with foul smelling breath (halitosis).

The periodontium can become acutely infected with abscess formation and swelling of the adjacent gingiva (Fig. 7.18). This is more likely to develop in areas with deep periodontal pockets and *furcation involvement* (exposure of the space between the roots of multirouted teeth). *Pericoronitis* is a condition in which the gingiva surrounding the crowns of partially erupted molars (usually the third molar or “wisdom tooth”) becomes painfully inflamed (Fig. 7.19).

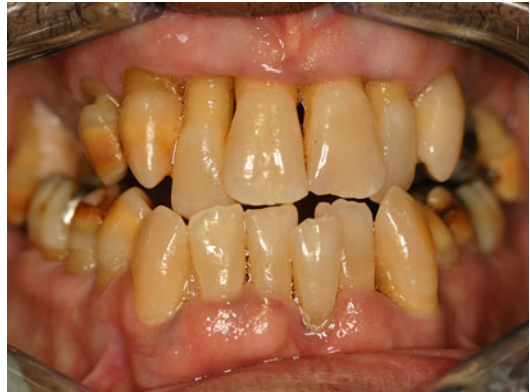

Fig. 7.15 Chronic periodontal disease. There is extensive alveolar bone loss, gingival recession, and blunting of the interdental papillae with subsequent root surface exposure

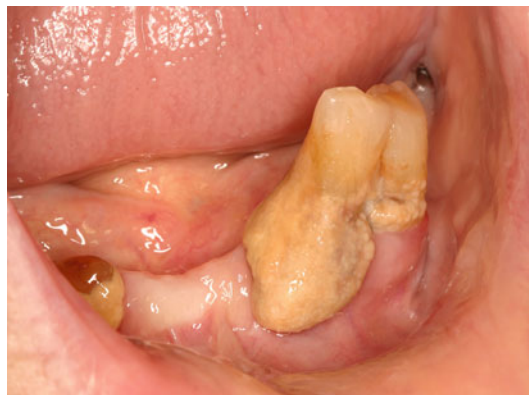

Fig. 7.16 Heavy calculus deposition on the mandibular anterior teeth

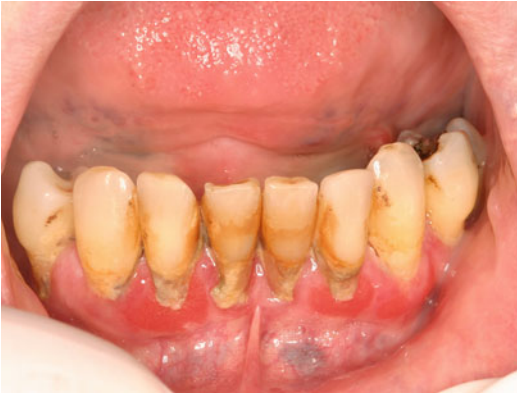

Fig. 7.17 Calculus accumulation on the mandibular anterior dentition with gingival recession and focal areas of severe inflammation

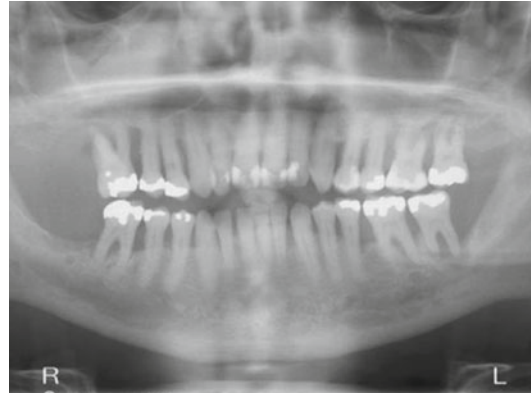


Fig. 7.20 Panoramic radiograph of a patient with advanced periodontal disease. Note advanced alveolar bone loss around the posterior teeth

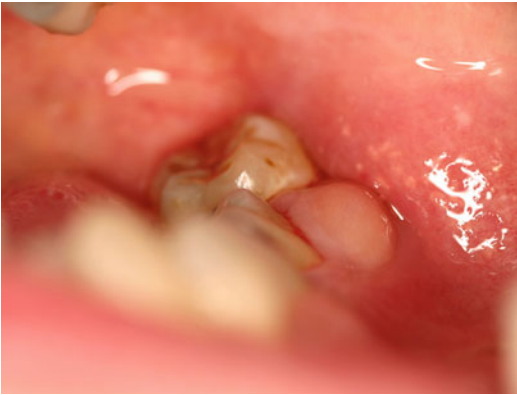

Fig. 7.18 Periodontal abscess formation with firm swelling in the buccal vestibule

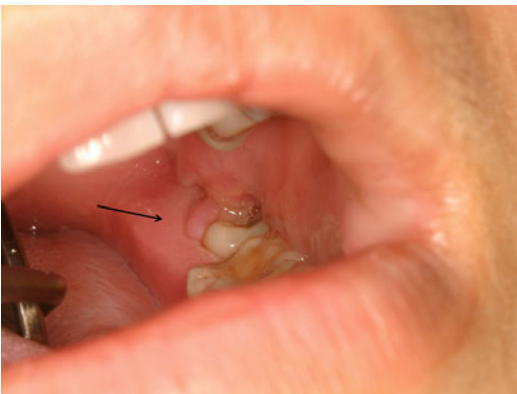






Fig. 7.19 Pericoronitis associated with the mandibular left third molar. Note inflammation and swelling (*arrow*) of the soft tissue as well as limited mouth opening

Radiographic features of periodontal disease include the presence of calculus both above (supragingival) and below (subgingival) the gingival margin, as well as loss of alveolar bone surrounding the teeth (Fig. 7.20). Generalized horizontal bone loss in all four quadrants signifies longstanding inflammation. Localized areas of vertical bony defects represent areas of advanced bone loss and are often associated with tooth mobility and an increased risk for abscess formation.

Primary management of periodontal disease includes professional *scaling* and *root planning*, with removal of calculus and inflammatory tissue from around the teeth and along root surfaces in conjunction with attention to improved oral hygiene. In more advanced cases, surgical procedures may be indicated to reduce pocket depth. Antimicrobial therapies include topical rinses, such as chlorhexidine gluconate; locally delivered antibiotics, such as minocycline injected subgingivally; and systemic antibiotics.

Periodontal Disease

	DIAGNOSTIC TESTS	Clinical exam and intraoral radiographs.
	BIOPSY	No.
	TREATMENT	Scaling and root planing and education regarding improved oral home care. In some cases antimicrobial and/or surgical therapy may be indicated. Pericoronitis should be initially managed with broad spectrum antibiotics (e.g., amoxicillin/clavulanic acid) and warm salt water rinses; extraction of the associated tooth is necessary in recurrent cases.
	FOLLOW-UP	Patients with periodontal disease may require professional dental cleaning three to four times annually. The patient is frequently managed in conjunction with a periodontist. Home oral hygiene instruction is important. Smoking cessation should be discussed and encouraged.

Inflammatory Gingival Hyperplasia

Although uncommon, the gingiva can become markedly enlarged in response to localized inflammation. This can be observed in the context of periodontal disease or in response to certain medications. Associated medications include calcium channel blockers (such as nifedipine), calcineurin inhibitors (cyclosporine), and anti-convulsants (phenytoin). In all cases, poor oral hygiene is believed to be a significant contributing factor. The underlying mechanism is thought to be related to calcium regulation of collagen degradation in fibroblasts resulting in increased production of dense connective tissue. Unlike the gingival enlargement that can be seen with leukemic infiltration (see Chap. 11), these lesions are generally firm and of a normal pink color without significant associated bleeding (Figs. 7.21, 7.22, and 7.23). Treatment includes gross debridement of plaque and calculus, which often results in partial or complete resolution. If associated with a medication, discontinuation or substitution is indicated and often effective in reducing progression of gingival enlargement. If this does not result in significant improvement, gingivectomy, usually performed by a periodontist, is indicated.

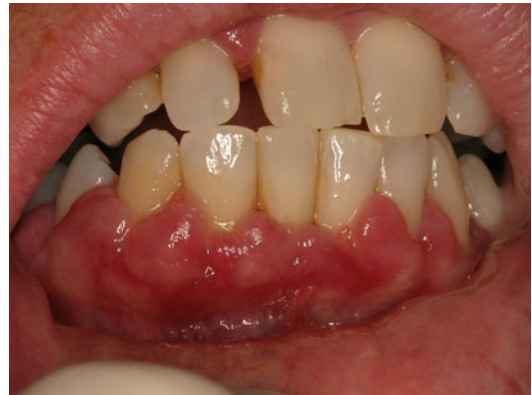

Fig. 7.21 Inflammatory gingival hyperplasia secondary to chronic periodontal disease

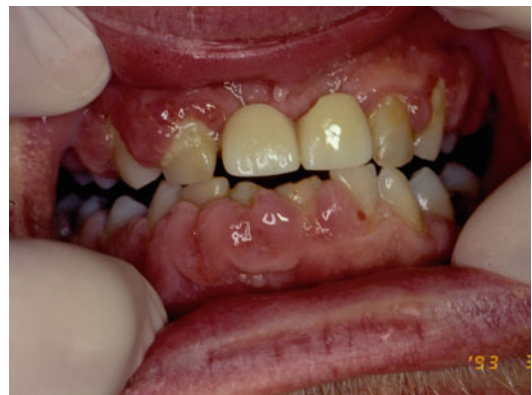
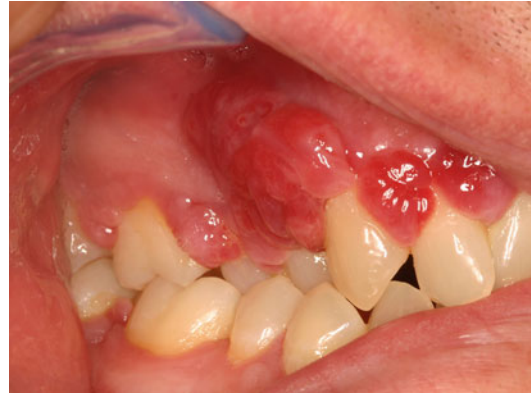




Fig. 7.22 Calcium channel blocker and calcineurin inhibitor associated gingival hyperplasia in a solid organ transplant recipient. There is considerable erythema in areas of heavy plaque accumulation. Photograph courtesy of Sook-Bin Woo, D.M.D., M.M.Sc., Boston, MA

Fig. 7.23 Severe inflammatory gingival hyperplasia secondary to chronic periodontal disease with spontaneous bleeding



Inflammatory Gingival Hyperplasia

	DIAGNOSTIC TESTS	None.
	BIOPSY	May be necessary for definitive diagnosis and to exclude malignancy, especially in cases where there are localized areas of prominent gingival enlargement.
	TREATMENT	Scaling and root planing as primary therapy; patients must also maintain strict oral hygiene practices. Discontinuation of any potentially causative medication if appropriate. For lesions that do not resolve following conservative therapy, referral to a periodontist for gingivectomy is indicated.
	FOLLOW-UP	None specifically indicated.

Acute Necrotizing Stomatitis

Previously referred to as “trench mouth” described in soldiers fighting on the front lines in World War I, *acute necrotizing stomatitis* is seen mainly in patients with severe malnutrition and very poor oral hygiene. It has also been observed disproportionately in patients with HIV disease. This aggressive and painful periodontal infection is caused by the convergence of poor oral hygiene, immune suppression, and inadequate nutrition. When localized to the gingiva, the condition is called *acute necrotizing gingivitis*; if it progresses to involve the periodontium, it is referred to as *acute necrotizing periodontitis*.

Rarely, this develops into a destructive and devastating infection of the hard and soft orofacial tissues resulting in a disfiguring condition termed *noma*, which is seen almost exclusively in developing countries.

Clinical features of necrotizing stomatitis include severe gingival inflammation with edema, bleeding, blunting of tissue contours, and “punched out” appearing interdental defects with varying areas of ulceration (Fig. 7.24). Necrotic alveolar bone may be evident, and heavy plaque and calculus accumulations are generally present. Intraoral radiographs demonstrate advanced bone loss with vertical defects

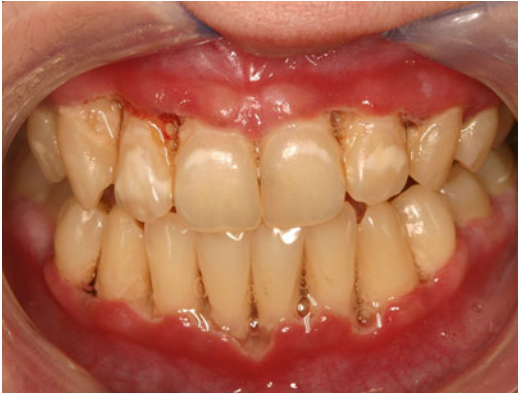





Fig. 7.24 Acute necrotizing ulcerative periodontitis in a 16-year-old female with AIDS. There is marginal ulceration of the gingiva, gingival recession with loss of attachment, and crater-like interdenal defects (“punched-out papillae”)

that often correspond to areas of extensive soft tissue destruction. This condition is associated with a very foul odor, reflective of the extent of infection and tissue necrosis.

Treatment includes aggressive debridement and administration of antibiotics. Due to the extent and depth of infection, local anesthesia is often required for adequate removal of all plaque and calculus deposits. In addition, daily rinses with chlorhexidine gluconate provide a topical effect, and this medication is continued indefinitely after systemic antibiotics are completed. Following initial therapy, home oral care maintenance is critical to prevent recurrence. Underlying factors such as poor nutrition and immunosuppression must also be addressed.

Acute Necrotizing Stomatitis

	DIAGNOSTIC TESTS	None.
	BIOPSY	No.
	TREATMENT	Gross periodontal debridement followed by thorough scaling and root planing. A 7–10-day course of amoxicillin/clavulanic acid (250/125 mg) and metronidazole (250 mg) should be prescribed in conjunction with daily chlorhexidine gluconate rinses. Medication for pain management may be necessary.
	FOLLOW-UP	Close follow-up with regularly scheduled professional dental cleanings and assessment of oral home care.

Parotitis

Bacterial parotitis is characterized by painful acute swelling of the parotid gland, commonly on one side (Fig. 7.25). Risk factors include dehydration, salivary gland hypofunction, and sialolithiasis. In the setting of diminished salivary outflow, commensal bacteria ascend the duct in a retrograde fashion resulting in infection within the parenchyma of the gland. It is usually caused by *Staphylococcus aureus*. Extraoral examina-

tion demonstrates visible fullness of the gland, often with erythema of the overlying skin and outward displacement of the ear. Palpation of the gland elicits discomfort, and intraoral examination may show swelling and erythema in the region of the duct orifice. Purulent discharge may be visible as well. Bacterial infections also affect the submandibular gland in a similar fashion.

Treatment includes broad spectrum systemic antibiotics, hydration to enhance salivary flow, and pain management. Drainage of the gland can

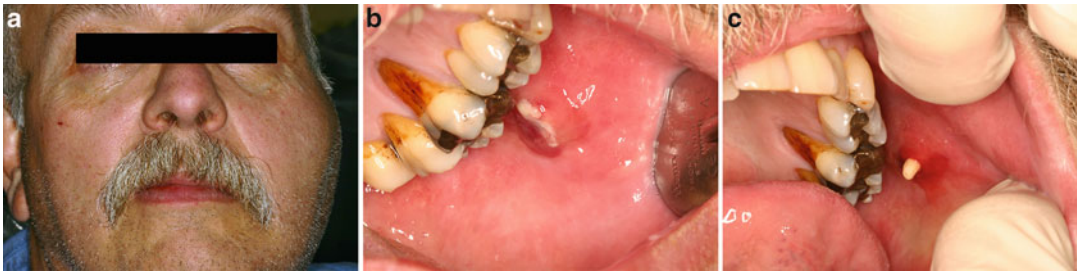





Fig. 7.25 Bacterial parotitis secondary to sialolith obstruction of Stenson duct. (a) Acutely painful left-sided facial swelling. (b) Purulent discharge at the parotid papilla. (c) Delivery and removal of the sialolith. The patient felt immediate relief following stone removal

be enhanced by “milking” it with gentle but steady pressure applied extraorally, which generally also improves pain. Use of sialogogues, such as sour lemon, stimulates salivary flow and helps flush out the gland. Purulent discharge should be collected for aerobic and anaerobic bacterial cultures, especially if the patient has already been treated with antibiotics without clinical improvement. Salivary stones (see Chap. 8), when present, should be removed if possible to prevent recurrence (Fig. 7.25c).

Viral salivary gland infections are characterized by nonsuppurative swelling that may or may not be painful and are usually bilateral. *Mumps* is the most common cause of viral parotitis, mediated by paramyxovirus. Given the widespread use of the MMR (measles/mumps/rubella) vaccine, this condition is encountered infrequently in most developed countries. Other viruses known to infect the salivary glands are cytomegalovirus (CMV), Epstein-Barr virus (EBV), and HIV.

Parotitis

	DIAGNOSTIC TESTS	Culture and sensitivity of purulent discharge, especially if nonresponsive to antibiotics. CT may be ordered to evaluate for the presence of salivary calcifications or abscess.
	BIOPSY	No.
	TREATMENT	Manual compression of gland to facilitate drainage of purulence via Stenson duct in conjunction with sialogogues and hydration. Broad spectrum antibiotics such as amoxicillin/clavulanic acid 875/125 twice daily for 2 weeks or until complete resolution of swelling and symptoms. Pain medication as needed. If a sialolith is identified clinically or radiographically, removal of the stone is indicated (see Chap. 8).
	FOLLOW-UP	Until condition resolves.

Fungal Infections

The vast majority of oral fungal infections are caused by *Candida albicans*, which is considered a component of the normal oral flora. Deep fungal infections are in comparison exceedingly rare and are generally only encountered in immunocompromised individuals; these will only be discussed briefly.

Oral Candidiasis

As candida species make up part of the commensal oral flora in most individuals, it is a change in the normal oral environment rather than actual exposure or “infection” per se, that results in clinical infection (*candidiasis* or *thrush*). This can be precipitated by reduced salivary flow (see Chap. 8), immunosuppression (including poorly controlled diabetes mellitus), and use of antibiotics or steroid medications. Oral candidiasis can be encountered in any age group; organisms colonize the mucosa resulting in a superficial infection that typically causes symptoms of soreness and burning. It is not uncommon for patients to also describe discomfort in the throat with swallowing, indicating the presence of oropharyngeal or esophageal involvement.

The most common clinical presentation is generalized patchy white to yellow spots or plaques that have a “cottage cheese” like appearance, referred to as *pseudomembranous candidiasis* (Figs. 7.26, 7.27, and 7.28). These can be easily wiped away with gauze leaving an erythematous base with minimal bleeding. Lesions can be seen anywhere but are frequently located on the tongue, buccal mucosa, and palate. Much less frequently, candidiasis can present with a purely erythematous macular lesion, and is termed *erythematous candidiasis* (Fig. 7.29). Very rarely, candidiasis can present as a white plaque that does not rub away and looks clinically identical to leukoplakia (see Chap. 9); this is referred to as *hyperplastic candidiasis*. The presence of oral lesions is frequently associated with infection of the corners of the mouth,

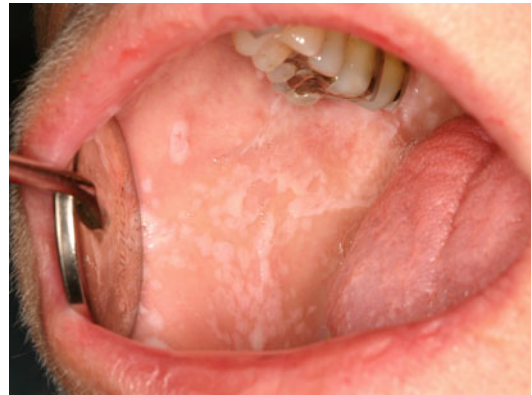

Fig. 7.26 Pseudomembranous candidiasis of the right buccal mucosa with white patches

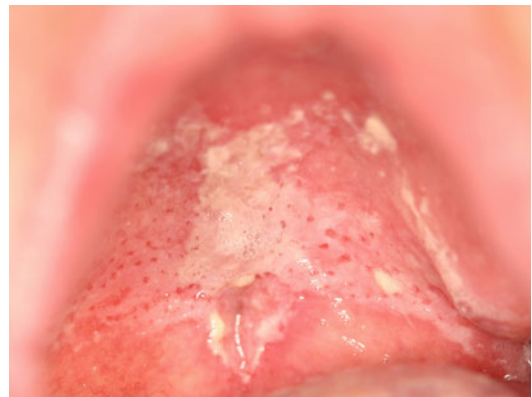

Fig. 7.27 Plaque-like pseudomembranous candidiasis of the palate in an edentulous patient whose denture hygiene was poor

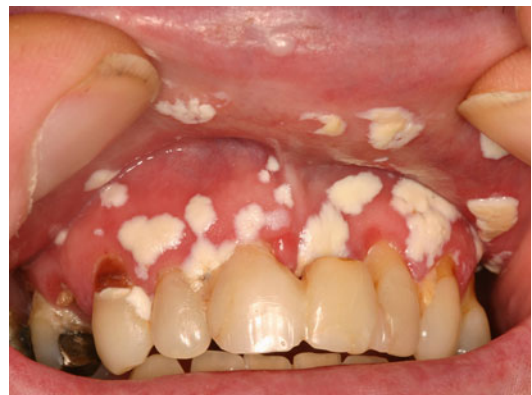

Fig. 7.28 Cottage cheese-like pseudomembranous candidiasis of the gingiva and labial mucosa

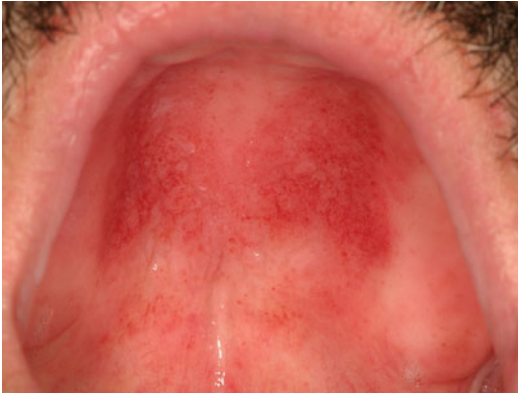

Fig. 7.29 Erythematous candidiasis of the palate in a patient that wears a full upper denture

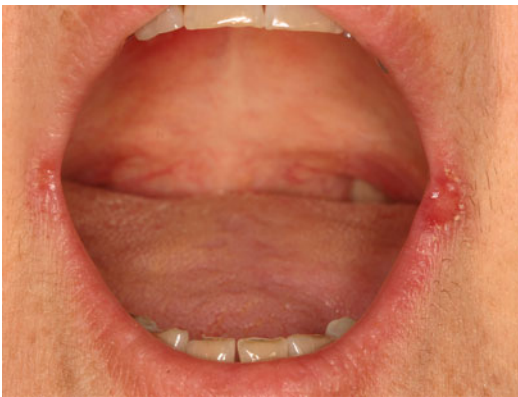

Fig. 7.30 Angular cheilitis. The commissures are fissured and erythematous

resulting in painful erythematous raw and cracked skin known as *angular cheilitis*. This is seen more frequently in edentulous patients with overclosure (collapse of jaws) and in individuals with a lip licking habit (Fig. 7.30).

Diagnosis of candidiasis can typically be made by clinical features alone. As the *hyperplastic* form cannot be distinguished clinically from leukoplakia, an incisional biopsy is required for diagnosis. Fungal culture should be reserved for lesions that are not responsive to empiric therapy. In such cases, sensitivity testing should also be requested. Clinical response to empirical anti-fungal therapy, with complete resolution of signs and symptoms, confirms the diagnosis.

Primary management of oral candidiasis is with topical and systemic antifungal agents (Table 7.1). The most commonly utilized topical agents include nystatin suspension and clotrimazole troches. While both can be effective, there is greater evidence to support the use of clotrimazole troches, although some cases may not respond even with adequate dosing. Systemic therapy using fluconazole is usually highly effective. If applicable, removable dentures should also be treated, as these are frequently colonized and will continue to re-infect the underlying soft tissue. Preparations for denture disinfection are commercially available; however, a simple and inexpensive alternative is to soak the prosthesis (if it does not contain metal) overnight in a 1:10 dilution of household bleach. Angular cheilitis is effectively managed with topical nystatin/triamcinolone cream.

Management of any underlying contributing factors is important in preventing recurrence. Long-term prophylaxis should be prescribed in cases of chronic recurrent disease. Topical agents may be effective; however, systemic treatment is often easier for the patient to manage due to more convenient dosing schedules. In most cases, fluconazole given once or twice weekly is highly effective at preventing recurrent infection.

Oral Candidiasis





	DIAGNOSTIC TESTS	Not generally indicated unless poorly responsive to empiric therapy, in which case fungal culture with sensitivity testing should be performed.
	BIOPSY	When the clinical diagnosis is uncertain, as with hyperplastic candidiasis.
	TREATMENT	See Table 7.1. Patients with recurrent candidiasis should be treated with a prophylactic regimen.
	FOLLOW-UP	Close follow-up during treatment of active infection; as needed for chronic conditions.

Table 7.1 Management of oral fungal infections

Antifungal agent	Class	How supplied	Dispensation instructions	Regimen	Notes
<i>Topical</i>					
Nystatin	Polyene	100,000 U/mL suspension	One bottle (473 mL)	Swish and spit (or swallow if esophageal lesions) for 1–2 min two to three times/day. Continue until lesions resolved	Efficacy varies. If lesions do not respond, treat with systemic agent
Clotrimazole	Azole	10 mg troche	One bottle (70 or 140 troches)	Let one troche dissolve fully in the mouth, four times/day	Troches will not dissolve in patients with significant dry mouth
Nystatin/triamcinolone acetamide	Polyene and corticosteroid	Cream	One tube (15, 30, or 60 g)	Apply a small amount to the corners of the mouth twice daily	Signs and symptoms generally respond within 2–3 days
<i>Systemic</i>					
Fluconazole	Azole	Tablet (100, 150, and 200 mg) oral suspension (40 mg/mL)	One month supply (30 tablets). While a full 30-day regimen is rarely required, this ensures sufficient medication in the event of recurrence or difficult-to-treat cases	Take one tablet once daily. A 7-day course is generally sufficient for complete clearing of candidiasis. In patients with recurrent infection (e.g., use of oral topical steroid, salivary gland hypofunction) treatment with one 100 mg tablet once or twice weekly is in most cases highly effective	True resistance to fluconazole is exceedingly rare. In the event of poor response, culture with sensitivity testing and empirically increase dose (e.g., from 100 to 200 mg). Oral suspension is useful for patients with difficulty swallowing pills. There is no evidence that topical fluconazole is any more effective than nystatin or clotrimazole





Deep Fungal Infections

Non-candidal oral fungal infections are rare and are seen almost exclusively in immunosuppressed individuals. Infections include *aspergillosis*, *cryptococcosis*, *blastomycosis*, *histoplasmosis*, *paracoccidioidomycosis*, and *mucormycosis*. Lesions typically present as deep necrotic ulcerations that can lead to localized destruction and tissue invasion as well as systemic dissemination (Fig. 7.31). Oral lesions are often accompanied by lesions within the respiratory tract, such as the lungs or sinuses, and diagnosis requires biopsy. Imaging studies should be ordered to evaluate the extent of underlying tissue involvement. Management includes aggressive systemic antifungal therapy in conjunction with surgical debridement. Despite aggressive therapy, these infections are associated with high rates of morbidity and mortality.

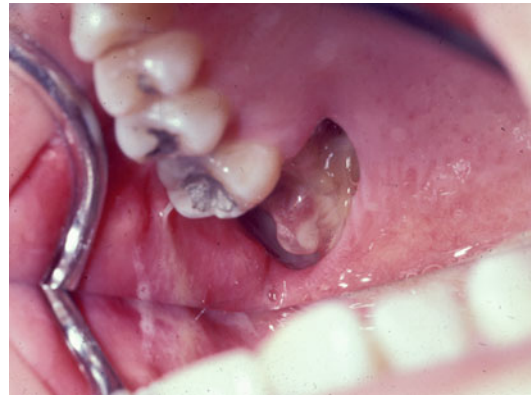

Fig. 7.31 Aspergillus infection of the maxillary sinus with invasive ulceration and necrosis of the posterior maxilla in an immunosuppressed patient following hematopoietic stem cell transplantation. Photograph courtesy of Mark Schubert, D.D.S., M.S.D., Seattle, WA

Deep Fungal Infections

	DIAGNOSTIC TESTS	Chest radiograph and advanced imaging of the head and neck (CT or MRI) to evaluate extent of involvement. Superficial cultures or swabs are of no diagnostic utility.
	BIOPSY	Yes; half of the specimen should be submitted in formalin and half fresh for tissue culture and advanced staining techniques.
	TREATMENT	Antifungal therapy and surgery.
	FOLLOW-UP	Close follow-up until condition resolves.

Viral Infections

A wide variety of viral infections affect the oral cavity (Table 7.2). These include members of the human herpes virus family (herpes simplex 1&2, varicella zoster virus [VZV], CMV, and EBV), human papillomaviruses, and enteroviruses. Some infections are common in normal health, while others are seen only in immunocompromised individuals. Clinical appearances are often very similar to noninfectious oral conditions and certain infections may present quite differently between the immunocompetent versus immunocompromised states. Accurate and prompt diagnosis is

necessary, as the choice of appropriate management will depend on the specific organism involved, and can vary from palliative treatment alone to antiviral therapy or surgery.

Herpes Simplex Virus

Herpes simplex virus (HSV) is a ubiquitous virus to which the majority of humans are exposed at some point during their lifetime, usually by the teenage years but occasionally later in adulthood. The virus is transmitted through saliva by direct contact, and becomes latent in the trigeminal nerve ganglion following primary infection.

Table 7.2 Viral infections that are known to cause oral lesions

Type of virus	Mode of transmission	Oral lesions	Diagnosis	Management
<i>Herpes family viruses</i>				
Herpes simplex virus (HHV1, HHV2)	Saliva, genital secretions	Primary:	Clinical primarily	Primary:
		<ul style="list-style-type: none"> Primary herpetic gingivostomatitis 	Viral culture PCR Cytology	Acyclovir 200 mg five times/day for 7 days Valacyclovir 2 g once daily for 7 days
		Secondary:	Direct fluorescence assay (DFA) Serology	Supportive care including pain control, nutritional support, and adequate hydration Secondary:
		<ul style="list-style-type: none"> Perioral crusted blistering lesions (cold sores) Intraoral irregular shallow ulcers affecting the keratinized mucosa 		Same as primary regimen, need to begin treatment at the earliest onset of prodrome symptoms Suppression: Acyclovir 400 mg twice daily Valacyclovir 500 mg or 1 g once daily
Varicella Zoster virus (HHV3)	Saliva, airborne droplets	Primary:	Clinical primarily	Acyclovir 800 mg five times/day for 7–10 days
		<ul style="list-style-type: none"> <i>Varicella</i> or “chicken pox”, may present with oral ulcers 	Viral culture PCR Cytology DFA biopsy	Valacyclovir 1000 mg three times/day for 7–10 days
		Secondary:		Famciclovir 500 mg three times/day for 7–10 days
		<ul style="list-style-type: none"> <i>Herpes zoster</i> or “shingles”, unilateral intraoral ulcers identical to those caused by HSV, when cranial nerve V involved 		No specific treatment necessary. May respond to acyclovir or valacyclovir therapy
Epstein-Barr virus (HHV4)	Saliva	Oral hairy leukoplakia (OHL)	Biopsy	Valganciclovir 900 mg twice a day until healed
<i>Cytomegalovirus</i> (HHV5)	Bodily fluids, including saliva	Oral ulcers, typically solitary and deep, in immunocompromised patients	Biopsy	Ganciclovir 1 g three times a day until healed
<i>Human papilloma virus</i>	Direct contact, however, lesions do not have to be present	Benign epithelial proliferations	Biopsy; HPV subtype analysis as clinically indicated	Surgical excision
<i>Enterovirus</i>	Fecal/oral	Squamous cell carcinoma of the oropharynx		If cancer diagnosed, referral to a cancer center
		Multiple aphthous-like ulcers, on the soft palate in particular	Clinical PCR	Supportive care only
		Respiratory/oral	Serology	

Once present, the virus remains dormant and has the potential to reactivate throughout the lifetime of the individual. Subclinical viral shedding in the saliva is common even in the absence of clinically evident lesions, likely explaining to some extent the widespread prevalence of this infection in the human population. Although HSV-1 was historically considered specific to the oral cavity and HSV-2 was considered specific to the anogenital region, either subtype can cause oral infections. Other than minor molecular differences between HSV-1 and HSV-2 strains, the resultant infection, natural course of disease, and treatment are exactly the same.

Primary HSV is characterized by flu-like symptoms that typically precede onset of oral lesions by 2–3 days and severe oral ulcerations that can affect both the keratinized and nonkeratinized mucosa (Fig. 7.32). The gingiva is typically very painful and fiery red in appearance. Ulcerative lesions begin as small vesicles that often develop in clusters and eventually break down to form coalescing, shallow, irregularly shaped ulcerations. The pain associated with these lesions is severe. In the absence of antiviral therapy, the clinical course of primary HSV is typically no more than 14 days with complete resolution of all signs and symptoms. There is a wide range of clinical presentations, however, and many primary infections are probably never diagnosed. A history of intimate physical contact within 1 week of developing signs and symptoms of primary HSV infection should be sought.

Diagnosis can often be made by history and clinical examination alone, and treatment should be initiated immediately. Viral culture, PCR or direct fluorescent antibody (DFA) testing of ulcerative lesions can confirm the diagnosis. Positive serology for HSV IgM antibodies signifies primary infection, but the presence of IgG antibodies can only confirm prior exposure. Although primary HSV is a self-limiting infection, early treatment with antiviral medication can reduce the severity and length of illness but will not prevent the establishment of latency. Most important is symptomatic and supportive care, as oral intake can be severely limited during primary infection due to pain. Use of systemic and topical analgesics in conjunction with hydration and

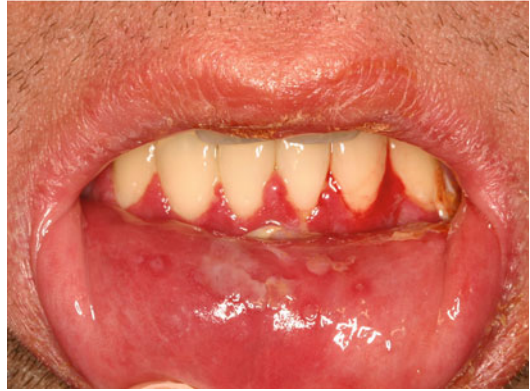

Fig. 7.32 Primary herpes simplex virus infection. There are freshly collapsed vesicles, irregularly shaped shallow ulcerations, and desquamation and erythema of the gingiva

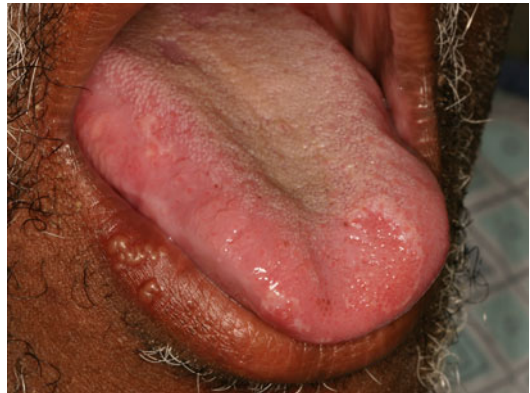

Fig. 7.33 Recrudescence herpes simplex virus infection in a patient following cardiac surgery. Note crop of intact vesicles on the lower right lip and coalescent ulceration of the anterior right tongue

nutritional support are critical aspects of management, especially in young children. Management of primary and secondary HSV infection is summarized in Table 7.2.

Once infected, the virus becomes latent in the trigeminal ganglion with the potential for reactivation or recrudescence. Well-known triggers include stress, hormonal changes, sun exposure, and trauma. Lesions are typically preceded by a prodrome, which is characterized by tingling, itching, or a painful sensation in the area where the lesion will appear. The majority of secondary lesions occur on and around the lips and nostrils and present initially with multiple small vesicles that break down and form a painful, crusted, ulceration (Fig. 7.33). Much less frequently,

lesions develop intraorally, where they are limited to the keratinized mucosa. Intraoral lesions look identical to those of primary infection but are generally unilateral and limited to one specific anatomic site (e.g., tongue, gingiva, lip, and hard palate). In immunocompromised patients lesions may develop extraorally as well as intraorally, and lesions can be much more extensive; multiple areas may be affected, including both the keratinized and nonkeratinized mucosa (Fig. 7.34). Patients are highly infectious during the period of active lesions; however, viral shedding can occur at any time regardless of the presence of lesions.





While the diagnosis of recrudescent HSV infection can be made by viral culture, this is rarely necessary except for atypical cases. Treatment at the initial onset of prodromal symptoms can effectively suppress vesicle formation or reduce the severity and length of the outbreak. Topical antiviral therapy can be effective if applied frequently throughout the day, but systemic therapy is generally preferable due to better compliance and efficacy.

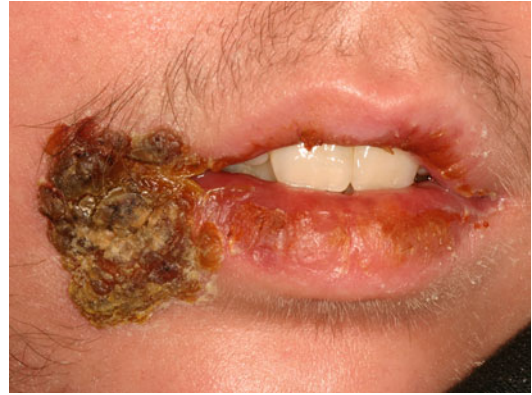

Fig. 7.34 Recrudescent herpes simplex virus infection in an immunosuppressed patient following allogeneic hematopoietic cell transplantation. The patient also had multiple ulcers of the right lateral tongue

Antiviral therapy is of limited utility following appearance of vesicles; lesions will heal completely within 7–10 days. For those with frequent recurrent herpes labialis, prophylactic suppressive antiviral therapy is safe and effective.

Herpes Simplex Virus

	DIAGNOSTIC TESTS	Viral culture, PCR, cytology, or DFA for definitive diagnosis. Empiric therapy should be initiated promptly when findings are clinically consistent with HSV.
	BIOPSY	No.
	TREATMENT	Antiviral therapy and appropriate supportive care when indicated; see Table 7.2.
	FOLLOW-UP	As needed.

Varicella Zoster Virus

Primary infection with VZV results in chicken pox, following which the virus becomes latent in the spinal dorsal root ganglia. While reactivation (*herpes zoster*; “shingles”) can develop at any time, this occurs at a much higher frequency in adults over 60 years of age, and is thought to be related to immunosenescence to VZV. With the introduction of the VZV vaccine, the epidemiology of herpes

zoster infection appears to be changing; the frequency of primary infection in children is reduced; and vaccination of older adults results in a lower risk of reactivation. A rare but significant complication of herpes zoster infection is *postherpetic neuralgia* (PHN), which is characterized by burning neuropathic pain in the area of previous lesions.

Similar to recrudescent HSV infection, herpes zoster lesions are preceded by a prodrome, typically characterized by a tingling or stabbing

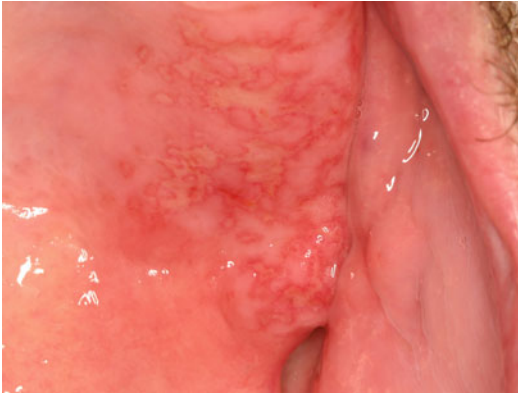





Fig. 7.35 Herpes zoster infection of the left palate. The pattern of shallow coalescing crop-like ulcers appears to follow the anatomy of the palatine nerve branches

sensation. The trigeminal nerve is involved in approximately 20 % of cases and most commonly affects the ophthalmic division (V1). Lesions are characteristically unilateral and appear identical clinically to those of HSV (Fig. 7.35). The distribution of lesions follows the dermatome of the affected nerve. Diagnosis is generally made on clinical findings alone, although viral culture and DFA testing can provide confirmation. When the

second or third divisions of the trigeminal nerve are affected (V2, V3), lesions may present both extraorally and intraorally. Prior to the appearance of vesicles and ulcers, intraoral herpes zoster may initially present with severe pain that can easily be confused with odontogenic infection, sinusitis, or myofascial pain dysfunction. When cranial nerves VII and VIII are involved, facial nerve paralysis and hearing loss can occur (known as *Ramsay Hunt syndrome* or *herpes zoster oticus*). In immunocompromised patients, multiple dermatomes may be affected, lesions may present bilaterally, and disseminated zoster can develop resulting in visceral pain, organ involvement, and death.

Antiviral therapy with acyclovir, valacyclovir, or famciclovir for 7–10 days within 48–72 h following appearance of lesions can be effective in reducing pain, promoting healing, and preventing or reducing the severity of PHN. While combined treatment of antiviral medication with high-dose corticosteroids has been evaluated to reduce the risk of developing PHN, its efficacy and clinical utility remain controversial. PHN can be managed with topical and systemic agents similar to other neuropathic pain conditions (see Chap. 10).

Varicella Zoster Virus

	DIAGNOSTIC TESTS	Viral culture, PCR, cytology, or DFA to confirm diagnosis. Serological testing is of limited utility.
	BIOPSY	No.
	TREATMENT	Antiviral therapy with acyclovir, valacyclovir, or famciclovir at the earliest suspicion of reactivation. Topical and systemic pain management as indicated.
	FOLLOW-UP	PHN is rare but should be considered when pain persists in the area of lesions after resolution of lesions.

Cytomegalovirus

Most individuals are infected with CMV at some point during their lifetime. Initial infection is usually asymptomatic but may present as a mild flu-like illness or mononucleosis-like syndrome that is clinically identical to that caused by EBV

(see below). The salivary glands become infected and provide a source of constant viral shedding. Clinically significant disease, such as pneumonia, gastroenteritis, and retinitis, due to reactivation only occurs in immunocompromised individuals. Blood tests used to evaluate CMV disease activity include antibody testing, antigen testing, shell





vial assay, and qualitative and quantitative PCR. Results from these tests may support a diagnosis, or be used as an indication to begin antiviral therapy in immunocompromised patients; however, no specific findings define infection.

Nonspecific painful oral ulcerations resembling *major aphthous* (see Chap. 5) may develop in immunocompromised patients, and CMV involvement can only be diagnosed by biopsy (Fig. 7.36). Histopathology demonstrates enlarged cells within the vascular endothelial cells in the connective tissue with intranuclear inclusions that have a classic “owl’s eye” appearance; immunohistochemistry and in situ hybridization for CMV antigens are both useful tests for confirmation of the diagnosis. Treatment with ganciclovir and valganciclovir are both highly effective in managing CMV disease.

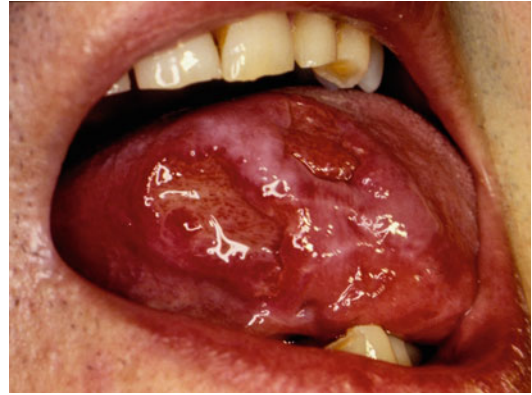

Fig. 7.36 Cytomegalovirus infection of the tongue in an HIV-positive patient with multiple large, penetrating ulcers. Incisional biopsy demonstrated cytopathological changes and immunohistochemistry confirmed presence of the virus. Photograph courtesy of Sook-Bin Woo, D.M.D., M.M.Sc., Boston, MA

Cytomegalovirus

	DIAGNOSTIC TESTS	Quantitative CMV viral load testing may help support a diagnosis of CMV induced oral ulcerations. The relationship is unclear and results must be interpreted carefully. Surface cultures, as are used for the diagnosis of HSV, are ineffective given the location of CMV deep in the connective tissue. Consider obtaining a complete blood count in the rare event of secondary pancytopenia.
	BIOPSY	Yes, for unexplained oral ulcers in immunocompromised patients. A sample should also be submitted fresh in viral culture medium.
	TREATMENT	Ganciclovir or valganciclovir.
	FOLLOW-UP	Patients should be followed carefully to assess for healing of oral lesions.

Epstein-Barr Virus





Similar to CMV, most humans are exposed to EBV. Primary infection (*acute infectious mononucleosis*) is most commonly seen in adolescents and young adults; when symptomatic, it is characterized by sore throat, fever, and lymphadenopathy. Diagnosis includes (a) lymphocytosis, (b) atypical lymphocytes on peripheral smear, and (c) positive EBV serology. The salivary glands and oropharyngeal lymphoid tissues become infected and are responsible for constant shedding in saliva during latency, which is most commonly responsible for viral transmission.

B lymphocytes are also an important site of infection and latency. EBV is associated with endemic Burkitt lymphoma, nasopharyngeal carcinoma, and non-Hodgkin lymphoma, including posttransplant lymphoproliferative disease. The only oral condition that is specifically attributed to EBV is *oral hairy leukoplakia* (OHL), a benign condition characterized by painless white plaques on the ventrolateral tongue (see Chaps. 4 and 11). OHL is only seen in immunosuppressed individuals and has primarily been reported in association with HIV disease. Biopsy shows classic EBV-associated viral cytopathic changes in the superficial epithelium characterized by nuclear

clearing and peripheral margination of chromatin (nuclear beading) caused by EBV viral replication. In situ hybridization can further confirm the presence of EBV in the tissue. Once diagnosed, specific treatment is not necessary; however,

antiviral therapy with acyclovir can be effective for clinical resolution of lesions. This should not be confused with *leukoplakia*, which is not EBV associated and is considered a potentially malignant lesion (see Chap. 9).

Epstein-Barr Virus

	DIAGNOSTIC TESTS	EBV serology and CBC for diagnosis of primary infectious mononucleosis. HIV testing indicated if OHL suspected.
	BIOPSY	Yes, for OHL.
	TREATMENT	Acyclovir can be effective for OHL.
	FOLLOW-UP	None specific for OHL; the patient’s underlying medical condition should be followed carefully.

Human Papilloma Virus

Human papilloma virus (HPV) is a ubiquitous virus with over 100 identified subtypes. It is associated with both benign and malignant epithelial growths of the aerodigestive and anogenital mucosa. Transmission is by direct contact and prevalence in the population is estimated to be at least 50 %. The most common subtypes associated with benign mucosal proliferative lesions are 2, 4, 6, 11, 13, and 32. Subtypes 16 and 18 have been associated with oropharyngeal *squamous cell carcinoma* as well as cancer of the cervix (see Chap. 9). HPV vaccine is now available for both women and men and is considered protective against cervical cancer, anogenital warts, and anal cancer. It has not been evaluated with respect to prevention of oropharyngeal carcinoma. The association of various sexual behaviors with primary infection, mechanisms of latency, and risk factors for the development of oral lesions are unclear.

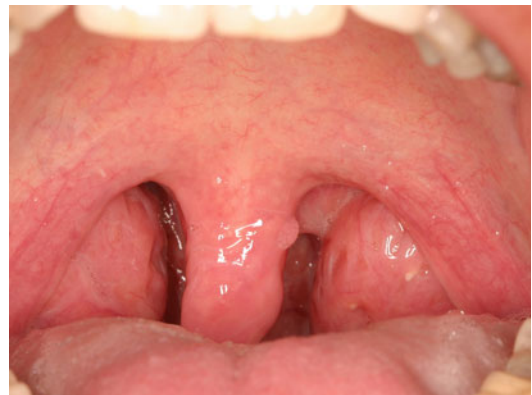

Fig. 7.37 Squamous papilloma on the lateral aspect of the uvula. The lesion is well-defined with a characteristic “papillary” or pebbly texture and normal pink color

Oral lesions caused by HPV infection include *squamous papilloma*, *verruca vulgaris*, *condyloma acuminatum*, and *focal epithelial hyperplasia* (or *Heck disease*; Figs. 7.37, 7.38, 7.39, and 7.40). While differences exist clinically between these lesions, they are all characterized

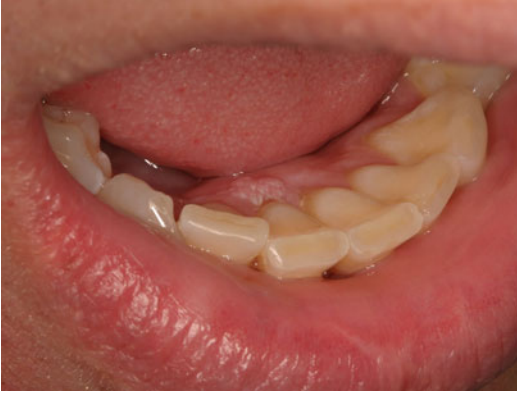

Fig. 7.38 Verruca vulgaris of the anterior lingual gingiva. The lesion is whiter than the surrounding tissue with prominent hair-like projections

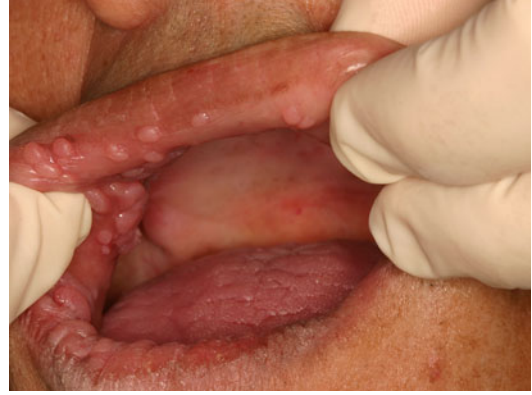

Fig. 7.41 Papillomatosis with numerous clustered lesions of the anterior oral cavity in an HIV-positive patient

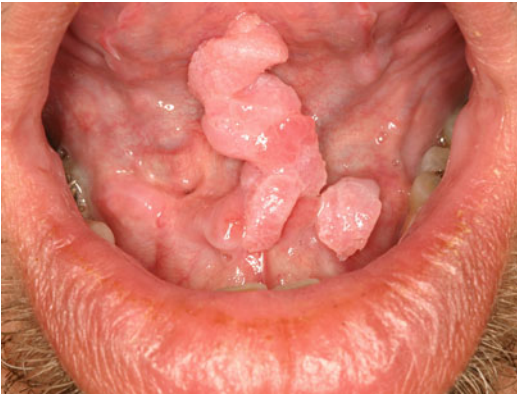

Fig. 7.39 Large condyloma acuminatum of the ventral tongue

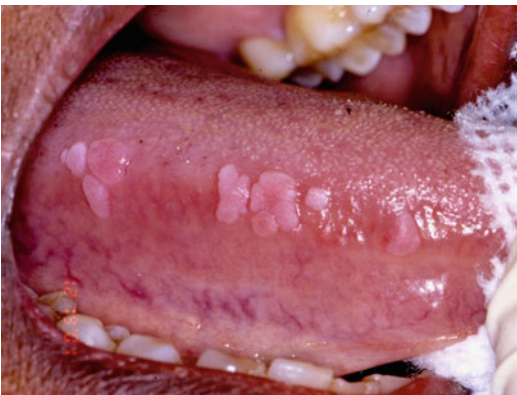





Fig. 7.40 Focal epithelial hyperplasia with multiple flat pink papillary lesions on the lateral tongue. Photograph courtesy of Sook-Bin Woo, D.M.D., M.M.Sc., Boston, MA

by well-defined epithelial proliferations that are pink to white in color, ranging from 1.0 mm to 1.0 cm in diameter, often with a pebbly or “wart-like” surface. Lesions, although painless, may be subject to trauma from the dentition, can be annoying, and may have cosmetic consequences when located on the lips or tongue. In immunocompromised patients, in particular those with HIV infection, multiple lesions may occur resulting in a condition called *papillomatosis* (Fig. 7.41). None of these benign lesions are considered to have any malignant potential.

Diagnosis is primarily based on clinical appearance; however, lesions may need to be biopsied to rule out dysplasia or malignancy, especially in patients who are at increased risk for oral cancer. Lesions are characterized histopathologically by marked epithelial hyperplasia and koilocytosis. Management of solitary lesions is by simple surgical excision. Treatment of multiple lesions can be more challenging and approaches include surgery, cryotherapy, laser ablation, and intralesional interferon alpha therapy; unfortunately recurrence is common in these cases. Lesions on the lip and vermilion border (but not intraoral mucosa) may be treated with topical immunomodulatory (imiquimod) or antineoplastic (5-fluorouracil) agents, although results are variable.

Human Papilloma Virus

	DIAGNOSTIC TESTS	None.
	BIOPSY	Yes, to rule out malignancy. HPV typing can be performed if clinically indicated.
	TREATMENT	Surgical excision.
	FOLLOW-UP	As needed.

Enterovirus

Enteroviruses belong to the Picornaviridae (small RNA virus) family of viruses and include, among many others, coxsackievirus. *Herpangina* and *hand-foot-and-mouth disease* are mediated by coxsackievirus and are both characterized by painful oropharyngeal ulcers (Fig. 7.42). Enteroviruses are transmitted primarily by the fecal–oral route, but may be transmitted by aerosolized saliva droplets as well during the acute phase of infection. Outbreaks tend to occur during the summer and fall, but in temperate climates can occur year round. Regular hand washing is the most effective preventive measure. The incubation period is 3–7 days, followed by acute onset of variable flu-like symptoms (sore throat, dysphagia, fever, and malaise), although in many cases infection is entirely subclinical. While more common in children, enterovirus infection can present at any time during life.





Herpangina is characterized by multiple small vesicles on the soft palate and tonsillar pillars that rapidly break down to form aphthous-like ulcers. Oral lesions may be more widespread in *hand-foot-and-mouth disease* and are accompanied by cutaneous vesicles. The infection is

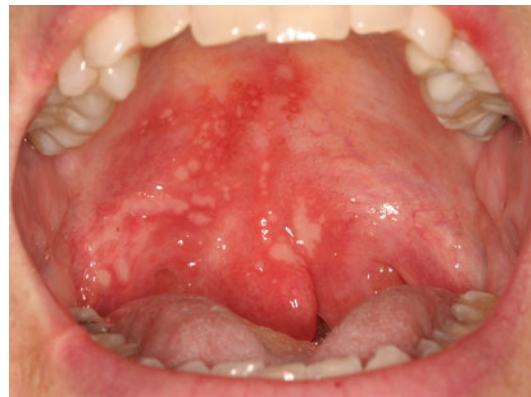

Fig. 7.42 Coxsackie virus infection with multiple shallow minor aphthous-like ulcers of the posterior soft palate and uvula with associated erythema

self-limiting, with systemic symptoms typically resolving within several days and oral lesions healing within 7–10 days. In most cases diagnosis is made by clinical findings alone, although various tests are available for atypical cases or for epidemiological purposes (e.g., culture, serology, and PCR). There is no specific antiviral therapy for enterovirus infection; supportive care including pain management, hydration, and soft diet should be provided until lesions and symptoms resolve.

Enterovirus

	DIAGNOSTIC TESTS	None; diagnosis is made based on characteristic clinical features in most cases. PCR and serologic testing are available for complex presentations.
	BIOPSY	No.
	TREATMENT	Supportive care measures.
	FOLLOW-UP	Condition is self-limiting; follow-up as clinically indicated.

Sources

- Arduino PG, Porter SR. Herpes simplex virus type 1 infection: overview on relevant clinico-pathological features. *J Oral Pathol Med.* 2008;37:107–21.
- Enwonwu CO, Falkler WA, Idigbe EO. Oro-facial gangrene (noma/cancrum oris): pathogenetic mechanisms. *Crit Rev Oral Biol Med.* 2000;11:159–71.
- Gnann JW, Whitley RJ. Herpes zoster. *N Engl J Med.* 2002;347:340–6.
- Horning GM. Necrotizing gingivostomatitis: NUG to noma. *Compend Contin Educ Dent.* 1996;17:951–4.
- Hosseini SM, Borghei P. Rhinocerebral mucormycosis: pathways of spread. *Eur Arch Otorhinolaryngol.* 2005;262:932–8.
- Lerman M, Laudenbach J, Marty F, et al. Management of oral infections in cancer patients. *Dent Clin N Am.* 2008;52:129–53.
- Nahlieli O, Bar T, Shacham R, et al. Management of chronic recurrent parotitis: current therapy. *J Oral Maxillofac Surg.* 2004;62:1150–5.
- Sitheeque MA, Samaranayake LP. Chronic hyperplastic candidosis/candidiasis (candidal leukoplakia). *Crit Rev Oral Biol Med.* 2003;14:253–67.
- Sweeney CJ, Gilden DH. Ramsay Hunt syndrome. *J Neurol Neurosurg Psychiatry.* 2001;71:149–54.
- Woo SB, Challacombe SJ. Management of recurrent oral herpes simplex infections. *Oral Surg Oral Med Oral Pathol Oral Radiol Endod.* 2007;103:S12e1–8.

Introduction

Saliva serves a variety of important functions, many of which are not appreciated until salivary flow decreases. Lubrication of tissue surfaces and the presence of salivary digestive enzymes, such as amylase and lipase, help initiate and facilitate mastication, deglutition, and digestion. Surface lubrication is also important in protecting the mucosa from mechanical trauma and enhancing taste receptor function. Salivary buffers, enzymes, and antibodies provide protection against microorganisms, dental caries, and demineralization of tooth enamel.

A variety of pathologic conditions, including inflammatory, infectious, and neoplastic, affect the major and minor salivary glands, resulting in potentially significant morbidity and diminished quality of life for the patient. An understanding of the anatomy and physiology is helpful in being able to accurately recognize and manage these conditions.

Mucus Extravasation and Retention Phenomena

Mucocele

Rupture of a minor salivary gland duct, most commonly on the inner aspect of the lower lip, may cause extravasation of mucin into the surrounding tissues (Figs. 8.1 and 8.2). There is usually no obvious inciting event although the patient may recall an episode of minor trauma (such as biting the lip) prior to its appearance. These lesions are typically painless, dome-shaped, and fluctuant; they appear clear, red, or even blue in color secondary to the presence of mucin under the mucosa (Figs. 8.3 and 8.4). They are subject to repetitive local trauma once formed, particularly if large or bulky, and may increase in size during mealtimes. Mucoceles sometimes resolve spontaneously, however, usually require surgical excision.

Fig. 8.1 Mucocele of the lower lip. The lesion is *dome-shaped* with a slightly *blue hue* and entirely normal surrounding mucosa

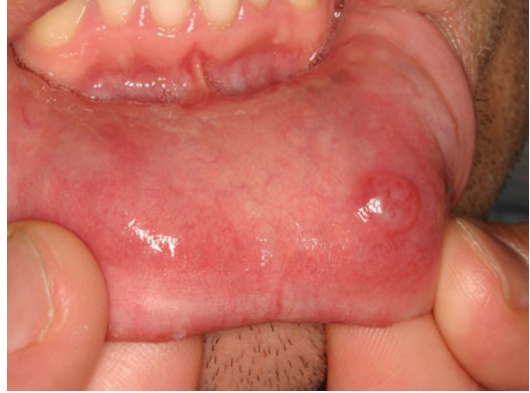

Fig. 8.2 Deep mucocele of the lower lip causing large fluctuant swelling

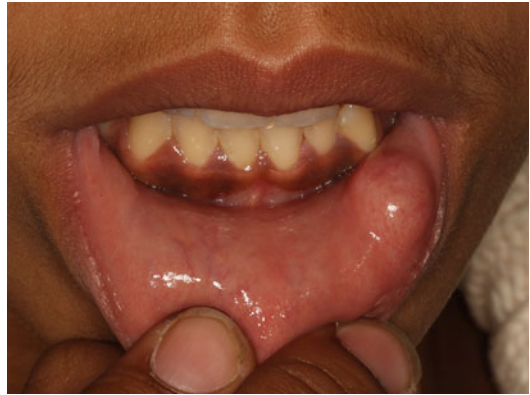
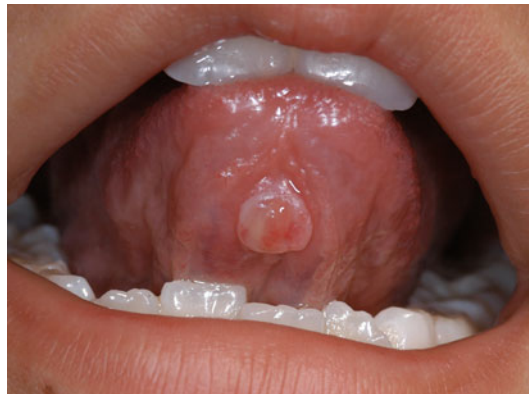
Fig. 8.3 Mucocele of the anterior ventral tongue. The lesion appears *white* due to ulceration from chronic trauma



Occurrence on the palate is unusual; lesions in this area present as smaller, clear colored vesicular swellings that are typically superficial and easily rupture (Fig. 8.5). Superficial mucoceles

may develop in the context of certain immune-mediated inflammatory conditions, such as oral lichen planus (see Chap. 5) and oral chronic graft-versus-host disease (see Chap. 12).

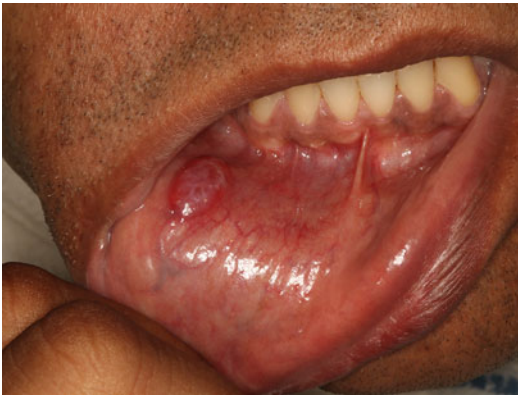

Fig. 8.4 Mucoccele of the lower lip with reddish hue

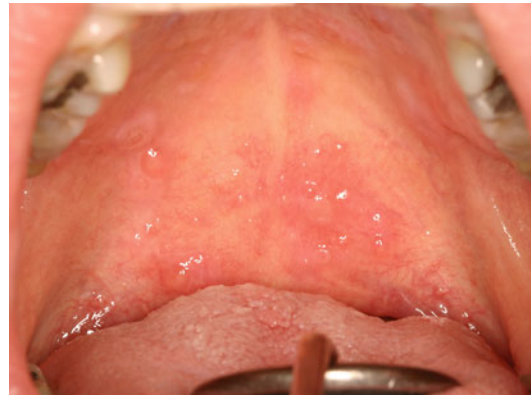

Fig. 8.5 Multiple superficial mucocceles of the palate in a patient with chronic graft-versus-host disease

Mucocele

	DIAGNOSTIC TESTS	None. Diagnosis is based on typical clinical appearance.
	BIOPSY	Only if diagnosis is uncertain.
	TREATMENT	Excision if lesion persists or is bothersome.
	FOLLOW-UP	None.

Ranula

This is a specific type of mucocele that arises in the anterolateral floor of mouth and represents extrusion of mucus from the sublingual gland. These are generally larger than mucocceles occurring in other locations; the tongue on the affected side may become elevated, making speaking and eating difficult (Fig. 8.6). The appearance has been likened

to that of a frog’s belly, hence the derivation of the name from the Latin term for frog (*rana*). They can become quite large and “plunge” below the mylohyoid muscle into the upper neck with subsequent visible neck swelling. Treatment is generally surgical and often includes removal of the feeding sublingual gland to prevent recurrence. Simple marsupialization, or “unroofing,” of the lesion often results in unacceptable rates of recurrence.

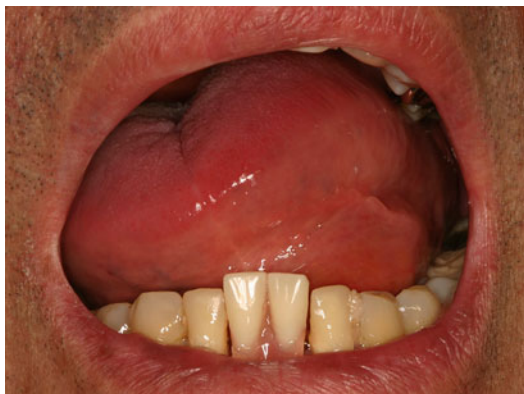

Fig. 8.6 Ranula of the left floor of mouth with notable elevation of the tongue. Note that the patient has a removable partial denture replacing the two mandibular central incisors

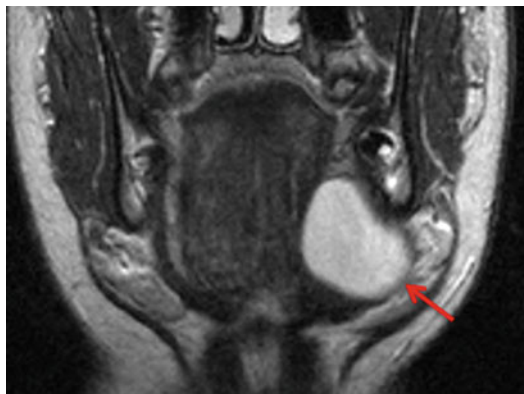


Fig. 8.7 MRI of a ranula (*arrow*) demonstrating the extent of the lesion and displacement of the tongue. The mylohyoid muscle is not breached

Ranula

	DIAGNOSTIC TESTS	Usually none, as the clinical diagnosis is generally sufficient; imaging studies (CT, MRI; Fig. 8.7) can be obtained in cases of plunging ranula.
	BIOPSY	No.
	TREATMENT	Surgical excision. Removal of the feeding salivary gland is also recommended (usually the sublingual, however, submandibular and minor salivary glands can be involved).
	FOLLOW-UP	Routine post-surgical evaluation.





Mucus Retention Cyst

Also called salivary duct cysts, mucus retention cysts are distinguished from mucoceles by the histologic presence of a true epithelial lining. These lesions are much less common than mucoceles although they often appear clinically similar and are usually painless (Fig. 8.8). They can occur in any of the major or minor salivary glands and probably result from ductal obstruction and dilatation rather than trauma. Intraorally, they are seen most commonly in the floor of mouth, buccal mucosa, and upper lip. Treatment is surgical and recurrence is unlikely.

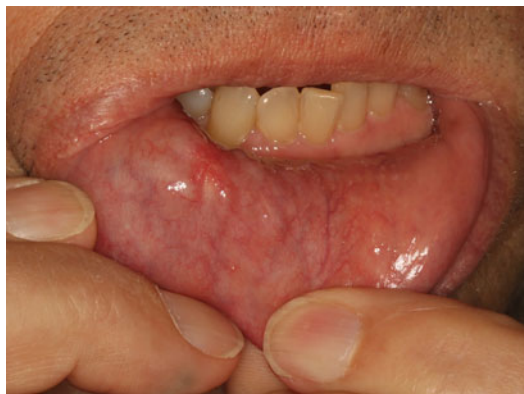

Fig. 8.8 Recurrent salivary duct cyst of the lower labial mucosa. Note the scarring of the oral mucosa from the initial excision procedure

Mucus Retention Cyst

	DIAGNOSTIC TESTS	None.
	BIOPSY	No.
	TREATMENT	Surgical excision.
	FOLLOW-UP	None.

Sialadenitis

Inflammatory conditions of the salivary glands generally present with pain and swelling of the affected gland, and are most often caused by ductal obstruction with secondary bacterial infection due to decreased salivary flow and stasis of secretions. Chronic immune-mediated inflammatory conditions that affect the salivary glands (e.g. Sjögren syndrome, chronic graft-versus-host disease) may also present with non-infectious sialadenitis (Fig. 8.9). Fibroinflammatory conditions, such as IgG4-related disorders, can affect the salivary glands and are characterized by tissue infiltration by IgG4 plasma cells. Conditions previously known as Mikulicz's disease and Kuttner's tumor fall into this spectrum of disorders. Chronic sialadenitis can also develop fol-

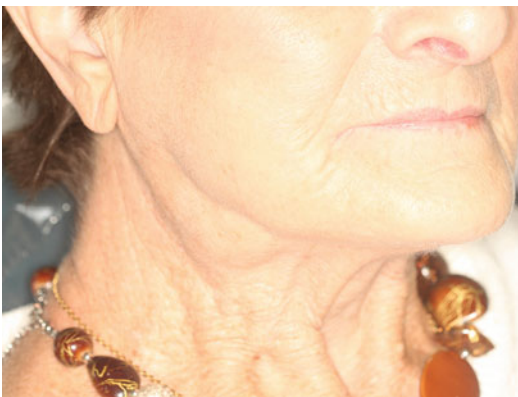

Fig. 8.9 Chronic sialadenitis in a patient with Sjögren syndrome with prominent submandibular gland enlargement

lowing radiation therapy to the head and neck, as well as radioactive iodine therapy. Infection of the salivary glands is also discussed in Chap. 7.

Sialolithiasis

Calculi, or “stones,” can develop within the salivary ducts from calcium salts that precipitate out of saliva in concentric layers around an initial nidus of debris. They occur most commonly in the submandibular gland, possibly due to the higher viscosity of the saliva in combination with a relatively long and tortuous course of the duct. The patient typically complains of episodic painful swelling in the region of the gland, which can be quite severe and tends to be more pronounced with food intake. A stone may be palpated on exam or visualized radiographically (Fig. 8.10); most salivary gland stones are radiopaque (Fig. 8.11). On exam, the gland should be gently compressed, or “milked,” to assess for adequacy of salivary flow from the gland as well as the presence of purulence in the saliva.

Treatment involves massage of the gland, hydration, and use of sialagogues (such as sour lemon drops) to promote forward movement of secretions. Antibiotics may also be necessary to treat secondary infection. Small stones may pass on their own or be removed intraorally from the duct orifice. Increasing success has been reported using minimally invasive endoscopic techniques for this (Fig. 8.12). Some institutions have reported the use of shock wave lithotripsy; however, this is not widely available. Large stones may require removal of the gland itself via an extraoral approach.

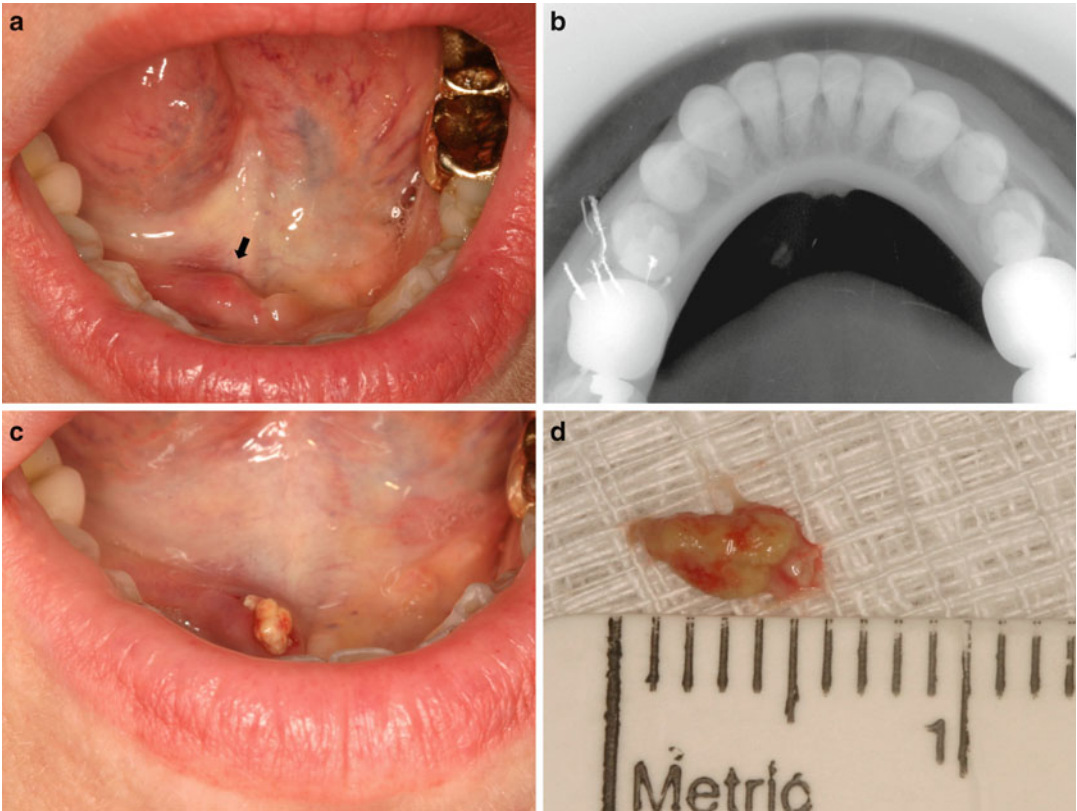


Fig. 8.10 Sialolith formation near the orifice of Wharton's duct. (a) Swelling and erythema of the right sublingual papilla (*arrow*). (b) Mandibular occlusal film

showing a welldefined radiopacity. (c) Delivery of the stone following a small lengthwise incision. (d) Gross pathology of the sialolith following removal

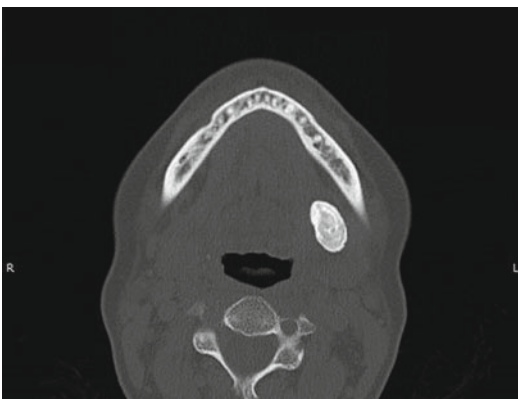






Fig. 8.11 Axial CT demonstrating a large sialolith located in the hilum of the left submandibular gland

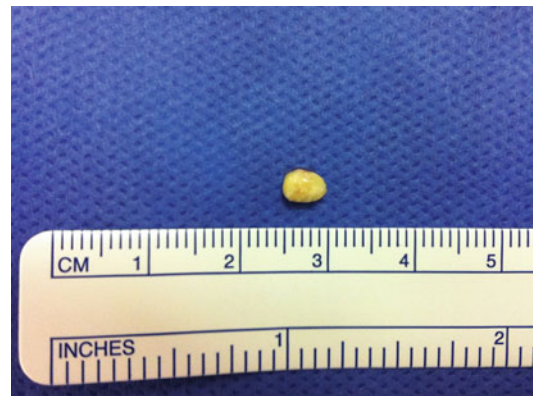

Fig. 8.12 Endoscopically removed salivary stone

Sialolithiasis

	DIAGNOSTIC TESTS	Only as clinically indicated. Plain radiographs of the anterior floor of mouth may be obtained to evaluate the size and location of stones within the duct; CT is useful to evaluate larger stones in the gland parenchyma or hilum (area where main duct joins body of gland), or to rule out abscess or tumor if suspected. Sialography is no longer commonly used, however, may be indicated in situations where a detailed image of internal ductal anatomy is desired.
	BIOPSY	No.
	TREATMENT	Sialagogues, manual massage of gland, maintain hydration, analgesics, and antibiotics if infection is present. Intraoral removal of stone if it does not pass spontaneously and is accessible; surgical removal of gland if necessary.
	FOLLOW-UP	As needed.





Necrotizing Sialometaplasia

This is a rare inflammatory condition of unclear etiology that affects the palatal minor salivary glands. It may possibly result from local ischemia and necrosis of these glands with subsequent painful swelling and ulceration that often appears clinically suspicious for malignancy (Fig. 8.13). Lesions are generally present on the posterolateral hard palate, however, can arise at any site where minor salivary tissue is found. Biopsy is indicated to establish the diagnosis, although even the histopathologic appearance can be mistaken for carcinoma. Once the benign nature of the lesion has been established, no further treatment is required, with spontaneous healing taking place over a period of several weeks.

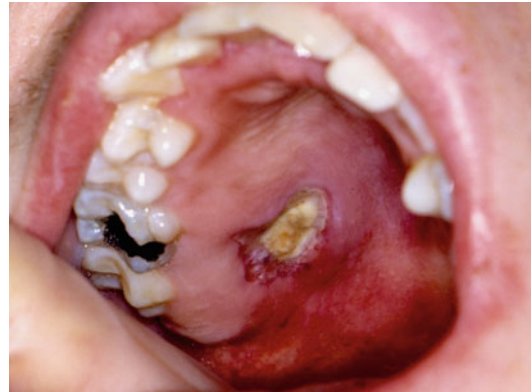

Fig. 8.13 Necrotizing sialometaplasia of the hard palate with erythema, ulceration, and focal soft tissue necrosis. Photograph courtesy of Sook-Bin Woo, D.M.D., M.M.Sc., Boston, MA

Necrotizing Sialometaplasia





	DIAGNOSTIC TESTS	None.
	BIOPSY	Yes.
	TREATMENT	None.
	FOLLOW-UP	None.

Sialadenosis (Sialosis)

Noninflammatory enlargement of the major salivary glands, primarily the parotid, can be seen in association with a variety of systemic disorders including alcoholism, diabetes, malnutri-

tion, and bulimia. This is generally bilateral and painless, and evolves slowly over time. Histologically, acinar hypertrophy is observed along with possible fatty infiltration. The etiology is unknown, however, may be related to autonomic dysregulation.

Sialadenosis (Sialosis)





	DIAGNOSTIC TESTS	Evaluate for an underlying systemic disorder, including endocrinopathy, nutritional deficiencies, alcoholism, and eating disorder. Consider imaging to rule out tumor if suspected, especially if unilateral.
	BIOPSY	No.
	TREATMENT	Treatment of underlying condition.
	FOLLOW-UP	As needed.

Xerostomia

Xerostomia is defined as the subjective complaint of oral dryness, which can be due to either true salivary gland hypofunction or a perception of dryness despite apparently normal salivary flow. Quantitative measurement of salivary flow is not routinely performed, therefore the diagnosis relies on visualization of salivary flow from duct orifices, pooling of saliva in the floor of mouth, and subjective assessment of mucosal moistness. Common symptoms of true salivary gland hypofunction consist of difficulty chewing or swallowing, altered taste, pain or burning sensation, and increased viscosity of the saliva. Patients may have problems wearing their dentures. Findings on exam include erythema and

tenderness of the mucosa, fissuring, and atrophy of the tongue dorsum, candidiasis, and potentially aggressive dental decay. Patients with complaint of xerostomia and objectively normal salivary function describe a sensation of dryness but do not typically exhibit associated physical findings. Specific causes of xerostomia are discussed further below. Treatment is symptomatic, with the use of various topical products aimed at increasing mucosal lubrication and moistness. Patients should maintain adequate hydration. They may also find use of salivary stimulants such as sugar-free candy or gum to be useful. Systemic medications, primarily consisting of cholinergic agonists, are also available to enhance production of saliva; however, these may produce adverse side effects. Fluoride treatments should be given regularly to limit caries.

Xerostomia

	DIAGNOSTIC TESTS	The diagnosis is based on clinical exam. Sialometry is used rarely, and mainly for research purposes.
	BIOPSY	No.
	TREATMENT	Hydration, over-the-counter mucosal lubricants/saliva substitutes, and sialagogues (sugar-free candy/gum). Daily fluoride treatments. Prescription pilocarpine and cevimeline.
	FOLLOW-UP	As needed. Patients with significant xerostomia must visit a dentist regularly to monitor for dental caries.

Sjögren Syndrome

This is a systemic autoimmune condition affecting salivary and lacrimal gland tissue that is seen primarily in middle-aged women. Clinical manifestations of dry eyes and mouth are referred to as *sicca syndrome*, which may occur in conjunction with other autoimmune diseases such as rheumatoid arthritis and lupus (Fig. 8.14). Diffuse non-tender enlargement of the major salivary glands may be present (Fig. 8.15). Histologically, focal lymphocytic infiltration of salivary gland tissue is seen with atrophy of acini and fibrosis. Biopsy of salivary gland tissue, often minor glands in the lower lip, is used to confirm the diagnosis along with serology to measure antinuclear antibodies (ANA), SSA (antiRo), and SSB (antiLa); these tests are often, but not always, positive in Sjögren syndrome. Patients are at increased risk for lymphoma, and require monitoring. Treatment is

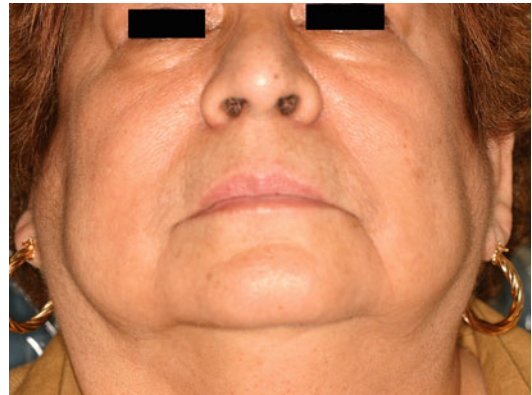

Fig. 8.15 Parotid enlargement in a patient with advanced Sjögren syndrome. Such patients should be evaluated for lymphoma

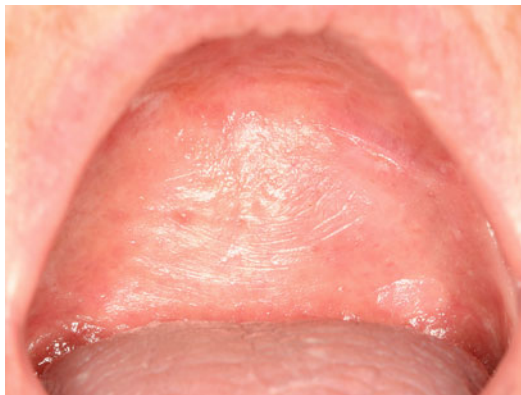





Fig. 8.14 Desiccated and atrophic palatal mucosa in a patient with Sjögren syndrome

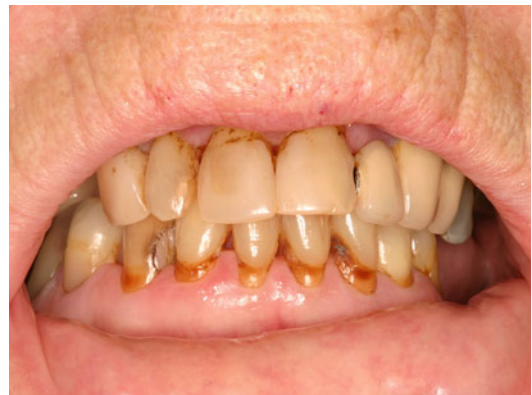

Fig. 8.16 Cervical dental decay in a patient with Sjögren syndrome

nonspecific and supportive, with the use of saliva substitutes, sialagogues, and fluoride treatments to minimize caries and alleviate sicca symptoms (Fig. 8.16).

Sjögren Syndrome

	DIAGNOSTIC TESTS	Serology to measure inflammatory and immune markers: ESR, ANA, RF, SS-A, and SS-B. Ophthalmologic evaluation and measurement of lacrimal flow (Schirmer test).
	BIOPSY	Biopsy of salivary gland tissue.
	TREATMENT	Xerostomia: Symptomatic and supportive as discussed above Xerophthalmia: artificial tears and medicated eye drops.
	FOLLOW-UP	Routine medical and dental examinations due to increased risk for lymphoma and dental caries.





Iatrogenic

Medication

Decreased salivary flow with sensation of dry mouth is a frequent side effect of medications,

including many commonly prescribed antihypertensives, antidepressants, and antihistamine/decongestants. Medications should be reviewed with this in mind when evaluating patients for complaints of dry mouth.

Medication

	DIAGNOSTIC TESTS	None; diagnosis is based on history and review of medications.
	BIOPSY	No.
	TREATMENT	Discontinue medication if feasible; otherwise symptomatic treatment as described above.
	FOLLOW-UP	As clinically indicated.

Radiation

External beam radiation therapy for head and neck cancer may cause irreversible damage to the salivary glands, particularly the serous acini, with resulting xerostomia that can be quite severe (Fig. 8.17). Patients often develop highly viscous secretions that can be difficult to clear from the throat (Figs. 8.18 and 8.19). These patients require close dental follow-up with aggressive preventive maintenance due to the high risk for rampant caries that tends to affect the cervical and root regions of the teeth (Fig. 8.20).

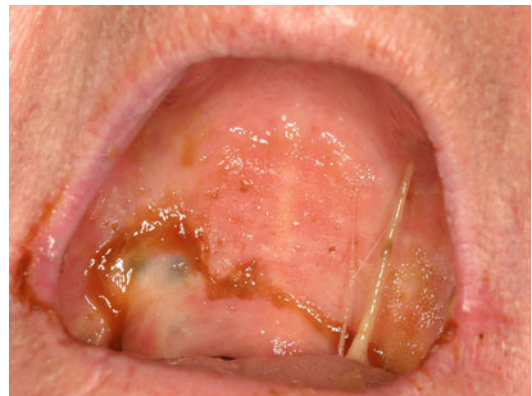

Fig. 8.18 Viscous and adherent secretions in a patient with radiation-induced salivary gland hypofunction

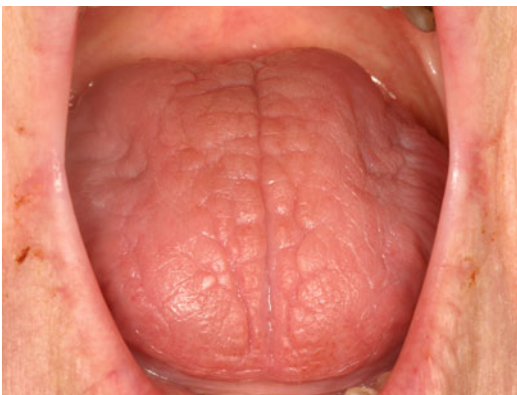

Fig. 8.17 Parched and atrophic tongue with total loss of papillae in a patient following radiation therapy

Restoration and preservation of teeth is very important given the potential for *osteoradionecrosis* of the jaws following extraction of teeth present in the field of radiation (see Chap. 9).

Treatment with *radioactive iodine* following surgery for thyroid cancer can also result in inflammation and damage to the major salivary glands in a small percentage of patients. Symptoms are usually temporary, unless strictures occur within the ducts resulting in chronic sialadenitis. Sialography, which has now been largely supplanted by cross-sectional imaging

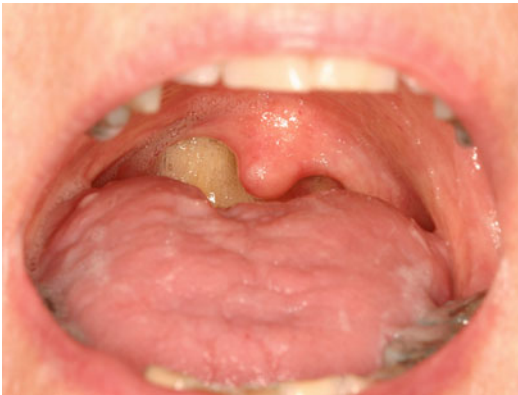

Fig. 8.19 Very thick, ropey, secretions in the oropharynx following radiation therapy. Such lesions can lead to a sensation of choking

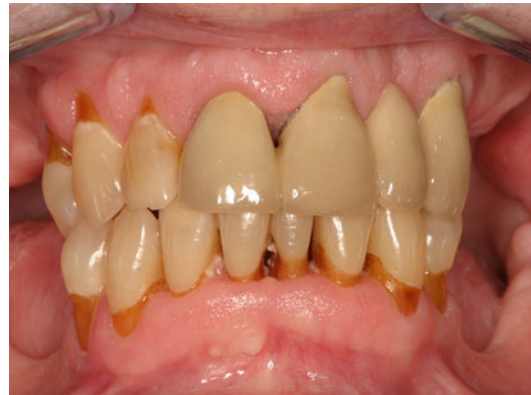





Fig. 8.20 Typical pattern of radiation-associated dental caries affecting the cervical areas

and is rarely indicated, may be useful in these patients to identify ductal strictures. Sialoendoscopy is used as both a diagnostic and potentially therapeutic modality in these patients.

In some cases, instillation of intraductal medications, such as steroid or antibiotics, can be helpful. Unfortunately, treatment of chronic salivary gland disease is difficult and often unsatisfactory.

Radiation

	DIAGNOSTIC TESTS	None; diagnosis is based on history of radiation therapy and clinical exam. Sialography may be indicated in select situations.
	BIOPSY	No.
	TREATMENT	Symptomatic, as discussed above, including pilocarpine and cevimeline as well as aggressive caries preventive measures. Cases in which a discrete duct stricture is identified may be amenable to endoscopic dilatation.
	FOLLOW-UP	As needed, including routine dental visits.

Neoplasia

Both benign and malignant lesions arise in the major and minor salivary glands, however, the overall incidence of primary salivary gland cancer is low. Approximately 65–80% of all salivary tumors occur in the parotid gland and the majority of these (about 80%) are benign. Ten to fifteen percent of tumors occur in minor salivary gland tissue with approximately half being malignant. Most minor salivary gland lesions are seen on the posterolateral palate; these may

exhibit a bluish hue and be mistaken initially for a mucocele (Fig. 8.21). Approximately 10% of tumors arise in the submandibular gland with up to 40% incidence of malignancy in these lesions. Tumors are very rare in the sublingual gland, but 70–90% of these prove to be malignant.

The majority of salivary gland neoplasms are of epithelial origin, arising from acinar, ductal, or supporting cells. Most present as asymptomatic swellings, however, they can be painful or ulcerated depending on tumor type and location. Paresthesia or facial nerve weakness may indicate neural involvement. Nonepithelial neo-

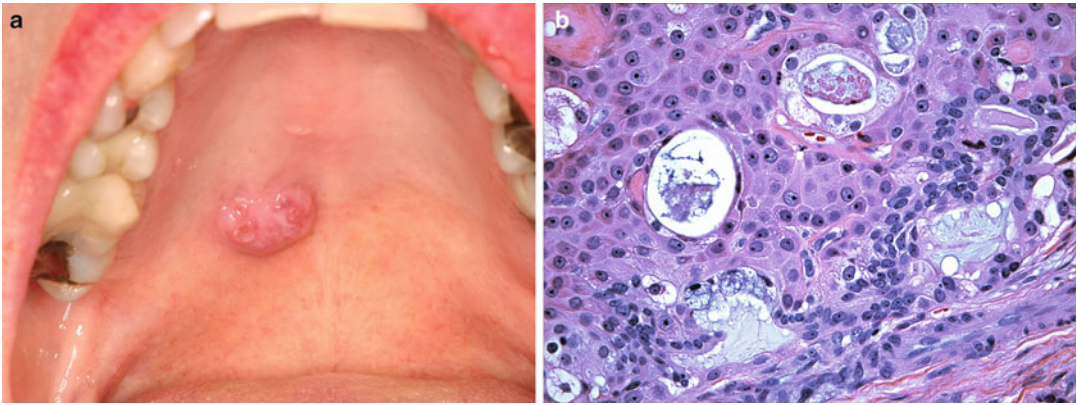


Fig. 8.21 Mucoepidermoid carcinoma of the hard palate. (a) The lesion is well-defined, exophytic, and reddish purple with focal areas of ulceration. (b) Incisional biopsy

was interpreted as *low grade* and the lesion was managed with wide excision. Photomicrograph courtesy of Mark Lerman, D.M.D., Boston, MA

plasms, such as lymphoma, hemangiopericytoma, schwannoma, and fibrosarcoma, are much less common but can occur within the salivary glands.

Benign Tumors

The *pleomorphic adenoma*, or “benign mixed tumor,” is the most common salivary gland neoplasm and occurs in all locations, although is seen most often in the parotid gland. These lesions are painless and slow growing, and are often noted incidentally on exam as a firm mass. Surgical excision is recommended, as they can become quite large and have the potential for malignant transformation over time. The lesion should be excised with a margin of surrounding tissue, as opposed to simple enucleation, to minimize recurrence.

The *Warthin tumor*, occurring almost exclusively in the parotid gland, is the second most common salivary neoplasm and may present bilaterally. It is slow growing, asymptomatic, and usually somewhat soft to palpation. Surgical excision is recommended, although malignant transformation is very rare.

Malignant Tumors

The most common malignant salivary tumor is the *mucoepidermoid carcinoma*, which generally presents as a painless swelling in the gland of origin. Treatment and prognosis depends on the location, histologic grade, and stage of the tumor. In general, low-grade lesions exhibit a fairly good prognosis, whereas high-grade tumors can be extremely aggressive and refractory to treatment.

Adenoid cystic carcinoma is seen in the oral cavity arising from minor salivary gland tissue, mainly in the palate. Intraoral lesions are slow growing and may appear ulcerated. This tumor is notorious for its predilection for perineural invasion, which results in pain and a propensity for recurrence. Management is complicated by a high incidence of local recurrence many years after treatment as well as distant metastasis; overall prognosis is poor.

Acinic cell carcinoma is a low-grade salivary malignancy that does not occur very often in the oral cavity, as it affects mainly serous glandular elements and presents primarily in the parotid gland. Prognosis is very good in general following

surgical resection. *Polymorphous low-grade adenocarcinoma* is another low-grade lesion with good prognosis. It is seen primarily in minor salivary gland tissue and can be found on the palate, lip, and buccal mucosa.

Metastasis of cancer to the salivary glands from another primary site is uncommon. This is seen primarily with skin cancer (mainly squamous cell carcinoma and melanoma) spreading to intraparotid lymph nodes. Attention to examination of the salivary glands in patients with a history of sun exposure who are at risk for skin cancer is therefore important, especially given the increasing incidence of skin cancer.

Sources

- Baurmash HD. Mucocoeles and ranulas. *J Oral Maxillofac Surg.* 2003;61:369–78.
- Bell RB, Dierks EJ, Horner L, et al. Management and outcome of patients with malignant salivary gland tumors. *J Oral Maxillofac Surg.* 2005;63:917–28.
- Guggenheimer J, Moore PA. Xerostomia: etiology, recognition and treatment. *J Am Dent Assoc.* 2003;134:61–9.
- Hinerman RW, Indelicato DJ, Amdur RJ, et al. Cutaneous squamous cell carcinoma metastatic to parotid-area lymph nodes. *Laryngoscope.* 2008;118:1989–96.
- Madani G, Beale T. Inflammatory conditions of the salivary glands. *Semin Ultrasound CT MR.* 2006;27:440–51.
- Mandel L, Liu F. Salivary gland injury resulting from exposure to radioactive iodine: case reports. *J Am Dent Assoc.* 2007;138:1582–7.
- Mathews S, Kurien B, Scofield R. Oral manifestations of Sjögren's syndrome. *J Dent Res.* 2008;87:308–18.
- Shiboski CH, Hidgson TA, Ship JA, et al. Management of salivary hypofunction during and after radiotherapy. *Oral Surg Oral Med Oral Pathol Oral Radiol Endod.* 2007;103:S66.e1–S66.e19.
- von Bültzingslöwen I, Sollecito TP, Fox PC, et al. Salivary dysfunction associated with systemic diseases: systematic review and clinical management recommendations. *Oral Surg Oral Med Oral Pathol Oral Radiol Endod.* 2007;103:S57.e1–S57.e15.

Introduction

Oral cancer imposes a significant burden on public health in the USA and many parts of the world. The morbidity of the disease and its treatment can be quite substantial, resulting in disfigurement, pain, impaired speech and swallowing, and overall decreased quality of life. Research into the molecular biology of carcinogenesis has provided greater insight into the etiology and pathogenesis of oral cancer, which has translated into new and potentially more effective strategies for diagnosis and treatment. In addition to alcohol and tobacco, traditionally recognized as the two major known causative agents of oral cancer, human papilloma virus (HPV) associated oropharyngeal cancer accounts for a growing proportion of cases. Education and prevention are therefore of high priority in the overall management of this problem.

Epidemiology

The incidence of oral and oropharyngeal cancer in the USA is approximately 30,000 cases per year, accounting for 2–4% of all cancers diagnosed annually. Worldwide, it ranks as the sixth leading cause of cancer. The vast majority of cancers are epithelial in origin, with *squamous cell*

carcinoma (SCCA) being the most common. Unfortunately, overall 5-year survival is only about 50%, which has not improved significantly over time despite technological advances in treatment. Survival is much higher for localized disease, with a survival rate 5 years after treatment of about 80% for patients with early disease versus approximately 20% for those with advanced stage disease. Only about one-third of oral cancer, however, is detected at an early stage, underscoring the importance of early diagnosis. Cancer screening in the community by physicians, nurses, dentists, hygienists, and other healthcare professionals is of critical importance in gaining ground against this disease.

The majority of oral cancer occurs in patients over the age of 40 with the average age at diagnosis between 60 and 65 years. Men are affected more than women by a factor of two, which is presumably related to differences in tobacco usage. This gender gap has been closing steadily over the past 50 years and is likely to continue. The incidence is higher in African-Americans than whites, with African-Americans also exhibiting a higher mortality rate from the disease. Patients diagnosed with oral cancer have an increased incidence of developing additional malignancies (*second primary tumors*) of the upper aerodigestive tract, particularly in smokers who continue the habit following treatment.

Risk Factors

There are a number of known risk factors for oral SCCA, with tobacco and alcohol being the most notable. Others have been implicated but are not as well characterized. It is important to remember that many cancers arise in the absence of identifiable risk factors and any patient who presents with suspicious signs or symptoms must be fully evaluated.

Tobacco

Tobacco in all forms is a major risk factor for oral SCCA. A large number of carcinogens have been identified in tobacco and its combustion products, the most important of which are polycyclic aromatic hydrocarbons containing benzene, tobacco-specific nitrosamines, and aromatic amines. These compounds result in damage to epithelium in a dose-dependent fashion, with disruption of DNA repair mechanisms and potentially critical genetic mutations leading to malignant transformation. Smokers have about a five- to tenfold risk of developing oral cancer over nonsmokers. This will decrease by approximately half over a 5-year period if they stop smoking and will reach the risk of a nonsmoker after about 10 years. Cigar and pipe smokers experience a risk profile similar to that of cigarette smokers. Oral cancer risk associated with use of electronic cigarettes remains unknown, but is likely to be low due to the absence of tobacco-associated carcinogens in the inhaled vapor.

Smokeless tobacco is associated with a considerably lower risk of oral cancer than smoked tobacco, however, it should not be considered “safe” to use or an acceptable substitute for cigarettes. Risk varies with the composition of the particular product that is used and can be up to fourfold higher than that of a non-user. It is thought that tobacco-specific nitrosamines induce dysplastic changes in the epithelium, which is probably intensified with prolonged surface contact.

Alcohol

Alcohol consumption by itself imparts an increased risk for oral cancer in “moderate to heavy” drinkers; this is variably defined but roughly equivalent to five to eight drinks per day (with one drink containing 1.5 oz or 10–15 g of alcohol). Importantly, the combined use of alcohol and tobacco produces a *synergistic effect*, in which the presence of one substance enhances the effect of the second. This results in a much greater risk than would be expected by a simple summation of the individual responses. It is thought that ethanol may alter the permeability of the oral mucosa to various substances, including carcinogens, thereby enhancing their penetration into the tissues.

Sun Exposure

Sun exposure is a risk factor for lip cancer due to the cumulative effects of ultraviolet damage. The lower lip is more commonly affected, as it tends to receive relatively more direct exposure to the sun than the upper lip. Sun exposure is not a risk factor for intraoral SCCA or mucosal melanoma.

Betel

Betel products, derived from the nut of the areca palm, are commonly used in parts of the world such as Southeast Asia and the Indian subcontinent, and are believed to be carcinogenic. Preparations usually consist of a mixture of areca nut, betel leaf, tobacco, and slaked lime (calcium hydroxide). Addition of lime enhances the euphoric effect, although it may also potentiate carcinogenicity. Long-term use is associated with the development of *submucous fibrosis* (see below). Clinicians should be aware that certain immigrant populations to the USA may continue to use these products and should be screened for cancer.

Viral

A number of viruses have been associated with benign and malignant neoplasia of the head and neck. *Epstein-Barr Virus* (EBV) has long been linked to nasopharyngeal carcinoma, Burkitt lymphoma, and other lymphomas. A strain of *human herpesvirus* (HHV-8) is believed to be associated with development of Kaposi sarcoma (see Chap. 6) in HIV-infected patients. *Human papillomavirus* (HPV) is well known to cause benign proliferative epithelial lesions throughout the head and neck region, including *squamous papilloma* and *condylomata* (see Chap. 7). High-risk strains of HPV (particularly 16 and 18; associated with cancer of the uterine cervix) have been identified in tumors of the posterior oral cavity/oropharynx. HPV associated oropharyngeal malignancies tend to arise in younger patients without traditional risk factors and exhibit overall improved prognosis and treatment outcomes.

Immunosuppression

Immunosuppressed individuals are at increased risk for malignancy in the oral cavity and elsewhere in the body. HIV-infected patients in particular can develop oral SCCA, Kaposi sarcoma, and non-Hodgkin lymphoma. Transplant patients are at risk for multiple malignancies including lip and mouth cancer. Patients with *dyskeratosis congenita*, which is a very rare inherited condition of progressive bone marrow failure leading to aplastic anemia, present with skin hyperpigmentation, dystrophic nail changes, and *leukoplakia* (see below). Leukoplakic lesions in these patients exhibit a particularly high risk of malignant transformation (Fig. 9.1). Patients with *Fanconi anemia*, a similarly rare bone marrow failure syndrome, are also at high risk for developing oral SCCA.

Nutrition

Nutritional factors, such as vitamin and mineral deficiencies, are thought to play some role in carcinogenesis, although no specific causative pathway has been elicited. This is possibly related to loss of

an antioxidant mechanism and formation of damaging free radicals. Patients with *Plummer-Vinson syndrome*, which is a rare condition presenting with dysphagia, esophageal webs, and iron-deficiency anemia in middle-aged women, are thought to be at increased risk for esophageal and oral carcinoma.

Sanguinaria

Extract derived from the common bloodroot plant *Sanguinaria canadensis*, has been used commercially in oral rinses and toothpaste as an antibacterial agent to reduce plaque and gingivitis. It has been linked to development of leukoplakia occurring particularly in the region of the maxillary vestibule. Monitoring of patients who have used these products is advised, although the risk of malignant change in these lesions is unclear and is probably not high. The main commercial marketer in the USA has removed sanguinaria from its products; however, dentifrices containing this herbal supplement may still be available in some parts of the world and their use should be discouraged.

Other

Marijuana smoking has been implicated as a potential risk factor for oral cancer; however, this has not been clearly substantiated to date. *Hyperplastic candidiasis* (see Chap. 7) may be associated with premalignancy, as invasion of fungal elements has been demonstrated in some thick or nodular leukoplakias, however, this relationship is unclear with respect to development of cancer. Historically, *syphilis* has been linked to an increased incidence of tongue cancer, although no definite causative relationship has been established.

High-Risk Sites

Tongue

The tongue is the most common location for oral cancer in the USA, with more than half of lesions presenting on the *oral tongue*, and the remainder

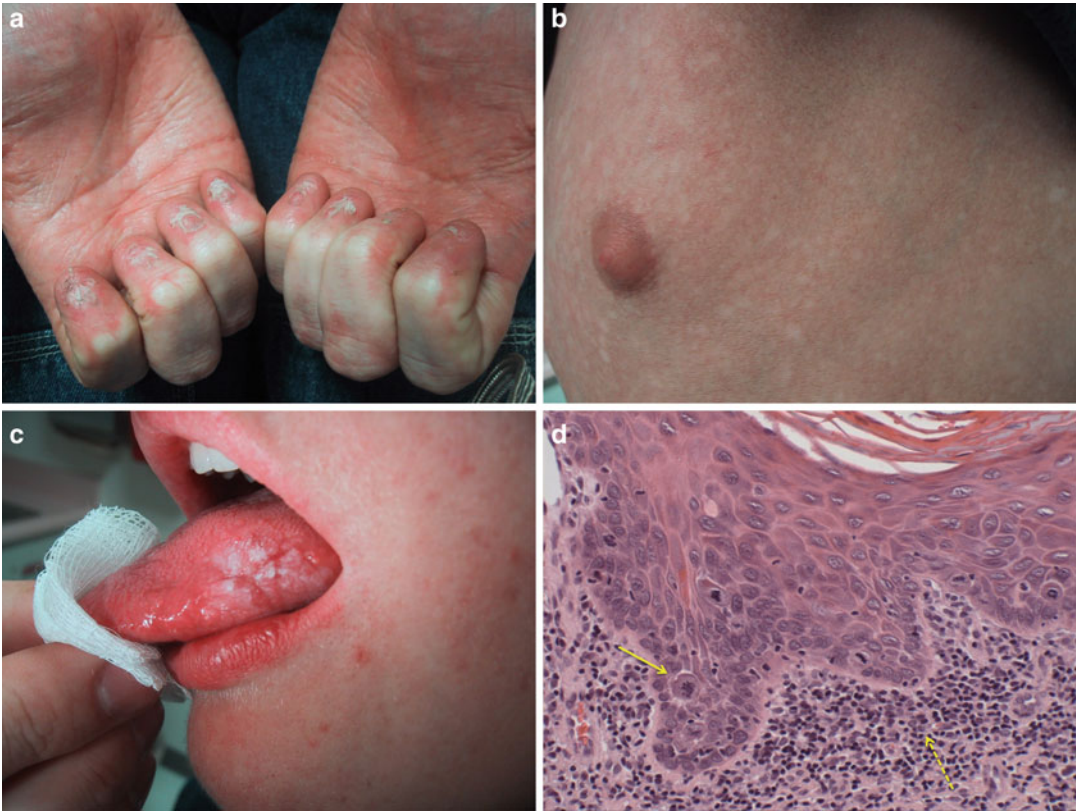


Fig. 9.1 Dyskeratosis congenita. (a) Dystrophic nails and leathery, cracked palms. (b) Hypo- and hyperpigmentation of the skin. (c) Diffuse lateral tongue leukoplakia. (d) Biopsy of the tongue demonstrated dysplasia with

maturational disarray and large mitotic figures (*solid arrow*) with an inflammatory infiltrate (*broken arrow*). Reprinted from Treister et al. (2004), with permission from Elsevier

occurring in the *tongue base*. In the oral cavity proper, lesions are most frequently seen on the lateral and ventral surfaces, and these areas are considered particularly high-risk sites. The overall incidence of tongue cancer has been rising, with some concern for increasing frequency at this site in patients under the age of 40 who do not have a history of tobacco use or other known risk factors. In general, malignancies of the tongue base tend to be more advanced at the time of diagnosis, with up to three-fourths already exhibiting metastasis to regional lymph nodes at presentation. This may be partly due to greater difficulty in visualizing and palpating the area on examination, causing these lesions to remain “hidden” longer.

Lip

The vermillion of the lip is the second most common site for oral cancer, and this has been decreasing in incidence over time. The majority of labial carcinomas occur on the lower lip, more frequently in men than women. Ultraviolet radiation exposure is the major risk factor for this area, and increased occupational and/or recreational sun exposure in men is thought to account for the gender difference. Use of lipstick and other topical protectants may also contribute to the lower incidence in women. Cancer can arise in pipe smokers where the pipestem contacts the lip repeatedly over a long period of time.

Lip cancers in general are diagnosed at an early stage due to their relatively high visibility, and can usually be treated surgically with an overall 5-year survival rate of 90%. Poorer prognosis is associated with lesions on the upper lip or commissure region. From an epidemiologic standpoint, lip cancers are often grouped with skin cancers, as they have a distinctive risk factor profile and prognosis compared to intraoral mucosal carcinomas.

Floor of Mouth

Pooling of secretions in the floor of mouth is thought to potentiate contact of carcinogens with the tissues. In addition, the very thin, nonkeratinized mucosa in this area may provide less of a barrier for penetration of toxic substances than might be found in other parts of the oral cavity. Cancers in this area can be quite aggressive and present with early lymph node involvement due to the rich lymphatic supply.

Signs and Symptoms

Squamous Cell Carcinoma

The clinical presentation of oral SCCA is quite varied, and necessitates a high level of awareness and vigilance during the oral examination. Lesions may appear flat (*macular*; Fig. 9.2), raised (*plaque-like*; Fig. 9.3), *exophytic* or *endophytic* (growing outward or inward; Fig. 9.4), or *ulcerated* (showing surface erosion; Figs. 9.5 and 9.6). The surface texture can range from smooth to irregular. *Induration* (firmness or hardness; Fig. 9.7) and *fixation* (immobility or palpable adherence to underlying structures) indicate infiltration of cancer cells into deeper tissues. These lesions have the potential for local bone destruction and nerve invasion as well as more distant spread via the lymphatics and bloodstream. Pain is a worrisome symptom, although lack of pain does not exclude malignancy.

Any nonhealing ulcer or extraction socket, as well as any white or red patch that cannot be rubbed off or induced to resolve, should be

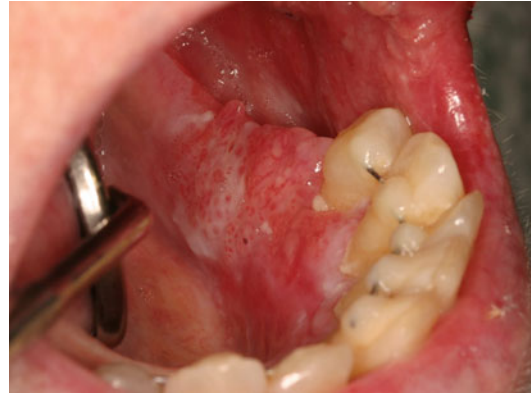

Fig. 9.2 Squamous cell carcinoma of the mandibular ridge with erythroleukoplakia and focal areas of ulceration. This patient developed multifocal involvement, suggestive of a *field cancerization* effect

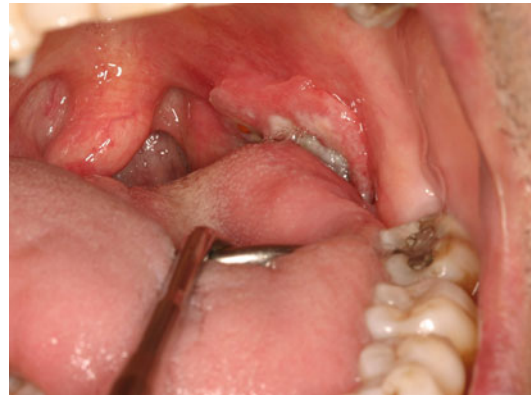

Fig. 9.3 Squamous cell carcinoma of the left soft palate presenting as an exophytic mass with central ulceration

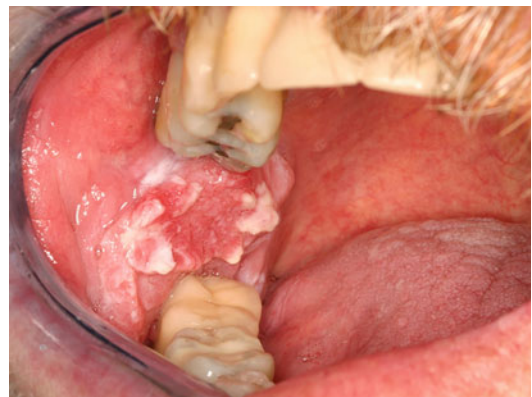

Fig. 9.4 Large exophytic squamous cell carcinoma of the buccal mucosa with heavy keratinization and induration

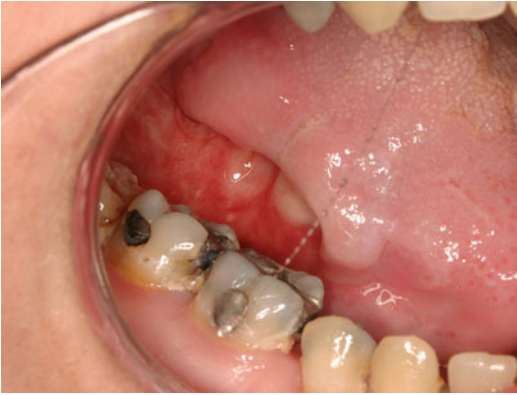

Fig. 9.5 Large squamous cell carcinoma of the right lateral tongue with ulceration and induration

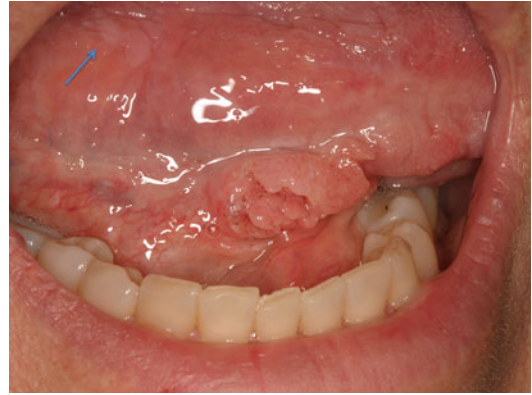

Fig. 9.8 Papillary verruciform squamous cell carcinoma of the ventral tongue. This lesion developed in the context of leukoplakic changes that can be partly seen on the superior aspect of the lateral tongue (*arrow*)

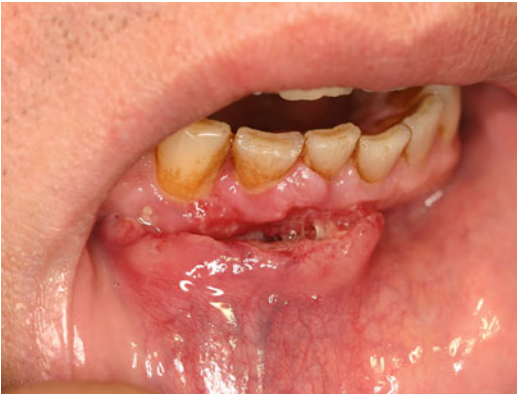

Fig. 9.6 Squamous cell carcinoma of the mandibular labial vestibule presenting as a clefted, indurated mass with central ulceration and necrosis

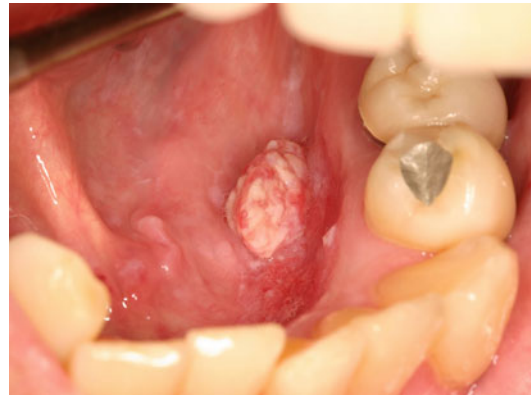

Fig. 9.9 Verrucous carcinoma of the floor of the mouth with surrounding erythroleukoplakia

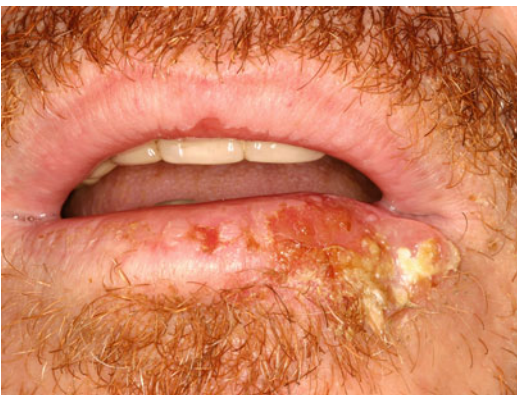

Fig. 9.7 Squamous cell carcinoma of the left lower lip with crusting, ulceration, and induration

biopsied. The following can all be warning signs for cancer: difficulty or pain with chewing or swallowing (*dysphagia*, *odynophagia*), ear pain (*otalgia*), limitation of mouth opening (*trismus*), alteration of speech (*dysarthria*), alteration of sensation such as numbness or tingling (*paresthesia*), cervical lymph node enlargement (*adenopathy*), tooth mobility, or change in the fit of a denture.

Verrucous Carcinoma

Verrucous carcinoma is a low-grade variant of SCCA with a distinctive exophytic and papillary, or warty, appearance (Fig. 9.8). Heavy keratinization causes a typically whitish or gray color (Fig. 9.9);

common sites are the buccal mucosa, gingiva, and vestibule. The prognosis is usually more favorable than that of conventional SCCA due to its slow growth, high degree of differentiation, and minimal propensity for metastasis. Treatment consists of local surgical excision without use of radiation or chemotherapy.

Histopathology

Terminology and Definitions

Epithelial *dysplasia* represents a disruption of the normal orderly growth and maturation process of oral mucosa, which may then progress to *carcinoma in situ* or *invasive carcinoma*. Normally, cell division occurs in the deep *basal layer* of the epithelium (see Chap. 1), which is separated from the underlying connective tissue by a *basement membrane*. New cells migrate upward through the layers of epithelium to replace those that are shed regularly from the surface. Cell maturation and differentiation take place in the process, with mature cells ultimately acquiring their flattened (*squamoid*) shape and ability to make keratin. Keratin production and deposition occurs only in the superficial layers of keratinized tissues. The entire process of epithelial regeneration and turnover is well organized and regulated, with dis-

tinct maturational layers (*stratification*) visible histologically (Fig. 9.10).

Cell alteration and *atypia* are seen in dysplastic epithelium, with evidence of abnormal cell division, hyperplasia of the basal cell layer, cell crowding, and loss of the usual stratification pattern (Fig. 9.11). Cell maturation is disordered, with appearance of keratin producing cells or clumps of keratin (*keratin pearls*) in the deeper layers and immature cells more superficially (Fig. 9.12). Dysplasia is a histological diagnosis, and the severity is determined according to the proportion of epithelium that exhibits these abnormal features.

Mild dysplasia involves the deeper layers only, generally estimated at no more than 1/3 of the total thickness of the epithelium. *Severe dysplasia* involves the entire thickness of epithelium without disruption of the basement membrane, and is considered equivalent to *carcinoma in situ*. Once the barrier basement membrane between epithelium and connective tissue has been breached by abnormal cells, the lesion is labeled *invasive carcinoma* and possesses the potential for spread (*metastasis*) through the lymphatic or vascular systems (Fig. 9.12). Not all dysplastic lesions will progress to invasive carcinoma, and in some cases they may actually regress; however the underlying mechanisms for this remain poorly understood.

Fig. 9.10 Histology of normal keratinized oral mucosa showing the keratin (a), spinous (b), and basal (c) layers, basement membrane (*solid arrow*), and underlying connective tissue (*broken arrow*). Photomicrograph courtesy of Mark Lerman, D.M.D., Boston, MA

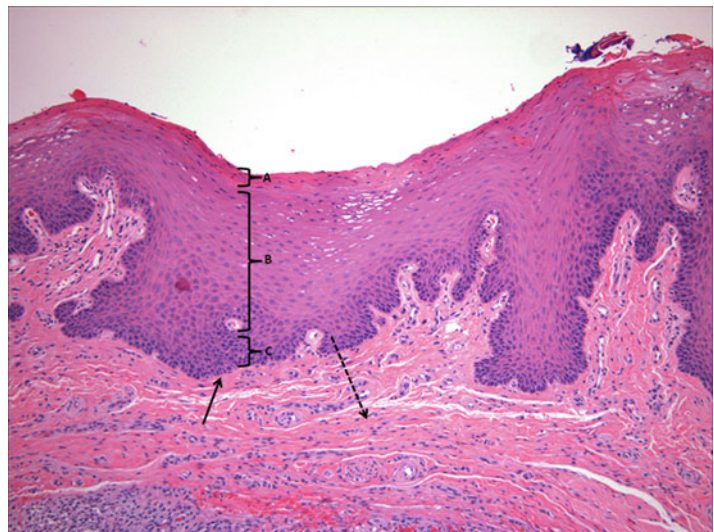


Fig. 9.11 Progression of cellular atypia and dysplasia to invasive squamous cell carcinoma: (a) mild dysplasia, (b) moderate dysplasia, (c) severe dysplasia (*carcinoma in situ*), and (d) invasive carcinoma; note breach of basement membrane

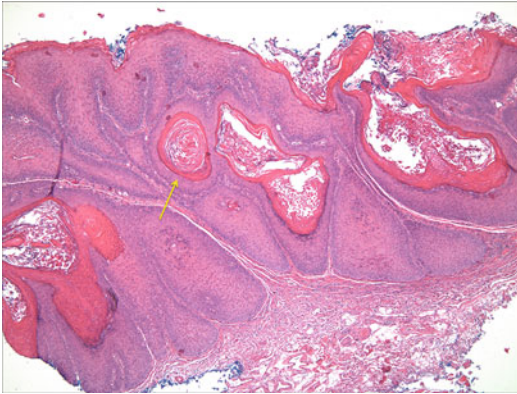
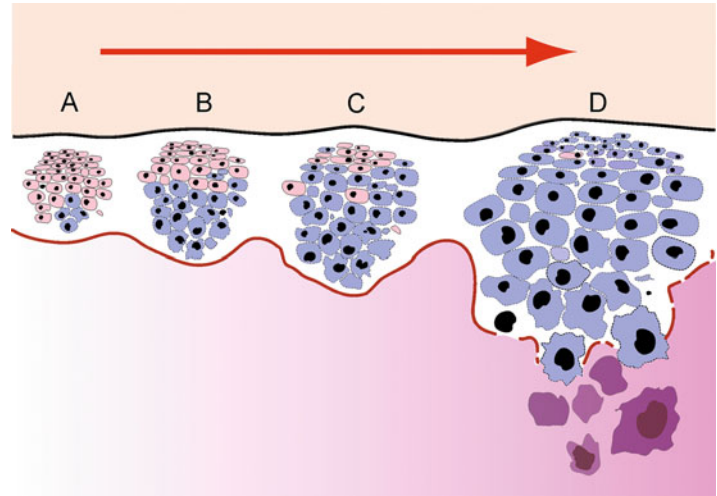


Fig. 9.12 Squamous cell carcinoma histopathology demonstrating dysplastic surface epithelium and invasive tumor islands with keratin pearl formation (*arrow*). Photomicrograph courtesy of Mark Lerman, D.M.D., Boston, MA

Biopsy Considerations

To adequately diagnose invasive carcinoma or determine the degree of dysplasia present, the biopsy specimen must include the full thickness of epithelium with adjacent basement membrane and connective tissue interface. This is obtained by either *incisional* or *excisional biopsy* (see Chap. 3). In general, small lesions are excised fully via excisional biopsy if possible. Incisional biopsy is preferred for larger lesions in order to initially establish the diagnosis and facilitate

treatment planning, as a subsequent major resection may be required in conjunction with other treatment modalities.

Exfoliative cytology and brush biopsy techniques (see Chap. 3) can be useful for detecting abnormal appearing cells in a specimen. However, as only individual cells are obtained, these tests do not provide information regarding epithelial architecture or basement membrane integrity. Therefore, the pathologist cannot make a determination regarding dysplasia or carcinoma. These methods may help to guide the practitioner in deciding whether formal biopsy should be performed, but clinical judgment in favor of biopsy should prevail if any suspicion for malignancy remains. *Vital stains*, such as toluidine blue, which bind to DNA and indicate areas of high cell turnover, can also be used as adjuncts for biopsy and monitoring of suspicious lesions.

Potentially Malignant Lesions

The term potentially malignant, or “pre-malignant” or “precancerous,” implies that there is a known potential for the lesion to transform into malignancy at a rate high enough to warrant preemptive action or close observation. As there is no way to predict whether a given lesion will undergo malignant change in a particular individual, a high level of vigilance is necessary.

Actinic Cheilitis (Sailor's Lip; Solar Cheilitis)

This is a type of *actinic keratosis* which classically occurs on the lower lip and is directly related to long-term sun exposure. It is most frequently seen in white males over age 40. The vermilion appears atrophic and pale, with a glossy surface and loss of demarcation at the vermilion border. With progression, fissuring and ulceration can occur along with crusting or scaling (Fig. 9.13). Epithelial atrophy and elastosis are seen histologically and these changes are irreversible. Areas of persistent ulceration should be biopsied due to a 6–10% rate of malignant transformation. Treatment of malignancy is primarily surgical; however, topical chemotherapy with 5-fluorouracil can be used with early lesions. Prophylactic laser ablation or vermilionectomy may be performed in cases where malignant transformation has not yet occurred. Close long-term follow-up is indicated, as these patients are at risk for additional cancers associated with solar damage.

Leukoplakia

The term leukoplakia is derived from Greek, meaning literally a “white patch,” and is defined by the World Health Organization as a white plaque that cannot be rubbed off or clinically identified as another named entity (such as

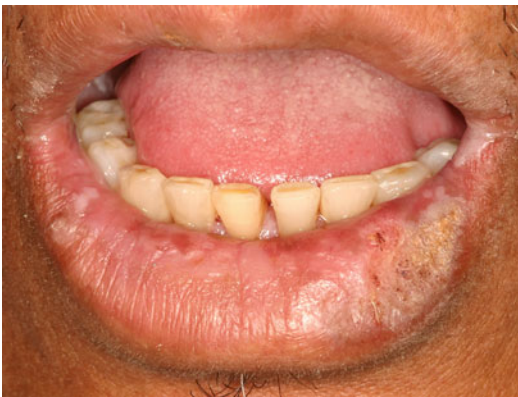

Fig. 9.13 Actinic cheilitis of the lower lip showing crusting, atrophic changes, and loss of vermilion border definition

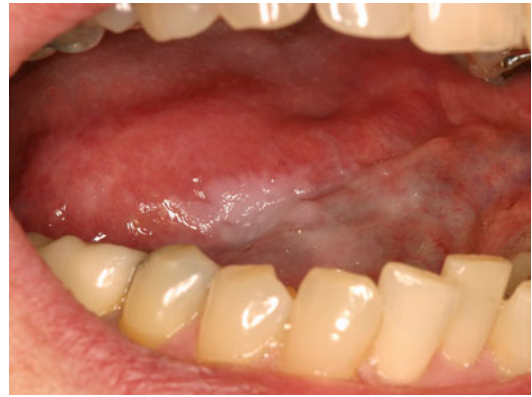

Fig. 9.14 Well-defined, smooth, and homogeneous leukoplakia of the right lateroventral tongue

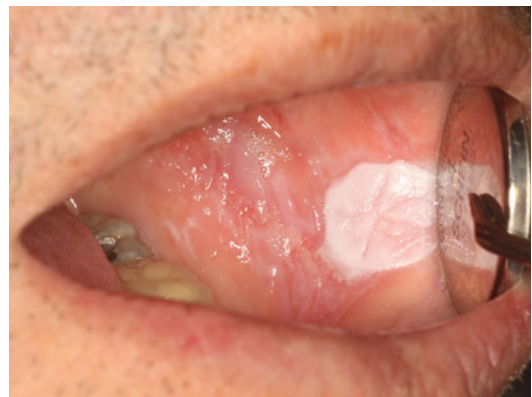

Fig. 9.15 Well-defined thick and slightly wrinkled appearing leukoplakia of the left buccal mucosa arising within the context of long-standing oral lichen planus

described in Chap. 4). It is therefore strictly a *clinical* label rather than a *histological* diagnosis. These lesions should be biopsied, after which a more definitive diagnosis can be assigned. Most prove to be histologically benign (usually hyperkeratosis or chronic inflammation), however, up to 20% may exhibit histological changes consistent with dysplasia or carcinoma. They should therefore be regarded with suspicion until proven otherwise, particularly if occurring in a high-risk site such as the ventral or lateral tongue or floor of mouth. The clinical appearance is extremely variable with respect to size, shape, thickness, and homogeneity of color (Figs. 9.14, 9.15, 9.16, 9.17, 9.18, and 9.19). They are usually asymptomatic.

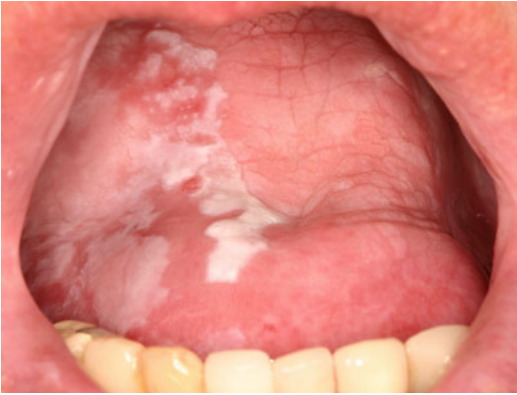

Fig. 9.16 Proliferative leukoplakia involving most of the tongue dorsum, with associated atrophy and depapillation

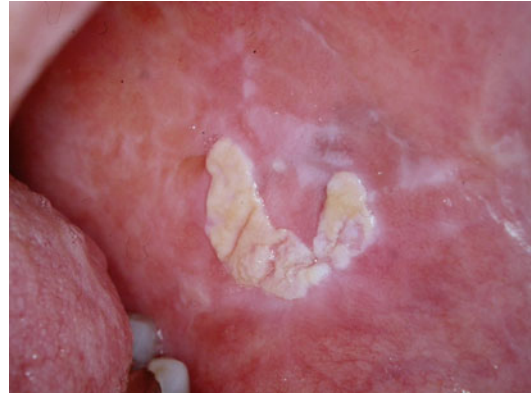

Fig. 9.18 Thick verrucous leukoplakia of the left buccal mucosa in the setting of extensive mucosal changes exhibiting a slightly *lichenoid* appearance. Photograph courtesy of Sook-Bin Woo, D.M.D., D.M.Sc., Boston, MA

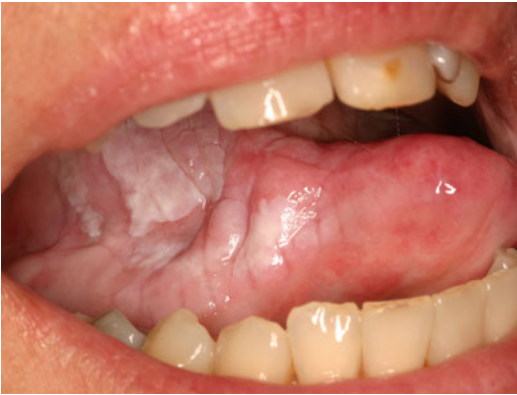

Fig. 9.17 Leukoplakia of the right lateral tongue in a patient previously treated for squamous cell carcinoma of the tongue

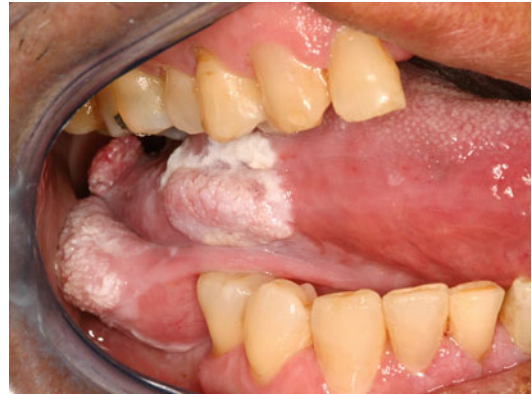

Fig. 9.19 Prominent multifocal, mass-like verrucous leukoplakia of the right lateral tongue in an HIV-positive patient

Proliferative Verrucous Leukoplakia

Proliferative verrucous leukoplakia (PVL) is an uncommon but specific type of leukoplakia that is known for a very high rate of malignant change. It is typically thick and exophytic in appearance, although may appear flat in the early stages (Fig. 9.20). Lesions often develop on the buccal mucosa and gingiva; this is in contrast to conventional leukoplakia which is more commonly seen on the ventral/lateral tongue and floor of mouth. There is an unusual predisposition for women over the age of 50 for unknown reasons. Specific risk factors have not been identified, and tobacco use does not appear to be related. It is generally

slowly progressive and often multifocal. The treatment of choice is surgical resection, although the extensive and “creeping” nature of these lesions can make definitive therapy extremely challenging. The recurrence rate is high and patients with PVL must be monitored closely.

Tobacco Pouch Keratosis

Tobacco pouch keratosis, also referred to as *snuff dipper's keratosis*, is a unique form of leukoplakia related to the direct effect of smokeless tobacco on the oral mucosa. Lesions occur at the

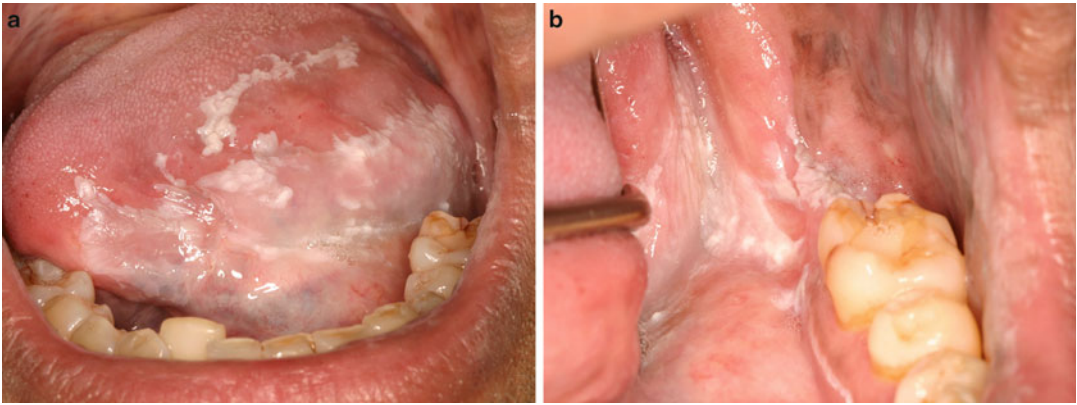


Fig. 9.20 Proliferative verrucous leukoplakia. (a) Extensive involvement of the tongue and (b) floor of mouth with a thick, wrinkled appearance. Photographs courtesy of Sook-Bin Woo, D.M.D., M.M.Sc., Boston, MA

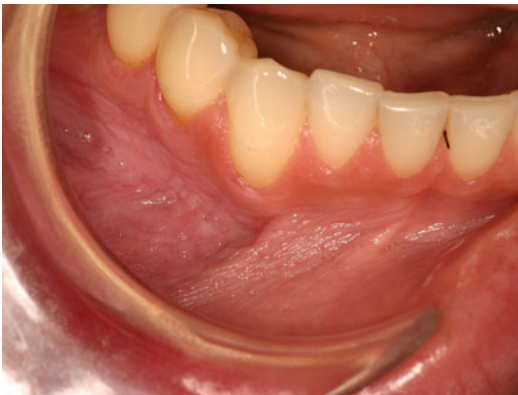

Fig. 9.21 Smokeless tobacco keratosis with thickened, corrugated appearing mucosa in the area where the tobacco is placed

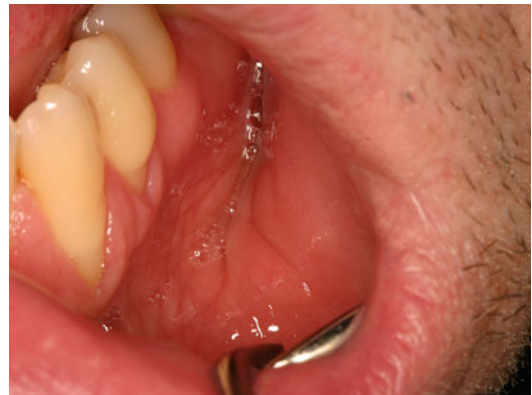

Fig. 9.22 Smokeless tobacco keratosis with deeply wrinkled and fissured appearance

site of contact, which is usually in the mandibular anterior labial vestibule or more posteriorly in the buccal vestibule. The mucosa is gray to whitish in color and wrinkled, and there may be an associated pouch-like depression secondary to stretching of the tissue from the mass of tobacco (Figs. 9.21 and 9.22). The lesion becomes increasingly white over time, as well as more leathery or nodular in texture. The neighboring gingiva is commonly inflamed or receded. The risk of malignant transformation is less than that of conventional leukoplakia, and most lesions will resolve several weeks after use of the product is discontinued. Lesions that show ulceration

or erythema or that persist despite tobacco cessation, must be biopsied.

Oral Submucous Fibrosis

This represents chronic inflammation with atrophy and fibrosis of the oral mucosa secondary to habitual use of betel products and is seen mainly in areas of the world where this practice is endemic. Development of this condition may also be influenced by nutritional and/or genetic factors. Mucosal stiffening occurs over time with formation of fibrotic bands, particularly in the buccal region and soft palate, with gradual onset

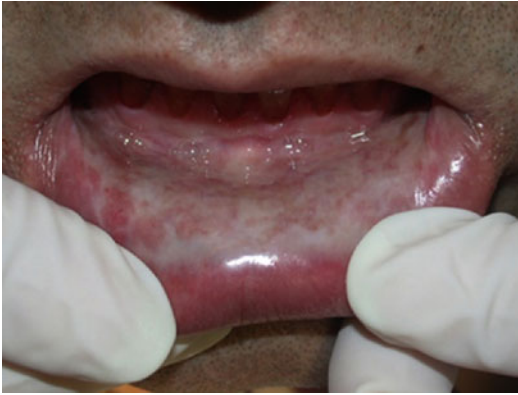

Fig. 9.23 Submucous fibrosis of the lower labial mucosa with loss of vestibule depth in a user of betel product. Photograph courtesy of Ross Kerr, D.D.S., M.S.D., New York, NY

of trismus (Fig. 9.23). This is progressive and irreversible, with a reported malignant transformation rate ranging from 4 to 13%. Treatment consists of local steroid injection and surgical disruption (*lysis*) of fibrous bands, however, outcomes are generally poor

Erythroplakia

Erythroplakia is derived from Greek, meaning “flat red area,” and is a clinically descriptive term without specific histologic definition. Lesions frequently exhibit a bright red, velvety appearance and are usually asymptomatic. The incidence of severe dysplasia or carcinoma in these lesions is very high (80–90%), and biopsy is mandatory. Areas of erythroplakia may also coexist with leukoplakia in the so-called mixed or speckled lesions (*erythroleukoplakia*; Figs. 9.24, 9.25, and 9.26). Care must be taken to obtain a representative biopsy specimen in such cases, with sampling of multiple areas within the lesion, as carcinoma may be present only focally.

Oral Lichen Planus

Development of cancer within an existing area of lichen planus (see Chap. 5) has long been a topic of controversy and no definite answer is

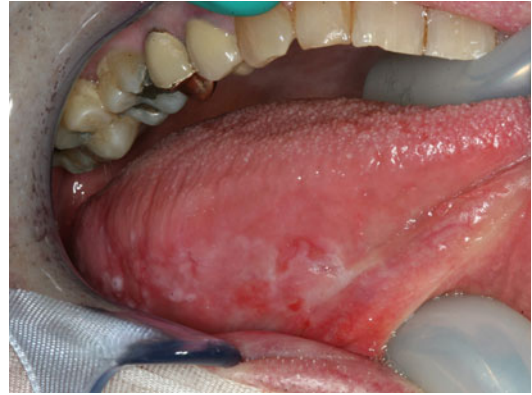

Fig. 9.24 Erythroleukoplakia of the right lateral tongue

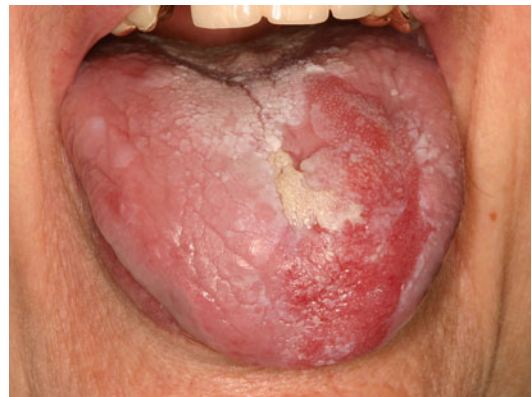

Fig. 9.25 Extensive erythroleukoplakia of the tongue dorsum that initially demonstrated inflammation without dysplasia on biopsy but subsequently transformed to squamous cell carcinoma

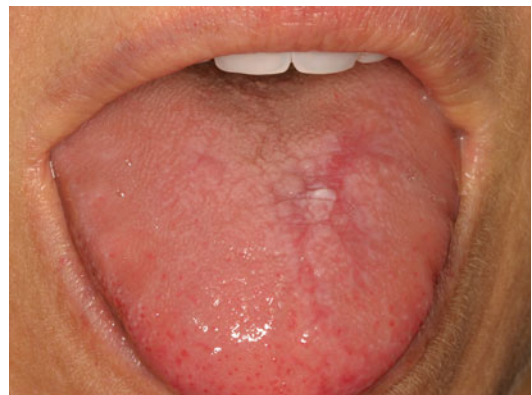

Fig. 9.26 Erythroleukoplakia of the tongue dorsum with thick plaque-like area of leukoplakia

available. Whether the two entities arise coincidentally or the atrophic epithelium seen in the erosive/ulcerative form of lichen planus is rendered more susceptible to carcinogens is unclear. Common wisdom dictates that patients with lichen planus be monitored regularly, with biopsy of any areas that are changing or otherwise appear suspicious.

Cancer Staging

Staging, or defining the extent of cancer, is important with respect to treatment planning and determination of prognosis. Patients in whom cancer is diagnosed at an early stage are generally expected to fare better, and may require less aggressive therapy than patients with more advanced disease. Accurate staging, with consistent use of accepted and uniform terminology, is also necessary to evaluate outcomes of cancer therapy and compare data across different populations.

The staging system for head and neck cancer that is currently in use follows the American Joint Committee on Cancer (AJCC) cancer staging manual, which was most recently revised in 2010 (7th edition). This is based on the clinically determined anatomic extent of the primary tumor and tumor spread. It does not take into account histological or biological features of the lesion. It is referred to as the “TNM system,” describing tumor size (T), lymph node involvement (N), and metastasis to distant sites (M). These three parameters taken together determine the stage of disease, with stage IV being the most advanced and carrying the worst prognosis (Tables 9.1 and 9.2).

Oral SCCA metastasizes primarily through the lymphatic system to regional cervical lymph nodes in a relatively predictable pattern. The neck is anatomically divided into “levels,” which help to define the extent of lymph node involvement and guide treatment planning (Fig. 9.27). The presence of lymph node involvement at the time of diagnosis dramatically worsens the patient’s prognosis. Lymphatic drainage from oral cavity sites (see Chap. 1) is primarily to level

Table 9.1 TNM classification for oral cancer

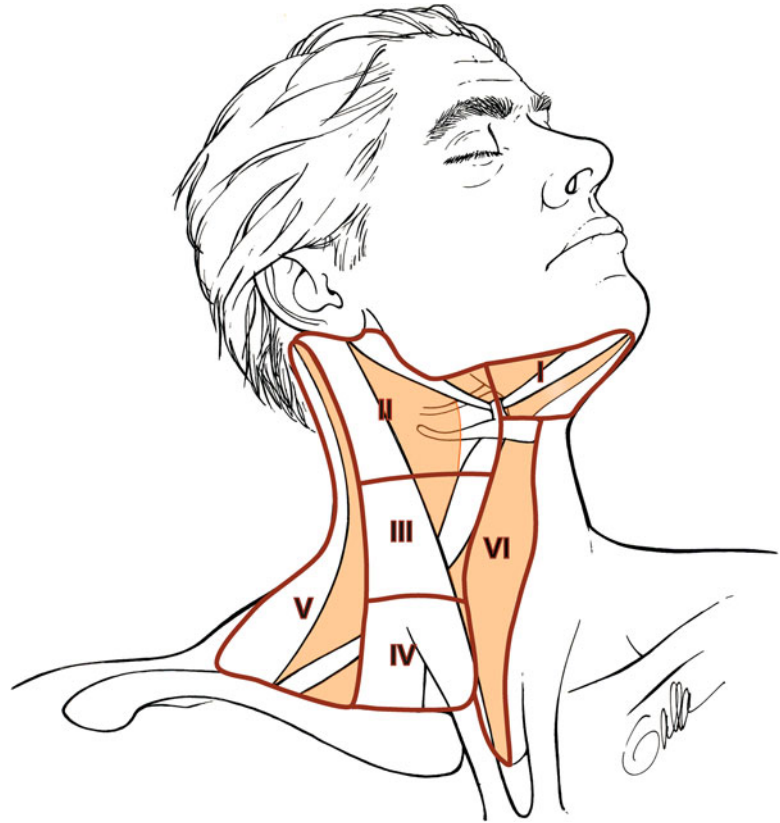
Primary tumor (T)	Tx	Primary tumor cannot be assessed
	T0	No evidence of primary tumor
	Tis	<i>Carcinoma in situ</i>
	T1	Tumor <2 cm in greatest dimension
	T2	Tumor >2 cm in greatest dimension but <4 cm
	T3	Tumor >4 cm
Regional lymph nodes (N)	T4	Tumor invades deep or adjacent structures (further subdivided into T4a and T4b)
	Nx	Lymph nodes cannot be assessed
	N0	No lymph node metastasis
	N1	Metastasis in a single ipsilateral lymph node measuring <3 cm in greatest dimension
	N2a	Metastasis in a single ipsilateral node measuring >3 cm but <6 cm
	N2b	Metastasis in multiple ipsilateral nodes, none measuring >6 cm
	N2c	Metastasis in bilateral or contralateral nodes, none >6 cm
N3	Metastasis in a node >6 cm	
Distant metastasis (M)	Mx	Distant metastasis cannot be assessed
	M0	No distant metastasis
	M1	Distant metastasis present

Table 9.2 Stage groupings for oral cancer

Stage	TNM classification
0	Tis N0 M0
I	T1 N0 M0
II	T2 N0 M0
III	T3 N0 M0 T1-3 N1 M0
IV (further subdivided into IVA, IVB, and IVC)	T4 N0 M0 T4 N1 M0 Tany N2-3 M0 Tany Nany M1

I (submental, submandibular) and level II (upper jugular) lymph nodes, however, other levels can be involved. Suspicious clinical signs include nontender node enlargement, very firm or hard consistency of the node on palpation, and fixation (immobility). Fixation indicates penetration of

Fig. 9.27 Cervical lymph node groups by levels. (Reprinted with permission from Janfaza (2001); Lippincott Williams & Wilkins)



cancer through the lymph node capsule with spread and adherence of tumor to adjacent tissues (*extracapsular extension*). In contrast, normal lymph nodes responding to an inflammatory insult (*reactive nodes*) are generally enlarged but tender, rubbery in consistency, and mobile.

Metastasis of cancer cells through the bloodstream results in spread to more distant tissues (*distant metastasis*), such as the brain and lungs. Presence of distant metastasis (M1 designation in the TNM system) indicates advanced disease and is classified as stage IV.

Treatment

Treatment is largely determined by location and extent of disease following full workup and staging. Other factors are taken into consideration,

including general health and nutritional status of the patient with respect to their ability to tolerate (or wish to pursue) various treatment options. Treatment planning is now frequently carried out in a multidisciplinary fashion, involving a team of practitioners from a range of specialty areas, including surgery (otolaryngology/head and neck or oral/ maxillofacial), radiation oncology, medical oncology, radiology, speech/swallowing pathology, and dentistry. Ancillary and support services are important to help the patient and family through a potentially long, difficult, and often debilitating course of therapy.

Lip cancer, particularly of the lower lip, generally responds very well to surgical excision with a 5-year survival rate of greater than 90%. Surgical resection is also the primary treatment modality for intraoral SCCA, with 5-year survival varying widely depending on the extent and

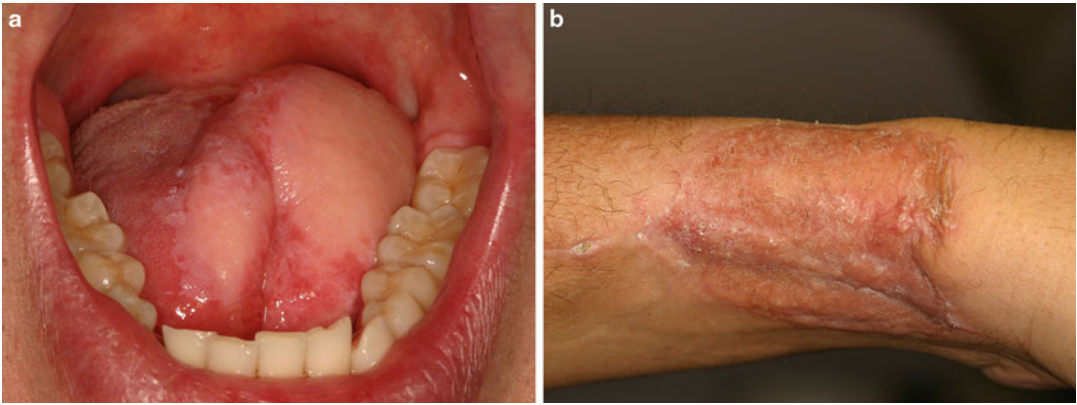


Fig. 9.28 Hemiglossectomy with surgical reconstruction using a free-tissue transfer graft from the forearm. (a) The left side of the tongue has a thick, pale, “skin-like” appear-

ance compared with the mucosa on the right. (b) Appearance of the healing graft harvest site

location of disease. Surgical removal of regional lymph nodes is indicated when there is evidence of lymph node involvement at the time of diagnosis or significant risk for spread to the lymph nodes. Postoperative chemoradiation therapy (i.e., concurrent platinum-based chemotherapy that renders the tissue more radiosensitive) is recommended for advanced stage cancers in which there is high risk for recurrent disease or metastasis. For tumors located more posteriorly, such as base of tongue, chemoradiation therapy may be chosen as the primary treatment modality with surgery reserved as a secondary option if needed.

All treatment modalities are associated with potentially unpleasant or debilitating side effects. Surgery can result in disfigurement and sensory changes of the mucosa as well as functional deficits in speech, swallowing, and breathing (Figs. 9.28, 9.29, and 9.30). These can lead to poor nutritional intake and social isolation. Radiation therapy causes both acute and chronic side effects; mucositis (Fig. 9.31) and reddening of the skin in the field of radiation are common acute effects. The major late effects include xerostomia (see Chap. 6), hypothyroid-

ism, trismus, and *osteoradionecrosis* (ORN) of the jaws (Fig. 9.32). Radiation-induced xerostomia can lead to rampant severe caries that can be quite problematic to treat and often lead to tooth loss. Aggressive preventive dental care is essential in these patients (see Chap. 8). ORN is a potentially devastating complication of radiation therapy that is often precipitated by trauma to irradiated bone or extraction of teeth within the field of radiation. Fibrosis and compromised blood supply secondary to radiation can lead to poor wound healing and bone necrosis. Surgical debridement and hyperbaric oxygen (used to encourage wound healing through increased oxygen tension and stimulation of vascular proliferation) may be required for treatment for this problem.

Treatment of oral cancer remains challenging despite best efforts, with poor overall survival rates for advanced disease. Research in the field is active, however, and the future will hopefully bring new advances. In the meantime, the clinician should be aware that the best chance for cure lies in detection and treatment of disease in the earliest stages.

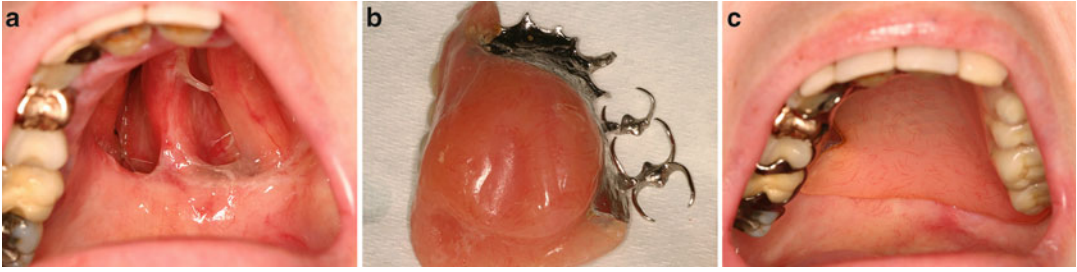

Fig. 9.29 Partial maxillectomy surgical defect functionally restored with a prosthesis. (a) Anatomical defect in the hard palate. (b) Maxillary prosthesis (obturator) used

to seal the opening from the oral cavity into the nasal cavity and maxillary sinus. (c) Prosthesis in place allowing patient to eat, swallow, and speak comfortably

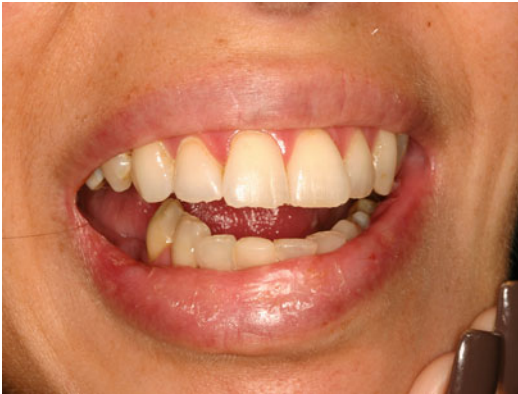

Fig. 9.30 A 22-year-old female with severe trismus following radiation therapy for nasopharyngeal carcinoma. This represents the patient's maximum opening

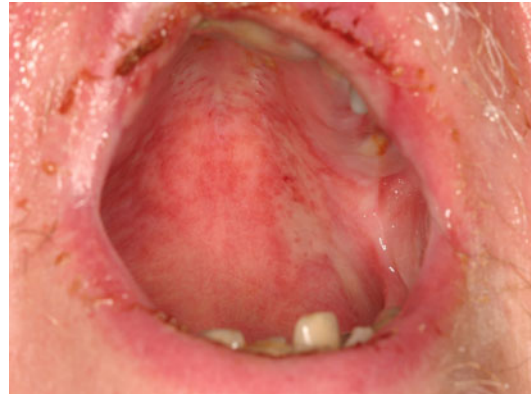

Fig. 9.31 Typical radiation mucositis of the palate with irregularly shaped ulcer and associated erythema. There is also ulceration of the upper labial mucosa

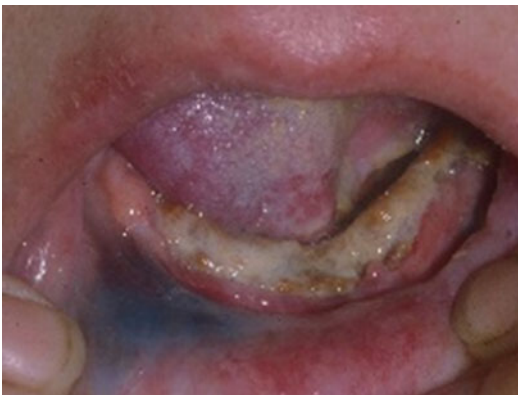

Fig. 9.32 Osteoradionecrosis of the mandible. The necrotic bone appears yellow and ragged with edematous surrounding gingiva. Note the large amalgam tattoo in the right labial mucosa. Photograph courtesy of Stephen Sonis, D.M.D., D.M.Sc., Boston, MA

Sources

- Aldington S, Harwood M, Cox B, et al. Cannabis use and cancer of the head and neck: case-control study. *Otolaryngol Head Neck Surg.* 2008;138:374–80.
- Atkinson JC, Harvey KE, Domingo DL, et al. Oral and dental phenotype of dyskeratosis congenita. *Oral Dis.* 2008;14:419–27.
- Brennan M, Migliorati CA, Lockhart PB, et al. Management of oral epithelial dysplasia: a review. *Oral Surg Oral Med Oral Pathol Oral Radiol Endod.* 2007;103:S19.e1–S19.e12.
- Cabay RJ, Morton TH, Epstein JB. Proliferative verrucous leukoplakia and its progression to oral carcinoma: a review of the literature. *J Oral Pathol Med.* 2007;36:255–61.
- Cavalcante A, Anbinder A, Carvalho Y. Actinic cheilitis: clinical and histological features. *J Oral Maxillofac Surg.* 2008;66:498–503.

- D'Souza G, Kreimer A, Viscidi R, et al. Case-control study of human papillomavirus and oropharyngeal cancer. *N Engl J Med*. 2007;356:1944–56.
- Eversole LR, Eversole GM, Kopcik J. Sanguinaria-associated oral leukoplakia. *Oral Surg Oral Med Oral Pathol Oral Radiol Endod*. 2000;89:455–64.
- Greene FL, Page DL, Fleming ID, et al., editors. *AJCC cancer staging manual*. 6th ed. New York: Springer; 2002.
- Haddad R, Annino D, Tishler RB. Multidisciplinary approach to cancer treatment: focus on head and neck cancer. *Dent Clin N Am*. 2008;52:1–17.
- Haddad R, Shin D. Recent advances in head and neck cancer. *N Engl J Med*. 2008;359:1143–54.
- Horowitz AM, Alfano MC. Performing a death-defying act. *J Am Dent Assoc*. 2001;132:5S–6S.
- Janfaza P. *Surgical anatomy of the head and neck*. Hagerstown: Lippincott Williams & Wilkins; 2001.
- Johnson NW, Bain CA, et al. Tobacco and oral disease. *Br Dent J*. 2000;189:200–6.
- Lodi G, Sardella A, Bez C. Interventions for treating leukoplakia. *Cochrane Database Syst Rev*. 2006;18:CD001829.
- Maserejian NN, Joshipura KJ, Rosner BA, et al. Prospective study of alcohol consumption and risk of oral premalignant lesions in men. *Cancer Epidemiol Biomarkers Prev*. 2006;15:774–81.
- Morse DE, Psoter WJ, Cleveland D, et al. Smoking and drinking in relation to oral cancer and oral epithelial dysplasia. *Cancer Causes Control*. 2007;18:919–29.
- Munoz AA, Haddad RI, Woo SB, et al. Behavior of oral squamous cell carcinoma in subjects with prior lichen planus. *Otolaryngol Head Neck Surg*. 2007;136:401–4.
- Mydlarz WK, Hennessey PT, Califano JA. Advances and perspectives in the molecular diagnosis of head and neck cancer. *Expert Opin Med Diagn*. 2010;4(1):53–65.
- Rodrigo JP, Suarez C, Shaha AR. New molecular diagnostic methods in head and neck cancer. *Head Neck*. 2005;27:995–1003.
- Tilakaratne WM, Klinikowski MF, Saku T, et al. Oral submucous fibrosis: a review of aetiology and pathogenesis. *Oral Oncol*. 2006;42:561–8.
- Treister NS, Lehmann L, Cherrick I, et al. Dyskeratosis congenita vs. chronic graft versus host disease: report of a case and a review of the literature. *Oral Surg Oral Med Oral Pathol Oral Radiol Endod*. 2004;98:566–71.
- Van der Waal I. Potentially malignant disorders of the oral and oropharyngeal mucosa; terminology, classification, and present concepts of management. *Oral Oncol*. 2008;45(4–5):317–23.
- Warnakulasuriya S, Reibel J, Boquot J, et al. Oral epithelial dysplasia classification systems: predictive value, utility, weakness, and scope for improvement. *J Oral Pathol Med*. 2008;37:127–33.

Introduction

Pain is defined as an unpleasant sensory and emotional experience that is associated with actual or potential tissue damage, or described in such terms even in the absence of any obvious damage. *Nociceptive pain*, on the one hand, is caused by actual tissue injury and inflammation, such as seen with pulpal involvement of a tooth secondary to dental caries, and is an important physiological protective mechanism. *Neuropathic pain*, on the other hand, is caused by dysfunction of the central and/or peripheral nervous system in the absence of active injury or inflammation, such as *post-herpetic neuralgia*, that results in neurosensory signs and symptoms. The term *dys-esthesia* refers to an unpleasant sensation, such as “burning”, that is either spontaneous or evoked. *Allodynia* is used to describe pain caused by a stimulus that would not normally induce pain, such as light touch or chewing. Importantly, management varies greatly depending on the type, duration, and quality of pain.

Orofacial pain is a common symptom that causes considerable morbidity throughout the population. Diagnosis requires a careful history and examination. As the trigeminal nerve supplies a significant proportion of sensory and motor innervation to the face and jaws, it is not surprising that branches of this nerve are most commonly responsible for orofacial pain

conditions. Cranial nerves VII, IX, X, and XII can also be involved. Although there are many different potential causes of pain in the head and neck region, the vast majority of cases can be categorized based on the structures affected: *odontogenic*, *myofascial*, *temporomandibular joint*, *neuropathic*, and *headache* (Table 10.1). Odontogenic pain is reviewed briefly later, as it is discussed in the context of odontogenic infection in Chap. 7. Headache conditions, which often have an underlying vascular and/or muscular etiology, are not included in this discussion. When signs or symptoms suggestive of a central lesion or tumor are present, appropriate testing and consultations should be obtained.

An individual’s perception of pain is highly subjective and is influenced by the underlying cause, which may not be clinically evident, as well as emotional and psychological factors. Key components of the history include: the timing, duration, quality, and intensity of pain; modifiers that make the pain better or worse other sites of pain; previous pain history; social history (including major life events); and sleep history. Psychiatric history is also important; specifically regarding treatment for anxiety, depression, and panic attacks, all of which can be associated with chronic pain conditions. A pain score using a 0–10 numerical scale with descriptors should be obtained consistently at each visit (Fig. 10.1).

A careful history accompanied by a comprehensive examination in most cases is sufficient to

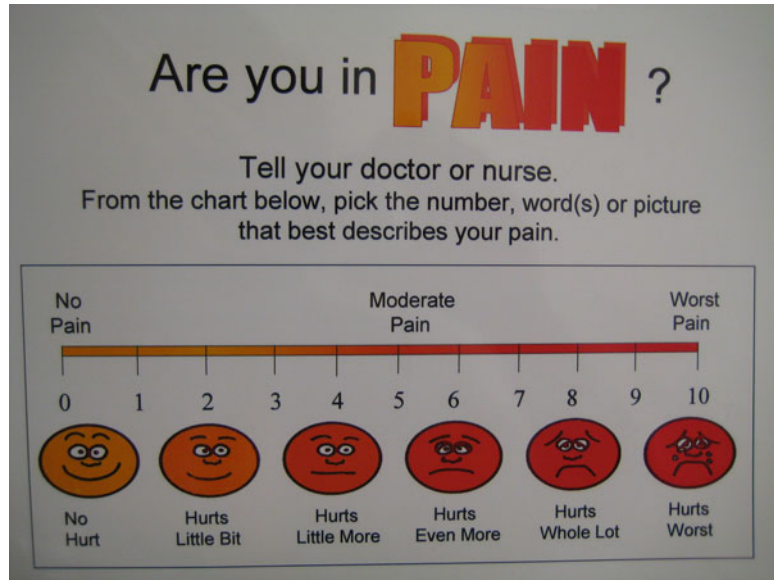
Table 10.1 Clinical characteristics of the most frequently encountered orofacial pain conditions

Orofacial pain condition	Pain quality	Pain location	Timing/pattern	Treatment
Myofascial pain	Deep ache, can be sharp	Along and behind the jaw Other areas can be affected Secondary headaches common Unilateral or bilateral	Often painful in the morning Generally gets worse throughout the day Pain with chewing and talking	Systemic and topical anti-inflammatory therapy Splint therapy Soft diet Physical therapy Other pharmacologic agents (e.g., anxiolytics, muscle relaxants)
Temporomandibular joint pain	Sharp	TMJ Often radiates to the ear Unilateral or bilateral	Worse with opening/closing	Systemic, topical, and intracapsular anti-inflammatory therapy Moist heat Soft diet
Atypical facial pain	Dull ache, crushing, burning	Poorly localized Often in the area of a tooth, extracted tooth, or previous surgical procedure Unilateral more common, but can cross midline	Continuous or intermittent throughout the day	Tricyclic antidepressants Second-line agents (clonazepam, gabapentin) Topical compounded agents
Burning mouth syndrome	Burning Sensations of “coated” and “dry” also common Bitter or metallic taste common	Tongue Inner lips Anterior hard palate Throat can be involved Bilateral most common	Continuous, or progressive throughout the day Can have symptom-free days	Clonazepam (systemic and topical)
Trigeminal neuralgia	Sharp, electric shock-like	May begin localized but spreads rapidly Unilateral	Unpredictable May be triggered by light touch or movement Lasts seconds	Anticonvulsants
Odontogenic pain	Ranges from dull ache to sharp and pounding	In location of tooth Unilateral	Stimulated by hot/cold Can be spontaneous	Definitive dental therapy

determine the correct diagnosis, although laboratory tests and imaging studies may be indicated on occasion. Careful explanation of the diagnosis and establishment of realistic treatment goals are critically important. For example, with neuropathic pain conditions, 50% improvement in symptoms would be considered a very good

response; even this may take several trials of medications in different combinations to achieve. All patients should be counseled on responsible use and storage of prescription medications. Nonpharmacologic methods of coping with pain should also be discussed. Patients receiving ongoing treatment should be monitored closely

Fig. 10.1 Pain scale numbered from 0 to 10 with corresponding face pictures and descriptors



to provide the greatest chance of successful outcome. Use of an accepted metric, such as the above-mentioned pain scale, is necessary to objectively assess the result of treatment.





Odontogenic Pain

As dental infections are common, these must always be included in the differential diagnosis for orofacial pain (see Chap. 7). Pain due to dental caries is quite variable, and depends on such factors as the proximity of decay to the dental pulp, pulp vitality, and presence of a periapical abscess. Hot or cold sensitivity that quickly resolves when the stimulus is removed is characteristic of reversible pulpal inflammation. Spontaneous, pounding pain often occurs once the pulp has become

severely inflamed or necrotic. Formation of a periapical abscess may cause pain with chewing and when the tooth is *percussed* (tapped gently with a dental instrument). Although uncommon, *referred pain* to an adjacent tooth or even a tooth in the opposing arch can occur.

In contrast, pain secondary to periodontal disease is typically dull, generalized to a larger area, and more constant. Some patients may complain of generalized cold sensitivity, which is due to loss of periodontal ligament attachment and exposure of the sensitive root surface. Periodontal abscesses can be sharply painful. Odontogenic pain unrelated to infection can be caused by a small crack in a tooth or maladjustment of the occlusion. If there is any concern regarding an odontogenic etiology, patients should be referred to a dentist for evaluation.

Odontogenic Pain

	DIAGNOSTIC TESTS	Comprehensive dental evaluation including visual inspection, percussion, palpation, pulp vitality testing, periodontal probing, and dental radiographs.
	BIOPSY	No.
	TREATMENT	Definitive treatment determined by specific diagnosis; see Chap. 7.
	FOLLOW-UP	Varies with specific nature of problem.

Myofascial and Temporomandibular Joint Pain

The TMJ and muscles of mastication function together as a unit that is one of the most heavily utilized structures in the human body. Overuse in the form of *parafunctional* activities, which include clenching, bruxism (grinding), and gum chewing is common. Inflammation causes a range of symptoms ranging from mild discomfort to severe debilitating pain. Pain can arise from any component of the masticatory system, including bony structures, the fibrous articular disc, ligamentous joint capsule, or muscles and associated fascia; however, the most common presentation is related to the muscles and fascia (*myofascial pain*) with or without associated TMJ *arthralgia*. History and careful examination are necessary to determine the correct diagnosis and provide appropriate therapy. In most cases, conservative nonsurgical measures are effective.

History and Examination

In addition to the required elements of a pain history described earlier, patients should be asked specifically if the pain is worse in the morning (typical of nocturnal bruxism), with chewing, or specifically with the act of opening and/or closing the mouth. A history of previous similar episodes, even if less severe, is also important.

Pain is typically described as dull and aching, and radiation throughout the entire side of the face including the temporal region and neck may occur. Pain can be bilateral, but one side is typically worse than the other. Many patients are seen initially by an otolaryngologist for referred ear pain which is most commonly due to arthralgia. Pain is often exacerbated with biting, chewing, talking for extended periods of time, or simply opening and closing the mouth. Patients with osteoarthritis and rheumatoid arthritis may experience pain from joint inflammation or actual bony destruction.

Patients should be examined for facial symmetry. Masseteric hypertrophy may be evident and is characterized by visibly enlarged muscles (Fig. 10.2). The patient is asked to open and close

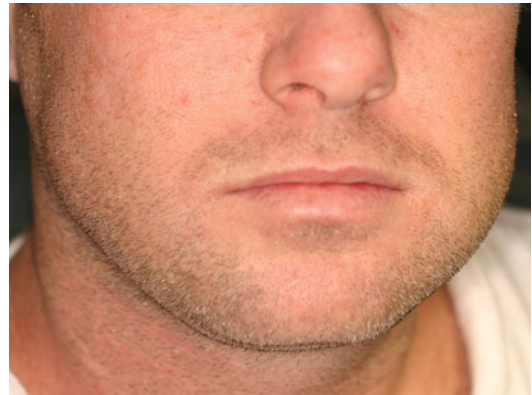

Fig. 10.2 Masseteric hypertrophy in a patient with chronic myofascial pain disorder

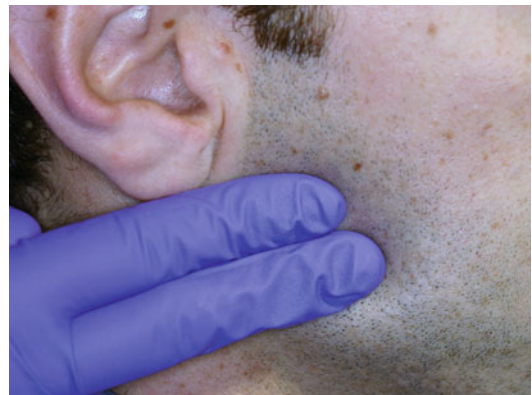

Fig. 10.3 Extraoral palpation of the masseter muscle. Sufficient pressure should be applied to assess for tenderness

repeatedly to look for limitation in opening, guarding, or deviation to the right or left. The masseter and all muscles of mastication should be palpated for tenderness (Fig. 10.3; see Chap. 3). The masseter and majority of the temporalis muscle can be palpated extraorally. Intraorally, the medial pterygoid muscle and mandibular attachment of the temporalis can be palpated by inserting the index finger into the posterior maxillary vestibule. Throughout the physical examination, it is important to ask the patient if they note any particular areas of tenderness or sharp pain areas, known as *trigger points*.

The TMJ is palpated initially with the mouth in the closed position (Fig. 10.4). With the first and second fingers positioned over the joint, the patient should then be asked to open and close

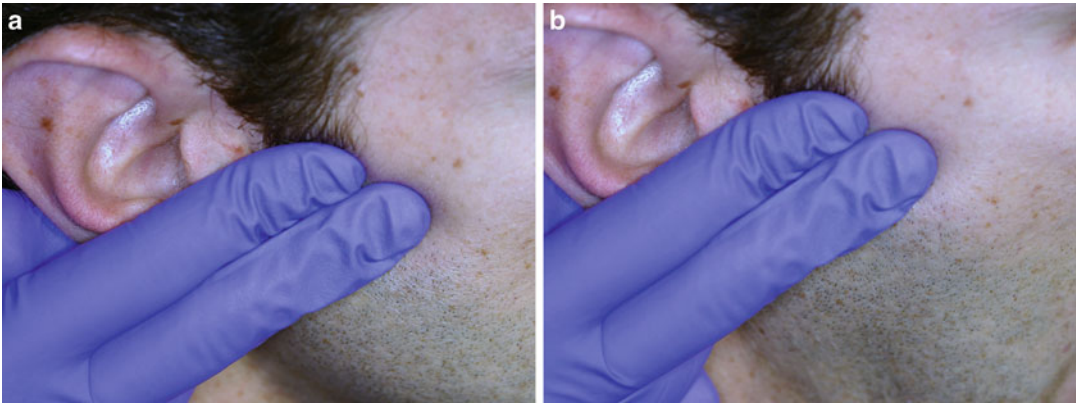


Fig. 10.4 Palpation of the temporomandibular joint (a) in the closed position, and (b) in the open position. Tenderness in this area generally indicates inflammation of the joint capsule

repeatedly, assessing for pain as well as any symptomatic clicking or *crepitus*.

Trismus, or limited mouth opening, is a potential complication of myofascial and TMJ pain disorders. Trismus can be due to myofascial inflammation with muscle guarding, or less frequently due to a displaced articular disc without *reduction* (see Chap. 1). In the latter case, the displaced disc in the affected joint prevents the mandibular condyle from translating forward along the articular eminence during mouth opening. The joint on the unaffected side typically opens fully, but deviates painfully to the opposite side. The easiest way to evaluate mouth opening is with a ruler or commercially available triangular measuring device (Fig. 10.5).

Radiographic studies are not routinely obtained in patients presenting with typical signs and symptoms of myofascial and TMJ pain. Plain films have limited benefit in these cases. CT may be useful to assess the degree of joint destruction in patients with arthritic conditions. The use of MRI is reserved for patients with evidence of disc derangement or displacement that fail initial conservative approaches to therapy.

Treatment

The mainstays of treatment include nonsteroidal anti-inflammatory agents (NSAIDs) and limitation of nonessential jaw movement. Patients



Fig. 10.5 Device used to measure mouth opening. The end of the triangle is inserted between the central incisors; maximal interincisal opening is measured in millimeters or centimeters

should be instructed to avoid foods that require forceful biting and chewing, keep their teeth apart except while eating, and minimize para-functional habits such as gum chewing, clenching, or chewing on other objects. Ice packs may be of some use.

In cases of myofascial pain, physical therapy with passive jaw stretching exercises should also be prescribed, with or without the use of moist heat packs (Fig. 10.6). The jaw is gently and progressively stretched open using the fingers or a prescribed device (Therabite, Atos Medical Inc., West Allis, WI; Dynasplint, Dynasplint Systems, Inc., Severna Park, MD). This is done to the point where it is just uncomfortable and held for 10 s

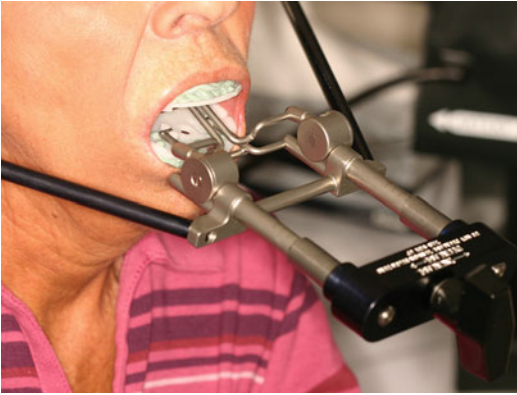

Fig. 10.6 Patient with trismus due to progressive systemic sclerosis using a commercially available physical therapy device to increase mouth opening

with 5–10 repetitions; this sequence is repeated several times throughout the day. To avoid systemic complications of long-term NSAID therapy, topical preparations, such as compounded 20% ketoprofen cream, or commercially available 1% diclofenac gel, can be applied several times throughout the day to the affected areas. During acutely painful episodes, a brief course of systemic corticosteroids can be helpful in initially decreasing the inflammation while initiating other measures.

When there is marked arthralgia, or when myofascial trigger points are identified, intralesional corticosteroid therapy can be very effective. The TMJ capsule or trigger point is carefully palpated and injected with 12–16 mg of triamcinolone acetonide (40 mg/mL), using a tuberculin syringe (Fig. 10.7). In some cases, immediate relief may be reported. Myofascial trigger points

can also be injected with a long-lasting anesthetic such as bupivacaine, either alone or in combination with triamcinolone (in a 1:1 ratio). Patients with significant disc derangement and pain whose symptoms do not improve with conservative measures should be referred to an oral and maxillofacial surgeon for evaluation regarding *arthrocentesis* of the TMJ, which is a minimally invasive surgical procedure.

Patients with a history of bruxism may benefit from a custom-fabricated occlusal splint, which functions by reducing the overall load on the muscles and TMJ during nocturnal grinding. The splint should provide full occlusal coverage with contact on all teeth to avoid any movement of teeth or adverse effect on the patient's bite, or *occlusion*. The appliance can be designed to fit either the upper or lower teeth. Patients who clench during the day may also benefit from such an appliance, as it can serve as an effective reminder to keep the teeth apart.

Medications directed at reducing parafunctional activity should be considered in some cases. Low-dose clonazepam (0.5–1.0 mg) or lorazepam (1.0–2.0 mg) at night before bed can improve sleep, decrease jaw activity, and provide analgesia. Muscle relaxants are similarly used but can be more sedating. In cases of severe pain, short courses of opioid analgesics may be necessary but should not be used for long-term management due to addiction potential.

All patients require careful follow-up, and should be seen regularly until their condition is stable. Any patient on long-term pharmacologic therapy should be reevaluated on a regular basis.

Treatment





	DIAGNOSTIC TESTS	Generally not required.
	BIOPSY	No.
	TREATMENT	Must be directed toward the specific diagnosis. Therapies for myofascial pain and arthralgia include systemic and topical NSAID therapy, soft diet, reducing parafunctional activity, splint therapy, passive stretching exercises, anxiolytics and muscle relaxants, systemic and intralesional corticosteroid therapy.
	FOLLOW-UP	All patients require short- and long-term follow-up.

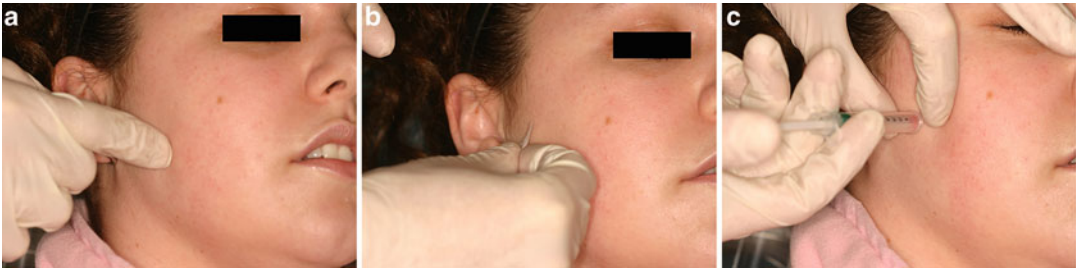

Fig. 10.7 Trigger point injection of the masseter muscle. (a) Identification of the trigger point. (b) The skin is cleaned with alcohol. (c) Injection of combined triamcinolone/mepivacaine directly into the muscle

Atypical Facial Pain

Atypical facial pain (AFP), sometimes referred to as *persistent idiopathic facial pain* or *atypical odontalgia*, is a neuropathic pain condition that is often mistakenly attributed to dental pathology and can be difficult to diagnose. The pain is typically dull, aching, or burning, and occurs intermittently or constantly throughout the day. The area affected is often poorly defined; over time it can spread or move, in some cases from one side of the face to the other. Intraoral symptoms are often initially associated with a tooth or extraction site, or arise in an area following some type of surgical therapy. Comprehensive dental evaluation is, therefore, a significant component of the workup of a patient suspected to have AFP. In fact, many patients are treated unnecessarily with root canal (*endodontic*) therapy or extraction of otherwise healthy teeth, after which symptoms persist. There is a strong association with a history of anxiety/depression in patients with AFP.

The pain associated with AFP tends to respond most reliably to low-dose tricyclic antidepressants, including amitriptyline and nortriptyline. If insufficient, addition of either gabapentin or clonazepam generally provides further improvement. Topical medications, including capsaicin and clonazepam, can be prepared by a compounding pharmacist for intra- or extra-oral use.





Given the association with a history of anxiety/depression, nonpharmacologic strategies must also be considered.

Trigeminal Neuralgia

Trigeminal neuralgia is characterized by severe unilateral paroxysmal electric shock-like pain that typically affects one division of the trigeminal nerve. The frequency of attacks is highly variable and symptoms may be quite debilitating. Pain can be stimulated by light touch of the trigger zone or by specific movements, such as smiling or chewing. In most cases, brain MRI is normal; however, vascular compression of the trigeminal ganglion is thought to be the most frequent underlying etiology. Occasionally localized peripheral pathology, such as osteomyelitis or a neoplasm, can result in secondary trigeminal neuralgia (Fig. 10.8). The prevalence of trigeminal neuralgia increases with age. Trigeminal neuralgia can be a feature of multiple sclerosis (although rarely a presenting symptom) and this should be considered in younger patients, particularly females. Clinical variants affecting other cranial nerves include *glossopharyngeal neuralgia* and *occipital neuralgia* also exist.

First-line therapy for trigeminal neuralgia is carbamazepine, and reduction or elimination of

Atypical Facial Pain

	DIAGNOSTIC TESTS	As clinically indicated. Must obtain appropriate radiographs and perform comprehensive dental evaluation if pain appears dental in origin.
	BIOPSY	No.
	TREATMENT	Low dose tricyclic antidepressants, clonazepam, gabapentin. Consider topical compounded formulations.
	FOLLOW-UP	Patients should be followed carefully until stable response is achieved, then seen at least twice annually.

symptoms in response to this medication is diagnostic. The response to anticonvulsants is so predictable that the diagnosis should be reconsidered in those without any evidence of improvement. Other effective medications, typically given in addition to carbamazepine, include gabapentin and baclofen. After several months of stable response, the dose and/or fre-

quency of therapy can be carefully reduced; however, it should be increased again if symptoms recur.

Surgical therapies include radiofrequency ablation of the ganglion, nerve blocks, and microvascular decompression. Although these can be effective, patients often have residual symptoms and there is risk of permanent complications.

Trigeminal Neuralgia





	DIAGNOSTIC TESTS	Consider brain MRI to rule out neoplasm or systemic disease such as multiple sclerosis, especially in younger individuals.
	BIOPSY	No.
	TREATMENT	Medical therapies include carbamazepine, gabapentin, and baclofen. Refractory cases should be referred for neurosurgical consultation.
	FOLLOW-UP	Patients must be followed carefully for response to medical therapy and adjustment of medications as needed. Dosage can be tapered after a stable response has been maintained for at least 3 months.

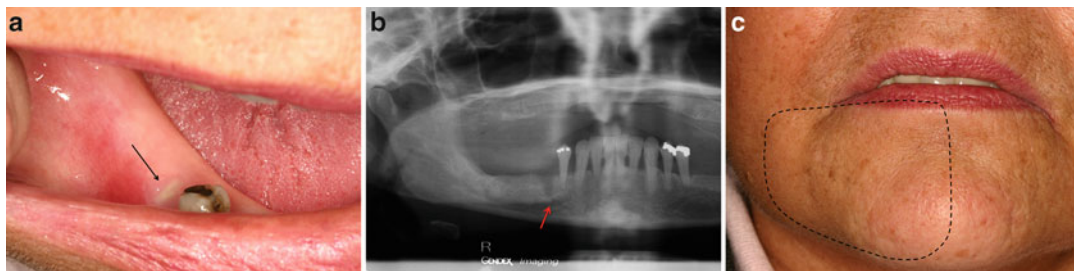

Fig. 10.8 Trigeminal neuralgia secondary to bisphosphonate-associated osteonecrosis of the mandible. (a) Area of exposed necrotic bone in the area of the previously extracted second premolar (*arrow*). (b) Persistent socket and bone sclerosis involving the area of the right

mental foramen (*arrow*). (c) The anatomic distribution of sharp shooting “electric shock-like” pain in the area innervated by the mental nerve. Combined treatment with carbamazepine and gabapentin provided near total resolution of symptoms

Burning Mouth Syndrome

Burning mouth syndrome (BMS), also referred to as *glossodynia* or *stomatodynia*, is characterized by burning dysesthesia that most commonly affects the tongue, but can also involve the inner aspect of the lips and anterior hard palate. The majority of patients are peri- and postmenopausal women; however, men and younger patients of both sexes can be affected. Most patients have a significant history of anxiety, depression, or panic attacks, and the onset of symptoms often correlates with a major life event or particularly stressful period in life. It is not uncommon for patients to see multiple providers, have numerous tests performed, receive treatment for various diagnoses, and ultimately be told that there is “nothing wrong” and no treatment is available. This only further increases their anxiety and emotional distress.

The pain is typically described as a “burning” or “scalded” sensation, but some may describe the tissues as feeling “different”, “swollen”, “tingling”, or “itchy”. Pain can be so severe as to be rated greater than 10 out of 10 on a 0–10 scale (where 10 is the worst pain they have ever experienced). It often becomes a fixation that the patient cannot ignore, interfering with daily activities, job responsibilities, and interpersonal relationships. Although the pain is almost always spontaneous, certain spicy and acidic foods can exacerbate symptoms. In most patients, however, eating or drinking diminishes or eliminates symptoms. Patients often describe observing “sores” or “lesions” on their tongue; however, these findings are invariably normal components of the tongue anatomy, such as papillae and vessels (Fig. 10.9; see Chap. 1).

Although there are several clinical patterns of BMS, most patients become aware of burning at some point soon after waking up. The pain usually persists throughout the day, generally becoming more severe toward evening. Altered taste, typically described as “bitter” or “metallic”, as well as complaint of xerostomia (despite normal objective salivary function), are both common symptoms associated with BMS. Patients may occasionally describe an associated sensation of throat constriction, presence of a “lump” in the

throat, or fear that they will not be able to breathe or swallow; clinical examination is invariably normal. Sleeping disturbances are also quite common in patients with BMS, characterized by difficulty falling asleep or waking easily and frequently throughout the night.

The diagnosis of BMS is one of exclusion. Clinical examination is within normal limits. Other causes of oral burning, such as infection, mucosal disease, uncontrolled diabetes, thyroid disease, and hematologic disorders, must be sufficiently ruled out. Precise guidelines for ordering such tests are vague and should be guided by best clinical judgment. It is critical for the medical provider to acknowledge that the pain is real, that the patient is not “making up” the condition, and that BMS is a well-recognized disorder. It is also important to explain that there is no way to predict how long the condition will last, but that therapy is available.

The first-line medication for BMS, especially when patients report a significant history of sleep disturbance, is clonazepam, which can be prescribed systemically and/or topically. The starting dose for systemic therapy is typically 0.5 mg just before bed, and most patients tolerate this dose without complication. If necessary, the tablet can be cut into half to reduce the dose to 0.25 mg. For patients who do not have sleep disturbances or are reluctant to take the medication systemically, topical clonazepam can be very effective. This is administered either by dissolving a tablet in the mouth or rinsing with a specially compounded solution.

All patients should be reevaluated after 1 month of therapy and the regimen adjusted as necessary. Depending on the tolerability of systemic therapy, sleep quality, and breakthrough of symptoms later in the day, the regimen can be altered as follows: the evening systemic dose can be increased (typically from 0.5 to 1.0 mg), a second systemic dose can be added midday (typically 0.5 mg), or topical therapy can be added if not already being used. Patients should be evaluated monthly until a stable response is achieved, then every 6 months.





For those who do not respond, or have an insufficient response with clonazepam, second-line

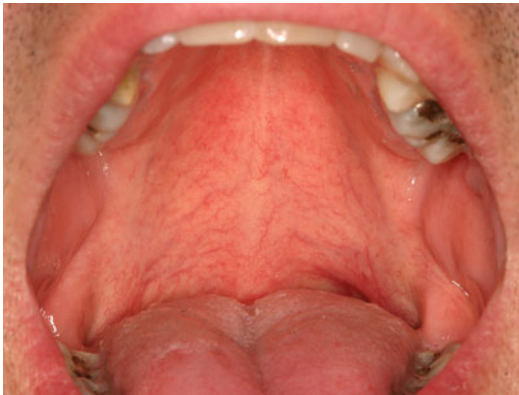

Fig. 10.9 Prominent palatal vasculature interpreted as “lacerations” following oral self-examination by a patient with burning mouth syndrome

agents include gabapentin and the tricyclic antidepressants. Although there are no reports in the literature, it is likely that these agents may also be effective topically. Evidence supporting the use of alpha lipoic acid, a commonly recommended supplement, is weak. Topical capsaicin applied repeatedly over an extended period of time can effectively deplete substance P production resulting in periods of remission. This is easily prepared at home by mixing 3–4 drops of hot sauce in a teaspoon of water and rinsing for several minutes, 2–3 times a day. Alternatively, a compounding pharmacy can prepare a 0.05 % rinse or gel. The effectiveness of complementary and alternative therapies, such as acupuncture and hypnosis, is unclear.

Burning Mouth Syndrome

	DIAGNOSTIC TESTS	None.
	BIOPSY	No.
	TREATMENT	Patient education is critical. First-line therapy with clonazepam (systemic and/or topical); second-therapy with gabapentin and tricyclic antidepressants. Topical capsaicin therapy can be offered; however, long-term compliance is generally poor.
	FOLLOW-UP	Every 1-2 months until a stable response is achieved, then twice yearly.

Sources

Clark GT. Persistent orodental pain, atypical odontalgia, and phantom tooth pain: when are they neuropathic disorders? *J Calif Dent Assoc.* 2006;34:599–609.

Lewis MA, Sankar V, De Laat A, Benoliel R. Management of neuropathic orofacial pain. *Oral Surg Oral Med Oral Pathol Oral Radiol Endod.* 2007;103(Suppl):S32.e1–e24.

Maltsman-Tseikhin A, Moricca P, Niv D. Burning mouth syndrome: will better understanding yield better management? *Pain Pract.* 2007;7(2):151–62.

Matwychuk MJ. Diagnostic challenges of neuropathic tooth pain. *J Can Dent Assoc.* 2004;70:542–6.

Okeson JP. Orofacial pain: guidelines for assessment, diagnosis, and management. Carol Stream: Quintessence; 1996.

Patton LL, Siegel MA, Benoliel R, De Laat A. Management of burning mouth syndrome: systematic review and management recommendations. *Oral Surg Oral Med Oral Pathol Oral Radiol Endod.* 2007;103(Suppl):S39.e1–e13.

Scrivani SJ, Keith DA, Kaban LB. Temporomandibular disorders. *N Engl J Med.* 2008;359:2693–705.

Siccoli MM, Bassetti CL, Sandor PS. Facial pain: clinical differential diagnosis. *Lancet Neurol.* 2006;5:257–67.

Introduction

Lesions inside the oral cavity can be associated with a number of systemic conditions, representing important indicators of active disease or heralding the onset of disease. Recognition of such lesions may facilitate prompt diagnosis and treatment of underlying disease with overall improvement in patient quality of life. In some cases, oral findings persist despite adequate systemic management of disease, necessitating targeted ancillary care measures. Management of these patients typically requires careful and close collaboration with other medical specialists for appropriate coordination of care and follow-up.

Immune-Mediated Diseases

Systemic Lupus Erythematosus

Production of autoantibodies to nuclear proteins in systemic lupus erythematosus (SLE) results in a chronic inflammatory condition with immune complex deposition that can affect any tissue in the body. Symptoms vary widely, and the disease

may follow an unpredictable course with relapses and remissions over a long period of time. Organs most commonly involved include the heart, skin, joints, kidney, and nervous system. Young women are most often affected, with peak age of onset between 15 and 40 years of age. An erythematous malar “butterfly” rash (Fig. 11.1) may be seen across the nose and cheeks in 30–60% of patients, which can intensify with sun exposure. The mainstays of treatment include high-dose steroids and other immunosuppressive and immunomodulatory agents.

Oral findings occur in up to 40% of patients with SLE, and their presence can be important in helping to initially establish the diagnosis. The appearance of oral lesions varies, without any one defining or common feature. *Lichenoid inflammation*, presenting with areas of erythema, ulceration, and white striations are most common (Fig. 11.2). *Aphthous-like* ulcerations or *granulomatous swellings* may also be seen. *Sjögren syndrome* is common in patients with SLE and can develop at any point during the course of the disease (see Chap. 8). Hematologic abnormalities are frequently present in patients with active SLE, and oral hematomas may be observed in thrombocytopenic patients (Fig. 11.3).

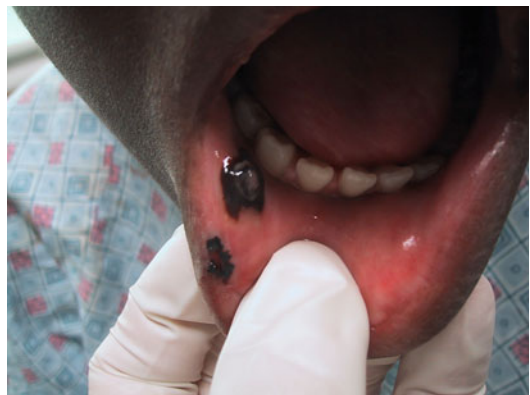
Fig. 11.1 Typical “butterfly” rash in a patient with systemic lupus erythematosus. Photograph courtesy of Stephen Sonis, D.M.D., D.M.Sc., Boston, MA

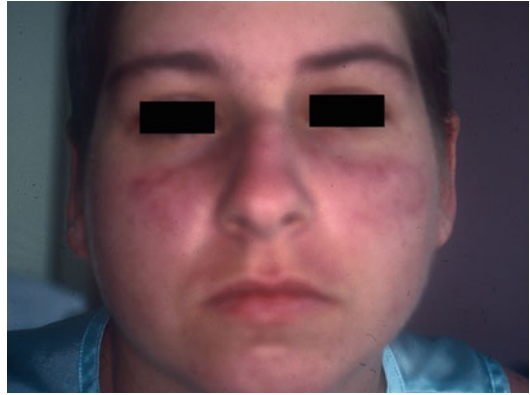





Fig. 11.2 Lichenoid changes of the right buccal mucosa in a patient with discoid lupus

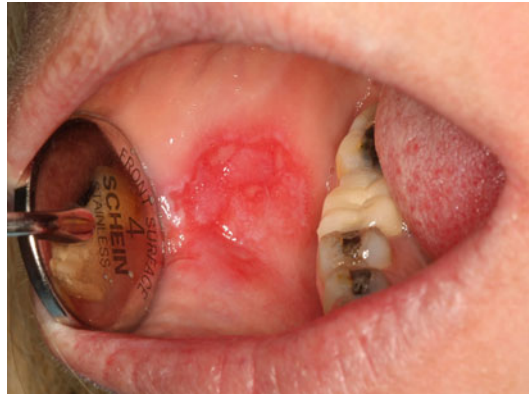

Fig. 11.3 Hematomas of the labial mucosa in a patient with thrombocytopenia secondary to a flare of systemic lupus erythematosus



Systemic Lupus Erythematosus





	DIAGNOSTIC TESTS	Medical work-up for SLE including measurement of antibodies (such as antinuclear antibody, antidouble-stranded DNA, lupus anticoagulant, anticardiolipin antibody) and complement.
	BIOPSY	Can be helpful in establishing a diagnosis. Immunofluorescence (“lupus band test”) shows linear band-like deposition of immunoreactants along basement membrane.
	TREATMENT	Avoidance of sun exposure. Use of systemic steroidal and nonsteroidal antiinflammatory agents, topical steroids, anti-malarials (hydroxychloroquine) for minor inflammatory or non major organ involvement. Use of high-dose systemic steroids (prednisone) and cytotoxic/immunosuppressive medications (cyclophosphamide, azathioprine, mycophenolate mofetil) for major organ system involvement.
	FOLLOW-UP	Monitor activity of disease and response to therapy.

Chronic Cutaneous Lupus Erythematosus

This is also known as *discoid lupus* and affects the skin without visceral involvement; however, it can progress to SLE in a minority of patients. Thick

scaly red patches occur on the scalp and face, which may scar or result in areas of hypopigmentation. Oral lesions can be seen on the buccal mucosa appearing as erythematous plaques with white striations that look clinically identical to oral lichen planus (see Chap. 5); ulceration may also be present.

Chronic Cutaneous Lupus Erythematosus

	DIAGNOSTIC TESTS	Generally no serologic findings as would be seen with SLE. Diagnosis is often based on the clinical appearance of skin lesions.
	BIOPSY	As above with SLE.
	TREATMENT	Avoid exposure to sun. Use of topical agents; systemic medications if refractory.
	FOLLOW-UP	Monitor activity of disease and response to therapy.

Progressive Systemic Sclerosis

Progressive systemic sclerosis, or *scleroderma*, is a rare autoimmune disease with the main feature consisting of progressive fibrosis of the skin and connective tissue resulting in significant disfigurement and disability. Other affected organs include the lungs, kidneys, heart, digestive system, muscles, and nervous system. Patients often develop restricted mouth opening secondary to fibrosis of the facial skin and perioral tissues, making eating, speaking, and maintenance of oral hygiene extremely challenging

(Figs. 11.4 and 11.5). Associated myofascial and temporomandibular joint pain is common. Dysphagia is also a frequent complication due to fibrosis and constriction of the esophagus as well as decreased salivary flow secondary to possible associated Sjögren syndrome. Management of oral complications includes jaw stretching exercises and physical therapy (see Fig. 10.6), treatment of xerostomia-related symptoms, use of an electric toothbrush (if unable to grip/manipulate a toothbrush), and frequent dental visits. Unfortunately, there is no treatment; management is palliative.

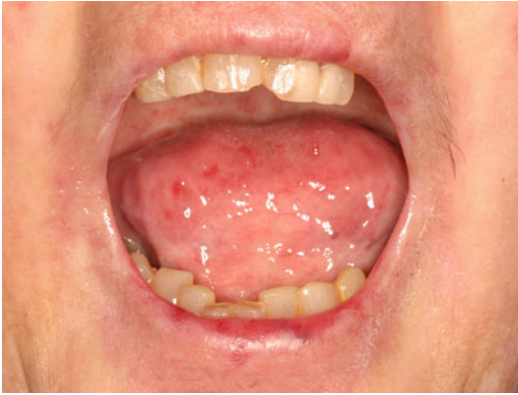





Fig. 11.4 Limited mouth opening due to fibrosis and contracture of the perioral soft tissue in a patient with progressive systemic sclerosis

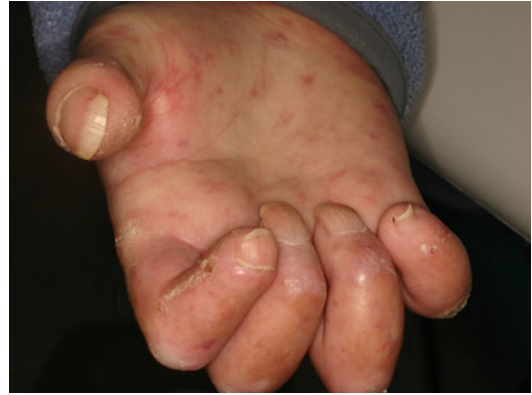

Fig. 11.5 Contracture and deformity of the hands in a patient with progressive systemic sclerosis making a simple daily activity such as brushing the teeth severely challenging

Progressive Systemic Sclerosis





	DIAGNOSTIC TESTS	Rheumatologic evaluation, including serologic testing (ESR, RF, ANA, anti-centromere antibody, SCL-70/scleroderma antibody). Evaluation of organ systems as indicated: pulmonary function testing, chest radiograph, barium swallow, etc.
	BIOPSY	Skin biopsy will show characteristic fibrotic changes; however, this is generally not needed for diagnosis.
	TREATMENT	None specifically; Symptomatic treatment of complications (dysphagia, pulmonary hypertension, Raynaud's, etc.). Use of immunomodulatory (prednisone, methotrexate, chlorambucil, cyclosporine, tacrolimus) or antifibrotic (penicillamine, colchicine) agents. See Chapter 10 for trismus management guidelines.
	FOLLOW-UP	Monitor activity of disease and response to therapy.

IgG4 Disease

Immunoglobulin G4-related disease (IgG4-RD) is a systemic fibroinflammatory condition first described in 2001 in association with sclerosing pancreatitis, which has since been recognized to affect almost all organ systems. Histologically, lesions are notable for IgG4-positive lymphoplasmacytic infiltrate, storiform fibrosis, obliterative phlebitis, and tissue eosinophilia. Serum IgG4 levels are often elevated as well. Head and neck involvement most frequently involves the orbit and lacrimal glands, salivary glands, and

thyroid gland, with the submandibular glands affected much more frequently than other salivary glands. Sinonasal, pituitary, laryngeal, and lymph node involvement may also occur. Previously described disparate entities, including some pseudotumors, Mikulicz's disease, Kuttner tumor, and Riedel thyroiditis, have now been included in the IgG4-RD spectrum. Sclerosing submandibular sialadenitis presents with tumor-like enlargement of the salivary glands and diagnosis often requires obtaining tissue for biopsy. Mainstay of treatment involves systemic glucocorticoids, generally with good response.

IgG4 Disease

	DIAGNOSTIC TESTS	Rheumatologic evaluation, including serologic testing (serum IgG4, ratio of IgG4 to total IgG, ESR, CRP). Evaluation of organ systems as indicated: lacrimal glands, thyroid gland, pancreas.
	BIOPSY	Salivary gland biopsy shows characteristic findings as noted above.
	TREATMENT	Systemic glucocorticoids; may require long term maintenance therapy.
	FOLLOW-UP	Monitor activity of disease and response to therapy.

Gastrointestinal Disorders

Oral lesions may be seen with a variety of gastrointestinal conditions and often correspond to active disease in the GI tract; however, they can appear prior to other GI manifestations.

Inflammatory Bowel Disease

Inflammatory bowel disease refers to a group of disorders causing chronic recurrent ulcerative inflammatory lesions in the gastrointestinal tract, with symptoms that include abdominal cramping, bloating, pain, diarrhea, weight loss, and bleeding.

Crohn Disease

This is a granulomatous inflammatory disorder of unknown etiology affecting primarily the distal small intestine, rectum, and proximal colon. Oral lesions may precede onset of GI symptoms or correlate with their activity, underscoring the importance of a good history. *Angular cheilitis* (see Chap. 7) may be evident, likely secondary to a combination of immunosuppressive therapy and malabsorption. Extension of mucosal inflammation to the oral cavity can result in edema or ulceration of the lips (Fig. 11.6). These lesions are virtually identical to those seen in idiopathic *orofacial granulomatosis* (see later and Chap. 5). Intraorally, the gingiva and buccal mucosa may exhibit hyperplasia and fissuring, with a thickened or “cobblestoned” appearance (Fig. 11.7 and 11.8). Aphthous-like ulcers may be present, which can be severe (Fig. 11.9).

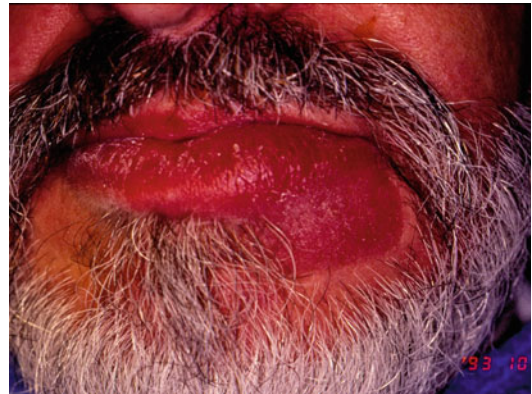

Fig. 11.6 Granulomatous inflammation of the lips and perioral skin with swelling and erythema in a patient with Crohn disease. Photograph courtesy of Sook-Bin Woo, D.M.D., M.M.Sc., Boston, MA

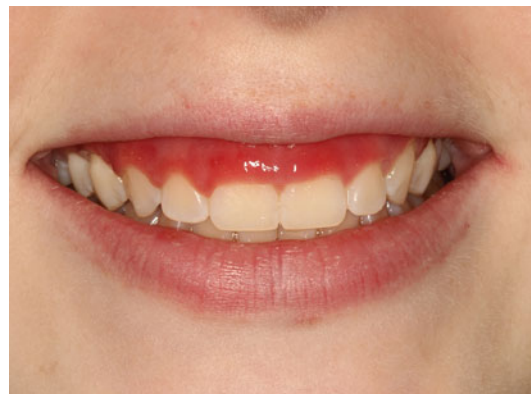

Fig. 11.7 Prominent swelling and erythema of the gingiva causing partial occlusion of the maxillary incisors in a patient with otherwise well-controlled Crohn disease

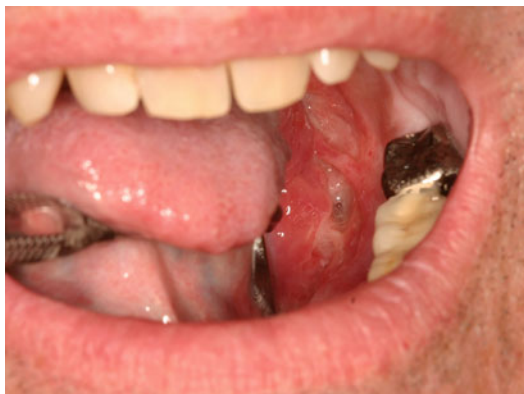

Fig. 11.8 Deeply fissured ulcerations of the left floor of mouth in a patient with Crohn disease

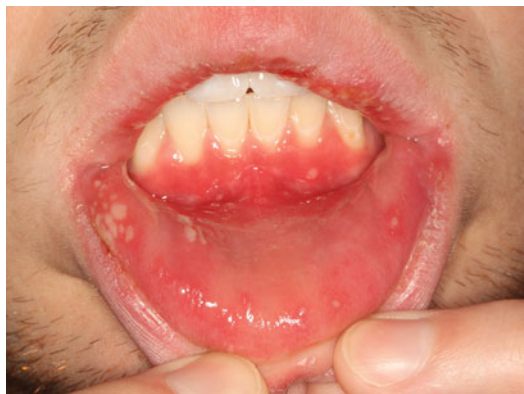

Fig. 11.9 Multiple aphthous-like ulcerations presenting in a diffuse herpetiform pattern in a patient experiencing a flare of Crohn disease

Oral lesions can be treated with topical or systemic steroids. Management of intestinal symptoms involves the use of systemic medications including steroids, sulfasalazine, immunosuppressant agents, and anti-TNFalpha biological

agents. Surgical resection of portions of the bowel or rectum is necessary in some cases; however, concurrent oral manifestations may not improve following such intervention.

Crohn Disease

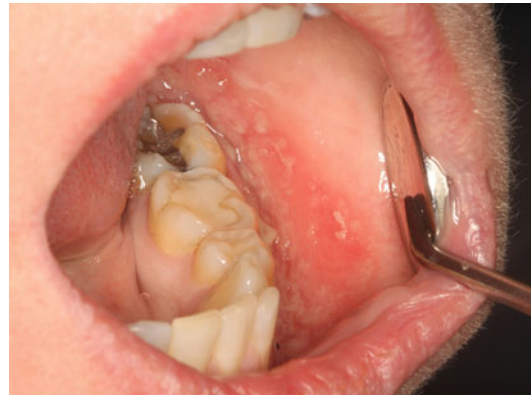	DIAGNOSTIC TESTS	Medical work-up with endoscopy and radiographic evaluation as indicated.
	BIOPSY	Histology is nonspecific, showing nonnecrotizing granulomatous inflammation. Biopsy of oral lesions may support the diagnosis in conjunction with history and GI findings or suggest the diagnosis in absence of GI signs or symptoms.
	TREATMENT	Topical steroids for oral lesions (see guidelines in Chap. 5 for recurrent aphthous stomatitis and orofacial granulomatosis); systemic steroids or azathioprine if refractory. For angular cheilitis, see guidelines in Chap. 7.
	FOLLOW-UP	Monitor activity of disease and response to therapy.

Ulcerative Colitis





This condition mainly affects the colon and rectum, with resulting hemorrhagic ulceration of the intestinal lining and abscess formation causing bloody diarrhea, weight loss, and fatigue. Oral manifestations include aphthous-like ulcers, which may coincide with flare-up of GI symp-

oms. Rarely, multiple small mucosal pustular-appearing lesions resembling “snail tracks” called *pyostomatitis vegetans* may be observed on the palate or buccal or labial mucosa (Fig. 11.10). The treatment for ulcerative colitis involves the use of both topical and systemic steroids.

Fig. 11.10 Pyostomatitis vegetans in a patient with ulcerative colitis demonstrating multiple yellowish white pustules on the buccal mucosa



Ulcerative Colitis

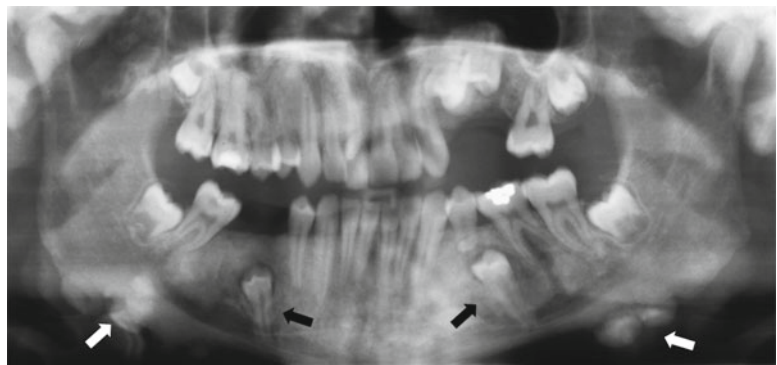
	DIAGNOSTIC TESTS	As above for Crohn disease. Stool evaluation to rule out infectious causes.
	BIOPSY	As indicated.
	TREATMENT	As above for Crohn disease.
	FOLLOW-UP	Monitor activity of disease and response to therapy. Close follow-up due to increased risk of colon cancer.

Gardner Syndrome





This is an inherited, autosomal dominant condition characterized by multiple adenomatous colorectal polyps as well as cutaneous cysts and fibromas. The intestinal lesions demonstrate a very

high rate of malignant transformation, and patients will often undergo prophylactic colectomy. Oral manifestations include multiple osteomas of the jaws and facial bones, supernumerary (extra) teeth, impacted teeth, and odontomas (Fig. 11.11). The oral lesions do not have malignant potential.

Fig. 11.11 Panoramic radiograph of a patient with Gardner syndrome showing multiple impacted teeth (*black arrows*) and osteomas (*white arrows*). Radiograph courtesy of Michael Pharoah, D.D.S., M.S.C., Toronto, ON



Gardner Syndrome





	DIAGNOSTIC TESTS	GI workup with colonoscopy.
	BIOPSY	Biopsy of GI lesions.
	TREATMENT	Colectomy due to high risk of malignant transformation. Treatment of extracolonic lesions is necessary only for symptomatic or cosmetic reasons.
	FOLLOW-UP	Close follow-up of GI lesions due to cancer risk.

Peutz-Jeghers Syndrome

This syndrome is characterized by autosomal dominant inheritance, benign intestinal polyps, and pigmented mucosal and cutaneous lesions. Patients are prone to bowel intussusception and

are at risk of epithelial malignancies. Skin lesions typically present as freckling in the perioral region and may fade with age. Diffuse brown patches can be seen intraorally and may resemble physiologic pigmentation.

Peutz-Jeghers Syndrome

	DIAGNOSTIC TESTS	GI workup as indicated. Genetic testing is available to identify mutations in the tumor suppressor gene <i>STK11</i> (<i>LKB1</i>), which is present in a majority of cases.
	BIOPSY	Oral and skin lesions are benign. Biopsy as indicated of GI or other lesions.
	TREATMENT	Treatment of GI complications and other non-oral manifestations as indicated.
	FOLLOW-UP	Monitoring for intussusception and tumor formation.

Granulomatous Diseases

Wegener Granulomatosis

This is an idiopathic, multiorgan system, small vessel granulomatous vasculitis, which mainly affects the upper and lower respiratory tracts and kidneys. This entity is now more commonly referred to as granulomatosis with polyangiitis (GPA). Measurement of antineutrophilic cytoplasmic antibody (ANCA) is frequently positive.

Oral lesions are not as common as sinonasal manifestations and are very rarely the initial presenting feature of the disease. The most common oral manifestations include mucosal ulcers of the palate or diffuse hyperplastic gingivitis (Fig. 11.12). The latter is sometimes referred to as “strawberry gingivitis” based on the color and pebbly surface texture. Treatment includes use of systemic steroids as well as other immunosuppressive or cytotoxic drugs such as methotrexate and cyclophosphamide. Oral lesions generally improve with treatment of the disease.

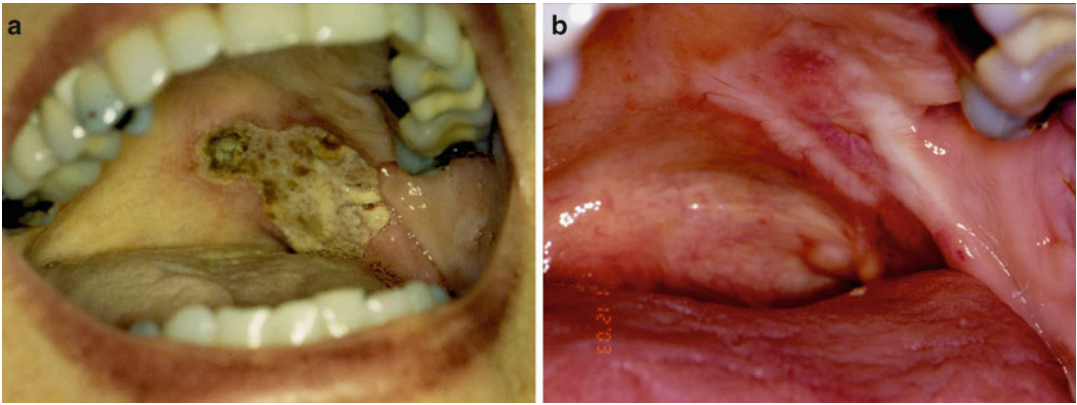






Fig. 11.12 Wegener disease of the palate. (a) Necrotic ulceration of the left soft palate diagnosed by histopathology and serology. The patient also had ulcerative lesions of the left tongue and posterior mandibular gingiva. (b) Healing lesion 2 months later following high-dose prednisone therapy. Photographs courtesy of Sook-Bin Woo, D.M.D., M.M.Sc., Boston, MA

Wegener Granulomatosis





	DIAGNOSTIC TESTS	Labwork to evaluate kidney function; c-ANCA; ESR; chest radiograph; ± sinus films.
	BIOPSY	Yes; histology shows features of necrotizing granulomatous vasculitis.
	TREATMENT	Systemic medication (steroids, cyclophosphamide, methotrexate). Topical palliative rinses for painful oral lesions.
	FOLLOW-UP	Monitor activity of disease and response to therapy.

Sarcoidosis

The etiology of this disease is unknown; however, it may represent an immune response to environmental exposures with underlying genetic predisposition. It is characterized by noncaseating granulomas primarily involving pulmonary and lymphoid tissues. Manifestations can be quite diverse, with involvement of multiple organ systems. It is usually seen in adults under the age of 40, with a higher incidence in females and African Americans. Painless enlargement of salivary tissue, most often the

parotid glands, can occur. The triad of parotid involvement, facial nerve weakness, and uveitis is known as *Heerfordt syndrome*, or *uveo-parotid fever*. Oral lesions are rare and can be seen in any location as asymptomatic submucosal masses. Diagnosis is based on clinical findings in conjunction with tissue biopsy. Levels of angiotensin-converting enzyme (ACE) may be elevated in 60–75% of patients; however, this is not pathognomonic for the disease. Depending on severity of symptoms, treatment may involve use of systemic steroids or other immunosuppressive medications.

Sarcoidosis

	DIAGNOSTIC TESTS	Blood tests including ACE, ESR, CBC; chest radiograph.
	BIOPSY	Yes; histology shows noncaseating granulomatous inflammation.
	TREATMENT	Mild cases may not require treatment and may resolve spontaneously. Systemic steroids are given for more severe cases; other immunosuppressive medications such as azathioprine, methotrexate, or cyclophosphamide if refractory.
	FOLLOW-UP	Close follow-up to monitor disease progression and medication side effects.

Orofacial Granulomatosis

This is an inflammatory condition characterized by noncaseating granulomas and nontender swelling of oral and facial soft tissues, most commonly involving the lips. Diagnosis is based on exclusion of other granulomatous inflammatory diseases, such as sarcoid, *Crohn disease*, allergy or foreign body reaction, and mycobacterial infection. This condition as well as its management is discussed in greater detail in Chap. 5.

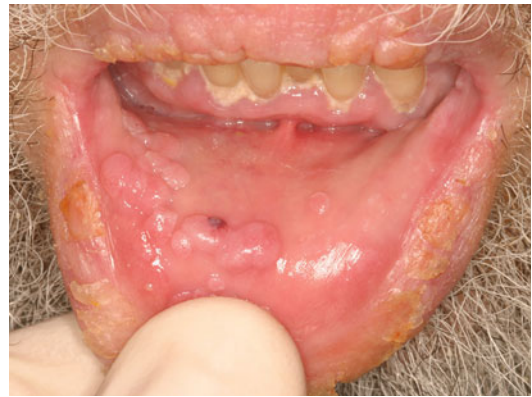

Fig. 11.13 Multiple condylomas of the lower labial mucosa in an HIV-positive patient

Human Immunodeficiency Virus

Treatment with highly active antiretroviral therapy (HAART) has changed the management and prognosis of human immunodeficiency virus (HIV)/AIDS dramatically in recent years. It has also decreased the prevalence of many oral findings associated with this disease in developed countries. HIV infected patients are subject to a variety of opportunistic infections because of diminished cellular immune activity, leading to oral manifestations such as candidiasis and reactivation of HSV and CMV ulcerations (see Chap. 7). Despite advances in management, oral candidiasis is seen commonly in HIV-positive patients, and can progress to invasive esophageal candidiasis if not appropriately treated.

Other virally mediated disorders, such as oral hairy leukoplakia related to EBV and Kaposi sarcoma associated with HHV-8, have been dis-

cussed elsewhere (see Chaps. 4 and 6). Oral HPV-related lesions, including squamous papillomas and condylomas (see Chap. 7), are found commonly in HIV-positive patients and involvement of the lips and mucosa can be quite extensive (Fig. 11.13).

HIV-positive patients may experience severe necrotizing gingivitis or periodontitis with need for extensive treatment including surgical debridement and antibiotics. They should be followed closely, with meticulous attention to oral hygiene and regular dental care (Fig. 11.14). AIDS patients are also prone to developing large, painful, major aphthous ulcers often requiring treatment with intralesional, topical, and/or systemic corticosteroids (Fig. 11.15). In refractory cases thalidomide, which is FDA approved for this use, should be considered. Of note, the

Fig. 11.14 Recrudescence herpes simplex virus infection along the entire gingival margin of the palate following deep dental scaling in a patient with AIDS

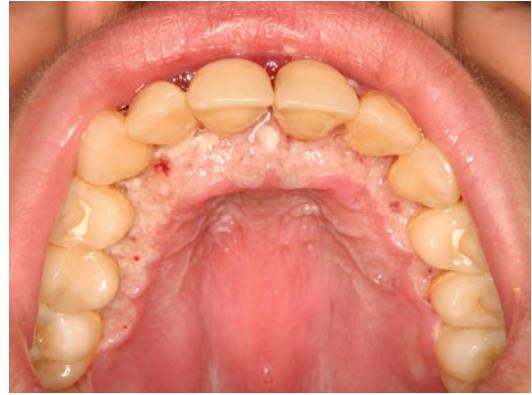

Fig. 11.15 HIV-associated major aphthous ulcers of the palate and lip in a patient with advanced AIDS

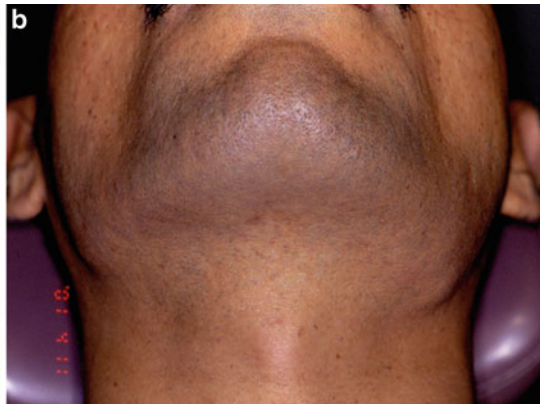
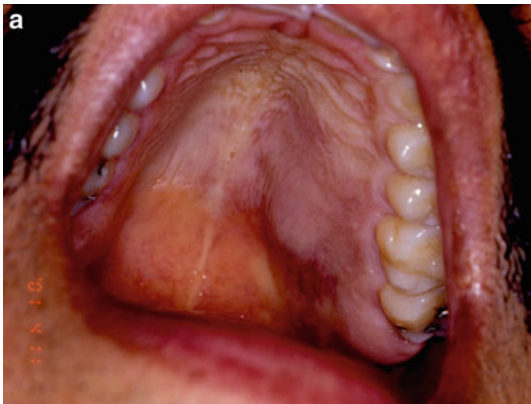
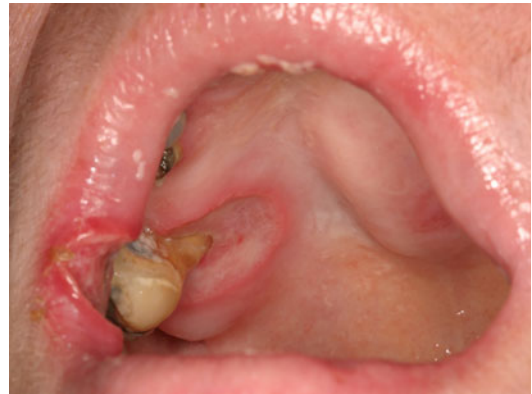Fig. 11.16 Swelling of the left posterior hard palate (a) and left submandibular lymphadenopathy, (b) diagnosed histopathologically as non-Hodgkin lymphoma in an

HIV-positive patient. Photograph courtesy of Sook-Bin Woo, D.M.D., M.M.Sc., Boston, MA

apparent severity of these lesions may parallel worsening immunosuppression.

As with other immunosuppressed individuals, AIDS patients are at increased risk for malignancy, including lymphoma, which is primarily

of the non-Hodgkin B cell type. Oral lymphomas may be seen as firm masses or shallow ulcerations anywhere in the oral cavity, although they occur most often on the palate or gingiva (Fig. 11.16). These can present as isolated lesions

without disseminated disease or associated constitutional symptoms.

Salivary gland involvement, including unilateral or bilateral parotid enlargement, xerostomia, and benign lymphoepithelial cysts, can be seen. As mentioned previously, xerostomia can result in significant morbidity from dental caries.

Hematologic Disorders

Anemia

Iron Deficiency Anemia

Iron deficiency, most commonly secondary to either physiologic blood loss in women during menses or pathologic blood loss from the gastrointestinal tract, results in microcytic hypochromic anemia with low serum iron and elevated total iron-binding capacity. Characteristic oral findings include pallor of the lips and mucosa and atrophy of the lingual papillae, with a shiny, “bald” appearance to the tongue dorsum (Fig. 11.17); patients may complain of a burning sensation of the tongue. Iron deficiency anemia is

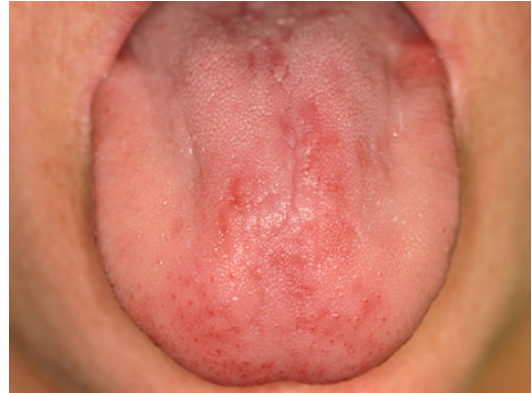





Fig. 11.17 Atrophic glossitis with depapillation and erythema in a patient with iron deficiency anemia

also implicated in a small subset of patients with recurrent aphthous stomatitis (see Chap. 5).

Chronic severe iron deficiency anemia is seen in *Plummer-Vinson syndrome*, which is associated with dysphagia secondary to esophageal webs and strictures as well as increased risk for squamous cell carcinoma (see Chap. 9) of the upper aerodigestive tract. Oral mucosal atrophy and pain can be quite pronounced. This condition is seen more frequently in women.

Iron Deficiency Anemia





	DIAGNOSTIC TESTS	Medical work-up for anemia, fatigue, and occult blood loss.
	BIOPSY	No.
	TREATMENT	Iron supplementation.
	FOLLOW-UP	As needed depending on etiology and response to treatment.

Pernicious Anemia

Deficiency of *intrinsic factor*, which is produced by parietal cells in the gastric mucosa, results in inability to absorb vitamin B₁₂ from the intestinal mucosa and subsequent vitamin B₁₂ deficiency. The resulting megaloblastic anemia shows a macrocytic,

hyperchromic pattern, with decreased serum B₁₂ levels. The tongue dorsum exhibits atrophy of the papillae, with a smooth surface that may be beefy or fiery red and sore. Vitamin B₁₂ deficiency is also associated with a small subset of patients suffering from recurrent aphthous stomatitis.

Pernicious Anemia

	DIAGNOSTIC TESTS	Medical work-up for anemia and associated symptoms.
	BIOPSY	No.
	TREATMENT	B ₁₂ supplementation; generally parenteral via injection on a monthly basis.
	FOLLOW-UP	Monitor activity of disease and response to therapy.





Thrombocytopenia

A decrease in the number of circulating platelets can result in inadequate hemostasis secondary to impaired clot formation. Small, pinpoint hemorrhagic lesions (*petechiae*) and larger areas of bruising (*ecchymosis*) may be seen in the oral cavity, particularly in areas exposed to masticatory stress such as the tongue, buccal mucosa, and palate (see Chap. 6). Mass-like collections of extravasated blood (*hematomas*) can develop; these range in color from blue, gray to black, and are characterized by a firm, rubbery consistency (Fig. 11.18). These lesions will not blanch with applied pressure, differentiating them from vascular lesions in which the blood is contained within the vessels, such as hemangiomas (see Chap. 6).

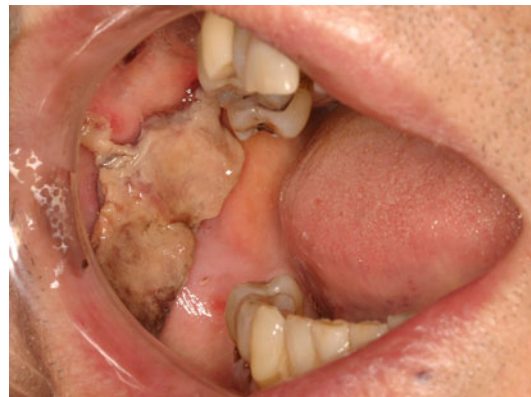

Fig. 11.18 Large hematoma of the right buccal mucosa in a patient with thrombocytopenia

Thrombocytopenia





	DIAGNOSTIC TESTS	Laboratory testing to evaluate for underlying bleeding disorder.
	BIOPSY	No.
	TREATMENT	Management of underlying medical issue, if applicable.
	FOLLOW-UP	As indicated for specific etiology.

Cyclic Neutropenia

This is a rare inherited condition in which the circulating neutrophil count fluctuates in a cyclical fashion with a decrease occurring every 21 days and lasting for 3–5 days. Patients are susceptible

to infections while the white blood cell count remains low and may report a history of recurrent fever, lymph node enlargement, malaise, and pharyngitis. Oral findings consist mainly of mucosal aphthous-like ulcers, gingivitis, and periodontal disease.

Cyclic Neutropenia

	DIAGNOSTIC TESTS	Serial blood testing demonstrating periodic fluctuation of neutrophil levels.
	BIOPSY	No.
	TREATMENT	Supportive treatment of symptoms. Antibiotics as needed for infection. Consideration for granulocyte colony-stimulating factor (G-CSF).
	FOLLOW-UP	As needed.

Malignancy

Lymphomas

Extranodal lymphoma can arise in tissues making up Waldeyer's ring as well as in focal aggregates of lymphoid tissue found throughout the oral cavity. These are most often of the non-Hodgkin B-cell type, and may or may not be associated with lymphadenopathy or systemic symptoms (the so-called B symptoms) such as fever, night sweats, or weight loss. Lesions generally present as painless submucosal oral masses or enlarged adenotonsillar tissue (Figs. 11.19, 11.20, and 11.21). Treatment depends on histologic grading and clinical staging of the tumor, and may involve chemotherapy and/or radiation therapy.

A rare form of Natural Killer/T-cell lymphoma, formerly known as *midline lethal granuloma*, can affect the midline hard palate. These lesions are typically very aggressive, with bone and vascular invasion resulting in extensive necrosis and destruction of the palate and nasal

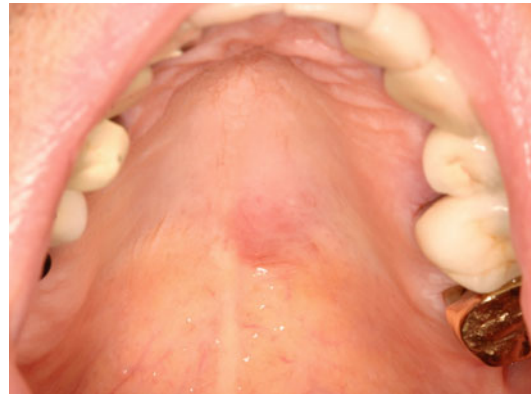

Fig. 11.19 Non-Hodgkin lymphoma of the palate with swelling and erythema

tissues. The differential diagnosis for a midline destructive process includes trauma, toxic exposure, infection, and inflammatory disorders. Biopsy is needed for definitive diagnosis, with special testing for immunohistochemical markers. This neoplasm can be very difficult to treat and has a generally poor prognosis.

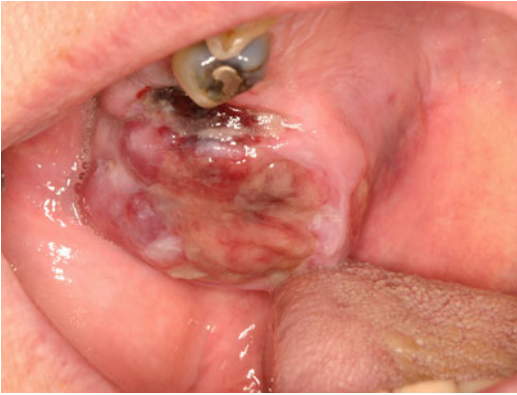

Fig. 11.20 Large right maxillary swelling with ulceration. Incisional biopsy confirmed localized recurrence of previously treated non-Hodgkin lymphoma

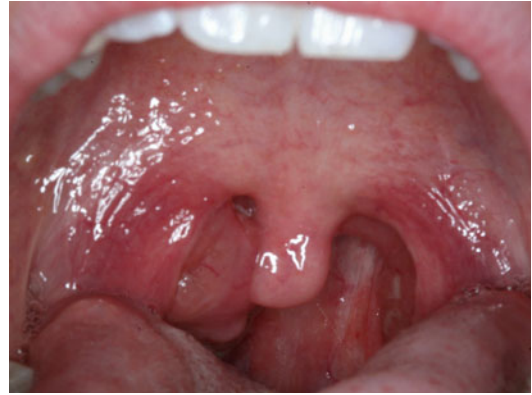

Fig. 11.21 Non-Hodgkin lymphoma of the right palatine tonsil. Note prominent asymmetric enlargement of the right tonsil

Leukemias

Overgrowth of malignant hematopoietic cells in the bone marrow with subsequent spillage into the peripheral blood leads to a reduction in the number of normal circulating blood cells. Patients can present with symptoms related to anemia, neutropenia, and thrombocytopenia. Oral findings may consist of gingival bleeding, petechiae, and mucosal ulcers (Fig. 11.22). Oral infections often present atypically, for example dental abscesses may present as soft tissue necrosis without swelling, and recrudescing HSV may present with widespread lesions affecting both the keratinized and nonkeratinized mucosa (Figs. 11.23 and 11.24). Infiltration of malignant cells into the tissues can result in mucosal nodules and gingival enlargement (Figs. 11.25 and 11.26).

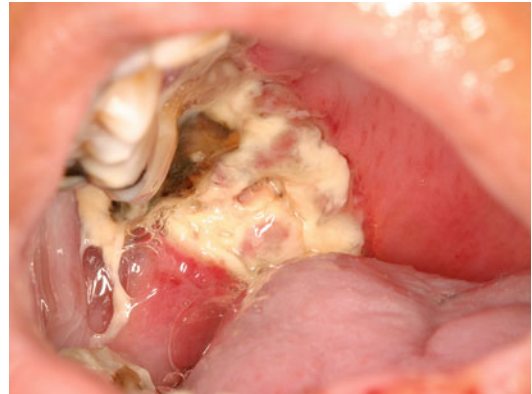

Fig. 11.22 Large neutropenic ulcer of the palate related to a carious molar in a patient with acute leukemia undergoing induction chemotherapy. The circular appearing depression within the ulcer represents the site of a punch biopsy

Metastatic Solid Tumors

Advanced solid cancers (e.g., breast, prostate, lung) have the potential to metastasize to the hard and soft tissues of the head and neck region, presenting with a wide range of possible signs and symptoms. Symptoms are typically unilateral and may include pain (constant, functional, paroxysmal), paresthesia/anesthesia (often affecting the mental region secondary to

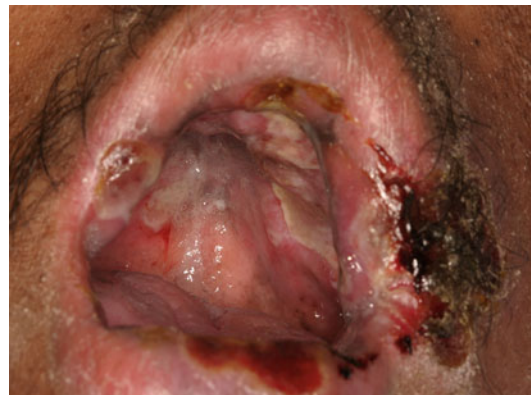

Fig. 11.23 Fulminant recrudescing herpes simplex virus infection in a patient with refractory leukemia

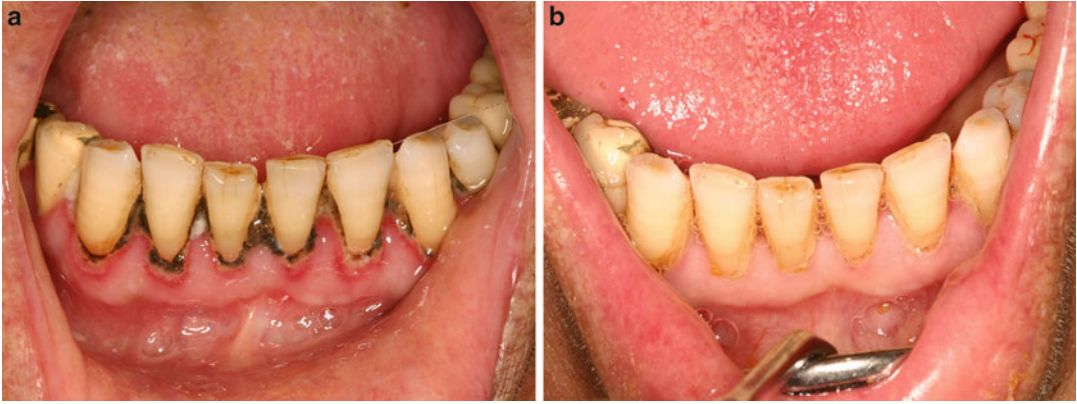


Fig. 11.24 Exacerbation of periodontal disease in a patient with acute leukemia. (a) Severe gingival erythema and marginal ulceration in response to heavy calculus deposits on the anterior mandibular teeth. (b) Complete resolution of lesions 1 week later following treatment with dental scaling and twice daily chlorhexidine rinses.

Reprinted from Oral Surgery Oral Medicine Oral Pathology Oral Radiology and Endodontology, Vol. 107, Mawardi H, Cutler C, Treister N, *Medical management update: Non-Hodgkin lymphoma*, Pages e19–e33, Copyright (2009), with permission from Elsevier

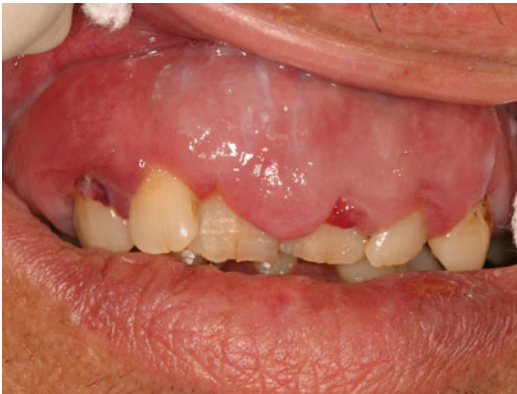

Fig. 11.25 Patient with acute myelogenous leukemia exhibiting prominent gingival involvement. Note sheet-like overgrowth, severe erythema, and focal areas of bleeding

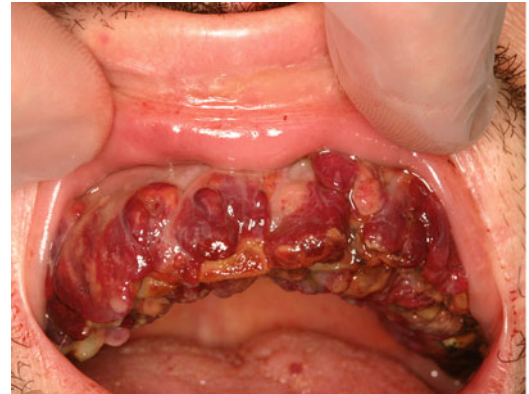

Fig. 11.26 Severe gingival overgrowth with spontaneous bleeding and areas of focal necrosis in a patient with recently diagnosed myeloproliferative disease

involvement of the body of the mandible), and muscle weakness/paralysis (due to central nervous system involvement). Clinical signs include focal swelling/enlargement, displacement/loosening of teeth, and mucosal abnormalities such as mass formation and ulceration (similar to features of squamous cell carcinoma (see Chap. 9) and lymphoma). Depending on response to cancer therapy and overall prognosis, metastatic disease may be managed palliatively (e.g., with focal radiation therapy), or symptomatically alone, with the goal of maintaining the quality of life.

Cowden Syndrome

This is an uncommon autosomal dominant disorder involving hamartomatous growths in multiple organ systems. Raised, nodular lesions can be seen on the lips, face, and intraoral mucosa, often giving tissues a “cobblestoned” or pebbly appearance (Fig. 11.27). The tongue may be prominently fissured. Mucocutaneous lesions are usually benign; however, lesions elsewhere, particularly of the breast and thyroid, have the potential for malignant transformation and must be monitored closely.

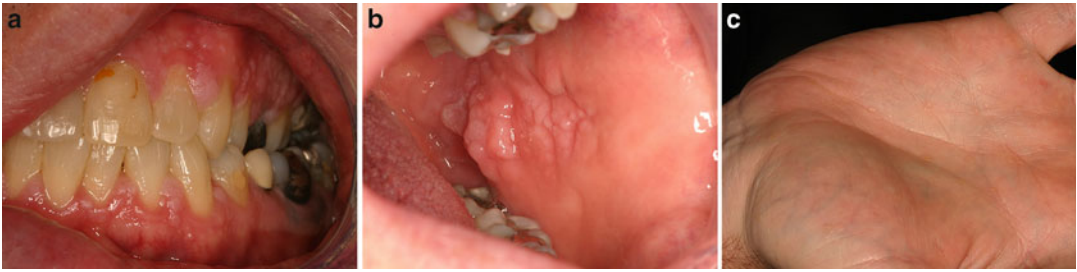

Fig. 11.27 Cowden syndrome. (a) *Pink*, papillary gingival lesions throughout the oral cavity. (b) Painless exophytic mass in the posterior buccal mucosa with focal areas of heavy keratinization. (c) Multiple painless papules of the palms





Jaundice

Jaundice, occurring secondary to liver disease, bile duct obstruction, and hemolytic disease, can be seen in the oral cavity. Tissue deposition of bilirubin, which is a byproduct of red blood cell breakdown, imparts a yellow color to the mucosa that is most pronounced in the soft palate and floor of mouth (Fig. 11.28).

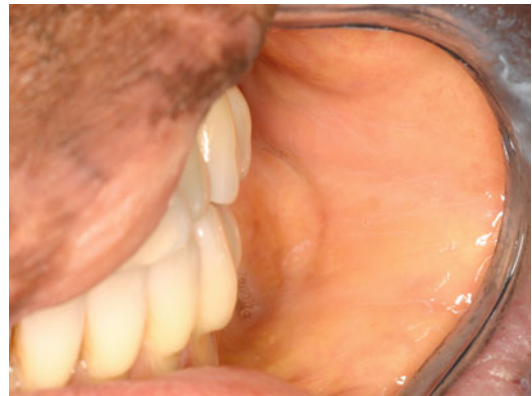

Fig. 11.28 Prominent yellow discoloration of the buccal mucosa in a patient with severe hepatic chronic graft-versus-host disease

Jaundice

	<p>DIAGNOSTIC TESTS</p>	<p>Work-up underlying cause of jaundice.</p>
	<p>BIOPSY</p>	<p>No.</p>
	<p>TREATMENT</p>	<p>Treatment of underlying medical issue.</p>
	<p>FOLLOW-UP</p>	<p>Medical follow-up.</p>

Sources

- Atmatzidis K, Papaziogas B, Pavlidis T, et al. Plummer-Vinson syndrome. *Dis Esophagus*. 2003;16:154–7.
- Baccaglioni L, Atkinson JC, Patton LL, et al. Management of oral lesions in HIV-positive patients. *Oral Surg Oral Med Oral Pathol Oral Radiol Endod*. 2007;103:S50.e1–e23.
- Badolato R, Fontana S, et al. Congenital neutropenia: advances in diagnosis and treatment. *Curr Opin Allergy Clin Immunol*. 2004;4:513–21.
- Borges A, Fink J, Villablanca P, et al. Midline destructive lesions of the sinonasal tract: simplified terminology based on histopathologic criteria. *AJNR Am J Neuroradiol*. 2000;21:331–6.
- Fatahzadeh M, Rinaggio J. Diagnosis of systemic sarcoidosis prompted by orofacial manifestations: a review of the literature. *J Am Dent Assoc*. 2006;137:54–60.
- Karlinger K, Gyorke T, Mako E, et al. The epidemiology and the pathogenesis of inflammatory bowel disease. *Eur J Radiol*. 2000;35:154–67.
- Lourenco SV, de Carvalho FR, Boggio P, et al. Lupus erythematosus: clinical and histopathological study of oral manifestations and immunohistochemical profile of the inflammatory infiltrate. *J Cutan Pathol*. 2007;34:558–64.
- Lu SY, Wu HC. Initial diagnosis of anemia from sore mouth and improved classification of anemias by MCV and RDW in 30 patients. *Oral Surg Oral Med Oral Pathol Oral Radiol Endod*. 2004;98:679–85.
- Mahajan VS, Mattoo H, Deshpande V, Pillai SS, Stone JH. IgG4-Related Disease. *Annu Rev Pathol*. 2014;9:315–47.
- Matucci-Cerinic M, Steen VD, Furst DE, et al. Clinical trials in systemic sclerosis: lessons learned and outcomes. *Arthritis Res Ther*. 2007;9 Suppl 2:S7.
- Ojha J, Cohen DM, Islam NM. Gingival involvement in Crohn disease. *J Am Dent Assoc*. 2008;138:1574–81.
- Orteu CH, Buchanan JA, Hutchison I, et al. Systemic lupus erythematosus presenting with oral mucosal lesions: easily missed? *Br J Dermatol*. 2001;144:1219–23.
- Pittock S, Drumm B, Fleming P, et al. The oral cavity in Crohn's disease. *J Pediatr*. 2001;138:767–71.
- Poate TW, Mouasim KA, Escudier MP, et al. Orofacial presentations of sarcoidosis—a case review and review of the literature. *Br Dent J*. 2008;205:437–42.
- Rahman A, Isenberg DA. Systemic lupus erythematosus. *N Engl J Med*. 2008;358:929–39.
- Rodrigo JP, Suarez C, Rinaldo A, et al. Idiopathic midline destructive disease: fact or fiction. *Oral Oncol*. 2005;41:340–8.
- Scheper MA, Nikitakis NG, Sarlani E, et al. Cowden syndrome: report of a case with immunohistochemical analysis and review of the literature. *Oral Surg Oral Med Oral Pathol Oral Radiol Endod*. 2006;101:625–31.
- Stewart C, Cohen D, Bhattacharyya I, et al. Oral manifestations of Wegerner's granulomatosis. *J Am Dent Assoc*. 2007;138:338–48.
- Tomlinson IPM, Houlston RS. Peutz-Jeghers syndrome. *J Med Genet*. 1997;34:1007–11.
- Wijn MA, Keller JJ, Giardiello FM, et al. Oral and maxillofacial manifestations of familial adenomatous polyposis. *Oral Dis*. 2007;13:360–5.

Introduction

Patients undergoing cancer therapy are at risk of developing a wide range of acute and late treatment-related toxicities and complications. Depending on the type and location of cancer as well as the treatment modality, the oral cavity may be at significant risk for development of complications. Acute oral toxicities, when severe, may contribute to the need for treatment breaks and/or dose reductions, which can negatively impact clinical outcomes. Late complications contribute to morbidity and reduced quality of life, and in some cases may be life-threatening. Management of an individual patient requires an understanding of risks specific to the cancer and planned therapy, the epidemiology, and clinical features of potential complications, and the principles of diagnosis and management. When appropriate, this chapter cross-references Chap. 7 (oral infections), Chap. 8 (salivary gland dysfunction), and Chap. 9 (oral cancer).

Principles of Dental Screening and Basic Oral Care

Principles of Dental Screening

While it is ideal for all patients undergoing cancer therapy to have a good baseline level of oral health, there are specific situations in which dental

screening prior to initiation of therapy can help reduce the risk of developing specific complications. These complications can be broadly classified as infection, mucositis, and osteonecrosis.

Infection: Patients undergoing intensive, high-dose chemotherapy regimens, including myeloablative conditioning regimens for hematopoietic cell transplantation, are at high risk for infection due to bone marrow toxicity and myelosuppression. As untreated dental disease is an important source of infection, all potential odontogenic infections should be identified and managed definitively prior to initiation of chemotherapy.

Mucositis: Patients undergoing intensive high-dose chemotherapy regimens, myeloablative hematopoietic cell transplantation, and chemoradiation therapy to the head and neck are all at significant risk for developing oral and oropharyngeal mucositis. As trauma to the oral mucosa is a well-recognized risk factor, any teeth with sharp and/or fractured cusps or restorations should be smoothed or replaced prior to initiation of cancer therapy. Removable oral prostheses should similarly be evaluated so that any poor fitting areas can be corrected. In patients undergoing head and neck chemoradiation therapy, teeth with large metallic dental restorations may be at increased risk due to localized scattering effect.

Osteonecrosis of the jaw (ONJ): Systemic administration of antiresorptive therapies as well as head and neck chemoradiation therapy are

both associated with an increased risk of developing ONJ. As dental extractions are a well-recognized risk factor for precipitating development of ONJ, it is ideal to avoid the need for extractions once exposed and at risk. Therefore any non-restorable teeth, or teeth with poor long-term prognosis, should be extracted prior to initiation of cancer therapy. Poorly fitting dentures have also been identified as a potential risk factor for development of ONJ.

Dental screening can be completed by a patient's community dentist (Table 12.1). Evaluation includes a dental history, dental radiographs, and clinical examination including complete dental charting. All patients should receive dental scaling and prophylaxis within 3 months of initiating cancer therapy. Dental caries should be treated definitively. Teeth with untreated periapical disease require endodontic therapy or extraction; however persistent and stable periapical radiolucencies in endodontically treated teeth that are otherwise asymptomatic do not require retreatment. Teeth with advanced periodontal disease and significant mobility should be extracted. Partially erupted third molars with history of recurrent pericoronitis (i.e., inflammation and infection of the overlying gingiva) should be extracted. When indicated, dental extractions should ideally be completed at least 1 week prior to initiation of cancer therapy to allow for adequate initial healing.

Table 12.1 Dental screening guidelines prior to initiation of cancer therapy

Clinical finding	Management
Dental caries	Caries control, endodontic therapy or extraction of non-vital/abscessed teeth
Defective or missing dental restorations	Replace restoration, eliminate sharp edges
Periapical pathology	Endodontic therapy or extraction. No treatment necessary for previously endodontically treated teeth with persistent periapical pathology without evidence of infection
Periodontal disease	Scaling and root planing, extraction of hopeless teeth
Pericoronitis	Extraction of associated third molar
Removable prostheses	Evaluate for fit and make adjustments as indicated

Basic Oral Care

Patients undergoing cancer therapy should maintain good oral hygiene throughout their course of care in order to reduce the risk of developing oral complications. Patients should brush their teeth with a soft toothbrush and toothpaste at least twice daily and whenever possible after meals. Patients should continue to floss their teeth daily, even in the context of chemotherapy-induced thrombocytopenia. Daily neutral oral rinses with saline or salt and baking soda can help to keep the mouth clean of debris, moist, and comfortable. Antimicrobial mouth rinses with chlorhexidine gluconate may be incorporated into basic oral care regimens, in particular in patients with a history of periodontal disease and gingival inflammation. Patients with dentures should remove and disinfect their prostheses nightly.

In addition to patient-directed oral hygiene measures, the oral cavity should be professionally assessed on a routine basis throughout the course of cancer care. The importance of good oral hygiene should be reinforced. Patients should be asked about any changes or discomfort in the mouth. A health professional (e.g. nurse, oncologist) should examine the oral cavity visually, with good illumination, to assess for the presence of candidiasis, mucositis, and other soft tissue abnormalities.

Surgery

Surgery for head and neck cancer causes a wide variety of functional, neurologic, and cosmetic impairments, some extremely debilitating and resulting in poor quality of life despite local control of disease.

Functional Deficits

Patients may be left with anatomic defects including oro-antral or oro-nasal communication requiring obturation with prosthetic appliances, large defects in tooth-bearing bone which cannot be effectively restored to a level supporting

adequate mastication, and trismus (see Chap. 9). Such defects can significantly impact the ability to maintain oral intake and basic oral hygiene. Obturators are often bulky, uncomfortable, functionally inadequate, and difficult for the patient to manipulate. Some surgical defects can be repaired or obliterated with bone and soft tissue transfer flaps, however the functional capability of the reconstructed tissue often does not fully replace what was lost, leaving patients with significant speech and swallowing deficits.

Neurologic Deficits

Surgical disruption of neural pathways results in denervation of tissue, with muscle atrophy, loss of motor function, and sensory impairment. Cranial nerve deficits are common following head and neck cancer procedures, with potential alteration of vision, taste, smell, tongue mobility, soft palatal movement, pharyngeal muscle contraction, pharyngeal sensation, and vocal fold mobility. Such deficits will additionally contribute to functional impairment of speech, mastication, swallowing, and respiration. Neuropathic pain is also common due to the poor regenerative capability of nerve tissue and can be a source of significant morbidity. Misguided nerve regeneration can result in Frey's syndrome, also known as *gustatory sweating*, following parotid surgery. In this condition, nerve fibers controlling salivary gland secretion are redirected to superficial sweat glands, causing sweat to form on the face with salivary stimulation.

Cosmetic Deficits

Surgical defects and scars involving the head and face, unlike other areas of the body, are difficult to hide or disguise and cause many patients to feel insecure or depressed and to withdraw socially. A multidisciplinary approach to this issue is important to address psychosocial as well as physical concerns. Well-constructed maxillofacial prostheses can camouflage certain defects that are hard to reconstruct otherwise, such as orbital defects. Secondary cosmetic procedures

are available to minimize scar visibility and facial asymmetry, as well as reanimation procedures to address facial nerve deficits.

Chemotherapy

Early or localized head and neck cancer is generally treated with primary surgery or radiation therapy, whereas chemotherapy is reserved for locally advanced, metastatic, or recurrent disease.

General Considerations

Platinum-based chemotherapy agents (cisplatin, carboplatin) are the mainstay of treatment for most head and neck malignancies, particularly if advanced. These agents have multiple adverse side effects, including neurotoxicity, nephrotoxicity, ototoxicity, and severe GI upset. Chemotherapy is often given concurrently with radiation therapy, adding to overall morbidity and compounding the patient's ability to tolerate treatment. Taxanes (paclitaxel, docetaxel) act on microtubule formation during mitosis to block cell division and are often used in conjunction with platinum-based agents. Side effects are numerous, with bone marrow suppression being the potentially most dangerous. Cetuximab is a monoclonal antibody-derived epidermal growth factor inhibitor used as a first-line treatment in conjunction with radiation therapy. Side effects include skin reactions, angioedema, and anaphylaxis; patients must be premedicated with systemic steroids and diphenhydramine. Autologous hematopoietic cell transplantation (also referred to as *bone marrow transplantation*) with autologous stem cell rescue for lymphoma, multiple myeloma, and other cancers involves intensive high-dose chemotherapy to eradicate the bone marrow and recondition the immune system for replacement with the patient's previously harvested stem cells. Patients are at high risk for complications related to myelosuppression following this aggressive chemotherapy regimen. Allogeneic hematopoietic cell transplantation is discussed below in Sect. 12.7.

Bleeding

Myelosuppression with thrombocytopenia can cause serious complications with respect to bruising and bleeding. Common sources are from the GI and respiratory tract, such as bleeding from the periodontium and epistaxis, as well as bleeding from minor skin wounds and heavy menstrual flow. Life-threatening internal bleeding can occur as well and patients are counseled to avoid behaviors that could lead to any injuries with bleeding consequences including avoidance of contact sports.

Infection

Progressive neutropenia increases potential for opportunistic infection, and prophylactic treatment with granulocyte/macrophage stimulating growth factors and/or antimicrobial agents may be required. Patients are particularly at risk for odontogenic infections, candidiasis, and HSV. Skin, respiratory, and urinary tract infections are also common. Patients are counseled to perform careful hand hygiene, avoid crowds, refrain from eating raw foods, and maintain good oral health.

Pain





Pain is unfortunately a common side effect of chemotherapy. Neurotoxicity causing neuropathy with burning, numbness, or shooting pain can be

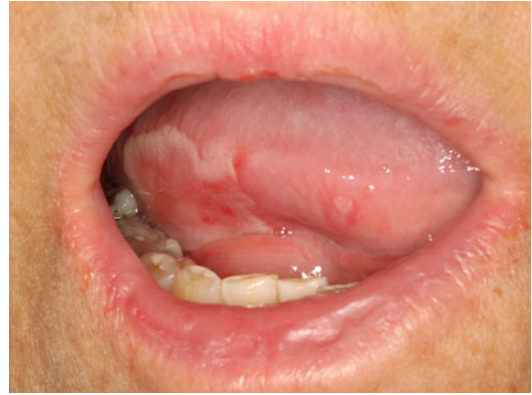

Fig. 12.1 Typical chemotherapy-induced oral mucositis of the right lateral tongue in a patient undergoing cycled chemotherapy for breast cancer

extremely debilitating for patients. Painful mucositis involving the oral cavity (*stomatitis*, Fig. 12.1), laryngopharynx (*pharyngitis*), and esophagus (*esophagitis*) can cause functional disability with respect to speech, mastication, and swallowing. Patients are advised to avoid astringent mouthwashes containing alcohol and eat soft/bland foods at room temperature. In severe cases, patients may require systemic pain medication, topical anesthetic/anodyne agents, or placement of a feeding tube. Headache, myalgia, joint pain, and abdominal pains also frequently plague patients on a daily basis and diminish the overall quality of life.

Pain

	DIAGNOSTIC TESTS	Blood work or cultures as needed to rule out other underlying cause for symptoms (anemia, vitamin deficiency, bacterial superinfection, candida).
	BIOPSY	No.
	TREATMENT	Topical anesthetics such as magic mouthwash. Limit diet to bland foods. Systemic analgesics. Consider therapies used for management of burning mouth syndrome such as topical clonazepam solution. Encourage continued oral hygiene measures.
	FOLLOW-UP	Patients should be followed to assess the response to therapy and/or changes in symptoms.

Dysgeusia and Dysphagia

Many chemotherapy agents result in decrease or loss of appetite as well as sense of taste. Patients may experience diminished sensation of basic flavors (*hypogeusia*) or alteration of taste with aberrations such as a metallic taste (*dysgeusia*). Associated conditions, such as mucositis, xerostomia, and oral candidiasis can compound taste issues as well. Taste alteration may be either temporary or permanent, but is generally very bothersome to the patient. Swallowing problems during chemotherapy are most often related to mucositis, causing painful swallowing and contributing to overall poor nutritional intake.

Targeted Therapy

Targeted therapies represent a novel approach to cancer therapy, targeting specific molecules and pathways that are abnormally expressed or activated in cancer cells. Targeted therapies have been associated with unique toxicities that differ significantly from those associated with traditional cytoreductive chemotherapy agents. Several classes of targeted therapies have been associated with oral adverse events, which when severe, can require dose modifications or even drug discontinuation.

Mammalian Target of Rapamycin Inhibitors

The mammalian target of rapamycin (mTOR) pathway plays a central role in cell growth and proliferation and is upregulated in a number of cancers. Inhibitors of mTOR, including everolimus and temsirolimus, are FDA approved for management of certain cancers (e.g. renal cell carcinoma and breast cancer) and are actively being evaluated in many other types of cancer. One of the most frequent side effects of mTOR inhibitors is oral aphthous-like ulcerations, termed *mTOR inhibitor associated stomatitis* so as to differentiate from classical mucositis secondary to chemotherapy (see Sect. 12.4). Oral

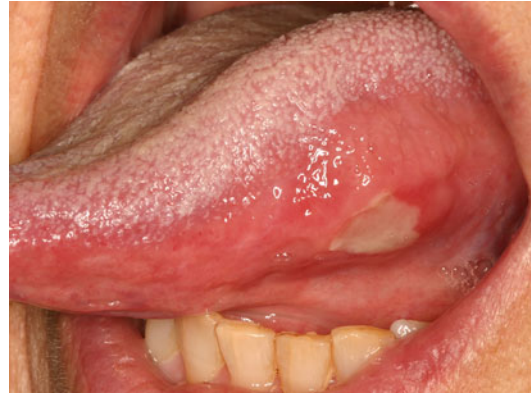

Fig. 12.2 Aphthous-like focal ulceration of the left ventrolateral tongue that developed within 1 week of initiation of mTOR inhibitor therapy

ulcers typically present within the first 2 weeks of therapy and tend to dissipate over time without dose reduction. Ulcers resemble classic aphthae, appearing round to ovoid with sharply demarcated erythematous borders and ranging in size from millimeters to 1–2 cm (Fig. 12.2). Case reports and series as well as expert opinion support the use of topical, intralesional, and in some cases systemic steroid therapy for management of these oral ulcers. In extensive cases associated with significant disability, dose reduction and/or discontinuation must be considered.

Multi-Targeted Tyrosine Kinase Inhibitors





Inappropriate tyrosine kinase signaling activity is a hallmark of a number of cancers, and as such, the class of multi-targeted tyrosine kinase inhibitors (TKIs) has demonstrated significant anti-cancer activity, with approvals for certain cancers and many ongoing trials in others. Multi-target TKIs include sunitinib, sorafenib, pazopanib and cabozantinib, with many others in development. Sunitinib was the first-approved agent of this class and clinical experience with this agent is greatest. “Stomatitis” or “Mucositis” is a frequently reported adverse event associated with multi-targeted TKI therapy, however, it is characterized by pain and sensitivity in the

absence of mucosal changes and therefore does not resemble the classic appearance of mucositis. Symptoms tend to lessen with time although dose reduction may be necessary. Management includes topical anesthetics and a bland diet.

Limited experience suggests the treatment approaches for burning mouth syndrome (see Chap. 10) may be effective.

Imatinib has been associated with mucosal pigmentation changes (see Chap. 6).

Multi-Targeted Tyrosine Kinase Inhibitors

	DIAGNOSTIC TESTS	None.
	BIOPSY	No.
	TREATMENT	Topical anesthetics such as magic mouthwash. Limit diet to bland foods. Consider therapies used for management of burning mouth syndrome such as topical clonazepam solution. In severe cases consider dose reduction or discontinuation.
	FOLLOW-UP	Patients should be followed to assess the response to therapy and/or changes in symptoms. Symptoms may resolve with time despite ongoing TKI therapy.

Antiresorptive Therapies

Antiresorptive therapies effectively inhibit progression of bone metastases and reduce the risk of developing skeletal-related events including fractures and pain. Bisphosphonates and denosumab, through different mechanisms of action, reduce osteoclast activity thereby resulting in profound antiresorptive effects.

Medication-related osteonecrosis of the jaws (MRONJ) is characterized by exposed non-vital bone in the mandible or maxilla in patients treated with various antiresorptive and antiangiogenic medications. The most frequently associated medications are bisphosphonates. Compared with the jaws, other bones in the body (e.g., temporal bone, limbs) have been rarely affected. Although the vast majority of cases occur in cancer patients treated with high-dose intravenous bisphosphonates and denosumab (primarily for multiple myeloma and metastatic breast, lung, and prostate cancers), there have also been reports of this occurring in patients taking oral bisphosphonates for osteoporosis. Antiangiogenic agents that have been associated with MRONJ, in the absence of concurrent antiresorptive therapies, include bevacizumab,

sunitinib, and cabozantinib. Osteoradionecrosis is a similar clinical condition associated with head and neck radiation therapy and is discussed below in Sect. 12.6 as well as in Chap. 9.

Precipitating factors include oral infections, dental extractions, and local trauma; however, cases may develop spontaneously with no obvious inciting event. Although the precise pathophysiology is unclear, it is likely due to a combination of the following factors: (a) osteoclast inhibition and profound suppression of bone turnover and repair mechanisms, as well as increased bone mineralization and loss of microvasculature, (b) oral microflora, separated from the periosteum by only a very thin layer of mucosa that is easily breached, (c) relative frequency of dental infection in the adult population, and (d) exposure and injury of alveolar bone during oral surgical procedures.

Lesions appear as yellow or white areas of exposed necrotic bone ranging from a few millimeters to several centimeters in length (Fig. 12.3). The surface may be rough, causing tongue irritation and occasionally traumatic ulceration (Fig. 12.4). The surrounding soft tissue is often erythematous and swollen in response to heavy bacterial colonization of the

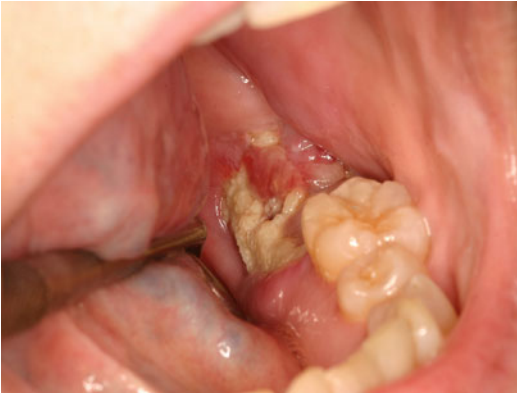

Fig. 12.3 Medication-related osteonecrosis of the jaw (MRONJ) affecting the posterior left mandible following dental extraction in a cancer patient with a history of IV bisphosphonate therapy. Note ragged-appearing necrotic bone and secondarily infected hyperplastic and edematous surrounding soft tissue

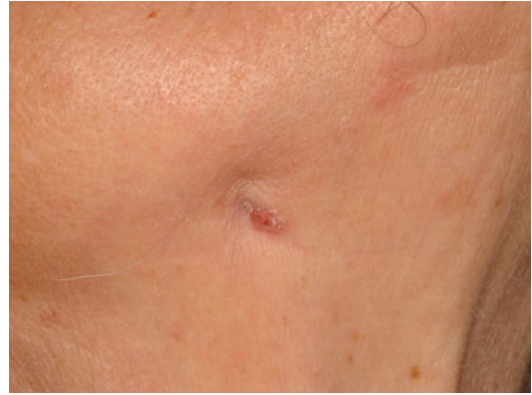

Fig. 12.5 Extraoral fistula in a patient with advanced MRONJ of the right mandible

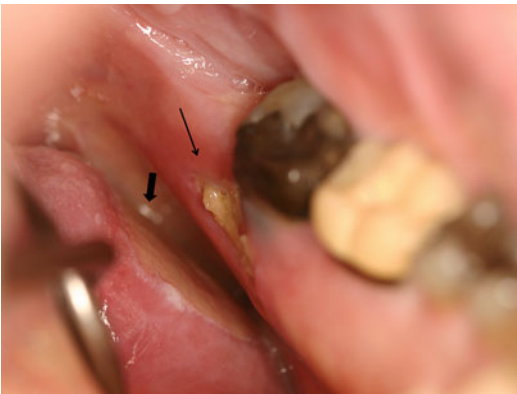

Fig. 12.4 Ulceration of left lateral tongue (*short arrow*) secondary to friction against sharp edges of exposed necrotic bone on the left mylohyoid ridge (*long arrow*). The patient experienced pain radiating down the throat. The bone was smoothed with a file and the ulcer was injected with triamcinolone acetonide, resulting in immediate pain relief and rapid healing. Reprinted from Oral Surgery Oral Medicine Oral Pathology Oral Radiology and Endodontology, Vol. 105, Treister NS, Richardson P, Schlossman R, et al., *Painful tongue ulcerations in patients with bisphosphonate-associated osteonecrosis of the jaws*, Pages e1–e4, Copyright (2008), with permission from Elsevier

non-vital bone, and purulent discharge may be noted. Rarely, extraoral fistula formation may develop secondary to deep infection into the

bone (Fig. 12.5), or the mandible may become severely brittle and be at risk for pathologic fracture. Although radiographic studies are not required for diagnosis, panoramic radiography, or CT imaging should be obtained if the response to initial therapy is inadequate or complications are suspected (Fig. 12.6).

Treatment is directed at alleviation of symptoms rather than achieving complete wound healing. Sharp bone edges can be smoothed with a bone file without the need for local anesthesia, as the bone is non-vital. Mobile bone fragments, or *sequestra*, can likewise be removed with a curette or rongeur (Fig. 12.7). Pain in most cases results from secondary adjacent soft tissue infection, which can be treated with topical and/or systemic antimicrobial agents. In cases of recurrent soft tissue infection or gross purulence, patients may require long-term antibiotics. Aggressive surgical intervention should be avoided in the majority of patients. If pain persists with eating despite conservative therapy and infection control, fabrication of a surgical stent can be effective in reducing or eliminating symptoms (Fig. 12.8).

Dental screening should be completed prior to initiation of antiresorptive therapies (see Sect. 12.1). For patients at risk for developing MRONJ (e.g. requiring a dental extraction) as well as patients with established MRONJ, the effectiveness of the alternate/reduced dosing regimens remains unclear.

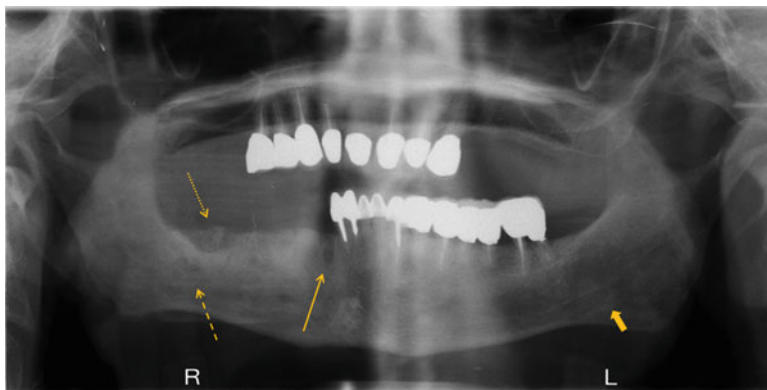


Fig. 12.6 Characteristic radiographic features of MRONJ. On the right side there is a persistent socket in the premolar region where a tooth was extracted 2 years previously (*long solid arrow*), surface irregularity with bone sequestration (*dotted arrow*), and generalized sclero-

sis with loss of definition of the inferior alveolar canal (*dashed arrow*). Note comparison to the left side, which appears relatively normal. The left inferior alveolar canal is clearly visualized (*short solid arrow*)

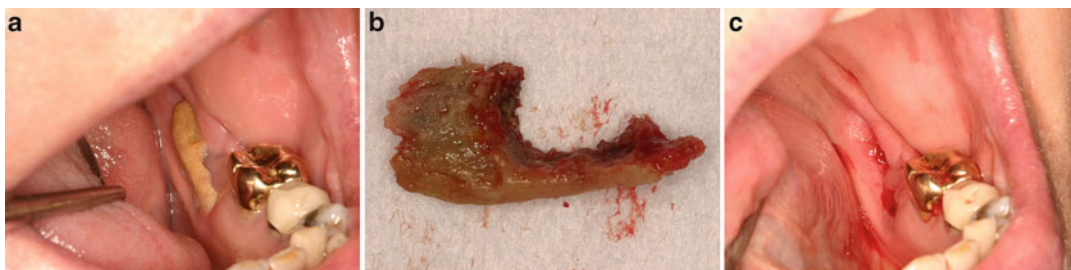

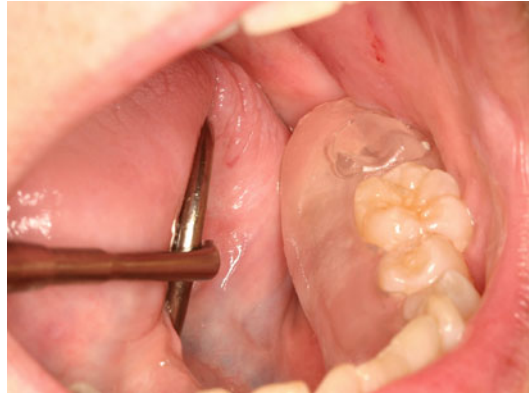Fig. 12.7 MRONJ with a large area of exposed necrotic bone on the left mylohyoid ridge with healthy appearing surrounding soft tissue. (a) Palpation of the bone demonstrated mobility, indicating a large necrotic bone seques-

trum. (b) Bony sequestrum that was removed painlessly with a rongeur without local anesthesia. (c) Immediately following sequestrum removal

Medication-related osteonecrosis of the jaw

	<p>DIAGNOSTIC TESTS</p>	<p>None; consider panoramic radiography or CT if presence of fracture or large sequestrum is suspected.</p>
	<p>BIOPSY</p>	<p>No, unless there is clinical suspicion for metastatic disease.</p>
	<p>TREATMENT</p>	<p>Only symptomatic lesions require treatment. Rough or irregular bone edges causing tissue irritation should be made smooth and loose nonvital bone fragments should be removed. Soft tissue infection without significant swelling or purulence can typically be managed with chlorhexidine rinses alone; otherwise a 7–10-day course of systemic antibiotic should be prescribed. Ideally, antibiotic selection should be culture directed; however, most organisms are sensitive to the penicillin group. Quinolones, metronidazole, clindamycin, and erythromycin are acceptable alternatives in penicillin-allergic patients. Long-term antibiotic management may be necessary in refractory situations, in particular those with recurrent episodes of pain and swelling.</p>
	<p>FOLLOW-UP</p>	<p>Patients must be followed closely initially to assess the response to therapy. Patients with stable lesions that are asymptomatic should be evaluated every 6 months.</p>

Fig. 12.8 Placement of a protective acrylic stent over the extraction site in the patient from Fig. 12.3 to prevent food impaction and soft tissue irritation



Radiation Therapy

General Considerations

External beam radiation therapy (EBRT) involves delivery of high energy X-rays or proton beams to the target tissue to destroy cancer cells, with additional collateral damage to non-cancerous tissues in the field of radiation. The total calculated dose is divided into daily or twice daily fractions over many weeks' time, as delivery in fewer doses would be too toxic to the host. Dosage is expressed as the amount of absorbed energy in units of Gray (Gy) or centigray (cGy). The unit of centigray is equivalent to (as previously used in the United States) "rad". For example, 70Gy=7000 cGy or rads. Intensity-modulated radiation therapy (IMRT) is a newer form of EBRT, in which computer programs precisely map the 3D configuration of the tumor and enable modulation of the intensity of the radiation beam to focus a higher dose to the tumor itself while minimizing the dose to surrounding tissue.

Mucositis

Mucositis occurs as a result of direct and indirect damage to the oropharyngeal epithelium, which

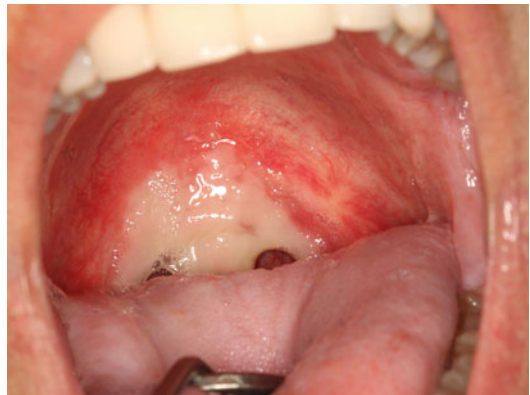

Fig. 12.9 Radiation-induced oral mucositis of the soft palate in a patient undergoing therapy for squamous cell carcinoma of the oropharynx

has a rapid rate of cell turnover and is thus very susceptible to injury. The incidence of mucositis during treatment for head and neck cancer is high, although varies with the dose of ionizing radiation as well as location and volume of the tumor. Painful erythematous and ulcerative mucosal lesions occur, affecting nutritional intake, overall quality of life, and serving as a potential portal of entry for infection (Fig. 12.9). If severe, mucositis can compromise the patient's ability to continue with the planned treatment protocol and thereby compromise treatment outcome. Management revolves around pain relief, nutritional support, and control of superinfection.

Xerostomia

Radiation therapy causes temporary and long-term effects on soft and hard tissues within the field of radiation, with resulting tissue hypocellularity, hypovascularity, and hypoxia. The salivary glands are particularly susceptible to injury and resulting hypofunction is common with standard radiation protocols used for head and neck cancer. The degree of salivary gland damage is dose-dependent and compounded by concurrent chemotherapy. Saliva serves a variety of functions, with antimicrobial, digestive, antacid, and lubricative properties. The ramifications of salivary hypofunction are broad, including increased incidence of oral infections and dental caries, dysgeusia, denture instability, pain, thickened secretions, and difficulty with mastication. Chronic xerostomia also contributes to atrophy of the oral mucosa and swallowing difficulties.

Dysgeusia, Trismus, Dental Caries

As with chemotherapy (Sect. 12.4.5), altered taste sensation is a common complication of radiotherapy. Decreased enjoyment of food significantly impacts on the patient's quality of life and is often compounded by other side effects of treatment including xerostomia, dysphagia, mucositis, and candidiasis. The mechanism is believed to be due to direct injury to taste buds and salivary glands, and recovery of taste following treatment is overall less likely to occur than seen with chemotherapy. Unfortunately, there is no specific treatment for this problem.

Trismus, with limited mouth opening due to radiation-induced fibrosis of both the joint itself as well as muscles of mastication, can severely limit a patient's ability to eat and maintain adequate oral hygiene. Symptoms generally manifest in the first several months following treatment and progress over ensuing months to years. Preventative strategies, including physical ther-

apy and stretching exercises, are helpful to decrease potential for developing trismus but are less effective in treating the condition once it has progressed.

Dental caries in setting of radiation-induced xerostomia can be quite rampant and devastating. The loss of protective elements in saliva promotes a shift in oral microflora to favor acidogenic and cariogenic organisms, with potentially rapid progression of disease. The cervical aspects of teeth at the junction of crown and root are particularly affected, however all tooth surfaces may be involved. Preventative strategies, including meticulous oral hygiene, regular professional dental care, and frequent fluoride applications, are critical to minimizing damage and must be maintained lifelong.

Osteoradionecrosis

Osteoradionecrosis (ORN) of the jaws is a potentially serious complication of radiation therapy which affects the viability of bone tissue and its ability to withstand even minor trauma such as dental extraction or superficial mucosal ulceration. It can occur spontaneously as well, although more likely to result in the setting of tissue injury. Risk for developing ORN is considered to be dose-related, particularly with total dose greater than 60 Gy. Risk does not diminish with time and is increased with combined chemo- and radiation therapy. Bone destruction can be extensive, with large segments of devitalized bone, bony sequestrae, orocutaneous fistulization, pathologic fracture, and potential superinfection. Treatment consists of surgical debridement of necrotic tissue, hyperbaric oxygen therapy (HBOT) to facilitate wound healing and promote neovascularization, and use of antibiotics if superinfection is suspected. Patients who are at high risk for development of ORN require procedures post-radiation, such as dental extractions, should be considered for prophylactic HBOT.

Dysphagia

Radiation treatment can affect swallowing function in early and late stages. Early effects are related to temporary xerostomia during treatment as well as pain, bleeding, or ulceration from mucositis. Late effects involve permanent xerostomia due to salivary gland damage, trismus, pharyngeal or esophageal strictures, and dental issues related to osteoradionecrosis and caries. Progressive fibrosis of soft tissues can result in fixation of the hypolaryngeal complex many years after treatment with functional reduction in the oral and pharyngeal phases of the swallow mechanism and increased potential for aspiration.

the less-intensive regimens associated with significantly lower risk of acute complications such as mucositis and infections (see Sect. 12.4). Conventional graft-versus-host disease prophylaxis regimens typically include methotrexate and a calcineurin inhibitor, with methotrexate also being a contributing factor to mucositis risk.

Allogeneic Hematopoietic Cell Transplantation

Allogeneic hematopoietic cell transplantation (HCT) is a cellular therapy that effectively treats a number of hematologic malignancies, hemoglobinopathies, and bone marrow failure syndromes by replacing diseased marrow with healthy HLA-matched marrow from a related or unrelated donor. Conditioning regimens can be myeloablative or reduced intensity/non-myeloablative, with

Acute Graft-Versus-Host Disease

Acute graft-versus-host disease (GVHD) typically develops within the first 100 days after allogeneic HCT and is characterized by an erythrodermatous skin rash, elevated liver transaminases, and gastrointestinal involvement. The oral cavity is infrequently affected, but when involved presents with erythema multiforme-like features that can be quite severe, including diffuse, non-specific ulcerations of the keratinized and non-keratinized oral mucosa, lip ulceration/crusting is also common (Fig. 12.10). Oral acute GVHD can be differentiated from mucositis based on the onset occurring after engraftment, following the period of mucositis risk. Acute GVHD is managed with systemic steroids and oral cavity involvement can be managed with ancillary topical steroids.

Acute Graft-Versus-Host Disease





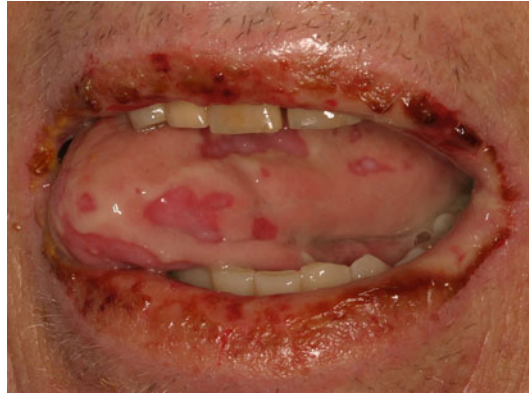	DIAGNOSTIC TESTS	Consider viral culture to rule out HSV recrudescence.
	BIOPSY	No, unless diagnosis is unclear.
	TREATMENT	In addition to systemic corticosteroids, topical steroid solution rinses for management of the oral cavity. Topical tacrolimus ointment for lip involvement.
	FOLLOW-UP	Patients must be followed carefully to assess response to therapy. Acute GVHD may transition into chronic GVHD.

Fig. 12.10 Acute GVHD affecting the oral cavity with diffuse ulceration and crusting of the lips and extensive ulceration of the ventrolateral and dorsal tongue



Chronic Graft-Versus-Host Disease

Chronic GVHD develops in greater than 50% of patients, usually within 6–12 months of allogeneic HCT, and frequently involves the oral cavity, skin, liver, and eyes. While chronic GVHD can follow acute GVHD, it can also develop without any history of acute GVHD. Alloreactive donor T-cells recognize host tissue antigens as “foreign” and mount an immune response to the host tissue that mimics a variety of autoimmune diseases. In addition to systemic immunosuppressive therapy, many patients require intensive organ-specific ancillary treatment for management of their symptoms. Although allogeneic HCT is only performed in highly specialized medical centers, most patients return to their local communities for follow-up care, so it is essential that their doctors are able to recognize the signs and symptoms of this disorder.

Oral chronic GVHD targets the mucosa and salivary glands. In some cases, these may be the initial (or only) sites exhibiting findings. Mucosal lesions are essentially identical to those of *oral lichen planus* (see Chap. 5) and are characterized clinically by reticulation, erythema, and ulceration (Fig. 12.11). *Superficial mucocelles* (see Chap. 8) of the palate, or less frequently on the labial and buccal mucosa, are common and are caused by inflammation of the minor salivary glands (Fig. 12.12). These noninfectious subepithelial vesicles often develop acutely

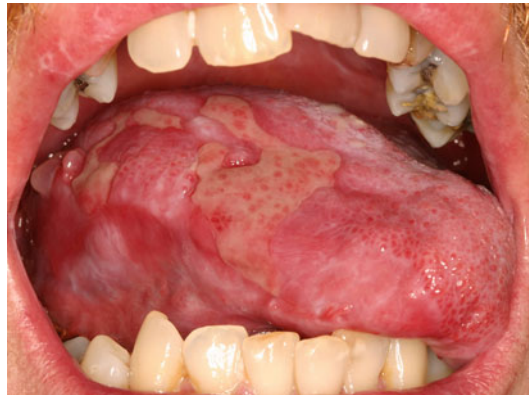

Fig. 12.11 Large ulceration with erythema and reticulation of the tongue in a patient with severe oral chronic graft-versus-host disease

during meals, are generally more annoying than painful, and resolve spontaneously within hours to days. If the major salivary glands are involved, patients may complain of xerostomia; the presentation in these cases is similar to that seen with *Sjögren syndrome* and patients are at significantly increased risk for developing dental caries (Fig. 12.13). Diagnosis of oral chronic GVHD is primarily based on history and clinical examination. Sclerodermatous cutaneous chronic GVHD can affect the perioral skin leading to limited opening and pain, similar to patients with *scleroderma* (see Chap. 11). Intraorally, fibrotic bands can develop following longstanding oral mucosal cGVHD, leading to similar complications (Fig. 12.14).

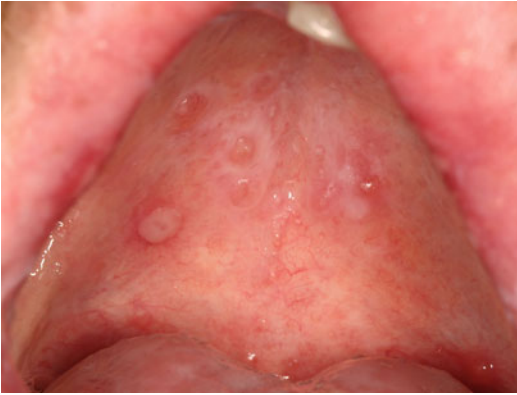

Fig. 12.12 Multiple superficial mucocoeles of the palate with associated reticulation in a patient with chronic graft-versus-host disease

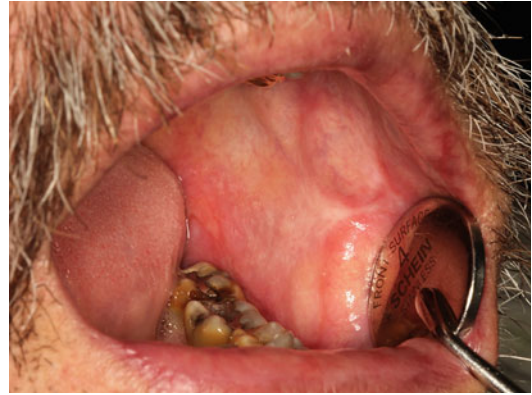

Fig. 12.14 Extensive fibrotic band formation of the buccal mucosa with limited mouth opening in a patient with longstanding and quite severe oral mucosal chronic GVHD

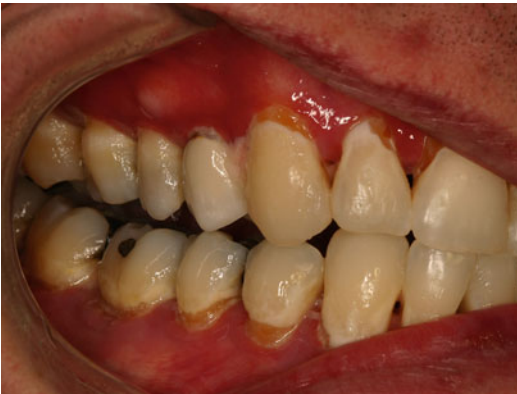

Fig. 12.13 Extensive cervical decay in a patient with oral chronic graft-versus-host disease





Treatment of mucosal lesions includes use of topical steroids and topical tacrolimus, both of which are easily and effectively applied in rinse form, especially when disease is extensive. Tacrolimus ointment works well for lesions on the lips. Salivary gland disease can be managed with prescription sialogogue therapy as well as over-the-counter dry mouth treatments. Patients

with evidence of salivary gland disease should receive daily topical fluoride therapy. Dental caries should be treated aggressively, and dental radiographs should be obtained annually to monitor for new carious lesions. Patients with significant oral sclerotic disease may benefit from intensive physical therapy.

Secondary Malignancy

Patients with a history of allogeneic HCT and chronic GVHD have a significantly increased risk for developing secondary malignancies, with oral squamous cell carcinoma being one of the most frequent (see Chap. 9, Fig. 12.15). The relative risk increases with time post-HCT. Even if asymptomatic, all patients must receive an annual oral cancer screening with biopsy of any suspicious lesions (Fig. 12.16). Atypical areas of oral chronic GVHD (e.g. dense hyperkeratotic plaques) should be followed closely.

Chronic Graft-Versus-Host Disease

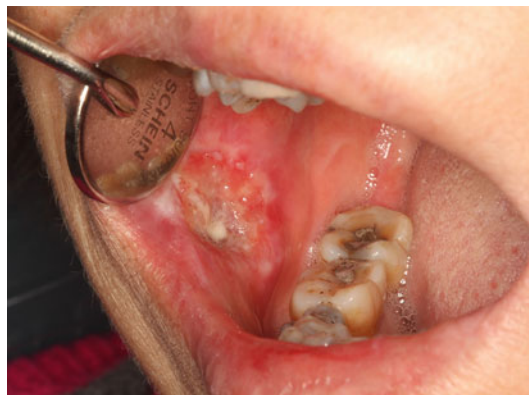	DIAGNOSTIC TESTS	None; consider viral culture of ulcerative lesions to rule out HSV infection.
	BIOPSY	No, unless diagnosis of chronic GVHD is unclear or there is concern for malignancy.
	TREATMENT	<p>Treatment is directed at managing symptoms. Many patients require intensive local therapy in addition to systemic immunosuppressive treatment.</p> <p>For <i>mucosal disease</i>: Topical steroid and tacrolimus rinses, which can be used in combination (swish for 5 min then spit, up to six times daily). Painful ulcerative lesions may benefit from intralesional triamcinolone therapy as well as intensive topical therapy with clobetasol gel. Use of mild toothpaste is effective for patients with toothpaste sensitivity. Depending on symptoms, patients should be advised to avoid acidic, spicy, and hard or crusty foods as well as carbonated beverages.</p> <p>For <i>salivary gland disease</i>: Over the counter lubricant rinses and gels as well as use of sugar-free gum and candy can be helpful. Prescription sialogogue therapy with pilocarpine or cevimeline can be effective. All patients should receive daily prescription topical fluoride (5,000 ppm). Regular dental visits with radiographic evaluation are necessary to identify and treat xerostomia-related dental caries.</p>
	FOLLOW-UP	Initially close follow-up to assess response to therapy, then annually for oral cancer screening and dental exam.

Pediatric Oncology Considerations

Pediatric cancer patients, depending on the diagnosis and treatment plan, are at risk for developing all of the potential complications described within this chapter. In addition pediatric patients are at risk for treatment-related dental/orofacial abnormalities. Chemotherapy and/or radiation

can adversely affect the developing teeth and jaws, with younger patients, especially below the age of 6, being at highest risk for developing abnormalities including tooth agenesis, microdontia, and stunted growth of the maxillofacial bones. While these changes can have esthetic and functional implications, most affected patients do not require any specific intervention.

Fig. 12.15 Invasive squamous cell carcinoma of the left buccal mucosa arising in a patient with longstanding oral mucosal chronic GVHD



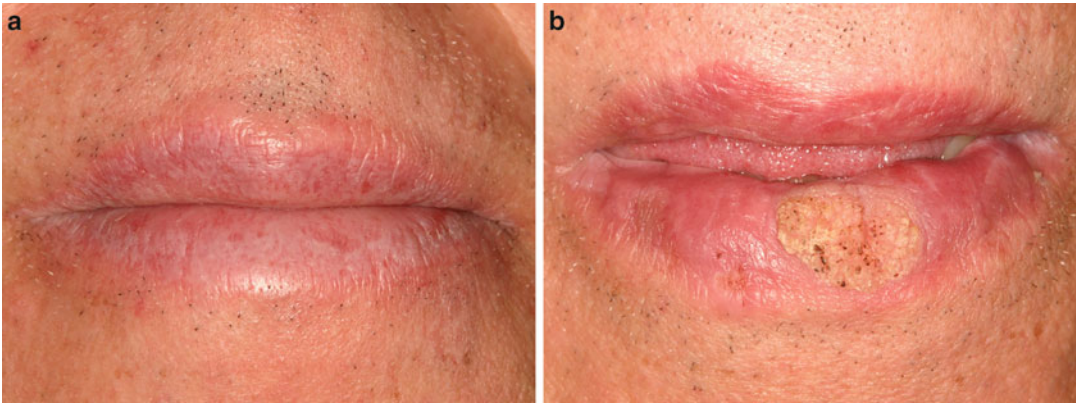






Fig. 12.16 Risk of malignant transformation in chronic graft-versus-host disease. (a) Prominent reticulation of the lips that was symptomatic and responded well to topical tacrolimus therapy. (b) Development of focal verru-

cous leukoplakia 7 months later that demonstrated dysplasia histopathologically. This was treated with wide excision followed by topical therapy with 5-fluorouracil

Pediatric Oncology Considerations

	DIAGNOSTIC TESTS	Panoramic radiograph to evaluate presence and developmental status of the dentition.
	BIOPSY	No.
	TREATMENT	None. Patients may require orthodontic and/or prosthodontic dental work due to missing/abnormal teeth.
	FOLLOW-UP	Routine dental visits every six months.

Summary

As discussed, complications and sequelae of cancer therapy are myriad, and are influenced by the specific nature of the disease as well as the type of treatment administered. Knowledge of these issues is essential to minimize morbidity and attend to the whole patient with respect to quality of life during and after treatment. In many cases, early complications can be managed to enable

the patient to continue with treatment and hopefully achieve disease remission. However late effects are often severely debilitating given their chronic nature and lack of effective management options. It is important to remember that these patients need ongoing support and encouragement from all of their medical providers, and providers should be educated in particular to the special needs of head and neck cancer patients and recipients of allogeneic hematopoietic cell transplantation.

Sources

- Elad S, Raber-Durlacher JE, Brennan MT, et al. Basic oral care for hematology-oncology patients and hematopoietic stem cell transplantation recipients: a position paper from the joint task force of the Multinational Association of Supportive Care in Cancer/International Society of Oral Oncology (MASCC/ISOO) and the European Society for Blood and Marrow Transplantation (EBMT). *Support Care Cancer*. 2015;23:223–36.
- Epstein JB, Raber-Durlacher JE, Wilkins A, et al. Advances in hematologic stem cell transplant: an update for oral health care providers. *Oral Surg Oral Med Oral Pathol Oral Radiol Endod*. 2009;107(3):301–12.
- Hölttä P, Alaluusua S, Saarinen-Pihkala UM, et al. Agenesis and microdontia of permanent teeth as late adverse effects after stem cell transplantation in young children. *Cancer*. 2005;103:181–90.
- Pilotte AP, Hohos MB, Polson KM, et al. Managing stomatitis in patients treated with mammalian target of rapamycin inhibitors. *Clin J Oncol Nurs*. 2011;15:E83–9.
- Ruggiero SL, Dodson TB, Fantasia J, et al. American Association of Oral and Maxillofacial Surgeons position paper on medication-related osteonecrosis of the jaw—2014 update. *J Oral Maxillofac Surg*. 2014;72:1938–56.
- Treister N, Duncan C, Cutler C, et al. How we treat oral chronic graft-versus-host disease. *Blood*. 2012;120:3407–18.

Inflammatory Conditions

Topical Immunomodulatory Agents

IMPORTANT NOTE: The package insert for many topical steroids will explicitly state that they are “not for internal use” or even specify that they may not be used in the oral cavity. Topical steroids are widely used in the management of oral mucosal diseases. It may be necessary to inform both the patient and the pharmacy to avoid any confusion or delays in initiating therapy.

For intraoral application, *gels* are preferable to *creams* or *ointments* as they are the most hydrophilic and therefore better absorbed by the wet mucosa. The affected area should be dried with gauze prior to application. The topical agent can be directly applied or mixed with equal parts of a mucoadhesive agent such as Orabase (Colgate–Palmolive, New York, NY) for improved soft tissue retention. Alternatively, the topical agent can be applied to gauze and then placed against the affected tissue for 10–15 min. For lesions restricted to the gingiva and alveolar mucosa, a

custom-fabricated tray can be used to contain the medication and treat the affected tissues in an intensive manner. Trays should be worn for 15–20 min. Solutions are useful for achieving more widespread topical therapy, or for targeting a difficult-to-reach area, and should be swished in the mouth for 5 min and then spit out. Regardless of the topical agent and formulation, patients should be instructed not to eat or drink for 15–20 min afterward.

Topical agents should be applied anywhere from one to six times per day. While topical therapies are very safe and can be used long-term, they should be applied as infrequently as possible, balancing the need to provide adequate control of symptoms with the ability to intensify therapy in the event of clinical flares. Secondary candidiasis related to topical corticosteroid therapy may develop in any patient, but is more likely to occur in patients who are particularly susceptible, such as diabetics. If this develops, patients can be treated with topical or systemic antifungal therapy (see Chap. 7). In recurrent cases, prophylactic treatment with fluconazole 100 mg once or twice weekly is generally effective.

- *Fluocinonide gel 0.05 %*. Dispense 15–60 g tube. Dry affected area with gauze and apply with finger. Systemic absorption is generally negligible but has been reported to cause adrenal suppression following prolonged therapy.

Please note that most of the medications included in this book are used “off-label” and are therefore not approved by the US Food and Drug Administration (FDA) for the specific clinical indications that are discussed. The information below is meant to be used as a guide and should not replace review of more comprehensive resources such as the Physicians’ Desk Reference.

This is a Class-II (high-potency) topical corticosteroid.

- *Clobetasol propionate gel 0.05%*. Instructions are the same as for fluocinonide gel. This is a Class-I (very-high-potency) topical corticosteroid, and should be reserved for severe/refractory lesions.
- *Dexamethasone solution 0.1 mg/mL*. Dispense 500 mL for 1 month supply. Swish with 3–5 mL for 5 min and then spit. This is the most commonly used topical corticosteroid for oral inflammatory conditions that is commercially available as a solution. Others, such as prednisolone may also be considered, but are generally less potent.
- *Clobetasol solution 0.05%*. This prescription must be prepared by a compounding pharmacy. Instructions are the same as for dexamethasone solution. This should be considered in patients that do not have an adequate response after four weeks of intensive (e.g., ≥ 4 times per day) dexamethasone solution rinses. Patients should be “stepped down” to dexamethasone solution if/when feasible.
- *Budesonide solution 3 mg/10 mL*. This can be considered if a patient’s medical insurance does not pay for compounded medications. Budesonide capsules can be prescribed for the patient to prepare at home as a solution. Budesonide is a high-potency corticosteroid with primarily topical activity used in the management of conditions such as inflammatory bowel disease and asthma. The patient should be instructed to open the capsules and crush the contents using a mortar and pestle. Multiple doses can be prepared together. For example, a 1-week supply of 5 mL four times daily (28 doses) requires the patient to crush the contents of 14 capsules and mix with 140 mL of water, which can then be kept in a small container. Instructions are the same for clobetasol solution.
- *Tacrolimus 0.1% ointment*. Dispense 30 or 60 g tube. Instructions are the same as for topical corticosteroids. Systemic absorption is negligible but has been reported. Topical tacrolimus is only available commercially as an ointment and can be challenging to apply intraorally. Topical tacrolimus has a FDA “black box” warning indicating that its use may be associated with an increased risk of cancer based on animal studies and isolated case reports. This should be discussed with the patient in advance to avoid any confusion or concern when they encounter the warning on the label.
- *Tacrolimus solution 0.1 mg/mL*. This prescription must be prepared by a compounding pharmacist. Dispensing and dosing instructions are the same as for dexamethasone solution. Tacrolimus and a steroid solution can be combined in equal parts of 2–3 mL each into a single 5 mL rinse for patients using both agents concurrently. In general this agent should be added to clobetasol or budesonide solutions if there has not been adequate clinical response.

Systemic Immunomodulatory Agents

- *Prednisone 1 mg/kg* orally as a single morning dose, for 1–2 weeks, for severe immune-mediated ulcerative conditions. Monitor for secondary candidiasis. Begin topical corticosteroid and/or additional nonsteroidal systemic therapy at the same time. The main side effects with short-term therapy include euphoria, insomnia, increased appetite, uncontrolled blood glucose in diabetics, and elevated blood pressure. For limited courses of up to 2 weeks, there is generally no need to taper the dose, although some conditions may require some tapering to avoid recurrence/flares. For longer treatment periods, the dose should be tapered by 5–10 mg every 1–2 days; there is no “standard” tapering protocol. Patients requiring long-term therapy, even at low doses (e.g., 10 mg), must be followed carefully by their primary care physician for prevention and management of steroid-related complications, such as osteoporosis, diabetes mellitus, avascular bone necrosis, and adrenal insufficiency.
- *Methylprednisolone 4 mg “dose pack”*. This is a convenient way to prescribe a short course

of corticosteroids for management of acute inflammation, such as intense temporomandibular joint pain. The package comes with 21 tablets and very clear dosing instructions for rapid taper over 6 days. *This formulation is generally inadequate for management of severe oral mucosal disease.*

- *Azathioprine 0.5–1.0 mg/kg/day.* The most common side effects include gastritis, nausea, and vomiting, which can be minimized by taking with food and/or in divided doses. A serious side effect is myelosuppression; therefore, CBC and platelet count should be checked weekly during the first month, twice monthly during the second and third months, and monthly thereafter. Patients with thiopurine *S*-methyl transferase deficiency have an increased risk of myelotoxicity; baseline screening is recommended. Liver function tests should be checked every 2 weeks during the first month and monthly thereafter.
- *Colchicine 0.6 mg* tablets once or twice daily. Begin once daily and monitor for response for 1–2 weeks before increasing the dose. Common side effects include diarrhea, nausea, and vomiting. CBC should be checked monthly for myelosuppression.
- *Dapsone 50–100 mg* once daily. Patients with glucose-6-phosphate dehydrogenase (G6PD) deficiency, methemoglobin reductase deficiency, or hemoglobin M are at risk for hemolysis. CBC should be monitored weekly for the first month, monthly for the next 6 months, then semiannually. Liver function tests should be drawn at baseline; periodically thereafter if abnormal.
- *Hydroxychloroquine 200 mg* twice daily with food. Common side effects include diarrhea, nausea, vomiting, myopathy, and headache. CBC should be checked periodically during prolonged therapy. Patients on long-term therapy are at risk for irreversible retinopathy and should see an ophthalmologist for a baseline exam and every 3 months thereafter.
- *Mycophenolate mofetil 500 mg* twice daily (1.0 g total daily dose); can increase to 1000 mg twice daily (2.0 g total daily dose).

Medication should be taken on an empty stomach. CBC should be checked weekly during the first month, twice monthly for the second and third months, then monthly through the first year. Renal, hepatic, cardiac, and pulmonary function as well as electrolyte panel should be evaluated periodically.

- *Pentoxifylline 400 mg* three times daily. Can increase to 800 mg three times daily. Side effects may include nausea, vomiting, dizziness, and headache. Evidence of positive response to medication may take weeks.
- *Thalidomide 50–200 mg* once daily, at night at least 1 h after dinner. The minimum effective dose should be used. Common side effects include edema, rash, hypocalcemia, constipation, nausea, leukopenia, sedation, and peripheral neuropathy. Serious risks include embryo–fetal toxicity and venous thromboembolism. Thalidomide must be discontinued if peripheral neuropathy develops. Because of the very high risk of embryo–fetal toxicity, this medication is only available under a special restricted distribution system called the S.T.E.P.S. Program (System for Thalidomide Education and Prescribing Safety) and prescribing doctors and their patients must be registered.

Infectious Conditions

Antibacterial Agents

- *Penicillin 500 mg* four times daily for 7–14 days. Take in an empty stomach 1 h before, or 2 h after meals.
- *Clindamycin 150–300 mg* three to four times daily for 7–14 days. This is a good alternative antibiotic for penicillin-allergic patients. The risk of developing secondary pseudomembranous colitis following short-term therapy is low.
- *Amoxicillin/clavulanic acid 500/125 or 875/125 mg* twice daily for 7–14 days. When used long-term for jaw osteonecrosis and recurrent soft tissue infection, a single daily

dose may be sufficient. This should be taken with meals.

- *Metronidazole 250 mg* once or twice daily for 7–14 days. Patients should be instructed not to consume alcohol while taking this medication due to a potential disulfiram-like reaction.
- *Chlorhexidine gluconate 0.12% mouthwash*. Rinse with 5.0 mL twice daily for 30–60 s and spit. This may cause burning in patients with inflammatory mucosal disease. It can also cause dark staining of the teeth that is removable by professional dental cleaning.

Antiviral Agents

- *Acyclovir 400 mg*. For primary herpes infection:
- 400 mg three times daily for 7–10 days. For episodic reactivation: 400 mg three times a day or 800 mg twice daily for 5 days beginning at the earliest indication of reactivation. For suppressive therapy: 400 mg twice daily. The medication is available in suspension form for patients with dysphagia and inability to swallow tablets. It is also available for intravenous delivery. Side effects are rare and may include abdominal pain and nausea, headache, and rash.
- *Valacyclovir 500 mg*. This has better bioavailability than acyclovir and requires less frequent dosing. For primary herpes infection: 1.0 g twice daily for 7–10 days. For episodic outbreak: 1–2 g twice daily for 5 days beginning at the earliest sign or symptom. For suppressive therapy: 500 mg once daily.

Antifungal Agents

- *Nystatin suspension 100,000 U/mL*. Swish 5.0 mL for 2–3 min and then swallow four times daily for 1 week. Can be used once daily for prophylaxis.
- *Clotrimazole troches*. Let troche dissolve slowly in the mouth 4–5 times daily for 1 week one troche daily for prophylaxis. This should not be prescribed in patients with

significant salivary gland hypofunction as the troches will not dissolve.

- *Nystatin and triamcinolone cream*. Apply to the corners of the mouth twice daily until angular cheilitis resolves; resume therapy as needed.
- *Fluconazole 100–200 mg* once daily for 7–14 days depending on extent and severity of candidiasis. For patients on long-term prophylaxis, 100–200 mg once or twice weekly is generally effective in preventing recurrence. Side effects are rare but may include nausea, vomiting, and increased liver enzyme levels.

Salivary Gland Hypofunction

Sialogogues

- *Pilocarpine 5 mg* three times daily. This can be increased to 7.5 or 10 mg three times daily but side effects are often poorly tolerated. Common side effects include skin flushing, sweating, lacrimation, nausea, and dizziness. This is contraindicated in patients with narrow angle glaucoma and poorly controlled asthma, and should generally be avoided in patients with chronic obstructive pulmonary disease.
- *Cevimeline 30 mg* three times daily. Instructions are the same as for pilocarpine. This is thought to have slightly more specific affinity for the salivary gland muscarinic receptors. As with pilocarpine, the dose can be increased, but may be associated with unpleasant side effects.

Fluoride

- *Sodium fluoride 1.1% gel*, applied with a toothbrush before bed. The patient should be instructed to expectorate but not rinse with water afterwards. Alternatively, this can be applied in a soft custom tray and left in place for at least 15 min or overnight. A prescription is required.

Pain Conditions

Nonsteroidal Anti-inflammatory Agents

- *Ibuprofen 200–400 mg*, every 4–6 h, not to exceed 3200 mg/day. Common side effects include abdominal pain, nausea, diarrhea, vomiting, rash, increased liver function tests, and renal failure. This should be used with caution and with dosing adjustment in patients with impaired renal function.
- *Ketoprofen cream 20%*. This prescription must be prepared by a compounding pharmacist. Apply to the skin of the affected area one to four times daily. Side effects from topical therapy are very rare.
- *Diclofenac sodium gel 1%*. Follow the package insert instructions.

Anticonvulsants

- *Clonazepam 0.5–1.0 mg* before bed. Patients may note sedation for the first several days but generally develop tolerance to this anticipated side effect. If symptoms recur midday, an additional daytime dose (0.25–0.5 mg) can be considered. Side effects include dizziness, impaired cognition, and sedation. Alcohol should be avoided as clonazepam may potentiate the sedative effects of other CNS depressants as well as prolong metabolism of other drugs that undergo hepatic clearance. Prescribe with caution in patients with a history of substance dependency, as use of benzodiazepines can be habit forming.
- *Clonazepam 1.0 mg tablet topical therapy*. Let the tablet dissolve fully in the mouth (without swallowing saliva) over a 5-min period and then spit out. Systemic absorption and associated side effects are generally negligible however patients must be cautioned.
- *Clonazepam solution 0.1–0.5 mg/mL*. This prescription must be prepared by a compounding pharmacist. Swish with 3–5 mL for 5 min and then spit, one to three times daily.

Dispense appropriate volume based on dosing frequency. Same safety considerations noted as above.

- *Gabapentin 300 mg*: take 300 mg on day 1, 300 mg twice daily on day 2 (600 mg total dose), and 300 mg three times daily on day 3 (900 mg total dose) with maintenance at 900 mg daily thereafter. The total daily dose may be increased up to 1800 mg in three divided doses if required for symptom control. Common side effects include ataxia, dizziness, sedation, fatigue, myalgia, and peripheral edema. *If side effects are noted with the initial 300 mg dose, then decrease to 100 mg on day 1, 200 mg on day 2, and 300 mg on day 3. The dose may then be carefully increased as tolerated.*
- *Carbamazepine 100 mg* twice daily; can increase by 200 mg/day (divided into two doses), not to exceed a total dose of 1200 mg/day. The lowest effective dose should be used. Common side effects include confusion, dizziness, sedation, nausea, vomiting, and lightheadedness. Uncommon but serious side effects include bone marrow suppression with pancytopenia and Stevens–Johnson syndrome. CBC, urinalysis, and liver function tests should be ordered at baseline and then periodically during long-term therapy.

Tricyclic Antidepressants

- *Amitriptyline 10–20 mg* at night before bed. Consider starting with 5.0 mg by splitting the tablet and slowly increasing dosage. Desired effects may not be noted for 2–3 weeks. Common side effects include xerostomia, constipation, dizziness, sedation, fatigue, and weight gain. Alcohol should be avoided due to potentiation of CNS sedative effects. This should not be used in conjunction with monoamine oxidase (MAO) inhibitors.
- *Nortriptyline 25 mg* at night before bed; may drop down to 10 mg if the higher dose is not well tolerated. Side effects are the same as with amitriptyline but may be less pronounced.

Topical Analgesics

- *Viscous lidocaine 2%*. Swish with 2–5 mL for 1 min and spit, as needed. Do not swallow. This can be particularly useful just prior to eating, and can also be used together with other topical therapies if there is associated burning.
- *Magic mouthwash*, consisting of equal parts of lidocaine, diphenhydramine, and bismuth subsalicylate solutions. Swish with 2–5 mL for 1 min and spit, as needed. A small amount can be swallowed for severe posterior oropharyngeal pain, but this should only be recommended in adults.
- *Morphine oral solution 10 mg/5 mL*. Swish with 2–5 mL for 5 min and spit, as needed. Do not swallow. This is available in a higher concentration (10 mg/mL) but should be prescribed with caution and is generally used as a salvage therapy to reduce the need for higher doses of systemic analgesics.

Index

A

Acinic cell carcinoma, 132
Actinic keratosis, 143
Acute necrotizing stomatitis, 105–106
Addison disease, 83
Adenoid cystic carcinoma, 132
Allodynia, 153
Amalgam tattoo, 85
Anemia
 iron deficiency, 174
 pernicious, 174
Angioedema, 57–59
Angiotensin-converting enzyme (ACE), 171
Angular cheilitis, 109, 167
Ankyloglossia, 29
Antineutrophilic cytoplasmic antibody (ANCA), 170
Apthous ulcers, 61
Arthralgia, 158
Atypical facial pain (AFP), 159

B

Bacterial parotitis, 106–108
Behcet disease, 65
Bilirubin, 79
Biopsy, 142
B lymphocytes, 116
Bruising, 175
Brush biopsy techniques, 142
Buccal, 9
Burning mouth syndrome (BMS), 161

C

Cancer therapy
 chemotherapy
 antiresorptive therapies, 186–189
 bleeding, 184
 cetuximab, 183
 dysguesia, 185
 dysphagia, 185
 infection, 184
 mTOR inhibitors, 185
 multi-target TKIs, 185

 pain, 184
 platinum-based agents, 183
 targeted therapies, 185
 complications, 181
 cosmetic deficits, 183
 dental screening, 181–182
 functional deficits, 182
 neurologic deficits, 183
 oral care, 182
 pediatric oncology, 194
 radiation therapy
 acute GVHD, 192–193
 allogeneic HCT, 191
 chronic GVHD, 192–193
 dental caries, 190
 dysguesia, 190
 dysphagia, 191
 EBT, 189
 GVHD, 192–193
 mucositis, 189
 ORN, 190
 secondary malignancy, 193
 trismus, 190
 xerostomia, 190
Carcinogens, 136
Circumvallate papillae, 4, 6
Cowden syndrome, 178
Coxsackievirus, 119
Crohn disease, 59, 167–169, 172
Cushing syndrome, 83
Cyclic neutropenia, 176
Cytomegalovirus (CMV), 34, 115–116

D

Degenerative change, 37
Dental screening, 181–182
Dentition, 7–9
Desquamative gingivitis, 72
Diffuse hyperplastic gingivitis, 170
Direct immunofluorescence (DIF), 66
Discoid lupus, 165
Dyskeratosis congenita, 137
Dysplasia, 141

E

Endocrine, 83
 Enteroviruses, 119–120
 Epidermolysis bullosa, 76
 Epstein-Barr virus (EBV), 137
 Erythema multiforme (EM), 65–69
 Erythroplakia, 146
 Exfoliative cheilitis, 53
 Exfoliative cytology, 142
 Exostoses, 27–29
 External beam radiation (EBT), 130, 189
 Extranodal lymphoma, 176

F

Fanconi anemia, 137
 Ferritin, 87
 Fibroma, 24–25
 Filiform papillae, 5, 49
 Fissured tongue, 21–22
 Floor of mouth, 6
 Focal argyrosis, 85
 Foramen cecum, 4
 Fordyce granules, 19
 Frey's syndrome, 183
 Fungal infections
 Candida albicans, 108
 deep fungal infections, 111
 oral candidiasis, 108

G

Gardner syndrome, 169
 Gastrointestinal disorders
 Gardner syndrome, 169
 inflammatory bowel disease
 Crohn's disease, 167–168
 ulcerative colitis, 168–169
 Peutz-Jeghers syndrome, 170
 Geographic tongue, 22, 23
 Gingival grafting, 20
 Gingival margin, 3
 Graft-versus-host disease (GVHD), 192–193
 Granulomatosis with polyangiitis (GPA), 170
 Granulomatous diseases
 orofacial granulomatosis, 172
 sarcoidosis, 171–172
 Wegener granulomatosis, 170–171
 Gustatory sweating, 183

H

Hand-foot-and-mouth disease, 119
 Hard palate, 7
 Heerfordt syndrome, 171
 Hemangiomas, 88–90
 Hematologic disorders
 anemia
 iron deficiency, 174
 pernicious, 174

 cyclic neutropenia, 176
 thrombocytopenia, 175
 Hematomas, 175
 Hematopoietic cell transplantation (HCT), 191
 Hemochromatosis, 87
 Hemosiderin, 87
 Herpangina, 119
 Herpes simplex virus (HSV), 33, 111–114
 Herpetiform aphthous ulcers, 62
 Highly active antiretroviral therapy (HAART), 172
 Human immunodeficiency virus (HIV), 172–174
 Human papilloma virus (HPV), 117–119, 137
 Hyperkeratosis, 48

I

Immune-mediated conditions
 angioedema, 57–59
 aphthous stomatitis (*see* Recurrent aphthous stomatitis (RAS))
 Behcet disease, 65
 epidermolysis bullosa acquisita, 76
 erythema multiforme, 65–69
 linear IgA disease, 77
 MMP, 73–75
 OFG, 59–60
 OLP (*see* Oral lichen planus (OLP))
 orofacial region, 57
 paraneoplastic pemphigus, 76
 pemphigus vulgaris, 75–76
 TUG, 60–61
 Immune-mediated diseases
 chronic cutaneous lupus erythematosus, 165
 IgG4, 166–167
 scleroderma, 165–166
 SLE, 163–165
 Immunoglobulin G4-related disease (IgG4-RD), 166–167
 Indirect immunofluorescence (IIF) studies, 75
 Infectious conditions
 antibacterial agents, 199
 antifungal agents, 200
 antiviral agents, 200
 Inflammatory bowel disease, 59
 Crohn's disease, 167–168
 ulcerative colitis, 168–169
 Inflammatory conditions
 systemic immunomodulatory agents, 198–199
 topical immunomodulatory agents, 197–198
 Inflammatory papillary hyperplasia, 25–27
 Inflammatory pigmentation, 82–83
 Intensity-modulated radiation therapy (IMRT), 189
 Internal derangement, 10
 Intrinsic factor, 174
 Iron deficiency anemia, 174

J
 Jaundice, 179
 Jaws and teeth, 10–12

K

Kaposi sarcoma, 91

L

Lichenoid inflammation, 163
 Lichen planus, 146
 Linea alba, 47–48
 Linear IgA disease, 77
 Lingual tonsils, 20, 21
 Lip cancers, 139
 Lymphatic system, 14–16

M

Malignancy

leukemias, 177
 lymphomas, 176
 metastatic solid tumors, 177

Mammalian target of rapamycin (mTOR) pathway, 185

Maxillary tuberosity, 7

Median rhomboid glossitis, 23–24

Medication-related osteonecrosis of the jaws (MRONJ), 186

Medications

infectious conditions, 199–200
 inflammatory conditions
 systemic immunomodulatory agents, 198–199
 topical immunomodulatory agents, 197–198
 pain conditions
 anticonvulsants, 201
 nonsteroidal anti-inflammatory agents, 201
 topical analgesics, 202
 tricyclic antidepressants, 201
 salivary gland hypofunction, 200

Melanin, 82

Melanocytes, 79, 82

Melanotic lesions

drug-induced pigmentation, 84–85
 endocrine, 83
 inflammation, 82–83
 malignant melanoma, 82
 melanotic macules, 79
 nevus, 81–82

Melanotic macules, 79

Melkersson-Rosenthal syndrome, 59

Metastatic solid tumors, 177

Midline lethal granuloma, 176

Mucocutaneous lesions, 178

Mucoepidermoid carcinoma, 132

Mucogingival junction, 3

Mucositis, 149, 150, 181

Mucous membrane pemphigoid (MMP), 73–75

Mucus retention cyst, 124–125

Multi-targeted tyrosine kinase inhibitors (TKIs), 185

Muscles of mastication, 11–13

Myofascial pain

examination, 156–157
 history, 156–157

parafunctional activity, 156
 treatment, 157–159

N

Neuropathic pain, 153, 183

Nicotinic stomatitis, 51

Nikolsky sign, 75

Nociceptive pain, 153

Nonmelanotic pigmentation

amalgam tattoo, 85
 heavy metals, 85
 hemochromatosis, 87

Nonsteroidal anti-inflammatory agents (NSAIDs), 157

O

Obstructive change, 37

Odontogenic infections

acute necrotizing stomatitis, 105–106
 dental caries, 96–102
 inflammatory gingival hyperplasia, 104–105
 periodontal disease, 102–104
 plaque and calculus, 96

Odontogenic pain, 155

Oral cancer

alcohol, 136
 betel, 136
 biopsy, 142
 definitions, 141
 epidemiology, 135
 floor of mouth, 139
 immunosuppression, 137
 lip, 138, 139
Marijuana smoking, 137
 nutrition, 137
 potentially malignant lesions
 actinic cheilitis, 143
 erythroplakia, 146
 leukoplakia, 143–144
 lichen planus, 146
 oral submucous fibrosis, 145–146
 PVL, 144
 tobacco pouch keratosis, 144–145
 sanguinaria, 137
 squamous cell carcinoma, 139–140
 staging, 147–148
 sun exposure, 136
syphilis, 137
 terminology, 141
 tobacco, 136
 tongue, 137
 treatment, 148–149
 verrucous carcinoma, 140
 viral, 137

Oral candidiasis, 108

Oral cavity

adjuvant diagnostic tests, 41
 antimicrobial susceptibilities, 33
 bacterial cultures, 33

- Oral cavity (*cont.*)
- blood tests, 34
 - computed tomography, 34, 36
 - cytology, 35–37, 39, 40
 - flash attachment, 35, 38
 - fungal cultures, 33
 - intraoral and extraoral plain film radiography, 34, 35
 - intraoral photography, 35, 38
 - magnetic resonance imaging, 35, 36
 - obstructive and degenerative changes, 35
 - physical examination, 31, 32
 - positron emission tomography, 35, 37
 - proper, 1–4
 - tissue biopsy, 37–42
 - viral cultures, 33
- Oral hairy leukoplakia (OHL), 116
- Oral infections
- clinical appearance, 95
 - EBV, 116–117
 - fungal infections
 - Candida albicans*, 108
 - deep necrotic ulcerations, 111
 - oral candidiasis, 108
 - medications, 95
 - odontogenic infections
 - acute necrotizing stomatitis, 105–106
 - dental caries, 96–102
 - inflammatory gingival hyperplasia, 104–105
 - periodontal disease, 102–104
 - plaque and calculus, 96
 - parotitis, 106–108
 - salivary glands, 95
 - viral infections (*see* Viral infections)
- Oral lesions, 111
- Oral lichen planus (OLP)
- adult population, 69
 - causative agent, 69
 - complication, 72
 - desquamative gingivitis, 70–72
 - erosive/ulcerative, 69
 - erythematous lesions, 69
 - lichenoid hypersensitivity reaction, 69
 - nonsteroidal systemic therapy, 72
 - reticular lesions, 69
 - skin lesions, 69
 - symptoms, 69
 - topical tacrolimus, 72
 - treatment, 72
- Oral mucosa, 1–5
- Oral sequelae. *See* Cancer therapy
- Oral submucous fibrosis, 145–146
- Oral tongue, 4–6
- Orofacial granulomatosis (OFG), 59–60
- Orofacial pain
- AFP, 159
 - allodynia, 153
 - BMS, 161
 - definition, 153
 - neuropathic pain, 153
 - nociceptive pain, 153
 - nonpharmacologic methods, 154
 - odontogenic pain, 155
 - psychiatric history, 153
 - structures, 153
 - TMJ and muscles
 - examination, 156–157
 - history, 156–157
 - parafunctional activity, 156
 - treatment, 157–159
 - trigeminal neuralgia, 159–161
- Osler-Weber-Rendu syndrome, 92
- Osteonecrosis of the jaw (ONJ), 181
- Osteoradionecrosis (ORN), 149, 186, 190
- P**
- Pain conditions
- anticonvulsants, 201
 - nonsteroidal anti-inflammatory agents, 201
 - topical analgesics, 202
 - tricyclic antidepressants, 201
- Palatal rugae, 7
- Paramyxovirus, 107
- Paraneoplastic autoimmune multiorgan syndrome, 76
- Parotid gland, 14
- Pediatric cancer, 194
- Pemphigus vulgaris, 75–76
- Periapical radiolucency, 98
- Periodontal disease, 102–104
- Pernicious anemia, 174
- Peutz-Jeghers syndrome, 79, 170
- Physiologic pigmentation, 17–19
- Pigmented lesions
- extrinsic pigmentation, 79
 - melanotic lesions (*see* Melanotic lesions)
 - nonmelanotic pigmentation, 85
 - physiologic pigmentation, 79
 - vascular lesions
 - hemangiomas, 88–90
 - hematomas, ecchymoses, and petechiae, 92
 - Kaposi sarcoma, 91
 - pyogenic granuloma, 90
 - varix, 87
- Pleomorphic adenoma, 132
- Plummer-Vinson syndrome, 137, 174
- Postherpetic neuralgia (PHN), 114
- Prodromal symptoms, 65
- Progressive systemic sclerosis, 165–166
- Proliferative epithelial lesions, 137
- Proliferative verrucous leukoplakia (PVL), 144
- Prominent frenula, 29
- Pseudomembranous candidiasis, 108
- Pyogenic granuloma, 90–91
- Pyostomatitis vegetans, 168
- R**
- Ramsay Hunt syndrome, 115
- Recurrent aphthous stomatitis (RAS)
- complex/severe aphthous stomatitis, 62, 64, 65

erythematous halo, 61
 etiology, 63
 feature, 62
 herpetiform aphthous ulcers, 62
 high-potency corticosteroid gels, 64
 major aphthous ulcers, 62
 minor aphthous ulcers, 62
 oral ulcerations, 61
 Reduction, 10
 Referred pain, 155

S

Salivary gland disease, 13–14
 mucocele, 121–123
 mucus retention cyst, 124–125
 neoplasia
 benign tumors, 132
 incidence, 131
 malignant tumors, 132, 133
 ranula, 123–124
 sialadenitis
 fibroinflammatory conditions, 125
 necrotizing sialometaplasia, 127
 sialolithiasis, 125–127
 sialadenosis, 128
 surface lubrication, 121
 xerostomia
 definition, 128
 fluoride treatments, 128
 medications, 130
 radiation, 130
 Sjögren syndrome, 129–130

Salivary gland hypofunction, 200
Sanguinaria canadensis, 137
 Sarcoidosis, 171–172
 Sialadenosis, 128
 Sialoendoscopy, 131
 Sicca syndrome, 129
 Sjögren syndrome, 129–130, 163, 192
 Smokeless tobacco, 136
 Smoker's melanosis, 82
 Soft palate, 7
 Squamous cell carcinoma, 139–140
Staphylococcus aureus, 106
 Stevens-Johnson syndrome, 65
 Strawberry gingivitis, 170
 Sublingual gland, 13
 Submandibular gland, 13, 14
 Synergistic effect, 136
 Systemic lupus erythematosus (SLE), 163–165

T

Temporomandibular joint pain (TMJ), 9–10
 examination, 156–157
 history, 156–157
 parafunctional activity, 156
 treatment, 157–159

Thrombocytopenia, 175
 Tongue base, 4, 10, 11
 Topical steroids, 197
 Tori, 27–29
 Translation, 10
 Traumatic ulcerative granuloma (TUG), 60–61
 Traumatic ulcerative granuloma with stromal
 eosinophilia (TUGSE), 60
 Trigeminal neuralgia, 159–161
 Trismus, 97

V

Varicella Zoster virus (VZV), 114–115
 Vascular lesions
 hemangiomas, 88–90
 hematomas, ecchymoses, and petechiae, 92
 Kaposi sarcoma, 91
 pyogenic granuloma, 90
 varix, 87

Verrucous carcinoma, 140

Viral infections
 cytomegalovirus, 115–116
 EBV, 116–117
 enteroviruses, 119–120
 HPV, 117–119
 HSV, 111–114
 immunocompetent vs. immunocompromised
 state, 111
 VZV, 114–115

Vitamin B₁₂ deficiency, 174

W

Waldeyer ring, 2
 Warthin tumor, 132

White lesions
 acanthosis, 45
 cheek biting, 48–49
 chemical burn, 52
 exfoliative cheilitis, 53
 hairy tongue, 49–50
 hypertrophy, 45
 leukoedema, 45–47
 linea alba, 47–48
 nicotinic stomatitis, 51
 oral hairy leukoplakia, 50
 white sponge nevus, 52

White sponge nevus, 52

X

Xerostomia
 definition, 128
 fluoride treatments, 128
 medications, 130
 radiation, 130
 Sjögren syndrome, 129–130