Orthopaedic Trauma in the Austere Environment

A Practical Guide to Care in the Humanitarian Setting

Juan de Dios Robinson
Editor

Springer

Orthopaedic Trauma in the Austere Environment

Juan de Dios Robinson
Editor

Orthopaedic Trauma in the Austere Environment

A Practical Guide to Care in the Humanitarian Setting

Springer

Editor
Juan de Dios Robinson
Consultant in Trauma and Orthopaedics
Major Trauma Centre
St. Mary's Hospital
Imperial College School of Medicine
London
UK

ISBN 978-3-319-29120-8 ISBN 978-3-319-29122-2 (eBook)
DOI 10.1007/978-3-319-29122-2

Library of Congress Control Number: 2016937525

© Springer International Publishing Switzerland 2016
This work is subject to copyright. All rights are reserved by the Publisher, whether the whole or part of the material is concerned, specifically the rights of translation, reprinting, reuse of illustrations, recitation, broadcasting, reproduction on microfilms or in any other physical way, and transmission or information storage and retrieval, electronic adaptation, computer software, or by similar or dissimilar methodology now known or hereafter developed.
The use of general descriptive names, registered names, trademarks, service marks, etc. in this publication does not imply, even in the absence of a specific statement, that such names are exempt from the relevant protective laws and regulations and therefore free for general use.
The publisher, the authors and the editors are safe to assume that the advice and information in this book are believed to be true and accurate at the date of publication. Neither the publisher nor the authors or the editors give a warranty, express or implied, with respect to the material contained herein or for any errors or omissions that may have been made.

Printed on acid-free paper

This Springer imprint is published by Springer Nature
The registered company is Springer International Publishing AG Switzerland

To my father
To my Jessica, thank you for your unconditional love and support
To Azela, Alan, Marie-Astrid, Alex and Alancito
To my friends, mentors, colleagues and patients throughout the world and especially to those who died or were injured during the attack on the MSF Kunduz Trauma Centre, Afghanistan, on October 3, 2015.

Foreword I

Going on a humanitarian deployment in a disaster or conflict zone can be life changing for both the clinician and the patient. It can be both positive and detrimental.

There are two important reasons why a different approach is demanded 'out there'.

1. Different circumstances: the lack of equipment and consumables, deficient post-operative care, non-reliable sterilisation and no guaranteed lab quality and other minimum requirements to deliver safe surgical treatment. It excludes certain procedures.
2. Different pathology, presented with delay and complications, especially in an armed conflict. It demands a different approach. The challenge of infection is considerable. The ever re-learned lesson of good wound debridement must be strictly applied.

Nowadays, 'orthopaedic treatment' is associated with the latest complex technology, mostly not applicable in the austere setting.

However, many modalities of valuable orthopaedic treatment have been forgotten or are considered obsolete for no good reason. You will be reminded of them in this practical guide.

In the past two decades we have learned to achieve better survival rates using Damage Control principles. These principles also apply in the austere setting.

We have the duty and responsibility to deliver quality care. We owe it to our patients to be well trained and well prepared and to adhere to established quality standards.

There is a minimum level of quality below which we cannot go. After the disaster in Haiti, the world realised that relief work can also be harmful. Serious attempts to show that humanitarian aid is beneficial have not been very successful. Humility is good starting point here.

With the 'Foreign Medical Team' project, the WHO has now formulated standards for surgical emergency teams, with clarity about treatment protocols and necessary equipment. Training opportunities, such as the 'Surgical Training in the Austere Environment' at the London Royal College of Surgeons, can increase further the quality and efficiency of the care as it is delivered 'in the field'.

This book will contribute to preparedness, and it will enable you to at least avoid making the standard mistakes. It will be to the benefit of the patients.

The needs are evident; there is a lot of work to be done.

I hope to meet you, well prepared, in the austere environment.

Harald Veen, FRCSEd
Chief Surgeon for the International Committee of the Red Cross
Geneva, Switzerland

Foreword II

It is a great pleasure to write a foreword to this new book on trauma surgery in the austere environment. In the 30 years that I have been involved in international surgery, I have seen an increase in interest and also understanding of the issues that is reflected in the chapters of this book.

Trauma on a global level is increasing. Wars and natural disasters will always be with us, and as motorised transport helps develop low-income regions of the world so road traffic injuries increase, exponentially more so in low- and middle-income countries. Sven Young in his chapter on femoral injuries quotes the WHO estimate that road crashes will be the fifth biggest cause of disability by 2030.

There is increased interest by surgeons globally in trauma and particularly in catastrophes. Many of us took up surgery because we wanted to make a difference to the lives of injured patients and naturally feel a calling to where this need is greatest. With the Internet bringing the need to our living rooms and easy air transport being available, there has been a massive increase in surgical volunteers from high-income countries who want to help both in wars and in natural disasters and also in the chronic disasters of day-to-day trauma in resource-poor settings.

There is also an improved understanding of how to manage trauma in disaster and low-resource settings. We are building up an evidence base in what techniques are effective in terms of rapid and cost-effective return to normal function.

Most gratifying to me however is that there is an increase in preparedness for surgical involvement in global trauma. In the analysis of disasters over the last decade, it is clear that much surgery has been inappropriately performed and organised. Enthusiasm and a sharp knife alone are not sufficient. There needs to be training, preparedness, on-site organisation and integration with existing healthcare systems. This book reflects many of the key initiatives that have been set up, such as the UK International Trauma Register, the Royal College of Surgeons' Surgery in the Austere Environment Course and the WHO cluster system for organisation of healthcare groups in disaster situations. We are not there yet, but we are learning, and this book is a welcome step in that direction.

Chris Lavy, OBE, MD, FRCS
Orthopaedics and Tropical Surgery
University of Oxford, Oxford, UK

Preface

Disasters, whether natural or human made, are part and parcel of our journey as inhabitants of this planet. There is nothing new about the carnage and misery that sectors of the Earth's population periodically face. The world is increasingly interconnected, and news of a disaster travel rapidly, if not accurately, across the Globe. This has led to an increase in interest among health service professionals in unaffected countries who then flock to help in areas afflicted by the disaster promoted in the media. This raise in interest, however, is not necessarily accompanied by enhanced preparation or training, and a naïve attitude accompanies many of these well-meaning volunteers.

The massive earthquake that struck Haiti in 2010 and the humanitarian effort that followed were the object of a post-mortem that no other disaster response has undergone previously. This examination revealed a lack of preparation from the many volunteers that largely just "showed up" and expected to be of help. This approach has resulted in high levels of complications, neglected external fixators, osteomyelitis from poorly judged internal fixation and unnecessary or poorly performed amputations.

We must maintain a professional attitude in humanitarian work. We must aim to pursue the same levels of excellence that we would normally practise in our respective countries. Participating in a humanitarian mission is not a licence to practise lower standards of medicine. The environment may be austere, but our patient management must live up to the standards that would be expected from us at home. To achieve this, we must prepare to face challenges of a very different nature. We must also think ahead on the consequences of our actions. Who will follow up the patient when we are gone? What are we leaving behind?

Historically, humanitarian orthopaedic care has been reduced to an extra skill required of general surgeons who find themselves working in disaster zones. I feel this is an outdated model, and fully trained orthopaedic surgeons should be actively recruited to serve the musculoskeletal needs of patients in austere environments, just as MSF and EMERGENCY have done. However, orthopaedic surgeons who engage in humanitarian work should be well prepared for that role.

The incentive to produce this book came from my observation of the need to increase the standards of practice and skill in orthopaedic traumatology in the austere environment, as well as the solutions been offered to patients. Despite an image characterised by large mechano-like sets of equipment,

Table 1 Nationalities, universities, orthopaedic and humanitarian organisations and range of professions of authors contributing to this book

Countries	Universities	Organisations	NGOs	Professions
Afghanistan	Stanford University	OTA	MSF	Vascular surgeons
Belgium	University of Oxford	AOUK	Broken Earth	Orthopaedic surgeons
Canada	University of California San Francisco	AOTrauma	SIGN Fracture Care International	Emergency medicine physicians
United Kingdom	McMaster University	United Kingdom International Emergency Trauma Registry	International Committee of the Red Cross	Physiotherapists
India	Swansea University	World Orthopaedic Concern	Save the Children	Anaesthetists
Italy	Karolinska Institutet	USA Army	CURE International	Plastic surgeons
Iraq	The University of Manchester	National Health Service UK	Emergency	Radiographers
Mexico	Basrah University	Royal Army Medical Corps UK	Interburns	Epidemiologists
Nepal	Imperial College of Science, Technology and Medicine	Orthopaedic Trauma Institute, San Francisco	World Orthopaedic Concern	Engineers
Sweden	University of Minnesota University of Utah University of Newfoundland Univerity of Winsconsin	Institute for Global Orthopaedics and Traumatology	Hospital and Rehabilitation Centre for Disabled Children (HRDC)	
USA		SICOT		

orthopaedic surgeons have the advantage over several other specialties that we do not depend on high technology to make a difference to our patients. It is essential, however, that principles of management are based on the best available evidence, sound clinical skills and experience and patient values. These are the tenants of evidence-based practice.

This book is the culmination of four years of intense work. Its chapters embody the combined experience of over 50 authors. The breadth and depth of the experience contained in this book is summarised in Table 1, which lists the contributors' nationalities, professions, academic centres, organisations and charities.

The aim is to provide a comprehensive source for those who plan to work in the austere environment and those already on the ground, as well as all other staff involved in the care of orthopaedic trauma patients. The book is divided into different sections, each one designed to provide guidance and information on a defined area;

1. Setting the scene: the austere environment
   How best to prepare for a mission in a conflict or disaster zone? What are the different types of scenario you may find yourself in? What is the epidemiology of trauma in austere environments? Can you really practise evidence-based medicine in an austere environment? What are the cultural challenges and ethical dilemmas you may face?
2. What are the causes of orthopaedic trauma in the austere environment?
   What are the causes of casualties in the austere environment? How do they differ from those in the developed world? How should you manage a blast injury or a ballistics injury? How will you cope with the complications of bone setters?
3. What are the specific challenges of caring for patients in the austere environment?
   In the less developed world, there are serious challenges in the management of orthopaedic injuries not faced as frequently in the developed world, such as malnutrition, AIDS, bone infections and serious complications of fracture mismanagement. How does this affect the management of your patients?
4. Perioperative care in an austere environment
   In this section, we provide a comprehensive guide to the perioperative management of the orthopaedic trauma patient for orthopaedic practitioners. We provide thorough coverage of pre-, peri- and postoperative care.
5. Principles of orthopaedic traumatology in the austere environment
   This section covers information which will help you gain an understanding on the principles required for the management of orthopaedic trauma in the austere environment, including information relevant to paediatric patients.
6. Practical guides to orthopaedic trauma management in the austere environment
   This section covers the management of orthopaedic trauma for each anatomical region.
7. Continuity of care, legacy and resilience
   The last section is in many ways the most important of this book, as we highlight the importance of creating proper follow-up of patients, leaving a legacy when we return home and building local resilience to better face the next disaster. We invite the reader to think laterally and consider using technology and lessons from the military.

The result of these unique international collaborations has been a comprehensive guide that will help you better understand the nature of orthopaedic traumatology in the austere environment, how to practise safely at a high standard and how to ensure that the population you have been privileged to serve will continue to benefit from your efforts. I am grateful to all the contributors for their hard work and commitment towards this project and to

Springer for taking up the challenge. I am very proud of the result, but I would invite the reader to forward their thoughts and constructive criticisms. Any omissions or mistakes are my responsibility and would appreciate feedback to improve any future editions. I wish you success in your humanitarian missions.

London, UK Juan de Dios Robinson

Contents

Part I Setting the Scene: The Austere Environment

Part II Causes of Trauma in the Austere Environment

Part III Management Challenges in the Austere Environment

Part IV Perioperative Management in the Austere Environment

Part V Principles of Orthopaedic Traumatology in the Austere Environment

Part VI Practical Guides to Orthopaedic Trauma Management in the Austere Environment

Part VII Continuity of Care, Legacy, and Resilience

Contributors

A. Akbari, BSc, MSc Research Officer, College of Medicine, Swansea University, Swansea, Wales, UK

Romney C. Andersen, MD, COL MC/USA Department of Orthopedics, Walter Reed National Military Medical Center, Bethesda, MD, USA

Samir Ayobi, MSc MSF Kunduz Trauma Centre, Kunduz, Afghanistan

Ashok K. Banskota, MD, FACS Department of Orthopaedics, Hospital & Rehabilitation Center for Disabled Children, Banepa, Nepal

B & B Hospital, Kathmandu, Nepal

Mohit Bhandari, MD, PhD, FRCSC Department of Orthopaedic Surgery, McMaster University, Hamilton, ON, Canada

Breanna Bolley, RN Clinical Outcomes and Data Engineering (CODE) Technology, Phoenix, AZ, USA

Deepa Bose, MBBS, FRCS, FRCS (Tr & Orth) Department of Trauma and Orthopaedics, Queen Elizabeth Hospital Birmingham, Birmingham, UK

Bonnie Chien, MD Medical School, Stanford University School of Medicine, Stanford, CA, USA

Peter A. Cole, MD Department of Orthopaedic Surgery, Regions Hospital, St. Paul, MN, USA

Department of Orthopedic Surgery, University of Minnesota, St. Paul, MN, USA

Sandro Contini, MD Department of Surgical Sciences, Parma University Hospital, Parma, Italy

Ralph Richard Coughlin, MD, MSc Department of Surgery, Institute for Global Orthopaedics and Traumatology, University of California, San Francisco, CA, USA

Andrew Creeden, BSc (Hons) Department of Radiology, University Hospitals Coventry and Warwickshire NHS Trust, Coventry, West Midlands, UK

Brian P. Cunningham, MD Orthopedic Trauma Institute, University of California San Francisco (UCSF) and San Francisco General Hospital (SFGH), San Francisco, CA, USA

Jean Claude G. D'Alleyrand, MD, LTC MC/USA Department of Orthopedics, Walter Reed National Military Medical Center, Bethesda, MD, USA

A. Doorgakant, MBBS, MRCS (Eng) Trauma and Orthopaedics, Mersey Deanery Rotation, Warrington, Cheshire, UK

Christine du Maine, MD Department of Anesthesia, Universitair Ziekenhuis Brussel, Brussels, Belgium

Iain Elliott, MD Department of Orthopaedics, University of Utah, Salt Lake City, UT, USA

Andrew Furey, MD, MSc, FRCSC Department of Surgery, Memorial University of Newfoundland, St. John's, NF, Canada

Tad L. Gerlinger, MD Department of Orthopaedic Surgery, Rush University Medical Center, Chicago, IL, USA

Bérangère Gohy, PT Physiotherapist, Handicap International, Verviers, Belgium

Richard A. Gosselin, MD, MSc, MPH, FRCS(C) Department of Orthopedic Surgery, Institute for Global Orthopedics and Traumatology, University of California in San Francisco, San Francisco, CA, USA

Barth A. Green, MD, FACS Executive Dean for Global Health, Community Service, University of Miami Miller School of Medicine, Miami, FL, USA

Thamer A. Hamdan, MBChB, FRCS, FRCP, FICS, FACS Department of Orthopedic Surgery, Basrah General Hospital, Basrah, Iraq

W.J. Harrison, MA(Oxon), FRCS (Tr & Orth) Department of Trauma & Orthopaedics, Countess of Chester NHS Foundation Trust, Chester, UK

Steve Hodgson, MBChB, FRCS (Orth), MD Trauma and Orthopaedic Surgery, Royal Bolton Hospital, Bolton, Lancashire, UK

Ryan Horazdovsky, MD Orthopaedic Surgery, Minneapolis, MN, USA

Zachary J. Kastenberg, MD Department of Surgery, Stanford University School of Medicine, Stanford, CA, USA

Mike Krosin, MD Department of Surgery, Alameda Health Systems, Highland Hospital, Oakland, CA, USA

Martial Ledecq, MD Vascular and Trauma Surgeon, Medecins Sans Frontieres, Libin, Belgium

Paul Ley, MD Trauma Surgeon, EMERGENCY NGO, Milan, Italy

Steve Mannion, MChir, FRCS (Tr&Orth), FCS(ECSA) Department of Conflict and Catastrophe Medicine, St George's, University of London, London, UK

Saam Morshed, MD, PhD, MPH Department of Orthopaedic Surgery, University of California San Francisco, San Francisco, CA, USA

San Francisco General Hospital, San Francisco, CA, USA

Orthopedic Trauma Institutes, San Francisco, CA, USA

Raman Mundi, MD Division of Orthopaedic Surgery, McMaster University, Hamilton, ON, Canada

David Nott, OBE, OStJ, BSC, MD, FRCS, DMCC Department of Surgery, Chelsea and Westminster Hospital, Imperial College Healthcare NHS Trust, London, UK

Ian Pallister, FRCS (Ed) FRCS DA (UK) DTM&H Department of Trauma and Orthopaedics, Morriston Hospital, University of Swansea, Swansea, Wales, UK

Rishee Parmar, MBChB, FRCS (Tr & Orth) Department of Orthopaedics, St Helen's and Knowlsley Teaching NHS Trust, Whiston, UK

J.B. Penny, MRCS, MBChB, MEng(Hons) North West Deanery (Mersey Sector) Rotation, Manchester, UK

Tom Potokar, FRCS(Ed), FRCS(Plast), DA, DTM&H Welsh Centre for Burns & Plastic Surgery, Morriston Hospital, Heol Maes Eglwys, Morriston, Swansea, Wales, UK

Anthony D. Redmond, OBE, MD, DSc (hon), FRCP Department of International Emergency Medicine, Humanitarian and Conflict Response Institute, University of Manchester, United Kingdom Interational Trauma Register (UKIETR), Manchester, UK

S.E. Roberts, BSc, MSc, PhD College of Medicine, Swansea University, Swansea, Wales, UK

Juan de Dios Robinson, FRCS (Tr & Orth) MSc (Trau Surg) Major Trauma Centre, St. Mary's Hospital, Imperial College, London, UK

James Rourke, MD, MSc, FCFP (EM) Office of the Dean of Medicine, Faculty of Medicine, Memorial University of Newfoundland, St. John's, NF, Canada

Jesse Alan Slade Shantz, MD, MBA, FRCS(C) Institute for Global Orthopaedics and Traumatology, University of California, San Francisco, CA, USA

David Shearer, MD, MPH Department of Orthopaedic Surgery, University of California San Francisco, San Francisco General Hospital, Orthopedic Trauma Institutes, San Francisco, CA, USA

San Francisco General Hospital, San Francisco, CA, USA

Orthopedic Trauma Institutes, San Francisco, CA, USA

James Shelton, MRCSEd Department of Orthopaedics, North West Deanery (Mersey Sector) Rotation, Manchester, UK

David Solfelt, MD Department of Orthopedic Trauma, Meriter Unity Point Hospital, Madison, WI, USA

Kyle R. Stephens, DO Spinal Surgery, Regions Hospital, St. Paul, MN, USA

Andrew J. Stevenson, BSc, MBBS, FRCS (Tr & Orth) Department of Trauma and Orthopedics, Royal Melbourne Hospital, Melbourne, VIC, Australia

K. Thorne, BSc, MPhil, PhD Research Officer, College of Medicine, Swansea University, Swansea, Wales, UK

Johan von Schreeb, MD, PhD Specialist in General Surgery, Department of Public Health, Karolinska Institute, Stockholm, Sweden

Scott C. Wagner, MD, MC/USN Department of Orthopaedics, Walter Reed National Military Medical Center, Bethesda, MD, USA

Paul S. Whiting, MD Department of Orthopaedics and Rehabilitation, University of Wisconsin, Madison, WI, USA

Sherry M. Wren, MD Department of Surgery, Stanford University School of Medicine, Stanford, CA, USA

Parirenyatwa Hospital, Harare, Zimbabwe

Sven Young, MD, PhD Department of Orthopeadic Surgery, Haukeland University Hospital, Bergen, Norway

Department of Surgery, Kamuzu Central Hospital, Lilongwe, Malawi

Lewis Zirkle, MD SIGN Fracture Care International, Richland, WA, USA

Biography

Mr. Juan de Dios Robinson BA MBBS MRCS Dip SICOT FRCS (Tr and Orth) MSc (Trauma Surgery) is a consultant in trauma and orthopaedics at the Major Trauma Centre in St Mary's Hospital, London. Mr. Robinson has had extensive experience in natural and man-made disasters. He has participated in rescue efforts and health projects following earthquakes and conflicts in Latin America and Asia. While working as an orthopaedic trauma consultant in the Medecins Sans Frontieres (MSF) Kunduz Trauma Centre, Afghanistan, he carried out close to 500 surgeries in 5 months. An active member of the UK International Emergency Trauma Register, Mr. Robinson has lectured on civilian orthopaedic trauma in the conflict and low resource environment in Europe, North America, and Asia. He is an ATLS and surgical skills instructor and is also a tutor in the University of Edinburgh Surgical Sciences Qualification.

He was awarded an MBBS by the Imperial College School of Medicine, London, in 1999 and gained his membership from the Royal College of Surgeons of Edinburgh, UK, in 2006. He then passed the Intercollegiate Fellowship in Trauma and Orthopaedics and was elected as a Fellow of the Royal College of Surgeons of Edinburgh in 2011. Mr. Robinson completed prestigious Trauma Fellowships at Dalhousie University, Canada and Oxford. He also holds a Diploma from the International Society of Trauma and is Orthopaedics (SICOT) and an MSc in Trauma Surgery (Military) and in completing an MSc in Surgical Science and Practice at the University of Oxford.

Part I

Setting the Scene: The Austere Environment

1

How to Prepare for a Mission in a Conflict or Disaster Zone

Anthony Damien Redmond

1.1 Skills and Experience

There is an obvious urge to go and help when a large-scale disaster occurs, fortified by pressure from the media and at times from those around you to respond. However, you must have something to offer to the victims of the conflict and/or disaster over and above what can be offered locally. Otherwise your presence may be adding to, rather than relieving, the burden of the affected country [1, 2]. Incorporating outside help into the host country response will always consume time and resources and must therefore be worth it in terms of a clear added benefit. If you only have generic medical skills and abilities, it is unlikely that you will add anything of great significance over and above what is already available.

Any true benefit you might bring is a function of the additional skills you have brought into play set against the cost to the local community of you being there. The balance tips in your favour when you are highly experienced in working in an austere environment and fully trained in conflict and disaster medicine and surgery and fully self-sufficient in food, water, medicines and medical/surgical equipment.

It is often said that any help is better than no help. This may be true in some circumstances but it is not true when delivering specialist surgical help. The experience of recent earthquakes, for example, has revealed excessively high amputation rates and inadequately performed operations by inexperienced surgeons leading to avoidable disability (Fig. 1.1) [3].

Fig. 1.1 Inappropriate guillotine amputation

A.D. Redmond, OBE, MD, DSc (hon), FRCP
Department of International Emergency Medicine, Humanitarian and Conflict Response Institute, University of Manchester, United Kingdom Interational Trauma Register (UKIETR), Manchester, UK
e-mail: tony.redmond@manchester.ac.uk

© Springer International Publishing Switzerland 2016

J.D. Robinson (ed.), *Orthopaedic Trauma in the Austere Environment: A Practical Guide to Care in the Humanitarian Setting*, DOI 10.1007/978-3-319-29122-2_1

1.2 Invitation to Respond

Particularly in sudden-onset disasters, it is extremely important to understand and accept that it is the locals who are in charge and to behave accordingly [4]. They were there before you arrived and will be there when you have gone. Failure to acknowledge this can be a major contributor to prolonging the period of apparent chaos and disorganisation in the immediate aftermath of a sudden-onset disaster. (Some degree of "chaos" is almost inevitable as the concept of a disaster involves personnel and facilities being overwhelmed.) The most effective medical care to the community can only be given when a degree of organisation and coordination is restored and limited resources are focused on those most in need. Local authorities therefore need to know what assets they have and deploy them to where they will be of most benefit. Incoming teams must therefore identify themselves to the local authorities and work within a local or national framework in order to be most effective. Setting up a parallel system whilst obviously treating some patients will fragment the national response and most importantly prevent appropriate follow-up of patients when the incoming team has gone.

1.3 Coordination

Lack of coordination in the immediate aftermath of a large-scale sudden-onset disaster is well recognised. Uninvited medical teams, no matter how good their intentions or even how skilled their members are, run a significant risk of adding to the chaos. For a sudden-onset disaster, the safest way of avoiding contributing to the inevitable immediate chaos is to only go if you have been invited. You are more likely to be invited if you are already part of a recognised national team/response that disaster-prone countries are aware of, such as the UK Emergency Medical Team (EMT) and AUSMAT in Australia or part of an established international organisation that responds to sudden-onset disasters such as the Red Cross/Red Crescent movement or NGOs such as MSF, IMC, Save The Children and Merlin. The cluster system has been established to coordinate the humanitarian response in the field and the lead for the health cluster is WHO [5].

1.4 Standards

The Emergency Medical Teams Initiative at WHO has published classification and standards for incoming emergency medical teams to assist host countries in identifying the medical assets available to them [6]. The term International Emergency Medical Team has been adopted to describe those international medical teams that have registered with the Global EMT Registry and agreed to comply with a set of standards and principles. It encompasses all, civilian/military/governmental/nongovernmental, "groups of health professionals and supporting staff working outside their country of origin, aiming to provide health care specifically to disaster affected populations" [6]. An important recommendation of the group and one that reinforces the above is: "Any individuals or groups that do not fit within the definition and cannot comply with the standard should either consider joining a recognised organisation that provides FMTs or not responding in the aftermath of a sudden onset disaster".

The classification of teams recommended by the EMT Initiative cumulative with each level adding additional capability.

- FMT Type 1: Outpatient Emergency Care – initial emergency care of injuries and other significant health-care needs
- FMT Type 2: Inpatient Surgical Emergency Care – inpatient acute care and may be fixed and/or mobile general and obstetric surgery for trauma and other major conditions
- FMT Type 3: Inpatient Referral Care – complex inpatient referral surgical care including intensive care capacity

It is recognised that there will be additional specialised care teams that can be incorporated within a type 2, 3, or local hospital. As yet classification does not equate with accreditation. It is a self-declaration of capacity and a commitment to comply with the standards.

1.5 Authorisation to Practice

Doctors must be accountable to their patients. National authorities guarantee this by a medical registration system and license to practice. This still applies during a disaster. Of course the special circumstances of a disaster will mean that the usual lengthy process of registration of foreign medical practitioners is too long to allow them to be of any benefit in the acute crisis. Governments overcome this by authorising individual practitioners or more commonly recognised agencies (e.g. Red Cross, MSF) to practice within that country either for the period of the declared emergency or as part of a longer term registration of that agency (Fig. 1.2). Clearly individuals or groups of medical practitioners who arrive uninvited do not have authorisation to practice and are therefore in breach of a basic medical tenet of good practice. They may also be practising illegally.

It is also important to recognise that particularly for surgery your patients need some form of medical indemnity should things not turn out as planned. Practising without authority and/or illegally will nullify any medical insurance/indemnity you have, placing your patient at further risk.

By joining an established internationally recognised agency, you can be assured that your presence in country following a sudden-onset disaster will be at the invitation of a recognised local authority and that you will have authorisation to practice and appropriate medical insurance/indemnity.

Fig. 1.2 A mission to China following a massive earthquake. A temporary facility was set up in the hospital grounds as aftershocks continued to rock the hospital’s buildings

1.6 The Exceptional Circumstances of Conflict

When responding to conflict in another country and not as part of medical support to the armed forces and particularly when working more on one side than another, then it's clear you will have not been invited by everyone involved. However, authority to practice can come from those working for an agency that is recognised to have a legitimate place in the field of conflict such as the UN and in particular the ICRC.

Working in a civil war is unlikely to be the result of an invitation from the existing government. As such you will be working uninvited by at least one faction and without government authority. Your judgement may be that the needs of victims override such concerns but it is important to recognise the circumstances in which you are practising. Detailed preparation has certain key stages.

1.6.1 Make Sure This Work Is for You

It is not without risk. It will place considerable physical, emotional and psychological strains upon you and your relationships. If the risk is to be worth the taking, it should produce tangible benefits. These can be secured by appropriate pre-deployment preparation and training.

1.6.2 Join an Established Organisation

The appropriate skills and competencies, an authoritative request to respond and an authorisation to practice can all be gained most easily by joining a recognised large international agency.

1.6.3 Mental and Physical Fitness

Working in an austere environment requires a certain basic level of mental and physical fitness. Whilst this may not necessarily be an exceptional standard, it must be appreciated that whatever mental and physical health issues you have before deployment are unlikely to resolve whilst on deployment and may very well be worsened by the mental and physical hardships endured. Becoming ill on mission threatens the success of that mission when resources intended for the victims of the disaster are diverted to you.

1.6.4 Garnering Core Skills and Competencies

Medical students and doctors in training are unlikely to be of benefit in an austere environment, as their ability to work independently is limited. The difficulties presented by disasters and conflicts render them places where people should not look to gain basic primary experience. The demands of working there are such that they are better viewed as places to where those with experience are deployed. However, there is obviously a certain "Catch-22" about this. This can be overcome again by deployment through an established agency where experience is gained in the field with the full support around you from those with more experience. In addition to basic general medical and surgical skills, the following are required before deployment.

1.6.5 Completion of Training in a Relevant Surgical Specialty

Orthopaedic, plastic and general surgery have a particular relevance in the response to earthquakes where crush injuries predominate. In addition vascular surgery has a special relevance to conflict (Fig. 1.3).

1.6.6 Surgical Training for the Austere Environment

Individual surgeons or small groupings responding on an ad hoc basis have raised considerable concerns in recent years due to their lack of measurable impact, lack of accountability, lack of

Fig. 1.3 Orthopaedic surgeon with rare access to a C-arm applying an external fixator

Fig. 1.4 Earthquake in Armenia

follow-up and poor standards due to practising outside of their recognised training. Such are the concerns internationally; the foreign medical teams' concept paper produced by the Global Health Cluster and the World Health Organisation specifically emphasises that surgeons responding to sudden-onset disasters should only carry out procedures for which they are licensed to so do in their own country. However, with ever increasing surgical specialisation, it is inevitable that surgeons deployed to a sudden-onset disaster might find themselves faced with a surgical problem outside their area of recognised expertise. It is imperative still that surgeons or indeed any medical practitioner strives to work only within the areas for which they are licensed to practice, whether in their own country or overseas, but faced with a large number of unsorted casualties presenting to limited resources; there may very well not be a realistic opportunity to refer a case onto a more appropriate specialist. Surgeons who respond to disasters need therefore to broaden their skills through further training prior to deployment. The ICRC and other established responders offer such training. In the UK the Royal College of Surgeons of England in collaboration with UK-Med offer the STAE (surgical training for the austere environment) course under the direction of Mr David Nott. Before deployment, in addition to broadening their technical surgical skills, surgeons also need to have an understanding of humanitarian principles, the social economic and political context in which they may work and the benefits and dangers of surgery in such a setting. In particular they need to understand the importance of follow-up and integration with local health services.

It is in the nature of a large-scale disaster that a range of problems can present to what is ostensibly a specialist surgical facility (Fig. 1.4). Surgeons deployed to earthquakes from overseas, for example, will usually not arrive in time to treat acute life-threatening surgical problems and will be there primarily to carry out limb salvage surgery. They obviously need therefore to understand the principles of wound management and establish skin cover with basic flaps and split skin graft. However coincidental surgical emergencies do arise. An orthopaedic surgeon working in an austere environment needs to be able to do an emergency thoracotomy and other resuscitative surgical procedures as well as laparotomy and packing of the abdomen to reduce/control haemorrhage. Whilst neurosurgery is usually beyond the remit of an International Emergency Medical Team, there are times when limited techniques can be of benefit and a surgeon needs to understand the principles of when neurosurgical intervention is indicated and when not.

Perhaps the most difficult and at times contentious issue is the management of obstetric emergencies by the non-specialist. Obviously obstetric haemorrhage and obstructed labour are best managed by a specialist obstetrician. However, such expertise may not be readily available in time to save a woman's life. Any surgeon working in an austere environment must therefore already have gained an understanding of when the woman's life depends upon their intervention and be able to safely carry out certain life-saving procedures. These include clearing the os cervix of retained products, controlling haemorrhage using balloon tamponade and deconstructive craniotomy following intrauterine death. In particular a surgeon must already understand the indications for, and be able to carry out, emergency caesarean section.

1.6.7 Experience Beyond Surgery

Public health and emergency medicine bring a knowledge of the effects of the disaster/conflict beyond the purely surgical and experience in these specialties can be of great value to a surgeon wishing to deploy [7, 8]. Experiences in obstetrics and paediatrics are also extremely useful, particularly when general health services have been compromised.

It is important in particular to understand public health principles that apply in sudden-onset disasters. For example, it is well established that the risk of epidemics following earthquakes is extremely low. The risk to the health of the living from the unburied dead following a sudden-onset disaster is minimal and so effort should be concentrated on survivors and not on the dead. Mass graves bring untold grief to relatives who are denied the opportunity to give a cultural/religious internment and in fact may not know if someone is dead or alive and ultimately have to identify their remains in extremely difficult circumstances. Governmental authorities may make a decision to remove dead bodies particularly when in large numbers but this should be viewed more as a civic than a medical issue. When the disaster itself is the consequence of an infectious disease, notably cholera or a viral haemorrhagic fever, the corpses themselves may be infectious for some time after death. In these special circumstances the unburied dead do pose a risk to the living and special measures by the public health authorities need to be employed. This is the exception to the rule.

1.6.8 Understanding the Context in Which You Will Work

To be most effective in the field, it is important to understand the nature of conflicts and disasters. There is a body of knowledge around the types of injuries and conditions that commonly occur and the safest approach to their management. There are a number of courses run by a range of agencies including the Red Cross/Red Crescent Movement, MSF, RedR and UK-Med.

It is essential also to understand the roles and responsibilities of key international agencies. Familiarisation with important UN and other large agency websites is an extremely useful exercise as are downloading and reading important documents. The role of the UN is particularly important to understand. There is a United Nations Disaster Assessment and Coordination team that, at the invitation of a country, will send a small team in immediately after the disaster has occurred to do a rapid assessment of needs and publish this online. The UNDAC Field Handbook is an extremely useful guide to needs assessment and the workings of the UN and can be downloaded from its website.

Much of the lack of coordination experienced by incoming teams may be due to lack of awareness of the established coordination mechanisms that will have been already put in place. The UN will have quickly established an On-Site Operations Coordination Centre (OSOCC) and it is to this incoming teams should report. The cluster system is now established and incoming medical team should report to the health cluster and report regularly their activities.

WHO are the lead for the health cluster and they will liaise closely with the National Department of Health to ensure health-care needs are met and health-care resources targeted appropriately.

When working in another country, it is important that members of International Emergency Medical Teams are aware of, and sensitive to, cultural issues that may impact upon their interaction with patients and their relatives. Paramount however is the maintenance of the humanitarian imperative and a commitment to the ethics of good medical practice that accompanies one's registration and licence to practice.

Principles of Conduct for the International Red Cross and Red Crescent Movement and NGOs in Disaster Response Programmes [9].

1. The humanitarian imperative comes first.
2. Aid is given regardless of the race, creed or nationality of the recipients and without adverse distinction of any kind. Aid priorities are calculated on the basis of need alone.
3. Aid will not be used to further a particular political or religious standpoint.
4. We shall endeavour not to act as instruments of government foreign policy.
5. We shall respect culture and custom.
6. We shall attempt to build disaster response on local capacities.
7. Ways shall be found to involve programme beneficiaries in the management of relief aid.
8. Relief aid must strive to reduce future vulnerabilities to disaster as well as meeting basic needs.
9. We hold ourselves accountable to both those we seek to assist and those from whom we accept resources.
10. In our information, publicity and advertising activities, we shall recognize disaster victims as dignified human beings, not hopeless objects.

1.6.9 Field Training

Specialist certification must be harnessed to an understanding of how these specialties are applied within the contingencies and context of a sudden-onset disaster or conflict. It is applying these specialist skills within limited resources and in an austere environment that completes readiness for deployment. Field training in simulated scenarios can be gained at home and overseas. It is essential to have experience of working in a low-resource setting before responding to a disaster and this is best gained by working with an established agency in one of their programmes. This will give you an understanding of the context in which you might work, working with limited resources and most importantly working within another country's health system.

1.6.10 Field Craft

The need for a full field hospital is usually limited; when outside surgical assistance is required, this can be usually accommodated within existing facilities. However it is essential that incoming International Emergency Medical Teams place a minimum burden on local resources and at times they may be required to live in tented accommodation, eat and drink from their own resources and on certain occasions work out of a tented hospital facility (Fig. 1.5). Part of the preparation for deployment is learning how to transport and erect tented living facilities and how to protect one's health and hygiene whilst living in such basic tented facilities.

1.6.11 Communications

Anyone who responds to a large-scale emergency must be able to communicate effectively and safely with colleagues both within one's team and also with other agencies. Everyone in the team needs to understand basic radio protocol and to be capable of using a handheld radio themselves, a GPS system and satellite technology so they can communicate with base and with others should they be separated from the team. The UNDAC Field Handbook, available to download from their website, is a very useful aid for this and other practical details of deployment and familiarisation with the UN system in the field [10].

Knowledge of foreign languages is extremely helpful and those employed by the UN are required to be able to communicate in English

Fig. 1.5 A field hospital operating room in a tent

and French. These days, English is probably the commonest international language in use. However, if one deploys through an established agency and particularly the local authorities, then a translator/interpreter will usually be provided. It takes some experience to communicate efficiently through an interpreter and one must get used to speaking slowly and in short sentences to allow the interpreter time to translate. It is also important to emphasise to the translator/interpreter and they must translate exactly what is said. There are sensitivities however; in some cultures a local translator will not translate intimate questions or comments that might be perceived as critical of someone in authority.

1.6.12 Safety and Security

Before deploying with an established organisation you will have had to have completed an online security course and in addition usually attended a security training exercise. The two commonest online security courses that are recommended by large agencies are those run by the UN and the IFRC [11, 12].

It was often said in the past that the biggest risk to humanitarian workers came from fatal road traffic accidents. This was due largely to inexperienced drivers negotiating poor roads unaccustomed to driving large 4x4 vehicles and failing to wear seat belts. These risks remain but unfortunately personal violence either from opportunistic robbery and/or hostage taking or politically motivated direct targeting of humanitarian workers now ranks alongside road traffic accidents as a leading cause of death amongst humanitarian workers [13]. Such risks cannot be avoided completely but can be mitigated by working with a large experienced organisation, heeding all security advice, not travelling alone and not travelling after dark. Nor are these risks limited to conflict zones. The presence of relatively wealthy aid workers in a poor country suffering the deprivations of a disaster can always present a target to someone.

Other risks to be mitigated are related to personal health. The commonest risks other than from road traffic accidents come from failure to take adequate malaria prophylaxis and gastrointestinal problems from consuming contaminated food and water. Boil it, cook it, peel it or discard it [14].

The drive to help those clearly in need must not override the need for adequate rest and nourishment. Difficult decisions are not made easier by lack of sleep and hunger. They are made even worse by over indulgence in alcohol.

1.6.13 Departure

One of the most important elements of preparation prior to departure from one's own country is preparation for departure from the other country. Each surgeon is responsible for the long-term follow-up of each of their patients. If they are not staying in country long enough to manage this for all their patients, they must establish a care plan and refer the patient onto colleagues or another facility and usually into the local health system.

References

1. Roy N, et al. The Gujurat earthquake (2001) experience in a seismically unprepared area: community hospital medical response. Prehosp Disaster Med. 2002;17(4):186–95.
2. Seyedin S, et al. The impact of international NGOs during and after the Bam earthquake: health systems consumers points of view. Am J Disaster Med. 2009;4(3):173–9.
3. Redmond AD, et al. A qualitative and quantitative study of the surgical and rehabilitation response to the earthquake in Haiti, January 2010. Prehosp Disaster Med. 2011;26(6):449–56.
4. Welling DR, et al. Seven sins of humanitarian medicine. World J Surg. 2010;34(3):466–70.
5. www.who.int/hac/global_health_cluster/en.
6. Foreign Medical teams – www.who.int/hac/global_health_cluster/fmt/en/.
7. Walsh L, et al. Core competencies for disaster medicine and public health. Disaster Med Public Health Preparedness. 2012;6:44–52.
8. www.paho.org/disasters/.
9. http://www.ifrc.org/en/publications-and-reports/code-of-conduct.
10. http://www.unocha.org/what-we-do/coordination-tools/undac/overview.
11. https://training.dss.un.org/consultants/index.php.
12. https://ifrc.csod.com/client/ifrc/default.aspx.
13. Rowley EA, et al. Violence-related mortality and morbidity of humanitarian workers. Am J Disaster Med. 2008;3(1):39–45.
14. http://www.nhs.uk/Livewell/travelhealth/Pages/Food-and-water-abroad.aspx.

2

What Can I Do Here? Understanding Your Working Environment

David Nott

For the past 20 years, I have worked voluntarily in areas of conflict and catastrophe throughout the world. My experience has taught me that it is essential to understand what sort of environment you are working in. Even though you may have the skill set to perform a certain procedure, it is essential that all factors are taken into account. You must ask yourself, what sort of terrain are you in? What is the hospital like? What is the state of the operating theatre? Do you have the right equipment? Do you have enough fluids available? Is the anaesthetist experienced enough? Is there sufficient staff in the recovery area? What are other wards like? Is there enough nursing staff during the day and night? Do they have enough knowledge to inform you when things may not be going well? What are the language barriers? Who will follow up your patient? The list can go on. So how do we decide what sort of environment we are in? It is easy when we are comparing extremes, such as an operating room in Camp Bastion in Afghanistan to a dressing station in Central Africa, but what about the wide range of settings in between?

Over the past 20 years, I have been fortunate to have worked in a variety of situations. The classifications below are based on my own personal experience, and to my knowledge there are no other similar references in the literature. These classifications are of necessity, arbitrarily. But they will help us understand the different scenarios you may find yourself in.

In general, the situations faced in humanitarian work can be broadly divided into five categories:

1. High public financing (Fig. 2.1)
2. Developed country
3. Lesser developed country
4. Non-state actors, guerrilla groups
5. Natural disaster, earthquake and tsunami

In all the scenarios above, the humanitarian surgeon is limited by the infrastructure, personnel and equipment available, as well as your experience and training.

The first category is exemplified by the defence medical services during the recent wars in Iraq and Afghanistan (Table 2.1). The last 10 years have produced significant advances in the way trauma is managed in war and civilian practice [1]. Since the inception of damage control surgery, a term first coined by Rotondo in 1993 [2] and whose main emphasis was treating the physiology of the trauma patient rather than the injury per se, a significant amount of research has provided more insight into the management of severe trauma. Damage control resuscitation,

---

D. Nott, OBE, OStJ, BSC, MD, FRCS, DMCC
Department of Surgery, Chelsea and Westminster Hospital, Imperial College Healthcare NHS Trust, London, UK
e-mail: d.nott@imperial.ac.uk

© Springer International Publishing Switzerland 2016

J.D. Robinson (ed.), *Orthopaedic Trauma in the Austere Environment: A Practical Guide to Care in the Humanitarian Setting*, DOI 10.1007/978-3-319-29122-2_2

which includes permissive hypotension and haemostatic resuscitation when combined with damage control surgery, has produced some of the best major trauma patient survival results in the world [3].

From point of wounding on the battlefield to the operating room, it takes on average less than 1 h. During that time, fully trained battlefield medics provide the initial life-saving procedures such as application of combat tourniquets, initiation of intravenous fluids and painkilling drugs. The medical emergency response team (MERT) helicopter flies to the scene of the injury, and the patient is transported back to the Role 3 Field Hospital at Camp Bastion. En route, the patient is given the best possible care by senior nurses and consultant emergency physicians. In cases of significant haemorrhage, blood may be given as well as all operative adjuncts available to support the patient. Upon arriving at Camp Bastion, the patient is transferred to the operating room within minutes. The hospital is supported by state-of-the-art digital x-ray machines and two CT scanners. The operating suite has all the latest equipment and can also run five operating tables simultaneously.

Fig. 2.1 High public financing - Camp Bastion

Damage control resuscitation, which began in the helicopter, continues as soon as the patient arrives in hospital. Minimal crystalloid is given followed by blood and blood components notably packed cells, fresh frozen plasma and platelets given in a 1:1:1 ratio (haemostatic resuscitation). A laboratory next to the operating theatre continues to provide more blood and also up-to-date haematological and biochemical investigations. The anaesthetist and the surgeon can decide, depending on the physiology of the patient, to continue to definitive surgery or to perform damage control surgery by stopping any bleeding, preventing sepsis, external fixation of fractures and maintaining arterial flow by shunts. An intensive care unit with full ventilatory support can provide continued support whether the patient goes back to the country of origin.

Table 2.1 Category 1: High public financing

Example	Environment	General resources	Medical resources
Camp Bastion, Afghanistan	War zone	Protected access and exit	Early prehospital transfer available
		Safe infrastructure	Emergency department led by a senior physician
		Adequate supply of power and water	Full scope for IV access Digital imaging CT scanner
		Full scope of trained staff	Full anaesthetic backup Level 1 infuser Damage control resuscitation
		Full access to communications and transport	Senior surgeon led surgical team Damage control/definitive surgery possible
		Reliable supply chain	Full laboratory backup Including well-stocked blood bank
		Good logistical support	Modern intensive care unit
		Rapid evacuation	Transfer back to Role 4 guaranteed

There is really no difference between what can be done in this environment and what can be done in a major trauma centre in the developed world. However, there are no so-called "primary amputations" performed in this environment. Patients that have traumatic amputations from blast injuries have debridement to remove all the nonviable tissue. The decision whether to perform an amputation is performed back in the Role 4 hospital.

All clinical staffs are senior clinicians and therefore fully trained in their specialty. Nevertheless, further military medical and surgical training is compulsory. For example, in the UK, all outbound medical staff have to pass a course in battlefield advanced trauma life support (BATLS), followed by a week of military operational surgical training (MOST) at the Royal College of Surgeons of England. So it can be seen that high public financing provides for a huge amount of infrastructure, resources and training that provide the best possible care.

2.1 Category 2: Developing Country with Higher Level of Resources

As an example of Category 2, I shall give Misrata, Libya, April 2011 (Table 2.2 and Fig. 2.2). At this time, Misrata was surrounded by troops loyal to Colonel Gaddafi. The only way in and out of the country was by boat via the port of Misrata sailing from and to Malta. The team comprising of two surgeons, two anaesthetists, an emergency physician, a scrub nurse and two ward nurses left Malta under cover of darkness and was escorted by US and French Navy until 20 nautical miles outside the port.

Most of the university hospitals had been overrun and were not working. There were only two functioning hospitals, Al Hikma and Al Abbad. Most of the nurses had left as had most of the senior and specialty surgeons. There were two other nongovernment organisations (NGOs) there, providing approximately six surgeons and six anaesthetists.

It soon became apparent that the medical staff was under intense stress from the number of casualties and also the inherent nature of the situation with tank shells pounding the city every day. The hospitals had adequate number of beds, a functioning intensive care unit with working ventilators and large number of medical students acting as orderlies and nurses.

War surgery is completely different from elective general and orthopaedic surgery and requires different thought processes, because the mechanisms of injury require different operative treatments. Surgeons often default to the operative technique they are comfortable with. For example, the default orthopaedic operation

Table 2.2 Category 2: Developing country with higher level of resources

Example	Environment	General resources	Medical resources
Libya/Syria	War zone	Difficult access and exit	Early prehospital transfer
		Unsafe infrastructure	Junior doctor/medical student led emergency department
		Electricity and water not continuous	Peripheral IV access X-ray machine with standard x-rays
		Significant reduction in senior medical staff	Anaesthetic technician backup
		Mobile phone communication possible. Infrequent internet	Surgical team probably not very experienced
		Disrupted chain of supplies	Blood bank laboratory Poorly stocked blood bank
		Logistical support variable	Intensive care unit
		Evacuation lines compromised	Patient transfer ability limited or dangerous


[redacted]

Fig. 2.2 In Libya, medical students are serving as ventilators

for a proximal femur fracture is internal fixation. In war surgery, most wounds, caused by fragmentation and gunshots are, by definition, contaminated. There is no place for immediate internal fixation due to the high risk of wound infection. The common treatments for fractures in an austere environment include skeletal traction, plaster of Paris and external fixation for fractures with large soft tissue wounds. Unfortunately, many patients underwent internal fixation, simply because radiology was present in the operating theatre and the surgeon was more used to internal fixation than any other method.

It is very important to develop an awareness of priorities. When the patient has had a period of ischaemia secondary to a gunshot wound to the leg, transecting the popliteal artery and vein, the correct treatment is to first perform a fasciotomy to decompress the muscles in the lower leg followed by immediate shunting of the vessel to reduce the time of warm ischaemia. Time can then be spent stabilising the fracture by external fixation whilst the vein can be harvested from the other leg. If these procedures are not done first, performing a reverse vein graft may be possible, but the patient will develop compartment syndrome. On one occasion, when the surgeon was asked why he did not perform a fasciotomy, his response was that in his practice at home he had never had to perform a fasciotomy, and he wasn't going to start now.

In a mass casualty event, the wounded are categorised into the degree of life-threatening injuries. T1 casualties requires immediate surgery, if not they will die from blood loss; T2 casualties need surgery within the next two hours; T3, the walking wounded; and T4, the expectant to die. For example, without a general understanding of triage, a wounded patient with a massive injury will probably die whatever is done; if that casualty is triaged into group T1 rather than T4, then all the available resources can be used up in trying to save life including blood and manpower, whilst other patients will not be attended to.

There were many examples that made it very obvious that there was a lack of training on how to deal with the war wounded. Complications that arose due to inappropriate management had to be dealt with in-house, increasing the workload significantly. An introduction to the correct management of war surgery and trauma was required, and our team provided as much war surgical training as possible including triage during this time.

Damage control is relevant to all environments. Although it may not be possible to perform damage control resuscitation to the sophistication of Camp Bastion, damage control is applicable to all levels of austerity. In fact, the lower the level of resources, the more important it is to think along the lines of damage control (see Chapter 26 on damage control orthopaedics). Adaptation strategies may be necessary. In the early days of damage control, for example, patients often developed abdominal compartment syndrome because of the large amount of crystalloid given [2]. Laparostomy was necessary because of the high incidence of abdominal compartment syndrome (ACS) owing to crystalloid extravasation. Modern damage control resuscitation using blood and components has significantly reduced this requirement. However, apart from high resource areas, access to significant amounts of blood and blood products may not be possible, and therefore large amounts of crystalloid may have to be given as part of the resuscitation process which increases the risk of ACS. It is important that the surgeon anticipates this risk as there is no provision for laparostomy. Cues for ACS include noticeable oedema of the small or large bowel, tightness in closure or a doughy feel of the abdominal wall. A technique called component separation whereby the myoaponeurosis of the external oblique muscle is transected longitudinally along its whole length can give on average 14 cm of laxity to the anterior abdominal wall for further expansion and subsequent reduction of intra-abdominal pressure. This technique has been used in Syria treating 61 patients who fell into the category requiring damage control. This is the first time that this technique has ever been used primarily in an attempt to stop the disastrous effect of ACS [4].

2.2 Category 3: Less-developed Country

Northern Yemen, a very beautiful but poor area of the world, is a very dangerous country with many foreigners kidnapped for ransom (Table 2.3). There are constant disagreements between the North and the South, and very often the South will attack the North with heavy weapons, fighter jets and artillery. The presence of snipers in the hills makes safe access to medical care very difficult. Everybody carries a weapon notably a Kalashnikov. There are disputes constantly and lots of gunshot wounds to deal with. There are few doctors present and hardly any surgeons. A lot of the country relies on help given to them by various NGOs. The team usually comprises of a surgeon, an anaesthetist who may be a nurse anaesthetist and a scrub nurse in charge of the theatre and can also double up as the runner. This means you probably have to operate without a scrub nurse, so you have to deal with your own instruments as well as perform the surgery without any help. Often, there may be a local surgeon who in real terms has not been to medical school but has had some experience in operating room and wants to gain more experience. You must be aware though of his skills and always take ultimate responsibility.

The hospital may have an adequate operating room light and anaesthetic equipment allowing ventilation using an oxygen concentrator. However, the electricity may fail at any stage and the generator may not provide backup, so have this in the back of your mind. There may be ward nurses, but assume little knowledge until you have had an opportunity to assess them. They may not be able to take relevant observations and may not be there at night. The patients remain your responsibility throughout the mission, and day-to-day ward rounds and provision of intravenous fluids and nutrition are also part of your routine.

There may be significant delays from point of wounding to transfer to the hospital. In very rural areas, there may be no roads or patients may be prevented from getting to the hospital because of roadblocks. When they do eventually make it to you, patients may be in a serious condition having lost significant amounts of blood. It is your responsibility to make sure that the blood bank

Table 2.3 Category 3: Less-developed country

Example	Environment	General resources	Medical resources
Yemen	War zone	Difficult access and exit	Long prehospital transfer
		Unsafe infrastructure	Poorly equipped emergency department
		Electricity and water not continuous	No imaging available
		Significant reduction in senior medical staff	Nurse anaesthetist
		Mobile phone communication possible. Infrequent internet	Local surgeons
		Disrupted chain of supplies	Haemoglobinometer Poorly stocked blood bank
		Logistical support variable	Primitive recovery area
		Evacuation lines compromised	No prospect of transfer

has sufficient amount of blood available. If possible, have two units of blood of each type with another two units of O negative. There is usually no equipment for measuring electrolytes only a haemoglobinometer for measuring haemoglobin. The most important factor in maintaining adequate fluids is the maintenance of a good urine output.

2.3 Category 4: Non-state Actors, Guerrilla Groups

In Darfur, the mission hospital was on the border between Chad and Sudan (Table 2.4). Five expats with around 40 local healthcare workers looked after a population of around eight million people. At the time there was a scorched earth policy and displaced people were in refugee camps along the border. The workload is intense as is the heat. Electricity will most probably be provided by generator which will more than often or not break down. You need to be self-sufficient and use a headlight that can provide enough light to operate with. There may not be a working ventilator, and maintenance of volatile anaesthesia may rely solely by manual means. The anaesthesia may be limited to nerve blocks and spinal anaesthesia. There will be no suction apart from a foot pump, and there may be no oxygen because the oxygen concentrator requires electricity. More likely than not, there may be no blood. There may be a monitor to measure haemoglobin but that is probably all. Patients will be transported to you via horse and cart and may take several days. Most patients are anaemic due to malaria, worms, chronic infections or nutritional deficiencies. Your starting haemoglobin is usually around 5 g/dl, so it does not take much loss of blood for patients to become severely compromised.

You will be limited in what you can do in this environment and to consider the surgical aspects of the hospital as dressing station may be the best option (Fig. 2.3). The environment is dangerous and at any time you may be confronted with armed militia. Always explain the diagnosis to the patient and his family and also the worst case scenario. Do not be too optimistic about the results of the surgery. There may not be facilities for external fixation, as most likely the equipment will have gone missing or taken by the patient on discharge. Stick to basic plaster of Paris, splints and traction.

In severe orthopaedic injuries, primary amputation may be the correct procedure. However, the patient may refuse on religious grounds. In that case, do not force the issue and understand the fact that patients would rather die with all their limbs than have an amputation. Always respect the wishes of the patient, but make sure they have full information and understand the risks.

Safety is a major concern, and in this environment the team may feel very vulnerable. In 2004 I was working in a small village in Darfur when the Janjaweed arrived and started shooting indiscriminately. The situation was extremely tense

Table 2.4 Category 4: Non-state actors, guerrilla groups

Example	Environment	General resources	Medical resources
Darfur	War zone Guerrilla groups	Dangerous access and exit	Very long prehospital transfer
		Unsafe infrastructure	No emergency department
		Electricity and water not continuous	No imaging available
		No surgical support	Nurse anaesthetist
		Communication via head of mission	Local surgeons
		Disrupted chain of supply	No laboratory investigations
		Logistical support variable	Poor ward care
		Evacuation lines dangerous	No facility for transfer

Fig. 2.3 What sort of environment will you be working in?

and was one of the most dangerous episodes of my career in humanitarian surgery. Always be aware of your escape route. Make sure that you listen to the daily briefings by the project manager. There is usually a vehicle full of petrol ready to leave. Never be alone especially at night.

2.4 Category 5: Non-man-made Disaster, Earthquake, Tsunami

Consider Haiti in 2010 following the earthquake measuring 7.0 on the Richter scale. The epicentre, close to the capital Port-au-Prince, caused tens of thousands of deaths and countless casualties. The difference between a conflict, as in the previous four categories, and a natural disaster is that a disaster usually strikes once. Its effects may be devastating, but the aftermath may be more predictable. A conflict zone can go on for weeks, months or even years and has a constant supply of wounded victims sometimes in large numbers (Table 2.5). There are always security issues with the team working in a war zone, less so in a disaster. However, one must not forget that due to lack of housing, food and water, the situation can get rapidly out of hand as did in Haiti, where violence and conflict began to produce lots of wounded due to gunfire.

Most patients who died did so because of asphyxia and crush injuries that caused massive tissue loss followed by renal failure. Most of the deaths occurred within the first 24 h. It is known that the most good can be done within the first 12 h, but it is almost impossible in any part of the world to get teams organised so rapidly. Usually it takes 3–4 days before help arrives. In January 2010 there was a massive influx of NGOs and do-gooders who came during the latter part of the first week. Surgery for catastrophes, such as tsunami and earthquakes, requires skilled osteoplastic management. Many of the wounds seen are soft tissue injuries with fractures which require fixation and debridement.

In this environment there is no place for microvascular free tissue transfer; however, a working knowledge of rotational muscle and skin flaps to cover bone, blood vessel and defects is necessary followed by split skin grafts if required. This sort of surgery can only be performed by well-experienced surgeons; it is not necessary to be a specialist orthopaedic surgeon or a specialist plastic surgeon; it is important to be careful,

Table 2.5 Category 5: Non-man-made disaster, earthquake, tsunami

Non-man-made disaster	Environment	General resources	Medical resources
Haiti/Philippines/ Pakistan China	Earthquake Tsunami	Entry may be by helicopter or boat, rarely by road	Infrastructure completely destroyed Tented field hospital
		Aftershocks probable	No emergency department
		No electricity or water in the initial phase	No imaging
		Many different NGOs	Local anaesthetists available
		Communication via satellite	Local surgeons available
		Supply chain begins usually 1 week after catastrophe	Few investigations
		Logistical support usually good	Ward care good after a few days
		Evacuation usually available	No facility for transfer

meticulous and have experience in the techniques of rotational myocutaneous flaps.

The hospital had around 250 beds and three operating theatres which were already well staffed and equipped with the best in anaesthetic equipment and stability. I visited two of her three other field hospitals during my stay and was dismayed at finding field hospitals not fit for purpose. Sterility was a huge issue, and a lot of surgery was performed by surgeons either too junior to understand that a table with a curtain swinging in the wind does not constitute an operating theatre or experienced surgeons who were performing surgery as if they were operating with laminar flow. As has been discussed before, it is really important that the surgeon appreciates the environment where he is working. He or she must have the experience and knowledge to be able to switch from elective work in his own hospital to conflict and catastrophe work in an environment which is completely alien to his normal working pattern.

Many papers have been written alluding to the fact that the response in Haiti could have been better [5, 6]. I worry that the lessons learned from Haiti will soon be forgotten, in the same manner that the lessons learned from other disasters before Haiti were. Surgeons and teams that respond to the next massive earthquake must be aware of clinical governance issues and be properly trained. In the UK, the first course to train civilian surgeons to work in the field was run at the Royal College of Surgeons of England in August 2013. 30 participants were taught by members of a faculty all experienced in work abroad, which included general surgeons, paediatric surgeons, cardiovascular surgeons, plastic surgeons, orthopaedic surgeons, neurosurgeons, fascio-maxillary surgeons and obstetricians and gynaecologists. The participants came from a wide variety of organisations, the UK International Emergency Trauma Register (UKIETR), Medecins Sans Frontieres (MSF) and the International Committee of the Red Cross (ICRC). It is envisaged that this course will run three times a year and hopefully provide the necessary clinical skills to provide the best possible care in the austere environment. There are other courses in Australia and the USA, such as the Disaster Response Course for Orthopaedic Surgeons, and the Arbeitsgemeinschaft für Osteosynthesefragen (AO) Foundation is running Disaster Surgery Workshops now.

Conclusion

There are many possible scenarios and limiting factors in austere environments. Understand where you are and the limitations and opportunities of your environment. Make sure you are as prepared, informed and trained as possible before you set off on your mission. Your patients', colleagues' and your own safety depend on this.

References

1. Guthrie HC, Ramasamy A, Kendrew JM, Clasper J. Modern military surgery lessons from Iraq and Afghanistan. J Bone Joint Surg. 2012;4:536–43.
2. Rotondo MF, Schwab CW, McGonigal MD, Phillips 3rd GR, Fruchterman TM, Kauder DR, Latenser BA, Angood PA. “Damage control”: an approach for improved survival in exsanguinating penetrating abdominal injury. J Trauma. 1993;35(3):375–82; discussion 382–3.
3. Morrison JJ, Ross JD, Poon H, Midwinter MJ, Jansen JO. Intraoperative correction of acidosis, coagulopathy and hypothermia in combat casualties with severe haemorrhagic shock. Anaesthesia. 2013;68:846–50.
4. Nott DM, Veen H, Matthew P. Damage Control in the Austere Environment. Ann R Coll Surg Engl. 2014;96(Suppl):82–3.
5. Teicher CL, Albertu K, Porten K, Elder G, Baron E, Herard P. Medecins Sans Frontieres, Medical Department, New York. Prehosp Disaster Med. 2014;29:21–6.
6. Moyad TF. Letter to the Editor: Critically assessing the Haiti Earthquake Response and the Barriers to Quality Orthopaedic Care. Clin Orthop Relat Res. 2013;471:690–1.

3

Epidemiology of Fatalities and Orthopaedic Trauma in Armed Conflicts and Natural Disasters

S.E. Roberts, K. Thorne, and A. Akbari

During the last 25 years, more than two million lives have been lost through wars or armed conflicts and more than 1.4 million through natural disasters. Countries affected by the heaviest fatalities are often less developed such as Afghanistan (armed conflict), Bangladesh (cyclone), China (earthquakes), the Congo Republic (conflict), Ethiopia (conflict), Indonesia (conflict and earthquakes), Iraq (conflict), Iran (earthquakes), Liberia (conflict), Myanmar (cyclone), Pakistan (conflict, earthquakes and floods) and Sudan (conflict).

Explosive devices, including improvised explosive devices (IEDs), have become increasingly the leading cause of fatalities and non-fatal injuries in many recent wars and armed conflicts. Major single explosive incidents with the highest fatality rates often refer to buildings hit by devices from nearby motor vehicles. Injuries to the head, neck and abdomen are the leading cause of fatalities with the worst prognosis, while lower limbs often account for most non-fatal injuries. Post-operative mortality has fallen over time, but is often strongly dependent on facilities and other external factors.

During the last 25 years, earthquakes and tsunamis have been the leading cause of mortality from natural disasters accounting for more than 900,000 fatalities or 65 % of all deaths, followed by typhoons/hurricanes/cyclones (>300,000) and heatwaves (>130,000).

Snakes account for more than 420,000 venomous bites and 20,000 fatalities worldwide each year, with highest mortality in Oceania, sub-Saharan West Africa, South and Southeast Asia and the Caribbean. Accidents at work and road traffic accidents cause approximately 350,000 and 1.25 million fatalities worldwide each year, with highest mortality mostly in lesser developed regions of Africa, Asia, the Middle East and Latin America.

In almost all of the wars and armed conflicts, the majority of casualties have been civilians rather than military personnel, and the longer term public health effects of the conflicts are often even greater than the direct effects of the conflict trauma. Many of the wars, armed conflicts and natural disasters occur in poor, low-resource countries medical school, with medical and health systems that struggle or fail to cope with the impact and require humanitarian aid. The public health effects variously include the impact of refugee camps and population displacements, inadequate production and provision of food, inadequate supplies of clean water, breakdowns in sanitation and the spread of infectious diseases.

S.E. Roberts, BSc, MSc, PhD (✉)
Lecturer, College of Medicine, Swansea University, Swansea, Wales, UK
e-mail: stephen.e.roberts@swansea.ac.uk

K. Thorne, BSc, MPhil, PhD • A. Akbari, BSc, MSc
Research Officer College of Medicine, Swansea University, Swansea, Wales, UK

© Springer International Publishing Switzerland 2016

J.D. Robinson (ed.), *Orthopaedic Trauma in the Austere Environment: A Practical Guide to Care in the Humanitarian Setting*, DOI 10.1007/978-3-319-29122-2_3

3.1 Methods

This review focuses, firstly, on wars and armed conflicts; secondly, on natural disasters; and thirdly on other major causes of fatalities and trauma, animal attacks, occupational injuries and road traffic accidents, particularly those that occur in low-resource, developing countries.

The review concentrates on the years from 1990 to April 2014, although for purposes of historical comparisons, it also covers wars, armed conflicts and natural disasters that date back to World War I and II. The information sources used in this review include Medline, Embase, the World Health Organisation (WHO), the Red Cross, grey literature, government reports, Internet searches and hand searching of reference lists from papers and reports.

3.1.1 Wars and Armed Conflicts

This review focuses on major wars and armed conflicts that resulted in at least 1000 lives lost, including both civilians and non-civilians. It excluded fatalities that occurred through causes which did not result directly from or involve armed conflict, for example, genocides, regime repressions and executions, policy and cultural revolutions, famines, starvation, drug gang wars, mass suicides and disease epidemics. The review similarly excluded fatalities and injuries that arose through mass population transfers following the end of World War II and elsewhere subsequently. Where information sources quoted fatality figures as a range, typically lowest and highest estimations, we took the midpoint of that range. Where multiple information sources quoted different figures for the same conflict or incident, the data was cross-referenced to assess the accuracy of the figures, and an average figure was taken.

When investigating the causes of casualties according to the type of device used, the following classification of major devices was adopted: (i) gunshot wounds; (ii) explosive devices and fragments, including explosive ordnance bombs and IEDs; (iii) anti-tank mines; (iv) anti-personnel mines; and (v) other devices including stab wounds and burns. Similarly, the review of casualties according to the anatomical and tissue type distribution adopted the following classification: (i) head and neck injuries, (ii) thoracic injuries, (iii) abdominal injuries, (iv) injuries to the (upper and lower) limbs and (v) multiple and other injuries.

3.1.2 Natural Disasters

This part of the worldwide review focused on the time period since 1990 and major natural disasters that resulted in at least 25 fatalities. The classification of natural disasters used was as follows: (i) geophysical natural disasters, comprising mainly of earthquakes, tsunamis, volcanic activity and landslides; (ii) meteorological disasters, including typhoons/hurricanes/tropical cyclones, tornadoes, storms, blizzards and monsoons; (iii) climatological disasters, including heatwaves, droughts and wildfires; and (iv) hydrological disasters, including floods and mudslides.

3.1.3 Other Causes of Fatalities and Trauma

This section of the review addressed the following major causes of fatalities and trauma worldwide: firstly, animal attacks including snakes, crocodiles and alligators and other animals such as sharks, lions, tigers, leopards and other large cats and also domesticated dogs; secondly, occupational injuries; and thirdly, road traffic accidents.

3.1.4 Strengths and Limitations of the Information Sources

Many studies and information sources do not distinguish fatalities and injuries among different population types such as military forces, police, insurgents, aid workers, contractors and all other personnel. Many of the available information sources were also imprecise when specifying information such as the exact numbers of fatalities, non-fatal injuries and casualties (fatalities and non-fatal injuries combined), the year and country in which the fatalities and casualties occurred, the forces affected (often troops from other countries) and the precise causes, circumstances and anatomical distribution of the dead and injured. Some of the information sources were affected by under-reporting and were incomplete in some cases, although it is expected that this would amount only to a minority of cases. There was also wide variation and a lack of clarity across studies as to the severity of the injuries included, which is naturally a very strong determinant of the subsequent case of fatality and post-operative mortality. There was also a lack of reporting or other evidence for some of the forms of fatalities and trauma, such as animal attacks and occupational injuries, across lesser developed countries.

3.2 Wars and Armed Conflicts

3.2.1 Type of Conflict, Geography and Fatalities

Figure 3.1 shows the worldwide geographical dispersion of fatalities through major wars and armed conflicts that led to at least 1000 fatalities since 1990, while Fig. 3.2 shows this geographical pattern over the longer period since 1945. Details of the individual wars and armed conflicts with (estimated) numbers of lives lost are provided in Table 3.1, for brevity restricted to 10,000+ fatalities. In the recent period since 1990, most of the major wars and armed conflicts with heavy loss of life have occurred in low-resource regions across Africa, South Asia and the Middle East, with others in parts of the south-west American continent and parts of Eastern Europe. In 1990 alone, there were more than half a million deaths worldwide that were attributable to wars and armed conflicts [1].

Since 1945, major wars and armed conflicts with heaviest loss of life have involved a large number of countries that are mostly low-resource countries. These include the Far East (such as Cambodia, China, North Korea, South Korea and Vietnam), South Asia (Afghanistan, Bangladesh, India, Indonesia and Pakistan), Africa (Algeria, Angola, the Congo Republic, Ethiopia, Liberia, Mozambique, Nigeria and Sudan), South America (Bolivia, Colombia and Guatemala) and the Middle East (Iraq and Iran). In the most recent years since the 1990s, countries affected by the

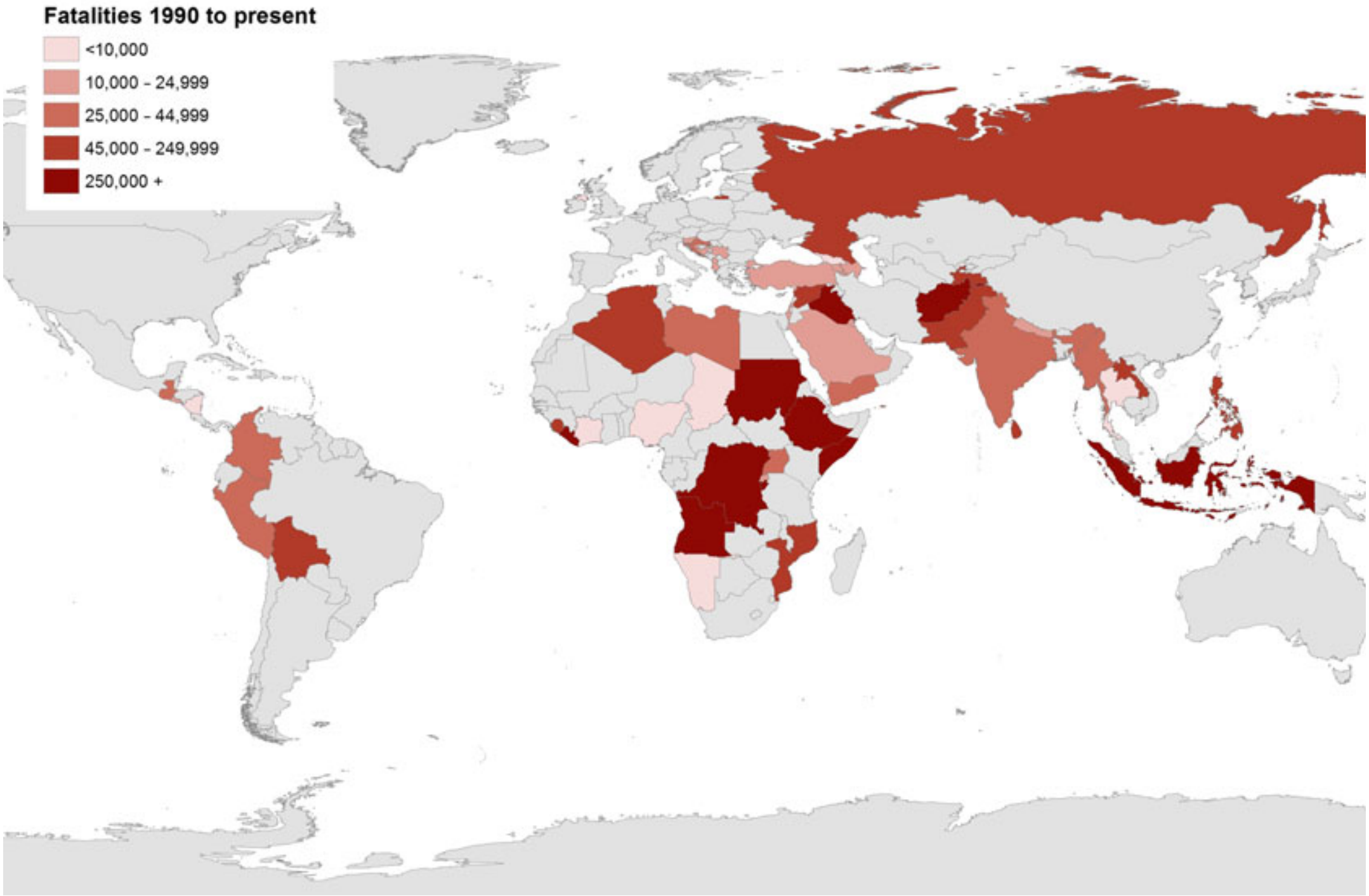

Fig. 3.1 Fatalities through wars and armed conflicts worldwide since 1990. Notes: Includes wars and armed conflicts that have led to at least 1000 fatalities

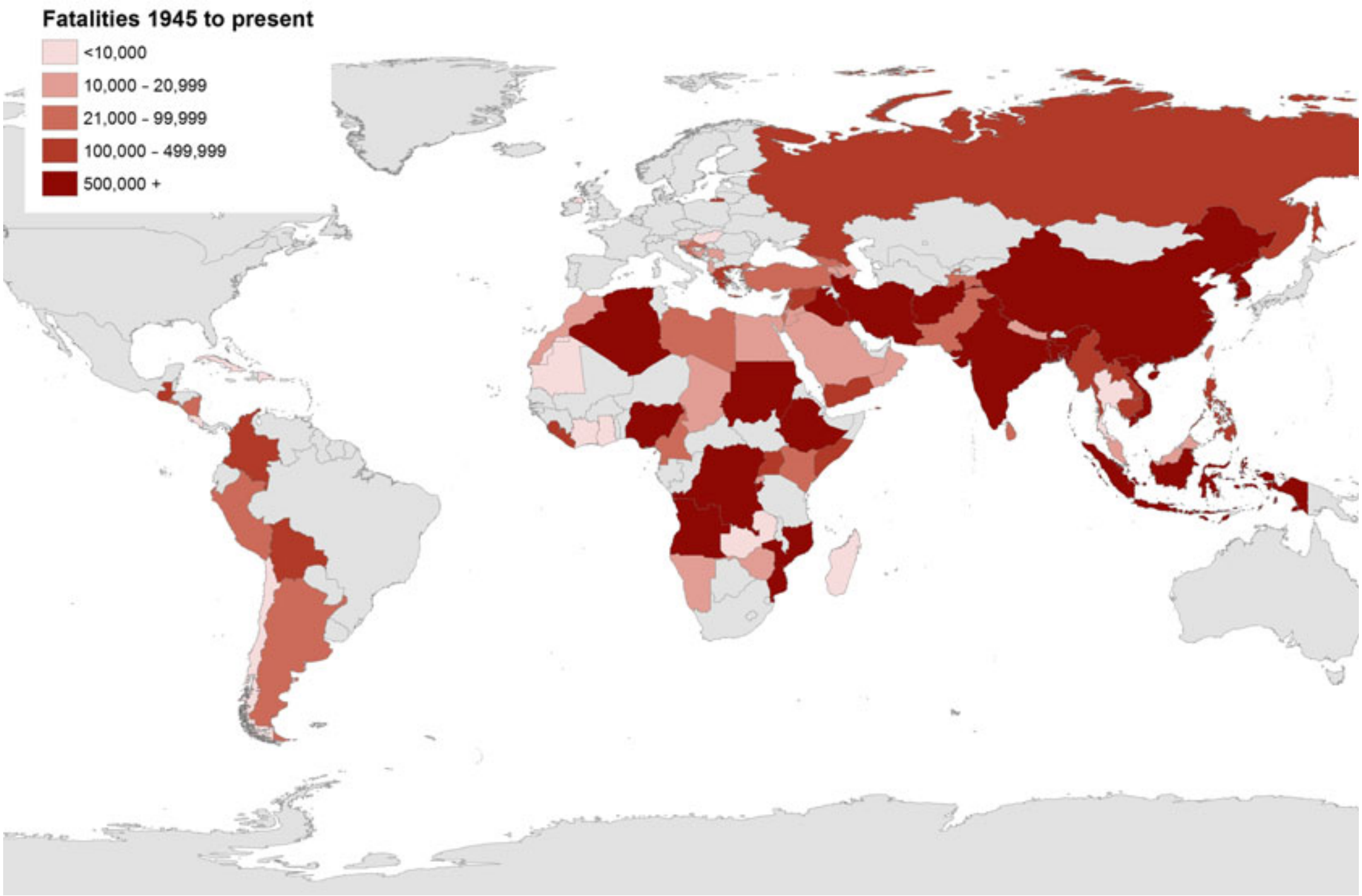

Fig. 3.2 Fatalities through wars and armed conflicts worldwide since 1945. Notes: Includes wars and armed conflicts that have led to at least 1000 fatalities

heaviest fatalities include Iraq, Lebanon, Palestine and Syria (in the Middle East); Angola, the Congo Republic, Ethiopia, Libya, Mozambique, Somalia and Sudan (in Africa); Afghanistan, Indonesia and Pakistan (in Asia); and Eastern European regions such as the Balkans and Chechnya.

3.2.2 Causes of Casualties: Type of Device

3.2.2.1 Explosive Devices and Fragments

Explosive devices are the primary cause of injury or death in conflicts, with casualties usually acquiring multiple injuries to different parts of the body. Explosive weapons can be subdivided by their method of manufacture into explosive ordnance (commonly used by military) and IEDs such as roadside bombs of home-made origins used more commonly by insurgents. In the Second Iraq War since 2003, IEDs were used extensively against US-led Coalition force vehicles, and by the end of 2007, they had become responsible for approximately 64 % of Coalition deaths in Iraq [2]. Common locations for placing these devices on the ground include animal carcasses, soft drink cans, road signs and trees. According to a report by Homeland Security in the USA, the number of IEDs used in Afghanistan had increased fourfold from 2007 to 2010, and the number of troops killed by them had also increased fourfold and those wounded by sevenfold, making them the leading cause of death among NATO troops in Afghanistan during this period [3].

Survival depends on the nature of the explosion, with more powerful explosions in close proximity resulting in higher fatality rates. For example, Table 3.2 provides details of major explosive incidents with particularly heavy loss of life that have occurred worldwide since 1980. Table 3.2 includes the numbers of fatalities and corresponding fatality rates which are measured conventionally as the percentage of fatalities relative to the total injured. Fatality rates and instant death are often highest in

Table 3.1 Fatalities through wars and armed conflicts worldwide since 1945: ordered chronologically

Time period, war or armed conflict and numbers of fatalities[a]	
1945–1949 Indonesian National Revolution (142,428)	1975–1990 Lebanese Wars (135,000)
1946–1949 Chinese Civil War (3,700,000)	1975–2007 Insurgency in Laos (94,000)
1946–1949 Greek Civil War (104,000)	1976–1993 Mozambique's Civil War (900,000)
1946–1954 First Indochina War (631,432)	1976–1998 Indonesia-East Timor Civil War (600,000)
1947 Taiwan's uprising against the Kuomintang (30,000)	1975–2002 Angolan Civil War (800,000)
1947 Kashmir conflict (86,000)	1976–2005 Insurgency in Aceh (13,500)
1948 Operation Polo, India (18,016)	1977–1978 Ogaden War (13,199)
1948–1949 First Arab-Israeli War (17,873)	1978–1979 Nicaraguan Civil War 1 (22,500)
1948–1960 Malayan Emergency (12,432)	1978 Kurdish-Turkish conflict (45,000)
1948 Internal conflicts in Burma (218,400)	1979 Sino-Vietnamese War (56,000)
1949–1962 Colombian Civil War (300,000)	1979–1988 Soviet Union invasion, Afghanistan (1,218,750)
1950–1953 Korean War (2,067,667)	1979–1992 Salvadoran Civil War (76,333)
1950–1966 Indonesian conflicts (386,000)	1980–1988 Iran-Iraq War (1,010,028)
1952–1960 Mau Mau Uprising, Kenya (19,038)	1980–1990 Civil strife, Somalia (10,000)
1953–1975 Laotian Civil War (34,500)	1980–2000 Internal conflict in Peru (70,000)
1954–1962 French-Algerian War (540,333)	1981–1986 Ugandan Bush War (300,000)
1955–1960 Cameroon Independence War (32,000)	1981–1990 Nicaraguan Civil War 2 (45,000)
1955–1967 Guerrilla Insurgency, Bolivia (200,000)	1983–2005 Second Sudanese Civil War (1,750,000)
1955–1972 First Sudanese Civil War (625,000)	1983–2009 Sri Lankan Civil War (80,000)
1955–1975 Vietnam War (2,212,313)	1986–1986 South Yemen Civil War (10,000)
1956–1959 Tibetan Revolt (200,000)	1987 Insurgency, Uganda (65,000)
1960–1966 Congo Crisis (100,000)	1988–1994 Nagorno-Karabakh War, Georgia (35,694)
1960–1996 Guatemalan Civil War (185,000)	1989–1996 First Liberian Civil War (190,000)
1961–2003 Kurdish-Iraqi conflicts (180,000)	1989–2001 Afghanistan Civil War (700,000)
1962–1970 North Yemen Civil War (80,000)	1990–1993 Rwandan Civil War (10,000)
1962–1975 Angolan-Portugal War of Independence (45,000)	1991–1991 Uprisings in Iraq (156,500)
1962–1976 Dhofar Rebellion, Oman (10,000)	1990–1991 Gulf War (64,225)
1964–1975 Mozambique War of Independence (22,000)	1991–1995 Croatian War of Independence (21,480)
1964–1979 Rhodesian Bush War (24,810)	1991–1996 Bolivian Civil War (100,000)

(continued)

Table 3.1 (continued)

Time period, war or armed conflict and numbers of fatalities[a]	
1964–2013 Columbian conflict (125,000)	1991–2002 Algerian Civil War (98,000)
1965–1965 Indo-Pakistani War (11,700)	1991–2002 Sierra Leone Civil War (100,000)
1966–1989 Guatemalan Civil War (212,500)	1991 Somali Civil Wars (400,000)
1966–1990 Namibian War of Independence (13,302)	1992–1993 War in Abkhazia, Georgia (22,874)
1967–1967 Six-Day War in Middle East (21,345)	1992–1995 Bosnian Wars (80,834)
1967–1970 Nigerian Civil War (1,588,750)	1992–1997 Civil War in Tajikistan (75,000)
1967–1975 Cambodian Civil War (250,000)	1994–1996 First Chechen War (85,893)
1969–1969 Philippine Insurgency (40,000)	1996–1997 First Congo War (541,500)
1969–1979 Francisco Nguema, Equatorial Guinea (50,000)	1996–2006 Nepalese Civil War (17,800)
1969 Papua conflict (275,000)	1999–2003 Liberian Civil War (225,000)
1971 Pakistan-Bangladesh Civil War (1,118,697)	1999–2007 Ituri conflict, Congo Republic (60,000)
1972 Burundi Civil War (300,000)	1999–2009 Second Chechen War (65,000)
1972- Philippine Insurgency (150,000)	2001 Afghanistan War (40,000)
1973–1973 Yom Kippur War, Middle East (13,331)	2003 Iraq War (49,736)
1973–1977 Balochistan conflict, Pakistan (8825)	2003 War in Darfur, Sudan (319,754)
1974–1991 Ethiopian Civil War (489,500)	2004 North Yemen Insurgency (30,140)
1975–1978 Dirty War, Argentina (22,000)	2004 Conflicts in north-west Pakistan (61,504)
1975–1989 Cambodian-Vietnamese War (88,000)	2011 Libyan Civil War (25,000)
1975–1989 Western Sahara War (12,000)	2011 Syrian Civil War (163,133)

Data from Scariffi [73], Leitenberg [74], and Wikipedia [75]

[a] Includes wars and armed conflicts with at least 10,000 fatalities. Numbers of fatalities are sometimes estimated. Wars and fatalities as of March 2014

Table 3.2 Major explosive incidents related to wars and armed conflicts with heavy loss of life since 1980: ordered in reverse chronological order

Major explosive incidents	Year(s)	Population type	No. of fatalities	Fatality rate (%)	Reference
Cairo bombings, Egypt	2014	Civilian	7	6.5	[76]
Peshawar cinema bombings, Pakistan	2014	Civilian	13	40.6	[76]
Quetta bombings, Pakistan	2013	Civilian	110	35.5	[76]
Damascus bombing, Syria	2012	Civilian	55	12.1	[76]
Alexandria bombing, Egypt	2011	Civilian	23	19.2	[76]
Abuja UN bombing, Nigeria	2011	Civilian	21	22.3	[76]
Marrakesh bombing, Morocco	2011	Civilian	17	40.5	[76]
Baqubah bombings, Iraq	2010	Civilian	33	37.5	[76]
Nepal	2008–2011	Civilian	–	7.8	[77]
Ahmedabad blasts, India	2008	Civilian	56	21.9	[76]
Iraq	2003–2010	Civilian	12,284	11	[78]
July 7 attacks, London, UK	2005	Civilian	56	7.2	[4]
Madrid train attacks, Spain	2004	Civilian	191	8.5	[4]
Israel	2002–2003	Civilian	56	21	[4]
Israel	2002–2003	Civilian	61	19.8	[4]
Bali bombing	2002	Civilian	202	49.1	[76]
Finland, Helsinki (shopping centre)	2002	Civilian	7	4.2	[4]
Khobar towers, Saudi Arabia	2001	Civilian	19	5	[4]
September 11 attacks, USA	2001	Civilian	2996	33.3	[76]
Apartment bombings, Russia	1999	Civilian	293	31	[76]
Omagh bombing, Ireland	1998	Civilian	29	8.8	[76]
Central Bank bombing, Sri Lanka	1996	Civilian	90	6	[76]
Israel/Lebanon bombings	1996	Military	100	20	[79]
Saudi Arabia US airbase bombing	1996	Military	19	10.6	[79]
Oklahoma city bombings, USA	1995	Civilian	168	17.4	[76]
Mumbai car bombings, India	1993	Civilian	257	26.5	[76]
World Trade Centre bombing, USA	1992	Civilian	6	0.6	[76]
Jerusalem, Israel	1988	Civilian	6	10.3	[4]
France, Paris	1985–1986	Civilian	20	7.5	[4]
Beirut barrack bombings, Lebanon	1983	US and French military	241	69.7	[4]
Italy	1980	Civilian	86	29.6	[4]

This table includes selected incidents rather than all all major explosive incidents buildings hit by large explosive devices, particularly when they are located adjacently or nearby in large motor vehicles. For example, this includes the bombing of US and French forces' barracks in Beirut in 1983 (69 % fatality rate) and the Bali bombing in 2002 (49 % fatality rate).

Death usually follows from multiple major injuries following blast impact, trauma following destruction of the surrounding environment (e.g. building collapse, fire) or carbonisation of the body following an intense blast. Non-fatal injuries sustained within the primary (or secondary) blast radius due to shrapnel fragments reportedly lead to up to 85 % of in-hospital injuries of a musculoskeletal nature [4]. Most major explosions also result in a large number of victims with minor superficial wounds which do not require hospitalisation and are consequently not recorded in casualty records. Fragments are often preformed, for example, nails embedded within the device, and, on detonation, are propelled at high velocity to cause maximum lethality and injury, relative to the impact of the explosion alone. Explosive devices and fragments are typically the main cause of fatalities and non-fatal injuries in recent conflicts (Table 3.3).

3.2.2.2 Anti-tank Mines

Anti-tank mines are activated by the weight of a heavy vehicle. Compared with anti-personnel mines, the greater explosive power and larger numbers of personnel in the tanks or armoured vehicles account for the larger numbers of people often killed and injured by a single anti-tank mine incident.

Few studies of wars and armed conflicts differentiate between casualties caused by anti-tank and anti-personal mines when referring to 'injured by mines'. One study of Angola which made this distinction reported that although anti-personnel mines accounted for the vast majority of incidents, injuring more people in total, the relatively few anti-tank mine incidents accounted for higher levels of fatalities [5].

3.2.2.3 Anti-personnel Mines

Anti-personnel mines (also referred to as landmines) are activated by the weight of a human rather than a vehicle, with the vast majority of subsequent injuries affecting the lower limbs. A study by the International Committee of the Red Cross (ICRC) reported an in-hospital mortality rate for anti-personnel mine victims of 3.7 % which increased to over 6 % for those who underwent traumatic amputation [4].

As well as causing significant wartime casualties and deaths, post-war injuries caused by land mines are extremely common, with fatality rates reaching 50 % in some areas (Table 3.4) as civilians and their families return to pre-war activities including farming and as children play with or near undetonated remnant devices. Bilukha et al. reported that of 5471 injuries caused by landmines in Afghanistan between 2002 and 2006, 92 % of the victims were civilians, of which 47 % were children [6]. The case fatality rate in this study was 17 %. The same author also investigated the impact of land mines in Chechnya between 1994 and 2005 and reported 3021 civilian injuries (approximately 25 % were children) with case fatality of 23 % [7].

Around the world, it is estimated that 88 countries still have landmines undetected, with South Korea considered the single country most affected [8]. It is also estimated that 35 % of the land in Cambodia and Afghanistan is unusable because of landmines [9]. Worldwide, mines kill or injure more than 2000 people a month, almost all of them civilians [10, 11]. Demining also often results in heavy injury or loss of life. In Croatia, efforts to demine the south of the country by 160 specialist personnel resulted in 53 injuries and two fatalities [12].

3.2.2.4 Gunshot Wounds

Gunshot wounds are typically the first or second leading cause of death in wars and armed conflicts, historically the leading cause of death (Table 3.3). Until recently, bullets have often been the main cause of penetrating injury to the limbs, but in recent conflicts, this has been replaced by explosive devices and fragments. Globally, firearm-related violence has been increasing [13], with arms becoming more accessible to civilians and insurgents in low-resource areas. Arms that have been provided to civilians during post-war periods sometimes become used during subsequent conflicts [13].

Table 3.3 Casualties in wars and armed conflicts according to the type of device used: as reported from various studies

War or armed conflict	% Gunshot wounds	% Explosive devices and fragments	% Anti-personnel mine	% Other devices	Reference
Afghanistan and Iraq (2005–2009)	20	74	–	–	[80]
Iraq (2004–2007)	–	78	4	18	[81]
Afghanistan and Iraq (2003–2011)	18	70	–	–	[82]
Iraq (2003, British forces)	37	73	–	–	[83]
Iraq (2003, US forces)	39	37	–	34	[83]
Iraq – Operation Iraqi Freedom (“Surge”) – US forces	9	88	–	3	[84]
Iraq – British field hospital	22	77	–	5	[85]
Iraq – Operations Iraqi Freedom and Enduring Freedom – US forces	19	81[a]	–	–	[86]
Afghanistan – Kandahar hospital	50	24	26	–	[29]
Afghanistan – Kabul hospital	29	52	19[b]	–	[29]
Pakistan – Peshawar hospital	23	42	35[b]	–	[29]
Pakistan – Quetta hospital	39	33	28[b]	–	[29]
Chechnya – Novye Atagi hospital	35	44	22[b]	–	[29]
Lebanon (2002)	64	15	–	9	[83]
Liberia – Monrovia hospital	62	38	–	–	[29]
Israel (2000–2002)	40	60	–	–	[23]
Timor Leste conflict (1999)	20	33[c]	–		[87]
Ethiopia	17	83	–	–	[88]
Somalia (1993)	55	31	–	14	[83]
Turkey (1992–1999)	32	68	–	–	[89]
Bosnia-Herzegovina (1992–1996)	59	37	4	–	[29]
Somalia – Mogadishu (1992)	55	31	–	14	[29]
Yugoslavia (1991)	41	2	52	–	[29]
Croatia (1991–1993)	16	72	–	13	[83]
Croatia (1991–1993)	25	70	6	–	[29]
Croatia (1991–1992)	27	61	–	12	[90]
Slovenia (1991–1992)	3	94	–	–	[83]
Iraq (1991, US forces)	10	84	–	–	[83]

(continued)

Table 3.3 (continued)

War or armed conflict	% Gunshot wounds	% Explosive devices and fragments	% Anti-personnel mine	% Other devices	Reference
Iraq (1991, US forces)	95	5	–	–	[83]
Rwanda – Butare hospital	92	8	–	–	[29]
Eritrea (1988–1991)	33	63	2	–	[29]
Kenya – Lokichogio hospital (1987–2006)	87	10	2	–	[29]
Algeria – French forces	71	23	–	–	[29]
Lebanon – refugee camp (1986–1997)	20	60	–	20	[29]
Israel – Lebanon (1982–1985)	16	74	–	9	[91]
Falkland Islands (1982)	32	56	–	12	[29]
Lebanon (1982)	12	53	–	35	[29]
Lebanon (1982)	29	71	–	–	[82]
Thailand (1981)	38	20	42	–	[29]
Thailand – Kao-I-Dang hospital	22	49	–	29	[92]
Iraq – Iran war (1980–1988)	11	72	–	17	[93]
Iraq	3	97	–	–	[94]
Iraq	10	90	–	–	[95]
Lebanon – Beirut (1975–1986)	49	36	–	14	[29]
Lebanon	37	63	–	–	[96]
Northern Ireland	55	22	–	20	[29]
Vietnam (1965–1972, US forces)	30	48	–	–	[83]
Vietnam – US forces	16	82	–	2	[97]
Vietnam – US forces	35	65[a]	–	–	[98]
Borneo, Indonesia – UK forces	90	9	–	1	[29]
Korea – US forces	31	69[a]	–	–	[99]
Indochina War – French forces	62	38	–	–	[29]
World War II – US forces	2	73[a]	–	–	[100]
World War I – US forces	65	35[a]	–	–	[100]

[a] Includes all explosions (including mines)

[b] Includes anti-tank mines as well as anti-personnel mines

[c] Described as sharp force trauma

Table 3.4 Fatality rates in wars and armed conflicts as a consequence of land mines: as reported from various studies, ordered in reverse chronological order

War or armed conflict	Years	Population type	No. of fatalities	Fatality rate (%)	Reference
Nepal	2006–2010	Civilian	42	14	[101]
Afghanistan	2002–2006	Civilian	939	17.2	[6]
Afghanistan	2001–2002	Civilian	154	9.6	[102]
Turkey, SE	2000–2006	Military	71	19.5	[103]
Erbil, Iraq	1998–2007	Civilian	6	2.1	[104]
Afghanistan	1996–1998	Civilian	94	16.4	[105]
Sri Lanka	1996–1997	Civilian	45	13.7	[106]
Chechnya	1994–2005	Civilian	687	22.7	[7]
Angola	1995	Civilian	1	1.7	[107]
Bosnia-Herzegovina[a]	1992–1994	Civilian	79	41	[108]
Croatia	1991–1995	Military	2	1.3	[12]
Greece	1988–2003	Civilian	21	53.5	[109]
Afghanistan[a]	1980–1994	Civilian	699	55	[108]
Mozambique[a]	1980–1994	Civilian	83	42	[108]
Mozambique[a]	1980–1993	Civilian	120	48	[110]
Cambodia[a]	1978–1994	Civilian	136	31	[108]
Rhodesian War	1972–1980	Civilian	544	3.3	[111]
Guantanamo Bay, Cuba	1967–1968	Civilian	15	51.9	[112]

[a] Based on a cluster survey of households performed in 1994

3.2.2.5 Other Devices: Stab Wounds, Burns and Infections

Stab wounds are often fatal if a major organ is punctured or if excessive blood loss occurs, with prognosis strongly linked to the anatomical location, depth of the stab wound and multiple versus single wounds. Stab wounds account for a high proportion of fatalities in civilian disputes in various settings [14–16], but a very low proportion of fatalities in most recent wars and armed conflicts (Table 3.3).

Burns are also seen less commonly during recent conflicts. In recent years, burns have instead been reported more often among military during non-combat operations, including waste burning, handling ammunitions and handling fuel [17]. One study reported that the surface body areas most affected by burn injuries include the limbs (54 %), thorax (18 %), abdomen (18 %) and head and neck (10 %) [18]. Mortality rates tend to be significantly higher for combat burns compared with non-combat burns [17] and in civilian (7.1 %) compared with military (3.8 %) casualties [19].

Infections are often a major cause of mortality and morbidity in wars and armed conflicts. Blast injuries are generally 'dirtier' than gunshot wounds and carry a higher potential for infection [20]. Factors influencing the development of wound infections include wound type and severity, the presence of embedded foreign material or fragments (such as dirt, debris from an explosion or clothing), evacuation time from point of injury to medical care, initiation of antimicrobial agents, adequacy of initial wound debridement, immediate wound care, definitive surgical care, rehabilitative care, prior antimicrobial pressure and the presence of nosocomial pathogens (especially multidrug resistant pathogens) at treatment facilities [21]. During the Vietnam War, sepsis was the third leading cause of death for combat casualties in the theatre [22].

3.2.3 Anatomical and Tissue Type Distribution

Injuries to the body can include open and closed injuries, with or without fractures. Table 3.5 shows the anatomic distribution of injuries reported for various wars or armed conflicts.

Table 3.5 Anatomic distribution of major wounds in wars and armed conflicts: as reported from various studies

War or armed conflict	% Head and neck	% Thorax	% Abdomen	% Upper limbs	% Lower limbs	% Others and multiple	Reference
Benghazi – Libya (2011, gunshot wounds)	–	13	–	25	44	–	[13]
Southwest Nigeria (2010–11, gunshot wounds)	15	2	7	30	39	7	[113]
ICRC surgical database (2007)	13	7	8	66		7	[29]
Iraq and Afghanistan (2005–2009)	28	10	10	52	–	–	[80]
Iraq – Operations Iraqi Freedom and Enduring Freedom – US forces	30	6	9	55		–	[86]
Afghanistan and Iran (2003–2011)	34	16	17	–	–	–	[82]
Iraq (2006, British field hospital)	21	6	4	30	38	1	[85]
Iraq (2004–2007)	37	9	41	–	–	–	[82]
Iraq (2003, US soldiers)	16	14	25	50		–	[83]
Iraq – Operation Iraqi Freedom (“Surge”)	36	8	7	49		–	[114]
Afghanistan (2002)	17	24		44		–	[83]
Lebanon (2002)	54	25		50		–	[83]
Israel (2000–2002)	11	69	47	–		–	[23]
Afghanistan – Kandahar hospital (1996–2001)	11	9	11	24	40	–	[29]
Afghanistan – USSR	16	12	11	61		–	[29]
Chechnya – Novye Atagi hospital (1996)	10	3	7	26	50	–	[29]
Somalia (1993)	43	14	20	7		14	[83]
Bosnia-Herzegovina (1993)	19	16	11	53		–	[29]
Bosnia-Herzegovina (1992)	14	15	9	62		–	[29]
Chechnya, Russia (1992)	24	9	4	63		–	[29]
Croatia (1991–1993)	15	11	4	69		1	[29]
Croatia (1991–1993)	40	24	9	–		–	[83]
Somalia – Mogadishu (1992, USA)	20	8	5	65		2	[29]
Slovenia (1991–1992)	38	17		45		–	[83]
Gulf War – US forces (1991)	11	8	7	56		18	[29]
Gulf War – UK forces (1991)	6	12	11	71		–	[29]
Eritrea (1988–1991)	20	9	6	63		2	[29]
Cambodia – Mongkol Borei hospital (1991)	8	14	13	15	84	2	[4]
Rwanda – Butare hospital	16	7	2	31	42	–	[29]

Afghanistan – Kabul hospital (1988–1992)	15	9	10	24	35	–	[29]
Kenya – Lokichogio hospital (1987–2006)	7	8	3	29	44	–	[29]
Lebanon: refugee camp (1986–1987)	12	16	18	54		–	[29]
Pakistan – Peshawar hospital (1984–1985)	5	9	14	21	87	1	[92]
ICRC Peshawar hospital (1984–1985)	5	9	14	21	87	1	[92]
Pakistan – Quetta hospital (1983–1996)	15	9	8	24	36	–	[29]
Liberia – Monrovia JFK hospital	14	13	4	21	43	–	[29]
Sarajevo – French field hospital (1982–1986)	12	11	15	78		6	[115]
Lebanon – Israel (1982)	14	5	5	41		34	[29]
Lebanon (1982)	34	45		21		–	[83]
Falkland Island/Maldives – UK (1982)	16	15	10	59		–	[29]
Thailand (1981)	10	12	4	66		8	[29]
Pakistan – Peshawar hospital (1981–1993)	18	8	6	25	35	–	[29]
Thailand – Kao-I-Dang hospital (1979–1992)	15	8	7	24	39	–	[29]
Arab-Israeli War – Israel (1973)	13	5	7	40		31	[29]
Northern Ireland	20	15	15	50		–	[29]
Vietnam (1965–1972, US forces)	43	38	9	7		2	[83]
Vietnam	16	13	9	61		–	[84]
Vietnam	46	24	9	3		–	[29]
Vietnam – US forces	10	4	8	73		5	[25]
Vietnam – US forces	14	7	5	74		–	[29]
Vietnam – US forces	16	13	9	61		–	[98]
Indonesia – Borneo – UK forces	12	12	20	56		–	[29]
Korea – US forces	21	10	8	60		–	[84, 99]
Korea – US forces	17	7	7	67		2	[29]
World War II	42	30	12	13		–	[29]
World War II – US forces	21	14	8	58		–	[84, 100]
World War II – USSR	19	9	5	67		–	[29]
World War II – Western Allies	4	8	4	79		9	[29]
World War I – Western allies	17	4	2	70		7	[29]

Some studies include both dead and survivors; others include minor injuries. Columns may not total 100 % as many patients had multiple injury points

Lower limbs are most commonly injured. The extent and severity of the injury is dependent strongly on the type of the injury-causing device and whether the casualty was wearing protective armour or clothing. Most non-fatal types of injury reported recently from military or field hospitals and trauma registries are located in the soft tissues of the limbs and tend to be caused by gunshot wounds, fragments and anti-personnel mines (Table 3.3; [23]). However, autopsy studies of US deceased in World War II and Vietnam and of Israeli deceased in the Lebanon have shown that most fatalities arose from injuries to the head and chest [24–26]. Nonetheless, many deaths occur as a result of multiple injuries, while many casualties ultimately die from infection or as a result of prolonged periods of time in transit to hospital rather than as a direct consequence of the injury suffered in combat.

3.2.3.1 Head and Neck Injuries

Injuries to the head or neck can sometimes account for up to 40 or 50 % of fatalities in wars or armed conflicts (Table 3.5). However, a minority of those with injuries to the head or neck have penetrating injuries that can sometimes be survived if airways can be maintained and infectious complications avoided. Historically, the case fatality of penetrating head wounds is about 80 %, while between 50 and 75 % of these deaths occur within the first 24 h of trauma [4].

3.2.3.2 Thoracic Injuries

Thoracic injuries are often the second leading cause of death after head injuries in wars or armed conflicts, often accounting for about 25 % of fatalities (Table 3.5). The case fatality for a thoracic wound is often about 70 % although it varies according to factors such as penetration, bullet velocity and proximity to a blast involving small fragments [4]. Body armour can improve survival prospects for thoracic injuries by preventing projectile penetration but provides little added protection against major blasts. Thoracic injuries also account typically for about 10 % of non-fatal injuries in wars and armed conflicts (Table 3.5).

3.2.3.3 Abdominal Injuries

Abdominal injuries typically account for up to 20 % of casualties in wars and armed conflicts (Table 3.5). About 10 % of casualties brought to hospital alive have wounds to the abdomen, with prognosis often linked to the projectile velocity and device [4]. Post-operative mortality was about 67 % in the late stages of World War I, 25 % in World War II, 12 % for US medical services in Korea, 8.5 % in Vietnam and about 10–15 % in recent conflicts [4]. Prognosis ultimately depends strongly on the severity of haemorrhage, which is the leading cause of immediate death.

Among less severe cases, Fig. 3.3 shows the anatomical distribution of abdominal injuries identified through large-scale studies of laparotomies in wars and armed conflicts in Vietnam, the Lebanon, Eritrea, the former Yugoslavia, Gaza and Iraq. Injuries to the small intestine, colon and duodenum have accounted typically for approximately half of all significant organ injuries, followed variously by injuries to other organs including the liver, stomach and spleen.

3.2.3.4 Injuries to the Limbs

Isolated injuries to the limbs account typically for the majority of all less critical war wounds (Table 3.5) usually involving single bullets or lower velocity fragments from longer proximity blasts. Although they are usually associated with a very low mortality rate when isolated, they are a major cause of long-term significant morbidity [27], particularly when treated surgically with amputations. Lower limb injuries are usually more common than upper limb injuries. Studies of US troops in Afghanistan and Iraq have reported that fractures occur in about one-quarter to one-third of all limb wounds [28, 29].

There have been few studies that have reported on injuries to joints. However, one study of major

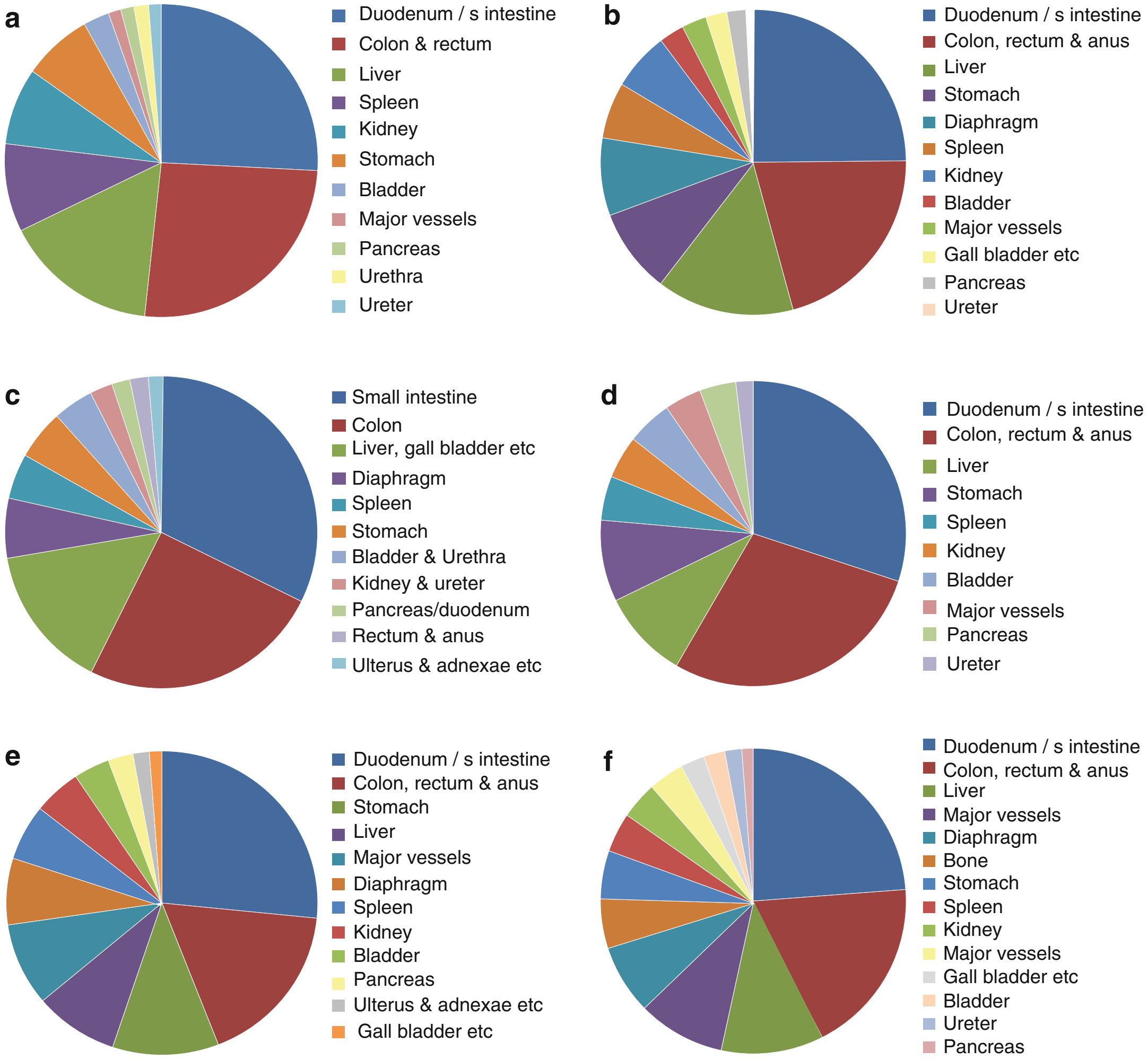

Fig. 3.3 Significant organ injuries found at laparotomy; percentage of total positive findings: as reported from various studies, ordered chronologically. (**a**). Vietnam War – USA, 1966–1967. (**b**). Lebanon, 1975–1986. (**c**). Eritrea, 1980–1982. (**d**). Former Yugoslavia, 1991–1995. (**e**). Gaza, 2000–2003. Notes: The study sizes (numbers of laparotomies) for the six studies are, respectively, 1350, 1314, 692, 93, 230 and 130 (Data from references [98, 116–120])

joint injuries in a large military hospital during the Bosnian wars in the former Yugoslavia reported a prevalence of 18 % joint injuries out of a total of 1860 casualties with limb wounds treated [30]. These most frequently affected the knee and elbow joints.

3.2.4 Case Fatality

Mortality rates for military forces killed in battle vary strongly across major wars and armed conflicts (Table 3.6) and also according to factors such as the main types of devices deployed, geo-

Table 3.6 Case fatality in wars and armed conflicts among armed forces: as reported from various studies, ordered in reverse chronological order

War or armed conflict	Year	No. of fatalities	Case fatality (per 1000 soldiers per year)	Reference
Operation Iraqi Freedom	–	–	8–10	[121]
Iraq and Afghanistan – coalition forces	2006	537	19	[122]
Iraq and Afghanistan – US forces	2006	280	5	[122]
Iraq and Afghanistan – coalition forces	2006–2007	18	6	[122]
Iraq and Afghanistan – US forces	2006–2007	416	7.5	[122]
Iraq – US Troops	2003–2004	1353	4.8	[24]
Iraq – US, other coalition troops	2003–2004	140	4.0	[24]
Iraq – Iraq security forces	2003–2004	2050	8.3	[24]
Second Gulf War – US troops	2003	171	11.9	[24]
First Gulf War – US troops	1991	293	3.6	[24]
US troops (multiple deployments)	1980–1992	–	0.6	[123]
Vietnam War – US troops	–	58,100	0.8	[24]
Korean War – US troops	–	33,650	1.9	[24]
World War II – US troops	–	407,300	6.8	[24]
World War I – US troops	–	106,700	14.2	[24]

Table 3.7 Case fatality in wars and armed conflicts among civilian populations: as reported from various studies, ordered in reverse chronological order

War or armed conflict	Year	Case fatality (per 1000 civilians)	Reference
Iraq	2005–2006	19.8[a]	[124]
Iraq	2003–2004	13.2[a]	[124]
Iraq	2003–2004	12.3	[125]
Democratic Republic of Congo, Katale	1990–	124[b]	[126]
Somalia, Baidoa	1990	50.4[b]	[126]
Somalia, Afgoi	1990	14.1[b]	[126]
Sudan, Mapel	1990	23.1[b]	[126]
Afghanistan, Kabul	1990	1.5[b]	[126]
Afghanistan, Kabul	1990	1.8[b]	[126]
Afghanistan, Kohistan	1990	7.8[b]	[126]

[a] Based on household surveys

[b] Per 1000 midtime civilian population per month

graphical world region and adherence to Geneva Conventions. Mortality rates among civilians typically vary even more strongly across wars and conflicts (Table 3.7).

Figure 3.4 shows post-operative mortality in various hospitals during wars and armed conflicts. A study of International Red Cross hospitals has similarly quoted post-operative mortality rates from the following locations: Quetta, Pakistan (2.2 %); Peshawar, Pakistan (3.3 %); Kao-I-Dang, Thailand (4.2 %); Kabul, Afghanistan (4.8 %); and Monrovia, Liberia (6.1 %) [29]. Although post-operative mortality has normally improved over time, it is often dependent strongly on external factors such as the surgical facilities available and the often austere environment, mass throughput of casualties and the volume of 'dead on table' and salvage cases with little prospect of survival.

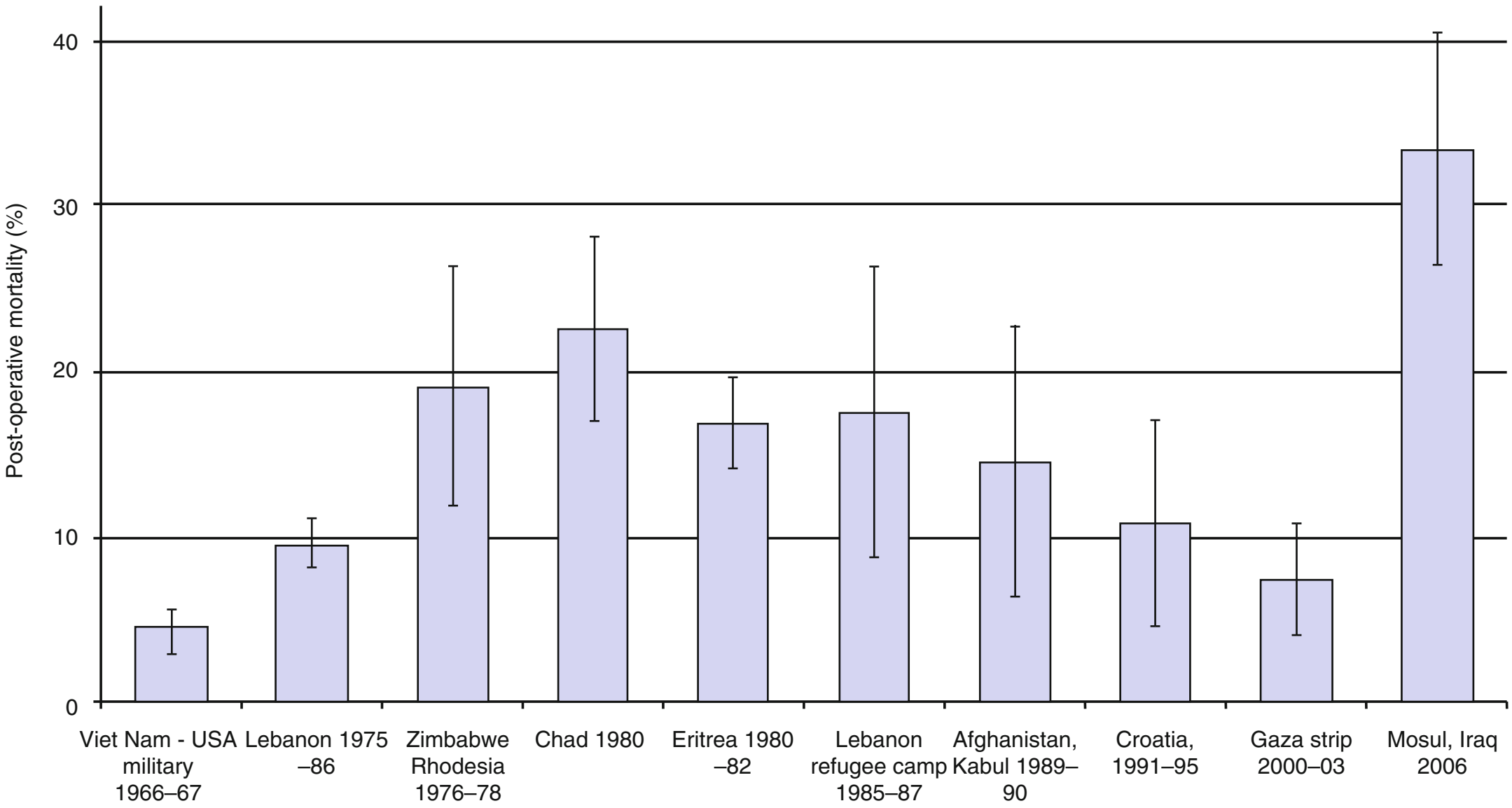

Fig. 3.4 Post-operative mortality in various wars and armed conflicts: as reported from various studies, ordered chronologically (Data from Giannou and Baldan [29]. Vertical bars represent 95 % confidence intervals

3.3 Natural Disasters

3.3.1 Type of Natural Disaster, Geography and Fatalities

Natural disasters account directly for approximately 50,000–100,000 lives lost worldwide each year on average, but have a far greater impact on civilian public health, subsequent mortality and morbidity. They often lead to a wide spectrum of health repercussions according to whether the disasters are largely predictable such as drought, famine and volcanic eruption or whether they are unpredictable disasters such as earthquakes, landslides or flash floods. Developing and low-resource countries are much more vulnerable to the longer term public health effects of a major disaster, often through poorly developed medical and health systems [27]. In both scenarios, there is devastation caused by the event itself, followed by the fatalities and illnesses caused by the secondary impacts of disasters including lack of habitation, clean water and food and by spread of communicable diseases.

Figure 3.5 shows the worldwide geographical dispersion of fatalities through natural disasters that led to at least 25 fatalities since 1990, while Fig. 3.6 shows this geographical pattern according to the type of disaster. Details of the natural disasters with at least 300 fatalities are provided in Table 3.8. Countries that have been most affected by heavy loss of life through natural disasters are often lesser developed countries and include Bangladesh, China, Haiti, India, Indonesia, Iran, Japan, Myanmar, Pakistan, the Philippines, Russia, Sri Lanka, Thailand and Venezuela.

3.3.2 Causes of Natural Disasters

Natural disasters can be classified into four categories: geophysical disasters which include earthquakes, tsunamis, volcanic activity and landslides; meteorological disasters which include typhoons/hurricanes/tropical cyclones, tornadoes and storms; climatological disasters which include heatwaves, droughts and wildfires; and hydrological disasters, including floods and mudslides.

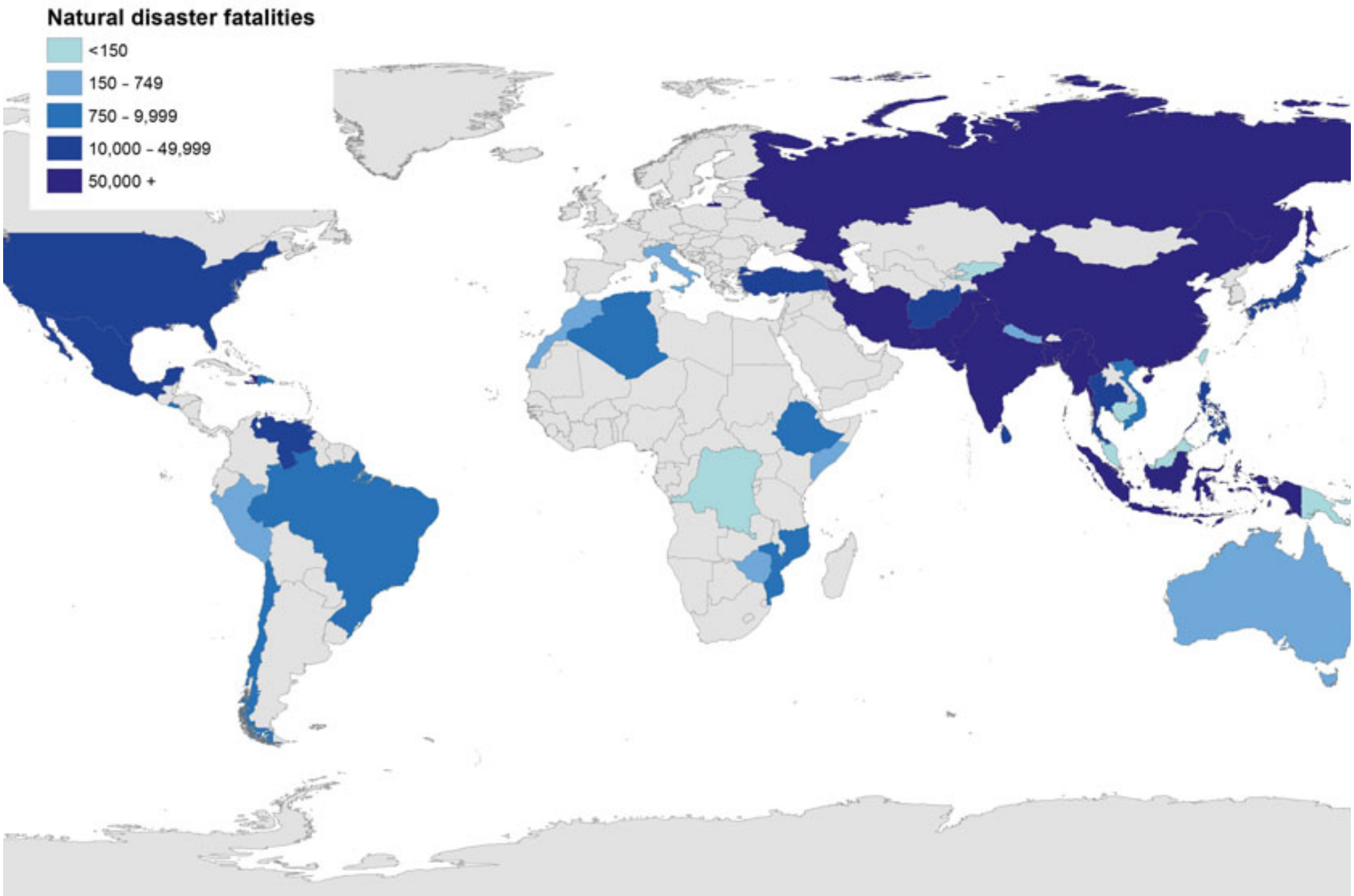

Fig. 3.5 Fatalities through natural disasters, 1990 to 2013 according to the numbers of fatalities. Notes: Includes natural disasters with at least 25 fatalities

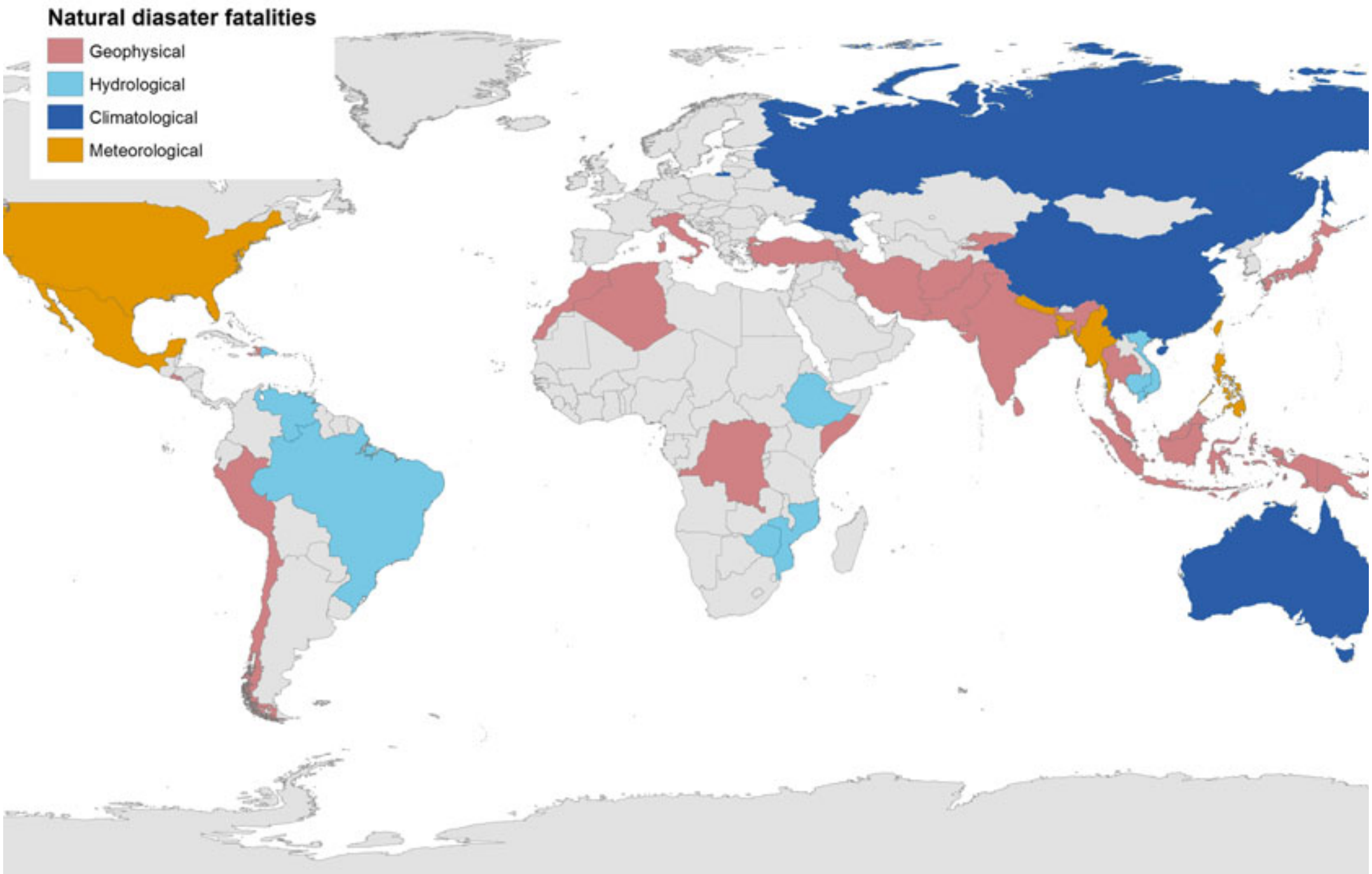

Fig. 3.6 Fatalities through natural disasters, 1990 to 2013; according to the type of disaster. Notes: Includes natural disasters with at least 25 fatalities. Geophysical disasters include earthquakes, tsunamis, volcanoes, landslides, etc. Hydrological disasters include floods, avalanches, etc. Climatological disasters include heatwaves, droughts, wildfires, etc. Meteorological disasters include typhoons, hurricanes, storms, monsoons, wave surges, etc.

Table 3.8 Fatalities and injuries through major natural disasters, 1990–2013: ordered chronologically

Year	Disaster type	Disaster name/details	Countries affected	No. of fatalities[a]	No. injured
1990	Earthquake		Iran	35,000	
1991	Volcano	Mount Pinatubo	Philippines	887	–
1991	Cyclone		Bangladesh	138,866	–
1995	Heatwave	Chicago heatwave	USA	750	–
1995	Earthquake	Hanshin earthquake	Japan	>5500	36,896
1998	Hurricane	Hurricane Georges	Gulf of Mexico	10,000	–
1998	Earthquake		Afghanistan	17,000	
1998	Floods	Yangtze river floods	China	3704	
1998	Hurricane	Hurricane Mitch	USA	~10,000	
1999	Flooding and mudslides	Vargas tragedy	Venezuela	15,100	–
1999	Earthquake		Turkey	35,000	
1999	Floods		Vietnam	>700	
1999	Floods and mudslides		Venezuela	12,500	
1999	Floods and mudslides		Mexico	>360	
1999	Storms	Vargas tragedy (mudslides)	Venezuela	15,100	
2000	Floods		Mozambique	800	
2000	Floods		Mozambique, Zimbabwe	>700	
2001	Earthquake		El Salvador	852	
2001	Earthquake		India	20,023	
2001	Earthquake		El Salvador	315	
2002	Earthquake		Afghanistan	1000	
2003	Earthquake		Iran	>26,000	300,000
2003	Earthquake		Algeria	2266	
2003	Earthquake		Iran	31,000	
2003	Heatwave	European heatwave	Europe wide	70,000	
2003	Heatwave	Southern India heatwave	India	1500	
2004	Earthquake	Tsunami (Indian Ocean)	Indonesia	204,862	
2004	Earthquake	Tsunami (Indian Ocean)	Sri Lanka	35,322	21,411
2004	Earthquake	Tsunami (Indian Ocean)	India	23,685	
2004	Earthquake	Tsunami (Indian Ocean)	Thailand	11,029	8457
2004	Earthquake	Tsunami (Indian Ocean)	Myanmar	700	45
2004	Earthquake		Morocco	628	
2004	Floods		Dominican Republic, Haiti	>2000	
2004	Monsoon		India, Nepal, Bangladesh	1800	
2005	Earthquake		Pakistan	75,000	
2005	Earthquake		Iran	612	
2005	Earthquake		Indonesia	1313	
2005	Earthquake		Pakistan	87,351	
2005	Earthquake	Kashmir earthquake	Pakistan	100,000	138,000
2005	Floods	Maharashtra floods	India, Mumbai	5000	
2005	Hurricane	Hurricane Katrina	USA	1833	
2005	Monsoon		India	1000	
2006	Earthquake		Indonesia	5749	

(continued)

Table 3.8 (continued)

Year	Disaster type	Disaster name/details	Countries affected	No. of fatalities[a]	No. injured
2006	Earthquake		Indonesia	730	
2006	Earthquake	Java earthquake	Indonesia	733	9299
2006	Floods		Ethiopia	>800	
2006	Monsoon		Philippines	1000	
2007	Earthquake		Peru	519	
2007	Monsoon		India	660	
2008	Blizzard		Afghanistan	926	100
2008	Cyclone	Cyclone Nargis	Myanmar	135,500	
2008	Earthquake		China	67,180	
2008	Earthquake	Great Sichuan earthquake	China	87,417	374,176
2009	Earthquake		Indonesia	1100	
2010	Earthquake		Chile	521	
2010	Earthquake		China	2698	
2010	Earthquake		Indonesia	435	
2010	Earthquake		Chile	550	
2010	Earthquake		Haiti	31,600	
2010	Volcano	Mount Merapi	Indonesia	353	
2010	Floods		Pakistan	1781	2966
2010	Heatwave	Russian heatwave	Russia	56,000	
2010	Heatwave	Japanese heatwave	Japan	1718	
2011	Earthquake		Turkey	604	
2011	Earthquake and tsunami	Great East Japan Earthquake	Japan	15,884	6148
2011	Floods	Rio de Janeiro floods	Brazil	1000	
2011	Floods	Tropical Storm Washi	Philippines	1268	
2013	Typhoon	Typhoon Haiyan	Philippines	>10,000	

Data from National Geographic [127], Wikipedia [128, 129], http://creativecommons.org/licenses/by-sa/3.0/

[a] Includes natural disasters with at least 300 fatalities

3.3.3 Geophysical Disasters

3.3.3.1 Earthquakes and Tsunamis

Most earthquakes occur along faults or fractures in the Earth's crust which vary in size from a few metres to hundreds of miles, when vast plates or rocks suddenly fracture or shift under stress. Earthquakes are also the main cause of tsunamis and account for most deaths from natural disasters.

Since 1990, earthquakes and tsunamis have caused more than 900,000 fatalities worldwide and major human aid catastrophes in countries including Indonesia, India, Sri Lanka, Thailand and Japan. Other earthquakes since 1990 that have caused heavy loss of life occurred in Afghanistan, China, Haiti, Iran, Pakistan and Turkey (Table 3.8; Figs. 3.5 and 3.6).

3.3.3.2 Volcanoes

There are approximately 1900 volcanoes that are either active today or are known to have been active in historical times. Almost 90 % of volcanoes are located in the 'Ring of Fire', a band of volcanoes circling the edges of the Pacific Ocean (Table 3.9; Fig. 3.6). There have been several volcanic eruptions with heavy loss of life since 1990, including Mount Pinatubo in the Philippines (with an estimated 847 fatalities), Mount Merapi in Indonesia (345) and Nyiragongo in the Congo Republic (245). Over the last few centuries, there have been many cataclysmic volcanic eruptions with devastating loss of life of more than 1000 fatalities (Table 3.9). Some volcanic eruptions, such as Laki in Iceland in 1783 and Huaynaputina in Peru in 1600, have occasionally led to severe

Table 3.9 Major volcanic eruptions with >1000 fatalities: ordered according to the number of fatalities

Volcano	Country	Year	No. of fatalities
Mount Tambora	Indonesia	1815	36,000
Krakatoa	Indonesia	1883	36,000
Mount Pelée	Martinique	1902	33,000
Nevado del Ruiz	Colombia	1985	23,000
Vesuvius	Italy	0079	18,000
Mount Unzen	Japan	1792	15,000
Mount Kelud	Indonesia	1586	10,000
Laki	Iceland	1783	9000
Santa Maria	Guatemala	1902	6000
Mount Kelud	Indonesia	1919	5115
Mount Galunggung	Indonesia	1822	4000
El Chichón	Mexico	1982	3500
Vesuvius	Italy	1631	3360
Mount Lamington	Papua New Guinea	1951	2942
Tseax Cone	Canada	1775	2000
Soufriere	St. Vincent	1902	1680
Mount Agung	Indonesia	1963	1584
Huaynaputina	Peru	1600	>1500
Mount Merapi	Indonesia	1930	1369
Mount Taal	Philippines	1911	1335
Mount Mayon	Philippines	1897	1335
Mount Asama	Japan	1783	1151
Cotopaxi	Ecuador	1877	1000

Data from Wikipedia [129]. http://creativecommons.org/licenses/by-sa/3.0/

longer term meteorological and humanitarian consequences including extreme weather, droughts and famines in countries as far away as other continents. These have often led to many more fatalities than those that resulted directly from the volcanic eruption alone. For example, it is considered that Laki and Huaynaputina led to more than six million and two million fatalities, respectively, in the longer term, largely through extreme weather and famine.

3.3.4 Meteorological Disasters

3.3.4.1 Typhoons

A typhoon (also known as a hurricane or tropical cyclone depending on the region of the world) is a rotating tropical storm with winds of at least 74 miles (119 km) per hour (Beaufort Wind Scale = 13+). There are seven typhoon/hurricane/tropical cyclone basins in the world. The northwest Pacific basin, which also includes the South and East China Seas, is the region of the world which experiences the most frequent and the most severe typhoons [31, 32]. This was the location of typhoon Haiyan which devastated the Philippines in 2013, causing more than 10,000 fatalities and a major human aid disaster. Typhoons can lead to storm surge, an abnormal rise in sea levels, which can decimate buildings and cause major flooding. They often result in wave heights of 50 or 60 ft or more over prolonged periods of time and have caused many major shipping disasters, particularly in the North West Pacific, the South and East China Seas and the north Atlantic. Since 1990, typhoons (or cyclones/hurricanes) have been responsible for more than 300,000 fatalities worldwide, principally affecting Bangladesh, the Philippines, the USA and the Gulf of Mexico region (Table 3.8; Figs. 3.5 and 3.6).

3.3.5 Hydrological Disasters

3.3.5.1 Floods

Major flooding can develop slowly, while flash floods often occur within a few minutes or hours of excessive rainfall, a dam or levee failure or a sudden release of water held by an ice jam. Flash floods occasionally have a dangerous wall of roaring water that carries rocks, mud and other debris. Since 1990, floods have been the cause of more than 30,000 fatalities worldwide (Table 3.8). Major flooding incidents that have caused heavy loss of life have affected regions of Brazil, China, the Dominican Republic, Haiti, India, Mozambique, the Philippines, Venezuela, Vietnam and Zimbabwe which are mostly low-resource countries (Table 3.8). Flooding can also be an important factor in even greater humanitarian disasters. For example, major flooding in North Korea in 1995 decimated crop harvests and grain reserves, leading to the North Korea famine and up to 3.5 million fatalities during the following 3 years.

3.3.6 Climatological Disasters

3.3.6.1 Heatwaves

A heatwave is an extended period of extreme or severe heat that is well above the norm for the local climate and is often accompanied by high humidity. As conditions that can induce heat-related illnesses include stagnant atmospheric conditions and poor air quality, people residing in urban locations inland are often at greater risk from the effects of prolonged heatwaves than those living in coastal or rural areas. In recent years since 1990, there have been several major heatwaves that have accounted for very heavy loss of life (Table 3.8), most notably across Russia in 2010 (>50,000 fatalities) and across Europe in 2003 (>70,000 fatalities). Globally, heatwaves have caused more than 130,000 fatalities over the last 25 years.

3.3.6.2 Wildfires

Wildfires occur mainly in forests and woodland settings during drought conditions and are usually triggered by lightning or human accidents. Typically, they spread very quickly and present major challenges to firefighting attempts. Although disastrous environmentally, wild fires seldom lead to high numbers of human fatalities or casualties (Table 3.8).

3.4 Other Causes of Trauma

Other major causes of trauma and fatalities worldwide that are managed by orthopaedic surgeons and emergency medicine specialists include attacks or bites from wild animals and reptiles, mostly involving venomous snakes, crocodiles and alligators, sharks, large cats such as lions, tigers and leopards, bears and 'domesticated' dogs. Other major causes of trauma that account for approximately 1.6 million fatalities worldwide each year are accidents at work and road traffic accidents. Further important causes of trauma include falls particularly among older people; injuries through sports such as motorbike and car racing, horse riding, ice hockey and rugby; civilian violence; self-harm and suicide attempts; and domestic burn and scald injuries.

3.4.1 Animal Attacks

Injuries from animal attacks are increasing as humans encroach on wild territory to expand land and settlements while many wild animals forage close to human settlements. In some countries, wild animals are sources of food or illegal trade of body parts, while tourism also accounts for a small number of attacks on naïve travellers. Most wild animals do not usually attack people without provocation but can become aggressive as a result of sickness or injury, defending territory or offspring or when mating. Although much less common, injuries and fatalities also arise through attacks by domesticated animals including dogs, along with horses and cattle.

Although the management of injuries resulting from domesticated animals tends to be facilitated by established emergency response systems, more unusual wild animal attacks in rural areas and the complex injuries arising often pose challenges to surgeons when practicing in resource-limited settings. Fortunately, most small animal-related injuries are minor and do not require hospitalisation. Of those that require medical attention, people in developing countries are hindered by a lack of adequate facilities and ambulatory services. Consequently, only the most severe cases are often hospitalised. Table 3.10 shows the proportions of all emergency hospital admissions reported from various settings that were attributable to animal attacks. The highest percentage reported was 12 % in Bangkok during 1995 and 1996, followed by 10.5 % in Maharashtra and India from 2003 to 2007. However, in most reports, animal attacks accounted for less than 3 % of all emergency hospitalisations.

Injuries following many animal attacks are susceptible to infections, including numerous zoonotic infections via bites and scratches including Staphylococcus aureus, Streptococci species, Pasteurella species, leptospirosis, brucellosis and tuberculosis. Animal bites are often prone to infection [33]. Most infections are polymicrobial with Pasteurella multocida being the most common isolate. Dendle and Looke provide a comprehensive list of organisms transmitted by different animals [34]. Early administration of antibiotics following animal-related injury is

Table 3.10 Proportion of emergency admissions caused by animal attacks: as reported from various studies, ordered in reverse chronological order

Country, region	Study period	Patient age group	% emergency admissions	Animal responsible	Reference
Tanzania, NW	2007–2012	All	2.2[a]	–	[130]
Tanzania, NW	2007–2011	All	8.3	–	[131]
India, Maharashtra	2005–2010	Children	3.2[b]	–	[132]
India, Kashmir	1990–1995, 2005–2007	All	3.8	Black bear	[56]
Turkey, east	2005–2006	All	0.2	–	[133]
India, Maharashtra	2003–2007	All	10.5	–	[134]
Nigeria, Zaria	2000–2010	All	0.3	Dog	[135]
Kenyan, Nyanza	2002–2003	All	1.3	Dog	[136]
South Africa, Cape Town	1991–2004	Children	1.5	Dog	[137]
Thailand, Bangkok	1995–1996	Children	12	–	[138]
Australia, national	–	All	2	–	[34]

[a] Admissions with ear, nose or throat injuries only

[b] Admissions with maxillofacial fractures only

always recommended. Viral infections can also be dangerous, for example, parvovirus, tetanus and rabies, which are sometimes fatal to the host. The World Health Organisation has reported that 55,000 people in Asia and Africa die from rabies each year, which is 95 % of the total deaths worldwide from rabies [35]. Frey et al. have reported an incidence of 13 per 100,000 population for attacks by rabid animals in N'Damena, Chad, in 2008 and 2009 which led to 0.7 rabies-related deaths per 100,000 population [36].

3.4.2 Snakes

Across the world, it has been estimated that there are at least 420,000 venomous snakebites each year and 20,000 fatalities each year [37]. Less than 10 % of the world's snake species are venomous. The most venomous include the inland taipan or fierce snake (found in Australia), the black mamba (across much of southern and eastern Africa), the eastern brown snake (Australia), the blue krait (Southeast Asia), the taipan (Australia), the Philippine cobra (the Philippines), the tiger snake (Australia), Russell's viper (Indian subcontinent), pit vipers and rattlesnakes (Central, South and North America) and the faint-banded sea snake (Indian Ocean). As well as venom toxicity, human fatalities and serious necrosis are dependent on factors including the aggression of the snake, its usual proximity to human habitation and the likelihood of envenomation during a bite. The most venomous snake in the world, the Australian inland taipan, seldom causes human fatalities as it is especially timid in character and usually found in remote locations. The African black mamba, however, is notoriously volatile, sometimes comes into proximity and conflict with humans when searching for rodent prey around habitations, envenomates with every bite and has the highest fatality rate of all snakes which is 100 % when untreated.

Table 3.11 shows population-based incidence and mortality from snakebites as reported from various studies across the world. The highest incidence has been reported from Nigeria (497 per 100,000 population) and Sri Lanka (200) with highest regional rates reported from sub-Saharan central and western Africa and from Southeast Asia. Population mortality however is highest in Oceania, sub-Saharan West Africa, South and Southeast Asia and the Caribbean. The majority of snakebites occur during the warmer months of the year [38–40]. The puff adder and black mamba account for most snakebites and most fatalities across Africa, while on the Indian subcontinent, most fatalities are caused by the Indian cobra, Russell's viper, the common krait and the saw-scaled viper. In Australia, although fatalities are fewer, most are caused by the eastern brown snake.

When the snakebite is not rapidly fatal, most patients are conscious at the time of presentation to

Table 3.11 Population-based incidence and mortality from snakebites: as reported from various studies, ordered in reverse chronological order

Country/continent	Study period	Annual incidence per 100,000 population	Annual mortality per 100,000 population	Reference
Nicaragua	2005–2009	56 (5 years)	0.6 (5 years)	[139]
Brazil, Paraiba	2006–2008	5.5	–	[140]
Iran, Kashan	2004–2010	2.5	–	[38]
Bolivia	1996–2000 and 2001–2009	8	0.1–3.9	[141]
Ecuador	1998–2007	11	0.5	[142]
India	2001–2003	–	4.1	[143]
India, Maharashtra	2002	6.0	–	[144]
Venezuela, Cojedes	1996–2004	21.5	–	[145]
India, Maharashtra	1998	6.8	–	[144]
Argentina	1978–1998	1.8	–	[146]
Nigeria	–	497	–	[147]
Sri Lanka	–	200	–	[148]
Asia, Pacific – high income	1985–2006	0.4–1.7	0.01–0.10	[37]
Asia, Central	1985–2006	0.3–1.6	0.01–0.04	[37]
Asia, East	1985–2006	0.3–15.7	0.03–0.35	[37]
Asia, Southern	1985–2006	7.8–30.0	0.91–2.18	[37]
Asia, SE	1985–2006	18.8–84.7	0.13–3.25	[37]
Australasia	1985–2006	4.4–5.1	0.008–0.02	[37]
Caribbean	1985–2006	2.8–20.7	0.28–2.98	[37]
Europe, Central	1985–2006	0.1–2.1	0.005–0.01	[37]
Europe, East	1985–2006	0.4–0.4	0.02–0.03	[37]
Europe, West	1985–2006	0.7–1.6	0.001–0.01	[37]
Latin America, Andean	1985–2006	12.9–54.5	0.48–1.05	[37]
Latin America, Central	1985–2006	19.0–30.5	0.09–0.66	[37]
Latin America, South	1985–2006	3.5–3.6	0.007–0.01	[37]
Latin America, tropical	1985–2006	15.0–16.1	0.05–0.15	[37]
North Africa/Middle East	1985–2006	0.71–18.9	0.01–0.02	[37]
North America, high income	1985–2006	0.8–1.1	0.001–0.002	[37]
Oceania	1985–2006	3.9–49.7	2.43–5.53	[37]
Sub-Saharan Africa, central	1985–2006	20.3–53.4	0.29–3.44	[37]
Sub-Saharan Africa, east	1985–2006	12.9–22.6	0.42–3.03	[37]
Sub-Saharan Africa, south	1985–2006	2.3–3.3	0.41–0.53	[37]
Sub-Saharan Africa, west	1985–2006	8.9–93.3	0.50–5.91	[37]

emergency facilities. Symptoms depend on the snake species and its type of venom but variously include tachycardia; fever; vomiting; blurring of vision; slurring of speech; abdominal pain; muscle cramp, spasms or paralysis; swelling or blisters; internal or external haemorrhaging; renal failure; necrosis; and respiratory failure [41, 42]. A review by Ranawaka et al. [43] comprehensively covered the neurotoxicity following snakebites. As many victims do not recognise the species of snake, often because of fear, anxiety, ignorance or poor visibility in darkness or in long grass, optimal treatment can be compromised. Intravenous snake antivenom is the most effective treatment for snakebites where it is possible to apply the appropriate antivenom from the identified snake in time.

Table 3.12 illustrates the characteristics and case fatality for snakebites as reported from various studies across the world, but mostly across the Indian subcontinent, west and central

Table 3.12 Case fatality and characteristics of snakebites: as reported from various studies, ordered according to case fatality

Country	Study period	No. of snakebites	Snake species	% male patients	Body area bitten	Case fatality (%)	Reference
India, Maharashtra	2005–2011	141	Krait	56	–	26	[149]
Niger	2005–2006	53	–	64	–	15	[150]
Nepal	2008–2010	6993	–		–	13	[39]
Chad	1997–2001	325	–	–	–	8	[151]
Morocco	1980–2008	1761	–	55	–	7.2	[40]
India, Manipal	2003–2005	31	Viper	–	–	6.5	[152]
India, Maharashtra	10 years	5639	–	65	–	5.4	[153]
India, Andhra Pradesh	2010–2012	87	Cobra (60 %) Krait (10 %) Viper (30 %)	74	Head (3 %) Lower limbs (86 %) Upper limbs (10 %)	4.6	[41]
India, Maharashtra	1998–2002	–	–	69	–	4.3	[144]
India, south	2010–2011	180	–	61	Lower limbs (67 %)	3.8	[154]
Iran, Kashan	2004–2011	50	–	96	Head (4 %) Legs (36 %) Hands (60 %)	2	[38]
India, Gujarat	–	–	–	74	Lower limbs (52 %) Upper limbs (36 %)	1.68	[155]
Nigeria	2009–2010	5367	–	–	–	1.5	[156]
Nicaragua	2005–2009	3286	Pit viper	–	–	1	[139]
Bangladesh	–	98	–	52	–	1	[157]
Bosnia and Herzegovina	1983–2006	341	Pit viper (67.5 %) Rattlesnake (0.7 %)	53	–	0.3	[158]
Brazil, NE	2003–2011	1063	Non-venomous (76 %)	71	Lower limbs (72 %) Upper limbs (27 %) Head (1 %)	0.2	[42]
Brazil, Paraiba	–	ns	–	75	Toes (53 %)	0.2	[140]
Argentina	1978–1998	8083	Pit viper (96.6 %) Rattlesnake (2.8 %) Coral snake (0.6 %)	–	Lower limbs (79 %) including foot (58 %)	0.04	[146]

(continued)

Table 3.12 (continued)

Country	Study period	No. of snakebites	Snake species	% male patients	Body area bitten	Case fatality (%)	Reference
Brazil, Paraiba	2007–2012	304	Pit viper (74.6 %) Rattlesnake (6.2 %) Coral snake (1.3 %)	–	–	0	[159]
Czech Republic	1999–2013	87	–	–	–	0	[160]
Argentina	1979–2003	46	Coral snake	–	–	0	[161]
Sri Lanka	2008–2010	114	Hump-nosed pit viper	–	Lower limbs highest	0	[162]
Arabian Peninsula, SE	4 years	64	–	88	Hands and feet (95 %)	0	[163]
KwaZulu-Natal	2007–2008	243	–	–	–	0	[164]
Tanzania	2007–2009	85	–	58	–	–	[165]
Amapa	2003–2006	909	–	81	Lower limbs (68 %)	–	[166]
Sri Lanka	2010	1018	–	69	–	–	[45]

sub-Saharan Africa, North Africa, South America, the Middle East and Eastern Europe. The case fatality reported in these studies is mostly quite low (8 % or less) although higher rates have been reported; 26 % from Maharashtra, India (involving kraits), 15 % from Niger and 13 % from Nepal, which would reflect some biases towards patients who survive long enough to attend medical facilities rather than fatalities that occur before presentation. Most of the snakebites from these studies occurred among males (ranging from 52 to 96 %) and involved the lower limbs (see Table 3.12) often as the snakes were accidentally trodden upon by humans farming in rural locations. Depending on the toxicity of the venom and how rapidly the snakebite can be treated, amputation is often required. Prognosis is often affected by remoteness to medical facilities as well as by local practices and culture, as native remedies and inappropriate first aid are often used in many locations instead of or prior to specialist medical treatment [44].

3.4.3 Crocodiles and Alligators

Primary injuries arising from crocodile or alligator attacks involve mainly bites with secondary injuries arising from crushing injuries to the limbs, while many people disappear altogether. Bites can cause lacerations, puncture wounds, contusions, fractures and loss of limbs, often involving various wound types on multiple body areas. In Africa, it is thought that several hundred people are killed through crocodile attacks each year. However, the limited literature on fatalities from crocodile and alligator attacks is based largely from Australia (crocodiles) and the USA (alligators) rather than in lesser developed, low-resource regions across Africa and Asia where fatalities are more common but are usually unreported (Table 3.13). In Australia and the USA, the fatalities which are not common often arise through recreational water-based activities [45].

3.4.4 Other Animals

Shark attacks are also a frequent cause of fatalities and severe trauma among humans, with most non-fatal injuries affecting the limbs. Table 3.14 illustrates case fatality from confirmed shark attacks across the world as compiled from a US centre [46]. The reported fatality rates ranged mostly from 20 to 50 %, although with much lower case fatality of 3.4 % in the USA and Hawaii. The Durban classification of shark-induced injuries can be used to predict the outcome of an attack [47]. Mortality following shark attacks worldwide was estimated at 12.3 % from 1990 to 1999 [48].

Attacks on humans by large cats typically carry a worse prognosis, usually through severe musculoskeletal injuries and haemorrhaging and sometimes subsequent infection. A study of 815 lion attacks in Tanzania from 1990 to 1994

Table 3.13 Case fatality for crocodile and alligator attacks: as reported from various studies, ordered in reverse chronological order

Country, region	Study period	Crocodile/alligator	No. of cases	Case fatality (%)	Reference
Tanzania, NW	2007–2011	Crocodile	6	–	[131]
Malawi, south	4 years	Crocodile	60	1.7	[167]
Australia, north	1971–2004	Crocodile (saltwater)	62	27.4	[48]
USA, national	1928–2009	Alligator	567	4.2	[168]
USA, Florida	1928–2009	Alligator	481	4.6	[168]
Australia	–	Crocodile (saltwater)	–	50	[169]
Malaysia	–	Crocodile (saltwater)	–	50	[169]
Africa, NE	–	Nile crocodile	–	63	[169]
USA	–	American alligator	–	<6	[169]

Table 3.14 Case fatality for confirmed shark attacks: ordered by case fatality

Country/region	Total attacks	Fatal attacks	Case fatality (%)	Most recent fatality
Europe	49	27	55	1974
Reunion Island	33	17	52	2013
USA, central	57	27	47	2011
Pacific/Oceania islands (e.g.. Hawaii)	126	49	39	2011
Asia	129	48	37	2000
Unspecified/ open ocean	21	7	33	1995
Australia	520	146	28	2013
Africa	339	93	27	2013
Antilles and Bahamas	70	16	23	2013
South America	117	26	22	2013
New Zealand	49	9	18	2013
Hawaii	129	9	7.0	2013
USA	1055	36	3.4	2012
World	**2666**	**493**	**18.5**	**2013**

Data from International Shark Attack File [46]

reported that 69 % of attacks were on men and only 18 % were on children under 10 years old, with a case fatality of 69 % [49]. A smaller study of 35 attacks from leopards from the Kashmir region of India from 2004 to 2007 reported a case fatality of 54 %.

Injuries from domesticated dogs are the most common cause of injury by any animal in many regions of the world, with WHO reporting that dogs account for 76–94 % of all animal bite injuries [50]. Data from lesser developed countries however are sparse, although reported incidence is often high. For example, reported incidences in three regions of Bhutan (Gelephu, Phuentsholing and Thimphu) were 870, 294 and 285 per 100,000 population, respectively [51]. Table 3.15 illustrates the characteristics of dog bite attacks in humans reported from various studies across the world, including the body areas affected by injury, the population socio-demographics and incidence rates (where available). The studies show that a high proportion of dog bite attacks affect children, with highest incidence often in mid- to late childhood. The risk of injury to the head and neck is greater in children than in adults, whereas attacks on adults usually affect the lower limbs. Bites to the hand and arm are common for all age groups. Single bite injuries tend to be more common than multiple bites [51].

Although fatality rates directly resulting from dog bite injuries are very low, infection with rabies contributes to a substantial mortality risk, particularly in lower and middle-income countries, which often lack of appropriate access to effective health care and treatment [50]. For example, the reported mortality from rabies following dog bite attacks in Bhutan during 2009 and 2010 was 3.1 per 100,000 population (95 % confidence interval = 1.6–6.3) [51].

A fatality rate of 29 % for wolf attacks was reported from India between 2005 and 2007 [52]. The injuries usually occurred from ‘pack’ attacks, with a predominance of injuries to the dorsal aspect of the body.

Injuries from bears usually involve mauling and bites. Most bear attacks are not fatal, with a highest fatality rate of 12.5 % in the very limited Medline literature (Table 3.16) identified for grizzly bears in Yellowstone Park, USA [53]. Bears attack typically from an upright position and strike the person’s torso and head, resulting in lacerations and fractures to the cranium and upper limbs [54, 55]. Loss of fingers is also commonly reported, with many people requiring amputation. Most bears will abandon their attacks once the perceived threat has been immobilised. Very few children are attacked by bears [56], with the majority of attacks on men [55, 56].

3.4.5 Occupational Injuries

Globally, it is estimated that approximately 350,000 fatalities occur through accidents at work each year with a total of 300 million non-fatal accidents that cause absences from work of at least 4 days [57]. Occupational diseases are also thought to account for a further two million deaths worldwide each year. Although reliable data on occupational fatalities are reported in

Table 3.15 Characteristics of dog attacks: as reported from various studies, ordered in reverse chronological order

Country, region	Study period	No. of cases	Incidence per 100,000 population	Body area affected			% males attacked	% children attacked	Reference
				Lower limbs (%)	Upper limbs (%)	Head and neck (%)			
India, Surat	2012	371	–	82	–	–	83	26	[170]
India, Karnataka	2011	536	–	42	–	–	71	100[a]	[171]
Bhutan, south	2009–2010	324	–	73	18		62	–	[50]
South Africa, KwaZulu-Natal Province	2007–2011	821	–	–	–	–	56	–	[172]
American Samoa	2004–2010		401	–	–	–	59	–	[173]
Guatemala, Todos Santos	2006–2008	85	–	86	–	–	–	51	[174]
Turkey Erzurum Province	2005–2006	275	–	–	–	–	79.6	59	[133]
Argentina, Tierra del Fuego	2005–2006	382	–	56	–	11	58	50	[175]
Nigeria, Zaria	2000–2010	81	–	33	43	–	82	56	[135]
Nigeria, Benin City	1997–2008	143	–	–	–	–	88	–	[176]
Trinidad	2002–2003		–	59	31	–	55	–	[177]
Kenya, Nyanza	2002–2003	207	–	–	–	–	64	–	[136]
Iran, Khuzestan	1997–2006	617	–	60	30	5	–	–	[178]
Spain, Aragon	1995–2004	4186	12.8[b] 71.3[c]	42	45	9	62	49.6	[179]
South Africa, Cape Town	1991–2004	1871	–	39	17	31	68	100[a]	[137]
Puerto Rico, San Juan	1996–1998	223	–	–	43	–	87	–	[180]

[a] Paediatric cases only
[b] High population area
[c] Low population area

Table 3.16 Characteristics of bear attacks: as reported from various studies, ordered in reverse chronological order

Country, region	Study period	Bear species	No. of cases	Body area wounded			Case fatality (%)	Reference
				Lower limbs (%)	Upper limbs (%)	Head and neck (%)		
USA, Yellowstone Park	1980–2011	Grizzly	32	–	–	–	13	[53]
India, Kashmir	2005–2007	Black	104	–	–	–	2	[52]
India, Kashmir	2005–2006	Black	32	–	–	–	–	[55]
India, Kashmir	1990–1995, 2005–2007	Black	417	15	23	81	–	[56]

most European, OECD and many other developed countries, the quality of reporting from low-resource countries is patchier and less reliable.

In many coastal countries, the maritime occupations of commercial fishing and (cargo) merchant seafaring have for long been the most hazardous of all occupations with drowning accounting for a high proportion of fatalities, followed by falls, fires, explosions, crushing and mechanical injuries [58]. These are followed by other occupations including farming and agricultural vehicle driving (with many deaths caused by mechanical injuries), mining (gas explosions, crushing injuries or asphyxiation through mine roof collapses and mine flooding), forestry work (crushing injuries), scaffolding, roofing, steel erection and certain construction trades (falls from heights and mechanical injuries), sewerage work (asphyxiation by fumes), oil or gas extraction and production (fires, explosions, mechanical injuries and drowning offshore), textile industries (mechanical injuries) along with railway and road construction work (traffic accidents).

The vast majority of fatal occupational injuries affect men with highest fatality among younger workers, who are often employed in the most high-risk industries and who lack long periods of experience. Non-fatal occupational injuries are usually far less reliably recorded than fatal occupational injuries as they are usually based either on (under-reporting in) accident surveillance systems or (often inaccurate) accident insurance claims.

Table 3.17 provides estimates of both fatal and non-fatal rates of accidents at work during 1999 from a study that covered most countries of the world, split into eight World Bank divisions (established market economies, former socialist economies, India, China, other Asia and islands, sub-Saharan Africa, Latin America and Caribbean and the Middle East Crescent). Regionally, both fatal and non-fatal accident rates are highest across low-resource regions of Asia and sub-Saharan Africa, followed by the Middle East Crescent and Latin America with intermediate fatal accident rates in India, China and former socialist (European) economies and lowest accident rates in the advanced market economies (Table 3.17).

Both fatal and non-fatal accident rates are highest in low-resource Asian countries such as Papua New Guinea (29.0 per 100,000 workers), Cambodia (28.3 per 100,000), Vietnam (27.0) and Bangladesh (26.4; Table 3.17). Industries in these countries are dominated by hazardous sectors such as mining, textile production and offshore oil/gas extraction. More recently, a study of Guinea during the single year 2007 reported a higher fatal accident rate of 62 per 100,000, with most fatalities caused by transportation accidents (37 %), fires and burns (22 %), falls (12 %) and drowning (6 %) [59].

Fatal accident rates are lowest in Europe and other developed or ‘post-industrial’ countries such as the UK (0.8 per 100,000), Sweden (1.9) and France (3.0). These fatality rates have reduced over many decades time with reductions in heavy industry such as mining, steel production and shipping and advances in safety practices at work. A lack of progress with improvements in safety contributes strongly to the very high fatal accident rates in many developing countries.

Of individual occupations, some of the highest fatal accident rates in the Medline literature in recent decades have been reported for trawler fishing in Alaska (415 per 100,000 workers) [60],

Table 3.17 Estimated fatal and non-fatal rates of occupational accidents at work worldwide, 1999

World Bank divisions and selected countries	Fatal accidents per 100,000 population	Non-fatal accidents per 1000 population	World Bank divisions and selected countries	Fatal accidents per 100,000 population	Non-fatal accidents per 1000 population
Established market economies	**4.2**	**32**	**Sub-Saharan Africa**	**21.0**	**160**
Australia	3.2	24	Angola	21.2	162
Canada	6.4	49	Cameroon	21.0	160
Japan	3.2	24	Ethiopia	21.5	164
USA	5.2	40	Ghana	20.6	157
France	3.0	23	Kenya	21.6	165
Germany	3.6	27	Mali	22.1	169
Italy	6.9	52	Nigeria	20.1	153
Sweden	1.9	15	Rwanda	22.2	169
UK	0.8	6	Somalia	21.4	163
			Uganda	21.7	165
Former socialist economies	**12.9**	**99**	Zimbabwe	20.9	160
Bulgaria	11.4	87			
Hungary	10.3	79	**Latin America and Caribbean**	**17.2**	**132**
Poland	10.0	77	Argentina	14.6	112
Romania	14.4	110	Brazil	16.6	127
Russia	11.0	81	Colombia	18.2	139
			Guatemala	22.4	171
India	**11.5**	**88**	Haiti	25.9	198
China	**10.5**	**80**	Mexico	15.9	122
			Peru	19.0	145
Other Asia and Islands	**21.5**	**164**	Venezuela	14.3	109
Afghanistan	19.9	152			
Bangladesh	26.4	201	**Middle East Crescent**	**18.6**	**142**
Cambodia	28.3	216	Egypt	24.0	183
Indonesia	20.9	160	Israel	14.6	111
Mongolia	19.9	152	Iran	16.8	128
Pakistan	20.7	158	Iraq	14.2	108
Papua New Guinea	29.0	221	Lebanon	15.9	121
Philippines	20.0	153	Syria	17.7	135
Viet Nam	27.0	206	Yemen	17.0	130

Data from Hamalainen et al. [180]
The table includes selected rather than all countries within each World Bank division

although following improvements in safety practices and legislation, this fatality rate has fallen to less than 100 per 100,000 in most recent years [61], Thailand (300 per 100,000) [62] and New Zealand (260) [63], forestry work in New Zealand (203) [64], merchant seafaring in Hong Kong [65], copper mining in Zambia (111) [66] and transportation occupations in China [67]. However, there is a distinct lack of reporting from most low-resource countries.

3.4.6 Road Traffic Accidents

Road traffic accidents are one of the world's leading causes of traumatic injury and mortality and cause approximately 1.25 million deaths worldwide each year [68]. They are the eighth leading cause of death globally and the leading cause of death among young people aged between 15 and 29 years. More than three-quarters of all fatal road traffic accidents involve young males, while almost 60 % of road traffic deaths are among people aged from 15 to 44 years.

Road traffic accidents broadly encompass collisions between two motor vehicles or motor vehicles with pedestrians or stationary objects such as roadside trees, buildings or road debris. The main factors that contribute to the risks of collisions include the design or aspects of the road, vehicle speed, weather conditions, safety of the motor vehicle and the skill/behaviour/impairment of the driver. Most fatal accidents are preventable, through the use of helmets and seat belts, avoidance of alcohol and drugs before driving, driving at suitable speeds and through being visible in traffic.

Injuries sustained through motor vehicle accidents can be divided into two broad categories: collisions where occupants are ejected from their vehicles and acceleration or deceleration forces which act upon internal organs. In frontal collisions, vehicle occupants unrestrained by seatbelts continue to move forward as the vehicle comes to an abrupt stop. The initial impact point with the chassis is often the lower extremities, resulting in fractures and/or dislocations of the ankles, knees or hips along with femoral fractures. As the body continues to move forward, the head, cervical spine and torso often impact on the windscreen, driving wheel, steering column and dashboard or on the seats or the heads of the occupants in front, leading to more severe or fatal injuries to the head, chest, abdomen, spine and upper limbs. In lateral impact collisions, victims are accelerated away from the sides of the vehicle, while ejection from vehicles is linked with increased risks of severe or critical injuries [69].

The risks of fatal road traffic accidents has been reported as more than 30 times higher for motorcyclists than for car occupants [70] with most fatal injuries affecting the head. Lower limb fractures are also very common in motorcycle accidents and have been reported for approximately 40 % of motorcyclists who were hospitalised with non-fatal injuries in one study from California [71]. The risks of road traffic accidents for pedestrians are highest among older people, children and people who are inebriated. Injuries to the head and upper and lower limbs are more common among pedestrians involved in road traffic accidents than among motor vehicle occupants, while chest and abdominal injuries are less common [72].

Across the world, World Health Organisation data show that half of all fatal road traffic accidents affect motorcyclists (23 %), pedestrians (22 %) and cyclists (5 %), with 31 % of deaths among car occupants and the remaining 19 % among unspecified road users [68].

Regionally, the highest road traffic fatality rate in the world is in Africa (24.1 per 100,000 population), followed by the eastern Mediterranean region (21.3 per 100,000), the western Pacific and the southeast regions (both 18.5) and the Americas (16.1), while Europe has the lowest fatality rate (10.3; Fig. 3.7).

Figure 3.8 shows the 40 countries in the world with the highest fatal accident rates in 2010 based on World Health Organisation figures [68]. The countries with the highest fatal accident rates are scattered mainly across Asia and the Middle East, Africa and Latin America. In particular, these include Niue (68 per 100,000 population), the Dominican Republic (42 per 100,000), Thailand (38), Venezuela (37) and Iran and Nigeria (both 34).

Key Messages

- During the last 25 years, more than two million lives have been lost through wars or armed conflicts and more than 1.4 million through natural disasters.
- Countries affected by the heaviest fatalities are often lesser developed. For armed conflicts, they include Afghanistan, the Congo Republic, Ethiopia, Indonesia, Iraq, Liberia, Pakistan and Sudan. For natural disas-

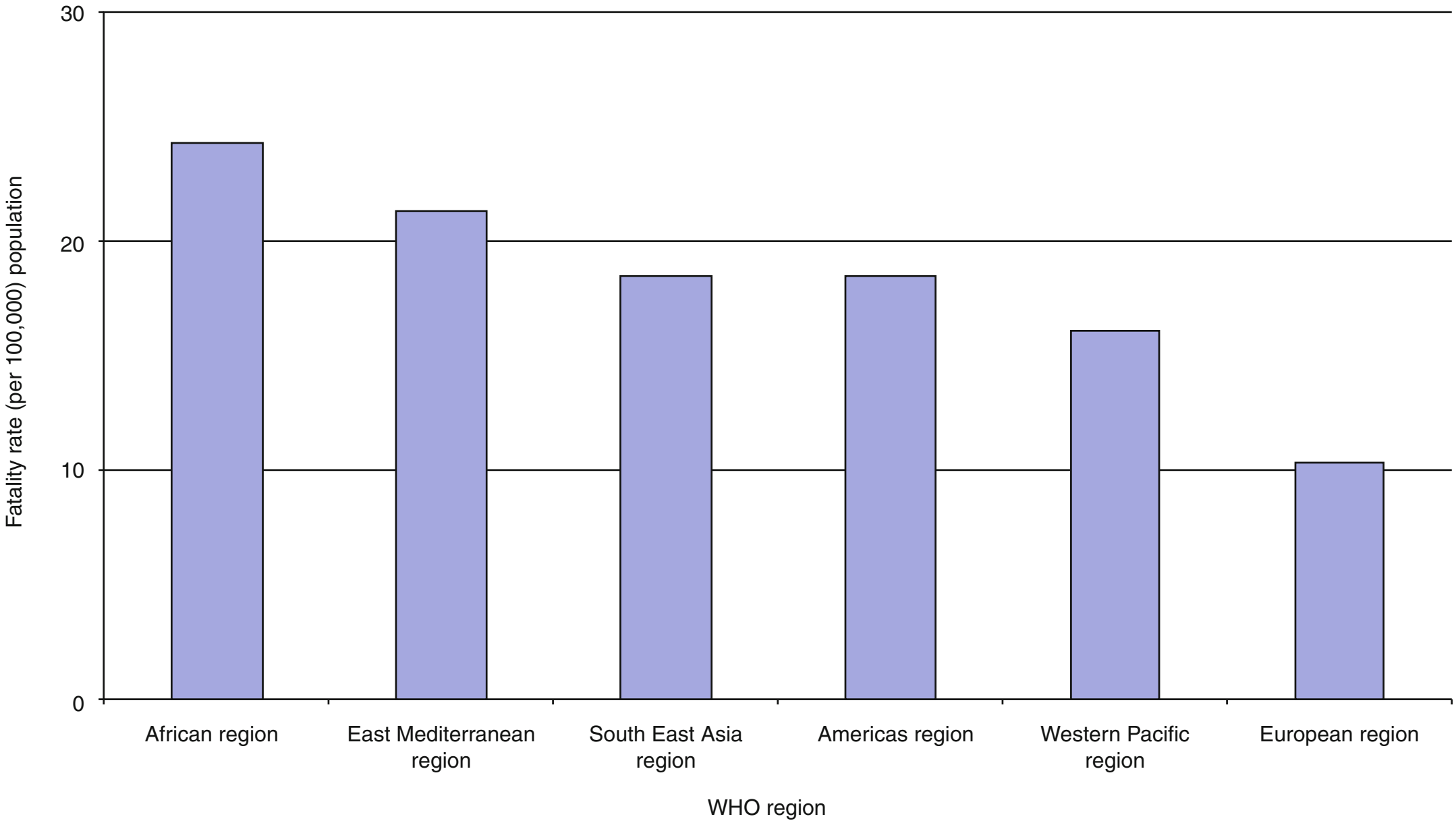

Fig. 3.7 Fatal road traffic accident rates worldwide regionally, 2010 (Data from World Health Organization [68])

ters, they include Bangladesh and Myanmar (cyclones); China, Indonesia and Iran (earthquakes); and Pakistan (earthquakes and floods).
- Explosive devices and fragments, including improvised explosive devices (IEDs), have become increasingly the leading cause of fatalities and non-fatal injuries in wars and armed conflicts.
- Major single explosive incidents with the highest fatality rates are often caused by large explosive devices that attack buildings from nearby vehicles.
- Injuries to the head, neck and abdomen are the leading cause of fatalities with the poorest prognosis in many wars and armed conflicts. However, lower limbs often account for most non-fatal injuries.
- Post-operative mortality has fallen over time but is often strongly dependent on external factors such as the available surgical facilities and the often austere environment, mass throughput of casualties and the volume of 'dead on table' and salvage cases with little prospect of survival.
- During the last 25 years, the leading cause of mortality from natural disasters is earthquakes and tsunamis, which accounted for more than 900,000 fatalities or 65 % of all deaths from natural disasters. They are followed by typhoons/hurricanes/cyclones (>300,000 fatalities) and heatwaves (>130,000).
- Animal attacks account for a low proportion of emergency admissions across the world, but fatality rates vary greatly according to the animal involved.
- Snakes account for more than 420,000 venomous bites and 20,000 fatalities worldwide each year, with highest mortality in Oceania, sub-Saharan West Africa, South and Southeast Asia and the Caribbean. Highest case fatality rates are often caused by the black mamba species.
- Accidents at work and road traffic accidents cause approximately 350,000 and 1.25 million fatalities worldwide each year, with highest mortality mostly in lesser developed regions of Africa, Asia, the Middle East and Latin America.

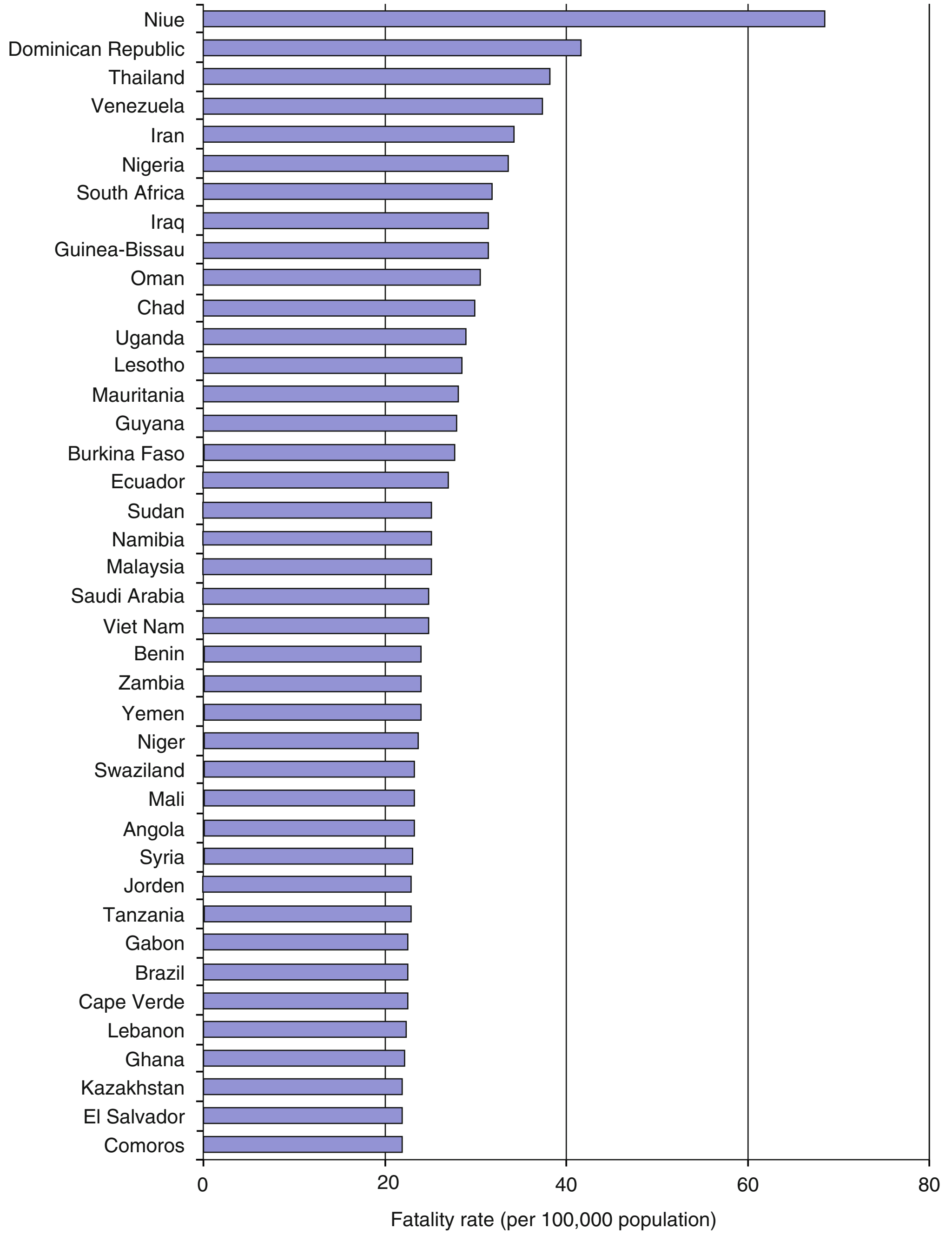

Fig. 3.8 The 40 countries with the highest fatal road traffic accident rates worldwide, 2010 (Data from Jin and Courtney [67]; World Health Organization [68]

References

1. Reza A, Mercy JA, Krug E. Epidemiology of violent deaths in the world. Inj Prev. 2001;7(2):104–11.
2. Iraq Coalition Casualty Count. http://icasualties.org/Iraq/Fatalities.aspx. 2009; Available from: http://icasualties.org/Iraq/Fatalities.aspx.
3. CNN World. Combating the No.1 killer of troops in Afghanistan. 2010; Available from:

http://afghanistan.blogs.cnn.com/2010/05/06/combating-the-no-1-killer-of-troops-in-afghanistan/.

4. Giannou C, Baldan M, Molde A. War surgery, vol. 2. Geneva: International Committee of the Red Cross; 2013. p. 640.
5. Chaloner E. Antipersonnel landmines. Ann R Coll Surg Engl. 1996;78(6):562–3.
6. Bilukha OO, Brennan M, Anderson M. The lasting legacy of war: epidemiology of injuries from landmines and unexploded ordnance in Afghanistan, 2002-2006. Prehosp Disaster Med. 2008;23(6):493–9.
7. Bilukha OO, et al. Seen but not heard: injuries and deaths from landmines and unexploded ordnance in Chechnya, 1994-2005. Prehosp Disaster Med. 2007;22(6):507–12.
8. Moszynski P. Mines still cause thousands of casualties despite ban. BMJ. 2004;329(7467):642.
9. Aboutanos MB, Baker SP. Wartime civilian injuries: epidemiology and intervention strategies. J Trauma. 1997;43(4):719–26.
10. Cobey JC. The land mine epidemic. Instr Course Lect. 2000;49:431–3.
11. Cobey JC, Raymond NA. Antipersonnel land mines: a vector for human suffering. Ann Intern Med. 2001;134(5):421–2.
12. Radonic V, et al. Mine clearance injuries in South Croatia. Mil Med. 2004;169(8):642–7.
13. Bodalal Z, Mansor S. Gunshot injuries in Benghazi-Libya in 2011: the Libyan conflict and beyond. Surgeon. 2013;11(5):258–63.
14. Demetriades D, van der Veen BW. Penetrating injuries of the heart: experience over two years in South Africa. J Trauma. 1983;23(12):1034–41.
15. Cros J, et al. Homicidal deaths in the Western suburbs of Paris: a 15-year-study. Am J Forensic Med Pathol. 2012;33(4):404–9.
16. Roberts SE. Work-related homicides among seafarers and fishermen. Int Marit Health. 2004;55(1-4):7–18.
17. Kauvar DS, Wade CE, Baer DG. Burn hazards of the deployed environment in wartime: epidemiology of noncombat burns from ongoing United States military operations. J Am Coll Surg. 2009;209(4):453–60.
18. Carey ME. Learning from traditional combat mortality and morbidity data used in the evaluation of combat medical care. Mil Med. 1987;152(1):6–13.
19. Wolf SE, et al. Comparison between civilian burns and combat burns from Operation Iraqi Freedom and Operation Enduring Freedom. Ann Surg. 2006;243(6):786–92; discussion 792–5.
20. Covey DC. Blast and fragment injuries of the musculoskeletal system. J Bone Joint Surg Am. 2002;84-A(7):1221–34.
21. Murray CK. Epidemiology of infections associated with combat-related injuries in Iraq and Afghanistan. J Trauma. 2008;64(3 Suppl):S232–8.
22. Arnold K, Cutting RT. Causes of death in United States Military personnel hospitalized in Vietnam. Mil Med. 1978;143(3):161–4.
23. Peleg K, et al. Gunshot and explosion injuries: characteristics, outcomes, and implications for care of terror-related injuries in Israel. Ann Surg. 2004;239(3):311–8.
24. Garfield RM, Neugut AI. Epidemiologic analysis of warfare. A historical review. JAMA. 1991;266(5):688–92.
25. Champion HR, et al. A profile of combat injury. J Trauma. 2003;54(5 Suppl):S13–9.
26. Gofrit ON, et al. Accurate anatomical location of war injuries: analysis of the Lebanon war fatal casualties and the proposition of new principles for the design of military personal armour system. Injury. 1996;27(8):577–81.
27. Gosselin RA. War injuries, trauma and disaster relief. Tech Orthop. 2005;20(2):97–108.
28. Owens BD, et al. Characterization of extremity wounds in Operation Iraqi Freedom and Operation Enduring Freedom. J Orthop Trauma. 2007;21(4):254–7.
29. Giannou C, Baldan M. War surgery, vol. 1. Geneva: International Committee of the Red Cross; 2010. p. 358.
30. Nikolic D, et al. Primary surgical treatment of war injuries of major joints of the limbs. Injury. 1999;30(2):129–34.
31. Landsea CW. Climate variability of tropical cyclones: past, present and future storms. New York: Routledge; 2000.
32. Atlantic Oceanographic and Meteorological Laboratory. Frequently asked questions. Miami: Hurricane Research Division, Atlantic Oceanographic and Meteorological Laboratory; 2010.
33. Anderson M, et al. Cervical spine injury: tiger attack. Orthopedics. 2008;31(12). doi: 10.3928/01477447-20081201-01.
34. Dendle C, Looke D. Review article: animal bites: an update for management with a focus on infections. Emerg Med Australas. 2008;20(6):458–67.
35. World Health Organization. Rabies – Factsheet No.99. 2013 May 2014]; Available from: http://www.who.int/mediacentre/factsheets/fs099/en/.
36. Frey J, et al. Survey of animal bite injuries and their management for an estimate of human rabies deaths in N'Djamena. Chad Trop Med Int Health. 2013;18(12):1555–62.
37. Kasturiratne A, et al. The global burden of snakebite: a literature analysis and modelling based on regional estimates of envenoming and deaths. PLoS Med. 2008;5(11), e218.
38. Dehghani R, et al. Epidemiology of venomous and semi-venomous snakebites (Ophidia: Viperidae, Colubridae) in the Kashan city of the Isfahan province in Central Iran. J Res Med Sci. 2014;19(1):33–40.
39. Magar CT, et al. A hospital based epidemiological study of snakebite in Western Development Region, Nepal. Toxicon. 2013;69:98–102.
40. Lallie H, et al. Epidemiology of snakebites in Morocco. Med Trop (Mars). 2011;71(3):267–71.

41. Kumar MR, et al. A retrospective review of snake bite victims admitted in a tertiary level teaching institute. Ann Afr Med. 2014;13(2):76–80.
42. Albuquerque PL, et al. Epidemiological profile of snakebite accidents in a metropolitan area of northeast Brazil. Rev Inst Med Trop Sao Paulo. 2013;55(5):347–51.
43. Ranawaka UK, Lalloo DG, de Silva HJ. Neurotoxicity in snakebite – the limits of our knowledge. PLoS Negl Trop Dis. 2013;7(10), e2302.
44. Kularatne AM, et al. Victims' response to snakebite and socio-epidemiological factors of 1018 snakebites in a tertiary care hospital in Sri Lanka. Wilderness Environ Med. 2014;25(1):35–40.
45. Langley RL. Adverse encounters with alligators in the United States: an update. Wilderness Environ Med. 2010;21(2):156–63.
46. International Shark Attack File. 1580–2013 map of world's confirmed unprovoked shark attacks. 2014; Available from: http://www.flmnh.ufl.edu/fish/sharks/statistics/GAttack/World.htm.
47. Davies DH, Campbell GD. The aetiology, clinical pathology and treatment of shark attack. J R Nav Med Serv. 1962;48:110–36.
48. Caldicott DG, et al. Crocodile attack in Australia: an analysis of its incidence and review of the pathology and management of crocodilian attacks in general. Wilderness Environ Med. 2005;16(3):143–59.
49. Packer C, et al. Conservation biology: lion attacks on humans in Tanzania. Nature. 2005;436(7053):927–8.
50. World Health Organization. Animal bites. 2013 May 2014]; Available from: http://www.who.int/mediacentre/factsheets/fs373/en/.
51. Tenzin, et al. Dog bites in humans and estimating human rabies mortality in rabies endemic areas of Bhutan. PLoS Negl Trop Dis. 2011;5(11):e1391.
52. Nabi DG, et al. Increasing incidence of injuries and fatalities inflicted by wild animals in Kashmir. Injury. 2009;40(1):87–9.
53. National Parks Service. Bear inflicted human injuries and fatalities in yellowstone. 2014; Available from: http://www.nps.gov/yell/naturescience/injuries.htm.
54. Nabi DG, et al. Injuries from leopard attacks in Kashmir. Injury. 2009;40(1):90–2.
55. Dhar SA, et al. Pattern of orthopaedic injuries in bear attacks: report from a tertiary care centre in Kashmir. Injury. 2008;39(2):249–55.
56. Rasool A, et al. Incidence and pattern of bear maul injuries in Kashmir. Injury. 2010;41(1):116–9.
57. Hamalainen P, Leena Saarela K, Takala J. Global trend according to estimated number of occupational accidents and fatal work-related diseases at region and country level. J Safety Res. 2009;40(2):125–39.
58. Roberts SE. Hazardous occupations in Great Britain. Lancet. 2002;360(9332):543–4.
59. Mamady K, et al. The injury mortality burden in Guinea. BMC Public Health. 2012;12:733.
60. Schnitzer PG, Landen DD, Russell JC. Occupational injury deaths in Alaska's fishing industry, 1980 through 1988. Am J Public Health. 1993;83(5):685–8.
61. Lucas DL, et al. Work-related traumatic injuries onboard freezer-trawlers and freezer-longliners operating in Alaskan waters during 2001–2012. Am J Ind Med. 2014;57(7):826–36. doi:10.1002/ajim.22310.
62. Gold D, et al. The indigenous fisherman divers of Thailand: diving-related mortality and morbidity. Int J Occup Saf Ergon. 2000;6(2):147–67.
63. Norrish AE, Cryer PC. Work related injury in New Zealand commercial fishermen. Br J Ind Med. 1990;47(11):726–32.
64. Marshall SW, et al. The epidemiology of forestry work-related injuries in New Zealand, 1975-88: fatalities and hospitalisations. N Z Med J. 1994;107(988):434–7.
65. Neilsen D, Roberts S. Fatalities among the world's merchant seafarers (1990-1994). Marine Policy. 1998;23(1):71–80.
66. Michelo P, Bratveit M, Moen BE. Occupational injuries and fatalities in copper mining in Zambia. Occup Med (Lond). 2009;59(3):191–4.
67. Jin K, Courtney TK. Work-related fatalities in the People's Republic of China. J Occup Environ Hyg. 2009;6(7):446–53.
68. World Health Organization. Global status report on road safety 2013: supporting a decade of action. 2013; Available from: http://www.who.int/violence_injury_prevention/road_safety_status/2013/en/.
69. McCoy GF, et al. Incidence and consequences of ejection in motor vehicle accidents. BMJ. 1988;297(6658):1244–5.
70. Rivara FP, Grossman DC, Cummings P. Injury prevention. First of two parts. N Engl J Med. 1997;337(8):543–8.
71. Peek C, et al. Lower extremity injuries from motorcycle crashes: a common cause of preventable injury. J Trauma. 1994;37(3):358–64.
72. Parkinson F, et al. Patterns of injury seen in road crash victims in a South African trauma centre. S Afr J Surg. 2013;51(4):131–4.
73. Scariffi P. Wars and casualties of the 20th and 21st centuries. 2014 [cited 3rd 2014 Apr 2014]; Available from: www.scaruffi.com/politics/massacre.html.
74. Leitenberg M. Deaths in wars and conflicts in the 20th century. New York: Cornell University, Peace Studies Program; 2006. p. 86.
75. Wikipedia. Outline of war. 2014; Available from: http://en.wikipedia.org/wiki/List_of_wars#Wars.
76. Wikipedia. List of terrorist incidents 2014 Jun 2014]; Available from: http://en.wikipedia.org/wiki/List_of_terrorist_attacks#1970.E2.80.93present.
77. Bilukha OO, et al. Fatal and non-fatal injuries due to intentional explosions in Nepal, 2008-2011: analysis of surveillance data. Confl Health. 2013;7(1):5.
78. Hicks MH, et al. Casualties in civilians and coalition soldiers from suicide bombings in Iraq, 2003-10: a descriptive study. Lancet. 2011;378(9794):906–14.

79. Coupland RM, Meddings DR. Mortality associated with use of weapons in armed conflicts, wartime atrocities, and civilian mass shootings: literature review. BMJ. 1999;319(7207):407–10.
80. Belmont Jr PJ, et al. Combat wounds in Iraq and Afghanistan from 2005 to 2009. J Trauma Acute Care Surg. 2012;73(1):3–12.
81. Eskridge SL, et al. Injuries from combat explosions in Iraq: injury type, location, and severity. Injury. 2012;43(10):1678–82.
82. Schoenfeld AJ, et al. The nature and extent of war injuries sustained by combat specialty personnel killed and wounded in Afghanistan and Iraq, 2003-2011. J Trauma Acute Care Surg. 2013;75(2):287–91.
83. Rustemeyer J, Kranz V, Bremerich A. Injuries in combat from 1982-2005 with particular reference to those to the head and neck: A review. Br J Oral Maxillofac Surg. 2007;45(7):556–60.
84. Belmont PJ, et al. Incidence and Epidemiology of Combat Injuries Sustained During “The Surge” Portion of Operation Iraqi Freedom by a U.S. Army Brigade Combat Team. J Trauma. 2010;68:204–10.
85. Ramasamy A, et al. A review of casualties during the Iraqi insurgency 2006 – A British field hospital experience. Inj Int J Care Inj. 2009;40:493–7.
86. Owens BD, et al. Combat wounds in operation Iraqi Freedom and operation Enduring Freedom. J Trauma. 2008;64(2):295–9.
87. Komar DA, Lathrop S. Patterns of trauma in conflict victims from Timor Leste. J Forensic Sci. 2012;57(1):3–5.
88. Bogale S. Management of penetrating brain injury: experience in the Armed Forces General Hospital, Addis Ababa, cited by War Surgery Volume 2, Table 26.1, Giannou C, Baldan M, and Molde A, Editors. 1999.
89. Erdogan E, Gonul E, Seber N. Craniocerebral gunshot wounds. Neurosurg Quart. 2002;12:1–18.
90. Marcikic M, Melada A, Kovacevic R. Management of war penetrating craniocerebral injuries during the war in Croatia. Injury. 1998;29(8):613–8.
91. Brandvold B, et al. Penetrating craniocerebral injuries in the Israeli involvement in the Lebanese conflict, 1982-1985. Analysis of a less aggressive surgical approach. J Neurosurg. 1990;72(1):15–21.
92. Trouwborst A, Weber BK, Dufour D. Medical statistics of battlefield casualties. Injury. 1987;18:96–9.
93. Aarabi B. Surgical outcome in 435 patients who sustained missile head wounds during the Iran-Iraq War. Neurosurgery. 1990;27(5):692–5; discussion 695.
94. Abdul-Wahid T. Analysis of 500 penetrating high velocity missile wounds of the brain. Méd Militaire. 1985;4:85–8.
95. Ameen AA. The management of acute craniocerebral injuries caused by missiles: analysis of 110 consecutive penetrating wounds of the brain from Basrah. Injury. 1984;16(2):88–90.
96. Haddad FS. Wilder Penfield Lecture: nature and management of penetrating head injuries during the Civil War in Lebanon. Can J Surg. 1978;21(3):233–7, 240.
97. Hammon WM. Analysis of 2187 consecutive penetrating wounds of the brain from Vietnam. J Neurosurg. 1971;34(2 Pt 1):127–31.
98. Hardaway III RM. Viet Nam wound analysis. J Trauma. 1978;18:635–43.
99. Reister FA. Battle casualties and medical statistics: US Army Experience. In: Korean War. Washington, DC: The Surgeon General, Department of the Army; 1973.
100. Beebe GW, DeBakey M. Death from wounding. In: Battle casualties. Springfield: Charles C Thomas; 1952. p. 74–147.
101. Bilukha OO, et al. Injuries and deaths due to victim-activated improvised explosive devices, landmines and other explosive remnants of war in Nepal. Inj Prev. 2011;17(5):326–31.
102. Bilukha OO, Brennan M, Woodruff BA. Death and injury from landmines and unexploded ordnance in Afghanistan. JAMA. 2003;290(5):650–3.
103. Secer HI, Gonul E, Izci Y. Head injuries due to landmines. Acta Neurochir (Wien). 2007;149(8):777–81; discussion 782.
104. Shabila NP, Taha HI, Al-Hadithi TS. Landmine injuries at the Emergency Management Center in Erbil. Iraq Confl Health. 2010;4:15.
105. Surrency AB, Graitcer PL, Henderson AK. Key factors for civilian injuries and deaths from exploding landmines and ordnance. Inj Prev. 2007;13(3):197–201.
106. Meade P, Mirocha J. Civilian landmine injuries in Sri Lanka. J Trauma. 2000;48(4):735–9.
107. Chaloner EJ. The incidence of landmine injuries in Kuito. Angola J R Coll Surg Edinb. 1996;41(6):398–400.
108. Andersson N, da Sousa CP, Paredes S. Social cost of land mines in four countries: Afghanistan, Bosnia, Cambodia, and Mozambique. BMJ. 1995;311(7007):718–21.
109. Papadakis SA, et al. Anti-personnel landmine injuries during peace: experience in a European country. Prehosp Disaster Med. 2006;21(4):237–40.
110. Ascherio A, et al. Deaths and injuries caused by land mines in Mozambique. Lancet. 1995;346(8977):721–4.
111. Ramasamy A, et al. Evaluating the effect of vehicle modification in reducing injuries from landmine blasts. An analysis of 2212 incidents and its application for humanitarian purposes. Accid Anal Prev. 2011;43(5):1878–86.
112. Adams DB, Schwab CW. Twenty-one-year experience with land mine injuries. J Trauma. 1988;28(1 Suppl):S159–62.
113. Aigoro NO, Abass GO. Epidemiology of gunshot injuries in Abeokuta, Southwest Nigeria. The Internet Journal of Orthopedic Surgery. 2013;20:1. print.ispub.com/api/0/ispub-article/14466.

114. Belmont PJ, et al. Incidence and epidemiology of combat injuries sustained during "the surge" portion of Operation Iraqi Freedom by a US Army Brigade Combat Team. J Trauma Inj Infect Crit Care. 2010;68(1):204–10.
115. Versier G, Le Marec C, Rouffi J. Quartre and de chirurgie de guerre au GMC de Sarajevo (Juillet 1992 à Aout 1996). Medicines at armées. 1998;26: 213–8.
116. Sikic N, et al. War abdominal trauma: usefulness of Penetrating Abdominal Trauma Index, Injury Severity Score, and number of injured abdominal organs as predictive factors. Mil Med. 2001;166(3): 226–30.
117. Kandil A. Gunshot wounds of the abdomen. Palestinian Med J. M.o. Health, Editor. Information Centre, Department of Electronic Publication. 2005.
118. Borhan MS, Al-Najafi HH. Analysis of abdominal missile injuries: prospective study in Mosul in Fellowship thesis; presented at ICRC War Surgery Seminar. Suleymanieh; 2008.
119. Nassoura Z, et al. Trauma management in a war zone: the Lebanese war experience. J Trauma. 1991;31(12):1596–9.
120. Fekadu T. Abdominal war wounds: challenges to field surgeons, I.E.s.W.f. Independence, Editor. Asmara: Hdri Publishers; 2006.
121. Belmont PJ, Schoenfeld AJ, Goodman G. Epidemiology of combat wounds in Operation Iraqi Freedom and Operation Enduring Freedom: orthopaedic burden of disease. J Surg Orthop Adv. 2010;19(1):2–7.
122. Bird SM, Fairweather CB. Military fatality rates (by cause) in Afghanistan and Iraq: a measure of hostilities. Int J Epidemiol. 2007;36(4):841–6.
123. Powell KE, et al. Deaths due to injury in the military. Am J Prev Med. 2000;18(3 Suppl):26–32.
124. Burnham G, et al. Mortality after the 2003 invasion of Iraq: a cross-sectional cluster sample survey. Lancet. 2006;368(9545):1421–8.
125. Roberts L, et al. Mortality before and after the 2003 invasion of Iraq: cluster sample survey. Lancet. 2004;364(9448):1857–64.
126. Guha-Sapir D, van Panhuis WG. The importance of conflict-related mortality in civilian populations. Lancet. 2003;361(9375):2126–8.
127. National Geographic. Forces of nature. 2014; Available from: http://www.nationalgeographic.com/features/04/forcesofnature/resources/famous-forces.html.
128. Wikipedia. List of natural disasters by death toll. 2014 3rd April 2014]; Available from: http://en.wikipedia.org/wiki/List_of_natural_disasters_by_death_toll.
129. Wikipedia. List of volcanic eruptions by death toll. 2014 3rd April 2014]; Available from: http://en.wikipedia.org/wiki/List_of_volcanic_eruptions_by_death_toll.
130. Gilyoma JM, Chalya PL. Ear, nose and throat injuries at Bugando Medical Centre in northwestern Tanzania: a five-year prospective review of 456 cases. BMC Ear Nose Throat Disord. 2013;13:4.
131. Gilyoma JM, Mabula JB, Chalya PL. Animal-related injuries in a resource-limited setting: experiences from a Tertiary health institution in northwestern Tanzania. World J Emerg Surg. 2013;8(1):7.
132. Joshi SR, et al. Pattern and prevalence of maxillofacial fractures in rural children of central Maharashtra, India. A retrospective study. J Maxillofac Oral Surg. 2013;12(3):307–11.
133. Emet M, et al. Animal-related injuries: epidemiological and meteorological features. Ann Agric Environ Med. 2009;16(1):87–92.
134. Bither S, et al. Incidence and pattern of mandibular fractures in rural population: a review of 324 patients at a tertiary hospital in Loni, Maharashtra. India Dent Traumatol. 2008;24(4):468–70.
135. Abubakar SA, Bakari AG. Incidence of dog bite injuries and clinical rabies in a tertiary health care institution: a 10-year retrospective study. Ann Afr Med. 2012;11(2):108–11.
136. Ogendi JO, Ayisi JG. Causes of injuries resulting in a visit to the emergency department of a Provincial General Hospital, Nyanza, western Kenya. Afr Health Sci. 2011;11(2):255–61.
137. Dwyer JP, Douglas TS, van As AB. Dog bite injuries in children – a review of data from a South African paediatric trauma unit. S Afr Med J. 2007;97(8): 597–600.
138. Plitponkarnpim A, Ruangkanchanasetr S, Thanjira S. Pediatric injuries in emergency room, Ramathibodi Hospital. J Med Assoc Thai. 1999;82 Suppl 1:S168–73.
139. Hansson E, et al. Mapping snakebite epidemiology in Nicaragua – pitfalls and possible solutions. PLoS Negl Trop Dis. 2010;4(11), e896.
140. Oliveira FN, et al. Accidents caused by Bothrops and Bothropoides in the State of Paraiba: epidemiological and clinical aspects. Rev Soc Bras Med Trop. 2010;43(6):662–7.
141. Chippaux JP, Postigo JR. Appraisal of snakebite incidence and mortality in Bolivia. Toxicon. 2014;84:28–35.
142. Gonzalez-Andrade F, Chippaux JP. Snake bite envenomation in Ecuador. Trans R Soc Trop Med Hyg. 2010;104(9):588–91.
143. Mohapatra B, et al. Snakebite mortality in India: a nationally representative mortality survey. PLoS Negl Trop Dis. 2011;5(4), e1018.
144. Kirte RC, Wahab SN, Bhathkule PR. Record based study of snake bite cases admitted at Shri Vasantrao Naik Government Medical College & Hospital, Yavatmal (Maharashtra). Indian J Public Health. 2006;50(1):35–7.
145. De Sousa L, et al. Epidemiology of ophidism in Venezuela (1996-2004). Invest Clin. 2013;54(2): 123–37.
146. Dolab JA, et al. Epidemiology of snakebite and use of antivenom in Argentina. Trans R Soc Trop Med Hyg. 2014;108(5):269–76.
147. Habib AG, Gebi UI, Onyemelukwe GC. Snake bite in Nigeria. Afr J Med Med Sci. 2001;30(3):171–8.

148. Keyler DE, et al. Antivenom for snakebite envenoming in Sri Lanka: the need for geographically specific antivenom and improved efficacy. Toxicon. 2013;69: 90–7.
149. Bawaskar HS. Snake bite poisoning: a neglected life-threatening occupational hazard. Indian J Crit Care Med. 2014;18(3):123–4.
150. Adehossi E, et al. Morsures de serpent à l'hôpital national de Niamey : à propos de 53 cas. Bull Soc Pathol Exot. 2011;104:357–60.
151. Bregani ER, Maraffi T, Tien TV. Snake bites in Moyen Chari district, Chad: a five-year experience. Trop Doct. 2011;41(2):123–6.
152. Monteiro FN, et al. Clinico-epidemiological features of viper bite envenomation: a study from Manipal. South India Singapore Med J. 2012;53(3):203–7.
153. Inamdar IF, et al. Snakebite: admissions at a tertiary health care centre in Maharashtra. India S Afr Med J. 2010;100(7):456–8.
154. Halesha BR, et al. A study on the clinico-epidemiological profile and the outcome of snake bite victims in a tertiary care centre in southern India. J Clin Diagn Res. 2013;7(1):122–6.
155. Jarwani B, Jadav P, Madaiya M. Demographic, epidemiologic and clinical profile of snake bite cases, presented to Emergency Medicine department, Ahmedabad. Gujarat J Emerg Trauma Shock. 2013;6(3):199–202.
156. Ademola-Majekodunmi FO, Oyediran FO, Abubakar SB. Incidence of snakebites in Kaltungo, Gombe State and the efficacy of a new highly purified monovalent antivenom in treating snakebite patients from January 2009 to December 2010. Bull Soc Pathol Exot. 2012;105(3):175–8.
157. Rahman R, et al. Annual incidence of snake bite in rural Bangladesh. PLoS Negl Trop Dis. 2010;4(10), e860.
158. Curic I, et al. Snakebites in Mostar region, Bosnia and Herzegovina. Coll Antropol. 2009;33 Suppl 2:93–8.
159. Oliveira HF, et al. Snakebite cases in the municipalities of the State of Paraiba. Brazil Rev Soc Bras Med Trop. 2013;46(5):617–24.
160. Valenta J, Stach Z, Michalek P. Exotic snake bites in the Czech Republic-Epidemiological and clinical aspects during 15-year period (1999-2013). Clin Toxicol (Phila). 2014;52(4):258–64.
161. de Roodt AR, et al. Envenoming by coral snakes (Micrurus) in Argentina, during the period between 1979-2003. Rev Inst Med Trop Sao Paulo. 2013;55(1):13–8.
162. Maduwage K, et al. Epidemiology and clinical effects of hump-nosed pit viper (Genus: Hypnale) envenoming in Sri Lanka. Toxicon. 2013;61:11–5.
163. Alkaabi JM, et al. Terrestrial snakebites in the South East of the Arabian Peninsula: patient characteristics, clinical presentations, and management. PLoS One. 2011;6(9), e24637.
164. Wood D, Webb C, DeMeyer J. Severe snakebites in northern KwaZulu-Natal: treatment modalities and outcomes. S Afr Med J. 2009;99(11):814–8.
165. Yates VM, et al. Management of snakebites by the staff of a rural clinic: the impact of providing free antivenom in a nurse-led clinic in Meserani. Tanzania Ann Trop Med Parasitol. 2010;104(5):439–48.
166. Lima AC, Campos CE, Ribeiro JR. Epidemiological profile of snake poisoning accidents in the State of Amapa. Rev Soc Bras Med Trop. 2009;42(3): 329–35.
167. Vanwersch K. Crocodile bite injury in southern Malawi. Trop Doct. 1998;28(4):221–2.
168. Crocodile Specialist group. Crocodilian attacks. 2014; Available from: http://www.iucncsg.org/pages/Crocodilian-Attacks.html
169. Umrigar P, et al. Epidemiology of animal bite cases attending municipal tertiary care centres in surat city: a cross-sectional study. Nat J Commu Med. 2013;4(1):153–7.
170. Hemagiri K, Someshwar GM, Karinagannanavar A. An epidemiological study on dog bite and its management in Bellary. Karnataka J Commun Dis. 2012;44(1):15–23.
171. Kent SJ, Naicker B, Wood DR. Demographics and management of dog bite victims at a level two hospital in KwaZulu-Natal. S Afr Med J. 2012;102(11 Pt 1):845–7.
172. Vargo D, DePasquale JM, Vargo AM. Incidence of dog bite injuries in American Samoa and their impact on society. Hawaii J Med Public Health. 2012;71(1):6–12.
173. Lunney M, et al. Assessing human-dog conflicts in Todos Santos, Guatemala: bite incidences and public perception. Prev Vet Med. 2011;102(4):315–20.
174. Zanini F, et al. Epidemiology of dog bite lesions in Tierra del Fuego, Argentina. Medicina (B Aires). 2008;68(1):1–5.
175. Aghahowa SE, Ogbevoen RN. Incidence of dog bite and anti-rabies vaccine utilization in the, University of Benin Teaching Hospital, Benin City, Nigeria: A 12-year assessment. Vaccine. 2010;28(30): 4847–50.
176. Georges K, Adesiyun A. An investigation into the prevalence of dog bites to primary school children in Trinidad. BMC Public Health. 2008;8:85.
177. Alavi SM, Alavi L. Epidemiology of animal bites and stings in Khuzestan, Iran, 1997-2006. J Infect Public Health. 2008;1(1):51–5.
178. Rosado B, et al. A comprehensive study of dog bites in Spain, 1995-2004. Vet J. 2009;179(3):383–91.
179. Quiles Cosme GM, Perez-Cardona CM, Aponte Ortiz FI. Descriptive study of animal attacks and bites in the municipality of San Juan, Puerto Rico, 1996-1998. P R Health Sci J. 2000;19(1):39–47.
180. Hamalainen P, Takala J, Saarela KA. Global estimates of occupational accidents. Safety Sci. 2006;44:137–56.

4 Is Evidence-Based Orthopedic Traumatology Possible in the Low-Resource Environment?

Saam Morshed and David Shearer

Historically, overseas involvement in developing countries has focused on short-term mission trips focused on clinical care and a large surgical caseload. Over time this has evolved toward more long-term partnerships through organizations such as Health Volunteers Overseas (HVO), professional societies, and academic departments. With this model, there is much greater opportunity for both education and collaborative research with local partners. In this chapter, we describe a roadmap for conducting clinical research in low-resource environments that emphasizes partnership and local capacity building.

4.1 Why Conduct Research?

The role of clinical research in support of under-resourced partners is an important question. It could be argued that what limited resources are available should be devoted toward direct clinical care of patients rather than research studies, which can be difficult and resource-intensive under the best circumstances. We sought to explore this question further through a qualitative study conducted at four academic medical centers in sub-Saharan Africa [1]. Orthopedic surgeons (faculty and trainees) at each of the four sites were interviewed to explore their interest in conducting clinical research and the perceived barriers to successful projects. Ubiquitous among their responses was a strong interest in participating in research activities. The most commonly cited barriers were lack of funding, protected research time, research culture, data management systems, and research training. In contrast, drivers of research were the desire to affect change (cited by 100 % of respondents), interest in collaborative partnership, and research requirements for academic advancement [1].

These results support the notion that research is valued, at least in an academic setting, and collaboration is important to help overcome barriers related to time and funding. These concepts form the foundation of our approach to supporting clinical research initiatives in developing countries. The value of this research is multifactorial. First, it

---

S. Morshed, MD, PhD, MPH (✉)
Department of Orthopaedic Surgery, University of California San Francisco, San Francisco, CA, USA

San Francisco General Hospital,
San Francisco, CA, USA

Orthopedic Trauma Institutes,
San Francisco, CA, USA
e-mail: MorshedS@orthosurg.ucsf.edu

D. Shearer, MD, MPH
Department of Orthopaedic Surgery,
University of California San Francisco, San Francisco General Hospital, Orthopedic Trauma Institutes,
San Francisco, CA, USA

San Francisco General Hospital,
San Francisco, CA, USA

Orthopedic Trauma Institutes,
San Francisco, CA, USA

© Springer International Publishing Switzerland 2016
J.D. Robinson (ed.), *Orthopaedic Trauma in the Austere Environment: A Practical Guide to Care in the Humanitarian Setting*, DOI 10.1007/978-3-319-29122-2_4

builds capacity for research and creates a culture of self-evaluation that permeates beyond the actual questions directly being investigated. We have also found that academic centers in most developing countries have a similar model of advancement as centers in high-income countries, creating further incentive to participate. Assisting residents in completing thesis projects and faculty in achieving a publication is highly valuable. Above all else, however, is that these studies address locally relevant clinical questions in a way that can directly impact patient care. Furthermore, the dissemination of results creates ammunition to affect policy change both locally and globally, which is crucial to generating greater financial and infrastructural support for clinical care.

4.2 Identifying Partners

The first and perhaps most important step in conducting clinical research in austere environments is establishing a good relationship with local partners. Successful completion of research requires sustained effort, trust, and communication by all investigators. Developing a good working relationship before embarking on a study that may span months to years is crucial. These relationships may begin through short-term mission trips, international meetings, or as part of a larger institutional partnership. Meetings such as the SIGN Conference, the Orthopaedic Trauma Association, or the American Academy of Orthopaedic Surgeons, to name a few, are increasingly attended by surgeons from developing countries. A key concept is that the interest in research and the questions under investigation should originate with local partners rather than being forced by the supporting partner.

4.3 The Research Question

Whether it arises from a dilemma in clinical practice, literature review, or in a discussion with colleagues, all studies begin with an unanswered question. The process of refining an initial question into a testable research hypothesis is at the foundation of every investigation. The "PICO Method" (*P*opulation, *I*ntervention, *C*omparison, *O*utcome) is a framework for designing a comprehensive research question that forms the basis of a testable hypothesis:

- *Population: What Is the Population Under Study?*
- Defining the specific population under investigation is important to determine who will be eligible to participate in the study and the generalizability of the results at the conclusion of the study. Population characteristics such as age, gender, setting (e.g., country, trauma center versus outpatient practice, etc.), and disease (e.g., fracture classification) should all be explicitly stated at a minimum. It is important that the population chosen be available in sufficient numbers to be feasible at a particular site. Generally, the goal is to choose as specific a population as possible while retaining the ability to achieve sufficient numbers to successfully complete the study.
- *Intervention or Exposures: What Is the Planned Intervention?*
- The intervention is the proposed treatment that will be evaluated by the study. In some cases, rather than a treatment, this may be an exposure or risk factor that is hypothesized to alter the outcome. Examples would be the timeliness of treatment, severity of injury, or age of the patient.
- *Comparison: What Is the Baseline Intervention for Comparison?*
- Any study that evaluates a treatment should ideally have a comparison group. Typically, this is the currently accepted local standard for treatment.
- *Outcome: What Are the Primary and Secondary Outcomes that Will Be Measured?*
- Selecting an appropriate outcome measure is one of the most important tasks in designing a study. Outcomes should be selected that are not only relevant to surgeons, but rather are valued by the patient population under study. Outcome instruments can span a spectrum from the pathophysiology of the underlying disease (e.g., fracture healing) to functional outcomes (e.g., strength or walking capacity) to clinical endpoints (e.g., reoperation) to

patient quality of life. Ultimately, the latter is the ultimate aim of any intervention, and a variety of survey instruments exist that help to quantify quality of life. Ideally, studies should seek to measure one primary outcome and 2–3 secondary outcomes from across the spectrum of outcome measures.

By systematically addressing each of these component parts, one can reliably develop a refined question that facilitates later study design. However, before embarking on an investigation that will demand extensive time and resources from all parties involved, the question should be vetted with a thorough review of the literature. One systematic approach to evaluating a research question is the FINER method (Feasible, Interesting, Novel, Ethical, Relevant).

4.3.1 Feasible

Particularly in a setting where resources are limited, the feasibility of a study is an important question to address at the outset. Is there adequate funding? Are there enough subjects to achieve adequate sample size? In many developing settings, the clinical volume is large, which diminishes the sample size issue, but the infrastructure and resources to conduct the study may be correspondingly less. This may lead to the selection of a less rigorous study design in order to make completion of the study more feasible. A multicenter randomized controlled trial, while desirable, is not realistic in many settings. At the same time, it is important that the principles of quality design are not compromised because the study is being conducted in a low-resource setting.

4.3.2 Interesting

The answer to the question being proposed should be intriguing to the investigators. This will make the ultimate result valuable and help motivate and maintain commitment to the study over its duration.

4.3.3 Novel

Addressing this aspect of study design requires a thorough review of the existing literature on the topic to determine whether the question has been previously addressed. If multiple randomized controlled trials have already addressed the question, conducting a retrospective chart review may not add substantially to the literature. At the same time, although some questions may have been previously studied, it is important to consider whether results are generalizable to the setting where the study is being proposed. For example, while a study from the United States may indicate that a new locking plate for distal femur fractures inserted under fluoroscopy is the best treatment, these results may not apply in settings where neither locking plates nor fluoroscopy is available. A study of locally available plates and nails may therefore be highly relevant.

4.3.4 Ethical

At the core of any clinical study is the requirement to follow established ethical principles. The National Institutes of Health in the United States has created guidelines for the conduct of ethical research [2]. Particularly for research in developing settings, it is imperative that the research benefits the local population and not only the population in the supporting country. A particularly troublesome scenario occurs if a "supporting" institution utilizes the large numbers and low cost of conducting research on impoverished populations in developing countries to their advantage. Ensuring that research is driven by local partners and aimed to benefit the local population avoids this dilemma.

4.3.5 Relevant

The results of the proposed research should be relevant to the target audience. Ideally, the results should directly impact clinical decision-making or form the foundation of a new guideline or policy. Investigators should ask the simple question – will this study impact clinical practice? If not, will it form the foundation of future research?

4.4 Choosing a Study Design

Concurrent with the process of refining a study question is the selection of an appropriate study design. The choice of study design is dictated by the clinical question, ethical constraints, and available resources. The classical hierarchy of study design for studies evaluating an intervention divides the different studies into levels of evidence (Fig. 4.1) [3]. At the top of the pyramid are randomized controlled trials, which randomly assign study subjects to each intervention. This creates two identical groups for comparison and reduces the risk of bias due to confounding. Although randomization is ideal, it may not always be feasible due to available resources or for ethical reasons. A key principle is that subjects cannot ethically be randomized to a treatment that is likely to be inferior. An example would be a study evaluation of early debridement for open fractures. It would not be feasible to randomize a patient to a delay in treatment if early treatment is available.

When randomized trials are not possible, the next best alternative is a prospective cohort study. In this design, the patients are enrolled in the study before their treatment has been administered or their outcome has occurred. Patients are followed over time until the outcome occurs. In contrast, a retrospective study chooses patients for the study after the outcome has occurred. Because the patients are often no longer available for evaluation, this leads to a review of medical records. This approach is fraught with difficulty in finding accurate data because it may not have been recorded in the desired manner, if at all. This study design is particularly difficult in many developing settings where record keeping is typically in a paper charting system with variable amounts of detail recorded.

As a general principle, the highest quality study that can be feasibly and ethically performed should be the ultimate goal. In some cases, beginning with a small pilot study may provide the preliminary results necessary to compete for the funding to implement the desired study design. In addition, a pilot study will expose many issues in the study protocol before the definitive study is performed.

It is important to recognize that there are a number of broader categories for study design that exist aside from studies evaluating specific clinical interventions. Rather than a hierarchy, these can be considered a logical stepwise progression (Fig. 4.2).

Qualitative studies can serve as an important starting point before embarking on the more hypothesis-driven interventional studies. These studies commonly involve a series of structured interviews or surveys. They commonly explore attitudes and opinions of the subject population. The results are, not surprisingly, less quantitative

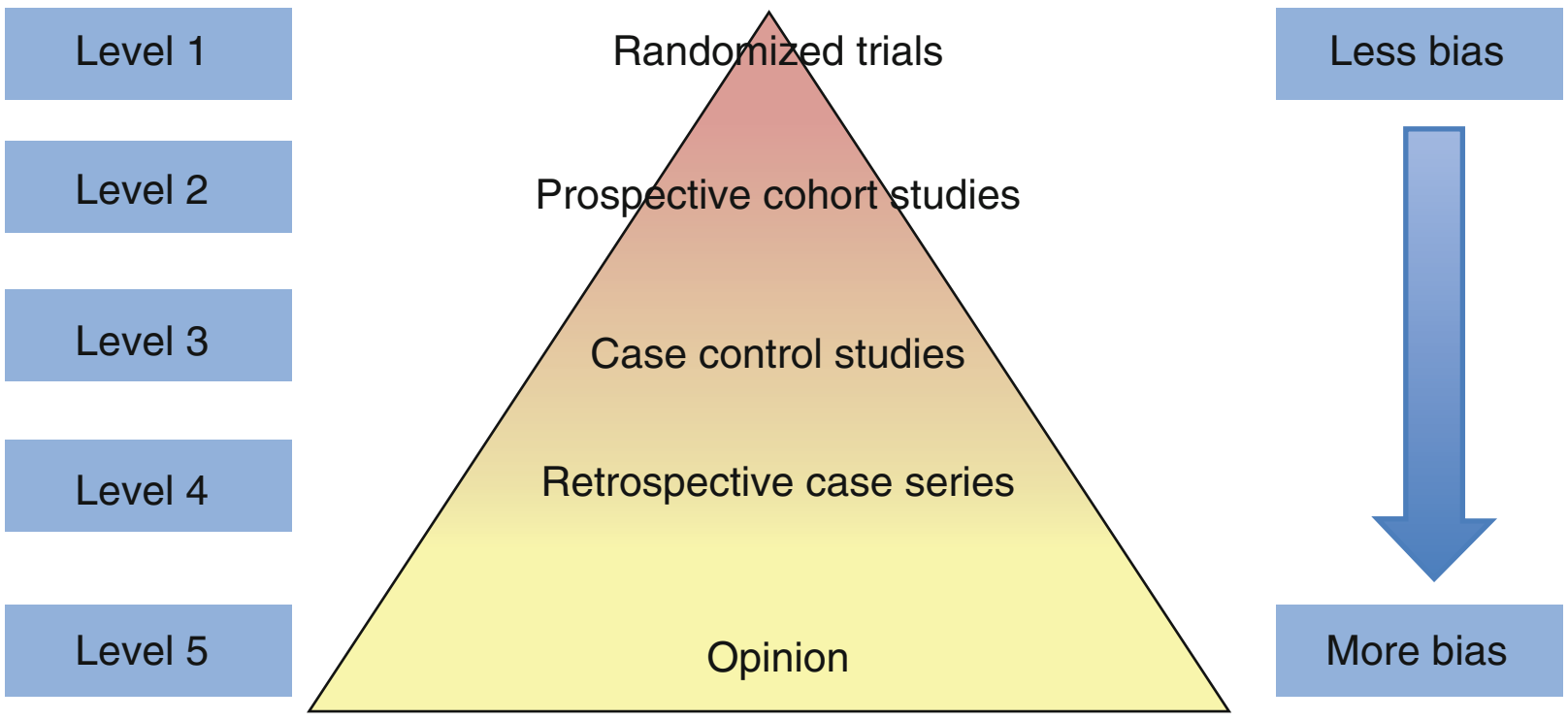

Fig. 4.1 The hierarchy of evidence

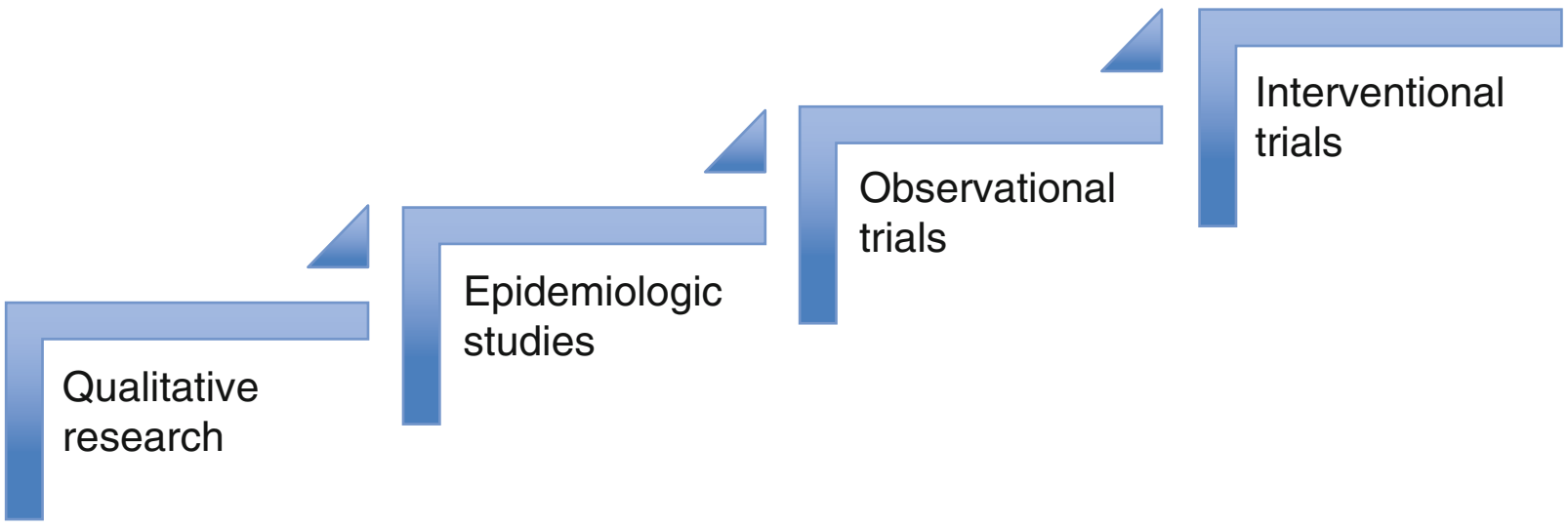

Fig. 4.2 The hierarchy of evidence as a stepwise progression

than other study designs, but the results can nonetheless be invaluable in forming a foundation for subsequent studies.

Unlike clinical trials, epidemiologic studies do not typically evaluate a specific clinical outcome. Rather, they are designed to estimate the incidence of a specific disease or condition in a population. This may be important in establishing the scope of a particular problem and help to advocate for resources from governments and other stakeholders. These studies may also inspire more specific clinical questions and form a foundation for understanding sample size and other issues that arise in future studies.

Clinical trials are those studies that fall under the classical hierarchy as shown in Fig. 4.1. In observational studies, the treatment is not altered based on whether or not a patient is participating in a study. Interventional studies alter the treatment for patients that elect to participate in a study, such as in a randomized controlled trial.

4.5 Implementing a Study Protocol

Once the study question and design have been determined, a detailed study protocol should be developed. This protocol will not only guide the investigation; it can be used in applications for funding and ethical review board approval. A detailed summation of every aspect of a study protocol is beyond the scope of this chapter. However, there are several important issues that are particularly relevant when research occurs in the context of a long-distance partnership (Table 4.1).

Table 4.1 Challenges encountered in collaborative research in austere environments and possible solutions

Challenges	Solutions
Expensive expatriate coordinator	Train locals
Paper case report forms slow and expensive	Electronic data capture
Study impedes busy clinic flow	Establish research clinic
Communication difficult	Regular web conferencing with all investigators
No addresses or conventional mail for reminders	Record cell phone numbers, provide regular reminder

Assembling a research team and assigning the role of each member is a necessary initial step in implementing a study. From the perspective of the supporting institution, there is often the desire to have a constant presence available in the form of an expatriate research coordinator. While this may have advantages in terms of ease of communication and familiarity with research methodology, this can be a large expense to a frequently limited study budget due to salary expectations, travel, housing, and visas among other issues. Perhaps more importantly, an expatriate coordinator may not have the language skills or understanding of local systems and culture to adequately interface with study subjects. Spending a shorter period of time in-country training local coordinators takes advantage of local expertise and is much more cost-effective. In addition, when the study ends, the research skillset remains at the local institution for future investigations that occur without foreign support.

Communication between team members who may be thousands of miles apart can be facilitated by Internet-based teleconferencing. As Internet connections have improved in most developing nations, particularly in urban areas, regularly schedule conference serves as a good method to help track study progress and troubleshoot issues as they arise.

The dramatic increase in access to the Internet has other advantages in conducting collaborative studies. Paper-based case report forms (CRFs) can be cumbersome and time consuming to record study data. Printers and printer paper may be intermittently available in many settings. Furthermore, there is an additional step of data entry, which is time consuming and error prone. Web-based electronic data capture is an attractive alternative. This allows real-time data entry, which can be monitored remotely by partners at supporting institutions. Most US university now have access to REDCap, a web-based data capture system that is free and fully customizable [4].

Another important barrier in any longitudinal study is the ability to achieve an adequate rate of follow-up. Returning to clinic may be difficult for patients due to cost of clinic appointments, transportation, long wait times, and lack of access to conventional mail for reminders. Each of these issues can be systematically addressed. Where possible, cost of clinic appointments and x-rays may be supplemented with modest study funding. Similarly, transportation may be provided to participants, or in-field data collection can be performed. Long wait times can be avoided by creating dedicated study clinics. Clinics performed outside the regular work week may be easier for subjects to attend because family members do not have to miss work to provide transportation. Perhaps the single most important factor is maintaining communication with study participants through the use of cell phones. Even in many of the world's most impoverished countries, cell phones have become ubiquitous, making the cell phone number a key data point to collect at the time patients are enrolled in a study.

4.6 Summary

As we evolve toward more long-term partnerships with our orthopedic colleagues in austere environments, it is important that we include support for clinical research in our armamentarium. The need for locally relevant studies to guide evidence-based clinical practice in low-resource environments is tremendous, and there is an earnest desire among surgeons in these settings to participate in such studies. By taking a thoughtful approach to study design and respecting ethical principles, high-quality collaborative clinical studies are not only feasible to successfully complete, but may indirectly benefit the institutional culture and build local capacity for similar studies to be conducted in an independent manner.

References

1. Caldwell A. Barriers to and drivers of orthopaedic surgery research in East Africa: a qualitative analysis of interviews. Paper presented at: Bethune Round Table. Vancouver. 2013.
2. Emanuel EJ, Wendler D, Grady C. What makes clinical research ethical? JAMA. 2000;283(20):2701–11.
3. Guyatt GH, Haynes RB, Jaeschke RZ, et al. Users' Guides to the Medical Literature: XXV. Evidence-based medicine: principles for applying the Users' Guides to patient care. Evidence-Based Medicine Working Group. JAMA. 2000;284(10):1290–6.
4. Harris PA, Taylor R, Thielke R, Payne J, Gonzalez N, Conde JG. Research electronic data capture (REDCap) – a metadata-driven methodology and workflow process for providing translational research informatics support. J Biomed Inform. 2009;42(2):377–81.

5 Cultural, Legal, and Ethical Considerations

Mike Krosin

International medical work can be a tremendously gratifying experience and bring considerable help to individuals in need of medical care. Typically, the setting of this work will be with a range of different resources from your home country and in unfamiliar medical and cultural environment. The combination of these factors present a number of ethical considerations and challenges one should be aware of prior to embarking. These ethical considerations can be divided into several categories: visiting surgeon issues, patient-centered issues of both safety and culture, host country physician issues, host country system issues, and special considerations in regard to disaster relief, areas of conflict, and research [1–8].

5.1 Are You Prepared?

Prior to embarking on international work, you must seriously ask yourself whether you are up to the challenge. Knowledge of the host site's living and work situation is imperative. It may be that 12 h in 100° heat and a night's sleep on a worn mattress may present a level of discomfort and stress you are not prepared for and may ultimately result in a scenario where you are unable to perform at the level the task demands. Make sure you get a sense of the equipment you will have access to. If possible, communicate with past and current volunteers. The lack of resources demands flexibility and improvisation at times. Without these traits, you may find yourself unhappy and stressed out which can create issues both in patient care and in visitor/host relationships. Make sure your own medical conditions are cared for and that your level of fitness is appropriate. You do no good if you yourself become a health-care burden. Get a sense as to whether your role will be that of primary provider versus a teaching or training role for host country physicians and tailor your actions as such.

5.2 Safety First

The foremost priority for any physician is patient safety. In a resource-deprived situation, surgical interventions, which might otherwise be standard, may ultimately create more harm than good. Lack of certain technologies, implants, and a proper sterile environment may create too much risk. For example, percutaneous sacroiliac screws without an adequate c-arm, radiolucent table, or cannulated screws may not be possible. A lengthy spine procedure on an individual highly susceptible to infection in an environment of lesser

---

M. Krosin, MD
Department of Surgery, Alameda Health Systems,
Highland Hospital, Oakland, CA, USA
e-mail: mikekrosin@gmail.com

© Springer International Publishing Switzerland 2016
J.D. Robinson (ed.), *Orthopaedic Trauma in the Austere Environment:*
A Practical Guide to Care in the Humanitarian Setting, DOI 10.1007/978-3-319-29122-2_5

sterility should be reconsidered as to whether the risk outweighs the benefit. Poor quality or questionable implants should not be considered. Despite an inherent desire to want to intervene, overly aggressive treatments which result in poor outcomes can create lasting mistrust and erode relationships between the host country and the visiting surgeon. “Heroic” high-risk surgeries should be avoided. There are certainly situations where proper implants and environments exist; however the aftercare, particularly in the face of complications, may be absent. An important principle to adhere to is do no surgery that cannot be undone. For example, while it may be feasible to perform a high volume of hip arthroplasties or fix flexor tendons, without the capacity to treat prosthetic infections and perform revision work or provide occupational therapy for flexor tendon protocols, the risks and outcomes of these procedures may ultimately create more harm. The need to assess aftercare both by host country surgeons and other postoperative team members should play a major consideration as to whether a procedure should be performed. Diligent record keeping and transfer of information should be prioritized and investigated by the visiting surgeon. It is necessary, in the face of an eventual reoperation, for the host surgeon to have access to these records. While in most countries, records are still paper, it may be a good idea for the visiting surgeon to keep an electronic file of implants, procedures, etc., in the event that the paper chart is unrecoverable. Every effort should be made by the visiting surgeon to establish and assist in an accurate and comprehensible medical record. Improvements in host country record keeping and systems issues, ultimately, make a more lasting contribution than handful of surgical interventions.

5.3 Patient Autonomy

Patient autonomy and cross-cultural issues can present unforeseen challenges to the visiting surgeon. Of primary importance is the consistent practice and standard of informed consent [9–15]. While the practice of informed consent may be considerably diminished or absent in certain cultures, it is the obligation of the visiting surgeon to adhere to a standard of informed consent. The challenge for the visiting surgeon may not only be language. Issues of patient education, comprehension, and the expectation of physician paternalism may make it difficult for a patient to truly make an informed decision. The only way to circumvent this is with time, patience, and alternative methods of communication. It may be necessary to explain patient autonomy, and it may be helpful to bring pictures or other educational resources to explain procedures to patients. More time will be needed to explain procedures and risks to patients with a translator. It is very important to set realistic expectations and clearly define the risks of a procedure and may be helpful to have the patient verbalize their understanding. Patient expectations of physician paternalism my lead them to minimize the risks and overestimate the benefits. Cultural expectations may lead the patient not to ask questions or understand their degree of autonomy. The host country physician may also adhere to their accepted standard of informed consent and discourage dissemination of information or the asking of questions. Moreover, in certain cultures, other family members may decide on intervention on behalf of a patient. It is up to the visiting physician to make sure that a standard of informed consent and dialogue commensurate with her own standard is maintained while respecting local culture (Fig. 5.1).

Autonomy of individuals as it pertains to sex, age, and role within family as well as society may be compromised. Particular attention and sensitivity must be paid to these scenarios in advance, and as a visiting surgeon, you should enlist the help of a local physician. However, keep in mind that a local physician may be subject to local cultural biases which may erode patient autonomy as well. It is best to preemptively broach this subject by clearly stating your concern for the patient’s autonomy specifically because of gender, status, etc., and how you feel it is important to uphold your standard of consent to all patients. Gender roles may be particularly challenging for both the female patient and the

[redacted]

Fig. 5.1 You must be aware of potential issues arising from cultural differences

female volunteer. One technique to help with female patients is to enlist the help of a female translator. This can help legitimize different cultural norms in a culture where female autonomy falls short of our accepted gender roles. Recognize that there may be a substantial gender gap both in education and work roles and take this into account both in the informed consent process and the types of procedures you perform.

Other cultural and societal considerations must be accounted for prior to therapeutic interventions. For example, certain cultures do a considerable amount of squatting and kneeling for basic hygiene. This may preclude certain elective procedures. Certain societies and beliefs may ostracize amputees in the workplace and, furthermore, may not have the amenities to provide for someone with limited mobility. Depending on the scenario, an amputee may never have the opportunity to work, marry, etc. Despite the fact that limb salvage may result in a functionally inferior limb even in the case of prosthetic availability, it may be the desired surgical path even in the absence of modern limb salvage techniques. Get a sense of the cultural issues before performing any procedures of this nature.

5.4 Relationships with Colleagues

In many instances, the visiting surgeon will be partnered with a host country physician. While this is often an extremely rewarding experience with the potential for lifelong friendships, the visiting surgeon should be sensitive to several scenarios. It is likely that conversations comparing the different medical systems and standards of care will come up. The visiting surgeon should be extremely cognizant that sentiments of inferiority could arise if the visiting surgeon criticizes the local standard or talks about the “better” standard in their home country. This can be very counterproductive in the long run. The same goes when discussing specific procedures. Instead of describing “The way this is done,” always talk about “one way this is done.” By describing certain methods as superior, the visiting surgeon can undermine not only the local physician confidence but may risk shaming or insulting certain members of the medical hierarchy. Always present any method or system as one of many good options. Remember, with the Internet, the host country surgeon has access to many of the same educational resources that you have. This may result, first, in a frustration that certain “modern techniques” are not available in the host country and lead to feelings of inferiority if these techniques are supported by you as the “best” treatment method. A second sequela of this knowledge may result in host surgeons wanting to “experiment” with procedures that you may be familiar with but, ultimately, may not be in the patient’s best interests due to issues of safety or aftercare.

The visiting surgeon should have an appreciation of seniority and understand that by spotlighting certain junior members, he may, ultimately, be creating problems for them in dealing with their superiors at a later date. Deference to the local medical leaders should be cultivated by encouraging and including host country doctors, particularly the senior members, in discussions and education. The visiting surgeon may encounter host country physicians genuinely criticizing their medical system and standard of care. Voicing agreement may create resentment in the same way that someone may criticize their life partner but may react strongly to outside criticism. Moreover, agreement may perpetuate feelings of inadequacy, which are counterproductive. The visiting surgeon should remain neutral or complementary in regard to the host country’s medical care.

5.5 Training

A large role played by visiting surgeons may be that of education. It is extremely important to foster education by participation as well as observation. It is much more effective to verbally walk a local physician through a procedure than have them watch you. Relevant educational topics should be presented to the local physicians. Topics which are too specialized or relevant only to a level of technology not present in the host country are of little use. Any educational materials should be presented in a workable format appropriate to the level of technology present. Not everyone may be able to benefit from pdf files, so preprinting articles and syllabi can be very helpful to disseminate information. One important and effective educational avenue to address is that of patient safety and systems development. Encouraging preoperative checklists, “sign-your-site” policies, and patterns of frequent hand washing and floor dressing management may ultimately be the most lasting contribution of your visit. Creating expectations of peer review in an informal and nonjudgmental environment where surgeons “air their dirty laundry” may be at cultural odds in certain societies but can ultimately model a path for honest discussion and improved patient care. Though it may not seem apparent, your behavior as a physician will be modeled and should be forefront in your actions and words in terms of behavior and professionalism. For example, while at home you may conduct yourself in a more informal and jocular manner, this may not be appropriate in the host setting. In the event that you are bringing a resident with you to a host site, apply the same level of supervision as you would in your home institution.

5.6 Equal Rights

As a visiting surgeon, one should be aware of potential system issues in general of the host country. The distribution of resources should be considered and conducted in a fair and ethical manner. Issues of favoritism for members of certain religions, political parties, and ethnicities may arise. Every effort should be made by the visiting surgeon to encourage a fair and equitable distribution of resources and to maintain impartiality based on religion, gender, and ethnicity, as well as political neutrality. It is a good idea, prior to arrival, to get a sense of the ethnic composition of a host site and the potential conflicts that may arise. For example, in certain West African countries, members of different tribes or linguistic groups may routinely receive lesser care. This may be something perpetuated by the host surgeons. Politely assert your impartiality from the beginning of your trip if this appears to be an issue.

5.7 Fostering Resilience

There are certain scenarios in which the host country has become reliant on visiting medical personnel and equipment. While this is certainly understandable in the setting of few resources, it may also stifle the development of a sustainable local health system. The visiting surgeon can play a role in helping host country physicians advocate for greater resources by encouraging or establishing data collection which can later be used to justify more resources. The potential contribution by the visiting physician does not end with a return flight. Opportunities for continued Internet-based mentorship and education as well as joint projects can continue without the physical presence of the visiting surgeon.

5.8 Research

The specific scenarios of international research and disaster relief introduce a complex set of ethical considerations. While beyond the scope of this chapter, international research subjects are characterized as a vulnerable population and certain considerations must be applied in research endeavors. The basic principles of respect, justice, and beneficence are outlined in the Belmont report on human subject research along with comments on how these principles apply in particular to vulnerable population principles

5.9 Your Own Safety

In scenarios of disaster relief, resource distribution and patient triage as well the appropriateness of certain procedures should be considered in the context. More importantly, surgeon coordination and personal safety are a must. The so-called spontaneous volunteer may be well intentioned but without coordinated teams, may present, at best, a burden and, at worst, a liability. Recognize your limitations and the limitations of infrastructure before embarking on any disaster relief endeavors. Much has been written about this in the wake of the Haiti earthquake. Volunteering in political conflict and war scenarios introduce additional concerns of safety. Work in this capacity should be undertaken with a coordinated and experienced team.

5.10 Case 1

You have recently arrived to the Philippines to assist local surgeons following a large hurricane. The city to which you have been assigned has a somewhat modern hospital (by developing world standards) and several local orthopedic surgeons with varying years of experience. Having worked tirelessly over the past few days treating injured civilians, you have come to establish a good relationship with your local host surgeons. Toward the end of the trip, you are assisting the junior-most surgeon with a closed distal femoral fracture on a 26-year-old using a retrograde intramedullary implant. You notice on the approach that there is a small intercondylar split and recommend placing fixation across the fracture before proceeding with the implant. The local surgeon disregards this advice, and during insertion of the nail, the articular surface splits apart. The nail is removed and fixation is placed, but upon further reintroduction of the nail, the articular surface again splits apart. Though you advice removing the nail and attempting fixation with another implant, the junior surgeon comments that "there is too much work to be done and we do not have the time, the patient will be fine. Also, we do not have the new plates that you use and all our other plates we have are not sterile." The surgeon finishes the case and the patient is taken to the recovery room.

5.10.1 Discussion

While this type of situation can transpire in any environment, there are certain factors at play specific to this being both a foreign environment and a disaster environment. Though the environment of “damage control” may need to be applied to a disaster area, this should not compromise care given appropriate tools. What may be more at play are cultural issues and issues of continuity of care. It may be that the host country surgeon is ashamed or embarrassed to admit their mistake or that there is not an appropriate forum to discuss medical error. Moreover, there may be relationships and consequences with this surgeon as it relates to his senior partners that you are not aware of. Nevertheless, both safety and outcomes need to be prioritized. First, you should question the surgeon how he will discuss this with the patient to ensure that the patient is aware of a medical mistake, and autonomy is respected. You may ask the surgeon if he would be interested in assisting you with a revision if this is of interest to the patient. Second, you should get a sense of how mistakes are handled within the department. This is a potential opportunity to help encourage peer review by using some of your own examples as well as other examples from the course of the week. If this is something new to the surgical staff, you can help by setting the tone of a peer review system. The last recourse may be speaking in private with one of the other surgeons and, perhaps, shifting some of the blame to yourself to help the host surgeon (who ultimately will assume long-term care of the patient) in creating a situation to perform a revision surgery. Short of making the decision to take the patient back yourself, all efforts should be made to try and revise the patient. Taking the patient back yourself has the potential to create both mistrust and potential eroding host country/visiting surgeon relationships in the long run as it is impossible to guess what the local culture is in dealing with error and how this might be interpreted not only by the operating surgeon but also by his senior partners.

5.11 Case 2

You are on a 2-week volunteer trip organized through a national organization. Your duties have included being both the primary surgeon on several cases that have been “saved up” for you as well as assisting and teaching the local surgeons in the operating room. There is also a large component of didactic teaching as part of your trip. Before embarking on your trip, you had communicated via e-mail with the lead local surgeon. This surgeon works both at her own private clinic as well as at the public hospital. She had informed you prior to coming that she had been saving up several anterior cruciate ligament reconstructions for you at her private clinic which has just purchased arthroscopy equipment. She seems very excited to watch you perform this case and you are bringing appropriate implants.

Your trip goes very well. You are able, over the course of 2 weeks, to perform four ACL reconstructions in the private setting in addition to many other cases at the public hospital. On all of the ACLs, the surgeon with whom you had communicated was present and you had her assist you. You were able to go through many of the arthroscopic basics with her. Up until this point, she has had very little arthroscopic training and no practical experience. You were also able to give several lectures on arthroscopic surgery and have educational meetings with the therapy department to guide treatment protocols.

On the final day of the trip, at your farewell dinner, this surgeon who had taken a keen interest approaches you. She asks you to write her an “official letter” of support stating her ability to perform arthroscopic ACL reconstructions. She tells you her hospital boss would like some verification of this training. What ethical issues are at play and how do you proceed?

5.11.1 Discussion

The ethical issues in this situation include host surgeon issues and, indirectly, patient protection issues. The resolution of this ultimately depends on, first, your comfort with the surgeon and, second, what the host surgeon’s motivation may be. There may be a clear financial gain for the surgeon to start performing these procedures, but there may also be altruistic reasons as well as a sincere desire to broaden her skill set. Moreover, unbeknownst to you, there may be an expectation from the hospital that the surgeon was “training” with you. It would be good to clarify expectations and experience from the outset. It may not be an easy subject to broach, but before you arrive or begin, ascertain whether or not the surgeon has done this procedure and is this something she has interest in doing in the future. Explain that, while you are happy to do several of these cases, you do not feel that this should substitute for formal training.

While you may not feel that it is in the best interest of a patient to have this surgery performed by an inexperienced surgeon, this is something that routinely happens in all scenarios and is something which we, as surgeons, have little control over – even at home. The prudent decision in this scenario would be to write a factual letter regarding the extent of her observership with you, but it should not be sanctioned as to imply competency. Also, a forthright discussion with the surgeon regarding courses, both online and live would be reasonable; however, this may not be something available to the surgeon. Providing the most comprehensive educational resources should be a priority. The most important aspect of this is to be truthful but at the same time, not create an obstacle for the surgeon’s further education and further surgical development to eventually perform these procedures.

5.12 Case 3

Following a magnitude 7.8 earthquake in Pakistan, you are dispatched as part of a forward surgical team. One of the patients is a late 30s female who is brought in with her husband following a crush injury and tibia fracture. It is open from an initial fasciotomy and grossly contaminated with massive bone loss. It has been placed in a rudimentary external fixator. It is clearly infected. You explain the options, which include serial debridement vs amputation, but that the ultimate likelihood of amputation is high. Throughout the interview, the translator speaks only to the husband and the husband answers all questions. Ultimately, the husband decides against any surgical treatment as, per him, he will refuse an amputation and anything that will lead to one no matter what. Throughout the interview, the patient does not speak even when the translator speaks to her directly. What issues are identified and how do you proceed?

5.12.1 Discussion

The ethical issues at play here are cultural, patient autonomy, and beneficence/patient protection. While there is a high likelihood of amputation, there is also a high likelihood of sepsis and death. The first step in this would be to discuss with the translator and the local surgeon/team members if the consent process could take place without the husband. This may not be possible, but every effort must be made to allow the patient to speak for themselves as well as allow the patient to verbalize understanding of likely outcomes. A discussion of the mortality needs to be clearly had with the patient and the husband with culturally competent locals present. If there is a discrepancy between the patient and the patient’s husband in terms of treatment desires, all efforts should be made to resolve this within the cultural context which may include the use of village elders, local leaders, or women of standing if possible. However, if none of this is an option, a discussion should be had regarding other treatments and options including washouts with closed treatment as well as trying to keep the patient monitored in the event of life-threatening complications.

References

1. Welling DR, et al. Seven sins of humanitarian surgery. World J Surg. 2010;34:466.
2. Chu K, et al. Quality of care in humanitarian surgery. World J Surg. 2011;35:1169–72.
3. Pollak AN, Born C, Kamal RN, et al. Updates on disaster preparedness and programs in disaster relief. J Am Acad Orthop Surg. 2012;20 Suppl 1:s54–8.
4. The sphere project handbook. 2011. www.sphereproject.org.
5. The Belmont report: ethical principles and guidelines for the protection of human subjects of research.

http://www.hhs.gov/ohrp/humansubjects/guidance/belmont.html, April 18, 1979.

6. Asia Pacific forum on Women, Law and Development. http://apwld.org, Accessed 2015.
7. Merchant R, et al. Health care volunteers and disaster response — first, be prepared. N Engl J Med. 2010;362:872–3.
8. Benatar SR, Singer PA. A new look at international research ethics. BMJ. 2000;321:824–6.
9. Lavori PW, Sugarman J, Hays MT, Feussner JR. Improving informed consent in clinical trials: a duty to experiment. Control Clin Trials. 1999;20:187–93.
10. Williams CJ, Zwitter M. Informed consent in European multicentre randomised clinical trials--are patients really informed? Eur J Cancer. 1994;30A:907–10.
11. White CS, Mason AC, Feehan M, Templeton PA. Informed consent for percutaneous lung biopsy: comparison of two consent protocols based on patient recall after the procedure. AJR Am J Roentgenol. 1995;165(5):1139–42.
12. Lynoe N, et al. Informed consent: a study of quality of information given to participants in a clinical trial. BMJ. 1991;303:610–3.
13. Joffe S, et al. Quality of informed consent in cancer clinical trials: a cross-sectional survey. Lancet. 2001;358:1772–7.
14. Molyneux CS, Peshu N, Marsh K. Understanding of informed consent in a low income setting: three case studies from the Kenyan coast. Soc Sci Med. 2004;59:2547–59.
15. Bergler JH, Pennington AC, Metcalfe M, Freis ED. Informed consent: how much does the patient understand? Clin Pharmacol Ther. 1980;27:435–40.

Part II

Causes of Trauma in the Austere Environment

Motor Vehicle Accidents: The Scourge of the Developing World

6

Iain Elliott and Richard A. Gosselin

Road traffic injuries (RTIs) are one of the leading causes of death and disability worldwide, are the leading cause of death in persons aged 15–29 [1], and are seeing increasing incidence in low- and middle-income countries (LMICs). According to the World Bank, countries are classified as low-income countries which have upon a gross national income (GNI) per capita of less than $1036 and as middle-income countries which have a GNI less than $12,615 [2]. Major increases in motorization without concomitant increases in infrastructure improvement and investment are driving the increase in road traffic injuries (RTIs) (Fig. 6.1). In many places roads are choked with cars, motorcycles, minibuses, trucks, pedestrians, bicyclists, livestock, and potholes. Traffic laws are typically all but nonexistent, and in many places where they do exist are rarely enforced [3]. The bedlam on the streets of a typical low-income (LIC) or middle-income country (MIC) is often indecipherable and intimidating to visitors from high-income countries (HICs), and for good reason, as these congested and raucous streets are the cause of much of the world's burden of road traffic injury.

By unanimous vote, United Nations member states designated the decade 2011–2020 "A Decade of Action for Road Traffic Safety" with the intention to focus international attention on the issue of road traffic safety. The World Health Organization (WHO) has been involved in gathering the existing evidence on road safety with the goals of focusing attention on the magnitude of the problem of road safety and to help identify solutions to the problems of road traffic injuries. The first *World report on road traffic injury prevention* was published by the WHO in 2004 [4] and reviewed the evidence for the burden of injury due to RTCs and recommended specific prevention measures be adopted by countries to reduce the burden of these injuries. A second report was published in 2009 *Global status report on road safety*: *A time for action* and outlined the progress to date on the recommendations made in 2004 [5]. There were improvements in many countries, yet most LICs had seen increases in death rates that seemed unchanged despite some enactment of preventive measures. To date, in many LICs, there are few laws designed to govern traffic safety, and those laws that do exist are hardly enforced. The WHO and UN initiative is pushing this agenda forward, and progress can be observed in the Global Status Report documents [3–5].

I. Elliott, MD
Department of Orthopaedics,
University of Utah,
Salt Lake City, UT, USA

R.A. Gosselin, MD, MSc, MPH, FRCS(C) (✉)
Department of Orthopedic Surgery,
Institute for Global Orthopedics and Traumatology,
University of California in San Francisco,
San Francisco, CA, USA
e-mail: froggydoc@comcast.net

© Springer International Publishing Switzerland 2016
J.D. Robinson (ed.), *Orthopaedic Trauma in the Austere Environment: A Practical Guide to Care in the Humanitarian Setting*, DOI 10.1007/978-3-319-29122-2_6

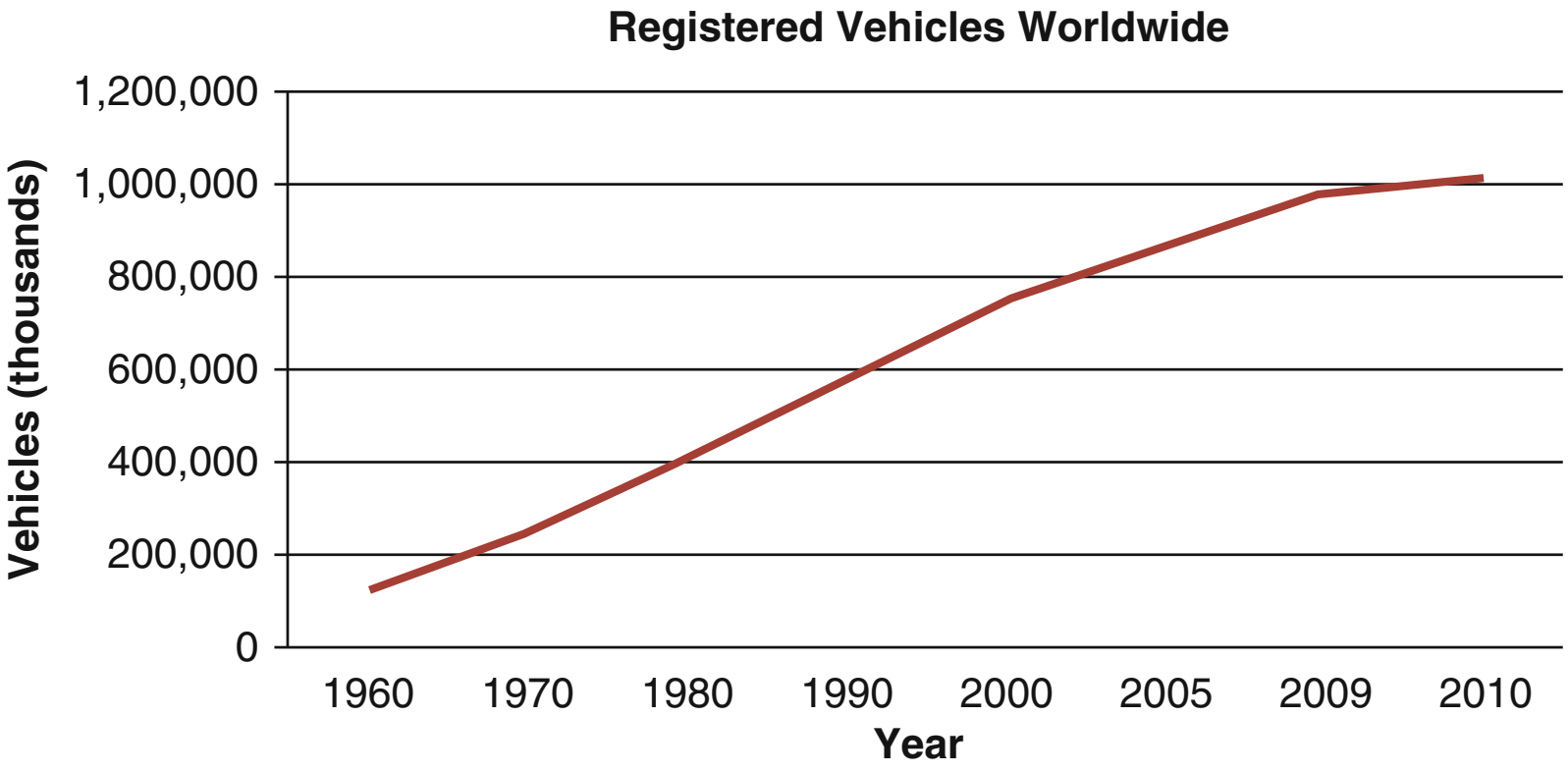

Fig. 6.1 Registered vehicles worldwide by year (From Davis SC, Boundy R, Diegel S. *2012 Vehicle Technologies Market Report*. Oak Ridge National Laboratory; 2013. http://www-cta.ornl.gov/cta/One_Pagers/VTMR_2012.pdf)

The *Global Status Report on Road Safety 2013* provides an update on progress from the 2004 and 2009 reports [3]. The data included in the 2013 report were collected via a survey tool administered to select persons within the governments of 184 participating countries. LICs had 12 % of RTC-related deaths but only 1 % of the world's registered vehicles. Most deaths in LICs were among pedestrians, followed by car occupants. MICs were found to have the highest burden of fatality due to road traffic injury, accounting for 80 % of all road traffic deaths worldwide but only 52 % of the world's registered vehicles. In middle-income countries, the proportion of deaths due to motorcycles or other two-wheeled motor vehicles was higher than in either LICs or HICs but still was not as high as the proportion of deaths among car occupants. Most of these are difficult to categorize into mechanism of death or diagnoses, so drawing conclusions on the type of injuries seen among RTC victims remain difficult. The makeup of road users, types of prevalent vehicles, and road speed will all influence the types of injuries seen. It may be useful to conceptualize RTIs in the same way as for many other human diseases: the interaction between host-vector-environment, as illustrated in Fig. 6.2a and shown in matrix form in Fig. 6.2b.

6.1 Road Traffic Injuries

In many LMICs, transport around cities can be challenging. Many people purchase motorcycles rather than cars, as they are inexpensive both in initial purchase price and operation costs. Countless entrepreneurial new owners have improved themselves as moto-taxi drivers. Oftentimes a single motorcycle is the only transport available for a family, so it is not unusual to see a family of four or more on a motorbike (Fig. 6.3). Unfortunately it is also not unusual to see members of these families in the accident and emergency departments of hospitals serving cities in LICs and MICs.

Pedestrians, two-wheeled motor vehicle drivers, and cyclists are all termed non-enclosed road users and are at higher risk for more devastating injury in road traffic crashes [6]. A typical motorcycle accident in Kumasi, Ghana, for example, involves a Gustilo grade IIIa–b open tibia fracture, a closed midshaft femur fracture, and multiple abrasions and lacerations. These patients often get transported to the hospital in a private car or taxi, and if they are lucky enough to make it to a trauma center in a reasonable time, they will receive some treatment. Unfortunately patients that have blunt abdominal trauma or severe head injuries resulting in life-threatening injuries typically do not make it to the hospital [7].

The types of injuries seen by surgeons treating road traffic victims vary by location, predominant type of vehicular transport, and the infrastructure of the location and country in which they are practicing. In high-resource settings, teams of surgeons and physicians respond to traumatic injury with highly coordinated trauma response systems. Prehospital care is highly effective at reducing mortality; surgeons, emergency physicians, and teams of highly trained responders all focus on quick assessment

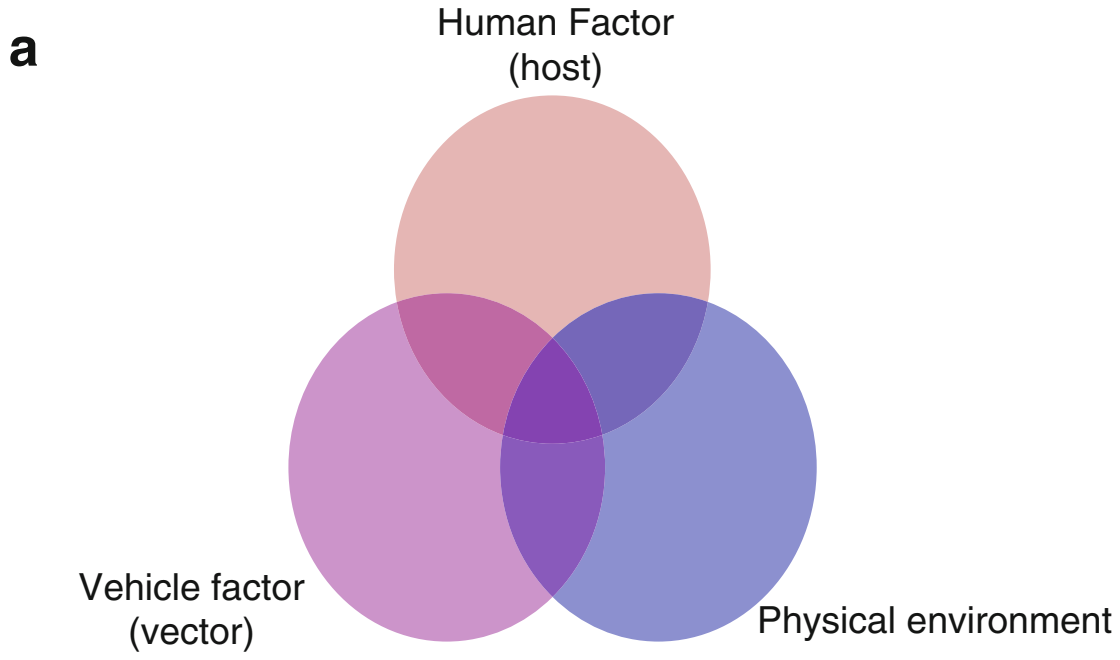

b

Phase	Goals	Human	Vehicle	Environment
Pre-Crash	Crash prevention	KAP Impairment Law enforcement	Roadworthiness Speed management	Road design/layout Speed limits Pedestrian facilities
Crash	Injury Prevention	Impairment Use of Restraints	Occupants restraints Other safety devices Crash protection	Crash protective roadside objects
Post-crash	Life & limb salvage	First aid skills Access to care	Ease of access Fire risk	Rescue facilities Congestion

Fig. 6.2 (**a**) The intersection of host, vector, and environmental factors lead to road traffic crashes and subsequent injuries. (**b**) These different factors can be split into their component parts and analyzed for planning potential interventions for pre-crash, crash, or post-crash time points

Fig. 6.3 A common sight on the roads of low- and middle-income countries

and treatment of major trauma, which results in good outcomes for patients. In most low-resource settings, these response systems are nonexistent, with trauma centers few and far between. Komfo Anokye Teaching Hospital (KATH) in Kumasi, Ghana, for example, has a catchment area that includes almost all of Northern Ghana and extends into neighboring countries of Benin, Togo, and Cote d'Ivoire. Patients will come in with minimal bandaging and occasionally splints to help stabilize their fractures, but they may have traveled days to get to KATH (Direct Observation at KATH).

In addition to acute fractures of all types, neglected trauma is a huge problem in these countries. Patients that sustain a closed or even an open fracture may go to traditional healers before presenting to a physician (very few actually make it to a trained orthopedic or trauma surgeon), as these healers are available, accessible, and significantly more affordable [8]. Especially in West Africa, traditional bonesetters are well known, so many people feel comfortable going to them for care before going to a hospital. The perception of many patients is that hospitals are "places to go to die," and therefore should be avoided at all costs. This is a self-fulfilling prophecy as many patients are brought in only when agonal. Many times patients treated by these traditional bonesetters end up with malunions, nonunions, limb length discrepancies, gangrene, osteomyelitis, and contractures [8, 9]. There are examples of orthopedic surgeons reaching out and teaching these bonesetters how to properly treat certain pathologies, when to refer a patient, and have been met with some success [9]. Nonetheless often significant complications due to delays and poor initial management must be dealt with by an orthopedic surgeon dealing with road traffic injury in LMICs.

6.2 Epidemiology

The first Global Burden of Disease (GBD) study was performed in 1990, and the latest iteration, the GBD 2010 study, was published at the end of 2012. The GBD study attempts to offer a baseline of what etiologies are responsible for what proportion of disease worldwide with an aim to inform policy decisions and resource allocation regarding health globally. The study attempts to quantify the burden of disease of each selected etiology and then compare that burden between diseases. It also aims at assessing the impact of selected risk factors. Comparison is achieved through the use of a composite unit of measurement made up of components of mortality and morbidity combined into one metric referred to as the disability-adjusted life year (DALY). All injuries account for 11 % (278,665,000 DALYs) of DALYs worldwide, more than HIV, malaria, and tuberculosis combined which together account for 8.5 % of total DALYs (213,628,000 DALYs). RTIs account for 27 % of the total DALYs attributable to injury [10], were the eighth highest overall cause (all ages) of death in 2010 [1], and were the leading cause of death in the age group 15–29 years old [1]. In countries that have limited access to orthopedic trauma care, musculoskeletal injuries due to RTCs cause lifelong disability and typically affect young people in their prime income earning years [3, 11, 12].

Despite the GBD and other studies, the total burden of injury due to RTCs remains poorly elucidated. Much of the data in the GBD study are ultimately based on extrapolations from "similar" locations or hospital bases studies. There have been many epidemiological studies examining the burden of road traffic injury in developing countries, yet most have been hospital based and therefore not capture patients that do not present to a hospital for treatment.

Bayan et al. profiled the injuries that presented to a hospital in Primpri, Pune, India [13]. Patients having multiple injuries were the most common admissions, followed by injuries to the lower limbs (38 %). Fractures (71 %) were by far the most common type of injury seen in patients presenting due to RTIs. Whiteside et al. profiled pediatric injuries presenting to the accident and emergency department (ED) at KATH in Kumasi, Ghana [14]. Most ED admissions were due to injury (66 %), and 43 % of these were due to RTIs. Fifty-eight percent of these RTIs occurred while the child was a passenger in a car, 26 % were pedestrian injuries, and 14 % were from motorcycle injuries. Musharrafieh et al. surveyed every 12th patient that presented to the ED after a traumatic event over the course of 1 year [15]. RTIs were responsible for only 11.8 % of all admissions, with the upper extremity (38 %) followed by the lower extremity (31.9 %) representing the most commonly injured body parts. Herbert et al. used national injury registry data to evaluate injury in children in South Africa [16]. Falls (39.8 %) were the most common cause of injury, followed by road traffic (15.7 %). The upper extremity (30 %) was the most commonly injured body part, and the child was most often a pedestrian (69 %). Ultimately, the patterns of injury seen in a given situation will reflect the types of transportation used locally.

Herman et al. performed a systematic review of the literature on RTIs in the Pacific region countries [17]. Most of the studies were performed in Papua New Guinea (PNG), and most of which are outdated. In a study of all postmortems performed at Port Moresby General Hospital between the years 1961–1989, RTIs were responsible for 45 % of all deaths, 75 % of which were male [18]. Two other studies included in the review examined the proportion of deaths that occurred prior to hospital arrival, 66 % prehospital in one study [19] and 81 % in another [20]. At least one study attempted to quantify the number of injury incidences in Accra, Ghana, using police records but was unable to describe the injuries incurred by the victims of RTIs [21]. A study from Nigeria highlights the increasing popularity of motorcycles as means of transportation and their impact on RTIs. One hundred and twenty-two admissions to the ED at the Federal Medical Center in Azare were reviewed for epidemiologic data. Motorcycles constituted 73 % of RTCs involving pedestrians 54 % of which were children or adolescents. The head and neck (43 %) were the most commonly injured area of the body followed by the extremities (37 %) [22] (Fig. 6.4a, b).

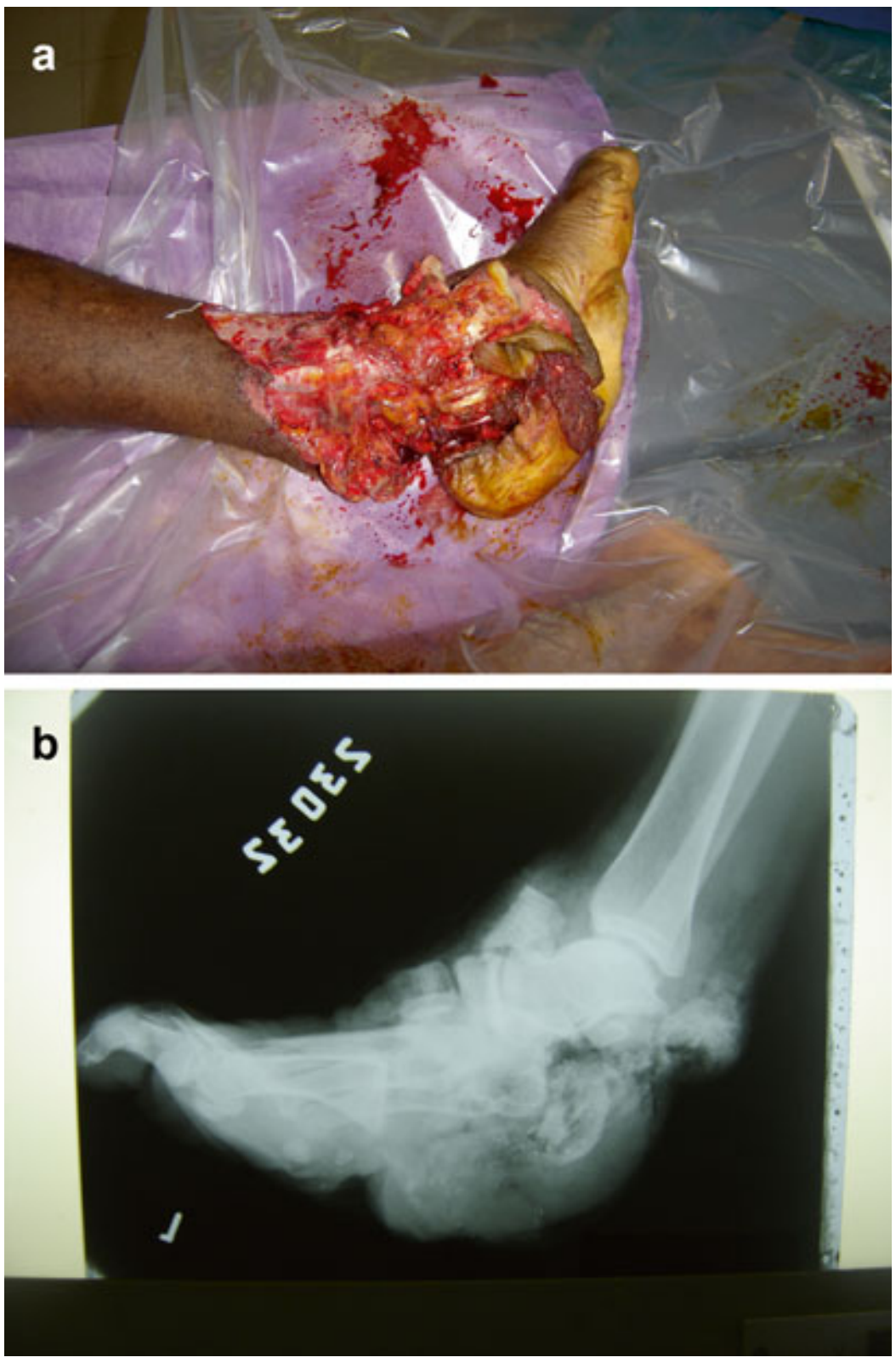

Fig. 6.4 (**a**) Severe lower extremity injury sustained in a motorcycle crash. This can be a typical presentation for open injury. (**b**) Radiograph showing extent of injury seen in (**a**)

Population-based studies allow the examination of the incidence of some problem within an entire population. Whereas hospital studies necessarily miss persons with RTIs, population-based surveys can elucidate the incidence and prevalence of a disease within a population regardless of access to healthcare. Well-designed cross-sectional studies are viewed as the gold standard for epidemiological study of diseases/conditions in areas without robust healthcare systems.

Moshiro et al. performed a population-based survey of injury in an urban vs. a rural area in Tanzania [23]. Residents of urban areas were four times as likely to have an RTI as residents of rural areas. In urban areas, transport-related injuries were the leading cause of major injuries (41.2 % of the total), but in rural areas, they were the second most common cause of major injury (30.4 %) behind falls (38.6 %), with young males accounting for the majority of transport-related injuries in both. Mock et al.

performed a population-based survey of injury in Ghana in 1998 comparing injury profiles in the urban to the rural environment [24]. Transport-related injury accounted for 16 % of the overall number of injuries, less than unintentional lacerations and falls, but was responsible for 75 % of injury-related deaths and accounted for 73 % of the overall long-term disability. In both environments, motorcycle crashes were less common than motor vehicle crashes or pedestrians hit by motor vehicles. The majority of RTIs were due to minibus crashes or pedestrians hit by minibuses. Since this survey, Ghana has seen an increase in two-wheeled transport, so the injury profile likely looks different 15 years after the study was performed. Zimmerman et al. performed a population-based study of road traffic injury and crash statistics in Dar es Salaam, Tanzania, in 2011 [25]. They showed an overall yearly incidence of 33 per 1000 people, with the majority of injuries occurring in the lower extremities. The most common road users injured were passengers in cars or minibuses followed by pedestrians. Stewart et al. performed a country-wide population-based survey of surgical disease in Sierra Leone in 2012 [26]. They found that transport-related injuries accounted for 13 % of total injuries sustained in the previous 12 months. RTIs were the most common cause of injury-related death, and for nonfatal injury, the extremities were the most commonly injured part of the body. Guerrero et al. performed a population-based study of the incidence of road traffic injury among children in Accra, Ghana [27]. The incidence was found to be 34 RTI per 1000 person years among the entire pediatric population but was higher 43 per 1000 person years in the age group 5–14. The upper extremity (56.5 %) and the back (14.4 %) were the most frequently injured body parts followed by the legs (7.5 %). Children were most commonly injured as pedestrians, which accounted for 78.5 % of pediatric RTIs (Guerrero).

The cost of road traffic injuries has been analyzed by several authors using different methods. One study in South Africa estimated the cost of care for RTI patients to be approximately $700 per patient in the hospital. They used a micro-costing approach and added up hospital overhead, orthopedic implant costs, consumables, and all medical testing to estimate their cost but did not include time away from work or cost of disability for these patients [28]. Nunez et al. estimated the cost of RTIs to the state of Jalisco in Mexico using a model that took into account all medical costs as well as time lost from work and time lost by caregivers [11]. They estimated that the cost of care for patients seen only in the ED was approximately $89 each, but for hospitalized patients it jumped to $800 each with an average stay of 10 days. The post-hospital cost for those patients that were hospitalized was approximately $588 each. In an area where the average monthly income is $398, this total cost of injury of $1388 is a very significant expense. Orthopedic care is often necessary for good functional outcome, for reducing long-term disability and lost income, but perceived to be outside the immediate means of many people in low- and middle-income countries. To challenge this assertion, Gosselin et al. examined the cost of locked intramedullary nailing versus Perkin's femoral traction for patients at a hospital in Cambodia [29]. They found an average cost per patient of $1107 in the Perkin's traction group compared to $888 in the locked intramedullary nail group ($p<0.01$). Their findings indicate that a more aggressive intervention can also be a more cost-effective intervention.

6.3 Own Experience

Road traffic injuries will present late in many countries, especially if the catchment areas are spread over a wide geographical distribution. Because of the generalized lack of formal prehospital care systems, first responders are usually lay persons with little or no first aid training. Victims are brought to healthcare facilities by private vehicles and most often based on their ability to pay more than the severity of the injuries. Management in the emergency department will depend on available human and material resources. Even the most basic tools for resuscitation and monitoring are often lacking: oxygen, pulse oximetry, chest tubes, etc. Blood banks, if present, are usually poorly stocked and then only with whole blood units. It is very common to find significant resistance to giving blood, even among family members, for sociocultural or religious reasons. The patterns of injury seen in any given hospital will reflect the modes of transportation that are most common in the given area, and the patient volume may depend on factors that are not readily apparent. Certain times of year may be "the busy season," in which mass casualty bus crashes come in more often than motorcycle crashes. Investigation and discussion with local partners is essential to understanding the patterns of injury, timing of injury presentation, and logistical necessities of the hospital.

Conclusions

Road traffic injury is a major cause of death and disability worldwide. Orthopedic trauma care is essential to providing the best functional outcomes for victims of RTIs. The surgeon practicing in the humanitarian setting is likely to see neglected trauma, open fractures, high rates of infection of open fractures, and patients from all age groups. The incidence and severity of trauma seen will depend on the country of practice and type of vehicles prevalent in the area. With increasing motorization, and lagging infrastructure improvements, the incidence of orthopedic trauma due to road traffic crashes will continue to increase.

References

1. Lozano R, Naghavi M, Foreman K, Lim S, Shibuya K, Aboyans V, et al. Global and regional mortality from 235 causes of death for 20 age groups in 1990 and 2010: a systematic analysis for the Global Burden of Disease Study 2010. Lancet. 2012;380:2095–128.
2. World Bank. How we classify countries [Internet]. [cited 2013 Nov 14]. Available from: http://data.worldbank.org/about/country-classifications.
3. World Health Organization. Global status report on road safety 2013 [Internet]. World Health Organization; 2013. Available from: http://www.who.int/violence_injury_prevention/road_safety_status/2013/en/index.html.
4. WHO. World report on road traffic injury prevention [Internet]. WHO. [cited 2013 Nov 15]. Available from: http://www.who.int/violence_injury_prevention/publications/road_traffic/world_report/en/.
5. World Health Organization. Global status report on road safety 2009 [Internet]. World Health Organization; 2009. Available from: http://www.who.int/violence_injury_prevention/road_safety_status/2009/en/.
6. Hettrich CM, Browner B. High-energy trauma. Best Pract Res Clin Rheumatol. 2012;26(2):281–8.
7. Mock CN, Adzotor E, Denno D, Conklin E, Rivara F. Admissions for injury at a rural hospital in Ghana: implications for prevention in the developing world. Am J Public Health. 1995;85(7):927–31.
8. Omololu B, Ogunlade SO, Alonge TO. The complications seen from the treatment by traditional bonesetters. West Afr J Med. 2002;21(4):335–7.
9. Omololu AB, Ogunlade SO, Gopaldasani VK. The practice of traditional bonesetting: training algorithm. Clin Orthop. 2008;466(10):2392–8.
10. Murray CJL, Vos T, Lozano R, Naghavi M, Flaxman AD, Michaud C, et al. Disability-adjusted life years (DALYs) for 291 diseases and injuries in 21 regions, 1990–2010: a systematic analysis for the Global Burden of Disease Study 2010. Lancet. 2012; 380(9859):2197–223.
11. Pérez-Núñez R, Ávila-Burgos L, Híjar-Medina M, Pelcastre-Villafuerte B, Celis A, Salinas-Rodríguez A. Economic impact of fatal and non-fatal road traffic injuries in Guadalajara Metropolitan Area and Jalisco, Mexico. Inj Prev. 2011;17(5):297–303.
12. Atijosan O, Rischewski D, Simms V, Kuper H, Linganwa B, Nuhi A, et al. A national survey of musculoskeletal impairment in Rwanda: prevalence, causes and service implications. PLoS One. 2008;3: e2851.
13. Bayan P, Bhawalkar JS, Jadhav SL, Banerjee A. Profile of non-fatal injuries due to road traffic accidents from a industrial town in India. Int J Crit Illn Inj Sci. 2013;3(1):8–11.
14. Whiteside LK, Oteng R, Carter P, Amuasi J, Abban E, Rominski S, et al. Non-fatal injuries among pediatric patients seeking care in an urban Ghanaian emergency department. Int J Emerg Med. 2012;5(1):36.
15. Musharrafieh U, Rahi AC, Taha A, Shamseddine W, Steitieh S, Jamali F, et al. Profile of injured patients presenting to a tertiary hospital in a developing country. J Med Liban. 2011;59(4):191–6.
16. Herbert HK, van As AB, Bachani AM, Mtambeka P, Stevens KA, Millar AJW, et al. Patterns of pediatric injury in South Africa: an analysis of hospital data between 1997 and 2006. J Trauma Acute Care Surg. 2012;73(1):168–74.
17. Herman J, Ameratunga S, Jackson R. Burden of road traffic injuries and related risk factors in low and middle-income Pacific Island countries and

territories: a systematic review of the scientific literature (TRIP 5). BMC Public Health. 2012;12:479.
18. Cooke RA, Wilkey IS, Aiken GH, Murthy P, Sengupta K. Forensic pathology in Papua New Guinea 1962–1989. Med J Aust. 1992;157(11–12):826–8.
19. Sinha SN, Sengupta SK, Purohit RC. A five year review of deaths following trauma. P N G Med J. 1981;24(4):222–8.
20. Palmer P. Autopsies at Goroka hospital from 1978–1982: a review. P N G Med J. 1982;25(3):166–7.
21. Afukaar FK, Antwi P, Ofosu-Amaah S. Pattern of road traffic injuries in Ghana: implications for control. Inj Control Saf Promot. 2003;10(1/2):69.
22. Umaru H, Ahidjo A, Dogo H. Pedestrian injuries resulting from road traffic accidents: the Azare experience. Niger J Med J Natl Assoc Resid Dr Niger. 2007;16(2):169–72.
23. Moshiro C, Heuch I, Astrøm AN, Setel P, Hemed Y, Kvåle G. Injury morbidity in an urban and a rural area in Tanzania: an epidemiological survey. BMC Public Health. 2005;5:11.
24. Mock CN, Forjuoh SN, Rivara FP. Epidemiology of transport-related injuries in Ghana. Accid Anal Prev. 1999;31(4):359–70.
25. Zimmerman K, Mzige AA, Kibatala PL, Museru LM, Guerrero A. Road traffic injury incidence and crash characteristics in Dar es Salaam: a population based study. Accid Anal Prev. 2012;45:204–10.
26. Stewart K-AA, Groen RS, Kamara TB, Farahzad MM, Samai M, Cassidy LD, et al. Traumatic injuries in developing countries: report from a Nationwide Cross-Sectional Survey of Sierra Leone. JAMA Surg. 2013;16:1–7.
27. Guerrero A, Amegashie J, Obiri-Yeboah M, Appiah N, Zakariah A. Paediatric road traffic injuries in urban Ghana: a population-based study. Inj Prev J Int Soc Child Adolesc Inj Prev. 2011;17(5):309–12.
28. Parkinson F, Kent SJW, Aldous C, Oosthuizen G, Clarke D. The hospital cost of road traffic accidents at a South African regional trauma centre: a micro-costing study. Injury. 2014;45(1):342–5.
29. Gosselin RA, Heitto M, Zirkle L. Cost-effectiveness of replacing skeletal traction by interlocked intramedullary nailing for femoral shaft fractures in a provincial trauma hospital in Cambodia. Int Orthop. 2009;33:1445–8.

Injuries After Natural Disasters

7

Richard A. Gosselin

Natural disasters may share initial chaos and mass casualty management principles with war/conflicts situations, but the comparison most often stops there [1]. Depending on the magnitude of the event, massive destruction of infrastructure and local capacity may completely obliterate the possibility of an effective first response, particularly in already resource-poor environments. Quickly establishing a chain of command; opening supply routes; and reestablishing reliable power sources, communication, security, water and sanitation, and food and shelter for the survivors are the immediate priorities. First aid for wounded victims, search and rescue efforts, and initial medical management of the injured are secondary priorities in the initial stage.

Definitive management of musculoskeletal (MSK) injuries comes much later, usually after the second week, and the surgical reconstruction phase may go on for months. A special tool has been developed for the initial assessment and subsequent monitoring of the effectiveness of the relief effort (Community Needs Assessment for Public Health Emergency Response – CASPER), which has been validated and proven useful in massive natural disasters, particularly in austere environments [2]. Unfortunately it seems that the lessons learned from a disaster are often forgotten by the time the next disaster strikes.

There are common findings to all natural disasters: there is a bimodal distribution of mortality. Deaths are usually due to head, chest, and abdominal trauma initially, metabolic, or septic complications later on. In survivors, MSK injuries are by far the most common: soft tissue wounds, fractures/dislocations, and crush injuries. The lower extremity (LE) is most commonly affected [3]. Children and the elderly are particularly vulnerable. Sudden overwhelming of what's left of the local health care system also impedes the provision of normal health services such as obstetrics, vaccination, oncology, dialysis, or geriatrics [4]. General management principles will be discussed below.

7.1 Earthquakes

There have been many earthquakes of devastating magnitudes in the last decade or so: Gujarat, India, in 2001; Bam, Iran, in 2003; Muzaffarabad, Pakistan, in 2005; Ica, Peru, in 2007; Sichuan province, China, in 2008; and of course the disastrous Haiti earthquake in 2010, near Port-au-Prince, which has created a surge of interest in disaster volunteerism. In Bam, almost 60 % of

---

R.A. Gosselin, MD, MSc, MPH, FRCS(C)
Department of Orthopedic Surgery,
Institute for Global Orthopedics and Traumatology,
University of California in San Francisco,
San Francisco, CA, USA
e-mail: froggydoc@comcast.net

© Springer International Publishing Switzerland 2016

J.D. Robinson (ed.), *Orthopaedic Trauma in the Austere Environment: A Practical Guide to Care in the Humanitarian Setting*, DOI 10.1007/978-3-319-29122-2_7

admissions were for MSK injuries, 2/3 of them in the LE [5]. In Ica, Peru, estimates were of 1.4 deaths and 29 injured/1000 exposed (at risk) population [6]. Higher age and lower socioeconomic status were found to be significant risk factors. In the 2008 China earthquake, Zhang et al. found that after MSK injuries, head injuries ranked a distant second [7]. Following the 2010 Haiti earthquake, the Centers for Disease Control and Prevention (CDC) initially estimated the death toil at around 225,000 and the injured at around 300,000 [8] (Fig. 7.1). They also found that the most common injuries were fracture/dislocations and infected soft tissue wounds. Using the same methodology as for previous disasters, Doocy et al. recently revised those estimates, significantly lowering them: 24 deaths/1000 exposed, for a total death estimate between 50,000 and 90,000, and 40 injured/1000 exposed, for a total estimate around 125,000 injuries [9, 10].

Such numbers are still enormous. The Haiti disaster is a case study of a "perfect storm": a weak health care system, resting significantly on foreign assistance before the event, a country where almost everything is centralized in the capital, weak construction codes and compliance, and a magnitude 7.0 earthquake with the epicenter near the capital. The understandable initial shock and chaos was compounded by the early realization that there were very little facilities left standing and functional and very few people available to care for the survivors, wounded or not.

An unprecedented humanitarian response followed, and lessons were learned, again [11]. Multiple nongovernmental organizations (NGOs), big and small; military personnel from many countries; and many volunteers rushed in to deliver aid as quickly as possible. Coordination between so many and so different actors was a painstaking process, which improved over time and allowed an increasingly efficient and safe use of various resources. Many patients, who survived the initial injury and extrication, eventually died of medical complications from crush syndrome or ARDS. A few critical patients were evacuated to the Dominican Republic, later on to hospital boats from the US military or even the continental USA.

The first 2 weeks consisted mostly of wound management of limb injuries, including external fixation of open fractures or early wound closure by skin graft or local flaps. Lower limb fractures were managed in casts or traction (not easy if the patient is on the ground). Definitive management of most orthopedic injuries can start when safe surgical environments have been restored, and appropriate skills, equipment, and materials are

Fig. 7.1 Haiti earthquake

Fig. 7.2 A tented hospital in Haiti

available (Fig. 7.2). Early and late reconstruction is done electively in the ensuing weeks and months. The repercussions of this earthquake on the Haitian society are still widely visible in all sectors, more than 6 years later.

7.2 Tsunamis

These are huge waves created by underwater earthquakes that travel at very high speed, can be both high and wide, and hit the coastline with devastating force. Two huge tsunamis were seen recently, one hitting the coasts of Indonesia and Thailand in 2004 and one the Japanese coast in 2010, following the undersea Miyagi earthquake. In 2004, Indonesia was hit the hardest and the northwestern province of Banda Aceh was partially wiped out. In Japan, the tsunami hit the Tohoku area after a 9.0 undersea earthquake, with almost 18,000 dead or missing and over 6000 injured. It made the news also because of the damage inflicted on the Fukushima nuclear power plant complex, causing major radioactive leaks.

Major floods and tsunamis have a high mortality rate, mostly from drowning, but proportionally few major injuries [12]. Still, they can cause major structural damages and overwhelm local resources. Many square kilometers in Banda were actually completely wiped out. The CDC estimated a total of 230,000 deaths from the tsunami, most of them in Indonesia [13]. In Banda itself, 75 % of health workers were killed or displaced. It was estimated that around 17 % of the Banda population was dead or missing and that 8.5 % of the survivors were injured [14]. Mortality was higher in young and old females and middle-aged males. Approximately 15 % of the injured sustained some form of permanent disability. In Thailand, half of the hospital admissions were for minor (50 %) or major (50 %) wounds, where only 7 % of patients had fractures/dislocations [15].

As for earthquakes, MSK injuries are the most common, particularly in the LE [16]. Soft tissue wounds can occur from floating debris or direct contact on immobile objects or structures. Wounds bathe in waters with multiple contaminants, especially when sewage systems are compromised, and lead? to severe contamination. Infections occurred early and spread rapidly. One of the most common chronic complications was persistent cutaneous infection with mixed and unusual pathogens. One lesson learned from the Thai experience was never to close wounds, even (and in fact particularly) the small ones.

7.3 Tornadoes

Tornadoes consist of violently rotating columns of air that touch both the clouds and the ground. They are common where geographical and meteorological conditions are favorable, such as Southeast Asia and the American Midwest. They are sudden and short-lived, thus difficult to predict and to prepare for. The most recent one in Moore, near Oklahoma City, in May 2013, claimed 24 lives, many of them children attending school. This was the third time in 10 years this area was hit with a category 4 or 5 (highest) tornado. Structures within the path of the tornado suffer extreme devastation, but nearby structures are usually spared and health care resources remain rapidly available. Heavy rains often complicate search and rescue efforts.

The severity of injuries depends on the magnitude of the tornado and whether victims where in anchored structures, mobile homes, or outdoors [17]. Victims thrown by tornadoes suffer more severe injuries than those hit by flying objects [18]. The elderly are at higher risk of death and injury [19]. The CDC has estimated that between 20 and 25 % of death are caused by head trauma [20]. The most common injuries in survivors are soft tissue wounds and fractures (Fig. 7.3) [21].

Fig. 7.3 Soft tissue injuries are common in natural disasters

7.4 Hurricanes/Tropical Cyclones/Typhoons

These are storm systems with a low-pressure center and a spiral arrangement of thunderstorms that produce strong winds and heavy rain. They are mostly seasonal and form relatively slowly over ocean masses and are now easily detectable and tractable with modern meteorological technology. Large hurricanes still cause massive destruction and havoc when they hit land: damage from the wind itself and also from the associated flooding. Because of the much wider radius, infrastructure damage can be extensive. Typhoon Nina killed more than 200,000 people in China in 1975, most of them after the failure of a major dam. The 2005 category 5 (highest) hurricane Katrina rapidly overwhelmed capacities in Louisiana and southern Mississippi. Over 1800 victims died and nearly 6000 were treated for injuries. This lasted for months and some areas are still not fully recovered 8 years later. One can only imagine the impact of a similar strength typhoon in less fortunate countries such as the Philippines or Bangladesh. Proportionally, deaths are less and injuries are more common than in tornadoes, and the LE is again the most common site of injury [22–24]. The effects of hurricanes of such magnitude, as for other natural disasters, can be felt long after the main event is over, particularly on vulnerable groups. At 12 months after Katrina, displaced elders had significantly more hip fractures than non-displaced elders, possibly related to the still relatively unfamiliar immediate environment [25].

7.5 Floods

Torrential rains may cause streams and rivers to overflow above their normal banks. This can lead to “flash floods” with high water velocity and a higher potential for drowning or direct/indirect injuries, similar to what is seen in a tsunami but at a much smaller scale. Or “slow flooding” can occur, with gradual rising of water levels and slow but constant progression of the water mass until it peaks and starts receding again. These can still create massive damage to structures and property, and incapacitate health care systems and facilities, particularly in LMICs, impeding emergency treatment of victims in need and also the care of routine medical conditions such as obstetrics or acute abdominal emergencies. Dermatological complications, such as chronic fungal infections or draining soft tissue wounds, are the most common long-term problems [13, 15].

7.6 Avalanches, Mudslides, and Other Causes of Structural Collapse

These are all events that occur on a much smaller scale and have no impact on the local capacity to deliver care but may occur in very isolated areas or may limit access to an affected area. Rapid search and rescue efforts are usually dependent on the level of available local technology and key in determining the outcome of victims. Avalanche victims usually die of asphyxiation and survivors most commonly have extremity injuries [26]. Mudslides are associated with deforestation, a common occurrence in LMICs. They cause deaths and few injuries as finding and extricating victims rapidly is very difficult. Poor building codes and regulations, shoddy construction, ill-repair by greedy owners or lack of maintenance, corruption, and overcrowding are all responsible for disasters such as the April 2013 collapse of the Ram Plaza building near Dhaka, Bangladesh, that housed garment factories, and with a toll of nearly 1200 dead and over 2500 injured. These are like “mini-earthquakes” and the amount of injured survivors can still rapidly overwhelm weak health care capacities. The rains bring about an epidemic of collapsing buildings in Afghanistan, with resultant crush injuries. Volcanic eruptions may bring about mudslides as in Colombia, and heavy rains can also bring about these mudslides which recently buried the town of La Pintada in Mexico after this country was hit by hurricanes from both the Pacific and Atlantic coasts at the same time.

7.7 Management Principles

Because of the suddenness of natural disasters, huge amounts of casualties may occur all at once. In the following chaos, multitudes of wounded may congregate in areas considered safe: remaining functional health facilities, high grounds, and open spaces such as stadiums or parking lots. While the hierarchy of priorities described earlier is established, basic first aid can be provided according to available human and material resources: splinting, dressing, and even basic fluid resuscitation. All wounds should be left *open*.

The importance of triaging in mass casualty situations cannot be overstated: establishing treatment priorities will prove invaluable when more sophisticated treatment centers become operational for the initial medical management of the wounded. There, lifesaving, rather than limb-saving, procedures can be performed. The goal is to do the best possible for the most possible, not the absolute very best for everybody. A 10-min amputation is preferable to a 4-h complex limb-saving procedure when scores of patients are waiting for care (Fig. 7.4). Treatment needs to be simple and efficient. As far as MSK injuries go, by far the earliest complications seen are due to premature closure of wounds, inadequate amputations, and inappropriate use of internal fixation. (See chapters on soft tissue management, infection, amputations, and external fixation for further guidance.)

7.7.1 Wounds

- Washing with clean water (drinkable), debridement, and sterile dressing, with splinting if necessary.
- NEVER primary closure.
- Delayed primary closure (DPC), local rotation flaps, or skin grafting at 5–7 days can provide definitive coverage for most wounds. Most of the others will eventually heal by secondary intention.
- Record in patient’s chart, if available, or directly on dressing or cast, what was done

Fig. 7.4 Amputations following natural disasters are common and many times carried out with poor technique

and when, and what needs to be done next, and when. You might not see this patient again yourself.

- Tetanus prophylaxis and appropriate antibiotics.

7.7.2 Amputations

- Be as conservative as possible, as long as the debridement is thorough and the remaining stump has a chance of surviving. A high BKA is still preferable to an AKA. It may still be revised later. This is also true for the upper extremity and for disarticulations. But a low BKA that has no chance of surviving may require an AKA as salvage, whereas a higher initial BKA would have been more appropriate.
- Stumps should be left open, with delayed primary closure (DCP) 4–6 days later. When primarily closed stumps get infected, a higher revision is usually necessary, and the patient has unnecessarily lost a joint.
- NEVER do a guillotine amputation. They always require proximal revision.
- Hand injuries usually appear worse than they are. Conservative debridement should be done, repeated as frequently as needed to salvage as many and as much digits as possible, particularly the thumb. A few mobile nubbins can yield surprising function.
- Amputations through the foot should aim at keeping calcaneus and a healthy heel pad if possible.

7.7.3 Fractures

- Closed fractures should remain closed in the immediate aftermath of a natural disaster!
- Open fractures need debridement and initial stabilization with splints, casts, traction, or external fixation. NO primary closure.
- There is NO indication for primary internal fixation, except maybe K-wires for some hand or foot open fractures.
- Skeletal traction through the distal femur, proximal tibia, or calcaneus can be indicated for fractures around the hip, femoral shaft, or complex lower limb injuries, especially before X-rays are available. Jerry-rigging the traction apparatus is often required, especially if there are no beds, and the patient is lying on the ground. The blind use of external fixation may be an appropriate alternative, not as much to reduce the fracture, but to stabilize enough for early mobilization, and leaving the door open for adjustment, repositioning, or substitution when X-rays become available or access to better operating conditions are achieved.
- A properly applied pelvic wrap with a simple sheet or towel can be lifesaving for the hemodynamically unstable pelvic with a clinically obvious pelvic ring fracture.
- Compartment syndromes are diagnosed clinically and require open decompression IF less than 18–24 h from time of injury (not time of admission). There is NO indication for decompression after 24 h: what is dead is dead, and what is alive will remain alive, and nearly 100 % of surgical fasciotomy wounds will get infected. Reconstruction of a partially functional extremity at a later stage is still preferable to an amputation for infected

wounds made necessary by an ill-advised fasciotomy.
- Crush injuries may lead to crush syndrome, and optimal medical management is mandatory, often difficult without basic laboratory capacity.
- Unless totally unavailable, appropriate anesthesia/sedation is necessary for all procedures, including many simple dressing changes.

Wherever available, critical patients should be evacuated to more appropriate facilities. Once appropriate surgical environments, equipment, and supplies have been secured, more definitive management of orthopedic conditions can begin, including internal fixation. In massive natural disasters in LMICs, such as seen in Haiti, this is rarely possible before 10–14 days. What happens in places where there is nowhere else to go?

References

1. Gosselin RA. War injuries, trauma and disaster relief. Tech Orthop. 2005;20(2):97–108.
2. Choudhary E, Chen TH, Martin C, Vagi S, et al. Public health needs assessments of Tutuila Island, American Samoa, after the 2009 tsunami. Disaster Med Public Health Prep. 2012;6(3):209–16.
3. Dewo P, Magetsari R, Busscher HJ, et al. Treating natural disaster victims is dealing with shortages: an orthopaedics perspective. Technol Health Care. 2008;16(4):255–9.
4. Guha-Sapir D, van Panhuis WG. Health impact of the 2004 Andaman Nicobar earthquake and tsunami in Indonesia. Prehosp Disaster Med. 2009;24(6):493–9.
5. Salimi J, Abbasi M, Khaji A, Zargar M. Analysis of 274 patients with extremity injuries caused by the Bam earthquake. Chin J Traumatol. 2009;12(1): 10–3.
6. Doocy S, Daniels A, Aspilcueta D, Inppares-JHSPH-CUNY Study Team. Mortality and injury following the 2007 Ica earthquake in Peru. Am J Disaster Med. 2009;4(1):15–22.
7. Zhang L, Li H, Carlton JR, Ursano R. The injury profile after the 2008 earthquakes in China. Injury. 2009;40(1):84–6.
8. Centers for Disease Control and Prevention (CDC). Post-earthquake injuries treated at a field hospital – Haiti, 2010. MMWR Morb Mortal Wkly Rep. 2011;59(51):1673–7.
9. Doocy S, Cherewick M, Kirsch T. Mortality following the Haitian earthquake of 2010: a stratified cluster survey. Popul Health Metr. 2013;11(1):5. doi:10.1186/1478-7954-11-5.
10. Doocy S, Jacquet G, Cherewick M, Kirsch TD. The injury burden of the 2010 Haiti earthquake: a stratified cluster survey. Injury. 2013;44(6):842–7.
11. Sonshine DB, Caldwell A, Gosselin RA, Born CT, Coughlin RR. Critically assessing the Haiti earthquake response and the barriers to quality orthopedic care. Clin Orthop Relat Res. 2012;470(10):2895–904.
12. Llewellyn M. Floods and tsunamis. Surg Clin North Am. 2006;86(3):557–78.
13. Center for Disease Control and Prevention (CDC). Assessment of health-related needs after tsunami and earthquake–three districts, Aceh Province, Indonesia, 2005. MMWR Morb Mortal Wkly Rep. 2006;55(4): 93–7.
14. Doocy S, Robinson C, Moodie C, Burnham G. Tsunami-related injury in Aceh Province, Indonesia. Glob Public Health. 2009;4(2):205–14.
15. Prasartritha T, Tungsiripat R, Warachit P. The revisit of 2004 tsunami in Thailand: characteristics of wounds. Int Wound J. 2008;5(1):8–19.
16. Sechriest 2nd VF, Lhowe DW. Orthopaedic care aboard the USNS Mercy during Operation Unified Assistance after the 2004 Asian tsunami. A case series. J Bone Joint Surg Am. 2008;90(4):849–61.
17. Daley WR, Brown S, Archer P, Kruger E, et al. Risk of tornado-related death and injury in Oklahoma, May 3, 1999. Am J Epidemiol. 2005;161(12):1144–50.
18. Millie M, Senkowski C, Stuart L, Davis F, et al. Tornado disaster in rural Georgia: triage response, injury patterns, lessons learned. Am J Surg. 2000;66(3):223–8.
19. Sugimoto JD, Labrique AB, Ahmad S, Rashid M, et al. Epidemiology of tornado destruction in rural northern Bangladesh: risk factors for death and injury. Disasters. 2011;35(2):329–45.
20. Center for Disease Control and Prevention (CDC). Tornado-related fatalities–five states, southeastern United States, April 25–28, 2011. MMWR Morb Mortal Wkly Rep. 2012;61(28):529–33.
21. Hartmann EH, Creel N, Lepard J, Maxwell RA. Mass casualty following unprecedented tornadic events in the Southeast: natural disaster outcomes at a Level I trauma center. Am J Surg. 2012;78(7):770–3.
22. Faul M, Weller NF, Jones JA. Injuries after Hurricane Katrina among Gulf Coast Evacuees sheltered in Houston, Texas. J Emerg Nurs. 2011;37(5):460–8.
23. Noe RS, Schnall AH, Wolkin AF, Podgornik MN, et al. Disaster-related injuries and illnesses treated by American Red Cross disaster health services during Hurricanes Gustav and Ike. South Med J. 2013; 106(1):102–8.
24. Shen J, Feng Z, Zeng G, Zhu BP. Risk factors for injury during Typhoon Saomei. Epidemiology. 2009;20(6):892–5.
25. Uscher-Pines L, Vernick JS, Curriero F, Lieberman R, Burke TA. Disaster-related injuries in the period of recovery: the effect of prolonged displacement on risk of injury in older adults. J Trauma. 2009;67(4): 834–40.
26. Grissom CK. Lessons learned from avalanche survival patterns. CMAJ. 2011;183(7):E366–7.

8

Orthopedic Ballistic Trauma

Paul Ley

In ballistic science, a bullet's journey may be divided into three stages [1]:

1. Initial stage: from firing to muzzle exit
2. Intermediate stage: bullet's path through the air
3. Terminal stage: from impact onwards

Understanding this later stage is important to understanding the mechanism of injury. All modern military weapons have a rifled barrel which imparts a rotational movement around the longitudinal axis of the bullet termed spinning. When the bullet leaves the barrel, other movements are present. Theoretically, they all are parasitic movements which decrease the accuracy of the projectile, but increase the wounding capacity after impact through oscillations (yawing), precession (wobbling), and nutation (rosette pattern). These parasitic movements increase the destabilization characteristics of a jacketed bullet inside the target, and this is crucial to the actual transfer of energy.

The precise description of what actually happens between impact and final arrest of the bullet has been a matter for debate for a long time, almost as long as the history of firearms itself. In the early 80s, Fackler, from the US Army, developed the concept of "wound profile" [2] (Figs. 8.1, 8.2, and 8.3).

This is still used today to study the behavior of different kinds of bullets. The wound profile is obtained by shooting a bullet in a block of tissue simulant [3] (glycerine soap or gelatine) and observing the characteristics of the bullet's path:

- Entry hole dimension and shape depending on the position of the bullet at impact.
- Initial narrow tract called the "neck."
- An intermediate zone, more or less wide, the "belly."
- Final tract at the end of which you find the bullet (if the block is long enough).

Fig. 8.1 (**a**) The ubiquitous Kalashnikov and 1 (**b**) the British SA80

P. Ley, MD
Trauma Surgeon, EMERGENCY NGO, Milan, Italy
e-mail: paulfley@libero.it

© Springer International Publishing Switzerland 2016

J.D. Robinson (ed.), *Orthopaedic Trauma in the Austere Environment: A Practical Guide to Care in the Humanitarian Setting*, DOI 10.1007/978-3-319-29122-2_8

Fig. 8.2 A 7.62×39 mm AK-47 round and fragments

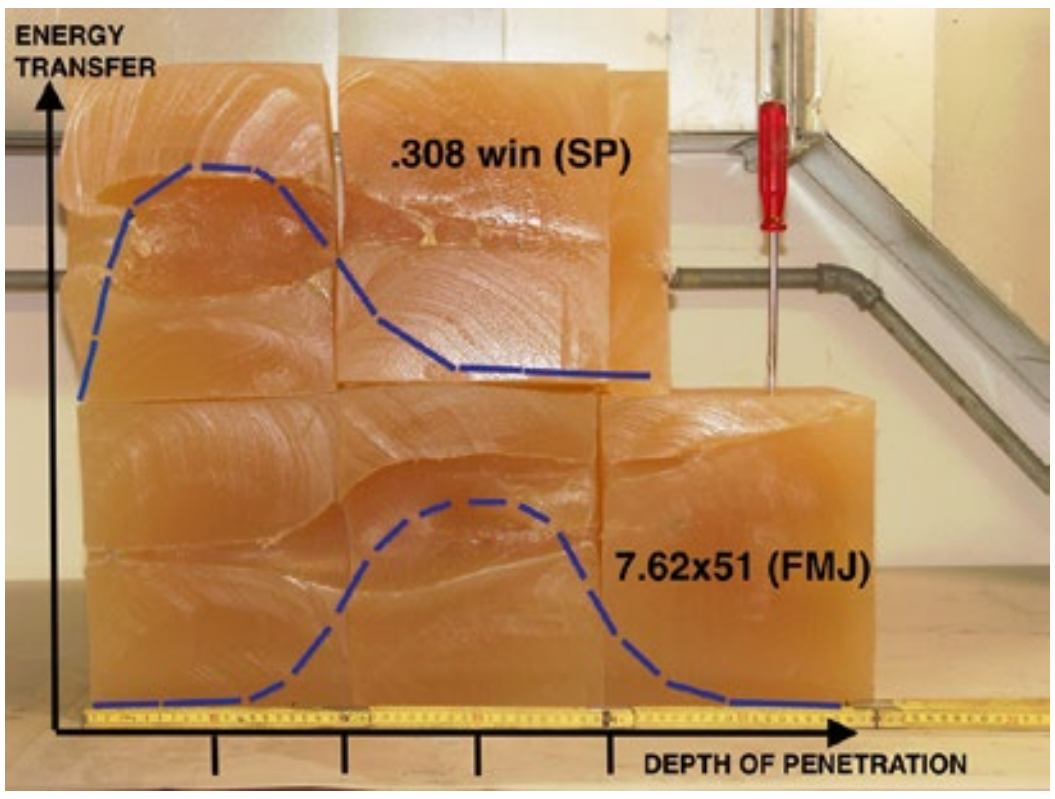

Fig. 8.3 Bullet paths in tissue simulant glycerine soap blocks (Swiss Army Ballistic Laboratory in Thun, Switzerland. ICRC war surgery seminar, 2005) lower blocks: NATO caliber 7.62×51 fmj bullet (full metal jacket) upper blocks: .308 WIN sp bullet (soft point) Despite their names, these bullets differ only by the fact that one is jacketed and the other is a "soft point." Same velocity and same mass: equal amount of kinetic energy but totally different "profile" of energy transfer along the bullet path. The amount of energy transfer but mainly the timing of this transfer is crucial in determining a particular profile. It is essential to realize that the maximum amount of energy transfer can take place deep in the tissue (with severe damage deep under an innocent-looking superficial wound) and that entry-exit wounds can occur in different combinations

Fig. 8.4 Ricochet effect (Swiss Army Ballistic Laboratory in Thun, Switzerland. ICRC war surgery seminar, 2005). A 7.62×51 fmj bullet (same as in lower blocks of 38–1) has been destabilized just before impact by placing a wooden broomstick along its flight path (note the small nick on the stick) resulting in a sideway impact of the bullet with a resulting almost instant transfer of energy totally different from the lower blocks profile in Fig. 9.3. This phenomenon is actually quite common in real cases when bullets are fired through vegetation or hit walls or ground before the final human target

- You may also observe fragmentation of the bullet with two or more secondary paths or deformation without fragmentation.

The entry hole may be small, corresponding to the actual caliber of the bullet presenting tip forward or it may be much greater, for example when a bullet strikes the target sideways. This latter mechanism was called "ricochet" [4] by Kneubuehl, and it happens every time the bullet hits something in flight, like a branch, or bounces off a hard surface and is destabilized before hitting the target (Fig. 8.4).

The "neck" is the initial tract. It is narrow, generally no more than twice the caliber of the bullet. The narrow tract indicates a very low energy transfer to surrounding tissues (Fig. 8.5). The critical feature here is its length as it

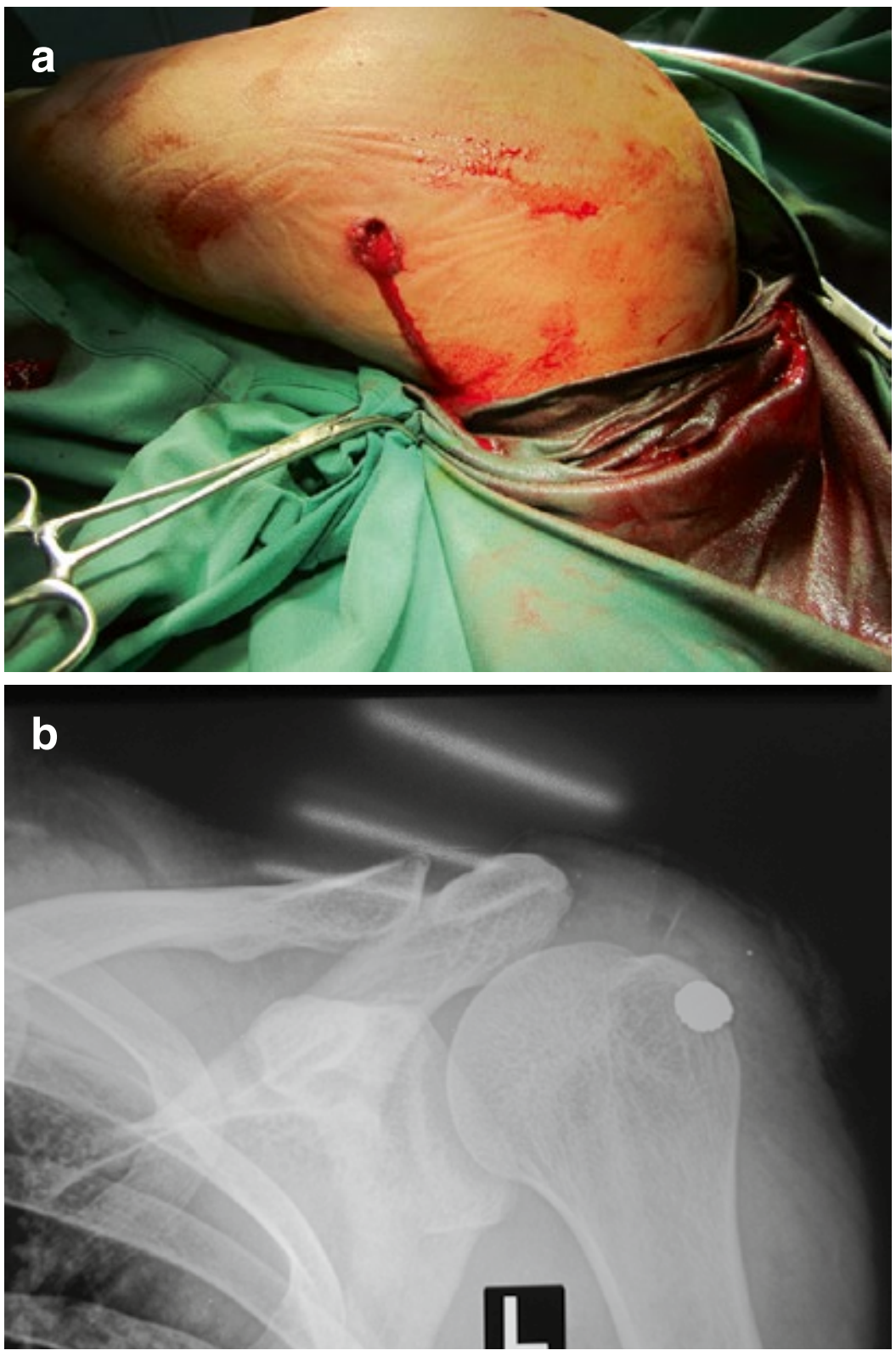

Fig. 8.5 (**a**) X-ray of low velocity bullet lodged adjacent to proximal humerus and (**b**) clinical picture. You can appreciate the entry wound

Fig. 8.6 (**a**) A fighter looking for targets from a roof in Libya and (**b**) A 50 mm caliber machine gun in an Afghan police vehicle

indicates the distance traveled by the bullet before tumbling.

After tumbling there is an intermediate part, the belly, of much larger diameter and volume. This is the part of the bullet path with maximum energy transfer, the amount of which can be visualized by the volume of the belly part. This part corresponds to the temporary cavity where tissues are stretched in a radial and outward way with respect to the bullet path. The final tract may be single or multiple according to a possible fragmentation of the bullet. In this part the energy transfer is low again as indicated by the narrowness of the tract.

This kind of wound profile is a conceptual tool. It shows the behavior of a particular bullet in a homogeneous medium. It can be used to compare different bullets' behavior. Obviously, every single bullet has its own wound profile depending on such factors as velocity, mass, ability to expand or not, and tumbling characteristics (Fig. 8.6). Mass and velocity are the two determinants of the kinetic energy carried by the bullet at the moment of impact. The kinetic energy is directly proportional to the mass while it is proportional to the square of the velocity. Thus, to increase the energy of a projectile, the firing system must increase the velocity, as it can be seen from the following equation:

$$\mathrm{KE} = {}^{1}\!/_{2}\, MV^{2}$$

where KE = kinetic energy in the bullet, M = mass of the bullet, and V = velocity of the bullet.

Increasing the mass is not practical in terms of magazine capacity or total number of rounds that can be carried around by a single soldier. Therefore, a quest for high velocity and small calibers has taken place in the last few decades. The important point to remember is that high velocity is associated with a higher kinetic energy, thus giving a particular bullet a higher wounding capacity. The actual wound is the result of how much of this energy is transferred to the tissues. The maximum energy transfer occurs when the bullet tumbles in the tissues, i.e., when the cross-sectional area abruptly increases, and obviously, this will reach 100 % if the bullet comes to a rest within the tissues. The velocity that determines the available amount of kinetic energy is the one at the point of impact on the target, which can be quite low, and not the muzzle velocity, which is supersonic in all modern assault rifles.

The analysis of wound profiles has some interesting surgical applications: First of all it is important to notice that the transfer of energy is not homogeneous along the bullet path. This is important regarding the extension of the debridement to be done in different parts of the wound. Maximum tissue damage will occur in correspondence of the temporary cavity while tissue surrounding the "neck" portion of the tract may experience very little damage. It also means that a wound can have a superficial benign aspect while deeper anatomic structures are severely damaged (Fig. 8.7). The length of the "neck" can exceed the width of a human limb as is the case of the 7.62×51mm wound profile where it is around twenty centimeters (see Figs. 8.3 and 8.4), or it can be significantly shorter like the one associated to the 5.45 mm fired by the AK-74 (less than 5 cm). Some bullets behave differently at different velocities, not only in terms of quantity of energy that is transported and released but also in terms of different morphology of the wound profile itself with maximum energy transfer occurring at different depths. The other point is that many jacketed bullets do break apart, especially at high velocities (short-range shooting), creating secondary tracts in different directions implying an even more thorough debridement and meticulous exploration of the wound.

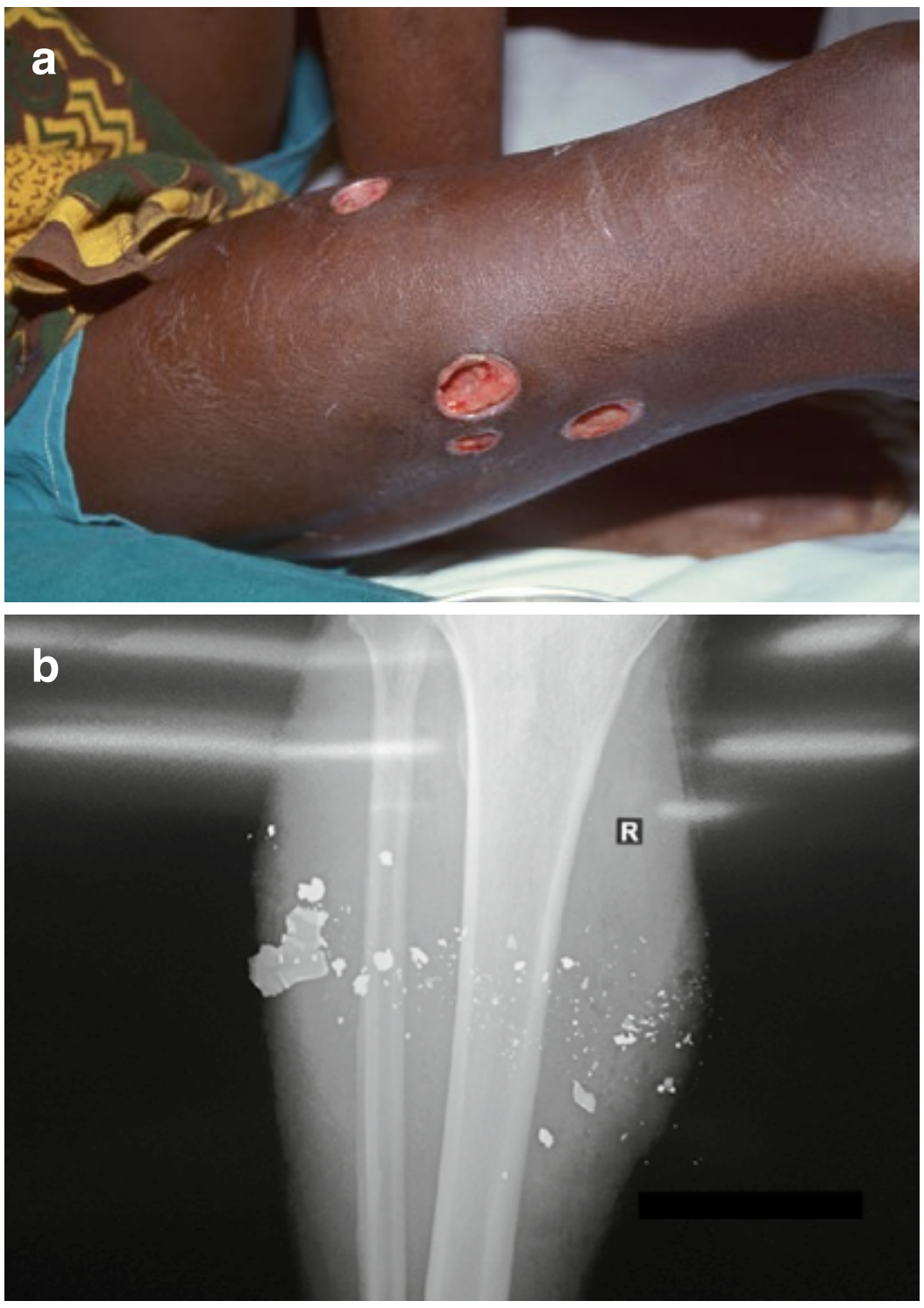

Fig. 8.7 (**a**) Entry-exit wounds at mid-thigh level (St. Kizito Hospital, Karamoja, Uganda, 1997), these wounds of identical appearance are most likely produced by a fmj bullet with a long initial "neck." The bullet exited the slim thigh before tumbling. (**b**) A bullet has penetrated this leg and impacted the bone. Significant fragmentation is evident

So far we've considered the behavior of bullets in glycerine soap (with a density very close to muscle) which is a human body tissue simulant. It is possible to add to glycerine soap some elements to simulate specific biological tissues structures, such as the bone or blood vessels. For the bone, in "wound ballistics," Kneubuehl uses hollow cylinders of different wall thicknesses filled with gelatin, to simulate bone marrow, and covered with a latex film, to simulate

Fig. 8.8 Severe fracture pattern in left distal femur (Emergency Hospital, Lashkar Gah, Afghanistan, 2008), this kind of severe fragmentation can be seen in patients that were hit while walking or running. Weight-bearing long bones like tibia and femur undergo a complex sequence of compression, flexion-extension, and rotational forces during the gait. If a bone is hit exactly when under maximum stress from flexion or rotation forces, extreme fracture patterns can be the result. According to witnesses, this young woman was hit by a single shot while running away from a firefight. She ultimately was amputated at thigh level

periosteum. This artificial bone is then inserted in a glycerine soap block. Many different fractures can be observed, from simple punch-hole fractures to butterfly patterns which are generated by an increase in hydraulic pressure in the marrow. It is interesting to note that, all the bone fragments are found within the temporary cavity and that they are not acting as secondary missiles.

Fracture patterns seen in the field on real patients are sometimes of such a severity (see Fig. 8.8) that some additional mechanism must have a role. Forces like compression, extension, and torque acting on a bone are modifying and amplifying the fracture pattern. This is more marked on lower limb skeletal structures because of body weight action. A bone, like the femur or tibia, hit during the weight-bearing part of the gait will fracture in a much more severe and unpredictable way than if not weight bearing. The lesion shown in Fig. 8.8 has been produced, according to witnesses, by a single shot on a running woman fleeing the firefight.

8.1 Treatment Principles

In treating ballistic fractures, some principles are firmly established. A broad review of the literature from different sources [5–8], either civilian or military, shows a wide consensus on some basic points:

- All war wounds are contaminated and the first goal of war surgery is the avoidance of infection.
- The single most important surgical procedure in the treatment of ballistic lesions is the initial debridement and irrigation.
- Irrigation is done with large volumes (from 3 l upwards) and low pressure (bulb or gravity fed systems).
- The first choice for irrigation fluid is sterile normal saline [9], the second choice is potable water.
- Although antibiotics should be given as soon as possible, they are NOT a substitute for proper surgical debridement.
- War wounds are NEVER closed primarily.
- Initial rigid internal fixation is contraindicated. Initial stabilization must be achieved by external fixation, skeletal traction, or splints/casts following the principles of damage control orthopedics.
- Treatment should systematically include soft tissue management from the beginning.
- Delayed primary closure for standard ballistic wounds is done at 4 or 5 days after initial debridement (Fig. 8.9).

8.1.1 First Steps

After life-threatening injuries have been ruled out or taken care of, the patient must be washed. This means tap water and soap (e.g., castile soap) in a suitable workspace in the emergency room or immediately before the operating room. All wounds should be covered by sterile dressings and these should NOT be removed at this point before surgery. The washing of the wound and its immediate surroundings is done in operating room under

Fig. 8.9 (**a**) X-ray of a young female's left foot gunshot wound, (**b**) clinical picture, and (**c**) an external fixator has been placed to reestablish length of the lateral column following thorough debridement and wash out

anesthesia. This initial washing is NOT part of the irrigation process which is done in conjunction with the debridement, which is the surgical removal by sharp excision of all debris and devitalized tissues:

- *Skin*: sharp excision of skin edges of the wound (1–2 mm). Skin is precious for soft tissue so spare as much as possible.
- *Muscle*: excision of dead or nonviable muscle is particularly important although it is often clinically difficult to distinguish viable muscle from nonviable one. The four C's may be used as a guide (color, consistency, contraction, circulation) but in many borderline instances they have proven unreliable.
- *Bone*: loose bone fragments with no soft tissue attachment to must be removed. If you decide to leave a bone fragment in situ, make sure it has a strong attachment to soft tissue and try to assess its vascularization by snipping a bit of it and check for bleeding. Exposed bone may be protected by soft tissue coverage. For example, medial gastrocnemius rotation flap is an excellent reliable technique for the proximal tibia.
- *Fat*: liberal excision of fat.
- *Nerves, vessels, and tendons*: as far as possible these structures must be protected.

Although debridement is based on simple principles, it is actually technically demanding and the surgeon must keep in mind that *it is the most important single surgical procedure determining the final outcome*. When performing a debridement a surgeon should always anticipate the needs of the delayed primary closure. The need for flaps or skin grafts should be assessed and anticipated for the next surgical plan of action. If there is a plastic surgeon in the field, or someone with similar expertise, the procedure should be carried in close coordination.

- *Irrigation*: This is closely associated with debridement. Its importance is such that in their excellent book *Combat orthopedic surgery*, Owens and Belmont dedicate a full chapter to this issue. Irrigation has been practiced for centuries yet with minimal scientific background. All kinds of additives have been used according to personal beliefs or experience of individual surgeons. The vast majority of them have been shown to be at least useless and potentially harmful (hydrogen peroxide, for example, is still occasionally used despite its recognized tissue toxicity). The current recommendations of the US Army Institute of Surgical Research which are used in the Joint Theater Trauma System Clinical Practice Guidelines (JTTS-CPG) are to

Fig. 8.10 (**a**) An x-ray showing a bullet in a knee, (**b**) medial incision and removal of bullet from inside the joint, and (**c**) removal of plastic cartridge from a bird-hunting rifle

use of normal saline, sterile water, or tap water (potable) if one of or both the former are not available. The optimal method of delivery is by gravity-fed systems or by bulb syringes, no pulse lavage or high-pressure systems.

The volume of fluid required is large, from one to over ten liters. For open fractures you may use the following volumes: 3 l for Gustilo I, 6 l for Gustilo II, and 9 l minimum. These large amounts can quickly deplete your normal saline stock, so be prepared and order more (if possible) or use sterile (boiled) or potable water in the initial phases of irrigation & debridement and use saline only for the final washout (see Fig. 8.9).

8.1.2 Intra-articular Bullets

One of the few indications to explore and remove bullets from patients is when these are lodged in a joint, the spinal canal. The presence of a bullet in a joint can cause a severe inflammatory reaction and synovitis which will damage the knee joint (see Fig. 8.10).

8.2 Compartment Syndrome and Fasciotomies

Compartment syndrome can occur in any limb segment but is prevalent in the leg and the forearm. The examination of patients must always be done with this possibility in mind. The indication for fasciotomy is based solely on the clinical examination. The presence of distal pulses *does NOT rule out* developing compartment syndrome, *neither does an open fracture*. Pain is greater than expected, relentless and doesn't subside even after splitting or removal of every bandage or cast, and is refractory to adequate analgesia. It is elicited by palpation of the

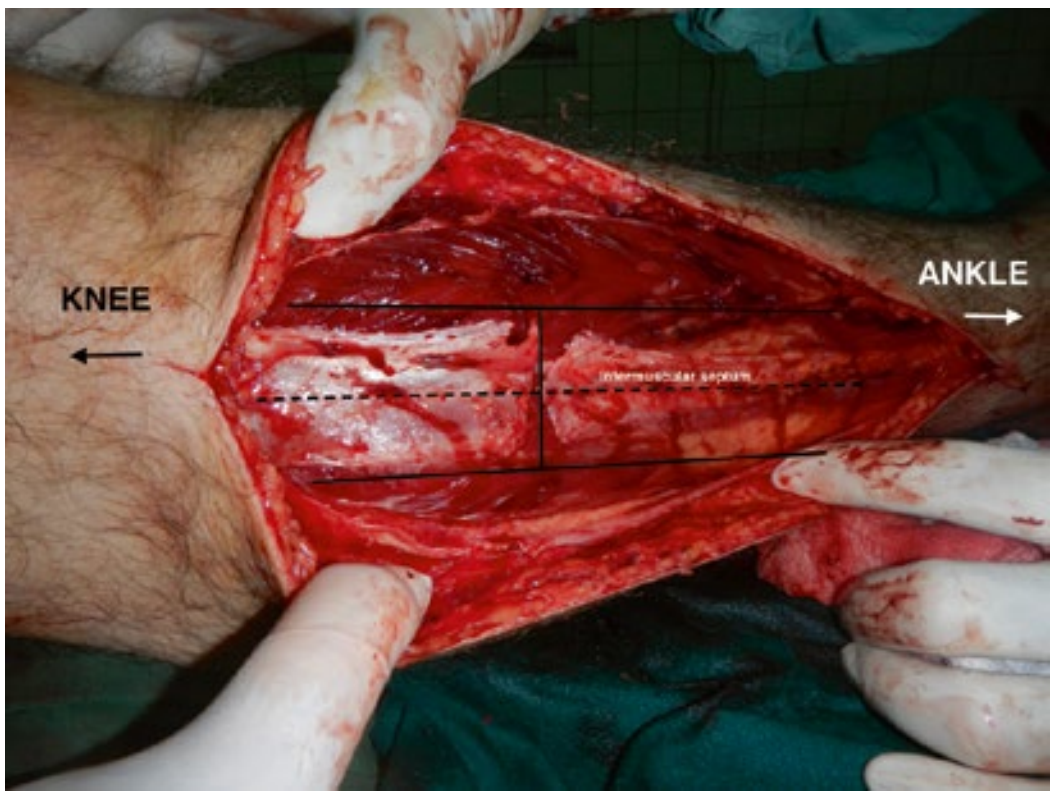

Fig. 8.11 A H-incision technique for decompression of anterior and lateral compartments (Emergency Hospital, Kabul, Afghanistan, 2012); the anterior compartment may be missed if the skin incision on the lateral side of the leg is too posterior. Don't incise more than two finger breadth from the tibial crest. When you encounter the deep fascia make a first, short, transverse cut to positively identify the intermuscular septum. From each end of this first transverse cut, you can then make two parallel longitudinal incisions to decompress the anterior and lateral compartments

involved compartment and by passive stretching of muscle compartments. The classic five P's (pain, paraesthesia, pallor, paralysis, pulselessness) are signs of advanced compartment syndrome, and you should never wait for these before making a decision. Military protocols following a gunshot wound to the extremities include prophylactic fasciotomies to prevent the development of compartment syndrome. There is no place for semi or partial fasciotomies. Always use full length skin incisions and make sure *ALL compartments* are decompressed (Fig. 8.11) (see Chap. 28).

8.3 Fracture Management

Always think about what is the simplest and safest solution. Conservative treatment should always be considered, even at some "functional" cost. In well-resourced healthcare systems, some conservative treatments are not acceptable because of inferior functional outcomes when compared with operative or complex reconstructive procedures. This higher functional outcome cannot be an argument in an austere environment, where either the equipment or the implants themselves are simply not available or the risks associated with internal fixation are not acceptable. A remote community farmer is much better with a femur fracture treated conservatively resulting in a modest degree of shortening that can be compensated with a shoe raise, than with an infected plate which may eventually lead to an osteomyelitis from which he may never recover. You must think in terms of reasonable results even if sometimes you'll have to choose the lesser evil.

- *Splints*: unless you have the luxury of ready-to-use fiberglass splints with padding and bandage, you'll have to make your own with POP (Plaster of Paris) in a traditional way. These POP splints are inexpensive and can be adapted to many clinical settings. They are most useful for upper limb fractures and for leg and foot fractures. The use of POP splints for femur fractures is much less efficient than traction or external fixation, but can be used in the pediatric setting. Do not forget however that POP in a tropical or equatorial environment, with high ambient humidity, will take a long time to harden and it may be difficult to tolerate.
- *Traction*: very efficient, fast, and easy to apply. Skeletal traction for lower limb is best done with Steinman pins through calcaneus for leg fractures and through proximal tibia for femur fractures. Traction through distal femur should not be used as it denies the possibility of further treatment with Perkins traction. For humerus fractures, traction is applied by means of a Kirschner wire (K-wire) through the olecranon. The use of a K-wire implies a tensioning traction bow is necessary, so you should make sure it is available. Inadequate traction, or poorly set up and monitored, can cause great harm, so you must be familiar in its application and use, and close attention to pin site care must be adhered to (Fig. 8.12).

Traction is applied through a transtibial Steinmann pin, a simple rope traction bow, and a custom-made traction weight. The distal half of the bed is removable and can easily be put back

Fig. 8.12 (**a**) Perkins traction for femur fractures (Complexe Pediatrique, Bangui, Central African Republic, 2013). (**b**) Transolecranon traction for open fracture of distal humerus (complexe pediatrique, Bangui, Central African Republic, 2013)

in position during the intervals between the exercise sessions (four to six times a day).

- Among conservative treatment options, only the Perkins traction is able to fulfill the following points: maintenance of alignment of bone fragment, excellent rotational control (when the knee is flexed and the leg is vertical, physiological rotation is automatic), avoidance of distraction (because of muscle contraction), encouragement of joint motion, and maintenance of muscle tone. Mean duration of traction is eight weeks. This method has been extensively used in many remote African hospitals and owed its popularity to Maurice King Peter Bewes who described it in details in *Primary Surgery*, a bible for low-tech environments published by Oxford University Press.
- In transolecranon traction for open fracture of distal humerus (Fig. 8.12b) after immediate surgical debridement in theater, the use, initially, of this makeshift overhead traction system allowed for optimal care of the wound in the anterior aspect of distal arm. An associated closed fracture of distal forearm is also present. This young patient was successively treated with a cast, applied with the traction in situ. In austere environments, it is impossible to engage in complex reconstruction and osteosynthesis of open comminuted periarticular fractures. The conservative approach is the safest alternate and, very often, gives satisfactory results.
- *External fixation*: if available, it is the best solution for treatment for fractures with soft tissue loss or vascular lesions. The realities in an austere environment require that an ex-fix should be simple, effective, and quick to apply. Generally half-pins and monoaxial static configurations, like the older Hofmann design, are adequate. Classic configuration of three pins above and three pins below the fracture site with a double bar should be the goal. This configuration is stable enough to allow weight bearing and can be progressively

Fig. 8.13 Proximal humerus fracture from bullet injury treated with T-shaped ex-fix (Emergency Hospital, Lashkar Gah, Afghanistan, 2008), when one of the fracture segments is short, this configuration is simple and effective. Notice the soft tissue wound safely healed. This patient was treated initially with thorough debridement and irrigation, followed by immediate stabilization with this ex-fix. A delayed primary closure (DPC) was performed 5 days later. The ex-fix was retained as a definitive stabilization

“deconstructed” to render it dynamic thus allowing for a better fracture site compression. When one of the bone fragments is short, you can use a T-shaped configuration to avoid spanning the joint and still allowing mobilization (Fig. 8.13). In many instances, an ex-fix can be used as definitive stabilization, otherwise they can be removed as soon as the soft tissue deficit has healed and substituted by a cast.

8.4 Soft Tissue Management

All war wounds, whether or not they are associated with fractures, are left open after the initial surgery. Nevertheless, you must plan your closure strategy right from the beginning. At initial surgery you should anticipate the need for eventual flaps or skin grafts. The standard classic procedure, strictly followed by such organizations like the international committee of the red cross (ICRC) and the NGOs Emergency and Medicines sans frontieres (MSF), is that the wound is treated by delayed primary closure (DPC) after 3 to 6 days post-op. This is a basic, safe strategy that proved successful in many civilian war hospitals in the last decades all over the world. Nevertheless, you will still encounter wounds that cannot be managed this way at the prescribed time and will need further debridement and irrigation before they become safe for closure, or the soft tissue defect is such that some sort of plastic or reconstruction procedure may be necessary [10, 11]. In this latter case, always start with the simplest procedures like spontaneous granulation (second intention), split-thickness skin graft (SSG), and local rotation flaps. (See Chap. 46) (Fig. 8.14).

Fig. 8.14 Cross-leg flap for open right leg fracture (Emergency Hospital, Kabul, Afghanistan, 2012), picture taken at three weeks post-op, just prior to weaning procedure. The pedicled flap was raised from the medial aspect of the left proximal leg at DPC time (five days after initial trauma), along with a cancellous bone graft from the iliac crest and stabilization with an ex-fix. Donor site was immediately covered with an SSG. Pedicled flaps like this one and the inguinal MacGregor flaps are still a workhorse in many remote parts of the world

8.4.1 Amputations

The decision to amputate is always a difficult one except when the magnitude of the trauma is such that there are no doubts in anybody’s mind, particularly in the patient’s mind. It is often the result of emotionally charged discussions with the patient and/or the relatives. Religious beliefs concerning body integrity are often involved. Not an easy task, there are no substitutes here for experience and surgical wisdom (see Chap. 29).

8.5 Physiotherapy

It is an integral part of the treatment and should be started immediately. It requires dedicated personnel that you will have to train on he spot to meet the specific needs of your patients. (See Chap. 23.)

References

1. Kneubuehl BP. Wound ballistics: basics and applications. Berlin/Heidelberg: Springer; 2011.
2. Fackler ML, Malinowski JA. The wound profile: a visual method for quantifying gunshot wounds components. J Trauma. 1985;25:522–9.
3. Kneubuehl BP. General wound ballistics. In: Wound ballistics: basics and applications. Berlin/Heidelberg: Springer; 2011. p. 87–160.
4. Coupland RM. Wound ballistics and surgery. In: Wound ballistics: basics and applications. Berlin Heidelberg: Springer; 2011. p. 305–19.
5. Giannou C, Baldan M, Molde A. War surgery: working with limited resources in armed conflict and other situations of violence, vol. 1 and 2. Geneva: ICRC; 2013.
6. Office of the Surgeon General. Emergency war surgery, fourth United States revision. Fort Sam Houston: Borden Institute; 2014.
7. Owens BD, Belmont PJ, editors. Combat orthopedic surgery: lessons learned in Iraq and Afghanistan. Thorofare: Slack Incorporated; 2011.
8. Mattox KL, Moore EE, Feliciano DV, editors. Trauma. 7th ed. New York: McGraw-Hill; 2013.
9. Waterman S, Fleming ME, Owens BD. Chapter 11: Irrigation and debridement. In: Owens BD, Belmont PJ, editors. Combat orthopedic surgery: lessons learned in Iraq and Afghanistan. Thorofare: Slack Incorporated; 2011.
10. US Army Institute of Surgical Research. Joint theater trauma system-clinical practice guidelines. Department of Defense; 2012.
11. Ritenour AE, Dorlac WC, Fang R, Woods T, Jenkins DH, Flaherty SF, Wade CE, Holcomb JB. Complications after fasciotomy revision and delayed compartment release in combat patients. J Trauma. 2008;64(2 Suppl):s153–62.

Further Reading

Courbil LJ, editor. Chirurgie d'urgence en situation precaire. Editions Pradel (in French). 1996.

Elsayed N, Atkins J. Explosion and blast-related injuries. Amsterdam: Elsevier Academic Press; 2008.

Hopperus Buma A, et al., editors. Conflict and catastrophe medicine. New York: Springer; 2009.

King M, Bewes P. Primary surgery (reprint). Vol. 2. Trauma. Oxford Medical Publications; 1993. Also available at http://www.primary-surgery.org/ps/vol2/html/index.html.

Lerner A, Soudry M. Armed conflict injuries to the extremities. Berlin: Springer; 2011.

Mahoney P, Ryan J, Brooks A, William Schwab C. Ballistic trauma. London: Springer; 2005.

Martin M, Beekley A, editors. Front line surgery. New York: Springer; 2011.

Masquelet A, Gilbert A. An atlas of flaps of the musculoskeletal system. Published by Informa Healthcare, 2001.

Moran SL, Cooney III WP. Soft tissue surgery. Philadelphia: Lippincott Williams & Wilkins; 2001.

Nessen SC, Lounsbury DE, Hetz SP, editors. War surgery in Afghanistan and Iraq. Washington, DC: Office of the Surgeon General, Borden Institute, Walter Reed Army Medical Center; 2008.

Trueta J. Principles and practice of war surgery. St. Louis: Mosby Company; 1943.

9

Orthopedic Blast and Shrapnel Trauma

Scott C. Wagner, Jean Claude G. D'Alleyrand, and Romney C. Andersen

Injuries caused by explosive mechanisms often manifest in devastating, complex patterns that involve multiple organ systems, extremity amputations, and extensive thermal damage [1]. Ongoing military experience in managing such injuries, which have been increasingly more common during the conflicts in Iraq and Afghanistan, has provided some insight into the biophysics of blast trauma and allowed for the development of various treatment algorithms [1]. Aggressive battlefield resuscitation protocols and rapid medical evacuation have produced survivability patterns never before seen in the history of warfare, despite a relative increase in injury severity as the wars have progressed [2, 3].

Improvements in tourniquet use and body armor have also contributed to the maintenance of this low mortality rate [4]. Multiple extremity amputations (MEAs) have also been encountered more frequently, representing up to 18 % of all military casualties in Afghanistan. Significant genitourinary trauma, fractures and/or dislocations, and severe soft tissue damage are the most commonly associated injuries in these patients [5]. The long-term medical resource requirements necessary for adequate management have been shown to be exceedingly high, including a high number of operative interventions per patient, increased blood product utilization, and intensive care unit (ICU) length of stay [5].

While it is often difficult to extrapolate high-energy combat blast trauma to injuries sustained in the civilian population, it is important to recognize that casualties from land mines occur every 20 min worldwide, while criminal bombings in the United States alone have been reported at a rate of 205 per year [6, 7]. Unexploded ordinance contaminates many poor, rural areas in underdeveloped countries, particularly those with recent history of conflicts (Fig. 9.1).

The lack of infrastructure in many of these countries typically makes their poorest citizens, often rural agrarian workers or children, significantly vulnerable to potentially devastating injuries [8]. Unexploded ordinance includes antipersonnel and antitank land mines, as well as mortar bombs, rocket-propelled and rifle grenades, artillery shells, cluster bomb submunitions, and aircraft bombs [8], all of which can cause severe injury to patients without available access to many basic medical technologies (Fig. 9.2). In rural Cambodia, 61.7 % of blast-injured pediatric patients were injured by unexploded ordinance in contrast to land mines, in comparison to 22.6 % of adult patients [8].

S.C. Wagner, MD, MC/USN
J.C.G. D'Alleyrand, MD, LTC MC/USA
R.C. Andersen, MD, COL MC/USA (✉)
Department of Orthopaedics,
Walter Reed National Military Medical Center,
Bethesda, MD, USA
e-mail: romney.c.andersen.mil@mail.mil

© Springer International Publishing Switzerland 2016

J.D. Robinson (ed.), *Orthopaedic Trauma in the Austere Environment: A Practical Guide to Care in the Humanitarian Setting*, DOI 10.1007/978-3-319-29122-2_9

Fig. 9.1 Sign displayed outside a minefield in the Republic of Kosovo. Between 1998 and 1999, the Kosovo War devastated the small, Eastern European country, which today is recognized as a sovereign nation by the United States and United Kingdom. The rate of injury from land mines remains relatively high


[redacted]

Fig. 9.2 The effects of a land mine on the lower limb. Land mines are a severe burden on the health and economic infrastructure of the developing world, as thousands of people are maimed and killed every year

Suicide bombings have also become more frequent in the civilian setting, with an associated increase in the rate of high-energy penetrating trauma [9]. Suicide attacks generally occur in densely populated urban areas, in contradistinction to landmine injuries, and have been shown to be associated with a novel pattern of injury directly related to the primary blast wave and fragment injuries after detonation [9, 10]. Patients injured in such terrorist explosions are more likely to sustain chest trauma when compared to blunt trauma, with severe lung contusions and penetrating injuries, as well as open limb fractures [9, 10]. Metal debris deliberately placed in the explosives, such as nails, bolts, or screws, increases the magnitude of the damage inflicted on injured patients and is the primary cause of morbidity in most terrorist attacks [9, 10]. However, thoracic vertebral injuries, as well as liver, spleen, and kidney damage are less common with suicide bombings when

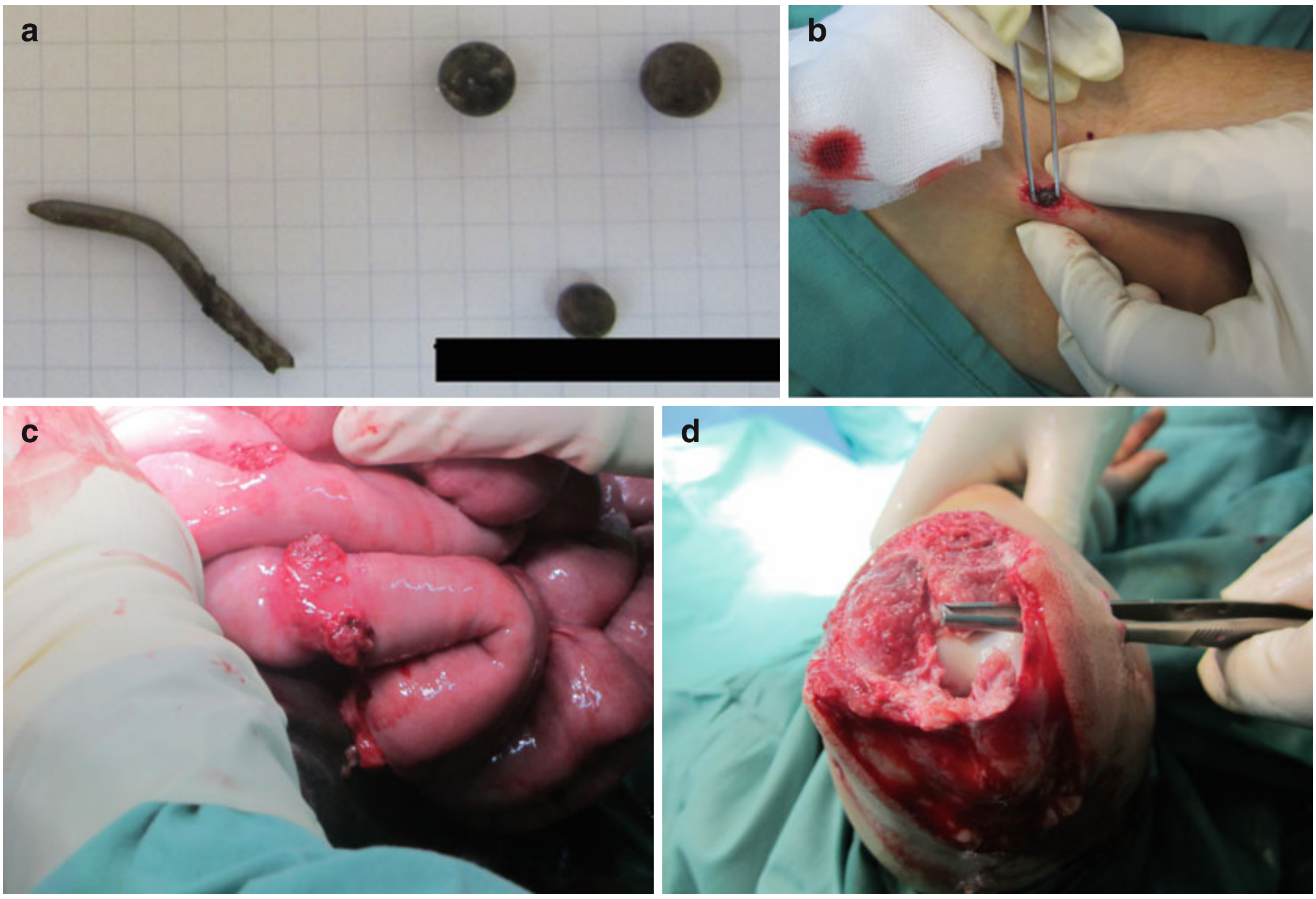

Fig. 9.3 (**a**) Shrapnel from a suicide bomber's jacket and (**b**) removal of ball bearing from a suicide bomber victim. The risks (e.g., further soft tissue damage) and benefits (e.g., prevention of infection) of shrapnel removal have to weighed carefully. (**c**) Multiple bowel perforations from ball bearings in this victim from another attack. The same patient had injury in the elbow(**d**)

compared to gunshot or blunt wounds, as the rib cage provides some level of protection against the blast trauma [10] (Fig. 9.3).

Novel surgical techniques and developments in extremity reconstruction continue to revolutionize the management of blast injury patterns, and strategies for resuscitation, as well as temporizing surgical measures to allow for successful definitive management, have evolved throughout the recent conflicts in the Middle East and Central Asia. While many of these techniques cannot be completely utilized in many austere environments, the principles guiding their implementation can be applied.

9.1 Biophysics of Blast Trauma

All explosive weapons are composed of three basic elements: the casing, the explosive mixture, and a fusing mechanism [7]. The casing is generally designed to maximize fragmentation after initiation of the explosion; the explosive mixture provides fuel for the reaction, while the fusing mechanism initiates the actual blast reaction [7]. At detonation, a rapid exothermic chemical reaction is initiated that releases the stored potential energy in a solid or liquid material by rapid conversion to its gaseous phase [11, 12]. The superheated gas rapidly expands and compresses the surrounding atmosphere, with local pressures ranging from 1.4 to 3 million pounds per square inch, creating a supersonic shock wave that propagates in all directions from the epicenter of the blast [12, 13] (Fig. 9.4).

The patterns of injury sustained by casualties involved in explosive attacks or accidents vary widely with the type of explosive material, but regardless of any other factors, all "blast injuries" can be categorized as primary, secondary, tertiary, or quaternary [11] (Table 9.1).

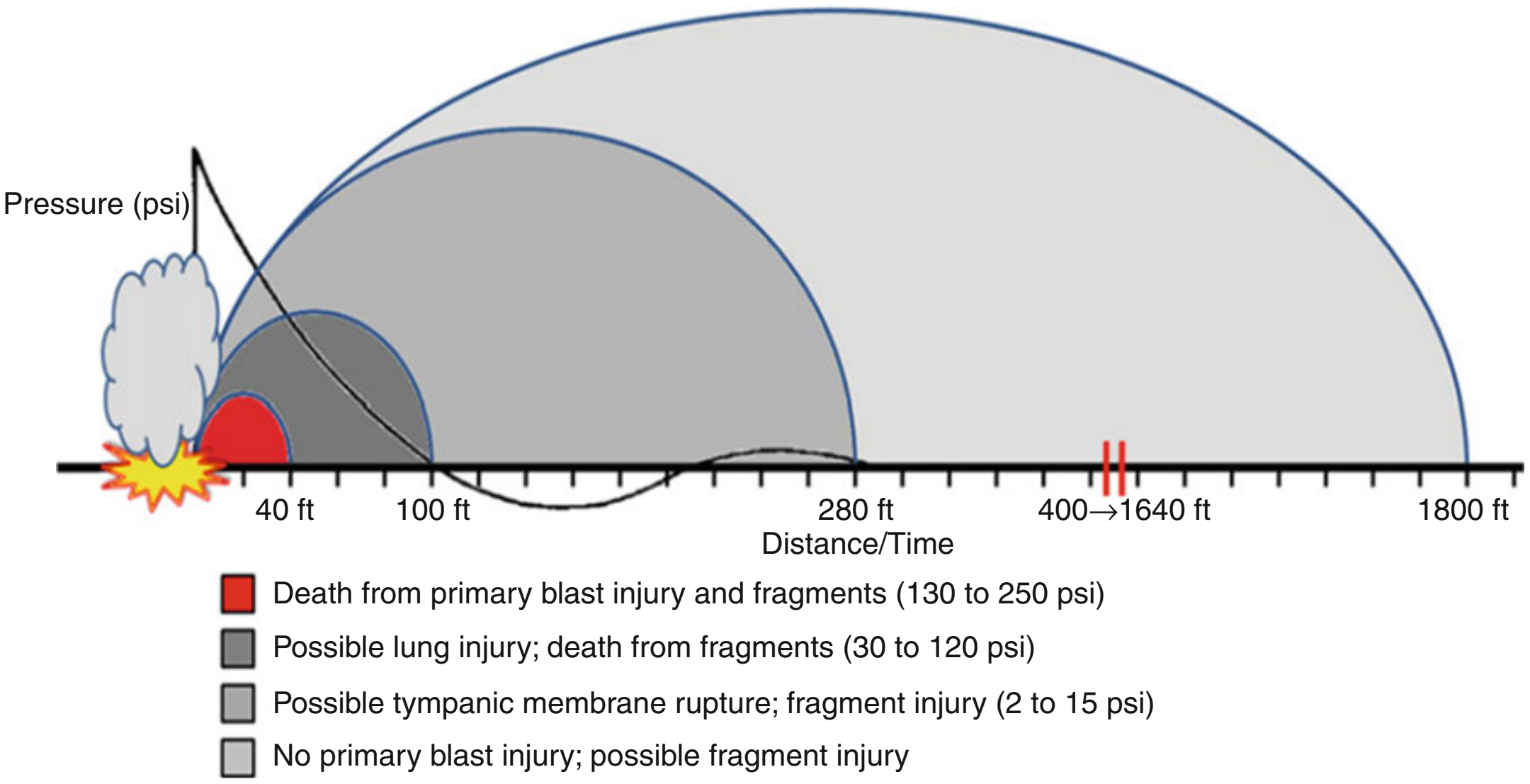

Fig. 9.4 Primary and secondary blast radii comprise the Friedlander curve, illustrated here for a 155 mm shell explosion with 100 kg of trinitrotoluene equivalent (adapted from Kang et al. [11], with permission)

Table 9.1 Classification, definition, and representative examples of blast injuries

Blast injury patterns		
Type	Definition	Examples
Primary	Blast wave propagates through body tissues, causes rapid movement of fluid and implosion-type injuries	Blast lung Traumatic brain injury Tympanic membrane rupture
Secondary	Ballistic injuries caused by penetration of body tissues by metallic fragments (e.g., nails, bolts, ball bearings)	Penetrating abdominal or thoracic injury Open fracture Traumatic amputation
Tertiary	Whole body displacement, or other large object may be violently translocated, or structure collapse	Crush injury Blunt trauma
Quaternary	Any associated injuries	Thermal injury Smoke inhalation Suffocation

The initial blast wave produced during detonation, which is termed the "blast front," is the major contributing factor to primary blast injuries [11]. Primary blast injuries are directly related to overpressure damage sustained by patients in the immediate vicinity [11, 14]. Propagation of the blast wave through human body tissues causes a violent change in pressure that transfers the energy impulse of the wave from the surrounding medium to the tissue itself, leading to rapid compression and reexpansion [15]. This phenomenon is termed "spalling" and involves the impartment of significant shear and stress forces to the tissue at air-fluid interfaces that cause an explosive shift in fluid to less dense tissue or potential anatomical spaces [11, 13, 15–17]. Most commonly, primary blast effects result in tympanic membrane rupture, air emboli, ossicular disruption, and alveolar hemorrhage, among other signs of physiologic disruption [18].

After dissipation of the initial blast wave, ballistic energized by the blast can cause severe penetrating or shear injuries. Prior to World War I, specific devices called "Shrapnel shells" were developed by the British artillery officer Major-General Henry Shrapnel to increase surrounding damage upon detonation. These devices utilized metal ball bearings encased in the shell that would scatter after the initial explosion, increasing secondary blast injury. Today, the casing of high-explosive shells fragments effectively at detonation without the need for Shrapnel

Fig. 9.5 (**a**, **b**) Severe soft tissue injuries and a traumatic forequarter amputation associated with blast trauma. (**c**) Lateral thigh and hip blast injury in a civilian. What will the options be following adequate debridement

bearings, but it is not uncommon for improvised explosive devices (IEDs) or other makeshift explosives to utilize similar objects (e.g., nails, ball bearings) to increase secondary injury [11] (Fig. 9.3). Secondary blast injuries are more common than primary injuries, because these ejected fragments typically travel long distances at high speed, and the effective range for such injuries exceeds that of the blast wave by a factor of 100 [6, 11]. Erratic, high velocity rotational movements of irregular fragments can lead to increased local tissue damage [6, 11, 19].

Secondary blast injuries are the primary cause of major extremity amputations and are often the most immediately life-threatening injuries, if the casualty survives the effects of primary blast injury [11]. These types of blast injuries comprise the majority of combat-related major trauma and are responsible for the increase in incidence of extremely severe amputations such as triple or quadruple extremity amputations, as well as traumatic hemipelvectomies [5, 20] (Fig. 9.5).

Tertiary blast injuries involve displacement of the entire body of the casualty, or crush injuries sustained by large projectiles, or even impalement of the patient on other objects [6, 11]. It is via the tertiary blast mechanism that most major extremity or axial skeleton fractures occur, including pelvic and low lumbar burst fractures [21, 22]. This mechanism is particularly relevant to occupants of vehicles that sustain a localized blast, as force-dependent vertical acceleration of the vehicle transfers energy to the seated occupants, which can lead to pelvic and lumbar fractures. At the peak of the vehicular displacement, the occupants can sustain head or cervical trauma, and the rapid return to the ground subjects the occupants to additional blunt trauma [6].

Lastly, quaternary injuries include all complications or other associated injuries, such as thermal damage, gas or smoke inhalation, and asphyxiation [6]. It must be emphasized that these types of injuries rarely occur in isolation, but rather occur in rapid succession and exist concurrently, thus leading to significant multisystem damage. Thermal injuries can be significant, and rapid successful initial management of these injury patterns is crucial to patient survival.

Fig. 9.6 Examples of blast injury patterns according to the International Red Cross. (**a**) Shows quaternary injury (flash burns), (**b**, **c**) show examples of tertiary blast injury (traumatic amputations) and (**d**) shows an example of secondary injury, with flying debris and bomb fragments causing injuries

The International Committee of Red Cross classification for blast injury pattern categorizes injuries based on location: Pattern 1 includes lower extremity trauma, typically caused by stepping on antipersonnel land mines [23]. Pattern 2 comprises random injuries sustained secondarily from a nearby explosion, while pattern 3 involves damage to the face, upper limbs, and torso [23] (see Fig. 9.6a). Pattern 3 injuries most often occur when the patient handles the explosive ordinance directly [23] (Fig. 9.6b). Children living in areas contaminated by a large amount of unexploded ordinance are at substantial risk for patterns 2- and 3-type injuries, because they are more likely to pick up or investigate explosives [8]. Adults, in contradistinction, are more likely to step on antipersonnel mines and sustain lower extremity trauma [8] (Fig. 9.3).

Wound infection is often the most devastating complication that can develop and is often related to contamination of the wounds at the time of injury. Osteomyelitis is a relatively common outcome following blast injuries in the civilian sector, as the burden of wound infections experienced in disaster scenarios is exceedingly complex and difficult to completely characterize [24]. Angioinvasive fungal infections have also been reported in association with blast injuries [25], with reportedly up to a 30 % mortality rate [26], likely related to severe immunocompromise that occurs in polytraumatized blast patients [25]. Civilian blast trauma from land mines or other ordinance often presents in a delayed

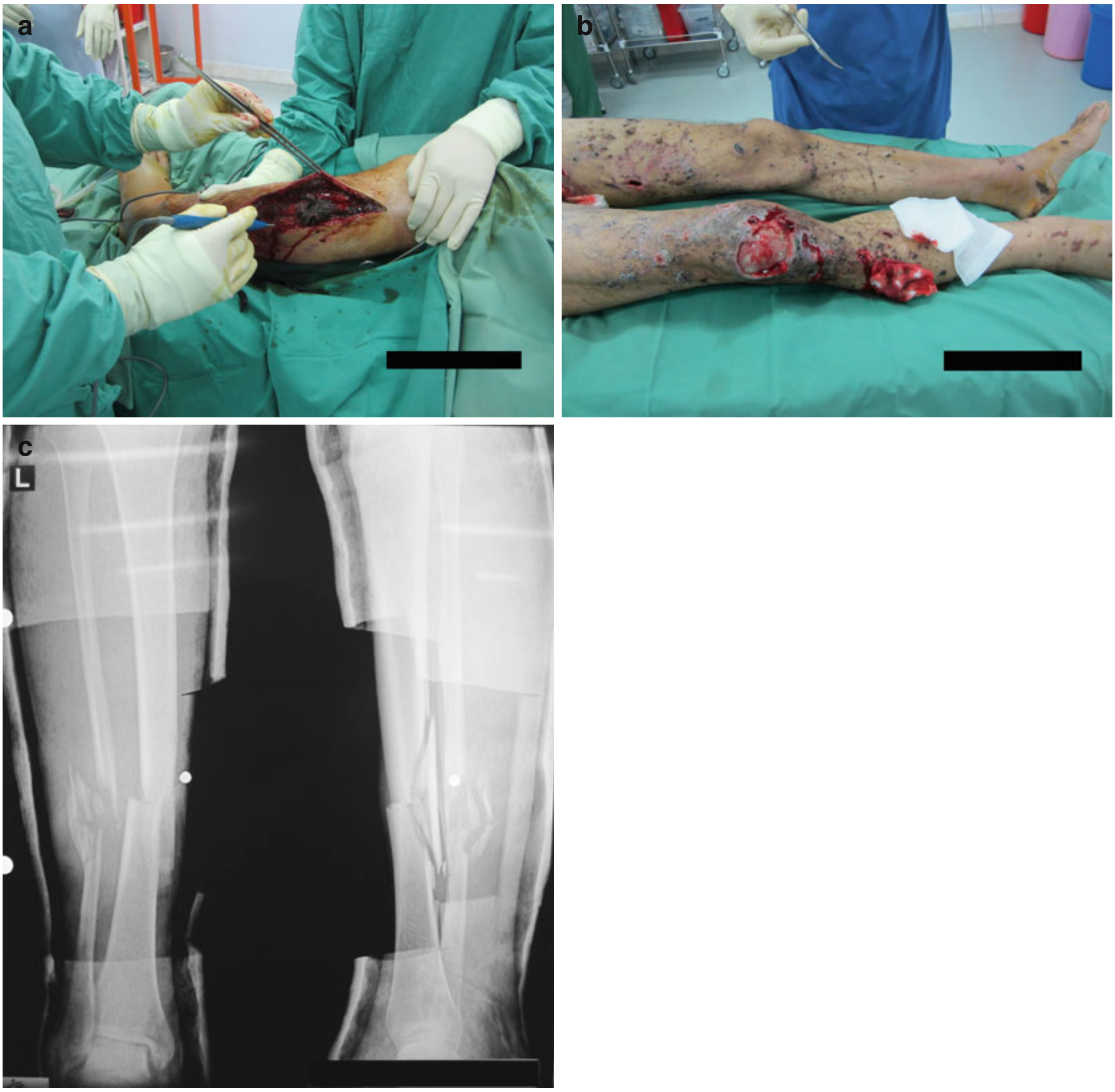

Fig. 9.7 (**a**) Debridement of deep contamination caused by a small mine. The original wound was a small area at the distal end of the wound in the photograph as an extended incision was necessary to debride the contaminated tissues. (**b**) A victim of a suicide bomber showing multiple shrapnel injuries and soft tissue loss. Thorough wound care is necessary to prevent infection and osteomyelitis. The apparently innocuous ball bearings can cause comminuted fractures (**c**)

fashion, with considerable contamination that leads to increased morbidity and mortality (Fig. 9.7).

9.2 Initial Management of Blast Injuries

Major orthopedic trauma in combat or disaster scenarios is often sustained in extreme or austere environments that are not entirely comparable to the civilian or community experience. Many nongovernmental organizations (NGOs) that provide medical care in areas where civilian blast injuries are common have found that dedicated prehospital trauma assistance and small, austere medical outposts can improve mortality, despite a general lack of medical resources [8]. The wartime experience in management of the multiply injured blast patient that has been subjected to rigorous evaluation in such settings has led to novel resuscitation techniques [27]. Emergent proximal hemorrhage control, hemostatic dressings, and temporary vascular shunts have also improved survivability in blast injuries [27]. Only relatively recently have specific treatment guidelines for the early management of severe, multisystem blast injuries been developed [28, 29].

The early use of tourniquets has been shown to be the most effective adaptation to the initial management of severe extremity or vascular injuries [4]. A tourniquet is defined as “any limb constrictive device, whether improvised or commercially manufactured, used in an attempt to stop extremity bleeding” [4]. Rapid exsanguination from compressible limb injuries is possible, though blast injured patients typically bleed more slowly [4]. Regardless, tourniquets should be applied as quickly as possible to the extremity, ideally within 10 min of injury, as the lifesaving benefits of the tourniquet are reduced if application occurs after the initiation of hemorrhage shock [4].

The tourniquet should be placed as proximally on the limb as possible, outside of the zone of injury. Morbidity from prolonged tourniquet use, such as nerve injuries or amputation shortening, has been previously reported [30, 31]. However, Kragh et al. [4] performed a prospective survey of tourniquet use in combat-injured patients and found that no limbs were lost as a result of tourniquet use, while any nerve palsies were transient and the overall survival benefits were clear. Currently, the American College of Surgeons Committee on Trauma recommends that at the time of injury, direct pressure or a pressure dressing should be applied to the injured extremity [32]. If the hemorrhage is not controlled and the wound is amenable to tourniquet placement, the tourniquet should be applied. The guidelines recommend using any commercially produced tourniquet with a windlass, ratchetting, or pneumatic device if available [32]. If commercial tourniquets are not readily obtainable, a tourniquet may be improvised using the *Spanish windlass technique* [33].

9.2.1 Spanish Windlass Technique

1. A piece of rubber tubing (not narrow) is wound around the extremity, and a length of cloth is tied around the tubing.
2. A long rigid object, such as a piece of wood or metal, is tied to the cloth, and the ends of the rubber tubing are tied to the ends of the rigid object.
3. The rigid object is then rotated to tighten the rubber tubing down on the extremity, until the arteries are occluded and hemorrhage is controlled [33].

Table 9.2 Recommendations for the use of tourniquets and hemostatic dressings at the time of injury, prior to definitive care

Prehospital hemorrhage control	
Tourniquets	Hemostatic dressings

Apply if hemorrhage not controlled with direct pressure, and:
Wound amenable to tourniquet
Commercial tourniquets recommended
  Avoid narrow, elastic, or bungee-type devices
  Can be quickly improvised if necessary
	Apply if hemorrhage not controlled with direct pressure, and:
	Wound is not amenable to tourniquet
	Available products include:
	  Kaolin-based granules or gauze
	  Chitosan bandages
	  Novel keratin or polyurethane biomaterials

In the prehospital setting, the Committee recommends against releasing a tourniquet until definitive care is available [32]. Hemorrhage control recommendations are summarized in Table 9.2.

Aggressive transfusion is often required, and it is imperative that blood product stores be maintained when possible [28]. If maintenance of blood components is difficult or unrealistic, any available treating staff and or family members and carers can be used as a “walking blood bank” to provide whole blood at the time of resuscitation [34]. However, initial management at the locus of injury begins with basic life support (BLS) and advanced trauma life support (ATLS) measures and continues with damage control surgery.

Blast casualties may arrive in extremis, often with severe pelvic or perineal injuries and/or extremity amputations. Resource demand for even one of these patients can deplete the entirety of the field hospital’s reserves [5, 27, 28]. Frequently, these patients arrive with cardiopulmonary resuscitation (CPR) in progress, which may have been continued for a relatively long period prior to arrival, and they may also present with hypothermia, acidosis, and hypercoagulability [28].

Focused assessment with sonography for trauma (FAST) is useful on initial evaluation for thoracic and abdominal injuries and in unresponsive patients sustaining penetrating trauma, appropriate pupillary reaction with organized cardiac electrical activity, should provide enough information to consider thoracotomy in the trauma bay for proximal vascular control [35]. Tourniquets placed prior to presentation should be appraised. Focused examination of the injury patterns should begin after initial hemostatic resuscitation has begun and after intravenous (IV) access and the airway have been secured.

Complex unstable pelvic fractures are often not readily apparent on presentation, and a thorough physical exam must include evaluation for any external lacerations or open injuries involving the rectum or genitourinary system, which can suggest open pelvic injury [1]. Pelvic fractures can be stabilized temporarily with application of a pelvic binder or compressive sheet if the binder is not available, which decreases the volume of the true pelvis and provides some level of hemostasis [36, 37] (see Chap. 39). Radiographic evaluation should be limited at the time of initial evaluation to those images that can be obtained quickly while in the trauma bay, unless stability permits a more thorough examination [28].

If thermal injuries are present, adequate estimation of the body surface area involved guides fluid resuscitation efforts, and the degree of the burns provides information regarding healing potential and the need for prophylactic escharotomies [38]. The “rule of nines” illustrates the process by which burn surface area can be estimated (Table 9.3).

The Parkland formula for fluid resuscitation in patients sustaining severe thermal injuries states that the 24-h volume of fluid to be infused is equal to the percentage of the total body surface area involved multiplied by the patient’s weight (in kilograms) multiplied by 4 (milliliters of lactated Ringer’s per kilogram) [38]. The first half of the calculated volume is infused over the initial 8 h after injury, followed by the second half over the subsequent 16 h [38].

Table 9.3 Algorithm to estimate the percentage of body surface area (BSA) involvement in thermal injuries

Thermal injury body surface area (BSA) estimation			
Adult		Pediatric	
Body part	*%BSA*	*Body part*	*%BSA*
Upper extremity	9 %	Upper extremity	9 %
Head	9 %	Head/neck	18 %
Neck	1 %	Lower extremity	14 %
Lower extremity	18 %	Anterior trunk	18 %
Anterior trunk	18 %	Posterior trunk	18 %
Posterior trunk	18 %		

Various other novel resuscitation techniques have also been developed that can be applied to civilian mass casualty or disaster scenarios, including deliberate induction of hypotension, the use of recombinant human clotting factor VIIa, and early support of coagulation [27]. By utilizing anesthesia with fluid loading to maintain hypotension, the vicious cycle of hypertensive hemorrhage or rebleeding, subsequent fluid resuscitation, and further hemorrhage is avoided [27].

Damage control resuscitation with a ratio of red blood cells to plasma to platelets of 1:1:1 became the US Army Medical Corps policy in 2007, and this policy has been shown to be associated with the lowest mortality rate when compared to other coagulation support algorithms [39]. A multidisciplinary approach is required, involving general/trauma surgeons, orthopedic surgeons, and anesthesiologists [1]. After initial stabilization in the trauma bay and initiation of resuscitative efforts, the index surgical procedure then follows immediately.

9.2.2 Index Surgical Procedure

The primary purpose of the index surgical procedure is twofold: obtain hemorrhage control and debride nonviable tissue [28]. Adequate debridement with irrigation at the time of injury is important to decrease potential risks of infection, as blast injuries sustained in combat or disaster scenarios impart a large degree of gross and microscopic contamination [1, 27]. Gravity or bulb irrigation is preferable to high-pressure

Fig. 9.8 Extensive thermal injuries, including third- or fourth-degree burns require prophylactic escharotomies through the skin (preserving the fascia below) to prevent burn contracture and compartment syndrome

irrigation, and sterile isotonic saline, sterile water, and potable tap water have all been shown to have similar efficacy and safety [40].

Debridement of the zone of injury must be expanded back to the viable soft and osseous tissue, as the evolution of such a high-energy ischemic insult progresses over several days [27, 28]. Patients with extensive thermal injuries (third or fourth degree/partial and full thickness) also require escharotomies through the skin to prevent burn contracture and compartment syndrome [41] (Fig. 9.8).

Amputations, which often include multiple extremities or extremely short residual limbs, are managed in accordance with generally accepted principles; limb length preservation is critical to maximize any future ambulatory potential, but proximal transfemoral amputations with associated pelvic or urologic injuries often require revision to hip disarticulation or hemipelvectomy [1, 20].

Rather than completing amputations through fractures proximal to the zone of amputation, temporary stabilization within the amputated limb should be performed [42]. Any open wounds that communicate with pelvic ring disruption should be evaluated, as gross contamination of these wounds is relatively common, and partial or complete hemipelvectomy may be required to allow for intrapelvic access for debridement purposes [1]. Rectal injuries characteristically require diverting colostomy, which can prevent the fecal stream from contacting lower extremity amputations or perineal wounds, but consideration for any future orthopedic incisions should guide placement of the colostomy [1, 28].

Serial debridements are typically mandatory in these patients. In the case of major vascular injury to the extremities, the use of temporary intravascular shunts (TIVS) has been shown to be an effective means of bypassing segmental injuries and providing immediate revascularization before transferring to a higher level of care [27, 43, 44]. While many devices have been designed for this specific purpose, in an austere or hostile environment where they may not be readily available, any sterile tubular structure—including Foley catheters, small gage feeding tubes, or intravenous tubing—can be utilized [27].

Fasciotomies should be performed in all blast trauma patients undergoing TIVS, particularly those with prolonged ischemia or combined arterial and venous injuries, as such injuries have been shown to be risk factors for the development of compartment syndrome [27, 45]. Damage control orthopedics is also initiated, with external fixation of long bone and pelvic fractures and completion of traumatic amputations [1].

It is important to consider all factors that may affect the decision-making process in the management of these patients, as the number of patients requiring treatment in mass casualty or disaster setting may be significant and requires triage. Surrounding weather conditions and availability of medical evacuation (medevac in military language) also play roles while performing damage control-type stabilization [1].

Prophylactic fasciotomies of the leg compartments should be considered in all patients with tibial fractures undergoing external fixation. Overall primary operative time should be minimized in order to prevent second-hit physiologic insults, and definitive fixation of orthopedic injuries should be avoided in the acute setting. *Closure of traumatic blast amputation wounds is inadvisable in the peri-injury period* [46, 47], though the most important technical consideration for management of such traumatic amputation wounds remains preservation of the residual limb length—perhaps even at the expense of increased risk of infection or heterotopic ossification [48, 49].

The inflammatory response begins to manifest early, and the systemic inflammatory response syndrome (SIRS) can develop depending on the type and extent of injuries and the interventions performed. Signs of SIRS include fever, tachycardia, and abnormal laboratory values and should be expected [28]. Serial debridements with irrigation, as well as other secondary procedures, should occur in conjunction with other intensive care strategies after initial resuscitation and stabilization. Repeat irrigation and debridement are essential, as the zone of injury continues to develop in the context of the systemic inflammatory response.

Stabilization of small fractures can also be performed if the necessary equipment is available [28]. As mentioned previously, delayed primary closure of blast wounds or amputations is more appropriate than early closure, considering the typical burden associated with severe open wounds in these scenarios [24]. The complex nature of the cytokine response and the typical polymicrobial nature of wound colonization lead to unique soft tissue challenges that are difficult to manage in the austere environment [28, 50, 51].

The use of novel dressings and negative pressure wound therapy have become exceedingly common during the latter stages of the conflicts in Iraq and Afghanistan, and these treatment modalities may be useful in noncombat scenarios, when available [1, 27, 28, 51]. Negative pressure or vacuum therapy devices have been utilized in the combat setting to manage severe soft tissue blast or thermal injuries or to provide temporary abdominal closure [51, 52]. Negative pressure wound dressings allow for temporary protection of the wounds without the need for frequent dressing changes [52]. However, the device must be functioning properly, as the loss of suction can lead to pooling of inflammatory fluid and development of a pro-infectious milieu [1], so close monitoring is necessary.

Recent developments in bacteriostatic or bactericidal dressings to complement the vacuum-assisted closure device, such as the GranuFoam Silver Dressing (Kinetic Concepts, Inc., San Antonio, TX) have provided improved protection in the presence of multi-organism infection [52]. The military orthopedic experience with negative pressure dressings has supported the use of these devices in most—if not all—combat- or disaster-related open extremity wounds, if available. However, a series examining the use of vacuum-assisted closure for temporizing coverage of Gustilo grade IIIB open tibial fractures found an increased rate of deep infection if the negative pressure dressing delayed definitive coverage by greater than 7 days [53].

Therefore, various reconstructive options for definitive wound closure should be considered as early as the clinical scenario will allow. If a negative pressure dressing is not available, one can be improvised utilizing the *Chariker-Jeter method*:

1. A layer of saline-soaked, non-adherent gauze is laid in the wound.
2. A silicone drain (or any available tubing) is layered in the gauze.
3. More gauze is placed over the drain, and a semipermeable film of any type is used to seal the wound.
4. The drain is then connected to a portable suction device at a range of 75–125 mmHg negative pressure [54].

9.3 Definitive Management of Blast Wounds

Expedited transport of injured personnel from forward support stations to higher levels of care is the standard medical doctrine used in current combat scenarios by the military [28, 55]. While not always possible in the civilian or disaster setting, numerous studies have shown improved outcomes with rapid transfer of severely injured patients (e.g., burns or open tibial fractures) to centers with experience in treating such injuries [56, 57].

Considerations for long-term management of blast wounds should guide initial management, as the ability to provide soft tissue coverage and maintain residual limb length is paramount. As previously discussed, extremity blast injuries are unique in that the wounds are often heavily contaminated and associated with multiple concurrent injuries. Thus, surgical treatment must focus on definitive reconstruction in the subacute period, despite the lack of any standardized protocol for the management strategy [58].

While the civilian literature has shown that providing wound coverage acutely is generally associated with better outcomes, the complexity of wartime or disaster blast injuries requires that reconstruction often be delayed up to 3 months post-injury [58, 59]. The reconstructive ladder (and subsequent modifications to its design) is a concept describing methods of wound reconstruction organized by technique complexity [60]. The various applications of the reconstructive microsurgery ladder to orthopedics are beyond the scope of this chapter and the austere environment. However, local rotational pedicled flaps can be considered to cover facial wounds or other vulnerable body areas if the treating surgeon is comfortable with the techniques required [61] (see Chap. 46). It is important that surgeons managing these types of injuries formulate their initial treatment plans in the context of future management alternatives.

Conclusions

Extensive osseous and soft tissue wounds associated with blast mechanisms present complex, challenging cases for the managing surgeon. Multiply injured patients, particularly those injured in hostile environments, utilize more hospital resources (e.g., blood products, intensive care unit days, number of operations) than most patients. Considerations for future long-term outcomes should guide the preliminary resuscitation of blast-injured patients in a mass casualty situation.

Increased tourniquet use, newly developed resuscitation algorithms, definitive fixation of long bone fractures proximal to or contiguous with amputations, and temporizing vascular shunts have evolved during the combat surgical experience of the last decade. The principles for burn management and definitive care of severe soft tissue wounds should remain constant, despite the austerity of the surrounding environment. Indeed, successful complex limb reconstruction and wound management rely heavily on the preparedness of the healthcare provider to employ the techniques described in this text.

Despite their devastating effects, blast injuries have become increasingly survivable over time. It is imperative that healthcare providers be aware of the injury patterns imposed by explosive mechanisms, as recent world events have highlighted that attacks or accidents can occur at any location and at any time.

References

1. Andersen RC, Fleming M, Forsberg JA, et al. Dismounted complex blast injury. J Surg Orthop Adv. 2012;21(1):2–7.
2. Kelly JF, Ritenour AE, McLaughlin DF, et al. Injury severity and causes of death from Operation Iraqi Freedom and Operation Enduring Freedom: 2003-2004 versus 2006. J Trauma. 2008;64(2 Suppl):S21–6; discussion S6–7.
3. Ritenour AE, Blackbourne LH, Kelly JF, et al. Incidence of primary blast injury in US military overseas contingency operations: a retrospective study. Ann Surg. 2010;251(6):1140–4.
4. Kragh Jr JF, Walters TJ, Baer DG, et al. Survival with emergency tourniquet use to stop bleeding in major limb trauma. Ann Surg. 2009;249(1):1–7.
5. Fleming M, Waterman S, Dunne J, D'Alleyrand JC, Andersen RC. Dismounted complex blast injuries: patterns of injuries and resource utilization associated

with the multiple extremity amputee. J Surg Orthop Adv. 2012;21(1):32–7.

6. Champion HR, Holcomb JB, Young LA. Injuries from explosions: physics, biophysics, pathology, and required research focus. J Trauma. 2009;66(5):1468–77; discussion 77.
7. Hayda R, Harris RM, Bass CD. Blast injury research: modeling injury effects of landmines, bullets, and bombs. Clin Orthop Relat Res. 2004;422:97–108.
8. Bendinelli C. Effects of land mines and unexploded ordnance on the pediatric population and comparison with adults in rural Cambodia. World J Surg. 2009; 33(5):1070–4.
9. Weil YA, Petrov K, Liebergall M, Mintz Y, Mosheiff R. Long bone fractures caused by penetrating injuries in terrorists attacks. J Trauma. 2007;62(4):909–12.
10. Bala M, Shussman N, Rivkind AI, Izhar U, Almogy G. The pattern of thoracic trauma after suicide terrorist bombing attacks. J Trauma. 2010;69(5):1022–8; discussion 8–9.
11. Kang DG, Lehman Jr RA, Carragee EJ. Wartime spine injuries: understanding the improvised explosive device and biophysics of blast trauma. Spine J Off J North Am Spine Soc. 2012;12(9):849–57.
12. Ramasamy A, Hill AM, Clasper JC. Improvised explosive devices: pathophysiology, injury profiles and current medical management. J R Army Med Corps. 2009;155(4):265–72.
13. Ramasamy A, Harrisson SE, Clasper JC, Stewart MP. Injuries from roadside improvised explosive devices. J Trauma. 2008;65(4):910–4.
14. Guy RJ, Glover MA, Cripps NP. Primary blast injury: pathophysiology and implications for treatment. Part III: injury to the central nervous system and the limbs. J R Nav Med Serv. 2000;86(1):27–31.
15. Covey DC, Born CT. Blast injuries: mechanics and wounding patterns. J Surg Orthop Adv. 2010;19(1): 8–12.
16. Ramasamy A, Hill AM, Hepper AE, Bull AM, Clasper JC. Blast mines: physics, injury mechanisms and vehicle protection. J R Army Med Corps. 2009; 155(4):258–64.
17. Mayorga MA. The pathology of primary blast overpressure injury. Toxicology. 1997;121(1):17–28.
18. Ritenour AE, Baskin TW. Primary blast injury: update on diagnosis and treatment. Crit Care Med. 2008;36(7 Suppl):S311–7.
19. Bowyer GW, Cooper GJ, Rice P. Small fragment wounds: biophysics and pathophysiology. J Trauma. 1996;40(3 Suppl):S159–64.
20. D'Alleyrand JC, Fleming M, Gordon WT, Andersen RC, Potter BK. Combat-related hemipelvectomy. J Surg Orthop Adv. 2012;21(1):38–43.
21. Kang DG, Dworak TC, Lehman Jr RA. Combat-related L5 burst fracture treated with L4-S1 posterior spinal fusion. Spine J Off J North Am Spine Soc. 2012;12(9):862–3.
22. Lehman Jr RA, Paik H, Eckel TT, Helgeson MD, Cooper PB, Bellabarba C. Low lumbar burst fractures: a unique fracture mechanism sustained in our current overseas conflicts. Spine J Off J North Am Spine Soc. 2012;12(9):784–90.
23. Coupland RM, Korver A. Injuries from antipersonnel mines: the experience of the International Committee of the Red Cross. BMJ. 1991;303(6816):1509–12.
24. Be NA, Allen JE, Brown TS, et al. Microbial profiling of combat wound infection through detection microarray and next-generation sequencing. J Clin Microbiol. 2014;52(7):2583–94.
25. Lewandowski L, Purcell R, Fleming M, Gordon WT. The use of dilute Dakin's solution for the treatment of angioinvasive fungal infection in the combat wounded: a case series. Mil Med. 2013;178(4):e503–7.
26. Simbli M, Hakim F, Koudieh M, Tleyjeh IM. Nosocomial post-traumatic cutaneous mucormycosis: a systematic review. Scand J Infect Dis. 2008;40(6-7):577–82.
27. D'Alleyrand JC, Dutton RP, Pollak AN. Extrapolation of battlefield resuscitative care to the civilian setting. J Surg Orthop Adv. 2010;19(1):62–9.
28. Mamczak CNEE. Complex dismounted IED blast injuries: the initial management of bilateral lower extremity amputations with and without pelvic and perineal involvement. J Surg Orthop Adv. 2012;21(1):8–14.
29. Joint Theater Trauma System Clinical Practice Guidelines. Institute of Surgical Research; [6/19/2014]. http://www.usaisr.amedd.army.mil/assets/cpgs/02_CENTCOM_JTTS_CPG_Process_2_Apr_12.pdf.
30. Wolf LH, Adkins TF. Tourniquet problems in war injuries. Bull U S Army Med Dep. 1945;87:77–84.
31. Lakstein D, Blumenfeld A, Sokolov T, et al. Tourniquets for hemorrhage control on the battlefield: a 4-year accumulated experience. J Trauma. 2003; 54(5 Suppl):S221–5.
32. Bulger EM, Snyder D, Schoelles K, et al. An evidence-based prehospital guideline for external hemorrhage control: American College of Surgeons Committee on Trauma. Prehosp Emerg Care Off J Natl Assoc EMS Phys Natl Assoc State EMS Directors. 2014;18(2): 163–73.
33. Swan Jr KG, Wright DS, Barbagiovanni SS, Swan BC, Swan KG. Tourniquets revisited. J Trauma. 2009;66(3): 672–5.
34. Malsby 3rd R, Frizzi J, Ray P, Raff J. Walking donor transfusion in a far forward environment. South Med J. 2005;98(8):809–10.
35. Edens JW, Beekley AC, Chung KK, et al. Longterm outcomes after combat casualty emergency department thoracotomy. J Am Coll Surg. 2009;209(2):188–97.
36. Routt Jr ML, Falicov A, Woodhouse E, Schildhauer TA. Circumferential pelvic antishock sheeting: a temporary resuscitation aid. J Orthop Trauma. 2002; 16(1):45–8.
37. Bottlang M, Simpson T, Sigg J, Krieg JC, Madey SM, Long WB. Noninvasive reduction of open-book pelvic fractures by circumferential compression. J Orthop Trauma. 2002;16(6):367–73.
38. Theron A, Bodger O, Williams D. Comparison of three techniques using the Parkland Formula to aid fluid resuscitation in adult burns. Emerg Med J. 2014; 31(9):730–5.

39. Borgman MA, Spinella PC, Perkins JG, et al. The ratio of blood products transfused affects mortality in patients receiving massive transfusions at a combat support hospital. J Trauma. 2007;63(4):805–13.
40. Svoboda SJ, Owens BD, Gooden HA, Melvin ML, Baer DG, Wenke JC. Irrigation with potable water versus normal saline in a contaminated musculoskeletal wound model. J Trauma. 2008;64(5):1357–9.
41. Orgill DP, Piccolo N. Escharotomy and decompressive therapies in burns. J Burn Care Res Off Pub Am Burn Assoc. 2009;30(5):759–68.
42. Gordon WT, O'Brien FP, Strauss JE, Andersen RC, Potter BK. Outcomes associated with the internal fixation of long-bone fractures proximal to traumatic amputations. J Bone Joint Surg Am. 2010;92(13):2312–8.
43. Taller J, Kamdar JP, Greene JA, et al. Temporary vascular shunts as initial treatment of proximal extremity vascular injuries during combat operations: the new standard of care at Echelon II facilities? J Trauma. 2008;65(3):595–603.
44. Chambers LW, Green DJ, Sample K, et al. Tactical surgical intervention with temporary shunting of peripheral vascular trauma sustained during Operation Iraqi Freedom: one unit's experience. J Trauma. 2006;61(4):824–30.
45. Reber PUP, Patel AG, Sapio NL, Ris HB, Beck M, Kniemeyer HW. Selective use of temporary intravascular shunts in coincident vascular and orthopedic upper and lower limb trauma. J Trauma Inj Infect Crit Care. 1999;47(1):72–6.
46. Mazurek MT, Ficke JR. The scope of wounds encountered in casualties from the global war on terrorism: from the battlefield to the tertiary treatment facility. J Am Acad Orthop Surg. 2006;14(10 Spec No):S18–23.
47. Bowyer G. Debridement of extremity war wounds. J Am Acad Orthop Surg. 2006;14(10 Spec No):S52–6.
48. Forsberg JA, Pepek JM, Wagner S, et al. Heterotopic ossification in high-energy wartime extremity injuries: prevalence and risk factors. J Bone Joint Surg Am. 2009;91(5):1084–91.
49. Potter BK, Burns TC, Lacap AP, Granville RR, Gajewski DA. Heterotopic ossification following traumatic and combat-related amputations. Prevalence, risk factors, and preliminary results of excision. J Bone Joint Surg Am. 2007;89(3):476–86.
50. Hawksworth JS, Stojadinovic A, Gage FA, et al. Inflammatory biomarkers in combat wound healing. Ann Surg. 2009;250(6):1002–7.
51. Leininger BE, Rasmussen TE, Smith DL, Jenkins DH, Coppola C. Experience with wound VAC and delayed primary closure of contaminated soft tissue injuries in Iraq. J Trauma. 2006;61(5):1207–11.
52. Couch KS, Stojadinovic A. Negative-pressure wound therapy in the military: lessons learned. Plast Reconstr Surg. 2011;127 Suppl 1:117S–30.
53. Bhattacharyya T, Mehta P, Smith M, Pomahac B. Routine use of wound vacuum-assisted closure does not allow coverage delay for open tibia fractures. Plast Reconstr Surg. 2008;121(4):1263–6.
54. Mansoor J, Ellahi I, Junaid Z, Habib A, Ilyas U. Clinical evaluation of improvised gauze-based negative pressure wound therapy in military wounds. International wound journal. Int Wound J. 2015;12(5): 559–63.
55. Andersen RCF, Frisch HM, Farber GL, Hayda RA. Definitive treatment of combat casualties at military medical centers. J Am Acad Orthop Surg. 2006;14(10): S24–31.
56. Sheridan R, Weber J, Prelack K, Petras L, Lydon M, Tompkins R. Early burn center transfer shortens the length of hospitalization and reduces complications in children with serious burn injuries. J Burn Care Rehabil. 1999;20(5):347–50.
57. Schemitsch EH, Bhandari M, Guyatt G, et al. Prognostic factors for predicting outcomes after intramedullary nailing of the tibia. J Bone Joint Surg Am. 2012;94(19):1786–93.
58. Tintle SM, Gwinn DE, Andersen RC, Kumar AR. Soft tissue coverage of combat wounds. J Surg Orthop Adv. 2010;19(1):29–34.
59. Kumar AR. Standard wound coverage techniques for extremity war injury. J Am Acad Orthop Surg. 2006; 14(10 Spec No):S62.
60. Janis JE, Kwon RK, Attinger CE. The new reconstructive ladder: modifications to the traditional model. Plast Reconstr Surg. 2011;127 Suppl 1: 205S–12.
61. Ray JM. The treatment of maxillofacial trauma in austere conditions. Atlas Oral Maxillofac Surg Clin North Am. 2013;21(1):9–14.

Injury from Traditional Bonesetter Fracture Management

10

Juan de Dios Robinson

Western concepts of fracture healing are relatively new to many parts of the world. The lack of healthcare facilities and trained personnel in many low-income countries means that the local population does not have another option when seeking help for illness or injuries. In many countries where there is some provision of modern health care, traditional methods are still widespread due to cultural, economic, geographical or financial reasons. The World Health Organization (WHO) reported that up to 40 % of health care in China and up to 80 % in Africa is provided by traditional healers [1]. As far as fracture care is concerned, there is a very large presence of bonesetters in many countries. In Nigeria, 70–90 % of fracture care is provided by these practitioners [2].

10.1 What Is a "Bonesetter"?

A bonesetter is a traditional healer that treats musculoskeletal disorders through methods involving mainly massage, fracture manipulation, application of topical preparations and splinting. The practice of bone setting is an ancient craft. It is a trade that is often passed from generation to generation. Nwachukwu et al. described one practice in an observational study in a Nigerian bone setting practice [3]; the practice was run by a woman and her son. The practice had up to 50 resident patients. Closed fractures were identified through palpation and splinted with cloth, cardboard or wood planks. The fractures were massaged with an herbal preparation called 'Ufie'. Fractures were then managed strictly with non-weight bearing for a standard period of 51 days. Open fractures were diverted to a local government hospital for closure and then were treated at the bonesetter's local in the same way. The splinting constructs are replaced every 4 days, and the herbal cream is applied weekly.

10.2 Who Do Bonesetters Treat?

The bonesetter clientele may include members from every social class and age group and is not necessarily dependant on the socioeconomic status of the patient. It is a practice deeply embedded in the culture of many countries in Africa, Asia and Latin America. The popularity of traditional remedies, including bone setting, is very real despite the presence and availability of modern facilities and trained staff. This is partially explained by the close relationship between healing and spiritual and religious practices.

J.D. Robinson, FRCS (Tr & Orth) MSc (Trau Surg)
Major Trauma Centre, St. Mary's Hospital,
Imperial College, London, UK
e-mail: jddrobinson@hotmail.co.uk

© Springer International Publishing Switzerland 2016
J.D. Robinson (ed.), *Orthopaedic Trauma in the Austere Environment:*
A Practical Guide to Care in the Humanitarian Setting, DOI 10.1007/978-3-319-29122-2_10

10.3 Why Do People Go to Bonesetters?

In the study by Nwachuku et al., five reasons were identified as the principal motivators for patients to select a bonesetter over Western medicine [3]:

1. Fear of implants and foreign objects including musculoskeletal traction devices
2. Belief in the spiritual powers of the bonesetter
3. Convenience and flexibility of traditional care setting
4. Prohibitive cost of orthopaedic care in a hospital setting
5. Familiarity with bonesetter culture and lack of familiarity with orthopaedic centres

The authors of this study interviewed bonesetters and found that:

> One of the bonesetters explained that she even counsels her patients and their families to avoid Orthopaedic centers because many of those who use such facilities "return with missing legs or with metal in their body" [3].

Aries et al. reported a qualitative study in Ghana where patients who attended bonesetters were interviewed in an attempt to find out what motivated them to choose this practice over conventional medicine [4]. They found that traditional bonesetters were perceived as offering more complete care (e.g. splints AND herbal medicines AND incantations), the need to go to bonesetters after attending hospitals for open fractures, lower costs of treatment, fear of internal fixation, fear of external fixation, fear of amputations and less personal care in conventional hospitals [5].

Other reasons may be that some of the facilities offering more modern treatments may actually be poorly supported in terms of equipment, staff and resources in general, offering effectively not much more than bonesetters. Some of these facilities may be staffed exclusively by men, and females may be discouraged from attending these clinics. Language barriers are another real barrier, as well as tribal divisions, where one community may have adopted western style practices whilst another may have not and continued to use traditional methods of health care.

10.4 Complications

A study carried out in the Dinajpur Medical College Hospital in Bangladesh and in the private chambers of two orthopaedic surgeons practicing in Dinajpur over 1 year included 120 patients treated by bonesetters (TBS) [6]. The TBS treated their patients for varying periods of time ranging from 3 days to 3 months. Table 10.1 summarises their findings.

Of the many complications resulting from bonesetter treatments, one of the most tragic is gangrene secondary to tight bandages. Many of the casualties of these treatments are children who have had one of these tight splints applied because of a relatively minor fracture. By the time anxious parents arrive to a clinic seeking help, the children's limbs have suffered irreversible damage and may require an amputation.

Eshete reported a series of 49 amputations from Ethiopia, of which 25 had been due to the application of tight splintage by traditional bonesetters [7]. Tepka et al. reported a study on bonesetter gangrene in children in Central Senegal. Twenty one children were treated during an 18-month period. Bonesetter gangrene was more common in boys from rural areas with limited access to health care. Sixteen children underwent upper limb amputations. The authors noted the same as other researchers that this was a preventable disaster and that health planners needed to recognise the seriousness of this situation [8].

Table 10.1 Complications of using bonesetters for orthopaedic problems

Complications	Number	Incidence
Mal union	114	83.9
Delayed union	10	7.4
No union	20	14.7
Gangrene	2	1.5
Compartment syndrome	6	4.4
Volkmann's ischaemic contracture	7	5.1
Joint stiffness	15	11
Chronic osteomyelitis	5	3.7
Soft tissue infection with blister formation	30	22.1
Tetanus	1	0.7
Unreduced dislocated joint	8	5

10.4.1 Management of Complications Secondary to Bone Setting

10.4.1.1 Early Presentation

The most common presentation will be of a patient with a limb in a splint or bandage that is extremely tight. Hence, the pressure must be relieved at once. The limb most be rapidly evaluated for:

- Soft tissue damage
- Compartment syndrome
- Vascular supply
- Nerve damage

The limb must be placed in elevation. If the limb presents with blisters, these must not be de-roofed as these may cause an infection.

10.4.1.2 Late Presentation

Unfortunately, the very fact that patients go to bonesetters before they attend a conventional clinic means that they present late too frequently. By this stage, the limb might be ischaemic and gangrene may have set in. The dressings must be removed anyhow and the limb examined. The patient must be aggressively resuscitated as in the case of crush injuries. By this stage, if compartment syndrome was part of the patient's injury, fasciotomy may not be appropriate, as late fasciotomies are associated with high incidence of infection. The limb may be dead and an amputation is indicated. The limb must be examined closely, and a determination of the level of amputation must be made based on the extent of the gangrene as well as the viability of the area adjacent to the necrotic tissue. You want to leave a stump as long as possible for future prosthesis fitting, but this must not prevent you from excising as much tissue as necessary to save the patient's life. In order to assess the limb, you must wash thoroughly the skin to gain a good appreciation of the demarcation areas which will guide your amputation.

10.5 Case Study

The author's experience in Afghanistan shares the same features described by the authors cited in this chapter. Patients presented late after consulting a traditional healer or bonesetter. By the time of presentation, gangrene had set in and amputations were required. The cases below illustrate examples of the consequences of some of the practices by bonesetters.

10.5.1 Case 1: Early Presentation

An 11-year-old boy presented with complaining of severe pain on his right forearm and an extremely tight bandage. His hand was pale and he could not move his fingers. The tight bandage was removed immediately (Fig. 10.1a).

The pain immediately improved and the colour of the hand began to return. The forearm was covered with severe blistering secondary to the tight dressings (Fig. 10.1b, c).

The child was resuscitated and the limb was elevated in a couple of pillows. Neurovascular observations were recorded every 15 min for the first 3 h and then every hour to monitor for compartment syndrome. The next day, examination of the limb revealed decreased swelling, normal sensation throughout the fingers and hand and normal movements. The following day, the blisters had dried and the forearm was almost back to normal (Fig. 10.2a, b).

10.5.2 Case 2: Late Presentation

A 9-year-old girl fell and hurt her elbow. She was taken to the local bonesetter who applied an herbal remedy and a very tight dressing. Following several hours of agonising pain, the little girl's concerned parents decided to take the girl to an MSF trauma centre. Here, the dressings were removed at once. Unfortunately, the fingers, hand and forearm were gangrenous, and the ischaemic process had affected the soft tissues above the elbow as well (Fig. 10.3).

The girl was taken to the operating theatre were the limb was washed and examined. The demarcation zones can be observed (Fig. 10.4a, b), but examination revealed that the erythematous tissue above the elbow was not viable either. There was no other alternative but to amputate above the elbow (Figs. 10.5 and 10.6).

Fig. 10.1 (**a**) The dressings were removed; the limb washed and examined thoroughly in theatre. The blisters were not de-roofed to avoid an increased risk of infection. (**b**, **c**) The severe blistering caused by the tight dressing applied by a bonesetter can be appreciated

Fig. 10.2 (**a**, **b**) One week after admission, elevation and observation, the forearm looks back to normal. The stigmata of blisters are still visible but the skin is healing well

Fig. 10.3 The right hand, forearm and elbow of this child have become gangrenous. The dressings that were released can also be seen

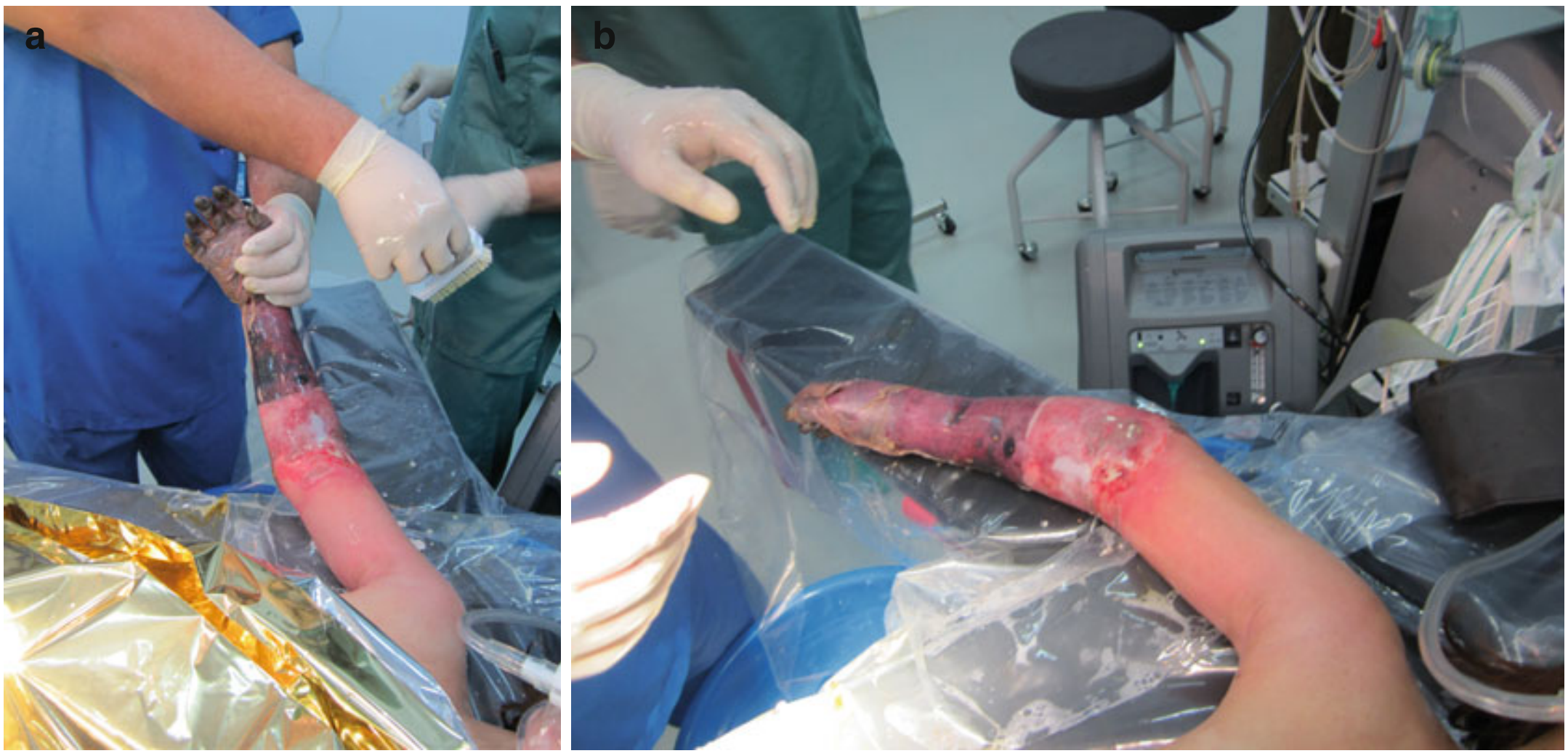

Fig. 10.4 Examination of the upper limb of this 9-year-old girl exhibits demarcation zones in the flexor (**a**) and extensor (**b**) surfaces

10.6 What Can Be Done to Prevent the Damage Done by Bonesetter Fracture Management?

It is unrealistic and probably undesirable to ignore the reality of bonesetters as a resource in communities where there is acute scarcity of healthcare facilities. There must be collaboration and partnership between governments, orthopaedic surgeons, non-governmental organisations (NGOs) and traditional healers in order to promote safe practice. Some authors have stated that:

> "…further integration between traditional and western practices will ultimately provide sustained long-term improvement of outcomes after musculoskeletal injuries" [3].

Fig. 10.5 Above-elbow amputation

[redacted]

Fig. 10.6 Another example of bonesetter gangrene due to tight splinting in a male teenager. Amputation was necessary to save his life

Healthcare organisations should aim to incorporate traditional healers into a major team with the patient's interests at its heart. Bonesetters should be offered training to understand that open fractures should be referred to hospital as soon as possible and of the consequences when this does not happen. Some authors have advocated equipping bonesetters with radiography to aid diagnosis [3]. The purpose of these initiatives would be to take advantage of the popularity and affinity that the local population has with traditional sources of health care and to establish partnerships with traditional healers instead of creating perceived rivalries and competitions for patients. It is hoped that this would achieve better outcomes and increase the number of patients that present to hospitals earlier.

Eshete carried out a study in Ethiopia during which he delivered a series of 1-day instructional courses to small groups of bonesetters. In total, 112 traditional bonesetters, 15 nonmedical 'local leaders' and ten community health workers received instruction. These courses were immediately followed by a 2-year prospective study of amputations performed in his hospital between 2001 and 2003 in order to assess the success of the courses. The results suggested that the courses were successful in reducing the incidence of gangrene and amputations by half. The rate of mortality and tetanus also decreased [7].

Another study by Onuminya in Nigeria showed there was a considerable decrease in the rate of gangrenous limbs, infection, non-union and malunion at the trained TBS centre compared with the untrained TBS centre (2.5 % vs. 10 %, 5 % vs. 12.5 %, 7.5 % vs. 15 % and 20.0 % vs. 30 %, respectively). The observed difference between the trained and untrained TBSs was statistically significant ($p<0.05$) [4]. Most importantly, this study demonstrated that TBSs were willing to work and cooperate with orthopaedic surgeons.

Agarwal et al. examined the tradition and practice of bone setting in India and concluded that 'Pending infrastructure and socioeconomic development, it appears that traditional bonesetters will remain providers of healthcare. Their methodology utilises regional resources and is commonly believed to be cheaper and effective. Although the deficiencies of traditional bonesetters have been shown, with adequate training in the basics of orthopaedic care, they can be utilised to provide useful health services at the primary care level' [5]. OlaOlorun et al. propose that the introduction of a health insurance scheme in Nigeria 'may make it easier for individuals and families to be able to afford proper fracture treatment in hospitals' [9].

Conclusion

The complications arising from bonesetter practices can be limb and life threatening [10]. However, the challenge for conventionally trained surgeons goes far beyond the mismanagement of fractures. This is also a cultural challenge that must be addressed tactfully and effectively for the good of patients. Bonesetters should be seen as potential partners and should be offered training and information. Patients should also be educated on the risks and benefits of conventional treatments, and the needs of the local population must be understood in order to offer an effective service which is not feared and misunderstood by the local population.

References

1. World Health Organization. WHO traditional medicine strategy. 2002–2005. Geneva: World Health Organization; 2002.
2. Omololu AB, Ogunlade SO, Gopaldasani VK. The practice of traditional bonesetting: training algorithm. Clin Orthop Relat Res. 2008;466(10):2392–8.
3. Nwachukwu B, Okwesili I, Harris M, Katz J. Traditional bonesetters and contemporary orthopaedic fracture care in a developing nation: historical aspects, contemporary status and future directions. Open Orthop J. 2011;5:20–6.
4. Onuminya JE. Performance of a trained traditional bonesetter in primary fracture care. S Afr Med J. 2006;96(4):320–2.
5. Argwal A, Argwal R. The practice and tradition of bone setting. Edu Health. 2010;23(1):1–8.
6. Chowdhury MA, Khandker HH, Ahsan K, Mostafa DG. Complications of fracture treatment by traditional bone setters at Dinajpur. Dinajpur Med Col J. 2011;4(1): 15–9.
7. Eshete M. The prevention of traditional bone setter's gangrene. J Bone Joint Surg Br. 2005; 87-B:102–3.
8. Tekpa BJD, Ngongang OGF, Keita K, Alumeti D, Sane AD, Dieme CB, Seye SIL. Traditional bonesetter's gangrene of limb in children in Regional Hospital of Kaolack (Senegal). Bull Soc Pathol Exot. 2013; 106(2):100–3.
9. OlaOlorun DA, Oladiran IO, Adeniran A. Complications of fracture treatment by Bone Setters in South West Nigeria. Fam Pract. 2001;18: 635–7.
10. Udosen AM, Otei OO, Onuba O. Role of traditional bone setters in Africa: experience in Calabar, Nigeria. Ann Afr Med. 2006;5(4):170–3.

Part III

Management Challenges in the Austere Environment

Malnutrition and Orthopedic Injuries

11

Sandro Contini

Malnutrition is a crucial issue in orthopedics [1, 2]. Orthopedic surgeons need to be aware of the presence of malnutrition in their patients and the marked increase in metabolic needs that their patients have. Since decades, a significant correlation has been identified between subnormal nutrition indices and the development of orthopedic complications [3]. An impaired nutritional status associated with older age may be an underlying cause for fractures and, as it has been well observed in hip fractures, may affect the clinical outcome [4–6]. Protein depletion has been correlated with impaired wound and bone healing, increased rate of wound infection, sepsis, pneumonia, progressive weakness, apathy, delayed union, and delayed physical rehabilitation [3].

In austere environments, the occurrence of malnutrition problems is not uncommon in orthopedic patients [7]. The relationship between malnutrition and orthopedic trauma outcomes has been studied to a very limited extent in the austere environment, but it is likely to have a negative impact on the healing process, callus formation, incidence of infections, and progression from acute to chronic osteomyelitis [8]. However, the relationship between nutrition and clinical outcome is often neglected and nutrition support is not frequently considered a critical target [9].

11.1 Epidemiology

Chronic food deficits affect about 842 million people in the world, including 20 % of the population in developing countries [10]. Malnutrition affects all age groups, but it is especially common among the poor and those with inadequate access to health education and to clean water and good sanitation [11]. Failure to thrive is a common consequence of malnutrition in developing countries due to the combined effects of food insecurity, low dietary diversity, a highly infectious environment, poor washing facilities, and poor understanding of the principles of nutrition and hygiene. Malnutrition is a significant cause of death among displaced populations [7]. Apart from intensive feeding programs aimed at rehabilitating severely malnourished children, there are few examples of successful nutrition interventions [12]. Therefore, it is not surprising that the relationship between malnutrition and its consequences on trauma in austere situations has a low advocacy, and reports about this issue are scanty.

The reported prevalence of patients malnourished or at risk for malnutrition among those hospitalized for surgical procedures in the developed

---

S. Contini, MD
Department of Surgical Sciences, Parma University Hospital, Parma, Italy
e-mail: sandrocontini46@gmail.com; sandro.contini@unipr.it

© Springer International Publishing Switzerland 2016
J.D. Robinson (ed.), *Orthopaedic Trauma in the Austere Environment: A Practical Guide to Care in the Humanitarian Setting*, DOI 10.1007/978-3-319-29122-2_11

world varies from 35 to 44 % [13] and is similar to the 23–33 %, [14, 15] observed in patients undergoing orthopedic surgery. Age plays often a significant role in the genesis of malnutrition. In Sweden, 90 % of malnourished patients were found in an elderly patients population (average age 80 years) submitted to below knee amputation; they are at a special risk to become even more malnourished because of decreased food intake due to pain, nausea, confusion, increased loss of nutrients from the wounds, diarrhea, vomiting, infection, and increased requirements of major surgery [16]. In India, a 50 % of malnutrition was reported at admission in patients after lower limb fractures [17]. Furthermore, the number of malnourished patients and the degree of malnutrition increase with time following injury and with a prolonged hospital stay [18, 19]. Forty percent of patients admitted for trauma (not only orthopedic) in a Paraguay referral hospital were malnourished or at risk of malnutrition, with the remarkable detail that the patients were primarily young workers in rural areas, hence showing an incidence of poor nutritional state similar to that usually found in older patient populations of western countries [20], very likely reflecting their poor socioeconomical conditions.

Among specific nutritional problems, vitamin D has received considerable attention in recent years, in part because of studies demonstrating inadequate levels in otherwise healthy populations [21]. Although these low levels are a matter of concern, many argue that these data are difficult to interpret because of a lack of consensus regarding normal and abnormal levels, as well as because of inconsistent diagnostic methodology. Vitamin D deficiency has been widely reported in orthopedic patient, even in developed countries [22, 23]. In the USA, 90 % of the screened children showed vitamin D deficiency or insufficiency, with African-American children being more likely to have severe vitamin D deficiency [24]. Vitamin D deficiency is more common and widespread in Northeast Asia [25], South Asia, and the Middle East [26]. Even in sunny countries, like Saudi Arabia [27], Turkey [28], and Mexico [29], most postmenopausal women show inadequate levels of vitamin D. The prevalence of vitamin D deficiency among healthy Saudi men is between 28 and 37 % [30], and a high prevalence of vitamin D insufficiency and secondary hyperparathyroidism was observed in a patient population with osteoporosis and hip fracture in Turkey [31]. A Cochrane review concluded that vitamin D supplementation alone is ineffective in preventing fractures but that vitamin D and calcium reduced the risk of hip fractures in elderly patients receiving institutional care [32]. There is no agreed protocol for oral vitamin D supplementation in the setting of hypovitaminosis D. Most observational and randomized studies have used doses of vitamin D ranging from 400 to 1000 IU per day. Currently, daily supplementation in lower doses is thought to be superior to large, annual doses, and vitamin D3 has been shown to be more effective than vitamin D2 in maintaining levels over time [33]. Increased knowledge of the potential role of vitamin D and metabolic bone disease in the care of complex and elderly orthopedic patients is needed before clear suggestions could be recommended for developing countries.

11.2 Definition and Evaluation of Malnutrition

A catabolic state is always observed after trauma, with loss of body protein and excessive nitrogen excretion which is proportional to the magnitude of the insult [34] and is associated to impaired hormonal and cellular immunity [35]. The body weight loss that is frequently observed comes not only from fat stores but from protein reserves broken down to their constituent amino acids to support increased protein synthesis. Initially, the majority of proteins come from the skeletal muscle; later, visceral protein is also used, thus determining a catabolic state [36]. Regardless of nutritional supplementation, patients on intensive care units can lose up to 1 % of their total body protein per day, worsening muscle weakness and delaying weaning and rehabilitation [37]. Patients wounded during combat may have reduced fat and glycogen stores, which could contribute to accelerated catabolism and further aggravate body weight loss [38]. Furthermore, a severe trauma is usually followed by a period of food deprivation, therefore accentuating the catabolic state. An increased incidence of nosocomial infections has been related to preoperative malnutrition [39], while wound healing has been shown to improve with an adequate food intake [16, 17, 40, 41].

Malnutrition and its relationship to growth have been extensively studied in children [42–44], but data in adults population are scanty and the role and importance of nutrition-screening tools is still debated [41, 45]. Several screening tools have been recommended, either to identify the need of a nutrition support or to relate them to the clinical outcome as the Mini Nutritional Assessment and its Short Form (MNA, MNA-SF) [46, 47] (Table 11.1), the Malnutrition Universal Screening Tool (MUST) [48], the Prognostic Nutritional Index [49], the Nutritional Risk Screening [50], and the Geriatric Nutritional Risk Index [51], but a comparison between tools designed for different age groups and different purposes is problematic. Age and screening tools incorporating risk factors that are non-modifiable by nutritional support (e.g., age, disease severity) may predict outcomes of disease, but are not necessarily suitable for predicting the result of a nutritional support. Anthropometric measurements (body mass index, triceps and biceps skin fold) and biochemical parameters, like plasma levels of albumin, transferrin, prealbumin, retinol-binding protein, nitrogen balance, total cholesterol, and creatinine, are accepted markers for malnutrition, some being included in the above mentioned indexes. The level of plasma albumin, in particular, is considered a classic marker to assess a malnourished state [52], and values below 2.5 g/dL [53] or 3.9 g/dL [54] are considered indicators of malnutrition. However, plasma albumin level is not specific, as many factors may modify the plasma protein levels [55]. In adjunct, serum albumin is decreased in acute inflammatory states seen after critical injury and its long half-life (approx. 20 days) makes it unreliable in assessing the response to a nutritional intervention particularly in the critical care setting [56]. In austere environment at the moment, the interpretation of these indicators, most of them not available, as well as their correlation with postoperative outcome [55] should be made with caution.

Table 11.1 Mini nutritional assessment scoring system

Rubrics and questions	Score range
Rubric I. Anthropometric assessment (maximum 8 points)	
Body weight and height and related calculation of BMI	0–3 points
Arm circumference	0–1 point
Calf circumference	0–1 point
3-month weight loss	0–3 points
Rubric II. General status assessment (maximum 9 points)	
Independence of living	0–1 points
Recent acute events (disease or psychological distress)	0–2 points
Presence of pressure or skin ulcers	0–1 points
Number of medications taken on	0–1 points
Cognition/depression	0–2 points
Mobility[a]	0–2 points
Rubric III. Dietary assessment (maximum 9 points)	
Eating problems (appetite, swallowing, chewing)	0–2 points
Number of full meals	0–2 points
Markers of protein intake	0–1 points
Intake of vegetables and fruit	0-1 points
Intake of liquids	0–1 points
Self-sufficiency in eating	0–2 points
Rubric IV. Self-perceived health and nutrition states (maximum 4 points)	
Self-perception of nutritional status	0–2 points
Self-perception of health status	0–2 points

From Bauer et al. [47], with permission

[a] History

Due to the influence of malnutrition on the immune status, low blood total lymphocyte count and altered tests for skin hypersensitivity have also been identified as markers of nutritional state. Delayed wound healing has been observed in nearly 81 % of patients with a total lymphocyte count of <1500/mm^3 [57] and a decreased risk of healing complications was reported among lower-limb amputees with a normal total lymphocyte count compared to patients with a low count [58].

Currently, a simple clinical assessment of the patient's status (subjective global assessment (SGA)) [59], although originally conceived for geriatric health care (Fig. 11.1), may be performed by an experienced physician even in austere settings and

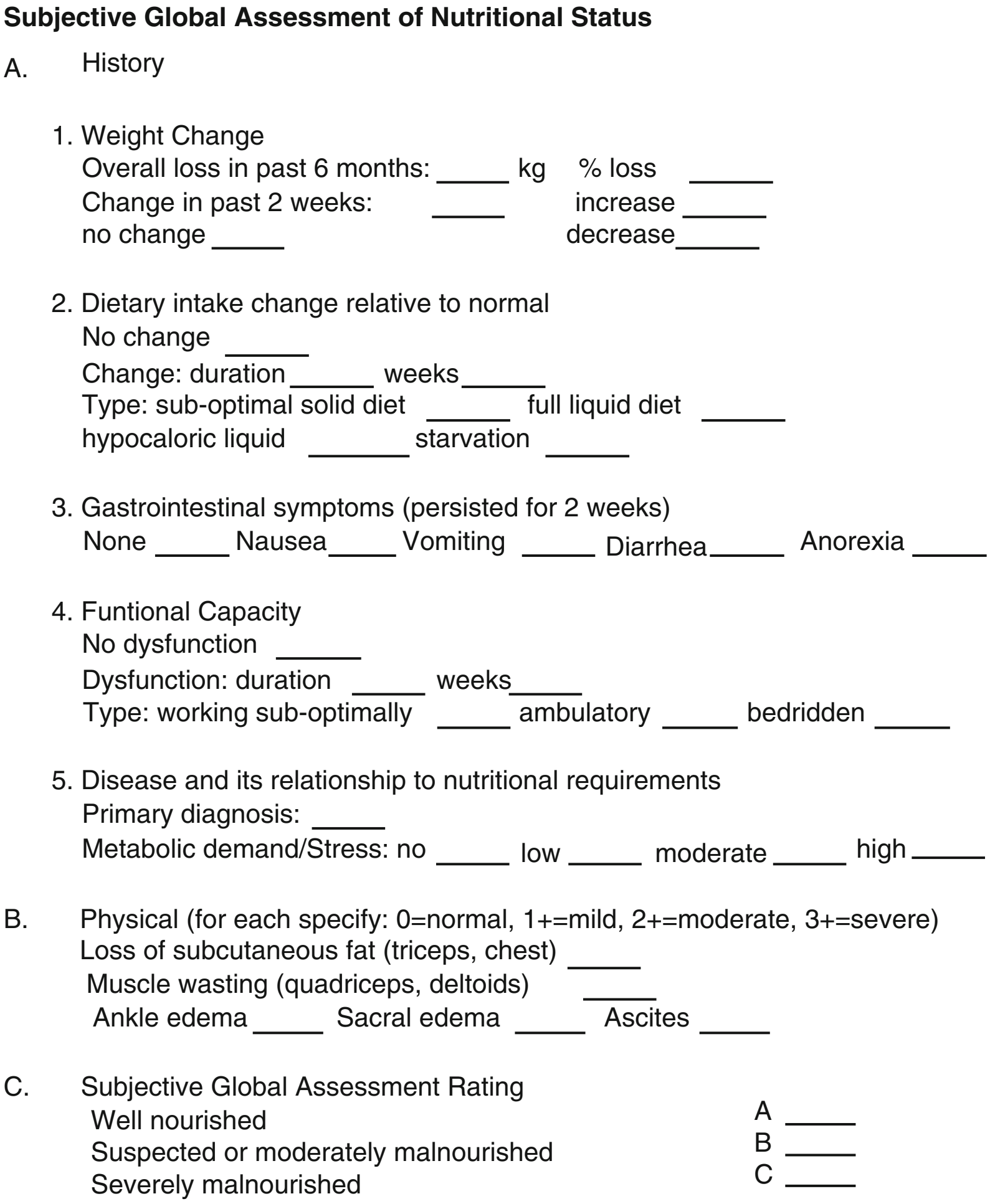

Subjective Global Assessment of Nutritional Status

A. History

1. Weight Change
Overall loss in past 6 months: _____ kg % loss ______
Change in past 2 weeks: _____ increase ______
no change _____ decrease______

2. Dietary intake change relative to normal
No change ______
Change: duration______ weeks______
Type: sub-optimal solid diet ______ full liquid diet ______
hypocaloric liquid _______ starvation ______

3. Gastrointestinal symptoms (persisted for 2 weeks)
None _____ Nausea_____ Vomiting _____ Diarrhea_____ Anorexia _____

4. Funtional Capacity
No dysfunction ______
Dysfunction: duration _____ weeks_____
Type: working sub-optimally _____ ambulatory _____ bedridden _____

5. Disease and its relationship to nutritional requirements
Primary diagnosis: _____
Metabolic demand/Stress: no _____ low _____ moderate _____ high _____

B. Physical (for each specify: 0=normal, 1+=mild, 2+=moderate, 3+=severe)
Loss of subcutaneous fat (triceps, chest) _____
Muscle wasting (quadriceps, deltoids) _____
Ankle edema _____ Sacral edema _____ Ascites _____

C. Subjective Global Assessment Rating
Well nourished A _____
Suspected or moderately malnourished B _____
Severely malnourished C _____

Fig. 11.1 Subjective global assessment form (From Covinsky et al. [59], with permission)

considered a reliable and validated method to sensibly estimate the nutritional state, although more consistently in adults than in pediatric patients [40, 60]. A complete history and physical examination have been found to be 80–90 % accurate in evaluating patient nutritional status, and the addition of multiple or complex biochemical, immune, or anthropometric measurements does not increase greatly the accuracy of this basic nutritional assessment [61]. This is of utmost importance for practice in developing countries, where sophisticated laboratory tests are rarely available. Recommendations on the screening tool selection for austere settings should consider such issues, remembering that, although guidelines can produce benefits, they may have limitations and detrimental effects [62].

In practice, an unintentional 20 % weight loss over time, an obvious muscle wasting, and the presence of a cause for alimentary malabsorption are all criteria to consider a patient malnourished. In such patients, a full evaluation for any comorbid conditions (diabetes, renal, or liver failure) is recommended, although frequently arduous in austere settings.

Vitamin deficiency (A, E, K, and of course D) and trace element scarcity are obviously linked to a dietary deficiency, with not negligible clinical consequences, even in orthopedic trauma patients. To properly evaluate, prevent, or treat such nutritional shortfalls in orthopedic trauma in developing countries, where reports on these topics are lacking, is a challenging task and will possibly be a future goal.

11.3 Consequences of Malnutrition on Orthopedic Injuries

Poor nutritional condition (before and after trauma) invariably decreases the endogenous tissue stores of protein, carbohydrate, and fat typically mobilized to provide energy for the catabolic process, therefore determining a less effective physiologic response. Later, malnutrition plays a significant role on wound healing by prolonging the inflammatory phase, decreasing fibroblast proliferation, and altering angiogenesis and collagen synthesis [63, 64], with a consequent reduction of the tensile strength. Poor nutrition also increases the risk for infection by decreasing T-cell function, phagocytic activity, and complement and antibody levels. Therefore, malnourished patients are prone to develop pressure ulcers, infections, and delayed wound healing that result in chronic non-healing wounds [63]. After amputation, patients with normal nutrition parameters tend to heal uneventfully, whereas malnourished patients suffer either local or systemic postoperative complications [58, 65]. Postoperative major wound complications increased five times among patients with a lymphocyte count of less than 1500 cells/mm and seven times when preoperative albumin was less than 3.5 g/dL [66, 67]. Protein supplementation following orthopedic surgery reduces infections, attenuates post-fracture bone loss, and tends to increase muscle strength [68]. In animal experiments, low protein levels affect callus composition early in the process of fracture healing, when the protein content of soft callus usually increases because of early cellular proliferation and protein synthesis [69]. Chronic malnutrition may influence negatively the early proliferation and differentiation events for fracture repair [70, 71], therefore contributing [72] to fracture nonunion, although this event is a multifactorial phenomenon with predisposing mechanical, anatomical, and biological factors. About infection, no correlation has been observed between a poor nutritional status and staphylococcus colonization after hip or knee replacement [73], although a convincing influence of malnutrition on the occurrence of infection is widely claimed. No definite data are available in developing countries regarding this issue.

11.4 Management

Broad-spectrum therapeutic interventions and programs against malnutrition, especially in developing countries, go beyond the scope of this chapter and only perioperative management aimed to prevent or to handle nutrition deficiencies will be taken into account. Is there any evidence about the indication and the role for nutritional support in the acute and post orthopedic trauma phase? A Cochrane review regarding nutritional supplementation in older patients after hip fracture shows a weak evidence for its effectiveness [74]. However, the peculiar clinical conditions of the patients, including age, and the features of the observed injuries make problematic to extend these conclusions to austere environment.

Nutritional supports could be employed, even in austere settings, not only after the acute management of injuries [75] but also to achieve better clinical conditions before attempting delayed surgical procedures following trauma, like amputations, where a preoperative effort to prevent catabolic states seems worthwhile. Unfortunately, most tools commonly used in developed countries, like enteric solutions, semi-elemental feeds, immunonutrition, and total parenteral nutrition, are often not available or are impractical.

11.4.1 Preoperative Treatment

Preoperative fasting and surgery cause metabolic stress and insulin resistance which is characterized by hyperglycemia and decreased responsiveness of tissues (mainly the skeletal muscle and liver) to the biological actions of insulin, a condition associated with increased postoperative morbidity, mortality, and length of hospital stay [76]. Therefore, measures to attenuate development of insulin resistance, such as oral preoperative carbohydrate treatment (PCT), can potentially have a clinical benefit. Feeding before surgery was traditionally avoided to decrease the risk of aspiration of gastric contents. However, a Cochrane review found no increased risk of aspiration in patients who were allowed fluids 2–3 h prior to surgery compared to patients having undergone a traditional fasting period [77]. Accordingly, the European Society for Parenteral and Enteral Nutrition [78] and the American Society of Anesthesiologists recommend that patients be allowed to eat up to 6 h before surgery and drink clear fluids until 2 h before surgery [79]. The current recommendations for PCT suggest a loading dose of 100 g the night before surgery, followed up with another 50 g dose 2 h before surgery [80]. A recent meta-analysis of randomized controlled trials on preoperative oral carbohydrate treatment in elective surgery showed that PCT may be associated with reduced length of stay in patients undergoing major abdominal surgery [81]. The metabolic and clinical benefits of PCT are now widely acknowledged and are incorporated in the so-called “fast track” approach. Regrettably, only two small orthopedic studies are mentioned in the meta-analysis [81], but are underpowered to give a reliable evaluation of preoperative carbohydrate treatment on length of hospital stay in orthopedic surgery [82, 83].

Supplementary enriched in protein local food could be administered in preparation to surgery in austere environment, but even in developed countries, there are no clear recommendations about when, or for how long, malnourished patients would need it; a period of 5–7 days of preoperative supplementary nourishment was considered appropriate for improving the wound healing (but not mortality) in patients submitted to transtibial amputation [16].

11.4.2 Postoperative Treatment

According to a previous summary report from the National Institutes of Health (NIH), the American Society for Parenteral and Enteral Nutrition (ASPEN), and the American Society for Clinical Nutrition (ASCN), nutritional support should be initiated in patients who are not expected to resume oral feeding for 7–10 days [84]. In severely injured patients, there is no outcome advantage to initiate enteral feedings within 24 h of admission, compared to 72 h after admission (level I evidence) [85].

Feeding routes after trauma may range from oral intake to enteral feeding (nasogastric, nasoduodenal, nasojejunal, or jejunostomy) and to parenteral nutrition. Although oral or by nasogastric tube administration of nutritional supplement appears to reduce the complication rate after hip fracture in an elderly population [74], most available studies present methodological limits, being short term, with a patient’s selection not always based on nutritional state, and with a poor compliance by the patients [86]. Nausea and diarrhea are not uncommon, and nasogastric tube is often poorly tolerated in a high percentage of patients, especially elderly, for neurological problems (nervousness, anxiety, etc.) [87].

In patients with intact alimentary tracts, enteral feeds are less expensive, more readily available, and are administered with less difficulty than total parenteral nutrition (TPN). TPN requires cooperation from supporting services such as pharmacy, infection control, surgical, and nursing care making challenging this route in austere environment. Hence, when feasible, enteral feeding should be the preferred route of nutrition. Enteral nutrition can modulate the metabolic response after injury and improve protein kinetics and amino acid flux across peripheral tissue preserving the integrity of the gut barrier and of the intestinal microvillus structure [88]. Conversely, intravenous feeding increases gut permeability and allows bacterial translocation to the mesenteric lymph nodes [89]. Septic complications represent the most critical problem of parenteral nutrition and are much more common than with enteral nutrition.

Robust evidence about the preferred enteral route is lacking. A jejunal (small bowel), rather than gastric (stomach) feeding tube, has been recommended for enteral nutrition [90, 91]. However, according to the eastern association for the surgery of trauma (EAST) [85], in critically injured patients, patient’s outcome is equivalent with gastric or duodenal feeding. For this reason and because access to the stomach can be obtained more quickly and easily than the duodenum, an initial attempt at gastric feedings appears warranted. Nasogastric tubes can be used for enteral feeding in those traumas where a laparotomy for injury is not required (e.g., mine blast with traumatic amputations). When a laparotomy is needed, a gastrostomy may be performed or the surgically placed feeding tube may be guided into the duodenum or jejunum. The amount of given protein should be 1.2–2.0 g/kg ideal body weight to compensate for large nitrogen losses seen in trauma and sepsis. It is recommended that protein should represent 15–20 % of artificial feed, carbohydrate (in the form of glucose) 30–70 %, and fats the remaining 15–30 % [92].

In the military experience, the field milk or pureed foods, readily accessible, have been used to prepare "homemade" enteral solutions [75]. It is unlikely that such "field-expedient" enteral nutrition would match the quality of nutrition in commercial tube feed formulas, but presumably it would preserve small bowel mucosa integrity and promote immune system function. The absence of pumps in austere settings makes bolus feeds the preferred method of administration, always beginning with small bolus (usually 30 ml/h) and increasing slowly to a 60 ml/h. Alternatively, a continuous feeding may be used utilizing intravenous bags and lines filled with solution, but the viscosity of the feeding may be a limit, clogging the intravenous or feeding tube.

Homemade solutions have the advantage to deal with local food culture, avoiding prohibited foods (like pork or derivate for instance) and utilizing foods or milk available locally. Moreover, local staff could undergo a useful training on the preparation, administration, and nutritive value of pureed enteral feedings, which are especially valuable for these patient's populations whose hospital stay is often characterized, in these settings, by weight loss, weakness, and starvation.

Enteral nutrition may be followed by metabolic complications, like tube feeding syndrome, a hypertonic dehydration state produced by overfeeding protein [93] or by administering inadequate free water, hence inducing hypernatremia. It can be managed simply avoiding hypertonic feeds and administering abundant free water. A common complication is diarrhea, classically osmotic but also consequent to *Clostridium difficile* enterocolitis and bacterial overgrowth. Diarrhea can significantly impair wound healing because of bacterial contamination, difficulty in maintaining a clean dressing, malabsorption, and gastrointestinal protein losses.

Some specific nutrients, like arginine, glutamine, nucleotides, and ω-3 fatty acids, given enterally or parenterally, induce a pharmacologic immune-enhancing effects independent of preventing acute protein malnutrition [93], and glutamine has been recommended in military trauma patients in a field intensive care unit (unless there is a brain injury) [94]. Early postoperative enteral immunonutrition may offer additional benefits over standard enteral formulas [95]. A meta-analysis published in 2001 about immunonutrition, limited to gastrointestinal surgery, concluded that immune-enhancing diet was able to improve healing of surgical wounds and to reduce complication rate and hospital stay, without influencing mortality, regardless of the time of administration (preoperative, postoperative, or both) [96]. However, the greatest benefit of immunonutrition appears to be in surgical patients rather than critically ill or trauma patients [60]; therefore, while there is evidence to support the use of immunonutrition in elective and gastrointestinal surgery, at present there is still controversy of its use in other settings. Moreover, according to EAST, the precise doses and lengths of treatment with arginine and glutamine required to obtain an immune-enhancing effect have not yet been determined.

Semi-elemental feeds have also been used for enteral nutrition, containing hydrolyzed protein as nitrogen source. They are differentiated from intact protein feeds (protein that has not been hydrolyzed) and elemental feeds (free amino acids as the sole source of nitrogen). The use of a semi-elemental feed is associated with better amino acid absorption, better insulin responses, and decreased diarrhea compared to an intact protein, enteral feed [97]. Again, their availability may be scarce in austere environment.

Conclusion

Weight loss, starvation, or poor nutritional state are frequently observed in orthopedic trauma patients in developing countries, and malnutrition increases during the hospital stay, therefore influencing negatively the clinical outcome. To recognize the significant role of nutrition in orthopedic trauma in order to prevent malnutrition or to offer a good nutritional support, at least during the period of hospital care, is a first important step. Regrettably, nutritional care is challenging in such settings, due to the nonavailability of TPN or enteral nutrition solutions as in western countries. Given the scarce level of resources, nutrition supplement should be administered by the simplest oral or enteral routes and based on local, available ingredients. The preparation of enriched food or enteral solution with local components, their administration to the patients, and the understanding regarding the importance of providing nutritional support will be especially valuable for the local staff, contributing to better care for orthopedic trauma patients and improved outcomes.

References

1. Smith TK. Prevention of complications in orthopedic surgery secondary to nutritional depletion. Clin Orthop Relat Res. 1987;222:91–7.
2. Smith TK. Nutrition: its relationship to orthopedic infections. Orthop Clin North Am. 1991;223:373–7.
3. Jensen JE, Jensen TG, Smith TK, et al. Nutrition in orthopaedic surgery. J Bone Joint Surg Am. 1982;64:1263–7.
4. Gumieiro DN, Rafacho BP, Gonçalves AF, et al. Mini nutritional assessment predicts gait status and mortality 6 months after hip fracture. Br J Nutr. 2012;28:1–5.
5. Symeonidis PD, Clark D. Assessment of malnutrition in hip fracture patients: effects on surgical delay, hospital stay and mortality. Acta Orthop Belg. 2006;72:420–7.
6. O'Daly BJ, Walsh JC, Quinlan JF, et al. Serum albumin and total lymphocyte count as predictors of outcome in hip fractures. Clin Nutr. 2010;29:89–93.
7. Salignon P, Cabrol JC, Liu J, et al. Health and war in Congo-Brazzaville. Lancet. 2000;356:1762.
8. Shretha BK, Rajbhandary T, Bijukachhe B, et al. Surgical interventions in chronic osteomyelitis. Kathmandu Univ Med J. 2005;3:50–4.
9. Baxter JP. Problems of the nutritional assessment in the acute setting. Proc Nutr Soc. 1999;58:39–46.
10. FAO. The state of food insecurity in the world. 2006. http://www.fao.org/docrep/009/a0750e/a0750e00.htm. Accessed 12 July 2013.
11. WHO. Management of severe malnutrition. A manual for physician s and other senior health workers. 1999. http://www.who.int/nutrition/publications/severemalnutrition/manage_severe_malnutrition_eng_cover.pdf. Accessed 4 June 2013.
12. Prentice AM, Moore SE, Fulford AJ. Growth faltering in low-income countries. World Rev Nutr Diet. 2013;106:90–9.
13. Corish CA, Kennedy NP. Protein energy undernutrition in hospital in-patients. Br J Nutr. 2000;83:575–91.
14. Middleton MH, Nazarenko G, Nivison-Smith I, et al. Prevalence of malnutrition and 12-month incidence of mortality in two Sydney teaching hospitals. Intern Med J. 2001;31:455–61.
15. Edington J, Boorman J, Durrant ER, et al. Prevalence of malnutrition on admission to four hospitals in England. The Malnutrition Prevalence Group. Clin Nutr. 2000;19:191–5.
16. Eneroth M, Apelqvist J, Larsson J, et al. Improved wound healing in transtibial amputees receiving supplementary nutrition. Int Orthop. 1997;21:104–8.
17. Dwyer AJ, John B, Mam MK, et al. Nutritional status and wound healing in open fractures of the lower limb. Int Orthop. 2005;29:251–4.
18. Dreblow DM, Anderson CF, Moxness K. Nutritional assessment of orthopedic patients. Mayo Clin Proc. 1981;56:51–4.
19. Foster MR, Heppenstall RB, Friedenberg ZB, et al. A prospective assessment of nutritional status and complications in patients with fractures of the hip. J Orthop Trauma. 1990;4:49–57.
20. Goiburu ME, Jure Goiburu MM, Bianco H, et al. The impact of malnutrition on morbidity, mortality and length of hospital stay in trauma patients. Nutr Hosp. 2006;21:604–10.
21. Patton CM, Powell AP, Patel AA. Vitamin D in orthopedics. J Am Acad Orthop Surg. 2012;20:123–9.
22. Bogunovic L, Kim AD, Beamer BS, et al. Hypovitaminosis D in patients scheduled to undergo orthopaedic surgery: a single-center analysis. J Bone Joint Surg Am. 2010;92:2300–4.
23. Nawabi DH, Chin KF, Keen RW, et al. Vitamin D deficiency in patients with osteoarthritis undergoing total hip replacement: a cause for concern? J Bone Joint Surg Br. 2010;92:496–9.
24. Parry J, Sullivan E, Scott AC. Vitamin D sufficiency screening in preoperative pediatric orthopaedic patients. J Pediatr Orthop. 2011;31:331–3.
25. Wahlqvist ML. Vitamin D status and food security in North-East Asia. Asia Pac J Clin Nutr. 2013;22:1–5.
26. Mithal A, Wahl DA, Bonjour JP, et al. Global vitamin D status and determinants of hypovitaminosis D. Osteoporos Int. 2009;2:1807–20.
27. Al-Mogbel ES. Vitamin D status among Adult Saudi Females visiting Primary Health Care Clinics. Int J Health Sci (Qassim). 2012;6:116–26.
28. Halicioglu O, Aksit S, Koc F, et al. Vitamin D deficiency in pregnant women and their neonates in spring

time in western Turkey. Paediatr Perinat Epidemiol. 2012;26:53–60.
29. Szalay EA, Tryon EB, Pleacher MD, et al. Pediatric vitamin D deficiency in a southwestern luminous climate. J Pediatr Orthop. 2011;31:469–73.
30. Sadat-Ali M, AlElq A, Al-Turki H, et al. Vitamin D levels in healthy men in eastern Saudi Arabia. Ann Saudi Med. 2010;29:378–82.
31. Tanriover MD, Oz SG, Tanriover A, et al. Hip fractures in a developing country: osteoporosis frequency, predisposing factors and treatment costs. Arch Gerontol Geriatr. 2010;50:e13–8.
32. Avenell A, Gillespie WJ, Gillespie LD, et al. Vitamin D and vitamin D analogues for preventing fractures associated with involutional and post- menopausal osteoporosis. Cochrane Database Syst Rev. 2009;(2):CD000227.
33. Sanders KM, Stuart AL, Williamson EJ, et al. Annual high-dose oral vitamin D and falls and fractures in older women: a randomized controlled trial. JAMA. 2010;303:1815–22.
34. Birkhahn RH, Long CL, Fitkin D, et al. Effects of major skeletal trauma on whole body protein turnover in man measured by L-[1,14C]-leucine. Surgery. 1980;88:294–300.
35. Manious MR, Deitch EA. Nutrition and infection. Surg Clin North Am. 1994;74:659–76.
36. Hill N, Fallowfield J, Price S, et al. Military nutrition: maintaining health and rebuilding injured tissue. Philos Trans R Soc Lond B Biol Sci. 2011;366:231–40.
37. Plank LD, Hill GL. Sequential metabolic changes following induction of systemic inflammatory response in patients with severe sepsis or major blunt trauma. World J Surg. 2000;24:630–8.
38. Duff S, Price S, Gray J. The role of nutrition in injured military personnel at Role 4: current practice. J R Army Med Corps. 2008;154:284–91.
39. Schneider SM, Veyres P, Pivot X, et al. Malnutrition is an independent factor associated with nosocomial infections. Br J Nutr. 2004;92:105–11.
40. Windsor JA, Knight GS, Hill GL. Wound healing response in surgical patients: recent food intake is more important than nutritional status. Br J Surg. 1988;75:135–7.
41. Meijers JM, van Bokhorst-de van der Schueren MA, Schols JM, et al. Defining malnutrition: mission or mission impossible? Nutrition. 2010;26:432–40.
42. WHO. Turning the tide of malnutrition: responding to the challenge of 21st century. 2000. http://www.who.int/nut/documents/nhd_brochure.pdf. Accessed 14 July 2013.
43. Lazzerini M, Rubert L, Ronfani L, et al. Specially formulated foods for treating children with acute moderate malnutrition in low- and middle-income countries (Protocol). The Cochrane Library. 2012;(1):CD009584.
44. Caleo GM, Penda A, Balandine S, et al. Sentinel site community surveillance of mortality and nutritional status in southwestern Central African Republic, 2010. Popul Health Metr. 2012;10:18.
45. Detsky AS, Baker JP, Mendelson RA, et al. Evaluating the accuracy of nutritional assessment techniques applied to hospitalized patients: methodology and comparisons. JPEN J Parenter Enteral Nutr. 1984;8:153–9.
46. Vellas B, Villars H, Abellan G, et al. Overview of MNA® – its history and challenges. J Nut Health Aging. 2006;10:456–65.
47. Bauer JM, Kaiser MJ, Anthony P, et al. The Mini Nutritional Assessment: its history, today's practice, and future perspectives. Nutr Clin Pract. 2008;23:388–96.
48. Elia M. The 'MUST' report. Nutritional screening for adults: a multidisciplinary responsibility. 2003. http://www.bapen.org.uk/pdfs/must/must_exec_sum.pdf. Accessed 14 July 2013.
49. Buzby GP, Knox LS, Crosby LO, et al. Study protocol: a randomized clinical trial of total parenteral nutrition in malnourished surgical patients. Am J Clin Nutr. 1988;47:366–81.
50. Kondrup J, Johansen N, Plum LM, et al. Incidence of nutritional risk and causes of inadequate nutritional care in hospitals. Clin Nutr. 2002;21:461–8.
51. Bouillanne O, Morineau G, Dupont C, et al. Geriatric Nutritional Risk Index: a new index for evaluating at-risk elderly medical patients. Am J Clin Nutr. 2005;82:777–83.
52. Falcao MC, Cardoso LEMB. Avaliação nutricional do recémnascido pré-termo. Rev Bras Nutr Clin. 2001;16:144–7.
53. McClave SA, Snider HL, Spain DA. Preoperative issues in clinical nutrition. Chest. 1999;115:64S–70.
54. Del Savio GC, Zelicof SB, Wexler LM, et al. Preoperative nutritional status and outcome of elective total hip replacement. Clin Orthop Relat Res. 1996;326:153–61.
55. Schwals WJ, Fernandez ME, Jamie AC, et al. Relationship of metabolic indices to postoperative mortality in surgical infants. J Pediatr Surg. 1993;28:819–22.
56. Fuhrman MP, Winkler M, Biesemeier C. The American Society for Parenteral and Enteral Nutrition (A.S.P.E.N.) Standards of Practice for nutrition support dietitians. J Am Diet Assoc. 2001;101:825–32.
57. Dickhaut SC, DeLee JC, Page CP. Nutritional status: importance in predicting wound-healing after amputation. J Bone Joint Surg Am. 1984;66:71–5.
58. Kay SP, Moreland JR, Schmitter E. Nutritional status and wound healing in lower extremity amputations. Clin Ortop. 1987;217:253–6.
59. Covinsky KE, Martin GE, Beyth RJ, et al. The relationship between clinical assessments of nutritional status and adverse outcomes in older hospitalized medical patients. J Am Geriatr Soc. 1999;47:532–8.
60. Windsor A, Braga M, Martindale R, et al. Fit for surgery: an expert panel review on optimising patients prior to surgery, with a particular focus on nutrition. Surgeon. 2004;2:315–9.
61. Jeejeebhoy KN, Detsky AS, Baker JP. Assessment of nutritional status. J Parenter Enteral Nutr. 1990;14:193S–6.
62. Woolf SH, Grol R, Hutchinson A, et al. Clinical guidelines: potential benefits, limitations, and harms of clinical guidelines. BMJ. 1999;318:527–30.

63. Arnold M, Barbul A. Nutrition and wound healing. Plast Reconstr Surg. 2006;117:42S–58.
64. Campos ACL, Groth AK, Branco A. Assessment and nutritional aspects of wound healing. Curr Opin Clin Nutr Metab Care. 2008;11:281–8.
65. Pratt WB, Veitch JM, McRoberts RL. Nutritional status of orthopedic patients with surgical complications. Clin Orthop Relat Res. 1981;155:81–4.
66. Greene KA, Wilde AH, Stulberg BN. Preoperative nutritional status of total joint patients. Relationship to postoperative wound complications. J Arthroplasty. 1991;6:321–5.
67. Koval KJ, Maurer SG, Su ET, et al. The effects of nutritional status on outcome after hip fracture. J Orthop Trauma. 1999;13:164–9.
68. Bonjour JP. Protein intake and bone health. Int J Vitam Nutr Res. 2011;81:134–42.
69. Bak B, Andreassen TT. Reduced energy absorption of healed fracture in the rat. Acta Orthop Scand. 1988;59:548–51.
70. Hughes MS, Kazmier P, Burd TA, et al. Enhanced fracture and soft-tissue healing by means of anabolic dietary supplementation. J Bone Joint Surg Am. 2006;88:2386–94.
71. Brinker MR. Nonunions: evaluation and treatment. In: Browner BD, Levine AM, Jupiter JB, et al., editors. Skeletal trauma: basic science, management, and reconstruction. Philadelphia: WB Saunders; 2003. p. 507–604.
72. Day SM, DeHeer DH. Reversal of the detrimental effects of chronic protein malnutrition on long bone fracture healing. J Orthop Trauma. 2001;15:47–53.
73. Schwarzkopf R, Russell TA, Shea M, et al. Correlation between nutritional status and staphylococcus colonization in hip and knee replacement patients. Bull NYU Hosp Jt Dis. 2011;9:308–11.
74. Avenell A, Handoll HH. Nutritional supplementation for hip fracture after care in older people. Cochrane Database Syst Rev. 2006;(4):CD001880.
75. Frizzi JD, Ray PD, Raff JB. Enteral nutrition by a Forward Surgical Team in Afghanistan. South Med J. 2005;98:273–8.
76. Awad S, Constantin-Teodosiu D, Macdonald IA, et al. Short-term starvation and mitochondrial dysfunction – a possible mechanism leading to post- operative insulin resistance. Clin Nutr. 2009;28:497–509.
77. Brady MC, Kinn S, Stuart P, et al. Preoperative fasting for adults to prevent perioperative complications (review). Cochrane Database Syst Rev. 2003. http://onlinelibrary.wiley.com/o/cochrane/clsysrev/articles/CD004423/frame.html. Accessed 11 July 2013.
78. Weimann A, Braga M, Harsanyic L, et al. ESPEN guidelines on enteral nutrition: surgery including organ transplantation. Clin Nutr. 2006;25:224–44.
79. American Society of Anesthesiologists. Guidelines for preoperative fasting and the use of pharmacologic agents to reduce the risk of pulmonary aspiration: application to healthy patients undergoing elective procedures an updated report by the American Society of Anesthesiologists Committee on Standards and Practice Parameters. Anesthesiology. 2011;114:495–511.
80. Kratzing C. Pre-operative nutrition and carbohydrate loading. Proc Nutr Soc. 2011;70:311–5.
81. Awad S, Varadhan KK, Ljungqvist O, et al. A meta-analysis of randomised controlled trials on preoperative oral carbohydrate treatment in elective surgery. Clin Nutr. 2013;32:34–44.
82. Soop M, Nygren J, Myrenfors P, et al. Preoperative oral carbohydrate treatment attenuates immediate postoperative insulin resistance. Am J Physiol Endocrinol Metab. 2001;280:E576–83.
83. Soop M, Nygren J, Thorell A, et al. Preoperative oral carbohydrate treatment attenuates endogenous glucose release 3 days after surgery. Clin Nutr. 2004;23:733–41.
84. Klein S, Kinney J, Jeejeebhoy K, et al. Nutrition support in clinical practice: review of published data and recommendations for future research directions. J Parenter Enteral Nutr. 1997;21:133–46.
85. Jacobs DG, Plaisier BR, Baries PS, et al. Practice management guidelines for nutritional support of the trauma patient. J Trauma. 2003;54:391–416.
86. Lawson RM, Doshi MK, Ingoe LE, et al. Compliance of orthopaedic patients with postoperative oral nutritional supplementation. Clin Nutr. 2000;19:171–5.
87. Sullivan DH, Nelson CL, Klimberg VS, et al. Nightly enteral nutrition support of elderly hip fracture patients: a pilot study. J Am Coll Nutr. 2004;23:683–91.
88. Kudsk KA. Gut mucosal nutritional support – enteral nutrition as primary therapy after multiple trauma. Gut. 1994;35:S52–541.
89. Deitch EA, Winterton J, Li M, et al. The gut as a portal of entry for bacteremia. Role of protein malnutrition. Ann Surg. 1987;205:681–92.
90. Henning J, Scott T, Price S. Nutrition of the critically ill patient in field hospitals on operations. J R Army Med Corps. 2008;154:279–81.
91. Critical Care Nutrition. Strategies to optimize delivery and minimize risks of EN: small bowel versus gastric feedings. 2009. http://www.criticalcarenutrition.com/docs/cpg/5.3Smallbowel_FINAL.pdf. Accessed 10 May 2013.
92. Cerra FB, Benitez MR, Blackburn GL, et al. Applied nutrition in ICU patients. A consensus statement of the American College of Chest Physicians. Chest. 1997;111:769–78.
93. Pardoe EM. Tube feeding syndrome revisited. Nutr Clin Pract. 2001;16:144–6.
94. Schloerb PR. Immune-enhancing diets: products, components, and their rationales. J Parenter Enteral Nutr. 2001;25:S3–7.
95. Stechmiller JK. Understanding the role of nutrition and wound healing. Nutr Clin Pract. 2010;25:61–8.
96. Cerantola Y, Hübner M, Grass F, et al. Immunonutrition in gastrointestinal surgery. Br J Surg. 2011;98:37–48.
97. Mechanik JA. Practical aspects of nutritional support for wound healing patients. Am J Surg. 2004;188:52S–6.

HIV/AIDS and Orthopaedic Trauma

12

W.J. Harrison

HIV/AIDS primarily affects patients in low-income settings, particularly in sub-Saharan Africa. Clinicians, especially orthopaedic trauma surgeons from high-income countries, may not be familiar with HIV disease or its impact on management of trauma patients. Local staff often have a good working knowledge of HIV disease and its treatment. Many of them now have some understanding of expected outcomes after surgery, although in the early years of the pandemic, there were a lot of misconceptions.

UNAIDS data indicated that an estimated 34 million persons were living with HIV by the end of 2011, with this number rising annually. 69 % of the 34 million were in sub-Saharan Africa with Asia contributing a further 5 million. Other regions with significant HIV problems include the Caribbean and Eastern Europe [1].

There were 2.5 million new HIV infections globally in 2011, less than in previous years. 1.7 million died of AIDS-related causes. 8 million were on highly active antiretroviral treatment (HAART) including 6 million in Africa.

The main aim of this chapter is to highlight aspects of HIV infection which may predict altered outcomes from the injury itself or result in different management strategies. Thus, I hope to provide some principles to guide management decisions in an evidence-based manner [2, 3].

12.1 HIV/AIDS: The Disease

Human immunodeficiency virus is a retrovirus which indicates that it copies its RNA back into the DNA inside cells using the reverse transcriptase enzyme. The newly formed DNA can then be 'copied' to make new virus particles which are subsequently released from the cell to infect other cells. The ability to 'hide' in the host DNA makes the virus inaccessible to conventional therapies.

The virus is taken up into T cells which are involved in the cellular immune response. These T helper cells have a protein receptor called the cluster of differentiation antigen number 4 or CD4. The viral onslaught against T helper cells weakens both the cellular and humoral immune responses.

When a person becomes infected with HIV, they manifest a brief flu-like illness before entering an asymptomatic phase in which they have generalised lymphadenopathy but are not unusually subject to disease. Their defences gradually fall over some years until they become subject to various infections and certain tumours. If unchecked, the loss of immunity progresses to

---

W.J. Harrison, MA(Oxon), FRCS (Tr & Orth)
Department of Trauma & Orthopaedics,
Countess of Chester NHS Foundation Trust,
Chester, UK
e-mail: jharrison@ao-alliance.org;
aojimh@gmail.com

© Springer International Publishing Switzerland 2016
J.D. Robinson (ed.), *Orthopaedic Trauma in the Austere Environment:*
A Practical Guide to Care in the Humanitarian Setting, DOI 10.1007/978-3-319-29122-2_12

the development of acquired immunodeficiency syndrome (AIDS). AIDS patients face life-threatening illnesses including tuberculosis, pneumocystis carinii pneumonia, cryptococcal meningitis, and Kaposi's sarcoma.

As the disease progresses, the CD4 cell count falls from its normal value of around 1000 cells/mm3. Few problems are normally encountered until the CD4 cell count drops below 500, whilst levels below 200 allow AIDS to develop.

The viral load reflects the number of virions per unit volume of blood and is high at initial seroconversion and later in the progression to AIDS. A high viral load also makes the patient more infectious to other parties. HAART is effective in reducing viral load, sometimes to very low levels. This controls disease progression, allows CD4 numbers to be partially restored and makes the patient less infectious to others. Current recommendations were adjusted in 2013 to suggest commencing HAART when the CD4 level drops below 500, but not all countries may be able to implement such a proactive approach.

HIV disease may be classified according to two common classifications – The World Health Organisation (updated 2005) and the Centre for Disease Control (updated 2008) classifications [4, 5]. The WHO classification bears more emphasis on clinical findings but both systems now require laboratory confirmation of HIV.

It should be noted that CD4 cell count testing is relatively expensive and not universally available and viral load is only available in specialist units. HIV tests themselves are cheap and widely available. Clinicians should also consider the nutritional status of patients with HIV disease. This is commonly impaired, and low albumin may be a predictor of poor surgical outcomes [6].

12.2 Closed Fractures

When considering operative fracture management on patients with HIV disease and fresh fractures or their sequelae, the question of expected wound healing and deep infection must be considered. There is now good data from prospective studies to guide decisions after closed fractures.

12.2.1 Wound Healing

Early studies of Jellis [7], Hoekman [8], and Paiement [9] highlighted potential problems after internal fracture fixation. The study designs of these early reports did not define risks accurately with regard to closed injuries. Furthermore, these studies were undertaken in the pre-HAART era.

The large prospective, controlled studies of our group in Malawi have subsequently shown that for closed fractures without severe soft tissue injury, excellent post-operative infection rates can be achieved [10, 11] (Table 12.1). These rates are equivalent to healthy controls and are below

Table 12.1 Published infection rates for internal fracture fixation of HIV-positive patients

First author	Year of publication	Number of patients	Open or closed fractures	Use of ARTs	Infection rate
Hoekman	1991	43	Closed	No	24 %
Paiement	1994	NK	Mixed	No	17 % overall, 56 % open
Jellis	1996	NK	Closed	No	33 %
Harrison	2002	41	Mixed stratified	No	4 % closed 42 % open
Bahabeck	2008	74	Closed	Yes	6 %
Abalo	2010	36	Mixed stratified	Some	8 of 28 closed 75 % open
Aird	2011	33	Open	Some	15%[a]
Bates	2012	132	Both, stratified results	Some	4 % closed 33 % open

NK not known

[a]Mixed internal and external fixation

5 % even by strict definition criteria to include minor transient infection. Disease stage may affect infection rates although we reported meaningful numbers of patients with CD4 counts below 200 cells/mm3 who nevertheless obtained sound wound healing. Most of these patients were recruited in the pre-HAART era, and the encouraging findings are unlikely to be impaired by the advances of HAART.

A smaller recent study of Abalo from Togo found higher infections rates, but this was a mixed group with open and closed fractures [12]. The large study of Bahabeck also found encouraging wound healing rates in such patients [13]. They employed a regime of extended intravenous prophylaxis and immediate commencement of HAART and attributed their success to such measures. Since our study had equally good results without these interventions, I do not feel that evidence substantiates this advice. HAART normally takes 6 or more weeks to translate into a significant rise in CD4 count and improvement in immunity – and one expects wound healing long ahead of this. HAART may be valuable before elective surgery where such a delay to surgery can be scheduled, and we have employed this strategy for arthroplasty surgery with apparent success [14]. Nutritional improvements may also be advocated in such a situation.

We used a single dose of appropriate intravenous antibiotics at induction of anaesthesia, and this regime gave results comparable to healthy controls. I am unaware of any evidence that extended prophylaxis is likely to improve operative wound infection rates.

12.2.2 Fracture Union

Since HIV alters the inflammatory response, there are some theoretical reasons why it might alter fracture union [15]. We recently published the first clinical paper looking prospectively at fracture union in a cohort of 100 internal fixations in patients with HIV disease [16]. This cohort contained a mixture of fracture types and fixation strategies and did not have a control group. Nevertheless the clinical results of 107 fracture cases with only 4 % non-union were encouraging. Of these, all bar one case had suboptimal fixations which were the more obvious cause of impaired fracture union.

12.2.3 Late Implant Sepsis

As patient immunity wanes in the progression towards AIDS, there is a concern that metallic implants could form the focus of a late infection. This concept has been promoted by the Durban group who have recorded a number of such cases [17, 18]. Such a finding has also been observed in haemophiliacs with HIV disease who have undergone arthroplasty surgery [19].

We published our findings of a prospective group of 36 patients with 38 implants in which no late sepsis had been identified at 1 year [20]. We are currently analysing our cohort of 100 HIV-positive patients with 3- to 8-year follow-up after internal fracture fixation. Again we have not identified any cases of late sepsis in this series [21].

Overall I believe that late implant sepsis may be an entity, but it is not sufficiently prevalent to alter common practice of leaving fixation implants in situ unless they are causing problems. It may be that the use of HAART will reduce further any risk of late implant sepsis. Should it occur, it can be treated in the standard manner of implant removal and local debridement, plus antibiotics.

12.3 Open Fractures

Whilst the evidence on closed fractures is fairly clear and gives an encouraging message, the evidence for open fractures is conflicting and appears to portray a more guarded outlook.

12.3.1 Wound Infection

Some of the early series which reported high rates of surgical infection contained some open fractures. In our early paper, we separated the analysis for patients with open fractures or severe soft tissue injuries [10]. This gave a small group of only 12 HIV-positive patients with open fractures fixed internally, but the infection rate was alarming at 42 %, and compared unfavourably with an infection rate of 11 % in 27 controls. We also published a small series of open tibia fractures treated with external fixation – again showing high wound infection rates [22]. The numbers in these series were too small to make meaningful sub-analysis for severity of open fracture or disease stage – although both seem likely to be important.

The largest published study looking at open fractures comes from Aird working in South Africa [23]. They had the practice of managing Gustilo grade 1 fractures on daytime trauma lists within 48 h, but managing grade 2 and 3 injuries as emergencies with emergency debridement and external or internal fixation. They also entered a larger number of gunshot injuries than other series. They showed a raised infection rate for grade 1 injuries compared to HIV-negative controls, but observed no such effect in grade 2 and 3 injuries. They suggested that delay to surgery was more important than wound severity. This finding conflicts somewhat with other literatures, and there may be study design factors which gave rise to this somewhat surprising finding.

I believe that the current literature indicates that contamination and soft tissue injury, delay to surgery, and disease stage are all likely to be relevant to the expected outcome after open fractures in patients with HIV disease. Wound infection in such patients is a significant clinical problem. The method of stabilisation employed may be relevant, although this is currently unproven [24].

12.3.2 Microbiology

Studies of wound infection of open and surgical wounds in patients with HIV disease have not been large or sophisticated enough to give definitive evidence regarding which pathogens are most relevant. *Staphylococcus aureus* appears to be the most common pathogen, but other organisms have been isolated. The role of fungi is unknown.

12.3.3 Pin Site Infection

Our study group looked prospectively at pin site infections during the use of conventional mono-lateral external fixators with Schantz screws [25]. We found increased rates of all grades of pin track infections, although the majority were minor and could be managed using increased cleaning and oral antibiotics. We concluded that it was reasonable to use external fixators in patients with HIV disease where the clinical situation favoured such an approach.

12.4 Fracture Union

Fracture union after open fractures has not been adequately studied. Many such injuries occur at the tibia and involve road trauma with significant energy. Our study [22] suggested that such injuries may have a delay in union, but this finding may have been distorted by the small study numbers and the presence of high numbers of open wound infections.

My advice would be to make infection prevention, or treatment, the top priority after open fracture in patients with HIV disease. This involves early and aggressive debridement, immediate skeletal stabilisation, repeat debridement, and early soft tissue cover. The use of internal versus external stabilisation of such fractures remains a surgeon choice. External fixation may be a safer option unless early and radical debridement can be achieved. Secondary issues of delayed union will be much easier to manage in the absence of infection.

12.4.1 Functional Outcome

To my knowledge, there are no studies which really assess functional outcome in patients with HIV disease after fractures. In some patients with deep chronic sepsis after open tibial fractures, a below knee amputation may be advised. The outcome of such surgery and the response to a prosthetic limb has not been defined.

12.5 Polytrauma

Since HIV affects all body systems and the inflammatory response, the impact of polytrauma may be altered. At the same time, standard supportive measures including ventilator support may be complicated by respiratory infections and other problems.

12.6 Osteoporosis and Fragility Fractures

The recent literature from high-income countries has featured a number of papers describing the association between HIV and osteoporosis and fragility fractures [26, 27]. Such problems arise in individuals who have been treated over many years and for whom HIV has become a chronic disease. It appears that osteoporosis in such patients is multifactorial, resulting from smoking, alcohol, steroid usage, direct viral effects, some antiretrovirals, low body weight, nutrition, and sedentary lifestyle.

I have not encountered clinical problems of this nature in Africa, and I am not aware of any literature on this aspect emerging from low-income countries. I will therefore not discuss it further in this chapter. It may be a problem for the future in low-income countries, as more people access HAART and have extended life expectancies.

12.7 Working with Patients Who Are HIV Positive

Interaction with patients with HIV disease throws up a complex psychosocial milieu which is both challenging and interesting. The public, and indeed medical, perception of such patients varies from country to country and between different individuals. In some cultures, the means of original infection transmission may affect perceptions. This may be through congenital, heterosexual sex, homosexual sex, intravenous drug use, or other means of blood contamination. The prevalent cause varies from country to country.

All patients appreciate being treated with the normal respect of fellow human beings. It is also helpful when the clinician indicates that he is comfortable touching the patient without gloves during examination – assuming there are no open wounds.

Clinicians must maintain the highest standards of confidentiality and maintain patient trust. Counselling is required when undertaking HIV tests. Visitors are advised to be gentle and respectful towards the local culture and take time to understand what forms local opinion, before coming to any conclusions.

Whilst pretest and post-test counselling is available in most low-income settings, wider psychological support may be limited. I have found that an honest and encouraging approach to the patient allays many fears and assists engagement in the processes of treatment and rehabilitation. It is also important to consider referral for antiretroviral therapy where appropriate.

The risk of a health worker contracting HIV during his duties is statistically fairly small. In some groups, excessive fears prevail in this regard. Lemaire's review of the relative dangers is helpful and indicates that the overall risk of contracting HIV after a clinical exposure is around 0.3 % [28]. This may be reduced up to tenfold by prompt and appropriate administration of post-exposure prophylaxis (PEP). Most larger centres in countries with high HIV seroprevalence can provide PEP. The visitor should check this availability before embarking on a visit and make appropriate arrangements.

The orthopaedic surgeon bears a higher occupational risk of blood exposure than most clinicians on account of the nature of his work. This risk can be reduced by adopting universal precautions. The discipline of the operating theatre team is critical. Gloves and eyewear should be worn whenever one is in proximity to an open wound. When operating, one should assume all patients are potentially HIV positive (they may also have hepatitis B or C). Always wear double gloves. Occasionally I have worn three gloves on the non-dominant hand. The use of a cloth or metal mesh over-glove has been advocated when using wires. These are not generally available in low-income countries and I have no experience of using them.

I do recommend the use of surgical instruments whenever handling wires or indeed surgical needles. Whilst it is obvious, one must re-emphasise that hollow needles must not be resheathed. The use of a kidney dish helps tremendously in putting down sharps safely before they can be disposed in a sharps bin. The scalpel should always be passed in a plastic kidney dish (a metal dish can blunt the blade). The dish should not be passed hand to hand, but rather placed on a flat stable surface from which the scalpel can be lifted. I am a great advocate of maximal communication as a safety measure. This includes the declaration of 'sharp coming' whenever one is moving a sharp into or away from the wound. It is also important not to point the sharp outwards at such times in case an assistant moves his hand across the path of the sharp.

Excessive use of force seems to predispose to an increased risk of surgeon sharp injury. Where possible, use instruments and traction to secure fracture reduction, rather than fingers in the wound or brute force. When fingers are out of sight inside a wound, the risk is greater. I have been injured when using a non-cutting needle for attempted skin suture. The excessive force required caused the needle to slip into my finger. Such dangers are occasionally encountered in resource-poor environments where optimal equipment may not be available.

Conclusion

Extensive data has emerged in the last decade regarding the outcome of patients with HIV disease after trauma surgery. On the whole, recent publications indicate encouraging outcomes, but concern remains regarding the rate of wound infection after open fractures.

References

1. UNAIDS report 2012. www.unaids.org.
2. Harrison WJ. HIV/AIDs and trauma and orthopaedic surgery (review). J Bone Joint Surg [Br]. 2005;87B:1178–81.
3. Lubega N, Harrison WJ. HIV in trauma and orthopaedic surgery. Orthop Trauma. 2010;24(4):298–302.
4. WHO classification. www.who.int/hiv/pub/guidelines/clinical.staging.pdf.
5. CDC Recommendations and Reports. 5 Dec 2008/57(RR10):1–8
6. Govender S, Harrison WJ, Lukhele M. Impact of HIV on bone and joint surgery. Best Pract Res Clin Rheumatol. 2008;22(4):605–19.
7. Jellis JE. Orthopaedic surgery and HIV disease in Africa. Int Orthop. 1996;20(4):253–6.
8. Hoekman P, van de Perre P, Nelissen J, Kwisanga B, Bogaerts J, Kanyangabo F. Increased risk of infection after open reduction of fractures in patients who are seropositive for human immunodeficiency virus. J Bone Joint Surg Am. 1991;73(5):675–9.
9. Paiement G, Hymes RA, LaDouceur MM, Gosselin RA, Green HD. Postoperative infections in asymptomatic HIV-seropositive trauma patients. J Trauma. 1994;37(4):545–50.
10. Harrison WJ, Lewis CP, Lavy CBD. Wound healing following implant surgery in HIV positive patients. J Bone Joint Surg [Br]. 2002;84-B:802–6.
11. Bates J, Mkandawire NC, Harrison WJ. The incidence and consequences of early wound infection after internal fixation for trauma in HIV-positive patients. J Bone Joint Surg. 2012;94B:1265–70.
12. Abalo A, Patassi A, Yaovi EJ, Atsi W, Aly S, Assang D. Risk factors for surgical wound infection in HIV positive patients undergoing surgery for orthopaedic trauma. J Orth Surg. 2010;18(2):224–7.
13. Bahabeck J, Handy-Eone D, Ngo Nonga B, Ndjie Kinque T, Sosso M. Implant orthopaedic surgery in HIV asymptomatic carriers: management and early outcome. Injury. 2009;40(11):1147–50.
14. Graham SM, Lubega N, Mkandawire N, Harrison WJ. Total hip replacement in HIV positive patients. Bone Joint J. 2014;96-B(4):462–6.
15. Richardson J, Hill AM, Johnston CJ, McGregor A, Norrish AR, Eastwood D, Lavy CB. Fracture healing in HIV-positive populations. J Bone Joint Surg [Br]. 2008;90B(8):988–94.
16. Gardner RO, Bates JH, Ng'oma E, Harrison WJ. Fracture union following internal fixation in the HIV population. Injury. 2013;44(6):830–3.
17. Brijlall S. Implant sepsis in HIV infected patients. J Bone Joint Surg [Br]. 2003;85B(Suppl II):48.
18. Brijlal S, Lioma ID, Govender S. Implant sepsis in the HIV-infected patient. SA Orth J. 2003;2:26–30.
19. Hicks JL, Ribbans WJ, Buzzard B, Kelley SS, Toft L, Torri G, Wiedel JD, York J. Infected joint replacements in HIV positive patients with haemophilia. J Bone Joint Surg [Br]. 2001;83B:1050–4.
20. Harrison WJ, Lavy CBD, Lewis CP. One-year follow-up of orthopaedic implants in HIV-positive patients. Int Orthop. 2004;28:329–32.
21. Graham S, Bates JHJ, Harrison WJ. Long term follow-up of trauma implants in patients with HIV disease. Unpublished data.
22. Harrison WJ, Lewis CP, Lavy CBD. Open fractures of the tibia in HIV-positive patients – a prospective, controlled, single-blind study. Injury. 2004;35:852–6.

23. Aird J, Noor S, Lavy C, Rollinson P. The effect of HIV on early wound healing after open fractures treated with internal and external fixation. J Bone Joint Surg. 2011;93B:678–83.
24. Harrison WJ. Open tibia fractures in HIV positive patients. Malawi Med J. 2009;21(4):174–5.
25. Norrish AR, Lewis CP, Harrison WJ. Pin-track infection in HIV positive and HIV negative patients with open fractures treated by external fixation. J Bone Joint Surg [Br]. 2007;89-B(6):790–3.
26. Mundy LM, Youk AO, McComsey GA, Bowlin SJ. Overall benefit of antiretroviral treatment on the risk of fracture in HIV: nested case–control analysis in a health-insured population. AIDS. 2012;26(9):1073–82.
27. Walker Harris V, Brown TT. Bone loss in the HIV-infected patient: evidence, clinical implications and treatment strategies. J Infect Dis. 2012;205:S391–8.
28. Lemaire R. Strategies for blood management in orthopaedic and trauma surgery. J Bone Joint Surg [Br]. 2008;90-B:1128–36.

13

Malunion, Non-union and Delayed Presentation: The Norm, Not the Exception

Deepa Bose

In most high-income countries, patients who have suffered physical trauma present within the first 24 h, and it is extremely unusual to see delayed presentations of acute limb injuries. In low- and middle-income countries, on the other hand, several problems collude to prevent immediate presentation of trauma. These include lack of access to medical facilities, lack of transportation, the services of traditional healers, and undiagnosed or missed injuries. As a result, the incidence of delayed presentations and sequelae of trauma is much greater in austere environments. Surgeons working in such conditions must be prepared to deal with malunions, non-unions and post-traumatic osteomyelitis on a regular basis.

13.1 Malunion

Fractures which do not heal in the anatomical position are referred to as malunions. The need for deformity correction depends on many factors, including the presence of visible deformity, disability and pain. Malunion results in shortening, angulation, rotation or various combinations of the above deformities. Some malunions are not clinically obvious and cause no disability; these injuries require no treatment. Deformities which result in loss of function should be treated where possible. Malunion of the long bones of the lower limb can alter the mechanical axis of the limb, resulting in pain and disability of joints; these benefit from correction at the earliest opportunity [1].

Decision-making in treatment of malunions:

1. Is it clinically evident?
2. Is it symptomatic?
3. Is it likely to become symptomatic in future?
4. Definition of deformity parameters.
5. Single or multiple level corrections?
6. Acute or gradual correction? What are the structures at risk during correction?
7. Internal or external fixation?
8. Treatment of periarticular malunions and non-unions: internal or external fixation?

13.1.1 Long Bone Malunions

13.1.1.1 Upper Limb

Malunion of the humeral diaphysis does not often result in a functional deficit, because of the range of motion in the shoulder and elbow joints, which can easily accommodate any residual deformity in the upper arm. Malunion of the proximal humerus may cause restriction of movement, but correction is complex and should only be

---

D. Bose, MBBS, FRCS, FRCS (Tr & Orth)
Department of Trauma and Orthopaedics, Queen Elizabeth Hospital Birmingham, Birmingham, UK
e-mail: deepa.bose@uhb.nhs.uk

© Springer International Publishing Switzerland 2016

J.D. Robinson (ed.), *Orthopaedic Trauma in the Austere Environment:*
A Practical Guide to Care in the Humanitarian Setting, DOI 10.1007/978-3-319-29122-2_13

undertaken if absolutely necessary on clinical grounds. This may be done by a metaphyseal osteotomy, but arthroplasty or arthroscopic acromioplasty and tuberoplasty can also be considered in a specialist centre if the expertise and equipment are available [2].

Malunions around the elbow can cause significant loss of motion, instability, neurological dysfunction and an unacceptable appearance (Fig. 13.1). Commonly encountered conditions in this region include malunion of the distal humerus, malunion of the olecranon or radial head, neglected humero-ulnar dislocation and neglected Monteggia lesions with chronic radial head dislocation [3]. These complex injuries are very difficult to treat and must only be undertaken by surgeons experienced in the field. Methods of treatment include osteotomies and stable fixation, distraction with hinged external fixators, complex bony and soft tissue reconstructions and arthroplasty [3–8].

Fig. 13.1 Neglected elbow fracture malunion

Malunion of the forearm bones can result in loss of rotation of the forearm and instability of the elbow and wrist. Osteotomy and internal fixation has yielded good results, although it can be difficult to define the three-dimensional deformity accurately [9, 10].

Malunions of the distal radius can also result in significant loss of function; the commonest treatment for this is corrective osteotomy and fixation [11, 12].

13.1.1.2 Lower Limb

Malunions of the femur and tibia may be acceptable depending on the degree of severity (Figs. 13.2 and 13.3). In resource-poor

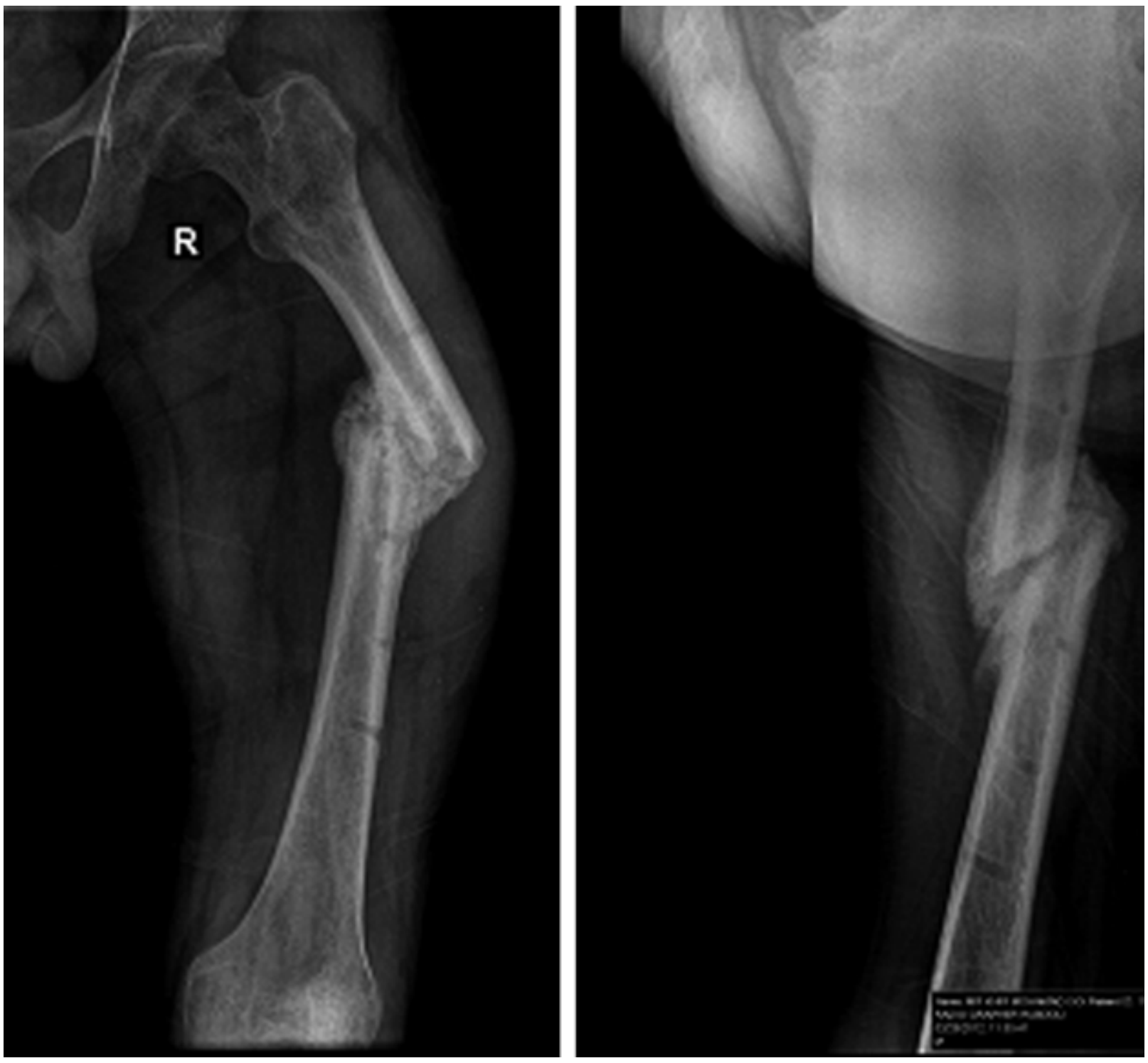

Fig. 13.2 Femoral shaft malreduction

environments, malunions which do not result in clinically evident deformity or deranged function of the joints are usually acceptable. The magnitude of acceptable deformity varies widely in the literature, and there is no clear consensus [13, 14]. Varus deformities are less well tolerated than valgus ones, and sagittal deformities are more forgiving that coronal ones [15]. Standing anteroposterior radiographs of the whole lower limb allow for measurement of the mechanical axis, which is a line drawn from the centre of rotation of the hip to the centre of the ankle. This will determine the nature and magnitude of the coronal plane deformity. Comparison with the opposite limb, if uninjured, is useful. Sagittal plane deformities are defined on standing lateral radiographs. Rotational deformities are best determined clinically, although a CT scan can provide accurate measurements if facilities are available.

If the decision has been taken to correct the deformity once it has been defined and evaluated, then the surgeon must decide whether to perform the correction acutely in one stage or gradually. The limiting factor to acute correction is the soft tissue; the neurovascular structures are most at risk. Valgus deformities, especially those close to the knee, place the common peroneal nerve under stretch if acutely corrected, and a gradual correction should be considered in these cases. Skin cover may also be required in a large angular correction. Acute surgical correction by a single osteotomy in the plane of the deformity and internal fixation using either intramedullary nails or plates and screws has been very successful [16, 17]. Osteotomies for angular deformity correction around the knee (distal femur and proximal tibia) often take the form of an opening (on the concave side) or closing (on the convex side) wedge [18]. Open wedge osteotomies require bone grafting to fill the gap created by the procedure. Small rotational deformities may be addressed by corrective osteotomy and internal fixation. Large acute rotational corrections may cause kinking of the neurovascular bundle, resulting in ischaemia of the leg; it is preferable to correct these gradually using external fixators.

Fig. 13.3 Distal femoral fracture malunion secondary to inappropriate traction

Gradual corrections may be achieved by external fixators, which can be adjusted everyday by the patient until an acceptable position is reached. These can be either monolateral or circular, such as an Ilizarov frame [19, 20]. The circular fixators have the advantage of allowing weight bearing in the immediate post-operative period, but special surgical and rehabilitation expertise is required for their application and use. Patient education and cooperation during the course of treatment is also essential, and pin site care must be taught and undertaken religiously.

In low-resource environments, acute one-stage deformity correction followed by pins and plaster may be sufficient to achieve healing in an acceptable position. Closed reduction under anaesthesia and maintenance of correction by pins above and below the fracture incorporated into a plaster cast has also been recommended [21].

Deformities in the axial plane of less than 2 cm are rarely noticeable, and if so can be dealt with with an orthotic, which can be worn either inside or outside footwear. Shortening of more than this may require correction. Lengthening is done using the technique of distraction osteogenesis [22, 23] in either a circular or monolateral fixator [24]. It is better to lengthen gradually in order to preserve the neurovascular function. Distraction osteogenesis is a technically demanding procedure and very labour intensive for both surgeon and patient. Ideally, access to physiotherapy and rehabilitation services should be provided if possible. In particular, it is important that regular physiotherapy is carried out to avoid or detect joint contractures [25]. Frequent outpatient visits are necessary during the lengthening period, and this may be difficult in low- and middle-income countries, where transportation is unreliable and expensive. It may be advisable in these cases to keep the patient in hospital until the desired length has been achieved.

Intramedullary lengthening nails are also available and have had good results in some hands, but they have been associated with some complications [26] and are currently less easy to control than external devices. These procedures should only be performed by specialist surgeons.

13.1.2 Malunions Around Joints and Neglected Dislocations

Malunited fractures around joints may result in special difficulties such as joint contractures, inadequate soft tissue cover, dense scarring and fibrosis and scar contractures. Correction of such deformities should only be attempted by surgeons experienced in this field. The specific treatment of individual periarticular malunions and neglected joint dislocations is beyond the scope of this chapter, but a few common strategies are outlined below.

Extra-articular malunions may be corrected by osteotomy and fixation. Plates are commonly used to secure osteotomies close to joints [27], although intramedullary nails may be used if the articular fragment is of sufficient size and shape to allow sufficient stabilization with this device.

Malunited intra-articular fractures are much more difficult to treat. Intra-articular osteotomies are required, and restoration of normal articular congruence is extremely hard to achieve. It is important to avoid soft tissue stripping of small articular fragments during surgery. The articular surface should be fixed, wherever possible, by rigid stability and interfragmentary compression, in accordance with the recommended principles of management of intra-articular fractures [28]. Post-traumatic degenerative changes of lower limb joints may necessitate arthrodesis in young, high-demand patients, or arthroplasty if facilities for this are available [29, 30].

Table 13.1 Treatment of periarticular malunions and non-unions

1. Osteotomy
Physically demanding
Mild/moderate degenerative changes
2. Arthrodesis
Physically demanding
Severe degenerative changes
3. Arthroplasty
Physically undemanding
Severe degenerative changes

Neglected dislocations of joints present a particularly challenging situation. Open reduction, soft tissue reconstruction and stabilisation has yielded good results in some cases of elbow and shoulder dislocations [31, 32]. In long-standing cases, external fixators can be used in combination with surgical arthrolysis to gradually distract the joint and correct the deformity [33, 34], but the resulting function may be poor. In cases where there is significant degenerative change in the joint, and the patient has low physical demand, a replacement arthroplasty may be considered, if this is available [35, 36]. In young and physically demanding patients, or if arthroplasty is unavailable, arthrodesis of the joint may be the best treatment option (Table 13.1).

13.2 Non-union

13.2.1 Definition

Non-union is a lack of progression towards fracture healing over a period of time. The US America Food and Drug Administration (FDA) panel in 1986 defined non-union as being established when a minimum of 9 months had elapsed, with no visible progressive signs of healing for three consecutive months [37]. The diagnosis of delayed union and non-union is notoriously difficult [38] and will vary widely with country, patient, clinician and nature of injury (Figs. 13.4a, b and 13.5).

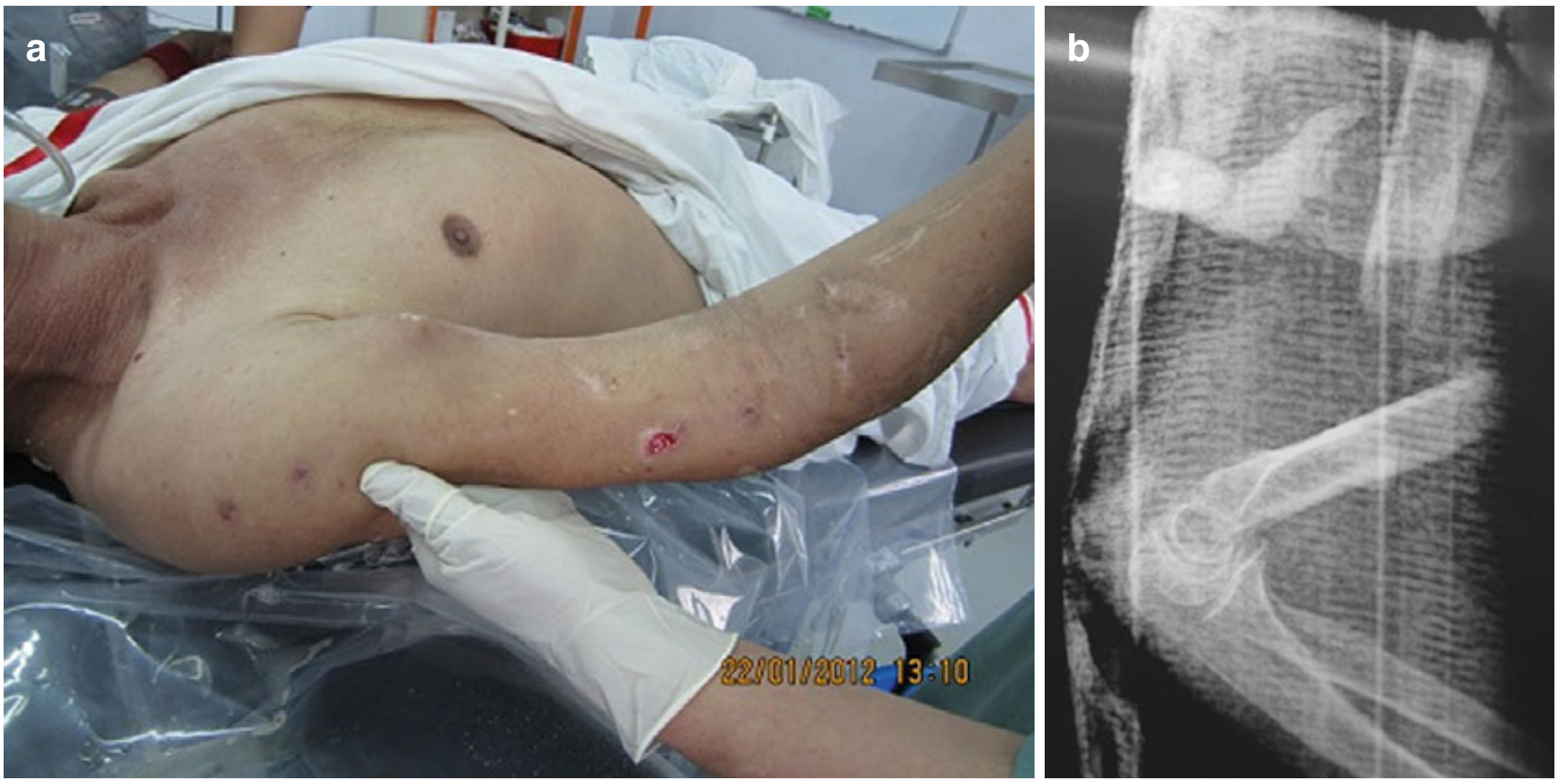

Fig. 13.4 (**a**) Clinical non union humeral fracture. (**b**) X-ray humeral non union

Fig. 13.5 Non-union femoral fracture and IM nail

13.2.2 Aetiology

Factors causing and contributing to non-union can be divided as follows:

1. *Injury-related factors*
   High-energy injury, open or closed fractures with soft tissue stripping and multifragmentary fractures
2. *Patient-related factors*

Systemic	Smoking
	Alcohol
	Endocrine disorders (thyroid, adrenal, pituitary)
	Deranged calcium metabolism
	Steroids
	Diabetes mellitus
	Metabolic bone disease
Local	Soft tissue stripping
	Soft tissue interposition
	Multifragmentary fracture, high-energy injury
	Osteomyelitis
	Infected implants
	Poor vascularity

3. *Treatment-related factors*
   Extensive dissection and soft tissue stripping.
   Poor fracture reduction.
   Large bony gap.
   Too rigid fixation – multisegmental fractures should not be rigidly fixed, as this increases the strain at the fracture gap to an unacceptable level [39]. Such fractures should be given relative stability.
   Too flexible fixation – simple fracture patterns need interfragmentary compression and rigid fixation to limit movement at the fracture site.

13.2.3 Classification

Non-unions have been classified using various systems. The Weber and Cech [40] and Paley's modification of the Ilizarov classification [41] are among the most commonly used.

Weber and Cech classification:

Hypervascular	"Elephant foot"	Hypertrophic
	"Horse hoof"	Mildly hypertrophic
	Oligotrophic	
Avascular	Torsional wedge	An un-united intermediate "butterfly" fragment
	Comminuted	Several un-united intermediate fragments
	Defect	Bony gap
	Atrophic	Intermediary fragment missing; fibrous tissue in gap

Ilizarov divided non-unions into mobile and stiff types. Mobile types responded best to compression, whereas stiff types tended to heal with distraction. Paley modified this as follows:

Type A	Non-unions with less than 1 cm of bone loss
A1	Lax non-unions
A2	Stiff non-unions with deformity
A3	Stiff non-unions without fixed deformity
Type B	Non-unions with more than 1 cm of bone loss
B1	No shortening
B2	Shortening but no gap
B3	Shortening with a gap
Type C	Infected non-unions

Personally, I find it useful to place non-unions into the following grid shown in Table 13.2. This table helps to identify the factors responsible for non-union, as well as providing an indication of the specific management strategy required in each case.

Table 13.2 Non-union classification

	Too mobile	Too rigid
Hypertrophic	Increased stability needed	
Oligotrophic or atrophic	Increased stability + biological stimulus needed	Decreased stability +/– biological stimulus needed

1. *Hypertrophic non-union*
   There is considerable evidence of attempts at fracture healing on radiographs, with abundant callus formation. These fractures usually have too much movement and need increased mechanical stability in order to unite.
2. *Oligotrophic non-union*
   There is some evidence of callus formation on radiographs. These can be associated with fractures which have been fixed too rigidly, or with inadequate reduction and a resulting bony gap.
3. *Atrophic non-union*
   There is little or no evidence of attempts at fracture healing on radiographs. These fractures usually need both appropriate mechanical stability and biological stimulation in order to unite. In some cases of atrophic non-union, the existing fixation may be too rigid, and the fracture pattern may require less rigid fixation for union to occur. In other cases, the fracture may have been fixed with a gap. Traditional teaching suggests that atrophic non-unions were avascular, but studies from Oxford have shown that this is not necessarily the case [42].
4. *Pseudarthrosis*
   This is a particular type of non-union where there is formation of a joint-like structure between the bone ends, with the presence of synovial fluid in the gap [43]. This type requires surgical debridement of the ends back to bleeding bone, followed by compression across the fracture and rigid internal or external fixation. Autologous bone grafting may be used between the bone ends to enhance fracture healing.

13.2.4 Management of Aseptic Non-union

13.2.4.1 Optimisation of the Patient's General Health

The first stage in management of non-unions is to determine the factors which are contributing to the failure to unite. These may be patient related, injury related or treatment related, as detailed above. The surgeon will have no control over the circumstances of the original injury or previous treatment, but every effort must be made to optimise patient-related factors as much as possible, prior to embarking upon potentially complex and difficult surgical procedures.

13.2.4.2 Increased Mechanical Stability Without Bony Resection

In some cases of non-union in long bones, additional stability of the fracture using closed methods may be all that is required for union to occur. An example of this is a stiff, hypertrophic non-union. Resection of the bone ends is not required, as they remain viable. X-rays show a periosteal reaction which extends to the tips of each fragment, indicating that each segment is biologically active. These cases can be treated by distraction in an external fixator, without the need to open the fracture site [44]. In long bones where previous fixation with intramedullary nailing is in situ, and the non-union is aseptic, with no associated deformity or gap, exchange nailing without opening the fracture site can also lead to union [45, 46]. Hypertrophic non-union of the tibia can also result from an intact fibula or early union of the fibular fracture, which splints the tibial fracture apart. Such cases have been successfully treated by fibulectomy and early weight bearing [47]. This treatment is attractive in a low-resource setting because it does not require special equipment and the surgical technique is straightforward.

13.2.4.3 Resection Back to Viable Bone

In most cases apart from those described above, the ends of a non-union are sclerosed and encased in fibrous tissue. They must be resected back to bleeding bone for healing to occur; the so-called "paprika sign" of punctate bleeding occurs in cortical bone [48]. Viable bone may be recognised by its capacity to bleed, its appearance and its texture. Dead bone does not bleed, is brittle and flakes easily when cut with an osteotome. It is also ivory in colour, as opposed to the greyish or pinkish appearance of living bone. Any soft tissue attachments should be carefully preserved by elevating small slivers of bone off with the adherent tissue, so that the plane of elevation remains intraosseous as much as possible. This has been referred to as "decortication" [40]. The medullary canal of long bones should be opened up using reamers and drills.

13.2.4.4 Provision of Appropriate Mechanical Stability

Stability can be provided by either internal or external fixation. Hypertrophic non-unions can be distracted in an external fixator or rigidly fixed internally. Mobile non-unions, especially those with gaps, should be compressed. In cases where the fixation has been too rigid, a bridging or wave plate technique should be employed [49].

13.2.4.5 Provision of Biologic Stimulus

In atrophic cases, the fracture healing process has been halted, and this needs to be restarted. This can be achieved by using one or more of the following:

(a) *Osteogenic stimulus*
This may be provided by autologous bone graft or autologous bone marrow aspirate [50]. Autologous graft may be morcellised or structural cancellous bone, such as is used in the onlay technique [51, 52].

(b) *Osteoinductive stimulus*
In addition to autologous bone graft, other biologic stimulants like recombinant bone morphogenetic protein (BMP) or platelet-rich plasma induce fracture healing by recruiting precursor cells, but these agents are costly, and their clinical effectiveness remains largely unproven [53, 54].

Mechanical stimuli such as pulsed electromagnetic field (PEMF) therapy and shock wave therapy have had a variable response[55, 56], but low-intensity ultrasound therapy, though not conclusively [57], has demonstrated good results [58, 59].

(c) *Osteoconductive stimulus*
Demineralised bone matrix and various calcium-based ceramics have an osteoconductive function, in addition to filling dead space, but their effectiveness as a bone graft substitute is debateable [60]. I prefer to use them as void fillers or to bulk up autologous graft.

13.2.4.6 Soft Tissue Reconstruction

Vascularised soft tissue cover is desirable in non-unions, as the following purposes are served:

(a) Soft tissue cover acts as a barrier to infection.
(b) Local delivery of systemic antibiotics is enhanced by increased vascular supply.
(c) Increased vascularity improves fracture healing [61].
(d) Mesenchymal stem cells present in soft tissues can be recruited into the fracture healing process [62].

13.2.5 Polytherapy

Giannoudis et al. [63] have suggested the term "diamond concept" to describe the four factors necessary for fracture healing: osteoprogenitor cells, osteoconductive scaffold, osteoinductive growth factors and the optimal mechanical environment. They suggest a "polytherapy" for non-unions, addressing all four factors at the same time. This strategy is still unproven [64] and would be an expensive one if all four factors were not needed.

13.2.6 Infected Non-union

13.2.6.1 Classification

The Cierny and Mader classification [65] for osteomyelitis is widely recognised and is particularly useful for its physiological component, which helps to determine the causative factors and to formulate the treatment options for individual cases:

Disease type:

Type 1	Intramedullary
Type 2	Cortical
Type 3	Corticomedullary (localised)
Type 4	Corticomedullary (widespread)

Host type:

Type A	Physiologically normal
Type B (local)	Localised comorbidities
Type B (systemic)	Systemic comorbidities
Type C	Significant comorbidities (the patient is better able to endure the disease than its treatment)

May et al. [66] and Gordon and Chiu [67] have also formulated classification systems based on the bony defect resulting from post-traumatic infection.

Jain and Sinha [68] have formulated a classification based on the presence of active infection and the size of the bone gap, which they find useful in choosing a treatment option:

Type A	Infected non-union with quiescent infection; with or without implants in situ	
	A1	Bone gap < or = 4 cm
	A2	Bone gap > 4 cm
Type B	Infected non-union with active (draining) infection	
	B1	Bone gap < or = 4 cm
	B2	Bone gap > 4 cm

They recommend single-stage debridement, bone grafting and stabilisation for A1 types, debridement, stabilisation and second-stage grafting for B1, and distraction osteogenesis for types A2 and B2.

13.2.6.2 Management of Infected Non-union

The desired end point of treatment in all infected non-unions is a healed bone without infection or deformity.

I consider that there are four broad treatment options in each case:

1. Accept the *status quo*
2. Long-term suppressive antibiotics to control symptoms
3. Limb salvage
4. Amputation

The best option for the patient is determined after taking clinical signs and symptoms and the general condition of the patient into consideration. I find the Cierny and Mader physiological classification particularly useful for this. In elderly or infirm patients, the first two options are preferable to complex surgical treatment with a prolonged course and unpredictable outcome.

In the majority of patients, limb salvage will be the preferred option. In some patients with long-standing or recurrent infection, who have had several attempts at salvage, an amputation is preferable. The presence of inadequate distal vascularity, severe loss of muscular or neurological function, or chronic pain all predispose to a poor result after limb salvage, and the functional outcome of a prosthesis may well be superior in such cases. Limb salvage which will result in worse function than a well-fitted prosthetic limb should only be undertaken after careful consideration and consultation with the patient. This is an emotionally charged decision under any circumstance, but in low- or middle-income countries, a certain stigma is attached to amputation, and the surgeon may be persuaded to undertake limb salvage in cases which would do better with a prosthetic in higher-income countries. Careful counselling of the patient is necessary in these cases. The availability of limb fitting services, and patients' access to this, should also be taken into account.

13.2.7 Limb Salvage for Infected Non-union

13.2.7.1 Optimisation of Patient's General Health

Conditions which will affect healing should be optimised as much as possible prior to surgery. This includes treatment of systemic diseases such as diabetes or endocrine disorders, and encouraging cessation of smoking and alcohol intake.

13.2.7.2 Radical Surgical Debridement

All devitalised tissue, bony and soft, should be meticulously excised back to healthy margins, just as in cancer resection. As with debridement of open fractures, it is useful to begin at twelve o'clock on an imaginary clock face and work all the way round. All implants should be removed. Any surface which has been in contact with metal should be debrided to bleeding bone, as this will remove the adherent biofilm. Cortical bone should be preserved as much as possible, but should display punctate bleeding ("paprika" sign) at the end of the procedure.

13.2.7.3 Skeletal Stabilisation

In the majority of infected cases, external fixation is preferable to internal fixation. Circular frames such as Ilizarov have several advantages over monolateral fixators; the patient may be allowed to weight bear, deformities may be corrected and bony length regained. Internal fixation may be appropriate if the anatomical site makes external fixation difficult for the patient, such as the subtrochanteric region of the femur, or in cases where the infection is well localised, and has been widely excised and the bone shortened to close the gap.

13.2.7.4 Dead Space Management

Following debridement of devitalised bone, a dead space is left behind. The walls of this space are rigid, as they are composed of bone, and so the space cannot collapse upon itself, as happens in soft tissue abscesses. If this space is left unfilled, it fills up with blood from debrided bone surfaces, resulting in an excellent culture medium which may be responsible for the recurrence of infection. The management of dead space is now recognised as an important part of the management of osteomyelitis and infected non-union [69]. If the dead space is filled with local antibiotic carriers, this serves two purposes at the same time, as some authors [70] suggest that local antibiotics act in synergy with systemic antibiotics to improve outcomes. Polymethylmethacrylate (PMMA) cement or cement beads loaded with antibiotics (e.g., gentamicin beads) are commonly used as dead space fillers. Locally made beads loaded with antibiotics appropriate for the region have been shown to be effective in the low-resource setting [71]. Antibiotic-loaded cement rods can also be used to fill the intramedullary cavity in long bones after removal of an infected nail. This is done by injecting cement into a chest tube, with a long wire embedded in the centre of it. Such fillers must be removed once all the antibiotics have been eluted (usually 6 weeks) or they may become a nidus for infection themselves. Resorbable antibiotic carriers such as calcium phosphate pellets obviate the need for another procedure to remove the filler, although they have been associated with sterile drainage from the wound, since they resorb by a process of hydrolysis [72].

13.2.7.5 Soft Tissue Reconstruction

It is important for debrided bone to be covered with vascularised soft tissue as soon as possible, and certainly preferable in the same sitting. Local options for cover are preferable to free tissue transfer if possible. These may range from simple mobilisation of surrounding muscles covered by a split skin graft to local fasciocutaneous or muscle flaps. Free tissue transfer may be necessary if there are no local options owing to scarring or induration, or if the area to be covered is large. Microvascular techniques are necessary for free tissue transfer and should only be undertaken by surgeons who are experienced in the field. Orthopaedic surgeons who expect to work in austere environments would do well to be familiar with the techniques of local flaps, as plastic surgery expertise may not be available. Some authors have recommended delaying soft tissue reconstruction until healthy granulation tissue is present [73], and this may be the appropriate plan in a low-resource situation.

13.2.7.6 Targeted Antibiotic Therapy

Ideally, several samples from the surgical debridement should be sent to the laboratory for bacterial culture and sensitivity testing, if this facility is available. If possible, each sample should be taken from deep tissue, using separate clean instruments for each sample. Care should be taken not to touch the skin, as this may yield contaminants when the sample is cultured. Broad spectrum empirical antibiotics should be started immediately following debridement, intraoperatively if possible, whilst awaiting culture and sensitivity results. Antibiotics which are active against Gram-positive and Gram-negative organisms should be chosen for this purpose. Definitive antibiotic therapy targeted towards the culture results can be decided when these are ready, in collaboration with microbiologists or clinical pathologists if their expertise is available.

In the absence of microbiology facilities, antibiotics should be chosen with reference to the spectrum of organisms which are associated with infection in that particular region or country. The commonest organism isolated appears to be *Staphylococcus aureus* [74, 75]. Gram-negative and anaerobic organisms are also common after open injuries [76]. In low-resource situations, it is preferable to switch from intravenous to oral antibiotics at the earliest opportunity. Recent studies [77] do not reveal an increased incidence of recurrence of infection with short intravenous courses compared with traditional longer courses.

13.2.7.7 Bony Reconstruction

Deformity correction without bone loss. External fixators can be used to correct deformity as well as provide initial skeletal stabilisation. Circular frames are advantageous here as they provide good 360° fragment control and allow weight bearing. In other cases, where soft tissues are pliable and will allow it, acute one-stage correction and compression across the non-union site may be undertaken.

Deformity correction with bone loss. Contained areas of bone loss are best managed by autologous grafting. This may be done at the same sitting as the surgical debridement [78], or as a second stage.

Segmental defects require specialist techniques, which will be dealt with in the chapter on bone defects. Broadly speaking, they may be divided into distraction osteogenesis or interposition grafting techniques.

Circular fixators are particularly useful in this scenario, as they achieve skeletal stability, deformity correction and lengthening using the same device, and without the need for further surgical procedures in the majority of cases [79].

References

1. Probe RA. Lower extremity angular malunion: evaluation and surgical correction. J Am Acad Orthop Surg. 2003;11(5):302–11.
2. Duparc F. Malunion of the proximal humerus. J Orthop Trauma Surg Res. 2013;99(1 Suppl):S1–11.
3. Chen N, Jupiter J. Neglected adult elbow trauma. In: Jain AK, Kumar S, editors. Neglected musculoskeletal injuries. New Delhi: Jaypee Brothers Medical Press; 2011.
4. Ring D, Jupiter J. Complex fractures of the distal humerus and their complications. J Shoulder Elbow Surg. 1999;8(1):85–97.
5. McKee M, Jupiter JB, Toh CL, Wilson L, Cotton C, Karras KK. Reconstruction after malunion and nonunion of intra-articular fractures of the distal humerus. Methods and results in 13 adults. J Bone Joint Surg Br. 1994;76(4):614–21.
6. Wang J, Li H, Zheng Q, Feng G, Li J, Pan Z. Distraction arthrolysis of posttraumatic elbow stiffness with a hinged external fixator. Orthopedics. 2012;35(11):e1625–30.
7. Sorensen AK, Seiberg JO. Treatment of persistent instability after posterior fracture-dislocation of the elbow: restoring stability and mobility with internal fixation and hinged external fixation. J Shoulder Elbow Surg. 2011;20(8):1300–9.
8. Shore BJ, Mozzon JB, MacDermid JC, Faber KJ, King GJ. Chronic posttraumatic elbow disorders treated with metallic radial head arthoplasty. J Bone Joint Surg Am. 2008;90(2):271–80.
9. Elidrissi M, Mechchaf A, Abid H, Shimi M, Elibrahimi A, Elmrini A. Surgical treatment of malunion of the two bones of the forearm: about a series of 11 cases. Pan Afr Med J. 2013;14:41.
10. Nagy L, Jankauskas L, Dumont CE. Correction of forearm malunion guided by the preoperative complaint. Clin Orthop Relat Res. 2008;466(6):1419–28.
11. Ring D. Treatment of the neglected distal radius fracture. Clin Orthop Relat Res. 2005;431:85–92.
12. Mahmoud M, El Shafie S, Kamal M. Correction of dorsally-malunited extra-articular distal radial fractures using volar locking plates without bone grafting. J Bone Joint Surg Br. 2012;94(8):1090–6.
13. Paige Whittle A. Malunited fractures. In: Canale ST, editor. Campbell's operative orthopaedics. St. Loius: Mosby; 1998.
14. Milner SA, Davis TR, Muir KR, Greenwood DC, Doherty M. Long-term outcome after tibial shaft fracture: is malunion important? J Bone Joint Surg Am. 2002;84A(6):971–80.
15. Seibert CH, Kortmann HR, Koch S, Niedhart C. Corrective osteotomies of the lower extremities following posttraumatic deformities. Z Orthop Ihre Grenzgeb. 1999;137(1):43–7.
16. Russell GV, Graves ML, Archdeacon MT, Barei DP, Brien Jr GA, Porter SE. The clamshell osteotomy: a new technique to correct complex diaphyseal malunions. J Bone Joint Surg Am. 2009;91(2):314–24.
17. Sangeorzan BJ, Sangeorzan BP, Hansen Jr ST, Judd RP. Mathematically directed single-cut osteotomy for correction of tibial malunion. J Orthop Trauma. 1989;3(4):267–75.
18. Koyonos L, Slenker N, Cohen S. Complications in brief: osteotomy for lower extremity malalignment. Clin Orthop Relat Res. 2012;470(12):3630–6.
19. Paley D, Chaudray M, Pirone AM, Lents P, Kautz D. Treatment of malunions and mal-nonunions of the

femur and tibia by detailed preoperative planning and the Ilizarov techniques. Orthop Clin North Am. 1990;21(4):667–91.

20. Feldman DS, Shin SS, Madan S, Koval KJ. Correction of tibial malunion and non-union with six-axis analysis deformity correction using the Taylor Spatial Frame. J Orthop Trauma. 2003;17(8):549–54.
21. Mukherjee SK, Pal SA. Neglected diaphyseal fractures. In: Jain AK, Kumar S, editors. Neglected musculoskeletal injuries. New Delhi: Jaypee Brothers Medical Press; 2011.
22. Ilizarov GA. The tension-stress effect on the genesis and growth of tissues. Part I. The influence of stability of fixation and soft-tissue preservation. Clin Orthop. 1989;238:249–81.
23. Ilizarov GA. The tension-stress effect on the genesis and growth of tissues. Part II. The influence of the rate and frequency of distraction. Clin Orthop. 1989;239: 263–85.
24. Sangkaew C. Distraction osteogenesis for the treatment of post traumatic complications using a conventional external fixator. A novel technique. Injury. 2005;36(1):185–93.
25. Paley D. Problems, obstacles, and complications of limb lengthening by the Ilizarov technique. Clin Orthop Relat Res. 1990;250:81–104.
26. Kenawey M, Krettek C, Liodakis E, Wiebking U, Hankemeier S. Leg lengthening using intramedullary skeletal kinetic distractor: results of 57 consecutive applications. Injury. 2011;42(2):150–5.
27. Sangkaew C, Piyapittavanum P. Intertrochanteric valgus-lengthening femoral neck osteotomy for developmental and posttraumatic conditions of the hips. J Med Assoc Thai. 2012;95 Suppl 10:S12–9.
28. Ruedi TP, Buckley R, Moran C, editors. AO principles of fracture management. Stuttgart: Thieme; 2007.
29. Bedi A, Haidukewych GJ. Management of the post-traumatic arthritic knee. J Am Acad Orthop Surg. 2009;17(2):88–101.
30. Glazebrrok M. End-stage ankle arthritis: magnitude of the problem and solutions. Instr Course Lect. 2010;59:359–65.
31. Rouhani A, Navali A. Treatment of chronic anterior shoulder dislocation by open reducation and simultaneous Bankart lesion repair. Sports Med Arthros Rehabil Ther Technol. 2010;16:2–15.
32. Islam S, Jahangir J, Manzur RM, Chowdury AA, Tripura N, Das A. Management of neglected elbow dislocations in a setting with low clinical resources. Orthop Surg. 2012;4(3):177–81.
33. Jupiter JB, Ring D. Treatment of unreduced elbow dislocations with hinged external fixation. J Bone Joint Surg Am. 2002;84A:1630–5.
34. Ullmann Y, Fodor L, Soudry M, Lerner A. The Ilizarov technique in joint contractures and dislocations. Acta Orthop Belg. 2007;73(1):77–82.
35. Petrie RS, Trousdale RT, Cabanela ME. Total knee arthroplasty for chronic posterior knee dislocation: Report of two cases with technical considerations. J Arthroplasty. 2000;15(3):380–6.
36. Sahaipal DT, Zuckerman JD. Chronic glenohumeral dislocation. J Am Acad Orthop Surg. 2008;16(7):385–98.
37. Wheeless' Textbook of Orthopaedics. www.wheelessonline.com/ortho/non_union.
38. Bhandari M, Fong K, Sprague S, Williams D, Petrisor B. Variability in the definition and perceived causes of delayed unions and nonunions: a cross-sectional multinational survey of orthopaedic surgeons. J Bone Joint Surg Am. 2012;94(15):e1091–6.
39. Perren SM. Evolution of the internal fixation of long bone fractures. The scientific basis of biological internal fixation: choosing a new balance between stability and biology. J Bone Joint Surg Br. 2002;84(8):1093–110.
40. Weber BG, Cech O, editors. Pseudoarthrosis. Switzerland: Hans Huber; 1976.
41. Paley D, Catagni MA, Argnani F, Villa A, Benedetti GB, Cattaneo R. Ilizarov treatment of tibial nonunions with bone loss. Clin Orthop Relat Res. 1989;241:146–65.
42. Reed AA, Joyner CJ, Brownlow HC, Simpson AH. Vascularity in a new model of atrophic non-union. J Bone Joint Surg Br. 2003;85(4):604–10.
43. Heppenstall RB, Brighton CT, Esterhai Jr JL, Katz M, Schumacher R. Synovial pseudarthrosis: a clinical, roentgenographic-scintigraphic, and pathologic study. J Trauma. 1987;27(5):463–70.
44. Catagni MA, Gurreschi F, Holman JA, Cattane R. Distraction osteogenesis in the treatment of stiff hypertrophic nonunions using the Ilizarov apparatus. Clin Orthop Relat Res. 1994;301:159–63.
45. Brinker MR, O'Connor DP. Exchange nailing of ununited fractures. J Bone Joint Surg Am. 2007;89(1): 177–88.
46. Shroeder JE, Mosheiff R, Khoury A, Liebergall M, Weil YA. The outcome of closed, intramedullary exchange nailing with reamed insertion in the treatment of femoral shaft nonunions. J Orthop Trauma. 2009;23(9):653–7.
47. DeLee JC, Heckman JD, Lewis AG. Partial fibulectomy for ununited fractures of the tibia. J Bone Joint Surg Am. 1981;63A:1390–5.
48. Sachs BL, Shaffer JW. Staged Papineau protocol for chronic osteomyelitis. Clin Orthop Relat Res. 1984;184:256–63.
49. Livani B, Belanegro W, Medina G, Pimenta C, Zoqaib R, Mongon M. Anterior plating as a surgical alternative in the treatment of humeral shaft non-union. Int Orthop. 2010;34(7):1025–31.
50. Bhargava R, Sankhla S, Gupta A, Changani R, Gagal K. Percutaneous autologous bone marrow injection in the treatment of delayed or non-union. Indian J Orthop. 2007;41(1):67–71.
51. Phemister DB. The classic: repair of bone in the presence of aseptic necrosis resulting from fractures, transplantations, and vascular obstruction. Clin Orthop Relat Res. 2008;466(5):1021–33.
52. Jayaswal A, Bhan S, Dave PK, Chandra P. Modified Phemister grafting in potentially infected non-union of tibial shaft fractures. Int Surg. 1985;70(1):67–70.

53. Griffin XL, Wallace D, Parsons N, Costa ML. Platelet rich therapies for long bone healing in adults. Cochrane Database Syst Rev. 2012;7:CD009496.
54. Garrison KR, Shemit I, Donell S, Ryder JJ, Mugford M, Harvey I, Song F, Alt V. Bone morphogenetic protein (BMP) for fracture healing in adults. Cochrane Database Syst Rev. 2010;(6):CD006950.
55. Griffin XL, Smith N, Parsons N, Costa ML. Ultrasound and shockwave therapy for acute fractures in adults. Cochrane Database Syst Rev. 2012;2:CD008579.
56. Griffin XL, Costa ML, Parsons N, Smith N. Electromagnetic field stimulation for treating delayed union or non-union of long bone fractures in adults. Cochrane Database Syst Rev. 2011;(4):CD008471.
57. Busse JW, Kaur J, Molton B, Bhandari M, Tornetta 3rd P, Schünemann HJ, Guyatt GH. Low intensity pulsed ultrasonography for fractures: systematic review of randomised controlled trials. BMJ. 2009;338:b351.
58. Schofer MD, Block JE, Aigner J, Schmelz A. Improved healing response in delayed unions of the tibia with low-intensity pulsed ultrasound: results of a randomized sham-controlled trial. BMC Musculoskelet Disord. 2010;11:229.
59. Watanabe Y, Arai Y, Takenaka N, Kobayahsi M, Matsushita T. Three key factors affecting treatment results of low-intensity pulsed ultrasound for delayed unions and non-union: instability, gap size, and atrophic non-union. J Orthop Sci. 2013;18(5):803–10.
60. Kurien T, Pearson RG, Scammell BE. Bone graft substitutes currently available in orthopaedic practice: the evidence for their use. Bone Joint J. 2013;95B(5): 583–97.
61. Keramaris NC, Calori GM, Nikolaou VS, Schemitsch EH, Giannoudis PV. Fracture vascularity and bone healing: a systematic review of the role of VEGF. Injury. 2008;39 Suppl 2:S45–57.
62. Shah K, Majeed Z, Jonason J, O'Keefe RJ. The role of muscle in bone repair: the cells, signals, and tissue responses to injury. Curr Osteoporos Rep. 2013;11(2): 130–5.
63. Giannoudis PV, Einhorn TA, Marsh D. Fracture healing: the diamond concept. Injury. 2007;38 Suppl 4:S3–6.
64. Calori GM, Mazza E, Colombo M, Ripamonti C, Tagliabue L. Treatment of long bone non-unions with polytherapy: indications and clinical results. Injury. 2011;42(6):58790.
65. Cierny III G, Mader JT, Penninck JJ. A clinical staging system for adult osteomyelitis. Contemp Orthop. 1985;10:17–37.
66. May Jr JW, Jupiter JB, Weland AJ, Byrd HS. Clinical classification of post-traumatic tibial osteomyelitis. Current concepts review. J Bone Joint Surg Am. 1989;71A:1422–8.
67. Gordon L, Chiu EJ. Treatment of infected nonunions and segmental defects of the tibia with staged microvascular muscle transplantation and bone grafting. J Bone Joint Surg Am. 1988;70A:377–86.
68. Jain AK, Sinha S. Infected non-union of the long bones. Clin Orthop Relat Res. 2005;431:57–65.
69. Lazzarini L, Mader JT, Calhoun JH. Current concepts review: osteomyelitis in long bones. J Bone Joint Surg Am. 2004;86:2305–18.
70. Zalavras CG, Patzakis MJ, Holtom P. Local antibiotic therapy in the treatment of open fractures and osteomyelitis. Clin Orthop Relat Res. 2004;427:86–93.
71. Alonge TO, Ogunlade SO, Omolulu AB, Fashina AN, Oluwatosin A. Management of chronic osteomyelitis in a developing country using ceftriaxone_PMMA beads: an initial study. Int J Clin Pract. 2002;56(3): 181–3.
72. McKee MD, Wild LM, Schemitsch EH, Waddell JP. The use of an antibiotic-impregnated, osteoconductive, bioabsorbable bone substitute in the treatment of infected long bone defects: early results of a prospective trial. J Orthop Trauma. 2002;16:622–7.
73. Toh CL, Jupiter JB. The infected nonunion of the tibia. Clin Orthop Relat Res. 1995;315:176–91.
74. Wu CC. Single-stage surgical treatment of infected non-union of the distal tibia. J Orthop Trauma. 2011;25(3):156–61.
75. Salvana J, Rodner C, Browner BD, Livingston K, Schreiber J, Pesanti E. Chronic osteomyelitis: results obtained by an integrated team approach to management. Conn Med. 2005;69:195–202.
76. Jain AK, Maheswari AV. Infected nonunions of long bones. In: Neglected musculoskeletal injuries. New Delhi: Jaypee Brothers Medical Publishers; 2011. pp 72.
77. Swiontkowski MF, Hanel DP, Vedder NB, Schwappach JR. Comparison of short- and long-term intravenous antibiotic therapy in the postoperative management of adult osteomyelitis. J Bone Joint Surg Br. 1999;81B:1046–50.
78. Chen ZW, Liu H, Zhai WL, Zeng JH. Treatmenmt of infected bone defect with one stage open cancellous bone grafting. Zhongguo Gu Shang. 2008;21(5): 377–8.
79. Paley D. Treatment of tibial non-union and bone loss with the Ilizarov technique. Instr Course Lect. 1990;39:185–97.

Osteomyelitis

14

Andrew J. Stevenson

Osteomyelitis is a relatively common condition in lesser developed nations, as compared to developed nations. However, there are few figures for incidence and prevalence of the disease. A study from the Gambia showed chronic osteomyelitis accounts for 15 % of all surgical admissions [1] and in Malawi accounts for 6.7 % of all operations in an orthopaedic unit [2]. The reported incidence of acute osteomyelitis in New Zealand aborigines is 200 in 100,000 [3].

The increased incidence of osteomyelitis in austere environments is secondary to both adverse patient and environmental factors [4]. Patient factors include malnutrition, immunodeficiency, poor dental care, prevalent skin lesions, anaemia and lack of healthcare knowledge. Environmental factors include poor access to clean water, poor infrastructure and lack of access to quality healthcare (Fig. 14.1). These factors contribute to frequent bacteraemias, lowered host immunity and delayed presentation, which in turn result in an increased incidence of bone infection. Even if diagnosed, treatment is often inadequate, and this compounds the already difficult-to-treat nature of osteomyelitis.

Osteomyelitis can arise via haematogenous spread from a distant site, via direct inoculation through a wound adjacent to the bone (e.g. open fractures, post surgery) or via spread from the adjacent infected soft tissue (e.g. cellulitis) [4]. It can be classified according to duration of symptoms into acute (days to weeks duration), subacute (weeks to months) and chronic (>3 months).

14.1 Pathophysiology

Haematogenous osteomyelitis is an infection of the bone occurring secondary to a bacteraemia. It is the most common form affecting children in the developing world. Causative organisms are *Staphylococcus aureus*, *Streptococcus pyogenes*, *Haemophilus influenzae* and *Escherichia coli* [2]. Atypical organisms (salmonella, tubercle bacillus (TB) and fungi) should also be considered. The most common bone affected is the tibia, followed by the femur and humerus [2] (Fig. 14.2). Bacteraemic emboli typically become lodged in the metaphyseal region of a bone where the organisms proliferate. The reason for this metaphyseal seeding is multifactorial. It is related to the slowing of the blood flow in this area and the deficient phagocytosis in these vessels. The fact that the capillary loops are 'end-vessels' also means that occlusion causes a localised necrosis, a further contributing factor [5]. As bacteria proliferate, pressure increase causes ischaemia,

---

A.J. Stevenson, BSc, MBBS, FRCS (Tr & Orth)
Department of Trauma and Orthopedics,
Royal Melbourne Hospital, Melbourne,
VIC, Australia
e-mail: Stevenson121@gmail.com

© Springer International Publishing Switzerland 2016

J.D. Robinson (ed.), *Orthopaedic Trauma in the Austere Environment:*
A Practical Guide to Care in the Humanitarian Setting, DOI 10.1007/978-3-319-29122-2_14

Fig. 14.1 This man had an open fracture of the tibia many years ago. The injury was probably mismanaged, sentencing him to a life with chronic osteomyelitis

acidosis and disruption of endosteal blood supply to the cortex.

At this stage the intramedullary abscess is painful and patients may present (acute osteomyelitis). If the host response (+/− antibiotics) is sufficient to arrest further bacterial proliferation and the abscess is 'walled-off', the infection may be remarkably well tolerated by the patient (subacute osteomyelitis) or indeed subside.

As the infection progresses, the pus follows the path of least resistance and flows out through the Volkmann canals and haversian system eventually emerging under the periosteum. The subperiosteal pus strips the cortex of its exosteal blood supply. As a result the cortical bone is completely cut-off from both endosteal and exosteal blood supplies, resulting in its death. This dead, devascularised bone is known as sequestrum.

The pus may track circumferentially around the bone, burst through the periosteum into the soft tissues or continue down the bone in an intramedullary fashion (Fig. 14.3). The elevated periosteum then begins to lay down new bone, surrounding the sequestrum. This new, reactive bone is called involucrum and is key to the maintenance of structural integrity of the affected bone. The sequestrum (dead bone) and involucrum (new bone) are the classical hallmarks of chronic osteomyelitis. If left untreated the sequestrum may undergo partial resorption, but often acts a nidus for persistent infection.

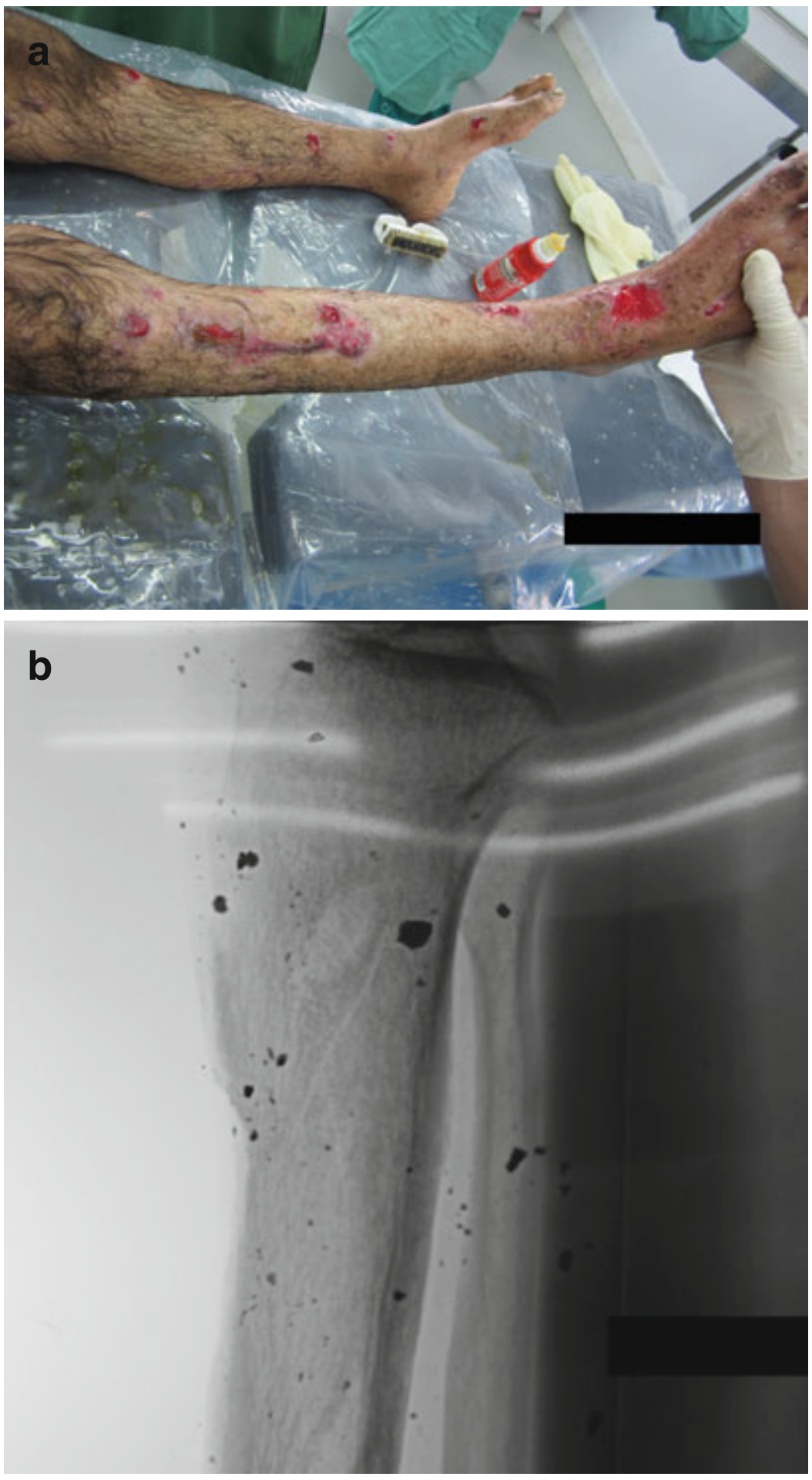

[redacted]
[redacted]

Fig. 14.2 (**a**) This young man was a casualty during a suicide bomber attack. Unfortunately, he developed multiple sinuses secondary to bone infection. (**b**) X-ray showing the shrapnel in the tibia


[redacted]

Fig. 14.3 Middle finger showing a draining sinus

14.2 Management ofOsteomyelitis: Review of the Evidence

High-quality research regarding osteomyelitis is sparse, with few prospective, randomised-controlled trials. However a recent systematic review of acute and subacute osteomyelitis has proposed the following recommendations [Level 1] [6]. In the early stages of acute/subacute osteomyelitis, medical treatment with initial intravenous antibiotics followed by a minimum 3-week oral course is advocated. Surgery is reserved for systemic sepsis, concurrent septic arthritis, failure to improve with antibiotics or pelvic abscess >2 cm [6].

The surgical treatment of chronic osteomyelitis is generally agreed [7, 8] [Level IV]. The removal of dead bone/sequestrectomy, debridement, drainage of pus and soft tissue care are the principals of infection control. The wider the margin of resection of the infected bone, the lower the recurrence rate [9] [Level III]. The role of antibiotics in treatment for chronic osteomyelitis (COM) remains a matter for debate. Some authors advocate that antibiotics should be used routinely [8], whilst others believe in selective antibiotic usage or only when patients are systemically unwell [2, 4] [Level IV]. Opinion on the treatment of bone defects also remains diverse [2] and is often influenced by surgical experience and availability of resources. From my own experience, bone defects should be addressed as simply as possible, with vascularised grafting and bone transport being more successful than non-vascularised graft options [10] [Level III].

14.3 Acute Osteomyelitis

Acute osteomyelitis (AO) typically presents with pain +/− malaise +/− fever and loss of use of the affected limb. This is sometimes attributed to trauma. Examination may reveal swelling, warmth and tenderness over the affected area. Blood tests (if available) may reveal high white cell count (WCC) and inflammatory markers – erythrocyte sedimentation rate (ESR) and C-reactive protein (CRP). Plain radiographs are usually unremarkable. Magnetic resonance imaging (MRI) is the most sensitive and specific test, however is rarely available in the areas where osteomyelitis is most common.

Early treatment of AO is nonoperative. Blood cultures should be taken before starting antibiotics. Intravenous antibiotic for 3–4 days followed by an oral course for 3–6 weeks is advocated [6]. As *Staphylococcus aureus* is the most common organism [2], flucloxacillin is the most appropriate choice, with a low threshold for adding in benzylpenicillin to cover *Haemophilus influenzae*, especially for patients who have not received the Hib vaccine. Patients need to be monitored closely, and if there is no clinical improvement within days of starting antibiotics, surgery is indicated. Surgery is also indicated in the case of a systemic sepsis in a child, concurrent septic arthritis, failure to improve with antibiotics or pelvic abscess >2 cm [6]. If there is concern regarding access to antibiotics, compliance or attendance at follow-up, then surgery should be considered, as this gives the best chance of eradication of infection in the absence of suitable ongoing care. Importance of follow-up must be stressed to the patient, and their guardian, as prompt treatment of complications and recurrence greatly reduces the risk of developing long-term problems.

14.3.1 Surgery for AO

A longitudinal incision is made over the point of maximal tenderness/swelling. Careful soft tissue inspection and drainage of collection is performed. Drilling the bone over the affected area should reveal pus. Multiple drill holes can be joined to create a window 1–2 cm across to allow adequate lavage and drainage. Wounds may be closed primarily at a second procedure if the wound bed looks entirely healthy, though leaving them open to heal by secondary intention is the safer option. Antibiotics should be continued for at least 3 weeks to give the best chance of first time eradication of infection.

14.3.2 Tip

If a child presents with bone pain, specifically in the tibia, blood tests are not available and x-ray shows no changes, specifically assess for percussion tenderness over the point of pain. If this is present, treat for AO as described as above. If in doubt treat as AO and monitor.

14.4 Subacute Osteomyelitis

Subacute osteomyelitis (SAO) is described as bone infection with insidious onset of symptoms >2 weeks, mild to moderate pain, little or no functional impairment, no systemic symptoms, negative blood cultures and positive x-ray findings [11].

Examination may reveal a slight limp, swelling and tenderness but joint movement is typically normal. Blood tests may be normal or reveal mildly raised ESR, WCC and CRP. Cultures are typically negative. X-rays characteristically show a radiolucent lesion most commonly in the metaphysis or diaphysis, but may also be found in the epiphysis. Occasionally a nidus or periosteal reaction is visible [12].

Treatment is surgical as described for surgical treatment of AO. Histological and microbiology samples should be sent if these resources are available. Differential diagnosis for SAO includes primary bone tumours, TB and atypical infection (e.g., fungal).

14.4.1 Tip

Lesions close to the physis should be monitored carefully due to risk of growth arrest that can later cause angular limb deformity or limb length discrepancy.

14.5 Chronic Osteomyelitis

Chronic osteomyelitis (COM) is a bone infection that has been present for >3months. Patients present with pain and disuse of the affected limb. Usually, there will be discharging sinuses, occasionally an exposed bone. Systemically, the patient will be unwell, often malnourished and will have suffered stigmatisation as a result of their condition. Patients sometimes present with complications of COM such as pathological fracture, limb deformity, joint stiffness or septic arthritis.

On examination there are often discharging sinuses, old surgical wounds, healed wounds, joint contractures, muscle wasting, limb deformity/shortening and cachexia. Blood tests often reveal anaemia and mildly raised WCC, ESR and CRP.

X-rays performed reveal the extent of bony involvement. Over-penetrated films are most useful in identifying sequestrum present [13]. Typical x-ray findings include sequestra, involucrum, periosteal reaction, bone abscesses, sclerosis and deformity.

Cross-sectional imaging can be used if available. MRI is good at defining extent of inflammation and collections, whilst computed tomography (CT) is better at illustrating bony anatomy and localising sequestra. COM almost always requires surgical treatment and cannot be cured with antibiotics alone. Removal of all dead bone and thorough debridement of infected tissue is essential.

14.6 Preoperative Care and Investigations

Patients need to be thoroughly assessed preoperatively. A full history and examination is mandatory, as multiple pathologies often coexist. Multifocal osteomyelitis must be considered. AP and lateral x-rays of the affected limb need to be performed.

Blood tests are useful if available. The most important are:

- Haemoglobin – to assess for anaemia.
- Malarial parasites – concurrent infection needs prompt treatment.
- HIV – retroviral treatment will be required if positive.
- Sickle cell – will affect perioperative care. Tourniquets must not be used.

Antibiotics should be given to patients with systemic signs of sepsis, as well as fluids and oxygen, if available. The limb should be splinted if bony stability is compromised.

14.6.1 Preoperative Planning

Infection control is achieved through removal of all dead bone and infected tissues, dead-space management and care of soft tissues. COM is a disease of the bone, and therefore the bony component must be understood and addressed. Surgical planning should include identification of all active sinuses, examination of the joints above and below preoperatively to assess for septic arthritis and the identification of any soft tissue collections.

AP and lateral x-rays (over-penetrated ideally) are used to identify sequestra for removal and bone abscesses for curettage. The Beit CURE classification [14] is a radiological classification that is useful in the surgical planning of disease. Though less well known than the Cierny-Mader classification [15], it has been developed specifically for use in resource-poor environments and is a valuable tool in surgical planning as well as comparative research.

14.6.2 Surgical Equipment

Theatre equipment can be sparse and of poor quality, and often adaptation and improvisation of equipment is required. The following constitute a good basic instrument set:

- Scalpel
- Tissue forceps
- Needle holders
- Scissors
- Soft tissue retractors (Langenbeck/self-retainers)
- Periosteal elevator
- Elevator (Penfield/Freer/Watson Cheyne)
- Osteotomes
- Curette
- Bone drill (hand-powered/electrical)
- Bone nibbler (Rongeur)
- Dental hook/probe

14.7 Infection Control Surgery

Infection control goals of surgery:

- Dead bone removal/sequestrectomy
- Pus drainage
- Debridement
- Dead-space management/drainage of cavities
- Soft tissue care
- Bony stabilisation

A ‘social wash’ with soap and water is essential prior to formal skin preparation; an initial wash on the ward is also advised. A tourniquet can be used to control blood loss and give a dry field; however, this is not essential. It must be deflated before the end of the procedure however to assess bone viability, through observation of punctate bleeding.

The incision should be planned to allow adequate access to the bone with minimal disruption to the periosteum and its blood supply.

Where it is necessary to incise the periosteum this should be done longitudinally, hard down to the bone and be elevated as a continuous flap with as much soft tissue continuity as possible. Whenever possible, soft tissue cover of the bone should be preserved unless plastic surgical input is available.

To access the medulla for sequestrectomy, windowing is often necessary. Pre-op planning of windows is essential, and measurements from x-rays and relations of bony landmarks are useful. Windows are made through removal of a rectangular piece of bone. This is done with an osteotome. Drill holes can be also used to guide the passage of the osteotome and to prevent propagation of cracks past the desired site. Drills should only be used on a low speed to prevent thermal bone necrosis. No more than one-third the circumference of the bone should be removed in a window, to prevent fracture.

Abscess drainage can be performed by enlarging sinuses or drilling and windowing the bone as necessary. Curettage of cavities is essential to remove infected material. Thorough lavage of all wounds, curettage/excision of active sinuses is also required. Lavage using syringes with catheters/feeding tubes attached is a good technique as this allows focused washing and retrograde lavage of blind-ending cavities. Cavities often communicate, so it is possible to wash through one and out of another. Samples for microbiology should be sent where this facility exists.

When the sequestrum is identified, a plane between it and viable bone should be developed using an elevator or probe to loosen it, which can then allow removal in one complete piece using haemostats. There is controversy as to the timing of sequestrectomy in those cases where the sequestrum provides stability, when the involucrum is not structurally sufficient.

Some advocate leaving the sequestrum in place until the periosteum has laid down sufficient structural involucrum. The advantage of this approach is that the sequestrum is ideally located to provide structural support whilst waiting for involucrum to form. The disadvantage is that the longer the infected sequestrum remains in situ, the more likely the periosteum will be damaged, potentially jeopardising formation of quality involucrum.

Others advocate removal of the ‘structural sequestrum’ at the earliest opportunity, leaving a bone defect that requites stabilisation either with plaster or frame. The advantage of this approach is that infection control is achieved at an earlier stage, and this potentially protects the periosteum. The disadvantage is this destabilises the bone segment that then requires stabilisation. The jury is still out on this particular point.

However, if there no structural involucrum after 3 months of monitoring, then sequestrectomy should be performed, and the bone defect dealt with subsequently.

Similarly, if sequestrectomy is performed (leaving a bone defect), then the bone should be stabilised for 3 months to allow for formation of structural involucrum. If this does not occur, then bony reconstructive surgery is required.

14.8 Soft Tissue Management

Soft tissue management can be problematic in the treatment of chronic osteomyelitis. The affected limb often has multiple wounds and discharging sinuses. Wounds should be left open to allow free drainage following infection control procedures. Negative pressure dressing are effective devices in wound management but are not always available; local adaptations are however possible [16]. Honey dressings have been shown to be more effective than sugar dressing, and this is generally widely available even in the most austere setting [17]. Patients should be encouraged to position themselves so as to allow dependent drainage of their wounds. Daily washing of wound with soap and water is also advocated. Soft tissue cover with skin grafts/soft tissue flap is sometimes required.

14.9 Dead-Space Management

This refers to the management of the void that is left following resection/debridement of tissue. This can be managed by

- Free drainage – this allows the tissue to heal by secondary intention.
- Packing with swabs.
- Negative pressure dressings.
- Prosthetic spacer (e.g. cement spacer, antibiotic beads).
- Nonvascularised graft (e.g. Papineau technique, cancellous bone graft).
- Vascularised graft (e.g. rotational/free flap).

The vascularised graft is the gold standard as this covers defects with viable, infection resistant tissues. Nonvascularised grafting requires a sterile bed prior to grafting and is a surgically demanding option. Prosthetic spacers have been used to good effect to sterilise a cavity; however, they do require removal with further procedures. Negative pressure dressings are effective but can be difficult to source and maintain. Free drainage is easily achieved, but the scar tissue that forms is relatively avascular and therefore more susceptible to infection.

14.10 Bony Stabilisation

Bone infection is difficult to treat. Bone infection in the presence of instability is impossible to treat. Prior to surgery, bony stability need to be assessed radiologically. There should be good quality cortical continuity in 3-out-of-4 of the cortices on the AP and lateral x-rays to ensure stability. If more than one-third of the bone is resected in any one segment intraoperatively, then the limb should be immobilised and weight-bearing restricted for 6 weeks, to manage the risk of fracture.

14.11 Bone Defects

Bone defects are present in 20 % of cases of COM [18] and can range from a pathological fracture to large segmental defects. The management of these is difficult. Infection control must be complete prior to reconstruction. Prerequisites to reconstruction surgery are fully healed skin, absence of sequestra on x-ray and no antibiotics for 2 months. Decision on the method of treatment of defect should be made depending on: patient age, defect size, viability of periosteum and physes, condition of soft tissues and coexisting deformity.

Treatment options include: plaster stabilisation, frame stabilisation, free fibula structural bone grafts, [staged] ipsilateral vascularised fibular graft, nonstructural [cancellous] bone graft, bone transport and amputation. The simplest method with a reasonable chance of success is the most appropriate choice. Options that involve vascular tissue (stabilisation, vascularised grafts and bone transport) are more infection resistant and more likely to succeed.

14.12 Postoperative Care

Patients should receive fluids and analgesia. All patients with systemic sepsis should be continued on antibiotics. Routine antibiotic prescription is not mandatory. The affected limb should be elevated to reduce swelling.

Post-op x-rays to ensure the entire sequestrum has been removed are essential. If sequestra remain in situ, then infection will persist unless it is removed. Dressings should be changed every 24–48 h, and patients and their carers should be educated as to wound management/hygiene from an early stage. If wounds are not settling, then further infection control procedures are required.

Patients should be encouraged to weight-bear (if appropriate) and move surrounding joints to try and prevent further muscle wasting, contractures and loss of bone density. Nutrition is vital to healing and prevention of reinfection. This should be assessed and addressed. Patients are often stigmatised due to their infection and can be excluded from social interaction and schooling. It is vital that this is addressed as best as possible as this can lead to long-term difficulties. Concurrent illnesses such as HIV, TB, malaria and diabetes need to be treated.

14.12.1 Follow-up

Early follow-up should be conducted to assess for infection control. Longer-term follow-up is desirable to monitor for recurrence of infection and complications such as contractures, fracture, deformity and growth arrest. Patients should be followed up for a minimum of 1 year, and if concern exists regarding growth arrest and deformity, then patients should be followed up until skeletal maturity.

14.12.2 Rehabilitation

Access to formal rehabilitation in austere environments is generally very limited. It is vital to educate patients as to their condition and rehabilitation goals whilst they are an inpatient or under medical care. The emphasis on follow-up is essential, as often patients will require further treatment.

14.13 Complications

Broadly speaking, these can be divided into infection related and musculoskeletal:

- Recurrent/persistent infection
- Septic arthritis
- Systemic infection
- Polyostotic osteomyelitis
- Joint contractures
- Muscle wasting
- Fracture

- Bone defects
- Angular limb deformity
- Growth arrest

14.13.1 Cautions

Though osteomyelitis is common in austere environments, other diagnoses need to be considered. Here are a few not to miss:

- *Bone infarction* – secondary to sickle cell disease. This can present in a very similar fashion to AO.
- *Bone tumours* (*primary and secondary*) – can present in a very similar fashion to osteomyelitis, and can have very similar x-ray appearances.
- *Malignant transformation* – this can occur in longstanding infection (e.g. Marjolin ulcers).
- *TB* – can cause atypical osteomyelitis/septic arthritis of a more indolent course.
- *Resistant/atypical bacteria* – though less common in the developing world, resistant bacteria (e.g. MRSA) can still occur. Atypical infections (e.g. fungal) are more prevalent due to host deficiencies and environmental factors.

14.14 Tutorials

14.14.1 Tutorial 1

An 8-year-old boy attends with a 6-month history of leg pain. He has the following x-ray (Fig. 14.4).

What is the likely diagnosis? [Subacute/chronic osteomyelitis]

What are the differential diagnoses? [Primary bone tumour]

The patient is systemically well and no blood tests are available, how would you treat him? [Initially 2–3 days IV, then minimum 3-weeks oral antibiotics and finally surgery if no improvement/lack of access to antibiotics.]

Fig. 14.4 X-ray of an 8-year-old boy with a 6-month history of leg pain

14.14.2 Tutorial 2

A 10-year-old girl presents with a year's history of malaise, leg pain and discharging sinuses. She has had two previous procedures performed. Her leg looks as shown in Fig. 14.5.

What can you identify? [Active sinuses, old surgical wound, healed wounds].

Her preoperative x-ray is shown in Fig. 14.6a. What are the 'classical features' that you can see? [Expanded tibia due to involucrum. Intramedullary sequestrum]

How has this been treated? [Sequestrectomy and debridement]

Fig. 14.5 A 10-year-old girl presents with a year's history of malaise, leg pain and discharging sinuses

The intraoperative picture shows the yellow sequestrum surrounded by the healthy looking 'pinkish' involucrum (Fig. 14.6b). Figure 14.6c shows the same field post sequestrectomy. Note the windowing of the bone and the creation of an intramedullary trough. Figure 14.6d shows the removed sequestrum. This x-ray (Fig. 14.6e) has been taken post-op. Note the creation of a window in the medial border of the tibia and the absence of the sequestrum evident on the previous x-ray. Always take a post-op x-ray to assess completeness of sequestrectomy.

14.14.3 Tutorial 3

A boy presents after a 2-year history of illness, leg pain and previously discharging sinuses. He has had no discharging wounds for 6 months but he is now unable to fully weight-bear. His x-ray is shown (Fig. 14.7).

What can you see? [Bone defect of the middle one-third of the tibia. Note the hypertrophied fibula.]

He undergoes an operation. What are the requirements before performing a reconstruction procedure? [Fully healed soft tissues, absence of sequestra on x-ray and no antibiotics for 2 months.]

What procedure has he had (Fig. 14.7b)? [Contralateral free fibula graft with ipsalateral fibula osteotomy and augmentation] What other procedures would have also been acceptable? [Ipsalateral, vascularised or staged fibula graft. Bone transport.] He requires plaster immobilisation for many months but goes on to heal (Fig. 14.7c).

14.15 Summary

Osteomyelitis is a common condition in resource-poor countries. Successful treatment is demanding. Surgery should be focused on a thorough debridement. Patient education about dressings, wound management and follow-up is essential.

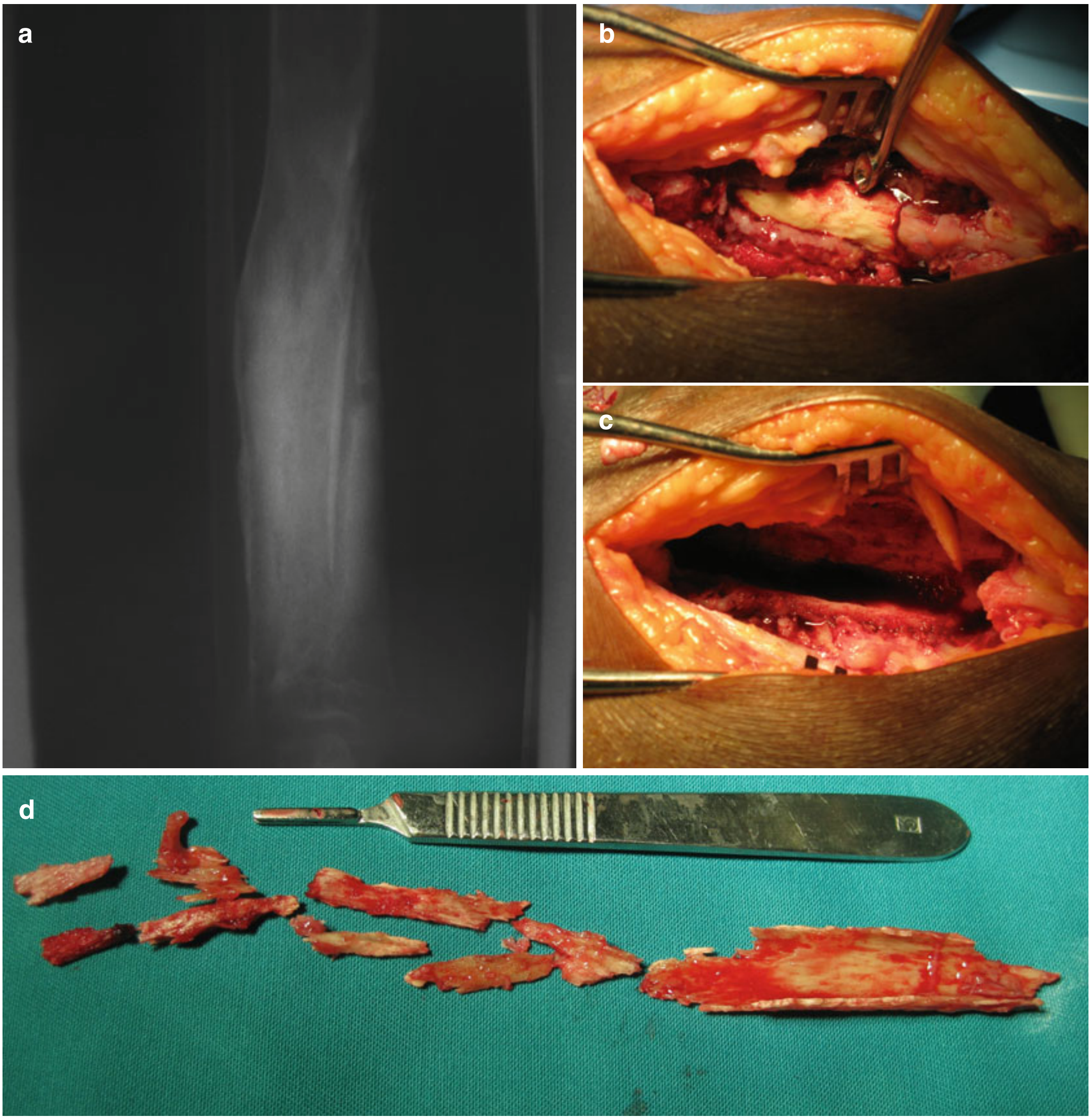

Fig. 14.6 (**a**) The preoperative x-ray of the patient's leg from Fig. 14.5. (**b**) This intraoperative picture shows the yellow sequestrum surrounded by the healthy looking 'pinkish' involucrum. (**c**) This picture shows the same field post sequestrectomy. Note the windowing of the bone and the creation of an intramedullary trough. (**d**) This is the removed sequestrum. (**e**) Postoperative x-ray. Note the creation of a window in the medial border of the tibia and the absence of the sequestrum evident on the previous x-ray

Fig. 14.6 (continued)

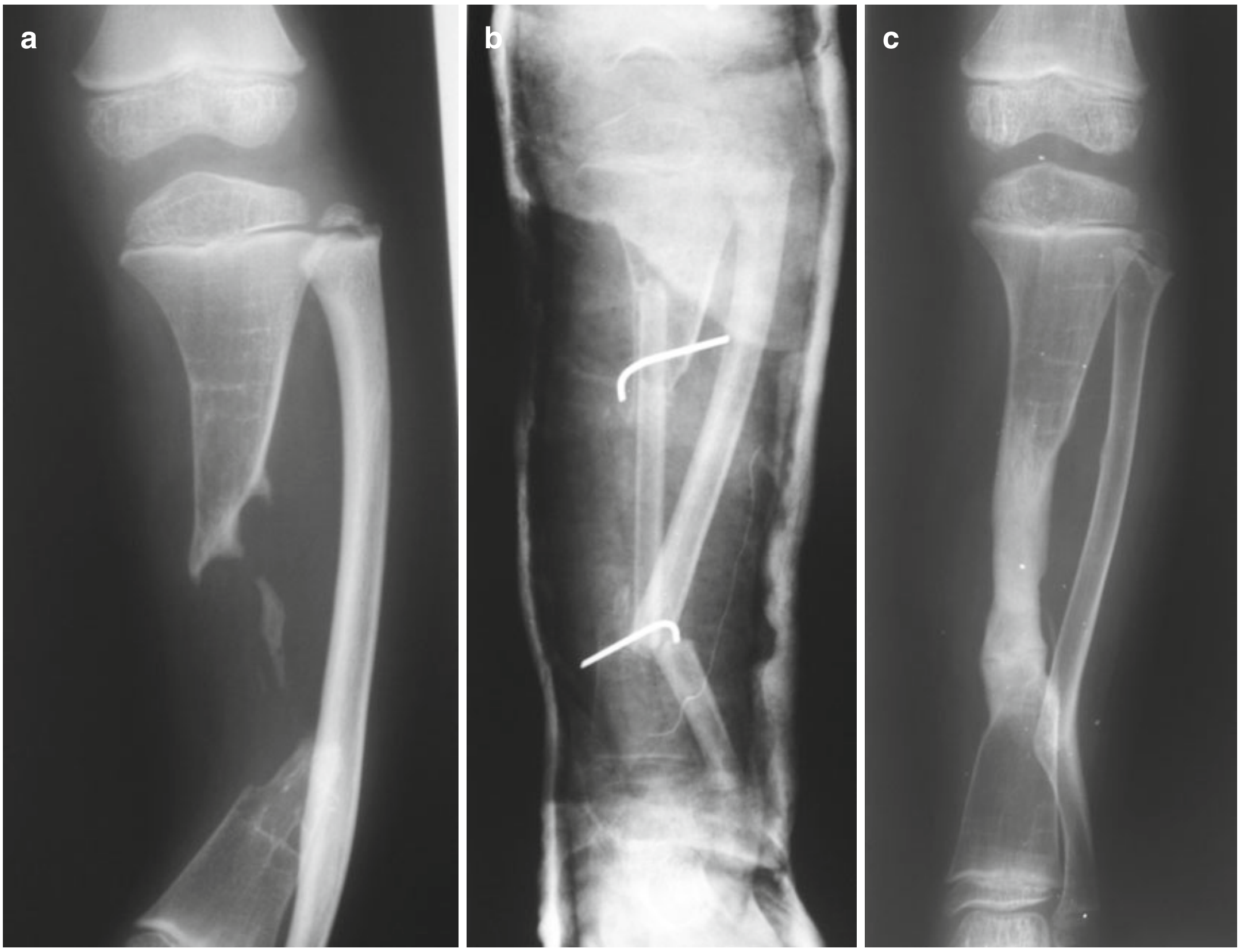

Fig. 14.7 (**a**) X-ray of a boy who presented after a 2-year history of illness, leg pain and previously discharging sinuses. (**b**) Contralateral free fibula graft with ipsalateral fibula osteotomy and augmentation has been performed. (**c**) X-ray after healing

References

1. Bickler SW, Sanno-Duanda B. Epidemiology of paediatric surgical admissions to a government referral hospital in the Gambia. Bull World Health Organ. 2000;78:1330–6.
2. Beckles VLL, Wynn Jones H, Harrison WJ. Chronic haematogenous osteomyelitis in children. A retrospective review of 167 patients in Malawi. J Bone Joint Surg [Br]. 2010;92-B:1138–43.
3. Gillespie W. The epidemiology of acute haematogenous osteomyelitis of childhood. Int J Epidemiol. 1985;14:600–6.
4. Meier DE, Rouma BS. Haematogenous Osteomyelitis and Septic Arthritis. In: Ameh EA, Bickler SW, Lakhoo K, Nwomeh BC, Poenaru D editors. Paediatric Surgery: A Comprehensive Text for Africa. Global Help, Seattle; 2010 p. 135–40.
5. Waldvogel FA, Medoff G, Swartz MM. Osteomyelitis: a review of clinical features, therapeutic considerations, and unusual aspects. N Engl J Med. 1970;282:198–206, 260–6, 316–22.
6. Dartnell J, Ramachandran M, Katchburian M. Haematogenous acute and subacute paediatric osteomyelitis: a systematic review of the literature. J Bone Joint Surg [Br]. 2012;94(5):584–95.
7. Wynn Jones H, Beckles VLL, Akinola B, Stevenson AJ, Harrison WJ. Chronic haematogenous osteomyelitis on children. An unsolved problem. J Bone Joint Surg [Br]. 2011;93-B:1005–1010.
8. Thomas DK, Sanchez P, Hoffman EB. Chronic haematogenous osteomyelitis in children. *South African Orthopaedic Journal* 2007;6:8–12.
9. Simpson AH, Deakin M, Latham JM. Chronic osteomyelitis. The effect of the extent of surgical resection on infection-free survival. J Bone Joint Surg [Br]. 2001;83(3):403–7.
10. Stevenson AJ, Stolbrink M, Moffatt D, Harrison WJ, Cashman C. Treatment of bone defects in children caused by chronic haematogenous osteomyelitis: a retrospective review of 57 patients. Bone Joint J. 2013;95-B(SUPP 9):15.
11. Rasool MN. Primary subacute haematogenous osteomyelitis in children. J Bone Joint Surg [Br]. 2001;83(1):93–8.
12. Roberts JM, Drummond DS, Breed AL, Chesney J. Subacute hematogenous osteomyelitis in children: a retrospective study. J Pediatr Orthop. 1982;2:249–54.
13. Wynn Jones H, Bates J, Harrison WJ. The use of over-penetrated radiographs for the assessment of chronic osteomyelitis in children. Ann R Coll Surg Eng. 2007;89:821–2.
14. Wynn Jones H, Harrison WJ, Bates J, Evans GA, Lubega N. Radiologic classification of chronic haematogenous osteomyelitis in children. J Pediatr Orthop. 2009;29(7):822–7.
15. Cierny G, Mader JT, Pennick H. A clinical staging system of adult osteomyelitis. Contemp Orthop. 1985;10:17–37. J Bone Joint Surg [Am]. 1990;72:104–10.
16. Plan B: A low cost alternative method of delivering negative pressure wound therapy. http://orthopodsworkbench.blogspot.co.uk. Accessed 28 Jan 2016.
17. Mphande ANG, Killowe C, Phalira S, Jones HW, Harrison WJ. Effects of honey and sugar dressings on wound healing. J Wound Care. 2007;16(7):317–9.
18. Stevenson AJ, Jones HW, Chokotho LC, Beckles VL, Harrison WJ. The Beit CURE Classification of Childhood Chronic Haematogenous Osteomyelitis – a guide to treatment. J Orthop Surg Res. 2015 Sep 17;10:144. doi: 10.1186/s13018-015-0282-9.

Where Is My BMP? Managing Bone Defects in the Austere Environment

15

Deepa Bose

Acute traumatic bone defects occur after open injuries or following excision of non-viable bone during debridement of high-energy closed injuries. Chronic post-traumatic defects may result from non-union, infection or disuse osteopenia. In a low-resource environment, without access to specialised techniques, such as distraction osteogenesis or microvascular anastomosis, or expensive adjuncts such as recombinant bone morphogenetic protein (BMP) [1], these injuries present a challenge for clinical decision-making and treatment.

15.1 Types of Bone Defects

Post-traumatic bone defects may be either contained (surrounded by healthy bone) or segmental (involving either the whole or a large percentage of the circumference of the bone). The former is easier to deal with, but there is no consensus regarding the percentage of lost circumference which constitutes a critical defect.

15.1.1 Contained Defects

These are commonly treated by autologous cancellous bone grafting [2]. This is usually taken from the iliac crest but may also be harvested from the proximal or distal tibia [3]. Cancellous graft can also be harvested by reaming the femoral canal with a special reamer termed a reamer irrigator aspirator (RIA) [4], if this is available. It is possible to perform grafting in the acute stage of treatment, immediately after debridement, providing soft tissue closure can be achieved at the same sitting. It may be preferable, however, to do this in two stages, as immediate soft tissue cover is often inadvisable after trauma or infection surgery, and the graft requires a stable, vascular bed to thrive.

The first stage consists of thorough debridement, followed by temporary filling of the defect with a local antibiotic carrier such as polymethylmethacrylate (PMMA) cement or resorbable calcium sulphate preparations. These can be removed and the defect filled with autologous cancellous bone after several weeks [5]. In low-resource environments, the Papineau technique [6] of placing morcellised cancellous bone chips into a bony defect following debridement, and allowing the wound to epithelialise, may be an appropriate method of treating contained defects [7]. In cases where epithelialisation is incomplete, a delayed skin graft may be required to complete closure.

D. Bose, MBBS, FRCS, FRCS (Tr & Orth)
Department of Trauma and Orthopaedics,
Queen Elizabeth Hospital Birmingham,
Birmingham, UK
e-mail: deepa.bose@nhs.net

© Springer International Publishing Switzerland 2016
J.D. Robinson (ed.), *Orthopaedic Trauma in the Austere Environment:*
A Practical Guide to Care in the Humanitarian Setting, DOI 10.1007/978-3-319-29122-2_15

Autologous graft is said to be the "gold standard", as it is osteogenic, osteoinductive and osteoconductive, but it has several drawbacks, such as donor site morbidity and limited availability [8]. Allograft materials in the form of cancellous or cortical strut grafts may not be available in low-resource environments, but even if they are, it is important to bear in mind the potential for transmission of infection [8]. Demineralised bone matrix is osteoconductive and osteoinductive, but this latter property is highly variable depending on the commercial preparation [8].

Cavitary defects may also be filled with artificially manufactured bone graft substitutes such as calcium phosphate ceramics and bioactive glasses, but the results are not always predictable, and they should be used only after careful consideration [9–11]. I use these as dead space fillers and local antibiotic delivery systems, rather than bone graft substitutes, in my practice.

15.1.2 Segmental Defects

All segmental bony defects do not require reconstruction. A lower limb length discrepancy of less than 1.5 cm is well tolerated [12]. In the upper limb, the humerus is more forgiving of loss of length, but the function of the forearm will be affected if the intricate relationship between the radius and ulna is disrupted by bone loss. Each case must be considered on its own merit. Critical bone defects measuring more than this may be filled by two broad strategies: distraction osteogenesis or interposition methods.

15.1.2.1 Distraction Osteogenesis

Distraction osteogenesis was first described by Ilizarov [13, 14] as the law of tension stress and signifies a process by which, under conditions of stable fixation, a low-energy iatrogenic corticotomy, when subjected to gradual stretch, results in the formation of bone in the gap through a process of endochondral ossification. This technique can be used to make up lost length in long bones by one of the following two methods:

Bifocal compression distraction. In this technique, the bony gap is acutely compressed and closed, following which the bone is lengthened through an iatrogenic corticotomy either proximal or distal to the fracture.

Bone transport. The overall length of the limb is maintained, while a corticotomy is created either proximal or distal to the fracture gap. The middle segment of the bone is then moved up or down to gradually close the gap. This has the advantage of maintaining soft tissue alignment during bone lengthening.

Distraction osteogenesis is commonly performed with the use of circular external fixators [15–17] but can also be achieved by monolateral external fixators [18, 19]. The technique of distraction osteogenesis requires special expertise and equipment, and the treatment course can be prolonged and beset with complications [20, 21]. It does, however, allow for gradual deformity correction if this is necessary. It also avoids the need for expensive internal fixation and unnecessary soft tissue dissection. This technique should only be carried out by appropriately trained surgeons.

Figure 15.1 shows a post-traumatic defect in an open tibial fracture which was dealt with by acute shortening and then distraction osteogenesis through a proximal corticotomy in an Ilizarov frame. Intramedullary devices have been developed for this purpose but have had variable outcomes owing to the difficulty in controlling the distraction [22].

15.1.3 Interposition Techniques

15.1.3.1 Non-vascular Tissue

Autograft

Autologous free fibular grafts without the accompanying vascular pedicle have been used to reconstruct segmental defects of long bones after trauma and tumour resection [23, 24]. This technique has the advantage of simplicity, as microvascular techniques are not required, but the surgeon must be aware of potential complications such as graft fracture [25]. This technique has yielded good results in children [26].

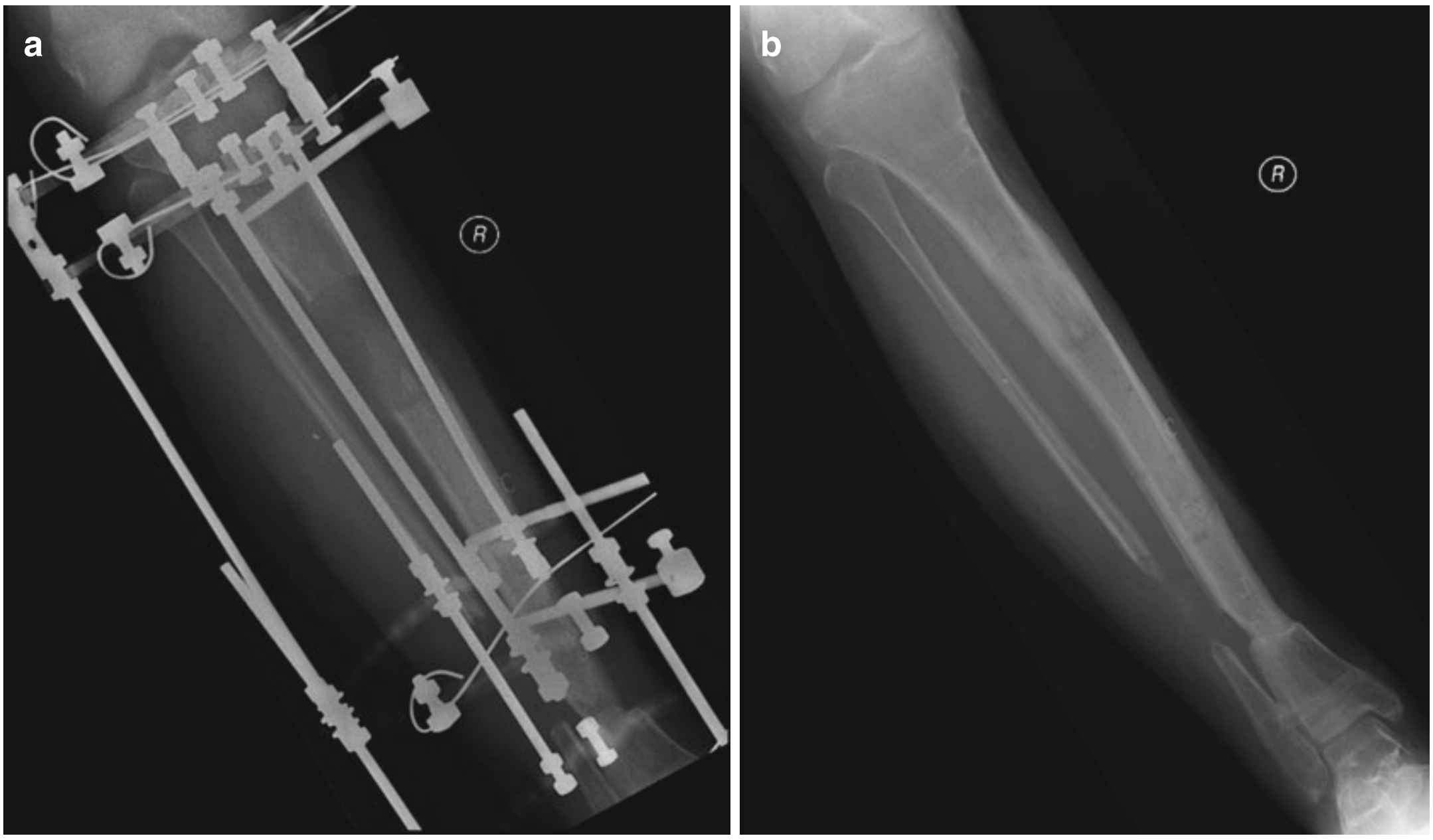

Fig. 15.1 (**a**) Acute shortening of open tibia with bone loss and lengthening through proximal corticotomy (bifocal technique). (**b**) United tibia restored to normal length after Ilizarov frame removal

Tibialisation of the fibula, where the ipsilateral fibula is used to fill a segmental gap in the tibia, has also been reported by some authors to have good results [27, 28]. The fibula can be stabilised by either internal or external fixation. This is accomplished in either one or two stages, without the need for microvascular anastomosis, and may also be achieved gradually using an Ilizarov frame. Blocks of cancellous bone and rigid fixation to bridge bony gaps have been described by Nicoll [29] and have demonstrated good results in the upper limb [30].

Allograft Cortical strut grafts may be used for stabilisation of atrophic non-unions or periprosthetic fractures and complex reconstructions of the femur [31, 32]. The risk of infection and unpredictable vascularisation [25] should be considered carefully in these cases, especially in an austere setting, where sterilisation techniques may be unreliable.

15.1.3.2 Vascular Tissue

Vascularised autologous grafts are harvested with their feeding vessels, which are anastomosed to recipient vessels around the bony gap. The fibula is a common donor site, but the ribs or iliac crest may also be used.

Figure 15.2 shows an infected humeral nonunion in which the defect resulting from debridement was filled with a vascularised fibular graft and internal fixation.

The vascularised bone facilitates healing not only by filling the gap but also by increasing vascularity and resisting infection [33]. It can also respond to biomechanical stimuli with hypertrophy and may provide osteogenic cells to participate in bony healing [25].

Vascularised fibular grafts have yielded good results in upper and lower limb defects [34–37], but there is a tendency towards stress fractures in the lower extremity [38] and a double strut may be better in this situation [35]. This technique requires special equipment and microvascular expertise and should be performed by experienced surgeons in order to minimise complications [39].

My personal preference is to reserve the use of this technique for the upper limb only, as the risk of stress fractures, and the time taken for incorporation and hypertrophy in the lower limb, makes

Fig. 15.2 (**a**) Infected non-union of the humerus. (**b**) Vascularised free fibula used to fill defect after debridement. (**c**) Consolidation of free fibula

it a less reliable technique in my experience, compared to distraction osteogenesis.

Inductive Membrane Technique

The concept of inducing the formation of a pseudomembrane within which bone graft can be placed was described by Masquelet et al. [40]. This is done in two stages; in the first, a cement spacer is used to fill the bony defect. A membrane forms around this, and in the second stage, the spacer is removed and the membrane filled with autologous cancellous bone (Fig. 15.3). Stability is enhanced by either internal or external fixation. The membrane serves to prevent graft resorption, but it also appears to have osteoinductive properties [41]. Early clinical results appear promising [42] and it is an attractive technique in low-resource situations because it does not require special equipment or expertise. More studies in austere settings are required to establish its role fully.

Figure 15.4 shows a flow diagram for filling bone defects.

Fig. 15.3 (**a**) Open tibial fracture with bone loss. (**b**) Filling defect with antibiotic-laden cement. (**c**) Removal of cement and insertion of autologous graft into induced membrane, resulting in consolidation of fracture

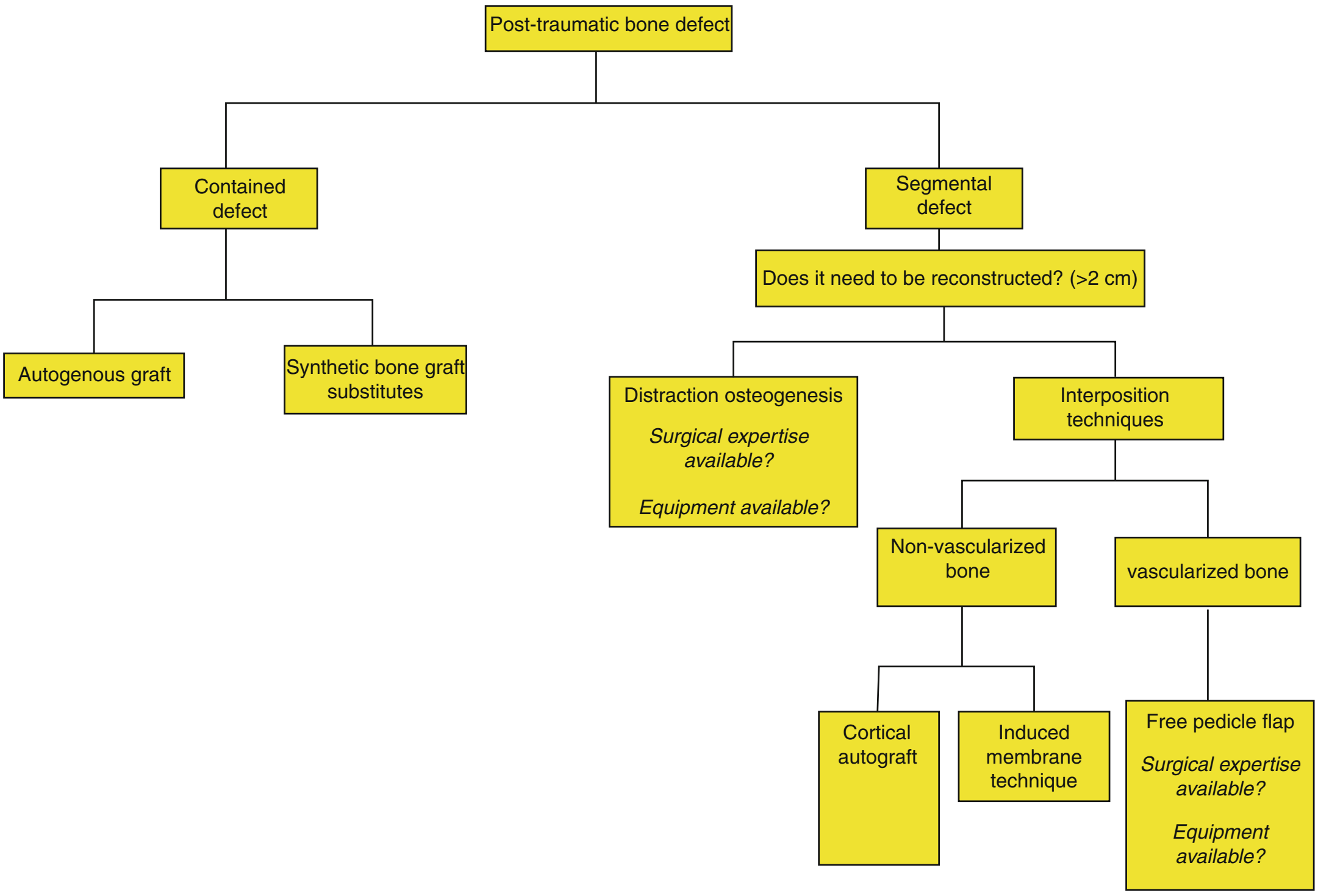

Fig. 15.4 Algorithm for management of bone defects

15.2 Special Considerations

15.2.1 Tibiofibular Synostosis

Recalcitrant tibial non-unions with or without bone loss in low-resource settings present a difficult problem. The deliberate creation of a tibiofibular synostosis is a tried and tested way of dealing with this problem [43]. Classically, this was done via a posterolateral approach to the distal tibia and fibula [43, 44]. Some authors now recommend the central technique, which involves a lateral approach, and grafting on to the anterior aspect of the interosseous membrane [45].

15.2.2 Articular Defects

Bone loss of the articular surface presents a challenge even in the best resourced environment. In a low-resource setting, it can be a daunting prospect for the surgeon. Smaller, contained defects which constitute a small percentage of the joint surface may be managed by allogenous grafts [46, 47] if these are available, but in larger defects, arthrodesis is indicated [48, 49]. If facilities for arthroplasty are available, this may be considered, but it should be borne in mind that such complex cases may require special types of prostheses, such as constrained joints [50, 51].

15.3 What About the BMP?

Bone morphogenetic protein (BMP) is found naturally in the body and plays an important role as a signalling protein in the recruitment of osteoprogenitor cells during the fracture healing process. There are several types of BMP, and their function was originally described in the classic paper by Urist [1].

Commercial preparations of recombinant BMP have found various clinical applications in promoting fracture healing and bony fusion

[10, 52, 53]. Recent studies, however, have failed to find conclusive evidence of its clinical effectiveness [54], and some authors have described serious complications associated with its use in spinal fusion [55]. We await the final verdict on the safety and effectiveness of commercial preparations of BMP.

References

1. Urist MR, Strates BS. Bone morphogenetic protein. J Dent Res. 1971;50(6):1392–406.
2. LaVelle DG. Delayed unions and nonunions of fractures. In: Canale T, editor. Campbell's operative orthopaedics. 9th ed. St Louis: Mosby; 1998. p. 2583.
3. Myeroff C, Archdeacon M. Autogenous bone graft: donor sites and techniques. J Bone Joint Surg Am. 2011;93(23):2227–36.
4. Giorgiadis GM, DeSilva SP. Reconstruction of skeletal defects in the forearm after trauma: treatment with cement spacer and delayed cancellous bone grafting. J Trauma. 1995;38(6):910–4.
5. Sagi HC, Young ML, Gerstenfeld L, Einhorn TA, Tornetta P. Qualitative and quantitative differences between bone graft obtained from the medullary canal (with a Reamer/Irrigator/Aspirator) and the iliac crest of the same patient. J Bone Joint Surg Am. 2012;94(23):2128–35.
6. Papineau LJ, Alfageme A, Delcourt JP, Plon BL. Chronic osteomyelitis of leg bones: resection and bone grafting with delayed skin closure. J Bone Joint Surg Br. 1976;58B:138.
7. Panda M, Ntungila N, Kalunda M, Hinsenkamp M. Treatment of chronic osteomyelitis using the Papineau technique. Int Orthop. 1998;22(1):37–40.
8. Zimmermann G, Moghaddam A. Allograft bone matrix versus synthetic bone graft substitutes. Injury. 2011;42 Suppl 2:S16–21.
9. Kurien T, Pearson RG, Scammell BE. Bone graft substitutes currently available in orthopaedic practice: the evidence for their use. Bone Joint J. 2013;95B(5):583–97.
10. Hagen A, Gorenoi V, Schonermark MP. Bone graft substitutes for the treatment of traumatic fractures of the extremities. GMS Health Technol Assess. 2012;8:Doc04.
11. Hak DJ. The use of osteoconductive bone graft substitutes in orthopaedic trauma. J Am Acad Orthop Surg. 2007;15(9):525–36.
12. Beaty JH. Congenital anomalies of the lower extremity. In: Campbell's operative orthopaedics. 9th ed. St. Louis: Mosby; 1998.
13. Ilizarov GA. The tension-stress effect on the genesis and growth of tissues. Part I. The influence of stability of fixation and soft-tissue preservation. Clin Orthop. 1989;238:249–81.
14. Ilizarov GA. The tension-stress effect on the genesis and growth of tissues. Part II. The influence of the rate and frequency of distraction. Clin Orthop. 1989;239: 263–85.
15. Marsh DR, Shah S, Elliott J, Kurdy N. The Ilizarov method in nonunion, malunion and infection of fractures. J Bone Joint Surg Br. 1997;79:273–9.
16. Sen C, Kocaoglu M, Eralp L, Gulsen M, Cinar M. Bifocal compression-distraction in the acute treatment of grade III open tibia fractures with bone and soft-tissue loss: a report of 24 cases. J Orthop Trauma. 2004;18(3):150–7.
17. Chaddha M, Gulati D, Singh AP, Singh AP, Maini L. Management of massive posttraumatic bone defects in the lower limb with the Ilizarov technique. J Orthop Belg. 2010;76(6):811–20.
18. Adegbehingbe OO, Ojo OD, Abiola PO, Ariyibi AL, Oginni LM, Obateru JA. Distraction by a monotube fixator to achieve limb lengthening: predictive factors for tibia trauma. J Trauma Manag Outcomes. 2013;7(1):3.
19. Arora S, Batra S, Gupta V, Goval A. Distraction osteogenesis using a monolateral fixator for infected nonunion of the femur with bone loss. J Orthop Surg (Hong Kong). 2012;20(2):185–9017.
20. Paley D. Problems, obstacles and complications of limb lengthening by the Ilizarov technique. Clin Orthop Relat Res. 1990;250:81–104.
21. Krappinger D, Irenberger A, Zegg M, Huber B. Treatment of large posttraumatic tibial bone defects using the Ilizarov method: a subjective outcome assessment. J Orthop Trauma. 2013;133(6):789–95.
22. Kenaway M, Krettek C, Liodakis E, Wiebking U, Hankmeier S. Leg lengthening using intramedullary skeletal kinetic distractor: results of 57 consecutive cases. Injury. 2011;42(2):150–5.
23. Gopisankar G, Justin AS, Nithvanath M, Cherian VM, Lee VN. Non-vascularised fibular graft as an intramedullary strut for infected non-union of the humerus. J Orthop Surg (Hong Kong). 2011;19(3):341–5.
24. Lawal YZ, Garba ES, Ogirima MO, Dahiru IL, Maitama MI, Abubaker K, Ejagwulu FS. Use of non-vascularized autologous fibula strut graft in the treatment of segmental bone loss. Ann Afr Med. 2011;10(1):25–8.
25. Jain AK, Maheshwari AV. Infected nonunions of long bones. In: Jain AK, Kumar S, editors. Neglected musculoskeletal injuries. New Delhi: Jaypee Brothers Medical Publishers; 2011.
26. Steinlechner CW, Mkandawire NC. Non-vascularised fibula transfer in the management of defects of long bones after sequestrectomy in children. J Bone Joint Surg Br. 2005;87(9):1259–63.
27. Tull SM. Tibialization of the fibula: a viable option to salvage limbs with extensive scarring and gap non-unions of the tibia. Clin Orthop Relat Res. 2005;431: 80–4.
28. Kundu ZS, Gupta V, Sangwan SS, Kamboi P. Gap non-union of tibia treated by Huntington's procedure. Indian J Orthop. 2012;46(6):653–8.
29. Nicoll EA. The treatment of gaps in long bones by cancellous insert grafts. J Bone Joint Surg Br. 1956;38B:70–82.

30. Gupta DK, Kumar G. Gap non-union of forearm bones treated by modified Nicoll's technique. Indian J Orthop. 2010;44(1):84–8.
31. Lee PT, Clayton RA, Safir OA, Backstein DJ, Gross AE. Structural allograft as an option for treating infected hip arthroplasty with massive bone loss. Clin Orthop Relat Res. 2011;469(4):1016–23.
32. Judas F, Saavedra MJ, Mendes AF, Dias R. Cortical strut allografting in reconstructive orthopaedic surgery. Acta Reumatol Port. 2011;36(1):24–8.
33. Tu YK, Yen CY. Role of vascularized bone grafts in lower extremity osteomyelitis. Orthop Clin North Am. 2007;38(1):37–49.
34. González del Pino J, Bartolomé del Valle E, Graña GL, Villanova JF. Free vascularized fibular grafts have a high union rate in atrophic nonunions. Clin Orthop Relat Res. 2004;419:38–45.
35. Chen MT, Chang MC, Chen CM, Chen TH. Double-strut free vascular fibular grafting for reconstruction of the lower extremities. Injury. 2003;34(10):763–9.
36. Safoury Y. Free vascularized fibula for the treatment of traumatic bone defects and non-union of the forearm bones. J Hand Surg Br. 2005;30(1):67–72.
37. Wood MB, Bishop AT. Massive bone defects of the upper limb: reconstruction by vascularized bone transfer. Hand Clin. 2007;23(1):49–56.
38. Lee KS, Han SB, Baek JR. Free vascularized osteocutaneous fibular graft to the tibia in 51 consecutive cases. J Reconstr Microsurg. 2004;20(4):277–84.
39. Arai K, Toh S, Tsubo K, Nishikawa S, Narita S, Miura H. Complications of vascularized fibula graft for reconstruction of long bones. Plast Reconstr Surg. 2002;109(7):2301–6.
40. Masquelet AC, Fitoussi F, Beque T, Muller GP. Reconstruction of the long bones by the induced membrane and spongy autograft. Ann Chir Plast Esthet. 2000;45(3):346–53.
41. Taylor BC, French BG, Fowler TT, Russell J, Poka A. Induced membrane technique for reconstruction to manage bone loss. J Am Acad Orthop Surg. 2012; 20(3):142–50.
42. Karger C, Kishi T, Schneider L, Fitoussi F, Masquelet AC. French Society of Orthopaedic Surgery and Traumatology (SoFCOT) Treatment of posttraumatic bone defects by the induced membrane technique. Orthop Traumatol Surg Res. 2012;98(1):97–102.
43. Freeland AE, Mutz SB. Posterior bone-grafting for infected ununited fracture of the tibia. J Bone Joint Surg Am. 1976;58(5):653–7.
44. Fitoussi F, Masquelet AC, Rigal S, Poichotte A, Bauer T, Fabre A. French Society of Orthopaedic Surgery and Traumatology (SoFCOT) Inter-tibiofibular graft for traumatic segmental bone defect of the tibia. Orthop Traumatol Surg Res. 2012;98(2):214–9.
45. Gulan G, Jotanović Z, Jurdana H, Sestan B, Rapan S, Rubinić D, Ravlić-Gulan J. Treatment of infected tibial non-union with bone defect using central bone grafting technique. Coll Antropol. 2012;36(2):617–21.
46. Gross AE, Shasha N, Aubin P. Long-term followup of the use of fresh osteochondral allografts for posttraumatic knee defects. Clin Orthop Relat Res. 2005;435:79–87.
47. Hofmann GO, Kirschner MH. Clinical experience in allogeneic vascularized bone and joint allografting. Microsurgery. 2000;20(8):375–83.
48. Kovoor CC, Padmanabhan V, Bhaskar D, George VV, Viswanath S. Ankle fusion for bone loss around the ankle joint using the Ilizarov technique. J Bone Joint Surg Br. 2009;91(3):361–6.
49. Barwick TW, Montgomery RJ. Knee arthrodesis with lengthening: experience of using Ilizarov techniques to salvage large asymmetric defects following infected peri-articular fractures. Injury. 2013;44(8):1043–8.
50. Lampert C. Ankle joint prosthesis for bone defects. Orthopade. 2011;40(11):978–83.
51. Yang JH, Yoon JR, Oh CH, Kim TS. Primary total knee arthroplasty using rotating-hinge prosthesis in severely affected knees. Knee Surg Sports Traumatol Arthrosc. 2012;20(3):517–23.
52. Sandhu HS, Boden SD. Biologic enhancement of spinal fusion. Orthop Clin North Am. 1998;29(4):621–31.
53. Moghaddam A, Elleser C, Biglari B, Wentzensen A, Zimmermann G. Clinical application of BMP 7 in long bone non-unions. Arch Orthop Trauma Surg. 2010;130(1):71–6.
54. Garrison KR, Shemit I, Donell S, Ryder JJ, Mugford M, Harvey I, Song F, Alt V. Bone morphogenetic protein (BMP) for fracture healing in adults. Cochrane Database Syst Rev. 2010;(6):CD006950.
55. Mroz TE, Wang JC, Hashimoto R, Norvell DC. Complications related to osteobiologics use in spine surgery: a systematic review. Spine (Phila Pa 1976). 2010;35(9 Suppl):S86–104.

Part IV

Perioperative Management in the Austere Environment

16

What? No Lab? Preparing the Patient for Operation

Sandro Contini

The estimated total global surgical volume in 2004 was 234·2 million of major operations, 73·6 % of them occurring in high- or middle-expenditure countries, with 30·2 % of the world population, whereas the poorest 34·8 % of the world's population received only 3·5 % of all surgery undertaken [1]. Essentially, 10–20 % of the world's health-care resources are utilized by the 70 % of the world's population living in the developing world that suffers a huge shortage of health staff, facilities, drugs, supplies, equipment, and technologies. Preparation to surgery and perioperative orthopedic care in austere environment typically reflect these drawbacks: a common experience in developing countries is to have few basic laboratory tests available, a condition that, to some degree, may not be perceived as a significant deficiency by local doctors, often used to trust more on their experience than on the results of the tests [2]. Every preoperative evaluation and treatment planning must therefore be essentially founded on good history taking, watchful clinical examination, and sound experience, without relying excessively on laboratory tests, frequently unavailable and sometimes unreliable.

Similarly, the technologically advanced orthopedic surgery of western countries, requiring high costs, appropriate sterility, thoughtful postoperative care, etc., should be offered with great caution in the usually poorly equipped facilities of developing countries and especially in peripheral hospitals. Introduction of health technology in austere environment needs to be culturally appropriate, affordable (not necessarily cheap), and sustainable and should be introduced with care (Fig. 16.1). Initial purchase costs are less important than long-term averaged costs taking into account all factors. Accordingly, donor aid linked to equipment purchase should avoid technological mismatches. The utilization of the equipment should be maximized and it should be always taken into account the wasteful lack of equipment maintenance.

After some considerations on the laboratory medicine in developing countries, the laboratory tests usually available in austere environment will be discussed, considering also the recommendations from anesthesiology or surgical societies of developed countries. The final assumption will be that orthopedic trauma care can be reasonably managed in austere conditions, in spite of the scarcity of laboratory tests, yet being able to fulfill satisfactorily the clinical needs and achieve an acceptable outcome.

S. Contini, MD
Department of Surgical Sciences, Parma University Hospital, Parma, Italy
e-mail: sandrocontini46@gmail.com;
sandro.contini@unipr.it

© Springer International Publishing Switzerland 2016
J.D. Robinson (ed.), *Orthopaedic Trauma in the Austere Environment: A Practical Guide to Care in the Humanitarian Setting*, DOI 10.1007/978-3-319-29122-2_16

Fig. 16.1 A basic but well-equipped laboratory in the austere setting

16.1 Laboratory Medicine in the Austere Environment

16.1.1 Clinical Concerns

In resource-limited settings, health facilities and peripheral hospitals have usually minimal or absent laboratory support, especially for communicable diseases, and a clinical diagnosis made without the support of basic diagnostic tests is the rule rather than the exception [3]. However, when diagnoses are based on clinical signs only and symptoms are ambiguous or unreliable, a correct management may be challenging [3]. Sometimes, the absence of laboratory support contributes to an overdiagnosis, e.g., for malaria, with consequent failure or delay in treatment of alternative life-threatening infections [4]. Moreover, with clinical overlapping of some diseases without a precise laboratory diagnosis, inappropriate therapy may be undertaken [5].

16.1.2 Social and Economical Concerns

The vast majority of financial resources from funding organizations and governments have been focused on disease prevention and provision of care, whereas relatively little funding has been allocated to build laboratory capability. There are several constraints against the spreading of laboratories' availability and on their use in austere settings: lack of consumables and expensive reactive, due to poor funding, shortage of trained personnel and technicians, and shortage of staff to obtain clinical specimens for laboratory testing, consequent to the overwhelming number of chronic or acute patients usually present in the hospitals. Moreover, skilled lab technicians, after achieving a good formation, may migrate to higher-paying positions within private hospitals, further weakening the existing public structure and aggravating a quality differential that encourages the increasing use of alternative health-care and laboratory systems. A further limit is that local physicians often perceive these tests as unreliable and unhelpful, such that they remain underutilized and undervalued [6]. Clinical decisions often occur in the absence of laboratory confirmation, even when tests were available. Conversely, when tests are performed and the results are contradictory to the clinical judgment, treatment may be based on clinical judgment alone [2].

A shift toward private structures is commonly observed. In Nigeria, people with financial means have a higher probability of accessing private laboratory resources [7]. In Uganda, within the same hospital ward, the physician preference, patient socioeconomic status, and laboratory reputation influence the decision to send a patient sample to a private or public laboratory. Hence, the public health-care infrastructure, although inadequate, is progressively destabilized by these competing parallel systems [2].

The problem is further complicated by the decentralization of the health-care system, in which governmental, not-for-profit (e.g., missionary or private philanthropic), or commercial (for-profit) organizations often operate independent laboratories, thus creating an environment of donor parallelism of not uniform quality level somewhat confusing.

16.1.3 Quality

In more remote areas, piped water and power supply are not available constantly and spaces for labs are limited. Laboratory equipment and supplies may be shortened even in some primary center [8]. Skilled staff is scarce and essential tests, as designated by the WHO (malaria microscopic evaluation and hemoglobin, glucose, and HIV testing) [9], are not provided in a quality-controlled fashion by the majority of hospitals in the sub-Saharan Africa. On these premises, an alarming number of simple tests like malaria or acid-fast bacilli smear are inaccurate and lead to misdiagnosis and mismanagement [2].

Although in austere environment the allocation of resources to laboratory testing may not be considered a priority, we should be aware that unreliable and inaccurate lab results:

- Lead to unnecessary costs
- Encourage the perception that laboratory testing is unhelpful
- Jeopardize the patient care

Table 16.1 well demonstrates the inadequacies in laboratory infrastructures in sub-Saharan Africa and their potential solutions [2].

Table 16.1 Inadequacy in laboratory infrastructures in sub-Saharan Africa and potential solutions

Laboratory infrastructures
Problems
Lack of laboratory consumables
Lack of basic essential equipment
Limited numbers of skilled personnel
Lack of educators and training programs
Inadequate logistical support
De-emphasis of laboratory testing
Insufficient monitoring of test quality
Decentralization of laboratory facilities
No governmental standards for laboratory testing
Potential solutions
Emphasize importance of laboratory testing
Balance the allocation of financial resources
Strengthen the existing health-care infrastructure
Routinely monitor test quality
Establish system for laboratory accreditation
Implement laboratory training programs
Encourage partnerships between public and private organizations
Develop affordable, rapid diagnostic tests

From Petti et al. [2], with permission

In recent years, rapid tests, non-cultured based, for the diagnosis of infectious diseases (e.g., for malaria or HIV) have become commercially available. They may be performed in peripheral health-care settings with little technical expertise, requiring minimal sample preparation or preservation, and are kit based (with reagents resistant to extreme temperatures). Although rather costly, these tests represent certainly an improvement in terms of wider availability of reliable diagnosis.

In conclusion, the acknowledgment of the critical importance of basic and good quality (although affordable and sustainable) laboratory testing among clinicians, nongovernmental organizations, and policy makers is mandatory to deliver more effective treatment and to optimize the expenditure of health-care resources.

16.2 Preparation for Surgery

Preparing the patients for operation is usually under the responsibility of the anesthesiologist, but in austere environment, trained nurses are quite frequently entrusted for anesthesia.

Nevertheless, the surgeon/orthopedic should be aware of his unique role in supervising the clinical procedures leading to surgery. Evaluation of patients' medical records, interview, physical examination, findings from medical tests, and consulting with other health-care professionals are all part of the preparation to surgery. The American Association of Anesthesiologist (ASA) [10], the European Association of Anesthesiologists (ESA) [11], and the National Institute for Clinical Excellence (NICE) [12] have published practice advisory and guidelines for evaluation before surgery, yet some issues are not easily applicable to austere environment, for lack of time, organization, diagnostic tools, and staff. In such environment, a sound clinical judgment, usually deriving from an extensive experience in poor-resources settings, can be the only reliable instrument in evaluating and planning treatment, keeping in mind that these patients are significantly different from those we are used to deal with in western countries, being affected by the consequences of war or disaster, malnutrition, poor quality water, infectious diseases, dehydration, etc.

Therefore, preoperative assessment is crucial but is limited by the context and only rarely surgery will not be performed for anesthetic reasons. Due to the lack of diagnostic facilities, extra investigations are usually not advised. When surgery is estimated unavoidable, delay is only beneficial if the patient's condition can be improved and not for waiting for more elaborate tests.

To assess the patients the day before surgery [10] may not be practical or possible in a limited resources setting, especially in trauma care or during situations of conflict or disaster. In any case, at a minimum, a physical examination should be performed before going to the operative theater and include a clinical evaluation of airways, lungs, and heart, with documentation of vital signs.

16.2.1 Preoperative Laboratory Test

Laboratory investigations in austere environment should only be used if their results will influence the therapeutic plan. A careful clinical examination must remain the mainstay of preoperative assessment. Ideally, preoperative laboratory tests are indicated to [10]:

- Discover diseases that may affect perioperative anesthetic care
- Assess an already known disease
- Formulate specific plans/alternatives for intraoperative anesthetic and surgical care and postoperative recovery

A *routine* test, defined as a test ordered in the absence of a specific clinical indication or purpose, does not make any contribution to the process of perioperative assessment and management of the patient, and terms such as "pre-op status" and "surgical screening" are not specific clinical indications for routine tests [10]. Conversely, an *indicated* test, ordered for a specific clinical indication, may guide or modify the therapeutic approach, but decision-making parameters for specific *indicated* preoperative tests are not yet determined clearly from the available literature [10].

Serum hemoglobin, glucose, malaria microscopic evaluation, and HIV testing have been defined by the WHO as essential tests for patients of sub-Saharan Africa [9]. In orthopedic trauma, the presence of malaria may not change the indication to surgery, but may warn to postpone it, when possible, after the acute phase, as well as HIV-positive patients may condition the planning of the treatment and the outcome, according to the severity of the disease. Some other laboratory tests, although not strictly linked to trauma or preparation to surgery, should be available in these settings due to the presence of tropical diseases. Table 16.2 shows the basic examinations suggested by Medecins Sans Frontieres in a low-resource setting [13].

Hemoglobin or hematocrit rarely leads to a change in the clinical management of the patients in western countries [14] and in austere environment have a clear indication only if severe anemia is suspected or in case of hemorrhage. Anemia can be expected more frequently in developing countries where malaria and sickle cell disease are observed frequently. It is well

Table 16.2 Basic examinations in low-resource setting

Blood	*Hematology* Hemoglobin WBC *Transfusion* Blood group + rhesus HIV, Hepatitis B and C, syphilis RPR *Thick and thin films* Malaria, some filariasis, trypanosomiasis, visceral leishmaniasis, borreliosis *Rapid tests* Malaria HIV, hepatitis B and C, etc.
Sputum	Koch's bacillus
Urine	Reagent strip test (glucose protein)
Genital discharge	Gonococcus, trichomonas
Stool	Examination of wet preparation (egg, helminthes, cysts, protozoa) Scotch test
CSF	Look for and identify pathogens (including rapid test for meningitis) Cell count and protein (Pandy test)

From Broek et al. [13], with permission

known that sickled red blood cells in low-oxygen states cause occlusion of blood vessels, increased viscosity, and inflammation, with possible stroke or acute chest syndrome. Severe burns are other frequent causes of anemia, especially in children, and Hb should be controlled before any skin graft. Preoperative transfusion may be needed in children in such conditions, but normally giving blood before surgery is not a routine practice. When a patient is found anemic, if surgery is scheduled electively, preoperative iron supplementation may be considered. *Leukocyte count* is not specifically useful, at least in the first period after trauma, and is often unreliable, especially in peripheral laboratories, as well as *platelets count*, rarely available, although platelet dysfunctions are the most common defects of hemostasis, occurring in up to 5 % of patients undergoing surgery [11].

Serum *glucose* is valuable to detect or monitor a diabetic state, not uncommon in developing countries, especially in elderly patient. The most important target during the perioperative glucose control in diabetic patients is avoiding hypoglycemia. If possible, during major surgery, the infusion of glucose and insulin should be controlled with frequent glucose testing at time intervals of 30–60 min if the insulin infusion rates have been stable. Due to a risk of overestimation, arterial blood sampling is preferable over capillary blood when measuring glucose [15]. Continuous glucose measuring devices are rarely available in austere setting.

Coagulation studies are rarely accessible. Bleeding disorders or liver dysfunction are usually diagnosed clinically, while anticoagulant therapies are rare in these environments. The scarcity of therapeutic options for correcting an abnormal coagulation state, especially in the acute phase of trauma, makes often these tests useless. According to ASA [10], there are not enough data to comment on the advisability of coagulation tests before regional anesthesia.

Potassium, *sodium*, *renal*, *and liver function studies* are not routinely available in low-resource setting, due also to their cost or shortage. If present, they should be reserved to selected patients with endocrine disorders, risk of renal and liver dysfunction, and use of certain medications or alternative therapies. Again, it is valid the rule that laboratory investigations in austere environment should only be used if their results can influence the therapeutic plan.

Serum albumin is not a compulsory test. However, it is of proven prognostic value, and it can be a marker of malnutrition, a condition that can influence clinical evolution and outcome in trauma.

Urinalysis is not indicated except for urologic procedures or when urinary tract symptoms are present. There is no good evidence that preoperative abnormal urinalysis is associated with any postoperative complication in non-urinary tract surgery [14]. However, reagent strips can be helpful for monitoring urinary glucose and protein. In some countries (Madagascar, Arabian Peninsula), the presence of urinary symptoms should promote the research of *Schistosoma haematobium* eggs in the urine. As a well-known general rule, urine output should be monitored preoperatively, and adequate fluid management should be provided in order to avoid worsening of preexisting renal failure for patients at risk for postoperative renal impairment.

ECG is not mandatory and seldom is of any significance in planning trauma treatment in poor-resources setting, unless to exclude a myocardial infarction in the presence of suggesting symptoms. The predictive power of preoperative ECGs for postoperative cardiac complications in non-cardiopulmonary surgery is weak [14]. Old age alone per se is not an indication for ECG, but may be valuable in patients with risk factors identified in the course of a preoperative evaluation [10]. The presence of cardiac valvular disease warrants a prophylactic antibiotic to protect the patient during surgery.

16.2.2 Preoperative Chest Radiography

Routine chest radiography is rarely of any value. The limited evidence on the value of a chest X-ray as a baseline measure suggests that it will be of value in less than 9 % of patients [14]. Extremes of age, smoking, stable chronic obstructive pulmonary disease, stable cardiac disease, or resolved recent upper respiratory infection are not considered unequivocal indications for chest radiography even in western countries [10]. Conversely, chest X-ray is indicated in trauma patients in the presence of acute respiratory symptoms, although it should never delay the treatment to confirm the clinical diagnosis, especially when a tension pneumothorax is suspected. About smoking habit, a short-term cessation (less than 4 weeks) may be beneficial to reduce the amount of carboxyhemoglobin in the blood in heavy smokers [11].

16.2.3 Pulse Oximeter

The use of a pulse oximeter is highly recommended. It gives indications about the oxygenation as well as the adequacy of the peripheral circulation either in the preoperative assessment or during surgery. However, a severe vasoconstriction, very low levels of Hb (<5 g/dL), hypothermia (<30°), and carbon monoxide poisoning make the results less reliable.

16.2.4 Blood Transfusion

Blood should be transfused only for lifesaving indications. In the acute setting, a class IV hemorrhage (>40 % loss of blood volume) will certainly need blood [16], while there is agreement that in surgical patients with chronic anemia, blood is required for Hb levels usually around 7 g/dL [17]. A lesson from austere environment is that patients can survive at very low hemoglobin levels, provided they are well oxygenated and filled. The provision of blood is often problematic and unreliable, with a substantial risk of disease transmission. Sometimes blood takes long time to get cross-matched and is available only after a relative has donated blood to fill the stock. Also the anesthetist in the theater must do sometimes the crossmatching and facilities should be available for this. Blood group and Rhesus should always be checked in each trauma patient at admission, although a small emergency blood bank may not be present in the very remote area. When an appropriate refrigerator is not available and transfusions are really needed, they may be done by bleeding the donors (if available), with the advantage to have fresh blood, containing clotting factors and platelets.

All bloods should be tested for hepatitis B and C and HIV. In high HIV prevalence area, it is probably better to screen before blood collection, instead of screening afterward, but it is well recognized that there is no absolute guarantee of safety with a negative testing [18].

It has been reported, in extreme acute cases, the possibility of intraoperative autotransfusion. This procedure is unlikely in orthopedic trauma, for the risk of infection in the presence of open fractures and wounds. Autotransfused blood contains significantly decreased coagulation factors and has lower hemoglobin when compared with venous blood [19] but can be lifesaving in classic indications like massive hemothorax or severe bleeding consequent to intra-abdominal hemorrhage, not contaminated, as in ectopic pregnancy [20].

16.3 Microbiology Laboratory in Trauma Care

Until recently, the target of deployed laboratory medicine in austere environment has been immediate casualty care, with basic hematology and clinical chemistry being the priorities, along with transfusion of blood and blood products. The usefulness of a microbiological support has been questioned and is not routinely recommended [21]. Pre- or post debridement cultures do not appear to be consistently predictive of infection or infecting bacteria, and initial choice of early antimicrobial agents can result in bacteria that escape the initial spectrum of activity. Health-care environmental contamination and nosocomial transmission are major factors contributing to the spread of multiple drug-resistant organisms: therefore, good infection control practices are probably more useful than microbiologic lab support.

16.4 Thromboprophylaxis

Although not strictly related to the preoperative evaluation, preparation to surgery in orthopedic trauma may involve thromboprophylaxis, whose efficacy in reducing morbidity/mortality in surgical patients has been well demonstrated [22]. In austere environment, 3 % of surgical deaths were attributed to pulmonary embolism, though on clinical grounds only [23]. Given the clinically silent nature of venous thromboembolism, its high prevalence in hospitalized patients, and its potentially disabling or fatal consequences, the management of thromboembolic risk in the perioperative period seems justified also in low-resource settings, especially in high-risk patients.

Of course the benefits should be balanced with its potential risks. In these contexts, often patients present with massive bleeding, there is limited ability to cope with bleeding, transfusions are associated with very high infectious and immunologic risks, and underlying anemia is the norm even before trauma. The significant rate of planned re-intervention in trauma and war surgery, due to infection, delayed primary closure, or other complications, as well as the rare availability of hematological investigations, are further concerns to prophylaxis. The rare availability of platelet count will also make difficult to evaluate the presence of a possible heparin-induced thrombocytopenia syndrome. Moreover, the administration of low molecular weight heparin at home after discharge is not reliable in these settings and may be risky. For all these reasons, the use of thromboprophylaxis in orthopedic surgery has been limited, in MSF context, to the advanced level structures only [24].

Patients with severe multitrauma, severe spinal and pelvic (unstable) trauma and sickle cell anemia are at risk for thrombosis and should likely be given low molecular weight heparin. Isolated femoral or lower limb fractures carry a relatively low risk of pulmonary embolism and possibly do not need any treatment. Moreover, many of these patients are younger than 40 years, usually due to the low life expectancy often present in these countries, and carry the lowest risk of thrombosis.

In conclusion, the need for complicated and costly lab examinations can be minimal for orthopedic surgery in austere environment. "Routine labs" are of negligible value and a satisfactory preoperative evaluation can be definitely achieved monitoring the patient with some basic test. Actually, unnecessary testing is plaguing modern medical practice in developed countries, and this attitude should be avoided especially in poor-resources settings, where costs have even more value. The lack of confidence and sometimes absence of a thoughtful assessment of the patient at the bed may be the reasons behind the decision to order not essential tests. The majority of lab investigations do not add too much to the surgical plan and to the quality of surgical care in such environment. Moreover, investigations claimed to be effective in technologically advanced settings may not duplicate their influence in other environments.

References

1. Weiser TG, Regenbogen SE, Thompson KD, et al. An estimation of the global volume of surgery: a modelling strategy based on available data. Lancet. 2008;372: 139–44.

2. Petti CA, Polage CR, Quinn TC, et al. Laboratory medicine in Africa: a barrier to effective health care. Clin Infect Dis. 2006;42:377–82.
3. Makani J, Matuja W, Liyombo E, et al. Admission diagnosis of cerebral malaria in adults in an endemic area of Tanzania: implications and clinical description. QJM. 2003;96:355–62.
4. Amexo M, Tolhurst R, Barnish G, et al. Malaria misdiagnosis: effects on the poor and vulnerable. Lancet. 2004;364:1896–8.
5. O'Dempsey TJ, McArdle TF, Laurence BE, et al. Overlap in the clinical features of pneumonia and malaria in African children. Trans R Soc Trop Med Hyg. 1993;87:662–5.
6. English M, Esamai F, Wasunna A, et al. Assessment of inpatient paediatric care in first referral level hospitals in 13 districts in Kenya. Lancet. 2004;363: 1948–53.
7. Uzochukwu BS, Onwujekwe OE. Socio-economic differences and health seeking behaviour for the diagnosis and treatment of malaria: a case study of four local government areas operating the Bamako initiative programme in south-east Nigeria. Int J Equity Health. 2004;3:6–11.
8. Mundy C, Ngwira M, Kadwele G, et al. Evaluation of microscope condition in Malawi. Trans R Soc Trop Med Hyg. 2000;94:583–4.
9. World Health Organization. Technical guidelines for integrated disease surveillance and response in the African region. 2010. http://www.afro.who.int/en/clusters-a-programmes/dpc/integrated-disease-surveillance/features/2775-technical-guidelines. Accessed 7 July 2013.
10. American Society of Anesthesiologist. Practice advisory for preanesthesia evaluation. Anesthesiology. 2012;116:522–38.
11. De Hert S, Imberger G, Carlisle J, et al. Preoperative evaluation of the adult patient undergoing non-cardiac surgery: guidelines from the European Society of Anaesthesiology. Eur J Anaesthesiol. 2011;28:684–722.
12. National Institute for Clinical Excellence. Preoperative tests. The use of routine preoperative tests for elective surgery. 2003. http://www.nice.org.uk/nicemedia/pdf/preop_fullguideline.pdf. Accessed 16 November 2013.
13. Broek I, Harris N, Henkens M, et al. Doctors without borders clinical guidelines – diagnosis and treatment manual. 2010. http://refbooks.msf.org/msf_docs/en/clinical_guide/cg_en.pdf. Accessed 4 July 2013.
14. Munro J, Booth A, Nicholl J. Routine preoperative testing: a systematic review of the evidence. Health Technol Assess. 1997;1:1–62.
15. Girard M, Schricker T. Perioperative glucose control: living in uncertain times – continuing professional development. Can J Anaesth. 2011;58:312–20.
16. British Committee for Standards in Haematology. Guidelines on the management of massive blood loss. Br J Haematol. 2006;2006(135):634–41.
17. Hill SR, Carless PA, Henry DA, et al. Transfusion thresholds and other strategies for guiding allogeneic red blood cell transfusion. Cochrane Database Syst Rev. 2002;2, CD002042.
18. Maari C, Guéguen M, Grouzard V. Blood transfusion. Doctors without borders (ed). 2009. http://refbooks.msf.org/msf_docs/en/transfusion/transfusion_en.pdf. Accessed 4 July 2013.
19. Salhanick M, Corneille M, Higgins R, et al. Autotransfusion of hemothorax blood in trauma patients: is it the same as fresh whole blood? Am J Surg. 2011;202:817–21.
20. Sing K, Kaur A, Singh A, et al. Intra-operative autotransfusion-a simple and cost effective method. J Indian Med Assoc. 2007;105:688.
21. Okike K. Trends in the management of open fractures. J Bone Joint Surg. 2006;88:2739–48.
22. Geerts WH, Pineo GF, Heit JA, et al. Prevention of venous thromboembolism: the seventh ACCP conference of antithrombotic and thrombolytic therapy. Chest. 2004;126:338S–46.
23. MSF International Working Group for Anesthesia. Thromboprophylaxis in MSF surgical missions. 2007.
24. Alvarado O, Trelles M, Tayler-Smith K, et al. Orthopedic surgery in natural disaster and conflict settings: how can quality care be ensured?. International Orthopaedics (SICOT). 2015;39:1901–8.

Anaesthesia in Austere Environments

17

Christine du Maine

It is important that surgeons are aware of the most important challenges and solutions in anaesthesia, as surgical options may need to take into account the limitations of anaesthetic possibilities available locally. Patient preparation and adequate post-anaesthesia care, both in a recovery room and in a postoperative ward, are part of the anaesthetic management of a patient. Access to modern drugs and technologies is limited in austere environments, so there has been very little change in the way cases have been handled over the last few decades [1–3]. This chapter presents tools to find an 'optimal' anaesthetic approach for your circumstances.

17.1 General Considerations

17.1.1 Availability of Staff

Training and relevant experience of staff (operating theater and post-operative) influence the surgical outcome [4–6] (Fig. 17.1). Anaesthesia is often performed by people with little medical background who have been trained on the job [7]. A properly equipped and staffed post-anaesthetic care unit (PACU) may not be available, requiring the patient to be kept in the operating room (OR) for a longer period [8]. It is important that the patient is fully awake, comfortable and properly hydrated before discharge to the ward, as educated staff and close surveillance may not be available [2, 3, 5, 9].

17.1.2 Equipment

International standards for safe practice are rarely met, with erratic electrical supplies, inconsistent oxygen delivery, lack of up-to-date drugs and equipment and sometimes even of running water [2]. This is even more apparent where anaesthesia for paediatric populations is concerned, as several different sizes of laryngoscope blades, intravenous cannulas (IVs) and airway devices are needed [2]. When the facilities to detect and deal with problems during and after anaesthesia are lacking, one needs to seriously consider whether the surgery should be performed [8]. Referral options need to be explored (Fig. 17.2).

17.1.3 Drugs

Extremes of temperature might impact the effectiveness of many drugs, requiring care during transportation and storage [10]. Custom formalities might also limit the ease of importation. There are no studies to determine the longevity of medications: they

---

C. du Maine, MD
Department of Anesthesia,
Universitair Ziekenhuis Brussel, Brussels, Belgium
e-mail: drdumc@gmail.com

© Springer International Publishing Switzerland 2016
J.D. Robinson (ed.), *Orthopaedic Trauma in the Austere Environment: A Practical Guide to Care in the Humanitarian Setting*, DOI 10.1007/978-3-319-29122-2_17

[redacted]

[redacted]

Fig. 17.1 Scarcity of staff is a challenge, so training has to be a part of any mission

may be effective long past their expiration dates, but there is a risk of providing or being perceived as providing less than an optimum quality of care [8]. Emergency drugs need to be available to counter adverse events. Atropine, epinephrine/adrenaline and ephedrine are essential whenever any anaesthesia is planned (Fig. 17.3) [3, 5].

17.1.4 Patients

A general preoperative evaluation is mandatory [11] (Table 17.1). Extreme delays in presentation are common in austere environments, resulting in a high incidence of dehydration and sepsis due to wound infections, pneumonia or traditional healing methods. These factors augment the surgical problem and anaesthetic risks [2, 12]. The physiological compensation mechanisms in young people can suddenly fail, resulting in cardiovascular collapse in an apparently stable patient, so adequate resuscitation is paramount.

Patients might never have had any medical care prior to their presentation for trauma, so some conditions may not be known, or they may omit to mention a condition out of fear of being dropped from the surgical programme [8, 11]. Thus, the physical examination is especially important in areas where there is a low access to healthcare. The physician must be alert to the physiological consequences of chronic malnutrition, poor hygiene and lack of vaccination

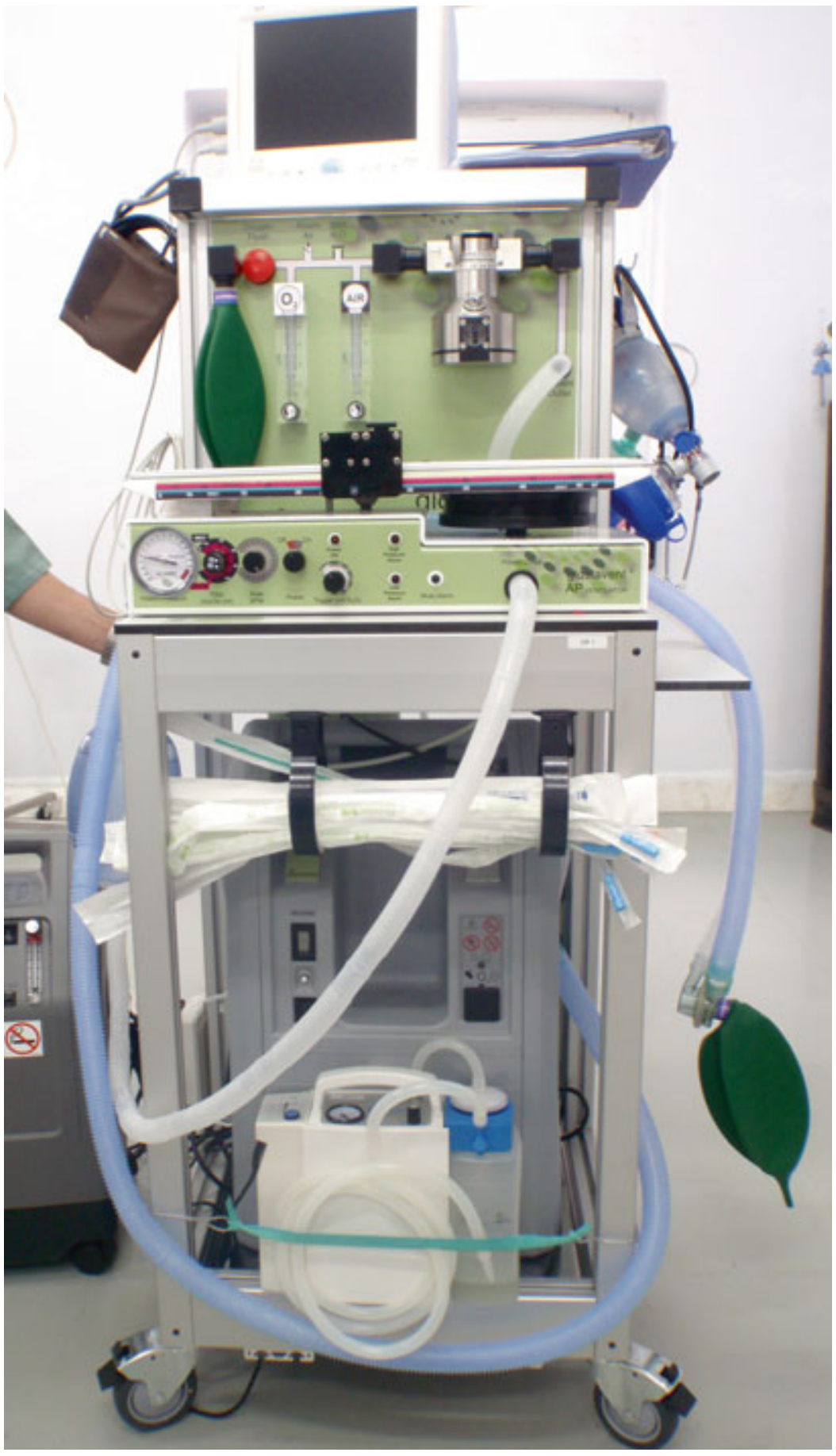

Fig. 17.2 Some units are relatively well equipped, while others have very little in the way of resources and equipment

programmes. The possibility of pregnancy must be explored as this may have consequences for the surgical and anaesthetic approach, such as patient positioning and fasting. Pre-existing anaemia is very common due to trauma, malnourishment and prevalent parasitic infections [8, 11].

The very old or very young carry a higher risk of potential complications, such as postoperative apnoea in newborns [2, 8] (Fig. 17.4). Many medical facilities lack the essentials for safe surgical care of children such as experienced staff, equipment and drug forms suitable for paediatric use [2].

Fasting/nil by mouth/NPO guidelines can be very difficult to enforce in places where the family members provide the care of the patient and where communication and nursing supervision is limited, so many elective patients may turn out to have eaten or drunk something prior to surgery increasing the risk of aspiration [11, 13] (Figs. 17.5 and 17.6). Any patient undergoing an emergency procedure and all pregnant patients are considered to have a full

Table 17.1 Mandatory preoperative evaluation

Date and time of injury
Previous medical problems
Verification of fasting
Allergies (drugs, disinfectants, etc.)
Physical examination

Fig. 17.3 The team must maintain close control on the precious drugs inventory

Fig. 17.4 Paediatric patients pose difficult challenges

NPO

No Food

غذا نيست

No drinking

اب نوشيدنى نيست

Date: تاريخ :

Time: وقت :

Fig. 17.5 Instructions must be clear and in the local language or dialect

stomach. Patient preferences and expectations should be acknowledged, and every effort should be made to comply with patients' wishes, even though resources and options are limited and it may not be possible [4].

17.1.5 Environment

Both hyper- and hypothermia can negatively influence a patient's outcome [3]. Excessive humidity or temperatures influence the functionality of some of our equipment. At higher altitude, the partial oxygen pressure is lower, influencing the oxygenation of tissues and an increased risk of desaturation [8].

17.1.6 Safety and Other Issues

The World Health Organization has designed and promoted a Surgical Safety Checklist (http://www.who.int/patientsafety/safesurgery/ss_checklist/en/). This list is designed to ensure optimum communication between the anaesthetic team, the surgical team and all other members of the healthcare team involved in the patient's care. It mandates that a 'time out' is taken to confirm the name of the patient, the operation planned, the surgical site and any concerns anyone may have.

Patients might need to be transfered to a different facility or even discharged shortly after the procedure due to safety or security reasons. In

Fig. 17.6 Surgeons and anaesthetists must work closely to ensure patient safety

Table 17.2 General considerations in choosing an anaesthesia technique

Manpower constraints
Equipment constraints
Drug availability
Patient considerations
Climatic and geographic considerations
General situational and safety considerations

emergencies with a large influx of patients, the time available for anaesthesia might be limited, influencing the choice of technique [4] (Table 17.2).

17.1.7 Local-Regional (RA) Versus General Anaesthesia (GA)

There is no major advantage proven of RA over GA [14]. Advantages of RA include the fact that it limits the exposure to incapacitating or sedating drugs and their side effects [10, 15–17]. This leaves the patient able to protect their airway [15] and with less respiratory depression, eliminating the need to control a patient's breathing or perform a potentially difficult intubation [2, 10, 15, 18]. The patient remains able to communicate, which is valuable when traditional one-on-one monitoring and intra- and postoperative monitoring equipment is unavailable or at a minimum [10, 15, 17, 18] and allows neurological monitoring of concomitant head injuries [17, 18]. RA is cost-effective [8] and logistically easier to provide as a minimum of consumables and equipment is necessary, especially when low doses are used to avoid dose-related side effects [15]. The consumables have long shelf lives and are stable at a range of temperatures [15].

Pain relief can be optimised in the pre-, per- and postoperative period, with decreased need for systemic analgesics [10, 15, 18] through site-specific, high-quality analgesia [17]. RA can play a valuable role in a multimodal approach to pain management in trauma patients [16], especially those with isolated orthopaedic injuries and burn patients [16]. The use of catheters in RA allows prolonged analgesia or repetitive dosing for treatments such as repeated wound debridements [16].

A rapid room turnover can be achieved if blocks are performed in a preoperative area with monitoring capacities [8, 10]. Due to the faster recovery

Fig. 17.7 Placing a chest drain into a paediatric patient

[10, 18], there is less need for a PACU and intensive nursing care [18], with a decreased length of emergency department (ED) [17, 18] and hospital stay [18]. The cardiac and pulmonary functions are improved postoperatively [18], and the neuroendocrine stress responses are decreased [17, 18]. Decreased pain and stress contribute to a potential reduction in risk of chronic pain syndromes and post-trauma sympathetic dystrophy (PTSD) [17].

Superficial wounds and lesions to the extremities tend to be survivable [10], in contrast to penetrating wounds of the head or thorax (Fig. 17.7). This increases the potential for RA in austere environment, as lesions to the extremities comprise the majority of surgical cases in areas struck by natural disasters [11–13, 19]. Advances in helmet and body armour have the same effect in modern warfare [10]. Neuraxial blocks significantly reduce postoperative mortality and complications such as deep vein thrombosis and pulmonary embolism compared to GA [16], while peripheral blocks avoid side effects of neuraxial blocks [16] such as hypotension. RA provides sympathectomy in the targeted limb, with advantages in graft surgery [16].

More skills and training are required to achieve these techniques [2, 14, 15, 17, 20, 21], achieving success rates between 75 and 90 % [14]. Each block needs to be mastered separately, as does the awareness and treatment of potential complications and side effects [20]. Equipment like neurostimulators, suitable needles and ultrasound [2] improve the success rate and efficacy and may decrease rates of complications like nerve injury and vascular or pleural punction [15, 18].

RA is more invasive than systemic analgesia [18]. The risk of infection increases as the duration of continuous techniques via a catheter is extended [15, 17, 18] or if the block is performed in less ideal or unsterile circumstances [18, 21]. The induction time [14, 15] is longer and more painful, sometimes requiring additional sedation [14]. A degree of patient cooperation is however required [18]. RA is unsuitable for major thoracic trauma [15] or multiple limb injuries. Local anaesthetic systemic toxicity (LAST) is a life-threatening complication. It requires monitoring and resuscitation facilities [20]. The antidote has a short shelf life and can be conserved at a maximum of 25 °C [14].

RA can interfere with the neurologic or vascular assessment of an injured limb [17]. Surgeon concerns of masking a compartment syndrome [14] seem largely unfounded [17, 20], as breakthrough pain in a previously well-working block is described in almost all cases. Close communication with the operating surgeon is important. Contraindications include an infection at the entry point [16, 18] or systemic infections [18], coagulopathy [18], patient refusal [16] and allergies [16].

GA is much easier to learn and perform and easier to remember [14]. The same protocols can be used for injuries on any or multiple parts of the body. It has almost 100 % success rate [14], and induction is faster and less painful [14]. GA and RA can be used in comination [10] (Table 17.3).

The cost and logistics of transportation make procedures using perishable supplies or heavy and large equipment prohibitive or impossible [15]. GA requires frequent compressed gas

Table 17.3 Regional anaesthesia vs. general anaesthesia

RA	GA
Limited need of sedation: No airway manipulation Less monitoring needed Neurological evaluation possible	Easier to learn: One technique can serve for all In addition to RA
Cost-effective	Near 100 % success rate
Optimised perioperative pain relief, with reduction of chronic pain syndromes	
Faster recovery	
Suited to majority of pathology in austere disaster settings	
Reduced postoperative morbidity and mortality	
Time-consuming skills and training required	More logistics required
More invasive: infections, nerve injuries, pleural punctures, haematoma	Need for airway manipulation, respiratory support
LAST	

resupply, ventilators and dependable sources of electricity [10]. To avoid the complexities and disadvantages of inhaled anaesthesia (e.g. waste gas), total intravenous anaesthesia (TIVA) could be used, but this requires IV pumps and an adequate supply of consumables [15].

17.2 Monitoring and Other Essential Equipment

It is important that whatever technique is chosen, the anaesthesia provider has materials at hand to provide resuscitation in case of adverse effects. An absolute minimum would include a self-inflating bag and a device allowing suctioning of the airways.

17.2.1 Respiratory Support

Different devices are available, some more complex than others. A self-inflating bag as backup is indispensable, regardless of the kind of anaesthesia practised.

17.2.2 Suctioning Apparatus

There are hand- or foot-operated devices but also electrical devices. It is important to check the function of these devices routinely [8] and before every intervention, especially check for circuit leaks and battery charge.

17.2.3 Monitoring

The options here vary depending on the situation. Ideally, monitoring should be similar to that used in the developed world.

17.2.3.1 Clinical Observation

The most basic monitoring is done by clinical observation: skin colour for oxygenation and anaemia; feeling the pulse for circulation (Table 17.4); and chest and abdominal movements (in the presence of open airways), air movement and breath sounds for respiration [9]. Of course these techniques are not very accurate and often only detect major problems.

17.2.3.2 Praecordial Stethoscope [8]

This technique is often used in paediatrics, but can also be used for adults. By using some tape to attach a stethoscope to the praecordial area of the heart of the patient's chest, heart rate and rhythm and respiration can be monitored throughout the surgical intervention.

17.2.3.3 Pulse Oximeter [8, 12]

A pulse oximeter should be used whenever available [9, 22], and it is the minimum monitoring for safe anaesthesia. It is small and portable, and relatively cheap and robust models exist. The simplest versions are battery operated. Not only does it give an indication (often audible) of the oxygenation, heart rate and rhythm, but it also helps establishing the adequacy of the peripheral circulation.

17.2.3.4 Sphygmomanometer [8, 12]

This is a accurate method of measuring the blood pressure in a non-invasive way. One can estimate the systolic blood pressure by feeling the pulse

Table 17.4 Estimation of blood pressure according to palpable pulses

Pulse palpation	Estimated blood pressure
Radial artery	>70 mmHg
Femoral artery	>50 mmHg
Carotid artery	>40 mmHg

while deflating the cuff, but it is more accurate and informative to use a stethoscope or an automated version (Table 17.4).

17.2.3.5 Temperature [8]

Hypothermia is most common in patients during surgery, but particularly in small children and hot environments, hyperthermia can occur.

17.2.3.6 Continuous ECG [8]

ECG helps detecting arrhythmias, myocardial ischaemia, conduction abnormalities and electrolyte disturbances [23]. Interpreting an ECG requires training, and the monitor screen often shows artefacts and distortions [12].

17.2.3.7 End-Tidal CO2 or Capnography [8]

Training in the interpretation of capnography is quite simple, although it is rarely utilised in an austere environment. Handheld combined SpO2 and EtCO2 monitors are available. Disposable devices showing the presence of CO2 in exhaled gases based on colour changes on the indicator paper exist can be used to check the correct placement of an endotracheal tube [8].

Capnography is best known as technique to confirm adequate ventilation, but a rapid fall of EtCO2 however is also a sensitive indicator of air embolism [23] and other states of low cardiac output. In patients in shock, blood pressure and pulse oximetry measurement can be difficult or impossible due to inadequate circulation. EtCO2 monitoring remains possible and provides rough but useful information on the circulation in environments where (invasive) monitoring options are limited.

17.2.3.8 Invasive Monitoring [8]

Availability of invasive monitoring, like arterial and central venous pressures, is extremely rare, and the risks of these techniques (air embolus, erroneous injection, bleeding, etc.) are often higher than the benefits in austere environments and in the hands of untrained personnel.

17.2.4 Registration

It is advisable to register the patient's vital parameters, the drug doses and timing and any events (surgical and other) during the anaesthesia and the surgical procedure. Usually this is done in a schematic way on an anaesthesia record. It helps for future anaesthesias in the same patient and helps identifying problems and ways to avoid them in future cases.

17.3 General Anaesthesia

General anaesthesia alters the consciousness and pain perception of a patient over the whole body by administration of an agent with systemic effects. The term covers a continuum spanning from a cooperative patient with protective reflexes to a completely unconscious and paralysed patient with full reliance on the anaesthesia provider for support of his or her vital functions [24]. Obviously the former is preferred in circumstances where human and other resources are scarce, but this does limit the type of surgery that can be performed (Table 17.5).

17.3.1 Drugs

17.3.1.1 Ketamine

Ketamine is an extremely versatile drug. Ketamine causes a dissociative state, with rapid and profound analgesia, amnesia and sedation [3, 14] while the patient breathes spontaneously and protective airway reflexes are usually maintained [5, 22]. Blood pressure and heart rate are

Table 17.5 Minimum set-up required for anaesthesia

Respiratory support
Suctioning apparatus
Monitoring
Registration

maintained or stimulated by a centrally mediated catecholamine reuptake inhibition [22]; therefore, caution needs to be used in patients with coronary artery disease or pre-existing hypertension. The analgesia outlasts the sedative effect [22], reducing the amount of postoperative pain experienced.

Ketamine has a large therapeutic window [22] with a wide safety margin [14], an easy and long storage [14] and a low cost [22], which makes it an anaesthetic of choice in resource-poor or austere environments, where monitoring equipment and temperature-controlled storage may be rudimentary or absent [11–14, 19, 22]. The drug attracts a lot of attention in the search for the safest, easiest and most efficient anaesthesia technique by non-anaesthesiologists [14]. Ketamine is even suggested to have neuroprotective properties in head injury and organophosphorous nerve agent exposure [3].

Ketamine can be administered IM (4–10 mg/kg; analgesic dose: 1 mg/kg), PO or IR (6–10 mg/kg), nasally (6 mg/kg), in IV bolus or continuous IV drip [3, 14]. Airway and breathing are rarely significantly compromised when ketamine is used as monotherapy, although there is a potential for respiratory depression and airway obstruction requiring chin lift or jaw thrust [22], especially in the first 2–3 min of rapid IV induction. Titration is necessary [5], and certain co-medications can increase the need for airway and respiratory support. Competence and facilities of airway management should be available when administering this drug [20].

Whereas ketamine provides much more haemodynamic and respiratory stability than any other anaesthetic or sedative, it can also be the final straw, decompensating a severely ill patient [14].

Contraindications are relative, but need to be considered on a case-by-case basis. These include psychiatric disease, mitral or aortic stenosis, untreated hyperthyroidism, eclampsia, epilepsy, ischaemic heart disease and pulmonary hypertension [14].

Like any drug, ketamine has adverse effects, most of which are dose dependant. One needs to be prepared to detect and treat complications. Side effects include hypersalivation, which can be prevented by administering atropine, and transient laryngospasm in children, responsive to BVM ventilation [22]. Vomiting can occur, generally after emergence (5–15 %) [22]. Patchy erythematous rash sometimes manifests itself shortly after injection, but usually disappears spontaneously, with no recurrence with further ketamine administrations [22]. Purposeless movements or hypertonus can interfere with planned procedures [22]. Overtime tolerance (in the NHS) for ketamine develops, requiring increased doses [22].

Psychiatric adverse events may include dreams, hallucinations and delirium, although the clinical significance is unclear [22]. 10–20 % can experience frightening depersonalisation during emergence. These emergence reactions can be effectively prevented and terminated by sedating agents. Other preventive strategies include preinduction counselling and environmental techniques such as provision of music [22] or a quiet room [3, 22]. S(+)-ketamine has been researched and offers higher potency and a shorter duration of action with a reduction of adverse effects, especially of the emergence reactions [3, 22].

17.3.1.2 Propofol

Propofol carries a higher risk of cardiovascular collapse and respiratory depression [14]. It requires more skills and equipment [3] to safely conduct an anaesthesia. Propofol is a lipid-based solution and as such supports rapid microbial growth at room temperature. Unintentional contamination of propofol has been associated with unusual outbreaks of bloodstream and surgical site infections [25].

17.3.1.3 Thiopentone

Thiopentone is not considered a safe drug for non-anaesthetists. It has a high risk of apnoea and even of cardiac arrest [3] or collapse [14] and arrhythmias when used by people without anaesthesia experience.

17.3.1.4 Etomidate

Etomidate causes less cardiovascular depression [26] than thiopentone and propofol, but is known to provoke adrenal insufficiency [14].

17.3.1.5 Opioids

These strong analgesics are often used during general anaesthesia. Apart from ketamine, no other sedative provides a clinically significant degree of analgesia. More on these drugs can be found under pain management.

17.3.1.6 Muscle Relaxants

In an austere environment, the use of muscle relaxants contains serious risks, especially if handled by personnel without a training in anaesthesia. Ventilation needs to be controlled non-stop until full recovery. In the absence of a machine, a second person will be required to handle drugs and regularly check vital signs. Intubation should be avoided by inexperienced people, and one needs to be prepared for an unexpected difficult airway. A muscle relaxant does not act on the consciousness or pain perception: never administer it to an awake patient [4, 9]. Different types of muscle relaxants exist, with varying speed and duration of action.

17.3.1.7 Inhalational Agents

These agents are used under the form of vapour. They require special equipment to administer, and they can contaminate a closed environment, like an OR [14]. There are many different types of vapour that can be used, all of which have some degree of negative impact on CV stability [14]. Specific side effects and possible complications for each agent should be checked before use. For example, ether vapours are highly flammable. Halothane can cause liver dysfunction [26], especially in shock and with repeated use, and cardiac arrhythmias, exacerbated by infiltration of adrenaline.

Different vaporisers exist, depending on the agent and the breathing system used [3, 4, 8, 27]. Some supplemental oxygen is usually required to avoid desaturation, especially in the patient without respiratory assistance. A scavenging system can be used to evacuate exhaled gases to the exterior, minimising work environment contamination [8]. Altitude (barometric pressure), temperature and the patient's minute volume [3, 8] might influence vapour concentration, and the vaporiser must always be in an upright position during use and filling, avoiding agent overflow.

Even agent-specific vaporisers might have been used with different products. If you are not 100 % sure of the age and nature of the residue in a vaporiser, empty it, rinse it with the required agent and empty it again before use [8]. Do not mix different agents [8]. Using a vaporiser calibrated for a different agent can be dangerous [8]. Ideally, end-tidal anaesthetic concentrations are measured and the vaporiser calibrations checked [8].

17.3.2 Breathing Systems

In its simplest form, a breathing system links the patient to the vaporiser or anaesthesia machine. Breathing systems exist in varying degrees of complexity [4, 23, 27]. A basic and safe system avoids rebreathing and allows assistance or control of breathing [4]. Adaptations, or a separate system, are necessary for paediatric patients.

The anaesthesia provider [4] is responsible for proper inspection, maintenance, repairs and routine (at least daily) testing to avoid dangerous situations. Correct placement and orientation of the valves are essential for the proper functioning of the breathing circuit. When in doubt of the orientation, try breathing through the system before administering anaesthesia to the patient [4]. Always have a self-inflating bag at hand in case of emergencies and breakdowns in the anaesthesia circuit, to administer emergency ventilation [8].

17.3.3 Anaesthesia Machines

Most anaesthesia machines are too fragile and difficult to maintain in an austere environment. They also tend to be dependant on a source of compressed gasses and a reliable source of electricity, two commodities that are scarce in austere environments. A ventilator specifically designed for austere environments does exist [28] and could be considered if sufficiently experienced staff and budget is available (Fig. 17.2).

17.3.4 Oxygen Supply

In austere environment, two main sources of oxygen exist: cylinders or concentrators. Wall outlets might be in place in existing health structures [8], but safety, contamination, wrong connections and reserve need to be checked before use [4].

Cylinders are useful as backup oxygen supply, even if it is not always feasible to use them as main source [8]. They come in all sorts of shapes, sizes and colours, and pressure gauges and regulators may be absent, malfunctioning or incompatible [4, 11, 12]. Always be aware of the fact that the gas in the cylinder might not actually be oxygen [4, 9].

Oxygen concentrators run on electricity and provide a reliable source of at least 90 % pure oxygen [4, 8] (Fig. 17.8). Standard machines have a rate of 5 l/min, but higher capacity concentrators do exist. The running costs are low (electricity and spare parts). Servicing is not complicated and can be done locally with simple training [4].

Fig. 17.8 An oxygen concentrator

17.4 Local-Regional Anaesthesia

The most basic and oldest techniques of LRA involve the identification of injection sites based on landmarks and paraesthesia. Nerve stimulators [21] aid in the identification of the nerve to be blocked. They are small and portable appliances, battery operated, lightweight and durable [15], but they require special insulated needles. Ultrasound [17] techniques allow real-time visualisation of the injection site and the LA spread.

17.4.1 Practical Aspects of RA in Trauma Patients

17.4.1.1 Local Anaesthetic Agents

There are many LA agents in use, with differences in the duration of action, dosage and therapeutic-toxic window. LA properties (like lipid solubility, pKa and protein binding [15]), the concentration and volume of the agent used, the size of the structures being anaesthetised and

Table 17.6 Maximum safe dose of anaesthetic [29]

Local anaesthetic	Maximum dose	Duration of action (h)
Bupivacaine	2 mg/kg (max 150 mg)	2–4
Levobupivacaine	150 mg	
Lidocaine	3 mg/kg	1
Lidocaine/ vasoconstrictor	5 mg/kg	1,5
Prilocaine	6 mg/kg	1,5
Mepivacaine	4,5 mg/kg (7 mg/kg with adren)	1–2
Ropivacaine	3 mg/kg (300 mg)	1,5–8

From Donald and Derbyshire [29], with permission

Table 17.7 Risk factors for neural injury

Neural ischaemia
Traumatic injury during needle or catheter placement
Anaesthetic techniques
Infections
Local anaesthetic solution
Additional causes of postoperative neurologic injury
Improper patient positioning
Tightly applied casts or surgical dressings
Surgical trauma
Tourniquet (>400 mmHg)
Patient body habitus or pre-existing (neurological) condition or coincidental worsening of a progressive neurological disease
Prolonged labour

From Horlocker [32], with permission

the relation of the needle or catheter placement to the nerve and its sheath influence the onset and duration of blocks [15, 29] (Table 17.6)

17.4.1.2 Adjuvants

Analgesic adjuvants are used to prolong the duration of a nerve block, to potentiate the analgesic effect, to reduce the dose of LA agent needed or to reduce toxicity by reducing systemic absorption. Of course each adjuvant has its own risks, side effects and contraindications. Examples include epinephrine, opioids [8, 16], clonidine [8, 16] and buprenorphine [16].

Careful selection of the type of opioid used in neuraxial anaesthesia needs to take place, as differences in lipid solubility change the times of onset and duration [30]. Neuraxial opioids should not be used unless postoperative monitoring of the cardiorespiratory function by staff that is able to intervene is available [8], e.g. intrathecal morphine can cause respiratory depression more than 12 h after administration.

17.4.1.3 Complications

There are some postulations about possible myotoxicity and inhibition of wound healing by LA agents; however, evidence thereof is conflicting [16, 31]. Complications of a specific loco-regional technique are mostly related to nearby anatomic structures (e.g. vascular or pleural punctions).

17.4.1.4 Perioperative Nerve Injuries

Perioperative nerve injuries are a recognised complication of RA and are thought to be the result of direct trauma, neural ischaemia, local anaesthetic toxicity or a combination thereof. Fortunately the occurrence of severe or disabling neurological complications is rare, but mild paraesthesia appears common the day after surgery in peripheral nerve blocks (PNB), with near complete resolution at 4 weeks. Identification of risk factors, prevention of complications and early diagnosis and treatment are important [32] (Table 17.7).

Neurotoxicity at the site of injection is possible. Permanent neurological deficits might result from prolonged exposure, high dose and/or high concentrations of LA, possibly aggravated by a restricted space [32]. Limited animal data suggest avoiding more potent LA and vasoconstrictive additives and reducing dose, volume and concentration of LA [32, 33].

Neural ischaemia may be caused by the blood supply being disrupted by intraneural injection, endoneural haematomas or vasopressors, especially in the presence of microvascular disease [32]. Warning signs include pain or paraesthesia on needle placement or injection and high injection pressures [32], and further deposition of LA and additive [32] on the same spot should be stopped immediately. In heavily sedated patients, this warning may be suppressed [32, 33].

Catheter insertion prolongs anaesthesia and analgesia, but increases the risk of nerve damage or catheter site infections [15] and should be avoided when lacking continuous surveillance by skilled personnel and pumps regulating infiltration speed [10]. A careful risk-to-benefit assessment needs to be considered on a case-by-case basis in patients with pre-existing neurological disorders or preoperative neurological deficits [33].

17.4.1.5 Local Anaesthetic Systemic Toxicity (LAST)

LAST is the direct effect of LA on more distant organs after systemic spread of the agent. It usually, but not necessarily, entails a progression of symptoms. These include CNS excitement (e.g. agitation, metallic taste, auditory changes (ringing), blurred vision), CNS depression (drowsiness, coma, respiratory arrest) [21, 33], cardiac toxicity with hypertension and arrhythmias or cardiac depression (bradycardia, decreased contractility, asystole).

LAST can be due to intravascular injection or delayed tissue absorption in an appropriately applied and dosed block, requiring every patient to be monitored for at least 30 min after receiving more than a minimal dose of LA [33]. Patient-related factors (age, pre-existing cardiac, hepatic or kidney disease) [33], concurrent medications [33], location and technique of the block [33], specific LA compound [33] and total dose [18, 33], and early and adequate detection and treatment [33] influence the degree of toxicity.

To reduce the incidence of LAST, suggestions include the use of the lowest effective dose of LA [18, 33], aspiration of the needle or catheter before each injection[33], the use of an intravascular marker (epinephrine, fentanyl) [33] and possibly incremental injection of LA (allowing for early symptom detection) and ultrasound guidance [33].

Hypoxia and acidoses are known to potentiate LAST, so rapid airway management and seizure control are vital. Standard ACLS should be performed, but the dose of epinephrine is reduced (10–100 mcg boluses in adults) and vasopressin, calcium channel and beta-blockers are avoided. Lipid emulsion therapy is a rare commodity in an austere environment, due to a limited shelf life at maximum 25 °C [14]. Patients need to be observed for at least 12 h after a significant LAST [33].

A PDF with a treatment checklist can be downloaded at www.asra.com/checklist-for-local-anaesthetic-toxicity-treatment-1-18-12.pdf.

17.4.1.6 Infectious Complications

In central blocks, infections manifest themselves as meningitis (in healthy patients) or abscess formation with cord compression (usually in immunocompromised patients), commonly presenting with fever and severe backache 2 days to 5 weeks after administration of anaesthesia. Uncomplicated cases are treated with antibiotics, but surgical decompression is required when neurological deficits develop, often with only moderate recovery [33]. Possible risk factors include underlying sepsis, a depressed immune status, an indwelling catheter or a localised bacterial colonisation or infection causing needle or catheter contamination.

To administer LRA aseptically, hand hygiene, sterile gloves and a surgical mask are a minimum requirement [33]. The skin should be disinfected with povidone or chlorhexidine, preferably in an alcohol-based solution [33].

17.4.2 Neuraxial Blocks

Surgery to the lower extremities, perineal area and lower abdomen (e.g. Caesarean section, appendicectomy) are the most common indications for these techniques. There are two main types of neuraxial block. The first is the subarachnoid or spinal block, a single-shot technique whereby local anaesthetic is deposited directly in the cerebrospinal fluid under the L2 vertebrae. The second technique is the epidural block, often leaving the catheter next to the dura. A caudal block is a form of single-shot epidural anaesthesia in children for interventions to the lower abdomen and legs, reducing the amount of systemic sedation and analgesia needed per- and postoperatively.

Problems in both techniques include difficulty in positioning of (trauma) patients and abnormal vertebral anatomy (e.g. scoliosis). The main contraindications to neuraxial blocks include coagulopathy, severe hypovolaemia or haemodynamic instability, elevated intracranial pressure and pre-existing neuropathy or vertebral trauma. In patients with severe aortic stenosis, the sudden sympathectomy and peripheral vasodilatation caused by the LA can lead to a severe decrease in cardiac output and sudden death.

Anticipation of hypotension includes proper patient hydration prior to the anaesthesia and having a vasoconstrictor like ephedrine or phenylephrine at hand. The first 30 min after subarachnoid block the blood pressure needs to be taken every 2–5 min. Nausea is often a symptom of hypotension.

17.4.2.1 Complications

Spinal anaesthesia seems to be associated with more cases of meningitis and a higher incidence of cardiac arrest, whereas epidural blocks have a higher risk of cauda equina, spinal haematoma and epidural abscess [32].

The risk of nerve damage increases in patients with spinal stenosis, mass lesions within the spinal canal or prior spinal surgery, even after uneventful neuraxial technique [33] by an experienced anaesthesiologist [32]. Modify the technique (position, baricity of LA) to avoid reinforcing the same restricted distribution in a failed spinal, preferably not exceeding the maximum dose reasonable for a single injection, and only if careful sensory examination reveals no evidence of block (including sacral dermatomes!) after sufficient time [32].

Paraesthesia during needle insertion or pain with injection is identified as a risk factor for a persistent radiculopathy with the same topography, leading some experts to suggest abandoning the procedure in this case, as any damage caused might be aggravated by the added pressure and toxicity of injecting a local anaesthetic in the surrounding area [32].

Transient neurologic symptom is a term used for cases of severe radicular back pain after the resolution of spinal anaesthesia, without sensory or motor deficits and with spontaneous resolution within several days. The exact cause and clinical significance is unknown, but LA toxicity is suspected [32].

Haematoma formation is associated with intrinsic or iatrogenic coagulopathy, difficulty during needle placement and indwelling neuraxial catheters during sustained anticoagulation. Pain is rarely present, and postoperative numbness or weakness is typically attributed to the LA effect rather than spinal cord ischaemia, so diagnosis is often delayed. Permanent deficit occurs in the majority of cases if decompressive laminectomy is not performed within 8 h of the onset of neurologic dysfunction [32]. Close neurologic monitoring postoperatively is therefore important.

17.4.3 Peripheral Blocks

In patients with coagulopathy (intrinsic or iatrogenic), plexus and peripheral blockade may lead to significant bleeding and major patient morbidity with prolonged and complicated hospitalisation [32]. However, the expandable nature of the site reduces the risk of irreversible neural ischaemia by compression [32]. When performing blocks, small doses of ketamine can be used to prevent pain [16].

The easiest forms of peripheral blocks will be briefly discussed here. As many handbooks are dedicated solely to loco-regional anaesthesia, it is impossible to give a full list of every technique, describing how to perform them and the advantages, disadvantages and dangers. A useful website is managed by the New York School of Regional Anaesthesia (http://www.nysora.com/) and includes step-by-step descriptions and images (Table 17.8).

Table 17.8 Examples of potentially useful LRA techniques in austere environment

Upper limb nerve blocks	Lower limb nerve blocks
Interscalene block	Sciatic nerve block
Supraclavicular and infraclavicular blocks	Femoral nerve block
Axillary block	Fascia iliaca nerve block
Ultrasound-guided blocks of the different forearm nerves	Obturator nerve block
	Popliteal sciatic nerve block
	Posterior tibial nerve block

17.4.3.1 Direct Infiltration in Fracture Haematoma

This block can be used for the reduction of fractures, especially to the wrist. It is quick to perform, with a reduced risk of an accidental IV bolus of LA agent [21]. The risk of infection is low if proper precautions are taken. The biggest advantage is that no extra equipment is needed [34].

17.4.3.2 Bier's Block (or IV Regional Anaesthesia)

This relatively simple block can be used for many kinds of procedures to the distal arm and hand [24, 34]. IV access needs to be assured in both arms (preferably as distal as possible in the injured arm). Blood is drained from the injured arm by elevation or a tightly wound elastic bandage. A pneumatic tourniquet is inflated to 100 mmHg above systolic pressure, followed by slow injection of an LA agent (prilocaine, mepivacaine, lidocaine), allowing manipulation after 5 min. It is most important that the tourniquet is not released until at least 30 min has passed after injection of the LA. The patient needs to be closely monitored for at least 5–10 min after the release of the tourniquet [34].

Double cuffs exist, whereby after about 15 min the distal cuff can be inflated and the proximal deflated to decrease the pain experienced at the site of the tourniquet. If a cuff switch is used, it is vital to palpate the inflation of the distal cuff as a check before releasing the proximal one. This extra manipulation and narrower individual cuffs do come with a higher risk of accidental systemic spread of the LA and LAST [24, 34]. A Bier's block is theoretically also possible for lower limb surgery, but as it requires higher doses of LA, it also carries a higher risk for LAST.

17.4.3.3 Digital Block

It is a relatively simple technique, familiar to most surgeons, providing analgesia and anaesthesia for procedures to the fingers, including debridement, suturing and amputation [17, 21] (Fig. 17.9a, b). Do not inject a digit with a mixture of adrenaline and LA as there is a risk of ischaemia.

17.4.3.4 Wrist Block

It is a simple block which provides anaesthesia of the wrist.

1. The ulnar nerve lies deep to the flexor carpi ulnaris (FCU). The point of the needle should get past the tendon just proximal to its insertion to the carpal bones (Fig. 17.10a).
2. Palpate the ulnar head (UH). The sensory branch of the ulnar nerve (SUN) passes inferior to this landmark and should be blocked

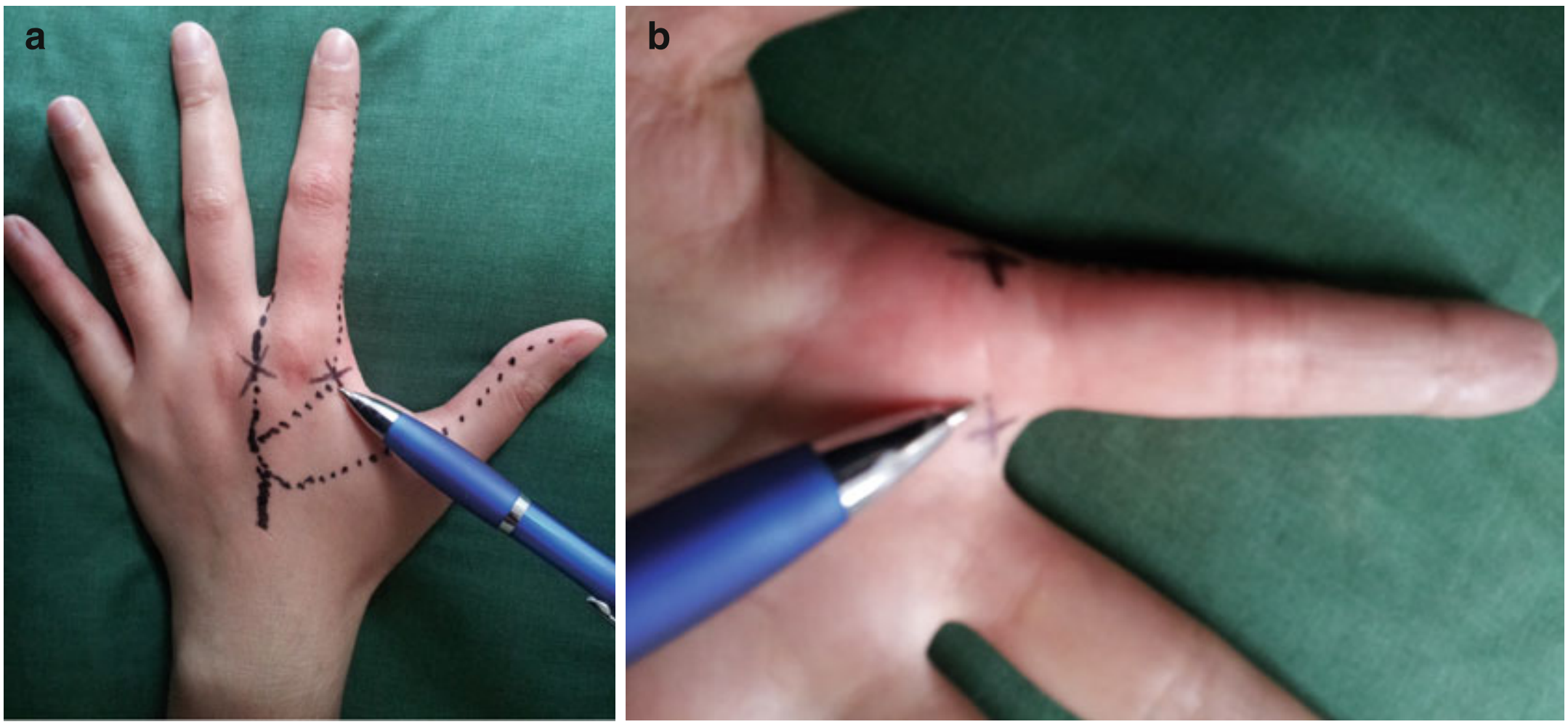

Fig. 17.9 (**a**, **b**) Digital block

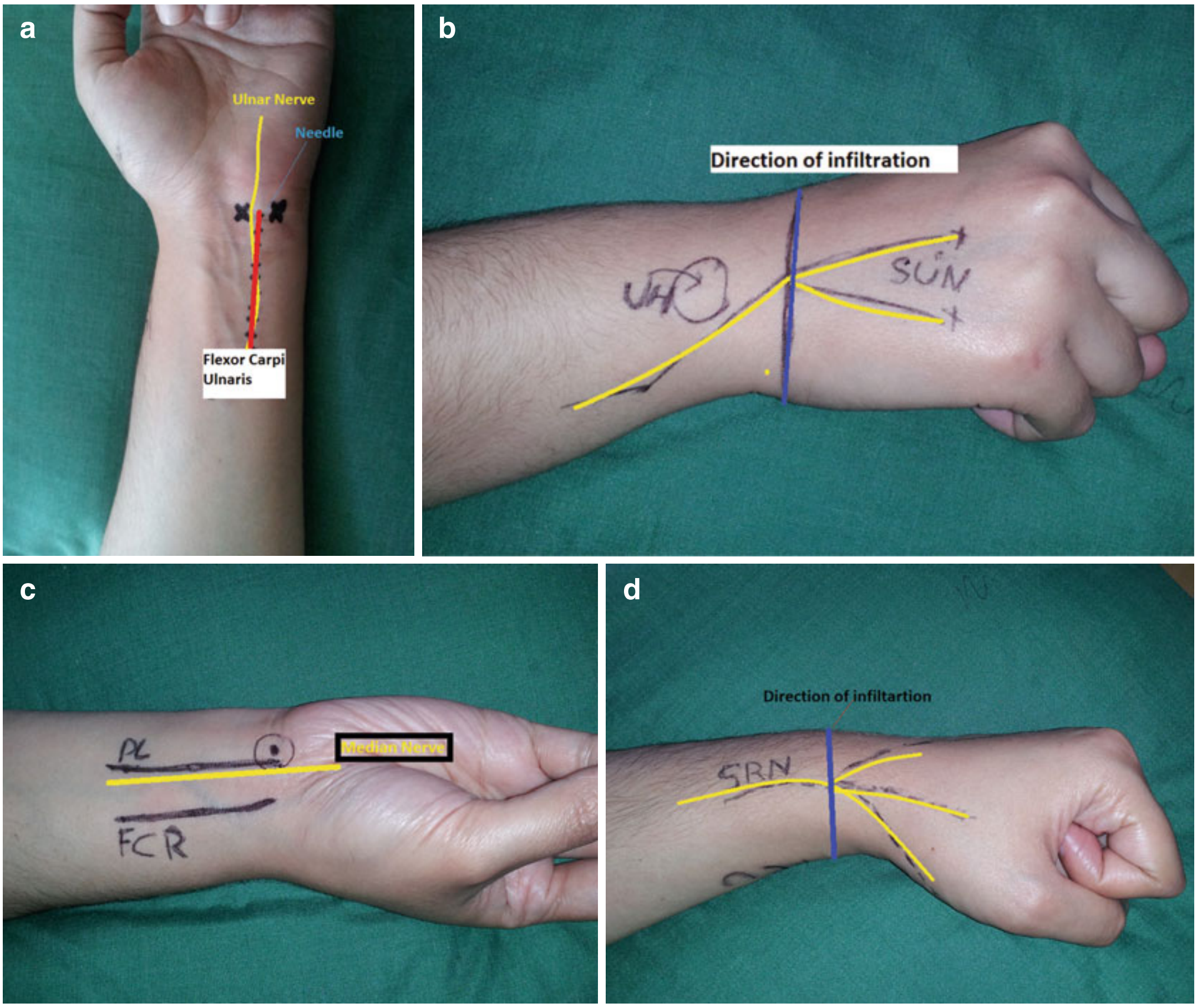

Fig. 17.10 (**a**) Surface markings for the FCU. (**b**) Surface markings for the superficial ulnar nerve. (**c**) Surface markings for palmaris longus and médian nerve block. (**d**) Superficial radial nerve surface markings

subcutaneously in a triangular or 'fan' field fashion on the dorsal-ulnar aspect of the wrist just distal to the UH (Fig. 17.10b).

3. If you ask a patient to put together the tips of the thumb and little fingers of the same hand, very often you can visualise the palmaris longus. Radially you will palpate the flexor carpi radialis and more radially the pulse of the radial artery. The median nerve lies in between the PL and FCR (Fig. 17.10c).
4. Over the dorso-radial aspect of the wrist, you can palpate the radial styloid. The sensory branch of the radial nerve (SRN) arises just dorsal to the tip of the styloid and travels under the skin. The best way to block this is by infiltrating the region in a transverse orientation (Fig. 17.10d).

17.4.3.5 Ankle Block

The ankle is also relatively easy to block. Infiltrate subcutaneously in a ringlike fashion.

(A) The saphenous nerve lies anterior to the medial malleolus, and the superficial peroneal nerve lies lateral to the extensor digitorum communis tendon (EDC). The deep peroneal nerve is blocked in the groove formed in between the extensor hallucis longus (EHL) and EDC tendons. Palpate the tip of the medial malleolus. Then move your finger 1 cm proximal and posterior to the tip of the malleolus. The posterior tibial nerve (PTN) is found in this région (Fig. 17.11a).

(B) Locate the midpoint between the lateral border of the Achilles tendon and the tip

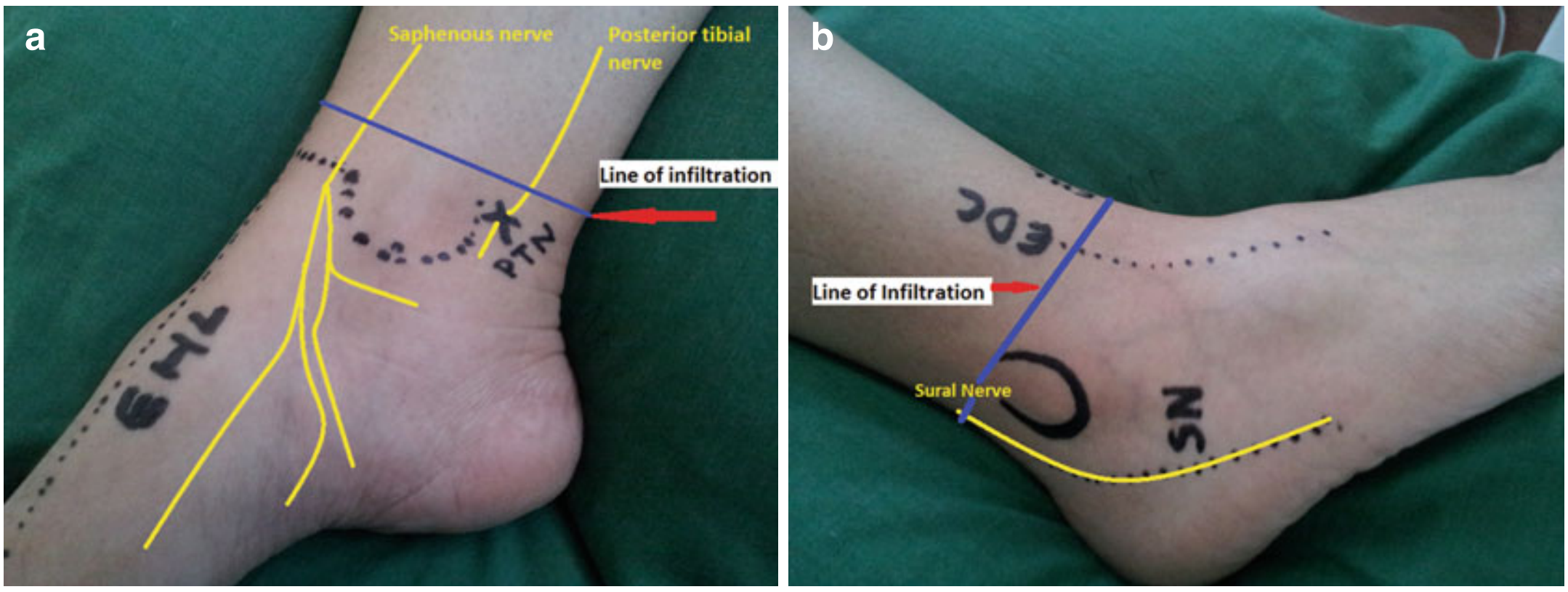

Fig. 17.11 (**a**) Posterior tibial nerve block. (**b**) Surface markings for the sural nerve

of the lateral malleolus and infiltrate this area. This will block the sural nerve (Fig. 17.11b).

17.4.4 Local Anaesthesia

Of course the simplest technique is just the infiltration of wound edges or skin site where superficial surgery is to be carried out. The main risk of this type of intervention is the risk of LAST, especially when suturing multiple and/or extensive lesions the maximum dose of an LA is easily exceeded or in the case of inadvertent intravascular injection.

17.4.5 Topical Anaesthesia

Local application of preparations like lidocaine-prilocaine cream or tetracaine gel can provide analgesia for superficial procedures to small areas. The gel or cream should not be applied to broken skin or mucous membranes like mouth, lips, anal or genital areas. An ethyl chloride spray does not contain an anaesthetic, but the cold induces numbness for a very short duration of time, allowing, for example, the incision of a (superficial) abscess.

17.5 Pain

Trauma patients generally present with significant levels of pain and stress. Advanced Trauma Life Support protocols however only mention pain as an important physical sign, but are silent on the assessment and treatment of pain. As a result, pain management has a low priority [20], even in the developed world [18]. There is a disproportionate fear of the impact on haemodynamic and respiratory function [18, 20], aspiration of gastric contents [20], an interference with the assessment of mental status [18], addiction [20], delirium [17], an inappropriate pain estimation [17, 20] and concern about potentially obliterating clinical signs[17, 20].

It has been demonstrated that improved pain management not only increases comfort and reduces suffering but that it also reduces the rate of intubation and morbidity in trauma patients and improves both short- and long-term outcomes [16, 20]. Not treating pain increases the stress response, resulting in hypertension and tachycardia and in some patients myocardial ischaemia. Pain management also improves patient cooperation [20]. Early, effective analgesia can provide better conditions and reduces the stress response during transport and the initial examination of trauma patients. Optimal pain control can theoretically reduce the chance of developing chronic pain and post-traumatic stress disorders [17, 18, 20].

The assessment of pain should occur as soon as possible in the initial management after primary survey [17, 20]. This can prove difficult, as the background of a patient influences the level of coping and expression of pain. Many pain assessment instruments are available, but few are validated in, for example, children from the developing world [2].

Suitable pain management protocols lead to earlier and more frequent administration of analgesia and a higher patient satisfaction [20]. Pain management protocols need to be adapted to the logistic realities of each situation and service, taking into account training, experience, monitoring and resuscitation facilities [20] but also patient factors like malnutrition and cultural issues [2].

Preoperative RA needs to be considered, especially nerve blocks for upper limb amputations and for patients who are poor candidates for neuraxial anaesthesia with injury limited to one limb [16, 18]. RA should especially be considered as part of a multimodal approach to pain, e.g. in patients presenting with isolated orthopaedic injuries and burn patients. Neuraxial blocks significantly reduce postoperative mortality and morbidity like DVT and PE [16].

In mass casualty situations and in many postoperative wards, the high patient-to-nurse ratio is a barrier to adequate pain relief [8]. In children in postoperative situations, it is a good idea to include the parents in the analgesia plan [8].

The lack of IV access is another main obstacle. Alternative routes of administration (e.g. rectal, local infiltration of the surgical wound) may need to be considered [8]. Due to peripheral vasoconstriction, the absorption of subcutaneous and intramuscular drugs is less effective and delayed in severely hypovolaemic patients. Effective resuscitation improves absorption, with a risk of overdose and respiratory depression [9]. Trauma is associated with gastroparesis, so the intestinal absorption of drugs may be suboptimal.

One of the major concerns with regional anaesthesia is missing a compartment syndrome. Several case reports suggest that breakthrough pain occurs in patients with compartment syndrome after a period of good initial analgesia and that the pain even persists after placement of a block [17, 18, 20]. This requires vigilance, including analgesic consumption, of all medical personnel involved as well as close communication with surgeons.

17.5.1 Paracetamol

It is the most basic of pain killers. Paracetamol is rarely sufficient in acute trauma situations, but can be very useful in pain treatment postoperatively, especially combined with other pain killers like NSAIDs (due to synergistic effects) or tramadol. It exists in oral and IV form, and intrarectal preparations are available in paediatric doses.

17.5.2 Nonsteroidal Anti-inflammatory Drugs (NSAIDs)

NSAIDs are associated with an increased risk of bleeding [17, 21] due to interference with the platelet function and clot formation, and with gastrointestinal distress. To diminish these effects, cyclooxygenase 2 (COX2)-selective drugs are suggested. These do not however diminish the risk of renal failure, which is especially high in trauma patients due to dehydration (blood loss and pre-existing trauma) [21], and provide an extra renal injury on top of kidneys possibly compromised by rhabdomyolysis or pre-existing disease (e.g. diabetes, age, etc.). The clinical impact of NSAIDs on bone healing is still unclear, and it might be prudent to restrict a treatment course to 1 week and patients at low risk for non-unions [35].

17.5.3 Opioids

Opioid analgesics might exacerbate haemodynamic instability. However there is a growing body of evidence for the judicial administration of opioids and other potent analgesics in this setting [20]. Correct analgesia administration might actually facilitate diagnosis [20]. The response to opiates is variable in trauma patients [21]. Antidotes such as naloxone must be available to treat overdoses.

Morphine. A classical pain therapy like titrated IV morphine of course still has its place. Titrating the drug helps find the balance between analgesia and side effects, including sedation [17].

Tramadol. Tramadol is shown to be as rapid and effective as analgesia with IV morphine, with a similar incidence of side effects [20]. Orodispersible tablets of tramadol and other opioids are available where an IV access is difficult to achieve.

Oral transmucosal fentanyl citrate. An interesting form with quite some potential in austere environment is 'oral transmucosal fentanyl citrate' (OTFC) [20], a lemon-tasting lollipop containing fentanyl. It has an immediate effect due to absorption by the oral mucosa and a delayed effect after the swallowing of saliva and absorption by the gastrointestinal mucosa. To avoid continued absorption after loss of consciousness, the simple technique of taping the lollipop to the finger of the patient has been described [21].

Nasal butorphanol. The administration of opiates through the nasal route is under investigation in trauma patients [8, 21].

Ketamine. The safety of titrated ketamine (0,2-0,5 mg/kg IV) [21] has been discussed earlier on [20].

17.5.4 Other Analgesic Techniques

17.5.4.1 Inhaled Nitrous Oxide [20]

This technique has been used in both prehospital and ED situations. It should not be used in patients with air-filled cavities where expansion of this air might cause problems, which includes patients with intracranial air (after skull fracture), pneumothorax (especially when untreated) and gastrointestinal distension or patients who have been exposed to hyperbaric conditions within a couple of hours before admission.

17.5.4.2 Regional Anaesthesia

Advantages, disadvantages and techniques for RA in pain management are the same as those discussed in the section on procedural anaesthesia.

17.5.4.3 Thoracic Nerve Blocks

These blocks play an important role in pain management of patients with rib fractures or major thoracic surgery, but are less used for surgical or procedural anaesthesia. They are especially superior to systemic analgesia when more than three or four ribs are fractured [18], as these patients have a higher risk of concomitant lung injury. Pain from fractures causes guarding and shallow breathing, leading to atelectasis, secondary pneumonia with lung consolidation and respiratory failure, possibly requiring ventilatory support. Adequate RA for (traumatic) chest pain improves the respiratory function [17, 18, 20], allows the patient to be in an upright or sitting position, permits chest physiotherapy [17] and improves coughing efficacy, decreasing the risk of atelectasis, hypoxaemia and associated morbidity and mortality. Possible techniques include thoracic epidural [17, 18, 20], thoracic paravertebral block [16–18, 20], intercostal nerve block [15–18, 20, 21] and intrapleural block [15, 18].

17.5.4.4 Non-pharmacological Techniques

Non-pharmacological techniques include splinting (minimising movement, pain and additional injury to tissues surrounding a fracture) [21], cryo-analgesia or ice compressions [21]. Elevating an injured limb to minimise swelling will also help pain control. *Do not apply tight bandages*.

Conclusion

A basic knowledge of anaesthesia is essential to the efficient and safe practice of trauma surgery. The orthopaedic trauma surgeon must work closely with the anaesthetic team to achieve the best possible results for their patients.

Acknowledgement I would like to dedicate this chapter to all those anaesthesia providers in austere environments, fighting for lives in circumstances unimaginable to many Western anaesthetists, in some cases also in unstable, volatile situations. I feel honoured to have been allowed to work with a few of these people. I was impressed with their motivation and hunger for knowledge and skills to perform an even better job and was glad to share what I knew in the limited time I spent with them and I am grateful for everything I learned from them.

References

1. Giannou G, Baldan M. War surgery. Geneva: ICRC; 2010.
2. Bösenberg AT. Pediatric anesthesia in developing countries. Curr Opin Anaesthesiol. 2007;20:204–10.
3. Mellor AJ. Anaesthesia in austere environments. J R Army Med Corps. 2005;151:272–6.
4. Dobson MB. Anaesthesia at the district hospital. 2nd ed. Geneva: WHO; 2000.
5. Hodges SC, Hodges AM. A protocol for safe anaesthesia for cleft lip and palate surgery in developing countries. Anaesthesia. 2000;55:436–41.
6. Chu K, Stokes C, et al. Improving effective surgical delivery in humanitarian disasters: lessons from Haiti. PLoS Med. 2011;8(4):e1001025. doi:10.1371/journal.pmed.1001025. Epub 2011 Apr 26.
7. Rosseel P, Trelles M, et al. Ten years of experience training non-physician anaesthesia providers in Haiti. World J Surg. 2010;34(3):453–8. doi:10.1007/s00268-009-0192-2.
8. Tobias JD, Kim Y, Davis J. Anesthetic care in developing countries: equipment and techniques. South Med J. 2002;95(2):230–47.
9. Vreede E. Field anaesthesia, basic practice. Medecins sans Frontières. Paris, France: An internal publication of MSF (MSF guide); 2001.
10. Buckenmaier CC, Lee EH, et al. Regional anesthesia in austere environments. Reg Anesth Pain Med. 2003;28(4):321–7.
11. Rice MJ, Gwertzman A, et al. Anesthetic practice in Haiti after the 2010 earthquake. Anesth Analg. 2010;111(6):1445–9.
12. Paix BR, Capps R, et al. Anaesthesia in a disaster zone: a report on the experience of an Australian medical team in Banda Aceh following the “Boxing Day Tsunami”. Anaesth Intensive Care. 2005;33:629–34.
13. Missair A, Gebhard R, et al. Surgery under extreme conditions in the aftermath of the 2010 Haiti Earthquake: the importance of regional anesthesia. Prehosp Disaster Med. 2010;25(6):487–93.
14. Komorowski M, Watkins SD, et al. Potential anesthesia protocols for space exploration missions. Aviat Space Environ Med. 2014;84(3):226–33.
15. Silverman GL, McCartney CJ, et al. Regional anesthesia for the management of limb injuries in space. Aviat Space Environ Med. 2008;79(6):620–5.
16. Gregoretti C, Decarli D, et al. Regional anesthesia in trauma patients. Anesthesiol Clin. 2007;25:99–116.
17. Choi JJ, Lin E, Gadsden J. Regional anesthesia for trauma outside the operation theatre. Curr Opin Anesthesiol. 2013;26(00):1–6.
18. De Buck F, Devroe S, et al. Regional anesthesia outside the operating room: indications and techniques. Curr Opin Anesthesiol. 2012;25(4):501–7.
19. Osteen K. Orthopedic anesthesia in Haiti. Ochsner J. 2011;11:12–3.
20. Davidson EM, Gionsar Y, Avidan A. Pain management and regional anaesthesia in the trauma patient. Curr Opin Anaesthesiol. 2005;18:169–74.
21. Wedmore IS, Johnson T, et al. Pain management in the wilderness and operational setting. Emerg Med Clin North Am. 2005;23:585–601.
22. Strayer RB, Nelson LS. Adverse events associated with ketamine for procedural sedation in adults. Am J Emerg Med. 2008;26:985–1028.
23. Morgan GE, Mikhail MS, Murray MJ. Clinical anesthesiology. 4th ed. New York: Lange Medical Boks/McGraw-Hill; 2006.
24. Barash PG, Cullen BF, Stoelting RK. Clinical anesthesia. 5th ed. Philadelphia, USA: Lipincott Williams & Wilkins; 2001.
25. Bennett SN, McNeill MM, et al. Postoperative infections traced to contamination of an intravenous anesthetic, propofol. N Engl J Med. 1995;333:147–54.
26. Paul AK. Drugs and equipment in anaesthetic practice. 6th ed. St. Louis: Elsevier; 2010.
27. Gegel BT. A field-expedient ohmeda universal portable anesthesia complete draw-over vaporizer setup. AANA J. 2008;76(3):185–7.
28. Beringer RM, Eltringham RJ. The Glostavent: evolution of an anaesthetic machine for developing countries. Anaesth Intensive Care. 2008;36:1–7.
29. Donald MJ, Derbyshire S. Lignocaine toxicity; a complication of local anaesthesia administered in the community. Emerg Med J. 2004;21:249–50.
30. Hadzic A. Textbook of regional anesthesia and acute pain management. NewYork: McGraw-Hill; 2007.
31. Abrao J, Fernandes CR, et al. Effect of local anaesthetic infiltration with bupivacaine and ropivacaine on wound healing: a placebo-controlled study. Int Wound J. 2012. doi:10.1111/j.1742-481X.2012.01101.x.
32. Horlocker TT. Complications of regional anesthesia and acute pain management. Anesthesiol Clin. 2011;29:257–78.
33. Neal JM, Bernards CM, et al. ASRA practice advisory on local anesthetic systemic toxicity. Reg Anesth Pain Med. 2010;35(2):152–61.
34. Wardrope J, Flowers M, Wilson DH. Comparison of local anaesthetic techniques in the reduction of Colles’ fracture. Arch Emerg Med. 1985;2:67–72.
35. Pountos I, Georgouli T, et al. Do non-steroidal anti-inflammatory drugs affect bone healing ? A critical analysis. ScientificWorldJournal. 2012;2012:606404. doi:10.1100/2012/606404. Epub 2012 Jan 4.

18

Intensive Care in the Austere Environment

Christine du Maine

Critical care may be necessary outside established hospitals, when local hospital capacity is exceeded or incapacitated, or at an evacuation hub such as an airport [1, 2]. Florence Nightingale's advice during the Crimean war to place the most heavily injured patients nearest to the nursing station [2] is the most basic form of intensive care. Many advances in this field still come from military medical services.

18.1 Review of Evidence

Adequate and aggressive ICU care, including resuscitation and stabilisation, influences the overall hospital mortality and length of stay [3]. The impact on mortality and morbidity of organisational ICU characteristics is demonstrated in observational studies. However, adherence to sound, evidence-based practice within bounds of the circumstances must underscore everything [1].

Whereas some of the discussed pathologies are still quite hot topics in medicine with recent qualitative reviews and studies, others are less frequent in the Western world and as a result are less well investigated. Their relatively low frequencies in research-oriented environments mean that there are no high-quality trials published.

18.2 General ICU Issues

Grouping the most severely injured patients to provide closer observation and nursing care is the root of intensive care. Support to the various organ systems (e.g. vasopressor therapy, ventilation) is then provided according to these observations and the means available. This principle allows basic critical care to be provided in absence of high-technologic equipment and without a large logistic burden [2].

Successful critical care requires proper, detailed planning and careful management of all resources, including equipment, team composition (skills) and evacuation options [1, 3]. An ideal ICU has enough space to support patients and staff and allows for temperature and dust to be controlled. Secure oxygen, electricity, water and vacuum sources should be present [3, 4], together with medical supplies, pharmaceutical agents and equipment and a ready access to surgical, radiographic, transfusion and laboratory capabilities [3].

C. du Maine, MD
Department of Anesthesia, Universitair Ziekenhuis Brussel, Brussels, Belgium
e-mail: drdumc@gmail.com

© Springer International Publishing Switzerland 2016

J.D. Robinson (ed.), *Orthopaedic Trauma in the Austere Environment: A Practical Guide to Care in the Humanitarian Setting*, DOI 10.1007/978-3-319-29122-2_18

18.2.1 Levels of Care

Definition of levels of care in trauma centres according to resource and staff requirements has improved outcome and decreased costs to the US healthcare system [5]. A similar system has now been developed for ICUs [5].

In military medical operations, the capacity and function of an austere ICU depends on the level of care that it is affiliated with: either resuscitation and stabilisation with overnight care and preparation for evacuation or including the management of complications and sequelae of critical illness and trauma [1].

Certain NGOs have defined their own levels of critical care in austere environments, according staff and equipment requirements for each level. This system allows quick decisions on what resources are needed in new or emergency missions and helps defining the limitations of a project and triaging of patient care.

18.2.2 Admission Criteria

As a rule of thumb, ICU admission needs to be considered if one or more vital functions are compromised. These criteria are often also stretched to those patients where a rapid deterioration needs to be anticipated (e.g. active bleeding, neurotrauma), requiring close surveillance, and sometimes also to patients requiring more or more frequent care than can be provided in a regular ward.

Triage decisions should however also be based on available resources. Standards of care might be modified to provide services to greater numbers of people, limiting critical care interventions to those clearly shown to improve survival (individually lifesaving, relatively simple and not requiring extensive resources). Sometimes care is withheld from a severely ill patient who under different circumstances would have been aggressively supported, to save resources for those with a better long-term prognosis. Preferably, the legal and ethical ramifications of these difficult decisions are investigated beforehand [1].

18.2.3 Medical Equipment

It is important to consider what procedures you can perform and what pathology you will be expecting in your ICU. The impact of power issues, environmental challenges and conditions on equipment functionality needs to be anticipated. Characteristics including size, weight, battery life and durability need to be taken into account [1, 4]. Also consider the need for supply lines of disposable items and ease of maintenance and solving of technical problems in the field. Standardisation within disaster response networks should be aimed for [1].

Useful equipment includes:

- Multiparameter monitors [1]: if unavailable regular manual vital parameter checks by a trained care provider.
- Ventilators [1, 4]: portable devices might be more adapted to resource poor environment, although they might not allow all preferred ventilatory modes.
- Infusion devices [1] for constant low-flow infusions (e.g. vasopressors, inotropic drugs), as they are more accurate than counting drops per minute in a drip chamber.
- Suction device [1].
- Point-of-care laboratory testing (POCT) devices [1, 4] for analysing arterial blood gas, glucose, basic electrolytes, cardiac markers, coagulation studies and lactate or a combination of tests exists [1]. Certain devices might not operate outside certain temperature and humidity ranges, so it is important to keep in mind the environment in which the devices are likely to be used [4].
- Ultrasound [1, 4] is particularly useful to rapidly assess haemodynamically unstable patients, e.g. focussed assessment for sonographic examination of trauma patient (FAST), lung ultrasound and echocardiography [1].
- Bronchoscopy.

18.2.4 Consumables and Drugs

Only use what is absolutely necessary and avoid waste (e.g. forgetting to turn off an oxygen supply) [1]. As discussed in the chapter on anaesthesia, oxygen can be a major issue. Low-flow O_2 requirements can be met by simple oxygen concentrators (providing there is a reliable source of electricity). Bigger concentrators, capable of generating large quantities of O_2, are being developed [1].

18.2.5 Staff Issues

Teamwork and cross-functioning improve effectiveness [3]. Where possible a multidisciplinary team with dedicated critical care physicians should be involved [2]. Keep in mind that unanticipated delays in transport might impact operational effectiveness when moving equipment and skilled staff when not absolutely necessary [1]. Operational effectiveness is also influenced by staff health; both physical (endemic diseases, context-related personal health risks) [4] and mental health problems need to be prevented or addressed early on. Post-traumatic stress disorder (PTSD) is more likely if staff is exposed to or perceives a direct personal threat [1].

Remote presence and electronic intensive care unit concepts that can project intensivists to multiple and/or austere locations worldwide are being investigated [2]. Nowadays, thanks to internet, an electronic device like a laptop or even a smartphone and free software can already project sound and real-time video footage across the world and rarely requires major supplemental logistical efforts.

18.2.6 Preparing for Critical Care in Austere Settings

Care in the field should aim to fall within accepted standards of care [1]. Advanced medical care can be successfully provided virtually anywhere on short notice [1], with comprehensive pre-disaster planning and practice [1, 4], and attention to logistic details (e.g. cold chain [1, 6]).

Two main tactics to critical care in emergency settings exist:

- In the “scoop and run” approach, critical patients receive initial stabilisation by medical teams which have been deployed near areas where mass casualties are expected, to provide lifesaving surgical resuscitation [3]. Stabilised critically ill patients can then be evacuated [1, 3].
- “Stay and play” requires portable, rapidly deployable teams to provide the major components of resuscitation and stabilisation [3]. Their speed, simplicity and lower cost come at the expense of limited capability, capacity and sustainability [3]. These ICU modules can be integrated in a pre-existing local medical system to augment their equipment and supplies [3], or they can serve as a buffer for critically ill casualties as evacuation is being arranged or until a more permanent capability is established [3].

In either case, critical care cannot be delivered without being integrated in a long-term plan to provide follow-up care to patients discharged from the ICU [3].

In an overwhelmed medical system, critical patients consume the attention of their caregivers to the exclusion of noncritical patients [3], and aid is often only focussed on disaster-related trauma. However, a population stricken by disaster is best served by a field hospital designed to provide urgent and nonurgent medical and surgical treatment within broad age categories [1, 3], as the collapse of pre-existing healthcare and the loss of daily treatments can lead to decompensation of patients with comorbid conditions [3].

Supplies based on military formulary are often not appropriate to treat paediatric, pregnant or chronically ill patients [3]. In the first 24 h after a natural disaster, the most common cause of death is secondary to haemorrhage and physiological exhaustion. After 24–48 h, causes include sepsis and complications from shock [2]. As the average time to field hospital operational status is approximately 2–3 days, most severe trauma patients die of their injuries during that time or will be temporised by existing medical services [1].

18.3 General Care Issues

18.3.1 ICU Organisational Model

In an open ICU, the patient is treated by independently working physicians who are not generally trained in critical care (e.g. the surgeon who did the operation), possibly with a trained intensivist available for consultation [2, 7]. In a closed model, unit patients are managed by a dedicated team of medical personnel lead by a physician formally trained in critical care [2, 7], consulting with the other treating physicians where necessary.

It has been illustrated that the intensivist-directed approach has a better patient outcome and less complications and is associated with improved resource use, resulting in overall cost savings [2, 5, 7, 8]. Differences observed in outcome may in part be attributed to increased physician availability [2] but also to the emphasis on the importance of clinical practice guidelines using evidence-based practices and protocols [2, 7]. The absolute reduction of mortality in intensivist-directed model exceeds any one single known ICU intervention to date [2], and it has been hypothesised that the benefit is likely to be greater in settings with limited resources [7].

18.3.2 Adhering to Routine Practice

Austerity amplifies the complexity of providing high-level critical care, because resources are frequently limited, providers may be asked to fill unexpected roles, security might be threatened and the population at risk and their afflictions can be highly diverse [1]. Confusion is reduced by following day-to-day medical care routines as closely as possible, so everybody knows their roles and responsibilities [1, 4]. Modifications of routine standards are influenced by supply and equipment availability, triage decisions, environmental challenges, provider role alterations, personnel availability and healthcare provider safety concerns [1].

Damage control surgery in itself should not take long, but requires ongoing, labour intensive stabilisation to appropriate end points in the intensive care unit, fighting hypothermia, acidosis, hypovolaemia and coagulopathies [1, 2]. Any missed injuries need to be identified during a tertiary trauma survey [2]. Tools and skills to perform these functions rely little on bulky or highly technologic equipment, but rather on well-trained multidisciplinary teams [2].

Quality improvement checklists prompt the application of well-established guidelines and protocols and help prevent omissions in applying routine beneficial treatments [1]. Goal-orientated, evidence-based interventions and clinical practice guidelines are important to avoid iatrogenic complications such as abdominal compartment syndrome, deep venous thrombosis, ventilator associated pneumonia, acute respiratory distress syndrome (ARDS), catheter-related bloodstream infections, renal failure and wound infections [2]. Mnemonics like "FASTHUG" (Feeding, Analgesia, Sedation, Thrombosis, Head elevation, Ulcer and Glycemia) [9] can easily be used on a daily basis. Most of these basic measures can be taken even in the most austere environments, although they might require a degree of creativity [1, 4], like creating recipes for enteral nutrition from available resources or propping up the heads of beds.

Locally available resources can be adapted to different functions (e.g. fighting hypothermia with a handheld dryer or warmed fluids) [1]. Other aspects that need to be monitored regularly include prevention of skin breakdown and ventilatory settings (limiting tidal volumes in acute lung injury) [1].

The basics of good infection control practices, like handwashing, must continually be emphasised [1]. The challenge of maintaining infection control in an improvised ICU includes control of environmental contamination from the exterior as well as the risk of cross-contamination between patients in crowded conditions and when basic supplies are limited [3].

18.3.3 Neurologic Support

Accurate neurological assessment is important in diagnosing and following up non-penetrating traumatic brain injury (TBI) without ready access to CT scanning. Guidelines help avoid secondary insults, achieve set haemodynamic and metabolic goals and implement a stepwise ICP management protocol [1]. Hypertonic saline is the first choice for hyperosmolar therapy, as it also improves haemodynamics in trauma [1].

18.3.4 Cardiovascular Support

A technique that should be used in fluid resuscitation is a fluid challenge [10, 11]. To avoid overloading a patient with fluids, boluses of 500–1000 ml should be given over a relatively short period, e.g. 30–60 min. A mnemonic used is TROL (Type, Rate, Objective and Limitations), as the type of fluid needs to be defined, the rate or time period over which a certain volume is given, the objective of the challenge (e.g. a mean blood pressure of 65 mmHg) and the limitations (e.g. an oxygen saturation under 96 % without oxygen or a central venous pressure above 12 mmHg). If the objective and limitation have not been reached, the challenge can be repeated. If objective or limitation has been met, or there appears to be no further haemodynamic changes, it is better to stop.

18.3.5 Renal Support

Renal failure can be associated with polytrauma, crush injuries, burns and sepsis [1]. Prevention is extremely important, as dialysis in the field is rarely available [1]. Preventive measures include fluid resuscitation, avoidance of nephrotoxic drugs in patients at risk and evidence-based strategies in the prevention of contrast-induced nephropathy [1].

18.4 Specific Pathologies

18.4.1 Sepsis

A systemic inflammatory response syndrome (SIRS) is a general inflammatory response, giving rise to symptoms such as fever. Various triggers for SIRS exist, but in sepsis the trigger is infection. In severe sepsis, this systemic response causes deterioration and failure of individual organs, which may not have been directly invaded by pathogens. Symptoms can include acute renal failure, confusion and insufficient tissue oxygenation. Septic shock is a manifestation of sepsis-induced cardiovascular failure, causing hypotension and hypoperfusion which persists despite adequate fluid resuscitation. Sepsis is the final common pathway for people dying from infections and the main cause of death in children worldwide.

Guidelines on the treatment of sepsis exist and are regularly published and updated. We will try and give a short summary of the latest guidelines [12].

18.4.1.1 Diagnosis

As appropriate treatment can only be started when a problem is diagnosed, screening of all potentially infected seriously ill patients is recommended. The (probable) source of infection needs to be identified. Appropriate cultures should be taken before initiating antimicrobial therapy, unless this significantly delays the therapy. Other diagnostic tools may include imaging and rapid antigen tests. Malaria testing in endemic areas should not be forgotten nor the possibility of co-infection or superinfection.

18.4.1.2 Initial Resuscitation

An early, protocol and goal-orientated resuscitation is recommended for patients with sepsis-induced tissue hypoperfusion, preferably completed within 6 h. Main goals suggested are a central venous pressure of 8–12 mmHg and a central venous oxygenation ($ScvO_2$) of 70 % or a normalisation of blood lactate levels. Urine output of more than 0.5 ml/kg/h and a mean arterial pressure (MAP) of minimum 65 mmHg may be the only available parameters in austere environments. Decrease of tachycardia with fluid resuscitation can also be a marker of improved intravascular filling.

A minimum initial fluid resuscitation of 30 ml/kg of crystalloid solutions within 3 h for hypotension or elevated lactate is recommended, under the form of fluid challenges. Synthetic colloids are currently not recommended in the treatment of severe sepsis and septic shock, although albumin may be considered when substantious amounts of crystalloids are necessary. Vasopressors, dobutamine infusion or blood transfusion (aiming for a haematocrit of 30 %) may be considered if fluid resuscitation alone does not suffice.

Norepinephrine, a potent vasoconstrictor, is recommended as first-choice vasopressor to target a MAP of 65 mmHg. Epinephrine can be added when an additional agent is needed. Dopamine should only be used in patients who are bradycardic or have a low risk of tachyarrhythmias, as cardiac output is raised primarily due to increases in stroke volume and heart rate. If available, an arterial catheter should be placed when vasopressors are required. Dobutamine can be added in cases of myocardial dysfunction or when signs of hypoperfusion continue, despite adequate MAP and intravascular volume.

If the patient remains haemodynamically unstable, despite adequate fluid resuscitation and vasopressor therapy, 200 mg/day of intravenous hydrocortisone is suggested, preferably by continuous infusion. A bolus of 50–100 mg is given to initiate the therapy. No benefit has been shown in patients without sustained shock. It is suggested that steroid therapy be tapered when vasopressors are no longer required.

18.4.1.3 Antimicrobial Therapy

Effective and adequately dosed intravenous antibiotics should be administered within the first hour of recognition of severe sepsis, as delays have been shown to increase mortality in patients with septic shock. When deciding on an empiric anti-infective therapy, tissue penetration of the suspected source of sepsis and the likely pathogens needs to be taken into account. Pathogens are often bacterial, but can also be viral, fungal or parasitic. Patient history, including comorbidities and exposure to antibiotics within the last 3 months, and local microbial resistance patterns are important information.

Source control needs to be performed in appropriate situations, preferably as minimally invasive as possible. This includes abscess drainage and removal of possibly infected foreign material and devices, including replacement of catheters. Obviously, routine ICU care practices and general infection control should be applied, including patient's oral hygiene.

Daily assessment of the regimen should identify de-escalation possibilities, to reduce toxicity, costs and the development of resistance. The duration of treatment is typically 7–10 days when the source is adequately controlled.

18.4.1.4 Supportive Therapy of Severe Sepsis

Once the patient has been haemodynamically stabilised and therapy has started, there is time for further supportive therapy and routine ICU practices, including protocolised glucose control, suitable prophylaxis against venous thromboembolism and stress ulcer prophylaxis for patients with risk factors for bleeding (proton pump inhibitors if possible). In the “surviving sepsis” guidelines, special attention is given to certain aspects.

Blood Products

After correction of tissue hypoperfusion, blood transfusion is recommended only when the haemoglobin concentration is less then 7.0 g/dl, targeting 7.0–9.0 g/dl in well-oxygenated, previously healthy adults. Clotting abnormalities should not be corrected if the patient is not bleeding and there are no invasive procedures planned.

Mechanical Ventilation

Sepsis can induce acute respiratory distress syndrome (ARDS). This is an inflammation of the lung, characterised by acute-onset lung injury and hypoxaemia despite high concentrations of inspiratory oxygen. Bilateral opacity is seen on chest X-rays, unexplained by fluid overload, cardiac failure or other respiratory pathologies. To reduce the risk, special attention needs to be paid to the ventilatory strategy, avoiding additional lung injury. As lung compliance is decreased, tidal volumes of 6 ml/kg (ideal body weight) are recommended in ARDS patients, while aiming for plateau pressures of less than

30 cmH_2O. Higher respiratory frequencies are often needed. Positive end-expiratory pressure (PEEP) should always be used in mechanical ventilation, to prevent alveolar collapse at the end of expiration.

In patients with moderate to severe ARDS, higher levels of PEEP are suggested, in combination with recruitment manoeuvres to open collapsed alveoli. Prone positioning in patients with severe ARDS may benefit the patient in experienced centres, although there is a higher risk of dislodging endotracheal and chest tubes and there is less access to the patient in case of emergencies. A minority of sepsis-induced ARDS patients may benefit from non-invasive mask ventilation (NIV), after weighing the risks. A weaning protocol should be in place, stipulating when and how mechanical ventilation is to be discontinued. Another important aspect in ARDS prevention is adopting a conservative fluid strategy in patients without evidence of tissue hypoperfusion.

Sedation, Analgesia and Neuromuscular Blockade

Sedation should be minimised, targeting specific titration end points. Neuromuscular blocking agents (NMBAs) should be avoided in septic patients without ARDS, but could be used in patients with early, sepsis-induced ARDS for short periods (up to 48 h).

Renal Replacement Therapy

Continuous therapies are suggested in haemodynamically unstable patients. In stable patients intermittent haemodialysis has similar short-term results.

Nutrition

Initiation of enteral nutritional support is suggested within the first 48 h after diagnosis, although full caloric feeding is not necessary during the first week. Nutritional intake can be increased as tolerated.

18.4.1.5 Paediatric Considerations

During initial resuscitation, it is suggested to administer oxygen by face mask. If central lines are unavailable, peripheral intravenous access or intra-osseous access can be used for fluid resuscitation and inotrope administration. Intubation and ventilation often cause cardiovascular instability in children, but appropriate cardiovascular resuscitation decreases the risk. Lactate is often normal in children during septic shock, so initial therapeutic end points of resuscitation include capillary refill, warm extremities, normal mental status and a urine output of more than 1 ml/kg/h. Children have a lower blood pressure than adults and can compensate hypovolaemia longer before a drop is detected. Boluses of up to 20 ml/kg of crystalloids or albumin can be given over 5–10 min, up to and over 60 ml/kg. Of course in severe haemolytic anaemia (malaria, sickle cell crises), blood transfusion is needed instead of crystalloids. Paediatric advanced life support guidelines should be used, and other reasons for refractory shock need to be excluded.

Suggested transfusion triggers in general are similar to those used in adults at the same stage of resuscitation, although correction of coagulation disorders with fresh frozen plasma is suggested in children with progressive sepsis-induced purpura disorders despite correction of shock. If hepatomegaly or rales develops, fluid resuscitation needs to be stopped and inotropic support implemented. Diuretics can be used in children with fluid overload.

The use of vasoactive drugs is a bit more complicated in children with septic shock, as they can present in three different haemodynamic states: low cardiac output (CO) and high systemic vascular resistance (SVR) (= cold shock with normal blood pressure), high CO and low SVR (= warm shock with low blood pressure) or low CO and low SVR (= cold shock with low blood pressure). In the high SVR-type shock, fluid and epinephrine should be titrated, with addition of a vasodilatator with volume loading if venous oxygenation remains low. Cold shock with low blood pressure also requires the titration of fluid and epinephrine, with the addition of norepinephrine if hypotension persists. The addition of dobutamine can be considered if there is an insufficient raise in venous oxygenation. In high output or warm shock fluid and norepinephrine are titrated, with low-dose epinephrine if venous oxygenation stays low.

Children who are unresponsive to fluid and catecholamines and in whom adrenal insufficiency is suspected could receive hydrocortisone (up to 50 mg/kg/day). Oral or intramuscular antibiotics administration should be considered if venous access is delayed. Clindamycin can reduce toxin production in children with toxic shock syndromes and refractory hypotension.

18.4.2 Tetanus

Tetanus remains endemic in developing countries with lower vaccination rates, where lack of modern supportive care results much lower recovery rates (around 50 %) [6, 13–15]. Careful monitoring and nursing care alone however already improve survival [6].

Spores of *Clostridium tetani* are relatively resistant to autoclaving and chemical agents [6, 14]. In the body, they transform to anaerobic, toxin-producing gram-positive bacteria [6, 12, 16]. The toxin tetanospasmin is released after cell death [14] and is transported to the spinal cord and brainstem via retrograde axonal transport, where it blocks neurotransmission of inhibitor excitatory impulses from the motor cortex via the GABA receptor [14, 17]. This increases muscle activity in the form of rigidity and spasms [13, 17], but also causes autonomic instability due to unopposed adrenal activation [13].

Conditions under which *C. tetani* flourishes include penetrating injuries with inoculation, co-infection with other bacteria [6, 18, 19], devitalised tissues [6, 13] or localised ischaemia [6, 13] and the presence of a foreign body. Wounds causing tetanus can be very small and are sometimes healed by the time the first symptoms develop. More difficult to tract sources include dental infections, acute otitis media and postsurgical patients (especially necrotic bowels) or when the patient omits to tell (e.g. septic abortions, intravenous drugs). In some cases, no cause can be found [6, 14].

The severity and rate of progression (days to weeks) of the illness varies, depending on the amount of tetanus toxin that reaches the central nervous system (CNS). This can be due to a smaller amount of spores inoculated to start with, the growth conditions, the presence of non-protective levels of antibodies or a site more distant to the CNS (longer nerve length, e.g. foot vs. head or neck). Typically the slower-progressing diseases with longer incubation periods have milder clinical features [6, 13, 14, 19, 20].

The diagnosis is based on history and clinical characteristics, as there is no specific diagnostic test. Differential diagnosis includes nuchal rigidity of meningitis, strychnine intoxication, cerebral malaria, meningoencephalitis, subarachnoid haemorrhage and alveolar ridge abscess [6]. The usual recovery takes 4–6 weeks, as it requires the growth of new axonal nerve terminals [13, 14, 20].

There are four clinical patterns of tetanus [6, 13, 14, 17]: generalised, local, cephalic and neonatal.

Generalised tetanus is characterised by a fully conscious patient with tonic contractions and intensely painful intermittent muscular spasms, often triggered by a sensory input like noise, physical contact or light [6, 14, 15]. A generalised tetanic spasm typically includes clenched fists with arms in flexion and abduction, an arched back, extended legs [6, 13] and often an episode of apnea [13]. They usually appear 1–4 days after the initial symptoms [14], like a sore throat, or difficulty chewing or swallowing, followed by generalised weakness and stiffness [14]. The classic clinical findings include trismus (giving rise to the colloquial name of “lockjaw”), a stiff neck, opisthotonus, risus sardonicus and a rigid abdomen [6, 13, 15] (Fig. 18.1).

Complications include aspiration pneumonia, spinal or long bone fractures, tendon separation and rhabdomyolysis [6, 14, 15]. Rigidity and spasms of the respiratory and laryngeal muscles may cause respiratory failure and death [14, 17].

Autonomic overactivity is often present, and is a contributor to mortality, especially in places where the respiratory insufficiency can be treated. It starts with irritability, restlessness, sweating and tachycardia and later on developing cardiac arrhythmias, labile hypertension or hypotension and fever [13–15, 17]. Profuse bronchial and salivary secretions are characteristic and gastrointestinal disturbance may also be seen [20].

Fig. 18.1 Opisthotonus in a young tetanus patient

Local tetanus usually precedes the generalised form. Tonic and spastic muscle contractions start in one extremity or body region [13], or a fixed rigidity of the muscles is associated with a site of injury [6, 13]. An abdominal presentation can be misdiagnosed as an acute surgical abdomen [13]. *Cephalic tetanus* is a form of local tetanus involving only the cranial nerves [6, 13]. Symptoms may include dysphagia, trismus and focal cranial neuropathies [6, 13, 14]. The *neonatal presentation* is usually due to contamination of the umbilical stump.

18.4.2.1 Treatment

The goals of treatment are prevention of further toxin absorption and neutralising unbound toxin. In the meantime, the normal ABC of patient care is applied in a general supportive way, preferably in an ICU setting [14], with special attention to airway management, management of the dysautonomic symptoms and control of the muscle spasms [13].

Neutralisation of unbound toxin is preferably achieved with human tetanus immune globulin, as soon as the diagnosis is made. 500 U of human tetanus immune globulin (HTIG) has been found to be as efficacious as higher dosing regimens [15]. Equine antitetanus serum (ATS) is the second choice due to hypersensitivity reactions [6, 13]. A dose of 1500–1600 units IM or IV (after an intradermal test dose of 0.1 ml in a 1:10 dilution [6, 13]) has been described [13] or three doses over a 48-h period using 750–1500 U per dose [14].

Intrathecal immune globulin in addition to the IM dose is not part of the standard care, as there is insufficient data from high-quality trials to prove a benefit [13, 17, 20, 21]. Infiltration of the wound with (part of the dose of) antitoxin has also been suggested, but without proven value [13, 14].

Eradicating *C. tetani* by debriding and irrigating the infection site, even if it already shows signs of healing, is suggested as a first step in *halting toxin production* [6, 13, 14]. In some cases, this may implicate a uterine curettage or even a hysterectomy [14].

Although there is no hard evidence for antibiotics, they are universally recommended. The first choice is metronidazole [6, 13, 14, 20]. A safe alternative is penicillin G [14], although it may increase spasms due to a synergistic action with tetanospasmin [6, 13, 20]. Doxycycline (100 mg twice daily), macrolides, clindamycin, cephalosporins and chloramphenicol are also effective [6]. Described duration of treatment ranges from 7 to 10–14 days [6, 13, 14, 22].

Tetanus does not confer immunity following recovery; therefore, all patients should receive active immunisation immediately upon diagnosis [15, 21]. The full immunisation requires a total of three doses spaced at least 2 weeks apart, preferably with a bivalent vaccine containing tetanus and diphtheria toxoids [13].

Control of muscle spasms is another vital step in treating tetanus. Ideally this should happen in an intensive care unit where continuous monitoring of the vital parameters is possible [13, 14], as both the spasms in themselves and the treatment can lead to respiratory failure and aspiration [6, 14]. Spasms can be triggered by sensory stimuli, so it is best to avoid these triggers by isolating the patient in a quiet room [6, 13, 14, 17]. Sensory deprivation can, however, predispose to delirium, which tetanus patients are already prone to [17].

The first therapeutic line for spasm control is sedatives. Traditionally *benzodiazepines* have been used and are considered effective. Diazepam is started at doses of 10–20 mg IV every 8 h, although dose (5 mg increments [6]) and frequency (sometimes hourly [14]) need to be titrated according to the severity of symptoms [6, 13, 14, 17, 20], trying to avoid significant hypoventilation [6]. Daily doses of 500 mg diazepam or more are sometimes required [6]. Oral regimes, if necessary through a nasogastric tube, should be considered when high doses are needed [6], as additives in the IV solutions of diazepam can cause lactic acidosis [13]. Other benzodiazepines are equally effective. Benzodiazepines should be tapered gradually to avoid withdrawal reactions [13].

Propofol may also control the spasms and rigidity [17], but in doses above 4 mg/kg/h propofol infusion syndrome (PRIS) might occur. *Phenothiazines*, *barbiturates* and *chlorpromazine* have been used in the past, but are now mostly displaced by neuromuscular blocking agents [6, 13, 20, 23].

When sedatives are inadequate, *non-depolarising neuromuscular blocking agents* can be administered [17], but this does require intubation and ventilation. Early tracheostomy should be considered [6, 14, 20]. Succinylcholine is contraindicated in tetanus patients due to an increased risk of hyperkalaemia [24] in patients who are already prone to arrhythmias due to the autonomic instability. Pancuronium is long acting, but may worsen autonomic instability due to vagal blockade and sympathomimetic effects [13, 20, 24]. Daily breaks are necessary to evaluate the need of these agents and to decrease accumulation and recovery time [13].

Magnesium appears to reduce the requirement for other drugs to control muscle spasms and the need of treatment of the *autonomic dysfunction*, although it does not seem to reduce the need for mechanical ventilation [6, 13–15, 17, 20, 25]. It has the added benefit that it is in use worldwide in the treatment of eclampsia [26], so it is widely known and available. A meta-analysis however could not demonstrate differences in mortality and could not draw conclusions on the duration of total ICU or hospital stay [16], so good quality research is still necessary. Within its therapeutic window, magnesium sulphate is a safe drug to use in established tetanus [16]. Magnesium toxicity due to overdose is characterised by muscle weakness, potentially leading to respiratory insufficiency, especially in patients with kidney failure. The first sign is the loss of the patellar reflex. Calcium gluconate (1 g) can be given as an antidote for magnesium toxicity.

Pure beta blockade should be avoided as it might lead to sudden death, but *labetalol* (0.25–1.0 mg/min) has frequently been given for its combined alpha- and beta-blocking properties, although there is conflicting evidence [6, 13, 20]. Esmolol [20] has been suggested as an alternative.

Morphine can be administered for the autonomic dysfunction, as well as adding its effects to the sedation and providing analgesia [6, 13, 14, 20].

Dantrolene [6, 14, 17], (intrathecal) baclofen [6, 13, 17, 20] and botulinum toxin [17] have been studied in spasm control, but are not part of standard care for tetanus. Case reports exist of the administration of atropine [13], clonidine [6, 14] and epidural bupivacaine [13, 14, 20] in cases of tetanus. Corticosteroids have been suggested as measure to counteract autonomic instability [14].

As with any ICU patient, *supportive care* is extremely important while waiting for the axonal nerve endings to regenerate. Patients are at risk of complications due to prolonged intubation and ventilation and prolonged immobilisation, like nosocomial infections, decubitus (especially on the pressure points in opisthotonic patients), critical illness myopathy, gastrointestinal haemorrhage and thromboembolic disease [6, 13–15, 20]. Acute renal failure has been associated with autonomic dysfunction and can be aggravated by dehydration and rhabdomyolysis [20]. Physical therapy should be started as soon as spasms have ceased [13, 20].

Early nutritional support, preferably enteral, with plenty of calories is important [6, 13]. The addition of parenteral thiamine should be considered in patients receiving glucose infusion as only source of calories to avoid Wernicke encephalopathy [19].

It has been suggested that tetanus patients might benefit from vitamin C supplementation, especially in austere environments where patients are more likely have a deficient diet [15]. However, more research is needed to determine dosing and route of administration. Vitamin C is a very safe substance and inexpensive.

18.4.2.2 Prevention

Of course, the best survival results from prevention. Table 18.1 represents the guidelines for tetanus prophylaxis in wound management. If a wound is more than 24 h old with necrotic tissue or obvious contamination, 500 U of HTIG should be administered. In all other cases, the standard dose of HTIG is 250 U IM and is sufficient [14].

18.4.3 Rhabdomyolysis

In rhabdomyolysis intracellular proteins, including myoglobin, lactate and electrolytes, leak into the circulation from damaged skeletal muscle cells [27, 28]. Hyperkalaemia puts the patient at risk of fatal dysrhythmias [28–30], whereas myoglobinuria is nephrotoxic [28, 29]. Muscle damage is often traumatic, but can also be due to drug effects or acute arterial thrombosis and ischaemia.

Three closely related and easily confused terms need to be differentiated. In *crush injury* direct external pressure, like compression of a limb by rubble, damages soft tissues like the skin, muscles, nerves and vasculature [29]. Damage and necrosis due to compression of tissue within a confined space is termed as *compartment syndrome* [29]. When substantial muscle cell necrosis occurs, systemic manifestations like renal failure and arrhythmias can appear. This is a *crush syndrome* [29], the second most frequent cause of death after earthquakes [31]. These three entities are not always entirely independent: restoration of the circulation in a crushed limb can also result in tissue swelling, putting the patient at risk of developing a compartment syndrome, which in turn can also cause rhabdomyolysis and crush syndrome [29].

Acute kidney injury (AKI) is common in crush victims, due to multiple causes: myoglobin precipitation in the renal tubules, but also concomitant intravascular volume depletion with renal hypoperfusion and systemic acidosis [28, 30]. Drug effects, other injuries and metabolic abnormalities can worsen the condition [28].

In April 2012, recommendations for the management of crush victims in mass disasters, with specific attention to the prevention and treatment

Table 18.1 Wound management and tetanus prophylaxis [53]

	Clean and minor wound		All other wounds	
Previous doses of tetanus toxoid	Vaccine	Anti-toxin	Vaccine	Anti-toxin
<3 doses or unknown	Yes	No	Yes	Yes
3 doses or more	Only if last dose 10 years or more ago	No	Only if last dose 5 years or more ago	No

of AKI, were published [32]. Most of these recommendations are expert opinions, as there are no high-quality randomised trials [27]. This is probably due to the difficulty of conducting a prospective study in a mass disaster setting, and the patient population is not homogenous: extent of injuries, duration of entrapment, age, comorbidities and body composition are only some of the factors that need to be taken into account. In existing publications, there is a large variation (or even absence) of the clinical definition of rhabdomyolysis and acute renal failure [27].

18.4.3.1 Reperfusion

Of course the longer an ischaemic insult lasts, the more damage occurs [31]. Training of local people in disaster-prone areas on rescue activities overcomes the delay in arrival of external rescue teams [31]. Tourniquets should only be used to prevent life-threatening haemorrhage.

Fasciotomies and amputations should only be performed when clearly indicated, not as a preventive measure [30, 31]. For fasciotomy this is in the absence of distal pulses, when a radical debridement of necrotic muscle is required or when measured intracompartmental pressures are consistently raised [31]. Amputation should only be considered when the affected limb cannot be rescued due to irreparable damage or life-threatening sepsis [29, 31]. When this is the case, surgery needs to be performed early on, before the patient deteriorates too far [31].

18.4.3.2 Fluid Resuscitation

Early and appropriate fluid resuscitation is vital [27, 29–31]. This entails considering starting fluid resuscitation even while the victim is still trapped, although there is no “one size fits all” rule [30, 31]. Some of the factors to be taken into account include the time delay to the start of resuscitation, the volume status of the patient and his diuresis, quality and quantity of monitoring, victim’s age and size, trauma severity and environmental conditions like temperature and humidity [30, 31].

A balance needs to be found between over- and underhydration [30, 31]. When resuscitation can be started early on, a rate of 1000 ml/h is recommended for the first 2 h, to be reduced to 500 ml/h afterwards [30, 31]. In the absence of close monitoring (e.g. because of the number of patients), a maximum of 3–6 L/day for adult patients without previous health issues is advised [30, 31]. Otherwise a diuresis of 300 ml/h may be aimed for [27]. For patients with sustained anuria, despite adequate hydration, fluid needs to be restricted to 500–100 ml/day on top of the measured or estimated losses [30]. Patients receiving aid only days after having been trapped are at a higher risk of already having acute kidney injury (AKI) with a low or even non-existent urine output [29, 31]. As a result, they have a high risk of fluid overload when an aggressive resuscitation protocol is enforced [31].

The “ideal liquid” is not identified. It is important however to avoid giving patients additional potassium, often part of many “balanced” crystalloids [30, 31]. In practice, normal saline is the most readily available solution and first choice [29–31], although the large amounts of chlorine administered in this way cause a hyperchloremic acidosis. Sodium bicarbonate solutions added to half isotonic saline has certain theoretic benefits, including renal protection, correction of metabolic acidosis and reducing hyperkalaemia, but is rarely available in sufficient amounts in mass disaster situations [30, 31]. The timing and dose of administration of sodium bicarbonate remains unclear.

18.4.3.3 Electrolytes

Hyperkalaemia causes lethal arrhythmias [28–31]. Potassium seeps from damaged muscle cells, and acute kidney injury and acidosis worsen the hyperkalaemia [29, 30]. Apart from measurement of potassium levels in blood, hyperkalaemia can sometimes be recognised by ECG changes [29, 30]. Administering even small amounts of potassium needs to be avoided, and temporary, rapid treatment options include beta-agonists, bicarbonate, glucose-insulin infusions and calcium gluconate. More definitive but slower options include kayexalate and dialysis [30].

Crush syndrome patients often go through an initial hypocalcaemic phase due to shifts of calcium from its unbound circulating form [31]. This can result in paraesthesia, tetany, seizures, hypotension and cardiotoxicity [30, 31]. However this is often followed by a hypercalcaemic phase as calcium is mobilised again [31]. It is therefore advised only to treat symptomatic hypocalcaemia [31].

Acidosis causes organ system dysfunction [30], but correction with bicarbonate can induce electrolyte disturbances [30].

18.4.3.4 Dialysis

There is no clear evidence that an early start of dialysis would be better than a conservative approach; however, crush-related AKI is often associated with more life-threatening fluid, metabolic and electrolyte imbalances than AKI due to other causes, lowering the threshold for dialysis when laboratory tests reveal a rapidly emerging, worrying trend [31]. Triggers for dialysis include fluid overload, hyperkalaemia and acidosis [29–31].

Peritoneal dialysis may be preferable in small children, but there is only limited experience in adults [31]. Medically and logistically, intermittent haemodialysis is the first choice in disaster crush victims, as it is efficient and reduces the need for anticoagulation, and one machine can treat several patients per day [30, 31].

18.4.3.5 Patient Selection

All crush victims need to be accepted for definitive care, so a strategy to prevent crush-related AKI can be put in place. This does not however mean that every victim needs to be hospitalised, as some can be discharged with clear instructions (preferably both verbal and written) on how to monitor themselves for signs of crush syndrome, like oedema, oliguria and red or brown urine [29, 31], and the importance of seeking medical attention immediately when they do occur [31].

The event at the root of a massive influx of crush victims is often a natural disaster, like earthquakes and hurricanes. This initial event will also impact the quantity and quality of available medical care, as healthcare structures are often damaged and general utilities such as water and electricity may be interrupted [31]. Treatment for crush victims is ideally provided in undamaged units outside the disaster zone, with immediate access to intensive care units, operation rooms, medical imaging and laboratories [31]. The risks (and logistics) of transportation dictate whether this is possible and impose the necessity of selecting the patients that may benefit most [31].

18.4.3.6 Other Pharmacological Interventions

Other interventions have some theoretical support, but for now are not recommended as there is no clinical evidence of their effectiveness [29, 33]. These include diuretics and mannitol, both of which need to be avoided in hypovolaemic patients.

18.4.4 Pulmonary Embolism (PE)

In a pulmonary embolism, the pulmonary artery or one of its branches is obstructed by material (e.g. thrombus, tumour, air or fat) originating from elsewhere in the body [33, 34], most frequently from deep venous thrombosis (DVT) of the lower extremities [33]. As non-thrombotic pulmonary embolism (NTPE) is much less frequent, it will be discussed separately. Unless otherwise specified, PE is considered to be of thrombotic origin in the following text.

Untreated PE has a mortality rate of approximately 30 % [33], an estimated 300,000 deaths annually in Europe [35]. Death can occur due to acute right ventricular failure, often within one or two hours of the event, although the patient remains at risk for 24–72 h [33, 34]. Complications of non-fatal PE, like post-thrombotic syndrome, may have a substantial impact on the quality of life [35].

Risk factors for PE include immobilisation, recent (<3 months) surgery, stroke, pareses, paralysis, central venous instrumentation, malignancy, chronic heart disease, autoimmune diseases and a history of venous thromboembolism. Additional risk factors in women include obesity, heavy smoking and hypertension [33].

Gas exchange abnormalities are not only due to vascular bed changes and alterations in the ventilation to perfusion ratio, but are also related to inflammatory mediators, resulting in surfactant dysfunction, atelectasis and functional intrapulmonary shunting.

A PE can be acute or chronic and massive or submassive [33, 34]. Clinical severity depends on factors such as cardiopulmonary reserve, embolus size and degree of occlusion of the pulmonary circulation [35].

A massive PE is a clinical diagnosis, based on hypotension for a period of more than 15 minutes, especially if accompanied by an elevated central venous pressure (recognised by neck vein distension) [33, 34]. Acute myocardial infarction, tension pneumothorax, pericardial tamponade or a new arrhythmia needs to be ruled out [33]. The hypotension is the result of a diminished cardiac output due to an increase in the pulmonary resistance impeding right ventricular outflow and reducing left ventricular preload, and it is more pronounced in patients with underlying cardiopulmonary disease.

Submassive PE typically describes acute PE where patients have evidence of RV dysfunction but have a normal blood pressure [34].

18.4.4.1 Signs and Symptoms

Five commonly recognised ways in which PE may present [35]:

- Sudden death [35], usually due to haemodynamic collapse caused by large thrombi lodging at the main pulmonary artery or lobar branch bifurcations [33]
- Typical clinical presentation [35]: dyspnoea, pleuritic chest pain, fainting or syncope when haemodynamic reserves are severely reduced
- Atypical clinical presentation: cough, substernal and pleuritic chest pain, haemoptysis and wheezing, cyanosis and fever
- Asymptomatic presentation on scanning
- Asymptomatic presentation in association with symptomatic DVT

Diagnostic testing is necessary before confirming or excluding the diagnosis of PE, as signs and symptoms are highly variable and nonspecific [33] and a large portion (up to 50 %) of PEs are undiagnosed [33].

The most common symptoms are acute dyspnoea (usually within seconds or minutes), pleuritic pain from pleural irritation due to smaller thrombi lodging distally in the lung arteries [33], pain, cough, orthopnoea and pain or swelling in the calf or thigh. Wheezing may be present. Signs include tachypnoea, tachycardia, rales, decreased breath sounds and jugular venous distension [33].

Prophylaxis of DVT, and the subsequent risk of embolisation, includes anticoagulation, graduated compression stockings and intermittent pneumatic compression devices [34]. Mechanical prophylaxis might be difficult in trauma patients, especially in the presence of lower limb fractures. The risks of anticoagulation need to be considered more seriously in austere environment as the diagnosis and treatment options for haemorrhages are more limited.

18.4.4.2 Diagnosis

Diagnostic approaches require a combination of diagnostic tests, depending on the probability of the diagnosis [34–36], the available tests and the experience of the institution [36] as there is no simple, non-invasive and clear-cut test available.

The clinical probability of PE can be calculated by a *scoring system*. These systems aim to stratify risk and focus resources on those most likely to benefit [34], though in critical and trauma care populations the majority of patients have major risk factors, and thus a high pretest probability of PE [34]. The Wells' score is the most extensively validated and commonly used score [35] (Table 18.2). PERC (PE rule-out criteria) can be used in low-risk outpatient populations to rule out PE [33, 35].

Routine laboratory findings (e.g. leukocytosis, erythrocyte sedimentation rate, serum LDH or AST (SGOT), serum bilirubin) are non-specific and non-sensitive [35, 36]. Other tests such as brain natriuretic peptide and serum troponins are often elevated [34], but not very specific [34]. Blood tests can however help exclude other causes for PE-like signs and symptoms [35] or may stratify risk and determine prognosis in confirmed PE [34].

Arterial blood gas (*ABG*) usually reveals hypoxaemia, hypocapnia and respiratory alkalo-

Table 18.2 Wells' scoring system [35]

Clinical characteristics	*Score*
Previous pulmonary embolism or deep vein thrombosis	+1.5
Heart rate > 100 beats per minute	+1.5
Recent surgery or immobilisation	+1.5
Clinical signs of deep vein thrombosis	+3
Alternative diagnosis less likely then PE	+3
Haemoptysis	+1
Cancer (treated within the last 6 months)	+1
Clinical probability of PE	*Score*
Low	0-1
Intermediate	2-6
High	≥7
Simplified Wells' score	
PE likely	≤4
PE unlikely	>4

sis [34, 36], although changes due to respiratory collapse and lactic acidosis could influence the results [36]. In up to 21 % of PE patients without a history of prior cardiopulmonary disease, ABG is normal [34, 35], and there are many other causes of abnormal ABGs [35]. Room-air pulse oximetry of less than 95 % at the time of diagnosis increases the risk of complications, including death.

D-dimer is a degradation product of cross-linked fibrin [34, 36], which can be quantified by several methods, each with its own sensitivity [36]. No test is specific [36]. The most commonly used tests are (semi-)quantitative enzyme-linked immunosorbent assays (ELISA) [35, 36]. Elevated levels are common in hospitalised patients, especially those with malignancy or recent surgery, so results need to be viewed in light of the clinical probability. Other possible causes include pregnancy, severe infections, cardiovascular disease, atrial fibrillation and vaso-occlusive episodes of sickle cell disease [35, 36].

Many patients with PE have *electrocardiogram* (*ECG*) non-specific abnormalities [34, 36], whereas a third of patients have a normal ECG [36]. An ECG is however important in screening for differential diagnoses [36]. Signs that were considered to be suggestive of PE, indicating right ventricle strain, are actually only common in patients with massive acute PE and cor pulmonale [34–36], and they do not exclude other causes [35].

Abnormal *chest X-rays* (atelectasis, pleural effusion, parenchymal abnormality, cardiomegaly) are common in patients with PE, but again are non-specific [35, 36]. They can help to exclude common differentials [34].

The *ventilation-perfusion* (*V/Q*) *scan* [34–36] and the *invasive pulmonary angiography* [35, 36] are now being overtaken by (*multi-detector*) *CT pulmonary angiography* (*CTPA*) as imaging procedure of choice in patients with suspected PE [34–36]. CTPA allows the possibility of making an alternative diagnosis and assessing of the severity of PE [34]. The clinical significance of chance detection of small peripheral emboli in subsegmental pulmonary arteries in critically ill patients is unclear [35].

The most promising diagnostic tool in an austere environment is probably the ultrasound (US), although this examination is operator dependent and requires significant training and experience [36–39]. Interest in ultrasound is increasing in Western medicine too, as it is a cheap, non-invasive test that can be performed bedside [39].

Lower-extremity ultrasound can be performed, as the presence of a proximal venous thrombosis requires anticoagulant treatment [35, 36], although false-positive results exist and a large portion of patients with PE does not have detectable venous thrombosis [36].

Suggestive *echocardiographic* abnormalities are only seen in 30–40 % of patients with PE [34, 36], but they are more common in case of massive PE and could help make a rapid presumptive diagnosis to justify the use of thrombolytic therapy [34–36]. The absence of signs of RV overload excludes PE as a reason for haemodynamic instability [35], and cardiac ultrasound allows for exclusion of other diagnoses like tamponade, myocardial infarction and aortic dissection [34]. Transthoracic echocardiography (TTE) is sometimes limited by a poor acoustic window [38]. Thrombosis is sometimes only seen on transoesophageal echocardiography (TEE) [35].

Lung ultrasound is not a routine practice yet [39]. It has however been proposed as an alternative to CTPA when this is contraindicated [37]. In the hands of a skilled operator, it can help in the diagnosis of patients with acute respiratory and circulatory failure [38–40]. The access of lung area is limited by the ribs [37, 38]. US penetrates insufficiently to detect centrally located lesions [37]. Especially in unstable patients, it is sometimes only possible to perform lung US anteriorly, whereas most PEs are visualised posterior and inferior in the lung [38, 41, 42].

"*Triple ultrasound*" (*TUS*) *or multiorgan sonography* is a combination of lung US, compression US of the lower limbs and echocardiography [37, 38, 40, 42]. It is more effective and reliable than single-organ US [38]. TUS has been suggested as screening method to allow initiation of anticoagulation in critically ill and immobile patients [38, 42] and for selecting patients who should undergo further testing. A negative result cannot rule out PE with certainty, but if an alternative explanation for the symptoms is found, a PE is highly unlikely [38, 40].

18.4.4.3 Risk Stratification

Certain factors are detectable early on and may suggest an increased risk for mortality [33].

Patients without shock and/or hypotension are considered non-high risk [35], whereas right ventricular dysfunction in hypotensive patients with PE predicts a higher mortality [33]. PE patients with a right ventricular thrombus and diagnosed with a coexisting deep vein thrombosis after their presentation with PE are also at increased risk of mortality [33]. The presence of RV dysfunction or signs of myocardial injury suggests an intermediate risk of early death [35].

Prognostic models, like the simplified Pulmonary Embolism Severity Index (sPESI), have been validated [33]. Any PE patient with one or more points is considered a high 30-day mortality risk [35] (Table 18.3).

Table 18.3 Variables considered in sPESI [33]

Age > 80 years
History of cancer
Chronic cardiopulmonary disease
Heart rate 110 or more beats per minute
Systolic blood pressure lower than 100 mmHg
Arterial oxyhaemoglobin saturation under 90 %

18.4.4.4 Treatment

The major principles of management are providing support of the vital functions while preventing further embolisation and thrombosis and removing the existing clot [34, 43].

Stabilisation needs to be started prior to diagnostic testing [43].

Respiratory support can range from supplemental oxygen to intubation and mechanical ventilation, while anticipating hypotension following intubation in patients with right ventricular failure [43].

Haemodynamic support is initiated depending on the patient's blood pressure and any clinical evidence of hypoperfusion (e.g. altered mental status, diminished urine output). In the first phase, a fluid challenge is conducted by giving an IV bolus of fluid of maximum 500–1000 ml, while monitoring any changes in the patients' vital signs. This technique avoids overloading an already stressed right ventricle [34, 43], as increased right ventricular wall stress can in fact decrease the ratio of oxygen supply to demand resulting in ischaemia and increased right ventricular failure [34, 43].

The second line of haemodynamic support includes vasopressor therapy. Norepinephrine produces less tachycardia [34, 43], but dopamine and epinephrine are also effective. Dobutamine increases myocardial contractility, but the more pronounced effect of vasodilation in low doses could worsen hypotension [34, 43]. Combinations of drugs can be used. Other inotropes have not been researched in humans with acute PE [43]. ECMO [34] falls outside the scope of this book.

Anticoagulant Therapy

Current standards of care dictate that in every patient with confirmed acute PE parenteral anticoagulant therapy should be initiated [34, 43, 44]. Guidelines suggest therapeutic anticoagulation is to be considered in patients with a high clinical suspicion of acute PE [34, 35, 43], but also in cases with low probability when diagnostic evaluation is suspected to take more than 24 h [43], to

Table 18.4 Risk factors for bleeding

Age over 65 years
Previous bleeding
Thrombocytopaenia
Anti-platelet therapy
Poor anticoagulant control
Recent surgery
Frequent falls
Reduced functional capacity
Previous stroke
Diabetes
Anaemia
Cancer
Renal failure
Alcohol abuse

Presence of two or more are considered a high risk [44]

be stopped when an acute PE is excluded [44]. Anticoagulation in patients with contraindications or an increased risk of bleeding needs to be considered on a case-by-case basis (Table 18.4) [34, 43]. Minimal data regarding anticoagulation in paediatric patients exists [35].

Treatment of PE can be categorised in three phases: initial (up to 7 days), long term (up to 3 months, usually considered a minimum duration) and extended (more than 3 months) [35, 45]. The duration of anticoagulation varies according to a patient's risk status, balancing the risk of bleeding with the presence of factors potentially contributing to the initial PE, and considering the patient's preference [35, 44]. Continuing the therapy reduces the risk of recurrence, but increases the risk of major bleeding [35, 44]. The role of new anticoagulants and acetylsalicylic acid in this setting is being investigated [35].

Heparins

Low molecular weight heparin (*LMWH*) is preferred for most haemodynamically stable patients with acute PE, as it is associated with a lower mortality, fewer recurrent thromboembolic events and less major bleeding than IV unfractionated heparin (UFH) [34, 44]. They have the added benefit of a greater bioavailability, more predictable pharmacokinetics, with once- or twice-daily fixed-dose administration, and a decreased likelihood of thrombocytopenia [34, 44]. There are different formulations of LMWH, each with their own dosing regimen and contraindications [44]. Fondaparinux has an equivalent profile (effectiveness, safety and administration) to LMWH [44].

Patients with low body weight (<45 kg women, <57 kg men) appear to be more exposed to the anticoagulant effects of LMWH [44]. There is significant accumulation in patients with severe renal insufficiency (clearance <30 ml/min), so requires adjustment of the dose. Therapeutic monitoring of LMWH is usually not necessary.

Intravenous *unfractionated heparin* (*UFH*) can be used when there is persistent hypotension due to massive PE, an increased risk of bleeding and concern about subcutaneous absorption (morbid obesity, anasarca) [44] or when thrombolysis is being considered [44]. A continuous IV infusion is associated with a lower incidence of major bleeding than intermittent IV bolus dosing [44]. UFH has the shortest duration of action and can be reversed by protamine sulphate in case of major bleeding [34, 44]. The UFH effect can be monitored by measuring the activated partial thromboplastin time (aPTT), which is more widely available than the anti-Xa assays required for therapeutic monitoring of LMWH and fondaparinux [34, 44]. Titration is then performed every 4–6 h to a aPTT goal of 1.5–2.5 times the control aPTT. Bedside measurement of activated clotting time (ACT) is used instead of aPTT in certain institutes and might be more practical in austere settings.

SC UFH has a safety and effectiveness comparable to LMWH but requires more frequent administration and is associated more often with thrombocytopenia [44]. APTT is not routinely monitored with these protocols [44]. In heparin-induced thrombocytopenia (HIT), antibodies are formed in an immunologic reaction during heparin therapy. Only a previous episode of HIT is a known risk factor.

Vitamin K Antagonists

Vitamin K antagonist, like warfarin, suppresses the production of vitamin K-dependent clotting factors (II, VII, IX and X), but also of anticoagulant factors like protein C and S. This mechanism causes a delay in action and can even induce a transient hypercoagulable state due to an imbalance between pro- and anticoagulant factors. Therefore an overlap with prior heparin treatment is needed until a therapeutic effect is achieved [34, 35, 44]. Vitamin K antagonists require regular monitoring of the international normalised ratio (INR), at least once every 4 weeks in stable conditions and more frequently when dose adjustments are necessary.

Direct Oral Anticoagulants (DOACs)

Recently new oral anticoagulants have been developed, which inhibit thrombin and Xa. They are currently not included in guidelines, but this might change [34, 35] as studies are starting to emerge showing similar efficacy with possibly less bleeding events compared to traditional VKA anticoagulation [35, 46]. These new drugs have a rapid onset of action, few drug or food interactions and a predictable pharmacokinetic profile and are used in fixed doses with no need for laboratory monitoring of their anticoagulant activity [35, 45, 46]. This makes them very interesting for use austere environment, although the cost is a major limitation [45].

Different formulations exist, although up till now only rivaroxaban has been approved for the treatment of acute PE [35, 44, 46]. It should not be used in patients with renal failure (creatinine clearance <30 ml/min), hepatic impairment or during pregnancy [44].

No specific antidotes to thrombin and Xa inhibitors exist [44, 46], so the optimal management of major bleeding under DOACs remains uncertain [45]. Possible recombinant proteins are being researched [45, 46]. Until these become available, non-specific agents such as PCC or activated PCC are advised as a first-line treatment [45], with recombinant activated factor VII as a second line [45]. Adjunctive therapy such as desmopressin or tranexamic acid may also be considered, although the data regarding their efficacy in DOAC-associated bleeding are even more scarce [45]. Despite this lack of data, the outcomes of patients with major bleeds on dabigatran appear no worse than those who have a major bleed on warfarin [46].

Thrombolytic Therapy

Thrombolytic agents accelerate the lysis of thrombi by activating plasminogen to form plasmin [47]. Thrombolytic therapy, followed by heparin [47], seems to lead to haemodynamic improvement in the short term, without significantly improving mortality or reducing the frequency of recurrent thromboembolism [34, 47]. Despite the lack of evidence, many clinicians believe that thrombolysis should be considered on a case-by-case basis, weighing the potential benefits against the risks [34, 47]. The only widely accepted indication is persistent hypotension or shock due to a massive PE [34, 47]. The main adverse event is bleeding [34, 47]; other complications include hypotension and allergic reactions [48]. Reduced dose thrombolysis in intermediate-risk patients is being researched [35]. As an alternative catheter-directed thrombolysis or catheter or surgical embolectomy could be used, if the expertise and resources are available [34, 47].

IVC Filter

An inferior vena caval (IVC) filter blocks the passage of large emboli from the pelvis or lower extremities before they reach the lung or fragment them, thus preventing (recurrent) massive PE [34, 48, 49]. It is considered in patients where anticoagulation is contraindicated or has failed or caused complications and when there is a high risk of recurrent VTE [34, 35, 43, 49]. There is however no hard evidence that filters to prevent death from pulmonary embolism [34, 43, 49], as a filter does not lessen the thrombotic predisposition or decrease the incidence of lower extremity DVT [34, 43]. Small thrombi can pass through the filter or collaterals and direct thrombus extension through the filter can occur [48, 49]. In situ thrombosis of the filter may even occur, due to the altered blood flow and the presence of a foreign object in a group of people with a thrombotic predisposition [49]. Prophylactic

VC filter insertion is controversial [49]. Filters are inserted percutaneously via a femoral or jugular approach and are usually positioned below the renal veins by fluoroscopy or ultrasound guidance [34, 48].

18.4.5 Non-thrombotic Pulmonary Embolism

Whereas in thrombotic PE the vascular obstruction is the main pathophysiological mechanism, in NTPE endothelial and parenchymal injuries, with inflammatory reactions in both systemic and pulmonary circulation, play a role [50]. When diagnosing NTPE, a clinician is again challenged by the low specificity of signs, symptoms and tests, contributing to underestimation of the frequency of the pathology [50]. Clinical history and active searching for underlying disease are important in making a differential diagnoses [50].

18.4.5.1 Fat Embolism Syndrome

A fat embolism syndrome (FES) is most commonly associated with closed long bone and pelvic fractures, but it can accompany many conditions, both traumatic (e.g. blunt trauma, orthopaedic procedures, burns) and non-traumatic (e.g. pancreatitis, lipid infusion and sickle cell crisis) [50–52]. It is a common, but underdiagnosed entity [52].

The pathophysiological mechanism is not clear [50–52]. A mechanical theory refers to obstruction of the pulmonary vasculature by fat droplets, with arteriovenous shunting or a patent foramen ovale responsible for neurological symptoms [40, 51]. The fat then causes local ischaemia, inflammation and platelet aggregation [50]. A second theory helps explaining non-traumatic forms of FES by stating that biochemical and inflammatory changes induced by trauma or sepsis release free fatty acids and chylomicrons systemically, which then coalesce, and give rise to the physiologic reactions described in the mechanical theory [50, 51]. This second theory helps explain the delay between time of injury and onset of symptoms [51].

As there are no clear diagnostic tests, a clinical diagnosis is necessary after exclusion of other aetiologies. A positive diagnosis of fat embolus syndrome is suggested when at least one major and four minor criteria are detected, in the presence of fat microglobulinaemia [50, 51]. The major criteria are respiratory symptoms, a petechial rash on nondependent, anterior skin areas (in less than 50 % of cases) and neurological disturbances [50–52]. Neurologic abnormalities typically occur after the development of respiratory distress and are often transient and fully reversible [51, 52]. Minor criteria include a rapid pulse, fever, retinal changes, renal dysfunction, jaundice, an acute drop in haemoglobin and/or platelets and an elevated sedimentation rate [50]. Other manifestations may include scotoma, lipiduria, fever, coagulation abnormalities and myocardial depression [52]. Onset is typically 24–72 h after the initial insult.

Imaging techniques are often normal, or unspecific changes are visible [50–52]. Fat globules can be recovered from the serum of more than 50 % of fracture patients without symptoms of FES [52], and the sensitivity and specificity of detecting fat droplets in broncho-alveolar lavage is unknown [52].

Prevention entails early immobilisation of fractures, preferably by operative correction rather than conservative [51, 52]. Intramedullary pressure needs to be reduced perioperatively, by placing a venting hole to drain the medullary cavity [51, 52]. A controversial prophylactic low-dose regimen might be considered for high-risk patients (e.g. closed long bone or pelvic fractures) [52].

Treatment is supportive [51, 52], including adequate oxygenation, haemodynamic stability, nutrition and gastric ulcer and thrombosis prophylaxis. Most patients recover fully with supportive care, making the routine use of corticosteroids in patients with confirmed FES controversial [51, 52]. In life-threatening cases, a trial of systemic corticosteroids could be considered, although optimal dosing and timing is unclear. High doses of *N*-acetylcysteine have also been suggested, based on a rat model [51].

18.4.5.2 Amniotic Fluid Embolism

This type of embolism is responsible for a significant portion of maternal deaths in Western medicine [50]. Although it is usually associated with active labour and delivery, it can also be provoked by trauma or manipulation of the pregnant uterus, e.g. during surgery [51].

AFE needs to be considered in pregnant women and within 48 h of delivery if acute medical treatment is needed for hypotension, respiratory distress, DIC or neurological symptoms like coma or seizures, without any other medical explanation [51]. Due to its fulminant nature (all deaths occur within 5 h of collapse), AFE is usually a clinical diagnosis [40, 51]. Detection of material like foetal squamous cells, meconium or lanugo hairs in the maternal pulmonary vasculature supports this diagnosis, although it is unspecific and should not rule out an alternative cause of instability [50, 51]. As with FES, the initial event triggers systemic reactions like complement activation, contributing to symptoms including disseminated intravascular coagulation (DIC) and leading to AFE being likened to an "anaphylactoid syndrome of pregnancy" [50, 51]. Respiratory, circulatory and neurological signs are usually the first to appear, although sometimes isolated DIC can be the initial presentation [50, 51].

Goals of treatment include maintenance of oxygenation, circulation and correction of the coagulopathy. Immediate caesarean section is advised in prepartum cases, as it facilitates resuscitation and limits foetal hypoxia [51], although in austere environments where transfusion and other supportive measures for both mother and child are limited, the risk-benefit balance might be different. Anecdotal treatment suggestions include corticosteroids and epinephrine, due to the similarities of AFE to anaphylaxis.

18.4.5.3 Other Aetiologies

Microorganisms such as bacteria, fungi and even parasites can migrate in the bloodstream [51]. Predisposing factors include underlying immune deficiencies, endocarditis, pneumonia, osteomyelitis, skin infections or infections of intravascular foreign devices like catheters [51, 51]. Embolisation of *foreign or particulate material* and *gas embolisms* are often iatrogenic or associated with intravenous drug abuse [50, 51].

References

1. Venticinque SG, Grathwohl KW, et al. Critical care in austere environment: providing exceptional care in unusual places. Crit Care Med. 2008;36(7 Suppl):S284–92.
2. Grathwohl KW, Venticinque SG. Organisational characteristics of the austere intensive care unit; The evolution of military trauma and critical care medicine, applications for civilian medical care systems. Crit care Med. 2008;36(7 Suppl):S275–83.
3. Rice DH, Kotti G, Beninati W. Clinical review: critical care transport and austere critical care. Crit Care. 2008;12(2):207. doi:10.1186/cc6782. Epub 2008 Mar 5.
4. Grissom TE, Farmer JC, et al. The provision of sophisticated critical care beyond the hospital: lessons from physiology and military experiences that apply to civil disaster medical response. Crit Care Med. 2005;33(1 Suppl):S13–21.
5. Haupt MT, Bekes CE, et al. Guidelines on critical care services and personnel: recommendations based on a system of categorization of three levels of care. Crit Care Med. 2003;31(11):2677–83.
6. Afshar M, Raju M, et al. Narrative review: tetanus – a health threat after natural disasters in developing countries. Ann Intern Med. 2011;154(5):329–36.
7. Lettieri CJ, Shah AA, Greenburg DL. An intensivist-directed intensive care unit improves clinical outcomes in a combat zone. Crit Care Med. 2009;37(4):1256–60.
8. Brilli RJ, Spevetz A, Braonson RD. Critical care delivery in the intensive care unit: defining clinical roles and the best practice model. Crit Care Med. 2001;29:2007–19.
9. Vincent JL. Give your patient a fast hug (at least) once a day. Crit Care Med. 2005;33(6):1225–9.
10. Vincent JL. "Let's give some fluid and see what happens" versus the "mini-fluid challenge". Anesthesiology. 2011;115(3):455–6.
11. Vincent JL, Weil MH. Fluid challenge revisited. Crit Care Med. 2006;34(5):1333–7.
12. Dellinger RP, Levy MM, et al. Surviving sepsis campaign: international guidelines for management of severe sepsis and septic shock: 2012. Crit Care Med. 2013;41(2):580–637. doi:10.1097/CCM.0b013e31827e83af.
13. Sexton DJ, Westerman EL. Tetanus. www.uptodate.com. Accessed July 2013.
14. Sheffield JS, Ramin SM. Tetanus in pregnancy. Am J Perinatol. 2004;21(4):173–82.
15. Hemila H, Koivulla T. Vitamin C for preventing and treating tetanus. Cochrane Database Syst Rev. 2013(11):CD006665. doi:10.1002/14651858.CD006665.pub3.

16. Rodrigo C, Samarkoon L, et al. A meta-analysis of magnesium for tetanus. Anaesthesia. 2012;67:1370–4.
17. Hassel B. Tetanus: pathophysiology, treatment and the possibility of using botulinum toxin against tetanus-induced rigidity and spasms. Toxins. 2013;5:73–83. doi:10.3390/toxins5010073.
18. Basu S, et al. Tetanus – still a scourge in the 21st century: a paediatric hospital-based study in India. Trop Doct. 2012;42(3):157–9. doi:10.1258/td.2012.110445. Epub 2012 Apr 19.
19. Bankole IA, Danesi MA, et al. Characteristics and outcome of tetanus in adolescent and adult patients admitted to the Lagos University Teaching Hospital between 2000 and 2009. J Neurol Sci. 2012;323:201–4.
20. Thwaites CL. Tetanus. Curr Anaesth Crit Care. 2005;16:50–7.
21. Kabura L, Ilibagiza D, et al. Intrathecal vs intramuscular administration of human tetanus immunoglobulin or equine tetanus antitoxin in the treatment of tetanus: a meta-analysis. Trop Med Int Health. 2006;11(7): 1075–81.
22. Relevant "summary of product characteristics" of medicinal products for human use. Approved for the Belgian market. Accessed through website of health ministry.http://ec.europa.eu/health/files/eudralex/vol--2/c/bluebox_06_2013_en.pdf.
23. Okoromah CAN, Lesi AFE. Diazepam for treating tetanus. Cochrane Database Syst Rev. 2004;(1):CD003954. doi:10.1002/14651858.CD003954.pub2.
24. Morgan GE, Mikhail MS, Murray MJ. Clinical anaesthesiology. 4th ed. New York: Lange Medical Books/McGraw-Hill Medical Pub. Division; 2006.
25. Thwaites CL, Yen LM, et al. Magnesium sulphate for treatment of severe tetanus: a randomised controlled trial. Lancet. 2006;368:1436.
26. World Health Organization. Pregnancy, childbirth, postpartum and newborn care: a guide for essential practice. Geneva: World Health Organization; 2003. p. B13.
27. Scharman EJ, Troutman WG. Prevention of Kidney injury following rhabdomyolysis: a systematic review. Ann Pharmacother. 2013;47:90–105.
28. Zimmerman JL, Shen MC. Rhabdomyolysis. Chest. 2013;144(3):1058–65.
29. Wolfson N. Amputations in natural disasters and mass casualties: staged approach. Int Orthop. 2012;36: 1983–8.
30. Vanholder R, Sever MS. Crush recommendations: a step forward in disaster nephrology. Nephrol Dial Transplant. 2012;27:1277–81.
31. Sever MS, Vanholder R. Management of crush victims in mass disasters: highlights from recently published recommendations. Clin J Am Soc Nephrol. 2013;8:328–35.
32. Sever MS, Vanholder R, et al. Recommendation of crush victims in mass disasters. Nephrol Dial Transplant. 2012;27 Suppl 1:i1–67 (free).
33. Taylor Thompson B, Hales CA. Overview of acute pulmonary embolism. Up to date. Accessed Jan 2014.
34. Strange JA, Pilcher D. Management of pulmonary embolism. Anaesth Intensive Care Med. 2014; 15(2):72–7.
35. Cohen AT, Debromirski M, Gurwith MMP. Managing pulmonary embolism from presentation to extended treatment. Thromb Res. 2014;133:139–48.
36. Taylor Thompson B, Hales CA. Diagnosis of acute pulmonary embolism. Wolters Kluwer Health, HQ: Alphen aan den Rijn, Netherlands; http://www.uptodate.com/home/about-us. Accessed Jan 2014.
37. Squizzato A, Rancan E, et al. Diagnostic accuracy of lung ultrasound for pulmonary embolism: a systematic review and meta-analysis. J Thromb Haemost. 2013; 11:1269–78.
38. Nazerian P, Vanni S, et al. Accuracy of point-of-care multiorgan ultrasonography for the diagnosis of pulmonary embolism. Chest. 2014;145(5):950–7. doi:10.1378/chest.13-1087.
39. Lichtenstein DA. Lung ultrasound in the critically ill. Ann Intensive Care. 2014;4(1):1. doi:10.1186/2110-5820-4-1.
40. Koenig S, Chandra S, et al. Ultrasound assessment of pulmonary embolism in patients receiving computerised tomography pulmonary angiography. Chest. 2014;145(4):818–23. doi:10.1378/chest.13-0797.
41. Chagnon I, Bounameaux H, et al. Comparison of two clinical prediction rules and implicit assessment among patients with suspected pulmonary embolism. Am J Med. 2002;113:269–75.
42. Comert SS, Caglaan B, et al. The role of thoracic ultrasonography in the diagnosis of pulmonary embolism. Ann Thorac Med. 2013;8(2):99–104. doi:10.4103/1817-1737.109822.
43. Tapson VF. Treatment of acute pulmonary embolism. Wolters Kluwer Health, HQ: Alphen aan den Rijn, Netherlands; http://www.uptodate.com/home/about-us. Accessed Jan 2014.
44. Valentine KA, Hull RD. Anticoagulation in acute pulmonary embolism. Wolters Kluwer Health, HQ: Alphen aan den Rijn, Netherlands; http://www.uptodate.com/home/about-us. Accessed Jan 2014.
45. Fontana P, Goldhaber SZ, Bounameaux H. Direct oral anticoagulants in the treatment and long-term prevention of venous thrombo-embolism. Eur Heart J. 2014; 35(28):1836–43.
46. Ghanny S, Crowther M. Treatment with novel oral anticoagulants: indications, efficacy and risks. Curr Opin Hematol. 2013;20(5):430–6.
47. Tapson FV. Fibrinolytic (thrombolytic) therapy in acute pulmonary embolism and low extremity deep vein thrombosis. Wolters Kluwer Health, HQ: Alphen aan den Rijn, Netherlands; http://www.uptodate.com/home/about-us. Accessed Jan 2014.
48. Fedullo PF. Placement of inferior vena cava filters and their complications. Wolters Kluwer Health, HQ: Alphen aan den Rijn, Netherlands; http://www.uptodate.com/home/about-us. Accessed Jan 2014.
49. Young T, Tang H, Hughes R. Vena caval filters for the prevention of pulmonary embolism. Cochrane Database Syst Rev. 2010;(2):CD006212.

50. Mongtagnana M, Cervellin G, et al. Pathophysiology, clinics and diagnostics of non-thrombotic pulmonary embolism. J Thromb Thrombolysis. 2011;31:436–44.
51. Jorens PG, Van Marck E, et al. Nonthrombotic pulmonary embolism. Eur Respir J. 2009;34:452–74.
52. Weinhouse GL. Fat embolism syndrome. Wolters Kluwer Health, HQ: Alphen aan den Rijn, Netherlands; http://www.uptodate.com/home/about-us. Accessed Jan 2014.
53. Atkinson W, Wolfe S, et al. Centers for disease control and prevention. In: Epidemiology and prevention of vaccine-preventable diseases. 11th ed. Washington, DC: Public Health Foundation; 2009 p.341–51. http://www.cdc.gov/vaccines/pubs/pinkbook/downloads/tetanus.pdf.

Management of Blood Loss in the Austere Environment

19

Zachary J. Kastenberg and Sherry M. Wren

The efficient management of blood loss in trauma patients is a complex and evolving science. The surgeon practicing in the austere environment must be acutely aware of the characteristics of available blood products, the local mechanisms for blood donation, and the region-specific risks associated with transfusion. The World Health Organization (WHO) advocates for the establishment of nationally coordinated blood transfusion services, collection of blood from voluntary unpaid donors, and quality-assured testing of all products for transfusion-transmissible infections [1]. In reality, however, few low-income countries are currently able to comply with these recommendations. This chapter will discuss existing evidence-based guidelines for transfusion in the trauma patient with interpretations of these guidelines for the practitioner confronted with resource limitations. The recommendations provided within this chapter are not intended to be prescriptive, but rather to serve as a guide to be tailored as appropriate to each individual setting.

Z.J. Kastenberg, MD (✉)
Department of Surgery, Stanford University School of Medicine, Stanford, CA, USA
e-mail: zjk1@stanford.edu

S.M. Wren, MD
Department of Surgery, Stanford University School of Medicine, Stanford, CA, USA

Parirenyatwa Hospital, Harare, Zimbabwe

19.1 Epidemiology

Injuries account for a disproportionate number of deaths in low-income countries, and hemorrhagic shock is a leading cause of death in trauma patients, second only to traumatic brain injury [2, 3]. In the setting of massive blood loss or active bleeding, blood products, whether component therapy or whole blood transfusion, are required to maintain oxygen delivery and to prevent the coagulopathy of trauma [4] (Fig. 19.1). In any setting, the potential physiologic benefit of transfusion must be weighed against the inherent risks of a transfusion: infectious, immunosuppressant, or transfusion reaction [1]. In much of the developing world, the much more pragmatic issue of blood availability must also be factored into the decision-making process.

In the developed world, the majority of transfusions are given as component therapy to patients over the age of 65 [1]. In the developing world, particularly sub-Saharan Africa, most transfusions are given as whole blood to children with malarial anemia, women with obstetrical complications, or patients of all ages with traumatic injuries [1]. In 2013, the WHO estimated that of the 107 million donations collected, half were collected in high-income countries representing only 15 % of the global population. The median blood donation rates in high-, middle-, and low-income countries were estimated at 39.2,

© Springer International Publishing Switzerland 2016

J.D. Robinson (ed.), *Orthopaedic Trauma in the Austere Environment: A Practical Guide to Care in the Humanitarian Setting*, DOI 10.1007/978-3-319-29122-2_19

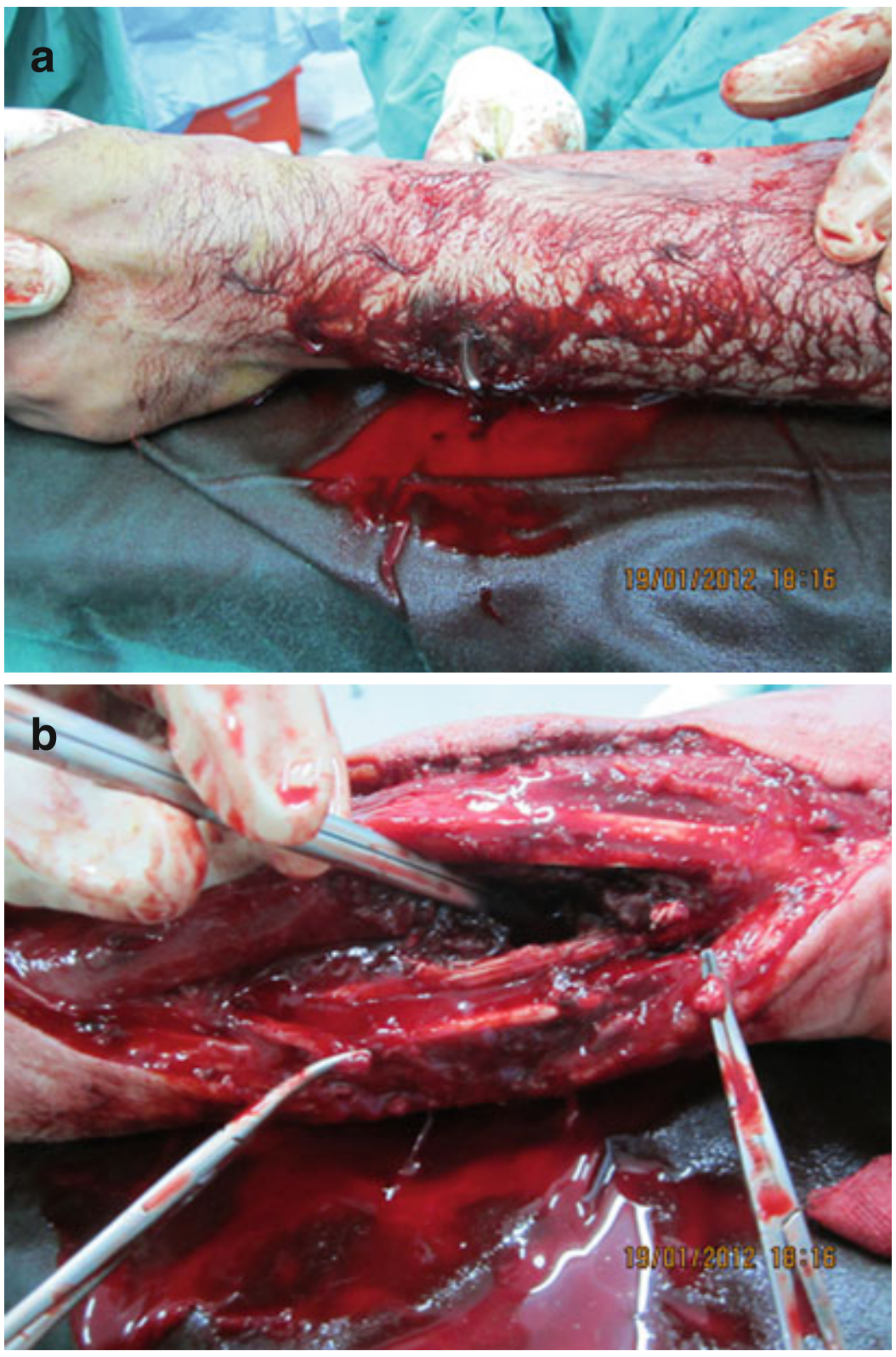

Fig. 19.1 (**a**) Bleeding secondary to ulnar artery transaction from a gunshot wound. (**b**) The ulnar artery has been ligated

12.6, and 4.0 per 1000 population, respectively [1].

While the reasons for this disparity are many, of equal importance to the practicing surgeon are the implications of this limited resource. In the absence of centralized transfusion services, many hospitals are tasked with procurement and screening of all locally used blood products. Ultimately, this means that 73 countries still obtain greater than 50 % of their blood products from family, replacement, or paid donations [1]. Furthermore, 24 % of all donations in low-income countries are procured without screening that meets the basic quality procedures recommended by the WHO for the human immunodeficiency virus (HIV), hepatitis C virus (HCV), and hepatitis B virus (HBV) [1].

19.2 Review of the Evidence

19.2.1 Transfusion Practices

The existing practice guidelines for blood transfusion in acute trauma and critical illness are based on evidence derived from studies conducted in non-resource-limited settings. These guidelines will form the basis of the discussion for this chapter and are supplemented with references from the developing world where possible.

19.2.1.1 Acute Hemorrhage

At the time of initial clinical presentation, the primary trauma survey should be performed with confirmation of the patient's airway patency and assessment of his or her breathing characteristics. The evaluation of the circulatory system begins with confirmation of cardiac function, followed by control of any active bleeding with direct pressure and tourniquet placement if possible.

After control of active hemorrhage, the level of hemorrhagic shock must be determined. The American College of Surgeons Advanced Trauma and Life Support (ATLS) protocol classifies hemorrhagic shock according to the volume of blood lost and the subsequent physiologic response (Table 19.1). Class I or class II hemorrhagic shock warrants an initial crystalloid

Table 19.1 Advanced trauma and life support classification of hemorrhagic shock

Class	Blood loss (% blood volume)	Physiologic response
I	0–15	Normal heart rate, normotensive, normal urine output, slightly anxious
II	15–30	Tachycardic, normotensive, normal urine output, slightly anxious
III	30–40	Tachycardic, hypotensive, decreased urine output, confused
IV	>40	Tachycardic, hypotensive, decreased urine output, lethargic

Adapted from Blood Loss Table, in American College of Surgeons Committee on Trauma [25], with permission bolus of up to two liters. In the absence of physiologic response or if the response is only transient, transfusion is indicated. Class III or class IV hemorrhagic shock requires immediate transfusion, often preceded by crystalloid bolus while waiting for the blood products to arrive at the bedside. The *Clinical Practice Guideline*: *Red Blood Cell Transfusion in Adult Trauma and Critical Care* classifies red blood cell transfusion in the patient with hemorrhagic shock as a level I recommendation (convincingly justifiable based on scientific evidence alone) [5, 6].

In the adult population, tachycardia is typically the first sign of impending hemodynamic collapse. Hypotension is an indication of more advanced hemorrhagic shock. Low urine output, however, is historically described as an extremely accurate indication of inadequate circulating blood volume, and early placement of a Foley catheter allows for close monitoring of urine output and enables a more accurate titration of ongoing volume resuscitation [7]. There is a growing body of evidence suggesting that the so-called damage control resuscitation may improve outcomes for trauma associated with hemorrhagic shock; in a recent prospective, randomized controlled trial, mean arterial pressures of 50 mmHg were associated with decreased blood product usage and decreased early perioperative mortality when compared to traditional mean arterial pressures of 65 mmHg [8].

In most resource-limited settings, whole blood will be the only available product for transfusion (Fig. 19.2). It is worth mentioning, however, that the proportionate administration of blood components is now favored for trauma resuscitation in settings where component therapy is available. A recent study showed decreased mortality and intensive care length of stay when a 1:1 ratio of red blood cells to fresh frozen plasma, as opposed to the more traditional 4:1 ratio, was administered to patients with trauma-induced coagulopathy requiring massive transfusion [9]. When component therapy is available, a 1:1:1 ratio (or as close to this ratio as possible) of red blood cells to fresh frozen plasma to platelets is preferred to limit the incidence of coagulopathy and to improve overall survival rates [10–13]. However, the addition of fresh whole blood to the transfusion protocol also appears to be superior to red blood cells alone or with fresh frozen plasma in the absence of platelets [14].


[redacted]

Fig. 19.2 Transfusion in the austere environment

Laboratory assessment should generally be considered adjunctive in the initial trauma resuscitation phase. There is no hemoglobin (Hb) cutoff at which transfusion should be given or withheld. Hemoglobin is an unreliable marker of blood loss in the acute setting as dilution of the plasma component occurs over a matter of hours. Likewise, analysis of the international normalized ratio (INR), prothrombin time (PT), and partial thromboplastin time (PTT) may be misleading as platelet dysfunction, hypothermia, and acidosis contribute heavily to the development of coagulopathy in the trauma patient.

Both serum lactate and base deficit have been recommended for use in evaluation of the response to initial resuscitation in the guidelines put forth by the European Task Force for

Advanced Bleeding Care in Trauma [15]. Both failure of normalization of lactate (<2 mmol/L) within 24 h of admission and a moderate (−6 to −9 mEq/L) or severe (>10 mEq/L) base deficit on admission are associated with poor outcomes in trauma patients [16, 17]. Depending on the local setting, these laboratory values may serve as adjunctive prognostic instruments, but the initial resuscitation should be guided by the surgeon's clinical assessment and close monitoring of the patients' physiologic response.

19.2.1.2 Guidelines for Transfusion After Stabilization

Over the past decade, the guidelines for transfusing patients without active hemorrhage have evolved. A landmark study by the Canadian Critical Care Trials Group in 1999 showed that a restrictive transfusion strategy with Hb threshold of 7 g/dL (with maintenance Hb goal of 7–9 g/dL) had similar outcomes when compared to the historical Hb threshold of 10 g/dL (with maintenance Hb goal of 10–12 g/dL) in the non-bleeding, critically ill patient [18]. The exception to this finding was in patients with acute myocardial ischemia or unstable angina. Restrictive transfusion practices are now commonplace for patients without active cardiac ischemia in developed countries. It seems prudent, therefore, to follow this strategy in settings with limited blood product availability and high rates of transfusion-transmissible infections.

19.2.2 Risks of Transfusion

19.2.2.1 Viral Infection

Blood products in any part of the world may harbor HIV, HCV, or HBV. Blood transfusions in resource-limited countries, however, involve increased risk given the endemicity of these viruses in such regions of the world. Exacerbating this problem is the large proportion of high-risk, paid blood donors. While the specific risks of virus transmission are region dependent, a recent analysis of sub-Saharan Africa estimated the risk of becoming infected with HIV, HCV, or HBV at 1, 2.5, and 4.3 per 1000 units transfused [19]. This equates to roughly 6650 HIV infections, 16,625 HCV infections, and 28,595 HBV infections caused by transfusion of each year. Such statistics highlight the necessity of transfusing only those patients with clear indications for transfusion and support restrictive transfusion goals for those without active bleeding.

19.2.2.2 Malaria

The malaria parasite is endemic to most of Sub-Saharan Africa and parts of both South America and Asia. A recent literature review of 17 studies spanning the years 1980–2009 identified a median malaria prevalence of 10 % among blood donors in sub-Saharan Africa with a range of 0.7 % in Kenya to 55 % in Nigeria [20]. Importantly, the prevalence of malaria in donated blood likely correlates to some degree with the prevalence in the general population. A large proportion of patients receiving transfusions in malaria-endemic regions are likely partially immune to the parasite, and the clinical relevance of this problem is not completely understood. Regardless, postoperative fever in the transfused patient must prompt consideration, and potential empiric therapy, for malarial parasitemia.

19.2.2.3 Bacterial Sepsis

A potentially fatal complication of transfusion is bacterial sepsis from blood contamination. While the clinical impact of this complication in the developing world is not well understood, existing data suggest that it may be a significant source of morbidity in the transfused population. Approximately 9 % of whole blood transfusions administered to children at a single hospital in Kenya were contaminated with bacteria of which 64 % were gram negative [21]. Such data speak to the importance of quality control mechanisms in the blood banking process and a low threshold for the empiric administration of antibiotics in the posttransfusion patient with early signs of sepsis.

19.2.2.4 Transfusion-Specific Complications

The two most common causes of death associated with transfusions are acute hemolytic reactions and transfusion-related acute lung injury (TRALI). Acute hemolytic reactions are the result of the presence of preformed recipient antibodies recognizing the major antigens on donor red blood cells. The cause is usually a clerical error resulting in the administration of ABO-incompatible blood or blood products. The clinical signs of an acute hemolytic reaction include chest tightness and pain, hypotension, decreased urine output, fever, and hemoglobinuria. In severe cases, renal failure and disseminated intravascular coagulation rapidly develop. The treatment is immediate cessation of the transfusion and aggressive supportive care.

TRALI is thought to be caused by donor antibodies against recipient leukocytes that localize to the pulmonary capillary beds and incite an inflammatory reaction. TRALI is diagnosed in patients with no preexisting lung injury who experience acute (within 6 h of transfusion) onset of hypoxemia and bilateral, non-cardiogenic pulmonary edema. The appearance of TRALI is often dramatic on chest radiography. As with acute hemolytic reactions, timely discontinuation of the transfusion is mandatory, and the treatment is mainly supportive. Mechanical ventilation is frequently required when available. Even with timely intervention, the mortality rate associated with TRALI is between 5 and 10 % [22].

19.3 Authors' Experience

The basic principles of managing blood loss include direct pressure, surgical ligation of identifiable arterial bleeding, and initial replacement of intravascular volume with crystalloid. These basic tenets of surgical practice remain true regardless of local environment. In resource-limited settings, particularly rural hospitals or clinics, temporizing measures are often lifesaving and may be required for prolonged periods while waiting either for supplies to arrive or for patient transfer to be arranged.

Tourniquets are of particular use in cases of extremity trauma and may be fashioned out of almost any material. Tourniquets have been extensively used in combat situations, but have also been found useful, potentially lifesaving, in the civilian setting [23]. Tourniquets are also associated with significant complications, however, and should be limited to settings in which direct pressure on arterial bleeding is insufficient to control hemorrhage [24]. There are numerous commercially available tourniquets, which, according to recent guidelines put forth by the American College of Surgeons Committee on Trauma, should be used whenever possible to avoid undue soft tissue ischemia that may be caused by improvised tourniquet devices [25]. However, in our experience, makeshift tourniquets can be lifesaving in severe cases of extremity trauma, and it becomes an issue of clinical judgment to weigh the effect of survival with potential limb loss against likely death in the absence of hemorrhage control (Fig. 19.3).

In cases of hemorrhagic shock that is either transiently responsive or nonresponsive to initial crystalloid bolus, the transfusion of packed red blood cells, fresh frozen plasma, and platelets in a 1:1:1 ratio is preferred as described above. Whole blood, however, is frequently all that is available and is sufficient. When the institutional blood supply is depleted, creativity on behalf of the surgeon may be required (Fig. 19.4). The recruitment of family members for donation, community blood donation requests, and calls to nearby health-care facilities may transiently increase local supply. Temporizing methods including tourniquet use, limb elevation, Trendelenburg positioning, delayed operations, and tolerance of anemia with continued crystalloid administration are continued until blood products are available.

An important aspect to the management of blood loss in the resource-limited setting is the pragmatic triage of the injured patient. In mass casualty settings, or many times even with just a few simultaneously injured patients, the local blood supply may be overwhelmed. The surgeon must be prepared to quickly identify those in most immediate need of transfusion and/or operation and prioritize resources, without exhausting valuable blood products in futile situations. The ability to quickly and efficiently navigate such difficult decisions often defines the narrow margin between clinical success and failure when resources are limited.

Fig. 19.3 Counting soaked sponges as a means to monitor blood loss

Fig. 19.4 This patient had an open femoral fracture and massive bleeding from several lacerations to his femoral artery. This was explored and repaired

References

1. Blood safety and availability. http://www.who.int/mediacentre/factsheets/fs279/en/index.html. Accessed 16 July 2013.
2. World Health Organization. World health statistics 2009: cause-specific mortality and morbidity. http://www.who.int/whosis/whostat/EN_WHS09_Table2.pdf. Accessed 3 Apr 2014.
3. Pfeifer R, Tarkin IS, Rocos B, Pape HC. Patterns of mortality and causes of death in polytrauma patients – has anything changed? Injury. 2009;40(9):907–11.
4. Hess JR, Holcomb JB. Transfusion practice in military trauma. Transfus Med. 2008;18(3):143–50.
5. Napolitano LM, Kurek S, Luchette FA, et al. Clinical practice guideline: red blood cell transfusion in adult trauma and critical care. J Trauma. 2009;67(6):1439–42.
6. Napolitano LM, Kurek S, Luchette FA, et al. Clinical practice guideline: red blood cell transfusion in adult

trauma and critical care. Crit Care Med. 2009;37(12):3124–57.

7. Shoemaker WC. Algorithm for resuscitation: a systematic plan for immediate care of the injured or postoperative patient. Crit Care Med. 1975;3(3):127–30.
8. Morrison CA, Carrick MM, Norman MA, et al. Hypotensive resuscitation strategy reduces transfusion requirements and severe postoperative coagulopathy in trauma patients with hemorrhagic shock: preliminary results of a randomized controlled trial. J Trauma. 2011;70(3):652–63.
9. Duchesne JC, Islam TM, Stuke L, et al. Hemostatic resuscitation during surgery improves survival in patients with traumatic-induced coagulopathy. J Trauma. 2009;67(1):33–7; discussion 37–9.
10. Beekley AC. Damage control resuscitation: a sensible approach to the exsanguinating surgical patient. Crit Care Med. 2008;36(7 Suppl):S267–74.
11. Borgman MA, Spinella PC, Perkins JG, et al. The ratio of blood products transfused affects mortality in patients receiving massive transfusions at a combat support hospital. J Trauma. 2007;63(4):805–13.
12. Holcomb JB, Jenkins D, Rhee P, et al. Damage control resuscitation: directly addressing the early coagulopathy of trauma. J Trauma. 2007;62(2):307–10.
13. Hess JR, Holcomb JB, Hoyt DB. Damage control resuscitation: the need for specific blood products to treat the coagulopathy of trauma. Transfusion. 2006;46(5):685–6.
14. Nessen SC, Eastridge BJ, Cronk D, et al. Fresh whole blood use by forward surgical teams in Afghanistan is associated with improved survival compared to component therapy without platelets. Transfusion. 2013; 53 Suppl 1:107S–13.
15. Spahn DR, Bouillon B, Cerny V, et al. Management of bleeding and coagulopathy following major trauma: an updated European guideline. Crit Care. 2013; 17(2):R76.
16. Abramson D, Scalea TM, Hitchcock R, Trooskin SZ, Henry SM, Greenspan J. Lactate clearance and survival following injury. J Trauma. 1993;35(4):584–8; discussion 588–9.
17. Davis JW, Parks SN, Kaups KL, Gladen HE, O'Donnell-Nicol S. Admission base deficit predicts transfusion requirements and risk of complications. J Trauma. 1996;41(5):769–74.
18. Hebert PC, Wells G, Blajchman MA, et al. A multicenter, randomized, controlled clinical trial of transfusion requirements in critical care. Transfusion Requirements in Critical Care Investigators, Canadian Critical Care Trials Group. N Engl J Med. 1999; 340(6):409–17.
19. Jayaraman S, Chalabi Z, Perel P, Guerriero C, Roberts I. The risk of transfusion-transmitted infections in sub-Saharan Africa. Transfusion. 2010;50(2): 433–42.
20. Owusu-Ofori AK, Parry C, Bates I. Transfusion-transmitted malaria in countries where malaria is endemic: a review of the literature from sub-Saharan Africa. Clin Infect Dis Off Publ Infect Dis Soc Am. 2010;51(10):1192–8.
21. Hassall O, Maitland K, Pole L, et al. Bacterial contamination of pediatric whole blood transfusions in a Kenyan hospital. Transfusion. 2009;49(12):2594–8.
22. Shander A, Popovsky MA. Understanding the consequences of transfusion-related acute lung injury. Chest. 2005;128(5 Suppl 2):598S–604.
23. Passos E, Dingley B, Smith A, et al. Tourniquet use for peripheral vascular injuries in the civilian setting. Injury. 2014;45(3):573–7.
24. Bulger EM, Snyder D, Schoelles K, et al. An evidence-based prehospital guideline for external hemorrhage control: American College of Surgeons Committee on Trauma. Prehosp Emerg Care Off J Natl Assoc EMS Physicians Natl Assoc State EMS Dir. 2014;18(2): 163–73.
25. American College of Surgeons Committee on Trauma. Advanced trauma life support student course manual. 9th ed. Chicago: American College of Surgeons Committee on Trauma; 2012.

Venous Thromboembolism Prophylaxis

20

Zachary J. Kastenberg and Sherry M. Wren

An understanding of the pathogenesis and prevention of venous thromboembolism (VTE) is of importance to the surgeon caring for patients in the developing world. A large proportion of patients encountered in the mass casualty setting, the emergency department, or the surgical clinic will present with either acute or subacute orthopedic trauma placing them a high risk for developing VTE. In the hospital, both medical and surgical patients are at significant risk for VTE. Estimates for rates of VTE in surgery patients without prophylaxis range from 10 to 40 % in general surgery to as high as 40–60 % after major orthopedic surgery [1].

There exists virtually no evidence originating from the developing world to guide the use of prophylactic anticoagulation. Therefore, it falls to the healthcare provider to interpret the appropriateness of evidence-based practices developed in the non-resource-limited setting within the local environment. This often requires the combined use of locally available pharmaceutical agents with either standard or improvised mechanical prophylaxis.

This chapter will summarize the *Antithrombotic Therapy and Prevention of Thrombosis, 9th Edition: American Association of Chest Physicians Evidence-Based Clinical Practice Guidelines* [2–4] and will be interspersed with interpretations of these guidelines for the practitioner confronted with resource limitations. The recommendations provided within this chapter are not intended to be prescriptive, but rather to serve as a guide to be tailored as appropriate to each individual setting.

20.1 Epidemiology

Venous thromboembolism is a common complication in the trauma patient. In the acute setting, VTE carries the potential for central propagation leading to extremity congestion, edema, and pain. The most feared complication is pulmonary embolism leading to cardiopulmonary compromise and possibly death. Long-term sequelae of lower extremity deep venous thrombosis include chronic venous insufficiency, extremity edema, and if left unchecked, chronic debilitating soft tissue ulceration. The inability to effectively manage these complications in the resource-limited setting highlights the importance of implementing prophylactic therapy whenever possible.

A prospective study of the incidence of VTE after major trauma in the United States revealed

Z.J. Kastenberg, MD (✉)
Department of Surgery, Stanford University School of Medicine, Stanford, CA, USA
e-mail: zjk1@stanford.edu

S.M. Wren, MD
Department of Surgery, Stanford University School of Medicine, Stanford, CA, USA

Parirenyatwa Hospital, Harare, Zimbabwe

© Springer International Publishing Switzerland 2016
J.D. Robinson (ed.), *Orthopaedic Trauma in the Austere Environment: A Practical Guide to Care in the Humanitarian Setting*, DOI 10.1007/978-3-319-29122-2_20

the near ubiquity of this problem [5]. With the caveat that this study used non-targeted imaging in asymptomatic patients, the results were quite impressive. Of the 716 patients admitted to a single trauma center, 201 (58 %) developed peripheral venous thrombosis and 63 (18 %) developed proximal venous thrombosis when no prophylactic anticoagulation was used. The incidence of thrombosis was dependent on location and type of injury with thrombosis identified in 65/129 (50 %) of those with chest or abdominal trauma, 49/91 (54 %) of those with major head trauma, 41/66 (62 %) of those with spinal trauma, and 126/182 (69 %) of those with lower-extremity orthopedic trauma. In a subsequent study of 312 patients with either pelvic, acetabular, femoral, or tibial fractures receiving either mechanical or chemical prophylaxis, 36 (12 %) developed deep venous thrombosis [6].

When limited to symptomatic VTE, the incidence is significantly lower, but still quite common in the major trauma population [3]. Across available studies of poly-trauma patients, the risk of symptomatic VTE ranges between 1 and 10 % with higher rates in those with spinal fractures (2 %), traumatic brain injury (5 %), and spinal cord injury (6 %) despite timely initiation of pharmacologic prophylaxis.

The epidemiology of VTE is less well defined in the developing world since these studies require access to significant numbers of subjects' medical records living in the same geographic areas. Two studies, one in California, USA, and the other in Waitemata, New Zealand, have looked at race and ethnicity in VTE prevalence [7, 8]. These studies demonstrate that African Americans have the highest risk of VTE, followed by Caucasians, Hispanics, and lastly Asians. Both of these studies included medical and surgical cases.

With respect to the trauma population, however, the dramatically increased risk of VTE exists regardless of race or ethnicity. In a post-mortem study of 989 patients in Nigeria, 29 cases of confirmed VTE were identified of which 24 % were associated with "neuromuscular paralysis"; 17 % associated with "multiple trauma of the pelvis, abdomen, and head"; and 14 % associated with "major surgery" [9].

20.2 Pathogenesis

The triad of venous stasis, endothelial injury, and hypercoagulable state, known eponymously as Virchow's triad, was first described in 1856 and continues to define the constellation of events that lead to VTE. In the absence of the muscular contractions that occur during normal movement in the non-debilitated individual, venous stasis allows for the aggregation of activated platelets and coagulation factors in the surgical patient.

Endothelial injury, a phenomenon present in all surgical patients, exposes procoagulant molecules such as tissue factor, von Willebrand factor, and collagen to circulating platelets and can serve as a nidus for thrombosis formation. Interestingly, postsurgical patients are at risk for developing thrombosis in veins distant from the surgical site. Microvascular injury does occur at these distant sites – the mechanism of which is not completely understood.

Hypercoagulable state often refers to genetic predispositions to thrombosis (e.g., Factor V Leiden, prothrombin gene mutation, and mutations to protein C, S, and antithrombin III, etc.). It is now appreciated, however, that even in the absence of such mutations the surgery patient is in a state of hypercoagulability from the endogenous release of tissue factor and from alterations in the normal coagulation and fibrinolysis pathways.

20.3 Review of the Evidence

When considering prophylactic anticoagulation in the patient with orthopedic trauma, the *American Association of Chest Physicians Evidence-Based Clinical Practice Guidelines* makes a clear distinction between the patient with multiple traumatic injuries and the patient with isolated lower extremity orthopedic trauma. In both cases, however, the existing evidence comes from non-resource-limited settings and in general is of relatively low quality with few adequately generalizable trials. Therefore, these guidelines must be interpreted with respect to each individual patient and the locally available resources.

When determining whether to initiate prophylactic anticoagulation in the poly-trauma patient, the surgeon must balance the estimated risk of VTE with the estimated risk of hemorrhagic complication. From the available evidence, as eluded to above, the estimated risk of symptomatic VTE is approximately 5 %, with rate of up to 10 % in those with spinal cord injuries. The risk of hemorrhage is directly related to the type and location of concomitant injury with higher bleeding risk associated with major head trauma, laceration of the liver or spleen, or the presence of an epidural hematoma. In the absence of pharmacologic prophylaxis, the estimated risk of hemorrhagic complication is approximately 1 %. This increases to approximately 3–4 % when chemical prophylaxis is initiated. The studies from which these data are derived typically define hemorrhagic complications as hemorrhagic changes identified by computed tomography scan of the head or as clinical bleeding requiring transfusion of more than 4 units of packed red blood cells.

It is estimated that the initiation of either pharmacologic or mechanical prophylaxis in major trauma patients with average-to-high risk of VTE and average bleeding risk will prevent between four and ten times the number of nonfatal thromboembolic events as the number of iatrogenic bleeding complications incurred. In the group at high risk of VTE, there is some evidence to suggest that the use of pharmacologic prophylaxis in combination with mechanical prophylaxis will provide added benefit [2–4]. For patients with major trauma at high risk of bleeding (i.e., those with major head injury or solid viscera injury), there is little relative benefit to pharmacologic prophylaxis. Mechanical prophylaxis in this group likely averts many thromboembolic events without significantly increasing risk of bleeding complications.

The *American Association of Chest Physicians Evidence-Based Clinical Practice Guidelines* include the following recommendations for patients with traumatic injuries (exclusive of those with isolated lower extremity injuries, see below):

- For major trauma patients, the use of low-dose unfractionated heparin (LDUH), low molecular weight heparin (LMWH), or mechanical prophylaxis with intermittent pneumatic compression (IPC) is recommended over no prophylaxis.
- For major trauma patients at high risk for venous thromboembolism (including those with acute spinal cord injury, traumatic brain injury, and spinal surgery for trauma), the addition of mechanical prophylaxis to pharmacologic prophylaxis is recommended when not contraindicated by extremity injury.

For major trauma patients in whom LDUH and LMWH are contraindicated, the use of mechanical prophylaxis with IPC is recommended over no prophylaxis. The addition of pharmacologic prophylaxis is recommended when the risk of bleeding diminishes. It should be noted that these recommendations are all classified as *Grade 2C*, which implies a basis on low- or very-low-quality evidence and existing uncertainty in the estimates of benefits and risks. When interpreting these recommendations with respect to the resource-limited setting, the major salient point is that mechanical prophylaxis is likely to be of benefit, with virtually no additional risk, in most situations when not contraindicated by extremity injury.

If pharmacologic prophylaxis is available, it should be initiated when no major risk of bleeding is present. However, one needs to consider the possibility of unidentified head or visceral injuries in settings where advanced diagnostic imaging is unavailable. A further consideration is the availability of blood products or intravenous fluids. If such resources are limited or unavailable, the ability to recognize and rescue a hemorrhagic complication is hindered and one may choose to err on the side of caution with respect to chemical prophylaxis.

The *American Association of Chest Physicians Evidence-Based Clinical Practice Guidelines* includes the following recommendations for patients with isolated lower extremity trauma:

- No prophylaxis rather than pharmacologic prophylaxis in patients with isolated lower-leg injuries requiring leg immobilization is recommended.

As with the guidelines for the major trauma population, this recommendation is classified as *Grade 2C* and should be interpreted with caution. It is known that the risk of VTE increases with the proximity of the injury and the degree of patient immobilization. With regard to the resource-limited setting, this patient group is at a much-decreased risk of VTE relative to the major trauma population, and pharmacologic agents should be reserved for those in higher-risk categories. The goals of care in this population should include early ambulation and return to daily activities as soon as possible.

Aspirin can also be considered as a prophylactic agent for VTE in this patient population. There has been a successful trial in orthopedic patients that demonstrated benefit of perioperative aspirin in VTE risk reduction. The Pulmonary Embolism Prevention (PEP) trial demonstrated efficacy of perioperative aspirin in preventing VTE after hip fracture surgery [10]. Treatment dose consisted of 160 mg aspirin daily for 5 weeks, starting with a presurgical dose. In the hip fracture population, there was a 36 % reduction in symptomatic DVT or pulmonary embolism (absolute risk reduction, 0.9 %; $P = .0003$) [10]. The cumulative data on aspirin resulted in the following Grade 1B recommendation in the *American Association of Chest Physicians Evidence-Based Clinical Practice Guidelines* for patients with hip fractures:

- In patients undergoing hip fracture surgery (HFS), the use of one of the following rather than no antithrombotic prophylaxis for a minimum of 10–14 days, LMWH, fondaparinux, LDUH, adjusted-dose VKA, *aspirin* (all Grade 1B), or an IPCD (Grade 1C), is recommended [3].

20.4 Authors' Experience

The patient with multiple traumatic injuries presents a challenging scenario in the developing world for prevention of VTE since resource availability varies contextually. Most anticoagulation guidelines are developed assuming unlimited access to common heparin-based anticoagulants, mechanical compression devices, and intravenous fluid or blood products if needed to rescue the patient from bleeding complications. The reality in the developing world is that in many situations, *none* of these resources are available. Factors such as lack of a constant source of power for pneumatic compression devices or sufficient supply chains and proper drug storage greatly influence available resources. In some settings, none of these things may be available leaving early mobilization, when possible, the only means by which VTE prophylaxis may be addressed.

A consideration for pharmacologic prophylaxis in the absence of heparin derivatives is standard aspirin. Antiplatelet agents are used as second-line prophylactic anticoagulants in elective orthopedic surgery when patients are unable or refuse to take injectable agents and when the newer oral anticoagulants are unavailable. While there is limited evidence for antiplatelet use as primary prophylaxis in the trauma patient, it likely provides some marginal benefit.

If the setting has no intermittent pneumatic compression devices or any chemoprophylaxis agents, elastic compression stockings can be used if available. Care must be exercised in the use of these stockings because there have been reports of skin breakdown or necrosis from the stockings.

In a large trial using thigh length gradual compression stockings for DVT prevention in stroke patients, there was a 5.1 % incidence of skin breaks, blisters, ulcers, or necrosis [11]. Stockings should be applied with care to avoid folds in the fabric, and skin should be examined at least daily to make sure there are no developing skin issues. If none of the above are available, mobilization by staff or family members should be encouraged. If the patient can ambulate, that is best, but if they are unable to do to fractures or spinal injuries, then active and passive range of motion exercises should be done on the extremities.

Prophylactic anticoagulation, like most aspects of surgical care in the developing world, provides the opportunity for the surgeon to make use of his or her creativity and ingenuity after assessing available resources. Attention to VTE prophylaxis is a critical consideration, regardless of setting, for anyone taking care of surgical and trauma patients and can help avert potential morbidity and mortality in these patients.

References

1. Geerts WH, Pineo GF, Heit JA, et al. Prevention of venous thromboembolism: the seventh ACCP conference on antithrombotic and thrombolytic therapy. Chest. 2004;126:338S–400.
2. Guyatt GH, Akl EA, Crowther M, Gutterman DD, Schuunemann HJ. Executive summary: antithrombotic therapy and prevention of thrombosis, 9th ed: American College of Chest Physicians Evidence-Based Clinical Practice Guidelines. Chest. 2012;141(2 Suppl):7S–47.
3. Falck-Ytter Y, Francis CW, Johanson NA, et al. Prevention of VTE in orthopedic surgery patients: antithrombotic therapy and prevention of thrombosis, 9th ed: American College of Chest Physicians Evidence-Based Clinical Practice Guidelines. Chest. 2012;141(2 Suppl):e278S–325.
4. Gould MK, Garcia DA, Wren SM, et al. Prevention of VTE in nonorthopedic surgical patients: antithrombotic therapy and prevention of thrombosis, 9th ed: American College of Chest Physicians Evidence-Based Clinical Practice Guidelines. Chest. 2012;141(2 Suppl):e227S–77.
5. Geerts WH, Code KI, Jay RM, Chen E, Szalai JP. A prospective study of venous thromboembolism after major trauma. N Engl J Med. 1994;331(24):1601–6.
6. Stannard JP, Singhania AK, Lopez-Ben RR, et al. Deep-vein thrombosis in high-energy skeletal trauma despite thromboprophylaxis. J Bone Joint Surg Br. 2005;87(7):965–8.
7. Liao S, Woulfe T, Hyder S, Merriman E, Simpson D, Chunilal S. Incidence of venous thromboembolism in different ethnic groups: a regional direct comparison study. J Thromb Haemost. 2014;12:214–9.
8. White RH, Keenan CR. Effects of race and ethnicity on the incidence of venous thromboembolism. Thromb Res. 2009;123 Suppl 4:S11–7.
9. Sotunmbi PT, Idowu AT, Akang EE, Aken'Ova YA. Prevalence of venous thromboembolism at postmortem in an African population: a cause for concern. Afr J Med Med Sci. 2006;35(3):345–8.
10. Pulmonary Embolism Prevention (PEP) trial Collaborative Group: prevention of pulmonary embolism and deep vein thrombosis with low dose aspirin: Pulmonary Embolism Prevention (PEP) trial. Lancet. 2000;355(9212):1295–302.
11. The CLOTS Trials Collaboration. Effectiveness of thigh-length graduated compression stockings to reduce the risk of deep vein thrombosis after stroke (CLOTS trial 1): a multicentre, randomised controlled trial. Lancet. 2009;373(9679):1958–65.

Microbiology in the Low-Resource Environment

21

Sandro Contini

In resource-limited settings, trauma-related infections are a leading, and often avoidable [1], source of complications and increased disability. The incidence of infections is significantly higher than in high-income countries [2] and is linked to various factors such as poor environmental hygiene, scarce resources of local health systems, malnutrition, concomitant chronic diseases, impaired immunity, late admissions, confidence in traditional healers, and poor follow-up.

A sound knowledge of the mechanisms of trauma and infection, and of the specific environment's and wound's microbiology/flora, is therefore valuable for health workers in such settings, always remembering that only a balanced approach between pharmacological treatment and a meticulous, proper surgical care will avoid such disaster as infections in austere environment [3–6].

21.1 Contamination, Colonization, and Infection

Microbes, dirt, clothing, and other materials carried into a wound are contaminants and open fractures are by definition contaminated. When nonreplicating bacteria on the wound surface *do not* initiate a host response, the microbiological term of colonization is applied. The critical inoculum for infection in a contaminated wound is unknown; usually no invasion of viable tissue takes place until the number of bacteria reaches a threshold of 10^6/g of tissue, but the presence of crushed tissues, dirt, and other foreign materials lowers the threshold of infection and invasion, by providing an environment where bacteria can grow and replicate, thus initiating a host reaction, with the common clinical features of pain, wound discharge, and fever. Accordingly, infection must be considered a clinical event modulated by microbe-related (toxins, enzymes, virulence) and host-related risk factors (malnutrition, immunocompetence).

Six hours has been considered by definition a critical period after contamination, after which the efficacy of surgery and antibiotics to prevent infection decreases with time from injury, while the bacterial load increases exponentially [7, 8]. However, it is probably restrictive to argue for or against a strict "six-hour rule" in the management of open injuries and fractures. Adequacy of debridement and timeliness of soft tissue coverage may play an equally important role as time from injury in the prevention of infection. From a practical point of view, although in resource-rich environments a short waiting between admission and debridement likely does not increase the incidence of

---

S. Contini, MD
Department of Surgical Sciences, Parma University Hospital, Parma, Italy
e-mail: sandrocontini46@gmail.com;
sandro.contini@unipr.it

© Springer International Publishing Switzerland 2016
J.D. Robinson (ed.), *Orthopaedic Trauma in the Austere Environment: A Practical Guide to Care in the Humanitarian Setting*, DOI 10.1007/978-3-319-29122-2_21

infection, in austere settings early debridement and wash out should be favored, due to the usual late presentation, the often unknown exact time of injury, the frequent previous mismanagement, and the gross contamination of tissues. Consequently, in austere environments, the key message is that any patient with an open fracture or wound should be always be evaluated and taken to the operating room on an urgent basis: the sooner a contaminated wound is properly debrided and antibiotic treatment is begun, the lower incidence of infection will probably be achieved.

21.2 Mechanism of Injury and Its Relation to Infection

For practical reasons, we distinguish high-energy transfer wounds, usually in military or violence settings, due to high-energy bullets, blasts, but also in civilian road traffic accidents and in natural disasters like earthquakes and tsunamis, and low-energy transfer wounds, typically consequent to lower-energy gunshot or minor road traffic accidents, falls, working accidents, or civil violence.

21.2.1 High-Energy Transfer Wounds

These wounds are characterized by heavy contamination and tissue destruction, with an extremely high risk of infection. Bacteria are carried into the tract by the projectile and are sucked in by the negative pressure of the temporary cavity at both entrance and exit wounds. Moreover, the usually high amount of destroyed and avascular soft tissue is the perfect culture media for the growth of bacteria. Mines and other explosive devices increase the risk of infection from ground material or other matter placed in the devices (e.g., animal carcasses, discarded dirty syringes, or fecal material) because the energy of the explosion drives contaminants deep into the soft tissues well past the obvious injury zone [9]. The likelihood of infection may depend on the different varieties of contaminating soils, associated with different organisms – which can vary according to weather and season. In addition, the chemical composition of some soils can inactivate antibodies and impair leukocyte phagocytosis [10, 11]. Wound infection remains the greatest risk to life and restoration of function in the combat casualty who survives beyond the first few hours from point of wounding [12–14] and is the most common reason for infectious disease consultations in military hospitals [15].

In natural disasters, the unusual high influx of patients, often simultaneously, lack of water supply, lack of equipment and of trained staff, and breakdown of communication and infrastructure make the risk of infection very high [16]. After an initial scenario with an often chaotic or very challenging access to care, in a second phase, the victims arrive with delayed and neglected presentation, both conditions strongly influencing the high wound infection rate up to 66.2 % [17].

21.2.2 Low-Energy Transfer Wounds

21.2.2.1 Small-Fragment (Shrapnel) Wounds

These are typically low-energy transfer extremity wounds, with usually no deep contamination by extrinsic material. They are typically observed in victims at relatively long distance from an explosion (Fig. 21.1). Although they could even carry organic debris, an accurate cleaning and brushing but not a true debridement has become accepted in military practice, provided antibiotic coverage is administered [18].

21.2.2.2 Low-Energy Transfer Gunshot

These injuries usually require a relatively less aggressive surgical approach in developed countries [19, 20] with an overall low infection rate [21, 22]. In developing countries where delayed presentation, lack of wound cleansing before hospital admittance, and low compliance after discharge are quite common, a more aggressive strategy may be necessary.

Fig. 21.1 Low-energy transfer extremity wounds, with usually no deep contamination by extrinsic material, typically observed in victims at relatively long distance from an explosion

21.2.2.3 Road Traffic Accidents

The likelihood of infection may be high in developing countries, even for low-energy road traffic injuries, due to gross contamination, frequent late admissions due to difficult/insufficient transport, and recurrent host-related factors such as malnutrition, chronic diseases, and impaired host immunity [23].

21.3 Wound Pathogens

Microbiology studies of wounds in austere environment may have several drawbacks, either from the difficulty to differentiate between incidental bacterial colonization and true infection or from the relative presence of different bacterial species varying with time, geography, topology of the terrain, and climate. Moreover, wound contaminations and infections are not static and evolve with time [8].

A polymicrobial contamination, particularly *Clostridia* and β-hemolytic streptococcus, is seen at the instant of wounding, with the risk of invasive infection occurring within a few hours [8]. This first contamination is followed by a self-contamination from the skin and gastrointestinal flora and, finally, by hospital-acquired nosocomial infection, which strongly emphasizes the imperative roles of hygiene and environmental control measures [24].

In World War I, sporulating anaerobes (e.g., *Clostridium* spp.) and *Streptococci* were responsible of the initial infection, followed after a week by non-sporulating bacteria of fecal origin (e.g., *Escherichia coli* and *Klebsiella* spp.) and finally by pyogenic organisms (e.g., *Staphylococcus* spp. and *Streptococcus pyogenes*) [25]. Aggressive surgical debridement strongly reduced the clostridial gas gangrene during World War I, and the use of penicillin in World War II resulted in the decline of infections due to pyogenic organisms [26]. Currently, the organisms traditionally associated with infection in combat-related trauma wounds involve *Staphylococcus aureus*, often methicillin-resistant (MRSA), *S. pyogenes* (β-hemolytic streptococcus), and Gram-negative bacteria such as *Pseudomonas aeruginosa, Enterobacter* spp., *E. coli,* and *Klebsiella* spp. [27, 28]. They are commonly drug resistant [29–32]. Among them, the Gram-negative *Acinetobacter baumannii* is observed with increasing frequency, as the result of nosocomial transmission and not of initial contamination [30]. It comes from the soil, colonizes easily, and has a high aptitude to develop resistance. The widespread availability of antibiotics – and their abuse – even in developing countries, has indeed complicated the bacteriology of wounds because of the selection of resistant strains. Nosocomial transmission of multiple drug-resistant (MDR) organisms is an important factor in the pathogenesis of a wound infection. The organisms contaminating an open fracture on presentation do not represent the microbes that will eventually cause infection, mostly triggered by nosocomial bacteria [33], therefore questioning the utility of early peri-debridement tissue samples and cultures [14], a rather uncommon luxury in developing countries [34]. Considering the very poor hygiene conditions in these settings and hospitals, nosocomial infections and the likelihood of contamination by new different bacteria are quite high.

A high rate of fungal infections has been reported after blast injuries in conflict settings [35], as in civilian severe extremity injuries in farms [36], although injury mechanisms are different as shockwave and fragmentation injuries are not present in farm injuries. Bacterial flora has been found different in war wounds of troops and in the civilian population [37]. Wound cultures from US troops in Iraq were growing mainly Gram-positive bacteria, while cultures from similar wounds in the Iraqi population included mostly Gram-negative bacteria, both groups being resistant to a broad array of antimicrobial agents [29]. Similarly, Gram-negative bacteria accounted for almost 80 % of infections in civilian wounds after the Wenchuan earthquake in China [17], and a high prevalence of Gram-negative bacteria (around 80 %) was found after the Haiti earthquake and in other disasters (Table 21.1) [38–45].

Contamination with fecal bacteria plays very likely an important role, but these pathogens are usually resistant to the antimicrobials suggested for managing this scenario by the Centers for Disease Control and Prevention [46] and the World Health Organization [47] that primarily target Gram-positive pathogens. Accordingly, teams responding to future earthquakes should be equipped with appropriate antibiotics to tailor their treatment to local pathogens [48].

The use and utility of tissue culture is controversial. Based upon available literature regarding combat-related and civilian open fractures, routine collection of pre- or post-debridement cultures is not recommended at any level of care for combat-related extremity injuries. If wound surveillance cultures are obtained at Level IV or V medical care as part of infection control procedures, these findings should not be used as part of clinical decision making [31].

Table 21.1 Percentage of Gram-negative and Gram-positive bacteria isolated from wounds of disaster victims

Author	Place and year	G pos %	G neg %
Keven 2003 [39]	Marmara-Turkey 1999	11.9	87.3
Oncül 2002 [40]	Marmara-Turkey 1999	18.8	81.3
Kazancioglu 2002 [41]	Marmara-Turkey 1999	17	79
Hiransuthikul 2005 [42]	Tsunami 2004	4.5	95.5
Kiani 2009 [43]	India-Pakistan 2005	11	89
Tao 2009 [44]	Wenchuan China 2008	24.4	73.2
Ran 2009 [45]	Wenchuan China 2008	16	82
Miskin 2010 [38]	Haiti 2010	11	89

In chronic infections and in mismanaged wounds, some bacteria develop microbial communities, referred to as biofilms, within the wound environment. Microbial biofilms are implicated in both the infection and failure to heal, by preventing antibiotics, macrophages, leukocytes, and antibodies from attacking them [49, 50]. Accumulation and dispersal of high numbers of microorganisms, as well as the presence of wide-ranging microenvironments facilitating multiple selection of bacteria, are the main mechanisms which facilitate pathogen survival [51]. A thorough debridement has a crucial role either in the prevention of biofilms or in its physical disruption, returning the bacteria back into the log phase when they are more susceptible to antibiotics and the natural defense mechanisms [50].

21.4 Severe Acute Infections Following Trauma

21.4.1 Anaerobic Soft Tissue Infection

21.4.1.1 Gas Gangrene

Gas gangrene is a rapidly spreading edematous myonecrosis occurring characteristically in severe wounds in muscles contaminated with pathogenic obligatory anaerobes, particularly *Clostridium perfringens,* a Gram-positive, true saprophyte spore-forming bacillus, ubiquitous in both soil and dust [52]. Aerobic bacterial flora in the wound uses the available oxygen, therefore promoting the anaerobic environment required by *Clostridia*. Disrupted or necrotic tissue provides the necessary enzymes and a low oxidation/reduction potential, allowing germination of spores. Foreign bodies and premature wound closure reduce the spore inoculum necessary to cause infection [8], a risk further increased by the prolonged application of tourniquets, tight plasters, and the presence of compartment syndrome [8].

The organism has a local action, producing acid and gas from muscle glucose and digesting muscle proteins, and a distant action, due to a soluble, potent toxin, responsible of further tissue destruction and profound toxemia, which come also from the products of the muscles breakdown. The clinical course depends on the spread of its toxins [53], although even in well established gas gangrene, the bloodstream is rarely invaded by *Clostridia* until immediately before death. Myonecrosis has a rapid onset (<3 days after injury) with extreme incubation periods from 1 h to 6 weeks [54].

Toxemia develops rapidly and mortality is high when severe toxemia supervenes. All patients with severe wounds should receive prophylactic antibiotics against *Clostridia* (penicillin, metronidazole, or erythromycin), but they are effective only if they reach tissues with a good blood supply and tissue perfusion: therefore, early debridement and washout is the mainstay of treatment. Established gas gangrene necessitates a thorough excision of dead tissue, which may require urgent amputation.

21.4.1.2 Tetanus

Clostridium tetani is a strict anaerobe producing an extremely potent toxin that spreads along peripheral nerves to the spinal cord and brainstem. Once the toxin is fixed to the nerves, antitoxin cannot longer neutralize it. The toxin affects the motor end plate by inhibiting cholinesterase, with consequent increase of acetylcholine and tonic muscle spasm. A hyper excitability of lower motor neurons is responsible of muscular rigidity and dysfunction of activity in antagonistic muscles, hence triggering unopposed reflex activity and the typical spastic phenomena (Fig. 21.2). The incubation period is 3–21 days but can be as short as 1 day to as long as several months. Tetanus is preventable with immunization, but in developing countries, the frequent disruption of public health programs keeps the risk of tetanus still high, and such possibility should be always considered, immunizing the patient at the time of observation [55], together with an aggressive debridement of the contaminated wound, ensuring the removal of all necrotic, avascular tissue, even in small wounds, which should never be sutured (Fig. 21.3).

Fig. 21.2 Opisthotonus in a young boy with tetanus following a penetrating injury to the right upper limb

21.4.1.3 Fasciitis and Myonecrosis

Streptococcal fasciitis. Group A *Streptococcus* (GAS) (*Streptococcus pyogenes*) and more recently Group B *Streptococcus* (GBS) [56] in pregnancy, in the neonatal period, and in immunocompromised adults, are the organism most frequently associated with bacterial fasciitis and myonecrosis. The powerful toxins trigger a rapid progression from local to systemic infection, which clinically resembles gas gangrene: short incubation time (3–4 days), severe swelling, tense and copper-colored skin, and sometimes the presence of gas. The initial lesion is mild erythema at the site of injury, which over the next 24–72 h undergoes a rapid evolution with pronounced inflammation. Prompt, aggressive surgical exploration and debridement (Fig. 21.4) are mandatory. High-dose penicillin and clindamycin are appropriate. Systemic toxicity can be severe, and mortality rate is high [57].

Fig. 21.3 Mismanagement of wounds, even small ones such as this one at the wrist which was primarily sutured, causes severe complications such as tetanus as observed in Fig. 21.2

This polymicrobial infection, which should be considered a true surgical emergency, is mostly found in immunocompromised patients. It is commonly initiated by Group A *Hemolytic Streptococci* or *Staphylococcus aureus,* acting synergistically with anaerobic organisms including *Bacteroides, Clostridium*, and *Peptostreptococcus,* as well as *Enterobacteriaceae, Coliforms, Proteus, Pseudomonas*, and *Klebsiella* [58].

The necrotic process interests the skin, with altered cutaneous microcirculation, subcutaneous tissues, and fascia but not the muscles. It can rapidly progress to systemic toxicity with compromise of systemic circulation and can be life-threatening. Pain is disproportionate to local findings, crepitus can often be felt, and soft tissue air is present on plain X-rays. The skin is discolored (blue, purple, or black) with blistering lead-

Fig. 21.4 Streptococcal fasciitis with myonecrosis. Prompt and aggressive surgical exploration and debridement are mandatory

ing to hemorrhagic bullae and induration. The diagnosis is primarily a clinical one, and early surgical treatment should be performed, including aggressive excision of necrotic tissue, relief of tension, and even amputation. Triple intravenous antibiotics (penicillin/cefazolin, gentamycin, and metronidazole), together with fluid transfusion and supportive treatment, are typically required.

21.4.2 Joint Infections

21.4.2.1 Open Joints

Penetration into a joint requires a thorough irrigation and removal of foreign bodies or free fragments. Synovial membranes should be closed; if this is not possible, the capsule alone should be sutured or covered with flaps.

21.4.2.2 Septic Arthritis

Septic arthritis (usually from *Staphylococcus aureus)* has been reported in western countries in children after a closed fracture involving a joint [59] and such possibility should be kept in mind also in developing countries. Clinical suspicion should prompt immediate synovial fluid aspiration under aseptic conditions, and the definitive diagnosis would require, if possible, identification of bacteria in the synovial fluid by Gram's stain or by culture.

Septic arthritis not linked to a trauma is fairly common in developing countries, especially in children and in sub-Saharan Africa, usually secondary to a transient or persistent bacteremia due to a microtrauma in a dirty environment. Alternatively, in children, a focus of osteomyelitis may spread to the adjacent joint. *Staphylococci* are the most common organisms, followed by Group A hemolytic streptococci in adults; Group B, C, and G *streptococci* and Gram-negative bacilli are reported in compromised hosts and in the elderly. Gram-negative bacilli and *Haemophilus influenza* are the most common pathogens in the newborn and in all children under age 5 years. *Salmonella* arthritis, involving especially the shoulder, has been observed in Africa during the rainy season among children younger than 5 years, often underweight and anemic [60].

Gonococcus arthritis has been reported in Australia's aboriginals at a greater prevalence respect to non-aboriginals. During the past two decades, Lyme disease and arthritis associated with HIV infection have arisen as important examples of infectious agents causing arthritis; mycobacterial and fungal arthritis have reemerged, partly related to the worldwide epidemic of HIV infection [61].

Preexisting joint disease, diabetes mellitus, and rheumatoid arthritis are all predisposing factors as well as chronic liver disease with portal hypertension, for the spontaneous bacteremia linked to the translocation of bacteria (*Escherichia coli*) from the gut lumen [60].

When Gram's stain and cultures are not available, broad-spectrum parenteral antibiotics should be started empirically. Most antibiotics penetrate well into the inflamed joints during either parenteral or oral administration. Intra-articular antibiotic instillation should never be performed as it may cause a chemical synovitis. Closed needle aspiration is often unsuccessful, and early open surgical drainage is often recommended, especially in hip infections [62]

21.4.2.3 Rheumatic Arthritis

Acute rheumatic fever (ARF) due to *Streptococcus* type A infection is endemic in many parts of the developing world but in primary care settings is frequently under diagnosed [63]. It should be always considered in children and young individuals presenting with fever, history of sore throat, and swollen (and painful) joints. Transient involvement of several joints, mainly knee, ankle and shoulders, is characteristic. In doubtful cases, penicillin should be started to prevent cardiac lesions.

21.5 Microbiological Cover

Antimicrobial agents are merely an adjunct to proper wound care, never replacing poor surgical technique. Aggressive and meticulous debridement is therefore compulsory, aiming to remove the non-vital tissues and helping to prevent the biofilms-complex microbial communities that are known to contribute to delayed wound healing and chronicity of wound infections.

The severity of contamination and wounds in austere settings may lead to use massive doses of broad-spectrum antimicrobials, attempting to "sterilize" the wound and favoring a false security with less reliance on good surgical technique, furthermore complicating the bacteriology of wounds because of the selection of resistant strains. Moreover, antibiotics usually do not reach the source of infection and are effective only in the contusion and concussion zones around the wound. Yet, early (as soon as possible) administration of systemic antibiotics may delay invasive infection, preventing spread to the blood stream [64], while waiting for the mandatory surgical management.

21.5.1 Timing

Antibiotics should be given as soon as possible following injury. Currently, US army recommends a rapid (<3 h after injury) delivery of oral or intravenous antimicrobial therapy, even immediately at the scene of injury if the tactical situation may preclude rapid evacuation [65]. The Eastern Association for the Surgery of Trauma (EAST) shares this view, [66], and this approach is supported by a Cochrane systematic review [67]. Any delay beyond 6 h increases greatly the risk of infection [68–70].

21.5.2 Duration

Ideal duration of antibiotic treatment is not clearly defined. A single dose of antibiotic, in both military and civilian settings, within 1 h from injury, has been reported to be a sufficient prophylaxis against infection, without evidence to support continuing antibiotics during evacuation [71]. If more than one broad-spectrum antibiotic is administered for more than 24 h, no additional protection has been reported against sepsis, organ failure, and death, whereas the probability of antibiotic-resistant infections can increase [72]. The International Committee of the Red Cross (ICRC) protocol for open fractures and limb wounds extends antibiotic treatment for 5 days (Table 21.2) [8], while Medecins Sans Frontieres (MSF) recommends administering antibiotics for 48 h after open fractures, increasing to 72 h in severe open fractures and high-velocity gunshot wounds, but possibly extending to 3–5 days according to the clinical evolution (as in Box 21.1) [73]. Although these protocols are not definitely evidence based, nevertheless both originate from a sound, extensive clinical practice in austere environments.

21.5.3 Which Antibiotic?

Optimal antibiotic treatment is not defined yet, although several options have been proposed:

- Narrow-spectrum agents at the time of initial surgical evaluation, typically penicillin with a beta-lactamase agent [74];
- First-generation cephalosporin: cefazolin [75]
- Combination of a first-generation cephalosporin and an aminoglycoside [76]
- Monotherapy with a first-generation cephalosporin for type-I and II fractures with the addition of an aminoglycoside [77] and metronidazole [73, 75] for type III fractures
- Cephalexin and metronidazole in case of predominant incidence of blasts and mine injuries [78]

Overall, cephalosporins alone perform as well as cephalosporins or penicillin in combination with aminoglycosides. Fluoroquinolones offer no advantage compared with cephalosporin/aminoglycoside regimen and may have a detrimental effect on fracture healing resulting in higher infection rates in type III open fractures [66]. Given the concern of antimicrobial resistance with broad-spectrum therapy for Gram-negative organisms, narrow-spectrum antibiotic therapy might be of greater long-term benefit [8], but this remains to be answered.

In severe injuries with soil or potential fecal contamination and tissue damage with areas of ischemia, as usually are war wounds, penicillin should be added to provide coverage against anaerobes, particularly *Clostridia* species [79].

Table 21.2 ICRC Antibiotic Protocols for use of Antibiotics in War Wounded patients

<table>
<tr><td colspan="3">Always begin tetanus immunization and administer anti-tetanus immunoglobulin</td></tr>
<tr><td colspan="2">Open fracture, traumatic amputation, major soft tissue wounds</td><td>*First 48 h:*
Benzylpenicillin five Million IU IV q 6 h
Followed by:
Penicillin V 500 mg qid
Continue **Pen V** for 5 days. After wound coverage no antibiotics unless signs of infection</td></tr>
<tr><td colspan="2">Landmine injuries, open fracture, and soft tissue injury more than 72 h old</td><td>*First 48 h:*
Benzylpenicillin five million IU IV q 6 h
+ Metronidazole 500 mg, IV q 8 h
Followed by:
Penicillin V 500 mg qid
+ Metronidazole 500 mg PO tid
Until wound closed/covered</td></tr>
<tr><td colspan="2">Hémothorax</td><td>*First 48 h:*
Ampicillin 1 g IV q 6 h
Continue with:
Amoxycillin 500 mg PO qid
Until 2 days after the removal of the chest tube</td></tr>
<tr><td colspan="2">Penetrating head trauma</td><td>*First 72 h:*
Benzylpenicillin five million IU IV q 6 h
+ Chloramphenicol 1 g IV q 8 h
Total duration 10 days IV or PO depending upon the condition of the patient</td></tr>
<tr><td rowspan="3">Abdominal Injury</td><td>A. Solid organ injury: liver, spleen, kidney, and isolated urinary bladder injury</td><td>**Benzylpenicillin five million IU IV q 6 h**
for 3–5 days according to the drainage</td></tr>
<tr><td>B. Hollow organ injury: stomach, small bowel</td><td>**Ampicillin 1 g IV q 6 h**
+ Metronidazole 500 mg IV
for 3–5 days</td></tr>
<tr><td>C. Colon, rectum, anus</td><td>**Ampicillin 1 g IV q 6 h**
+ Gentamicin 80 mg IV q 8 h
+ Metronidazole 500 mg, IV q 8 h
for 3–5 day</td></tr>
</table>

From War Surgery: working with limited resources in armed conflict and other situations of violence – Volume 2. International Committee of the Red Cross, with permission

Although this approach is not uniformly shared [80] and there are concerns for the possible in vitro resistance of the etiologic agents causing gangrene [81, 82], the administration of penicillin is still recommended in severe, contaminated wounds [83].

Given the absence of evidence to support the use of a particular antibiotic coverage, a realistic approach in austere environment is likely an immediate delivery of penicillin or cefazolin, with a G-negative coverage in presence of major wounds or of a delay more than 72 h. Again, the role of antibiotics as *an adjunct* to a proper, sound surgical debridement must be highlighted, especially in austere environments.

21.6 Perioperative Management

21.6.1 Preparation of the Patient

The incidence of infections can be reduced simply meeting the fundamental hygiene standards at admission, like washing the whole body and removing clothes and substituting them with clean ones [84]. Hair removal can increase the incidence of infection [85]: in case of need, they should be removed immediately before surgery and never by shaving but, if possible, by clipping with care to avoid skin damage. In preparation to surgery, the skin over a large area surrounding the wound must be cleansed with soap, water, and

Box 21.1. Orthopedic Antibiotic Protocol

I. Prophylactic antibiotic therapy is mandatory in all MSF surgical missions.

II. Treatment guideline for late infection (chronic osteomyelitis): available for specialized MSF missions (reconstructive surgery, Amman, Mehran, and for all MSF settings as a help guide

I. Prophylactic antibiotic therapy

1. Internal fixation, closed fracture

Usual organisms: G*ram-positive bacteria (S. epidermidis, S. aureus)*

Antimicrobial prophylaxis	Cefazolin	2 g IV at induction of anesthesia plus additional dose of 1 g intraoperatively, when surgery is prolonged (>4 h)

2. Type I and II open fracture

Usual organisms: G*ram-positive and aerobic Gram-negative bacteria*

Antimicrobial prophylaxis for 48 h	Cefazolin +	2 g IV every 12 h (=4 g/day) *immediately upon admission*
	Gentamicin	4 mg/kg/day (give by slow IV push over 30 min)

3. Type III open fracture

Usual organisms: *Mixed aerobic and anaerobic Gram-negative and Gram-positive bacteria*

Antimicrobial prophylaxis for 72 h	Cefazolin +	2 g IV every 12 h (=4 g/day) *immediately upon admission*
	Gentamicin +	4 mg/kg/day (give by slow IV push over 30 min)
	Metronidazole	500 mg IV every 8 h

Subsequently, **depending on clinical course**:

Amoxicillin/clavulanic acid +	1 g IV 4 times daily (=4 g/day)	3–5 days
Gentamicin	1 mg/kg IV every 12 h (=2 mg/kg/day)	3–5 days

Comments: never substitute oral agent for intravenous therapy.

II. Treatment guideline for *late infection*

This protocol has been elaborated following MSF Amman Orthopedic and Reconstructive Surgery Mission; it results from the contributions of Dr. Sophie Abgrall, specialist in Infectiology at Avicenne Hospital (APHP) in Paris, and Nikki Blackwell, anesthesiologist and responsible for Infectology in Amman and Mehran and Delphine Poussin.

The foundation of treatment for chronic osteomyelitis is adequate surgical debridement. Nevertheless antibiotic therapy plays an important adjunctive role in achieving successful outcomes.

- General rules:
  - **No antibiotic before organism**(s) **identification** and culture and sensitivity tests.
  - As large and thorough surgical debridement as necessary, with strict cleaning of the wound.
  - Fracture immobilization: almost always with external fixation.
  - Aerobic and anaerobic cultures of bone and/or soft tissue or liquids:
    - On Portagerm®, for solids
    - On blood culture mediums, for liquids

      Ideally, culture should be started within 4 h after surgery. If not, samples should be kept in a fridge (4 °C) for a maximum duration of 48 h if a reliable result is expected. Anaerobic cultures into anaerobic transport system, transport time ≤2 h, *room temperature*.

- No clinical, biological or radiological exam allows early interruption or alleviation of the treatment: treatment duration is stated from the beginning. The only criterion for success is no infection after the end of the treatment and 2 years follow-up.

- The following protocols are designed to guide antibiotic choice on the ward, according to the results of culture and sensitivity.
  - If you are unsure about which antibiotic regime to choose, ask for help!
  - If the medical director cannot assist you, they will contact the regional medical coordinator, and if necessary, the case can be discussed with Dr. S. Abgrall in Paris.

Summary

1. Mandatory investigations and monitoring
2. *Staphylococcus aureus* (MSSA)
3. *Staphylococcus aureus* (ORSA/MRSA)
4. *Streptococcus or Enterococcus*
5. *Enterobacteriaceae*, i.e., *E. coli, Klebsiella* sp. (non ESBL), *Proteus mirabilis*
6. *Enterobacteriaceae* from ESCPPM group = *Enterobacter* sp., *Serratia* sp., *Citrobacter* sp., *Proteus vulgaris, Providencia* sp., *Morganella* sp.
7. ESBL – producing organisms (e.g., *E. coli*, *Proteus* sp., *Klebsiella* sp., resistant to ceftazidime, ceftriaxone)
8. *Acinetobacter baumanii*
9. *Pseudomonas aeruginosa*
10. *Stenotrophomonas maltophilia*
11. Anaerobes

MSSA: methicillin-sensitive *Staphylococcus aureus*
MRSA: methicillin-resistant *Staphylococcus aureus*
ORSA: oxacillin-resistant *Staphylococcus aureus*
ESBL: extended spectrum beta-lactamases

1. **Mandatory investigations and monitoring**
   - The total course of treatment is 6–12 weeks.
   - *Usually* 4–6 weeks *bi-antibiotherapy* followed by 6–8 weeks *single*-agent antibiotherapy.
   - When validity of bacteriology results is uncertain, initial IV treatment during 2–3 weeks is preferable.
   - The antibiotics used to treat osteomyelitis have significant side effects and regular laboratory monitoring is essential.
   - All patients should have:
     - ESR, CRP, FBC: preoperatively
     - Renal and liver function: prior to starting antibiotic therapy
   - **The following investigations should be performed weekly** while the patient is on antibiotics (regardless of whether they are an inpatient or outpatient or have returned home to Iraq to complete their course of antibiotics): ESR, CRP, FBC, renal and liver function

Special Cases

- Patients receiving linezolid treatment are at risk of thrombocytopenia and should have a full blood count performed weekly for the duration of their treatment. They are also at risk of peripheral neuropathy and should have regular clinical examination. Maximal duration of treatment: 28 days.

- Patients receiving colistin therapy are at risk of renal impairment and should have their renal function monitored twice a week.
- Patients being treated with gentamicin or amikacin should have the trough drug level measured after the third day of treatment and weekly thereafter if the level is within the acceptable range. They should also have renal function monitored twice a week

Linezolid	=> FBC	Weekly
Colistin	=> Renal function	Twice weekly
Gentamicin or amikacin	=> Renal function	Twice weekly
	=> Gentamicin/ amikacin Through medication level	After third day and then weekly if level satisfactory
All doses should be adjusted to a mg/kg/dose basis for children		

2. ***Staphylococcus aureus*, sensitive to oxacillin or methicillin (MSSA)**

   Phase 1:

   Weeks 1–6 → two antibiotics.

   Ideally recommended for the first two weeks, but if there are no clinical sign of sepsis, then oral antibiotics can be started as soon as possible, according to the antibiogram. Do not use gentamicin for more than 15 days.

Cloxacillin +	IV	2 g × 4 (8 g total). Children: 150 mg/kg/day in 3–4 infusions
Gentamicin	IV	4 mg/kg × 1 (30 min infusion)

Then → *two from the list below* (depending on the organism sensitivity results)

Rifampicin	PO	600 mg × 2 should never be used alone. Children: 10 mg/kg × 2
Check liver function tests – before starting treatment then weekly; review antibiotic choice if rising		

Clindamycin	PO	600 mg × 4 (if erythromycin and clindamycin sensitive). Children: 30 mg/kg/day
Can cause severe diarrhea due to an overgrowth of *Clostridium difficile*; review and consider stopping the antibiotic if this develops; send a stool specimen for a *C. difficile* toxin test if there is any doubt		

Ofloxacin	PO	200 mg × 3. Children: 15 mg/kg/day
If ofloxacin cannot be obtained or if polymicrobial infection, ciprofloxacin oral 750 mg × 2 (children: 20 mg/kg/day) can be used but should usually be reserved for *P. aeruginosa* infection		

Co-trimoxazole	PO	800 mg sulfamethoxazole/160 mg trimethoprim × 3, Consider if polymicrobial infection. Children: 60 mg/kg/day SMX or 12 mg/kg/day TMP.

Fusidic acid	PO	500 mg × 3. Should never be used alone. Children: 50 mg/kg/day

Fosfomycin	IV	4 g × 4. Should never be used alone. Consider if polymicrobial infection. Children: 200 mg/kg/day

Cloxacillin	IV	2 g × 4 (8 g total). Never as oral antibiotic. Children: 150 mg/kg/day in 3 to Four infusions.

Phase 2:

Weeks 7–12 → one antibiotic

Clindamycin	PO	600 mg × 4 (if erythromycin and clindamycin sensitive). Children: 30 mg/kg/day
Can cause severe diarrhea due to an overgrowth of *Clostridium difficile*; review and consider stopping the antibiotic if this develops; send a stool specimen for a *C. difficile* toxin test if there is any doubt		

Or

Ofloxacin	PO	200 mg × 3. Children: 15 mg/kg/day
If ofloxacin cannot be obtained or if polymicrobial infection, ciprofloxacin oral 750 mg × 2 (children: 20 mg/kg/day) can be used but should usually be reserved for *P. aeruginosa* infection		

or

Co-trimoxazole	PO	800 mg sulfamethoxazole/ 160 mg trimethoprim × 3 Consider if polymicrobial infection. Children: 60 mg/kg/day SMX/ 12 mg/kg/day TMP.

Or

Cloxacillin	PO	2 g × 4 oral cloxacillin is not well absorbed, so choose this only when clindamycin, co-trimoxazole, or ofloxacin cannot be used. Children: 150 mg/kg/day
Should usually not be used orally, but if no other oral antibiotic is available and if intravenous infusion is not possible, cloxacillin can only be used orally for long-term suppressant treatment of osteomyelitis Liver function tests must be monitored regularly to look for drug-induced hepatitis, FBC also. If liver function tests are rising, review choice of antibiotic		

3. ***Staphylococcus aureus* resistant to oxacillin or methicillin (ORSA/MRSA)** ***Phase 1***:
   Weeks 1–6 → two antibiotics

   Ideally recommended for the first two weeks, but if there are no clinical sign of sepsis, then oral antibiotics can be started as soon as possible, according to the antibiogram. Do not use gentamicin for more than 15 days.

Teicoplanin	SC	12 mg/kg every 12 h for the first 5 doses and then 12 mg/kg/day
Vancomycin	IV	Loading dose 15 mg/kg followed by 40 mg/kg/24 h given continuously or, if not possible, in 4 divided doses (infused over 2 h)
Plus (+)		
Gentamicin	IV	4 mg/kg × 1 (30 min infusion)

Then → *two from the list below* (depending on the organism sensitivity results)

Rifampicin	PO	600 mg × 2 (if sensitive). Should never be used alone, Children: 10 mg/kg × 2

Fusidic acid	PO	500 mg × 3 (if sensitive). Should never be used alone, Children: 50 mg/kg/day

Co-trimoxazole	PO	800 mg sulfamethoxazole/160 mg trimethoprim × 3 (if sensitive) Consider if polymicrobial infection, Children: 60 mg/kg/day SMX or 12 mg/kg/day TMP

Clindamycin	PO	600 mg × 4 (if erythromycin and clindamycin sensitive). Children: 30 mg/kg/day

Linezolid	PO	600 mg × 2. No longer than 4 weeks. Not with glycopeptides (i.e., vancomycin/teicoplanin). Children: 30 mg/kg/day

Teicoplanin or	SC	12 mg/kg every 12 hours for the first 5 doses, then 12 mg/kg/day

Vancomycin	IV	Loading dose 15 mg/kg followed by 40 mg/kg/24 hs given continuously or, if not possible, in 4 divided doses (infused over 2 hours)

Fosfomycin	IV	4 g × 4. Should never be used alone. Consider if polymicrobial infection. Children: 200 mg/kg/day

Comment: MRSA is usually resistant to ofloxacin and ciprofloxacin, so these should not be used for treatment.

Phase 2:
Weeks 7–12 (10 weeks) → **except linezolid during 4 weeks and then cease**.

Preferably a **single oral antibiotic** from the list below, according to the sensitivities of the organism, except rifampicin and fusidic acid which must always be given together *or with another antibiotic*

Linezolid	PO	600 mg × 2. No longer than 4 weeks. Not with glycopeptides (i.e., vancomycin/teicoplanin). Children: 30 mg/kg/day

or

Co-trimoxazole	PO	800 mg sulfamethoxazole/160 mg trimethoprim × 3. Consider if polymicrobial infection. Children: 60 mg/kg/day SMX or 12 mg/kg/day TMP

or if there is no alternative available, then use teicoplanin as follows:

Teicoplanin	SC	12 mg/kg every 12 h for the first 5 doses then 12 mg/kg/day

Or

Rifampicin	PO	600 mg × 2 (if sensitive). Should never be used alone. Children: 10 mg/kg × 2
plus (+)		
Fusidic acid	PO	500 mg × 3 (if sensitive). Should never be used alone. Children: 50 mg/kg/day

4. *Streptococcus* or *Enterococcus*
   Phase 1:
   Weeks 1–6 → two antibiotics

   Ideally recommended for the **first two weeks**, but if there are **no clinical sign of sepsis**, then **oral antibiotics** can be started as soon as possible, according to the antibiogram. Do not use gentamicin for more than 15 days.

Amoxicillin	IV	3 g × 4. Children: 200 mg/kg/day
plus (+)		
Gentamicin	IV	4 mg/kg × 1 (30 min infusion)

It is only necessary to give gentamicin for the first 7 days or less if no clinical sepsis and then continue with further 1 week of IV amoxicillin before moving to oral single-agent treatment.
Then → *two from the list below* (depending on the organism sensitivity results)

Amoxicillin	IV	3 g × 4. Not for *Enterococcus faecium.* Children: 200 mg/kg/day

Rifampicin	PO	600 mg × 2 (if sensitive) Should never be used alone. Children: 10 mg/kg × 2

Co-trimoxazole	PO	800 mg sulfamethoxazole/160 mg trimethoprim × 3 if sensitive Never for *Enterococcus*. Consider if polymicrobial infection. Children: 60 mg/kg/day SMX or 12 mg/kg/day TMP

Clindamycin	PO	600 mg × 4 (if erythromycin and clindamycin sensitive) Never for *Enterococcus.* Children: 30 mg/kg/day

Teicoplanin	SC	12 mg/kg every 12 h for the first 5 doses then 12 mg/kg/day For *Enterococcus faecium*

Piperacillin, **piperacillin/tazobactam**, **and imipenem** are sensitive (in case of polymicrobial infection with Gram-negative organisms). However, be very cautious about ***Enterococcus faecium*** that is mostly resistant *to* ampicillin and will also be resistant to piperacillin/tazobactam and should be treated with a **glycopeptide**. Seek help if you are unsure.
See below for dosages

Phase 2:
Weeks 7–12 → one antibiotic

Amoxicillin	PO	2 g × 3 (=6 g total)

or

Amoxicillin	PO	2 g × 3 (=6 g total)

Clindamycin	PO	600 mg × 4 (if erythromycin and clindamycin sensitive) Never for *Enterococcus.* Children: 30 mg/kg/day

or

Co-trimoxazole	PO	800 mg sulfamethoxazole/160 mg trimethoprim × 3 (if sensitive) Never for *Enterococcus*. Consider if polymicrobial infection. Children: 60 mg/kg/day SMX or 12 mg/kg/day TMP

Or

Teicoplanin	SC	12 mg/kg every 12 h for the first 5 doses then 12 mg/kg/day For *Enterococcus faecium.* Consider if polymicrobial infection with MRSA

Or

If Gram-negative resistant organisms are associated, *Streptococcus* and *Enterococcus* will usually be sensitive to piperacillin/tazobactam, in the case of very resistant Gram-negative organisms to imipenem. However, be very cautious about *Enterococcus faecium* that is mostly resistant to ampicillin and will also be resistant to piperacillin/tazobactam and should be treated with aglycopeptide such as vancomycin

Seek help if you are unsure.

5. ***Enterobacteriaceae*, i.e., *E. coli, Klebsiella*** sp. (**non-ESBL**), ***Proteus mirabilis***
   Phase 1:
   Weeks 1–6 → two antibiotics

   Ideally recommended for the first two weeks, but if there are no clinical sign of sepsis, then oral antibiotics can be started as soon as possible, according to the antibiogram. Do not use amikacin for more than 15 days.

Ceftriaxone	IV	2 g × 2. Children: 50 mg/kg.
If ceftriaxone cannot be obtained, cefotaxime IV 2 g ×4 (children: 150 mg/kg) can be used		

plus (+)

Amikacin	IV	15 mg/kg × 1 (30 min infusion)
If Gram-positive infection associated and if sensitive, use gentamicin IV 4 mg/kg × 1 (30 min infusion)		

Then → two *from the list below* (depending on the organism sensitivity results)

Ofloxacin	PO	200 mg × 3. Children: 15 mg/kg/day
If ofloxacin cannot be obtained or if polymicrobial infection, ciprofloxacin oral 750 mg × 2 (children: 20 mg/kg/day) can be used but should usually be reserved for *Pseudomonas aeruginosa* infection		

Co-trimoxazole	PO	800 mg sulfamethoxazole/160 mg trimethoprim × 3 if sensitive Consider if polymicrobial infection. Children: 60 mg/kg/day SMX or 12 mg/kg/day TMP

Fosfomycin	IV	4 g × 4. Should never be used alone. Consider if polymicrobial infection. Children: 200 mg/kg/day

Colistin	IV	Three million units × 3 (if sensitive). *Proteus, Providencia, and Serratia* always resistant. Consider if polymicrobial infection. Children: 100,000 units/kg/day

If Gram-positive organisms or resistant Gram-negative organisms are associated, piperacillin (4 g × 4), piperacillin/tazobactam (4 g × 4) or imipenem in case of very resistant Gram-negative organisms can be used. See below for dosages

Phase 2:
Weeks 7–2 → one antibiotic

Ofloxacin	PO	200 mg × 3. Children: 15 mg/kg/day
If ofloxacin can not be obtained or if polymicrobial infection, ciprofloxacin oral 750 mg × 2 (children: 20 mg/kg/day) can be used but should usually be reserved for *Pseudomonas aeruginosa* infection		

Co-trimoxazole	PO	800 mg sulfamethoxazole/160 mg trimethoprim × 3 if sensitive Consider if polymicrobial infection. Children: 60 mg/kg/day SMX or 12 mg/kg/day TMP

6. ***Enterobacteriaceae* from ESCPPM group**: ***Enterobacter*** sp., ***Serratia*** sp., ***Citrobacter*** sp., ***Proteus vulgaris***, ***Providencia*** sp., ***Morganella*** sp. ESCPPM organisms are all automatically resistant to cephalosporins (i.e., cefazolin, ceftriaxone) even if they are reported as being sensitive on the laboratory report. It is very important not to fall into this trap.

Phase 1:
Weeks 1–6 → two antibiotics

Ideally recommended for the **first two weeks**, but if there are **no clinical sign of sepsis**, then **oral antibiotics** can be started as soon as possible, according to the antibiogram. Do not use amikacin for more than 15 days.

Cefepime	IV	2 g × 3 (30 min infusion). Children: 100 mg/kg/day

plus (+)

Amikacin	IV	15 mg/kg × 1 (30 min infusion)
If Gram-positive infection associated and if sensitive, use gentamicin IV 4 mg/kg × 1 (30 min infusion)		

Then → *two from the list below* (depending on the organism sensitivity results)

Ofloxacin	PO	200 mg × 3. Children: 15 mg/kg/day
If ofloxacin cannot be obtained or if polymicrobial infection, ciprofloxacin oral 750 mg × 2 (children: 20 mg/kg/day) can be used but should usually be reserved for *Pseudomonas aeruginosa* infection		

Co-trimoxazole	PO	800 mg sulfamethoxazole/160 mg trimethoprim × 3 if sensitive Consider if polymicrobial infection. Children: 60 mg/kg/day SMX or 12 mg/kg/day TMP

Fosfomycin	IV	4 g × 4. Should never be used alone. Consider if polymicrobial infection. Children: 200 mg/kg/day

Colistin	IV	Three million units × 3 (if sensitive). *Proteus, Providencia, and Serratia* always resistant. Consider if polymicrobial infection. Children: 100,000 units/kg/day

If Gram-positive organisms or resistant Gram-negative organisms are associated, piperacillin/tazobactam (4 g × 4) or imipenem in case of very resistant Gram-negative organisms can be used. See below for dosages

Phase 2:
Weeks 7–12 → one antibiotic

Ofloxacin	PO	200 mg × 3. Children: 15 mg/kg/day
If ofloxacin cannot be obtained or if polymicrobial infection, ciprofloxacin oral 750 mg × 2 (children: 20 mg/kg/day) can be used but should usually be reserved for *Pseudomonas aeruginosa* infection		

or

Co-trimoxazole	PO	800 mg sulfamethoxazole/160 mg trimethoprim × 3 if sensitive Consider if polymicrobial infection. Children: 60 mg/kg/day SMX or 12 mg/kg/day TMP

Seek advice if the organism you are treating is not sensitive to any of these combinations of antibiotics.

7. **ESBL – producing organisms (e.g., *E. coli*, *Proteus* sp., *Klebsiella* sp. resistant to ceftazidime, ceftriaxone)**
   Phase 1:
   Weeks 1–6 → two antibiotics

   Ideally recommended for the **first two weeks**, but if there are **no clinical sign of sepsis**, then **oral antibiotics** can be started as soon as possible, according to the antibiogram. Do not use amikacin for more than 15 days.

Imipenem	IV	2 g × 3. Children: 100 mg/kg/day

plus (+)

Amikacin	IV	15 mg/kg × 1 (30 min infusion)
If Gram-positive infection associated and if sensitive, use gentamicin IV 4 mg/kg × 1 (30 min infusion)		

Then → *two from the list below* (depending on the organism sensitivity results)

Ofloxacin	PO	200 mg × 3. Children: 15 mg/kg/day
If ofloxacin cannot be obtained or if polymicrobial infection, ciprofloxacin oral 750 mg × 2 (children: 20 mg/kg/day) can be used but should usually be reserved for *Pseudomonas aeruginosa* infection		

Co-trimoxazole	PO	800 mg sulfamethoxazole/160 mg trimethoprim × 3 if sensitive Consider if polymicrobial infection. Children: 60 mg/kg/day SMX or 12 mg/kg/day TMP

Fosfomycin	IV	4 g × 4. Should never be used alone. Consider if polymicrobial infection. Children: 200 mg/kg/day

Colistin	IV	Three million units × 3 (if sensitive). *Proteus, Providencia, and Serratia* always resistant. Consider if polymicrobial infection. Children: 100,000 units/kg/day

If Gram-positive organisms or resistant Gram-negative organisms are associated, piperacillin/tazobactam (4 g × 4) or imipenem in case of very resistant Gram-negative organisms can be used. See below for dosages

Phase 2:
Weeks 7–12 → one antibiotic

Ofloxacin	PO	200 mg × 3. Children: 15 mg/kg/day
If ofloxacin cannot be obtained or if polymicrobial infection, ciprofloxacin oral 750 mg × 2 (children: 20 mg/kg/day) can be used but should usually be reserved for *Pseudomonas aeruginosa* infection		

or

Co-trimoxazole	PO	800 mg sulfamethoxazole/160 mg trimethoprim × 3 if sensitive Consider if polymicrobial infection. Children: 60 mg/kg/day SMX or 12 mg/kg/day TMP

Seek advice if the organism you are treating is not sensitive to any of these combinations of antibiotics.

8. ***Acinetobacter baumanii***
   Automatically resistant to cephalosporins (i.e., cefazolin, ceftriaxone) even if they are reported as being sensitive on the lab report. It is very important not to fall into this trap.

   Phase 1:
   Weeks 1–6 → two antibiotics

   Ideally recommended for the first two weeks, but if there are no clinical sign of sepsis, then oral antibiotics can be started as soon as possible, according to the antibiogram. Do not use amikacin for more than 15 days.

Piperacillin/ tazobactam	IV	Loading dose of 4 g in 60 min infusion followed by 16 g/24 h given continuously or, if not possible, in 4 divided doses. Children: 240 mg–30 mg/kg/day

or

Imipenem	IV	2 g × 3 if resistant *Acinetobacter.* Children: 200 mg/kg/day
plus (+)		
Amikacin	IV	15 mg/kg × 1 (30 min infusion)

Then → *two from the list below* (depending on the organism sensitivity results)

Piperacillin/ tazobactam	IV	Loading dose of 4 g in 60 min infusion followed by 16 g/24 h given continuously or, if not possible, in 4 divided doses. Children: 240 mg – 30 mg/kg/day

Imipenem	IV	2 g × 3 if resistant *Acinetobacter.* Children: 200 mg/kg/day

Ofloxacin	PO	200 mg × 3. Children: 15 mg/kg/day
If ofloxacin cannot be obtained or if polymicrobial infection, ciprofloxacin oral 750 mg × 2 (children: 20 mg/kg/day) can be used but should usually be reserved for *Pseudomonas aeruginosa* infection		

Colistin	IV	Three million units × 3 (if sensitive). *Proteus, Providencia, and Serratia* always resistant. Consider if polymicrobial infection. Children: 100,000 units/kg/day

Rifampicin	PO	600 mg × 2 (if sensitive). Should never be used alone. Children: 10 mg/kg × 2

Phase 2:
Weeks 7–12 → one antibiotic

Piperacillin/ tazobactam	IV	Loading dose of 4 g in 60 min infusion followed by 16 g/24 h given continuously or, if not possible, in 4 divided doses. Children: 240 mg–30 mg/kg/day

Imipenem	IV	2 g × 3 if resistant *Acinetobacter.* Children: 200 mg/kg/day

Ofloxacin	PO	200 mg × 3. Children: 15 mg/kg/day
If ofloxacin cannot be obtained or if polymicrobial infection, ciprofloxacin oral 750 mg × 2 (children: 20 mg/kg/day) can be used but should usually be reserved for *Pseudomonas aeruginosa* infection		

Colistin	IV	Three million units × 3 (if sensitive). *Proteus, Providencia, and Serratia* always resistant. Consider if polymicrobial infection. Children: 100,000 units/kg/day

Seek advice if the organism you are treating is not sensitive to any of these combinations of antibiotics.

9. ***Pseudomonas aeruginosa***
   Phase 1:
   Weeks 1–6 → two antibiotics

   Ideally recommended for the first two weeks, but if there are no clinical sign of sepsis, then oral antibiotics can be started as soon as possible, according to the antibiogram. Do not use amikacin for more than 15 days.

Ceftazidime	IV	Loading dose of 2 g in 60 min infusion followed by 6 g/24 h given continuously or, if not possible, in 3 divided doses. Children: 25 mg/kg then 100 mg/kg/day

or

Imipenem	IV	2 g × 3 if resistant *Pseudomonas.* Children: 200 mg/kg/day

plus (+)

Amikacin	IV	15 mg/kg × 1 (30 min infusion)

Then → two *for at least 4 weeks* (depending on the organism sensitivity results) and then one

Ceftazidime	IV	Loading dose of 2 g in 60 min infusion followed by 6 g/24 h given continuously or, if not possible, in 3 divided doses. Children: 25 mg/kg then 100 mg/kg/day

Imipenem	IV	2 g × 3 if resistant *Pseudomonas.* Children: 200 mg/kg/day

Ciprofloxacin	PO	750 mg × 2 after checking for the sensitivity. Children: 20 mg/kg/day

Fosfomycin	IV	4 g × 4. Should never be used alone. Consider if polymicrobial infection. Children: 200 mg/kg/day

Colistin	IV	Three million units × 3 (if sensitive). *Proteus, Providencia, and Serratia* always resistant. Consider if polymicrobial infection. Children: 100,000 units/kg/day

If needed (polymicrobial infection or resistance):

- Piperacillin/tazobactam, cefepime, imipenem
- Fosfomycin, colistin

But these are complex infections and you should seek advice from the medical director.

Note that ertapenem is ineffective against *Pseudomonas aeruginosa* so is not a cause for concern if it is reported as being resistant on the laboratory report.

10. ***Stenotrophomonas maltophilia***

See antibiogram – only **three antibiotics** are potentially active.

Combination treatment with two *antibiotics* should be used for *at least 3–4 weeks* and then *one antibiotic*

Ticarcillin/ clavulanic acid +	IV	5 g × 3. Children: 250 mg/kg/day
Co-trimoxazole	PO	800 mg sulfamethoxazol/160 mg trimethoprim × 3 . Consider if polymicrobial infection. Children: 60 mg/kg/day SMX or 12 mg/kg/day TMP

or

Ticarcillin/ clavulanic acid +	IV	5 g × 3. Children: 250 mg/kg/day
Ciprofloxacin	PO	750 mg × 2 after checking for the sensitivity. Children: 20 mg/kg/day

11. **Anaerobes**

Metronidazole	PO	500 mg × 3/day. Children: 50 mg/kg/day

Clindamycin	PO	600 mg × 4/day. Children: 30 mg/kg/day

From MSF International. Guide to antibiotic therapy for MSF orthopedic surgery missions. 11 July 2008, with permission

brush, dried, and then painted with either povidone iodine or chlorhexidine both achieving the best reduction in microbes at the operative site.

21.6.2 Irrigation

A copious wound irrigation should be performed as soon as possible to improve bacterial clearance [86]. The standard volume of washing fluid (3 L for grade I, 6 L for grade II fractures, and 9 L or more for grade III fractures) has never been proven but is a consistent practice throughout the world. The evidence supports the use of normal saline or sterile water and even tap water [87]. Groundwater may be used, treating it with sodium hypochlorite to reach a concentration of 0.025 % (5 ml of bleach in one L of water) [8].

There is no evidence for the irrigation of open fracture wounds with any particular additive (antiseptics, antibiotics or soap) [46]. The potential effect of inhibition of fibroblasts activity and wound healing by povidone iodine [88] is known, but its clinical impact is still debated [89, 90]. High pulsatile irrigation might be more effective in removing bacteria although it has been found associated, in vitro and experimentally, with macroscopic bone damage, large cortical bone defects [91], and increased depths of bacterial penetration compared to low-pressure pulsatile lavage [92]. Low-pressure lavage with high volumes is likely the best option in austere environment.

21.6.3 Dressing

Large and excavating wounds should be covered with a bulky absorbent dressing [8], and a *tight bandage should be avoided* as it may have a tourniquet-like effect when it dries. Exposed tendons and joint capsules should be covered with saline-soaked compresses. Simply covering with dry gauzes may help in removing dead tissues during a second look debridement. The wound should not be "packed"in any way with gauze that will form a plug and prevent the free outflow of fluid. Dressing should not be removed until the time of delayed primary closure. Each dressing change potentially constitutes trauma to the healing granulation tissue, exposes it to nosocomial infection, and increases costs and the workload of the staff.

When a dressing is soaked with exudate (but not pus), overdressing is advised. The use of sterile or not sterile gloves for dressing does not change the rate of wound infection [85]. Negative-pressure wound therapy (NWPT) recently suggested to deal with complex wounds [93] and could be potentially useful, but there is concern on the overgrowth of granulation tissue, excessive bleeding at dressing change, recurrent infections, and maceration of adjacent skin [94]. For its relative complexity and the poor training of the local staff, this procedure is not recommended in poor resources settings, unless there are well-equipped facilities and trained staff.

21.7 Common Systemic Infections in Developing Countries and Their Relation to Trauma

21.7.1 HIV Infection

HIV infection may raise the incidence of wound infection and delay bone union [95]. HIV-associated arthritis and spondyloarthropathies are now detected more often where HIV is epidemic; avascular necrosis of the bone in HIV-positive patients has also been reported [96]. Low CD4 counts before urgent orthopedic procedures in HIV-positive patients may increase the risk for infection, while antiretroviral medication, decreasing viral load and elevating the CD4 count, could possibly help in reducing wound and fracture healing complications [97].

The risk of transmission of infection by needle stick is not statistically high but should be managed with postexposure prophylaxis (PEP) even in dubious cases, in spite of the high reported incidence of unpleasant side effects (70–90 %) [98]. A kit for PEP should be in the equipment of workers in austere environment: the sooner the delivery, the higher the possibility of prevention. A WHO overview of the use of retrovirals to prevent HIV infection has been recently published [99]

21.7.2 Hepatitis B and C Infection

HBsAg has more than 8 % prevalence in many developing countries [100]. Chronic liver diseases consequent to hepatitis B or C infection may influence the immunological status of the patient with reduced resistance to trauma and infection. The risk of transmission to caregivers and victims may be high. Prophylaxis has been recommended to victims in Israel [101] according to reports in of hepatitis B virus recovered from bomber's bone fragment. Vaccination is advocated for health staff working in these countries, unless a protective serum antibodies level (10 mIU/L) is already present. Without vaccination, and when anti-HBs is below 10 mIU/L, hepatitis B immunoglobulin should be administered as soon as possible after a needle stick injury and/or vaccination should be considered. Immune globulin and antiviral agents are not recommended for PEP of hepatitis C [102].

21.7.3 *Mycobacterium tuberculosis* Infection

Soft tissues or bone infections due to *Mycobacterium tuberculosis* following a fracture in an otherwise healthy immunocompetent patient are rare, but a concomitant HIV infection can increase this likelihood. Such infections have been observed at the pin sites of external fixators [103], at the site of previous fractures [104] at weight-bearing joints [105] usually without history of clinical manifestations of tuberculosis and without evidence of a pulmonary primary focus at the time of the initial injury. When direct inoculation of mycobacteria is unlikely, the reduced humoral and cellular immunity following a major trauma could be responsible of the reactivation of latent bacteria at a distant focus.

References

1. Haynes AB, Weiser TG, Berry WR, et al. A surgical safety checklist to reduce morbidity and mortality in a global population. N Engl J Med. 2009;360:491–9.
2. Allegranzi B, Bagheri Nejad S, et al. Burden of endemic health-care-associated infection in

developing countries: systematic review and meta-analysis. Lancet. 2011;377:228–41.
3. Anderson DJ, Kaye KS, Classen D, et al. Strategies to prevent surgical site infections in acute care hospitals. Infect Control Hosp Epidemiol. 2008;29 Suppl 1:S51–61.
4. Antimicrobial prophylaxis for surgery. Treat Guidel Med Lett. 2009;7:47–52.
5. Scottish Intercollegiate Guidelines Network. Antibiotic prophylaxis in surgery. www.sign.ac.uk/pdf/sign104.pdf. Accessed 30 Jul 2009.
6. Mangram AJ, Horan TC, Pearson ML, et al. Guideline for prevention of surgical site infection. Infect Control Hosp Epidemiol. 1999;20:250–78.
7. Prokusky L. Treatment of acute infection. J Am Acad Orthop Surg. 2006;14:S101–4.
8. Giannou C, Baldan M. Infections in war wounds. In: Giannou C, Baldan M, editors. War surgery-volume 1. Geneva: International Committee of the Red Cross; 2009. p. 253–66.
9. Coupland RM. War wounds of bones and external fixation. Injury. 1994;25:211–7.
10. Dougherty SH, Fiegel VD, Nelson RD, et al. Effects of soil infection potentiating factors on neutrophils in vitro. Am J Surg. 1985;150:306–11.
11. Haury BB, Rodeheaver GT, Pettry D, et al. Inhibition of nonspecific defenses by soil infection potentiating factors. Surg Gynecol Obstet. 1977;144:19–24.
12. Eardley WGP, Brown KV, Bonner TJ, et al. Infection in conflict wounded. Philos Trans R Soc B. 2011;366:204–18.
13. Tong MJ. Septic complications of war wounds. JAMA. 1972;219:1044–7.
14. Murray CK. Infectious disease complications of combat-related injuries. Crit Care Med. 2008;36 Suppl 7:S358–64.
15. Zapor MJ, Moran KA. Infectious diseases during wartime. Curr Opin Infect Dis. 2005;18:395–9.
16. Sonshine DB, Caldwell A, Gosselin RA, et al. Critically assessing the Haiti earthquake response and the barriers to quality orthopaedic care. Clin Orthop Relat Res. 2012;470:2895–904. doi:10.1007/s11999-012-2333-4.
17. Wang HY, Duan X, Chen Y, et al. Microbiologic study on the pathogens isolated from wound culture among orthopaedic patients after Wenchuan. Zhongguo Gu Shang. 2009;22:910–2. Chineese.
18. Hill PF, Edwards DP, Bowyer GW. Small fragment wounds: biophysics, pathophysiology and principles of management. J R Army Med Corps. 2001;147:41–51.
19. Ritchie AJ, Harvey CF. Experience in low velocity gunshot injuries: a more conservative approach in selected cases. J R Coll Surg Edinb. 1990;35:302–4.
20. Byrne A, Curran P. Necessity breeds invention: a study of outpatient management of low velocity gunshot wounds. Emerg Med J. 2006;23:376–8.
21. Marcus NA, Blair WF, Shuck JM, et al. Low-velocity gunshot wounds to extremities. J Trauma. 1980;20:1061–4.
22. Ordog GJ, Sheppard GF, Wasserberger JS, et al. Infection in minor gunshot wounds. J Trauma. 1993;34:358–65.
23. Global Road Safety Partnership. 2004. Annual report. Available at: http://www.grsproadsafety.org/themes/default/pdfs/AR04%20FINAL.pdf.
24. Bowyer G. Debridement of extremity war wounds. J Am Acad Orthop Surg. 2006;14 Suppl 10:S52–6.
25. Fleming A. On the bacteriology of septic wounds. Lancet. 1915;2:638–43.
26. Murray CK, Yun HC, Griffith ME, et al. Acinetobacter infection: what was the true impact during the Vietnam conflict? Clin Infect Dis. 2006;43:383–4.
27. Aronson NE, Sanders JW, Moran KA. In harm's way: infections in deployed American military forces. Clin Infect Dis. 2006;43:1045–51.
28. Dewa AST, Green AD. Wound infection surveillance. Presented at military surgery. 2010. Gosport, 29 April 2010. Available at: http://www.militarysurgery.org.uk.
29. Yun HC, Murray CK, Roop SA, et al. Bacteria recovered from patients admitted to a deployed U.S. military hospital in Baghdad, Iraq. Mil Med. 2006;171:821–5.
30. Calhoun JH, Murray CK, Manring MM. Multidrug-resistant organisms in military wounds from Iraq and Afghanistan. Clin Orthop Relat Res. 2008;466:1356–62.
31. Murray CK, Hsu JR, Solomkin JS, et al. Prevention and management of infections associated with combat-related extremity injuries. J Trauma. 2008;64:S239–51.
32. Okike K. Trends in the management of open fractures. J Bone Joint Surg. 2006;88:2739–48.
33. Carsenti-Etesse H, Doyon F, Desplaces N, et al. Epidemiology of bacterial infection during management of open leg fractures. Eur J Clin Microbiol Infect Dis. 1999;18:315–23.
34. Murray CK, Obremskey WT, Hsu JR, et al; Prevention of Combat-Related Infections Guidelines. Panel prevention of infections associated with combat-related extremity injuries. J Trauma. 2011;71:S235–57.
35. Varkentien T, Rodriguez C, Lloyd B, et al; Infectious Disease Clinical Research Program Trauma Infectious Disease Outcomes Study Group. Invasive mold infections following combat-related injuries. Clin Infect Dis. 2012;55:1441–9.
36. Ali MH, Hoekzema NA, Bakleh M, et al. The microbiology and risk of infection following open, agricultural upper extremity injuries. J Hand Surg Am. 2008;33:87–93.
37. O'Shea MK. Acinetobacter in modern warfare. Int J Antimicrob Agents. 2012;39:363–75.
38. Miskin IN, Nir-Paz R, Block C, et al. Antimicrobial therapy for wound infections after catastrophic earthquakes. N Engl J Med. 2010;363:2571–3.
39. Keven K, Ates K, Sever MS, et al. Infectious complications after mass disasters: the Marmara earth-

quake experience. Scand J Infect Dis. 2003;35: 110–3.
40. Öncül O, Keskin O, Acar HV, et al. Hospital-acquired infections following the 1999 Marmara earthquake. J Hosp Infect. 2002;51:47–51.
41. Kazancioglu R, Cagatay A, Calangu S, et al. The characteristics of infections in crush syndrome. Clin Microbiol Infect. 2002;8:202–6.
42. Hiransuthikul N, Tantisiriwat W, Lertutsahakul K, et al. Skin and soft-tissue infections among tsunami survivors in southern Thailand. Clin Infect Dis. 2005;41:e93–6. Epub 2005 Oct 13.
43. Kiani QH, Amir M, Ghazanfar MA, et al. Microbiology of wound infections among hospitalised patients following the 2005 Pakistan earthquake. J Hosp Infect. 2009;73:71–8.
44. Tao C, Kang M, Chen Z, et al. Microbiologic study of the pathogens isolated from wound culture among Wenchuan earthquake survivors. Diagn Microbiol Infect Dis. 2009;63:268–70.
45. Ran YC, Ao XX, Liu L, et al. Distribution and drug resistance of pathogenic bacteria isolated from infected wounds of children after Wenchuan earthquake. Chin J Pediatr [Zhonghua Er Ke Za Zhi]. 2009;47:332–6.
46. Emergency preparedness and response: emergency wound management for healthcare professionals. Centers for Disease Control and Prevention, Atlanta. 2010. (http://emergency.cdc.gov/disasters/emergwoundhcp.asp#guidance or http://www.bt.cdc.gov/disasters/pdf/emergwoundhcp.pdf).
47. World Health Organization, Dep of Violence and Injury Prevention and Disability. Prevention and management of wound infection: core principles and protocols. (http://www.who.int/hac/techguidance/tools/Prevention%20and%20management%20of%20wound%20infection.pdf).
48. Cressey D. Disaster doctors may be using the wrong drugs. Nature. Published online 22 December. 2010;doi:10.1038/news.2010.695.
49. James GA, Swogger E, Wolcott R, et al. Biofilms in chronic wounds. Wound Repair Regen. 2008;16:37–44.
50. Percival SL, Hill KE, Williams DW, et al. A review of the scientific evidence for biofilms in wounds. Wound Repair Regen. 2012;20:647–57.
51. Hall-Stoodley L, Stoodley P. Biofilm formation and dispersal and the transmission of human pathogens. Trends Microbiol. 2005;13:7–10. doi:10.1016/j.tim.2004.11.004. Available online 7 December 2004.
52. Weinstein L, Barza MA. Gas gangrene. N Engl J Med. 1973;289:1129–31.
53. Pellegrini Jr VD, Reid S, Evarts CM. Complications. In: Rockwood Jr CA, Green DP, Bucholz RW, Heckman JD, editors. Rockwood and Green's fractures in adults. 4th ed. Philadelphia: Lippincott-Raven; 1996. p. 458–82.
54. Rehka A, Gopalan TR; Civilian Gas Gangrene. A Clinical Challenge. Lower Extr Wounds. 2007;6:98–101.
55. Médicins sans Frontières. Tetanus in: clinical guidelines. Paris: Médicins sans Frontières; 2010. p. 170–3.
56. Wong CH, Kurup A, Tan KC. Group B streptococcus necrotizing fasciitis: an emerging disease? Eur J Clin Microbiol Infect Dis. 2004;23:573–5.
57. Wong CH, Chang HC, Pasupathy S, et al. Necrotizing fasciitis: clinical presentation, microbiology, and determinants of mortality. J Bone Joint Surg Am. 2003;85:1454–60.
58. Taviloglu K, Cabioglu N, Cagatay A, et al. Idiopathic necrotizing fasciitis: risk factors and strategies for management. Am Surg. 2005;71:315–23.
59. Kulkarni VA, Schiffman E, Baitner AC, et al. Septic arthritis associated with closed intra-articular fracture: a case series. J Pediatr Orthop. 2011;31:e8–15.
60. Molyneux EM, Lavy CBD, Lavy VR, et al. Septic arthritis. Lancet. 1998;351:1060–1.
61. Goldenberg DL. Septic arthritis. Lancet. 1998;351:197–202.
62. Nunn TR, Cheung WY, Rollinson PD. A prospective study of pyogenic sepsis of the hip in childhood. J Bone Joint Surg Br. 2007;89:100–6.
63. Parks T, Kado J, Colquhoun S, et al. Underdiagnosis of acute rheumatic fever in primary care settings in a developing country. Trop Med Int Health. 2009;14:1407–13.
64. Mellor SG, Cooper GJ, Bowyer GW. Efficacy of delayed administration of benzylpenicillin in the control of infection in penetrating soft-tissue injuries in war. J Trauma. 1996;40(3 Suppl):S128–34.
65. Butler F, O'Connor K. Antibiotics in tactical combat casualty care 2002. Mil Med. 2003;168:911–4.
66. Hoff WS, Bonadies JA, Cachecho R, et al. EAST Practice Management Guidelines Work Group: update to practice management guidelines for prophylactic antibiotic use in open fractures. J Trauma. 2011;70:751–4.
67. Gosselin RA, Roberts I, Gillespie WJ. Antibiotics for preventing infection in open limb fractures. Cochrane Database Syst Rev. 2004;1:CD003764.
68. Al-Arabi YB, Nader M, Hamidian-Jahromi AR, et al. The effect of the timing of antibiotics and surgical treatment on infection rates in open long-bone fractures: a 9-year prospective study from a district general hospital. Injury. 2007;38:900–5.
69. Pollak AN, Jones AL, Castillo RC, et al; LEAP Study Group. The relationship between time to surgical debridement and incidence of infection after open high-energy lower extremity trauma. J Bone Joint Surg Am. 2010;92:7–15.
70. Patzakis MJ, Harvey Jr JP, Ivler D. The role of antibiotics in the management of open fractures. J Bone Joint Surg Am. 1974;56:532–41.
71. Bratzler DW. Use of antimicrobial prophylaxis for major surgery: baseline results from the National Surgical Infection Prevention Project. Arch Surg. 2005;140:174–82.
72. Velmahos GC, Toutouzas KG, Sarkisyan G, Chan LS, et al. Severe trauma is not an excuse for prolonged antibiotic prophylaxis. Arch Surg. 2002;137:537–41.

73. MSF-OCP. Guide to antibiotic therapy for MSF orthopedic surgery missions. 2008. http://association.msf.org/.
74. Hutley EJ, Green AD. Infection in wounds of conflict-old lessons and new challenges. J R Army Med Corps. 2009;155:315–9.
75. Murray CK, Hospenthal DR, Holcomb JB. Antibiotics use and selection at the point of injury in tactical combat casualty care for casualties with penetrating abdominal injury, shock, or unable to tolerate an oral agent. J Spec Oper Med. 2005;5:56–61.
76. Zalavras CG, Patzakis MJ, Holtom PD, et al. Management of open fractures. Infect Dis Clin North Am. 2005;19:915–29.
77. Olson SA, Finkemeier CG, Moehring ND. Open fractures. In: Bucholz RW, Heckman JD, editors. Rockwood and Greene's fractures in adults. 5th ed. Philadelphia: Lippincott, Williams and Wilkins; 2001. p. 285–318.
78. Hamouda HM, Witso E, Moghani NK, et al. Soft tissue infection after missile injuries to the extremities. A non- randomized, prospective study in Gaza city. Prehosp Disaster Med. 2007;22:106–8.
79. Murray CK. Epidemiology of infections associated with combat-related injuries in Iraq and Afghanistan. J Trauma. 2008;64:S232–8.
80. Hauser CJ, Adams Jr CA, Eachempati SR. Surgical infection society guideline: prophylactic antibiotic use in open fractures: an evidence-based guideline. Surg Infect (Larchmt). 2006;7:379–405.
81. Campbell JI, Lam TM, Huynh TL, et al. Microbiologic characterization and antimicrobial susceptibility of Clostridium tetani isolated from wounds of patients with clinically diagnosed tetanus. Am J Trop Med Hyg. 2009;80:827–31.
82. Stevens DL, Maier KA, Laine BM, et al. Comparison of clindamycin, rifampicin, tetracycline, metronidazole, and penicillin for efficacy in prevention of experimental gas gangrene due to Clostridium perfringens. J Infect Dis. 1987;155:220–8.
83. Holtom PD. Antibiotic prophylaxis: current recommendations. J Am Acad Orthop Surg. 2006; 14:S98–100.
84. Alexander JW, Solomkin JS, Edwards MJ. Up-dated recommendations for control of surgical site infections. Ann Surg. 2011;253:1082–93.
85. Brolmann FE, Ubbink DT, Nelson EA, et al. Evidence-based decisions for local and systemic wound care. Br J Surg. 2012;99:1172–83.
86. Owens BD, Wenke JC. Early wound irrigation improves the ability to remove bacteria. J Bone Joint Surg Am. 2007;89:1723–6.
87. Hall S. A review of the effect of tap water versus normal saline on infection rates in acute traumatic wounds. J Wound Care. 2007;16:38–41.
88. Khan MN, Naqvi AH. Antiseptics, iodine, povidone iodine and traumatic wound cleansing. J Tissue Viability. 2006;16:6–10.
89. Buddensick TJ, Cunningham SC, Kamangar F. Updated literature on povidone-iodine for control of surgical site infections. Ann Surg. 2012; 256:e1–2.
90. Fournel I, Tiv M, Soulias M, et al. Meta- analysis of intraoperative povidone-iodine application to prevent surgical-site infection. Br J Surg. 2010; 97:1603–13.
91. Bhandari M, Schemitsch EH, Adili A, et al. High and low pressure pulsatile lavage of contaminated tibial fractures: an in vitro study of bacterial adherence and bone damage. J Orthop Trauma. 1999;13:526–33.
92. Hassinger SM, Harding G, Wongworawat MD. High-pressure pulsatile lavage propagates bacteria into soft tissue. Clin Orthop Relat Res. 2005;439:27–31.
93. Argenta LC, Morykwas MJ. Vacuum-assisted closure: a new method for wound control and treatment: clinical experience. Ann Plast Surg. 1997; 38:563–77.
94. Mendonca DA. Negative pressure wound therapy. An important adjunct to wound care. South Med J. 2006;99:562–3.
95. Harrison WJ. Open tibia fractures in HIV positive patients. Malawi Med J. 2009;21:174–5.
96. Mody GM, Parke FA, Reveille JD. Articular manifestations of human immunodeficiency virus infection. Best Pract Res Clin Rheumatol. 2003;17:265–87.
97. Guild GN, Moore TJ, Barnes W, et al. CD4 count is associated with postoperative infection in patients with orthopaedic trauma who are HIV positive. Clin Orthop Relat Res. 2012;470:1507–12.
98. Himmelreich H, Rabenau HF, Rindermann M, et al. The management of needlestick injuries. Dtsch Arztebl Int. 2013;110:61–7.
99. Baggaley R, Doherty M, Ball A, et al. The strategic use of antiretrovirals to prevent HIV infection: a converging agenda. Clin Infect Dis 2015;60:S159–60.
100. Mast EE, Weinbaum CM, Fiore AE, et al; Advisory Committee on Immunization Practices (ACIP) Centers for Disease Control and Prevention (CDC). A comprehensive immunization strategy to eliminate transmission of hepatitis B virus infection in the United States: recommendations of the Advisory Committee on Immunization Practices (ACIP) part II: immunization of adults. MMWR Recomm Rep. 2006;55:1–33.
101. Aharonson-Daniel L, Klein Y, Peleg K. Suicide bombers form a new injury profile. Ann Surg. 2006;244:1018–23.
102. CDC. Updated U.S. Public Health Service guidelines for the management of occupational exposures to HBV, HCV, and HIV and recommendations for postexposure prophylaxis. MMWR. 2001;50(No. RR-11):1–55.
103. Kumar S, Agarwal A, Arora A. Skeletal tuberculosis following fracture fixation. J Bone Joint Surg (Amer). 2006;88:1101–6.
104. Barr DA, Whittington AM, White B, et al. Extrapulmonary tuberculosis developing at sites of previous trauma. J Infect. 2013;66:313–9.
105. Hopewell PC. Overview of clinical tuberculosis. In: Bloom BR, editor. Tuberculosis. Washington, DC: American Society for Microbiology; 2005. p. 25–46.

Rehabilitation, Physiotherapy and Prosthetics

22

Bérangère Gohy

Following a humanitarian crisis, the international response tends to be quicker and more efficient than it used to be, which leads to a higher survival rate of critical ill patients, whose injuries tend to be complex and associated with a number of long-term disabilities [1]. Moreover, health care structures are often overwhelmed which makes the discharges difficult [2, 3].

Following the 2010 Haiti earthquake, it became obvious that the integration of a skilled physical rehabilitation team was necessary to optimise the benefits of medical or surgical interventions [3, 4]. It also gives patients an increased chance of social reintegration in the long term by restoring their functional capacities, improving their quality of life [5], preventing and helping reduce secondary complications and shortening hospital stay [1, 6].

Too often, the patient's role is relatively passive, assisted by relatives and expecting the therapist to heal/cure all injuries [7–9]. Cultural systems can also pose challenges. In some areas of Africa, for example, the disability is seen as a result of evil forces, and therefore patients suffering from disability are stigmatised and their rehabilitation is often neglected [10]. Hence, the rehabilitation team also has an important educational role, explaining the benefits of physiotherapy and encouraging the patient to be an active participant in his own recovery.

Rehabilitation should be routinely integrated to emergency humanitarian response as it allows to:

- Improve the clinical and functional outcomes
- Improve quality of life
- Reduce lengths of hospital stay
- Reduce the secondary complications (e.g. chest infection, stiffness, muscle weakness)
- Promote the proactive role of the patient in the rehabilitation process

22.1 Rehabilitation Actors

In conflict zones and following natural disasters, the personnel of humanitarian teams changes constantly due to the rotation of expatriates. Thus interdisciplinary consultation and teamwork is imperative to give coherent, efficient and sustainable care [4, 11]. The physiotherapist is part of this team and should be integrated in the discussions about the patient's treatment management, his evolution and discharge plan. This can be achieved during the daily multidisciplinary ward rounds and can certainly improve the quality of care [11].

Unfortunately, due to the lack of physiotherapy schools, the so-called brain drain and poor security conditions, qualified physiotherapists

---

B. Gohy, PT
Physiotherapist, Handicap International,
Verviers, Belgium
e-mail: berangere.gohy@gmail.com

© Springer International Publishing Switzerland 2016
J.D. Robinson (ed.), *Orthopaedic Trauma in the Austere Environment:*
A Practical Guide to Care in the Humanitarian Setting, DOI 10.1007/978-3-319-29122-2_22

may be difficult to find [10]. Medical staff such as nurses can be trained to provide basic physiotherapy care, to help educating the patient and preventing secondary complications. In case no other solution is available, non-medical staff can be trained as physiotherapist assistants. However, one must remember that they are not trained to perform a comprehensive physiotherapy assessment nor to set up an individually tailored treatment plan.

Caregivers' (usually the patient's relatives) involvement is really essential as they follow the patient throughout the full course of recovery, from the inpatient ward where the caregiver is often constantly present, washing and feeding the patient until the patient's reintegration to the community [12]. From the very beginning, caregivers need to be involved and should receive clear explanations about the pathology, possible complications as well as their role and expected involvement in the patient's management [13]. Patient positioning in bed, mobilisation and basic hygiene are important topics to describe and explain to caregivers, emphasising the patient's gain of function/autonomy and the need for an active rehabilitation [13]. Special caution should be paid to patients without a caregiver as they are at great risk of delayed recovery and are more vulnerable to complications.

After a conflict or a natural disaster, patients are not only physically injured but also psychologically traumatised. Therefore, mental health support is everything but superfluous in such settings [7].

Following a humanitarian crisis:

- Multidisciplinary work is essential and physiotherapist should be part of the team.
- Daily ward rounds helps improving patient care.
- If no graduated physiotherapists, medical (usually nurses) or non-medical staff should be trained to perform basic physiotherapy techniques.
- Involve the caregivers from the beginning.
- Empower the patient.
- Involve mental health staff.

22.2 Physiotherapy, Needs Assessment and Prescription

Prolonged bed rest and immobility gives rise to a number of complications such as muscle atrophy, bedsores, joint stiffness, deep vein thrombosis [14], loss of independence [6] and pulmonary complications [15]. Early mobilisation protocols have been proved to reduce mentioned complications [6, 14].

The medical team should assess the patients at risk of complications and therefore in need for rehabilitation. Patients who are unconscious and bedridden, with difficulties to perform bed transfers or to mobilise, post-surgery, with an immobilised limb, respiratory problems or muscle weakness, should be referred to the physiotherapist.

Surgeons should share realistic goals that can be expected for each patient with the rehabilitation team. All relevant information such as the degree of bone healing, infection, weight-bearing status and any limitations to movement should be clearly documented in the doctor's prescription (Fig. 22.1).

As stated by Reinhardt et al.: "Delay in treatment reduces effectiveness of rehabilitative therapies, resulting in poorer outcomes" [7]. Physiotherapy treatment should be started as early as possible [6, 7] and only delayed if the patient presents with any cardiovascular, pulmonary or musculoskeletal pathology that requires treatment first [14].

22.3 Discharge and Follow-Up

At discharge, the responsible doctor is asked to write a detailed discharge form to give clear information about the surgery performed, the patient's condition, possible complications and the treatment plan [8]. Regular outpatient follow-up appointments [4], including physiotherapy sessions, should be arranged. Physiotherapy follow-up should continue until the patient has regained the target function level.

Additional contributions by the proactive physiotherapist include monitoring for undetected injuries, infection, non-union or malunion, peripheral nerve injury or reflex sympathetic syn-

Prescription for OPD Rehab Care

1. **General Information (patient)**

Patient's name ______________

Adm date __________ **Reg n°**

2. **Medical information**

Date of injury ___________

Diagnosis: ______________________

Cast/pin removal: no / yes (if yes, date: _______)

X-ray (date ________): callus: ☐no ☐min ☐good

3. **Prescription**

Type of care:

Mob. ☐ passive ______________
☐ auto-passive ______________
☐ active ______________
☐ Strengthening ______________
☐ Stretching ______________
☐ Chest

NWB/PWB/FWB. for .... weeks

Made by (doctor' signature) Date

Fig. 22.1 Prescription for physiotherapy care

drome and communicating this information to the medical staff. The physiotherapist should also help with maintaining hygiene standards where sanitation is not ideal. Referral to local structures should also be encouraged for those living in remote areas.

For every trauma patient:

- Assess the physiotherapy needs (according to his mobility, respiratory and functional status) and write a detailed prescription.
- Start (very) early rehabilitation as soon as the patient has cardiovascular, pulmonary and musculoskeletal stability.
- Integrate physiotherapy in the outpatient follow-up as long as function is not regained.
- Pay attention to undetected injuries and complications.
- Set rehabilitation treatment plan.
- Consider referral to other rehabilitation structures for patients coming from far away.

22.3.1 Physiotherapy Assessment

A thorough assessment such as advised by the American Physical Therapy Association should be performed; it includes history review and cardiovascular, respiratory, musculoskeletal, neurologic and skin assessment [16] paying special attention to the pain assessment. Indeed, pain is one of the main complains and it affects both function and compliance to treatment. In order to evaluate the effectiveness of the analgesic treatment and depending on the patient's general health status, pain should also be assessed in a dynamic way, asking the patient to score his pain while performing daily life activities and/or basic "activities" such as deep breathing, coughing and bed mobility [17, 18].

22.3.2 Functional Evaluation

In austere environments, any condition that limits a patient's physical capabilities may be very detrimental to his ability to support himself and his family [10, 19]. Hence, functional evaluation of the patient is essential. The existing functional scales, however, are not always appropriate to the emergency setting in an austere environment. The administration time is often too long (e.g. 30 min for the Functional Independence Measure and the Sickness Impact Profile [20]) for a service which is usually understaffed. The evaluations are often not culturally validated and some are self-administrated which is impractical in regions with high levels of illiteracy [7]. The existing orthopaedics scales are frequently focused on one joint or limb (e.g. Harris hip score, UCLA shoulder rating score, Mayo Wrist or Elbow score) while patients are often polytraumatised and preferably need a holistic approach. Fine dexterity items are important to elicit changes in patients with upper limb injuries [21]. Differences in patient ages are important. In an armed conflict zone, patients are often young, while in the aftermath of a natural disaster, people of all ages are injured. Therefore, a life-course harmonisation of the items is essential [22]. Finally, the scores developed in resource-rich countries are not always applicable to resource-poor areas. Scores should be culturally relevant [22], adapted to the community's religion, lifestyle and occupations. Handicap International designed its own functional measure to meet the needs of the types of injuries inclusive of the cultural context, for example, for a trauma centre within a Muslim country (see Fig. 22.2).

IPD ☐
OPD ☐

Functional Evaluation

Patient Name .... Registration number .... Date ....

Score	
5	The person is capable of doing the activity alone (the person is autonomous)
4	The person is capable of doing the activity alone, with difficulties
3	The person is capable of doing the activity with external support (equipment-device)
2	The person is active during the activity but requires external human support (person)
1	The person is completely passive during the activity (not capable of doing the activity by herself)

Lower limb activities

Transfers					
Sitting up (from lying position)	1	2	3	4	5
Standing up (from sitting position)	1	2	3	4	5
Sitting down (from standing position)	1	2	3	4	5
Lying down (from sitting position)	1	2	3	4	5
Going around					
Walking around (less than 50 yards)	1	2	3	4	5
Walking around (more than 50 yards)	1	2	3	4	5
Going up stairs	1	2	3	4	5
Going down stairs	1	2	3	4	5
Toilet					
Squat down	1	2	3	4	5
Pray					
Kneeling (sitting)	1	2	3	4	5

Total LL score: .... / 50

Upper limb activities

Manipulation/handling					
Opening a jar	1	2	3	4	5
Opposition thumb-5th finger	1	2	3	4	5
Grabbing pen	1	2	3	4	5
Hygiene					
Washing the back	1	2	3	4	5
Feeding					
Grabbing a cup	1	2	3	4	5
Eating	1	2	3	4	5
Dressing					
Dress upper body	1	2	3	4	5
Dress lower body	1	2	3	4	5

Total UL score: .... / 50

	Initial result (upon registration)	Intermediary result	Intermediary result	**Final result (upon discharge)**
Date				
Result				

Fig. 22.2 Functional evaluation measure

With the identified patients:

- Perform a subjective and objective physiotherapy assessment, with emphasis on the pain functional assessment.

In such context, the functional evaluation is essential and should be:

- Global (upper limb and lower limb) and precise (include fine dexterity items)
- Quick and easy (emergency settings)
- Objective (not self-administrated as there are a lot of illiterate people)
- Applicable to all age groups
- Culturally adapted

22.3.3 Equipment

Only a few items are indispensable for rehabilitation (Fig. 22.3). They include treatment beds, parallel bars, wall bars, stairs, few pillows, a mirror, standard balls, elastic bands (elastic material used by the tailors can replace the usual exercise bands), sand weights (bottle or sewed pieces of tissue filled with sand) and compressive elastic bandage which should be washable in order to be reusable. If available, gym balls, stationary cycle or pedal ergometer (bicycle pedals mounted on iron structure (Fig. 22.4)) and small equipment for fine dexterity are also useful. Most of these items can be produced locally from wood, steel, foam and fabrics. Manual/mechanical technologies are preferred to electronic devices, as these are cheap and easy to repair or replace.

22.3.4 Provision of Assistive Devices and Mobility Aids

The assistive devices and mobility aids not only increase patients' mobility but also their quality of life thus increasing their ability to integrate back into society [21]. To best meet the patient's needs, the devices should be:

- Individually tailored to fit the user.
- Provided with instructions (i.e. how to use it correctly, e.g. wheelchair skills programme proposed by Dalhousie University in Canada [23], how to adjust and clean it).
- Culturally acceptable [24, 25].
- Adequate to the local environment (e.g. wet and humid, rough surfaces, intensive usage). In fact, incompatibility with the environment

Fig. 22.3 Physiotherapy room

Fig. 22.4 Locally produced pedal ergometer

may result in the technologies to be abandoned [26].

- Functional: the devices should be easy to use, not too bulky or heavy and should really improve the function in the activities of daily life (ADLs).
- Affordable, durable and easy to fabricate and repair (with local materials if possible) and compatible with technological standards [7].
- Tested on quality [4] and safety [21].
- Only basic equipment is needed to provide quality physiotherapy care and can be often produced locally.
- Manual physiotherapy techniques and creativity are sufficient to offer a qualitative treatment.
- Assistive devices can improve the patient's quality of life and mobility.
- They should be tailored, provided with strict instructions, functional, adapted to the culture and environment, functional, affordable, sustainable, safe and quality proofed.

22.4 Prevention of Complications

22.4.1 Prevention of Deep Venous Thrombosis

Together with the pharmacologic prophylaxis treatment, non-pharmacological means such as adapted pain management to allow [8] early mobilisation (more specifically calf pumps and stretching), limb elevation and compressive garment when available (or simple elastic bandaging applying in figure of eight) should be prescribed [27].

22.4.2 Prevention of Pulmonary Complications

Respiratory complications such as decreased ventilation, atelectasis and pneumonia are common in bedridden patients [28] and following surgery and anaesthesia, especially after thoracic and abdominal interventions [29]. Chest physiotherapy should be seen as a prevention technique [29, 30] and not only as a treatment. It helps clearing secretions, increasing ventilation, promoting lung expansion and improving cardiovascular conditioning [31].

There are different chest physiotherapy techniques that can be used, depending on the patient's condition:

22.4.2.1 Deep Breathing Exercises

Deep breathing exercises are the basic, encouraging both diaphragmatic and thoracic breathing, limiting the use of accessory muscles. Manual feedback can be given to the patient by placing the hand on the patient's thorax or abdomen, encouraging him to expand the underlying area [32] (Fig. 22.5). The inspiration is done through the nose, asking a 3-s inspiratory pause at the total lung capacity to help distributing the air in the ventilated areas [32]. The expiration is performed through the mouth, with open glottis (exhaling warm air out). Adjuvant devices such as the incentive spirometer, when available, can help promoting deep inspiration by giving the patient a visual feedback [32].

Fig. 22.5 A manual feedback upper thorax

22.4.2.2 Airway Clearance Techniques

In the literature, few techniques are advocated to clear up the secretions, none of them are proved to be more efficient than another [32]. Amongst them, the autogenic drainage is a breathing technique where the patient is taught how to modulate his lung volume to unstick, collect and mobilise the mucus to the upper airways where it can be breathed out easily without any forced expiration [33]. While the active cycle of breathing is composed of breathing control, thoracic expansion exercises and forced expiration technique (huffing) [34], the physiotherapist can also help the patient manually, following the technique principles. Manual pressures should be used with caution, and forced manoeuvres are contraindicated with osteoporosis, important chest trauma and asthma exacerbation [35]. The therapist should apply his hands on the patient's chest, in the same direction as the rib cage movements to avoid any injuries to the ribs. Another technique is the positive expiratory pressure (PEP) which, by increasing the pressure at the mouth, allows keeping the intrathoracic airways open for longer period of time and allows secretions to be mobilised more easily [35]. PEP can be achieved by breathing out against a resistance at the mouth, such as the blow-bottle system (see Fig. 22.6) where a bottle is filled with 5–20 cm of water [36], the patient blowing into the water through a tube 1 cm diameter and 30 cm long (suction silicon tube can be used). The water must be changed every day and the bottle and tube sterilised between each patient.

Fig. 22.6 Chest physiotherapy PEP and manual technique

22.4.2.3 Positioning

Position has an impact on lung ventilation and perfusion [37] and the position should be adapted to the patient's condition [32, 38]. For bedridden patients, regular change of position is also recommended to prevent atelectasis and further pulmonary complications [31]. Seated position should be promoted as soon as possible as it promotes gas exchanges, as compared to the supine position [39].

22.4.2.4 Postural Correction

Since the posture influences the way the respiratory muscles function and the ribs and thoracic spine mobility, it may also affect the pattern of breathing in patients with musculoskeletal, respiratory or neurologic impairments [40]. Promoting the neutral position of the shoulder girdle, spine and pelvis [32] allows the muscles and especially the diaphragm to work optimally.

22.4.2.5 Upper Limb Movements

Upper limb movements (mainly in extension, abduction and external rotation) and thoracic spine mobilisation (extension, rotation and lateral flexion) can also help opening the rib cage and increasing the breathing volume [32].

22.4.2.6 Coughing

Coughing should only be used by the patient when secretions reached the upper airways; the airways easily get irritated while the patient gets tired by coughing too frequently, often not at the appropriate time [35].

22.4.3 Prevention of Pressure Sores

There is a high risk of bedsores for severe trauma and bedridden patients such as ICU patients and patients in traction or with unstable pelvic fractures.

The main principles for prevention are:

- Basic hygiene of the patient and clean bed sheets.
- Regular change of position (every 2 h) and protection of the bony areas with pillows.
- Teaching proper transfer to the staff and relatives, avoiding friction (i.e. lifting up the patient).
- Daily skin check [28].
- Careful choice of mattress [41].
- Provision of monkey pole and early active mobilisation can also be helpful.

22.4.4 Prevention of Muscle Atrophy

Bed rest and inactivity provoke loss in muscle mass and muscle strength in young healthy subjects but to a greater extent in the elderly [42, 43] and the critically ill [44]. This loss is significant in the lower limb muscles [45] such as the quadriceps, the triceps sural [46] and other antigravity muscles [47]. Rectus femoris cross-sectional area decreases significantly after 1 week of bed rest in intensive care patients [44]. Muscle wasting has a negative impact on the patient's functional capacity [43].

Early mobilisation is essential. A resistive exercises programme has been proven to diminish the loss in muscle mass and strength [48, 49]. However, the patient's condition does not always allow active mobilisation. Passive mobilisation can be beneficial as well, as in the case of continuous passive mobilisation [50, 51].

22.4.5 Prevention of Joint Stiffness

Because of immobility, muscles and connective tissues surrounding the joints tend to shorten in the immobilised position which further causes joint stiffness and permanent functional deficit [52]. The elbow is the most susceptible joint to stiffness, followed by the ankle, the knee, the hip and the shoulder [52]. Therefore, stiffness prevention is essential, performing early and regular passive and active mobilisation [53] as well as positioning (e.g. splinting the ankle in neutral position to prevent contraction of the Achilles tendon in ICU patients [54]). Moreover, a physiotherapist must alert the surgeon when a patient has been splinted or casted in positions that are not functional.

22.4.6 Prevention of Bone Demineralisation

Bone demineralisation occurs rapidly with bed rest, as early as 1 week of traction in the elderly [55], but it also occurs in young patients [56]. This can increase the risk of osteoporosis and future fracture [47]. Early weight bearing and active mobilisation against resistance stress the bone which increase its density and limits the bone loss [57].

22.4.7 Prevention of Loss of Function and Independence

Rehabilitation aims to help the patient to improve his participation in daily life activities, following the International Classification for Functioning, Disability and Health (ICF) proposed by the WHO [58]. The exercises must be task orientated and tailored to the individual's ADLs and interests [59]. For example,

- Upper limbs: grabbing a cup, pen, eating, grooming
- Lower limbs: walking, climbing stairs, kneeling (pray position)

Making the patient as active as possible and as soon as possible is crucial, starting by teaching bed mobility and transfers, progressing then to sitting and standing balance. At discharge, as far as possible, all patients must be ambulated (either with crutches, walker or wheelchair) and should know how to climb up and down stairs with crutches or to move around with a wheelchair.

Trauma and prolonged immobilisation give rise to a number of secondary complications. Early rehabilitation can help preventing and reducing the risk of:

- Deep venous thrombosis
- Pulmonary complications
- Bedsores
- Muscle atrophy
- Joint stiffness
- Bone demineralisation
- Loss of function/independence

22.5 Specific Physiotherapy Regimens

Injury and/or the surgery performed is often associated with known residual impairments [60]. The rehabilitation programme should be tailored to the expected impairments and secondary complications in order to improve the function and limit disabilities over time [6, 60]. In this section, you will find the advised physical therapy techniques for the most common types of treatment in austere environments.

22.5.1 Fractures Treated by External Fixation

Once an external fixation (EF) is in place, several complications can arise in the early stages such as pin tract infection [61], nerve injury and muscle impalement (which can lead to tendon lesion, muscle fibrosis, pain and stiffness) [8, 62]. Later, delayed union or malunion, osteomyelitis [61], reflex sympathetic dystrophy [63] and stiffness [64] can occur. It has been reported that in war-wounded patients with femoral shaft fractures treated by external fixation, only less than half of the sample population had knee flexion greater than 110° [65].

22.5.1.1 Physiotherapy Treatment with the EF in Place

For the physiotherapist, stiffness is often the greatest challenge. Therefore, it is crucial to start as early as possible with self-mobilisation (i.e. mobilising the affected limb with the healthy one), passive mobilisation [66] and stretching. Either low-load long-duration postures [67, 68], short [62] or dynamic stretching [69, 70] is generally prescribed in the treatment of joint stiffness. Femoral and forearm external fixation are particularly associated with great stiffness of the knee, the wrist and the fingers. For femoral fractures, from the first postoperative day, the patient should regularly be placed in a flexion posture (using pillows, a locally produced box or traction frame) (see Fig. 22.7) as well as in a continuous passive mobilisation machine (CPM) when available and feasible. During the physiotherapy session, the level of comfort should be respected and pain medication should be given prior to mobilisation and posture, especially during the early days. Cryotherapy can also be applied routinely as it helps to reduce the pain and oedema in soft tissue injuries [71].

Fig. 22.7 Knee flexion low-load long-duration posture in a patient with external fixation

All the joints should be mobilised, as the patient tends to protect his whole limb (e.g. fully mobilise the shoulder, elbow and wrist in humerus fracture stabilised with EF). Furthermore, placing the distal joint in functional position (e.g. removable splinting) is often needed to prevent further stiffness, especially for the wrist, fingers and the ankle [66] which will tend to present stiffness otherwise.

With some types of fractures (e.g. pelvic, humerus), the bulky frame size of some EF might compromise or limit mobilisation [62]. Therefore, this should be discussed with the surgeon early on to take this parameter into account as much as possible when putting external fixators in place, even though this is not always possible.

All the muscle groups should be exercised to keep the patient as active as possible, starting with isometrics (static contraction of the muscle, with no movement of the limb) which are more comfortable for the patients. Once tolerated, concentric (dynamic contraction, the muscle shortens as it contracts) can be performed without resistance on the segment distal to the fracture, helped by the healthy limb if necessary [66]. Patients with upper limb EF tend to lose function. This is especially the case in forearm EF where the fingers extensors are spanned which causes limited flexion of the fingers and impaired function in a later stage. Early on, patients should be instructed to perform functional activities with the EF, without any weights or resistance (e.g. grabbing a cup of tea and lifting it up with a forearm EF in place). However, in some particular cases, as reported by Sommerkamp et al., early active mobilisation can be contraindicated (e.g. for unstable distal radius fracture) [72].

Bed mobility and ambulation with crutches should be taught to the patient from the first days. For lower limb fractures, the level and the timing of the weight bearing will be decided depending on the stability of the fracture and the type of external fixation. Comfort in walking is primordial too and will guide the progression in weight bearing [61]. Progressive exercises in standing position can be performed, starting with body weight transfer and lunge forward/sideways, step up/down. All of these prepare the patient to weight-bearing gait.

Once an external fixation is in place:

- Promote early mobilisation and strengthening of all joints.
- Emphasise mobilisation of the joint distal to the fracture: postures and positioning are essential from the beginning together with an adequate pain management.
- Promote active ROM: start with isometric exercises and integrate functional exercises.
- Encourage mobility and start early weight bearing according to surgeon's advice and pain.

22.5.1.2 Physiotherapy Post EF Removal

Once there is evidence of bone healing and the EF is removed, more aggressive exercises can be started to regain the range of motion (ROM) and to strengthen the limb. In order to gain further mobility, gravity and weights can be added to the low-load long-duration postures, and techniques such as the "contract-relax" can be really effective. This technique is a proprioceptive neuromuscular facilitation (PNF) technique where, with the muscle in a stretched position, the patient is asked a static muscle contraction, followed by few seconds rest and then passive mobilisation to a further stretched position is done [73, 74] (see Fig. 22.8).

In terms of strengthening, resistance can be increased gradually. Stationary bikes or pedal ergometers are an easy way to mobilise and strengthen globally the lower limb but also the upper limb. Gait training allows working the balance and weight bearing functionally, trying to prevent gait pattern deviation such as vaulting (i.e. during the swing phase, pelvic itching and hip abduction to swing the leg forward, with the knee extended).

22.6 Case Study

Patient H, 40 years old, road traffic accident (arrived in the hospital 3 weeks post trauma), distal ulna-radius open fracture treated with an external fixation spanning the wrist.

Fig. 22.8 Knee extensors contract-relax technique

At discharge, the shoulder mobility was full, the elbow extension as well while flexion was limited to 80° range of motion (ROM), metacarpophalangeal joint flexion was 10° ROM, the proximal interphalangeal joint flexion was 90° ROM and there was a distal interphalangeal flexion of 90° ROM.

After 3 weeks at home, with the arm in a sling and with the fingers wrapped with a piece of fabric, the shoulder mobility was limited to 90° of flexion and abduction, the elbow extension was now also limited (−30° ROM) and the fingers were already stiffer and extremely painful. The UL function was greatly impaired (UL score of 13). Pendular exercises and self-mobilisation of the shoulder, elbow and fingers were instructed and emphasised again as well as education promoting movement.

The external fixator was removed 2 months post injury and wrist mobilisation started.

Three months post injury, the shoulder mobility was still limited, but the elbow, wrist and fingers were slightly better with an increased UL function (UL score of 30). The focus was put on active range of motion, contract-relax exercises and functional exercises such as grabbing a cup, eating and hand to head. Passive range of motion of the fingers as well as scapula and shoulder was realised. Six months post injury, the shoulder, elbow, wrist and fingers mobilities were greatly improved and now functional (UL function score of 40).

This case clearly shows the importance of patient education and home exercises from discharge and of a close outpatient (OPD) follow-up. Without these, the patient will tend to stay passive (arm in a sling, fingers not moving) and will only experience more pain and stiffness as time goes by. It also shows that ROM and function assessments are essential during the OPD medical consultation in order to refer that kind of patients to physiotherapy sooner rather than later. An adequate pain management also helps in keeping such patients mobile and active.

22.6.1 Fractures Treated with Skeletal/Skin Traction

Even though traction has traditionally been used in austere environments for the treatment of femoral fractures, it can lead to a number of complications such as pin infection, knee stiffness, muscle atrophy, bone malunion/non-union and limb shortening and therefore necessitates close management [75–77]. Staff must be well versed in the technique of setting up any form of traction, and the physiotherapist should highlight deficiencies early to the medical staff.

Traction can be applied as definitive treatment or preoperatively, for example, for femoral shaft fractures before internal fixation [78]. There are different kinds of tractions that can be used, depending on the type of fracture, the limb injured and the age of the patient:

- Skeletal traction: the leg is placed in a Braun frame (hip and the knee in flexion). It is suitable for patients over 18 years old and for most of the femur, tibia and pelvic fractures.
- Perkins traction: skeletal traction which does not require any frame. The leg is positioned on the mattress. By the drop of the second half of the mattress, it allows earlier and easier mobilisation as well as easier nursing care [76]. Unfortunately, it is not indicated in certain types of femoral fractures such as complete neck fractures, condylar fractures with rotated fragment and fractures with displaced distal epiphysis [79].
- Gallows traction: skin traction applied on both legs which are then suspended overhead, the buttock being just off the mattress to allow counter-traction [79]. This traction is suitable for young children under the age of 2–3 and under 10–15 kg [79, 80].
- Traditional extension skin traction: skin traction, suitable for older children (up to 18 years old) to avoid damaging the epiphysis, in patients with unstable hip after reduced dislocation and in patients with trochanteric femur fracture when no other treatment is available [79].

22.6.1.1 Physiotherapy and Nursing Care for Patients in Traction

Patients in traction are particularly at risk of bedsores. Thus, on top of the previously mentioned general precautions, it is essential to correctly pad the frame and the patients' pressure areas (i.e. the groin area, the knee fold and the heel for skeletal tractions and the head of fibula and malleoli for the skin tractions). In order to detect any signs of ischaemia or peripheral nerve damage, regular review of the foot and toes neurovascular status is essential, especially in Gallows traction [79].

Efficient traction load and its counterforces are necessary to promote an optimal bone alignment. Therefore, daily management of the following points is necessary [8]: the weights should hang free, never be removed, the foot of the bed should be lifted up and the patient should remain lying flat (no more than 20° up), the patient's foot sole should not rest on anything, overall alignment of the limb is essential [8], and the height and length of the frame should be adjusted to the patient's size. For distal femur fractures placed in a Braun frame, a pillow/foam pad can be put under the thigh, or the frame can be put a little bit more proximally to avoid posterior sag [8, 81]. In sub-trochanteric fractures, the leg should be abducted [79] and flexed to allow good alignment of the proximal fragment. Note that in skin traction, the adhesive bandage should stop under the fracture site in order to be efficient [79].

In skeletal traction, knee mobilisation up to 90° will not affect the forces applied to the fracture site [8]. Therefore, early passive and active assisted mobilisation (up to 90°) should be realised, with the weights still pulling. With the Perkins frame, self-mobilisation is also possible, using the unaffected leg [76].

In the early phase, start with isometric contractions of the quadriceps, hamstrings and glutes [62, 79, 82]. An endurance programme for the quadriceps muscle (20 min daily) has been proposed by Eggers and Mennen [77] for patients in skeletal traction and showed significant increase in quadriceps endurance compared to the control group [77]. For Perkins traction, after 7–10 days, and as tolerated, start gentle active assisted knee mobilisation without resistance [76, 81]. For all types of traction, resisted exercises should also be realised for the toes and ankle joints, as well as for the noninvolved limbs (using elastic band or weights) (see Fig. 22.9).

For displaced acetabulum fractures, minimum 6 weeks in 90–90° traction is advised [83]. More intensive knee mobilisation can be encouraged. Once the fracture is sticky (after 2–3 weeks minimum), some authors have prescribed gentle hip mobilisation with the weights being removed for 30 min daily [84]. For open-book fractures, a hammock sling traction can be

Fig. 22.9 Resistive exercise (using elastic band) for the healthy lower limb in a patient in skeletal traction

applied, especially for children, when EF is not possible [85].

Due to the slumped posture adopted by most patients and the bed rest consequent to the traction, patients are highly prone to chest pain and infections. Prevention chest physiotherapy exercises such as deep breathing and upper limb movements are beneficial to those patients [62, 79].

For patients in traction:

- Close monitoring of the traction (e.g. alignment, position, frame and weight).
- Bedsore prevention.
- Static contractions of the quadriceps, hamstrings and gluteus.
- Depending on the type of traction, different types of exercises are prescribed.
- Early mobilisation (passive and active assisted range of motion of the knee up to 90°; active knee exercises for Perkin's traction).
- Active ankle, toe and healthy limb exercises.
- Chest physiotherapy exercises.

22.6.1.2 Physiotherapy Post Traction Removal

If satisfactory bone healing is established based on clinical (assessment of the fracture site movement and straight leg raise performance without pain) and radiographic findings, the traction can be removed [76]. The removal is usually after 1–2 weeks for children [80] and around 6 for adults [76, 79]. After removal, hip spica cast is applied for children [86], while in adults, depending on the patient's compliance, a cast (preferably a brace/hinge cast) will be applied for few weeks [76]. However, if the union is satisfactory and the patient is young and healthy, the patient can be discharged only with crutches [76]. Indeed, immobilisation in cast will only increase the chances of knee stiffness.

Progressive mobilisation is prescribed, starting with knee and hip self-mobilisation (see Fig. 22.10), psoas and quadriceps stretching, strengthening and bed weight bearing (i.e. bridging: in supine position, lift up the buttock). Depending on the clinics, start touch weight bearing after 1–2 weeks [8, 79] and keep the crutches another 6 weeks, gradually adding more weight [76]. Some authors recommend a short bed rest period once the traction is removed [8, 79].

22.6.2 Fracture Treated by Hip Spica

A hip spica is mainly applied for femoral shaft fracture in young children, either directly [87]

Fig. 22.10 Knee and hip self-mobilisation after traction removal

or following a short period in skin traction [80]. d'Ollone et al. suggest that, for children younger than 6 years, immediate spica, compared to skin traction followed by spica, gives better outcomes and reduces the cost and complications [88].

Spica casting presents a number of possible complications such as limb shortening, bone angulation, peroneal nerve palsy, gait abnormality, pressure sores and compartment syndrome [80, 89]. However, in children, rapid bone healing, overgrowth and remodelling of the fractured bone allow to achieve relatively good outcomes [80, 90]. Nevertheless, spica cast is often uncomfortable as the patient's mobility is highly restricted. It can have a psychological impact on the child and requires a lot of care from the family [91].

22.6.2.1 While Applying the Cast

The edges of the cast must be padded [87], and enough space should be made for the patient's stomach, buttock and groin in order to avoid any skin lesion, for the patient's comfort, and also to allow easier toileting. Knees should be in slight flexion (60–75°) to allow the patient to sit (e.g. car seats) [87] and to help maintaining the reduction of the fracture [92].

22.6.2.2 Physiotherapy and Nursing Care Once the Spica Cast Is in Place

In order to achieve successful treatment outcomes, children need regular follow-up, and time should be spent with the carers to make them aware of the complications and their prevention in the daily life as well as the basic principles of the rehabilitation. The National Health Service in the UK has published an excellent booklet for carers [93] with extended information. On the field, we use a simplified leaflet with pictures to cover the illiterate population (Fig. 22.11). Here are the main pieces of information to mention:

- Complications: how to detect early signs of compartment syndrome or nerve palsy [87].
- Hygiene and skin care: the cast should remain dry and clean to avoid cast breakage, soakage and pressure sores. Regular checks and refreshing of nappies are necessary to prevent leakage. The child will be strip-washed only and dried [93]. No sharp item should be used to scratch under the cast [93].
- Skin and cast inspection: check the pressures areas at the edges but also under the cast (e.g. sacrum) [93].
- Mobilisation: encourage general resistive active exercises of the healthy limbs, isometrics con-

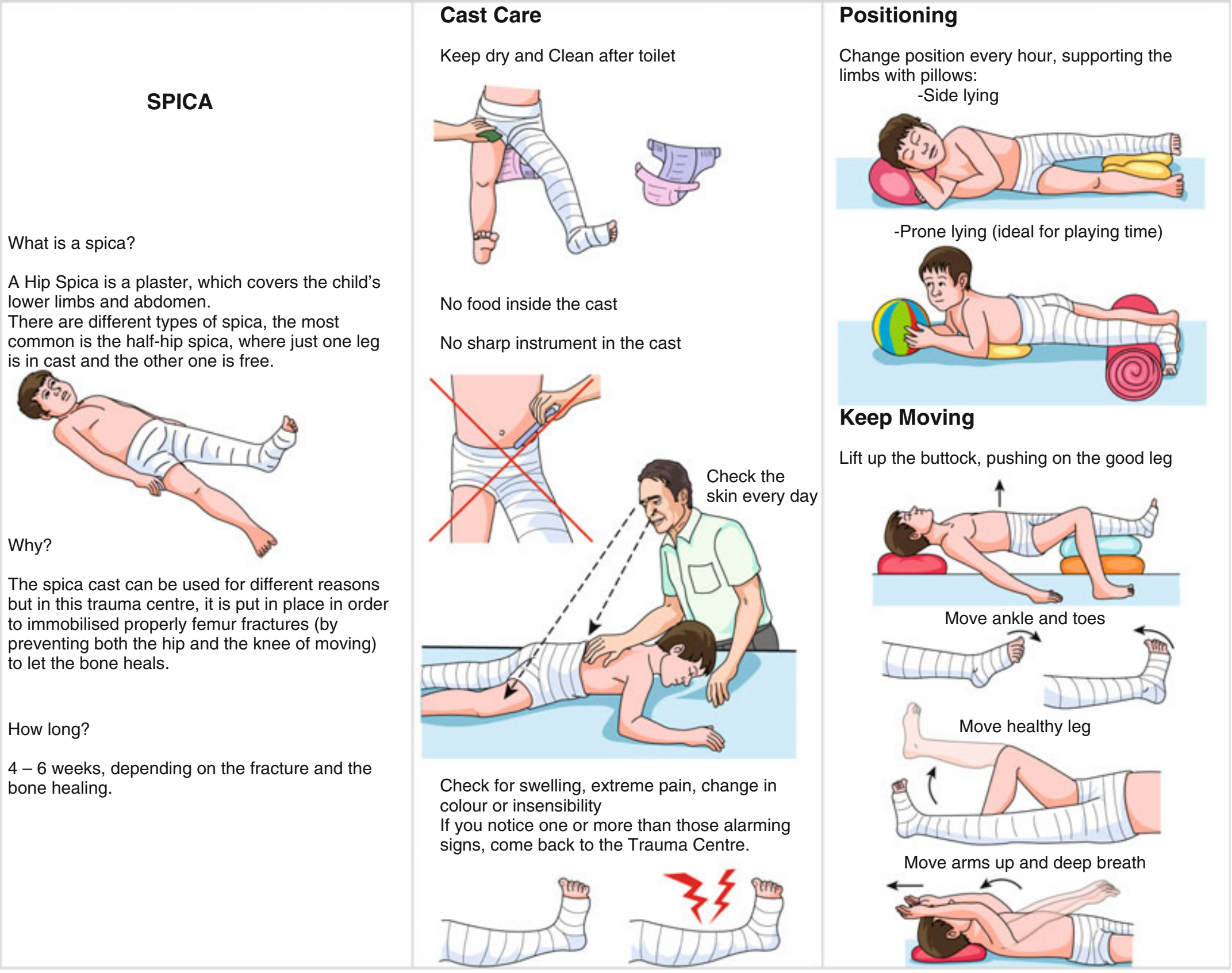

SPICA

What is a spica?

A Hip Spica is a plaster, which covers the child's lower limbs and abdomen.
There are different types of spica, the most common is the half-hip spica, where just one leg is in cast and the other one is free.

Why?

The spica cast can be used for different reasons but in this trauma centre, it is put in place in order to immobilised properly femur fractures (by preventing both the hip and the knee of moving) to let the bone heals.

How long?

4 – 6 weeks, depending on the fracture and the bone healing.

Cast Care

Keep dry and Clean after toilet

No food inside the cast

No sharp instrument in the cast

Check the skin every day

Check for swelling, extreme pain, change in colour or insensibility
If you notice one or more than those alarming signs, come back to the Trauma Centre.

Positioning

Change position every hour, supporting the limbs with pillows:
-Side lying

-Prone lying (ideal for playing time)

Keep Moving

Lift up the buttock, pushing on the good leg

Move ankle and toes

Move healthy leg

Move arms up and deep breath

Fig. 22.11 Spica cast information leaflet

traction of the hip and knee muscles in spica [94] and bridging and pushing on the unaffected leg to relieve the buttock from pressure.

- Positioning: instruct safe transfer (i.e. supported log roll in bed [94] and good positioning of the child, using pillows). The position should be changed every 2–4 h. The prone position is a good playing and pressure-relieving position.
- Promote functionality: it is important to keep stimulating the child while in hip spica. Adapt the positioning to allow the child to play, read and participate in the social activities.

22.6.2.3 Physiotherapy Post Spica Removal

In the first few days, it might be difficult for the child to sit and move his hip and knee again; he might even be afraid to move. Therefore, self-mobilisation should be preferred to passive mobilisation and the parents should be instructed home exercises. A step by step, playful and active approach is essential:

- Start with long sitting position, then sit on the edge of bed (insist on erected back position).
- Continue with knee flexion and weight-bearing exercises such as bridging and four-point kneeling.
- Then, progressive weight bearing if the patient is old enough to use a frame or crutches, otherwise, non-weight bearing as long as the bone is not healed.
- Gait training: from the start, assess gait abnormalities (knee extended walk, hip itching) to correct immediately.

These patients usually require usually only few physiotherapy sessions as the ROM is rapidly regained. If any limitation or pain remains present, the patient should be immediately referred to the doctor as refracture or non-union is a possible complication.

Spica cast rehabilitation:

- Educate and prevent (insist on hygiene and skin care).
- Encourage mobilisation of healthy leg and upper limbs.
- Promote function and participation in ADLs.

Post spica removal:

- Promote self-mobilisation and playful mobilisation.
- Progressive mobilisation (long sitting, sit, bridging, kneeling, stand up).
- Progressive weight bearing.

22.6.3 Closed or Open Reduction with Percutaneous Kirschner Wire (K-Wire) in Children

Supracondylar humerus fractures are common injuries in children and usually occur after a fall with the elbow extended [95]. For undisplaced fractures, a posterior splint is applied, while for displaced and unstable fractures, closed reduction and percutaneous K-wire are used [96]. If not reducible closed, open reduction is then performed. Following supracondylar fractures, complications can arise such as traumatic and iatrogenic neurovascular injury, varus or valgus deformity and compartment syndrome [95].

22.6.3.1 Immobilisation Period

After closed reduction, the elbow is immobilised at 90°, forearm in neutral position, first in a splint, then in a long arm cast [95]. During the immobilisation period, the fingers and shoulder active movements should be encouraged. For the shoulder mobilisation, pendular exercises (leaning forward on a table with the healthy hand, the injured limb hangs down) and flexion are preferred. Abduction should be avoided, as advised for conservative treatment [97]; indeed, shoulder abduction stresses the elbow into varus [98]. Close monitoring of the neurovascular status of the fingers and instructing the patient to do so is mandatory as the chances for complications are high.

22.6.3.2 Pin and Splint Removal

On average after 3–4 weeks [99, 100], the wires and the splint are removed and the early mobilisation can start. The elbow is a joint prone to stiffness, but it is also likely to present hypertrophic ossification and myositis ossificans (especially in the brachialis muscle) caused by the injury itself, by repeated reduction attempts but also when aggressively mobilised and massaged [101]. Therefore, even though an early mobilisation is important, it should be mainly active (without resistance), encouraging functional activities (no weight lifting and sport during 3 months) and allowing time to recover [100]. Active range of motion of the fingers, wrist and shoulder is also important. Even though proper physical therapy is sometimes not prescribed [100] and does not change the 1-year outcomes [102], education and home exercises are necessary. Depending on the reduction achieved, the range of motion will vary. In closed reduction with K-wire fixation, return to function should be expected around 3–4 weeks after pin removal [100], with 72 % of elbow range of motion regained [100], and almost full range of motion (98 %) should be achieved after 1 year [100].

For supracondylar fractures, the following exercises should be performed:

During the immobilisation period

- Pendular shoulder exercises and auto-mobilisation in shoulder flexion
- Fingers active mobilisation

After pin and splint removal

- Early gentle elbow active mobilisation
- Fingers, wrist and shoulder strengthening
- Sport and weight-bearing avoidance during 9–12 weeks

22.6.4 Skin Injuries (Laceration, Skin Graft, Burn) and Vascular Injuries

After any severe soft tissue damage, there will be scar tissue formation. Even when the wound is small (e.g. gunshot entry wound), the amount of tissues damaged inside is often greater. Due to pain and/or fear of pain, most of the patients will tend to adopt an antalgic position. This is also true for vascular injuries. Moreover, in patients with burns [103] and skin grafts [104], the skin will naturally retract for 6–12 months as part of the healing process. It can lead to severe stiffness, joint deformity, muscle shortening and functional disabilities [103]. Scar tissue is inevitable [103], but the level of postoperative care will determine greatly the functional outcomes of soft tissue injuries [105]. A good analgesia management is crucial to keep a certain level of comfort to allow mobility, function and therapy [59].

22.6.5 Physiotherapy Treatment Following Severe Skin Injuries

- Splinting: splints are applied to allow the tissues to heal, especially when in regard to a joint. They should be worn usually up to 3 weeks for burn patients [103], few days for superficial wounds and vascular injuries and until there is healing for skin grafts and flaps. Splinting is also used to immobilise the joint in a functional position and avoid contractures in a disabling position (i.e. for upper limb: 30° wrist extension, 90° metacarpophalangeal and extension of the interphalangeal joints [106] and 0° of dorsal flexion for the ankle). For burn patients, the splint should be removed regularly for mobilisation [103].
- Mobilisation and stretching: after the immobilisation period, all the proximal and distal joints should be gently mobilised [8] actively and with self-mobilisation. It is especially important when the wound is in regard to a joint (e.g. popliteal fossa, ankle, hand dorsal face). Early mobilisation stretches the scaring tissues and takes advantage of the scar malleability in its early stages [103]. After burn or skin graft, full range of motion mobilisation should be performed up to 1 year after injury [103]. Different kinds of stretching can also be performed as well as active range of motion. Note that for vascular injuries, the range of motion authorised and its timing will depend on the quality of the repair and the tension applied in the vessel during the surgery.
- Scar massage: through the fascia, any scar adhesion will restrict the joint mobility. Scar massage will allow the skin to be thinner and more elastic [107]. Note that for skin graft, only gentle massage with neutral oil is authorised the first weeks.
- Skin care for skin grafts and burns: emollient (moisturising neutral oil/cream) can be applied on the skin to help making the skin supple, less itchy and less dry. The skin should be pat dry after washing, avoiding rubbing, it should be kept away from the sunlight during the healing time [103, 104], and compressive bandages can help decreasing hypertrophic scars [103].

After soft tissue injury, the main physiotherapy techniques are:

- Pain management
- Splinting in functional position
- Early mobilisation and stretching
- Scar massage
- Skin care (moisturising, sun protection, no rubbing and compressive bandage)

22.6.6 Case Report

Patient M., 12 years old, gunshot femoral artery injury, sutured the same day. The patient was extremely weak the first few days and remained in the ICU in critical status. He has not received any physiotherapy in IPD.

After 2 weeks, the patient arrives for his OPD medical follow-up to remove the sutures. He is on a stretcher, unable to walk. Because of pain, he has adopted an antalgic position in hip flexion and was not encouraged to move at home. However, the scar is healed without any trace of infection. The patient is discharged from OPD.

By chance, he is spotted in the corridor by one of the physiotherapists. His lower limb functional score is 14; he has hip flexion of 30° ROM and pelvic posterior tilt. The physiotherapist starts with gentle hip and knee mobilisation, psoas and adductor stretching as well as pelvic tilt exercises and erected posture education. The patient is given a walking frame and started partial weight-bearing gait. The patient and the father are instructed on mobilisations and exercises to perform at home.

Two weeks later, after two sessions, the patient leaves the physiotherapy department without walking frame, with full hip extension and a lower limb functional score of 42.

Fortunately for him, he was young and was rapidly seen by the physiotherapist. Assessing the patient's function is as important as checking the wound site or the x-ray. In this case, simple advice at IPD discharge (e.g. self-mobilisation, gentle active mobilisation and early weight-bearing exercises, according to the surgeon's advice) would already have made a big difference for function and prevent further impairments.

22.6.7 Amputation

For amputee patients, the rehabilitation starts long before the fitting of the prosthetics and will continue long after. Therefore, a real continuum of care is necessary for the patient to acquire a better functionality [4]. However, not all the patients will benefit from a prosthetics, this is determined by the team based on the level of activity pre-amputation, the level of amputation, the age of the patient and the co-morbidities [108].

Each stump has to be one that later fits one prosthesis [109]. While performing the amputation, few principles should be followed to allow optimal rehabilitation and future prosthesis fitting [108] taking in consideration the prosthesis available locally:

- Scar: location and quality of the scar (i.e. mobile, non-tender, avoiding weight-bearing areas as much as possible) [109]
- Bone: length (optimal length depending on the level of amputation and height of the patient) and shape of the remaining bone(s) (bevel the bone to avoid bony prominence) [109]
- Muscles and soft tissue: balance between agonist and antagonist muscles (by myodesis and/or myoplasty or tenodesis) to avoid joint deformity; soft tissues quality (good vascularisation) and quantity (sufficient soft tissue to cover the bone), finding a compromise between bone length and tissue coverage [108]
- Nerve: avoid superficial neuroma (by cutting the peripheral nerves under traction and high enough to allow its retraction above the level of amputation) [109]

During the rehabilitation process, it should also be a priority to prevent secondary complications such as oedema, muscle contracture, joint stiffness, muscle atrophy, skin abrasion and scar adhesion. Indeed such complications have an impact on the future prosthesis fitting and will affect the patient's mobility and functionality [108].

22.6.7.1 Pre-fitting Rehabilitation

- Postsurgical dressings: soft dressings are commonly used (compressive elastic bandages if available or Velpeau bandages) in order to help with the oedema control and to shape the stump (e.g. cone shape) while not impairing the circulation [108]. The compressive bandage should be applied from distal to proximal (see Fig. 22.12), in a figure of eight pattern, wrinkle-free, with more pressure distal than proximal and going over at least one joint. It can be applied immediately after surgery, over sterile gauzes covering the scar. It has to be reapplied few times a day as it tends to loosen easily.

Note that shrinkers (socks sewed for stumps) are commonly used in western countries but need to be tailored to the patient's stump size, which is not always available in humanitarian contexts. Shrinkers should only be used once the sutures are removed [108].

From the first few days post-surgery, a rigid splint can be applied to protect the scar line and

Fig. 22.12 Transtibial stump bandage

help preventing the oedema and knee contractures. Removable rigid dressings have been reported to provide quicker scar healing [110], decrease oedema and relieve pains [111], but they require fitted socks and regular management which are not always feasible and available on the field. Padded posterior splint folded over the anterior part of the stump and wrapped up with bandage can be used instead.

- Passive and active mobilisation: as long as not too much tension is applied on the scar (check with the surgeon), gentle passive and active mobilisation can be started early.
- Strengthening: even though general mobilisation is essential (lower limb as well as upper limb), more targeted muscle strengthening is also really important, especially when temporary prosthesis is not available. In transfemoral amputees, hip abductors and extensors and pelvic muscles [108] should be strengthened, as well as the hip adductors, especially if the stump is short. Indeed, the stump will tend to remain flexed and abducted with time [112]. In transtibial amputees, the focus is put on the hip and knee extensors and hip abductors [108].
- Positioning: educate the patient to avoid prolonged positions in hip and/or knee flexion (e.g. sitting with knee flexed or lying supine with pillow under the knee) and rather promote positioning in extension (e.g. sitting

using a stump board (see Fig. 22.12a) or lying in prone position [108]).
- Stretching: performing either low-load long-duration, short self-stretching or active stretching, mainly for the hip and knee flexors, is also essential to prevent contractures [113].
- Scar mobilisation: as long as the scar is not healed, gentle massage can be performed at distance, carefully moving the skin on the residual limb. Once healing is achieved, the scar itself can be massaged [26], avoiding to pull the scar edges away from each other.
- Transfer: safe transfers and bed mobility are instructed in the early stage, paying attention to protect the stump and the scar line. Pivot transfers are preferred in unilateral amputees, while sliding backward transfers are taught for bilateral amputees. Later on, teaching how to fall and get up from the floor is always useful.
- Balance and gait training: standing balance should be trained as early as possible since it will play a great role in the prosthetic rehabilitation; for bilateral amputees or older patients, sitting balance is also really important [108, 112]. When the patient's health condition allows it, crutches skills should be taught as early as possible [108] in order to work the balance, stay active and independent. Otherwise, for bilateral amputees, a wheelchair is given, with a stump board for transtibial amputees.
- Weight bearing: once the scar is healed, the stump should be loaded progressively, the stump resting/pushing on a soft support (e.g. a pillow) (Fig. 22.13).
- Cardiovascular training: in early rehabilitation, upper limb endurance training [112] such as the arm pedal ergometer can be used to work the cardiovascular condition.
- Pain management: in amputees there are two kinds of pain:
  (i) Residual limb nociceptive pain whose cause(s), e.g. neuromas, wrong prosthesis fit, skin abrasion, osteomyelitis and exostosis, should be searched and treated to alleviate the pain.
  (ii) Phantom limb pain which can be treated with techniques such as desensitisation, massage, gentle tapping, gentle rubbing using different materials [112] and the graded motor imagery. The latter progresses in three stages [114]: laterality reconstruction (i.e. through card games, each card representing the part of the body that is impaired in different positions, training of the ability to recognise left from right limb), motor imagery (i.e. imaging a movement of the limb while not actually moving it) and finally mirror box exercises (i.e. the affected limb is placed in a box or behind a mirror while the healthy contralateral limb is in front of the mirror and moves, which gives to the patient the impression that his affected side is moving in a healthy way) [115–117].

Fig. 22.13 Early weight bearing on a transtibial stump

Pre-fitting rehabilitation includes:

- Dressing/bandaging
- Early mobilisation and strengthening
- Positioning precautions
- Stretching
- Scar massage
- Balance exercises
- Weight bearing and gait training (crutches)
- Transfer (bed mobility, ground and chair transfer)
- Cardiovascular training
- Pain management

In austere environments, temporary prosthetics are usually not available. Therefore, a 3–6 month period is commonly necessary before sending the patient for fitting for definitive prosthesis, allowing the swelling to resume and the stump to achieve its more stable shape. When available, temporary prosthesis allows the patient to remain active and maintain a higher level of function while also helping controlling oedema [108].

22.6.7.2 Post-fitting Rehabilitation

- Assessment: A thorough stump and prosthetic fitting assessment is essential to detect any complication, sources of pain or restriction and also to ensure a good prosthetic fitting [108].
  - (i) Stump: assessment of skin (e.g. healing, vascular status, abrasion), swelling, quality and quantity of flesh, scar quality, bony edge and presence of superficial neuromas
  - (ii) Prosthetic fitting: static and dynamic assessment of comfort, alignment, stability, equal limb length and end contact
- Strengthening: continue intensive muscle strengthening and mobilisation. The unaffected limb should also be strengthened as it tends to bear a greater part of the weight [118].
- Balance: after amputation, the hip (and the knee for the transtibial amputation) balances the limb and takes over the role of proprioception of the foot [109]. Therefore, standing balance exercises are essential to gain knee, hip and pelvic control, working the body weight transfer, loading the prosthesis progressively and challenging the patient's balance. Balance exercises are realised in a secure environment (e.g. parallels bars), without any support from the upper limbs if possible. Working with a mirror gives visual feedback, which improves equal weight bearing [118] and promotes erect position [108]. A good standing balance is essential before progressing to walking [108].
- Gait analysis and training: the therapist should promote equal step length, trunk rotation and arm swing [108]. Possible gait deviations such as uneven step length, vaulting, foot external rotation and abducted gait [108] are frequent and should be detected as early as possible. The therapist should seek for their cause (e.g. muscle contracture, poor prosthetic fit or alignment [119].

In the beginning, the prosthetics should be worn gradually (few hours at a time) to avoid skin abrasion and overloading, which could delay the fitting and have a negative impact on the function [120]. After removing the prosthetics, the stump should be bandaged again to prevent oedema. The use of a walker or any assistive device should be avoided if possible, since it promotes an asymmetrical gait pattern and a higher energy expenditure [108].

Pain management should be continued, according to the patient's complains.

Prosthetic rehabilitation:

- Stump assessment
- Prosthetic fitting assessment
- Strengthening
- Standing balance with the prosthetics
- Gait analysis and training with the prosthetics
- Pain management

22.6.8 Peripheral Nerve Injury (PNI)

Peripheral nerve injuries are quite common in polytraumatised patients and sometimes diagnosed later on. Therefore, careful physical and functional assessment should be performed at the time of injury to detect it. Depending on the severity of the lesion, the symptoms and the recovery time can vary greatly [121]. Sensory impairment, pressure sores, joint stiffness, muscle atrophy and weakness, neuropathic pain and functional impairment can be present [122]. In general, even after nerve repair, the recovery is often a long process; therefore preventive measures should be put in place to avoid long-term complications such as deformity, skin lesion due to loss of sensation and sprain due to joint instability [123].

- Education: warn the patients over skin lesions (burn, wound) due to the loss of protective reaction and educate the patient to assess dangerous situations and perform regular skin inspection [123].
- Sensory relearning: the impaired limb has to be progressively stimulated with different shapes, textures, temperatures [122] and pro-

prioception exercises [122]. Such sensory rehabilitation is traditionally started only when sensation recovery starts. However, motor imaging such as the mirror therapy is also indicated [124] and can start earlier [125].
- Positioning:
  (i) Static and dynamic splints: splints are used to maintain the length of the affected muscles and prevent joint stiffness and deformity. Static splints position the limb according to the impaired muscles (e.g. with radial nerve injury, use a splint in wrist and finger extension). Such splints should be regularly removed to mobilise the joints [122]. Dynamic splints position the limb while still allowing the antagonist movement (e.g. grasping in the case of radial nerve palsy) [123]. The splints should be correctly padded to prevent any further skin damage [122].
  (ii) Joint protection braces: protective devices are provided if there is any joint instability (e.g. for the ankle joint when there is a peroneal nerve palsy, as the eversion muscles are impaired) [123].

- Mobilisation and self-mobilisation of all the joints: passive mobilisations should be performed [126], especially in the direction of the affected muscle group(s). The contralateral limb can help mobilising the affected limb.

Note that after nerve repair, a relatively short immobilisation period is prescribed, followed by gradual mobilisation of the limb [126]. The tension applied to the nerve during the surgery has to be taken into consideration. In that regard, older injury and nerve sutured after a big defect will experience more tension and should be mobilised more carefully.

- Active mobilisation and muscle strengthening: global limb strengthening (i.e. active exercises of the whole limb) is essential. Techniques such as the proprioceptive neuromuscular facilitation (PNF) have been reported to be effective in the management of PNI [121]. The PNF technique, using functional diagonal movements, allows stronger healthier muscles to help stimulating impaired ones [121]. Once the impaired muscles start to show a recovery, assisted active movements and progressive strengthening should be performed [126]. The use of the impaired limb in the daily life should be encouraged, and functional task relearning (e.g. fine motor tasks for upper limb injuries) will help the recovery process [122].
- Neuropathic pain management: pharmacologic treatment [122] and any adjuvant available therapies such as desensitisation [123] and mirror therapy can help the patient, in case of severe hyperesthesia, for example [124].

Physiotherapy for patients with peripheral nerve injury:

- Education regarding complications
- Positioning of the impaired joints
- Sensory relearning
- Passive and self-mobilisation of the impaired joints
- Active mobilisation and strengthening (analytic and global/functional) of the impaired muscles and the adjacent healthy muscles
- Neuropathic pain management

22.6.9 Patients in Intensive Care Unit (ICU)

22.6.9.1 Early Mobilisation

Early physical and occupational therapy for patients in the ICU is safe and allows a quicker and greater return to independent functional status at hospital discharge [6].

- For unresponsive patients, routine passive mobilisation [6] and regular change of position in bed are performed (promoting supported sitting up to 45° and alternative side lying) [35].
- For conscious patients, active assisted and active mobilisation are realised as well as bed mobility and sitting up as soon as possible. Then, sitting and standing balance exercises are done, together with functional activities [6].

22.6.9.2 Chest Physiotherapy

In ICU patients, chest physiotherapy should also be performed as a preventive measure but more specifically for chest trauma patients. The physiotherapy techniques will depend on the patient's level of participation and his condition. At all time, vital signs should be monitored and the suction machine should be ready to use.

Note that sometimes, chest physiotherapy can provoke bronchospasm in already hyperreactive airways. A bronchodilator aerosol can be administrated before the physiotherapy to prevent such constriction [35].

In general, the supine position should be used as less as possible and the patients should preferably sit up [39]. In unilateral lung pathology/trauma, the affected lung is usually placed uppermost to promote the ventilation-perfusion ratio [127] and lung expansion [32]. While to drain peripheral secretions, the affected lung is placed lowermost. This position allows deflating the lung deeper in order to recruit lower lung volume and help collecting the deep secretions [128]. For flail chest, the patient is also rather positioned on the affected side to "splint" his injury and decrease the pain [127]. For acute rib fractures, pain management is the key [129]. However, even though rib belts are thought to decrease the pain, they are not recommended as it might decrease the ventilated volume and then increase the risk of respiratory complications [130]. Early mobilisation should also be encouraged [129]. The prone position has also been used for patients with acute respiratory distress syndrome, improving the oxygenation compared to the supine position, while not decreasing the mortality rate [131].

In intensive care unit, routine physiotherapy should be performed, including:

- Mobilisation (passive followed by active when possible)
- Encouraging erect position and functional activities
- Chest physiotherapy as prevention
- Regular change of positioning (adapting the position to the type of chest trauma)

22.6.10 Abdominal Surgery: Laparotomy

In humanitarian context, laparotomies are commonly performed. Due to the size of the scar, its localisation and the pain resulting, the general anaesthesia, bed rest and the medication administrated, the respiratory function is greatly altered during 5–10 days post-surgery [32]. Therefore, to prevent respiratory complications as atelectasis and pneumonia, the physiotherapist has to focus on the respiratory function as well as the functionality of the patient.

22.6.10.1 Physiotherapy Postoperatively

- Breathing exercises: post laparotomy, chest physiotherapy should focus on lung expansion techniques using deep and sustained inspiration [32] asking an inspiratory pause [132]. Performing cycles of deep breathing exercises every waking hour has been recommended [32]. Manual feedback (see Fig. 22.5) and PEP (blow bottle once or twice daily, making sure that the patient takes deep inspirations prior blowing out [36]) (see Fig. 22.6) are good adjuvants to the deep breathing exercises. The use of incentive spirometer has been questioned and there is no evidence of its benefits in patients post-surgery [133, 134].
- Abdominal binder: it is controversial whether abdominal binder helps improving pulmonary function or not; however, it does help reducing the pain and improving patient's comfort [135]. Hence, such binder can be advised from the first day as decreased pain may also have a positive effect on the patient's function.
- Correct posture: postoperatively, patients tend to crunch down to alleviate pain. Therefore, it is important to stimulate them to straighten their back and tilt the pelvis anteriorly in order to adopt an optimal posture [32]. Upper limb and back exercises using a stick can be useful.
- Positioning: If the patient is bedridden, regular change of position and general mobilisation is essential. As soon as it is authorised by the surgeon and that the abdominal wall is closed,

the erected position has to be promoted (first sitting supported then at the edge of the bed), with abdominal binder if available. Indeed, the functional residual capacity is greatly increased in erected position compared to supine [32, 136].
- Coughing efforts: postoperatively, given that the cough is painful and less effective, it affects, amongst other factors, the secretion clearance [32]. When coughing, the patient should be taught to put a pillow on his abdomen or to bring his abdomen skin/the edges of the scar tightly together with his hands (as an abdominal belt would do), to avoid extra pressure on the abdominal scar and muscles and help improving the cough effectiveness [137].
- Bed mobility and transfers: encourage active bed mobility and teach safe transfer (i.e. from supine to sitting, the patient should go through side lying in order to protect the abdominal muscles).
- Gait: stimulate the patient to move as soon as possible, starting with simple active upper and lower limb exercises and progressing to more walking. In the beginning, assistive device might be helpful but it should be used only for few days to avoid further crunched posture.

Post laparotomy, the physiotherapy should educate the patient to perform:

- Deep breathing exercises (thoracic and diaphragmatic breathing)
- Positive expiratory pressure (blow bottle)
- Abdominal binder
- Early upright positioning (sitting and standing)
- Upper limb exercises
- Protected cough
- Transfer through side lying
- Early active mobilisation and gait

References

1. Landry MD, O'Connell C, Tardif G, Burns A. Post-earthquake Haïti: the critical role for rehabilitation services following a humanitarian crisis. Disabil Rehabil. 2010;32(19):1616–8.
2. Gosney J, Reinhardt J, Haig A, Li J. Developing post-disaster physical rehabilitation: role of the World Health Organization Liaison Sub-Committee on Rehabilitation Disaster Relief of the International Society of Physical and Rehabilitation Medicine. J Rehabil Med. 2011;43(11):965–8.
3. Tataryn M, Blanchet K. Evaluation of post-earthquake physical rehabilitation response in Haiti, 2010 – a systems analysis. International Centre for Evidence on Disability (ICED); UK, 2012.
4. Humanitarian Action Summit. 2011. http://hhi.harvard.edu/sites/default/files/publications/publications%20-%20humanitarian%20-%202011%20summit.pdf. Accessed 24 June 2013.
5. The Sphere Project. Humanitarian charter and minimum standards in humanitarian response. 2011. http://www.ifrc.org/PageFiles/95530/The-Sphere-Project-Handbook-20111.pdf. Accessed 22 June 2013.
6. Schweickert WD, Pohlman MC, Pohlman AS, Nigos C, Pawlik AJ. Early physical and occupational therapy in mechanically ventilated, critically ill patients: a randomised controlled trial. Lancet. 2009;373:1874–82.
7. Reinhardt J, Li J, Gosney J, et al. Disability and health-related rehabilitation in international disaster relief. Glob Health Action. 2011;4:7191.
8. Giannou C, Baldan M, Molde A. War surgery, working with limited resources in armed conflict and other situations of violence, vol. 2. Geneva: International Committee of the Red Cross; 2013.
9. Wickford J, Hultberg J, Rosberg S. Physiotherapy in Afghanistan, needs and challenges for development. Disabil Rehabil. 2008;30(4):305–13.
10. Tinney MJ, Chiodo A, Haig A, Wiredu E. Medical rehabilitation in Ghana. Disabil Rehabil. 2007;29(11–12):921–7.
11. Multidisciplinary ward rounds, a resource. 2011. www.health.nsw.gov.au. Accessed 4 July 2014.
12. Reinhard SC, Given B, Petlick NH, Bemis A. Chapter 14: Supporting family caregivers in providing care. In: Hughes RG, editor. Patient safety and quality: an evidence-based handbook for nurses. Rockville: Agency for Healthcare Research and Quality; 2008.
13. Stokes M. Physical management in neurological rehabilitation. Philadelphia: Elsevier Health Sciences; 2004.
14. Clark DE, Lowman JD, Griffin RL, Matthews HM, Reiff DA. Effectiveness of an early mobilization protocol in a trauma and burns intensive care unit: a retrospective cohort study. Phys Ther. 2013;93(2):186–96.
15. Knight J, Nigam Y. Effects of bedrest 1: cardiovascular, respiratory and haematological systems. Nurs Times. 2009;105(21):16–20.
16. Guidelines: physical therapy documentation of patient/client management. 2005. http://www.apta.org/uploadedFiles/APTAorg/About_Us/Policies/BOD/Practice/DocumentationPatientClientMgmt.pdf. Accessed 20 June 2014.

17. McDonald W, Bell E. Acute pain management: measurement toolkit. http://www.health.vic.gov.au/qualitycouncil/downloads/toolkit_introduction.pdf. Accessed 13 June 2014.
18. Macintyre PE, Schug SA. Chapter 3: Assessment of the patient with acute pain. In: Acute pain management: a practical guide. Philadelphia: Elsevier Health Sciences; 2007.
19. May-Teerink T. A survey of rehabilitative services and people coping with physical disabilities in Uganda, East Africa. Int J Rehabil Res. 1999; 22:311–6.
20. Salter K, Campbell N, Richardson M, et al. Outcomes measures in stroke rehabilitation. Evidence-based review of stroke rehabilitation. 2013. http://www.ebrsr.com/sites/default/files/Chapter21_Outcome-Measures_FINAL_16ed.pdf. Accessed 15 July 2014.
21. Borg J, Lindstrom A, Larsson S. Assistive technology in developing countries: a review from the perspective of the Convention of the Rights of Persons with Disabilities. Prosthet Orthot Int. 2011;35: 20–9.
22. PROMIS: instrument development and psychometric evaluation, scientific standards. 2012. http://www.nihpromis.org/Documents/PROMIS_Standards_050212.pdf. Accessed 8 Feb 2014.
23. Dalhousie University. The wheelchair skills programme. 2013. www.wheelchairskillsprogramme.ca. Accessed 25 Aug 2013.
24. Evmenova A. Cultural barriers to assistive technology. East Carolina University; 2002.
25. Cook AM, Miller Polgar J. Cook and Hussey's assistive technologies: principles and practice. St. Louis: Mosby Elsevier; 2008.
26. Saha R, Dey A, Hatoj M, Podder S. Study of wheelchair operations in rural areas covered under the District Rehabilitation Centre (DRC) scheme. Indian J Disabil Rehabil. 1990;74–87.
27. Toker S, Hak DJ, Morgan SJ. Deep vein thrombosis prophylaxis in trauma patients. Thrombosis. 2011;2011:1–11.
28. Teasell R, Dittmer DK. Complications of immobilization and bed rest. Part 2: other complications. Can Fam Physician. 1993;39:1440–2, 1445–6.
29. Canet J, Mazo V. Postoperative pulmonary complications. Minerva Anestesiol. 2010;76(2):138–43.
30. Makhabah DN, Martino F, Ambrosino N. Perioperative physiotherapy. Multidiscip Med. 2013;8(4):1–6.
31. Kigin CM. Chest physical therapy for the postoperative or traumatic injury patient. Phys Ther. 1981;61:1724–36.
32. Pryor JA, Prasad SA. Physiotherapy for respiratory and cardiac problems: adults and paediatrics. Philadelphia: Elsevier Limited; 2012.
33. Agostini P, Knowles N. Autogenic drainage: the technique, physiological basis and evidence. Physiotherapy. 2007;93(2007):157–63.
34. Fink JB. Forced expiratory technique, directed cough, and autogenic drainage. Respir Care. 2007;52(9):1210–23.
35. Reychler G, Roeseleer J, Delguste P. Kinésithérapie respiratoire. In: Bobu D, editor. Issy-les-Moulineaux: Elsevier Masson; 2009.
36. Orman J, Westerdahl E. Chest physiotherapy with positive expiratory pressure breathing after abdominal and thoracic surgery: a systematic review. Acta Anaesthesiol Scand. 2010;54(3):261–7.
37. George EL, Hoffman LA, Boujoukos A, Zullo TG. Effect of positioning on oxygenation in single-lung transplant recipients. Am J Crit Care. 2002; 11(1):65–75.
38. Johnson KL, Meyenburg T. Physiological rationale and current evidence for therapeutic positioning of critically ill patients. AACN Adv Crit Care. 2009;20(3):228–40.
39. Dean E. Effect of body position on pulmonary function. Phys Ther. 1985;64:613–8.
40. Lee L-J, Chang AT, Coppieters MW, Hodges PW. Changes in sitting posture induce multiplanar changes in chest wall shape and motion with breathing. Respir Physiol Neurobiol. 2010;170:236–45.
41. McInnes E, Jammali-Blasi A, Bell-Syer SEM, Dumville JC, Cullum N. Support surfaces for pressure ulcer prevention (review). Cochrane Database Syst Rev. 2011(4):CD001735, 1–125.
42. Kortebein P, Ferrando A, Lombeida J, Wolfe RE, Evans WJ. Effect of 10 days of bed rest on skeletal muscle in healthy older adults. JAMA. 2007;297:1772–4.
43. English KL, Paddon-Jones D. Protecting muscle mass and function in older adults during bed rest. Curr Opin Clin Nutr Metab Care. 2010;13(1):34–9.
44. Puthucheary ZA, Rawal J, McPhail M, et al. Acute skeletal muscle wasting in critical illness. JAMA. 2013;10(15):1591–600.
45. LeBlanc AD, Schneider VS, Evans HJ, Pientok C, Rowe R, Spector E. Regional changes in muscle mass following 17 weeks of bed rest. J Appl Physiol. 1992;73:2172–8.
46. Trappe TA, Burd NA, Louis ES, Lee GA, Trappe SW. Influence of concurrent exercise or nutrition countermeasures on thigh and calf muscle size and function during 60 days of bed rest in women. Acta Physiol (Oxf). 2007;191(2):147–59.
47. Stuempfle KJ, Drury DG. The physiological consequences of bed rest. J Exerc Physiol Online. 2007;10(3):32–41.
48. Bamman MM, Clarke MS, Feedback DL, et al. Impact of resistance exercise during bed rest on skeletal muscle sarcopenia and myosin isoform distribution. J Appl Physiol (1985). 1998;84(1):157–63.
49. Ferrando AA, Tipton KD, Bamman MM, Wolfe RR. Resistance exercise maintains skeletal muscle protein synthesis during bed rest. J Appl Physiol. 1997;82:807–10.

50. Griffiths RD, Palmer TE, Helliwell T, MacLennan P, MacMillan RR. Effect of passive stretching on the wasting of muscle in the critically ill. Nutrition. 1995;11(5):428–32.
51. Llano-Diez M, Renaud G, Andersson M, et al. Mechanisms underlying ICU muscle wasting and effects of passive mechanical loading. Crit Care. 2012;16(R209):1–16.
52. Clavet H, Hebert PC, Fergusson D, Doucette S, Trudel G. Joint contracture following prolonged stay in the intensive care unit. CMAJ. 2008;178(6): 691–7.
53. Dittmer DK, Teasell R. Complications of immobilization and bed rest. Part 1: musculoskeletal and cardiovascular complications. Can Fam Physician. 1993;39:1428–37.
54. Mac Neil HL. Splinting in the intensive care unit. CMAJ. 2008;178(13):1688.
55. Takata S, Yamashita Y, Masaki K, Morimoto K, Nakano M. Effects of bed rest on bone metabolism in patients with femoral neck fracture. Ann Physiol Anthropol. 1993;12(6):321–5.
56. Bloomfield SA. Changes in musculoskeletal structure and function with prolonged bed rest. Med Sci Sports Exerc. 1997;29(2):197–206.
57. Topp R, Ditmyer M, King K, Doherty K, Hornyak J. The effect of bed rest and potential of prehabilitation on patients in the intensive care unit. AACN Clin Issues. 2002;13(2):263–76.
58. WHO. Towards a common language for functioning, disability and health: ICF. 2002. http://www.who.int/classifications/icf/training/icfbeginnersguide.pdf. Accessed 5 July 2014.
59. Australian and New Zealand Burn Association. Burn survivor rehabilitation: principles and guidelines for the allied health professional. 2008. http://www.aci.health.nsw.gov.au/__data/assets/pdf_file/0008/162629/anzba_ahp_guidelines_october_2007.pdf. Accessed 29 Aug 2013.
60. Paterno MV, Archdeacon MT, Ford KR. Early rehabilitation following surgical fixation of a femoral shaft fracture. Phys Ther. 2006;86:558–72.
61. Fragomen A, Rozbruch S. The mechanics of external fixation. HSS J. 2007;3:13–29.
62. Atkinson K, Coutts F, Hassenkamp A-M. Physiotherapy in orthopaedics: a problem-solving approach. Philadelphia: Elsevier Churchill Livingstone; 2005.
63. Gausepohl T, Pennig K, Mader K. Principles of external fixation and supplementary techniques in distal radius fractures. Injury Int J Care Injured. 2000;31:56–70.
64. Handoll H, Huntley J, Madhok R. External fixation versus conservative treatment for distal radial fractures in adults (review). Cochrane Libr. 2008;4:1–78.
65. Stojiljkovic P, Golubovic Z, Mladenovic D, et al. External fixation in primary treatment of the femoral shaft fracture. Acta Fac Med NAISS. 2007;24(1):21–6.
66. Lerner A, Reis D, Soudry M. Severe injuries to the limbs: staged treatment. Berlin/Heidelberg: Springer; 2007.
67. Usaba M, Akai M, Shirasaki Y, Miyakawa S. Experimental joint contracture correction with low torque-long duration repeated stretching. Clin Orthop Relat Res. 2007;456:70–8.
68. Shah N. Increasing knee range of motion using a unique sustained method. N Am J Sports Phys Ther. 2008;3(2):110–3.
69. Samukawa M, Hattori M, Sugama N, Takeda N. The effects of dynamic stretching on plantar flexor muscle-tendon tissue properties. Man Ther. 2011;16(6):618–22.
70. Herda TJ, Herda ND, Costa PB, Walter-Herda AA, Valdez AM, Cramer JT. The effects of dynamic stretching on the passive properties of the muscle-tendon unit. J Sport Sci. 2013;31(5):479–87.
71. Airaksinen OV, Kyrklund N, Latvala K, Kouri JP, Gronblad M, Kolari P. Efficacy of cold gel for soft tissue injuries, a prospective randomized double-blinded trial. Am J Sports Med. 2003;31(5):680–4.
72. Sommerkamp TG, Seeman M, Silliman J, et al. Dynamic external fixation of unstable fractures of the distal part of the radius. A prospective, randomized comparison with static external fixation. J Bone Joint Surg Am. 1994;76(8):1149–61.
73. Voss DE, Ionta MK, Myers BJ. Proprioceptive neuromuscular facilitation: patterns and techniques. 3rd ed. Philadelphia: Lippincott Williams & Wilkins; 1985.
74. Sharman MJ, Cresswell AG, Riek S. Proprioceptive neuromuscular facilitation stretching: mechanisms and clinical implications. Sports Med. 2006;36(11):929–39.
75. Opondo E, Wanzala P, Makokha A. Cost effectiveness of using surgery versus skeletal traction in management of femoral shaft fractures at Thika level 5 hospital, Kenya. Pan Afr Med J. 2013;15:42.
76. Gosselin R, Lavaly D. Perkins traction for adult femoral shaft fractures: a report on 53 patients in Sierra Leone. Int Orthop. 2007;31:697–702.
77. Eggers IM, Mennen U. Application of a quadriceps endurance programme to patients with femur fractures immobilised by skeletal traction. S Afr Med J. 1992;81(7):258–61.
78. Even JL, Richards JE, Crosby CG, et al. Preoperative skeletal versus cutaneous traction for femoral shaft fractures treated within 24 hours. J Orthop Trauma. 2012;26:177–82.
79. King M, Bewes P. Fracture of the shaft of the femur. In: Primary surgery: trauma, vol. 2. Oxford: Oxford Medical; 1987.
80. Lee YHD, Lim KBL, Gao GX, et al. Traction and spica casting for closed femoral shaft fractures in children. J Orthop Surg (Hong Kong). 2007;15(1):37–40.
81. Demmer P. Femoral shaft fracture management with minimal resources. 2007. www2.aofoundation.org. Accessed 15 July 2014.

82. O'Connell Smeltzer SC, Bare BG, Hinkle JL, Cheever KH. Musculoskeletal care modalities. In: Brunner & Suddarth's textbook of medical-surgical nursing, vol. 1. Philadelphia: Lippincott Williams & Wilkins; 2010.
83. King M, Bewes P. Pelvis. In: Primary surgery: trauma, vol. 2. Oxford: Oxford Medical; 1987.
84. Xhardez Y. Vade-mecum de kinésithérapie et de rééducation fonctionnelle. Paris: Maloine; 2004.
85. Maheshwari J. Pelvic fractures. In: Essential orthopaedics. New Delhi: JP Medical Ltd; 2012.
86. King M, Bewes P. The hip. In: Primary surgery: trauma, vol. 2. Oxford: Oxford Medical; 1987.
87. Leu D, Sargent C, Ain MC, Leet AI, Tis JE, Sponseller PD. Spica casting for pediatric femoral fractures. J Bone Joint Surg. 2012;94:1259–64.
88. d'Ollone T, Rubio A, Leroux J, Lusakisimo S, Hayek T, Griffet J. Early reduction versus skin traction in the orthopaedic treatment of femoral shaft fractures in children under 6 years old. J Child Orthop. 2009;3(3):209–15.
89. Soomro BA, Kella NL. Femoral shaft fractures in children treated by early spica cast. J Surg Pak. 2008;13(3):103–7.
90. Wallace ME, Hoffman EB. Remodeling of angular deformity after femoral shaft fractures in children. J Bone Joint Surg. 1992;74(5):765–9.
91. Hughes BF, Sponseller PD, Thompson JD. Pediatric femur fractures: effects of spica cast treatment on family and community. J Pediatr Orthop. 1995;15(4):457–60.
92. Illgen R, Rodgers WB, Hresko MT, Waters PM, Zurakowski D, Kasser JR. Femur fractures in children: treatment with early sitting spica casting. J Pediatr Orthop. 1998;18(4):481–7.
93. Wilkins J. Some practical advice on caring for your child in a Hip Spica. 2007. http://www.nnuh.nhs.uk/docs%5Cleaflets%5C638.pdf. Accessed 17 Oct 2011.
94. Joshi J, Kotwal P. Essentials of orthopaedics and applied physiotherapy. New Delhi: Elsevier India; 1999.
95. Brubacher JW, Dodds SD. Pediatric supracondylar fractures of the distal humerus. Curr Rev Musculoskelet Med. 2008;1(3–4):190–6.
96. Mazda K, Boggione C, Fitoussi F, Penneçot GF. Systematic pinning of displaced extension-type supracondylar fractures of the humerus in children. J Bone Joint Surg Br. 2001;83(B):888–93.
97. Bonczar M, Rikli D, Ring D. Distal humerus 13-C1 ORIF, Aftercare. AO Foundation. 2013. https://www2.aofoundation.org. Accessed 6 July 2014.
98. Duckworth AD, Kulijdian A, McKee MD, Ring D. Residual subluxation of the elbow after dislocation or fracture-dislocation: treatment with active elbow exercises and avoidance of varus stress. J Shoulder Elbow Surg. 2008;17(2):276–80.
99. Young S, Fevang JM, Gullaksen G, Nilsen PT, Engesaeter LB. Deformity and functional outcome after treatment for supracondylar humerus fractures in children: a 5- to 10-year follow-up of 139 supracondylar humerus fractures treated by plaster cast, skeletal traction or crossed wire fixation. J Child Orthop. 2010;4(5):445–53.
100. Zionts LE, Woodson CJ, Manjra N, Charalampos Z. Time of return of elbow motion after percutaneous pinning of pediatric supracondylar humerus fractures. Clin Orthop Relat Res. 2009;467(8):2007–10.
101. King M, Bewes P. The elbow. In: Primary surgery: trauma, vol. 2. Oxford: Oxford Medical; 1987.
102. Keppler P, Salem K, Schwarting B, Kinzl L. The effectiveness of physiotherapy after operative treatment of supracondylar humeral fractures in children. J Pediatr Orthop. 2005;25(3):314–6.
103. Goel A, Shrivastava P. Post-burns scars and scar contractures. Indian J Plast Surg. 2010;43(Suppl):S63–71.
104. Beldon P. What you need to know about skin grafts and donor site wounds. Wound Essent. 2007;2. Accessed 12 May 2014;149–155.
105. Giannou C, Baldan M. War surgery, working with limited resources in armed conflict and other situations of violence, vol. 1. Geneva: International Committee of the Red Cross; 2011.
106. Stutzmann S, Buch-Jaeger N. Place de l'orthèse dans la prévention et le traitement des raideurs. La Lett Med Phys Readapt. 2006;22(3):105–11.
107. Cho YS, Jeon JH, Hong A, et al. The effect of burn rehabilitation massage therapy on hypertrophic scar after burn: a randomized controlled trial. Burns. 2014;40(8):1513–20. pii(14):S0305-4179.
108. May BJ, Lockard AL. Prosthetics and orthotics in clinical practice, a case study approach. Philadelphia: F.A. Davis Company; 2011.
109. King M, Bewes P. Amputations. In: Primary surgery: trauma, vol. 2. Oxford: Oxford Medical; 1987.
110. Deutsch A, English RD, Vermeer TC, Murray PS, Condous M. Removable rigid dressings versus soft dressings: a randomized, controlled study with dysvascular, trans-tibial amputees. Prosthet Orthot Int. 2005;29(2):193–200.
111. Hidayati ERN, Ilyas E, Murdana IN, Tarigan TJE, Werdhani RA. Efficacy of removable rigid dressing after transtibial amputation in diabetes mellitus patients. Med J Indones. 2013;22(1):16–21.
112. Esquenazi A, DiGiacomo R. Rehabilitation after amputation. J Am Podiatr Med Assoc. 2001;91(1):13–22.
113. PIRPAG. Physiotherapy exercises following transfemoral amputation. 2004. London, UK Accessed 15 Jan 2014.
114. Bowering KJ, O'Connell NE, Tabor A, et al. The effects of graded motor imagery and its components on chronic pain: a systematic review and meta-analysis. J Pain. 2013;14(1):3–13.
115. Ramachandran VS, Rogers-Ramachandran D. Synaesthesia in phantom limbs induced with mirrors. Proc Biol Sci. 1996;263:377–86.
116. Darnall BD, Li H. Home-based self-delivered mirror for phantom pain: a pilot study. J Rehabil Med. 2012;44:254–60.

117. Kim SY, Kim YY. Mirror therapy for phantom limb pain. Korean J Pain. 2012;25(4):372–4.
118. Sethy D, Kujur ES, Sau K. Effect of balance exercise on balance control in unilateral lower limb amputees. Indian J Occup Ther. 2009;61(3):63–8.
119. Gailey R, Allen K, Castles J, Kucharik J, Roeder M. Review of secondary physical conditions associated with lower-limb amputation and long-term prosthesis use. J Rehabil Res Dev. 2008; 45(1):15–30.
120. Verhoeff T, Rau B, Friedel F. Exercises for lower-limb amputees, gait training. Geneva: International Committee of the Red Cross; 2008.
121. Orsini M, Silva JG, Correa CL, et al. Physical therapy improved hand function in a patient with traumatic peripheral lesion: a case study. Am Med J. 2012;3(2):161–8.
122. Roghani RS, Rayegani SM. Basics of peripheral nerve injury rehabilitation. Basic principles of peripheral nerve disorders. 2012. http://cdn.intechopen.com/pdfs-wm/34134.pdf. Accessed 5 July 2014.
123. Armantrout EA. Physical therapy management of patients with peripheral nerve injury. In: Topics in physical therapy: neurology. Alexandria: American Physical Therapy Association; 2002.
124. Rosen B, Lundborg G. Training with a mirror in rehabilitation of the hand. Scand J Plast Reconstr Surg Hand Surg, 2005;39: 104–109.
125. Svens B, Rosen B. Early sensory re-learning after median nerve repair using mirror training and sense substitution. Hand Ther. 2009;14(3):75–82.
126. Barbosa RI, de Cassia Registro Fonseca M, Elui VMC, Barbieri CH. Median and ulnar nerves traumatic injuries rehabilitation. In: Basic principles of peripheral nerve disorders. 2012. http://cdn.intechopen.com/pdfs/34135/InTech-Median_and_ulnar_nerves_traumatic_injuries_rehabilitation.pdf. Accessed 11 July 2014.
127. Lee C, Revell M, Porter K, Steyn R. The prehospital management of chest injuries: a consensus statement. Emerg Med J. 2007;24(3):220–4.
128. Postiaux G. Des techniques expiratoires lentes pour l'épuration des voies aériennes distales. Ann Kinésithér. 1997;24(4):166–77.
129. Easter A. Management of patients with multiple rib fractures. Am J Crit Care. 2001;10(5):320–7.
130. Lazcano A, Doughert JM, Kruger M. Use of rib belts in acute rib fractures. Am J Emerg Med. 1989; 7(1):97–100.
131. Pelosi P, Brazzi L, Gattinoni L. Prone position in acute respiratory distress syndrome. Eur Respir J. 2002;20:1017–28.
132. Manzano RM, Carvalho CR, Saraiva-Romanholo BM, Viera JE. Chest physiotherapy during immediate postoperative period among patients undergoing upper abdominal surgery: randomized clinical trial. Sao Paulo Med J. 2008;126(5):269–73.
133. Overend TJ, Anderson CM, Lucy SD, Bhatia C, Jonsson BI, Timmermans C. The effect of incentive spirometry on postoperative pulmonary complications, a systematic review. Chest. 2001;120(3): 971–8.
134. Carvalho CR, Paisani DM, Lunardi AC. Incentive spirometry in major surgeries: a systematic review. Rev Bras Fisioter. 2011;15(5):343–50.
135. Larson CM, Ratzer ER, Davis-Merritt D, Clark JR. The effect of abdominal binders on postoperative pulmonary function. Am Surg. 2009;75(2):169–71.
136. Richardson J, Sabanathan S. Prevention of respiratory complications after abdominal surgery. Thorax. 1997;52 Suppl 3:S35–40.
137. NHS. Physiotherapy advice after abdominal surgery, information for patients. 2013. http://www.ouh.nhs.uk/patient-guide/leaflets/files%5C101108abdominalsurgery.pdf. Accessed 12 May 2014.

Imaging in the Austere Environment

23

Andy Creeden

23.1 Imaging Modalities

The range and quality of imaging services varies enormously across the developing world. This section looks at the equipment which might be encountered and considers technologies which might be deployed in new facilities.

23.1.1 Plain Film

Most secondary care hospitals have some form of basic X-ray unit although the type could range from a domiciliary unit (originally designed to be easily transported to a patient's home) or a mobile unit to a full ceiling suspended system (Figs. 23.1 and 23.2).

The World Health Organization (WHO) developed specifications for an X-ray system focussed on the needs of rural hospitals in developing countries. Originally known as the basic radiographic system (BRS), the World Health Imaging System for Radiology (WHIS-RAD) has an install base of approximately 1400 [1]. The system is designed to provide excellent images, to be safe for patients and operators, easy to install and train, usable where power is not stable and to require minimal maintenance. The specifications intentionally limit the exposure parameters which can be manipulated by the operator in order to make the system easier to learn and enable acceptable images to be obtained by staff with limited training. A system compliant

Fig. 23.1 Domiciliary X-ray unit

A. Creeden, BSc (Hons)
Department of Radiology, University Hospitals
Coventry and Warwickshire NHS Trust,
Coventry, West Midlands, UK
e-mail: idcsig@yahoo.co.uk

© Springer International Publishing Switzerland 2016

J.D. Robinson (ed.), *Orthopaedic Trauma in the Austere Environment:*
A Practical Guide to Care in the Humanitarian Setting, DOI 10.1007/978-3-319-29122-2_23

Fig. 23.2 MzCH general room

Fig. 23.3 WHIS-RAD unit

with these specifications may be manufactured by any supplier.

The WHO has produced a free training manual intended for use with WHIS-RAD, although its simple approach may also be useful to operators of other systems (Fig. 23.3) [2].

23.1.1.1 Film Processing

Manual darkroom 'wet' processing of X-ray films is still prevalent in developing countries and if performed correctly can produce excellent results. Best results are achieved through 'developing by time'; films are held in the developer for a length of time determined by a number of factors, most importantly the temperature of the developer solution. In practice however films are often 'developed by inspection'; the films are periodically removed from the developer and held up to the safelight to identify whether the image is suitably developed (Fig. 23.4).

Ideally darkrooms will have a heated drying cabinet but where not available films are often hung out in the sun to dry (Fig. 23.5). The same process is used in automatic processors but because the process is automated more variables are controlled, resulting in more reproducible quality. Automatic processing also results in significant time savings in a busy department. Where workload is low however (<15 patients/day) automatic processors can use larger amounts of expensive chemicals per film. The processing chemicals also need a reasonably high through-

Fig. 23.4 Rack for drying films outside

Fig. 23.5 Manual processor

put in order to maintain their efficiency (Fig. 23.6).

23.1.2 Computed Radiography (CR)

CR enables images to be acquired in a digital format. Instead of conventional film, the X-ray cassette contains a phosphor plate upon which the image is captured. The image is read by a CR reader and viewed and manipulated on a workstation. The image can be stored electronically either locally on the PC or, where available, sent to a picture archiving and communication system (PACS).

Fig. 23.6 Automatic processor

CR has much wider exposure latitude (higher tolerance to errors in exposure factor selection) than film, resulting in fewer repeats being required. Unless images are subsequently printed, there are no film costs.

Successful CR deployments have been reported in Nigeria, Guatemala and Angola [3–5]. Elimination of the requirement for processing chemicals and reliable water supply may also make it appropriate for rapid deployment disaster relief.

Most systems are however sensitive to extremes of temperature or humidity, and operators inexperienced in the use of computers may require considerable training. Additionally, whilst the price of CR continues to fall, the capital and maintenance costs of CR remain significantly greater than for conventional processors.

23.1.3 Portable Direct Digital Radiography (DDR or DR)

With DR the X-ray cassette is replaced by a flat panel digital detector to generate near instant digital images. Due to their high cost and complexity at present, DR is unlikely to be attain-able for hospitals in resource-poor environments. However, compact and rugged transportable units are becoming available and might be appropriate for rapid deployment for disaster relief.

23.1.4 Interventional Radiology (IR)

IR services are rare in developing countries although availability is increasing; a 2008 study found IR in countries including Algeria, Kenya and Sudan [6]. Before IR is performed, consideration must be given to the 'exit plan', the ability of local healthcare to provide any ongoing care that will be required [7].

23.1.5 Ultrasound (US)

Basic ultrasound units are relatively inexpensive and require few consumables. Ultrasound is therefore relatively widespread in developing countries. However, accuracy is extremely operator dependant and requires significant training and experience. It is prudent to carefully cross-reference ultrasound reports with clinical findings until confidence in the operator has developed.

Ultrasound has an established role in the evaluation of trauma in austere environments including swamp, jungle, mountain, desert and even space, particularly through focussed assessment with sonography in trauma (FAST) scans [8–10].

Simple interventional procedures may be performed under ultrasound guidance, including the insertion of simple drains.

Diagnosis of fifth metatarsal fractures [11] has been documented, and ultrasound-guided long bone fracture detection by operators with limited training has been proposed [12–15]. However, there is not yet consensus; Bolandparvaz et al. [16] found that ultrasound was insufficiently sensitive for diagnosing long bone fractures in the acute trauma setting.

The WHO has produced an excellent manual for operators without formal academic training in ultrasound [17].

23.1.6 Mobile Image Intensifiers

Availability of mobile image intensifiers is usually limited to larger central hospitals. Some orthopaedic procedures can be guided by a series of plain film images taken intraoperatively with a standard mobile X-ray unit.

Alternatively, techniques for undertaking long bone nailing guided by ultrasound and limited plain film radiography [18], or without any imaging guidance [19–21], have been proposed. Successful reduction of forearm fractures in children [22, 23] and Schanz pin placement [24] under ultrasound guidance have also been documented.

23.1.7 CT and MRI

Prevalence of CT and MRI scanners is increasing in developing countries although actual numbers remain small with scanners generally only found in larger cities or private hospitals. Servicing and repairs are expensive, with qualified engineers often needing to be brought in from overseas, resulting in extended periods of downtime.

Textbooks published prior to the widespread availability of CT/MRI in developed countries may prove useful in suggesting strategies for patient management in the absence of CT/MRI.

23.2 Improving Plain Film Images

Where the operator has received formal training, standards are often high. However, many countries have a shortage of qualified staff; Zimbabwe reported having only 180 radiographers for the entire population of around 12 million people [25]. Frequently in smaller hospitals, X-rays are undertaken by staff including doctors, clinical officers, nurses, electricians, gardeners or auxiliaries.

Consequently, whilst standards vary significantly, a survey of images in 12 developing countries rated up to 53 % of radiographs as poor [26]. Multiple factors may lead to image quality issues such as:

23.2.1 Acquisition Issues

(a) Inappropriate exposure factor selection (kV, mA and exposure time). One of the most frequent causes of suboptimal image quality, particularly images that appear ‘too dark’ or ‘too light/thin’. Departments should have written standard exposure charts for each X-ray unit. Persistent problems can sometimes be resolved quickly following review of these charts by an experienced radiographer.

(b) Dirt on intensifying screens. Causes sharp white artefacts. Screens can be gently cleaned using lint-free gauze dipped in proprietary screen cleaner or water (*not* solvent) and then left to air-dry (Fig. 23.7).

(c) Damaged secondary radiation grids. Repairs are almost impossible – replacement is usually required.

(d) Mismatched film and screens. Spectral sensitivity of the film must match the colour of the light emitted by the intensifying screen (usually green or blue). Where cassettes have been donated or are of varying ages, it is common to find a mixture of intensifying screen types in use.

(e) Films out of date/stored incorrectly. Films must be stored upright (like books on a shelf) in a cool environment well away from X-ray sources. Open packets should be stored in a light-tight hopper and only handled under safelight conditions.

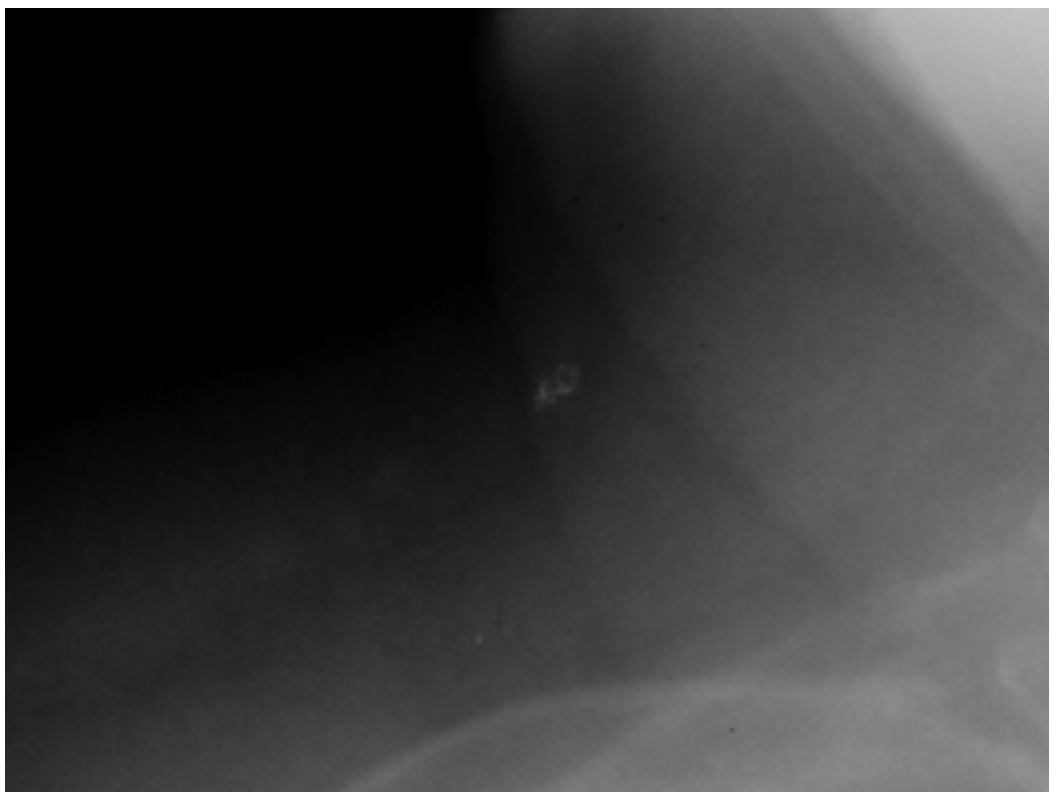

Fig. 23.7 Artefact caused by dirt on intensifying screen

(f) Patient movement. Immobilisation aids such as sandbags and foam pads can be improvised using locally available resources.

(g) Absence of left/right side markers. Markers can be improvised by cutting letters out from a sheet of lead rubber or an old lead apron.

23.2.2 Processing Issues

(a) Films processed ‘by inspection’ rather than ‘by time’. Hospitals often do not have the required thermometers or timing clock but these can be purchased at low cost.

(b) Film fogged (exposed to white light). Safelight bulbs can normally be white light but must be low wattage to avoid melting the red filter (it is common for a 100 w bulb to be inadvertently used and the filter damaged). Check the age/condition of the filters – filters can normally be replaced without changing the entire light fitting.

(c) Exhausted processing chemicals. Chemicals must be changed after a maximum of 6 weeks regardless of use. Higher throughput will require chemicals to be changed more frequently.

(d) Chemicals not mixed correctly/incorrect chemicals used. Chemistry intended for manual processors cannot be used in automatic processors and vice versa.

(e) Static artefacts. Distinctive artefact caused by an electrical discharge from the finger of the person handling the film in the darkroom. ‘Grounding yourself’ prior to handling film may reduce the occurrence (Fig. 23.8).

(f) No running water for wash tanks. Water in the stop bath and the wash tank can be changed manually, but this is time consuming and needs to be done frequently.

(g) Developer solution contaminated with fixer. Even a small amount of fixer splashing over into developer can significantly impair its effectiveness.

(h) Dirty processor. Causes small, sharp black artefacts on films. Processors should be drained and cleaned regularly (Fig. 23.9).

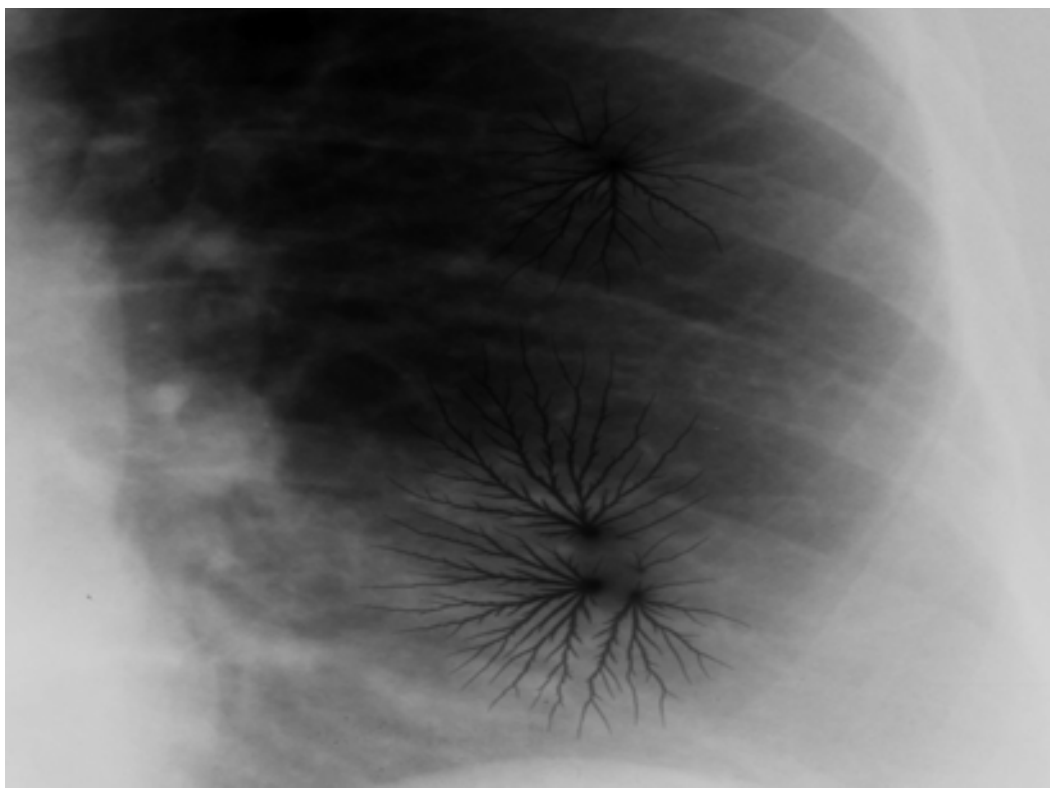

Fig. 23.8 Static artefact



Fig. 23.9 Artefact caused by dirty processor

A full discussion of darkroom technique is beyond the scope of this chapter, but a number of free resources provide greater depth [27, 28].

23.2.3 Maintenance Issues

A quality control (QC) programme may help to identify equipment faults before they impact on image quality; a QC programme introduced in six African countries resulted in significant improvements in image quality and reductions in patient dose [26].

Some simple faults can be remedied by the radiographer – useful resources are available to download [29, 30].

23.3 Image Interpretation

Radiologists are scarce in developing countries; Zimbabwe has 15 radiologists, and the Maldives have only 3 [25], whilst 14 African countries have no radiologists [1]. The responsibility for interpretation often falls to the referring clinician. The WHO has produced a number of free to download books to support non-radiologists in image interpretation [31–33].

23.3.1 Administration

A logbook should be kept to record the details of each patient. Films should be identified with patient demographics, ideally prior to being developed. Where actinic markers are not available, a white chinagraph pencil can be used.

Where patients have contributed to the cost of their imaging, it is common for patients to take their films home. Unfortunately, they are often then stored inappropriately and not returned for follow-up clinics. A departmental film store should be encouraged. Films should be stored in cardboard wallets, one per patient, vertically on shelves and organised by patient hospital number. Most hospitals keep X-rays for a minimum of 5 years. Where images are acquired digitally, they can be stored either on the local PC or, where available, sent to the hospital PACS. Copies can also be burnt onto CD/DVD.

23.3.2 Teleradiology

Shortage of radiologists has led to interest in teleradiology, whereby images are transmitted electronically for remote interpretation. Images might be transferred in-country from multiple rural hospitals to a radiologist based at a central hospital. Alternatively schemes have been trialled where images are sent from hospitals in the developing world to 'volunteer' radiologists overseas.

A simple teleradiology system utilising a domestic digital camera for transmitting TB chest X-rays has proved successful [34], whilst a system for transmitting live ultrasound images from remote clinics to tertiary care centres via satellite is being developed [35]. Imaging the World, a US-based charity, has developed a simple scanning protocol to allow operators with very limited training to undertake scans in rural areas with the live images being transmitted to a remote radiologist for real-time interpretation [36].

23.4 Radiation Protection

Possibly the greatest priority is reducing the dose to the operator, who may be involved with many X-rays a day throughout their career. If X-ray equipment and shielding is appropriate and correct procedures are followed, however, there should be no cause for concern.

Shielding requirements will vary, being determined by a range of factors including room size and layout, equipment type, workload, etc. For a standard X-ray room, other than a lead glass window in front of the control panel, it should be possible to provide all necessary shielding using bricks and/or concrete. There should be no requirement for the operator to wear a lead apron whilst undertaking plain film X-rays; the screen in front of the control panel should provide sufficient protection (Fig. 23.10).

Fig. 23.10 Lack of protective equipment may give rise to humorous pictures but is not acceptable. Anyone not required for the examination must leave the room before an X-ray is taken

Anyone not required for the examination must leave the room before an X-ray is taken. Persons who are essential to the examination must either stand behind the control panel screen or if they need to remain with the patient should stand as far away as possible and wear a lead apron.

Where a patient needs to be supported during their investigation, this task should be undertaken by one of the patient's adult relatives or a member of staff from another department (not be the same member of staff on every occasion).

Personal dose monitoring does not in itself protect the operator from radiation but can provide reassurance that adequate protection measures are in place. Personal dose monitoring in developing countries is often limited due to cost and lack of monitor reading facilities; in Kenya in 2009, only around 25 % of radiation workers were monitored [37].

Where fluoroscopy is used (e.g. image intensifier cases in the operating theatre), all staff must wear lead aprons. Aprons must be checked for damage visually before each use and should be checked regularly with X-ray for internal damage.

For patient safety an ALARA (as low as reasonably achievable) approach is adopted; where radiation dose cannot be eliminated, it should be minimised as far as practicable. Strategies include avoiding unnecessary referrals, selecting the minimum exposure factors consistent with acceptable image quality and reducing the need for repeats.

A number of free to download publications provide much greater information, including advice on where a new installation is being planned (Fig. 23.11) [38–40].

Fig. 23.11 Ball bearing in skull following suicide bomber attack

23.5 Donating Imaging Equipment

Where funds are available to allow the purchase of new imaging equipment for hospitals direct from the manufacturer, 'Diagnostic Imaging in the Community: A Manual for Clinics and Small Hospitals' provides invaluable advice [41]. However, purchasing new imaging equipment is often prohibitively expensive in the austere environment and consequently donation of used imaging equipment is common.

Unfortunately the donation of medical equipment is complicated and frequently ineffective. The WHO estimates that in sub-Saharan Africa, up to 70 % of medical technology lies idle due to failings in the acquisition process, lack of user training and lack of effective technical support [42]. Equipment donations in general are discussed elsewhere in this book, but the factors which relate specifically to imaging equipment are discussed here.

23.5.1 Needs Analysis

Consideration should be given as to whether the imaging equipment is actually needed. The intended benefits should be clearly defined at the outset and the senior management at the recipient hospital fully engaged. The donation must be driven by a clearly defined need of the recipient, not by the availability of equipment for donation. The potential impact on patient management should also be considered; the ability to diagnose an injury or condition does not necessarily improve patient care if any required treatment is not available locally.

23.5.2 Sourcing Imaging Equipment for Donation

Institutions with imaging equipment to donate may have concerns regarding ensuring that their liabilities on the equipment are fully discharged and require a disclaimer/waiver to be signed.

The IDC-SIG website (www.idcsig.org) maintains a 'Wanted/Available' list of imaging equipment for hospitals in developing countries. Alternatively, there are a range of commercial dealers in pre-owned imaging equipment.

23.5.3 Availability/Cost of Consumables

Consumables readily available in developed countries may not be so readily available in the developing world (e.g. film with green sensitive emulsion is not widely available in sub-Saharan Africa). The cost of consumables should also be considered (e.g. automatic processing chemicals are more expensive than those for manual processing).

In addition, government-funded hospitals in developing countries are often only allowed to spend their funding allocation through government-run purchasing bodies; if the consumables are not stocked by the purchasing body, then the hospital has to find other sources of funding to pay for them (Fig. 23.12).

23.5.4 Electrical Supply

Power surges and voltage fluctuations are common in developing countries; a surge protector is essential and a voltage stabiliser should be considered. Some imaging equipment

Fig. 23.12 This C-arm was obtained second hand by an NGO, broke down very quickly and was impossible to repair

requires a three-phase supply which is not necessarily available at all hospitals.

23.5.5 Climate

Imaging equipment often has a narrow recommended operating range in terms of temperature and humidity. Air conditioning may be required. Automatic processors are also prone to algae build-up in hot climates.

23.5.6 Alternatives to Shipping

Imaging systems are frequently heavy and bulky resulting in high shipping costs. Buying equipment from a local supplier may be cheaper than shipping pre-owned equipment.

23.5.7 Maintenance

Equipment is becoming more sophisticated and consequently maintenance has become increasingly specialised. Ensure any imaging equipment is checked for faults before shipping; if possible arrange a full manufacturer's service. Consideration should be given to installation in the recipient country, availability of parts, availability of qualified service personnel and the funding of preventative and corrective maintenance.

23.5.8 Training

Training might be delivered by the supplier; staff experienced in using similar equipment at other hospitals within the recipient country may require a training programme to be delivered by the donor.

23.6 Rational Requesting

Patients in many developing countries are required to pay for or contribute towards their care. Simple X-rays cost around $3.50 [1], but many of the world's poor live on less than $1/day. It is therefore important that imaging is limited to circumstances where it is absolutely essential. Consider:

1. Who can interpret the images?
2. Will imaging alter patient management (e.g. detecting osteoarthritis in a resource-poor country is unlikely to change treatment)?

3. Minimising the number of views requested for each examination.
4. ‘Routine’ imaging should be discouraged; referrals should be made on an individual basis.

Further advice on rational referring is available from the WHO [43].

23.7 Other Organisations

1. Imaging in Developing Countries Special Interest Group (IDC-SIG) www.idcsig.org
   Information and best practice sharing network. Works primarily through its website and e-mail mailing list
2. RAD-AID www.rad-aid.org
   Network for improving provision of radiology in developing countries through dialog, education, resources and collaboration
3. International Society of Radiographers and Radiological Technologists (ISRRT) www.isrrt.org
   Umbrella organisation of nearly 90 member societies across the world
4. World Radiography Education Trust Fund (WRETF) www.wretf.org
   Supports radiography education through the distribution of books, journals, educational material and limited financial assistance
5. International Society of Radiology www.isradiology.org
   Confederation of around 80 national radiological societies
6. Go-Rad www.isradiology.org/gorad
   Free online access to articles of interest to radiologists and radiographers in developing countries sourced from major radiology journals (including AJR, EJR, radiology, radiography and radiographics)
7. Medical Imaging Partnership http://medicalimagingpartnership.org/
   Provides access to equipment, expertise, training and encouragement to local organisations in developing countries with emphasis on Africa and Latin America

References

1. Integrated digital X-ray system for the WHIS-RAD. https://www.yumpu.com/en/document/view/8781598/integrated-digital-x-ray-system-for-the-whis-rad-diagnostic. Accessed 18 Mar 2014.
2. WHO manual of diagnostic imaging: radiographic technique and projections. http://www.who.int/diagnostic_imaging/publications/dim_radiotech/en/. Accessed 18 Mar 2014.
3. Nigeria Team Presentation. Digital mobile chest X-ray – the Nigeria field experience. 2010. http://www.who.int/tb/advisory_bodies/impact_measurement_taskforce/meetings/prevalence_survey/ps_oct10_pr_mobile_cxr_ng.pdf. Accessed 18 Mar 2014.
4. WHITIA scores win with Guatemala digital x-ray install. http://www.auntminnie.com/index.aspx?sec=ser&sub=def&pag=dis&ItemID=95001. Accessed 18 Mar 2014.
5. Zannaro F, et al. Digital radiology to improve the quality of care in countries with limited resources: a feasibility study from Angola. PLoS One. 2013;8(9):e73939.
6. Tsapaki V, et al. Radiation exposure to patients during interventional procedures in 20 countries: initial IAEA project results. AJR Am J Roentgenol. 2009; 193:559–69.
7. Ferrara S. Interventional radiology in the austere environment. Semin Intervent Radiol. 2010;27:3–13.
8. Russell TC, Crawford PF. Ultrasound in the austere environment: a review of the history, indication, and specifications. Mil Med. 2013;178(1):21–8.
9. Nelson BP, Melnick ER, Li J. Portable ultrasound for remote environments, part II: current indications. J Emerg Med. 2011;40(3):313–21.
10. Ma OJ, Norvell JG, Subramanian S. Ultrasound applications in mass casualties and extreme environments. Crit Care Med. 2007;35(5):S275–9.
11. Yesilaras M, et al. The accuracy of bedside ultrasonography as a diagnostic tool for the fifth metatarsal fractures. Am J Emerg Med. 2014;32(2):171–4.
12. Heiner JD, McArthur TJ. The ultrasound identification of simulated long bone fractures by prehospital providers. Wilderness Environ Med. 2010;21(2):137–40.
13. Marshburn T, et al. Goal-directed ultrasound in the detection of long-bone fractures. J Trauma. 2004; 57(2):329–32.
14. Waterbrook AL, et al. The accuracy of point-of-care ultrasound to diagnose long bone fractures in the ED. Am J Emerg Med. 2013;31(9):1352–6.
15. Joshi N, et al. Diagnostic accuracy of history, physical examination, and bedside ultrasound for the diagnosis of extremity fractures in the emergency department: a systematic review. Acad Emerg Med. 2013;20(1):1–15.
16. Bolandparvaz S, et al. Comparing diagnostic accuracy of bedside ultrasound and radiography for bone fracture screening in multiple trauma patients at the ED. Am J Emerg Med. 2013;31(11):1583–5.

17. Lutz H, Buscarini E. Manual of diagnostic ultrasound. 2nd ed. Geneva: WHO; 2011 (free download from http://apps.who.int/iris/handle/10665/85386).
18. Mahaisavariya B, Laupattaraksem W. Ultrasound or image intensifier for closed femoral nailing. J Bone Joint Surg Br. 1992;75B:66–8.
19. Soni RK, et al. Radiation-free insertion of distal interlocking screw in tibial and femur nailing: a simple technique. J Surg Tech Case Rep. 2012;4(1):15–8.
20. Ogbemudia AO, Bafor A, Igbinovia E, Ogbemudia PE. Open interlocked nailing without a targeting device or X-ray guidance for non-union of the femur: a case series. Strat Traum Limb Recon. 2010;5:121–5.
21. Ikem IC, Ogunlusi JD, Ine HR. Achieving interlocking nails without an image intensifier. Int Orthop. 2007;31:487–90.
22. Chen L, Kim Y, Moore CL. Diagnosis and guided reduction of forearm fractures in children using bedside ultrasound. Pediatr Emerg Care. 2007;23(8):528–31.
23. Durston W, Swartzentruber R. Ultrasound guided reduction of pediatric forearm fractures in the ED. Am J Emerg Med. 2000;18:72–7.
24. Dahl BP, et al. Is portable ultrasonography accurate in the evaluation of Schanz pin placement during extremity fracture fixation in austere environments? Am J Disaster Med. 2013;8(2):91–6.
25. United Nations. Scientific Committee on the Effects of Atomic Radiation. Effects of Ionizing Radiation: Report to the General Assembly, with scientific annexes (Vol. 1). New York: United Nations Publications. 2008.
26. Muhogora WE, et al. Patient doses in radiographic examinations in 12 countries in Asia, Africa, and Eastern Europe: initial results from IAEA projects. AJR Am J Roentgenol. 2008;190:1453–61.
27. Palmer PES. WHO manual of darkroom technique. Geneva: WHO; 1985 (free download available from http://apps.who.int/iris/handle/10665/39690).
28. Palmer PES, Hanson GP, Honeyman-Buck J. Chapter 7: The darkroom – cassettes, screens, film, processing equipment. In: Honeyman-Buck J, editor. Diagnostic imaging in the community: a manual for clinics and small hospitals. Rotary International/PAHO; 2011. p. 125–70 (free download from http://www.paho.org/hq/index.php?option=com_content&view=article&id=5576%3Adiagnostic-imaging-in-the-community-a-manual-for-clinics-and-small--hospitals&catid=1162%3Ahss-radiological-health-program&Itemid=2164&lang=en).
29. Lloyd PJ. Quality assurance workbook for radiographers and radiological technologists. Geneva: WHO; 2001 (free download available from http://www.who.int/diagnostic_imaging/publications/en/index.html).
30. Franks Hospital workshop. http://www.frankshospitalworkshop.com/. Accessed 18 Mar 2014.
31. Corr P. Pattern recognition in diagnostic imaging. Geneva: WHO; 2001 (free download from http://www.who.int/diagnostic_imaging/publications/en/index.html).
32. Ostensen H, Pettersson H. The WHO manual of diagnostic imaging: radiographic anatomy and interpretation of the musculoskeletal system. Geneva: WHO; 2002 (free download from http://www.who.int/diagnostic_imaging/publications/en/index.html).
33. Ostensen H, Petterson H. The WHO manual of diagnostic imaging: radiographic anatomy and interpretation of the chest and pulmonary system. Geneva: WHO; 2006 (free download from http://www.who.int/diagnostic_imaging/publications/en/index.html).
34. Coulborn RN, et al. Feasibility of using teleradiology to improve tuberculosis screening and case management in a district hospital in Malawi. Bull World Health Organ. 2012;90(9):705–11.
35. Pyke J, et al. A tele-ultrasound system for real-time medical imaging in resource limited settings. Conf Proc IEEE Eng Med Biol Soc. 2007:3094–7.
36. Ultrasound scan protocols for non-medical personnel offer value. http://www.auntminnie.com/index.aspx?sec=ser&sub=def&pag=dis&ItemID=80911. Accessed 19 Mar 2014.
37. Henriques S. Africa's nightmare – the struggle to protect medical workers in radiological services. IAEA Bull. 2009;50(2):4–5.
38. Ostensen H, Ingolfsdottir G. Basics of radiation protection for everyday use – how to achieve ALARA: working tips and guidelines. Geneva: WHO; 2004 (free download from http://www.who.int/diagnostic_imaging/publications/en/index.html).
39. Palmer PES, Hanson GP, Honeyman-Buck J. Chapter 2: Radiation Protection. In: Honeyman-Buck J, editor. Diagnostic imaging in the community: a manual for clinics and small hospitals. Rotary International/PAHO; 2011. p. 125–70 (free download from http://www.paho.org/hq/index.php?option=com_content&view=article&id=5576%3Adiagnostic-imaging-in-the-community-a-manual-for-clinics-and-small--hospitals&catid=1162%3Ahss-radiological-health-program&Itemid=2164&lang=en).
40. Hanson GP, Palmer PES. Radiation shielding for clinics and small hospitals with a WHIS-RAD. Rotary International/PAHO; 2013 (free download from http://www.paho.org/hq/index.php?option=com_content&view=article&id=8961%3Aradiation&catid=3316%3Ahss-0101-publishing&Itemid=3562&lang=en).
41. Palmer PES, Hanson GP, Honeyman-Buck J. Diagnostic imaging in the community: a manual for clinics and small hospitals. Rotary International/PAHO (free download from http://www.paho.org/hq/index.php?option=com_content&view=article&id=5576%3Adiagnostic-imaging-in-the-community-a-manual-for-clinics-and-small--hospitals&catid=1162%3Ahss-radiological-health-program&Itemid=2164&lang=en).
42. WHO guidelines for health care equipment donations. http://www.who.int/medical_devices/publications/en/Donation_Guidelines.pdf. Accessed 19 Mar 2014.
43. Ostensen H. Diagnostic imaging: what is it? When and how to use it when resources are limited. Geneva: WHO; 2001 (free to download from http://www.who.int/diagnostic_imaging/publications/en/index.html).

Part V

Principles of Orthopaedic Traumatology in the Austere Environment

Damage Control Orthopaedics in the Low Resource Environment

24

Ian Pallister

Damage control is an expression which has been borrowed from naval conflicts. In these circumstances, when a ship was damaged in action, running repairs would be performed with whatever materials available in order to either enable the ship to complete its mission or safely travel to a base where more definitive repairs could be made. The parallel to emergency interventions for those of critically injured is obvious. A number of clinical definitions for damage control interventions have been coined; however, one of the most practical defines the role of damage control surgery to provide sufficient anatomical stability, which will prevent physiological deterioration [1]. Although not described in these terms at the time, perhaps the first recognisable damage control intervention was the use of the Thomas splint in the First World War. In the early part of the war, the mortality rate in casualties with open fractures of the femur was approximately 80 %. The Thomas splint was introduced at the First Aid Posts close to the front line [2, 3] (Fig. 24.1).

The mortality rate subsequently improved to 20 %. As an archetype of a mass casualty situation in austere environment, the First World War is without parallel. This was an era without antibiotics and in which the management of the hypovolaemic shock was only just beginning to be understood. A simple intervention which prevented excessive movement of the injured limb was introduced purely on humanitarian grounds. Its survival impact could never have been anticipated but was clearly documented. The management of an open femoral fracture in the First World War did not stop with the application of the Thomas splint but was supplemented with surgical wound care. This clearly foreshadowed the modern concept of damage control, being a systematic approach to major trauma a series of techniques from the point of wounding to definitive treatment in order to minimise blood loss, maximise tissue oxygenation and optimise outcome.

Damage control interventions may extend from direct pressure or tourniquet application in the presence of life-threatening bleeding to laparotomy or fasciotomy and external fixation. Any of these interventions can be life-saving. However, there may be circumstances in which the rapid application of simple orthopaedic principles may well avoid complications which could prove ultimately limb or even life-threatening, especially in austere circumstances. An archetypal example of this may be an injury as simple as a fracture/dislocation of the ankle. The displaced injury results in pressure on the skin in the medial malleolus area which becomes ischaemic very rapidly. Unless the ankle is reduced, the skin

---

I. Pallister, FRCS (Ed) FRCS DA (UK) DTM&H
Department of Trauma and Orthopaedics,
Morriston Hospital, University of Swansea,
Swansea, Wales, UK
e-mail: ianpallister@hotmail.com

© Springer International Publishing Switzerland 2016
J.D. Robinson (ed.), *Orthopaedic Trauma in the Austere Environment:*
A Practical Guide to Care in the Humanitarian Setting, DOI 10.1007/978-3-319-29122-2_24

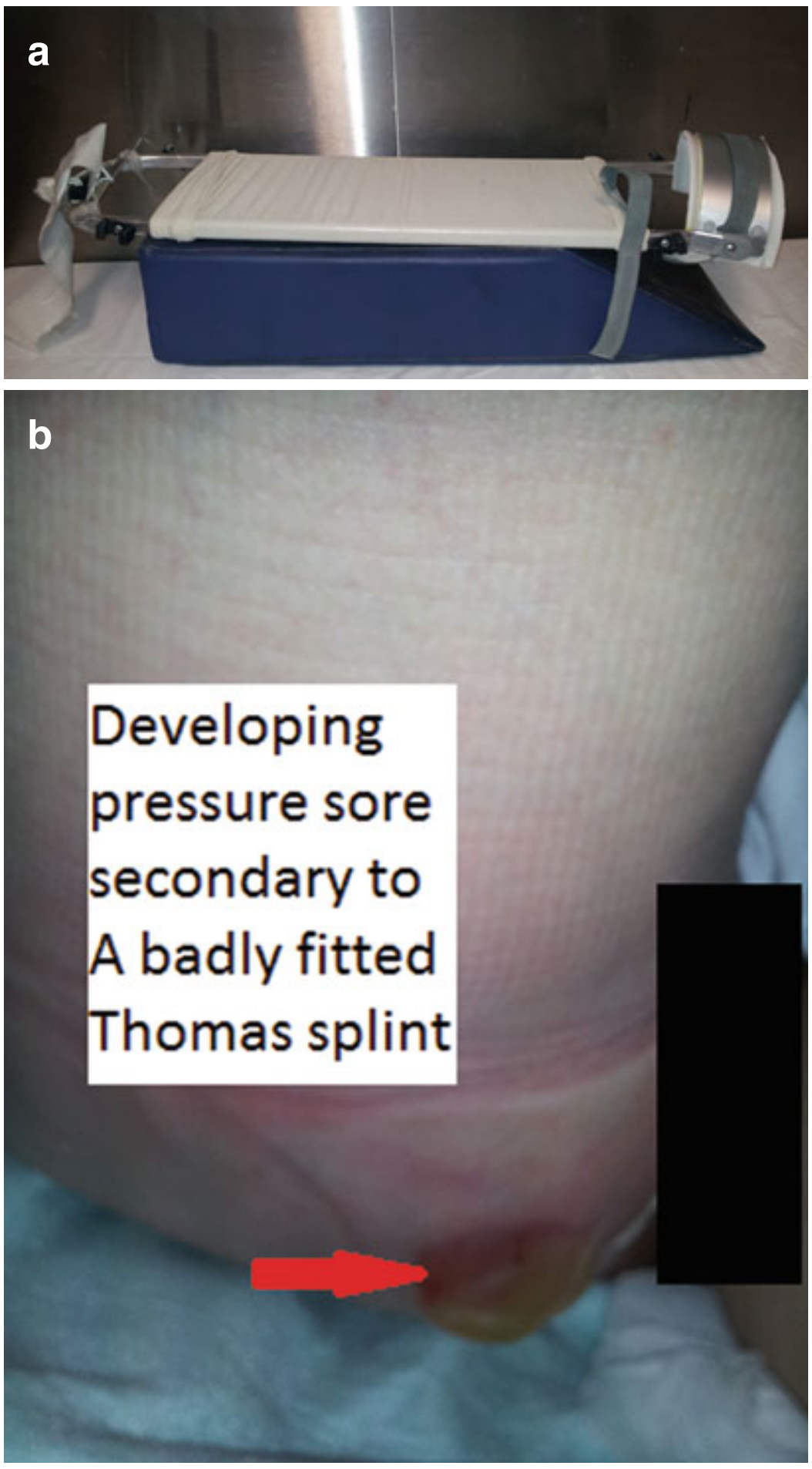

[redacted]

Fig. 24.1 (**a**) Thomas splint and 1 (**b**) complications of a poorly fitted Thomas splint. You must be aware of pressure areas as pressure sores may develop (*red arrow*)

will become necrotic, and a full-thickness wound communicating with the ankle joint and fracture services will result. Depending upon circumstances, such a complication will certainly be limb threatening and may even become life-threatening.

The simple orthopaedic paradigms of reduce, hold and rehabilitate do extend into the field of damage control. Whilst in a developed healthcare setting damage control interventions will usually be reserved for the most severely injured, requiring extended resuscitation prior to definitive fracture surgery, those interventions must still be sufficiently robust and reliable for the patient to be managed in this fashion "indefinitely". In an austere environment, if a severe limb injury can be reduced and held satisfactorily with a simple cast, then no further intervention may prove necessary. This would still constitute a damage control intervention.

Pelvic injuries and fractures of the femoral shaft are well recognised to be serious injuries. Both carry significant associated mortality, even in the developed healthcare setting [4, 5]. Death directly resulting from pelvic injury is usually due to bleeding, whereas the mortality seen with femoral fracture may be due to associated injuries, bleeding or complications such as fat embolism and the problems associated with prolonged recumbency such as pneumonia and acute respiratory distress syndrome.

Whilst highly specialist surgical reconstruction is the mainstay of the operative treatment for severe pelvic trauma in developed healthcare systems, the simplest interventions at or close to the point of wounding are the most likely to prove life-saving [6]. When a pelvic injury results in an increase in the pelvic volume, then the rich venous plexus within the pelvic musculature and surrounding the pelvic viscera is ruptured. Venous bleeding is low-pressure bleeding; however, because there are no valves between the pelvic veins and the right atrium, the bleeding can be catastrophic. If the pelvis is reduced into a normal alignment, intrapelvic pressure will rise. If this pressure exceeds venous pressure, then venous bleeding will be controlled and stable clot will form. Simple techniques to achieve this can be employed using commercially available or improvised equipment [7]. The sooner after injury that a pelvic binder is applied, the more likely it is to prove effective.

The structure of the pelvic ring is immensely strong and correspondingly requires a great deal of force to disrupt. The direction of the force determines the pattern of underlying pelvic injury [8]. When the force is directed from side to side, a lateral compression injury results. In these circumstances, because the pelvic injury results in the bones being folded inwards, the pelvic veins remain intact. Bleeding associated with such a mechanism of injury is usually related to associated injuries such as a ruptured spleen if the impact was from the left-hand side, or a liver injury if the impact was from the right-hand side. Straddle injuries, such as those seen in motorcyclists or those crushed under horses having reared up and fallen backwards upon them whilst they were riding, result in wide separation of the symphysis pubis. The distraction of the anterior pelvis results in rupture of the posterior venous plexus and catastrophic bleeding. Similarly vertical shear injuries which are seen in patients falling from height and landing on their feet may also result in severe bleeding. It is these two latter patterns of injury which are likely to respond best to pelvic binder application (Fig. 24.2).

A conscious patient with significant pelvic injury will be in a great deal of pain and will more or less tell the clinician that they have a broken pelvis. No attempt should ever be made to determine whether the pelvic ring is stable by springing the pelvis. Even in the slimmest individuals, it is almost impossible to detect movement in the pelvis, and the act of attempting this may result in dislodging blood clot and aggravating bleeding. Instead the assessment should be made of the patient's heart rate and blood pressure to determine whether there are signs of hypovolaemic shock. If a diastasis has occurred, gentle palpation just above the external genitalia will reveal a gap even in obese patients. If the patient is not shocked, then there is no clear indication for the use of a pelvic binder as there are potential hazards in terms of soft tissue complications from pressure of the binder on the skin.

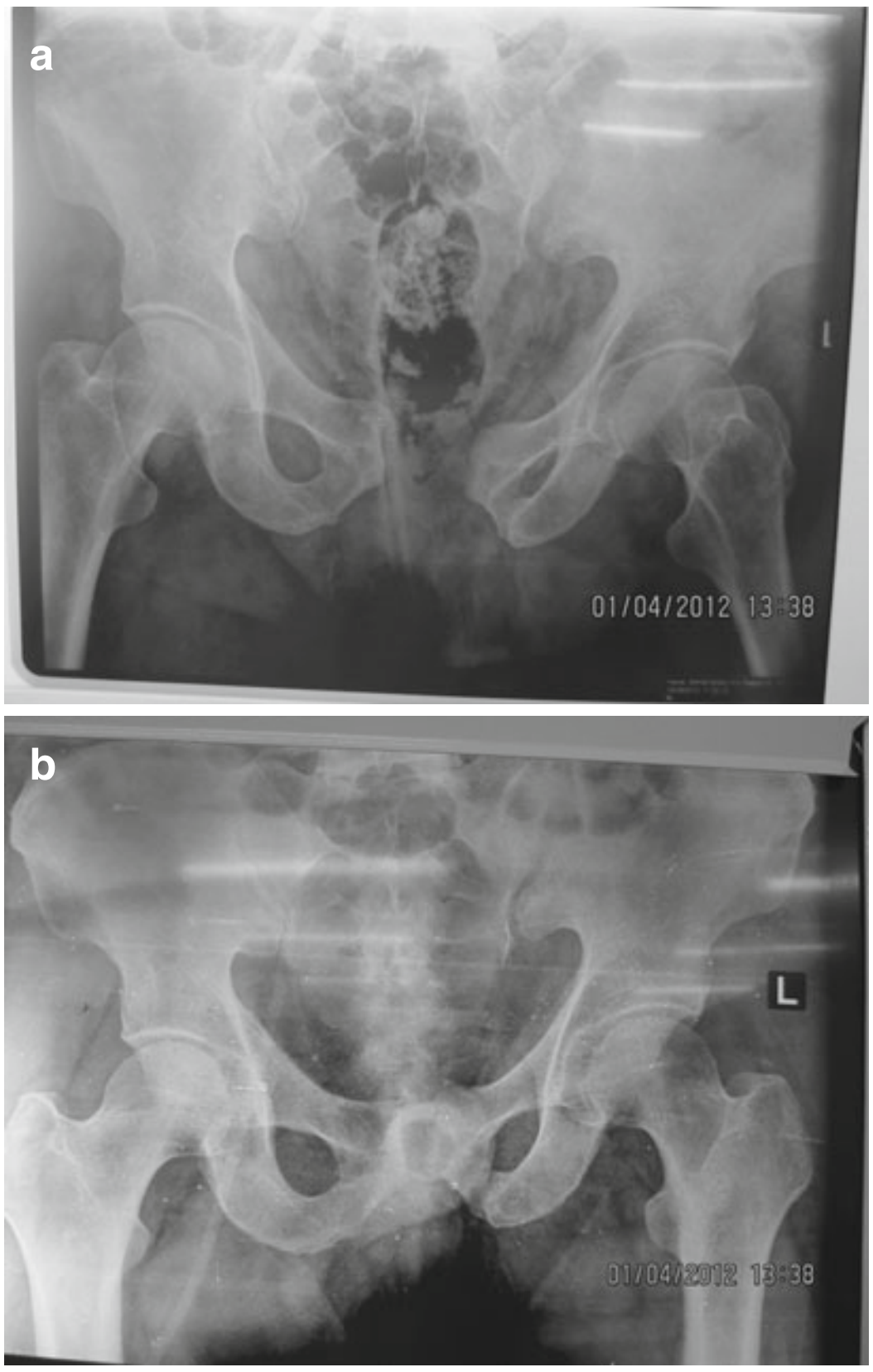

Fig. 24.2 (**a**) APC pelvic fracture and 2 (**b**) the same fracture following the application of a pelvic binder

The application of a pelvic binder is executed in two steps [7]. First, with a patient position supine, the knees should be squeezed together and lifted up to allow a bolster to be slipped beneath thus slightly flexing hips. By doing this the femoral shafts are used as levers and this simple manoeuvre will often produce the symphysis pubis. The thighs should be bandaged to each other in this position. If circumstances allow, a little padding should be placed between the knees and between the medial malleolus, and the ankle should also be bandaged together. Second comes the application of the binder itself. With the hips flexed, a small passage has been created posterior to the upper thighs, which allows the pelvic binder to be passed under the patient easily. A simple sheet can be used for this purpose, although there are commercially available devices. If sheet is used, it should be folded until it is about 15 cm wide and then manoeuvred so the sheet is centred of the patient's greater trochanters. The ends of the sheet then crossed over and three cable ties loosely secured around the sheet at the point where it lies superior/proximal to the external genitalia. The clinicians applying the pelvic binder then perform a push-pull manoeuvre, with one hand pressing on the greater trochanter and the other pulling on the sheet. The cable ties then pulled snugly down and the binder is secure (Fig. 24.3). The adequacy of the reduction can be checked clinically by gently palpating deep to the binder just above the external genitalia. If the binder has been applied correctly, the diastasis should have disappeared.

A binder should only be left in place long enough for stable clot to form. Exchange of a binder for an external fixator has widely been advocated, but experience with some commercially available binders suggests that they may, with appropriate precautions, be left in place for up to 24 h. If a patient has responded well to the interventions described and signs of hypovolaemic shock have resolved, it could be argued that a binder can be safely removed once the patient has been haemodynamically normal for an hour or so, provided the injured pelvis can be controlled utilising traction. However, this goes well beyond the damage control phase. It is vitally important to appreciate that as binders are effective interventions, they also carry danger. Catastrophic skin and muscle necrosis has been reported following binder application [9]. Vigilance is necessary.

Fig. 24.3 Application of an improvised pelvic binder. The additional binding of knees and ankles increases stability. Make sure the binder is placed over the greater trochanters

Femoral external fixation can convey the benefits of fracture stabilisation and provide the patient with “mobile traction” (Fig. 24.4). However, there are significant risks relating to

Fig. 24.4 Bulky but functional external fixation system used in the field by a major NGO

pin-site infection, which may then hinder definitive treatment such as femoral nailing. Femoral external fixation was widely used both as a temporary and definitive means of fracture fixation in the aftermath of the 2010 Haitian earthquake [10, 11]. The long-term results in terms of infective or malunion complications may never be clear; however, alternatives such as balanced traction were unfeasible in the circumstances. Successful conversion to femoral nailing after prolonged external fixation has been reported [12]. In the case in question, repeated pin and fracture site debridements were performed as a prelude to nailing. At 2 years post nailing, the fracture had fully healed and there were no infective problems manifest.

24.1 Diamond Frames

24.1.1 Femoral Frame

If a strategy of external fixation is adopted, then the technique employed should be safe and swift to apply whilst providing reliable stability. The diamond frame construct has been used in damage control situations in the UK and also as definitive treatment in austere settings. This is a "frame-first" technique in which a pair of threaded half pins is inserted in each side of the fracture. These are positioned in a near-far configuration, as the further apart they are, the more stable the resulting frame. Care must be taken to avoid the zone of injury, or being too close to the groin which can impair hip flexion, or too close to the knee, which risks going through the synovial reflections of the joint. A handlebar is then created for both the proximal and distal fragments by securing a rod to the pins at an angle of about 45° to the axis of the femur. The handlebars should be parallel to each other and can easily be used to reduce the fracture as detailed below. In this way the modules of the frame are created first, prior to any attempt at reduction. The frame is a diamond frame because of the shape created when two more bars are added to the frame to connect the end of one handlebar to the middle of the other. The resulting frame is very stable (Fig. 24.5). The most posterior part of the diamond frame lies to

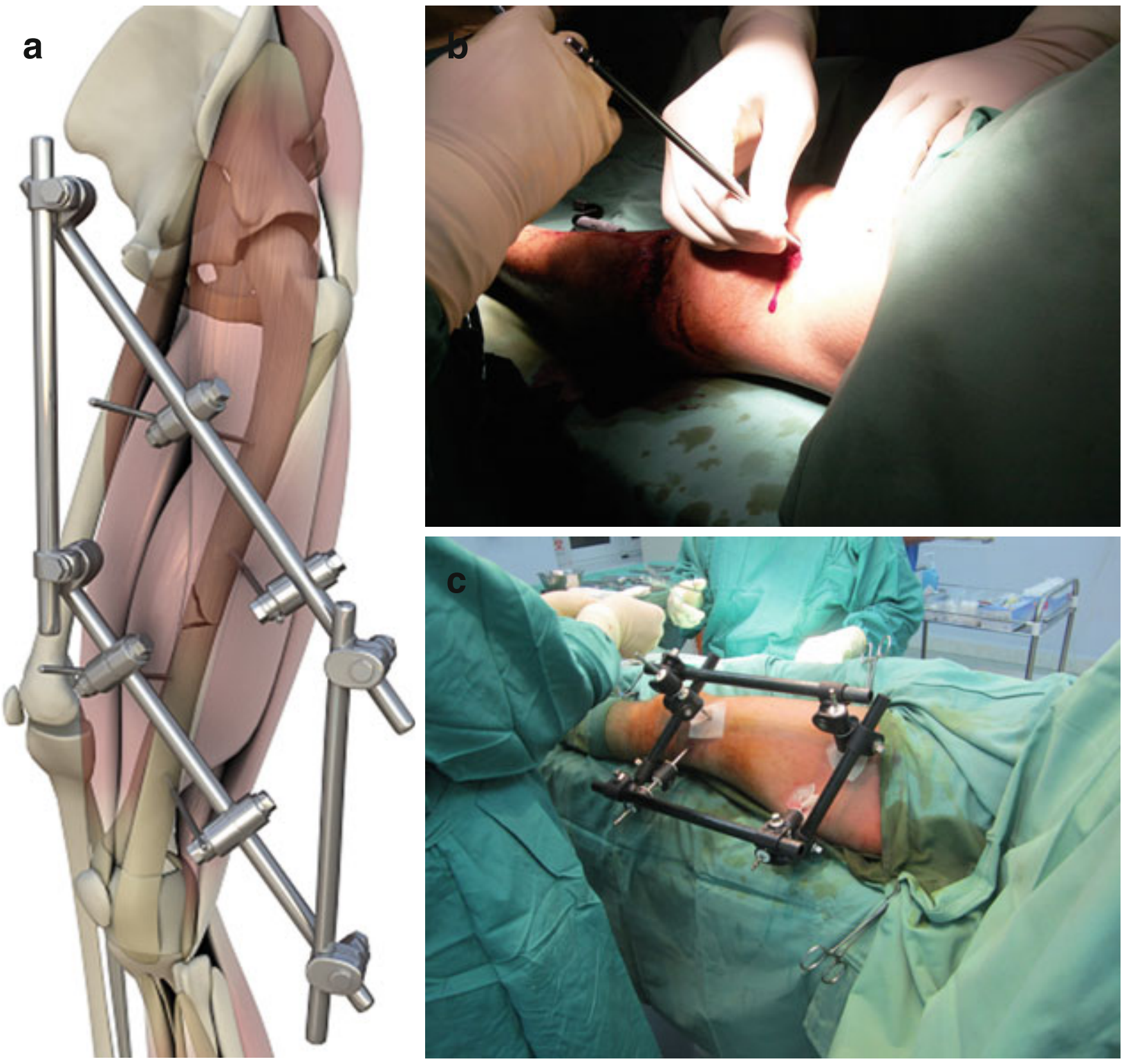

Fig. 24.5 (**a**) Illustration of diamond frame and (**b**, **c**) diamond frame applied with a bulky but functional external fixator in the field. (**a**, Courtesy of Steve Atherton BSc (Hons) MA RMIP, Medical Illustrator/Honorary Associate, Morriston Hospital)

the lateral side of the limb, and rests on the bed, supporting the limb and preventing external rotation at the hip. This can be a problem with other frame configurations.

24.1.2 Method

1. Position the patient supine on a suitable table allowing C-arm or plain radiograph access up to the hip if necessary.
2. Apply manual traction at the ankle and mark the fracture using C-arm or a plain radiograph in the anteroposterior view. If C-arm is used, now reverse it out of the way. This will prevent unnecessary screening.
3. Insert near-far lateral and anterolateral pins into each major fragment, avoiding the zone of injury (approximately 6 cm each side of the fracture).
4. Avoid the knee synovial reflections by inserting the lateral distal pin proximal to mid-patella level and the anterolateral pin at least two fingerbreadths proximal to the upper pole.
5. Via an oblique incision, locate the femur by pushing closed straight scissors to the centre of the limb, perpendicular to the skin. The shaft is "sounded out" by feeling each surface, then the apex of the curved cortex.
6. Drill a 5 mm self-drilling/tapping Schanz pin through the near cortex and then brace it into the far cortex by hand.
7. Create two parallel handlebars by connecting the pins in each fragment to each other with a bar running diagonal (~45°) to the axis of the limb. Tighten the pin-to-bar clamps fully.
8. Loosely connect the handlebars with two parallel bars creating a diamond. Use the handlebars to manipulate each fragment and reduce the fracture (supplemented with traction by an assistant at the ankle), and then tighten the bar-to-bar clamps. Use C-arm (if available) and tactile feedback to assure the bone ends are hitched and reduced.
9. Release the skin tension around the pin sites, and use absorbent padding as dressing.

24.2 The Knee-Spanning Diamond Frame

In this version, a spanning external fixator is created to cross the knee (Fig. 24.6). This may be required in knee dislocations, tibial plateau, distal femoral or floating knee fractures.

24.2.1 Technique

1. As previously described, insert two anterolateral 5 mm self-drilling/tapping Schanz pins into the femur with the distal pin more than

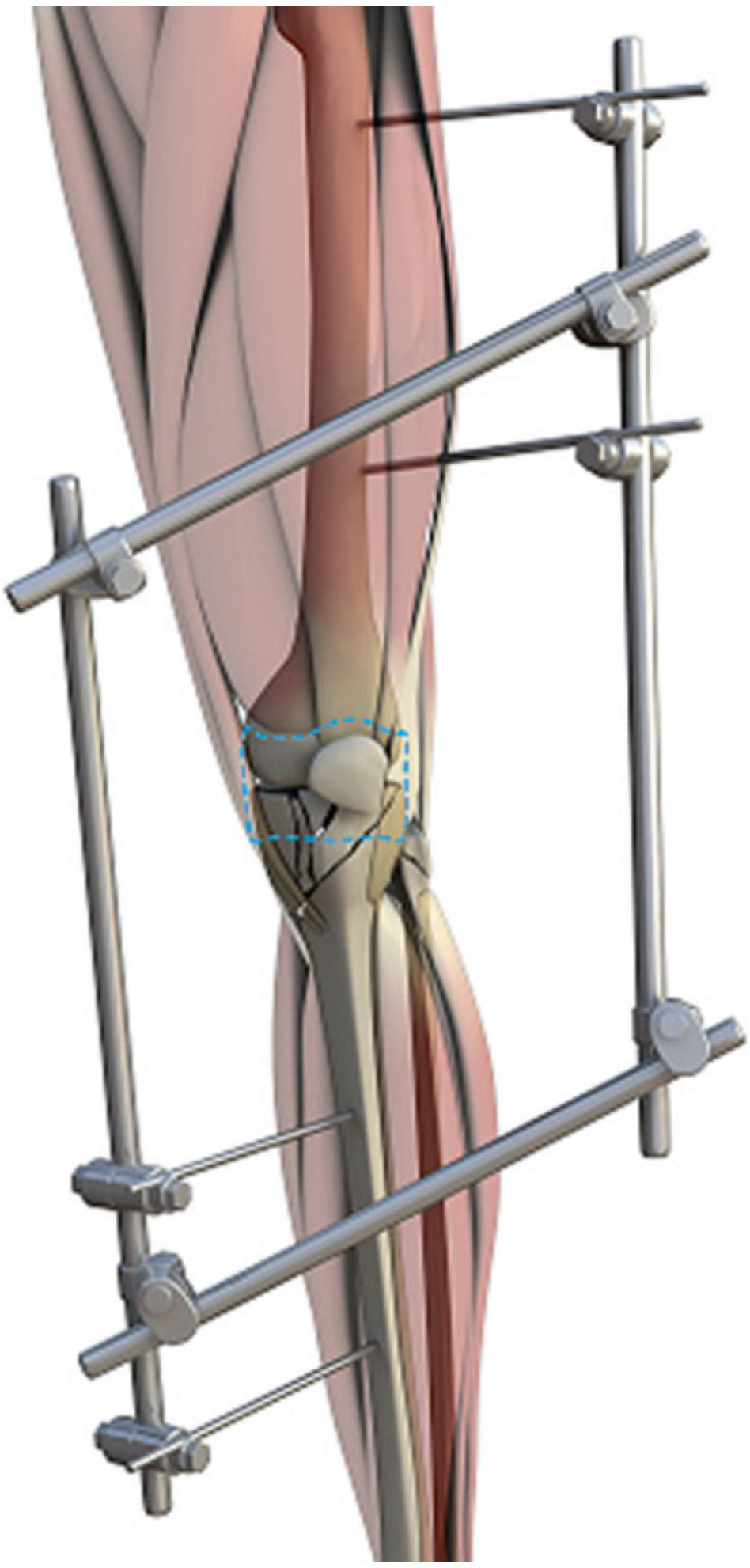

Fig. 24.6 Illustration of knee-spanning diamond frame (Courtesy of Steve Atherton BSc (Hons) MA RMIP, Medical Illustrator/Honorary Associate, Morriston Hospital)

two fingers proximal to superior pole of the patella, to avoid the synovial reflection of the knee.
2. Create a handlebar by connecting these pins using a long bar which must extend distally well beyond the knee. This handlebar runs parallel to the axis of the limb. Fully tighten the pin-to-bar clamps.
3. Insert two antero-medial Schanz pins perpendicular to the subcutaneous border of the tibia outside the zone of injury, locating the centre of the tibia by palpation (Fig. 24.3). Here the handlebar must extend proximally well above the knee, again, parallel to the axis of the tibia. Fully tighten the pin-to-bar clamps.
4. Loosely connect two parallel bars from the very end of one handlebar to the midpoint between the pins on the other. Use the handlebars to reduce the fracture/dislocation under C-arm control (if available) and additional traction to provide ligamentotaxis in fractures.
5. Once the alignment of the leg is satisfactory (~15° knee flexion), the remaining bar-to-bar clamps are tightened securing the diamond.
6. Pin sites are released and dressed as previously described. A supplementary backslab is a good adjunct to prevent equinus contracture.

This simple stable diamond construct can be consistently constructed with speed and minimal C-arm screening. Access for fasciotomies, revascularisation or soft tissue care is not compromised. Radiographs (including CT if available) are minimally affected by metal artefact as the clamps are not overlying the affected area.

24.3 Quadrilateral (Quad) Frame for Tibial and Ankle Injuries

24.3.1 Background

The quad frame is a simple, rapidly applied temporary bridging external fixator construct which can be used to rapidly stabilise fractures of the tibial shaft, plafond (pylon) and unstable ankle fractures (Fig. 24.7). It may also be useful in some talar injuries. It is a form of mobile traction requiring the minimum possible number of pins in the tibia to achieve stability in both the sagittal and coronal planes. In particular, the avoidance of additional wounds from pin sites in the subcutaneous border of the tibia has meant that this frame is especially useful in open fractures as injury zone extension is minimised.

Fig. 24.7 Illustration of quadrilateral frame for tibial and ankle injuries (Courtesy of Steve Atherton BSc (Hons) MA RMIP, Medical Illustrator/Honorary Associate, Morriston Hospital)

24.3.2 Method

1. The patient is positioned supine with a bolster under the mid-thigh and sandbag under the buttock.
2. After draping, the ankle is supported with a tightly rolled bundle of sterile towels at the level of the Achilles tendon. In this way the limb is slightly internally rotated and lifted clear of the uninjured limb, making radiographic assessment (if available) much easier.
3. A centrally threaded (Denham) pin is inserted transfixing the tibial plateau from lateral to medial, with an entry point just anterior to the fibula head exactly at the point where the flare of the tibial metaphysis plunges under the proximal edge of the anterior compartment muscles. This can be tricky as the pin tends to slip, so it is often necessary to make a key point by directing the tip of the pin perpendicular to the bone until it just starts to penetrate, before correcting the direction so that the pin passes parallel to the joint, or perpendicular to the axis of the limb. Inserted in this way, the pin will lie outside the synovial reflection of the knee joint whilst avoiding transfixing any muscle and avoiding injury to the common peroneal nerve. Positioned correctly the pin will lie proximal and posterior to the path of a future tibial nail.
4. A second centrally threaded (Denham) pin is inserted transfixing the tuberosity of the calcaneus from medial to lateral. A diagonal incision is made centred on a point 2.5 cm from the posterior border of the heel and 2.5 cm proximal to the sole. The incision (~1.5 cm long) should be oriented along a line from the point of the heel towards the medial malleolus.
5. Select appropriate length of bars to reach between the proximal and distal pins with traction applied. It is often necessary to connect two bars to each other with a bar-to-bar clamp to make a bar long enough. Fully tighten the bar-to-bar clamp before attempting to position this extended bar in the frame – position the bar-to-bar clamp towards the proximal end of the frame to avoid it obscuring the area of interest when imaging. The medial bar should lie anterior to the plane of the transfixion pins.
6. Connect the bars tightly to the proximal pin with pin-to-bar clamps, concealing the sharp end of the pin in the clamp, medially and laterally posterior to the pins.
7. Apply traction and tighten the distal pin-to-bar clamps.
8. The frame is now stable in the coronal plane but unstable in the sagittal plane.
9. Check the reduction is satisfactory on the AP and lateral C-arm views and clinically in terms of rotation.
10. To achieve sagittal stability, add a proximal tibial threaded half pin from the medial bar 8–10 cm distal to the transfixion pin. Apply a pin-to-bar clamp to the medial bar (which lies anterior to the plane of the pins, giving the surgeon a good angle of insertion), and insert the pin through drill sleeves held in the pin part of the clamp. Drill on power through the near cortex and brace against the far cortex by hand. Tighten the clamp fully.
11. The frame is now complete. Recheck the reduction with C-arm, release any tight pin sites and dress with Jelonet and padding. A supplementary backslab is a good adjunct to prevent equinus contracture. A first metatarsal half pin can be added, building the frame out to connect it, and this will help prevent equinus if correctly constructed. It is very important to realise that the first metatarsal half pin provides absolutely no sagittal stability. Without this problem being addressed, complete displacement of the fracture or dislocation of the ankle can occur in the sagittal plane post-operatively. The use of the proximal tibial threaded half pin is always recommended.

References

1. Duchesne JC, McSwain Jr NE, Cotton BA, Hunt JP, Dellavolpe J, Lafaro K, et al. Damage control resuscitation: the new face of damage control. J Trauma Acute Care Surg. 2010;69(4):976–90.
2. Gray HM. An address on the application of the professional lessons of the war to civil work. Br Med J. 1921;1(3134):109.

3. Jones R. A few surgical lessons of the war: an address delivered to the American College of Surgeons. Br Med J. 1919;2(3071):587.
4. Giannoudis PV, Grotz MR, Tzioupis C, Dinopoulos H, Wells GE, Bouamra O, et al. Prevalence of pelvic fractures, associated injuries, and mortality: the United Kingdom perspective. J Trauma Injury Infect Crit Care. 2007;63(4):875–83.
5. Willett K, Al-Khateeb H, Kotnis R, Bouamra O, Lecky F. Risk of mortality: the relationship with associated injuries and fracture treatment methods in patients with unilateral or bilateral femoral shaft fractures. J Trauma Injury Infect Crit Care. 2010;69(2):405–10.
6. Nunn T, Pallister I. Fractures of the pelvic ring. Surgery (Oxford). 2007;25(10):420–3.
7. Nunn T, Cosker T, Bose D, Pallister I. Immediate application of improvised pelvic binder as first step in extended resuscitation from life-threatening hypovolaemic shock in conscious patients with unstable pelvic injuries. Injury. 2007;38(1):125–8.
8. Burgess AR, Eastridge BJ, Young JW, Ellison TS, Ellison Jr PS, Poka A, et al. Pelvic ring disruptions: effective classification system and treatment protocols. J Trauma Injury Infect Crit Care. 1990; 30(7):848–56.
9. Mason LW, Boyce DE, Pallister I. Catastrophic myonecrosis following circumferential pelvic binding after massive crush injury: a case report. Injury Extra. 2009;40(5):84–6.
10. Bar-On E, Lebel E, Kreiss Y, Merin O, Benedict S, Gill A, et al. Orthopaedic management in a mega mass casualty situation. The Israel Defence Forces Field Hospital in Haiti following the January 2010 earthquake. Injury. 2011;42(10):1053–9.
11. Lebel E, Blumberg N, Gill A, Merin O, Gelfond R, Bar-On E. External fixator frames as interim damage control for limb injuries: experience in the 2010 Haiti earthquake. J Trauma Acute Care Surg. 2011;71(6): E128–31.
12. Sechriest 2nd V, Lhowe D. Prolonged femoral external fixation after natural disaster: successful late conversion to intramedullary nail aboard the USNS Mercy hospital ship. Am J Disaster Med. 2007; 3(5):307–12.

The Closed Treatment of Fractures

25

A. Doorgakant and Steve Mannion

In order to treat fractures without making a surgical wound, other than perhaps that required for the insertion of a traction pin, one needs to understand the pattern of the fracture as well as the deforming forces that caused the fracture. The soft tissue envelope needs to be carefully managed simultaneously with the bony injury.

There are many factors that dictate the approach to the closed treatment of fractures [1] and they are summarised as below:

1. The anatomy of the fracture
   (a) The site (metaphysis, shaft)
   (b) The configuration (transverse, spiral, oblique, comminuted)
   (c) The displacement (translation, angulation, rotation, impaction/distraction)
   (d) Extension into adjacent joint(s)
   (e) Association with dislocation (e.g. posterior shoulder dislocation with greater tuberosity fracture)
2. The age of the fracture – fractures older than 2–3 weeks will be very difficult to reduce
3. The severity of soft tissue damage – will windows be required in the plaster to monitor an area of soft tissue damage?
   (a) Degree of swelling
   (b) Blisters
   (c) Open vs. closed injury
   (d) Neurovascular damage
4. The mechanism of the injury – twisting; direct blow?
5. The treatment already received – has the fracture been manipulated recently?
6. Medical and anaesthetic issues
7. Patient factors
   (a) Age of the patient
   (b) Function required
   (c) Compliance with or ability to tolerate treatment
   (d) Financial means

Many of the patient factors have greater relevance in the austere environment where the social circumstances and financial situation of the patient may be in such a tight balance that they are forced to choose the treatment – or lack of it – that suits them rather than the best treatment we can offer them.

Paediatric fractures on the one hand have greater remodelling potential and heal quicker, but on the other hand, if the growth plate is involved, a small initial deformity can be magnified after years of bone growth and become a significant functional hindrance in later life. In order

---

A. Doorgakant, MBBS, MRCS (Eng)
Trauma and Orthopaedics, Mersey Deanery Rotation, Warrington, Cheshire, UK
e-mail: ashtindoorgakant@yahoo.co.uk

S. Mannion, MChir, FRCS (Tr&Orth), FCS(ECSA) (✉)
Department of Conflict and Catastrophe Medicine, St George's, University of London, London, UK
e-mail: stevejmannion@aol.com; smannion@sgul.ac.uk

© Springer International Publishing Switzerland 2016

J.D. Robinson (ed.), *Orthopaedic Trauma in the Austere Environment: A Practical Guide to Care in the Humanitarian Setting*, DOI 10.1007/978-3-319-29122-2_25

to decide what approach to take to treat the patient, the following questions need to be addressed.

25.1 Steps to Treating the Patient

25.1.1 Can the Fracture Be Treated Definitively Now?

If the swelling is too severe, then a full cast will often have to be delayed till the swelling has subsided. Instead a temporary slab may be indicated. Presence of blisters or an open wound may also delay definitive management [2]. If a stable fracture needs early *mobilisation* instead of *immobilisation*, a temporary cast or splint may still be required for pain control.

25.1.2 If the Fracture Cannot Be Treated Definitely Now, What Intermediate Treatment Can We Apply?

Whilst waiting for definitive treatment, the fracture still needs to be controlled somehow to minimise damage to the soft tissues and optimise pain control. This temporary treatment may take the form of skin traction, skeletal traction or a plaster backslab. This is often combined with rest, elevation and ice packs (if available) to control swelling.

25.1.3 Does the Fracture Need to Be Reduced?

This is one of the key decisions that will influence overall function and appearance of the limb or other body part at the end of the treatment period. Not all fractures need manipulating. Every fracture tolerates a certain degree of "malalignment" with no impact on overall function. Each fracture needs to be assessed individually. The manipulation manoeuvre is chosen that best suits that particular fracture (see section below). Some fractures need an anatomical reduction. Examples of these are intra-articular fractures, ankle fractures [3] and forearm fractures, including greenstick ones in children. Achieving the adequate reduction of these closed fractures requires a lot of skill and a compromise may need to be accepted [4].

25.1.4 Does the Fracture Need Immobilisation?

Stable fractures often only need temporary immobilisation for pain relief. Unstable fractures are typically immobilised for longer. As a rule, if a fracture has required a manipulation to achieve reduction, it requires immobilisation.

25.1.5 What Form of Immobilisation Best Suits This Fracture?

The individual fracture should dictate the form of immobilisation. This can range from backslabs/simple splints, through full casts to skeletal traction. Unstable long bone injuries often need the joint above and the joint below immobilised to prevent displacement. Periarticular fractures on the other hand usually need the bone above and the bone(s) below immobilised. Thus, a radial shaft fracture is treated in an above elbow cast, immobilising the wrist and elbow, whereas a distal radius fracture is typically managed in a below elbow cast, immobilising the carpus and forearm bones. Similarly ankle fractures are immobilised in a below knee cast, whilst tibial fractures in an above knee cast. Very unstable periarticular fractures such as volarly displaced distal radius fractures do sometimes need the joint above and below immobilised. The key is to understand each fracture individually and to know when a diversion from the general norm is required. Casts are predominantly used but some areas pose particular challenges, such as the hip, spine and shoulder regions. Plaster hip spicas can be technically challenging to apply, consume large amounts of materials and require a lot of supervision and maintenance. Plaster jackets for the spine are similarly another very specialist skill.

25.1.6 Skin Traction

Skin traction can be used to aid swelling reduction in upper limb fractures, especially paediatric ones, but is sometimes used as definitive management, for example, in paediatric femoral fractures (Fig. 25.1). In elderly patients with intracapsular hip fractures, skin traction can be used to aid with pain relief until the patient can be mobilised, when there is no access to surgical management. A maximum of 5 kg should be applied to avoid damaging the skin, and close monitoring and care of elderly people are necessary as the skin is delicate and easy to injure.

25.1.7 Skeletal Traction

Skeletal traction differs from skin traction in that the force is directly applied to bone. As a consequence greater force can be applied and some degree of mobilisation of the limb is permitted. It therefore can be used in the treatment of fractures of larger bones such as adult femoral fractures [5] (Fig. 25.2).

25.1.8 Slings

Slings can be all that is needed to treat some fractures, especially in the upper limb. A broad arm sling supports the entire weight of the upper limb and is appropriate when we want to relieve the limb from any "weight bearing" which can relieve symptoms following a clavicular fracture, for example. A collar and cuff can be used to encourage the pull of gravity on the elbow and thus promote better alignment in humeral fractures, for example.

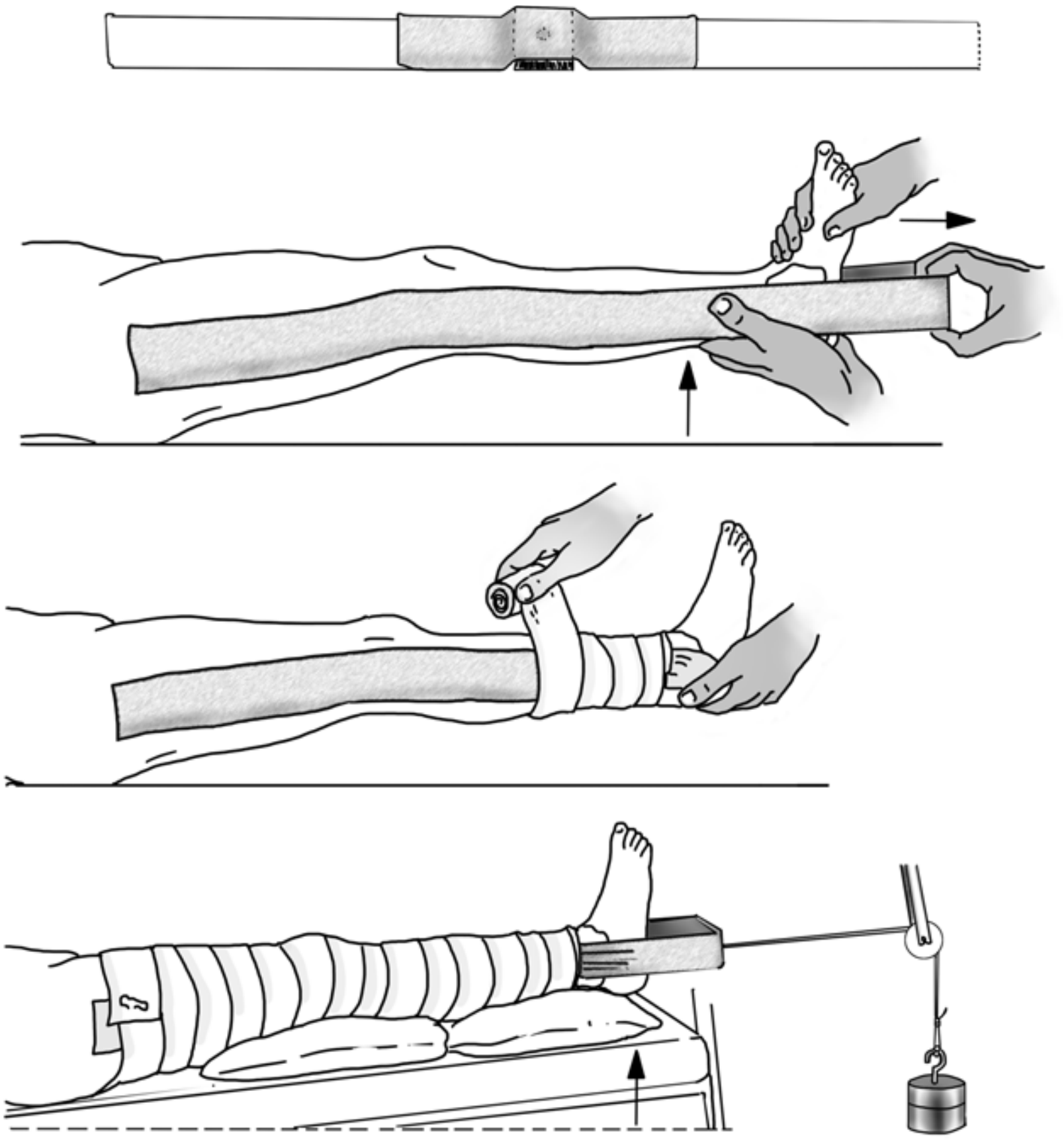

Fig. 25.1 Steps in the application of skin traction

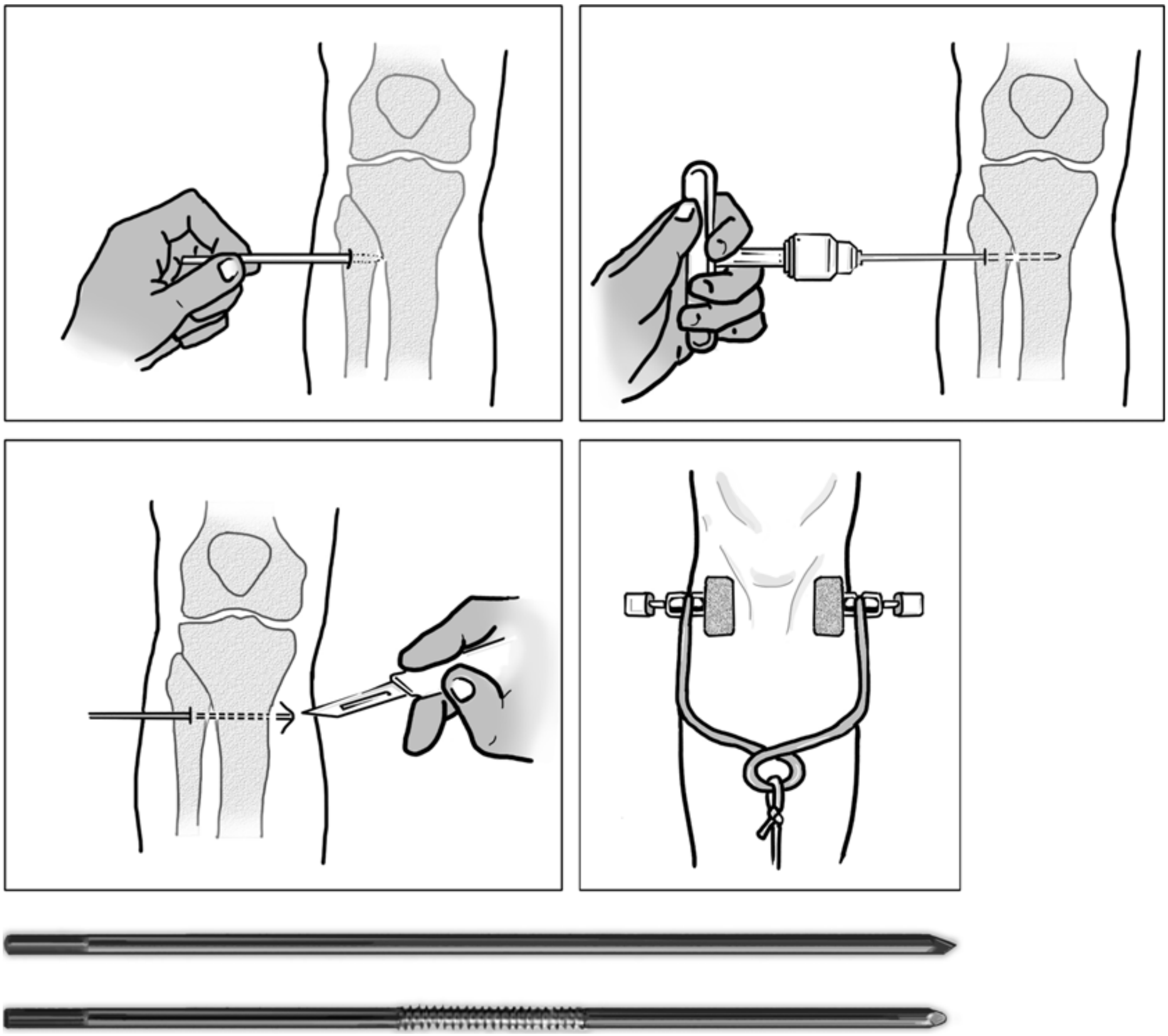

Fig. 25.2 Steps in the application of skeletal traction

25.1.9 Strapping

For digital fractures in both hands and feet, “buddy” or “neighbour” strapping supports and stabilises the fracture whilst permitting early active motion of the joints.

25.1.10 What Position of Immobilisation Would Be Most Appropriate?

The above question has significant implications for function at the end of treatment. There is no point in having a perfectly reduced fracture if the ultimate outcome for the patient is severe functional limitation from contracted joints. Choosing the most functional position likewise can impair the stability of the fracture. A balance between stable position and functional position is therefore often required. This may evolve, for example, towards less stability and more functionality as the fracture heals and becomes inherently more stable. An awareness of the functional position of the main joints, especially in the hands and feet, is crucial.

As a rule, it is the position where the soft tissues (ligaments, capsule, tendons) are at maximal length and tension, and therefore the potential for contracture is reduced. A clear example of this principle is the Edinburgh splint or “cobra splint” for hand injuries. The wrist is dorsiflexed, the metacarpophalangeal joints are flexed to 90° and the digits are maintained straight. Thus, all the ligaments are maintained tout and this prevents contraction and therefore stiffness during immobilisation. The same applies to the ankle, which should be immobilised in neutral position.

25.1.11 How Long Does It Need to Be Immobilised for?

Each fracture has its own typical healing time. The size of the bone is one factor that determines that time, but other factors like patient age, blood supply and bone quality are also important. The stability of the fracture and that of the treatment applied will influence whether to increase or decrease that typical period. Patient compliance may also be a consideration.

Typically a small bone with good blood supply is immobilised for 6 weeks (e.g. distal radius, distal fibula, etc.). Where blood supply is poor, the immobilisation is extended. Scaphoid fractures and Jones' fractures of the fifth metatarsal usually need 8 or more weeks as a result. Larger bones need even more time. A tibial or femoral fracture can require in excess of 3–6 months [6, 7].

25.1.12 What Changes of Treatment Are Required in the Full Course of the Treatment?

As fractures heal, they become inherently more stable and require less rigid immobilisation. This provides an opportunity to change the method of immobilisation during the course of treatment to gradually provide more mobility, thereby enhancing the return to function. Other information gathered during follow-up will also indicate changes in the treatment. A common example is that of a tibia fracture that needs wedging of the cast to correct for varus or valgus angulation. Casts may also need changing if they become damaged (e.g. wet) or loose as the swelling subsides, causing them to lose the desired hold on the fracture.

25.1.13 What Rehabilitation Plan Will Be Needed and When to Institute It?

Rehabilitation should be considered throughout the course of treatment, not only once bony union has occurred as is often the case. Joints that do not need immobilising should be kept free and mobile (e.g. the MCP joint and elbow in most wrist fractures). Generally a rehab regime is directed at mitigating the development of joint contractures and muscle atrophy whilst maintaining proprioception and function. Optimal pain management ensures the best compliance with the rehab exercises. Weight bearing, where permitted forms an integral part of this, maintaining both muscle and bone strength. Often non-weight bearing is advised for lower limb fractures, followed by a period of protected weight bearing before allowing full weight bearing. Weight bearing for the upper limb, e.g. shoulder fractures can also be relevant. The more unstable the fracture is, the longer the period of non-weight bearing and partial weight bearing.

25.1.14 Other Factors We Need to Take into Account?

25.1.14.1 Swelling and Blisters

As discussed above, the definitive treatment modality may need delaying to allow for swelling and blisters to come under control or operating before they appear. Blood blisters are usually not burst and need extra padding until they resolve. Clear blisters may be de-roofed under very clean and aseptic conditions and then dressed [8].

25.1.14.2 Open Fractures

Open fracture wounds should be managed as per the local open fracture protocol, and the wound should remain accessible for inspection until it is fully healed. That may mean choosing a mode of immobilisation such as skeletal traction rather than casting. Alternatively a full cast may be windowed to allow access to the wound (see Chap. 27).

25.1.14.3 Compartment Syndrome

The manipulating and immobilisation of the fracture only represent the first stage of its treatment. Unless the patient and treatment are kept continually under review, adverse events can occur which could have disastrous effects. The soft tissues that are hidden within a cast or out of sight during the course of traction are at risk and vigilance is needed with regard to these. The most serious of these risks is arguably that of a compartment syndrome. This is particularly high for fractures of the tibia or the forearm treated in a full cast. If compartment syndrome is suspected, the cast should be fully divided all the way down to the skin. *Never ignore a patient who is complaining of pain or a tight cast*.

25.1.14.4 Pressure Sores

These can easily occur within a cast over high-pressure areas such as the heel and bony prominences such as the olecranon, malleoli or patella. All of these areas should be well padded within the cast. Any complaint of localised pain to these areas should alert to this possibility and a change of cast is indicated [9].

25.1.14.5 Infection

In the case of skin traction, the condition of the skin where the tape ought to be applied might preclude its application. One of the problems with skeletal traction is pin-site infection. If this does not resolve with simple measures and antibiotics, the traction pin will then have to be resited or skeletal traction discontinued.

25.1.14.6 Patient Compliance

Ultimately, any proposed treatment option should be discussed with the patient to ensure it is acceptable to them and that they will cooperate with it. Not all patients can afford to stay in the hospital for an average of 12 weeks in traction, and they may be prepared/obliged to accept a less optimal result of their fracture treatment in exchange for an earlier discharge, perhaps in a plaster cast.

As a summary of the above, a 4-“R” approach may help as quick aide-memoire:

- *Recognise* – make the correct diagnosis
- *Reduce* – manipulate the fracture as required
- *Retain* – immobilise the fracture as required
- *Rehabilitate* – facilitate return to function

25.1.14.7 Manipulation

Fractures that are in an unacceptable position of displacement/rotation/angulation should ideally be manipulated to a better position. An unreduced fracture can cause serious soft tissue damage and make a subsequent operation more difficult if required. What determines an acceptable position for a fracture depends on the exact injury and the requirements of the patient. Dislocations should also be reduced as soon as possible. The following represents the usual sequence for a successful manipulation (Fig. 25.3):

- Have a plan and get all necessary equipment, including splints, ready before starting.
- Ideally this should be done with an assistant and one who is also versed in the procedure. If not, they should be briefed carefully about what to do.
- Adequate analgesia/anaesthesia (haematoma block, entonox, ketamine, etc.).
- Enough muscle (and psychological) relaxation: Unrelaxed muscles (and minds) exert a displacing force on the fracture fragments and make reduction harder.
- On application of the reduction manoeuvre:
    1. Longitudinal traction is often the main force that helps to restore alignment.

       Traction should be controlled, firm and continuous rather than jerky and forceful.
    2. Preliminary gravity-assisted traction for a short time can help, e.g. by connecting fingers to Chinese finger traps in order to disimpact a Colles fracture. Sometimes this will suffice to effect the reduction (dependent reduction, by gravity alone).
    3. Not infrequently, more “persuasion” is required and the fracture deformity needs to be exaggerated, before it is corrected. Once the matching fracture points hitch

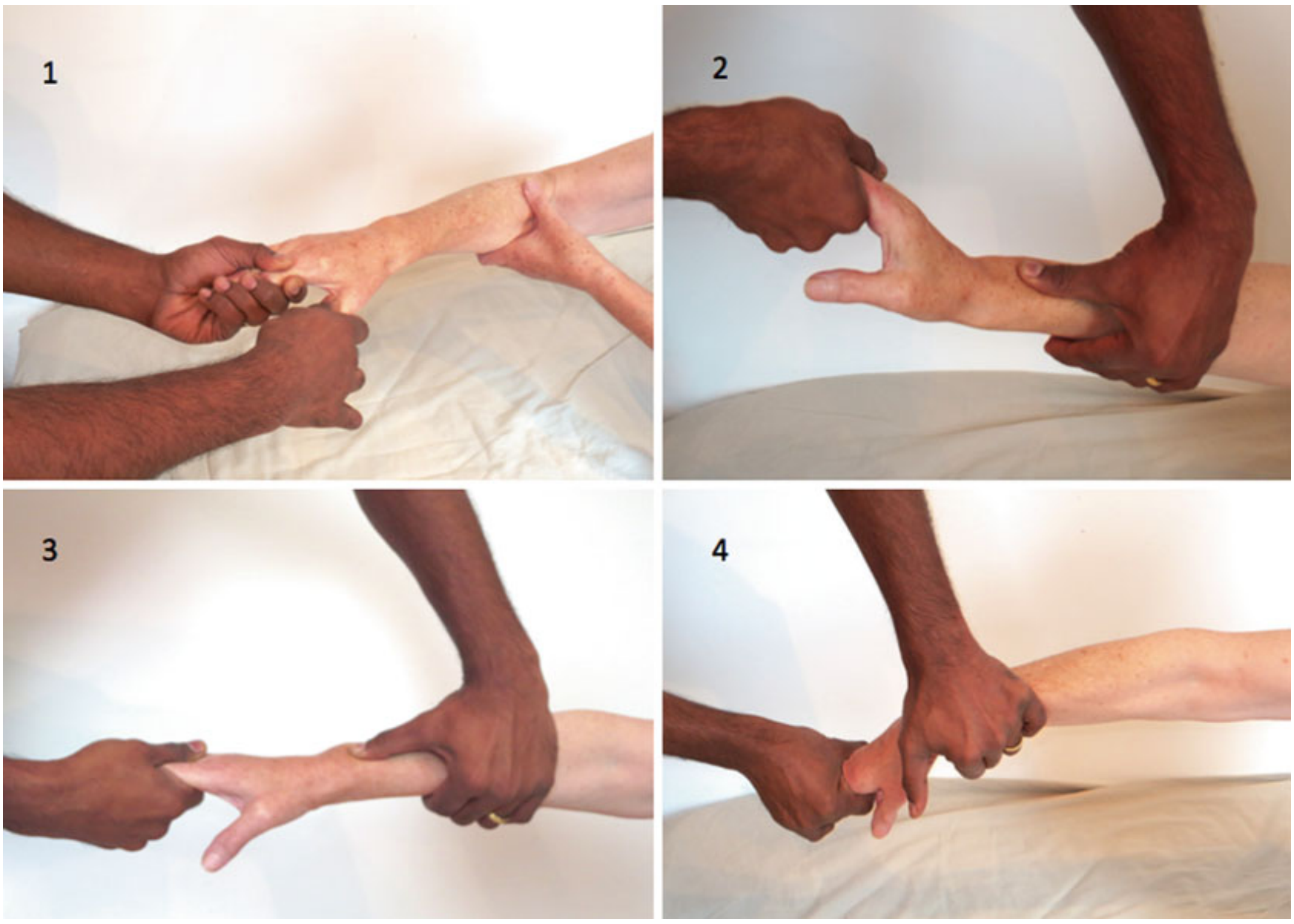

Fig. 25.3 Manipulating a Colles fracture with overcorrection. *1* Longitudinal traction, *2* exaggerating the fracture displacement, *3* advancing the distal fragment whilst maintaining traction, *4* final reduction manoeuvre

onto each other, an opposite correcting force is applied in the direction you want the fracture to be reduced. This technique is relying on the presence of an intact periosteum on the opposite cortex and uses it as a hinge. This is especially useful in paediatric fractures as children have a strong and thick periosteum. If there is an intact periosteal sleeve, this can then be used in maintaining the reduction through moulding (see section below).

4. Specific manoeuvres are sometimes required in order to tease out an intra-articular fragment of bone, for example, a medial epicondyle still attached to the soft tissues. This involves stretching the pronator/flexor unit by oversupinating and extending the forearm whilst applying traction in the direction of abduction, so that the offending fragment can be pulled out of the joint. In certain situations, the deforming forces need to be addressed in reverse order, such as in ankle fractures.
5. The manipulation of a dislocation associated with a fracture, such as in shoulder dislocations with a potential greater tuberosity fracture, can complicate the issue and careless manipulation can make the fracture worse or displace a previously undisplaced fracture. Equally, mobility at the fracture site may render the dislocation irreducible by closed means.

When using traction, suitable counter-traction is also needed. The assistant usually provides this in a direction opposite to the pulling force. Care must be taken with the skin in elderly patients and one should not pull through a child's joint.

If after 2–3 attempts, the fracture or dislocation still has not reduced, another approach may be required. The failure of reduction might indicate that the fracture has united and further attempts would simply worsen the soft tissue injury and further complicate the reduction. Children's Salter-Harris-type fractures should not be manipulated repeatedly, as this may damage the growth plate causing more trouble than a slightly malreduced fracture would.

25.1.14.8 Immobilisation

Once the fracture is in an acceptable position, it needs to be held and that can be achieved non-surgically by a number of methods including casting, traction, slings or other splints.

Casting A cast can be made out of plaster of Paris (POP) or other synthetic material (resin/fibreglass). If the cost of commercially made POP casting rolls is prohibitive, it is possible to improvise using bulk plaster powder and bandaging. POP allows better moulding, whilst synthetic materials are usually lighter, more rigid and weather resistant. A combination of the two, with a layer of synthetic material applied over a POP cast, can be a good compromise.

The choice of which cast to apply is critical. A slab is a cast that is not circumferentially complete. It accommodates swelling better than a full cast and is therefore ideal when soft tissue injury is extensive and swelling is anticipated. If a full cast is used from the beginning, the following measures can mitigate against catastrophic swelling:

1. Splitting the cast: before the plaster sets, a surgical blade is run carefully along its entire length down to wool, without actually opening it. It will be easier to open it without the need for a plaster shear or saw if swelling develops later
2. Bivalving the cast: a full cast is applied as per usual. It is then split on both sides to allow it to be open. Once it is dry, it is fully divided along the splits and removed. The two halves are secured around the edges and reapplied over the limb with a crepe bandage or Velcro stickers.

Pre-split or bivalved casts allow a degree of expansion in case of swelling and also make expedient removal easier. This technique must be considered if the patient leaves far away and/or will find it difficult to return in an emergency.

Full circular cast application The layers of a full circular cast are:

- A stockinette: a sock-like elastic bandage which lines the skin. It can be omitted if not available. It must be loose fitting.
- Padding: ready-made synthetic material (e.g. Velband©) or custom-made from bulk cotton wool rolls. Very rarely, skintight casts are applied without padding. The padding must be adequate but not too thick as this will reduce the stability conferred by the cast. Do not overlap the padding material more than once.
- Cast material: POP/synthetic. A basic knowledge of the properties of POP is useful. The colder the water and the wetter the roll after dipping, the longer the setting time. By adjusting these two parameters, it is possible to alter the working time available to apply and mould the cast. The minimum dipping time should be until all the bubbles have come out, otherwise there will still be dry patches when unrolling.

25.1.15 Full Cast Method of Application

- Measure the length over which the cast is needed. The opposite limb if uninjured could help as a useful guide for this. Cut the stockinette to length, allowing some extra length at each end. These are then rolled back onto the cast before it is completed to incorporate the free ends in the final pass. When the cast needs to go round the thumb, a hole can be cut to slide it through (Fig. 25.4).
- Apply the padding in uniform thickness to avoid causing raised pressure areas. A degree of overlap of about 50 % is desirable. A thickness of about 0.5 cm is ideal. Bony prominences will need extra padding. When going over joints, an extra small piece may be required over missed areas. If one has made their own roll from cotton wool sheets, one should try hard to make it smooth and uniform.

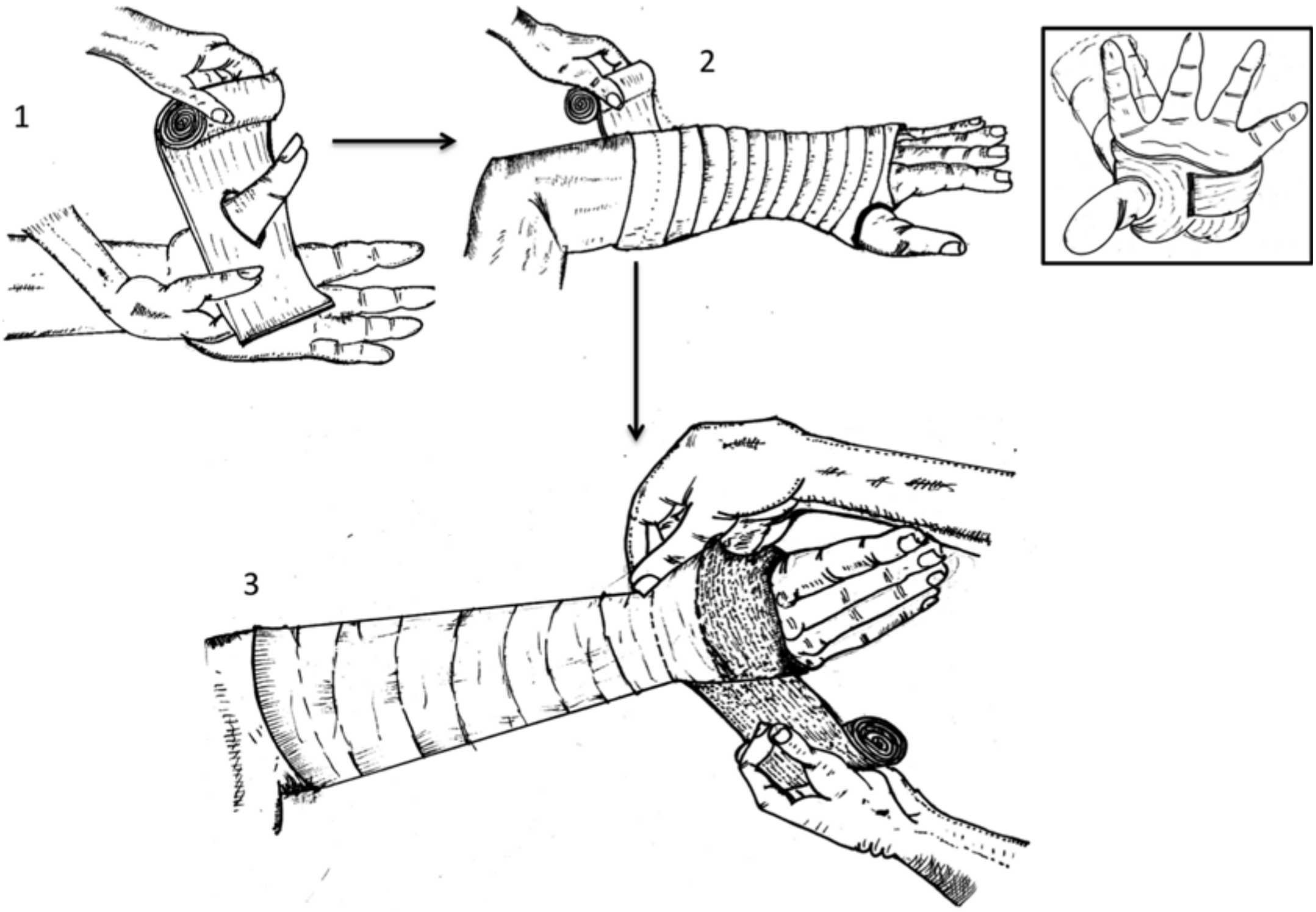

Fig. 25.4 Full cast application on forearm: *1* Wool around thumb, *2* uniform 50 % layering up to elbow, *3* wrap with wet cast material with appropriate overlap, *Inset* MCP joints kept free (Reproduced from Orthopaedic Care at the District Hospital Eds. Doorgakant, Mkandawire. http://www.orthopaedic-care.co.uk/ Drawing by of B. Kapesi [OCO])

- Now apply the cast material. Choose the width of the roll to match the job, e.g. 10 cm/4 in for the forearm and 20 cm/6 in for the tibia and femur. If many rolls are to be used, have them already out of their packages before starting. The next roll could be dipped whilst one is being applied. The thickness of the cast should be uniform throughout except for where it is more likely to break. This, counter-intuitively, is often not at the fracture site, and therefore applying more layers there only adds unnecessary weight for the patient to carry. Hold the roll in one hand and unroll a small piece in the other before dipping, so it becomes easier to unroll.
- Each wrap should overlap the next by about 50 %, such that a full length pass will be two layers thick. Only enough tension to keep the material taut should be applied on the roll, whilst the thumb and thenar eminence sweeps over it as it goes round the limb to ensure smooth application. Localised pressure points, such as finger indentations, are to be avoided.
- The number of layers recommended is 6–8 for the upper limb and 8–10 for the lower limb. This is subject to variation. It is the ends where the cast is most likely to fail, as well as joints which are crossed. The latter can be reinforced with an extra piece of slab (6–10 layers) laid over it. Fashioning a central “spine” by pinching the middle of the slab further reinforces it. The cast ends usually need 2–3 extra layers.

Slab Application There are many different types of slabs. The commonest are dorsal (i.e. backslabs) and volar slabs; alternatively, they can be applied to one side such as gutter slabs or in the shape of a U (U-slab or sugar tong slab).

25.1.16 Slab Method of Application

- Get your material ready in advance. Measure the length of the slab as for a full cast. The width of material to be cut should be between 50 and 70 % of the limb circumference if it is to hold the fracture. Allow slightly more length and width, to allow for shrinkage after dipping. Allow also an extra two layers compared to a full cast to make up for the decreased circumferential cover (Fig. 25.5).
- Apply the stockinette (optional) and then complete using either method below:
- *Method 1*: Apply padding as for a full cast over the limb area to be immobilised. Dip the slab in water (usually warm as moulding is rarely done for slabs) and apply on desired side.
- *Method 2*: Have a piece of wool slightly bigger than the plaster slab laid out on a flat surface. Wet the slab and lay it on top of the wool. Lift both together and apply on desired side with the cast material on the outside.
- Finally wrap the whole lot in a crepe bandage and secure it with some tape. Refrain from tying the last turn of crepe into a knot as this can form a tight band in case of swelling. If using a piece of wet POP instead of tape, never apply it on the soft side as it effectively completes the cast for a very short distance and increase the risk of a compartment syndrome.

25.1.16.1 Special Casts

Slabs for ankle injuries: Due to the anterior position of the malleoli, a stirrup is usually wrapped sideways from the ankle up to mid-leg level on top of the standard backslab.

Forearm casts: The method of application should take into account the relation of the radius and ulna cross sectionally. By compressing slightly between the two bones, they are placed optimally apart. This is done in addition to standard moulding of the fracture as described. The radiological expression of this is called the cast index, which is the ratio of the maximal width of

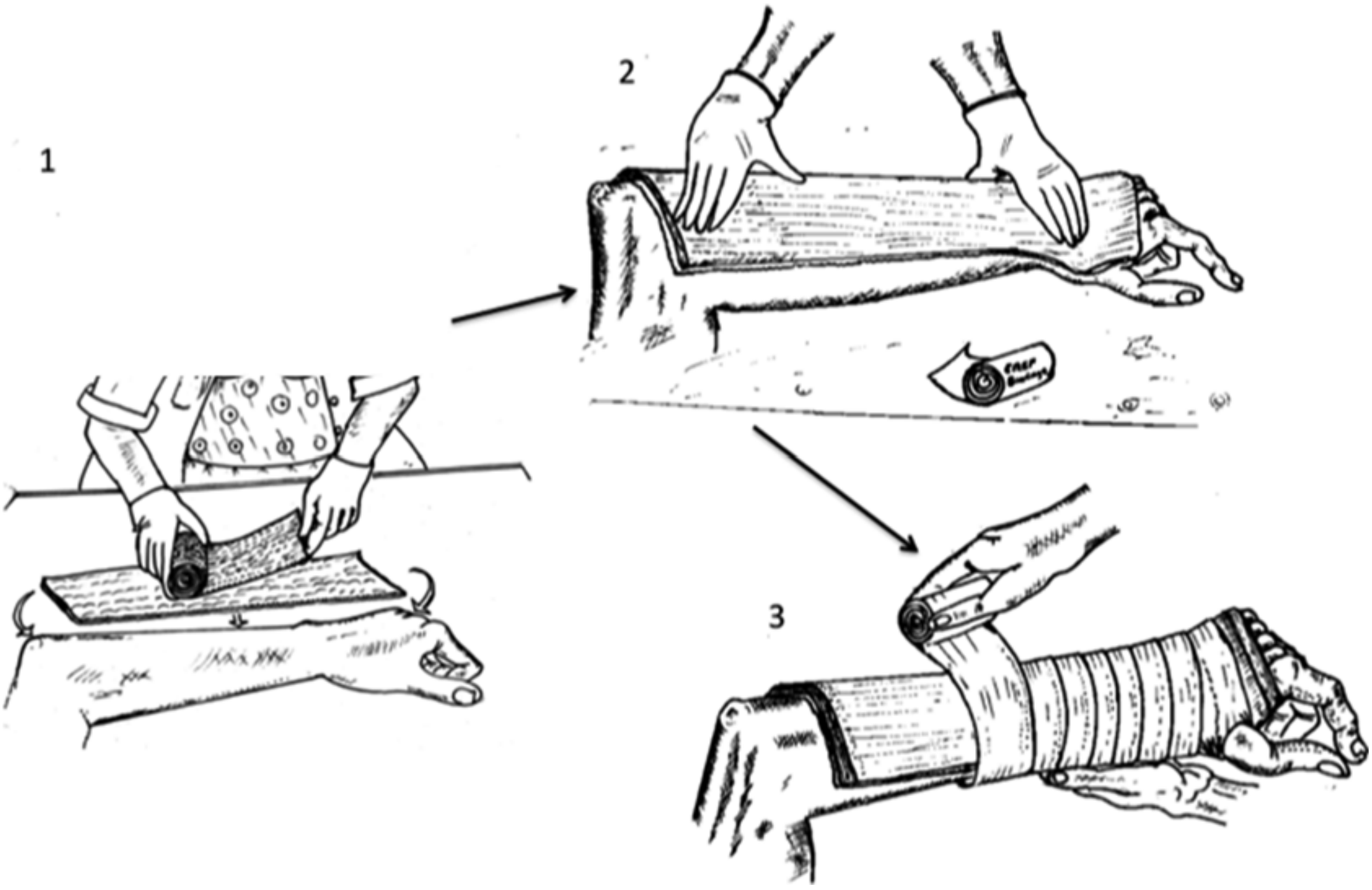

Fig. 25.5 Backslab application method 2: *1* Measuring and preparing slab, *2* laying slab and wool as one on limb, *3* wrapping in bandage (Adapted from Orthopaedic Care at the District Hospital Eds. Doorgakant, Mkandawire. http://www.orthopaedic-care.co.uk/ Drawing by B. Kapesi (OCO))

the cast measured on the sagittal (seen on lateral view) to that on the coronal (PA view) at the fracture site. The ideal ratio has been quoted as 0.8 [10, 11].

Above knee circular casts: Padding is applied for the full length of the cast. Cast application is then done in two stages. First, a below knee cast is applied, and then it is extended above the knee. A good position for applying the below knee cast is with patient sitting up, knee flexed. This helps relax the hamstrings and aids fracture reduction through gravity.

Patella tendon bearing cast (Sarmiento): This specialised cast is used for tibia fractures once they have started to show signs of healing. They are moulded around the patella to control rotation instead of using a full above knee section, thereby permitting early knee flexion and avoiding stiffness. The below knee component is also shaped differently to provide a snugger fit [12].

Wedging: Wedging involves making a split (wedge) in the cast on the side towards which a fracture is drifting and applying a wooden or plastic block in that space. This is most often done for tibial fractures. A few fresh turns of cast material are then wrapped around this area.

If plaster material or splints are not available for whatever reason, an improvised support is better than none. This can be made, for example, out of cardboard folded into an appropriate gutter or with wooden sticks tied around the limb. Do make sure if wood is used, that it is clean, particularly if there is an open wound. These improvisations are only suitable for short-term use and should be reviewed to make sure they are not causing excessive compression

25.1.17 Removal of a Cast

This needs to be done carefully and with the right instruments. It needs to be done as an emergency when there is a suspicion of compartment syndrome. Slabs can be cut along their soft side with scissors. For full casts, a stepwise approach is described here:

Look out for premade splits. If not present, mark out two lines along which the cast will be split. Rarely a single split will suffice. Around the ankle it is best to go round either side with a right angle inferiorly.

Use an oscillating saw if available. This instrument works best on hard cast material, not whilst it is still setting. The cast should be cut bit by bit rather than by sliding the machine over it as this will cause it to overheat and break down.

The manual plaster cutter (Stille Lorenz shears) has keel-shaped shears, which cut through all layers of the cast. The horizontal blade needs to be slid parallel to the skin whilst advancing up the line of cut. The two arms are closed whilst controlling the angle of the blade inside the plaster so it does not dig into the skin. The groove inside the shear needs occasional unplugging.

Once the split is completed down to skin, plaster spreaders and scissors are employed to expand the split and divide residual strands before gently pulling the cast off.

Sometimes instruments are not available to remove a POP cast. One way around this is to ask the patient to pre-soak it in warm water and then simply cutting if off with scissors once it has softened.

25.1.18 Splints and Slings

Some relatively stable fractures can be managed in simple commercially available splints. These are usually metal-backed fabric materials shaped for specific injuries, and they can be strapped on with Velcro or buckles.

Slings are mostly used to support upper limb fractures. Where the weight of the arm is needed to distract the injury, such as an impacted humeral neck fracture, then a collar and cuff is preferred. If the weight of the arm needs to be neutralised so it does not pull on the fracture, as in clavicle fractures, then a Polysling or broad arm sling is preferred. These are also often used in combination with upper limb casts to support their weight and make the patient more comfortable.

25.1.19 Moulding

Moulding does not mean simple compression of a cast over the fracture site. If anything, that will apply too much pressure, increasing the risk of pressure sores and compartment syndrome.

Moulding is a technique used to improve the stability of a fracture in a cast. Its underlying principle is the intact periosteal hinge. If a fracture is caused by a deforming force in one direction, considering this is not too violent an injury, the concave side of the fracture will have an intact periosteum. By stretching that periosteum in a cast, one can provide some internal tension which will help hold the fracture better [13] (Fig. 25.6).

Moulding is applied mostly through a full circular cast. POP is much better for this than fibreglass. Allow enough time to get the moulding right, hence avoiding hot water or a too dry roll of POP.

Moulding employs the principle of three-point fixation. One point is applied directly under the fracture site on the convex side. The other two points are applied either side of the fracture site on the opposite (concave) side near the extremities of the cast.

25.1.20 Moulding of a Colles Fracture

Moulding can cause a cast to look irregular, but it must be recognised that plaster craft is not about aesthetics but about restoring function. Moulding is not possible through most slabs, unless especially shaped, e.g. a radial gutter splint.

25.2 Principles of Traction

Traction involves pulling the fracture margins into an approximate reduction and holding this position until union occurs or until the fracture is sufficiently stable to be treated by cast immobilisation. By definition some form of counter-traction is required to achieve the distracting force. For lower limb traction, this can be provided by raising the bed end (on bricks if bed not adapted) or by raising the limb in some form of traction frame. This is termed “Balanced Traction”.

Many fractures cannot be managed in casts. This can be due to their location, e.g. near the shoulder or hip joint, the specific injury and patient factors.

25.2.1 Skin Traction

Skin traction is used for pain relief, control of swelling (upper limbs) and temporary or definitive immobilisation of a fracture. Different types exist such as straight leg (Buck’s traction), straight arm and Gallows traction.

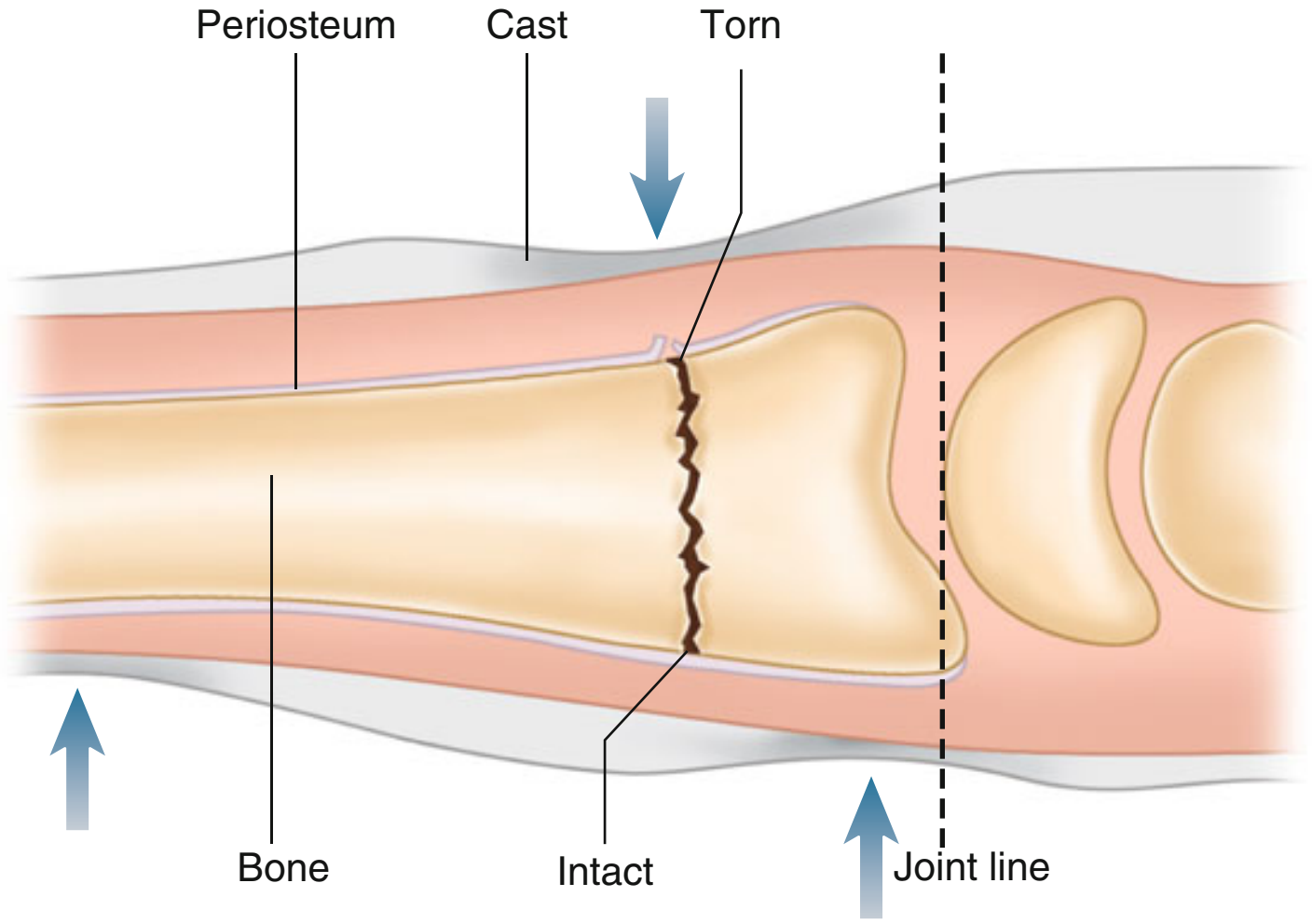

Fig. 25.6 Moulding is a technique used to improve the stability of a fracture in a cast

Skin traction should only be used with a maximum weight of 5 kg. This is usually suitable for children and also avoids damage to growth plates from skeletal pins.

25.2.2 Method of Application (Example)

- Provide adequate analgesia and find a suitable assistant.
- Choose a tape carefully. Aim for specialised tape and only improvise if necessary.
- Pre-assemble your equipment: tape, spreader with a central hole (made of wood or POP; have a premade supply ready), cord (ideally rope but thinly rolled out gauze bandages can be used) and weights.
- Clean skin with wet swab ± alcohol. Shave (carefully) if hairy. If available some agents can be applied to enhance stickiness, e.g. tincture of benzoin.
- Measure length of main tape required. Use the uninjured limb for this. Allow extra length for spreader. Mark the halfway position with a pen.
- Measure length of reverse tape.
- Peel main tape to a length of ½ its own full length +½ of reverse tape length.
- Apply reverse tape over a centrally placed spreader, guided by previous marking.
- Stick main tape to one side of the limb.
- With an assistant maintaining spreader in desired position, peel second half of tape and stick to the opposite side.
- Desirable position of spreader is midline and perpendicular to axis of pull.
- Protect bony prominences (malleoli/ulna head) further with some padding.
- Hold tape in position with loose circumferential straps of tape. Do not overtighten.
- Pass a cord through a hole made into tape at level of spreader hole. Fashion a bulky knot on the inside which will not go through the hole when pulled.
- Attach the other end of the cord to the weight.
- In the lower limb, use a derotation splint [14] to avoid rotational deformity (Fig. 25.7).

The above method is essentially a guide, and many variations are possible, including commercially available packs which can be applied straight on and wrapped. The latter often have a non-adhesive surface. One should be very careful when removing adhesive tape as it can damage fragile skin. If you want to avoid circumferential strapping, a figure of eight configuration with a crepe bandage can be used.

The *Thomas splint* is a very specific splint that uses skin traction to pull on a femoral fracture in a closed system. Its use is usually temporary for pain relief, pending other forms of fracture treatment. It can be used as definitive femoral fracture treatment in children or, when combined with skeletal traction in various ways as definitive treatment in adults.

When applying Gallows traction (Bryant's method), its use is exclusive to children aged less than 2 and the cut-off body weight is 12 kg. Both legs are put in traction to prevent imbalance with the hip should be in about 90° of flexion and 10° of abduction. The cords are tied such that the child's bottom lies about a hand's breadth from the mattress. One should observe very carefully for neurovascular status of the leg, as this method predisposes to ischaemia. If there is any doubt, one should discontinue Gallows and switch to extension type.

25.2.3 Skeletal Traction

These are effectively operative procedures and should follow strict precautions: antisepsis, draping if possible, aseptic no touch technique, sterile equipment, post-procedure wound care and appropriate disposal of equipment. They can be done under general or local anaesthesia.

The weights attached depend on the condition being treated. Maintenance weights are roughly estimated at 1/10–1/7th of the patient's body weight. The site of insertion and configuration used depend on the injury.

Fig. 25.7 A few examples of derotation splints, including improvised (**b**) and custom-made (**a**, **c**) ones

25.2.4 Method of Application

- Gather all the equipment required: sterile gloves, gauze, iodine/spirit, local anaesthetic, blade and small artery forceps or dissecting scissors, Steinman (smooth) or Denham (threaded) pin, T-handle or hand drill, stirrup or small POP roll, cord and weights, pulleys, frames and bars.
- Prepare sufficient area of skin around surgical site with antiseptic and drape.
- Administer LA down to bone (if not using GA).
- Make stab incision at entry point, about 1–2 cm long. Blunt dissection to bone.
- Insert pin through near cortex into middle of bone to ensure two cortices are engaged. Predict the exiting point through far cortex and skin and infiltrate LA onto that side. Make exit point incision over tented skin made as tip of pin becomes subcutaneous.
- Aim for same length of pin on both sides of limb whilst making sure threads (if any) are in the bone.
- Apply stirrup over pin. This can be made of metal or out of POP. Make sure pin ends are covered, especially the sharp end to avoid accidental injuries during the course of traction. Secure stirrup such that it does not slide over pin, to avoid loosening and pin-site contamination.

- Connect stirrup to cord and cord to weights via most desirable pulley ± bar configuration.
- Post-procedure, clean pin sites with spirit/iodine. Then apply a gauze bandage around each. Remove gauze after 48 h and advise twice-daily pin-site cleaning with antiseptic solution or saline.

25.2.4.1 Specific Points

Due to the displacing effect of muscle pull, the position of the limb may need adjusting, e.g. proximal femoral shaft fractures, where 20–30° of abduction is used to counteract the hip abductors; subtrochanteric femoral fractures, where flexing the hip and knee to 90° counteracts the flexing force of the iliopsoas muscle; or distal femur fractures, where a bolster placed under the fracture site and flexing the knee counteracts the posterior pull of the gastrocnemius muscle.

Be aware of specific neurovascular structures that can be injured, e.g. common peroneal nerve during proximal tibial pin insertion.

For tibial/femoral traction, rotational instability should be controlled with an anti-rotation splint [14].

Specific rehabilitation programmes need to be tailored to the injury, the classic one being Perkin's traction for femoral shaft fractures, where the knee is mobilised early to avoid flexion contractures [15, 16].

The commonest sites for skeletal traction are:

1. Proximal tibia for most adult fractures of the femur, the acetabulum and pelvis and hip dislocations.
2. Distal tibia used as for proximal tibia and in certain tibial plateau fractures. Useful when proximal tibial pin has to be resited.
3. Distal femur often used for 90/90 traction for subtrochanteric fractures. Because the pin has to be inserted through bulky muscle, there is a higher risk of infection.
4. Calcaneum used for some comminuted tibial fractures.
5. Olecranon, indicated for supra/intra-condylar fractures of the distal humerus.
6. Greater trochanteric traction – to reduce central hips dislocations.
7. Metacarpal traction – for forearm/wrist fractures and to control swelling.
8. Cervical traction (skull traction or Halo jacket) – to immobilise C-spine fractures.

Once traction is on, post traction care is essential. This includes:

1. Regular pressure area monitoring and care.
2. Skin review for skin traction and pin-site care for skeletal traction.
3. Medical observation due increased risk of nosocomial infections and thromboembolic events. Give mechanical and/or pharmacological thromboprophylaxis as required.
4. Physiotherapy/rehabilitation, especially isometric exercises to prevent muscle wasting and stiffness.
5. Psychological support.
6. Review of limb position clinically and radiographically to detect loss of position.

25.3 X-Rays and Follow-Up

The use of X-ray in the course of fracture management will be determined partly by access to it and the clinical need for it. Its clinical uses are primarily for diagnostic purposes, to assess the effect of a treatment and for follow-up.

Ideally every injury where a bone is suspected to be involved should have an X-ray. Certain purely soft tissue injuries may also do sometimes. Once a fracture or dislocation has been manipulated, a check X-ray is usually obtained. This may not be required if it will not alter your management plan. The result of many manipulations can be judged on the overall alignment of the limb and/or movement of a joint. Check X-rays are useful when the position of the fracture will require you to change your management irrespective of the external appearance. Follow-up X-rays follow the same logic. Their timing is key. They should be done in a time when an alternative plan, adjustment or redo of the original treatment can still be administered if required. A general guide of 1–2 weeks applies when a remanipulation may be required and up to 6 weeks for wedging of a cast for tibial fractures. This time will be shorter in children. Past that period, follow-up is predominantly geared at recording complications, the management of which, if necessary, is often surgical.

Conclusion

Fracture care is a very complex field, where every fracture type has its own very specific properties and dictates its own management. Rather than hone in on the detail, a process which would require volumes of writing, this chapter has aimed to provide a template for the surgeon to approach orthopaedic injuries non-operatively. It is true to say that even when access to all surgical facilities is available, most injuries would still be treated without surgery. The skills, however, for undertaking the different non-surgical treatments are often forgotten unless one practises them with the same frequency and discipline as one would their surgical skills. We hope this chapter serves as a useful reminder, and we point you to some other works which expand on this subject.

References

1. Buckley R, Page J, Calhoun J, editors. General principles of fracture care. http://emedicine.medscape.com/article/1270717-overview#a03. Last Accessed 20 Oct 2014.
2. Uebbing C, Walsh M, Miller J, Abraham M, Arnold C. Fracture blisters. West J Emerg Med. 2011;12(1):131–3.
3. Ramsey P, Hamilton W. Changes in tibiotalar area of contact caused by lateral talar shift. J Bone Joint Surg Am. 1976;58(3):356–7.
4. Thomas B. Reduction of smith's fracture. J Bone Joint Surg Br. 1957;39-B(3):463–70.
5. Anderson RL. Conservative treatment of fractures of the femur. J Bone Joint Surg Am. 1967;49:1371–5.
6. Marsh D. Concepts of fracture union, delayed union, and nonunion. Clin Orthop Related Res. 1998;355:S22–30.
7. Sarmiento A, Gersten L, Sobol P, Shankwiler J, Vangsness C. Tibial shaft fractures treated with functional braces. Experience with 780 fractures. J Bone Joint Surg Br. 1989;71-B(4):602–9.
8. Giordano C, Koval K. Treatment of fracture blisters: a prospective study of 53 cases. J Orthop Trauma. 1995;9(2):171–6.
9. Halanski M, Noonan K. Cast and splint immobilization: complications. J Am Acad Orthop Surg. 2008;16:30–40.
10. Kamat AS, Pierse N, Devane P, Mutimer J, Horne G. Redefining the cast index: the optimum technique to reduce redisplacement in pediatric distal forearm fractures. J Pediatr Orthop. 2012;32(8):787–9.
11. Debnath U, Guha A, Das S. Distal forearm fractures in children: cast index as predictor of re-manipulation. Indian J Orthop. 2011;45(4):341–6.
12. Sarmiento A. Functional bracing of tibial fractures. Clin Orthop Rel Res. 1974;105:202–9.
13. Gupta A. The treatment of Colles' fracture. Immobilisation with the wrist dorsiflexed. J Bone Joint Surg Br. 1991;73(2):312–5.
14. Doorgakant A, Parmar R, Ngulube C. The Ntcheu derotation splint for lower limb traction. Trop Doct. 2012;42(4):214–6.
15. Buxton RA. The use of Perkins' traction in the treatment of femoral shaft fractures. J Bone Joint Surg Br. 1981;63-B(3):362–6.
16. Gosselin R, Lavaly D. Perkins traction for adult femoral shaft fractures: a report on 53 patients in Sierra Leone. Int Orthop. 2007;31(5):697–702.

Suggested Reading

Charnley J. The closed treatment of common fractures. 4th ed. Cambridge: Cambridge University Press; 2005. First published 1950.

Cook J, Sankaran B, Wasunna AEO, editors. Surgery at the district hospital: obstetrics, gynaecology, orthopaedics, and traumatology. Geneva: World Health Organization (WHO), 1991.

Doorgakant A, Mkandawire N, editors. Orthopaedic care at the district hospital. Ashtin Doorgakant; 2013.

Gosselin R, Spiegel D, Holtz M, editors. Global orthopaedics- caring for musculoskeletal conditions and injuries in austere settings. New York: Springer-Verlag; 2014.

King M, Bewes P. Primary surgery, vol. 2, Trauma. Oxford University Press. First published 1987.

McRae R Clinical Orthopaedic Examination 5th ed. Edinburgh: Churchill Livingstone, 2010.

Minimal Requirements for Open Reduction Internal Fixation in Austere Environments

26

James Benjamin Penny and Steve Mannion

In low- to middle-income nations, trauma is a leading cause of mortality and morbidity. Poorer trauma care facilities desperately require development as injury-related disability leads to major socioeconomic consequences to patients, their families and local communities. Notwithstanding the merits of trauma surveillance and prevention programmes, the provision of internal fracture fixation surgery has the potential to improve patient outcomes and alleviate the significant burden of trauma-associated musculoskeletal disability.

In the austere environment, performing internal fixation surgery requires a comprehensive appreciation of adverse factors, risk and potential harm when working with limited resources and infrastructure. The organisation and maintenance of a hospital with a surgical orthopaedic facility requires substantial resources, technical complexity and requires all key elements to function effectively. Significant barriers can prevent the successful delivery of internal fracture fixation in the developing world or austere setting; these can be grouped into social/cultural, financial and structural factors.

Visiting surgeons from high-income countries must remain mindful of their own operative skill set and experience when contemplating the decision to offer operative fixation within a hosting nation. Generally low energy, closed fractures can be treated definitively with closed techniques such as manipulation and casting, brace, cast wedging or traction. Local expertise in these nonoperative forms of management may well be the safest option for the patient especially if this tends to form the mainstay of local treatment and normally have predicable outcomes. A particular challenge of administering medical care in austere environment is continuity of care where rehabilitation or follow-up care is minimal or not available.

26.1 Alternatives to Internal Fixation

Before proceeding with open reduction and internal fixation of any fracture, all alternative options of treatment should be considered. Many fractures, even those now routinely treated with ORIF in the developed world, can still be satisfactorily treated with manipulation and plaster casting. Adjuncts to this process include windowing the plaster to allow access to open wounds, wedging to correct angular deformities and the incorporation of traction pins within the cast to ensure correct alignment and effect end-to-end reduction of long bone fractures. Many hand and foot fractures

J.B. Penny, MRCS, MBChB, MEng(Hons)
Northern Deanery, Newcastle Upon Tyne, UK
e-mail: James.Penny@doctors.org.uk

S. Mannion, MChir, FRCS (Tr&Orth), FCS(ECSA) (✉)
Department of Conflict and Catastrophe Medicine,
St George's, University of London, London, UK
e-mail: stevejmannion@aol.com

© Springer International Publishing Switzerland 2016
J.D. Robinson (ed.), *Orthopaedic Trauma in the Austere Environment:*
A Practical Guide to Care in the Humanitarian Setting, DOI 10.1007/978-3-319-29122-2_26

can be treated with manipulation and K-wiring, often done under local anaesthetic techniques, rather than formal ORIF with plates and screws.

External fixation is a valid treatment option if transfer to higher level of host nation care exists or as a temporising phase pending delayed definitive internal stabilisation at the local treatment facility. In the austere setting, definitive care with external fixation may also be considered.

Lastly, on occasion fracture patterns and associated soft tissue injury will be of such severity that the chances of successful reconstruction and ultimately reasonable function are limited, and in such circumstances, primary amputation must be appraised.

26.2 Aims and Principles of Open Reduction and Internal Fixation

The fundamental principles of open reduction and internal fracture fixation are described by the international AO organisation:

- Anatomical reduction of the fracture fragments, particularly articular
- Stable fixation, absolute or relative
- Preservation of the blood supply and soft tissue envelope
- Early active mobilisation to reduce joint contracture, loss of motion and muscular atrophy

These tenets are declared in an idealised world irrespective of setting and assume no resource limitation or rationing of services. The inherent challenges and potential barriers to internal fixation surgery in the austere environment should not allow a surgical team to detract or deviate away from the established doctrine. The team has the duty and responsibility to establish a 'safe' surgical environment whereby challenges and shortfalls are identified and controlled to ensure that patient's outcomes are maximised and adverse risks minimised. In the austere setting when contemplating internal fixation, there should always be a careful rational appreciation of health promoting and risk factors.

26.2.1 Providing a Safe Surgical Environment

The World Health Organization has published evidence-based guidance that should be accepted as an international standard for any operative team to adhere to in order to establish a safe surgical healthcare facility. Three main areas are identified to promote a safe surgical environment: effective teamwork, safe anaesthesia and prevention of surgical site infection (Table 26.1).

The complete document by the World Health Organization can be found at the WHO guidelines for Safe Surgery 2009 – Safe Surgery Saves Lives, World Health Organisation [1]. A safe environment requires dependable infrastructure and utilities such as a clean water supply and electricity for sterile services and lighting systems. Theatre resources generally require supplemental oxygen, suction, diathermy, fluroscopy, implants, instrumentation and consumables. Additionally clinical governance must not be ignored; quality assurance, surveillance, audit and peer review objectively measure service delivery and ensure the maintenance of high standards and facilitate improvement.

Table 26.1 The three main areas identified by the World Health Organization to promote a safe surgical environment

Safe surgical teams	Safe anaesthesia	Prevention of surgical site infection
Effective communication	Trained anaesthetist	Hand washing
Correct patient, site and procedure	Anaesthesia machine	Personal protective equipment
Informed consent	Medication safety check	Appropriate use of antibiotics
Availability of all team members	Patient Monitoring (oximetry, heart rate, blood pressure, temperature)	Antiseptic skin preparation and draping
Adequate team preparation and procedure planning		Atraumatic wound care
Confirmation of patient allergies		Instrument and implant decontamination and sterility

26.2.2 Anaesthesia

In contrast to closed or conservative fracture treatment, internal fixation requires sophisticated anaesthetic provision. Depending on resources, this might take the form of general anaesthesia, spinal anaesthesia or regional anaesthesia. Ketamine is regarded as a safe anaesthetic agent in a less developed world setting. Whilst often taken for granted in the developed world, general anaesthesia has inherent risk, especially if carried out by non-medical anaesthetic practitioners in the absence of what would be regarded as 'adequate' patient monitoring. Local or spinal anaesthesia is often seen as much safer alternatives, and the expertise of an anaesthesiologist who is experienced in less than ideal environments should never be underestimated.

26.2.3 Patient-Related Factors

Particularly if general anaesthesia is being contemplated, patient fitness needs to be optimised prior to surgery. Particular attention should be given to haemoglobin levels and hydration state. Many patients in the austere environment will be suffering from malnutrition or concurrent co-morbidities (malaria, respiratory infections, helminths), and this may lower resistance to infection and complicate surgery.

Much concern has arisen with regard to patient HIV status and the risk of deep infection in ORIF. In parts of sub-Saharan Africa, where the surgical environment is often regarded as 'austere', HIV seroprevalence in the population can be up to 20 %. Although initial papers cited a high rate of deep infection following ORIF in these patients, and a deterioration in their WHO grading of their HIV-related disease [2], subsequent research has largely refuted this, concluding that internal fixation can be undertaken in HIV-positive patients without incurring an unacceptably high deep infection rate [3] (Table 26.2).

Table 26.2 Patient factors for minimising complications

Patient Factor	Recommendation
Cessation of smoking	Highly essential
Diabetic control	Optimise all factors
Stopping immunosuppressant	
Nutrition	
Concomitant infection	
Remove jewellery	

26.2.4 ORIF Planning and Delivery

The orthopaedic team must consider the indication for open reduction on an individual patient basis. The general indication for performing open reduction and internal fixation is when there is a failure to obtain or maintain a satisfactory closed reduction, specifically this is for fractures that are:

- Irreducible
- Intra-articular
- Unstable
- Pathological
- High risk of avascular necrosis/non union
- Multiple, where fixation of polytrauma supports systemic treatment
- Otherwise difficult to nurse and rehabilitate

It is paramount that the preoperative, surgical tactic and contingency plans are reviewed with an emphasis on fixation principles, required implants and associated hardware, supporting materials, instrumentation, adjuvant equipment and human resources. An operative risk assessment should include identification and minimisation of potential complications in combination with an appraisal of the available means to manage adverse outcomes. The personalities, previous experiences and healthcare team dynamics will determine the successful delivery of high-quality care. Adaptability, resourcefulness and previous successful experiences in less than ideal environments are desirable qualities where resources are limited and uncertainty is commonplace. Team members can expect to work very long hours and frequently in areas out with their expertise to help facilitate the overall running of theatre.

In terms of the clinical indications for ORIF, in practice there is a fracture "hierarchy" in terms of the value of such. Displaced intra-articular ankle fractures often do badly with conservative treatment, with a high rate of malunion and subsequent painful and limited mobility for the patient. In contrast, although conservatively treated displaced, intra-articular distal radial fractures often result in wrist stiffness, in the overall spectrum of physical disability, especially in an austere environment, this is a relatively minor handicap. As a similar contrast, intertrochanteric fractures of the proximal femur, being metaphyseal, have a high rate of union on traction of only a few weeks, but the majority displaced intracapsular fractures treated conservatively fail to unite and lead to profound morbidity.

26.2.5 Timing of Surgery

The 'window' of opportunity for acute fracture ORIF is believed to be 2 weeks following injury. Beyond this period, fracture healing will have usually progressed to the extent that difficulty can be anticipated in fracture reduction and more complex reconstructive techniques may be required.

In a natural disaster, medical teams may only arrive a few days post injury and then be faced with healthcare units with poor facilities, limited provision of equipment, no intraoperative imaging, no fracture table and questionable sterility [4]. This presents a difficult situation for the surgical team looking to deliver optimal treatment strategies. What can be performed is dependent upon many factors, and this is really for the 'on the ground team' to assess and consider when contemplating and performing ORIF. Often the treatment of closed fractures, worthy and appropriate for internal fixation, will be deferred, with priority given to acute open injury or amputation.

26.2.6 Implants

A considerable challenge to the provision of ORIF in the austere environment is the cost and availability of implants. With a developed world procured *Small Fragment Set* costing upwards of $15,000, and individual screws costing $25 or more, the cost is often beyond the means of governmental or patient funding in less developed economies.

The surgical team is responsible for assessing the suitability, quality and sterility of implants used for fracture fixation. The last decade has seen the advent of alternative suppliers, often based in the Indian subcontinent, who are able to produce and supply ORIF implants at a lower cost. Many austere environment surgical projects also benefit from the donation of obsolete fixation implants from the more developed world. Very often, however, the range of sizes of screws and plates in such donations is limited. One solution to this is to cut down plates and screws to the required size with bolt-croppers preoperatively.

One of the most significant developments in less developed world orthopaedics over the past decade has been the *SIGN nail* (Surgical Implant Generation Network). This is a minimally (hand) reamed, solid, locked intramedullary nail with potential application to tibial, femoral and humeral fractures. Use of a rigid jig and a "feeler gauge" to effect distal locking means that intraoperative fluoroscopy (see below) is not a prerequisite for its use. Depending upon circumstances, the initial set of instruments are often provided at a highly subsidised price, with replacement nails being provided free by the SIGN Foundation provided data is returned on the use of each nail. Nailing of a femoral fracture, for example, allows the patient to mobilise early and avoids the average of 12 weeks on traction would be required for conservative treatment (See Chap. 27) (Table 26.3).

26.2.7 Surgical Skills and Knowledge

Of great importance in ORIF is the *surgical approach* necessary to gain access to and fix the fracture. In many instances, this necessitates considerable anatomical knowledge in order to avoid iatrogenic injury to nerves and vessels and to minimise soft tissue damage such as to optimise limb function once bony union has occurred. Experience of having undertaken under supervision, assisted at or observed should be considered a prerequisite to attempting any particular ORIF procedure.

Table 26.3 Fracture fixation techniques and hardware

Type	Information	Hardware
Lag screws	Stability is achieved by compression and bone contact. Load transfer occurs from fragment to fragment, not via the implant 2000–4000 N of compressive force Apply perpendicular to fracture line to minimise shear force 2–3 screws are required for multi planar stability	Standard small fragment set Screw diameters Cortex 2.7/3.5 mm Cancellous 4 mm Standard large fragment set Screw diameters Cortex 4.5 mm Cancellous 6.5 mm
Plates	*Modes* *Neutralisation*: protect from bending, shear and rotational forces *Compression*: apply to tension side of eccentrically loaded bone *Buttress*: support *Bridging*: spanning – relative stability *Antiglide*: used as a physical block to shortening or displacement *Tension-band*: apply to eccentrically loaded bone to utilise and convert tensile to compressive force *Spring*	1/3rd tubular Dynamic compression plates (DCP) Limited contact DCP Anatomical site specific Reconstruction
Intramedullary nails	Fixation of diaphyseal fractures – humeral, femoral tibial Reamed/unreamed Cylindrical/slotted Locked/unlocked Anterograde/retrograde	Proprietary SIGN nail
Tension-band wiring	Compression by the dynamic component of the functional load Conversion of tension forces to compression forces Allows some load-induced movement	Patella and olecranon fractures Wires (varying gauges) K-wires and Driver Wire benders/Cutter/AO bending tool – pliers

As well as the soft tissue surgical approach, the surgeon should be experienced in the principles of internal fixation in terms of plate and screw design and function, minimal requirements for stability, proficiency in fixation techniques and familiarity with hardware. Whilst the skills and knowledge referenced above are often assumed in the orthopaedic specialist in the more developed world, in the austere environment fracture care is often delegated to general surgeons who may not have had exposure to the relevant training.

26.2.8 Postoperative Care

A basic tenet of ORIF osteosynthesis is *early active pain-free mobilisation of muscles and joints adjacent to the fracture.* For mobilisation to occur, adequate postoperative analgesia must be prescribed for the patient. Provision of physiotherapy, taken for granted in the more developed world, is often not available in the austere environment. If this is not the case, then rehabilitation advice needs to be provided by the non-physiotherapist, often the surgeon or nursing staff with the actual therapy being undertaken by the patient's attendant or relative. Provision of *crutches* is vital in mobilising those with lower limb fractures (see Chap. 22 on rehabilitation).

26.2.9 The Operating Theatre Environment

The organisation and daily routine of the operating room requires strict administration and maintenance (Tables 26.4 and 26.5). Immediately prior to operative intervention, the use of the

Table 26.4 Operating room requirements and protocol

Requirements	Daily protocol
Specifically designated room for use by anaesthetic and surgical teams	Uncluttered room, doors closed by default
Good lighting and ventilation	Minimise theatre traffic, minimum people in theatre especially once an operation has commenced
Dedicated equipment for procedures	Adequate in theatre store of consumables
Equipment to monitor patients, as required for the procedure	Clean and disinfection of table and instrument surfaces between cases
Drugs and other consumables for routine and emergency use	End of day top to bottom clean, including all furniture, equipment and surfaces
Waste disposal	Sterilisation and storage of all surgical instruments and supplies

Table 26.5 Theatre environment factors for optimising success

Theatre environment		
Factor	Information and evidence	Recommendation
Physical resources	Infrastructure and equipment: Water Electricity Oxygen Sterilisation Drapes Emergency equipment Repair and maintenance	Highly essential Standard practice
Theatre cleaning/decontamination and operating list order	Association between bacterial counts in theatre air and isolated from surgical wounds [6]	Highly essential Routine cleaning protocol, infected cases last on list
Laminar air flow	Ultraclean air (UCA) of less than 10 colony-forming units per metre cubed (cfu/m^3) of bacteria 22 times lower airborne bacterial count seen in laminar flow theatres and associated with a 50 % reduction in infection rates in joint replacement. Lidwell et al. [5]	Desirable for ORIF Unlikely to be available Essential for arthroplasty Unlikely to be available See Antibiotic prophylaxis Equally effective as laminar flow.
Ultraviolet light	Similar results to laminar flow/air filtration systems in reducing SSI [7]	Unlikely to be available Typically used in wound dressing rooms

WHO checklist ensures the correct operation is about to be undertaken, with the right equipment available and all members of the surgical team briefed as to the intended procedure. All patients undergoing ORIF should have *prophylactic antibiotics*. Several different regimes exist, and the exact one followed in each institution will depend on availability and cost of antibiotics locally as well as the local bacterial prevalence.

All members of the theatre team should be aware of the principles of aseptic surgery and the need for sterility. Given the sophistication of many internal fracture fixation systems, specific training in the relevant devices should have taken place before the operation. The predominance of sharp instruments (drills, screws etc.) means that meticulous handling and transfer of sharp devices should be adopted in order to minimise the risk of needle-stick injury. Staff should also be provided with adequate *personal protective equipment:* waterproof gowns, boots, face mask and eye protection.

Increasingly in the more developed world, *laminar flow o*perating theatres are seen as a prerequisite for implant surgery. Such technology is usually not available in the austere environment due to cost constraints. In joint replacement surgery, the use of laminar flow reduces deep infection rates by 50 % [5]. Whilst this figure is significant, if the background deep infection rate is already low by virtue of the adoption of other, achievable sterile practice, then the increased risk of deep infection incurred by the absence of laminar flow is acceptable, depending on the relative benefit of ORIF over more conservative forms of treatment.

Another important consideration in the provision of ORIF of fractures is the availability of *power tools*. Although internal fixation can be achieved with hand drills (and saws), the use of such much increases operation time, leading to an increased risk of deep sepsis. Commercially available orthopaedic power tools are, however, prohibitively expensive for most austere or less developed world surgical institutions. Some units have overcome this difficulty by using commercially available, battery-driven ‘hardware store’ drills, which, although not able to be sterilised themselves, can be wrapped in a sterile drape enabling power drilling to be undertaken under aseptic conditions.

Another resource often regarded in the more developed world as a prerequisite for ORIF is that of the availability of *intraoperative fluoroscopy*. Unfortunately the cost of C-arm fluoroscope, at least $15,000–£25,000, is usually prohibitive in austere surgical settings. However, in the majority of cases, adequate fixation can be obtained without the need for intraoperative X-ray; preoperative planning and templating, direct visualisation of the fracture and appreciation of three-dimensional anatomy can in many ways compensate for the absence. However, for some fractures, most notably dynamic hip screw and plate fixation of intertrochanteric fractures, intraoperative X-ray control remains essential.

26.2.10 Sterility

The lack of adequate sterilisation facilities in the less developed world has led to some authors suggesting that ORIF is contraindicated in many austere surgical settings. Infection associated with internal fixation metalwork is resistant to treatment with antibiotics and, if the infection spreads, may compromise the patient’s life or limb.

Although several types of surgical sterilisation exist, in austere settings, most will employ steam sterilisation in an autoclave, a pressurised chamber which sterilises by subjecting equipment to high pressure, 121°C steam for 15–20 minutes. Pre-packed instruments should undergo a preceding vacuum cycle to extract trapped air as otherwise air pockets will result in the desired temperature not being achieved throughout. Unwrapped instruments should be thoroughly cleaned and dried and then placed on a perforated steel tray which slides into the autoclave. Indicator tape, packed with the instruments, can be used to ensure that satisfactory sterilisation has been achieved. Theatre and sterility services can be severely disrupted with outages of electricity or fresh running water; therefore, adequate engineering maintenance and contingency plans need to be established if utility services are unreliable.

The deep infection rate following ORIF of closed fractures in the developed world is around 1–2 %. In the austere environment, infection rates need to be audited and compared with this figure. A significantly increased rate may lead to a revised assessment of the relative risk and benefit of ORIF.

26.2.11 Minimising Surgical Infection

Surgical site infection (SSI) in less than ideal conditions will always be a genuine concern for a surgical team when contemplating open reduction internal fixation where postoperative infection may herald disastrous consequences.

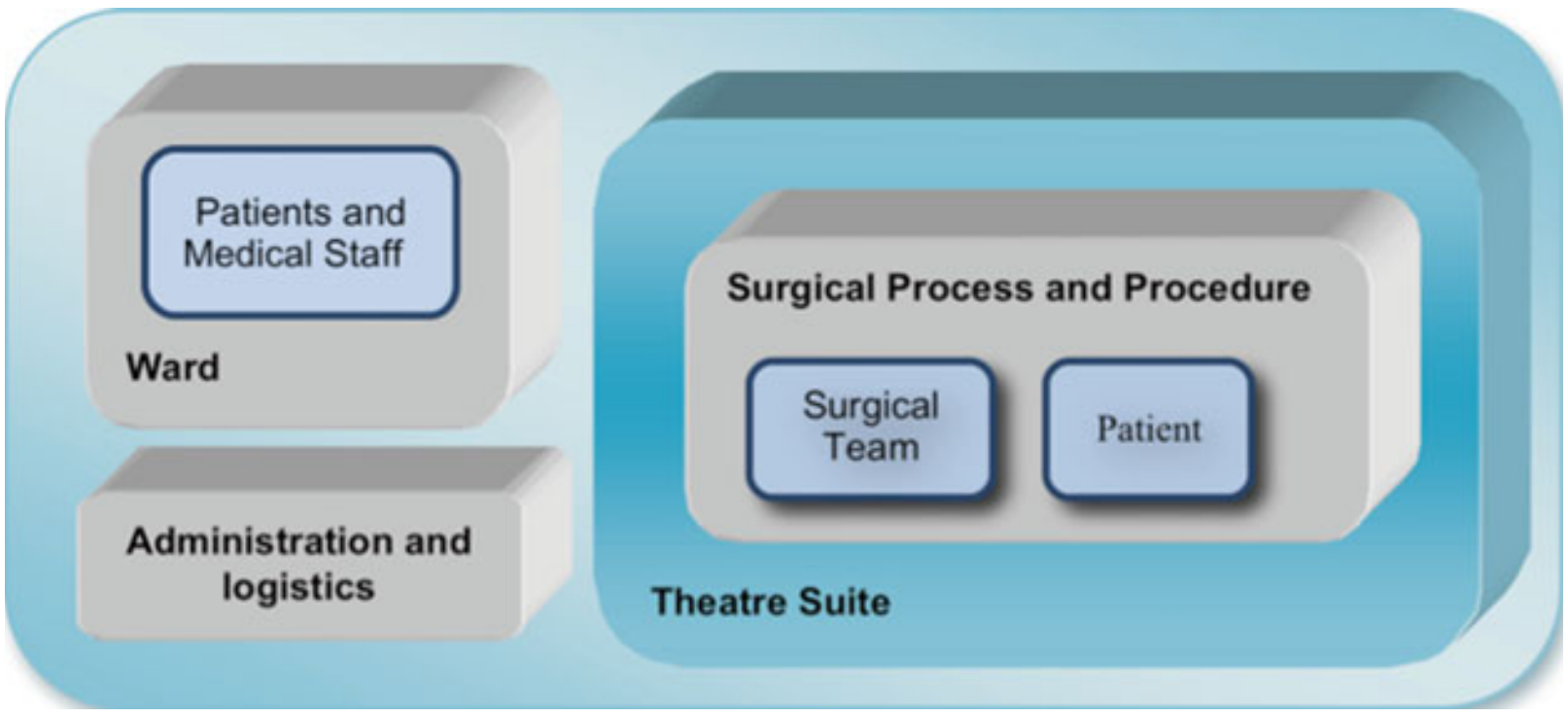

Fig. 26.1 Complex Interplay of surgical environmental factors affecting delivery and infection risk

Table 26.6 Theatre staff practices for minimising infection

Theatre staff		
Factor	Information and evidence	Recommendation
Hand washing	4 % chlorhexidine reduces contamination by 80 %, optimum time of 2 min of washing [8]	Highly essential 2 min of hand washing with antiseptic soap
Gloves	29 % of gloves are contaminated during draping [5] Infection increases 1.7–5.7 % after glove perforation [9] 50–67 % of surgical gloves are perforated in arthroplasty [10] Double gloving reduces this incidence by between three to nine times [11]	Highly essential Double glove and change after draping
Face masks	Deflect bacteria away from the surgical field 95 % effective barriers, once damp, bacteria can translocate through the mask [12]	Highly essential Masks for all staff and change after each case
Head and ears	Head and ears when exposed are significant source of sheading [13]	Essential – theatre cap/hood to cover ears
Clothing	Exhaust suits uncomfortable and expensive. Polyester gowns and balaclava type hats have similar reduction in bacterial shedding [14, 15] Cotton fabrics provide no barrier to skin squames. ~80 μm pore size Polyester gowns significant improvement as barriers to bacteria translocation. Dispose after 70 washing cycles. ~0.2 μm pore size	Essential – wear gowns to minimise bacterial translocation as available 1st line disposable 2nd line polyester 3rd line cotton

Fortunately, surgical acumen has matured to a position whereby the adoption of evidence-based surgical techniques and systems allows metalware to be routinely implanted with consistently low infection rates. The cumulative layering of sophistication in theatre leads to a highly complex surgical environment which represents a significant financial and resource rich cost to a healthcare facility. In austere environment, the facility will, to varying extent, be denuded of these luxurious layers of protection which will warrant a careful appreciation of the relevant factors that adversely affect the risk and benefit balance of any proposed surgery. The factors affecting the contribution to infection can be classified into patient, theatre environment, theatre staff and surgical groups, illustrated in Fig. 26.1.

The evidence of factors and theatre rituals or dogma with respect to minimising surgical infection ORIF/arthroplasty are reviewed and categorised as highly essential, essential or desirable in Tables 26.6 and 26.7.

Table 26.7 Surgical factors for optimising success

Surgical factors		
Factor	Information and evidence	Recommendation
Duration of surgery	Length of surgery 2.6 % for procedures lasting 1 h, 4.9 % 1–2 h, 8.5 % greater than 3 h [16]	Essential Planning, surgical tactic and operative skills
Shaving	Preoperative dry shaving is associated with the highest risk of infection [17]	Desirable In theatre perioperative shaving if required
Antiseptic preoperative skin cleansing	Prospective, randomised study, 849 patients showed chlorhexidine-alcohol is superior to cleansing with povidone-iodine for preventing SSI [18]	Highly essential Skin cleaning 1st line – chlorhexidine-alcohol 2nd line – povidone-iodine
Chlorhexidine wash pre op shower	64 % relative risk reduction (risk ratio 0.36, 95 % CI 0.17–0.79) of SSI [19] Although systematic review of trials involving over 10,000 patients found no difference between showering with chlorhexidine, soap, or with water alone [20]	Desirable Shower with soap and water preoperatively
Antibiotic prophylaxis	Antibiotic prophylaxis showed to be most effective when given prior to incision [21] In arthroplasy, meta-analysis report of antibiotic prophylaxis reduces the absolute risk of infection by 8 % and the relative risk by 81 % [22] Antibiotic given at least 15 min prior to inflation of tourniquet [23] Antibiotic prophylaxis was analysed as a secondary outcome measure in laminar flow study and was found to be equally as effective. [5]	Highly essential Routine antibiotic prophylaxis perioperatively and before tourniquet inflation
Wound Lavage	Pulse lavage reduces SSI in hip hemiarthroplasty 15.6–5.5 % compared to traditional washing with normal saline [24] No level one evidence supporting chlorhexidine or iodine washes – may kill healthy cells and impair local tissue response. In vitro evidence, 0.05 % chlorhexidine reduces wound contamination. 1 % iodine is not effective and 5 % solution is effective but is tissue toxic [25]	Highly essential Wound wash with normal warm saline to reduce bacterial load at surgical site Desirable Pulse lavage. Unlikely to be available

26.3 Summary

Whilst it is recognised that *open reduction and internal fixation* is the optimum for the treatment of many fractures, considerable barriers exist in the provision of such in the austere environment. What can or should be performed is dependent upon many factors, and this is really for the 'on the ground team' to assess and consider when contemplating and offering ORIF.

An operational orthopaedic facility is a highly complex system that demands the coordination of a large healthcare team, adequate infrastructure and material resources to ensure the safe delivery of surgical procedures. The functional status and level of sophistication of the theatre suite is paramount as well as the availability of implant, instrumentation, supporting equipment, patient status and surgical team skills and experience. Barriers or limitations as to what can be provided are mainly grouped into social/cultural, financial and structural factors. Offering internal fixation will require a delicate and cautious balance of these factors to determine if and what types of ORIF are achievable and safe and which will result in a net functional benefit to the patient over conservative methods of treatment, and particularly without suffering the complication of deep infection.

References

1. WHO guidelines for safe surgery 2009 – safe surgery saves lives. World Health Organisation. http://whqlibdoc.who.int/publications/2009/9789241598552_eng.pdf.
2. Jellis JE. Orthopaedic surgery and HIV disease in Africa. Int Orthop. 1996;20:253–6.
3. Harrison WJ. HIV/AIDS in trauma and orthopaedic surgery. J Bone Joint Surg Br. 2005;87-B(9):1178–81.
4. Smith RM. 2012 disaster triage after the Hiatian earthquake. Injury. 2012;43(11):1811–5. doi:10.1016/j.injury.2011.07.015.
5. Lidwell OM, Lowbury EJL, Whyte W, Blowers R, Stanley SJ, Lowe D. Effect of ultraclean air in operating rooms on deep sepsis in the joint after total hip or study. Br Med J. 1982;285:10–4.
6. Lidwell OM, Lowbury EJ, Whyte W, Blowers R, Stanley SJ, Lowe D. Airborne contamination of wound in joint replacement operations: the relationship to sepsis rates. J Hosp Infect. 1983;4:111–31.
7. Berg M, Bergman BR, Hoborn J. Ultraviolet radiation compared to an ultra-clean air enclosure. Comparison of air bacteria counts in operating rooms. J Bone Joint Surg. 1991;73(5):811–5.
8. O'Saughnessy M, O'Mailey VP, Corbelt G, Given HF. Optimum duration of surgical scrub time. Br J Surg. 1991;78:685–96.
9. Cruse PJE, Foord R. A five-year prospective study of 23,649 surgical wounds. Arch Surg. 1973;107:206–10.
10. Lankaster BJA, Bartlett GE, Garneti N, Blom AW, Bowker KE, Bannister GC. Direct measurement of bacterial penetration through surgical gowns: a new method. J Hosp Infect. 2002;50:281–5.
11. Sandiford N, Skinner J. The prevention of infection in total hip arthroplasty. Orthop Trauma. 2009;23(1):8–16.
12. Mitchell NJ, Hunt S. Surgical face masks in modern operating rooms – a costly unnecessary ritual? J Hosp Infect. 1991;18(3):239–42.
13. Owers K, James E, Bannister GC. Source of bacterial shedding in laminar flow theatres. J Hosp Infect. 2004;58:230–2.
14. Whyte W, Bailey PV, Hamblen DL, Fisher WD, Kelly IG. A bacteriologically occlusive clothing system for use in the operating room. J Bone Joint Surg. 1983;65:502–6.
15. Hubble MJ, Weale AE, Perez JV, Bowker KE, MacGowan AP, Bannister GC. Clothing in laminar-flow operating theatres. J Hosp Infect. 1996;32(1):1–7.
16. Pavel A, Smith RL, Ballard A, Larsen IJ. Prophylactic antibiotics in clean orthopaedic surgery. J Bone Joint Surg. 1974;56:777–82.
17. Serodian R, Reynolds BM. Wound infections after preoperative depilatory versus razor preparation. Am J Surg. 1971;121:251–4.
18. Darouiche R, Wall M, Itani K, et al. Chlorhexidine-alcohol versus povidone iodine for surgical-site antisepsis. N Engl J Med. 2010;326:18–26.
19. Wihlborg O. The effect of washing with chlorhexidine soap on wound infection rate in general surgery. A controlled clinical study. Ann Chir Gynaecol. 1987;76:263–5.
20. Webster J, Osbourne S. Preoperative bathing or showering with skin antiseptics to prevent surgical site infection. Cochrane Database Syst Rev. 2007;18(2):CD003949.
21. Burke JF. The effective period of preventative antibiotic action in experimental incisions and dermal lesions. Surgery. 1961;50:161–8.
22. Al Buhairian B, Hind D, Hutchinson A. Antibiotic prophylaxis for wound infections in total joint arthroplasty: a systematic review. J Joint Bone Surg. 2008;90B:915–9.
23. Bannister GC, Auchincloss JR, Johnson DP, Newman JH. The timing of tourniquet application in relation to prophylactic antibiotic administration. J Bone Joint Surg. 1988;70B:322–4.
24. Hargrove R, Ridgeway S, Russell R, Norris M, Packham I, Levy B. Does pulse lavage reduce hemiarthroplasty infection rate? J Hosp Infect. 2006;62:446–9.
25. Taylor GJ, Leeming JP, Bannister GC. Effect of antiseptics, ultraviolet light and lavage on airborne bacteria in a model wound. J Bone Joint Surg. 1993;75:724–30.

Further Reading

Gosselin RA, Spiegel DA, Foltz M. Global orthopaedics – caring for musculoskeletal conditions and injuries in austere settings. New York: Springer; 2014.

Doorgakant A, Mkhandawire N, editors. Orthopaedic care at the district hospital. UK: Tyson Press; 2013. ISBN: 978-0-9927018-0-2.

King MH. Primary surgery, vol. 2, Trauma. Oxford University Press; 1987. http://www.primary-surgery.org/ps/vol2/html/.

Surgery at the District Hospital. The WHO manual publication, DVD & book. http://www.who.int/surgery/publications/scdh_manual/en/.

SIGN IM nail – sign fracture care international. http://signfracturecare.org/.

Surgical site infection: prevention and treatment of surgical site infection, NICE – National Institute for Clinical Excellence; 2008. http://www.nice.org.uk/guidance/cg74.

Woodhead K, Taylorz EW, Bannister G, Chesworth T, Hoffmank P, Humphreys H. Behaviours and rituals in the operating theatre. A report from the Hospital Infection Society Working Party on Infection Control in Operating Theatres. J Hosp Infect. 2002;51:241–55.

Management of Open Fractures in Austere Environments

27

Deepa Bose

The World Health Organization (WHO) Global Burden of Disease (GBD) study in 2002 revealed that open fractures are one of the leading nonfatal injuries sustained following road traffic collisions in the world [1]. As most of the world's population live in low- to middle-income countries (LMICs), such countries are disproportionately affected. The GBD estimated that extremity injuries from falls and road traffic collisions ranged from 1000 to 2600/100,000 per year in LMICs compared with 500/100,000 per year in high-income countries [2]. Fortunately, it is possible to improve outcomes from such injuries using fairly low-cost improvements [1], as demonstrated in Malawi [3]. Combat-related injuries, industrial accidents, sports and animal attacks are other causes of open fractures.

27.1 Clinical Features

Fig. 27.1 An open fracture of the tibia

The term open fracture refers to any broken bone which is associated with a breach in the surrounding soft tissue envelope, such that the bony fragments are exposed to the exterior. This was previously commonly called a "compound" fracture. Bone ends may protrude through the wound or may be visible in the base of it. The clinical diagnosis is easy in such cases, but initial appearances may be deceptive and open fractures with severe internal de-gloving, vascular or neurological injuries may be associated with very small, innocuous-looking wounds in the skin (Fig. 27.1).

27.2 Complications

Open fractures are associated with poor outcomes because of a number of reasons. The foremost of these is the damage to the surrounding soft tissue envelope. In many cases, the periosteal cover is stripped off not only the fracture site but also from

---

D. Bose, MBBS, FRCS, FRCS (Tr & Orth)
Department of Trauma and Orthopaedics,
Queen Elizabeth Hospital Birmingham,
Birmingham, UK
e-mail: deepa.bose@uhb.nhs.uk

© Springer International Publishing Switzerland 2016

J.D. Robinson (ed.), *Orthopaedic Trauma in the Austere Environment:*
A Practical Guide to Care in the Humanitarian Setting, DOI 10.1007/978-3-319-29122-2_27

the bone some distance away from the fracture. In this way, the "zone of injury" may extend some distance away from the facture and immediately surrounding soft tissues. This is an important concept in understanding the extent of injury and in planning its management. In cortical bones, the blood supply comes primarily from periosteal vessels [4, 5]. If this supply is lost following an open fracture, the stripped bone is likely to die and become a source of infection or non-union. Infection can be a devastating complication of open fractures. The literature quotes wide-ranging incidence rates, between 10 and 40 % [6, 7]. Open fractures are also associated with a high risk of non-union [8], probably resulting from the loss of blood supply to the bone following both the injury and surgical procedures, in addition to the high rate of infection. Open fractures sustained in combat-related injuries demonstrate a high rate of complications [9]; this is likely to be related to the high energy transfer involved, for example, in blast injuries [10].

27.3 Emergency Management

Open fractures must receive emergency treatment as soon as possible after injury. This should include the following:

1. Assessment of distal neurovascular status
2. Pain relief
3. Clinical photographs
4. Reduction and splintage
5. Reassessment of neurovascular status
6. Temporary wound cover
7. Broad-spectrum antibiotics
8. Tetanus prophylaxis

27.3.1 Assessment of Distal Neurovascular Status

It is vital that the distal neurovascular status is assessed prior to manipulation of the fracture. This will indicate whether there has been any compromise of the blood or nervous supply, but will also provide a baseline reading with which the post-reduction status can be compared. Documentation is as important as assessment. An effort should be made to record the individual pulses and capillary refill time, as well as the function of individual peripheral nerves in the region. It is important to note *that the presence of sensation does not rule out a compartment syndrome*, which can occur in open fractures, contrary to popular belief.

27.3.2 Administration of Pain Relief

The quickest and most effective pain relief available should be administered once the neurovascular status has been recorded. Ideally this should be a form of opiate analgesia, but any form of analgesia is preferable to none.

27.3.3 Clinical Photographs

The wound should be photographed if possible, both for documentation and communication purposes. This helps other members of the team to appreciate the nature and extent of the injury. Once the wound is covered, it should remain so until the patient is taken to the operating theatre, as repeated uncovering may increase the risk of infection.

27.3.4 Removal of Any Gross Contamination

It is *no longer recommended* that the wound be washed out in the emergency department, as a formal surgical debridement will have to be carried out in all cases, and unless the contamination is gross, e.g., earth or large particulate foreign matter, there is no benefit to washing prior to this [11].

27.3.5 Reduction of Fracture

The fracture should be reduced at the earliest possible opportunity, as this will restore the alignment of the soft tissues and in particular of the neurovascular structures, thus ensuring the best chance of preserving the limb. In the event that bone is protruding from the skin, it is debatable whether the fracture or dislocation should be reduced before or after washing. If operating facilities are readily available, then it may be acceptable to wait until the wound has been excised and washed thoroughly in theatre prior to reduction. On the other hand, if facilities are not to hand, then preliminary washing and early reduction to preserve the soft tissues should be considered prior to surgery.

27.3.6 Splinting of Limb

The limb should be splinted as soon as it has been reduced, to maintain the anatomical alignment. This may be achieved by a Thomas splint or any other form of traction splint in the case of a femoral fracture or by a simple plaster of Paris backslab in the case of the tibia. The humerus can be splinted with a plaster of Paris U slab, and the forearm bones should be put in an above elbow backslab

If simple splints are not readily available, any suitable material which comes to hand can be used. In austere environments, planks of wood, stout branches or sticks can act as splints, as long as these are padded to prevent pressure sores. Lower limbs can be strapped to the opposite intact limb in the absence of any form of splintage, and the upper limbs can be strapped to the trunk; these methods should only be used temporarily.

27.3.7 Reassessment of Distal Neurovascular Status

It is vital to reassess the distal neurovascular status after manipulation of the limb. Although it is more likely that this will improve following reduction, the act of manipulation itself may cause a worsening of the neurovascular status [12].

27.3.8 Broad-Spectrum Antibiotic Cover

Open fractures are associated with a high incidence of infection [8, 9]. This risk may be greatly increased because of the environment in which the injury occurs, such as in conditions of combat (see Chap. 21). Antibiotics should be administered at the earliest opportunity after injury [13]. It is difficult to recommend a particular antibiotic, because types of prevalent microorganisms, resistance patterns and antibiotic availability may vary widely in austere environments. There is also a lack of consensus in the literature on this point. The International Committee of the Red Cross (ICRC) has drawn up a protocol for antibiotic use in war injuries [14] and recommend intravenous penicillin G 5 million international units (MIU) four times a day for 48 h, with the addition of metronidazole 500 mg three times a day if there has been a delay in debridement or in the case of all landmine injuries. Alonge et al. [15] have shown that the commonest organism isolated from open fractures in a teaching hospital in Nigeria is *Staphylococcus aureus*, and *Gram-negative rods* are also common in this region [16]. Alonge et al. [17] found that the isolated microorganisms in this setting were sensitive to pefloxacin, ciprofloxacin and ceftriaxone. Anaerobic cover may be required in specific circumstances. The ideal duration of antibiotic cover is also difficult to determine. The ICRC recommend continuing therapy until wound closure or repeat debridement, if this becomes necessary [14].

27.3.9 Tetanus Prophylaxis

Tetanus prophylaxis should be administered. The ICRC recommends that a booster vaccine be administered in a combat environment regardless of the immunisation status of the patient. If the patient has never been immunised, then human tetanus immunoglobulin should be considered in addition to vaccination, if this is available [18]. Death due to tetanus is not an uncommon event in an austere environment (Fig. 27.2).

27.3.10 Radiographs

At this stage, x-rays should be taken in two planes which are perpendicular to each other and should include the joints above and below the

Fig. 27.2 An open fracture of the tibia presenting late. The patient died of tetanus

fracture. If x-rays are not readily available, it is best to perform the reduction first, although there is evidence to show that in the absence of neurovascular compromise or skin under pressure from bony fragments, there is no harm in performing x-rays prior to reduction [19].

27.4 Initial Surgical Treatment

Initial surgical management of open fractures should include the following:

1. Wound excision and lavage
2. Temporary skeletal stabilization
3. Temporary dressings
4. Classification of injury
5. Planning of definitive management

27.4.1 Wound Excision and Lavage

A thorough surgical debridement and lavage of the wound is absolutely essential in order to prevent serious complications. Recent evidence [20, 21] suggests that the timing from injury to debridement is not as important as the quality of the debridement. The exceptions to this are in situations of gross contamination, compartment syndrome or vascular compromise [22], but in the austere environment, late presentations and severely contaminated wounds are the norm, so it is often safer to perform initial surgical treatment at the earliest opportunity. If available, it is preferable that senior orthopaedic and plastic surgeons are involved in this initial debridement. This ensures that the injury is fully assessed, and plans for definitive management can be made and carried out in a timely manner.

The first step is to excise the skin margins of the wound and to extend it in order to inspect the underlying soft tissues and bone. The term “excision” is used here in preference to “debridement”, as it implies removal rather than a mere laying open or “unbridling” (the term “debridement” is derived from this) [23]. Wounds should be extended along the lines of fasciotomy incisions [24]. If the wound does not reach a fasciotomy line, it should be extended to the nearest one and then developed along this line. This not only makes it easy to perform a fasciotomy if necessary but also ensures that the perforator vessels are preserved, as these may be required in the use of local flaps to achieve soft tissue cover.

The value of swabs of superficial and deep tissues taken before commencing debridement is unclear; these have been shown to correlate with organisms responsible for subsequent infections in Nigeria [16], but this was not found to be the case in Malaysia [25]. D’Souza et al. [26] in India examined the results of both pre- and post-debridement cultures and found that these were indicative of later infection, but these were based on swabs rather than tissue samples. The significance of organisms isolated at the first surgical debridement remains dubious. My preference is to take clean (not contaminated by dirty instruments) deep tissue samples where possible, prior to contamination of the field by commensal organisms during debridement.

The initial debridement should involve removal of all contaminated and devitalised tissue. It is helpful to perform this in a systematic manner, beginning at one point (12 o’clock on an imaginary clock face is a good place to start) and moving around in a circular fashion to complete the round. Debridement should also proceed from superficial to deep tissues: skin, fat, fascia, muscle and bone. It is advisable to be conservative with skin excision, in order to minimise the need for additional skin cover, but muscle and fat can be excised generously if necessary.

Bone ends should be delivered into the wound and debrided back to healthy bleeding bone with the aid of bone nibblers or cutters. The medullary canal of long bones should be carefully examined and curetted to remove any foreign material which may be lodged within. Loose fragments of bone which fail the "tug test" [24] (a pull on the fragment) should be removed, as they may be a nidus for future infection, and do not participate in the fracture healing process. Cortical bone which is stripped of periosteum should also be excised back to bleeding bone. Articular fragments should be preserved and, if possible, fixed rigidly in place. Serial debridements may be necessary before the limb is ready for definitive management.

The concept of the "zone of injury" is an important one in debridement of open fractures. It was first used for skin burns [27] and emphasises the fact that the damage may extend into tissues which are not immediately apparent on external inspection. This explains the need to extend wounds and perform meticulous inspection and debridement of deeper tissues. This is particularly vital in wounds resulting from combat, such as gunshot or blast injuries, which result in extensive damage of soft tissues far from the site of the visible skin wound [28]. The ICRC suggest that the "best antibiotic is good surgery" [29].

Thorough and copious washout should be carried out with sterile water or saline. Several litres (at least 6) should be used for this purpose. "The solution to pollution is dilution [30]". The addition of antibiotics or antiseptics to the fluid has not been shown to have any benefit [31]. An intravenous infusion set may be used to facilitate the delivery of large volumes of fluid, but a large syringe is just as effective. If this is not available, simply pouring the fluid onto the wound is also effective. It is important, just as with debridement, to make sure that all parts of the wound are washed effectively.

The temptation to close the wound prematurely should be resisted, as any tissue of dubious viability remaining behind will cause infection, resulting in a situation which is very difficult to treat, and may have devastating consequences, such as amputation and even death.

27.4.2 Temporary Stabilisation of Fracture

The next step will be to stabilise the fracture, and the safest and easiest way of achieving this in a resource poor setting is by the use of external fixation [32, 33]. A well-applied external fixator buys time before the final management, and in many cases, it will also be the definitive fixation (see chapters on Tools available in the Austere Environment and External Fixation). There are many types of external fixator, but the principles of application remain the same. A stable fixation is no less important merely because it is temporary.

Stability of fixation depends on these factors [34]:

1. "Near–far" fixation: pins should be placed as close to (bearing in mind the zone of injury) and as far away from the fracture as possible in each fragment.
2. Increasing the number of pins per fragment increases stability.
3. Pins in different planes increase stability.
4. Reducing the distance between the fixator construct and the bone increases stability.

Consideration should also be given to the placement of external fixator pins in order to facilitate access to neurovascular structures if necessary [35]. This can usually be achieved in the lower leg by keeping the pins in the sagittal plane (anterior to posterior). In the upper limb, the pins should be kept in the coronal plane.

27.4.3 Dressing the Wound

At the end of the procedure, the wound should be dressed with an occlusive dressing. If facilities for topical negative pressure (vacuum) dressings are available, these provide a closed system which shuts off the wound effectively whilst at the same time preventing desiccation of the tissues [36, 37]. Alternatively, insertion of local antibiotic carriers such as gentamicin beads, under a transparent occlusive dressing, will deliver antibiotics to the area whilst preventing contamination from the exterior [38]. In an austere environment, any clean occlusive dressing, such as gauze, wrapped in wool and then bandage, may be used. The gauze may be moistened or used dry on top of a non-stick layer. If these types of dressings are used, it is essential to monitor them closely for "strike through". This is when the outer layer of dressing becomes soaked through with blood or exudate, and this has been shown to greatly increase the risk of infection [39]. If "strike through" occurs, then the dressing should be changed as soon as possible. This should ideally be done in the operating theatre but may be done in a ward or clinic if circumstances dictate otherwise; in this case, analgesia and sterility should be given due consideration. The ICRC recommends using a dressing of loosely packed gauze [40] and also stresses the importance of avoiding dressing changes outside the operating theatre.

27.4.4 Classification of Open Fractures

There is no single reliable system for classification of open fractures, but the Gustilo and Anderson grading is the most widely used [41]. This system should be used only after wound debridement, and does not describe the extent of bony damage particularly well. It also has very poor interobserver reliability [42]. Other more comprehensive systems are the AO classification [43], which is very detailed but difficult to memorise, and the Ganga Hospital score [44]. The Orthopaedic Trauma Association (OTA)'s classification of open fractures has been recently reported to have good interobserver reliability [45].

The Red Cross Wound Score [46] both grades the wound according to its severity and types it according to the tissues injured. The grade and type can then be placed into a grid to provide a classification. This can be used to formulate management plans.

Classification systems are not useful unless they provide a guide to management and give an indication of prognosis; the ideal system does not exist currently. Further research in this area would be beneficial for both high- and low-income countries.

27.5 Limb Salvage Versus Primary Amputation

The damage to the limb may be so severe that in certain cases a primary amputation is the better option. Injury scoring systems such as the Mangled Extremity Severity Score (MESS) [47] and the Limb Salvage Index (LSI) [48] were devised to help in the decision-making process regarding primary amputation versus limb salvage, but none are particularly fool-proof [49]. The Ganga Hospital score [44] also gives an indication of when amputation should be considered.

Generally speaking, if limb salvage will result in poorer function than an amputation, then the latter is preferable. If there are no prosthetic services, and amputation is not required to save life, then it may be better to save the limb if possible, as a limb with poor function may be preferable to none. Amputations may be culturally unacceptable in some countries, so this should be carefully considered (Fig. 27.3).

Fig. 27.3 A comminuted open fracture of the tibia due to a high velocity round. Is this leg salvageable? How do you decide?

27.6 Definitive Surgical Treatment

27.6.1 Bone

External fixators may be used as definitive fixation, and in austere environments, may be the only form of stabilisation available, although the disadvantages of this have been recognised by some authors [49]. A well-applied fixator provides sufficient stability to allow fracture healing to take place, providing the soft tissues are dealt with appropriately. External fixators are also readily adjustable, so can be used to correct deformity or provide compression to the fracture as necessary, during the course of treatment. In addition, external fixators can be locally manufactured, making them cheap and readily available [50, 51].

Internal fixation of fractures, where used, should occur at the time of definitive soft tissue cover, in order to avoid exposed implants [52]. The fixation most appropriate for the fracture should be used wherever possible, although it is necessary to formulate combined plans for bony stabilisation and soft tissue cover, as the latter may influence the type of fixation used; for example, using a plate may increase the girth of the limb and increase the complexity of the soft tissue procedure required to achieve closure.

Long bones of the lower limb can be treated by either plating or intramedullary nailing, depending on availability of implants (see chapter on SIGN nails and internal fixation), equipment, staff and surgeon capabilities. Plating may further disrupt the soft tissue envelope and make soft tissue closure more difficult. Reamed intramedullary nailing disrupts endosteal circulation, and in severe injuries with periosteal stripping, this may further compromise the vascular supply to the bone. A risk of infection also exists if intramedullary nailing is undertaken after a period of external fixation. Early conversion (approximately 2 weeks) is safe, even in low resource settings [53, 54].

In the absence of either internal or external fixation devices, pins at the two ends of a long bone, followed by a plaster of Paris cast, will maintain gross alignment and stability [55, 56]. In cases of large or segmental bone loss, several techniques may be used to fill the defect. See chapter on managing bone defects for more information (Fig. 27.4).

Fig. 27.4 (**a**) Radiograph of an open fracture of a tibia. (**b**) Temporary splinting with an external fixator. (**c**) Definitive management with an Ilizarov frame. (**d**) Tibia has healed

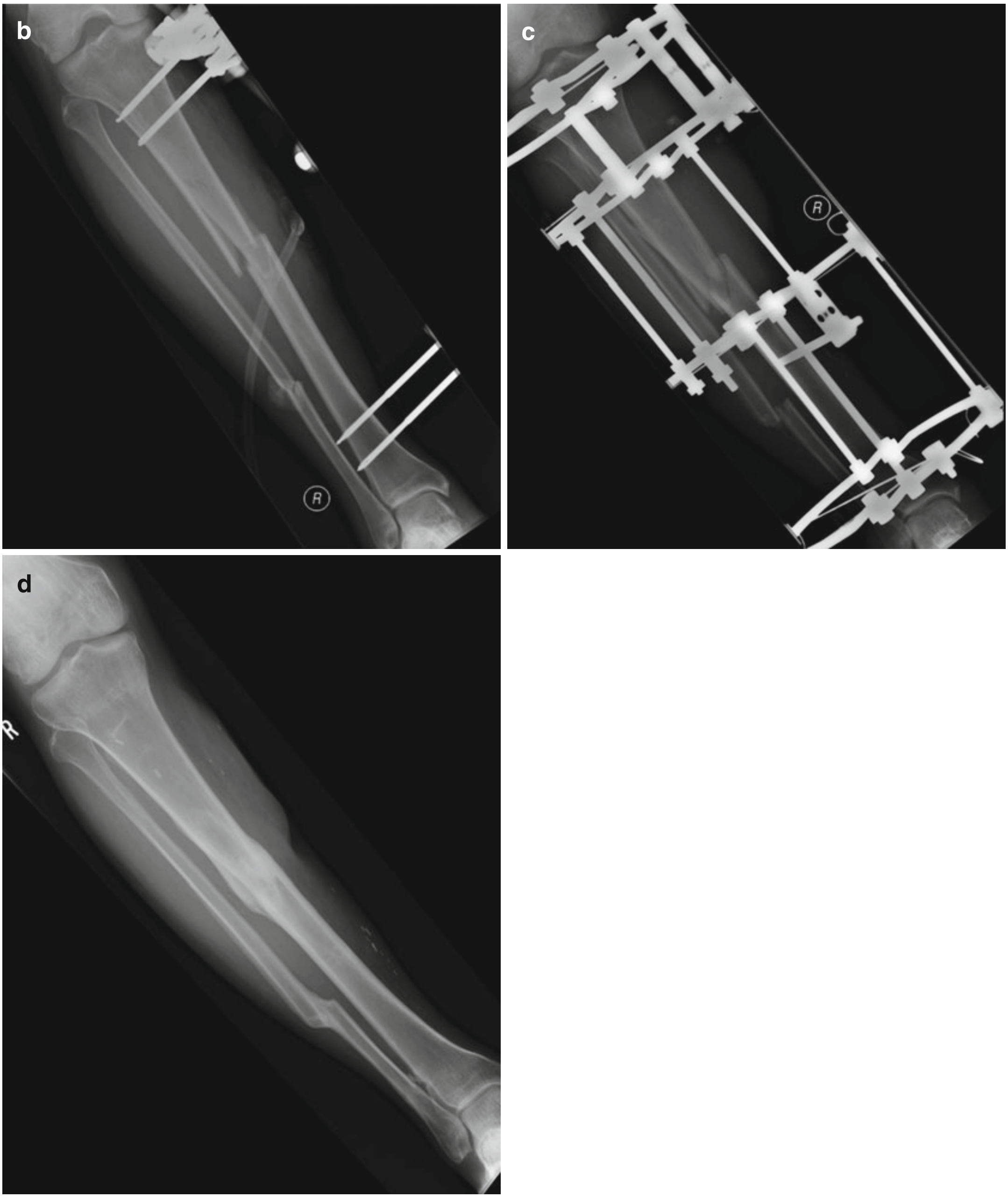

Fig. 27.4 (continued)

27.6.2 Soft Tissues

Exposed bone should be covered with vascularised tissue. This not only brings a blood supply to the area but also serves as a source of mesenchymal stem cells [57], which contribute to fracture healing, and in infected cases as a delivery system for antibiotics [58]. See chapter on soft tissue reconstruction for more information.

27.7 International Standards and Guidelines

The British Orthopaedic Association (BOA) and the British Association of Plastic, Reconstructive and Aesthetic Surgeons (BAPRAS) have published standards for the management of open fractures of the lower limb [59]. They emphasize the importance of the quality of the initial debridement and the planning of definitive bony stabilisation and soft tissue reconstruction by senior surgeons. Although these standards were devised for a high resource setting, the underlying principles are as relevant in an austere environment.

The International Committee of the Red Cross (ICRC) [60] presents the following guidelines for the care of war wounds in environments with limited resources:

1. Early and thorough wound excision and irrigation
2. Adequate wound drainage
3. No unnecessary dressing changes
4. Delayed primary closure
5. Antibiotics as an adjuvant
6. Anti-tetanus vaccine and immunoglobulin if necessary
7. No internal bone fixation
8. Early physiotherapy

References

1. Mock C, Cherian MN. The global burden of musculoskeletal injuries: challenges and solutions. Clin Orthop Relat Res. 2008;466(10):2306–16.
2. World Health Organization. The burden of musculoskeletal conditions at the start of the New Millennium, report of a WHO Scientific Group, WHO Technical Report Series 919. Geneva: WHO; 2003.
3. Bach O, Hope MJ, Chaheka CV, Dzimbiri KM. Disability can be avoided after open fractures in Africa – results from Malawi. Injury. 2004;35(9):846–51.
4. Oni OO, Gregg PJ. The relative contribution of individual osseous circulations to diaphyseal cortical blood supply. J Orthop Trauma. 1990;4(4):441–8.
5. Chanavaz M. Anatomy and histopathology of the periosteum: quantification of the periosteal blood supply to the adjacent bone with 85Sr and gamma spectrometry. J Oral Implantol. 1995;21(3):214–9.
6. Chen AF, Schreiber VM, Washington W, Rao N, Evans AR. What is the rate of methicillin-resistant Staphylococcus aureus and Gram negative infections in open fractures? Clin Orthop Relat Res. 2013;471(10):3135–40.
7. Chua W, Murphy D, Siow W, Kagda F, Thambiah J. Epidemiological analysis of outcomes in 323 open tibial diaphyseal fractures: a nine year experience. Singapore Med J. 2012;53(6):385–9.
8. Papakostidis C, Kanakaris NK, Pretel J, Faour O, Morell DJ, Giannoudis PV. Prevalence of complications of open tibial fractures stratified as per the Gustilo-Anderson classification. Injury. 2011;42(12):1408–15.
9. Burns TC, Stinner DJ, Mack AW, Potter BK, Beer R, Eckel TT, Possley DR, Beltran MJ, Hayda RA, Andersen RC, Keeling JJ, Frisch HM, Murray CK, Wenke JC, Ficke JR, Hsu JR, Skeletal Trauma Research Consortium. Microbiology and injury characteristics in severe open tibia fractures from combat. J Trauma Acute Care Surg. 2012;72(4):1062–7.
10. Belmont Jr PJ, McCriskin BJ, Sieg RN, Burks R, Schoenfeld AJ. Combat wounds in Iraq and Afghanistan from 2005 to 2009. J Trauma Acute Care Surg. 2012;73(1):3–12.
11. Nanchahal J, Nayagam S, Khan U, Moran C, Barrett S, Sanderson F, Pallister I. Standards for the management of open fractures of the lower limb. London: Royal Society of Medicine Press; 2009. p. 6.
12. Somville FJ. Plexus injury after reduction of anterior caudal dislocation of the shoulder. Acta Chir Belg. 2008;108(1):122–4.
13. Nanchahal J, Nayagam S, Khan U, Moran C, Barrett S, Sanderson F, Pallister I. Standards for the management of open fractures of the lower limb. London: Royal Society of Medicine Press; 2009. p. 9.
14. Giannou C, Baldan M. War surgery. Working with limited resources in armed conflict and other situations of violence, vol 1. Geneva: International Committee of the Red Cross; 2010. p. 266.
15. Alonge TO, Salawu SA, Adebisi AT, Fashina AN. The choice of antibiotics in open fractures in a teaching hospital in a developing country. Int J Clin Pract. 2002;56(5):353–6.
16. Ojo OD, Oluwadiya KS, Ikem IC, Oginni LM, Ako-Nai AK, Daniel FV. Superficial swab cultures in open fracture management: insights from a resource-poor setting. J Wound Care. 2010;19(10):432–8.
17. Alonge TO, Ogunlade SO, Salawu SA, Fashina AN. Microbial isolates in open fractures seen in the accident and emergency unit of a teaching hospital in a developing country. West Afr J Med. 2002;21(4):302–4.
18. Giannou C, Baldan M. War surgery. Working with limited resources in armed conflict and other situations of violence, vol 1. Geneva: International Committee of the Red Cross; 2010. p. 262.
19. Hastie GR, Divecha H, Javed S, Zubairy A. Ankle injury manipulation before or after x-ray – does it influence success? Injury. 2014;45(3):583–5.

20. Singh J, Rambani R, Hashmi Z, Raman R, Sharma HK. The relationship between time to surgical debridement and incidence of infection in grade III open fractures. Strategies Trauma Limb Reconstr. 2012;7(1):33–7.
21. Schenker ML, Yannascoli S, Baldwin KD, Ahn J, Mehta S. Does timing to operative debridement affect infectious complications in open long-bone fractures? A systematic review. J Bone Joint Surg Am. 2012;94(12):1057–64.
22. Nanchahal J, Nayagam S, Khan U, Moran C, Barrett S, Sanderson F, Pallister I. Standards for the management of open fractures of the lower limb. London: Royal Society of Medicine Press; 2009. p. 12.
23. Reichert FL. The historical development of the procedure termed debridement: Pierre Joseph Desault. Bull Johns Hopkins Hosp. 1928;42:93–104.
24. Nanchahal J, Nayagam S, Khan U, Moran C, Barrett S, Sanderson F, Pallister I. Standards for the management of open fractures of the lower limb. London: Royal Society of Medicine Press; 2009. p. 17.
25. Faisham WI, Nordin S, Aldura M. Bacteriological study and its role in the management of open tibial fracture. Med J Malaysia. 2001;56(2):201–6.
26. D'Souza A, Rajagopalan N, Amaravati RS. The use of qualitative cultures for detecting infection in open fractures. J Orthop Surg (Hong Kong). 2008;16(2):175–8.
27. Yaremchuk MJ, Gan BS. Soft tissue management of open tibia fractures. Acta Orthop Belg. 1996;62 Suppl 1:188–92.
28. Trueta J. The principles and practice of war surgery, with reference to the biological method of the treatment of war wounds and fractures. St. Louis: Mosby; 1943. p. 1–441.
29. Giannou C, Baldan M. War surgery. Working with limited resources in armed conflict and other situations of violence, vol. 1. Geneva: International Committee of the Red Cross; 2010. p. 263.
30. Chapman MW, Olson SA. Rockwood & Green's fractures in adults. 4th ed, Open fractures. Philadelphia: Lippincott-Raven; 1996. p. 315.
31. Crowley DJ, Kanakaris NK, Giannoudis PV. Irrigation of the wounds in open fractures. J Bone Joint Surg Br. 2007;89B:580–5.
32. Pedrini G, Cardi M, Landini A, Strada G. Management of severe open ankle-foot trauma by a simple external fixation technique: an alternative during war and in resource-poor and low-technology environments. J Orthop Trauma. 2011;25(3):180–7.
33. Gordon WT, Grijalva S, Potter BK. Damage control and austere environment external fixation: techniques for the civilian provider. J Surg Orthop Adv. 2012;21(1):22–31.
34. Behrens F. A primer of fixator devices and configurations. Clin Orthop Relat Res. 1989;241:5–14.
35. Giotakis N, Narayan B. Stability with unilateral external fixation in the tibia. Strategies Trauma Limb Reconstr. 2006;2:13–20.
36. DeFranzo AJ, Argenta LC, Marks MW, Molnar JA, David LR, Webb LX, Ward WG, Teasdall RG. The use of vacuum-assisted closure therapy for the treatment of lower-extremity wounds with exposed bone. Plast Reconstr Surg. 2001;108(5): 1184–91.
37. Liu DS, Sofiadellis F, Ashton M, MacGill K, Webb A. Early soft tissue coverage and negative pressure wound therapy optimises patient outcomes in lower limb trauma. Injury. 2012;43(6):772–8.
38. Henry SL, Ostermann PA, Seligson D. The antibiotic bead pouch technique. The management of severe compound fractures. Clin Orthop Relat Res. 1993;295:54–62.
39. Alexander D, Gammage D, Nichols A, Gaskins D. Analysis of strike-through contamination in saturated sterile dressings. Clin Nurs Res. 1992;1(1):28–34.
40. Giannou C, Baldan M. War surgery. Working with limited resources in armed conflict and other situations of violence, vol 1. Geneva: International Committee of the Red Cross; 2010. p. 225.
41. Gustilo RB, Mendoza RM, Williams DN. Problems in the management of type III (severe) open fractures: a new classification of type III open fractures. J Trauma. 1984;24:742–6.
42. Brumback RJ, Jones AL. Interobserver agreement in the classification of open fractures of the tibia. The results of a survey of two hundred and forty-five orthopaedic surgeons. J Bone Joint Surg Am. 1994;76A:1162–6.
43. Rüedi TP, Murphy WM. In: Rüedi TR, Buckley R, Moran C, editors. Principles of management of open fractures. AO principles of fracture management. Stuttgart: Thieme; 2007.
44. Rajasekaran S, Sabarpathy SR. A philosophy of care of open injuries based on the Ganga Hospital Score. Injury. 2007;38:137–46.
45. Agel J, Evans AR, Marsh JL, DeCoster TA, Lundy DW, Kellam JF, Jones CB, DeSilva GL. The OTA open fracture classification: a study of reliability and agreement. J Orthop Trauma. 2013;27(7): 379–84.
46. Giannou C, Baldan M. War surgery. Working with limited resources in armed conflict and other situations of violence, vol. 1. Geneva: International Committee of the Red Cross; 2010. p. 88.
47. Johansen K, Daines M, Howey T, Helfet D, Hansen Jr ST. Objective criteria accurately predict amputation following lower extremity trauma. J Trauma. 1990;30:568–72.
48. Russell WL, Sailors DM, Whittle TB, Fisher Jr DF, Burns RP. Limb salvage versus traumatic amputation. A decision based on a seven-part predictive index. Ann Surg. 1991;213:473–80.
49. O'Sullivan ST, O'Sullivan M, Pasha N, O'Shaughnessy M, O'Connor TP. Is it possible to predict limb viability in complex Gustilo IIIB and IIIC fractures? A comparison of two predictive indices. Injury. 1997;28(9–10):639–42.

50. Padhi NR, Padhi P. Use of external fixators for open tibial injuries in the rural third world: panacea of the poor? Injury. 2007;38(2):150–9.
51. Pulate A, Olivier LC, Agashe S, Rallan R, Kamal V, Nast-Kolb D. Adaptation of Ilizarov ring fixator to the economic situation of developing countries. Arch Orthop Trauma Surg. 2001;121(1–2):79–82.
52. Gopal S, Majumder S, Batchelor AG, Knight SL, De Boer P, Smith RM. Fix and flap: the radical orthopaedic and plastic treatment of severe open fractures of the tibia. J Bone Joint Surg Br. 2000;82(7):959–66.
53. Sechriest 2nd VF, Lhowe DW. Prolonged femoral external fixation after natural disaster: successful late conversion to intramedullary nail aboard the USNS Mercy hospital ship. Am J Disaster Med. 2008;3(5):307–12.
54. Malik ZU, Hanif MS, Safdar A, Masood T. Planned external fixation to locked intramedullary nailing conversion for open fractures of shaft of femur and tibia. J Coll Physicians Surg Pak. 2005;15(3):133–6.
55. Wood RL, Marsh HQ. Tibial fractures treated with pins and plaster. Orthop Rev. 1986;15(8):516–20.
56. Sladek EC, Kopta JA. Management of open fractures of the tibial shaft. South Med J. 1977;70(6):662–5.
57. Shah K, Majeed Z, Jonason J, O'Keefe RJ. The role of muscle in bone repair: the cells, signals, and tissue responses to injury. Curr Osteoporos Rep. 2013;11(2):130–5.
58. Keramaris NC, Calori GM, Nikolaou VS, Schemitsch EH, Giannoudis PV. Fracture vascularity and bone healing: a systematic review of the role of VEGF. Injury. 2008;39 Suppl 2:S45–57.
59. British Orthopaedic Association Standards for Trauma 4. Management of severe open lower limb fractures. 2009. http://www.boa.ac.uk/LIB/LIBPUB/Documents/BOAST%204%20-%20The%20Management%20of%20Severe%20Open%20Lower%20Limb%20Fractures.pdf.
60. Giannou C, Baldan M. War surgery. Working with limited resources in armed conflict and other situations of violence, vol 1. Geneva: International Committee of the Red Cross; 2010.

Management of Compartment Syndrome and Crush Syndrome

28

Ian Pallister

Compartment syndrome and crush syndrome are two closely related clinical entities, which are potentially catastrophic. A neglected compartment syndrome will leave the patient with crippling ischaemic contractures in the affected limb (Fig. 28.1), whereas crush syndrome is lethal if untreated [1–3]. Both arise as a consequence of trauma to muscle, which results in swelling and a compromised circulation at the microvascular level. The tissue ischaemia can release toxic products as cells breakdown and may culminate in cell death.

It may be useful to think of compartment syndrome in terms of a localised problem within an osteo-fascial muscle compartment. Crush syndrome results when the products of muscle cell damage lead to systemic problems which manifest as hyperkalaemia, acidosis, myoglobinuria, and renal failure. When a patient is freed from limb entrapment, reperfusion initiates this process, the most urgent of which is hyperkalaemia leading to cardiac dysrhythmias and sudden death.

Compartment syndrome is typically associated with certain archetypal injury patterns. These include fractures of the tibia, forearm, and distal humerus (particularly in children) and also snake bites. If untreated, provided the patient does not develop the associated problems of crush syndrome, the best outcome that can be hoped for is the development of muscle contracture, often associated with impaired peripheral sensation. Classically described as Volkmann's ischaemic contracture, the clawing toes and equinus contractures seen in the lower limb may be so severe that the patient requests amputation (Fig. 28.1). The only proven treatment for acute compartment syndrome is fasciotomy, which must be executed as soon as possible. Once decompressed the muscle compartment reperfuses, and if executed in time, both muscle and nerve function should be preserved [2–4].

Fig. 28.1 Ischaemic contractures secondary to neglected compartment syndrome

---

I. Pallister, FRCS (Ed) FRCS DA (UK) DTM&H
Department of Trauma and Orthopaedics,
Morriston Hospital, University of Swansea,
Swansea, Wales, UK
e-mail: ianpallister@hotmail.com

© Springer International Publishing Switzerland 2016

J.D. Robinson (ed.), *Orthopaedic Trauma in the Austere Environment: A Practical Guide to Care in the Humanitarian Setting*, DOI 10.1007/978-3-319-29122-2_28

Diagnosis hinges upon index of suspicion, an understanding of the mechanism and environment of injury, and clinical examination. In the conscious patient, worsening pain not in keeping with expected natural history is a key feature. A fractured limb should normally become less painful with the passage of time once properly splinted and elevated. Worsening pain exacerbated by active movement and passive stretch are hallmarks of the clinical picture. All bandaging or cast material around the limb (including cotton wool roll) should be carefully split over the whole length of the cast or splint, which must then be gently prised apart. The relief will be almost instantaneous, if the problem is simply due to the limb having swollen tightly inside its splint. Next, gently assess the limb from a neurovascular point of view, checking pulses and gently palpating the muscle groups taking care to keep the limb still. The muscle groups will be obviously swollen, tender and firm, or even woody to palpation. Remember skin perfusion and pulses will remain normal unless there is an associated major vascular injury.

Early in the development of compartment syndrome, nerves which pass deep though the affected compartment will become ischaemic. Ischaemic neuropraxia of the anterior interosseous nerve in the upper limb can be detected by asking the patient to make an ‘OK sign’. This nerve is the deep terminal motor branch of the median nerve and it is the exclusive innervation of the flexor digitorum profundus. Voluntary movement will be difficult anyway, but there will be no flexion at the distal interphalangeal joint, indicating impairment of the nerve. The corresponding test in the lower limb involves assessing altered sensation in the deep branch of the common peroneal nerve. Examine the patient’s sensation in the first dorsal web space of both feet simultaneously with a light touch saying ‘Does this feel the same or different?’ This choice of words is important, because *diminished* sensation will be revealed easily in this manner. If the patient is asked simply whether they can feel the touch or not, altered sensation is likely to be overlooked.

Once compartment syndrome has been diagnosed, further elevation is not helpful and fasciotomy must be completed as soon as possible. The limb should be placed at the level of the patient’s heart, in the hope that some improvement of perfusion may occur as the transfer to the operating theatre takes place, on the basis that the heart does no longer have to pump blood ‘uphill’ into the limb. Commercially available and improvised devices can be used to measure intra-compartment pressure [5–7]. However, there is no substitute for the maxim ‘if there is any doubt, there is no doubt, the patient has compartment syndrome’.

Crush syndrome may be seen as a consequence of a neglected severe compartment syndrome, or as the result of a sudden brief application of severe force to a limb (such as a leg being run over by a truck), or more classically when a casualty is trapped beneath fallen rubble following an earthquake or bombing [1, 8, 9]. A similar cycle of skeletal muscle swelling occurs, which impairs circulation and cellular metabolism. As a result of the breakdown the sarcolemma membrane, intracellular potassium and myoglobin leak into the circulation. In the case of an entrapped casualty, reperfusion of limb compressed by rubble is likely to occur at the time of their rescue. Sudden death was reported at the time of the original description of crush syndrome seen in the London Blitz. Reperfusion will result in the products of cell leakage and breakdown entering circulation. Hyperkalaemia may prove fatal. When dealing with individual patients, or those in relatively small groups, it may be possible to manage acute hyperkalaemia via standard emergency medical means and avoid acute renal failure by the use of forced alkaline diuresis supplemented with appropriate fluid volume restoration. Biochemical tests are without doubt very helpful in aiding the diagnosis and management of crush syndrome; however, hazardous changes on an electrocardiogram can be seen with hyperkalaemia (such as tented t-waves), and the urine is a striking red-brown colour (similar to port) in the presence of myoglobinuria (Fig. 28.2). If these interventions are unsuccessful, then the patient may be supported through acute renal failure using either haemodiafiltration or haemodialysis.

Decompression of the affected muscle compartments should be undertaken if the initial assessment indicates that the limb may be viable and the entrapment has been less than 6–8 h. Decompression attempts beyond this time window will then oblige the surgical team to undertake massive muscle debridement and face the possibility of deep-seated infection occurring as an iatrogenic complication. In a resource constrained or true mass casualty situation, consideration must be given to early amputation as the required medical intervention may be impossible. In such circumstances, it is better to lose a limb than a life.

Fig. 28.2 Myoglobinuria in crush syndrome

28.1 Fasciotomy

The successful treatment of acute compartment syndrome depends entirely upon early recognition and rapid complete compartment decompression. Fasciotomy rescues muscle from irretrievable ischaemia, allows debridement of dead tissue, and enables resuscitation from shock in the severely injured.

Correctly placing fasciotomy incisions in the distorted, swollen, injured limb can be difficult. Two key questions must be foremost in the surgeons mind when executing fasciotomy [10]:

- Which compartment has been entered?
- Has each compartment been adequately decompressed?

Delayed or incomplete fasciotomy may result in limb loss of or even death in severe polytrauma [2]. In the forearm, an extensile incision is recommended which curves along the volar aspect of the forearm as illustrated (Fig. 28.3a).

This line of incision is recommended in the hope of leaving important structures (such as the median nerve at the wrist and antecubital fossa) still covered with the resulting fasciocutaneous flaps. The direction of the incision at the wrist

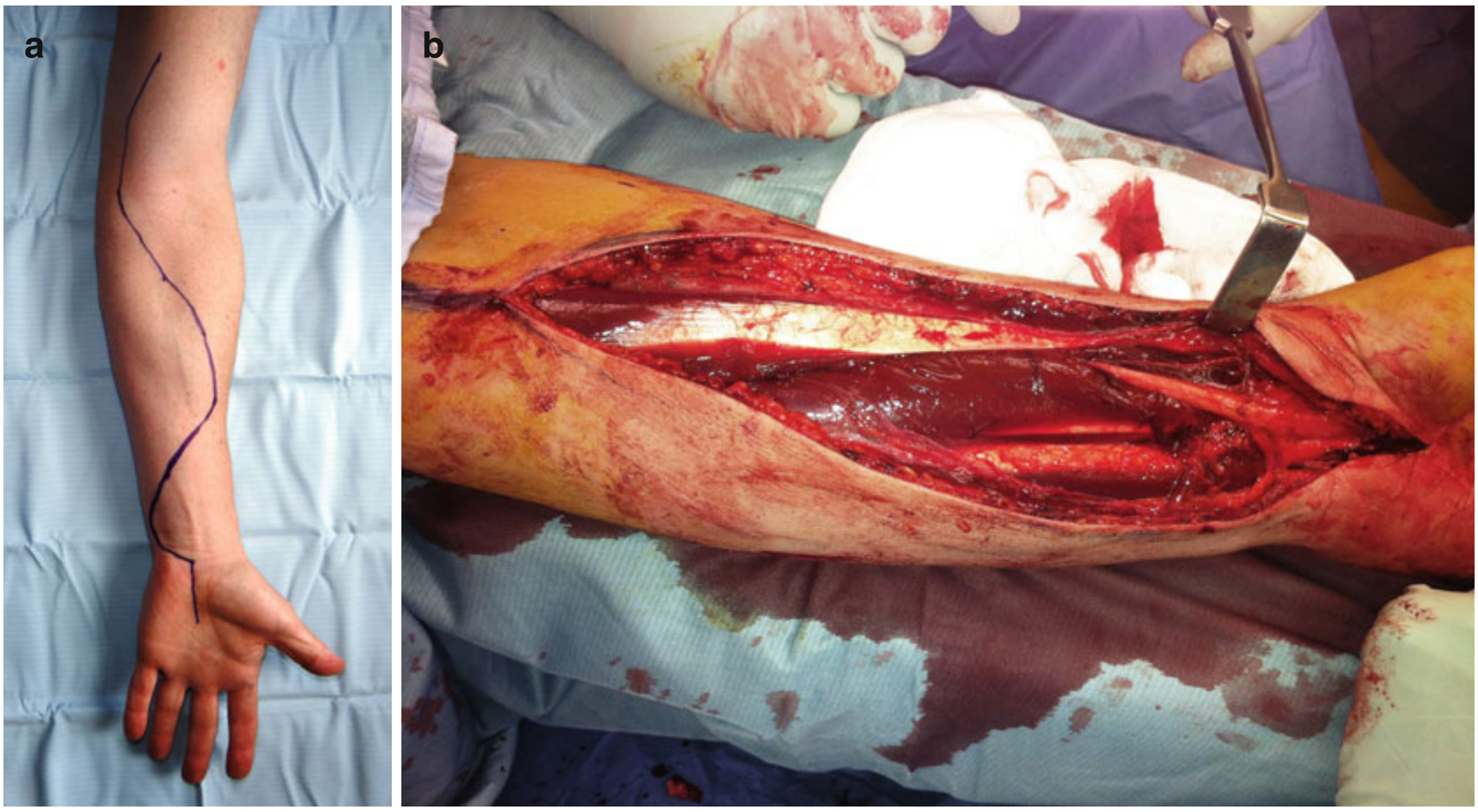

Fig. 28.3 (**a**) Forearm skin markings for volar fasciotomy and (**b**) executing the forearm volar fasciotomy

avoids directly crossing a flexure crease and so minimised the risk of contracture. Equally important, the incision allows decompression of the ulna nerve in Guyon's canal if needed, while taking the incision away from the palmar branch of the median nerve, which could be divided accidentally with a straight incision. The incision is deepened straight to the fascial layer and care must be taken to decompress the deep flexor compartment, and the mobile wad. Swelling postdecompression can be extreme as shown in Fig. 28.3b. However, 48 h later, 2/3 of this wound was closed primarily, the remainder skin grafted. At 3 months postinjury, the patient has normal hand sensation and function.

In the lower limb, the angiosomal blood supply assumes greater importance. An angiosome is a 3-dimensional volume of tissue dependent upon a particular blood vessel for its survival. This arrangement seems to make the anterior compartment particularly vulnerable if not correctly decompressed [11]. Swelling and local trauma distort anatomy significantly, making it possible to 'miss' the intended compartment without some simple means of double checking. The anterior and lateral compartments may be decompressed via separate fascial incisions through an axial skin incision (running midway between the fibula head and the tibial tuberosity proximally and the lateral malleolus and the anterior tibia distally) [4] (Fig. 28.4). Alternatively, the anterior compartment is decompressed via an incision 2 cm lateral to the tibial crest. The lateral compartment is then decompressed into the anterior by incising the intermuscular septum [12].

Failure the decompress the deep posterior compartment will result in ischaemic contracture which manifest as clawing of the toes, with some equinus contracture, which will be compounded if the superficial posterior compartment is also involved (Fig. 28.1).

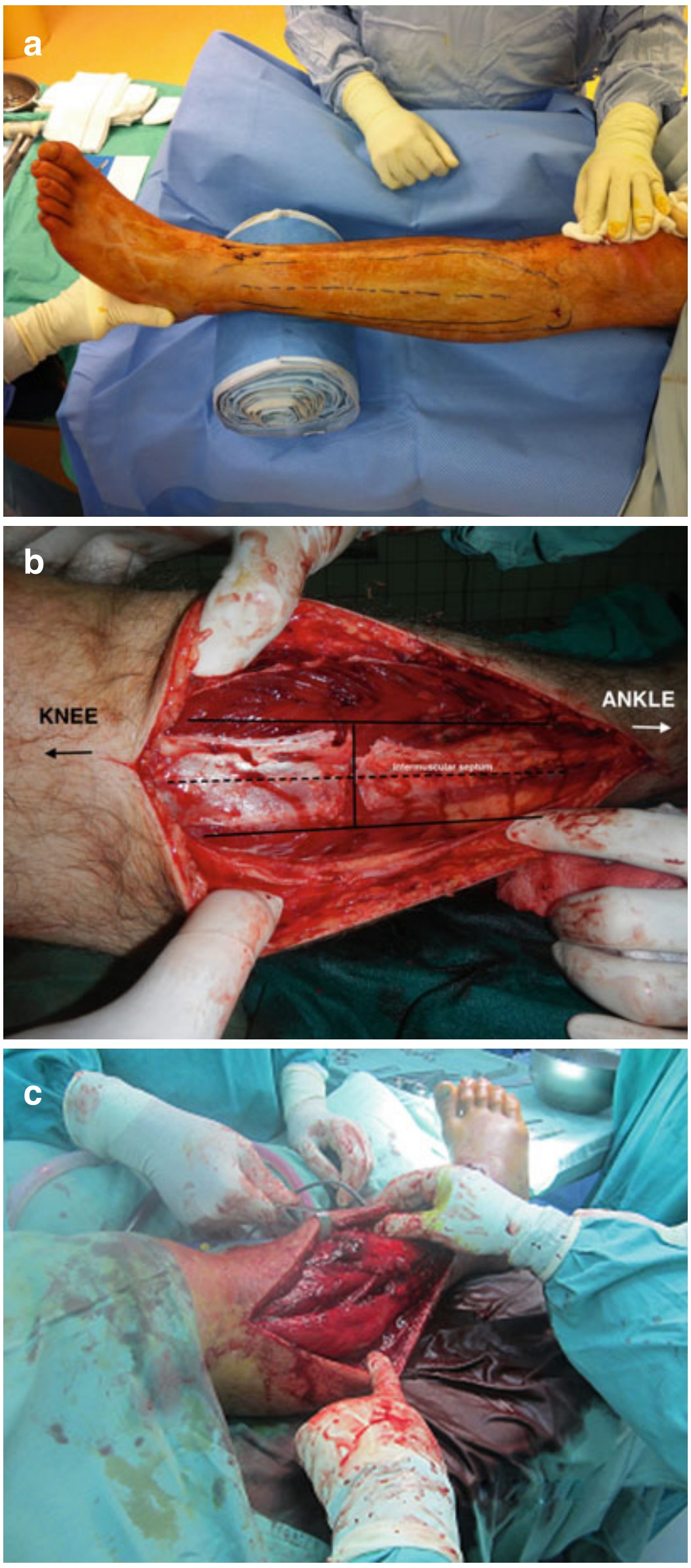

Fig. 28.4 (**a**) Skin and (**b**) deep landmarks for lateral fasciotomy. (**c**) Lateral fasciotomy in the field

28.2 Method

Using the 'military method' described by Clasper et al., the incision to decompress the anterior and lateral compartments lies over the intermuscular septum. Mark the lateral subcutaneous border of the tibia and the line of the fibula. Incise in a line midway between these lines (Fig. 28.4).

Having dissected through fat to the fascia, identify the intermuscular septum by the presence of a fat stripe. Confirm this by making a transverse incision over the intermuscular septum and palpate the septum which feels like the blunt edge of a knife. After identifying the intermuscular septum, incise the deep fascia anterior to it and insert ('poke') a finger superficial to the muscle – but deep to the fascia towards the midline [10]. If the finger is in the anterior compartment, it will touch the tibia easily. If, however, the finger is in the lateral compartment, this will be impossible. However, if the direction of the finger is reversed and advanced, the fibula will be felt.

It is imperative to 'poke' the finger in and *never* to sweep it along the length of the wound. This would avulse perforators, with potentially disastrous results. The fascia overlying each of the anterior and lateral compartments is incised along its entire length through two separate incisions, one each side of the intermuscular septum. Care must be taken distally to avoid injury to the superficial branch of the common peroneal nerve which emerges adjacent to the intermuscular septum roughly at its distal 1/3.

The alternative method is to incise the skin 1.5 cm lateral to the lateral subcutaneous border of the tibia. The anterior compartment is decompressed directly and then the muscle must be retracted medially to expose the intermuscular septum. This is then incised and thus the lateral compartment decompressed into the anterior compartment. In the presence of severe swelling, seeing the intermuscular septum could prove very difficult, and there is an appreciable risk to the superficial branch of the common peroneal nerve.

The medial incision is made approximately 1.5 cm medial to the medial subcutaneous border of the tibia. Don't waste time cauterising the veins which cross the incision (Fig. 28.5). Clip them and return to them later.

The anatomy medially is variable. The superficial posterior compartment is usually entered easily. Decompress the muscle by incising the fascia in line with the skin incision. Then incise/release the gastrocnemius from its tibial origin and retract it posteriorly to expose the fascia overlying the deep posterior compartment. Decompress this again by incising the whole of the overlying fascia. In some individuals, the fascia encountered immediately deep to the skin incision is that of the deep posterior compartment, thus it is possible to 'miss' the superficial compartment.

Fig. 28.5 Landmarks for leg medial fasciotomy

Incisions which initially appear adequate in terms of length may be evidently too short once the compartments have been decompressed. Care must be taken to extend the incisions accordingly, with extension of the fasciotomies.

By using these simple steps consistently, including the poke test, the surgeon can identify swiftly and with certainty which of the anterior of lateral compartments have been entered and decompressed. The wounds can be dressed using paraffin gauze directly onto the muscle, then dry gauze on top with copious padding such as Gamgee. The decompressed limb should be splinted to help prevent contracture even if the fracture has been operatively stabilised. For example, a posterior backslab to hold the foot at 90° at the ankle is a wise precaution to prevent equinus contracture which will tend to develop in a painful limb even when the fasciotomies have been performed correctly and in good time.

At the return trip to theatre in 48 h, it is often possible to close part of both, or even all of one fasciotomy wounds. While techniques have been described for achieving gradual closure, split skin grafting at 48 h will have an excellent chance of taking completely by 5 days and may be the most simple and reliable means of closure.

References

1. Porter K, Greaves I. Crush injury and crush syndrome: a consensus statement. Emerg Nurs J RCN Accid Emerg Nurs Assoc. 2003;11(6):26.
2. Ritenour AE, Dorlac WC, Fang R, Woods T, Jenkins DH, Flaherty SF, et al. Complications after fasciotomy revision and delayed compartment release in combat patients. J Trauma. 2008;64(2):S153–62.
3. Tornetta Iii P, Templeman D. Instructional course lectures, the American academy of orthopaedic surgeons – compartment syndrome associated with tibial fracture*†. J Bone Joint Surg. 1996;78(9):1438–44.
4. Clasper JC, Standley D, Heppel S, Jeffrey S, Parker PJ. Limb compartment syndrome and fasciotomy. J R Army Med Corps. 2009;155(4):298–301.
5. Mars M, Hadley G. Raised intracompartmental pressure and compartment syndromes. Injury. 1998;29(6):403–11.
6. Mars M, Hadley G. Raised compartmental pressure in children: a basis for management. Injury. 1998;29(3):183–5.
7. McQueen M. Compartment monitoring in tibial fractures. The pressure threshold for decompression. J Bone Joint Surg Br. 1996;78(1):99–104.
8. Kuwagata Y, Oda J, Tanaka H, Iwai A, Matsuoka T, Takaoka M, et al. Analysis of 2,702 traumatized patients in the 1995 Hanshin-Awaji earthquake. J Trauma Acute Care Surg. 1997;43(3): 427–32.
9. Oda J, Tanaka H, Yoshida T. Analysis of 3732 patients with crush syndrome caused by the Hanshin-Awaji earthquake. J Trauma. 1997;42:470–6.
10. Pallister I, Rahman S, Atherton S. The poke test in lower limb fasciotomy: a potentially limb saving technical note. Ann R Coll Surg Engl. 2012; 94:532.
11. Taylor G, Pan W. Angiosomes of the leg: anatomic study and clinical implications. Plast Reconstr Surg. 1998;102(3):599–616.
12. Nanchahal J, Nayagam S, Khan U, Moran C, Barrett S, Sanderson F, et al. Standards for the management of open fractures of the lower limb. UK: The Royal Society of Medicine Press Ltd; 2009.

29

Amputations

Richard A. Gosselin

The actual worldwide incidence and prevalence of amputations (major and minor) are unknown. The incidence is estimated at around 1.5/1000 population for a total greater than 10 million per year. The prevalence is estimated at around 5/1000 population, meaning there are at least 35 million amputees worldwide [1, 2]. Most austere environments lack in sophisticated prosthetics and rehabilitation resources. Any amputee faces a greater challenge to return to a productive, functional lifestyle [3, 4]. The stigma attached to amputation varies greatly across cultural, religious, and socioeconomic determinants. In some places, patients would rather die than lose a limb. In other places, the consent to perform or not an amputation is given by a second party: fathers, husbands, elder brother, village elders, or military commanders. These can sometimes take days to obtain. The decision to refuse or seek a "second opinion" at another facility or with traditional healers may not seem "medically rational" but needs to be respected, even if there is no doubt as to the final outcome [5].

An upper extremity (UE) amputee almost always loses significant function, particularly where white-collar jobs are scarce. A lower extremity (LE) amputee loses more or less function depending on the level and quality of the amputation but, unless fitted with a comfortable and appropriate prosthesis, also loses UE function while in motion (using crutches or wheelchair). When amputation is necessary in such environments, it should be as conservative as possible, within the constraints of the available prosthetic capacities. Amputation is not just a procedure; it is a process that goes from the disease/injury to the definitive prosthetic fitting, maintenance, and replacement [6]. An amputee is a patient for life.

The ideal stump is painless, well-padded, well-balanced, end-bearing, and easy to fit. The ideal prosthesis is sturdy, light, made with local materials by local technicians, adapted to local environment, easy to maintain, repair or replace when needed, cosmetically acceptable, and inexpensive. The International Committee of the Red Cross (ICRC) and Handicap International (HI) have been very successful over the years in designing and implementing programs that meet these criteria. Elective amputations for congenital malformations, tumors, or chronic infections can be planned on an elective basis with the involvement of the prosthetist, using helpful diagnostic studies such as the arm/ankle index, vascular ultrasound examination, or even angiography where available [7].

R.A. Gosselin, MD, MSc, MPH, FRCS(C)
Department of Orthopedic Surgery,
Institute for Global Orthopedics and Traumatology,
University of California in San Francisco,
San Francisco, CA, USA
e-mail: froggydoc@comcast.net

© Springer International Publishing Switzerland 2016

J.D. Robinson (ed.), *Orthopaedic Trauma in the Austere Environment:*
A Practical Guide to Care in the Humanitarian Setting, DOI 10.1007/978-3-319-29122-2_29

Amputations for trauma, either primary or delayed, are different: they most often involve healthy young adults, and the flaps and amputation level are most often dictated by the injury itself. Salvaging the proximal joint should be the first goal of a traumatic amputation, if at all possible, as energy requirements for ambulating with a shorter prosthesis are significantly less. A mangled extremity may require immediate amputation rather than a heroic attempt at salvage that will require many subsequent complex procedures spanning a long period of time and of dubious final functional outcome (Fig. 29.1). The extent of the injury should be documented with photographs, and a second opinion obtained and added to the file, if possible. Debridement and immobilization with a splint, cast, or external fixator may be appropriate while waiting for the proper consent, but the surgeon needs to be clear and explicit as to the anticipated outcome and not give false hopes if the situation is hopeless. The definitive amputation should be done before septic or metabolic complications start to occur. Once consent is obtained, further delays will only jeopardize the outcome at the proposed level of amputation, with the risk of having to go more proximally.

Injuries sustained in a battle zone are usually more severe and extensive than nonconflict-associated injuries, the vast majority of which are from road traffic crashes or farming/industrial injuries (Figs. 29.2 and 29.3). In austere

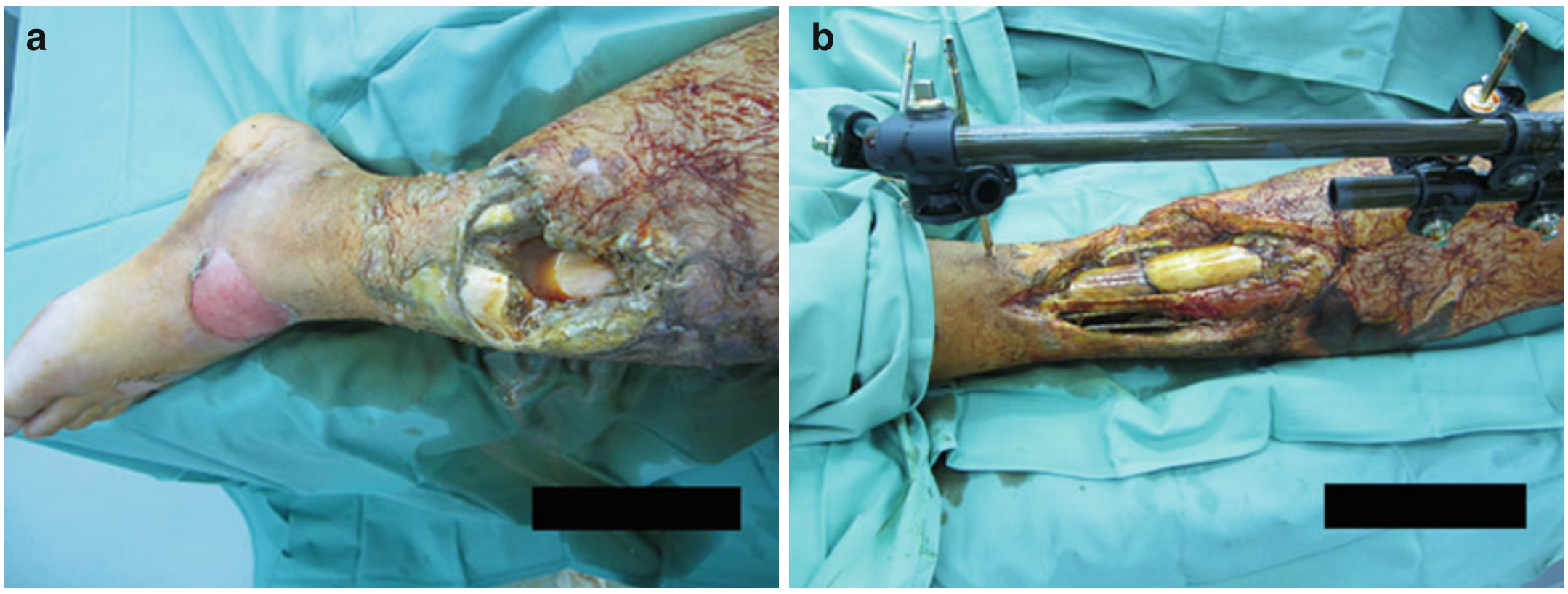

[redacted]

[redacted]

Fig. 29.1 (**a**) A man presented with an open fracture following a road traffic accident several days old. The appropriate management is a below-knee amputation. However, this surgeon unwisely attempted salvage (**b**) The patient died

[redacted]

Fig. 29.2 A traumatic amputation from stepping on a mine

Fig. 29.3 A tibia open fracture caused by a high velocity round

environments, heavy contamination and delayed presentation is common, and stumps should not be closed primarily but rather in a delayed fashion 4–6 days later [8, 9].

In the developing world, most amputations are done for injuries, contrary to high-income countries where vascular disease, including diabetes, is the most common etiology. Other indications include acute (gas gangrene) or chronic (osteomyelitis, ulcers, leprosy) infections, palliative or curative tumor surgery, and more rarely congenital deformities [10].

29.1 General Principles

The extent of the initial debridement of any stump will vary according to the type and severity of the injury, and also according to the type of tissue. A tourniquet should always be applied but, unless there is active bleeding, may be inflated only if needed. This allows easier demarcation between vascularized and devitalized tissues, particularly important for skin and muscles. If the patient has already lost a lot of blood and/or if blood procurement is an issue, the tourniquet should be inflated from the beginning.

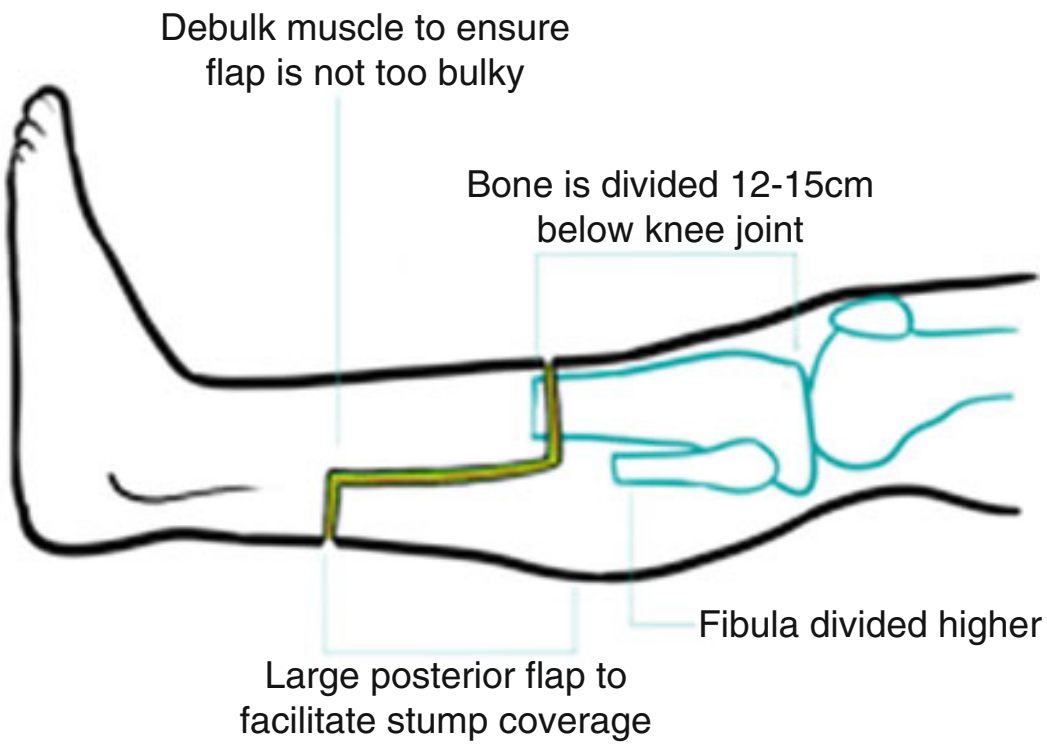

Fig. 29.4 Planning the soft tissue flap prior to the amputation (Courtesy of Konstantinos Doudoulakis)

Skin excision needs to be as conservative as possible as this is a valuable commodity (Fig. 29.4). No more than 3–4 mm need to be removed from the edges into bleeding tissue. Where storage capacity is available, healthy skin from the amputated segment can be harvested for future use if needed: the harvested skin is folded in half so that the dermal layer is touching itself, covered with a sterile gauze and submerged in saline solution, It can be kept up to 14 days in a refrigerator between 0 and 4° [11].

Fat tissue and fascia are poorly vascularized and excision should be generous. Viable muscle tissue contracts when pinched (unless paralyzed, check with the anesthetist) and bleeds when cut. Contused but living muscle may not, so it is important to debride the obviously devitalized tissue but be conservative where there is a doubt, and reassess at 4–6 days, at the time of the proposed delayed primary closure (DPC). If more necrosis has declared itself, re-debridement is carried out, the stump again left open, and DPC planned again 4–6 days later. In general, muscle masses are beveled from superficial to deep and from distal to proximal, so they will still cover the bone when they retract. *There is no indication for guillotine amputations*, except to extricate a trapped patient

Fig. 29.5 A guillotine amputation. A common presentation in the immediate aftermath of disasters such as the Haiti earthquake

Fig. 29.6 Prosthetics for above-knee and through-joint amputees. It is important to become aware on the indications and characteristics of different prosthetics

in the field, as they always require shortening before closure [12]. This was unfortunately still too commonly seen after the Haiti earthquake [13] (Fig. 29.5). It is better to shape regular flaps, even if their viability is in doubt, and revise at a second look than do a guillotine that often causes the joint above to be later sacrificed.

Major arteries and veins should be ligated separately, using a transfixing ligature and another simple ligature proximally on the artery. Nerves are identified separately and never ligated. Ligating nerves with the vascular bundle may lead to painful "pulsatile" neuromas. Nerves are transected sharply under gentle traction so they can retract proximally and burry themselves in the surrounding muscle masses. Long bones need to be cut perpendicular to their long axis and the edges smoothen with a rasp or rongeur.

The anterior tibial crest needs to be beveled at a 45° angle. As opposed to through-bone amputations, LE disarticulations provide an end-bearing stump, which is preferable, but prosthetic fitting is more complicated and, more often than not, unavailable. The input of the prosthetic specialist will be essential in the decision-making process (Fig. 29.6).

In the pediatric group, every effort should be made to preserve physes, so disarticulation is preferred to diaphyseal amputation. When the amputation is through bone, stump overgrowth or exostosis formation is more common. The end of the bone needs to be capped, either by dissecting the periosteum as a separate layer and suturing it to itself or by plugging the medullary canal with a piece of bone or cartilage from the specimen.

29.2 Upper Extremity Amputations

As a general rule, stumps should be as long as possible provided skin coverage is adequate. In such environments, some prostheses may provide basic function (passive pinch or hook) but most will be used as a paddle or only for cosmetic purposes [14].

3–1 Injuries to the hand: they often appear worse than they actually are. Conservative debridement and amputation of only the obviously non-viable segments are in order. Tissues of questionable viability should be retained and addressed during a “second look” procedure at 48–72 h, keeping in mind that finger function depends in great part on some sensory preservation. Immobilization of all unstable bony injuries of fingers, metacarpals, or carpal bones should be achieved with K-wires or Steinmann pins. Fluoroscopic imaging will make this task easier where available. K-wires passed through a needle cap can make a surprisingly sturdy improvised external fixator. A fluffy hand dressing, with a backslab, and elevation of the limb should provide the damaged tissues the best healing environment [8].

Every attempt should be made to salvage as much of the thumb as possible (Fig. 29.7). Amputations through or proximal to the MP joint are very disabling, and toe-to-thumb transfer is not an option. As long as one digit is present and functional, some degree of pinching should be possible. But losing fingers four and/or five affects grip strength much more than losing fingers two and/or three. An open digit amputation, even of the guillotine type, through a more distal segment is preferable to a more proximal one that is closed.

If delayed primary closure or closure by secondary intention of the stump is not possible, simple procedures such as V-Y advancement flap or burying the digit in the abdomen for 2–3 weeks can provide definitive coverage. Split-thickness skin grafts should be avoided as they are not sensate and break down easily. Finger tip injuries are best managed by nibbling the distal phalanx and primary closure without tension, V-Y advancement, or just letting the wound heal by secondary intention. All these techniques provide a finger tip with normal or near-normal sensation. Amputation through the hand can still allow some pinching if the thumb is intact. Otherwise, it will serve as an articulated paddle. If none of the hand is salvageable, a disarticulation through the radio-carpal joint is indicated [6].

Fig. 29.7 This child suffered a severe injury to the hand after grabbing an explosive device. The surgeon has saved the thumb, thus helping this child to have some ability to grasp

3–2 Forearm amputations: the more distal the better, provided there is good soft tissue coverage. Both bones should be cut at the same level, and edges smoothen to prevent sharp tenting of the overlying skin. Amputations through the proximal or middle third of the forearm allow myodesis (preferable) or myoplasty of available muscle bellies over the tips of the bones.

Amputations through the middle or distal third tend to have some balance between pronation and supination of the stump, whereas those through the proximal third tend to have a supination contracture. Still, even a short below-elbow stump is more functional than an elbow disarticulation.

Much has been written about the Krukenberg procedure, particularly in the aftermath of the civil war in Sierra Leone where many civilian victims were mutilated with machetes and sustained uni- or bilateral UE amputations, mostly through the wrist or distal forearm. Initially described as a salvage procedure to produce a sensate claw for deminers who were blinded and lost both hands in the line of duty, it is a technically demanding procedure that very few "western" surgeons have the opportunity to learn during their training (Fig. 29.8). Cutaneous flaps must respect sensory innervation, deep dissection cannot go too far proximally to preserve blood supply, and the resulting claw affords only minimal active pro-supination. Still, many recipients of this procedure are happier with a passive claw than with the paddle stump they had before. There is not much tissue to cover the ends of the bones distally, and wound healing problems or sores are not rare. If they require a revision to a proximal below-elbow amputation, the patient is functionally worse that how he started [15].

Fig. 29.8 Krukenberg procedure is not advisable in the austere environment

29.2.1 Arm Amputations

The longer the segment, the better the stump can cross the midline in adduction, thus improving function. An elbow disarticulation is a good procedure, provided the distal humerus is well covered and better than a through-humerus amputation (Fig. 29.9). Through-humerus amputations should have the brachialis/triceps groups myodezed to the humerus, as opposed to simple myoplasty, to avoid "slinging." A proximal humerus amputation is not very functional, and abduction contractures are common if done proximal to the pectoralis major insertion (most often the case). Shoulder disarticulation and forequarter amputations are heroic measures reserved for severe trauma or gas gangrene. Once palpable gas has reached the chest wall, curative treatment is out of reach, as hyperbaric treatment is never an option.

29.3 Lower Extremity Amputations

In environments where most of the gainful employment is either from manual labor or farming, hands-free locomotion is of paramount importance. This can be achieved with good prosthetic fitting and maintenance for more proximal

[redacted]

Fig. 29.9 (**a**) A young man suffered a mangled forearm and elbow after been trapped in a heavy metal roller and (**b**) Following above elbow amputation

amputations or with a sound end-bearing stump around the foot and ankle area. The increase in high-energy vehicular trauma translates into more severe lower limb injuries. It is of utmost importance that if amputation is the only option, it be carried out in a timely fashion and with optimal technique, to preserve the most functionality. Unfortunately sociocultural determinants often prevent the appropriate surgical decision to be taken when it should.

Surgeons themselves often make the situation worse by giving false hopes to the patient and family about limb-saving surgery, and the protracted treatment afterwards. The result of procrastination is often that the window of opportunity for a more distal amputation is lost, and a joint needs to be sacrificed needlessly for a more proximal amputation. The surgeon's responsibility is to make hard decisions when they need to be made. Clearly explaining, and documenting the pros and cons of

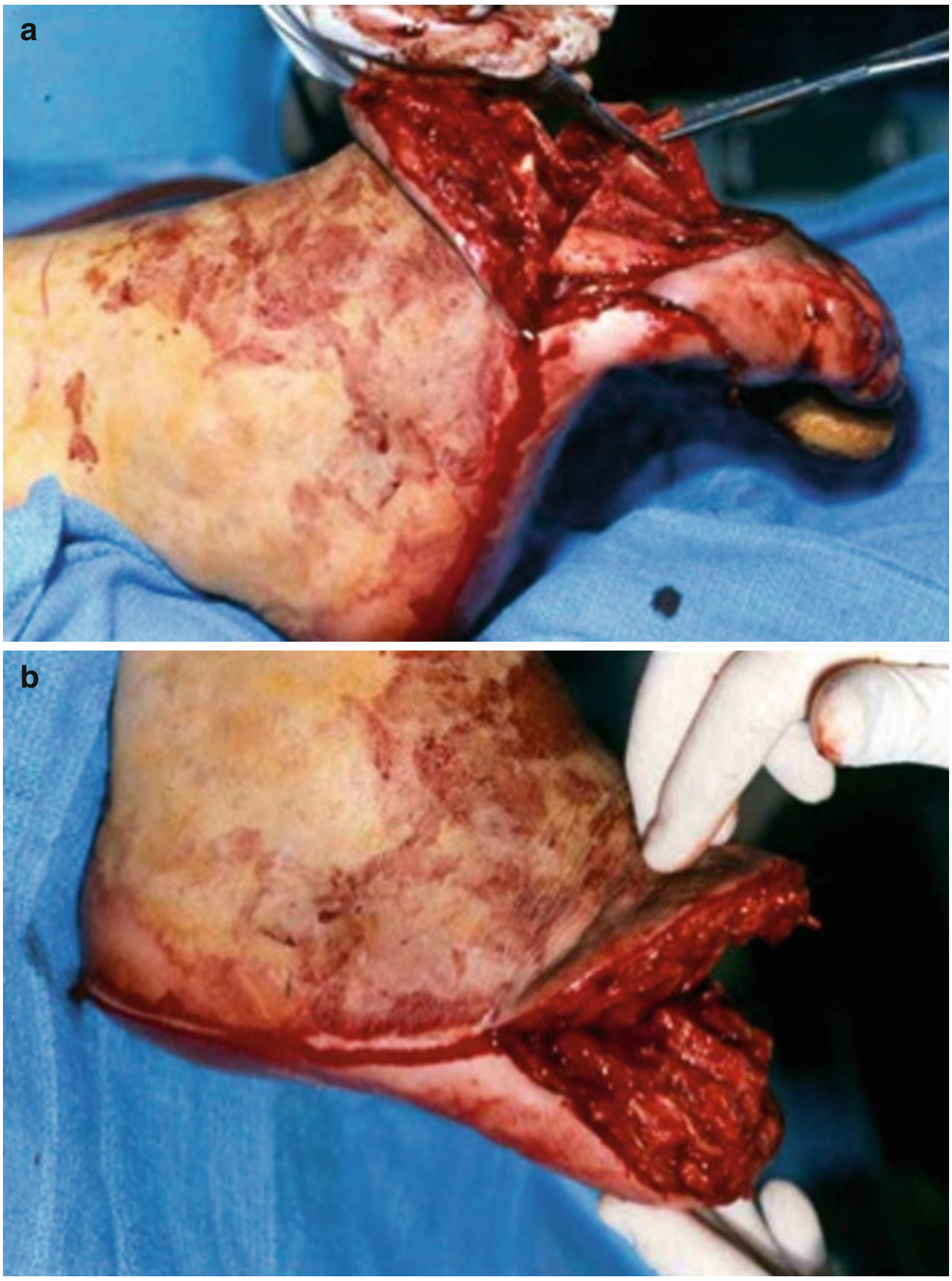

Fig. 29.10 (**a** and **b**) A trans-metatarsal amputation ensuring adequate soft tissue cover

early versus late amputation to the patient and his family will allow them to take the best "informed" decision, which then needs to be respected.

29.3.1 Foot Amputations

An intact heel pad and preserved plantar sensation make an ideal end-bearing stump for any mid- or fore-foot amputation. Toe amputations, ray resection, and transmetatarsal amputations may all create a varying degree of gait disturbance, but in austere environments, patients cope and adapt well, and prostheses are not required (Fig. 29.10). Except for the os calcis, tarsal bones contribute very little to the function and quality of a more proximal stump and should not be retained. If the talus is kept, normal leg length can be maintained, but a calcaneo-talo-tibial arthrodesis is needed to avoid instability of the stump. On the other hand, every attempt should be made to retain the os calcis, the heel pad and as much viable the plantar flap as possible. When these conditions are met, the Boyd procedure is very effective [6]: the talus is excised, a calcaneo-tibial fusion is achieved in a calcaneus position and secured with one or two

Steinmann pins, the Achilles tendon is released percutaneously to remove any equinus deforming force while the fusion is taking place. Once the wound is healed, the stump can be secured in a non-weight-bearing below-knee cast to be removed at 12 weeks, with the pins. By then a sound fusion will allow rapid progression to full weight bearing on the hell pad, with minimal shortening, and most patients actually prefer not using a prosthesis.

29.3.2 Ankle Amputation

The Syme amputation is a time-proven procedure and of particular importance in resource-poor countries as it also provides an end-bearing stump. A healthy and sensate heel pad is a prerequisite. When done for trauma, dissection of the os calcis should be done as close to the bone as possible, and the maleoli can be primarily beveled obliquely at the level of the pilon, but it is safer to leave the wound open and wait 4–6 days for DPC. The heel pad is best anchored to the distal tibia with trans-osseous sutures. The limb will be a little shorter, and most patients will agree to use a prosthesis. The stump is well padded and, unless not enough of the malleoli have been removed, quite resistant to skin breakdown.

29.3.3 Transtibial Amputations

Below-knee amputation (BKA) is the most common long bone amputation in LMICs (Fig. 29.11). Often the amount of injury will dictate not only the level of amputation but also the type of coverage. The initial debridement should be conservative with the skin. Better to have too much than not enough, and these “flaps of opportunity” can often be fashioned to provide sound, albeit unorthodox tissue for coverage at time of DPC. Otherwise, the Burgess “step” incision remains the classic approach if soft tissues allow. Ideally, the tibia should be cut at around 15 cms below the tibial tubercle (2.5 cm for every 30 cm of patient height) for best prosthetic fitting. The distal 2 cm of the anterior crest need to be beveled at roughly a 45° angle, and all edges smoothen. The fibula is cut 2 cm proximal to the tibial cut. Techniques have been described, such as the Ertl procedure, to prevent “chopsticking” of the two bones, by creating a distal synostosis. This may create problems of their own (nonunion, graft migration). and the purported benefits are at best controversial. In austere environments, this should be reserved for elective stump revision where distal instability is indeed severe enough to impact

Fig. 29.11 (**a**) The soft tissue is cut at 45° to create a flap that is thick enough to provide padding but not too bulky that it cannot be closed loosely. (**b**) The bone is cut and the edges are trimmed and filed to remove any sharp edges. (**c**) A healed below-knee amputation. The scar of the “fish mouth” flap can be appreciated

Fig. 29.11 (continued)

the use of a prosthesis. More proximal amputations leave less and less stump for the prosthetist to work with, and anything at or proximal to 5–6 cm from the tubercle is practically unfittable in austere environments. Whatever level of the bone cut, good padding is essential and achieved with a myodesis of the gastoc-soleus complex on the anterior tibial periosteum or, preferably, using trans-osseous sutures. This also insures good balance with extensor mechanism. In general, very good functional outcomes are achieved even with basic prostheses that are well adapted to the local environment and easy to repair or replace [14].

29.3.4 Knee Disarticulation

This procedure provides an end-bearing stump but requires sophisticated prosthetics capacity rarely available in these environments. It should be done only with the guarantee from the prosthetic specialist that he/she can handle it; otherwise a low above-knee amputation (AKA) is indicated. If done, the epicondyles should be trimmed, the patellar tendon sutured to the PCL remnant, and some gastrocnemii used anteriorly, avoiding to make the stump too bulky. A knee disarticulation is also a better procedure than an AKA for wheelchair bound patients, as it provides better sitting balance [6].

29.3.5 Transfemoral Amputations

The key to an AKA is to ensure balance between the various deforming forces. If adduction is lost, an abduction contracture will develop at the hip, and if extension is lost, a flexion contracture will occur. Both may impede good prosthetic fitting and efficient ambulation. The classic AKA is done at the distal metaphyso-diaphyseal junction, usually through a sagittal or coronal fish mouth incision. It is important to preserve the adductor magnus muscle after it is cut near Hunter's canal, and anchor it to the lateral aspect of the femoral stump, preferably with trans-osseous sutures. The quadriceps is then passed over the adductor belly and anchored posteriorly on the femur. This is preferable to a simple myoplasty with the hamstrings and the risk of painful "slinging," the back and forth rocking of the muscle sleeve over the end of the bone. The same principles apply to amputations thought the middle third of the bone. Amputations at or above the proximal third are at risk of a flexion contracture, and every effort should be made to preserve or tenodese the gluteus maximus insertion on the linea aspera. The patient should be asked to lie prone at least twice a day for 30 min as soon as pain allows. If necessary, a hip spica in extension can be applied for 6 weeks, but they are poorly tolerated, particularly in hot climates.

Short thigh stumps are difficult to fit, particularly in obese patients. Few patients are ever comfortable enough for hands-free ambulation, and it is not uncommon for the cumbersome and heavy prosthesis to be "left in the corner" and used only on special occasions. Hip disarticulation and hindquarter amputation cannot be fitted in austere environments and are indicated only as life-saving procedures in some acute infections, or as palliative treatment of advanced cancers or chronic infections [6].

29.4 Postoperative Management

The vast majority of amputations for trauma are left open, and DPC is done 4–6 days later if clean, usually over a suction or a Penrose drain. A plaster back slab can immobilize the proximal joint in the desired position and helps with pain. Appropriate analgesia should be provided, parenterally for 48–72 h, orally after that. Pillows under the knee should be avoided to prevent hip and knee flexion contractures. The drain is removed at 24–48 h, and distal to proximal compressive dressings can be started. Immediate or early prosthetic fitting is rarely available, and prosthetists prefer to work with more mature stumps. Sutures are removed at 2 weeks, compressive dressings and/or stockings are then used for the next 6–12 weeks until initial "maturation": all soft tissues have healed and securely scarred down to the bone, the stump is painless, with no or minimal swelling when dependent. It is crucial to maintain strength and mobility of the proximal segments throughout the process. When the size of the stump of the stump is stable, it can be molded and the initial prosthesis assembled. Simple yet sturdy components should be used, such as the Jaipur foot. Sophisticated prosthetics using myoelectric components or advanced materials such as carbon fiber are not available.

UE prostheses can provide some basic pinching or grasping function or be purely cosmetic. The initial LE prosthesis needs to be replaced with the definitive one at 6–12 months, as the final stump maturation process comes to an end. It is of critical importance that the patient and the family are well instructed and comfortable with all aspects of the life of an amputee: care of the stump, knowledge of potential complications, access and maintenance of supplies such as stockings or socks, cleaning and maintenance of the prosthesis itself and sustainable access to repair or replacement when needed. This is part of the amputation process.

29.5 Complications

29.5.1 Wound Problems

Dehiscence or necrosis occurs when closure is done under too much tension, not accounting for postoperative edema. Re-debridement needs to be done, the bone shortened only if necessary, and the wound left open for later DPC. A chronic stump wound comes from excessive from the prosthesis over bony prominences insufficiently padded. It is common over the tip of a BKA, especially if the tibia has not been beveled or if the fibula is too long. It can also come from pressure on an exostosis, a chronic osteomyelitis or an ill-fitting prosthesis. Stump-related problems almost always require surgical revision with bone shortening [8, 16].

29.5.2 Neuroma

100 % of cut nerves develop a neuroma, most of them asymptomatic. A neuroma may be painful at rest or only when under pressure. Phantom sensation is a normal occurrence where the patient feels as if the amputated limb or part of it is still there. It is a temporary phenomenon, which usually moves proximally over a few weeks or months and then disappears. It needs to be differentiated from phantom pain, an abnormal phenomenon where the amputated limb or part of it is actually painful for the patient. This is a neuroma issue; more common if the nerve has been ligated or cauterized, ligated with a vessel, or stretched too hard before being divided. This may also resolve over time, but if not, the neuroma needs to be explored and revised. Pain when the patient bears weight in his prosthesis is because of inadequate or insufficient padding around the neuroma, and if debilitating enough, requires revision surgery [6].

29.5.3 Phantom Pain

This is a common occurrence, occurring in varying degrees in more than half the patients [6]. It is to be differentiated from phantom sensation (the feeling the amputated limb is still present), which is a normal occurrence in nearly all amputees and resolves on its own after 1–2 years. Phantom pain refers to residual painful sensations in the missing segment and is also different from the mechanically induced neuroma pain. Its management is controversial and often disappointing, as there appears to be a significant psychological component. Mechanical devices such as transdermal electrical neurostimulation (TENS) have not proven successful in randomized controlled trials. A great number of pharmaceuticals have been tried over time, including aspirin, acetaminophen, NSAIDs, tricyclic antidepressants, benzodiazepines, opiates, and others, without much success. The antiseizure drug carbamazepine (Tegretol) showed initial promise and today gabapentin (Neurontin) has proven effective at least partially, in most patients, and has become the first-line medication [17].

29.5.4 Overgrowth/Exostosis

These are more common in the pediatric group, especially if the bone end has not been “capped.” They are less common in the adult and associated with aggressive periosteal stripping. Soft tissue heterotopic calcification or ossification can also rarely be seen resulting more often from the injury than the surgery. All of these may create pressure point and pain, or fitting difficulties, in which case they need to be removed. Overgrowth is addressed with shortening and capping: the end of the bone is “plugged” with and osteochondral fragment harvested from the amputated segment, over which the periosteum is sutured whenever possible [6].

29.5.5 Contractures

These should be prevented by adequate muscular balancing at the time of surgery and appropriate rehabilitation after surgery. If conservative management with physiotherapy is unsuccessful, and effective use of the prosthesis is impeded, surgery is indicated. If myodesis or tenodesis of antagonist muscle groups is possible, it is always preferable to tendon lengthening or tenotomy, both of which weaken the stump [6].

29.5.6 Psychological/Sociological Issues

The sociocultural stigma of amputation is very significant in many LMICs. Young, previously healthy patients, often the family bread winners, are suddenly confronted with a life-altering event. Body image issues, the prospect of having to beg for food, and the fear of rejection, particularly for females can all be extremely distressing. Children may be kept from school, and young adults may not marry. It is not rare to see depression severe enough to lead to suicide, particularly in patients who were not the ones giving consent for surgery. Psychological support from family and friends, and occasionally from a professional, is a very important aspect of the amputation process [18].

References

1. Renzi R, Unwin N, Jubelirer R, Haag L. An international comparison of lower extremity amputation rates. Ann Vasc Surg. 2006;20(3):346–50.
2. Aleccia J. Lomb loss, a grim, growing lobal crisis. 2010. Available at http://haitiamputees.msnbc.msn.com/news/2010/03/19/4040341-limb-loss-a-grim-growing-global-crisis. Accessed 19 Oct 2013.
3. Chalya P, Mabula JB, Dass RM, et al. Major limb amputations: a tertiary hospital experience in northwestern Tanzania. J Orthop Surg Res. 2012. Available at http://www.josr-online.com/content/7/1/18. Accessed 19 Oct 2013.
4. Akiode O, Shonubi AM, Musa A, Sule G. Major limb amputations: an audit of indications in a suburban surgical practice. J Natl Med Assoc. 2005;97(1):74–8.
5. Swann M, Walker GF. Amputations in developing countries. Br Med J. 1966;1(5494):1041–3.
6. Smith DG, Michael JW, Bowker JH, editors. Atlas of amputations and limb deficiencies. 3rd ed. Chicago: AAOS Publication; 2004.
7. Abbas ZG, Archibald LK. Challenges for management of the diabetic foot in Africa: doing more with less. Int Wound J. 2007;4:305–13.
8. Giannou C, Baldan M. War surgery, vol. 1. Geneva: ICRC; 2009.
9. Wolfson N. Amputations in natural disasters and mass casualties: staged approach. Int Orthop. 2012;36(10):1983–8.
10. Rigal S. Extremity amputation: how to face challenging problems in a precarious environment. Int Orthop. 2012;36(10):1989–93.
11. Ge L, et al. Skin grafts – indications, applications and current research. Available at http://www.intechopen.com/books/skin-grafts-indications-applications-and-current-research/skin-graft-preservation. Accessed 19 Oct 2013.
12. Brown KV, Clasper JC. The changing pattern of amputations. J R Army Med Corps. 2013;159(4):300–3.
13. Herard P, Boillot F. Amputation in emergency situations: indications, techniques and Medecins Sans Frontieres France's experience in Haiti. Int Orthop. 2012;36(10):1979–81.
14. Knowlton LM, Gosney JE, Chackungal S, et al. Consensus statements regarding the multidisciplinary care of limb amputation patients in disasters or humanitarian emergencies: report of the 2011 Humanitarian Action Summit Surgical Working Group on amputations following disasters or conflict. Prehosp Disaster Med. 2011;26(6):438–48.
15. Sivathasan N, Chatterjee SS, Jain A. The Krukenberg procedure revisited. J Hand Surg Eur Vol. 2011;36(6):514–5.
16. Awais SM, Dar UZ, Saeed A. Amputations of limbs during the 2005 earthquake in Pakistan: a firsthand experience of the author. Int Orthop. 2012;36(11):2323–6.
17. Le Feuvre P, Aldington D. Know pain know gain: proposing a treatment approach for phantom limb pain. J R Army Med Corps. 2013;160(1):16–21. doi:10.1136/jramc-2013-000141.
18. Hamdan TA. Psychiatric aspects of orthopaedics. J Am Acad Orthop Surg. 2008;16(1):41–6. Review.

30

Pediatric Trauma Care in Austere Environments

Ashok K. Banskota

The child presenting with orthopedic trauma needs to be thoroughly assessed using all standard protocols for primary survey including establishment of airway and protecting the cervical spine, breathing, and circulation. Periodic resurvey to ensure that the general condition of the patient is not deteriorating is an important part of the secondary survey. Although the majority of pediatric trauma is the result of low-energy injuries, these protocols must always be followed to ensure nothing is missed. Be mindful of the differences between adults and children in terms of resuscitation, such as airway management and fluid requirements.

Many patients in developing countries do not have access to immediate and appropriate care and late presentation is common. Late presentation may predispose to serious complications such as infection, compartment syndrome, and other systemic complications. The evaluating physician must always be prepared to refer the patient—if at all possible—to a better center with more skills and facilities. Appropriate care of pediatric trauma requires facilities that are equipped with skilled workforce (surgeon, physiotherapist, plaster technicians) and appropriate equipment (x-ray machine, a fluoroscope, and basic hardware). This setup is usually unavailable in austere settings, so a realistic approach to what can be delivered has to be adopted. While an open fracture may pose special challenges in a resource-poor setup, washing the wound with tap water, applying a splint, and early referral may still go a long way in avoiding disastrous complications such as an osteomyelitis. Often in austere environments, primary care is delivered by practitioners who may not have had appropriate training (Fig. 30.1). Education and training coupled with establishment of a referral ladder involving

Fig. 30.1 Gangrene of the forearm and hand due to a tight plaster

---

A.K. Banskota, MD, FACS
Department of Orthopaedics,
Hospital & Rehabilitation Center for Disabled Children, Banepa, Nepal

B & B Hospital, Kathmandu, Nepal
e-mail: ashokbanskota@gmail.com

© Springer International Publishing Switzerland 2016
J.D. Robinson (ed.), *Orthopaedic Trauma in the Austere Environment:*
A Practical Guide to Care in the Humanitarian Setting, DOI 10.1007/978-3-319-29122-2_30

nearby institutions equipped to manage pediatric trauma is the need of the hour, if appropriate care delivery is to be ensured and serious complications are to be avoided.

Whenever surgical intervention is contemplated, "safety" should be the primary issue. Technology alone can never be a substitute for time-tested methods of treatment if the other issues of safe practice are not addressed. Where facilities for general anesthesia are absent, a skilled physician may be able to employ regional blocks or local (hematoma) blocks to aid reduction in selected fractures. These techniques may, however, be limited by the lack of cooperation from the injured child. Effective pain management by early splinting of the fracture and use of safe analgesic drugs can curtail a lot of anxiety for the patients as well as the parents.

Where facilities for surgical intervention are not developed, the following approach may be useful to prevent potential complications:

1. Identification of neurovascular/limb-threatening problems and referring them immediately after resuscitation if possible
2. Primary debridement/washout and splinting of open fractures and early referral if possible
3. Early referral for any fracture that is thought to require surgical intervention if possible

For fractures managed conservatively:

(a) Achieve an acceptable reduction
(b) Maintain the reduction in plaster or some form of immobilization
(c) Counsel the patient and family to possible complications of closed treatment
(d) Arrange for specialist follow-up in the near future

30.1 General Principles

30.1.1 Open Fractures

Early antibiotics and aggressive wound care are the most important steps in the management of open fractures. Copious irrigation is instituted, making sure that the pulsation of the irrigating fluid is away from the center, to prevent contaminating particulate debris from being projected into the inner depths of the wound. Irrigation is generally achieved through use of normal saline in large quantities. If this is not available, clean tap water should be used. Gustilo grade III wounds should be irrigated with a minimum of 5–6 l of fluids. If facilities exist, wound swab for culture sensitivity must be taken, and based on the history and circumstances of the incident, prophylactic antibiotics started keeping in mind the probable organisms that may already be active in the wound (Figs. 30.2, 30.3, and 30.4).

Coverage should be provided for both gram-positive and gram-negative bacteria along with anaerobes. When spores are suspected, a combination of penicillin with an aminoglycoside and metronidazole and sometimes a cephalosporin forms the first-line antibiotic coverage. When cultures are available, the spectrum of drug must be narrowed and appropriate target antibiotics instituted. Debridement and wound care should be undertaken in the operating room in a controlled environment. Under anesthesia, the injured limb is examined and then thoroughly debrided of all dead and devitalized tissues, irrigated further and the fracture stabilized by the use of simple external fixation or, when this is unavailable, by using splints or casts through which large windows are made to inspect and nurse the wounds.

Fig. 30.2 A child presenting with a contaminated open radius fracture with osteomyelitis


[redacted]

Fig. 30.3 Shot gun injury to a child's forearm causing loss of soft tissue and comminuted fracture. Following debridement and stabilization with an external fixator, a split skin graft has been applied

Fig. 30.4 Ground transportation in rural Nepal

30.1.2 Anesthesia and Supporting Team

The proper care of a traumatized child who requires anesthetic support depends on the "quality" and "safety" of anesthesia available. The treating doctor must familiarize himself with who is available, who are his team members, which equipments are in a safe and working condition, and whether or not drugs for delivery of anesthesia are available. Although this does not fall into the realm of responsibilities of the orthopedic surgeon practicing in non-austere environments, they are extremely important when one is practicing in an environment where facilities are suboptimal. Sometimes the surgeon may need to function as an anesthetist and sedate and administer basic anesthesia. It is important to be familiar with the use of basic drugs

Fig. 30.5 Volkmann's ischemic contracture following open supracondylar fracture with vascular injury that was not managed appropriately

(e.g., ketamine for fracture reductions), with modes of oxygen delivery and also techniques to intubate a patient.

30.1.3 Imaging

After a detailed history and a thorough clinical examination including the advanced trauma life support (ATLS) protocol for multisystem injuries, standard anteroposterior radiographs of the affected parts are taken to define the fracture. Special views (inlet–outlet for pelvis, obturator–iliac obliques for acetabulum) may help better define fracture patterns, especially to identify unstable injuries. An ultrasound may be used as an adjunct to look for fluid collection, soft tissue, cartilage and bony architecture, and incarcerated fragments. Ideally, closed reductions will be done with a fluoroscopy machine, but in its absence, a check x-ray must be done following the procedure and one must be ready to take the patient back if necessary. Do not accept an inadequate reduction.

30.1.4 Tractions, Splints, and Casts

The majority of pediatric fractures can be successfully managed by closed methods, and these include the applications of splints, circular casts, and traction. Gypsona/plaster of Paris is available and is safe to use. Lukewarm water at room temperate is appropriate. These allow for slow setting time and do not generate as much heat rapidly so as to prevent superficial skin burns. Casts should be applied over layers of cotton padding, which are uniformly gently wrapped with about 1/3 overlap. Bony prominences should be adequately padded. The plaster should be applied snugly but without too much tightness. Anatomical contours should be gently molded and the position of function of the extremity must be maintained. Three-point cast molding is done to prevent displacement inside the plaster. Generally, 4–5 layers of plaster are adequate and the plaster is not too heavy. The "cast index" defined as the anteroposterior to lateral cast width ratio of more than 0.7 has been shown to increase the incidence of late displacement [1].

In acute fractures, it is always advisable to bivalve the cast. This is easier done when the cast is semi-set, by using a knife blade which easily cuts through the setting plaster. A plaster saw should be used when available and in dry casts. It should be taken very seriously whenever a child in a cast complains of pain. It is imperative to check for the circulation, tightness, leg or hand edema, and if any doubt exits, to remove the bivalved cast and keep the limb elevated in a splint (Fig. 30.5). The cast can be reapplied once the swelling settles. It is far better to lose a reduction than to lose a limb. Most pediatric fractures heal well with 4–6 weeks of immobilization. Some fractures require longer periods, such as Greenstick fractures or shaft of the radius and ulna fractures. Lower extremity fractures are kept non-weight bearing for 6–8 weeks. Early motion is priority in intra-articular fractures.

30.2 Surgical Considerations

Where facilities for safe anesthesia are available and sterilization processes are standard, an external fixator may be used to treat open or even closed long bone fractures. When dealing with large contaminated wounds or ballistic injuries, external fixator should be used where available. Such injuries call for repeated debridements before soft tissue coverage can be achieved and an external fixator facilitates this. Definitive fixation is deferred until adequate soft tissue healing occurs. Open reduction and internal fixation should be done only when postoperative wound care can be ensured. ORIF may have an advantage in settings where expertise is available but fluoroscopy and/or intramedullary implants are unavailable. In the scenario of open articular injuries (e.g., around the knee joint) when referral is not possible, wound management protocols should be initiated and the limb placed in skeletal traction (proximal or distal tibia or calcaneal pin), or a spanning external fixator applied. A displaced intraarticular fracture may reduce with traction or it may be stabilized with k-wires. Again, do not accept inadequate reductions!

In managing missile and blast injuries, the severity and extent of involvement may warrant an early amputation, along with all the adjunct supportive measures. Again, it has to be emphasized that a conservative approach with early referral is a far better option than a surgical adventure in a suboptimal environment that culminates into florid infection.

30.2.1 Upper Extremity

Almost all fractures involving the pediatric upper extremity with the exception of the elbow region can be managed nonoperatively [1, 2].

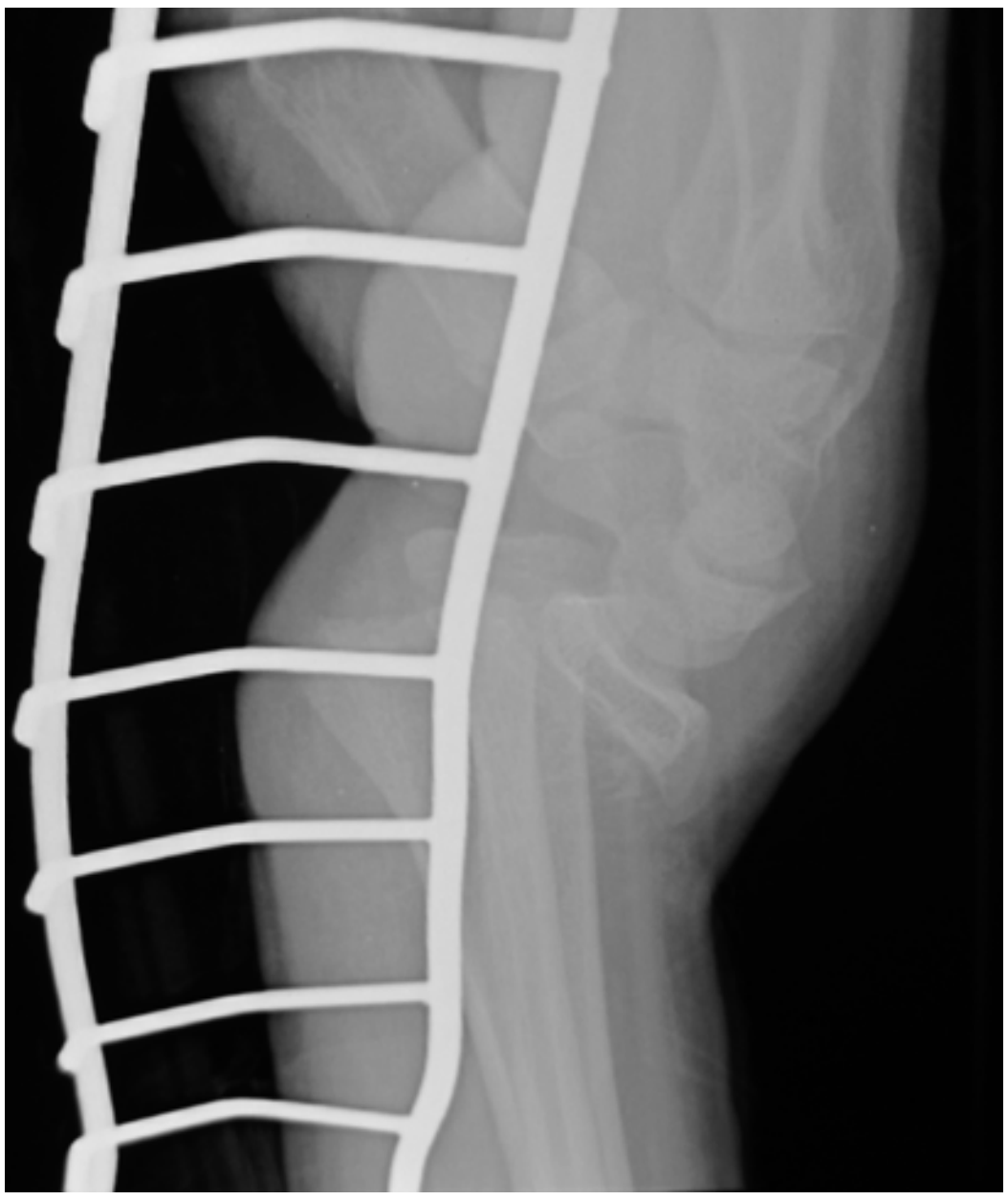

Fig. 30.6 Distal radial fractures may stretch the median nerve and need to be reduced urgently

Distal Radius Physeal Fractures Distal radius physeal fractures in children have been shown to remodel completely even with complete displacement, if one and a half years of growth is remaining [1–5]. A significantly displaced fracture may compress the median nerve and precipitate an acute carpal tunnel syndrome which is an emergency (Fig. 30.6). Shear forces across the physis during the reduction should be avoided by longitudinal traction. One must be alert to the possibility of a compartment syndrome.

Distal Radius Metaphyseal Fractures Distal radius metaphyseal fractures can be a buckle (torus) fracture, a greenstick fracture with one cortex intact, undisplaced or partially displaced fractures, or completely displaced fractures with bayonet opposition. All torus fractures, greenstick fractures with sagittal angulation less than 30° and coronal angulation less than 10°, undisplaced or partially displaced fractures with more than 50 % contact and minimal angulation, and bayonet opposition can be managed conservatively [1, 2, 6, 7]. Some authorities believe that it is a waste of time and resources to even attempt reduction of these fractures in children less than

12 years of age [1. 2] Complete remodeling can be expected if further displacement is prevented in a well-applied plaster.

Shaft of Radius and Ulna Fractures Shaft of radius and ulna fractures do not remodel as well and as early as distal radial fractures owing to cortical bone. A lower threshold for manipulation is recommended, especially if the child is above 9 years of age [1, 6]. Even over 9 years, angulation of 10°, malrotation of 30°, bayonet displacement and partial loss of radial bow can still be expected to remodel. A well-applied long arm cast (in supination for dorsal apex and in pronation for volar apex fractures) for 6–8 weeks is the preferred treatment. When manipulating plastic deformations, restoration of forearm rotation and correction of clinical deformity is taken as the endpoint before cast application. Complete fractures of the shafts should be immobilized only after molding adequately to spread the interosseous space. Bayonet opposition and shortening in these fractures are acceptable. In children with short and chubby forearms, casting with the elbow in extension and incorporation of the thumb may be preferred to prevent the tendency for the limb to migrate proximally inside the cast [1, 6].

Monteggia Lesions Monteggia lesions consist of a proximal ulnar fracture with associated radial head dislocation [8]. These injuries require detailed understanding of the mechanism of injury to achieve successful outcome by closed methods. A setup consisting of a fluoro machine is the minimum if treatment is contemplated. In areas where a fluoro is unavailable, an above elbow splint to reduce pain and early referral to a higher center is recommended. In type I lesions, both the fracture and dislocation are anterior. Because this is an extension injury, reduction involves flexion maneuver to reduce the fracture to regain ulnar length and bow which in turn facilitates reduction of the radial head. Immobilization in hyperflexion helps keep the radial head reduced.

In type II lesions, both the fracture and dislocation are posterior. Because type II lesions are flexion injuries, reduction is achieved with extension and the reduction is maintained in a long arm cast applied in extension. Type III lesions are a result of varus force on the elbow, where both the fracture and dislocation are lateral. A valgus force is applied to correct type III lesions which are then immobilized in a long arm cast in 90° of elbow flexion and neutral rotation. Type IV lesions are complex and perhaps not usually amenable to closed techniques except in the most experienced hands. Type IV lesions have a proximal radius and ulna fracture with a dislocated radial head. Early referral to facilities where open reduction can be done is recommended.

Radial Head Fractures Radial head fractures can be managed without manipulation if the degree of angulation is less than 45° and the degree of forearm rotation is more than 45° [2, 9, 10]. For greater degrees of angulation or restriction of rotation, reduction can be achieved by flexing the elbow to 90° and pronating the forearm while applying direct pressure to the displaced head. Immobilization in a long arm cast in 90° of elbow flexion and full pronation is recommended.

Supracondylar Fractures Supracondylar fractures of the distal humerus are extremely common in children, and the vast majority of these are extension type fractures. Fractures associated with vascular compromise are limb threatening. The patient presents with a cold and pulseless extremity with delayed or absent capillary refill. Every minute is important so referral to appropriate facilities for vascular exploration and repair is top priority if available. The presence of adequate capillary refill in the absence of distal pulses is usually the result of vasospasm and can be managed in Dunlop traction until definitive management or referral is done. Extension type I supracondylar fractures are undisplaced and can be managed in a long arm backslab as can most type II fractures after gentle manipulation. Type III fractures require fluoro assessment and pinning after closed reduction, sometimes open reduction, so appropriate setup is necessary.

We feel that supracondylar fractures presenting a week after the initial injury are best left alone and a delayed corrective osteotomy performed later to address cosmetic and functional problems. Repeated manipulation required to obtain even a reasonable reduction in late presenting fractures often causes the elbow to stiffen up. Immobilization of extension fractures is in an above elbow slab or a bivalved cast with the elbow in 90° flexion. It is critical not to exceed an elbow flexion of more than 120°, to prevent vascular problems [1]. The less common flexion type supracondylar fractures are best referred to centers where there is expertise to manage them by closed or if needed, open means. Flexion type fractures are immobilized in an above elbow slab or bivalved cast with the elbow in extension.

Medial Epicondyle Fractures Medial epicondyle fractures are important in that they may be associated with an elbow dislocation or ulnar nerve problems. A detailed history is critical as these injuries may lead to stiffness of the elbow. Immobilization is done in an above elbow cast. Widely displaced fractures are fixed and intra-articular incarcerated fragment necessitates operative removal.

A *lateral condyle fracture*, except for the totally undisplaced fracture, requires surgical intervention for optimal results (Fig. 30.7). Being an intra-articular fracture, anatomical reduction and early motion is the goal of surgery. Minimally displaced cases are amenable to closed reduction and percutaneous pins, whereas highly displaced or rotated fractures often require open reduction to restore articular congruity. It is imperative to avoid extensive dissection of the posterolateral soft tissue of the fracture to prevent avascular necrosis of the fragment, which can be more debilitating than the fracture itself [2, 11]. Immobilization is in an above elbow slab or bivalved cast. The management of late-presenting lateral condyle fractures is a subject of debate. While most authors agree that a fracture presenting up to 3 weeks and even 6 weeks in some cases can be restored to achieve good function, those presenting beyond this time period should probably be left alone. Indications to intervene in late cases include symptomatic nonunion causing pain, valgus deformity of the elbow, or tardy ulnar nerve palsy. Valgus deformity can be addressed with an osteotomy (Milch) and ulnar palsy by transposition of the nerve anteriorly.


Fig. 30.7 Lateral condyle fracture

Fractures of the Humeral Shaft Fractures of the humeral shaft in children can largely be managed nonoperatively in a coaptation splint supplemented with a collar and cuff bandage. This treatment relies on gravity to achieve and maintain the reduction. Alternatively, a hanging cast can be used but this requires the child to sleep on a reclining chair for about 2 weeks until the fracture gets “sticky” [1, 6].

Proximal Humerus and Clavicle Fractures Proximal humerus and clavicle fractures in children possess tremendous remodeling potential. Even significant displacement, including bayonet opposition, remodels completely (Fig. 30.8).

Fig. 30.8 Five months old dislocation of the shoulder. Any form of treatment cannot salvage normal function that would have been possible after acute relocation

30.2.2 Lower Extremity Fractures

Pelvis and Acetabular Fractures Pelvis and acetabular fractures are usually high-velocity injuries due to motor vehicle accidents or fall from heights and have and overall mortality rate of about 5 %. The overriding priority in treatment is to address the polytrauma that is associated with these injuries, the fracture itself being low priority [2, 9, 12–15]. Treatment must follow ATLS guidelines. An attempt should be made to identify and differentiate the stable pelvic ring injury from an unstable one as unstable injuries have higher morbidity and mortality.

The management of pelvic injuries in skeletally immature children should primarily focus on management of associated injuries, and these injuries determine the eventual outcome [9]. Many pelvic ring injuries in children remodel adequately over a period of time [16]. Skeletal traction with the traction pin placed in either in the distal femur or proximal tibia avoiding injury to the physis can provide stability to the fracture. Traction is usually applied for 4–6 weeks and radiographic evaluation made to assess the progress in healing. Gradual weight bearing and range of motion of adjacent joints is instituted. Pelvic asymmetry can be a problem in future child bearing in females and needs to be discussed and counseled appropriately.

Fig. 30.9 Failed fixation in hip fracture. The screw placement was incorrect (in varus)

Acetabular fractures may be associated with a hip dislocation in which case reduction of dislocation is a priority and requires anesthesia. Undisplaced or minimally displaced fractures may be treated in skeleton traction to the distal femur or by simply recommending bed rest or non-weight bearing on crutches for a period of 6–8 weeks. Improved outcomes are reported with early fixation (less than 24 h) for displaced fractures because early healing in children can make reduction difficult later on [17]. Avascular necrosis, traumatic arthritis, and limb length discrepancy can occur in a long run.

In contrast to hip fractures in the elderly, *hip fractures in children* are usually high-velocity injuries. The priority is to identify and address associated injuries and achieve anatomical reduction of the fracture (Fig. 30.9). The extremity in a child with hip fracture is usually held in a position of flexion abduction and external rotation. Transcervical and cervicotrochanteric fractures have a high incidence of avascular necrosis [2, 9]. The family has to be counseled appropriately when embarking on treatment. Differential diagnosis includes septic arthritis, synovitis, or hemarthrosis. Transepiphyseal fractures must be differentiated with a slipped capital femoral epiphysis. SCFE presents in preadolescent children, usually with underlying pathology such as an endocrinopathy.

Hip Dislocation in Children [27] Hip dislocation in children is uncommon, and again, the priority is to identify and address any associated injuries as these are usually a result of high-velocity injuries. The dislocation is usually posterior in direction, and the affected child may present with pain and swelling and a shortened limb that is flexed and adducted. Anterior dislocations are less common and the child will have the limb in a position of extension, abduction, and external rotation. Treatment includes early concentric reduction of the hip. This may reduce the incidence of late avascular necrosis. If concentric reduction is not possible, then soft tissue or bony incarceration must be suspected and investigated appropriately.

If incarceration is confirmed, open relocation is warranted. Spontaneous dislocation–relocation is known, and a detailed history, a thorough clinical examination, and appropriate investigations, as well as high index of suspicion recommended [2]. Complications may include vascular injury, nerve injury (sciatic nerve in posterior dislocation and femoral nerve in anterior dislocation), avascular necrosis (10 % of hip dislocation in children), recurrent dislocation, and chondrolysis.

Late-Presenting Hip Dislocations Late-presenting hip dislocations are challenging injuries to manage. The child may even be ambulatory with a limb length discrepancy. Treatment becomes increasingly difficult as the duration of dislocation prolongs and may include heavy traction to reduce the dislocation or open reduction. The incidence of avascular necrosis as well as stiffness and pain in the hip is higher than in acute dislocation. Postoperative rehabilitation usually includes the period of recumbence followed by early return to activities as tolerated.

Femoral Shaft Fracture in Children Femoral shaft fracture in children follows a bimodal distribution. The first peak occurs in early childhood and the second in adolescence. The child usually presents with pain and inability to move the affected extremity. There may be sign of associated head, chest, abdomen, or other system injuries (Fig. 30.10). Hemodynamic instability may be present in a multisystem injury, and the ATLS protocol should be followed. It is estimated up to 80 % of femoral fractures in children below walking age may be related to abuse [18, 19]. A detailed history and a thorough search for signs of non-accidental injuries are mandatory.

Osteopenia due to osteogenesis imperfecta, cerebral palsy, myelomeningocele, or tumors should also be entertained in the diagnosis. Birth trauma is another cause. In austere environments where most children are born unsupervised at home, this may be more common. Young children have tremendous remodeling potential so conservative management in a pelvic harness, a splint, a hip spica cast, or traction (Gallow’s) can be used effectively to facilitate healing. The younger the age of the child, the less invasive is the preferred treatment. Shortening up to 2–3 cm is accepted as there is overgrowth about one and half centimeter during the remodeling phase [20]. Rotational deformity of less than 25° is thought to remodel well.

Application of a hip spica requires sedation/anesthesia and a hip spica table with fluoroscopy. The preferred position in the spica is a hip and knee flexion of 90°, hip abduction about 30° and external rotation of the distal fragment of about 15°. This “sitting spica” facilitates carrying the child on the parent’s hip [21].

Skin traction is tolerated up to 5 lb, but beyond this, skin complications such as blistering and sore can occur, and skeleton traction is preferable [2]. A distal femoral skeletal traction at the level just above the adductor tubercle is the preferred method. In older children, flexible intramedullary rods may be used to avoid prolonged recumbence [22]. Open fractures or highly comminuted fractures can be treated in an external fixator to preserve length and facilitate wound

[redacted]

[redacted]

[redacted]

Fig. 30.10 (**a**) X-ray showing right femoral shaft fracture and contralateral distal femoral fracture. (**b**) Clinical picture of the left fracture showing soft tissue circumferential degloving. (**c**) Plaster cast spica and left leg backslab to facilitate soft tissue management

care. Compression plating and antegrade nailing are other options for skeletally mature children. Internal fixation with flexible rods or external fixation is also recommended in a poly-traumatized or multiply injured child [14].

A compartment syndrome presenting with tense swelling of the thigh has to be recognized and addressed urgently. Complications of femur fractures may include muscle weakness, shortening, overgrowth, angular deformities, rotational

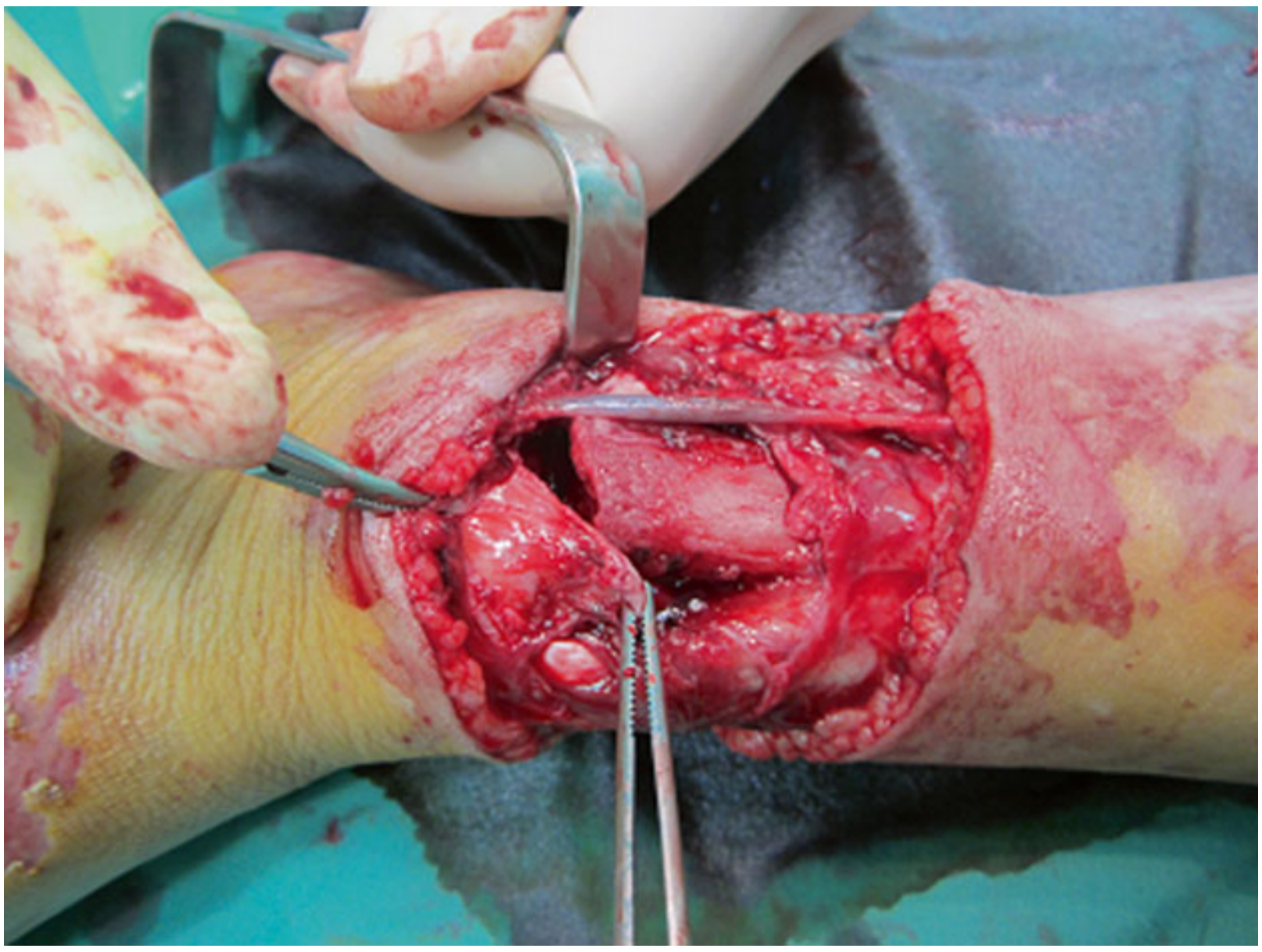

Fig. 30.11 Open fracture involving the growth plate of the distal tibia. The thick periosteum can be appreciated

deformities, delayed union, nonunion, infections, and neurovascular injuries. Special implants (expansile rods) are necessary for treating fractures in osteogenesis imperfecta. Floating knee injuries are high-velocity injuries, usually road traffic accidents. Associated injuries are common and ATLS guidelines should be followed. It is recommended that one of the fractures, usually the tibia, should be fixed and the femoral fracture is managed as appropriate for age of the child. Knee stiffness, limb length discrepancy, or angular deformities due to physeal injuries may be evident at follow-up.

Fractures Around the Distal Femoral and Proximal Tibial Epiphysis Salter–Harris type II injuries which extend from the physis to the metaphysis are most common. The degree of displacement detects the form of treatment chosen. It is important to rule out child abuse. A physeal separation may also be associated with breech birth. An ultrasonogram can help differentiate an epiphyseal separation from hematogenous osteomyelitis. Salter–Harris type III, IV, and specially V are associated with high incidence of growth disturbances and consequent limb length problems and angular deformities [23, 24]. Displaced fractures usually require reduction and fixation. A high index of suspicion for associated vascular injuries or compartment syndrome should be entertained. A color Doppler is useful where available. Internal fixation may be stabilized with smooth pins or cannulated screws taking care to avoid the physis wherever possible. Postoperatively, a period of non-weight bearing and physiotherapy for the quadriceps and hamstring muscles is done.

The principles of treatment of *tibial shaft fractures* are similar to femoral shaft fractures outlined above. Open tibia fractures are common and all effort must be directed to preventing or controlling infection [25, 26] (Fig. 30.11). Options for treatment include a long leg splint or cast, external fixation, or internal fixation using flexible nails or sometimes plates. Late-presenting fractures or those with delayed or malunion may warrant ORIF depending on the degree of displacement and age of the child. Bone grafting is used for avascular nonunions. A sagittal plane deformity of more than 10° or a coronal plane deformity of more than 5° warrants reduction and treatment by closed or open means.

Epiphyseal injuries around the ankle can lead to growth disturbances. Treatment follows the principles of physeal injuries around the knee outlined above. Most closed foot fractures can be managed nonoperatively in a bivalved cast or splint with non-weight bearing for 4–6 weeks. Open injuries and crush require vigilance, and urgent management is along the lines of open fractures elsewhere.

References

1. Wilkins KE. Nonoperative management of pediatric upper extremity fractures or 'Don't Throw Away the Cast'. Tech Orthop. 2005;20(2):115–41.
2. Rockwood and Wilkins' fractures in children. 5th ed. Philadelphia: Lippincott Williams & Wilkins; 2001. p. 443–82.
3. Do TT, Strub WM, et al. Reduction versus remodeling in pediatric distal forearm fractures: a preliminary cost analysis. J Pediatr Orthop. 2003;12B:109–15.
4. Price CT, Mencio GA, et al. Injuries to the shaft of the radius and ulna. In: Rockwood CA, Wilkins KE, Beaty JH, editors. Rockwood and Wilkins' fractures in children. 5th ed. Philadelphia: Lippincott Williams & Wilkins; 2001. p. 443–82.
5. Aitken AP. The end results of the fractured distal radial epiphysis. J Bone Joint Surg. 1935;17:302–8.
6. Rang M. Children's fractures. Philadelphia: JB Lippincott Co; 1974.
7. Charnley J. Closed treatment of common fractures. London: E & S Livingstone Ltd; 1957.
8. Bado J. The Monteggia lesion. Clin Orthop. 1967;50: 71–86.
9. Green NF, Swinkowski MF, editors. Skeletal trauma in children, vol. 3. 2nd ed. Philadelphia: WB Saunders; 2003.
10. Kaufman B, Rinott MG, Tanzman M. Closed reduction of fractures of the proximal radius in children. J Bone Joint Surg [Br]. 1989;71:66–7.
11. Wilkins KE, editor. Operative management of upper extremity fractures in children. Rosemont: American Academy of Orthopaedic Surgeons; 1994. p. 34.
12. Chia JP, Holland AJ, Little D, et al. Pelvic fractures and associated injuries in children. J Trauma. 2004;56(1):83–8.
13. Ismail N, Bellemare JF, Mollitt DL, et al. Death from pelvic fracture: children are different. J Pediatr Surg. 1996;31(1):82–5.
14. Tolo VT. Orthopaedic treatment of fractures of the long bones and pelvis in children who have multiple injuries. Instr Course Lect. 2000;49:415–23.
15. McIntyre Jr RC, Bensard DD, Moore EE, et al. Pelvic fracture geometry predicts risk of life-threatening hemorrhage in children. J Trauma. 1993; 35(3):423–9.
16. Lane-O'Kelly A, Fogarty E, Dowling F. The pelvic fracture in childhood: a report supporting nonoperative management. Injury. 1995;26(5):327–9.
17. Plaisier BR, Meldon SW, Super DM, et al. Improved outcome after early fixation of acetabular fractures. Injury. 2000;31(2):81–4.
18. Hinton RY, Lincoln A, Crockett MM, et al. Fractures of the femoral shaft in children: incidence, mechanisms, and sociodemographic risk factors. J Bone Joint Surg Am. 1999;81:5009.
19. Beals RK, Tufts E. Fractured femur in infancy: the role of child abuse. J Pediatr Orthop. 1983;3:583–6.
20. Shapiro F. Fractures of the femoral shaft in children: the overgrowth phenomenon. Acta Orthop Scand. 1981;52:649–55.
21. Czertak DJ, Hennrikus WL. The treatment of pediatric femur fractures with early 90–90 spica casting. J Pediatr Orthop. 1999;19:229–32.
22. Flynn JM, Hresko T, Reynolds RA, et al. Titanium elastic nails for pediatric femur fractures: a multicenter study of early results with analysis of complications. J Pediatr Orthop. 2001;21:4–8.
23. Riseborough EJ, Barrett IR, Shapiro F. Growth disturbances following distal femoral physeal fracture-separations. J Bone Joint Surg Am. 1983; 65:885–93.
24. Beaty JH, Kumar A. Fractures about the knee in children. J Bone Joint Surg Am. 1994;76:1870–80.
25. Gustilo RB. Current concepts in the management of open fractures. Instr Course Lect. 1987;36:359–66.
26. Kreder HJ, Armstrong P. A review of open tibia fractures in children. J Pediatr Orthop. 1995;15:482–8.
27. Banskota AK, Spiegel DA, Shrestha S, Shrestha OP, Rajbhandary T. Open reduction for neglected traumatic hip dislocation in children and adolescents J Pediatr Orthop. 2007;27(2):187–91.

31

Experience Using the IM Interlocking Screw System in Austere Environment

David Shearer and Lewis Zirkle

Surgeons in developing countries are heuristic and frequently learn to solve problems using the equipment available to them. Because C-arm technology is often unavailable, surgeons commonly use tactile rather than visual sense to treat fractures. SIGN implants and instruments rely on this tactile sense to successfully treat long-bone fractures with intramedullary nails. For the surgeon unaccustomed to operating without image guidance, learning these techniques requires practice and initially may require reliance on colleagues from developing countries who have more experience operating under these conditions. Nonetheless, for those willing to learn, they will find that the technique is easy to teach, highly versatile and reproducible and reliably facilitates effective stabilization of long-bone fractures.

Since its inception in 1999, SIGN implants have been used to treat 160,000 fractures in 49 developing countries. The approximately 5000 SIGN surgeons worldwide have reported 68,581 of the SIGN surgeries to an online surgical database [1]. This allows case by case feedback and increasingly facilitates clinical outcome research. The follow-up rate at the time of this publication is 43 % [1].

There are several publications documenting outcomes of the SIGN nail. Among the first publications was a small series of open tibia fractures in Nepal managed with IM nailing using SIGN technique who reported one nonunion and one deep infection in 32 consecutive patients [2]. Subsequent series have documented the feasibility and effectiveness of the SIGN nail for femoral shaft and other long-bone fractures [3–6]. In studies utilizing the SIGN database that include more than 30,000 patients, the infection rate has been shown to be 3.5 % for all femurs and 7.3 % for all tibias overall, similar to rates in developed countries [7–9]. Importantly, the benefits of IM nailing do not require excessive monetary expenditure with total treatment cost actually lower than skeletal traction [10].

31.1 Tibia

The approach and reduction of tibial fractures is similar in austere environments. The knee can be held in the flexed position using a towel bump, triangle or by hanging the leg over the side of

D. Shearer, MD, MPH (✉)
Department of Orthopaedic Surgery,
University of California San Francisco, San Francisco
General Hospital, Orthopedic Trauma Institutes,
San Francisco, CA, USA

San Francisco General Hospital,
San Francisco, CA, USA

Orthopedic Trauma Institutes,
San Francisco, CA, USA
e-mail: David.Shearer@ucsf.edu

L. Zirkle, MD
SIGN Fracture Care International,
Richland, WA, USA

© Springer International Publishing Switzerland 2016
J.D. Robinson (ed.), *Orthopaedic Trauma in the Austere Environment: A Practical Guide to Care in the Humanitarian Setting*, DOI 10.1007/978-3-319-29122-2_31

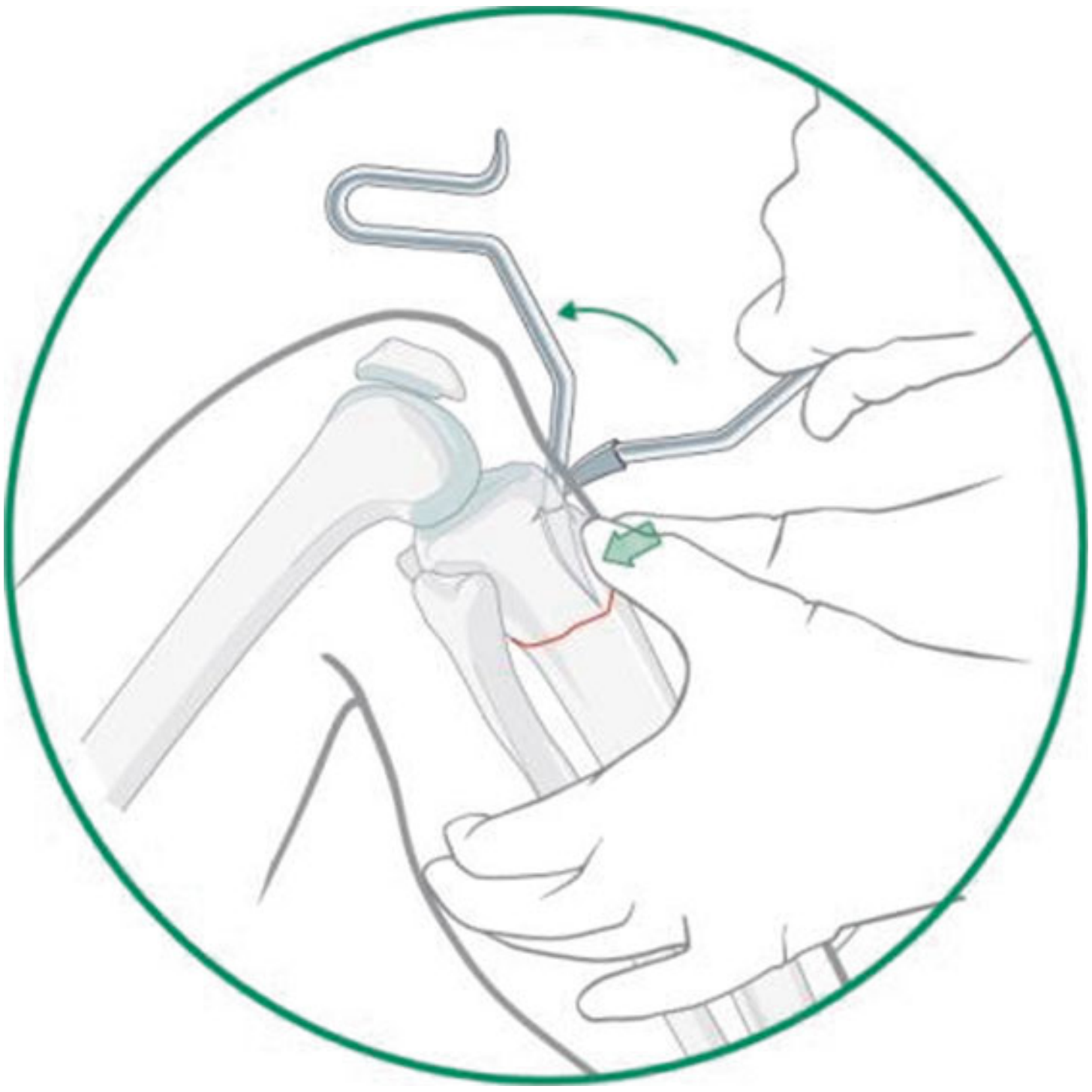

Fig. 31.1 In the Fig. 31.4 position, a surgeon can apply pressure proximal to the fracture to reduce the fracture (Figures and graphics courtesy of SIGN Fracture Care International, Richland, WA, USA, all rights reserved)

the table. Fractures of the proximal tibia can be reduced using the Fig. 31.4 position with an assistant placing pressure on the proximal fragment during reaming and nail insertion (Fig. 31.1). We have not found the suprapatellar approach to be necessary, and blocking screws are rarely needed. Fractures of the middle and distal tibia can generally be reduced by closed reduction within 10 days from injury.

Measurements of the tibia canal reveal an isthmus, which has led some surgeons to use the fin nail for proximal tibia fractures [1]. Placement of the interlocking screws is performed as described for the femur (Figs. 31.2 and 31.3).

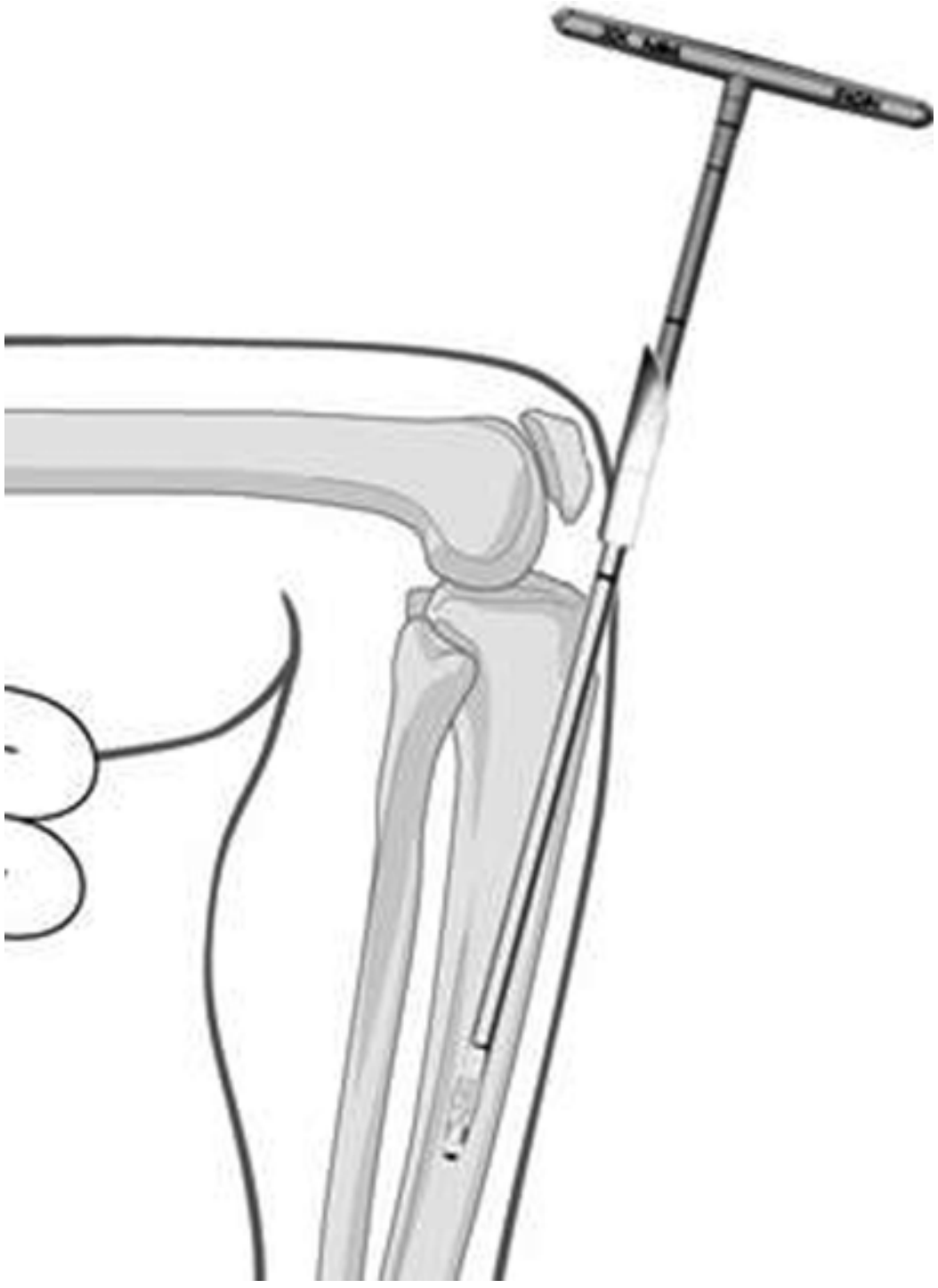

Fig. 31.2 110° of flexion is necessary to ream the tibia (Figures and graphics courtesy of SIGN Fracture Care International, Richland, WA, USA, all rights reserved)

31.2 Femur

A fractured femur is a devastating injury in developing countries. The patient usually must purchase the implant and surgical supplies prior to surgery, which makes surgical treatment unaffordable for a large number of patients. The primary alternative for adolescent and adult patients is skeletal traction, which in the best case scenario may lead to a healed fracture, but at the expense

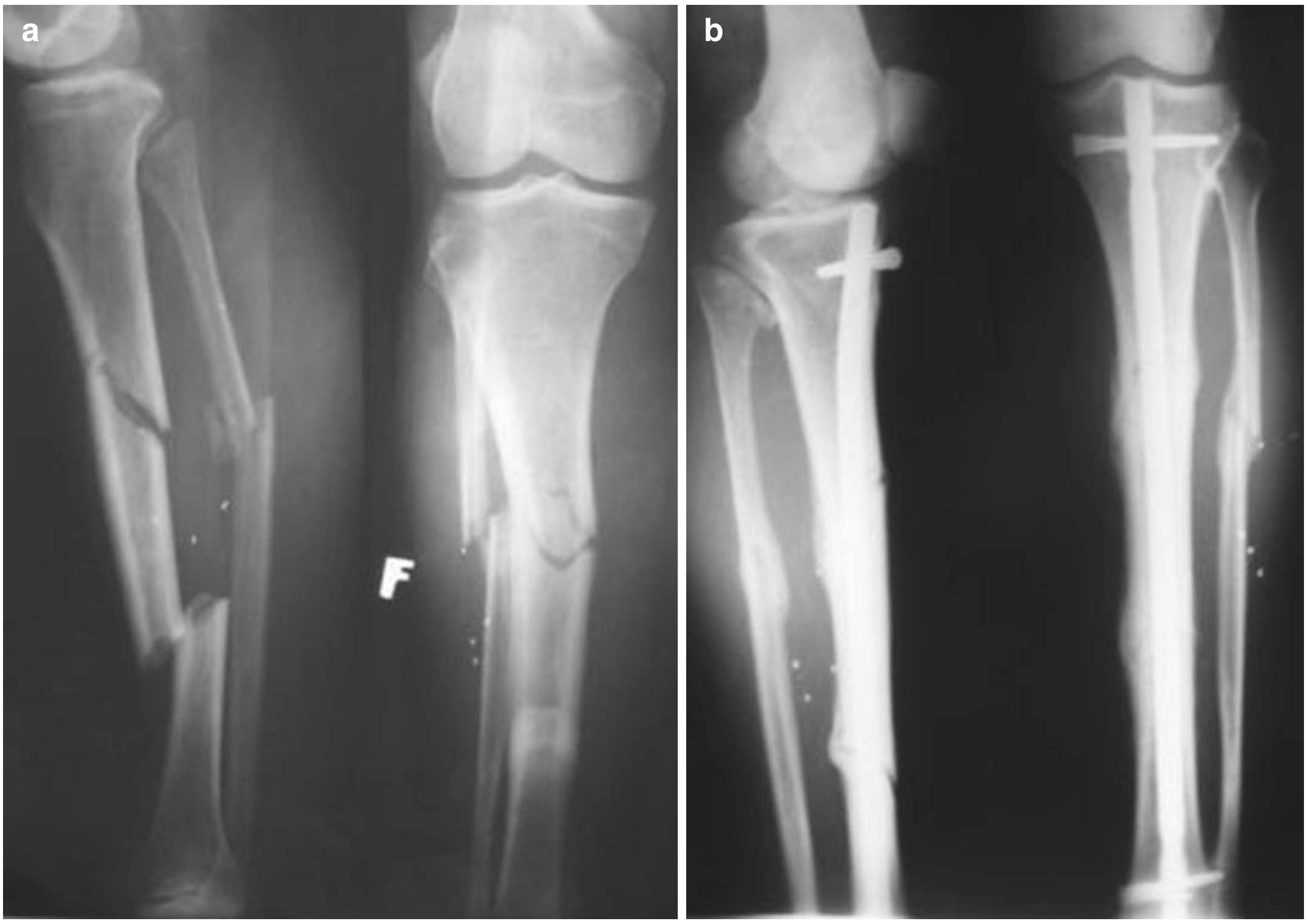

Fig. 31.3 (**a**, **b**) SIGN nail after closed reduction (Figures and graphics courtesy of SIGN Fracture Care International, Richland, WA, USA, all rights reserved)

of weeks or months of missed work for the patient and their caregivers. In addition, the duration of treatment contributes to overcrowding of hospital wards. In the worst case, skeletal traction may lead to permanent disability from malunion or nonunion [11].

Alternative implants that may be used for operative treatment include plating and external fixation. Outcomes of definitive treatment using these modalities are scant in the literature due to the relatively rapid adoption of intramedullary nailing in most developed settings several decades ago. In the authors' experience, plating remains a commonly employed alternative due to its relatively low cost and technical familiarity. However, it is generally accepted that plates are biomechanically disadvantaged and less "biologically friendly" than intramedullary nails due to the soft-tissue stripping necessary for plate application. This combination likely contributes to a higher rate of nonunion and plate breakage, though direct comparative studies are lacking. External fixation is considered an option for definitive treatment in children with open physes [12–14] or as a bridge to definitive fixation in unstable polytrauma patients unfit for early total care or severe soft-tissue or vascular injury [15]. While these alternative implants may be available in some settings, based on personal experience of the senior author, the lack of optimal implants leads many good surgeons to grow frustrated and leave their country of origin to practice where they can more easily utilize their surgical training.

Even when there is an appropriate implant available, there will often not be a functioning C-arm. Without imaging guidance, open reduction of the fracture is usually necessary if the patient is operated within 10 days of injury. Review of the SIGN database has shown that the infection rate using predominantly open reduction with the SIGN nail is similar to published rates of long-bone fractures treated by both closed and open reduction [8]. A key benefit of open reduction is improved rotational alignment,

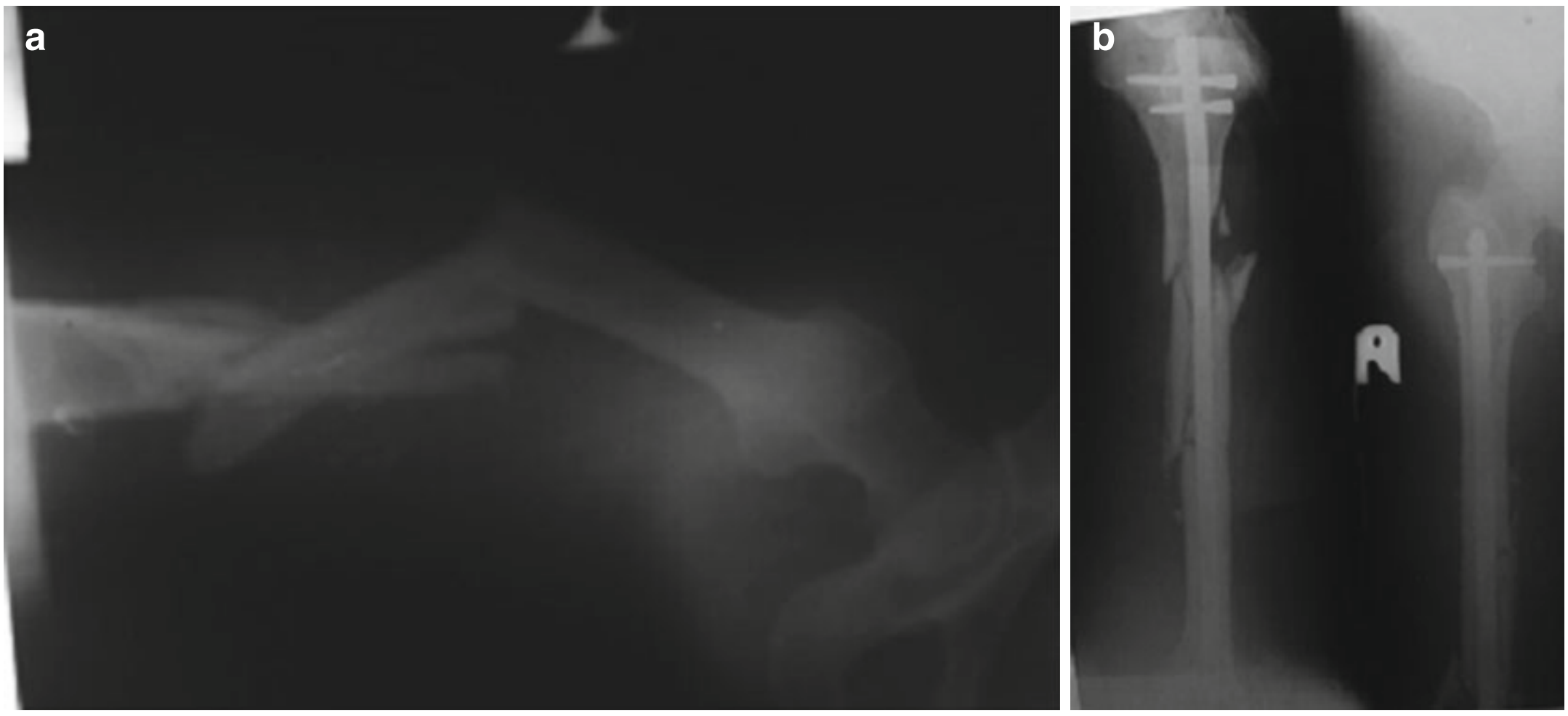

Fig. 31.4 (**a**, **b**) After exposure of the two major fragments, the femur is pulled out to length and the nail passed without exposing the comminuted fragments (Figures and graphics courtesy of SIGN Fracture Care International, Richland, WA, USA, all rights reserved)

which is achieved by palpating the linea aspera to orient the bone fragments. If the fracture is comminuted, only the intact bone at the proximal and distal ends of the fracture is exposed, leaving the comminuted segment undisturbed with intact blood supply (Fig. 31.4). If there is a delay to the operating room, reduction will be much easier if the patient is maintained in skeletal traction on the ward prior to surgery.

Due to irregular electricity, hand reaming is performed rather than power reaming prior to nail insertion. Hand reaming has the advantage of lower risk of thermal necrosis and perforation of the canal [16–20]. In addition, bone can be saved from the flutes of the reamer for use as autograft at the fracture site. The graduated size of the reamers prepares the canal for acceptance of the straight nail.

The SIGN nail is a solid, stainless steel nail with no arc of radius. The solid nail has the theoretical benefit of a lower rate of infection [21]. Although stainless steel does not adhere to the bone to the same degree as titanium, the straight nail achieves three-point fixation for additional stability in the bowed femoral canal (Fig. 31.5). A 9° proximal bend allows for a trochanteric start site and the 1.5° distal bend provides added tactile feel as the nail passes through the canal. The SIGN nail follows a helical path as the proximal bend enters the proximal femoral canal. We recommend allowing the nail to rotate along the path of least resistance during insertion to minimize hoop stresses in the femoral neck. This may lead to interlocking screw trajectories that take an anterior-to-posterior rather than lateral-to-medial trajectory, which are equally stable (Figs. 31.6 and 31.7).

A target arm that matches the length of the nail is used to determine longitudinal orientation of the interlocking screw slots. The SIGN nail has slots rather than holes which allow for compression and distraction of the fracture to accelerate healing. After inserting the nail and attaching the target arm, a hole is drilled through the near cortex and enlarged using a hand-operated step drill. The step drill is designed to lock into the slot if appropriately aligned. There are three different types of slot finders used to locate the distal slots. After removing the step drill, the solid slot finder is inserted. If successful, the solid slot finder will turn 10–15°, known as the “SIGN feel.” Next, a cannulated slot finder is inserted to act as a drill guide for the far cortex. In some cases, the nail must be rotated to find the slot. A curved slot

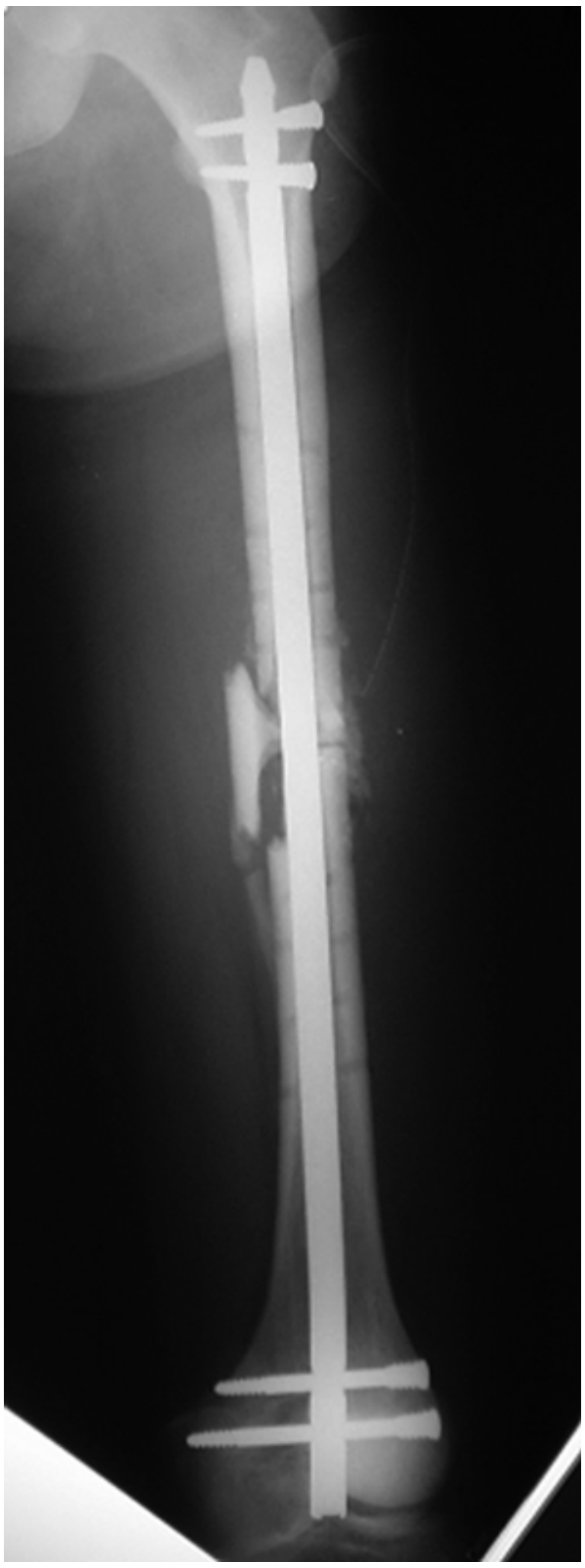

Fig. 31.5 Retrograde SIGN nail to treat a midshaft femur fracture (Figures and graphics courtesy of SIGN Fracture Care International, Richland, WA, USA, all rights reserved)

finder is provided to allow identification of the slot when there is mismatch between the nail and the target arm. Once the distal interlocking screws have been placed, the fracture is compressed and the proximal interlocking screws are placed using the target arm (Figs. 31.8, 31.9, and 31.10).

The patient is allowed to walk on crutches with weight bearing as tolerated within days after the surgery. After 6 weeks, pictures are taken of the patient squatting and smiling to evaluate bone healing. These images are submitted along with postoperative and follow-up x-rays on the SIGN database. In the experience of the senior author, the photographs of a patient squatting and smiling are more accurate in determining bone healing than x-rays (Fig. 31.11).

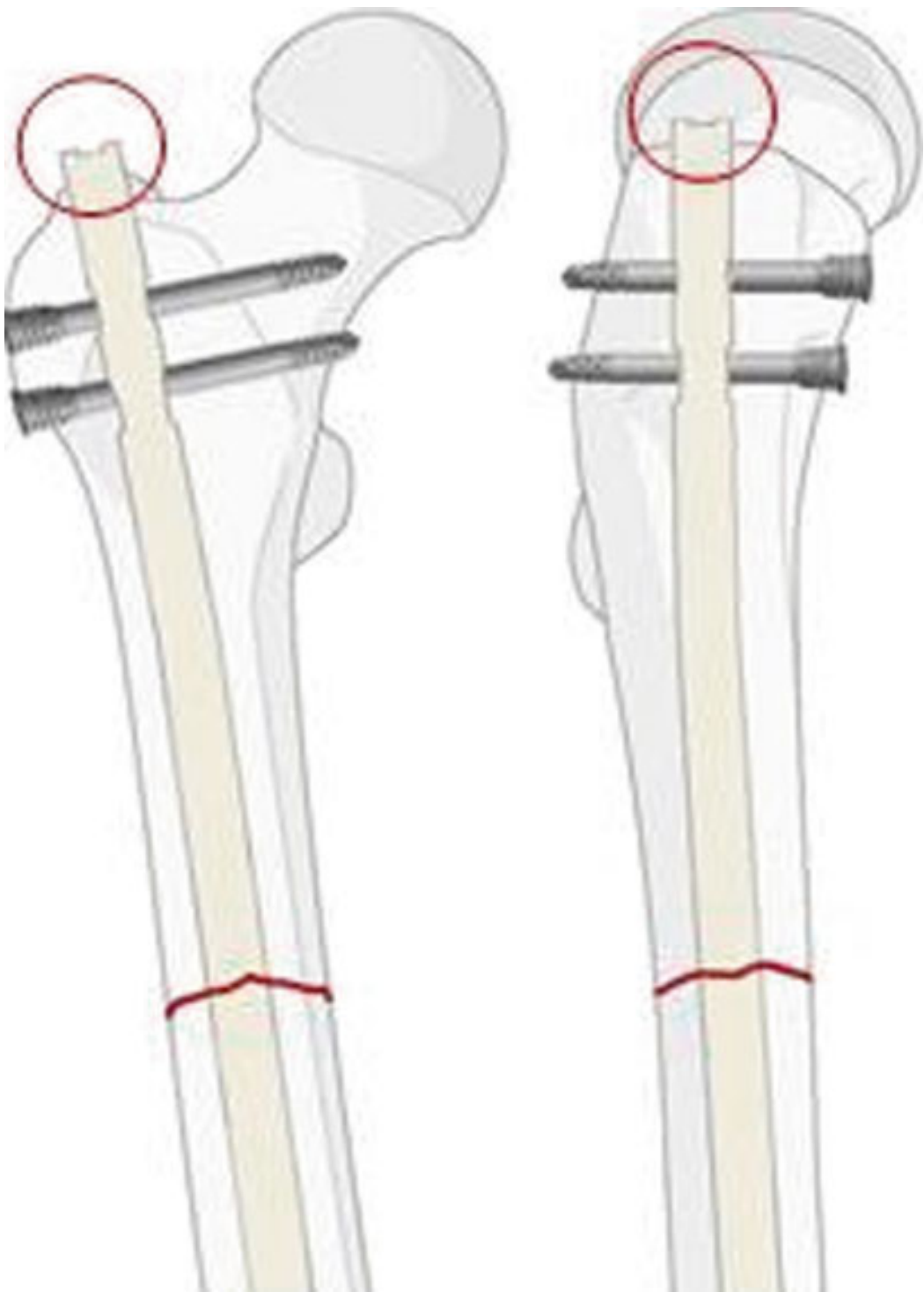

Fig. 31.6 The interlocking screws placed lateral to medial (Figures and graphics courtesy of SIGN Fracture Care International, Richland, WA, USA, all rights reserved)

As with other IM nail systems, the SIGN nail can be used with either an antegrade or retrograde approach. Fractures of the distal femur are well suited for the retrograde approach. A patellar splitting or medial parapatellar approach may be used. The medial parapatellar approach has the added benefit of being extensile, which may be helpful when learning to perform the technique without C-arm. Ending a retrograde nail or placing interlocking screw holes within 6 cm distal to the lesser trochanter is not recommended to avoid periprosthetic fracture.

31.2.1 Fin Nail

As an alternative to interlocking using the target arm, SIGN has designed and manufactures a fin nail that relies on an interference fit for distal fixation. The fin has a fluted configuration at the distal end, which is similar in shape to the end of the hand reamer. The straight nail in the curved canal leads to three-point fixation with the fin engaging the side of the canal (Fig. 31.12). The technique is similar to the standard nail insertion except that the distal canal is left under-reamed to allow for improved interference fit. It can be used with the antegrade or retrograde approach to the femur. There have been approximately 2700 femur and humerus fractures stabilized with the fin nail reported in the SIGN database to date [1]. Published comparisons of the fin nail to conventional interlocking nails are lacking, but in the senior author's experience the design has successfully stabilized a variety of fracture patterns with good clinical outcomes.

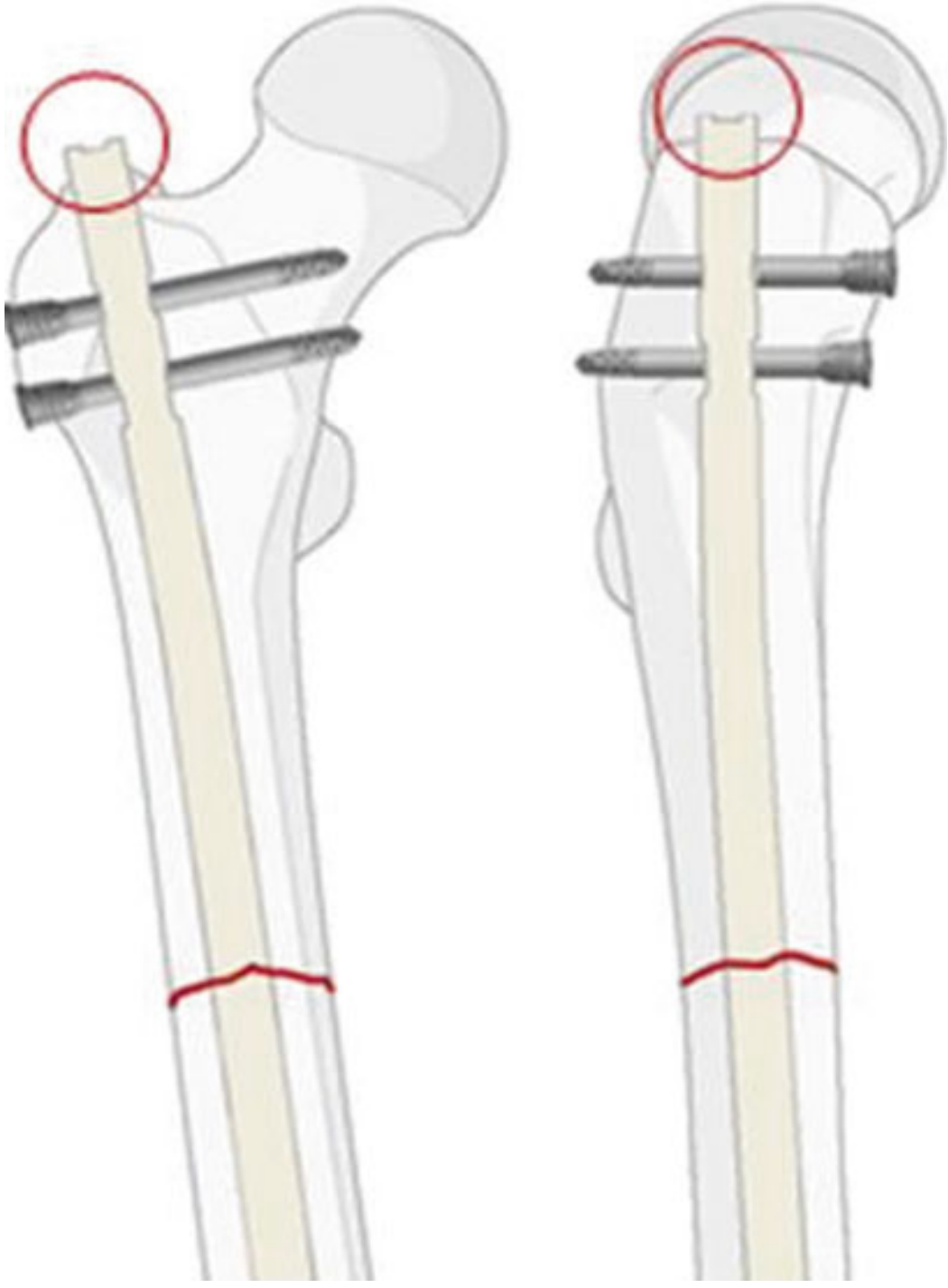

Fig. 31.7 The interlocking screws passed anterior to posterior (Figures and graphics courtesy of SIGN Fracture Care International, Richland, WA, USA, all rights reserved)

31.3 Humerus

Fractures of the humerus have been successfully treated using both standard SIGN nails and fin nails (Fig. 31.13). It is important that the elbow be placed on the operating table during nail insertion to avoid the fracture becoming distracted. These fractures are usually treated using the antegrade approach although some surgeons have routinely used the retrograde approach.

Fig. 31.8 The SIGN nail uses a long target arm to achieve distal interlocking without C-arm (Figures and graphics courtesy of SIGN Fracture Care International, Richland, WA, USA, all rights reserved)

31.4 Adolescent Pediatric Femur Fractures

The increase in trauma in developing countries as a result of road traffic injuries, especially motorcycles, has led to a large volume of pediatric femur fractures in addition to fractures in adults [22]. SIGN has designed a semirigid pediatric femoral nail that uses the fin design for distal fixation rather than interlocking screws below (Fig. 31.14). The 4 mm diameter shaft is flexible enough to conform to the femoral canal and allows some fracture subsidence that helps to compensate for the overgrowth that typically occurs with pediatric femur fractures. Because we have found canals in some countries are larger than those in the United States, SIGN has developed and obtained FDA approval to manufacture a 6 mm diameter pediatric femoral nail. For larger children, the adult fin nail has been used successfully.

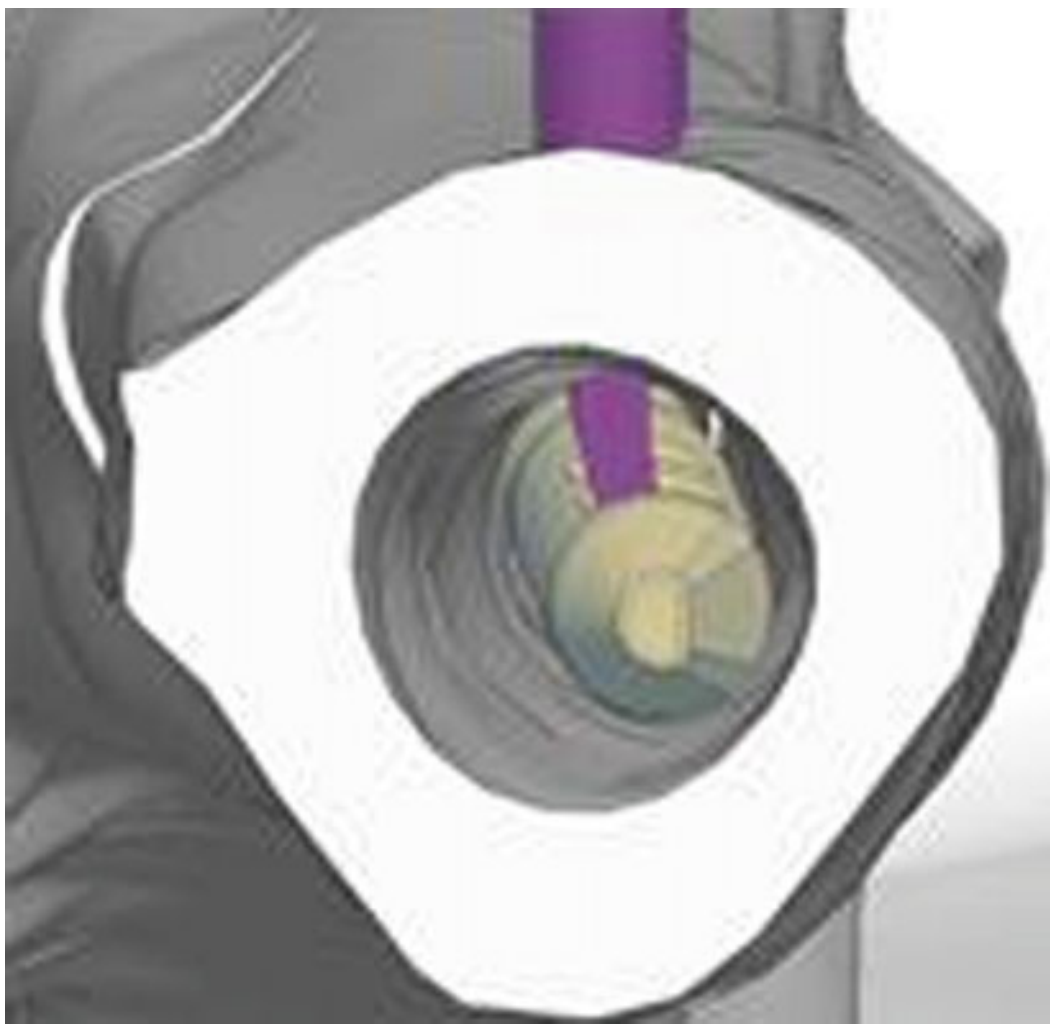

Fig. 31.9 The curved slot finder is rotated 180° and fully enters the slot with rotation of the nail (Figures and graphics courtesy of SIGN Fracture Care International, Richland, WA, USA, all rights reserved)

The nails are placed through the lateral trochanteric apophysis. To date, there have been over 135 adolescent femur fractures treated using the SIGN pediatric fin nail [20].

31.5 Extracapsular Hip Fractures

The SIGN hip construct (SHC) is a unique implant designed to treat stable and unstable pertrochanteric fractures without C-arm or a fracture table. SIGN surgeons provided the stimulus to develop the SHC; in the absence of a suitable alternative, they were using the standard SIGN

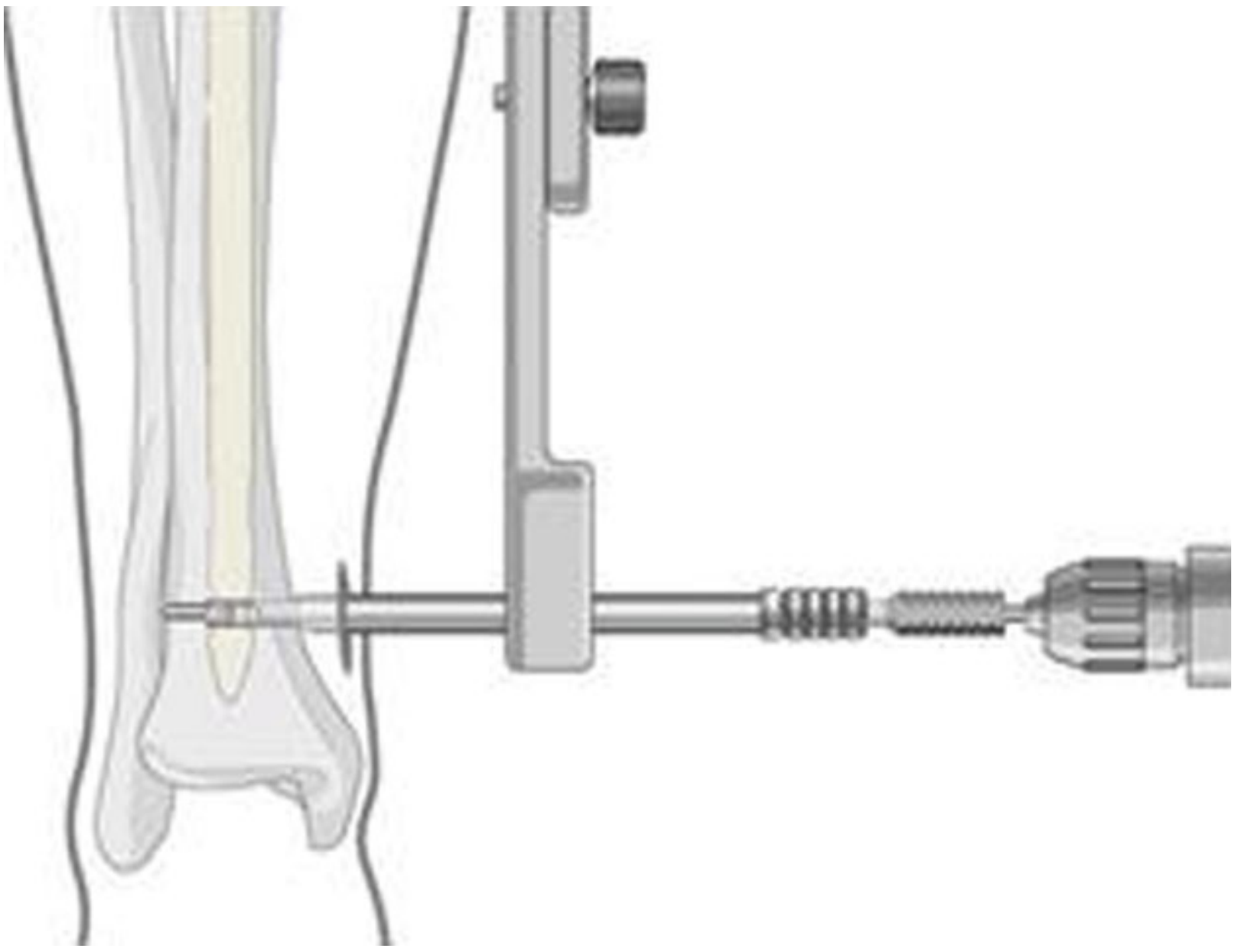

Fig. 31.10 After placement of the cannulated slot finder in the slot of the nail, the far cortex is drilled (Figures and graphics courtesy of SIGN Fracture Care International, Richland, WA, USA, all rights reserved)

Fig. 31.11 The squat and smile picture indicates fracture healing (Figures and graphics courtesy of SIGN Fracture Care International, Richland, WA, USA, all rights reserved)

nail to treat hip fractures. A large percentage of hip fractures in developing countries occur in young males injured in motorcycle accidents, which are often high-energy injuries with extension into the femoral shaft. This suggested that the proper implant would need the versatility to treat a wide variety of fracture patterns from the standard intertrochanteric fracture to the comminuted pertrochanteric fracture, neither of which was adequately treated with the standard nail.

The SHC utilizes a modular design with similar instrumentation to the standard SIGN nail but with additional components that can be used depending on the fracture pattern. The key components are the nail, two compression screws that pass along the nail into the femoral head, a single proximal interlocking screw, and an optional lateral plate for fractures with an unstable lateral wall (Fig. 31.15).

The length and angle of the compression screws is determined by templating from the uninvolved hip x-rays. The patient is placed in the lateral position and a lateral incision is made over the greater trochanter distal to the vastus ridge. To assess fracture reduction without C-arm, the vastus lateralis is incised and a finger can be placed anteriorly along the fracture site. In contrast to the comminution that frequently takes place posteromedially, the anterior femur is usually not comminuted because it is a tension failure. The surgeon can direct the assistant to provide rotation and traction on the limb while palpating the fracture until a satisfactory reduction is obtained. Fractures treated within 4 weeks of injury can usually be reduced without directly exposing the fracture site. We do not suggest routine direct open reduction of intertrochanteric fractures as this often leaves little vascularized bone for healing.

After reduction has been obtained, an entry hole for the first compression screw is drilled 1 cm below the vastus tubercle at the angle determined in preoperative templating. This hole is enlarged using the step drill and chamfered to the proper angle. A hand instrument, known as the pilot, is directed along the anterior femoral neck into the femoral head. The pilot has a rigid T-handle that gives the surgeon the tactile sense to keep the drill in cancellous bone as it progresses into the femoral head. The anterior compression screw is placed after removing the pilot, which provides provisional fixation and compresses the fracture site anteriorly. This screw is often sufficient to hold reduction during placement of the rest of the SHC construct. Nonetheless, the fracture site should be checked periodically by palpation to ensure that reduction is not lost. The nail is inserted through the tip of the greater trochanter and rotated such that the interlocking screw is directed into the femoral head. The target arm and slot finders are used to place the distal interlocking screw. Bench testing has demonstrated that the distal interlocking screw improves the stability of the construct.

Fig. 31.12 The antegrade fin nail used to treat a proximal femur fracture (Figures and graphics courtesy of SIGN Fracture Care International, Richland, WA, USA, all rights reserved)

Fig. 31.13 Standard SIGN nail for a midshaft humerus fracture (Figures and graphics courtesy of SIGN Fracture Care International, Richland, WA, USA, all rights reserved)

The proximal interlocking screw for the SHC is larger than the interlocking screw for the standard nail. There is only a single interlocking screw because the femoral neck cannot accommodate two interlocking screws and two compression screws. Prior to placing the proximal interlocking screw, the femur should be assessed for a fracture in the lateral wall of the trochanter distal to the interlocking screw, which may not be apparent on the preoperative radiographs. If a fracture is detected, a plate can be placed to link the interlocking screw with a second screw inserted more distally. The plate is aimed to prevent unstable fractures from falling into varus, which is supported by our biomechanical testing and review of cases reported to the SIGN Database [1, 23]. The final screw is the posterior compression screw. This is placed 1 cm distal to the anterior compression screw through the posterior lateral cortex and angled to enter the femoral head. The patient is usually allowed to walk the day following surgery. The SHC has been used in 950 patients with hip fractures as reported to the SIGN database [1].

31.6 Other Tools

There are several other useful innovations that may help the surgeon attempting to treat long-bone fractures in austere conditions. Drill covers that can be easily sterilized allow more affordable commercially available carpenter drills to be safely used in the operating room. The drill is placed within the sterile cover, and a sterile chuck is placed through a hole in the cover into the drill (Fig. 31.16). In addition to much lower cost, multiple drill covers and chucks can be sterilized simultaneously at the beginning of the day, which saves time.

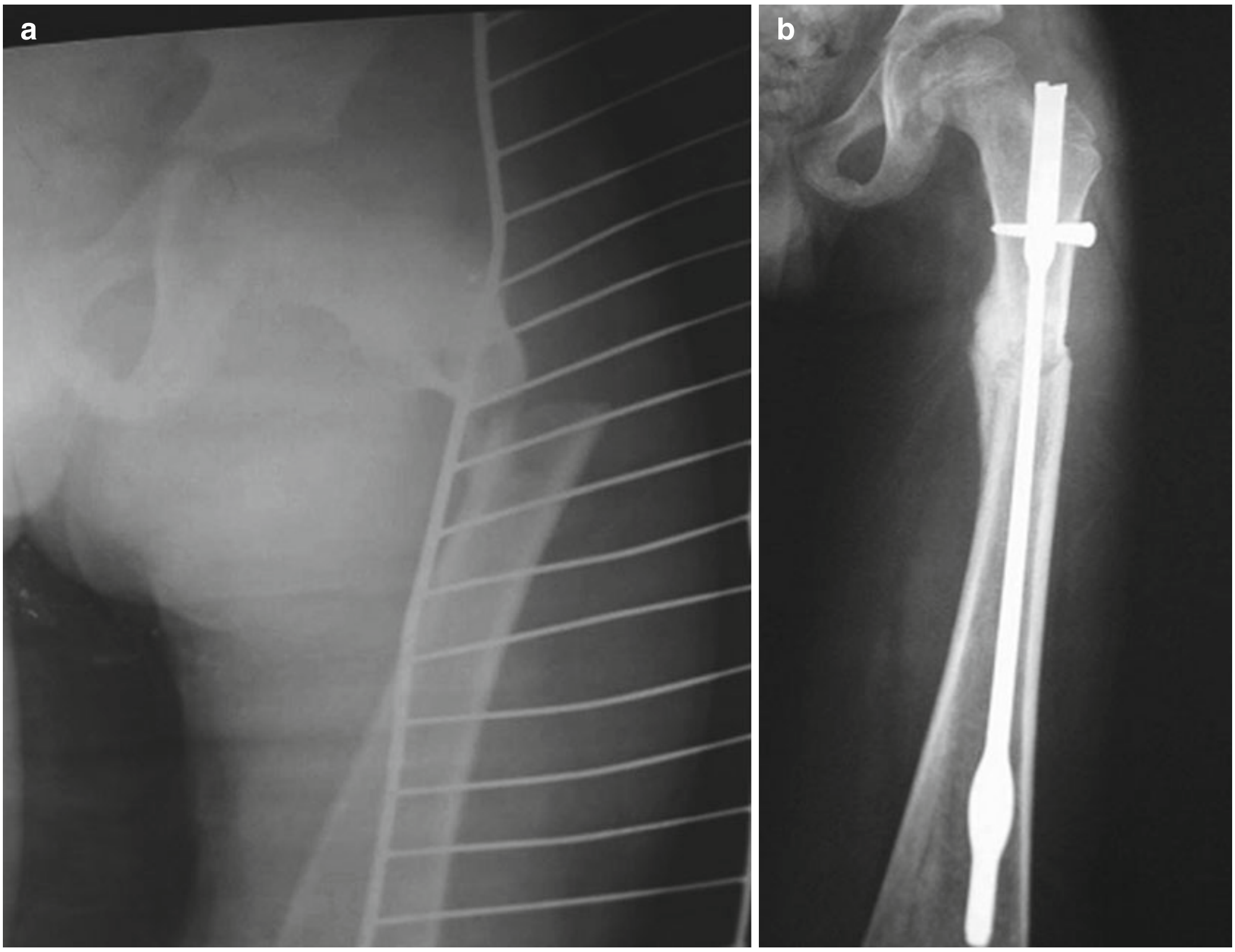

Fig. 31.14 (**a**, **b**) The SIGN pediatric nail (Figures and graphics courtesy of SIGN Fracture Care International, Richland, WA, USA, all rights reserved)

Fig. 31.15 The SHC uses two compression screws placed along the nail into the femoral head with a single proximal interlocking screw for proximal fixation. The lateral plate helps to act as a buttress in cases with lateral wall involvement (Figures and graphics courtesy of SIGN Fracture Care International, Richland, WA, USA, all rights reserved)

Fig. 31.16 (**a**, **b**) The drill cover is sterilized and placed over the drill which has the quick release already placed. The sterile chuck is then placed into the quick release. A hardware drill can then be used in a sterile fashion in surgery (Figures and graphics courtesy of SIGN Fracture Care International, Richland, WA, USA, all rights reserved)

References

1. SIGN Surgical Database. SIGN Fracture Care International. 2014. Accessed 2/14/2014.
2. Shah RK, Moehring HD, Singh RP, Dhakal A. Surgical Implant Generation Network (SIGN) intramedullary nailing of open fractures of the tibia. Int Orthop. 2004;28:163–6.
3. Ikem IC, Ogunlusi JD, Ine HR. Achieving interlocking nails without using an image intensifier. Int Orthop. 2007;31:487–90.
4. Ikpeme I, Ngim N, Udosen A, Onuba O, Enembe O, Bello S. External jig-aided intramedullary interlocking nailing of diaphyseal fractures: experience from a tropical developing centre. Int Orthop. 2011;35:107–11.
5. Naeem-Ur-Razaq M, Qasim M, Khan MA, Sahibzada AS, Sultan S. Management outcome of closed femoral shaft fractures by open Surgical Implant Generation Network (SIGN) interlocking nails. J Ayub Med Coll Abbottabad. 2009;21:21–4.
6. Ogunlusi JD, St Rose RS, Davids T. Interlocking nailing without imaging: the challenges of locating distal slots and how to overcome them in SIGN intramedullary nailing. Int Orthop. 2010;34:891–5.
7. Shearer D, Cunningham B, Zirkle L. Population characteristics and clinical outcomes from the SIGN online surgical database. Tech Orthop. 2009;24:273–6.
8. Young S, Lie SA, Hallan G, Zirkle LG, Engesaeter LB, Havelin LI. Low infection rates after 34,361 intramedullary nail operations in 55 low- and middle-income countries: validation of the Surgical Implant Generation Network (SIGN) online surgical database. Acta Orthop. 2011;82:737–43.
9. Young S, Lie SA, Hallan G, Zirkle LG, Engesaeter LB, Havelin LI. Risk factors for infection after 46,113 intramedullary nail operations in low- and middle-income countries. World J Surg. 2013;37:349–55.
10. Gosselin RA, Heitto M, Zirkle L. Cost-effectiveness of replacing skeletal traction by interlocked intramedullary nailing for femoral shaft fractures in a provincial trauma hospital in Cambodia. Int Orthop. 2009;33:1445–8.
11. Gosselin R, Lavaly D. Perkins traction for adult femoral shaft fractures: a report on 53 patients in Sierra Leone. Int Orthop. 2007;31:697–702.
12. Blasier RD, Aronson J, Tursky EA. External fixation of pediatric femur fractures. J Pediatr Orthop. 1997;17:342–6.
13. Domb BG, Sponseller PD, Ain M, Miller NH. Comparison of dynamic versus static external fixation for pediatric femur fractures. J Pediatr Orthop. 2002;22:428–30.
14. Skaggs DL, Leet AI, Money MD, Shaw BA, Hale JM, Tolo VT. Secondary fractures associated with external fixation in pediatric femur fractures. J Pediatr Orthop. 1999;19:582–6.

15. Nowotarski PJ, Turen CH, Brumback RJ, Scarboro JM. Conversion of external fixation to intramedullary nailing for fractures of the shaft of the femur in multiply injured patients. J Bone Joint Surg Am. 2000;82:781–8.
16. Bedi A, Karunakar MA. Physiologic effects of intramedullary reaming. Instr Course Lect. 2006;55:359–66.
17. Giannoudis PV, Snowden S, Matthews SJ, Smye SW, Smith RM. Temperature rise during reamed tibial nailing. Clin Orthop Relat Res. 2002:(395)255–61. PubMed PMID: 11937890.
18. Henry SL, Adcock RA, Von Fraunhofer JA, Seligson D. Heat of intramedullary reaming. South Med J. 1987;80:173–6.
19. Leunig M, Hertel R. Thermal necrosis after tibial reaming for intramedullary nail fixation. A report of three cases. J Bone Joint Surg Br. 1996;78:584–7.
20. Roberts JW, Libet LA, Wolinsky PR. Who is in danger? Impingement and penetration of the anterior cortex of the distal femur during intramedullary nailing of proximal femur fractures: preoperatively measurable risk factors. J Trauma Acute Care Surg. 2012;73:249–54.
21. Horn J, Schlegel U, Krettek C, Ito K. Infection resistance of unreamed solid, hollow slotted and cannulated intramedullary nails: an in-vivo experimental comparison. J Orthop Res. 2005;23:810–5.
22. Patton GC, Coffey C, Sawyer SM, Viner RM, Haller DM, Bose K, Vos T, Ferguson J, Mathers CD. Global patterns of mortality in young people: a systematic analysis of population health data. Lancet. 2009;374:881–92.
23. Roth J, Shearer D, Zirkle LGJ, Johnson A, LaBarre P. Development and biomechanical testing of the SIGN hip construct. Tech Orthop. 2009;24:265–72. 210.1097/BTO.1090b1013e3181c1093ef1047.

Part VI

Practical Guides to Orthopaedic Trauma Management in the Austere Environment

32

Management of Spine Injuries in the Austere Environment

Kyle R. Stephens

Proper management of spinal injuries in resource-poor environments poses many challenges. In developed nations, these injuries are identified and transported via professional emergency medical personnel to specialized spine trauma centers where their care is provided by specialists and subspecialists from multiple disciplines. Such centers are equipped with advanced imaging capabilities and can coordinate surgical interventions among multiple surgical disciplines. Well-trained rehabilitation staff is also available to assist with the recovery process. Low- and middle-income countries often do not have these resources. Thus, these injuries present late to local hospitals, without proper immobilization and where they are treated with whatever means are available. Unfortunately, little information exists in the literature about the management of such injuries in resource-poor settings and ways to improve the care of these complex patients.

32.1 Epidemiology

The global incidence of spinal cord injury is reported as 23 per million (179,312 cases per year) [1–8]. Although developed countries have higher numbers of traumatic spinal cord injuries, the incidence is relatively stable. Data from some developed countries is well recorded in national databases and readily available for analysis. This is not the case in less developed regions of the world. Nevertheless, the trends show that developing countries are showing increasing rates of traumatic spinal cord injuries associated with a dramatic rise in motorized transportation [9]. Reports of traumatic spinal cord injuries from the United States show a relatively unchanged rate of 40 cases per million which is significantly higher than developing countries. Data for sub-Saharan Africa is less readily available, but extrapolated totals show rates between 21 and 29 cases per million. It is possible that the real figures are higher, as the accuracy of such numbers is questionable [8].

Spinal cord injuries show a bimodal distribution, with injuries peaking in young active people less than 40 years of age and in the elderly over the age of 65 [8–10]. Among the young, the most commonly reported mechanisms of injury are high-energy road traffic accidents and falls from significant heights, typically trees that people climb to gather fruit, for example. Spinal cord injuries in the elderly are typically the result of low-energy mechanisms such as falls from a standing height directly onto their forehead forcing their cervical spines into hyperextension.

The majority of injuries among young people occur in males during their most active and

---

K.R. Stephens, DO
Spinal Surgery, Regions Hospital, St Paul, MN, USA
e-mail: Kyle.R.Stephens@HealthPartners.Com

© Springer International Publishing Switzerland 2016

J.D. Robinson (ed.), *Orthopaedic Trauma in the Austere Environment: A Practical Guide to Care in the Humanitarian Setting*, DOI 10.1007/978-3-319-29122-2_32

Fig. 32.1 Proper immobilization includes a hard collar, flanked by a bag of saline or sand, and secured with tape from one side of the bed, across the forehead, and to the other side of the bed. An additional piece of tape should be placed across the chin (not shown in above example)

productive years. In most developing countries, males are the financial providers for their household and a traumatic spinal cord injury has severe socioeconomic consequences for the families, often plunging them further into poverty with very little chance of recovery [7].

32.2 Initial Management

It is important to identify spinal injuries early and accurately in order to provide optimal care and to limit associated morbidity. Remember that, because many injuries are secondary to high-energy trauma, associated injuries are common.

Patients with suspected spinal cord injuries should ideally be transported secured on a hard spinal board, with the head immobilized by triple immobilization (Fig. 32.1). This means the head should be in between two 1-l saline bags or sand bags and secured with tape across the forehead and across the chin. Anything less *is not immobilization.* The rigid backboard is important for transporting a spinal trauma patient though it is important to remember that prolonged time on the backboard increases the likelihood of pressure sores (Fig. 32.2). Once the patient has arrived at a hospital, the patient should be logrolled for a spine and rectal exam and the board removed.

Many patients present to the hospital obtunded or unconscious, making a thorough and accurate physical examination challenging. Initial management of all trauma patients is based on established trauma life-support principles of airway maintenance with c-spine control, respiratory, and hemodynamic support. ATLS (Advanced Trauma Life Support) principles follow the ABCDE pathway with the intent to address those issues that will kill the patient the quickest [11].

32.3 ATLS Protocol Summary

A: airway maintenance with cervical spine protection
B: breathing and ventilation
C: circulation with control of hemorrhage
D: disability and neurologic evaluation
E: exposure

Only after these steps have been completed is a secondary survey performed. This entails a complete physical exam from head to toe. Each extremity should be palpated and each joint taken through a range of motion assessing for crepitus or instability that may alert one to the presence of additional injuries, particularly in the unconscious patient.

Fig. 32.2 Example of a rigid backboard used for transporting spinal trauma patients. Prolonged time on the board may cause pressure sores so it is important to remove the board once the patient has arrived at the hospital and a proper log roll can be performed

32.3.1 Log Roll

As a team, the patient should be *logrolled* in order to palpate the spinous processes to assess for pain, tenderness, obvious step-off, or other signs of injury (i.e., ecchymosis, lacerations, etc.) (Fig. 32.3). Imaging should also be obtained which includes a chest x-ray, AP pelvis, lateral cervical spine, and any additional images of affected extremities (Table 32.1).

32.3.2 Neurological Assessment

A detailed neurological review is part of the secondary survey and involves a careful examination of both upper and lower extremities for motor function, sensation, and reflexes (Tables 32.2 and 32.3). It is crucial to check for perianal sensation and voluntary sphincter contraction as these differentiate a complete spinal cord injury from an incomplete injury. Upper cervical injuries are often lethal due to involvement of the diaphragm and require emergent intubation to sustain life ("C3, 4, 5 keeps the diaphragm alive"). The level of affected sensation and motor function should be accurately documented in order to compare to future examinations. The higher the level of injury in the cervical spine, the greater the morbidity is accompanying the injury. In the lumbar spine, L4 is typically required for independent ambulation. Upper motor neuron signs such as Babinski's reflex, Hoffman's reflex, and sustained clonus are important to assess to differentiate upper and lower motor neuron injuries.

32.3.3 Classification of Neurologic Injuries

Neurologic injuries from spinal trauma are typically differentiated between injuries to the nerve root and those that affect the spinal cord. Nerve root injuries, such as those from a herniated disk, are lower motor neuron injuries and have the potential to recover, whereas cord injuries affect upper motor neuron tracts with less ability to recover. Spinal cord injuries are broadly differentiated between complete and incomplete. Complete injuries lack motor function and sensation below the injured level, whereas incomplete injuries retain some degree of sensation and/or function below the level of the injury. Two primary classifications are commonly used to describe the degree of severity of neurologic deficits – the Frankel Classification and the ASIA (American Spinal Injury Association) Impairment Scale.

The Frankel Classification, popularized in the 1970s, divided the level of injury into five

Fig. 32.3 Log-rolling technique. (**a**) Secure head and c-spine. The person securing the c-spine calls the timing of the roll. (**b**) Two other people positioned at the patients side, the person (i) closer to patient's head has a hand on the greater trochanter area and a hand on the shoulder, and the person (ii) who is closer to the feet has a hand on the hip and the other on the knee. The person securing the c-spine gives command to coordinate the smooth log roll. The physician examines the spine for any signs of injury (steps, crepitus, alignment) and tenderness. A rectal examination may also be carried out at this stage looking for blood, a high-riding prostate, and muscle tone and sensation around the perineum. Make sure your team practices this skill

categories given the notation of grades A through E. Grade A notes complete paralysis with no motor or sensory function below the injury level. Grades B, C, and D all note incomplete spinal cord injuries. Grade B is no motor function but retained sensory function below the level of the injury. Grade C is the presence of incomplete motor function below the injury level. Grade D is fair to good motor function below the injury level. Type E is normal function.

The ASIA Impairment Scale (AIS) replaced the Frankel Classification in 1982 as the internationally accepted definition of spinal cord injury. Like the Frankel scale, Grade A is a complete cord injury, Grades B, C, and D are incomplete injuries, and Grade E is normal

Table 32.1 Summary: initial management of spinal trauma

1. ATLS protocol
2. Immobilization
(a) At scene of injury: hard cervical collar, backboard, sandbags with tape
(b) Proper log-roll technique
(c) Transfer to nearest hospital with highest level of care
3. Imaging
(a) Radiographs: AP, lateral, open-mouth odontoid x-ray in cervical collar
(b) CT scan (if available)
(c) Do *not* remove cervical collar for imaging! It stays in place until cervical spine is cleared!
4. Hospital management
(a) *Prevent hypotension:* keep MAP (mean arterial pressure) >85 mmHg
(b) *Oxygen*: via nasal cannula. Intubation without moving cervical spine if required
(c) *Foley catheter*: urinary retention is common with spinal cord injury
(d) *Nasogastric tube*: may be necessary to decompress abdomen (watch for paralytic ileus)
(e) *Intravenous fluids*: monitor fluid status with urine output. Do not overhydrate
(f) *Cervical spine clearance*: negative exam (no neurologic findings) and negative imaging studies

Table 32.2 Strength testing grading system

Grade	Description
1	Palpable or visible contraction but no motion
2	Motion with gravity eliminated
3	Motion against gravity
4	Motion against gravity and some resistance
5	Normal strength against full resistance

function and sensation. The AIS emphasizes the involvement of sacral segments S4–S5 with anal sensation and voluntary sphincter contraction as a means of differentiating complete from incomplete injuries. ASIA A is a complete injury with no anal sensation or voluntary sphincter contraction. ASIA B is intact sensation but no motor function below the neurological level. ASIA C is intact sensation and intact motor function below the neurological level, but more than 50 % of key muscles have muscle strength of 1 or 2. ASIA D is intact sensation and intact motor function below the neurological level, but more than 50 % of key muscles have a muscle strength grade of 3 or more. ASIA E is a normal exam with normal sensation and motor function.

Incomplete spinal cord injuries can also occur in distinct patterns. *Central cord syndrome* is the most common pattern seen and occurs when the cord is compressed peripherally toward the core. Because of the anatomic arrangement of the spinal cord – the cervical and upper extremity tracts are located centrally within the cord compared to the more peripheral sacral and lower extremity tracts – the upper extremities are more affected than the lower extremities (Fig. 32.4). Central cord syndrome is a common injury in the elderly with preexisting spondylosis who fall and hit their head. The prognosis for regaining function is good. *Anterior cord syndrome* is typically a vascular-related injury that affects the anterior spinal tracts of motor function and pain/temperature sensation. *Posterior cord syndrome* is very similar to anterior cord syndrome except that it affects the posterior columns responsible for vibration and proprioception. It is quite rare as the result of a traumatic injury. *Brown-Sequard syndrome* is an injury to half of the spinal cord, typically from a penetrating stab or gunshot wound, where motor function is impaired on the ipsilateral side of the injury but pain/temperature are impaired on the contralateral side because of the decussation of the neuronal tracts.

32.3.4 Shock: Spinal Versus Neurogenic

Patients with spinal injuries, particularly those with injuries to the spinal cord, often present in shock. Hemorrhagic shock is typical with many

Table 32.3 Examination chart of upper and lower extremity motor function, sensation, and reflexes important to examine during the exam

Examination: sensory, motor, and reflexes				
	Root	Motor function	Sensation	Reflex
Upper extremity	C5	Shoulder abduction, elbow flexion	Lateral shoulder and arm	Biceps
	C6	Wrist extension	Thumb	Brachioradialis
	C7	Elbow extension, wrist flexion	Middle finger	Triceps
	C8	Finger flexion	Small finger	None
	T1	Finger abduction	Medial elbow	None
Lower extremity	L2/L3	Hip flexion	Anterior groin and thigh	None
	L4	Knee extension	Anterior knee	Patellar
	L5	Ankle dorsiflexion	Lateral leg, dorsal foot	None
	S1	Ankle plantarflexion	Posterior leg	Achilles
	S3/S4	Bowel and bladder function	Perianal	Cremasteric
Upper motor neuron findings	Hyperactive reflexes, clonus >3 beats, Hoffman's reflex, Babinski's reflex			

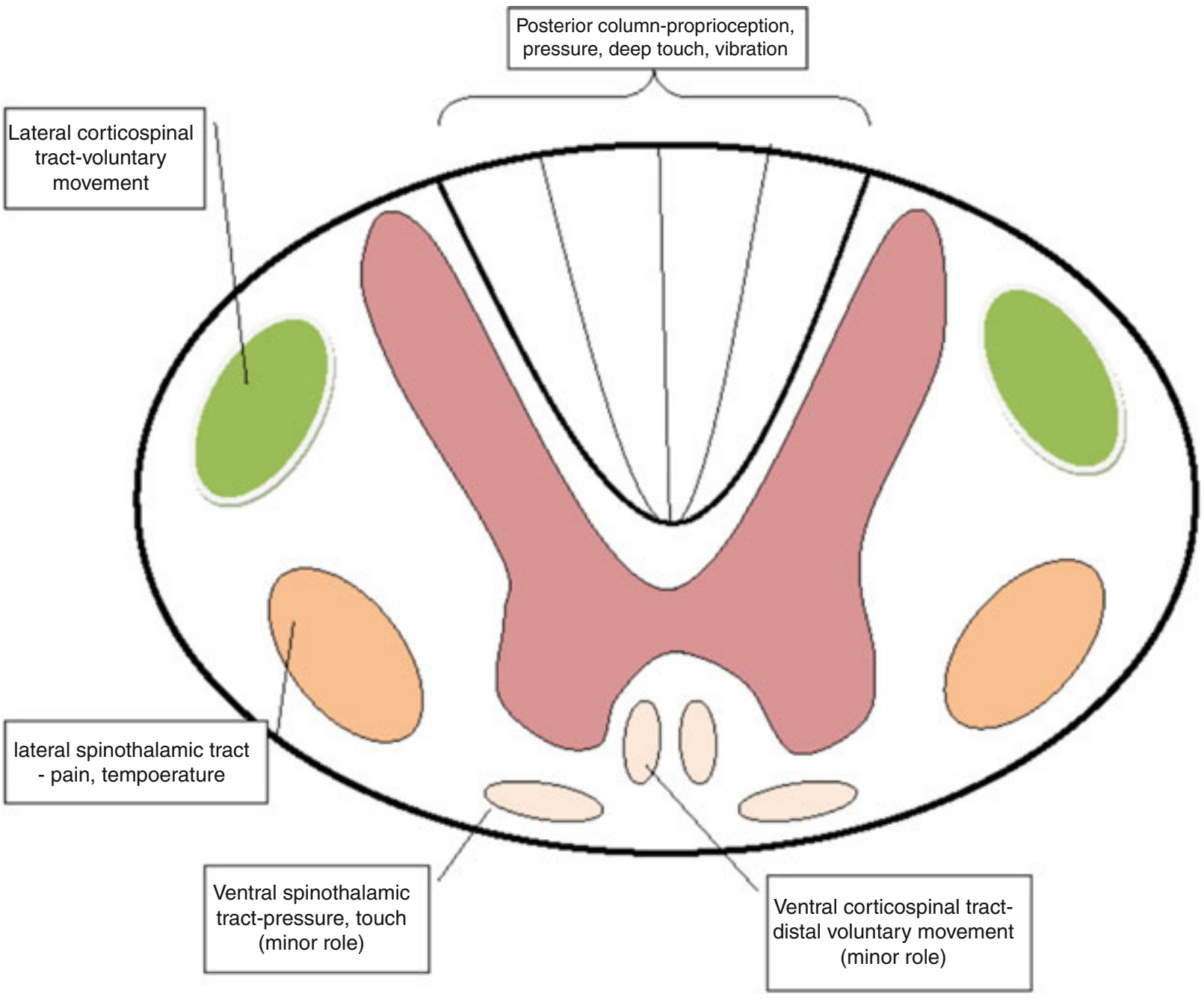

Fig. 32.4 Anatomy of the spinal cord. The dorsal column is primary responsible for proprioception, deep touch, and vibration. The lateral corticospinal tract is responsible for voluntary muscle movement. The lateral spinothalamic tract is responsible primarily for pain and temperature sensation

high velocity injuries and is the most common cause of death in trauma patients. It is characterized by hypotension and tachycardia depending on the amount of blood volume lost. Spinal shock and neurogenic shock are more common with spinal cord injuries and it is important to differentiate them. Both are characterized by flaccid paralysis with hypotension and *bradycardia* due to systemic vasodilation from loss of sympathetic tone. Spinal shock, however, is temporary and is considered complete with the return of the bulbocavernosus reflex – indicated by anal sphincter contraction with a tug on a patient's foley catheter. This reflex, if it returns, typically does so within 48–72 h of injury. Management of both spinal shock and neurogenic shock requires vasopressors as isolated intravenous fluids will not regulate the patient's hemodynamics.

32.3.5 Steroids and Spinal Cord Injury

High-dose methlyprednisolone has been a popular treatment for patients with spinal cord injuries with the goal of interrupting the inflammatory cascade responsible for many of the permanent neurologic deficits observed. Early literature seemed to suggest that patients who received high-dose steroids within 8 h of injury showed superior neurologic recovery. However, recent studies have not validated these findings and unveiled significant side effects of such large doses of steroids, leading the majority of spine trauma centers to avoid high-dose intravenous steroids as a treatment option [12].

32.4 Cervical Spine Injuries

The cervical spine is a common site of injury because it is the most mobile of the all the spine segments. The most common mechanism of injury in both developing and developed countries is a road traffic accident followed by falls from significant heights [9]. Motorcycle crashes are a very common etiology for cervical spine injuries, particularly in developing countries where helmets are worn infrequently [12]. These injuries have a higher tendency toward complete spinal cord injuries than lower spinal injuries and thus account for a large number of deaths, typically secondary to respiratory failure. As expected, cervical spine injuries tend to have extremely high rates of tetraplegia compared with paraplegia.

Cervical spine injuries are typically divided into upper cervical (occiput – C2) and lower cervical injuries (C3–C7). Upper cervical injuries – including craniocervical dissociation, displaced odontoid fractures, and traumatic spondylolisthesis of C2 – often have a high associated morbidity and mortality, especially in developing countries (Figs. 32.5 and 32.6). Many of these injuries are fatal at the site of the accident or shortly thereafter. Injuries above C4 also impact the function of the diaphragm, and thus, many patients who survive the injury succumb to respiratory failure within days of their injury. Lower cervical spine injuries also have the potential for devastating consequences to the patient. Though classifications attempt to describe injuries based on the position of the neck during injury (i.e., flexion vs. extension, compression vs. distraction, etc.), the most common classification is a simple descriptive classification. Common injury patterns noted in the cervical spine are facet fracture-dislocations (unilateral or bilateral), axial load injuries (burst and compression fractures), and extension injuries (teardrop fractures).

Fig. 32.5 CT scan of an odontoid fracture (C2) in an elderly female with significant osteoarthritis changes from a fall from standing height hitting her forehead forcing her cervical spine in hyperextension. She was treated nonoperatively in a hard cervical collar and suffered no neurologic deficits

Fig. 32.6 C5-6 bilateral facet dislocation with complete spinal cord injury in a 17-year-old female after a high-speed motor vehicle accident. Note the translation of more than 50 % of the vertebral body. Spinal cord injuries are very common in cervical bilateral facet dislocations

Table 32.4 Summary: cervical spine clearance

Must clear occiput – T1
Should be performed by emergency room physician, neurosurgeon, or orthopedic surgeon
Cervical spine may be cleared without imaging if patient has:
No difficulty answering questions or participating in exam
No neck pain at rest or to palpation
No neurologic deficits with full range of motion
No drugs or alcohol in their system
No distracting injuries
Cervical radiographs (AP, lateral, open-mouth odontoid) should be obtained if any of the above criteria are not met

All unconscious and obtunded patients should receive imaging including CT and/or MRI if available

The majority of cervical spine injuries can be detected on plain radiographs. A typical series includes an anteroposterior (AP), lateral, and open-mouth odontoid views. It is important to be able to visualize the cervicothoracic junction (C7–T1), and sometimes a swimmer's view is necessary to accomplish this. The radiographs, particularly the lateral view, should be carefully reviewed looking for disruptions to any of the four normal lines: anterior vertebral line, posterior vertebral line, spinolaminar line, and the posterior spinous process lines. Translation of one vertebral body on another can also be detected on the lateral radiograph, particularly with a facet dislocation which largely occurs in the lower cervical spine. Unilateral facet dislocations will translate approximately 25 %, whereas bilateral facet dislocations may translate 50 % or more. The open-mouth odontoid view can identify instability of the upper cervical spine, specifically an injury to the transverse ligament, if there is greater than 7 mm of lateral mass step-off seen on the radiograph. The presence of deformity (i.e., kyphosis) should also clue the observer to the presence of an injury with potential instability. If the patient is neurologically stable, additional radiographs such as flexion-extension views are helpful to assess for spinal column stability.

32.4.1 Management

Management of cervical injuries requires identification and stabilization of the spinal column. This begins at the scene of the accident where basic trauma principles are crucial (Table 32.4). Multiple studies report that a large number of patients are transported to hospitals by either a bystander or a family member via any means possible. Many are transported in personal vehicles, sometimes animal-drawn carts or even motorcycles, without any cervical support device which tragically converts some incomplete injuries into complete spinal cord injuries en route to the hospital [13].

Conservative treatment is the modus operandi of cervical spine trauma in countries without surgical capabilities. Once an unstable cervical injury is identified on radiographs, the patient is placed in skull traction and kept supine in bed for

Table 32.5 Application of cervical spine traction

Perform in an awake patient. Stop if neurologic exam changes
Avoid in patients with possible skull fractures or occipital-atlantal injuries
Method of temporary stabilization
Pin placement: apply pins 1 cm proximal to the pinna of the ear in line with the external auditory meatus
Apply pressure to the pins until the spring-loaded button protrudes 1 mm
Weight: begin with 10 lbs. May add 5–10 lbs per level as you descend down the spine in 10–20 min intervals. Maximum necessary usually less than 100 lbs
Hard collar may be removed while patient is in traction
Clean pin sites daily with povidone-iodine solution
Monitor with frequent radiographs with every weight addition and daily while in traction

approximately 6 weeks (Table 32.5). They are then placed in a rigid collar for an additional 3–6 months. Upper cervical spine injuries – occiput through C3 – are often best treated in a halo device when available. In the setting of a facet dislocation, closed reduction is indicated with the used of cervical traction and confirmed with repeat lateral cervical spine radiographs. Urgent decompression is indicated in the setting of a progressive neurologic deficit and can be performed from either an anterior, posterior, or combined approach. Papers report open posterior stabilization performed with wiring of the posterior spinous processes with success [14]. Postoperatively, the patients are placed in a cervical collar for 3–6 months and monitored for neurologic deterioration (Figs. 32.7, 32.8, 32.9, and 32.10).

32.5 Thoracic Spine Injuries

Fractures of the thoracic spine are less commonly seen, presumably because of the stabilizing force of the rib cage and sternum anteriorly. However, the spinal cord extends through the thoracic spine down to approximately the L1vertebrae through a narrow spinal canal, and thus, there are still a significant number of complete spinal cord injuries reported. Injuries are most commonly seen at each end of the thoracic spine at the cervicothoracic junction (C7–T1) and thoracolumbar junction (T11–L2). As expected, the majority of thoracic spinal cord injuries result in far less incidence of quadriplegia though injuries involving the uppermost thoracic vertebral levels near the cervicothoracic junction have reported neurological deficits in all four extremities. Typical fracture patterns include axial load fractures (compression fracture, burst fractures) or distraction injuries (posterior ligamentous or bony disruption) (Fig. 32.11).

Management of thoracic spine fractures is typically conservative, especially where surgical capabilities are limited. Compression and burst fractures with no or little neurological injury have been shown to have excellent outcomes with conservative treatment including bracing for up to 12 weeks. Operative intervention is reserved for patients with progressive neurologic deficits and unstable injuries. The literature is varied regarding surgical stabilization of fractures with spinal cord injuries. In patients with incomplete cord injuries, stabilization to prevent further injury is often supported, especially if the symptoms are progressing. Complete injuries, however, have no sensation or motor function distal to the injury site and nonoperative management is preferred [15]. The primary form of treatment consists of placing patients with a thoracic fracture in a thoracolumbar cast or brace with bed rest for approximately 6 weeks. Then, they are discharged home in a brace for an additional few months, regardless of their neurologic status.

32.6 Thoracolumbar Junction and Lumbar Spine Injuries

Lumbar spine fractures are the most common spine fracture noted with the most common injuries occurring at the thoracolumbar junction (T11–L2). Anatomically, the lumbar spine is normally in lordosis as compared with the natural kyphosis of the thoracic spine. The facet orientation also shifts from the coronal-oriented

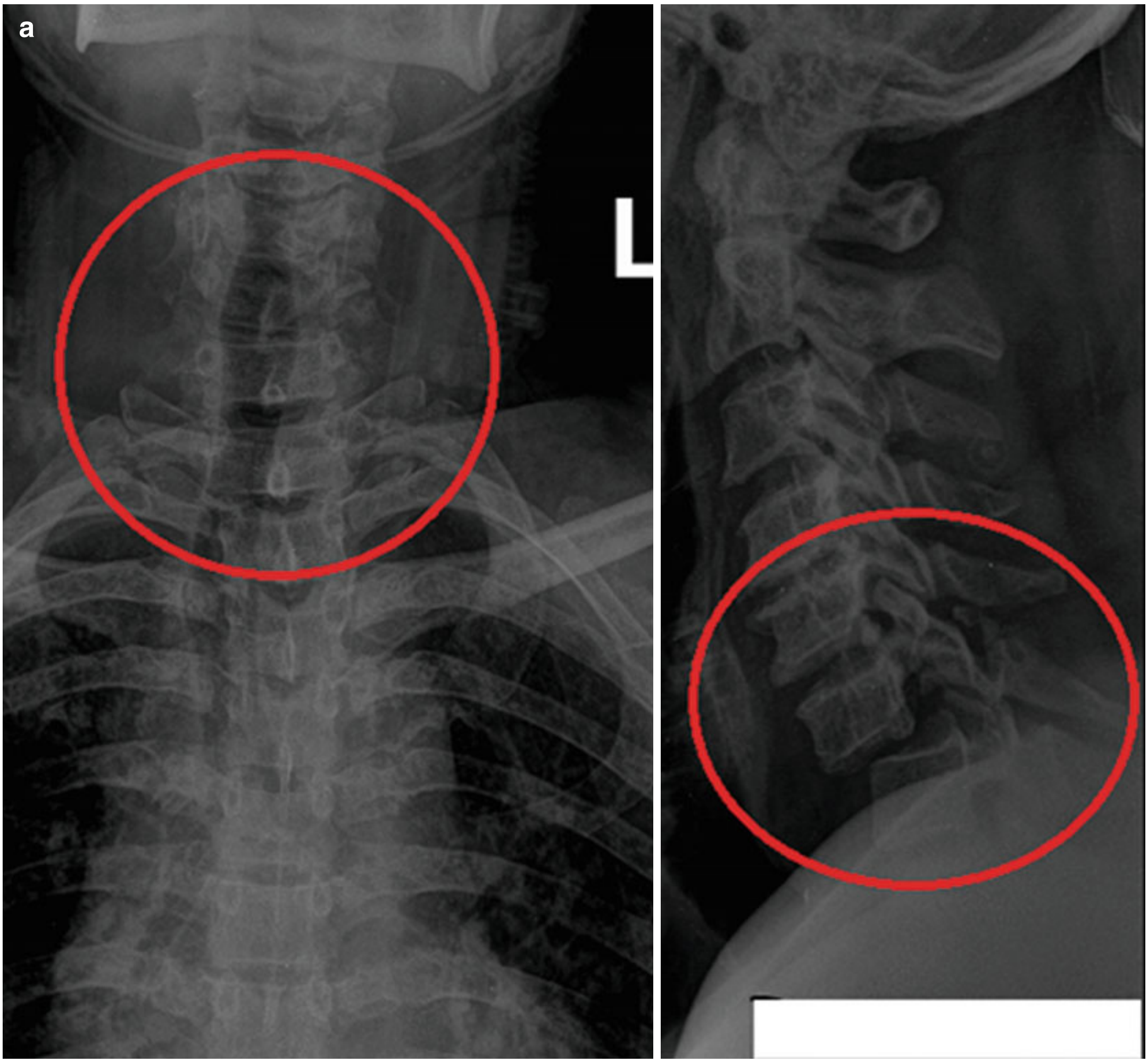

Fig. 32.7 (**a**) C6–C7 bilateral facet dislocation. Note the anterior subluxation greater than 50 % of the vertebral body. (**b**) C6–7 bilateral facet fracture postreduction being treated in a Minerva collar and brace made of fiber glass. These braces can be made of plaster of Paris as well. It is vital to stabilize the sternum, occiput, and mandible with these braces. (**c**) As seen, a Miami J cervical collar can be incorporated into the brace if a Minerva brace is not available commercially

Fig. 32.7 (continued)

[redacted] [redacted] [redacted] [redacted] [redacted] [redacted]

Fig. 32.8 Commercially available Minerva brace

thoracic spine into the more sagittal orientation of the lumbar spine facets. The most widely used concept for understanding fracture stability in this region is the three-column theory – anterior, middle, and posterior – introduced by Denis [16]. The anterior column consists of the anterior longitudinal ligament, the anterior annulus, and the anterior vertebral body. The middle column consists of the posterior vertebral body wall, the posterior longitudinal ligament, and posterior annulus. The posterior column includes the posterior spinal elements posterior to the posterior longitudinal ligaments – pedicles, lamina, facets, transverse processes, spinous processes, and the ligamentous attachments.

The three-column theory is also used to describe the common fractures seen in the lumbar spine though it does not offer treatment recommendations (Fig. 32.12). *Compression fractures*, the most common fracture seen, are axial load injuries that involve only the anterior column. The middle column remains intact, and thus, there is a very low incidence of neurologic deficit. *Burst fractures* also result from axial forces but are fractures that involve both the anterior and middle columns. The posterior vertebral body wall is often retropulsed into the spinal canal toward the neural elements. X-rays typically show loss of height and fracture of the posterior vertebral body wall, while the AP view often shows widening of the interpedicular distance compared with adjacent vertebrae. Chance fractures are the third type of fracture described by Denis and involve all three columns. Commonly seen with seat-belt wearers, the anterior column typically fails in compression, while the middle and posterior columns fail in tension.

32.6.1 Management

Management of lumbar fractures is typically dependent on the degree of vertebral body collapse, degree of kyphosis, and the presence of neurologic compromise. Compression fractures are generally treated nonoperatively unless relative indications of 20° of kyphosis or over 50 % of vertebral body collapse are met (Fig. 32.13). These are the values at which the posterior ligamentous complex is stretched beyond its ability to maintain stability. Most patients have excellent

Fig. 32.9 Proper placement of Gardner-Wells tongs for cervical traction. The tongs should be placed 1 cm above the ear pinna in line with the external auditory meatus

outcomes with brace treatment which can help to lessen pain. *Burst fracture* treatment guidelines are also controversial with varying operative indications (Fig. 32.14). Commonly reported surgical indications include kyphosis over 20°, over 50 % vertebral collapse, and greater than 50 % canal compromise though there are no absolute values that mandate surgical intervention. Injuries with progressive neurologic deficits should be decompressed and stabilized with either instrumentation and/or bracing. *Flexion-distraction injuries* (i.e., Chance fractures) of all three columns can either be osseous or ligamentous with surgical intervention warranted for purely ligamentous injuries and unstable fractures (Fig. 32.15). Thoracolumbar and lumbar injuries are treated almost exclusively nonoperatively much like thoracic fractures [17]. Regardless of neurological deficit, patients are placed in a thoracolumbar brace and stay in bed for approximately 6 weeks. Afterward, they are discharged in a brace for an additional 3–6 months.

Fig. 32.10 Young Kenyan man involved in high-energy trauma who presented with C5–6 bilateral facet dislocation. He was reduced closed and underwent open posterior stabilization with plate and screw fixation. Patient was neurologically intact postoperatively and note the restoration of alignment of the anterior and posterior vertebral body lines (Courtesty of Dr Daniel Galat, MD)

32.7 Emergency Operative Management: Decompression and/or Fusion

Spinal injuries can present with symptoms that require emergent decompression and/or fusion in order to preserve or prevent further neurologic injury. Such surgeries are performed for typically either compression of the spinal cord and/or nerve roots or mechanical instability of the spinal column. Incomplete spinal cord injuries or injuries with progressive neurologic deficits should be decompressed as quickly as possible, preferably within 24 h of injury. Complete spinal cord injuries do not require such urgent timing and may be performed within 3–5 days post-injury once the patient is optimized medically. In other instances such as central cord syndrome, it is recommended to wait 2–3 weeks for surgical stabilization.

32.8 Rehabilitation

Postoperative rehabilitation is a vital yet often overlooked aspect of spinal injuries. It is well documented that patients who are unable to mobilize and spend significant time in bed are more susceptible to a host of complications including respiratory complications, venous thromboembolism, pressure sores, and joint contractures. Once an injury is stabilized, whether by operative or nonoperative treatment, it is imperative that patients be mobilized as much as possible. Patients confined to bed rest for long periods of time should undergo daily therapy sessions with at minimum passive range of motion of unaffected joints in both the upper and lower extremities to avoid contractures and general stiffness. Once ambulation is allowed, daily walks several times per day are typically sufficient to prevent most of the abovementioned complications while the fracture is healing. Occupational therapy with simple daily tasks is also important for those patients with upper extremity deficits to work on fine motor control.

32.9 Complications

Spinal injuries are associated with a high morbidity for the patient. In low-resource countries, these complications are amplified because many patients are not treated in specialized spine centers where they have the individualized care and rehabilitation staff necessary. Multiple studies from developing countries report common complications of urinary tract infections, decubitus ulcers from prolonged time in bed, and respiratory complications such as pneumonia, particularly patients with quadriplegia [18–21]. All this is

Fig. 32.11 (**a**) A 63-year-old male with unstable T8–T9 three-column fracture through the disk space who presented neurologically intact after a high-speed MVA with other abdominal injuries. (**b**) MRI of 63-year-old male with an unstable T8–9 three-column fracture. (**c**) A 63-year-old male with an unstable T8–T9 chance fracture who underwent T6–T11 posterior spinal fusion with T8 laminectomy

further complicated by the state of poverty that many of the patients come from which is often associated with poor hygiene and malnutrition. Contractures and joint stiffness are also common in patients that are confined to bed for prolonged periods of time.

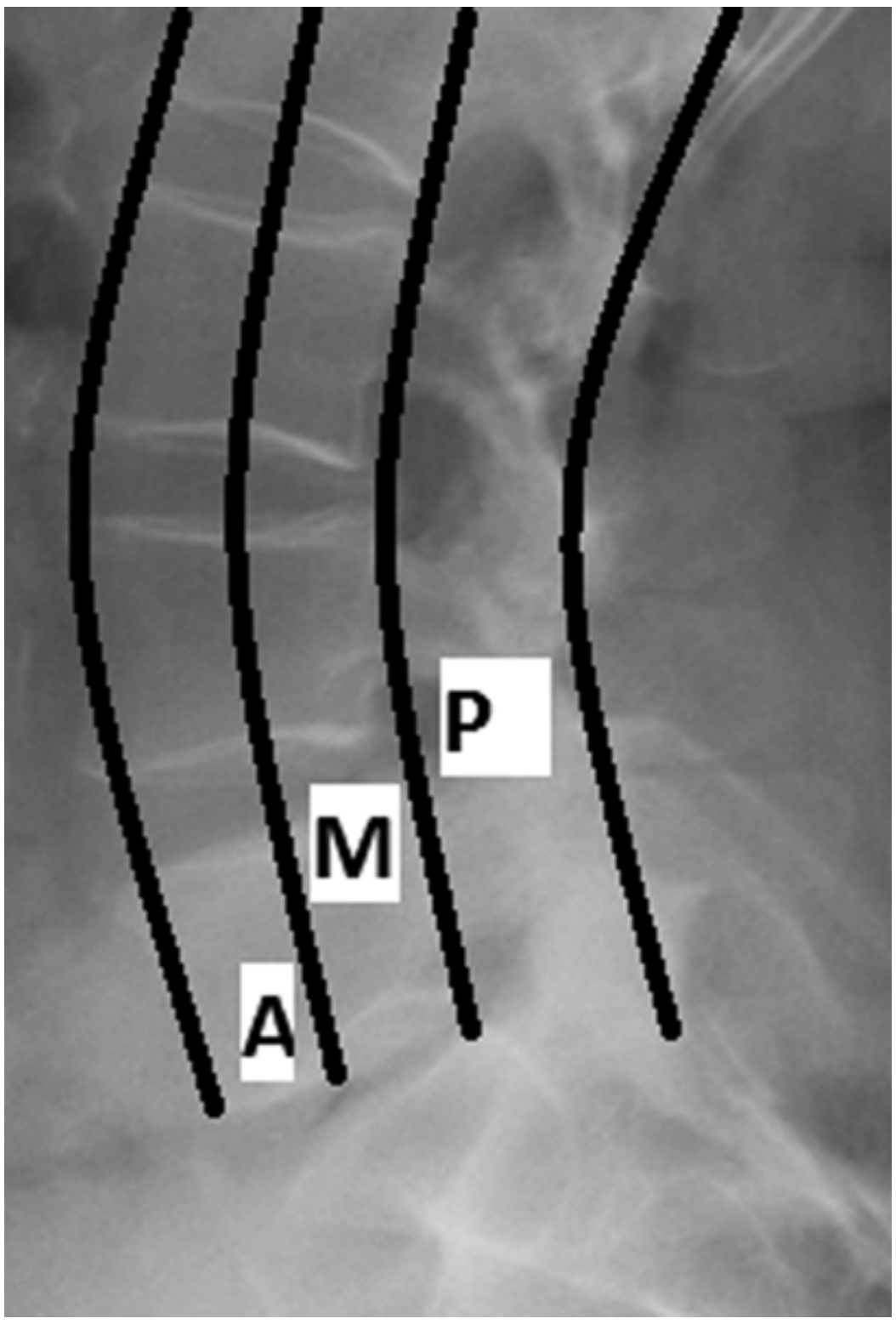

Fig. 32.12 The three columns of the lumbar spine include the anterior (ALL, anterior vertebral body), middle (PLL, posterior vertebral body wall), and posterior (pedicles, lamina, spinous processes, transverse processes, posterior ligamentous complex)

32.10 Pediatric Spinal Injuries

Pediatric spinal column injuries are thankfully uncommon injuries though potentially devastating. Although an in-depth assessment of pediatric spinal injuries is outside the scope of this chapter, the primary difference between pediatric and adult spinal injuries is the disproportionately large head of the child in relation to the rest of the body. When children are transported to clinics or hospitals with suspected spinal injuries, it is vital to allow a recess in the board to prevent unintended flexion of the cervical spine and thus continued neural compression while en route. Of note, children may also have a spinal cord injury without any radiographic abnormality, commonly known as SCIWORA. As with most pediatric spinal injuries, treatment is conservative with serial examinations.

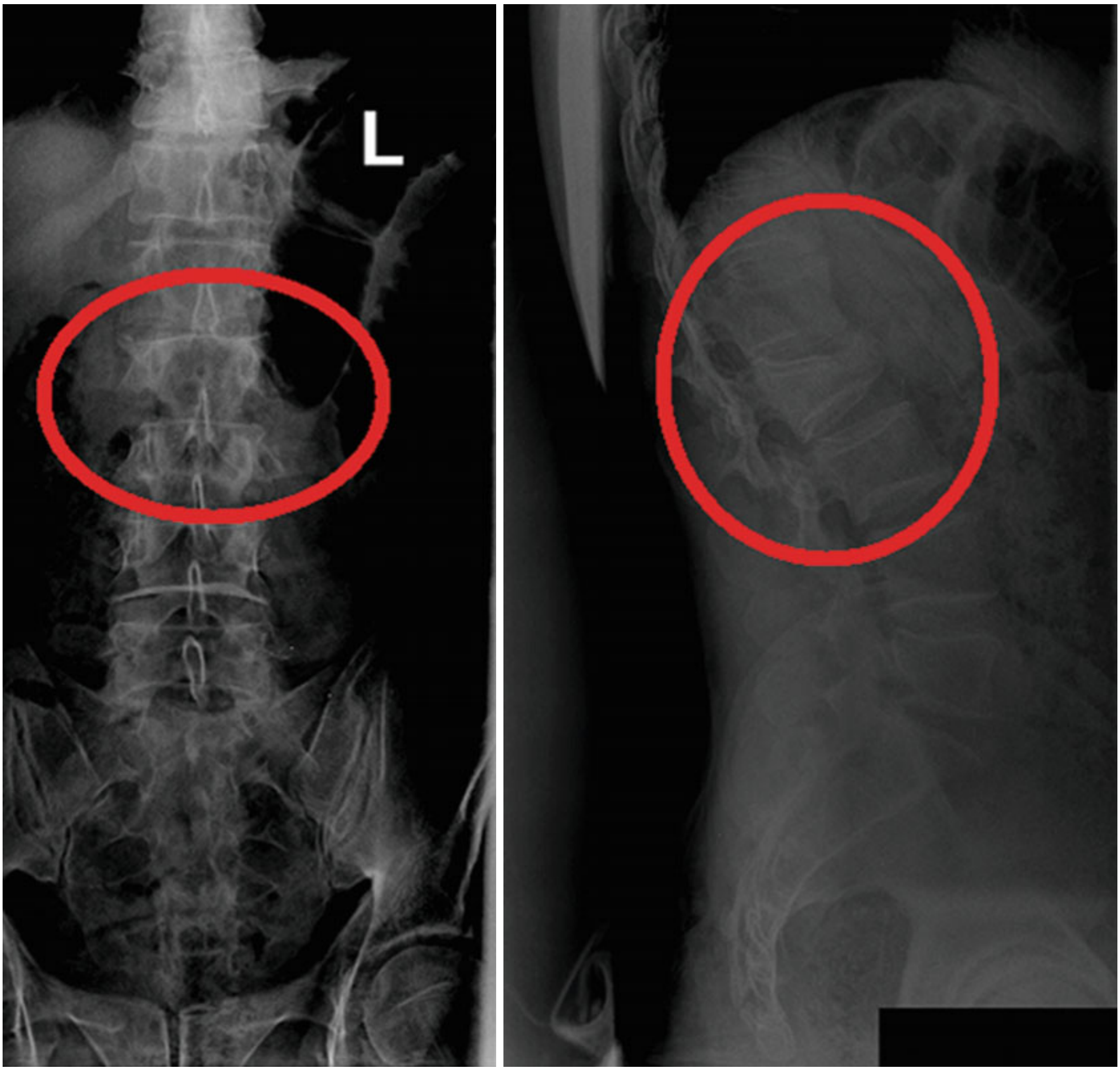

Fig. 32.13 L2 vertebral body compression fracture – no involvement of the middle column. Patients with compression factors typically do very well when treated nonoperatively

Fig. 32.14 Young Kenyan male patient with L1 burst fracture – note involvement of both anterior and middle columns – stabilized with T1–L2 posterior spinal instrumentation (Picture courtesy of Dr Daniel Galat MD)

Conclusion

Traumatic spine injuries, especially those with spinal cord injuries, are often devastating injuries to both the patient and their family. Such injuries require urgent identification and transfer to a hospital capable of caring for complex injuries, including any associated injuries in addition to the spinal injuries. Developing countries are seeing an increase in the number of traumatic spinal cord injuries, mostly due to road traffic accidents, and yet too often lack the infrastructure and resources to adequately manage these patients and their morbidity. Despite significant limitations, basic principles of patient management and conservative treatment can help eliminate many unnecessary complications associated with these injuries.

Fig. 32.15 A 42-year-old male with minimally displaced L1 Chance fracture and L2 vertebral compression fracture with maintained alignment. Note the fracture line extending from the anterosuperior aspect of the L1 vertebral body posteriorly through the bilateral pedicles and superior articular facets

References

1. Nantulya V, Reich M. The neglected epidemic: road traffic injuries in developing countries. BMJ. 2002;324:1139–41.
2. Gosselin RA, Spiegel DA, Coughlin R, Zirkle LG. Injuries: the neglected burden in developing countries. Bull World Health Organ. 2009;87: 246–246a.

3. Beveridge M, Howard A. The burden of orthopaedic disease in developing countries. J Bone Joint Surg Am. 2004;86:1819–22.
4. Spiegel D, Gosselin R, Coughlin R, Joshipura M, Browner B, Dormans J. The burden of musculoskeletal disease in low and middle-income countries: challenges and opportunities. J Bone Joint Surg Am. 2008;90:915–23.
5. Mock C, Cherian MN. The global burden of musculoskeletal injuries: challenges and solutions. Clin Orthop Relat Res. 2008;466:2306–16.
6. Gosselin RA. The increasing burden of injuries in developing countries: direct and indirect consequences. Tech Orthop. 2009;24(4):230–2.
7. Zirkle LG. Injuries in developing countries: how can we help? Clin Orthop Rel Res. 2008;466:2443–50.
8. Lee BB, Cripps RA, Fitzharris M, Wing PC. The global map for traumatic spinal cord injury epidemiology: update, global incidence rate. Spinal Cord. 2011;2013:1–7.
9. Chiu WT, Lin HC, Lam C, Chu SF, Chiang YH, Tsai SH. Epidemiology of traumatic spinal cord injury: comparisons between developed and developing countries. Asia Pac J Public Health. 2010;22(1): 9–18.
10. Leucht P, Fischer K, Muhr G, Mueller EJ. Epidemiology of traumatic spine fractures. Injury. 2009;40:166–72.
11. Short DJ, El Masry WS, Jones PW. High dose methyprednisolone in the management of acute spinal cord injury – a systematic review from a clinical perspective. Spinal Cord. 2000;38(5):273–86.
12. American College of Surgeons Committee on Trauma. Advanced trauma life support program for doctors. 7th ed. Chicago: American College of Surgeons; 2004.
13. Robertson A, Giannoudis PV, Branfoot T, Barlow I, Matthews SJ, Smith RM. Spinal injuries in motorcycle crashes: patterns and outcomes. J Trauma. 2002;53:5–8.
14. Solagberu BA, Ofoegbu CKP, Abdur-Rahman LO, Adekanye AO, Udoffa US, Taiwo J. Pre-hospital care in Nigeria: a country without emergency medical services. Niger J Clin Pract. 2009;12(1):29–33.
15. Igun GO, Obekpa OP, Ugwu BT, Nwadiaro HC. Spinal injuries in the plateau state, Nigeria. East Afr Med J. 1999;76(2):75–9.
16. Shamim MS, Ali SF, Enam SA. Non-operative management is superior to surgical stabilization in spine patients with complete neurological deficits: a perspective from a developing country Pakistan. Surg Neurol Int. 2011;2:166.
17. Denis F. The three column spine and its significance in the classification of acute thoracolumbar spinal injuries. Spine (Phila Pa 1976). 1983;8(8):817–31.
18. Moler A, Hasserius R, Redlund-Johnell I, Ohlin A, Karlsson MK. Non-operatively treated burst fractures of the thoracic and lumbar spine in adults: a 23- to 41-year follow-up. Spine J. 2007;7:701–7.
19. Umaru H, Ahidjo A. Pattern of spinal cord injury in Maiduguri, north eastern Nigeria. Niger J Med. 2005;14(3):276–8.
20. Obalum DC, Giwa SO, Adekoya-Cole TO, Enweluzo GO. Profile of spinal injuries in Lagos, Nigeria. Spinal Cord. 2009;47:134–7.
21. Nwadinigwe CU, Iloabuchi TC, Nwabude IA. Traumatic spinal cord injuries: a study of 104 cases. Niger J Med. 2004;13(2):161–5.

Shoulder Girdle Injuries

33

Peter A. Cole and Ryan Horazdovsky

The shoulder girdle is a complex osseous chain consisting of the clavicle, scapula, and humerus, linked by ligamentous and capsular structures which collectively provide the origins and insertions for over twenty muscles which allow for coordinated movement of the upper extremity. Dysfunction therefore follows disruption or deformity in this linkage; however, since the sternoclavicular joint allows for 45° of motion, the acromioclavicular joint 20° of motion, and the glenohumeral joint up to 170° of motion in multiple planes, there is also more forgiveness for deformity than in any other anatomical region. This fact allows different interpretations of thresholds for operation based on the resources available in a particular underdeveloped hospital setting. Malunion in the clavicle or scapula, for example, is not generally as morbid as a malunion of the femur and tibia, and therefore the technical expertise must be balanced with the risks of surgery, and the baseline function of the patient. Nevertheless, if the goal is optimal function rather than reasonable function, and the likelihood of surgical success is great based on available expertise and management of risks, then there are plenty of reasons to operate. In this chapter, we will review diagnosis and management of the sternoclavicular, acromioclavicular joint, and glenohumeral joint, as well as the clavicle and scapula in the context of austere conditions.

33.1 Sternoclavicular Injuries

The sternoclavicular joint is a diarthrodial joint between the medial clavicle and the clavicular notch of the sternum. The sternoclavicular joint allows for motion in all planes and is where the majority of scapulothoracic motion occurs. Because of strong ligamentous support, injuries to the sternoclavicular joint are rare, representing only 3 % of shoulder girdle injuries [1]. A sternoclavicular injury is always a high-energy event, and, therefore, exploration for other injuries is paramount. Due to the posterior proximity of structures such as the great vessels, phrenic and vagus nerves, trachea, and esophagus, associated injuries should be suspected and diagnosed promptly.

The mechanism of injury can either be from a direct blow to the clavicle, or an indirect force applied to the shoulder. The sternoclavicular joint may sustain a simple sprain characterized by a non- or minimally displaced injury, in which there is a lack of deformity in the setting of pain

---

P.A. Cole, MD (✉)
Department of Orthopaedic Surgery, Regions Hospital, St. Paul, MN, USA

Department of Orthopedic Surgery, University of Minnesota, St. Paul, MN, USA
e-mail: Peter.A.Cole@HealthPartners.Com

R. Horazdovsky, MD
Orthopaedic Surgery, Minneapolis, MN, USA

© Springer International Publishing Switzerland 2016

J.D. Robinson (ed.), *Orthopaedic Trauma in the Austere Environment: A Practical Guide to Care in the Humanitarian Setting*, DOI 10.1007/978-3-319-29122-2_33

and possibly swelling. This injury is stable, but frank dislocation is associated with complete ligament disruption which warrants surgical consideration [2]. Sternoclavicular dislocations are described according to the direction of dislocation, anterior or posterior. Anterior dislocations being more common because they result from a posterolateral blow to the shoulder.

A medial clavicular physeal fracture, which can displace anteriorly or posteriorly as well, mimics a dislocation and is common under the age of 25 as this the last epiphysis to close (23–25 years) [3]. Most of these injuries heal and remodel without surgical intervention [1].

33.1.1 Initial Management

Given the assumption of a higher-energy mechanism, the patient should be asked about difficulty breathing or swallowing, particularly upon recognition of a posterior dislocation. Hoarseness, persistent cough, or stridor should be documented. Patients may have distended neck veins and surrounding tissues secondary to local venous congestion (Fig. 33.1). Pain localized to the sternoclavicular joint is associated with swelling and possibly ecchymosis. There is usually a palpable and mobile prominence just anterior and lateral to the sternal notch in the case of an anterior dislocation, or a puckering of the skin with a sense of fluctuance in the posterior dislocation. Chest auscultation and a thorough neurovascular exam to the ipsilateral extremity are important.

Anteroposterior radiographs of the chest or clavicle are of limited usefulness when assessing for sternoclavicular joint injuries. A serendipity x-ray view of the shoulder is a 40° cephalic tilt view centered on the manubrium [3]. In this view, an anterior dislocation will be manifested with a superior appearing clavicular head. If a posterior dislocation is suspected, a computed tomography (CT) examination with 2 mm interval cuts is helpful to visualize the location and extent of dislocation, evaluate the retrosternal region for soft tissue injury, or elucidate a physeal injury. If a vascular injury is suspected, the CT scan should be combined with an arteriogram of the great vessels if possible.

33.1.2 Nonoperative Treatment

The majority of sternoclavicular injuries are anterior dislocations, and these should be treated nonoperatively with the expectation of a cosmetic manifestation of a large bump, resolution of pain, and restoration of good function [4]. Closed reduction can be attempted; however, the joint will not remain reduced. This

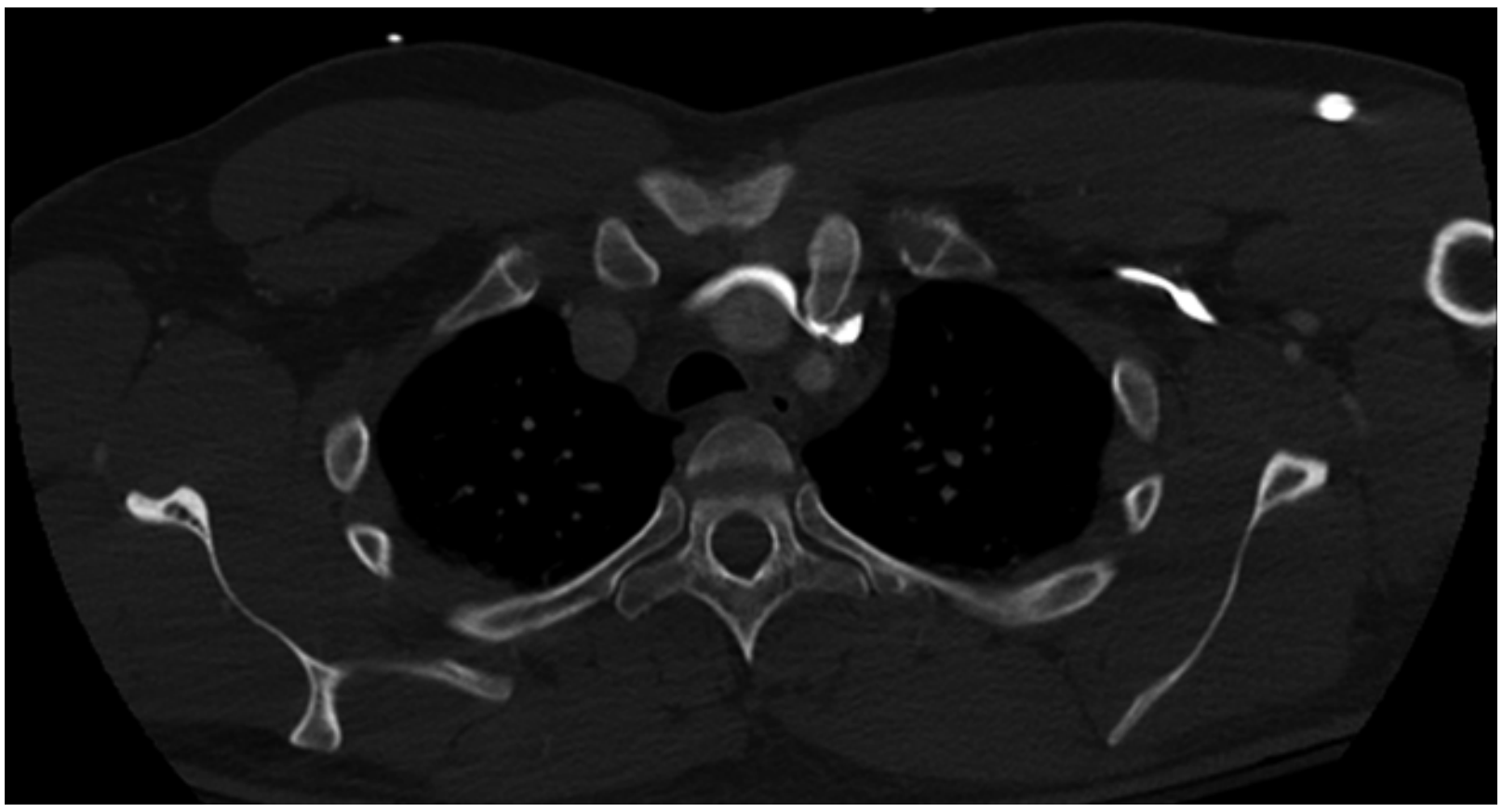

Fig. 33.1 Posterior sternoclavicular dislocation with impingement of posterior great vessels and significant venous congestion as evidenced by local soft tissue swelling. This patient was treated with an open reduction and suturing fixation through drill holes

expectant result also holds true for the medial clavicle physeal injuries that are displaced anteriorly.

33.1.3 Operative Treatment

Surgical intervention of anterior sternoclavicular joint dislocations is usually unwarranted given the high failure rates from open reduction [2]. A symptomatic posterior dislocation should undergo a manipulative reduction to unlock the retrosternal clavicular head to relieve impingement on critical structures and avoid late sequelae compression on critical structures [5].

A pointed bone tenaculum may be useful to grasp the head of the clavicle and pull it back to its proper manubrium relation (Fig. 33.2a). A roll between the shoulder blades while the patient is supine, in combination with lateral traction of the abducted arm, is a helpful adjunctive maneuver. A closed reduction maneuver is not always successful. Due to possible violation of critical structures in the mediastinum, it has been recommended to have anesthesia on hand to manage the airway and a thoracic surgeon on standby during the procedure for the unlikely event of disrupting a pseudoaneurysm or clot at the level of the great vessels.

Transfixing wires across the sternoclavicular joint is ill advised throughout the literature due to the reported problem of wire migration. In posterior dislocations or physeal injuries, a reduction of the dislocated distal fragment can be reinforced with heavy braided suture through drill holes in the distal fragment (Fig. 33.2b). A medial clavicle resection is the best option for symptomatic unstable posterior dislocations or painful chronic anterior dislocations. In such cases, the remnant scar tissue and capsule should be imbricated and tethered to the clavicle to help prevent instability.

33.1.4 Complications

Retrosternal dislocations are frequently missed, likely due to the lack of physical exam findings in the context of a multiply injured patient [6]. Missed or late diagnosis of associated injuries of the mediastinum and brachial plexus is well documented. Failure of fixation, hardware migration, and redislocation have also been reported after operative stabilization and are likely due to the high forces acting on this main articulation between the upper extremity and the axial skeleton [7]. Lastly, arthritic symptoms of the sternoclavicular joint are not uncommon, and many authors have described resection of the clavicular head to address refractory pain [8].

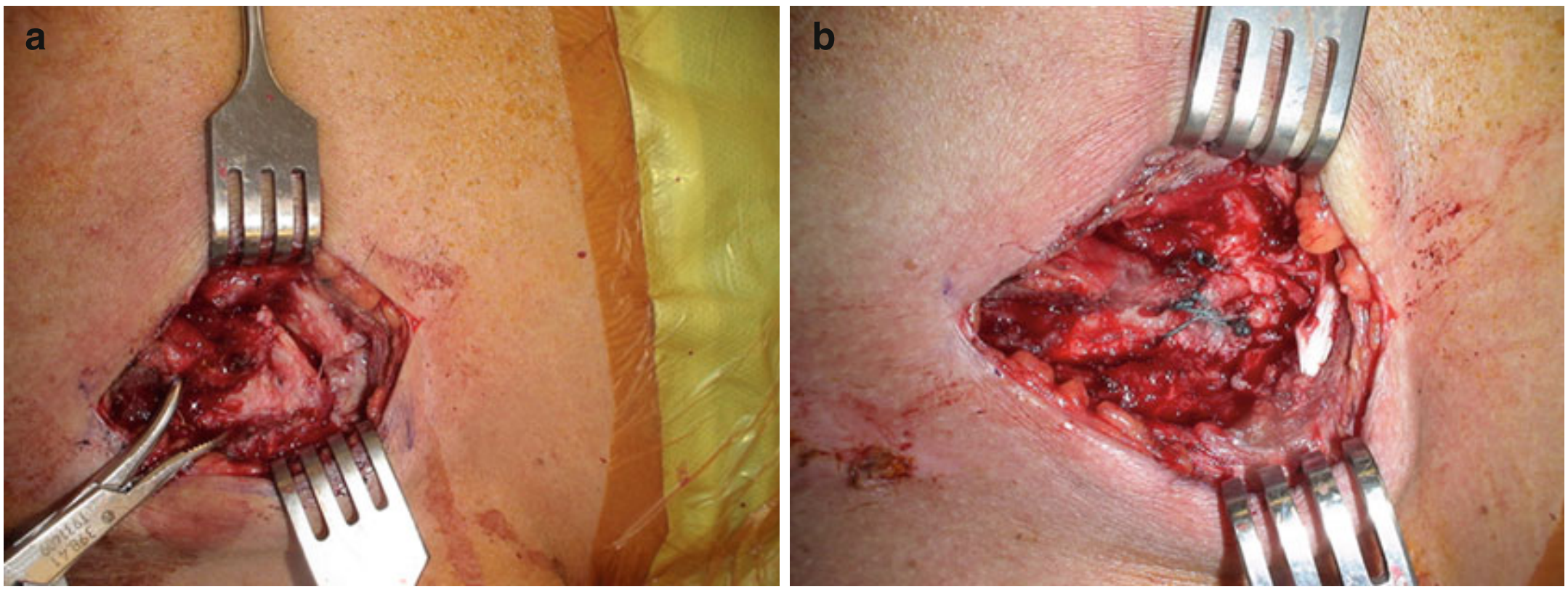

Fig. 33.2 (**a**) This is the medial clavicle grasped by a pointed bone reduction forceps to reduce it from its posterior dislocated position. To the right side of the incision next to the arrow is the heavy capsular tissue of the SC joint. (**b**) Is the repair of the unstable SC joint with drill holes through the clavicle repaired to the capsule with heavy braided suture

33.2 Acromioclavicular Joint Dislocation

The prominence of the acromioclavicular (AC) joint makes it vulnerable to dislocation from a direct blow to the shoulder, such as during a fall or lateral impact in a motor vehicle crash. The AC joint is a synovial joint that contains a fibrocartilage meniscus that is surrounded by capsule strongest at its superior and posterior margin [9]. The upper extremity is suspended in part by its connections to the lateral clavicle through the coracoclavicular (CC) and coracoacromial (CA) ligaments and AC joint capsule. The acromioclavicular AC joint dislocation occurs when there is at least partial disruption of these structures. This articulation may allow for up to 20° of rotation [10] and is further affected by the weight of the upper extremity as well as large muscular forces that act across a small surface area. These factors help to explain why internal fixation failures are common and why there are so many described techniques to repair fractures and dislocations of the AC joint: because, most have been associated with a high failure rate.

Distal clavicle fractures will be handled separately at the end of this chapter; however, much of the same discussion regarding the diagnosis and treatment of AC dislocations is relevant to the displaced or intraarticular distal clavicle fracture as well since fixation strategies are very similar and the use of distal clavicle resection for salvage.

33.2.1 Classification

Tossy et al. [11] and Allman et al. [12] developed classification systems for AC dislocations based on the degree of ligament injury and radiographic evidence of displacement and classified these as types I–III. A *type I* injury is a nondisplaced. The *type II* injury is incompletely displaced and associated with complete tearing of the acromioclavicular ligaments and sparing of the coracoclavicular ligaments. The *type III* dislocation represents complete disruption of the coracoclavicular ligaments and acromioclavicular joint capsule with superior displacement. Rockwood et al. [13] later described three additional types of more severe injury (types IV through VI) based on the direction as well as the amount of dislocation. Rockwood's *type IV* AC dislocation is complete, and the clavicle is displaced posteriorly. The *type V* injury is an extreme variation of type III, where the clavicle buttonholes through the trapezius into the subcutaneous tissue (High FIVE), whereas the *type VI* dislocation is dislocated inferiorly (Deep SIX).

33.2.2 Initial Management

Usually, there is history of a direct blow to the shoulder in which the patient presents with a swollen and painful AC joint. Evaluate the patient for other chest, neck, or brachial plexus injuries that may be associated, including the sternoclavicular joint since bifocal injury has been observed many times by the senior author (PAC). If a visual or palpable step off exists, or the distal clavicle feels unstable, then there is at least a type II injury. It is not uncommon for type I and II injuries to have a longer duration of pain than type III injuries due to residual articular contact and tethering of partially torn ligamentous structures. Ice relieves pain and swelling in the acute setting. A sling is useful for support of the upper extremity against gravity, but the joint cannot be maintained in a reduced position with any orthosis, including a figure-of-eight sling because of the deforming forces of the sternocleidomastoid and strap muscles of the neck.

Diagnosis can be confirmed by including both AC joints on one large x-ray cassette demonstrating relative displacement on one side, as well as anatomical variations of the AC facets.

33.2.3 Nonoperative Treatment

Type I and II AC injuries should be treated nonoperatively with the expectation of excellent short- to midterm results [14]. In the event that late, symptomatic AC arthrosis occurs, elective distal clavicle excision can predictably relieve pain and restore function [15]. Nonoperative management of type III AC dislocations is most appropriate in the austere environment as the collective weight of evidence reveals no clear benefit from surgical treatment [16, 17].

33.2.4 Surgical Treatment

33.2.4.1 Indications for Surgical Treatment

Surgical reconstruction should be considered in patients with type IV to VI AC injuries to prevent chronic dysfunction and pain. These injuries are associated with grotesque deformity which is uncomfortable and unacceptable by most reasonable standards (Fig. 33.3).

33.2.4.2 Surgical Techniques

Many surgical procedures have been described to repair AC dislocations, which belies the fact that until recently failure rates have been high. The strategies have included temporarily fixing the distal clavicle to the acromion, along with repair or augmentation of the CC ligaments. Each strategy can be employed in the acute or delayed setting. If a late reconstruction is done, it is usually combined with a distal clavicle resection.

The most widely known historical procedure is that described by Weaver and Dunn, in which the CA ligament is released from the acromion and transferred through the end of a resected distal clavicle [18]. The CA ligament plays a role in maintaining the concentricity of the humeral head, however, and its mobilization may lead to superior escape of the humeral head [19–21]. Today, some surgeons prefer either allograft or autograft tendon reconstructions to replace the CC ligaments. These are typically reinforced with a strong nonabsorbable suture such as Fiberwire® or Mersilene® tape preferably passed around the base of the coracoid process and then through a boney tunnel in the clavicle. In either case, fixation across the AC joint or into the coracoid base can be added to augment the soft tissue repair during healing. A 6.5 mm partially threaded screw from the clavicle to coracoid can be used for this purpose, so that with the lag effect, the Mersilene tape is off-loaded to help prevent erosion. K-wires and a tension band wire/suture technique have also been used. Plan for elective removal of the hardware 3–4 months postoperatively after CC ligament healing is important to prevent erosion of the bone and is paramount for fixation which crosses a joint.

Fig. 33.3 A clinical image of a patient with a type IV AC dislocation and the resultant grotesque deformity

The hook plate (Synthes USA, Westchester, PA) is gaining popularity as an option for acromioclavicular joint stabilization after dislocation [22–26]. If unavailable locally, a hook plate can be fashioned out of a 3.5 recon plate in the shop and sterilized prior to surgery. The plate is fixed to the cephalad border of the distal clavicle, and a terminal hook sweeps under the acromion so the clavicle is restrained from springing superiorly (Fig. 33.4a–d). To do this, the terminal hook should angle 90 and 90°, be at least 2.0 cm, and have a depth of approximately 1.5 cm for an average-sized individual, so the implant can make the turn posterior to the clavicle and under the acromion along its inferior surface (Fig. 33.4c). An attempt to repair the acromioclavicular joint as well as the coracoclavicular ligaments should accompany the use of the Hook Plate. These elements are torn, but approximation forms a scaffold for scarring back down. It is necessary to remove the plate at 3–4 months after surgery to prevent the complication of acromial osteolysis and possibly acromial fracture [23, 27–29] and impingement [30, 31]. The necessity of a second operation for hook plate removal may make this an inappropriate implant if a patient's ability to follow up is uncertain.

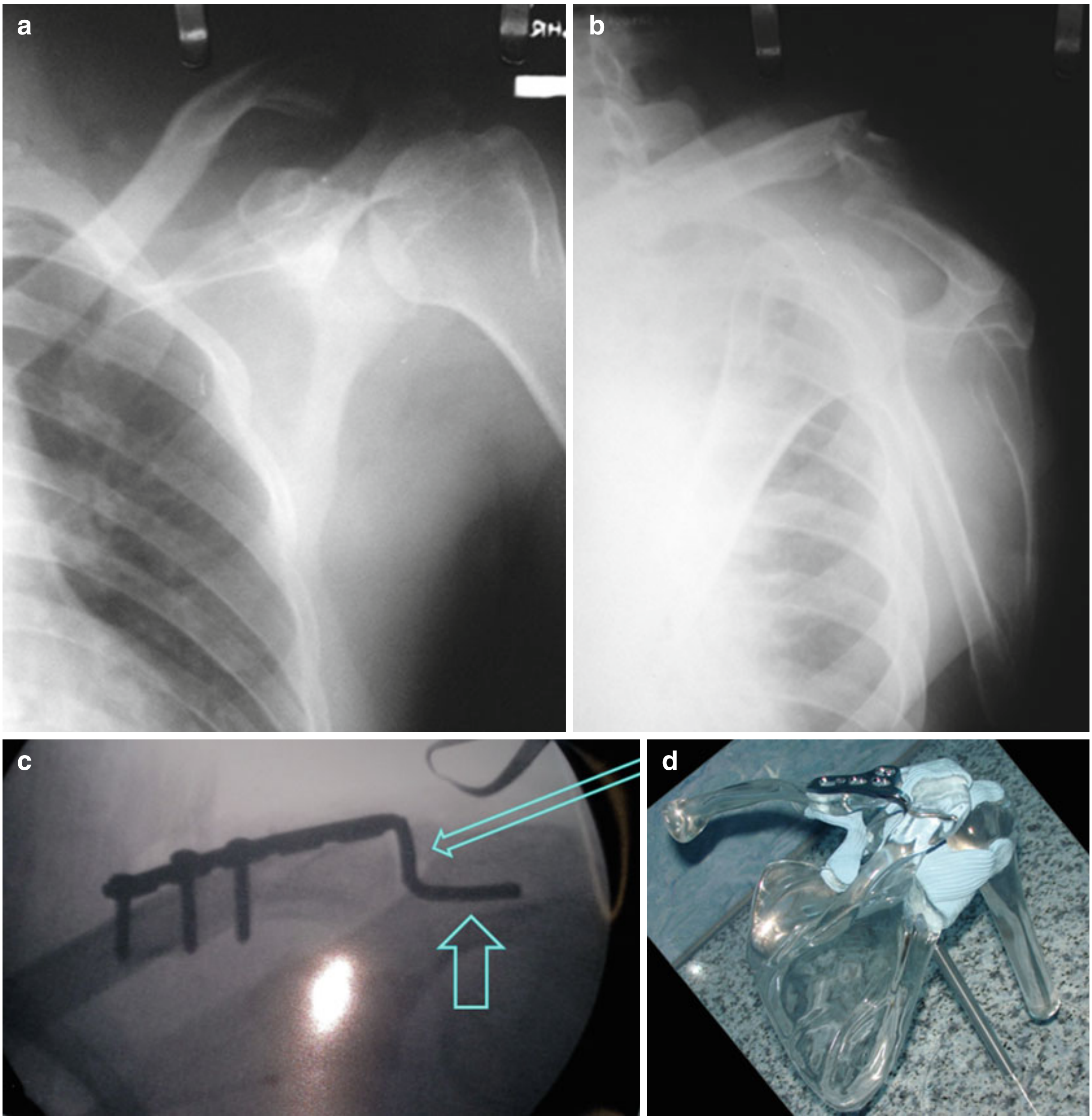

Fig. 33.4 (**a**) Grashey and (**b**) scapula Y radiographs showing a displaced and comminuted distal clavicle fracture. The surgeon opted to perform ORIF with a hook plate. (**c**) This hook plate can be fashioned in the hospital workshop out of a 3.5 mm recon plate preoperatively and sterilized for surgery (courtesy of Dr. Tul Bdr Pun, Tansen Mission Hospital, Nepal). It's "depth" from the distal clavicle to the inferior acromion should be approximately 1.5 cm (*thin arrow*) and the length of the hook no less than 2.0 cm (*fat arrow*). (**d**) Shown is a bone model which shows the hook plate design and its relationship to the clavicle and acromion

Another form of fixation which has become popular recently is the “tightrope” technique (Arthrex, Naples, FL, USA) which is an approximation of the clavicle to the coracoid using heavy braided suture and suture buttons which lie down on the clavicle and under the base of the coracoid (Fig. 33.5). Though this technology is prepackaged for surgery, and rather slick, it can be mimicked easily with heavy #5 braided suture and minifragment plates to serve as the buttons (Fig. 33.6).

The beach chair position is utilized draping the entire forequarter onto the neck. The entire extremity should be prepped to allow for

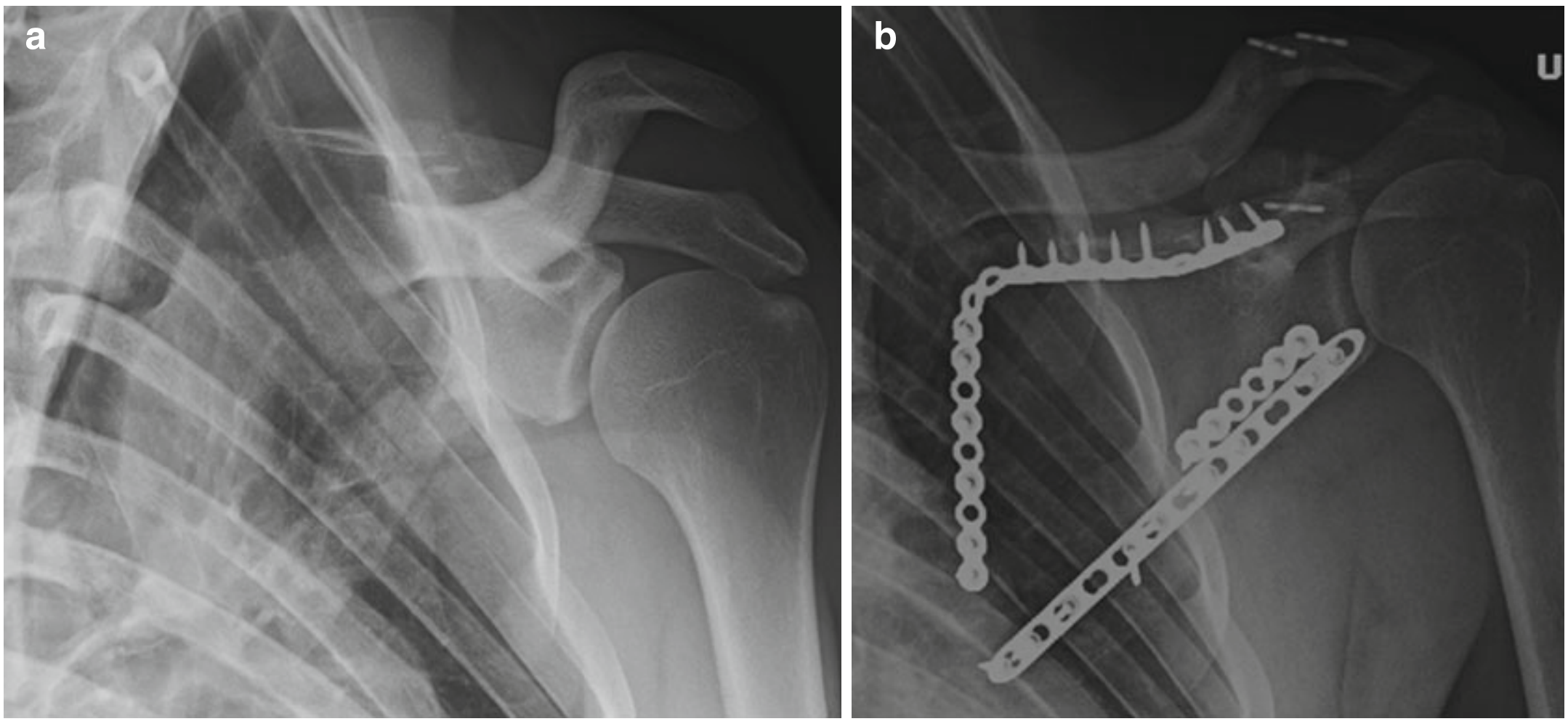

Fig. 33.5 (**a**) Grashey radiograph demonstrating an acromioclavicular dislocation as well as a comminuted extraarticular scapula fracture. (**b**) Postoperative image showing the reduced acromioclavicular joint with a Tightrope (Arthrex Inc., Naples, Florida) construct. This construct can be mimicked with heavy #5 braided suture and minifragment plates to serve as the buttons



Fig. 33.6 Shows a heavy braided suture with minifragment plates which can be used to mimic the tightrope technique, which allows for execution in settings without the prepackaged technology. Minifragment plates can be used to reproduce the “tightrope” concept with the plates substituting for the buttons to dissipate stress on the clavicle and coracoid

manipulation of the arm aiding in evaluation of rotational nuances and reduction of the dislocation. A 6 cm incision centered over the anterior edge of the distal clavicle is made to expose the dislocated AC joint. The incision is made in Langer's lines and thus is vertically oriented, allowing for direct exposure of the torn ligaments and an adequate exposure of the coracoid. In distal clavicle fracture variants, a horizontal incision can be made over the distal clavicle and AC joint for easier exposure. Develop the flaps between the deltoid and trapezius for later closure of the deltotrapezial tissue plane. After the distal clavicle and AC joint are exposed, an evaluation of the articular integrity is made, removing pieces of detached articular cartilage if present. In the acute setting, the clavicle should be noted to reduce rather readily by an inferior directed force on it (in a type III), or pistoning the arm cephalad to meet the clavicle. The CC ligaments are then inspected and repaired if possible, but only after fixation of the AC joint with the technique of choice.

33.2.4.3 AC Ligament Tips

- Augmentation of a ligament reconstruction with some type of fixation to off-load the repair is prudent to take the stress off of any one point of fixation. A screw, such as the historical "modified Bosworth screw" described by Rockwood, or a partially threaded 6.5 mm screw, from the superior clavicle down into the coracoid, is stronger than Kirschner wires that cross the AC joint or a plate that traverses (bridges) the AC joint because the fixation is perpendicular rather than parallel to the deforming force. Any hardware which crosses a joint should be removed after 3–4 months.
- Due to the curved and slender shape of the distal coracoid, the surgeon should dissect along the proximal and posterior edge to appreciate the broader base into which fixation can be more securely attained. The screw vector from this position will be in a vector heading slightly lateral to purchase the bone of the glenoid neck. If the surgeon directs the drill directly inferior or medial, the bone is thin and difficult to purchase. If such screws are too distal on the coracoid, it is not uncommon to either fracture the coracoid or simply obtain poor purchase.
- Draping the arm free during the reconstruction of an AC joint (and clavicle fracture) allows aid for reduction and minimizes soft tissue stripping with repeated clamp applications.

33.2.5 Outcomes

The prognosis for type I injuries managed nonoperatively is excellent, whereas type II injuries have a good to excellent long-term prognosis [13]. A small percentage of patients, mostly with type II injuries, will develop symptomatic AC joint arthritis, requiring a distal clavicle resection [13, 32]. If conservative management of this fails, resection of the distal clavicle can be done by removing the distal 1.5 cm of bone, and results have generally been favorable [13, 33–35]. In such cases, after distal clavicle resection, a coracoclavicular ligament augmentation should be performed to mitigate the superior migration and instability of the distal clavicle.

33.2.6 Complications

Most of the complications related to surgery involve fixation failure resulting in recurrent prominence of the distal clavicle, instability, and pain. All described techniques can have hardware failure including slippage of Kirschner wires, cutout of CC screws, failure of grafts, or suture cutting through the distal clavicle or coracoid. Acromial erosion and fracture from retained hook plates, as well as fracture at the proximal end of the plate, are known. These various modes of failure underscore the technically demanding nature of the reconstruction.

33.3 Scapula Fractures

Scapula fractures represent about 5 % of all fractures about the shoulder girdle [36–42]. A study of 6986 fractures found that 52 (0.7 %) involved the scapula, which made it more common than distal humerus and distal femur fractures [43]. Scapula fractures are evidence that considerable energy has been imparted to the body. Large forces are required to cause a displaced scapula fracture because of the muscular envelope in which it lies, the mobility of the scapula on the thoracic cage, and surrounding musculoskeletal structures (proximal humerus, AC joint, and clavicle), which usually yield first [38]. Approximately 90 % of these patients have associated injuries highlighting the high-energy mechanisms generally involved [36, 39, 40, 44].

33.3.1 Initial Management

A thorough physical examination is important to detect these commonly associated injuries, particularly those that are life threatening. A majority of these patients have multiple broken ribs and resultant hemopneumothorax, 15 % have cervical spine injuries, 15 % have a traumatic brain injury, and 15 % have brachial plexus and peripheral nerve injury, and many of these injuries often mandate greater diagnostic and treatment urgency.

Radiographic evaluation of a scapula fracture includes three views of the shoulder, including an axillary view to assess the glenoid and its humeral relationship. Obtain an opposite shoulder AP radiograph to compare to the normal side if there is any doubt as to the interpretation of deformity. If available, a 3-D CT scan can be helpful to understand the deformity, take measurements, and place the surgical decision-making process in proper context. It is not uncommon to see worsening angulation and medialization over the first few weeks on radiographic examination, so serial x-rays are warranted [45].

33.3.2 Nonoperative Treatment

Moderate scapular displacement is well tolerated since the shoulder has such great motion in many planes. It is estimated that 90 % of scapula fractures are minimally displaced and therefore should be treated expectantly [40, 41, 46–54]. Treatment emphasizes early motion with symptom relief. After motion is restored in the first 4–6 weeks, therapy is directed at rehabilitating the rotator cuff and strengthening parascapular musculature.

If nonoperative treatment is chosen for severely displaced scapula fractures, there may be some consolation in the fact that it is almost reportable that a scapula fracture does not unite. And, if there is felt to be no expertise for scapula fracture ORIF, malunions can be dealt with at a later timing when an expert arrives to the mission hospital setting.

33.3.3 Surgical Treatment

Severe scapula fracture displacement is associated with symptoms of stiffness, pain, and dysfunction as evidenced by subsets of patients in many studies who have fared poorly.

A summary of our relative operative indications is based on educated conjecture and limited evidence in the literature on patients who have not fared well. The term relative indications is used, because it is reasonable to expect that any scapula fracture will unite, and maximizing function needs to be balanced with baseline function and future expectations.

Operative indications for open reduction and fixation of scapula fractures include [55–57]:

(a) Lateral border displacement (medialization) of >2 cm
(b) Angulation as determined by a scapula Y view of >45°
(c) Medialization plus angulation of >15 mm and 30°, respectively
(d) A glenopolar angle of <20°
(e) Displacement of a clavicle and scapula fracture of >1 cm (or complete disruption of an AC joint)
(f) Intraarticular step-off or gap of the glenoid >4 mm
(g) Displacement of the scapular spine, coracoid, and acromion process fractures greater than 1 cm

These indications are based on measurement techniques shown in Fig. 33.7.

33.3.3.1 Surgical Anatomy

The scapula is largely flat and triangular, with a thin body, surrounded by thicker borders that reflect the stresses from muscular origins and insertions. The scapular spine separates the superior and inferior fossae of the scapula, which are origins for their respectively named muscles. The subscapularis muscular origin occupies the concave anterior surface of the scapula.

The pear-shaped glenoid fossa has a peripheral margin covered by fibrocartilaginous labral tissue deepening the glenoid by 50 %. The intraarticular long head of the biceps tendon inserts at the supraglenoid tubercle.

33.3.3.2 Surgical Techniques

Most scapula fractures are best operated through some modification of the posterior approach of Judet or the anterior deltopectoral approach.

33.3.3.3 Posterior Approach

This is the approach best used for the majority of operative scapular fractures. The patient is placed in the lateral decubitus position, slightly forward facing for better access to the posterior scapular surface. A bump must be appropriately positioned on the contralateral side under the latissimus to protect the brachial plexus. The entire forequarter should be prepped and draped, including the arm, and the patient's neck superiorly, the vertebral column medially, and the latissimus fold caudally. Palpate the prominent posterolateral acromion and follow it medially along the spine of the

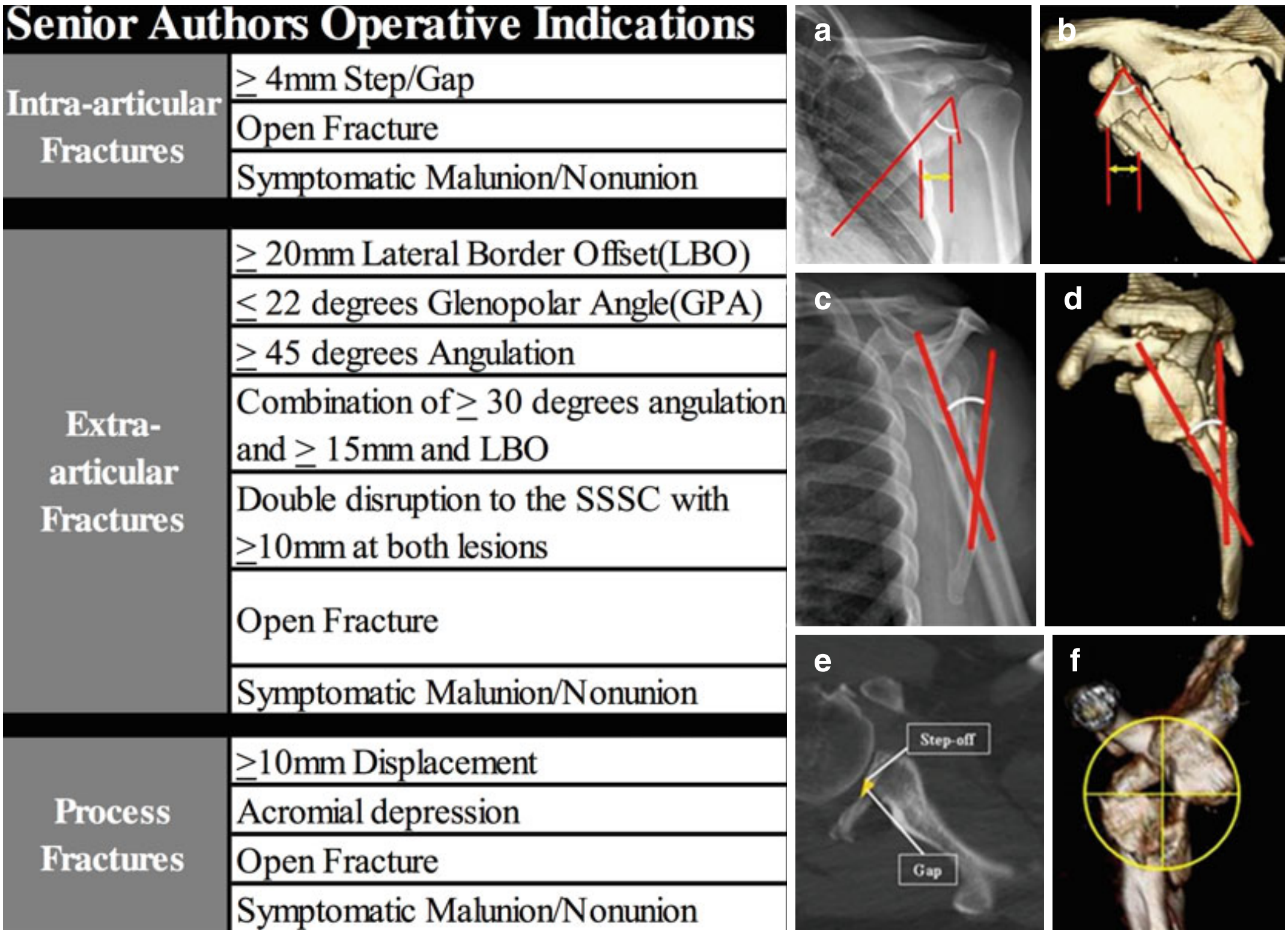

Senior Authors Operative Indications

Intra-articular Fractures	≥ 4mm Step/Gap
	Open Fracture
	Symptomatic Malunion/Nonunion
Extra-articular Fractures	≥ 20mm Lateral Border Offset(LBO)
	≤ 22 degrees Glenopolar Angle(GPA)
	≥ 45 degrees Angulation
	Combination of ≥ 30 degrees angulation and ≥ 15mm and LBO
	Double disruption to the SSSC with ≥10mm at both lesions
	Open Fracture
	Symptomatic Malunion/Nonunion
Process Fractures	≥10mm Displacement
	Acromial depression
	Open Fracture
	Symptomatic Malunion/Nonunion

Fig. 33.7 Operative indications, x-ray and 3-D reconstructed CT images illustrating displacement measurement. (**a**, **b**) Measurements of lateral border offset (*yellow arrow*) and glenopolar angle (blue angle), which are measured on the Grashey x-ray view and 3-D oriented in the true AP plane. (**c**, **d**) Measurement of angulation (blue angle), which is measured on the scapula Y x-ray and 3-D CT views. (**e**, **f**) Intraarticular step-off and gap. These measurements can be performed on axial, sagittal, coronal, or 3-D CT reformats, depending on orientation of fracture line

scapula and then caudad along the medial border. Shuck the shoulder to feel the landmarks better.

A Judet posterior incision is made using these landmarks, with the horizontal limb slightly caudad to the scapular spine and the vertical limb 1 cm lateral to the medial border. Incise through subcutaneous tissue and then come directly down onto the bony ridge of the scapula spine around to the medial angle and down the vertebral scapular border. A generous incision allows for easy flap retraction and access to the lateral scapular border. The fascial incision along the acromial spine and medial border should provide a cuff of tissue to suture back to its bony origin at closure.

The muscle plane entered at the spine of the scapula is between the trapezius and the deltoid at the inferior margin. A Cobb elevator is used to elevate the infraspinatus from its origin in the infraspinatus fossa from the acromial superior border or at the medial vertebral border. At the vertebral border of the scapula, the intermuscular plane is between the infraspinatus and the rhomboids which are left attached. Look for a subtle fat strip to identify the important window between the infraspinatus and teres minor. This interval is developed to access the lateral border of the scapula, the scapular neck, and the glenohumeral joint.

33.3.4 Reduction Technique

The lateral border of the scapula and glenoid neck provide the best bone stock, so manual reduction maneuvers and fixation are best performed at these locations. Schanz pins can be used to manipulate main fragments.

A combination of clamps on the lateral and medial border and acromion is what it takes to perfect the reduction before a straight 2.7 mm plate application along the lateral border should be executed. Optimally, there should be at least four screws distal to the fracture along the lateral border and two in the glenoid neck to obtain balanced fixation for a simple fracture pattern (Fig. 33.8a). Contour a second plate to fit along the superomedial border where the plate often spans two fracture lines (Fig. 33.8b). Strive to place six screws on either side of the fracture in this region as each screw is typically 8–10 mm long with limited purchase. If these are not locking screws, then every screw should be angled in a different direction. In the most common fracture pattern extending from the lateral border to the superior angle, commonly two plates suffice for fixation (Fig. 33.8c, d).

33.3.5 Closure

Manipulate the shoulder to free adhesions, especially in patients whose care has been delayed. Repair the muscular origin with heavy, braided, nonabsorbable, no. 2 suture, through 2.5 mm drill holes in the scapular spine and medial border to prevent detachment during rehabilitation. A drain should be placed under the flap and exit proximal and anterior to the wound through a long subcutaneous tunnel to lessen persistent drainage due to dependency in the supine position.

33.3.5.1 Anterior Approach

A deltopectoral approach with the patient in a beach chair position is used for the fixation of anterior glenoid fractures, making an intraarticular assessment possible. An arthrotomy can be performed just lateral to the palpable glenoid rim just over the labrum. If there is articular comminution, then capsulotomy is mandatory, and work can be executed on either side of the capsule. A retractor can be placed on the posterior edge of the glenoid, to lever the humeral head laterally away from the glenoid articular surface. Reduction can be effected with a dental pick or shoulder hook, and provisional fixation with Kirschner wires is performed. Use screws (2.0–3.5 mm) and/or a mini buttress plate along the anteroinferior edge of the glenoid.

33.3.6 Scapular Tips

33.3.6.1 Straight Incision

A posterior glenoid or an intraarticular glenoid fracture with involvement of the glenoid neck, with minimal involvement or displacement of the scapular spine and vertebral border, can be approached with a simple straight posterior incision. Reduction maneuvers and fixation can then be achieved through the interval between the teres minor and infraspinatus.

33.3.6.2 Infraspinatus Tenotomy

If greater exposure to the glenoid fossa or superior glenoid is desired, an infraspinatus tenotomy can be performed. Leave a 1 cm of cuff insertion at the greater tuberosity for repair. This allows the musculotendinous portion of infraspinatus to be retracted off the superior glenoid and neck region for access to the glenohumeral joint. This maneuver is particularly helpful in large muscular patients with comminuted glenoid fractures.

33.3.6.3 Border Reduction

Manipulate the lateral border (distal fragment) with a shoulder hook through a drill hole. Medially, use pointed bone reduction forceps into small drill holes through the posteromedial aspect of the body, rather than clamping the medial border itself, to facilitate plate application without clamp removal.

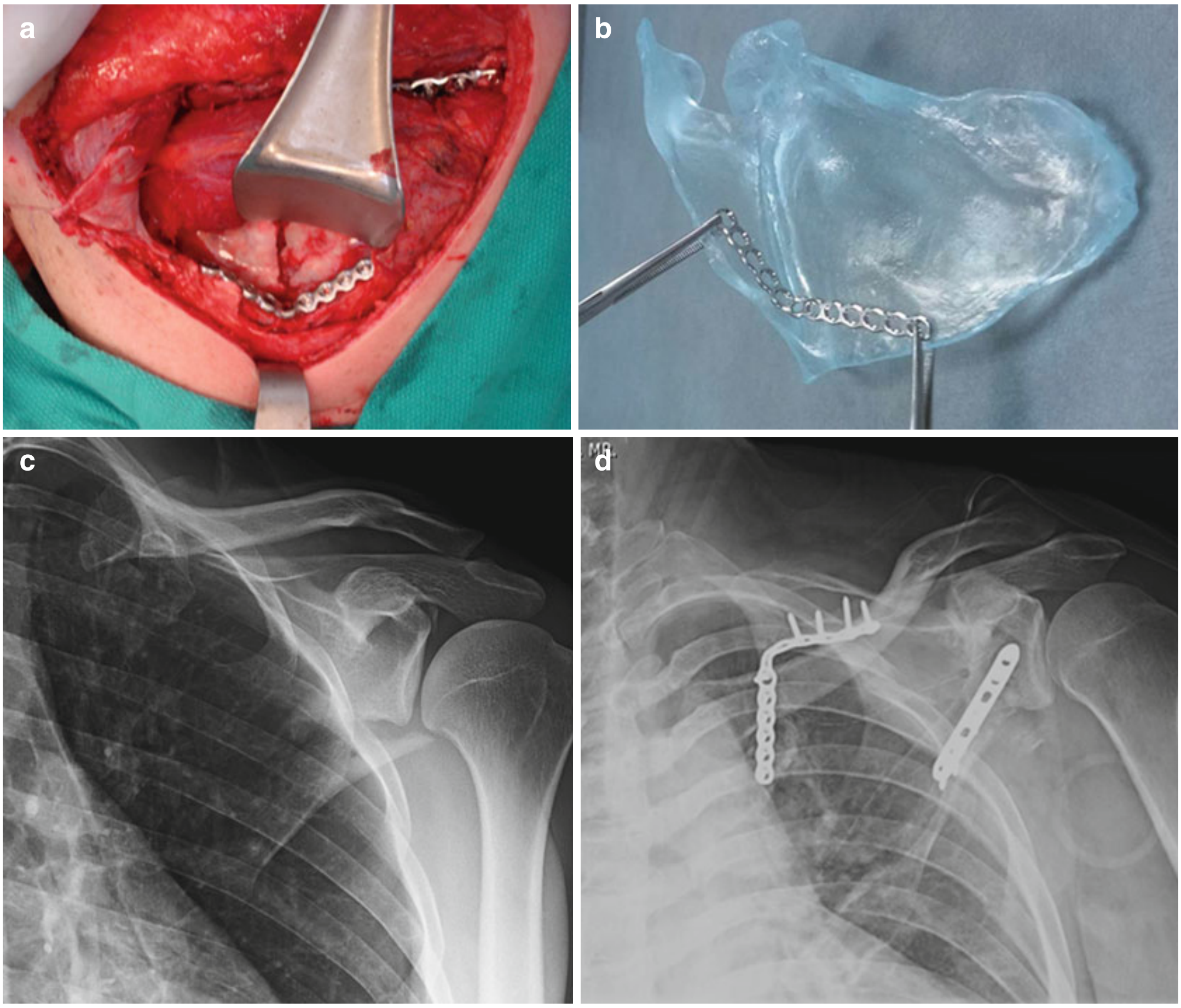

Fig. 33.8 (**a**) Intraoperative image of Judet approach with medial and lateral border plating. (**b**) Though a Judet incision was made, intermuscular windows were developed to access the borders for reduction and fixation. The lateral border is accessed through the interval between teres minor and infraspinatus. (**c**) An AP injury x-ray showing a highly displaced and medialized glenoid in an extraarticular scapula body and neck fracture. (**d**) A postoperative AP image showing a simple two-plate fixation strategy which was applied to allow for immediate active and passive range of motion

33.3.7 Complications

The most serious complications associated with scapular fractures pertain to accompanying injuries of adjacent and distant structures that occurred at the time of injury.

Complications from a fracture of the scapula itself are rare. A robust blood supply in this region likely contributes to nonunion and infection rates which are almost reportable. Other reported complications include malunion, glenohumeral degenerative joint disease, shoulder stiffness, and instability from poorly fixed glenoid fractures.

33.3.8 Rehabilitation

Postoperatively, after stable fixation of the scapula, a sling may be given to the patient for comfort, but immediate active and passive range of motion should begin on post-op day 1 as allowed by their pain. After one month, 3–5 lb. weights and resistance can be started, increasing gradually through the 2-month period at which time endurance activities begin. After 3 months, restrictions can be removed.

33.4 Scapulothoracic Dissociation

Scapulothoracic dissociation is a condition in which the forequarter dissociates from the thoracic cage from a traction injury. This injury almost never occurs with a scapula fracture and does not need to be suspected in the setting of scapula fractures since their injury mechanism is almost opposite – traction vs. lateral compression. The scapulothoracic dissociation has a high correlation with catastrophic injuries, including subclavian thrombosis or avulsion, plexus lesions, and cervical nerve root avulsion.

33.4.1 Initial Management

Physical exam reveals a boggy mobile posterior scapula region with swelling, pain, and at times ecchymosis. A detailed neurological exam and pulses of the extremity should be documented and recorded on a serial basis in the setting of detected lesions. Generally, appropriate workup should include an MRI or cervical myelogram to assess the integrity of the nerve roots and brachial plexus. Furthermore, a CT angiogram, or arteriogram, should be obtained to assess integrity of the subclavian vessels if asymmetric pulses are detected. These tests are generally not possible in an austere setting, and therefore careful documentation of serial exams is important. If there are dense neurologic lesions, then brachial plexus or nerve root lesions can be assumed, and the prognosis for recovery is poor, especially if there has been no return of function by 6 weeks post-injury. If there has been partial recovery detected in that time, then greater hope can be rendered to the patient, but expectations that it will take months to achieve ultimate results are important, and full recovery may never occur. Younger patients have much better prognoses, as do patients with partial lesions or lesions with evidence of early return of function.

A chest x-ray will reveal one scapula more lateralized from the midline than the other side. Measurements can be taken from the midline spinous processes for comparison. CT scans will reveal massive hematoma around the thorax and adjacent to the scapula.

In the developed world, an EMG and nerve conduction study would be performed to establish baseline nerve and muscle function between 6 and 12 weeks, which can be used as a basis for prognostication and surgical decision making, but this study is generally not available in an austere setting. Likewise, advanced nerve transfers for cervical avulsions and brachial plexus exploration and muscle transfers around the shoulder are done in only a few centers in countries with advanced medicine.

33.4.2 Surgical Indications

Salvage procedures should be executed for dense or complete brachial plexus lesions, because a “dead arm” or flail extremity is very morbid and will cause chronic pain in the neck. In these cases, there is little to no function below the elbow. This is a highly debilitating condition. The two salvage options for the austere setting which can provide great advantage to the patient include a glenohumeral disarticulation or a glenohumeral arthrodesis with an above-elbow amputation. The ladder is favored when motor function of the scapula is possible, because the stump can then be used as an adjunctive appendage.

33.4.3 Operative Management

The position for arthrodesis of the proximal humerus to the scapula should include 5° of abduction and 10–15° of forward flexion. Double plating should be performed across the joint, and iliac crest bone graft considered to augment the site of arthrodesis. The patient should be operated in the beach chair position with a large roll posterior to the shoulder to thrust the shoulder forward and help gain access to the spine of the scapula posteriorly.

An incision is executed one centimeter off the scapular spine and extending distally over the anterolateral proximal humerus down along the upper brachium over the deltopectoral interval. This interval is used to access the joint in order to denude all cartilage from the glenohumeral joint. Compression across the glenohumeral joint should be accomplished with a large fragment lag screw from the proximal humerus at the greater tuberosity into the glenoid neck. A large fragment plate and screws should then be used, extending from the humeral shaft across the glenoid neck where excellent fixation can be obtained. A second small fragment plate can be used along the scapula spine, extending down over the neck of the acromion to the humeral shaft adjacent to the first plate. This second plate provides a tension band for fixation which is a great mechanical advantage.

If there is no ability to protract or retract the scapula after many months, then the surgeon should proceed to a forequarter amputation. However, one of the advantages to saving the scapula includes shoulder symmetry for clothing wear which is not a small detail for the patient.

33.5 Fractures of the Clavicle

Clavicle fractures are the most common fracture, constituting 5–10 % of all fractures [58] and accounting for about 35 % of all injuries to the shoulder [59]. Functional results and symptoms are measurably improved in the correctly stabilized fracture, so the risk and reward ratio must be assessed based on the context of the hospital and OR setting. However, in the austere environment with limited resources, it must be remembered that reasonable function after clavicle fracture is possible in the setting of malunions and nonunions and that these conditions are rarely debilitating. In regard to operative vs. nonoperative management of displaced midshaft clavicle fractures – the clearest difference shown in a number of studies is a higher rate of nonunions in the nonoperative group [60, 61]. The number needed to treat is between 4 and 7 patients depending on the study to prevent a nonunion [60]. In the truly austere environment, a reasonable algorithm would be to treat nearly all displaced midshaft clavicle fractures with a sling and reserve operative treatment of clavicle fractures for open injuries, severe displacement, or symptomatic nonunions.

33.5.1 Initial Management

Pain and deformity localized to the clavicle is the typical presentation. Ecchymosis and tenting of the skin may be recognized and physical exam will detect bony crepitus. Inspection of the skin should rule out punctures or lacerations. Due to its proximity to the brachial plexus and the subclavian vessels, physical examination should also include neurovascular assessment, particularly in injuries associated with high-energy mechanisms.

Open wounds should be emergently managed. In the case of a distracted clavicle fracture, consider the diagnosis of scapulothoracic dissociation, which may be associated with vascular injury that demands immediate attention. Whereas orthogonal views of the clavicle have not been recommended, workup should include clavicle x-rays done at different angles, such as a 20° caudal and a

20° cephalic tilt view. A bilateral clavicle AP view allows measurement of relative shortening.

33.5.2 Nonoperative Treatment

The mainstay of treatment for proximal and middle one-third clavicle fractures which have bony contact is nonoperative. Middle one-third fractures should be followed closely until consolidation begins, because these injuries can displace substantially [62]. With distal third clavicle fractures, there will not be much displacement of the clavicle shaft if the CC ligaments are intact. Extraarticular fractures, displaced less than 1 cm, are treated with a simple sling or a sling-and-swath immobilizer for comfort.

Intraarticular distal clavicle fractures most often also warrant nonoperative treatment, particularly if comminuted, but the patient should be warned of the possibility of arthritic symptoms if there is step-off or comminution at the AC joint. A distal clavicle resection can be performed later if arthrosis ensues. In children, 2 weeks of relative immobilization is required before callus forms and pain resolves, a period which is longer by a couple of weeks in the adult.

Though some orthopedists favor a figure-of-eight sling [63–65], it is generally well accepted that this modality offers no advantage over simple support with a sling. Comparative studies have demonstrated no difference in shoulder function, residual deformity, or time to return to full range of motion with either modality [64, 66]. Evidence also suggests that patient satisfaction is higher with simple sling treatment [66]. The figure-of-eight bandage or sling may be discontinued at 2 weeks for young children and 4 weeks for adults [67].

33.5.3 Indications for Surgical Treatment

The clearest indication for surgical treatment is the case of an open fracture, which requires irrigation, debridement, and fixation. The most common form of internal fixation is with plate and screws. Fractures lateral to the coracoid may be associated with torn CC ligaments, in which case the shaft of the clavicle displaces proximally, while the distal fragment remains anchored to the acromion and coracoid. This injury variant is associated with a higher rate of nonunion and consideration should be given to open reduction internal fixation in displaced distal clavicle fractures.

Another relative indication for surgery is medialization of the distal clavicle by more than 2 cm, as indicated by the amount of overriding (shortening) of the shaft. McKee et al. documented poorer performance on endurance testing, as well as on a validated outcome test, in patients with more than 2 cm of shortening and showed that operative correction of malunions can improve function and strength [68]. The Canadian Orthopaedic Trauma Society performed a randomized controlled trial comparing nonoperative treatment to plate fixation in patients with a completely displaced, middle third clavicle shaft fracture with no bony contact [69]. Operative treatment was associated with better outcomes as assessed by function and strength, complications, malunion, nonunion, and patient satisfaction [69].

Functional results and symptoms are measurably diminished from the correctly stabilized fracture, so the risk and reward ratio must be assessed based on the context of the hospital and OR setting. However, in the austere environment with limited resources, it must be remembered that reasonable function after clavicle fracture is possible in the setting of malunions and nonunions and that these conditions are rarely debilitating. In regard to operative vs. nonoperative management of displaced midshaft clavicle fractures – the clearest difference shown in a number of studies is a higher rate of nonunions in the nonoperative group. The number needed to treat is between 4–7 patients depending on the study to prevent a nonunion [60]. In the truly austere environment, a reasonable algorithm would be to treat nearly all displaced midshaft clavicle fractures with a sling and reserve operative treatment of clavicle fractures for open injuries, severe displacement, or symptomatic nonunions.

33.5.4 Surgical Treatment

33.5.4.1 Surgical Technique

Make a straight horizontal incision approximately 1 cm inferior to the palpable clavicle, centered over the fracture. In the subcutaneous tissue, there are two or three supraclavicular nerves, which can be preserved; however, morbidity from their ablation is nearly absent and limited to a patch of numbness.

After the superficial dissection, the platysma is divided along the anterior border of the clavicle. A supraperiosteal dissection of the anterior or superior margin of the clavicle is performed and the fracture appreciated. In simple oblique fractures, reduction is easily obtained with a pointed bone tenaculum, followed by a 2.7 or 3.5 mm lag screw placed perpendicular to the fracture. A clamp is strategically placed out of the way of the proposed plate position. A neutralization plate is then applied with at least six cortices of purchase on either side of the fracture, though in comminuted patterns, a longer plate is desired and the zone of comminution bridged with butterfly fragments simply approximated to the plate with #1 braided suture. A 3.5 mm dynamic compression plate is preferred for its strength in most, though a 2.7 mm dynamic compression plate or 3.5 mm reconstruction plate may be sufficient in smaller or younger patients.

Fracture reduction is particularly difficult when there is significant intercalary comminution. Rather than attempting to put together a comminuted segment, which will promote devitalization of the bone and compromise blood supply, a bridge plate should be used. Manipulation of the shoulder through the arm can be used to reduce the lateral fragment. Fixation can be achieved without "touching" the fracture. Fixation is then performed with no less than six cortices of purchase on the proximal and distal fragments.

Some authors have reported favorable results with intramedullary fixation [70–72]. Obtain fracture reduction and then displace the fracture and predrill the clavicle each way with a 2.5 mm drill to ream the medullary canal. Then starting at the fracture, drill a 3/16 threaded pin laterally until it exits the skin. Move the drill to the opposite end of pin and continue to advance pin by drilling in reverse until pin clears the medial fragment enough to reduce fracture. Observe visible portion of pin to determine depth into medial fragment if C-arm is not available with a goal of 3–5 cm of pin on each side of the fracture. Cut off pin at lateral clavicle leaving enough to grab for removal 3 months later.

The same procedures have been employed for AC disruption can be employed for distal clavicle fractures, specifically those in which the shaft displaces superiorly due to ruptured CC ligaments (see *AC section*). The fixation and repair challenges of distal clavicle fractures, regarding maintaining reduction, are similar to the surgical challenges of AC dislocations due to the deforming force of the sternocleidomastoid muscle on the proximal clavicle shaft. However, in the case of distal clavicle, eventual bony union helps to maintain reduction after plate removal.

33.5.5 Clavicle Tips

- The push-pull technique is a helpful reduction technique for clavicle fractures treated in a delayed fashion. A blocking screw is placed on the medial aspect of the clavicle and the plate is fixed to the lateral shaft. A lamina spreader is then placed between the plate and blocking screw and leverage is used to disrupt callus and bring the clavicle out to length with reduced periosteal stripping. Do not overlengthen because this can promote nonunion.
- Prep the arm free, because manipulating the arm can greatly simplify obtaining a reduction without directly handling the fractured site.

33.5.6 Complications

Patients managed nonoperatively should be counseled to anticipate a lump in the region of the fracture if treated nonoperatively. Earlier reports of nonunion rates were less than 1 %, although more recent studies show higher rates in the range of 15 %, possibly reflecting different fracture patterns from higher-energy mechanisms [58, 67]. Studies have shown higher nonunion rates for the distal clavicle in the range of 30 %. Identified risk factors for nonunion include displacement, advancing age, female, and displaced distal clavicle fractures [73]. Complications associated with nonunion and symptomatic malunion include limited function of the shoulder, neurological symptoms, thoracic outlet syndrome, and arterial ischemia, though the latter is very rare [74–76].

The clavicle superficial location causes high rates of symptomatic hardware necessitating implant removal. Wait for a minimum of 1-year post-fixation before removal is performed on a united clavicle. Less common complications include infection, implant failure, and nonunion. The greatest risk for catastrophic injury is medially since at times the subclavian vessels can be touching the posterior surface of the clavicle. Newer implants and techniques have reduced the rates of pin migration and soft tissue breakdown for intramedullary devices, but these alarming complications have been widely reported in the literature both in the developing and developed world.

33.5.7 Follow-Up in Shoulder Girdle Injuries

Nonoperatively managed patients with scapula and clavicle fractures must be followed closely until consolidation begins, because these injuries can displace substantially in the first 3 weeks [62]. If they do displace, it is possible that operative intervention may become warranted. We routinely see both our operatively managed patients at 2, 6, and 12 weeks postoperatively, whereas when managed nonoperatively, x-rays are obtained each week for the first three. Patients with limited motion are more common after brachial plexus injury, a head injury, a halo vest for spine injury, or complex associated fractures of the ipsilateral extremity. This is an excellent time for a manipulation under anesthesia to jump-start the motion for the patient. If range of motion is not regained during this period, the patient may have permanent loss of function.

After nonoperative management, in the first 2 weeks, patients are encouraged to perform pendulum activities, but after this juncture, passive and gentle active-assisted range of motion should be encouraged up to the sixth week. Pulleys and push-pull sticks powered by the opposite extremity, and supine-assisted motion, are effective modalities. Ipsilateral elbow, wrist, and hand exercises using 3–5 lb. weights (on a supported elbow) are encouraged. These exercises will lessen upper extremity muscular atrophy and promote edema reduction. After 6 weeks, the patient can then begin more aggressive active range of motion and light lifting, starting with 3–5 lb. repetitions, advancing as tolerated. Good function is usually restored by 3 months post-injury, at which time restrictions can be lifted.

In the operative patient properly stabilized, immediate passive and active range of motion is begun after surgery and ramped up with a goal of full motion after a month. In the second month, 3–5 lb weights and resistance is begun, ramping up to full strength in the 2–3-month time frame. Restrictions are lifted after 3 months.

33.6 Shoulder Dislocation

The management of shoulder dislocation is an important consideration for medical caretakers in the developing world setting because it is a common injury. The rehabilitation from this injury differs from the above regimen because longer periods of immobilization are necessary to allow for capsular healing and stability to be restored. The patient with an acute shoulder dislocation presents with pain, swelling, deformity, and decreased range of motion. Perform a thorough neurovascular examination. A most often transient injury to the axillary nerve is present in 5 % of patients. A posterior dislocation will present adducted and internally rotated with limited external rotation. An anterior dislocation will present externally rotated with a block to internal rotation. Obtain a trauma series of the shoulder including an AP of the shoulder, scapular Y, and an axillary view to demonstrate the humeral head is located within the glenoid. Missing a posterior dislocation is common due to failure to obtain an axillary view. The shoulder dislocation must be diagnosed and reduced to prevent permanent disability.

Injecting 10 cc of 1 % lidocaine into the glenohumeral joint and waiting 5 min before a reduction attempt while gently applying traction is an efficient, effective, and safe way to address this problem. This technique has been successful for dislocations presenting a week out. Alternatively, the patient can be sedated. Traction counter traction is necessary to reduce these injuries. An assistant holds a sheet passed through the axillae while traction is applied to through the forearm. It can be helpful to have another assistant pass a towel around the proximal humerus to apply lateral traction while directly pushing on the humeral head in the desired lateral and anterior/posterior direction to disengage the humeral head from the glenoid. For posterior dislocation, traction is applied with the arm held in adduction and internal rotation. With reduction, there is a palpable or audible clunk, decrease in pain, and improved passive range of motion. Post-reduction assess the stability of the shoulder and then obtain x-rays to confirm reduction and evaluate for fractures of the glenoid or humeral head. If closed methods fail, the patient will require an open reduction. Patients younger than 40 are immobilized for 3–6 weeks in a sling while those older than 40 are immobilized for 1–2 weeks.

Because of the lack of access to appropriate facilities and lack of education, patients not uncommonly present with chronic dislocations which manifest in a stiff, painful, dysfunctional shoulder. Posterior dislocations are characterized by an internally rotated shoulder which is stuck, and anterior dislocations are characterized with an inability to internally rotate. Forward elevation is minimal and the limited arc of motion is overcompensated by the patient's scapulothoracic motion.

These circumstances can be managed with a proximal humeral resection through a deltopectoral approach. The goal of this surgery is to provide pain relief and a better arc of motion, though even this is limited to below shoulder plane function. Nevertheless, patients are much happier with this enhanced arc of motion which is often enough for employment opportunities or the simple abilities needed to provide for a family.

The deltopectoral interval is developed down to the subscapularis and capsule. This is often a mass of scar, which should be incised and tagged with heavy braided suture to allow for open access to the glenohumeral joint. The scar tissue needs to be resected, as well as fracture remnants from the anterior or posterior glenoid (bony Bankart fragments). The dislocated humeral head needs to be resected with an osteotome and rongeur until it is evacuated from its dislocated position. A "joystick" will never be possible to simply pop the humeral head out because of chronic scarring. A piecemeal dissection will be necessary with the goal to leave the greater and lesser tuberosities intact (Fig. 33.9a). Once the humeral head is resected at the anatomical neck, the remnant capsule and scar tissue are imbricated with heavy braided suture. If the greater tuberosity is taken, the supraspinatus is advanced through a drill hole at the surgical neck to provide an anchor for healing. The reattachment of the supraspinatus and infraspinatus is important for upper extremity function, and these steps are critical for best success in this procedure. The pseudo-joint now is not under great tension and mobility is now possible.

A postoperative sling and early pendulum exercises, advancing to gentle passive- and active-assisted range of motion, are encouraged as allowed by symptoms. No resistive activities with weights are done until 6 weeks postoperative. All restrictions can be removed at 3 months.

33.7 Tutorial

A 26-year-old male laborer was involved in a motorcycle accident in a remote part of Nepal. He presented to a mission hospital one week later with left shoulder pain. On exam he had intact skin, tenderness to palpation, significant deformity, pain with range of motion, and intact

Fig. 33.9 (**a**) X-ray showing a chronic anteroinferior shoulder dislocation resulting in an irreparable Hill-Sachs lesion. (**b**) Shoulder radiograph obtained after shoulder resection arthroplasty. (**c**) This patient had a functional and painless arc of motion below the 90° shoulder plane which allowed him to effectively return to work as a motorcycle mechanic

motor, sensation, and normal pulses distally. X-rays revealed a significantly displaced distal clavicle fracture. Risk, benefits, and alternatives were explained and the patient elected to proceed with open reduction and internal fixation with hook plate with a planned plate removal 3 months after initial operation. The patient healed, had removal of hardware, and was able to return to work (Fig. 33.4).

References

1. Yeh GL, Williams Jr GR. Conservative management of sternoclavicular injuries. Orthop Clin North Am. 2000;31(2):189–203.
2. Groh GI, Wirth MA. Management of traumatic sternoclavicular joint injuries. J Am Acad Orthop Surg. 2011;19(1):1–7.
3. Rockwood CA. Disorders of the sternoclavicular joint. In: Rockwood Jr C, Matsen III F, Wirth M,

Lippitt S, editors. The shoulder. 4th ed. Philadelphia: Saunders/Elsevier; 2009. p. 527.

4. de Jong KP, Sukul DM. Anterior sternoclavicular dislocation: a long-term follow-up study. J Orthop Trauma. 1990;4(4):420–3.
5. Groh GI, Wirth MA, Rockwood Jr CA. Treatment of traumatic posterior sternoclavicular dislocations. J Shoulder Elbow Surg. 2011;20(1):107–13.
6. Thomas DP, Davies A, Hoddinott HC. Posterior sternoclavicular dislocations – a diagnosis easily missed. Ann R Coll Surg Engl. 1999;81(3):201–4.
7. Flatow EL. The biomechanics of the acromioclavicular, sternoclavicular, and scapulothoracic joints. Instr Course Lect. 1993;42:237–45.
8. Rockwood Jr CA, Groh GI, Wirth MA, Grassi FA. Resection arthroplasty of the sternoclavicular joint. J Bone Joint Surg Am. 1997;79(3):387–93.
9. Fukuda K, Craig EV, An KN, Cofield RH, Chao EY. Biomechanical study of the ligamentous system of the acromioclavicular joint. J Bone Joint Surg Am. 1986;68(3):434–40.
10. Inman VT, Abbott LC. Observations on the function of the shoulder joint. J Bone Joint Surg. 1944;26(1):1–30.
11. Tossy JD, Mead NC, Sigmond HM. Acromioclavicular separations: useful and practical classification for treatment. Clin Orthop Relat Res. 1963;28:111–9.
12. Allman Jr FL. Fractures and ligamentous injuries of the clavicle and its articulation. J Bone Joint Surg Am. 1967;49(4):774–84.
13. Rockwood CA, Williams G, Young D. Disorders of the acromioclavicular joint. In: Rockwood CA, Matsen FA, eds. The shoulder. 2nd ed. Vol. 1. Philadelphia: WB Saunders; 1998:483–553.
14. Taft TN, Wilson FC, Oglesby JW. Dislocation of the acromioclavicular joint. An end-result study. J Bone Joint Surg Am. 1987;69(7):1045–51.
15. Shaffer BS. Painful conditions of the acromioclavicular joint. J Am Acad Orthop Surg. 1999;7(3):176–88.
16. Bannister GC, Wallace WA, Stableforth PG, Hutson MA. The management of acute acromioclavicular dislocation. A randomised prospective controlled trial. J Bone Joint Surg Br. 1989;71(5):848–50.
17. URIST MR. Complete dislocations of the acromiclavicular joint; the nature of the traumatic lesion and effective methods of treatment with an analysis of forty-one cases. J Bone Joint Surg Am. 1946;28(4):813–37.
18. Weaver JK, Dunn HK. Treatment of acromioclavicular injuries, especially complete acromioclavicular separation. J Bone Joint Surg Am. 1972;54(6):1187–94.
19. Wu CH, Wang YC, Wang HK, Chen WS, Wang TG. Evaluating displacement of the coracoacromial ligament in painful shoulders of overhead athletes through dynamic ultrasonographic examination. Arch Phys Med Rehabil. 2010;91(2):278–82.
20. Chen J, Budoff JE, Luo CF, Luo ZP. Initiatory biomechanical study on humeral head migration after coracoacromial ligament cut. Arch Orthop Trauma Surg. 2009;129(1):133–7.
21. Su W, Budoff JE, Luo Z. The effect of coracoacromial ligament excision and acromioplasty on superior and anterosuperior glenohumeral stability. Arthroscopy. 2009;25(1):13–8.
22. Collins D. Disorders of the acromioclavicular joint. The Shoulder. 2009;1:453–526.
23. Sim E, Schwarz N, Höcker K, Berzlanovich A. Repair of complete acromioclavicular separations using the acromioclavicular-hook plate. Clin Orthop Relat Res. 1995;314:134–42.
24. Jensen G, Katthagen JC, Alvarado LE, Lill H, Voigt C. Has the arthroscopically assisted reduction of acute AC joint separations with the double tight-rope technique advantages over the clavicular hook plate fixation? Knee Surg Sports Traumatol Arthrosc. 2014;22(2):422–30.
25. von Heideken J, Bostrom Windhamre H, Une-Larsson V, Ekelund A. Acute surgical treatment of acromioclavicular dislocation type V with a hook plate: superiority to late reconstruction. J Shoulder Elbow Surg. 2013;22(1):9–17.
26. Di Francesco A, Zoccali C, Colafarina O, Pizzoferrato R, Flamini S. The use of hook plate in type III and V acromio-clavicular Rockwood dislocations: clinical and radiological midterm results and MRI evaluation in 42 patients. Injury. 2012;43(2):147–52.
27. Chiang CL, Yang SW, Tsai MY, Kuen-Huang CC. Acromion osteolysis and fracture after hook plate fixation for acromioclavicular joint dislocation: a case report. J Shoulder Elbow Surg. 2010;19(4):e13–5.
28. Nadarajah R, Mahaluxmivala J, Amin A, Goodier DW. Clavicular hook-plate: complications of retaining the implant. Injury. 2005;36(5):681–3.
29. Flinkkila T, Ristiniemi J, Hyvonen P, Hamalainen M. Surgical treatment of unstable fractures of the distal clavicle: a comparative study of Kirschner wire and clavicular hook plate fixation. Acta Orthop Scand. 2002;73(1):50–3.
30. Muramatsu K, Shigetomi M, Matsunaga T, Murata Y, Taguchi T. Use of the AO hook-plate for treatment of unstable fractures of the distal clavicle. Arch Orthop Trauma Surg. 2007;127(3):191–4.
31. Meda PV, Machani B, Sinopidis C, Braithwaite I, Brownson P, Frostick SP. Clavicular hook plate for lateral end fractures:- a prospective study. Injury. 2006;37(3):277–83.
32. Mumford E. Acromioclavicular dislocation a new operative treatment. J Bone Joint Surg. 1941;23(4):799–802.
33. Elhassan B, Ozbaydar M, Diller D, Massimini D, Higgins LD, Warner JJ. Open versus arthroscopic acromioclavicular joint resection: a retrospective comparison study. Arthroscopy. 2009;25(11):1224–32.
34. Freedman BA, Javernick MA, O'Brien FP, Ross AE, Doukas WC. Arthroscopic versus open distal clavicle excision: comparative results at six months and one year from a randomized, prospective clinical trial. J Shoulder Elbow Surg. 2007;16(4):413–8.
35. Rabalais RD, McCarty E. Surgical treatment of symptomatic acromioclavicular joint problems: a systematic review. Clin Orthop Relat Res. 2007;455:30–7.

36. Butters KP. The scapula. In: Rockwood Jr CA, Matsen II FA, editors. The shoulder, vol. 1. Philadelphia: WB Saunders; 1990.
37. Wilson PD. Experience of the management of fractures and dislocations (based on analysis of 4,390 cases) by staff of the fracture service MGH. Boston/Philadelphia: JB Lippincott; 1938.
38. Cole PA. Scapula fractures. Orthop Clin North Am. 2002;33(1):1–18. vii.
39. Ideberg R, Grevsten S, Larsson S. Epidemiology of scapular fractures. Incidence and classification of 338 fractures. Acta Orthop Scand. 1995;66(5):395–7.
40. McGahan JP, Rab GT, Dublin A. Fractures of the scapula. J Trauma. 1980;20(10):880–3.
41. Ada JR, Miller ME. Scapular fractures. Analysis of 113 cases. Clin Orthop Relat Res. 1991;269:174–80.
42. Hardegger FH, Simpson LA, Weber BG. The operative treatment of scapular fractures. J Bone Joint Surg Br. 1984;66(5):725–31.
43. Court-Brown CM, Aitken SA, Forward DR, O'Toole RV. The epidemiology of fractures. In: Bucholz RW, editor. Fractures in adults. 7th ed. Philadelphia: Lippincott Williams & Wilkins; 2009.
44. Baldwin KD, Ohman-Strickland P, Mehta S, Hume E. Scapula fractures: a marker for concomitant injury? A retrospective review of data in the National Trauma Database. J Trauma. 2008;65(2):430–5.
45. Anavian J, Khanna G, Plocher EK, Wijdicks CA, Cole PA. Progressive displacement of scapula fractures. J Trauma. 2010;69(1):156–61.
46. Armstrong CP, Van der Spuy J. The fractured scapula: importance and management based on a series of 62 patients. Injury. 1984;15(5):324–9.
47. Goss TP. Fractures of the glenoid cavity. J Bone Joint Surg Am. 1992;74(2):299–305.
48. Guttentag IJ, Rechtine GR. Fractures of the scapula. A review of the literature. Orthop Rev. 1988;17(2):147–58.
49. Goss TP. Double disruptions of the superior shoulder suspensory complex. J Orthop Trauma. 1993;7(2):99–106.
50. Goss TP. The scapula: coracoid, acromial, and avulsion fractures. Am J Orthop. 1996;25(2):106–15.
51. Ogawa K, Naniwa T. Fractures of the acromion and the lateral scapular spine. J Shoulder Elbow Surg. 1997;6(6):544–8.
52. Ogawa K, Yoshida A. Fracture of the superior border of the scapula. Int Orthop. 1997;21(6):371–3.
53. Howell SM, Galinat BJ. The glenoid-labral socket. A constrained articular surface. Clin Orthop Relat Res. 1989;243:122–5.
54. Iannotti JP, Gabriel JP, Schneck SL, Evans BG, Misra S. The normal glenohumeral relationships. An anatomical study of one hundred and forty shoulders. J Bone Joint Surg Am. 1992;74(4):491–500.
55. Anavian J, Conflitti JM, Khanna G, Guthrie ST, Cole PA. A reliable radiographic measurement technique for extra-articular scapular fractures. Clin Orthop Relat Res. 2011;469(12):3371–8.
56. Anavian J, Gauger EM, Schroder LK, Wijdicks CA, Cole PA. Surgical and functional outcomes after operative management of complex and displaced intra-articular glenoid fractures. J Bone Joint Surg Am. 2012;94(7):645–53.
57. Cole PA, Freeman G, Dubin JR. Scapula fractures. Curr Rev Musculoskelet Med. 2013;6(1):79–87.
58. Neer CS. Nonunion of the clavicle. JAMA. 1960;172:1006–11.
59. Nordqvist A, Petersson C. The incidence of fractures of the clavicle. Clin Orthop Relat Res. 1994;300:127–32.
60. Robinson CM, Goudie EB, Murray IR, Jenkins PJ, Ahktar MA, Read EO, et al. Open reduction and plate fixation versus nonoperative treatment for displaced midshaft clavicular fractures: a multicenter, randomized, controlled trial. J Bone Joint Surg Am. 2013;95(17):1576–84.
61. Kulshrestha V, Roy T, Audige L. Operative versus nonoperative management of displaced midshaft clavicle fractures: a prospective cohort study. J Orthop Trauma. 2011;25(1):31–8.
62. Plocher EK, Anavian J, Vang S, Cole PA. Progressive displacement of clavicular fractures in the early postinjury period. J Trauma. 2011;70(5):1263–7.
63. McCandless DN, Mowbray MA. Treatment of displaced fractures of the clavicle. Sling versus figure-of-eight bandage. Practitioner. 1979;223(1334):266–7.
64. Andersen K, Jensen PO, Lauritzen J. Treatment of clavicular fractures. Figure-of-eight bandage versus a simple sling. Acta Orthop Scand. 1987;58(1):71–4.
65. Stanley D, Norris SH. Recovery following fractures of the clavicle treated conservatively. Injury. 1988;19(3):162–4.
66. Lenza M, Belloti JC, Andriolo RB, Gomes Dos Santos JB, Faloppa F. Conservative interventions for treating middle third clavicle fractures in adolescents and adults. Cochrane Database Syst Rev. 2009;(2):CD007121.
67. ROWE CR. An atlas of anatomy and treatment of mid-clavicular fractures. Clin Orthop. 1968;58:29–42.
68. McKee MD, Pedersen EM, Jones C, Stephen DJ, Kreder HJ, Schemitsch EH, et al. Deficits following nonoperative treatment of displaced midshaft clavicular fractures. J Bone Joint Surg Am. 2006;88(1):35–40.
69. Canadian Orthopaedic Trauma Society. Nonoperative treatment compared with plate fixation of displaced midshaft clavicular fractures. J Bone Joint Surg Am. 2007;89(1):1–10.
70. Frigg A, Rillmann P, Perren T, Gerber M, Ryf C. Intramedullary nailing of clavicular midshaft fractures with the titanium elastic nail: problems and complications. Am J Sports Med. 2009;37(2):352–9.
71. Frigg A, Rillmann P, Ryf C, Glaab R, Reissner L. Can complications of titanium elastic nailing with end cap for clavicular fractures be reduced? Clin Orthop. 2011;469(12):3356.
72. Liu PC, Chien SH, Chen JC, Hsieh CH, Chou PH, Lu CC. Minimally invasive fixation of displaced midclavicular fractures with titanium elastic nails. J Orthop Trauma. 2010;24(4):217–23.

73. Robinson CM, Court-Brown CM, McQueen MM, Wakefield AE. Estimating the risk of nonunion following nonoperative treatment of a clavicular fracture. J Bone Joint Surg Am. 2004;86-A(7):1359–65.
74. Guilfoil PH, Christiansen T. An unusual vascular complication of fractured clavicle. JAMA. 1967;200(1):72–3.
75. Toledo LC, MacEwen GD. Severe complication of surgical treatment of congenital pseudarthrosis of the clavicle. Clin Orthop. 1979;139:64–7.
76. Der Tavitian J, Davison JN, Dias JJ. Clavicular fracture non-union surgical outcome and complications. Injury. 2002;33(2):135–43.

Fractures of the Proximal Humerus

34

Paul S. Whiting

Proximal humerus fractures occur most commonly in the elderly as the result of falls or other low-energy mechanisms of injury. Most fractures of the proximal humerus can be treated nonoperatively with good outcomes. However, the twenty-first century has seen a dramatic trend toward increasing surgical treatment of these fractures in the developed world, whether by internal fixation or arthroplasty [1]. Significant geographic variation in rates and type of surgical treatment underscores the lack of consensus regarding the optimal management of these injuries [ibid]. Emerging literature has reignited the debate regarding the appropriate indications for operative treatment as well as the role of nonoperative management for proximal humerus fractures.

34.1 Epidemiology

Although fractures of the proximal humerus account for only 5 % of all appendicular skeletal injuries, they represent a disproportionate number of fractures in the elderly [2, 3]. Unlike many fractures that follow a bimodal age distribution, the incidence of proximal humerus fractures in adults increases with age [4]. Roughly 75 % of these fractures occur in patients over 60 years of age [3] and 77 % occur in women [5]. The annual incidence of proximal humerus fractures in the developed world has been estimated between 63 and 105 per 100,000 population [6], with the highest incidence (294 per 100,000) occurring in women 80 years of age and above [7]. Annual incidence tripled between 1970 and 2002, and current epidemiologic trends predict proximal humeral fracture incidence to triple again by 2036 [7].

The vast majority of these injuries (75–87 %) occur as the result of simple falls or other low-energy mechanisms of injury [2, 4], making them the third most common osteoporotic fracture [8]. Conversely, high-energy injuries are much more common in adolescents and young adults and result from road traffic accidents, falls from a height, athletic injuries, and gunshot wounds [4, 6].

34.2 Review of the Evidence

There is a paucity of literature specific to the treatment of proximal humerus fractures in the developing world. However, a critical evaluation of the best available literature from the developed world is instructive and can offer guidance in the treatment of these injuries in the austere environment (see Sect. 34.2.3 below).

P.S. Whiting, MD
Department of Orthopaedics and Rehabilitation,
University of Wisconsin, Madison, WI, USA
e-mail: whiting@ortho.wisc.edu

© Springer International Publishing Switzerland 2016
J.D. Robinson (ed.), *Orthopaedic Trauma in the Austere Environment:*
A Practical Guide to Care in the Humanitarian Setting, DOI 10.1007/978-3-319-29122-2_34

34.2.1 Operative Versus Nonoperative Treatment

A randomized controlled trial by Boons et al. [9] comparing hemiarthroplasty to nonoperative treatment for four-part proximal humerus fractures in patients 65 years and older found no differences in 12-month functional outcomes or pain scores. Patients in the nonoperative group actually had improved abduction strength at 3 and 12 months compared with those who underwent hemiarthroplasty. A similar randomized controlled trial by Olerud et al. [10] found a statistically significant difference favoring hemiarthroplasty in the EuroQol (EQ)-5D index but not the Constant or DASH scores at 24 months. Fjalestad et al. [11] randomized patients 60 years and older with displaced three- or four-part fractures to locking plate fixation or nonoperative treatment. There were no significant differences between groups in Constant score or patient self-assessment (ASES) score at 12 months. Olerud et al. [12] also performed a randomized controlled trial comparing locked plating to nonoperative treatment for displaced three-part fractures. The authors found no difference between groups in EQ-5D, Constant, or DASH scores at 24 months. The most recent Cochrane database systematic review found insufficient evidence to demonstrate that surgical treatment provided consistently better outcomes in the long-term compared with nonoperative treatment [13]. For isolated greater tuberosity fractures displaced more than 5 mm, surgical reduction and fixation has been shown to produce improved outcomes compared with nonoperative treatment [14].

34.2.2 Comparison of Surgical Treatments

A multicenter prospective study comparing locked intramedullary nailing and locked plating for displaced proximal humerus fractures found equivalent 12-month outcomes scores in both groups [15]. A randomized controlled trial comparing these same two methods of fixation found no difference in clinical outcomes scores, pain, or range of motion at 3 years [16]. In a study comparing hemiarthroplasty to locked plating, complication rates were high for both procedures (77.2 % and 63.6 %, respectively), and there were no differences in 12-month functional outcomes between groups [17]. A prospective randomized multicenter trial comparing hemiarthroplasty, open reduction internal fixation (ORIF) with a locking plate, and nonoperative treatment is currently underway, with results expected in 2017–2018 [18].

Several recent studies have investigated the role of reverse total shoulder arthroplasty (rTSA) in the treatment of acute proximal humerus fractures. A prospective cohort study comparing rTSA to hemiarthroplasty demonstrated improved functional outcome scores, patient satisfaction, and forward elevation in the rTSA group with no differences in external or internal rotation or complications [19]. Using data from the New Zealand Joint Registry, a multicenter study found that patients treated with rTSA achieved better functional outcomes at 5 years than patients treated with hemiarthroplasty for acute proximal humerus fractures [20]. However, a systematic review comparing these two procedures with a minimum follow-up of 6 months found no significant differences in functional outcomes or range-of-motion parameters, and odds of a postoperative complication were 4 times higher for rTSA than for hemiarthroplasty [21]. Furthermore, studies demonstrating a significant improvement in functional outcomes between rTSA and nonoperative treatment are lacking. In the austere environment, reverse total shoulder arthroplasty implants are not readily available. And even if such technology becomes available in the developing world, where considerations of cost are paramount, the higher cost of rTSA (roughly twice that of hemiarthroplasty) combined with the higher likelihood of revision surgery is a significant barrier to its use, especially in the absence of clear data supporting its superiority.

34.2.3 Summary of Evidence

Although the twenty-first century has witnessed a dramatic trend toward increasing surgical management of proximal humerus fractures in the developed world, several recent randomized controlled trials have demonstrated equivalent functional outcomes when comparing nonoperative treatment with either locking plate fixation or hemiarthroplasty for displaced three- and four-part proximal humerus fractures. In the absence of clear evidence demonstrating superior outcomes with operative treatment using state-of-the-art implants (e.g., locking plates and modular hemiarthroplasty components), surgeons in the austere environment who may not have access to such implants should exercise judicious surgical indications for proximal humerus fractures and utilize sound surgical techniques when appropriate. Doing so will maximize clinical outcomes of these injuries while minimizing complications and need for revision surgery.

34.3 Author's Preferred Approach or Treatment Algorithm

34.3.1 Initial Management

As with any fracture, careful history and detailed physical examination of the injured extremity are essential. Particular attention should be paid to the neurovascular status of the limb. Despite the proximity of the axillary nerve and artery to the surgical neck of the proximal humerus, neurovascular injuries are uncommon following proximal humerus fractures [22]. Vascular injuries occur more commonly in the setting of severe displacement or fracture-dislocation of the proximal humerus, and rich collateral blood supply around the shoulder can make the initial diagnosis of these injuries challenging [23]. Doppler ultrasonography or, if available, angiography can assist in identifying and localizing the vascular injury. Nerve injuries can occur either as direct injuries to branches of the brachial plexus or from traction on the axillary nerve [24]. With high-energy mechanisms of injury, the presence of associated injuries should be investigated, particularly of the chest (pneumo or hemothorax, rib fractures) and cervical spine [6].

Standard radiographs are usually sufficient to diagnose and classify proximal humerus fractures. Ideal radiographic imaging includes three views: true AP, scapular Y, and axillary (or Velpeau view if the axillary view is too uncomfortable to obtain acutely). Though not typically required, CT scan if available can further clarify the fracture pattern and assist in preoperative planning, especially in the setting of comminution or head-splitting fractures. While ultrasound is not routinely used in the diagnosis of proximal humerus fractures, a promising sonographic finding termed the "double-line sign" has been shown to be reliable in diagnosing proximal humerus fractures [25]. The role of musculoskeletal ultrasound in the setting of trauma has yet to be determined but holds promise for resource-poor settings, where X-ray may not always be readily available.

The Neer classification system, introduced in 1970, is still the most widely used for proximal humerus fractures. Neer's system [26] defines fractures as one-, two-, three-, or four-part based upon the number of segments that are displaced >1 cm or angulated >45° (Fig. 34.1). Other classification systems have been proposed including that of Resch et al. [27], which divides fractures into varus and valgus types, and the AO/OTA classification [28], which divides fractures into a total of 27 subtypes. Perhaps the most clinically useful classification system is that of Hertel et al. [29], a binary system which used Codman's original description of fracture lines [30] but also identified reliable radiographic predictors of humeral head ischemia. Short metaphyseal extension of the head fragment (<8 mm), disruption of the medial calcar hinge (>2 mm), and fracture types with an anatomic neck component were good predictors of humeral head ischemia. When combined, these three factors have a positive predictive value for ischemia of 97 %. Other radiographic parameters were found to be only moderate (four-part

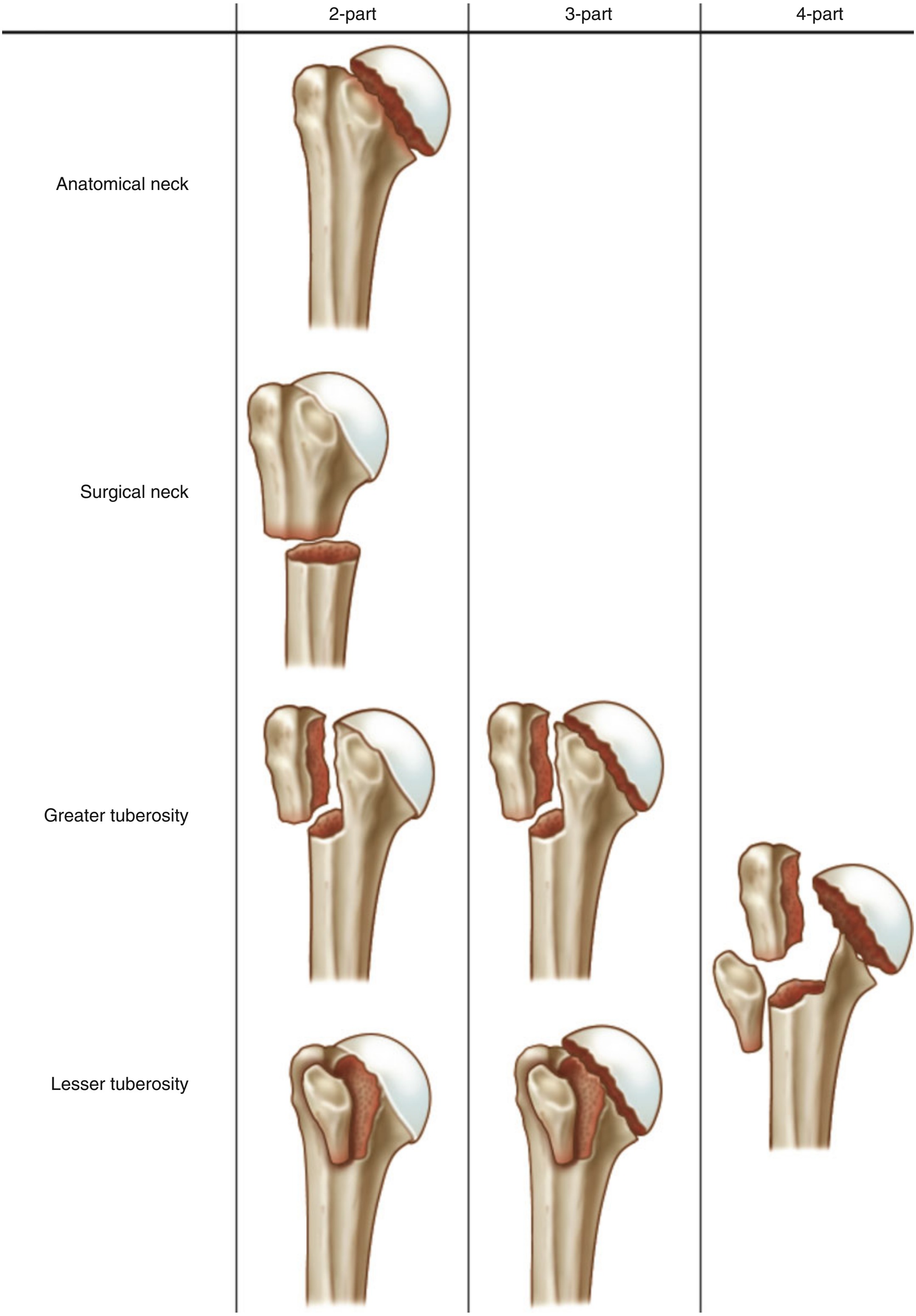

Fig. 34.1 The Neer classification for proximal humerus fractures

fracture type, head angulation >45°, and tuberosity displacement >10 mm) or poor (glenohumeral dislocation, head-split component, and three-part fracture type) predictors of ischemia. The Codman-Hertel classification system was also found to have the highest interobserver score [31].

34.3.2 Decision-Making

Selecting an appropriate treatment plan for a proximal humerus fracture must involve consideration of several important variables including the patient's age, functional capacity, medical comorbidities, fracture pattern, bone quality, surgeon's experience, and availability of implants. It is critical to understand that nonoperative management is appropriate for the vast majority of proximal humerus fractures, especially those that are minimally displaced. Radiographic characteristics of stability include cortical contact between the shaft and head fragments, fragment impaction, and minimal displacement (<5 mm) of the tuberosities [6].

Although there are no evidence-based indications for surgical treatment, reasonable criteria for considering operative fixation in adults include varus or valgus angulation >20° (from the physiologic head-shaft angle of 130°), head-shaft displacement greater than 50 % of the shaft diameter, fracture-dislocations not reducible by closed means, and isolated greater tuberosity fractures displaced >5 mm [22]. The full armamentarium of surgical treatment for proximal humerus fractures includes interfragmentary suture, percutaneous pinning or screw fixation, intramedullary nailing, non-locking or locking plates, and primary arthroplasty – both hemiarthroplasty and reverse total shoulder arthroplasty. In the austere environment, however, availability of implants may be limited. As a result, it is critical to exercise judicious surgical indications, choosing surgical management only when the available implants offer a distinct advantage to nonoperative treatment for the fracture in question.

Table 34.1 Acceptable angulation by age in pediatric proximal humerus fracture treatment

Age (years)	<8	8–11	>11
Acceptable angulation (degrees)	<70	<60	<45

If initial fracture angulation is not acceptable, closed reduction should be performed followed by sling-and-swathe application. If acceptable alignment cannot be maintained by closed means, percutaneous pinning or ORIF must be considered

In pediatric patients, due to the significant remodeling potential of the proximal humerus, the vast majority of fractures in this region can be managed nonoperatively with immobilization in a simple sling or sling and swathe. Depending on the patient's age, angular deformity ranging from 45° to upwards of 70° is acceptable (Table 34.1). Closed manipulation followed by immobilization in a sling and swathe is usually successful in achieving an acceptable reduction [32]. If there is significant instability of the fracture, two or three K-wires placed percutaneously under fluoroscopic guidance is typically sufficient to stabilize the fracture and obviates the need for cumbersome immobilization techniques such as a Velpeau bandage or shoulder spica cast.

34.3.3 Equipment

For operative fixation of proximal humerus fractures in adults, fluoroscopy is an extremely important tool for assessing fracture reduction and ensuring extra-articular placement of implants in the humeral head fragment. A proposed modification to the surgical technique for locations without access to fluoroscopy is discussed below. Arthroplasty can generally be performed without the use of fluoroscopy. The appropriate implant system, including any required power instrumentation, must be available.

34.3.4 Techniques (Tips/Pitfalls)

Regardless of the surgical technique planned, patient positioning will be dependent upon the availability of operative tables. Beach chair positioning is commonly used for surgery of the proximal humerus and provides excellent access to the shoulder for both the surgeon and the assistant. However, supine positioning with the patient as proximal and lateral on the table as possible provides a viable alternative when specialized tables are not available and may even be preferable due to the relative ease of obtaining intraoperative AP and axillary lateral views. A piece of plexiglass or wood can be placed under the operating table pad, providing a radiolucent surface to support the injured arm [33]. The C-arm is brought in from the head of the bed, parallel to the long axis of the table, and the arm is prepped and draped free (Fig. 34.2). Regardless of the position selected, it is essential to obtain fluoroscopic imaging prior to prepping and draping to ensure that the required views can be obtained intraoperatively.

34.3.5 Percutaneous Fixation

Percutaneous fixation using cannulated screws or K-wires is best reserved for minimally displaced fractures that can be closed reduced [22] and when fluoroscopy is available. A 2.5 mm terminally threaded pin inserted through the greater tuberosity into the head can be used as a joystick to reduce the head fragment, and other instruments including bone tamps, elevators, and hooks can also be used percutaneously to aid in reduction of the tuberosities, if necessary [34] (Fig. 34.3). Placing three or four 2.5 mm terminally threaded pins in parallel fashion along the humeral neck provides favorable biomechanical fixation of the head fragment [35]. Tuberosity fractures, if present, can be fixed percutaneously with K-wires or with 3.5 mm or 4.0 mm cannulated screws using appropriate guidewires from the set. Antegrade placement of K-wires through the proximal segment and into the intramedullary canal is an alternative construct.

34.3.6 Intramedullary Nail Fixation

Locked intramedullary nail fixation is effective for surgical neck fractures with metaphyseal comminution or extension into the diaphysis and minimal tuberosity displacement but should not be used in fractures involving the anatomic neck [22]. A longitudinal incision is made just lateral to the acromion, and the deltoid is split

Fig. 34.2 Supine positioning with the injured arm on a plexiglass or wood board makes it much easier to obtain an axillary lateral view intraoperatively

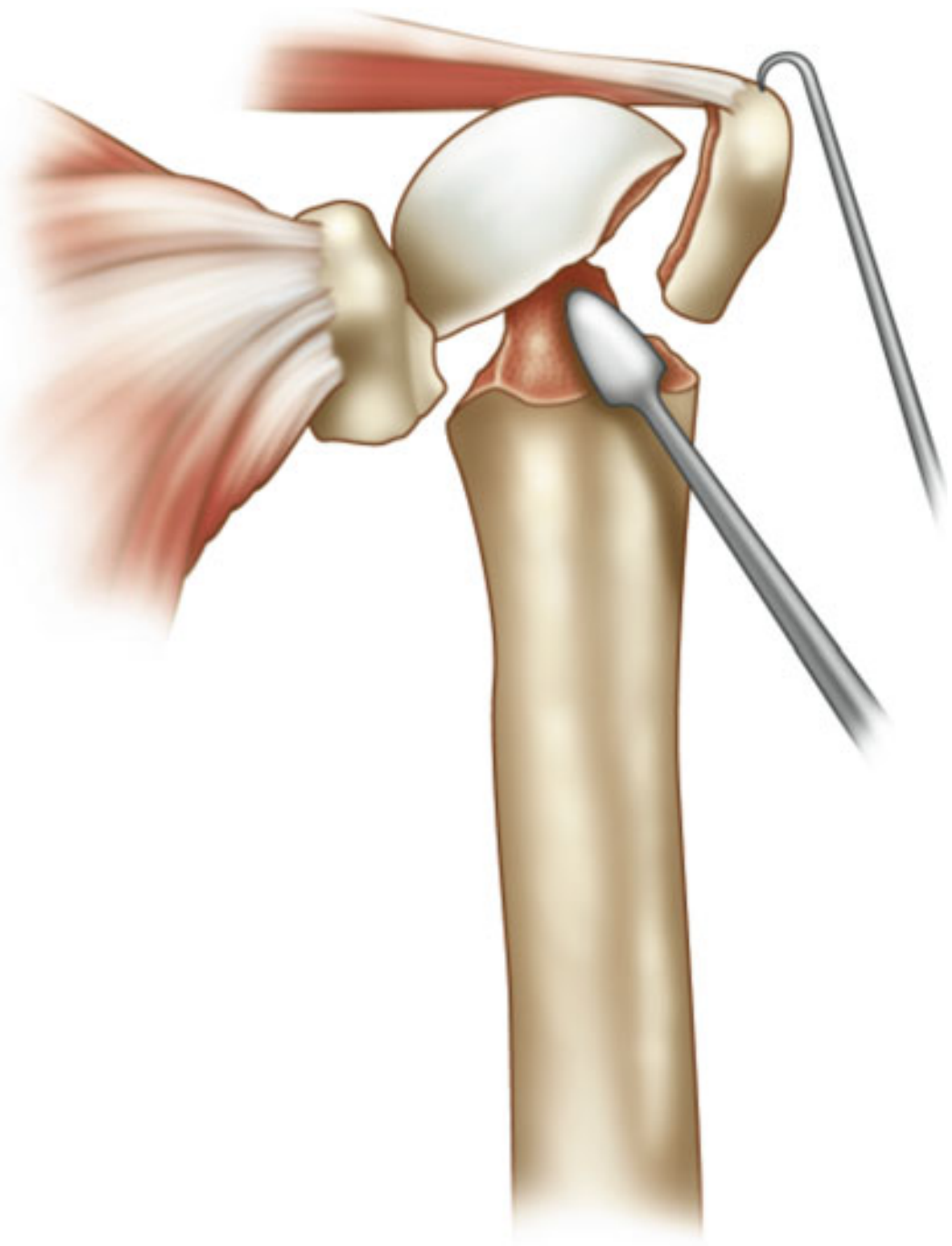

Fig. 34.3 Using fluoroscopy, an elevator or bone tamp can be used percutaneously to elevate the humeral head fragment while a sharp bone hook can be used percutaneously to reduce the greater tuberosity fragment. Percutaneous pinning or screw fixation can then be performed

no more than 4–5 cm distally to avoid injury to the axillary nerve. The supraspinatus tendon is incised longitudinally to allow insertion of the guide pin or awl into the intramedullary canal. Though the desired entry point varies by implant system, it is generally located between the greater tuberosity and the articular margin [34]. Proximal and distal interlocking screws are inserted using mini-open techniques and/or protection sleeves to avoid neurovascular injury [36]. The Surgical Implant Generation Network (SIGN) nail is an intramedullary implant that can be used for fixation in the femur, tibia, and humerus and does not require fluoroscopy for insertion. However, since it only has two proximal interlocking holes, it is not an ideal implant for proximal humerus fractures and is best reserved for fractures of the humeral diaphysis requiring fixation.

34.3.7 Open Reduction and Internal Fixation

Although deltoid-splitting and two-incision lateral techniques have been developed to provide access to the proximal humerus, only the classic deltopectoral approach exploits a truly internervous plane between the deltoid (axillary nerve) and pectoralis major (medial and lateral pectoral nerves) [37]. The cephalic vein is retracted laterally to preserve its branches from the deltoid muscle and dissection continues through the clavipectoral fascia lateral to the conjoint tendon (coracobrachialis and short head of the biceps). The tendon of the long head of the biceps is identified in its intertubercular groove and followed proximally to where it enters the glenohumeral joint. A biceps tenotomy or tenodesis to the pectoralis muscle is often performed so that the intra-articular tendon does not become a source of pain postoperatively [34].

Once the tuberosity fragments are identified and tagged with nonabsorbable suture at the bone-tendon interface, reduction of the head fragment onto the shaft is performed both indirectly by manipulating the arm and directly by disimpacting the head fragment with elevators. To counteract the medial pull of the pectoralis major on the shaft fragment, the proximal humerus plate can be placed on the lateral surface of the proximal fragment and secured with one or more K-wires. Next, a non-locking cortical screw can be placed in the distal portion of the plate to reduce the fracture by pulling the shaft fragment laterally to the plate (see Fig. 34.4). Care should be taken to place the plate 1–2 cm lateral to the bicipital groove and approximately 1.5–2 cm below the greater tuberosity (with slight variations depending on the implant system). This helps avoid subacromial impingement from placement of the plate too far proximally and ensures adequate fixation in the head fragment, which can be compromised with plate placement too far distally [22]. Depending on bone quality and plate characteristics (locking or non-locking), at least two additional bicortical screws are placed in the shaft fragment, ensuring fixation in a minimum of six cortices in the shaft.

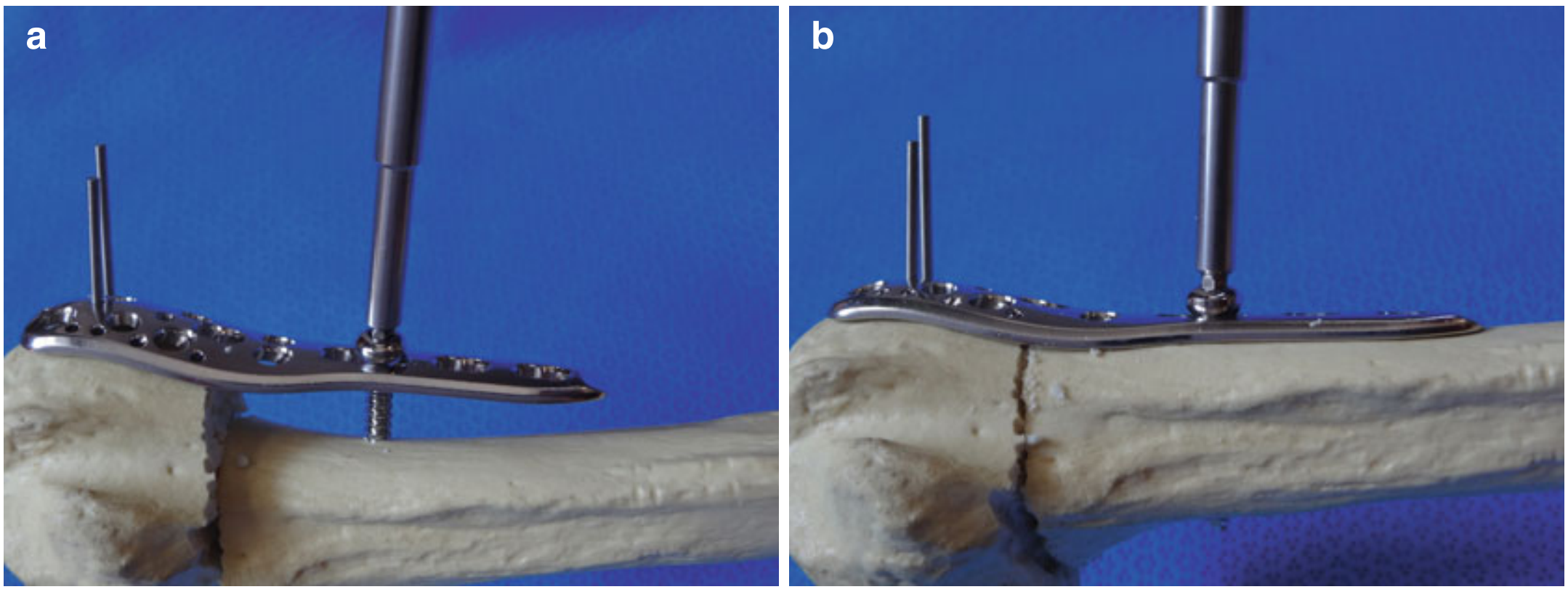

Fig. 34.4 (**a**) To overcome the medial pull of the pectoralis major muscle, the plate is positioned laterally on the proximal fragment, where it can be temporarily fixed with K-wires. Next, a 3.5 mm non-locking cortical screw can be inserted into the shaft through the first hole distal to the fracture. (**b**) As the screw is tightened, the shaft is pulled laterally to the plate, effecting reduction of the fracture

Because the proximal fragment is comprised of cancellous bone and bicortical fixation is not possible (the second cortex would be the subchondral bone of the humeral head), fixation in the proximal fragment is less robust than in the shaft. If only non-locking plates are available, screw trajectory is not constrained and can be planned to maximize fixation in the head fragment. Utilizing cancellous screws will increase screw purchase in the proximal segment. If available, locking plates provide an angular stable construct with improved fixation in poor-quality bone. Most locking plate sets contain locking drill guides that determine the trajectory of the head screws, which further underscores the importance of proper plate positioning [37]. Regardless of the implants used, the humeral head must be taken through a range of motion (internal and external rotation) with multiple fluoroscopic views obtained to ensure that none of the screw tips have been placed intra-articularly. If fluoroscopy is not available, safe screw placement must be confirmed by direct inspection of the joint. This can be accomplished by making a small incision in the rotator interval and visually inspecting the humeral head or by feeling the entire humeral articular surface with a blunt instrument. Any prominent screws must be replaced with shorter ones. Finally, previously tagged tuberosity fragments are reduced anatomically and tied in place using their tagging sutures, which can be passed through small holes or eyelets in the plate (see Fig. 34.5) or through drill holes in the bone. Isolated fractures of the lesser and/or greater tuberosity that are too small to accommodate a 3.5 mm screw can be reduced and fixed with suture alone. This can be accomplished by passing suture in a mattress fashion through the respective tendon (subscapularis or supraspinatus) adjacent to its bony insertion. Suture ends are then passed through drill holes in the intact bone and tied over a bony bridge.

34.3.8 Biomechanical Considerations

Locking plates provide angular-stable fixation of displaced two-, three-, and four-part proximal humerus fractures. The biomechanical stability afforded by locked plates effectively counteracts the bending and rotational forces that cause proximal humerus fractures to fail [34]. Several studies have demonstrated the importance of obtaining fixation in the inferomedial portion of the proximal segment, often referred to as the "calcar" [38, 39]. In a well-designed biomechanical study of locking plate fixation, removal of a 10 mm wedge of bone at the calcar to simulate medial comminution significantly

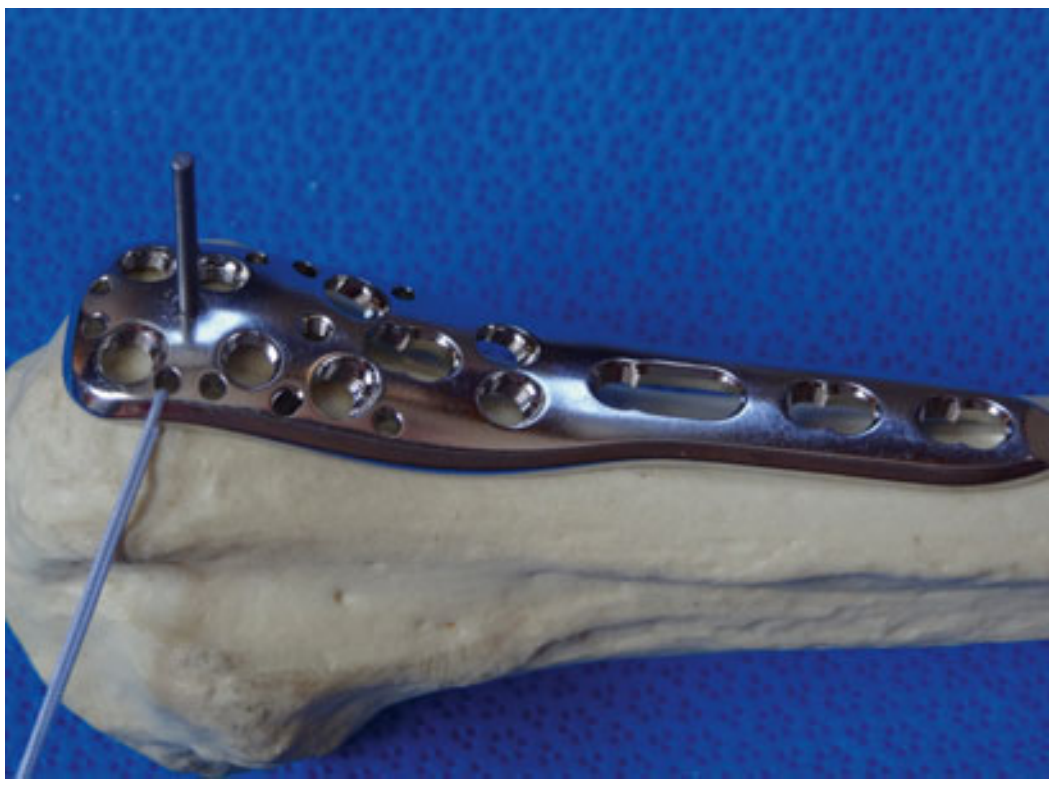

Fig. 34.5 Provisional fixation of the plate can be performed with K-wires. Some plates have eyelets (*small holes*), through which sutures can be passed that can help to secure the tuberosity fragments in place. If no eyelets are available, the suture can be passed through drill holes that can be made in the distal fragment

decreased the mean load to failure (by 48 %) and the mean energy to failure (by 44 %) [40]. However, locking screw fixation across this gap (so-called medial calcar restoration) significantly increased the mean load and energy to failure by 31 % and 44 %, respectively. Newer locking plates with polyaxial screws offer even more options for humeral head fixation without compromising biomechanical stability [41].

34.3.9 Shoulder Arthroplasty

Certain fracture patterns not amenable to internal fixation can be managed with shoulder arthroplasty if the proper implants and instrumentation are available. Suggested indications for hemiarthroplasty include fractures with short (<8 mm) extension of the head fragment into the metaphysis, disruption of the medial periosteal hinge, or severe damage to the head fragment, including head-splitting, head impaction, or a shell-like residual head [22]. Important intraoperative considerations include restoration of humeral height, offset, and retroversion, but these parameters are often difficult to determine in the setting of severe fracture displacement and comminution. The upper edge of the pectoralis major tendon insertion sits an average of 5.6 mm below the top of the humeral head and has proven to be a reliable reference point for restoring both humeral height and retroversion in patients undergoing hemiarthroplasty [42]. Fixation of the humeral stem with cement is standard in the setting of osteoporotic bone. A large retrospective multicenter study of hemiarthroplasty for four-part proximal humerus fractures found that both subjective patient satisfaction and functional outcomes scores were significantly higher if anatomic tuberosity healing had occurred [43].

Recently, reverse total shoulder arthroplasty (rTSA) has been utilized increasingly for the acute treatment of proximal humerus fractures with significant comminution in which the fractured tuberosities are unlikely to heal, in the setting of pre-existing rotator cuff deficiency, or as a salvage procedure after failed nonoperative treatment, ORIF, or hemiarthroplasty [22]. A standard deltopectoral approach to the shoulder is used for both hemiarthroplasty and rTSA.

34.3.10 Complications

Whether nonoperative or operative treatment is chosen, numerous complications can occur in the management of proximal humerus fractures. Depending on the degree of displacement, osteonecrosis develops in 6.5–21.6 % of fractures treated nonoperatively [22]. Reported rates of osteonecrosis range from 8 to 26 % [44, 45] following percutaneous fixation and from 10.8 to 16.4 % following open reduction with locking plate fixation [34, 46]. Implant loosening and migration can occur in up to a third of cases fixed with K-wires or non-locking intramedullary implants [34]. Posttraumatic arthritis occurred in 37 % of proximal humerus fractures treated percutaneously at minimum 3-year follow-up [47]. Intra-articular screw penetration is the most common complication of locking plate fixation, affecting 13.7–23.0 % of cases [34]. Overall reported complication rates following locked plate fixation range from 28 to 48 % [16, 46].

Complications following hemiarthroplasty for proximal humerus fractures can be categorized as intraoperative (including iatrogenic fracture and malpositioned components), early postoperative (such as tuberosity pull-off, instability, and infection), or late postoperative (which includes tuberosity nonunion, glenoid arthrosis, loosening, infection, heterotopic ossification, and periprosthetic fracture) [34]. Patients with proximal humerus fractures complicated by tuberosity nonunion have significantly lower outcomes scores than patients whose tuberosities heal [43, 48]. Scapular notching, acromial stress fractures, and iatrogenic lengthening of the injured arm are common complications following rTSA [34].

34.3.11 Follow-Up

For fractures treated nonoperatively or with internal fixation, weekly radiographic evaluation is recommended for the first several weeks in order to monitor fracture reduction and alignment as well as hardware position. Percutaneously placed K-wires can typically be removed after 6 weeks, provided that radiographic evidence of healing is present. Regular radiographic follow-up should continue until fracture healing has occurred, followed by yearly X-rays for the first few years. Certain complications may not become apparent radiographically for several years. In one series of proximal humerus fractures treated with percutaneous fixation, osteonecrosis was first seen an average of 50 months postoperatively (range 11–100 months) [47]. Regular follow-up also permits monitoring of wound healing and pain and is essential for determining when to initiate a rehabilitation program.

34.3.12 Rehabilitation

Nonoperative treatment involves rest and immobilization of the injured arm in a standard sling. Hanging-arm casts have not been found to improve outcomes and may even increase the likelihood of nonunion due to excessive distraction at the fracture site [6]. A systematic review of proximal humerus treatment found consistently favorable results with earlier mobilization of proximal humerus fractures [34]. In one series of patients with minimally displaced proximal humerus fractures managed nonoperatively, outcomes were significantly better when physical therapy was initiated within 2 weeks of the injury compared with therapy initiation after 2 weeks [49]. A comprehensive rehabilitation regimen for nonoperative treatment includes early pendulum exercises started within 2 weeks (or as early as pain permits) followed by active and active-assisted range-of-motion exercises and finally progression to strengthening exercises between 6 and 12 weeks [45]. In fractures treated with internal fixation, a similar rehabilitation regimen can be followed, provided the stability of the construct will permit early motion [34]. Rehabilitation after shoulder arthroplasty is dependent upon the stability of the tuberosity repair and surgeon preference. In general, rehabilitation can commence sooner after reverse total shoulder arthroplasty compared with hemiarthroplasty. Regardless of the treatment modality employed, immediate mobilization of the elbow, wrist, and hand is encouraged to prevent stiffness.

34.4 Tutorial/Case Presentation

A 39-year-old right-hand dominant female was involved in a motor vehicle accident and sustained an isolated left shoulder injury. The skin is intact and she has normal neurovascular function in the injured arm. X-rays (AP and Velpeau views) are shown (Fig. 34.6a, b). Your hospital is equipped with the capacity to perform surgery, and standard pins/plates/screws and intraoperative fluoroscopy are available. However, site-specific (proximal humerus) plates are not available, nor is shoulder arthroplasty. What is the most appropriate treatment plan?

34.4.1 Discussion

The patient has sustained a two-part proximal humerus fracture involving the surgical neck as

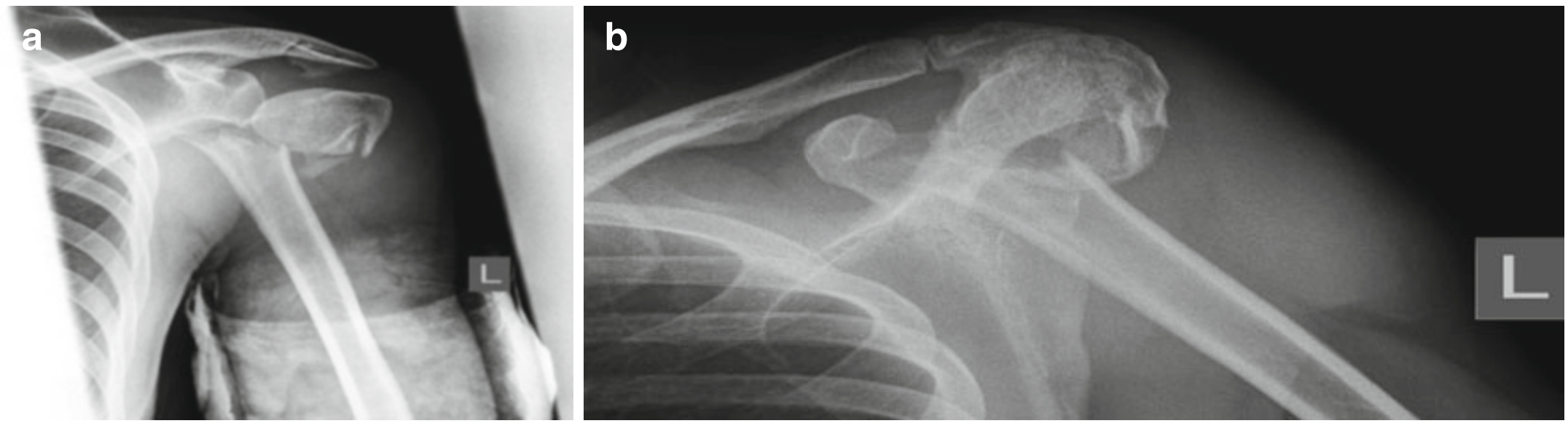

Fig. 34.6 A 39-year-old right-hand dominant female sustained an isolated left shoulder injury. X-rays (**a**) AP and (**b**) Velpeau views are shown

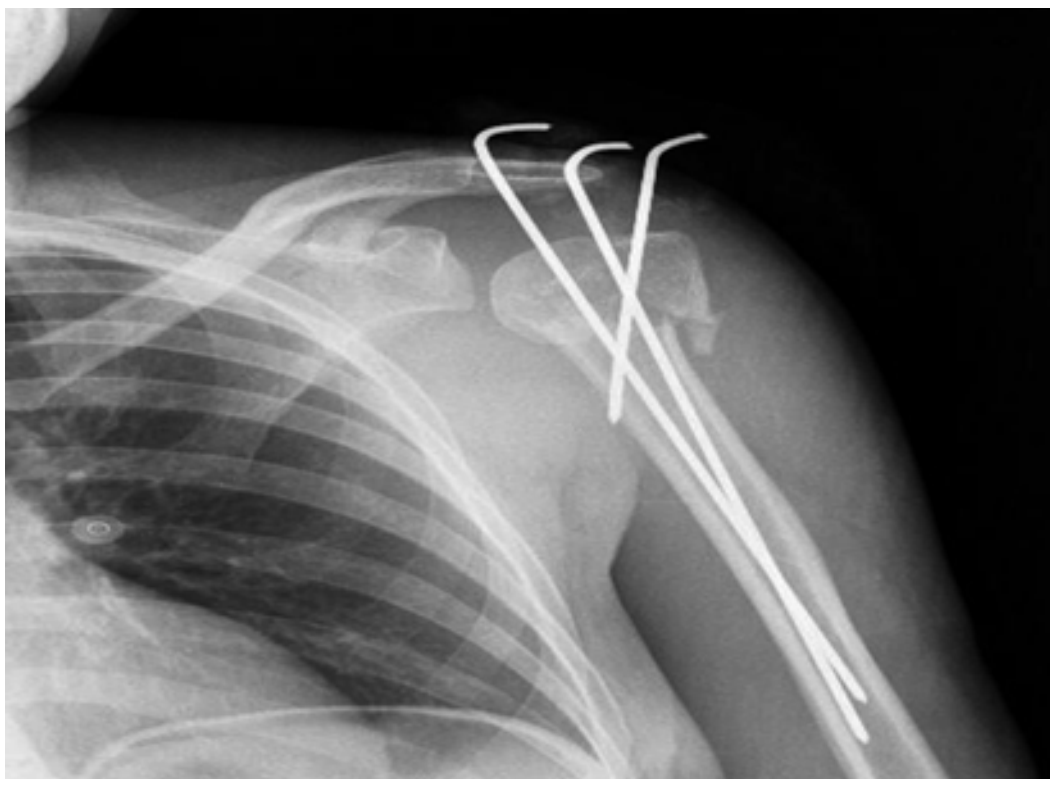

Fig. 34.7 Postoperative X-ray of patient shown in Fig. 34.6 after placement of K wires

well as a non-displaced greater tuberosity fracture. There is displacement of the head fragment of approximately 100 % of the shaft diameter and no significant angulation. The Velpeau view shows that the glenohumeral joint is reduced. With the available equipment, treatment options include closed reduction and immobilization with a sling and swathe, percutaneous pinning with K-wires, or percutaneous screw fixation. Due to the relatively transverse fracture pattern, two K-wires were placed through the proximal fragment and into the intramedullary canal to maintain reduction. A third K-wire was passed obliquely through the greater tuberosity fragment and into the medial calcar. The K-wires were bent and cut outside the skin for later removal in the clinic. Immediate postoperative AP X-ray shows acceptable reduction of the fracture (Fig. 34.7).

References

1. Bell JE, Leung BC, Spratt KF, Koval KJ, Weinstein JD, Goodman DC, Tosteson AN. Trends and variation in incidence, surgical treatment, and repeat surgery of proximal humeral fractures in the elderly. J Bone Joint Surg Am. 2011;93(2):121–31.
2. Court Brown CM, Caesar B. Epidemiology of adult fractures: a review. Injury. 2006;37:691–7.
3. Lind T, Kroner K, Jensen J. The epidemiology of fractures of the proximal humerus. Arch Orthop Trauma Surg. 1989;108:285–7.
4. Court Brown CM, Garg A, McQueen MM. The epidemiology of proximal humeral fractures. Acta Orthop Scand. 2001;72:365–71.
5. Kristiansen B, Barfod G, Bredesen J, et al. Epidemiology of proximal humeral fractures. Acta Orthop Scand. 1987;58:75–7.
6. Robinson CM. Proximal humerus fractures. In: Bucholz H, Court-Brown T, editors. Rockwood and Green's fractures in adults. 7th ed. Philadelphia: Lippincott Williams, and Wilkins; 2010. p. 1039–105.
7. Palvanen M, Kannus P, Niemi S, et al. Update in the epidemiology of proximal humeral fractures. Clin Orthop Relat Res. 2006;442:87–92.
8. Calvo E, Morcillo D, Foruria AM, Redondo-Santamarı'a E, Osorio-Picorne F, Caeiro JR, GEIOS-SECOT Outpatient Osteoporotic Fracture Study Group. Nondisplaced proximal humeral fractures: high incidence among outpatient-treated osteoporotic fractures and severe impact on upper extremity function and patient subjective health perception. J Shoulder Elbow Surg. 2011;20(5):795–801. Epub 2010 Dec 31.
9. Boons HW, Goosen JH, van Grinsven S, van Susante JL, van Loon CJ. Hemiarthroplasty for humeral four-part fractures for patients 65 years and older: a randomized controlled trial. Clin Orthop Relat Res. 2012;470(12):3483–91. Epub 2012 Aug 16.
10. Olerud P, Ahrengart L, Ponzer S, Saving J, Tidermark J. Hemiarthroplasty versus nonoperative treatment of displaced 4-part proximal humeral fractures in elderly

patients: a randomized controlled trial. J Shoulder Elbow Surg. 2011;20(7):1025–33. Epub 2011 Jul 23.

11. Fjalestad T, Hole MO, Hovden IA, Blücher J, Strømsøe K. Surgical treatment with an angular stable plate for complex displaced proximal humeral fractures in elderly patients: a randomized controlled trial. J Orthop Trauma. 2012;26(2):98–106.
12. Olerud P, Ahrengart L, Ponzer S, Saving J, Tidermark J. Internal fixation versus nonoperative treatment of displaced 3-part proximal humeral fractures in elderly patients: a randomized controlled trial. J Shoulder Elbow Surg. 2011;20(5):747–55. Epub 2011 Mar 24.
13. Handoll HH, Ollivere BJ, Rollins KE. Interventions for treating proximal humeral fractures in adults. Cochrane Database Syst Rev. 2012;12:CD000434. Epub 2012 Dec 12.
14. Yin B, Moen TC, Thompson SA, Bigliani LU, Ahmad CS, Levine WN. Operative treatment of isolated greater tuberosity fractures: retrospective review of clinical and functional outcomes. Orthopedics. 2012;35(6):e807–14.
15. Gradl G, Dietze A, Kaab M, Hopfenmuller W, Mittlmeier T. Is locking nailing of humeral head fractures superior to locking plate fixation? Clin Orthop Relat Res. 2009;467(11):2986–93. Epub 2009 Jun 13.
16. Zhu Y, Lu Y, Shen J, Zhang J, Jiang C. Locking intramedullary nails and locking plates in the treatment of two-part proximal humeral surgical neck fractures: a prospective randomized trial with a minimum of three years of follow-up. J Bone Joint Surg Am. 2011;93(2):159–68.
17. Spross C, Platz A, Erschbamer M, Lattmann T, Dietrich M. Surgical treatment of Neer Group VI proximal humeral fractures: retrospective comparison of PHILOS® and hemiarthroplasty. Clin Orthop Relat Res. 2012;470(7):2035–42. Epub 2011 Dec 13.
18. Launonen AP, Lepola V, Flinkkilä T, Strandberg N, Ojanperä J, Rissanen P, Malmivaara A, Mattila VM, Elo P, Viljakka T, Laitinen M. Conservative treatment, plate fixation, or prosthesis for proximal humeral fracture. A prospective randomized study. BMC Musculoskelet Disord. 2012;13:167.
19. Cuff DJ, Pupello DR. Comparison of hemiarthroplasty and reverse shoulder arthroplasty for the treatment of proximal humeral fractures in elderly patients. J Bone Joint Surg Am. 2013;95(22):2050–5.
20. Boyle MJ, Youn SM, Frampton CM, Ball CM. Functional outcomes of reverse shoulder arthroplasty compared with hemiarthroplasty for acute proximal humeral fractures. J Shoulder Elbow Surg. 2013;22(1):32–7. Epub 2012 May 29.
21. Namdari S, Horneff JG, Baldwin K. Comparison of hemiarthroplasty and reverse arthroplasty for treatment of proximal humeral fractures: a systematic review. J Bone Joint Surg Am. 2013;95(18):1701–8.
22. Maier D, Jaeger M, Izadpanah K, Strohm PC, Suedkamp NP. Proximal humeral fracture treatment in adults. J Bone Joint Surg Am. 2014;96(3): 251–61.
23. Chervu A, Quinones Baldrich WJ. Vascular complications in orthopedic surgery. Clin Orthop Relat Res. 1988;275–288.
24. de Laat EA, Visser CP, Coene LN, et al. Nerve lesions in primary shoulder dislocations and humeral neck fractures. A prospective clinical and EMG study. J Bone Joint Surg Br. 1994;76B:381–3.
25. Rutten MJ, Jager GJ, de Waal Malefijt MC, Blickman JG. Double line sign: a helpful sonographic sign to detect occult fractures of the proximal humerus. Eur Radiol. 2007;17(3):762–7. Epub 2006 Jun 7.
26. Neer CS. Displaced proximal humeral fractures. I. Classification and evaluation. J Bone Joint Surg Am. 1970;52A:1077–89.
27. Resch H, Beck E, Bayley I. Reconstruction of the valgus-impacted humeral head fracture. J Shoulder Elbow Surg. 1995;4(2):73–80.
28. Muller ME. The comprehensive classification of fractures of long bones. New York: Springer; 1990.
29. Hertel R, Hempfing A, Stiehler M, Leunig M. Predictors of humeral head ischemia after intracapsular fracture of the proximal humerus. J Shoulder Elbow Surg. 2004;13(4):427–33.
30. Codman EA. The shoulder; rupture of the supraspinatus tendon and other lesions in or about the subacromial bursa. Boston: Thomas Todd Company; 1934.
31. Majed A, Macleod I, Bull AM, Zyto K, Resch H, Hertel R, Reilly P, Emery RJ. Proximal humeral fracture classification systems revisited. J Shoulder Elbow Surg. 2011;20(7):1125–32. Epub 2011 Apr 9.
32. Sarwark JF, King EC, Janicki JA. Proximal humerus, scapula, and clavicle. In: Beaty JH, Kasser JR, editors. Rockwood and Wilkins' fractures in children. 7th ed. Philadelphia: Lippincott Williams & Wilkins; 2010. p. 620–81.
33. Brennan ML, Taitsman LA. Patient positioning. In: Gardner MJ, Henley MB, editors. Harborview illustrated tips and tricks in fracture surgery. Philadelphia: Lippincott, Williams, and Wilkins; 2011. p. 3–21.
34. Aaron D, Shatsky J, Paredes JC, Jiang C, Parsons BO, Flatow EL. Proximal humeral fractures: internal fixation. Instr Course Lect. 2013;62:143–54.
35. Jiang C, Zhu Y, Wang M, Rong G. Biomechanical comparison of different pin configurations during percutaneous pinning for the treatment of proximal humeral fractures. J Shoulder Elbow Surg. 2007;16(2):235–9. Epub 2007 Jan 31.
36. Nijs S, Sermon A, Broos P. Intramedullary fixation of proximal humerus fractures: do locking bolts endanger the axillary nerve or the ascending branch of the anterior circumflex artery? A cadaveric study. Patient Saf Surg. 2008;2(1):33.
37. Konrad G, Bayer J, Hepp P, Voigt C, Oestern H, Kääb M, Luo C, Plecko M, Wendt K, Köstler W, Südkamp N. Open reduction and internal fixation of proximal humeral fractures with use of the locking proximal humerus plate. Surgical technique. J Bone Joint Surg Am. 2010;92(Suppl 1 Pt 1):85–95.

38. Lescheid J, Zdero R, Shah S, Kuzyk PR, Schemitsch EH. The biomechanics of locked plating for repairing proximal humerus fractures with or without medial cortical support. J Trauma. 2010;69(5):1235–42.
39. Gardner MJ, Weil Y, Barker JU, Kelly BT, Helfet DL, Lorich DG. The importance of medial support in locked plating of proximal humerus fractures. J Orthop Trauma. 2007;21(3):185–91.
40. Ponce BA, Thompson KJ, Raghava P, Eberhardt AW, Tate JP, Volgas DA, Stannard JP. The role of medial comminution and calcar restoration in varus collapse of proximal humeral fractures treated with locking plates. J Bone Joint Surg Am. 2013;95(16):e113(1–7).
41. Zettl R, Muller T, Topp T, Lewan U, Kruger A, Kuhne C, Ruchholtz S. Monoaxial versus polyaxial locking systems: a biomechanical analysis of different locking systems for the fixation of proximal humeral fractures. Int Orthop. 2011;35(8):1245–50. Epub 2011 Feb 8.
42. Torrens C, Corrales M, Melendo E, Solano A, Rodrıguez-Baeza A, Caceres E. The pectoralis major tendon as a reference for restoring humeral length and retroversion with hemiarthroplasty for fracture. J Shoulder Elbow Surg. 2008;17(6):947–50. Epub 2008 Sep 6.
43. Kralinger F, Schwaiger R, Wambacher M, Farrell E, Menth-Chiari W, Lajtai G, Hubner C, Resch H. Outcome after primary hemiarthroplasty for fracture of the head of the humerus. A retrospective multicentre study of 167 patients. J Bone Joint Surg Br. 2004;86(2):217–9.
44. Bogner R, Hubner C, Matis N, Auffarth A, Lederer S, Resch H. Minimally-invasive treatment of three- and four-part fractures of the proximal humerus in elderly patients. J Bone Joint Surg Br. 2008;90(12):1602–7.
45. Koval KJ, Gallagher MA, Marsicano JG, Cuomo F, McShinawy A, Zuckerman JD. Functional outcome after minimally displaced fractures of the proximal part of the humerus. J Bone Joint Surg Am. 1997;79(2):203–7.
46. Sproul RC, Iyengar JJ, Devcic Z, Feeley BT. A systematic review of locking plate fixation of proximal humerus fractures. Injury. 2011;42(4):408–13. Epub 2010 Dec 19.
47. Harrison AK, Gruson KI, Zmistowski B, Keener J, Galatz L, Williams G, Parsons BO, Flatow EL. Intermediate outcomes following percutaneous fixation of proximal humeral fractures. J Bone Joint Surg Am. 2012;94(13):1223–8.
48. Solberg BD, Moon CN, Franco DP, Paiement GD. Surgical treatment of three and four-part proximal humeral fractures. J Bone Joint Surg Am. 2009;91(7):1689–97.
49. Leighton R. Internal fixation with a locking plate was not more effective than nonoperative treatment in older patients with three-part proximal humeral fractures. J Bone Joint Surg Am. 2012;94(4):367.

Diaphyseal and Distal Humerus Fractures

35

Paul S. Whiting

In adults, 47 % of all humeral fractures occur in the proximal portion (see Chap. 34), 20 % occur in the shaft, and 33 % occur in the distal portion [1]. In his classic publication, John Charnley remarked that the humerus "is perhaps the easiest of the major long bones to treat by conservative methods" due to its robust blood supply, generous soft tissue envelope, ease of splinting, and status as a non-weight-bearing bone [2]. As such, the vast majority of humeral shaft injuries can be managed nonoperatively. Specific indications for operative treatment have been established, and fixation can be performed using a plate and screws or intramedullary nailing. Fractures of the distal humerus are often intra-articular and typically require anatomic reduction and internal fixation in order to restore elbow function. The majority of humerus fractures in children occur in the supracondylar region. This distinct fracture pattern is typically managed with closed reduction and either long-arm casting or percutaneous pinning, depending on the fracture pattern.

35.1 Epidemiology

Although humeral shaft fractures have been reported in the literature to represent approximately 3–5 % of all fractures [3–5], more recent reports suggest that 1 % is a more accurate estimate [6, 7]. As is the case with many injuries, fractures of the humeral shaft follow a bimodal age distribution; the first peak occurs in young, primarily male adults, aged 21–30, and the second occurs in older, primarily female patients over 60. The estimated annual incidence among these two demographic groups is 25 and 100 per 100,000 population per year, respectively.

The majority of humeral shaft fractures, especially in the elderly, occur as the result of low-energy falls, but higher-energy mechanisms of injury are more common in younger patients [4]. Approximately 15 % of humeral shaft fractures are associated with other orthopedic injuries, the most common of which are fractures of the proximal humerus, distal radius, and pelvis [6]. Fractures of the distal humerus represent approximately 2 % of all fractures, with an estimated annual incidence of 5.7 per 100,000 population [8]. These injuries follow a similar bimodal age distribution.

In children, humeral shaft fractures represent between 2 and 5 % of all children's fractures and occur most commonly before age 3 and after age 12 [9]. Fractures of the distal humerus represent approximately 6 % of all fractures in children and

---

P.S. Whiting, MD
Department of Orthopaedics and Rehabilitation,
University of Wisconsin, Madison, WI, USA
e-mail: whiting@ortho.wisc.edu

© Springer International Publishing Switzerland 2016
J.D. Robinson (ed.), *Orthopaedic Trauma in the Austere Environment: A Practical Guide to Care in the Humanitarian Setting*, DOI 10.1007/978-3-319-29122-2_35

occur most commonly between the ages of 5 and 10 [10]. Supracondylar humerus fractures account for approximately 75 % of fractures of the distal humerus and 58 % of fractures about the elbow in children [11].

35.2 Review of the Evidence: Humeral Shaft Fractures

35.2.1 Nonoperative Treatment

Nonoperative management has long been the mainstay of treatment for humeral shaft fractures. Multiple techniques of immobilization have been utilized for humeral shaft fractures including hanging arm casts, coaptation splints, sling and swathes, long-arm or shoulder spica casts, and skeletal traction [7]. However, with the advent in 1977 of the functional brace and its associated treatment protocol by Sarmiento et al. [12], this method of treatment has become the standard of care for fractures of the humeral shaft. The rigid walls of the functional brace provide firm compression of the soft tissues surrounding the fractured bone which, combined with the pull of gravity, maintains "sufficient stability to permit uninterrupted osteogenesis" [12].

Sarmiento's original case series included 51 fractures managed with a functional brace after being initially immobilized for an average of 11 days. Patients used the brace an average of 10 weeks (range 3–22.5 weeks). One nonunion occurred in a pathologic fracture, and union occurred in the remaining 50 fractures. 82 % of patients achieved full shoulder and elbow range of motion, and the remaining 18 % lacked less than 15° of shoulder abduction or external rotation. 84 % of patients healed with an angular deformity of less than 5°, and the remaining 16 % had deformity less than 20°. In a follow-up series of 922 patients, 620 of whom followed up, Sarmiento et al. reported nonunion in 1.5 % of 465 closed fractures and 5.8 % of open fractures [13]. In adults, posttreatment deformities including shortening of 2–3 cm, angulation up to 20° in the sagittal plane, and varus or valgus malunion of up to 30° are well tolerated and do not compromise functional outcomes [14]. In children, nonoperative management of humeral shaft fractures is the preferred method of treatment, and a variety of techniques for immobilization have proven to be successful [9].

35.2.2 Comparison of Surgical Treatments

Due to the high rates of success with functional bracing and limited indications for surgical management, relatively few studies have directly compared operative and nonoperative treatment of humeral shaft fractures. A retrospective comparative study demonstrated one case of nonunion among 45 patients treated with locked intramedullary nailing and two cases among 44 patients treated in a functional brace [15]. However, 52 % of patients in the nailing group had restricted shoulder ROM at final follow-up, compared with only 14 % in the nonoperative group. A similar retrospective study comparing functional bracing to ORIF with compression plating found a significantly higher rate of nonunion (20.6 vs. 8.7 %) and malunion >20° (12.7 vs. 1.3 %) with functional bracing, but there were no differences in rates of infection, iatrogenic nerve palsy, or final elbow ROM, and functional outcomes were not reported [16].

A study comparing ORIF with compression plating and functional bracing of distal 1/3 diaphyseal humerus fractures found no difference in union rates, shoulder, or elbow ROM at 6 months [17]. Several studies have compared plating and intramedullary nailing of humeral shaft fractures. A randomized controlled trial comparing these two methods of fixation found no difference in final elbow or shoulder ROM or ASES functional outcome scores, but IM nailing was associated with significantly higher complication and reoperation rates compared with plating [18]. Another RCT also found a significantly higher complication rate with IM nailing but no difference in union rates or ASES scores [19]. No differences in rate of union, infection, reoperation, or nerve palsy was found between these techniques in a recent meta-analysis, although there was a trend toward a higher rate of complications with IM nailing ($p = 0.07$) [20].

35.2.3 Summary of the Evidence: Humeral Shaft Fractures

The vast majority of humeral shaft fractures in adults and children can be managed nonoperatively. After initial immobilization, functional bracing is the preferred method of definitive treatment with expected union rates approaching 98 %. Specific indications for operative treatment of humeral shaft fractures are detailed below. When required, surgical fixation with IM nailing or compression plating leads to predictable rates of union and favorable functional outcomes, although IM nailing is associated with a higher rate of total complications.

35.3 Review of the Evidence: Distal Humerus Fractures

Fractures of the distal humerus generally require surgical reduction and fixation. Although multiple surgical approaches to the distal humerus have been described [21], olecranon osteotomy provides the most reliable visualization of the distal humeral articular surface, facilitating anatomic reduction and stabilization of articular fractures. In a comprehensive review of 67 distal humerus fractures in which olecranon osteotomies were performed and repaired with a tension band wire or plate fixation, there were no cases of osteotomy nonunion, and there was an 8 % rate of symptomatic hardware requiring removal [22]. Another study using a specific tension band wire technique in 45 consecutive patients reported a union rate of 98 %, and only 13 % of patients required hardware removal for symptomatic hardware [23].

Dual plating is recommended for distal humerus fractures that extend into the articular surface or for extra-articular distal humerus fractures with poor bone quality. The optimal plate configuration (“parallel plating” – plates applied on the medial and lateral surfaces – or “orthogonal plating” – with plates applied on the posterolateral and medial surfaces) has remained a topic of controversy and has been investigated in several biomechanical studies. Although one study found no difference between these configurations in axial compression or torsional strain [24], another study found significantly higher strength and stiffness with parallel plating in sagittal bending, a biomechanical model that more closely approximates physiologic forces [25].

Although locking plates have been found to be more stable than non-locking plates in biomechanical testing [26], a large retrospective multicenter study comparing locking and non-locking plates for intra-articular distal humerus fractures found no difference in rates of nonunion, infection, and reoperation at 6 weeks and 6 months [27]. The authors found that locking plate constructs were 3.5 times more expensive than non-locking constructs. In the austere environment, where precontoured locking plates are not readily available or are cost prohibitive, by using sound surgical techniques [28], excellent radiographic and functional outcomes can still be achieved with lower cost 3.5 mm DCP or reconstruction plates.

In the pediatric population, the optimal management of type II supracondylar fractures has been a subject of controversy. Support for nonoperative management of these injuries comes from two separate studies, which reported successful radiographic and clinical outcomes in 77 and 72 % of type II fractures with closed reduction and casting [29, 30]. However, in two large clinical series totaling 260 patients with type II fractures treated operatively, there were no cases of cubitus varus, loss of reduction, or malunion, and pin tract infection occurred in only 2 % of patients [31, 32]. Such favorable results and low associated complication rates with CRPP have led most pediatric orthopedic surgeons to recommend CRPP for all type II supracondylar fractures.

The optimal pin configuration for supracondylar fractures has also been a controversial topic in the literature. Both lateral-entry and crossed (medial and lateral) pin configurations have good clinical track records, but iatrogenic injury to the ulnar nerve with medial pin placement has an incidence of 5 and 6 % in the two largest series of supracondylar fractures reported in the literature [11]. Two randomized controlled trials comparing these two techniques showed no significant differences in clinical or radiographic outcomes [33, 34]. Biomechanical testing has demonstrated that two divergent lateral-entry pins were equally stable in valgus and stronger in varus and extension than crossed pins [35]. Finally, a protocol has been described for sequential pin placement based on intraoperative assessment of construct stability [11]. Two divergent lateral-entry pins are placed followed by fluoroscopic stress views in internal and external rotation. A third lateral-entry pin is inserted if necessary, and stress views are again obtained; a medial pin is added only if rotational instability persists.

35.3.1 Summary of the Evidence: Distal Humerus Fractures

Distal humerus fractures in adults generally require operative reduction and stabilization with dual plating, and following sound surgical principles can lead to excellent results with standard, low-cost implants. Triceps-splitting or sparing approaches may be sufficient for some fracture patterns, but olecranon osteotomy provides the best visualization of the articular surface. A carefully performed tension band wire construct is a low-cost method of osteotomy fixation with excellent clinical results. Closed vs. open reduction and pinning is required for type III and IV supracondylar humerus fractures. Surgical management of type II fractures leads to more predictable outcomes, but closed reduction and casting may still be considered, especially in centers without fluoroscopy.

35.4 Author's Preferred Approach

35.4.1 Initial Management

As with any fracture, careful history and detailed physical exam of the injured extremity is essential. Particular attention should be paid to the neurovascular status of the limb. Radial nerve palsy is relatively common in association with humerus fractures, affecting 11 % of mid-shaft and 26 % of distal diaphyseal fractures in adults [36] and 4.4 % of diaphyseal fractures in children [37]. Most radial nerve palsies are neurapraxias, and spontaneous resolution can be expected in 70 % of adults [38] and 78–100 % in children [9]. Vascular injuries in adults are more common in high-energy injuries, and a high index of suspicion is required. With high-energy mechanisms of injury, the presence of associated injuries to the chest (pneumo- or hemothorax, rib fractures) and cervical spine should be investigated.

Special attention must be paid to the vascular status of the injured limb in children with supracondylar humerus fractures. A palpable pulse is reassuring. If the radial pulse cannot be palpated, perfusion of the hand must be assessed. If the hand is well perfused as judged by warmth, color, and arterial capillary refill <2 s, the patient should be splinted in 20–40° of flexion and observed closely in the hospital, but no immediate intervention is required. In a large-scale review of 1255 pediatric supracondylar fractures by Choi et al. [39], of the 33 patients who presented with absent radial pulses, none of the 24 patients with well-perfused hands developed compartment syndrome or required vascular repair. However a pulseless, poorly perfused hand requires emergent reduction and fixation. In the above-referenced study, five of the nine patients with poorly perfused hands had adequate perfusion restored with fracture reduction and pinning alone and did not require vascular repair.

Standard radiographs are usually sufficient to diagnose and classify diaphyseal and distal humerus fractures in adults and children. AP and transthoracic lateral views are adequate for the humeral shaft. Internal and external rotation views should be avoided as these maneuvers simply rotate the distal arm through the fracture site. For fractures of the distal humerus, AP and true lateral views of the elbow should also be obtained. Even if CT scanning is available, this modality is rarely required for treatment decisions and the added expense is not justified.

35.4.2 Decision-Making

The functional brace is the mainstay of treatment for the vast majority of humeral shaft fractures in adults. As discussed above, posttreatment deformities including shortening of 2–3 cm, angulation up to 20° in the sagittal plane, and varus or valgus malunion of up to 30° are well tolerated and do not compromise functional outcomes [14]. Indications for surgical treatment of humeral shaft fractures in adults include failure to achieve or maintain acceptable alignment (20° in the sagittal plane, 30° of varus/valgus) with closed reduction; open, segmental, or pathologic fractures; associated brachial plexus or vascular injury; ipsilateral forearm, elbow, or shoulder fracture (floating elbow or shoulder); fractures extending into the shoulder or elbow; high-velocity gunshot injuries; bilateral humerus fractures; and polytrauma with lower extremity fractures requiring upper extremity weight bearing [7]. Since the majority of radial nerve palsies recover spontaneously, early exploration does not improve outcomes except in certain situations, such as open fractures, concomitant forearm injury, or floating elbow; these injuries have less than a 40 % chance of spontaneous recovery, so early exploration is advised [40].

In children, due to the significant capacity of growing bones to remodel, significant amounts of humeral shaft angulation are well tolerated. Acceptable angulation by age includes 70° or more in children younger than 5, 40–70° in children 5–12, and up to 40° in children older than 12 [41]. Operative indications for humeral shaft fractures in children are similar to those in adults [9].

The Gartland classification system is the most widely used for supracondylar humerus fractures in children (Table 35.1). Type I fractures are managed nonoperatively with a long-arm cast for 3 weeks. Type III and IV fractures require reduction and pinning. If fluoroscopy is not available, open reduction must be performed prior to pinning. Although management of type II fractures remains somewhat controversial, better outcomes can be expected with reduction and pinning. In the austere environment, however, if fluoroscopy is not available, treatment of type II fractures must be determined on a case-by-case basis, and the proposed benefit of improved alignment and stability with surgery must be weighed against the potential risks associated with open reduction.

Table 35.1 Modified Gartland classification of supracondylar humerus fractures

Type	Description	Radiographic features
I	Non-displaced	Posterior fat pad sign
II	Displaced with intact posterior periosteal hinge	Capitellum posterior to anterior humeral line
III	Completely displaced, no posterior periosteal hinge	Complete absence of cortical continuity
IV	Completely displaced, unstable in extension and flexion	Intraoperative determination (fluoro views)

35.4.3 Equipment

If functional bracing will be used, prefabricated braces can be applied off the shelf. Thermoplastic materials enable custom-made functional braces to be made for patients whose arms are too large or too small to accommodate a prefabricated brace. Fluoroscopy is not generally required for functional brace application, but the availability of X-rays immediately after brace application ensures adequate fit and proper reduction. Should operative management be required, fluoroscopy allows intraoperative assessment of length, alignment, and rotation of humeral shaft fractures and is helpful for determining the starting point and for distal interlocking of intramedullary nails. While typically not necessary for ORIF of the distal humerus in adults, fluoroscopy is essential for closed reduction and percutaneous pinning of supracondylar humerus fractures in children. Any available orthopedic implants, including external fixation equipment, K-wires, plate and screw sets, and IM nail systems, may prove useful for specific fracture patterns (see Sect. 35.4.4 below).

35.4.4 Techniques, Tips, and Pitfalls

Provisional reduction and immobilization of humeral shaft fractures in adults can be accomplished using the same methods used in children (see below). Functional brace fitting is generally better tolerated if the fracture is provisionally immobilized for 7–14 days [12]. Sarmiento and Latta have described the functional bracing technique in detail in their monograph, which is an invaluable tool for the management of this common injury in the resource-poor setting [42] (See Fig. 35.1). The following is a summary of the key principles of management [43]:

- Shoulder pendulum exercises begin immediately after injury (once provisional immobilization is applied) and are continued after brace application.
- Brace is first applied approximately 7–10 days post-injury. Cuff and collar sling is used.
- Position of the brace is from 5 cm distal to the axilla to 5 cm proximal to the olecranon, allowing for complete ROM of the shoulder and elbow.
- Active and passive ROM of the elbow (several times a day) starts immediately after brace application.
- Patients instructed to avoid active shoulder elevation/abduction and to avoid leaning the elbow on a chair, table, or lap.
- Adjustable straps are tightened progressively (several times a day) as swelling resolves.
- Brace should be worn at all times except for hygiene.
- Cuff and collar discontinued during ambulation once full elbow extension achieved (but maintained during recumbency).
- Passive shoulder flexion permitted after 1 week in the brace.

Fig. 35.1 Application of a functional brace. At follow-up visits, the brace must be appropriately tightened in order to maintain proper fit and function

In children, humeral shaft fractures can be managed nonoperatively using a variety of techniques for immobilization [9]. In newborns with humerus fractures from birth trauma, wrapping the injured extremity to the chest with an elastic bandage results in acceptable reduction and facilitates feeding and patient mobilization. For older children, the sling and swathe is the simplest form of immobilization but is the least powerful in controlling apex anterior angulation and varus malalignment. A “hanging arm cast” is accomplished by applying a long-arm cast followed by fashioning a cloth “cuff and collar” sling around the patient’s neck and around the wrist of the cast (Fig. 35.2a). The cast’s weight provides axial traction but does not provide any resistance to apex anterior angulation, especially during sleep. The U-shaped plaster (or “coaptation”) splint is placed inside a cloth stockinette, applied from the axilla, around the elbow, and up to the tip of the acromion, and secured in place with an elastic bandage (see Fig. 35.2b). Extending the plaster more proximally over the ipsilateral shoulder and neck prevents slippage and allows for a more proximal mold to prevent varus malalignment. The major challenge in treating pediatric humeral shaft fractures with a prefabricated functional brace is size

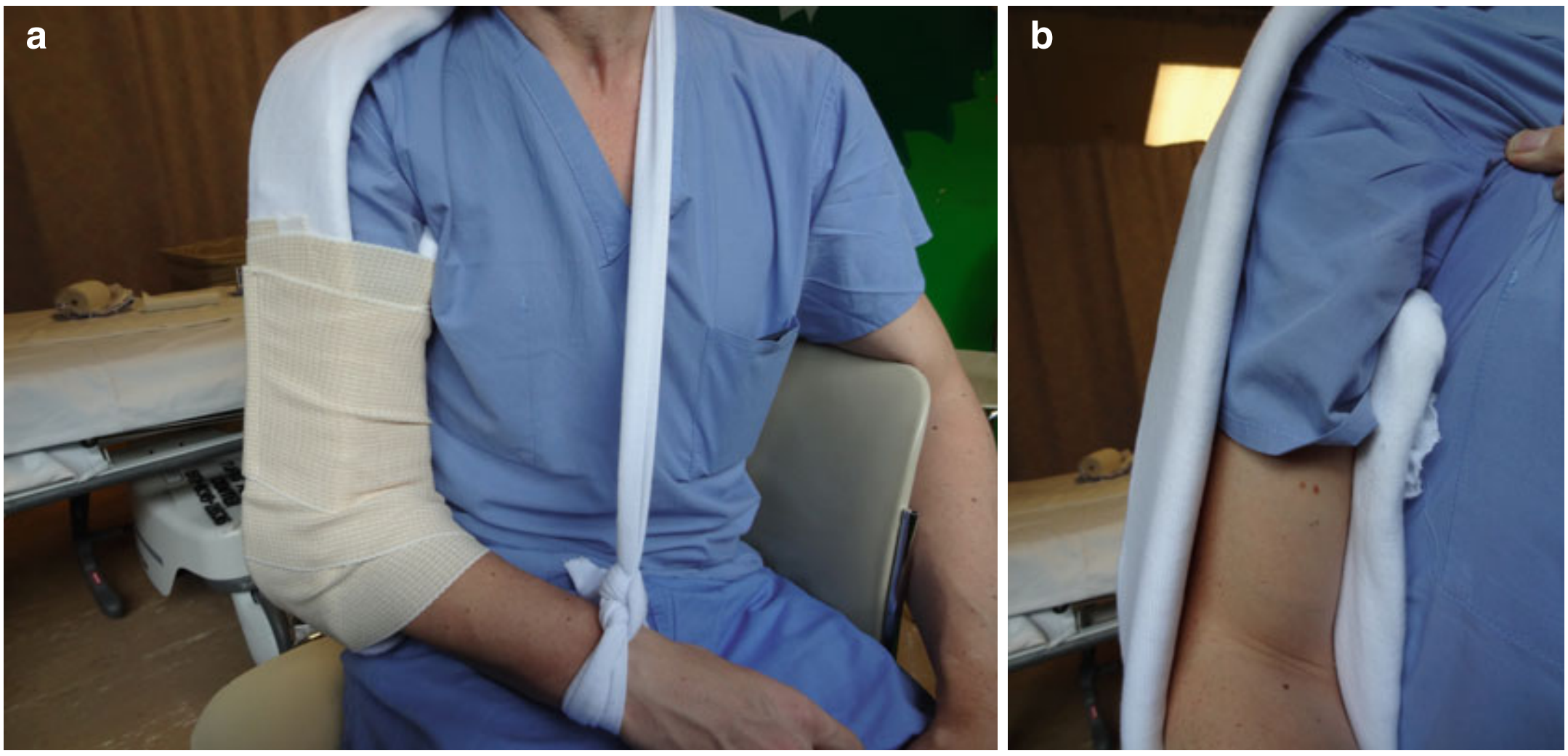

Fig. 35.2 (**a**) Coaptation splint with "cuff and collar" sling. (**b**) The medial limb of the coaptation splint must be placed as high in the axilla as possible

mismatch. However, if thermoplastic equipment is available, a low-cost customized brace can be made for pediatric patients.

If surgical management is required, ORIF with a plate and screw construct can be performed using either an anterolateral or posterior approach. The anterolateral approach is a continuation of the deltopectoral approach and is preferable for proximal and mid-shaft fractures. Distal extension is carried out by splitting the brachialis, which is dually innervated by the musculocutaneous nerve (medially) and the radial nerve (laterally). The posterior approach requires either splitting the triceps or using a paratricipital approach in which the triceps is mobilized from lateral to medial. Regardless of the approach used, the radial nerve should be identified and protected while the plate is placed under the nerve, directly on the bone surface. At a distance 14 cm proximal to the lateral epicondyle, the radial nerve is located directly posterior to the humeral shaft in the spiral groove. As it courses distally and laterally, it pierces the lateral intermuscular septum approximately 10 cm proximal to the lateral epicondyle [44]. Taking care to document in the operative note the exact location where the nerve crosses over the plate will assist in finding the nerve should exploration for neurolysis become necessary.

In adults, 4.5 mm dynamic compression plates provide sufficient stability for ORIF. If the fracture pattern permits, placing a lag screw perpendicular to the fracture can increase the construct stability by 30–40 %. Three bicortical screws (or four if no lag screw was used) should be placed on either side of the fracture for adequate neutralization [7]. Patients are positioned supine with an arm board or in a beach chair position for the anterolateral approach. If the posterior approach is used, the patient must be placed prone with a small arm board or in the lateral decubitus position with the arm positioned over a bolster.

Intramedullary nails can be placed antegrade via a longitudinal incision through the distal fibers of the supraspinatus tendon or retrograde through an osseous portal made just proximal to the olecranon fossa. The Surgical Implant Generation Network (SIGN) intramedullary nail permits locked intramedullary nailing of diaphyseal humerus fractures even in the absence of fluoroscopy and power instrumentation [45]. If a retrograde approach is chosen, an 8–10 cm posterior triceps-splitting approach is made just proximal to the olecranon fossa, and care is taken to avoid entering the elbow joint capsule [46]. The bony triangle between the olecranon fossa and the medial and lateral supracondylar ridges is identified, and three 3.2 mm drill holes are made in a triangular configuration with the apex proximally (see Fig. 35.3a). The holes are enlarged with a 4.5 mm drill, and an 8.5–9 mm power reamer or large drill bit is then used to remove the remaining bone in the triangle, thus creating a portal to the intramedullary canal (Fig. 35.3b). IM nailing proceeds according to the system's specifications. All proximal and distal interlocking screws are placed using open techniques to avoid iatrogenic neurovascular injury.

In children, 3.5 mm (dynamic compression, pelvic reconstruction, or even double stacked 1/3 tubular) plates provide adequate stability for ORIF of humeral shaft fractures [9]. Several techniques of intramedullary nailing are useful in children. One or more Rush rods or Enders nails can be placed retrograde from a starting point just proximal to the olecranon fossa using a posterior triceps-splitting approach [47]. The Hackenthal method involves a similar starting point, but multiple blunt-tipped Steinman pins of progressively smaller sizes are passed until the intramedullary canal is filled [48]. Pin ends are bent 90° and cut for later removal in the operating room. Insertion of large pins from the medial and lateral epicondyles should be avoided due to high rates of pin backout [49], but smaller diameter titanium flexible nails or blunt-tipped Steinman pins can be placed from the medial and lateral epicondyles [50]. Placing a bend in the pins prior to insertion (with the apex at the level of the fracture) more effectively reduces the fracture. The combined diameter of the two pins should be approximately 80 % of the canal diameter. Intramedullary nails should not be placed in an antegrade manner in children so as to avoid injury to the proximal humeral physis [51].

For ORIF of distal humerus fractures, a midline posterior incision is used almost universally. Multiple approaches to gain access to the distal humerus for reduction and fixation have been described, including the triceps splitting, triceps sparing (paratricipital), and triceps reflecting (Bryan-Morrey) [21]. Olecranon osteotomy provides the best intraoperative visualization. Ring et al. described a successful technique of repairing a chevron-shaped osteotomy with a tension band wire construct [23]. Directing the K-wires toward and through the anterior ulnar cortex distal to the coronoid process provides extra fixation. Pins are backed out a few millimeters, bent to 180°, cut, and impacted into the olecranon proximally. Two 22-gauge, figure-of-eight, stainless steel tension wires are passed through a medial-to-lateral drill hole made in the dorsal ulnar cortex. Creating two wire loops that are tensioned simultaneously generally leads to less hardware prominence.

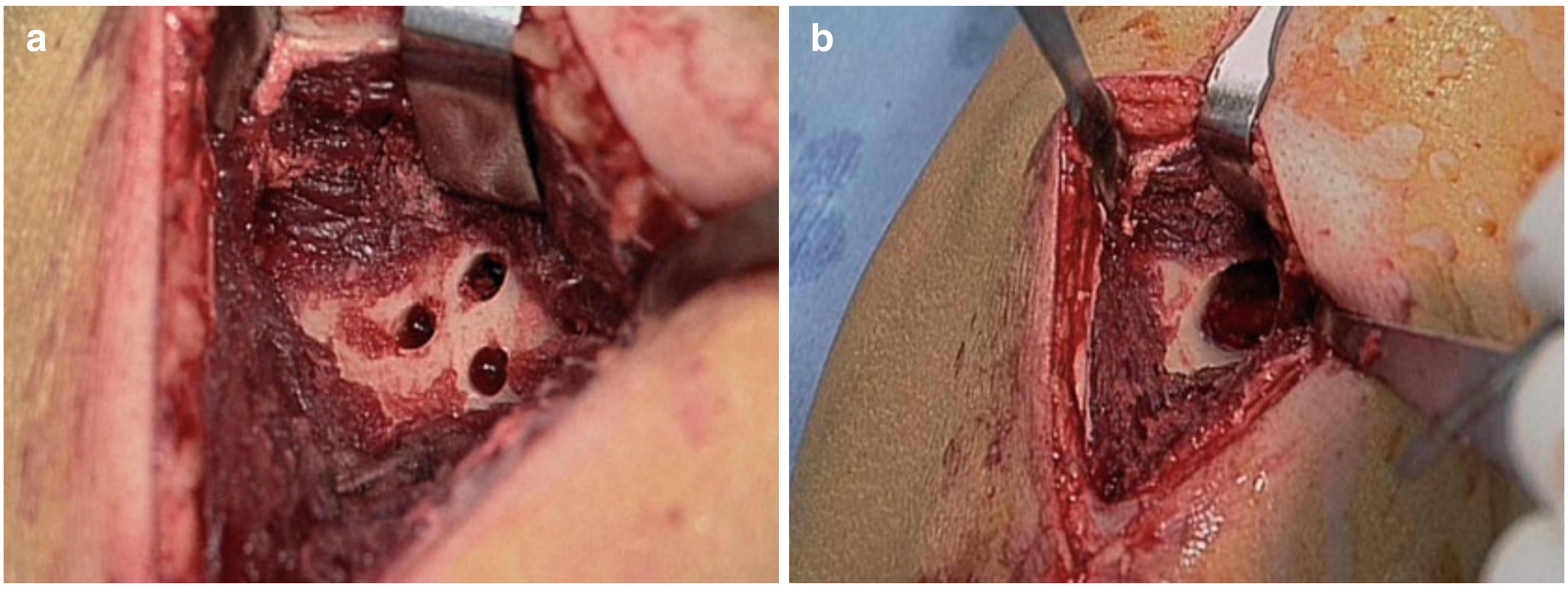

Fig. 35.3 (**a**) Three holes are made with a 3.2 mm drill in the posterior humerus proximal to the olecranon fossa. As the holes are enlarged with a 4.5 mm drill, the drill bit should be angled proximally to enter the intramedullary canal. (**b**) An 8.5 or 9 mm straight reamer or larger drill bit is used to convert the three holes into a single portal giving access to the intramedullary canal (Courtesy of Dr. Hedayatullah Hedayat)

Either an orthogonal ("90–90") plating or parallel plating configuration can be used successfully. Both configurations include a 3.5 mm DCP or pelvic reconstruction plate, which must be contoured to the medial column. Semi-tubular plates provide insufficient stability and should not generally be used. In parallel plating, another 3.5 mm plate would be placed on the lateral column. A more robust 4.5 mm plate can be placed posterolaterally if orthogonal plating is chosen. Since parallel plating was found to be superior biomechanically, patients with poor bone quality should be fixed with this configuration, especially in the austere environment, where locking plates are not readily available. Applying the following principles outlined by O'Driscoll [28] will optimize construct stability:

- Place as many screws as possible in the distal fragments.
- Each screw should pass through a plate and be as long as possible.
- Each screw should engage as many articular fragments as possible.
- Each screw in the distal fragment should be anchored in a fragment on the opposite side that is fixed by a plate.
- Distal screws lock together by interdigitation (thus creating a fixed-angle construct).
- Plates should be applied with compression at the supracondylar level.
- Plates must be strong and stiff enough to resist bending/breakage until the bone heals.

The articular surface should be reduced and provisionally fixed with small K-wires, followed by provisional reduction of the articular block to the shaft using cortical reads from the fracture line. Care should be taken not to change the geometry of the distal humerus; in the setting of bone loss or comminution, the olecranon can serve as a template on which the distal humeral articular surface can be anatomically reconstructed.

For closed reduction and pinning of supracondylar humerus fractures, fluoroscopy is essential. The injured arm may be placed on a radiolucent arm board and draped free. Alternatively, if brought in from the foot of the bed, parallel to the operating table, the image intensifier of the C-arm can be utilized as a table to support the fractured arm. Standing near the patient's head, the surgeon has access to the injured arm for reduction and pin placement. The reduction maneuver for extension type supracondylar fractures involves longitudinal traction, correction of medial/lateral translation or rotation, and finally elbow flexion while pushing on the olecranon with the thumb [52]. Taping or holding the elbow in a hyperflexed position maintains fracture reduction during pin placement. Oblique views in slight internal and external rotation of the humerus permits better visualization of the lateral and medial columns, respectively [52]. As discussed previously, lateral entry pinning is safer than crossed pinning and provides equivalent stability if proper pin divergence is achieved [28]. Maximum pin separation at the fracture improves stability and achieves fixation in both the lateral and medial columns [31] (Fig 35.4). If a medial pin is required for added stability, making a small incision, dissecting bluntly down to the medial epicondyle, and passing the pin with the elbow extended can all decrease the likelihood of iatrogenic injury to the ulnar nerve. For open reduction or exploration of a neurovascular injury, a transverse incision at the antecubital fossa provides the most direct access

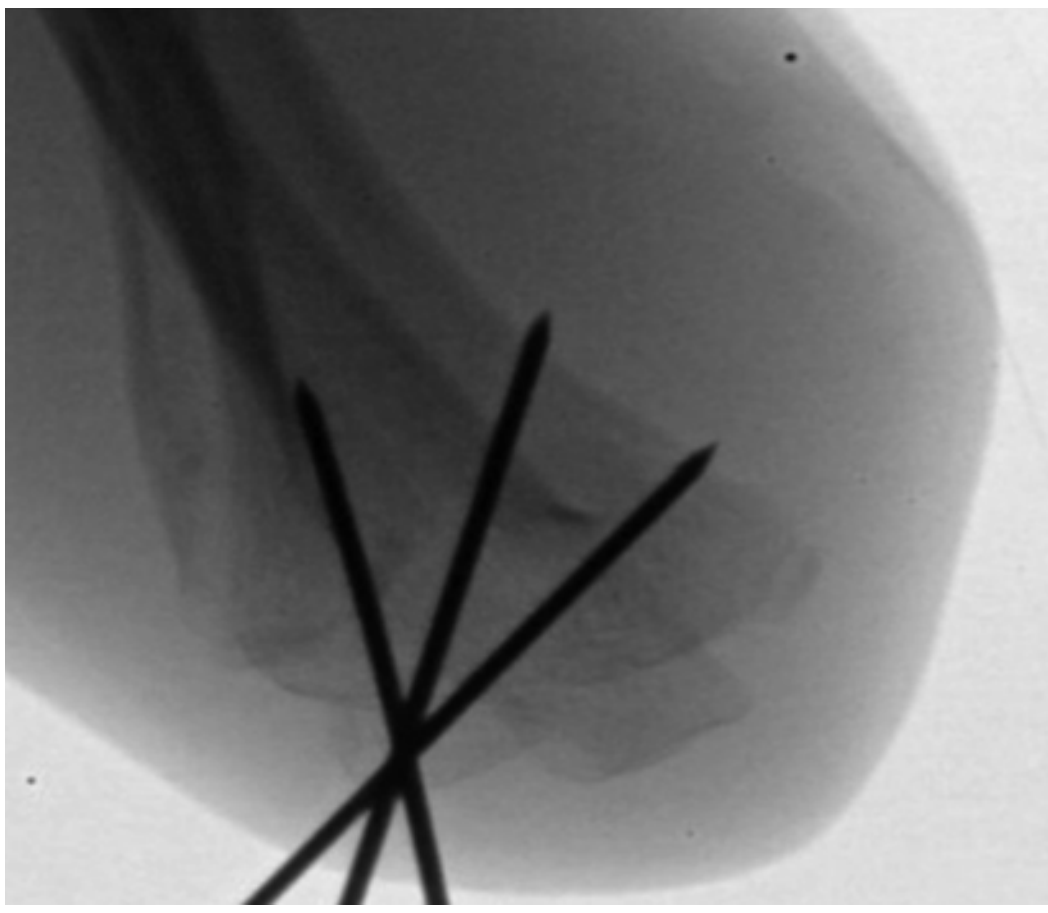

Fig. 35.4 Two or three divergent lateral-entry pins are the preferable construct, providing equivalent stability to a crossed pinning construct with a significantly lower risk of iatrogenic ulnar nerve injury

to the fracture site as well as the neurovascular structures. The brachial artery is located at the medial edge of the biceps tendon, and the median nerve is just medial to the artery. After pinning and closure, a long-arm, bivalved cast should be applied in no more than 70° of flexion in order to decrease the risk of compartment syndrome.

35.4.5 Complications

Radial nerve palsy after humeral shaft fracture was discussed previously. Humeral shaft nonunion is rare, but when it occurs, radiographs can classify the nonunion as hypertrophic or atrophic/oligotrophic. Hypertrophic nonunions require added stability, whereas oligotrophic nonunions require biologic stimulation (typically iliac crest bone graft) in addition to rigid fixation. Metabolic or endocrine abnormalities [53], smoking, or infection may also be a cause. Elbow stiffness following distal humerus fractures is common but can be avoided with early ROM.

Following pediatric supracondylar fracture, hyperextension and cubitus varus deformities are the most common types of malunion. Although neither of these complications typically leads to a functional deficit, correction can be achieved by osteotomy or by hemiepiphysiodesis. Vascular injury was discussed in detail above.

35.4.6 Follow-Up

In fractures treated nonoperatively, weekly radiographs should be obtained to assess alignment and maintenance of reduction. Functional brace treatment requires close follow-up (every 1–2 weeks) with proper brace adjustment at each visit. In general, all fractures should be followed to radiographic union.

35.4.7 Rehabilitation

The rehabilitation plan for functional bracing is detailed above. After ORIF or IM nailing of humeral shaft fractures, immediate shoulder and elbow ROM motion should be initiated. Fixation constructs should be strong enough to permit upper extremity weight bearing if needed for transfers or crutch use. Depending on stability and radiographic evidence of healing, strengthening exercises can be initiated between 6 and 12 weeks post-op. Distal humerus fractures should not be immobilized for more than 7–10 days in order to prevent elbow stiffness. Active ROM is encouraged, but strengthening should not begin until 12 weeks post-op. Fractures in pediatric patients rarely require formal physical therapy.

35.5 Tutorial/Case 1 (Case Courtesy of Dr. Hedayatullah Hedayat)

An 18 year-old right-hand dominant male sustained an isolated gunshot wound to the left humerus. There is a 12 cm wound over the anterolateral arm with exposed bone and minimal contamination. He has a palpable radial pulse and brisk capillary refill. He is able to make a fist and cross his fingers but cannot actively extend his wrist or digit, and he has numbness in the first dorsal webspace. AP and lateral X-rays of the humerus are shown in Fig. 35.5a, b. Your hospital is equipped with the capacity to perform surgery, and standard pins, plates, and screws are available, as is the Surgical Implant Generation Network (SIGN) nail. Intraoperative fluoroscopy is not available. What is the most appropriate treatment plan?

35.5.1 Discussion

The patient has a type III open humeral shaft fracture. The patient underwent urgent irrigation and debridement, exploration of the traumatic wound, and primary closure. The radial nerve was contused but was in continuity. The arm was provisionally immobilized in a coaptation splint. Due to the comminution at the frac-

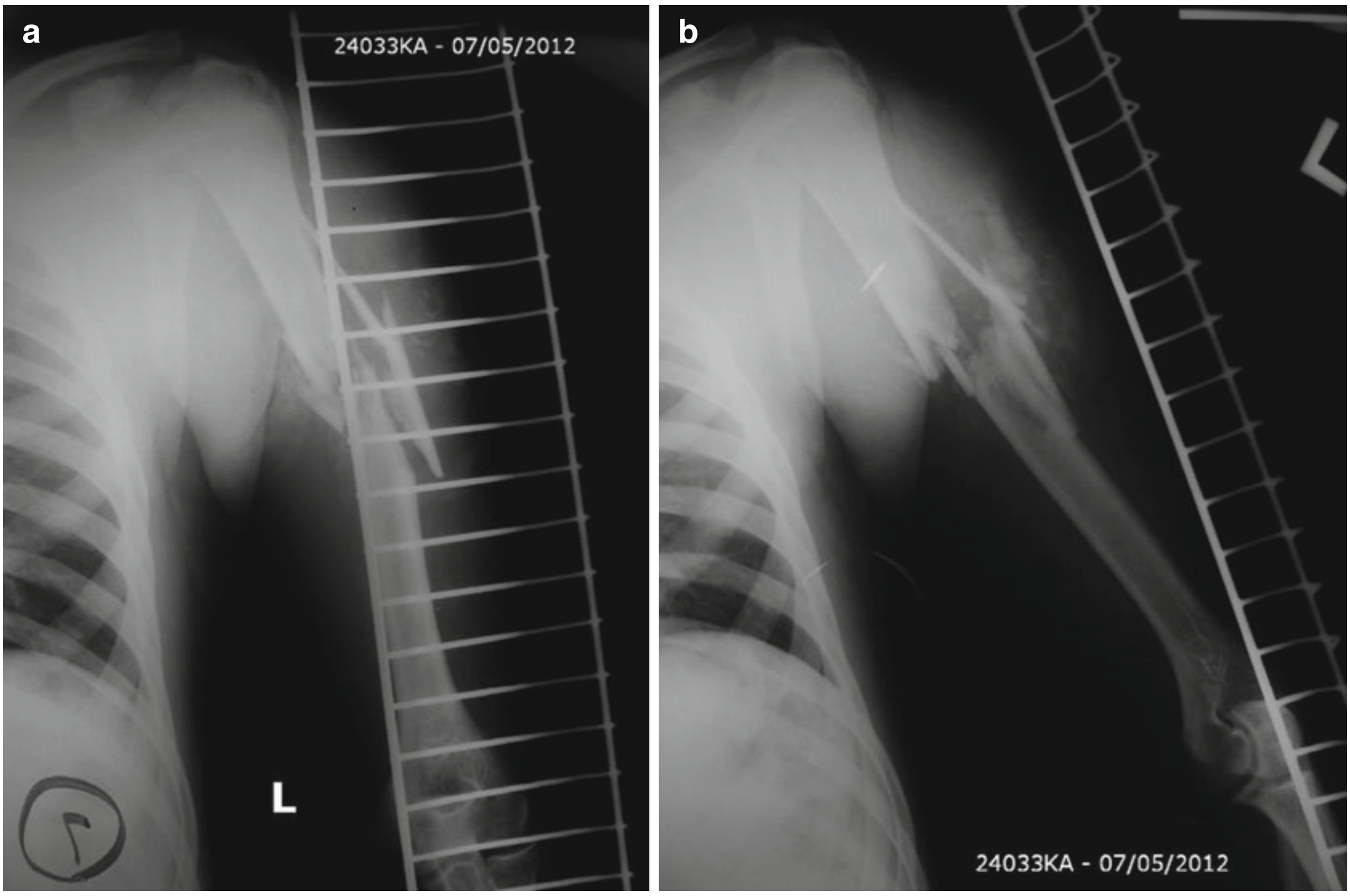

Fig. 35.5 Preoperative (**a**) AP and (**b**) lateral X-rays of patient discussed in Case 1

ture site, IM nailing was chosen as the method of definitive stabilization. A SIGN nail was placed via a retrograde approach without the use of fluoroscopy. One interlocking lateral to medial screw was placed proximally and distally using open techniques to avoid neurovascular injury. Satisfactory alignment in the coronal and sagittal planes was achieved (Fig. 35.6a, b).

35.6 Tutorial/Case 2

A 23 year-old right-hand dominant male sustained an isolated left elbow injury during a sporting activity. The skin is intact and he has normal neurovascular function in the injured arm. AP and lateral X-rays of the humerus are shown in Fig. 35.7. Your hospital is equipped with the capacity to perform surgery, and standard pins/plates/screws are available, but intraoperative fluoroscopy and site-specific (precontoured distal humerus) plates are not available. What is the most appropriate treatment plan?

35.6.1 Discussion

The patient has sustained an extra-articular distal humerus fracture at the junction of the diaphysis and metaphysis. With the available equipment, treatment options include posterolateral plating alone or dual plating (either orthogonal or parallel). In this young patient with excellent bone stock, posterolateral plating was performed with a 4.5 mm dynamic compression plate using a posterior triceps-splitting approach. The radial nerve was identified at the proximal extent of the triceps split and protected. Anatomic reduction was achieved, and the single 4.5 mm DCP provided adequate stability, so a second plate was not required. A postoperative splint was applied, but elbow ROM was permitted at 1 week (Fig. 35.8).

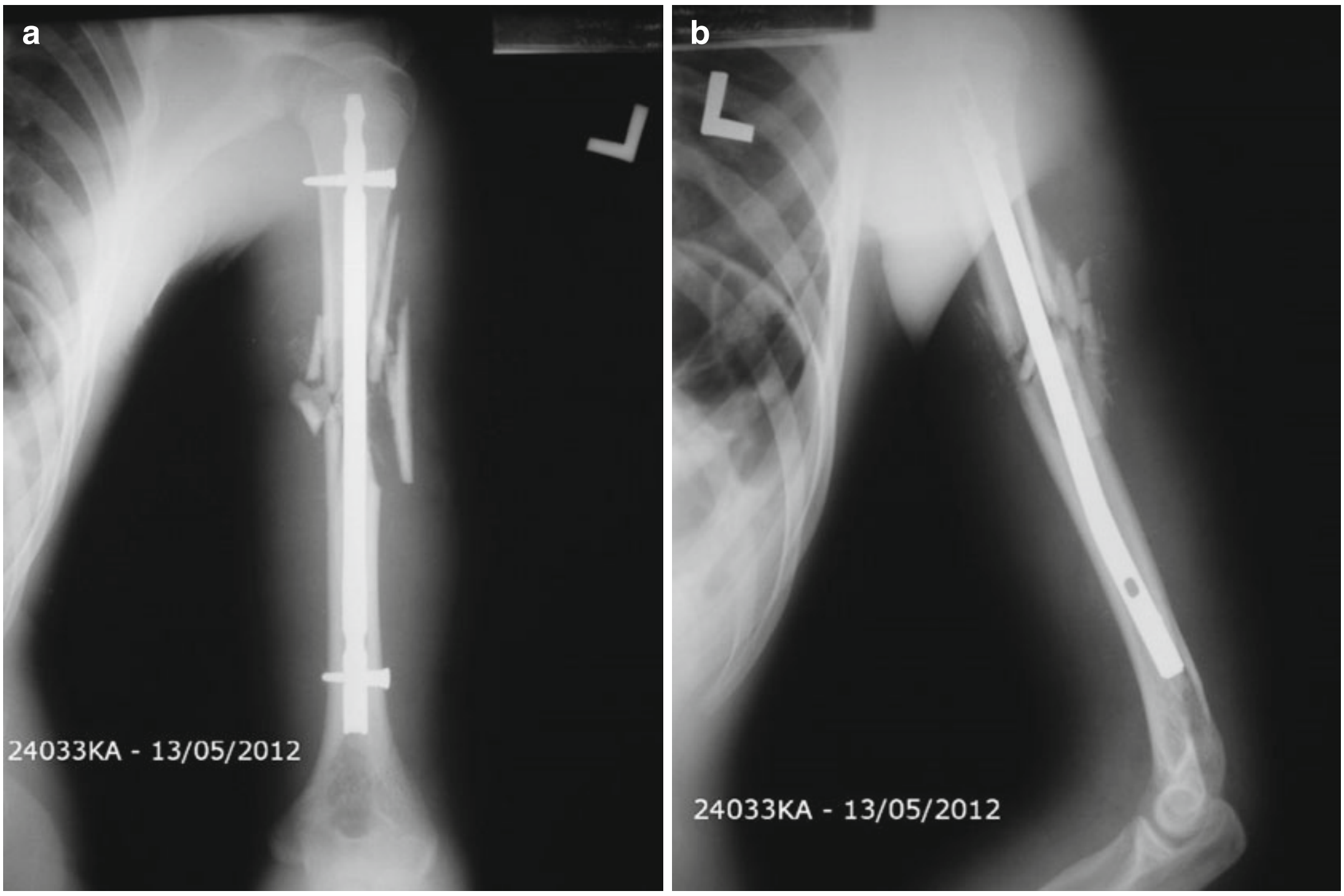

Fig. 35.6 Postoperative (**a**) AP and (**b**) lateral X-rays of patient discussed in Case 1

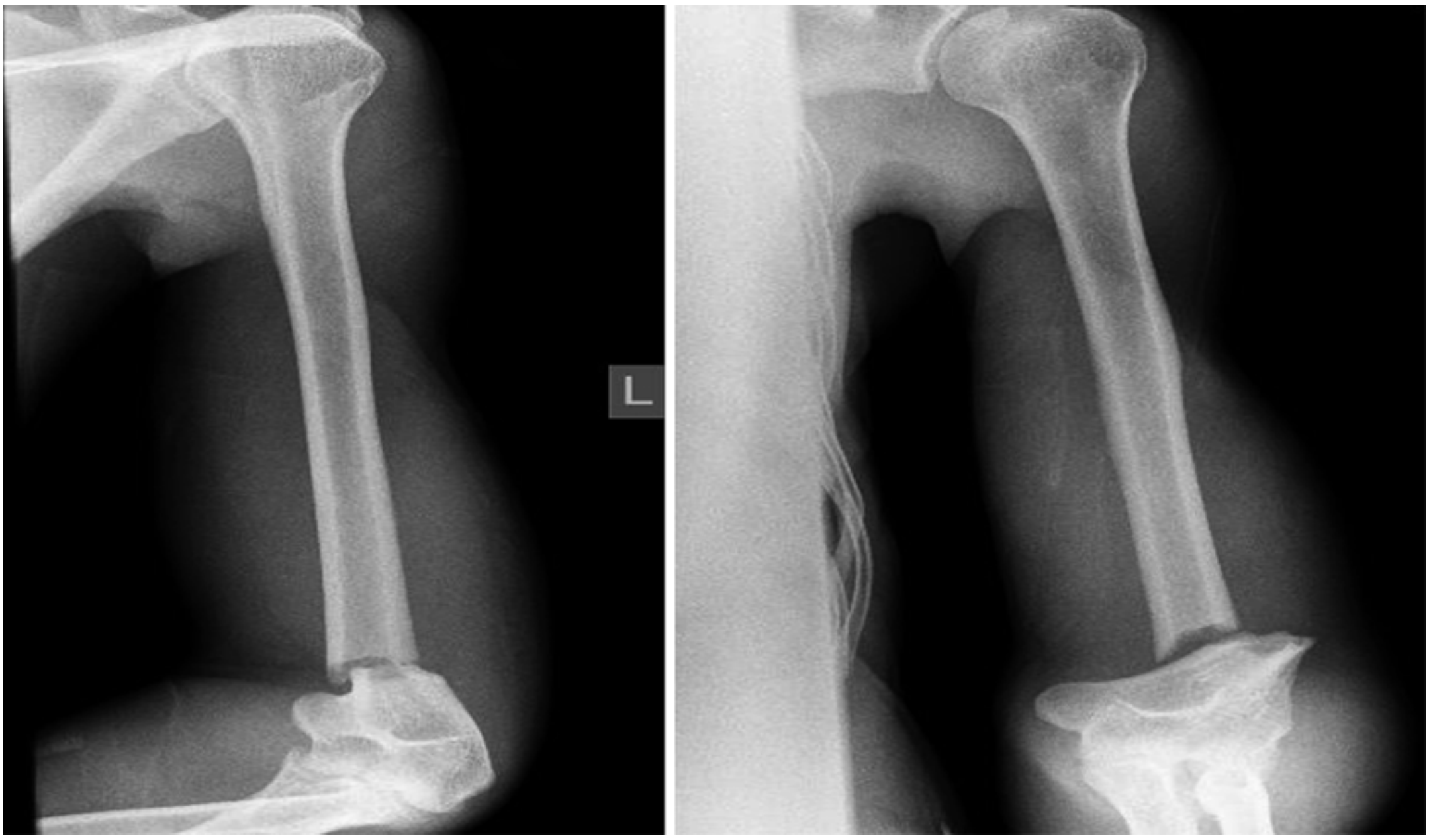

Fig. 35.7 Preoperative X-ray of patient discussed in Case 2

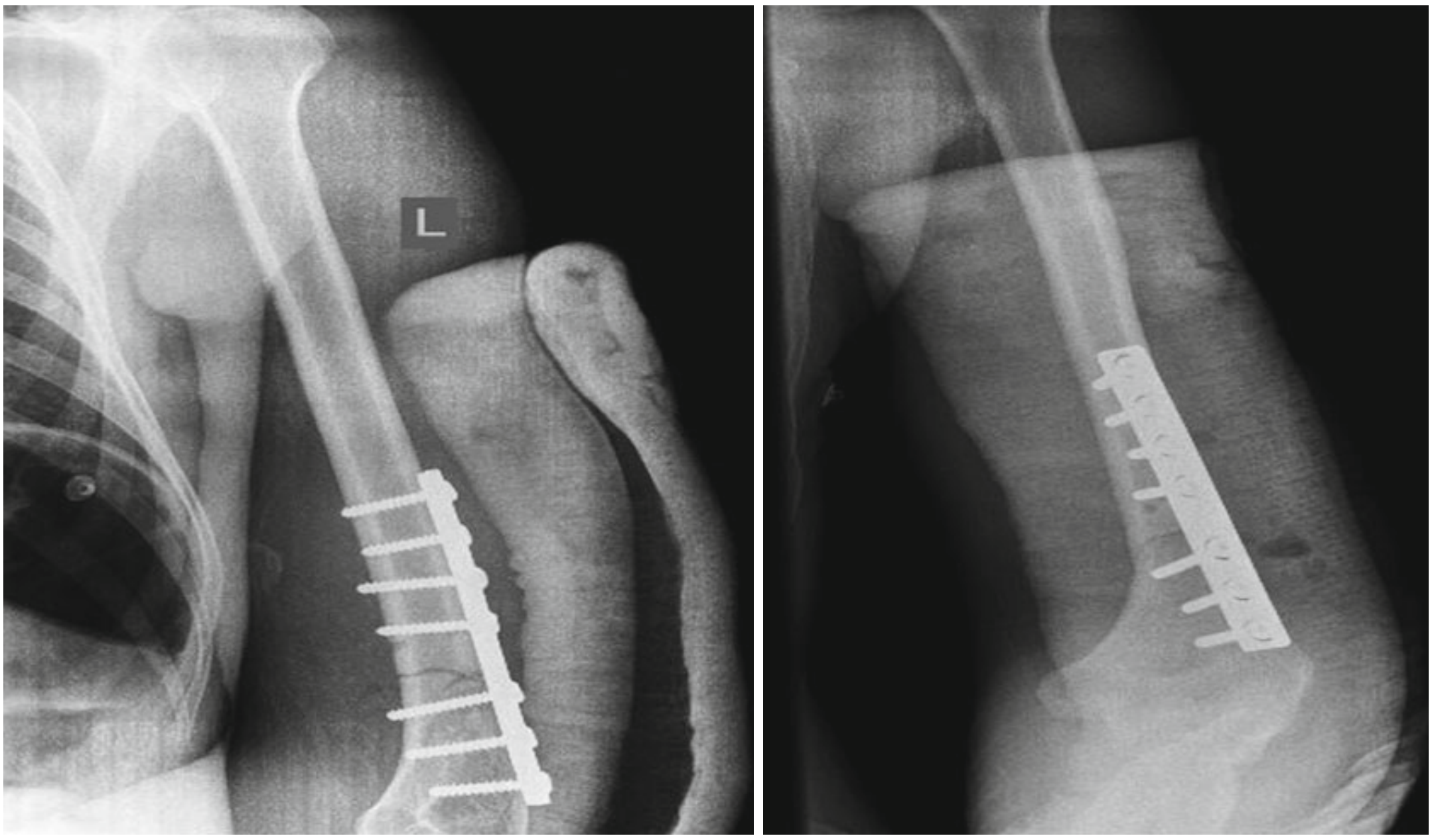

Fig. 35.8 Postoperative X-ray of patient discussed in Case 2

References

1. Rose S, Melton J, Morrey B, et al. Epidemiological features of humeral fractures. Clin Orthop Relat Res. 1982;168:24–30.
2. Charnley J. The closed treatment of common fractures. Baltimore: Williams & Wilkins; 1961.
3. Brinker MR, O'Connor DP. The incidence of fractures and dislocations referred for orthopaedic services in a capitated population. J Bone Joint Surg Am. 2004;86:290–7.
4. Tytherleigh-Strong G, Walls N, McQueen MM. The epidemiology of humeral shaft fractures. J Bone Joint Surg Br. 1998;80(12):249–53.
5. Ekholm R, Adami J, Tidermark J, et al. Fractures of the shaft of the Humerus. An epidemiological study of 401 fractures. J Bone Joint Surg Br. 2006;88(11):1469–73.
6. Court-Brown CM, Aitken SA, Forward D, O'Toole RV. The epidemiology of fractures. In: Bucholz H, Court-Brown T, editors. Rockwood and Green's fractures in adults. 7th ed. Philadelphia: Lippincott Williams, and Wilkins; 2010. p. 53–84.
7. McKee MD, Larsson S. Humeral shaft fractures. In: Bucholz H, Court-Brown T, editors. Rockwood and Green's fractures in adults. 7th ed. Philadelphia: Lippincott Williams, and Wilkins; 2010. p. 999–1038.
8. Athwal GS. Distal humerus fractures. In: Bucholz H, Court-Brown T, editors. Rockwood and Green's fractures in adults. 7th ed. Philadelphia: Lippincott Williams, and Wilkins; 2010. p. 945–98.
9. Sarwark JF, King EC, Janicki JA. Proximal humerus, scapula, and clavicle. In: Beaty JH, Kasser JR, editors. Rockwood and Wilkins' fractures in children. 7th ed. Philadelphia: Lippincott Williams & Wilkins; 2010. p. 620–81.
10. Beaty JH, Kasser JR. The elbow region: general concepts in the pediatric patient. In: Beaty JH, Kasser JR, editors. Rockwood and Wilkins' fractures in children. 7th ed. Philadelphia: Lippincott Williams & Wilkins; 2010. p. 475–86.
11. Skaggs DL, Flynn JM. Supracondylar fractures of the distal humerus. In: Beaty JH, Kasser JR, editors. Rockwood and Wilkins' fractures in children. 7th ed. Philadelphia: Lippincott Williams & Wilkins; 2010. p. 487–532.
12. Sarmiento A, Kinman PB, Calvin EG, et al. Functional bracing of fractures of the shaft of the humerus. J Bone Joint Surg Am. 1977;59:596–601.
13. Sarmiento A, Zagorski JB, Zych G, et al. Functional bracing for the treatment of fractures of the humeral diaphysis. J Bone Joint Surg Am. 2000;82:478–86.
14. Klenerman L. Fractures of the shaft of the humerus. J Bone Joint Surg Br. 1966;48(1):105–11.
15. Wallny T, Sagebiel C, Westerman K, Wagner UA, Reimer M. Comparative results of bracing and interlocking nailing in the treatment of humeral shaft fractures. Int Orthop. 1997;21(6):374–9.
16. Denard A Jr, Richards JE, Obremskey WT, Tucker MC, Floyd M, Herzog GA. Outcome of nonoperative vs operative treatment of humeral shaft fractures: a retrospective study of 213 patients. Orthopedics 2010;33(8): doi 10.3928/01477447-20100625-16.

17. Jawa A, McCarty P, Doornberg J, Harris M, Ring D. Extra-articular distal-third diaphyseal fractures of the humerus: a comparison of functional bracing and plate fixation. J Bone Joint Surg Am. 2006;88(11):2343–7.
18. McCormack RG, Brien D, Buckley RE, McKee MD, Powell J, Schemitsch EH. Fixation of fractures of the shaft of the humerus by dynamic compression plate or intramedullary nail: a prospective, randomized trial. J Bone Joint Surg Br. 2000;82(3):336–9.
19. Putti AB, Uppin RB, Putti BB. Locked intramedullary nailing versus dynamic compression plating for humeral shaft fractures. J Orthop Surg (Hong Kong). 2009;17(2):139–41.
20. Heineman DJ, Poolman RW, Nork SE, Ponsen KJ, Bhandari M. Plate fixation or intramedullary fixation of humeral shaft fractures. Acta Orthop. 2010;81(2):216–23.
21. Galano GJ, Ahmad CS, Levine WN. Current treatment strategies for bicolumnar distal humerus fractures. J Am Acad Orthop Surg. 2010;18(1):20–30.
22. Coles CP, Barei DP, Nork SE, Taitsman LA, Hanel DP, Henley MB. The olecranon osteotomy: a six-year experience in the treatment of intraarticular fractures of the distal humerus. J Orthop Trauma. 2006;20:164–71.
23. Ring D, Gulotta L, Chin K, Jupiter JB. Olecranon osteotomy for exposure of fractures and nonunions of the distal humerus. J Orthop Trauma. 2004;18:446–9.
24. Schwartz A, Oka R, Odell T, Mahar A. Biomechanical comparison of two different periarticular plating systems for stabilization of complex distal humerus fractures. Clin Biomech (Bristol, Avon). 2006;21:950–5.
25. Arnander MW, Reeves A, MacLeod IA, Pinto TM, Khaleel A. A biomechanical comparison of plate configuration in distal humerus fractures. J Orthop Trauma. 2008;22:332–6.
26. Korner J, Diederichs G, Arzdorf M, et al. A biomechanical evaluation of methods of distal humerus fracture fixation using locking compression plates versus conventional reconstruction plates. J Orthop Trauma. 2004;18:286–93.
27. Berkes M, Garrigues G, Solic J, Van Zeeland N, Shourbaji N, Brouwer K, Jupiter J, Ruch D, Obremskey WT. Locking and non-locking constructs achieve similar radiographic and clinical outcomes for internal fixation of intra-articular distal humerus fractures. HSS J. 2011;7(3):244–50. Epub 2011 Sep 15.
28. O'Driscoll SW. Optimizing stability in distal humeral fracture fixation. J Shoulder Elbow Surg. 2005;14(1 Suppl S):186S–94.
29. Hadlow AT, Devane P, Nicol RO. A selective treatment approach to supracondylar fracture of the humerus in children. J Pediatr Orthop. 1996;16(1):104–6.
30. Flynn JC, Matthews JG, Benoit RL. Blind pinning of displaced supracondylar fractures of the humerus in children. Sixteen years' experience with long-term follow-up. J Bone Joint Surg Am. 1974;56(2):263–72.
31. Skaggs DL, Cluck MW, Mostofi A, et al. Lateral-entry pin fixation in the management of supracondylar fractures in children. J Bone Joint Surg Am. 2004;86A(4):702–7.
32. Skaggs DL, Sankar WN, Albrektson J, et al. How safe is the operative treatment of Gartland type 2 supracondylar humerus fractures in children? J Pediatr Orthop. 2008;28(2):139–41.
33. Kocher MS, Kasser JR, Waters PM, et al. Lateral entry compared with medial and lateral entry pin fixation for completely displaced supracondylar humeral fractures in children. A randomized clinical trail. J Bone Joint Surg Am. 2007;89(4):706–12.
34. Blanco JS, Gaston G, Cates T, et al. Lateral pin vs crossed pin fixation in type 3 supracondylar (SC) humerus fractures: a randomized prospective study. Presented at 2007 Annual Meeting of the Pediatric Orthopaedic Society of North America, Hollywood, Floida, May 23–26, 2007.
35. Lee SS, Mahar AT, Miesen D, et al. Displaced pediatric supracondylar humerus fractures: biomechanical analysis of percutaneous pinning techniques. J Pediatr Orthop. 2002;22(4):440–3.
36. Shao YC, Harwood P, Grotz MR, Limb D, Giannoudis PV. Radial nerve palsy associated with fractures of the shaft of the humerus: a systematic review. J Bone Joint Surg Br. 2005;87(12):1647–52.
37. Machan FG, Vinz H. Humeral shaft fracture in childhood. Unfallchirurgie. 1993;19:166–74.
38. Ring D, Chin K, Jupiter JB. Radial nerve palsy associated with high-energy humeral shaft fractures. J Hand Surg Am. 2004;29(1):144–7.
39. Choi PD, Melikian R, Skaggs DL. Risk factors for vascular repair and compartment syndrome in the pulseless supracondylar humerus fracture in children. J Pediatr Orthop. 2010;30(1):50–6.
40. Bishop J, Ring D. Management of radial nerve palsy associated with humeral shaft fracture: a decision analysis model. J Hand Surg Am. 2009;34(6):991–6, e1.
41. Beaty JH. Fractures of the proximal humerus and shaft in children. Instr Course Lect. 1992;41:369–72.
42. Sarmiento A, Latta L. Functional fracture bracing: a manual. Philadelphia: Lippincott, Williams, and Wilkins; 2002.
43. Sarmiento A, Waddell JP, Latta LL. Diaphyseal humeral fractures: treatment options. Instr Course Lect. 2002;51:257–69.
44. Carroll EA, Schweppe M, Langfitt M, Miller AN, Halvorson JJ. Management of humeral shaft fractures. J Am Acad Orthop Surg. 2012;20(7):423–33.
45. Surgical Implant Generation Network Website: http://www.signfracturecare.org. Accessed 22 June 2014.

46. Hedayat H. Retrograde humeral approach: technique and case reports. Presented at the surgical implant generation network (SIGN) conference, Richland, WA, 21 Sept 2012.
47. DeLong Jr WG, Born CT, Marcelli E, et al. Ender nail fixation in long bone fractures: experience in a level I trauma center. J Trauma. 1989;29:571–6.
48. Hackethal KH. Die Bundel-Nagelung. Berlin: Springer; 1961.
49. Hall Jr RF, Pankovich AM. Ender nailing of acute fractures of the humerus. A study of closed fixation by intramedullary nails without reaming. J Bone Joint Surg Am. 1987;69:558–67.
50. Ligier JN, Metaizeau JP, Prevot J. Closed flexible medullary nailing in pediatric traumatology. Chir Pediatr. 1983;24:383–5.
51. Mackay I. Closed Rush pinning of fractures of the humeral shaft. Injury. 1984;16:178–81.
52. Skaggs DL. Closed reduction and pinning of supracondylar humerus fractures. In: Tolo VT, Skaggs DL, editors. Master techniques in orthopaedic surgery: pediatric orthopaedics. Philadelphia: Lippincott Williams & Wilkins; 2007. p. 1–15.
53. Brinker MR, O'Connor DP, Monla YT, Earthman TP. Metabolic and endocrine abnormalities in patient with nonunions. J Orthop Trauma. 2007;21(8):557–70.

36

Elbow Injuries in the Austere Environment

Steve Hodgson

The function of the elbow joint is to position the hand in space in order for it to perform its tactile and grasping functions. To perform each function well, it requires a good range of flexion, extension, pronation and supination, reasonable comfort, strength and stability.

The elbow joint comprises of three closely related individual articulations. The humeroulnar joint between the articulations of the olecranon process of the ulnar and the trochlea of the distal humerus is essentially a hinged joint allowing a free range of flexion extension. A small amount (5–10°) of abduction/adduction and pronation/supination takes place at this articulation between extension and flexion. The radiocapitellar joint between the concave surface of the proximal radius and the convex surface of the capitellum on the lateral portion of the distal humerus allows the radius to pronate and supinate with a changing centre of rotation from elbow flexion to extension.

In combination with the medial collateral ligament, it provides a significant contribution to stability against valgus forces. Most studies suggest that the radius transmits over 50 % of the compressive force of the forearm. The proximal radioulnar joint is an articulation between the cylindrical portion of the radial head and the concave cylindrical facet on the lateral surface of the coronoid process. Stability to this joint is provided by the annular ligament. The proximal radioulnar joint is part of the general articulation in the forearm between the radius and ulna with stability for the overall complex being provided by the interosseous ligament of the forearm and the distal radioulnar joint.

The main motors that move the elbow joint along with their nerve supply are located some distance away from the joint and rarely directly involved in elbow trauma. However, the main flexor and extensor muscles of the wrist and hand and pronators and supinators of the forearm have their origins close to the elbow joint, many of them crossing the joint. In addition the nervous and arterial supply of the forearm, wrist and hand pass in close proximity to the elbow joint and can be damaged by elbow trauma.

The articular surfaces of the overall elbow joint make it a fairly constrained joint, well able to resist loads placed across it through a wide range of positions. This degree of constraint contributes to the tendency for the elbow to develop stiffness following trauma and subsequent immobilisation.

The fully functioning upper limb undoubtedly requires a mobile, comfortable, strong and stable elbow. Many basic activities of daily living require the hand to be able to reach both ends of the

---

S. Hodgson, MBChB, FRCS (Orth), MD
Trauma and Orthopaedic Surgery, Royal Bolton Hospital, Bolton, Lancashire, UK
e-mail: wslpla.hodgson@btopenworld.com; stephen.hodgson@boltonft.nhs.uk

© Springer International Publishing Switzerland 2016

J.D. Robinson (ed.), *Orthopaedic Trauma in the Austere Environment: A Practical Guide to Care in the Humanitarian Setting*, DOI 10.1007/978-3-319-29122-2_36

Table 36.1 Elbow function required for different activities

	Activities of daily living (mouth, perineal hygiene)	Non-manual job	Light manual job (driving, machine operator)	Heavy manual job (agriculture, construction)
Motion	+++	+	++	++
Comfort	+	+	++	+++
Strength/stability	+	+	++	+++
Intact hand neurovascular function	+++	++	++	+++

Key:
+ desirable
++ useful
+++ essential

gastrointestinal tract thereby requiring almost a full range of flexion and extension (Table 36.1). Loss of elbow motion means that the limb tends to become the assisting limb being used to support, stabilise or carry in order to help the other normal limb being the prime performer of these tasks. A rather stiff, comfortable elbow still allows that limb to contribute to overall function.

The most disabling elbow is an unstable “flail” that can be seen following an un-united fracture. In this type of scenario, the other good limb has to be used to position the hand of the bad limb in space. Whilst the goal of elbow trauma management is to preserve as much function as possible, realistic goals should be set giving consideration to the status of the other upper limb and the lower limbs as it must not be forgotten that the injured limb may be required for weight-bearing purposes.

In a heavy manual worker with a normal other limb, it may be better to go for strength and stability at the expense of some motion, particularly if the injured elbow is in the non-dominant arm. The table attempts to summarise the balance of motion, pain, strength and stability required in different types of tasks and further emphasises the importance of preserving hand function.

36.1 Basic Principles and Management

These principles apply mainly in the situation of acute trauma and should be considered in the context of the patient’s pre-injury status, health status, occupation, social needs and any other injuries sustained in the accident.

1. Ensure that airway, breathing and circulation are all secured and stabilised [1].
2. Ensure vascularity of hand.
3. Consider associated neurological injuries.
4. Open wound management.
5. Joint reduction and primary skeletal stabilisation.
6. Definitive management.
7. Rehabilitation including where possible, early motion.

All of the above represent a logical order of priorities. It should not be regarded as a rigid, chronological order of management. A full, well-documented initial assessment allows construction of a logical management plan aiming for realistic, long-term goals. In an austere environment, full consideration will have to be given to expertise and resources available. The primary focus will be on limb preservation and reducing the risk of long-term complications such as infection or impaired distal neurovascular function.

Primary management, including preservation of life and limb and initial wound management, will have to be performed as soon as possible. Definitive management will be able to wait allowing possible patient transfer to the required expertise and resource. Ideally, the acute management will be planned with full awareness and understanding of likely definitive management to avoid early decisions being made that compromise subsequent management and the final outcome.

36.1.1 Advanced Trauma Life Support

In all patients with acute elbow trauma, consideration should be given to the presence of other injuries [1]. This is more likely with a high-energy mechanism of injury. A primary survey to identify life-threatening conditions should be performed simultaneously. Initial focus is on A (airway maintenance with cervical spine control), B (breathing and ventilation), and C (circulation with haemorrhage control). Only once it is satisfied that the elbow trauma is the dominant problem should attention focus on the elbow injury. On very rare occasions such as a partial amputation, the elbow injury may be the source of life-threatening haemorrhage. In an austere environment, emergency amputation may be the only therapeutic option available to save life.

36.1.2 Distal Vascular Status

The brachial artery lies close to the anterior aspect of the distal humerus and elbow joint, meaning elbow trauma can cause distal vascular compromise which is most likely with severely displaced supracondylar fractures or penetrating trauma [2]. An open injury with a history of significant bleeding and distal vascular compromise should raise a high index of suspicion of vascular injury. If the patient is stable and the limb cold and pulseless, this would be an indication for vascular exploration if resources for repair are available. In a closed injury with a pulseless hand, the risk of a severed artery is much less, the vascular compromise being more likely to be due to kinking of an artery over a displaced bony fragment.

In this situation with a pulseless hand, if the hand is cold with poor capillary filling, reduction of the bones into good alignment is an emergency (see supracondylar fracture section). If this restores good capillary filling and warmth to the hand though the radial pulse is still absent, there is good evidence that the hand will survive and that acute vascular exploration is not required. Where there has been a period of vascular compromise, a high index of suspicion of the development of forearm compartment syndrome should be present and, if suspected, fasciotomy performed.

36.1.3 Distal Neurological Compromise

All three major nerves that cross the elbow joint (ulnar, median and radial) are at some risk in elbow trauma [3]. Distal neurological function should be documented. That is an indication for reduction of joint or bony displacement as soon as possible. In an austere environment, exploration of the nerves is not always advisable.

36.1.4 Open Wound Management

The presence of an open wound should be documented and the wound cleaned and covered with an antiseptic dressing. Broad-spectrum antibiotics should be administered intravenously. The basic principle of open wound management in addition to antibiotics is early wound debridement and lavage, ideally within 12 h (Fig. 36.1). If delayed beyond 12 h, the risk of deep infection increases. The more severe and contaminated the wound, the more urgent the formal debridement. At the time of wound debridement, the primary skeletal stabilisation should be secured.

36.1.5 Joint Reduction/Primary Bony Stabilisation

In the presence of distal neurovascular compromise or an open wound, this should be provided with urgency. In the absence of distal neurovascular compromise with a closed injury, joint reduction and primary stabilisation may well be the definitive management of the injury. Useful methods of primary stabilisation include longitudinal traction, splintage with either a cast or sling or in extreme circumstances, if available, external fixation.

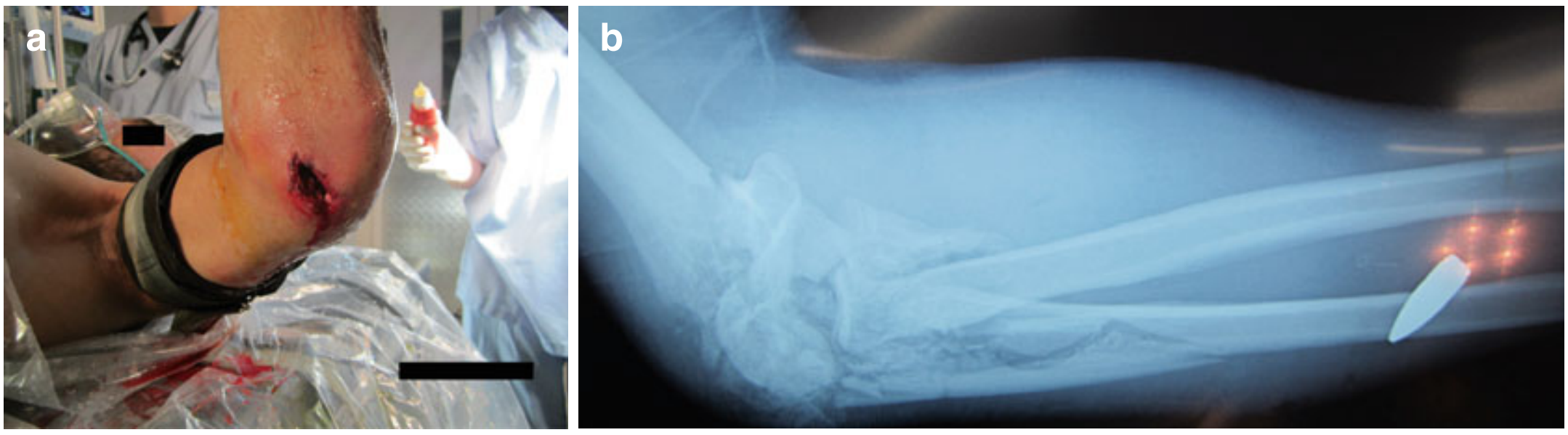

Fig. 36.1 (**a**) Gunshot wound to elbow causing an open very comminuted fracture to elbow (**b**)

36.1.6 Definitive Management

The goal of definitive management is to restore anatomy and provide enough stability to allow early motion. Relatively conservative methods of closed reduction and then a short period of immobilisation in a plaster of Paris cast remains a safe method of treatment with predictable results for many types of elbow trauma. Where it is not possible to achieve good bony reduction via closed methods, operative treatment should be considered depending on the available expertise and resource.

36.1.7 Early Motion

Given the importance of a good range of elbow motion to overall upper limb function, prolonged periods of immobilisation post-injury should be avoided where possible, but this is always a balanced judgement taking into consideration factors such as realistic goals for the injury, the risk of loss of joint or fracture reduction and access to supervised rehabilitation and likely patient compliance.

36.2 Surgical Approaches

Treating elbow trauma in an austere environment requires a sound anatomical knowledge and, in particular, a full understanding of the path of the three main nerves (median, ulnar and radial/posterior interosseous) and brachial artery as they cross the elbow region [4]. The author would not recommend attempting elbow surgery without this knowledge which is beyond the scope of this chapter.

Structures most at risk in surgical approaches to the elbow are the ulnar and radial/posterior interosseous nerves. The ulnar nerve is most at risk in the cubital tunnel passing very close to the medial capsule of the elbow joint. The author would recommend identifying it early in the surgical exposure performing a limited gentle mobilisation and, if felt necessary, widening the tunnel between the two heads of the flexor carpi-ulnaris muscle. Regular checking its location during the surgical procedure is recommended. Routine anterior transposition is usually not necessary. The radial nerve is vulnerable to over enthusiastic retraction for approximately 10 cm above the elbow joint to where it passes from medial to lateral just below the midpoint of the humerus. The posterior interosseous nerve is at risk in lateral approaches beyond three fingers breadths distal to the lateral joint line and lies close to the anterior capsule.

When planning a surgical approach, it is important to appreciate the likely degree of exposure required and whether triceps may need to be lengthened. Most elbow trauma can be dealt with using either variations of the posterior approach or a lateral approach.

The posterior approach is the most versatile for elbow trauma, a triceps splitting variation being used for extra-articular distal humeral fractures and open reduction of elbow dislocations. The better exposure of the articular surfaces offered by an olecranon osteotomy makes it the approach of choice for intra-articular fractures. The author favours the patient being positioned laterally with the arm over a support such as an ether screen so that it hangs free at 90°. The use of a tourniquet is recommended.

The initial incision is longitudinal, centred on the olecranon. It should not pass directly over the olecranon. Curving to the radial side of the joint ensures good vascularity to the medial flap. The skin incision is deepened through the superficial fascia and then flaps reflected out to the medial and lateral condyles. The ulnar nerve should be identified. Although there are many modifications of triceps splitting or reflecting deep exposures, a distally based 'V' is simple and can be extended down either side of the olecranon. When treating a chronic dislocation, this also allows to lengthen triceps by closing in a 'V' to 'Y' fashion.

When treating an intra-articular fracture, after the superficial dissection, the author would recommend performing a Chevron osteotomy of the olecranon, having pre-drilled a hole for subsequent fixation using a partially threaded cancellous screw if necessary supplemented by a figure of eight tension bands. The Chevron should be performed with a fine sawblade, sawing through 90 % of the bone before completing the osteotomy with an osteotome. The proximal olecranon can be retracted proximally with the whole triceps to offer excellent exposure to the whole of the distal humerus.

The lateral approach allows good exposure of the lateral condyle, including shear fractures of the anterior capitellum, and is the exposure of choice for radial head fractures and delayed radial head excision. This approach is best performed with the patient supine with the arm on an arm table, the elbow flexed approximately 70° and the forearm pronated. Again, a tourniquet is recommended. An incision approximately 10 cm long is centred on the lateral joint line.

After superficial dissection, the exposure is between triceps and anconeus posteriorly and brachial radialis and extensor carpi radialis anteriorly. The extensor origin can be elevated off the humerus to allow wide exposure of the lateral portion of the joint. The posterior interosseous nerve is at risk during dissection of the proximal radius beyond three finger breadths below the lateral condyle. This risk can be reduced by ensuring that the forearm is pronated.

36.3 Elbow Dislocations

Elbow dislocations occur in both children and adults, in children usually in later childhood/adolescence. Posterior and posterolateral directions of dislocation are the most common, the usual mechanism being a fall onto the outstretched hand often with a valgus and external rotation force. This mechanism of injury damages the medial collateral ligament complex which is the key to elbow joint stability. A clinical diagnosis is usually fairly straightforward with obvious deformity, loss of the normal triangle between the two condyles and the olecranon. The elbow is usually in an extended posture. Neurovascular complications are very rare. The diagnosis should be confirmed by plain x-rays looking carefully to identify any associated fractures (Fig. 36.2).

Closed reduction, either under sedation or general anaesthetic, should be performed using hyper-supination and longitudinal trac-

Fig. 36.2 Elbow dislocation

tion. The main obstacle to reduction is muscle spasm. If the reduction is felt to be stable, immobilisation in a plaster of Paris backslab in a mid-pronated position for 1 week is recommended. If the reduction is felt to be unstable, then immobilisation for 3 weeks is recommended. Immobilisation longer than 4 weeks has been shown to increase risks of long-term stiffness and is not recommended. It may take patients up to 6 months to reach an end point of recovery. Long-term studies have shown an average loss of 12° of extension at 2 years post dislocation. More serious, long-term problems such as chronic instability are uncommon.

In an austere environment, unfortunately not all elbow dislocations present acutely. Chronic elbow dislocation rarely seen in the western world is commonly seen in the austere environment. Beyond 1 week post-injury, the chances of a successful closed reduction begin to diminish, and certainly beyond 3 weeks post-injury, there is a fair likelihood that closed reduction will not be successful and that open reduction should be considered (Fig. 36.3). Most patients with a chronic posterior dislocation have very poor elbow function.

Although the acute pain usually settles, the elbow becomes stiff in the extended posture. There is an extensive literature describing very satisfactory results from open reduction of chronic elbow dislocations [5–8]. These four papers cover a total of 175 patients aged from 6 to 76 with durations of dislocation ranging from 1 week to 24 months with a preoperative range of movement of approximately 35° from the extended position. With a less than 3-month duration of dislocation, a lateral excision allowed satisfactory exposure, clearance of scar tissue and reduction of the joint. Beyond 3 months post-injury, a V to Y triceps splitting approach was required. If the elbow was stable once reduced, immobilisation for 3 weeks in a cast was recommended. If unstable, temporary transfixion with a thick K-wire for a period of 2–3 weeks is recommended. Post-operatively, patients regained a very functional range of movement of typically 35–115° with a low risk of complications. The findings of these papers are summarised in Fig. 36.4.

Fig. 36.3 Chronic dislocation presenting 6 weeks late

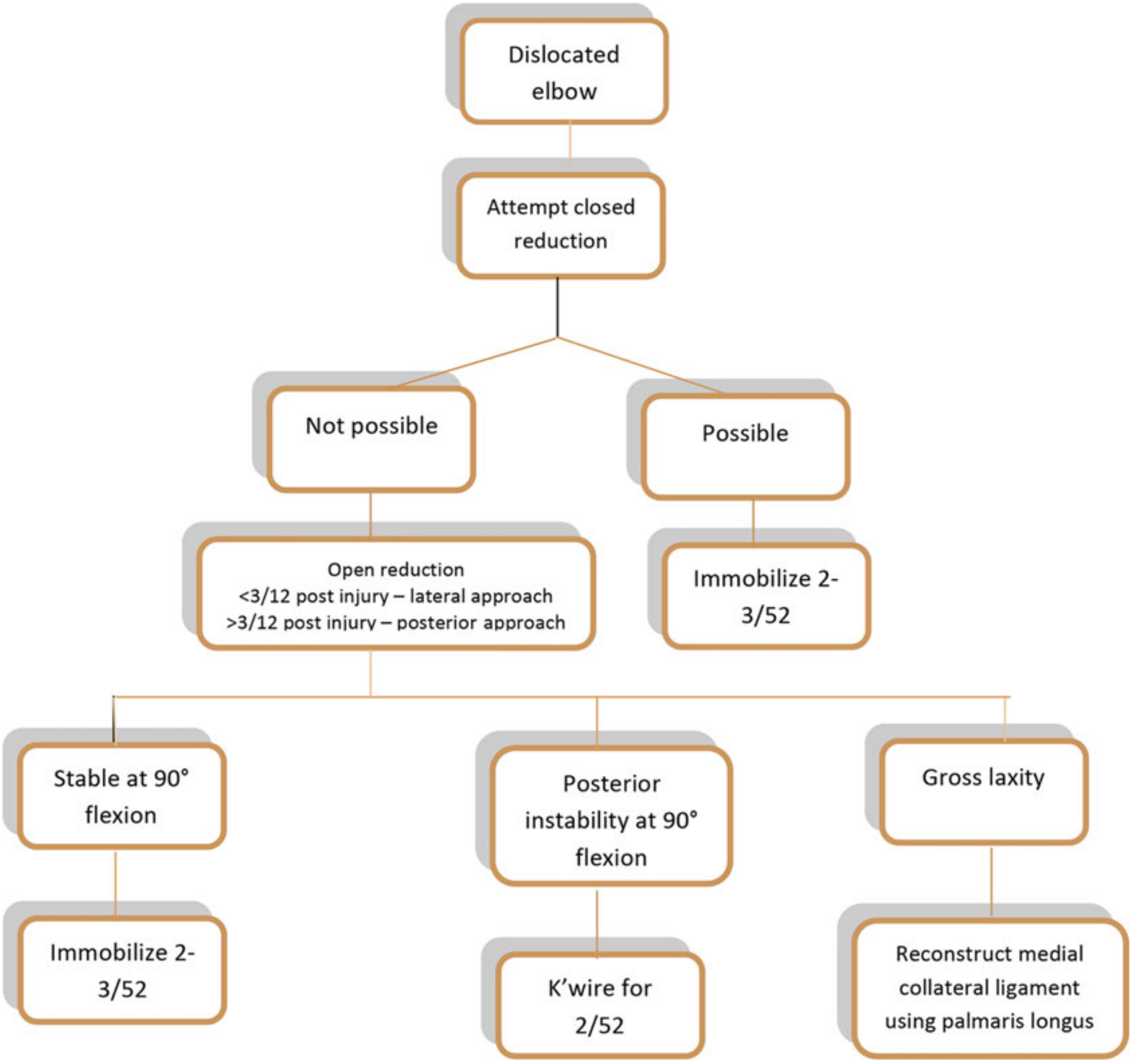

Fig. 36.4 Evidence-based recommendations for elbow dislocation management

36.4 Distal Humeral Fractures in Paediatrics

Supracondylar fractures of the distal humerus are the most common elbow fractures in children. They most commonly occur between the ages of four and ten due to a fall on the outstretched hand with a hyperextension force, often with a varus/valgus and rotational element. As a result, 95 % are posteriorly displaced. They have the potential for vascular compromise which if not dealt with urgently can result in serious long-term impairment of upper limb function.

There is an extensive body of evidence regarding management though much of this is from individual case studies or comparative trials with small numbers of patients. The evidence is best summarised by the American Academy of Orthopaedic Surgeons' new Paediatric Supracondylar Humerus Fracture Clinical Practice Guidelines published in 2011 [9].

Recommendations worthy of note are as follows:

1. We suggest non-surgical immobilisation of the injured limb for patients with acute Gartland type I fractures.
2. We suggest closed reduction with pin fixation for patients with displaced Gartland II and III fractures.
3. We are unable to recommend for or against a time threshold for reduction of displaced supracondylar fractures of the humerus without neurovascular injury.
4. In the absence of reliable evidence, the opinion of the work group is that closed reduction of displaced paediatric supracondylar humerus fractures be performed in patients with decreased perfusion of the hand.
5. In the absence of reliable evidence, the opinion of the work group is that open exploration of the antecubital fossa be performed in patients who have absent wrist pulses and are under perfused after reduction and pinning of displaced paediatric supracondylar humerus fractures. They were unable to make recommendations regarding exploration of the antecubital fossa with absent wrist pulses and a well-perfused hand.

The most widely accepted classification system for children's supracondylar fractures is that of Gartland.

- Gartland I undisplaced fractures
- Gartland II displacement though still some bony contact
- Gartland III complete displacement

When presenting acutely, the pain and deformity usually make the diagnosis simple. It is vital to assess for capillary filling in the hand, presence of the radial pulse and neurological status. Vascular compromise makes fracture reduction an emergency. Plain x-rays will reveal the degree of displacement.

Gartland type I fractures do well with conservative management consisting of a splint and sling for 2–3 weeks. Treatment options for Gartland type II and III fractures will depend upon the resources available. They range through blind reduction and cast immobilisation, reduction under X-ray control and either cast immobilisation or percutaneous pinning. An alternative to operative intervention is elevated straight arm traction as a means of definitive management.

The technique for closed reduction of supracondylar fractures remains best described by John Charnley in his book "The Closed Treatment of Common Fractures" [10]. He stresses the importance of focusing on the attached soft tissues, namely, the triceps muscle and posterior periosteum. These can be kept tight by longitudinal traction in the axis of the arm to draw the distal fragment into a reduced position. With the elbow still in a position of extension and then after a pause to allow correction of the extension component of the deformity, it is then possible to correct any lateral displacement and rotation before flexing the elbow, now applying traction in the axis of the forearm to lock the fragments in position.

In the absence of X-ray facilities in the operating theatre, a plaster of Paris backslab should be applied. This has been shown to give very reasonable results for Gartland type II fractures [11]. The results are much better for Gartland type II fractures with 64 % good-excellent results compared with Gartland type II fractures where 47 % of patients achieved a good-excellent result. If there is an image intensifier present in the operating theatre, the results are improved by inserting percutaneous K-wires to stabilize the fracture reduction [12]. Closed reduction and long-arm slab stabilization showed 68 % good-excellent results, while closed reduction and percutaneous K-wire fixation showed 87 % good-excellent results (Fig. 36.5).

The most challenging situation in the management of supracondylar fractures in children is the presence of vascular compromise. Cold pulseless hand is an indication for emergency reduction of the fracture. In most cases, fracture reduction allows a good recovery of circulation. However, in the operating theatre with the fracture reduced, there may still be concerns regarding the vascularity of the hand.

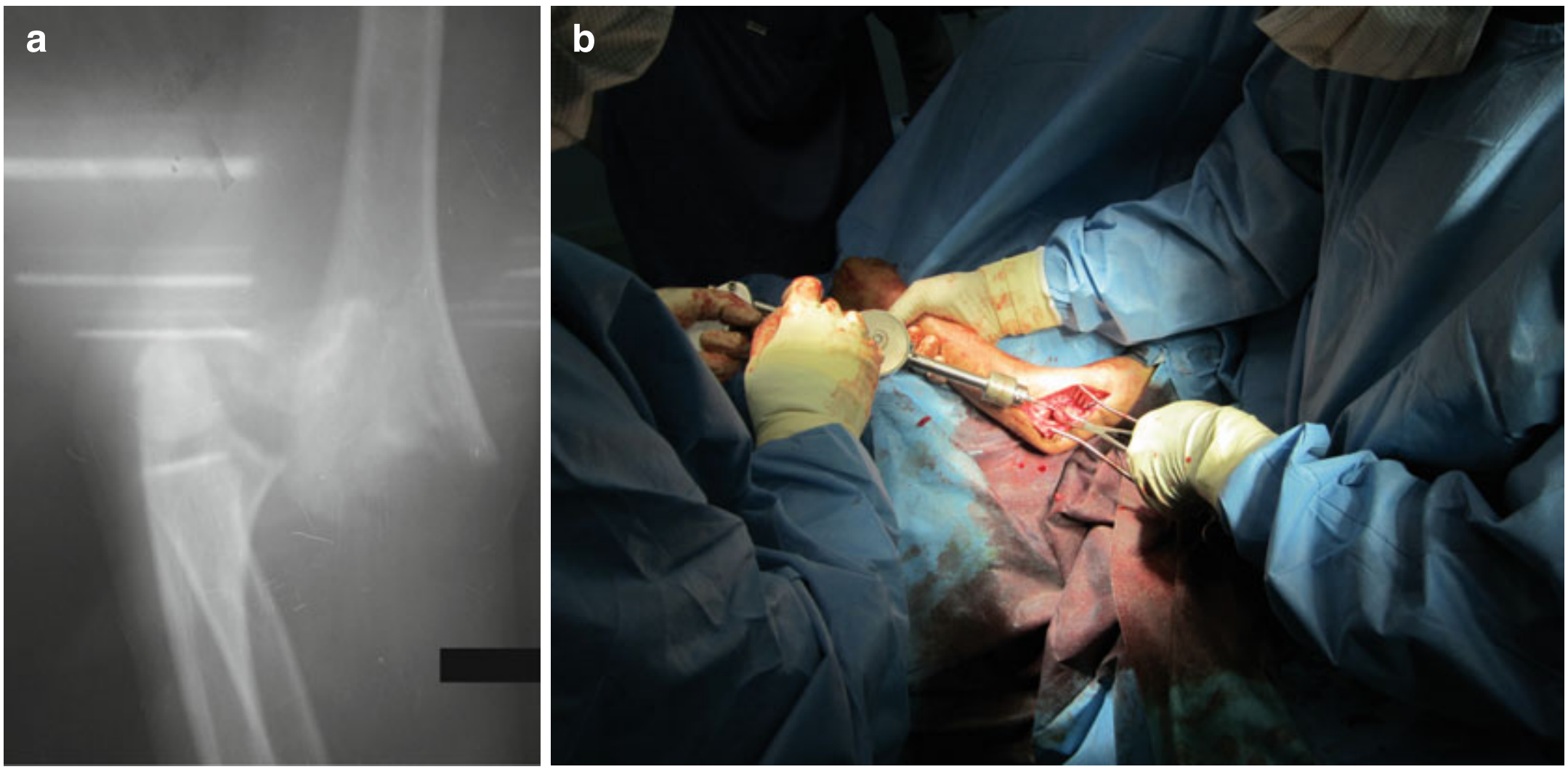

Fig 36.5 (**a**) Gartland III supracondylar fracture and (**b**) open reduction and K-wire fixation of a neglected supracondylar fracture

This may be due to elbow flexion in the presence of significant soft tissue swelling causing external compression on the brachial artery or, more rarely, actual damage to the artery by the initial injury.

Absence of a radial pulse in the presence of a well-perfused hand post-reduction can be managed conservatively without vascular exploration [13]. In this series, the radial pulse returned by 6-week follow-up with no long-term dysfunction. Surgical exploration should be recommended only if there is either severe pain in the forearm persisting for more than 12 h after the injury or if there are signs of deteriorating neurological function. This would require the presence of a surgeon competent in vascular reconstructive surgery and would often have to be combined by a fasciotomy of the forearm muscles.

In the situation where circulation is compromised with the elbow flexed but present with the elbow extended, a period of longitudinal skin traction is a very reasonable option. This maintains the fracture is an aligned position with good circulation. Indeed, this is a valid method of definitive management of Gartland type III fractures. The most common method of traction is that described by Dunlop with skin traction applied to the forearm and a counterweight over the upper arm. This has shown very good results for the definitive management of Gartland type III fractures with up to 93 % good-excellent results that compare very favourably with closed reduction and percutaneous pinning [14, 15].

Interestingly, although this method of treatment has continued to be used in the western world, in spite of an extensive literature search, the author was unable to find any references to the results of its use in the austere environment. This suggests that the resource of 2–3 weeks in a hospital bed can be as limiting a factor as surgical resources. However, it does offer a safe predictable method of managing these injuries where surgical resources are extremely limited.

In addition to vascular complications, some patients have neurological deficits at presentation, most commonly the ulnar and median nerves. These can be managed expectantly as they carry an excellent prognosis. Due to the young age of patients and the extra-articular nature of these fractures, the prognosis for recovery of a good range of motion is excellent. Mal-union is fairly common but, whilst cosmetically unsightly, does not compromise upper limb function. If these injuries present beyond 1–2 weeks post-injury, mal-union is likely and should be accepted. It is hard to see any justification for operating on a mal-union of the distal humerus in a child in an austere environment.

In summary, the key to management of supracondylar fractures in children is to avoid vascular compromise and be prepared to tolerate a degree of mal-union being confident that when the bone unites, stiffness will rarely be a problem. The definitive surgical management needs to be tailored to the resources available.

36.5 Intra-articular Elbow Fractures in Children

The complete ossification of the bones around the elbow until 10–11 years of age makes the diagnosis of intra-articular fractures in children difficult. Knowledge of the order of ossification is helpful (mnemonic = CRITOE – capitellum, radial head, internal (medial) epicondyle, trochlea, olecranon, external epicondyle lateral). Prompt diagnosis requires a high index of suspicion. Oblique images will help diagnose lateral condyle fractures. X-rays of the uninjured elbow can be helpful.

Most intra-articular fractures occur in older children. The most difficult fractures are the lateral condylar (Milch) fractures that occur in younger children. Oblique x-rays help identify the common rotational displacement that is a relative indication for operative treatment. The other indication is associated elbow subluxation. Open reduction is best performed through an anterolateral approach with internal fixation with one or two k-wires.

36.6 Distal Humeral Fractures in Adults

Compared with supracondylar fractures in children, these are relatively rare injuries. They are mostly intra-articular in nature, the transverse supracondylar component being associated with a T or Y extension into the elbow joint. Undisplaced or minimally displaced fractures can be treated in a cast and sling for 3 weeks and then early mobilisation with the expectation of a very reasonable result.

The gold standard of treatment for displaced fractures is open reduction and internal fixation to allow early mobilisation [16]. This requires complex equipment and a high level of surgical expertise. The basic principles consist of an olecranon osteotomy to obtain good exposure to the articular surfaces, provisional reduction of the articular component of the injury with temporary K-wires, reduction of the articular component to the shaft and then definitive fixation using two plates. These can be placed medial and lateral or medial and posterolateral. The aim is to achieve rigid enough fixation to allow early mobilisation and reduce the risks of long-term stiffness.

In the absence of the availability of this type of resource and expertise, closed reduction and percutaneous K-wire fixation will achieve a reasonable position for bony union. It is likely that this will require protection in a cast for a few weeks, leading to some inevitable elbow stiffness. In the absence of any methods of fixation, cast immobilisation of a short period of time and then early mobilisation is the chosen method of treatment though carries a high risk of mal- or non-union and long-term stiffness.

36.7 Radial Head Fractures

These are common injuries, occurring more commonly in women with a peak incidence between 30 and 40 years of age. Classification [17, 18]:

- Mason type I – undisplaced segmental fracture
- Mason type II – displaced segmental fracture
- Mason type III – displaced comminuted fracture
- Mason type IV – displaced comminuted fracture associated with elbow dislocation

Whilst in the western world type II and III fractures tend to be treated operatively, the results of conservative management are very reasonable. The author would recommend a sling for comfort and then early mobilisation. A small number of patients may be left with some long-term discomfort and difficulty with pronation and supination. These could be treated beyond 3–6 months post-injury with a radial head excision (Fig. 36.6). A Mason type IV fracture represents an unstable type of elbow dislocation. If it is not possible to hold the reduction closed, percutaneous pinning should be considered.

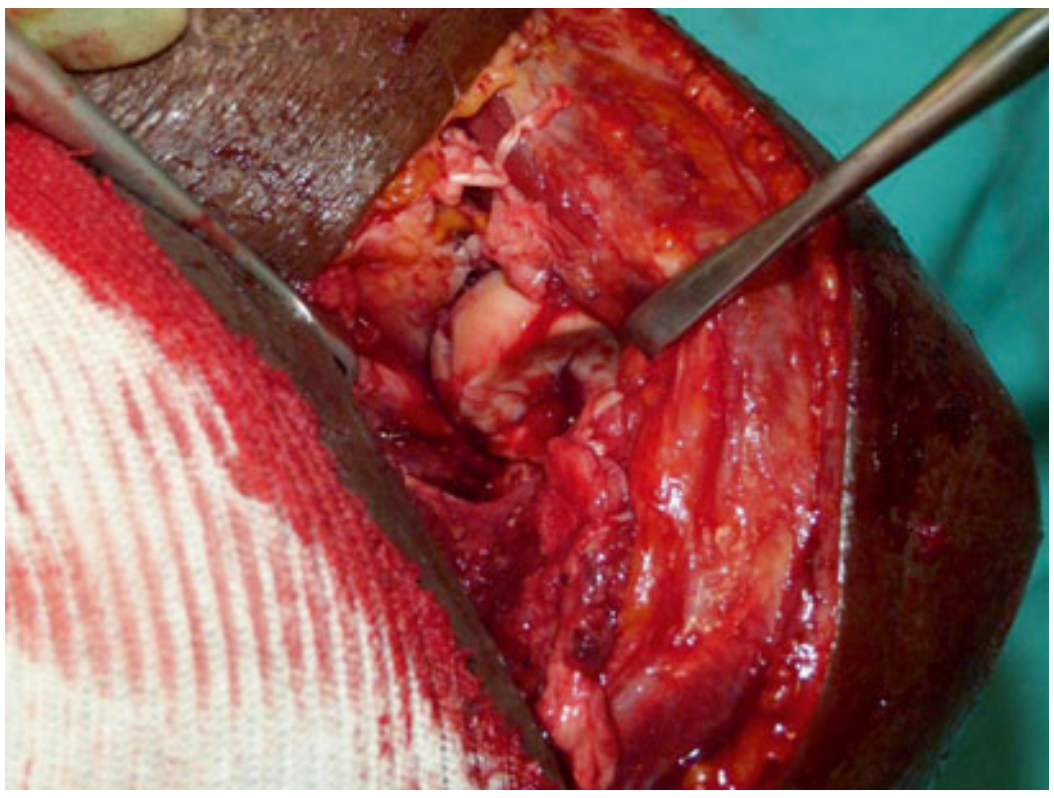

Fig. 36.6 Radial head fracture seen intraoperatively

36.8 Proximal Ulna/Olecranon Fractures

Fractures of the proximal ulna may be intra-articular (olecranon fractures), associated with radial head dislocation (Monteggia fractures) or both. The mechanism of injury is usually either a direct blow such as landing on the point of the elbow or an avulsion fracture when landing with the elbow slightly flexed. Displacement is common due to the pull of the triceps muscle.

Conservative management is recommended for undisplaced fractures and in elderly patients. Undisplaced fractures should be immobilised for 2–3 weeks and monitored for displacement. In the elderly, displacement can be accepted as long as the elbow is not subluxed. Early motion is recommended, the loss of extension strength being tolerated well.

If surgical skills and equipment is available, operative management is recommended for displaced fractures. This author recommends parallel 1.2 mm k-wires supplemented by a figure of eight tension band wire on the extensor surface for avulsion fractures without comminution (Fig. 36.7). This should be successful without intraoperative x-rays if care is taken to avoid pen-

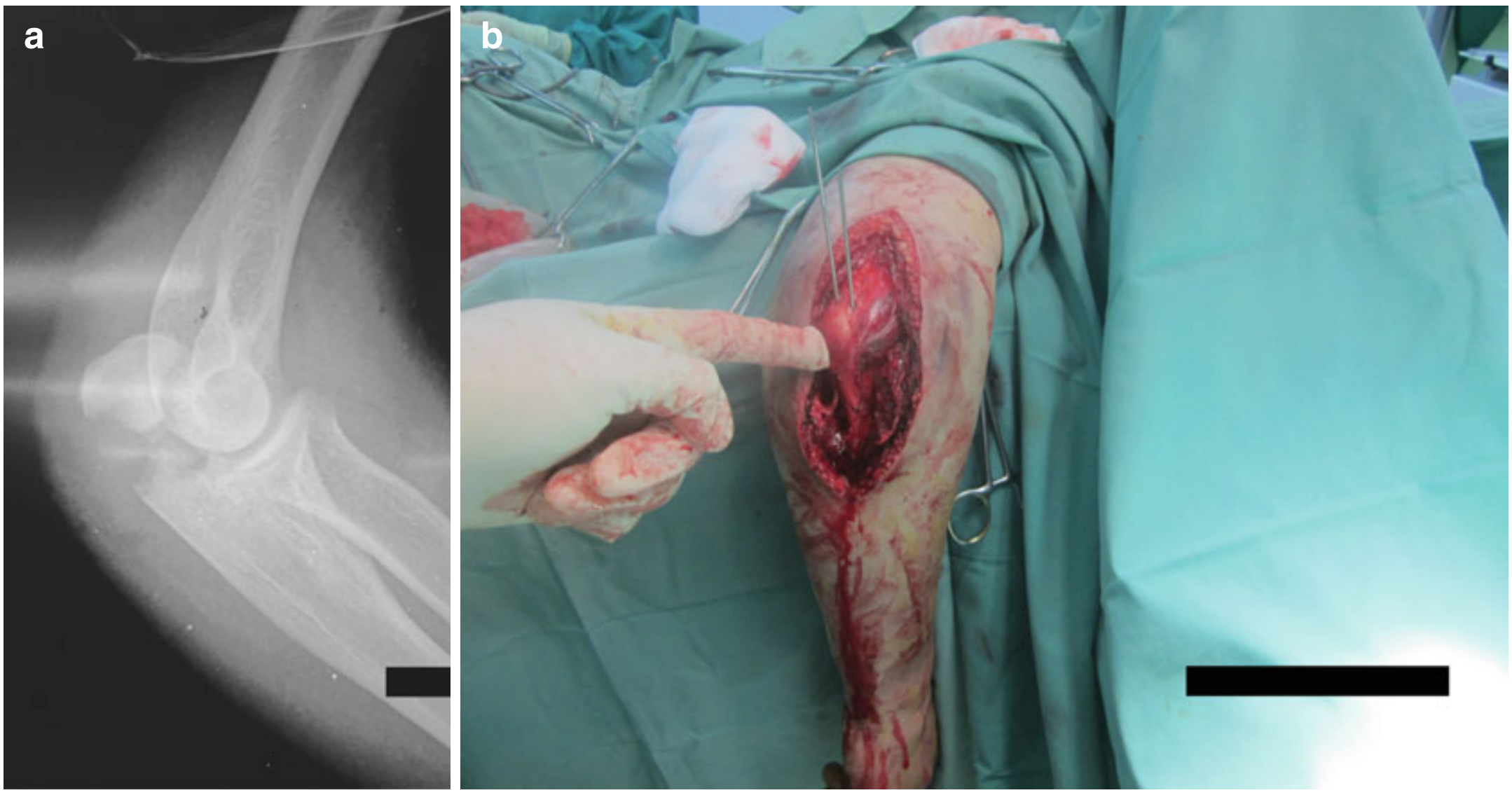

Fig. 36.7 (**a**) Olecranon fracture. (**b**) Placing of wires for tension band wire

etrating the elbow point with the wires. It is worth taking care to bury the ends of the wires to reduce the need for subsequent wire removal.

Fractures in the distal third of the olecranon, with associated comminution or Monteggia fractures, require open reduction and internal fixation with a plate and screws.

36.9 Summary

Prompt, safe competent management of elbow trauma is important to preserve overall function of the upper limb. Early diagnosis and management gives far superior results to delayed management. In an austere environment, equal effort should be given to encouraging early presentation as to developing operative resources and expertise. In any setting, a clinician with sound anatomical knowledge and a good understanding of the treatment options available by setting reasonable outcome goals can achieve good results. The keys to management consist of avoidance of neurovascular and infective complications, prompt joint reduction and aiming for maintenance of reduction in a way that allows early motion.

36.10 Elbow Trauma Case Report

36.10.1 Situation and Resources Available

The location was a small hospital in Makeni, Sierra Leone. Full surgical team include orthopaedic surgeon, anaesthetist, scrub nurse and therapist. Hospital possessed a well-equipped operating theatre and a limited plain x-ray facility. After the 2-week visit, any post-operative supervision is to be provided by a local nurse and physiotherapist.

36.10.2 Clinical Case

On the first day of our visit, we were presented with a 37-year-old female who worked as a secretary, complaining of pain in her dominant right elbow. There was a history of a fall from a moped 3 weeks previously with ongoing pain and loss of function. Treatment from local healers had consisted of application of medicinal herbs. On examination there was a clinical deformity consistent with a posterior dislocation. There was no wound. Movements were from 10° to 30° with associated pain. There was no distal neurovascular deficit. X-rays showed a posterior dislocation without any associated fractures (see Fig. 36.3).

36.10.3 Treatment Rationale

Without intervention this lady would be condemned to a very poor result. Overall, the post-injury pain would be expected to reduce over the next few months. She would be left with significant loss of motion. The elbow would be fixed in a fairly extended posture, seriously compromising her ability to position her still very functional hand in space.

Although there were some concerns regarding supervision and compliance with a post-operative rehabilitation during the first 2–3 months post-surgery, these were felt to be acceptable. Although the local team had no experience of managing patients following open elbow surgery, they were capable of managing a surgical wound, fabricating a splint and constructing and supervising an exercise programme. The patient was educated and demonstrated a strong commitment to obtaining a good result. She lived within reach of the hospital.

The decision was made to plan surgical intervention under general anaesthetic. This would consist of an initial attempt at a closed reduction though with a low threshold for an open reduction. As there was only 3 weeks since injury, this would be through a lateral approach.

36.10.4 Procedure

Under general anaesthetic, it was not possible to obtain a closed reduction. Through a lateral approach, it was possible to achieve a fairly easy reduction after limited soft tissue mobilisation.

The lateral ligaments were found to be torn; they were in good condition and therefore repaired. The elbow was stable through a range of motion from 30° to 120°. The wound was closed, a plaster of Paris backslab applied with the elbow at 90° of flexion. The plan was for 3 weeks of immobilisation and then supervised mobilisation from a collar-and-cuff-type sling which would be worn until 6 weeks post-injury. The patient was reviewed at 10 days post-surgery. The wound was healing well and sutures were removed. There was a range of movement from 50° to 110°. A further plaster of Paris backslab was applied.

She was followed up locally until 3 months post-injury, at which stage she was found to be making reasonable progress. She had a comfortable elbow with a range of motion from 20° to 130° and full pronation-supination.

References

1. Advanced trauma life support. American college of surgeons; 2014. Edited by GmbH Elsevier.
2. Stanley D, Kay NRM. Surgery of the elbow: practical and scientific aspects. Arnold: London; 1998. pp. 11–2.
3. Stanley D, Kay NRM. Surgery of the elbow: practical and scientific aspects. Arnold: London; 1998. p. 267–80. Chapter 21.
4. Hoppenfeld S, De Boer P. Surgical exposures in orthopaedics: the anatomic approach. J.B. Lippincott Company: Philadelphia; 1994. p. 83–117. Chapter 3.
5. Krishnamoorthy S, Bose K, Wong KP. Treatment of old unreduced dislocation of the elbow. Injury. 1976;8:39–42.
6. Mahaisavariya B, Laupattarakasem W, Supachutikul A. Late reduction of dislocation of the elbow. Need triceps be lengthened. J Bone Joint Surg. 1993;75B:426–8.
7. Naidoo KS. Unreduced posterior dislocation of the elbow. J Bone Joint Surg. 1982;64B:603–6.
8. Laupattarakasem W, Mahaisavariya B, Mahakkanukrauh C. Old elbow dislocation: joint mobility after open reduction. J Med Assoc Thai. 1988;71:289–92.
9. Pediatric supracondylar humerus fractures clinica practice guideline. AAOS: Rosemont, Illinois. www.aaos.org/guidelines. 2011.
10. John C. The closed treatment of common fractures. London: Churchill Livingstone; New York; 1974.
11. Ullah I, Alikhan L. Results of conservative treatment of displaced extension-type surpacondylar fractures of the humerus in children. J Postgrad Med Inst. 2009;23:1.
12. Pandley S, Shrestha D, Gorg M, Sing GK, Sinagh MP. Treatment of supracondylar fractures of the humerus (type IIB and III) in children. A prospective randomised controlled trial comparing two methods. Kathamandu Univ Med J. 2008;6(3):310–8.
13. Ramesh P, Avadhani A, Shetty AP, Dheenadhayalan J, Rajasekaran S. Management of acute "pink pulseless" hand in paediatric supracondylar fractures of the humerus. J Pediatr Orthop B. 2011;20(3):124–8.
14. Gadgill A, Hayhurst C, Maffuli N, Dawyer JS. Elevated straight arm traction for supracondylar fractures of the humerus in children. J Bone Joint Surg Br. 2005;87(1):82–7.
15. Sadiq MZ, Syed T, Travlos J. Management of grade III supracondylar fracture of the humerus by straight arm lateral traction. Int Orthop. 2007;31(2):155–8.
16. Babhulkar S, Babhulkar S. Controversies in the management of intra-articular fractures of distal humerus in adults. Indian J Orthop. 2011;45(3):216–25.
17. Radial head fractures of the elbow. The American Academy of Orthopaedic Surgeons. Rosemont, IL. Available at OrthoInfo.aaos.org.
18. Miller G, Humadi A, Unni R, Hav R. Surgical management of mason type III radial head fractures. Indian J Orthop. 2013;47(4):323–32.

37

Forearm Injuries

David Solfelt

Forearm fractures present a unique challenge to the physician who must properly manage the alignment of two bones which function in concert to allow the important upper extremity motions of pronation and supination. While restoration of length, alignment, and rotation is the goal of all long bone fracture treatment, the physician treating forearm fractures should also strive to preserve the curvature of the radius and interosseous spacing. Without attention to these details, pronation and supination and the ability of the patient to position the hand in space may be restricted. Treatment of forearm fractures will be different in children and adults as children heal quickly and those with greater than 2 years growth remaining retain the potential for significant remodeling. Because of the potential for remodeling, most closed children's both bone forearm fractures can be treated nonoperatively and perfect reduction is not required. In contrast, operative treatment to restore alignment is the standard of care for displaced and unstable adult forearm fractures where resources are available.

Preservation of full pronation and supination after forearm fractures is dependent upon achieving the correct rotational and angular alignment of both bones. Because the ulna is a straight bone and reduction is easier to achieve and assess, the critical reduction is usually dependent upon restoring radial alignment, rotation, and curvature. Cadaveric studies have demonstrated that even a 5° reduction in radial bowing will produce a 15° loss of rotation due to alteration of interosseous spacing [1]. Even after perfect reduction, however, restriction of motion is often observed perhaps due to prolonged immobilization and contracture of the interosseous membrane. Fortunately, patients are often unaware of minor decreases in motion, and function can be satisfactory even with some loss of pronation or supination due to compensatory rotation through the shoulder joint. Morrey et al. reported adequate forearm function to require 100° total rotation with 50° of pronation and supination [2].

The most common midshaft both-bone forearm fracture mechanism of injury is a fall on the outstretched arm producing a combination of axial loading and rotation [3] (Fig. 37.1). Understanding of the mechanism of injury is important, as full reduction of angular deformity requires correction of rotational malalignment. Incomplete both-bone fractures demonstrating an apex-volar deformity result from supination forces, whereas the less common apex-dorsal deformity results from some component of

D. Solfelt, MD
Department of Orthopedic Trauma,
Meriter Unity Point Hospital, Madison, WI, USA
e-mail: dsolfelt@yahoo.com

© Springer International Publishing Switzerland 2016

J.D. Robinson (ed.), *Orthopaedic Trauma in the Austere Environment: A Practical Guide to Care in the Humanitarian Setting*, DOI 10.1007/978-3-319-29122-2_37

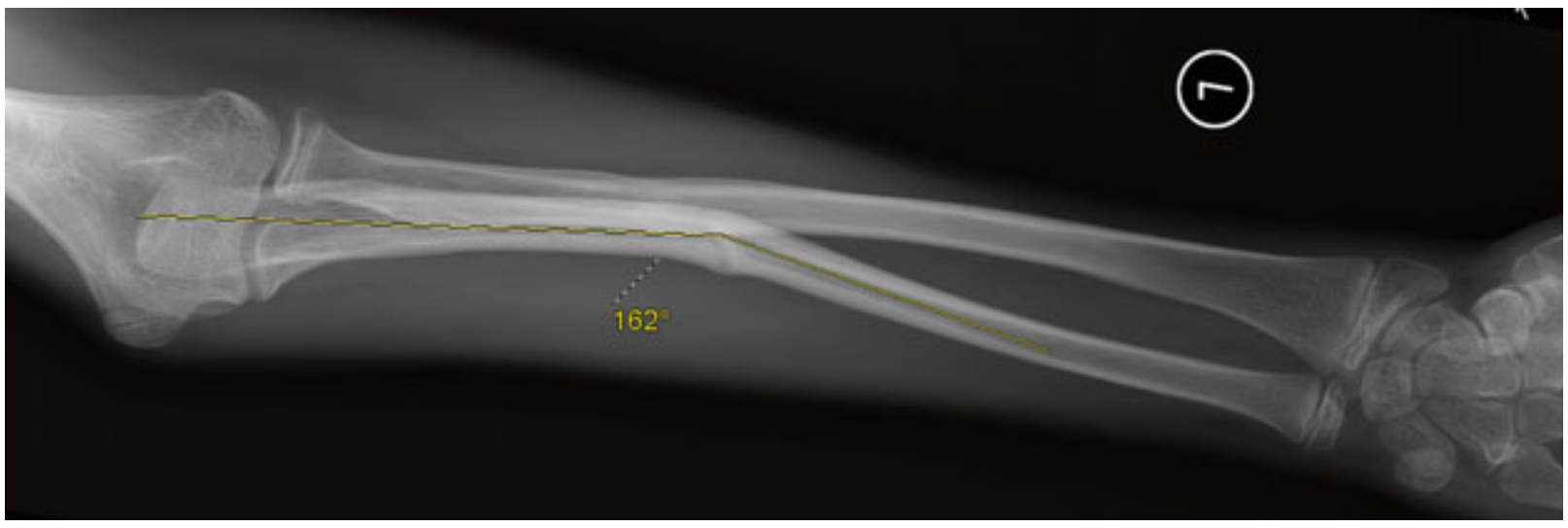

Fig. 37.1 Malunion of a forearm fracture. This patient with an 18° angulation of the ulna demonstrated full supination but only 8° of pronation

pronation [4]. The final position of completely displaced both-bone forearm fractures depends on the location of the fracture in reference to muscular deforming forces. Isolated fractures of the radial shaft are rare, whereas isolated fractures of the ulna are common because of the subcutaneous position of the ulna and its exposure to direct blows such as occur in a fall against a sharp object or when putting the arm up as a shield and under attack.

37.1 Treatment of Forearm Fractures in Children

37.1.1 Greenstick Fractures

Incomplete fractures of the radial or ulnar shaft occur in children and are referred to as greenstick fractures. They feature an intact cortex and periosteum on the concave side of the deformity and are therefore partially stable. Closed reduction is generally successful but requires reversal of malrotation in addition to counterpressure at the apex of the deformity. The intact periosteum on the concave side of the deformity typically prevents overcorrection, but a crack through the remaining intact cortex is often heard or palpated during the reduction maneuver. Completion of the fracture without disruption of the intact periosteum has been recommended in order to decrease recurrence of deformity, delayed healing, and the risk of refracture [5]. Since most greenstick fractures result from supination and present with an apex-volar deformity, full reduction will require a degree of pronation. A helpful tip when considering reduction of angulated both-bone forearm fractures is to rotate the palm toward the deformity [6]. The forearm should be immobilized in the position required to reduce the fracture with a long-arm cast and three-point molding.

37.1.2 Complete Pediatric Forearm Fractures

Reduction of displaced both-bone forearm fractures in children is best preceded by longitudinal traction. With appropriate anesthesia producing muscle relaxation, the patient should be positioned supine with the affected arm supported in finger traps, if available, and with the elbow in 90° of flexion. A 4–5 kg counterweight can be placed around the upper arm with a cloth sling. Traction assists in the correction of malrotation due to longitudinal muscular tension on the fracture fragments. When sufficient mobility of the fracture is recognized by the ability to translate the bones at the fracture site, reduction of the fractures is accomplished by manipulation. Manipulation may require exaggeration of the fracture deformity to “hook on” displaced fracture ends, one bone at a time, after which rotation can be adjusted. The traction counterweight is removed if exaggeration of the fracture deformity is required. While re-manipulation is acceptable for incomplete reduction, avoid iatrogenic injury produced by excessive manipulation attempts remembering that complete translation (bayonet apposition) can be accepted, particularly in the younger child, as long as rotation and angulation are minimized (Fig. 37.2).

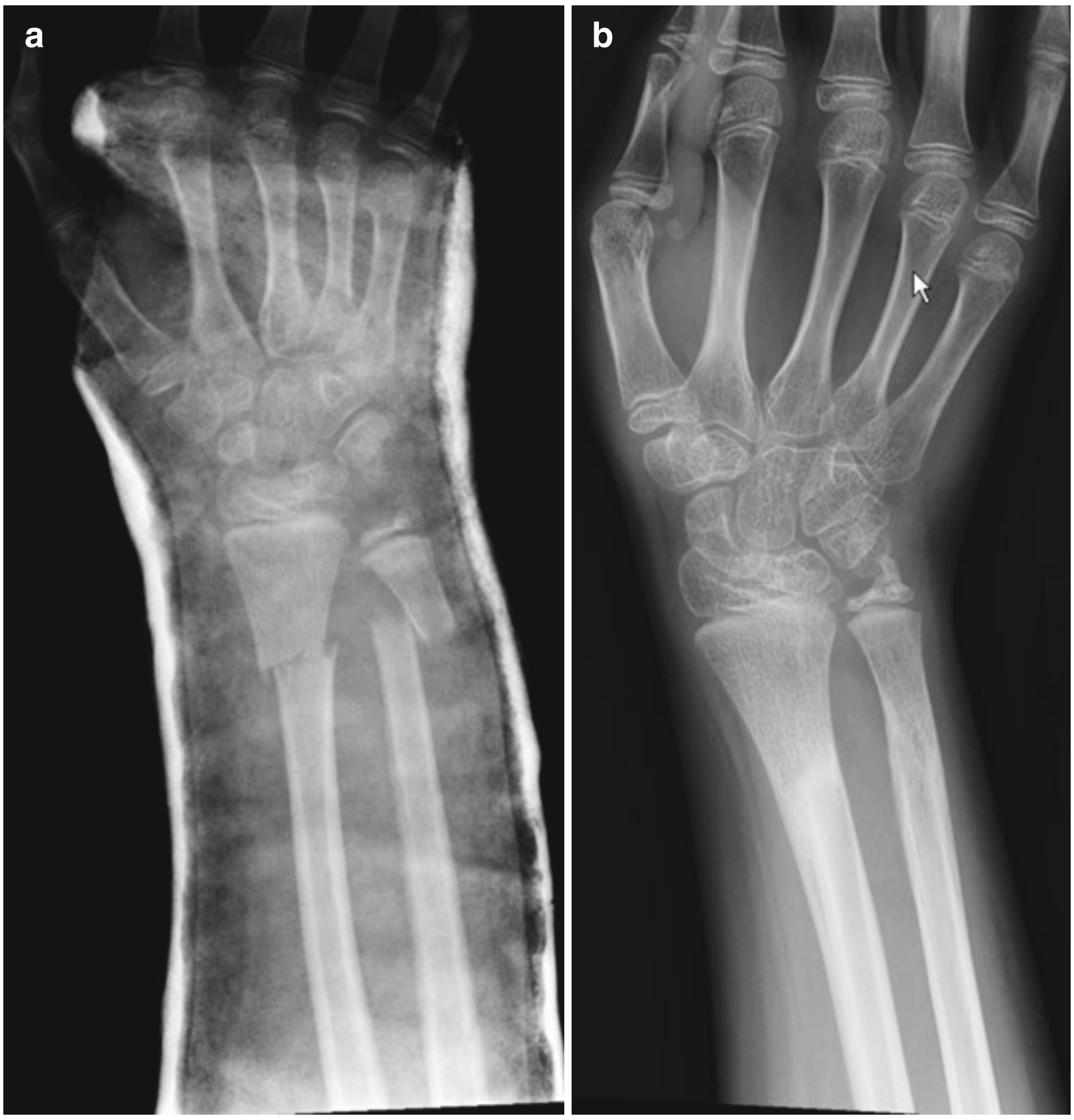

Fig. 37.2 Pediatric remodeling potential demonstrated for residual fracture translation and shortening. (**a**) Best possible reduction of a distal both-bone forearm fracture accepted in a 9-year-old child. (**b**) Near complete remodeling at 5 months post injury

Keys to assessing rotation include matching of cortical widths and bone diameters at the fracture site. If length and angulation of one bone are corrected but the other remains displaced, then there may be a rotational malalignment. X-ray assessment of midshaft fracture rotation is aided by reference to normal bony landmarks. On an AP image, the radial tuberosity should be 180° opposite of the radial styloid process. When assessing the ulna on a lateral x-ray, the ulnar styloid process should be 180° opposite of the coronoid process [6]. Cast the forearm in the position that reduces the fracture. Pronation of the mid- to distal radius results from activity of the pronator quadratus and pronator teres and is opposed by supination forces from the biceps and supinator muscles proximally. Proximal radial fractures occurring between the supinator and pronator teres may therefore require some degree of supination. Fractures in the midshaft are generally placed in neutral to slight supination. Fractures distally generally require neutral rotation to slight pronation.

37.1.3 Cast Technique

After reduction of the pediatric both-bone forearm fracture, application of a long-arm cast is best performed in sections. The arm may be casted hanging or placed in the position where periosteal hinges maintain reduction while the upper arm is supported. The entire upper limb is prepared with cast padding, and I prefer application of the short forearm section first. Interosseous molding (flattening of the of the forearm section to a “figure 8” shape) is performed to maintain radial bow and interosseous spacing with three-point molding to preserve the position that reduced the fracture.

After the forearm section of the cast is hardened, rotation can be fine tuned while a

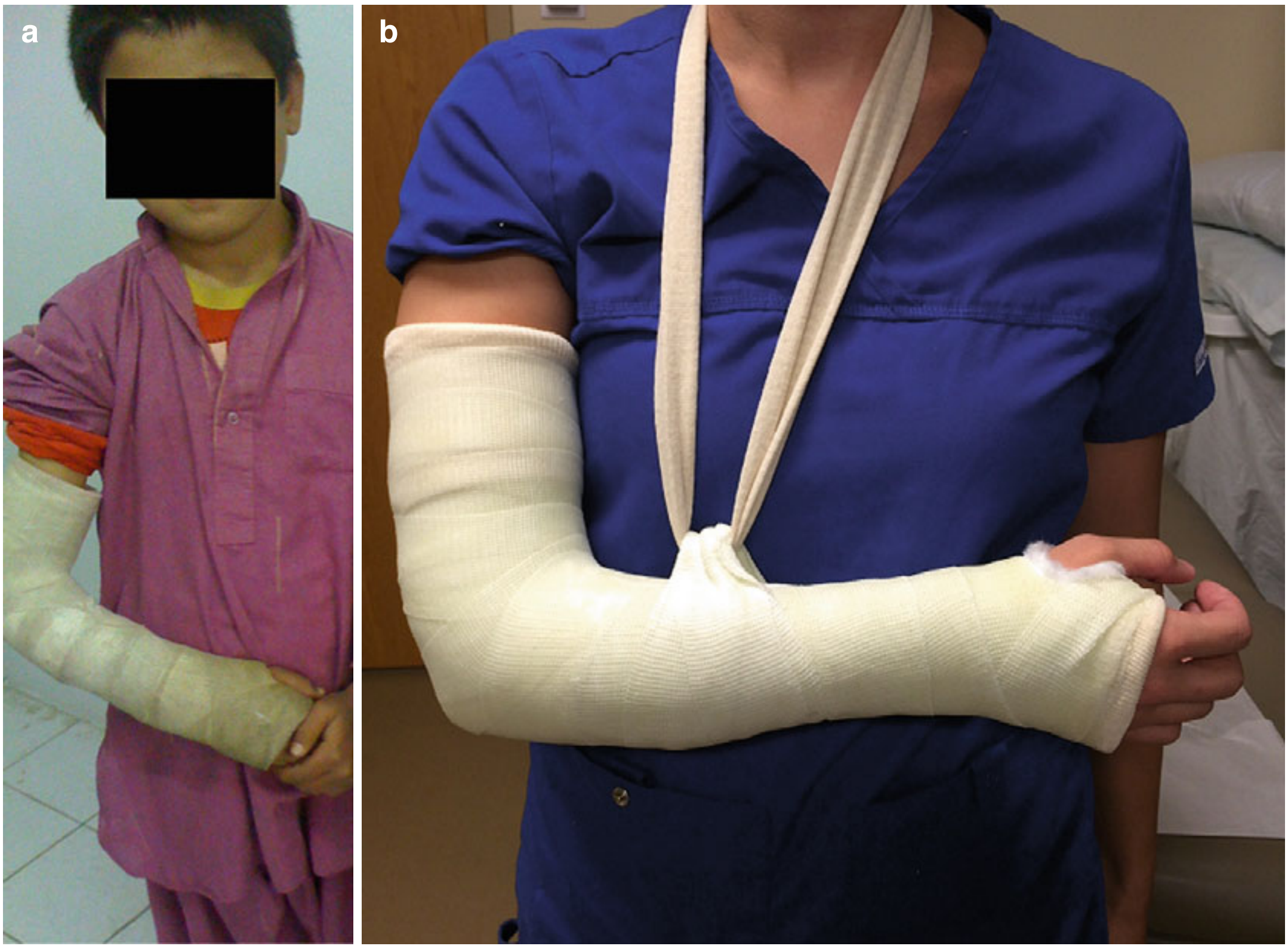

Fig. 37.3 In children, better support of fracture reduction in a long-arm cast can be achieved with the addition of a forearm loop and cloth collar as described by Rang [4]. (**a**) Unsupported ulnar border allows sliding of the arm within the cast and angulation of the fracture as swelling decreases. (**b**) Cast loop and collar keeps cast tight against the ulnar border and helps prevent fracture angulation due to traction from the weight of the cast

long-arm extension is applied. When applying a cast in 90° of flexion at the elbow, a hand should flatten the posterior above elbow section of the cast so that the arm does sink into the cast as swelling decreases. Mercer Rang's discussion of pediatric reduction and casting techniques is an excellent resource, and I agree with his recommendation that the weight of the cast be supported by an incorporated mid-forearm loop and cloth collar which maintains support along the ulnar border [4] (Fig. 37.3). Some authors report excellent outcomes with no loss of reduction by casting both-bone forearm fractures in extension [7]. This is particularly helpful in young children with fat arms or with very proximal forearm fractures. A cast in extension needs a supracondylar mold to prevent distal migration caused by gravity.

When a child cannot be closely observed after casting, the cast should be bivalved and taped. The tape can easily be removed to allow later spreading with the turn of a flathead screwdriver or edge of a coin if signs of neurocirculatory compromise develop. A bivalved cast can be overwrapped with plaster or fiberglass when a child leaves the hospital or at the first clinic visit if reduction has been maintained and neurocirculatory status of the arm is intact. Alternatively, if excessive swelling is observed during reduction, a coaptation "U" splint can be applied extending from the metacarpal heads dorsally, around the elbow, and up the volar forearm to the palmar flexion crease. The splint of 2–3 inch plaster or fiberglass is secured with Ace bandages and can be overwrapped with casting material if the reduction is maintained at the first clinic visit or when discharged from the hospital.

Parents should be informed that re-manipulation for a lost reduction after splinting is preferable to development of compartment syndrome if a rigid cast becomes too tight.

37.1.4 Acceptable Reduction in Children

What constitutes acceptable reduction in both-bone forearm fractures is age dependent. In young children, complete translation (bayonet apposition) can be accepted along with some residual angular or rotational deformity. Noonan and Price [6] reviewed the literature and reported angulation of 15° and malrotation up to 45° can be accepted in children 0–9 years of age. Angulation of 10° and malrotation of 30° can be accepted in children nine years of age and older. Reduction criteria should be more strictly applied to fractures in the proximal third of the forearm as these have less potential to remodel.

Wedging of a cast at the first postreduction clinic visit remains an effective means of improving unacceptable angulation [8]. A near circumferential defect is made at the apex of the deformity preserving a hinge large enough to maintain stability when cracked and during opening with a cast spreader. The location for the opening wedge is planned on x-ray by measurement of the distance from the apex of the fracture deformity to a metallic reference marker taped on the cast. The opening wedge is filled with a firm material, such as felt, before overwrapping with cast material. This prevents sharp edges against the skin and herniation of the skin into the opening.

The duration of cast immobilization depends upon the age of the child and the appearance of bridging fracture callus. Long-arm cast immobilization is typically for 3–4 weeks in children less than ten years of age and up to six weeks in older children. This is followed by a brief period of short-arm cast protection, the length of which is guided by clinical findings and fracture maturation observed on x-ray. When possible, we prefer examination and x-ray reevaluation of the fracture within two weeks of injury which allows opportunity for cast wedging, recasting, and fracture adjustment in all but the youngest patients.

37.1.5 Operative Fixation of Pediatric Fractures

While operative fixation of forearm fractures in children is seldom required, indications include open fractures requiring debridement, fractures in the older child nearing skeletal maturity, unreducible fractures with interposed soft tissues, and inability to maintain acceptable reduction. Because perfect reduction is not required in children, closed intramedullary rodding has become the first choice for pediatric internal fixation of unstable forearm fractures. The technique of elastic stable intramedullary nailing (ESIN) of forearm fractures has been well described [9–12]. As there is limited availability of flexible nails in resource-poor areas of the world, potential intramedullary devices available to the surgeon include K-wires, Steinmann pins, Rush rods, or rods fabricated from commercially available stainless steel stock in various thicknesses [13]. Good results have been reported with no difference in outcomes comparing ESIN and intramedullary nailing with K-wires [14]. At Soddo Christian Hospital, commercially available 316L stainless steel stock rods, 125 in (1/8″) thick, are cut to length. A Rush rodlike bend at one end allows control of rotation, while the insertion end is rounded on a grinder [15].

Closed intramedullary fixation is attempted, and control of radial and ulnar fracture fragments with the intramedullary rod tip facilitates reduction. The tip of the olecranon is opened with a straight awl or drill and the olecranon apophysis crossed by a smooth rod without fear of significant growth disturbance. Alternatively, the ulna may be addressed from the lateral olecranon with an elastic nail, thus protecting the apophysis and ulnar nerve. Passage across the fracture can be guided fluoroscopically or with a limited open approach. After reduction, the rod should be measured and advanced to end approximately 2 cm above the distal growth plate. The rod has a 90° bend at the olecranon and can be buried or left external to the skin for easy removal in the clinic.

With elastic nailing, the radius is normally entered from the radial styloid process as a flexible nail will "turn the corner" without penetrating the ulnar cortex. Alternative entry points for a radial intramedullary rod when using nonelastic devices are just radial to Lister's tubercle or between the fourth and fifth compartments with retraction of the contents of the fourth dorsal compartment. A starter hole is made with a 3.2 mm drill after palpation of the radiocarpal joint to insure positioning proximal to the growth plate. These approaches are more direct and avoid a distal turn but still require a central prebend of 15–25° to preserve radial bowing. A slight bend of the rod tip helps to avoid penetration of the volar-radial cortex during insertion after which the rod can be rotated to recreate the radial bow. The distal end of the radial rod is left subcutaneous for removal in the pediatric population.

The size of the rod selected (typically 2.0–2.5 mm) should be large enough to preserve radial alignment while flexible enough to remain intracortical during insertion. Single-bone intramedullary fixation of the radius or ulna can be accepted if the other bone can be reduced and is stable with supplemental immobilization. Intramedullary fixation effectively controls angulation and translation but does not control rotation well. For this reason, supplemental external fixation is required until sufficient callus formation is formed. If one forearm bone is rodded, supplemental fixation will be required for a longer period of time (typically 6 weeks). When both bones are rodded, the time of immobilization can be shortened and range of motion initiated sooner (3–4 weeks). Intramedullary rods in children should be removed after union is established.

Temporary percutaneous K-wire pin fixation is often used in metaphyseal fractures but is rarely applicable in diaphyseal fractures as pins tend to deflect off the cortical bone and appropriate angles are difficult to achieve in transverse fractures. There is also a risk that percutaneously placed pins will displace incomplete butterfly fragments. Percutaneous K-wire pin fixation remains an option, however, for fractures at the metaphyseal-diaphyseal junction or as temporary unicortical "joysticks" for fracture manipulation. When plating forearm fractures in children for any reason, smaller 2.7 or 3.5 mm plates should be used. Dynamic compression plating produces stress shielding, however, and there is a risk of refracture after plate removal in adults and children [16]. After plating, a long-arm splint may be applied for several days for purposes of pain management and wound healing. Early range of motion is desirable, however, when fracture stability is achieved intraoperatively. When the patient is compliant, a short-arm splint provides supplemental protection and easy removal for early active range of motion of the wrist and elbow including pronation and supination. If the patient is young or unreliable, a supplemental short-arm cast is indicated for 3–4 weeks.

37.2 Forearm Fracture Treatment in Adults

The principles of closed manipulation and casting of forearm fractures in children can also be applied to adults, but there is less margin for error in the absence of remodeling. In adults, up to 10° of angulation and malrotation can be accepted provided radial bow and interosseous spacing are preserved. Because this is difficult to achieve in adults, open reduction and internal fixation is the standard of care where resources permit. Internal plate fixation allows anatomic restoration of length, alignment, and rotation, limits the need for postoperative immobilization, and allows early range of motion (Fig. 37.4). Small (3.5 mm) dynamic compression plates are optimal, but other plating options can also be effective. The risk of infection and nonunion is minimized by good sterile technique, careful soft tissue dissection, and limited periosteal stripping.

While 3.5 mm dynamic compression plates are ideal for the open treatment of forearm fractures, compression of radial and ulnar fractures can also be achieved by eccentric drilling away from the fracture in the screw holes of non-compression plates such as a semi-tubular plate. As the beveled head of a screw is tightened into the plate, it will

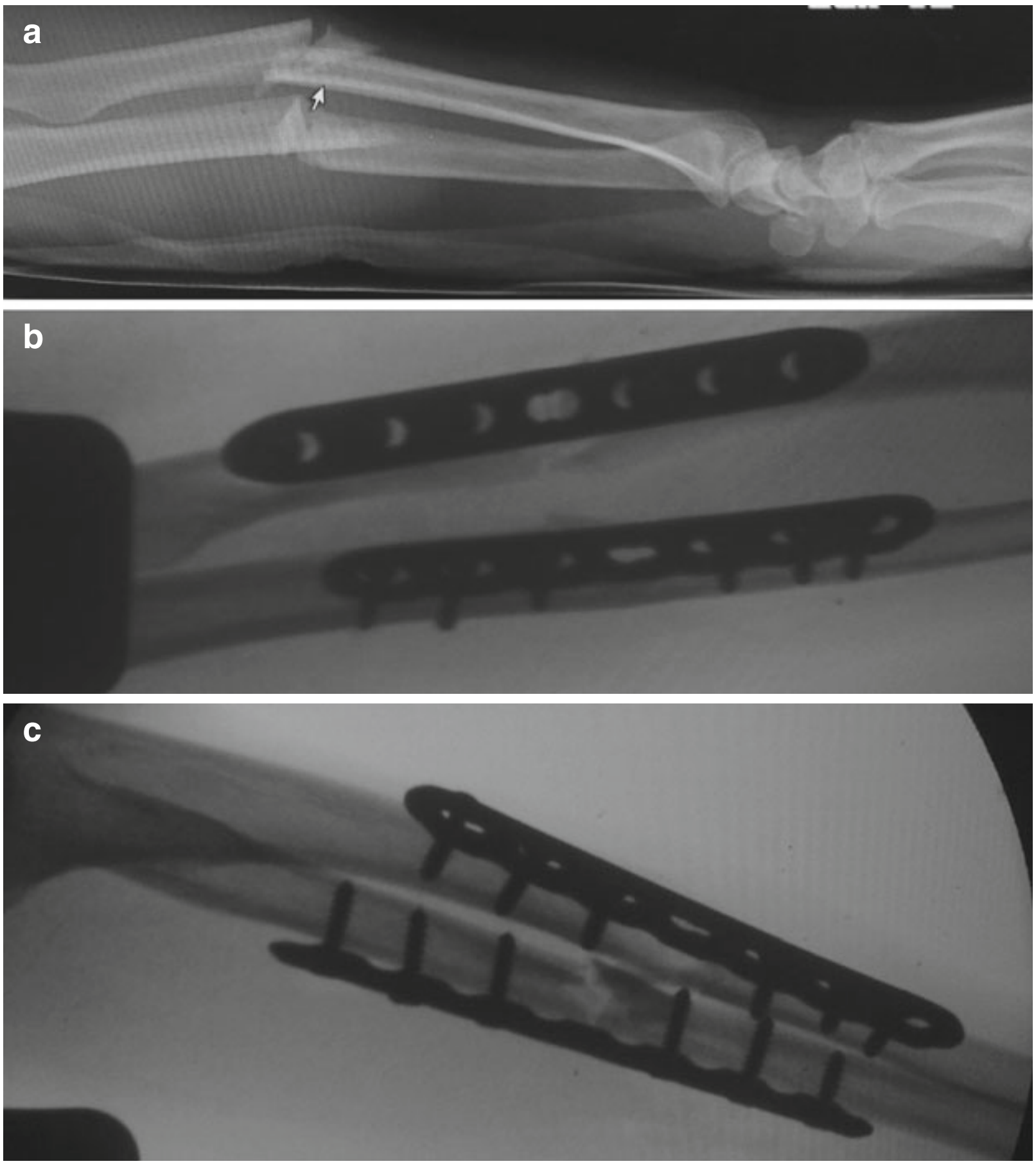

Fig. 37.4 (**a**–**c**) An example of a comminuted midshaft forearm fracture treated with plate fixation. Given only these images, one might suggest that bending of the radial plate may have been helpful to preserve normal radial bowing. The necessity for additional plate contouring in comminuted fractures where anatomic reduction is not possible is best determined by intraoperative assessment of range of motion and imaging

center itself in the hole and push the bone applying some degree of compression. Alternatively, inter-fragmental screws can provide compression in oblique or spiral fracture patterns after which a non-compression neutralization plate is applied. A slight concave prebend of dynamic compression plates toward the opposite cortex will help prevent gapping of the far cortex. The soft tissue attachments to butterfly fragments should be preserved whenever possible and larger butterfly fragments secured with inter-fragmental compression screws. When plating fractures where limited plate sizes are available, we have often cut plates or accepted plates that are long while placing only enough screws to fix six cortices on either side of the fracture. I have sometimes accepted less than six cortices when stabilizing very proximal radius fractures rather than perform extensive dissection that might lead to a radioulnar synostosis. When faced with limited screw sizes, the surgeon can pre-tap screw holes and then cut excessively long screws with a pin or bolt cutter to the appropriate length.

37.2.1 Operative Exposure of the Forearm

Operative exposure of the forearm, whether for plating or minimally open intramedullary nailing, is accomplished through three “workhorse” incisions that exploit the internervous planes. The anterior approach to the radius described by Henry allows exposure of the entire bone in the interval between the flexor/pronator and mobile wad (brachioradialis, extensor carpi radialis brevis, and extensor carpi radialis longus) muscle groups. Any portion of the incision can be utilized depending upon the level of the fracture. In the distal forearm, the radial artery can be mobilized to the radial or ulnar side but is best mobilized ulnarly in the mid- and proximal forearm because it tracks to the ulnar side of the elbow. Branches of the radial artery to the brachioradialis are divided in the proximal forearm including the major radial recurrent branch near the elbow.

Distally, the radius is exposed in pronation by elevation along the radial attachments of the pronator quadratus and flexor pollicis longus. In the midshaft portion of the radius, the pronator teres is elevated along with the radial attachment of the flexor digitorum superficialis. The superficial radial nerve should be protected as it tracks under the cover of the brachioradialis muscle. In the proximal forearm, full supination of the radius is obtained prior to release of the supinator along its ulnar border to protect the posterior interosseous nerve. The posterior interosseous nerve lies within the supinator muscle and exits the muscle dorsally approximately 1 cm proximal to the distal border of the muscle. The anterior approach does not allow direct visualization of the posterior interosseous nerve, and therefore care must be taken to place retractors directly on the bone during exposure of the proximal radius.

The midshaft portion of the radius can be exposed dorsally through Thompson's approach. The most useful portion of this incision is proximal to the thumb "outcroppers" (extensor pollicis brevis and abductor pollicis longus) in the interval between the mobile wad and wrist extensors. We find this incision most useful for midshaft fractures and when a plate is desirable on the tension side of an apex-dorsal fracture pattern. While this approach is appealing because the radius can be palpated subcutaneously in the interval, the volar approach is more easily extended and cosmetic.

Exposure of the entire length of the ulna is accomplished along the subcutaneous border of the ulna between the flexor and extensor carpi ulnaris muscles. Ulnar plates can be positioned volar or dorsal in the location best minimizing soft tissue damage and depending on the fracture pattern.

Any portion of the three common operative exposures can be utilized for limited exposure to facilitate open reduction and intramedullary rodding in adults. In a resource-poor environment where plate fixation is not available, intramedullary rodding with Rush rods, or those fabricated from commercially available stainless steel stock, has been reported to be an effective treatment technique for displaced both-bone forearm fractures in adults [15]. In adults, the ulna is approached from the olecranon tip as in children. The radius is approached from a dorsal incision between the fourth and fifth dorsal compartments. A rod placed through this interval follows the natural bow of the radius, but a central prebend and slight upturn of the tip is applied. An example of a patient treated with this technique is illustrated in Figs. 37.5 and 37.6.

37.2.2 Treatment of Open Forearm Fractures

Open fractures of the forearm require urgent treatment to reduce the risk of infection (Fig. 37.7). Parenteral antibiotics and tetanus prophylaxis should be given upon admission and open wounds covered prior to transport to the operating room to reduce colonization with hospital-acquired organisms [17]. While there is controversy regarding choice of antibiotics and choices may be few in a resource-limited environment, a first-generation cephalosporin is generally recommended for Gustilo type I and II open fractures with the addition of an aminoglycoside for type III fractures [18]. Penicillin or ampicillin should be added for anaerobic coverage in fractures contaminated with soil or resulting from farm exposure. While the importance of immediate antibiotic treatment is well supported, the optimal duration of antibiotic coverage is less clear with some authors recommending a three-day course of antibiotics with additional three-day courses at the time of subsequent procedures [19]. Others have recommended 1 g cefazolin every 8 h until 24 h after wound closure with the addition of gentamicin (weight-adjusted dosing)

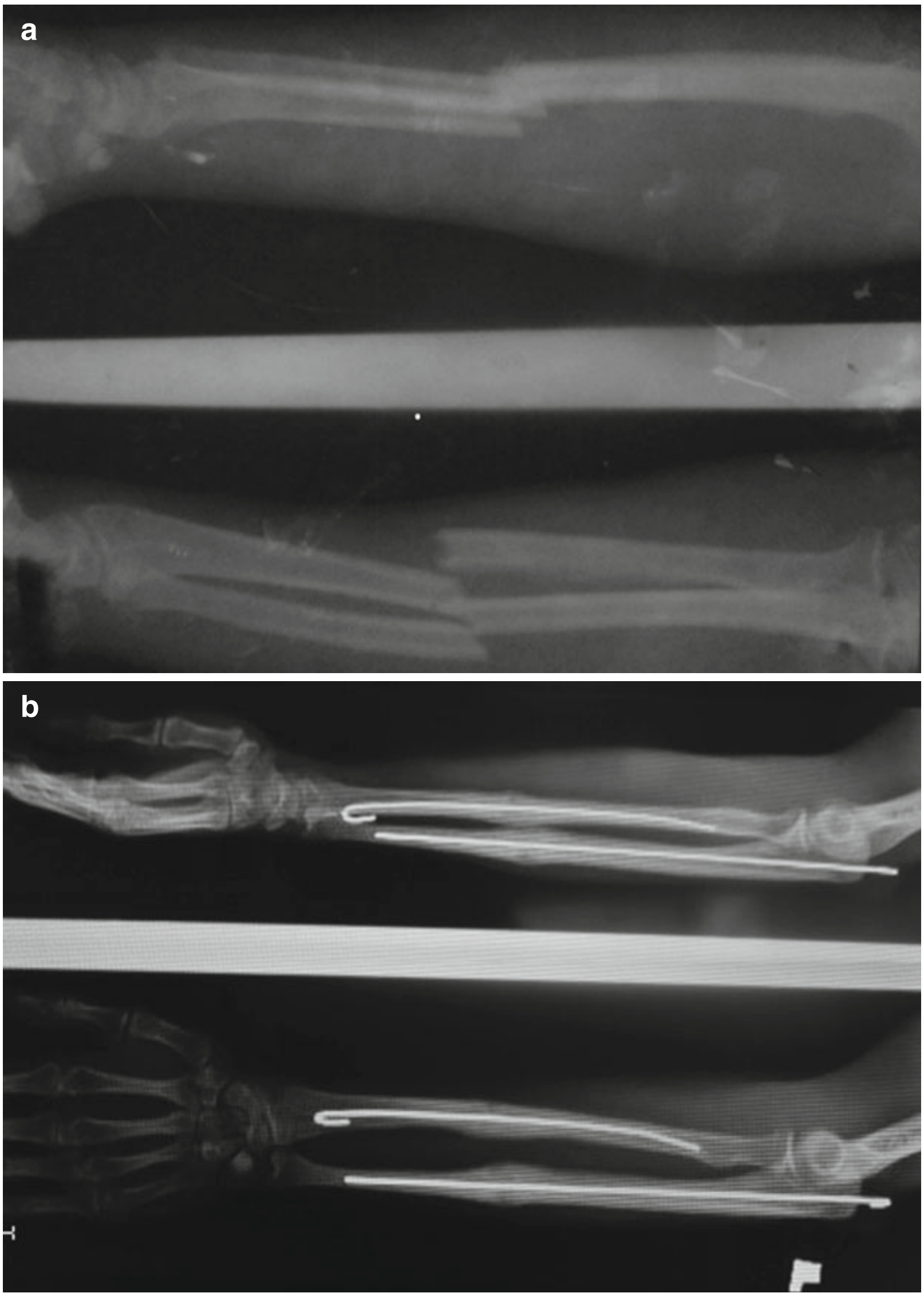

Fig. 37.5 Case 1. (**a**) 28-year-old East African male with a closed both-bone forearm fracture. (**b**) Treatment with limited open intramedullary nailing utilizing "Rush-type" rods fabricated from stainless steel stock. Union occurred after initiation of early range of motion at 4 weeks

or levofloxacin (500 mg every 24 h) for Gustilo type III fractures [20].

Initial operative goals include meticulous and systematic debridement, irrigation, and provisional stabilization. All devitalized and heavily contaminated soft tissues are sharply excised beginning with the skin, continuing with subcutaneous tissue and muscle, and ending with the bone. The bone often requires debridement with a curette and rongeur to remove impregnated contamination. Bone fragments without soft tissue attachment are discarded in an open fracture with obvious contamination as they will become a nidus for infection and osseous defects can be reconstructed and grafted later. After debridement of highly contaminated wounds, an antibiotic bead pouch is useful for delivery of a high local antibiotic concentration and for filling of soft tissue voids pending definitive soft tissue coverage procedures. Antibiotic beads can be locally made with a batch of bone cement incorporating powdered aminoglycoside or

Fig. 37.6 Clinical photographs for Case 1. (**a**) Photograph demonstrates limited ulnar incision and prominent rod tip at the olecranon. (**b**, **c**) Final range of motion achieved prior to rod removal in the clinic

Fig. 37.7 Open midshaft ulna fracture

vancomycin and molded like pearls along a small gauge wire with a knot at each end [21]. Smaller beads and smaller gauge wire allow flexibility for conformity to soft tissue defects. The number of beads incorporated into each string should be recorded so that all beads are retrieved at the time of subsequent procedures. When using antibiotic beads, an occlusive seal is desirable utilizing a dressing such as Ioban or sterile plastic "cling" wrap in order to maintain a seroma with high antibiotic levels. During debridement, every effort is made to preserve

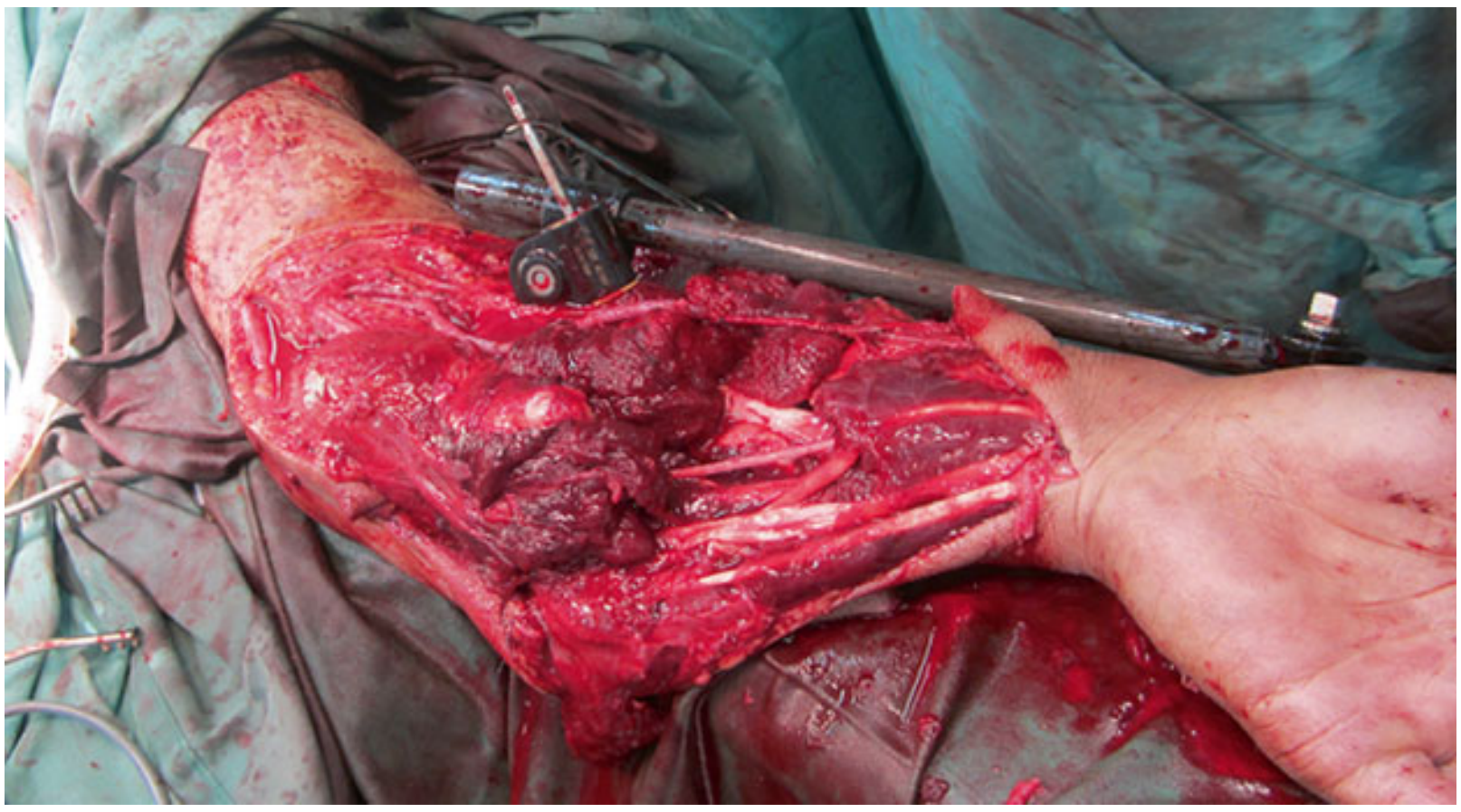

Fig. 37.8 This teenager sustained a crush injury to the forearm, causing an open comminuted fracture and extensive soft tissue loss. An external fixator was used to stabilize his forearm, while attempts were made to manage the soft tissue injuries and revascularize the hand

Fig. 37.9 An example of a delayed split-thickness skin grafting and external fixation for management of a type III open fracture following a gunshot wound to a child's forearm

the median, ulnar, and radial nerves. When there is traumatic nerve loss, nerve ends should be identified and tagged with a colored monofilament suture to facilitate identification for later reconstruction and nerve grafting. Vacuum-assisted closure has been found to be effective in the management of open fracture wounds where resources for this technique are available or can be fabricated [22]. Negative-pressure wound care is reported to improve wound healing and decrease infection by reducing edema and bacterial counts, increasing blood flow, and stimulating granulation tissue [23].

Gustilo type I and II open fractures can be stabilized with the same fixation options as closed fractures provided skin closure is possible and there is limited soft tissue contamination. For more serious grade II and grade III open fractures, spanning external fixation is the treatment of choice to preserve length and stability while awaiting soft tissue stabilization and skin coverage procedures. Definitive skeletal fixation can often be performed at the time of soft tissue coverage. Intramedullary fixation is often preferable to plate fixation in Gustilo grade II and III open fractures to avoid additional dissection in already compromised tissues. When the condition of the wound has stabilized without signs of infection, soft tissue defects can be treated with split-thickness skin grafting and groin or abdominal flaps when more extensive coverage is required (Figs. 37.8 and 37.9).

External fixation is the ideal solution for preserving length and alignment in cases where soft tissue injury or contamination does not permit internal fixation. External fixation pins should be located with incisions large enough to protect the neurovascular structures and in the subcutaneous bone wherever possible. The skin around pin sites must be released fully to avoid tethering which can predispose to skin necrosis and infection. It is essential to prevent thermal necrosis during pin insertion in the cortical bone by predrilling pin sites and cooling the pins during insertion with irrigation. After an initial period of compression wrapping while pin sites are stabilized, pin sites are left open and daily pin care can be managed by cleansing with soap and water only. Pin tract infections can usually be managed by cleansing the involved pin site with sponges moistened with a dilute bleach solution (one capful in a large wash basin of water) and an antibiotic course of trimethoprim sulfamethoxazole. If the pin site infection does not clear, the pin will need to be relocated and the prior pin site curetted.

Where external fixation is not available, pins and plaster can be applied on a temporary basis. A small transverse Steinmann pin in the hand is passed obliquely from the radial base of the second metacarpal exiting dorsally the third metacarpal. A second transverse pin is placed from medial to lateral in the olecranon avoiding the ulnar nerve. Longitudinal traction is maintained while a cast is applied over the dressing and pins. This method can preserve length where there are no other alternatives or until soft tissues permit a definitive solution. A window can be placed in the cast to allow frequent dressing changes to an open wound.

When faced with bone loss in the treatment of an open fracture, consider early autologous bone grafting when the soft tissues permit. Only small amounts of the local bone can be harvested from the distal radius or olecranon, and iliac crest bone is better and necessary for larger defects. In fractures that are extensively comminuted, avoid extensive soft tissue stripping required for anatomic reduction and use a spanning plate to maintain length and preserve vascularity. Warn the patient that a secondary procedure may be required later.

37.2.3 Delayed Presentation of Forearm Trauma

In a resource-poor environment, patients often take time to reach appropriate care. They may present days to weeks after the original injury. Preoperative elevation of the extremity is initiated on admission to reduce swelling and decrease difficulties with manipulation or operative exposure. The patient should be started on a program of therapy and self-directed exercises for hand, wrist, and elbow range of motion. Fracture alignment may be improved by manipulation under anesthesia but expect soft tissue shortening to prevent anatomic reduction. The physician must then decide whether or not to allow the fracture to proceed to union with planned delayed osteotomy of a malunion or to attempt open reduction and internal fixation. In a child with growth remaining, acceptance of a “best possible” reduction is preferable with delayed osteotomy for those who end up with unacceptable alignment or function. In adults, open fracture reduction is feasible within 3–4 weeks of injury. Judicious use of a lamina spreader is an effective tool to regain length. Callus that is removed during fracture exposure should be saved for grafting. Symmetrical and limited shortening of the radius and ulna is an acceptable solution if it avoids devitalization of the bone caused by excessive soft tissue stripping when struggling to attain anatomic “end to end” reduction.

When the presentation is very delayed, malunion or nonunion is common and the patient will present with severely restricted motion. Operative treatment of a malunion or nonunion will require preoperative planning not only to correct angular deformity but to restore radial bow and rotational alignment. Oblique osteotomies are effective because they allow inter-fragmental compression screw fixation followed by neutralization plating. In the case of a nonunion, the intramedullary canal should be recannulated with a drill and the cortical bone lightly fish scaled with a small osteotome to stimulate a healing response. A hypertrophic nonunion requires primarily stability to heal, whereas an atrophic nonunion requires stability and reactivation of a biologic healing response with autologous bone graft. The patient should be counseled that the risk of infection and synostosis is higher after this type of reconstruction effort.

37.2.4 Monteggia and Galeazzi Fractures

When evaluating the patient with a forearm injury, inspect for deformity at the wrist or elbow. Prominence of the radial head suggests a Monteggia fracture with fracture of the proximal ulna in association with a radial head dislocation. The Bado classification for Monteggia fractures is widely referenced [24]:

Type 1 – ulnar fracture with anterior dislocation of the radial head
Type 2 – ulnar fracture with posterior dislocation of the radial head
Type 3 – ulnar fracture with lateral dislocation of the radial head
Type 4 – dislocation of the radial head with fractures of the radius and ulna

In all Monteggia fracture types, the radial head will not reduce until the ulnar fracture is reduced. The radial head is typically stable after reduction of the ulnar fracture, and if not, the quality of the ulnar reduction should be reassessed. Radiocapitellar joint pinning should be avoided if at all possible as it invariably results in unacceptable elbow stiffness or fracture of the pin. If the radial head is pinned, it should be for no longer than ten days and the arm should be immobilized in a long-arm cast.

Deformity with prominence of the distal ulna may indicate a Galeazzi fracture with an isolated fracture of the radial shaft in association with distal radioulnar joint (DRUJ) dislocation or subluxation. Anatomic reduction of the radius is required followed by assessment of distal radial ulnar joint stability. Immobilization in supination is often required to maintain reduction of the distal radioulnar joint. If stability cannot be maintained, internal fixation of the distal radioulnar joint with two pins placed proximal to the joint from the ulna into the radius is effective but fixation should be limited to no more than two weeks. If the DRUJ is unreducible, open reduction and repair of capsular structures is required.

37.2.5 Compartment Syndrome

Compartment syndrome of the forearm is infrequent but vigilance is required to prevent a catastrophic result. Of the five “Ps” commonly referenced for the clinical diagnosis of compartment syndrome (pain, pallor, paresthesia, pulselessness, and pain with passive stretch), the most useful signs are pain unrelieved by appropriate narcotic medication and pain with passive stretch of the involved compartment muscles. By the time pallor, paresthesia, or pulselessness is observed, muscle tissue is already dying.

Compartment pressures can be measured by observation of the pressure required to move a fluid meniscus in IV tubing connected to a large-volume syringe and a mercury-filled manometer via a three-way stopcock. An 18-gauge or smaller needle is connected to the IV tubing and inserted in the compartment to be measured. The stopcock is opened and the air in the syringe injected until the sterile saline fluid meniscus begins to move at which point the pressure is read off the manometer. While a measurement of greater than 30 mmHg is confirmatory, the diagnosis of compartment syndrome is ultimately clinical, and the surgeon must be prepared to act upon clinical findings. Compartment releases can be performed at the time of internal fixation, and wounds left open for delayed primary closure or split-thickness skin grafting (Fig. 37.10). If compartment syndrome is suspected, Henry’s anterior approach is sufficient to release the volar forearm compartment, but a separate carpal tunnel incision should be considered to release the median nerve. A longitudinal dorsal approach is sufficient to release the dorsal compartment.

37.2.6 Isolated Fractures of the Ulna

Isolated shaft fractures of the ulna are often referred to as “nightstick” fractures. Closed reduction of displaced fractures is difficult due to

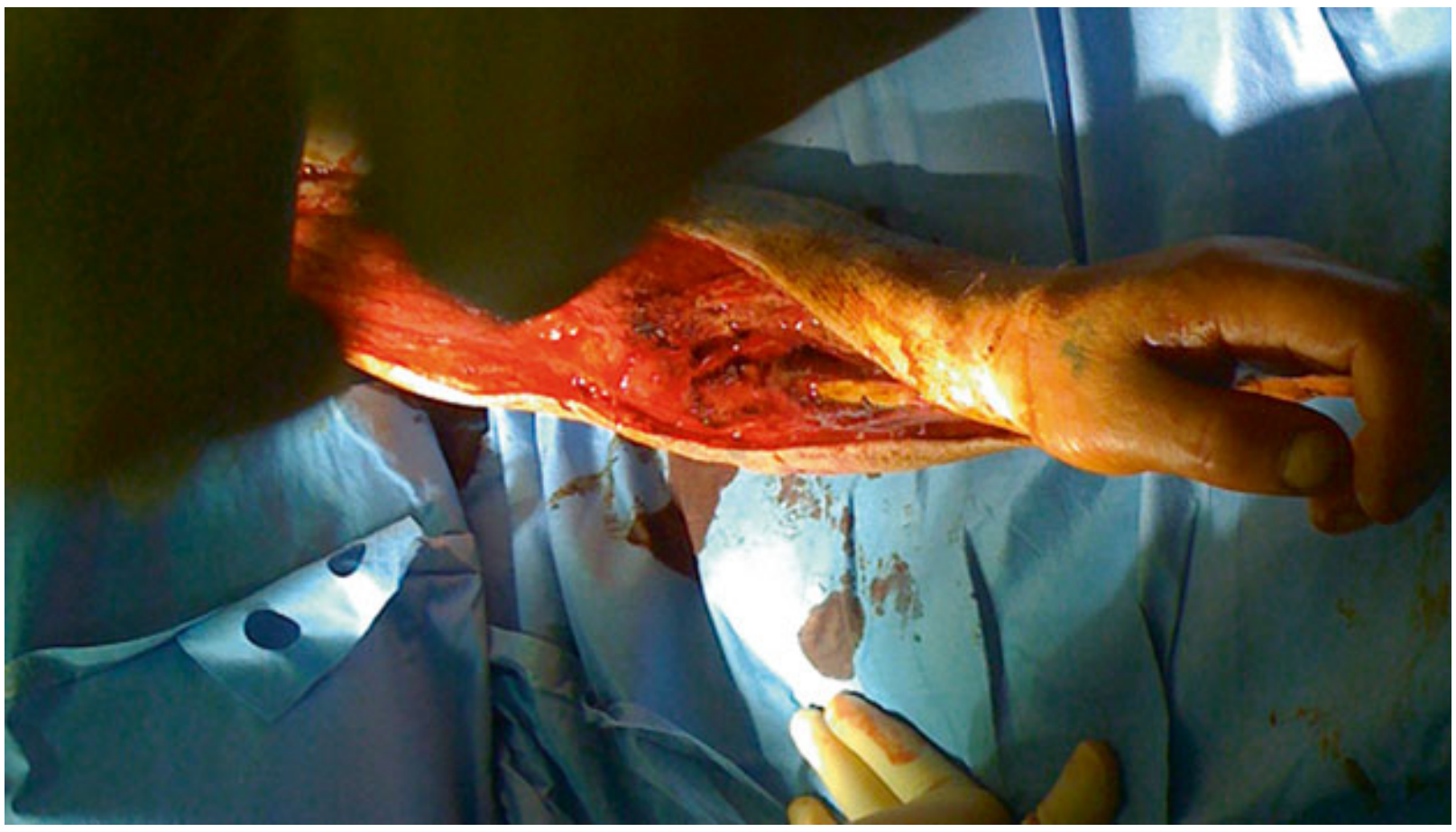

Fig. 37.10 Anterior fasciotomy to treat compartment syndrome following a forearm fracture

the intact radius and interosseous membrane. Closed treatment is acceptable when there is minimal translation at the fracture site and angulation of less than 10°. Because these fractures are typically stable, immobilization can be accomplished in a below elbow cast, splint, or functional Sarmiento-type sleeve. Fully displaced fractures of the ulna should be treated operatively.

37.2.7 Amputation

When trauma is so severe that limb salvage is not an option, mid-level forearm amputation with length preservation may be necessary. Rounded bone edges and myodesis of flexor and extensor muscle groups to stabilize the amputation stump are desirable. Forearm length is especially important for patients where access to prosthetic limb replacement is limited and is necessary to provide a strong lever arm for lifting activity. In order to preserve length, soft tissue coverage procedures may include abdominal or groin flaps and split-thickness skin grafting. These procedures are well tolerated in the upper extremity as the limb will not be end weight bearing. The Krukenberg operation to provide a bifid hand with "pincer"-type grip is an option for patients with bilateral upper extremity amputations where a functional prosthesis cannot be obtained or is rejected [25, 26]. If a Krukenberg procedure is contemplated, every effort should be made to preserve length of the radius and ulna and the pronator teres muscle which provides the power for the pincer function. The ability to provide sensate skin at the tip of the "pincer" is also a requirement for consideration of this procedure.

References

1. Tarr RR, Garfinkel AI, Sarmiento A. The effects of angular and rotational deformities of both bones of the forearm: an in vitro study. J Bone Joint Surg Am. 1984;66:65–70.
2. Morrey BF, Askew LJ, An KN, Chao EY. A biomechanical study of normal and functional elbow motion. J Bone Joint Surg Am. 1981;63:872–7.
3. Evans EM. Fractures of the radius and ulna. J Bone Joint Surg Am. 1951;33:548–61.
4. Rang ML. Children's fractures. 2nd ed. Philadelphia: JB Lippincott; 1983. p. 197–220.
5. Schmittenbecher PP. State-of-the-art treatment of forearm shaft fractures. Injury Int J Care Injured. 2005;36:S-A25–34.
6. Noonan KJ, Price CT. Forearm and distal radius fractures in children. J Am Acad Orthop Surg. 1998; 6(3):146–56.
7. Bochang C, Jie Y, Zhigang W, Bar-On E, Katz K. Immobilization of forearm fractures in children-extended versus flexed elbow. J Bone Joint Surg Br. 2005;87-B(7):994–6.
8. Samora JB, Klingele KE, Beebe AC, Kean JR, Klamar J, Beran MC, Willis LM, Yin H, Samora WP. Is there still a place for cast wedging in pediatric forearm fractures? J Pediatr Orthop. 2014;34(3):246–52.
9. Barry M, Paterson JMH. Aspects of current management; flexible intramedullary nails for fractures in children. J Bone Joint Surg Br. 2004;86:947–53.

10. Garg NK, Ballal MS, Malek IA, Webster RA, Bruce CE. Use of elastic stable intramedullary nailing for treating forearm fractures in children. J Trauma. 2008;65(1):109–15.
11. Lascombes P, Prevat J, Ligier JN, Metaizeau JP, Poncelet T. Elastic stable intramedullary nailing in forearm shaft fractures in children: 85 cases. J Pediatr Orthop. 1990;10:167–71.
12. Vransky P, Bourdelat D, Al Faour A. Flexible stable intramedullary pinning technique in the treatment of pediatric fractures. J Pediatr Orthop. 2000;20:23–7.
13. Boston Centerless company. A supplier of medical grade stainless steel stock. Woburn, MA. www.bostoncenterless.com.
14. Calder PR, Achan P, Barry M. Diaphyseal forearm fractures in children treated with intramedullary fixation: outcome of k-wire versus elastic stable intramedullary nail. Injury J Int Care Injured. 2003;34(4):278–82.
15. Personal communication, Dr. Duane Anderson, Director of Orthopedics, Soddo Christian Hospital, Soddo, Ethiopia
16. Fernanadez FF, Egenolf M, Carsten C, Holz F, Schneider S, Wentzensen A. Unstable diaphyseal fractures of both bones of the forearm in children: plate fixation versus intramedullary nailing. Injury J Int Care Injured. 2005;36(10):1210–6.
17. Carseni-Etesse H, Doyon F, Desplaces N, Gagey O, Tancrede C, Pradier C, Dunais B, Dellamonica P. Epidemiology of bacterial infection during management of open leg fractures. Eur J Clin Microbiol Infect Dis. 1999;18:315–23.
18. Olson SA, Finkemeier CG, Moehring ND. Open fractures. In: Bucholz RW, Heckman JD, editors. Rockwood and Greene's fractures in adults. 5th ed. Philadelphia: Lippincott, Williams and Wilkins; 2001. p. 285–318.
19. Zalavras CG, Patzakis MJ, Holtom PD, Sherman R. Management of open fractures. Infect Dis Clin North Am. 2005;19:915–29.
20. Okike K, Bhattacharyya T. Trends in the management of open fractures. A critical analysis. J Bone Joint Surg Am. 2006;88-A(12):2739–48.
21. Zalvaras CG, Patzakis MJ, Holtom PD. Local antibiotic therapy in the treatment of open fractures and osteomyelitis. Clin Orthop Relat Res. 2004;427:86–93.
22. Perez D, Bramkamp M, Exe C, von Ruden C, Ziegler A. Modern wound care for the poor: a randomized clinical trial comparing the vacuum system with conventional saline-soaked gauze dressings. Am J Surg. 2010;199(1):14–20.
23. DeFranzo AJ, Argenta LC, Marks MW, Molnar JA, David LR, Webb LX, Ward WG, Teasdall RG. The use of vacuum-assisted closure therapy for the treatment of lower-extremity wounds with exposed bone. Plast Reconstr Surg. 2001;108:1184–91.
24. Bruce HE, Harvey JP, Wilson JL. Monteggia fractures. J Bone Joint Surg Am. 1974;56-A(8):1563–676.
25. Garst RJ. The Krukenberg hand. J Bone Joint Surg [Br]. 1991;73-B(3):385–8.
26. Kleman LT, Shafritz AB. The Krukenberg procedure. JHS. 2013;38A:173–5.

Hand and Wrist Orthopaedic Injuries

38

Rishee Parmar

Hand and wrist injuries are fairly common around the world. The majority can be treated conservatively, especially in an environment where the resources are limited. The main goal is to return the patient to a level of function that is acceptable to them. Education about their injury and the prognosis will help them understand the rehabilitation process. Stiffness, mal-union and infection can lead to great functional loss. Operative fixation can help with early mobility and avoid mal-union but the risk and the difficulties of dealing with an infection can be very considerable in the austere environment. Therefore, the decision to operate has to be based on careful consideration of the case and the local situation. A healed fracture with an element of mal-union or stiffness will be better than an infected operative fixation with a risk of amputation.

38.1 Epidemiology

Hand and wrist injuries are common complaints in the austere environment. A study from Nigeria found the male/female ratio was 1.8:1, and the average age was 26.9 years. Engineers and technicians represented 27 % of patients with hand injuries. Most cases occurred because of road traffic injuries, followed by machine injuries. 57.1 % of patients with mechanical injuries were admitted to the hospital. The majority received minor surgical treatment, and 16.2 % had a digit amputated. Hand injuries are commonly seen amongst technicians and civil or public servants; these people constitute the economic work force [1].

Ooates et al. found 1130 upper extremity injuries per 100,000 persons per year, meaning that the average American has a 1-in-88 chance of presenting to the emergency department with an upper extremity injury in a given year. Of those injuries the wrist accounted for 15.2 % and finger injuries 38.4 %. Fractures account for 40 % of the injuries [2], which is similar to prior reported incidences of finger fractures of 380 per 100,000 in the UK [3].

Angermann et al. reports the causes, characteristics and treatment of injuries to the hand and wrist which presented to five accident and emergency departments in a 2-year survey of 13 % of the Danish population. The rate of injury to the hand or wrist was 28.6 % of all injuries, or 3.7 per 100,000 inhabitants per year. 34 % of the accidents were domestic, 35 % were leisure accidents, 26 % were occupational and 5 % were traffic accidents. The most frequent causes for admission were fractures (42 %), tendon lesions (29 %) and wounds (12 %) [4].

R. Parmar, MBChB, FRCS (Tr & Orth)
Department of Orthopaedics, St Helen's and
Knowlsley Teaching NHS Trust, Whiston, UK
e-mail: rishparmar@hotmail.co.uk

© Springer International Publishing Switzerland 2016

J.D. Robinson (ed.), *Orthopaedic Trauma in the Austere Environment:*
A Practical Guide to Care in the Humanitarian Setting, DOI 10.1007/978-3-319-29122-2_38

The economic impact is great. A study in Holland highlighted that hand and wrist fractures are ranked first in injuries of this area for loss of productivity and healthcare costs [5].

38.2 Management

Thankfully the management of hand and wrist injuries is not too reliant on equipment – except for an image intensifier – for the best results, although plain films can be used intraoperatively, or if this is not possible, your clinical acumen. A good knowledge of surface anatomy and fracture pathoanatomy will get you very far in these situations.

38.2.1 Conservative Treatment

The majority of fractures can be treated conservatively with splintage or casting and hand therapy. This is a skill in itself and I would encourage you to spend some time with the therapists before you go on your missions, especially as you may not have any physiotherapists, hand therapists or plaster technicians. Questions to ask yourself before embarking on conservative treatment are: Do you have the capacity for intensive follow-up? Can the patient attend? Have they travelled a large distance with money they really cannot afford to spend? Is your splint going to last the course of treatment?

You can make splints for fingers from many objects, from pieces of wood and cardboard to rolled-up pieces of plaster of Paris. Below elbow splinting can be achieved with similar materials. The plaster may be of poor quality which cracks very easily. One method to reinforce your casting is to roll up a piece into a snake-like structure and lay it on your cast and then roll a few more turns of plaster over the top, thereby incorporating a dowel-like strut within your cast over potential stress areas.

38.2.2 Operative Management

For the operative management of hand and wrist fractures, the gold standard should be attempted if resources are available. However, in an austere environment, the majority of fractures can be treated with Kirschner wires (K wires). Remember your K wires are precious and try and use the cut end as another implant. Sharpen pieces with an oblique cut at the end with your wire cutters to reuse the K wire. Check all your available resources before you start. These should include theatre and or capacity, anaesthetist, nurses, theatre runners, X-ray or image intensifier, drugs including general or local anaesthetic agents, blood and antibiotics, tourniquet, preparation fluids, drapes, theatre and arm table, operative equipment, power sources and suture material. Are there drills and saws and if so which type? Are there hand chucks available? Do you have any implants and if so are they sterile and the correct size and appropriate for the set you have?

In an ideal situation, you would be in a clean air theatre with a patient under a regional or general anaesthetic with a tourniquet applied and inflated with a safe regulated pressure. The arm would be prepped with a chlorhexidine or Betadine with alcohol and draped with sterile impervious drapes. The reality may be very different. You may not have an anaesthetist but the advantage of the hand and wrist is that it is easily anaesthetised peripherally in the distal forearm, with a good knowledge of anatomy, but keep in mind the pain from a tourniquet will not be tackled unless it is a finger tourniquet.

The tourniquet may be hand pumped without a gauge or in absolute necessity a tight bandage after using it as an Esmarch-like device. The drapes may have huge holes in them in which case overlapping or folding them over is a way to minimise the holes.

Use the available resources to the best of your ability, and be sure you have done the most possible in that environment for that patient in terms of infection control using all your basic principles. Try and maintain your standards in an environment where people around you may think it is futile, as they do not have resources. At the Queen Elizabeth Central Hospital (QECH) in Malawi, there were no differences in infection between HIV-positive and HIV-negative patients, and despite having cloth drapes and gowns and no laminar flow and using antiseptic bars of

Fig. 38.1 (**a**) Sterile cloth bags to drop battery-powered drills into. (**b**) A long sterile chuck through a metal ring to allow the use of a powered drill

soap, an infection rate of around 5 % was achieved [6]. A study also shows that union rates with HIV are no different if standards are maintained [7].

In terms of equipment, using with K wires with a hand chuck is much more controlled than trying to use a hand drill to place them. The local environment may have engineered sterile cloth bags to drop battery-powered drills into which you can then use a long sterile chuck through a metal ring to allow use of a powered drill (Fig. 38.1a, b).

A spiked towel clip is an invaluable piece of equipment. It can act as a reduction tool for many a hand fracture and also to provide traction and rotational control on a finger by holding the distal bone through some stab incisions; this is much better than using a swab and sponge holder as it is less traumatic and gives much better control.

I generally find with hand injuries that less is more. The less disruption of the soft tissues you can achieve, the more likely you will have a good result especially in an environment where rehabilitation specialists are not available. Attempt to achieve the best reduction and rotational alignment possible with the least amount of soft tissue disruption to allow the most postoperative movement. This is the art of hand injury management. For bone loss, K wires can be shaped to act as intramedullary spacers, or bones can be cross K wired to the adjacent normal bone to keep length if feasible, until definitive management can be planned.

38.3 Distal Phalanx

The majority of distal phalanx fractures can be treated with splinting for 2–3 weeks leaving the PIPJ free. Occasionally a displaced fracture may require a longitudinal K wire or screw, with a screw allowing faster return to function. Warn patients that tip pinch may take months to fully recover [8, 9].

38.3.1 Mallet Injuries

Simple mallet fingers can be managed with a mallet splint, ensuring hyperextension of the DIPJ for 6 weeks full time and 2–6 weeks at night. Simple bony mallet can be treated similarly if the bone is reduced with splinting. However, if there is >1/3 articular surface without subluxation or actual subluxation of the joint, then an extension block K wire with a trans-articular wire for maintaining joint reduction will be needed. The wires stay in for 6 weeks and the joint splinted to avoid K-wire complications [10].

Screw fixation does lead to earlier return to work but this has to be offset against higher complications and longer operative time [11].

38.4 Middle Phalanx

Treating middle phalanges is fairly similar to the proximal phalanx but there are more studies relating to the proximal phalanx. Stable injuries should be treated with splinting or buddy strapping to the adjacent finger to allow early motion.

Intra-articular condylar injuries need fixation in adults. There is some evidence to show children can remodel [12]. The principle is to restore the articular surface and allow early movement. This is achieved with screws or K wires. The en bloc reconstruction of the articular surface has to be fixed to the proximal part of the fracture to allow stability. There is no biomechanical difference in cadavers [13]. K-wire irritation may occur with early movement, whereas splinting may be protective against this [14].

If K wires are used, splint the DIPJ but allow tendon gliding by allowing MCPJ and PIPJ movement. The wires stay for 4 weeks.

Neck fractures can be treated by extending the DP and placing a trans-articular wire retrograde through the base of the DP into the middle phalanx head; then reduce the fracture and drive the wire into the bone [15].

An alternative technique is to flex the DP after reducing the fracture. Insert a K wire through the head into the proximal part of the phalanx and then back out the wire until it sits just under the articular surface [16].

Transverse fractures tend to angulate dorsally. These are difficult to reduce and hold. Flexing the PIPJ and DIPJ helps with the reduction. A plate can be used and has the advantage of early return to function [8].

Cross K wiring is technically demanding as the bone is small. An image intensifier would be helpful to ensure the joints are avoided. I would use a double-ended K wire and place them retrograde from the condyles and then drive the wire out through the proximal bone and pull the wire back from there until the collaterals are no longer tethered. This is a very good technique to avoid the joint and be able to have more safety without image intensifier. If you need to open the fracture to see the reduction, then you can drive a wire anterograde into the distal part of the fracture and then retrograde [9, 17].

Unstable oblique fractures can be treated by screws or K wires as described in the proximal phalanx section [8].

Unstable extra-articular base fractures may be treated with cross K wiring from the articular lip into the shaft, or if this is not feasible, then reduce the fracture with flexion of the joint and place a trans-articular wire through the head of the proximal phalanx down into the base and across the fracture site into the shaft [9].

38.5 PIPJ

A recent Cochrane review of conservative treatment of hyperextension injuries stated there was a lack of robust evidence to state one method is better or worse than another between splinting, protected mobility and free mobility [18]. Therefore strapping the finger is probably the best combination of protection and mobility.

Intra-articular base fractures with greater than 30 % fractured are potentially unstable. They can be treated conservatively but need very close monitoring. They can be fixed with a screw if not comminuted to allow for early movement [8, 19], ideally percutaneously. If this is not feasible, K wires can be used with an extension block splint to allow some movement, while the K wire runs parallel to the joint to hold the fragment in place. Keep the wires for 3–4 weeks [20, 21]. A volar plate arthroplasty can be used for comminuted volar lip fractures [9, 20].

As with the middle phalanx, condylar injuries need fixation if possible and the principles are the same. If an open reduction is required because of the lack of image intensifier or X-ray, then approach the PIPJ while respecting the central slip to avoid a deformity later. Numerous approaches are described.

Pilon-type injuries to the PIPJ are horrendous injuries and the patient must be given a guarded prognosis. The results are very variable and a relatively stiff and non-painful joint is a good result.

There are a number of dynamic traction devices reported [20, 21]. These can be quite complicated to apply and require an image intensifier to ensure the placement is correct, and the movement does not cause the joint to sublux. The various studies advocating these methods are usually small. A simple solution in an austere environment is to apply traction and reduce the joint and then apply a trans-articular wire for 3–4 weeks and then allow movement once some callus has formed [20–22].

38.6 Proximal Phalanx

The mainstay of treatment for proximal phalangeal fractures is conservative, either with buddy taping, dynamic splinting or static splinting. Dynamic splinting with the wrist included in the intrinsic plus position yields excellent to good results in the majority, with some results up to 10 years [23, 24]. Extra-articular fractures may be left with the wrist free [25].

For oblique or spiral shaft fractures, there have been many studies that state that screw fixation is biomechanically stronger than K wires and therefore allows earlier rehabilitation [8]. However, Horton et al. ran a RCT of K-wire fixation and splinting for 4 weeks versus open reduction and screw fixation with early mobilisation. An independent observer assessed function, pain, movement, grip strength and intrinsic muscle function. There was no significant difference in the functional recovery rates or in the pain scores for the two groups. X-rays showed similar rates of mal-union and there were no statistically significant differences in range of movement or grip strength. There is no mention of analysis earlier in the study to see if there is a significant difference earlier in the post-operative period [26].

The operative method for closed reduction and K wiring is similar to the middle phalanx. If an open reduction is required, a lateral approach, while respecting the intrinsics proximally, is used.

38.7 Metacarpal

The majority of metacarpal fractures can be treated conservatively, even if the fracture requires a manipulation under local anaesthesia. A moulded splint yields good results [9, 27, 28].

Head-splitting fractures require fixation and a similar approach to the phalanges should be taken.

An ulna collateral ligament injury of the thumb should always be looked for in thumb injuries. An avulsed thumb UCL should be fixed if complete and also if a Stener lesion is present. Partial injuries can be treated conservatively [29, 30]. In the absence of bone anchors, a pull-through suture technique can be used.

With unstable injuries of the shaft, more angulation, in the flexion/extension plane, can be accepted in the little and ring fingers due to a mobile CMCJ. ORIF leads to an earlier return to sport [19]. This can be undertaken with lag screws or a plate [27, 28]. This does risk stiffness without a rehabilitation programme.

In an austere environment, K wires can be used in a multitude of ways with good results with all [28]. Cross pinning to uninjured metacarpal is one accepted method. Intramedullary K wires can also be used either anterograde or retrograde, single or multiple [27, 28]. Rotational control is not as great with intramedullary K wires. The entry point is the most important factor in intramedullary K wiring; so knowledge of anatomy is extremely important in the absence of an image intensifier. Making a larger skin incision to view your anatomy may be required.

Wires should be removed at 4 weeks for metacarpal shaft fractures or cut flush to bone for intramedullary wires, if they cannot be removed in the future for any reason.

38.8 CMCJ

The thumb CMCJ can sustain a Bennett or Rolando fracture depending on the degree of comminution. A completely undisplaced fracture can be treated conservatively; however, the majority requires a closed reduction and K-wire placement. For a Bennett fracture, the wires can be placed into the trapezium or one in the trapezium and one across to the index metacarpal [9, 27]. This may be more difficult without image intensifier, although not impossible, due to the relationship of the index to the thumb metacarpal. For a Rolando fracture, the aim is to maintain the length and ensure the articular surface is reduced and has nutrition. The ideal method would involve open reduction, internal fixation, bone grafting and enough stability to allow early movement. This risks devascularising the fragments and in the austere environment may not be possible. Length can be maintained by cross K wiring to the index metacarpal; a mini open incision will allow a periosteal elevator to reduce the articular surface with autograft to support the reduction and maybe a subchondral cross K wire [9]. The wires for both fracture patterns should be kept for 6 weeks and then movement started.

CMCJ injuries of the index through to little fingers are fairly rare. There is no consensus in the treatment. Articular congruency seems to be less important than originally thought. A lot of these patients have long-term residual pain even with congruent joints. Closed reduction and trans-articular wiring for displaced fractures seem to be the accepted treatment. Wires are kept for 6 weeks. Open reduction may be necessary to remove soft tissue interposition or very small fragments. However, in simple fractures a stable reduction can sometimes be achieved and maintained with a cast [9, 31].

38.9 Carpal Bones

The scaphoid is the most common carpal bone fractured. It is notoriously difficult to diagnose on X-rays at times. An early MRI to detect the fracture is cost saving in terms of socio-economic impact, assessment and treatment costs [32].

Minimally displaced or undisplaced waist fractures should be treated conservatively as level 1 evidence showed no significant difference in union rates, at over 90 %, between conservative and operative treatment. However, there was a greater rate of complications with operative management [33]. However, another systematic review suggested percutaneous fixation leads to an earlier return to work and sports [34].

A meta-analysis of displaced waist of scaphoid fractures showed four times nonunion rate with conservative management and therefore should be fixed, although they still achieved a union rate of 80 % with conservative management [35].

A meta-analysis of proximal pole fractures shows that over a third do not unite with conservative treatment and have a seven times relative risk of nonunion compared to more distal fractures [36].

In an austere environment, the majority of these can be treated conservatively unless there is access to headless compression screws and an image intensifier is available. As a last resort, K wires can be used for a scaphoid fracture, but an image intensifier is required as open reduction in acute situation can further disrupt the blood supply. Insertion through the non-articular portion of the scaphoid is performed. A lag screw can also be used although this is technically demanding.

Fractures of the rest of the carpus are relatively rare. If they do occur, they tend to be avulsion fractures, which can be treated conservatively as long as the fragments are not too displaced or large.

Perilunate injuries are rare and high-energy injuries, which require expertise to manage. They can be debilitating if missed. Mayfield described the injury patterns and the progressive nature of injury. The rate of force decided whether a greater arc or lesser arc injury was sustained [37]. Even with ideal management, these patients may have pain, weakness and stiffness. They should be informed of this.

Initial management is one of closed reduction under general anaesthesia with paralysis. These can be difficult to reduce. The lunate should be reduced onto the capitate first with pressure on the lunate and a flexion force on the capitate. The lunate is then reduced into its fossa on the radius with extension.

Ideal management is anatomical reduction and repair of all ligaments with anchors and protection of repairs with K wires. This is due to the fact that long-term results of conservative management have shown loss of reduction over time [38–40].

In an austere environment, a closed reduction of a lesser arc injury with K wires to maintain alignment for 12 weeks would be a sensible approach. An image intensifier or X-rays would be mandatory to assure correct alignment. If these are absent, an open placement of wires could be attempted but after a week or so to allow the soft tissue to settle but an immediate closed reduction should be made.

Greater arc injuries require anatomical reduction and internal fixation of the fractures to maintain alignment as well as the ligament repairs and carpal realignment [38–40].

There has been some work on delayed open reduction and internal fixation. The mean time to operation was 29 weeks and the patients who could be reduced had satisfactory outcomes. The irreducible patients require salvage procedures [41].

38.10 Distal Radius and Ulna

The management of distal radius and ulna fractures has changed over recent years. The trend is towards open reduction and internal fixation. The evidence for this change is heterogeneous. There is a Cochrane review ongoing looking at the evidence.

Distal radius and ulna fractures can still be treated conservatively for acceptable positions. For the distal radius, this would be a 2 mm articular step or gap, normal carpal alignment and restoration of length to within 2 mm [42]. Kopylov showed that a 30-year follow-up of young distal radius fractures articular congruency was important [43]. This includes the distal radioulnar joint.

A Cochrane review showed weak evidence that hand therapy post cast removal was advantageous and that actual physiotherapy was better than an advice sheet [44]. In children a removable splint is better for return to function [45, 46].

Various operative methods have been or are being used. These include closed reduction and moulded cast, closed reduction and K wiring and external fixation and bridging or non-bridging, open reduction and internal fixation either dorsally or volarly.

K wiring can be used in various techniques. There is evidence to say that when compared to external fixation, there is little difference in radiological outcomes [47].

External fixation can be used in a non-bridging or bridging manner; a Cochrane review stated that there is insufficient evidence to show the superiority of one method over the other [47]. Another Cochrane review looked at external fixation and conservative management; this showed there is weak evidence that external fixation gives better radiological results at the expense of minor complications. The evidence is lacking to support whether this translates into better clinical outcomes [48]. There is evidence to show that external fixation can lead to more cases of complex regional pain syndrome [49]. A Cochrane review looking at K wiring and conservative management showed weak evidence supporting its use but the method of K wiring is in doubt. There were increased complications with the Kapandji technique. Early movement also leads to more complications [50]. As plaster may be of poor quality in austere environments, this may be the strongest evidence to support external fixation or K-wire fixation for distal radius fractures. Looking at external fixation against K wiring in a RCT, they had similar results but external fixation had greater costs and more minor complications [51].

Operative reduction and fixation leads to a better radiographic outcome but this has not been shown to improve clinical outcomes at a year [52].

A study looking at pin site care has found no difference between dry dressings, chlorhexidine-impregnated dressings or using saline with hydrogen peroxide pin site care [53].

Dorsal plating was in vogue a few years ago due to its ease of application. Tendon problems led to the newer trend of volar locking plates [54]. Now low-profile dorsal plating seems to have similar results to volar locking plate [55].

Newer level 3 evidence comparing external fixation against volar locking plates has shown better range of movement, function and grip strength with the plates [56].

Elderly patients seem to do similar with conservative management when compared to K wiring in a RCT with respect to function and clinical outcomes [57, 58]. They also seem to lack improved clinical outcomes with locking plates in a more recent RCT with conservative treatment, but they had better grip strength [59].

Rozental et al. performed a RCT looking at younger patients and found locking plates led to an earlier return of function when compared to external fixation or K wiring at 6 and 12 weeks, but this evened out at a year [60]. Grewal et al. found similar results with open reduction and internal fixation of the surgeon’s choice and external fixation [61].

Taking all this into consideration, treatment of distal radius fractures can be performed to the standards of the developed world. External fixation or K wiring is perfectly acceptable, and although they may not lead to an early return to function, they will have good results with less major complications like flexor tendon ruptures. K wiring and external fixation can also be performed without image intensifier if surface anatomy is taken into consideration.

I find the intra-focal technique dorsally with a trans-styloid wire very easy to perform without image intensifier. A bridging external fixator is also easy to perform without image intensifier but hardware may be an issue in an austere environment and resulting stiffness from the ligamentotaxis.

38.11 Background

My experience of the austere environment was a year volunteering as a Consultant at the Queen Elizabeth Central Hospital (QECH) in Blantyre, Malawi. Malawi is consistently one of the ten poorest countries in the world. However, QECH has an orthopaedic department with two consultants overseeing care. There was a theatre/OR image intensifier but it goes out of action fairly frequently and was out of action during my experience. There were basic instruments and sets. Non-locking plates, screws, external fixators and Kirschner wires (K wires) were available as they were either donated or purchased from developing world suppliers with donated money. The nailing system was the SIGN nail as described in the SIGN-system chapter. Any implant that could be resterilised was reused.

The austere environment is very variable and your treatment will depend heavily on what is in your environment. Learning to adapt to your environment is the greatest skill you will need to develop. The voice of the experienced is a gold mine of information and do not hesitate to use it when available. There will be absolute pearls that you may not heard of. There will be many in this book and I hope this chapter will give you some helpful tips and tricks.

38.12 Case Tutorial

A male in his young twenties attended from a local biscuit factory after an industrial accident. His hand was crushed in a machine. He was brought to the on-call team's attention within 1 h of his accident. There is no accident and emergency department at the hospital.

What else would you like to know from this patient's history to help with your management?

As in all cases, the patient's history is of paramount importance. What is it like to be that patient in that environment? How far did they travel? Do they have to walk 10 km for a local health centre for dressing changes? What do they need to do with his hands? Is this his dominant hand? Do they need to farm or build to stay alive? All these aspects may be overlooked when you are used to patients being able to get to healthcare easily with a fantastic transport and healthcare infrastructure. The outcome of your surgery may be the difference between this patient feeding their family and not being able to work in a country without a social security system.

This patient had a young family. He has injured his dominant hand and is the only earner in the family. He is otherwise fit and well, HIV negative, nonsmoker or drinker and has no allergies. Except being wrapped in a sheet, there has been no first aid administered.

What aspects of his examination would you like to know?

He has sustained a large amount of skin injury over the hand with obvious crushing. There is a large flap laceration over the palm extending from the distal end of the carpal tunnel to the metacarpal joints. He has a decreased capillary refill to the fingers but not the thumb. Sensation was intact. He has generalised tenderness over the whole hand in the zone of injury. He has deformed and rotated fingers and thumb. This is an isolated injury.

What investigations would you like?

Unfortunately there are no films available due to the lack of water; therefore, you are unable to get X-rays. There is no CT or MRI at the hospital. How would you like to proceed?

The patient actually presented late in the evening and was taken to theatre by the paramedical staff (clinical officers) for a debridement and washout; there was no formal exploration or stabilisation.

The next morning, X-rays were obtained and his capillary refill was still very sluggish (Fig. 38.2a, b).

What is your management plan? What do you need to consider before proceeding? Remember the environment you are in and the resources you have available.

This gentleman seemed to have a vascular injury but we did not know the level or extent. We did not have a vascular surgeon. I had a pair of loupes but no microscope. With respect to sutures, we did not have formal vascular sutures but managed to ask the paediatric surgeon for some vascular sutures he had for cases like this.

The patient came in the day before my list so I could rearrange it to take him for a formal exploration, stabilisation and potential vascular repair if I was able with the resources and skills I had.

We had an anaesthetist, capacity and antibiotics. We had a table with an arm board and a tourniquet with a hand pump without a working gauge.

On formal exploration, it was found that this man had severed his arteries at the level of the carpal tunnel to all fingers. The nerves were intact. The tips of his fingers were dusky but the flap laceration seemed to bleed.

What are your options?

The options I thought about were:

1. Arterial repair
2. Amputation at the level of arterial damage
3. Stabilisation of fractures and await demarcation with the potential for infection
4. How to get skin coverage as the whole area was crushed

I did not have the necessary skills or resources for an arterial repair. The warm ischaemic time was also very long. If I amputated it, it would leave the man with a useless hand but the level of arterial damage could also leave him with a useless hand as it may demarcate at that level. I thought that I could not consider an amputation until I had spoke to some colleagues and the patient and watched his level of demarcation

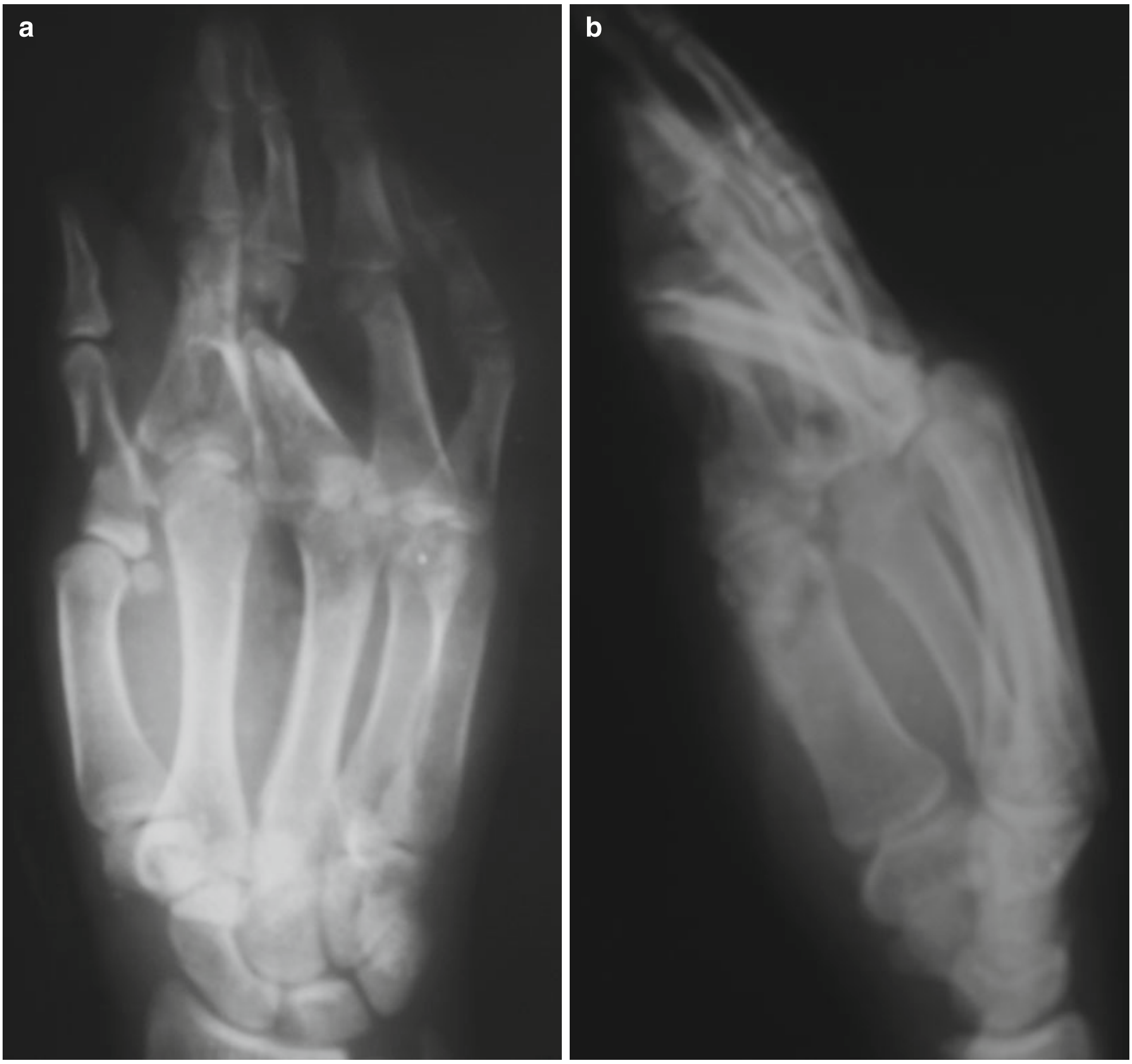

Fig. 38.2 (**a**, **b**) X-rays of patient in case

while hoping he did not get infected. I stabilised all the finger fractures with single K wires as we had no image intensifier and washed out the wounds and sutured the lacerations.

I spoke to the plastic surgeon we had in the department regarding skin cover with a crush injury and the vascular injury. He agreed that allowing demarcation was a good idea with the hope that some dorsal supply would be sufficient to save some of his finger and palm length. After reviewing the patient, he thought we could cover with a reverse radial flap depending on the amount of skin loss at the next operation.

After a day or two, we took the patient back to theatre with my plastic surgery colleague. Photos were taken of his hand's look at that time (Fig. 38.3a, b). We operated without a tourniquet this time.

We were hopeful that we could try and save his index and little finger to allow him to have some sort of grip and cover the remainder with a reverse radial flap.

On testing bleeding, we found that the index finger bled at the level of mid-proximal phalanx only and the middle and little bled at MCPJ and the little had a little bleeding all the way up.

The patient's hand at the end of this operation is seen in Fig. 38.4.

Unfortunately the little finger became dusky after a couple of days. The rest of the hand seemed to have a good vascular supply.

Fig. 38.3 (**a, b**) Photographs of patient’s hand

Fig. 38.4 Patient’s hand at the end of surgery

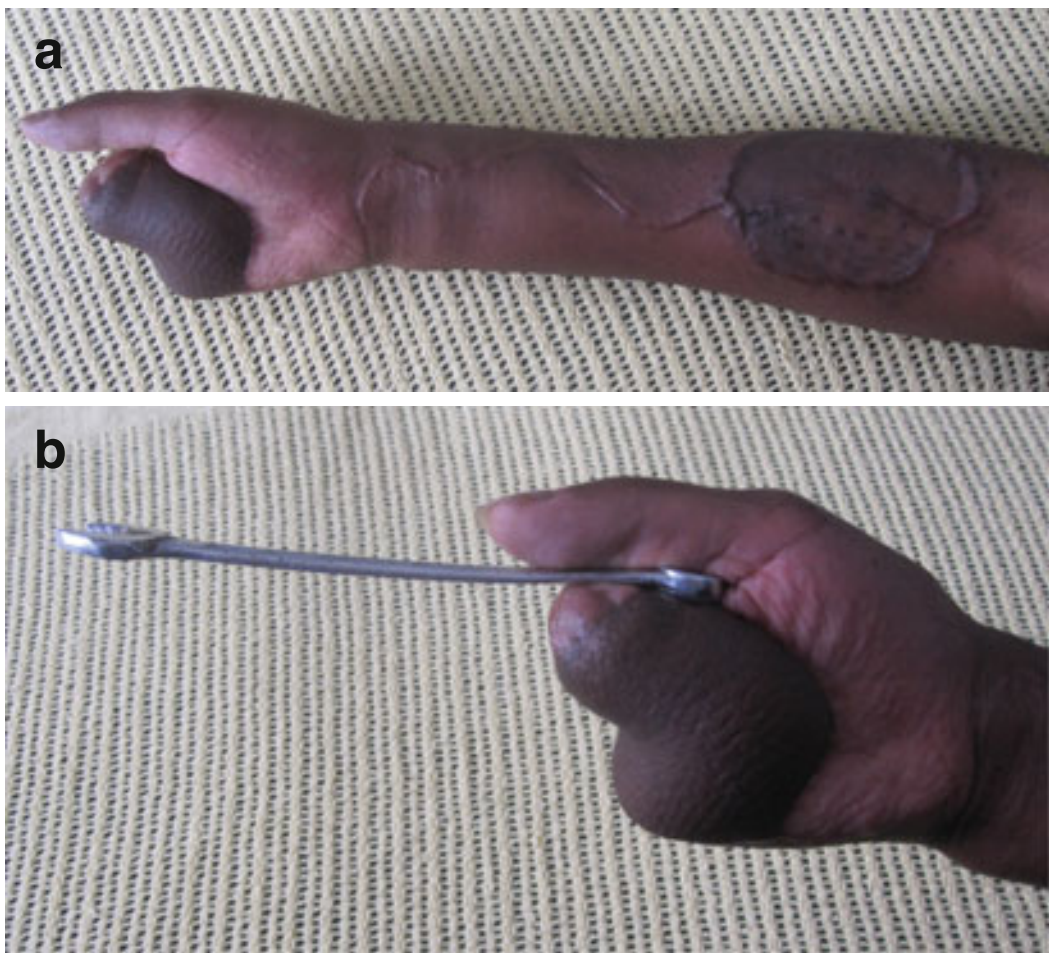

Fig. 38.5 (**a**, **b**) The patient's hand post-operatively

What is your plan now?

We took the man back to theatre and amputated the little finger as the blood supply had been lost.

He went on to heal very well with a minor wound infection, which was treated with dressings and antibiotics. His final result is shown in Fig. 38.5.

He had function of his hand, and due to the communication that had taken place, he was extremely aware of his situation and the potential for complete functional loss. He was very happy with his final result and was able to get back to his vocation.

38.13 Further Reading and Advice

I would ensure you have a copy, whether electronic or paper, of a good trauma book, an anatomy text and an approach book. Having a plastic surgery book with reconstructive techniques is extremely helpful. Make sure you have contact details of senior consultants at home to ask advice and if possible contact details of people who have been in an austere environment. Remember there is always help whether locally or internationally.

References

1. Ihekire O, Salawu SA, Opadele T. International surgery: causes of hand injuries in a developing country. Can J Surg. 2010;53(3):161–6.
2. Ootes D, Lambers KT, Ring DC. The epidemiology of upper extremity injuries presenting to the emergency department in the United States. Hand (NY). 2012; 7(1):18–22.
3. Downing ND. Fractures of the hand. Surgery. 2003;21(10):256–8.
4. Angermann P, Lohmann M. Injuries to the hand and wrist. A study of 50,272 injuries. J Hand Surg Br. 1993;18(5):642–4.
5. de Putter CE et al. Economic impact of hand and wrist injuries: health-care costs and productivity costs in a population-based study. J Bone Joint Surg Am. 2012;94(9):e56.
6. Bates J, Mkandawire N, Harrison WJ. The incidence and consequences of early wound infection after internal fixation for trauma in HIV-positive patients. J Bone Joint Surg Br. 2012;94(9):1265–70.
7. Gardner RO et al. Fracture union following internal fixation in the HIV population. Injury. 2013;44(6): 830–3.
8. Gaston RG, Chadderdon C. Phalangeal fractures: displaced/nondisplaced. Hand Clin. 2012;28(3):395–401, x.
9. Rockwood CA, Green DP, Bucholz RW. Rockwood and Green's fractures in adults. 6th ed. Philadelphia: Lippincott Williams & Wilkins; 2006.
10. Cheung JP, Fung B, Ip WY. Review on mallet finger treatment. Hand Surg. 2012;17(3):439–47.
11. Lucchina S et al. Unstable mallet fractures: a comparison between three different techniques in a multicenter study. Chin J Traumatol. 2010;13(4):195–200.
12. Puckett BN et al. Remodeling potential of phalangeal distal condylar malunions in children. J Hand Surg Am. 2012;37(1):34–41.
13. Sirota MA et al. Stability of fixation of proximal phalanx unicondylar fractures of the hand: a biomechanical cadaver study. J Hand Surg Am. 2013;38(1): 77–81.
14. Hsu LP et al. Complications of K-wire fixation in procedures involving the hand and wrist. J Hand Surg Am. 2011;36(4):610–6.
15. Al-Qattan MM. Phalangeal neck fractures in adults. J Hand Surg Br. 2006;31(5):484–8.
16. Paksima N et al. Percutaneous pinning of middle phalangeal neck fractures: surgical technique. J Hand Surg Am. 2012;37(9):1913–6.
17. Edwards Jr GS, O'Brien ET, Heckman MM. Retrograde cross-pinning of transverse metacarpal and phalangeal fractures. Hand. 1982;14(2):141–8.
18. Chalmer J, et al. Conservative interventions for treating hyperextension injuries of the proximal interphalangeal joints of the fingers. Cochrane Database Syst Rev. 2013;(2):CD009030.

19. Geissler WB. Operative fixation of metacarpal and phalangeal fractures in athletes. Hand Clin. 2009;25(3):409–21.
20. Ng CY, Oliver CW. Fractures of the proximal interphalangeal joints of the fingers. J Bone Joint Surg Br. 2009;91(6):705–12.
21. Williams CS. Proximal interphalangeal joint fracture dislocations: stable and unstable. Hand Clin. 2012;28(3):409–16. xi.
22. Aladin A, Davis TR. Dorsal fracture-dislocation of the proximal interphalangeal joint: a comparative study of percutaneous Kirschner wire fixation versus open reduction and internal fixation. J Hand Surg Br. 2005;30(2):120–8.
23. Fok MW et al. Ten-year results using a dynamic treatment for proximal phalangeal fractures of the hands. Orthopedics. 2013;36(3):e348–52.
24. Figl M et al. Results of dynamic treatment of fractures of the proximal phalanx of the hand. J Trauma. 2011;70(4):852–6.
25. Franz T et al. Extra-articular fractures of the proximal phalanges of the fingers: a comparison of 2 methods of functional, conservative treatment. J Hand Surg Am. 2012;37(5):889–98.
26. Horton TC, Hatton M, Davis TR. A prospective randomized controlled study of fixation of long oblique and spiral shaft fractures of the proximal phalanx: closed reduction and percutaneous Kirschner wiring versus open reduction and lag screw fixation. J Hand Surg Br. 2003;28(1):5–9.
27. Jones NF, Jupiter JB, Lalonde DH. Common fractures and dislocations of the hand. Plast Reconstr Surg. 2012;130(5):722e–36.
28. Friedrich JB, Vedder NB. An evidence-based approach to metacarpal fractures. Plast Reconstr Surg. 2010;126(6):2205–9.
29. Rhee PC, Jones DB, Kakar S. Management of thumb metacarpophalangeal ulnar collateral ligament injuries. J Bone Joint Surg Am. 2012;94(21):2005–12.
30. Lee AT, Carlson MG. Thumb metacarpophalangeal joint collateral ligament injury management. Hand Clin. 2012;28(3):361–70, ix–x.
31. Bushnell BD et al. Management of intra-articular metacarpal base fractures of the second through fifth metacarpals. J Hand Surg Am. 2008;33(4):573–83.
32. Patel NK et al. Cost and clinical effectiveness of MRI in occult scaphoid fractures: a randomised controlled trial. Emerg Med J. 2013;30(3):202–7.
33. Ibrahim T et al. Surgical versus nonsurgical treatment of acute minimally displaced and undisplaced scaphoid waist fractures: pairwise and network meta-analyses of randomized controlled trials. J Hand Surg Am. 2011;36(11):1759–68. e1.
34. Modi CS et al. Operative versus nonoperative treatment of acute undisplaced and minimally displaced scaphoid waist fractures--a systematic review. Injury. 2009;40(3):268–73.
35. Singh HP, Taub N, Dias JJ. Management of displaced fractures of the waist of the scaphoid: meta-analyses of comparative studies. Injury. 2012;43(6):933–9.
36. Eastley N et al. Union rates after proximal scaphoid fractures; meta-analyses and review of available evidence. J Hand Surg Eur. 2012;38(8):888–97.
37. Mayfield JK, Johnson RP, Kilcoyne RK. Carpal dislocations: pathomechanics and progressive perilunar instability. J Hand Surg Am. 1980;5(3):226–41.
38. Sawardeker PJ, Kindt KE, Baratz ME. Fracture-dislocations of the carpus: perilunate injury. Orthop Clin North Am. 2013;44(1):93–106.
39. Najarian R et al. Perilunate injuries. Hand (NY). 2011;6(1):1–7.
40. Neuhaus V, Jupiter JB. Current concepts review: carpal injuries – fractures, ligaments, dislocations. Acta Chir Orthop Traumatol Cech. 2011;78(5):395–403.
41. Massoud AH, Naam NH. Functional outcome of open reduction of chronic perilunate injuries. J Hand Surg Am. 2012;37(9):1852–60.
42. Ng CY, McQueen MM. What are the radiological predictors of functional outcome following fractures of the distal radius? J Bone Joint Surg Br. 2011;93(2):145–50.
43. Kopylov P et al. Fractures of the distal end of the radius in young adults: a 30-year follow-up. J Hand Surg Br. 1993;18(1):45–9.
44. Handoll HH, Madhok R, Howe TE. Rehabilitation for distal radial fractures in adults. Cochrane Database Syst Rev. 2006;(3):CD003324.
45. Abraham A, Handoll HH, Khan T. Interventions for treating wrist fractures in children. Cochrane Database Syst Rev. 2008;(2):CD004576.
46. Plint AC et al. A randomized, controlled trial of removable splinting versus casting for wrist buckle fractures in children. Pediatrics. 2006;117(3):691–7.
47. Handoll HH, Huntley JS, Madhok R. Different methods of external fixation for treating distal radial fractures in adults. Cochrane Database Syst Rev. 2008;(1):CD006522.
48. Handoll HH, Huntley JS, Madhok R. External fixation versus conservative treatment for distal radial fractures in adults. Cochrane Database Syst Rev. 2007;(3):CD006194.
49. Harley BJ et al. Augmented external fixation versus percutaneous pinning and casting for unstable fractures of the distal radius--a prospective randomized trial. J Hand Surg Am. 2004;29(5):815–24.
50. Handoll HH, Vaghela MV, Madhok R. Percutaneous pinning for treating distal radial fractures in adults. Cochrane Database Syst Rev. 2007;(3):CD006080.
51. Hutchinson DT, Strenz GO, Cautilli RA. Pins and plaster vs external fixation in the treatment of unstable distal radial fractures. A randomized prospective study. J Hand Surg Br. 1995;20(3):365–72.
52. Handoll HH, Madhok R. Surgical interventions for treating distal radial fractures in adults. Cochrane Database Syst Rev. 2003;(3):CD003209.

53. Egol KA et al. Treatment of external fixation pins about the wrist: a prospective, randomized trial. J Bone Joint Surg Am. 2006;88(2):349–54.
54. Grewal R et al. A randomized prospective study on the treatment of intra-articular distal radius fractures: open reduction and internal fixation with dorsal plating versus mini open reduction, percutaneous fixation, and external fixation. J Hand Surg Am. 2005;30(4): 764–72.
55. Yu YR et al. Complications of low-profile dorsal versus volar locking plates in the distal radius: a comparative study. J Hand Surg Am. 2011;36(7):1135–41.
56. Richard MJ et al. Analysis of the complications of palmar plating versus external fixation for fractures of the distal radius. J Hand Surg Am. 2011;36(10):1614–20.
57. Wong TC et al. Casting versus percutaneous pinning for extra-articular fractures of the distal radius in an elderly Chinese population: a prospective randomised controlled trial. J Hand Surg Eur Vol. 2010;35(3):202–8.
58. Azzopardi T et al. Unstable extra-articular fractures of the distal radius: a prospective, randomised study of immobilisation in a cast versus supplementary percutaneous pinning. J Bone Joint Surg Br. 2005;87(6): 837–40.
59. Arora R et al. A prospective randomized trial comparing nonoperative treatment with volar locking plate fixation for displaced and unstable distal radial fractures in patients sixty-five years of age and older. J Bone Joint Surg Am. 2011;93(23):2146–53.
60. Rozental TD et al. Functional outcomes for unstable distal radial fractures treated with open reduction and internal fixation or closed reduction and percutaneous fixation. A prospective randomized trial. J Bone Joint Surg Am. 2009;91(8):1837–46.
61. Grewal R et al. Open reduction internal fixation versus percutaneous pinning with external fixation of distal radius fractures: a prospective, randomized clinical trial. J Hand Surg Am. 2011;36(12):1899–906.

39 Pelvis and Acetabular Fractures

Richard A. Gosselin

Although still relatively rare, pelvic injuries are on the rise as the developing world motorizes and high-energy road traffic crashes increase. Pedestrians, cyclists, and motorcyclists are particularly vulnerable road users. High-energy pelvic ring injuries are commonly associated with other injuries: head, chest, abdomen, lower urinary tract, and limb injuries [1]. The ABCs of resuscitation always are priorities. The initial or secondary surveys will raise suspicion of a pelvic ring injury, and compressive hemorrhage control can be instituted early, if not already done in the field.

39.1 Physical Examination

Inspection of the pelvic area will reveal gross deformity, wounds, bruises, or ecchymoses. Swelling and/or ecchymosis of the penis and scrotum in the male or labia in the female should elicit a high index of suspicion of an anterior pelvic ring injury, with possible involvement of the lower urinary tract. Examination of the lower back and perineum is more difficult because of pain but should nevertheless be systematic to rule out wounds that may suggest an open pelvic injury. Obvious deformities of the limbs such as shortening, asymmetrical position of the greater trochanters, flexion, or external rotation of the thigh are all suggestive of associated fractures/dislocations of the acetabulum or proximal femur. Palpation of the pelvic ring may reveal crepitation, gaps, or step-offs over the iliac wing or the symphysis pubis. It is mandatory to palpate both posterior sacroiliac areas, as this may provide important information regarding the stability of the injury. It is also mandatory to do a rectal examination to rule out a protruding spike of the bone through the rectal mucosa or a high-riding prostate in the male. Inability to void, in the conscious patient, especially if associated with blood at the meatus, a high-riding prostate, and/or bladder distension, is a ruptured urethra until proven otherwise and a contraindication to retrograde Foley catheterization. A thorough neurovascular examination of both lower limbs is necessary to assess potential vascular injuries or injuries to the lumbosacral plexus or peripheral nerves. All the physical findings need to be clearly recorded in the patient's chart.

39.2 Imaging

A plain AP pelvis X-ray is all that is needed initially [2]. Always keep in mind that the AP pelvis shows the amount of residual displacement, not

---

R.A. Gosselin, MD, MSc, MPH, FRCS(C)
Department of Orthopedic Surgery, Institute for Global Orthopedics and Traumatology, University of California in San Francisco, San Francisco, CA, USA
e-mail: froggydoc@comcast.net

© Springer International Publishing Switzerland 2016

J.D. Robinson (ed.), *Orthopaedic Trauma in the Austere Environment: A Practical Guide to Care in the Humanitarian Setting*, DOI 10.1007/978-3-319-29122-2_39

necessarily the amount of initial displacement. If a lower urinary tract injury is suspected, this is a good opportunity to perform a retrograde urethrogram with whatever water-soluble contrast medium is available: iodine-based products (all the "grafins") or even diluted barium sulfate. Obvious bony injuries will be evident, but subtle findings need close scrutiny in comparing both hemi-pelvises for asymmetry of the lower border of the sacroiliac (SI) joints, the iliac wings, the obturator foramen, the tear drop, and the superior border of the pubic rami. If the spinous processes line up in the center of the pedicles of the lower lumbar spine, then the X-ray is a true AP view. If not, caution is required to interpret findings (Fig. 39.1). Indirect signs of instability include fracture of the transverse processes of the lower lumbar spine, avulsion of the ischial spine, ischial tuberosity, or lateral border of the sacrum [3]. Proximal femur injuries should be visible, but true AP and lateral views of the hip may be necessary if clinically suspicious. If available, inlet/outlet (Pennal) views can add valuable information and are painless. Iliac and obturator oblique (Judet) views are painful and not indicated unless acetabular surgery is contemplated. Push-pull maneuvers can be useful in determining the extent of instability but are painful and have a slight risk of increase in hemorrhage [4]. CT scans are rarely available and do not add much valuable information if conservative management is the only option.

Fig. 39.1 Anteroposterior X-ray of the pelvis showing diastasis of the symphysis pubis and a left sacro-iliac joint disruption

39.3 Classification

If conservative management is the only option, the duration and type of bed rest are the only issues. This is determined by the degree of instability, which relies on the integrity of the posterior sacroiliac ligamentous complex (PSILC), the strongest in the body. The Bucholz classification is the simplest and the most useful [5]:

Type 1 – vertically and rotationally stable: avulsion fractures, isolated fractures of the iliac wing, or rami fractures.

Type 2 – vertically stable but rotationally unstable: the PSLIC is intact but structures anterior to it may be disrupted to varying degrees allowing rotation, mostly around the *Y*-axis. These include open book and laterolateral compression injuries.

Type 3 – vertically and rotationally unstable: the PSLIC is disrupted allowing rotation in all planes but also translation of the hemi-pelvis along the *Y*- and *Z*-axes. These are truly unstable injuries that usually involve a significant shear component along the *Y*-axis (Malgaigne pattern) and less frequently an anteroposterior force along the *Z*-axis. The resulting instability is almost always multiplanar, and all combinations of ligamentous and bony injuries to the anterior ring, sacrum, or contralateral hemi-pelvis can be seen.

39.4 Management

Even an isolated pelvic ring injury can lead to hemodynamic instability from bleeding in the retroperitoneal or the pelvic floor spaces [6]. Most often the source is venous, but this is irrelevant in austere environments since arterial embolization is not an option. A pelvic binder with a folded sheet or towel properly applied over the greater trochanters can be life-saving, particularly where blood products are scarce [7] (Fig. 39.2).

If the patient does not stabilize after adequate pelvic binding, other sources of bleeding need to be ruled out: chest, abdomen, closed femur

Fig. 39.2 Pelvic binder

[redacted]

Fig. 39.3 External fixation of pelvis and Foley catheter in situ

fracture, or deep wounds of the limbs. A chest X-ray and/or peritoneal tap/lavage may determine the need for chest drainage or laparotomy. Peritoneal lavage needs to be interpreted with caution if performed later than 24–48 h after the injury as red cells may suffuse from the retroperitoneal hematoma into the abdominal cavity and give false-positive results. The pelvic wrap is usually well tolerated for up to 24 h if needed. If hemodynamic instability recurs when the wrap is released, and other sources of hemorrhage have been ruled out, a pelvic external fixator can be applied "electively" in the operating room [8] (Fig. 39.3). I prefer the open technique where the iliac crest is exposed enough to allow access of thumb and index fingers on both inner and outer tables, and the pins inserted under direct vision, between the two tables. Since external fixators are almost always loaded in compression, protrusion of a pin medially is acceptable, but not protrusion laterally [9].

When a laparotomy is performed, external fixation may be done before, leaving enough room for the midline incision, or after, depending on intraoperative findings. Some authors advocate retroperitoneal packing at the time of mini-laparotomy/ laparotomy if no active bleeding source is identified [10]. This requires a return to the operating room at 24–48 h to remove the packing and has no obvious advantage over external fixation when it's available. If a laparotomy is performed, and the anterior ring injury is amenable to it (pubic dislocation through or near the symphysis), the lower part of the incision can be extended to perform an ORIF of the pubis using one or two plates with three screws on each side. Whatever is done anteriorly will only partially stabilize a type 3 injury. Open pelvic fractures through the rectum or perineum require a diverting left colostomy with washout of the distal fragment and appropriate antibiotic coverage, including metronidazole [11].

As stated above, lower urinary tract injuries are common with pelvic ring disruptions. Gross hematuria is suggestive of a bladder injury (more common in a full than an empty bladder), but again, results need to be interpreted with caution after 48 h from the injury. If contrast is available, a retrograde urethrogram will rule out a urethral injury, and a Foley catheter can be inserted and used for a cystogram. Retroperitoneal or more rarely intraperitoneal extravasation will confirm a bladder tear, and surgery may be indicated. If the urethrogram shows a partial or more commonly a complete urethral tear, a cystostomy is done initially, without any attempt at Foley catheter insertion. Further management will depend on the availability of local skills and resources (urology expertise and equipment) [12]. In many LMICs, it is also important to reassure females and their families that their pelvic injury is very unlikely to create fertility or vaginal delivery problems.

Type 1 injuries: they are stable and require only symptomatic treatment, with mobilization and weight bearing as tolerated. Many elderly osteoporotic patients are still treated unnecessarily with 4–6 weeks of bed rest for rami fractures.

Type 2 injuries: these are still relatively stable, but not enough for immediate weight bearing. Open book fractures with pubic diastasis than 2–3 cms can benefit from postural reduction by having the patient lie on one side or the other, according to pain. There is NO indication to suspend a patient in a pelvic sling or hammock. This is extremely uncomfortable and a nightmare for nursing care. External fixation or anterior plating is relatively straightforward surgical alternatives. Skin (only very temporarily) or preferably skeletal traction is used for comfort for more severe latero-lateral compression fractures, and 2–3 weeks is usually sufficient before starting partial toe-touch weight bearing on the involved side. Sitting and rolling in bed should be allowed as soon as tolerated.

Type 3 injuries: these unstable fractures have the potential to displace even further if loaded prematurely, particularly proximally along the *Y*-axis or posteriorly along the *Z*-axis. Skeletal traction may be necessary for 3–6 weeks depending on fracture pattern and pain tolerance. Traction may even partially reduce the displaced hemi-pelvis, but other than elevating the foot of the bed, there is no really efficient countertraction, so the main goal is mostly pain management. When pain allows, the patient should be encouraged to move as tolerated in bed, sitting and rolling, first with traction then without. When there is no pain while sitting without traction and with active ROM of the ipsilateral hip, the patient can be mobilized out of bed, but needs to remain non-weight bearing for at least 6 weeks after the injury. An anterior external fixator may partially stabilize a type 3 injury and decrease the amount of needed bed rest or traction, but is never sufficient to completely stabilize a complete disruption of the PSILC [13]. In rare cases, when all the stated requirements are met, ORIF allows earlier mobilization and possibly better long-term functional results [6].

Long-term complications include painful malunions or nonunions, leg length discrepancy, chronic neurologic deficits, and/or chronic low back pain. Their management is beyond the scope of this chapter.

39.5 Acetabular Fractures

Acetabular fractures are relatively rare [14]. They occur when force is transmitted through the hip joint either from a direct blow to the trochanteric

Fig. 39.4 AP of the pelvis showing a minimally displaced transverse fracture of the acetabulum, anterior wall fracture of the left acetabulum with anterior dislocation of the left hip. There may also be a fracture of the left femoral head

area or from axial loading of the femur in different degrees of flexion and rotation. They may be associated with a hip dislocation (posterior, anterior, or "central"), a fracture of the femoral head or neck or an injury to the ipsi- or contralateral pelvic ring (Fig. 39.4).

Judet and Letournel have identified five simple fracture patterns and five complex patterns combining two or more of the simple ones [15]. The "both column" fracture pattern stands alone in that no intact acetabulum is left in continuity with the proximal pelvic segment (giving the "gull sign" on the obturator oblique view). The posterior wall fracture, with or without posterior dislocation of the femoral head, is the most common. Posterior instability occurs depending on fragment size and location. After reduction of a dislocation, it is essential to determine the "safe zone" of stability. Re-dislocation between 0° and 45° of flexion usually requires open reduction if the posterior wall fragment is big enough for fixation It is always essential after reduction to obtain a good AP pelvis X-ray that shows both hips so one can assess and compare the width of the joint line and the congruency of the reduction. Any asymmetry within the joint or compared to the opposite one is highly suggestive of an interposed intra-articular fragment and is an indication for ORIF. These procedures are done through a posterior approach and are relatively straight forward, even with only standard instruments and plates. Surgical management of more complex acetabular fractures is technically difficult and requires adequate imaging, special instrumentation and implants, and often two separate approaches. An intraoperative injury to the gluteal or femoral vascular bundles can be life-threatening. In austere environments, conservative treatment with skeletal traction is preferred, accepting the fact that malunion with an articular incongruity of more than 2–3 mm will likely lead to premature degenerative joint disease as a result of accelerated cartilage wear from the prominent ridges. Four to six weeks of traction through the distal femur or proximal tibia will allow the fracture to be "sticky" enough to start gentle ROM exercises and patient mobilization. A below-knee "airplane" cast can be used to control rotation as needed. Only toe-touch weight bearing is allowed initially, progressing to full weight bearing at 3 months. "Both column" fractures showing "neo-congruency on all three views are a rare occurrence, but they should be treated with simple bed rest, without traction. The so-called central dislocations occur when the femoral head displaces medially through the acetabulum which occurs most commonly with transverse and T-type fracture patterns. Longitudinal traction (Fig. 39.5) will improve the reduction by ligamentotaxis, but rarely to near anatomical level. The goal is to at least bring the femoral head back under what is left of the acetabular dome. Lateral traction with devices such as a T-handle corkscrew positioned in the cervico-trochanteric area is still commonly used. In our opinion *there is no indication for this technique*: accurate positioning of the device is difficult, especially without a C-arm, reduction is rarely improved significantly compared to longitudinal traction only, the entry site rapidly becomes "soupy", it is difficult to apply counter-traction, and most importantly it confines the patient to the supine position. The alleged benefits have never been a match for the known disadvantages.

It is not unusual to see chronic posterior fractures/dislocations, sometimes of many months or even years. Not all femoral heads undergo avascular necrosis (AVN), and open reduction, either extemporaneously or after a period of skeletal

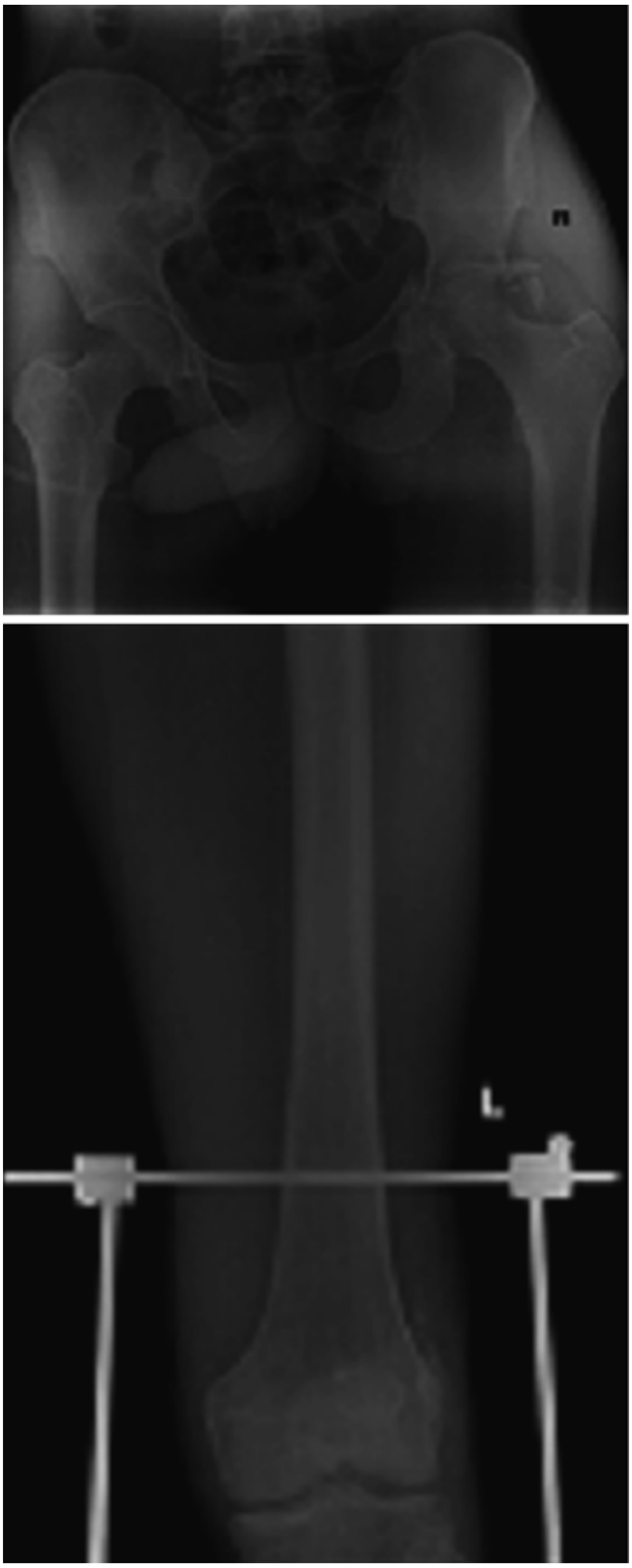

Fig. 39.5 Acetabular fracture and skeletal traction

traction, has been reported successfully as late as 6 years. This has the obvious advantages of restoring leg length and improving range of motion and gait. It is not indicated with an acetabular malunion or if AVN has deformed the femoral head [16].

Late complications of neglected acetabular fractures are painful malunions or nonunions and premature degenerative joint disease: replacement arthroplasty is rarely an option in austere environments, leaving only arthrodesis or Girdlestone resection arthroplasty as alternatives.

Key Points

- Surgical management of pelvic ring injuries and acetabular fractures is difficult and risky in austere environments. Conservative management with longitudinal skeletal traction and postural reduction is indicated for most.
- Hemodynamically unstable patients can safely be treated initially with a properly applied pelvic binder, electively replaced in the OR with an anterior external fixator if needed.
- Lower urinary tract injuries are common and are relatively easy to diagnose, and definitive surgical treatment can be done in a delayed fashion when necessary.
- An external fixator may control rotational instability but is rarely sufficient to control translational instability.
- Unstable or incongruous hip joints after reduction of a posterior fracture/dislocation are best treated operatively. Even this relatively simple procedure can be quite challenging in austere environments: unreliable patient positioning, poor lighting, unreliable suction, lack of blood, and availability of only basic instruments and implants can test the nerves of even an experienced pelvic surgeon.
- The vast majority of pelvic ring injuries in females do not lead to fertility or obstetric complications.

References

1. van Vugt AB, van Kampen A. Review article – an unstable pelvic ring – the killing fracture. J Bone Joint Surg (Br). 2006;88-B:427–33.

2. Young JW, Burgess AR, Brumback RJ, Poka A. Pelvic fractures: value of plain radiography in early assessment and management. Radiology. 1986;160(2):445–51.
3. Starks I, Frost A, Wall P, Lim J. Is a fracture of the transverse process of L5 a predictor of pelvic fracture instability? J Bone Joint Surg (Br). 2011;93-B:967–9.
4. Sagi HC, Coniglione FM, Stanford JH. Examination under anesthetic for occult pelvic ring instability. J Orthop Trauma. 2011;9:529–36.
5. Bucholz RW. Injuries of the pelvis and hip. Emerg Med Clin North Am. 1984;2:331–46.
6. Guthrie HC, Owens RW, Bircher MD. Review article – fractures of the pelvis. J Bone Joint Surg (Br). 2010;92-B:1481–8.
7. Krieg JC, Mohr M, Ellis TJ, Simpson TS, Madey SM, Bottlang M. Emergent stabilization of pelvic ring injuries by controlled circumferential compression: a clinical trial. J Trauma. 2005;59(3):659–64.
8. Majeed SA. External fixation of the injured pelvis: the functional outcome. J Bone Joint Surg (Br). 1990;72-B:612–4.
9. Kim WY, Hearn TC, Seleem O, et al. Effect of pin location on stability of pelvic external fixation. Clin Orthop Relat Res. 1999;361:237–44.
10. Ordonez C, Pino L, Badiel M, et al. The 1-2-3 approach to abdominal packing. World J Surg. 2012;36(12):2761–6.
11. Hanson PB, Milne JC, Chapman MW. Open fractures of the pelvis. J Bone Joint Surg (Br). 1991;73-B:325–9.
12. Keel M, Trentz O. In mini symposium: pelvic fractures – part II – acute management of pelvic ring fractures. Current Orthop. 2005;19:334–44.
13. Lindhal J, Hirvensalo E, Bostman O, Santavirta S. Failure of reduction with external fixator in the management of pelvic ring injuries. J Bone Joint Surg (Br). 1999;81-B:955–62.
14. Gupta RK, Singh H, Dev B, et al. Results of operative treatment of acetabular fractures from the Third World: how local factors affect the outcome. Int Orthop. 2009;33(2):347–52.
15. Letournel E, Judet R. Fractures of the acetabulum. 2nd ed. Berlin/New York: Springer; 1993.
16. Butler D, Archer C, Gollogly J, Ou Cheng N. Chronic traumatic hip dislocation: the Cambodian experience. Asian Biomed. 2011;5(5):705–12.

Hip Injuries in the Austere Environment

40

Raman Mundi, Bonnie Chien, and Mohit Bhandari

Hip fractures represent a global public health issue, as worldwide incidence is rising while the long-term sequelae of pain, functional decline, and increased mortality associated with this injury continue to persist [1]. Of concern is that 1-year mortality rates have been estimated to reach nearly a third of all hip fracture patients [2] (Fig. 40.1).

It is projected that the annual global incidence of hip fractures will surpass 6 million by the year 2050 [3]. Although musculoskeletal injury and mortality due to trauma are highest in low- and middle-income countries—in large part due to road traffic accidents and underdeveloped trauma care systems—hip fracture rates are at odds with this statistic and highest in developed countries [4, 5]. In particular, Northern Europe carries the highest hip fracture rate in countries including Denmark, Norway, Sweden, and Austria [5]. The hip fracture rates in these regions are more than tenfold greater than developing regions such as Latin America and Africa [1, 5]. Such geographic variations may be explained by decreased life expectancy in developing countries, genetic factors, geographic latitude, and environmental differences (i.e. physical activity) [1].

Fig. 40.1 Intracapsular neck of femur fracture

Despite lower incidence rates, a substantial portion of the world's hip fracture burden is still comprised by the developing world due to the magnitude of its population. In

---

R. Mundi, MD (✉)
Division of Orthopaedic Surgery,
McMaster University, 1280 Main St W,
Hamilton, ON L8S 4L8, Canada
e-mail: raman.mundi@medportal.ca

B. Chien, MD (cand)
Medical School, Stanford University School
of Medicine, Stanford, CA, USA

M. Bhandari, MD, PhD, FRCSC
Department of Orthopaedic Surgery,
McMaster University, Hamilton, ON, Canada

© Springer International Publishing Switzerland 2016

J.D. Robinson (ed.), *Orthopaedic Trauma in the Austere Environment: A Practical Guide to Care in the Humanitarian Setting*, DOI 10.1007/978-3-319-29122-2_40

fact, it is anticipated that three-quarters of the global population aged 65 or over will reside in Asia, Africa, and Latin America by 2050. Collectively, these three regions will be responsible for nearly two-thirds of all hip fractures by 2050, with Asia solely carrying over 50 % of the burden [1, 3].

The incidence of hip dislocations has also been on the rise and increasingly occurring in the younger population as a result of motor vehicle accidents. As with hip fractures, these injuries have devastating consequences. This damaging injury in the setting of a young patient population may lead to prolonged disability from osteoarthritis and osteonecrosis. Degenerative arthritis following hip dislocation is estimated at 24 % for simple dislocations and up to 88 % for dislocations associated with acetabular fractures [6] (Fig. 40.2).

As with the management of any medical condition, hip injury care should follow the principles of evidence-based medicine. As such, treatment decisions must combine the best available evidence, a judgement of clinical resources, and patient preferences [7]. A particular challenge for clinicians working in the austere environment will likely include both a paucity of high-quality evidence and limited clinical resources. This chapter will explore the evidence-based treatment of hip fractures and dislocations and practical approaches to the management of these injuries in the austere environment.

Fig. 40.2 Left posterior dislocation of the hip

40.1 Hip Fractures

40.1.1 Presentation and Diagnosis

The majority of hip fractures occur as a result of a low-energy fall from standing height. Those experiencing higher energy mechanisms should be initially evaluated and managed per the advanced trauma life support (ATLS) protocol [8]. A full history should be obtained, eliciting both the details surrounding the injury mechanism and medical comorbidities. The most common presenting history includes proximal thigh pain and an inability to ambulate subsequent to a fall. Medical comorbidities are important, as they may have precipitated the fall or have important implications for management [9, 10].

Examination of patients with hip fractures may reveal no gross deformity on inspection of patients with non-displaced fractures. However, shortening and external rotation of the affected extremity are commonly observed in the setting of displaced fractures. Range of motion testing will typically elicit pain in all motions and for such reasons should generally be avoided. Neurovascular injuries are rare with low-energy mechanisms, but full neurovascular examination must always be performed, in particular with high-energy injuries [9].

A definitive diagnosis of hip fracture can routinely be made with plain radiographs, and imaging should include an anteroposterior (AP) view of the pelvis and both AP and lateral views of the affected hip. The diagnosis is most easily made with the AP views. Distal extension of an intertrochanteric hip fracture warrants full-length AP and lateral views of the affected femur. Although magnetic resonance imaging (MRI) may not be accessible in the austere environment, it is the preferred imaging modality if radiographs remain equivocal. Fortunately, however, most hip fractures can be routinely diagnosed with plain radiographs [9, 10].

Decisions surrounding definitive hip fracture management must take into account both fracture characteristics (fracture type, displacement) and patient characteristics (age, cognitive status, ambulatory status) [11]. An important approach to categorizing hip fractures with important implications for management is the distinction between femoral neck (intracapsular) and intertrochanteric fractures (extracapsular). The surgical management of hip fractures according to this classification scheme is discussed below.

40.1.2 Femoral Neck Fractures

A commonly used classification for femoral neck fractures is the Garden classification, which subdivides these fractures into four categories based on displacement. The classification scheme progresses as follows [8]:

Type 1: incomplete fracture and valgus impacted
Type 2: complete fracture, non-displaced
Type 3: compete fracture, partially displaced
Type 4: completely displaced

Non-displaced fractures (Garden 1 and 2) account for only 15 % of all femoral neck fractures. Although there remains a paucity of high-quality evidence to guide the management of non-displaced femoral neck fractures, in practice, the majority of these injuries are treated with internal fixation [9, 11] (Fig. 40.3). Surgical management allows for earlier mobilization and carries a decreased risk of nonunion compared to nonoperative management. However, it inevitably poses the risks inherent to surgery, including the risks of anaesthesia [12]. Patients with medical comorbidities that place them at high risk of such surgical complications and those suffering from severe cognitive impairment with an inability to ambulate preinjury are the few for which non-surgical management should be considered [11, 12].

For all other patients with non-displaced fractures, internal fixation can be successfully accomplished with either cannulated screws or a sliding hip screw. In a recently updated Cochrane review that identified eight randomized trials comparing the sliding hip screw to cancellous screw fixation, pooled analysis demonstrated no difference in non-union rates, (RR 0.94; 0.57–1.57), an insignificant trend towards lower avascular necrosis rates with the sliding hip screw (RR 0.62; 0.38–1.01), and no difference in mortality (RR 1.25; 0.83–1.89). It must be noted, however, that the majority of these trials also included patients with displaced femoral neck fractures [13].

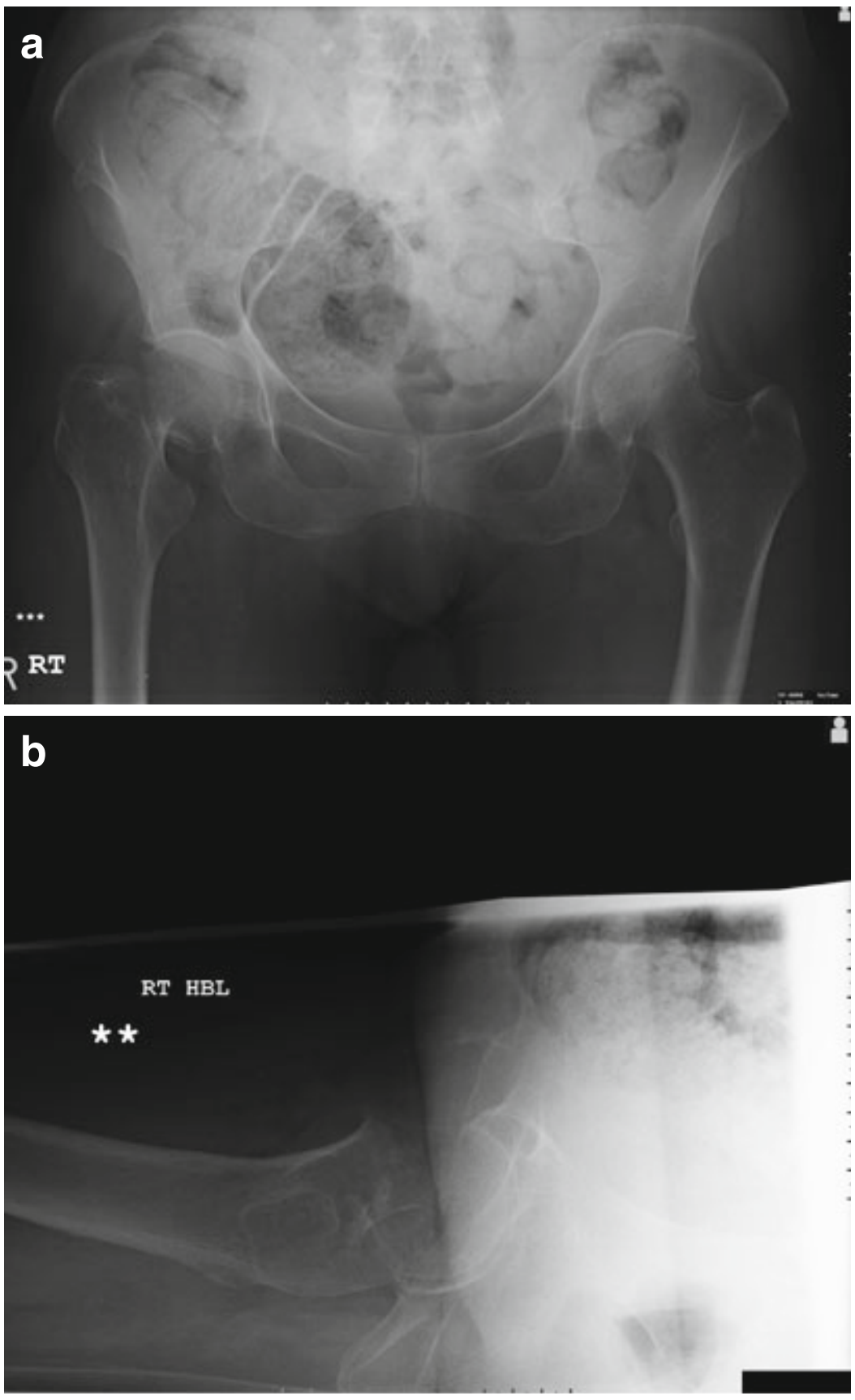

Fig. 40.3 (**a**) Anteroposterior and (**b**) lateral views of a right intracapsular fracture of the neck of the femur

Albeit the more common fracture pattern, the management of displaced femoral neck fractures remains varied amongst surgeons [9, 14]. Conventionally, younger patients (<60 years of age) are treated with reduction and internal fixation, with no significant difference between cannulated screws or sliding hip screw as noted in the above-mentioned review [9, 13]. When using cannulated screws in the setting of displaced fractures, it is suggested that a minimum of three screws be utilized, typically in a triangular configuration with parallel placement. In all patients undergoing internal fixation, a particular emphasis must be placed on ensuring an adequate

Fig. 40.4 Right cemented Thompson's hemiarthroplasty

reduction, as varus alignment considerably increases the risk of fixation failure [9].

In patients above 60 years of age, hemiarthroplasty or total hip arthroplasty is the preferred treatment option for displaced femoral neck fractures (Fig. 40.4). In a comprehensive review of 20 randomized trials comparing internal fixation to arthroplasty in elderly patients (11 HA, 4 THA, 5 HA+THA), Gao et al. demonstrated a significant reduction in major surgical complications at 5 years (RR 0.22; 0.16–0.31), fewer reoperations at 5 years (RR 0.13; 0.08–0.24), and improved function in those treated with arthroplasty [15].

There is ongoing debate, however, as to whether the optimal form of arthroplasty is hemiarthroplasty or total hip arthroplasty. Proponents of hemiarthroplasty cite the decreased complexity of surgery, reduced operating time, and lower dislocation rates as key reasons to favour such treatment [16]. Amongst such advocates of hemiarthroplasty, cemented fixation in particular has gained attention for the prospect of offering a more secure fixation with less post-operative thigh pain as compared to uncemented arthroplasty. Despite this, pooled analysis from randomized trials has shown no substantial difference between cemented and uncemented hemiarthroplasty with respect to post-operative complications, residual pain, and mortality [17].

There is accumulating evidence that total hip arthroplasty is superior in improving functional outcomes compared to hemiarthroplasty altogether. In a systematic review of eight randomized trials comparing these two interventions in cognitively intact and ambulatory patients, there was no significant difference with respect to reoperation, 1-year mortality, or major complication rates. There was an increased risk of dislocation with total hip arthroplasty (THA) (9 % THA vs. 3 % HA) but also superior functional outcomes, pain scores, and quality of life [16]. Accordingly, THA is becoming the favoured treatment option for displaced femoral neck fractures in healthy, mobile, and cognitive intact elderly patients [9].

40.1.3 Intertrochanteric Fractures

Intertrochanteric fractures are extracapsular and extend between the greater and lesser trochanter [18] (Fig. 40.5). The most popular classification scheme for these injuries is based on the OTA/AO classification that divides them into three main groups [10]:

- *Group 1*: simple, two-part fractures with typical oblique fracture line and an intact lateral cortex
- *Group 2*: comminuted fractures with a posteromedial fragment and an intact lateral cortex
- *Group 3*: fractures with fracture line passing through both the medial and lateral cortex (include reverse obliquity)

Fractures that are comminuted in the posteromedial cortex (Group 2) or reverse obliquity (Group 3) or have subtrochanteric extension are considered unstable [10, 18]. As non-union and avascular necrosis are of less concern with intertrochanteric fractures, the majority of these injuries are managed with internal fixation. Nonoperative management is rarely indicated and reserved for those patients whose medical comorbidities place them at an unacceptable risk for surgery [18]. The most

Fig. 40.5 Intertrochanteric fracture

commonly used implants are the sliding hip screw (SHS) with a side plate or an intramedullary nail (IM) with a sliding hip screw component. Purported benefits of the cephalomedullary nail include decreased surgical dissection and buttressing to prevent both fracture collapse and medialization of the distal fragment [18]. In a Cochrane review of 42 randomized trials comparing femoral nails to the sliding hip screw, there was no significant difference with respect to mortality, nonunion, pain at follow-up, deep infection of the wound, or femoral head cut-out between these two types of implants. However, the femoral nails were associated with a significant increase in operative and post-operative femoral fractures and, thus, a higher reoperation rate. The large majority of studies ($n = 22$) evaluated the gamma nail specifically [19]. Given these fracture rates, it was deemed that the SHS was favourable to intramedullary nails in managing most intertrochanteric fractures. Although IM nailing is likely superior in the setting of subtrochanteric and unstable fractures, the evidence remains equivocal [19].

40.2 Hip Fracture Care in the Austere Environment

High-quality evidence conducted in the austere environment is unfortunately scarce. The majority of randomized clinical trials informing the surgical care of hip fractures have emanated from Europe. A recent study evaluating the geographic distribution of hip fracture randomized trials was unable to identify a single study from the developing regions of Africa and Latin America, let alone the austere environment [20]. This is likely attributable to the fact that organized clinical research is difficult to conduct in a resource-limited, nonacademic, and unpredictable environment. Despite the paucity of hip fracture research in the austere environment, certain diagnostic modalities, management principals, and surgical techniques are either universal or of particular importance for a resource-limited environment.

As mentioned, the diagnosis of hip fractures can typically be suspected based on history (fall, pain in the hip region, inability to weight-bear) and physical examination (shortened and externally rotated extremity, pain with ROM testing) [9]. Although radiographs are the mainstay of diagnosis, other tests to aid in hip fracture diagnosis have been described that may be of value in the field or when immediate imaging is not available. *The Lippmann test* is a test of auscultation, in which the bell of a stethoscope is placed over the pubic symphysis while the examiner percusses the patella of both extremities.

A decreased pitch results from cortical discontinuity and suggests a proximal femur or pelvic fracture [10]. Furthermore, portable ultrasound has demonstrated high sensitivity (100 %) and specificity (94 %) in diagnosing fractures in a study conducted in the austere environment using emergency physicians trained in ultrasonography. Importantly, however, this study did not evaluate all patients with gold standard imaging (radiographs) to verify the accuracy of ultrasound. Furthermore, there were no hip injuries evaluated, as the fractures studied involved bones in more superficial anatomic locations (distal fibula, distal radius, fifth metatarsal, etc.) [21]. As such, the use of ultrasound may have potential in diagnosing hip fracture in the austere environment, although there is a lack of evidence at present.

Fortunately, patients with isolated and closed hip fractures are generally stable and do not require emergent field management or damage control interventions prior to definitive surgery. For patients sustaining high-energy injuries, however, unstable pelvic injuries and femoral shaft fractures should be ruled out, as these injuries can result in haemodynamic instability requiring emergent management, such as the application of a pelvic binder or extremity traction.

In circumstances where surgeons are able to offer the evidence-based surgical interventions discussed above—but must nevertheless be cognizant of limited healthcare resources—optimization of techniques and perioperative management to reduce complications and costs should be a priority. In patients with displaced femoral neck fractures who are candidates for internal fixation (sliding hip screw or cancellous screws), emphasis should be placed on achieving anatomic reduction, as varus malreduction has been associated with an increased rate of fixation failure [9].

Furthermore, in patients with hip fractures being treated with internal fixation, there is strong evidence to suggest a combined tip-to-apex distance of >25 mm on the AP and lateral views leads to increased rates of hardware failure (lag screw cut-out) [22]. In the post-operative period, it is has been estimated that nearly 50 % of hip fracture patients require allogeneic blood transfusions [23]. As the availability of blood products may be limited in the austere environment and transfusions must be given judiciously, it is important to highlight that recent evidence supports the use of a restrictive transfusion protocol that utilizes a transfusion trigger of <80 g/L in the absence of hypoxic symptoms (chest pain, tachycardia, unresponsive hypotension, congestive heart failure) [24, 25].

In regions where resources are further limited, unconventional surgical strategies have been described. It is important to note, however, that these strategies are largely based on the experiences of individual practitioners or the results of small series of patients. Thus, these techniques cannot be recommended for routine application, as evidence on outcomes is insufficient. Nevertheless, they are presented here as examples of techniques historically used in dire circumstances.

Internal fixation of femoral neck fractures has been accomplished using the *Smith-Petersen triflange nail*, *Knowles pins*, and threaded *Steinmann pins*. If intraoperative radiography is not available, direct visualization of the head and neck should be made with the use of a lateral incision extended anteriorly [26]. In patients with ongoing pain due to non-union or avascular necrosis, reoperation with arthroplasty is the conventional approach after failed internal fixation. In settings where arthroplasty is not a feasible option, excision arthroplasty (Girdlestone procedure) has shown satisfactory results with respect to healing, pain, and function in a small series of patients [27] (Fig. 40.6).

Various methods of nonoperative management of intertrochanteric fractures using *traction* have been described, including modified Russell's traction and skeletal traction (tibial pin with plaster antirotation boot) (Fig. 40.7).

Neurovascular function should routinely be evaluated in patients treated with traction, as there is some evidence to suggest that sciatic nerve palsy may be an associated complication [28].

Fig. 40.6 A failed fixation of a NOF in a young patient

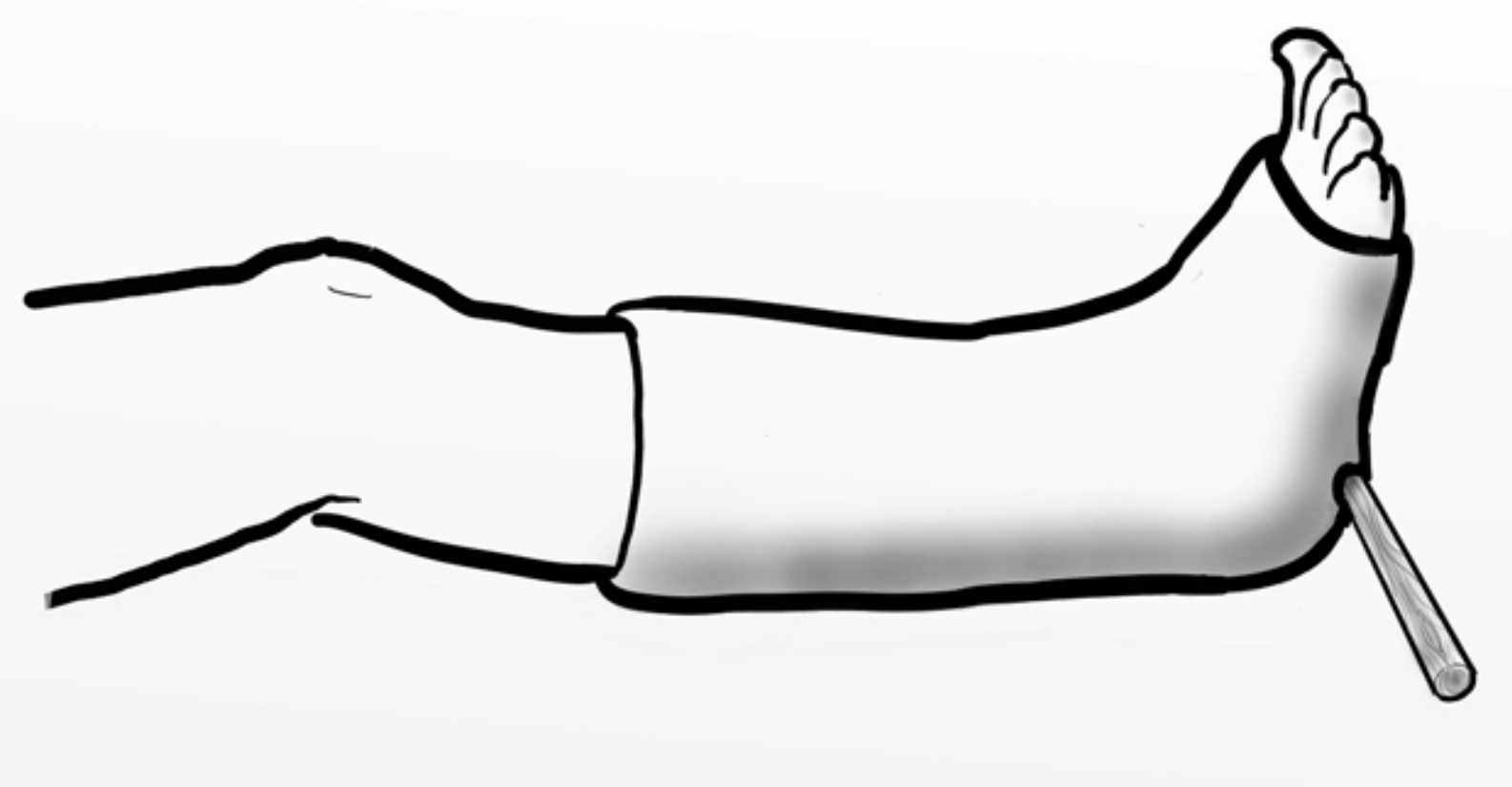

Fig. 40.7 Derotation cast (Courtesy of Konstantinos Doudoulakis)

Internal fixation can be achieved with *Jewett nails*—a fixed angled device with the nail welded to the plate—if sliding hip screws or cephalomedullary nails are unavailable [26]. Unfortunately, however, the Jewett nails have been associated with a higher rate of cut-out into the joint compared to sliding hip screws [10, 29] (Table 40.1).

Another option in resource-constrained settings and for elderly patients with high surgical risk is *external fixation*. Multiple studies in Egypt, India, and Greece have demonstrated relatively short operative times and hospital stays with external fixation [30–32]. Other advantages include application of the external fixator under local anaesthesia for many high-risk patients.

During follow-up of up to 3 years, a high percentage of patients ambulated with support or better and managed ADLs [31]. Union rates on average varied from 2 to 6 months across the different studies. The mortality rates were comparable to a series of open reduction and internal fixation [31]. However, the three studies also consistently reported complications related to either pin tract infections, or superficial skin inflammation, which was as high as 39 % in one study [32]. Other concerns include inadequate stability through the external fixator in unstable fractures and knee stiffness [31].

While conservative treatment with traction might be suitable for high-risk patients, it is likely not feasible for a developing country setting given high bed occupancy rates [30]. In addition, there may be further complications related to recumbence such as thromboembolism, UTI, and pneumonia.

As such, external fixation may be a viable option for elderly patients with numerous medical comorbidities since there is minimal surgical

Table 40.1 Diagnostic and treatment options for hip fractures in the austere environment

Clinical evaluation	History: fall, pain in hip, inability to weight-bear
	Examination: shortened and externally rotated extremity, pain with range of motion
Diagnostic modalities	Radiographs (AP and lateral)
	Lippmann test
Optimize conventional surgery	ORIF for femoral neck fracture
	Anatomic reduction; avoid varus malreduction
	Internal fixation
	Tip-to-apex distance <25 mm (AP + lateral)
	Transfusion trigger
	80 g/L (higher if symptoms of anaemia)
Unconventional surgical techniques	Femoral neck
	Internal fixation with Smith-Petersen triflange nail, Knowles pins, threaded Steinmann pins
	Arthroplasty or Girdlestone if failed fixation
	Intertrochanteric fractures
	Traction
	Jewett nails
	External fixation

trauma, negligible blood loss, early ambulation, shorter hospital stay, decreased expense of the procedure, and simple outpatient removal of the implants.

40.3 Hip Dislocations

40.3.1 Classification and Diagnosis

Hip dislocations usually occur by way of an axial load through high-energy trauma such as MVA or fall from height. Depending on the direction of dislocation, the clinical presentation of a posterior dislocation includes a flexed, internally rotated, and adducted leg (Fig. 40.8), while an anterior dislocation involves a slightly flexed, externally rotated, and abducted leg (Fig. 40.9).

A hip dislocation constitutes an orthopaedic emergency and reduction should ideally be performed within 6 h of injury to reduce risks of osteonecrosis of the femoral head [33]. The classification of hip dislocation is based on the direction of dislocation and presence or absence of associated acetabular or femoral head fracture [34]. *Thompson and Epstein* have classified posterior dislocations into five types:

Type I: with or without a minor fracture
Type II: with a large single fracture of the posterior acetabular rim
Type III: with a comminuted fracture of the rim of the acetabulum, with or without a major fragment
Type IV: with fracture of the acetabular rim and floor:
Type V: with fracture of the femoral head.

Anterior dislocations have also been classified by *Epstein* as follows:

Type *I*: superior dislocations, including the pubic and subspinous
  IA: no associated fractures
  IB: associated fracture or impaction of the femoral head
  IC: associated fracture of the acetabulum
Type *II*: inferior dislocations, including the obturator and perineal
  IIA: no associated fractures
  IIB: associated fracture or impaction of the femoral head
  IIC: associated fracture of the acetabulum

Posterior dislocations are most common and can be associated with posterior wall acetabular fractures and anterior femoral head fractures given that the leg is internally rotated, flexed, and adducted at the hip on impact. Anterior dislocations are

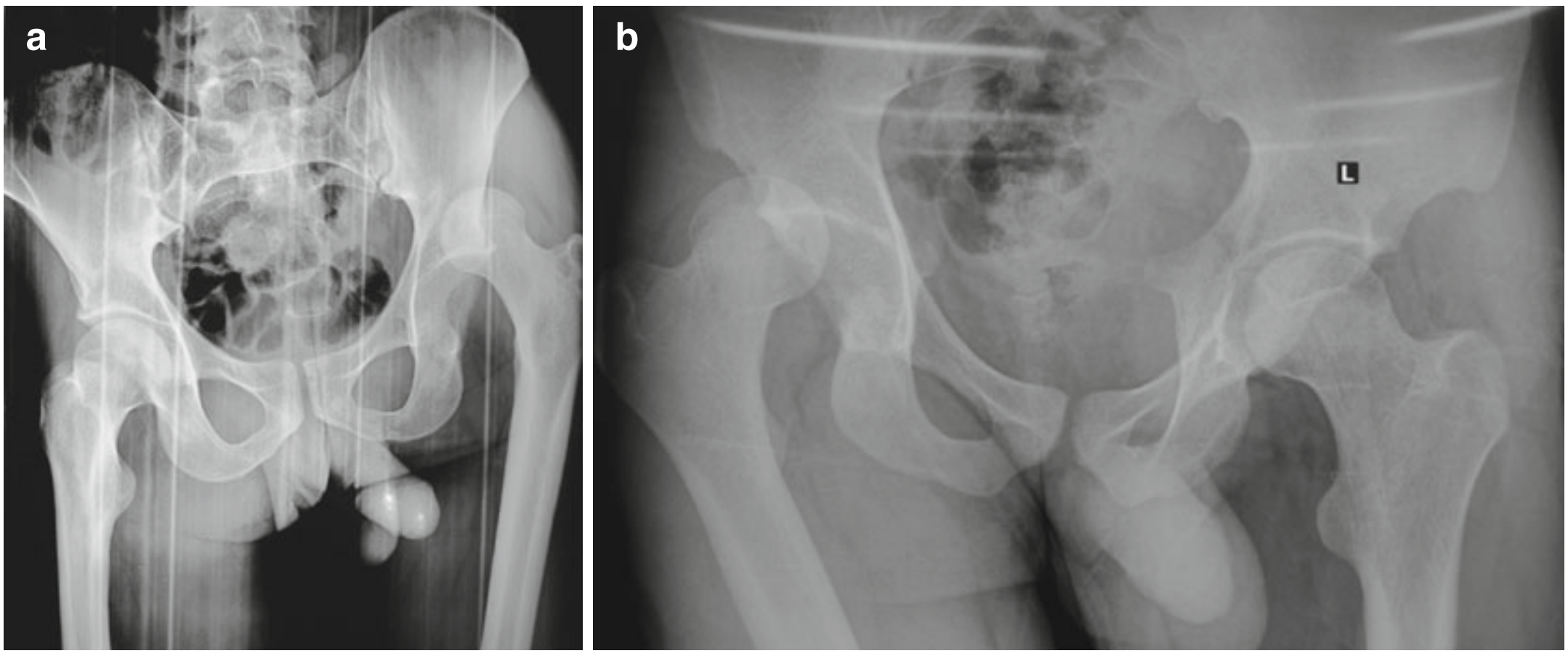

Fig. 40.8 (**a**, **b**) The typical position of a posterior fracture dislocation of the hip is internally rotated and shortened. An anterior dislocation may present with external rotation

Fig. 40.9 X-ray of a patient with an anterior fracture dislocation of the hip

uncommon (<10 %), which occur with the leg externally rotated, extended, and abducted at the hip, but are associated with a higher incidence of femoral head fracture. There is also about a 30 % rate of ipsilateral meniscal tear injury to the knee associated with dislocations overall [35]. Figure 40.2b shows the patient in Fig. 40.2a after reduction; the attitude of the limb has been re-established.

For diagnosis, AP and lateral views of the hip are needed to exclude the hairline or undisplaced femoral neck fracture [36]. The direction of dislocation can be determined based on the size of the femoral head and the projection of the lesser trochanter compared with the contralateral side. For a posterior dislocation, the femoral head is smaller and the lesser trochanter is less visible because of internal rotation whereas it is opposite for an anterior dislocation. Loss of concentricity of the femoral head with the acetabulum can also be seen with dislocation [37].

40.3.2 Management

The aim of treatment is anatomic reduction of the dislocated hip to restore articular congruency [36]. Treatment involves emergent closed reduction under sedation. Numerous reduction techniques for posterior dislocations all involve traction in line with the femur in a flexed and adducted position, including the *East Baltimore lift*, *Allis*, *and Bigelow* manoeuvres (Fig. 40.10a–c). In the presence of a femoral neck fracture, reduction should be attempted in the operating room after fixation of the fracture [6].

Once the femoral head has been reduced, the hip can then be abducted, extended, and accompanied by external rotation, which will restore leg length [38] (Fig. 40.11). Anterior hip dislocations can be reduced with longitudinal traction, laterally directed force on the thigh, and internal rotation with progressive flexion. Regardless of the method, only two or three attempts should be made with closed reduction to minimize iatrogenic fractures or cartilaginous injury [37].

The AP pelvis and Judet views after reduction are obtained to evaluate for associated femoral head, neck, and acetabular fractures, incongruence between the femoral head and acetabulum, and retained osteochondral fragments [35, 38]. Cross-table lateral view of the hip can be obtained to assess adequacy of the reduction [38]. Although a CT scan can ideally be performed to evaluate for associated acetabular and/or femoral head fractures, hip joint incongruence along with intra-articular loose bodies [37], this may not be feasible in the austere environment.

After closed reduction, a neurovascular exam should be performed. The hip should then be examined for stability by gently flexing the hip from 0° to 90° in neutral rotation. Those patients who have a stable hip to 90° of hip flexion must avoid putting the hip in the position of the dislocation – excessive flexion, adduction, and internal rotation. Immediately following the reduction and until the patient gains full consciousness, an abduction pillow can be fitted or improvised (Fig. 40.12). The patient can weight-bear as tolerated while initiating hip abductor and flexor strengthening, as well as gentle range-of-motion exercises. Posterior hip precautions should be maintained for at least 6 weeks post injury [38].

Open reduction is reserved for irreducible closed reduction, a displaced femoral neck fracture, and intra-articular fragments from the posterior wall or femoral head that result in an incongruous reduction [38]. Patients with the latter can alternatively be placed in distal femoral skeletal traction. Posterior dislocations can be

[redacted]

Fig. 40.10 (**a**–**c**) The patient shown in Fig. 40.8 following closed reduction of his dislocated right hip. Vectors of direction of pull when reducing the dislocated hip (*red arrows*)

Fig. 40.11 Following reduction, the limbs' attitude has been re-established. Limb in external rotation (normal attitude) following reduction of dislocated hip (*red arrow*)

treated by the posterior Kocher-Langenbeck approach. For anterior dislocation, surgical approaches include the Smith-Petersen (direct anterior) for better access to femoral head fractures or Watson-Jones (anterolateral) and Hardinge (direct lateral) for better access to the posterior capsule as needed [37] (Fig. 40.13).

The main complication involved with hip dislocation is osteonecrosis (up to 15 %), while post-traumatic arthritis, sciatic nerve injury particularly in the peroneal distribution, femoral

Fig. 40.12 Improvised abduction pillow to protect the patient and prevent redislocation of the hip until patient is fully conscious

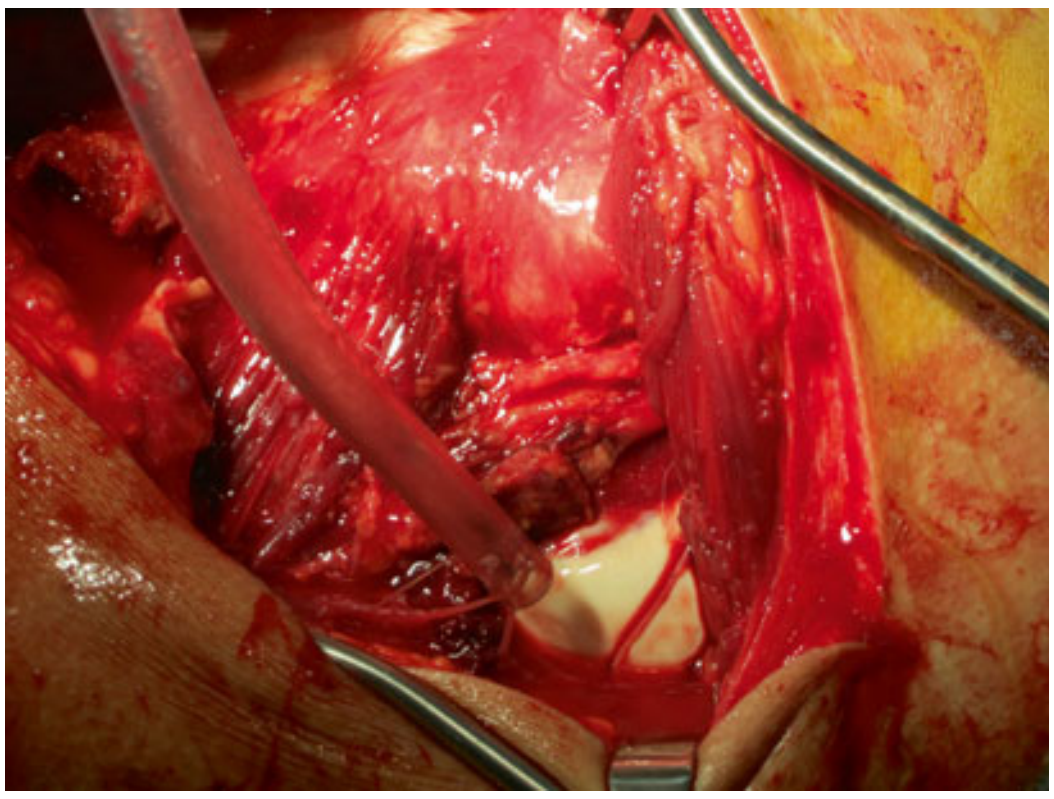

Fig. 40.13 Kocher-Langenbeck approach for open reduction of unreducible posterior dislocation of the hip

artery/nerve injuries (anterior dislocation), and instability are other considerations [35]. Rarely, recurrent instability occurs and is caused by capsular or labral defects or capsular laxity [37].

40.3.3 Delayed Management

It may not be feasible to attain reduction in the recommended time frame in developing countries. One small case series in India applied traction for 5–17 days to patients who had old isolated posterior dislocations (up to 75 days) and found that for several patients, the femoral heads became fully concentric without avascular necrosis or osteoarthritis during follow-up of 6 months to 3 years. However, heavy traction failed to reduce the hip in one patient with a very old dislocation of 9 months duration associated with a comminuted acetabulum fracture and other pelvis fractures [39].

Although early reduction is ideal, in areas with medical care shortages, it appears that satisfactory outcomes can still be achieved even with delay. Another study in India suggests that closed reduction under anaesthesia should generally at least be attempted in dislocations up to 3 weeks old. Over 3 weeks but less than 1 year, heavy traction abduction or open reduction can produce decent outcomes [40]. In patients with neglected dislocations in a developing country, traction can be useful in that it causes less trauma to the femoral head, soft tissues, and articular cartilage of the acetabulum [40].

40.3.4 Femoral Head Fractures

These types of fractures are relatively rare and associated with hip dislocations, although the incidence may be increasing due to the increase in road traffic accidents. Five to fifteen percent of posterior hip dislocations are complicated with a femoral head fracture. These fractures are classified using the Pipkin classification:

Fig. 40.14 A right Pipkin I femoral head fracture not involving the weight-bearing region of the head. However, the fracture is displaced and may require open excision of the fragment

Type I: fracture below the fovea/ligamentum. These fractures do not involve the weight-bearing region of the femoral head.

Type II: fracture above the fovea/ligamentum and involving the weight-bearing portion of the head.

Type III: type I or II with an associated femoral neck fracture. These fractures have a high incidence of avascular necrosis.

Type IV: type I or II associated with an acetabular fracture, usually of the posterior wall.

For the purposes of management in the austere environment, Pipkin I and II with less than 1 mm step off can be treated conservatively in a stable hip. Pipkin III–IV will probably require some form of surgical intervention and transfer should be considered if possible. Displaced Pipkin I and II–IV may require arthroplasty (Fig. 40.14).

Conclusion

As hip injuries represent a condition with ubiquitous prevalence across the globe, orthopaedists working in circumstances with varying resources are all confronted with the need to manage such patients. Although there remains some variation in the surgical management of hip fractures in developed regions, it is well accepted that these patients are best managed with timely surgical intervention using internal fixations methods or joint arthroplasty. For practitioners working in the austere environment, several challenges exist, including the limited availability and quality of resources. As such, even nonoperative methods deserve consideration when surgical interventions may pose increased complication risks [26].

In any circumstance, patients presenting with hip fractures should not be treated with prolonged bed rest. Prompt mobilization should be a goal for all hip fracture patients, so as to minimize complications associated with prolonged immobility [26]. Hip dislocations can generally be treated initially through several nonoperative reduction techniques as described above. Even those patients with delayed presentation can achieve successful results through the use of heavy traction.

Ideally, surgeons working in the austere environment will have access to basic implants that will allow them to care for hip fracture patients in an evidence-based manner. As the global hip fracture burden continues to rise, there is a dire need for international collaborative efforts in conducting hip fracture trials in the austere environment. It is only through such efforts that patients in these regions can be offered optimal care in the setting of a condition with unfortunate and often devastating sequelae.

References

1. Dhanwal DK, Dennison EM, Harvey NC, et al. Epidemiology of hip fracture: worldwide geographic variation. Indian J Orthop. 2011;45(1):15–22.
2. Haleem S, Lutchman L, Mayahi R, et al. Mortality following hip fracture: trends and geographical variations over the last 40 years. Injury. 2008; 39(10):1157–63.
3. Cooper C, Campion G, Melton 3rd LJ. Hip fractures in the elderly: a world-wide projection. Osteoporos Int. 1992;2(6):285–9.
4. Mock C, Cherian MN. The global burden of musculoskeletal injuries: challenges and solutions. Clin Orthop Relat Res. 2008;466(10):2306–16.
5. Kanis JA, Odén A, McCloskey EV, et al. A systematic review of hip fracture incidence and probability of fracture worldwide. Osteoporos Int. 2012;23(9):2239–56.

6. Foulk DM, Mullis BH. Hip dislocation: evaluation and management. J Am Acad Orthop Surg. 2010;18(4):199–209. Review.
7. Guyatt GH, Haynes RB, Jaeschke R. The philosophy of evidence-based medicine. In: Guyatt GH, Rennie D, Meade MO, Cook DJ, editors. Users' guides to the medical literature: a manual for evidence-based clinical practice. 2nd ed. New York: McGraw-Hill Medica; 2008. Part A.
8. Egol KA, Koval K, Zuckerman JD. Femoral neck fractures. In: Egol et al. Handbook of fractures. 4th ed. Philadelphia: Wolters Kluwer/Lippincott Williams & Wilkins Health; 2010. pp. 360–71.
9. Keating J. Chapter 47. Femoral neck fractures. In: Bucholz RW, Heckman JD, Court-Brown CM, Tornetta 3rd P, editors. Rockwood and green's fractures in adults. 7th ed. Philadelphia: Wolters Kluwer Health/Lippincott Williams & Wilkins; 2010.
10. Russell TA. Chapter 48. Intertrochanteric fractures. In: Bucholz RW, Heckman JD, Court-Brown CM, Tornetta 3rd P, editors. Rockwood and green's fractures in adults. 7th ed. Philadelphia: Wolters Kluwer Health/Lippincott Williams & Wilkins; 2010.
11. Miyamoto RG, Kaplan KM, Levine BR, et al. Surgical management of hip fractures: an evidence-based review of the literature. I: femoral neck fractures. J Am Acad Orthop Surg. 2008;16:596–607.
12. Koval KJ, Zuckerman JD. Hip fractures: I. overview and evaluation and treatment of femoral-neck fractures. J Am Acad Orthop Surg. 1994;2:141–9.
13. Parker MJ, Gurusamy KS. Internal fixation implants for intracapsular hip fractures in adults. Cochrane Database Syst Rev. 2001;(4):CD001467. doi:10.1002/14651858.CD001467.
14. Bhandari M, Devereaux PJ, Tornetta 3rd P, et al. Operative management of displaced femoral neck fractures in elderly patients. an international survey. J Bone Joint Surg Am. 2005;87(9):2122–30.
15. Gao H, Liu Z, Xing D, et al. Which is the best alternative for displaced femoral neck fractures in the elderly?: a meta-analysis. Clin Orthop Relat Res. 2012;470(6):1782–91.
16. Burgers PT, Van Geene AR, Van den Bekerom MP, et al. Total hip arthroplasty versus hemiarthroplasty for displaced femoral neck fractures in the healthy elderly: a meta-analysis and systematic review of randomized trials. Int Orthop. 2012;36(8):1549–60.
17. Ning GZ, Li YL, Wu Q, et al. Cemented versus uncemented hemiarthroplasty for displaced femoral neck fractures: an updated meta-analysis. Eur J Orthop Surg Traumatol. 2014;24(1):7–14.
18. Kaplan K, Miyamoto R, Levine BR, et al. Surgical management of hip fractures: an evidence-based review of the literature. II: intertrochanteric fractures. J Am Acad Orthop Surg. 2008;16:665–73.
19. Parker MJ, Handoll HHG. Gamma and other cephalocondylic intramedullary nails versus extramedullary implants for extracapsular hip fractures in adults. Cochrane Database Syst Rev. 2010;(9):CD000093. doi;10.1002/14651858.CD000093.pub5.
20. Yeung M, Bhandari M. Uneven global distribution of randomized trials in hip fracture surgery. Acta Orthop. 2012;83(4):328–33.
21. McNeil CR, McManus J, Mehta S. The accuracy of portable ultrasonography to diagnose fractures in an austere environment. Prehosp Emerg Care. 2009;13(1):50–2.
22. Rubio-Avila J, Madden K, Simunovic N, et al. Tip to apex distance in femoral intertrochanteric fractures: a systematic review. J Orthop Sci. 2013;18(4):592–8.
23. Eriksson BI, Bauer KA, Lassen MR, et al. Fondaparinux compared with enoxaparin for the prevention of venous thromboembolism after hip-fracture surgery. N Engl J Med. 2001;345(18): 1298–304.
24. Carson JL, Terrin ML, Noveck H, et al. Liberal or restrictive transfusion in high-risk patients after hip surgery. N Engl J Med. 2011;365(26):2453–62.
25. Carson JL, Grossman BJ, Kleinman S, et al. Red blood cell transfusion: a clinical practice guideline from the ABBB. Ann Intern Med. 2012;157(1):49–58.
26. Alms M, Barnechea G, Cobey J, et al. Proximal femoral fractures. a perspective from developing countries. Clin Orthop Relat Res. 1987;218:90–6.
27. Zabihi T, Kohanim M, Amir-Jahed AK. A modified Girdlestone operation in the treatment of complications of the femoral neck. J Bone Joint Surg Am. 1973;55(1):129–36.
28. Kemler MA, de Vries M, van der Tol A. Duration of preoperative traction associated with sciatic neuropathy after hip fracture surgery. Clin Orthop Relat Res. 2006;445:230–2.
29. MacEachern AG, Heyse-Moore GH. Stable intertrochanteric femoral fractures. a misnomer? J Bone Joint Surg Br. 1983;65(5):582–3.
30. Ali AM, Abdelkhalek M, El-Ganiney A. External fixation of intertrochanteric fractures in elderly high-risk patients. Acta Orthop Belg. 2009;75(6): 748–53.
31. Devgan A, Sangwan SS. External fixator in the management of trochanteric fractures in high risk geriatric patients—a friend to the elderly. Indian J Med Sci. 2002;56(8):385–90.
32. Kazakos K, Lyras DN, Verettas D, Galanis V, Psillakis I, Xarchas K. External fixation of intertrochanteric fractures in elderly high-risk patients. Acta Orthop Belg. 2007;73(1):44–8.
33. Sanders S, Tejwani N, Egol KA. Traumatic hip dislocation. a review. Bull NYU Hosp Jt Dis. 2010;68(2):91–6.
34. Egol KA, Koval KJ, Joseph DZ, Kenneth JK. Handbook of fractures. 4th ed. Philadelphia: Wolters Kluwer/Lippincott Williams & Wilkins Health; 2010. Ovid. Web.
35. Miller MD, Carcel M. Review of orthopaedics: expert consult. 6th ed. Philadelphia: Saunders; 2012. Print.
36. Tripathy SK, Sen RK, Goyal T. Conservative versus surgical management of pipkin type I fractures associated with posterior dislocation of the hip: a randomised controlled trial. Int Orthop. 2011;35(12):1907–8. doi:10.1007/s00264-011-1352-1. Epub 2011 Sep 17.

37. Canale ST, Beaty JH. Campbell's operative orthopaedics. 12th ed. Philadelphia: Elsevier/Mosby; 2012. MD Consult. Web.
38. Chapman MW. Chapman's orthopaedic surgery. 3rd ed. Philadelphia: Lippincott Williams & Wilkins; 2001. Ovid. Web.
39. Gupta RC, Shravat BP. Reduction of neglected traumatic dislocation of the hip by heavy traction. J Bone Joint Surg Am. 1977;59(2):249–51.
40. Pai VS. The management of unreduced traumatic dislocation of the hip in developing countries. Int Orthop. 1992;16(2):136–9.

Femoral Injuries

41

Sven Young

As an orthopaedic surgeon working in a low-income country (LIC), you will see a lot of femoral fractures. Like open tibia fractures, they are usually the result of the increasing epidemic of road traffic accidents (RTA) in low- and middle-income countries (LMIC). Even in conflict areas, hospital wards are often full of RTA victims, and in civilian hospitals, they can even outnumber the blast injuries and gunshot wounds one might be expecting to see as a visitor. The treatment of femoral fractures in a limited resource setting, and your own role as a surgeon, is dependent on many factors. Some of these include the available resources and equipment, the availability of local staff to train and supply with equipment and the length and goals of your visit. A disaster relief mission is very different in its goal to an equally short visit to a Southern African hospital, for example. Whereas after a disaster, one would want to treat as many injured people as possible in a short time to manage the spike in the incidence of trauma (Fig. 41.1); a planned visit to a hospital in a low-income country should have a more sustainable approach.

At a small district hospital in a low-income country, you might have very little equipment and will have to improvise to provide as good treatment as the local resources will allow (Fig. 41.2). At a central hospital in the same country, you might have all the equipment you need, but the huge burden of injuries in your ward and lack of theatre time might force you to prioritise quite differently than you would at home. In a military field hospital, one would usually only debride, stabilise and send to a fully equipped facility away from the frontline.

The same might apply to a businessperson, politician or tourist with full health insurance admitted to a local hospital in a LIC. However unfair this may seem, sending those that have the opportunity quickly on to a better-equipped and staffed hospital saves resources at the local hospital and probably helps those individual patients as well. In short, you need to know where you are going and to have realistic expectations of your own role. Though we all want to contribute and operate as much as possible, a short visit to some hospitals in LIC might be better spent teaching the staff in the outpatient department good reduction and casting techniques than doing surgery that is being done by others already anyway. In the following, I will try to outline some practical tips that may be useful as a visiting orthopaedic surgeon to a low-income country.

S. Young, MD, PhD
Department of Orthopaedic Surgery,
Haukeland University Hospital, Bergen, Norway

Department of Surgery, Kamuzu Central Hospital,
Lilongwe, Malawi
e-mail: svenyoung@gmail.com

© Springer International Publishing Switzerland 2016

J.D. Robinson (ed.), *Orthopaedic Trauma in the Austere Environment: A Practical Guide to Care in the Humanitarian Setting*, DOI 10.1007/978-3-319-29122-2_41

Fig. 41.1 Femoral fracture following a suicide bomber attack. A ball bearing used in suicide bomber vests can be seen

41.1 Epidemiology

Injury is the most common cause of death globally in young people between 10 and 24 years old, and the most common mechanism of injury is road traffic accidents (RTA) [1]. Ninety-seven percent of these deaths occur in low- and middle-income countries, and for every death we can expect another 3–10 people that survive with some disability [2, 3]. In Malawi, RTAs are the most common cause of injury overall [4].

The global burden of injuries is growing very rapidly and almost entirely in LMICs. The main cause of this is the rapid increase in RTAs [5, 6]. By 2030, the World Health Organization (WHO) expects RTAs to have risen from the ninth to the

Fig. 41.2 Traffic accident casualty on traction for bilateral femur fractures and a right tibia fracture. In the past several surgeons have called the use of traction for poly-trauma victims “horizontal crucifixion”. This picture should explain why. This young man was on traction for 3 months and ended up with nonunion of both femurs (© Sven Young, used with permission)

fifth leading cause of all deaths globally, only surpassed by the diseases of old age such as cardiovascular, cerebrovascular and pulmonary disease [7]. In high-income countries, the incidence of femoral shaft fractures is approximately 10–37 per 100 000 person years [8]. The incidence of femoral fractures is bound to be many times higher in LMIC. In Malawi, we found that 87 % of femoral fractures were due to high-energy trauma, and 25 % of the patients were polytrauma victims [9].

41.1.1 Review of Evidence

There should be little doubt about what is the best available treatment for femoral shaft fractures today. Intramedullary (IM) nailing has been the established gold standard of treatment for over half a century [10]. However, as the technique has evolved in high-income countries, we now use a lot of expensive equipment to do intramedullary nailing. In most low-resource settings, you will not have access to a modern traction table, a C-arm image intensifier (II) or flexible motorised reamers. Most likely, you will not have autoclaveable surgical power tools. As a consequence, there has been a need for new technology specifically designed for use under these conditions, and over the last decade, this has gradually been emerging.

SIGN Fracture Care International (SIGN) have designed an interlocking IM nail that can be used without a C-arm [11]. More importantly, SIGN supplies replacement nails and instruments to the hospital free of charge once the first set has been paid for, effectively solving the common problem of sustainable implant replacement in LICs. Using an IM nail without a C-arm usually means having to do open reduction of the fracture. This is not something surgeons are used to in high-income countries, and some surgeons feel strongly that this should be avoided. Küntscher emphasised as early as 1940 the importance of closed reduction and nailing under x-ray guidance to avoid infection and to improve healing [12]. However, he did not have access to antibiotics.

After the Second World War, IM nailing rapidly became used in many countries, but because of the questionable safety for the surgeon with the use of the early head worn fluoroscopy, most surgeons used open reduction instead [10]. With the use of prophylactic antibiotics, infection rates were still low enough after open reduction for the technique to be widely used for many years until the new C-arm image intensifiers were more available. We now have evidence that this is also the case with the use of open reduction with the SIGN nail in LMICs. In several recent reports, infection rates have been shown to be low after IM nailing in LMIC [13–15], and open reduction does not seem to increase the risk of infection significantly [15–18]. What does increase risk of infection is; failing to use preoperative prophylactic antibiotics [15, 16], the degree of soft tissue damage and operating neglected femoral fractures [15]. The possibility for increased risk of venous thromboembolism (VTE) because of the unavailability of low molecular weight heparin is probably no argument against IM nailing in LMIC either, as VTE, including pulmonary embolism (PE), occurs also while on traction for femoral fracture [13].

In many sub-Saharan countries, the prevalence of HIV is very high. HIV status should not be used as a contraindication to surgical treatment of femoral fractures. HIV-positive trauma patients have similar outcomes to HIV-negative patients [19–21]. Infection rates are not significantly increased, and they are mobilised just as quickly postoperatively [9]. HIV-positive patients do, however, have an increased risk of VTE [22] and possibly an increased risk of postoperative mortality after femoral nailing [9]. It is therefore probably even more important for HIV-positive trauma patients to receive some kind of VTE prophylaxis (e.g. Aspirin and/or compressive stockings) if possible; whether they are being treated on traction or by IM nailing.

If acceptable infrastructure and well-trained personnel are available, there is no doubt that IM nailing is the best treatment for femoral fractures. However, these important prerequisites for surgery are not always present in LIC. In these circumstances one is forced to use traction, and this is unfortunately still the case in the majority of hospitals in many LICs. However, despite the obvious inconvenience and discomfort for the patient, acceptable end results can be achieved with traction [23]. Traction times can be reduced significantly if followed up closely, especially with Perkins traction [24]. Contrary to what many surgeons think, however, traction is not without its risks. Up to 42 % of the patients get pin tract infection, 10–14 % end up with a nonunion or refracture, 12–14 % with malunion and 6 % with pressure sores [24]. pulmonary embolism (PE) can occur while on traction [13] and pin tract infection can spread to the fracture site [25]. In Malawi, we have also seen gangrene of the foot in an old man with arteriosclerosis as a complication to skin traction, and if you do not have the staff or the necessary beds to do Perkins traction, patients invariably end up with a stiff knee for months or even permanently. As surgeons in a setting with limited resources, we need to know about these risks and try to avoid them.

41.2 Treatment

Treatment protocols must, of course, be adapted to the resources available and the training and skills of the available staff. If infrastructure, equipment, operating capacity and the skill of the surgeon allows, then IM nailing should be the treatment of choice. However, in a low-income country, taking a patient with a fractured femur straight to theatre for an IM nail is usually not possible. X-rays and an Hb might not be available at night or at all, and blood is usually not available on short notice. As such, you probably will not know when you will be able to do this surgery. If you do not expect the patient to wait long for surgery, it makes sense to use skin traction to avoid pin tract infection while waiting for surgery. However, skin traction does not allow sufficient weight to be applied to the traction and if you expect the patient to be waiting for a long time, or there is a possibility that traction will be the definitive treatment, skeletal traction should be used.

Open femoral fractures are emergencies and should go to theatre for thorough debridement and irrigation of the wound at the first possible opportunity. Give IV prophylactic antibiotics upon arrival to casualty (e.g. ceftriaxone 1 g IV OD); do not just order it in the file and hope the only nurse in the ward will have time to read it. Depending on the severity of the soft tissue injury, and position of the wound, you can choose to stabilise the fracture with traction or an external fixator while waiting for definitive surgery with an IM nail or put straight on skeletal traction or external fixation as definitive treatment.

41.2.1 Initial Management

In LMICs, femoral fractures in adults are usually the result of high-energy trauma. They are often associated with other injuries. Never forget the basics: The ABCDE of the ATLS! Get IV access and start IV fluids. Morphine is usually available. There is no reason to leave the patient in pain! Stabilise the fracture with skin traction or (if traction is the definitive treatment or the wait for surgery likely to be long) skeletal traction.

41.2.2 Skin Traction

Skin traction is usually only used as temporary stabilisation for femoral fractures while waiting for surgery. The exception is in children (see Sect. 41.2.3). It is usually applied as extension traction with the leg straight and flat on the bed. The main reason skin traction is not good enough for definitive treatment is that it will not allow enough weight to be applied. Applying any more than 5–7 kg will often end with blistering of the skin or loosening of the strapping. As a rule of thumb, 1/7 of bodyweight is needed to correct and hold the deformity in a femoral shaft fracture, i.e., usually 10–14 kg in a young man and 7–10 kg in a woman.

For skin traction to work, you will need:

1. Good, nonelastic, adhesive strapping (“sticky plaster”) 50 mm wide.
2. Wooden “spreaders”; pieces of wood 5 by 5 cm (2″ × 2″) preferably with a hole in the

Fig. 41.3 (**a**) Straightly skin traction with spreader and anti-rotation rock used on a patient. (**b**) Dr. Kumbukani Manda weighing a rock for use as a traction weight on the paediatric ward's scales and (**c**) inappropriate skin traction ((**a**, **b**) © Sven Young, used with permission. (**c**) © Lasse Efskind, used with permission)

middle for the traction cord (Fig. 41.3a). If spreaders are not available, a tightly folded piece of thick cardboard etc can be used.

3. Crepe/elastic bandage to hold the plaster on the skin. If crepe bandages are not available, strapping/sticky plaster can be used, but must not be applied circumferentially. Apply it around half the limb only at different levels or in a spiral/figure-of-eight configuration to avoid compromising circulation.
4. Traction cord. Any nonelastic string, washing line, etc. can be used. If none is available, gauze bandage is usually strong enough if unrolled and twisted into a cord (Fig. 41.3a).
5. 1, 2 and 5 kg weights. These are often not available. A pillowcase, sheet or even plastic bag filled with sand, rocks or bricks will do the trick (Fig. 41.3c). Use scales to check the weight (Fig. 41.3b). Scales are usually available in paediatric wards at least. Needing to

improvise does not mean you can get away with anything (Fig. 41.3c). The traction on this patient is obviously done by someone who does not understand the principles that apply. A disposable syringe has been used as a spreader. Putting it in the sagittal plane only gives a point of fixation for the cord; it does not spread the strapping to protect the foot and ankle. It might have worked if it could be fixed transversely. No anti-rotation "device" has been used, and there is obvious external rotation of the limb. A bed without an end board or bar has been used leaving the cord on the mattress. This reduces the effect of traction due to friction. In this case, you can also see from the size of the bundle used for traction that a much too small weight must have been applied.

6. Pulleys or at least a bar on the end of the bed to run the traction cord over (Fig. 41.5). If the traction cord lies on the mattress, the friction is too high for traction to be effective (Fig. 41.3c).
7. Blocks to place under the legs of the bed to raise the end for counter-traction (Fig. 41.4).

41.2.3 Paediatric Femoral Fractures

Children under 12 kg (often about two years old in high-income countries, but can vary a lot in LICs) are best treated in Gallows traction. Skin traction is applied to both legs all the way up to the proximal thigh, and the traction cords are tied to a bar above the bed. The buttocks of the child should only just be lifted off the bed.

Children above 12 kg were traditionally treated in 90-90 traction in high-income countries before the widespread introduction of elastic stable intramedullary nailing (ESIN) from the 1990s. 90-90 traction, however, necessitates the use of skeletal traction, and in children that means the use of ketamine or General Anesthesia (GA). The main argument for the use of 90-90 traction is the good control of rotation it offers. However, this can be solved in other ways. Straight leg extension traction does not lead to a permanently stiff knee in children under the age of 14 or so. Also, because less weight is needed to reduce and hold the fracture and less time is needed until union in children, skin traction works well. We usually use 10 % of the child's weight for traction. The rotation is controlled by placing an anti-rotation block (usually a litre of IV fluid or a brick wrapped in some cloth) on each side of the child's foot and instructing the guardian to make sure the big toe is always pointing at the ceiling. Skak and Jensen [26] showed that a femoral fracture in a child heals roughly in as many weeks as the child's age in years. This can be a good rule of thumb to inform the parents of the expected length of stay. When the fracture is no longer mobile or painful on manipulation and the child can lift the limb from the bed, the child is discharged home. The parents are instructed not to force the kid to try to stand or walk until the child does so on his/her own.

41.2.4 Skeletal Traction

Skeletal traction (Fig. 41.4) is still the most widely used treatment for femoral fractures in district hospitals in LICs and many places; it will remain so for many years until enough fully trained orthopaedic surgeons are available for the introduction of IM nailing outside the central hospitals. However, do not be fooled into thinking skeletal traction is an easy option. For good results with treating femoral fractures in traction, you need to pay meticulous attention to detail and follow up the patients very closely. To avoid stiffness of the knee and promote rapid healing, early mobilisation of the knee is needed. The most efficient way of attaining this is probably the use of Perkins traction [24–27] (Fig. 41.4).

A normal hospital bed can be modified to allow exercises of the knee joint. Daily exercises must be encouraged from around three days after the injury. However, this requires a dedicated health worker with time to follow up these patients daily. In many hospitals, that will be difficult. Often straight leg extension traction is what is available. If this is the case, make sure that it at least is done as well as possible [23]. Some important points are:

Fig. 41.4 Perkins traction. Notice the front legs of the bed have been elevated on wooden blocks

1. Give some form of pain relief and sedation (e.g. pethidine and diazepam) as well as local anaesthetic when inserting the traction pin. Use sterile technique, preferably in a minor theatre or treatment room, and try to find someone to assist you.
2. Use a large enough Steinmann or Denham traction pin, usually (at least) 4 mm thick, so it will not bend. Thinner K-wires need to be tensioned with a tensioning clamp/stirrup.
3. Place the pin in the proximal tibia parallel to the knee joint and the posterior condylar plane ensuring correct rotation and angulation of the fracture with the pin parallel to the surface of the mattress and the end of the bed.
4. Though this is often called “tibial tuberosity traction”, the pin should be placed posterior to the tibial tuberosity to avoid pull-out and damage to the extensor mechanism. Insert the pin from the lateral side to avoid peroneal nerve injury.
5. Don’t cut the pin. It can be sharpened, sterilised and used again.

Fig. 41.5 Traction stirrup made of plaster of paris bandage. (© Sven Young, used with permission)

6. If a traction stirrup is not available, one can easily be made out of plaster of paris (POP) (Fig. 41.5). Tying the cord straight to the pin does not work well. It will slip and press on the skin. If corks are available (and POP is not), they can be threaded onto the pin and be used to tie the cord on. This will stop the cord from slipping. They can also be used to cover the point of the pin to protect staff and the patient’s other leg from injury. An empty medicine vial can also be used to cover the point of the traction pin.
7. Use enough traction weight (approx. one-seventh of body weight) to clinically correct the shortening and angulation of the fracture. Remember to raise the bed end to provide counter-traction (Fig. 41.4).
8. The pins should be cleaned daily by the patient or a guardian with methylated spirits or chlorhexidine.
9. Use an anti-rotation device of some kind. This can be a POP boot with a stick attached distal to the heel to prevent rotation or just some objects on either side of the foot to keep the big toe pointing at the ceiling (Fig. 41.3a). Inform the patient why this is important.
10. Patients should be taught quadriceps exercises early and encouraged to pull against the traction weight. If a physiotherapist or rehabilitation technician is available at your hospital, ask for them to follow up the patient several times a week.

11. When the fracture is clinically stable and painless, and the patient can straight leg raise, traction can be removed.

The patient should be on non-weight bearing crutches for at least 6 weeks, depending on fracture configuration and healing, and only gradually increase weight bearing after this. Inform the patient to return if increasing deformity arises after discharge. Encourage range of motion (ROM) exercises for the knee, and enlist the help of a physiotherapist or rehabilitation technician if available to instruct the patient thoroughly about these exercises on discharge.

41.2.5 IM Nailing

Preparing for surgery should be much the same as in a high-income country. Don't compromise with the safety of the patient. Before surgery, you should know the patient's Hb and save 2 pints of blood. Unfortunately, this is not always possible. If an Hb is not possible to do, you can get a good impression if a patient is anaemic or not by examining the conjunctiva and tongue of the patient. In LIC, we are usually doing open reduction with some extra risk of blood loss compared to closed reduction. If blood is not available, you should consider postponing the case, especially if it is a neglected case with a higher risk of blood loss. If the patient has been on skeletal traction, the wounds should be completely healed before IM nailing. Any infection, any place on the body surface, is a contraindication to surgery. Any scabs should be removed to ensure there is no pus underneath. Give prophylactic antibiotics IV (e.g. ceftriaxone 1 g IV stat) preoperatively as soon as the patient is in theatre [18].

For antegrade IM nailing of the femur without a traction table or C-arm, the lateral decubitus position provides the best access and sterility [28]. The lateral position can even be used with a C-arm if one is available, but a traction table is not [29]. Make sure the patient is securely positioned with side supports. Flex the contralateral leg for better stability. Thoroughly clean the whole leg from the ankle to above the iliac crest and from the groin to the rima internates. Also clean the exposed surface of the contralateral leg. We do not usually have nonabsorbent disposable drapes, and cotton drapes will quickly absorb any dirt when wet.

For retrograde nailing, the patient should be in the supine position. Retrograde nailing is often used in bilateral femoral fractures, so both femurs can be fixed without changing the position of the patient. Distal femoral fractures are also fixed with greater stability and control of angulation with retrograde nailing. If you have II available, use it to get the entry point exactly right. Also the use of II can make closed reduction possible in reasonably fresh distal femoral fractures. However, there are reports of increased complications after retrograde nailing, and this technique should only be used when necessary and only by surgeons experienced in the use of retrograde nails [13, 30].

Put the towel clips through the skin to hold the drapes in place. Try never to touch the metal implant with your gloves or let it touch the skin of the patient. Think infection prevention throughout the procedure.

Do not rush cleaning, draping or surgery. It is over a century since the best surgeon was the fastest surgeon. Just because we have to compromise on the choice of treatment or improvise when missing equipment, you should never compromise on getting as good results as possible.

The operating technique is of course dependent on the implant being used. If you are operating without a C-arm, you will probably be using the SIGN IM nail. If you are not familiar with this implant, make sure to read the manual very carefully before doing any surgery. Even if you are very experienced with other IM implants, there are several important differences that you need to be aware of. Take your time finding and preparing the correct entry point for the nail! Save bone from the reamers and any resected bone. Hard cortical bone should probably not be used, but all bone that can be mashed nicely to a pulp with a rongeur or similar can be returned to the fracture site before closing the wound. Even in nonunions, you usually get enough bone from the reamers and resected callus to graft the fracture site without the need to harvest bone from the iliac crest.

Getting used to placing distal interlocking screws without a C-arm can take some time. If you know you will be using the SIGN IM nail system for the first time on a planned visit, I recommend bringing a few saw bones to practise using the instruments used to find the slots in the nail. Drill some holes purposely out of place, and practice aligning the nail with the help only of the tactile sense of your fingers and the "slot finder" instruments. Once you have the feel of this in your hands, you will "never" miss an interlock.

41.2.6 External Fixation

External fixation is an alternative to IM nailing either as temporary treatment in open fractures, as definitive treatment in infections or if good quality fixators are available and IM nails are not. If you are planning to use an external fixator as definitive treatment for a femoral fracture in an adult, you must ensure the fixator you plan to use is stable enough for the fracture constellation you are treating. Many simple monoplanar trauma fixators were designed mostly for stabilisation before transport and are not very strong. Good placement of pins and adequate reduction of the fracture should be ensured by using C-arm II (or intraoperative conventional x-rays) if available or a mini open reduction if needed. An anatomically reduced transverse fracture might be stable enough to partially weight bear on with a simple trauma fixator. However, a severely comminuted fracture might need a strong monolateral or a circular fixator to hold it. Make sure there is full ROM at the knee intraoperatively without tenting of the skin around the pins (see Chap. 26, on External Fixation) (Fig. 41.6).

41.2.7 Distal Femur Fractures

Intraarticular fractures of the distal femur should be treated the same way as in high-income countries if resources are available, the fracture is displaced and you have experience with this surgery. Large fragment screws can be used to repair the condyles, and a blade plate or retrograde nail can be used to fix the condyles to the shaft. If a large fragment set is not available to fix the condyles, closed manipulation and skeletal traction, or a bridging external fixator, can produce acceptable

Fig. 41.6 (**a**) A "diamond" frame configuration (as described in the chapter on damage control) and (**b**) x-ray showing early healing of a femoral fracture with bone loss

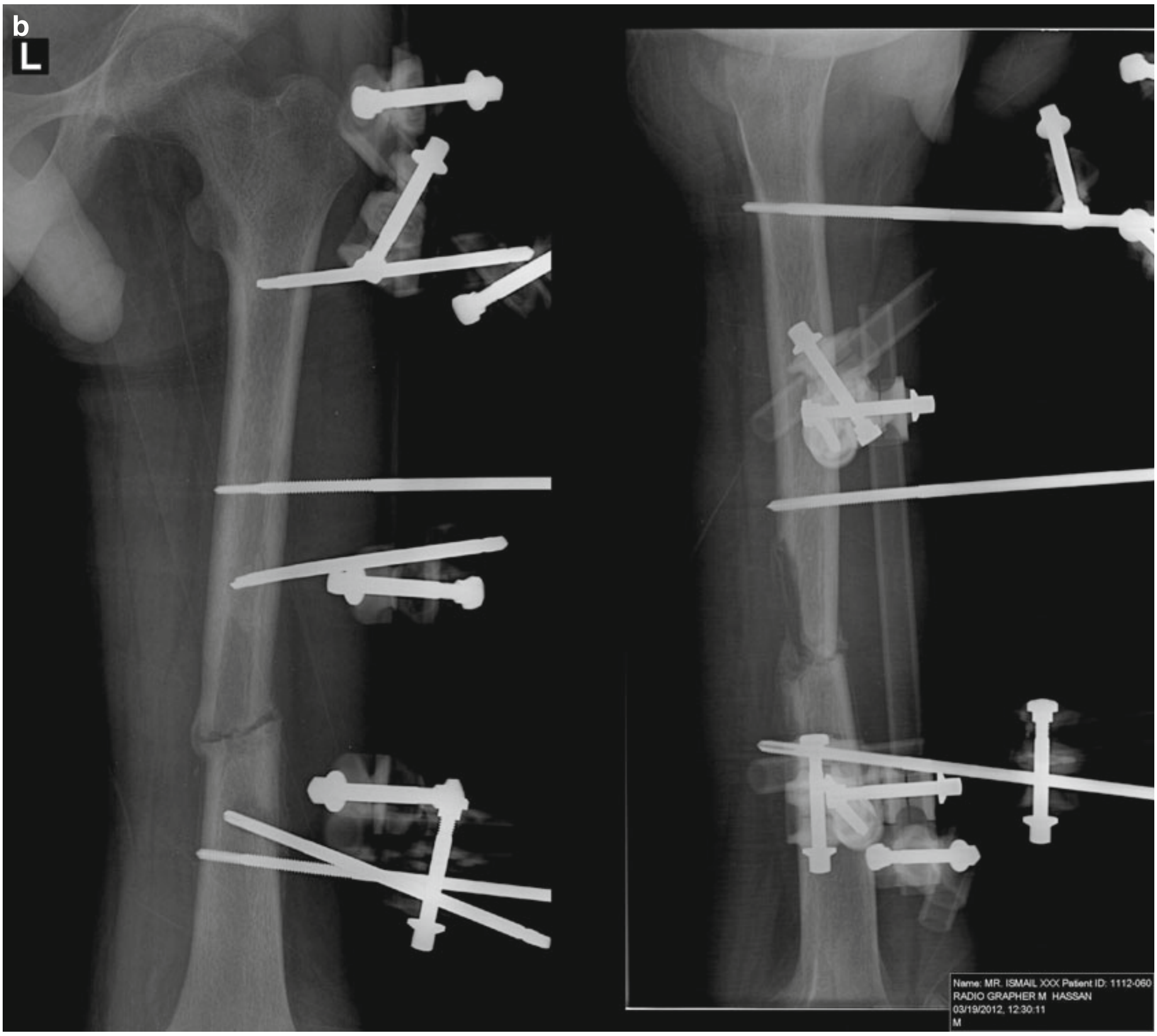

Fig. 41.6 (continued)

functional results (Fig. 41.7). Some surgeons have described success with the use of limited open reduction and fixation of the joint surface with K-wires and stabilisation with a bridging external fixator. However, open reduction of the knee joint combined with insufficient fixation should be avoided.

41.3 Complications

Infection rates after IM nailing of the femur in most LMIC lie somewhere between 1 and 5 % [9, 15]. This might sound too much to surgeons from high-income countries; however, considering the spectrum of serious trauma and the environment the surgery is being done, these are quite acceptable rates. The deep infection of an IM nail is a serious complication and often leads to some degree of permanent knee stiffness, but it can usually be treated well by debridement and washout followed by suppressive antibiotics until the fracture has healed [31]. On removal of the nail, the IM canal should be reamed to remove as much infected tissue as possible [32].

Sudden death due to venous thromboembolism (VTE) does occur after surgery and on traction. Mechanical VTE prophylaxis in the form of exercises to use the muscles of both legs regularly

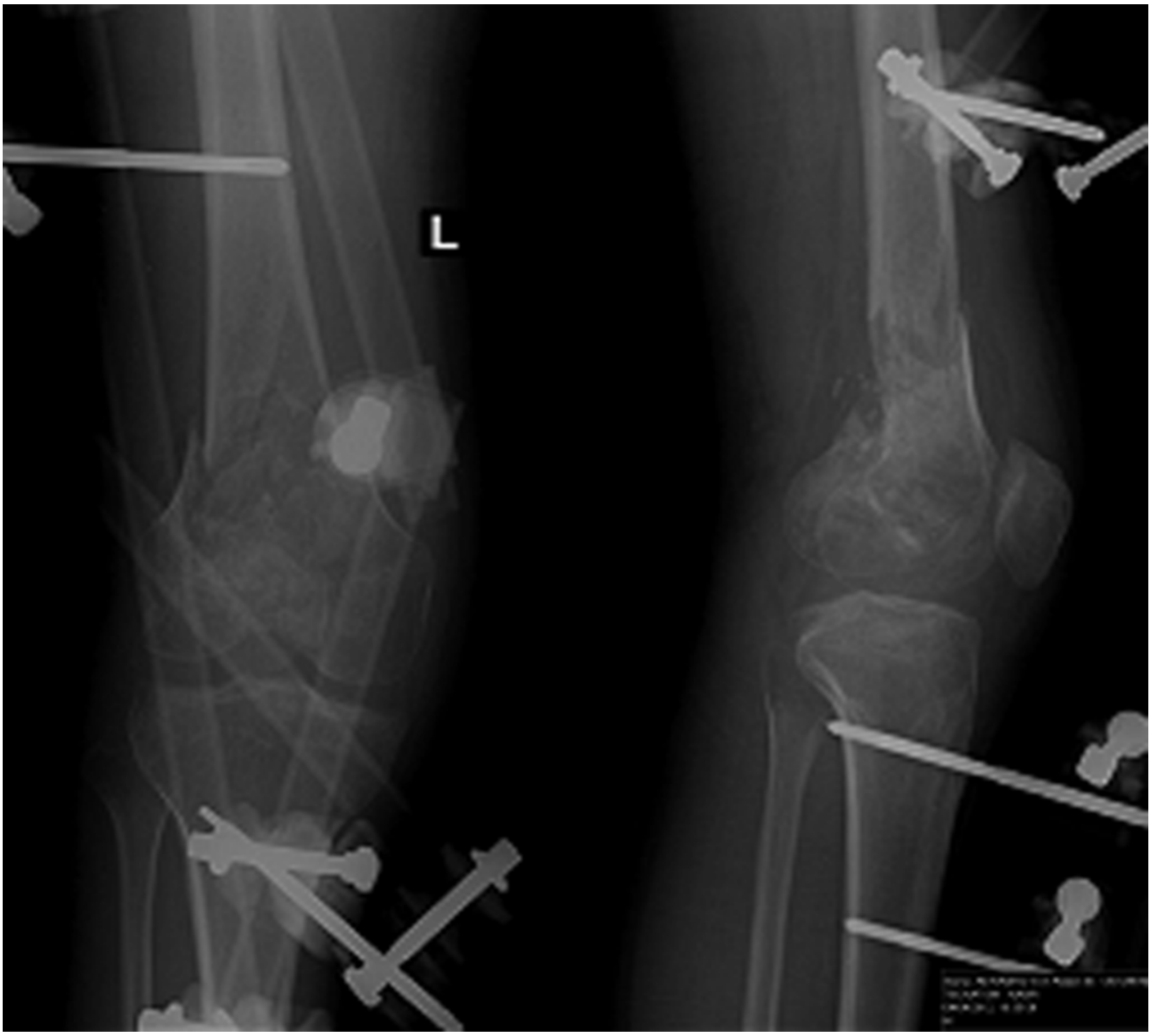

Fig. 41.7 A distal femoral fracture was stabilised with an external fixator spanning the knee. Excellent alignment was achieved and maintained until bony union

every day (and if available compressive stockings) should be used. Aspirin 75–100 mg OD for a week postoperatively is also recommended, though the evidence for the effect of this is rather thin. As blood is hard to come by in our setting in Malawi, we do not give aspirin preoperatively for fear of increased bleeding.

Infections, mechanical complications and hardware failure all arise from poor use of sound mechanical and surgical principles (Fig. 41.8). Having to improvise in a resource-constrained environment does not mean we can ignore these principles. If our skills, equipment or the setting does not allow us to follow this, it is better for the patient that we use nonoperative methods of treatment.

Pin site infections are common with external fixators in all settings, possibly even more so in resource-constrained settings. Advise washing the pins with chlorhexidine or methylated spirits daily and cover pin sites with clean gauze. Treat pin site infection with a two-week course of oral cloxacillin early if available. Very infected or loose pins should be removed, and the pin hole in the bone curetted. Give a long course of cloxacillin to try to avoid chronic osteomyelitis.

Fig. 41.8 A femoral fracture nonunion with failure of the plate fixation

41.4 Rehabilitation

Rehabilitation after IM nailing depends on the fracture configuration ("the personality of the fracture"), the quality of the bone, patient compliance and the quality of the surgery. A patient with a stable transverse fracture with a well-placed IM nail of the right size and length can weight bear as tolerated day 1 postop. In a very unstable comminuted fracture, we would normally advise 6 weeks partial weight bearing to start with. In all cases, encourage full active ROM exercises for the knee while standing on the good leg with support and/or while sitting on a chair. This is especially important with infected nails. In these cases, it is useful enlisting the help of a physiotherapist as early as possible.

For rehabilitation after traction, please see above.

41.4.1 Follow-Up

Follow-up can be a challenge in LIC. Many patients do not return even if encouraged to. Often the reason for this is the cost and availability of transport [33, 34]. However, probably most of the patients that have serious problems will return for review [9]. Inform the patients and the guardians of the most common complications and that they can be helped if they return.

41.5 Case Study

A 40-year-old Chinese businessman was brought to casualty at Kamuzu Central Hospital in Malawi after having been shot in the thigh with a handgun. He had tried to refuse to give up his wallet when his car was hijacked by armed robbers. The laboratory machine for full blood count (FBC) had broken down and there was no way to get an Hb. His conjunctiva and tongue were pale; he was tachycardiac but BP was normal. No other injuries were found. There was a small entry wound on the anterior aspect of the right distal thigh (Fig. 41.9a) and a small 4 by 4 cm exit wound on the posterior aspect of the thigh. Distal pulses were present and neurological function was intact. The x-rays showed a comminuted distal femoral shaft fracture (Fig. 41.9b). He was taken to theatre and debridement was done with the help of an Esmarch rubber bandage tourniquet. Small fragments that were not attached to soft tissue were removed along with all dead or dirty tissue. The wound was also mechanically cleaned by pulling gauze through the wound canal and irrigated with many litres of saline. What would you do next?

Gunshot wounds (GSWs) can be treated with traction only [35]; however, external fixation

Fig. 41.9 (**a**) Clinical picture of entry point gunshot wound and (**b**) x-ray of comminuted femoral fracture (© Sven Young, used with permission)

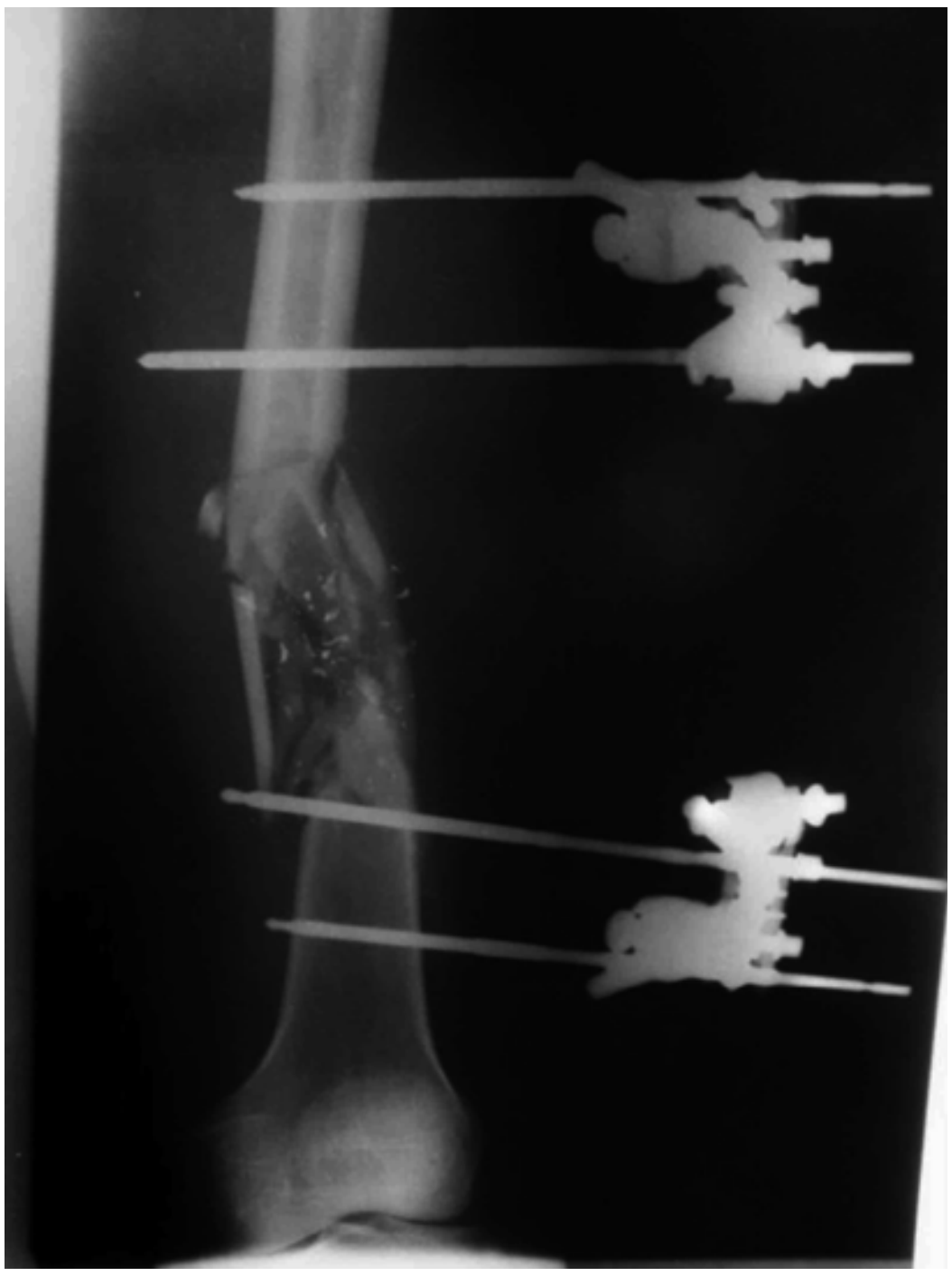

Fig. 41.10 External fixation stabilising comminuted femoral fracture. Only small, loose fragments were removed. Yet again only one projection was taken (© Sven Young, used with permission)

offers better stability and ease of wound care if the equipment and a surgeon experienced with the technique is available. A wound on the posterior aspect of the thigh is especially difficult to care for on traction. We were lucky to have an external fixator available, but the C-arm was out of order (Fig. 41.10).

After 3 weeks, the fracture was still completely loose. The wounds were dry but one of the pin sites was red and painful and the ex fix was not stable enough for him to be mobilised comfortably. The ex fix was removed and replaced by skin traction, and the patient was put back on IV antibiotics while waiting for surgery. He was taken to theatre a week later. The pin sites were dry and a retrograde SIGN IM nail was placed. The C-arm was still not working and a limited open reduction through a small lateral incision was done. He was kept on IV antibiotics for another 2 weeks. The fracture healed without infection. Eight weeks later he was walking normally without a limp. The end result at 2 years can be seen in Fig. 41.11. Retrograde nailing after GSW involving the distal femur has been shown to be successful also when nailing within 7 days [36].

Fig. 41.11 (**a**) A SIGN nail was used to treat the comminuted femoral fracture and this healed uneventfully, and (**b**) the patient has no knee or thigh pain and is functioning normally (© Sven Young, used with permission)

References

1. Patton GC, Coffey C, Sawyer SM, et al. Global patterns of mortality in young people: a systematic analysis of population health data. Lancet. 2009;374(9693):881–92.
2. Kobusingye O, Guwatudde D, Lett R. Injury patterns in rural and urban Uganda. Inj Prev. 2001;7(1):46–50.
3. Peden M. World report on road traffic injury prevention. Geneva: World Health Organization; 2004.
4. Samuel JC, Akinkuotu A, Villaveces A, et al. Epidemiology of injuries at a tertiary care center in Malawi. World J Surg. 2009;33(9):1836–41.
5. Hsia RY, Ozgediz D, Mutto M, Jayaraman S, Kyamanywa P, Kobusingye OC. Epidemiology of injuries presenting to the national hospital in Kampala, Uganda: implications for research and policy. Int J Emerg Med. 2010;3(3):165–72.
6. Lagarde E. Road traffic injury is an escalating burden in Africa and deserves proportionate research efforts. PLoS Med. 2007;4(6):e170.
7. Global status report on road safety: time for action. Geneva: World Health Organization; 2009. (www.who.int/violence_injury_prevention/road_safety_status/2009).
8. Weiss RJ, Montgomery SM, Al Dabbagh Z, Jansson K-A. National data of 6409 Swedish inpatients with femoral shaft fractures: stable incidence between 1998 and 2004. Injury. 2009;40(3):304–8.
9. Young S, Banza L, Hallan G, et al. Complications after intramedullary nailing of femoral fractures in a low-income country. A prospective study of follow-up, HIV and infection rates after IM nailing of 141 femoral fractures at a central hospital in Malawi. Acta Orthop. 2013;84(5):460–7.
10. Bong MR, Koval KJ, Egol KA. The history of intramedullary nailing. Bull NYU Hosp Jt Dis. 2006;64(3/4):94–7.

11. Phillips J, Zirkle LG, Gosselin RA. Achieving locked intramedullary fixation of long bone fractures: technology for the developing world. Int Orthop. 2012; 36:2007–13.
12. Küntscher G. Die Marknagelung von Knochenbruchen. Arch Klin Chir. 1940;200:443–55.
13. Sekimpi P, Okike K, Zirkle L, Jawa A. Femoral fracture fixation in developing countries: an evaluation of the surgical implant generation network (SIGN) intramedullary nail. J Bone Joint Surg Am. 2011;93(19):1811–8.
14. Young S, Lie SA, Hallan G, Zirkle LG, Engeseter LB, Havelin LI. Low infection rates after 34,361 intramedullary nail operations in 55 low- and middle-income countries. Acta Orthop. 2011;82(6):737–43.
15. Young S, Lie SA, Hallan G, Zirkle LG, Engesæter LB, Havelin LI. Risk factors for infection after 46,113 intramedullary nail operations in low- and middle-income countries. World J Surg. 2013;37(2):349–55.
16. Tang P, Gates C, Hawes J, Vogt M, Prayson MJ. Does open reduction increase the chance of infection during intramedullary nailing of closed tibial shaft fractures? J Orthop Trauma. 2006;20(5):317–22.
17. Bishop JA, Dikos GD, Mickelson D, Barei DP. Open reduction and intramedullary nail fixation of closed tibial fractures. Orthopedics. 2012;35(11):e1631–4.
18. Gillespie WJ, Walenkamp GH. Antibiotic prophylaxis for surgery for proximal femoral and other closed long bone fractures. Cochrane Database Syst Rev. 2010;(3):CD000244.
19. Cacala SR, Mafana E, Thomson SR, Smith A. Prevalence of HIV status and CD4 counts in a surgical cohort: their relationship to clinical outcome. Ann R Coll Surg Engl. 2006;88(1):46–51.
20. Duane TM, Sekel S, Wolfe LG, Malhotra AK, Aboutanos MB, Ivatury RR. Does HIV infection influence outcomes after trauma? J Trauma. 2008;65(1): 63–5.
21. Bates J, Mkandawire N, Harrison WJ. The incidence and consequences of early wound infection after internal fixation for trauma in HIV-positive patients. J Bone Joint Surg Br. 2012;94(9):1265–70.
22. Ahonkhai AA, Gebo KA, Streiff MB, Moore RD, Segal JB. Venous thromboembolism in patients with HIV/AIDS: a case-control study. J Acquir Immune Defic Syndr. 2008;48(3):310–4.
23. Doorgakant A, Mkandawire NC. The management of isolated closed femoral shaft fractures in a district hospital in Malawi. Trop Doct. 2012;42(1):8–12.
24. Gosselin R, Lavaly D. Perkins traction for adult femoral shaft fractures: a report on 53 patients in Sierra Leone. Int Orthop. 2007;31(5):697–702.
25. Young S, Beniyasi FJ, Munthali B, Banza L. Infection of the fracture hematoma from skeletal traction in an asymptomatic HIV-positive patient. Acta Orthop. 2012;83(4):423–5.
26. Skak SV, Jensen TT. Femoral shaft fracture in 265 children. Log-normal correlation with age of speed of healing. Acta Orthop Scand. 1988;59(6):704–7.
27. Bezabeh B, Wamisho BL, Coles MJ. Treatment of adult femoral shaft fractures using the Perkins traction at Addis Ababa Tikur Anbessa University Hospital: the Ethiopian experience. Int Surg. 2012;97(1):78–85.
28. Zirkle Jr LG, Shearer D. SIGN technique for retrograde and antegrade approaches to femur. Techn Orthop. 2009;24(4):247.
29. Bishop JA, Rodriguez EK. Closed intramedullary nailing of the femur in the lateral decubitus position. J Trauma. 2010;68(1):231.
30. Leggon RE, Feldmann DD. Retrograde femoral nailing: a focus on the knee. Am J Knee Surg. 2001; 14(2):109–18.
31. Berkes M, Obremskey WT, Scannell B, et al. Maintenance of hardware after early postoperative infection following fracture internal fixation. J Bone Joint Surg Am. 2010;92(4):823–8.
32. Court-Brown CM, Keating JF, McQueen MM. Infection after intramedullary nailing of the tibia. Incidence and protocol for management. J Bone Joint Surg Br. 1992;74(5):770–4.
33. Bedford KJA, Chidothi P, Sakala H, Cashman J, Lavy C. Clubfoot in Malawi: treatment-seeking behaviour. Trop Doct. 2011;41(4):211–4.
34. Yu JK-L, Chen SC-C, Wang K-Y, et al. True outcomes for patients on antiretroviral therapy who are “lost to follow-up” in Malawi. Bull World Health Organ. 2007;85(7):550–4.
35. Clasper JC, Rowley DI. Outcome, following significant delays in initial surgery, of ballistic femoral fractures managed without internal or external fixation. J Bone Joint Surg Br. 2009;91(1):97–101.
36. Poyanli O, Unay K, Akan K, Guven M, Ozkan K. No evidence of infection after retrograde nailing of supracondylar femur fracture in gunshot wounds. J Trauma. 2010;68(4):970–4.

Further Reading and Training

Attend the annual SIGN conference in Richland, Washington State, USA, if you have the opportunity.

Doorgakant A, Mkandawire N, editors. Orthopaedic Care at the District Hospital. This is a pocket-sized handbook mainly intended for orthopaedic clinical officers working in district hospitals in Malawi, but should be a handy guide for anybody working in the districts in a low-income country.

Giannou C, Baldan M, Molde Å. War surgery. Working with limited resources in armed conflict and other situations of violence, vol. 2. International Committee of the Red Cross. Good guide to war surgery. Must be read with the situation of armed conflict in mind. In other situations with limited resources one might not need to be quite so conservative with the use of IM nailing or other internal fixation. Can be downloaded from the ICRC: http://www.icrc.org/eng/resources/documents/publication/p4105.htm.

King M, editor. Primary surgery, vol. 2, Trauma. Chapters 70 and 78 contain good descriptions of and many good tips about treatment in traction, as well as many tips on what to do when you are missing important equipment or consumables. How do you make a POP bandage or convert a normal hospital bed to a bed suitable for Perkins traction? The trauma chapters can be downloaded as pdf-files from: http://www.primary-surgery.org/download.html.

The *SIGN IM nail manual* is absolutely essential to read thoroughly if you are going to be using SIGN IM nails. You can download it by contacting SIGN Fracture Care International at: http://signsurgeons.org/publications/.

WHO. Surgical Care at the District Hospital. Chapters 17 and 18 contain some tips on orthopaedic care, including tips on treatment with traction. It can be downloaded as a pdf-file from: http://www.who.int/surgery/publications/scdh_manual/en/.

42

Distal Femoral Fractures and Knee Injuries in the Austere Environment

James Shelton and Steve Mannion

Although knee injuries are relatively common, a serious knee injury is relatively rare with an extrapolated incidence of 1 in 800 per year in the developed world [1]. In an austere environment, with poor infrastructure and the additional burden of war and natural disasters, it is reasonable to assume that knee injuries will form a significant part of the caseload.

In this chapter, knee injuries will be divided into fractures without soft tissue compromise, soft tissue injuries, combined injuries and dislocations. Distal femoral fractures will be dealt with as well, as they can present together following high-energy mechanisms.

42.1 Anatomy

The knee joint comprises of a number of important structures. The bony anatomy consists of the distal femur, proximal tibia and the patella. The articulation between the femoral trochlea and the medial and lateral facets of the patella form the patellofemoral joint. The articulation between the medial and lateral femoral condyles and the medial and lateral tibial plateau forms the tibiofemoral joints.

42.2 Supracondylar Femoral Fractures

Supracondylar femoral fractures have a bimodal distribution, classically seen in low-energy trauma to elderly osteoporotic females or in high-energy trauma to young men as a result of axial loading to a flexed knee [2]. An increased incidence of high-energy injuries in developing nations due to poor road safety will likely skew this distribution towards young males [3]; all patients with high-energy fractures should be managed as per the Advanced Trauma Life Support (ATLS) approach as there is a high chance of concurrent injuries.

Radiographic classification of this fracture uses the AO classification: A (extra-articular), B (partial articular [unicondylar]) and C (complete articular [bicondylar]) [4].

The equipment available at your facility will limit the management choices of these injuries. Indications for nonoperative management in developed nations include up to 10° of angular deformity in the sagittal plane and <2 mm step in articular surface [2]. Dependent on your equipment availability, skill set and available staff,

J. Shelton, MRCSEd
Department of Orthopaedics,
North West Deanery (Mersey Sector) Rotation,
Manchester, UK

S. Mannion, MChir, FRCS (Tr&Orth), FCS(ECSA) (✉)
Department of Conflict and Catastrophe Medicine,
St George's, University of London, London, UK
e-mail: stevejmannion@aol.com

© Springer International Publishing Switzerland 2016
J.D. Robinson (ed.), *Orthopaedic Trauma in the Austere Environment: A Practical Guide to Care in the Humanitarian Setting*, DOI 10.1007/978-3-319-29122-2_42

the conventional criteria for fixation in the developed world may not be relevant to your setting.

42.3 Nonoperative Management

42.3.1 Indications

Distal femoral fractures may be treated nonoperatively, provided the lasting deformity would not result in significant and life-long loss of function. Up to 15° of internal/external rotation is relatively well tolerated; however, once past this threshold, patients report pain and limitation of higher-demand activities such as running and climbing stairs. Interestingly, those with an external rotation deformity of over 15° have reported more symptoms than those with internal malrotation [5]. With respect to sagittal plane deformity, if the lateral distal femoral angle has less than 5° of deformity in valgus or varus, it is generally well tolerated. More than 5° of varus or valgus deformity will result in significant symptoms. The same is true for anterecurvatum. A deformity of more than 5° gives a poorer outcome [6]. Hence, if you are able to achieve an end product with less than 15° of malrotation and less than 5° of sagittal and/or coronal plane malalignment, casting or manipulation under anaesthetic casting may be appropriate. Patient factors are important in choosing a nonoperative treatment pathway – if they are medically unfit for an operation or non-ambulant, the risks may outweigh the benefits.

42.3.2 Reduction and Casting Technique

A manipulation under anaesthetic or sedation may improve sagittal malalignment and hence the patient's outcome. These patients can be immobilised in an above knee cast including the foot at 20–30°of flexion for 6–8 weeks [7].

42.3.2.1 Follow-Up

Initially weekly radiographs should be performed, as with all casting techniques, to monitor for any loss in reduction. The priority is to try to prevent a nonunion. Nonunions in these environments can be incredibly difficult to manage [2].

42.3.2.2 Complications

- Tight cast
- Compartment syndrome
- Non-/malunion
- Poor mobility/stiffness

42.3.2.3 Rehabilitation

After 6–8 weeks (or until radiographic evidence of union), these patients can be taken out of cast and must adhere to protected weight bearing for a further 4–6 weeks until clinical union has been achieved. Whilst in this period, it is essential to gain full knee extension and flexion to at least 90° as this is the functional range of movement at the knee [7].

42.3.3 Thomas Splint Application

An alternative to cast immobilisation in fractures of the distal femur or proximal tibia is the Thomas splint, a low-cost, balanced traction device which is widely available, even in austere settings (Figs. 42.1 and 42.2):

1. Select the correct size of Thomas splint for the patient.
2. Under general anaesthesia/sedation, apply steady longitudinal traction to the leg.
3. Apply the sticky skin traction on the leg and reinforce it with dressing.
4. Gently slide a Thomas splint under the thigh and attach the slings between the side bars to support the region of the knee.
5. With an assistant applying longitudinal traction to the foot, compress the knee from side to side and lower the limb on to the slings of the splint.
6. Attach the traction cords to the foot of the splint.
7. Once an acceptable reduction has been obtained, the traction can be eased, with a view to maintaining the limb at the same length as the uninjured side.
8. Encourage quadriceps contraction and watch for the first signs of the patient being able to

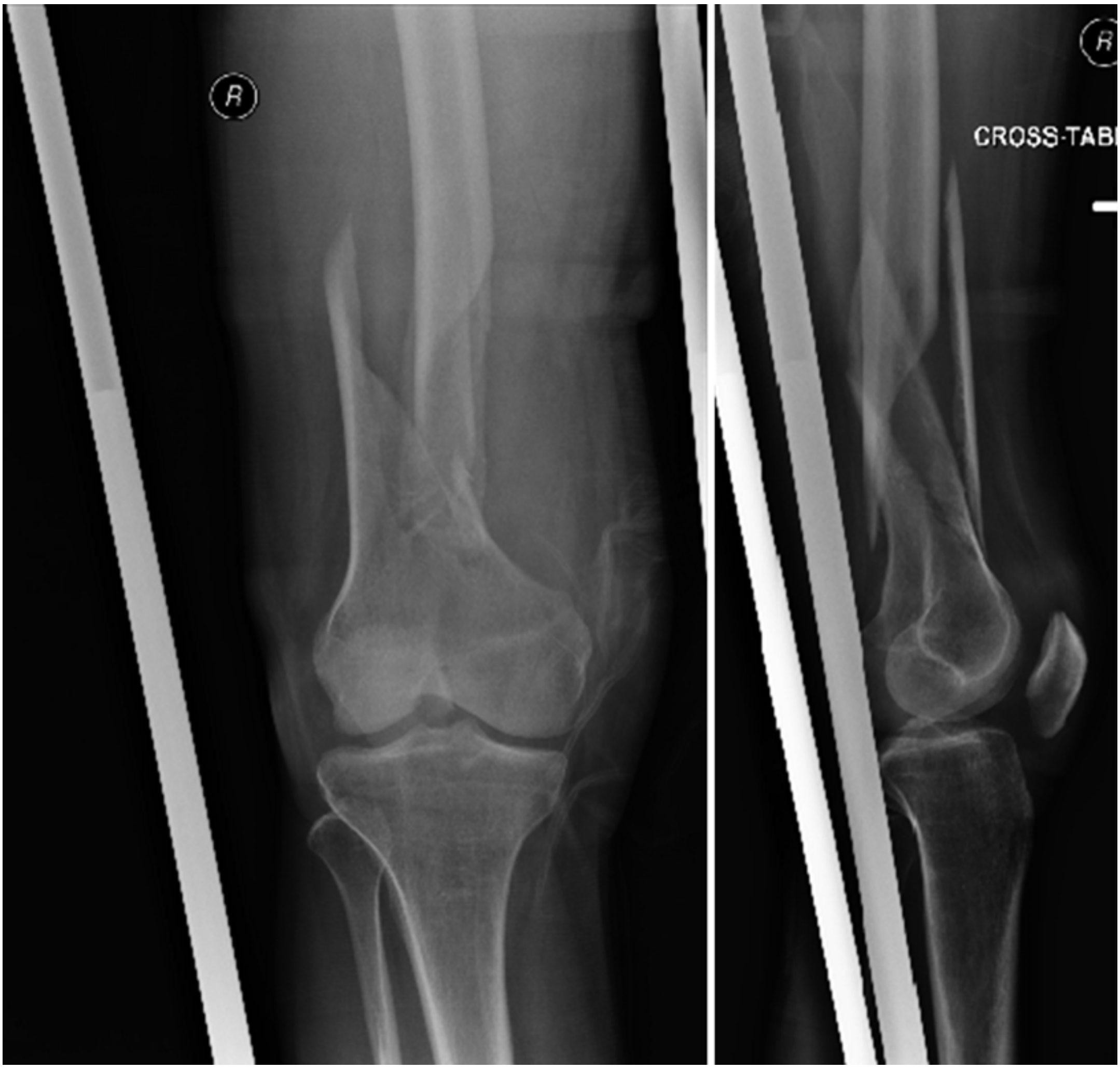

Fig. 42.1 Distal femoral fracture in Thomas splint with poor traction

lift the knee and inch or so off the splint – this will be about 3 weeks after the injury.

9. When signs of active knee lifting are seen, untie the traction cords daily and encourage active flexion exercises with the knee supported.
10. Abandon the splint when active straight-leg raising is easy (4–8 weeks) and rest knee on a pillow.
11. Do not worry if a little valgus deformity recurs in elderly patient, it is unlikely to be of functional significance.
12. Permit weight bearing between 9 and 12 weeks [8].

42.3.4 Skeletal Traction

42.3.4.1 Indications

Skeletal traction can be helpful in patients who cannot tolerate a Thomas splint; this may be due to blistering of the skin over the lower leg or pressure sores where the splint abuts the pelvis [9, 10].

42.3.4.2 Technique

If the fracture configuration permits, a distal femoral traction Schanz pin is inserted through the distal femur a couple of centimetres proximal to the intercondylar axis identified by palpating the femoral epicondyles. This is to ensure you stay

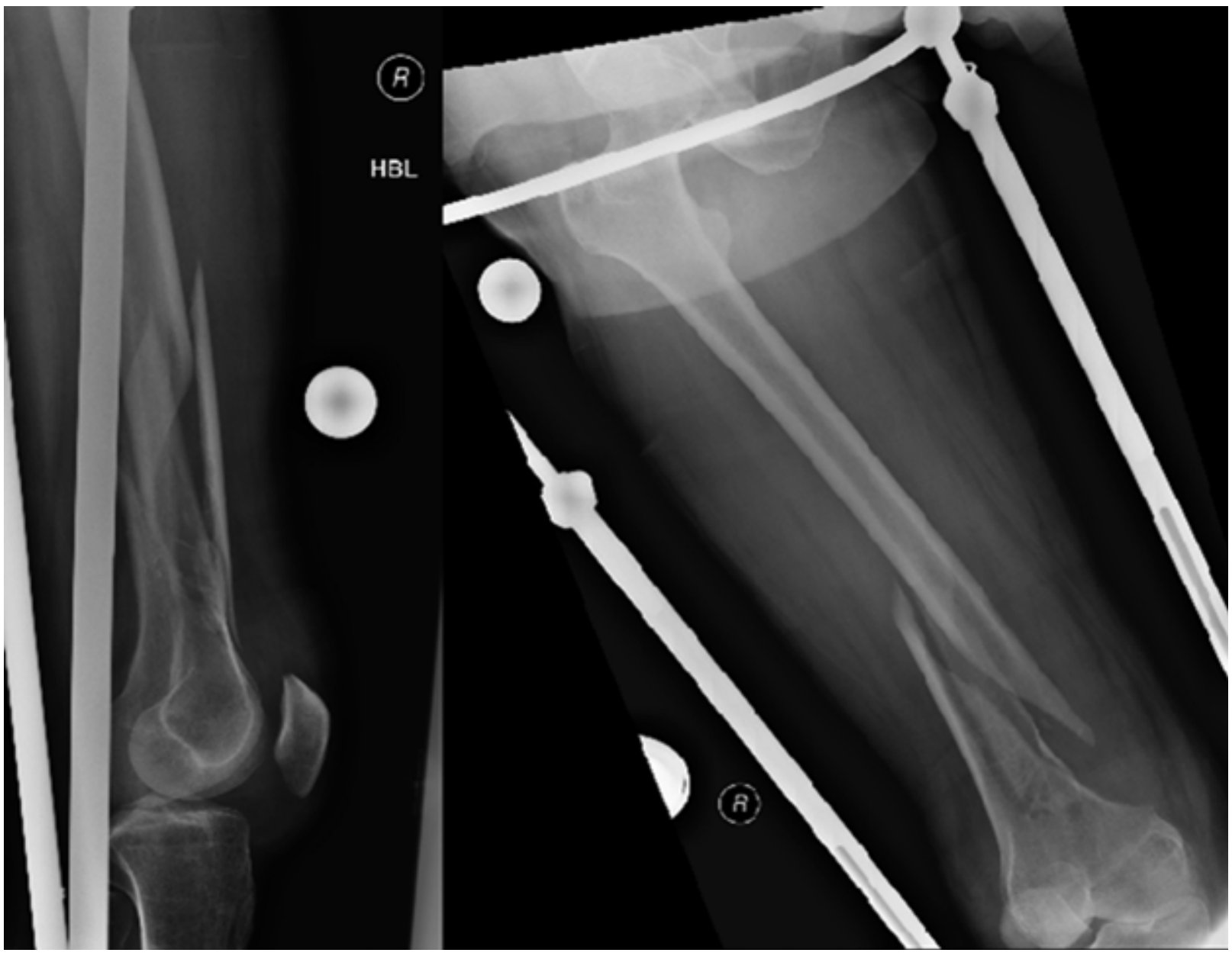

Fig. 42.2 Distal femoral fracture in Thomas splint with optimal traction; this has improved the position of the fracture. This patient underwent ORIF; however, in the austere environment, a manipulation under sedation or anaesthetic could improve the position

extra-articular. Once your pin is in position, dress it with gauze soaked in antiseptic and affix a stirrup to the pin, you can now start to add traction weights until the leg length had been restored.

If the fracture is too distal to insert a femoral pin, a proximal tibial pin is a good alternative. However, you may find you require more weight as some of the force is absorbed by the soft tissues of the knee. Insert the pin 2.5 cm posterior and 2.5 cm distal to the tibial tubercle [11, 12].

42.3.4.3 Follow-Up

Weekly radiographs must be taken to ensure no loss of alignment and to see evidence of callus formation; this can often be palpated as well.

42.3.4.4 Complications

Femoral Pin Must be cautious of entering the intercondylar notch if too potentially causing a septic arthritis.

To prevent injury to the femoral artery as it passes through Hunter's canal the Schanz pin should be inserted medial to lateral with opening dissection to the bone medially.

Tibial Pin Ensure no concomitant ligamentous damage to the knee. Insert from the lateral with opening dissection to the bone to minimise risk to the peroneal nerve [11].

42.3.4.5 Rehabilitation

This also allows closed chain exercises at 3–4 weeks which will reduce stiffness and improve function [7]. Equally once there is evidence of union at around 6–8 weeks, the patient may be able to start protected weight bearing without traction and follow standard knee rehabilitation [2].

42.3.5 External Fixation

42.3.5.1 Indications

Severe swelling or injuries to the soft tissue envelope are indications for a temporary spanning external fixator which will provide stability whilst the soft tissue injury heals. External fixators can be used as definitive management of fractures around the knee. However, due to the cantilever loading that takes place in these devices, there can be too much motion, thus creating a poor biological environment for fracture healing. A more advanced technique would be the use of a ring fixator. The advantage of these ring fixators is the ability to beam load the fracture causing uniform compression as opposed to the compression and tension sides seen in cantilever loading [11]. These techniques require specialised training and are beyond the scope of this chapter.

42.3.5.2 Technique

The basic principles for fixators are to use a ‘near-near, far-far’ configurations to provide maximal stability. Remember that pins should be placed outside the zone of injury and away from areas where a surgical approach may take place.

Femoral half pins should be placed anterolateral on the femur in order to facilitate patient care and avoid important anatomical structures. Tibial pins are placed anteromedially down the tibial crest. These are then joined by affixing bars to the pins in a stable configuration. There are some self-drilling, self-tapping systems now in use in austere environments, but do not expect the system available to you have these features [12].

42.3.5.3 Complications

- Pin site infection
- Neurovascular injury
- Loosening
- Non-/malunion [12]
- Arthrofibrosis
- Stiffness

42.3.5.4 Follow-Up

Weekly follow up for evidence of union clinically and radiographically and for pin site wound checks. Tightening of the external fixator may be necessary when planning a medical excursion to an austere environment an adjustable wrench is a key necessity.

42.3.5.5 Rehabilitation

Whilst the patient could theoretically weight bear on a strong frame, micromotion at the fracture site in conjunction with the cantilever loading should be avoided if possible. Hence, we would recommend protected or non-weight bearing for the first 6–8 weeks at least.

42.3.6 Intramedullary Nailing

42.3.6.1 Indications

A closed fracture that is extra-articular and is >7 cm from the intercondylar line [12]

42.3.6.2 Technique

If available, retrograde femoral nailing involves closed reduction of the fracture followed by opening the knee joint through a medial parapatellar approach to expose the intercondylar notch – using Whiteside’s line and the intercondylar axis to achieve access to the intramedullary canal, this is then reamed to an appropriate size and a retrograde nail passed over the fracture site, this is then locked both proximally and distally in order to achieve coronal, sagittal, axial and rotational stability – it may be necessary to insert Poller (blocking) screws to ensure satisfactory position of the nail as the wide metaphysis particularly in the elderly can cause malposition of the nail. A secondary caution is in the anterior-posterior angulation on these fractures; they can easily end up flexed if utmost care is not taken [12]. The SIGN nail is a good option in the austere environment (see the chapter on SIGN nails).

42.3.6.3 Complications

- Infection (septic arthritis)
- Malunion particularly in flexed fracture site
- Quadriceps/patellar tendon injury [12]

42.3.6.4 Follow-Up

A wound check at 10–14 days and a check x-ray at 6 weeks should be sufficient for this form of fracture fixation.

42.3.6.5 Rehabilitation

The benefit of intramedullary nailing (IM) of these extra-articular fractures is the ability to immediate risks weight bear after the operation which will reduce the medial risks of venous thromboembolism significantly; however, caution should be taken if you suspect the fracture extends into the joint itself.

42.3.7 Plates and Screws

42.3.7.1 Indications

Open reduction internal fixation of distal femoral fractures remains the gold standard for reconstruction of intraarticular fractures; this can range from simple lag screws for an intercondylar split through fixed angle blade plates and dynamic condylar screws to anatomic contoured locking plates for complex fractures – the implants available to you and access to an image intensifier will be the limiting factors in this form of fixation [11, 12].

42.3.7.2 Technique

Open reduction internal fixation of the distal femur can be performed through anterolateral, medial or lateral parapatella or medial or lateral posterior approaches depending on the fracture configuration. Reduction clamps or K-wires can be used to hold the fracture reduced whilst definitive fixation is implanted. Fixed angle blade plates and dynamic condylar screw plates have fallen out of favour in recent years owing to them being technically challenging, removing a large amount of bone stock and being contraindicated in AOC3 type fractures. Non-fixed angle plates have also fallen out of favour as they have a tendency to fall off into varus alignment. Fixed angle-locking plates have become the mainstay of modern orthopaedic fixation often used in 'hybrid' mode combining the locking screws with lag screws to provide compression at the fracture site [11, 12]. If you do not have the appropriate staff, facilities or training, *do not attempt internal fixation*.

42.3.7.3 Complications

- Infection
- Nerve or vessel damage
- Further fractures
- Compartment syndrome
- DVT/PE
- Symptomatic metalwork – classically lateral plates on flexion due to the iliotibial band moving over the plate
- Mal-/nonunion

42.3.7.4 Follow-Up

Wound check and x-ray at 10–14 days to ensure satisfactory position of the hardware at the surgeon's discretion thereafter.

42.3.7.5 Rehabilitation

Initially non-weight bearing until some radiological evidence of healing working up to full weight bearing at 12 weeks – unilateral fixations can fail through cantilever bending just as in external fixators, for this reason we would recommend the above regime.

42.4 Tibial Plateau Fractures

Tibial plateau fractures have a bimodal distribution with high-energy injuries in young patients and low-energy falls in the elderly and osteoporotic. It is a result of axial loading with varus or valgus stress [2, 7]. Tibial plateau fractures frequently have concomitant ligamentous or meniscal injuries [>50 %] [7, 13] which may become apparent upon fracture healing and mobilisation. This injury also has a high incidence of compartment syndrome affecting up to 11 % of cases [2] which must be treated as a priority over the fracture.

Radiological classification of tibial plateau fractures is classically performed using the Schatzker classification [14] which describes the location, cleavage, depression and extension of the fracture. Although in developed nations a preoperative CT scan will be obtained in order to better classify the fracture, such will usually not be available in the austere setting (Fig. 42.3). The goal of management in these fractures is to restore normal alignment, with articular step-off not having been shown to be a prognostic factor in posttraumatic osteoarthritis [11].

42.4.1 Nonoperative Management

42.4.1.1 MUA and Casts

Indications Indications for nonoperative management would include a stable knee with <10° malalignment in the coronal plane with the knee in extension, condylar widening [<5 mm] and <3 mm step in the articular surface [11]. If your facility does not have the resources for operative management, your criteria for nonoperative management will have to be expanded.

Technique Nonoperative management consists of immobilisation and strict non-weight bearing for 6 weeks followed by protected weight

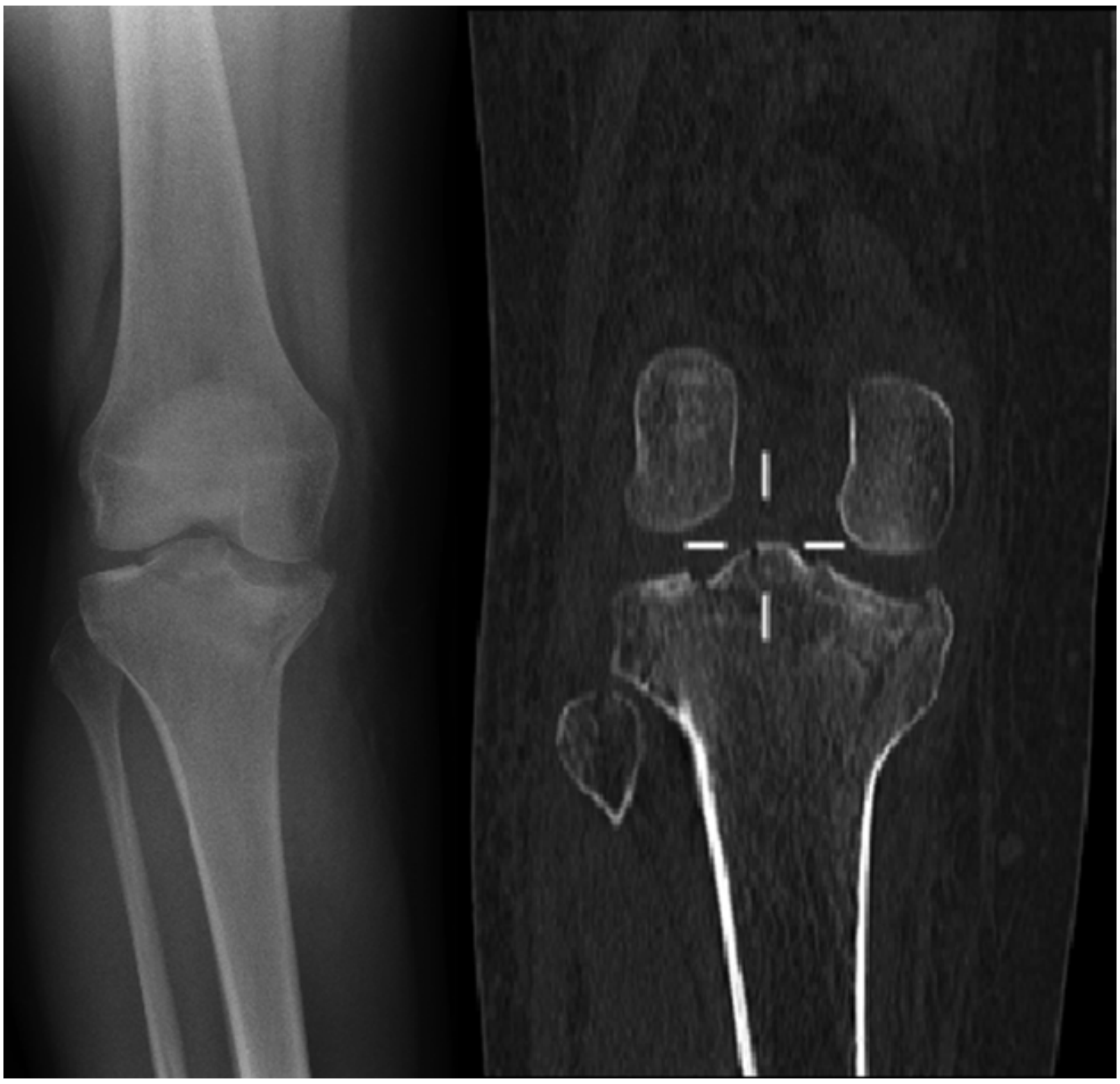

Fig. 42.3 AP radiograph and coronal CT images of what may appear to be a Schatzker 2 fracture but is in fact a Schatzker 5; we would advise caution in areas without CT scanners as the true severity is often worse than that which can be seen on plain films

bearing until union in all cases. This can be achieved through a plaster of Paris cast or a functional brace, dependent on the availability of equipment [2].

Traction (ligamentotaxis) as above, for distal femoral fractures.

42.4.1.2 External Fixation (Ligamentotaxis)

Indications External fixation of tibial plateau fractures performs a variety of functions. Spanning external fixators would classically be used in order to provide temporary stabilisation in patients who have grossly swollen legs precluding immediate fixation. In developed healthcare environments, fixators would usually be taken off and exchanged for internal fixation once the soft tissues were amenable to open reduction and internal fixation. External fixation, as discussed above, can be a definitive treatment modality, but you will have to accept significant knee stiffness when the fixator comes off. Ring fixators can often be used as definitive management of tibial plateau fractures, the wires of the top ring acting as raft screws in internal fixation. However, if these wires are placed within the capsule, patients can develop septic arthritis.

Technique Spanning external fixators are applied in the classical 'near-near, far-far' configuration – it is preferable to have anteromedial tibial half pins and anterolateral femoral pins in order to make a stable 'diamond' linkage over the knee – this is demonstrated in the radiographs below [15] (Fig. 42.4).

Ring fixators, whilst an excellent option particularly in highly comminuted fractures too fragmented for open reduction and internal fixation in the right hands, are beyond the scope of this chapter [16].

Fig. 42.4 Spanning external fixator for Schatzker 5 tibial plateau fracture with profound soft tissue swelling later converted to internal fixation; we can see in this instance whilst the articular surface is not reduced; the coronal and sagittal planes are in satisfactory alignment as such if this was treated in external fixation alone, they should have a functional limb

42.4.1.3 Complications

- Pin site infections
- Loosening of half pins
- Loosening of frame
- Mal-/nonunion [15]

Follow-Up As above to monitor malalignment, displacement, loosening, pin site infections and healing.

Rehabilitation Intensive physiotherapy may be required to address the stiff knee following a prolonged period of immobilisation with a spanning external fixator.

42.4.1.4 Open Reduction and Internal Fixation

Indications Open reduction internal fixation of tibial plateau fractures has become the mainstay of treatment for patient with an articular step of >2 mm, condylar widening of >5 mm, coronal plane instability, medial or bicondylar fractures [11].

Technique The proximal tibia can be approached via lateral 'hockey stick' incisions, posteromedial and posterior or combined approaches dependent on fracture configuration. There has been controversy over the use of a single midline incision for dual plating due to the significant soft tissue stripping, but it is argued that it is beneficial if the patient requires arthroplasty in the future. In the context of the austere environment, we feel this should be avoided as arthroplasty is not likely a feasible and as such promoting boney union is the main priority [11].

Reduction of the fracture involves restoration of the articular surface by reduction of any articular splits and using a punch to elevate any depressed areas. The void created by this process must be grafted usually with autologous graft in order to prevent collapse of the depression back down, hence causing coronal plane deformity – the worst predictor for long-term function.

Fixations can range from simple raft screws through non-locking buttress plates to fixed and locking plates giving the stiffest constructs [11].

42.4.1.5 Complications

- Post-traumatic arthritis
- Compartment syndrome
- Stiffness
- Loss of function
- Instability
- Malalignment – most commonly varus alignment due to medial plateau collapse [11]

Follow-Up 10–14 days for wound check and check x-rays.

42.4.1.6 Rehabilitation

Non-weight bearing for a minimum of 8 weeks, partial weight bearing for 4 weeks and full weight bearing at 12 weeks [11].

42.4.2 Tibial Spine Fractures

Tibial spine avulsions/fractures most commonly happen in children aged 8–14 [2] as a result of a tieh avulsion of the anterior cruciate ligament (ACL) on the tibial spine. Common mechanisms include a fall from a bicycle, as a result of forced hyperextension of the knee, or direct trauma to the distal femur with the knee flexed.

Tibial spine fractures are classified using the Meyers and McKeever classification [17], which describes the degree of displacement [I (non-displaced), II (partially displaced [anterior elevation with posterior hinge], and III (fully displaced: A as elevated above the tibial bed and B as rotated and hence non-reducible].

Management of these fractures is dependent on the degree of displacement and rotation of the fragment. Types I and II may be treated nonoperatively [18] dependent on satisfactory position with the leg in extension [2, 11]. There is controversy over the preferred position of immobilisation in these fractures. Traditionally the leg is immobilised in extension in order to keep the fracture reduced; however, it has been suggested by biomechanical studies that the ACL is at its most relaxed at 20° of flexion; hence, to minimise the displacing forces on the avulsed fragment, the leg should be immobilised in 20° of flexion [2, 18].

42.4.2.1 Operative Fixation

Indications In Myers and McKeever classification III A and B where the tibial spine has become fully avulsed and non-reducible in extension, the fragment must be keyed back into its origin and fixed in place whilst it heals [18].

Technique A medial parapatellar arthrotomy is required for this procedure. This does not need to be as extensile as for a total knee replacement and a window the length of the patellar tendon will be sufficient. The fragment once identified must be reduced and fixed in place. This would classically be performed using cannulated headless screws, two if there is space to achieve rotational stability. Fixation can also be achieved by the use of 'hooked' K-wires [11, 18, 19].

42.4.2.2 Complications

- Loose bodies
- Stiffness
- Loss of extension
- ACL instability
- Follow-Up
- Wound check and x-rays at 10–14 days.

Rehabilitation Immobilisation in extension cast for 6 weeks non-weight bearing followed by partial weight bearing for 4 weeks.

42.4.3 Patella Fractures and Quadriceps Mechanism Injuries

Patella fractures are predominantly as a result of either direct trauma or unexpected flexion of the knee against contracted quadriceps. They are more common in men than in women with a 2:1 ratio [11]. Radiographic classification is purely descriptive and describes non-displaced, transverse, pole or sleeve, vertical, marginal, osteochondral and stellate [11]. Management of these fractures can be nonoperative or operative.

42.4.3.1 Nonoperative Management

Indications Nonoperative indications would be a minimally displaced, less than 2 mm fracture, with an intact extensor mechanism [able to straight leg raise] [11]. In the austere environment, displaced transverse or polar fractures may be treated in a cylinder cast in full extension, with a check x-ray to ensure closing of the fracture gap.

Technique This technique comprises of encasing the leg in plaster from the hip to ankle, keeping the foot free in order to allow weight bearing; as long as no force is put through the patellar tendon, union should be achieved. It is vital to take a check x-ray in cast to ensure the fragments are within 2 mm of one another [8].

42.4.3.2 Complications

- Pressure areas/skin necrosis
- Nonunion
- Stiffness

Follow-Up See at 6 weeks out of cast if clinically united, start rehabilitation.

Rehabilitation Can mobilise full weight bearing in the cast. Once out, the patient will need to work on range of motion as the knee will be stiff.

42.4.3.3 Operative Management

Indications Patella fractures that are displaced and cannot be reduced closed.

Techniques In a transverse displaced fracture, the extensor expansion anterior to the patella will usually also have been torn. Suture repair of this using strong absorbable suture will help reduce and hold the fracture. This repair can be augmented by a cerclage suture around the patella, incorporating both the quadriceps tendon and patellar tendon. If available, bony wire fixation is preferable, forming a tension band construct around the patella. This can be achieved with tensioned wire loops with or without the use of K-wires dependent on availability [2] (Figs. 42.5 and 42.6).

Fig. 42.5 Lateral radiograph demonstrating a transverse fracture of the patella suitable for cylinder casting in extension or tension band wiring

All efforts must be made to preserve the patella; if this is impossible due to a severely comminuted fracture, excision of the peripheries and preservation of the largest fragment for reattachment of the patella and quadriceps tendon is recommended. If this is impossible, medial and lateral retinacula repair is vital to have any function of the extensor mechanism [11, 15].

42.4.3.4 Complications

- Symptomatic metalwork
- Non-/malunion
- Stiffness
- Osteonecrosis of proximal fragment

Follow-Up Wound check and x-ray at 10–14 days to ensure no loss of reduction.

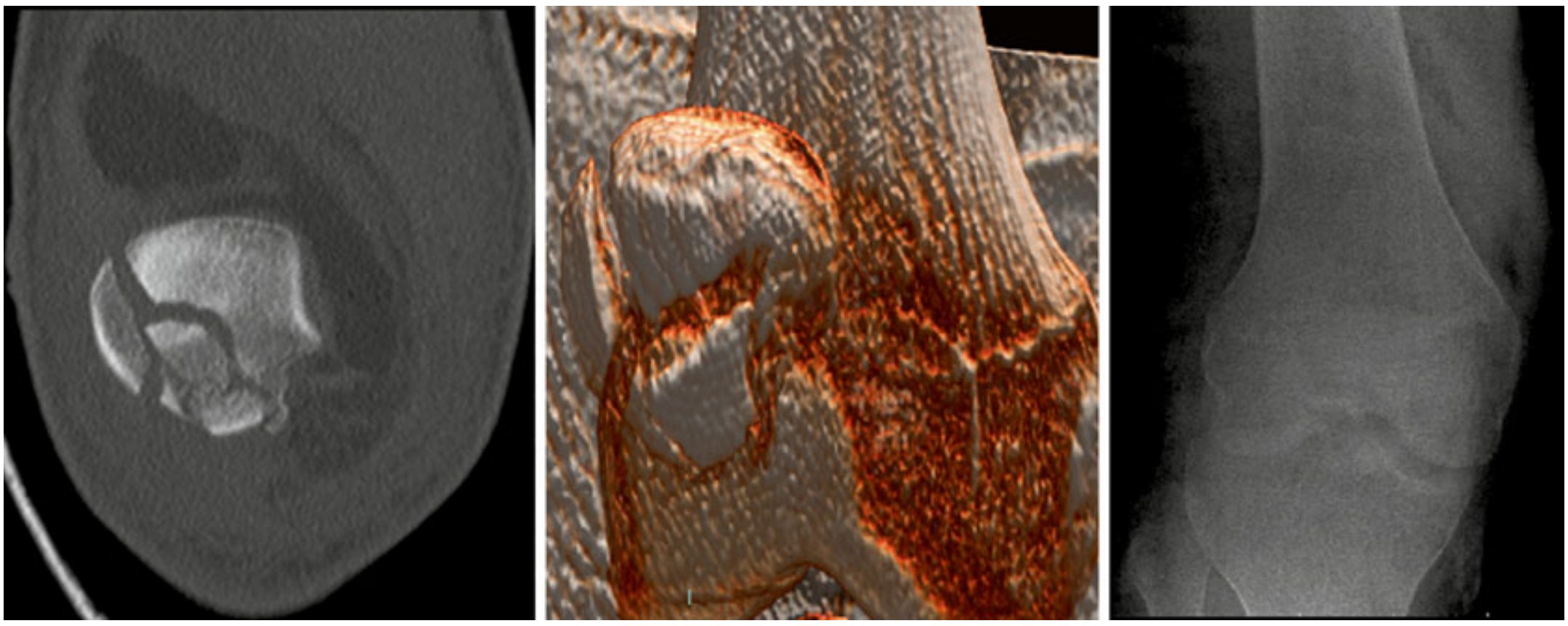

Fig. 42.6 Plain radiograph, coronal CT and 3D reconstruction of a stellate [comminuted] fracture of the patella

Rehabilitation These patients, depending on quality of fixation, may be able to mobilise full weight bearing postoperatively. However, they should avoid any strenuous activity for 6 weeks postoperation.

42.4.4 Soft Tissue Extensor Mechanism

Injuries to the extensor mechanism of the knee can also be in the form of rupture of the quadriceps or patellar tendons. Typical mechanisms include a fall onto the knee at the same time as the quadriceps is contracting. A palpable gap can often be felt at the site of the rupture and the patient will be unable to straight leg raise.

42.4.4.1 Nonoperative Management

Indications Where tears are partial, or with a minimal gap, conservative treatment in a plaster of Paris cylinder cast can be adopted.

Technique See conservative management of fractures.

42.4.4.2 Complications

- Stiffness
- Soft tissue/skin breakdown

Follow-Up Patients should be assessed periodically to protect their skin. Following 6 weeks in cast, early rehabilitation may commence.

Rehabilitation Knee stiffness will have to be managed with intensive physiotherapy, as well as muscle disuse atrophy.

42.4.4.3 Operative Management

Indications Ruptured extensor mechanism with a palpable gap in the tendon and an inability to straight leg raise.

Technique A longitudinal incision is made and the tendon ends are visualised. The two ends are then sutured together using a robust absorbable suture. If the rupture is close to the tendon's insertion into bone, then it may be necessary to drill holes through the patella are required to pass sutures through, which, can be tied around the medial and lateral border of the patella firmly affixing the avulsed tendon. We would also recommend over-sewing this repair [15].

42.4.4.4 Complications

- Infection
- Stiffness
- Failure of repair

Follow-Up

Wound check at 10–14 days. Protected weight bearing for 6–8weeks.

Rehabilitation Gradual mobilisation of the knee after 6–8 weeks. On removal of the cast, the knee is often stiff with limited flexion. Full flexion may not return for several months.

42.4.5 Soft Tissue Injuries

Whilst management of fractures around the knee may be frustrating due to lack of equipment or advanced imaging, diagnosis of the majority of bony injuries is straightforward by virtue of radiographs, which are usually available even in the many austere environments. In contrast, soft tissue injuries of the knee can be extremely challenging due to the absence of ultrasound or MRI. It is very important to take a good history and conduct an appropriate examination of the knee.

42.4.5.1 Anatomy

The relevant soft tissue anatomy of the knee consists of the medial and lateral menisci, medial and lateral collateral ligaments and anterior and posterior cruciate ligaments and, for injury classification, the posterolateral corner.

42.4.5.2 Assessment

A detailed history and special tests can help differentiate various ligamentous injuries to the knee in lieu of more advanced imaging; however, these have to be after the acute phase when the patient is comfortable enough to be examined.

42.4.6 Meniscal Injuries

A classical history of a twisting mechanism of injury with the foot planted and feeling painful. The patient will usually have been able to continue the activity; however, over the next few hours, the patient may have an increasingly painful and swollen knee. They may also complain of locking of the knee and mechanical impingement as pain on walking. On examination the patient may have an effusion, but usually has a full range of movement unless there is a large bucket-handle tear locking the knee. Palpation may reveal tenderness over the affected side at the joint line, and McMurray's test may be positive in up to 70 % of patients [11, 20].

Radiographs taken acutely in an isolated meniscal injury should not show any fractures, but may, however, show a haemarthrosis. If this is a lipohaemarthrosis, suspicion of fracture may be raised and alternate views may be requested.

42.4.6.1 Nonoperative Management

Indications In an austere environment, the majority of knee injuries that have no bony component should be managed nonoperatively in the initial stages until reliable clinical examination can be performed particularly without advanced imaging techniques or arthroscopic stacks. This may require the patient to remain weight bearing as tolerated with crutches and return for further assessment in 2 weeks when pain and swelling will have subsided.

Technique Weight bearing as tolerated with crutches for up to 6 weeks will let the injured knee settle. Signs and symptoms that remain after this time are likely to persist.

42.4.6.2 Complications

- Failure to resolve
- Undiagnosed fracture
- Pain and stiffness

Follow-Up Two weeks for reassessment if necessary and 6 weeks for assessment of the knee.

42.4.6.3 Operative Management

Indications If the knee remains highly symptomatic as a result of a suspected meniscal tear, for example, a permanently ‘locked’ knee with an inability for fully extend, then surgery might be contemplated [21].

Technique The operation of subtotal meniscectomy, via a lateral or medial parapatellar incision, depending on the suspicion of which meniscus is injured, should only be undertaken if the symptoms make it necessary. Although routinely performed for suspected meniscal tears in the pre-arthroscopic era, it is now recognised that the absence of a meniscus, especially on the lateral side, predisposes the knee to the early onset of osteoarthritis [20, 21].

42.4.6.4 Complications

- Unnecessary operation (wrong diagnosis)
- Infection
- Nerve and vessel damage
- Arthritis
- Pain and stiffness

Follow-Up 10–14 days for wound check.

Rehabilitation Can weight bear as tolerated and early range of motion exercises.

42.4.7 Collateral Ligament Injuries

These injuries are as a result of valgus or varus stress to the knee. Pain will classically be exhibited on varus or valgus stressing of the knee flexed at 30°. Gapping and pain with the knee in full extension is suggestive of additional ligamentous injury such as ACL or PCL injury [11]. Tenderness on palpating the origin, insertion and course of the medial collateral ligament (MCL)/lateral collateral ligament (LCL) may be evident. Collateral ligament injuries are graded according to the severity of injury to the ligament:

Grade I – Sprain, the ligament is stretched but will continue to act as a knee stabiliser.
Grade II – Partial tear, some gapping on stressing, may suffer some instability.
Grade III – Complete tear, gapping with no end point on stressing [22].

42.4.7.1 Nonoperative Management

Indications There have been a variety of trends in management of collateral ligament injuries; however, there is a consensus that all grade I and II injuries should be treated nonoperatively in a hinged knee brace of cylinder cast [23]. With regard to grade III injuries, after a number of comparative studies showing no subjective or objective difference in outcome for surgical versus nonsurgical treatment, current opinion would favour nonsurgical treatment of isolated collateral ligament injuries. In an austere environment, we would also recommend nonoperative management, unless the symptoms are very severe.

Technique Coronal plane stability is achieved through the use of a hinged knee brace which allows flexion and extension whilst negating the varus and valgus forces on the knee. However, such devices are expensive and may not be available. If this is the case, it is acceptable to treat these injuries in a cylinder cast from the ankle to the hip; this again stabilises the coronal plane at the expense of keeping the knee moving; these patients will have a much higher chance of stiffness once out of cast.

42.4.7.2 Complications

- Stiffness
- Failure to heal ligament
- Chronic collateral ligament injury after conservative management may indicate concomitant ACL or PCL injury.

Follow-Up Time in cast is dependent on the severity of the original injury. In grade I and II injuries, Derschied and Garrick [24] describes a mean time of return to playing football of 20 days in comparison to potentially 6 weeks immobilisation for grade III tears, particularly if concomitant ACL injury is suspected [25]. Based on current evidence, the safest option is to take your patient out of cast at 3 weeks and examine him/her. This will allow you to make a decision on whether to continue immobilisation or to start exercising the knee.

Rehabilitation Mobilise full weight bearing in a cylinder cast once out of cast; range of movement exercises are imperative to regain knee function.

Chronic or missed MCL injury may result in the radiographic finding of a Pellegrini-Stieda lesion on plain films – this is caused by calcification of the proximally avulsed MCL. This could be confused with an avulsion fracture of the medial femoral epicondyle, however tends to be well rounded hence indicative of an old injury [2].

42.4.8 Cruciate Ligament Injuries

The cruciate ligaments are responsible for the anterior/posterior stability of the knee. The ACL is commonly injured during noncontacting pivoting movements of the knee and is associated with an audible crack or popping noise, an immediate haemarthrosis and cessation of activity [11]. Concomitant meniscal injuries are common with up to 75 % of ACL ruptures having a meniscal injury, the lateral more common than medial. Radiographic assessment of the knee may reveal a Segond fracture – a small avulsion fragment from the lateral tibial condyle which is pathognomonic for ACL injury [2].

In the immediate aftermath of an acute injury, it may be extremely difficult to assess for the presence of knee instability associated with cruciate ligament rupture. A period of time in a support bandage and weight bearing as tolerated with crutches allows the knee swelling and tenderness to subside, at which point stability can be assessed. Signs of ACL rupture include a positive *anterior draw test* or a positive *Lachman's test* [performed in 15° of flexion and internal rotation].

42.4.8.1 Nonoperative Management

Indications Nonoperative management of ACL injuries in developed healthcare systems is reserved for low-demand patients in whom quadriceps and hamstring strengthening exercises are able to compensate for the majority of their lifestyle activities. The knee will only buckle whilst performing strenuous tasks such as jumping, cutting side to side during sports or heavy manual labour. High-demand young patients would normally be considered for ACL reconstruction; however, in the austere environment without access to allograft or tendon stripping implements, it is reasonable to extend the indication of nonoperative management to encompass the majority of patients.

Technique The ACL is highly vascular, owing to a rich supply from the middle geniculate artery; hence when it ruptures, it causes a rapid and tense haemarthrosis. It is advisable to see patients 2 weeks after the injury to assess the ligaments once they are over the acute episode. At this stage advice on strengthening of the quadriceps should be given in addition to advice on lifestyle modification to avoid exacerbating movements described above.

Complications Failure to stabilise the knee leading to frequent buckling.

42.4.8.2 Operative Management

Indications ACL reconstruction is indicated in young patients including children in whom activity modification is difficult to justify or symptoms or instability cannot be controlled nonoperatively. It can be performed in athletic patients of any age, but this would be considered on a case by case basis. In an austere environment, nonoperative measures are more likely to form the mainstay of management, but in exceptional cases where the skills and equipment are available, reconstruction may be a viable option.

Technique A hamstring tendon autograft ACL reconstruction involves harvesting the semitendinosus and gracilis tendons from the pes anserinus of the ipsilateral limb using a specially designed tendon stripper. These tendons are then doubled up and sutured together under tension to form a 'quadruple strand graft'. A 'bone-tendon-bone' graft may also be obtained in the patellar tendon graft technique. Both of these can be used to reconstruct the ACL through an open approach. Following a medial parapatellar approach, a femoral tunnel is drilled in the lateral intercondylar notch at the 10 o'clock position, leaving a 1–2mm shell of cortex posteriorly. The tibial tunnel is drilled from the anterior tibia at an angle of <75° entering the joint at the ACL insertion point 10 mm anterior to the PCL insertion. A button is used at the proximal end of the graft to brace the graft at the lateral femoral cortex, and under tension an interference screw (absorbable or nonabsorbable) is screwed into the tibal tunnel to fix the graft in position. The knee is then cycled 40 times to ensure correct tension and no impingement [2].

42.4.8.3 Complications

- Failure of graft
- Tunnel malposition
- Inadequate fixation
- Infection
- Arthrofibrosis
- Patella fracture or tendon rupture
- Symptomatic hardware

Follow-Up Immediate postoperative x-ray to check tunnel position, then 6 weeks in clinic to adjust rehabilitation protocol.

Rehabilitation The performing surgeon can decide the best and most practical rehabilitation regime given staff and resources. Need to emphasise full extension and perform closed chain exercise.

Posterior cruciate ligament injury is much rarer than ACL rupture. There are very limited indications for PCL reconstruction, even in the developed world, such that conservative treatment is always adopted in an austere healthcare setting. In very symptomatic, unstable cases, the limb can be immobilised in 60° of flexion for 2–6 weeks.

42.5 Dislocations

Dislocations around the knee joint consist of patella dislocation and dislocation of the knee itself.

42.5.1 Patella Dislocations

Patella dislocations can be grouped into recurrent dislocations and traumatic dislocations. Recurrent dislocators generally dislocate due to an anatomical predisposition, e.g. hypoplastic lateral femoral condyle, dysplastic trochlea, patella mal-tracking or failure of the medial patellofemoral ligament (MPFL). These patients tend to have a strongly positive patellar apprehension test. The second group of patella dislocators tend to be sportsmen suffering an acute traumatic dislocation [15].

42.5.1.1 Nonoperative Management

Indications Patella dislocations should be treated as any other dislocated joint with immediate closed reduction. The secondary aims of treatment are to rehabilitate the knee and prevent further dislocations. Operative management of patella dislocations is a specialist field, and as such, the majority of patella dislocations in the austere environment would be treated nonoperatively.

Technique Reduction is performed by extension of the knee; if this manoeuvre alone does not reduce the patella, grip both the thigh and leg whilst placing your thumbs under the lateral surface of the dislocated patella and push anterior and medial. This should reduce the patella back into the trochlea. Once reduced, many patients feel the benefit of an extension brace; however, be wary of a cylinder cast as this will cause unnecessary stiffness of the knee. Immobilisation should be performed for 2–3 weeks [15].

Complications Failure to reduce the patella may require sedation/general anaesthetic.

Follow-Up No requirements for formal follow-up.

Rehabilitation Rehabilitation centres on reduction of risk of further dislocations. There is no way to treat hypoplastic femoral condyles, ruptured medial patellofemoral ligaments or shallow trochlea nonoperatively; however, improving the patella tracking through strengthening the vastus medialis has merit. This can be achieved by externally rotating the foot and performing straight leg raises.

42.5.1.2 Operative Management

Indications Operative management of recurrent patella dislocations whether posttraumatic indicating rupture of the MPFL or due to a congenital hypoplasia of the lateral femoral condyle, shallow trochlea or an incompetent MPFL such as is seen in patients with joint hypermobility syndromes confirmed by high Beighton hypermobility score are a specialise area of practice in developed healthcare systems. If patella dislocations are so frequent that the patient is unable to perform activities of daily living or work, a medial patellofemoral ligament reconstruction may be indicated. In the austere environment, there is no place for trochleoplasty.

Technique This reconstruction would require an autograft, most commonly the hamstring tendons described and harvested above. A medial parapatellar approach is made to expose the medial tibia, medial femoral epocondyle and patella. A drill is used to make two tunnels in the patella. The graft is then anchored into the femoral epicondyle, passed through the patella and anchored under tension into the tibia [26].

42.5.1.3 Complications

- Infection
- Failure of the reconstruction
- Dislocation
- Patella fracture [26]

Follow-Up Wound check and x-ray at 10–14 days in order to ensure the patella has no fractures and tunnel placement is satisfactory.

Rehabilitation Mobilise full weight bearing postoperation and start closed chain exercises; building up medial quadriceps is imperative.

42.5.2 Knee Dislocations

Knee dislocations are by definition a high-energy injury that has ruptured both cruciate ligaments and often the joint capsule as well. This injury requires emergency reduction with inline traction. Careful assessment of the distal pulses is required; due to the relatively fixed position of the popliteal artery as the geniculate vessels branch off, it is at particular risk of injury that can lead to an ischaemic leg. Dependent on the surgeon's skills, this may necessitate a shunt, embolectomy, grafting or, if you are isolated without access to vascular services and no other options, an amputation. Another major risk on knee dislocation is that of compartment syndrome. The joint capsule is frequently breached and the highly vascular ACL stump can bleed profusely into the compartments of the leg. If there is clinical suspicion of compartment syndrome, urgent fasciotomies must be performed [15].

42.5.2.1 Nonoperative Management

Indications Management of knee dislocations is an emergency. Anyone presenting with a dislocated knee must have it reduced and stabilised. Blood and neurological supply must be assessed and the patient monitored for compartment syndrome.

Technique Once reduced, the limb should be rested in a backslab and neurovascular assessment performed regularly for 48 h postinjury. It is important to splint the knee in neutral position – hyperextension can cause further vascular compromise by creating traction on the popliteal artery [15].

Complications Complications arising from this injury can be categorised into early and late. Early complications include common personal nerve injury, if injured has a 20 % chance of recovery, and vascular injury previously covered. Late complications are that of anterior-posterior instability of the knee caused by rupture of both ACL and PCL and stiffness of the knee due to prolonged immobilisation in plaster [15]. There have been moves to combat this by using a hinged external fixator instead of plaster or a standard spanning ex-fix. This has shown a reduction in failure of ligament reconstructions after knee dislocations [27]. However, this is unlikely to have great relevance in the austere environment.

Follow-Up Knee dislocations have the potential energy transfer to damage any of the ligaments of the knee; once the patient is over the initial injury, careful assessments of all ligaments should be undertaken.

Rehabilitation Careful assessment and treatment of injuries must be undertaken; once the injury is quantified in the context of ligamentous injuries, a rehabilitation plan can be made.

42.5.2.2 Operative Management

Indications Knee dislocation with significant soft tissue compromise is an indication for a spanning external fixator across the knee joint.

Not only does this method of fixation provide a rigid construct on which the patient can mobilise; it also allows ready access to the soft tissues for assessment of wounds and monitoring of compartment syndrome.

Technique A standard spanning knee external fixator is applied in the 'near-near, far-far' configuration. Anteromedial tibial half pins and anterolateral femoral halfpins with a diamond cross-linking configuration are best.

42.5.2.3 Complications

- Compartment syndrome
- Pin site infection
- Vascular compromise
- Unstable knee requiring ligamentous reconstruction

Follow-Up Immediately postoperative, careful monitoring for compartment syndrome and vascular compromise is imperative for at least 24 h.

Rehabilitation As above, for knee dislocations, it is imperative to assess the residual ligament damage once the acute inflammation settles in order to enact a rehabilitation plan.

References

1. Bollen S. Epidemiology of knee injuries: diagnosis and triage. Br J Sports Med. 2000;34:227–8.
2. Wheeless C. Tibial plateau fractures. In: Wheeless C, editor. Wheeless' textbook of orthopaedics. Online: Duke Orthopaedics; 2013. Available from http://www.wheelessonline.com.
3. World Health Organisation. World report on road traffic injury prevention – main messages. 2004. Retrieved 31 Jan 2015. From WHO: http://www.who.int/violence_injury_prevention/publications/road_traffic/world_report/main_messages_en.pdf.
4. Orthopaedic Trauma Association Committee for Coding and Classification. AO supracondyler femoral fracture classification. Orthop Trauma. 1996;10:41–5.
5. Jaarsma RL, Van Kampen A. Rotational malalignment after fractures of the femur. J Bone Joint Surg Br. 2004;86(B):1100–4.
6. Zehntner M, Marchesi D, Burch H, Ganz R. Alignment of supracondylar/intercondylar fractures of the femur after internal fixation by AO/ASIF technique. J Orthop Trauma. 1992;6(3):318–26.
7. Weiss DB, Milewski MD, Thompson SR, Stannard JP. Trauma. In: Miller MD, Thompson SR, Hart JA, editors. Review of orthopaedics. Philadelphia: Elsevier; 2012. p. 752–3.
8. Charnley SJ. The closed treatment of common fractures. Cambridge: Cambridge University Press; 1999.
9. Shelton JA. Clinical photograph of an applied. Thomas Splint: Mersey Deanery; 2014.
10. Royal Liverpool & Broadgreen University Teaching Hospital. Images of radiographs reproduced in accordance with GMC (2011) Making and using visual and audio recording of patients. Section 10–12; 2014.
11. Miller MD, Thompson SR, Hart JA. Review of orthopaedics. Philadelphia: Elsevier; 2012.
12. Rockwood C, Buchloz R, Court-Brown C, Heckman J, Tournetta P. Rockwood and Green's fractures in adults. Philadelphia: Lippincott Williams & Wilkins; 2010.
13. Gardner MJ, Yacoubian S, Geller D, Suk M, Mintz D, Potter H, et al. The incidence of soft tissue injury in operative tibial plateau fractures: a magnetic resonance imagin analysis of 103 patients. J Orthop Trauma. 2005;19(2):79–84.
14. Schatzker J, McBroom R, Bruce D. The tibial plateau fracture: the Toronto experience 1968-1975. Clin Orthop. 1979;138:94–104.
15. Warwick D, Nayagam S. Apley's system of orthopaedics and fractures. London: Hodder Arnold; 2010.
16. Ahmad A, Burton M, Hashmi M. Outcome of complex fractures of the tibial plateau treated with a beam-loading ring fixation system. Bone Joint J. 2003;85-B(5):691–9.
17. Meyers MH, McKeever IM. Fracture of the intercondyler eminence of the tibia. J Bone Joint Surg Am. 1970;52:1677–84.
18. Leeberg V, Lekdorf J, Wong C, Sonne-Holm S. Tibial eminentia avulsion fracture in children – a systematic review of the current literature. Danish Med J. 2014;61(3):A4792.
19. Gans I, Baldwin K, Ganley T. Treatment and management outcomes of tibial eminence fractures in pediatric patients a systematic review. Am J Sports Med. 2014;42(7):1743–50.
20. Hing W, White S, Reid D, Marshall R. Validity of the McMurray's test and modified versions of the test: a systematic literature review. J Man Manipul Ther. 2009;17(1):22–35.
21. Roos H, Lauren M, Adalberth T, Roos E, Jonsson K, Lohmander S. Knee osteoarthritis after meniscectomy: prevalence of radiographic changes after twenty-one years, compared with matched controls. Arthrit Rheumatol. 1998;41(4):687–93.
22. American Association of Orthopaedic Surgeons. Collateral ligament injuries. 2014. Retrieved 26 Aug 2014. From Orthoinfo: http://orthoinfo.aaos.org/topic.cfm?topic=a00550.
23. Chen L, Kim P, Ahmad C, Levine W. Medial collateral ligament injuries of the knee: current treatment concepts. Curr Rev Musculoskel Med. 2008;1(2):108–13.

24. Derschied G, Garrick J. Medial collateral ligament injuries in football. Nonoperative management of grade I and II sprains. Am J Sports Med. 1981;9(6):365–8.
25. Halinen J. Operative and nonoperative treatments of medial collateral ligament rupture with early anterior cruciate ligament reconstruction: a prospective randomized study. Am J Sports Med. 2006;34(7):1134–40.
26. Carmont M, Maffulli N. Medial patellofemoral ligament reconstruction: a new technique. BMC Musculoskelet Disord. 2007;8:22.
27. Stannard J, Nuelle C, McGwin G, Volgas D. Hinged external fixation in the treatment of knee dislocations a prospective randomized study. J Bone Joint Surg Am. 2014;96(3):184–91.

The Management of Closed Tibia Shaft Fractures in the Austere Environment

43

Samir Ayobi and Juan de Dios Robinson

43.1 Epidemiology

The available knowledge regarding tibia fractures is based on research carried out in the developed world. Tibial fractures are the most common long-bone fracture with a reported frequency of 26 fractures per 100,000 populations per year. Because one third of the tibial surface is subcutaneous throughout most of its length, open fractures are more common in the tibia than in any other major long bone [1, 2]. Males suffer three times more tibial fractures than females and the average age is 37. There is a bimodal age distribution, with the adolescent age group generally associated with higher-energy trauma. The frequency increases again later in life with the development of osteoporosis [3–5]. In this chapter, we will review the immediate and definitive management of closed tibial shaft fractures.

43.2 Diagnosis and Initial Management

43.2.1 ATLS

Whether you are dealing with a closed fracture or a mangled extremity, it is mandatory to assess the patient's airway, breathing and circulation *before* being distracted by the tibial fracture. Having ensured that the patient is stable, we can then turn our attention to the secondary survey and examine the patient from top of the head to tip of toes.

43.2.2 Initial Management of a Closed Tibia Fracture

As with any other fracture, your mission can be summarised by:

1. Reduce the fracture the best you can (do not forget to give the patient adequate analgesia). Your goal is to achieve as an anatomical reduction as possible, paying attention to length, varus and valgus alignment, procurvatum and recurvatum and rotation. Ensure that the soft tissue cover does not suffer further insult by allowing a deformity to impinge on the skin, as this could result in a soft tissue defect where there was none before.
2. Stabilise the reduced fracture (a long-limb backslab, including the foot in neutral and

---

S. Ayobi, MSc
MSF Kunduz Trauma Centre, Kunduz, Afghanistan

J.D. Robinson, FRCS (Tr & Orth) MSc (Trau Surg) (✉)
Major Trauma Centre, St. Mary's Hospital,
Imperial College, London, UK
e-mail: jddrobinson@hotmail.co.uk

© Springer International Publishing Switzerland 2016
J.D. Robinson (ed.), *Orthopaedic Trauma in the Austere Environment:*
A Practical Guide to Care in the Humanitarian Setting, DOI 10.1007/978-3-319-29122-2_43

Fig. 43.1 Unstable tibia and fibula fracture splinted with a wire splint in an MSF trauma centre

reaching just distal to the buttock crease). Ensure the ankle is in neutral and not in equinus. Remember the limb will swell. The patient may present with provisional splinting that has been fitted elsewhere. In some countries, materials such as carton or wood are used to splint the fracture with *very tight circumferential dressings which are very dangerous to the viability of the limb. Release these dressings immediately or you will have a gangrenous limb to amputate* (Fig. 43.1).

3. Rehabilitate (start thinking what the patient's rehabilitation and follow-up needs will be). How can you prevent muscle wasting? Joint stiffness?

43.2.3 Immediate Assessment

Asses the vascular supply to the limb. Feel for the dorsalis pedis and posterior tibial pulses and assess capillary refill. Next asses the nerve supply to the foot by assessing sensation to the dorsum of the foot (superficial peroneal nerve), first web space (deep peroneal nerve), heel and sole of the foot (posterior tibial nerve, sural nerve, saphenous nerve, medial plantar and lateral plantar nerves). The assessment should be done before and after reducing the fracture. Assess the patient for a potential developing compartment syndrome.

Now that the patient's clinical stability has been confirmed and that the soft tissue structures

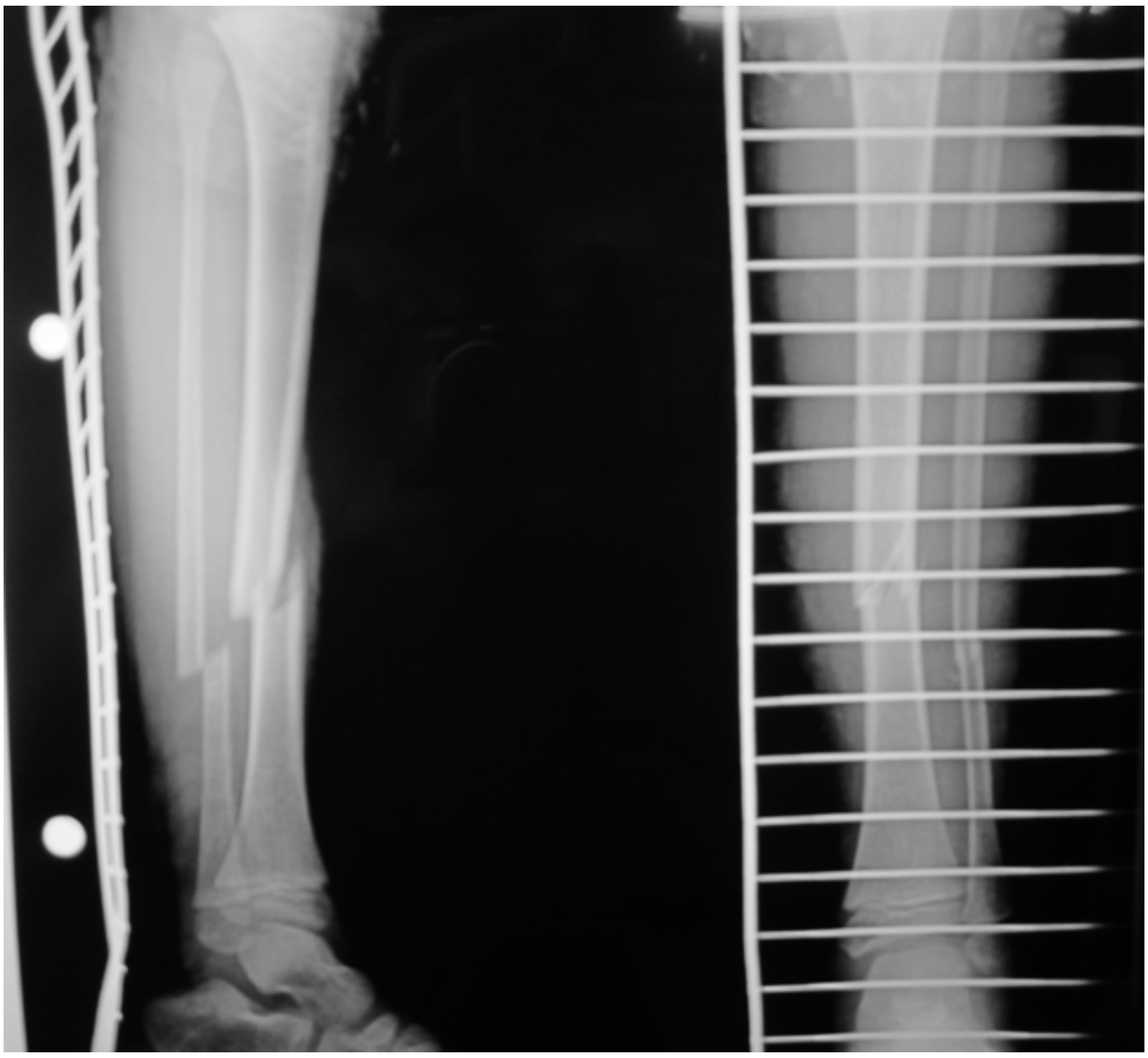

Fig. 43.2 AP and lateral views of a tibia fracture with segmental fibula fracture

are not under immediate threat, you must make sure you obtain a full history and physical examination. The mechanism of injury and the timing of the injury should also be elicited. By now you should know whether the mechanism of injury was high or low energy. This is important as high-energy injuries have significant soft tissue injuries associated with them, while low-energy injuries may be associated with pathologic conditions, such as osteoporosis.

In the unconscious patient, a high index of suspicion for compartment syndrome should be maintained for at least 48 h after the fracture, and compartment monitoring should be used where possible. If a specific device is not available, you can improvise one as suggested in the compartment syndrome chap. 28. You must maintain very close clinical observation of the patient, and fasciotomies must be performed if you suspect compartment syndrome. On the other hand, as mentioned above, patients may arrive to you with tight bandages from traditional bone setters, and you must not waste any time in releasing these bandages.

43.2.4 Radiographic Evaluation

Orthogonal tibial X-ray views (anteroposterior and lateral) of the full length of the tibia should be obtained (Fig. 43.2). The knee and ankle should be included. This is because proximal third fractures or distal third shaft fractures can be associated with intra-articular fracture line extension [6]. This is important, because it may determine the weight-bearing status of the patient, as you may need to keep the patient non-weight-bearing for longer if there is intra-articular extension, or it may even change the management to an operative plan. Oblique views can elicit a non-displaced spiral fracture.

43.3 Definitive Treatment of a Closed Tibial Shaft Fracture

The aim of the definitive treatment is to obtain a healed, well-aligned tibia which is pain-free, can bare weight and has good functional range of motion of the knee and ankle joints. The optimal treatment method will depend on the personality of the fracture (comminuted, stable) and the personality of the patient (co-morbidities, compliance, age).

Broadly speaking, there are five methods of treating closed tibial shaft fractures;

1. Casting, which includes long-limb casting, followed by a patellar tendon-bearing Sarmiento cast and finally a below-knee cast or functional bracing.
2. Traction – used mainly in proximal tibia fractures.
3. External fixation using either a uniplanar, multiplanar or circular tensioned fine-wire fixator.
4. Plate fixation, which can be either compression plating or bridge plating – not usually recommended as primary treatment due the thin soft tissue cover over the tibia and the relatively high risk of infection and wound breakdown when compared to a nail. Plate fixation is used most frequently in distal or proximal fractures.
5. Intramedullary nailing – the preferred option in diaphyseal fractures which cannot be treated nonoperatively.

43.3.1 Nonoperative Management: Casting

In resource poor environments, nonoperative management should be strongly considered in all cases, due to the potential risks for infection following operative treatment. Nonoperative treatment is most appropriate when the tibia fracture is closed and the fracture can be reduced into an acceptable position and maintained reduced until there is enough callous formation to allow for partial weight-bearing.

The results of nonoperative management depend on the amount of initial displacement and the degree of comminution. You should aim for less than 5° of varus-valgus angulation, less than 10° of anteroposterior angulation, less than 10° of rotation and less than 15 mm of shortening [1, 7].

43.3.1.1 Closed Reduction and Cast Immobilisation Technique

In adults, a long-leg cast is used initially for 6 weeks.

1. The patient should be positioned supine. Adequate analgesia must be provided. The leg may be hanging with the knee flexed at 90° so that gravity assists in reduction, as well as relaxing the gastroc-soleus complex which may otherwise displace the fracture indirectly.
2. The lower limb is covered in a stockinette and wrapped in wool or cotton. Make sure the material touching the skin is not creased as this may be a source for pressure sores.
3. A preliminary reduction is carried out. A couple of layers of plaster are applied to the leg below the knee and moulded to encourage stability and maintenance of the reduction.
4. Confirm the reduction with an X-ray if possible. Then apply the final coat of cast material or fibreglass.
5. Once the leg portion of the cast has been completed, the thigh portion is done, extending from just distal to the crease of the gluteus maximus to below the knee.
6. A small sandbag, kidney dish or bottle can be placed behind the knee to encourage about 10–15° of flexion. Take care not to indent the plaster against the popliteal fossa.
7. The plaster is reinforced as necessary from top to bottom.
8. Allow the plaster to be dry, and obtain X-rays as necessary after the procedure to confirm reduction and alignment.

If the reduction is stable, the patient may partially weight bare from the outset. If the fracture is likely to displace, the patient should be non-weight-bearing for the first 6 weeks, mobilising with crutches. During this time, especially if the fracture is deemed unstable, the patient may need closer supervision as the fracture may displace. X-rays should be done weekly until there are signs of callus formation, at which time the fracture may be deemed “sticky” enough to assume that displacement is unlikely.

Fig. 43.3 (**a**, **b**) An above-knee cast with knee flexion and ankle in neutral. There is slightly too much flexion in this cast

If the fracture displaces, re-manipulation may be necessary. You may not need to remove the cast to achieve realignment. You can determine where the point of deformity or angulation is with an X-ray and mark the level on the cast. The cast is then *cut circumferentially* at the marked level, and this is used to correct the deformity. Once the correct alignment is achieved, the cut ends of the cast are repaired and reinforced with new plaster layers. A check X-ray is necessary.

Another technique if malalignment is elicited during the early treatment of a tibial fracture is *wedging the cast*. This is achieved by again determining the level of the cast to be cut by marking the level and opposite to where the angulation is most pronounced. On this situation, however, the cast is not cut circumferentially, only have way. A wedge of cork-like material or anything similar is then wedged into the cut section to encourage the desired change in shape of the cast, and thus the alignment of the fracture ends. After a check X-ray, if the position is satisfactory, this area is reinforced with plaster to secure the wedge (Fig. 43.3).

Following this initial period and when there is evidence of callus formation on AP and lateral X-rays, you can then change to a Sarmiento or patellar-bearing cast.

43.3.1.2 Application of a Sarmiento Cast

1. After applying the below-knee cast as just described, carry the padding and plaster 5 cm

proximal to the patella. Mould the leg portion of the cast and extend the knee to 45° of flexion.

2. Mould the plaster to the flares of the tibia and over both femoral epicondyles. Mould the cast to gently grip the epicondyles, thereby creating an anterior channel for the patella and patellar tendon and a posterior channel for the hamstrings. Flatten the popliteal fossa to keep the leg against the anterior aspect of the cast.
3. Trim the cast. Notice that it is above the patella to avoid patellar impingement and give good support. Trim out the popliteal fossa to allow the amount of flexion desired. You may choose to limit flexion to 45° initially and then gradually increase it as fracture stability increases.

Another simpler option if possible is to simply cut and fashion the long-leg cast into a Sarmiento cast. However, this should only be done if the cast is well fitting and in good shape (Fig. 43.4).

Fig. 43.4 A Sarmiento patellar-bearing cast. This one was adapted from the above-knee cast

43.3.2 External Fixation

A further option is to treat the tibial shaft fracture with an external fixator for the first 6 weeks, instead of a long-leg cast, and then changing or removing the ex fix and treating the patient with a Sarmiento cast for the rest of the treatment. This avoids the inconvenience of the long-leg cast, stiffness and decrease in muscle bulk as physiotherapy can be started immediately while at the same time minimising the risk of pin-site infection. Children can sometimes be better managed with an external fixation as well. Careful follow-up of the patient is necessary to succeed with these techniques. Read the chapter of external fixation and damage control orthopaedics.

43.3.2.1 Follow-Up and Rehabilitation

- If the fracture configuration is stable, there is no need to follow up the patient weekly. A first check X-ray at 4–6 weeks may be adequate to assess healing. For unstable configurations, weekly follow-up with X-ray check to confirm alignment until evidence of callus formation may be required. Non-weight-bearing for 6 weeks in unstable patterns is also necessary. Partial weight-bearing in stable well-reduced patterns, such as a transverse fracture with no displacement.
- Six weeks reduce long-limb cast to Sarmiento patellar-bearing cast. Depending on callus and stability, partial to total weight-bearing may be initiated. Start physiotherapy for knee range of motion and strengthening of quads and hamstrings.
- Twelve weeks. Examine the patient for radiological signs of healing progression, tenderness and pain on weight-bearing. If there is no pain and no tenderness, and there is obvious callous and cortical bridging, consider increasing weight-bearing status to full weight-bearing if not yet done. A functional brace to protect the tibia may also be prescribed.

43.3.2.2 Complications

- Clots: There is no strong evidence guiding anti-DVT prophylaxis. In the UK, the National


[redacted]

Fig. 43.5 A fasciotomy for compartment syndrome following tibial fracture

Institute for Clinical Evidence has recently recommended that patients with lower limb fractures who are managed non-weight-bearing in a cast should be offered anti-DVT prophylaxis in the form of low-molecular-weight heparin subcutaneous injections 5000 units daily. Patients should be assessed for their personal risk to develop clots as far as possible. Obviously, the local material realities will dictate what anti-DVT prophylaxis, if any, can be offered to patients. At the very least, make sure that patients are non-weight-bearing only when necessary and that they remain well hydrated.

- Compartment syndrome: Even low-energy fractures can develop compartment syndrome. You must remain vigilant to this serious complication. If a patient complains of pain which is beyond that you would expect for the injury and is not responsive to adequate analgesia, you must think "compartment syndrome".
- If the patient complains of pain due to a tight cast:
  - (i) Split the plaster in two planes and cut the cotton, stockinette, etc., until the skin is visible. If this relieves the pain, maintain close observation.
  - (ii) If you have removed all possible sources of external pressure, such as the cast, bandages, and the pain is still present, stretch the muscles in the posterior and anterior compartment by flexing and extending the ankle and toes. If this elicits increased pain, you must prepare the patient for a fasciotomy. See the chapter on compartment syndrome (Fig. 43.5).
- Skin and soft tissue injury: If fracture deformity is compromising the skin or there is decrease perfusion to the foot, the fracture needs urgent reduction and splinting.
- Vascular Injury: There are reports of pseudoaneurysms secondary to tibia shaft fractures.
- Pulmonary embolism: Shortness of breath, cardiovascular collapse, neurological disturbance.
- Fat embolism: Fat emboli may be the result of fat globules entering the bloodstream through tissue that has been disrupted by trauma. Shortness of breath, tachypnoea, tachycardia, petechial rash (look in the axilla), neurological disturbance.
- Complex regional pain syndrome: Even minor trauma can set off this strange condition when patients develop a constellation of symptoms including stiffness, hypersensitivity, pain, discolouration and skin temperature changes.

Look for this if patients complain of the above symptoms after cast removal. Management is mainly symptomatic with aggressive physiotherapy, simple analgesia, anti-inflammatories and psychological support.

- Arthrofibrosis: Following prolonged knee immobilisation, scar tissue may form in the knee joint, causing severe stiffness. The primary treatment is aggressive physiotherapy and serial splinting to achieve flexion. Only as a last resort is debridement of the scar tissue indicated, especially in the austere environment. This can be a complication not only of prolonged casting but also of traction and external fixation. Thus, as soon as it is clinically possible, the knee should be mobilised and range of motion exercises prescribed.
- Malunion: If malalignment is not corrected early (within the first 2 weeks), then a malunion will occur. You can prevent this complication by being vigilant and having a proper follow-up system that monitors patients closely over the first few weeks following a tibial fracture. If the fracture is not reduced or reducible in the first place, then you must consider if the predictable malunion will translate into a functional deficit for the patient and if the patient will cope with this deficit. Otherwise, operative reduction may have to be considered. See the chapter on malunion.
- Delayed union
- Nonunion: Nonunion is a very serious problem in the austere environment, due to the limited options for management available.

According to Hoaglund et al. [2], fractures with 50–90 % of normal apposition heal significantly faster than fractures in which contact was less. Displacement of more than 50 % of the width of the tibia at the fracture site was a significant cause of delayed union or nonunion according to Suman et al. If fractures had more than 50 % initial displacement, reduction was difficult to maintain according to Böstman et al. [8]. This group also found that comminution delayed fracture healing. There is a debate on the effects of an intact fibula on healing of a tibial fracture. However, Nicoll [9] found that this did not influence prognosis. On the other hand, other authors such as Teitz et al. [10] did find that fracture healing was inhibited in 26 % of closed tibial fractures with an intact fibula.

43.3.3 Operative Management

As described previously, nonoperative management is the preferred method of treatment in the austere environment because it avoids the risk of infection. Unfortunately, nonoperative management is sometimes not adequate to manage high-energy, unstable fractures. In these situations, operative treatment allows early motion, provides access to the soft tissues and avoids complications associated with immobilisation.

43.3.3.1 External Fixation

External fixation has been used for the temporary and definitive fixation method of tibial shaft fractures. The advantages are that they allow soft tissue management and monitoring and a more stable construct around the fracture and thus can be used instead of a long-limb cast which in turn allows knee mobilisation avoiding stiffness. External fixation is also an option when managing paediatric fractures avoiding intramedullary nails or plates.

43.3.3.2 Indications

External fixation is indicated in high-energy comminuted fractures, open fractures, following fasciotomy for compartment syndrome secondary to a fracture. External fixation can be used to span the joint in cases of tibia and femur fractures (a floating knee). External fixation can also be used instead of a long-leg cast.

43.3.3.3 Preoperative Planning

Make sure you have all your equipment and that you are familiar with the external fixation system you are going to use. Have the available imaging accessible so that you can consult regularly during the procedure as necessary. Make a plan A, a plan B and a plan C. Have enough assistants to help you reduce the fracture, and maintain reduction while you tighten the ex fix. How are you going to dress the pin sites? Will you need padding under the knee? A triangle or knee support?

43.3.3.4 Positioning

Patients should be supine. Make sure you do a preliminary skin wash. The full leg should be painted/prepped with chlorhexidine or Betadine, well above the knee and including the foot. No tourniquet is necessary, unless there is a combined vascular approach or a fasciotomy, in which case you can fit a tourniquet but do not inflate it. Make sure you keep more than the area you think you will need sterile.

43.3.3.5 Approach Technique

- Often, you will not have intraoperative imaging, so you must be very familiar with the equipment you are using and how the pins work, as you will be using tactile feedback to place your pins.
- Chose the area where you want your pin to go. Remember the basics of "far-far/near-near" configuration, and *stay away from the zone of injury. Do not introduce a pin through the wound of an open fracture, but go through intact skin instead.*
- Once you have selected your placement, make a 1 cm incision in an oblique fashion, as this will allow the skin to mobilise and not be tight once the final construct is secured.
- The tibia is roughly a triangle-shaped bone. You may have seen pins placed in an AP orientation, which is fine, but is not the easiest orientation, as this may cause the tip of the pin to skid off the medial surface. I prefer to place the long axis of the pin obliquely to the medial surface of the tibia. This provides the largest surface area for placement and helps prevent this sudden slipping off the medial slope.
- You may need to tap gently the head of the pin to create a small indentation for the tip to engage and thus make it easier to start screwing in the pin. This should be done by hand, in slow but firm movements.
- You want to avoid jerking movements because this may cause pin loosening. Also, by going slowly, your tactile feedback is maximised.
- After you free the first cortex, you will get a sensation that the pin is screwing in much easier. Continue to introduce the pin in a controlled fashion until you meet resistance again. This is the far cortex. Continue as you did for the near cortex. However, you must take care not to go through the far cortex more than a couple of turns. I tend to wait until I feel twisting the wrist is getting difficult, and then do another two and a half turns. This helps to place the threaded part of the tip in the far cortex. Again, the turning movement must be controlled and slow.
- Place your second pin and subsequent pins in a similar fashion.
- I like constructing units which I can then use to manipulate the fracture ends. Fix a medium- or long-size bar to the proximal two pins and another medium to the distal two pins. Place a bar-to-bar clamp between the proximal and distal bars. Ask your assistant to put some traction to achieve length gently, while, based on your preoperative plan, you reduce the two ends, gently feeling for the friction between the bone ends. Ask your other assistant to secure the clamp once you are happy that you have achieved the reduction. You can run your finger up and down the tibia crest to confirm if there are any steps and alignment (Fig. 43.6).
- Place a second bar-bar parallel to the first one to increase the stability of the construct. Make sure all the clamps are nice and tight.
- Clean the entire construct and leg thoroughly.
- Dress the pin sites. I do this by applying paraffin gauze around the pin wound, then a small gauze square, and then I dress the leg with a crepe bandage. In reality, there are many pin sites regimens and not much evidence as to which is the best one.
- Obtain a check X-ray.

43.3.3.6 Complications

The complications of external fixation include:

1. Fracture – from selecting the wrong diameter pin, too close to the fracture, through fracture extensions, forcing the pin, etc.


[redacted] [redacted] [redacted]

Fig. 43.6 A surgical team in an austere environment applying an external fixator bridging the knee joint

2. Pin loosening – from hurried, uncontrolled pin placement, not tightening the construct, lack of stability, premature weight-bearing, infection
3. Nerve damage – unusual but possible from excess traction, drilling over a nerve, drilling through the far cortex and injuring a nerve, uncontrolled pin placement
4. Infection – damaging the skin during placement or too tight after reduction, lack of pin care, poor sterile technique during placement, not treating aggressively at the first sign of erythema
5. Malunion – not following up patients closely enough, premature weight-bearing, unbalanced external fixation, unstable constructs
6. Nonunion – all of the above, distracting the fracture, too rigid, too unstable

43.3.4 Intramedullary Nail

Intramedullary nailing is the gold standard for tibial shaft fracture fixation. This does not mean that it is essential in all cases. As we have said previously, nonoperative methods with good casting techniques will suffice to manage the majority of closed tibial fractures. Nevertheless, there are cases when casting will not be sufficient and an intramedullary nail is the best option.

If your facility has the ability to use the SIGN nail, then you have a very powerful tool to treat tibial shaft fractures with no need for fluoroscopy (Fig. 43.7) (see Chap. 32). I strongly recommend that you become acquainted with this technique as it has the longest track record in the austere environment, as well as one of the most complete databases on results and cases. If you have access to other equipment, make sure you are completely familiar in how to use it (see Chap. 31). It is beyond this chapter to provide a detailed description of surgical techniques. What follows is a list of important points to remember.

43.3.4.1 Preoperative Planning

Obtain AP and lateral X-rays. Make a plan as to the best way to achieve reduction and make sure you have all the equipment you will need. Do not forget about antibiotic prophylaxis at induction.

43.3.4.2 Positioning

You can position the patient supine on a traction table with leg on traction knee bent at 90° or free with a triangle under the knee to achieve flexion of the knee to at least 90°. Some surgeons have the leg hanging over table to achieve 90° of flexion.

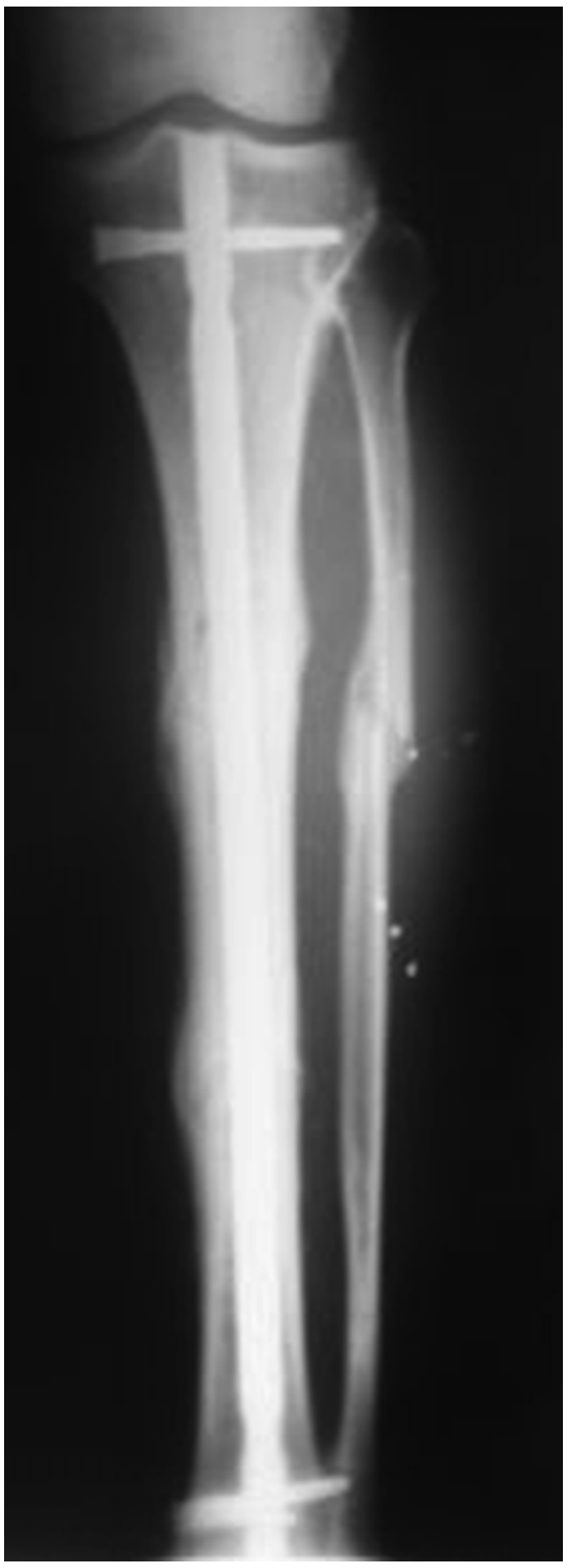

Fig. 43.7 Intramedullary nail of a tibia fracture using the SIGN nail

Make sure you wash the limb before formal scrubbing. Tourniquets are not required. If you have fluoroscopy available, incorporate this into your positioning planning so that you know you can achieve satisfactory views in AP and lateral.

43.3.4.3 Approach

Can make an incision through the patella tendon or medial parapatellar approach. Make sure not to damage the patella tendon!

43.3.4.4 Techniques

In the AP plane, the entry point is located in line with the medullary canal (3 mm medial of the tibial crest). In the lateral plane, the entry point should be located just inferior to the angle between tibial plateau and anterior tibial metaphysis.

43.3.4.5 Pearls and Pitfalls

Remember to try to introduce your guide wire as vertical as possible to avoid hitting the posterior wall of the tibia.

Make sure you measure for length and width. If you have reaming equipment, start small and increase in 1 mm steps until you detect good contact throughout the shaft and you hear chatter at the isthmus. Insert a nail that is 1–1.5 mm smaller than your last reaming size.

After haemostasis and washout, take care to close the soft tissues appropriately. Place the leg either in a well-padded back slab to rest the leg for a day or two with the foot plantigrade or a bulky dressing.

43.3.4.6 Postoperative Care

Do not forget thromboprophylaxis for 6 weeks.

Plan follow-up including for wound check and removal of sutures or clips.

Check X-rays post-op, at 4 weeks and then as necessary.

Weight bare as tolerated from day 1 post-op and physiotherapy.

43.3.4.7 Complications

Immediate:

- Nerve damage
- Compartment syndrome
- Bleeding
- Malreduction

Early

- Compartment syndrome
- Infection
- DVT, PE

Late

- Malunion
- Nonunion
- Failure of nail
- Anterior knee pain

43.3.5 Plates and Screws

Plating requires good levels of surgical skills, availability of equipment, properly trained staff, sterilisation equipment, intraoperative imaging and the ability to deal with complications. Plating is indicated in more distal and proximal tibial fractures where a nail may not have sufficient area for locking. It is also used in tibia shafts, but it usually means more soft tissue stripping, and nails are preferred. Again, a detailed description of the techniques and different types of plates is beyond this chapter. Below is a summary of the most important points.

43.3.5.1 Preoperative Planning

As in the case of nailing, make an operative plan and confirm the availability of all required equipment and imaging.

43.3.5.2 Positioning

It is advisable to place the leg over a cushion or wrapped pillow to elevate the leg facilitating taking X-rays if available. Tourniquet in situ. Inflate tourniquet to 250–300 mmHg after elevating the limb. Tourniquet time should be a maximum of 2 h. If more time is needed, release the tourniquet and allow the leg to perfuse for at least 10 min.

43.3.5.3 Approach

Make sure the soft tissues are healthy. Plan your incisions to facilitate fixation and do not undermine the skin. Thick flaps are necessary. Review your surgical anatomy before every case. Beware of neurovascular bundles. Closure should not be too tight. If possible, use a minimally invasive approach or MIPO technique.

43.3.5.4 Pearls and Pitfalls

Comminuted fractures should not be reduced anatomically at the expense of biology and blood supply to the bone and soft tissues. Bridge the comminuted section and focus on alignment, rotation and length. If anatomical reduction is possible, aim for absolute stability with compression. Always respect the soft tissues. Be aware of the length of the crews you use, and do not use more implants or screws that are absolutely necessary to achieve stability. When fixing a long-bone comminuted fracture, one of the difficulties is determining length and rotation. Radiographs of the contralateral tibia can help [6].

43.3.5.5 Postoperative Care

Antithrombotic prophylaxis as per nailing. Postoperative X-ray. Weight-bearing depends on stability of the construct, but usually not weight-bearing for 4 weeks, touch weight-bearing for 4 weeks. Physiotherapy referral for strength and range of motion early. Wound check at 5 days and removal of sutures at 12 days.

43.3.5.6 Complications

Immediate

- Nerve damage
- Vessel damage
- Compartment syndrome
- Malreduction

Early

- Infection
- Compartment syndrome
- Failure of fixation
- DVT, PE

Late

- Malunion
- Nonunion
- Failure of implant
- Pain
- Stiffness

References

1. Anderson LD, Hutchin WC. Fractures of the tibia and fibula treated with casts and transfixing pins. South Med J. 1966;59:1026.
2. Anderson LD, Hutchins WC, Wright PE, et al. Fractures of the tibia and fibula treated by casts and transfixing pins. Clin Orthop Relat Res. 1974;105:179.
3. Court-Brown CM. Fractures of the tibia and fibula. In: Bucholz R, Heckman J, Court Brown C, et al., editors.

Rockwood and Green's fractures in adults. 6th ed. Philadelphia: Lippincott Williams and Wilkins; 2005. p. 2079–146.

4. Court-brown CM, McBirnie J. The epidemiology of tibial fractures. J Bone Joint Surg Br. 1995;77(3):417–21.
5. Court-Brown CM, Caesar B. Epidemiology of adult fractures: a review. Injury. 2006;37(8):691–7.
6. Bostman OM. Displaced malleolar fractures associated with spiral fractures of tibial shaft. Clin Orthop Relat Res. 1988;228:202–7.
7. Rockwood CA, Green DP, Bucholz RW. Rockwood and Green's Fractures in adults. 7th ed. Philadelphia: Lippincott Williams and Wilkins; 2010.
8. Bostman OM. Spiral fractures of the shaft of the tibia: initial displacement and stability of reduction. J Bone Joint Surg. 1986;68:462.
9. Nicoll EA. Closed and open management of tibial fractures. Clin Orthop Relat Res. 1974;105:144.
10. Teitz CC, Carter DR, Frankel VH. Problems associated with tibial fractures with intact fibulae. J Bone Joint Surg. 1980;62A:770.

The Management of Ankle Injuries in the Austere Environment

44

Jesse Alan Slade Shantz, Juan de Dios Robinson, and Ralph Richard Coughlin

44.1 Epidemiology

No significant epidemiological data regarding ankle fractures has been collected in the austere environment. Experience demonstrates that the full gamete of low-energy injuries can be found, from sporting injuries to osteoporotic fractures. In addition, socioeconomic and cultural characteristics can conspire to increase the burden of trauma. For example, the frequent use of bicycles for transport, carrying a child in the back, gives rise to frequent bicycle spoke injuries, where the child's foot gets trapped in the wheel (Fig. 44.1).

High-energy mechanisms of injury include road traffic accidents and pedestrians hit by vehicles. Other mechanisms of injury include work-related crush injuries, falls from heights, animal attacks and, in conflict zones, firearm and blast injuries, among others.

44.2 Assessment

44.2.1 History

A good patient history should include the presenting complaint, history of presenting complaint including the mechanism of injury, past medical history including any diabetic vascular complications, medications, allergies, relevant family history and a social history to include family structure, occupation and consumption of any drugs and smoking. Patients with ankle injuries broadly fall into one of the following presentations.

44.2.1.1 Low-Energy Sports Injuries

These ankle injuries are the result of twisting the joint at low speed. Patients typically describe rolling the ankle when tripping on uneven ground or stepping downstairs or on a curb. Injury patterns are associated with specific foot positions and rotational movements. Although it appears complex, the Lauge-Hansen classification of ankle fractures is a useful tool to understand the mechanics of ankle injuries [1–3]. The most important difference to determine, however, is whether a fracture is stable or unstable (Fig. 44.2).

J.A.S. Shantz, MD, MBA, FRCS(C)
Institute for Global Orthopaedics and Traumatology,
University of California, San Francisco, CA, USA

J.D. Robinson, FRCS (Tr & Orth) MSc (Tr Surg) (✉)
Major Trauma Centre, St. Mary's Hospital,
Imperial College, London, UK
e-mail: jddrobinson@hotmail.co.uk

R.R. Coughlin, MD, MSc
Department of Surgery,
Institute for Global Orthopaedics and Traumatology,
University of California, San Francisco, CA, USA

© Springer International Publishing Switzerland 2016

J.D. Robinson (ed.), *Orthopaedic Trauma in the Austere Environment: A Practical Guide to Care in the Humanitarian Setting*, DOI 10.1007/978-3-319-29122-2_44

Fig. 44.1 Road traffic accidents and unregulated transport practices result in many severe injuries

Fig. 44.2 Low-energy ankle fracture with significant swelling

44.2.1.2 High-Energy Rotational Injuries

Patients commonly present with gross deformity of the ankle, often after motorcycle accidents or motor vehicle crashes (Fig. 44.3). Subluxation or dislocation of the tibiotalar joint requiring reduction is common. In addition, wounds over the medial malleolus in these injuries are usually open fractures communicating with the medial malleolar fracture and hence the tibiotalar joint and require urgent washout.

44.2.1.3 High-Energy Axial Load Injuries

Falls from height result in a different subset of injuries: tibial plafond injuries. Falls from greater

Fig. 44.3 Open ankle fracture

than 3 m result in a transfer of force from the foot to the distal tibial articular surface through the relatively dense talar body. This results in a typical injury pattern consisting of a split of the distal tibia into three fragments with associated comminution at the metaphyseal-diaphyseal junction [4]. Care should be taken in these patients to rule out associated injuries of the knee, femoral neck and lumbar spine. Close attention to the soft tissue envelope is essential. These injuries can be very different in nature from ankle fractures and the soft tissue integrity and safety is paramount!

44.2.1.4 Blast and Fire Arm Injuries

Blast and firearm injuries can cause catastrophic injuries involving extensive bone and soft tissue loss. As in any other trauma scenario, the patient must first be treated for life-threatening injuries. A thorough debridement of nonviable tissue is carried out, and bony stability must be established with an external fixator to stabilise the soft tissues. There is a very high risk of infection, and as with all open injuries, adequate antibiotic and tetanus cover is mandatory.

44.2.1.5 Delayed Presentation

Patients often present in a delayed fashion due to the large travelling distances and poor transportation links. Reducing dislocations and displaced fractures in delayed presentations can be much more difficult, often requiring open reduction.

44.2.1.6 Open Fractures

Again, obtain a full medical history, including tetanus vaccinations and antibiotic allergies. Assess the soft tissues and soft tissue deficit, pulses and nerve supply (Fig. 44.2).

44.2.2 Examination

Always follow the mantra: ‘Look, feel, move’.

- Look: Deformity, asymmetry, bruising and skin integrity (any pressure on the skin from deformity? Reduce fracture ASAP)
- Feel: skin temperature, infection blood supply (pulses, capillary refill) and compartment syndrome
- Move:
  - (i) Active: What can the patient do? Is the problem only a painful fracture or is there motor nerve injury?
  - (ii) Passive: Every joint! Have a system that will allow you to assess the ankle and foot for range of motion, crepitus and stability.

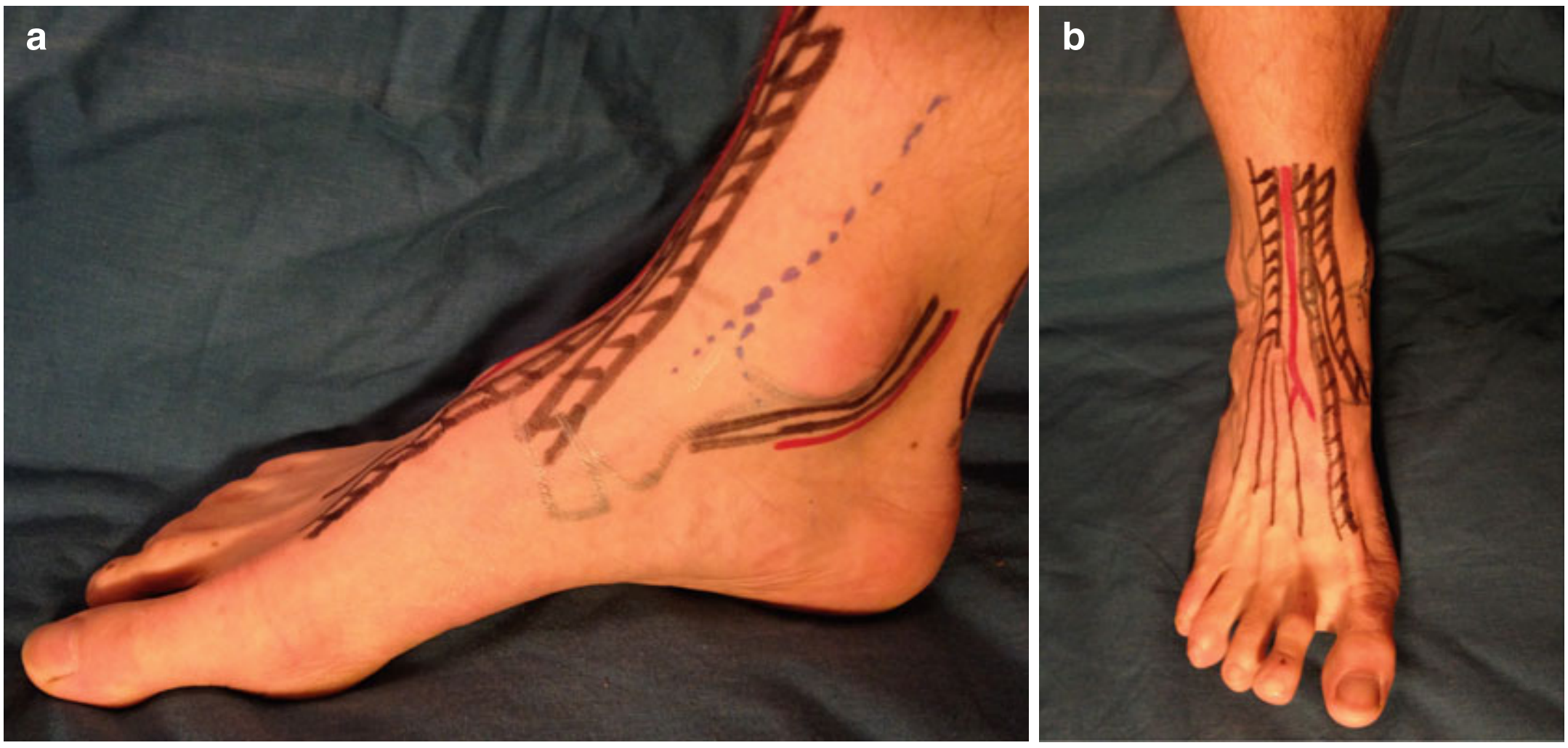

Fig. 44.4 The vascular and tendon surface anatomy of the foot and ankle. Tendons are denoted in black with vascular structures outlined in red. (**a**) Posterior tibial artery, (**b**) dorsalis pedis from the anterior tibial artery

44.2.2.1 Vascular Assessment

Look at the colour of the skin. Is it pale or bluish? Feel the temperature. Is it cold? Palpate the dorsalis pedis and posterior tibial pulses (Fig. 44.4) and check for distal capillary refill which should be less than 2 s.

44.2.2.2 Neurological Assessment

Neurologic examination involves confirming sensation in the nerve distributions of the foot: saphenous, deep peroneal, superficial peroneal, sural and tibial. Motor testing is done by documenting patient's active movements and opposing the action of muscles. The muscles to test include the tibialis posterior (resist inversion, tibial nerve), tibialis anterior (ankle dorsiflexion, peroneal nerve), extensor hallucis longus (extensor of the great toe, deep peroneal nerve) and the peroneal muscles (foot eversion, superficial peroneal nerve).

44.2.2.3 Soft Tissues Assessment

The ankle is a subcutaneous joint and is prone to soft tissue complications if due care is not observed. Delayed manipulation and closed reduction of a skin tenting deformity, poor maintenance of reduction or poorly performed surgery, especially in the face of swelling and angry blistering, risks breakdown of the soft tissue envelope, dehiscence of surgical wound and infection.

The formation of blisters is relatively common in this area and should prompt a delay in any surgical treatment until the blisters have resolved completely. Silver sulfadiazine has been found to result in improved cosmetic results in one study [5]. No difference could be found in the infection rates when blisters are drained versus those that were left intact [6]. *Tight bandages and plasters should be avoided*, the limb should be placed in strict elevation (at least two pillows when patient sitting), and if available, ice compressions should be applied regularly with the aim to reduce swelling. This will also help with pain control.

44.2.2.4 Ligaments and Tendons

Look for obvious deformity; abnormal position of the toes may suggest abnormal tendon tension from tibiotalar dislocation. Feel and move for stability. Stability of the ankle is done through an anterior drawer test to test the anterior talofibular ligament (more that 8 mm movement compared to the other ankle?) and external rotation stress test to assess the syndesmosis. If in doubt, these stress tests can be done with X-rays and both sides can then be compared.

Ligament assessment, particularly the deltoid ligament in rotational ankle fractures, has been found to be unreliable in the assessment of tibiotalar stability. Medial bruising and tenderness should not be relied upon to guide ankle fracture treatment.

44.3 Investigations

In the austere environment, you are often limited to your clinical acumen and skills. However, if you have even the basics of an imaging department, you must have a rational system to determine what patients require an X-ray; otherwise, you may overwhelm the service and gather an infinite collection of useless plain films. Ankle ligament injuries represent 14–21 % of total sport lesions. Close to 18 % of patients have an associated foot and/or ankle fracture. The application of the Ottawa Ankle Rules [3] can provide guidance on the necessity for radiographic evaluation in these patients.

44.3.1 Ottawa Ankle Rules [3, 7]

Ankle X-ray is only required if there is any pain in the malleolar zone and *any one* of the following:

- Bone tenderness along the distal 6 cm of the posterior edge of the tibia or tip of the medial malleolus
- Bone tenderness along the distal 6 cm of the posterior edge of the fibula or tip of the lateral malleolus
- An inability to bear weight both immediately and in the emergency department for four steps

An X-ray series is indicated if there is any pain in the midfoot zone and *any one* of the following:

- Bone tenderness at the base of the fifth metatarsal (for foot injuries)
- Bone tenderness at the navicular bone (for foot injuries)
- An inability to bear weight both immediately and in the emergency department for four steps
- Again, your clinical acumen is paramount as some patients, such as those with head injuries or under the influence of drugs, or very young children, will not be able to help you.
- A radiographic examination of the ankle, consisting of anteroposterior, lateral and oblique (mortise) views, remains the gold standard investigation for the formulation of treatment plans for ankle injuries.

Several key factors should be noted about the X-rays:

1. The presence of talar shift suggests that the rotational ankle fracture is unstable and requires close radiographic follow-up to avoid missing subsequent displacement.
2. The talar dome should be scrutinised as there is a high association of talar osteochondral lesions with rotation ankle fractures. Some lesions may not appear radiographically so direct visualisation should be attempted during medial malleolar fixation in wherever open reduction and internal fixation is feasible.
3. Tibiofibular instability, or syndesmotic injury, should be ruled out by the measurement of tibiofibular overlap on the AP view and tibiofibular clear space on the mortise view (although each of these measurements has poor correlation with MRI findings of syndesmotic injury). In addition, palpation of the entire length of the fibula, as well as a proximal plain film, can identify Maisonneuve fractures, which may be associated with syndesmotic injuries. Conversely, if you diagnose a Maisonneuve fracture, make sure you do not miss a bony injury in the medial ankle.
4. In tibial plafond fractures, both the complexity of the fibular fracture and the axial stability of the tibial fracture should be considered. Fibular fixation can provide axial stability to the injured limb segment during external fixator or cast immobilisation. However, it is best to leave any form of internal fixation to the surgeon who *will be carrying the definitive fixation*. Making an incision in a suboptimal location and inadequate reduction of length and rotation of the fibula acutely will lead to great difficulties during the definitive fixation.

44.4 Acute Management C2845, 2910

Remember, “life before limb”. Assess the patient following swiftly your ATLS protocol.

As with all fractures you will manage, remember to:

1. Provide effective pain relief.
2. Prevent ischaemia, both to the soft tissues and the foot as a whole.
3. Remove any potential sources of infection.
4. Reduce the fracture (which needs to be done often to ensure preventing ischaemia and further soft tissue damage).
5. Stabilise the fracture.

The primary goal of the initial management of ankle injuries is pain control and to preserve the integrity of the soft tissue envelope. The ultimate goal of treatment is a stable ankle with a good range of motion. Irrespective of the resources available, it is important to expediently provide relative stability to the injured limb segment. In addition to the reduction of gross deformity and splinting, any open soft tissue wounds should receive antibiotic and tetanus prophylaxis, be covered with a sterile dressing and not uncovered until a more formal debridement is performed. In fact, repeated assessment of open fracture wounds has been suggested as a factor in increased infection rates in open fractures (see Chap. 28 on management of open fractures).

44.4.1 Closed Reduction

The closed reduction of ankle injuries provides a simple method for the preservation of soft tissue integrity about the ankle. The goal of closed reduction is to restore the talus to the anatomic position under the tibial plafond. An excellent coverage of this principle-based closed management algorithm is given by Charnley in *The Closed Treatment of Common Fractures* [8]. To achieve this goal, the practitioner needs to create an environment that maximises the possibility of successful reduction by supplying adequate pain relief, optimising positioning and having casting/splinting supplies close at hand. All ankle injuries should receive maximal attempts to achieve and maintain a closed reduction given the rate of successful treatment of ankle injuries using this method in austere environments and the risks associated with operative treatment (Fig. 44.5).

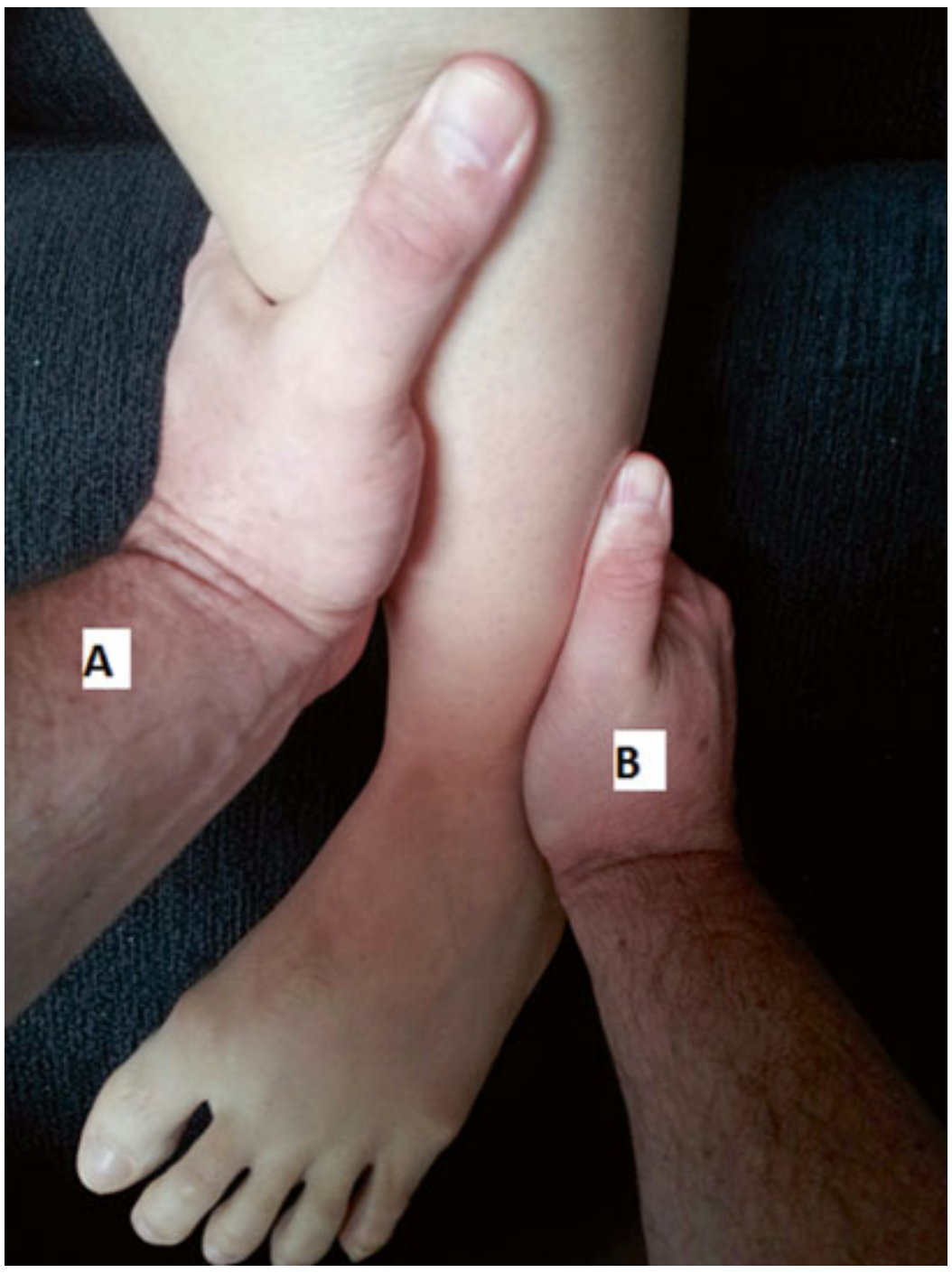

Fig. 44.5 Closed manipulation of an ankle fracture. Ensure the knee is flexed to relax the Achilles tendon. Make sure the hindfoot, not the forefoot, is plantigrade. Apply a posterolateral directed force on the tibia proximal to the medial malleolus with one hand and an anteromedially directed force with the opposite hand on the heel distal to lateral malleolus. Aim to reproduce a 'mortise view' position, with slight internal rotation of the foot

44.4.2 Analgesia and Anaesthesia

Pain relief can be supplied locally through the use of a hematoma block in acute injuries. Generally, this technique works best when employed in the first 48 h after fracture to avoid hematoma consolidation. Systemic opioids can also improve patient comfort but will not provide the relaxation of complete analgesia. Conscious sedation with ketamine or other dissociative parenteral medications provides both pain relief and relaxation of spastic muscles. This approach is more resource intensive though, requiring monitoring equipment and a second provider to manage the airway and breathing of the patient during reduction and splinting. No difference in the ability to achieve a closed reduction in rotational ankle fractures could be found between a group offered sedation and a group provided an intra-articular

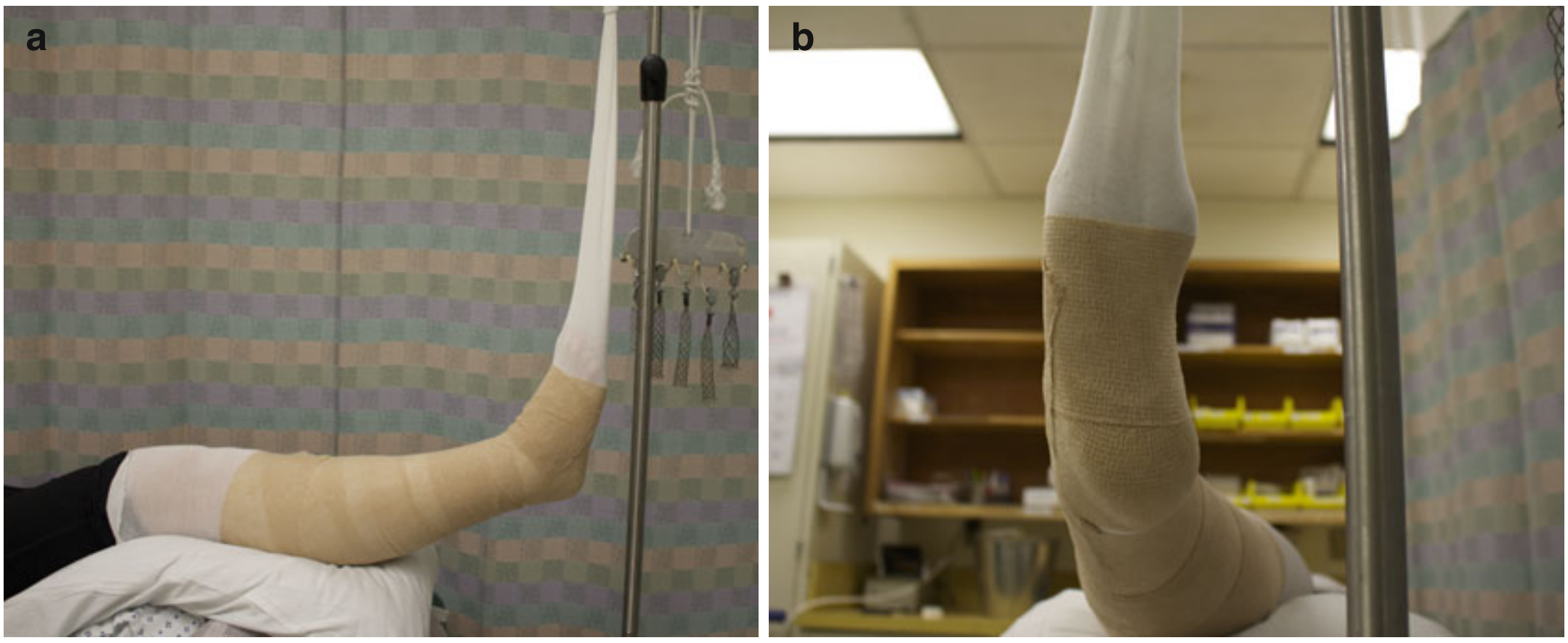

Fig. 44.6 Quigley reduction method. (**a**) Lateral and (**b**) anterior views. The Quigley method of ankle reduction with traction and internal rotation at the ankle combined with relaxation of the gastrocnemius. This suspension technique can be employed to attempt closed reduction in subacute fractures. In addition, the technique can be used to maintain grossly unstable fractures in a reduced position prior to casting after soft tissue healing proceeds

lidocaine block in a recent study [9] (see Chap. 18 on Anaesthetics).

Optimal positioning during reduction requires minimising the displacing forces of the fracture. Typically, the triceps surae provides the bulk of the deforming force, both shortening the facture and posteriorly translating the hindfoot. Decreasing the influence of the gastrocnemius muscle can be achieved through flexion of the hip and knee but requires an assistant to provide countertraction. In the situation where a patient is on a stretcher or bed, the affected limb can be dangled off the side achieving 90° of knee flexion without hip flexion.

Another method of reduction was proposed by Quigley and involves hanging the affected limb with the hip and knee at 90° of flexion [10]. The simultaneous relaxation of the gastrocnemius and anteriorly directed force on the foot provide the reduction force. Improvisation of the methods for securing the foot exists for instances where gauze bandages are scarce (Fig. 44.6).

44.4.3 Splinting, Casting and Bracing

Once reduction has been attempted, definitive stabilisation is accomplished using splints, circumferential casts or braces. The goal of immobilisation is to maintain the reduction of the fracture or dislocation during healing and to allow mobilisation of the patient. The choice of immobilisation should be based on the stability of the reduction and the chronicity of the injury including the risk of ongoing swelling as a circumferential cast does not allow for subsequent soft tissue swelling and may result in compartment syndrome.

Many complications are seen which are related to the application of tight circumferential casts by traditional healers. When swelling makes a backslab necessary, a cast can be applied 3–7 days later for definitive management. This can be done by ‘completing the cast’ to avoid disturbing the position achieved after the manipulation. If a second manipulation is necessary to improve the position, this can also be achieved at that point as well. In addition, attention should be paid to placing the foot at 90° to the tibia after reduction to prevent equinus contracture by shortening of the Achilles tendon. If blisters are present, or there is a suspect area of skin which may suggest possible breakdown, the cast must not be completed, until the soft tissues are healthy, and there is no danger of necrosis (Fig. 44.7).

44.4.4 Skeletal Traction

Skeletal traction, in the form of a transfixion pin inserted in the calcaneus or talus, allows for

Fig. 44.7 (**a**) Plaster of Paris and (**b**) whether POP or fibre glass, appropriate moulding is essential to maintain reduction. The ankle must be in neutral as prolonged equinus will cause tendoachilles contracture. (**c**) A finished fibreglass cast with a walking sandal. These sandals can be improvised with rubber tyre segments strapped to the soul of the foot

the restoration of length in axial load injuries. Administering traction generally necessitates the availability of a bed in order to allow suspension of a weight from the transfixion pin or a Bohler frame. Also, careful clinical assessment, either visually or radiographically, is necessary to ensure that appropriate alignment is maintained. Also, the risk of distraction-induced nerve damage mandates close follow-up of neurovascular function.

In patients managed acutely using skeletal traction, it may be possible to transition to outpatient management by incorporating the transfixion pin into a plaster cast. This 'pins and plaster' technique provides additional stability to the injured leg and may aid in the maintenance of length in tibial plafond injuries with metaphyseal-diaphyseal comminution (Fig. 44.8). Still, the pins and plaster technique does prevent the assessment of underlying soft tissues which are often tenuous in injuries requiring the additional stability of a transfixion pin.

Fig. 44.8 Position for placement of traction pin and external fixation in calcaneus

44.4.5 External Fixation

In many settings external fixation provides a stable and available means of maintaining a reduction in the ankle. External fixation is particularly useful in treating ankle injuries associated with severe soft tissue injuries as it allows access to the

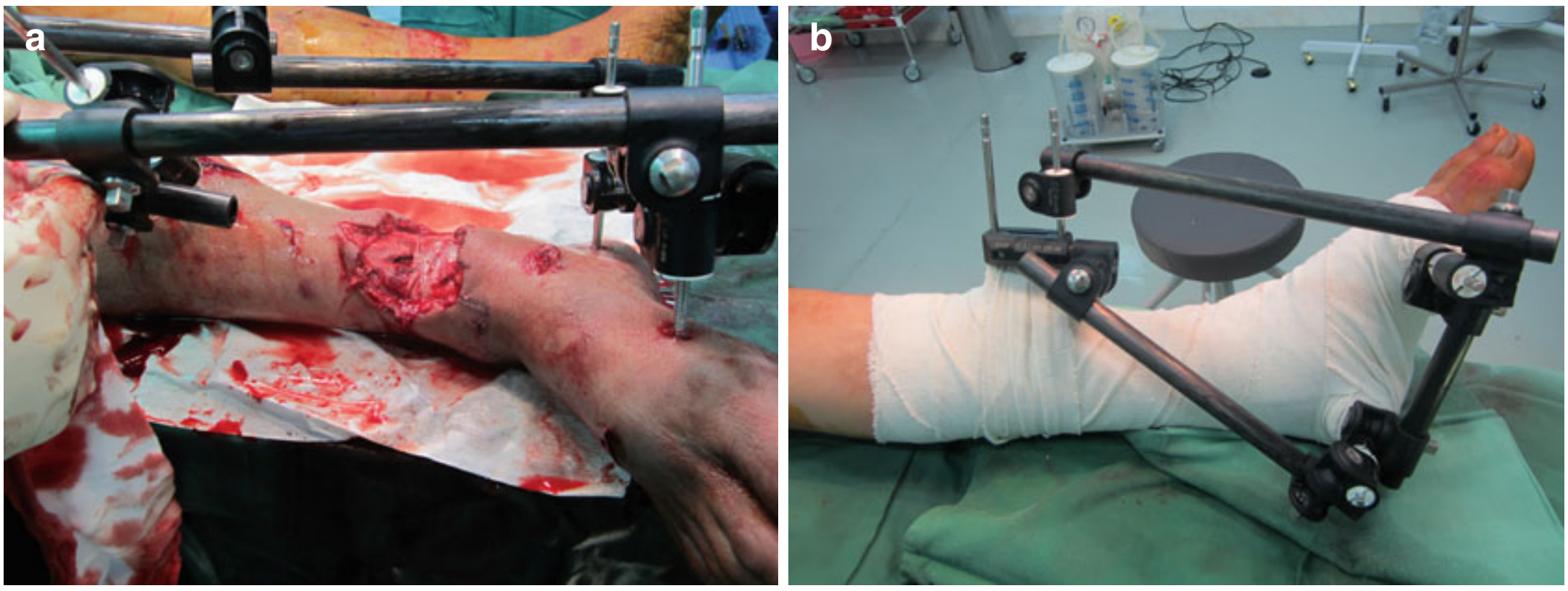

Fig. 44.9 (**a**) External fixation of a degloved open fracture in the field and (**b**) even when using external fixators, all effort must be made to prevent equinus, which was not achieved in this case

Fig. 44.10 (**a**–**c**) A low-resource technique to improvise an 'external fixator'

wound and avoids incisions in the zone of injury. Additionally, fractures that cannot be maintained in a reduced position with external immobilisation may be stabilised using external fixation, particularly length-unstable fractures (Fig. 44.9).

Resource constraints mandate that the construct used for stabilisation should utilise the minimal amount of components to provide stability to the limb segment. Some authors employ a construct of two Steinman pins passed retrograde from the plantar first and fifth metatarsal to the diaphyseal tibia [11] (Fig. 44.10). Steinman pins passed retrograde through the calcaneus and transfixing the ankle provide another means to

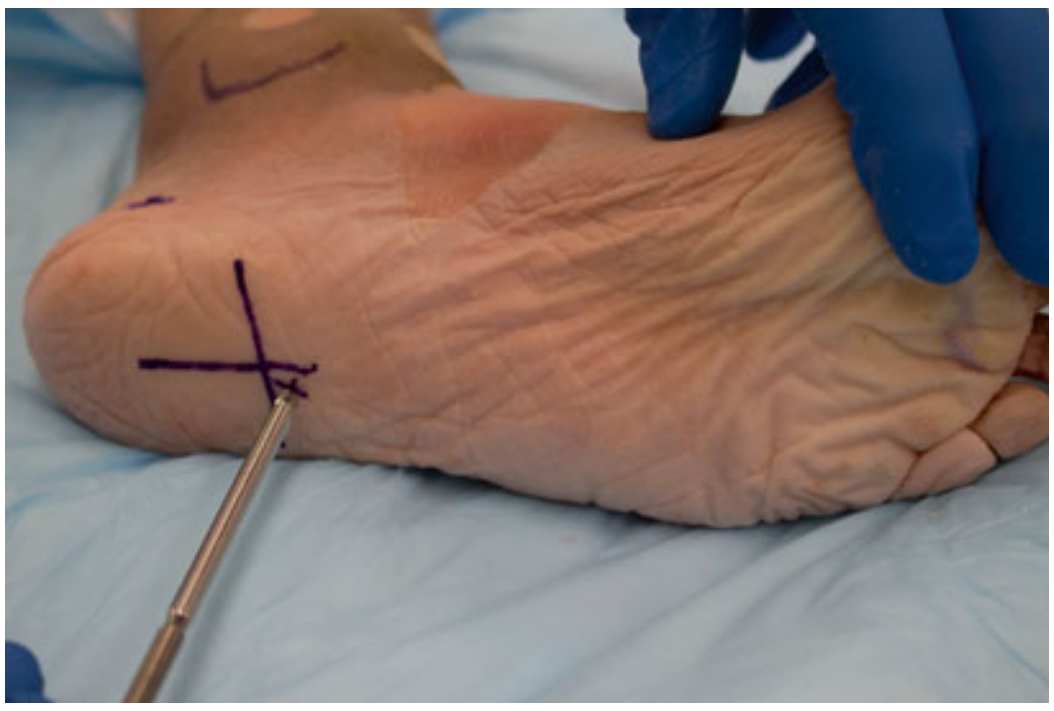

Fig. 44.11 Location of insertion of retrograde transfixion pin. This technique can be utilised to maintain the reduction of a grossly unstable ankle fracture. The pin can then be incorporated into a cast to allow the discharge of the patient from hospital

prevent instability after reduction of extremely unstable ankle injuries and pose less soft tissue risk than open approaches and internal fixation (Fig. 44.11).

44.5 Definitive Treatment Strategies

44.5.1 Nonoperative Treatment

Despite a recent trend towards the anatomic reduction of all malleolar fractures, uncontrolled historical studies suggest that nonoperative management can result in durable and satisfactory function [12]. These results are echoed in a recent Cochrane Review which failed to show a superiority of nonoperative or operative management of ankle fractures [13].

Although admittedly less consistent in providing uneventful healing of fractures, nonoperative management avoids the potential complications of wound breakdown, infection and implant prominence that can become limb threatening. This provides more impetus to attempt nonoperative treatment given the scarcity of appropriate antibiotics, plastic surgeons and other resources needed for limb salvage in the case of complications.

Nevertheless, whether operative or nonoperative treatment of ankle fractures is carried out, adequate follow-up is essential. In order to confirm the maintenance of reduction, frequent radiographic follow-up is also necessary. Makwana et al. [14], in determining the efficacy of open reduction and internal fixation of the ankle in patients 55 years old or greater, found that only 57 % of manipulated ankles treated nonoperatively were reduced anatomically. In addition, these investigators found that 38 % of ankles managed with immobilisation changed position during radiographic follow-up. Therefore, in order to avoid debilitating deformity, skilled follow-up and potentially repeated manipulation under anaesthesia are necessary to achieve satisfactory healing.

In resource-constrained environments, it is only in the treatment of grossly unstable or irreducible ankle injuries not maintained in a reduced position that percutaneous or open treatment should be undertaken in the author's opinion. A late fusion with a plantigrade foot will be more advantageous to a patient than an amputation in the setting of a severe wound complication after acute surgery.

44.5.2 Percutaneous Treatment

Treatment of ankle fractures using percutaneously inserted wires, although underutilised in modern fracture treatment algorithms, can be a useful method in low-resource settings. Given the limited availability of fluoroscopy and X-ray equipment, such treatment should not be undertaken lightly. The use of Steinman pins to hold a subluxed talus reduced within the mortise is an exception and should be a technique familiar to all surgeons treating unstable ankle injuries (Fig. 44.10).

44.5.3 Limited Open Reduction and External Fixation

Advocates for limited open reduction and external fixation focus on the restoration of the joint surface as the main goal of open surgery. The joint surface can be stabilised with K-wires and the alignment of the limb maintained using an external fixator. This approach avoids multiple skin incisions and associated complications. Given an anatomically reduced joint surface, even angular malalignment of the limb can be corrected through the use of supramalleolar osteotomy performed electively. Other possible interventions include reduction of malleolar fractures, securing with K-wires and holding the entire construct with an external fixator (Figs. 44.12 and 44.13).

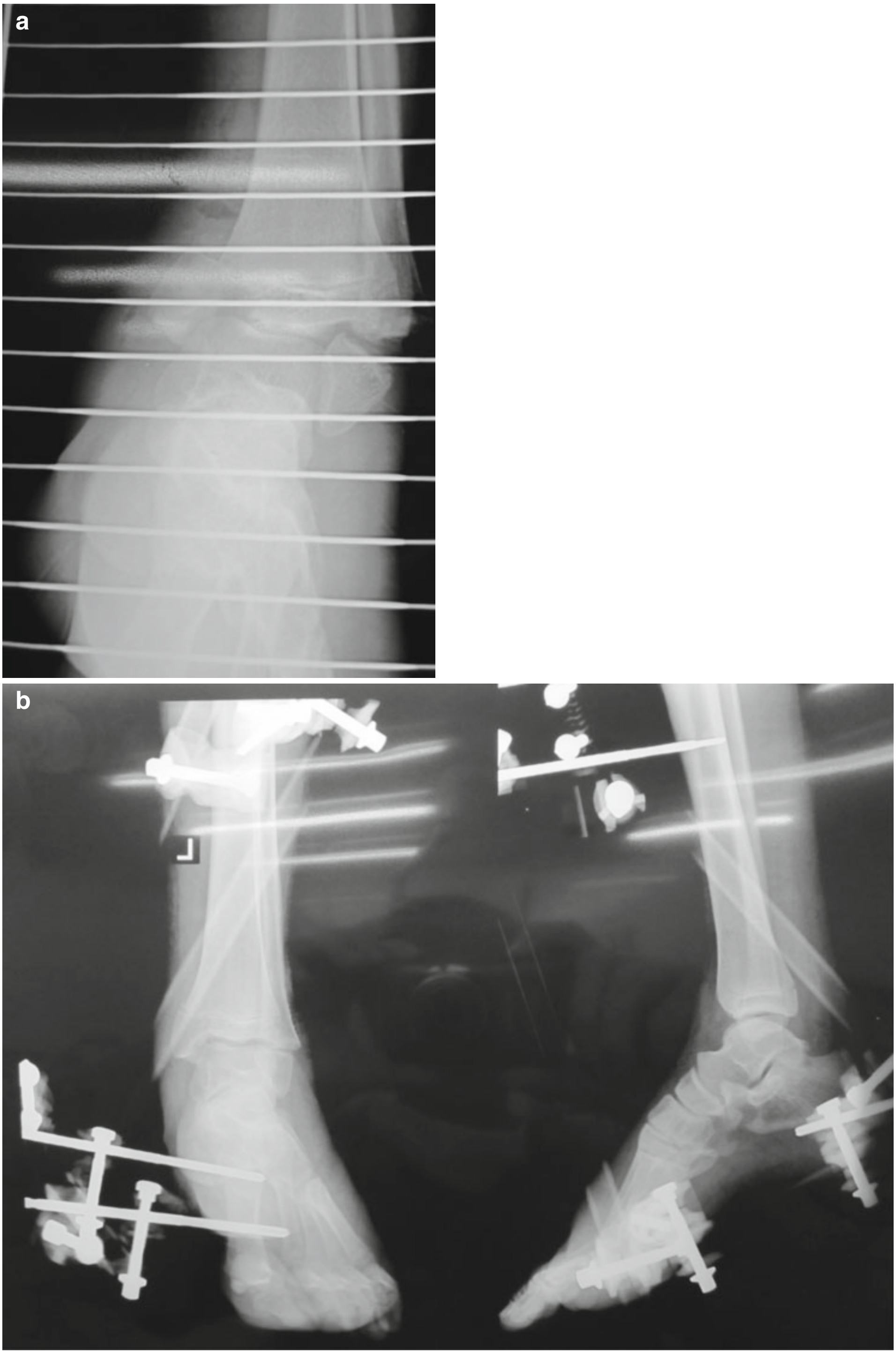

Fig. 44.12 (**a**) A bimalleolar displaced ankle fracture and (**b**) AP and lateral X-ray showing fracture reduced indirectly and stabilised with an external fixation

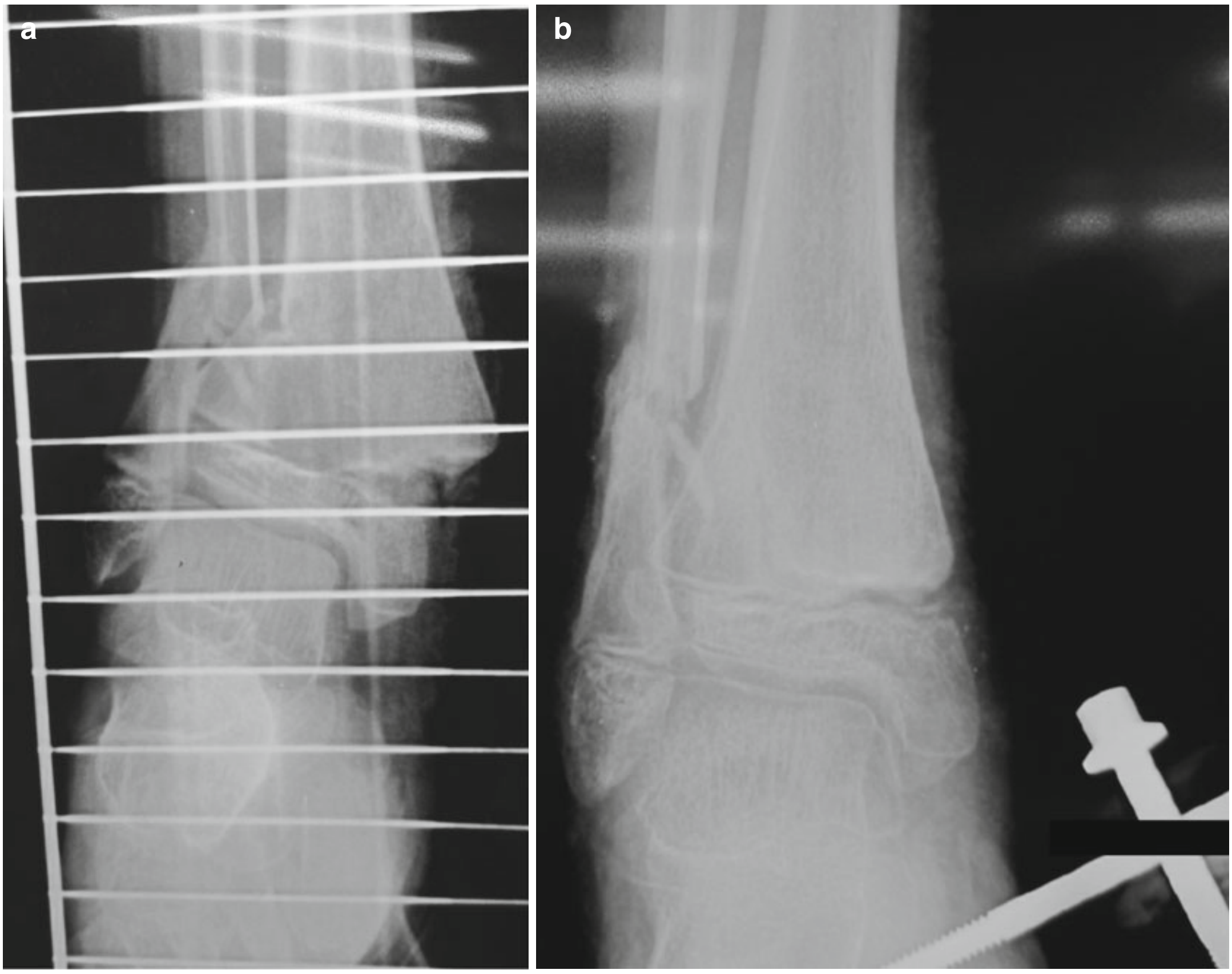

Fig. 44.13 (**a**) A displaced Harris II/triplanar fracture? And (**b**) the same fracture reduced and stabilised with an external fixator. Callous can be seen in the fibular fracture

44.5.4 Open Reduction and Internal Fixation

If there are facilities with better equipment and skills than yours, *transfer the patient*. ORIF must only take place if the material and staff conditions allow for patient safety and successful interventions. The availability of an image intensifier, by enabling the surgeon to obtain intraoperative images, can help to limit the surgical exposure. A detailed description on appropriate internal fixation is beyond the remit of this chapter. Before attempting any internal fixation, you must be well versed in the basics of osteosynthesis. Assuming that you are, what follows is a brief description of key points not to neglect when fixing ankles:

1. The soft tissues must be ready and any swelling must have subsided. This can be checked by examining the foot and ankle for skin wrinkles and absence of blisters. No incisions must be made through blisters.
2. *Always use antibiotic prophylaxis at induction.*
3. Always be mindful of the *superficial peroneal nerve* when exposing the fibula.
4. There is no point in doing an ORIF if you fail to restore length and rotation of the fibula and a well-reduced syndesmosis. If necessary, you can compare with the other ankle to gain a better idea of length and rotation.
5. Only use implants you are familiar with, and keep it simple!
6. Make sure you are proficient with lag screws. Do not use a lag screw in comminuted fractures. If you use a lag screw, the fibula only requires 1/3 semitubular plate with six cortices above and below the fracture to neutralise rotation.

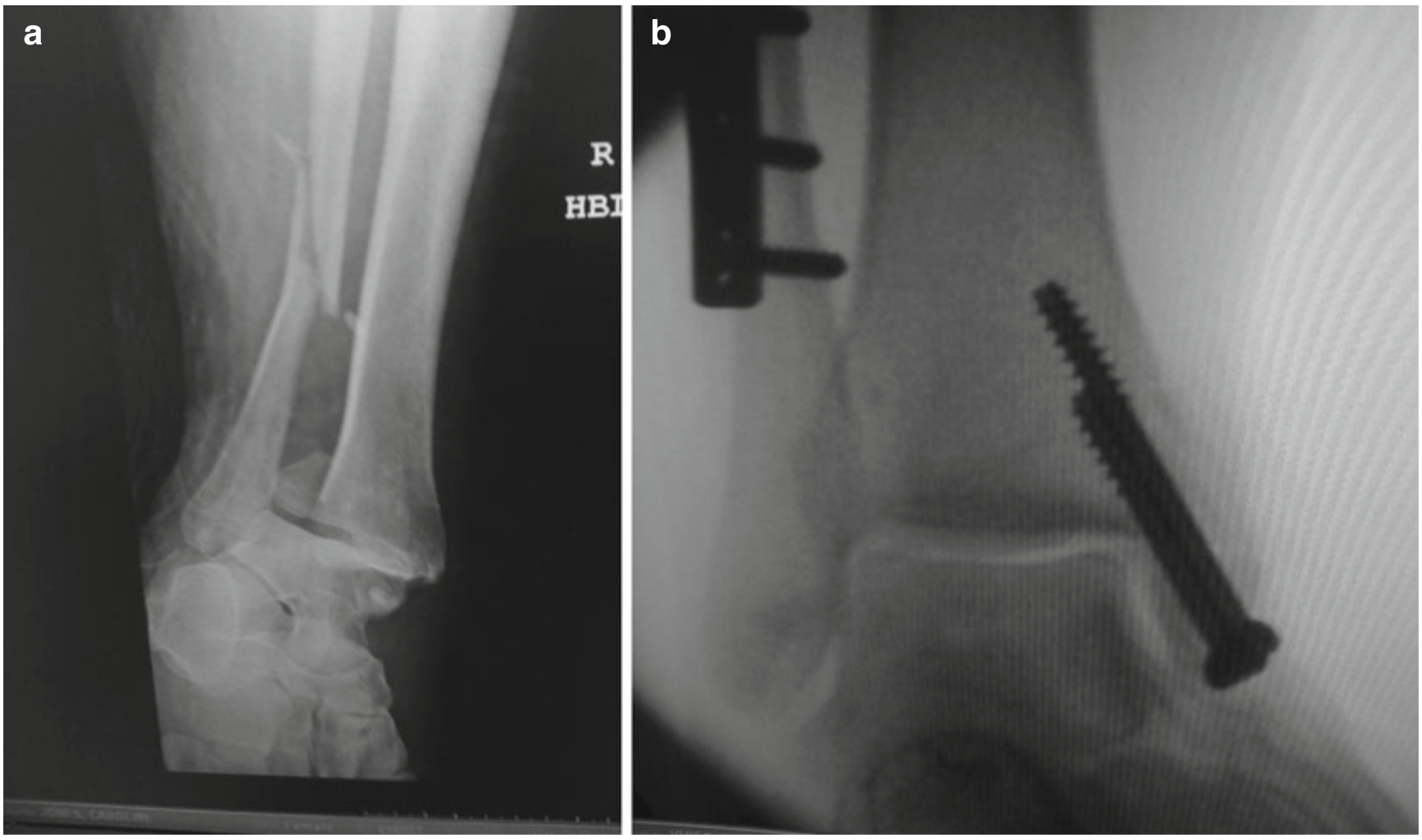

Fig. 44.14 (**a**) AP and lateral of a trimalleolar fracture and (**b**) AP of fibular plate fixation and mortise view showing medial malleolus screws. The posterior malleolus has been reduced by fixing the fibula. Notice the thick plate bridging the long comminuted fibular fracture. The syndesmosis was reduced and stable under stress, so no syndesmosis screws were required

7. The screws should be bicortical, except the distal screws which usually are cancellous and do not need to engage the second cortex.
8. You can also use a large K-wire, a Rush rod or the guide wire for a tibia nail as a rod for the fibula.
9. For more proximal fibular fractures, a stronger plate, like a DCP, may be required (Fig. 44.14). Again, if the fracture is very comminuted, your plate will be used to bridge the comminution, and your construct should not be too stiff (too many screws) or the fracture will not unite.
10. For syndesmosis, remember that the screw goes from posterolateral (the fibula) to anteromedial (the tibia) at a 30° angle.
11. The medial malleolus can be fixed with screws. If the purchase is poor, you can use long screws and gain purchase by engaging the lateral cortex of the tibia.
12. A tension band wire can be used in smaller medial malleolar fragments, or a tension band plate can be made with a 1/3 semitubular plate cut to size.
13. Always irrigate profusely with copious amounts of sterile fluid at the end of the operation. You have created an open fracture, treated as such!
14. Closure must ensure that the *metal work is covered* and that the sutures in the *skin are not too tight*, as this will lead to skin necrosis, wound breakdown or dehiscence. This does not mean that your knots are inadequate. *Respect the soft tissues* and you will minimise the risk of soft tissue complications.
15. Do not use a drain. Minimise the use of tourniquets but have one in place.

Place the limb in a below knee *well-padded backslab* with the ankle *in neutral. Do not accept plantar flexion*. The limb should be placed on several pillows or a frame to maintain elevation above the level of the heart. Prescribe two more doses of cephalosporins 8 and 16 h postoperatively (or whatever the local protocol dictates) and adequate analgesia. Monitor the patient for compartment syndrome and obtain a check X-ray to confirm anatomic reduction, especially if no II images available. Prescribe physiotherapy for the knee flexors and extensors. The backslab should be converted to a complete cast before discharge, once the risk of swelling has subsided, and a check X-ray has confirmed adequate reduction.

44.6 Rehabilitation and Follow-Up

44.6.1 Nonoperative Follow-Up

The nonoperative management of ankle fractures requires absolute non-weight bearing for 4–6 weeks or until clinical and radiographic union of the fracture. It may take longer in diabetic patients or secondary to malnutrition or other chronic diseases. If there is evidence of callous at 4 weeks, partial weight bearing with crutches may be allowed, as this will improve rehabilitation and proprioception.

Crutches and other mobility aids allow patients to maintain weight-bearing restrictions when discharged. In general, a well-fitting cast or splint can be left in place for several weeks with weekly radiographs to confirm maintenance of reduction up to week three. By week 4, there should be evidence of callous formation. As rehabilitation services are not routinely available, it is necessary to examine the patient during follow-up for range of motion and prescribe and demonstrate simple exercises to return the range of motion and strength to the injured limb. This promotes the expedient return to work for the patient.

44.6.2 Operative Management Follow-Up

The patient should return for a wound check and removal of sutures or staples 10–12 days postoperatively. A check X-ray should be done and if everything is fine, placed in a below knee cast for a minimum of 4 weeks. It is advisable to bring the patient back after 2 weeks to make sure all is in order and answer any questions the patient may have, as well as to reinforce the treatment plan to increase compliance.

When there is evidence of callous formation, and examination elicits no bony tenderness, the patient can start a physiotherapy regimen to recover range of motion and gradual return to full weight bearing.

If you know you will not be available for follow-up, make sure you document clearly the diagnosis, treatment and detailed plan to follow and that there is proper handover to the next responsible surgeon.

44.7 Early Complications and Management

44.7.1 Loss of Reduction

As discussed above, the early loss of reduction should be looked for and managed with a repeat manipulation under anaesthesia in order to provide the best chance of successful healing. Grossly unstable fractures may require percutaneous fixation of the talus in a reduced position prior to casting in order to maintain the position of the talus. Only do ORIF if it is safe for the patient.

44.7.2 Infection

Any sign of infection – pain, erythema, discharge and swelling – requires immediate attention. Antibiotic therapy and wound debridement are the mainstays of treatment. If intact, any fixation should be maintained until bone healing is achieved. Supplementary stabilisation with a splint or external fixator may also be necessary if implants are not stable. If the treatment is successful in suppressing infection until bony union, implants should be removed along with any infected tissue. In such cases, familiarity with local soft tissue coverage methods is essential given the likelihood soft tissue defects.

44.7.3 Deep Vein Thrombosis

Do not forget that patients must be assessed for their risk for deep vein thrombosis (DVT) and appropriate prophylaxis must be administered (see Chap. 21 on clots). All patients who have been operated on need prophylaxis for 3 weeks.

44.7.4 Complex Regional Pain Syndrome (CRPS)

If the patient begins to experience pain out of proportion within 3 months of the fracture, the problem may be the acute phase of CRPS. You must first rule out a DVT or compartment syndrome. To treat CRPS:

1. NSAIDs
2. Aggressive physiotherapy
3. Nerve block
4. Psychosocial support

Conclusion

Ankle fractures are common. Soft tissue integrity is paramount, so make sure closed fractures remain closed by prompt reduction and stabilisation and do not forget to manage the swelling. Most fractures can be treated with a well-moulded cast. Other options are traction and external fixation, especially when there is soft tissue damage. ORIF should only take place when the surgical team and resources allow for a safe intervention. There is no point in doing an internal fixation if you fail to reduce the fracture and re-establish fibular rotation and length as well as the mortise view. Never operate on an ankle which is swollen or through damaged tissues. Never forget antibiotic cover and proper irrigation. Administer appropriate antithrombotic prophylaxis. Make sure you can follow up patients and that there is a system for handover so that these patients can be followed up effectively when you have left the area and do not neglect rehabilitation.

References

1. Yde J. The Lauge Hansen classification of malleolar fractures. Acta Orthop Scand. 1980;51(1):181–92.
2. Okanobo H, Khurana B, Sheehan S, Duran-Mendicuti A, Arianjam A, Ledbetter S. Simplified diagnostic algorithm for Lauge-Hansen classification of ankle injuries. Radiographics. 2012;32(2):E71–84.
3. Wang X, Chang SM, Yu GR, Rao ZT. Clinical value of the Ottawa ankle rules for diagnosis of fractures in acute ankle injuries. PLoS One. 2013;8(4), e63228.
4. Crist BD, Khazzam M, Murtha YM, Della Rocca GJ. Pilon fractures: advances in surgical management. J Am Acad Orthop Surg. 2011;19(10):612–22.
5. Strauss EJ, Petrucelli G, Bong M, Koval KJ, Egol KA. Blisters associated with lower-extremity fracture: results of a prospective treatment protocol. J Orthop Trauma. 2006;20(9):618–22.
6. Giordano CP, Koval KJ. Treatment of fracture blisters: a prospective study of 53 cases. J Orthop Trauma. 1995;9(2):171–6.
7. Dowling SK, Wishart I. Use of the Ottawa Ankle rules in children: a survey of physicians' practice patterns. CJEM. 2011;13:333–8.
8. Charnley J. The closed treatment of common fractures. Baltimore: Williams and Wilkins; 1950. p. xi. 190.
9. White BJ, Walsh M, Egol KA, Tejwani NC. Intra-articular block compared with conscious sedation for closed reduction of ankle fracture-dislocations. A prospective randomized trial. J Bone Joint Surg Am. 2008;90(4):731–4.
10. Quigley TB. A simple aid to the reduction of abduction-external rotation fractures of the ankle. Am J Surg. 1959;97(4):488–93.
11. Pedrini G, Cardi M, Landini A, Strada G. Management of severe open ankle-foot trauma by a simple external fixation technique: an alternative during war and in resource-poor and low-technology environments. J Orthop Trauma. 2011;25(3):180–7.
12. Sanders DW, Tieszer C, Corbett B. Operative versus nonoperative treatment of unstable lateral malleolar fractures: a randomized multicenter trial. J Orthop Trauma. 2012;26(3):129–34.
13. Donken CC, Al-Khateeb H, Verhofstad MH, van Laarhoven CJ. Surgical versus conservative interventions for treating ankle fractures in adults. Cochrane Database Syst Rev. 2012;(8):Cd008470.
14. Makwana NK, Bhowal B, Harper WM, Hui AW. Conservative versus operative treatment for displaced ankle fractures in patients over 55 years of age. A prospective, randomised study. J Bone Joint Surg Br. 2001;83(4):525–9.

Foot Injuries in the Austere Environment

45

Jesse Alan Slade Shantz, Juan de Dios Robinson, and Ralph Richard Coughlin

45.1 Epidemiology

Epidemiological studies on foot injuries in the developing world are very scarce. Research from a high-income developing country showed that the majority of foot injuries were sustained in falls from a significant height [1]. More than half of the injuries reported in that single-centre study were work related. Other mechanisms of injury include road traffic accidents, as the increasing motorisation of LMICs means that a raise in the number of foot injuries. Motorcycle accidents where bony and soft tissue injuries threaten the viability of the foot are common. Ballistic injuries are also common, and explosive devices such as mines continue to maim well after the conflict is over.

45.1.1 Low-Energy Injuries: Twisting Injuries

Although less likely to present acutely, low-energy injuries represent the majority of foot injuries sustained. Common injuries encountered will be ligament sprains and stress fractures from poorly fitting shoes and long walking distances. A common example is the "Jones" fracture. During a forced inversion of the foot/ankle, the peroneus brevis pulls on its insertion at the base of the 5th metatarsal, causing an avulsion fracture (Fig. 45.1).

45.1.2 High-Energy Injuries

The foot can experience axial loads during falls from height or as the footplate of cars intrude during motor vehicle crashes, for example. In such situations, the foot often experiences loads resulting in the failure of bony elements with subsequent shortening (Fig. 45.2).

45.1.3 Penetrating Injuries

Injuries ranging from puncture wounds from rusty nails to high-velocity gunshot wounds occur, each with its own treatment considerations. Puncture wounds often present late due to complications given that they are relatively common in places where shoes are not worn regularly.

J.A.S. Shantz, MD, MBA, FRCS(C)
Institute for Global Orthopaedics and Traumatology,
University of California, San Francisco, CA, USA

J.D. Robinson, FRCS (Tr & Orth)
MSc (Tr Surg) (✉)
Trauma centre, St. Mary's Hospital,
Imperial College, London, UK
e-mail: jddrobinson@hotmail.co.uk

R.R. Coughlin, MD, MSc
Department of Surgery,
Institute for Global Orthopaedics and Traumatology,
University of California, San Francisco,
CA, USA

© Springer International Publishing Switzerland 2016
J.D. Robinson (ed.), *Orthopaedic Trauma in the Austere Environment: A Practical Guide to Care in the Humanitarian Setting*, DOI 10.1007/978-3-319-29122-2_45

Fig. 45.1 A Jones fracture. Treatment is nonoperative with a cast to prevent further displacement by stopping the ankle from inverting again. The patient may heel weight bare

Blade-related foot wounds resulting from accidents or violence are also more commonly seen. In such cases, an accurate survey of the damaged structures is important after initial removal of contamination. Gunshot wounds often result in the loss of soft tissue and bone requiring careful treatment planning and difficult decisions about the viability of limb reconstruction (Fig. 45.3).

45.1.4 Crush Injuries and Soft Tissue Degloving

Crush injury commonly occurs to pedestrians or in occupational situations. Shoes may partially protect the foot from contamination in these situations, but these injuries can be devastating if they disrupt the nervous and vascular supply to the foot, resulting in chronic wound healing difficulties and ongoing pain.

45.1.5 Plantar and Heel Pad Avulsion

A specific presentation of soft tissue degloving encountered is plantar and heel pad avulsion. The specific mechanism for these injuries relates to the use of motorcycles with minimal shoe wear. These injuries are best managed with serial debridements, if contaminated, followed by reattachment of the plantar pad to the plantar fascia with multiple sutures over skin buttons or gauze pads. This technique prevents the hematoma formation and encourages scarring of the plantar pad to the fascia providing a stable weight-bearing platform. In such cases of motorcycle riders experiencing foot injuries, special care should be taken to debride any chain grease from the wound as the foot is often caught in the bike chain depositing debris in the soft tissues (Fig. 45.4).

45.1.6 Blast Injuries

Given the proliferation of landmines in LMICs, it is not surprising that blast injuries are a common mechanism of foot injuries in the austere environment. Conflict zones will also present other similar mechanisms of foot injuries such as improvised explosive devices (IEDs) (Fig. 45.5).

45.2 Assessment

See Chap. 44, for full assessment description.

45.2.1 Vascular Status

The most important predictor of successful treatment for foot injuries is the vascular supply. Assessing and documenting the presence or absence of dorsalis pedis and posterior tibial

Fig. 45.2 Divergent Lisfranc fracture dislocation secondary to high-energy injury

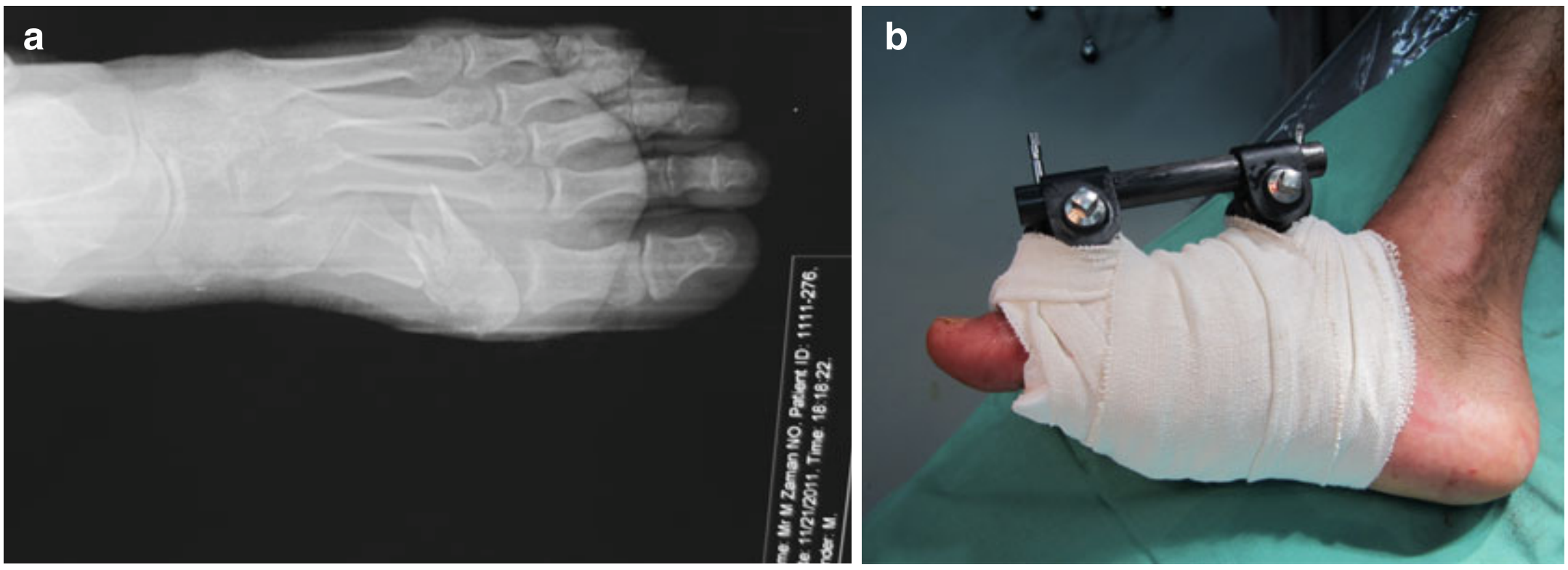

Fig. 45.3 (**a**) AP view of first metatarsal fracture secondary to a gunshot wound. (**b**) External fixation maintaining length and alignment

Fig. 45.4 A calcaneal fracture with degloving of the heel pad. This type of injury can endanger the entire foot if soft tissue cover fails to be re-established (See case tutorial)

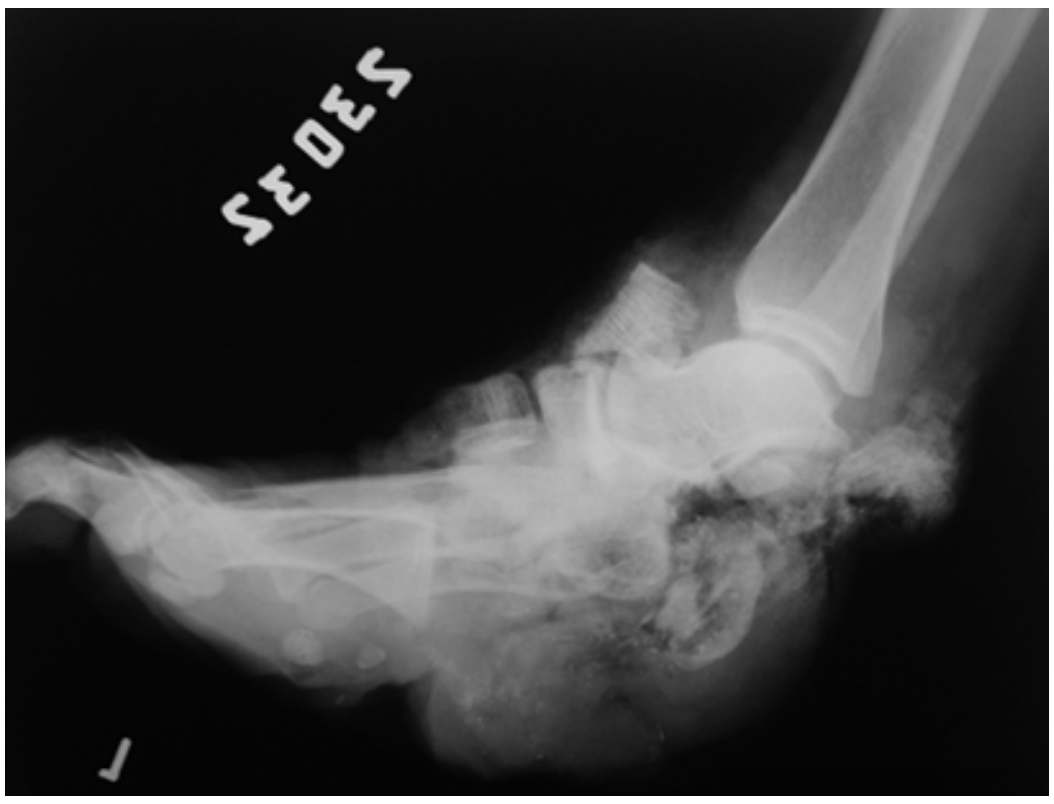

Fig. 45.5 This unfortunate man stepped on a small mine

pulses is specific for the identification of arterial compromise proximal to the foot. More subtle signs such as skin and nail changes, hair loss and neurologic abnormalities point to the presence of microvascular changes in the foot. Doppler assessment also provides a means of confirming arterial flow in larger arteries; however, the presence of Doppler signal should not be interpreted as a sign of adequate tissue perfusion in the face of other signs of relative ischemia.

45.2.2 Neurologic Status

Nerves in the foot occupy a relatively superficial location predisposing them to injury, particularly with penetrating trauma. Five main nerves supply the foot including superficial peroneal, deep peroneal, saphenous, sural and tibial. The tibial nerve is further divided at the medial malleolus into calcaneal, medial and lateral branches. Documentation of nerve function is an important part of the ongoing assessment for compartment syndrome and should be routine in all patient encounters. In addition, the anatomic severance of plantar sensory nerves has a major impact on the success of limb salvage [2].

45.2.3 Soft Tissue Injury Assessment

Reconstruction of the foot relies on both bony scaffold stability and soft tissue integrity. Large plantar wounds, including plantar pad avulsions, threaten the viability of the foot for locomotion. Soft tissue assessment combines the estimation of several related elements: amount of contamination, viability of tissue bed and probability of tensionless closure. By simultaneously considering these factors, the treating surgeon is able to predict the success of a repair of the underlying structures and can better choose an appropriate treatment modality (e.g. avoidance of implants in a contaminated bed).

45.2.4 Tendon and Ligament Injury

Although difficult to examine acutely, injuries to tendons and ligaments should be suspected during assessment. In terms of treatment, the presence of a ligament disruption may not alter the surgical management of a foot injury; however, tendon disruptions of the ankle and hallux flexors and extensors might prompt an acute repair (Fig. 45.6). In such situations, an ultrasound, if available, can identify the retracted tendon end which can be marked for easier retrieval during surgery. Otherwise, a larger proximal incision may become necessary to allow identification of the tendon end.

45.3 Acute Management

45.3.1 Closed Reduction

The thin soft tissue coverage of the foot reduces the tolerance to deformity and displacement.


[redacted]

Fig. 45.6 Extensive tendon damage secondary to gunshot injury

Fractures and dislocations often tent the skin causing blanching and bruising at the apex of deformity. If left in an unreduced or malreduced position, the foot may progress to blistering and eventually to skin breakdown. It is therefore imperative that closed reduction be performed expediently with maintenance of reduction with plaster, smooth wires or an external fixator as appropriate. When using plaster casts, particular attention should be given to the moulding of the arches to preserve the architecture of the foot.

45.3.2 Acute Pain Management

Foot injuries lend themselves to regional anaesthesia for immediate pain relief. This is particularly useful in paediatric patients and in those patients requiring reductions and debridements acutely. Anaesthesia of the foot can be provided by the injection of local anaesthetic at the level of the ankle joint in the vicinity of the five nerves supplying the foot. Care should be taken as long-acting local anaesthetics could obscure the early assessment for compartment syndrome (see Anaesthetics, Chap. 18).

45.3.3 Principles of Definitive Management

45.3.3.1 Maintenance of Column Length

The foot is composed of a rigid medial and a more flexible, compliant lateral column. The bony architecture of these columns forms a tripod-like weight-bearing structure with points at the first metatarsal head, the fifth metatarsal head and the os calcis. The balance and dynamic function of the foot is influenced by the maintenance of the length of each column. In order to preserve the normal function of the foot after trauma, the columns must be brought into proper balance to provide proper alignment of the remainder of the limb. This reflects the importance of the first ray in the gait cycle as the main weight-bearing conduit during toe-off phase. This influences treatment in that fusion of the medial Lisfranc joint (first through third tarsometatarsal joint) has been shown to have benefit in certain Lisfranc ligament and joint injuries [3–5].

45.3.3.2 Calcaneocuboid Joint

The calcaneocuboid joint is relatively constrained providing the opportunity to bridge severely comminuted calcaneal fractures with relatively little effect on foot function and good maintenance of lateral column length.

45.3.3.3 Lateral Lisfranc Joint

The lateral Lisfranc joint requires mobility to allow the foot to establish full contact with uneven ground. Constraining the motion of the fourth and fifth tarsometatarsal joints through fusion, therefore, is contraindicated.

45.3.3.4 The Hindfoot

In addition to maintaining column length, the biomechanics of the foot require the treating physician to consider the alignment of the hindfoot during treatment. Hindfoot varus results in the failure to unlock the transverse tarsal joint severely limiting the ability of the foot to accommodate to uneven ground. Neutral alignment should be the goal of immobilisation.

45.3.4 Treatment Strategies

45.3.4.1 Nonoperative Management

Undisplaced fractures should be managed nonoperatively. Hindfoot injuries should be immobilised only to facilitate soft tissue protection as necessary. Early range of motion and

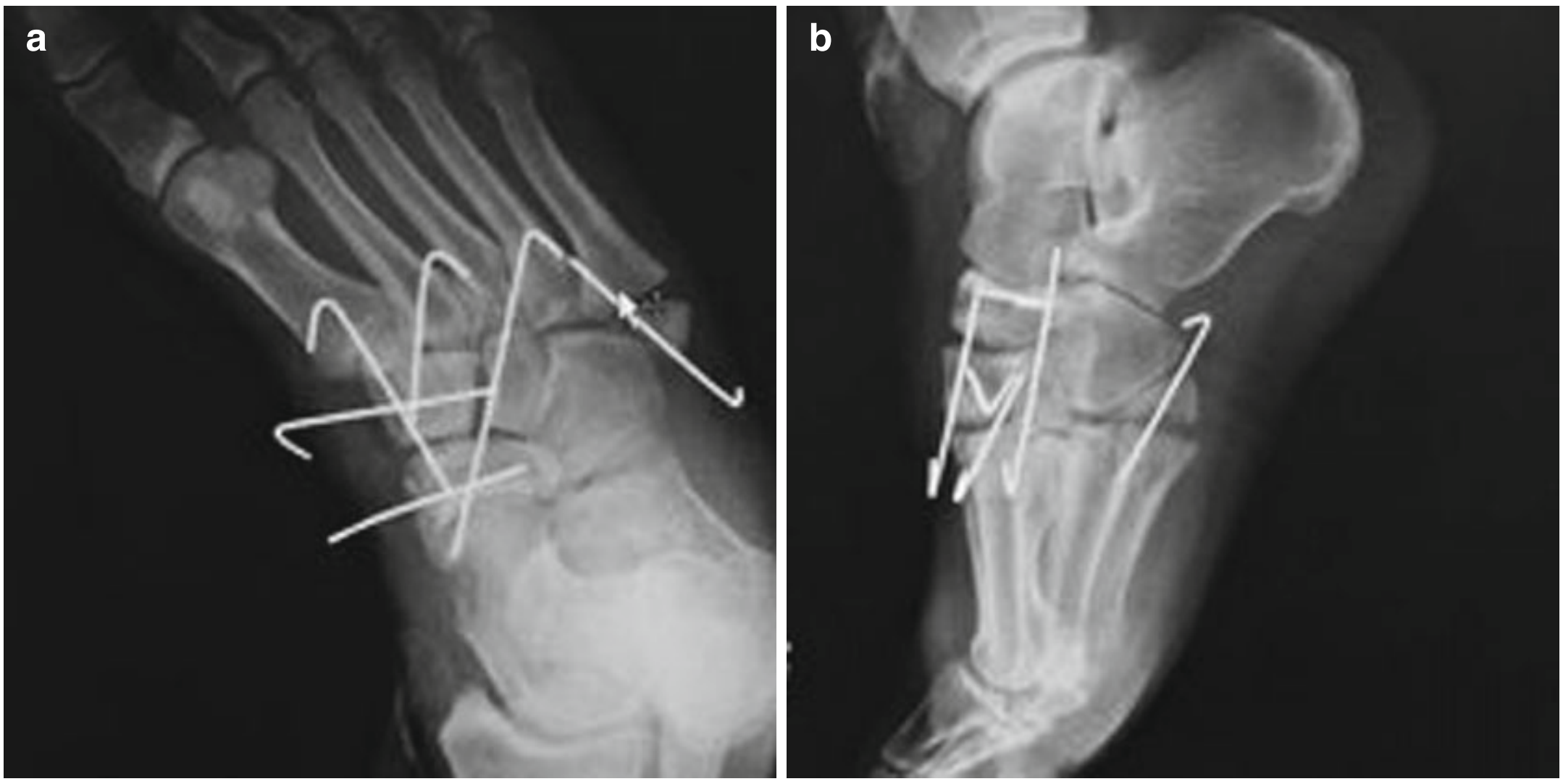

Fig. 45.7 (**a**) AP and (**b**) lateral of pin fixation of the divergent Lisfranc fracture dislocation in Fig. 45.2. A complex fracture dislocation of the midfoot resulting from a motor vehicle crash. A closed reduction and moulded cast failed to maintain the reduction of the injury, and therefore multiple smooth Kirschner wires were employed to maintain the reduction until scarring had provide stability allowing casting until healing

sensitisation therapy with water soaks can benefit soft tissue recovery and ready the patient for protected weight-bearing. Midfoot and forefoot injuries should be approximately reduced and immobilised in a well-moulded splint maintaining the longitudinal arch of the foot to facilitate foot function after healing. Finger traps can be an excellent adjunct to the reduction of midfoot and forefoot fractures and dislocations and provide a means to maintain column length during pinning and plaster application.

45.3.4.2 Flexible Fixation and Percutaneous Methods

The use of smooth wires in the foot and ankle provides surgeons with a minimally invasive way of maintaining closed or open reductions of fractures or dislocations. Although helpful in these applications, smooth pins are less effective in the maintenance of column length, particularly when inserted longitudinally. Pins incorporated into plaster can be successfully used to maintain column length when inserted perpendicular to the longitudinal axis of the foot and pushed apart prior to the setting of the plaster. This is particularly useful when treating cuboid crush injuries. In some injuries, smooth wires can be inserted through an injured bony segment and into an intact segment to maintain length, such as in a blast injury with metatarsal defect where pins could hold the viable distal segment at length by transfixing intact and fractured metatarsals (Fig. 45.7).

Shanz pins are particularly useful to achieve and maintain the reduction of a tongue-type calcaneus fracture with skin tenting (see below). Given the risk of skin necrosis, the failure to maintain reduction of the Essex-Lopresti fragment with plantar flexion should prompt immediate percutaneous manipulation and fixation before skin integrity is compromised.

45.3.4.3 External Fixation

External fixation provides the surgeon with the ability to maintain column length without the need for large incisions or indwelling implants [6]. For many foot applications, small pins and bars facilitate the use of external fixators. The primary sites of application in the foot are on the medial and lateral sides with pins generally placed in the calcaneus, first or fifth metatarsal and talar neck as needed. Such frames can be connected to ankle-spanning frames to control ankle motion. Under austere conditions, a simple

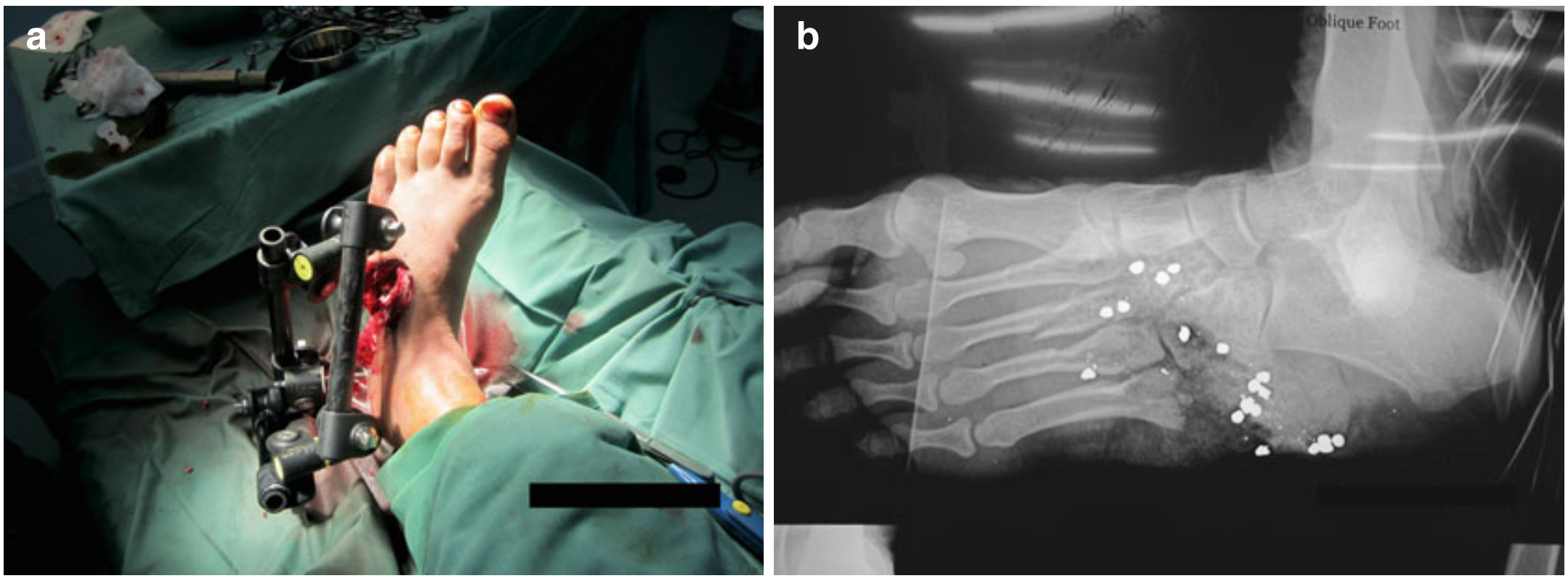

Fig. 45.8 (**a**) An external fixation maintaining length in this foot following a gunshot injury. (**b**) Oblique view of the same injury. Also see Fig. 45.6. The external fixator confers stability and length while facilitating debridement and soft tissue management

version of an external fixator can be fashioned by employing two Steinmann pins. These pins are inserted retrograde through the plantar foot, through the first and fifth metatarsal and into the tibia [7] (see Chap. 44). During use of an external fixator, patients are customarily kept non-weight-bearing to allow healing of bone and soft tissue components of the injury and to prevent pin loosening and implant breakage (Fig. 45.8).

45.3.4.4 Open Reduction and Internal Fixation

There is a limited role for open reduction and internal fixation in the austere environment. In too many cases, a well-meaning surgical reduction can be converted into a chronic osteomyelitis with skin defect that will haunt a patient for the rest of their life. The type of scenarios where the balance should be tipped towards operative management includes an irreducible fracture and dislocation, where the skin is at risk such as with talar body extrusions and subtalar dislocations with interposed tibialis posterior tendon. In such cases, open reduction with percutaneous pinning relieved skin tenting and preserves the soft tissue envelope (see case tutorials). Always ensure the skin and soft tissues are fit for surgery.

45.3.4.5 Amputations

Amputations are a very sensitive topic. Despite the fact that in many situations local resources and injury characteristics suggest that early amputation should be the treatment of choice, this may not be the wishes of the patient or the family [8]. The level of amputation will be determined by the injury, but it may also be influenced by the local resources for prosthetic fitting, with a lower level being chosen despite increasing risk of wound complications due to soft tissue concerns. In addition, the lack of prosthetists demands careful planning of amputation level to allow patients to maximise function postoperatively (see Chap. 30 on amputations)

45.4 Rehabilitation, Prosthetics and Orthotics

45.4.1 Rehabilitation

The rehabilitation of foot injuries, particularly those with a severe soft tissue component, requires a balanced approach between non-weight-bearing and early re-sensitisation to pressure on the plantar surface.

45.4.2 Desensitisation

Foot injuries, and particularly those with crush injuries, can be complicated by complex regional pain syndrome (CRPS), a syndrome characterised by nonanatomic severe pain in the recuperation period. Early recognition and treatment of CRPS is essential to shortening duration and reducing the associated disability. In austere environments, the opportunity to follow up patients may be limited, and therefore, communication of the diagnosis and some strategies for treatment are essential. These strategies include aggressive physiotherapy and NSAIDs.

45.4.3 Complications

45.4.3.1 Neuroma Formation

The foot has an abundant supply of subcutaneous sensory nerve branches which may be encountered during surgical approaches. The incidence of symptomatic neuromas is compounded by the thin subcutaneous tissue envelope. Although a percentage of patients will develop neuromas after operative treatment, several principles theoretically lower the risks. Marking branches of the superficial peroneal nerve distal to the ankle can allow the surgeon to identify and protect these nerves. They are often visible in thin patients when the foot is plantar flexed and supinated. Careful use of dissecting scissors with minimal soft tissue spreading causes less stretch and injury to nerves.

45.4.3.2 Infection

Infection risk is high following open fractures, inappropriate internal fixation or the complications of blast and gunshot injuries. Infection in areas with scarcity of antibiotics, surgical care and other measures such as vacuum dressings are limb and life-threatening. The treatment of ulcers and open foot wounds can incur a significant expense to the patient given the intensity of treatments [9]. At the earliest signs of infection, the wound must be treated aggressively with incision and drainage, debridement and copious washout and IV antibiotics. All affected tissue must be removed. *Tissues must never be closed in the presence of infection or contamination.* The patient must undergo a second look, often after 48 h, and the process repeated until any signs of infection are absent. The foot must be splinted to rest the soft tissues and elevated to reduce swelling.

If cavities exist (dead space), these must be filled with a sponge or preferably with antibiotic beads, which can be made locally with cement and powdered antibiotics. A homemade suction device can also be applied by applying a saline-soaked sponge or gauze, applying some tubing or even a catheter, covering all this with another gauze and an occlusive dressing and connecting the catheter or tubing to a suction device (wall suction, portable suction or even a large syringe with its plunger held in suction with smaller plungers from other syringes).

45.4.4 Salvage Procedures: Fusion

Acute trauma may have caused extensive articular damage or bone loss. In this case, a fusion as a primary treatment may be considered. The aim is to achieve a plantigrade, painless foot that is functional. External fixation and k-wires may be used, but the most effective technique of fusion involves compression, so screws may be required.

Fusion is also the primary method of salvage in post-traumatic foot pain. The results of fusion are best when symptoms can be isolated to a specific joint.

The primary evaluation requires the careful palpation and movement of surrounding joints to identify the source of pain. In addition, lidocaine injection can provide an indication of the amount of pain and disability caused by a given joint if injected intra-articularly. Corticosteroid injection should be avoided if fusion is planned imminently due to the effect on bone healing. Of primary importance is the adequate preparation of the joint for fusion through removal of cartilage and subchondral bone. Care also needs to be taken in maintaining the length of columns of the foot when decorticating subchondral bone.

Most forefoot and midfoot fusions can be achieved with the use of local bone graft from the distal tibia, calcaneus or proximal tibia. Compression and fixation can generally be accomplished using fully threaded screws placed using lag technique or with dynamic compression plates. Subtalar fusion is performed using partially threaded screws, when available, to provide compression across the joint. When combined with tibiotalar fusion, a retrograde nail can be used to fuse subtalar and tibiotalar joints simultaneously.

45.4.5 Specific Injury Management

45.4.5.1 Calcaneal Fractures

(a) Nonoperative management:

Extra-articular and either undisplaced or minimally displaced fractures should be managed nonoperatively in a cast or even without a cast. Maintaining ankle joint movement as tolerated is important for early rehabilitation.

(b) Operative management:

(i) Indications:

- Joint depression type with significant varus position of the tuberosity
- "Tongue type", with or without skin compromise

Skin compromise (contusion, tight tenting, blanching) is an emergency, and the fracture should be reduced as soon as possible. Manipulate the foot/hindfoot into plantar flexion, carefully attempting to bring the fragments together. If the fracture is not reducible manually, then an Essex-Lopresti manoeuvre is indicated.

Essex-Lopresti Manoeuvre

1. The patient must be given adequate analgesia/anaesthetic.
2. The foot is thoroughly cleaned and draped appropriately.
3. A Shanz pin or long screw is inserted into the tuberosity, taking care not to fracture the fragment or to damage the skin any further. A small puncture incision with the blade will suffice.
4. Make sure the Achilles tendon is relaxed by bending the knee.
5. The pin is used as a joy stick to manipulate the fragments together, reducing the varus and restoring Bohler's angle, height and alignment as much as possible.
6. The pin/screw can be incorporated into a cast to maintain the position, or K-wires can be used to secure the fragment to other bones in the foot.
7. After 3–4 weeks, when the fracture is "sticky" enough, the position of the foot is changed to a more plantigrade orientation to prevent equinus deformity.
8. Patients must be mobilised as soon as tolerated and safe to maximise function. A weight-bearing cast may be helpful, but some patients may be able to mobilise with a plaster cast booty. It is important to initiate ankle joint rehabilitation and Achilles stretching exercises early (Fig. 45.9).

Fig. 45.9 Lateral view pre-op. A calcaneus fracture with proximal migration of the proximal fragment placing the skin over the Achilles tendon insertion at risk. A Steinmann pin has been used to secure the displaced fragment and protect the soft tissues during healing

45.4.5.2 Talar Fractures/Dislocations (Subtalar, Talonavicular)

(a) Nonoperative management:

Non-displaced intra-articular and extra-articular talus fractures can be treated nonoperatively with a cast.

(b) Operative:

1. Indications:
   - Hawkins type 2 talar neck fractures or
   - Neck fractures with subtalar and ankle joint dislocation (Hawkins type 3) which have higher rates of avascular necrosis (AVN)

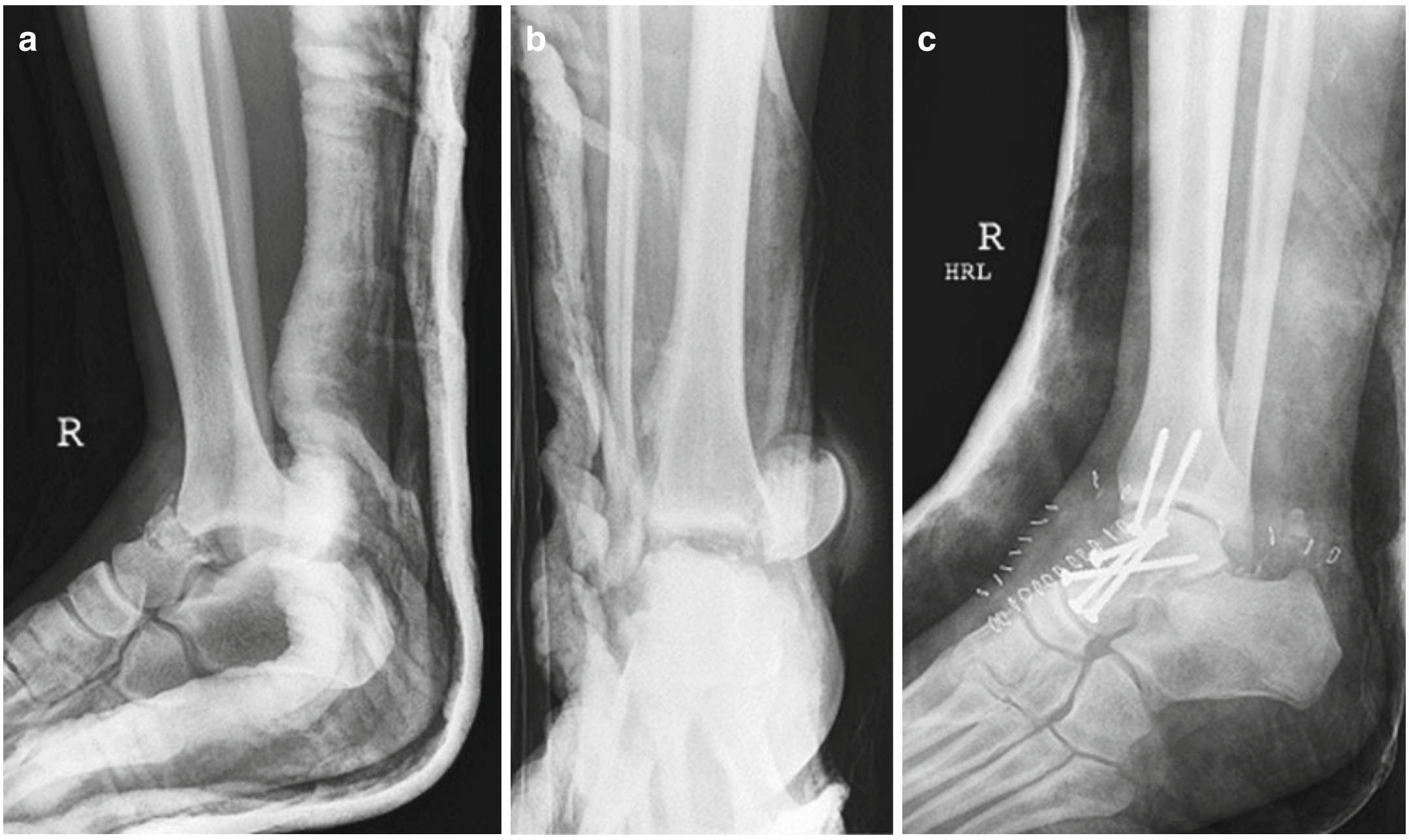

Fig. 45.10 (**a**) Lateral (**b**) AP of talar fracture dislocation. (**c**) Post-operative X-ray. The anterolateral and anteromedial incisions can be appreciated as well as the screws securing the medial malleolus back following a medial malleolar osteotomy have facilitated the reduction of this difficult fracture

2. The patient must be fully anaesthetised to enable reduction.
3. This is achieved by plantar flexion to bring in the body of the talus into the ankle joint and re-establish the subtalar joint as well.
4. The fracture usually has a varus position, and thus the Lisfranc joint must be everted.
5. Traction may be required to increase the space in the joint, and this can be achieved by introducing a traction pin through the calcaneus.
6. If the fracture cannot be reduced by this means, an open reduction is necessary. This can be achieved through an anteromedial and anterolateral incisions.
7. If reduction is still difficult, consider a medial malleolar osteotomy. This must only be done if you have the means to fix the medial malleolus back securely.
8. Once the fracture is reduced, the position can be fixed by transfixing with K-wires (multiple if necessary), and additional stability can be achieved with an external fixator. If screws are available, two lag screws can be used to achieve compression if the fracture is not comminuted. If extensive comminution exists, the screws should be fully treaded and serve as holding screws (Fig. 45.10).
9. Ensure the patient has adequate follow-up, and look for Hawkins' sign in the AP X-ray 6–8 weeks post-operatively, a subchondral radiolucency in the dome of the talus which indicates resorption of the bone, which only occurs if there is an adequate blood supply.

45.4.5.3 Peri-talar Dislocations

1. The patient must be adequately sedated.
2. Knee fully flexed.
3. Percutaneous pinning can be used to hold the reduction if necessary.

Midfoot, Navicular, Cuboid, Cuneiforms Fractures and Dislocations

1. Rest the foot in elevation.
2. Apply traction if reduction is necessary.

3. Weight until swelling has subsided.
4. Can use K-wires to achieve fixation and maintain reduction. Additional support can be achieved with an external fixator or a plaster (see case tutorials).

45.4.5.4 Lisfranc Joint Fracture Dislocations

Again, soft tissue integrity is paramount. The majority of these injuries will be able to be managed closed. Traction with "Chinese" finger straps can help re-establish alignment. K-wires can be used to achieve stability, and again this can be supplemented with cast or external fixation.

If closed reduction is not successful, a one- or two-incision approach can be used to reduce the joint, and K-wires can be used to achieve fixation. Patients most remain protected in a cast for 3 months and remain non-weight-bearing to give a chance to the joint to stabilise (see case tutorials).

45.4.5.5 Metatarsals

Nonoperative: Undisplaced or minimally displaced fractures can be treated nonoperatively in a cast, heel weight-bearing, for 4–6 weeks. Additional protection can be given in the form of neighbour strapping of the toe of the affected metatarsal to the neighbouring toe. This can help as an indirect splint and prevents rotation.

If the metatarsal is grossly displaced and closed attempts to reduce fail, a limited incision can be made dorsally to free the fragments and reduce them, while securing the reduction with a K-wire. The K-wire can transfix from one metatarsal to another, or it can be introduced from the distal to the proximal fragments. This can then be protected with a cast for 4–6 weeks.

45.4.5.6 Phalangeal Fractures

Toe fractures need to be treated symptomatically. adequate analgesia should be provided, manipulation of gross deformities, neighbour strapping to prevent rotation and protected with a weight-bearing cast or hard sole shoe. Intra-articular fractures of the IPJ will result in stiff joints and may cause pain in the future.

45.4.5.7 Achilles Tendon Rupture and Serial Casting

Treat acute presentations in an full equinus cast for 2 weeks, a 30° of plantar flexion cast for another 2 weeks, 15° of plantar flexion for another 2 weeks and then in a neutral cast for 2 weeks for a total of 8 weeks (see Chap. 48). Intensive rehabilitation will be required following the end of this treatment to achieve full ankle range of motion and tendoachilles strengthening.

References

1. Tadros AM, Eid HO, Abu-Zidan FM. Epidemiology of foot injury in a high-income developing country. Injury. 2010;41(2):137–40.
2. Bosse MJ, McCarthy ML, Jones AL, Webb LX, Sims SH, Sanders RW, et al. The insensate foot following severe lower extremity trauma: an indication for amputation? J Bone Joint Surg Am. 2005;87(12):2601–8.
3. Coetzee JC. Making sense of lisfranc injuries. Foot Ankle Clin. 2008;13(4):695–704, ix.
4. Coetzee JC, Ly TV. Treatment of primarily ligamentous Lisfranc joint injuries: primary arthrodesis compared with open reduction and internal fixation. Surgical technique. J Bone Joint Surg Am. 2007;89(Suppl 2 Pt.1):122–7.
5. Sheibani-Rad S, Coetzee JC, Giveans MR, DiGiovanni C. Arthrodesis versus ORIF for Lisfranc fractures. Orthopedics. 2012;35(6):e868–73.
6. Klaue K. The role of external fixation in acute foot trauma. Foot Ankle Clin. 2004;9(3):583–94.
7. Pedrini G, Cardi M, Landini A, Strada G. Management of severe open ankle-foot trauma by a simple external fixation technique: an alternative during war and in resource-poor and low-technology environments. J Orthop Trauma. 2011;25(3):180–7.
8. Bosse MJ, MacKenzie EJ, Kellam JF, Burgess AR, Webb LX, Swiontkowski MF, et al. An analysis of outcomes of reconstruction or amputation after leg-threatening injuries. N Engl J Med. 2002;347(24):1924–31.
9. Jeong JJ, Lee HS, Choi YR, Kim SW, Seo JH. Surgical treatment of non-diabetic chronic osteomyelitis involving the foot and ankle. Foot Ankle Int. 2012;33(2):128–32.

46

Soft Tissue Management and Reconstructive Options in the Austere Environment

Tom Potokar

As it is the case with orthopaedic trauma anywhere, appropriate and timely management of the surrounding soft tissues is critical to a successful outcome. However, in an austere environment, there are many factors that need to be considered. There may be an influx of casualties all at once requiring care, limited technical expertise, insufficient time available for prolonged procedures, and the absence of rehabilitation and follow-up. In addition, potential language and communication barriers, cultural differences, an insecure environment, media interest and perhaps other teams with a less than professional attitude can add to the difficulty and it is easy to then see how a crisis can become a disaster.

Adhering to basic principles, avoiding a 'have a go' attitude, and doing simple things well are the key to success. It is important to accept your limitations, understand that different situations and environments demand different approaches and that whilst you must always endeavour to do the best for your patient, you must also consider the needs of the majority. Spending the whole day doing a complex reconstruction in the acute stages of a disaster when there are numerous other patients waiting for urgent life and/or simple limb saving procedures such as a fasciotomy is not appropriate, and sometimes tough decisions need to be made to ensure the greatest good for the largest number of patients.

We must remember that working in an austere environment can represent many different situations, from a remote mountainous area suffering from a massive earthquake in North-West Pakistan, to providing routine care for an isolated population in rural India, to dealing with victims of a road traffic accident in the desert of North Africa. One must gain a rapid appreciation of the local conditions and what is possible and safe to achieve (Fig. 46.1).

46.1 Getting the Basics Right

Before discussing any surgical options and techniques, it is vital that you step back and take some time to get as much information as possible to guide your decision making process. Even if working in a highly pressurised environment, it is essential to remain calm and not forget the basics of good medical practice – taking a proper history and physical examination. If this is done well, it makes the subsequent decision making easier, more logical and based on facts, thus enhancing the likelihood of making the right choice in terms of management. In all cases you should follow the mantra, 'It is not what could be done, but what should be done'.

T. Potokar, FRCS(Ed), FRCS(Plast), DA, DTM&H
Welsh Centre for Burns & Plastic Surgery,
Morriston Hospital, Heol Maes Eglwys,
Morriston, Swansea, Wales, UK
e-mail: tom.potokar@wales.nhs.uk

© Springer International Publishing Switzerland 2016
J.D. Robinson (ed.), *Orthopaedic Trauma in the Austere Environment:
A Practical Guide to Care in the Humanitarian Setting*, DOI 10.1007/978-3-319-29122-2_46

[redacted]

Fig. 46.1 This man was hit by a truck and suffered extensive circumferential de-gloving of his lower limb – what could you do here? You could harvest as much skin as possible from the de-gloved area. But could you store it? How will you prevent infection?

46.2 History

Factors pertinent in the history relate to both the wound and the patient. You cannot properly assess a wound if you do not assess the whole patient. Contrary to a high-income well-resourced environment, in an austere environment, patients often arrive days or even weeks after an injury, and the patient may well be suffering from medical problems such as malnutrition, chest infection, undiagnosed diabetes, etc.

The first priority is to find out what happened, when, where, how and why and any treatment they have had to date. Then focus on any significant past medical history, medications and allergies and most importantly their family and social background (including occupation and handedness) as this can have a significant influence on the management plan.

Table 46.1 Important wound characteristics

Size of the wound	Is the wound small, medium or large?
Shape of the wound	Circular, longitudinal?
Site of the wound	Over a joint, anterior or posterior surface, circumferential?
Depth of the wound	Superficial or deep?
State of the wound	Clean, contaminated, mucky or frankly infected?
Tissues and structures damaged	Skin, muscle, tendon, nerve or vascular damage. Underlying fracture or dislocation?
Surrounding area	Healthy or unhealthy tissue?

46.3 Examination

As with the history, the examination is not complete unless both the patient in general and the wound have been thoroughly examined. General examination should include a rapid assessment of the general health status of the patient – firstly, are they acutely unwell (perhaps due to shock or sepsis) or are they stable. Evidently in an acute situation with a patient arriving soon after an incident, it would be appropriate to perform a full assessment based on protocols such as the ATLS or PTC system. However, as mentioned, patients often arrive a long time after the initial injury so it is important to see if they appear anaemic, malnourished, etc. With limb involvement as well as examining the wound itself, you must not forget to assess the neurovascular status on every patient.

Finally, once this has been done, move on to assessing the wound itself, paying particular attention to wound characteristics as shown in Table 46.1.

46.4 Fundamental Principles

There are a number of guiding principles that should be adhered to when making decisions and planning care as well as a number of confounding factors that need to be taken into consideration [1];

1. *All devitalised* (dead, devascularised and necrotic) tissue needs to be thoroughly debrided.
2. *All foreign* material needs to be removed (including dirt, debris, mud, gravel, etc.).
3. The wound bed needs to be clean and healthy *before* any soft tissue cover is attempted.
4. The best reconstructive option is the one that is most likely to be successful in your hands.

We will now discuss each of these in turn in more detail, expanding on the issues and discussing the compounding factors.

1. All devitalised (dead, devascularised and necrotic) tissue needs to be thoroughly debrided.

This is a critical phase of management, and often, especially in a disaster situation, patients arrive late with heavily contaminated wounds and extensive necrosis and infection. Debridement of limbs is best done *under tourniquet control*, but it is important to remember that the tourniquet is on and therefore presence of bleeding is not a reliable indicator of tissue viability at this stage. Always do a *thorough cleaning* of the wound, removing any obvious gross contamination pre-sterile scrub.

This can be with clean water, sterile saline, or soap and water. Once this is done, use standard sterile scrub (Betadine or chlorhexidine) and a brush [2]. Obvious necrotic tissue needs to be sharply debrided and any pus removed (and sent for microbiology if available). Nerves, tendons and vessels *should be preserved* unless already cut or avulsed. It is very important to *remove all devitalised muscle* (non-twitching, dark red or grey in colour, non-bleeding) [3]. When happy with the debridement, let the tourniquet down and reassess. If there is evidence of further areas of devitalised tissue, *re-excise* these areas [1].

2. All foreign material needs to be removed (including dirt, debris, mud, gravel, etc.)

Gross contamination can be removed in the pre-wash phase; then once the wounds have been scrubbed meticulously, remove all contaminants, including grass, gravel, clothing remnants, shrapnel fragments, etc. Make sure tissue planes are opened to ensure foreign material is not lurking deep in the wound, between muscles, etc.

Once all foreign material has been removed and devitalised tissue excised, copiously irrigate the area with normal saline using a bladder syringe or directly from the bag (*at least 3 l*). If saline is too precious for irrigation, do the following:

1. Boil water for 15 min in a covered container and add 1 teaspoon of salt. Keep in a safe place with a tight lid on. *Do not use for eyewash.*
2. Make some *Dakin's solution* by adding 1½ teaspoons of household liquid bleach. This will give you ¼ strength solution. If double the strength is required, add 3 teaspoons to one litre of saline. Make sure you use this solution within three days, and keep away from sunlight.

Then apply saline- or Betadine-soaked gauze directly to the wound bed, followed by a dry dressing, wool and a firm (but not tight) crepe bandage. Alternatively, if a negative-pressure dressing is available, this can be utilised [4]. It is best not to apply Vaseline dressing first, as when the soaked gauze directly against the wound dry out, it provides a useful physical debridement at the next dressing change. However, this can be painful; so if the dressing is not going to be under an anaesthetic, it might be necessary to use Vaseline dressing first. Under no circumstances, try and close the wound at this stage.

3. The wound bed needs to be clean and healthy before any soft tissue cover is attempted.

If the initial debridement has been thorough, hopefully the first dressing change (which should be 48–72 h later) will reveal a clean healthy wound bed with no further necrosis. However, if the wound was a delayed presentation and especially if there was a crush injury, it may take more than one debridement to render the wound bed healthy. The same principles apply to a second or third debridement.

4. The best reconstructive option is the one that is most likely to be successful in your hands.

There are often a number of soft tissue reconstructive options, and the one that is chosen should be the one that is most likely to be successful in your hands. If there is nothing suitable within your capability, you should endeavour to either transfer the patient or seek assistance. The simplest option is not necessarily the best option, but neither is the most complex.

46.5 Surgical Techniques

46.5.1 Debridement

This is the key initial procedure. If debridement is not done properly, the rest of the management of the patient is put at risk. Its aim is to render a dirty, contaminated or frankly infected wound into a clean healthy wound ready for the second stage of reconstruction [1].

46.5.1.1 Tips and Pitfalls

- Irrigate and scrub the wound prior to the 'official' sterile scrub and remove any gross contamination – this is best done with sterile saline.
- During the surgical debridement, *open up the tissue planes* as dirt and foreign material can often find its way between muscle planes.
- Particularly in the lower limb, be aware of *de-gloving injuries* where the blood supply to the skin coming from the perforating blood vessels through the fascia has been disrupted. Initially, the skin may appear viable, but it will not bleed from the edges, and over a few days, it will show signs of progressive necrosis.

46.5.2 Delayed Primary Closure

This is only likely to be possible for relatively small wounds. If the skin edges are healthy and opposable *without tension*, and the deeper parts of the wound are clean, then the edges can be directly sutured. In general, simple skin sutures or mattress sutures are more appropriate than a subcuticular closure [5].

46.5.2.1 Tips and Pitfalls

- Always give the wound a thorough clean before the final closure and excise the edge of the skin wounds by *one or two millimetres*.
- Because of the risk of infection, it is best to use a monofilament, unbraided suture both for the deeper tissue and the skin itself [5].
- Closing a wound that is still dirty, has any retained foreign material, or is under too much tension will inevitably lead to breakdown.

46.5.3 Healing by Secondary Intention

Small wounds that have been heavily contaminated or infected are often best left to heal by secondary intention, with alternate day dressings. When limbs are involved, be sure to splint them appropriately and encourage mobilisation and activity when possible [6].

46.5.3.1 Tips and Pitfalls

- Sometimes larger wounds can be partially closed and the rest left to heal by secondary intention.
- *Do not leave any large dead spaces* where bacteria will grow. Make sure any large cavities are packed well.
- Moist dressings can become quite mucky and smelly. However, upon removal when they dry up, there is also a degree of physical debridement that will then leave behind a healthy base. Crush injuries can look reasonably healthy but then deteriorate and require multiple debridements [3].

46.5.4 Vacuum-Assisted Closure

When available, vacuum-assisted closure (VAC) can be a very useful technique. The VAC can help shrink the size of the wound, encourages vascularisation and prevents infection. It can be used

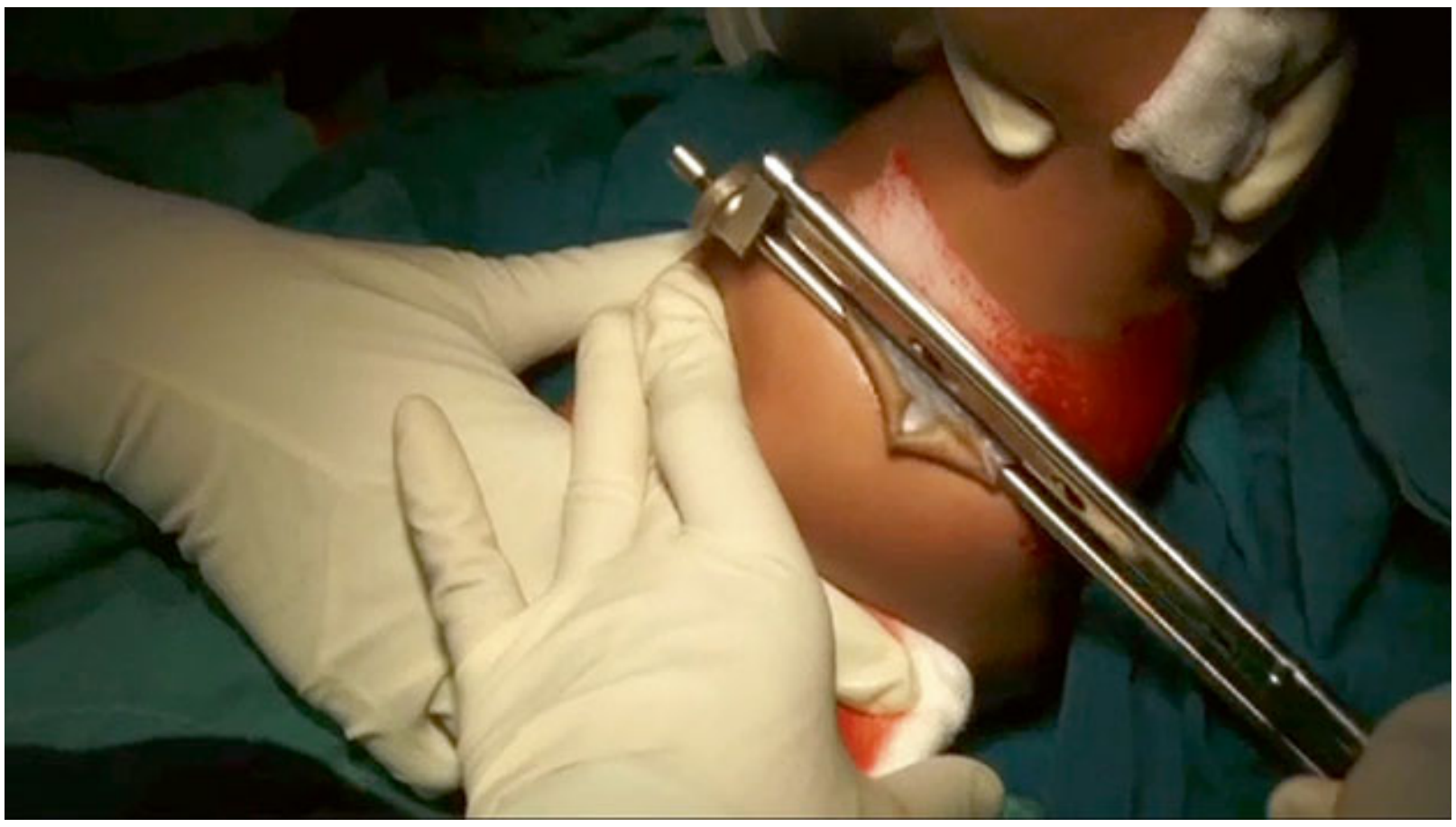

Fig. 46.2 Using a Watson knife to harvest a skin graft. Make sure the area to harvest is well lubricated and the skin is kept under tension between you and your assistant

as a definitive procedure or as a temporising procedure whilst the patient awaits definitive closure [7, 8].

46.5.4.1 Tips and Pitfalls

- If a VAC system is not available, it is possible to use wall suction and gauze dressings covered by an impermeable layer. You can improvise a suction apparatus with flexible tubing. Apply sponge or gauzes or other absorbing material over the wound and wrap it with Opsite. Connect the tubing to a wall suction or a portable suction device. Getting a seal can be difficult, especially in certain areas such as around the anus. However, it is worth persevering as once in place the VAC system can be left for 5 days, and it is a very effective device to manage wounds.

46.5.5 Split Skin Grafting

Split skin grafting is probably the most useful skill to have in your armamentarium. Many wounds can be closed by the application of a simple split skin graft. These can be harvested either with an electric or air-driven dermatome or with a simple Watson knife. For a skin graft to take, the recipient bed must be well vascularised and clean. The commonest causes of graft failure are haematoma, infection and shearing; therefore, ensure the wound bed is dry and utilise a firm conforming dressing.

Fig. 46.3 Donor site. The area can be infiltrated with local anaesthetic and adrenaline prior to the harvesting. Following the harvesting of the graft, dress the area with sterile bulky dressing and leave untouched for ten days, unless evidence of infection

46.5.5.1 Tips and Pitfalls

- Always check the Watson knife or dermatome before using it to ensure that the depth is correctly set. A standard depth would be 10–12 thousandths of an inch for a medium-depth skin graft. Children and the very elderly may require 8–10 thousandths of an inch due to the thinner skin (Fig. 46.2).
- The assistant is as important as the surgeon taking the graft as they can ensure the skin is appropriately stretched and put under tension which makes harvesting of the graft much easier. The skin can be taken from more or less anywhere, but always think of the impact of the donor site (Figs. 46.3 and 46.4).

Fig. 46.4 Applying a split skin graft over a forearm following skin loss due to a gunshot wound

- For facial skin grafts, the scalp is a good donor, but always mark the edge of the hair-bearing area so that you do not go beyond this when taking the graft. Remember that a split-thickness skin graft from a hair-bearing area will NOT produce hair once it has been transferred as the hair follicles are deeper.
- Skin graft donor sites are not invisible, although with time, they tend to fade and leave only a pale area. Donor sites can be harvested more than once, although usually take a couple of weeks to heal in between.
- The securing and dressing of skin grafts is important; the commonest causes of failure are haematoma, shearing and infection. Meshing or fenestrating the skin graft not only allows a piece of skin graft to cover a larger area but also allows exudates and blood to evacuate rather than building up under the graft preventing adherence.
- Meshing is done with a specific meshing device, and the standard ratio would be 1:1.5 or 1:2. However, a size 10 or 15 blade can also be used to make regular cuts (fenestrations) in the skin graft. These should be spaced regularly about 1 cm apart and 0.5–1 cm in length (Fig. 46.5).
- Infiltration with local anaesthetic solution containing adrenaline to the donor site can help with postoperative analgesia as well as reducing bleeding. The donor site must be left undisturbed for ten days.
- At the recipient site, ensure the wound bed is dry, use quilting stitches when necessary and use a Vaseline gauze dressing covered by firm gauze, wool and crepe dressing.
- Plaster of Paris can help to immobilise the area and maintain the correct position. Normally, grafts are best left for 5 days before removing the dressings.

46.5.6 Local Flaps

A local flap transfers tissue from the immediately adjacent area, based on its own blood supply. This tissue can compromise skin, fascia, muscle or even bone depending on the requirement and the possibilities. They are less reliable if there has been extensive soft tissue injury surrounding any actual defect. The base of the flap needs to be wide in a 'random' pattern flap. However, if there is a known blood vessel that is included, then the base can be thinner [9] (Figs. 46.6 and 46.7).

Fig. 46.5 Child's forearm with a gunshot wound following debridement and skin graft. Notice fenestration and suturing of graft which must be carried out in an 'inside to outside' direction, preferably with dissolvable sutures

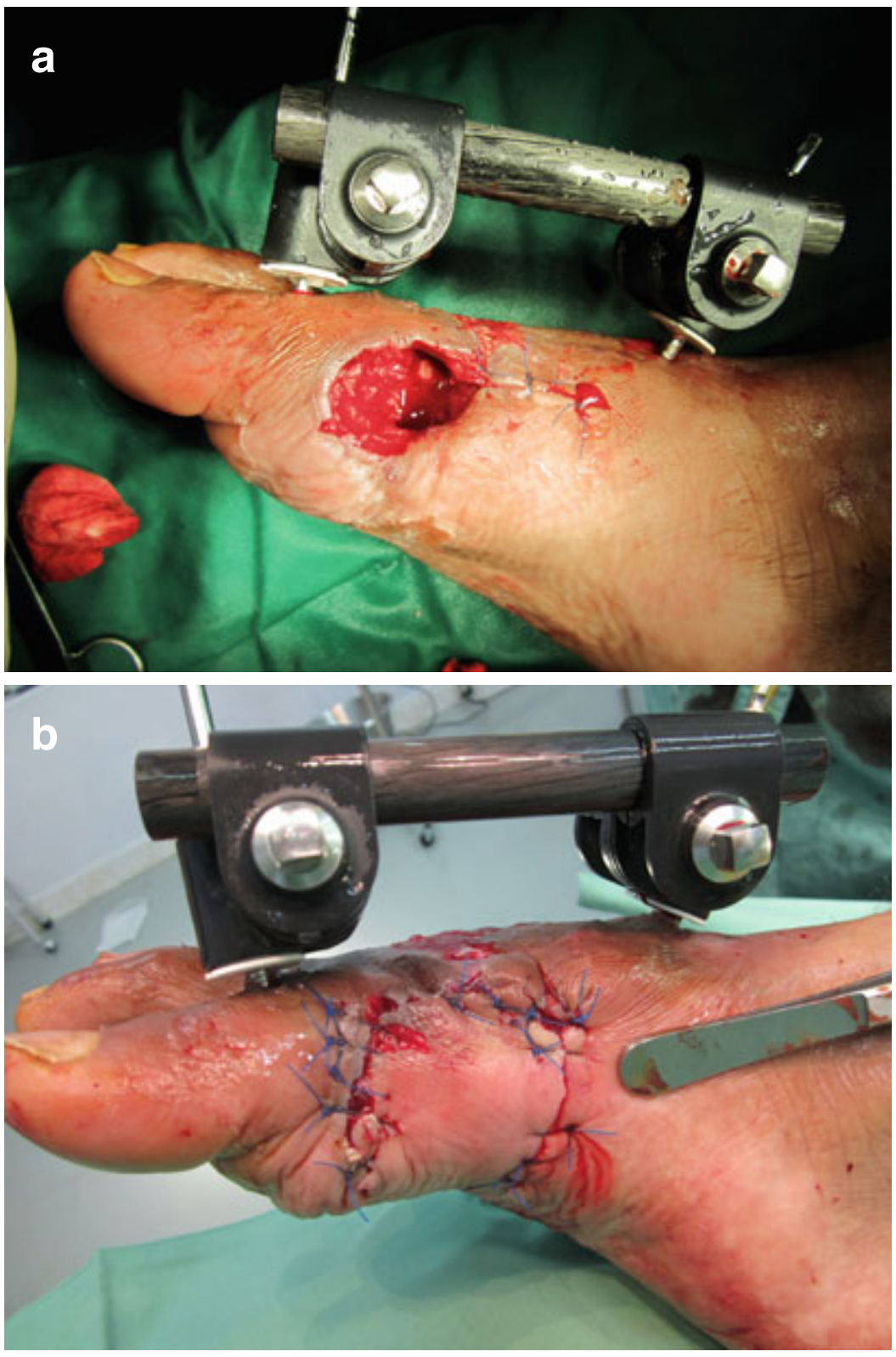

Fig. 46.6 (**a**) Right forefoot soft tissue deficit secondary to gunshot wound and (**b**) a local transposition flap

Fig. 46.7 (**a**) A chronic scalp wound with exposed skull and (**b**) soft tissue cover achieved local transposition flap and split skin graft

46.5.6.1 Tips and Pitfalls

- Local flaps are particularly useful on the limbs as the fasciocutaneous blood supply lends itself to elevating and transposing both small and large skin paddles.
- A small handheld Doppler device is extremely useful for checking the patency of perforating blood vessels. It is important to think of the blood supply of skin flaps in the initial debridement, especially if skin extension incisions are used to make sure they do not jeopardise future reconstructive options [10].
- Do not excise dog ears at the initial operation as this will risk the blood supply of the flap. The initial procedure is to ensure safe and robust coverage of soft tissue defects; tidying up of the flap, debulking and improving the appearance can be done at a later stage.
- It is better to leave a small area to heal by secondary intention or add a small skin graft than trying to advance or transpose a flap too far, putting it under undue tension which is likely to lead to partial necrosis.

Fig. 46.8 Markings for sural flap

46.5.7 Examples of Local Flaps

46.5.7.1 Sural Flap

The sural flap is a versatile and simple flap that allows soft tissue coverage around the ankle and heel as well as distal part of the leg.

46.5.7.2 Technique Summary

1. If available, use a handheld Doppler to detect the vessel which lies two to three fingerbreadths superior and approximately halfway between the lateral malleolus and the Achilles tendon.
2. Mark out the size of the flap required and ensure that the pedicle length is long enough to reach defect (Fig. 46.8).
3. Use a curved or zigzag incision and lift up thin skin flaps for 2 cm on either side of the incision over the pedicle.
4. Raise the subcutaneous tissue and fascia on a 4 cm pedicle up to the skin paddle.
5. Elevate the skin paddle subfascially (Fig. 46.9).
6. Divide the sural nerve and associated vessel proximally and transfer the flap to the defect (Fig. 46.10).
7. Use a skin graft to cover the pedicle.
8. Close the donor site primarily if small or else with a split skin graft.

46.5.7.3 Key Points

- Explain to the patient that they will have some numbness along the lateral border of the foot.
- Make sure you include a wide pedicle (4 cm) and that you include the sural nerve in the flap right up to the proximal part of the skin paddle.
- If the skin paddle is very proximal, this sometimes means taking a small cuff of gastrocnemius as well.
- Beware of this flap in obese patients as the pedicle will be very thick and not so mobile.

Fig. 46.9 Sural flap elevated with 4-cm-wide pedicle and demonstrating sural nerve in flap

Fig. 46.10 Sural flap transposed to defect over lateral ankle. Pedicle will be covered with skin graft

46.5.8 Gastrocnemius and Soleus Muscle Flaps

This is a robust and simple flap that is excellent for coverage of the upper third of the leg and around the knee joint.

46.5.8.1 Technique Summary

1. The easiest way to approach the muscle is through a midline posterior skin incision. Some surgeons also approach medially following a line parallel to the tibia from the medial tibial plateau to 10 cm proximal to the medial malleolus (Fig. 46.11).
2. Identify and preserve the sural nerve which runs in the midline.
3. Approach the muscle from the external side first and enter the plane between gastrocnemius and soleus which is relatively bloodless proximally (Fig. 46.12).
4. Distally the plane is harder to identify, and it is necessary to peel off the superficial tendinous extension of the muscle, making sure to preserve the deeper contributions to the Achilles tendon from the soleus.
5. Then elevate from distal to proximal, dividing the medial attachments (Fig. 46.13).
6. Transfer the flap to the defect either by tunnelling under the skin or incising the skin (Fig. 46.14).
7. Apply a meshed or fenestrated split skin graft over the muscle and close directly the donor defect in the calf over a drain (Fig. 46.15).
8. Splint the leg with POP to avoid movement and plan the first dressing change for 5 days time.

46.5.8.2 Key Points

- The medial head of gastrocnemius is simpler (the lateral involves dissection around

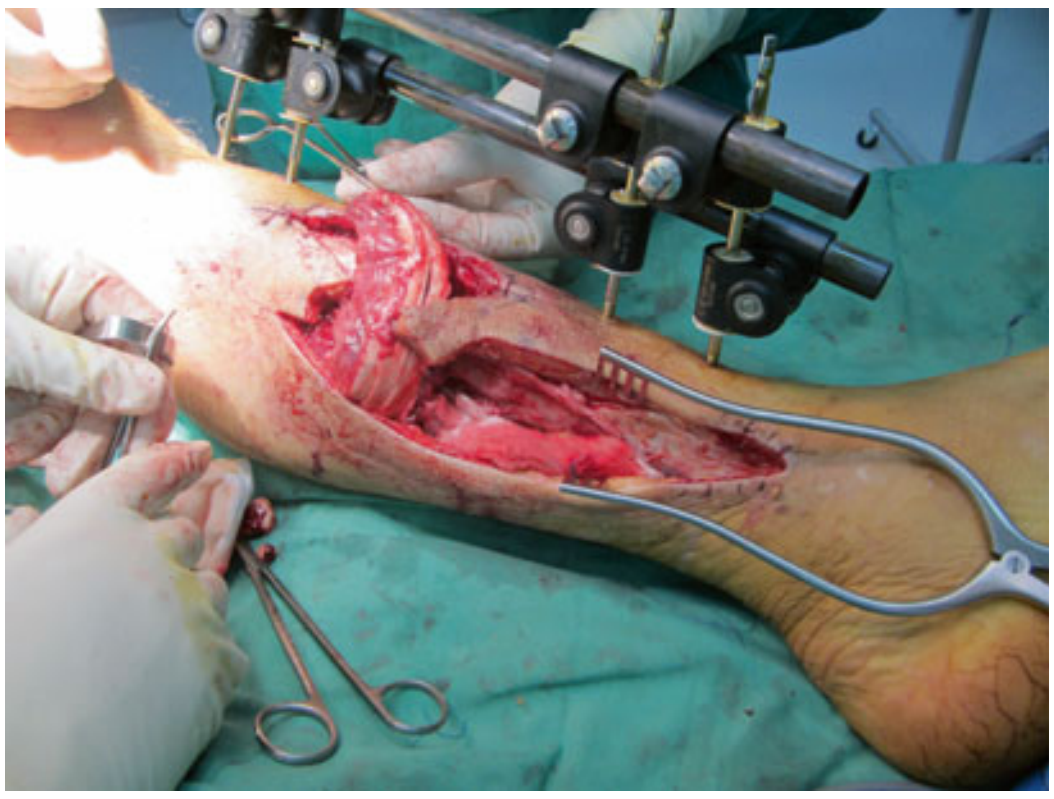

Fig. 46.11 Harvesting of medial head of gastrocnemius to cover a soft tissue deficit over an open tibia fracture

Fig. 46.12 A 5-week-old open upper third tibial fracture

Fig. 46.13 Medial gastrocnemius flap elevated

Fig. 46.14 Muscle flap transposed to defect

the common peroneal nerve) and usually has slightly more length.

- When the defect to be covered is more proximal around the knee, it is sometimes necessary to divide the origin of the muscle to allow it to reach the defect.
- For small middle third defects, the *hemisoleus flap* can be used. This is elevated in similar fashion to the gastrocnemius being deep to gastrocnemius, however, is slightly less reliable and best reserved for relatively small middle third defects.

46.5.9 Regional and Distant Flaps

Regional and distant flaps transfer tissue from a nonadjacent area (either within the same region

Fig. 46.15 Muscle flap in situ with skin graft applied

such as the same limb or from another area), but they still maintain their own blood supply and do not require microsurgical skills. An example is the pedicled latissimus dorsi flap which can be used to cover large defects over the shoulder.

46.5.9.1 Tips and Pitfalls

- Regional and distant flaps require more in-depth knowledge of the anatomy and blood supply, and you must consider the position that the patient will have to maintain until the flap is divided which may not be for 2 or 3 weeks.
- The groin flap is an excellent example which is very useful for coverage of hand defects as it is simple and the hand rests in a reasonably comfortable position.
- The radial forearm flap is another good example of a very versatile and robust flap that can even be used as a pedicled flap to cover defects of the face, although maintaining the flap in position for a few weeks can be challenging (Fig. 46.16).

These flaps can be divided after approximately 3–4 weeks. However, a proper examination of the flap must be carried out to ensure an adequate blood supply before the pedicle is divided.

Fig. 46.16 Medial leg cross flap secured with an external fixator. These types of flaps are very powerful tools but can be difficult to tolerate for the patient

46.5.10 Free Flaps

A free flap or free tissue transfer involves removing tissue from one area of the body, transferring it to another area and then anastamosing it to the local blood vessels. This requires microsurgical skills, loupe magnification as a minimum, but a microscope in most instances. It is an extremely versatile technique but highly demanding and necessitates specific training, expert anaesthesia and close postoperative monitoring. *Do not attempt this technique if you are not fully trained in how to do it and have sufficient staff and resources to manage the patient.*

46.5.11 A Note on Dressings

There are many different types of dressing available today, although what is important is not the name nor the price of the dressing, but *its properties*. A dressing has several different objectives, and different types of wound require dressings with different properties. For a fresh wound that has undergone early debridement, applying dry gauze directly to the wound followed by bulky absorbent dressing and a crepe bandage is simple and useful. This can be left on for 48 h and then removed (which will require *analgesia*/anaesthetic). Applying the gauze to the wound allows it to act as a *physical debriding* agent upon removal.

For wounds that have been open some time and are either sloughy or infected, then a dressing with antimicrobial properties such as Betadine-soaked gauze or an absorbent silver dressing can be useful. If a skin graft has been dressed, then a nonstick layer should be applied such as Vaseline-soaked gauze, followed by dry gauze and then an absorbent layer. This needs to be held in place by a firm crepe layer with splinting if necessary.

In a situation where there are many casualties and the opportunity to review patients and their wounds regularly might be difficult, then it is best to apply a dressing with antimicrobial properties. Topical antimicrobials such as silver sulphadiazine can be very useful but needs to be changed every 48 h at least. Some of the newer silver dressings such as Acticoat can be left on for up to 5 days which can be very useful although are expensive.

Another type of dressing that has been applied with good results historically is sugar or honey. The mode of action is not fully understood, but it may be through pH, osmotic effects or promoting epithelialisation. Moisten some gauze with saline- or iodine-based solution (Betadine). Cover with 0.5 cm of sugar. The sugar will absorb moist from the wound. However, the dressing needs to be changed regularly as it can paradoxically become a good medium for bacteria.

46.5.12 Complications

Flaps may become swollen or develop a bluish tinge, indicating possible venous congestion.

1. Ensure the pedicle of the flap is not kinked.
2. Loosen all dressings.
3. It may be necessary to remove every other suture to decrease the pressure on the flap.
4. Ensure there are no sources of pressure such as clots or haematoma beneath the flap.
5. Ensure the patient is warm and properly resuscitated and has adequate analgesia.

Fig. 46.17 Highly contaminated open knee wound pre-debridement

Table 46.2 Case example

Size of the wound	Medium (about 10 × 12 cm)
Shape of the wound	Circular
Site of the wound	Over right knee joint
Depth of the wound	Deep
State of the wound	Highly contaminated
Tissues and structures damaged	Skin and soft tissue including muscle, possible underlying bony injury
Surrounding area	Devitalised skin

46.6 Case 1: Wound Debridement

This is the typical appearance of an acute highly contaminated wound that includes skin and soft tissue loss, as well evidence of friction burn to the skin edges (Fig. 46.17). Going back to our first principles, the first thing to do is assess the wound (Table 46.2). Next, the wound needs to undergo comprehensive debridement including removal of all devitalised (dead, devascularised and necrotic) tissue and all foreign material.

This will need to be done under a general or regional anaesthetic and tourniquet control. The resultant wound should look healthy with bleeding skin edges and no evidence of any dead tissue or foreign material. It is then ready to be dressed (a dry gauze dressing applied directly followed by absorbent layer and crepe) which can be left for 48 h before review and definitive closure (Fig. 46.18).

Fig. 46.18 Highly contaminated open knee wound post-debridement

Fig. 46.19 Five-week-old open middle third tibial fracture with leg deformity

46.7 Case 2: Wound Closure

A six-year-old boy with a chronic wound associated with an open fracture of the middle third of tibia and fibula (Fig. 46.19).

The problems here can be summarised as:

- Exposed fracture
- No soft tissue cover
- Partial malunion
- Dirty wound

Fig. 46.20 Five-week-old open fracture after debridement, manipulation and local fasciocutaneous flap

Fig. 46.21 POP applied with date of dressing change written on to plaster

Both the bony injury and the soft tissue defect need to be addressed which when available will require the services of both an orthopaedic and plastic surgeon. The principles remain the same; however, the fracture site needs to be thoroughly debrided and realigned with antibiotics given; then stable soft tissue cover needs to be achieved which could be in a number of ways including local fasciocutaneous flap or muscle flap. In this instance, a medially based fasciocutaneous flap was used with skin graft to the secondary defect (Figs. 46.20 and 46.21). Note the date for the next change of dressing written on the plaster as well as the indication that this should be done under a general anaesthetic.

Conclusions

Managing the soft tissues is as important as any underlying bony injury, and often even more so, as a healthy soft tissue envelope is essential for bony healing and prevention of

> infection. In an austere environment, wounds of all types can be very challenging, especially when there are chronic wounds that may be colonised with resistant bacteria in patients that are malnourished, anaemic and in a catabolic state. It is vital to address the whole patient and not 'just the wound', this means all factors that might lead to delayed wound healing as well as social and psychological factors. Without specialist plastic surgery support, it is far better to adhere to tried and tested basic principles rather than undertaking complex, time-consuming and high-risk procedures.

Inadequate initial debridement and closing wounds too early are typical mistakes that will lead to significant problems, with delayed healing, multiple procedures and perhaps even condemn someone to an unnecessary amputation.

The important thing to remember is not what can be done, but *what should be done*, and this reflects the condition of the patient, the physical environment and the experience of the team. Make sure you become familiar with the techniques described and the indications.

References

1. Haury B, Rodeheaver G, Vensko J, Edgerton MT, Edlich RF. Debridement: an essential component of traumatic wound care. Am J Surg. 1978;135(2):238–42.
2. Chundamala J, Wright JG. The efficacy and risks of using povidone-iodine irrigation to prevent surgical site infection: an evidence-based review. Can J Surg. 2007;50(6):473–81.
3. Reis ND, Better OS. Mechanical muscle-crush injury and acute muscle-crush compartment syndrome: with special reference to earthquake casualties. J Bone Joint Surg Br. 2005;87(4):450–3.
4. Pirela-Cruz MA, Machen MS, Esquivel D. Management of large soft-tissue wounds with negative pressure therapy-lessons learned from the war zone. J Hand Ther. 2008;21(2):196–202; quiz 203.
5. Mehta PH, Dunn KA, Bradfield JF, Austin PE. Contaminated wounds: infection rates with subcutaneous sutures. Ann Emerg Med. 1996;27(1):43–8.
6. Nash CE, Mickan SM, Del Mar CB, Glasziou PP. Resting injured limbs delays recovery: a systematic review. J Fam Pract. 2004;53(9):706–12. Review.
7. Bollero D, Carnino R, Risso D, Gangemi EN, Stella M. Acute complex traumas of the lower limbs: a modern reconstructive approach with negative pressure therapy. Wound Repair Regen. 2007;15(4):589–94.
8. Bovill E, Banwell PE, Teot L, Eriksson E, Song C, Mahoney J, Gustafsson R, Horch R, Deva A, Whitworth I, International Advisory Panel on Topical Negative Pressure. Topical negative pressure wound therapy: a review of its role and guidelines for its use in the management of acute wounds. Int Wound J. 2008;5(4):511–29.
9. McGregor IA, McGregor AD. Fundamental techniques in plastic surgery and their surgical applications. 9th ed. Churchill Livingstone: Pearson Professional Limited; 1995.
10. Nanchahal J, Nayagam S, Khan U, Moran C, Barret S, Sanderson F, Pallister I. Standards for the management of open fractures of the lower limb. BAPRAS/BOA working Group; 2009. http://www.bapras.org.uk/downloaddoc.asp?id=141. Accessed 16 June 2014.

47 Vascular Injuries

Martial Ledecq

In a recent study [1], *civilian vascular injuries* were present in 4.4 % of the total trauma admissions. Penetrating trauma caused 53 % of vascular injuries, whilst the remainder resulted from blunt trauma. Compared to penetrating vascular trauma, patients with blunt trauma were more severely injured and had greater mortality (26 % vs. 10 %) and higher limb amputation rates (12 % vs. 0 %).

The reported incidence of *combat vascular trauma* has been low in the past, with a range of only 0.2–4 %. This was probably due to excessive mortality during prolonged evacuation time. In more recent reports from the wars in Afghanistan and Iraq, this incidence has increased to 6.8 %, [1] probably due to better immediate resuscitation and evacuation from the battleground.

Whether in civilian or military practice, lower extremities are involved in two thirds of all patients with vascular injuries [2]. Therefore, this chapter will focus on peripheral vascular injuries, excluding thoracic and abdominal vascular trauma.

47.1 Temporary Measures

47.1.1 Immediate Haemorrhage Control

Immediate control is usually achievable by direct pressure over the site of injury. This pressure does not need to be great (systolic pressure is often around 100 mmHg), but it does need to be directed over the site of haemorrhage. Large bandages and pads applied over the wound, with more and more bandaging applied as the bandages soak with blood, are not controlling haemorrhage. It is better to dedicate one individual to manually compress the site of haemorrhage until the patient reaches the operating room. In that case, the compressing hand will be prepared as part of the operative field.

Where haemorrhage is welling up from a deep knife or gunshot track, control may be temporarily achieved by passing a urinary catheter into the track as far as possible, inflating the balloon, and then applying traction to the catheter. The catheter can be sutured in place if the patient is to be transferred to another department or hospital. Blind clamping in the depths of a wound is dangerous, likely to fail and likely to injure other structures.

The use of tourniquets, whilst helpful in the operating room, should be limited to patients at risk for exsanguination in the prehospital and field environments who are not responsive to

M. Ledecq, MD
Vascular and Trauma Surgeon,
Medecins Sans Frontieres, Libin, Belgium
e-mail: drmledecq@yahoo.fr

© Springer International Publishing Switzerland 2016

J.D. Robinson (ed.), *Orthopaedic Trauma in the Austere Environment:*
A Practical Guide to Care in the Humanitarian Setting, DOI 10.1007/978-3-319-29122-2_47

direct pressure for haemorrhage control. The use of tourniquets, especially those left for prolonged periods, markedly increases the incidence of amputation of an injured extremity. Keep in mind that an inflated tourniquet cuts off collateral circulation. Some authors strongly suggest 30 min as the time limit for replacing a tourniquet with a pressure dressing. Although most of the studies indicate 2 h to be a safe limit, 30 min is recommended as a protocol guideline to ensure a wide margin of safety [2]. Any medical personnel applying a prehospital tourniquet for extremity vascular injury should clearly document its necessity as a lifesaving anti-exsanguination device when direct pressure fails and should understand that, in many cases, a tourniquet saves a life but results in loss of an extremity.

47.1.2 Shunting

Intraluminal shunt may be employed to temporarily restore flow when there is a significant risk of limb loss due to a major vascular trauma. Temporary vascular shunts in wartime casualties were used beneficially [2]. Many commercial plastic intraluminal shunts are available. However, plastic IV tubing, or connecting tubing that accompanies many closed suction drains, is sufficient if irrigated with heparinised saline before use.

47.1.3 Technique

Injuries are exposed, proximal and distal control is achieved, vessel edges are debrided, thrombectomy is performed, and then the ends of the tubing are placed in the proximal and distal segments of the injured artery, secured by a silk suture tied around the vessel over the shunt and then also tied directly on the shunt itself to prevent dislodgement (Fig. 47.1). Flow through the shunt should be monitored regularly by palpating distal arterial pulsation and/or using a Doppler device to detect flow signals through the shunt or distal vessel.

Consider the use of a shunt in the following situations:

- Damage control surgery that supposes a prompt transfer of the patient to the ICU
- Transfer from a remote facility to a third-level hospital
- Maintenance of perfusion whilst skeletal alignment is accomplished

47.2 Definitive Repair

47.2.1 Minimum Equipment

Vascular repair requires minimum equipment:

- Unfractionated heparin
- Fogarty catheter (diameter of inflated balloon 5 and 9 mm)
- Polypropylene sutures 5–0 and 6–0 (synthetic, monofilament, nonabsorbable, double needled)
- A few vascular clamps, notably DeBakey Clamps and Bulldogs [1]
- Vessel loops if vascular clamps not available or improvised Rummel tourniquets using Penrose drains [2]
- Delicate needle holder (Fig. 47.2) and vascular forceps

Fig. 47.1 The shunt for vascular injuries

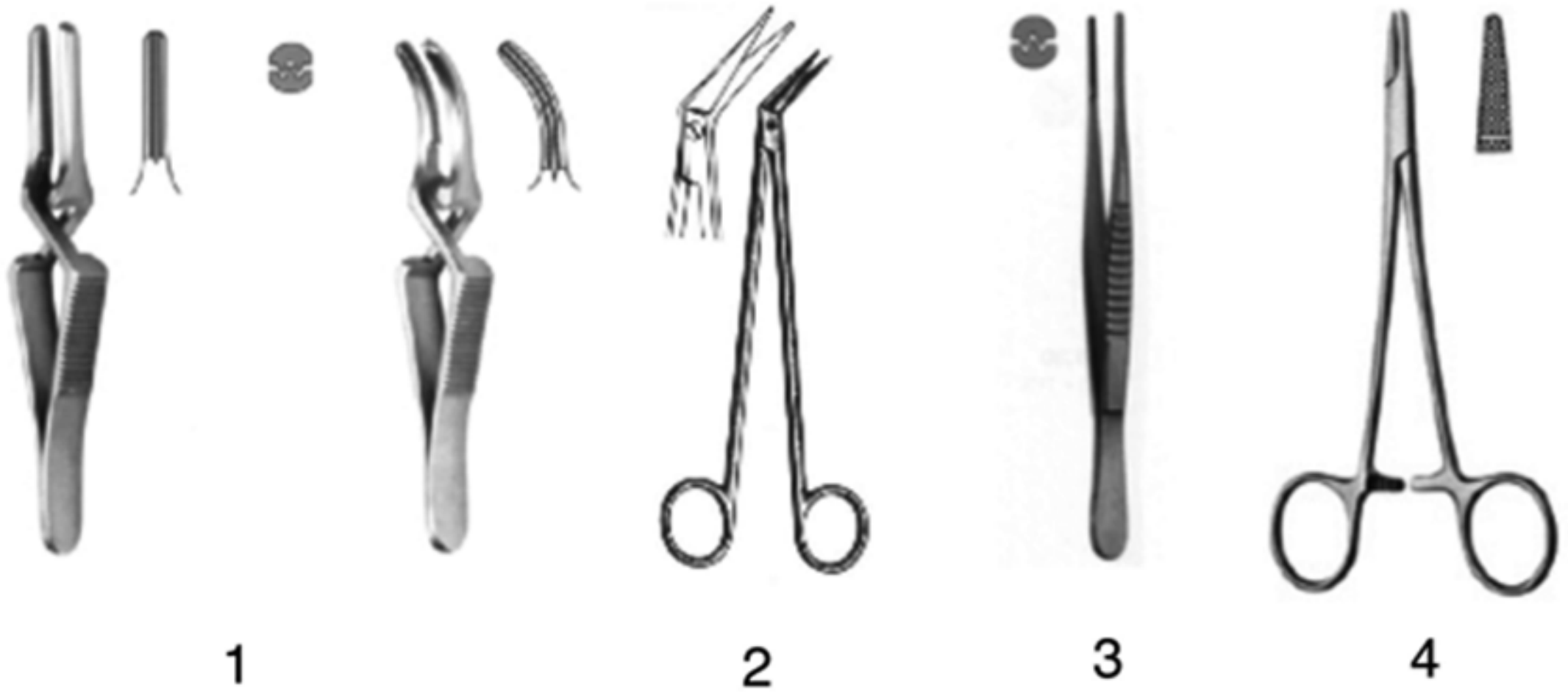

Fig. 47.2 Delicate needle holder and vascular forceps

47.2.2 Technique of Arterial Repair

1. Preparation and draping of the entire injured extremity.
2. Draping of the uninjured extremity in order to harvest an autogenous vein graft (great saphenous vein or cephalic vein). Avoid harvesting the vein graft from the injured limb to preserve the maximum venous drainage system of this side.
3. Incision: Obtaining proximal and distal control for vascular reconstruction requires intimate knowledge of vascular, muscular and bony anatomy to allow rapid access to the arterial tree proximally and distally. Operative identification of arterial and venous injury requires proximal and distal control of the artery or vein, which may require extending the wound in both directions or making counter incisions (e.g. clamping the external iliac artery to control a complex wound of femoral triangle, the superficial femoral artery to control a popliteal injury).
4. Proximal and distal control. Blind clamping is dangerous. If the haemorrhage is profuse, proximal control is best achieved through a separate incision away from the site of injury. If bleeding is modest, use a suction machine and apply a digital pressure on the haemorrhagic site. Once the extremities are identified, a temporary control can be achieved by endoluminal balloon occlusion with a Fogarty catheter.
5. Debridement. The first step is to cut off the necrotic surrounding tissues. This is particularly important after a penetrating wound by a high-energy missile (Fig. 47.3). High-velocity projectiles cause significant soft tissue injury that can extend well beyond the zone of obvious injury. Careful debridement will guard against repair in the setting of late infection from devitalised and contaminated soft tissues.

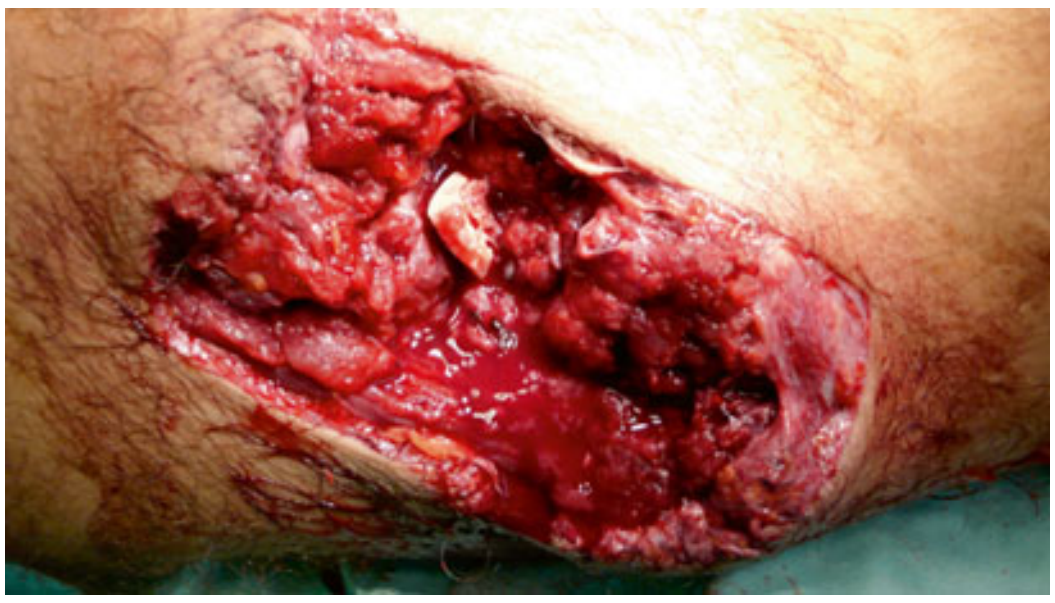

Fig. 47.3 Gunshot fracture of the femur with transection of the superficial femoral artery. The first step is to debride the wound

The second step is to cut the extremities of the damaged artery to a macroscopically normal arterial wall (Fig. 47.4). Keep in mind that a gunshot wound results not only in tissue loss but also in microscopic changes to all layers

Fig. 47.4 Extremities of the damaged artery are cut off. Note the extraction of a thrombus from the arterial lumen

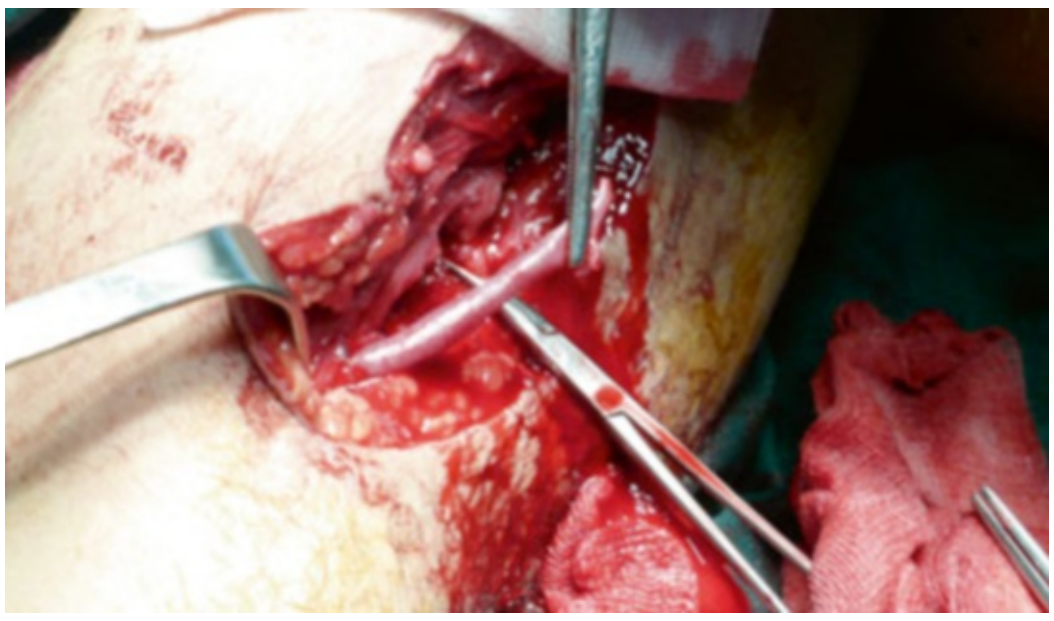

Fig. 47.5 The proximal anastomosis is completed

of the arterial wall in a variable length of the vessel, up to 2 cm and more at both cut ends.

6. Remove thrombi using a Fogarty catheter. If the back bleeding or inflow is weak or absent, this step is crucial. If you do not have Fogarty, it is possible to remove any thrombus by squeezing muscles repeatedly in the direction of the wound.
7. Flush proximally and distally with heparinised saline solution. Inject 10–20 ml of a solution of 200 ml saline containing 5000 IU heparin. Do not use systemic heparinisation in case of multiple trauma (head injury) and if you cannot check the activated cephalin time (ACT).
8. Suture technique:
    - (a) In most cases in which the injured segment is 1 cm or less, dissection proximally and distally along the artery with division and ligation of nearby branches may provide enough mobility for a successful tension-free primary end-to-end anastomosis.
    - (b) If the patient's condition and haemodynamic status allow prolonged operative intervention, general replacement of an injured peripheral arterial segment is accomplished with an autologous vein. To restore the arterial flow, use a reversed saphenous or cephalic veins harvested from the contralateral uninjured limb (Figs. 47.5 and 47.6). Using a "parachute technique" to start the anastomosis can be very helpful (Fig. 47.7).

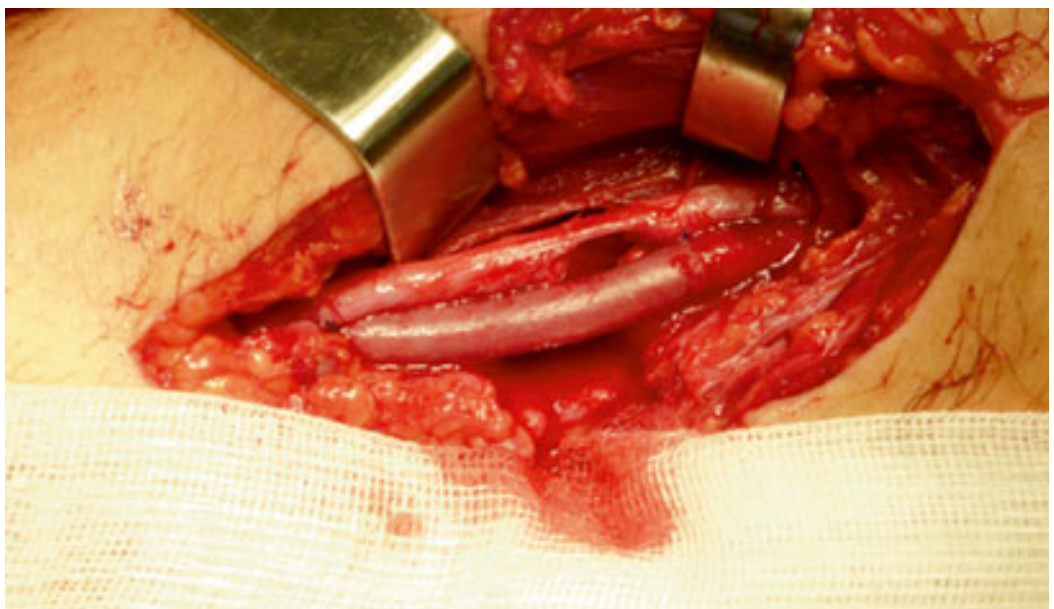

Fig. 47.6 Arterial flow is restored. Note that venous repair was deliberately neglected in this case

    - (c) Lateral repair can be accomplished quickly in the particular case of a partial transection after a stab wound. Nevertheless, direct suture can result in constriction of the lumen. This can be avoided by using a venous patch (Fig. 47.8).

    Most of the time, a simple repair is usually not realistic in wounds from high-energy missile, as segmental loss is very common.
9. All vascular repairs must be covered by viable soft tissue. A myocutaneous flap is to be considered (see Chap. 46 on soft tissue techniques).
10. Postoperative anticoagulation.

Anticoagulation by low-molecular weight heparin after vascular repair is recommended [2]. The usual dose of enoxaparin is 1 mg/kg every 12 h. Half of this dose must be considered for a patient with a high risk of bleeding.

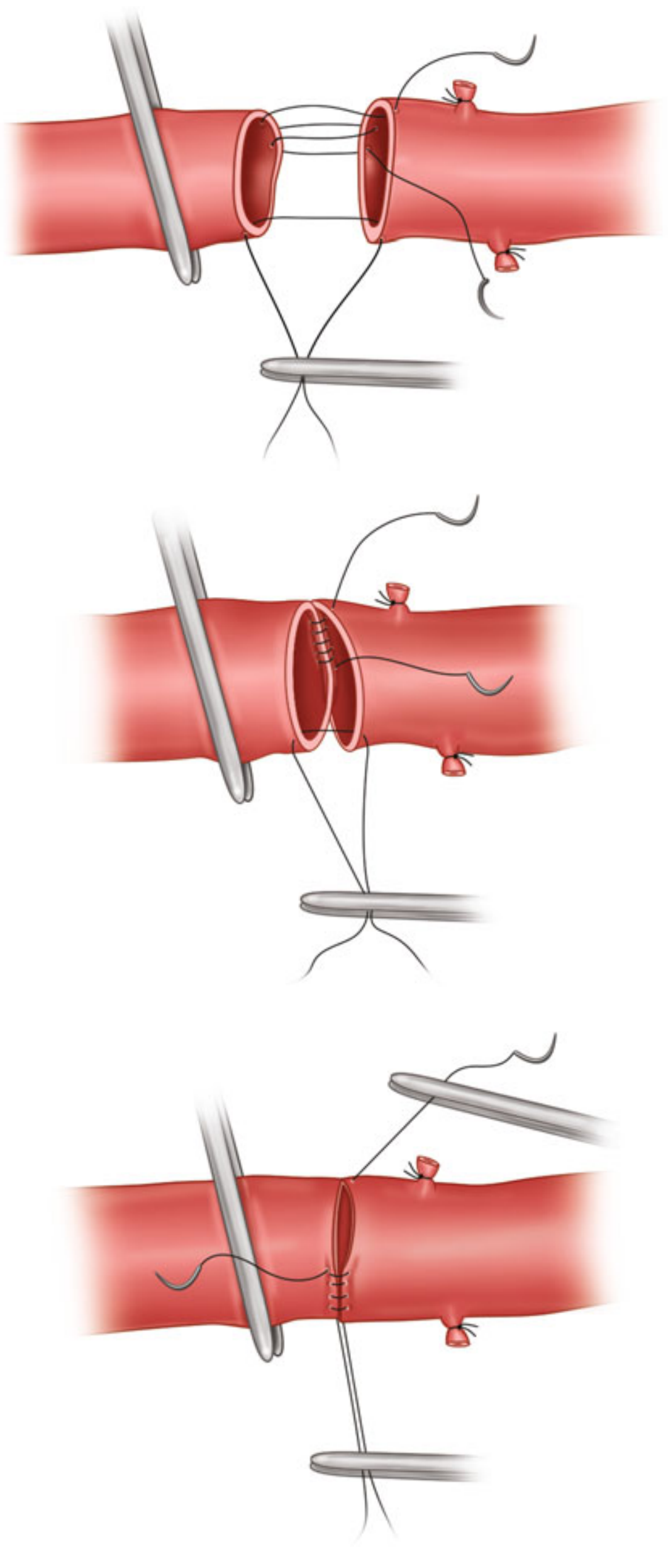

Fig. 47.7 Anastomosis using parachute technique

In a precarious or austere environment, LMWH treatment is maintained as long as the patient is hospitalised. When discharged, aspirin (300 mg daily for an adult) is prescribed for a few months.

The superiority of clopidogrel over aspirin for optimising graft patency after coronary artery bypass grafting has not yet been established, and thus, aspirin should be regarded as the drug of first choice (grade B recommendation based on individual level 1b studies).

47.2.3 Venous Injury

Repair of major venous injuries of the extremities has been advocated to improve limb salvage rates and to prevent the early and late sequelae of venous interruption, but the contribution of venous repair to the surgical outcome remains controversial: limb salvage does not seem to be adversely influenced by an unexpectedly high rate of venous repair thrombosis [3].

Many injured veins can be ligated with impunity due to the richness of the venous system.

Two exceptions, the common femoral and the popliteal veins, which represent a bottle neck in the drainage system of the lower limb, are worth repairing if the patient's condition is stable.

In all cases, care must be taken to postural drainage during the immediate postoperative phase.

47.2.4 Combined Vascular and Skeletal Trauma

The question is: fracture immobilisation first versus vascular repair?

When dealing with a combined vascular, skeletal and soft tissue trauma, treatment priorities are dictated by limb ischemia. These injuries, especially when involving the popliteal artery, are associated with high limb loss rates. As a rule, restoration of limb perfusion takes priority on bone fixation. This is particularly true for a stable fracture: the vascular surgeon can perform the definitive repair followed by fracture immobilisation.

This is still true if the fracture is unstable and the limb ischemic: the fear that orthopaedic manipulation may disrupt the vascular repair is unfounded. The risk to the graft can be reduced

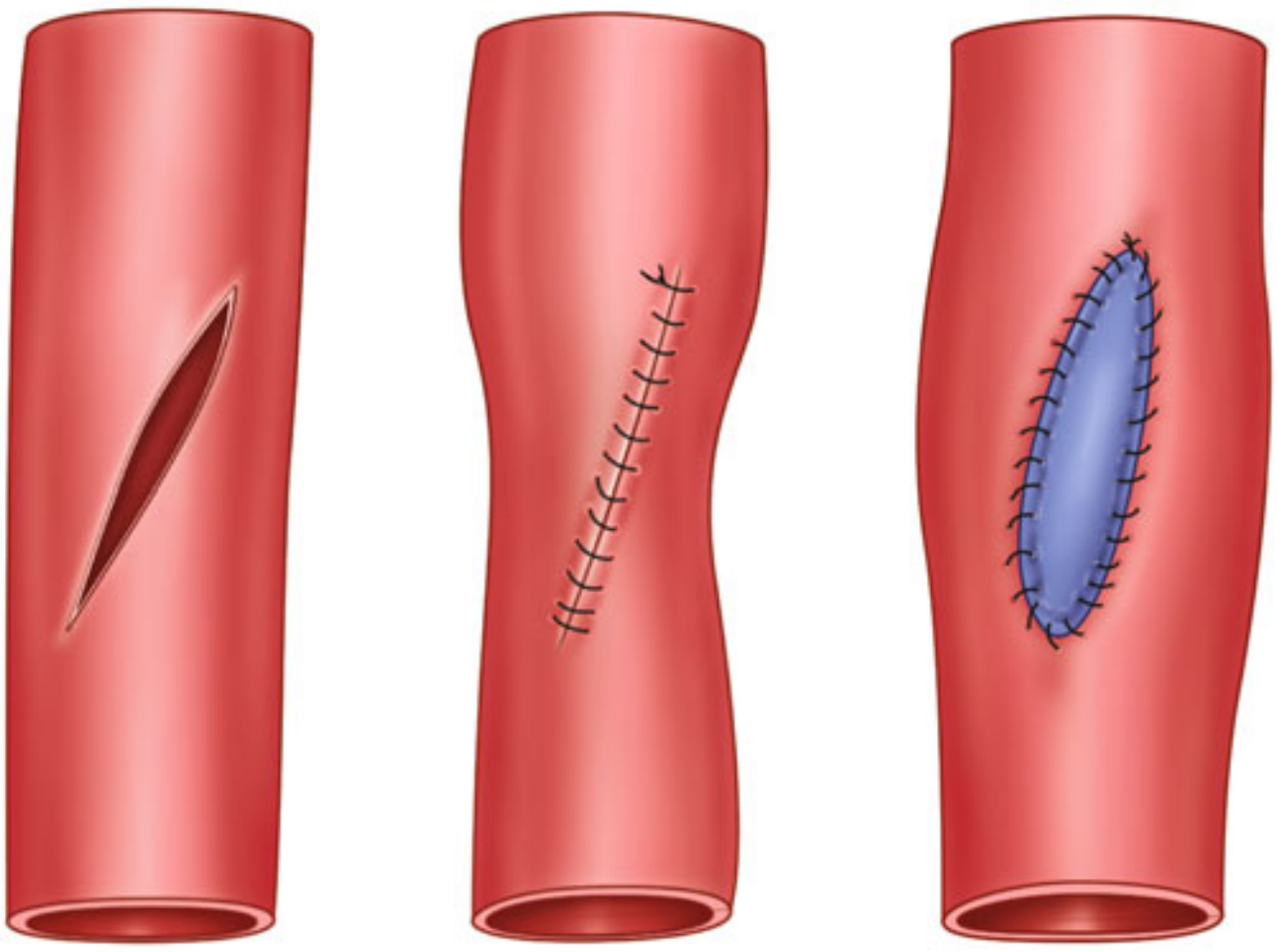

Fig. 47.8 Lateral repair of a partial transection, without and with the use of a venous patch

if it is fashioned slightly longer than necessary and if it is guarded by the active presence of the vascular surgeon during the orthopaedic procedure [3].

If, however, the fracture is unstable or the orthopaedic surgeon needs to shorten the limb or there is a clear risk of orthopaedic manoeuvres disrupting an arterial repair, a temporary vascular shunt is needed, and the definitive vascular repair will be performed after the orthopaedic treatment. The presence of an external fixator does not make it more difficult to access major vessels, at least for the humerus or the femur, as the fixator is generally located in the lateral aspect of the limb.

47.3 Late Complications of Vascular Injury

False aneurysm and arteriovenous fistula are both complications that usually develop weeks or months after the causative trauma. Even if they can represent a life-threatening condition in the long term, the treatment is not an emergency. Ideally, both require routine angiography at the time of presentation. Today, endovascular techniques play an important role in treating most of pseudoaneurysms and arteriovenous fistulae using stent graft repair and coil embolisation.

Unfortunately, angiogram and endovascular techniques are outside the possibilities encountered in the field. Therefore, it is wise to consider first the possibility of referring the patient to a tertiary level facility if possible.

47.3.1 False Aneurysm (or Pseudoaneurysm)

False aneurysm is the result of an unnoticed lateral wound of the arterial wall at the time of the initial trauma. It represents a pulsating, growing, encapsulated haematoma communicating with a ruptured artery. False aneurysm often presents with pain, bruising and a pulsatile swelling. Diagnosis can be confirmed by Doppler ultrasound.

After a significant trauma, a false aneurysm does not respond to ultrasound-guided compression therapy, as it usually does after a post puncture iatrogenic one, and a simple suture of the lateral wound is rarely possible. Therefore, if a false aneurysm develops from a major vessel, it needs to be excluded from the arterial tree. The parietal haematoma of the false aneurysm is removed, and the arterial continuity has to be restored by a reversed vein graft bypass.

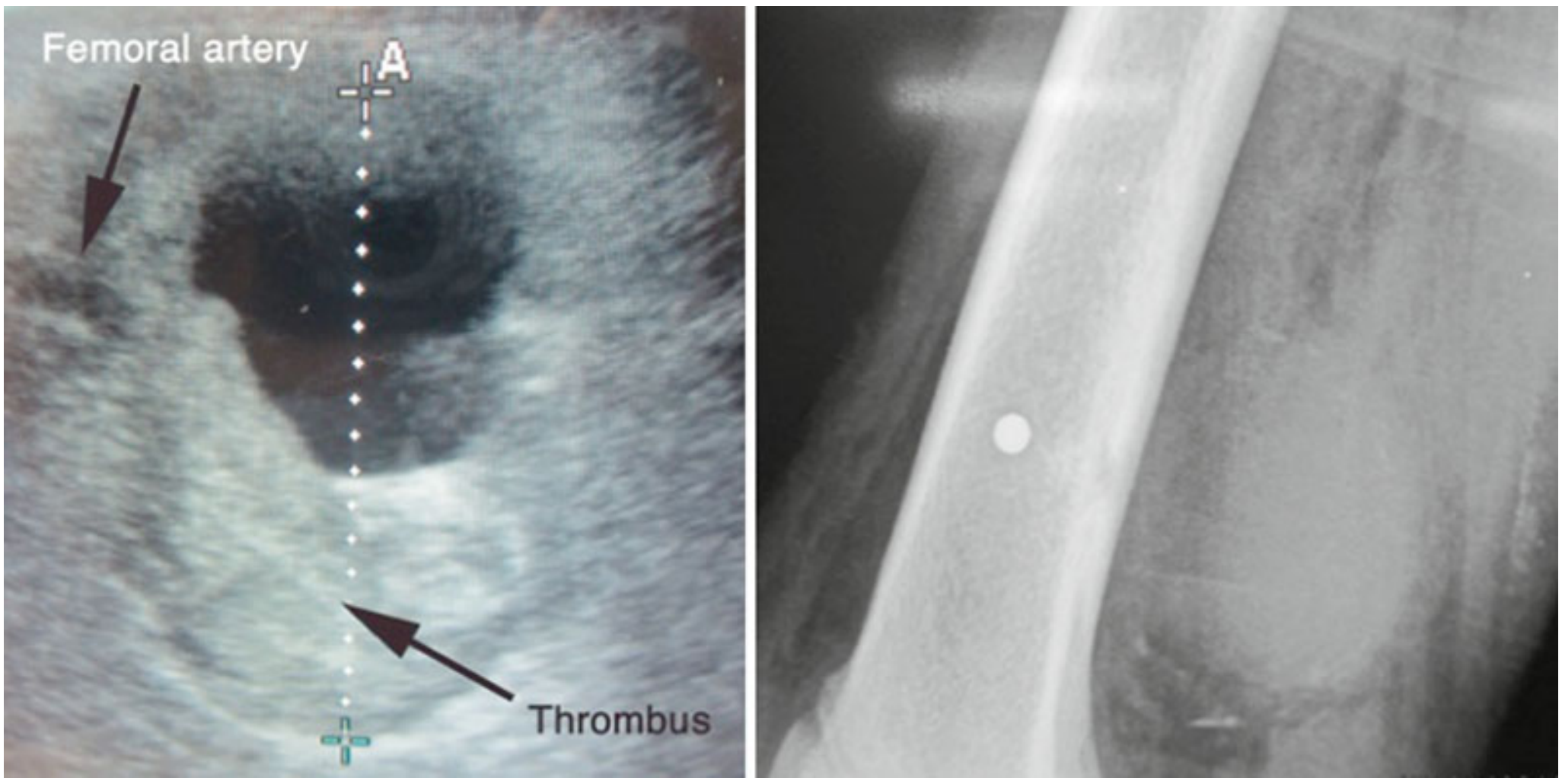

Fig. 47.9 *On the left*, Doppler ultrasound shows the lesion partially thrombosed along the course of the femoral artery. *On the right*, the pellet at the origin of the lesion is clearly visible as well as the shadow of the pseudoaneurysm behind the femur. The *arrow* shows the segment of the femoral artery, longitudinal sectional view, at the origin of the pseudoaneurysm

Fig. 47.10 The distal anastomosis of the femoro-popliteal bypass is completed

Here is an example of a false aneurysm that developed a few weeks after a lateral wound of the femoral artery by a pellet. It was classically treated by a femoro-popliteal bypass (Figs. 47.9 and 47.10).

A false aneurysm growing from a non-vital artery can simply be excluded by a proximal and distal ligation. Here is an example of a false aneurysm originating from the anterior tibial artery developing insidiously under a cast (Fig. 47.11).

47.3.2 Arteriovenous Fistula

An arteriovenous fistula is an abnormal communication between the venous and arterial system. Arteriovenous fistula is rare after trauma. It may be secondary to piercing injury, such as a gunshot or a stab wound, or bony fragments of a fracture, which damage adjacent veins and arteries. Classic clinical manifestations include pain, varicosity, palpable thrill or audible bruit locally and diminished pulses distally. Colour Doppler duplex sonography is a non-invasive and accurate technique for confirming the fistula in most patients, but angiography is a gold standard. The earlier treatment is instituted, the better the results.

As to therapy – in contrast to the older quadruple ligature (Fig. 47.12a) – the separation method should be the method of choice. Following debridement, if end-to-end anastomosis is not possible, a saphenous vein segment

Fig. 47.11 *From left to right*, the causal pellet on the X-ray film, the clinical picture and the false aneurysm dissected. After proximal and distal ligation of the anterior tibial artery, the parietal haematoma was simply removed

from the uninjured leg is used to restore arterial and venous continuity (Fig. 47.12b). (Remember most of the veins can simply be ligated.) A small strip of muscle is interposed between two repair vessels to prevent re-fistulisation.

47.4 Summary and Conclusion

The basic principles for the management of injury to peripheral blood vessels could be summarised as follow:

- Prehospital control of haemorrhage and rapid evacuation.
- Definitive haemorrhage control in the operating theatre/room.
- Resuscitation and management of all life-threatening injuries must take priority over any extremity problems.
- Early arterial repair.
- Coverage of the arterial repair with appropriate soft tissue.
- Repair of venous injury when possible.
- Low threshold to perform a fasciotomy at the time of initial revascularization.
- Proper wound care (debridement and irrigation), stabilisation of any fractures and physiotherapy

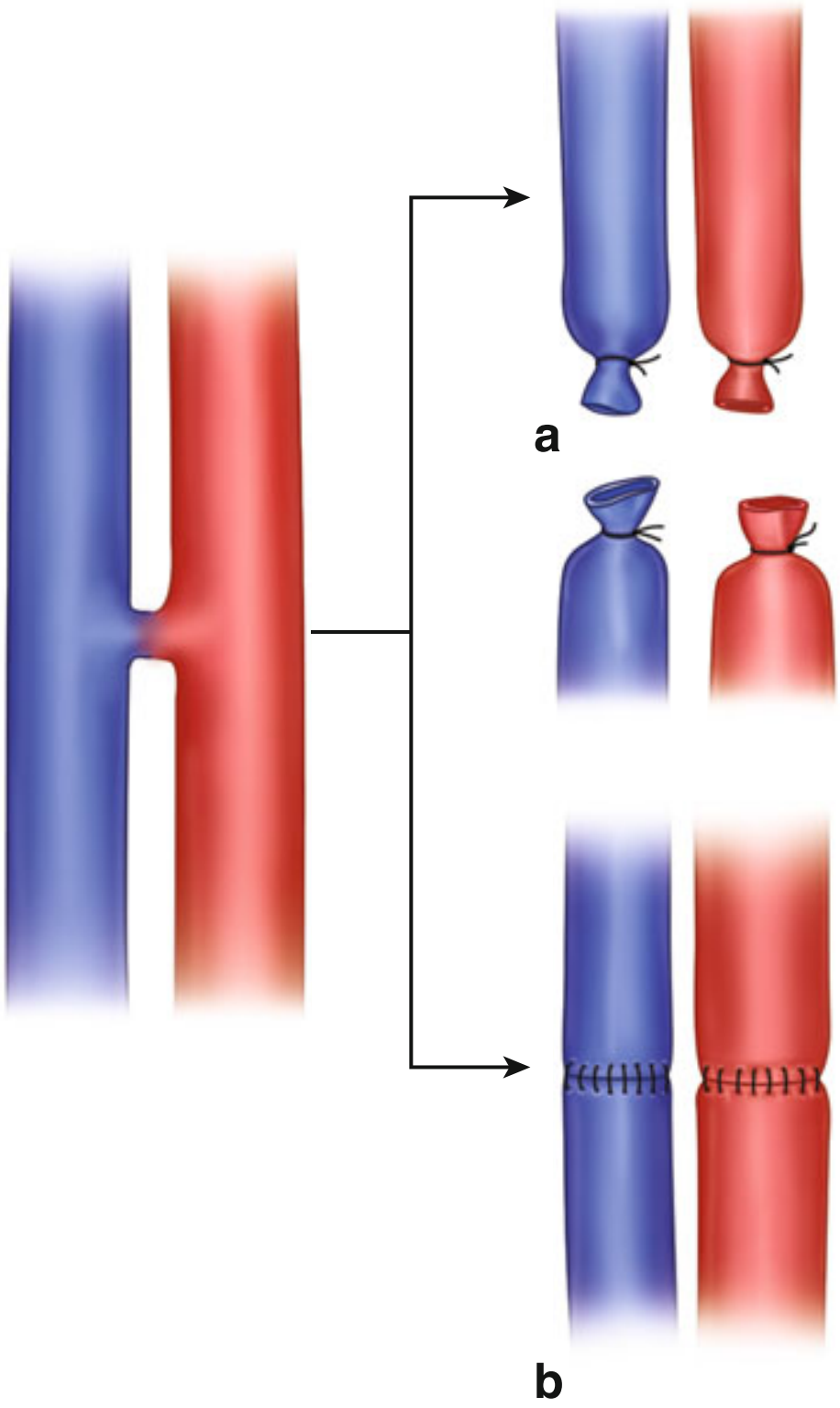

Fig. 47.12 In contrast to the older quadruple ligature for arteriovenous fistula (**a**), the separation method should be the method of choice. (**b**) Following debridement, if end-to-end anastomosis is not possible, a saphenous vein segment from the uninjured leg is used to restore arterial and venous continuity

References

1. Fox CJ, Gillespie DL, O'Donnell SD, et al. Contemporary management of wartime vascular trauma. J Vasc Surg. 2005;41(4):638–44.
2. Gramse CA, Hingorani A, Ascher E. Postoperative anticoagulation in vascular surgery. J Vasc Nurs. 2001;19(2):42–9.
3. Meyer J, Walsh J, Schuler J, Barrett J, Durham J, Eldrup-Jorgensen J, Schwarcz T, Flanigan DP. The early fate of venous repair after civilian vascular trauma. A clinical, hemodynamic, and venographic assessment. Ann Surg. 1987;206(4): 458–64.

Tendon Injuries

48

Thamer A. Hamdan and Juan de Dios Robinson

It is good practice to examine for nerve, vessel, and tendon injury after any trauma no matter how trivial. Early diagnosis is very important because the outcome of treatment is directly related to the time delay before treatment. The mechanism of injury usually involves machinery whether in an industrial or agricultural setting. Sadly, in our locality, children are often involved by inserting their hands inside a meat cleaver or food processing machine. Grenade injuries are another cause of severe hand injuries in war zones.

48.1 Incidence of Tendon Injuries

Tendon injuries a common problem faced in the accident and emergency department. Angermann et al. [1] proved that 28.6 % of patients in the emergency care were hand injuries; on average, hand injuries account for 14–30 % of all patients in the emergency care. Fracture comes first with incidence of 42 %, followed by tendon injury (29 %), and skin injury comes third [2]. Tendon injuries play a major rule in the surgical treatment of hand injury.

The site of injury means a lot for the treatment; both dorsal and palmar aspects of the hand are divided into two zones. Norman's zone II is known as the "critical zone" due to its special anatomical structures.

48.2 Diagnosis of Tendon Injury

48.2.1 History

A proper history taking in regard to the time of injury, the magnitude of the force, mechanism of injury, associated injury in other structures, and the general medical condition like diabetes, collagen disease, immune-compromised condition, drug intake, and systemic hypertension should be done because all of the above affect the line of treatment and the outcome of treatment.

48.2.2 Physical Examination

The injured tendon is part of a human body so looking for associated injuries far apart is probably as vital as the local examination of the injured part. All vital signs should be examined and recorded in the case note, that is, the local

---

T.A. Hamdan, MBChB, FRCS, FRCP, FICS, FACS
Department of Orthopedic Surgery,
Basrah General Hospital., Basrah, Iraq
e-mail: thamerhamdan_170@yahoo.com

J.D. Robinson, FRCS (Tr & Orth) MSc (Trau Surg)
Major Trauma Centre, St. Mary's Hospital,
Imperial College, London, UK
e-mail: jddrobinson@hotmail.co.uk

© Springer International Publishing Switzerland 2016

J.D. Robinson (ed.), *Orthopaedic Trauma in the Austere Environment:*
A Practical Guide to Care in the Humanitarian Setting, DOI 10.1007/978-3-319-29122-2_48

physical examination for the wound status, the extent of the injury, and the associated local injuries for the soft tissue, joints, and fracture. Muscle power and movements of the fingers, toes and movement is necessary. The size of the external wound does not reflect the extent of damage to the deep structures. Partial injury of the tendon may lead to misdiagnosis; each tendon should be examined separately according to its function.

Local examination at the site of injury may reveal swelling, tenderness, and change in shape, palpable tendon interruption, and weakness in the muscle power [3].

48.2.3 Investigations

A plain X-ray is required to exclude associated fracture even if the injury was minor.

48.2.4 Misdiagnosis of Tendon Injury

The common sites of tendon injuries as in the hand can be diagnosed easily, though partial injury may escape diagnosis. Rare sites of tendon injury as the peroneal tendons in lateral aspect of ankle may be diagnosed as ankle sprain. Rupture of triceps tendon is another site of misdiagnosis; it is uncommon injury, probably the rarest of all tendinous rupture [4]. Distal biceps tendon injury is a relatively rare injury [5] so there is a risk of misdiagnosis. Rupture of the pectoralis major is another uncommon injury [6] because it occurs usually in active athletic young patients and may be a site of misdiagnosis.

48.2.5 Macroscopic Structure of Tendons

The tendon may be surrounded by:

1. The fibrous sheaths or retinacula
2. The pulleys
3. The synovial sheaths
4. Peritendinous sheet (paratenon)
5. The tendon bursa

48.2.6 Blood Supply of Tendons

Three sources of blood supplying the tendon with almost one third from each are as follows:

1. Musculotendinous junction. Small blood vessels divide at the junction and supply both muscle and tendon. There is no direct capillary circulation between muscle and tendon, but there are small vessels in the outer covering of the muscle traversing the junction.
2. Along the length of the tendon. This blood comes either from the paratenon or the synovial sheath.
3. Some blood supply comes from the junction between the tendon and the bone [7].
4. Vascularity of the tendon is reduced in site of friction, compression, and excessive wear; this makes the tendon easily ruptured by even minor force.

48.3 Repair and Regeneration of the Injured Tendon

Three phases are required for tendon healing:

1. In the first week, it is the inflammatory phase.
2. The proliferative phase happen between the 2nd and 4th weeks.
3. The remodeling phase which occurs between the 2nd and 6th months [8].

Several factors may affect the healing process, which include the anatomical site of the injury, magnitude of the injury, and postoperative rehabilitation.

48.4 Treatment of Tendon Injuries

To achieve the best therapeutic regimen, we need to answer the following before drawing the lines of treatment:

- The site of injury
- Duration since injury
- Associated local or distal injuries
- Patient’s general condition

- Mechanism of injury
- The pattern of injury, e.g., clean cut or laceration
- Clean or contaminated wound

Early repair of any ruptured tendon is the goal. Early repair is required for a good functional outcome. It is a well-known fact that the outcome of treatment is always better with extensor tendon injuries than with flexor tendon injuries; this is related to anatomical facts, but the extensor tendon is more vulnerable to injuries than flexor tendons [9] because of the lack of soft tissue coverage.

Usually the extensor tendon repair can be achieved as a primary procedure if the wound is not contaminated, while the flexor tendons repair may be performed as a second or third stage depending on the wound status and other factors, but the best result is always with primary repair of both tendons.

It is always preferable to do a *primary repair* if:

- The joints are free to move
- No trace of contamination
- No contracture or scarring
- Intact neurovascular structures

Secondary tendon repair may be performed in the following conditions:

- Failure of primary repair
- Neglected injury
- Heavily contaminated wound
- Segment loss of tendon
- Complicated injuries

It is vital to adhere to the strict surgical technique of minimal tendon dissection and handling and preservation of the pulleys and tendon sheath. All scars should be excised; if excessive scarring was noticed, a third-stage surgery may be required.

48.4.1 Tendon Graft

Grafting is required to bridge a defect in the tendon which is either due to primary loss or secondary loss because of ischemia or infection. Common tendons used as a graft include plantaris, palmaris longus, to a lesser extent the toe extensor tendons, and flexor digitorum longus of the second toe. Extensor indicis proprius can be useful particularly if palmaris longus and plantaris are absent. Lewis et al. [10] used allograft for the treatment of chronic patellar tendon with gratifying short-term success.

48.4.2 Suture Material Used in Tendon Surgery [11]

1) Stainless steel and monofilament polyglyconate have been found to be the most suitable with high tensile strength with good knot-holding security. Steel is difficult to use and makes bulky knots. Polyglyconate is absorbable and may not last long enough for the tendon to heal.

2) Polypropylene and braided polyester exhibit lower tensile strength and good knot-holding security; they are nonabsorbable and have low tissue reaction.

48.4.3 Techniques of Tendon Suture

1. Core suture techniques [12–14] (Figs. 48.1, 48.2, 48.3, and 48.4).
    1. Kessler repair: 2 strand, knot outside the tendon.
    2. Modified Kessler repair: 2 strand, knot inside.
    3. Four-strand cruciate repair: knot inside.
    4. Tsuge: 2-, 4-, and 6-strand suture technique.
    5. Savage 6-strand core suture: the knot inside tendon, more core strands, decreased incidence of repair site rupture with programs of early active exercises. But more strands result in a more bulky repair site, with decrease in glide and increase possibility of adhesions. (Knot outside interfere with glide. Knot inside interfere with healing).
2. Epitendenious circumferential suture: it increases repair strength and improves gliding.


[redacted]

Fig. 48.1 This patient suffered a gunshot wound that perforated the palm of the right hand. The middle finger is extended as the flexor tendon has been lacerated and the extensor tendons are unopposed.

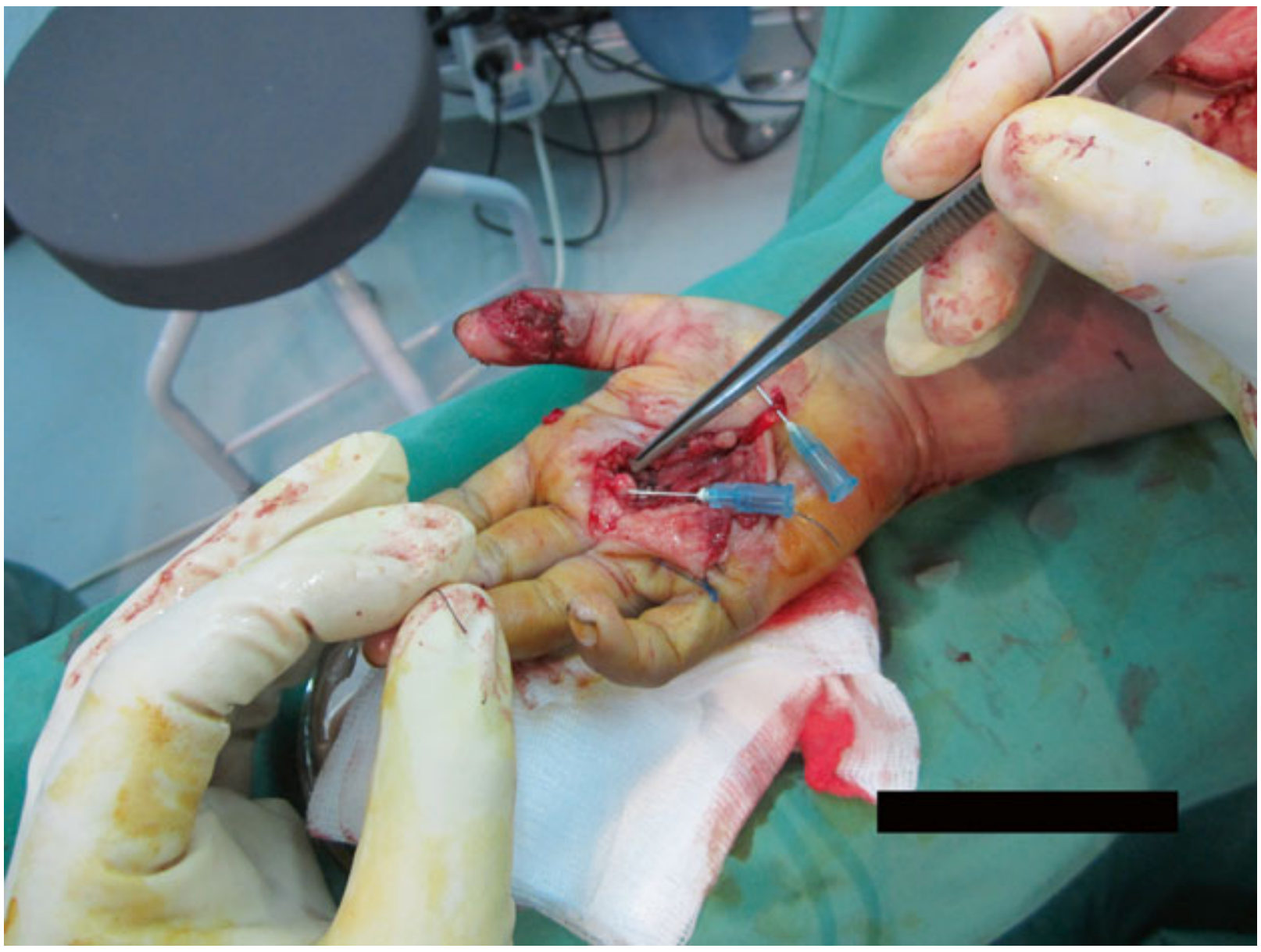
[redacted]

Fig. 48.2 The palm skin is incised, and the flexor tendon proximal and distal stumps are exposed and secured with a couple of blue needles in preparation to repair the tendon with a modified Kessler technique with no tension

48.4.4 Splinting

Evans [15] advocates early passive controlled motion for a complex tendon injury because it is a safe and effective rehabilitation technique and will reduce the complications. Movement enhances tendon repair by reducing edema which in turn reduces adhesions. Mobilization after 3–5 postoperative days is beneficial. Klienert's [16] elastic band traction has been used by most hand surgeons for a long time, but it may induce contracture of the small joints if used throughout the day. Narender Saini et al. [17] advocated a special static splint to be used intermittently for the extensor tendon, and he claims equal results if compared with the dynamic splints. Parakash [18] advocated the use of the dorsal splint involving the wrist in 20–30 degrees of flexion with the metacarpophalangeal joint at 80–90 degree of flexion and keeping the proximal interphalangeal joint in extension during the night and during the day controlled active extension with passive flexion.

48.5 Complications of Tendon Injury

1. Infection. In contaminated or infected wounds, aggressive wound excision is required.
2. Re-rupture or failure of repair. May be due to subclinical infection or faulty suture technique or even aggressive uncontrolled rehabilitation.
3. Joint contracture and stiffness. This complication is related to the loss of movement, lack of exercise, and immobilization. The joint may become stiff whether it is injured directly or it was not injured.
4. Tendon adhesion and loss of tendon gliding is probably the commonest complications following tendon injury. If the limitation is minor, conservative treatment is sufficient, but if the loss of movement is major, tenolysis may be required.

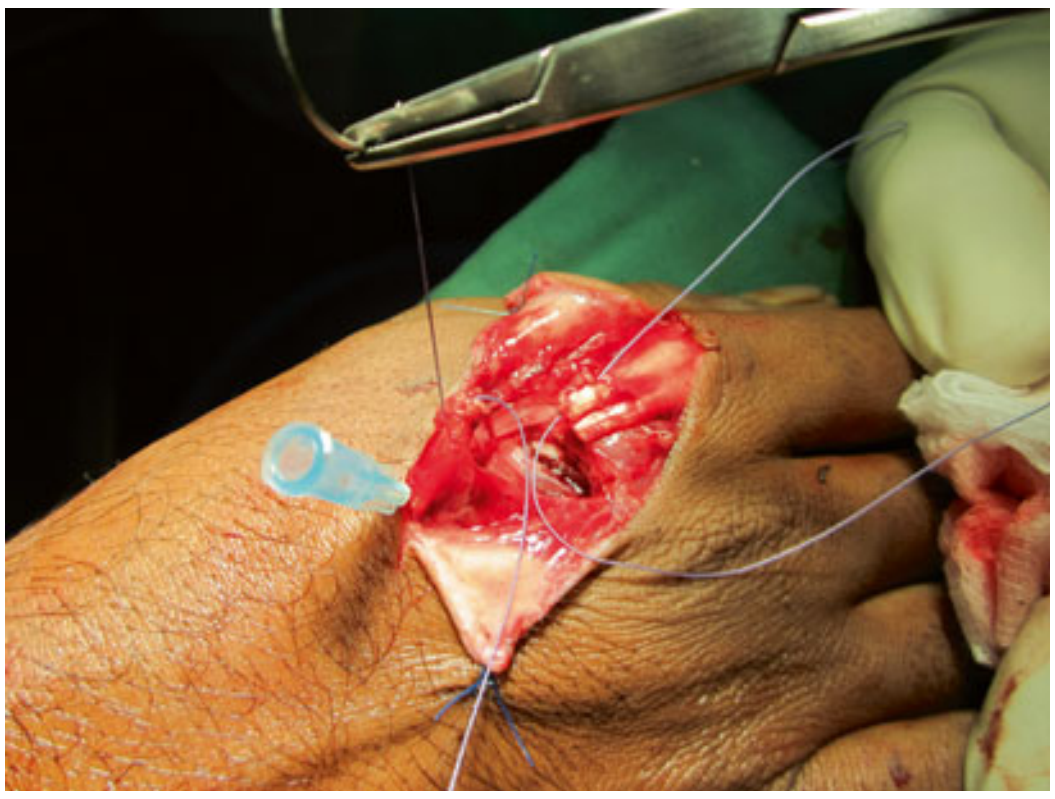

Fig. 48.3 This patient suffered a laceration of the extensor tendons of the fingers. The image shows a 5.0 nonabsorbable nylon suture being used to repair the tendons. A simple mattress suture can be done in the flat extensor tendons

48.6 Rehabilitation After Tendon Repair

Postoperative rehabilitation is as important as a good repair. There is a delicate balance between rest for tendon healing and movement to prevent scarring and stiffness. There is insufficient evidence to define the best mobilization strategy [19]. Early motion of the repaired tendons will prevent the formation of scarring and adhesion.

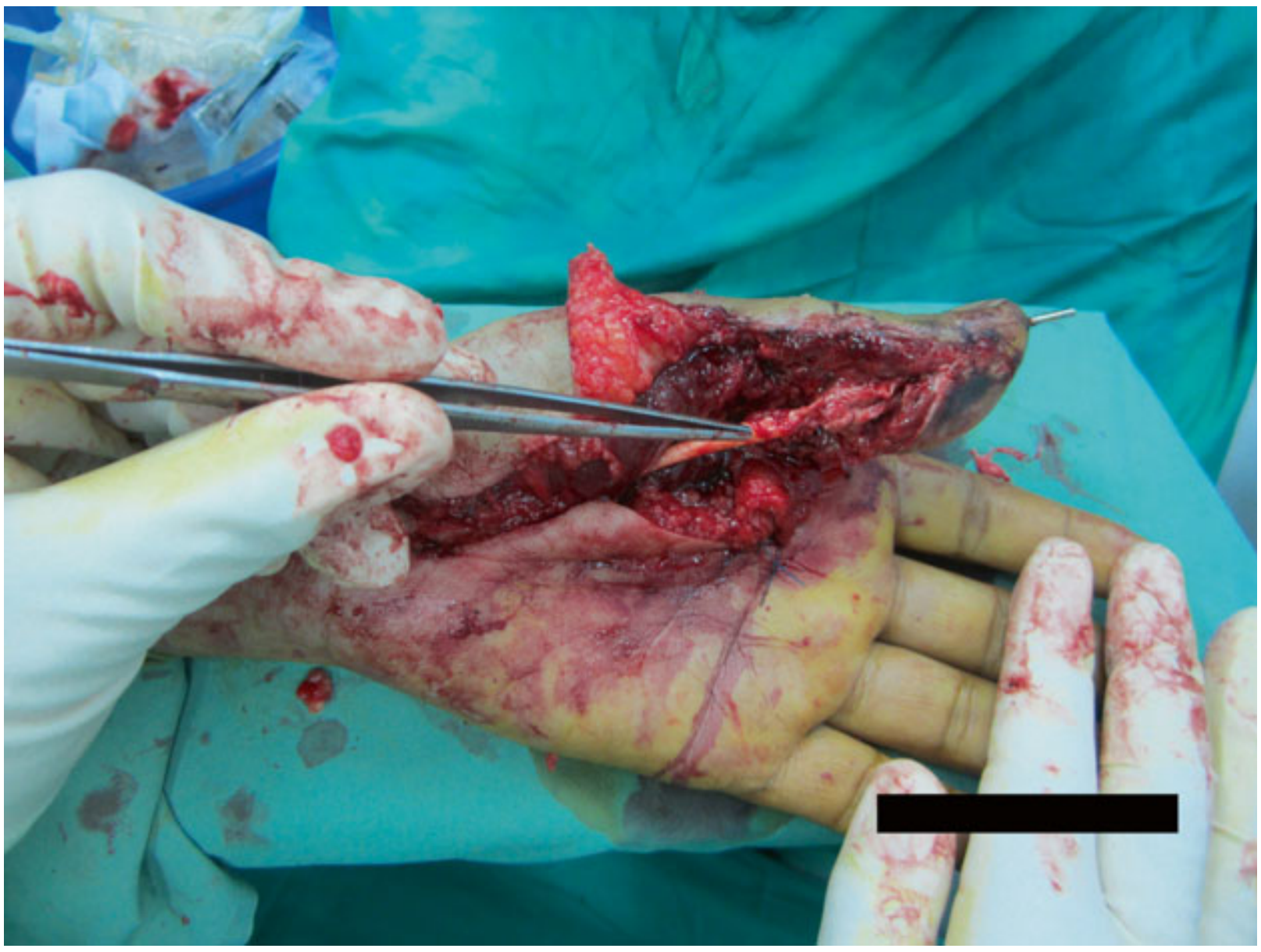

[redacted]

Fig. 48.4 A serious laceration of the flexor tendons of the thumb has been repaired in this case. A Kirschner wire has been used to stabilize a fracture as well

References

1. Angermann P, Lohmann M. Injuries to the hand and wrist, A study of 50.272 injuries. J Hand Surg Br. 1993;18:642–4.
2. Schoffl V, Andereas H, Thomas K. Tendon injuries of the hand. World J Orthop. 2012;3(6):62–9.
3. Konečný J, Veverková L, Reška M. Current possibilities of treatment of achilles tendon rupture, a review. Scripta Medica (BRNO). 2006;79(2): 75–84.
4. Sharma SC, Singh R, Goel T. Missed diagnosis of triceps tendon rupture, a case report and review of literature. J Orthop Surg. 2005;13(3):307–9.
5. Miymoto RG, Elser F, Millet PJ. Current concept review, distal biceps tendon injuries. J Bone Joint Surg Am. 2010;22:2128–38.
6. van Antosh J, Grassbaugh JA, Parada SA, et al. Pectoralis major tendon repairs in the active-duty population. Am J Orthop (Belle Mead NJ). 2009;38(1):26–30.
7. Schatzker J, Branemark PI. Intravital observations on the microvascular anatomy and microcirculation of the tendon. Acta Orthop Scand. 1969;126: 1–23.
8. Abdelfattah AIF, Amer TA, Hassan MSM, et al. Flexor tendon injuries; a protocol based on factors that enhance intrinsic tendon healing and improves the postoperative outcome. Egypt J Plastic Reconstr Surg. 2009;33(2):145–50.
9. Hague MF. The result of tendon suture of the hand, A review of 500 patients. Acta Orthop Scand. 1954;24:258.
10. Lewis PB, Rue JP, Bach BR. Chronic patellar tendon rupture. J Knee Surge. 2008;1(2):130–35.
11. Lawrence TM, Davis TR. A biomechanical analysis of suture materials and influence on a four-strand flexor tendon repair. J Hand Surg. 2005;30:836–41.
12. Seiler JG. Flexor tendon repair. J Am Soc Surg Hand. 2001;1(3):177–99.
13. Noquchi M, Seiler JG, Gelberman RH, et al. In vitro biomechanical analysis of suture methods for flexor tendon repair. J Orthop Res. 1993;11(4):603–11.
14. Trail IA, Powell ES, Nobel J. The mechanical strength of various suture techniques. J Hand Surg Br. 1992;17(1):89–91.
15. Evans RB. Clinical application of controlled stress to the healing extensor tendon: a review of 112 cases. Phys Ther. 1989;69(12):1041–9.
16. Klinert HE, Verdant C. Report of the committee of tendon injuries. J Hand Surg. 1993;8:794–8.
17. Narendar S, Sharma M, Sharma VD, et al. Outcome of early active mobilization after extensor tendon repair. Indian J Orthop. 2013;42:336–41.
18. Kotwal PP, Ansari MT. Zone II flexor tendon injuries: Venturing in to the noman's land. Indian J Orthop. 2012;46(6):608–15.
19. Thien TB, Becker JH, Theis JC. Rehabilitation after surgery for flexor tendon injuries in the hand . Cochrane Data Base Syst Rev. 2004;18(4):CD003979.

Part VII

Continuity of Care, Legacy, and Resilience

49

So What Happened Then? Follow-Up and the Challenge of Measuring Results

Johan von Schreeb

The real impact of International Emergency Medical Teams (EMTs) will be measured not only by their willingness and readiness to help in a crisis or disaster but by the results and consequences of their member's actions. Thus, among the several challenges faced by EMTs, providing international surgical relief is to have an efficient system to ensure accountability and measure their results and patient outcomes (Fig. 49.1).

It may be argued that the provision of surgery in a context where there is lack of resources should not be assessed using the same professional standards as in a society with sufficient resources. Nevertheless, whilst the equipment, local training, and technology may be found wanting in an austere and difficult environment, all health care workers should aim to maintain the same standards of professionalism expected from them back in their countries of origin.

The available resources may be limited, but the principles of ensuring as good a service as possible, including the appropriate follow-up of patients, should be adhered to in any setting (Fig. 49.2). There should be no escape from professional standards even if the care is provided on a "charitable basis" and the health worker or surgeon is working for free. It is the context and not the individual surgeon's professional attitude that changes. We need to ensure that the surgical care we provide reflects our best ability. If not, we should stay at home.

In this chapter, I will focus on the results from International Emergency Medical Teams' (EMTs) (Formerly known as Foreign Medical Teams, FMTs) surgical performance; what was left behind once these teams went home and what can be done to improve outcome measures and accountability. I will specifically explore:

1. Why is a system for assessing surgical outcome and patient follow-up essential?
2. The role for a timely and thorough handover between health providers
3. Methods and systems to ensure accountability and measure results and outcomes

49.1 Why is a System Needed for Assessing Surgical Outcome and Patient Follow-Up?

Following a disaster, whether natural or human-made, with injured patients everywhere, the first instinct is to start operating. After all, we are there to help! During the first days, there is limited time and energy to think about "data collection", "accountability", "follow-up", "handover"

Nothing spoils good results as much as follow-up.
B. Ramana, from Moshe Schein, *Aphorisms & Quotations for the Surgeon*, 2004

J. von Schreeb, MD, PhD
Specialist in General Surgery, Department of Public Health, Karolinska Institute, Stockholm, Sweden
e-mail: Johan.Von.Schreeb@ki.se

© Springer International Publishing Switzerland 2016
J.D. Robinson (ed.), *Orthopaedic Trauma in the Austere Environment: A Practical Guide to Care in the Humanitarian Setting*, DOI 10.1007/978-3-319-29122-2_49

Fig. 49.1 Unskilled amputation in Haiti

Fig. 49.2 Scarce resources is not a licence to relax high professional standards

and "exit strategy". Nevertheless, such aspects are all essential and part of the surgeon's responsibility when working in an austere environment. Surgery is not only what happens inside the operation theatre. A system for efficient follow-up of patients is fundamental. Before signing in with an organisation or EMT, ask if there is a system for patient follow-up, and how surgeons are held accountable for their actions. The system does not need to be overly complex or sophisticated, but it has to be there.

In an attempt to improve accountability and increase professionalisation of EMTs, the World Health Organization (WHO) and the Global Health Cluster (GHC) have published the "*Classification and minimum standards for foreign medical teams in sudden onset disasters*" [1]. This document is a product of the "EMT Working Group" process that aims at improving performance and accountability of EMTs [2]. Adherence to these minimum standards will serve as basis when EMTs register their capacities before deployment. This first sets of standards are focused on Sudden Onset disaster but in due time, minimum standards for other type of disaster and outbreak, to which EMTs are deployed are being produced.

The development of EMT standards is one part of several initiatives to improve the quality of services provided by EMTs [3]. This development was accelerated following the criticisms that were raised against the performance of EMTs following the 2010 Haiti earthquake. Terms such as "disaster medical tourism" have been used to describe the situation [4]. Some of the most serious criticisms were that many surgeons did not have proper training for the context and teams stayed for a short time and had no system for follow-up. Further, lack of data regarding patient outcomes made it impossible to evaluate EMT performance [5]. One study compiled for-

Fig. 49.3 Local facilities are often destroyed. EMTs must contribute to re-establishing quality medical care

eign field hospital surgical output data from 80 % of the 44 hospitals identified on Haiti. Based on extrapolations, it was estimated that around 12,000 surgeries were done at these hospitals during the first 30-days following the disaster (Fig. 49.3).

The study poses several questions. How many of the operated got well? What happened to the reported 300,000 injured? [6] How many injured does 12,000 operations correspond to? Important questions that unfortunately are impossible to answer. There is a severe scarcity of data on the types and volume of surgical output and no data on outcome. We can sadly conclude that, although the Haiti earthquake triggered a massive solidarity movement in terms of thousands of foreign medical staff deployed, we do not have sufficient data to conclude to what extent our well-intentioned efforts were beneficial. The follow-up studies from Haiti are few. MSF reported on its activities in an inflatable hospital that was erected within 2 weeks of the earthquake. A total of 248 earthquake-injured with 264 fractures were included in the study. There were 204 long bone fractures (87 % of the lower limb) [7–9]. 192 long bone fractures were treated with surgery (94 %), 36.5 % received external fixation, whilst traction was applied in 16.7 %.

Intramedullary nailing was done for 15.1 %, open reduction and internal fixation with plates in 9.9 %, whilst amputations were carried out in 14.6 % of cases. Two out of 36 patients (5.5 %) with closed femur fractures treated by IM nailing developed an infection. At 90 days follow-up, 31.6 % of the femur-fractured patients returned, and in total 42.2 % of the 192 patients with long bone fractures operated on returned for follow-up. Due to lack of data documentation, only 96 patients (103 fractures) could be evaluated for outcome. In total 68 of these fractures (66 %) were recorded to have callus.

Other outcome measures such as return to professional life, strength and mobility were only available for less than one third of these fractures. It should be noted that MSF has been working on Haiti for 20 years and already before the earthquake was offering trauma orthopaedic care. The pre-earthquake staff included nine Haitian orthopaedic specialists.

Another study of outcomes of surgeries done in Haiti concluded that only half of the patients with severe limb injuries, whether amputated or managed by limb salvage, classified their functional status as “satisfactory” 2 years after the earthquake [10]. It is difficult to attribute the results to the quality of care alone, as the initial injury also influences outcome. However, it has been shown that lower limb reconstruction is more acceptable psychologically to patients with severe trauma compared to amputations even if the physical outcome for both treatments was comparable [11].

Stump revision was estimated to be necessary for 30 % of those amputated in Haiti. This rate far exceeds the 5.4 % revision amputation rate among patients with severe lower extremity trauma in high-income settings [12]. There are several limitations of this study, first of all the difficult context that led to a 24 % drop out rate, but also the lack of medical records and the variability of both the wounds and their initial treatment that made it difficult to analyse outcomes in relation to initial injuries.

Another study measured the surgical outcomes in a 2-year follow-up of operated casualties of the 2001 Gujarat Earthquake. The study found a 10 % incidence of missed injuries, 19 % infection rate, 12 % restricted range of motion and 23 % non-union rate and revision surgeries were done in 30.5 % of the patients over a period of 2 years [13].

What can be expected from surgery in the austere setting? What is an acceptable result? The results from the above studies are difficult to interpret. If the incidence of postoperative infections ranges from 5 to 19 %, given the difficult conditions faced, is that acceptable? The relatively low follow-up rate of operated patients makes it difficult to judge the results. There are so many variables, including the selection of, type and severity of trauma, timing of operations and hygiene conditions in the OT as well as during the postoperative period. All of these factors can be blamed for non-satisfactory results. There is always an excuse that can be found outside our own immediate area of responsibility. Established benchmark levels for outcome and complication rates are unlikely due to the diversity of context and fracture type severity as well as incomplete, non-uniform data. Nevertheless, it may be safe to conclude that if close to one third of all amputations needed stump revision and if close to one fourth of all fractures did not heal, not all complications will be due to the environment alone, and some of these complications will be due to poor surgical, orthopedic training for the context, judgement and follow-up. It highlights the fact that the treatment strategy must be adapted to the context, to what extent similar treatment practice can be applied as in a stable high-income country must be carefully defined. It remains difficult to determine when it remains safe to use internal fixation for fracture. At this stage, the availability of high-quality studies is so limited that we cannot make fully informed judgements. This calls for EMTs to systematically collect data and to attempt to measure outcome. There are several ways to do this as suggested below.

No study that quantifies the volume of surgery done by national hospitals in Haiti has been identified, but lack of resources before and after the earthquake in combination with the destruction of health facilities and injury and death of hospital staff suggests that the capacity was severely hampered.

49.2 The Role for a Timely and Thorough "Handover" Between Health Providers

"Handover" include anything between donating the EMT facility to ensuring that patients are cared for after departure. This does not only include taking over hospitalised patients but also to guarantee the follow-up of patients treated, including rehabilitation. "Handover" may be to the existing health system or to other EMTs that plan to stay for a significant time period. Currently, there is no clear system for how this should be done. It remains largely context specific, i.e. to who "handover" can be done depend on resources and capacities in the existing health system. For example, in Haiti 2010, handover was to a large extent made to other EMTs, whilst on the Philippines 2013, available health system resources were sufficient to manage handover from departing EMTs (Fig. 49.4).

However, in recent SODs, most EMTs functioned independently rather than as part of a health system. "Handover" of patients were not considered until late, just before departure and

Fig. 49.4 Lack of planning may cause a sense of chaos. All aspects of an EMT intervention must be as planned as possible

was often ad hoc. Already on arrival, all EMT must have a clear exit plan and strategy. To plan their work and focus their work and not make promises they cannot keep, EMT staff must from the start know how long the EMT intend to stay and what type and level of services that will be provided. Plans for all patients need to be developed and communicated to the patients. For example, if an amputation is done, who will arrange for prosthesis? How will the patient be rehabilitated? And who will ensure this? This becomes especially important for EMTs that only stay for a few weeks or even shorter. As soon as possible after arrival, a system for rehabilitation and handover of patients should be developed. Partners within the local health providers, Ministry of Health or from other EMTs that stay for longer time should be identified and agreements made. In upcoming SODs, EMT coordination (WHO and affected country agencies such as Ministry of Health) will be an important part of the response to ensure that resources are optimally used, standards met and that referral between EMTs as well as the national health services is working as a system. The EMT exit plan has to be clear and announced to the local authorities as well as to the EMT coordination team. The exit plan should also include information to what extent materials and medicines will be donated and left behind. If so, WHO guidelines should be followed [14].

In an ideal setting, the EMTs form a surge function, an extension of the local health system. Requests for surge capacities can be based on estimated need for EMTs on different levels, using the classification mentioned above.

49.3 Methods and Systems to Ensure Accountability, Measure Results and Outcomes

Without a system that measure results and outcomes, it is impossible to ensure accountability. For surgery, this is even more pertinent, as we subject patients to potentially dangerous procedures. However, there is a long-standing perception that humanitarian work in low resource settings is beyond considerations of malpractice and negligence. Words such as liability and indemnity, representing the legal consequence of accountability, have not been used in connection with humanitarian surgery until recently. It is likely that humanitarian organisations increasingly will be held accountable to their actions. In the future, it is not unlikely that there may be legal claims of indemnity from patients operated on by EMTs. To face that challenge, EMTs must have systems to document practice and monitor performance. As surgeons, we must strive for accountability for our work, not only to avoid legal consequences but to not cause unnecessary suffering.

One way to ensure professional accountability is to adhere to and follow the EMT minimal standards that were introduced in the beginning of the chapter [15]. The standards build on a simple classification system that is based on the level of services (EMT I, II, III + specialized cells). This corresponds to different levels of medical services provided. EMT I offer basic, outpatient care, whilst EMT III offer advanced facility-based services that include a sterile environment enough to perform internal nailing of fractures services for EMTs. This means that orthopedic care should be available at all levels from fracture splinting to advanced surgical care, adapted to the level of care provided.

For each level of EMT, there are minimal technical standards, i.e. what type of service and equipment that must be available. In addition, there are common core standards for all EMTs that include reference to medical ethics as well as Sphere standards, which are standards developed for agencies providing relief in the humanitarian setting [16]. Updates of the standards and the process accompanying them will be available on the WHO's homepage [17].

A first test of the relevance of the EMT classification and standards was typhoon Haiyan that hit the Philippines in November 2013 (Fig. 49.5). The government of the Philippines, with support from the WHO, rapidly imposed the EMT classification system. EMTs arriving had to classify their teams as either EMT 1–3. In a review based on WHO data om EMTs arriving before day 30, a total of 108 EMTs were on ground, 91 of these were classified. A total of 76 as Type I, 12 as II while 3 as III [18].

Although the level of EMTs were based on self-classification and that adherence to the EMT standards were not assessed, the EMT classification and standards were widely acknowledged for being simple and serving a purpose that allowed improved coordination and overview of available EMT capacity [19]. Following the 2015 Nepal earthquake, based on WHO data, a total of 148 EMTs with close to 3000 staff from 36 counties were dispatched to Nepal out of which 120 were registered by the strong MoH-WHO led EMT coordination unit. A total of 17 of these teams were classified as type II while only one was a

Fig. 49.5 An outdoors clinic in the Philippines following Typhoon Haiyan

type III. An evaluation of the performance of these teams are yet to be done while it remains clear that there were more EMT capacity available than needed. More efforts are needed to rapidly define the surge needs adapted to the context and the severity of the SOD.

So how can EMTs set up systems to measure results and outcome? In the non-disaster but austere setting, foreign plastic surgeons operating cleft lips have proposed systems to monitor quality of care and follow-up [20]. Photographs are taken and entered into a database before surgery, right after surgery and at the follow-up consultations, 6–9 months after the operation. The photographs and data from postoperative consultations as well as complications are used to evaluate surgical outcomes objectively by independent unbiased evaluators. Data from a total of 562 out of 4100 patients (13 %) was evaluated. Despite the fact that the operations were done in a non-disaster area and that results of a cleft lip operation may be evaluated from a photograph, only a minority of these was evaluated.

Among global health-interested general surgeons, a system that assesses outcome of emergency intra-abdominal surgery across international settings is being tested. It builds primarily on one indicator, Peri Operative Mortaility (POM) mortality 24-h post-surgery. In addition, it promotes data collection on any in-hospital complications by 30 days [1].

There are thus ways to set up systems to monitor and assess quality of care. One method that has been proposed for assessing quality of surgical care is the Donabedian's framework of quality of care. In this framework, the three components of health care quality are structure, process and outcome [21]. This framework has been used to assess the quality of surgery [22]. "Structure" is the environment in which surgery is provided and comprises that certain equipment, materials and human resources should be available. "Process" includes the method and techniques by which surgery is provided and include that equipment should be functioning, that staff are trained and have activated treatment protocols and that evidence-based surgical techniques are implemented and that follow-up of patients is included in protocols. "Outcome" is the result of surgery and may be captured by mortality levels and that morbidity is actually decreased by the surgical intervention, both in the short as well as long-term perspective.

For each of the three domains, benchmark performance indicators should be set and defined based on feasibility of actually collecting them. The focus should be on indicators that are possible to collect rather than those we want to collect. This framework is not dependent on context, whilst the performance indicators may be adjusted for the austere setting. One article has outlined some key recommendations based on the above-mentioned framework, adapted to the humanitarian setting [23]. In this paper, Medecins Sans Frontieres (MSF) outlines a set of minimum criteria for structural inputs that should be in place before surgery can be delivered. MSF suggests availability of the following minimal structures; a safe structure, electricity, clean water, a blood bank, sterilisation equipment, a post-anaesthesia recovery unit, anaesthetics, analgesics, antibiotics and qualified surgery and anaesthesia providers. In addition, the MSF authors highlight the need for specific training for surgeons in the field of surgery in the austere setting.

However, professional organisations, such as societies for trauma and orthopaedics as well as the various colleges of surgeons, have been limitedly involved in developing specific trainings in the field of surgery and trauma care in the austere setting (Fig. 49.6). There is a significant need for training curriculum and practical courses. Some of the few courses offered include the STAE or "Surgery Training in the Austere Environment" a 1-week training offered by the Royal College of Surgeons of England. In this course, the participants are trained to perform life-saving basic procedures as well as context-adapted orthopaedic procedures such as applying external fixators. Another example is the Disaster Preparedness and Response Training course for orthopaedic surgeons offered by the Society of Military Surgeons in the USA.

Thus, among the process indicators, a check list that include the basic trainings needed for the austere environment can be used to assess EMT

Fig. 49.6 The various colleges of surgeons have been limitedly involved in developing specific trainings in the field of surgery and trauma care in the austere setting

staff quality. In addition, the staff competencies should be assessed by also including previous experience in the austere disaster setting. Another process quality indicator is the availability and use of evidence-based treatment protocols.

Care should be well thought out and adapted to the place and timing of a situation. The fact that EMTs become operationally too late (after 72 h of SOD onset [5, 8]) to provide emergency care for the most critically injured challenges existing treatment protocols that are based on patients arriving to emergency centres shortly after injury.

For example, a patient with crush injury that is suspected to have a compartment syndrome should undergo a fasciotomy urgently. However, a systematic review found no evidence for performing fasciotomies after 72 h of injury [7]. This means that treatment protocols for EMTs should not only be adapted to the austere context but also to EMT time of being operational [5, 8]. It is recommended that protocols are developed and implemented for common procedures such as caesarean section, burn care, open fractures, and amputations in addition to protocols for antibiotic prophylaxis and postoperative pain management. This becomes especially important in a setting where the turnover of surgeons is very high.

Few studies have attempted to critically assess the outcome of surgery done in the austere setting. One may argue that the difficult context, chaos and often short time on ground limit the ability to collect follow-up data, but instead these challenges should trigger EMTs to ensure the quality of care offered and that their services are adapted to the demanding context. Some lateral thinking may be necessary to achieve better data collection. For example, EMTs could send researchers back later to collect follow-up data. In the absence of outcome indicators, it is suggested to implement a modified version of WHO safe surgery checklist [24] that takes into account the austere context (Table 49.1).

It may thus be assumed that minimum standards for structure and process may be relatively easy to reach. In the EMT standards, a number of benchmarks levels for structure and process has been defined (e.g. number of staff in relation to hospital beds that staff must have training and experience and data is collected). This means that EMTs adhering to the standards in its current form are likely to be well equipped to carry out their work; they have the right material, medicines and staff that are trained and have experience; and data is collected. What

Table 49.1 Elements of humanitarian surgery checklist

1. Perform anaesthesia preoperative evaluation
2. Pulse oximetry is available and working
3. Procedure explained to patient and written consent signed
4. Confirm patient identification
5. Mark operative site
6. If significant fluid/blood loss is expected, obtain appropriate intravenous access and ensure availability of fluid/blood products
7. The appropriate surgical instruments are available to perform procedure
8. Antibiotics have been given if wound is expected to be contaminated
9. Post-anaesthesia care is available
10. Postoperative care protocol is established
11. In a mass casualty, the procedure performed, date of dressing change or re-intervention are written on the bandage
12. Patient and surgical data entered into a database

remains is to demonstrate that quality of care is acceptable.

Even if, as shown above, this is difficult, the fact that data is systematically collected is a sign of quality. It could be that the collection of data is more important that the data itself. If you know your actions are monitored, you may likely perform better. There is no consensus on what type of indicators should be collected in the austere setting. Several authors have suggested lists of indicators [25] to be collected, whilst experience from the disaster setting show that data is not systematically collected or at least not shared, which makes it impossible to evaluate EMT performance [5, 8].

Until there is a set of uniform outcome indicators agreed upon, it remains the responsibility for each EMT to implement a systematic and rigorous data collection system including indicators that are feasible to collect. They may include complication rates including 24 h peri-operative mortality, postoperative infections, length of hospital stay, readmission rates, patient satisfaction, functional health status, and other types of measures for health-related quality of life. For orthopaedic surgery, a "blunt" indicator such as 24 h perioperative mortality may not be a apropriate indicator, but it nevertheless remains a good indicator on the overall performance of the EMT and is relatively easy to collect.

The lack of data on outcome remains a main challenge in the austere setting. However, in due time, it must be tackled to ensure accountability of EMTs and to allow comparison between different EMT providers and also serve as a tool to improve the care provided. In addition to the practical challenges with data collection in the austere environment, there are also ethical concerns. For example, mobile telephone number of discharged patients may be collected and use for follow-up. In a conflict setting, this may cause security problem for the patients. Besides collecting data on outcome and introducing checklists, innovative, simple measures are needed to improve the performance of surgical care in the austere settings.

Lessons may be learned from trauma research that has made significant steps to improve quality of care. Among the successful tools has been the introduction of trauma registers and benchmarking of performance indicators such as injury severity-adjusted mortality rates. However, the only valid performance indicator that had evidence for validity or reliability was the use of peer review of deaths [26]. This suggests that, besides from documenting mortality and postoperative infections rates, qualitative processes that include structured peer discussions on avoidable and potentially avoided deaths (preventable deaths panels) could be a valuable tool to improve quality of care for EMTs.

49.4 Recommendations

Surgeons considering working in austere settings are strongly advised to join an international register for humanitarian action in their respective country, such as the one maintained by the American College of Surgeons (http://www.operationgivingback.facs.org/) or the United Kingdom International Emergency Trauma Register (http://www.uk-med.org/). These registers provide guidance, training and certification to be as well prepared as possible to work in a humanitarian setting. Specific competence in global health gives valuable insights in understanding the challenges low and middle-income countries face. Moreover, clinicians are required to participate in trainings that teach them how to adapt clinical practice to make them adequate to a context dominated by lack of resources. It is a significant problem for clinicians trained in advanced, high tech health care to adapt their practice of working unless they have specific training for this.

Teams of surgeons who are available for deployment need to register as an EMT with the WHO and adhere to the minimum standards. It is also important that the surgeons ensure that the EMT they work for has a system for accountability that includes data collection and ways to document follow-up. If this is not available, the surgeon should question why this is the case?

Disaster response is multi-speciality and multidisciplinary, and it is mandatory to build this into EMT surgical disaster planning. We need to work alongside with public and global health specialist and epidemiologists to develop and design outcome models that are based on data that are feasible to collect. The minimum standards of surgical record-keeping and handover protocols to the local healthcare system and between all healthcare workers involved in the patient's management are available in the forms of various competency guidelines, and surgeons are advised to read them before deployment.

Surgical EMTs need to have a holistic perspective of the role they may play. The activities in the operating room/theatre (OT) are obviously important, but it is only one part of the system process that leads to a patient outcome. Once the patient leaves the OT, there must be services to assist the rehabilitation of the injured, such as physiotherapists. Surgeons working in the austere setting should have understanding of what goes on outside the OT, including cultural and gender issues, and take that into account when planning surgery. We must remember that we are guests and we must respect and work alongside and on request of our hosting colleagues. They will stay; we will not. If we do not apply a respectful attitude, our good intended actions may turn out to hurt the patient more than it helps them.

References

1. WHO. Classification and minimum standards for foreign medical teams in sudden onset disasters. Developed by the Foreign Medical Team Working Group under the Global Health Cluster. 2013. Available on the WHO web site www.who.int.
2. WHO. Foreign Medical Teams Working Group. Developed by the Foreign Medical Team Working Group under the Global Health Cluster. 2014. Available on the WHO web site www.who.int.
3. Redmond AD, O'Dempsey TJ, Taithe B. Disasters and a register for foreign medical teams. Lancet. 2011;377(9771):1054–5. Epub 2011/03/29.
4. Van Hoving DJ, Wallis LA, Docrat F, De Vries S. Haiti disaster tourism–a medical shame. Prehosp Disaster Med. 2010;25(3):201–2. Epub 2010/06/30.
5. Gerdin M, Wladis A, von Schreeb J. Foreign field hospitals after the 2010 Haiti earthquake: how good were we? Emerg Med J. 2012. Epub 2012/03/09.
6. Government H. Haiti earthquake results. 2013. http://www.lessonsfromhaiti.org/relief-and-recovery/key-statistics/.
7. Gerdin M. Wladis A. Accepted Journal of Trauma: von Schreeb J. Surgical management of closed crush injury-induced compartment syndrome following earthquakes in resource scarce settings - An overview of reviews; 2012.
8. von Schreeb J, Riddez L, Samnegard H, Rosling H. Foreign field hospitals in the recent sudden-onset disasters in Iran, Haiti, Indonesia, and Pakistan. Prehosp Disaster Med. 2008;23(2):144–51; discussion 52–3. Epub 2008/06/19.
9. Teicher CL, Alberti K, Porten K, Elder G, Baron E, Herard P. Medecins sans frontieres experience in orthopedic surgery in postearthquake haiti in 2010. Prehosp Disaster Med. 2014;29(1):21–6. Epub 2014/01/17.
10. Delauche MC, Blackwell N, Le Perff H, Khallaf N, Müller J, Callens S, et al. A prospective study of the outcome of patients with limb trauma following the Haitian earthquake in 2010 at one-and two-year (The SuTra2 Study). Plos Curr Disasters. 2013. pp. 1–21.
11. Akula M, Gella S, Shaw CJ, Mohsen AM, McShane P. A meta-analysis of amputation versus limb salvage in mangled lower limb injuries – the patient perspective. Injury. 2011;42:1194–7.
12. Harris AM, Althausen PL, Kellam J, Bosse MJ, Castillo R. Complications following limb-threatening lower extremity trauma. J Orthop Trauma. 2009;23:1–6.
13. Roy N, Shah H, Patel V, Bagalkote H. Surgical and psychosocial outcomes in the rural injured–a follow-up study of the 2001 earthquake victims. Injury. 2005;36(8):927–34. Epub 2005/06/28.
14. WHO. Guidelines for donations of medicine and equipment in emergencies. 2010. Available online on http://www.who.int/selection_medicines/emergencies/guidelines_medicine_donations/en/.

15. WHO GHCa. Classification and minimum standards for foreign medical teams in sudden onset disasters WHO and the Global Health Cluster. Developed by the Foreign Medical Team Working Group under the Global Health Cluster. 2013. Available on the WHO web site www.who.int.
16. Standards S. Humanitarian charter and minimum standards in humanitarian response. 2011. Available from: http://www.sphereproject.org/.
17. WHO. Foreign Medical Teams homepage. 2014. Available on line https://extranet.who.int/emt/page/home.
18. Nevio Zagaria SP; Charles Blanch. Initial review of the effectiveness and coordination of Foreign Medical Teams to Typhoon Yolanda; 2014. Available at https://extranet.who.int/emt/sites/default/files/documents/Draft%20review%20of%20FMT%20response%20to%20Typhoon%20Haiyan.pdf.
19. Blanch Charles, Zagaria Nevio, Peiris Sasha. Initial review of the effectiveness and coordination of Foreign Medical Teams to Typhoon Yolanda, WHO; 2015.
20. Bermudez L, Carter V, Magee Jr W, Sherman R, Ayala R. Surgical outcomes auditing systems in humanitarian organizations. World J Surg. 2010;34(3):403–10.
21. Donabedian A. Evaluating the quality of medical care. Milbank Mem Fund Q. 1966;44(3):166. Epub 1966/07/01.
22. Birkmeyer JD, Dimick JB, Birkmeyer NJ. Measuring the quality of surgical care: structure, process, or outcomes? J Am Coll Surg. 2004;198(4):626–32.
23. Chu KM, Trelles M, Ford NP. Quality of care in humanitarian surgery. World J Surg. 2011;35(6):1169–72; discussion 73–4.
24. World Health O. WHO guidelines for safe surgery 2009: Safe surgery saves lives. Ginebra: World Health Organization; 2009.
25. Burkle FJ, Nickerson J, von Schreeb J, Redmond A, McQueen K, Norton I, et al. Emergency surgery data and documentation reporting forms for sudden-onset humanitarian crises, natural disasters and the existing burden of surgical disease. Prehosp Disaster Med. 2012;27(6):1–6.
26. Gruen RL, Gabbe BJ, Stelfox HT, Cameron PA. Indicators of the quality of trauma care and the performance of trauma systems. Br J Surg. 2012;99 Suppl 1:97–104. Epub 2012/03/28.

Legacy: What Are You Leaving Behind?

50

Andrew Furey, James Rourke, and Barth A. Green

> When one teaches, two learn
>
> Robert A. Heinlein

Natural disasters have affected more than 200 million people a year in the last 10 years [1]. The stages of a natural disaster have been defined in different ways by different agencies. The United Nations Educational, Scientific and Cultural Organization (UNESCO) names these stages as prevention, preparedness, response, and recovery [2]. In the UK, the Department for International Development (DFID) talks of context, disturbance, capacity to deal with disturbance, and reaction to the disturbance [3]. Perhaps the most frequently terminology used is as follows: preparedness, response, reconstruction, and mitigation [2].

The effectiveness and speed of the initial response to a disaster are largely influenced by the degree of local preparedness and the physical, geographical, and economic challenges of the region [2]. Following the initial emergency response, the efforts for rebuilding and reconstruction begin. The lessons learned from the acute phase are noted during the mitigation phase in an effort to eliminate mistakes and better prepare for future disasters [2]. Thus, volunteer trauma care should be thought of as a number of stages leading to the "mitigation phase" which involves establishing effective continuity of care. It is this final phase, continuity of care – or perhaps the lack of it – which often causes a barrage of criticism directed at international relief organizations and has lead many institutions to reconsider the approach to resilience and capacity building [1–3].

During the response phase, the primary focus is on rescue and first aid. This phase often involves national, international, and military organizations supplying relief and aid to the affected areas [1]. With respect to trauma care, the focus remains on rescue and treatment of acute injuries sustained in the natural disaster. This often occurs without access to medical infrastructure or appropriately trained personnel. The triage of injuries becomes paramount. Injuries largely dealt with are life and limb threatening and the treatment plan should be largely based on damage control principles.

As organizations assist with the response phase of disaster relief, the reconstruction phase becomes more urgent [2]. Some organizations begin to establish makeshift hospitals and treatment centers to deal with ongoing medical issues such as non-life-threatening injuries and diseases related to lack of

---

A. Furey, MD, MSc, FRCSC (✉)
Department of Surgery,
Memorial University of Newfoundland,
St. John's, NF, Canada
e-mail: andrewfurey@hotmail.com

J. Rourke, MD, MSc, FCFP (EM)
Office of the Dean of Medicine, Memorial University
of Newfoundland, St. John's, NF, Canada

B.A. Green, MD, FACS
Executive Dean for Global Health, Community
Service, University of Miami Miller School of
Medicine, Miami, FL, USA

© Springer International Publishing Switzerland 2016
J.D. Robinson (ed.), *Orthopaedic Trauma in the Austere Environment: A Practical Guide to Care in the Humanitarian Setting*, DOI 10.1007/978-3-319-29122-2_50

clean water and sewage. In developed countries this phase may occur rapidly, but in a developing country, this process can take much longer [2]. International relief efforts generally work with local organizations to establish a working environment in order to meet on going healthcare needs with limited access to facilities and medical supplies. Volunteers and volunteer task forces must consider what effect any plans have on the local government, healthcare system, and any future disaster preparations [2].

Although strategies such as the UN International Decade for Disaster Response [4], the Yokohama strategy [5], the HYOGO framework for action 2005–2015 [6], and the work by the Pan American Health Organization [7], among others, have improved performance during the mitigation phase, questions remain as to the effectiveness of establishing continuity of medical and trauma care.

As humanitarian surgeons, we have been privileged to be allowed to volunteer in areas of great need, and we must ensure these are left in a better situation than the one we arrived to. By this stage, the world's media has probably turned its attention to the next war or natural disaster. However, although less dramatic, this is the time when humanitarian organizations can have their greatest impact, by assisting the country's capacity to respond to the next disaster or *resilience*.

In humanitarian work, resilience can be defined as "the ability of countries, communities and households to manage change by maintaining or transforming living standards in the face of shocks or stresses without compromising their long term prospects"[3]. Resilience can be promoted through improving training of medical and paramedical personnel, infrastructure development, effective communication protocols, and interdisciplinary relations and networking.

50.1 Education and Training

The World Health Organization (WHO) has reported that one of the greatest disease burdens among younger individuals is trauma and injury [8]. As the demand for and use of motor vehicles in the developing nations continues to increase, this burden will continue to rise. In East Africa, for example, without improved surgical services, up to 10 % of the population will die from trauma [9]. One barrier to preventing such a tragedy is the lack of trained medical professionals. While volunteer surgical teams can assist in the delivery of trauma care, especially in the face of a disaster, intermittent and staggered surgical and acute care teams are insufficient to build local capacity and establish a legacy of improved healthcare delivery. To achieve the latter, cooperation must exist between local authorities and international organizations, and systems for training of local medical staff and personnel must be established (Fig. 50.1).

Fig. 50.1 (**a**, **b**) Training of local staff

In Haiti, there are very few orthopedic surgeons to service a population of 10.4 million people [10]. As in East Africa, recruitment and retention of junior surgeons are often difficult as they are attracted to higher-income employment opportunities [9]. Often the best surgical care is provided in private and nongovernment organization (NGO) hospitals [9]. While providing a service to the population, it is essential that these hospitals take more active leadership roles in promoting education and help to develop well-trained surgeons.

The most direct way that surgical training and support can occur on the ground is with volunteers directly teaching local staff in the operating room [4, 11]. Local staff can also take part in courses, such as those offered by the International Committee of the Red Cross in areas of war and post-conflict areas [9] or the Orthopedic Trauma Symposium in Haiti. These courses provide short duration but high impact teaching on a variety of skills. The next logical step to ensure capacity building and advancing care of trauma patients is establishing a curriculum that meets the needs of the local health staff (Fig. 50.2). One such program is being actively developed in Haiti and is called the Orthopedic Trauma Care Specialist (OTCS) program for Haitian physicians [12]. This program aims to create surgeons for Haiti in cooperation with the local Haitian Orthopedic Societies. Participants do not graduate as traditional orthopedic surgeons capable of performing all orthopedic procedures. The focus is on recently graduated interns to become able to manage acute orthopedic injuries [12]. A 3-year program would offer a series of lectures, laboratories, and training in teaching skills, thereby creating the future trainers that are so needed in Haiti.

When implementing such a program, levels of costs and benefits should be always examined. The OTCS program is projected to have a cost-effectiveness ratio of $133.97 per disability-adjusted life years (DALY) averted, well below the threshold for Haiti of an estimated $1200 per DALY [12]. Whether it is a short-term or a long-term educational programs and curricula, volunteering in trauma surgical teams should involve training of local future educators.

Fig. 50.2 Training of future trauma carers

50.2 Infrastructure

Volunteer trauma teams should be encouraged and challenged to promote local resilience and to leave a positive legacy. Often in a disaster, there is an immediate collapse of the public health infrastructure (Fig. 50.3). More people may die as a result of the ensuing chaos than from the disaster itself [10]. Medical facilities are frequently lacking, with poor working conditions as reported by the Ptolemy Project [13]. Volunteer trauma teams should liaise with local administrators to determine the local needs of the population. A very important contribution may also be to engage in direct fundraising and grant applications to be used to improve local medical infrastructure [14]. Adequate facilities will allow for continued delivery of care in the absence of volunteers, continued education and improved public health delivery to facilitate future projects. In addition to the immediate medical benefits of improved facilities, engaging local contractors and private sector and government agencies will foster shared responsibility and ownership of the new and improved facilities [1].

The WHO recognized the importance of establishing appropriate health facilities in their position paper from 2011. They urge the development of safe and prepared facilities built and located safely and for existing facilities to be examined for safety concerns and updated if required [15].

50.3 Communication

Communication is a critical component to success of volunteer trauma care [16]. In a disaster, communications are hampered initially by the effects of the disaster itself. However, communications between NGOs and agencies can also be affected negatively by perceived rivalries and lack of cooperation [16]. This is a hurdle that must be overcome in order to establish effective continuity of care of trauma patients.

In the initial response phase in Haiti, for example, when relief workers and NGOs arrived, they assumed that the UN, who had been involved in Haiti for years prior to the 2010 earthquake, would have substantial information and data about existing infrastructure and operations [16]. Many assumed they would have access to the data and demographic information on health facilities and available systems. Instead there was a void of information, resulting in relief agencies starting the collection of data from the beginning [16]. This not only highlighted the importance of communication in the effective delivery of an early response, but more importantly, it highlighted the need for an adequate system for sharing information (Fig. 50.4). The rapid exchange of relevant information and data among agencies and organizations is of critical importance [17]. Agencies and NGOs often conduct reconnaissance missions on

Fig. 50.3 A total loss of local infrastructure undermines local resilience

health facilities, water centers, etc., but the data is often not shared, resulting in a lack of coordination, duplication of services, and inefficient use of time [17]. Some relief databases have been created in an attempt to address this issue, but they have not been met with great success. For example, the UN's established Relief Web has suffered from a lack of submissions from NGOs and academics [17]. This lack of data can not only lead to a reduced level of care but in fact hamper the delivery of care [18].

Volunteer trauma missions should be willing to share trauma databases and information. Sharing information will minimize redundancies and maximize the efficient use of limited funds.

50.4 Interdisciplinary Cooperation and Networking

Operating in isolation will not allow a volunteer medical project to be sustainable. Creating strategic relationships is an integral part of building the capacity to ensure a positive legacy. The interdisciplinary nature of this approach requires cross-sectional cooperation and interdisciplinary partnerships, in order to achieve maximal benefit [1] (Fig. 50.5). Creating an adequate trauma care infrastructure and educational opportunities cannot take place in a vacuum. All stakeholders must be involved in the process of attempting to advance local healthcare delivery. It is necessary to integrate government

Fig. 50.4 International teams must establish effective communication systems between agencies and with local officials

Fig. 50.5 Interdisciplinary cooperation and networking

departments, private sector investors, contractors, small business, healthcare administrators, university administrators, and national/international support agencies to create a shared framework and responsibility [1]. There is often the criticism that volunteer missions implement their strategy without the transfer of knowledge or the consideration of the local management skills or strategies [1]. The WHO suggests that in order to strengthen the role of local healthcare authorities, these must be provided with leadership roles and access to resources and enhanced training and planning [15]. Communities and local and national governments are empowered at all levels by their involvement in the development of a sustainable effort and process. The UN, recognizing the importance of sociopolitical relationships in order to achieve a sustainable approach to relief and development, has suggested several guidelines, many of which emphasize the importance of capacity building within local communities and governments [1].

50.5 Economics of Building a Legacy in Trauma Care

Surgical disease has not been a main focus for aid or political attention in developing countries. Yet surgical conditions often lead to permanent disability or death and contribute to the economic burden of illness of any country. Four major types of surgery have been identified as critical for saving lives: trauma, obstetrics, acute abdominal surgery (e.g., appendicitis), and elective care for relatively simple procedures (e.g., cleft lip repair) [19]. There is an abundance of evidence suggesting that providing surgical care is cost-effective by limiting the disability of surgical conditions such as trauma.

Given that treating surgical injuries and diseases can be cost-effective lifesaving measures in developing countries, one must consider how the economics of these programs can assist in developing resilience and legacy building. The answer to this lies in the cost-effective analysis of training local medical professionals to treat injuries surgically. As previously mentioned the benefits of this have been suggested in a cost-effective analysis of a new orthopedic surgical residency training program for Haiti OTCS [12].

50.6 A Case Study: Team Broken Earth-Project Medishare

Haiti's health indicators published by the WHO are alarming [20]. Medecins Sans Frontieres (MSF) has reported that Haiti has a public health crisis [21]. One of the notable issues contributing to the crisis is the insufficiency of numbers of trained medical professionals, and the weaknesses in the training programs that exist, with only 25 doctors per 100,000 people [22].

The current mission of Project Medishare [14] and Team Broken Earth is to train physicians, nurses, and allied healthcare professionals in the proper medical procedures for trauma, critical care, and rehabilitation in order to provide services on par with the World Health Organization (WHO) critical care standards in Haiti [20]. These specially trained personnel are expected to become leaders in their field and will proceed to train and instruct the next generation of healthcare providers.

Team Broken Earth was founded following the 2010 earthquake with the intention to provide a fully self-contained multidisciplinary team to provide medical aid in a hospital setting. The concept was to provide a team of nurses and doctors in fields including ICU, family practice, pediatrics, emergency medicine, internal medicine, surgery, orthopedic surgery, plastic surgery, anesthesia, and rehabilitation medicine. Since its inaugural trip, multiple full teams from across Canada, with 26–30 professionals per team, have traveled and worked in one of the few trauma critical care hospitals in Port-au-Prince. With the support initially of Memorial University and now other Canadian medical schools residents have become key team members, highlighting bi-directional clinical service learning.

Each team has four distinct tasks: to help local staff provide care to the patients of Port-au-Prince; to provide education to local staff; to work with them to develop safer policies, protocols, and procedures; and finally to provide resources to improve facilities within the hospital infrastructure.

Education remains one of the key mandates for every team. Team members are involved with working closely with local staff to ensure that practical skills are passed on to them through each procedure and facet of patient care. Training takes place through a series of lectures on a variety of topics in trauma and acute pediatric care. In addition the team has provided local simulation training for emergency situations and an orthopedic lecture series.

The team has secured funds to build new infrastructure and water treatment facilities on site. The team sits on the administrative board of the hospital working with local administration and staff to establish working guidelines and a common approach to fundraising, grant writing, and program management. Information and data are also shared with multiple agencies. The team has developed and maintained close relationships with local universities and the Ministry of Health to ensure it is providing a desired partnership that is being delivered in a way that is mutually beneficial.

Beyond direct patient care, the most significant contribution has been teaching and training. Team Broken Earth works with the local doctors and nurses to build their capacity and expertise to deal safely and effectively with patients who require major medical and surgical care. The management of logistics is also vitally important. Each team must ensure maximum effectiveness and efficiency but also safety and security.

Conclusion

When considering the delivery of volunteer trauma care in austere environments, it is essential that more than the immediate needs following a disaster are planned for. Humanitarian organizations must develop a plan to build local capacity and resilience.

Education and training, infrastructure, economics, communications, and interdisciplinary relations should all be considered. Employing this framework will allow for effective continuity of care of trauma patients and ensure a positive legacy.

References

1. Sustainable relief in post-crisis situations: transforming disasters into opportunities for sustainable development in human settlements. UN-Habitat online. http://ww2.unhabitat.org/programmes/rdmu/documents/WUF-Draft.doc. Accessed 1 June 2014.
2. The Johns Hopkins and International Federation of Red Cross and Red Crescent Societies. Public Health Guide for Emergencies. 2007; 24–43. http://www.jhsph.edu/research/centers-and-institutes/center-for-refugee-and-disaster. Accessed 27 Dec 2013.
3. Department of International Development, UK Aid. Promoting innovation and evidenced based approaches to building resilience and responding to humanitarian crises: a DFID strategy paper. 2012; P1–33 Published by the department for International Development, February 2012.
4. United nations general assembly resolution 236 session 44. 1989. http://www.un.org/depts/dhl/resguide/r44_en.shtml. Accessed 27 Dec 2013.
5. Yokohama strategy and plan for action for a safer world: guidelines for natural disaster prevention, preparedness and mitigation. World conference on natural disaster reduction. 1994. http://www.ifrc.org. Accessed 4 June 2014.
6. Hyogo framework for action 2005–2015: building resilience of nations and communities to disasters. World conference on disaster reduction A/CONF.206/6) United Nations. http://www.coe.int/t/dg4/majorhazards/ressources/Apcat2005/APCAT-2005-25-Hyogo-frameworkISDR.pdf. Accessed 4 June 2014.
7. PanAmerican orginizations. Emergency preparedness and disaster relief. www.paho.org/disasters. Accessed 4 June 2014.
8. World Health Organization. World report on road traffic injury prevention: summary. Geneva; 2004.
9. Beveridge M. Surgical training in east africa. Lancet. 2004;363:2196.
10. Pollak A, Born C, et al. Updates on disaster preparedness and progress in disaster relief. J Am Acad Orthop Surg. 2012;20:S54–8.
11. DeGennaro Jr VA, et al. Accelerating surgical training and reducing the burden of surgical disease in Haiti before and after the earthquake. J Craniofac Surg. 2012;23(7 Suppl1):2028–32.
12. Carlson LC, Slobogean GP, Pollak AN. Orthopaedic Trauma Care in Haiti: a cost-effectiveness analysis of an innovative surgical residency program. Value Health. 2012;15(6):887–93.
13. Beveridge M, Howard A, et al. The Ptolemy project: a scalable model for delivering health information in Africa. BMJ. 2003;327:790–3.
14. Project Medishare. www.projectmedishare.org. Accessed 4 June 2014.
15. Strengthening national health emergency and disaster management capacity and resilience of health system. EB128.R10. Agenda Item 4.5. 128th Session Jan 2011.
16. Harvard Humanitarian Initiative. Disaster Relief 2.0: the future od information sharing in humanitarian emergencies. Washington, DC/Berkshire: UN Foundations and Vodafone Foundation Technology Partnership; 2011.
17. Mills E. Sharing evidence on humanitarian relief. BMJ. 2005;331:1485–6.

18. Chalmers I. Government regulation is needed to prevent biased under-reporting of clinical trials. BMJ. 2004;329:462.
19. Disease control priorities project. Promoting essential surgery in low-Income countries: a hidden cost-effective treasure. 2008. www.dcp2.org/file/158/dcpp-surgery.pdf. 4 June 2014.
20. World Health Organization. Global health observatory data repository. 2012. www.who.int/gho/en/. Accessed 5 June 2014.
21. Medecins Sans Frontieres. Annual report 2012. www.msf.ca. Accessed 27 Dec 2013.
22. World Health Organization. Global health observatory data repository. 1998. www.apps.who.int/gho.data/node.main.A1444. Accessed 27 Dec 2013.

Further Reading

Bradt D. Evidence-based-decision-making in humanitarian assistance, 67. London: Humanitarian Practice Network; 2009.

Chen AT, Pedtke A, et al. Volunteer orthopedic surgical trips in Nicaragua: a cost-effectiveness evaluation. World J Surg. 2012;36(12):2802–8.

Darcy J, Hofman A. According to need? Needs assessment and decision-making in humanitarian sector, HPG Report 15 Sept 2003.

de Ville de Goyet C, Moriniere LC. The role of needs assessment in tsunami response. London: Tsunami Evaluation Coalition; 2006.

Debas HT, et al. Surgery. In: Jamison DT et al., editors. Disease control priorities in developing countries. 2nd ed. Washington, DC: World Bank Group; 2006.

Harvey P. Towards good humanitarian government. London: Overseas Development Institute; 2009.

Moon w, Perry H, Baek RM. Is international volunteer surgery for cleft lip and palate a cost-effective and justifiable intervention? A case study from East Asia. World J Surg. 2012;36(12):2819–30.

Tsunami evaluation coalition. Synthesis report: expanded summary: Joint evaluation of the international response to Indian Ocean Tsunami. 2007. www.alnap.org/pool/files/Syn_Report_Sum.pdf.

51

Telemedicine and Smartphones: Is There a Role for Technology in the Austere Environment?

Brian P. Cunningham and Breanna Bolley

Mobile phones are the most ubiquitous type of equipment in the world [1], and smartphones are on pace to be the most rapid adoption of technology ever [2]. There are currently more cell phones in the world than people, and the latest statistics from the UN annual report support what has been a decade-long revolution (Fig. 51.1). The driving force for the continued growth in the number of cellular phones is the developing world. Recent reports illustrate the trend as the worldwide market begins to saturate the demand for mobile devices has fallen to record lows in both developed countries 4 % and developing counties 6 % [3]. The cellular divide between the developed and developing world has shrunken. 77 % of all devices are in the developing world [3]. Other reports show that mobile penetration rates in Africa, Asia-Pacific, and Latin America are expected to reach 82 %, 98 %, and 120 %, respectively, in 2014 [4]. Cisco reports worldwide 48 million people without electricity and landline Internet access have a mobile phone, showing that mobile use outpaces basic infrastructure in many rural and developing areas [5]. An example of this is seen in Senegal, who has been classified in the category of least developed country (LDC). The 48 countries that compose the LDCs comprise more than 880 million people (about 12 % of world population), but account for less than 2 % of world GDP and about 1 % of global trade in goods [3]. Senegal recently reported that mobile penetration in the country has passed the 88 % mark with more than 10 million devices [6].

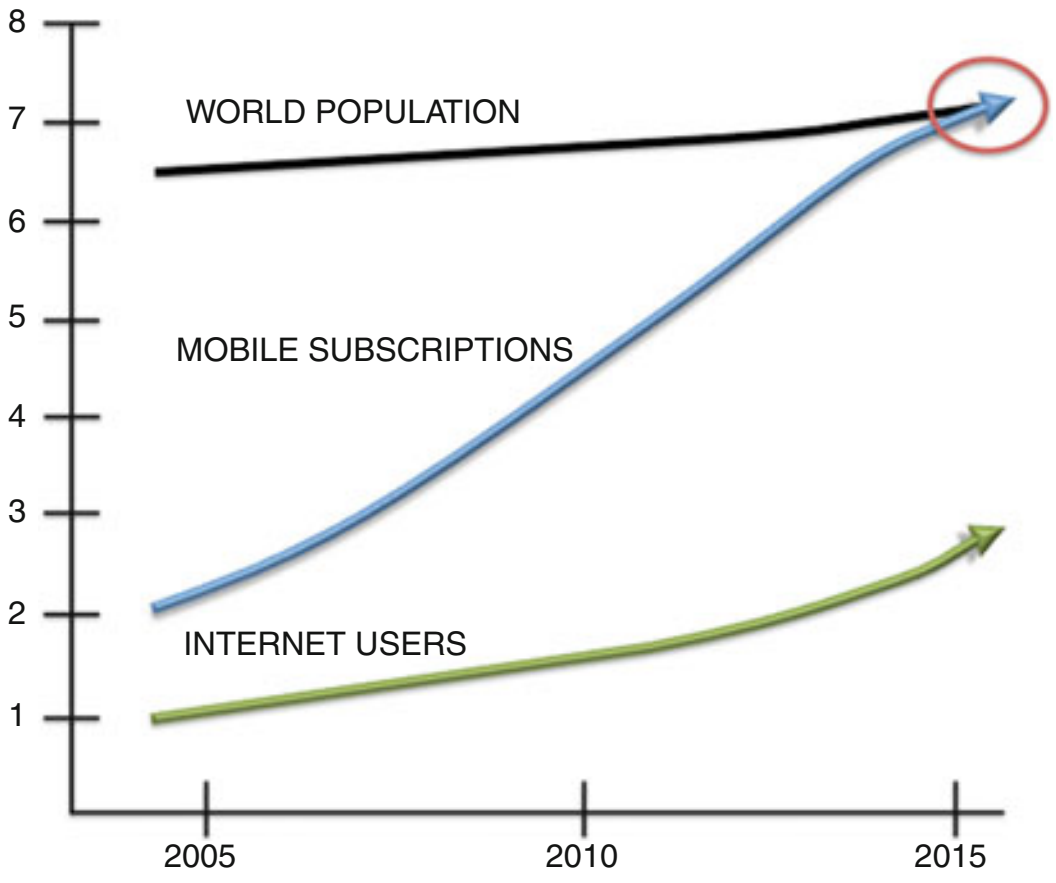

Fig. 51.1 Worldwide mobile subscriptions. Mobile subscriptions will soon surpass the world population according to ITU data

While a growing majority of the world has access to a mobile phone, smartphones make up only 15 % of the global market [7]. Although

---

B.P. Cunningham, MD (✉)
Orthopedic Trauma Institute,
University of California San Francisco (UCSF)
and San Francisco General Hospital (SFGH),
San Francisco, CA, USA
e-mail: brian.cunningham.phx@gmail.com

B. Bolley, RN
CEO, Clinical Outcomes and Data Engineering (CODE)
Technology, Phoenix, AZ, USA

© Springer International Publishing Switzerland 2016
J.D. Robinson (ed.), *Orthopaedic Trauma in the Austere Environment:*
A Practical Guide to Care in the Humanitarian Setting, DOI 10.1007/978-3-319-29122-2_51

technological advances in hardware often occur in developed countries, advances in software are more widespread [1]. A number of software platforms have been developed to close this gap such as biNu, a platform that allows those with feature phones to have a smartphone-like experience through cloud-based apps and services, providing them with immediate access to e-mail, news, books, health information, and social features.

The proliferation of broadband Internet has been seen a more traditional spread across the Atlantic. The classic barriers to stand-alone Internet connection have slowed the penetration into resource-limited areas secondary to a lack of infrastructure and logistical challenges associated with large land areas with well-dispersed small populations. Current estimates show that 39 % of the world's population has Internet access with large discrepancies existing between demonstrated by the 77 % of the developed world compared to 31 % of the developing world with Internet access [3]. The development of 3G wireless Internet has dramatically changed the landscape in resource poor countries. Let us use Senegal again as an example where the country had 528,358 Internet subscribers by the end of June this year – most of them using 3G accounts. There were 375,556 mobile Internet users, and 95,412 people were connected to DSL lines [8]. Both the number of fixed and mobile broadband subscriptions in developing countries surpassed those in developed countries, but penetration rates in the developing world continue to lag behind comparing 27 % and 75 % in the developed world versus 6 % for fixed and 20 % for mobile broadband subscriptions in the developing world. While the proliferation of high-speed Internet continues to make inroads into the developing world, some areas continue to remain isolated like sub-Saharan Africa where the broadband penetration is below 1 % [3].

51.1 Application

The potential for the use of mHealth and telemedicine for orthopedic care of patients in the developing world is extensive, although largely untested and extrapolated from other medical specialties and resource settings (Table 51.1). The introduction and application of clinical decision support via multimedia or interactive discussion with a remote expert demand much more than technology. The success of this process depends on the integration of the system into the environment and society of the geographic location where it is being implemented. This integration process quickly becomes more important than

Table 51.1 Terminology appendix

Telemedicine: Evolved over the last two decades from essentially video conferencing to smartphone application and cloud-based software on mobile or fixed devices. For the purposes of this article, we define telemedicine as the utilization of information and communications technology to provide medical services between patients and providers separated by a geographic distance
mHealth: Although there is no uniform definition of "mHealth," the term generally connotes mobile health as medical and public health practice supported by mobile devices, such as mobile phones, patient monitoring devices, personal digital assistants (PDAs), and other wireless devices; mHealth involves the use and capitalization on a mobile phone's core utility of voice and short messaging service (SMS) as well as more complex functionalities and applications including general packet radio service (PRS), third- and fourth-generation mobile telecommunications (3G and 4G systems), global positioning system (GPS), and Bluetooth technology
eHealth: eHealth covers all uses of network-based information and communication technology to promote longer, healthier lives
Informational privacy: an individual's right to control the acquisition, use, and disclosure of identifiable health data
Confidentiality: refers to the obligations of those persons who receive mHealth data to preserve secrecy of information entrusted to them and use it only as instructed by the patient and/or as necessary to provide the services for which the patient entrusted the information to this person
Information security: physical, technological, or administrative safeguards or tools used to protect identifiable health data from unwarranted access or disclosure, including security of wireless networks, security of devices, application security, back-end systems security, and secure user practices

the technology or infrastructure available. Once the environmental and societal barriers have been overcome, the potential applications broadly fall under one of three categories: clinical decision-making, follow-up, and research. Each category will be briefly discussed with case examples used to illustrate key points.

Clinical decision-making is a collection of information from a patient history, a physician's personal experience, and resources available to improve or augment this experience. A portion of the available resources include a personal network of contacts that a clinician can access when the diagnosis and management of cases exceeds the breadth of their own knowledge and experience. However, personal networks are not always sufficient and have shown many limitations in practice [9]. Telemedicine networks provide access to a wider range of contacts and expertise, not readily available in a personal network, and this is particularly useful for rural or resource-challenged environments. Some argue that telemedicine is becoming a key aspect of providing expert subspecialty medical care in remote settings. The most basic form of this kind of resource reallocation of expertise is the transmission of radiographs and clinical pictures. While digitized radiographs have been reported to have better image transmission, digital pictures of x-rays were still found to have a sensitivity and specificity of 83 % and 80 %, respectively, for fracture diagnosis [10].

Clinical photographs have also been useful in the evaluation of upper extremity trauma, allowing more detailed evaluations and reliable treatment plans [11, 12]. Previous studies have validated the use of telemedicine consultation in the field of orthopedic surgery including a recent report from the US Army. This study reviewed a newly established program consisting of e-mail consultations from deployed health-care providers to subspecialty consultants. A total of 208 consults were reviewed from Iraq, Afghanistan, and Navy medical ships. Of the 170 consults requesting specific treatment recommendations for patients who likely would have been evacuated for further evaluation, surgical intervention or medical evacuation was only recommended in 25 % and 16 % of the consultations, respectively. The authors concluded that deployed health-care providers located in austere combat environments can better determine both the necessity of medical evacuation and appropriate treatments for service members with musculoskeletal injuries when aided by orthopedic surgery consultants, thereby limiting the number of unnecessary medical evacuations [13] (Fig. 51.2).

Numerous questions remain regarding the utility and application of telemedicine to orthopedic surgery in the developing world. One recent study supported and highlighted the potential benefit of telemedicine network in an austere environment. According to the International Monetary

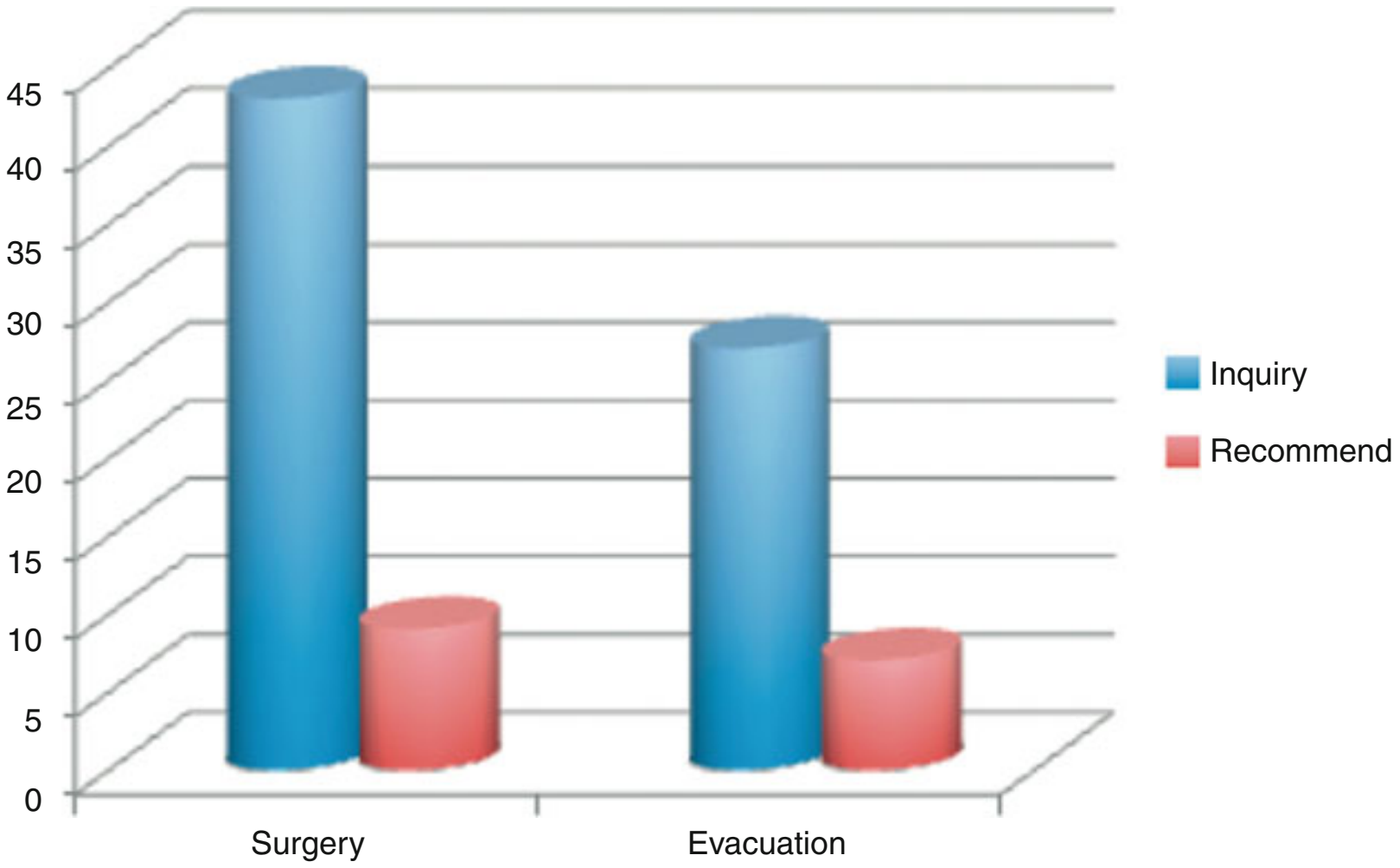

Fig. 51.2 Evacuation rates decrease from 25 to 16 % after telemedicine orthopedic consultation program implementation (From Blank et al. [13]. Used with permission from Data Trace Publishing Company copyright 2011. www.datatrace.com)

Fund (IMF), Djibouti is one of the most poverty-stricken places in Africa, with an unemployment rate estimated to be over 60 %. There is no pediatric orthopedic department, and when pediatric cases arrive, they are either transferred to another country, to a specialized mission team brought in for treatment, or a local orthopedic surgeon manages the patient.

The extreme poverty of part of the population of Djibouti often precludes the first two options. A recent study examined 48 consecutive telemedicine consultations for 39 pediatric orthopedic patients. The results were very encouraging, with the diagnostic question resolved in 90 % of cases. Advice from the expert modified the management in 37 (77 %) consultations. Overall, a change in surgical indication was seen in 18 cases, the surgical technique in 13 cases, and both in six cases. The authors concluded that this study established the feasibility and usefulness of pediatric orthopedic telemedicine consultations in Djibouti [14]. Certainly the evidence is not overwhelming; however, there is growing optimism that with the ubiquity of cellular technology and 3G wireless networks, the ability to implement telemedicine programs will become less resource intense and benefits to improve patient more predicable.

Clinical follow-up remains challenging in all surgical fields particularly in low-income settings or communities without infrastructure to facilitate transportation. The setting in developing world is often the most challenging environment that providers face. Patients often have to travel hundreds of miles where there is little transportation available, typically supported by local or national governmental services. The ability to provide clinical follow-up in a patient's local environment at the lowest possible cost would be transformational for the care of surgical patients in the developing world.

A recent study in Ecuador developed a mobile phone-based program as a method of delivering post-hospitalization care. Over a 1-month period, 32 patients were enrolled and corresponded with a nurse via text messaging or phone calls. 99 % of eligible patients participated and nurses completed 262 contacts with 32 patients, clarifying discharge instructions, providing preventive education, and facilitating clinic appointments. By this method, 87 % of patients were successfully linked to follow-up appointments. The authors concluded that "high levels of patient participation and successful delivery of follow-up services indicate the mobile phone program's acceptability and feasibility" [15].

Another application for mHealth in the developing world is recruitment and human resources. A recent study evaluated the effectiveness of using text messages in the "Smile for You" campaign to provide cleft palate surgery for children in South Africa. A free text message was sent which said "Please Call Me," to identify potential candidates for this free care. The results lead to phone and text message inquiries rising tenfold, and 42 children were identified for surgery – more than three times the number identified during a traditional media campaign lasting 6 weeks [16].

Other studies have also found promising results utilizing mHealth techniques of text message reminders and patient communication specifically citing "significant improvements in compliance with medicine taking, asthma symptoms, HbA1C, stress levels, smoking quit rates, and self-efficacy [17]". Many of these studies show promise; however, they are not directly related to orthopedic surgery. Recently, more promising data has been generated examining follow-up for the treatment of nonunions, a particularly demanding condition regardless of resource setting.

Circular frame treatment for limb reconstruction involves repeated follow-up visits, and a substantial number of these appointments are for pin site review only. A small study out of the UK enrolled five patients who have had their pin sites reviewed remotely using this method. The authors concluded that patients have expressed a high level of satisfaction and that these early results are encouraging [18]. The potential for exclusively utilizing electronic based follow-up, such as text messaging and clinical photographs or video, appears to be both feasible and effective. The system, however, has yet to be thoroughly validated in the developing world setting looking exclusively at orthopedic patients.

Research in the developing world has a number of unique challenges including poor follow-up rates, challenges identifying patients, and the acquisition of meaningful outcome data. Probably the best example of the power of technology in the developing world is the Surgical Implant Generation Network outcome network. This system has been utilized to track almost 35,000 long bone fractures worldwide. The database is called SIGN Online Surgical Database (SOSD). This system can be utilized with mobile technology updating data fields and uploading clinical and radiographic images. While currently no mobile application exist, the rapid expansion of 3G wireless technology has improved access for clinicians and decreased upload times [19].

This database provides basic information for demographic and fracture characteristics, but the clinical outcomes are challenging to extrapolate. A recent study evaluated conducting validated clinical outcome surveys over a free software platform called Skype. Following Microsoft acquisition in 2011, Skype has surged to more than 300 million users worldwide through phones, computers, and tablets. A recent group in Ireland prospectively reviewed all acromioclavicular joint hook plates for lateral-third clavicle fractures over a 5-year period. Functional assessment with Oxford and Constant Shoulder Scores were carried out using Skype.

When compared to outpatient scores taken in office, the results were not clinically significant, confirming that Skype can be used as an alternative to goniometry in this clinical setting. Patients also preferred the use of Skype for follow-up, mainly due to the convenience and cost saving involved. The authors concluded that this study demonstrates the potential for this new technique in providing patients with more options for follow-up [20].

51.2 Privacy and Confidentiality

Protection of health information is often cited as a concern for the utilization of technology for health care in the developing world. Certainly in the United States, most of the population has an understanding of HIPAA (the Health Insurance Portability and Accountability Act of 1996) and the broad sweeping ramification related to the protection of personal health information. The developing world has variable standards on the protection of health information from country to country and even among various local areas [21]. This typically is a synthesis of a number of different inputs, most commonly from the culture of a specific area, the legal system that governs that area and the specific technology in question (Fig. 51.3).

It is also important to understand that mobile security is itself a layered issue. There is security at the level of the application, the mobile operating software, the hardware device, the wireless network, and the wireless carrier, not to mention the servers that transmit, process, and store the data and the security practices of the mobile phone users themselves (e.g., setting strong passwords, storing the phone securely). Deciding where to place the obligation to maintain adequate security is a complex question. There are security options available at each of the layers shown below, including secure networks for transmission of data at the server and network level, encryption and password protection at the device level,

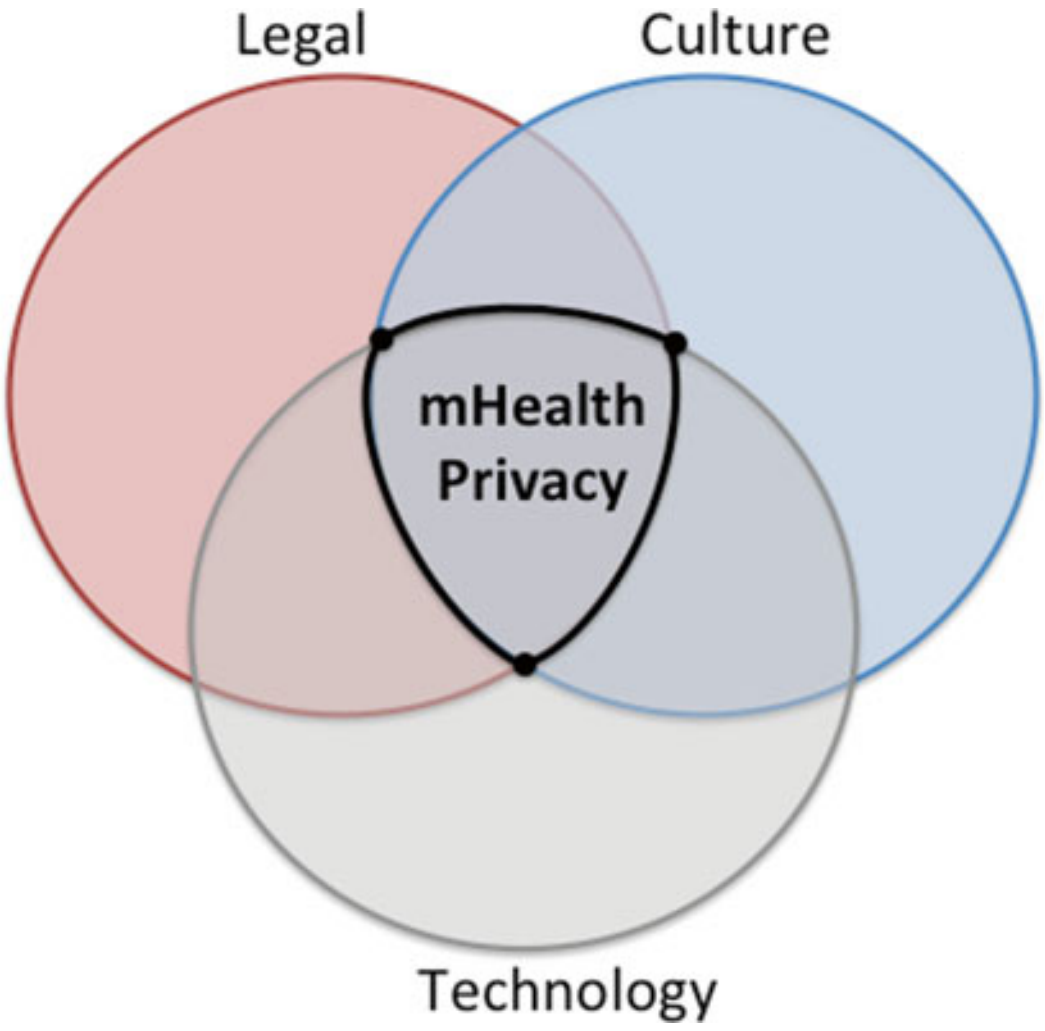

Fig. 51.3 Framework to develop privacy standards for mHealth in the developing world. The development of standards for privacy, particularly with an unregulated entity like mHealth, varies widely between countries in the developing world; however, they consistently are developed from three core components

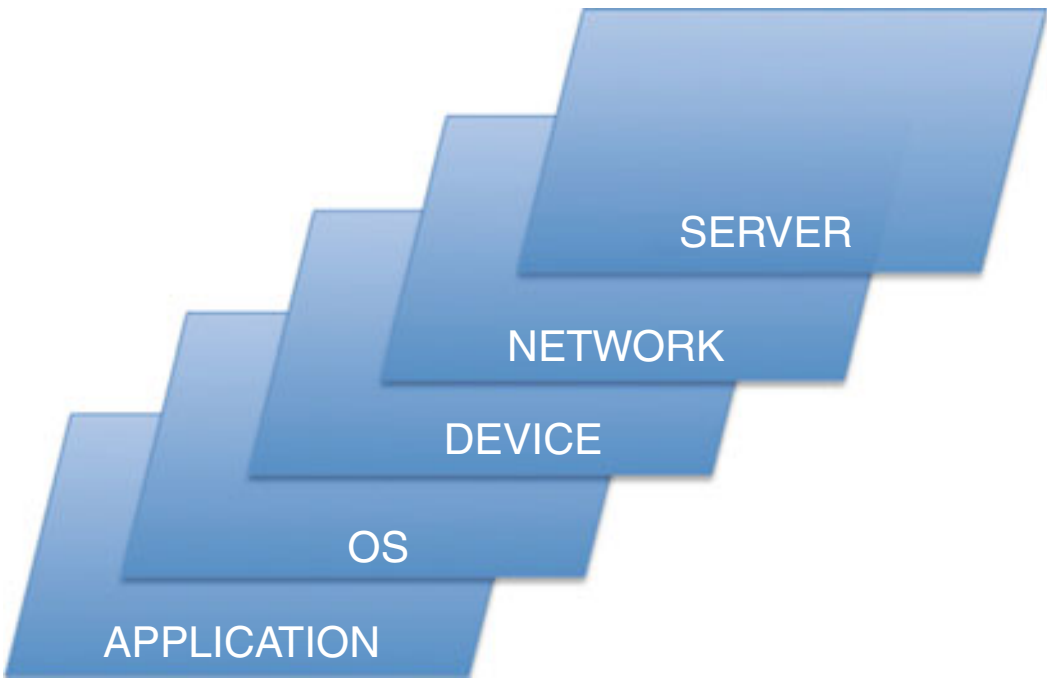

Fig. 51.4 The security that protects mHealth information has built in multiplicity that creates levels of security with overlapping layers of responsibilities with the end result of a fairly sophisticated system often more secure than paper charts in an office

firewalls and access controls at the operating software level, and secure transmission and limited access to other functions of the mobile device at the application level [22] (Fig. 51.4).

Ironically the perception is that the utilization of information technology to improve the delivery of care in the developing world is assumed to increase the risk of a breach in confidential health information or lapse in patient privacy. A recent study from Pakistan suggested that this might not be the case. The principles of informed consent, confidentiality, and privacy are often neglected during patient care in developing countries. Humayun et al. prospectively studied the degree to which physicians met common standard in patient privacy, confidentiality, and informed consent at a large public hospital in Pakistan.

Some degree of informed consent was obtained from only 9.7 % patients in the public hospital, and confidentiality was maintained only in 10.8 %. Informed consent and confidentiality were better practiced in the private compared to the public hospital (p-value < 0.05) [23]. Without question that application of new technology will demand careful attention and analysis, however the perception of increased patient vulnerability may not reflect the reality of a carefully implemented system.

51.3 Future Directions

The question of whether mobile technology and telemedicine can be utilized to improve orthopedic care in the developing world has rapidly transitioned to the question of how best to implement solutions. The rapid expansion of wireless connectivity, cloud data storage solution, and the mobile/smartphone revolution has dramatically closed the digital divide between the developed world and the developing world. Over 90 % of the world's population lives within 2G wireless network area [24]. As the technology becomes more ubiquitous, the barriers transition from technical to cultural. While quality data does not exist in the orthopedic literature, evidence continues to mount from other specialties. One high-quality trial has reported increased adherence to malaria treatment guidelines by health-care workers in Kenya [25]. However, the evidence from controlled trials to date is mostly from high-income countries where the control group "standard care" may be very different to "standard care" available in low- or middle-income countries [26, 27].

Mobile technology-based diagnosis and management support may be most relevant to health-care providers in developing countries. Mobile phones allow the potential for remote follow-up, clinical support, and evidence-based guidance to be delivered to health-care professionals working remotely and in circumstances where senior health-care professional support or other infrastructure is lacking. The solutions are not obvious at this point; however, we must remember the advice of Albert Einstein, "The world we have made as a result of the level of thinking we have done thus far, creates problems we cannot solve at the same level of thinking at which we created them." Telemedicine and mHealth will be the future of health care in the developing world, and exactly how the solutions are developed and implemented remains to be seen.

References

1. Kahn JG et al. Mobile health needs and opportunities in developing countries. Health Aff. 2010;29(2):252–8.
2. DeGusta M. Are smart phones spreading faster than any technology in human history? MIT Business Impact. May 2012.
3. The Millennium Development Goals Report. New York: United Nations; 2013.
4. GSM Association. Touching lives through mobile health: an assessment of the global market opportunity. 2012. http://www.pwc.in/assets/pdfs/telecom/gsma-pwc_mhealth_report.pdf.
5. Janet Maragiolio, Mobiledia, The future of medicine: wiping out third world diseases (10 Feb 2012), at http://www.mobiledia.com/news/127632.html.Harno.
6. Eto D. http://www.itnewsafrica.com/2012/10/senegals-mobile-penetration-passes-88-percent/15 Oct 2012.
7. Martínez-Pérez B. Mobile health applications for the most prevalent conditions by the world health organization: review and analysis. J Med Internet Res. 2013;15(6):e120.
8. IT News Africa. Mobile and telecoms. 15 Oct 2012 http://www.itnewsafrica.com/2012/10/senegals-mobile-penetration-passes-88-percent/.
9. Bonnardot L, Rainis R. Store-and-forward telemedicine for doctors working in remote areas. J Telemed Telecare. 2009;15:1–6.
10. Tangtrakulwanich B, Kwunpiroj W, Chongsuvivatwong V, et al. Teleconsultation with digital camera images is useful for fracture care. Clin Orthop Relat Res. 2006;449:308–12.
11. Buntic RF, Siko PP, Buncke GM, et al. Using the internet for rapid exchange of photographs and x-ray images to evaluate potential extremity replantation candidates. J Trauma. 1997;43(2):342–4.
12. Lam TK, Preketes A, Gates R. Mobile phone photo messaging assisted communication in the assessment of hand trauma. ANZ J Surg. 2004;74:598–602.
13. Blank E et al. Early analysis of the united states Army's telemedicine orthopaedic consultation program. J Surg Orthop Adv. 2011;20(1):50–5.
14. Bertani A et al. Teleconsultation in paediatric orthopaedics in Djibouti: evaluation of response performance. Orthop Traumatol Surg Res. 2012;98(7):803–7.
15. Maslowsky J et al. Engaging patients via mobile phone technology to assist follow-Up after hospitalization in Quito, Ecuador. Telemed J E Health. 2012;18(4):277–83.
16. Vital Wave Consulting. The opportunity of mobile technology for healthcare in the developing world. Washington (DC) and Berkshire (UK): UN Foundation–Vodafone Foundation Partnership; 2009.
17. Krishna S et al. Healthcare via cell phones: a systematic review. Telemed J E Health. 2009;15(3):231–40.
18. Kahn SK, Abraham A. Telesurveillance of circular frame pin sites: one year's experience at a specialist unit. J Telemed Telecare. 2011;17:210–3.
19. Young S. Low infection rates after 34,361 intramedullary nail operations in 55 low- and middle-income countries. Acta Orthop. 2011;82(6):737–43.
20. Good DW. Skype: a tool for functional assessment in orthopaedic research. J Telemed Telecare. 2012;18(2):94–8.
21. Avancha S et al. Privacy in mobile technology for personal healthcare. ACM Computing Surveys. 45(1), Article No. 3.
22. Patient privacy in a mobile world: a framework to address privacy law issues in mobile health. Thomson Reuters Foundation. JUNE 2013 http://www.mhealthalliance.org/images/content/trustlaw_connect_report.pdf.
23. Humayun A et al. Patients' perception and actual practice of informed consent, privacy and confidentiality in general medical outpatient departments of two tertiary care hospitals of Lahore. BMC Med Ethics. 2008;9:14.
24. The World in 2011: ITC Facts and Figures, International Telecommunications Unions (ITU), Geneva, 2011. http://www.itu.int/ITU-D/ict/facts/2011/material/ICTFactsFigures2011.pdf.
25. Zurovac D, Sudoi RK, Akhwale WS, Ndiritu M, Hamer DH, et al. The effect of mobile phone text-message reminders on Kenyan health workers' adherence to malaria treatment guidelines: a cluster randomised trial. Lancet. 2011;378:795–803.
26. Free C, Phillips G, Watson L, Galli L, Felix L, et al. The effectiveness of mobile-health technologies to improve health care service delivery processes: a systematic review and meta-analysis. PLoS Med. 2013;10(1):e1001363.
27. Harno K, Arajarvi E, Paavola T, et al. Clinical effectiveness and cost analysis of patient referral by videoconferencing in orthopaedics. J Telemed Telecare. 2001;7(4):219–25.

52 Military Orthopedic Trauma Experience: Civilian Applications in an Austere Environment

Tad L. Gerlinger

US military forces have been engaged in combat operations in Afghanistan, Iraq, and Africa since 2001. These forces have experienced penetrating, blast, and burn injuries from modern and improvised weapons, resulting in very severe injuries. Advances in military medicine have improved survival rates to the highest level ever attained, but this has subsequently presented unique challenges in reconstructive and rehabilitative care. These lessons learned can be applied to the care of civilian casualties in war zones, natural disasters, and the austere environments of developing countries (Fig. 52.1). Civilian providers employed in these environments can now benefit from the wealth of severe trauma experience of military orthopedic surgeons.

52.1 Data Collection Systems

In order to develop a list of lessons learned, and to develop evidence-based treatment protocols with regard to the care of those injured in war and disaster, it is essential to first collect data and then analyze it. Unfortunately, the nature of disasters and wartime health care is frequently not amenable to continuity of patient care and standard data gathering. Surgeons are frequently temporary volunteers and patient follow-up is unreliable. Most scientific reports are epidemiologic in nature, and case examples prevail for treatment papers. Very little outcomes research is reported and it is almost entirely short term.

The US military employs several data collection tools. The Department of Defense Trauma Registry, Armed Forces Medical Examiner data set, Department of Defense Medical Metrics (M2) database, Military Orthopaedic Trauma Registry (MOTR) based at Brooke Army Medical Center, and the US Army Institute of Surgical Research's Joint Theater Trauma Registry (JTTR) are somewhat overlapping databases that have allowed analysis of illness, wounding patterns, injuries, and outcomes. Of these, MOTR is specific to orthopedic injuries, procedures, and outcomes and has led to sound science in the treatment of extremity war trauma [1].

Employment of these data collection tools and the development of registries to specifically track extremity trauma, treatment, and outcomes is potentially the greatest lesson learned from the military. Surgeons are obligated to log and track patients and their injuries to ensure the greatest quality of care through evidence-based medicine. The advent of handheld electronic devices and user-friendly database software has made this significantly easier; however, it still requires dedication on the part of the medical team and leadership emphasis on its importance.

T.L. Gerlinger, MD
Department of Orthopaedic Surgery,
Rush University Medical Center, Chicago, IL, USA
e-mail: tadgerlinger@me.com

© Springer International Publishing Switzerland 2016
J.D. Robinson (ed.), *Orthopaedic Trauma in the Austere Environment: A Practical Guide to Care in the Humanitarian Setting*, DOI 10.1007/978-3-319-29122-2_52

Fig. 52.1 Land mine injury to the lower extremity

52.2 Damage Control Orthopedics

Damage control orthopedics, to include early debridement, external fixation, and evacuation for definitive care, has successfully been employed and studied by military surgeons in the recent conflicts. Debridement is the most basic of surgical techniques in dealing with traumatic wounds. However, it is difficult to quantify, study, and teach.

Animal models have been developed to study the effects of *early debridement, irrigation, and antibiotic administration in open wounds*. Studies using these models have demonstrated the effectiveness of this technique and validated the necessity of the basic concepts of early surgical debridement of wounds [2, 3]. Further research has demonstrated the deleterious effects of high-pressure irrigation on traumatic, contaminated wounds. This has been further evaluated with animal studies verifying these results and suggesting that low-pressure irrigation with basic cystoscopy tubing is less likely to create a rebound effect in the bacterial presence in wounds that sees a delayed increase in wound bacterial colony counts after higher-pressure irrigation [4–6].

The *biomarkers* procalcitonin and cytokine have been identified as potentially helping determine the timing of definitive wound closure [7]. Although not likely available in the austere environment, advances in technology may someday allow for handheld blood analysis devices to assist with the determination of when traumatic wounds may be optimally closed.

External fixation has long been employed in the treatment of extremity trauma and fracture care. Some controversy exists in the austere environment employment of these devices, and data from the wartime use of temporary external fixation in damage control has been evaluated. It appears that temporary external fixation is safe to utilize in the combat environment and may likely be safely applied in many austere environments [8] (Fig. 52.2).

Fasciotomy for the prophylactic and therapeutic treatment of leg compartment syndrome in extremity trauma is a mainstay of military orthopedics. Decompression of damaged muscle compartments, with or without fracture, by fasciotomy prevents progression of soft tissue injury in these high-energy trauma wounds (Fig. 52.3). This treatment is the standard of care in civilian trauma as well as combat settings.

Fig. 52.2 External fixation for a supracondylar femur fracture due to a Gun Shot Wound (GSW)

Fig. 52.3 Lower extremity fasciotomy

The use of either single- or double-incision fasciotomy of the foot for prophylactic treatment of foot compartment syndrome is controversial and has been evaluated by military surgeons in the recent conflicts. It appears that foot fasciotomy is beneficial in the face of major combat trauma to the foot with severe swelling and unremitting pain. Prophylactic fasciotomy of the foot in this setting is controversial, and the data remains inconclusive as to its safety and efficacy in preventing morbidity. The recommendation is that prophylactic fasciotomy of the foot be performed on a case by case basis, depending on factors that include access to continued care and definitive surgery [9].

Thigh compartment syndrome is reported to have a significant mortality in the civilian literature, which is likely related to the associated injury patterns and not simply due to the compartment syndrome in isolation. Thigh compartment syndromes, as reported in combat casualties, carried significant morbidity which is consistent with that reported in civilian trauma publications and appears to confirm the significance of this injury [10]. The experience of military surgeons confirms that a high index of suspicion should remain for the development of compartment syndrome in the combat casualty with extremity trauma. Similar experiences can be expected by surgeons serving in the austere environment treating high-energy extremity trauma.

Military surgeons have extensively used *negative pressure wound dressings* in the treatment of combat wounds since their advent. Combat wounds routinely see early debridement, extremity stabilization through external fixation, and the application of negative pressure wound dressings. Military studies of this treatment protocol suggest that this early application on open combat wounds reduces subsequent treatment complications and may lower the rate of infection [11, 12].

Evacuation of casualties according to a theater evacuation policy optimizes return to duty for service members and facilitates efficient combat casualty care. Personnel requiring care that prevents them from effectively returning to their units for duty are evacuated to the level of care required to definitively care for their injuries. The safety of the temporary external fixation and negative pressure wound dressings used in damage control, during aeromedical evacuation, has been drawn into question. Furthermore, concern for the effects of altitude on the development of compartment syndrome has been raised. Military studies demonstrate that negative pressure dressings may be safely used in flight and that they do not appear to harm wounds [13, 14]. Furthermore, three animal studies conducted by military researchers demonstrated that altitude may subtly affect muscle physiology; however, there is no evidence that it causes compartment syndrome in injured or uninjured muscle [15–17].

52.3 Definitive Care

The improvements in combat casualty care and early medical evacuation have led to increased survivability. Military orthopedic surgeons have been faced with significant reconstructive challenges as a result. These challenges include timing of definitive care, management of bone loss, effective antibiotic treatment, and decisions regarding limb salvage versus amputation [18]. Level one and two data on the timing of soft tissue coverage for extremity wounds are lacking; however, guidelines have been developed based on military and civilian trauma data from the best information available. With 15 % of military combat extremity wounds developing osteomyelitis, aggressive management is required. The guidelines suggest that early debridement, application of antibiotic-impregnated materials, and administration of antibiotics to include gram-negative coverage, as well as early soft tissue coverage, are beneficial for these high-energy extremity injuries [19]. It is reasonable to assume that the experience of surgeons in the austere environment will be similar.

Bone loss is a significant challenge in the limb reconstruction of combat casualties and is a determining factor in the decision of limb salvage versus amputation (Fig. 52.4). Bone transport, segmental grafting, and biomaterial application are treatment options, all with unique risks and benefits. Bone transport is a challenging, resource intense process that requires a surgeon experienced in the technique, a medical system able to support this treatment, frequent and reliable patient follow-up, and continuity of care. Although employed at some tertiary military treatment facilities, this technique may be difficult to safely employ in the austere environment with its limited resources and challenges in continuity of care [20, 21].

Standard bone-grafting techniques, as well as the use of biomaterials, are also options and all have been collectively discussed in the military's experience with limb salvage after combat trauma, the Military Extremity Trauma Amputation/Limb Salvage (METALS) study [21]. Most importantly, the METALS study suggests that better functional outcomes are achieved through


[redacted]

Fig. 52.4 High-velocity GSW resulting in segmental bone loss

amputation rather than limb salvage. Although the study had a limited response rate that may imply bias, patients undergoing amputation had higher Short Musculoskeletal Functional Assessment (SMFA) scores in all domains and lesser incidence of post-traumatic stress disorder (PTSD) and were more likely to be involved in sports activities [21]. The recent development of sophisticated lower extremity braces may impact the decision for limb salvage. The Intrepid Dynamic Exoskeletal Orthosis (IDEO), when used with a comprehensive return to run (RTR) clinical pathway, may improve functional outcomes and physical performance and decrease pain [22]. Furthermore, use of the RTR clinical pathway was responsible for allowing 19.5 % of wounded soldiers to return to a high enough functional level to deploy overseas [23].

Management of segmental bone loss continues to be a focus of military extremity trauma research. The ideal material to use in these injuries will facilitate limb salvage and would be effective in a contaminated wound. These studies are ongoing, and the ideal material has not been identified. Surgeons in the austere environment need to consider many factors to include efficiency of resources, continuity of care, access to prostheses, and societal and cultural factors when deciding limb salvage and amputation.

52.4 Antibiotic Management

Acinetobacter took an early center stage as the pathogen of concern in the recent conflicts. Subsequent research revealed that the multidrug resistant organism might have been a result of broad-spectrum antibiotic treatment and nosocomial transmission in the combat wounded [24]. Military experts now recommend that early treatment consists of standard antibiotic coverage for extremity wounds and that late infections be treated based on culture-driven coverage. Infection control remains important during the care of the combat casualty, and the use of *indiscriminate broad-spectrum antibiotics is discouraged* [19].

52.5 Amputee Care

Lower extremity amputation has long been associated with combat trauma (Fig. 52.5). Optimizing function of lower extremity amputations is multifactorial and remains a focus of study in warrior

Fig. 52.5 Acute amputation for land mine injury

care. Stabilizing the residual fibula through the use of a bridging synostosis to the tibia, the Ertl technique, has been studied in the contemporary care of the military amputee. Comparing amputees who received a bridge synostosis with those treated with non-bone-bridging transtibial combat-related amputations, there appears to be no difference in functional outcomes [25]. The results in the young, active-duty military population managed with transtibial amputation may assist surgeons in the austere environment when caring for a similar patient population.

Reoperation rates were also studied in the care of the combat lower extremity amputee. It appears that the need to treat urgent surgical complications in the combat-wounded amputee was similar to previous reports evaluating trauma-related amputations. Furthermore, patients with symptomatic amputations can expect a decrease in pain and improvement in ambulatory status when treated surgically [26]. The decision for amputation in severe hindfoot injuries as a result of combat trauma is a difficult. When comparing hindfoot reconstruction or ankle fusion to transtibial amputation, military researchers found that return to function rates appeared better in the reconstruction and fusion patients. The data also suggested that this group had more psychiatric conditions and that both groups had relatively poor return to military duty [27].

Fluid collections or seromas can represent a treatment dilemma in the care of combat-related amputations. Military surgeons studying this condition reported that these fluid collections in the immediate postoperative period became smaller and less frequent over time. Their recommendations were that amputations not presenting with erythema or wound drainage had little indication for surgical treatment and that imaging is likely unnecessary [28].

52.6 Heterotopic Ossification

Heterotopic ossification (HO) is commonly seen in the high-energy combat wound, presenting in 64 % of casualties. It is defined as the formation of mature lamellar bone in nonosseous tissue. The residual limbs of military amputees see a high incidence of HO, and military surgeons are presented with decreased function and increased disability in these patients. It is thought that the development of HO follows a similar course in the traumatized tissues ending in endochondral ossification. HO prophylaxis is difficult to employ in the combat casualty. Most commonly, symptomatic HO is addressed after definitive reconstruction and rehabilitation of the patient. Surgical excision appears to be associated with low recurrence rates in the combat wounded [29].

A study by military researchers found that risk factors for HO include high Injury Severity Score (ISS) and injury location to the shoulder, hip, and femur. The elbow, forearm, and hip were the anatomic locations with the greatest incidence of symptomatic HO and subsequently were the most commonly addressed with surgical excision. The results of excision in this study were somewhat inconsistent. They also reported that HO did not routinely occur in open high-grade tibia fractures [30]. HO remains a topic of significant interest for military researchers and is the source of ongoing research [31].

Conclusion

The experience of military orthopedic surgeons in caring for combat casualties from the conflicts in Afghanistan and Iraq has reconfirmed the importance of early surgical treatment of war-injured extremities. The mainstays of debridement, extremity stabilization, and fasciotomy remain paramount. The development of data collection tools to track extremity trauma, treatment, and outcomes has allowed for lessons learned to be developed from this military medical experience. Advances have been made in antibiotic treatment, definitive reconstruction, amputee care, and the understanding of HO. The lessons learned can be applied to the care of civilian casualties in war zones, natural disasters, and the austere environments of developing countries. Civilian providers employed in these environments can learn from the experiences of military orthopedic surgeons.

References

1. Cross JD, Wenke JC, Ficke JR, Johnson AE. Data-driven disaster management requires data: implementation of a military orthopaedic trauma registry. J Surg Orthop Adv. 2011;20(1):56–61.
2. Brown KV, Walker JA, Cortez DS, Murray CK, Wenke JC. Earlier debridement and antibiotic administration decrease infection. J Surg Orthop Adv. 2010;19(1):18–22.
3. Penn-Barwell JG, Murray CK, Wenke JC. Early antibiotics and debridement independently reduce infection in an open fracture model. J Bone Joint Surg Br. 2012;94(1):107–12.
4. Owens BD, Wenke JC. Early wound irrigation improves the ability to remove bacteria. J Bone Joint Surg Am. 2007;89(8):1723–6.
5. Petrisor B, Sun X, Bhandari M, FLOW Investigators, et al. Fluid lavage of open wounds (FLOW): a multicenter, blinded, factorial pilot trial comparing alternative irrigating solutions and pressures in patients with open fractures. J Trauma. 2011;71(3):596–606.
6. Owens BD, White DW, Wenke JC. Comparison of irrigation solutions and devices in a contaminated musculoskeletal wound survival model. J Bone Joint Surg Am. 2009;91(1):92–8.
7. Forsberg JA, Elster EA, Andersen RC, et al. Correlation of procalcitonin and cytokine expression with dehiscence of wartime extremity wounds. J Bone Joint Surg Am. 2008;90(3):580–8.
8. Possley DR, Burns TC, Stinner DJ, Murray CK, Wenke JC, Hsu JR, Skeletal Trauma Research Consortium. Temporary external fixation is safe in a combat environment. J Trauma. 2010;69 Suppl 1:S135–9. doi:10.1097/TA.0b013e3181e44fcb. PMID: 20622607.
9. Kirk KL, Hayda R. Compartment syndrome and lower-limb fasciotomies in the combat environment. Foot Ankle Clin. 2010;15(1):41–61.
10. Masini BD, Racusin AW, Wenke JC, Gerlinger TL, Hsu JR. Acute compartment syndrome of the thigh in combat casualties. J Surg Orthop Adv. 2013;22(1):42–9. PMID: 23449054.
11. Stannard JP, Volgas DA, Stewart R, McGwin Jr G, Alonso JE. Negative pressure wound therapy after severe open fractures: a prospective randomized study. J Orthop Trauma. 2009;23(8):552–7.
12. Leininger BE, Rasmussen TE, Smith DL, Jenkins DH, Coppola C. Experience with wound VAC and delayed primary closure of contaminated soft tissue injuries in Iraq. J Trauma. 2006;61(5):1207–11.
13. Pollak AN, Powell ET, Fang R, Cooper EO, Ficke JR, Flaherty SF. Use of negative pressure wound therapy during aeromedical evacuation of patients with combat-related blast injuries. J Surg Orthop Adv. 2010;19(1):44–8.
14. Fang R, Dorlac WC, Flaherty SF, et al. Feasibility of negative pressure wound therapy during intercontinental aeromedical evacuation of combat casualties. J Trauma. 2010;69(1 Suppl):S140–5.
15. Ritenour AE, Christy RJ, Roe JL, et al. The effect of a hypobaric, hypoxic environment on acute skeletal muscle edema after ischemia-reperfusion injury in rats. J Surg Res. 2010;160(2):253–9.
16. McGill R, Jones E, Robinson B, Kryzak T, Kadrmas W. Correlation of altitude and compartment pressures in porcine hind limbs. J Surg Orthop Adv. 2011;20(1):30–3.

17. Kalns J, Cox J, Baskin J, Santos A, Odland R, Fecura Jr S. Extremity compartment syndrome in pigs during hypobaric simulation of aeromedical evacuation. Aviat Space Environ Med. 2011;82(2):87–91.
18. Andersen RC, D'Alleyrand JC, Swiontkowski MF, Ficke JR, Extremity War Injuries VIII Session Moderators. Extremity war injuries VIII: sequelae of combat injuries. J Am Acad Orthop Surg. 2014;22(1):57–62. doi:10.5435/JAAOS-22-01-57. PMID: 24382880.
19. Murray CK, Obremskey WT, Hsu JR, et al. Prevention of combat-related infections guidelines panel: prevention of infections associated with combat-related extremity injuries. J Trauma. 2011;71(2 Suppl 2):S235–57.
20. McHale KA, Ross AE. Treatment of infected tibial nonunions with debridement, antibiotic beads, and the Ilizarov method. Mil Med. 2004;169(9):728–34.
21. Doukas WC, Hayda RA, Frisch HM, Andersen RC, Mazurek MT, Ficke JR, Keeling JJ, Pasquina PF, Wain HJ, Carlini AR, MacKenzie EJ. The Military Extremity Trauma Amputation/Limb Salvage (METALS) study: outcomes of amputation versus limb salvage following major lower-extremity trauma. J Bone Joint Surg Am. 2013;95(2):138–45.
22. Bedigrew KM, Patzkowski JC, Wilken JM, Owens JG, Blanck RV, Stinner DJ, Kirk KL, Hsu JR, Skeletal Trauma Research Consortium (STReC). Can an integrated orthotic and rehabilitation program decrease pain and improve function after lower extremity trauma? Clin Orthop Relat Res. 2014;472: 3017–25.
23. Patzkowski JC, Owens JG, Blanck RV, Kirk KL, Hsu JR, Skeletal Trauma Research Consortium (STReC). Deployment after limb salvage for high-energy lower-extremity trauma. J Trauma Acute Care Surg. 2012;73(2 Suppl 1):S112–5.
24. Wenke JC, Hsu JR, Extremity War Injuries VII Research Panel. Axioms altered with research. J Am Acad Orthop Surg. 2012;20 Suppl 1:S88–93.
25. Keeling JJ, Shawen SB, Forsberg JA, Kirk KL, Hsu JR, Gwinn DE, Potter BK. Comparison of functional outcomes following bridge synostosis with non-bone-bridging transtibial combat-related amputations. J Bone Joint Surg Am. 2013;95(10):888–93. doi:10.2106/JBJS.L.00423.
26. Tintle SM, Shawen SB, Forsberg JA, Gajewski DA, Keeling JJ, Andersen RC, Potter BK. Reoperation after combat-related major lower extremity amputations. J Orthop Trauma. 2014;28(4):232–7.
27. Sheean AJ, Krueger CA, Hsu JR. Return to duty and disability after combat related hind foot injury. J Orthop Trauma. 2014;28:e258–62. PMID: 24694555.
28. Polfer EM, Hoyt BW, Senchak LT, Murphey MD, Forsberg JA, Potter BK. Fluid collections in amputations are not indicative or predictive of infection. Clin Orthop Relat Res. 2014;472:2978–83.
29. Forsberg JA, Potter BK. Heterotopic ossification in wartime wounds. J Surg Orthop Adv. 2010;19(1):54–61. Review.
30. Ahmed SI, Burns TC, Landt C, Hayda R. Heterotopic ossification in high-grade open fractures sustained in combat: risk factors and prevalence. J Orthop Trauma. 2013;27(3):162–9.
31. Potter BK, Forsberg JA, Davis TA, et al. Heterotopic ossification following combat-related trauma. J Bone Joint Surg Am. 2010;92(2 Suppl):74–89.

Index

© Springer International Publishing Switzerland 2016
J.D. Robinson (ed.), *Orthopaedic Trauma in the Austere Environment: A Practical Guide to Care in the Humanitarian Setting*, DOI 10.1007/978-3-319-29122-2