

# New Concepts on Abdominoplasty and Further Applications

Juarez M. Avelar  
*Editor*

 Springer

# New Concepts on Abdominoplasty and Further Applications

Juarez M. Avelar  
Editor

# New Concepts on Abdominoplasty and Further Applications

 Springer

*Editor*

Juarez M. Avelar  
Head of the Brazilian Scientific  
Institute of Plastic and  
Reconstructive Surgery  
Al Gabriel Monteiro da Silva  
São Paulo  
SP  
Brazil

The original version of this book was revised. An erratum to this book can be found at DOI [10.1007/978-3-319-27851-3\\_39](https://doi.org/10.1007/978-3-319-27851-3_39)

ISBN 978-3-319-27849-0                      ISBN 978-3-319-27851-3 (eBook)  
DOI 10.1007/978-3-319-27851-3

Library of Congress Control Number: 2016947075

© Springer International Publishing Switzerland 2016

This work is subject to copyright. All rights are reserved by the Publisher, whether the whole or part of the material is concerned, specifically the rights of translation, reprinting, reuse of illustrations, recitation, broadcasting, reproduction on microfilms or in any other physical way, and transmission or information storage and retrieval, electronic adaptation, computer software, or by similar or dissimilar methodology now known or hereafter developed.

The use of general descriptive names, registered names, trademarks, service marks, etc. in this publication does not imply, even in the absence of a specific statement, that such names are exempt from the relevant protective laws and regulations and therefore free for general use.

The publisher, the authors and the editors are safe to assume that the advice and information in this book are believed to be true and accurate at the date of publication. Neither the publisher nor the authors or the editors give a warranty, express or implied, with respect to the material contained herein or for any errors or omissions that may have been made.

Printed on acid-free paper

This Springer imprint is published by Springer Nature  
The registered company is Springer International Publishing AG Switzerland

# Foreword

Body contour deformities have kept plastic surgeons busy since the beginning of our specialty. Indeed, the simple resection of excess skin from the lower abdomen can be cited as the first true dermolipectomy. The aim initially was simply to eliminate unwanted weight and skin folds, and alleviate complaints such as bad posture and skin rash. As fashion changed, especially swimwear, the female body became more revealed, and surgeons had to adapt their approach to keep scars hidden and less extensive. Plication of the rectus abdominis muscles allowed for correction of weakness of the abdominal wall. This reinforcement, done by plication of the rectus abdominis muscles without opening of the fascia, was emphasized by myself when I published my own approach, in 1967, and assured a return of function to a flaccid abdominal wall. With the advent of suction-assisted lipectomy, the surgeon was finally able to sculpture the abdominal region, including the flanks and posterior torso.

Currently, as this book attests, we have witnessed the revival of those procedures, mainly in patients who have undergone great weight loss. Here the reader will find all the different approaches, clearly presented by surgeons who are leaders in their field of work. I am certain that this book will prove to be an important contribution to plastic surgeons who intend to correct abdominal deformities, and I congratulate Dr. Juarez M. Avelar and his co-authors for their effort and dedication.

Ivo Pitanguy, MD  
Head Professor, Plastic Surgery, of the Pontifical Catholic University  
and the Carlos Chagas Institute of Post-Graduate Medical Studies.  
Member, the Brazilian Society of Plastic Surgery, the American Society of  
Aesthetic Plastic Surgery, visiting professor of the International  
Society of Aesthetic Plastic Surgery. FICS, FACS.

# Foreword

Abominoplasty is one of the most common surgical procedures in our specialty. Since many years ago, several techniques have been described to correct localized adiposity, skin flaccidity, and rectus diastasis. And many new advances has been published during the last years as we have seen in this outstanding book edited by Dr. Juarez M. Avelar, representing one of the most important surgeons from Brazil in this field of body contouring.

Dr. Avelar has published many papers about abdominoplasty, but three of them have been considered landmarks in body contouring. The first one was published in 78 [1] in one of the first Aesthetic Plastic Journal issues about his “Mercedes” umbilicoplasty without external scar. At that time, it was a great contribution and is nowadays extensively used by many surgeons. The second paper was an extensive histo-anatomical research done in the subcutaneous abdominal fat. This study allowed all of us to understand the panniculous adiposity levels and the neurovascular bundles of the abdomen wall, and it was the first step to open the window to the lipoabdominal techniques. This was published in the APS Journal in 1989 [2] about abdominal lipodystrophy earning from the Aesthetic Plastic Surgery Journal (ISAPS official journal) the first prize for outstanding research paper in the Year of 1988.

The third one and certainly the most important paper was presented and published in 1999 [3–5] and in 2000 [6] – and so the lipoabdominoplasty technique started a new era for body contouring surgery.

The contribution to the lipoabdominoplasty technique of Dr. Avelar is unquestionable combining assisted liposuction without undermining the abdomen wall, preserving Scarpa’s fascia. From this principle, many other surgeons started with similar procedures like Doctors Ricardo Baroudi [7], João Erfon, Farid Hakme [8], Ronildo Storck, Oswaldo Saldanha [9], Sebastião N. Guerra [10], Carlos Uebel [11–14], Claudio Cardoso [15], etc. – only to give a few of them.

Other important chapters can be appreciated in this book – the “history of abdominoplasty” by Dr. Ramil Sinder describing different techniques published in the last 100 years, to post-bariatric surgeries and other approaches to the abdomen wall. And at least the chapter of Dr. Marco Aurelio Faria Correa describing the robotic approach – a pioneer in this field. Dr. Correa started many years ago using

the endoscopy approach to rectus diastasis abdomen wall plication and now surprising us with this new tool – really something for the modern surgical practice. His ability to play with this equipment will certainly improve many other procedures in the future.

This book is a reference for experienced plastic surgeons but certainly a remarkable textbook for residents and young plastic surgeons who want to learn and to get new approaches and techniques written by an outstanding faculty group from our country and abroad. Pictures and drawings are of excellent quality, and I can congratulate Dr. Juarez M. Avelar and all their contributors for the excellence of the chapters. Really, this is a book to keep in our libraries forever.

Carlos Oscar Uebel, MD, PhD  
Professor and Chair Division of Plastic Surgery  
PUCRS University – Porto Alegre, Brazil

## References

1. Avelar JM (1978) Abdominoplasty – systematization of a technique without external umbilical scar. *Aesthetic Plast Surg* 2:141–151
2. Avelar JM (1989) Regional distribution and behavior of the subcutaneous tissue concerning selection and indication for liposuction. *Aesthetic Plast Surg* 13:155–165
3. Avelar JM (1999) Uma nova técnica de abdominoplastia – sistema vascular fechado de retalho subdérmico dobrado sobre si mesmo combinado com lipoaspiração (A new technique for abdominoplasty – Closed vascular system of subdermal flap folded over itself combined to liposuction). *Rev Bras Cir* 88/89(1/6):3–20
4. Avelar JM (1999) Novos conceitos para abdominoplastia (New concepts for abdominoplasty). Paper presented at the 36th Congress of the Brazilian Society of Plastic Surgery. Rio de Janeiro, November 1999
5. Avelar JM (1999) Abdominoplastia: Nuevos conceptos para una nueva técnica (Abdominoplasty: new concepts for a new technique). XXVI Annual International Symposium of Aesthetic Plastic Surgery, Chairman: Prof. Jose Guerrerosantos, Puerto Vallarta, pp 10–13
6. Avelar JM (2000) A New Technique for abdominoplasty subdermal flap folded over itself. The XV ISAPS Congress, Tokyo – April
7. Baroudi R, Ferreira CAAP (1998) Seroma: how to avoid it and how to treat it. *Aesthet Surg J* 18:439–441
8. Hakme F (1985) Technical details in the liposuction associated with liposuction. *Rev Bras Cir Plást* 75:331
9. Saldanha OR (2003) Lipoabdominoplasty with selective and safe undermining. *Aesthet Plast Surg* 27(4):322–327

10. Guerra SN (2013) Liposuction of upper back/bra rolls; Body Contouring and Liposuction. Elsevier. Chapter 15. pp 149–165
11. Uebel CO (1987) Miniabdominoplasty – a new approach for the body contouring. Annals of the 9th Congress of the International Society of Aesthetic Surgeons, New York
12. Uebel CO (1994) Cirurgia do abdomen associada à lipoescultura. In: Tourniex AAB (ed) Atualização em Cirurgia Plástica Estética. Robe Editorial, São Paulo. pp 483–489
13. Uebel CO (2004) Minilipoabdominoplasty – its evolution. Lipoabdominoplasty. Di Livros, São Paulo, pp 73–85
14. Uebel CO (2009) Lipoabdominoplasty: revisiting the superior pull-down abdominal flap and new approaches. *Aesthet Plast Surg* 33(3):366–376
15. Castro CC, Cupello A, Cintra H (1987) Limited incisions in abdominoplasty. *Ann Plast Surg* 19:436



# Preface

Upon my postgraduation study with Professor Ivo Pitanguy at 38th Infirmary of Santa Casa da Misericordia, and also I was resident at his Clinic of Plastic Surgery in Rio de Janeiro, I took an important decision to visit other renowned professors of plastic surgery. So during one year, I was in fellowship with Ralph Millard (Miami University), John Converse, Thomas Rees, Blair Rogers (New York University), Paul Tessier (Foch Hospital), Claude Dufurmentel, Roger Mouli (Saint Louis Hospital), Raul Tubiana (Victor Hugo Clinic) all in Paris (France), Davis Mathews at Children Hospital in London (England), John Mustarde, Chanisburn Hospital in Glasgow (Scotland). So, after 4 years of training and fellowship, I concluded that aesthetic surgery of the abdomen wall still presented some surgical problems as well as some challenges ever since Kelly in 1899 published the first abdominoplasty. Although remarkable contributions were introduced to this field until 1974 when I started my professional activities, I felt that some topics still posed challenges to all plastic surgeons.

Nevertheless, the new umbilical region after abdominoplasty quite often used to be ungraceful results due to scar retraction and contraction caused by circular incision around the umbilicus and on the abdominal wall for its reimplantation. Meantime, I developed a personal technique to create a natural umbilicus during full abdominoplasty (Avelar, 1976). According to my approach, some surgical principles present a significant difference in comparison to the other procedures. Before my publication, several authors introduced other approaches pulling the umbilicus in order to suture on the abdominal wall doing other types of incisions such as vertical, horizontal, circular, and semicircular ones. The final scar is a circular one with very high incidence of scar retraction and contraction, as mentioned by Grazer and Goldwing in 1977, in a memorial survey among 10,740 abdominoplasties performed by outstanding plastic surgeons all over the world. Therefore, in 1976, I introduced my first contribution on abdominoplasty though which became possible to achieve smooth umbilical area with inconspicuous surgical scars. I had the opportunity to present my new procedure in several Congresses all over the world as well as to publish in some plastic surgery journals.

When Prof. Illouz introduced liposuction in 1980, I went to visit him in order to learn the revolutionary technique. Few years later, I introduced the combination of liposuction with conventional abdominoplasty improving surgical results, but brought very high rate of complications, that I became so disappointed that I took a radical decision of do not perform any more such combined procedure during 10 years. However, I did not stop to study and I dedicated much time searching for a new procedure. Finally in 1998, I concluded my research and started performing a new abdominoplasty technique which was published and presented everywhere several times. The new concepts are to perform abdominoplasty without panniculus undermining, with preservation of perforator vessels on the abdominal wall which work as multiple pedicles to supply adequate vascularization to the remaining abdominal wall.

In the use of my new concepts, minimal complications may occur during and after abdominoplasty since the perforator vessels are not damaged peroperatively, which became a much more frequent procedure among plastic surgeons during the last two decades.

The new concepts for abdominoplasty were published and presented several times during 1999 and 2000 which were so easy to learn that some other one learned my surgical principles and published as he supposes to be the author of the technique. His publication is his first one concerning on abdominoplasty procedures. Nevertheless, during many years of my practice, I had the opportunity to publish and to present several new approaches concerning abdominoplasty as well as in other areas of plastic surgery. Therefore, the publication of this book is an opportunity to present once again to plastic surgeons the surgical principles of my new concepts on abdominoplasty, even further applications in our specialty. I wonder that the rights of my new concepts can be recognized by my colleagues who currently employ the technique.

So far, the history of abdominoplasty described in this book is a complete description since Kelly in 1899 that performed the first tummy operation, until 1999 and 2000 when I presented and published new concepts on abdominoplasty which are very useful in several other fields in plastic surgery.

São Paulo, SP, Brazil

Juarez M. Avelar

# Acknowledgments

Ever since I described new concepts on abdominoplasty, it was my dream to publish this book which gives me a peculiar sensation of personal well-being with material and spiritual gain. Therefore, it is much more than simply presenting another option or new knowledge; it was created through myriad contributions and I dedicate this book to them:

- To my parents, Anisio and Maria Ana. Although they are not with me in this world, I continuously feel their presence and I am thankful for their continuous enthusiasm and incentive.
- To my loving son Thiago, and my wife Gloria, who have been constant sources of inspiration for this publication and permanent witnesses to my scientific activities.
- To Professor Pitanguy, for all the knowledge I have acquired from him and for his constant encouragement for my scientific activities. He helped me throughout my professional practice by developing in me great motivation and stimulus for the field of science.
- To Dr. Edgar Bolanho for very high level of technical illustrations of this book concerning the chapters I wrote as well as of other authors.
- To my colleagues, Professor Hélio de Rezende Paoliello Jr., Marcelo Paulo Vaccari-Mazzetti, for their friendship and enthusiasm during the preparation of this book.
- To Mrs. Sandra Eberhardt for the great support to review the chapters I wrote in this book.
- To the Plastic Surgery Unit at the Surgery Department of the Medicine School in Marilia (Science and Technology Department of São Paulo State), and the Hospital das Clinicas of Marilia in São Paulo. Professor Helio de Rezende Paoliello Jr. is the Head of the Plastic Surgery Unit, who presented me with excellent conditions and support to organize and to publish this book.

São Paulo, Brazil

Juarez M. Avelar, MD

# Contents

## Part I Surgical Fundaments of New Concepts on Abdominoplasty

<b>1</b>	<b>New Concepts in Abdominoplasty: Origin and Evolution</b> . . . . .	<b>3</b>
	Juarez M. Avelar	
<b>2</b>	<b>Anatomy of the Abdominal Panniculus</b> . . . . .	<b>19</b>
	Juarez M. Avelar	
<b>3</b>	<b>Surgical Principles and Classification of Abdominolipoplasty or Lipoabdominoplasty</b> . . . . .	<b>31</b>
	Juarez M. Avelar	
<b>4</b>	<b>Lower Lipoabdominoplasty</b> . . . . .	<b>47</b>
	Juarez M. Avelar	
<b>5</b>	<b>Upper Lipoabdominoplasty</b> . . . . .	<b>59</b>
	Juarez M. Avelar	
<b>6</b>	<b>Lower and Upper Abdominolipoplasty</b> . . . . .	<b>73</b>
	Juarez M. Avelar	
<b>7</b>	<b>Full Lipoabdominoplasty</b> . . . . .	<b>85</b>
	Juarez M. Avelar	
<b>8</b>	<b>Creation of the New Umbilicus: My Technique on Abdominolipoplasty and Further Applications</b> . . . . .	<b>107</b>
	Juarez M. Avelar	
<b>9</b>	<b>Abdominolipoplasty</b> . . . . .	<b>127</b>
	Paulo Roberto de Sousa Jatene and Maria Cristina Vargas Jatene	

## Part II Further Applications of New Concepts on Abdominoplasty

<b>10 Importance of Concepts in Abdominoplasty and Liposuction in Breast Reconstructions</b> . . . . .	147
Márcio Paulino Costa, Alex Boso Fioravanti, and Guilherme Cardinal Barreiro	
<b>11 Robotic Procedure for Plication of the Muscle Aponeurotic Abdominal Wall</b> . . . . .	161
Marco Aurelio Faria Correa	
<b>12 Lipoabdominoplasty Combining a Wide Undermining of the Upper Abdomen with Complete Body Liposuction</b> . . . . .	179
Márcio Paulino Costa, Nuberto Hopfgartner Teixeira, Alex Boso Fioravanti, and Guilherme Cardinal Barreiro	
<b>13 Rhytidolipoplasty: Improvement by Tunnelization Through New Concepts of Abdominolipoplasty</b> . . . . .	207
Juarez M. Avelar	
<b>14 Ear Reconstruction: Preservation of Perforator Vessels on the Pedicle to Improve Results</b> . . . . .	225
Juarez M. Avelar	
<b>15 Reverse Lower Blepharoplasty: An Eclectic Procedure Without Cutaneous Undermining</b> . . . . .	239
Juarez M. Avelar	
<b>16 Medial Thigh Lipoplasty: New Concepts (A Technique Without Skin and Panniculus Undermining)</b> . . . . .	253
Juarez M. Avelar	
<b>17 Flanklipoplasty and Torsolipoplasty</b> . . . . .	269
Juarez M. Avelar	
<b>18 Gluteus Lipoplasty: Improvement Results on Buttocks Through New Concepts on Abdominoplasty</b> . . . . .	287
Juarez M. Avelar	
<b>19 Plication of the Abdominal Wall in Lipoabdominoplasty</b> . . . . .	303
João Erfon and Claudio Maurício	
<b>20 Dorsolipoabdominoplasty</b> . . . . .	317
Célio Ferreira Leão and Geisa Moura Leão	
<b>21 Buttock Lipografting and Augmentation Combined with Avelar's Abdominoplasty</b> . . . . .	329
Marcelo Paulo Vaccari-Mazzetti and Ryane Schmidt Brock	

<b>22 Vertical Abdominoplasty: Indications and Refinements</b> . . . . .	345
Everardo Abramo de Oliveira and Fabio Neves	
<b>23 Abdominoplasty After Massive Weight Loss</b> . . . . .	365
Flavio Mendes and Fausto Viterbo	
<b>24 Silicon Breast Implant Inclusions Through Abdominal Approach</b> . . . . .	389
Helio Paoliello Jr. and Ricardo Paoliello	
<b>25 Post-Bariatric Abdominoplasty</b> . . . . .	403
Paulo Kharmandayan, Marco Antonio de Camargo Bueno, and Jorge M. Psillakis	
<b>Part III Surgical Principles on Abdominoplasty</b>	
<b>26 Historical Evolution of Abdominoplasty</b> . . . . .	417
Ramil Sinder	
<b>27 Abdominoplasties: Classification (Bozola and Psillakis) and Concepts of Treatment Strategies</b> . . . . .	441
Antonio Roberto Bozola	
<b>28 Abdominoplasty Planning</b> . . . . .	463
Rolf Gemperli, Cristina Pires Camargo, and Alexandre M. Munhoz	
<b>29 Abdominoplasty in Male Patients</b> . . . . .	471
Sérgio Carreirão	
<b>30 Challenges in Abdominoplasty</b> . . . . .	481
Alberto M. Lott Caldeira and Martin B.M. Robles	
<b>31 Abdominoplasty: The Role of the External Oblique Muscle</b> . . . . .	497
Jorge M. Psillakis	
<b>32 Correction of Minor Abdominal Diastasis and Acquired and Congenital Deformities of the Umbilicus</b> . . . . .	511
José Carlos Miranda and Lincoln Graça Neto	
<b>33 Abdominoplasty on Patients with Previous Surgical Scars</b> . . . . .	523
João Medeiros Tavares Filho, Diogo Franco, and Talita Franco	
<b>34 The “Lying” H-Shaped with Double Contour Plication of the Anterior Aponeurosis Wall in Abdominoplasty</b> . . . . .	531
Antonio Carlos Abramo	
<b>35 Reverse Abdominoplasty</b> . . . . .	545
Talita Franco, Diogo Franco, and João Medeiros Tavares Filho	

**36 Extended Reverse Abdominoplasty: A Technical Alternative for Breast Reconstruction. . . . . 555**  
Cecin Daoud Yacoub

**37 Abdominoplasty: Pearls and Pitfalls. . . . . 571**  
Ithamar Nogueira Stocchero, Gustavo Flosi Stocchero,  
Guilherme Flosi Stocchero, and Alexandre Siqueira Franco Fonseca

**38 Complications During and After Abdominoplasties . . . . . 585**  
Paulo Roberto de Sousa Jatene and Maria Cristina Vargas Jatene

**Erratum . . . . . E1**

**Index. . . . . 599**

# Contributors

**Antonio Carlos Abramo, MD, PhD** Division of Plastic and Reconstructive Surgery, Escola Paulista de Medicina, Federal University of São Paulo – UNIFESP, São Paulo, SP, Brazil

ACA – Institute of Assistance in Plastic Surgery of São Paulo, Brazilian Society of Plastic Surgery and Brazilian Association of Medicine, São Paulo, SP, Brazil

**Juarez M. Avelar, MD** Head of the Brazilian Scientific Institute of Plastic and Reconstructive Surgery, Al Gabriel Monteiro da Silva, São Paulo, SP, Brazil

**Guilherme Cardinal Barreiro, MD, PhD** Brazilian Society of Plastic Surgery, ICESP Hospital, University of São Paulo Medical School, São Paulo, SP, Brazil

**Antonio Roberto Bozola, MD** Members of the Brazilian Society of Plastic Surgery, CEPlástica – Centro de Estudos em Cirurgia Plástica, Sao Jose do Rio Preto, SP, Brazil

**Ryane Schmidt Brock, MD, MSc** Members of the Brazilian Society of Plastic Surgery, Department of Plastic Surgery, São Paulo, SP, Brazil

**Marco Antonio de Camargo Bueno, MD** Member of the Brazilian Society of Plastic Surgery, Plastic Surgeon, Staff Unicamp University Hospital, São Paulo, Brazil

**Alberto M. Lott Caldeira, MD, MSc, FICS** Plastic and Reconstructive Surgery Department, Advanced Plastic Surgery – Caldeira-Roth Institute, Rio de Janeiro, RJ, Brazil

**Cristina Pires Camargo, MD** Plastic Division of São Paulo University (USP) School of Medicine, Assistant of Plastic Surgery lab (LIM04) School of Medicine, Bairro Itaim Bibi – São Paulo, SP, Brazil

**Sérgio Carreirão, MD** Full Member of the Brazilian Society of Plastic Surgery (TSBCP), Full Member of the Brazilian College of Surgeons (ECBC), Fellow of the American College of Surgeons (FACS), Rio De Janeiro, RJ, Brazil



**Marco Aurelio Faria Correa, MD** Members of the Brazilian Society of Plastic Surgery, Plastic Surgery PLE Ltd., Mount Elizabeth Novena Specialist Centre, Singapore, Singapore

**Márcio Paulino Costa, MD, PhD** Members of the Brazilian Society of Plastic Surgery, ISAPS, FILACAP, AS PS, Hospital das Clínicas, University of São Paulo Medical School, São Paulo, SP, Brazil

**Fabio Neves, MD, MS, PhD** Private Practice, Rio de Janeiro, RJ, Brazil  
Members of the Brazilian Society of Plastic Surgery, Department of Plastic Surgery, Hospital Federal de Ipanema, Rio de Janeiro, RJ, Brazil

**José Carlos Miranda, MD** Members of the Brazilian Society of Plastic Surgery, ISAPS Member, Curitiba, Paraná, Brazil

**Everardo Abramo de Oliveira, MD** Private Practice, Rio de Janeiro, RJ, Brazil  
Prof. Ronaldo Pontes Plastic Surgery Service, Niterói D'Or Hospital, Niterói, RJ, Brazil

**Paulo Roberto de Sousa Jatene, MD** Members of the Brazilian Society of Plastic Surgery, São Paulo, SP, Brazil

**João Erfon, MD** Director, Artclinic Ltda., Fortaleza, Ceará, Brazil

**João Medeiros Tavares Filho, MD, PhD** Plastic Surgery Division, Members of the Brazilian Society of Plastic Surgery, Federal University of Rio de Janeiro, Rio de Janeiro, Brazil

**Alex Boso Fioravanti, MD** Brazilian Society of Plastic Surgery, Hospital das Clínicas, University of São Paulo Medical School, São Paulo, SP, Brazil

**Alexandre Siqueira Franco Fonseca, MD, PhD** Department of Plastic Surgery, Centro Médico Viver Melhor, São Paulo, SP, Brazil  
Sociedade Brasileira de Cirurgia Plástica, São Paulo, SP, Brazil  
Plastic Surgeon at Instituto do Câncer do Estado de São Paulo, São Paulo, SP, Brazil

**Diogo Franco, MD, PhD** Plastic Surgery Division of the Federal University of Rio de Janeiro, Brazilian Society of Plastic Surgery, Rio de Janeiro, RJ, Brazil

**Talita Franco, MD, PhD** Plastic Surgery Division, Member of the Brazilian Society of Plastic Surgery, Federal University of Rio de Janeiro, Rio de Janeiro, RJ, Brazil

**Rolf Gemperli, MD** Chief of Plastic Surgery Division University of São Paulo (USP) Medical School, Bairro Itaim Bibi – São Paulo, SP, Brazil

**Maria Cristina Vargas Jatene, MD** Master of Science of Anesthesiology, Pain Management Specialist, São Paulo, SP, Brazil

**Paulo Kharmandayan, MD** Members of the Brazilian Society of Plastic Surgery, Department of Surgery, Division of Plastic and Reconstructive Surgery, School of Medical Sciences-UNICAMP, University of Campinas, São Paulo, SP, Brazil

**Célio Ferreira Leão, MD** Members of the Brazilian Society of Plastic Surgery, UFG Goiás Medical School, PUC Goiás Medical School, Goiânia, GO, Brazil  
Residency Service, Santa Casa de Misericórdia de Goiânia Hospital, Goiânia, GO, Brazil

**Geisa Moura Leão** Members of the Brazilian Society of Plastic Surgery, Marcos Vinícius Calazans de Sousa – R3 – Santa Casa de Misericórdia de Goiânia Hospital, Goiânia, GO, Brazil  
Mário Junqueira de Souza – R2 – Santa Casa de Misericórdia de Goiânia Hospital, Goiânia, GO, Brazil

Célio Coelho Neto Leão – R2 – Plastic Surgery Hospital, Rio de Janeiro – RJ, Rio de Janeiro, Brazil

**Claudio Maurício, MD** Preceptor of the Plastic Surgery Post-Graduate Course, Department of Surgery, Walter Cantídio Hosp of the Federal University of Ceará, Fortaleza, Ceará, Brazil

**Martin B.M. Robles, MD** Plastic and Reconstructive Surgery Department, Caldeira-Roth Institute, Rio de Janeiro, RJ, Brazil

**Flavio Mendes, MD** Division of Plastic Surgery, Botucatu Medical School – UNESP, Botucatu, SP, Brazil

**Alexandre M. Munhoz, MD, PhD** Plastic Division of São Paulo University (USP) School of Medicine, Assistant of São Paulo Cancer Institute (ICESP), Bairro Itaim Bibi – São Paulo, SP, Brazil

**Lincoln Graça Neto, MD** Members of the Brazilian Society of Plastic Surgery, ISAPS Member, Curitiba, Paraná, Brazil

**Helio Paoliello Jr, MD** Plastic Surgery Discipline, Faculdade de Medicina de Marília (FAMEMA), Marília, SP, Brazil

**Ricardo Paoliello, MD** Plastic Surgery Discipline, Faculdade de Medicina de Marília (FAMEMA), Marília, SP, Brazil

**Jorge M. Psillakis, MD** Members of the Brazilian Society of Plastic Surgery, Department of Plastic Surgery, Hospital “Alemão Oswaldo Cruz”, São Paulo, Brazil

**Ramil Sinder, MD** Members of the Brazilian Society of Plastic Surgery, Plastic Surgery Department of Fluminense Medical School, Niteroi, Rio de Janeiro, Brazil

**Guilherme Flosi Stocchero, MD** Department of Plastic Surgery, Centro Médico Viver Melhor, São Paulo, SP, Brazil

Sociedade Brasileira de Cirurgia Plástica, São Paulo, SP, Brazil

University of São Paulo Hospital, São Paulo, SP, Brazil

**Gustavo Flosi Stocchero, MD, MBA** Department of Plastic Surgery, Centro Médico Viver Melhor, São Paulo, SP, Brazil

Sociedade Brasileira de Cirurgia Plástica, São Paulo, SP, Brazil

**Ithamar Nogueira Stocchero, MD** Department of Plastic Surgery, Centro Médico Viver Melhor, São Paulo, SP, Brazil

Hospital Santa Catarina, São Paulo, SP, Brazil

Sociedade Brasileira de Cirurgia Plástica, São Paulo, SP, Brazil

**Nuberto Hopfgartner Teixeira, MD** Brazilian Society of Plastic Surgery, Hospital das Clínicas, University of São Paulo Medical School, São Paulo, SP, Brazil

**Marcelo Paulo Vaccari-Mazzetti, MD, MSc** Department of Plastic Surgery, Brazilian Society of Plastic Surgery, Face Defects Research and Study Center, São Paulo, SP, Brazil

**Fausto Viterbo, MD** Division of Plastic Surgery, Botucatu Medical School – UNESP, Botucatu, SP, Brazil

**Cecin Daoud Yacoub, MD** Sociedade Brasileira de Cirurgia Plástica (Brazilian Society of Plastic Surgery), São Paulo, SP, Brazil

Plastic Surgery Department, Instituto de Cirurgia Plástica Santa Cruz (Dr. José Marcos Mélega), São Paulo, SP, Brazil

**Part I**  
**Surgical Fundamentals of New**  
**Concepts on Abdominoplasty**

# Chapter 1

## New Concepts in Abdominoplasty: Origin and Evolution

Juarez M. Avelar

### Introduction

The roots of the origin of my new concepts in abdominoplasty arose a long time ago since the time that I started performing traditional abdominoplasty and later liposuction. In fact, when I learned from Prof. Pitanguy, during my period of residence, and later from Prof. Illouz, respectively, how to perform abdominoplasty and liposuction procedures, I already thought of searching for a safer approach. In my private practice, beginning in 1974, I used to have a rate of local and systemic complications after abdominoplasty similar to that mentioned by other plastic surgeons. According to Grazer and Goldwyn [47] and later Guerrerosantos et al. [48], complications after abdominoplasty were a constant problem among plastic surgeons. With the combination of traditional abdominoplasty and a liposuction technique, the complications became even more frequent, as reported by Goldwyn [46] a few years after liposuction was introduced and popularized by Illouz. No longer was I so disappointed with all the complications that used to occur with most plastic surgeons. In my judgment the troubles were related to vascular damage during surgery, and as there was no adequate solution for the problems I then made the decision of not performing such combined operations anymore [16]. Of note, Hetter et al. [49], Dellerud [43], and later Flageul et al. [45] reported that seroma formation, hematoma, sloughing of the skin, minor and major areas of panniculus necrosis of the abdominal wall, thromboembolism, and unesthetic scars around the umbilicus were some of the most frequent complications after abdominoplasty. Since the earlier period of the practice, these kinds of complications concerned me so much that I was motivated to study and research the anatomy of the abdominal panniculus, searching for a new method in order to avoid these complications. In

---

J.M. Avelar, MD

Head of the Brazilian Scientific Institute of Plastic and Reconstructive Surgery,  
Al Gabriel Monteiro da Silva, 620 Jd Europa, São Paulo, SP 01442-000, Brazil  
e-mail: [juarezavelar@bol.com.br](mailto:juarezavelar@bol.com.br); [institudoaorelha@uol.com.br](mailto:institudoaorelha@uol.com.br)

2006, Matarasso et al. [56] reported the findings of the American Society for Aesthetic Plastic Surgery's 2004 Cosmetic National Data Bank: during the previous 7 years, the number of abdominoplasty operations performed had increased by 344%. This is important information; due to safety procedures, surgical results have improved, with minimal rates of complications, encouraging plastic surgeons to perform abdominoplasties.

## Technique

Among the complications after abdominoplasty, the creation of a new umbilicus was a constant task that used to be reported by most plastic surgeons. It bothered me so much that during my first 2 years of practice, I developed a personal approach to create a new umbilical area during abdominoplasty [2–6]. The main surgical principle of my procedure is to avoid a circular scar around the umbilicus during surgery. The first reference for transposition of the umbilicus is credited to Vernon [62], who performed a circular incision around the umbilicus during surgery for abdominal panniculus, and for its reimplantation, he removed a circle of skin on the abdominal flap and sutured the wound. All procedures described afterward were similar to that, since with a vertical, horizontal, or a curved incision, the final scar around the new umbilical area is a circular one. Until my publications all authors used to make a circular incision around the umbilicus according to Vernon's method. Instead of a circle, I proposed creating three cutaneous flaps on the umbilicus, and another three cutaneous flaps on the abdominal panniculus in order to suture alternately between them. The final scar, instead of a circular one, is an asymmetric triple Z-plasty which avoids retraction and contraction, which were frequent complications in an worldwide survey reported by Grazer and Goldwyn [47]. Therefore, in my operations the problems regarding creation of the new umbilicus were adequately solved.

Nevertheless, other complications occurring perioperatively and also after abdominoplasty were a constant challenge for several years. Regarding the origin of my new concepts, an important step occurred in August 1975 when I participated in the Sixth Congress of the International Confederation of Plastic and Reconstructive Surgery (IPRS) held in Paris. During that meeting I was invited to attend a private reception at a plastic surgeon's office. That surgeon was Dr. Illouz. As soon as we met each other, a strong friendship developed between us. As he was an active member of the French Society of Aesthetic Plastic Surgery, he invited me to speak at the next congress, to be held in Paris in 1976. My talks were about umbilicoplasty and negroid nose procedures [3]. So, due to my original publications, I met Dr. Illouz some years before his first publication concerning the liposuction technique [50].

Later, I quite often used to hear about a French surgeon who had developed a new technique for fat removal. In 1980 Dr. Illouz came to speak about it at the Brazilian Congress of Plastic Surgery (held in Fortaleza, Ceara State), which was quite controversial since most surgeons were not convinced about the method. In the meantime, I often heard about his procedure. Early in 1982 I called him with the purpose of learning his technique. For 1 week I attended several surgeries and I saw some patients in

postoperative recovery showing very good results. I was impressed and convinced about his technique. During my stay he gave me a copy of his publication printed in a public journal (tabloid) with a clear description in French of his methodology; this is still at my institute as a special souvenir (Fig. 1.1). At that time I was the President of the Brazilian Society of Plastic Surgery ( São Paulo State region), and I invited him to come to São Paulo to give a course to introduce his technique. So, in November 1982 he came to give a course, and he performed six surgical demonstrations with excellent results, which were a success; the course was a memorable event [51]. As I had already learned his technique, during the first course, I introduced to Dr. Illouz some of my patients who had undergone the procedure on the abdomen, neck, and torso. Afterward I invited him again several times to come once a year to teach his technique at other courses and also to give lectures at the Brazilian Congress of Plastic Surgery [52]. As he used to come to São Paulo quite often, and as we were so involved in introducing and teaching his technique, we decided to publish our book, in which we described the basic fundamentals and advanced technical information.

During that period of introduction, learning, practising, and teaching the liposuction technique, several questions about it came to mind:

1. The limit of the patient's age for undergoing liposuction
2. The limit of fat tissue to be removed in each operation
3. Criteria of indications for overweight patients
4. The anatomy of the panniculus
5. The clinical and metabolic alterations after liposuction
6. Redundancy of the skin secondary to the liposuction procedure
7. Liposuction combined with traditional procedures
8. Behavior of the remaining fat tissue after surgery.

The first three questions mentioned above led to the establishment of adequate rules and criteria for plastic surgeons; these have been useful from that period to the present.

However, regarding the anatomy of the panniculus, I devoted much time to research in cadavers in order to know fat tissue, as well as its distribution in all regions of the human body (Fig. 1.2) [12]. That knowledge was a good support at that time, providing proper conditions to employ the new technique of liposuction. Even nowadays that anatomical information is still very useful when fat-suction is done.

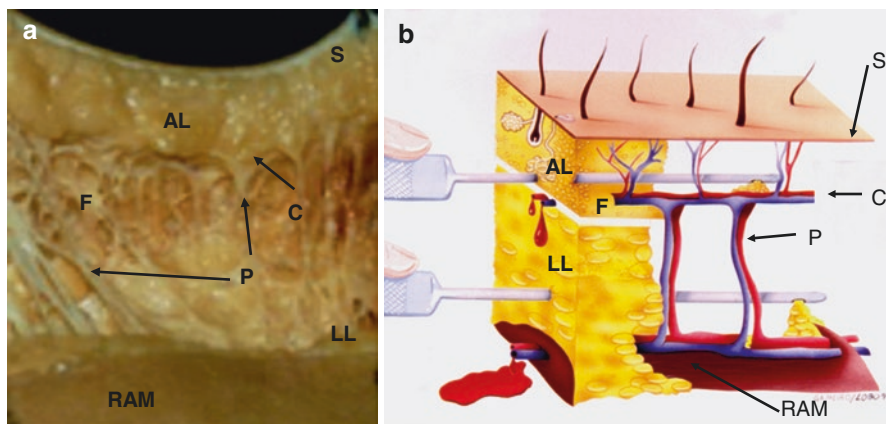
Regarding clinical and metabolic alterations, I demonstrated, in a comparative study with patients who underwent esthetic procedures (reduction mastoplasty, abdominoplasty, rhytidoplasty), that there was no specific disturbance in patients after liposuction [7–9, 12, 14, 15]. Apart from my research, other surgeons studied the same subject and had similar results [1].

To solve the problem concerning redundancy of the skin after the liposuction procedure, it became mandatory to remove such skin in order to achieve a good balance of the regions with harmony in body contouring. In fact, the traditional abdominoplasty described by Callia [42] and popularized by Pitanguy [57] used to be the fundamental procedure for combination with the liposuction technique developed by Illouz [50, 51]. However, when such a combined procedure was performed on the abdomen, several kinds of local complications were seen quite often: seroma



Fig. 1.1 First Illouz publication. Photos (a, b) in the French journal in 1978. Photos (c, d) on other pages in the French journal in 1978





**Fig. 1.2** Sophisticated structures of the abdominal panniculus. Photo (a) after liposuction procedure on a cadaver showing: skin (S), areolar layer (AL), fascia superficialis (F), communicating vessels (C), perforator vessels (P), lamellar layer (LL), and rectus abdominis muscle (RAM). Drawing (b) showing the same structures

formation, hematoma, cutaneous sloughing, and skin and panniculus necrosis. As well, systemic complications and even, unfortunately, deaths, were reported worldwide. Although that combined procedure was performed by most plastic surgeons, I was deeply concerned about the procedure, as described in my publications [10, 11].

The behavior of the remaining fat tissue after liposuction, the selection of patients, and the indications for liposuction are meticulously emphasized in my publication [17]. It is described that the fibrotic and thick tissue developed secondarily to fat-suction is very difficult to dissect and to undermine, and even makes it difficult to move the panniculus for resection [10]. It is mentioned that in cases of a secondary liposuction on the abdominal wall, the procedure must be done carefully, since the cannula may accidentally perforate the muscular structures, causing severe damage to the internal organs.

Besides these situations, several other problems used to occur during and after liposuction procedures. Bleeding during operation was a frequent problem, requiring transfusion of donated or autologous blood [61]. Nowadays, most of these problems have been adequately solved. But during that time it was my obsessive pursuit to learn widely and very broadly about these problems. Nevertheless, performing liposuction on the abdominal wall used to be even more complex than previously, since physical abnormalities as well as expectations of the results were a constant challenge.

Undoubtedly a very high incidence of local complications used to occur after liposuction in conjunction with conventional procedures with most surgeons, as reported by Goldwyn [46], Hetter et al. [49], and Dellerud [43]. These problems intrigued me so much that I became discouraged from performing combined approaches due to the psychological repercussions for the patients [15], [58]. So, in

1988 (only 6 years into my practice in the use of the fat-suction technique), even after the publication of our book [13], I decided not to perform such associated procedures anymore [16]. During a period of 10 years, from 1988 to 1998, I used to perform only conventional abdominoplasty in patients without localized adiposities, or isolated fat-suction in young patients to remove only localized adiposities without skin resection. Although I no longer performed the combined procedure, I followed my research in my previous study of the anatomy and behavior of the remaining fat tissue [12, 14, 15, 17]. As well as studying these complications, I was looking for a new approach to solve both deformities – flaccidity with the excess skin associated with treatment of localized adiposities on the abdominal wall.

During a long period of anatomical studies and analyzing the complications of conventional abdominoplasty, I concluded that most of the problems were caused by venous and lymphatic stasis, due to the cutting of the perforator vessels (Fig. 1.2). However, after the liposuction procedure the perforator vessels coming from the rectus abdominalis to the remaining panniculus were preserved, as demonstrated in some slides that Prof. Callia gave me. He had performed conventional abdominoplasty in a group of female patients 6 months after liposuction because of their complaints about the redundant skin. I analyzed his slides in comparison with mine, taken from my previous anatomical research in cadavers, and came to the conclusion that it would be possible to perform panniculus resection combined with liposuction, as long as the perforator vessels coming from the rectus abdominalis would be preserved. That is the basis of my new concepts, which I pursued in order to perform abdominoplasty safely.

Due to my conclusion, I was motivated to perform, on cadavers, full-thickness suction of the subcutaneous tissue in an elliptical area on the suprapubic region and on the medial thigh. Afterwards skin resection was done and I identified structures similar to those I had found on cadavers after liposuction procedures in my previous anatomical research, which was a fundamental support of information [12, 17]. Later, liposuction was done below the fascia superficialis that is underneath the areolar layer of the panniculus which is moved from one border to another to facilitate the suture of the surgical wound. At that moment I was sure that such an operation could be performed safely without any bleeding during or after surgery.

My first patients were operated in early 1998, 10 years after my radical decision of not performing combined procedures of liposuction with skin resection. My first operation was done in a female patient presenting unesthetic and deep surgical scars in the suprapubic region. The second patient was another female, with dark, thick skin with localized adiposity on the medial thigh region. First, I demarcated the excess skin that should be removed and also the area to perform fat-suction. The operations were successfully done through a liposuction procedure on a full thickness area of the skin which was removed afterward without bleeding. Following the operation liposuction was done underneath the remaining panniculus without undermining, and the wound was sutured.

It was clear to me that a new procedure could be performed, with minimal complications, in order to suction the accumulated fat, combined with skin resection of the redundant cutaneous covering after the fat-suction. In my original publications

[18–21], this method was employed for treatment of the abdominal wall, medial thigh lifting, flanks, and axilla, as well as in a closed vascular system, since no vessels are damaged.

Therefore, the final conclusions of my new approach were to treat not only the abdominal wall, since the whole body may present localized adiposities and redundant skin as well. Due to my anatomical investigations, several segments of the human body were adequately repaired with minimal complications using the same surgical principles, which are to preserve the perforator vessels to work as multiple pedicles for the abdominal wall, medial thigh, flanks, and torso, as well as in the axillary regions. I have also employed similar surgical principles to perform face lifting, ear reconstruction, and reverse lower blepharoplasty, and to treat other segments of the human body. Also I perform rhytidoplasty with reduced cutaneous undermining by tunnelization preserving the perforator vessels to assure adequate blood supply. My technique for ear reconstruction involves the same surgical principles as those described for abdominoplasty. The reconstructed auricles present a vascular and nervous pedicle through which an adequate blood supply and adequate sensibility are provided. My reverse lower blepharoplasty approach is performed using the same surgical principles, since no liposuction procedure is done, nor is there cutaneous or muscle undermining.

Apart from my publications in 1999, I presented the new concepts at a congresses in Brazil [22] and abroad ([23]). In early 2000 Prof. Callia's unit invited me to demonstrate the new concepts in abdominoplasty at a course at the Municipal Hospital in São Paulo City. Apart from my classes, I also performed a surgical demonstration [24]. In 2000 I was invited to speak about my abdominoplasty procedure at several meetings in Brazil [25–27] and abroad. It is referred to by Matarasso [55] as new concepts in abdominoplasty. Also I presented again at other international congresses [28–30]. In October 2000, I organized The Second Course of Abdominoplasty at the Heart Hospital (Hospital do Coração) in São Paulo when several of the plastic surgeons who had attended the First Course presented their experience in the use of the new technique [31]. Among these plastic surgeons, Erfon introduced the plication of the aponeurosis below the umbilicus to reduce the extent of the final scar of the abdominoplasty [44]. Also, Leao presented, during the Second Course, plication of the superior segment of the abdomen creating a tunnel from the umbilicus to the xiphoid process, preserving the perforator vessels on each side [53]. Following my presentations, I spoke again at the 37th Brazilian Congress of Plastic Surgery [32]. At the Brazilian Congress, Leão presented his procedure for plication of the superior abdominal wall without panniculus undermining [54]. In 2001 I was invited to participate in many congresses abroad-- in Spain [33, 34], at the Balkan Congress in Belgrade [35], at the American Congress in New York [36], and again at the International Society of Aesthetic and Plastic Surgery (ISAPS) Course in Rio de Janeiro [37]. Also, early in 2002, details of my findings were published in the American Aesthetic Journal [38], presented at the ISAPS Congress in Turkey [39], and again presented at the American Congress in Boston [41].

My descriptions in publications and my presentations at congresses, symposiums, and courses were very clear, convincing other plastic surgeons to perform abdominoplasty combined with liposuction, so that in December 2001 there were

other reports [59]. My first publication and presentations were in 1999; therefore, the long period of 2 years was enough for other surgeons to learn, to employ, and to confirm the basic principles of my new concepts in abdominoplasty.

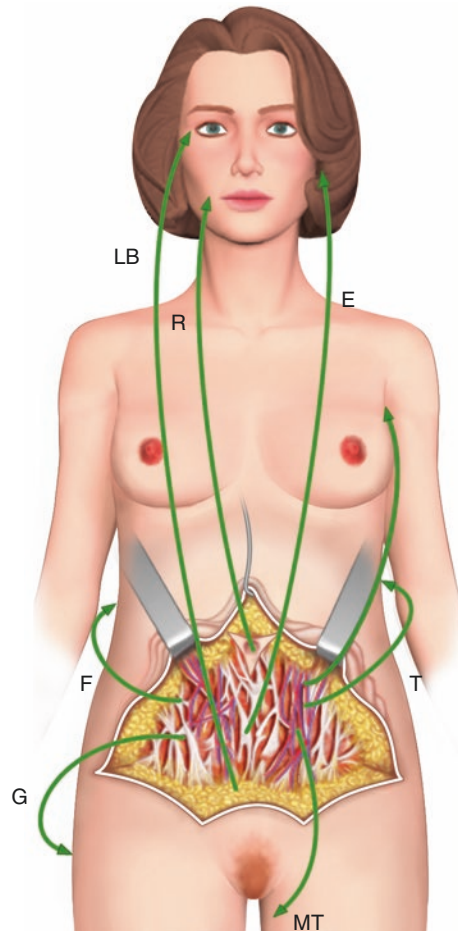
## Discussion

Abdominoplasty is an important procedure to improve the harmony of the body contour. The treatment must be done through a technique that achieves esthetic, reconstructive, and functional results. For this reason patient selection, correct indications, and the choice of a suitable surgical technique are essential steps before surgery. Therefore, before any esthetic procedure is performed on the abdomen, the patients must be well evaluated in order to analyze all abnormalities according to the scientific knowledge and sense of beauty of the surgeon.

For various reasons, all layers covering the abdominal wall--skin, subcutaneous tissues, aponeurosis, and muscles--may be damaged, resulting in deformities that require surgical repair. Such deformities may be caused by repeated pregnancies, cutaneous flaccidity, striae, retracted scars secondary to previous operations, severe local trauma, hernia, diastasis of the rectus abdominalis, localized adiposities, and weight loss, among others. It is well known that several kinds of complications may occur after abdominoplasty, as well as after combined procedures with liposuction. All complications were quite common before the liposuction era introduced by Illouz [50, 51]. However, in the combined surgeries the rate of complications increased very much, which prompted me to search for an adequate solution. During a few years of practising the associated procedure, I made the radical decision of not performing the procedure anymore until I developed a new approach avoiding such complications. I was greatly concerned about all the problems occurring after surgeries, encouraging me to study and research the anatomy of the panniculus and the behavior of the remaining fat tissue following my previous studies on cadavers [12, 14, 15, 17].

I devoted much time to research on anatomy dissection to study the subcutaneous compartment, which was not well known previously, since few surgical procedures needed knowledge about it. As the cannulas used to perform liposuction work specifically on the level between the skin and muscles underneath, I became motivated to study and research this segment of the human body. The anatomy of the panniculus is formed by the areolar layer and lamellar layer divided by the fascia superficialis (Fig. 1.2). After my anatomical studies of the abdominal panniculus, it seemed suitable to mention that the fascia superficialis is a symbol of the new concepts in lipoabdominoplasty, since it covers whole regions of the body and is particularly important in the abdominal wall. The perforator vessels come from the muscles passing through the lamellar layer until they reach the fascia superficialis, where a strong arch of channels of communicating vessels is created. From that arch small vessels cross the areolar layer perpendicularly until they reach the subdermal level. Therefore, preservation of the perforator vessels is the main surgical principle, as this preservation provides adequate blood supply to the areolar layer and to the fat tissue remaining after liposuction.

**Fig. 1.3** Further applications of the surgical principles of new concepts in abdominoplasty. *LB* lower blepharoplasty, *R* rhytidoplasty, *E* ear reconstruction, *T* torso, *F* flanks, *G* gluteus, *MT* medial thigh



According to the American Society for Aesthetic Plastic Surgery's 2004 Cosmetic Surgery National Data Bank, the number of abdominoplasties increased by 344% between 1997 and 2004. This increase is a result of the combination of abdominoplasty with the liposuction technique, which is a safe procedure with a minimal rate of complications after operation. Therefore, the minor complications occurring during and after such combined abdominoplasties have stimulated patients and plastic surgeons to perform the combined procedures.

Other authors have also searched for suitable procedures for abdominoplasty, as mentioned by Shestak, with his marriage of liposuction combined with abdominoplasty [60].

The surgical principles of lipoabdominoplasty are also employed to perform medial thigh lipoplasty, face-lifting procedures (rhytidoplasties), ear reconstruction, reverse lower blepharoplasty, torso and flank lipoplasty, and gluteus lipoplasty (Fig. 1.3).

My ideas in searching for new concepts in abdominoplasty did not come immediately. In fact, I was wondering and thinking about the problems for some time, and more than that, I was looking for a safe procedure. My previous publications in a wide field concerning abdominoplasty before the liposuction era, as well as my publications on the use of combined procedures, are permanent witnesses to my scientific activities.

I am deeply thankful to Prof. Pitanguy for giving me a good level of specialization, to Prof. Illouz for the opportunity to learn his technique, and to Prof. Callia for his useful support during the period of researching a new approach for abdominoplasty. They gave me great sensibility and the scientific spirit for searching for a new way in plastic surgery. It was a privilege to give Prof. Illouz some commemorative plaques in recognition of and gratitude for his outstanding scientific contribution to plastic surgery (Figs. 1.4 and 1.5).

## Conclusions

The first operation for esthetic treatment to reinstate the abdominal wall is credited to Kelly (1899). During all of the period since then, much attention has been focused on finding a procedure through which good results could be achieved. However, the very high incidence of complications in abdominoplasty was a problem to be solved, since the perforator vessels were cut in order to achieve wide undermining.

When the liposuction technique was developed and popularized worldwide by Illouz ([50, 51], 1992), I found a new way to improve my surgical results, performing this technique in association with traditional abdominoplasty [10, 11, 40]. Several complications after abdominoplasty were reported by all plastic surgeons; however, with the use of the liposuction procedure combined with conventional techniques, the rate of these complications became even higher and the complications more complex. I was concerned about these problems, since seroma formation, hematoma, skin sloughing, cutaneous infection, and panniculus necrosis, as well as systemic complications, were a constant challenge.


After reports in my publications [18, 19, 24–32], abdominoplasty showed significant technical improvements, because it became possible to perform it in combination with a liposuction technique, in which preservation of the perforator vessels is the main surgical principle of the lipoabdominoplasty. In fact, during this operation, the perforator vessels are not cut, providing blood supply to the remaining abdominal panniculus, working as multiple pedicles. This is a major surgical contribution, with a minor rate of complications, because the operation can be carried out without panniculus undermining and resection.

These surgical principles are essential for the lipoabdominoplasty procedure to improve body contouring; as well, the principles are employed in several other regions, according to my original descriptions for flankplasty, torsoplasty, medial thigh lifting, and esthetic surgery of the axillary regions [18–21].



**Fig. 1.4** During the 45th Brazilian Congress of Plastic Surgery held in Brasília in 2008, the “Prof. Illouz Association” gave Prof. Illouz a gold plaque in recognition of his superb improvement of technique through the liposuction procedure. (a) Photo of the moment Prof. Illouz received the homage with a plaque; (b) the gold plaque is a map of Brazil; (c) on the plaque a cannula is pointed from Fortaleza (Ceara) to São Paulo to demonstrate that it was the place of the first Prof. Illouz conference. Afterward he came to São Paulo several times to teach the liposuction technique; (d) another plaque was given to Prof. Illouz in gratitude for his wonderful scientific contribution

Similar surgical principles may also be employed to perform face lifting, ear reconstruction, reverse lower blepharoplasty, and plastic surgery procedures in other segments of the human body. Such a combined approach, with its suitable physiological surgical principles, in which the vascular nervous pedicles are not cut, is very important in plastic surgery, as these structures contain arteries, veins, lymphatics, and nerves. . As long as these structures are properly preserved, they provide smooth and esthetic results with good sensibility for the remnant abdominal panniculus.



**Fig. 1.5** A gold cannula with a plaque was given to Prof. Illouz in celebration of the twentieth anniversary of the creation and development of the liposuction technique. (a) Photo of the cannula and plaque; (b) photo of the plaque

## References

1. Andrews JM (1984) Fisiopatologia na lipoaspiração (Physiopathology in liposuction). Simp Bras do Contorno Corporal. Soc Bras Cir Plas – Reg São Paulo, São Paulo
2. Avelar JM (1976) Umbilicoplastia – uma técnica sem cicatriz externa (Umbilicoplasty – a technique without external scar). 13° Congr Bras Cir Plast, 1° Congr Bras Cir Estética 13th Braz. Congr. of Plastic Surgery and First Braz. Congr. of Aesthetic Surgery, Porto Alegre, pp 81–82
3. Avelar JM (1976) Umbilicoplasty. A technique without external scar. Cahiers de chirurgie Esthétique. Journées internationales de Chirurgie Esthetique. Vendredi 21 mai, pp 5–25
4. Avelar JM (1978) Abdominoplasty – systematization of a technique without external umbilical scar. Aesthetic Plast Surg 2:141–151
5. Avelar JM (1979) Cicatriz umbilical – da sua importância e da técnica de confecção nas abdominoplastias (Umbilical scar – its importance and technique for creating during abdominoplasty). Rev Bras Cir 1(2):41–52
6. Avelar JM (1983) Abdominoplasty: technical refinements and analysis of 130 cases in 8 years' follow-up. Aesthetic Plast Surg 7:205–212
7. Avelar JM (1983) Análise metabólica comparativa entre cirurgia estética e lipoaspiração (metabolic comparative analysis between aesthetic surgery and liposuction). XX Congr Bras. Cir. Plas. Nov, Brasília
8. Avelar JM (1984) Fisiopatologia na lipoaspiração (Physiopathology in liposuction) Simp Bras do Contorno Corporal. Soc Bras Cir Plas – Reg São Paulo, São Paulo
9. Avelar JM (1984) Estudo comparativo das alterações metabólicas na lipoaspiração e cirurgia convencional (comparative study of metabolic changes in conventional surgery and liposuction) Simp Bras do Contorno Corporal. Soc Bras Cir Plas – Reg São Paulo, São Paulo
10. Avelar JM (1985) Fat-suction versus abdominoplasty. Aesthetic Plast Surg 9:265–276
11. Avelar JM (1985) Combined liposuction with traditional surgery in abdomen lipodystrophy. XXIV Instructional course of Aesth Plast Surg of ISAPS, Madrid
12. Avelar JM (1986) Anatomia cirúrgica e distribuição do tecido celular no organismo humano (surgical anatomy and distribution of the cellular tissue on human organism). In: Avelar JM, Illouz IG (eds) Lipoaspiração (liposuction). Editora Hipócrates, São Paulo, pp 45–57
13. Avelar JM, Illouz YG (1986) Lipoaspiração (liposuction). In: Avelar JM, Illouz YG (eds) Lipoaspiração; Editora Hipócrates, São Paulo



14. Avelar JM (1986) Perfil psicológico do paciente – introdução ao estudo (psychological profile of the patient – introducing to the subject). In: Avelar JM, Illouz IG (eds) Lipoaspiração (liposuction). Editora Hipócrates, São Paulo, pp 8–12
15. Avelar JM (1986) Fisiopatologia e Estudo Metabólico da Lipoaspiração (physiopathology and metabolic study of the liposuction). In: Avelar JM, Illouz IG (eds) Lipoaspiração (liposuction). Editora Hipócrates, São Paulo, pp 42–44
16. Avelar JM (1988) Abdominoplastia – reflexões e perspectivas biopsicológicas (abdominoplasty – reflections and bio-psychological perspectives). Rev Soc Bras Cir Plast 3(2):152–154
17. Avelar JM (1989) Regional distribution and behavior of the subcutaneous tissue concerning selection and indication for liposuction. Aesthetic Plast Surg 13:155–165
18. Avelar JM (1999) Uma nova técnica de abdominoplastia – sistema vascular fechado de retalho subdérmico dobrado sobre si mesmo combinado com lipoaspiração (a new technique for abdominoplasty – closed vascular system of subdermal flap folded over itself combined to liposuction). Rev Bras Cir 88/89(1/6):3–20
19. Avelar JM (1999) Cirurgia Plástica de Face Interna de Coxas/aesthetic plastic in the inner side of the thigh – new concepts and technique without cutaneous or subcutaneous undermining. Rev Bras Cir 88/89(1/6):57–67
20. Avelar JM (1999) Flancoplastia e Torsoplastia - Nova Abordagem Cirúrgica/flankplasty and torsoplasty – a new surgical approach. Rev Bras Cir 88/89(1/6):21–35
21. Avelar JM (1999) Cirurgia Plástica e Estética de Axilas/aesthetic plastic surgery of the axilla – a new technique to the treatment of excess skin, hyperhidrosis, cutaneous flaccidity, hyperhidrosis and bromidrosis. Rev Bras Cir 88/89(1/6):41–54
22. Avelar JM (1999) Novos conceitos para abdominoplastia (new concepts for abdominoplasty). Paper presented at the 36th congress of the Brazilian society of plastic surgery, Rio de Janeiro, November
23. Avelar JM (1999) Abdominoplastia: nuevos conceptos para una nueva técnica (Abdominoplasty: new concepts for a new technique). XXVI Annual international symposium of aesthetic plastic surgery, Chairman: Prof. Jose Guerrerosantos, Puerto Vallarta, pp 10–13
24. Avelar JM (2000) I Curso de abdominoplastia (first course of abdominoplasty). Chairman: Prof. William EP Callia. Invited Professor: Dr. Juarez M. Avelar. Municipal Hospital, São Paulo, March
25. Avelar JM (2000) Abdominoplastia sem descolamento (abdominoplasty without undermining). XX Jorn. Paulista Cir Plast, São Paulo
26. Avelar JM (2000) Abdominoplasty: a new technique without undermining and fat layer removal (Abdominoplastia: uma nova técnica sem descolamento e remoção da camada de gordura). Arq Catarinense de Med 29:147–149
27. Avelar JM (2000) Abdominoplastia com preservação do sistema vascular profundo. Comunicação Pessoal. Abdominoplasty with preservation of the deep vascular system. Personal communication. Reunião Mensal da Sociedade Brasileira de Cirurgia Plástica do Rio Grande do Sul – Porto Alegre – maio. Monthly meeting of the Brazilian Society of Plastic Surgery of Rio Grande do Sul, Porto Alegre, May
28. Avelar JM (2000) A new technique for abdominoplasty subdermal flap folded over itself. The XV ISAPS congress, Tokyo, April
29. Avelar JM (2000) Aesthetic plastic surgery of the axilla. The XV congress of the International Society of Aesthetic Plastic Surgery (ISAPS), Tokyo, April
30. Avelar JM (2000) Abdominoplasty: a new technique without panniculus undermining and without panniculus resection. 57th instructional course of ISAPS, Chairman: Lloyd Carlsen, in Montreal, Canada
31. Avelar JM (2000) 2nd Curso de abdominoplastia (2nd course of abdominoplasty). Chairman: Prof. Juarez M. Avelar. Hospital do Coração (Heart Hospital), São Paulo, October
32. Avelar JM (2000): Abdominoplasty without panniculus undermining and resection. Presented at the 37th Brazilian Congress of Plastic Surgery, Porto Alegre (Rio Grande do Sul), November
33. Avelar JM (2001) Abdominoplasty without lipectomy. International Society of Aesthetic Plastic Surgery Education Foundation (ISAPS) – Spain, March.

34. Avelar JM (2001) Abdominoplasty without lipectomy. Mini course of ISAPS with aesthetic plastic surgery congress, Valladolid
35. Avelar JM (2001) Abdominoplasty without panniculus undermining or resection. Second Balkan Congress for Plastic, Reconstructive and Aesthetic Surgery and ISAPS mini-Course, Yugoslavia, May
36. Avelar JM (2001) The new abdominoplasty and derived technique. International course – American Society for Aesthetic Plastic Surgery annual meeting. The aesthetic meeting. New York
37. Avelar JM (2001e) Abdominoplasty without panniculus undermining and resection – analysis about 97 cases after 3 years. ISAPS Course at Jornada Carioca, Rio de Janeiro, August
38. Avelar JM (2002) Abdominoplasty without panniculus undermining and resection: analysis and 3-year follow-up of 97 consecutive cases. *Aesthetic Surg J* 22:16–25
39. Avelar JM (2002) Abdominoplasty. Congress of International Society of Aesthetic Plastic Surgery (ISAPS), Istanbul
40. Avelar JM (2002) Full abdominoplasty without panniculus undermining and resection. In: Avelar JM (ed) Abdominoplasty without panniculus undermining and resection. Editora Hipocrates, São Paulo, pp 201–215
41. Avelar JM (2004) New concepts on abdominoplasty. American Society for Aesthetic Plastic Surgery annual meeting. The Aesthetic Meeting, Boston
42. Callia WEP (1965) Contribuição ao estudo de correção cirúrgica do abdômen pêndulo e globus (contribution to the study of surgical correction of the pendulum abdomen and globus). original art. Doctoral Thesis Fac Med USP, São Paulo
43. Dellerud E (1990) Abdominoplasty combined with suction lipoplasty a study of complication, revisions, and risk factors in 487 cases. *Ann Plast Surg* 25(5):333–338
44. Erfon JA (2000) Ressecção da fascia abdominal inferior para plicatura infra umbilical em lipoabdominoplastia sem descolamento do panículo. 2º Curso de Abdominoplastia, Hospital do Coração – São Paulo – SP (resection of the lower abdominal fascia to improve plication of infraumbilical aponeurosis during lipoabdominoplasty without panniculus undermining) – 2nd course of abdominoplasty at the Heart Hospital, São Paulo
45. Flageul G, Elbaz JS, Karcenty B (1999) Complications of plastic surgery of the abdomen. *Ann Chir Plast Esthet* 44(4):497–505
46. Goldwyn RM (1986) Abdominoplasty as a combined procedure: added benefit or double trouble? *Plast Reconstr Surg* 78:383
47. Grazer FM, Goldwyn RM (1977) Abdominoplasty assessed by survey with emphasis on complications. *Plast Reconstr Surg* 59(4):513–517
48. Guerrerosantos J, Spaillat L, Morales F, Dickeheet S (1980) Some problems and solutions in abdominoplasty. *Aesthetic Plast Surg* 4:227
49. Hetter TR et al (1989) Abdominoplasty combined with other major surgical procedures: safe or sorry? *Plast Reconstr Surg* 83:997–1004
50. Illouz YG (1980) Une nouvelle technique pour les lipodystrophies localisées. *Rev Cir Esth Franc* 6(9):Ap
51. Illouz YG (1982) Liposuction technique. First instructional course with surgical demonstrations at São Paulo Hospital, Prof. Andrews' Service. Organized by Brazilian Society of Plastic Surgery – Regional São Paulo, Endorsed by Brazilian Society of Plastic Surgery (BSPS), October
52. Illouz YG (1984) Refinements in Liposuction to improve body contour. Theory and Practical Course with surgical demonstrations at “Nove de Julho” Hospital. Organized by Brazilian Society of Plastic Surgery (BSPS) with collaboration of Regional São Paulo, May
53. Leão CF (2000) Plicatura da parede músculo-aponeurótica por um tunel no abdômen superior na linha média em lipoabdominoplastia sem descolamento. 2º Curso de abdominoplastia, no Hospital do Coração, outubro – São Paulo (Plication of the musculoaponeurotic wall through a tunnel on the superior abdominal on the midline during lipoabdominoplasty without panniculus undermining). 2nd course of abdominoplasty at Heart Hospital (Hospital do Coração), São Paulo, October

54. Leão CF (2000b) Plicatura da parede músculo-aponeurótica por um tunel criado abaixo do panículo abdominal na linha média em lipoabdominoplastia sem descolamento. 37° Congresso Brasileiro de Cirurgia Plástica, novembro – Porto Alegre. (Reinforcement of the musculoaponeurotic wall through a tunnel created below the abdominal panniculus during lipoabdominoplasty). 37th Brazilian Congress of Plastic Surgery, Porto Alegre, November
55. Matarasso A (2000) Liposuction as an adjunct to full abdominoplasty revisited. *Plast Reconstr Surg* 106:1197–1206
56. Matarasso A, Swift RW, Rankin M (2006) Abdominoplasty and abdominal contour surgery: a national plastic surgery survey. *Plast Reconstr Surg* 117:1797–1808
57. Pitanguy I (1967) Abdominal lipectomy: an approach to it through an analysis of 300 consecutive cases. *Plast Reconstr Surg* 40(4):384–391
58. Pitanguy I (1986) Perspectivas filosóficas e psicossociais do contorno corporal. (philosophical and psychosocial perspectives of the body contour). In: Avelar JM, Illouz YG (eds) Lipoaspiração (liposuction). Editora Hipócrates, São Paulo, pp 3–7
59. Saldanha OR (2001) Lipoabdominoplasty without undermining. *Aesthetic Surg J* 21: 518–526
60. Shestak KC (1999) Marriage of abdominal and liposuction expands abdominoplasty concept. *Plast Reconstr Surg* 3(103):1027
61. Uebel CO (1986) Autotransusão e hemodiluição aplicada à lipoaspiração. (auto transfusion and hemodilution employing in liposuction). In: Avelar JM, Illouz YG (eds) Lipoaspiração (liposuction). Editora Hipócrates, São Paulo, pp 123–126
62. Vernon S (1957) Umbilical trasplantation upward and abdominal contouring in lipectomy. *Am J Surg* 94:490–492

# Chapter 2

## Anatomy of the Abdominal Panniculus

Juarez M. Avelar

### Introduction

When I visited Professor Illouz in early 1982 in Paris with the purpose of learning how to perform liposuction, one question came up in my mind: where and how does the cannula work to remove the amount of fat tissue? At that moment, I reviewed my knowledge about the anatomy of the subcutaneous layer and recognized that it was mandatory to study this little-known compartment of the human body. It was Professor Illouz's talent and genius to create and develop a single but very important surgical instrument – a cannula specific for liposuction.

All surgeons must know the anatomy of the relevant organs and regions before performing any operation. In plastic surgery this is even more important, since, to improve the patient's physical appearance, one performs an operation in a segment of a region or organ that will change the anatomical structures involved in the physical appearance. The distribution of subcutaneous fat presents particular characteristics in each region of the body and needs to be studied before a liposuction technique is employed.

The anatomical study described in this chapter is limited to the panniculus of the abdominal wall, since the new concepts of abdominolipoplasty require adequate knowledge of the sophisticated structures between the skin and the musculoaponeurotic wall. Descriptions of the vascularization are given in detail, since this was the main reason that motivated me to look for new concepts in abdominolipoplasty (the combination of a liposuction procedure with traditional abdominoplasty). The vascular network coming from the rectus abdominis originates in a strong arterial arch that runs inside the muscle coming from the superior and inferior epigastric arteries. When severe complications occurred due to combined procedures my conclusions

---

J.M. Avelar, MD

Head of the Brazilian Scientific Institute of Plastic and Reconstructive Surgery,  
Al Gabriel Monteiro da Silva, 620 Jd Europa, São Paulo, SP 01442-000, Brazil  
e-mail: [juarezavelar@bol.com.br](mailto:juarezavelar@bol.com.br); [institutodaorelha@uol.com.br](mailto:institutodaorelha@uol.com.br)

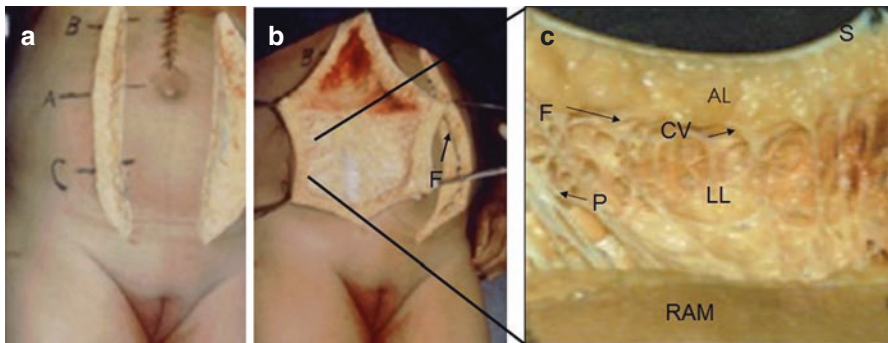
were directed to trauma of the vascularization during liposuction and abdominoplasty. Therefore, the anatomical descriptions are concerned with the vascular network, as well as with the lymphatics and nerves.

## Technique

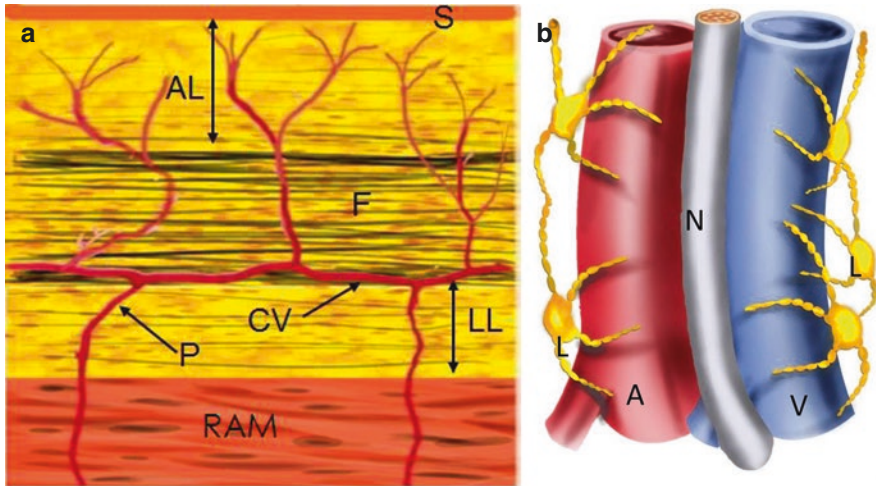
In order to improve my knowledge of this matter, I have devoted some effort to anatomical dissections and have also performed liposuction in several regions on cadavers. In my previous publications [3–5, 8] on this subject, I described measurements of the subcutaneous layers in all regions relevant to liposuction. I also emphasized a comparison between fat and thin people concerning localized adiposities and the thickness of the subcutaneous tissue.

The behavior of the tissue varies according to the degree of nutrition and to the excess of adiposity in the organism, and these factors were studied by Illouz and meticulously described [10–12]. Studying the same regions in fat and thin people, I found great anatomical variations. These differences are fundamentally important when it comes to performing liposuction and abdominoplasty or lipoabdominoplasty without panniculus undermining and resection [1, 2, 6].

As already described by Gray [9] and Testut [19], the subcutaneous tissue consists of two layers: the first is more superficial, external, and situated underneath the skin, and is called the areolar layer (Fig. 2.1) [3, 5]. The other, immediately below the first and separated from it by the fascia superficialis, including the lymphatic and blood vessels, is called the lamellar layer (Figs. 2.1 and 2.2).



**Fig. 2.1** Anatomical study of the abdominal panniculus in a cadaver. (a) A female cadaver in which liposuction was performed only on the right side, and a cutaneous incision was made with demarcation in three levels for the measurement of panniculus thickness: *B* upper abdomen, *A* umbilical, *C* infraumbilical. The areolar layer is preserved, and the lamellar layer is reduced to the fascia superficialis with perforator and communicating vessels. (b) The same cadaver, showing the panniculus on the *right side* after liposuction; the fascia superficialis (*F*) is marked with blue ink on the raw surface of the *left side*. (c) A close-up of the panniculus after liposuction where one can see from top to bottom: skin (*S*), areolar layer (*AL*), fascia superficialis (*F*) with communicating vessels (*CV*), lamellar layer (*LL*) with preserved perforator vessels (*P*) coming from the rectus abdominis muscle (*RAM*)



**Fig. 2.2** Drawings to demonstrate the anatomical structures of the abdominal panniculus. (a) Diagram of the panniculus showing its layers, from *top to bottom*: skin (S), areolar layer indicated by arrow (AL), fascia superficialis (F) with communicating vessels (CV), lamellar layer indicated by arrow (LL) with perforator vessels (P), which must be preserved during liposuction, and rectus abdominis muscle (RAM). From the communicating vessels (CV), small vessels go perpendicularly to cross the areolar layer (AL) to irrigate the subdermal region and skin as well. (b) The anatomical structure of the perforator vessels, which are formed by artery (A), vein (V), nerve (N), and lymphatic (L)

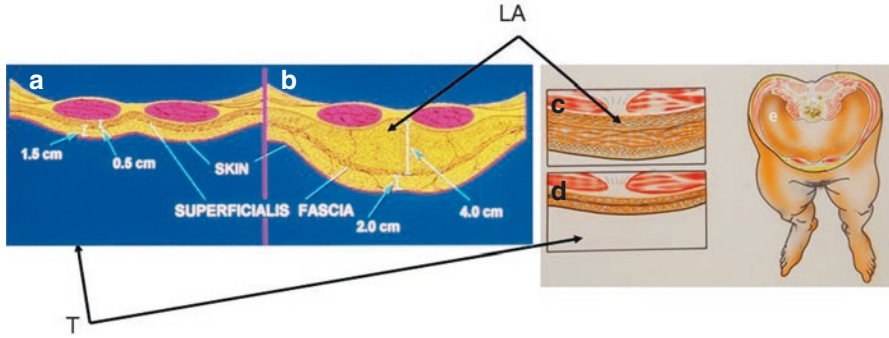
I have described that the areolar layer is formed by large, round, and turgid cells with the nucleus located on the border of the cellular membrane, and the cells piled one over the other. Between the columns of fat cells, small vessels coming from the communicating vessels situated on the fascia superficialis pass perpendicularly to irrigate the subdermal region and skin (Figs. 2.1 and 2.2) [4].

The lamellar layer, which is situated beneath the areolar layer, presents smaller fat cells, which seem to be “empty” with less fat inside; these cells are horizontally elongated and fusiform. This layer looks like a mesh formed by long cells including the connective tissue. Perforator vessels come from the rectus abdominis muscle and go to the fascia superficialis where they communicate with each other, creating communicating vessels that are similar to multiple arches (Figs. 2.1 and 2.2).

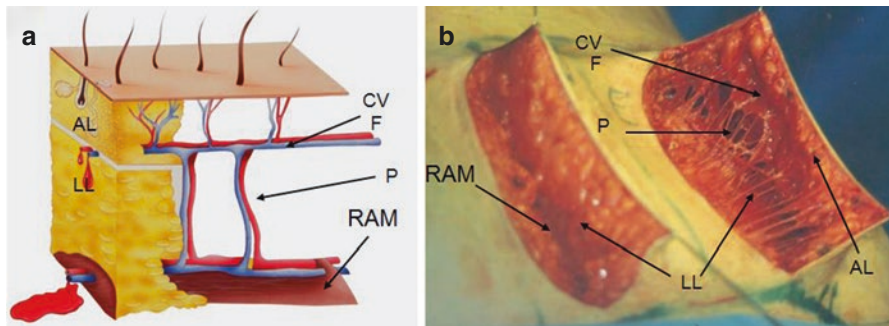
The connective tissue that forms the fascia superficialis behaves in a distinct manner in each region of the human body. The long fat cells seem to be ready to receive excess fat molecules from the blood circulation.

The lamellar layer increases in thickness when the fusiform cells receive more fat. For this reason, the thickness of this layer changes much more than that of the areolar layer (Figs. 2.3 and 2.4).

It is important to point out the anatomical findings of my research in other regions, especially in regard to comparisons between children and adults, females and males, and also between people with and without localized adiposities in all regions of the human body. In my first publication regarding the anatomy of the panniculus, I described the measurements of the subcutaneous layers in all regions of the human body relevant to liposuction [3].

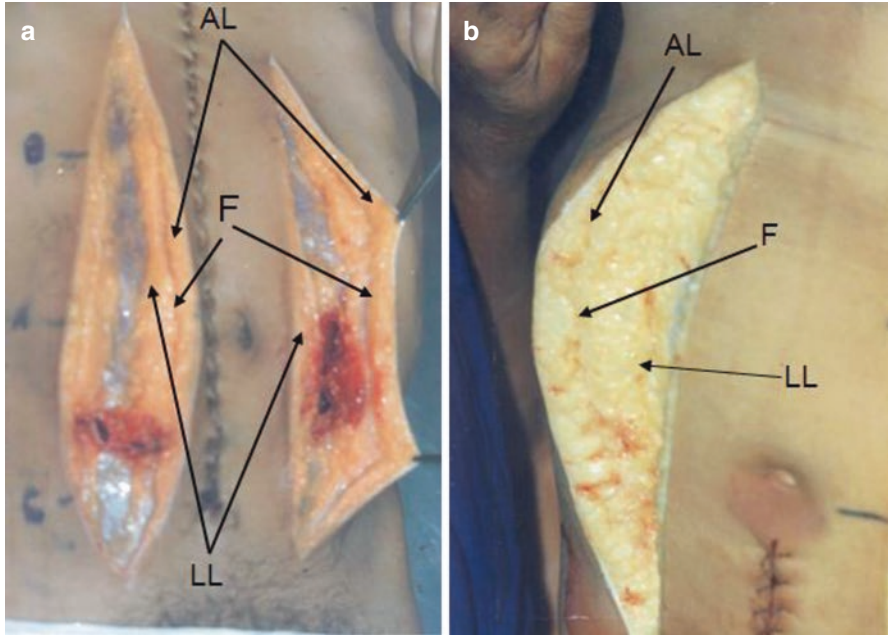


**Fig. 2.3** Schemes demonstrate comparison of the subcutaneous panniculus of the abdominal wall in a thin person (*T*) and in a person with localized adiposity (*LA*). The thickness of the fascia superficialis and lamellar layer in the person with localized adiposity is increased much more than that in the areolar layer. (**a**, **d**) Drawings show the thickness of the panniculus in a thin person (*T*). (**b**, **c**) Drawings show the thickness of the panniculus in a person with localized adiposity. (**e**) Scheme shows a section on the level of the umbilicus



**Fig. 2.4** Drawing and anatomical study in a fresh cadaver to show the relationship of the layers of the subcutaneous panniculus in the abdominal wall. (**a**) Scheme of the panniculus. (**b**) Photo of the cadaver's panniculus after liposuction was performed on the left side of the abdomen. The right side of the abdomen was incised but liposuction was not performed, where one can see the full thickness of the panniculus. *CV* and *F* communicating vessels (*CV*) and fascia superficialis (*F*). The communicating vessels (*CV*) create an arch between the perforator vessels (*P*) from where small vessels go perpendicularly through the areolar layer (*AL*) to vascularize the cutaneous and subcutaneous layers. The lamellar layer (*LL*) is located between the rectus abdominis muscle (*RAM*) and the fascia superficialis (*F*), and this is the correct level to perform the liposuction technique

I also showed a comparison between fat and thin people concerning the thickness of the subcutaneous tissue. I found very important and significant variations in the anatomical analysis of the thickness of the layers of the panniculus in all regions in children and adults. I published some of these drawings and schemes showing the results and my conclusions (Figs. 2.3 and 2.4).



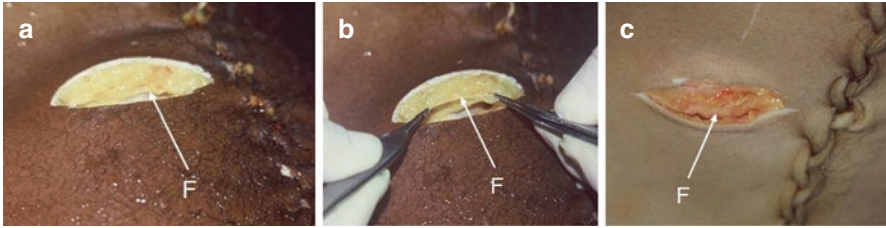
**Fig. 2.5** Anatomical study in cadavers to demonstrate a comparison of the subcutaneous panniculus in the abdominal wall of a person without localized adiposity (**a**) with that in a person with localized adiposity (**b**). In the person without localized adiposity, the fascia superficialis and the lamellar layer are very thin ; however, in the person with localized adiposity, the thickness of the lamellar layer is much greater than that of the areolar layer. *AL* areolar layer, *F* fascia, *LL* lamellar layer

In fat people and those presenting localized adiposities, the areolar layer changes less than the lamellar layer because the fat particles coming from the circulation will accumulate preferably in the lamellar layer inside the fusiform cells. The round large fat cells of the areolar layer will deposit fewer fat particles since they are already full. Therefore, the number of adipose cells in the lamellar layer is the main phenomenon responsible for the hypertrophy and the increase in thickness of the subcutaneous panniculus [5]. In different regions in the same person, very important anatomical differences occur in the lamellar layer (Figs. 2.5 and 2.6).

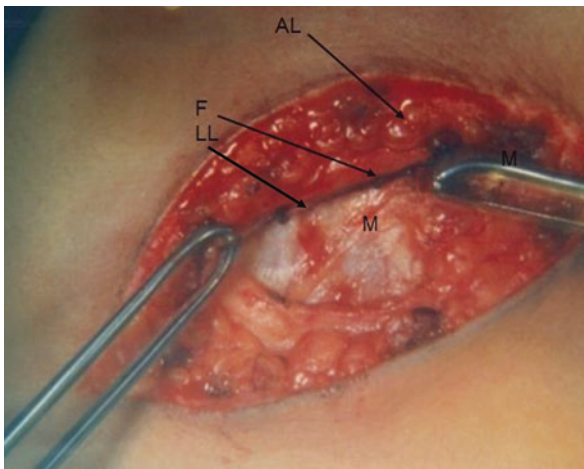
In fact, in thin people without localized adiposities, with the potential to accumulate fat, there is an excess of “empty” adipose cells situated in the lamellar layer, which are in a latent stage. On studying adipose cells, Illouz reported that they only develop the property to accumulate fat particles when activated by a biochemical mechanism [15, 17].

This phenomenon occurs in almost all regions of the human body, although there are specific differences between one region and another, even in the same person, as, for example, in the abdominal panniculus. These anatomical characteristics show the close relationship between the skin and the subcutaneous tissue layers





**Fig. 2.6** Anatomy of the panniculus of the abdominal wall in cadavers, showing the relationship of the fascia superficialis with the areolar layer without accumulated fat. (a) The arrow shows the fascia superficialis very close to the muscular level, when the lamellar layer is very thin. (b) The same cadaver, with two forceps holding the fascia superficialis (*F*), which is very near the aponeurosis of the rectus abdominis muscle. (c) Another cadaver showing that the areolar layer is very thin and the fascia superficialis (*F*) is very close to the muscles underneath



**Fig. 2.7** Photo during surgery, showing the subcutaneous panniculus of the chest wall. The areolar layer (*AL*) occupies the full thickness of the panniculus, since the lamellar layer (*LL*) is very thin associated with the fascia superficialis (*F*), which slides easily on the muscles (*M*) underneath. One can see the fascia superficialis (*F*), which is printed with blue ink and is held with forceps. When the thickness of the panniculus is increased, the lamellar layer (*LL*) presents insignificant change, but the areolar layer (*AL*) becomes very thick due to the accumulation of fat

underneath. Therefore, in the regions presenting thick and firm skin, such as in the region of the chest and torso, the areolar layer is thicker due to the greater vascularization and all the structures that provide blood supply to the dermis (Fig. 2.7). The opposite occurs in regions presenting thin and soft skin: the subcutaneous tissue shows a reduced areolar layer, whereas the lamellar layer is thicker, with an important vascular network inside the fascia superficialis [5].

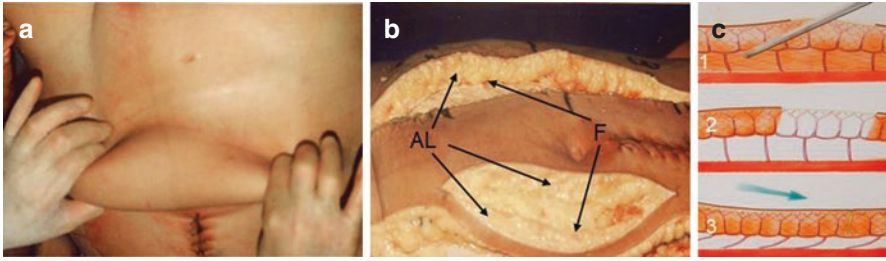
My anatomical research in seven children, aged 9–12, has demonstrated that, in children, the lamellar layer is very thin in all regions of the body. It presents only

areolar layers of the connective tissue without any firm structure between the panniculus and the musculoaponeurotic level. Therefore the panniculus slides easily over the muscular structure beneath. On the other hand, the areolar layer is present and thick in all regions of the body, and it is responsible for the thickness of the subcutaneous panniculus [3, 8].

## Discussion

The following important information can be observed through my anatomical research [3]:

1. The areolar layer is the most resistant structure, presenting a great number of large round fat cells, and less connective tissue, and this layer is responsible for the terminal vascularization of the dermis (Figs. 2.1 and 2.2).
2. The lamellar layer has small fusiform fat cells and a great number of connective tissue layers through which important vessels pass coming from the musculoaponeurotic level (Fig. 2.6).
3. In regions where the areolar layer is thicker, the panniculus slides easily in a block over the musculoaponeurotic level.
4. It is suitable to perform liposuction on the lamellar layer because the fat cells are distributed between the layers of the connective tissue.
5. Between the areolar and lamellar layers is the fascia superficialis, which is an important anatomical structure of the abdominal panniculus that is useful to consider as a symbol of the new concepts in lipoabdominoplasty.
6. Liposuction in the areolar layer should be done very carefully because adipose cells are piled one over the other with few layers of connective tissue. It is advisable to use a thin cannula (3–4 mm in diameter).
7. In regions presenting very thin skin, the areolar layer is also very thin.
8. When the lamellar layer is thick, the fat cells are situated between the layers of connective tissue, and the panniculus does not slide easily over the musculoaponeurotic level because there are many perforator vessels coming from the muscles underneath (Fig. 2.8).
9. The perforator vessels present anatomical structures formed by arteries, veins, lymphatics, and nerves to provide blood supply to the lamellar layer, and they join with other perforator vessels creating the communicating vessels (Fig. 2.2b).
10. From the communicating vessels, small vessels go perpendicularly to provide blood supply to the subcutaneous region and to the dermis (Fig. 2.2).
11. When the lamellar layer is quite thin, there are few and small perforator vessels coming from the musculoaponeurotic level; the fascia superficialis is more evident; and the panniculus slides easily over the muscles (Fig. 2.5a).
12. In children, the lamellar layer is very thin due to the small number of perforator vessels, and the panniculus slides in a block over the musculoaponeurotic level.



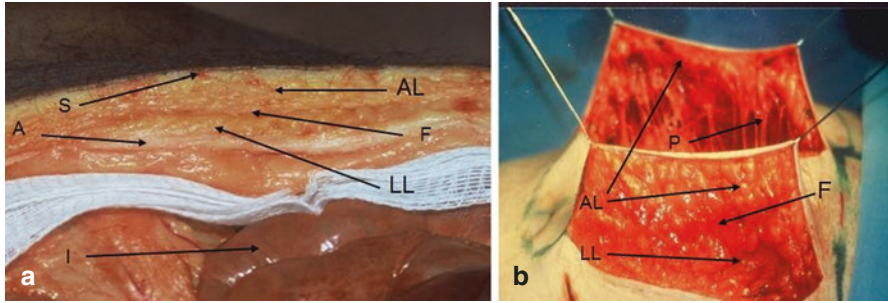
**Fig. 2.8** Anatomical study of cadaver to show modifications of the subcutaneous panniculus in the abdominal wall after a liposuction procedure. (a) Frontal view of the abdomen after liposuction performed on the *left side*. With my hands pinching the panniculus, one can see the difference of thickness compared with that of the right side without the liposuction procedure. (b) In the same cadaver, an incision was made on the *left side* and another on the *right*. On the *left side*, the areolar layer is preserved, since liposuction was properly performed on the lamellar layer. The fascia superficialis with perforator vessels was preserved in the lamellar layer lying smoothly on the muscular abdominal wall. On the *right side*, the areolar layer, fascia superficialis, and lamellar layer are identified. (c) Drawing of the abdominal panniculus showing the proper level to perform liposuction: 1 on top one can see the cannula introduced through the skin incision with its tip in the lamellar layer (below the fascia superficialis), 2 the middle shows that perforator vessels are preserved without fat in the lamellar layer, 3 on the bottom, the arrow indicates that the areolar layer is pulled downward with inclination of the perforator vessels which work as multiple pedicles to provide blood supply to the remnant panniculus. AL areolar layer, F fascia, LL lamellar layer

In my previous publications concerning this subject, I reported the anatomical findings of the abdominal panniculus in thorough and in-depth research, which consisted of dissection and liposuction on cadavers [3–5]. According to my descriptions, the behavior of the subcutaneous tissue in people presenting with localized adiposity shows enormous variations from one region to another.

The epigastric, umbilical, and hypogastric regions are the most important ones regarding complex anatomical alterations, because the fat infiltrates into the panniculus (Fig. 2.1). In these regions, the lamellar layer shows modifications of its thickness. It becomes thicker than the areolar layer due to the larger volume of fat cells situated between the connective layers of the fascia superficialis. On the flanks and in the hypochondriac and inguinal regions in the same person, I found fewer anatomical alterations than in other regions.

The main anatomical characteristic of the lateral regions is the thickness of the areolar layer, which is thicker than the lamellar layer. Since the lamellar layer is very thin, the fascia superficialis in these regions is a compact structure formed by several layers of connective tissue, with blood vessels and lymphatics as well. The fascia superficialis is situated very close to the abdominal musculature; consequently, the panniculus slides easily over the muscles because there are not so many perforator vessels (Fig. 2.5a). It is also quite easy to hold the panniculus with two fingers, described by Illouz as “the pinch test.”

It is important to emphasize that in the epigastric, umbilical, and hypogastric regions, the umbilical region corresponds to the middle of the abdomen, with the umbilicus in the center (Fig. 2.1). The umbilical region shows the same anatomical

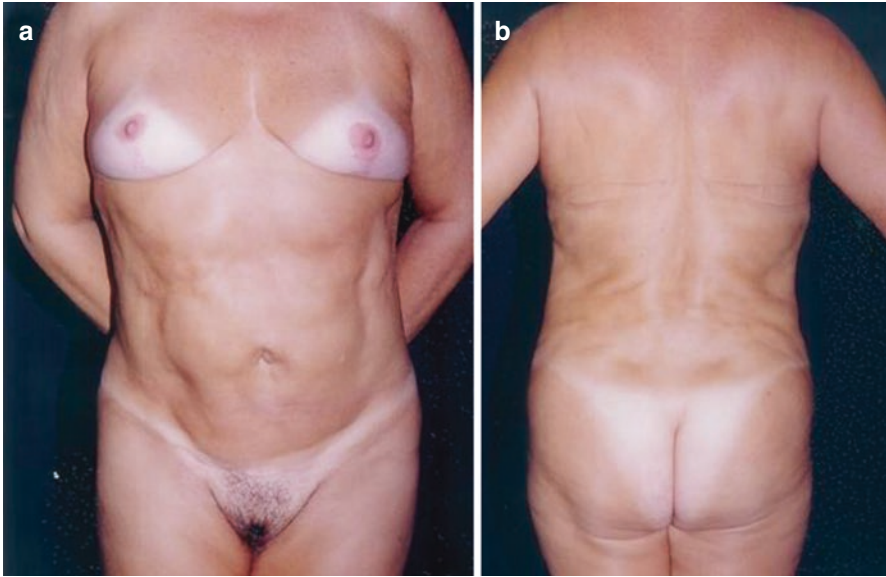


**Fig. 2.9** Anatomical study in cadavers to show the relationship of the subcutaneous panniculus layers in the abdominal wall. **(a)** The whole panniculus was sectioned, where one can see all the layers and internal viscera in the abdominal cavity of a cadaver without localized adiposity: skin (*S*), muscular aponeurosis of the abdomen (*A*), internal viscera (*I*), areolar layer (*AL*), fascia superficialis (*F*), lamellar layer (*LL*). In the photo **(b)** one can see a fresh cadaver after liposuction performed on the *left side* of the abdomen and the whole thickness of the panniculus on the *right side* without liposuction. On the *left side* of the abdomen, the perforator vessels (*P*) and areolar layer were preserved. On the *right side*, one can see the areolar layer (*AL*) and fascia superficialis (*F*), as well as the lamellar layer (*LL*) with perforator vessels included

panniculus constitution as that in the epigastric and hypogastric regions, except in the umbilicus itself, where the scar tissue forms a compact skin structure, with the subcutaneous cicatricial tissue adhered to the midline of the abdominal musculo-aponeurotic wall.

The abdominal panniculus shows a wide variety of anatomical differences that are described in detail in my previous publications. The lateral regions on the right and the left do not exhibit modifications in the fascia superficialis, which is isolated and very seldom presents localized adiposity, as mentioned by Illouz [13, 14]. However, the medial regions (supraumbilical, umbilical, and infraumbilical) are the ones that show deep and important differences. The fascia superficialis in these regions presents several layers separated by adipose tissue in patients with adiposity (Figs. 2.8 and 2.9). The measurements and variations in the thickness of the areolar and lamellar layers are described in detail elsewhere [8]. The thicker zone of the abdomen corresponds to the projection of the rectus abdominis muscle, where the large perforator vessels are situated (Fig. 2.5b). The thickness of the lamellar layer progressively decreases in the lateral regions of the abdomen. When the lamellar layer is thick, the panniculus adheres firmly to the muscular level underneath, a feature that can also be observed through the Illouz “pinch test” (Fig. 2.8). However, in regions with a thin lamellar layer, the panniculus slides easily over the abdominal musculature.

My anatomical study on cadavers has shown that, after liposuction, the areolar layer maintains almost the same thickness as before the procedure, but the lamellar layer is reduced by aspiration of the adipose tissue (Fig. 2.1). The fascia superficialis shows several layers that make a network with the communicating vessels included (Fig. 2.4). Therefore, the final result in the patient is a lamellar layer without adipose tissue. I have reported that internal cicatricial tissue is evident



**Fig. 2.10** Unsatisfactory result after liposuction on the abdomen and torso. Photos (a, b) show front and back views of a 54-year-old female patient who had undergone liposuction elsewhere. It is evident that the areolar layer was damaged in all regions due to excess fat removal

6 months after liposuction. The thick layer of cicatricial tissue demonstrates the behavior of the subcutaneous tissue. Also, the perforator vessels should not be damaged by the cannula during liposuction (Figs. 2.2 and 2.4). The areolar layer must be preserved in all its thickness. If it is damaged during fat suction, the scar tissue will cause irregularity below the skin, producing “waves” on the surface (Fig. 2.10). Performing a second fat suction in the same region is a very difficult procedure that should be done carefully. The hard thickness of the cicatricial tissue does not allow the cannula to cross it (Fig. 2.10). It is also dangerous because the second stage may damage the areolar layer even more, resulting in ungraceful irregularities on the skin surface. Lockwood [18] has described important concepts regarding the anatomy of the superficial fascial system, similar to previous descriptions of the anatomy; as well, the behavior of the panniculus after the liposuction procedure has also been described [5].

## Torso

The posterior wall of the trunk has benefited from the advent of liposuction for the treatment of localized adiposities. Conventional procedures performed through wide undermining and panniculus resection leaves undesirable and unesthetic scars, factors that have not encouraged plastic surgeons to treat those deformities.

Usually all regions of the torso present a similar constitution in both the cutaneous and subcutaneous tissues. The skin shows a thick and firm areolar layer, as described elsewhere [3], while the lamellar layer is much thinner. However, in patients presenting with localized adiposities, the thickness of the lamellar layer may be greatly changed, leading to deformity of the body contour. Therefore, when liposuction is performed in those areas, they must be well demarcated before surgery, as I have described for abdominoplasty without panniculus undermining [6]. Thus, torsolipoplasty and flanklipoplasty may be performed for improving the body contour, in accordance with my findings published simultaneously with new concepts in abdominoplasty [6].

## Conclusions

In conclusion, I emphasize again that fat suction should be done on the deep (lamellar) layer, keeping the thickness of the areolar layer intact; this provides a smooth final result. When the areolar layer is damaged, the outline of the abdominal wall may present ungraceful irregularities with an unesthetic appearance. Knowledge of the abdominal panniculus, with its sophisticated architecture formed by special vascular structures, as well as its peculiar distribution of fat layers, is very important for achieving a good surgical result. The indications for isolated liposuction procedures, and also their combination with abdominoplasty, suggest that, with appropriate patient selection, the procedures may be performed with caution in all such patients. The operation is done through the cutaneous panniculus in order to achieve a good and natural result, aiming for harmonious body contours.

## References

1. Avelar JM (1985) Fat-suction versus abdominoplasty. *Aesthetic Plast Surg* 9:265–276
2. Avelar JM (1985) Combined liposuction with traditional surgery in abdomen lipodystrophy. XIV instructional course of aesthetic plastic surgery of the ISAPS, Madrid, September
3. Avelar JM (1986) Surgical anatomy and distribution of cellular tissue on human body. *Anatomia cirurgica e distribuição do tecido celular no organismo humano*. In: Avelar JM, Illouz YG (eds) *Liposuction (lipoaspiração)*. Editora Hipócrates, Sao Paulo, pp 45–47
4. Avelar JM (1987) Study of the subcutaneous adipose tissue applied for fat-suction technique. In: Manesksha RJ (ed) *Trans. IX Int. Congr. Plast. Reconstr. Surg, New Delhi, 1–6 Mar*, pp 377–379
5. Avelar JM (1989) Regional distribution and behaviour of the subcutaneous tissue concerning selection and indication for liposuction. *Aesthetic Plast Surg* 13:155–156
6. Avelar JM (1999) A new technique for abdominoplasty – closed vascular system of subdermal flap folded over itself combined to liposuction. *Rev Bras Cir* 88/89(1/6):3–20
7. Avelar JM (1999) Flankplasty and torsoplasty – new surgical approach. *flancoplastia e torso-plastia- nova abordagem cirúrgica*. *Rev Bras Cir* 88/89(1/6):21–35
8. Avelar JM (2002) Anatomy of the abdominal panniculus. In: Avelar JM (ed) *Abdominoplasty without panniculus undermining and resection*, Ed Hipócrates, São Paulo, pp 59–86

9. Gray H (1974) *Anatomy descriptive and surgical*. Running Press, Philadelphia
10. Illouz YG (1978) A new technique. (Une nouvelle technique) Communication a la Societe Française de Chirurgie Esthetique, Juin, São Paulo
11. Illouz YG (1980) A new technique for localized lipodystrophy. (Une nouvelle technique pour les lipodystrophies localisees). *Rev Chir Esthet* 4:19
12. Illouz YG (1982) Liposuction technique. First instructional course with surgical demonstrations at São Paulo Hospital, Prof. Andrews' Service. Organized by Brazilian Society of Plastic Surgery – Regional São Paulo, Endorsed by Brazilian Society of Plastic Surgery (BSPS), October
13. Illouz YG (1983) Body contouring by lipolysis: a 5 – year experience with over 3000 cases. *Plast Reconstr Surg* 72:591
14. Illouz YG (1983) My technique of suction lipectomy. Meeting of the American Society of Aesthetic and Plastic Surgeons and Instructional Course, April
15. Illouz YG (1984) Refinements in Liposuction to improve body contour. Theory and practical course with surgical demonstrations at “Nove de Julho” Hospital. Organized by Brazilian Society of Plastic Surgery (BSPS) with collaboration of regional, São Paulo, May
16. Illouz YG (1986) Estudo do adipócito nas lipodistrofias. In: Avelar JM, Illouz YG (eds) *Liposuction (lipoaspiração)*. Hipocrates, Sao Paulo, pp 19–23
17. Illouz YG (1986) Princípios básicos da Técnica de Lipoaspiração. In: Avelar JM, Illouz YG (eds) *Liposuction (lipoaspiração)*. Editora Hipocrates, Sao Paulo, pp 13–18
18. Lockwood T (1995) High lateral-tension abdominoplasty with superficial fascial system suspension. *Plast Reconstr Surg* 96:603–615
19. Testut L, Jacob O (1975) *Tratado de anatomia topografica*. Salvat Editores, Barcelona

# Chapter 3

## Surgical Principles and Classification of Abdominoplasty or Lipoabdominoplasty

Juarez M. Avelar

### Introduction

Aesthetic treatment of the abdomen has been performed since the end of the nineteenth century when Kelly [31] performed elliptical horizontal skin with adipose tissue resection of the abdominal wall including the umbilical area. He created the expression “lipectomy” which is specifically employed for aesthetic procedures on the abdominal wall. Afterward other expressions came out such as “dermolipectomy” and “dermolipex” which are currently employed for other surgeons. For this reason he popularized the operation and his name is a symbol of abdominoplasty.

Nevertheless, according to Sinder [42], there is a publication by two surgeons in France, Demars and Marx [24], regarding resection of skin and subcutaneous of the abdomen wall. Such publication maybe is the first reference of an aesthetic procedure on the abdomen wall. However, I consider it natural to give credit to Kelly as the first publication concerning abdominoplasty since his surgical principles opened a wide field for many authors. Thanks to him who searched and developed new approaches which are essential for the harmonious balance of the body. Even all techniques described by several authors during the twentieth century are fundamental for the fantastic progress of plastic surgery.

Therefore this was the beginning of a long and rich history followed by many other scientific publications all over the world. This field of plastic surgery presents a remarkable evolution and improvement of the surgical results of the body contour.

---

J.M. Avelar, MD

Head of the Brazilian Scientific Institute of Plastic and Reconstructive Surgery,  
Al Gabriel Monteiro da Silva, 620 Jd Europa, São Paulo, SP 01442-000, Brazil  
e-mail: [juarezavelar@bol.com.br](mailto:juarezavelar@bol.com.br); [institutodaorelha@uol.com.br](mailto:institutodaorelha@uol.com.br)



As it is published in medical literature, the panniculus resection can be done by several different approaches according to the deformity of the abdomen and torso. One may classify it in five types of incisions:

- A. Horizontal incisions – This is the most common incision to perform abdominoplasty since most of the patients present abnormalities on the abdominal wall, which may be treated by small incisions on the suprapubic area. In fact, the first description of abdominoplasty by Kelly is a good example of horizontal incision to rebuild the abdominal wall. Several authors such as Jolly [29], Malbec [33], Callia [23], Pontes [35, 36], Pitanguy [34], Serson [40], Baroudi et al. [22], Regnault [38], Sinder [41, 42], Avelar [1–5, 10], and others introduced substantial contribution to the field through horizontal incisions.
- B. Vertical incisions – Although they seem to be the most reasonable approach to perform abdominoplasty since they reshape the body, they did not become popularized because they leave an undesirable scar on the midline of the abdomen. Babcock [21], Kuster [32], and Fernandez-Correa Iturraspe [25] described such an approach, which nowadays is more important for treatment of patients after massive weight loss as well as after bariatric surgeries, as emphasized by Roxo et al. [39] and Kaluf et al. [30] with outstanding surgical results.
- C. Circular incision – This type of operation was first described by Somalo [43], who was the first to make use of the expression abdominal dermolipectomy. Later Gonzales-Ulloa [26] called the operation as “belt lipectomy” and few years later Vilain and Dubousset [46] who named it “lipectomie circulaire.” When this kind of operation is performed, the panniculus (skin and subcutaneous tissue) is resected all around the body in order to remove the redundant skin and subcutaneous layers. This procedure is specifically indicated for patients after weight loss because the whole body presents excess skin and panniculus as well.
- D. Submammary incisions – The first description regarding this approach was done by Thorek [44] to remove the excess skin of the upper abdomen. The author did not draw the skin resection exactly on the submammary fold, but the objective of the operation was to remove the panniculus on the upper abdomen below the breasts. Important contribution is introduced by Rebello and Franco [37] who advocated submammary incisions in order to remove the whole anterior segment of the upper abdomen. They performed wide undermining on the supra-aponeurotic level until the umbilical region in order to pull the superior flap upwards.
- E. Half-moon skin resection on bilateral submammary folds – Since my previous publications [10, 11, 16–19] regarding lipoabdominoplasty or abdominolipoplasty which is performed without panniculus undermining, I have described new concepts concerning the submammary approach. A half-moon skin is resected on each side of the hypochondriac region in order to treat the upper abdominal wall through upper incisions without panniculus undermining. Therefore it is adequate to add my approach to those previous incisions described in medical literature.

It doesn't matter what type of incisions were done; all techniques described until 1999 used to be performed through wide undermining and resection of the abdominal

panniculus. Therefore, through the traditional procedures, all perforator vessels coming from the muscular level were cut when panniculus is carrying out.

Undoubtedly since abdominal lipectomy was published by Kelly in 1899, the most revolutionary surgical technique for aesthetic treatment of the abdominal wall is liposuction described by Illouz [27, 28]. In fact, Illouz developed and popularized fat suction which gave substantial improvement to the aesthetic treatment of the abdominal wall with excellent results and few complications during and after operation. However, the liposuction technique is very useful only to remove localized adiposity. The correction of excess skin of the abdominal wall required cutaneous undermining followed by panniculus resection according to traditional procedures. I used to perform the same combined procedure since liposuction became a routine method in my practice [4, 5]. Meantime I used to have similar rate of complications during and after operation which was uncomfortable for my patients and for me also. Due to that high incidence of complications in 1988, I took a radical decision to not perform such procedures of liposuction associated with panniculus resection [8].

## Technique

### *Lipoabdominoplasty or Abdominoplasty: A Method Without Panniculus Undermining and Resection*

Although no longer perform combined procedure of panniculus resect with liposuction, I followed intensive research in my previous anatomical study in cadaver looking for new method which could avoid those complications.

After long period of anatomical research in cadavers with obsessive pursuit, I reached a scientific conclusion that it is possible to associate liposuction with panniculus resection since the perforator vessels are preserved during surgery. Therefore I developed and published a new method to remove excess skin of the redundant panniculus combined with fat tissue [10–12]. According to my new concepts, conventional abdominoplasty through lipectomy is not performed in my method as it is described in my previous publications [2–5].

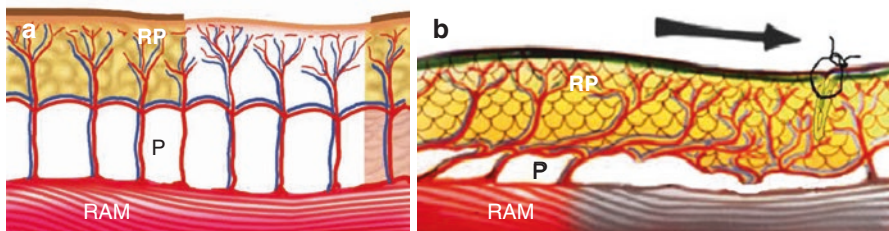
My technique presents new surgical principles which were not described in other methods in medical literature. For this reason I would like to present to the readers the following surgical principles which represent new concepts in order to improve safest abdominoplasty.

### *Surgical Principles*

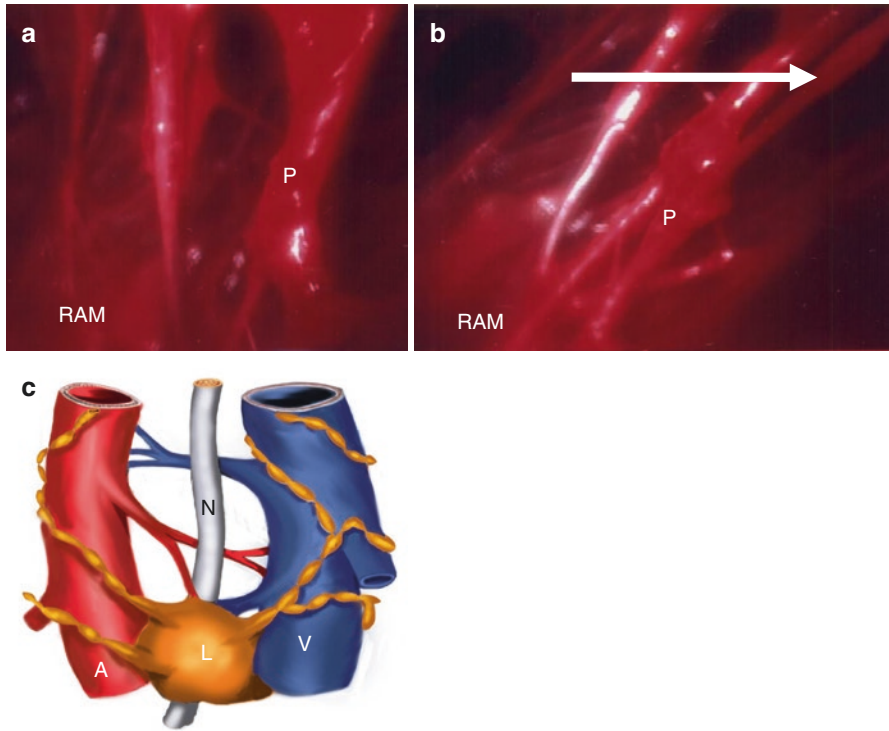
The technique is recommended for patients presenting excess skin, localized adiposity, redundant panniculus, striae, muscular flaccidity, and diastasis of the rectus abdominalis. Knowledge of the anatomy of the abdominal panniculus,

particularly the vascularization described in my previous publications [6, 9], is fundamental to perform this procedure. Key elements of the technique include the following:

1. The operation is performed as a closed vascular system, which represents new concepts for improving the body contour [10–12, 16]. Since the vascular network is not damaged, the perforator vessels supply the abdominal panniculus (Figs. 3.1 and 3.2).
2. Full-thickness lipoplasty is made on the areas where skin resection will be performed (Fig. 3.3).
3. Deep lipoplasty is performed on all abdominal regions that present localized adiposity (Fig. 3.4).
4. Full-thickness skin resection (Fig. 3.3).
5. The cutaneous excess is resected on infraumbilical and/or submammary regions after full-thickness liposuction of the panniculus (Fig. 3.3).
6. Do not perform cutaneous or panniculus undermining, as used to be performed on traditional abdominoplasty (Fig. 3.5).
7. The connective tissue and all vessels of the skin on resected areas are also preserved. This prevents the destruction of perforator vessels and small vessels coursing perpendicularly from the communicating network vessels situated in the fascia superficialis provided by the subdermal vascularization [6, 7, 9].
8. Perforator vessels are preserved during operation which works afterward as multiple pedicles providing adequate blood supply to the remaining abdominal panniculus (Figs. 3.2 and 3.4).
9. As perforator vessels are a neurovascular pedicle since there is a sensitive nerve that passes together with the artery and veins which is not damaged during surgery. For this reason the sensibility of the remaining panniculus after lipoabdominoplasty is preserved (Fig. 3.2).

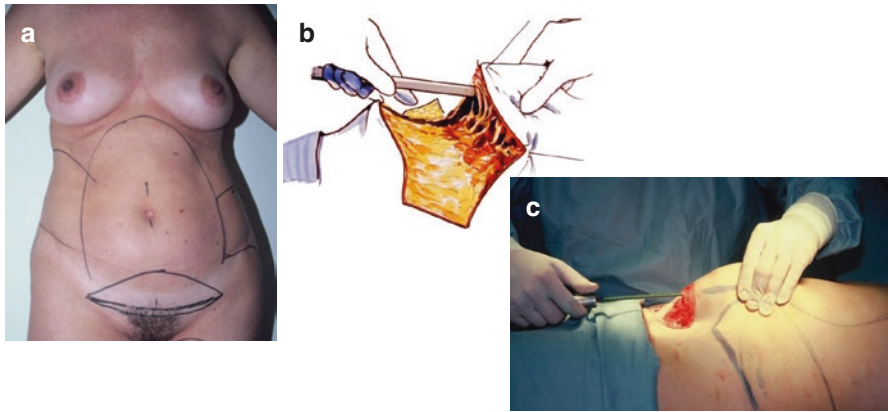


**Fig. 3.1** Surgical principles: closed vascular system, full-thickness liposuction with skin resection and deep liposuction – the remaining panniculus slides over the rectus abdominis muscles (RAM) after deep liposuction to replace the space created after full-thickness liposuction on the area of skin resection and the perforator vessels (P) are preserved. Scheme (a) shows the panniculus after deep liposuction below the remaining panniculus (RP) and full-thickness liposuction of the area of skin resection. The perforator vessels are not damaged, and they fold by traction of the remaining panniculus (RP); scheme (b) shows the movement of the remaining panniculus (RP) after traction and suture. The arrow indicates that the remaining panniculus (RP) slides over the muscles

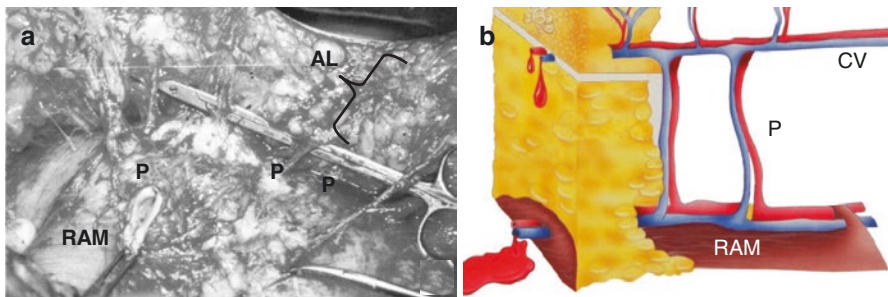


**Fig. 3.2** Closed vascular system – preservation of the perforator vessels emerging from the rectus abdominalis muscle (*RAM*): peroperative photos (**a**, **b**) taken from inside of the remaining panniculus after deep liposuction showing that the perforator vessels (*P*) are preserved and they work as multiples pedicles to the remaining panniculus. The *arrow* indicates the inclination of the perforator vessels (*P*) after traction and suture of the remaining panniculus; (**c**) a unit of anatomical structures of the perforator vessels formed by artery (*A*), vein (*V*), nerve (*N*), and lymphatics (*L*)

10. The lymphatics that surround the arteries and veins are preserved, since the perforator vessels are not cut. Therefore, the lymph coming from the abdominal panniculus maintains its normal circulation after surgery, avoiding seroma formation (Fig. 3.2).
11. Cauterization during surgery usually is not necessary since there is no damage to the blood vessels.
12. Differently from the classical abdominoplasty, in which drainage is an important procedure, in this new surgical technique drainage is not necessary because there is no bleeding during or after surgery.
13. Blood transfusion was a necessary support until 1998 because abdominoplasty operations caused so much bleeding (Fig. 3.5) that there is a chapter in our book “Liposuction” [45]. Nevertheless, in the use of my new concepts for abdominoplasty and further applications, blood transfusion has not been necessary since there is no bleeding during or after surgery (Fig. 3.6).

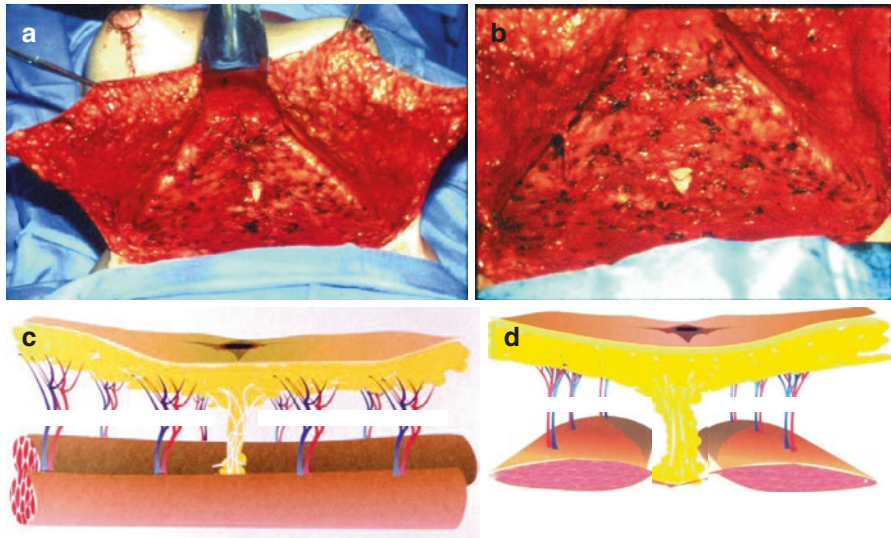


**Fig. 3.3** Surgical demarcation of full-thickness liposuction on the area of skin resection, deep liposuction on the remaining panniculus. (a) Preoperative showing surgical demarcations: full-thickness liposuction on suprapubic area and deep liposuction on other regions; scheme (b) demonstrates deep liposuction on remaining abdominal panniculus; (c) peroperative photo shows deep liposuction procedure on the remaining panniculus. Full-thickness liposuction and skin resection on suprapubic region were already done

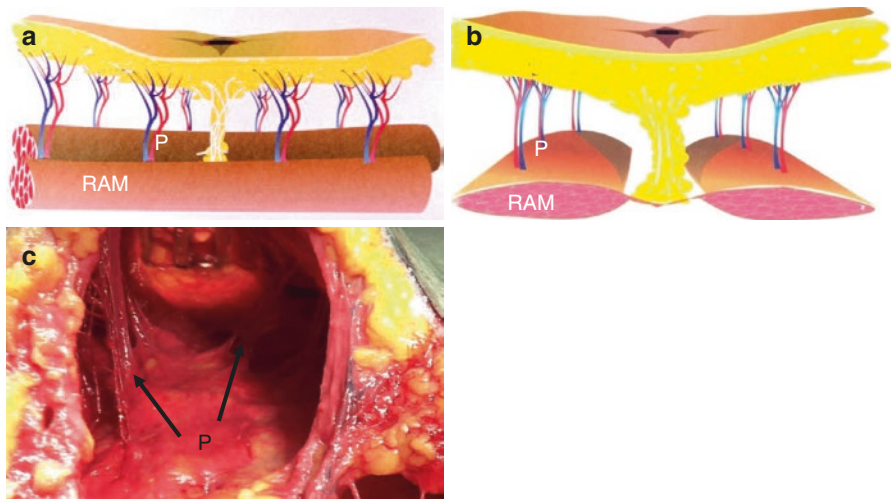


**Fig. 3.4** Preservation of the perforator vessels (*P*) during liposuction procedure. Peroperative photo (a): a scissor is introduced behind the perforator vessels (*P*) showing that they were not damaged. This black and white photo was taken by Prof. Callia and Dr. Batuirra during conventional abdominoplasty performed 6 months after liposuction procedure on the abdomen, who kindly gave me with permission to publish. One can see the areolar layer (*AL*) below the skin and the rectus abdominis muscle (*RAM*); (b) scheme showing the anatomical structure of the vascular system in the abdominal panniculus: perforator vessels (*P*) coming from rectus abdominis muscle (*RAM*) to the communicator vessels (*CV*) which are inside the fascia superficialis

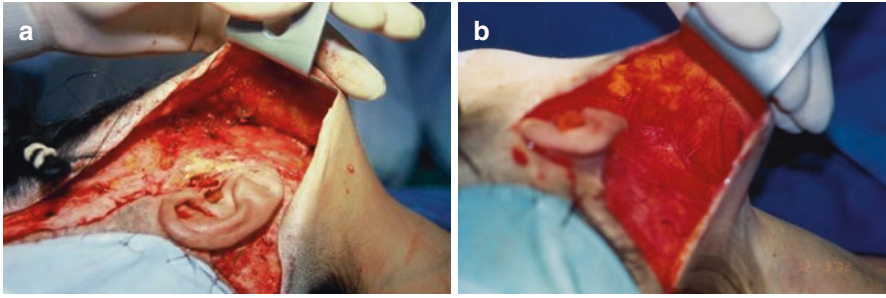
14. The new surgical principles are employed for treatment of localized abnormalities on several regions of the human body such as aesthetic surgery of axilla [15], face lifting (Fig. 3.7) [18–20], ear reconstruction (Figs. 3.8 and 3.9), lower reverse blepharoplasty (Fig. 3.10), aesthetic surgery of the buttocks, medial thigh lipoplasty (Fig. 3.11) [13], torsoplasty, and flankplasty (Fig. 3.12) [14].



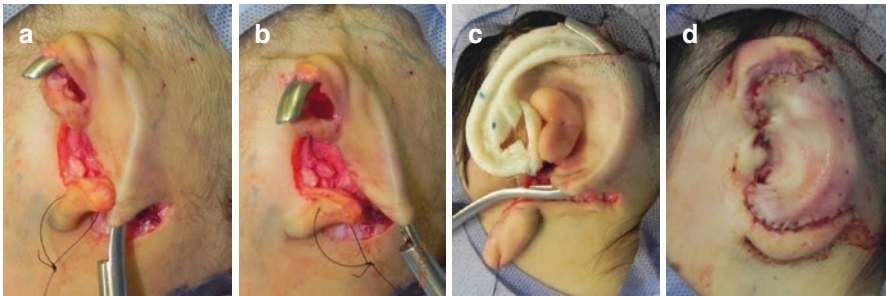
**Fig. 3.5** Traditional abdominoplasty performed with wide panniculus undermining since all perforator vessels were cut during operation: peroperative photos (a, b) show in frontal view the abdominal panniculus already undermined with the umbilicus with triangular shape on its natural place on the muscular abdominal wall. On the raw area, one can see multiple black points that indicate cauterization of the perforator vessels; drawing (c) shows the lateral view of the panniculus since the perforator vessels coming from the rectus abdominalis muscles were cut and on drawing (d) in frontal view



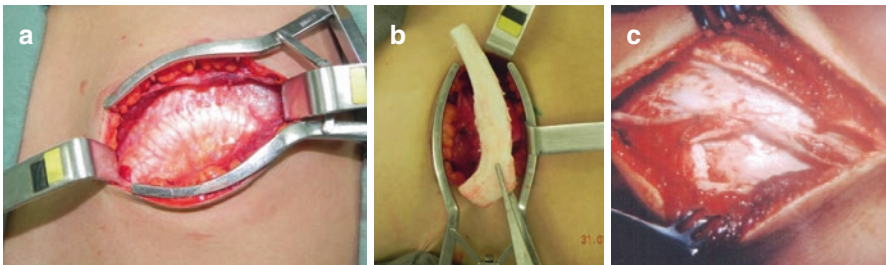
**Fig. 3.6** Preservation of the perforator vessels (*P*) when abdominolipoplasty is performed through new concepts are properly employed: scheme (a) shows the perforator vessels (*P*) on lateral view coming from the rectus abdominalis muscles (*RAM*); (b) scheme in frontal view; (c) peroperative photo taken from below the remaining panniculus after liposuction procedure showing that the perforator vessels (*P*) were preserved which indicate the rectus abdominalis muscles



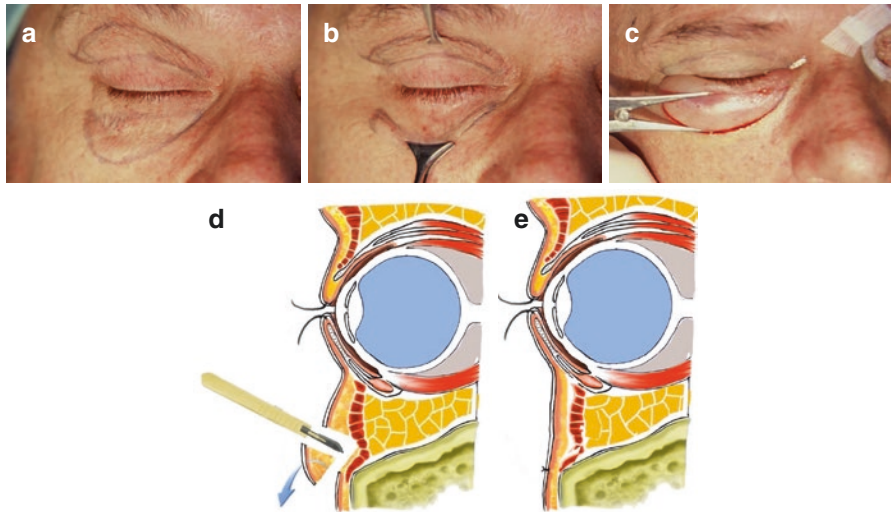
**Fig. 3.7** Application of the new concepts on abdominoplasty during rhytidolipoplasty without cutaneous undermining: photo (a) peroperatively showing cutaneous flap undermined with scissor according to traditional techniques – all perforator vessels were cut; photo (b) rhytidolipoplasty performed according to tunnelization without damaging the perforator vessels similar to procedure performed with new concepts on abdominoplasty



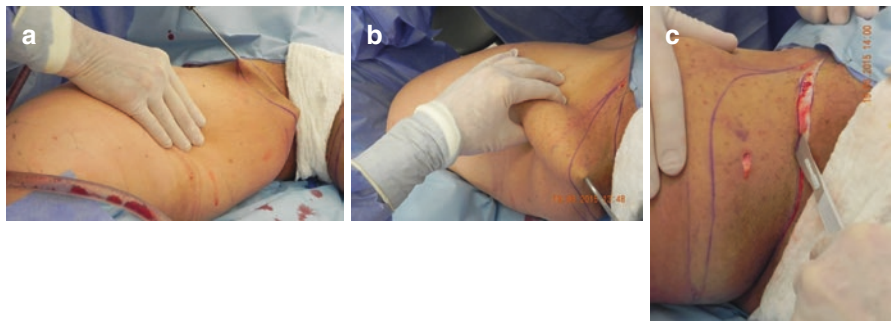
**Fig. 3.8** Sequential photos during surgery showing creation and preservation of a neurovascular pedicle on ear reconstruction which are surgical principles from new concepts on abdominoplasty: photo (a) shows that selective cutaneous undermining was done limited on the future helix and antihelix; (b) one can see the neurovascular pedicle on the conchal cavity; (c) the auricular skeleton is being introduced through the subcutaneous tunnel; (d) the auricular framework is already introduced and the lobule and upper segments are sutured



**Fig. 3.9** Sequential photos during operation showing removal of the rib cartilage to excavate the new auricular framework employing the basic surgical principles from new concepts on abdominoplasty, since the perichondrium is carefully undermined in a closed vascular system: (a) a cutaneous incision was done on the right side of the chest and the rib cartilage with perichondrium exposed; (b) with a knife an incision is done on the perichondrium and careful dissection to remove the cartilage on similar procedure as it is done on dissection of the perforator vessels to be preserved alike on new concepts on abdominoplasty and the rib cartilage is already removed; (c) afterward the perichondrium will be sutured to regenerate another rib cartilage



**Fig. 3.10** Application of the surgical principles of skin resection on reverse lower blepharoplasty without skin undermining: preoperative photos (a) demarcation; (b) evaluation of the excess skin; (c) excising the excess skin; drawing (d, e) showing skin resection on lower lid without any undermining and final suture



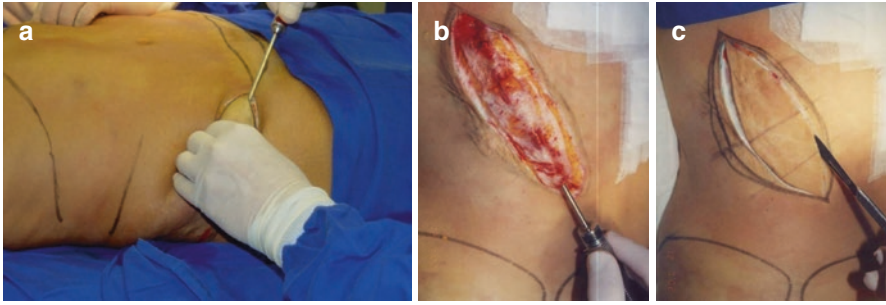
**Fig. 3.11** Application of the surgical principles: closed vascular system, full-thickness liposuction, deep liposuction, and skin resection on medial thigh lipoplasty – preoperative photos showing a sequential stages of operation: (a) full-thickness liposuction; (b) deep liposuction; (c) skin resection without panniculus undermining

## Technique

### *Preoperative Demarcations*

All areas requiring treatment (localized adiposity and skin excess) must be demarcated before surgery with the patient in a standing position. According to surgical demarcations, three areas must be well marked for adequate orientation of the later surgical stages: the first one for lipoplasty of the abdominal wall, the second one for





**Fig. 3.12** Application of the surgical principles: closed vascular system, full-thickness liposuction, deep liposuction, and skin resection on flank lipoplasty and torso lipoplasty – photos during operation: (a) full-thickness liposuction on flank area; (b) close-up of the procedure; (c) skin resection after full-thickness liposuction without panniculus undermining

skin resection on the suprapubic region (Fig. 3.3a) or all infraumbilical areas, and the third in half-moon-shaped incisions on the submammary fold.

### *Liposuction*

Liposuction is performed on two different levels: (1) full thickness of the panniculus where skin resection will be performed and (2) on deep level on the lamellar layer (below fascia superficialis), as described in my previous publications (Fig. 3.1a) The volume of fat aspirate is according to surgical demarcations from 250 mL to 1500 mL.

After liposuction procedure, the cutaneous and subcutaneous panniculus slides easily over the muscular aponeurotic wall, preserving all perforating vessels (Fig. 3.1b). This is analogous to the panniculus on a child, in which minimal subcutaneous fat is present in the lamellar layer. The areolar layer is preserved to achieve a uniform thickness of the remaining panniculus, which provided a harmonious result and well-balanced body contour.

### *Skin Resection*

Skin resection is performed following the preoperative markings (Fig. 3.3a). The subdermal structures and the fat layers are preserved in all regions. All histologic elements of the dermis must be resected. Since the vascularization of the subdermal layer is preserved, there was no bleeding during or after skin resection.

With regard to the areas where skin resection is performed, a fundamental element of my concept is to perform lipoplasty of the full thickness of the panniculus, leaving only the connective tissue and the arterial, venous, and lymphatic vessels between the muscles below the panniculus and the thin layer of subdermal structures above it (Fig. 3.3b).

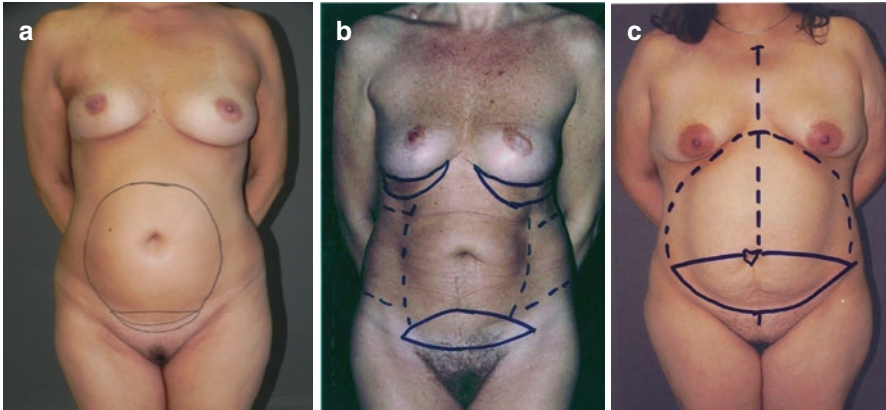
### ***Reinforcement of the Muscular Aponeurotic Abdominal Wall***

Although the abdominal panniculus is not undermined during operation, it is possible to perform plication of the musculoaponeurotic wall when patient presents diastasis. The presence of the perforator vessels indicate clearly location of the inner borders of the rectus abdominalis which are good references points during reinforcement of the muscular aponeurotic wall (Fig. 3.6).

### ***Classification of Lipoabdominoplasty or Abdominolipoplasty***

The abdominal wall is anatomically divided into nine regions: three odd, epigastric, umbilical, and hypogastric, and three even, hypochondriac, flank, and inguinal [9]. Nevertheless, concerning aesthetic surgery, I suggest to classify only in two segments: superior and inferior (above and below the umbilical area, respectively). A careful analysis of my patients I classify into four types:

- A. Lower lipoabdominoplasty or lower abdominolipoplasty
- B. Upper lipoabdominoplasty or upper abdominolipoplasty
- C. Lower and upper lipoabdominoplasty or lower and upper abdominolipoplasty (combined procedure)
- D. Full abdominolipoplasty or full lipoabdominoplasty
  - A. Lower abdominolipoplasty or lower lipoabdominoplasty – This operation must be employed for correction of unaesthetic deformities on the inferior segment of the abdomen. Skin resection is performed on suprapubic region where liposuction is done on full thickness of the panniculus. The umbilicus is not transposed (Fig. 3.13a).
  - B. Upper abdominolipoplasty or upper lipoabdominoplasty – When there are deformities localized specifically on the upper segment of the abdomen, that is above the umbilical region (Fig. 3.13b).
  - C. Upper and lower lipoabdominoplasty or upper and lower abdominolipoplasty – This type of combined procedure is performed when both segments of the abdomen (the superior and the inferior) need to be repaired simultaneously, in patients presenting very high umbilicus in which it is not possible to do transposition of the umbilicus (Fig. 3.13b). Once again it is important to emphasize adequate surgical evaluation and surgical planning prior operation.
  - D. Full lipoabdominoplasty or full abdominolipoplasty – This operation is performed when there is indication of conventional abdominolipoplasty, because there are abnormalities on all area of the inferior segment of the abdomen in which transposition of the umbilicus must be done. It is the most complex type of abdominolipoplasty since abdominal panniculus is not undermined but it is mandatory to resect the entire skin of the infraumbilical area (Fig. 3.13c).



**Fig. 3.13** Classification of the abdominoplasty with its indication, surgical planning, and demarcation: (a) a patient demarcated for lower abdominoplasty combined with liposuction on upper abdomen; (b) a patient demarcated for upper and lower abdominoplasty showing areas for skin resection on suprapubic and submammary folds, and the areas for liposuction is drawing with dotted line; (c) a patient with demarcation for full lipoabdominoplasty. The area below the umbilicus will be resected, and a vertical dotted line shows the midline and a curve dotted line shows the area for deep liposuction

## Discussion

I found my nomenclature very useful since the operation must be indicated and performed in order to repair the anatomical alterations located on one segment or on the other, or on both. The correct choice of the technique is essential because it has to be performed in order to achieve the aesthetic improvement of all the regions of the abdomen as a whole. For this reason it is necessary to select patients and to have a proper surgical planning before an lipoabdominoplasty.

### *Advantages of the Technique*

1. Since no neurovascular trauma occurs during procedure, postoperative recovery is more comfortable for patients (Fig. 3.2). In fact, most patients do not complain about pain after surgery.
2. There is less pain for patients because ending of sensitive nerves are removed along with the full-thickness skin resection.
3. The perforator vessels work as multiple pedicles of the abdominal panniculus, providing enough vascularization after surgery, without ischemia or necrosis (Figs. 3.2, 3.4 and 3.6).
4. Cauterization during surgery, drainage, and blood transfusion are unnecessary because there is no bleeding during or after surgery.
5. Since the vascularization of the borders of the surgical wound is entirely preserved, usually healing and scarring have been suitable in most patients.

## Conclusions

Although I was very pleased with my aesthetic results after conventional abdominoplasty performed in combination with liposuction, I was also very disappointed with some complications, such as seroma formation, panniculus slough, panniculus necrosis, and systemic complications. Those circumstances upset very much many patients and me. Seroma formation used to occur in more than 50 % of my combined operations of liposuction with traditional abdominoplasty. Although I used to have a very high incidence of seroma formation after abdominoplasty, I never had any severe consequences during its treatment, which was performed by syringe aspiration once a week.

Due to all these complications in 1988, I took a decision to not perform conventional abdominoplasty combined with liposuction technique. At the same time, I started an intensive research in my previous anatomical studies until I achieved a conclusion that it is possible to perform associated procedures since the perforator vessels are preserved which provide good blood supply to the remaining panniculus avoiding seroma formation and other severe complications.

## References

1. Avelar JM (1976) Umbilicoplasty – a technique without external scar. 13rd Braz Cong of Plast Surg and First Brazilian Cong of Aesthetic Surgery. (Umbilicoplastia – uma técnica sem cicatriz externa). 13° Congresso Brasileiro de Cirurgia Plástica e 1° Congr Bras Cir Estética, Porto Alegre, pp 81–82
2. Avelar JM (1978) Abdominoplasty – systematization of a technique without external umbilical scar. *Aesthetic Plast Surg* 2:141–151
3. Avelar JM (1983) Abdominoplasty: technical refinements and analysis of 130 cases in 8 years follow-up. *Aesthetic Plast Surg* 7:205–212
4. Avelar JM (1985) Fat-suction versus abdominoplasty. *Aesthetic Plast Surg* 9:265–276
5. Avelar JM (1985) Combined liposuction with traditional surgery in abdomen lipodystrophy. XIV Instructional course of aesthetic plastic surgery of the ISAPS. Madrid, September
6. Avelar JM (1986) Anatomia cirúrgica e distribuição do tecido celular no organismo humano (surgical anatomy and distribution of the celular tissue on human organism). In: Avelar JM, Illouz IG (eds) *Lipoaspiração (liposuction)*. Editora Hipócrates, São Paulo, pp 45–57
7. Avelar JM (1987) Study of the subcutaneous adipous tissue applied for fat-suction technique. In: Manesksha RJ (ed) *Transactions of the IX international congress of plastic and reconstructive surgery*. New Delhi, 1–6 Mar, pp 377–379
8. Avelar JM (1988) Abdominoplastia – reflexões e perspectiva biopsicológicas (Abdominoplasty - Reflections and bio-psychological perspectives). *Revista Soc Bras Cir Plast* 3(2)
9. Avelar JM (1989) Regional distribution and behavior of the subcutaneous tissue concerning selection and indication for liposuction. *Aesthetic Plast Surg* 13:155–165
10. Avelar JM (1999) A new technique for abdominoplasty – closed vascular system of subdermal flap folded over itself combined to liposuction. (Uma nova técnica de abdominoplastia – sistema vascular fechado de retalho subdérmico dobrado sobre si mesmo combinado com lipoaspiração). Editora Cidade Científica Ltda. Rio de Janeiro (Brasil). *Rev Bras Cir* 88/89(1/6):3–20
11. Avelar JM (1999) New concepts for abdominoplasty (Novos conceitos para abdominoplastia). Paper presented at the 36th congress of the brazilian society of plastic surgery. Trabalho apresentado no 36° Congresso da sociedade Brasileira de Cirurgia Plástica. Rio de Janeiro

12. Avelar JM (1999) Abdominoplastia: nuevos conceptos para una nueva técnica (abdominoplasty: new concepts for a new technique). XXVI Annual international symposium of aesthetic plastic surgery, Chairman: Prof. Jose Guerrerosantos – Puerto Vallarta, Jalisco
13. Avelar JM (1999) Plastic surgery on inner side of thigh – new concepts and technique without cutaneous or subcutaneous undermining. (Cirurgia plástica de face interna de coxas – Novos conceitos e técnica sem descolamento cutâneo ou subcutâneo). Ed Cidade científica Ltda. Rio de Janeiro (Brasil). Rev Bras Cir 88/89(1/6):57–67
14. Avelar JM (1999) Flankplasty and torsoplasty – new surgical approach. (Flancoplastia e Torsoplastia – Nova abordagem cirúrgica). Ed Cidade Científica Ltda. Rio de Janeiro (Brasil). Rev Bras Cir 88/89(1/6):21–35
15. Avelar (1999) Aesthetic plastic surgery of the axilla – a new technique to the treatment of excess skin, hiperhidrosis, cutaneous flaccidity, hypertrichosis and bromhidrosis. (Cirurgia plastica e estética de axila – Uma nova técnica para tratamento de excesso de pele, hiperhidrose flacidez cutânea, hipertricose e bromidrose – Editora Cidade Científica Ltda. Rio de Janeiro (Brasil). Rev Bras Cir 88/89(1/6):41–54
16. Avelar JM (2000) Abdominoplasty : a new technique without undermining and fat layer removal (Abdominoplastia: uma nova técnica sem prejudicar e remoção da camada de gordura) Arq. Catarinense de Med 29:147–149
17. Avelar JM (2001) The new abdominoplasty and derived technique. ISAPS and ASERF Annual Meeting. The Aesthetic Meeting, New York
18. Avelar JM (2002) Abdominoplasty without panniculus undermining and resection: analysis and 3-year follow-up of 97 consecutive cases. Aesthetic Surg 22:16–25
19. Avelar JM (2002) Rhytidoplasty with non-traumatic undermining. Panel of facial rejuvenation: ultimate achievement with additional procedures. XVI Congress of ISAPS, Istanbul, May
20. Avelar JM, Ilouz YG (2007) Nontraumatic undermining in rhytidectomies. Aesthet Surg Facial Mosaic. Ed. Springer 39:243–254
21. Babcock WW (1916) On diseases of women and children. Am J Obstet 74:596
22. Baroudi R, Keppke EM, Tozzi Netto F (1974) Abdominoplasty. Plast Reconstr Surg 54:161–168
23. Callia WEP (1965) Contribuição ao estudo de correção cirúrgica do abdomen pêndulo e globus (contribution to the study of surgical correction of the pendulum abdomen and globus). original art. Doctoral Thesis Fac Med USP, São Paulo
24. Demars and Marx (1890) Referred in Voloir P – Opérations plastique SUS-aponévrotiques sur la paroi abdominale antérieure. Thèse
25. Fernandez JC, Iturraspe C (1951) Dermolipectomia vertical en el delantal grasoso. Dia Med 23:1483
26. Gonzalles-Ulloa M (1960) Belt lipectomy. Br J Plast Surg 13:179–186
27. Ilouz YG (1980) Une nouvelle technique pour les lipodystrophies localisées. Rev Cir Esthet Franc 6(9)
28. Ilouz YG (1982) Liposuction technique. First instructional course with surgical demonstrations at São Paulo Hospital, Prof. Andrews' Service. Organized by Brazilian Society of Plastic Surgery – Regional São Paulo, Endorsed by Brazilian Society of Plastic Surgery (BSPS), October
29. Jolly R (1911) Die operation des Fettbauches. Berl Klin Wochenschr 29:1317
30. Kaluf R, Azevedo FN, Rodrigues LO (2006) Sistemática Cirúrgica em Pacientes Ex-Obesos. Revista Brasileira de Cirurgia Plástica 21(3) Jul/Ago/Set
31. Kelly HA (1899) Report of gynecological cases. John Hopkins Med J 10:19
32. Kuster H (1926) Operation bei Hängebrust unt Hängeleib. Monatsschr. F.Geburst. Gynak 73:316
33. Malbec EF (1948) Lipectomia abdominal. La Prensa Méd Arg 35(26)
34. Pitanguy I (1967) Abdominal lipectomy: an approach to it through an analysis of 300 consecutive cases. Plast Reconstr Surg 4(40):384–391

35. Pontes R (1965) Plástica abdominal: importância da sua associação com a correção de hernia incisional (abdominal plastic: importance of its association with the correction of incisional hernias). *Rev Bras Cir* 52:8
36. Pontes R (1982) Plástica Abdominal – Resultados insatisfatórios (Abdominal plastic – unsatisfactory results). In: Juarez M, Avelar (ed) *Anais do Simpósio Brasileiro de Abdominoplastia, Soc. Brasileira de Cirurgia Plastica-Regional São Paulo*
37. Rebello C, Lion P and Franco T (1972) Abdominoplasty through submammary incision. *International Cong of Aest Plast Surg, Rio de Janeiro*
38. Regnault P (1975) Abdominal dermolipectomies. *Clin Plast Surg* 2(3):411–429
39. Roxo CDP, Roxo ACW and Roxo CW (2012) Oblique thighplasty in patients after massive weight loss. *Rev Bras Cir Plast* 27(1):119–23
40. Serson Neto D (1970) Abdominal dermolipectomies – geometric approach (Dermolipectomias abdominais – abordagem Geométrica). *Rev Col Bras Cir* 10:17
41. Sinder R (1975) Plastic surgery of the abdomen – personal technique with prior undermining of the supraumbilical flap – before infraumbilical resection and the use of the dermo adipose flap. (Cirurgia Plástica do Abdomen – Técnica Pessoal com prévio descolamento do retalho supraumbilical – antes da Ressecção Infraumbilical e uso de retalho dermo adiposo) VI Int Congr of Plast and Reconstructive Surg, Paris, 25 Aug
42. Sinder R (1979) *Cirurgia plástica abdominal (abdominal plastic surgery)*. Sinder, Niteroi
43. Somalo M (1940) Circular dermolipectomy of trunk. *La Semana Med* 24:1435–1443
44. Thorek M (1942) *Plastic surgery of the breast and abdominal wall*. Ed. Charles C. Thomas, Springfield
45. Uebel CO (1986) Self transfusion and hemodilution applicate to liposuction. (Autotransfusão e Hemodiluição Aplicada à Lipoaspiração). In: Avelar JM, Illouz YG (eds) *Lipoaspiração (liposuction)*. Editora Hipócrates, São Paulo, pp 123–126
46. Vilain R, Dubouset J (1964) Technique et indications de la lipectomie circulaire. 150 observations. *Ann Chir* 18:289–300

# Chapter 4

## Lower Lipoabdominoplasty

Juarez M. Avelar

### Introduction

The abdominal wall is an important anatomical structure on body contour. Surgical correction of the abdomen has been performed since 1899 when Kelly introduced basic surgical principles which are the fundamentals of many techniques ever since [17]. Another remarkable contribution is liposuction procedure developed and introduced by Illouz [15, 16] which opened a new era on abdominoplasty.

Body-contouring operation presents a great improvement due to combination of abdominoplasty with liposuction technique [1, 2]. It is more common in women, as a result of disorders caused by repeated pregnancies, previous operations, accumulated adiposity on the panniculus on all regions, flaccidity of the abdominal wall, and diastasis of the rectus muscles (Fig. 4.1). Unpleasant stria and scars on the skin are the consequences of these problems. Nevertheless, this aesthetic operation became frequent also for men, particularly after weight loss or when repeated surgeries were previously performed leaving retracted and unaesthetic scars on the abdominal wall (Fig. 4.2).

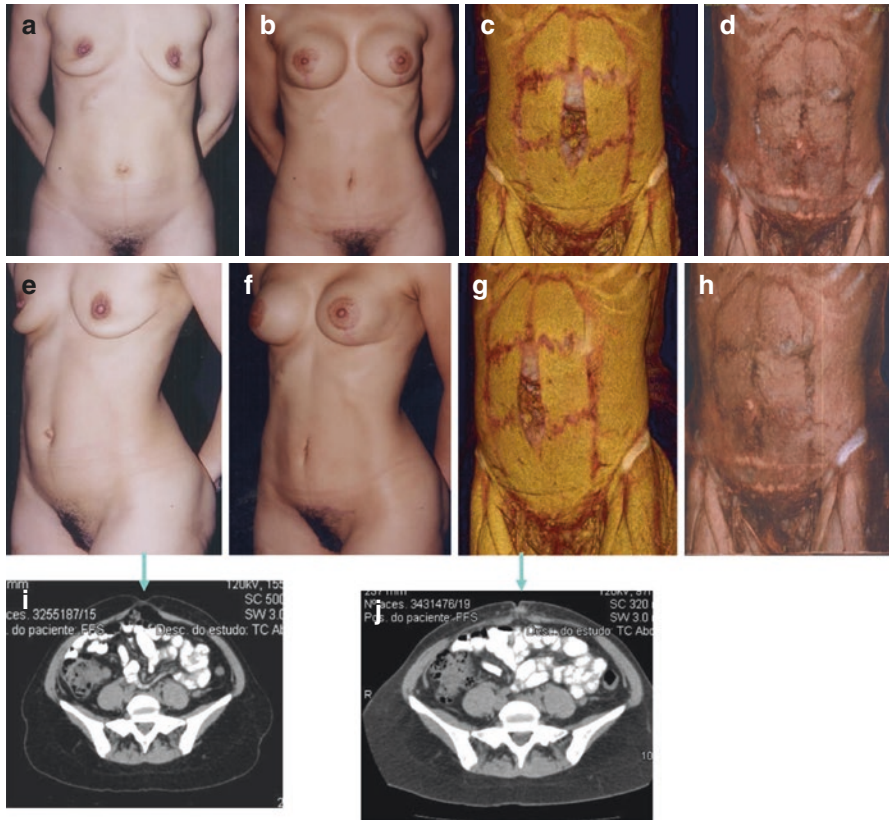
The subject of this chapter is to discuss the reparation of the abnormalities on the lower segment of the abdomen, which is located below the umbilical area, specifically on the suprapubic region. Very often gynecological surgeries or other operations on the infraumbilical area may also leave some unaesthetic scars, sometimes retractile cicatricial tissue, or several other undesirable circumstances which require adequate reparation (Fig. 4.3).

Since 1965 when Callia presented his historical technique, he already mentioned about patients with very high implantation of the navel. Due to his exceptional creativity, he performed sectioning of the umbilical pedicle after panniculus undermining

---

J.M. Avelar, MD

Head of the Brazilian Scientific Institute of Plastic and Reconstructive Surgery,  
Al Gabriel Monteiro da Silva, 620 Jd Europa, São Paulo, SP 01442-000, Brazil  
e-mail: [juarezavelar@bol.com.br](mailto:juarezavelar@bol.com.br); [institutodaorelha@uol.com.br](mailto:institutodaorelha@uol.com.br)

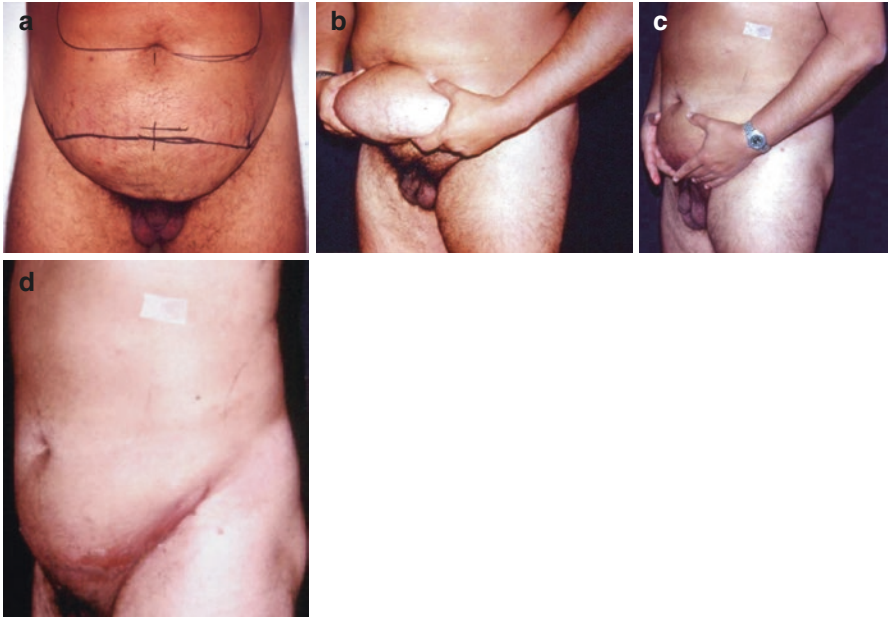


**Fig. 4.1** Flaccidity of the abdomen with severe umbilical hernia and diastasis of the rectus abdominis muscle and hypomasty: **(a, e)** preoperative photos in frontal and lateral views; **(b, f)** postoperative view showing improvement of body contour with lower abdominoplasty combined with reinforcement of musculo-abdominal wall by sectioning the umbilical pedicle (Callia's technique); **(c, g)** computed tomography before surgery; **(d, h)** tomography after operation **(i)** – tomography before surgery showing umbilical hernia; **(j)** tomography after abdominoplasty with reinforcement of the muscular flaccidity

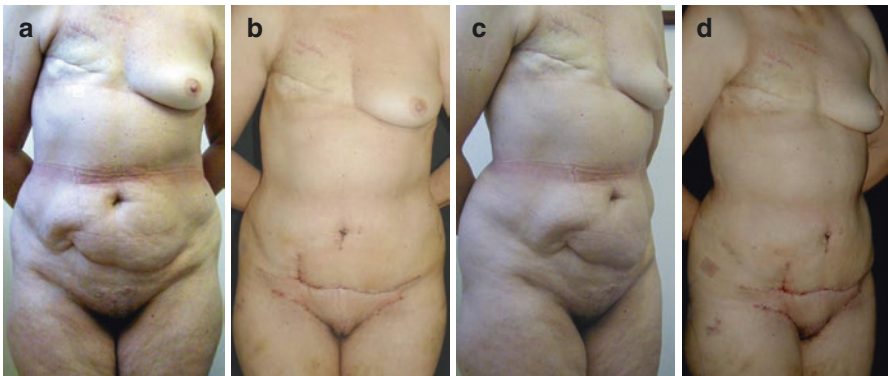
of the infraumbilical segment in order to plicate the musculoaponeurotic wall on the midline until xiphoid process. Afterward reimplantation of umbilical pedicle was done on the rectus abdominalis [13].

Lower abdominoplasty is also indicated when the patient presents moderate flaccidity and excess skin associated with localized adiposity on other regions of the torso. During surgical planning the surgeon should evaluate how much cutaneous resection must be done and the volume of fat that should be aspirated. The patient should see his or her body, in front of a mirror, and be informed about details regarding the operation, with special emphasis on the cutaneous incisions and possible scarring.





**Fig. 4.2** Surgical demarcations. A 38-year-old male patient after massive weight loss still remaining localized adiposity on lower abdomen: (a) an elliptical area for skin resection and full-thickness liposuction is marked on suprapubic region and another area for deep liposuction procedure on abdomen and flanks; (b) before operation patient holds the excess of abdominal panniculus; (c, d) after lower abdominoplasty



**Fig. 4.3** A 68-year-old female patient presented severe surgical and unaesthetic scars on abdomen who underwent radical mastectomy on right side. Lower abdominoplasty associated with medial thigh lipoplasty was planned: (a, c) preoperative frontal and oblique view; (b, d) postoperative surgical results 2 months after surgery

Ever since liposuction was introduced by Illouz, he proposed a procedure of skin resection on the infraumbilical area after liposuction which he named as “bikini resection” [16]. Another terminology was suggested by Hakme [14] as mini abdominoplasty and later emphasized by Stork [18] and Uebel [19], but Pitanguy [20] prefers partial abdominoplasty, to express similar approach proposed by Illouz. As I was so much concerned about liposuction technique quite often, such combined procedure was used to be performed following those terminologies in my presentations and publications [1, 2, 5]. Also Callia’s procedure is employed with sectioning of the umbilical pedicle in order to perform reinforcement of the muscular aponeurotic wall (Fig. 4.1). However most plastic surgeons used to have very high incidence of complications especially seroma formation and panniculus necrosis with severe consequences. I also used to have those problems that bothered me so much which encouraged me to take a radical decision in 1988 to no longer perform such associated procedure [7].

Nevertheless, I started again intensive research in my previous anatomical study when liposuction technique was introduced in my practice [3, 6, 8] especially concerning the physiology of adipose cells looking for a safe procedure on abdominoplasty. In my brainstorming regarding the complications during combined procedures of liposuction with traditional abdominoplasty, I concluded that the main cause was due to vascular trauma during surgery. Again I performed anatomical study in cadavers looking with obsessive pursuit for a solution for those problems. Therefore 10 years after my voluntary decision to not perform liposuction associated with panniculus resection, I found out that it would be possible to perform such combined procedure since the abdominal panniculus was not undermined, and the perforator vessels were not cut which provide normal blood supply to the remaining panniculus. After my convinced conclusion, I achieved the basic fundamentals of my new concepts for abdominoplasty which were published and presented at several congresses of plastic surgery everywhere [9–11].

Nevertheless instead of employing the other terms of mini abdominoplasty, “bikini resection” and partial abdominoplasty, I introduced the terminology of lower abdominoplasty or lower lipoabdominoplasty, since it expresses better such a wide procedure. In reality the operation must treat several deformities of the anterior abdominal wall and the whole torso as well, with smaller scar on the suprapubic region [12]. Therefore, the new concepts of the operation have changed including other surgical steps in order to rebuild the body contour.

## Technique

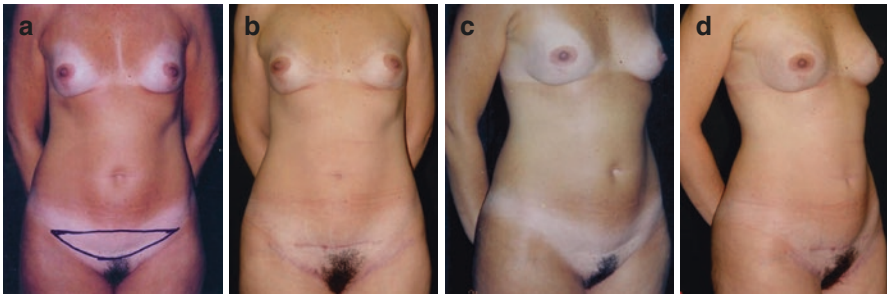
The physical evaluation and the surgical planning are mandatory steps before any operation, but when a patient complains about unaesthetic aspect on the abdomen, they are even more important. Indication of this procedure is a question of selecting patients who present basically abnormalities on the infraumbilical segment where the resection of skin will be done. If the patient presents localized adiposity on the supraumbilical segment and/or on the lateral and posterior regions of the torso, these must be treated simultaneously. This approach has been employed for a long

time, but only after the liposuction era, it became more popular due to more patients requesting abdominoplasty.

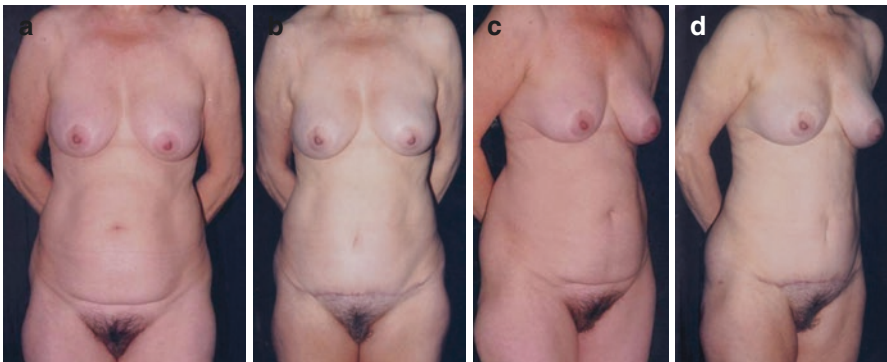
This situation demonstrates once again the importance of careful evaluation pre-operatively including measuring the distance from the external furcula to the umbilicus (FU) and from the umbilicus to the pubis (UP) (Figs. 4.4 and 4.5). Usually when the distance FU is less than 36, it means that the patient is a good candidate for lower lipoabdominoplasty that he or she should not undergo full lipoabdominoplasty in which transposition of the umbilicus is a mandatory procedure.

### *The Operation*

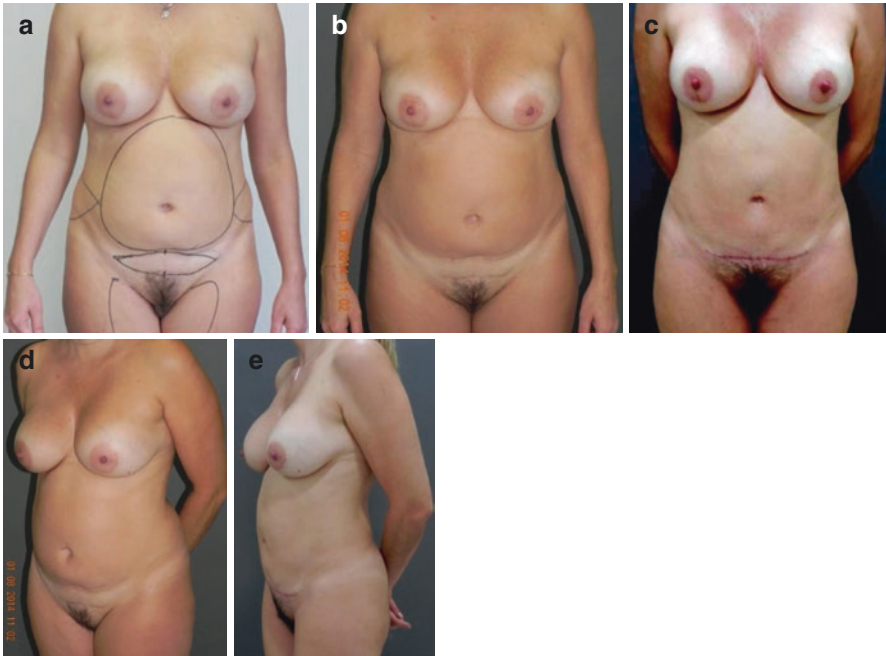
The operation is performed at a hospital under general or epidural anesthesia, but surgical demarcation is done at my clinic one day prior since it is an opportunity to see the patient's deformities once more and to explain to him or her all the surgical



**Fig. 4.4** Surgical evaluation: (a, c) before surgery showing very high umbilicus. The distance from umbilicus to pubis demonstrates that lower abdominolipoplasty is adequate indication. (b, d) postoperative result



**Fig. 4.5** Surgical evaluation and surgical planning: (a, c) a 45-year-old female patient before operation presenting the umbilicus in very high location. The distance from umbilicus to pubis shows that lower abdominolipoplasty is a good indication; (b, d) after operation



**Fig. 4.6** Surgical demarcations: (a) a 33-year-old female patient; an elliptical area for skin resection is marked on suprapubic region as well as localized adiposities for liposuction on abdomen and flanks; (b, d) preoperative; (c, e) after lower abdominoplasty

details. It is also useful to show the patient, in front of the mirror, the cutaneous resection area and localized adiposities and to point out the location of the final scar.

After careful analysis, all deformities are drawn. Two areas must be well demarcated: (A) the area for skin resection (Fig. 4.2) and (B) the areas for liposuction on the abdomen, as well as on the lateral and posterior regions (Figs. 4.5 and 4.6).

- A. Illouz “pinch test” is an important step during demarcation to evaluate the amount of skin which must be resected, and it is marked on the suprapubic area. It is a personal approach since each surgeon has his or her own preference. Anyway the demarcation of the incisions must be done aiming at keeping the final scar as low as possible. This is the main step during demarcation which is a fundamental support preoperatively (Figs. 4.5 and 4.6).
- B. The areas presenting localized adiposities all over the torso must be drawn in order to identify the volume of fat to be aspirated. Quite often there is some sort of asymmetry, which must be shown to the patient. It is important to emphasize the location of the cutaneous incisions even if they are small.

Even though an abdominoplasty has been planned, the whole torso of the patient must be prepared for the operation. I have always been concerned about this subject, as it is previously described [4]. In fact, it is very important to prepare all regions of the torso in order to perform the operation all over the anterior, lateral, and posterior regions of the abdomen aiming at achieving a harmonious result.

Local infiltration is a useful step to be done according to surgical planning on two levels: (a) deep infiltration on the supramuscular plan on all regions for liposuction and (b) superficial and deep infiltration on area for skin resection. The solution of serum 1000 mL plus 2 mg of epinephrine (2/1,000,000) is used. With this volume, it is usually possible to infiltrate the abdomen and lateral sides of the torso as well. The infiltration is done at two levels in two areas:

1. In all demarcated regions for liposuction, it is carried out in the deep layer, under the panniculus (below the fascia superficialis),
2. In area of skin resection that is in the suprapubic region, the infiltration must be done underneath the skin and the full thickness of the panniculus (in the areolar and lamellar layers).

### *Surgical Principles of the Technique*

According to my new concepts, there are five surgical principles:

First principle, full-thickness liposuction is performed where skin resection will be carried out.

Second principle, deep liposuction on remaining regions where skin will not be resected.

Third principle, full-thickness skin resection where there is redundancy of panniculus.

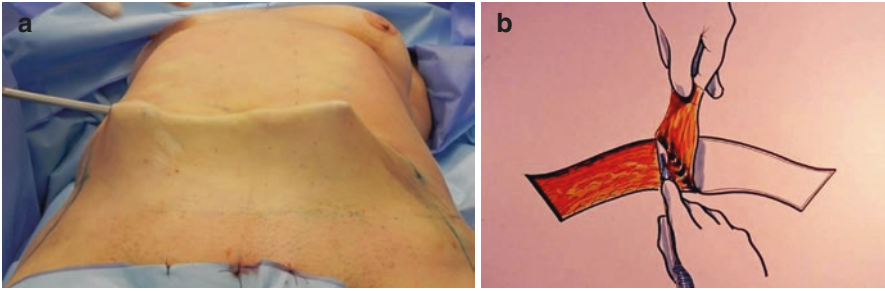
Fourth principle, the perforator vessels are preserved which will work as multiple vascular pedicles.

Fifth principle, the remaining panniculus slides easily on the muscular level.

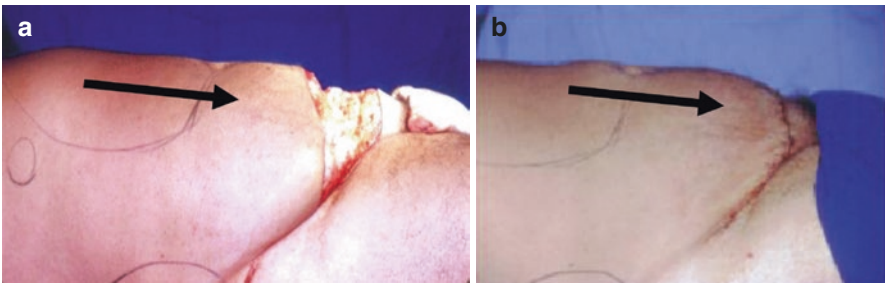
The operation starts performing liposuction on two types:

- A. Full,thickness of the panniculus
  - B. Deep liposuction
- A. Following previous demarcation liposuction is performed on the full thickness of the panniculus on the area where the skin will be resected (Fig. 4.7a). After this procedure the connective tissue and all perforator vessels remain attached to the musculoaponeurotic plane without any fat, which creates a depression (Fig. 4.8a).
  - B. Afterward, deep liposuction is done on all regions of the abdominal wall presenting localized adiposity where skin resection will not be performed (Fig. 4.9b). It is done on the lamellar layer (below the fascia superficialis) preserving the areolar layer above it in order to provide normal blood supply to the dermis according to my previous publications [3–5, 8]. Also, preservation of the areolar layer gives smooth and harmonious surface to the areas where skin resection is not performed.

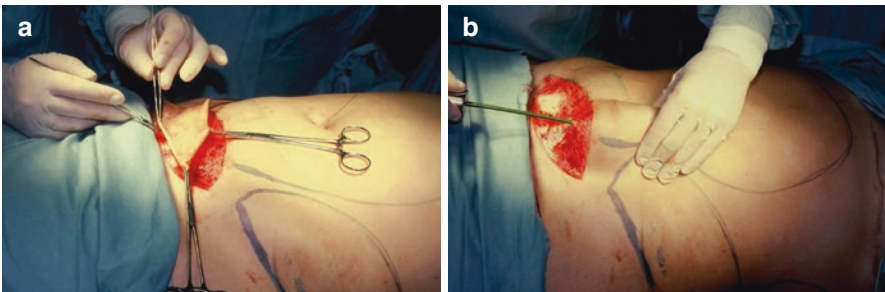
Afterward skin resection is done on the area of liposuction performed on full thickness of the panniculus. It is important to emphasize that the remaining panniculus



**Fig. 4.7** Surgical principles of the technique to perform lower abdominoplasty in a closed vascular system: (a) preoperative photo showing full-thickness liposuction being performed on the area of skin resection; (b) diagram to demonstrate full-thickness skin resection after liposuction according to surgical demarcation



**Fig. 4.8** During lower abdominoplasty the remaining panniculus slides easily over the muscles, since it is a closed vascular system: (a) preoperative photo showing the remaining panniculus with a depression on suprapubic region due to full-thickness liposuction already performed; (b) after traction of the abdominal panniculus and sutured to the suprapubic region. The arrows indicate the movement of the panniculus from up to down



**Fig. 4.9** Lower abdominoplasty is performed as a closed vascular system. Preoperative photos showing the surgical principles of the technique: (a) skin resection has been performed on suprapubic area; (b) afterward deep liposuction procedure being performed below the fascia superficialis. The surgeon must hold the panniculus with one hand and with other hand work with cannula

above the raw area slides easily over the musculoaponeurotic wall because there is no fat below the fascia superficialis and all perforator vessels are preserved which work as multiple pedicles to the abdominal panniculus.

### ***Plication of the Musculoaponeurotic Wall***

Reinforcement of the muscular abdominal wall is a useful procedure during abdominoplasty when patients present diastasis of the rectus abdominalis muscles which must be identified preoperatively. Computed tomography is a routine examination in my clinic which demonstrates the distance between the muscles and even hernia on the midline and laterally as well (Fig. 4.1).

According to Callia's technique, sectioning the umbilical pedicle after liposuction and skin resection on infraumbilical segment must be done in order to perform plication of superior segment of the musculoaponeurotic wall on the midline (Fig. 4.1). Afterward the umbilical pedicle is reimplanted at muscular level. This situation demonstrates once again the importance of careful evaluation preoperatively including measuring the distance from the external furcula to the umbilicus and from the umbilicus to the pubis. The plication of the muscular aponeurotic wall is done from the level of rib margin to pubic area.

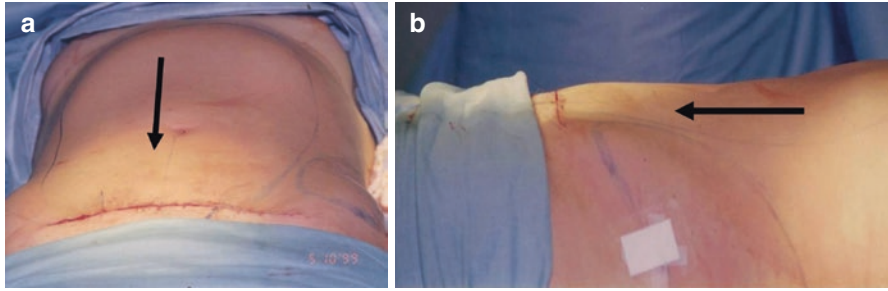
Afterward the upper border of the abdominal panniculus is pulled downward to be sutured to the inferior border in order to close the surgical wound (Fig. 4.8). Three levels of suture must be done: on the fascia superficialis, on the subdermal layer, and on the dermis. The first level of suture is the fascia superficialis in order to approximate the border of the upper flap to the lower border, which is the suprapubic margin. Such suture avoids any scar depression after surgery. Following the closure the subdermis and dermis are stitched.

## **Discussion**

Surgical demarcation must be a routine procedure for adequate orientation during surgery and also to keep the patient well informed about the operation. Always some more photos may be taken after demarcation as a registration of the surgical planning as well as to increase the photographic documentation preoperatively.

Two types of cutaneous incisions may be used. Sometimes a fusiform-shaped cutaneous incision is drawn when the patient has some previous scars so it is advisable to follow them. However, the most frequent one and my personal preference is to draw the lower incision as a convex line on the suprapubic area with its concavity directed downward followed by a straight line on each side similar to Callia's demarcation.

My personal preference is to perform skin resection after liposuction using a knife, since if scissors are used at this stage, they may damage the vascular network of the



**Fig. 4.10** After traction and suture, the abdominal panniculus on lower abdominoplasty: (a, b) show the final procedure of lower abdominoplasty, since the umbilicus was not transposed and liposuction was carried out as a complementary procedure. The arrows indicate the direction of traction of the remaining abdominal panniculus

subdermal layer causing bleeding (Figs. 4.7b and 4.9a). Using a knife the subdermal structures as well as the superficial dermal fat layers are preserved in all regions.

This step of the surgery must be well emphasized since many surgeons think that I recommend de-epithelialization. This is not true because it is necessary to resect full thickness of the skin in order to remove all its histological elements.

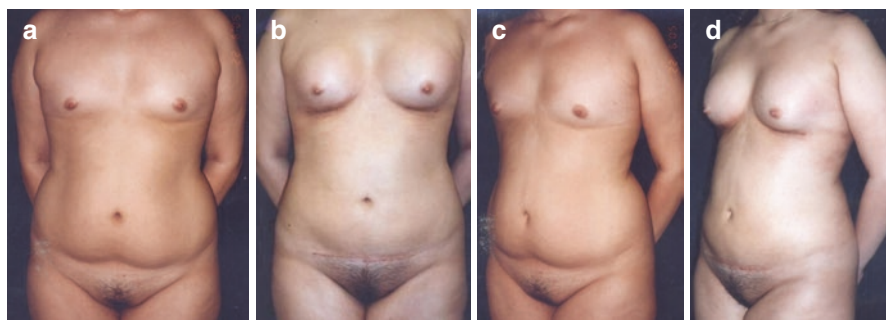
Suture of the musculoaponeurotic structures may be performed on midline when there is adequate indication. The perforator vessels emerge from the central part of the rectus abdominalis muscles which are helpful to identify and to suture the internal borders of the muscles and the aponeurosis (Fig. 4.10). Although the abdominal panniculus is not undermined, reinforcement of the rectus abdominalis is performed when patients present diastasis of the musculoaponeurotic wall (Fig. 4.1). This plication is a useful procedure, but it should not be done in all cases during abdominoplasty [1, 2].

After liposuction procedure on the raw area, there are only connective tissue, fascia superficialis, perforator vessels (arterial, venous) with the lymphatics surrounding them, and a thin layer of subdermal tissue.

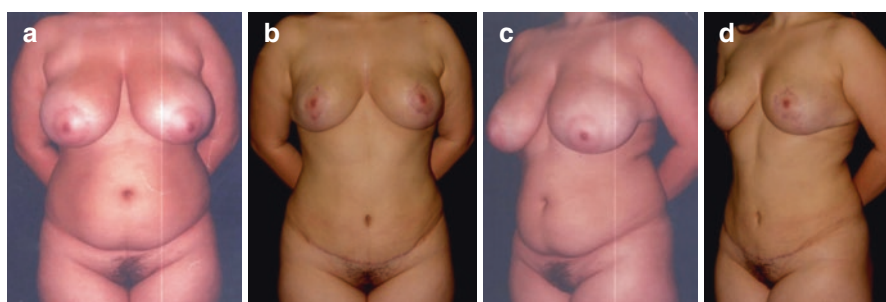## Conclusions

Lower lipoabdominoplasty is a complex procedure since the anterior abdominal wall is treated in order to achieve harmonious result on body contouring (Figs. 4.11 and 4.12). It is a combination of abdominoplasty with liposuction leaving the final scar on the lower segment of the abdomen. Although the abdominal panniculus is not undermined during operation, it is possible to perform plication of the musculoaponeurotic structures when the patient presents diastasis of the rectus abdominalis, hernia, and other disorders. This kind of lower abdominoplasty is indicated to perform on female and male patients. The operation is performed without damage to the perforator vessels which work as multiple pedicles to provide normal blood supply to the remaining abdominal panniculus.





**Fig. 4.11** An 18-year-old girl underwent lower abdominoplasty combined with mammary implant: (a, c) preoperative frontal oblique view; (b, d) postoperative surgical results



**Fig. 4.12** A 19-year-old girl underwent lower abdominoplasty combined with reduction mastopasty: (a, c) preoperative frontal lateral view showing hypertrophic breast and cutaneous flaccidity on lower abdomen; (b, d) postoperative surgical results of lower lipoabdominoplasty associated with reduction mastopasty

## References

1. Avelar JM (1985) Fat-suction versus abdominoplasty. *Aesthetic Plast Surg* 9:265–276
2. Avelar JM (1985) Combined liposuction with traditional surgery in abdomen lipodystrophy. XXIV Instructional Course of Aesthetic Plastic Surgery of ISAPS, Madrid
3. Avelar JM (1986) Anatomia cirúrgica e distribuição do tecido celular no organismo humano (surgical anatomy and distribution of the celular tissue on human organism). In: Avelar JM, Illouz IG (eds) *Lipoaspiração (liposuction)*. Editora Hipócrates, São Paulo, pp 45–57
4. Avelar JM (1986) Preparo do Paciente para Lipoaspiração (preparation of the patient fo liposuction operation). In: Avelar JM, Illouz YG (eds) *Lipoaspiração (liposuction)*. Editora Hipócrates, São Paulo, pp 63–72
5. Avelar JM (1986) Lipoaspiração da Parede Abdominal (fat-suction of the abdominal wall). In: Avelar JM, Illouz YG (eds) *Lipoaspiração (liposuction)*. Editora Hipócrates, São Paulo, pp 157–176
6. Avelar JM (1987) Study of the subcutaneous adipose tissue applied for fat-suction technique. In: Manesksha RJ (ed) *Transactions of the IX international congress of plastic and reconstructive surgery*, New Delhi, 1–6 March, pp 377–379
7. Avelar JM (1988) Abdominoplasty – reflections and biopsychological perspective (abdominoplastia – Reflexões e Perspectivas Biopsicológicas). *Revista Soc Bras Cir Plast* 3(2)

8. Avelar JM (1989) Regional distribution and behavior of the subcutaneous tissue concerning selection and indication for liposuction. *Aesthetic Plast Surg* 13:155–165
9. Avelar JM (1999) Uma nova técnica de abdominoplastia – sistema vascular fechado de retalho subdérmico dobrado sobre si mesmo combinado com lipoaspiração (a new technique for abdominoplasty – closed vascular system of subdermal flap folded over itself combined to liposuction). *Rev Bras Cir* 88/89(1/6):3–20
10. Avelar JM (1999) Abdominoplastia: Nuevos conceptos para una nueva técnica (abdominoplasty: new concepts for a new technique). XXVI annual international symposium of aesthetic plastic surgery, Chairman: Prof. Jose Guerrerosantos, Puerto Vallarta
11. Avelar JM (1999) Novos conceitos para abdominoplastia (new concepts for abdominoplasty). Paper presented at the 36th Congress of the Brazilian Society of Plastic Surgery, Rio de Janeiro
12. Avelar JM (2002) Lower abdominoplasty without panniculus undermining and resection. In: Avelar JM (ed) *Abdominoplasty without panniculus undermining and resection*. Hypocrates, São Paulo, pp 153–170
13. Callia WEP (1965) Contribuição ao estudo de correção cirúrgica do abdomen pêndulo e globus (Contribution to the study of surgical correction of the pendulum abdomen and globus). Original art. Doctoral Thesis Fac Med USP, São Paulo
14. Hakme F, Toledo OMR, Moojen JDN, Sjostedt CO (1985) Lipectomias Abdominais: Um novo “APROACH”(Abdominal Lipectomies: a new approach) *Anais do XXII Congr. Bras. Cir. Plást.*- 591, Gramado, Nov 1985
15. Illouz YG (1980) Une nouvelle technique pour les lipodystrophies localisées. *Rev Cir Esth Franc* 6(9)
16. Illouz YG (1982) Liposuction technique. First instructional course with surgical demonstrations at São Paulo Hospital, Prof. Andrews’ Service. Organized by Brazilian Society of Plastic Surgery – Regional São Paulo, Endorsed by Brazilian Society of Plastic Surgery(BSPS), October
17. Kelly HA (1899) Report of gynecological cases. *John Hopkins Med J* 10:197
18. Stork R (1986) Lipoaspiração como complementação cirurgia do mini- abdome – painel apresentado no XXIII Congresso Brasileiro de Cirurgia Plástica Belo Horizonte Nov [15:21:24] Pitanguy (1987)
19. Uebel CO (1987) Miniabdominoplasty – a new approach for the body contouring. Annual 9th congress of the international society for aesthetic plastic surgery, New York
20. Pitanguy (1987) Body Contour. *Am J Cosmet Surg* 4(4): 283–93

# Chapter 5

## Upper Lipoabdominoplasty

Juarez M. Avelar

### Introduction

The first publication of abdominoplasty was done by Kelly [7], but it is credited to Thorek [11] the first description regarding panniculus resection of the upper abdomen, which was not popularized maybe due to the final unaesthetic scars. During many decades no other author referred to this approach until early 1972 when Rebello et al. [8] presented at the first ISAPS Congress an important contribution as reverse abdominoplasty. That was the first step for treatment of the upper abdomen which opened a wide field, even with possibility for breast reconstruction. Again, Rebello and Franco [9] published their abdominoplasty through submammary approach performed with panniculus undermining of the upper abdomen until to reach the umbilicus [10].

Surgical treatment of the upper abdomen is not a routine procedure, but there are several deformities which require specific approach. Since I developed new concepts on abdominoplasty, the superior segment of the abdomen wall was included in my surgical planning. Skin scar tissue has been a great challenge to plastic surgeons and their knowledge. When abdominoplasty is carried out, this problem is even more serious because it may be visible and leaves a stigma of the operation. For this reason, after the era of liposuction technique introduced and popularized by Illouz [5, 6], women and men became more stimulated to reinstate the body silhouette looking for the close-to-the-ideal self-image because after the operation only very small and adequate scars are left near the deformities.

There are some deformities on the superior region of the abdomen wall, specifically on the epigastric and hypochondriac regions, which require proper treatment in order to reach smooth results. When the abnormalities are restricted to localized adiposity, it is possible to achieve good aesthetic results using isolated liposuction.

---

J.M. Avelar, MD

Head of the Brazilian Scientific Institute of Plastic and Reconstructive Surgery,  
Al Gabriel Monteiro da Silva, 620 Jd Europa, São Paulo, SP 01442-000, Brazil  
e-mail: [juarezavelar@bol.com.br](mailto:juarezavelar@bol.com.br); [institutodaorelha@uol.com.br](mailto:institutodaorelha@uol.com.br)

However, when there is redundant panniculus, it is not possible to reach adequate surgical results without performing skin resection.

There is a reference mentioned by Flageul et al. [4] that Stuckey in 1975 described as “midabdomen” abdominoplasty, but it was published only in 1979, therefore 7 years after the remarkable publication of Rebello and Franco.

Even after more than two decades, the submammary approach did not become popular among plastic surgeons, probably due to the long scar on the anterior aspect of the chest. In fact, such procedure is not a common one, so it is only performed in exceptional cases. I employed it in only one female patient presenting diastasis of the aponeurosis on the midline of the epigastric region and with cutaneous flaccidity. The surgical result was acceptable, but she developed severe seroma, which lasted more than 2 months with aspiration sessions every 4 days.

Using Illouz’s technique [5], the upper abdomen may achieve good aesthetic result when patients present only localized fat deposits without skin flaccidity or redundant panniculus. Since I was very disappointed and frustrated with seroma formation after conventional abdominoplasty combined with liposuction, this segment of the abdomen was not properly treated during any conventional aesthetic procedure on the abdominal wall. Therefore I used to perform only isolated liposuction on this region.

Frequently patients complained about excess adiposity and laxity of the skin on the supraumbilical area as well as on the hypochondriac region with ever-increasing requests for harmonious body contour surgery. Nowadays, plastic surgeons must understand that the most essential aspect for a patient is his or her motivation to reinstate and reshape the whole body. So the main purpose of my original publications [1–3] is to give plastic surgeons a technique with minimal morbidity when performing abdominoplasty associated with liposuction procedure. In those publications I emphasized the treatment of the upper abdomen in combination with lower abdominoplasty without panniculus undermining and resection.

In fact, it is a new field in our specialty and the treatment and attainment of good aesthetic results have been a great challenge. Nowadays, one may inform the patients of the possibility of correction on that region leaving satisfactory scars on the submammary sulcus. Such procedure is not yet well understood by patients not even by some plastic surgeons since they accept cicatricial tissue after mastoplasty, but in case of abdominoplasty to have another scar seems to be very unusual. In fact, one may achieve favorable aesthetic result, but it will leave scars on the submammary folds. The patient must be well informed in detail about the surgery and also regarding the incisions and particularly the final scars.

## **Technique**

### ***Selection of Patients***

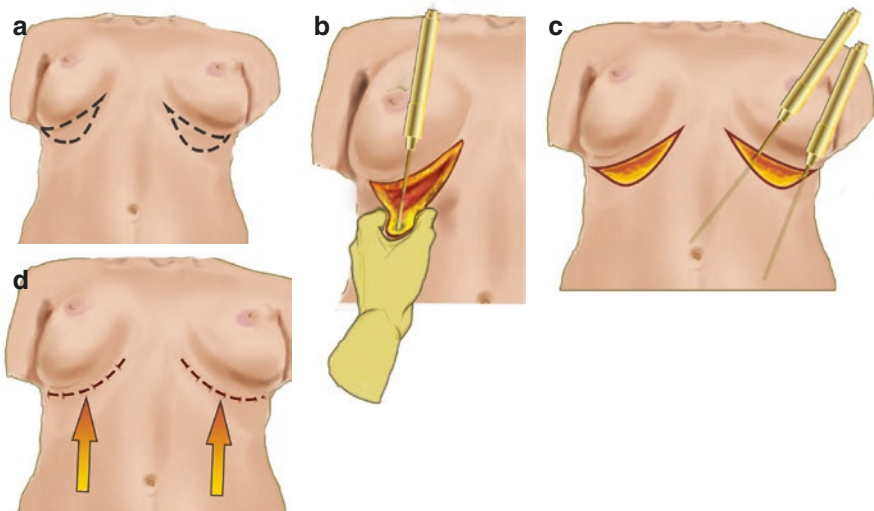
Clinical evaluation and adequate surgical planning are mandatory steps before operation since patients complain about deformities and they are looking for a solution of excess fat accumulated and flabby skin on the upper abdomen (epigastric and

hypochondriac regions) which I named as upper abdominoplasty. It is not an isolated procedure since the whole abdomen will undergo aesthetic surgery. For this reason, a plastic surgeon must understand that his or her patients should be well chosen in order to indicate and perform such procedure.

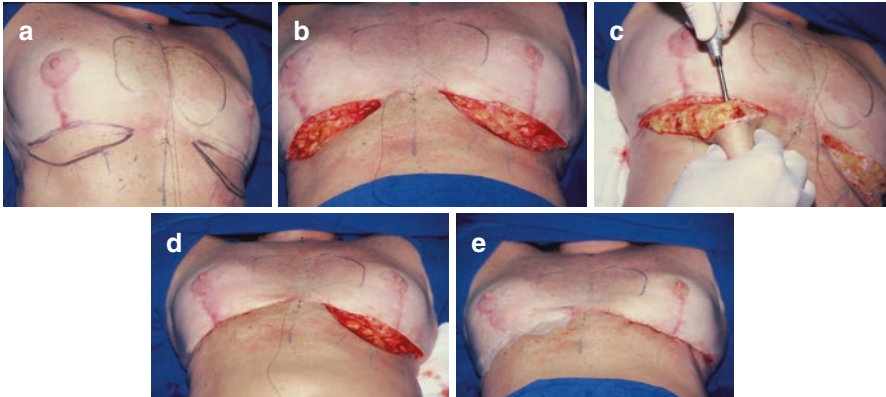
### *Surgical Demarcations*

My preference is to demarcate 1 day before operation at the office when patient comes to my clinic so I can see him or her once again and to check the preoperative blood test, as well as the clinical evaluation under the care of a physician. By this time the photos are ready and he or she can also see all the physical abnormalities in front of some mirrors. The measurements of the patient's circumferences of the torso as well as the vertical distance from the external furcula to the umbilicus (FU) and from the external furcula to the pubis (FP) and from the umbilicus to the pubis (UP) were done previously during the first consultation, and it is reconfirmed again.

Surgical demarcation is done with the patient in standing position and without clothes with my nurses inside the room. The first reference line is marked on the submammary fold on each side. If there is a scar in good location, I follow it; otherwise it is necessary to plan a correct one. Afterward, another line (a curved one) is marked below the submammary sulcus creating a half-moon-shaped area on the hypochondriac regions on the right and left sides (Fig. 5.1). The width and height of



**Fig. 5.1** Sequential drawing to demonstrate the technique for upper abdominoplasty: (a) With dotted line a half-moon elliptical area is marked on the submammary fold on both sides; (b, c) full-thickness liposuction followed by skin resection of half-moon area and liposuction is performed on all the upper abdomen; (d) afterward the lower border of the wound is sutured to the submammary folds as indicated by arrows



**Fig. 5.2** Sequential photos during operation to show the technique: (a) A half-moon area is drawing on the submammary fold bilaterally; (b) full-thickness liposuction was done underneath the skin followed by cutaneous resection; (c) liposuction is being done on all areas of the superior abdomen; (d) the lower border of the wound is sutured in three layers to the submammary fold on right side, since the fascia superficialis is the main structure; (e) both sides are already sutured

that area must represent the amount of skin that will be resected during operation. Also, it is time to demarcate the areas with localized adiposity on the anterior and posterior aspects of the torso and laterally as well.

It is useful to show the patient where the final scars will be and to explain once again the scarring and surgical steps as well. I find it appropriate to talk about this information since it is a new procedure and probably he or she has not seen such surgical results before (Fig. 5.2).

## The Operation

### *Surgical Preparation*

When isolated upper abdominoplasty is performed, my preference is to apply under local anesthesia combined with intravenous sedation. However, most of the operations are done in combination with some other procedures, so I choose epidural anesthesia also associated with intravenous sedation under the care of an anesthesiologist. Once the anesthesia is given, the surgical team must prepare the patient's torso for the operation when those areas are previously demarcated. The next step is to infiltrate all areas for the operation. On the area for skin resection, the infiltration is done on the subdermal level, but on the areas for liposuction will be done only deeply one (on the lamellar layer).

## ***Liposuction***

Liposuction procedure is done in two different levels according to each area: (a) full thickness of the panniculus and (b) deep liposuction (this means below the fascia superficialis):

- (a) The full thickness of the panniculus is aspirated on the submammary regions on half-moon-shaped areas creating a smooth mesh composed by perforator vessels, lymphatics, and connective tissue as well (Figs. 5.1 and 5.2).
- (b) Deep liposuction (below the fascia superficially) is performed in all regions presenting localized adiposity. Afterward, the remaining panniculus slides easily over the muscular level on the hypochondriac regions on each side and on the epigastric region as well.

Using this method all the vascularization of the subdermal layer and below the fascia superficialis is preserved, so there is no bleeding during the operation nor afterward. Therefore, none of the perforator vessels are damaged, and they work as multiple pedicles in order to maintain normal blood supply to the remaining panniculus flap.

## ***Skin Resection***

In all operations concerning abdominoplasty without panniculus undermining and resection, the skin on the half-moon areas is excised in full thickness including of course all histological cutaneous elements, specially hair follicles, sweat glands, and sebaceous glands as well. The subdermal structures must be preserved on all regions to avoid any damage to the vascularization (arterial and venous) as well as to the lymphatics and nerves. It does not matter if the patient has previous scars, the skin resection must be done according to the demarcation trying to recreate the new submammary sulcus.

## ***Suture and Closure of the Wound***

After aspirating all the regions, the final step of the operation is to close the wound. Three levels of suture must be done:

- (a) Suture of the fascia superficialis of the remaining panniculus flap to the aponeurosis on the projection of the previous submammary sulcus. It works like a plication of the remnant subcutaneous tissues. I use at least eight stitches on each side in order to achieve firm fixation of the panniculus to the

musculo-aponeurotic structures of the chest. Therefore the main structures of the panniculus are reinforced.

- (b) Next, the subdermal structure is sutured and folded over itself to approximate the cutaneous border of the surgical wound and to avoid scar depression and retraction.
- (c) Following these technical steps, the final scar is smooth and naturally located on the submammary sulcus. Finally, a running suture is performed on the dermis with absorbent material (Figs. 5.1 and 5.2).

### ***Local Dressing the Bandaging***

Adhesive tapes are placed on the scars crossing each other, and finally strong elastic tape strips are applied over all the region to pull the panniculus upward. On top of them a garment is put covering all the regions of the torso making a slight compression over the panniculus.

The first bandage is removed 1 week after the surgery at the clinic. A new one is put covering the whole scar. This bandage is changed every 10 days and kept for 2–3 months, to avoid traction on the scar caused by involuntary movements. During this period the patient should not do physical exercise that elevates the arms. The elbow should never pass the level of the shoulders.

### **Complications**

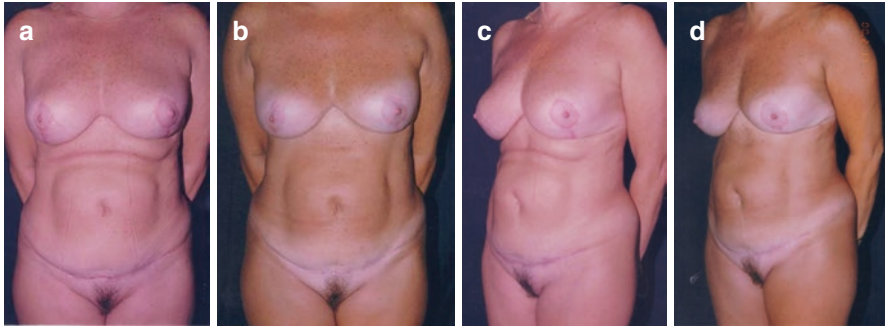
As long as the operation is properly indicated and well performed, some complications are very rare during and after surgery. The most important step of the operation is to demarcate the half-moon area for skin resection on the submammary fold. The superior line must be 2 or 3 mm just below the natural sulcus of the breast where there are strong anatomical structures from subdermal passing from fascia superficialis to the aponeurosis of the pectoralis muscles. If the demarcation is not properly done, it may damage the sulcus since the upper abdominal panniculus pulls the submammary fold downward.

Most of my patients have already underwent mastoplasty and then they have previous scars where the incisions should be placed.

Again it is fundamental step to suture fascia superficialis of the upper border of abdominal flap to fascia superficialis of the remaining border of the submammary fold. In fact, the upper abdominal flap is hanged to the submammary sulcus.

Only two of my first patients needed scar revision 6 months after surgery.





**Fig. 5.3** A 52-year-old female patient underwent reduction mastoplasty combined with liposuction of the abdomen elsewhere presented unaesthetic folds on the superior abdomen area: (a, c) before operation; (b, d) postoperative result after upper abdominoplasty

## Discussion

The operation will leave a scar on each submammary fold for an aesthetic treatment of the upper abdomen (Figs. 5.3 and 5.4). In fact, this is not a great problem since several of my female patients who have undergone this operation had already been submitted to mastoplasty, so they had previously a surgical scar on the submammary sulcus. Some of my patients have been operated previously with ungraceful surgical result. So upper abdominoplasty was performed for reparation of the breast and simultaneously the superior region of the abdomen. Therefore, the final scars are located adequately on submammary folds (Fig. 5.5).

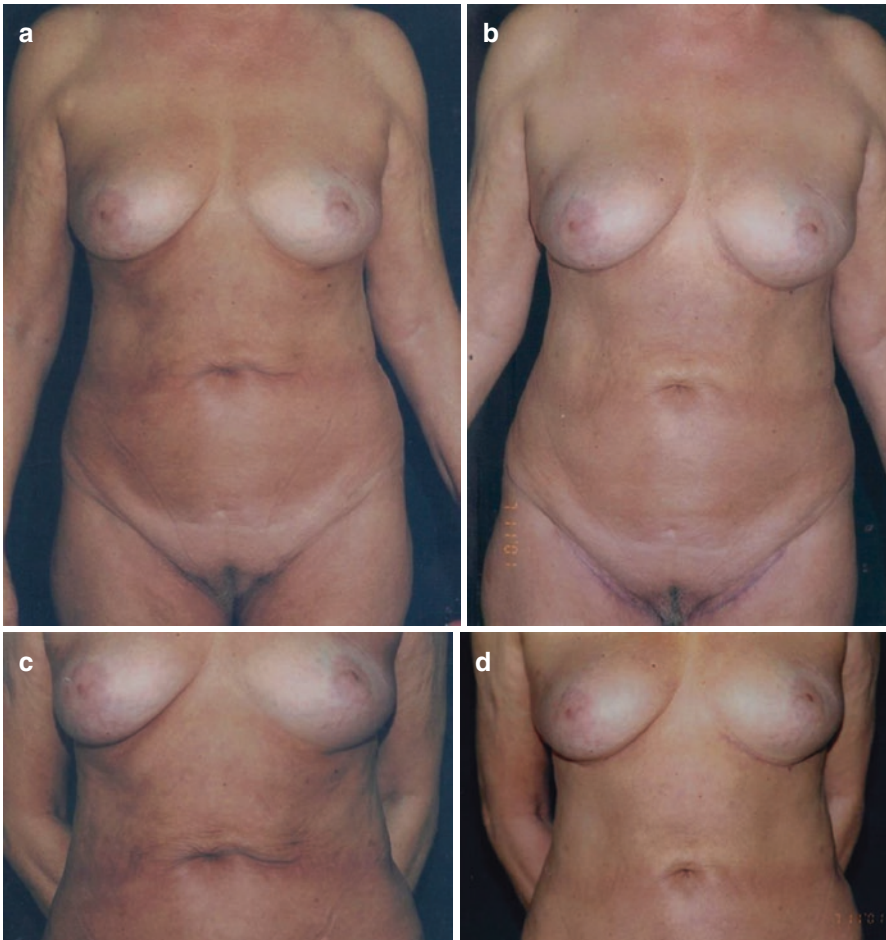Patients presenting unaesthetic results after superficial liposuction on the abdomen show severe irregularities on the surface of the upper abdomen which is unpleasant one. Upper lipoabdominoplasty is indicated with a purpose to improve those unsatisfactory results (Fig. 5.6). When unaesthetic deformities occur on the whole abdominal wall, it is indicated to perform lower and upper lipoabdominoplasty.

I also performed this operation on a male patient who had scars on both sides of the chest due to surgical treatment of bilateral gynecomastia. So after my approach, inconspicuous scars were left and favorable surgical result was achieved.

Patients (female and male) after massive weight loss usually present unaesthetic deformities on the upper abdomen which are good candidates for this operation.

Liposuction procedure is performed on full thickness of the panniculus of the half-moon-shaped area where skin resection is performed. On the lower and lateral areas, liposuction is performed on deep layer (on lamellar layer, i.e., on fascia superficialis). However, in some cases, it is necessary to perform superficial liposuction in order to improve the aesthetic result on the midline area.

The direction of traction of the remaining panniculus is done obliquely to the right and to the left, similar to a “V.” Following this direction the lower border of the wound is sutured to the upper border in order to pull the epigastric region upward to the right and left avoiding cutaneous excess on the midline. The fascia superficialis of the lower segment must be stitched to the same anatomical structure on the mammary fold which is the main suture.



**Fig. 5.4** A 54-year-old patient complains about the unaesthetic appearance of the superior abdomen. She underwent liposuction of the abdomen elsewhere and presented excess panniculus given ungraceful aspect to the umbilicus: (a, c) Before operation in front view; (b, d) postoperative result 2 years after operation. (e, g) Before operation in oblique view where one can see excess panniculus above the umbilicus; (f, h) postoperative result 2 years after upper abdominoplasty

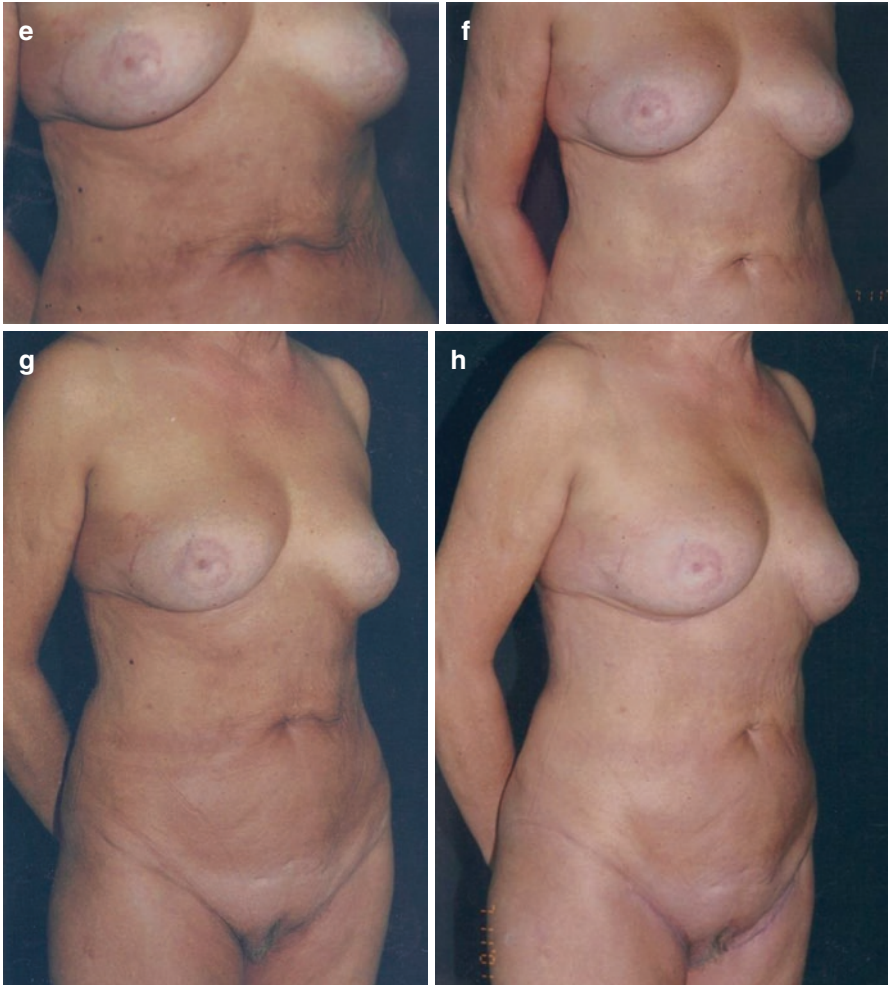
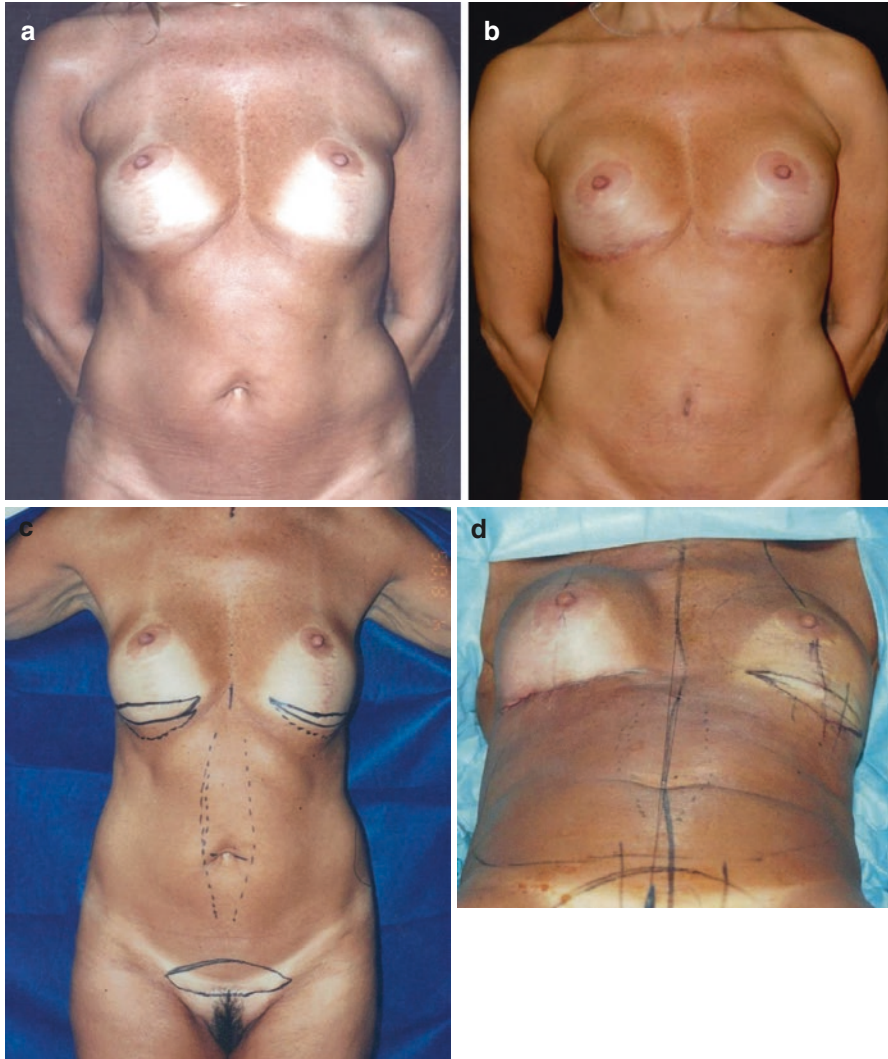


Fig. 5.4 (continued)

## Conclusions

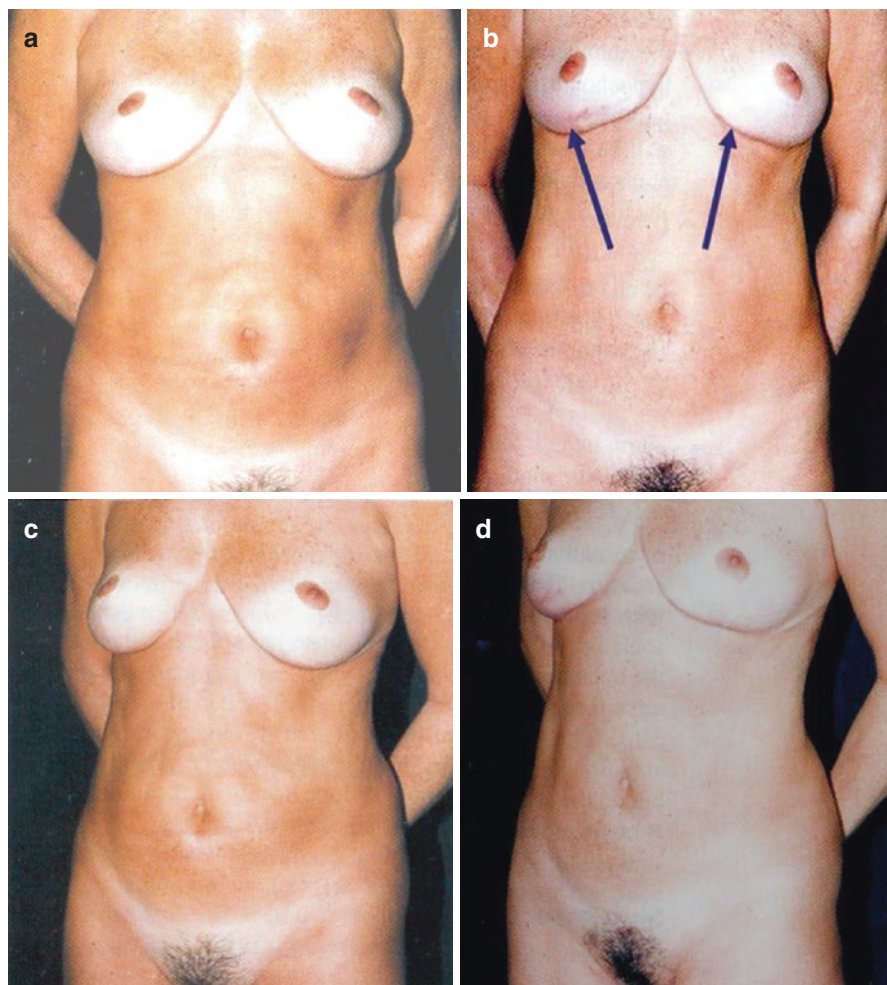
It is important to emphasize that this new procedure gives good aesthetic result if the surgical evaluation and selection of the patients are properly done during consultation. Surgical demarcation is an important step to be performed by the surgeon with the patient in a standing position in order to understand the final location of the surgical scars (Fig. 5.2). The final scars may be placed on the submammary folds. Localized adiposities as well as excess skin on the submammary sulcus are essential indications for upper abdominoplasty.



**Fig. 5.5** A 48-year-old patient underwent mastopexy 3 years ago performed elsewhere presented unsatisfactory result of the breast and localized adiposities on superior abdomen. The surgical planning was to perform upper abdominoplasty combined with mastopexy: **(a)** Before surgery showing unaesthetic aspect of the submammary fold on right and left and adipose tissue above the umbilicus; **(b)** 1 year after upper abdominoplasty showing the improvement of the breast and the superior abdomen **(c)** Surgical planning for upper abdominoplasty combined with plication of the musculo-aponeurotic wall through suprapubic incision. The umbilical pedicle was sectioned according to Callia's procedure and reimplanted afterward. A half-moon area of the skin is drawn on the submammary region in order to create the natural sulcus; **(d)** shows the operation performed on right side of the patient where one can see the submammary sulcus already created and the demarcations on the left breast; **(e)** after surgery on both sides **(f)** lateral view during surgery showing the right breast already operated and the left with surgical demarcations; **(g)** final result on the operating table showing both breasts; **(h)** same patient on oblique view before operation; **(i)** post-operative result 1 year later showing the improvement of the upper abdomen and breast as well

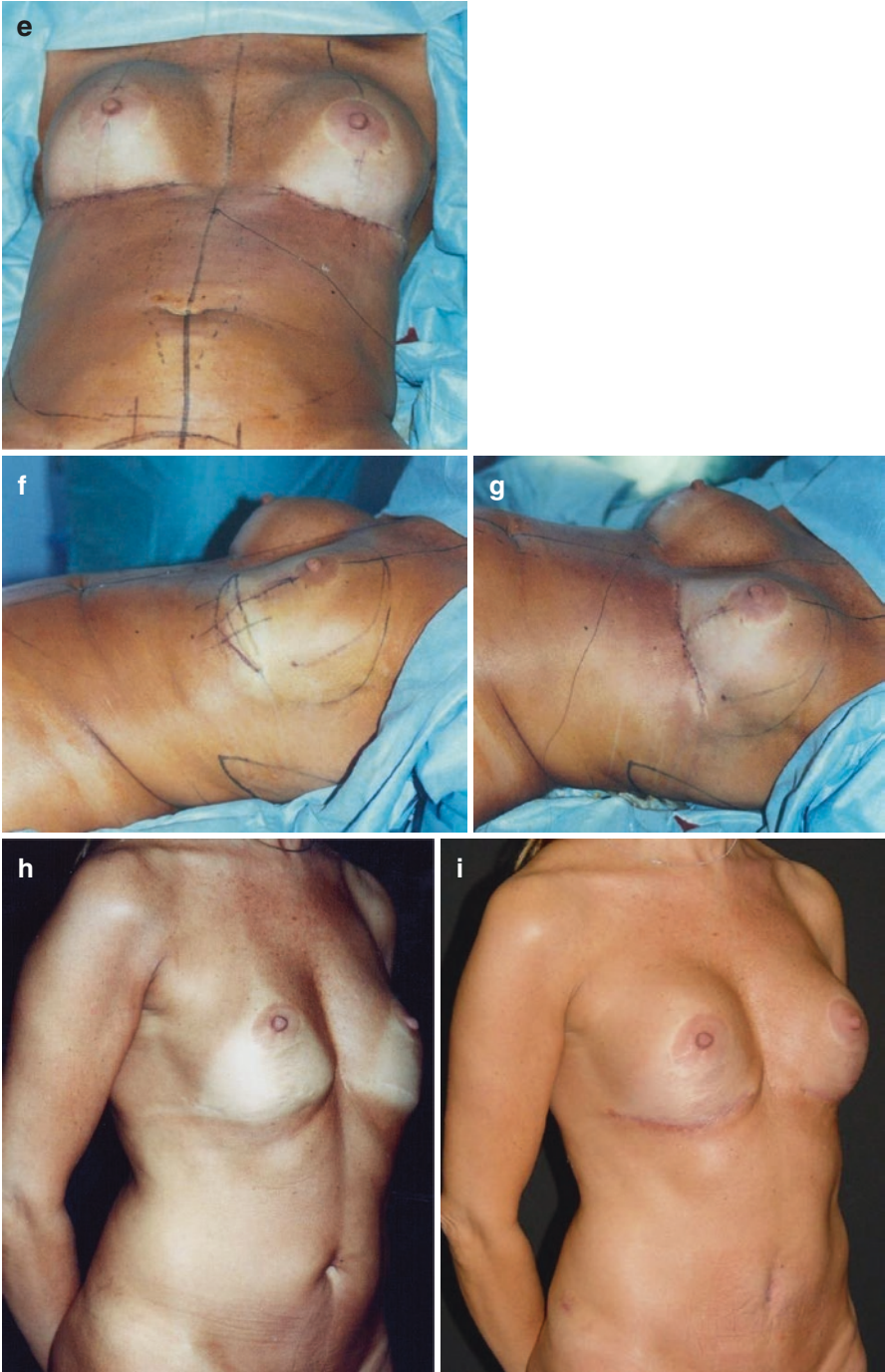

Fig. 5.5 (continued)



**Fig. 5.6** Application of upper abdominoplasty for correction of unsatisfactory result of superficial liposuction performed by somebody else: **(a, c)** Preoperative aspect showing unaesthetic undulations on the superior abdomen; **(b, d)** postoperative result 1 year after upper abdominoplasty. The arrows on the photo **(b)** show the direction of traction of the upper abdomen

## References

1. Avelar JM (1999) Uma nova técnica de abdominoplastia – sistema vascular fechado de retalho subdérmico dobrado sobre si mesmo combinado com lipoaspiração (a new technique for abdominoplasty – closed vascular system of subdermal flap folded over itself combined to liposuction). *Rev Bras Cir* 88/89(1/6):3–20
2. Avelar JM (2000) Abdominoplastia sem descolamento (Abdominoplasty without undermining). São Paulo: XX Jorn. Paulista Cir Plast. Avelar JM (2000) Abdominoplasty: a new tech-

- nique without undermining and fat layer removal (Abdominoplastia: uma nova técnica sem esclamento e remoção da camada de gordura). *Arq Catarinense de Med* 29:147–149
3. Avelar JM (2002) Upper abdominoplasty without panniculus undermining and resection. In: Avelar JM (ed) *Abdominoplasty without panniculus undermining and resection*. Editora Hipocrates, São Paulo, pp 173–182
  4. Flageul G, Elbaz JS, Karcenty B (1999) Complications of plastic surgery of the abdomen. *Ann Chir Plast Esthet* 44(4):497–505
  5. Illouz YG (1980) Une nouvelle technique pour les lipodystrophies localisées. *Rev Chir Esth Franc* 6(9)
  6. Illouz YG (1982) Liposuction technique. First Instructional Course with surgical demonstrations at São Paulo Hospital, Prof. Andrews' Service. Organized by Brazilian Society of Plastic Surgery – Regional São Paulo, Endorsed by Brazilian Society of Plastic Surgery (BSPS), October
  7. Kelly HA (1899) Report of gynecological cases. *Johns Hopkins Med J* 10:197
  8. Rebello C, Lion P, Franco T (1972) Abdominoplasty through submammary incision. International Congress of ISAPS. Rio de Janeiro. Ed. Publicaciones Comntroladas, 58, Madrid
  9. Rebello C, Franco T (1972) Abdominoplastia por incisão submamaria. *Rev Bras Cir* 62:249–252
  10. Rebello C (1982) Abdominoplastia por incisão submamária. In: *Anais simp bras: abdominoplastia*. Soc Bras Cir Plast – Reg, São Paulo, pp 52–53
  11. Thorek M (1939) Plastic reconstruction of the female breasts and abdomen. *Am J Surg* 43:268–278

# Chapter 6

## Lower and Upper Abdominoplasty

Juarez M. Avelar

### Introduction

Nowadays more and more persons give so much importance to the body contour particularly in the tropical countries. For that reason all operations regarding correction of physical abnormalities concern very much on patients and surgeons. Both must have a precise idea of what can be accomplished by the procedure and try to achieve the best surgical results. Unfortunately, due to severe pre- and postoperative complications, during the last decades of the twentieth century, abdominoplasty became one of the least frequent procedures in plastic surgery. This subject seldom was discussed in our congresses since there were no new topics to be presented. However, from 1999 it became an important subject for discussion in our meetings due to the great technical development of abdominoplasty which increases the number of the operations and scientific publications as well. These good circumstances happened because new concepts and surgical principles were introduced in this field, which encouraged specialists to perform and to speak about abdominoplasty. As soon as I developed new concepts on abdominoplasty, upper abdominoplasty is a standpoint described since my first publications and presentations [4–6]. Looking back to the history of abdominoplasty, Thorek (1942) [12] described the first procedure regarding panniculus resection of the superior segment of the abdomen. Probably due to the final scar, such procedure did not become popular among plastic surgeons. For a long time no other author referred to this approach until early 1972 when Rebello et al. [9, 11] presented at the first ISAPS Congress in Rio de Janeiro remarkable contribution of abdominoplasty through submammary approach.

---

J.M. Avelar, MD

Head of the Brazilian Scientific Institute of Plastic and Reconstructive Surgery,  
Al Gabriel Monteiro da Silva, 620 Jd Europa, São Paulo, SP 01442-000, Brazil  
e-mail: [juarezavelar@bol.com.br](mailto:juarezavelar@bol.com.br); [institutodaorelha@uol.com.br](mailto:institutodaorelha@uol.com.br)



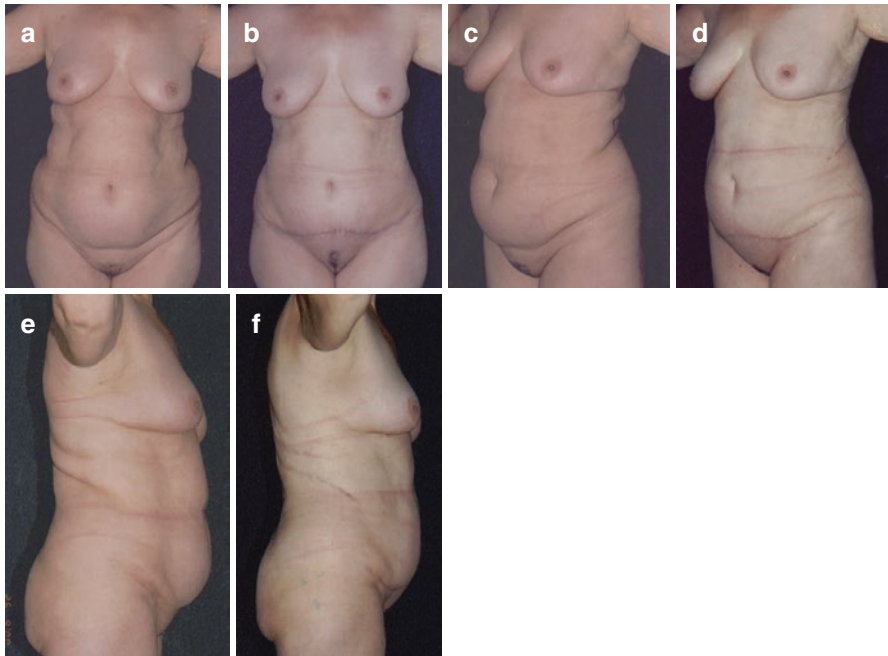
Once more, Rebello and Franco [10] published their abdominoplasty through submammary incision with the panniculus undermining of the upper abdomen until to reach the umbilicus.

The main purpose of this Chapter is to present a new approach for abdominoplasty through which the aesthetic operation may treat simultaneously the upper and lower segments of the abdominal wall without transposition of the umbilicus through an angle, which was not mentioned until a few years ago [8]. In fact, the abdomen may be improved from the aesthetic point of view once the correction of the physical deformities is treated adequately.

## Technique

### *Selection of Patients*

The surgical planning for a combined approach on the abdominal wall is based on careful evaluation of each patient. Upper and lower abdominoplasty is not a full abdominoplasty. This misunderstanding is common among surgeons after some of my presentations at congresses. When upper and lower abdominoplasty is performed, the umbilicus is not transplanted as in full abdominoplasty similar to a traditional abdominoplasty (Fig. 6.1). The main anatomical point of reference for indication of



**Fig. 6.1** Upper and lower lipoabdominoplasty on a patient presenting high position of the umbilicus: (a, c, e) Before surgery; (b, d, f) after upper and lower lipoabdominoplasty

the surgery is the high implantation of the umbilicus which means that the upper segment of the abdomen is quite short and consequently does not present enough cutaneous covering to be pulled downward to replace the inferior segment.

The location of the umbilicus is a matter of much discussion since its variation of position is very common; therefore, it is not possible to establish a pattern of measurement for classification.

This anatomical area is still a point for discussion everywhere, since the abdominal wall is the only (unique) movable region of the torso due to about 20 breathing movements per minute. Therefore the umbilical area does not maintain a standard position in relation to other skeletal structures of the chest such as the costal margin, the xiphoid process, or even concerning the vertebral column. Even in the same person, it may change its position, due to several circumstances, which may happen during lifetime such as pregnancies, obesity, weight loss, and many others.

Furthermore, as a consequence of the high implantation of the umbilicus, the lower segment of the abdomen is even larger since the vertical distance from the umbilicus to the pubis is very long. The supraumbilical area may also present unaesthetic disturbances with redundant panniculus or skin flaccidity which require aesthetic correction by cutaneous resection.

Basically, the clinical aspects of the patient who will undergo lower and upper abdominoplasty are determined by the location of the umbilicus similar to the indications for lower abdominoplasty, but associated with some unaesthetic aspects of the upper segment of the abdomen.

From 1988 to 1998 I devoted much time looking for new concepts for abdominoplasty through reviewing my anatomical study of the abdominal panniculus previously described [1, 2, 3, 7]. During that period no patient came to my office asking for this kind of combined procedure, since it was unknown for plastic surgeons and patients as well. For this reason, the indication and selection of patients for the operation were done according to my evaluation to identify clinical disturbances which would be treated by simultaneous procedures on the upper and lower abdominal segments.

Surgical evaluation is the key to select patients for this operation. Therefore, when a patient presents severe physical alterations on the lower segment with low position of the umbilicus, as well as other deformities on superior segment of the abdomen, this procedure is indicated.

### ***Surgical Demarcations and Operation***

As mentioned above, upper and lower abdominoplasty is a combination of each procedure performed according to the technique described in each chapter. Furthermore, when a patient presents indication for both approaches, it means that each individual region shows local abnormalities, which may be treated separately. Nevertheless some other information regarding criteria for indication and how to choose the right technique to be employed must be emphasized in order to perform this combined procedure.

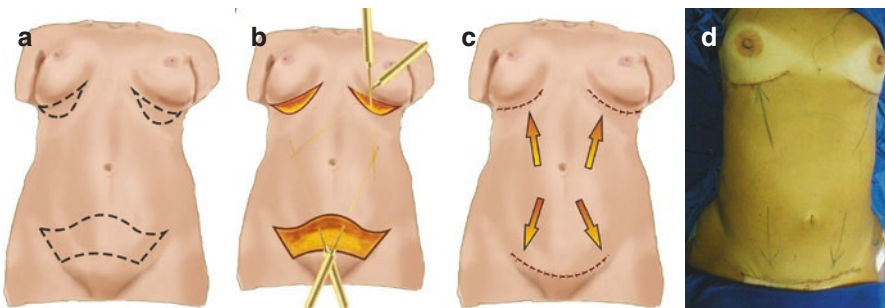
Surgical demarcation is an important procedure before surgery and it should be done under meticulous measurement (Fig. 6.2). I do that at my office 1 day prior the surgery with the patient in stand position in front of some mirrors adequately located. The areas for skin resection are marked on suprapubic region inferiorly, and on the superior abdomen, two half-moon-shaped areas are drawn below the submammary fold bilaterally. Also, the areas for liposuction are marked all over the abdominal wall.

The operation is performed at the hospital following all steps concerning the routine procedures. General anesthesia is done combined with local infiltration. According to surgical planning, two levels of local infiltration must be done: a deep one on the supramuscular on all regions for liposuction and superficial infiltration on areas for skin resection. The solution is 1000 ml of serum + 2 ml of epinephrine (1/1000), that is, 2/1,000,000.

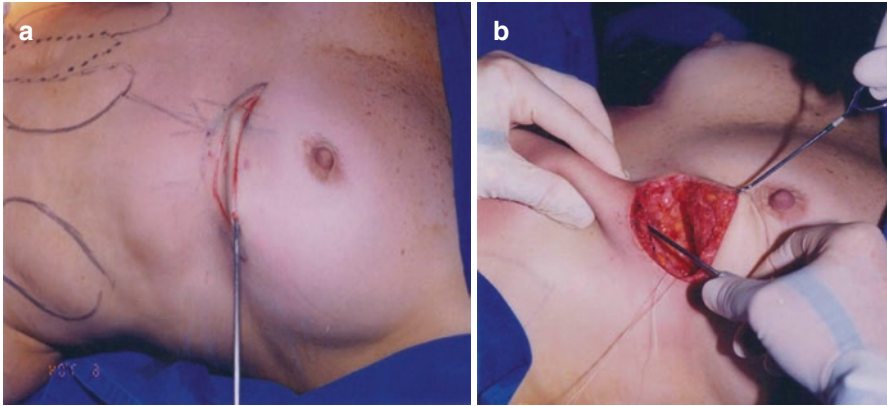
After preparation, liposuction procedure is the first step of the operation which is performed on two types: on full thickness of the panniculus where skin resection will be performed and on deep level all over presenting localized adiposities (Fig. 6.2).

Following previous demarcation liposuction is performed on the full thickness of the panniculus on the areas where the skin will be resected. After this procedure the connective tissue and all perforator vessels remain attached to the musculo-aponeurotic plane without any fat, which create a depression on the suprapubic area and below the submammary fold (Fig. 6.3).

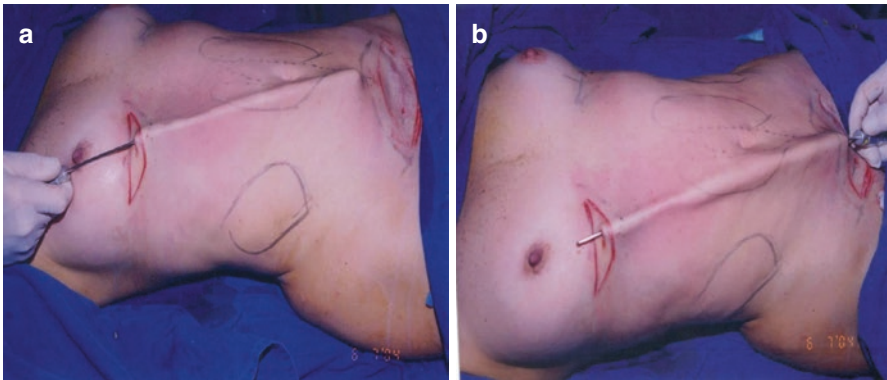
Afterward, deep liposuction is done on all regions of the abdominal wall presenting localized adiposities where skin resection will not be performed (Fig. 6.4). It is done on the lamellar layer (below the fascia superficialis) preserving the areolar layer above in order to provide normal blood supply to the dermis, according to my previous publications [1, 3]. Also, preservation of the areolar layer gives smooth and harmonious surface to the areas where skin resection is not performed.



**Fig. 6.2** Surgical planning and surgical demarcations: Scheme (a) the area for full-skin resection is demarcated with *dotted line* on suprapubic region and a half-moon-shaped areas on the submammary region; (b) full-skin resection has been performed showing two canulas introduced from up to down and from down to up; (c) the *arrows* indicate the direction of traction of the flaps from downward and upward. (d) Perioperative photo showing the final result after upper and lower lipoabdominoplasty



**Fig. 6.3** Full-thickness liposuction and deep liposuction on the upper abdomen: Perioperative photo (a) full-thickness on submammary fold is being performed, where skin resection will be done; photo (b) showing deep liposuction on upper abdominal wall, which is below fascia superficialis



**Fig. 6.4** Surgical planning and surgical demarcations. Perioperative photos showing tunnelization with cannula in a patient with unsatisfactory result after superficial liposuction: Photo (a) A cannula is introduced through the submammary fold where full-thickness skin resection will be done; photo (b) the same cannula is introduced through the suprapubic region where full thickness skin will be resected

Afterward skin resection is done on that local depressions corresponding to the areas of liposuction performed on full thickness of the panniculus. It is important to emphasize that the remaining panniculus slides easily over the musculo-aponeurotic wall because there is no fat below the fascia superficialis, and all perforator vessels were preserved which work as multiple pedicles to the abdominal panniculus.

Although the abdominal panniculus is not undermined, but plication of the musculo-aponeurotic wall may be performed, and it is a useful procedure during abdominoplasty when patients present diastasis of the rectus abdominis which must be identified perioperatively. Computerized tomography (CT scan) is a routine

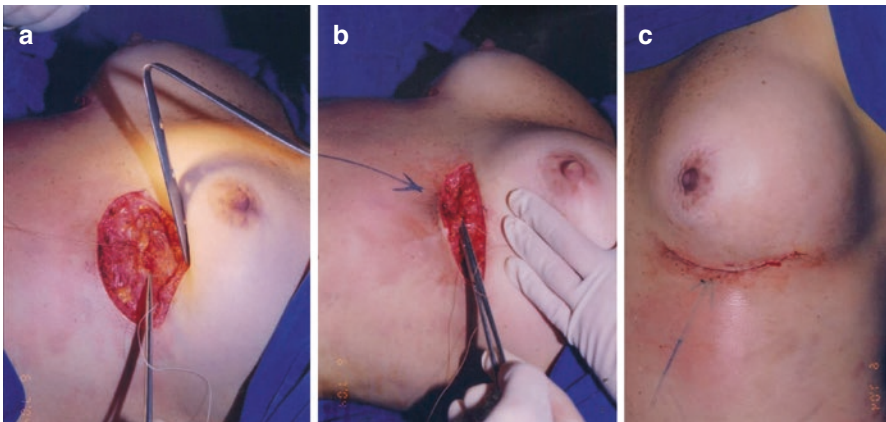
examination in my clinic which demonstrates the distance between the muscles even some hernia on the midline and laterally as well.

Afterward the remaining panniculus is pulled upper and downward (Fig. 6.2). The inferior segment of the abdominal panniculus is pulled downward to be sutured to the inferior border of the raw area. Three levels of suture must be done: on the fascia superficialis, on the subdermal layer, and on the dermis (Fig. 6.5). The first level of suture is the fascia superficialis in order to approximate the border of the upper flap to the lower border, which is the suprapubic margin. Following the closure the subdermal and dermis are stitched.

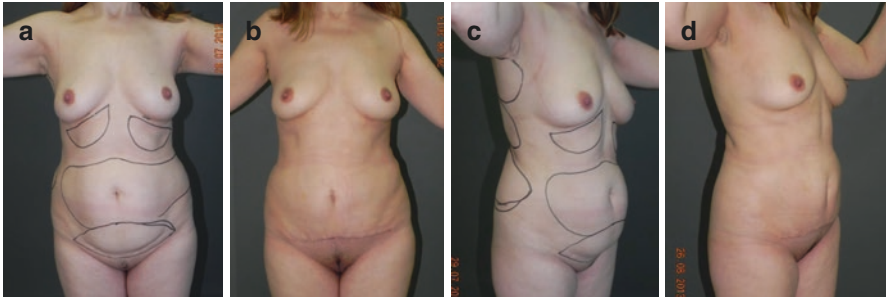
The direction of traction of the superior segment of the remaining abdomen panniculus is done obliquely to the right and to the left, similar to a “V” (Fig. 6.2). Following this direction the lower border of the wound is sutured to the upper border which is very close (3 mm) to submammary fold in order to pull the epigastric region upward to the right and left avoiding cutaneous excess on the midline. The fascia superficialis of the lower segment must be stitched to the same anatomical structure quite near to the submammary fold which is the main suture.

It works like a plication of the remnant subcutaneous tissues. I use to do at least eight stitches on each side in order to achieve firm fixation of the panniculus to the musculo-aponeurotic structures of the chest. Therefore the main structures of the panniculus are reinforced.

Following these technical steps, the final scar is smooth and naturally located on the submammary sulcus (Figs. 6.6 and 6.7). Finally, a running suture is performed on the dermis with absorbent material. Adhesive tapes are applied on the surgical scars without any traction.



**Fig. 6.5** Suture of the wound on submammary fold: Photo (a) After full-thickness liposuction on the submammary fold the excess skin has been resected and fascia superficialis is sutured with isolated stitches to fascia superficialis of the superior border. Photo (b) subdermal suture is done with isolated stitches. Photo (c) afterward running suture is done and the final scar lays on the future submammary fold



**Fig. 6.6** Upper and lower lipoabdominoplasty was indicated due to very high implantation of the umbilicus. Photo (a, c) Before surgery with demarcation of skin resection on suprapubic region for skin resection and deep liposuction above and skin resection was done on submammary folds. Photos (b, d) after upper and lower lipoabdominoplasty

A garment is used covering the whole area of torso and the abdominal wall which is maintained during 1 week. At this time patient comes to my clinic for the removal of the previous dressing and new adhesive tapes are applied. This kind of bandaging is changed once every 10–15 days during 2 months.

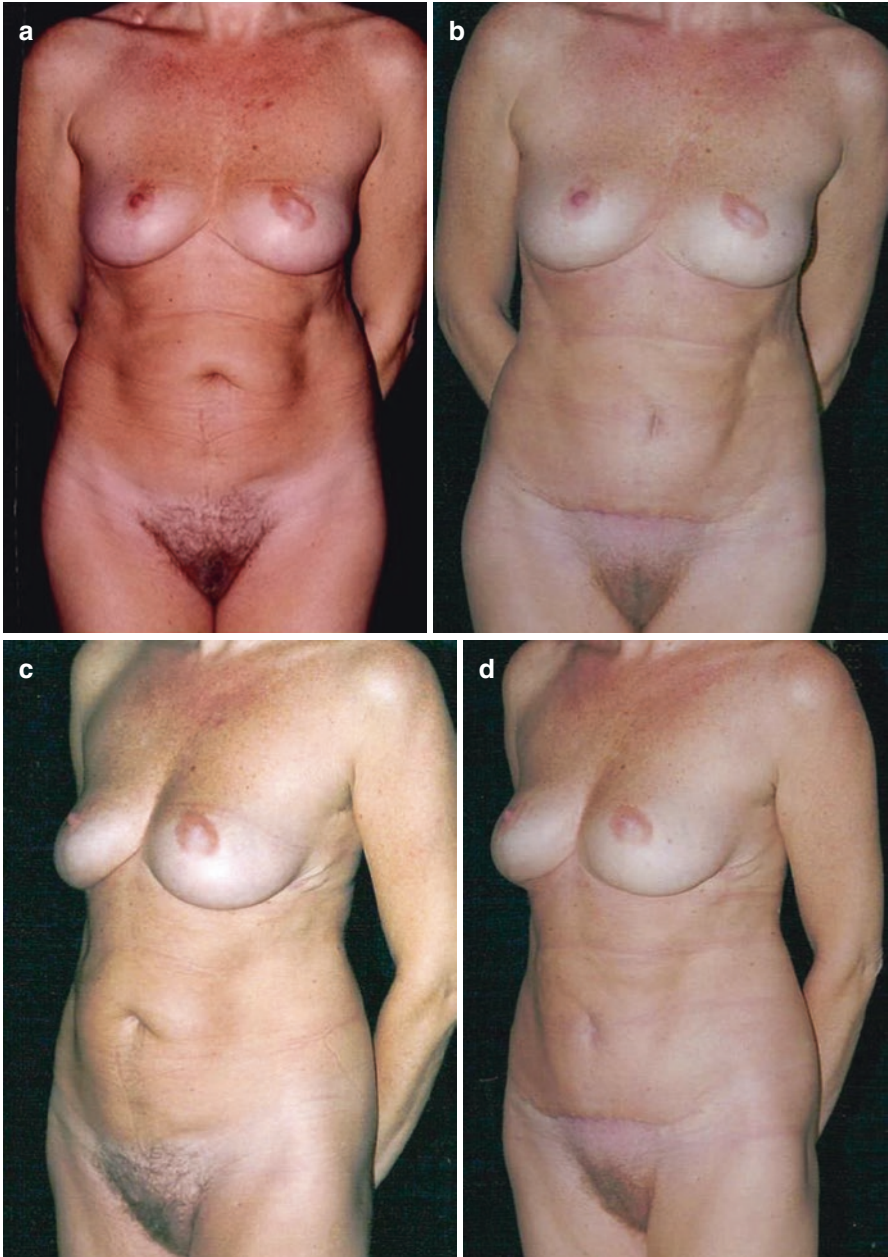
## Complications

When patients are well selected, the indication of the operation is adequate and lower and upper abdominoplasty is properly performed; it may achieve a good final surgical result. I have not had any severe complication after operation as far as patients follow all instructions of the surgeon and staff.

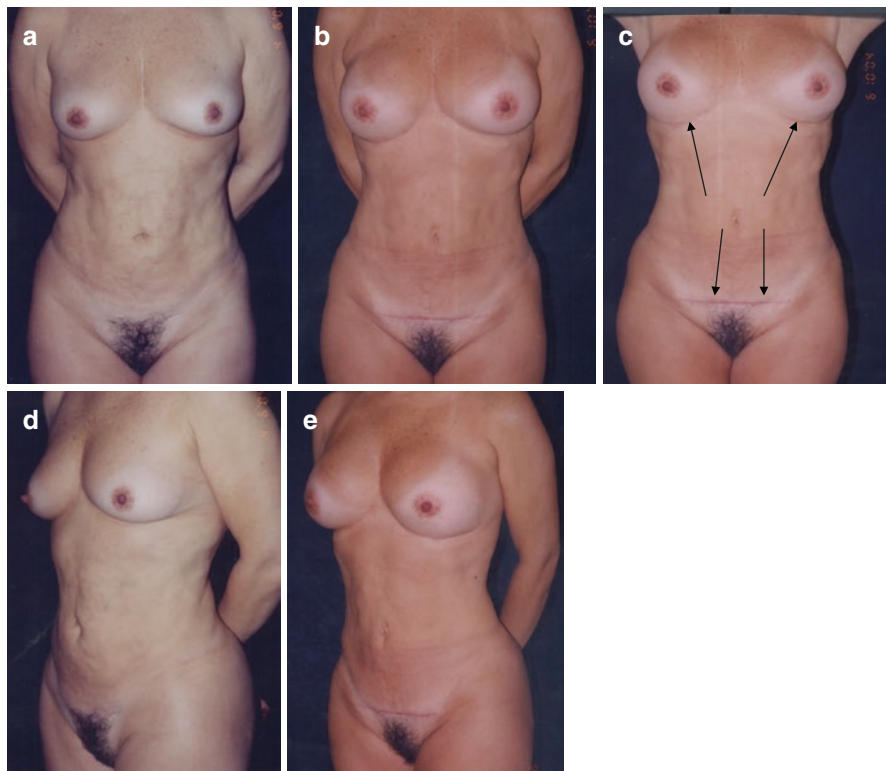
## Discussion

Before performing any procedure regarding body contouring, the choice of the adequate technique for each patient is the main topic. In fact, a decision for upper and lower abdominoplasty is a matter of correct criteria, since it is one more surgical option in the complex field of aesthetic surgery of the abdominal wall [8]. It is important to emphasize some more considerations:

1. When a patient presents only isolated accumulated fat on the anterior aspect of the abdominal wall without skin flaccidity or any other abnormality, isolated liposuction is the adequate procedure.
2. In case of accumulated fat on the anterior side of the abdominal wall, plus skin flaccidity with redundant panniculus localized only on the lower segment of the abdomen presenting a high navel implantation without enlargement of the musculo-aponeurotic abdominal wall, the adequate technique is lower



**Fig. 6.7** Upper and lower lipoabdominoplasty on a patient presenting high position of the umbilicus: Photo (a, c) Before surgery; photos (b, d) after upper and lower lipoabdominoplasty



**Fig. 6.8** Upper and lower lipoabdominoplasty to repair unsatisfactory result after superficial lipo-plasty performed elsewhere. (a, d) Before surgery; photos (b, c, e) after upper and lower lipoabdominoplasty

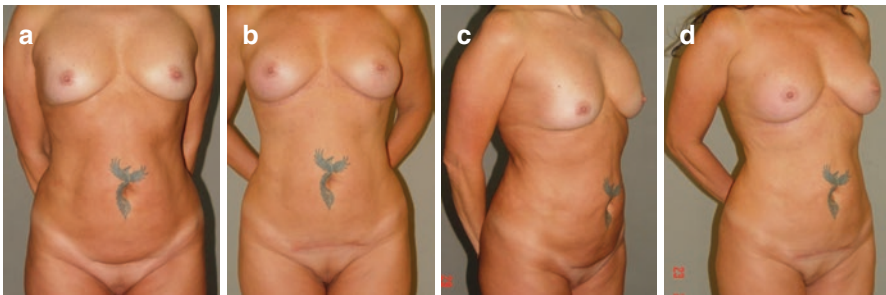abdominoplasty combined with liposuction without reinforcement of the abdominal muscular structures.

3. When a patient presents all the abovementioned deformities plus diastasis of the musculo-aponeurotic abdominal wall, the best procedure is lower abdominoplasty combined with liposuction and plication of the muscles through the raw area of the skin resection on the suprapubic region.
4. Upper abdominoplasty is indicated when a patient presents redundant panniculus only on the upper segment of the abdomen as well as localized adiposity, and the umbilicus shows high location. Liposuction must also be performed in combination with skin resection on the submammary folds.
5. Upper and lower abdominoplasty should be done in those patients presenting excess abdominal panniculus on the upper and lower segments of the abdomen, and the umbilicus is located on high position (Fig. 6.1).
6. Upper and lower abdominoplasty in combination with plication of the muscular abdominal wall must be done in cases of muscular diastasis and abundant panniculus both on the lower and on the upper segment of the abdomen. Skin resection is

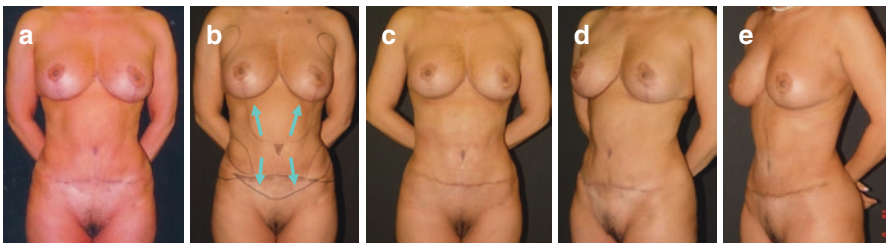


done on the suprapubic region and also below the submammary sulcus. Reinforcement of the musculo-aponeurotic abdominal wall is performed through the raw area and through the umbilicus in order to reach the aponeurosis, if there is muscular flaccidity with enlargement of the abdominal volume. The umbilicus is not transplanted since it presents high implantation (Figs. 6.1 and 6.7).

7. Full abdominoplasty must be performed in a patient presenting redundant panniculus on the lower abdomen with low implantation of the umbilicus. Therefore, the distance between the navel and the pubic area is quite short. On the other hand, the distance between the navel and the external furcula is quite long. It means that the cutaneous covering of the upper segment must cover all the new area of the inferior segment. If there is muscular flaccidity, reinforcement of the musculo-aponeurosis is required.
8. Upper and lower abdominoplasty is a good indication when patients presenting unsatisfactory result of superficial liposuction (Figs. 6.8 and 6.9). Also patients with unaesthetic result after abdominoplasty with high surgical scar and ungraceful appearance of the abdominal wall (Fig. 6.10).



**Fig. 6.9** Upper and lower lipoabdominoplasty on a patient presenting high position of the umbilicus: Photo (a, c) – before surgery; photos (b, d) after upper and lower lipoabdominoplasty



**Fig. 6.10** Upper and lower lipoabdominoplasty on a patient presenting high position of the umbilicus: Photo (a, b, d) before surgery; photos (c, e) after upper and lower lipoabdominoplasty

## Conclusions

Selection of patients and adequate indication are the main important steps before indication of lower and upper abdominoplasty which is a combination of both procedures simultaneously. Patient must present redundant cutaneous covering and excess localized adiposities on suprapubic areas as well as on hypochondriac regions bilaterally. The position of the navel must be high with long distance of the inferior segment of the abdomen. Measurement of the abdominal wall is a useful maneuver during examination and surgical planning. The external furcula and pubic sinfisis are important references points during measurement of the dimensions of the abdomen with purpose for indication of lower and upper abdominoplasty.

## References

1. Avelar JM (1986) Anatomia cirúrgica e distribuição do tecido celular no organismo humano (Surgical anatomy and distribution of the cellular tissue on human organism. In: Avelar JM, Illouz YG (eds) Lipoaspiração (Liposuction). Editora Hipócrates, São Paulo, pp 45–57
2. Avelar JM (1987) Study of the anatomy of the subcutaneous adipose tissue applied for fat-suction technique. In: Maneksha RJ (ed) Transactions of the IX International Congress on Plastic and Reconstructive Surgery. Tata McGraw-Hill, New Delhi, pp 377–379
3. Avelar JM (1989) Regional distribution and behavior of the subcutaneous tissue concerning selection and indication for liposuction. *Aesthetic Plast Surg* 13:155–165
4. Avelar JM (1999) Uma nova técnica de abdominoplastia – sistema vascular fechado de retalho subdérmico dobrado sobre si mesmo combinado com lipoaspiração (A new technique for abdominoplasty – Closed vascular system of subdermal flap folded over itself combined to liposuction). *Rev Bras Cir* 88/89(1/6):3–20
5. Avelar JM (1999) Novos conceitos para abdominoplastia (New concepts for abdominoplasty). Paper presented at the 36th Congress of the Brazilian Society of Plastic Surgery. Rio de Janeiro
6. Avelar JM (1999) Abdominoplastia: Nuevos conceptos para una nueva técnica. Abdominoplasty: new concepts for a new technique). XXVI annual international symposium of aesthetic plastic surgery, Chairman: Prof. Jose Guerrerosantos - Puerto Vallarta, pp 10–13
7. Avelar JM (2000) Abdominoplastia sem descolamento (Abdominoplasty without undermining). São Paulo: XX Jorn. Paulista Cir Plast. Avelar JM (2000) Abdominoplasty: a new technique without undermining and fat layer removal (Abdominoplastia: uma nova técnica sem descolamento e remoção da camada de gordura). *Arq Catarinense de Med* 29:147–149
8. Avelar JM (2002) Upper and lower abdominoplasty without panniculus undermining and resection. In: Avelar JM (ed) Abdominoplasty without panniculus undermining and resection. Editora Hipocrates, São Paulo, pp 183–198
9. Rebello C, Lion P, Franco T (1972) Abdominoplasty through submammary incision. International Congress of ISAPS, Rio de Janeiro. Ed. Publicaciones Comntroladas, 58, Madrid
10. Rebello C, Franco T (1972) Abdominoplastia por incisão submamaria. *Rev Bras Cir* 62(7–8):249–252
11. Rebello C (1982) Abdominoplastia por incisão submamária. In: Anais simp bras: abdominoplastia. Soc Bras Cir Plast – Reg, São Paulo, p 52
12. Thorek M (1942) Plastic surgery of the breast and abdominal wall. Charles C. Thomas. Ed, Springfield, III, 120

# Chapter 7

## Full Lipoabdominoplasty

Juarez M. Avelar

### Introduction

The first publication about abdominoplasty is reported by Kelly [48] with full panniculus resection of the abdominal wall. Due to his original description, it is credited to him the expression lipectomy since an elliptical horizontal skin with adipose tissue including the umbilical area was removed. So far, Sinder [70] mentioned about a publication by two surgeons in France, Demars and Marx [36], regarding resection of the skin and subcutaneous layer of the abdominal wall which may be the first reference of an aesthetic procedure on the abdominal wall. However, I give to Kelly the credit as the pioneer on abdominoplasty procedure.

Afterward other authors aid important contributions through cutaneous incisions by Babcock [31] Thorek [71], and Malbec [53]; panniculus undermining and resection with reinforcement of the musculoaponeurotic structures by Callia [33], Pontes [61], and Pitanguy [58]; geometric approach by Serson Neto [67]; and abdominoplasty through a submammary incision by Rebello et al. [66] and Sinder [69] described important approach through incision followed by panniculus undermining of the supraumbilical segment, and special improvement on abdominoplasty without panniculus undermining was introduced by Pontes [62]. Transposition with reimplantation of the umbilicus was presented by Vernon [72], and later a new meticulous approach is described [4, 5, 7].

So far, when Illouz [43–46] developed and popularized liposuction technique, the aesthetic treatment of the abdomen gained a new approach to reshape it by removing localized adiposities. Therefore, Illouz' procedure is the first surgical method for aesthetic treatment of the abdominal wall without performing skin resection. So, from 1899 [48] until 1980, aesthetic surgery of the abdominal wall

---

J.M. Avelar, MD

Head of the Brazilian Scientific Institute of Plastic and Reconstructive Surgery,  
Al Gabriel Monteiro da Silva, 620 Jd Europa, São Paulo, SP 01442-000, Brazil  
e-mail: [juarezavelar@bol.com.br](mailto:juarezavelar@bol.com.br); [institutodaorelha@uol.com.br](mailto:institutodaorelha@uol.com.br)

was performed through panniculus undermining and resection to improve the harmony of body contouring following those surgical steps which may be considered as traditional abdominoplasty.

Nevertheless the use of lipoplasty enabled only localized adiposity since the skin excess and musculoaponeurotic disturbances require traditional techniques. For these reasons, the indication of isolated fat suction is restricting to patients presenting only excess of adipose tissue on the anterior abdominal wall. When patients present associated deformities, the adequate treatment requires combined procedure [9, 10]. This combined approach was performed since liposuction technique became a routine among plastic surgeons. But very high incidence of local and systemic complications used to occur, such as seroma formation, hematoma, hemorrhage during and after surgery, skin slough, panniculus necrosis, and also thromboembolism, which was firstly reported by Goldwyn [39] few years after liposuction became widely popularized by Illouz. No longer had myself become so disappointed with all complications that used to be the main topic for discussion on our meetings and also in publications as well. In my mind most of the troubles were related to vascular damage during surgery. As there was no adequate solution for the problems, I took a radical decision of not to perform anymore such combined operation [14]. Later, Hetter [42], Delleru [35], and Flageul et al. [38] mentioned about local and systemic complications which had occurred pre- and postoperatively. All these troubles gave me more reasons to decline to do associated procedures from 1988, but I did not stop to think about, even to research, looking for the origin of those adverse consequences and also to find a new and safety method [14]. Nevertheless, complications during and after conventional abdominoplasty used to be a constant task even before liposuction era as described by Grazer and Goldwyn [40] later by Guerrerosantos [41] and also by Mélega [55].

For 10 years, I devoted much time of perseverance research to my previous anatomic studies on cadaver described when I started to perform liposuction [11–13, 15]. After a long period of intensive research of the abdominal panniculus, I concluded that it would be possible to combine liposuction with traditional abdominoplasty since the perforator vessels are not cut during surgery, as it is a routine step during conventional operation. I am thankful to Prof. Callia who understood my inquietude with obsessive pursuit to find a safe abdominoplasty approach. Even he gave me some slides that were taken during abdominoplasty performed in some of his patients that underwent previous liposuction on the abdomen. My anatomical research was improved with his slides even with some technical information coming from his observations during surgery which were very useful in my study. So, in 1998 I concluded my anatomical research and started to perform some abdominoplasty operations as well as medial thigh lifting following the same surgical principles. Therefore I presented and published my combined approach of fat suction with conventional abdominoplasty, without cutting the perforator vessels in order to preserve and maintain adequate blood supply to the remaining abdominal panniculus [16–18]. Also the same surgical principles were employed for treatment of accumulated fat on the medial thigh, torso and flanks, and axillary regions as well [19–21]. My combined procedure minimizes the high incidence of local and systemic complications during and after operation which was presented at several meetings [22–25]. Also I was

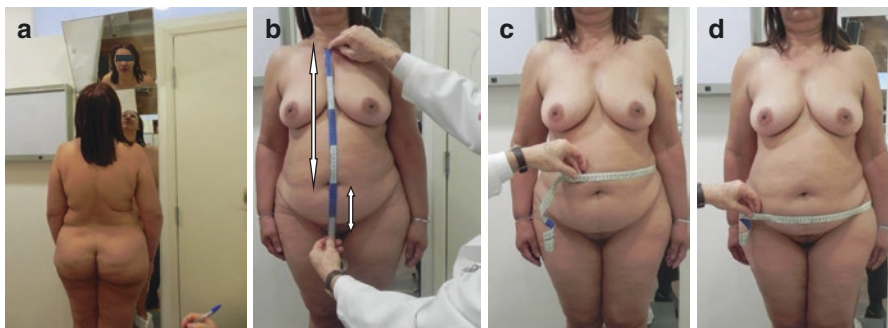
invited to speak about my new concepts in several congresses abroad ([26–29], Even, my procedure was classified by Matarasso as new concepts to improve abdominoplasty [54]. Prof. Callia was so proud about my new concepts that he invited me to give a course at his service at the Municipal Hospital in São Paulo [23]. My method may be employed with smooth and harmonious results on the abdomen and further applications.

## Technique

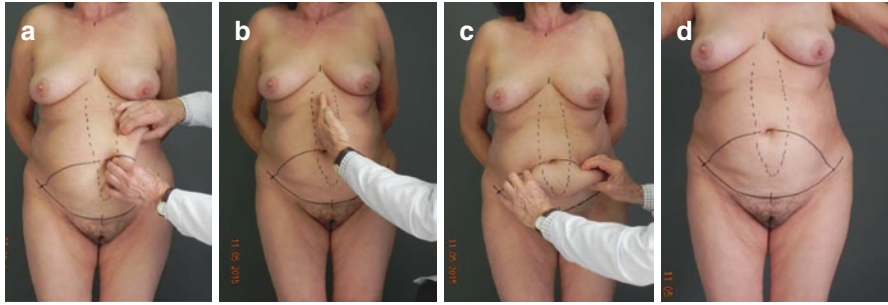
Before performing abdominoplasty, the surgeon must talk with patients to hear their complaints with meticulous examination of the abdomen and all regions on the lateral and posterior aspects. Although the abdomen is a region of concern for patients, the entire body should be well evaluated.

Several abnormalities on the abdominal wall such as unaesthetic and retracted scars, cutaneous stria, skin flaccidity, weakness and diastasis of the musculoaponeurosis, and herniations require adequate aesthetic and reconstructive treatment. Therefore abdominoplasty is a combined procedure since the disorder of the external appearance of the abdomen in association with anatomical structures should be treated properly to achieve the harmony of the body contour.

In my office, there are two mirrors placed on walls: one in the front of the other and another on the ceiling that gives the patient the possibility to see her or his body in all views simultaneously during my examination (Fig. 7.1a). Even some sort of asymmetry may be observed by the patient during examination since it was not yet noticed. Measurement of the abdomen is done on three levels of circumferences: hypochondriac, umbilical, and iliac crest. Also the vertical distances on the midline



**Fig. 7.1** Patient in standing position in front of two vertical mirrors is looking upward to the 45° angle mirror to observe my examination and measurement of the abdominal wall: (a) She sees her back view as her image on the oblique mirror in conjunction with both vertical mirrors; (b) measurement of the vertical distance from the external furcula to the umbilicus must be more than 38 cm and to the pubis; (c) measurement of the circumference on the umbilical level; (d) circumference on the iliac crest



**Fig. 7.2** Patient in standing position in front of two vertical mirrors follows my examination and surgical planning as well: **(a)** with Illouz' pinch test, the thickness of the superior abdominal panniculus is evaluated in order to check the cutaneous integument and adipose tissue; **(b)** with one hand, the surgeon may evaluate the abdominal muscles and if there is diastasis on upper abdomen; **(c)** with two hands, the surgeon holds the inferior abdomen which will be resected; **(d)** surgical planning and demarcations are done day prior the operation

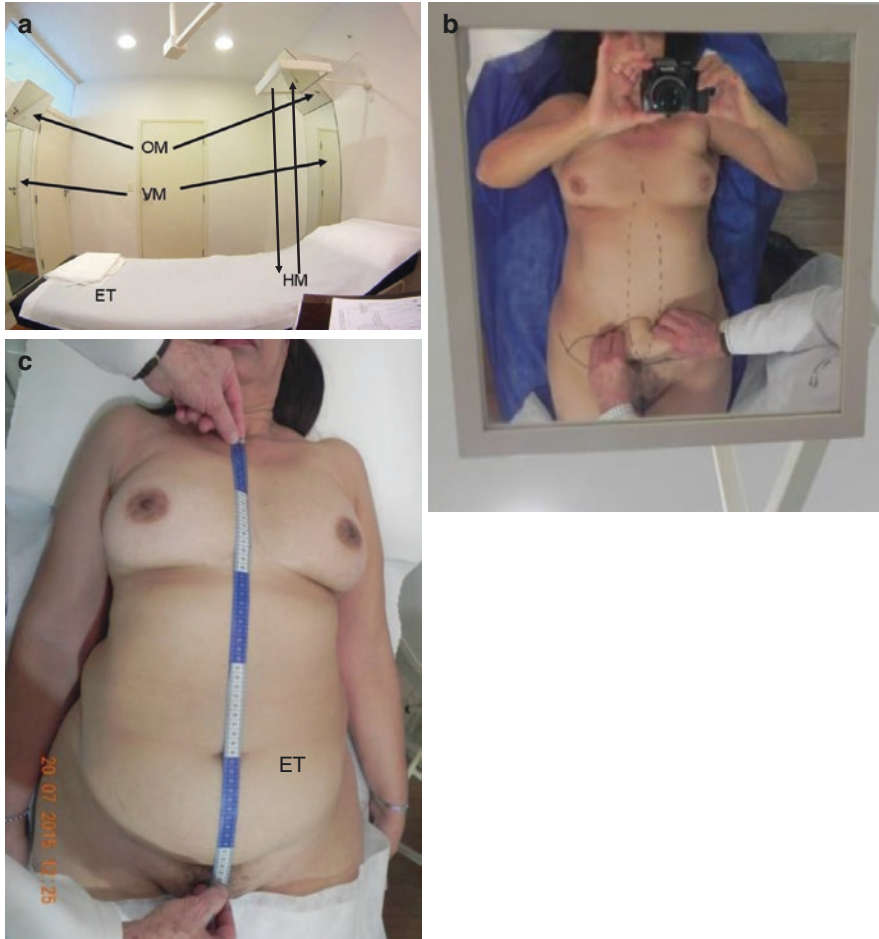are carefully measured to evaluate the amount of skin for resection during surgery (Fig. 7.1b–d). By palpation, the excess skin is properly evaluated and patient can see himself or herself in front of the mirror in a standing position (Fig. 7.2a–d). Also with the patient on lying-down positions on the examination table, he or she follows the examination and takes photos on a mirror placed horizontally above the table (Fig. 7.3). The sternal furcula is an important anatomical reference to measure the vertical distance of the abdomen. The distance from that point to the umbilicus must be more than 38 cm (Fig. 7.1). When it is less than that, it means that it is not a good candidate for panniculus resection on the suprapubic region since it may damage the blood supply to the remaining abdominal structures. On the other hand, the distance between the umbilicus and the pubis must be less than 15 cm, and when it is more than that, it may be difficult to perform skin resection on all regions.

Finally patients presenting excess adipose tissue on the abdominal wall associated with anatomical disorders on the structures which give an unpleasant appearance to the body, demanding appropriate surgical treatment for reparation, are good candidates for abdominoplasty. However, when a patient presents only localized adiposity in the abdominal wall, liposuction is the best choice for treatment.

Overweight patients should not undergo abdominoplasty. Even psychologically unstable persons, expecting too much about the results and scars, demonstrate unrealistic postoperative results, and other situations are not good candidates for operation [11, 14, 59].

## The Operation

Surgical demarcation is a useful step which may be done on the day before the operation with the patient in standing position in front of the mirrors in order to follow the surgeon's work (Figs. 7.2 and 7.3). Two areas must be well demarcated for adequate orientation during operation:



**Fig. 7.3** To examine the patient in standing position, she sees in front and back view on vertical mirrors (*VM*) and through oblique mirrors (*OM*). Afterward she lies on the examination table (*ET*) on supine position with another mirror situated horizontally above (*HM*) so that she can see again the deformities as well as follow the surgeon's examination and demarcations: Photo (a) panoramic view of the examination room; photo (b) was taken from the patient through horizontal mirror (*HM*) to confirm the surgeon's evaluation concerning the amount of excess panniculus, grasping the inferior segment of the abdomen placing the thumbs and finger of both hands; (c) measurement of the position of the umbilicus, taken as references of the distance from the external furcula to the umbilicus and to the mons pubis

- A. The area for skin resection which is the whole segment that is below the umbilicus on the suprapubic region is drawn following Callia's technique [33], leaving the final scar as lower as possible with the lateral segment placed on the inguinal folds on each side and a convex line on the pubic area (Fig. 7.2).
- B. The area for liposuction on the abdominal wall on the lateral and posterior aspects of the torso as well (Fig. 7.2).

- C. All areas for liposuction must be well demarcated all around the body with emphasis on some asymmetric regions where more volume of fat will be aspirated.

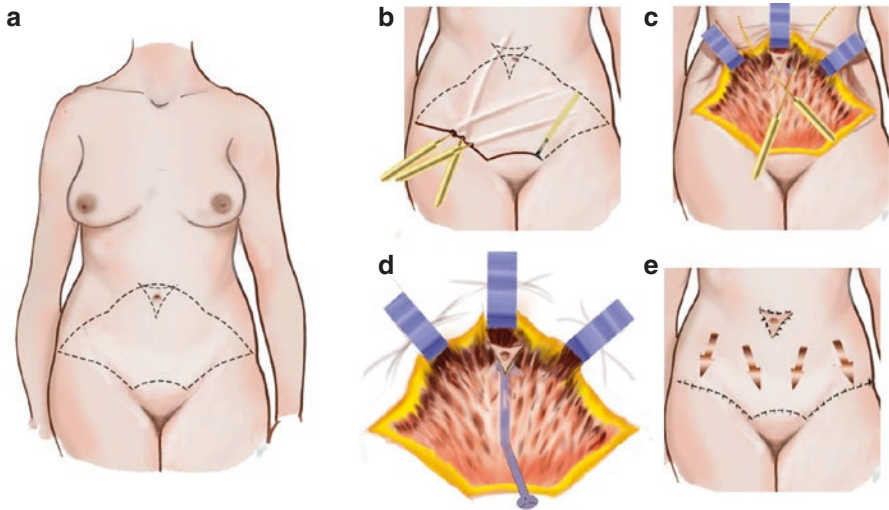
Therefore all deformities (localized adiposity and skin excess) must be drawn and shown to the patient 1 day prior to the operation.

Abdominoplasty may be performed under epidural or general anesthesia under the care of the anesthetist. Afterward, local infiltration is done according to surgical planning on two levels: deep infiltration on the supramuscular plan on all regions for liposuction and superficial and deep infiltration inside the panniculus on the area for skin resection. The solution is 1000 mL of sodium + 2 mg of epinephrine (1/1000), which is 2/1.000.000.

Liposuction is performed on two different levels. The first one is done in the full thickness of the panniculus on the area where skin resection will be performed with preservation of perforator vessels and connective tissue (Fig. 7.4). After liposuction, that area shows a deep depression due to the absence of fat tissue (Fig. 7.5).

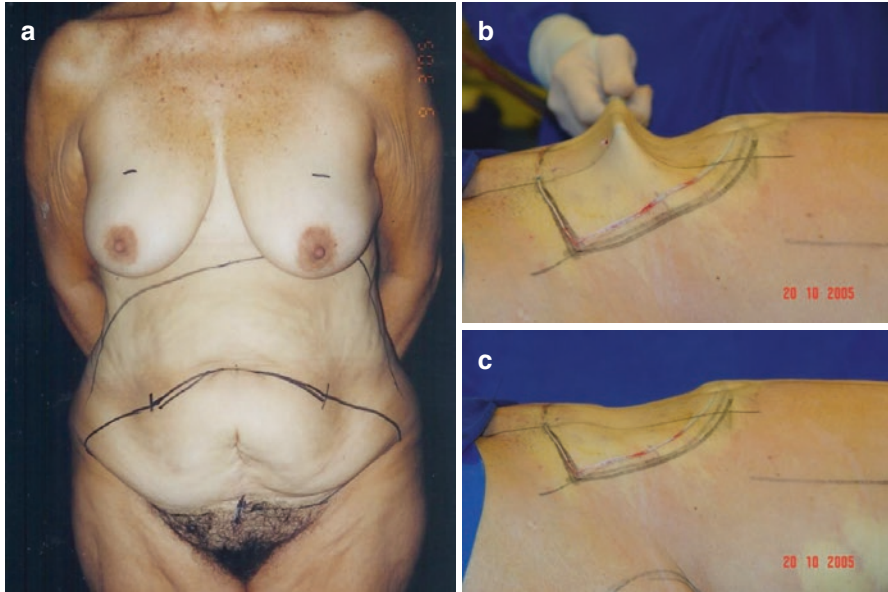
The second level of liposuction is performed on all regions of the remaining abdominal panniculus with its normal cutaneous covering (Fig. 7.6). Therefore, all fat tissue of the lamellar layer, which is below the fascia superficialis, is aspirated [16].

Afterward, cutaneous incisions on the umbilicus are done following the star-shaped drawing inside the umbilical region to create a natural and aesthetic area

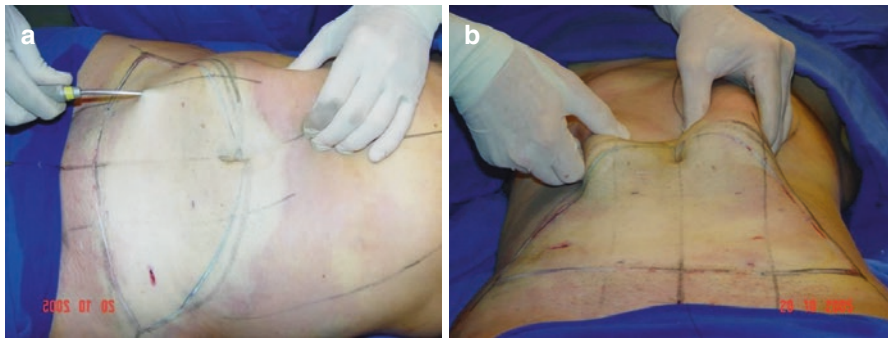


**Fig. 7.4** Sequential drawings show the technique of full lipoabdominoplasty: (a) surgical demarcation of the operation; (b) liposuction on full thickness of the panniculus is done and deep liposuction (below fascia superficialis) of the remaining panniculus is performed; (c) afterward the entire skin of the area below the umbilicus and above the pubis is resected. The perforator vessels and the connective tissue are preserved; (d) demarcation of the new umbilical area is done placing the lower segment of my personal umbilical marker instrument on the umbilicus. Then the abdominal flap is pulled downward, and the upper segment of my instrument is placed on the abdominal flap which determines the new umbilical region; (e) final aspect of full lipoabdominoplasty operation with the umbilicus created according to my technique





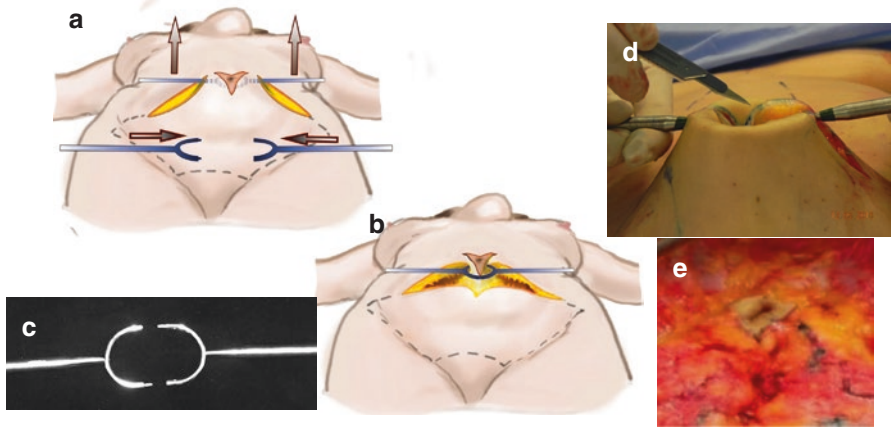
**Fig. 7.5** Full-thickness liposuction of the inferior segment of the abdomen. (a) a 65-year-old patient with surgical demarcations for full lipoabdominoplasty; (b) during surgery a profile view from the left side showing the full thickness of the panniculus being done; (c) a photo from the left side showing a significant depression of the skin on the lower abdomen due to absence of the panniculus already aspirated



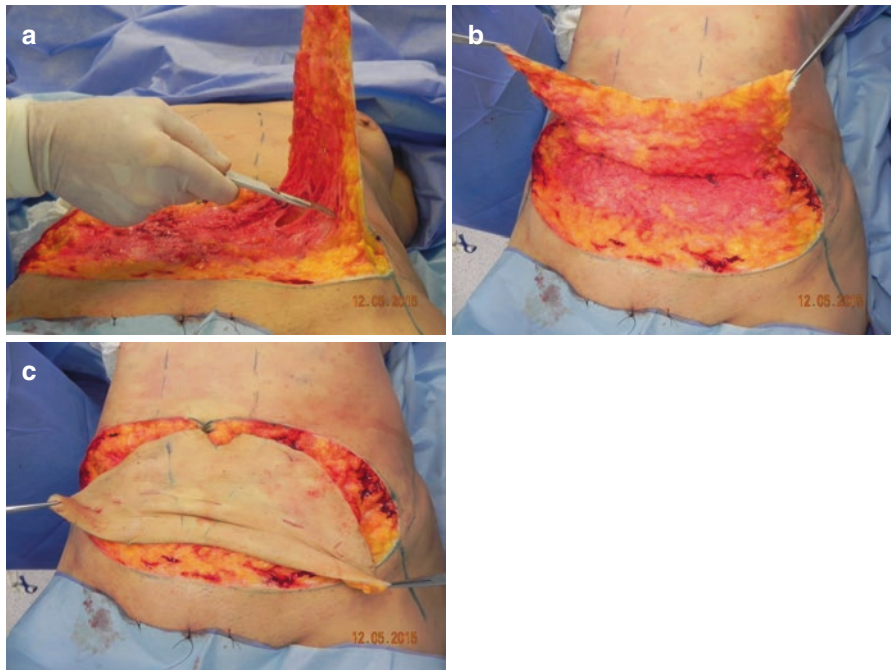
**Fig. 7.6** Deep liposuction (below fascia superficialis) of the remaining panniculus which is an essential surgical principle for lipoabdominoplasty. (a) Photo shows the cannula working on deep layer of the panniculus passing between the surgeon's fingers preserving the perforator vessels; (b) first it is performed on the right side until it reaches the ideal thickness shown in comparison with the left side

after abdominoplasty [4–6] followed by anatomical dissection of the umbilical pedicle (Fig. 7.7).

Afterward full-thickness skin resection is performed with a knife on the suprapubic region following previous demarcations (Fig. 7.8). Since the perforator vessels are not damaged, there is no bleeding during or after skin resection. As far as the



**Fig. 7.7** The technique of creating the new umbilical area during lipoabdominoplasty. (a) Schematic shows a star with three tips on the umbilicus after two small incisions on each side to introduce my special instrument in order to pull the umbilicus upward; (b) the umbilicus has been incised keeping the instrument around it; (c) photo of my double half instrument; (d) photo during surgery showing the incisions on the umbilicus following demarcations since the special instrument has been introduced one segment on each side; (e) photo of the umbilicus with three triangular flaps



**Fig. 7.8** Resection of the skin of the entire area below the umbilicus: (a) The skin is being resected; (b) the entire skin is lifted to show the raw area without any bleeding since the perforator vessels are preserved; (c) the resected skin lies on the raw area

adipose tissue is aspirated, the perforator vessels present reduced diameter of their caliber due to absence of blood passing through them.

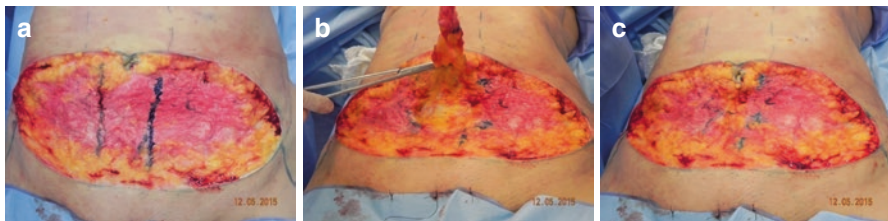Regarding the areas of skin resection, a fundamental aspect of my method is that after liposuction on full thickness of the panniculus, the only anatomical structures that remain are the connective tissue and all neurovascular branches: the vessels (arterial, venous, and lymphatics) and nerves.

Although the abdominal panniculus is not undermined during my method for abdominoplasty, it is possible to perform plication of the abdominal aponeurotic structures in order to reinforce the muscular wall and to treat the diastasis of the rectus abdominis up to the umbilicus. This surgical step was not described in my original publication [16] because there was no indication in my first 22 patients. Plication with endoscopic approach is a useful one performed by Correa [34]. Later I found other patients presenting situations for reinforcement of the aponeurosis during abdominoplasty without panniculus undermining which has been done in all cases of diastasis (Fig. 7.9).

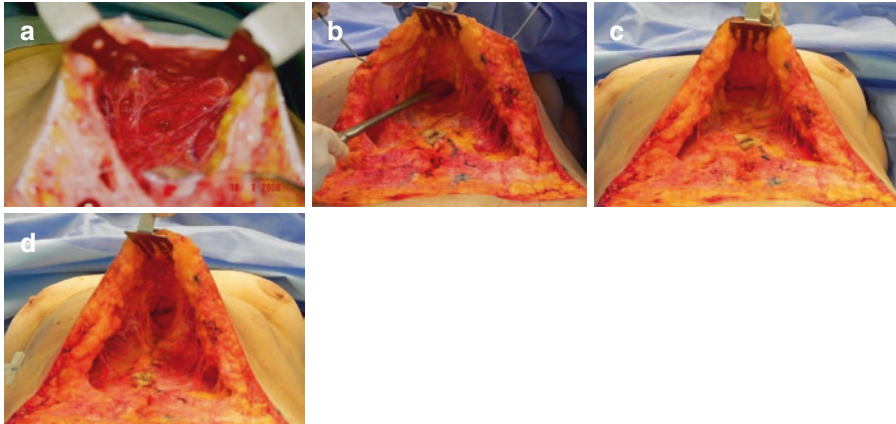
The infraumbilical segment is plicated through open view as described by Erfon with block resection of the connective tissue [37]. On another hand, reinforcement of the musculoaponeurotic wall above the umbilicus has been performed by Leão through tunnel dissection on the midline [49] (Figs. 7.10, 7.11, and 7.12).

Dissection and advancement of the external oblique muscle is described by Psillakis [64, 65] to improve reshaping the body and more recently has been studied by Nahas [56, 57] which is a useful approach. In specific patients presenting double diastasis on the midline (between the rectus abdominis) and also laterally (between the rectus abdominis and external oblique muscles), it is possible to perform reinforcement simultaneously without panniculus undermining which preserve perforating vessels (Figs. 7.13 and 7.14). Among several procedures for plication of the abdominal aponeurotic wall, Abramo et al. [1–3] introduced the “H” approach which offers harmonious reinforcement of the aponeurosis providing smooth surgical results. Flaccidity of the abdominal wall has been studied by Caldeira et al. [32] with useful reinforcement of the aponeurosis.

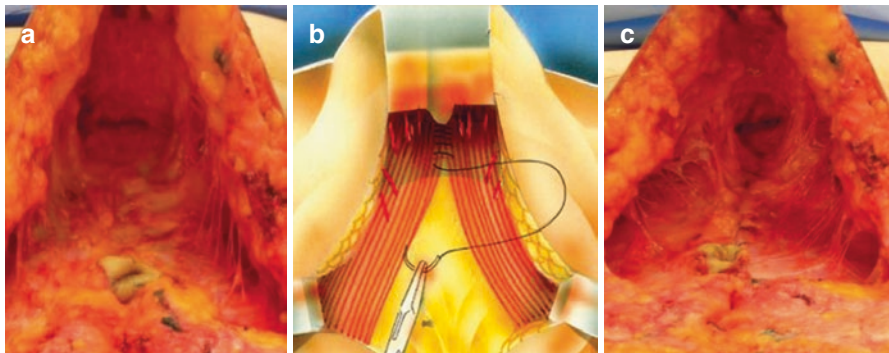
Following the operation, after plication procedure, the umbilical site which is exteriorized on the abdominal flap is done by pulling downward the remaining abdominal flap (Figs. 7.15 and 7.16). The three skin flaps of the umbilicus are sutured



**Fig. 7.9** Photos during surgery showing the plication on the midline of the infraumbilical aponeurosis: (a) the fascia is drawn with blue ink; (b) the fascia has been incised and lifted upward; (c) after plication



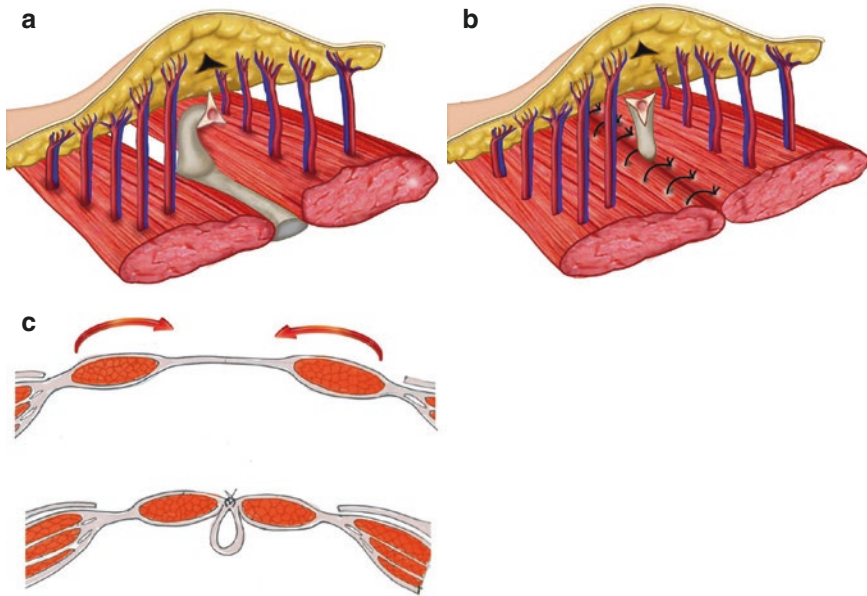
**Fig. 7.10** Photos during lipoabdominoplasty to demonstrate plication on the midline of the supraumbilical aponeurosis: (a) the abdominal panniculus flap is pulled upward to show the connective tissue and preservation of perforator vessels; (b) by using my blunt instrument below the remaining abdominal flap by dissection, a tunnel is created having the perforator vessels on each side; (c) after tunnelization the perforator vessels indicate the location of the internal border of the rectus abdominis and the aponeurosis which are sutured without any damage to the perforator vessels; (d) after reinforcement, the perforator vessels are preserved



**Fig. 7.11** The main surgical principle of new concepts on lipoabdominoplasty is the preservation of the perforator vessels on each side coming from the rectus abdominis in the supraumbilical area. When the patient presents diastasis, there is a significant distance between the muscles since there is no perforator vessels in the area of diastasis: (a) photo during operation showing the perforator vessels on each side; (b) schematic demonstrates plication of the rectus abdominis, but it is sutured with isolated stitches; (c) after reinforcement, the perforator vessels are positioned on the midline. Note that there is no bleeding during operation

with the three skin flaps created on the cutaneous abdominal wall as a triple “Z” on faloplasty procedure [4, 5]. Full description with technical details is on Chapter 8.

Closing of the surgical wound is performed with absorbent material with isolated stitches in three or four layers. According to the description above, the raw areas preserve the connective tissue, the fascia superficialis, and all perforator vessels.



**Fig. 7.12** Schematics (a, b) to demonstrate reinforcement of the abdominal aponeurotic wall with presence of the perforator vessels. Schematic (c) transversal section shows the rectus abdominis being sutured on the midline

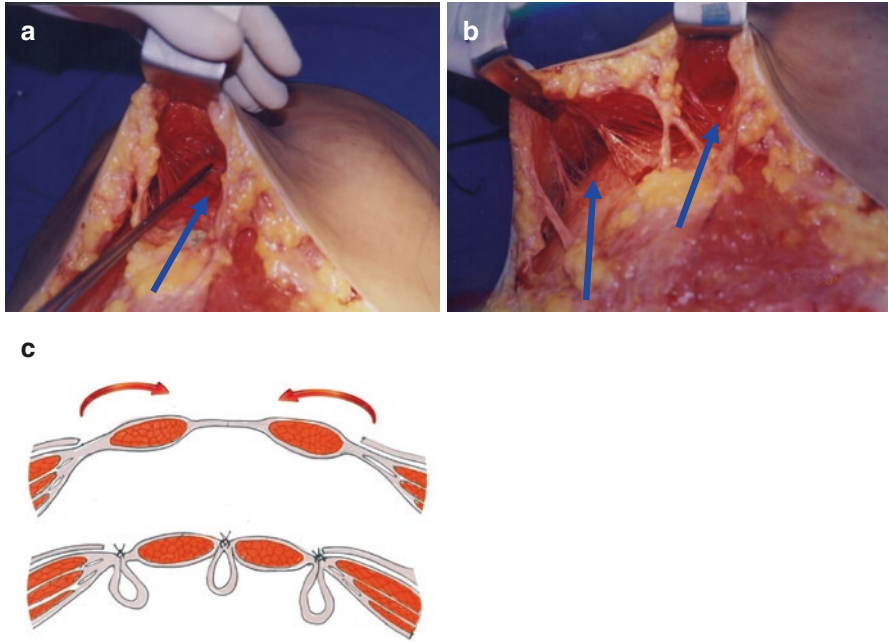
It is an important step to suture the fascia superficialis from the border of the upper panniculus flap to the fascia superficialis on the lower border where liposuction is not performed, to avoid unaesthetic depression of the scar (Figs. 7.17 and 7.18).

After suturing the subdermal layers, a running intradermal suture is done using absorbent material. On top of it, adhesive tapes are used for covering the surgical wound.

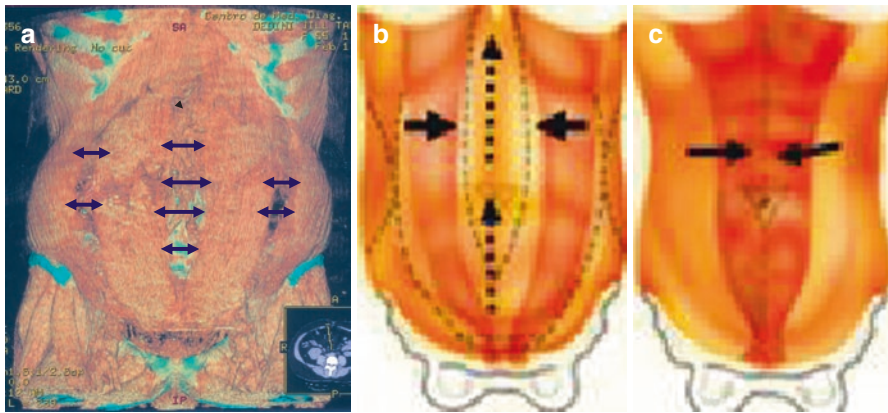
Bandaging is done using a garment and no drainage is necessary since there is no bleeding during or after operation. According to the descriptions above, no vessels are damaged during the operation because it is performed as a closed vascular system.

## Complications

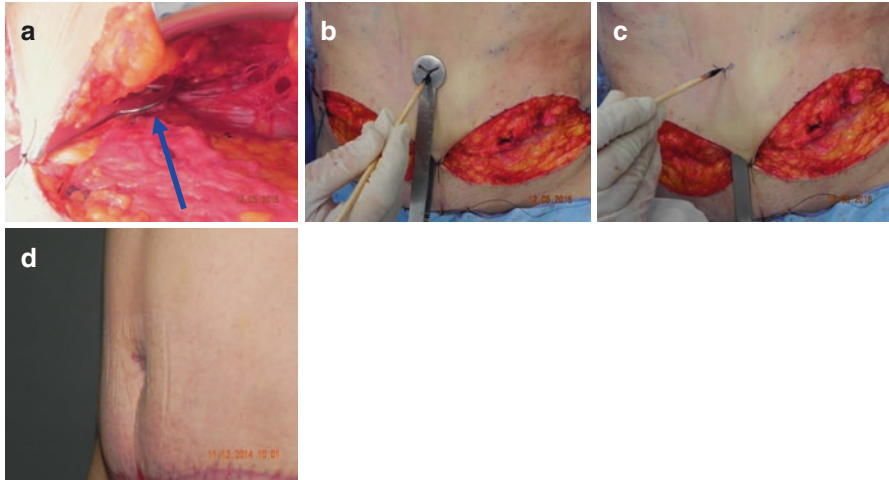
High incidence of local and systemic complications after abdominoplasty combined with liposuction was the main reason that motivated me to review my anatomical studies of the abdominal panniculus, searching for a new and safe method. Using my procedure, it is performed in a closed vascular system; since the perforator vessels are not cut, there are no severe complications after operation. I have not had panniculus necrosis, but only four patients presented skin slough which were recovered by local dressing without any reoperations.



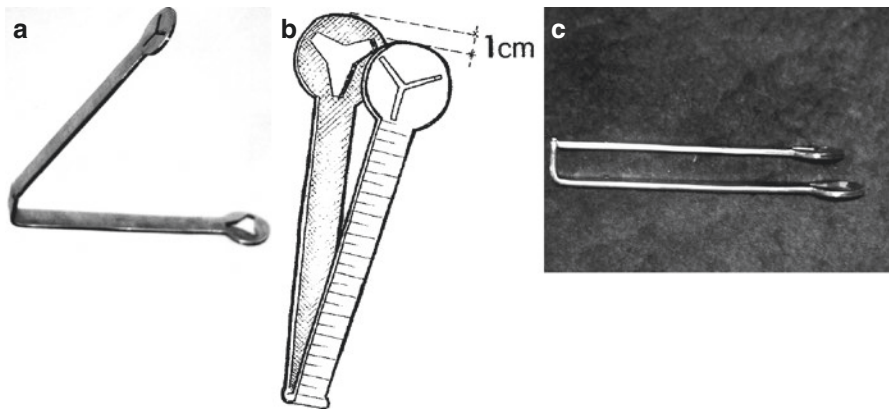
**Fig. 7.13** Reinforcement of the aponeurotic wall on the midline and lateral as well: Photo (a) shows plication on the midline indicated by an *arrow*; photo (b) shows plication on the midline and lateral as indicated by *arrows*; Schematic (c) transversal section shows plication of the rectus abdominis on midline and lateral plication



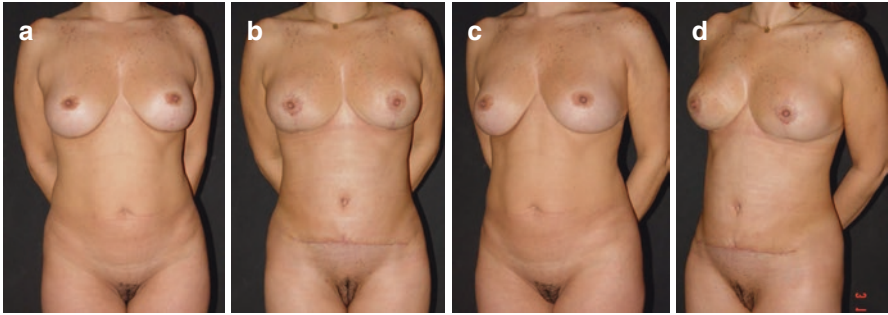
**Fig. 7.14** Plication of the musculoaponeurotic abdominal wall: (a) computerized tomography of a patient with diastasis on the midline and lateral as well. Although the abdominal panniculus is not undermined, it is possible to perform lateral plication; (b) schematic shows the diastasis; (c) after plication of the rectus abdominis



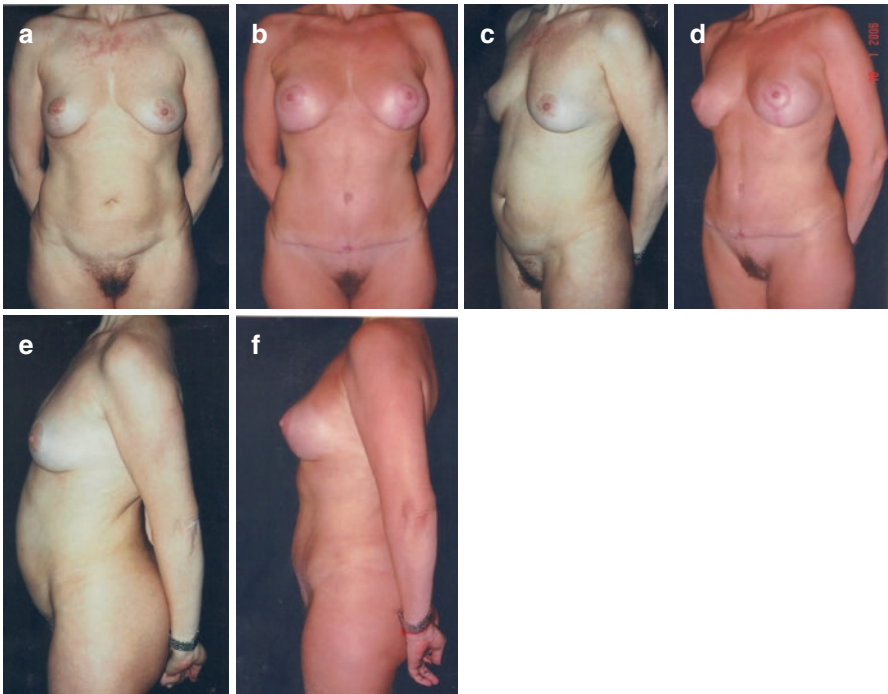
**Fig. 7.15** Demarcation of the new umbilical region during full lipoabdominoplasty operation is performed as a complement of the umbilicus: (a) the remaining abdominal panniculus flap is pulled downward and a stitch is done on the midline. The lower segment of Avelar's umbilicus marker (indicated by *arrow*) is placed on the umbilicus since there is a triangular area in which the umbilicus is located; (b) afterward the upper segment, which has space for three small incisions, lies smoothly on the abdominal flap; (c) three incisions will be done in order to create three cutaneous flaps which will be sutured to the three triangular flaps of the umbilicus; (d) the final result 2 weeks after surgery



**Fig. 7.16** Avelar's umbilicus marker has two segments similar to a compass, since the superior is 1 cm shorter than the inferior one. It is articulated in order to place one segment on the umbilicus and the other one lays on the abdominal flap: Photo (a) oblique view; (b) schematic showing details of the instrument; (c) photo on profile view



**Fig. 7.17** A 44-year-old patient presenting localized adiposities on the abdominal wall and diastasis of the rectus: Photos (a, c) before surgery; photos (b, d) 1 year after lipoabdominoplasty associated with mastopexy



**Fig. 7.18** A 48-year-old patient presenting localized adiposities on the abdominal wall and diastasis of the rectus: Photos (a, c, e) before surgery showing diastasis of the rectus; photos (b, d, f) after lipoabdominoplasty with plication of the rectus abdominis combined with mastopexy and inclusion of prosthesis on the breast

Local reactions of the internal stitches are the most common situation postoperatively which are removed under local anesthesia. Until nowadays, there is no systemic complication among all my patients.



## Discussion

My method is an association of liposuction with conventional abdominoplasty to treat unaesthetic alterations on the abdominal wall which is performed as closed vascular system [16–18]. In my concepts, liposuction procedure is performed with specific criteria which provide smooth and harmonious results on two levels: a deep one and a full thickness of the panniculus.

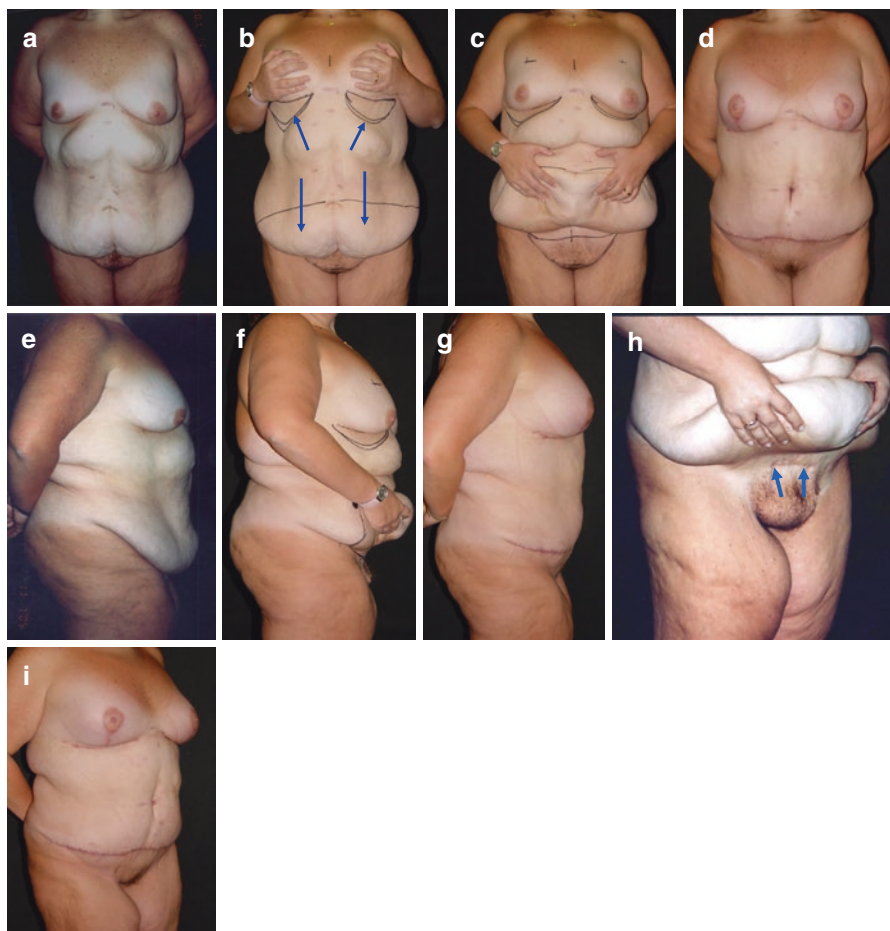After deep liposuction on the lamellar layer, the panniculus slides easily over the musculoaponeurotic wall, keeping all perforator vessels as multiple pedicles to the remaining panniculus. This situation is similar to that on a child's panniculus because they do not have adiposity in the lamellar layer on all regions of the abdomen [12, 15].

The areolar layer must be preserved in order to achieve regular thickness of the remaining panniculus, giving a harmonious result and good balance to the body contour. Nevertheless, in some cases, one may perform carefully liposuction in the areolar layer of the abdominal flap with the purpose to reduce its thickness. Even superficial tunnelization with 3 mm cannula is a useful procedure to facilitate the traction of the skin from up to down for dermal suture.

Due to high incidence of complications after combined procedure of liposuction with traditional abdominoplasty performed by Goldwyn [39], myself [14], and other authors, there was a tendency among plastic surgeons to find a safe approach in this field as reported by Shestak [68]. So far, the new concept I developed is a combination of surgical principles to improve and minimize complications during and after abdominoplasty.

There are no perforator vessels on the midline of the abdomen, since in a normal person there is a distance of 2–3 cm between both rectus abdominis. Nevertheless, that distance is much wider when patients present diastasis on the midline and consequently the perforator vessels are far away from one side to the other. I do not perform any panniculus undermining, but midline tunnelization is done using Avelar's dissector with the purpose to visualize the inner border of the muscles on each side (Fig. 7.10b). The perforator vessels emerging from the medial part of both rectus abdominis muscles give a natural indication of the location of the inner border of both muscles on each side (Figs. 7.10, 7.11, and 7.12). Therefore, the plication is done from up to down until the umbilicus as described by Leão [49–51]. The plication must start 5–6 cm below the xiphoid process, since the insertion of the rectus abdominis on the costal arch presents a natural distance from each other. In case of suture, the muscles too close to the xiphoid process may be damaged. Abdominolipoplasty or lipoabdominoplasty on patients after weight lost is an updated field in which Kaluf et al. [47] have presented outstanding contribution to improve surgical results. In some cases, it may be performed in association with other procedures to modeling the body contour (Fig. 7.19).

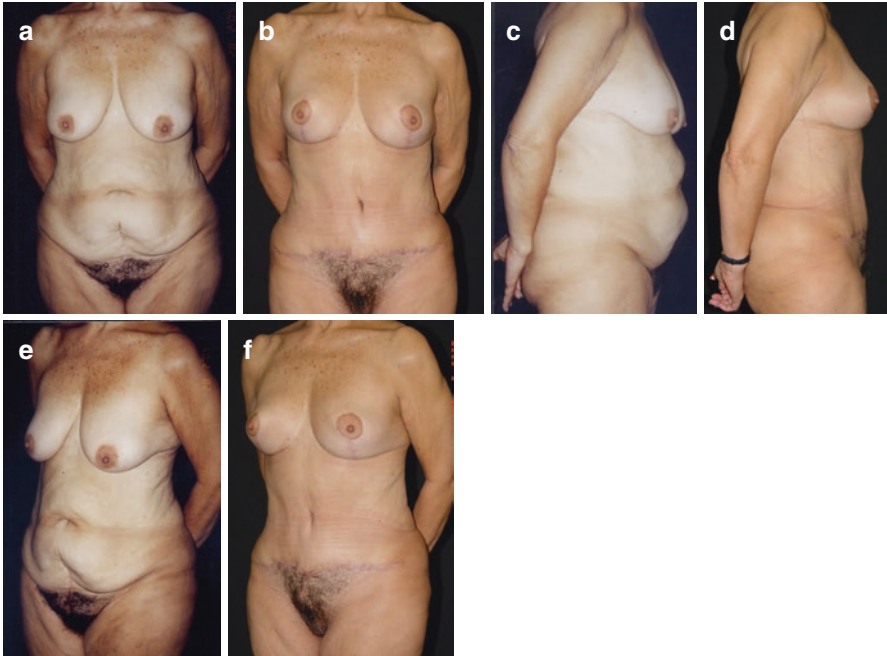
It is important to emphasize that very often when a patient presents long umbilical pedicle, as occur after severe weight lost, it is necessary to shorten it by isolated stitches. Afterward, plication of the inferior segment is done following Erfon's procedure, that is, after full-thickness resection of the fascia on the midline [37].



**Fig. 7.19** A 42-year-old patient after bariatric surgery with 49 kg weight lost. She underwent full lipoabdominoplasty combined with upper lipoabdominoplasty and pexy of the pubis: Photo (a) shows ptosis of the upper and lower abdomen covering her genitalia; (b) surgical planning of the upper lipoabdominoplasty and full lipoabdominoplasty as indicated by *arrows*; (c) she is hanging her abdomen to show ptosis of the pubic region; (d) the same patient 6 months after operation. Photo (e) on profile view showing ptosis of the abdomen and the upper abdomen as well; (f) she hangs her lower abdomen; (g) the final result. Photo (h) on oblique view, patient is hanging her abdomen to show the ptosis of the pubis with *arrows* indicating the correction of the pubis with pexy; (i) final result after full lipoabdominoplasty combined with upper lipoabdominoplasty pexy of the pubis and mastopexy with prosthetic implant

Reinforcement of the aponeurotic abdominal wall is done on the midline and also laterally in some patients (Figs. 7.20 and 7.21).

Plication of the muscles is a useful procedure, but it is not a routine one during traditional abdominoplasty [8, 13]. It is a helpful surgical step when patients present moderate or severe muscular flaccidity, diastasis of the rectus abdominis, or hernia-

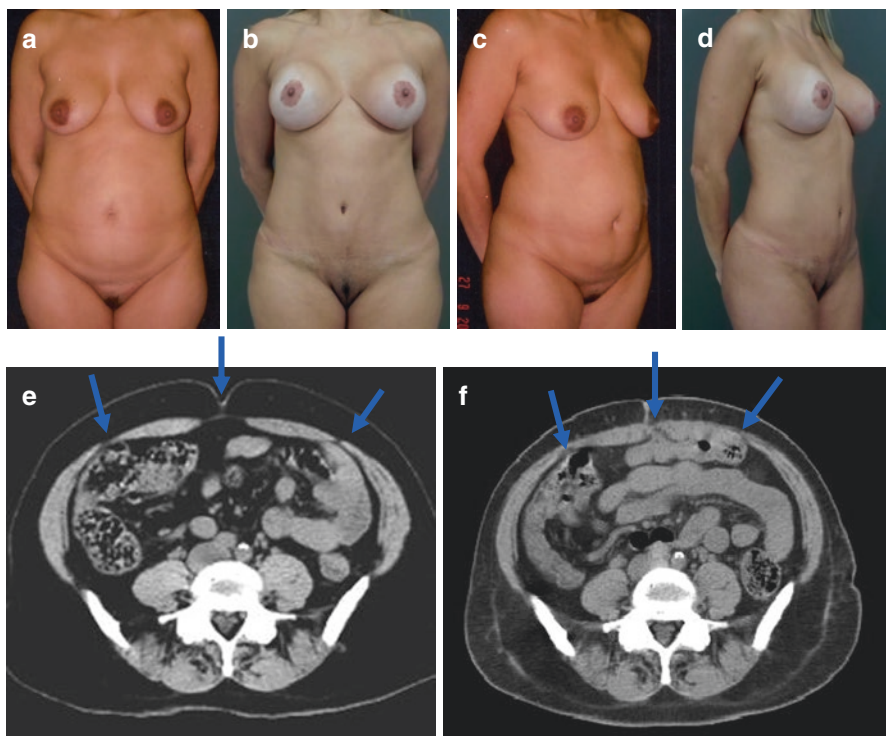


**Fig. 7.20** A 64-year-old patient presenting localized adiposities on the abdominal wall and diastasis of the rectus. Photos (a, c) and (e) preoperative view showing unaesthetic alterations of the abdomen with diastasis of the rectus; photos (b, d) and (f) after lipoabdominoplasty with plication of the rectus abdominis combined with mastopexy without breast implant

tion of the abdominal wall as reported by Pontes [61, 63] and emphasized and popularized by Pitanguy [58, 60]. Later Lockwood [52] suggested suspension with superficial fascia which is a useful contribution to improve surgical results after abdominoplasty. The anatomy he presented is similar to previous descriptions concerning abdominal panniculus [11, 12, 15].

### *Surgical Principles of My Method*

1. The perforating vessels coming from abdominal muscles are not sectioned during operation since the abdominal panniculus is not undermined and they work as multiple pedicles providing normal blood supply to the remaining panniculus (Figs. 7.10 and 7.11).
2. The operation is performed as a closed vascular system, since the cannula does not damage the intra-panniculus vascular network (Fig. 7.12).
3. The cutaneous excess is treated by full-thickness skin resection of the infraumbilical region (Fig. 7.8).



**Fig. 7.21** A 41-year-old patient presenting localized adiposities on the abdominal wall, diastasis of the rectus abdominis, and unaesthetic projection of the abdomen. Photos (a, c) of preoperative view showing flaccidity of the abdomen with diastasis of the rectus; photos (b, d) after lipoabdominoplasty with plication of the rectus abdominis combined with mastopexy with breast implant. Photo (e) computerized tomography (TC) is a routine before lipoabdominoplasty showing diastasis of the rectus abdominis on the midline and lateral indicated by *arrows*; (f) same patient after lipoabdominoplasty with reinforcement of the rectus on the midline and lateral indicated by *arrows*

4. Liposuction procedure is performed on two levels: (a) full thickness of the excess panniculus and (b) on deep level on the lamellar layer, above the abdominal musculature to preserve the perforator vessels (Figs. 7.5 and 7.6).
5. The remaining panniculus presents normal vascular network in its full thickness with small vessels coursing perpendicularly from the communicating vessels situated in the fascia superficialis to subdermal plan providing adequate vascularization (Fig. 7.10).
6. Fascia superficialis is an important anatomical structure located between the areolar and lamellar layer which is a fundamental organic architecture of the abdominal panniculus. For this reason, it is suitable to consider fascia superficialis as a symbol of the new concepts on lipoabdominoplasty.
7. The lymphatic vessels, which surround the arteries and veins, are preserved, since the perforator vessels are not cut. Therefore the lymph coming from the

abdominal panniculus maintains its normal circulation after surgery, avoiding seroma formation.

8. The nerves passing together to the perforator vessels on each pedicle are also preserved, providing good sensibility to the abdominal wall after surgery.

The patients can go home on the first day after surgery, but they must be cautioned for the first week. They can walk carefully at home but they must avoid any straight position of the body in order to keep the abdominal flap without any tension on the scar. They present good recovery without pain, but it is mandatory to give patients adequate instructions to be cautious after operation.

## Conclusions

According to the clinical evaluation, selection of patients and indication for surgery (full abdominoplasty as referred by Avelar [30]) is performed when all the skin above the suprapubic region and below the umbilicus must be resected. Consequently the panniculus above the umbilicus by traction may reach the suprapubic region.

The technique is recommended for patients presenting excess skin, localized adiposity, muscular flaccidity, and diastasis of the rectus abdominis. Knowledge of the anatomy of the abdominal panniculus, particularly the vascularization described in our previous publications, is fundamental for the performance of this procedure.

My method of abdominoplasty is performed as a closed vascular system due to preservation of the perforator vessels, since the panniculus is not undermined and they work as multiples pedicles to provide good blood supply to the remaining abdominal panniculus.

## References

1. Abramo AC, Viola JC, Marques A (1990) The H approach to abdominal muscle aponeurosis for the improvement of body contour. *Plast Reconstr Surg* 86(5):1008–1013
2. Abramo AC, Viola JC, Marquez A, Jung KS (1998) Abdominoplasty: a transversal and longitudinal Pleating to Muscle Aponeurosis. *Wordplast* 2(1):52–58
3. Abramo AC, Casas SG, Oliveira VR, Marquez A (1999) H-shaped double contour plication in abdominoplasty. *Aesthetic Plast Surg* 23:260–266
4. Avelar JM (1976) Umbilicoplastia – uma técnica sem cicatriz externa (Umbilicoplasty – a technique without external scar). 13 Congr Bras Cir Plast, 1 Congr Bras Cir Estética 13rd Brazil Congress of Plastic Surgery and First Brazil Congress of Aesthetic Surgery, Porto Alegre, pp 81–82
5. Avelar JM (1976) Umbilicoplasty – a technique without external umbilical scar. *Cahiéés de Chirurgie Esthetic. Societé Française de Chirurgie Esthetic, Paris*
6. Avelar JM (1978) Abdominoplasty – systematization of a technique without external umbilical scar. *Aesthetic Plast Surg* 2:141–151
7. Avelar JM (1979) Cicatriz umbilical – da sua importância e da técnica de confecção nas abdominoplastias (umbilical scar – its importance and technique for creating during abdominoplasty). *Rev Bras Cir* 1(2):41–52

8. Avelar JM (1983) Abdominoplasty: technical refinements and analysis of 130 cases in 8 Years' follow-up. *Aesthetic Plast Surg* 7:205–212
9. Avelar JM (1985) Fat-suction versus abdominoplasty. *Aesthetic Plast Surg* 9:265–276
10. Avelar JM (1985) Combined liposuction with traditional surgery in abdomen lipodystrophy. XXIV Instructional Course of Aesthetic Plastic Surgery of ISAPS, Madrid
11. Avelar JM (1986) Perfil psicológico do paciente – introdução ao estudo (Psychological profile of the patient – introducing to the subject). In: Avelar JM, Illouz YG (eds) *Lipoaspiração (Liposuction)*. Editora Hipócrates, São Paulo, pp 8–12
12. Avelar JM (1986) Anatomia cirúrgica e distribuição do tecido celular no organismo humano (surgical anatomy and distribution of the cellular tissue on human organism). In: Avelar JM, Illouz YG (eds) *Lipoaspiração (liposuction)*. Editora Hipócrates, São Paulo, pp 45–57
13. Avelar J (1987) Study of the anatomy of the subcutaneous adipose tissue applied for fat suction technique. In: Maneksha RJ (ed) *Transactions of the IX international congress on plastic and reconstructive surgery*. Tata McGraw-Hill, New Delhi, pp 377–379
14. Avelar JM (1988) Abdominoplastia – reflexões e perspectiva biopsicológicas (abdominoplasty – reflections and bio-psychological perspectives). *Rev Soc Bras Cir Plast* 3(2):152–154
15. Avelar JM (1989) Regional distribution and behavior of the subcutaneous tissue concerning selection and indication for liposuction. *Aesthetic Plast Surg* 13:155–165
16. Avelar JM (1999) Uma nova técnica de abdominoplastia – sistema vascular fechado de retalho subdérmico dobrado sobre si mesmo combinado com lipoaspiração (a new technique for abdominoplasty – closed vascular system of subdermal flap folded over itself combined to liposuction). *Rev Bras Cir* 88/89(1/6):3–20
17. Avelar JM (1999) Novos conceitos para abdominoplastia (new concepts for abdominoplasty). Paper presented at the 36th Congress of the Brazilian Society of plastic surgery. Rio de Janeiro
18. Avelar JM (1999) Abdominoplastia: nuevos conceptos para una nueva técnica. *Abdominoplasty: new concepts for a new technique*. XXVI annual international symposium of aesthetic plastic surgery, Chairman: Prof. Jose Guerrerosantos – Puerto Vallarta, pp 10–13
19. Avelar JM (1999) Cirurgia plástica de face interna de coxas/aesthetic plastic in the inner side of the thigh – New concepts and technique without cutaneous or subcutaneous undermining. *Rev Bras Cir* 88/89(1/6):57–67
20. Avelar JM (1999) Flancoplastia e torsoplastia – nova abordagem cirúrgica. Flankplasty and torsoplasty – a New surgical approach. *Rev Bras Cir* 88/89(1/6):21–35
21. Avelar JM (1999) Cirurgia plástica e estética de axilas/aesthetic plastic surgery of the axilla. New technique to the treatment of excess skin, hyperhidrosis, cutaneous flaccidity, hyperhidrosis and bromidrosis. *Rev Bras Cir* 88/89(1/6):41–54
22. Avelar JM (2000) I Curso de abdominoplastia (first course of abdominoplasty). Chairman: Prof. WEP Callia. Municipal Hospital. São Paulo
23. Avelar JM (2000) Abdominoplastia sem descolamento (Abdominoplasty without undermining). São Paulo: XX Jorn. Paulista Cir Plast. Avelar JM (2000) Abdominoplasty: a new technique without undermining and fat layer removal (Abdominoplastia: uma nova técnica sem descolamento e remoção da camada de gordura). *Arq Catarinense de Med* 29:147–149
24. Avelar JM (2000) 2Curso de abdominoplastia (2nd course of abdominoplasty). Chairman: Prof. Juarez M. Avelar. Hospital do Coração (Heart Hospital). São Paulo
25. Avelar JM (2000) Abdominoplastia com preservação do sistema vascular profundo. Comunicação Pessoal. (Abdominoplasty with preservation of the deep vascular system. Personal communication. Reunião Mensal da Sociedade Brasileira de Cirurgia Plástica do Rio Grande do Sul – Porto Alegre – maio monthly meeting of the Brazilian Society of Plastic Surgery of Rio Grande do Sul. Porto Alegre
26. Avelar JM (2000) A new technique for abdominoplasty subdermal flap folded over itself. The XV ISAPS Congress, Tokyo
27. Avelar JM (2000) Aesthetic plastic surgery of the axilla. The XV Congress of the International Society of Aesthetic Plastic Surgery (ISAPS), Tokyo
28. Avelar JM (2000) Abdominoplasty: a new technique without panniculus undermining and without panniculus resection. 57th instructional course of ISAPS, Chairman: Lloyd Carlsen, Montreal

29. Avelar JM (2000h) 2nd Course of abdominoplasty (2nd Curso de abdominoplastia). Juarez M. Avelar. Hospital do Coração (Heart Hospital), São Paulo City
30. Avelar JM (2002) Abdominoplasty without panniculus undermining and resection: analysis and 3-year follow-up of 97 consecutive cases. *Aesthet Surg J* 22(1):16–25
31. Babcock WW (1916) On diseases of women and children. *Am J Obstet Gynecol* 74:596
32. Caldeira AML, Lucas A (1998) Flacidez músculo-aponeurótica abdominal intensa. Su tratamento. *Cir Plast Ibero-Latinoamericana* 24(1):9–15
33. Callia WEP (1965) Contribuição ao estudo de correção cirúrgica do abdomen pêndulo e globus. (Contribution to the study of surgical correction of the pendulum abdomen and globus). Original art. Doctoral Thesis Fac Med USP, São Paulo
34. Correa MA (1995) Videoesoscopia técnicas subcutâneas para cirurgias autênticas e reconstrutivas (videoendoscopy subcutaneous techniques for authentic and reconstructive surgery). *Plast Reconstr Surg* 446
35. Delleru E (1990) Abdominoplasty combined with suction lipoplasty a study of complication, revisions, and risk factors in 487 cases. *Ann Plast Surg* 25(5):333–338
36. Demars M, Marx M (1890) Surgical treatment of obesity. *Prog Med* 11:283
37. Erfon JAR (2000) Ressecção da fascia abdominal inferior para plicatura infra umbilical em lipoabdominoplastia sem descolamento do panículo. 2 Curso de Abdominoplastia, Hospital do Coração, São Paulo, (Resection of the lower abdominal fascia to improve plication of infraumbilical aponeurosis during lipoabdominoplasty without panniculus undermining) 2nd Course of Abdominoplasty Heart Hospital, São Paulo
38. Flageul G, Elbaz JS, Karcenty B (1999) Complications of plastic surgery of the abdomen. *Ann Chir Plast Esthet* 44(4):497–505
39. Goldwyn RM (1986) Abdominoplasty as a combined procedure: added benefit or double trouble? *Plast Reconstr Surg* 78:383–384
40. Grazer FM, Goldwyn RM (1977) Abdominoplasty assessed by survey with emphasis on complications. *Plast Reconstr Surg* 59(4):513–517
41. Guerrerosantos J, Spaillet L, Morales F, Dickeheet S (1980) Some problems and solutions in abdominoplasty. *Aesthetic Plast Surg* 4:227
42. Hester TR Jr et al (1989) Abdominoplasty combined with other major surgical procedures: safe or sorry? *Plast Reconstr Surg* 83:997
43. Illouz YG (1980) Une nouvelle technique pour les lipodystrophies localisées. *Rev Chir Esth Franc* 6:9–14
44. Illouz YG (1982) Liposuction technique. First Instructional Course with surgical demonstrations at São Paulo Hospital, Prof. Andrews' Service. Organized by Brazilian Society of Plastic Surgery – Regional São Paulo, Endorsed by Brazilian Society of Plastic Surgery (BSPS)
45. Illouz YG (1982) My technique of selective suction lipectomy. Annual meeting of the American Society of Plastic and Reconstructive Surgeons. Honolulu
46. Illouz YG (1984) Refinements in Liposuction to improve body contour. Theory and practical course with surgical demonstrations at “Nove de Julho” Hospital. Organized by Brazilian Society of Plastic Surgery (BSPS) with collaboration of Regional São Paulo
47. Kaluf R, Azevedo FN, Rodrigues LO (2006) Sistemática Cirúrgica em Pacientes Ex-Obesos. *Revista Brasileira de Cirurgia Plástica* 21(3)
48. Kelly HA (1899) Report of gynecological cases. *Johns Hopkins Med J* 10:197
49. Leão CF (2000) Plicatura da parede músculo-aponeurótica por um tunel criado abaixo do panículo abdominal na linha média em lipoabdominoplastia sem descolamento. 37º Congresso Brasileiro de Cirurgia Plástica, novembro – Porto Alegre. (Reinforcement of the musculoaponeurotic wall through a tunnel created below the abdominal panniculus during lipoabdominoplasty). 37th Brazilian Congress of Plastic Surgery, Porto Alegre
50. Leão CF (2000a) Plication of the musculoaponeurotic wall through a tunnel on the superior abdominal on the midline during lipoabdominoplasty without panniculus undermining. 2nd Course of abdominoplasty at Heart Hospital. Juarez Avelar (Plicatura da parede músculoaponeurótica por um tunel no abdômen superior na linha média em lipoabdominoplastia sem descolamento. 2º Curso de abdominoplastia, no Hospital do Coração), São Paulo - Brazil

51. Leão CF (2000b) Reinforcement of the musculoaponeurotic wall through a tunnel created below the abdominal panniculus during lipoabdominoplasty. 37th Brazilian congress of plastic surgery. (Plicatura da parede músculo-aponeurótica por um tunel criado abaixo do panículo abdominal na linha média em lipoabdominoplastia sem descolamento. 37° Congresso Brasileiro de Cirurgia Plástica, novembro), Porto Alegre, November 2000
52. Lockwood T (1995) High lateral-tension abdominoplasty with superficial fascial system suspension. *Plast Reconstr Surg* 96(3):603–615
53. Malbec EF (1948) Lipectomia abdominal. *La Prensa Méd Arg* 35(26)
54. Matarasso A (2000) Liposuction as an adjunct to full abdominoplasty revisited. *Plast Reconstr Surg* 106:1197–1206
55. Mélega JM (1982) Tromboembolismo Como complicação de abdominoplastia: etiologia, prevenção e tratamento (thromboembolism as a complication of abdominoplasty : etiology, prevention and treatment). In: Avelar JM (ed) *Proceedings of the Brazilian symposium of abdominoplasty*. Soc Bras Cir Plástica, Reg, São Paulo, pp 73–76
56. Nahas FX (2001) Advancement of the external oblique muscle flap to improve the waistline: a study in cadavers. *Plast Reconstr Surg* 108(2):550–555
57. Nahas FX, Ferreira LM, Augusto SM, Ghelfond C (2005) Long-term follow-up of correction of rectus diastasis. *Plast Reconstr Surg* 115(6):1736–1741
58. Pitanguy I (1967) Abdominal lipectomy: an approach to it through an analysis of 300 consecutive cases. *Plast Reconstr Surg* 40(4):38
59. Pitanguy (1986) Perspectivas filosóficas e psicossociais do contorno corporal. (philosophical and psychosocial perspectives of the body contour. In: Avelar JM, Illouz YG (eds) *Lipoaspiração (liposuction)*. Editora Hipócrates, São Paulo, pp 1:3–7
60. Pitanguy I (1977) Dermolipectomy of the abdominal wall, thighs, buttocks, and upper extremity. In: Converse JM (ed) *Reconstructive plastic surgery*, 2nd edn. Saunders, Philadelphia, pp 3800–3823
61. Pontes R (1965) Plástica abdominal: importância da sua associação com a correção de hernia incisional (abdominal plastic : importance of its association with the correction of incisional hernia). *Rev Bras Cir* 52:58
62. Pontes R (1971) Sistematização e variantes da excisão prévia do excesso cutâneo adiposo nas abdominoplastias. VIII Cong. Bras. Cir. Plast – Salvador, Bahia
63. Pontes R (1982) Plástica abdominal – resultados insatisfatórios. (plastic of the abdomen – unsatisfactory results). In: Avelar JM (ed) *Proceedings of the brazilian symposium of abdominoplasty*. Soc Bras Cir Plástica, Reg, São Paulo, pp 47–51
64. Psillakis JM (1984) Plastic surgery of the abdomen with improvement in the body contour. *Clin Plast Surg* 11(3):465–477
65. Psillakis JM (1984) Abdominoplasty: treatment of the external oblique muscle to obtain a better waist. *Ann Jornada Sul Bras Plast Surg SBCP* 85–89
66. Rebello C, Lion P, Franco T (1972) Abdominoplasty through submammary incision. International Congress of ISAPS, Rio de Janeiro. Ed. Publicaciones Comntroladas, 58, Madrid
67. Serson Neto D (1970) Abdominal dermolipectomies – geometric approach (dermolipectomias abdominais – abordagem) geométrica. *Rev Col Bras Cir* 10:17
68. Shestak KC (1999) Marriage of abdominal and liposuction expands abdominoplasty concept. *Plast Reconstr Surg* 103(3):1027
69. Sinder R (1975) Plastic surgery of the abdomen – personal technique with prior undermining of the supraumbilical flap – before infraumbilical resection and the use of the dermo adipose flap. (Cirurgia Plastica do Abdomen – Técnica Pessoal com prévio descolamento do retalho supraumbilical – antes da Ressecção Infraumbilical e uso de retalho dermo adiposo) VI International Congress of Plastic and Reconstructive Surgery, Paris
70. Sinder R (1979) Cirurgia plástica abdominal (abdominal plastic surgery). Sinder, Niteroi
71. Thorek M (1939) Plastic reconstruction of the female breasts and abdomen. *Am J Surg* 43:268–278
72. Vernon S (1957) Umbilical transplantation upward and abdominal contouring in lipectomy. *Am J Surg* 94:490–492



# Chapter 8

## Creation of the New Umbilicus: My Technique on Abdominoplasty and Further Applications

Juarez M. Avelar

### Introduction

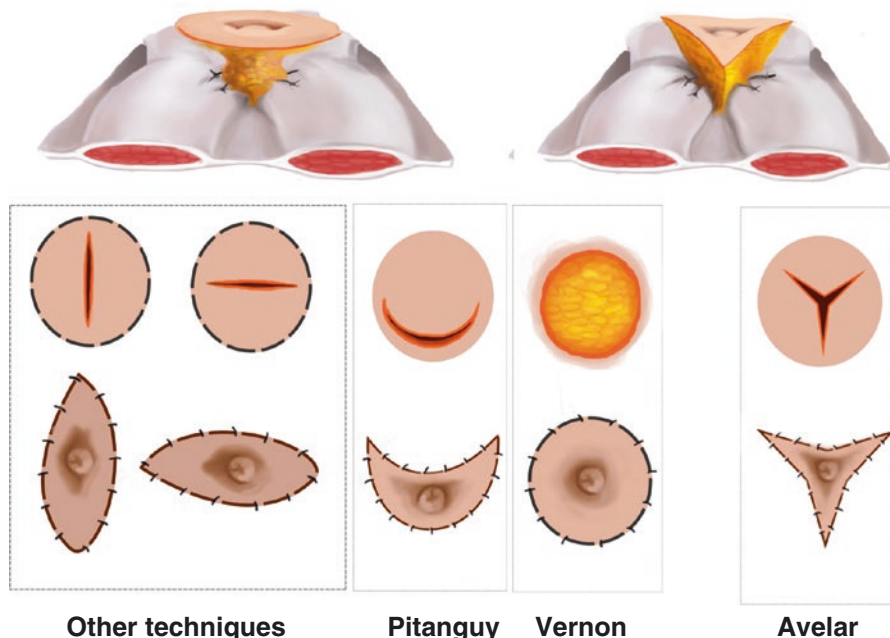
Abdominoplasty has been performed since 1899 on the first publication by Kelly performing resection of a segment of excess panniculus creating the expression “abdominal lipectomy” [22]. Such procedure used to be the basic principle of several techniques during a long period through panniculus resection without transposition of the umbilicus. However, Vernon in 1957 was the first author to describe umbilical transposition upward during abdominal lipectomy [27]. In his original publication, a circular incision around the umbilicus was performed in order to separate it from the abdominal panniculus wall. Consequently, the cutaneous surface of the umbilicus was a circle (Fig. 8.1). Afterward, traction of the abdominal flap is done downward for resection of the excess panniculus. For reimplantation of the umbilicus on the abdominal flap, another circular incision was done and a circle of skin and a tube of subcutaneous fat tissue were resected in order to introduce the new navel.

Following Vernon’s description, many authors have published other procedures with vertical or horizontal incisions and also a semicircular incision [23], resulting always in a circular scar around the transposed umbilicus. Even when outstanding surgeons perform the operation, the final results have not been satisfactory in most patients. According to a survey by Grazer and Goldwyn [21] regarding 10,540 abdominoplasties earned out by plastic surgeons from the USA and other countries, umbilical scar contractures may occur in 45 % of the surgeries. In that survey, they mentioned that 2 % of the surgeons believe that some sort of retraction or contraction of the umbilical scar always occurs after abdominoplasty when transposition is done.

---

J.M. Avelar, MD

Head of the Brazilian Scientific Institute of Plastic and Reconstructive Surgery,  
Al Gabriel Monteiro da Silva, 620 Jd Europa, São Paulo, SP 01442-000, Brazil  
e-mail: [juarezavelar@bol.com.br](mailto:juarezavelar@bol.com.br); [institutodaorelha@uol.com.br](mailto:institutodaorelha@uol.com.br)



**Fig. 8.1** Different cutaneous incisions used in umbilicoplasty and their implantation on the abdominal flap. *Top*: The circular incision used in other techniques and the triangular one in mine for umbilicoplasty; *Middle*: Different cutaneous incisions on the abdominal flap and my triangular one; *Bottom*: Different shapes of the surgical wound after implantation of the umbilicus according to each technique

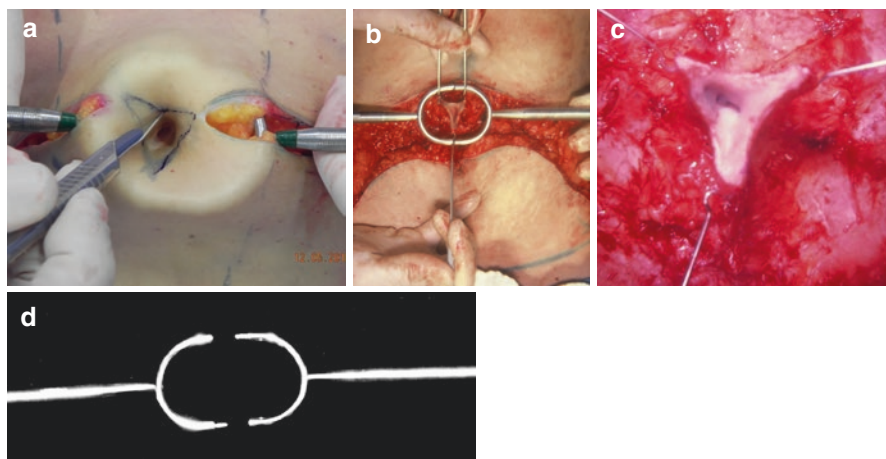
Since I started my practice in 1974, I gave special attention to create a natural umbilical region during abdominoplasty in attempt to solve some severe problems associated with abdominoplasty. In my original publications [1–3], there are descriptions of an approach that proposed a new possibility, avoiding problems regarding scar retraction and even contraction (Fig. 8.1). Over the years, the basic principles of the method have remained the same, but according to my observations, some technical details have been revised to improve the aesthetic results [4] even later when full lipoabdominoplasty is performed [6–8].

## Technique

### Surgical demarcations

#### The operation

- A. Preparation and liberation of the umbilicus
- B. Implantation of the umbilicus
- C. Suture of the umbilicus
- D. Dressing



**Fig. 8.2** Creation of the umbilicus during full abdominoplasty after liposuction procedure: (a) using my double half-circular instrument, the umbilical area is pulled upward to avoid accidental damage to intra-abdominal organs and triangular cutaneous incisions inside the umbilical cavity are done, one flap being directed downward and the other ones directed obliquely upward to the right and left; (b) after incisions, the triangular umbilicus is isolated; (c) triangular shape of the umbilicus according to my technique; (d) my double half-circular instrument

### *Surgical Demarcations*

Creation of a new umbilical region is a mandatory procedure during all full abdominoplasties since the umbilicus must be transposed during operation. When one performs full abdominoplasty or full lipoabdominoplasty, creation of a new umbilical region is also an obliged stage in order to rebuild the abdominal wall. Surgical planning and demarcations are essential steps before any procedure in plastic surgery. Regarding full abdominoplasty or lipoabdominoplasty, both steps are even fundamental prior to operation and must be done with patient in stand and also in lay-down positions. My preference is to demarcate all reference points at my office on the day before surgery with my patient in front of some mirrors in order to follow my drawings. The demarcations on umbilical region are also done according to my approach published in 1976 and presented at the Brazilian Congress of Plastic Surgery and French Congress of Aesthetic Surgery (Fig. 8.2) [1, 2]. Firstly, a circle of about 2 cm in diameter must be drawn around the umbilicus with the purpose to delimitate the umbilical area on the surface of the abdominal wall. After drawing the circle around the umbilicus, a star-shaped incision with three triangular flaps is also done. One flap must be directed downward and other flaps are directed obliquely upward to the right and to the left (Fig. 8.2).

In patients after massive weight loss or when present with excessive cutaneous flaccidity, the umbilical area shows some downward inclination. However, the umbilical region is always well identified due to its peculiar constitution of skin with depression in the center which is the first scar in every human body due to necrosis of the umbilicus during few days after birth.

The skin area of the abdomen to be resected is also demarcated before operation. My preference is to follow Callia's technique with purpose to achieve the final scar as low as possible [20].

## ***The Operation***

Epidural or general anesthesia may be employed to perform full lipoabdominoplasty which is a combination of abdominoplasty without panniculus detachment with liposuction procedure. Local infiltration with a special solution is done prior to liposuction and skin resection which are fundamental procedures during operation. The solution is: 1000 mL of serum plus 2 mg of epinephrine (1/1000), which makes the dilution 2/1,000,000. In the use of this volume, it is possible to infiltrate the entire abdominal wall and lateral sides as well.

All those technical details are meticulously described on a chapter in this book regarding full lipoabdominoplasty.

## **Preparation and Liberation of the Umbilicus**

The first surgical procedure on the umbilical region is to make cutaneous incisions following the star-shaped drawing inside the umbilicus according to my demarcations (Fig. 8.2a–c). In order to do this, I created a new surgical instrument, which is a double half circle with two-in-one type, to be articulated around the umbilical pedicle (Fig. 8.2d). Using this double half-circle instrument, the surgeon's assistant pulls the umbilical area upward. Such maneuver is useful to elevate the cutaneous surface of the umbilical region from the abdominal cavity in order to avoid any accidental perforation of the internal abdominal organs. I have heard about this kind of severe complication during surgery even when it is performed by well-qualified plastic surgeons.

Afterward, with a scissor, the pedicle is dissected downward to reach the aponeurosis of the musculoaponeurotic wall in order to isolate the umbilicus. At the end of this stage, the cutaneous surface of the umbilicus is free, showing its triangular shape (Fig. 8.2).

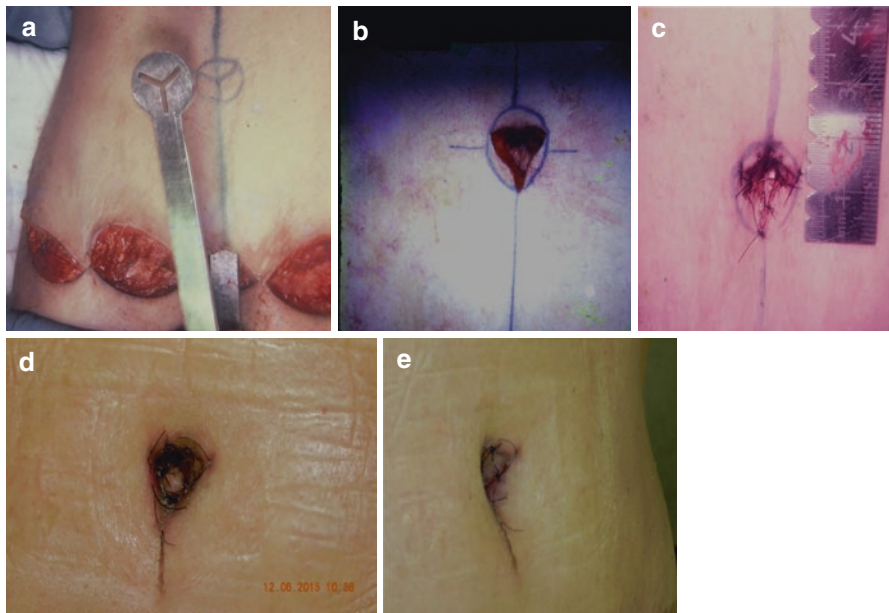
Afterward, skin resection of the abdominal wall following the demarcated area is a mandatory procedure. My operation is done according to Sinder's technique through which the upper incision of the area of skin to be resected begins at the junction of the curved line on both sides of the umbilicus, with a slight curvature downward following the demarcation [25, 26]. The subcutaneous tissue is held so that the knife does not damage the subdermal layer underneath, and consequently, there is no bleeding.

When there is indication for reinforcement of the musculoaponeurotic structures, this is the appropriate time to do it. I created a device (a dissector instrument) which is introduced from the umbilical area upward on the midline through the connective


tissue in order to expose the central border of the rectus abdominis. The procedure regarding its plication is described in chapter Full Lipoabdominoplasty in this book.

### Reimplantation of the Umbilicus

Once the abdominal flap has been pulled downward, the new umbilical area is marked at the point corresponding to its projection on the cutaneous abdominal surface. The midline of the abdominal wall must be drawn before operation in order to give the correct orientation to demarcate the new umbilicus on the aesthetic location on the abdomen. To determine the new location, I created an appropriate surgical instrument (Fig. 8.3) that permits to achieve the exact position of the new umbilicus and simultaneously where the adequate distance from the final scar will be, since the instrument is a marker as well as a ruler (Fig. 8.4). This instrument also protects the aponeurotic wall underneath as well as avoids any damage to the intra-abdominal organs since it lies smoothly on the aponeurotic wall already reinforced. According to my previous publications [4, 5] on late follow-up, the umbilicus is pulled upward by the upper abdominal segment. For this reason, the final position



**Fig. 8.3** Incisions on the abdominal panniculus flap for reimplantation of the umbilicus: (a) The abdominal flap is already pulled and temporary stitches are done, and one segment of my umbilicus marker is placed on the umbilicus and the other segment lies on the flap where the new area is drawn; (b) three incisions were done to create three triangular flaps inside the circle; (c) the three skin flaps of the umbilicus are sutured to the three flaps created on the abdominal panniculus; (d) after suture in front view; (e) oblique view showing that the three skin flaps of the abdominal panniculus turn downward creating a natural depression on the new umbilical cavity



**Fig. 8.4** Umbilicus marker has two segments. The superior segment is 1 cm shorter than the inferior one. It is articulated in order to place the lower segment on the umbilicus and the other one lies on the abdominal flap: photo (a) Avelar's instrument in lateral view; (b) photo on oblique view

of the umbilicus is marked at least 1 cm lower than its projection on the abdominal flap (Fig. 8.3).

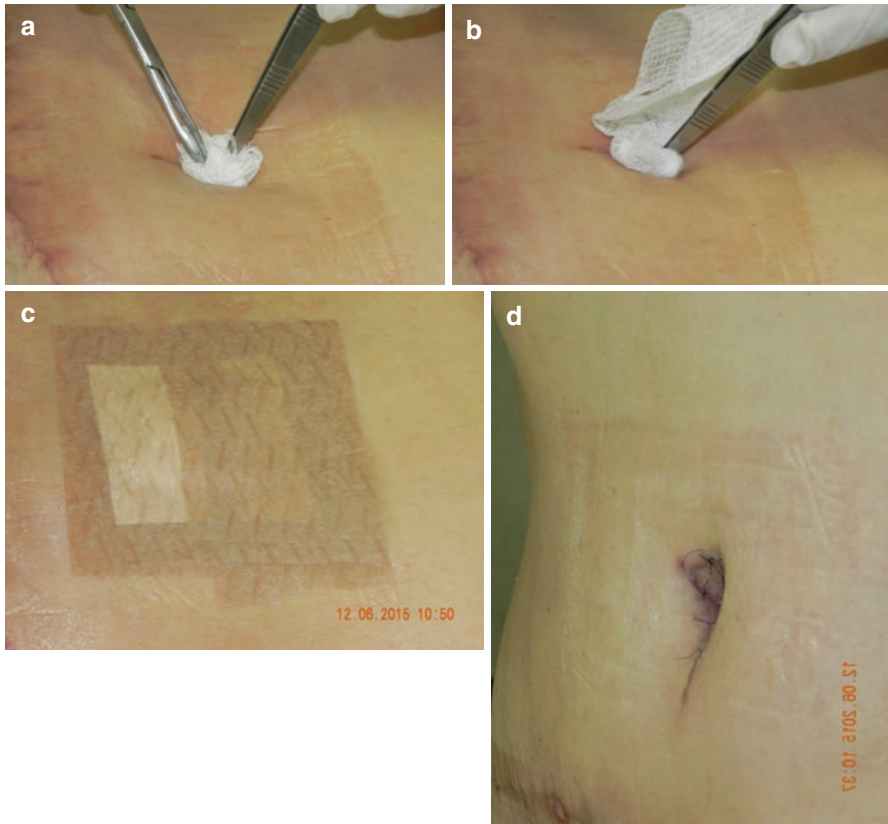
My personal instrument to determine the new umbilical area has two segments like a forceps, the upper one being 1 cm shorter than the inferior one in order to mark the exact projection of the umbilicus postoperative (Fig. 8.4). Usually, it is placed approximately 7–9 cm above the suprapubic incision. Very frequently, some patients present elongation of that distance from 2 to 4 cm more 1 year after operation.

### Suture of the Umbilicus

The umbilicus is then sutured with individual stitches of mononylon 5.0. Following my technique, the tips of the three cutaneous flaps of the umbilicus are sutured between each small triangular skin flap created on the future umbilical region on the abdominal flap. On the other hand, the tips of the skin flaps of the abdominal wall are sutured between the cutaneous flaps of the umbilicus. Therefore, the final scar instead of being a circular one around the umbilicus will be a “broken” line like an atypical multiple Z-plasty (Fig. 8.3) [1–3]. The final scar has a triangular shape, which is very important to avoid scar retraction and even contracture.

### Dressing

Dry gauze is placed inside the umbilical cavity and more gauze over it with purpose to make some light pressure over the umbilical area (Fig. 8.5a–c). Performing such procedure keeps the flaps in their adequate position, avoiding scar tissue contracture. The final scar has a triangular shape, which is also very important to achieve good aesthetical result without any scar tissue contracture or even retraction. The dressing



**Fig. 8.5** Sequential photos (a–c) To demonstrate how to do dressing after surgery and during postoperative care; photo (d) shows the final aspect after 3 weeks

is removed 5–6 days after surgery when another dressing with dry gauze is placed inside the umbilicus which is changed every 10 days for at least 2 months (Fig. 8.5d). The final result of the umbilical region after abdominoplasty always presents a smooth scar around the umbilicus in harmony with the abdominal wall [4].

## Complications

Since Vernon [27] introduced transposition of the umbilicus during abdominoplasty, such technique became a mandatory stage in all operations which may be considered one of the most important contributions on this field. Nevertheless, it brought also many problems to patients and surgeons due to undesirable circumstances after operations, as reported by Grazer and Goldwyn [21] in a remarkable survey in which they found very high incidence of abnormality scars around the umbilicus

with retraction and contraction. Those complications motivated me to create my technique to solve some of them. In fact, when my procedure is properly performed, the final result avoids circular scar around the umbilicus. Therefore, in my patients, it is very seldom such adverse scars appear after surgery. For only one patient I had to make scar revision on the umbilicus since she presented a very bad scar on her suprapubic region. I have repaired and reconstructed the umbilicus in several patients secondarily to abdominoplasty (Figs. 8.6 and 8.7).

In other methods described in medical literature, in the final result, there is tendency to present circular scars which may retract or even contract.

### *Further Applications of the Technique*

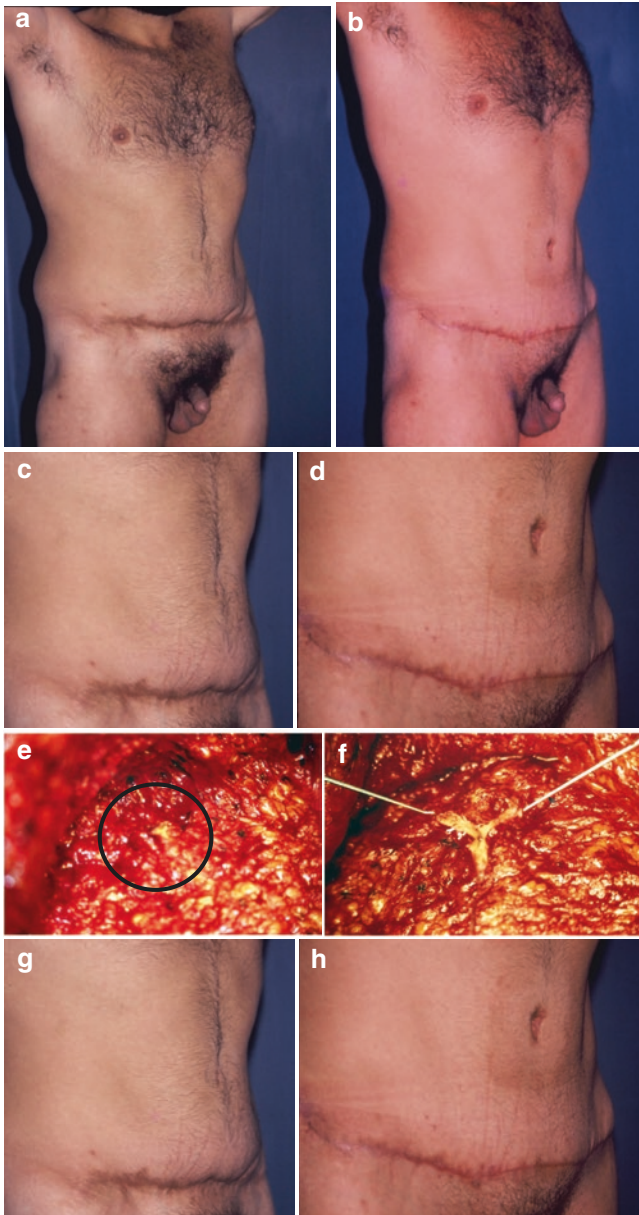
Besides employing my technique on abdominoplasty, there are several circumstances that are adequate indication to solving unaesthetic situations on umbilical area as this may happen in children and adults as well. I have had some patients in infancy with umbilical hernia associated with diastasis of the rectus abdominal on midline in supraumbilical and infraumbilical areas (Fig. 8.8). It is useful to employ the surgical principles to solve the problems since the umbilical incisions provide excellent approach with minimal panniculus undermining. Due to evident elasticity of the panniculus, my triangular incisions offer wide view to perform placcation of the aponeurosis and the umbilical hernia as well. Even children with unaesthetic redundancy of skin may also be repaired using the technique through which create a “broken” scar around the umbilicus. The excess skin is removed following surgical demarcations according to my technique (Fig. 8.9).

So far, adult patients with umbilical hernia are good candidates for treatment through application of the technique, even when other procedures on the abdominal wall will be done (Fig. 8.10). Again, it is important to emphasize that the elasticity of the panniculus is a good anatomical characteristic to allow enough view to perform the operation. Although the elasticity of the panniculus in adult is much less than in infancy patients, it is possible to carry out reinforcement of the aponeurosis and correction of umbilical hernia as well.

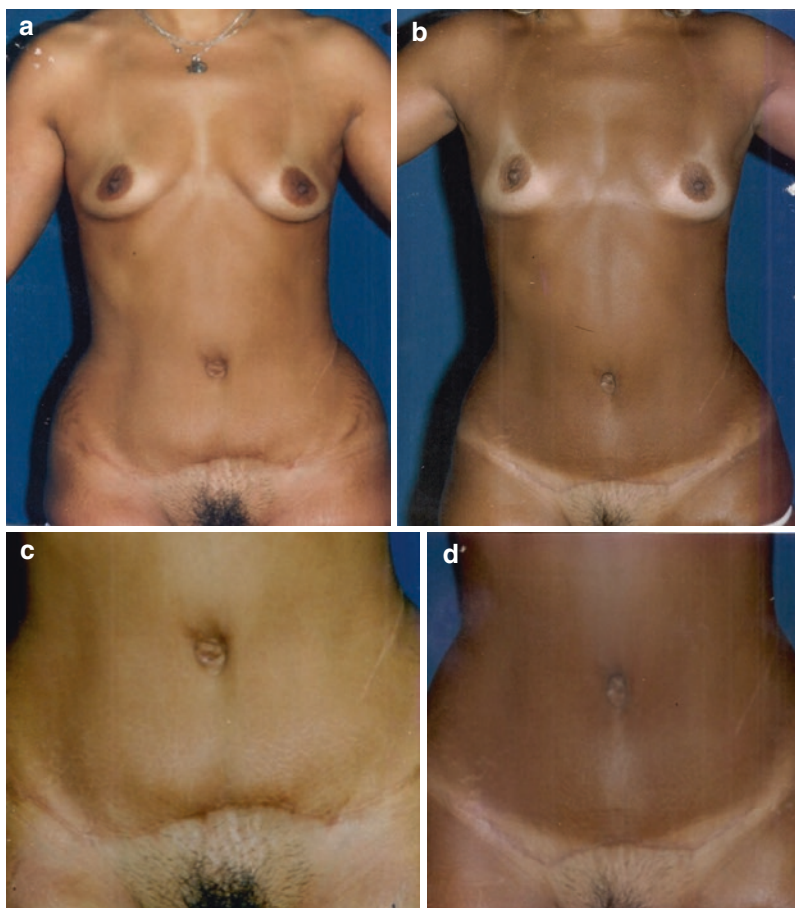
Nowadays, vertical abdominoplasty is quite frequent due to a great amount of patients after massive weight loss and after bariatric surgery look for operation on the umbilicus that may be treated in the use of umbilical technique (Fig. 8.11). In those peculiar patients, the surgical principles of the technique are helpful to create a smooth scar on the umbilicus which makes a useful interruption of the straight and long scar from the xiphoid process to the pubis. One of the surgical principles of the technique is to push the skin of the abdominal wall to the depth which is very important to achieve good aesthetic result on the new umbilical region when vertical abdominoplasty is performed.

So far, there are severe deformities on the abdominal wall caused by local as well as by burnt traumatism which damaged the skin missing some amount of integument. For reparation and reconstruction of some unaesthetic abnormalities on





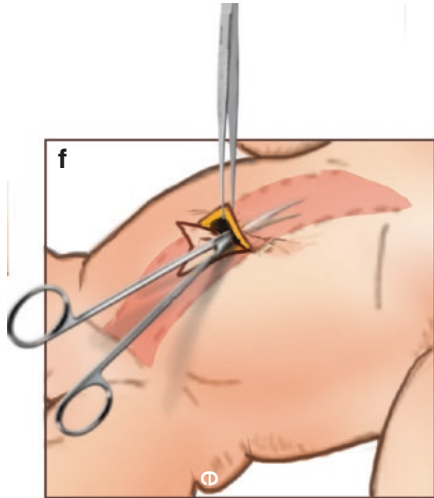
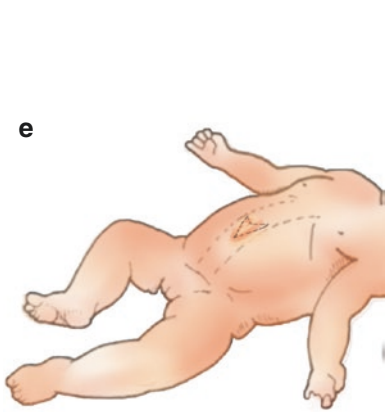
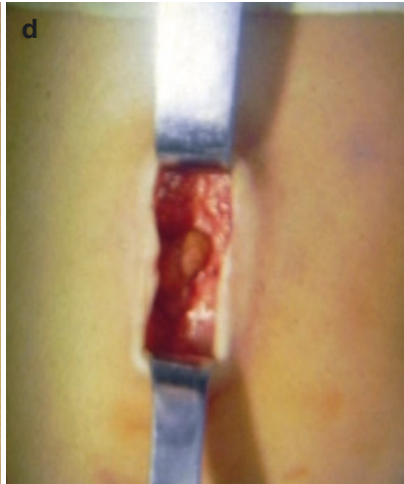
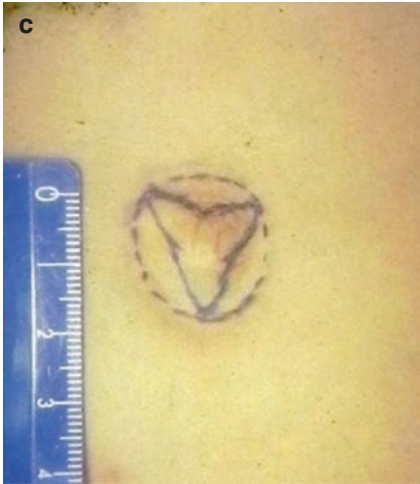
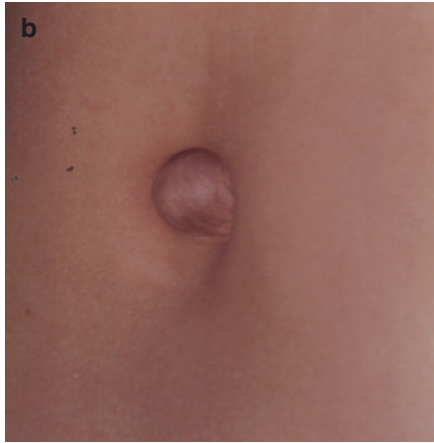
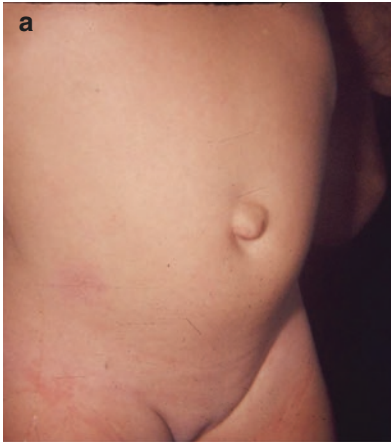
**Fig. 8.6** Application of the technique to reconstruct the umbilicus on an unfavorable result after conventional abdominoplasty: (a) A 44-year-old male patient presents unaesthetic scar of the operation and absence of the umbilicus; (b) after reconstruction of the umbilicus created with the remnant cutaneous surface of the umbilicus; (c) close-up of the patient showing ungraceful result and absence of the umbilicus; (d) final surgical result. Photo (e) perioperative view taken from the raw area during conventional abdominoplasty. The *circle* indicates the remaining segment of the umbilicus; (f) two hulks pull the superior flaps created on the remaining surface of the umbilicus; (g) same patient on oblique view showing the unaesthetic scar and absence of the umbilicus; (h) after reconstruction of the umbilicus and reparation of the scar of the abdominoplasty



**Fig. 8.7** Application of the technique for correction of the umbilicus in unfavorable result after abdominoplasty: (a) ungraceful result after abdominoplasty performed elsewhere with too wide umbilicus; (b) after correction of the umbilicus and secondary abdominoplasty; (c) close-up showing the unaesthetic appearance of the umbilicus and suprapubic scar; (d) surgical result 2 years after surgery

---

**Fig. 8.8** Application of my technique for treatment of umbilical hernia in child with diastasis of the aponeurosis on supra- and infraumbilical. Photo (a) a 2-year-old female child with umbilical hernia and diastasis on midline of the rectus abdominis muscles; (b) close-up of the umbilicus with herniation; (c) during operation with demarcation of the technique: a circle of 2 cm in diameter is marked with dotted line around the umbilicus and a star-shaped incision is drawn in the center; (d) after incisions, one can see the umbilicus on depth; Drawing (e) a child where it is marked with dotted line the projection of the internal borders of the rectura and the triangular incision around the umbilicus; (f) scheme in close-up showing dissection with a scissor through the incisions on the umbilicus; (g) perioperative photo showing panniculus undermining with a scissor above and below the umbilicus; Drawing (h) showing three stages of reinforcement of the aponeurosis above and below the umbilicus and the final cutaneous suture of the umbilicus to the skin of the umbilical region; (i) perioperative photo showing the umbilicus on the center of the umbilical region with three cutaneous flaps around it; photo (j) the same child 1 year after operation showing the natural umbilical region; (k) same patient 18 years later presenting the surgical result



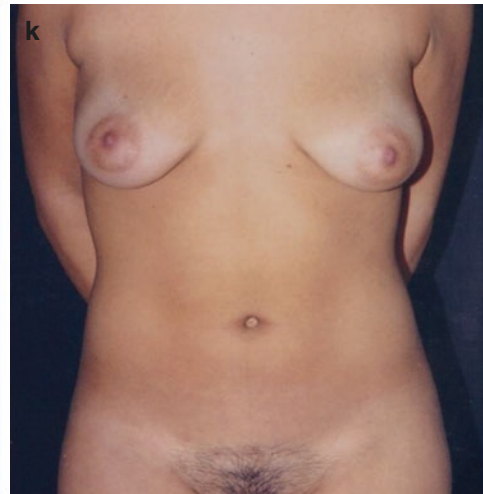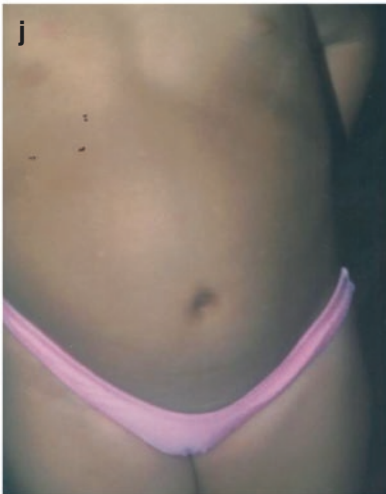
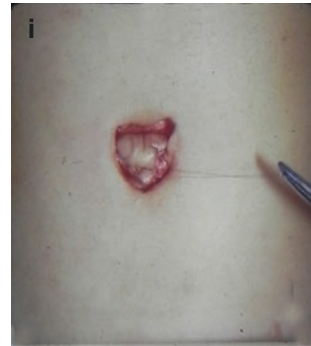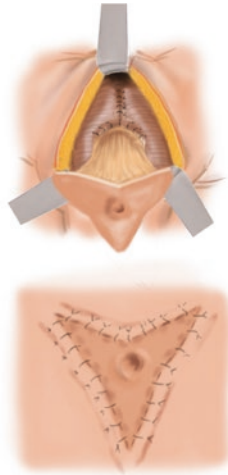
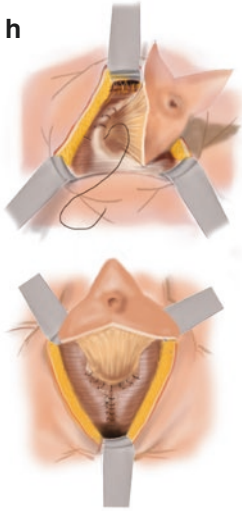
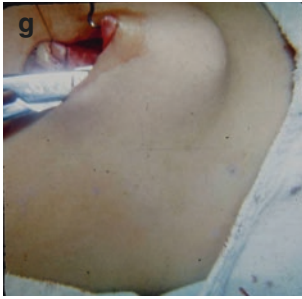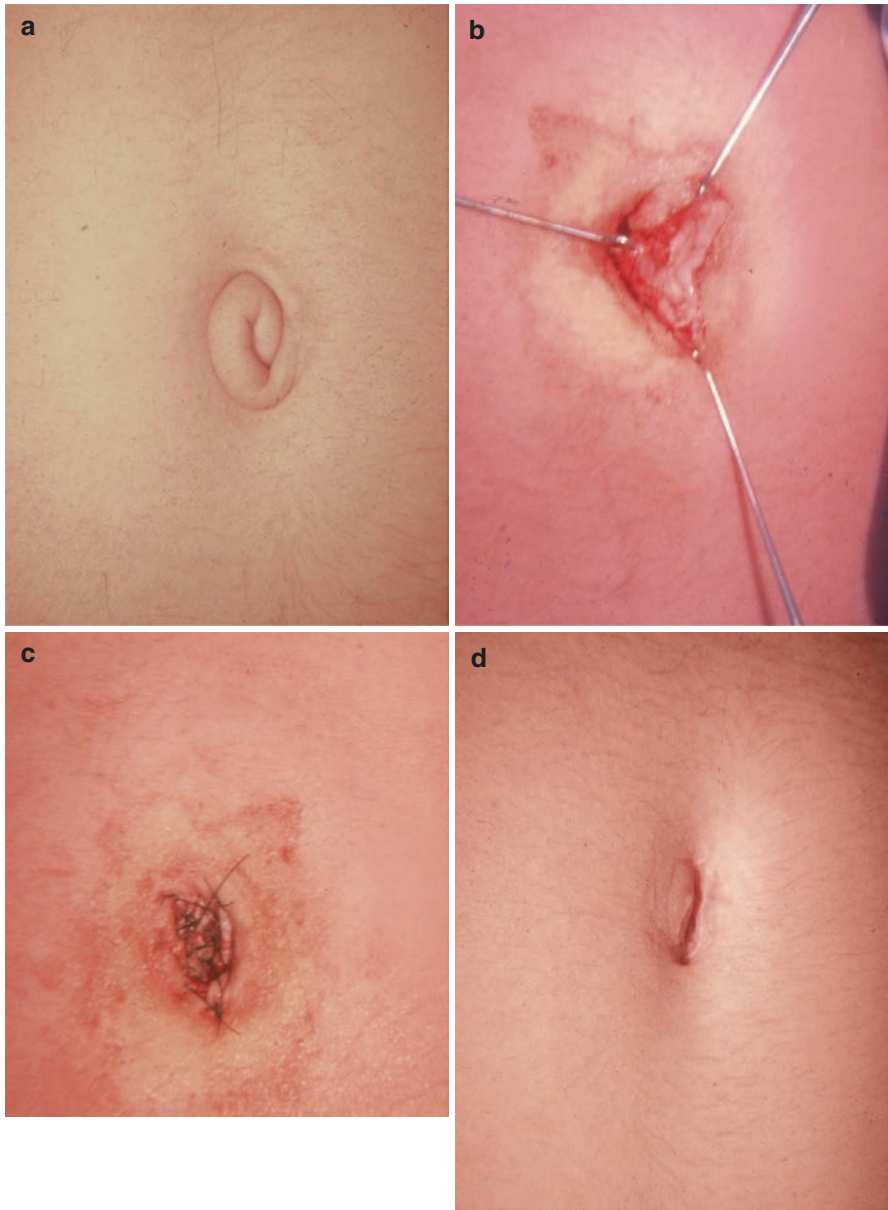
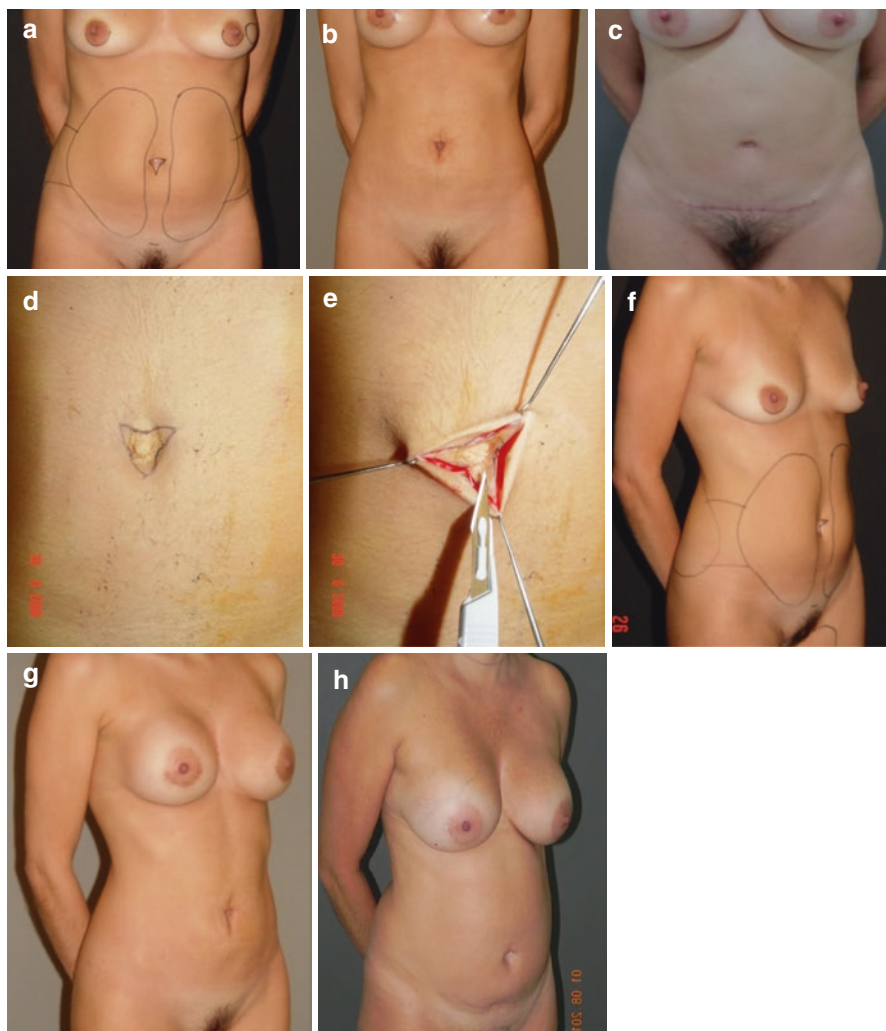


Fig. 8.8 (continued)

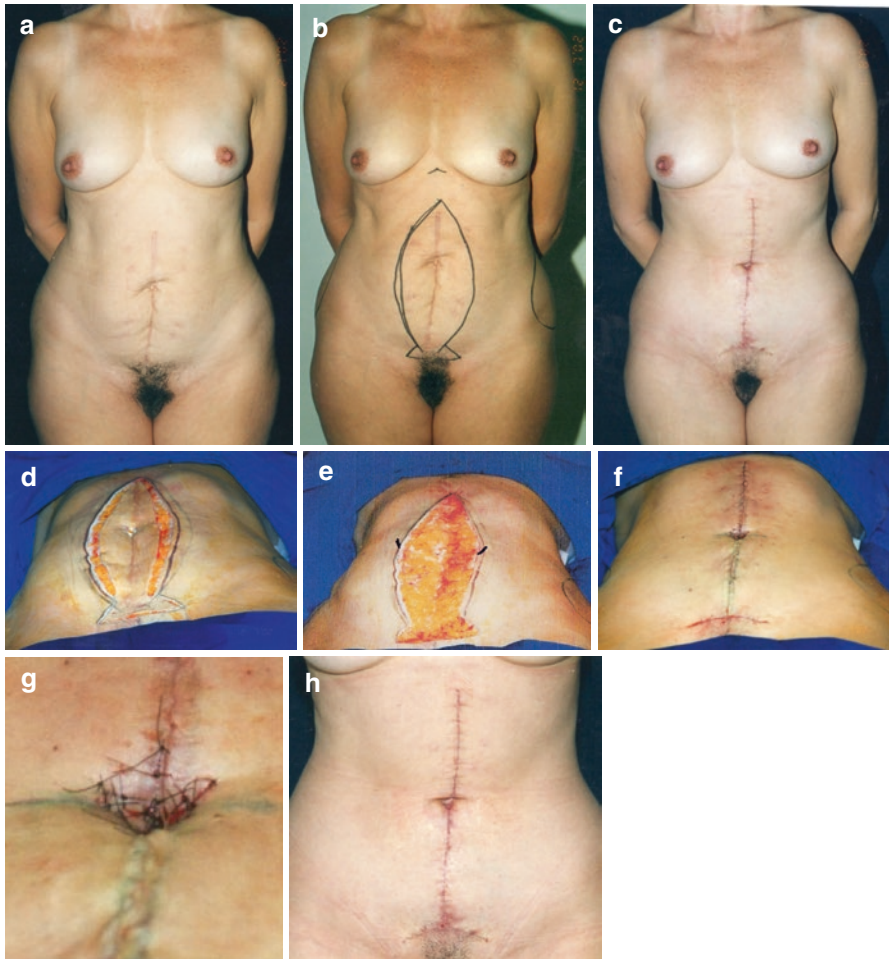


**Fig. 8.9** Application of the technique for correction of redundant skin with umbilical hernia. Photo (a) preoperative photo of an 8-year-old girl showing the redundant skin of the umbilicus folded over itself with ungraceful appearance; (b) during operation showing the umbilicus pulled by three hucks after cutaneous incisions with triangular surface of the umbilicus since the excess skin was already resected; (c) photo after suture of the umbilicus to the skin around it; (d) same patient 2 years later



**Fig. 8.10** Correction of umbilical hernia employing the technique in a female patient. Photo (a) before surgery showing surgical demarcations on the area for liposuction; (b) same patient 3 months after correction of umbilical area; (c) same patient 6 months after liposuction of abdomen showing the correction of the umbilical hernia; (d) preoperative photo showing demarcations of the incision inside of the umbilical area; (e) incisions are being made inside of the umbilicus; photo (f) same patient in oblique view before surgery showing unaesthetic umbilical area; (g) 3 months after correction of the umbilical hernia; (h) same patient 8 years after operation 2 years after the second pregnancy showing natural umbilical region

abdominal wall and breast, when the umbilicus is deviated from midline, it is possible to transfer it to its normal position on midline (Fig. 8.12a, b). The surgical planning is a fundamental step to demarcate the technique on the umbilicus and



**Fig. 8.11** Application of my technique on vertical abdominoplasty with creation of the new umbilical region. Photo (a) preoperative view of a patient presenting ungraceful surgical scar on midline with diastasis of the rectus muscles; (b) surgical planning; (c) postoperative view 6 months later. Photos during operation: (d) cutaneous incisions on each side and short one on suprapubic; (e) after vertical panniculus resection keeping the triangular skin flaps of the umbilicus; (f) after cutaneous suture creating the umbilical cavity on its natural position; (g) close up of the umbilicus; (h) the surgical result of the umbilicus four months after operation

another demarcation on the normal position on midline (Fig. 8.12c, d). After transposition of the umbilicus, the donor area is sutured since the three triangular skin flaps may reconstruct the raw area (Fig. 8.12e–h). After reparation of the abdomen wall with transposition of the umbilicus associated with breast reconstruction, the final aspect may achieve satisfactory result (Fig. 8.12i–l).

## Discussion

Following Vernon's description, many authors have published other procedures with vertical or horizontal incisions and also a semicircular incision [24], resulting always in a circular scar around the transposed umbilicus. Even when outstanding surgeons perform the operation, the final results have not been satisfactory in most patients. One of the most important surgical principles of my technique is to push the skin of the abdominal wall to the deep structures of the musculoaponeurosis (Fig. 8.3). In other methods described in medical literature, the umbilicus is pulled from the depth to the surface of the abdominal wall, leaving a circular scar which may cause retraction and frequent contraction according to Grazer and Goldwing's survey in 1977.

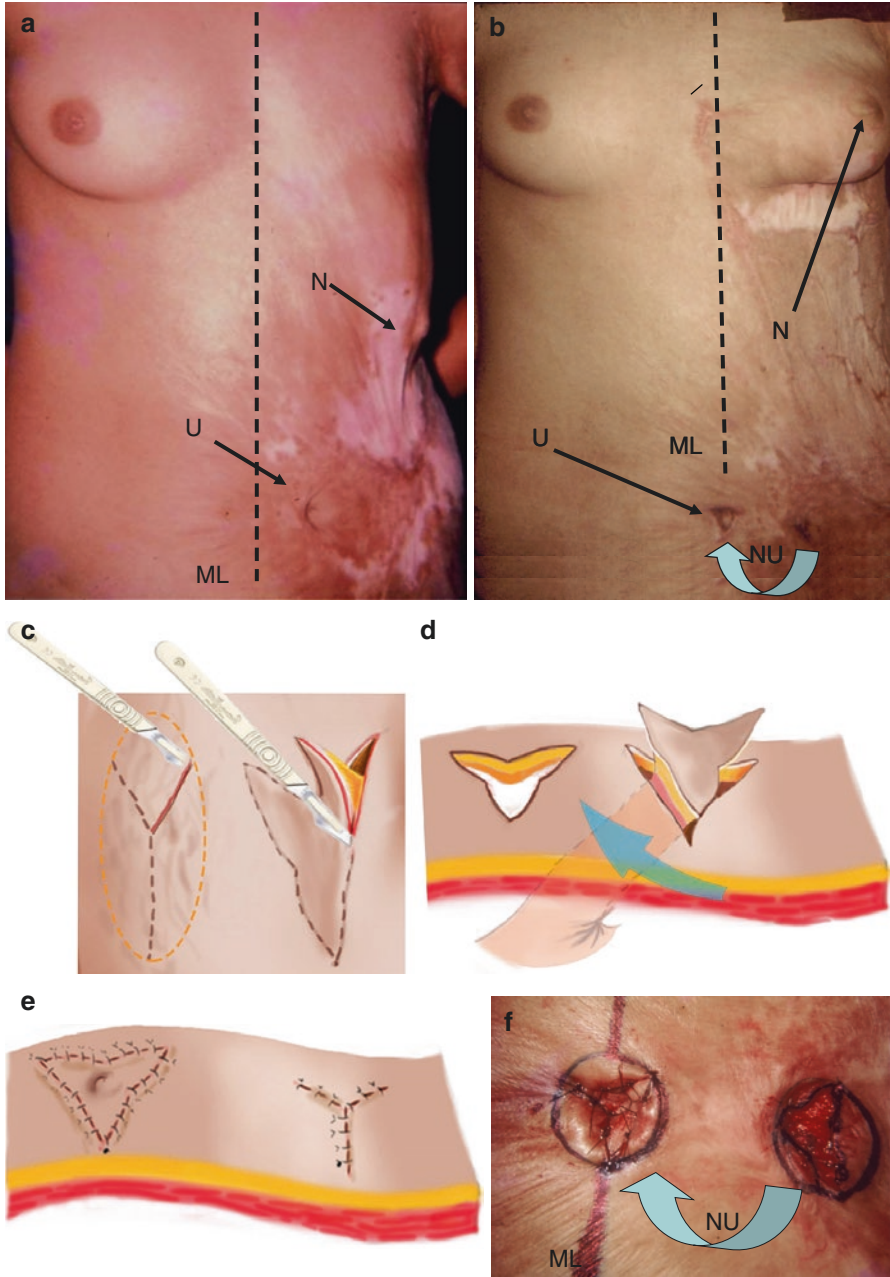
I take this opportunity to point out that no matter how many flaps are created on the umbilical surface as well as on the cutaneous covering of the abdominal panniculus, the main surgical principle is to avoid circular scars afterward. In order to develop my method, I studied all geometric figures and I found out that the most "opposite" one to the circle is a triangle. In case of any other figure with a greater number of cutaneous flaps, there is a tendency to approximate to a circle. Therefore, there are descriptions that four flaps are created on the umbilicus; of course, four small cutaneous flaps must be created on the abdominal wall, and the final scar will be a square star-shaped figure with four tips with four small scars around the umbilicus. Such a procedure is not a new one, since the basic principles are based on my method described in 1976 [1, 2].

Therefore, my technique is a new one because when it was presented and published in the Annals of the XIII Brazilian Congress of Plastic Surgery, held in Porto

---

**Fig. 8.12** A 17-year-old girl presented severe damage of the abdomen and left breast caused by burn. Photo (a) before surgery showing the deviation of the umbilicus (*U*) out of the midline (*ML*) marked with dotted line, the left breast is destroyed and the nipple (*N*) is retracted on the abdomen due to scar tissue formation; photo (b) after breast and nipple-areola reconstruction (*N*) is transposed to the normal position on the breast and the umbilicus (*U*) is transplanted to the new area on midline (*NU*) by my technique. Surgical planning of the operation for transposition of the umbilicus from the lateral position to midline: drawings (c) the dotted line shows the skin incision around the umbilicus and "Y" incision on midline; drawing (d) shows the umbilicus already incised still on lateral position out of midline and the skin incisions where the umbilicus was transposed. (e) on drawing, one can see the location of the final result after transposition of the umbilicus and the triangular skin flaps on donor are sutured; (f) preoperative photo showing the umbilicus (*NU*) is already transposed from its anomaly position to midline (*ML*). One can see the three skin triangular flaps are not yet sutured; (g) photo on close up during operation shows the umbilicus deviated from the midline (*ML*) and the new area is demarcated according to the technique with "Y" shaped incisions inside of a circle; (h) 6 months postoperative photo of the same patient showing transposition of the umbilicus to midline indicate by arrow, and the previous umbilical is adequately repaired by suture of the skin flaps; photos (i, k) before operation showing the left breast destroyed by burnt with the nipple (*N*) is retracted downwards to the abdominal wall; photos (j, l) after two surgical stages of reconstruction the breast and skin graft on the abdomen as well as the nipple was transposed to its normal position on the reconstructed breast





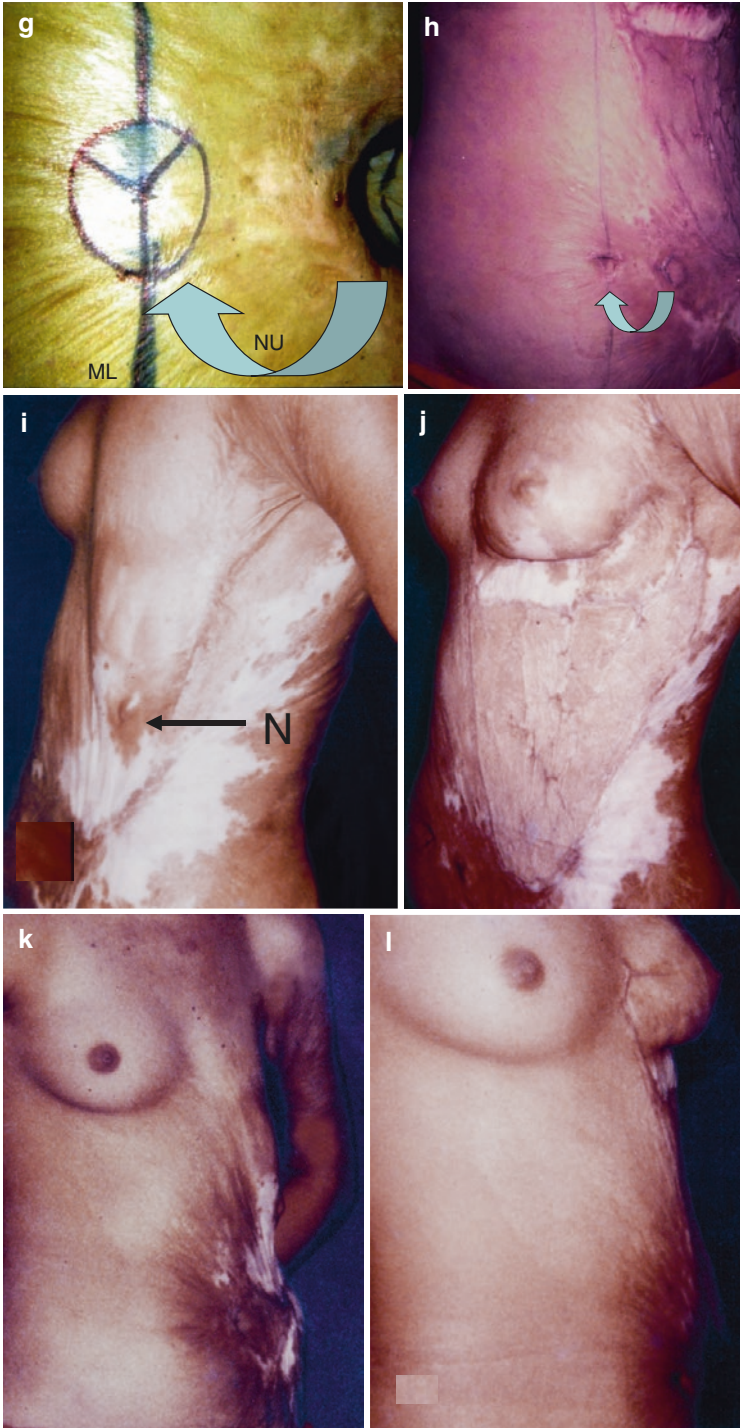


Fig. 8.12 (continued)

Alegre, in 1976, there were no descriptions regarding these fundamental principles. For these reasons, I dedicated a chapter of this book to emphasize the importance of creating a new umbilical area during abdominoplasty, especially when this operation is performed without panniculus undermining and resection [9–15].

## Conclusion

Creating the new umbilical region during full lipoabdominoplasty is a mandatory procedure which is a constant challenge, since it is located in the geometric central area of the abdomen and always remains scarred around the umbilicus. Using my technique, it is possible to achieve good aesthetical results, avoiding scar retraction and contraction which are unfavorable stigma postoperatively. According to previous evaluation, planning, and demarcation, the whole area of cutaneous covering of the infraumbilical region is always resected. Cutaneous incisions on the umbilicus are done prior to skin resection [16–19]. When lower and upper abdominoplasty are performed, the umbilicus is not transplanted because the skin resection is limited to the suprapubic area and submammary folds.

## References

1. Avelar JM (1976) Umbilicoplasty – a technique without external scar. 13rd Braz Cong of Plast Surg and First Brazilian Cong of Aesthetic Surgery. (Umbilicoplastia – uma técnica sem cicatriz externa). 13° Congresso Brasileiro de Cirurgia Plástica e 1° Congr Bras Cir Estética, Porto Alegre, pp 81–82
2. Avelar JM (1976) Umbilicoplasty. A technique without external scar. Cahiers de chirurgie Esthétique. Journées internationales de Chirurgie Esthétique. Vendredi 21 mai
3. Avelar JM (1979) Cicatriz umbilical – da sua importância e da técnica de c Avelar onfeção nas abdominoplastias (Umbilical scar – importance and technique for creating during abdominoplasty). Rev Bras Cir 1(2):41–52
4. Avelar JM (1983) Abdominoplasty: technical refinements and analysis of 130 cases in 8 years follow-up. Aesthetic Plast Surg 7:205–212
5. Avelar JM (1985) Combined liposuction with traditional surgery in abdomen lipodystrophy. XXIV Instructional Course of Aesth Plast Surg of ISAPS, Madrid
6. Avelar JM (1999) Uma nova técnica de abdominoplastia – sistema vascular fechado de retalho subdérmico dobrado sobre si mesmo combinado com lipoaspiração (A new technique for abdominoplasty – closed vascular system of subdermal flap folded over itself combined to liposuction). Rev Bras Cir 88/89(1/6):3–20
7. Avelar JM (1999) Novos conceitos para abdominoplastia (new concepts for abdominoplasty). Paper presented at the 36th Congress of the Brazilian Society of Plastic Surgery, Rio de Janeiro
8. Avelar JM (1999) Abdominoplastia: Nuevos conceptos para una nueva técnica (Abdominoplasty: New concepts for a new technique). XXVI Annual International Symposium of Aesthetic Plastic Surgery, Chairman: Prof. Jose Guerrerosantos - Puerto Vallarta, Jalisco – México, pp 10–13
9. Avelar JM (2000) Abdominoplasty without detachment (Abdominoplastia sem descolamento). XX Jorn Paulista Cir Plast, São Paulo
10. Avelar JM (2000) Abdominoplastia com preservação do sistema vascular profundo. Comunicação Pessoal. Reunião Mensal da Sociedade Brasileira de Cirurgia Plástica do Rio Grande do Sul

11. Avelar JM (2000) Abdominoplasty : a new technique without undermining and fat layer removal (Abdominoplastia: uma nova técnica sem prejudicar e remoção da camada de gordura) *Arq. Catarinense de Med* 29:147–149
12. Avelar JM (2000) I Curso de abdominoplastia (First course of abdominoplasty). Chairman: Prof. Willian Callia. Invited Professor: Dr. Juarez M. Avelar. Municipal Hospital, São Paulo
13. Avelar JM (2000) II Curso de abdominoplastia (Second course of abdominoplasty). Chairman: Prof. Juarez M. Avelar. Hospital do Coração, São Paulo
14. Avelar JM (2000) A new technique for abdominoplasty subdermal flap folded over itself. XV ISAPS Congress, Tokyo
15. Avelar JM (2000) Abdominoplasty: a new technique without panniculus undermining and without panniculus resection. 57th Instructional Course of ISAPS, Chairman: Lloyd Carlsen Montreal, Quebec
16. Avelar JM (2001) Abdominoplasty without lipectomy. Mini Course of ISAPS with Aesthetic Plastic Surgery Congress of Spain, Valladolid
17. Avelar JM (2001) The new abdominoplasty and derived technique. ISAPS and ASERF Annual Meeting. The Aesthetic Meeting, New York
18. Avelar JM (2002) Abdominoplasty without panniculus undermining and resection: analysis and 3-year follow-up of 97 consecutive cases. *Aesthetic Surg* 16–25
19. Avelar JM (2002) Abdominoplasty. The Aesthetic Meeting, Istanbul
20. Callia WEP (1965) Contribuição ao estudo de correção cirúrgica do abdomen pêndulo e globus (Contribution to the study of surgical correction of the pendulum abdomen and globus). original art. Doctoral Thesis Fac Med USP, São Paulo
21. Grazer FM, Goldwyn RM (1977) Abdominoplasty assessed by survey with emphasis on complications. *Plast Reconstr Surg* 59(4):513–517
22. Kelly HA (1899) Report of gynecological cases. *John Hopkins Med J* 10:197
23. Pitanguy I (1967) Abdominallipectomy: an approach to it through an analysis of 300 consecutive cases. *Plast Reconstr Surg* 40(4):384–391
24. Pitanguy I (1977) Dermolipectomy of the abdominal wall, thighs, buttocks, and upper extremity. In: Converse JM (ed) *Reconstructive plastic surgery*, 2nd edn. Saunders, Philadelphia, pp 3800–3823
25. Sinder R (1975) Plastic surgery of the abdomen. Personal technique. In: Abstracts of the 6th International Congress of plastic and reconstructive surgery. Masson, Paris, pp 584–591
26. Sinder R (1979) Cirurgia plástica abdominal (Abdominal plastic surgery). Ed. by Sinder, Niteroi
27. Vernon S (1957) Umbilical transplantation upward and abdominal contouring in lipectomy. *Am J Surg* 94:490–492

# Chapter 9

## Abdominoplasty

Paulo Roberto de Sousa Jatene and Maria Cristina Vargas Jatene

### Introduction

The harmony of body contouring is strangely influenced by the aesthetic aspects of the abdomen because it occupies a prominent central position in the body.

The shape of the abdominal wall is determined by the interaction of the following elements: skeletal structure, amount and distribution of fat, appearance and skin condition, muscle–aponeurotic system integrity, and intracavitary content [14].

The abdominal wall, as well as its aesthetic connotation, plays an important role in containing the abdominal viscera, as well as in maintaining the orthostatic and walking [19].

Pitanguy divides the deformities that can affect the abdominal wall into two categories: aesthetic=cosmetic changes (sagging, stretch marks, fat accumulation, muscle–aponeurotic weakness) and functional (hernias, scars) [19].

Abdominal cosmetic surgery (abdominoplasty) has the purpose of correcting these deformities.

The first publications on abdominoplasty date from 1890 [9]. At the time, it was called abdominal lipectomy. Currently, it is called abdominoplasty, which consists of low abdominoplasty.

Abdominal lipectomy is associated with muscle–fascial repairing or plastic, which is achieved with aponeurosis plication of the rectus abdominis muscles. Many variations of the incisions and musculo–fascial repair have been reported since then [7, 10].

---

P.R. de Sousa Jatene, MD (✉)

Member of the Brazilian Society of Plastic Surgery, Avenida Angélica,  
2530/cj 21 Higienópolis, São Paulo, SP CEP 01228-200, Brazil  
e-mail: [paulojatene@uol.com.br](mailto:paulojatene@uol.com.br); <http://www.paulojatene.com.br>

M.C.V. Jatene, MD

Master of Science of Anesthesiology, Pain Management Specialist, Avenida Angélica,  
2530/cj 21 Higienópolis, São Paulo, SP CEP 01228-200, Brazil

Kelly, in 1899, performed abdominal lipectomy, with transverse incision in ellipse, which included the umbilicus. Thorek (1924), Andrews (1956), Vernon (1957), Callia (1960), Pitanguy (1967), Avelar (1976), Jury (1979), and Baraudi (1984) presented evolutionary refinements of the technique describing scars increasingly lower, with a new position of the umbilicus [19].

In 1972, Rebello and Franco described the reverse tummy tuck, with infra-mammary incision [20].

In 1980, Illouz, with the introduction of liposuction, led a breakthrough in improving body contour [12]. Later, this technique associated with abdominoplasty was of great value in obtaining better aesthetic results.

Thus, Avelar, in 1985 [3], described the liposuction technique associated with abdominoplasty in patients with prominent abdomen and large deposition of fat above and below the navel [13].

Matarasso, in 1991 and 1995, described abdominoplasty associated with liposuction of the back and flanks [16, 17]. In this last publication, we find the first reference using the definition of lipoabdominoplasty or abdominolipoplastia is defined as a set of procedures that combine liposuction with changes in traditional abdominoplasty technique. Jatene [15], in a review of his clinical experience, indicates that when he associated back and flanks liposuction with reverse tummy tucks, he with liposuction obtained more satisfactory results. Illouz, in 1992, described a case of abdominoplasty associated with liposuction.

However, it was a first breakthrough for the prophylaxis of major complications that accompanying abdominoplasty was lipoabdominoplasty with minimum detachment of the abdominal wall. It was first described by Avelar in 1999 [2] and 2000 [4], and a variant this technique was presented by Saldanha in 2001 [21] and 2003 [22].

The minimum detachment of the skin flap preserves the blood supply, providing lower rates of the most common complications: Seromas, necrosis, hematoma, and dehiscence [15], as shown by the study, through color Doppler, performed by Graf in 2006 [8].

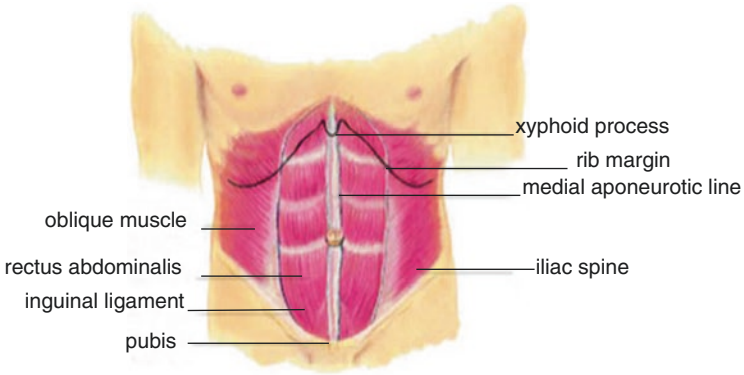
## **Anatomy of Abdominal Wall**

Limits of the abdominal wall is a polygonal diamond-shaped area limited by:

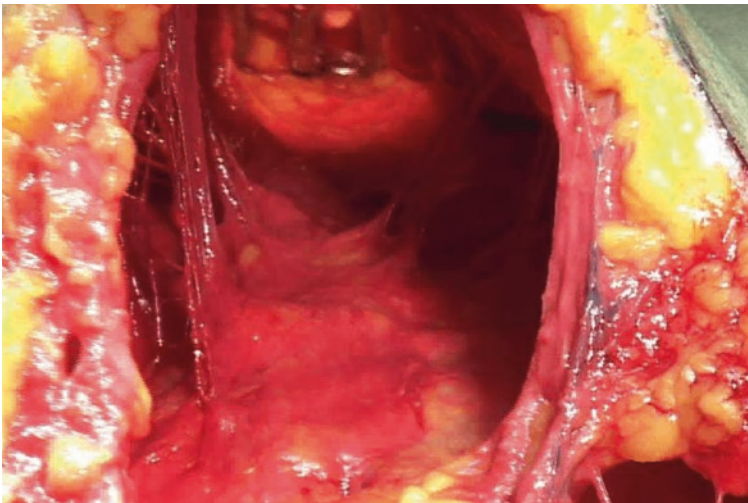
- Above: Xiphoid appendix and costal margins
- Laterally: Oblique muscles and iliac crest
- Below: External inguinal ligament [14] (see Figs. 9.1 and 9.2)

The circumference located between the base of the chest and the apex of the pelvis (iliac crests) is known as the waist, the fundamental harmony of body contouring.

The umbilicus, the unique natural scar of the body, is positioned in the corresponding height of the vertebrae L3 and L4 [14], and its position defines the upper abdomen and the lower one.



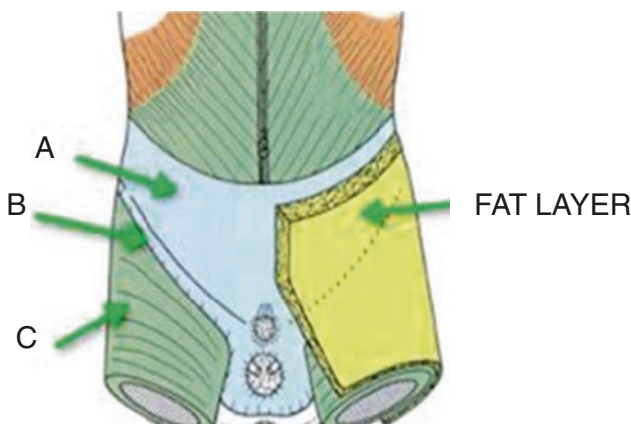
**Fig. 9.1** Limits of the abdominal wall



**Fig. 9.2** Muscles of the abdominal wall

The so-called Dumm line is an imaginary line that separates the lower abdomen of the Mount of Venus. The distance between the vulva and the wishbone Dumm line is approximately 6 cm and it must be respected in abdominoplasty.

Another structure with an important role in the abdominal aesthetic is the Fascia of Camper–Scarpa or superficial fascia, clear in the region of the iliac or fossa tanks. Failures in the continuity of this fascia lead to an undesirable aesthetic result; therefore, one must proceed to careful resuture by planes, particularly in abdominoplasty where the best aesthetic effect is expected (see Fig. 9.3).



**Fig. 9.3** Fatty layer. *A* Schematic image of the Camper–Scarpa fascia; *B* Inguinal ligament; *C* Fascia lata

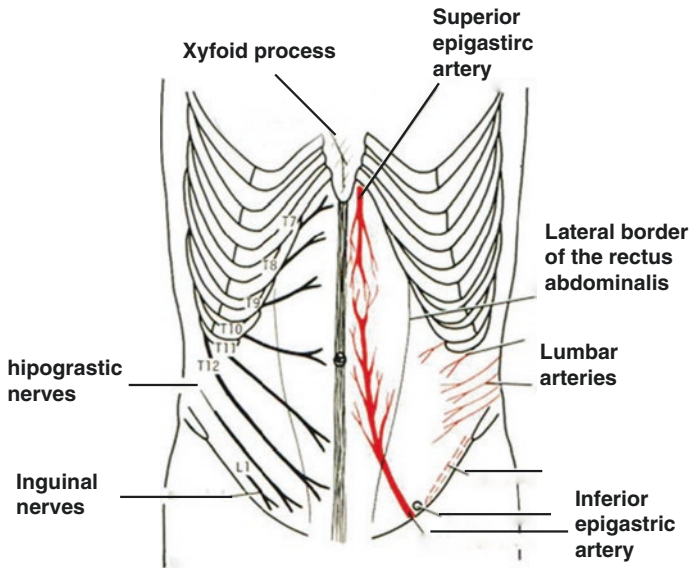
### ***Vascularization of Abdominal Wall***

In the cranial–caudal area, there are three branches of the femoral artery irrigating lower the abdominal wall: superficial iliac circumflex artery, SIEA, and superficial external pudental artery [5]. This network of arteries has connection with deep branches located between the transverse abdominal muscle and the internal oblique muscle. These deep branches are the tenth and eleventh posterior intercostal arteries; the anterior branch of the subcostal artery, the anterior branches of the lumbar arteries, and the deep circumflex iliac artery. The sheath of the rectus abdominis muscle is nourished by the superior epigastric artery, which originates from the internal thoracic artery and inferior epigastric artery, which in turn comes from the external iliac artery, just above the inguinal ligament. The superior epigastric artery enters the proximal end of the rectus abdominis muscle at the height of the seventh costal vertebra through the sternum–costal triangle and its myocutaneous branches pierce the anterior sheath of the rectum to supply the skin above [8].

### ***Innervation of the Abdominal Wall***

The innervation of the abdominal wall is made through the intercostal nerves from T5 to T12 and abdominocrural major and minor nerves, originating from L1. The dermatome distribution of the abdominal wall changes after abdominoplasty [14] (see Fig. 9.4).





**Fig. 9.4** Vascularization and innervation of the abdominal wall

### ***Muscle: Aponeurotic System of the Abdominal Wall***

It consists of three large muscles on either side: external, internal oblique, and transverse oblique, reinforced in the midline by the rectus muscles and the pyramidal muscle [14] (Fig. 9.5).

In cases of repeated pregnancies, there may be diastases or clearances of the abdominal rectus muscles, compromising the aesthetic aspect of the abdomen (see Fig. 9.6).

## **Technique**

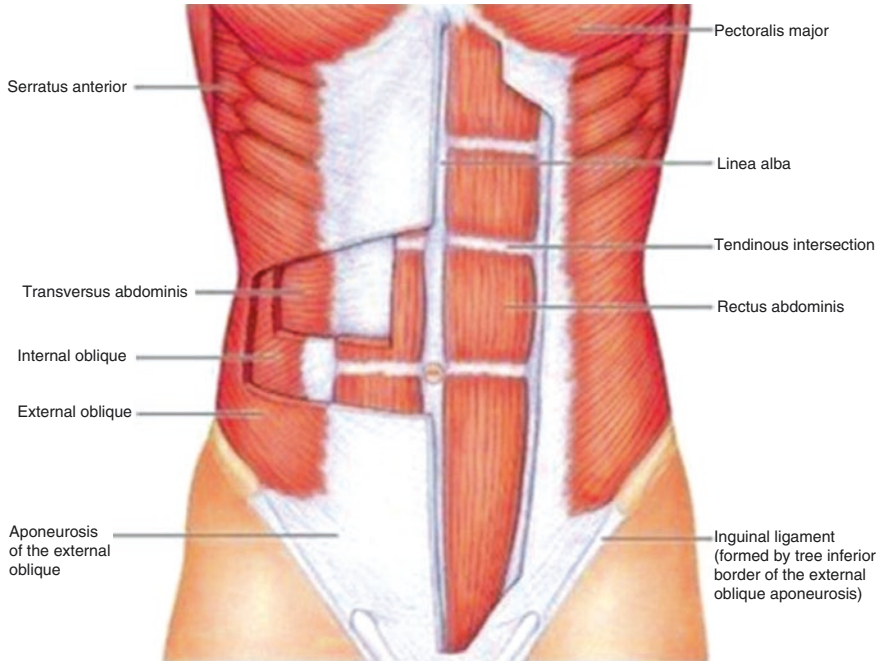
### ***Surgical Technique in Abdominolipoplasties***

Classification system in abdominolipoplasties

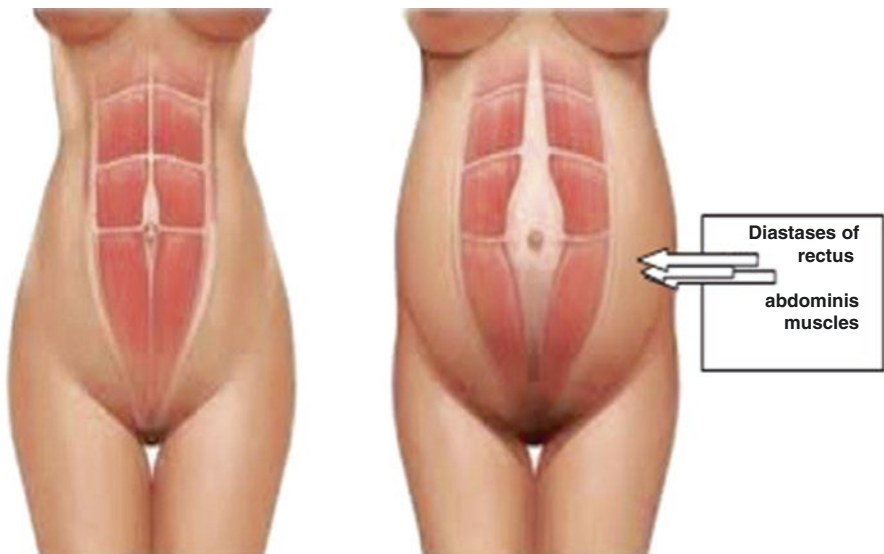
This classification system categorizes patients according to the physical examination, evaluating the characteristics of the skin, fat, and muscle–fascial system and also establishing standards of conduct in the treatment [16, 17].

Pitanguy [19] and Bozola [6] also suggested similar classification, with some variations.

According to the classification system in abdominolipoplasty, there are four types of abdomen:

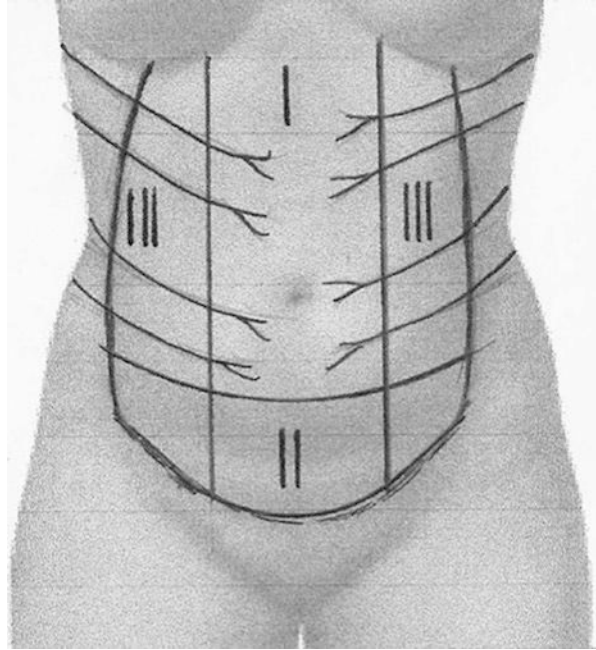


**Fig. 9.5** Muscles of the abdominal wall



**Fig. 9.6** Diastases of rectus abdominis muscles

**Fig. 9.7** Vascular areas of the abdominal irrigation



*Type I* – Muscle–aponeurotic system with minimal sagging; the recommended treatment is isolated liposuction.

*Type II* – Displays average sagging skin, variable accumulation of abdominal fat, and average flaccid muscle–aponeurotic system of the lower abdomen; the recommended treatment is miniabdominoplasty.

*Type III* – Displays skin with moderate sagging, variable fat accumulation, and moderate sagging of muscle–aponeurotic system of higher and lower abdomen; the proposed treatment is a modified abdominoplasty (tummy tuck classic, but with less detachment and less extensive scar, which does not exceed the height of the superior iliac spines).

*Type IV* – It has severe skin flaccidity, variable accumulation of fat, and severe sagging of the muscle–aponeurotic system of higher and lower abdomen; the proposed treatment is liposuction associated with classic abdominoplasty.

Currently, liposuction has been also associated with the treatment conduct types II and III.

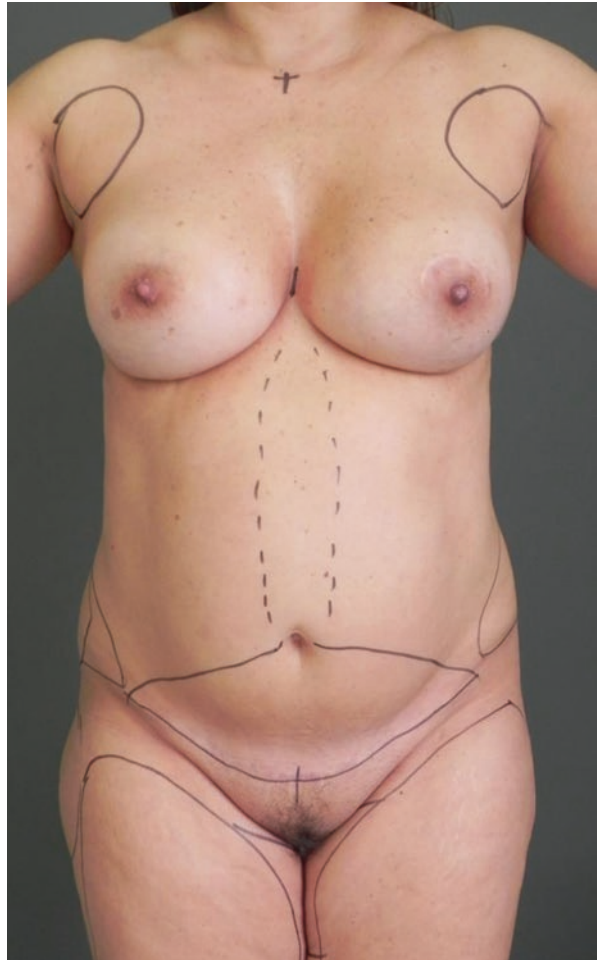
In the early days of using liposuction associated with abdominoplasty, questions arose as to the possible impairment of abdominal vascularization and possible caused vascular necrosis caused by the combination of the two procedures. However, Huger [11] described three vascular areas, taking into account the abdominal irrigation, as can be seen in Fig. 9.7. Based on these elements, it was noted that when the dermocutaneous flap elevated, the blood supply to the areas I and II that would be committed to the detachment is now done through the perforans. Nevertheless, the

concomitant suction of area 3 can be done safely but without exaggeration. It must not overcome 5–10 cm beyond the detachment area and it should not be taken vigorously in more of these three regions: lateral costal margin, flanks, and hips [16].

### Surgical Technique

The traditional abdominoplasty is performed at the following times:

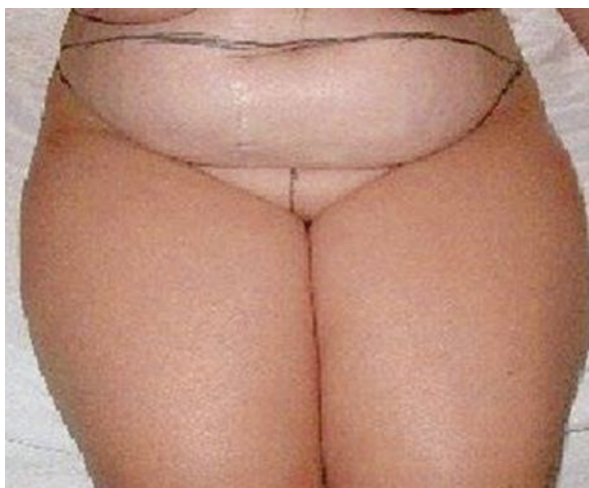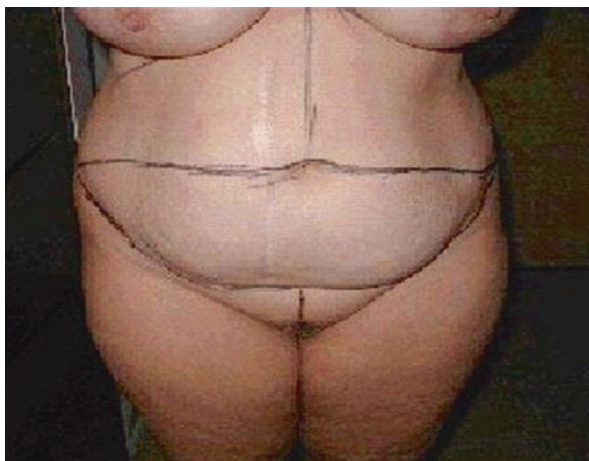- The skin is marked with the patient in a sitting position and standing (Figs. 9.8, 9.9 and 9.10).
- Liposuction of the abdomen and the previously delimited areas is done (the author also does liposuction in the back and gets better aesthetic results) [15] (Figs. 9.11, 9.12 and 9.13).



**Fig. 9.8** Patient marking standing

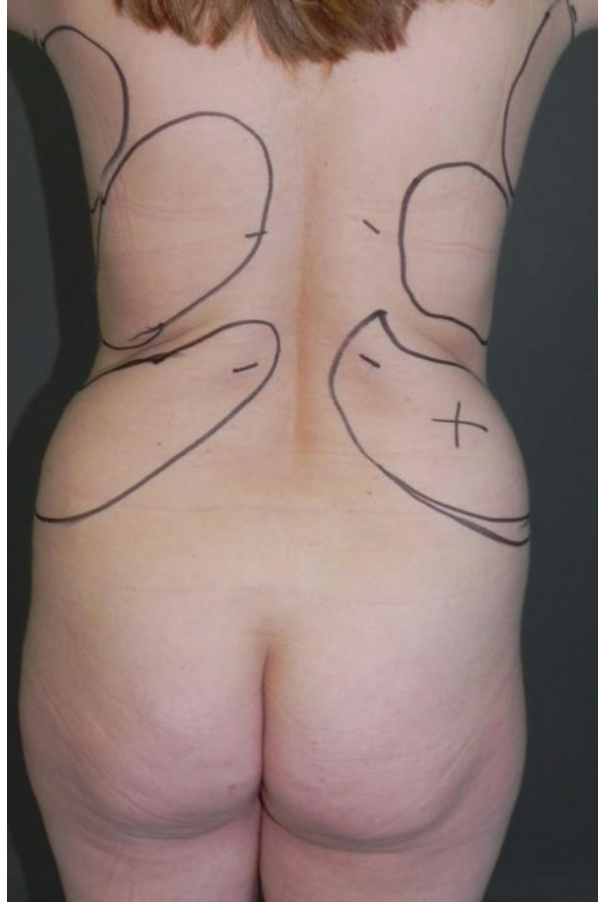
- Incision and detachment of dermocutanoerous flap (Fig. 9.14).
- Muscle–fascial repair (aponeurosis plication of the rectus abdominis) (Fig. 9.15)
- Navel repositioning (Fig. 9.16)
- Abdominal lipectomy (Fig. 9.17)

**Fig. 9.9** Patient marking sitting

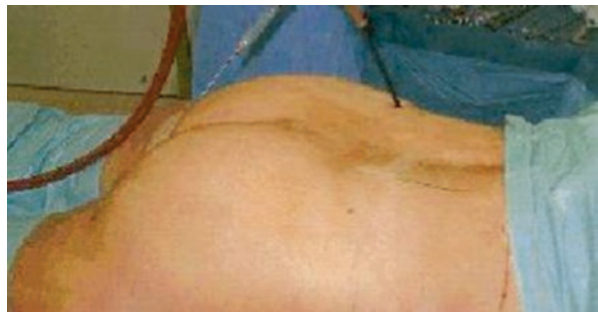

**Fig. 9.10** Back tag for liposuction

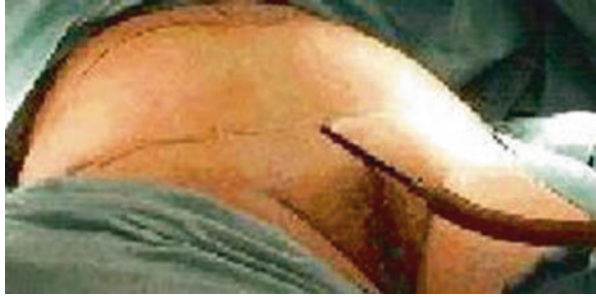**Fig. 9.11** Liposuction back



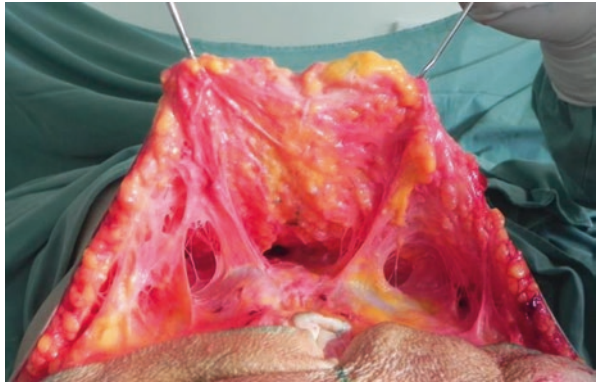
**Fig. 9.12** Liposuction of the abdomen



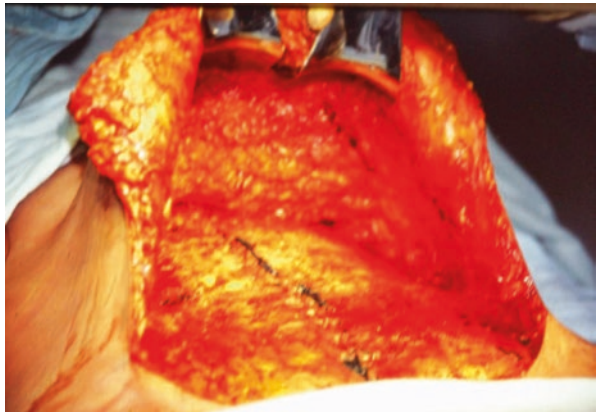
**Fig. 9.13** Incision and flap undermining dermocutaneous



**Fig. 9.14** Repair muscle–fascial



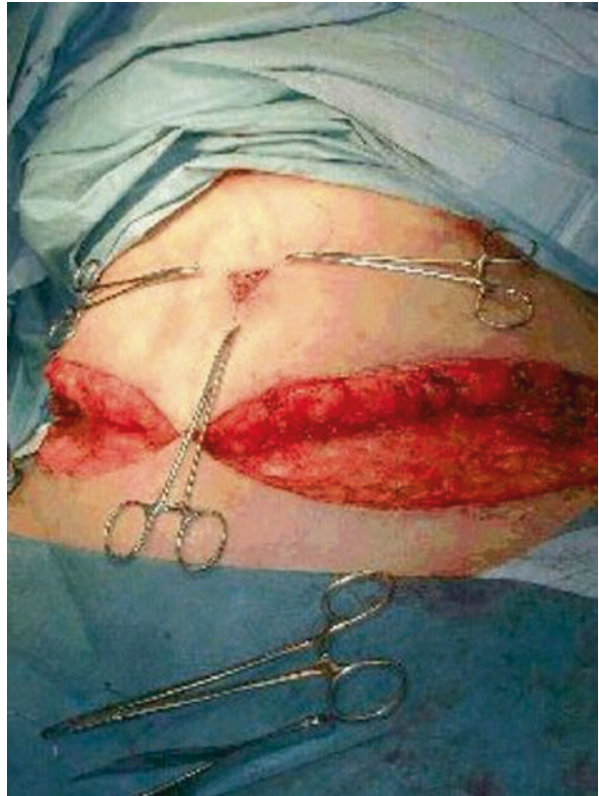
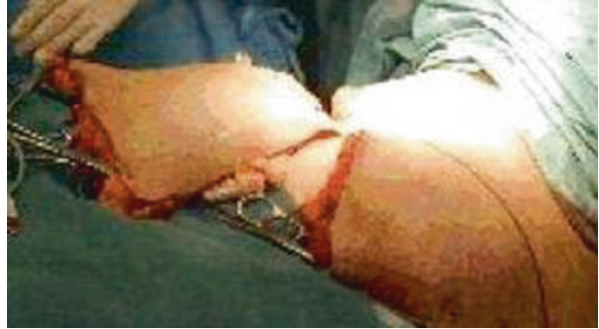**Fig. 9.15** Repositioning the umbilicus



- Sutures (Fig. 9.18)
- Outcome (Figs. 9.19 and 9.20)

Avelar [4] added great contribution to the development of abdominolipoplasties with his technique with minimal detachment and conservation of vascularization.

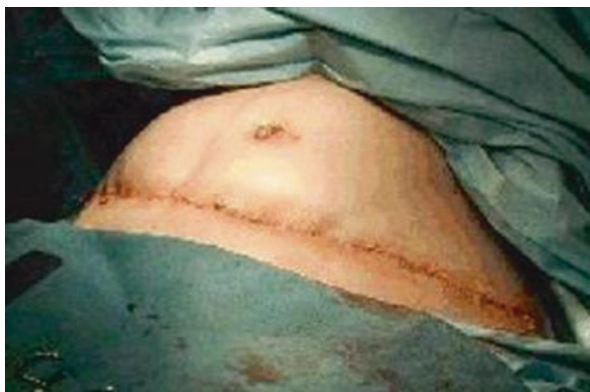**Fig. 9.16** Abdominal lipectomy



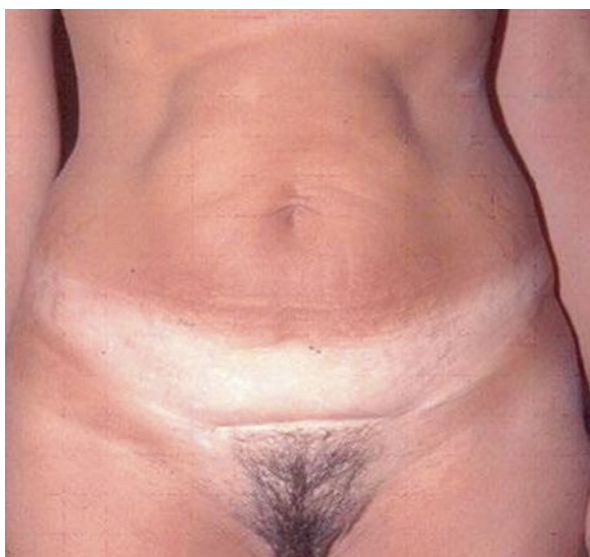**Fig. 9.17** Sutures



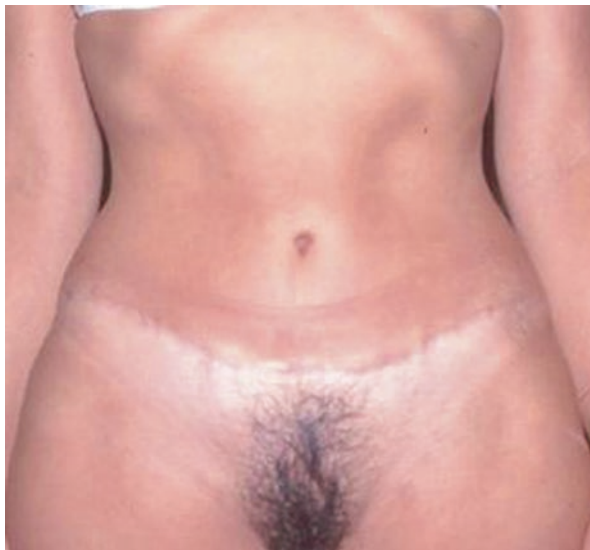**Fig. 9.18** 43 patient preoperative



**Fig. 9.19** Lipoabdominoplasty postoperatively in 43-year-old patient



**Fig. 9.20** Final aspect of the abdomen after lipoabdominoplasty



The method consists of the removal of the fat from the white abdomen through the liposuction of the lamellar layer of adipose tissue, beneath the fascia superficialis. This deep liposuction preserves entire thickness of the areolar layer of fatty tissue, along with its vascularization. Thus, the dermocutaneous flap is free of the underlying muscular structures, sliding easily at the same time as the perforating vessels and connective tissue are preserved. Resection of skin excess is made only to the subdermal plan, which subsequently is folded over itself and sutured in two or three layers using absorbable sutures.

The plication of the aponeurosis of the rectus abdominis, when necessary, is done endoscopically.

Another variant of abdominolipoplastia with minimum detachment was described by Saldanha et al. [21] and consists of liposuction of the whole abdomen and flanks, lower abdomen skin resection, detachment of only the midline between the medial edges of the rectus abdominis and plication. In this way, much of the blood supply to the abdominal wall is preserved.

### **Anesthetic Considerations**

The anesthetic procedures used in lipoabdominoplasties are spinal anesthesia (spinal or epidural) or general anesthesia. The spinal anesthesia have advantages over general anesthesia since they are associated with lower incidence of thromboembolic events [1], and they encourage better management of postoperative pain, favoring early ambulation, which is also a factor of preventing thromboembolism.

## Complications in Abdominolipoplasties

The most feared complication after abdominolipoplasties is thromboembolism. The author recommends prophylaxis through the protocol prepared by the Brazilian Society of Vascular Surgery, which is heparin [15].

Other complications include seroma, hematoma, dehiscence, necrosis, infection, and blood transfusion. In abdominolipoplasties with minimal detachment, there is decreased incidence of seroma, hematoma, and necrosis [2, 4, 8, 21, 22]. Graf [8], in his work with color Doppler, confirmed the preservation of perforating arteries in the abdomen after liposuction, which shows that it does not damage the vessels larger than 1 mm of diameter.

In Tables 9.1, 9.2 and 9.3, we can see the most common complications of abdominoplasty, a study conducted by Parrizi et al. in 2015 [18].

**Table 9.1** Intraoperative

Complications Referring to the anesthesia (0.2–26%)	Drug interactions Clinical changes arising from previous diseases, such as heart disease, pneumopathy, blood dyscrasias, previous hydro-electrolytic (electrolyte) Complications resulting from the use and, or excessive absorption of local Systemic anesthetics Technical mistakes
Referring to surgery (0.8–30%)	Excessive bleeding Excessive surgical time Excessive plication of the rectus abdominis

**Table 9.2** Major and minor postoperative complications

Complications	Incidence
Major	10.3 to 10.9%
Minor	40.1 to 43.2%

**Table 9.3** Major and minor postoperative complications

Complications	Incidence
<i>Major complications</i>	<i>Percentage</i>
Deep vein thrombosis	0.2 to 1.29
Systemic infection	0.4 to 0.99
Hematoma	10. to 22.29
Dehiscence of wall	0.9 to 1.69
Tissue necrosis	0.5 to 1.09
Death	0.2 to 0.79
<i>Minor complications</i>	<i>Percentage</i>
Seroma	5.0 to 25.09
Small dehiscences	16.0 to 41.09
Local infection	05. to 6.29
Unsightly scars	4.0 to 22.09

## Discussion

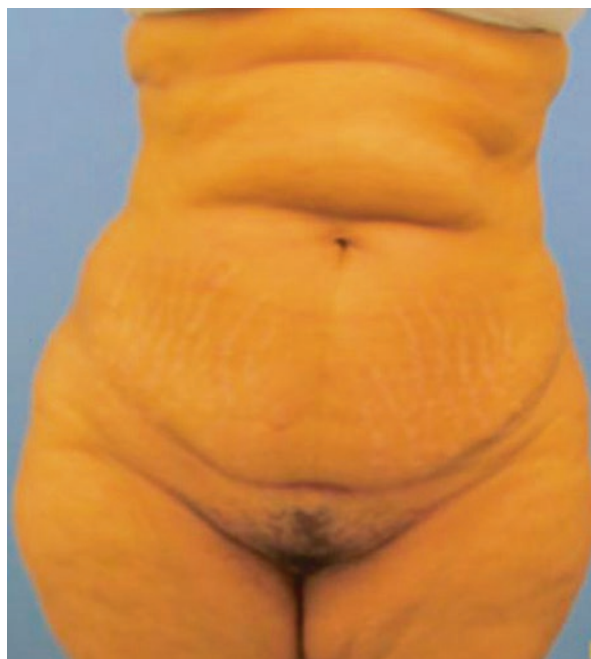Abdominoplasty is a common aesthetic procedure in plastic surgery. However, it presents major complication rates in both the aesthetic aspects and the aspects that compromise life.

Despite being a technique that goes back over 501 years, its steps remain unchanged, i.e., detachment, skin resection, plication of aponeurosis of rectus abdominis muscles, and transposition of umbilical scar.

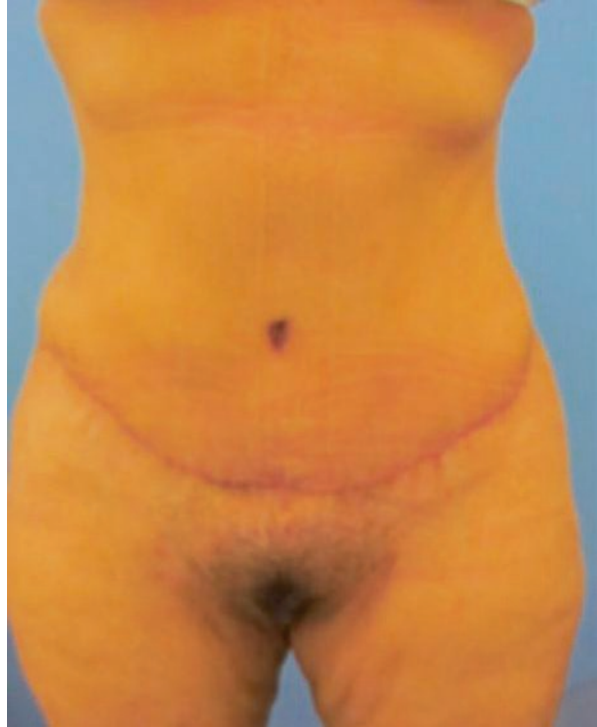It is noteworthy that the high rates of complication can be minimized if certain parameters are met, such as real surgery need, appropriate postoperative care with repeated returns, and evaluations.

With the advent of lipoabdominoplasty, some of the most frequent complications might be minimized, for example, the occurrence of seroma postoperatively, resulting from extensive detachment of tissues.

Even with the technical advance, the abdominoplasties remain the record holders in complications from plastic surgery, which dates back to the premise that to minimize them it is not enough, just technical advances. Basic aspects, concerning all aesthetic or general surgical procedures, which include common sense indicating surgery, anatomical and technical knowledge, and, especially, adequate doctor–patient relationship, are also of paramount importance (Figs. 9.21 and 9.22).



**Fig. 9.21** Before the surgery

**Fig. 9.22** After surgery

## Conclusion

The abdominoplasty technique has undergone major changes over time all in order to achieve better aesthetic results, coupled with decreased incidence of complications. With the advent of liposuction, there was a big step in that direction, which was corroborated by the description of the techniques. Where minimum detachments, are employed, there is blood supply and therefore less adverse effects.

## Bibliography

1. Abs R (2000) Accidents thromboemboliques em cirurgia plastica: revue de La litature ET proposition d'un algorithme de prophylaxie. *Ann Chir Plast Esthet* 45:604–609
2. Avelar JM (2000) Abdominoplasty: a new technique without undermining and fat layer removal. *Arq Catarinense Med* 29:147–149
3. Avelar JM (1985) Fat suction versus abdominoplasty. *Aesthetic Plast Surg* 18:439
4. Avelar JM (1999) Uma nova Técnica de abdominoplastia : sistema vascular fechado de retalho subdérnico dobrado sobre si mesmo, combinado com lipoaspiração. *Rev Bras Cir* 88/89:3–20

5. Boyd BJ, Taylor GL (1984) The vascular territories of the superior epigastric and deep inferior epigastric systems. *Plast Reconstr Surg* 73:1
6. Bozola AR, Psikiakis JN (1988) Abdominoplasty: new concept and classification for treatment. *Plast Reconstr Surg* 82:983–993
7. Elbaz JS, Flageul G (1979) *Plastic surgery of the abdomen*. Masson, New York, p 42
8. Graf R et al (2006) Lipoabdominoplasty : liposuction with reduced undermining and tridiotal abdominal skin flap resection. *Aesthetic Plast Surg* 30:1–8
9. Grazer FM, Kingbell JR (1980) *Body image: a surgical prospective*. Mosby, St Louis, pp 146–149
10. Grazer FM (1973) Abdominoplasty. *Plast Reconstr Surg* 51:617–623
11. Huger WE Jr (1979) The anatomic rationale for abdominal lipectomy. *Am Surg* 45:612
12. Illouz YG (1992) A new safe and aesthetic approach to suction abdominoplasty. *Aesthetic Plast Surg* 16:237–245
13. Illouz YG (1980) Une nouvelle technique pour çles lipodystrophies localisées. *Rev Chir Esth Franc* 6:19
14. Jaimovich CA, Mazzarone F, Parra JFN, Pitanguy I (1999) Semiologia da parede abdominal: seu valor no planejamento das abdominoplastias. *Rev Soc Bras Cir Plast* 14:21–50
15. Jatene PRS, Jatene MCV, Barbosa ALM (2005) Adominoplastia: experiência clinica, complicações e revisão da literatura. *Rev Soc Bras Cir Plást* 20:65–71
16. Matarasso A (1991) Abdominoplasty : a system of classification and treatment for combined abdominoplasty and suction-assisted lipectomy. *Aesthetic Plast Surg* 15:111
17. Matarasso A (1995) Liposuction as na adjunct to full abdominoplasty. *Plast Reconstr Surg* 95:829–836
18. Parvizi DE et al (2015) A multiple regression analysis of postoperative complications after body-contouring surgery: a retrospective analysis of 250 patients: regression analysis of complications. *Obes Surg* 25(8):1482–1490
19. Pitanguy I, Salgado F, Murakami R, Radwanski HN, Mauad R Jr (1995) Abdominoplastia: classificação e técnicas cirúrgicas. *Rev Bras Cir* 85:23–44
20. Rebello C, Franco T (1972) Abdominoplastia por incisão sub-mamária. *Rev Bras Cir* 62:249
21. Saldanha O et al (2001) Lipoabdominoplasty with selective and safe undermining. *Aesthetic Surg J* 21:518–526
22. Saldanha O et al (2003) Lipoabdominoplasty with selective and safe undermining. *Aesthetic Plast Surg* 27:322–327

**Part II**  
**Further Applications of New**  
**Concepts on Abdominoplasty**

# Chapter 10

## Importance of Concepts in Abdominoplasty and Liposuction in Breast Reconstructions

Márcio Paulino Costa, Alex Boso Fioravanti,  
and Guilherme Cardinal Barreiro

### Introduction

The breast is made up of glands, called lobules that can make milk and thin tubes, called ducts that carry the milk from the lobules to the nipple. Breast tissue also contains fat and connective tissue, lymph nodes, and blood vessels.

The most common type of breast cancer is ductal carcinoma, which begins in the cells of the ducts. Breast cancer can also begin in the cells of the lobules and in other tissues in the breast. Invasive breast cancer is breast cancer that has spread from where it began in the ducts or lobules to surrounding tissue.

In the USA, breast cancer is the second most common cancer in women after skin cancer. It can occur in both men and women, but it is very rare in men. Each year there are about 2,300 new cases of breast cancer in men and about 230,000 new cases in women.

The number of new cases of breast cancer was 124.8 per 100,000 women per year. The number of deaths was 21.9 per 100,000 women per year. These rates are age adjusted and based on 2008–2012 cases and deaths.

---

The original version of this chapter was revised: The spelling of the second author name was corrected. The Erratum to this chapter is available at DOI: [10.1007/978-3-319-27851-3\\_39](https://doi.org/10.1007/978-3-319-27851-3_39)

M.P. Costa, MD, PhD (✉)

Members of the Brazilian Society of Plastic Surgery, ISAPS, FILACAP, AS PS,  
Hospital das Clínicas, University of São Paulo Medical School, Rua Gabriel dos Santos,  
759 12° andar, Santa Cecília, 01231-011 São Paulo, SP, Brazil  
e-mail: [marciopaulino@bol.com.br](mailto:marciopaulino@bol.com.br)

A.B. Fioravanti, MD

Brazilian Society of Plastic Surgery, Hospital das Clínicas, University of São Paulo  
Medical School, São Paulo, SP, Brazil

G.C. Barreiro, MD, PhD

Brazilian Society of Plastic Surgery, ICESP Hospital, University of São Paulo  
Medical School, Rua Gabriel dos Santos, 759 12° andar,  
Santa Cecília, 01231-011 São Paulo, SP, Brazil



Approximately 12.3% of women will be diagnosed with breast cancer at some point during their lifetime, based on 2010–2012 data. In 2012, there were an estimated 2,975,314 women living with breast cancer in the USA. In 2015, it is estimated that there will be 231,840 new cases of breast cancer and an estimated 40,290 people will die of this disease.

Each year, about 22% of new cancer cases in women are breast cancer, according to the “National Cancer Institute Jose Alencar Gomes da Silva” – INCA (Brazil); the number of new cases of breast cancer expected for Brazil in the year 2014 is 57,120, with an estimated risk of 56.09 cases per 100,000 women.

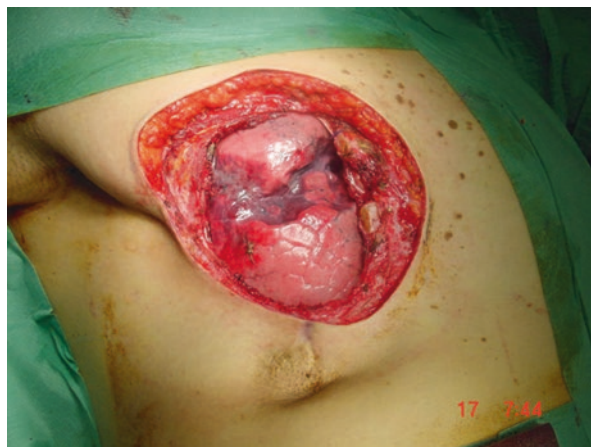Excluding nonmelanoma skin cancers, breast cancer is the most common type in women of the Southeast (71.18/100,000), South (70.98/100,000), Center/West (51.30/100,000), and Northeast (36.74/100,000) in Brazil. In the North, it is the second most frequent tumor (21.29/100,000) (INCA).

In addition to this fact, the psychosocial trauma caused by this disease and the consequences determined by the mutilation of the breast removal for women will require special attention from the plastic surgeon.

## Technique

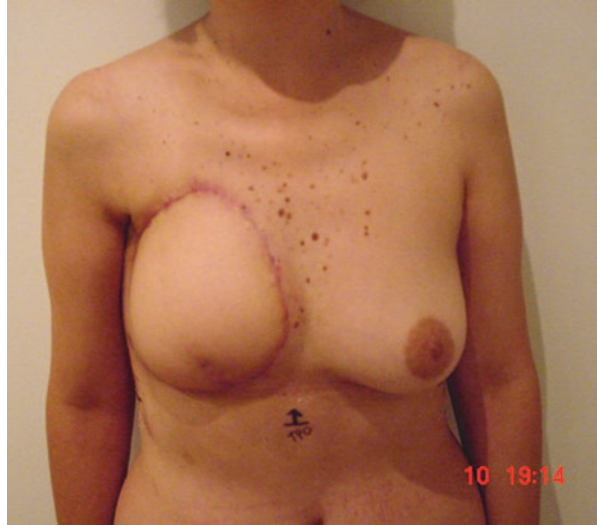Breast reconstruction has as initial objective to reconstruct the breast in order to make it symmetrical with respect to the contralateral breast. Sometimes, in advanced cases, the reconstruction of the chest wall is also necessary in the same surgery (Figs. 10.1 and 10.2).

One of the possibilities to reconstruct the breast is to use a myocutaneous transverse flap from the abdomen based on the rectus abdominis muscle (TRAM)

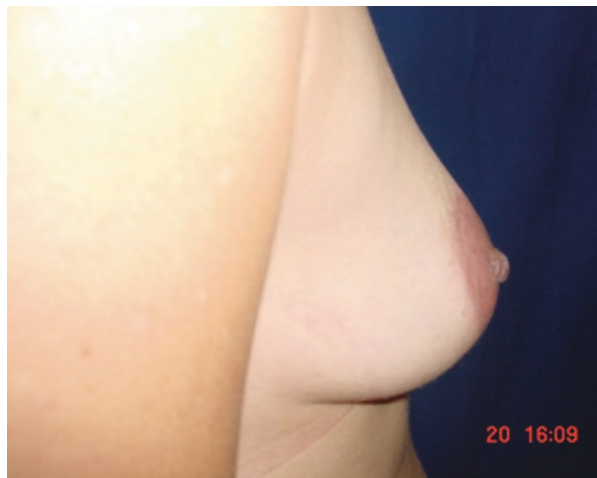

**Fig. 10.1** Sometimes, reconstruction of the chest wall is necessary in the same surgery

**Fig. 10.2** Patient A, postoperative (frontal view)

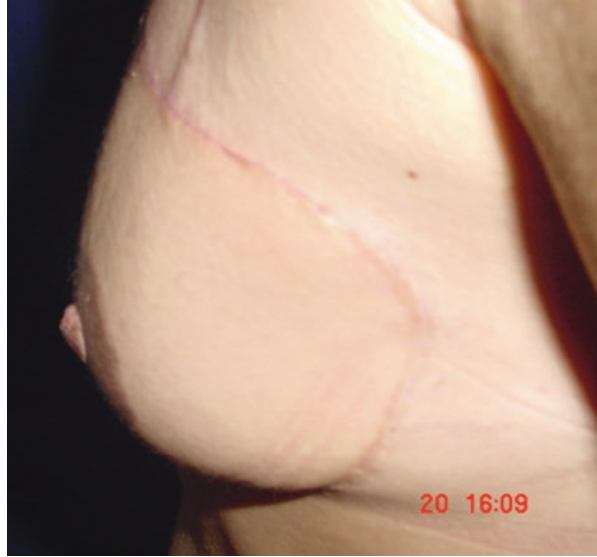

**Fig. 10.3** Patient B, 48 years, normal breast

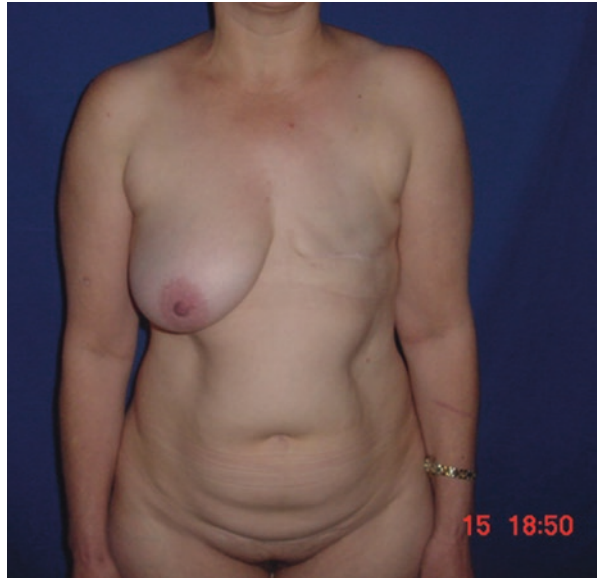

and its variations (single pedicled, bipedicled, or free TRAM flap with microsurgical vascular anastomosis). The good results obtained with this type of surgery are to achieve reconstructed breasts increasingly similar to normal. One of the advantages of using the TRAM for breast reconstruction is that it may also improve the abdominal contour of the patient (Figs. 10.3, 10.4, 10.5, and 10.6).

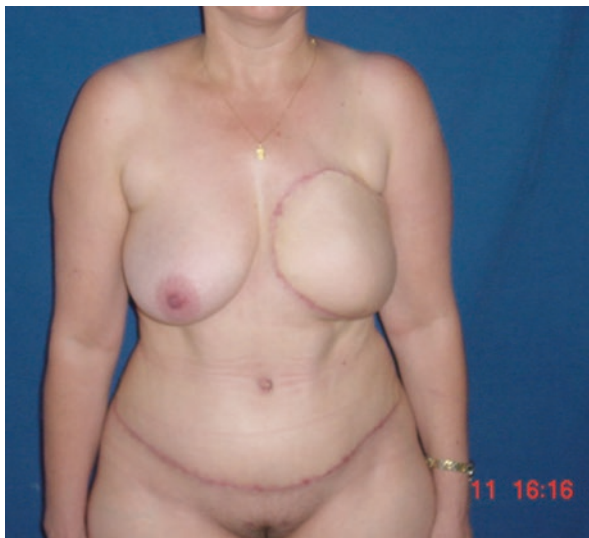**Fig. 10.4** Patient B, 48 years, reconstructed breast



**Fig. 10.5** Patient C, 56 years, preoperative (frontal view)



**Fig. 10.6** Patient C, 56 years, postoperative (frontal view)



## Discussion

There are several concepts of aesthetic plastic surgery of the abdomen that can be transferred while reconstructing the breast with the TRAM. Issues related to the incision, umbilicus, presence of bulging, sagging, and hernia must be considered, addressed, and evaluated.

The incision in the abdomen should be positioned in such a way that, as in cosmetic surgery, can be concealed by a bathing suit. In order to avoid an overly high incision, almost in the middle of the abdomen, the upper incision of the transverse abdominal flap should superiorly border the umbilicus (Fig. 10.7).

The incision does not need to be positioned far above the umbilicus in order to include a greater number of perforators, since these are enough for a good flap viability if incised just above the umbilicus.

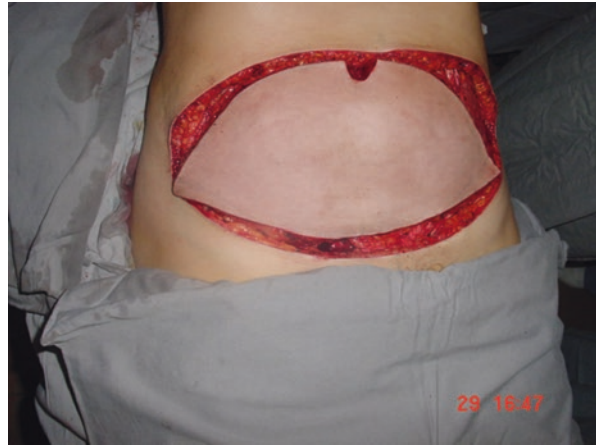The umbilicus should be positioned the same way as cosmetic surgery, centered on the abdomen. Care should be taken when closing the abdominal wall so that it is centered (Fig. 10.8).

In the case of single peddled TRAM, a plication of the contralateral rectus abdominis sheath is necessary to keep the umbilical position centered. A round incision in the abdominal flap to insert the umbilicus should be avoided in order to prevent scar contraction and stenosis.

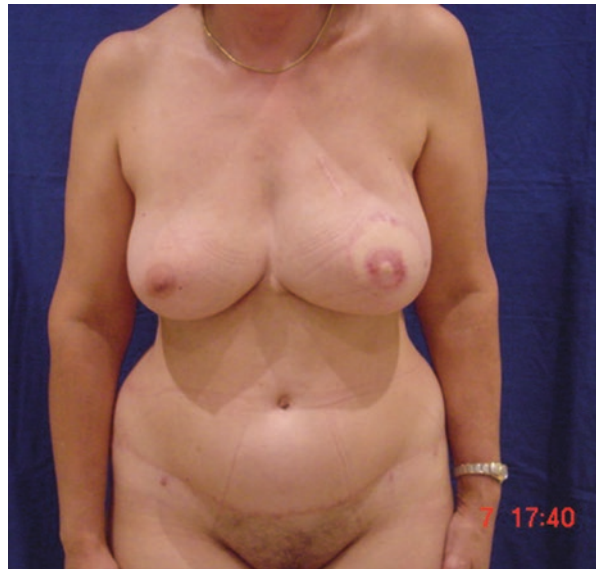Breast reconstruction with TRAM implies reconstruction of the abdominal wall. Caution concerning the herniation, bulging, and sagging should be taken when suturing the remaining abdominal fascia.

The use of polypropylene mesh (Marlex®) to repair the fascial defect after the removal of the rectus abdominis greatly decreased the incidence of hernias, bulging, and sagging. Hartrampf, in 1994, evaluated 662 patients who underwent breast reconstruction with TRAM and demonstrated that the use of Marlex mesh reduced the number of

**Fig. 10.7** The incision in the abdomen should be positioned in such a way that can be concealed by a bathing suit



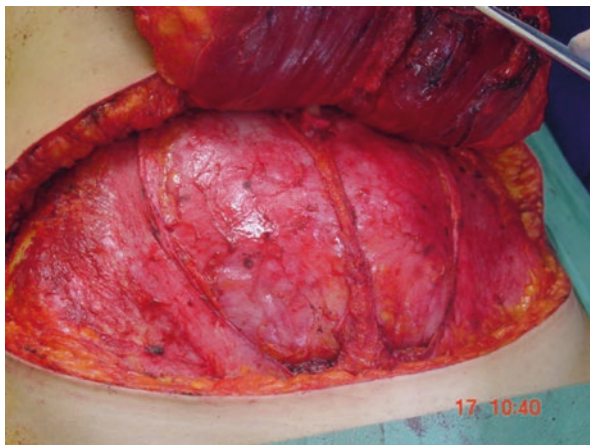**Fig. 10.8** The umbilicus should be positioned centered on the abdomen



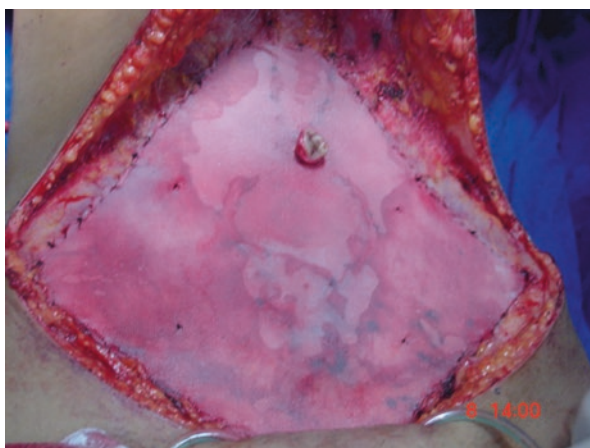
complications from 1.7 to 0% herniation [1]. Beasley, also in 1994, did not observe the presence of sagging or bulging of the abdominal wall postoperative in 59 patients [2].

Even in cases of microsurgical TRAM (muscle sparing or perforator based – DIEP, SIEA), it is necessary to strengthen the abdominal wall with polypropylene mesh in the lower abdomen and plicate the aponeurosis of the superior rectus abdominis.

**Fig. 10.9** The mesh is intended to cover the whole abdominal wall

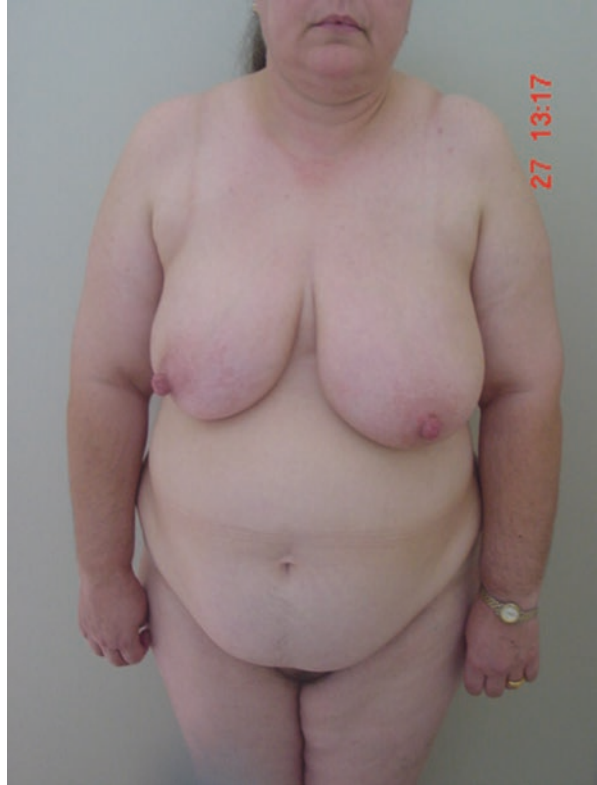

**Fig. 10.10** The fixation of the mesh is in fixed anatomic structures of the anterior abdominal wall: anterior superior iliac spine bilaterally and pubis in the lower portion



The mesh is intended to cover the whole abdominal wall. The fixation of the mesh is in fixed anatomic structures of the anterior abdominal wall: anterior superior iliac spine bilaterally and pubis in the lower portion (Figs. 10.9 and 10.10). When it is impossible to primarily suture the aponeurosis in the lower abdomen, below the umbilicus, a preperitoneal mesh in the size of the defect is placed (Fig. 10.11). Laying on top of this mesh, another mesh occupying the entire abdomen is sutured as described above. All these precautions are taken to avoid weakness of the abdominal wall and to improve body contour of the patient [1, 2].

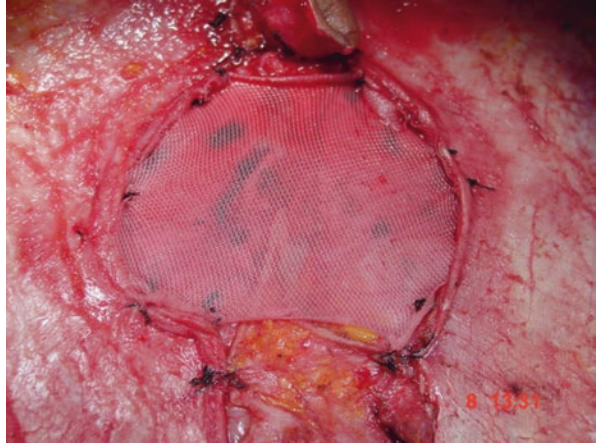
**Fig. 10.11** When it is impossible to primarily suture the aponeurosis in the lower abdomen, below the umbilicus, a preperitoneal mesh in the size of the defect is placed



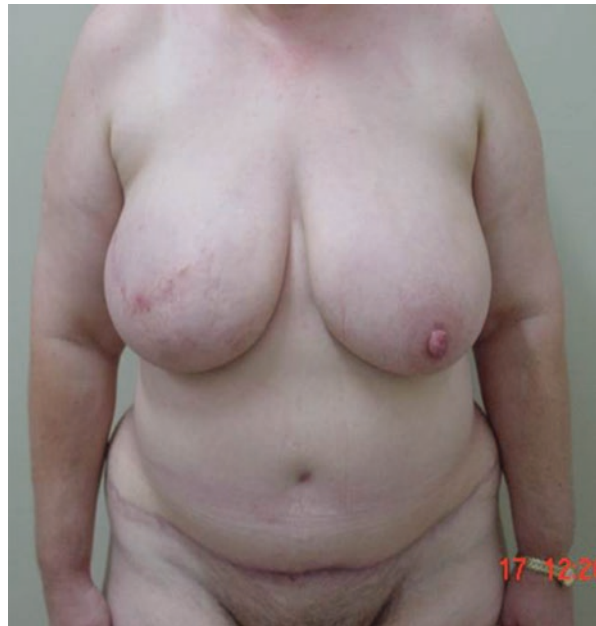Another concept that is also borrowed from aesthetic lipoabdominoplasty is a smaller detachment of the abdominal skin flap [3–9]. In lipoabdominoplasty, this made it possible to liposuct the abdominal flap, with lower risk of flap suffering.

In breast reconstruction using the TRAM, limited undermining of the flap allowed for reconstruction of morbidly obese, elderly, diabetic, hypertensive, heart disease, and smoking patients, with less risk of abdominal skin congestion or ischemia (Figs. 10.12 and 10.13).

**Fig. 10.12** Patient E, 58 years, diabetic, obese, hypertension, preoperative (frontal view)

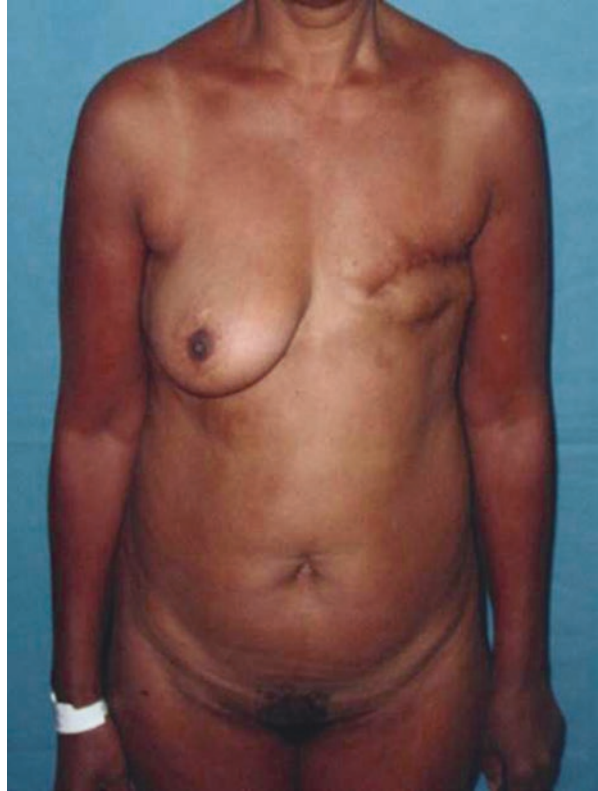

**Fig. 10.13** Patient E, postoperative (frontal view)



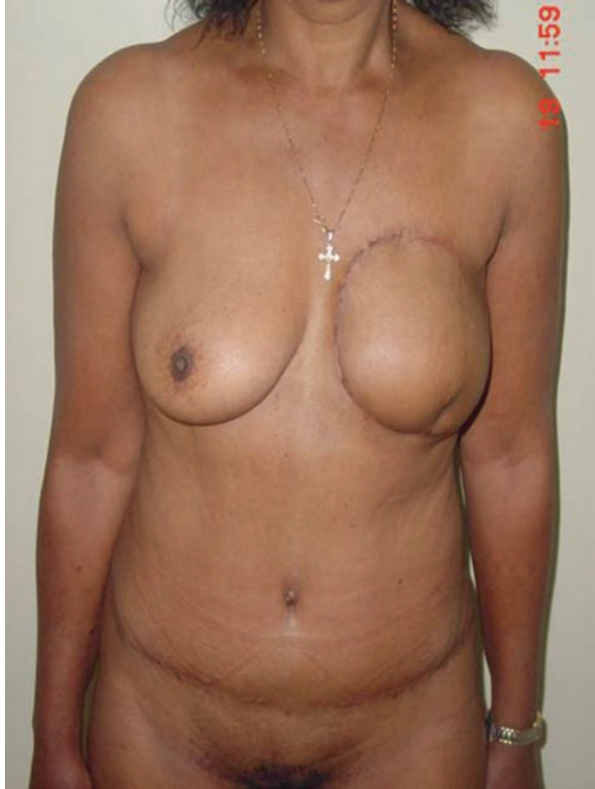

**Fig. 10.14** Patient F, 59 years, preoperative (frontal view)

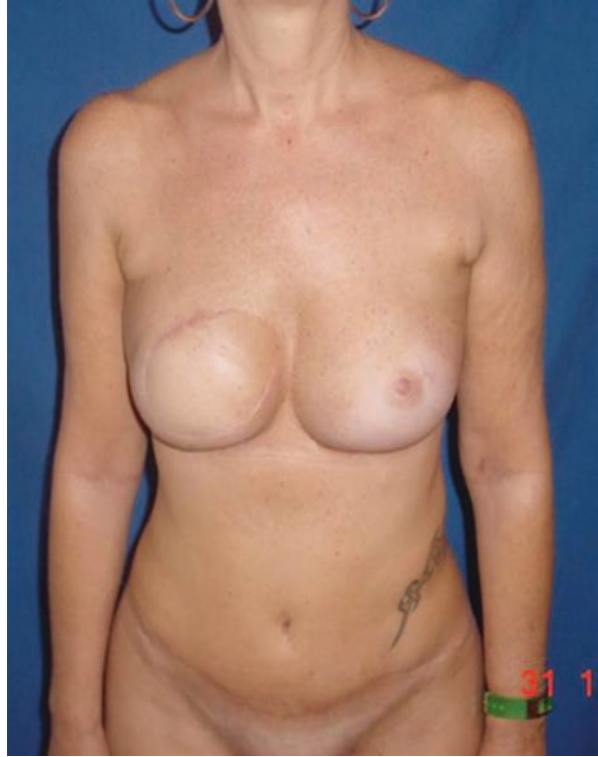

The body contour of patients undergoing breast reconstruction can also be improved during revision of the breast. In this surgical procedure, in addition to achieving better symmetry between the reconstructed breast and the contralateral breast, complementary abdominal liposuction can optimize [10] contour of the patient (Figs. 10.14, 10.15, 10.16, and 10.17).

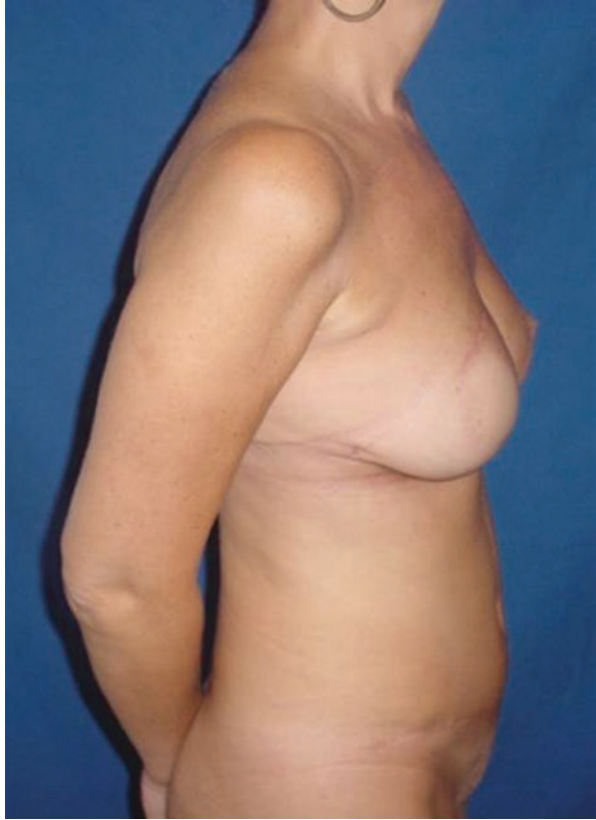**Fig. 10.15** Patient F, postoperative (frontal view)



**Fig. 10.16** Patient G, 48 years, preoperative (frontal view)



**Fig. 10.17** Patient G,  
postoperative (lateral view)



## Conclusion

In conclusion, many of the concepts of aesthetic abdominoplasty and liposuction are used in the abdominoplasty associated with the harvesting of the TRAM flap for breast reconstruction, in order to achieve better body contour for the patient.

## References

1. Hartrampf CR Jr (1994) A mechanical leech for transverse rectus abdominis musculocutaneous flaps. *Ann Plast Surg* 31(2):103–5
2. Beasley ME (1994) The pedicled TRAM as preference for immediate autogenous tissue breast reconstruction. *Clin Plast Surg* 21(2):191–205. Review
3. Avelar JM (1978) Abdominoplasty: Methodization of a technique without external umbilical scar. *Aest Plast Surg* 2:141
4. Avelar JM (1983) Abdominoplasty: technical refinement and analysis of 130 cases in 8 years' follow-up. [Journal Article]. *Aesthet Plast Surg* 7(4):205–212

5. Avelar JM (1985) Fat-suction versus abdominoplasty. *Aesthet Plast Surg* 9:265–276
6. Avelar JM (1999) A new technique for abdominoplasty- closed vascular system of subdermal flap folded over itself combined to liposuction. *Rev Bras Cir* 88/89(1/6):3–20
7. Avelar JM (2000) Abdominoplasty- a new technique without panniculus undermining and without panniculus resection. Presented at the international society of aesthetic plastic surgery. Postgraduate Instructional Course, Montreal, 7 Sept 2000
8. Avelar JM (2002) Abdominoplasty without panniculus undermining and resection. Analysis and 3 year follow up of 97 consecutive cases. *Aesthet Surg J* 22:16–25
9. Avelar JM (2006) Abdominoplasty combined with lipoplasty without panniculus undermining: abdominolipoplasty – a safe technique [Journal Article. Research Support, Non-U.S. Gov't]. *Clin Plast Surg* 33(1):79–90, vii
10. Illouz YG (2006) Complications of liposuction. *Clin Plast Surg* 33(1):129–163

# Chapter 11

## Robotic Procedure for Plication of the Muscle Aponeurotic Abdominal Wall

Marco Aurelio Faria Correa

### Introduction

The cosmetic appearance of the abdomen is one of the most popular concerns in the modern society. We are seeing an increasing number of female and male patients presenting with small- and medium-sized abdominal cosmetic deformities coming to our clinics asking for minimally invasive and scarless procedures that can effectively improve the aesthetic appearance of the abdomen. In many cases the problem is not over-redundant skin, overweight, or abdominal lipodystrophy, but rectus diastasis (Figs. 11.1, 11.4, 11.5, 11.7 and 11.10). They complain that despite working hard at losing weight, having a strict and rigorous workout regime, they cannot get rid of that bulging stomach. The weakening of the muscle aponeurotic abdominal wall due to congenital conditions, weight variation, ageing or pregnancy is a frequent cause of rectus diastasis and/or umbilical hernia that can alter the cosmetic aspect of the abdomen [4, 7, 17]. The rectus abdominal muscle plays an important role, not only in the cosmetic appearance of the abdomen but also in the stability of the spine. Depending of the degree of the rectus diastasis, it can lead to a vicious posture, spine problems, back pain, slipped disc, etc. Rectus plication can effectively restore function providing a balance between the anterior and posterior muscle of the abdominal wall and improve the cosmetic appearance of the abdomen [4, 7, 16]. The long-term evaluation by ultrasonography and CT scan of the plication of the anterior rectus sheath [18, 19] as well as our long-term clinic follow-up (Fig. 11.1) as shown, the efficiency of the rectus plication when properly performed.

---

M.A.F. Correa, M.D.

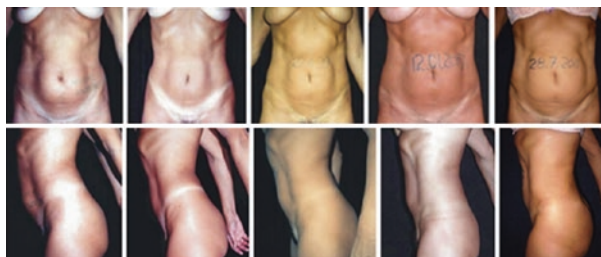Members of the Brazilian Society of Plastic Surgery, Plastic Surgery PLE Ltd.,

Mount Elizabeth Novena Specialist Centre, 38 Irrawaddy road,

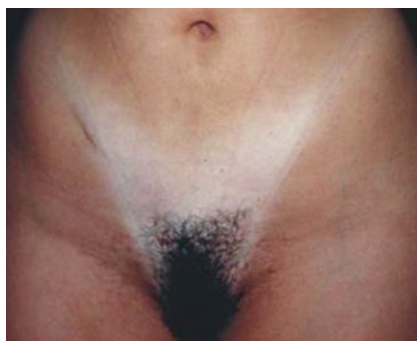
Singapore 329563, Singapore

e-mail: [drmarco@drmarco.com](mailto:drmarco@drmarco.com)

**Fig. 11.1** Endoscopic abdominoplasty 20 years follow-up showing the maintenance of the result of the rectus plication even after patient ageing 20 years and put on 8 kg



**Fig. 11.2** Endoscopic abdominoplasty scars hidden inside the navel/umbilical and inside the pubic hair-bearing area



In 1991 I started using endoscopy for the treatment of patients presenting with rectus diastasis and no redundant skin, working through the previous C-section scars or even using incisions as small as 4–5 cm hidden in the pubic hair-bearing area and inside the umbilical area [4–8]. More than 20 years follow-up shows the effectiveness of the technique and the beauty of restoring the original anatomy leaving minimal and inconspicuous scars (Fig. 11.2).

Robotic surgery is becoming the “gold standard” of the minimally invasive surgery in many surgical fields. In urology, robotic prostatectomy is such a solid application, presenting so many advantages over the open methods as well as over the endoscopic methods [11, 12] that, if a patient has the chance to choose which methods to undergo, the best choice would be to go for robotics assisted. In cardiothoracic surgery, the surgical robots are also proving to be the key in transforming technically challenging open procedures like mitral valve repair and heart revascularisation into technically feasible, minimally invasive procedures. In any institution where robotic “da Vinci Surgical System” is available, the tendency for laparoscopic surgery (in gynaecology, colon-rectum surgery and general surgery) is being replaced by robotics-assisted surgery due to the many advantages that robotics-assisted surgery presents over laparoscopic methods.

The robot high-definition three-dimensional view and the amplification of images give us a much better depth sensation of the surgical field than the 2D endoscopic

view; it is even better than our naked eyes. Laparoscopic instruments have a limited range of motion; the robot EndoWrist range of movements is comparable to the human wrist. The surgeon's hand tremors are transmitted through the rigid laparoscopic instrument; this limitation makes delicate procedures more difficult [12, 15]. The superb precision and stability of the robot arms, surgical field and instruments, all controlled by the surgeon seated at the console in a comfortable ergonomic position, without the need of coordinating camera and instrument movement with a surgical assistant make the surgery much easier, more precise and less stressful.

Robot is becoming a promising technology in many surgical fields.

In reconstructive plastic surgery, it has already been used for the harvesting of latissimus dorsi in breast reconstruction, super microsurgery, hand surgery [10, 20, 21] and hair transplant.

So far I didn't find in the literature any report of other applications of robotics in aesthetic plastic surgery.

As a cosmetic plastic surgeon, I feel it is very interesting that there is a fast growing trend for the use of robot for performing transaxillary robotic thyroidectomy and robot retroauricular submandibular gland resection [12, 13], procedures that are improved or tweaked to minimize visible scars or even relocate scars to other body areas that could be hidden. Yet little is done in the area of aesthetic plastic surgery, where scarring is of an important concern for patients.

## History of Robots

The idea of creating machines for carrying or assisting human activities can be found in early Greek mythology [14].

In the fourth century BC, Aristotle came up with the original concept of automation, self-moving machine constructed for the purpose of imitating the motions of men and animals [9].

The first generation of such machines is dated back to the fourteenth century – an automated rooster erected on top of the Cathedral of Strasbourg in 1350 – a clock-controlled ornamentation, designed to flap its wings and crow every day at noon [9].

The second generation (eighteenth century) was based on self-contained clock-work mechanisms. 1774 inventors Pierre and Henri-Louis Jacquet-Droz unveiled the "Automatic Scribe," a lifelike figure of a boy who could draw and write any message up to 40 characters long. Also a "robot" woman playing a piano was a great invention [9].

The invention of the term "robot" is credited to Karel Capek, a Czech writer who used such nomenclature in order to describe intelligent machines that functioned as slaves in his play Rossum's Universal Robots [14].



According to the Robotic Institute of America, the term “robot” can be defined as “a reprogrammable, multifunctional manipulator designed to move materials, parts, tools or other specialized devices through various programmed motions for performance of a variety of tasks”[14].

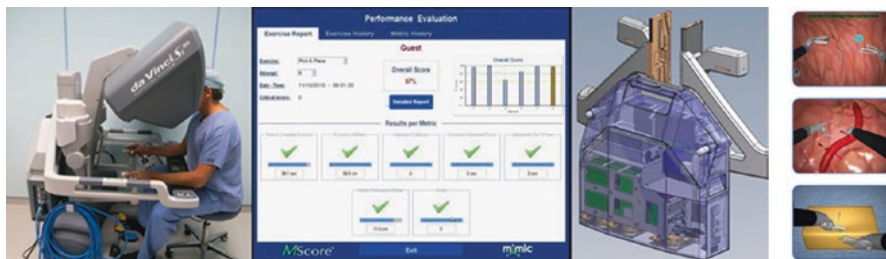In 1927, the first robot called Televox was built by the Westinghouse Electric Corporation/USA to mimic specific human function; it was operated through a telephone system and was able to accept phone calls by lifting the receiver and operating some switches depending on the signals that were received [9, 14]. In 1928, Japan’s first robot, Gakutensoku, was designed and constructed by biologist Makoto Nishimura. In the following years, a few more models of more advanced robots were built by Westinghouse and can be seen at Westinghouse Museum [9].

In 1948, after the invention of transistor, many robots were used in conjunction with the computer; the first patent for computer-controlled industrial robot was developed in 1954; George Devol created a computerized memory and control system and started the industrial robot revolution [14]. In 1961, the robot called Unimate was the first robot in the industrial setting and was installed in an auto assembly line by General Motors [9, 14].

In 1983, the first surgical robot was called Arthrobot which was developed by a team led by Dr. James McEwen and Geof Auchinleck, in collaboration with an orthopaedic surgeon, Dr. Brian Day. In 1985, the PUMA 560 was first introduced in neurosurgery which can be used to hold and manipulate a needle for CT-guided stereotactic biopsy. In 1987, the neuromate platform was developed by Integrated Surgical Systems and was the first robot used for stereotactic. The birth of robots in the field surgery was started in 1987. It was first introduced in laparoscopic cholecystectomy applications other than biopsies. In 1988, the PROBOT, developed at Imperial College London, was used to perform prostatic surgery. In 1992, the ROBODOC from Integrated Surgical Systems (ISS) was introduced to mill out precise fittings in the femur for hip replacement. In 1999, the da Vinci Surgical System by Intuitive Surgical began marketing in Europe while waiting FDA approval in the United States. In 2000, the FDA approved use of the da Vinci Surgical System for general laparoscopic surgery, which can be used to address gall bladder disease and gastroesophageal disease. In 2001, the FDA approved use of the system for prostate surgery. The FDA has subsequently approved the system for thoracoscopic surgery and cardiac procedures performed with adjunctive incisions [3, 11, 14].

## **Training to Be a Robotic Surgeon**

Intuitive Surgical developed the da Vinci Technology Training Pathway. The goal is to help teams develop the knowledge and skills needed to use the da Vinci System technology safely and efficiently. The da Vinci Technology Training Pathway is divided into four phases, with reinforcing activities and supporting tools for both surgeons and OR staff.



**Fig. 11.3** Training with the real console with simulator that measures result and evaluate the performance of the trainee and improving skills before go for the real case and to maintain the skills

Phase 1: Introduction to da Vinci Surgery (Product Training) designed to give teams a foundational understanding of the da Vinci Surgical System.

Phase 2: da Vinci Technology Training (Product Training) introduces surgeons to the core of da Vinci Technology (Fig. 11.3).

Phase 3: Initial Case Series Plan (Skills Application). At this stage, new da Vinci surgeons are assisted by experienced proctoring surgeons during their first da Vinci procedures.

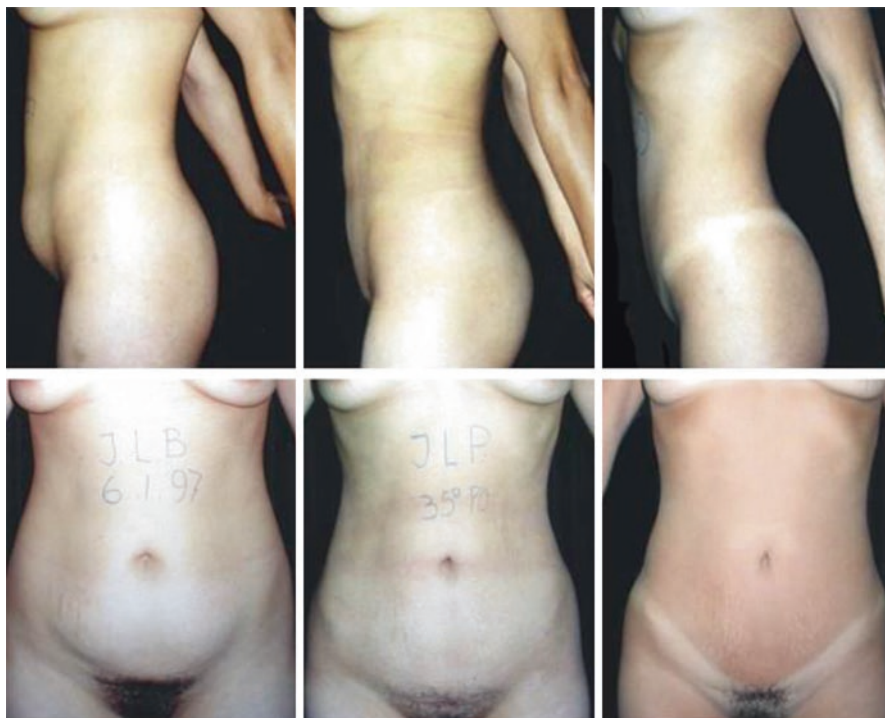Phase 4: Continuing Development (Skills Application). The Technology Training Pathway does not end after the initial da Vinci cases. Advanced da Vinci training in multiple specialties is available through select training centres. Programs are led by experienced, independent da Vinci surgeons who contract with Intuitive Surgical.

## *Patient Selection*

Minimally Invasive methods in plastic surgery are indicated for the treatment of patients presenting with no redundant folds of skin [4–8]. We have been using “sub-cutaneouscopy” since 1991 for the treatment of rectus diastasis and umbilical hernia and for the treatment of fat diastasis at the periumbilical area to restore the anatomy and the beauty of the abdomen through minimal incisions (Figs. 11.1, 11.4, 11.5, 11.7 and 11.10). We are still at the early stage of the use of robot for the rectus plication, but I already can feel the advantages of robot surgery over the conventional endoscopic methods for performing stitches for the rectus plication.

## *Materials and Methods*

We are redesigning and tuning some surgical technical details of endoscopic abdominoplasty technique for the next level of minimally invasive surgery, robot surgery (Figs. 11.6 and 11.7).

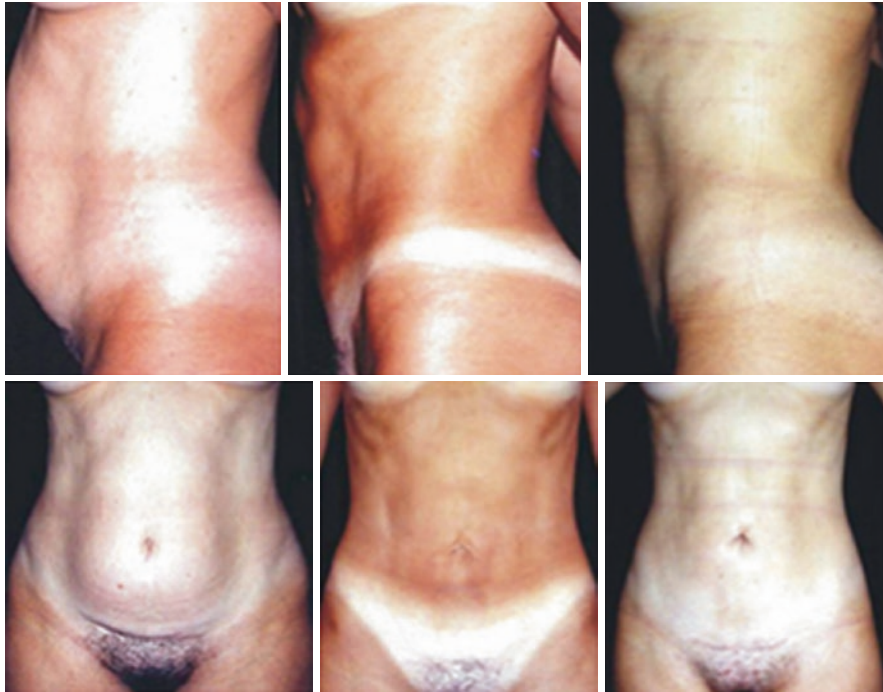

**Fig. 11.4** Long-term follow-up of endoscopic abdominoplasty after 35 days showing a very fast recovery with minimal swelling. After 5 years showing maintenance of the result of the rectus plications and fat plication

### Surgical Robots

The da Vinci Surgical System is the equipment that we are using. It consists of three components (Fig. 11.8): (c) the console where the surgeon sits to operate the robotic arms, (a) the patient site robotic cart with 3 or 4 arms and (b) the high-definition 3D vision system.

Every single movement is operated and controlled by the surgeon. The robot system does not have autonomy to do anything by its own. It is the surgeon that operates. The surgeon seats at the console, uses the joysticks and drives the robot arms and EndoWrist instrument, operating very precise miniaturized tools (Fig. 11.9). With the feet, the surgeon controls the camera, zoom-in zoom-out, monopolar, bipolar cut and cauterization, as well as switching use of the second and the third robot-working arms, without the need of coordinating the movements with an assistant. There are a few different robot models presenting with different features; we are using the da Vinci S and the da Vinci SI. The da Vinci XI still not available in my practice but is more versatile.



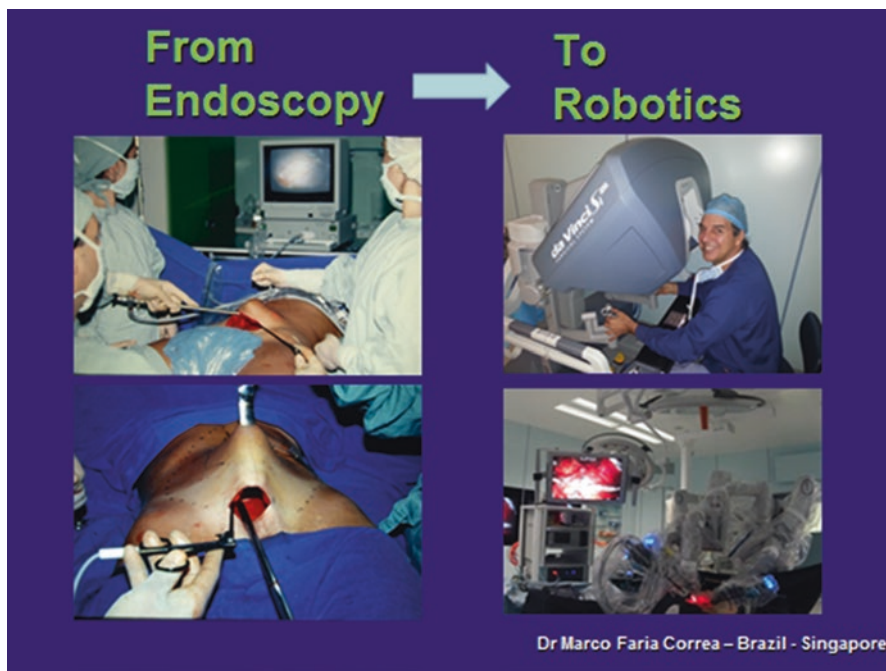
**Fig. 11.5** The before photo showing patient had abdominal deformities after delivery of twins and 4 kg weight gain. 1-year follow-up after patient cut down 8 kg. After 5 years post-op, patient put back 2 kg. We observe the long-term maintenance of the result

### **Anaesthesia**

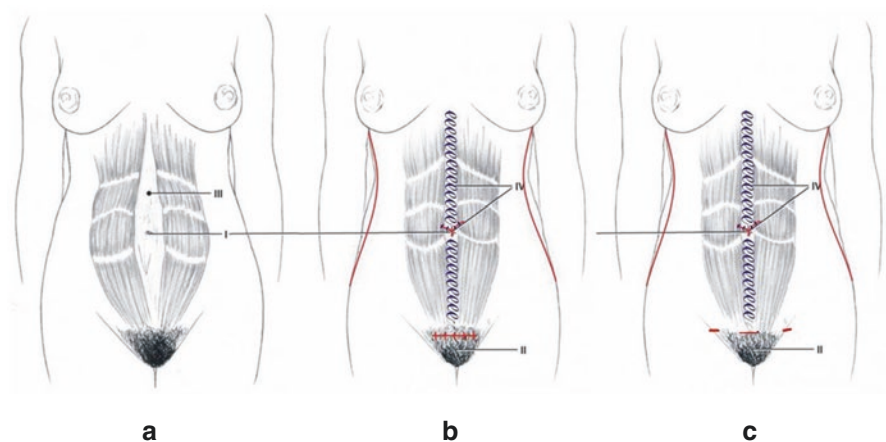
I prefer to work under general anaesthesia because once we dock in the patient side cart, the patient should not be in a state where she could move as a reaction to pain or other stimuli – in other words, to be completely still. There is a so-called remote centre in the trocar that must stay in place to avoid tearing the skin. All the movement of the robot arms are around a fixed rotating point.

### **Infiltration**

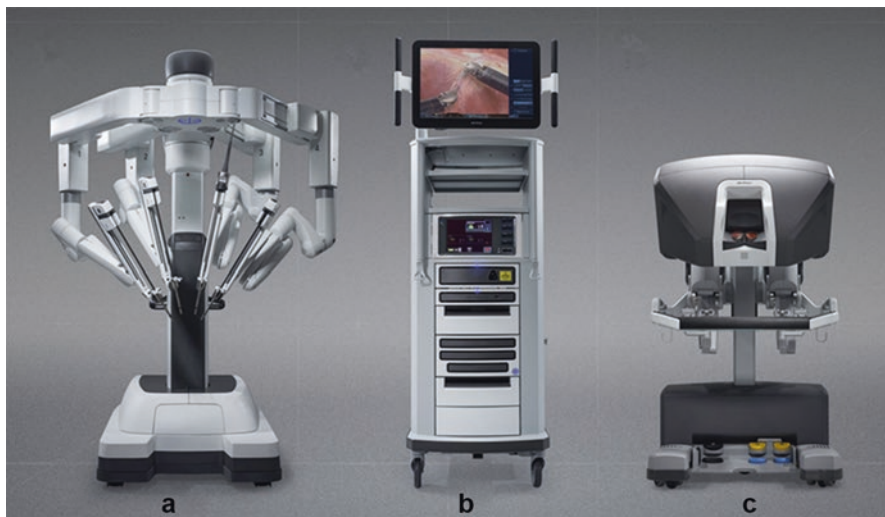To facilitate dissection and reduce bleeding, the incision areas and the region between the fat tissue and the muscular aponeurosis are infiltrated with 500 ml of saline solution and epinephrine (1:500,000).



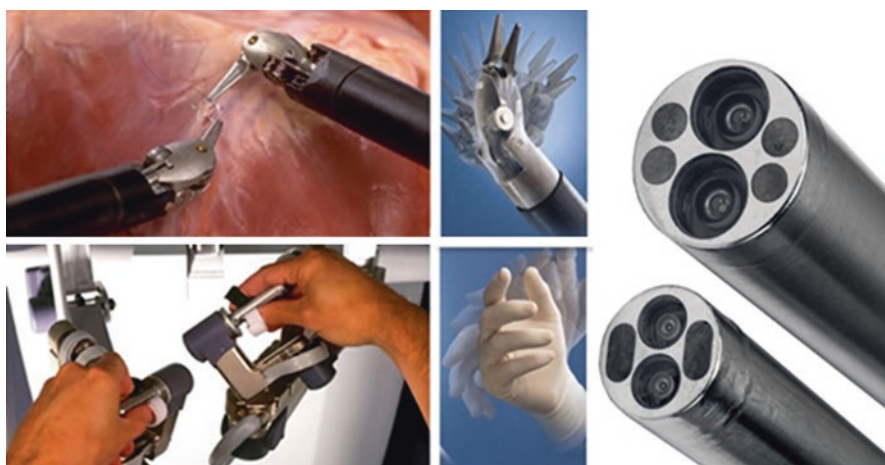**Fig. 11.6** *Left side* endoscopic abdominoplasty; the patient and surgical team position with the video monitor and incisions. *Right side* doctor seated at the console and operating the robotic arms



**Fig. 11.7** (a) Rectus diastasis. (b) Rectus plication and incision in endoscopy abdominoplasty technique. (c) Rectus plication with the aid of robot. *I* Y-shaped umbilicus incision. *II* pubic incision. *III* rectus diastasis. *IV* rectus diastasis repair



**Fig. 11.8** Da Vinci Xi System. (a) Patient side cart. (b) 3D vision recorder. (c) Surgeon control console



**Fig. 11.9** Surgeon manipulates the joysticks operating the EndoWrist instruments that have a range of motion comparable to the human risk motion. The two-lens robotic scopes that provide a fantastic high-definition three-dimensional view

**Incisions**

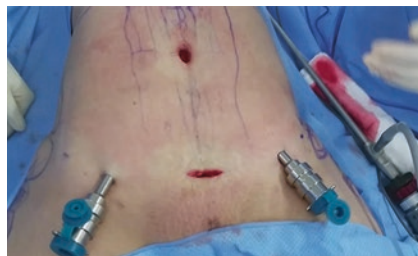If patient presents with previous scars from caesarean sections or other abdominal surgeries (Fig. 11.10), the surgeon assesses the need to repair the scars as well as the possibility of using them for access [4, 7].



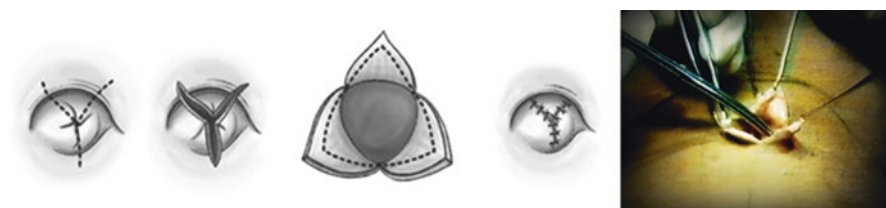
**Fig. 11.10** Performed through C-section scar: before and after

In our original endoscopic abdominoplasty technique, if there is no previous C-section scar, a 5 cm incision is made at the pubic hair-bearing area and another one inside the umbilical scar (Fig. 11.7b).

In our robot studies, we found that the distance between the docking points of the robotic arms cannot be less than 8–10 cm to avoid instrumental collision. The incision for the camera arm is the midline of the patient's abdomen, inside the pubic hair-bearing area at the pubic bone level, 3 cm above the vaginal furcula, measuring 2–4 cm. Docking incisions for the two instruments arms should have a distance of 18–20 cm over the bikini line area, each incision measuring 7–8 mm (Fig. 11.7c). A 4th incision is made within the umbilical scar (Fig. 11.11). The umbilical port is used for the introduction of retractors for tenting the abdominal flap, for supplying sutures and gauze into the operative field and for surgical assistant also to help with laparoscopic instruments if necessary. Additional 0.5 cm incisions can be made at the iliac crest level each on bilateral sides, in cases of lipo-abdominoplasty when the lower back needs to be treated. These incisions can also be used as an extra port for the surgical assistant (Fig. 11.11).



**Fig. 11.11** The incisions: at the bikini line, 3 incisions, one at the midline, 2.5 cm for the robot endoscope, and two at the bikini line, 1 cm length distant and 12–16 cm from each other for the robot arms, and one at the navel for passing the sutures, gaze, suction and helper instruments. Additional 0.5 cm incisions can be made at the iliac crest level each on bilateral sides, in cases of lipo-abdominoplasty when the lower back needs to be treated. These incisions can also be used as an extra port for the surgical assistant



**Fig. 11.12** The surgical sequence of umblicoplasty technique is as follows, Intraumbilical Y-shaped incision, Three triangular flaps and a wide entrance port, Partial resection of these flaps to treat flabbiness, Closure leaving inconspicuous converging scars

The skin of the umbilical scar is detached from its stalk. The umbilical stalk is then transfixed using a 2-0 mono-nylon suture. The suture is not cut short. Instead, the spare suture is left at its full length with the needle attached for further reinsertion of the skin flaps in their original site, deep inside the plication [7]. If there is redundant skin at the navel, a Y-shaped or cross-shaped incision is made generating 3 or 4 triangular flaps [4, 7]; the closure of it will leave inconspicuous converging scars, following Avelar’s original idea [2]. By resecting part of these triangular flaps, we treat the redundant skin (Fig. 11.12). If there is no redundant skin at the umbilicus, a single vertical incision is made [4, 7].

### Dissection and Elevation of the Abdominal Flap

The undermining starts from the umbilicus progressing downwards through the midline towards the pubis and from the pubic incision upwards, or vice versa, to meet each other. The procedure begins with the use of traditional methods with conventional instruments as far as our eyes, fingers and instruments allow us to work safely and comfortably. With the aid of a 4 or 7 mm 30° endoscope, retractors and the “subcutaneous tomoscope” [7] or electrocautery, we progress dissecting a tunnel from the pubic bone to the xiphoid process (Fig. 11.13), up to the outer borders of the

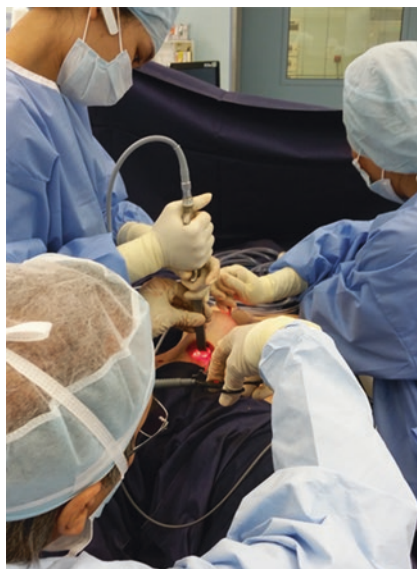

rectus abdominal muscles to create the optical cavity. The undermining can be done endoscopically or with the aid of the robot system. If further undermining is necessary for a proper redistribution of the abdominal flap, we do a blunt dissection, creating tunnels, preserving vessels and nerves. Tunnelling preserves the sensitive innervation of the abdominal wall and provides faster recovery with earlier reduction of the oedema [7] (Fig. 11.4). If there is any area that requires liposuction, the liposuction will be performed after the rectus plication. We aspirate only the deep surface of the derma-adipose flap. In the undermined areas, we use the cannula with the holes facing up. In the non-undermined areas, we use the cannula with the holes facing down in the traditional way, liposuction of the deep fat tissue area, creating tunnels preserving vessels creating a closed vascular system like described by Avelar [1].

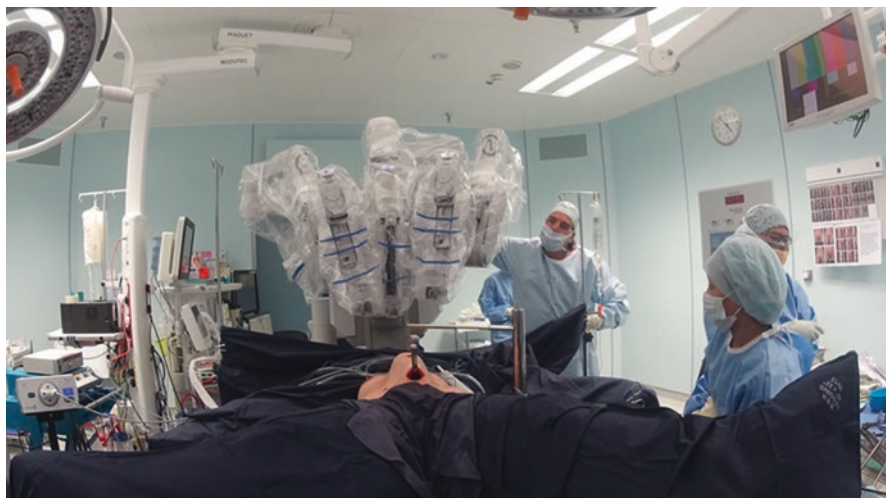At this stage we are still doing the undermining in our conventional “subcutaneousoscopic” method [4–8] (Fig. 11.13). I am working in developing dissectors and retractors (Fig. 11.14) to facilitate the keyhole gasless robotic subcutaneous techniques(Figs. 11.15 and 11.16).

### Rectus Plication

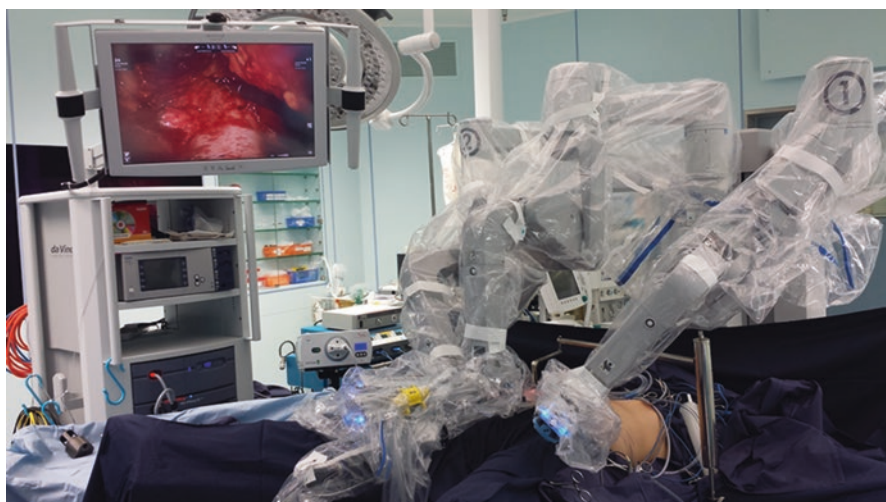We identify the rectus diastasis (Fig. 11.17a), and with a small cotton bud tinted with methylene blue, we demarcate the inner border of the rectus abdominal muscle aponeurosis to be plicated (Fig. 11.17b). Plication of the anterior rectus sheath is performed in two layers, the first layer using 2-0 or 3-0 nylon buried stitches 1.0 cm distant from each other (Fig. 11.17c) and the second layer of two continuous sutures using V-Loc 00 nylon (Fig. 11.17d): one starting from the xiphoid process running till just above the umbilical stalk and another continuous running suture starting from just below the umbilical stalk to the pubic bone.



**Fig. 11.13** Surgeon undermining the dermo-adipous abdominal flap from the muscle aponeurotic fascia, preparing for robotic rectus aponeurotic plication

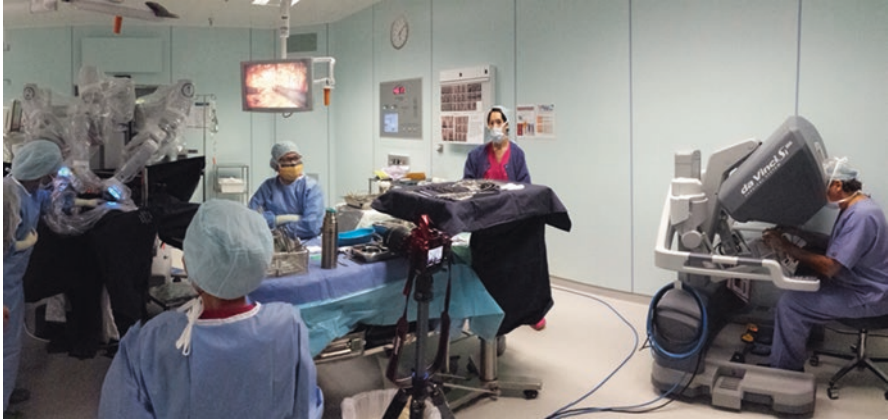

**Fig. 11.14** The surgeon positioning the robot arms and camera

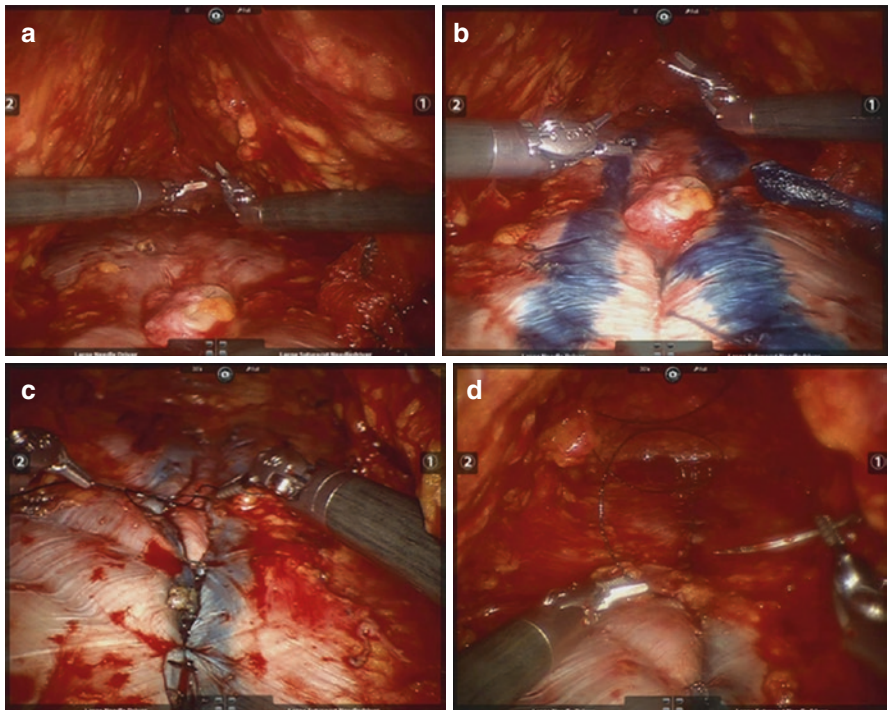


**Fig. 11.15** Robot arms and camera docked in and positioned ready to start the rectus plication

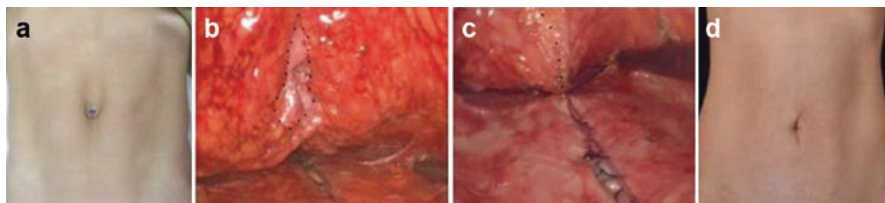
Supra-umbilical or periumbilical flabbiness is a frequent finding (Fig. 11.18a). This deformity occurs during pregnancy when the abdominal muscles stretch and the subcutaneous fatty tissue attached to them is pulled away, creating a gap with skin flabbiness in the region. This subcutaneous fat gap is repaired by suturing the two edges of the fat tissue together with 4-0 Monocryl interrupted sutures (Fig. 11.18b, c). A small hole is left between the edges to permit these small triangular umbilical skin flaps to pass through it for the reinsertion into the umbilical stalk, which was previously secured by the spare suture mentioned earlier [7].



**Fig. 11.16** Surgeon seated at the robot console distant about 4–5 metres from the patient, operating the robot arms and camera with joysticks and pedals



**Fig. 11.17** Robot rectus aponeurotic plication. Surgeon's HD 3D view in the console. **(a)** Identify the rectus diastasis. **(b)** Drawing the inner border of the rectus abdominis using a small cotton bud. **(c)** Plication starts using 2-0 nylon interruptive stitches 1 cm distant from each other. **(d)** A second layer of plication by using a 2-0 V-Loc nylon running suture



**Fig. 11.18** (a) Pre-op showing the rectus and periumbilical fat diastasis. (b) Intraoperative view of repaired rectus diastasis and the mark of the edges of the subcutaneous fat gap to be repaired. (c) Intra-op view of the rectus diastasis repaired and subcutaneous fat gap repaired. (d) Immediate post-operative result

## Complications

We anticipate that complications would be similar to those encountered in endoscopic abdominoplasty. Seroma was the most common one. We manage to reduce the incidence of seroma by reducing as much as possible the undermining area, creating a closed vascular system [1] and stitching the dermo-adipous flap to the muscle fascia as preconized by Baroudi, and suction drainage would have to be maintained minimal for 2 or 3 days or until the drainage over 24 h is not more than 30 cc [4, 7].

## Discussion

Minimally invasive surgery presents many advantages compared to open methods, like fast recovery, less pain, lower risk of infection and minimal scars that are our goals in cosmetic surgery. But there are a number of limitations even though minimally invasive surgery appears attractive. The few most obvious limitations include loss of haptic feedback (force and tactile) and natural hand-eye coordination and dexterity. The da Vinci System proves to be superior in compensating these aspects of limitations. Conventional endoscopy presents with a 2D image view, whereas the da Vinci System presents with a high-definition precise 3D image that compensates the loss of haptic feedback.

## Conclusion

Robotics in aesthetic plastic surgery is still at its infancy stage, but it is very promising considering its many advantages of minimally invasive surgery associated with high technology that helps us work through minimal scars with incisions at remotes sites, leaving inconspicuous scars that are the hallmark of plastic surgery. Over the

past 30 years, we are seeing an increasing number of female and male patients coming for the treatment of small- and medium-sized abdominal deformities. Many of them are presenting with rectus diastasis, no redundant folds of the skin and good skin elasticity and with or without abdominal lipodystrophy. They demand for scarless procedures that can effectively correct it. Liposuction alone will not be effective enough in many cases. The long-term evaluation of midline aponeurotic rectus plication, when properly performed, has proved its efficiency. Plastic surgeons are always looking for tools and instruments that can help us to better perform our procedures with more precision, efficacy, less trauma and faster recovery for our patients, leaving minimal scars. Since 1991, I started using endoscopic methods for the treatment of the described deformities. The efficacy of the method in patients with more than 20 years follow-up gives me the enthusiasm of going for the next level. The “gold standard” of the minimal invasive video surgery, the use of robot “da Vinci Surgery System” for the plication of the rectus diastasis. In many areas of application like urology, gynaecology, general surgery, neurosurgery and heart surgery, robot surgery has proved to have many advantages over conventional endoscopic methods due to the robot high-definition three-dimensional surgical view and amplification of images that makes it much more accurate than the 2D view provided by the conventional endoscopic methods, the superb precision and a much larger range of motion of the robot EndoWrist instruments that are comparable to the human wrist and the stability of the surgical field, camera and instruments, all controlled by the surgeon seated at the console in a comfortable position.

## References

1. Avelar JM (1999) Uma nova tecnica de abdominoplastia-sistema vascular fechado de retalho subdermico dobrado sobre si mesmo combinado com lipoaspiracao. *Rev Bras Cir* 88/89(1/6):3–20
2. Avelar JM (1976) Umbilicoplastia-uma tecnica sem cicatriz externa. *An do XIII Cong Bra de Cir Plast Porto Alegre*, pp 81–82
3. Brown University (2004) History of robotic surgery. Retrieved from [http://biomed.brown.edu/Courses/BI108/BI108\\_2004\\_Groups/Group02/Group%2002%20Website/history\\_robotic.htm](http://biomed.brown.edu/Courses/BI108/BI108_2004_Groups/Group02/Group%2002%20Website/history_robotic.htm)
4. Faria-Correa MA (1995) Abdominoplasty: the South America style. In: Ramirez OM, Daniel RK (eds) *Endoscopic plastic surgery*. Springer, New York
5. Faria-Correa MA (1994) Abdominoplastia videoendoscopica (subcutaneoscopica). In: *Atualizacao em Cirurgia Plastica Estetica e Reconstructiva*. Robe Editorial, Sao Paulo
6. Faria-Correa MA (1992) Videoendoscopic abdominoplasty (subcutaneouscopy). *Rev Soc Bras Cir Plast Est Reconstr* 7:32–34
7. Faria-Correa MA (2008) Videoendoscopic subcutaneous abdominoplasty. In: *Endoscopic plastic surgery*, 2nd edn., vol 4(16). Quality Medical Publishing, Inc., Missouri, pp 559–586
8. Faria-Correa MA (1992) Videoendoscopy in plastic surgery: brief communication. *Rev Soc Bras Cir Plast Est Reconstr* 7:80–82
9. History of Robotics [PowerPoint slides]. Retrieved from OPCS Teacher Server: <https://teachers.ocps.net/cynthia.andrews/media/historyofrobotics.ppt>

10. Ibrahim AE, Sarhane KA, Baroud JS, Atiyeh BS (2012) Robotics in plastic surgery, a review. *Eur J Plast Surg* 35(8):571–578. doi:[10.1007/s00238-012-0737-8](https://doi.org/10.1007/s00238-012-0737-8)
11. Lanfranco AR, Castellanos AE, Desai JP, Meyers WC (2004) Robot Surg Curr Perspect 239(1):14–21. doi:[10.1097/01.sla.0000103020.19595.7d](https://doi.org/10.1097/01.sla.0000103020.19595.7d)
12. Lee HS, Kim D, Lee SY, Byeon HK, Kim WS, Hong HJ, Koh YW, Choi EC (2014) Robot – assisted versus endoscopic submandibular gland resection via retroauricular approach: a prospective nonrandomized study. *British J Oral Maxillofac Surg* 52(2):179–184. doi:[10.1016/j.bjoms.2013.11.002](https://doi.org/10.1016/j.bjoms.2013.11.002)
13. Lee J, Chung WY (2014) Robotic thyroidectomy and radical neck dissection using a gasless transaxillary approach. *Robot Gen Surg* 24:269–270. doi:[10.1007/978-1-4614-8739-5\\_24](https://doi.org/10.1007/978-1-4614-8739-5_24)
14. Mattei TA, Rodriguez AH, Sambhara D (2014) Mendel Ehud. *Curr State Art Future Perspect Robot Technol Neurosurg* 37(3):357–366. doi:[10.1007/s10143-014-0540-z](https://doi.org/10.1007/s10143-014-0540-z)
15. Morris B (2005) Robotic surgery: applications, limitations, and impact on surgical education. All about robotic surgery. Retrieved from <http://www.allaboutroboticsurgery.com/avrasurgic-alrobotics.html>
16. Nahas FX, Augusto SM, Ghelfond C (2001) Suture materials for rectus diastasis: nylon versus polydioxanone in the correction of rectus diastasis. *Plastic and Reconstructive Surgery*. The division of plastic surgery and radiology, hospital Jaragua. Sao Paulo BR 107(3):700–706
17. Nahas FX, Ferreira LM (2010) Concepts on correction of the musculoaponeurotic layer in abdominoplasty. *Clin Plast Surg* 37:527–538. doi:[10.1016/j.cps.2010.03.001](https://doi.org/10.1016/j.cps.2010.03.001)
18. Nahas FX, Ferreira LM, Augusto SM, Ghelfond C (2004) Correction of diastasis: long-term follow up of correction of rectus diastasis. *Plas Reconstr Surg* 115(6):1736–1741. doi:[10.1097/01.PRS.0000161675.55337.F1](https://doi.org/10.1097/01.PRS.0000161675.55337.F1)
19. Nahas FX, Ferreira LM, Ely PB, Ghelfond C (2011) Rectus diastasis corrected with absorbable suture: a long-term evaluation. *Aesth Plast Surg* 35:43–48. doi:[10.1007/s00266-010-9554-2](https://doi.org/10.1007/s00266-010-9554-2)
20. Selber JC (2009) The role of robotics in plastic surgery. Quality Medical Publishing, Inc. Retrieved from [http://www.plasticsurgerypulsenews.com/12/article\\_dtl.php?QnCategoryID=112&QnArticleID=236](http://www.plasticsurgerypulsenews.com/12/article_dtl.php?QnCategoryID=112&QnArticleID=236)
21. Selber JC, Baumann DP, Holsinger FC (2012) Robotic latissimus dorsi flap for breast reconstruction. *Plast Reconstr Surg* 129(6):1305–1312. doi:[10.1097/PRS.0b013e31824ecc0b](https://doi.org/10.1097/PRS.0b013e31824ecc0b)

# Chapter 12

## Lipoabdominoplasty Combining a Wide Undermining of the Upper Abdomen with Complete Body Liposuction

Márcio Paulino Costa, Nuberto Hopfgartner Teixeira, Alex Boso Fioravanti, and Guilherme Cardinal Barreiro

### Introduction

Abdominoplasty is one of the most common operations in plastic surgery [1, 3, 4, 11, 12, 14, 18–20]. Studies have shown that there is a safe method for combining liposuction [7, 9] and abdominoplasty in the same procedure [6, 13, 19].

The evolution of techniques in abdominal surgery has lowered postoperative morbidity and complications rates and has continually encouraged surgeons to search for new innovations.

This study describes an abdominoplasty technique that combines a wide undermining (2–3 cm lateral to the external border of the rectus muscles) with complete body liposuction, not preserving the Scarpa's fascia.

This technique does not simply use liposuction during the abdominoplasty. It is based on the concept that the abdominal contour is not an isolated anatomic unit but rather that it is a part of the entire body contour, where the final shape also depends on the other treated areas.

---

The original version of this chapter was revised: The spelling of the second author name was corrected. The Erratum to this chapter is available at DOI: [10.1007/978-3-319-27851-3\\_39](https://doi.org/10.1007/978-3-319-27851-3_39)

M.P. Costa, MD, PhD (✉)

Members of the Brazilian Society of Plastic Surgery, ISAPS, FILACAP, AS PS, Hospital das Clínicas, University of São Paulo Medical School, Rua Gabriel dos Santos, 759 12° andar, Santa Cecília, São Paulo 01231-011, SP, Brazil  
e-mail: [marciopaulino@bol.com.br](mailto:marciopaulino@bol.com.br)

N.H. Teixeira, MD • A.B. Fioravanti, MD

Brazilian Society of Plastic Surgery, Hospital das Clínicas, University of São Paulo Medical School, São Paulo, SP, Brazil

G.C. Barreiro, MD, PhD

Brazilian Society of Plastic Surgery, ICESP Hospital, University of São Paulo Medical School, São Paulo, SP, Brazil

## History

Since the 1990s, undermining has decreased because of a large number of complications, reaching zero in 1992 with the abdominoplasty mesh undermining described by Illouz [11].

The trend of lipoabdominoplasty without or with small undermining continued until 1999 when Avelar [1] and Shestak [19] presented an abdominolipoplasty with no undermining associated with liposuction.

Since 2004, Costa has used an abdominoplasty technique that combines a wide undermining (2–3 cm lateral to the external borders of the rectus muscles) with complete body liposuction, without preserving Scarpa's fascia. This technique is described herein.

## Methods

### *Patient Selection*

From January 2005 to May 2011, abdominoplasty associated with liposuction was performed on 203 patients (14 males and 189 females). Before with an average use from the private practice of the senior author (MPC), with an average age of 45 years. Seventy-seven (37.93%) patients were smokers.

Inclusion factors – All patients with indications for a traditional abdominoplasty were eligible for lipoabdominoplasty. Exclusion factors – supraumbilical incisions.

## Surgical Procedure

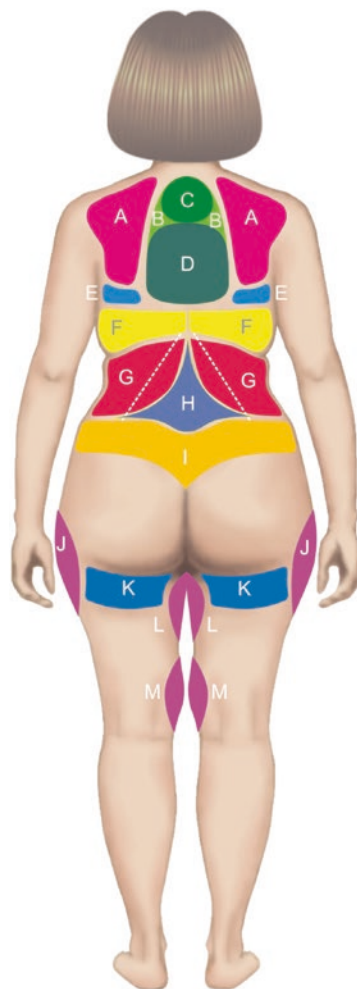
### *Surgical Marking*

The areas to be liposuctioned were marked preoperatively with the patient standing (the upper third of the back, lumbosacral region, subgluteal folds, legs, knees, abdominal regions, flanks, and trochanteric regions) (Fig. 12.1).

With the patient in the sitting position, we estimated the amount of skin to be resected. We identified the lateral inguinal folds, and a low abdominal curved line was delineated approximately 7–10 cm from the labia majora vertex. With the patient in a supine position, a line drawn from the superior umbilicus was connected to both extremities, which estimated the amount of skin to be resected.



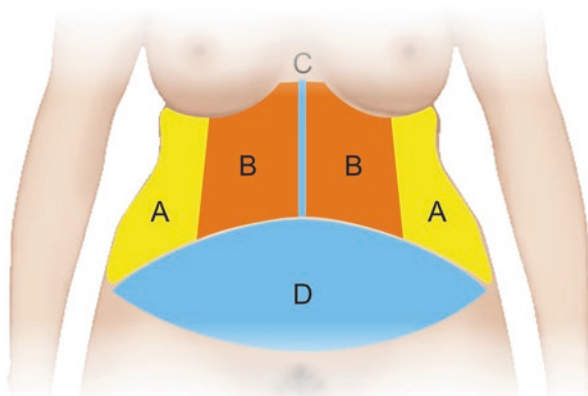
**Fig. 12.1** The area to be liposuctioned marked with the patient standing



### ***Tumescent Infiltration and Assisted Liposuction***

Liposuction was performed using the tumescent technique in all patients. Antibiotic coverage was administered using 2 g of cephalexin given every 2 h during the surgery and 1 g every 6 h for 24 h during the postoperative period. In the immediate preoperative period, a single hydrocortisone dose was given. All patients were managed with general anesthesia.

The areas to be lipoaspirated and undermined were injected with a saline solution containing epinephrine at a 1:500,000 concentration to avoid excessive bleeding.



**Fig. 12.2** Liposuction performed in the entire abdominal areas

With the patient in the ventral decubitus position, liposuction of the back was performed using three incisions along the spinal column: (1) approximately 5 cm from the distal margin of the neck, (2) 5 cm from the medial margin of the scapula, and (3) 2 cm from sacral bone. Liposuction was performed using a liposuction machine with 3- and 3.5-mm cannulas (Fig. 12.3).

### ***Liposuction of the Abdomen***

The patient was then rotated to the supine position, and extended liposuction was performed in the entire abdominal and epigastric areas. It was important to reach the inframammary regions and the xiphoid process, extending to the costochondral border, to fully loosen this area (Fig. 12.2).

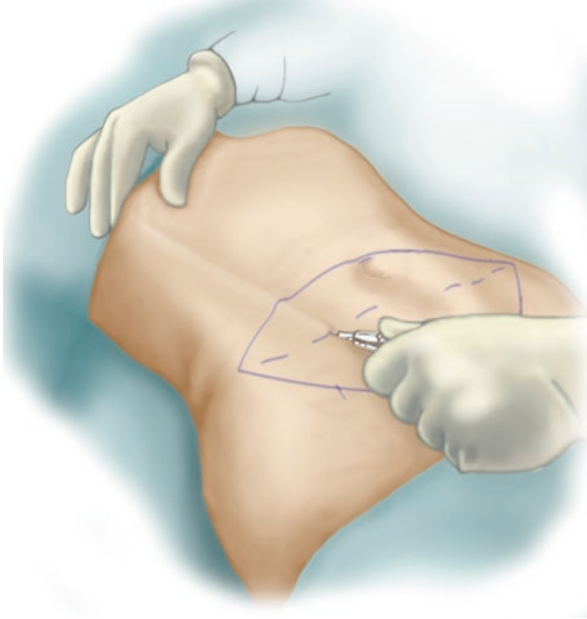
Liposuction of the abdomen was performed using seven incisions: six in the lower abdominal skin, which was to be resected, and one in the umbilicus (Fig. 12.3).

We began by liposuctioning the flank region with 3- and 3.5-mm cannulas, removing the fat of the deep and superficial layers and then progressing to the supra-umbilical region. The liposuction movements were made at an intersection between the tunnels, not only in the vertical direction, but also in the central (region C) and paraumbilical regions (Figs. 12.2 and 12.3).

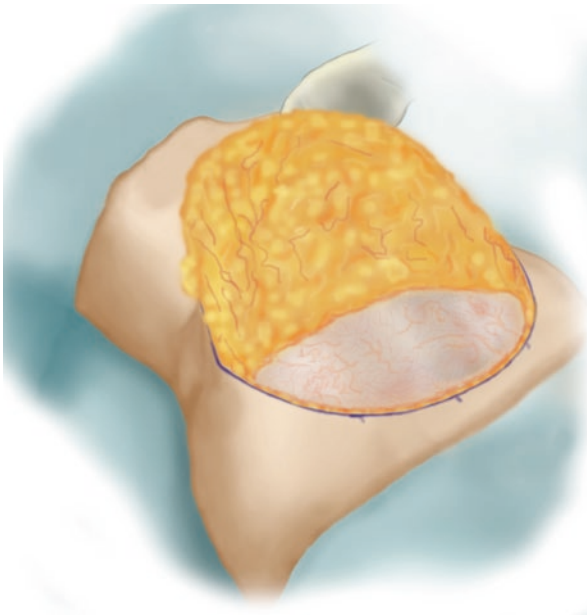
Liposuction of legs, knees, and trochanteric region was performed when necessary.

### ***Undermining of the Lower Abdomen Flap***

After liposuction, the lower abdomen flap was undermined up to the umbilicus, as in a traditional abdominoplasty. We did not preserve the Scarpa's fascia (Fig. 12.4).



**Fig. 12.3** Liposuction of the abdomen was performed using seven incisions



**Fig. 12.4** The lower abdominal flap was undermined with no preservation of the Scarpa's fascia

### ***Extensive Detachment of the Upper Abdomen***

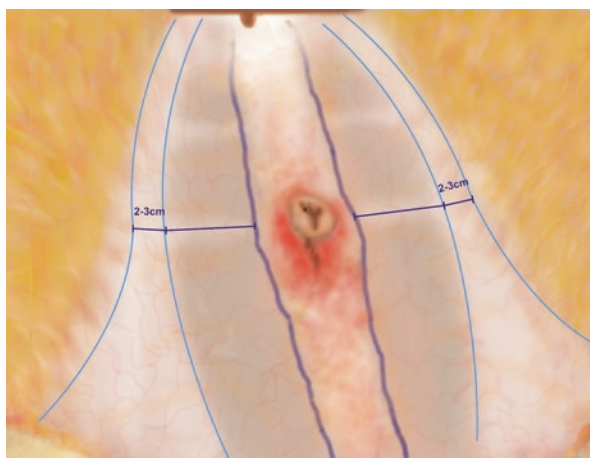
We started the undermining of the tunnel in the midline of the upper abdomen and extended 2–3 cm lateral to the external border of the rectus abdominal muscles (Fig. 12.5). The wider the diastasis, the wider the tunnel was because the perforating vessels follow the separation of the muscles. The tunnel undermining extended to the xiphoid.

### ***Anatomical Basis for a More Extensive Displacement***

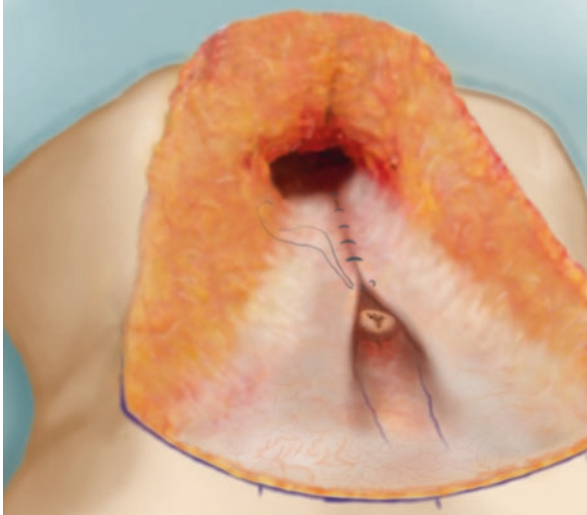
The lower abdominal flap was supplied by the posterior and lateral perforating intercostal, subcostal, and lumbar blood vessels [8, 20].

### ***Rectus Muscle Aponeurotic Plication***

The rectus muscle diastasis was identified, and two straight lines were drawn from the xiphoid process to the suprapubic area. A 2–0 nylon non-absorbable suture was used in two layers: one with interrupted sutures and one with running suture. Sutures started from the xiphoid process and were extended down to the pubis, including the umbilicus, with a medium-to-firm fixation (Fig. 12.6).



**Fig. 12.5** The undermine of the upper abdomens and extended 2–3 cm lateral to the external border



**Fig. 12.6** A non-absorbable suture was used from the xiphoid to the pubis

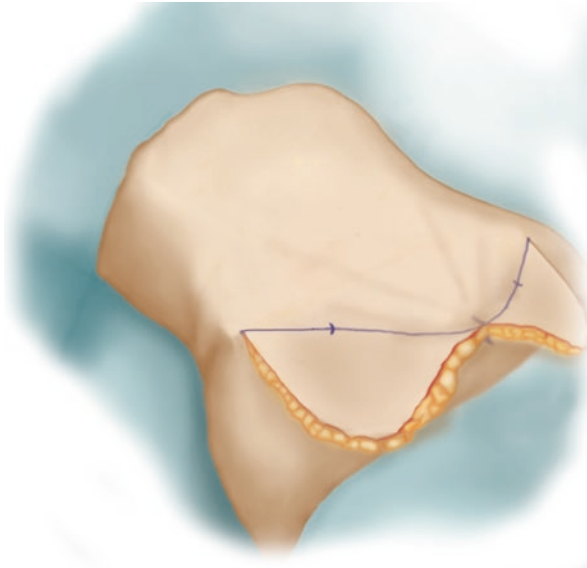
### ***Traction of the Abdominal Flap***

The patient was placed in the semi-Fowler position, and the lower abdominal flap was retracted to the inferior suprapubic incision to estimate whether the flap resection could be performed without complications. This maneuver was critical to determine whether the defect could be closed without stretching. If stretching occurred, we could undermine laterally using a 3.0 cannula to solve this problem.

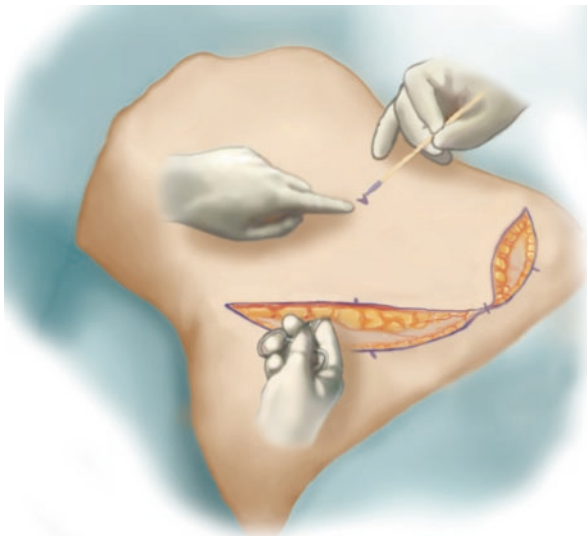
The inferior suprapubic incision could be moved down, depending on the laxity and elasticity of the skin and the patient's body type. It was very important to avoid stretching or vascular damage to the suprapubic area. A 2-0 nylon stitch was placed to support the flap (Fig. 12.7).

### ***Resection of the Lower Abdominal Skin Flap***

After retracting and fixing the lower abdominal flap, an excess flap resection could be performed. The exact amount of skin to be resected was evaluated at this time, regardless of the preoperative markings, so that the excess skin was removed without strain after closure. This incision was made in a curved manner (Fig. 12.8).



**Fig. 12.7** The lower abdominal flap was retracted to the inferior suprapubis incision



**Fig. 12.8** Exteriorization of the umbilicus with a V or Y shaped incision

### ***Exteriorization of the Umbilicus***

We identified the umbilicus and marked its new position with blue methylene. With a no. 11 blade, we made a “V”-shaped incision approximately 2 cm long and 1 cm wide (Fig. 12.8). Using Allis forceps, the umbilicus was grasped and projected to the

abdominal wall. We trimmed the surrounding fat, and four repairing stitches were placed to fix the umbilicus deep into the flap dermis and muscle aponeurotic plane.

### *Closing Sutures*

Subcutaneous, subdermic, and intradermic stitches were made with 3–0 Monocryl sutures, and micropore sterile strips were attached to the new scar. In the postoperative period, suction drainage was discontinued if it was less than 30 ml/day.

During the operation, all patients wore antithrombotic socks and a thermal blanket and received a lower limb massage during and after the operation. Prophylactic thromboembolism medications were also given when necessary.

## **Results**

The safe combination of liposuction and abdominoplasty during the same surgical procedure had improved results, including a greater reduction in abdominal measurements and improved body contour (Figs. 12.9, 12.10, 12.11, 12.12, 12.13, 12.14, 12.15, 12.16, 12.17, 12.18, 12.19, 12.20, 12.21, 12.22, 12.23, 12.24, 12.25 and 12.26).

The average follow-up time for these patients was 2 years (from 3 months to 5 years). Table 12.1 displays the data on complications.

## **Discussion**

There are three important principles that must be followed when performing this type of lipoabdominoplasty. First, superficial and deep liposuction allows more mobility to the abdominal flap so that it can slide down easily and reach the suprapubic region.

The second principle is based on the wide undermining on the upper abdomen (2–3 cm lateral to the external border of the rectus abdominal muscles). This is an important difference in lipoabdominoplasty when compared to other procedures [1, 6, 15, 16, 17, 19] because it improves skin redraping, allows space to perform an excellent plication even in wide rectus diastasis, and decreases the risk of obtaining a high-positioned abdominal scar.

The concept of crossover tunnels in the liposuction procedure should be applied to this type of lipoabdominoplasty so that there are no skin irregularities in either the abdomen or other areas of the body (back, trochanteric region, and lower limbs).

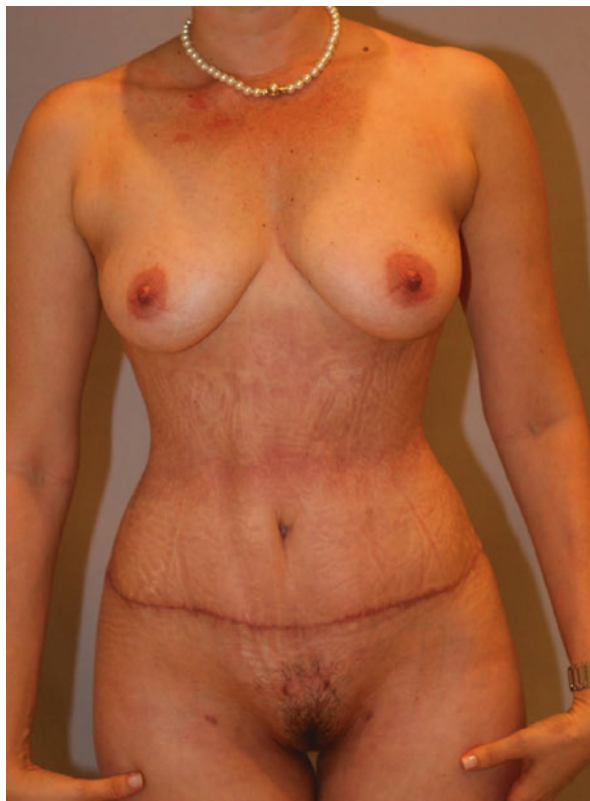

**Fig. 12.9** Patient A, 56 years old, preoperative (*frontal view*)

The resection of Scarpa's fascia did not result in increased edema, skin necrosis, or seromas following surgery. This resection facilitates the lowering of the abdominal flap, allowing for easier incision closure.

The possibility of a larger displacement lateral to the edges of the rectus abdominis muscles originated from experiences in breast reconstruction with bipedicle myocutaneous transverse rectus abdominal flaps (TRAM). When performing these types of flaps, all muscles are undermined from their anterior sheaths, and the upper abdomen is undermined laterally to the lateral aspect of these muscles. In TRAM flap, perforators of the abdominal rectus muscles do not contribute to the viability of the lower abdominal skin. Even with this condition, in our experience, there were no issues related to abdominal flap necrosis in most cases on which TRAM flap was performed. When performing the lipoabdominoplasty as described in this paper, the upper abdominal undermining is not as extensive as the TRAM flap procedure, and muscle rotation was not performed.



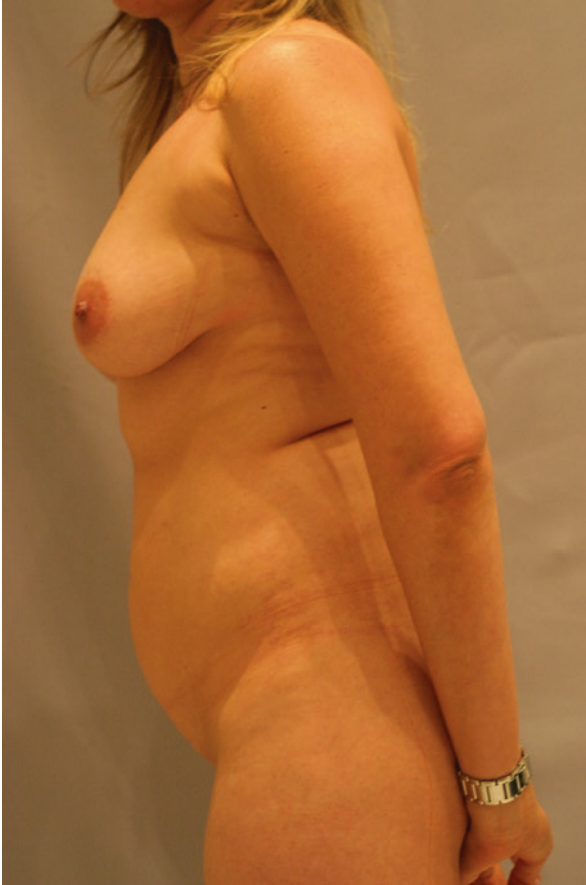

**Fig. 12.10** Patient A, postoperative (*frontal view*)

The preservation of subcostal, intercostal, and lumbar perforating vessels is responsible in preventing suprapubic skin necrosis during these surgeries. This result occurred despite the large detachment in the upper abdomen and extensive liposuction performed around the abdomen, back, and other parts the body [5, 20].

The third principle is that the use liposuction in others areas of the body permitted better results, reshaping the body as a whole. The combination of liposuction of the abdomen and the back, for example, is extremely important in delineating the waist and defining the gluteal region. Lacking this combination would lead to poorer results. The previous concept of lipoabdominoplasty surgeries, in which only the abdominal region was remodeled through the combination of abdominal liposuction and classic dermolipectomy, has been replaced by a much broader concept in which liposuction of the abdomen, back, and other areas of the body achieves a more balanced body contour.

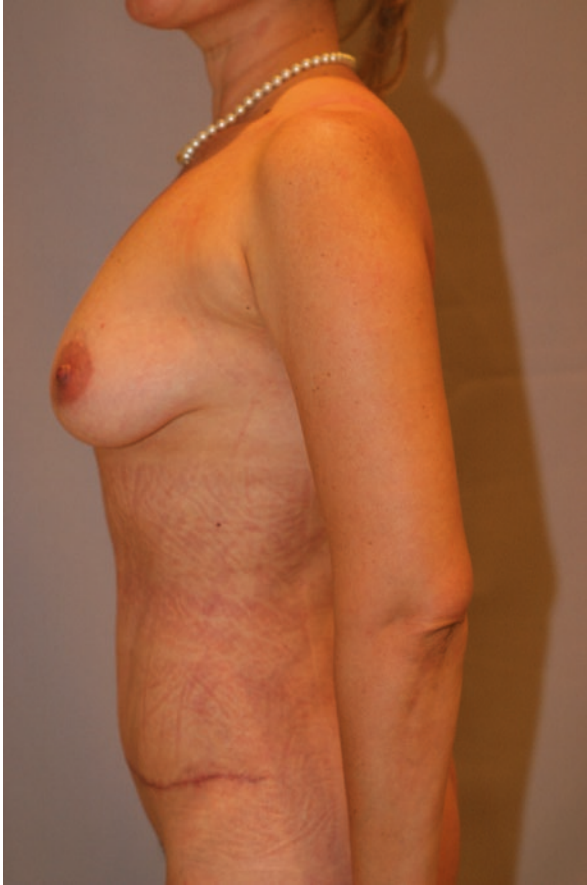There were a similar number of complications when this method is compared to those described in the literature [2, 10, 19]. However, the most important advantages



**Fig. 12.11** Patient A, preoperative (*lateral view*)

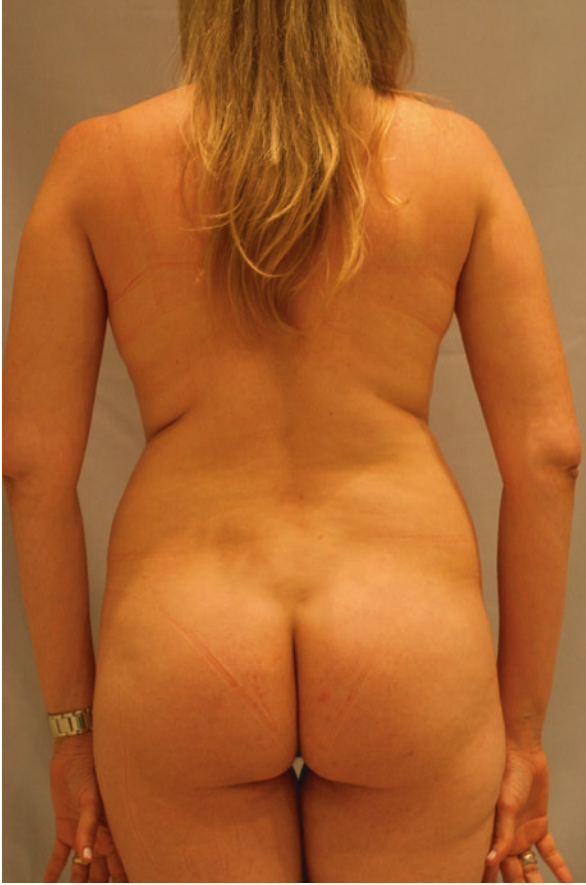of this method are that there was a larger displacement of the upper abdominal flap, and the liposuction was also performed on the back and other parts of the body.

The presence of postoperative suction drainage resulted in less swelling, bruising, and pain sensation when compared to liposuction performed alone. This finding

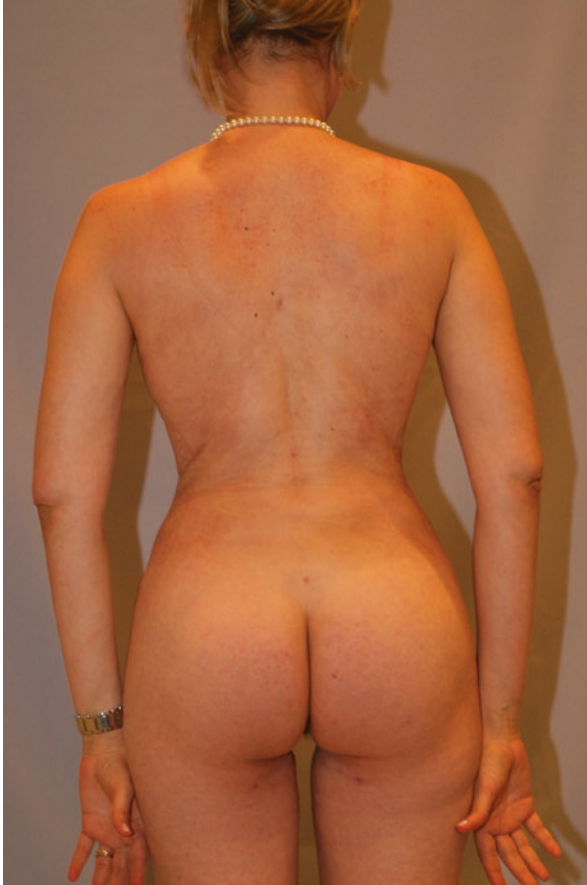

**Fig. 12.12** Patient A, postoperative (*lateral view*)

was due to the communication between the abdominal regions and the back via the tunnels made by the cannula, causing the liposuction drainage to decrease the fluid collection in the back (decreasing bruising). Therefore, the sensation of pain due to decreased expansion of the skin was reduced.



**Fig. 12.13** Patient A, preoperative (*back view*)



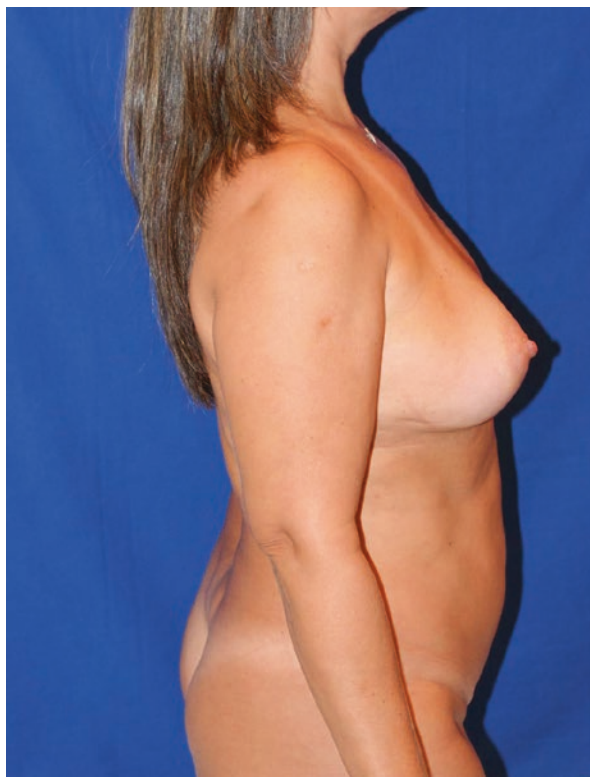**Fig. 12.14** Patient A, postoperative (*back view*)



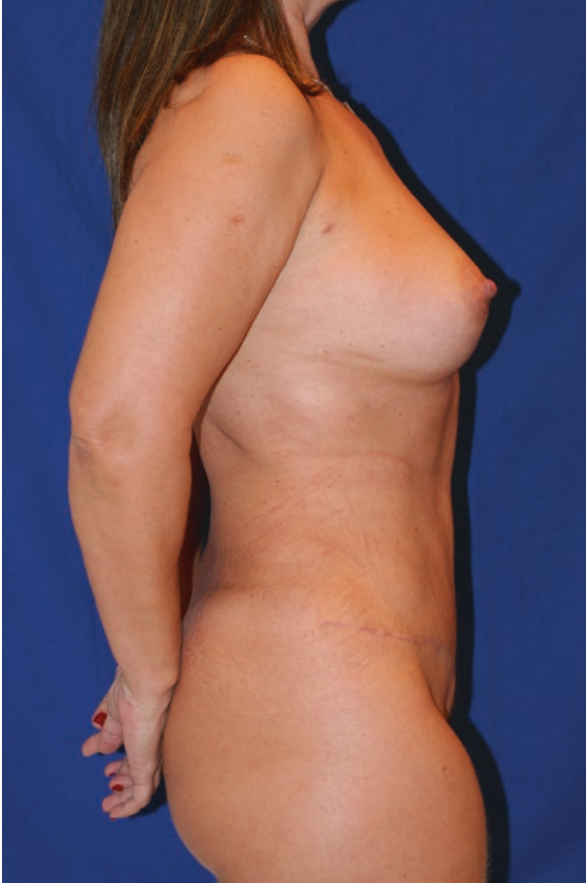**Fig. 12.15** Patient B, 26 years old, preoperative (*frontal view*)



**Fig. 12.16** Patient B, postoperative (*frontal view*)

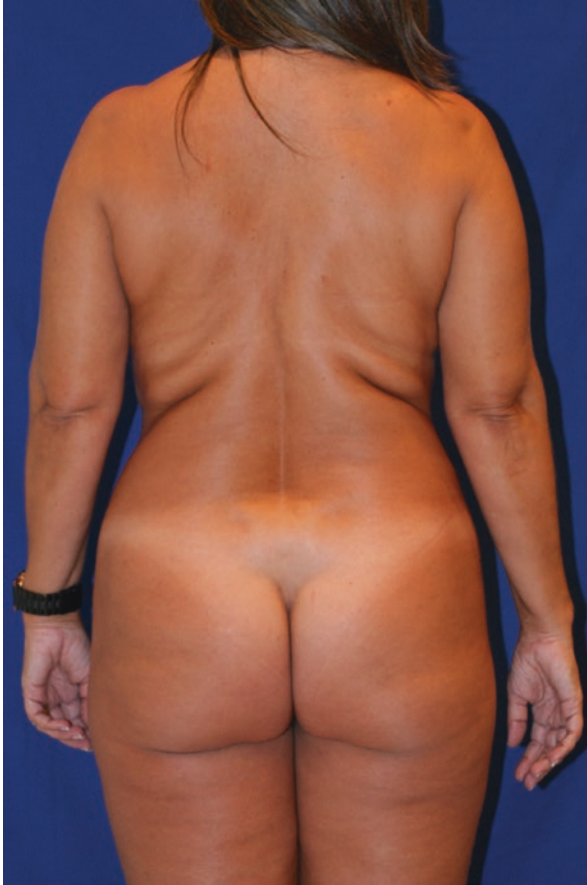

**Fig. 12.17** Patient B, preoperative (*lateral view*)

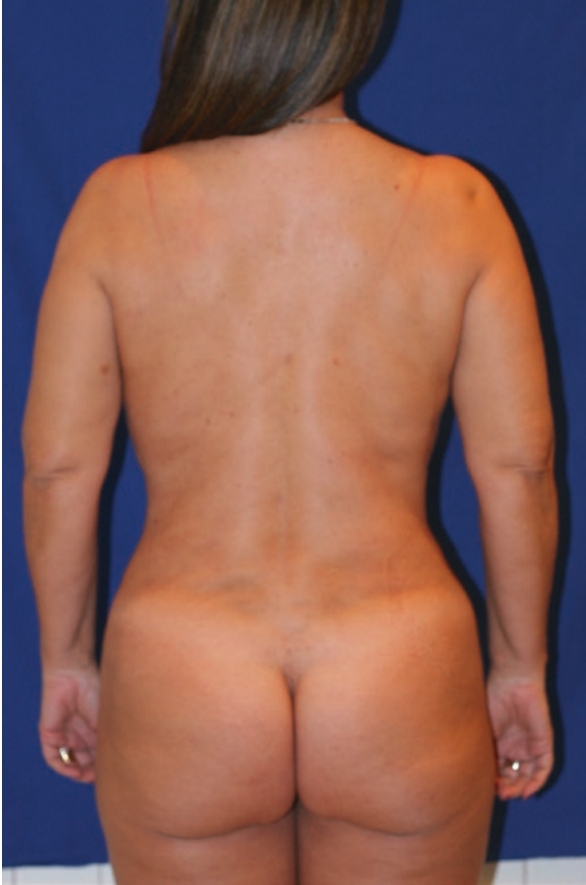

**Fig. 12.18** Patient B, postoperative (*lateral view*)

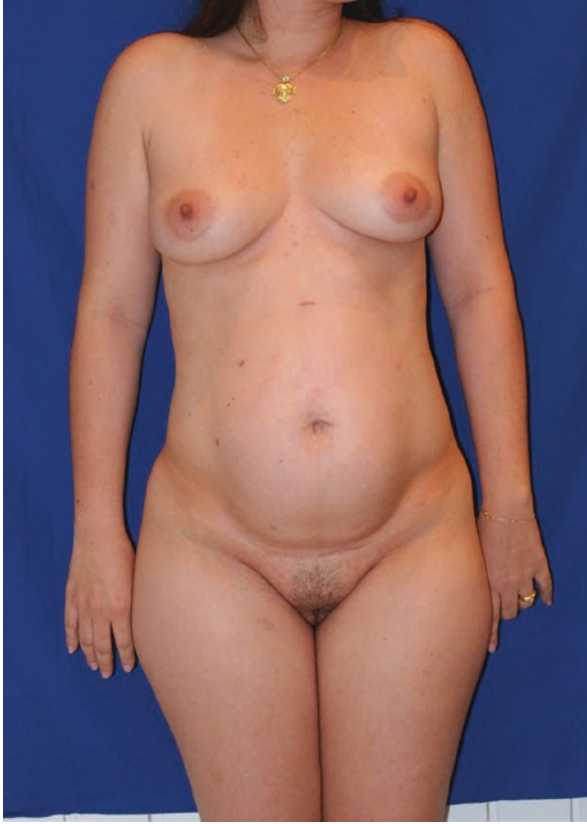



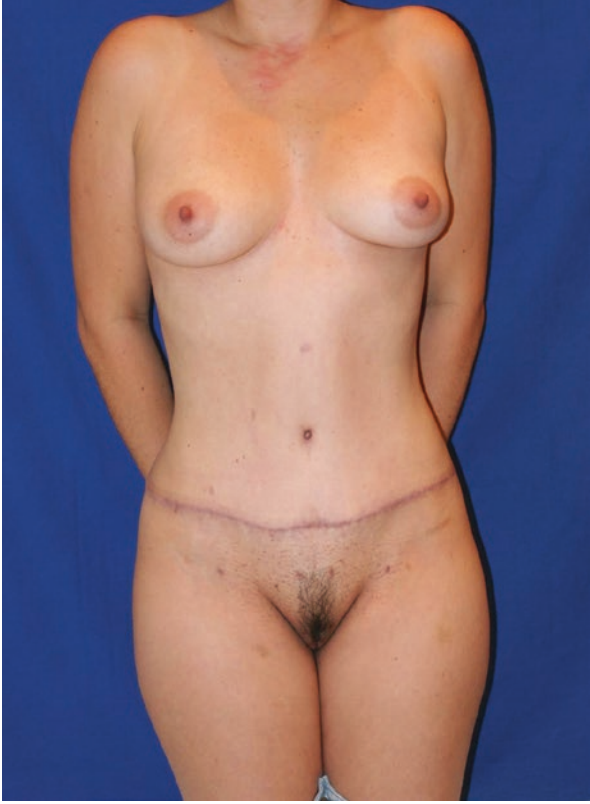**Fig. 12.19** Patient B, preoperative (*back view*)



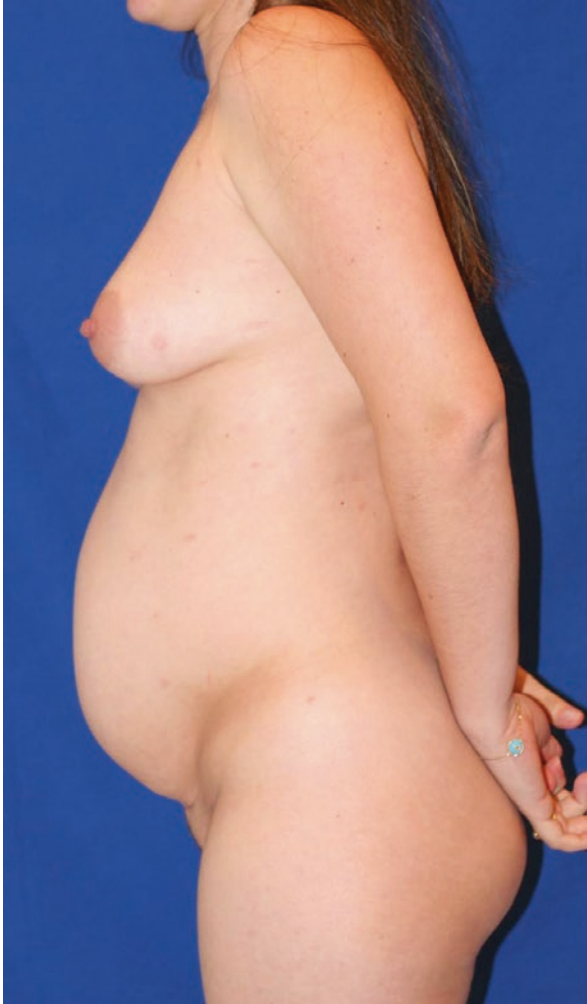**Fig. 12.20** Patient B, postoperative (*back view*)



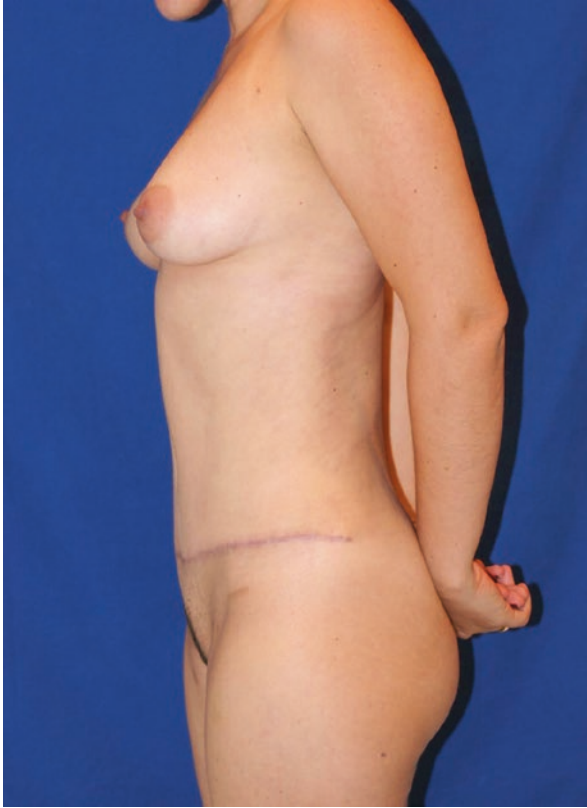**Fig. 12.21** Patient B, 44 years old, preoperative (*frontal view*)



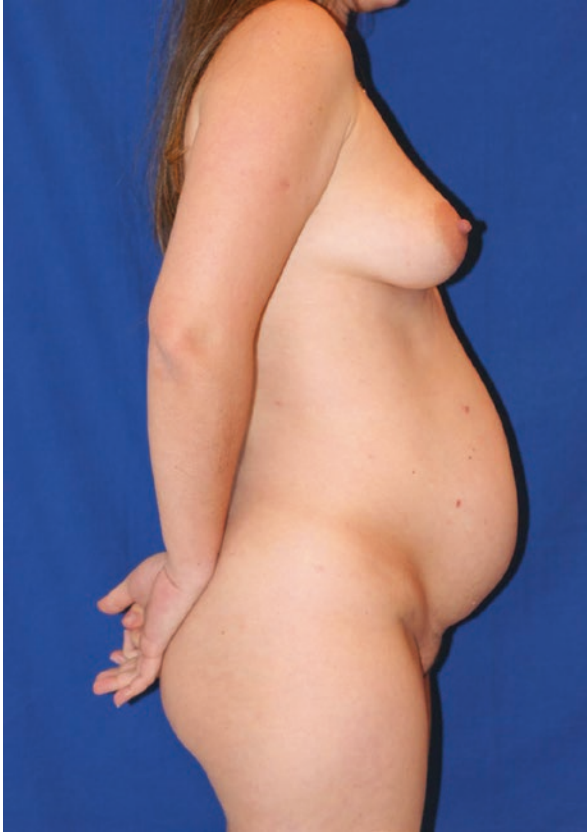**Fig. 12.22** Patient B, postoperative (*frontal view*)



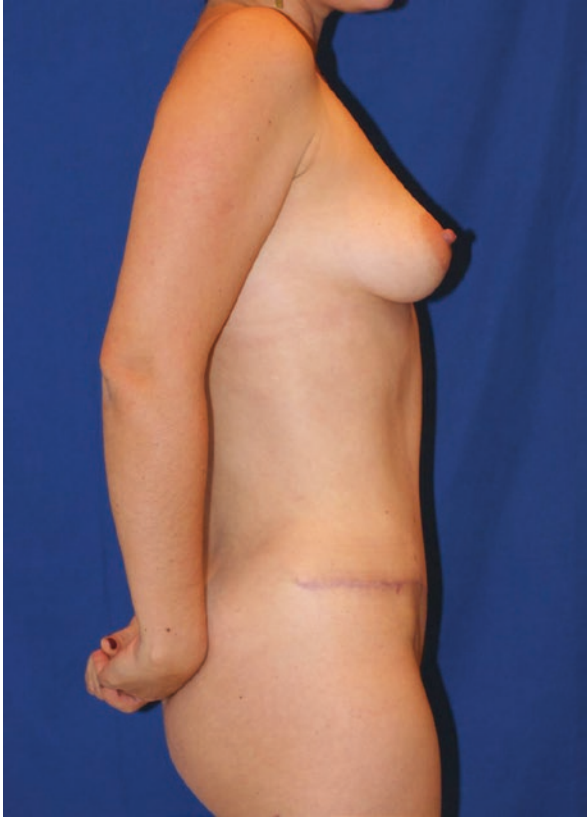**Fig. 12.23** Patient B, preoperative (*lateral view*)



**Fig. 12.24** Patient B, postoperative (*lateral view*)



**Fig. 12.25** Patient B, preoperative (*back view*)



**Fig. 12.26** Patient B, postoperative (*back view*)

**Table 12.1** Complications on lipoabdominoplasty combining a wide undermining of the upper abdomen with complete body liposuction

Complications	No. of patients	%
Suprapubic epidermolyses	0	0
Suprapubic necrosis	0	0
Hematomas	0	0
Seromas	2	0.98
Hypertrophic scars	8	3.94
Infections	0	0
Dog-ear scar revision	6	2.95
Thromboembolisms	0	0



## Conclusion

The technique presented in this study has a low complication rate and achieves a more extensive improvement of the body contouring.

## References

1. Avelar JM (2002) Abdominoplasty without panniculus undermining and resection: analysis and 3 years follow up and 97 consecutives. *Aesthet Surg J* 22:16–25
2. Baroudi R, Ferreira CAAP (1998) Seroma: how to avoid it and how to treat it. *Aesthet Surg J* 18:439–441
3. Baroudi R, Keppke EM, Neto FT (1974) Abdominoplasty. *Plast Reconstr Surg* 54:161–168
4. Baroudi R, Moraes M (1995) A “bicycle-handlebar” type of incision for primary and secondary abdominoplasty. *Aesthetic Plast Surg J* 19:307
5. Boyd JB, Taylor CI, Corlett R (1984) The vascular territories of the superior epigastric and the deep inferior epigastric systems. *Plast Reconstr Surg* 73:1–16
6. Carlos Oscar Uebel (2009) Lipoabdominoplasty: revisiting the superior pull-down abdominal flap and new approaches. *Aesthetic Plast Surg* 33:366–376
7. De Souza Pinto EB (1983) Our experience in liposuction. *Ann Cong Bras Plast Surg* 1:9
8. El-Mrakby HH, Milner RH (2002) The vascular anatomy of the lower anterior abdominal wall: a microdissection study on the deep inferior epigastric vessels and the perforator branches. *Plast Reconstr Surg* 109:539–543; discussion 544–547
9. Hakme F (1985) Technical details in the lipoaspiration associate with liposuction. *Rev Bras Cir* 75:331–337
10. Heller JB, Teng E, Knoll BI, Persing J (2008) Outcome analysis of combined lipoabdominoplasty versus conventional abdominoplasty. *Plast Reconstr Surg* 121(5):1821–1829
11. Illouz YG (1992) A new safe and aesthetic approach to suction abdominoplasty. *Aesthetic Plast Surg* 16:237–245
12. Lockwood T (1995) High-lateral-tension abdominoplasty with superficial fascial system suspension. *Plast Reconstr Surg* 96:603–608
13. Matarasso A (1991) Abdominoplasty: a system of classification and treatment for combined abdominoplasty and suction-assisted lipectomy. *Aesthetic Plast Surg* 15:111–121
14. Nahas FX, Ishida J, Gemperli R, Ferreira MC (1998) Abdominal wall closure after selective aponeurotic incision and undermining. *Ann Plast Surg* 41:606–613
15. Pitanguy I (1967) Abdominal lipectomy: an approach to it through an analysis of 300 consecutive cases. *Plast Reconstr Surg* 40(4):384–391
16. Planas J (1978) The “vest over pants” abdominoplasty. *Plast Reconstr Surg* 61:694–700
17. Psillakis J (1978) Abdominoplasty – some ideas to improve results. *Aesthetic Plast Surg* 2:205–215
18. Pollock H, Pollock T (2000) Progressive tension sutures: a technique to reduce local complications in abdominoplasty. *Plast Reconstr Surg* 105(7):2583–2586
19. Shestak KC (1999) Marriage abdominoplasty expands the mini-abdominoplasty concept. *Plast Reconstr Surg* 103:1020–1031
20. Taylor GI, Watterson PA, Zelt RG (1991) The vascular anatomy of the anterior abdominal wall: the basis for flap design. *Perspect Plast Surg* 5:1

# Chapter 13

## Rhytidolipoplasty: Improvement by Tunnelization Through New Concepts of Abdominoplasty

Juarez M. Avelar

### Introduction

Since 1999, when the result of my anatomical studies and research I founded and published the new concepts for abdominoplasty [5–7], it was evident that those surgical principles would be employed to improve rhytidoplasty procedures avoiding complications. In fact, skin slough and necrosis, infection, nerve injuries, and other postoperative problems during and after face-lifting were related to traumatic operations. Therefore, similar procedure of basic fundamentals concerning preservation of perforator vessels due to combination of liposuction with minimal cutaneous undermining was useful also in facial rejuvenation.

Rhytidoplasty is a very important field in plastic surgery since everybody will need and consequently some people may look for some improvement on the facial contour. For this reason, it is one of the most frequent operations and the whole population potentially may think about self-image. The aim of the operation is not to provide eternal youth but to improve the physical appearance to an image which is more pleasant and better accepted. Vanity is a necessity for each person to value himself/herself as an individual but not as a product of social competition.

The aging phenomenon is inherent to human beings that cause changes to the skin and underlying tissues, skeletal and muscular atrophy. Skin loses its natural structures which is common in youth and acquires typical alterations of color and irregularities on the surface in older age. The purpose of any procedure for the aging face is to help the individual cross with enhanced self-confidence the sometimes difficult path to a mature age and not to return the patient to an earlier stage of life.

---

J.M. Avelar, MD

Head of the Brazilian Scientific Institute of Plastic and Reconstructive Surgery,  
Al Gabriel Monteiro da Silva, 620 Jd Europa, São Paulo, SP 01442-000, Brazil  
e-mail: [juarezavelar@bol.com.br](mailto:juarezavelar@bol.com.br); [institutodaorelha@uol.com.br](mailto:institutodaorelha@uol.com.br)

When face-lifting is planned, the surgeon should analyze the biological age of the patient besides the chronological and also psychological aspects.

Rhytidoplasty is relatively a new procedure since starting with Passot in 1919 [24], who removed multiple elliptical areas of the skin of the face at the hairline. Few years later, Joseph in 1928 [18] and Lexer in 1931 [19] introduced similar concepts into the “classic” rhytidectomy which was essentially a large rotation with advancement of the skin flap. Malbec [20] was a pioneer in Latin America and improved the technique with his superb talent. Anatomic studies concerning frontal branch of the facial nerve performed by Pitanguy and Ramos [25] are an outstanding contribution on rhytidoplasty. Remarkable systematization of the direction of traction of the skin flap introduced by Pitanguy [26] is a fundamental concept in face-lifting operation ever since up to nowadays. Skoog [29] set the stage for new development when he described the subfascial face-lift. Then, the superficial musculoaponeurotic system (SMAS), described by Mitz and Peyronie [23], platysma flaps introduced by Guerrerosantos et al. [13] opened a new era. The development of the deep plane and composite rhytidectomies by Hamra [14] is a valuable step for the standard operation. Nevertheless, liposuction described and popularized by Illouz [15, 16] is a great support during rhytidoplasty which was introduced and published on my systematization [1, 2]. Besides, creation of a natural tragus during operation is my constant effort, since the auricles are essential to analyze the surgical results [3, 4]. As soon as I developed new concepts on abdominoplasty, it was evident that the same combined procedure could be employed in several other regions of the human body [5–7]. Therefore, rhytidoplasty is also performed in the use of such associated operation which improved surgical results and reduced very much the complications during and after surgery [8, 9]. Nevertheless, to perform the new concepts, it was necessary to create new surgical instruments in order to do progressive tunnelization to achieve all regions of the face preserving the perforator vessels without bleeding and also to avoid nerve injury during surgery. I continuously presented and published such associated procedure showed usefully in rhytidoplasty reducing very many severe and complex complications [10]. As far as the surgical principles of abdominoplasty are employed on operation, it is adequate to suggest a terminology as rhytidolipoplasty, since it is a combination of rhytidoplasty with liposuction procedure.

## Technique

Clinical evaluation under a physician examination besides blood tests is a routine preoperatively at my institution.

The operation may be performed under general anesthesia or with local anesthesia combined with intravenous sedation both under the care of an anesthesiologist. In most of my patients, blepharoplasty is done combined with rhytidoplasty. Firstly, eyelid surgery is performed and afterward the face and neck operation. Local infiltration is a mandatory step even when the procedure is carried out under general

anesthesia. As a matter of routine, I do initially one side of the face and neck following the sequential steps: local infiltration, liposuction, tunnelization following cutaneous incisions with reduced area of cutaneous undermining, and suture of the SMAS if necessary, and the final step traction of the cutaneous facial and neck flap is pulled, resected, and sutured.

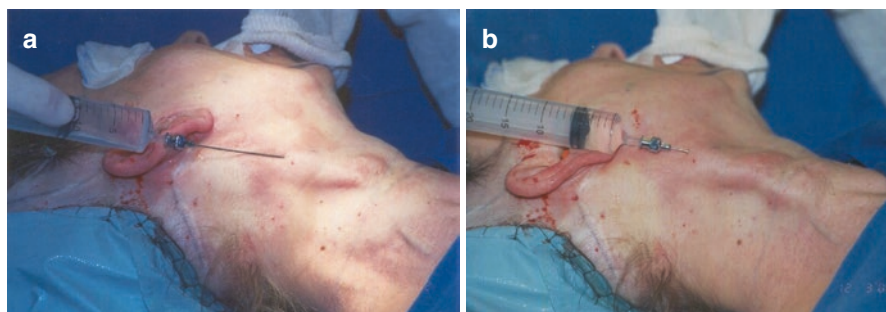
## Local Infiltration, Tunnelization, and Liposuction

Two types of infiltrations must be done: (1) local anesthesia, even if the operation is performed under general anesthesia, and (2) hyperinfiltration or tumescent infiltration.

My preference is to employ local anesthesia (with dilution of 1:200,000), that is, 0.4% lidocaine with epinephrine. A practical formula is 40 ml 2% lidocaine, 1 mL (1:1000) epinephrine, and 160 ml water, giving a total volume of 201 ml. In the use of this volume of solution, it is possible to infiltrate local anesthesia throughout the entire area just under the dermis, in order to reduce bleeding and facilitate undermining, all over the face and neck on both sides. This is a routine procedure similar to that performed during conventional rhytidoplasty. Afterward, hyperinfiltration or tumescent one is done with serum underneath the skin all over of one side of the face and neck (Fig. 13.1).

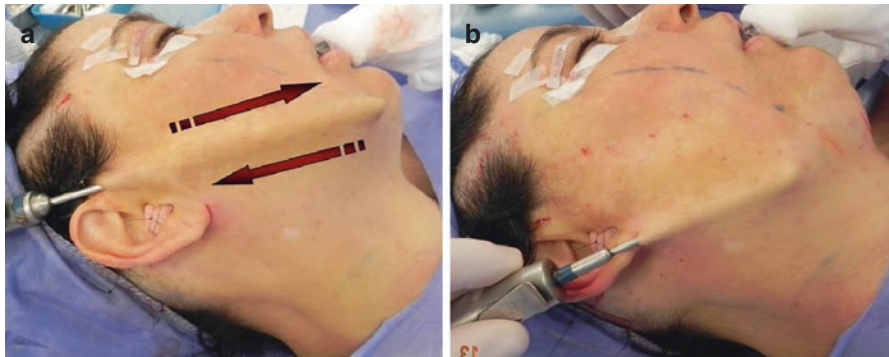
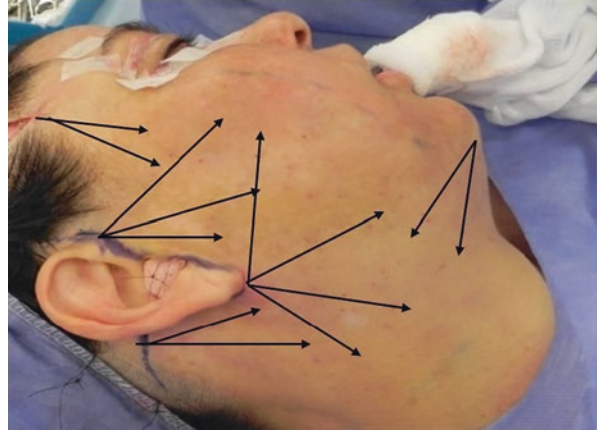
It must be emphasized that such hyperinfiltration should be performed by the surgeon on one side of the face and neck, since the operation must start immediately afterward. It is not recommended to use a needle to perform this type of infiltration because it may change the plane of the tissue cleavage [8]. Special microcannula is used just beneath the skin of the face and neck in order to separate the skin from the subcutaneous fatty layers and soft deeper tissues as well (Fig. 13.1). Approximately 300 ml of serum is used on one side of the face and neck.

The next step of the operation is subcutaneous tunnelization, which should be performed immediately. Owing to hyperinfiltration, the skin is separated from the



**Fig. 13.1** Hyper-infiltration or tumescent infiltration: (a, b) during surgery. Using a special microcannula, 100 ml of solution one side of the face and neck is infiltrated beneath the skin. One side is infiltrated in order to perform the operation and afterward the other side is done

**Fig. 13.2** Direction of tunnelization after tumescent infiltration all over the face and neck. The instrument is introduced on temporal region, on anterior border of the auricle, on lobule, on mastoid region, and on submental area

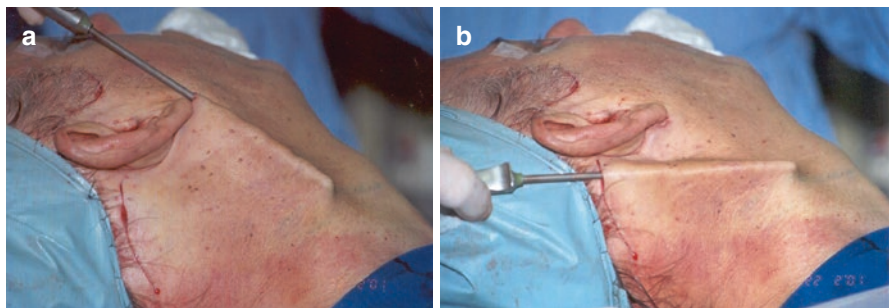


**Fig. 13.3** Direction of tunnelization of the face on photos during operation using a blunt instrument similar to cannula but without open: (a) from the anterior border of the auricle and (b) from the lobule

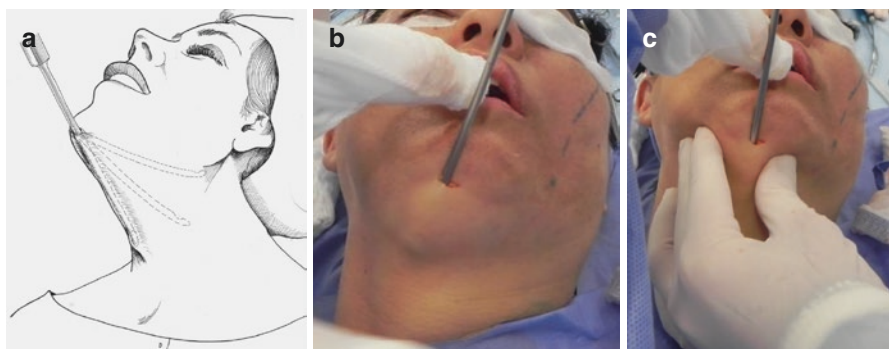
subcutaneous adipose tissue beneath the skin, on areas with localized adiposities even on those regions where the panniculus is very thin as occurs on the postauricular and mastoid areas. For patients with a thin face without localized adiposities, this procedure is very useful in order to preserve all anatomical structures below the cutaneous flap.

To perform tunnelization procedure, five incisions of 0.5 cm in length are done just to introduce the instrument: on temporal region, on preauricular region, on the earlobe and another on the posterior sulcus of the ear, and on the submental region (Fig. 13.2). Back and forth movements are done just below the overlying skin all over the face and neck (Figs. 13.3 and 13.4).

Afterward, a 3 mm Illouz cannula is introduced through the incisions followed by back and forth movements that are done just below the overlying skin all over the face and neck on one side. The surgeon must fold the skin while he/she does the movements with the cannula with its openings turned toward the depth in order to



**Fig. 13.4** Photos during rhytidolipoplasty to demonstrate tunnelization of the neck with blunt instrument: (a) from the lobule to backward movements and (b) from retroauricular

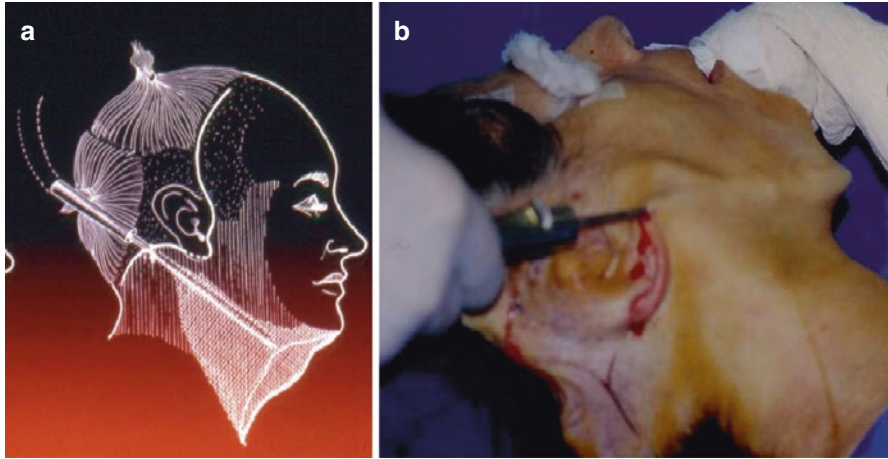


**Fig. 13.5** Liposuction on submental and submandibular regions: (a) Schematic shows the different directions of the cannula introduced through submental incision, (b, c) photos during surgery

perform tunnelization all around. If the openings are turned upward to the deep raw surface skin flap, it may damage the subdermal fat layer with its small vessels which may become very thin and there is a risk of waves on the skin even necrosis postoperatively. When the patient does not present localized adiposity, liposuction is not indicated, but similar maneuver must be done to perform tunnelization procedure.

However, according to the surgical planning, in case of localized adiposities, liposuction should be performed, and then the machine is turned on to aspirate fat on all regions (Figs. 13.5 and 13.6). At the end, the thickness of the skin flap is appropriate with all anatomical structures which provide normal vascularization avoiding any damage postoperatively.

After liposuction procedure, small tunnels are created in the use of nontraumatic surgical instruments with different width I have developed for this purpose, similar to a cannula but without openers (Fig. 13.7). These instruments are introduced one by one – first the thinnest one and then progressively a wider is employed until the widest one always doing back and forth movements just below the overlying skin all over the face and neck (Fig. 13.8). Thus, the small tunnels created by the Illouz cannula are progressively widened all over the face and neck. These instruments are



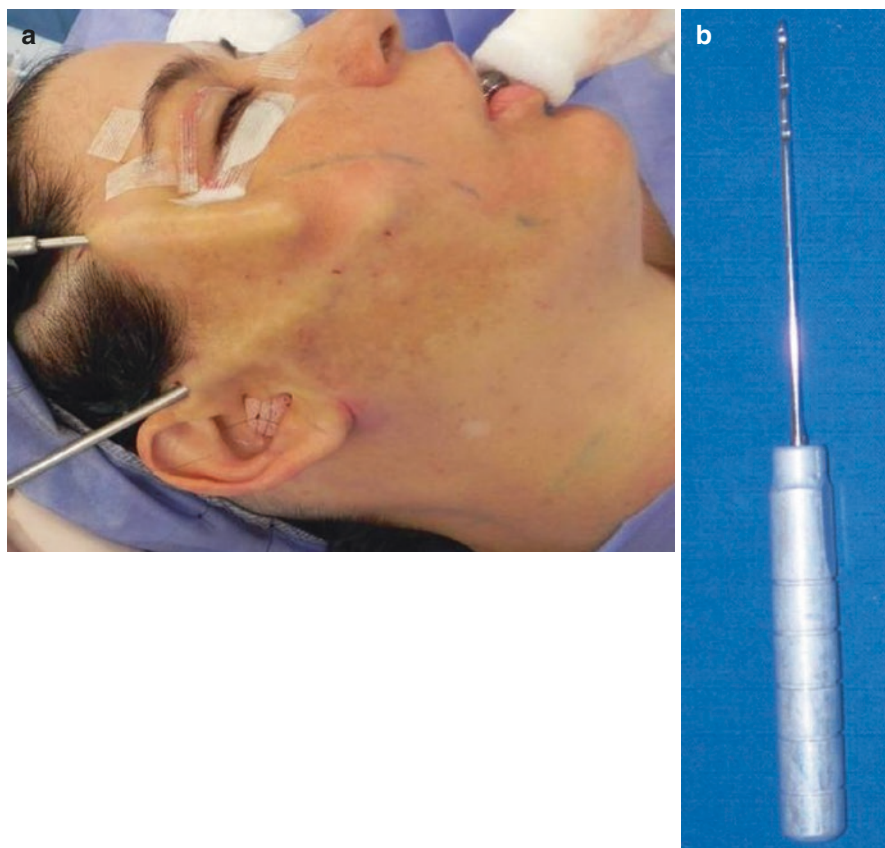
**Fig. 13.6** Liposuction on lateral and anterior sides of the neck: (a) Schematic shows the direction of the cannula introduced through retroauricular incision, (b) photo during surgery shows the instrument introduced through the base of the lobule

introduced through the same skin incisions where liposuction was done all over the hemiface and neck and are responsible for the cutaneous dissection without cutting the blood vessels as well as the lymphatics or the nerves. All these procedures are done in a closed-pocket system since the cutaneous incisions have not yet been performed. In addition, using extensive supraplatysmal tunnelization undermining communicates in the midline, from one side to the other, which makes the skin flap slide over the muscle.

This sort of tunnelization with a “blunt” and flat instrument, with some irregularities on the border of each side, is similar to my new concepts on abdominoplasty [5–7]. This is the fundamental difference between my procedure and the traditional techniques using scissors for cutaneous undermining which cut all vessels from the depth to the skin flap with abundant bleeding during and after (Fig. 13.8).

The whole area of the skin of the face and neck is dissected by tunnelization with minimal bleeding, since the vessels are preserved. Therefore, all vascularization from the depth to the cutaneous flap is preserved. The tunnelization procedure on the cheek until the mandible arch goes farther, close to the nasolabial fold. On the neck, it goes even farther until it crosses over the midline. The thickness of the skin flap which includes the subdermal layer is quite thick.

After tunnelization procedure, the next step is to perform the traditional cutaneous incisions with a knife following Pitanguy’s technique [27] that I learned from him (Fig. 13.9). Owing to tunnelization, the whole cutaneous flap is already loose and some “bridges” may remain between the cutaneous flap and the depth. Some of those “bridges” may be sawed with my nonsharp S-shaped instrument which was specially developed for this procedure without cutting the connective tissue and vessels [8–10]. With the use of special instruments, minimum cauterization is done.

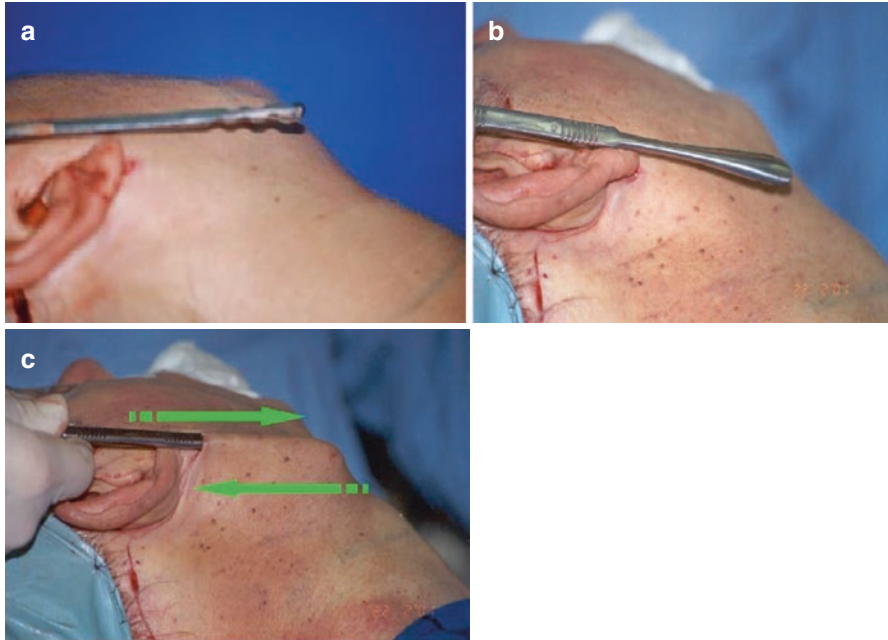


**Fig. 13.7** Perioperative photo: (a) Showing the thin instruments being introduced beneath the subdermal level in different directions with back and forth movements to perform tunnelization which preserves the vascular network. Photo (b) one can see an instrument to perform tunnelization

Although there is no bleeding during the operation, careful hemostasis must be done (Fig. 13.10).

The treatment of the SMAS is performed according to the surgical planning when patients present muscular flaccidity. Usually, when the platysma muscle is flabby, one can see its border laterally and medially. Plication procedure of the lateral border of the platysma is done by pulling with minimal undermining (Fig. 13.11). By traction, the platysma is lifted up and backward to be sutured to the aponeurosis of the sternocleidomastoid muscle posteriorly. On the face, in front of the ear, the fascia is grasped with small hooks and also pulled and overlapped, so it can be sutured along a line that begins at the lower margin of the zygomatic arch and extends downward around the ear. Clear or colorless stitches are done. If colored suture is used, it may show through the cutaneous flap. After suture, the soft tissue may be palpable as a bridge over the deeper structures.





**Fig. 13.8** Photos during surgery to showing tunnelization with wider instruments: (a, b) Two special flat and wider instruments with irregularities on each border, (c) instrument introduced through the incision on the lobule

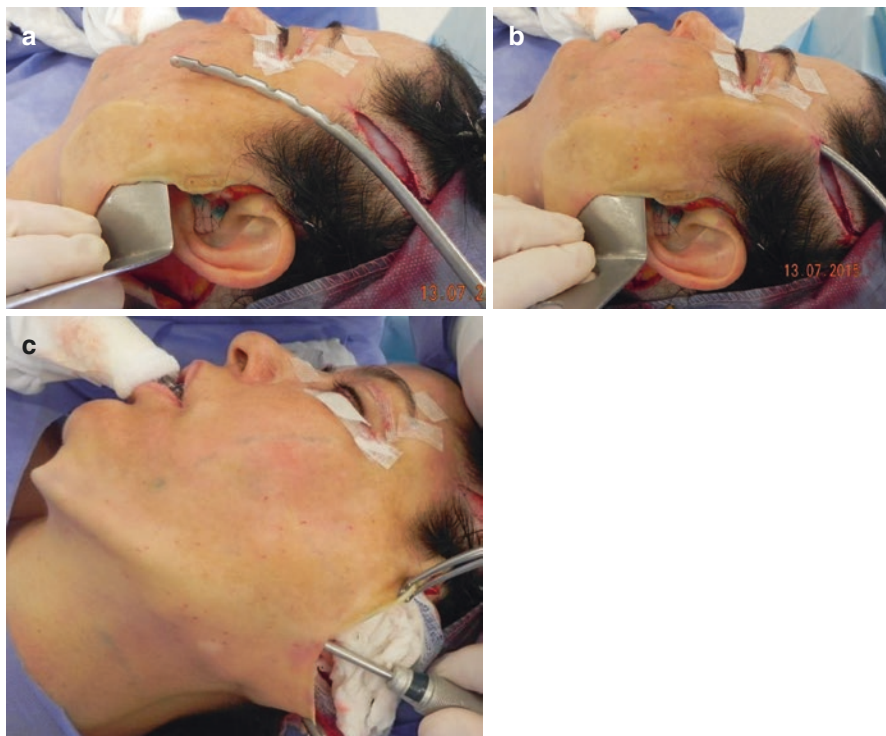In fact, performing only the lateral suture with suspension of the platysma improves the whole area on each side of the neck with a natural and smooth result. The platysma flaps described by Skoog [29] and Guerrerosantos et al. [13] may present beautiful results, but my preference is for a single plication and suture to the aponeurosis laterally.

The next step of the operation is done by pulling the cutaneous flap posteriorly and superiorly following the direction and traction of the cutaneous facial and neck flap described by Pitanguy [26, 27] (Figs. 13.12 and 13.13). In the use of his forceps (Fig. 13.13d) to mark the projection of the incisions on the skin, a temporary stitch is done on the projection of the anterior and posterior borders of the ear in order to block the skin flap as emphasized by Pitanguy [27] providing a natural result avoiding the stigma of the surgery.

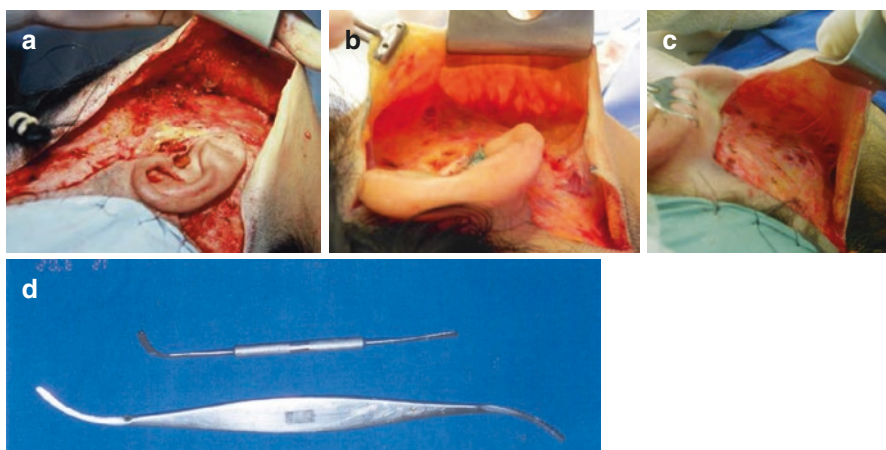
Once the cutaneous flap has been pulled, the redundant skin is excised with a knife all around the ear. The amount of traction which is applied depends on the state of the skin and the nature and degree of correction required [8, 9].

After performing completely the operation described on one side, the same procedure is carry out on the other side of the face and neck.

Afterward, a gentle dressing is done on the area of the head and neck, leaving the eyes, mouth, and nostrils free. I do not use any kind of drain, since there is no bleeding during and after face-lifting procedure. The bandage is changed on the day after the operation and a new one is placed over the face and neck, and this is completely removed two days later (Fig. 13.14).

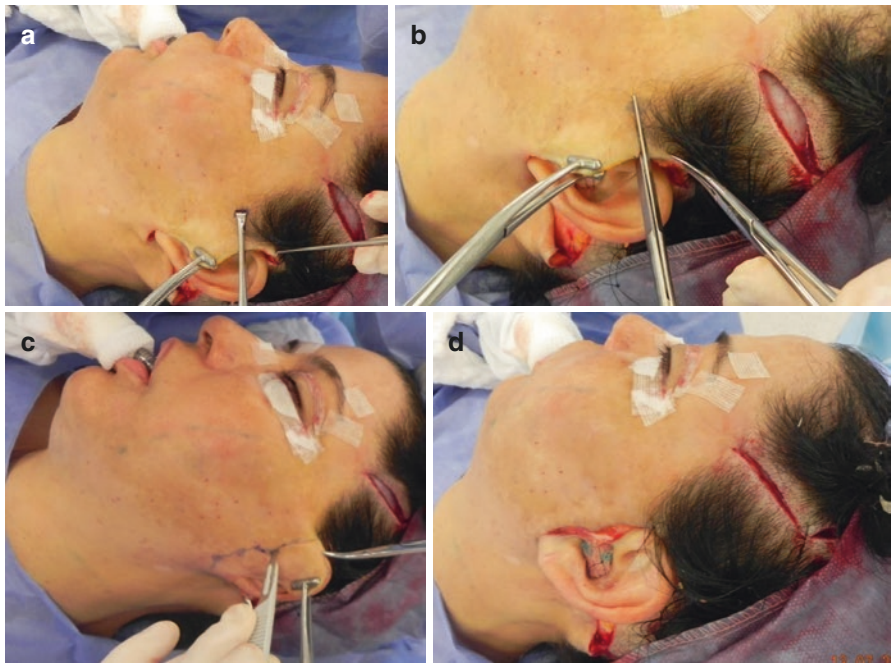
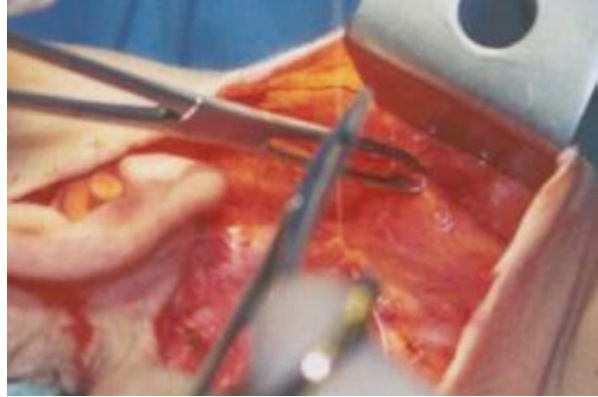


**Fig. 13.9** Perioperative photos showing tunnelization: photos (a, b) the instruments are introduced beneath the subdermal level with back and forth movements to perform tunnelization which preserves the vascular network as well as does not damage the nerves, (c) cannula and tunnelization go from one side to the other

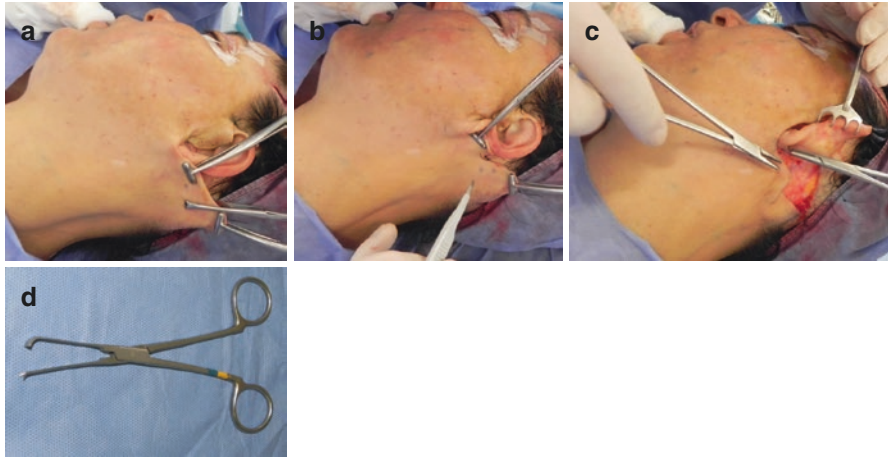


**Fig. 13.10** Perioperative photos showing the right side of the face and neck during rhytidoplasty: photo (a) after traditional undermining with scissor, (b) tunnelization procedure with my special instruments maintains normal blood supply to the cutaneous flap, (c) another patient showing that there is no bleeding during operation, and (d) photo shows two instruments to see some remaining “bridges” after tunnelization procedure

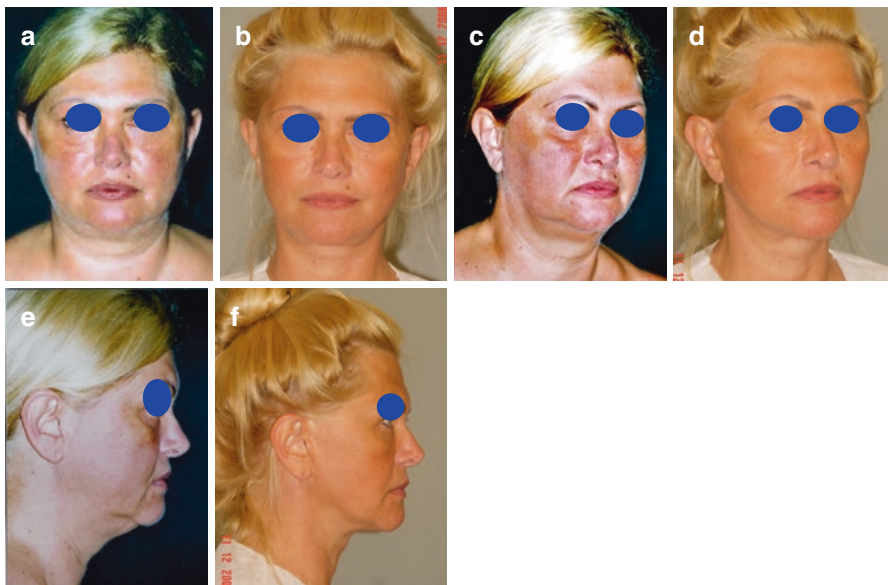**Fig. 13.11** Plication of the lateral border of the platysma can be performed during rhytidoplasty



**Fig. 13.12** Perioperative photos showing the direction of traction of the facial cutaneous flap: (a) with two forceps, the flap is pulled backwards, and with Pitanguy's marker, a point is marked in front of the ear, (b) with scissor, the flap is sectioned and a temporary stitch is done, (c) the excess skin flap is resected with knife, (d) subdermal stitches are done in order to avoid excessive traction to the final suture



**Fig. 13.13** Perioperative photos showing direction of traction of the cervical cutaneous flap:(a) with two forceps, the flap is pulled upwards, and with Pitanguy's marker, a point is marked behind of the ear, (b) with knife the flap is excised, (c) after resection, subdermal stitches are done, and (d) Pitanguy's marker



**Fig. 13.14** A patient presenting facial flaccidity with localized adiposities: photos (a, c, e) before operation. Photos (b, d, f) after rhytidolipoplasty performed following the technique described above combined with liposuction on the face and submental region

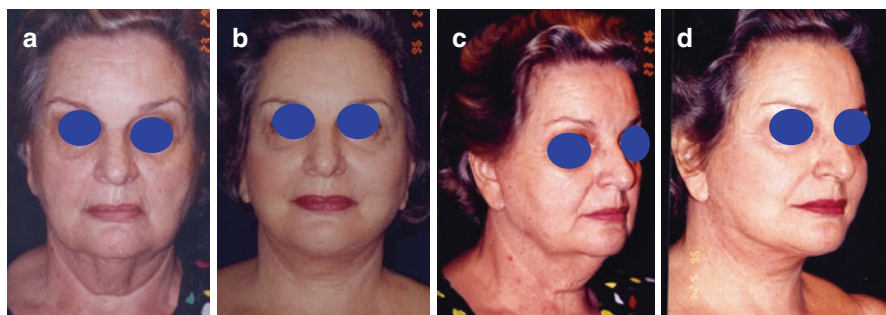## Complications

Rhytidolipoplasty performed through nontraumatic cutaneous tunnelization with reduced area of undermining offers a good skin thickness. Postoperative recovery is calm and comfortable and patients do not complain about pain. This technique has been used since my new concepts on abdominoplasty through a closed vascular system were developed and described [5–7]. There is minimal bleeding during the operation, but careful hemostasis is done and no drain is used. I have not had major complications such as hematoma postoperatively which required evacuation as happened sometimes when traumatic undermining with scissors was performed. Skin necrosis or even cutaneous slough did not occur since the vascularity is well preserved when performing tunnelization with limited area of skin undermining [8, 9]. Some years later, Jones and Grover [17] proposed similar tumescent infiltration to avoid complications. Prior to develop my method, I usually avoided operating on smokers owing to the possibility of skin necrosis or any other complications. Nowadays, although I do not like at all to operate smokers but rhytidoplasty is performed on those patients without any major problems.

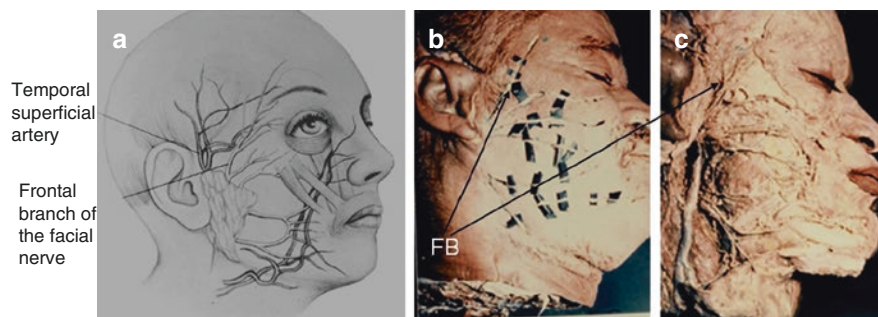
## Discussion

To employ knowledge as well as surgical principles coming from my new concepts on abdominoplasty in my hands has been a thankful procedure in order to achieve good results with minimal complications. Due to these combined procedures, I propose the term of rhytidolipoplasty. One must say that facial aging is only a segment of the deep alterations on the whole body as time goes by. There is no precise age or date that such complex phenomenon starts. The face is the most visible part but all body contours show evidences of the age. The wrinkles are a sign of profound changes in skin losing its elasticity which are more visible and noticed on the face owing to physical and psychological aspects that are not well known until today. Therefore, face-lifting is not a definitive surgery but a palliative one since its result lasts for a limited period of time. Also, internal organs and all tissues present significant structures modifications.

After 1960, more and more techniques were developed by several authors in the attempt to improve results. In a fatty neck, lipectomy was performed which is a very traumatic procedure which uses bleeding during and afterward. From the beginning, rhytidoplasty has always been a very aggressive and traumatic operation to the cutaneous and subcutaneous tissues. Tunnelization procedure is a combination of liposuction techniques developed and wordily popularized by Illouz [15, 16] one more surgical option to minimize the trauma of the tissues and reducing the rate of complications.



**Fig. 13.15** A 73-year-old patient presenting aging facial flaccidity with localized adiposities on submental and submandibular regions: photos (a, c) – before operation. Photos (b, d) after rhytidolipoplasty associated with liposuction on the face, submandibular and submental regions

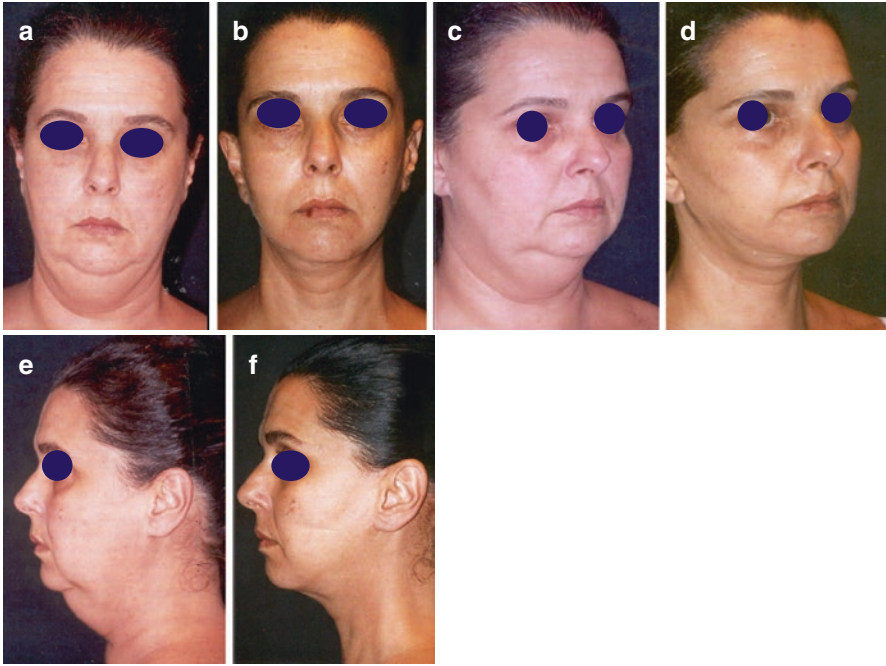

**Fig. 13.16** Surgical anatomy of the temporal region. Drawing (a) demonstrates the superficial temporal artery and frontal branch of the facial nerve, photos (b, c) anatomy on cadaver showing the frontal branch (FB) of the facial nerve

The natural appearance of the facial expression after operation must be the essential of any facial rejuvenation technique, since each person presents peculiar facial architecture structures which should not be changed (Fig. 13.15).

On the area above the zygomatic arch, the tunnelization procedure is done beneath the temporal fascia in order to avoid any damage to the hair follicles. In that area, the vascular network passes parallel to the skin in the galea. Therefore, there are no vessels coming from depth to the cutaneous flap. According to Pitanguy and Ramos [25], the temporal branch of the facial nerves emerges in front of the ear and passes underneath the level of tunnelization without any damage during rhytidolipoplasty (Fig. 13.16).

Mostly of rhytidoplasties, plication of the SMAS is done only laterally. Seldom suture on midline of the neck is performed on submental region because it may create a thick and fibrotic tissue which is ungraceful and hard, forming a “bridge” from the chin to the neck. As there is some asymmetry on anterior border of the platysma,

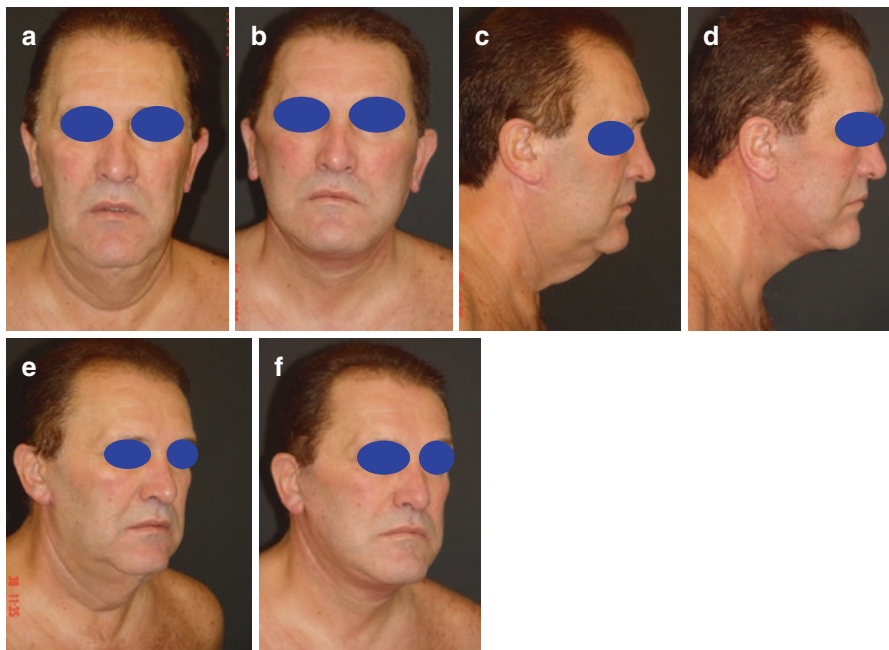


**Fig. 13.17** A 45-year-old patient presenting a fatty face and neck with localized adiposities: photos (a, c, e) before surgery. Photos (b, d, f) after rhytidoplasty combined with liposuction on the face, submandibular and submental regions

its anterior border is not sutured. Also sometimes the platysma may present a significant distance between them as described by Cardoso de Castro [12]. Even when the medial margin of the platysma is visible owing to its projection on the skin, I do not perform any plication on the submental region (Fig. 13.17).

My idea came by observing male rhytidoplasty since men have very thick skin, and normally, abundant bleeding is present which bothers greatly the surgeon during and after the operation, which may develop severe seroma formation. In fact, I do not use any kind of drainage since there is no bleeding during or after surgery. Even I have not had any case of severe hematoma in the postoperative recovery [8, 9]. Since I published my new concepts for abdominoplasty as a closed vascular system, I started to employ a similar procedure in rhytidoplasty since the surgical principles are the same, i.e., to preserve most vessels in the cutaneous flap. In fact, the arteries maintain regular blood supply to the skin and the venous and lymphatic circulations work as multiples pedicles [5–7].

Traditional rhytidoplasty with lipectomy on the submental and submandibular regions used to be a quite traumatic procedure since the dissection by scissors and removal of excess fat at the same time may provide good results, but the skin flap may present excessive scarring and adhesions with an unpleasant aspect [11, 21, 22]. Before the lipoplasty era, lipectomy and also wide skin undermining were a very



**Fig. 13.18** A 55-year-old male patient presenting a fatty face and neck with skin flaccidity: photos (a, c, e) – before surgery. Photos (b, d, f) after rhytidoplasty associated with liposuction on the face, submandibular and submental regions

popular method described and advocated by Pontes [28]. However, such procedure is also very radical and aggressive through which quite often a high rate of complications reported by Wilkinson [30], skin necrosis, infection, and dehiscence of the wound are frequent problems after rhytidoplasty. Also, trauma to the nerves may happen when scissors are used, although careful operation is performed by outstanding surgeons (Fig. 13.18).

Therefore, nowadays a proper evaluation is a mandatory step before surgery and it is possible to choose a less traumatic technique.

## Conclusions

New concepts for rhytidolipoplasty with less trauma of the subcutaneous tissue are useful application of my new concepts on abdominoplasty surgery. The operation is performed in a closed vascular system by tunnelization, which represents minimal blood loss and good postoperative recovery. The surgery is a safety one which last the same period of time to be performed. Hyperhydratation or tumescent infiltration is a helpful stage which must be done immediately before to start the operation.



## References

1. Avelar JM (1983) Adiposidade submentoniana e submandibular – Lipoaspiração X Lipectomia. In: Anais do Simpósio Brasileiro do Contorno Facial. Ed. by Avelar. Soc Bras de Cir Plast – Regional São Paulo, São Paulo, pp 69–72
2. Avelar JM (1985) Fat Suction of the submental and submandibular regions. *Aesthetic Plast Surg* 9:257–263
3. Avelar JM (1989) Creation of natural tragus in rhytidoplasty. In: Recent advances in plastic surgery-RAPS. Ed. by Toledo, São Paulo
4. Avelar JM (1990) Recientes adelantos quirurgicos en las ritidoplastias cervicofaciales. In: Historia Ciencia y Arte en Cirugia Estética. Ed. By Avelar and Malbec. Ed. Hipócrates, São Paulo, pp 294–311
5. Avelar JM (1999) Uma nova técnica de abdominoplastia sistema vascular fechado de retalho subdérmico dobrado sobre si mesmo combinado com lipoaspiração (A new technique for abdominoplasty – closed vascular system of subdermal flap folded over itself combined to liposuction). *Rev Bras Cir* 88/89(1/6):3–20
6. Avelar JM (1999) Novos conceitos para abdominoplastia New concepts for abdominoplasty. Paper presented at the 36th Congress of the brazilian society of plastic surgery. Rio de Janeiro
7. Avelar JM (1999) Abdominoplastia: Nuevos conceptos para una nueva técnica (Abdominoplasty: new concepts for a new technique). XXVI Annual International Symposium of Aesthetic Plastic Surgery, Chairman: Prof. Jose Guerrerosantos – Puerto Vallarta, Jalisco, México, pp 10–13
8. Avelar JM (2001) Lifting facial. Abordage Personal. ISAPS Course and I Congreso Nacional de la Asociación Española de Cirugía Estética (AECE), Valladolid, Spain
9. Avelar JM (2002) Rhytidoplasty with non-traumatic undermining. Panel of facial rejuvenation: ultimate achievement with additional procedures. XVI Congress of ISAPS, Istanbul
10. Avelar JM, Ilouz YG (2007) Nontraumatic undermining in rhytidectomies. In: *Aesthetic surgery of the facial mosaic*, vol 39. Editora Springer, Heidelberg, Germany, pp 243–254
11. Badim J (1972) Rejuvenescimento facial. Nova técnica de lipecto-mia submaxilar e submentoneana. *Rev Bras Cir* 62:99
12. Cardoso de Castro C (1980) The anatomy of the platysma muscle. *Plast Reconstr Surg* 66:680
13. Guerrero-Santos J, Espaillat L, Morales P (1974) Muscular lift in cervical rhytidoplasty. *Plast Reconstr Surg* 54:127
14. Hamra ST (1990) The deep-plane rhytidectomy. *Plast Reconstr Surg* 86:53–61
15. Ilouz YG (1980) Une nouvelle technique pour les lipodystrophies localisées. *Rev Chir Esth Franc* 6(9):Ap
16. Ilouz YG (1982) Liposuction technique. First Instructional Course with surgical demonstrations at São Paulo Hospital, Prof. Andrews' Service. Organized by Brazilian Society of Plastic Surgery – Regional São Paulo, Endorsed by Brazilian Society of Plastic Surgery(BSPS)
17. Jones BM, Grover RBS (2004) Reducing complications in cervicofacial rhytidectomy by tumescent infiltration: a comparative trial evaluating 678 consecutive face lifts. *Plast Reconstr Surg* 113(1):398–403
18. Joseph J (1928) Verbesserung meiner Hängewangenplastik (Melomioplastik). *Dtsch Med Wochenschr* 54:567
19. Lexer E (1931) Die gesamte Wiederherstellungschirurgie. Barth, Leipzig
20. Malbec EF (1957) Arrugas de la cara: Técnica operatoria. *Semana Med* 111:517
21. Millard DR et al (1968) Submandibular lipectomy. *Plast Reconstr Surg* 41:513
22. Millard DR Jr, Garts WP, Beck R et al (1972) Submental and sub-mandibular lipectomy in conjunction with a face lift in male or female. *Plast Reconstr Surg* 49:385
23. Mitz V, Peyronie M (1976) The superficial musculo-aponeurotic system (SMAS) in the parotid and cheek area. *Plast Reconstr Surg* 58:80
24. Passot R (1919) La correction chirurgicale des rides du visage. *Presse Med* 27:258
25. Pitanguy I, Ramos AS (1966) Considerações sobre as variações do ramo frontal do nervo facial. *Rev Bras Cir* 52:1

26. Pitanguy I (1967) La ritidoplastica: soluzione eclettica del problema. *Minerva Chir* 22:942
27. Pitanguy I et al (1981) Considerações sobre nossa experiências com disseções e plicaturas do SMAS em meloplastia. *Rev Bras Cir* 71(1):57
28. Pontes R (1983) Contribuição ao tratamento da região cérvicomandibular nas ritidoplastias. *Anais do Simpósio Brasileiro do Contorno Facial*. Ed. by Avelar. Soc Bras de Cir Plast – Region São Paulo, São Paulo, pp 73–74
29. Skoog T (1973) *Plastic surgery. Surgery of the aging face*. Saunders, Philadelphia
30. Wilkinson TS (1976) The repair of a submental depression occurring after rhytidectomy. *Plast Reconstr Surg* 57:33

# Chapter 14

## Ear Reconstruction: Preservation of Perforator Vessels on the Pedicle to Improve Results

Juarez M. Avelar

### Introduction

My new concepts on abdominoplasty [9–11] have been an important knowledge to improve ear reconstruction on congenital and acquired deformities. In my anatomical research performing dissections on cadaver looking for new surgical operations to perform safe abdominoplasty, it was evident to me that those surgical principles were also correlated with ear reconstruction procedures. As far as normal auricles present important anatomical structures for their support on the lateral sides of the head, when ear reconstruction is done, I was deeply concerned that it is mandatory to create a main pedicle for the new auricle [4, 16–18]. Since I started my professional activities, the fascinating field of ear reconstruction was a constant challenge in plastic surgery. To solve several problems, it needed more and more surgeons to present scientific contribution to minimize patient's sufferings. Meantime, I identified narrow technical knowledge to create a new auricle which stimulated me to devote much effort to find new procedures to improve surgical results in order to achieve well balance to facial contour [7]. Even creation of the temporoparietal fascial flaps [2, 3, 5] is a useful step forward to identify a vascular pedicle to provide adequate blood supply to the reconstructed ear which is similar to the preservation of perforator vessels on new concepts on abdominoplasty.

During log time of my brainstorm, I concluded that for reconstruction of a new pinna it was a fundamental approach to create a neurovascular pedicle to provide adequate blood supply and sensitivity as well. Based on this goal, I was looking for, with obsessive pursuit to perform safety abdominoplasty, technique with reduced rate of complications. In my mind ear reconstruction used to require cre-

---

J.M. Avelar, MD

Head of the Brazilian Scientific Institute of Plastic and Reconstructive Surgery,  
Al Gabriel Monteiro da Silva, 620 Jd Europa, São Paulo, SP 01442-000, Brazil  
e-mail: [juarezavelar@bol.com.br](mailto:juarezavelar@bol.com.br); [institutodaorelha@uol.com.br](mailto:institutodaorelha@uol.com.br)

ation of a basic anatomical support for the new organ. Thus, I developed new methods which came from my new concepts on abdominoplasty operation, since the perforator vessel branches of the internal carotid artery are preserved to provide adequate blood supply as well as the lymphatic circulation after surgery. They come from depth passing near the anterior border of the mastoid bone for vascularization of the skin of the mastoid area [16, 18]. Therefore, my methods concerning ear reconstruction were improved very much due to my knowledge and surgical principles introduced and published on abdominoplasty (Avelar [12–14]).

When a person presents normal auricles, another one may not see them on each side of the head. However, any alterations on size, shape, position, and location of one or two pinnae will be noticed by most people even from a distance.

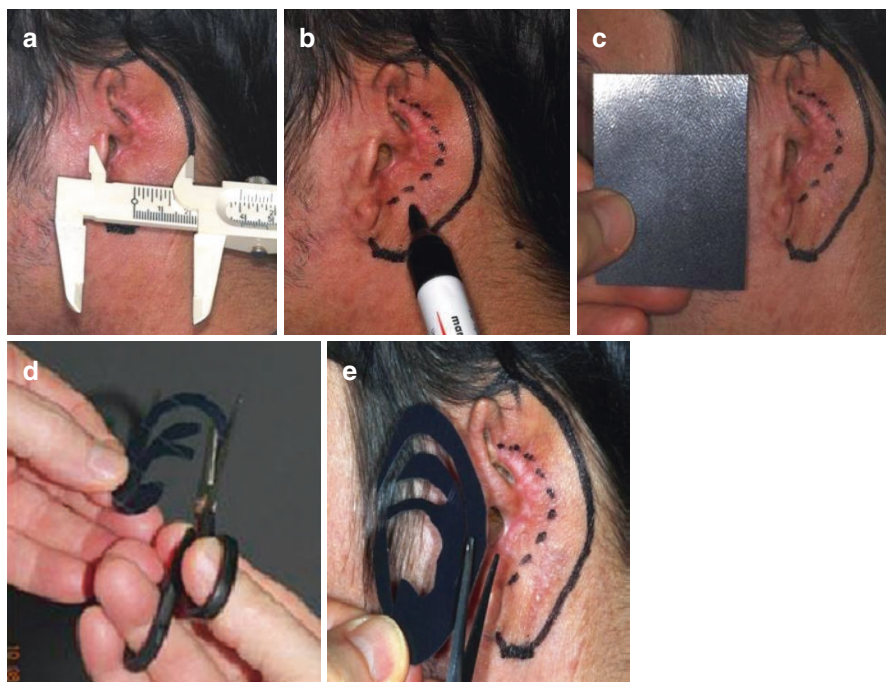
## **Surgical Planning**

Since Gillies [21] introduced the necessity of creating a new auricular framework to replace the structure of the auricle to reconstruct a new organ, he opened a wide field in this area. That was the first step on surgical planning because the size, shape, and location of the future ear must be planned before the day of operation. Later, Gillies [22] introduced the use of a model made from x-ray film taken from the opposite auricle; it is a useful procedure until today. In bilateral deformities the planning needs surgeon's imagination. Later, Converse [19, 20] and also Tanzer [26] had a similar preparation. I had the privilege to learn from Prof. Pitanguy the similar approach, and later I saw Prof. Converse planning his operation at New York University. Therefore, such organization is deep in my mind giving me the necessity to plan adequate ear reconstruction (Fig. 14.1).

Meantime, to create a new auricular skeleton, another valuable Gillies' orientation [22] is on the way to reconstruct an auricle in which rib cartilage is the best organic material (Fig. 14.2). In fact, to sculpture a new frame is a handwork to excavate the cartilage.

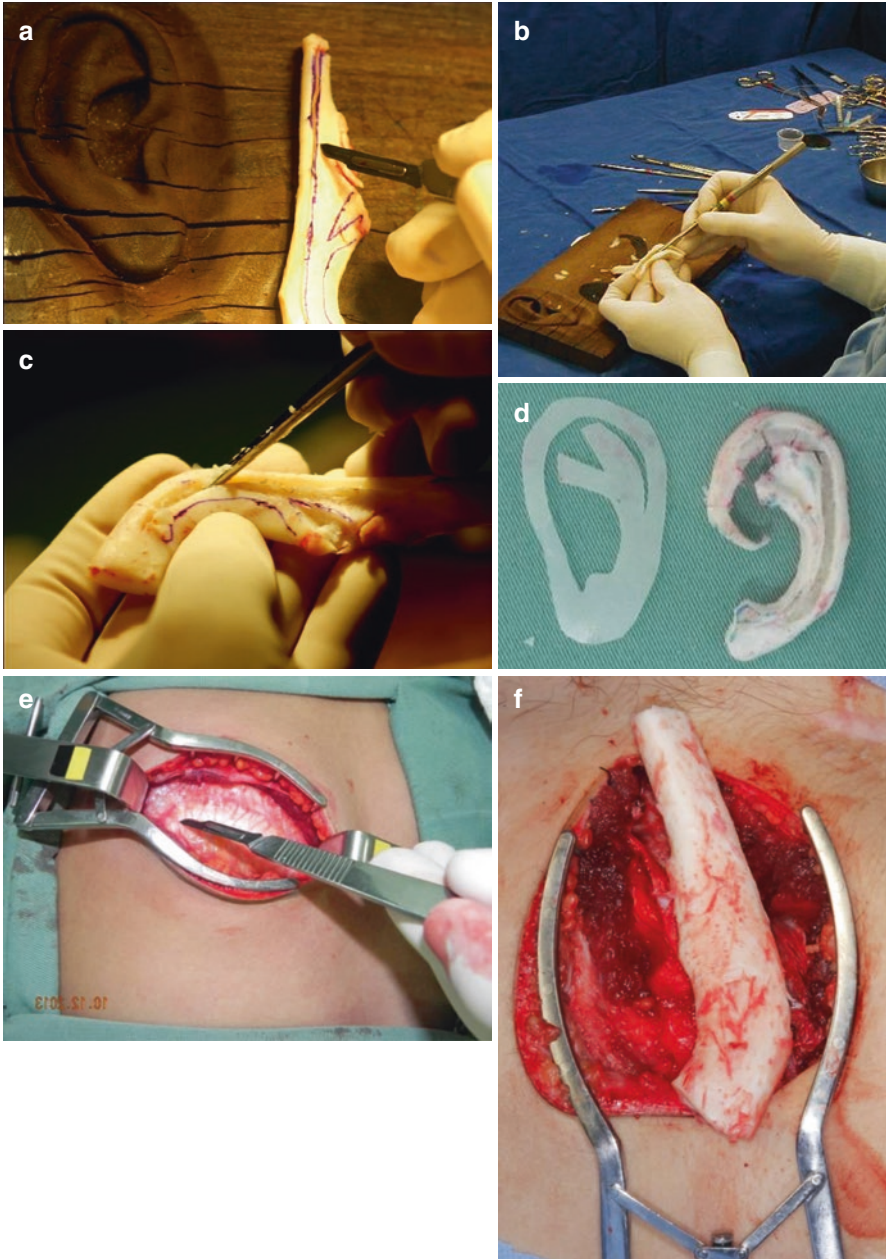
## **Classification of Congenital Abnormalities of the Ear**

Congenital anomalies of the auricles present wide varieties of clinical forms which require adequate analysis before performing their reconstructions. The classification is a useful step to choose the best procedure for reconstruction. The deformities are classified in four groups: anotia, moderate eutopic microtia, moderate ectopic microtia, and severe microtia [17]. I named anotia in all congenital deformities which do not present remnant cartilaginous tissues of the ear, absence of the



**Fig. 14.1** Surgical planning and demarcation before surgery: (a) through the use of a paquimeter, the size and shape of the future ear are established; (b) the location and position of the future auricle are marked taking as reference the opposite ear when it is normal. (c) The model of the future auricular skeleton is carefully created using x-ray film; (d, e) the model is then placed into the area of the projected auricle

auditory canal, alterations of the local skin and hair, superior hairline not well defined due to thin hair on the border, very thin skin, and others. Patients with moderate microtia (eutopic and ectopic) always have tragus, concha, lobule, and cutaneous covering. All remnant cartilaginous and cutaneous tissues are employed for reconstruction of the ear. This is an important point for reconstruction and a substantial difference in comparison with other groups of congenital anomalies according to my classification. Those anomalies present severe associated deformities of the face, skull, chest, and upper and lower extremities. On the other hand, the fourth group – severe microtia – always presents two cutaneous folders located vertically with one on top of the other. The superior one covers the remnant cartilaginous tissue underneath, and the lower one has its histological characteristics very similar to the lobules. The skin is thick; the hairline is well defined with thick hair. The associated deformities are not as severe as what happened with other groups of my classification.



**Fig. 14.2** Modeling by meticulous excavation of the new auricular framework: (a, b) the ninth costal cartilage is removed. (c) The new skeleton is being drawn. (d, e) Excavation of the new auricular framework with sharp instruments. (f) With the model on the side, the new auricular framework is already sculptured

## **Etiology of Traumatic Ear Deformities**

Traumatic amputation of the ear presents several causes which may destroy partial or totally one or two auricles [8, 18]. The most frequent origins are:

1. Car accidents
2. Amputations by cutting instruments (knife, scissors)
3. Amputation by avulsion of the scalp
4. Unfavorable results after correction of the prominent ear
5. Burns
  - (a) Fire caused by combustion with ethanol, benzene, and other liquids
  - (b) Fireworks
  - (c) Hot liquids (water, milk, oil)
  - (d) Cold temperatures (ice and snow)
  - (e) Chemical liquids and acid
  - (f) Venomous animal secretions
  - (g) Electricity
6. Bites
  - (a) Animal bites caused by horses cows, dogs, pigs, and camels
  - (b) Human bites during fighting or lovemaking
7. Piercings
8. Acupuncture
9. Earrings
10. Marshall arts: judo, boxing, jujitsu, karate
11. Infections

## **Technique**

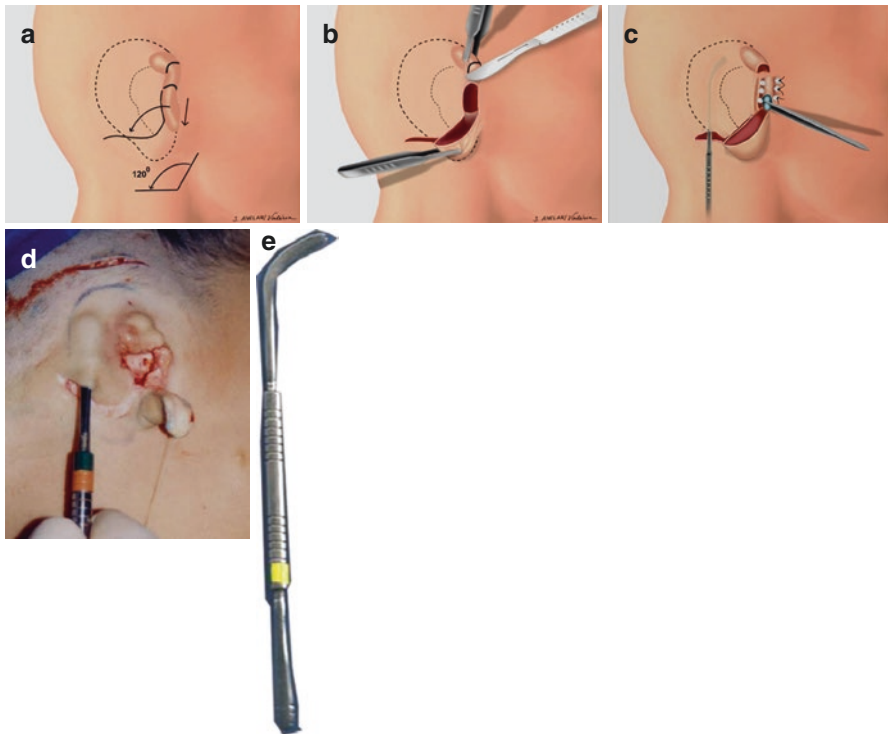
I consider that the success of ear reconstruction on congenital abnormalities and after traumatic amputation is mandatory to create two anatomical elements: (a) cutaneous covering (Figs. 14.3 and 14.4) and (b) new auricular framework which is performed in two surgical stages [7].

During the first stage the cutaneous covering is created on mastoid region since it is the closest one, even presenting hairless skin. On the other hand, the future auricular skeleton is provided by sculpture with meticulous excavation on rib cartilage removed from the chest of the same patient as described by Pitanguy et al. [24].

## *Creation of the Cutaneous Covering*

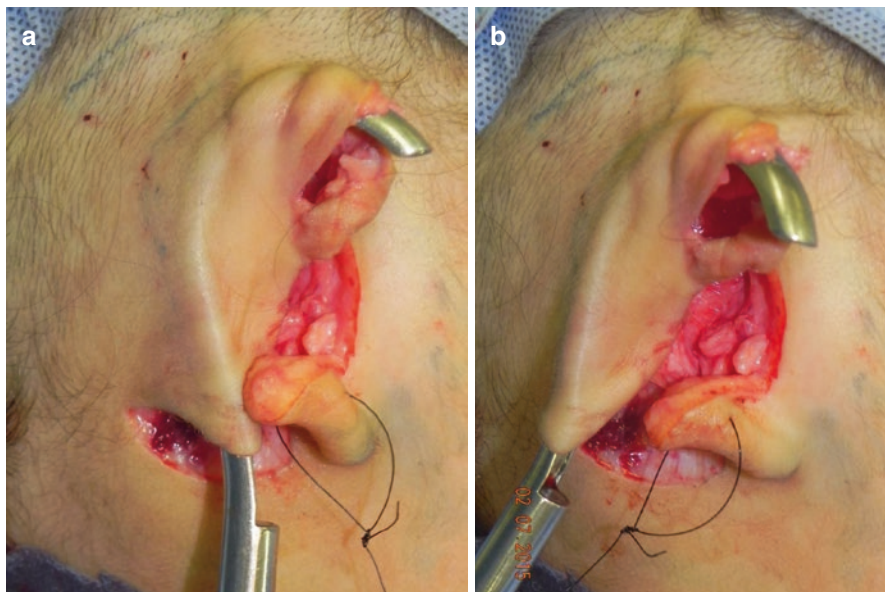
During all my professional activities, I have described that the skin of the mastoid region must be undermined only on the area of the future helix and antihelix creating a subcutaneous tunnel [7]. Thus, the future conchal cavity will be the fundamental pedicle of the ear which presents same surgical principles as to preserve the perforator vessels on my new concepts of abdominoplasty (Figs. 14.3 and 14.4). Also cutaneous dissection of the future helix and antihelix is performed under the same surgical principle of the abdominoplasty since the vessels come from the depth passing close to the anterior border of the mastoid bone which must be entirely preserved. Even this pedicle is also a neurovascular one (similar with perforator vessels with sensate nerve) since there is a branch of sensitive nerve which will provide sensibility to the reconstructed auricle.

The operation is performed under general anesthesia. The ninth rib cartilage is removed where the new auricular framework is sculptured by meticulous excavation

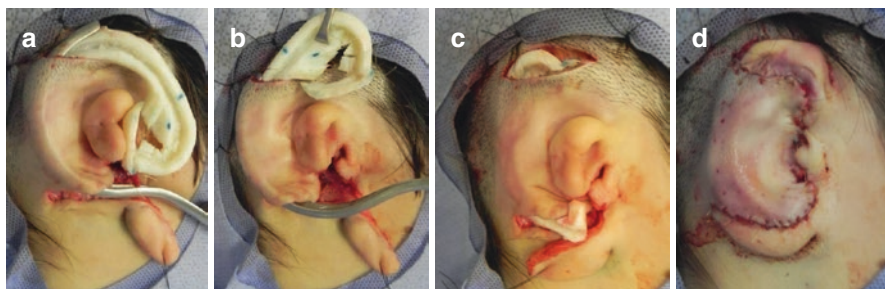


**Fig. 14.3** Subcutaneous tunelization to create a neurovascular pedicle for the new ear on microtia operation: scheme of (a) cutaneous incision on the congenital fold; (b) the lower segment will create the lobule; (c) with the use of Avelar's underminder, a tunnel is created; photo (d) tunelization with nontraumatic instrument; (e) photo of the underminder





**Fig. 14.4** Creating the neurovascular pedicle for the future ear: after tunelization an instrument is introduced through the tunnel; the blood supply for the new ear came through neurovascular pedicle



**Fig. 14.5** Sequential photos demonstrating how to embed the new auricular skeleton through the subcutaneous tunnel to reconstruct the right ear: (a) with a special instrument, the new frame is introduced following it; (b) the new frame is being introduced; (c) the new frame is introduced; (d) afterward, the cutaneous folds are sutured to create the lobule and the upper pole

(Fig. 14.2) which is introduced subcutaneously through the tunnel already created on the mastoid area (Fig. 14.5).

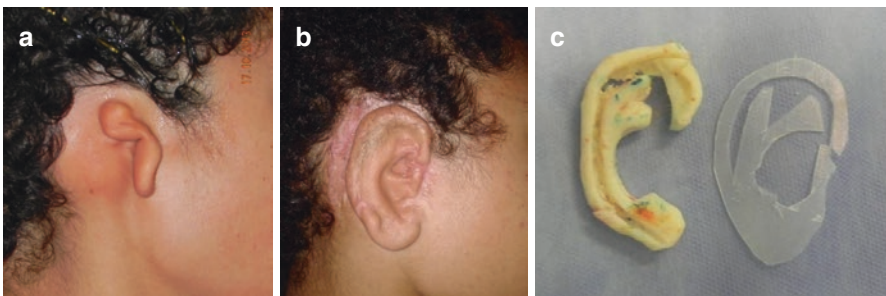
On congenital abnormalities the lobule is created by rotation back and downward of the lower segment of the cutaneous fold of the deformity. The remnant cartilage tissue always present on all patients with severe microtia must be removed in order to create the new auditory canal and conchal cavity as well (Fig. 14.3).

The second stage of reconstruction is performed 6 months after the first one by cutaneous incisions following the posterior border of the new auricle. Afterward,

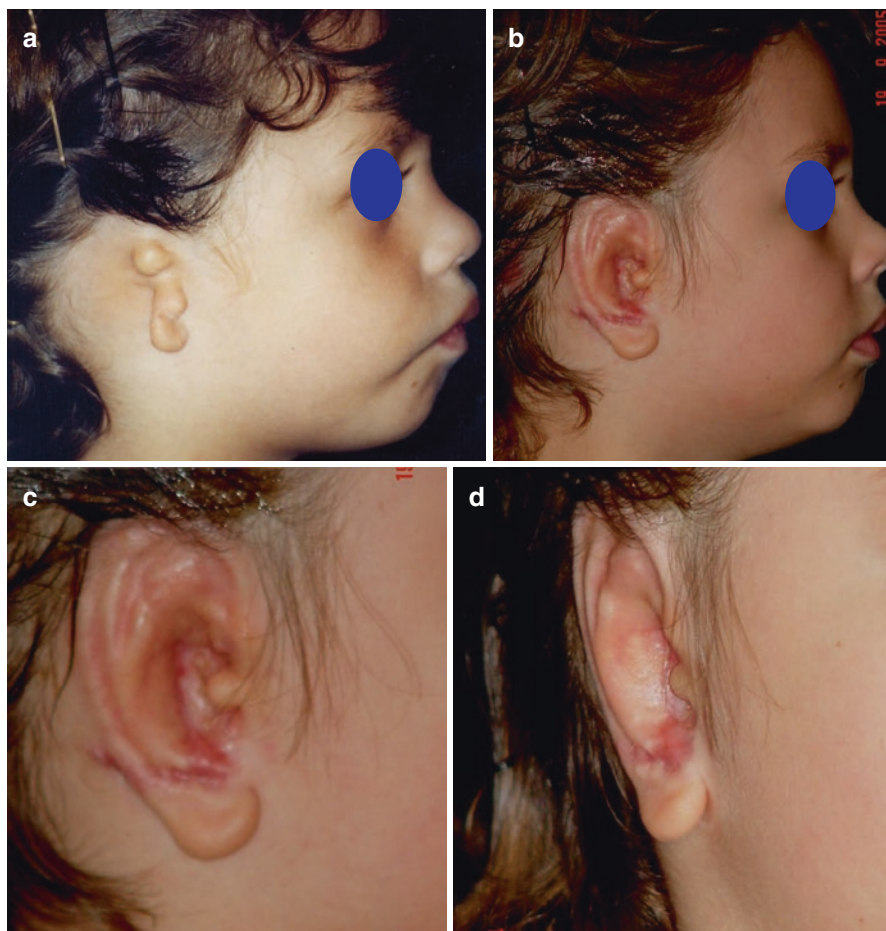
the new ear is lifted by dissection below the fascial flap which covers the entire posterior aspect of the auricle. At this point it is fundamental to create the main pedicle of the future auricle.

Follow the operation skin graft removed by knife from the scalp or any other region of the patient is done. A careful dressing is performed and must be kept for 1 week, and when it is removed, apply another one for 1 month. The final result gives harmonious facial contour (Figs. 14.6, 14.7, and 14.8).

Reconstruction of the ear after traumatic amputation under same surgical principles which concerns creating the main neurovascular pedicle is employed, since the future conchal cavity is not undermined (Fig. 14.9). In cases of total amputation of the ear, the location of the incisions is planned in order to avoid any final scar on the skin covering after insertion of the auricular framework since two vascular pedicles are not dissected (Fig. 14.10). The first one is the future conchal cavity which is the main pedicle for adequate blood supply for the future auricle, and the second one is the posterior border of the subcutaneous tunnel [15]. The second stage of reconstruction is also performed 6 months after the first operation by cutaneous incisions on border of the posterior border of the auricular framework inserted during the first stage. Afterward, the new ear is pulled, and skin graft is performed on raw area and posterior aspect of the new ear (Figs. 14.10 and 14.11). For partial reconstruction of the auricle, its reconstruction is according to each deformity, since it follows the same surgical principles. Even the new auricular frame must be excavated taking the remaining anatomical elements as reference in order to keep the segment amputated during trauma (Figs. 14.12 and 14.13). In specific cases of partial reconstruction, it is possible to employ local flaps on the ear as proposed by Medeiros et al. [23]. The advancement chondrocutaneous flap described by Antia is a useful procedure for reparation of some deformities on the upper part of the ear [1]. When the deformities amputate a segment of cartilage of the superior part of the ear, it is necessary to replace the missing skeleton as I described in my previous publications [8]. Even composite graft is also a good procedure to repair partial deformities of the auricle as well as the nose [6].



**Fig. 14.6** A 10-year-old boy with microtia on right side: (a) before surgery; (b) after two-stage reconstruction; (c) the auricular framework excavated on the rib cartilage beside the model in x-ray film



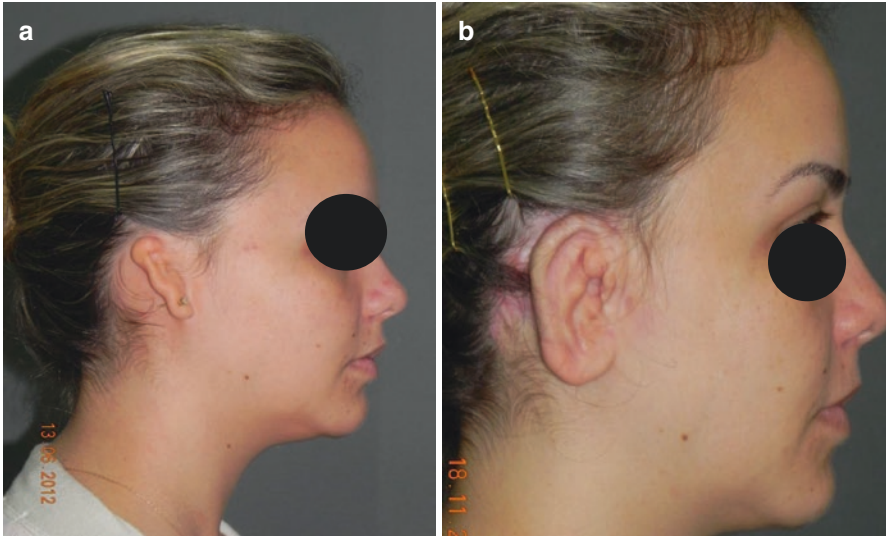
**Fig. 14.7** A 7-year-old boy with microtia on right side. (a) before surgery; (b–d) after two-stage reconstruction

## Complications

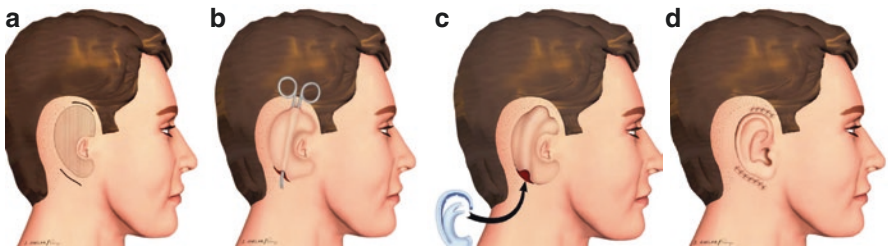
Complications during and after ear reconstruction may occur even when the operation is well performed, and good postoperative care is taken.

Such unexpected situations are some of the most difficult problems regarding reconstruction of the auricles.

The complications may occur during surgery, immediately after surgery, or in the long term afterward. The most feared complications during operation are a pleural perforation. Fortunately until now I have not had this problem, but it has referred by Tanzer [26] on five patients among 44 operations he performed. Spina et al. [25] reported such complications after 48 operations underwent ear reconstruction. I am sure that my method is safer since it is done employing the surgical principles of



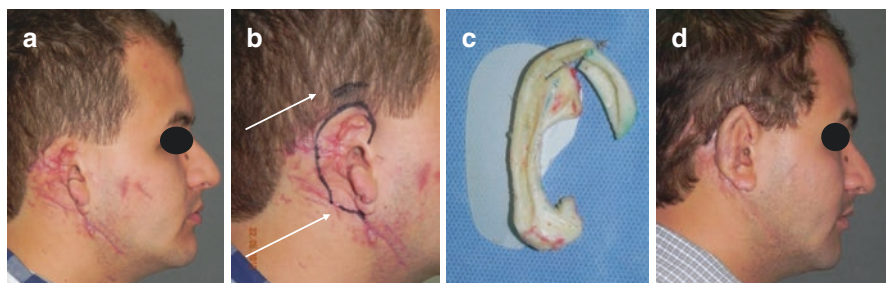
**Fig. 14.8** A 21-year-old girl with microtia on right side: (a) before surgery; photo (b) after two-stage reconstruction



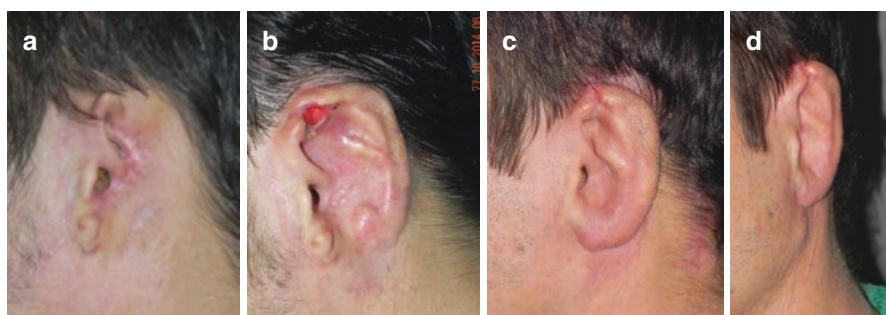
**Fig. 14.9** Sequence drawing of the technique for the first stage of total reconstruction of the ear: (a) the scheme shows the surgical planning for reconstruction. The projection of the future ear is done with demarcation of two incisions above and below the future ear; (b) cutaneous undermining is performed only on the projection of the future helix and antihelix, creating a subcutaneous tunnel; (c) the new auricular framework will be embedded through the subcutaneous tunnel after skin distention during surgery; (d) the scheme of the final aspect after the first stage of total ear reconstruction after traumatic amputation

dissection of the perichondrium on similar procedure under new concepts on abdominoplasty [9].

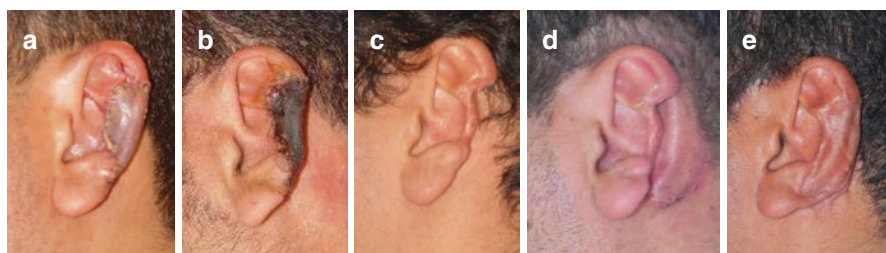Complications immediately after surgery may occur few days to 2 weeks later in which bleeding, hematoma, dehiscence of the wound, and cutaneous necrosis may occur. However, if surgeon and staff take a good care, it may not present later consequences. Long-term complications may happen up to 2 months even later. Absorption of the cartilaginous auricular skeleton, displacement of the framework, and fading of the auricular relief are the most frequent which may cause unsatisfactory results. Undauntedly these situations are due to inadequate blood supply to the auricular framework which requires another surgical operation for reparation.



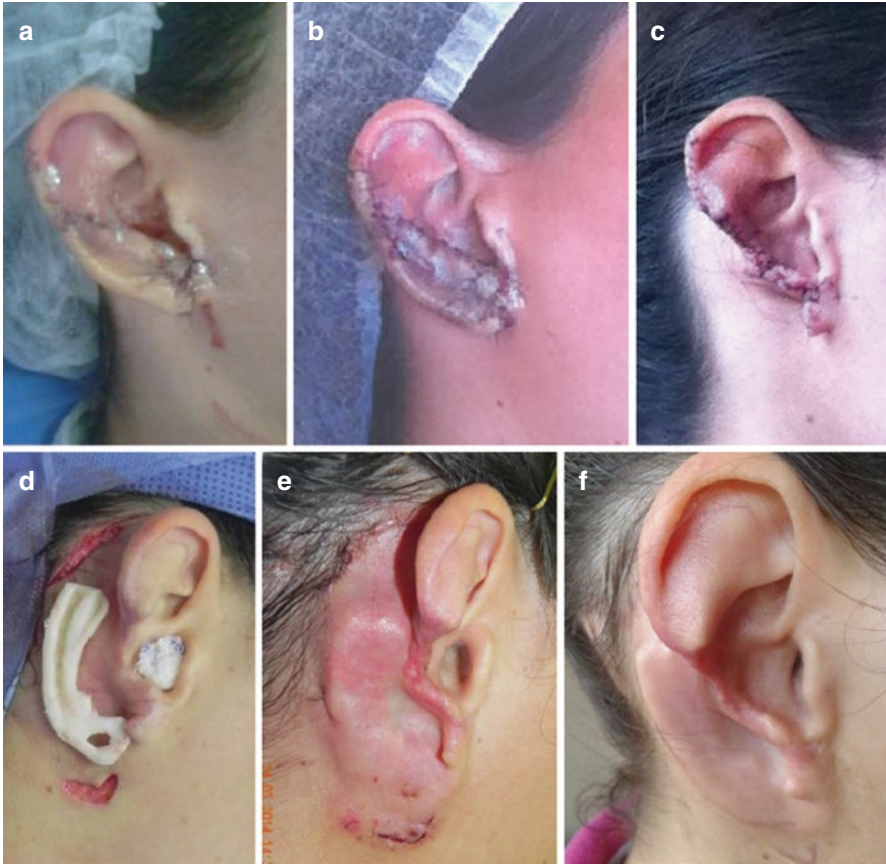**Fig. 14.10** Total reconstruction of the right ear after amputation caused by a car accident: (a) a 23-year-old male patient with total amputation of the right ear, with the tragus, external auditory meatus, and a reduced area of conchal cavity remaining; (b) surgical planning of the future auricle where two *arrows* indicate the incisions above and below the projection of the future auricle; (c) the new auricular framework excavated on the rib cartilage; (d) the same patient after two stages of ear reconstruction



**Fig. 14.11** Total ear reconstruction of the left ear caused by a car accident: (a) a 19-year-old young male patient with total amputation of the left auricle with remaining tragus and external auditory meatus and without any conchal cavity; (b) after the first surgical stage, the new auricular framework was embedded underneath the skin of the mastoid area; (c, d) the same patient after two stages of ear reconstruction



**Fig. 14.12** Unsuccessful reimplantation of a partial amputated left ear caused by a human bite: (a) a 35-year-old male patient presented amputation of a segment of the ear that had been reimplanted elsewhere; (b) the same patient 5 days later with necrosis of the segment; (c) the final aspect of the ear after reimplantation; (d) photo after the first stage of ear reconstruction with costal cartilage inserted underneath the skin on mastoid area; (e) final result 1 year after the second stage



**Fig. 14.13** Unsuccessful reimplantation of the lower segment of the right ear amputated by a horse bite: (a) a 22-year-old girl presented suture of the amputated segment of the ear that had been performed elsewhere; (b) the same patient 6 days after reimplantation with necrosis of all segment; (c) 2 months after removing the necrotic segment of the lower half of the ear; (d) photo during first stage of ear reconstruction with the new auricular skeleton excavated on costal cartilage; (e) same patient 1 week after insertion of the cartilage graft underneath; (f) 3 months after the first stage of reconstruction

No matter when a complication occurs, the surgeon must take immediate good care with adequate treatment. Reconstruction of the auricle after traumatic amputation and secondary operations may present more complications due to scar tissue formation on the neighboring auricular regions.

## Discussion

In the use of the new concepts for abdominoplasty, I employ the same surgical principles during the first stage of ear reconstruction on congenital and acquired deformities in which an important pedicle is created (Figs. 14.2, 14.3, and 14.9). In my

anatomical research, I found and described some neurovascular structures which come from depth passing on the anterior border of the mastoid bone [15].

A good pedicle for the reconstructed auricle is a fundamental anatomical structure. Ever since I started my practice, it was evident for me that the high rate of complications after ear reconstruction was due to the deficiency of blood supply. For this reason my first step in this field was to describe my temporoparietal fascial flap [2, 3, 5] which encouraged me to follow my career.

Therefore, my knowledge coming from new concepts on abdominoplasty as well as from anatomical research on temporal structures gives me a good support to perform ear reconstruction.

Reconstruction of the ear in congenital abnormalities as well as after traumatic amputation must be performed in accordance with clinical and anatomical evaluation preoperatively (Fig. 14.1). I have described that it is necessary to create two anatomical elements: new auricular framework and skin covering which may be performed in two surgical stages. During the first operation, a new auricular cartilaginous framework is excavated meticulously on the rib that is removed from the patient. The cutaneous covering is created by the skin undermined similar to a tunnel on the mastoid area through which the new skeleton is introduced. The second stage is done 6 months after the first one.

## Conclusions

Due to my new concepts on abdominoplasty, I developed meticulous dissection of the perforator vessels that are branches from the internal carotid artery that improves ear reconstruction. To create a neurovascular pedicle during operation is a new concept to provide adequate blood supply to the future ear. After two stages of reconstruction of the auricle, the facial contour is improved due to well balance with the opposite ear (Figs. 14.8 and 14.9). The technique is employed for reconstruction of the ear after traumatic amputation and congenital anomalies as well. It is a useful method to rebuild the organ and also to reinstate the harmony of the face giving the patient improvement in his inside well-being.

## References

1. Antia NH, Buch VI (1967) Chondro-cutaneous advancement flap for the marginal defects of the ear. *Plast Reconstr Surg* 39:472
2. Avelar JM (1977) Total reconstruction of the auricular pavilion in one stage. *Reconstrução total do pavilhão auricular num único tempo cirúrgico. Rev Bras Cir* 67:139
3. Avelar JM (1978) Total reconstruction of the ear in one single stage – technical variation with cutaneous flap with inferior pedicle. *Folha Med* 76:457–467
4. Avelar JM (1979) Microtia – simplified technique for total reconstruction of the auricle in one single stage. In: Fonseca Ely J (ed) *Transactions of the Seventh International Congress of Plastic and Reconstructive Surgery. Cartgraf, Rio de Janeiro*, p 353

5. Avelar JM (1983) A new fascial flap for use in craniofacial surgery. *Ann Acad Med Singapore* 2:382–387
6. Avelar JM, Psillakis JM, Viterbo F (1984) Use of large composite grafts in the reconstruction of deformities of the nose and ear. *Br J Plast Surg* 37(1):55–60
7. Avelar JM (1986) Importance of ear reconstruction for the aesthetic balance of the facial contour. *Aesthetic Plast Surg* 10:147–156
8. Avelar JM (1987) A new technique for reconstruction of the auricle in acquired deformities. *Ann Plast Surg* 18(5):454–464
9. Avelar JM (1999) Uma nova técnica de abdominoplastia – sistema vascular fechado de retalho subdérmico dobrado sobre si mesmo combinado com lipoaspiração (a new technique for abdominoplasty – closed vascular system of subdermal flap folded over itself combined to liposuction). *Rev Bras Cir* 88/89(1/6):3–20
10. Avelar JM (1999) Novos conceitos para abdominoplastia (new concepts for abdominoplasty). Paper presented at the 36th Congress of the Brazilian Society of Plastic Surgery. Rio de Janeiro
11. Avelar JM (1999) Abdominoplastia: Nuevos conceptos para una nueva técnica (Abdominoplasty: new concepts for a new technique). XXVI Annual International Symposium of Aesthetic Plastic Surgery, Chairman: Prof. Jose Guerrerosantos – Puerto Vallarta, Jalisco – México
12. Avelar JM (2000a) I Curso de abdominoplastia (First Course of abdominoplasty). William EP Callia, Juárez M. Avelar, Municipal Hospital, São Paulo
13. Avelar JM (2000b) Abdominoplastia sem descolamento (Abdominoplasty without undermining). XX Jorn. Paulista Cir Plast, São Paulo City
14. Avelar JM (2000c) Abdominoplasty: a new technique without undermining and fat layer removal (Abdominoplastia: uma nova técnica sem descolamento e remoção da camada de gordura). *Arq Catarinense Med* 29:147–149
15. Avelar JM (2011) Deformidades congênitas da orelha – Microtia. In: Carreirão S (ed) *Cirurgia Plástica*. Editora Atheneu, Rio de Janeiro, pp 349–364. ISBN 978-85-388-0223-5
16. Avelar JM (2013) Acquired deformities of the auricle. In: Avelar JM (ed) *Ear reconstruction*. Springer, Heidelberg/New York, p 129
17. Avelar JM (2013) Microtia. In: Avelar JM (ed) *Ear reconstruction*. Springer, Heidelberg/New York, pp 65–77
18. Avelar JM (2013) Surgical anatomy of the ear and neighboring regions. In: Avelar JM (ed) *Ear reconstruction*. Springer, Heidelberg/New York, pp 1–14
19. Converse JM (1958) Reconstruction of the auricle: part I. *Plast Reconstr Surg* 22:150
20. Converse JM (1958) Reconstruction of the auricle: part II. *Plast Reconstr Surg* 22:230
21. Gillies HD (1920) *Plastic of the face*. H. Frowde, Hodder Stoughton, London
22. Gillies HD (1937) Reconstruction of the external ear with special references to the use of maternal ear cartilage as the supporting structure. *Rev Chir Structive* 7:169
23. Medeiros J, Belerique M, Franco D, Franco T (2009) Chondrocutaneous marginal ear flap. *J Craniofac Surg* 20:862–863
24. Pitanguy I, Cansanção A, Avelar JM (1971) Reconstrução de orelha nas lesões por mordida humana. *Rev Bras Cir* 61(9/10):158–164, *Bol Cir Plástica* 3
25. Spina V, Kamakura L, Psillakis JM (1971) Total reconstruction of the ear in congenital microtia. *Plast Reconstr Surg* 48:349
26. Tanzer RC (1971) Total reconstruction of the auricle: the evolution of a plan of treatment. *Plast Reconstr Surg* 47:523



# Chapter 15

## Reverse Lower Blepharoplasty: An Eclectic Procedure Without Cutaneous Undermining

Juarez M. Avelar

### Introduction

In my judgment, 1988 was a remarkable date for the beginning of my new concepts on lipoabdominoplasty in very wide fields: Firstly, I stopped to perform the liposuction technique in combination with conventional abdominoplasty due to high incidence of complications coming from traumatic panniculus undermining during operations [1]. Secondly, I published an article concerning reverse lower blepharoplasty which is performed through skin resection but without cutaneous undermining of the remaining panniculus of the lower lid [2]. Thirdly, I started to research the anatomy of the abdominal panniculus, since in my conclusions, those complications used to happen due to traumatic dissection of the subcutaneous fat tissue [3]. Fourthly, my conclusion that lower reverse blepharoplasty operation is performed on similar principles of lipoabdominoplasty which are (a) full-thickness skin resection, (b) without panniculus undermining, and (c) preservation of the perforator vessels [5–8].

Obviously, liposuction is not carried out during lower reverse blepharoplasty, but full-thickness skin resection is performed in similar way as it is done on abdomen when excess cutaneous must be resected and the remaining panniculus is not undermined. The main deformity in the lower lid for adequate indication for reverse lower blepharoplasty procedure is a depression near the inferior rim margin. Such deformity is similar to that one created on abdomen, medial thigh, torso, flanks as well as in other regions when liposuction procedure is employed following the surgical principles of the new concepts. Once again, it is fundamental to emphasize that the liposuction technique is not performed on reverse lower blepharoplasty operation.

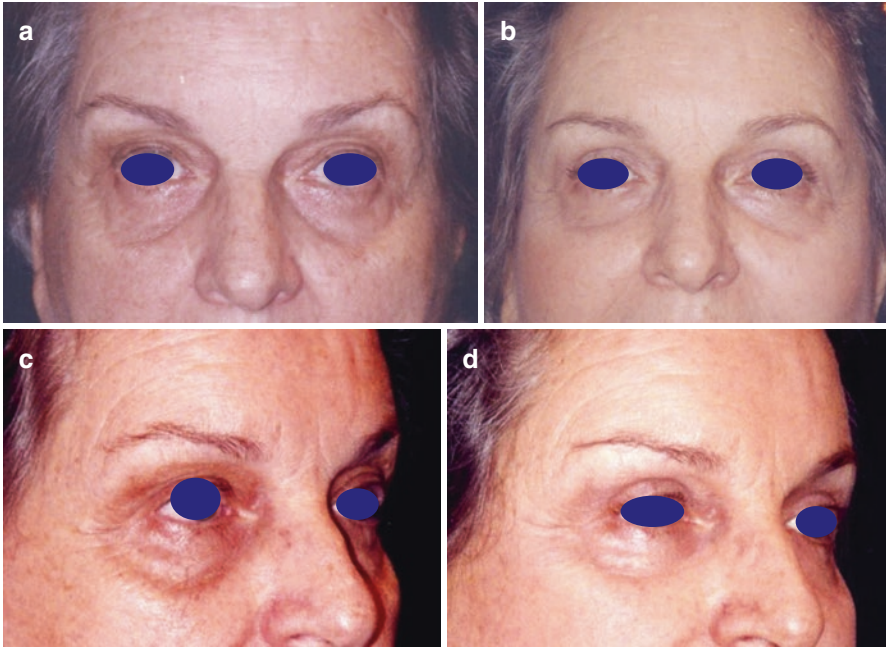
---

J.M. Avelar, MD

Head of the Brazilian Scientific Institute of Plastic and Reconstructive Surgery,  
Al Gabriel Monteiro da Silva, 620 Jd Europa,

São Paulo, SP 01442-000, Brazil

e-mail: [juarezavelar@bol.com.br](mailto:juarezavelar@bol.com.br); [institudodaorelha@uol.com.br](mailto:institudodaorelha@uol.com.br)



**Fig. 15.1** A 72-year-old female patient presenting unaesthetic pigmentation on lower lids with deep depression with fat bags: (a, c) before operation; (b, d) same patient after reverse lower blepharoplasty combined with face lifting

I found that there are several abnormalities on lower lid and on malar eminency which require specific procedures, and I suggested doing blepharoplasty with minimal trauma to the remaining panniculus.

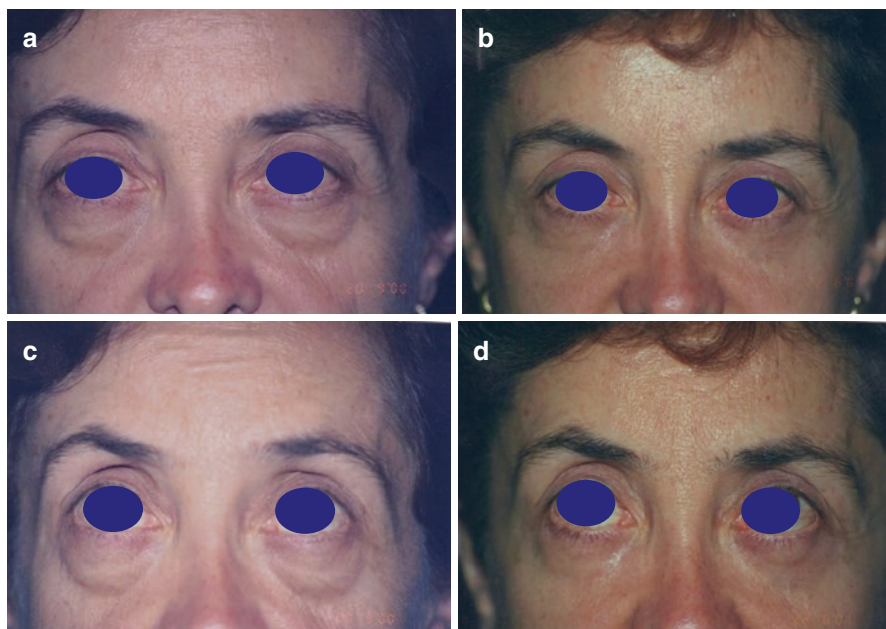
Among all unaesthetic deformities, it is useful to mention:

Blepharoplasty is a quite frequent operation regarding aesthetic plastic surgery since it may be performed and combined with ritydoplasty or as an isolated procedure. All segments of the face must be carefully evaluated preoperatively; even eyelids require more meticulous study, since they are involved in the complex structures of facial expression.

The anatomical and histological changes that are part of the aging process of the skin and the subcutaneous level present several modifications concerning a person's appearance. These changes usually manifest in the eyelids more severely frequently before other areas of the face.

There are some deformities on the eyelids that Loeb proposed fat grafting or by muscle resections in order to solve the problems [13, 14].

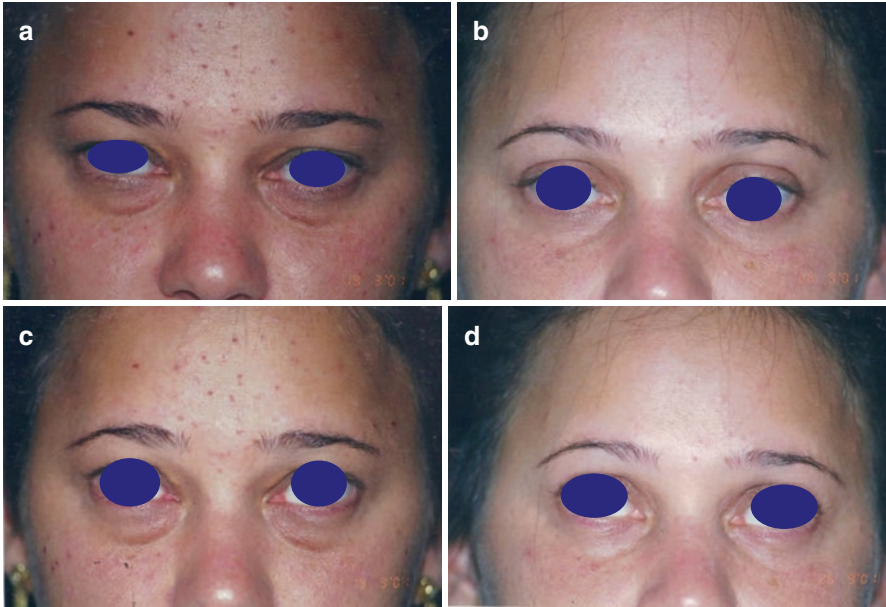
Nevertheless, I have found several unaesthetic abnormalities on cutaneous and subcutaneous tissue on the malar eminences, which is not the projection of the classical fat bags below the orbicularis oculi muscle and the orbital septum. In fact, there is some deep depression just above the rim margin of the inferior orbital bone (Fig. 15.1).



**Fig. 15.2** Female patient presenting cutaneous folds and depression on malar rim with abundant fat bag on both sides: photos (a, c) before surgery; (b, d) show the final result after lower reverse blepharoplasty

Also, exaggerated projection of fat bags above the orbital margin which develops unaesthetic deep level of the skin either exuberates cutaneous fold on limit of palpebromalar with severe unaesthetic appearance (Fig. 15.2). Some patients present wide and unaesthetic striae which require specific resection for adequate treatment (Fig. 15.3). The most frequent abnormality on the lower lid is hyperpigmented skin, which is responsible for very dark skin (Fig. 15.1).

Meanwhile, I have noticed that these problems usually are asymmetric which cause even more unbalance to facial contour. Such situations have been mentioned for a long time, since Rees called them as secondary bags, and in some cases, he referred to a history of recurrent swelling during the menstrual period [16]. I do not agree with that, since most of my patients presenting malar abnormalities are males. In fact, in almost all male patients, reverse lower blepharoplasty must be performed, since the orbicularis muscles are very thick and heavy which sometimes needs to be removed. Also, Castañares mentioned those adiposities as a palpebromalar bag or a blepharogenian bag or a secondary eyelid pocket [10, 11]. He suggested secondary skin resection 3 months after a standard blepharoplasty. Again, I disagree with this secondary procedure in a very short period postoperatively. Thus, indication of the technique and selection of the patients for it were very important steps in achieving harmonious results.



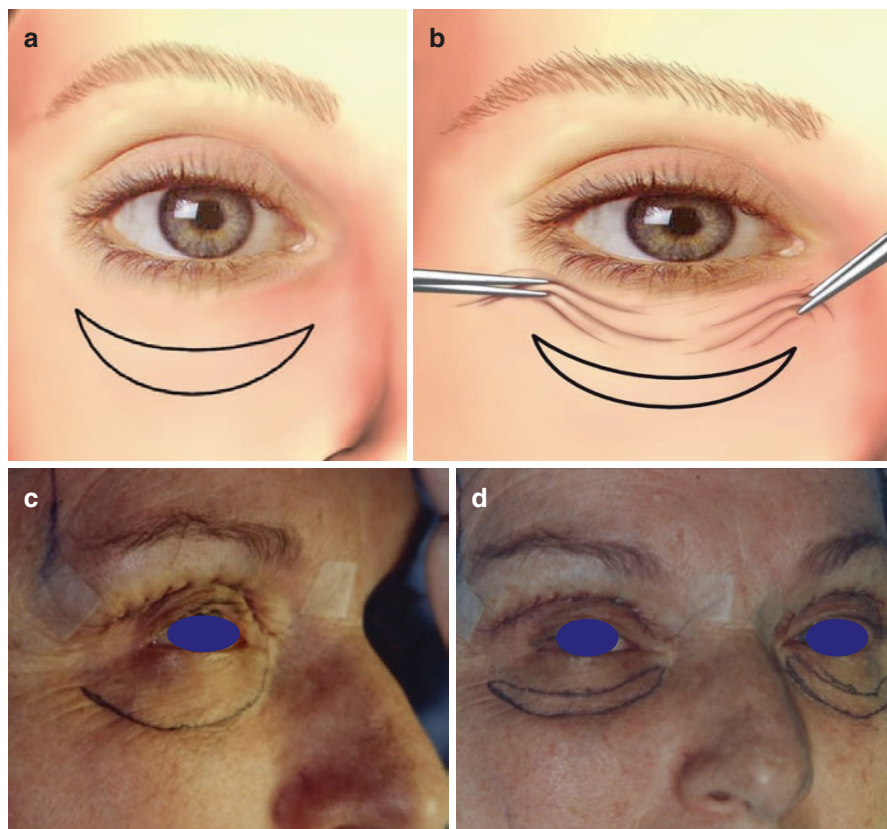
**Fig. 15.3** A 22-year-old female patient presenting unaesthetic striae and cutaneous depression on malar rim with abundant fat bag fold: photos (a, c) before surgery; (b, d) surgical result after lower reverse blepharoplasty

## Technique

There are several abnormalities on lower lid and on palpebromalar eminence that require more than a traditional blepharoplasty. The excess skin, fat bags, and other situations may be solved through conventional procedures, but there are severe depressions, cutaneous folds, hyperpigmented skin on lower lids, and other unaesthetic anomalies that may be treated with the use of my approach previously described [2, 4].

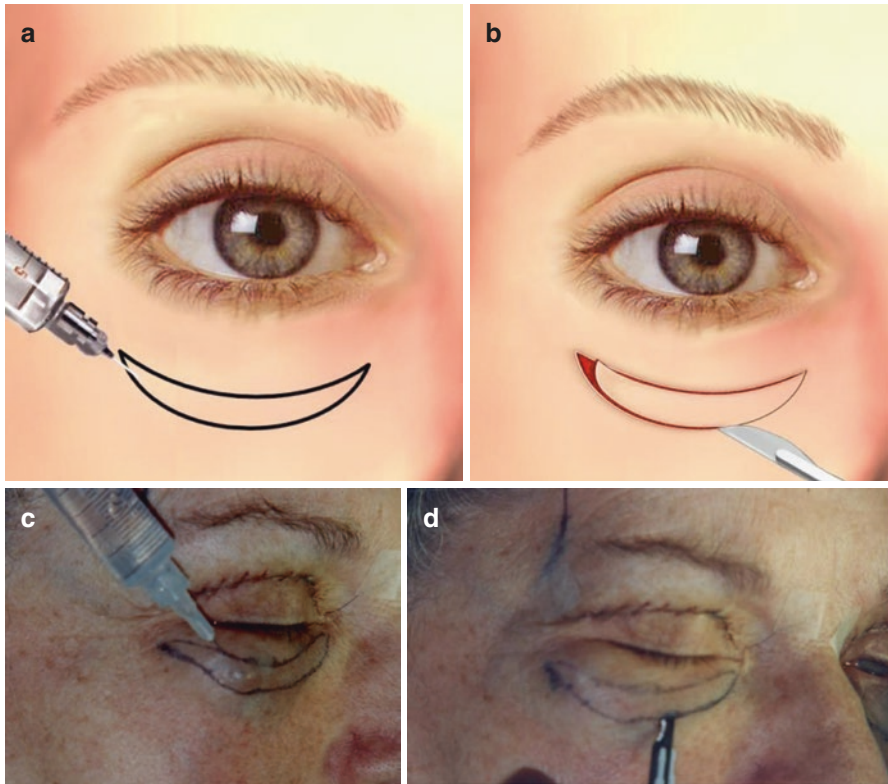
All my patients that underwent reverse lower blepharoplasty in the upper lids were operated at the same procedure which is done before lower lid surgery. The cutaneous resection should not extend beyond the palpebral area, as recommended by Pitanguy et al. [15].

Surgical demarcation must be done carefully, with the patient in the operating room under intravenous sedation (Fig. 15.4). That is an opposite situation when lipoabdominoplasty is performed since the patient must stay in standing position for proper demarcations. The first reference line is the palpebromalar line from the nasojugal fold to the lateral end of the malar margin. The demarcation of this line is the key for the further steps before surgery. It should be done on the proper limit, since if it is drawn out of it, the final scar will not be so good. The width of the cutaneous resection depends on the abnormality of each patient, but the amount of skin excised is much larger than that in conventional lower blepharoplasty. When patients present complex deformities on lower lids, it is mandatory to identify them during demarcation. The remaining skin above the area where skin resection will be done must be wide enough



**Fig. 15.4** Surgical demarcations: drawing (a, b) the lower eyelid is demarcated as a skin ellipse near the inferior orbital margin; perioperative photos (c, d) demarcation is done

to cover the entire lower lid (Fig. 15.4). The operation is performed under local anesthesia combined with intravenous sedation. Local infiltration is done subcutaneously using 0.40 mg xylocaine with epinephrine (1/200,000) to separate the skin from the orbicularis muscle (Fig. 15.5). Cutaneous incisions follow the drawn lines, and the skin is resected so that the subcutaneous adiposity or skin depression when it is present is included (Fig. 15.6). A raw area is created after skin resection is performed where each patient presents local abnormalities (Fig. 15.7). The orbicularis muscle is opened with scissors to expose the orbital septum which is also incised. The excess fat bag is resected, and careful hemostasis is done (Fig. 15.7). The necessity to remove some amount of orbicularis oculi muscle is very rare, since it lies smoothly over the fat bags underneath. It is not necessary to suture either the orbital septum or the orbicularis oculi muscle. Cauterization is done only when the excess of bag fat is removed. The skin incision is stitched with a subcuticular running suture of 60 mononylon and covered with adhesive tape (Fig. 15.8). I do not use any closed dressing on the eyelids, just wet gauze or cotton which may be changed at any time. The running suture is removed 4 or 5 days after surgery. Once again, tape covers the wound during the next 10 days.

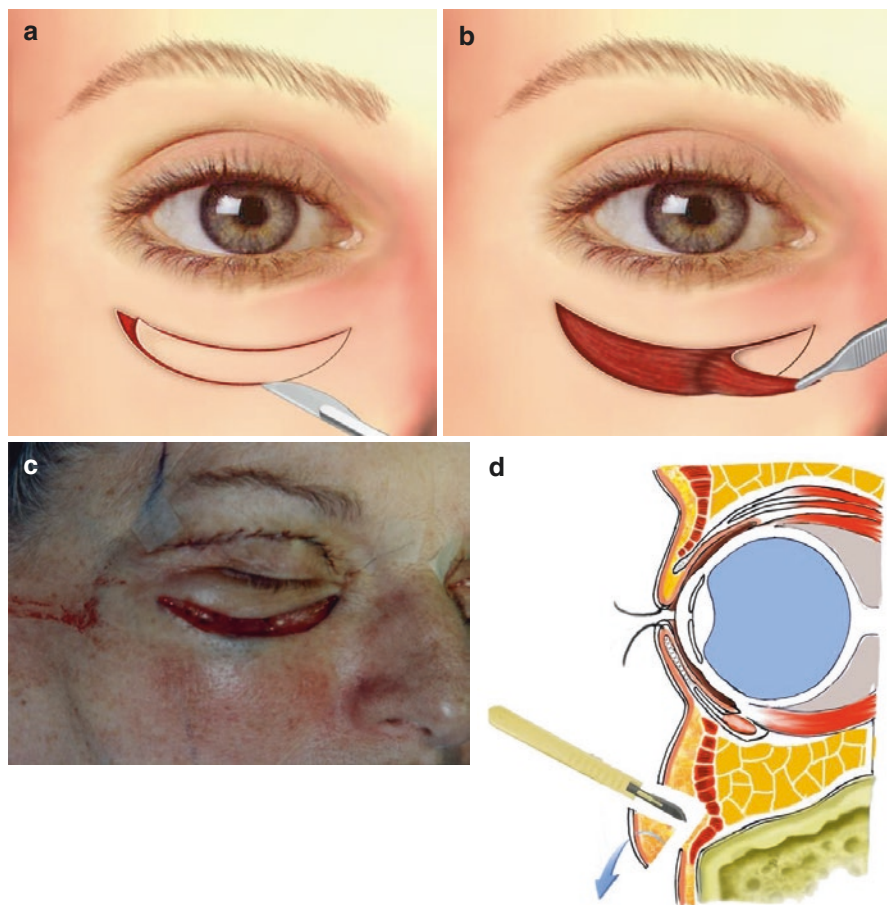


**Fig. 15.5** Local infiltration and cutaneous incisions: drawing (a, b) perioperative; photos (c, d) showing both procedures

## Complications

Some complications after blepharoplasty such as ectropion may be due to excess removal of skin and muscles on the lower eyelids. According to Castañares, ectropion following blepharoplasty is one of the most frequent and severe complications [11]. As several abnormalities on lower lids are not possible to solve in the use of conventional blepharoplasty, the reverse lower blepharoplasty is a useful method to properly treat those deformities [2].

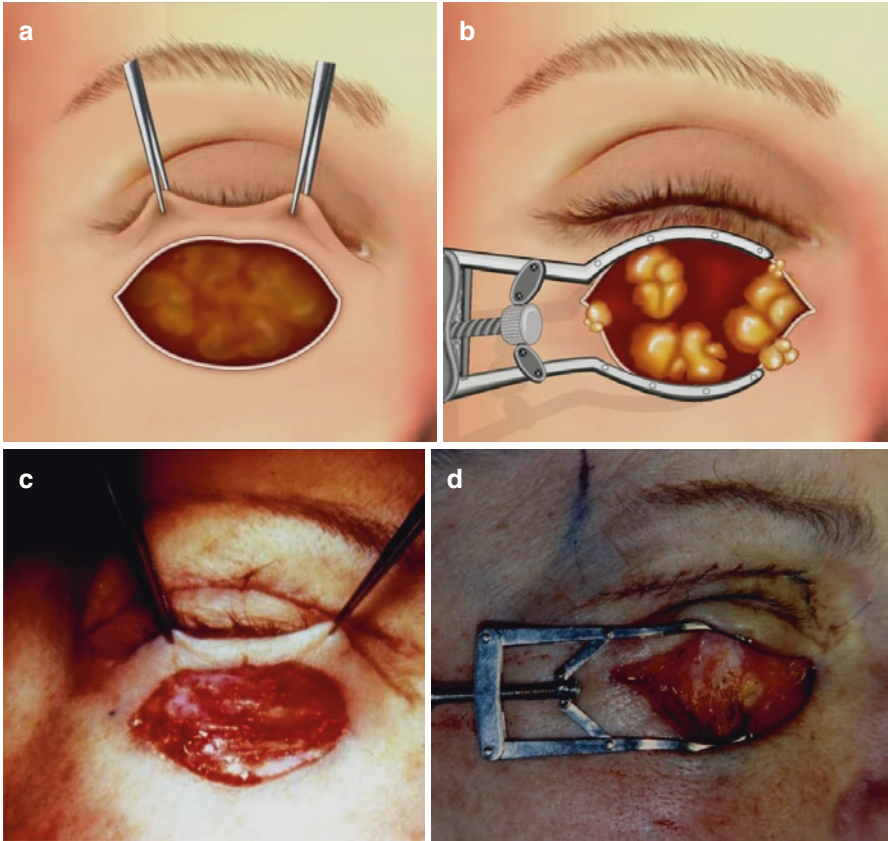
The final cutaneous scars look good and are not noticeable, even invisible in most patients. I have not had any postoperative complications, but it is important to mention again careful preoperative evaluation and adequate surgical planning. Once again, it should be emphasized that the majority of my patients present severe asymmetry of the deformities. In some patients, I perform conventional operation in one side of the lower lid and reverse lower blepharoplasty in the other. The lower eyelids present comfortable postoperative recovery with few edema or any other problems after surgery (Figs. 15.9 and 15.10). It is important to say that the use of adhesive tapes covering the surgical scars may avoid unaesthetic results.



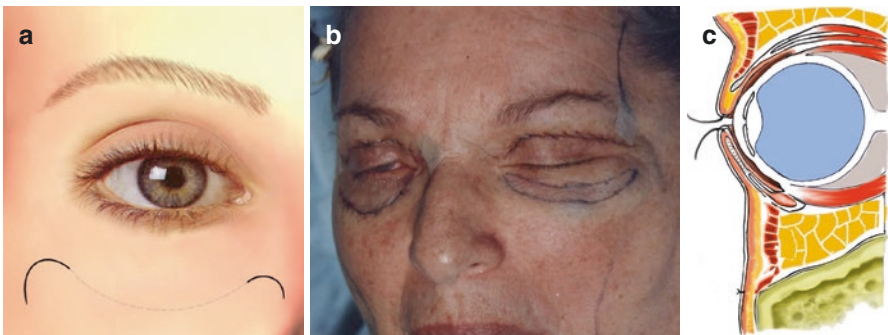
**Fig. 15.6** Cutaneous resection: drawings (a, b) incisions following surgical demarcations; (c) perioperative photo showing the raw area after resection; (d) drawing on lateral view to demonstrate cutaneous and subcutaneous resection

## Discussion

Ever since I described reverse lower blepharoplasty [2] which is a useful procedure for treatment multiples abnormalities on the lower lid, I founded similar surgical principles with my new concepts for lipoabdominoplasty which are employed for treatment of flank lipoplasty, inner thigh lifting, and aesthetic surgery of the axilla [5–9]. Patients presenting excess subcutaneous adiposity, redundancy of skin, unaesthetic fold on the malar eminence, severe depression above the malar rim as well as many other situations in their treatment present some relationship with surgical principles of lipoabdominoplasty. In fact, when lipoabdominoplasty is performed, liposuction is done in order to remove the excess of localized adiposity. Therefore, after liposuction localizes, adipose tissue is removed, and the local skin

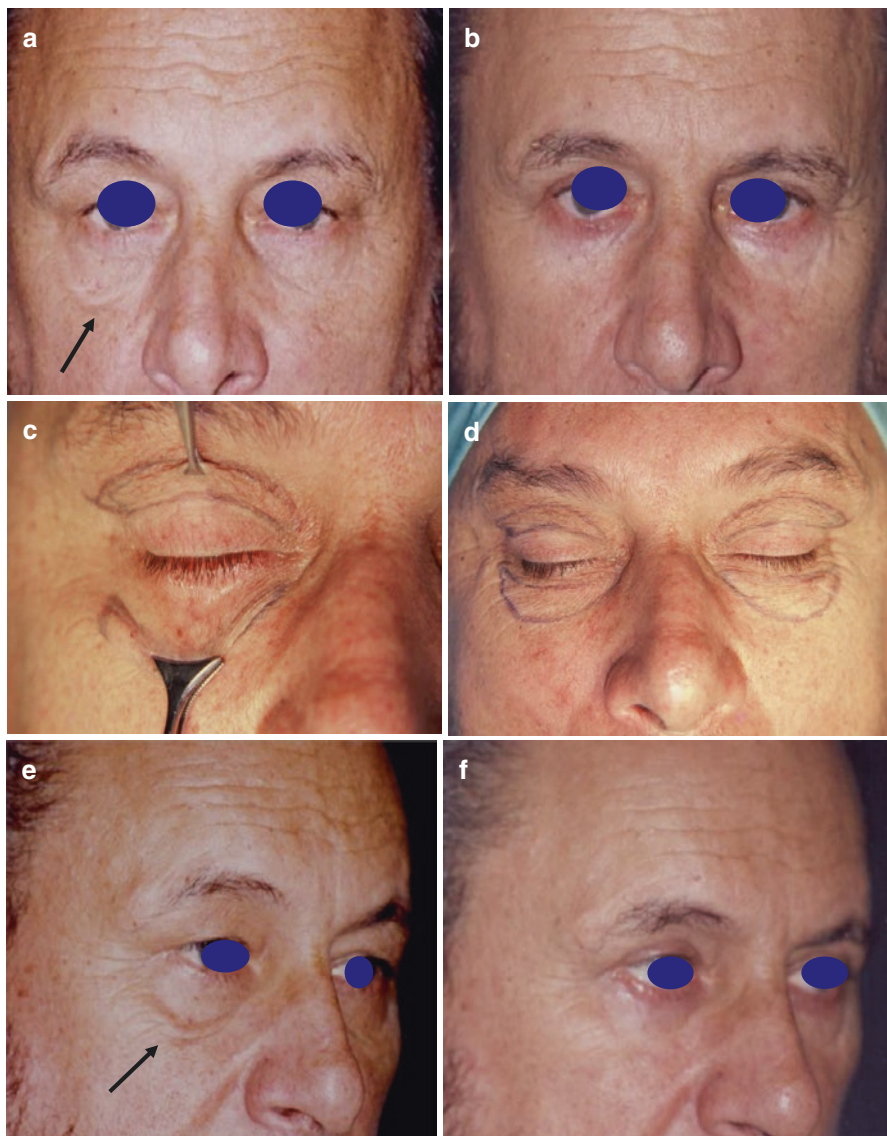


**Fig. 15.7** After cutaneous resection, the fat bags are removed: (a, b) drawings show the skin was resected; photos (c, d) demonstrate perioperative procedures

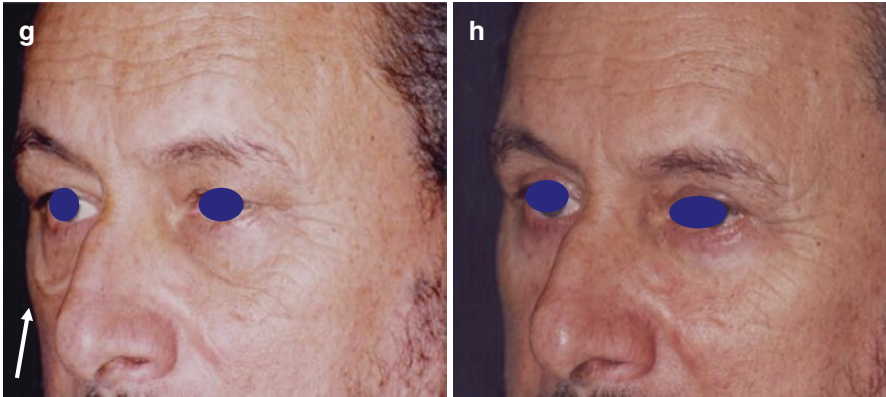


**Fig. 15.8** After cutaneous suture on right side: drawing (a, d) photo (b) show the final suture on right lower lid; scheme (c) on profile view presents the final result after suture, since the remaining panniculus without any cutaneous undermining lies smoothly on the raw area

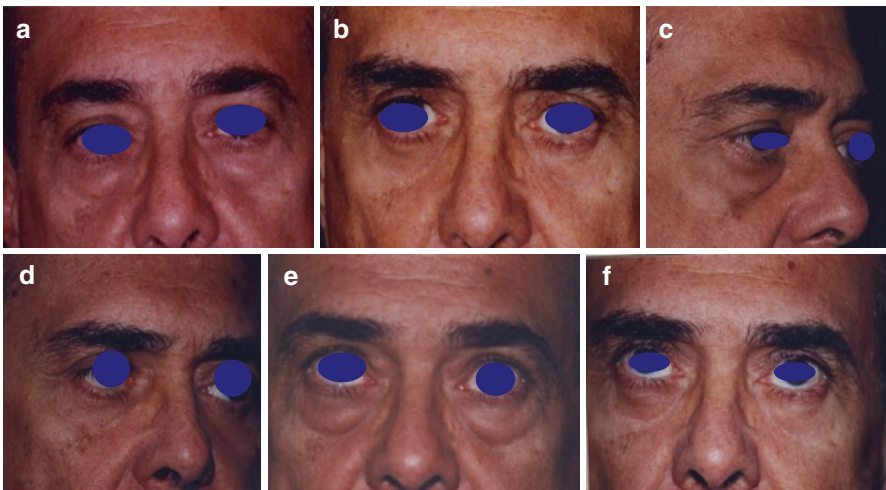




**Fig. 15.9** Male patient presenting cutaneous fold on malar margin of the lower lid on right side: photo (a) before operation, the arrow shows unaesthetic cutaneous fold on the right side; (b) photo after surgery without cutaneous fold; (c) – during demarcation – using a forceps evaluates the excess of skin that will be resected; (d) after demarcation. Photos (e, g) oblique view the arrows indicate the cutaneous fold before operation: photos (f, h) postoperative photos showing inconspicuous scars on lower malar rim



**Fig. 15.9** (continued)



**Fig. 15.10** A 68-year-old male patient presenting unaesthetic and cutaneous depression on malar rim with abundant fat bags on both sides: photos (a, c, e) before operation; (b, d, f) after reverse lower blepharoplasty. Photos (e, f) show the patient looking upward

shows accentuated depression similar to that on lower lids with unaesthetic appearance. Usually, these unaesthetic deformities are very difficult to remove through conventional blepharoplasty. These cases present very heavy and ptotic lower lids which sometimes show unsatisfactory results for the treatment of these problems with traditional lower blepharoplasty. The excess skin, cutaneous depressions, redundancy of muscles, and subcutaneous fat are not removed properly when standard methods are employed. Removing these excess skin and muscles through a cutaneous incision close to the ciliary border of the lower eyelid does not produce a good result in complex cases.

During long periods of time, I have used my method on more than 65 patients with several years follow-up with smooth and anatomical configuration to the eyelids showing very good results.

My first patient was a 48-year-old female that presented severe deformity due to xanthelasma on the lower and the upper lids on both sides. As the skin color presented colorless areas on upper lids corresponding to the area of skin resection on conventional cutaneous demarcation, it was natural to perform upper blepharoplasty. However, the problem on the lower lids was out of the range of the skin resection of traditional blepharoplasty. The xanthelasma covered a wide area along the palpebral fold on the projection of the lower orbital rim. That area would not be resected if the standard procedure was used. Therefore, the main problem of the patient would not be totally solved. Therefore, skin resection has to be done to solve her problem concerning the removal of the unaesthetic presence of the xanthelasma area and simultaneously perform a cutaneous excision in order to rebuild the lower lid and yield a good aesthetic result. An interesting suggestion was proposed by Le Roux to modify incisions for lower and upper blepharoplasty that most deposits of xanthelasma are within the area to be excised [12].

Skin resection should extend from the nasojugal fold to the lateral border of the orbit. Despite these considerations, the final scars have been smooth and excellent in appearance. To perform the operation for removal of the xanthelasma area via a direct approach is only one problem, but every other abnormality may be treated as well.

During the postoperative period, the patients did not develop edema or any other disagreeable feature on the lower lids. Also, the final scars were not unsightly; this could be attributed to the site of the surgical incision. The final aesthetic result was good. The scars were well located and less visible than a fine wrinkle that is seen when looked for closely. For this reason, I am continuously indicating my procedure to solve several deformities of the lower lid that have been dealt with unsatisfactorily with standard blepharoplasty.

Selection of the patients is an important step for indication of the method. Candidates are those patients with excess skin and subcutaneous adiposity that cause an unaesthetic fold on the malar eminence (Figs. 15.1, 15.2, and 15.3). Using this procedure, it is possible to remove an amount of skin, localized subcutaneous adiposities, and deep and ungraceful depressions above the rim margin of the orbital bone that would be impossible with conventional blepharoplasty.

Secondary operation 3 months after lower blepharoplasty was proposed by Castañares [11]. Furthermore [16], also advocated secondary resection of the cutaneous fold or several small-dose injections of steroid [17]. I do not recommend such treatment because the skin of lower lid is very thin and that every single irregularity underneath may be noticed through the cutaneous covering.

Also, I have employed my reverse lower blepharoplasty as an adequate approach to be used as another way to treat malar fractures as well as this bone's osteotomy.

## Conclusion

Similar surgical principles of lipoabdominoplasty are employed to perform reverse lower blepharoplasty: full-thickness skin resection combined with preservation of perforator vessels and absence of panniculus undermining are the essential fundamentals in this method. Although liposuction technique is performed in all cases of lipoabdominoplasty, it is obvious that it is not done in lower reverse blepharoplasty.

Postoperative follow-up of my technique shows that the scars must be properly situated in order to present good result even after a few months after surgery. For this reason, I have employed this method more often. When the lower lid shows a typical appearance, a reverse lower blepharoplasty is indicated. This method is a good one for those cases where conventional blepharoplasty would seem to give unsatisfactory results, such as cutaneous fold on malar rim due to redundancy of skin.

This method is a new one for lower blepharoplasty to correct excess skin, subcutaneous adiposity, and deep depression on the rim margin localized on the malar eminence. When the conventional procedure is used, those problems are not solved properly by requiring a secondary operation, and the results are not satisfactory. The surgery is performed under local anesthesia, removing skin and subcutaneous tissue and leaving a fine and invisible scar on the lower malar rim.

## References

1. Avelar JM (1988) Abdominoplastia – reflexões e perspectiva biopsicológicas (Abdominoplasty – Reflections and bio-psychological perspectives). *Rev Soc Bras Cir Plast* 3(2):152–154
2. Avelar JM (1988) Reverse lower blepharoplasty: a new approach. *Aesthetic Plast Surg* 12:45–50
3. Avelar JM (1989) Regional distribution and behavior of the subcutaneous tissue concerning selection and indication for liposuction. *Aesthetic Plast Surg* 13:155–165
4. Avelar JM (1996) New surgical technique for correction hyper pigmentation of the eyelids. (Dark eyelid). Nova técnica cirúrgica para corrigir hiperpigmentação das palpebras (olheiras) *Rev Bras Cir* vol 229–237
5. Avelar JM (1999) A new technique for abdominoplasty – closed vascular system of subdermal flap folded over itself combined to liposuction. Editora Cidade Científica Ltda. Rio de Janeiro (Brasil). *Rev Bras Cir* 88/89(1/6):3–20
6. Avelar JM (1999) New concepts for abdominoplasty (Novos conceitos para abdominoplastia). Paper presented at the 36th Congress of the Brazilian Society of Plastic Surgery. Trabalho apresentado no 36º Congresso da sociedade Brasileira de Cirurgia Plástica. Rio de Janeiro
7. Avelar JM (1999) Plastic surgery on inner side of thigh - New Concepts and Technique without cutaneous or subcutaneous undermining. Editora Cidade científica Ltda. Rio de Janeiro (Brasil). *Rev Bras Cir* 88/89(1/6):57–67
8. Avelar JM (1999) Flankplasty and Torsoplasty – New surgical approach. (Flancoplastia e Torsoplastia – Nova abordagem cirúrgica). Editora Cidade Científica Ltda. Rio de Janeiro (Brasil). *Rev Bras Cir* 88/89(1/6):21–35

9. Avelar (1999e) Aesthetic Plastic surgery of the axilla – A new technique to the treatment of excess skin, hiperhidrosis, cutaneous flaccidity, hypertrichosis and bromhidrosis. (Cirurgia plastica e estética de axila – Uma nova técnica para tratamento de excesso de pele, hiperhidrose flacidez cutânea, hipertrícose e bromidrose – Editora Cidade científica Ltda. Rio de Janeiro (Brasil). *Rev Bras Cir* 88/89, (1/6), pp 41–54
10. Castañares S (1951) Blepharoplasty for herniated intraorbital fat. *Plast Reconstr Surg* 8:46
11. Catañares S (1977) Classifications of baggy eyelid deformity. *Plast Reconstr Surg* 59:629
12. Le Roux P (1977) Modified blepharoplasty incisions: their use in xanthelasma. *Br J Plast Surg* 30:81–83
13. Loeb R (1976) Hypertrophy of the orbicularis muscle and its influence on the bulk of the palpebral pouches. *Cir Estét* 1:7
14. Loeb R (1981) Fat pad sliding and fat grafting for level in lid depressions. *Clin Plat Surg* 8:4
15. Pitanguy et al (1971) Blepharoplasty (Blefaroplastia). *Rev Bras Cir* 11–12:193–199
16. Rees TD (1973) Blepharoplasty. In: Rees TD (ed) *Cosmetic facial surgery*. W.B. Saunders, Philadelphia, pp 44–50
17. Rees TD (1980) Baggy eyelids. In: Rees TD (ed) *Aesthetic plastic surgery*. W.B. Saunders, Philadelphia, pp 463–469

# Chapter 16

## Medial Thigh Lipoplasty: New Concepts (A Technique Without Skin and Panniculus Undermining)

Juarez M. Avelar

### Introduction

My new concepts for abdominoplasty are also employed for treatment of unaesthetic deformities of localized adiposities with excess panniculus on medial thigh [8, 9]. In fact, the surgical principles of the procedures on both regions are similar since the inner thigh presents the same abnormalities as may occur on the abdominal wall. Even, the anatomy of both regions presents similarity on structures as described in my previous publications [4–6]. For these reasons, the aesthetic surgery on medial thigh is improved, although it is not a frequent procedure among most plastic surgeons.

Since the remarkable Pitanguy's publication [26] regarding trochanteric lipodystrophy operation, medial thigh may be treated simultaneously. It is an eclectic procedure to treat several unaesthetic deformities of the buttocks, posterior and inner aspects of the thigh to remove local adiposities, as well as cutaneous flaccidity. The scientific publications regarding treatment give more attention to trochanteric regions and buttocks but less emphasis to the inner side of the thighs. The surgical principle is the subcutaneous undermining described by Farina et al. [14], with vertical incision in the thigh. Delerm and Cirotteau [13] had described dermis flap in the search sustentation to the gluteo-cruris scars, as well as Vilain [29], Baroudi [12], and Planas [27]. Guerrero Santos [18] used dermal flap to maintain the scar of the gluteal sulcus. Grazer [17] and Agris [1] proposed dermal fat flap also with wide undermining. Later, suspension by superficial fascia of the buttocks, flanks, and thigh was described by Lookwood [25], but all those procedures are performed

---

J.M. Avelar, MD

Head of the Brazilian Scientific Institute of Plastic and Reconstructive Surgery,  
Al Gabriel Monteiro da Silva, 620 Jd Europa,  
São Paulo, SP 01442-000, Brazil  
e-mail: [juarezavelar@bol.com.br](mailto:juarezavelar@bol.com.br); [institudodaorelha@uol.com.br](mailto:institudodaorelha@uol.com.br)

through wide subcutaneous undermining with so many traumas to the panniculus as described by Franco [16]. My anatomic descriptions of the panniculus [4–6] were fundamental steps some years before other publications concerning fascia superficialis. In fact, since my anatomical research, I was looking for a safe abdominoplasty procedure to avoid all severe complications that used to occur during and after surgery. Later I will describe a procedure to create a natural and definitive inguino-crural crease during the treatment of medial thigh lipoplasty [7] which was the beginning of new concepts for surgical correction without panniculus undermining.

Nevertheless, with the advent of liposuction technique developed and popularized by Illouz [19–21, 24], aesthetic treatment of lower limbs was improved to reshape body contouring but the excess of cutaneous and panniculus was still a problem.

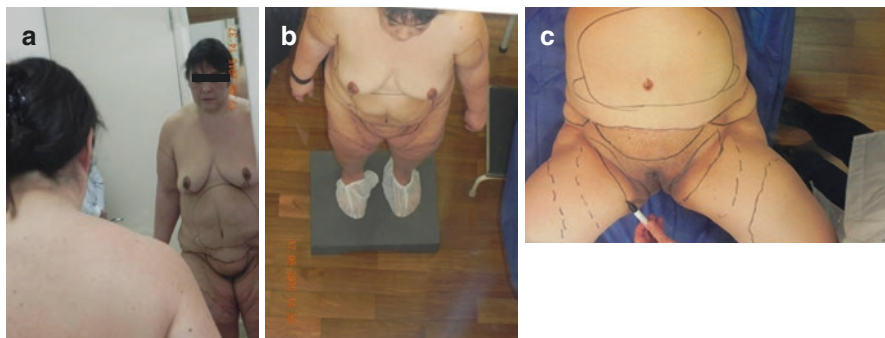
In the meantime, accumulated adiposities, excess and flaccidity of skin, and presence of hair are the main abnormalities of the inner thighs, causing aesthetic and functional disorder. A combination of liposuction with panniculus resection was a traumatic procedure since bleeding during and after operation used to be quite often even leaving ungraceful final scars.

Due to that associated procedures [3], several complications used to occur during and after operations which instigated me to devote much time performing anatomical dissections on cadaver to find out about the unknown compartment until that time, corresponding to the subcutaneous layers [4, 5]. Therefore, application of my surgical principles is the result of anatomical research and the necessity of removal of excess skin after performing liposuction to achieve adequate improvement on body contouring.

My previous anatomic research in cadavers demonstrated that it would be possible to perform panniculus resection combined with liposuction, as far as the perforator vessels would be preserved. That is the basic fundament of my new concepts which I was looking for with obsessive pursuit. According to my studies, full-thickness suction of the subcutaneous tissue was done on an elliptic area near to the sulcus on medial thigh followed by skin resection. Afterward liposuction was done below the fascia superficialis that is underneath the areolar layer of the panniculus which slides from dawn upward from one border to another to facilitate the suture of the surgical wound [9].

My first patient was a female with dark and thick skin with localized adiposity on medial thigh region. Constant contact from one side of the thigh to the other due to the volume of accumulated fat can achieve exaggerated proportions causing disfigurement of the region with impaired walking causing dermatitis and consequently immense physical discomfort. Very often the appearance of the skin is modify due to the friction between the two surfaces of the thighs which can develop areas of pigmentation (very dark skin) and even hard and thick skin, further increasing the intimate disturbances.

According to my anatomical dissection on cadavers, it was clear to me that a new procedure could be performed in order to suck the accumulated fat combined with skin resection due to redundant cutaneous covering after fat suction with



**Fig. 16.1** Surgical planning and surgical demarcations for medial thigh lipoplasty: (a, b) a 48-year-old female patient in front of two vertical mirrors with the other one placed on 45° angle on the ceiling. So she can see herself in front and back and also from the top following my demarcation procedure. (c) The photo of the patient on supine position on my examining bed taken from herself. So she knows where the scars will be located and the areas for liposuction procedure

minimal complications. In my original publications [8–11], this method was employed for treatment of abdominal wall, medial thigh lift, flanks, and axilla as well.

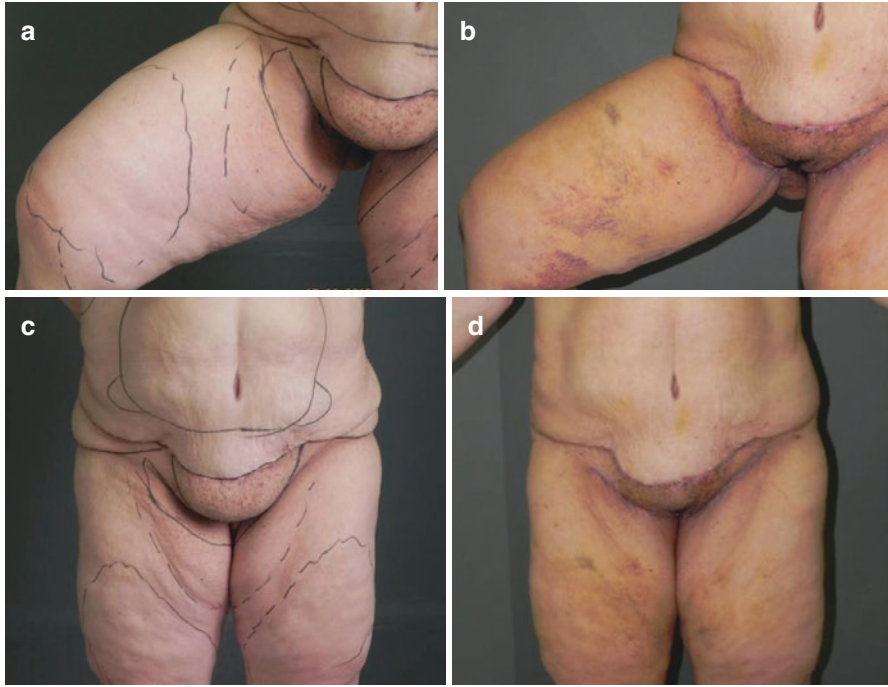
## Technique

### *Surgical Demarcations*

Surgical evaluation and planning is an obliged stage before performing medial thigh lipoplasty operation [15]. I used to do physical evaluation with the patient in standing position between two vertical mirrors, one in front of the other. It is very useful since the patient can see her/his body in front and back view at the same time (Fig. 16.1a, b). I created such organization with mirrors because quite often patients present some body asymmetries which were not yet noticed. Besides the vertical mirrors, there is another one horizontally located above the examine table through which patient can see her/his medial thigh while surgical demarcations are done (Fig. 16.1c). It is useful to show to the patient all abnormalities on medial thigh such as localized adiposities, excess and flaccidity skin, dark and thick panniculus, and other unaesthetic anomalies. The “pinching test” introduced by Illouz is an adequate procedure during clinical evaluation and surgical planning and demarcations on the internal regions of the thigh [20, 22, 23].

Adequate evaluation of the excess skin on those regions depends on the surgeon’s experience and appropriate analysis of the cutaneous covering to judge how much it should be resected (Fig. 16.2). In cases without skin flaccidity and without cutaneous excess, liposuction technique alone may achieve excellent results. Nevertheless, when there is excess skin and flaccidity, it is mandatory to perform a combined procedure according to my original description [9].





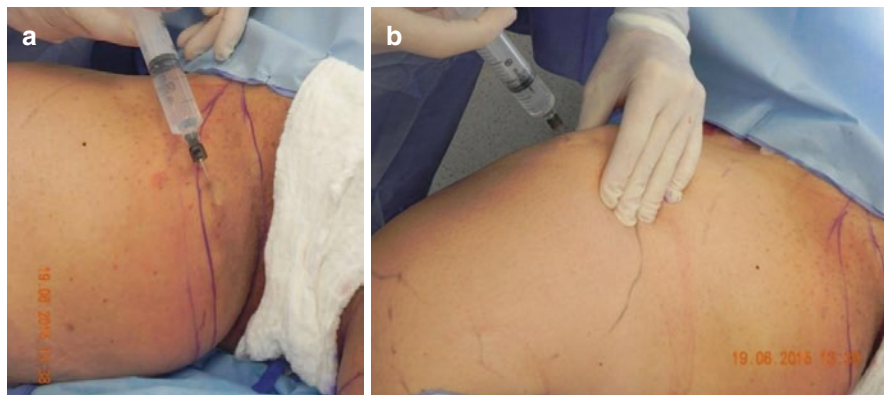
**Fig. 16.2** Surgical demarcations for medial thigh lipoplasty: photos (a, c) of a 48-year-old female patient show the area for skin resection with continuous lines on inguino- and genitocrural sulcus; the area for liposuction is demarcated with dotted lines. Photos (b, d) of the same patient three weeks after surgery

Initially one marks the line on inguino-crural and genitocrural sulcus on each side. Following demarcation, two cutaneous areas are delimited. The first one is around the volume of adiposity usually on upper third of the inner side of the thighs (Fig. 16.1c). The second one is placed inside the area previously demarcated to establish the region of skin resection.

Local anesthesia combined with intravenous sedation in the restricted procedures to the internal face of the thighs may be used. However, in the association with other procedures in the inferior segment of the body, epidural or general anesthesia may be employed. In areas of future cutaneous resection, I do local anesthetic infiltration in the subcutaneous level with solution lidocaine 0.4 mg% with epinephrine 2 mg and serum 1.000 ml (Fig. 16.3a). Also deep infiltration is performed all over the area for liposuction below fascia superficialis (Fig. 16.3b).

## Liposuction Procedure

The first step of the operation is to perform liposuction procedure with bidigital maneuver of the panniculus all over the medial thigh area. It is performed on two levels:



**Fig. 16.3** Perioperative photos illustrate the infiltration procedure before surgery on two levels: (a) medial thigh of the right side being infiltrated on subcutaneous level and full thickness of the panniculus delimited with continuous line where full-thickness liposuction will be done and afterward skin resection. (b) Infiltration on full thickness of the panniculus on the anterior aspect of the thigh delimited with dotted lines where deep liposuction will be made

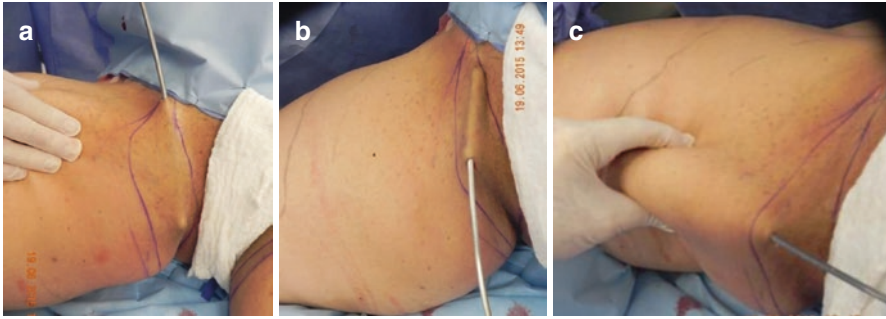
- (a) On full thickness of the panniculus
- (b) Deep liposuction

Full-thickness liposuction of the panniculus is done on area where skin resection will be performed (Fig. 16.4a, b). After liposuction procedure, one can see that the skin becomes deep and very close to the muscle level due to the absence of adipose tissue.

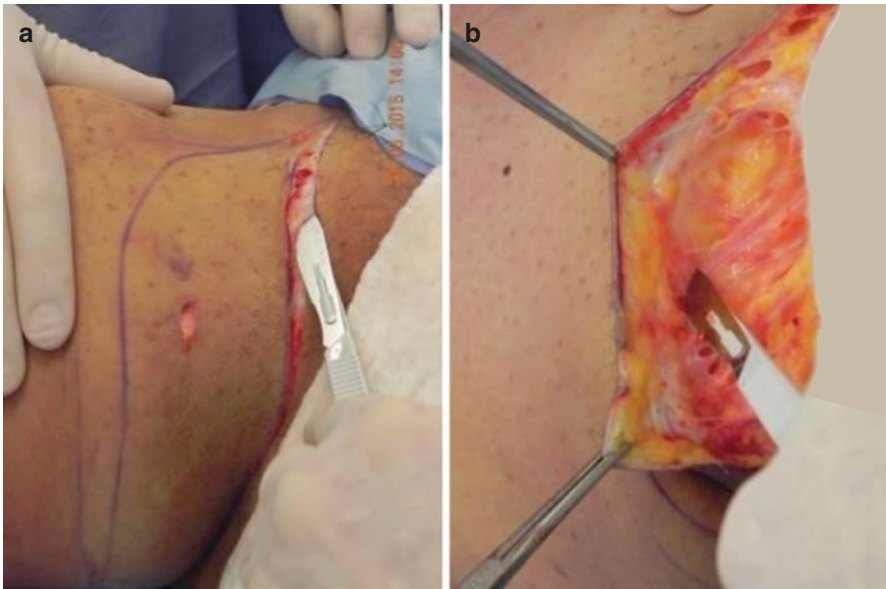
Deep liposuction is performed all over the remaining panniculus with accumulated adiposities. Deep liposuction means below fascia superficialis preserving all perforator vessels coming from the muscles underneath (Fig. 16.4c). For better performance, I use arched cannula, flattened with its open always directed toward the deep level. When the panniculus reaches the desired thickness means, it means that the areolar layer is regularly preserved.

## Skin Incisions and Cutaneous Resection

Skin incisions are done following surgical demarcations on the area where skin resection must be performed. It is carried out through the plan rigorously below the skin and above the vascular network of the region. The superior incision must be done 0.4–0.6 cm above of the inguino-crural and genitocrural creases creating a small dermal flap (Fig. 16.5a, b). This is the very small reproduction of the remnant dermal flap of my previous publication [7]. Afterward the knife goes deep until it reaches the subdermal level without any bleeding. Thus resection of full thickness of the skin is made, with all the histological elements, including follicles, sweat and sebaceous glands, and nervous ends (Fig. 16.6). It is possible to see connective tissues, vascular network, and the subdermal layer without any adipose tissue (Fig. 16.5).

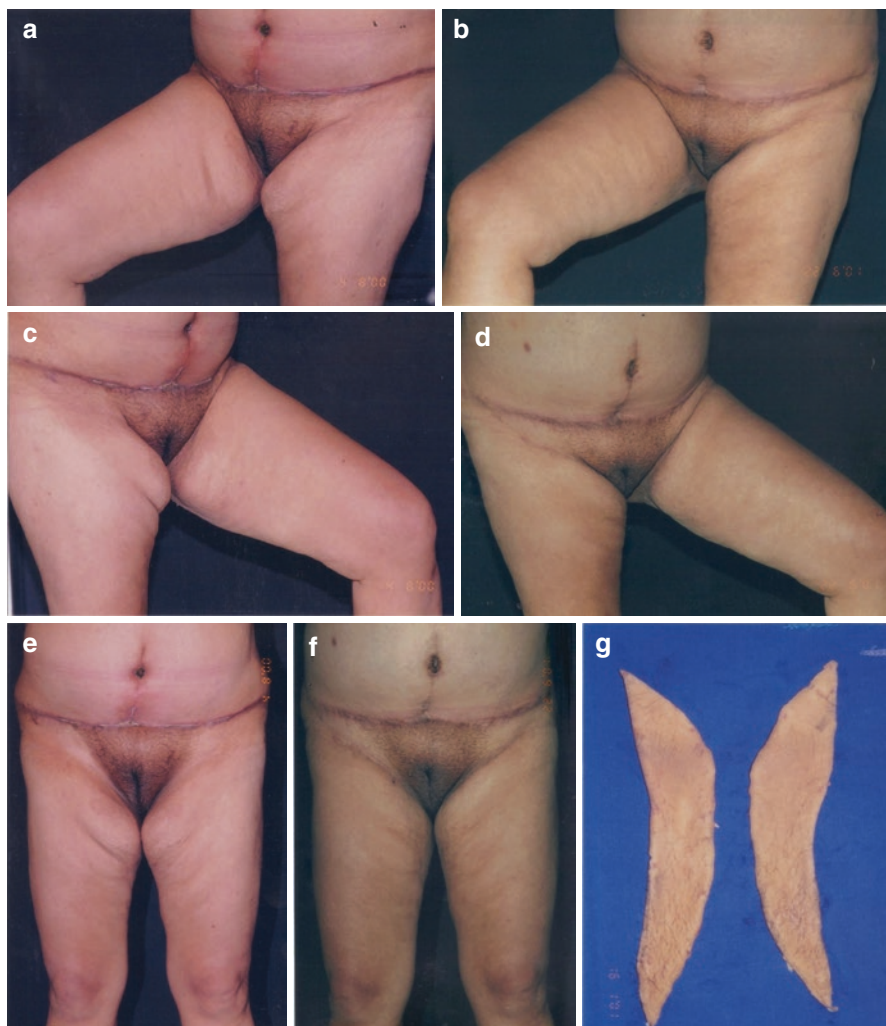

**Fig. 16.4** Perioperative photos showing liposuction procedure on the right side of medial thigh being performed as a closed vascular system: (a) liposuction being done on full thickness of the panniculus on area delimited with continuous line with the cannula introduced from up to down; (b) liposuction is done on the same area with the cannula introduced from down to up; (c) fat suction being performed on deep layer of the medial thigh with the cannula introduced from the inguinal crease downward



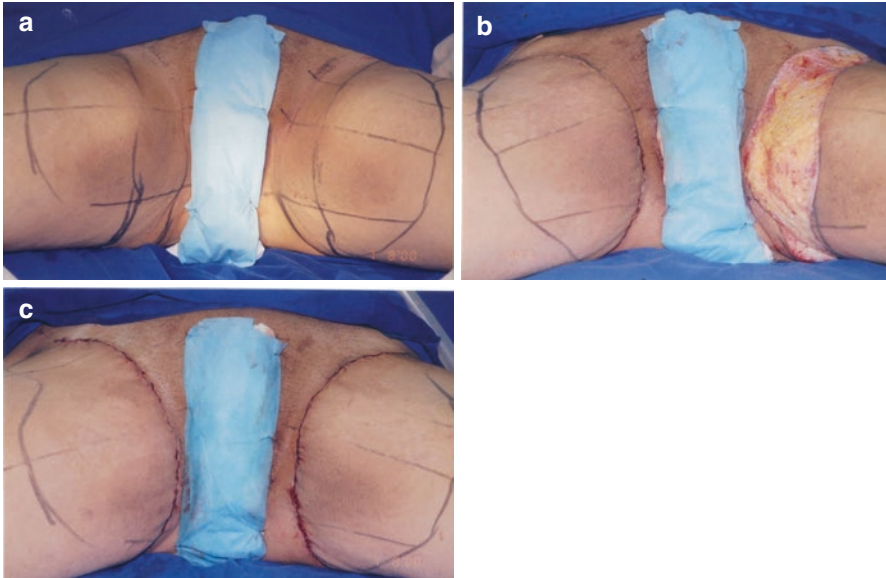
**Fig. 16.5** Perioperative photos showing skin resection on the right side of the medial thigh: (a) the incision is done with the knife incising the skin obliquely in order to create a dermal flap underneath; (b) the knife goes just below the skin until it reach the delimited with continuous line. One can see that there is no bleeding during surgery due to liposuction when it was performed as a closed vascular system

The suture of the surgical wound is done in three levels on the way to fix the upper border of the inferior cutaneous flap to the border of the superior segment. The main suture must be performed from fascia superficialis of lower border to the



**Fig. 16.6** Photos (a, c, and e) of a 49-year-old female patient presenting bilateral cutaneous flaccidity on the inner side of the thigh with hairy skin and abundant local adiposities. Photos (b, d, and f) of the same patient two years after medial thigh lifting combined with liposuction procedure. Photo (g) of the skin resected from both sides of the medial thigh showing excessive hair which caused discomfort and inferiority complex

same structures of the ligament of the inguino-crural and genitocrural fold with nonabsorbable mattress with isolated stitches (Fig. 16.7). Afterward subcutaneous suture is done with isolated stitches. Another important suture is from dermis of the lower border to the dermis of upper border. If it is necessary, a running suture may be done.



**Fig. 16.7** Perioperative photos of a female patient in supine position taken from down to up showing the right and left sides of medial thigh to demonstrate the sequence of the operation: (a) bilateral demarcation; (b) on right side the cutaneous suture is done after full-thickness liposuction followed by skin resection. On left side one can see the raw area where liposuction was made and also skin resection showing that the vessels are preserved and there is no bleeding; (c) final suture on bilateral inguino- and genitocrural sulcus

## Postoperative Dressing and Cares

As I do not perform subcutaneous undermining, there is no dead space, or any cavity below of the remnant internal surface of the thigh. Therefore, it does not have necessity of external compressive dressing as if it uses in other surgical modalities. Local adhesive tapes are applied to cover the wound which promote approximation of the border of the surgical wounds. When planning to do liposuction in other regions of the body, it must be done using garment over the thighs without any specific pressing.

## Complications

The final scars in the inguino-crural sulcus after medial thigh lipoplasty may migrate inferiorly below the level covered by normal swimwear even when there is not a great deal of tension on the incision. However, my procedure create a dermal flap which is a permanent anchoring sutures in the deep fascia as described help retard the inferior migration but will not prevent at all. A low inguino-crural incision can

be improved in some patients by de-epithelialization and repositioning. However, further full-thickness skin excision may be made as scar revision when it is necessary. Posterior scars may migrate down out of the gluteal crease if there is an excess resection from the upper portion of the posterior thigh. Scars that become displaced too low posteriorly are difficult to correct because of the distortion in shape of the buttock associated with a scar that has been pulled down, and the constant downward pull of the thigh exacerbates the problem.

A 45-year-old female patient, who had intensive hair on inner thigh, developed subdermal growth of hair 10 days after surgery with scratch (Fig. 16.6). Few days later, she underwent scar revision with the purpose of removing some hair follicles underneath the skin. Also another female patient developed a subcutaneous cyst due to growth of few hair follicles which were removed few days later. Those cases of complications demonstrated that all hair follicles must be removed during medial thigh lipoplasty operations.

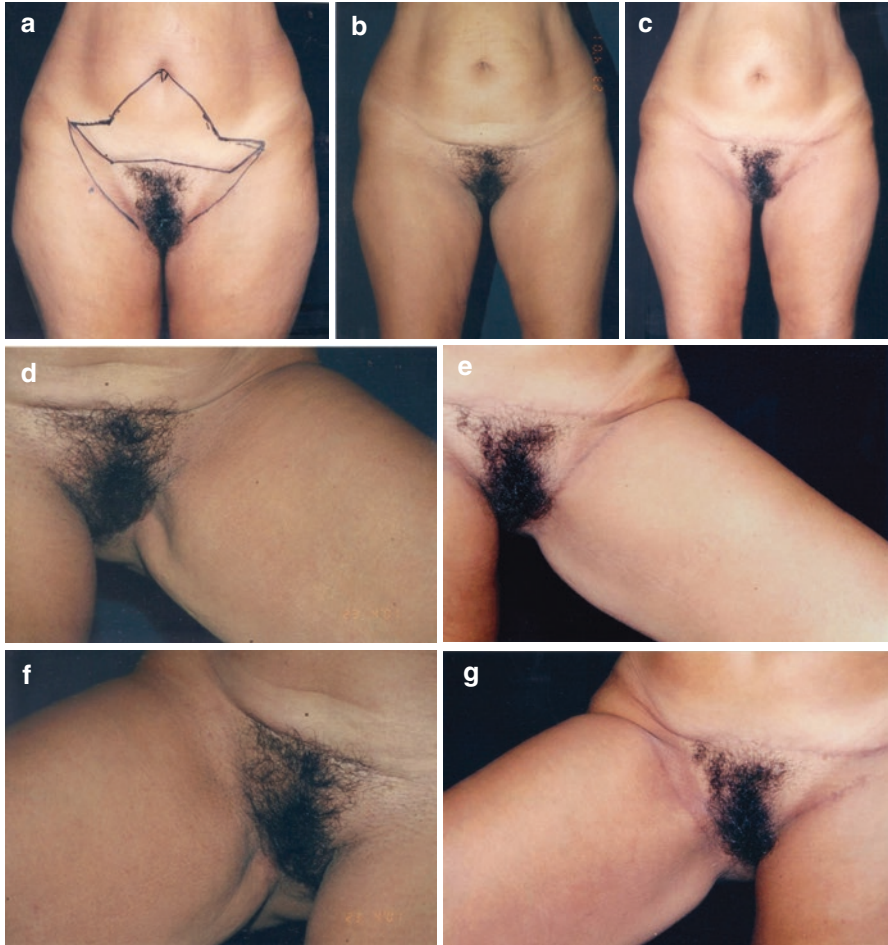The occurrence of two cases of growth of hair among more than a hundred operated patients does not invalidate the method. It means that when the patient presents hairy skin, the surgeon must be cautious to remove it during surgery. It is important to emphasize that the skin of the inguinal sulcus is quite thin presenting hairiness where one must perform cutaneous incisions and resection.

Three female patients with very flabby skin complain about the scars that were too low after surgery which require scar revision in order to lift them upward with suture to the deep structures.

For this reason, selection of patients and adequate surgical planning are so important before performing operation on medial thigh lipoplasty.

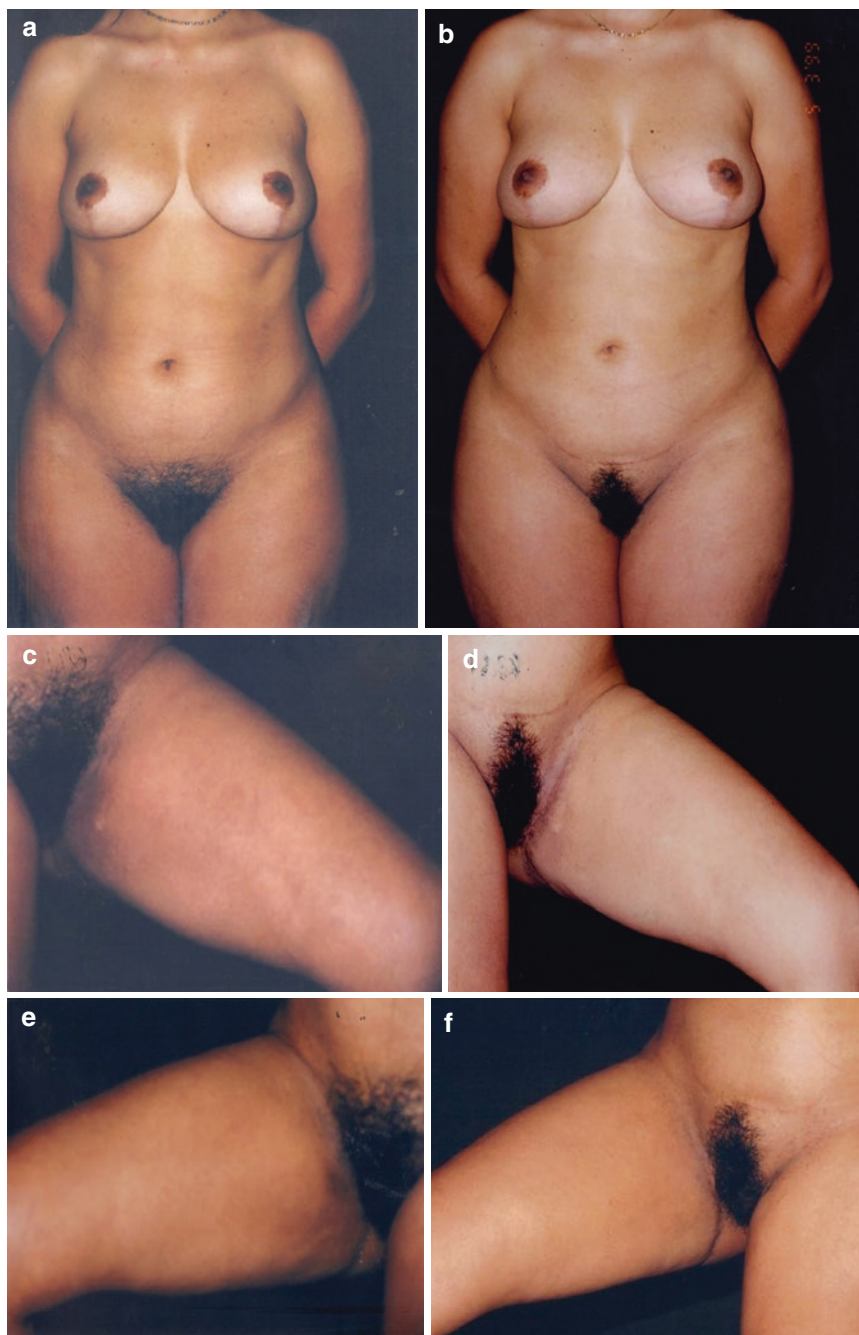
## Discussion

The technique for medial thigh lipoplasty is indicated on female and male patients presenting flaccidity and excess cutaneous covering and accumulated adiposities. This operation became more popular after Pitanguy's [26] publication which introduced wide treatment for reparation of buttocks, trochanteric regions, and medial thigh lifting. Afterward several authors presented their contributions to improve the contour on lower extremities. However the most important improvement came through liposuction technique introduced and popularized by Illouz [19, 20]. Nevertheless by using liposuction procedure, the excess of skin could not be treated properly. I was so much concerned about the problem that it became evident to me to perform liposuction combined with panniculus resection to reshape the body contour [2, 3, 7]. However a combined procedure of liposuction with skin or panniculus resection used to be a traumatic one since bleeding during and after operation was quite often even leaving ungraceful final scars. Those complications were not peculiar only on medial thigh lifting operation but in all regions of the body. After few years performing that associated procedures with severe undesirable complications in 1988, I took a radical decision of not performing it any more. Although no longer



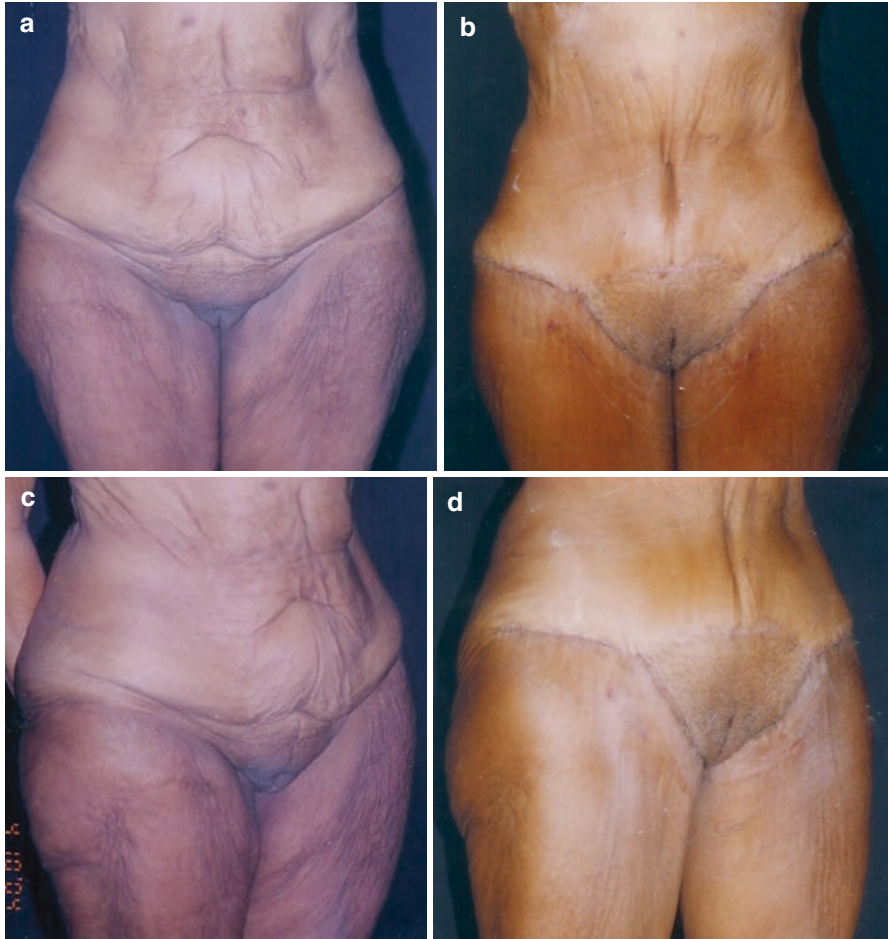**Fig. 16.8** Surgical result of medial thigh lipoplasty combined with lower abdominoplasty: (a) patient with demarcation of the area of skin resection where liposuction will be performed; (b) before surgery; (c) same patient after lower abdominoplasty combined with medial thigh lipoplasty. Photos of the same patient in close up: (d, f) before surgery; (e, g) – postoperative result of medial thigh lifting associated with lower abdominoplasty

caring out that combined operation, I devoted much effort to research on my previous study on the anatomy of the panniculus on all regions of the human body [4, 6]. As a consequence of my research, I concluded that it would be possible to perform that associated procedures since the perforator vessels were not cutting, such as without panniculus undermining nor resection (Fig. 16.8). In fact, my first patient was operated early 1998, meaning 10 years after my decision of not performing combined procedures of liposuction with skin resection. She presented very dark and thick skin on inner side of the thigh. The cutaneous covering was so hard and thick that she begged me to do liposuction and to remove a segment of the skin (Fig. 16.9). That new surgical condition instigated me to review my anatomical study on



**Fig. 16.9** Surgical result of medial thigh lipoplasty associated with lipoplasty of the abdomen: (a) before surgery with adipose tissue on abdomen and inner side of the thigh; (b) same patient after liposuction of the abdomen combined with medial thigh lipoplasty. Photos of the same patient in closed up of the inner side of the thigh: (c, e) before surgery showing very dark skin with localized adiposities; (d, f) postoperative result of medial thigh lipoplasty



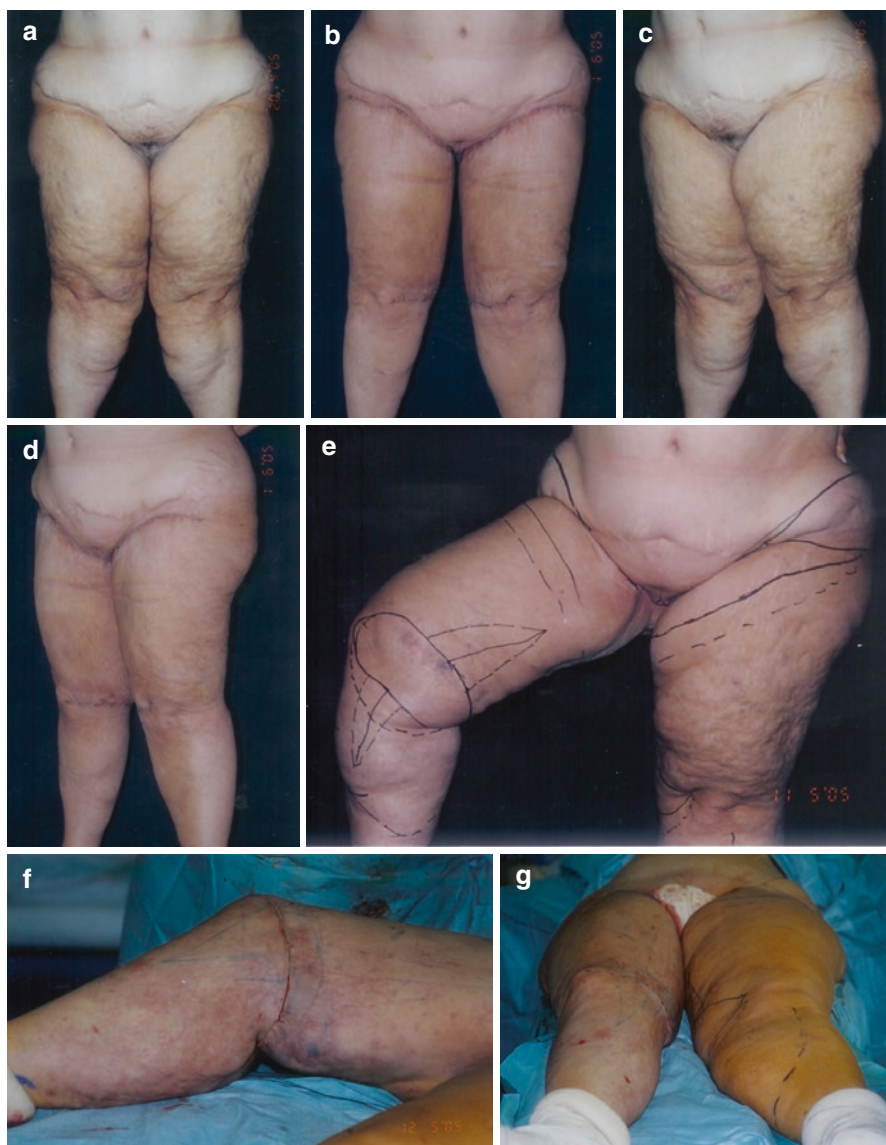

**Fig. 16.10** A 65-year-old female patient lost 48 kg after bariatric surgery. (a, c) Before surgery; (b, d) 6 months after abdominoplasty and 3 months after medial thigh lipoplasty

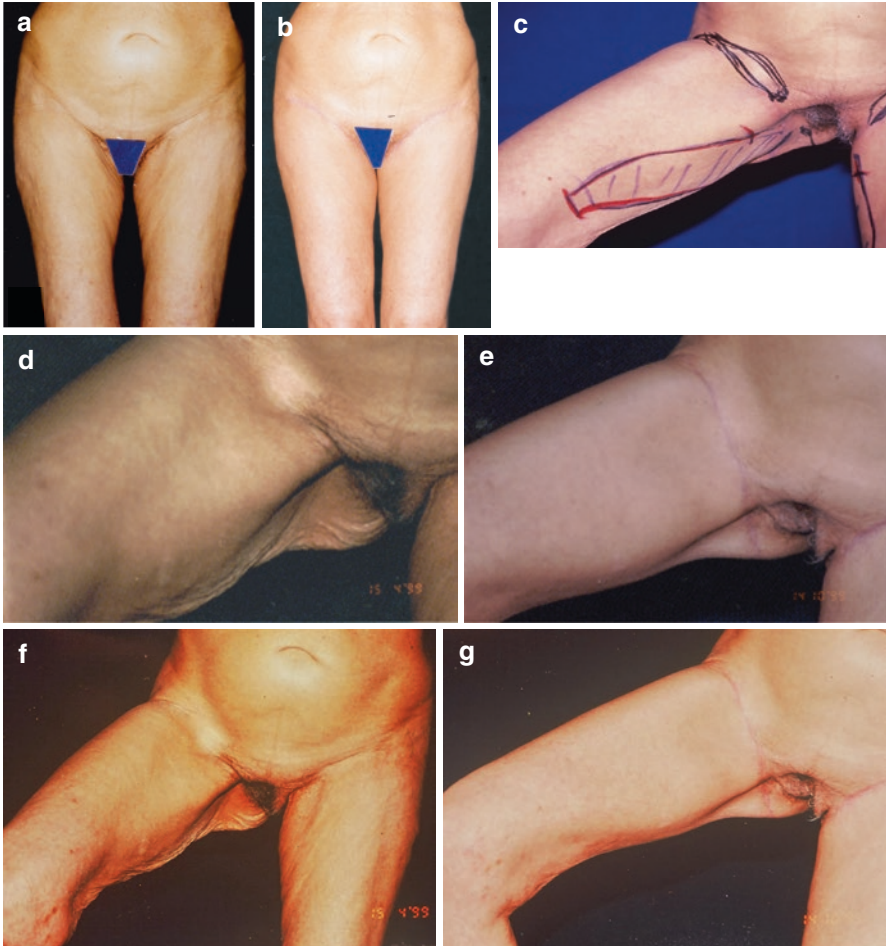
cadavers which gave enough scientific information on the way to perform liposuction underneath the skin following cutaneous resection. That associated procedure of liposuction with skin resection was done just to get better physical conditions removing dark and thick skin.

In patients after massive weight loss as may happen after bariatric operation, the treatment of medial thigh requires a complex operation for the removal of the excess panniculus (Figs. 16.10 and 16.11). There are procedures with vertical incisions on internal surface of the thigh and also with oblique incisions as performed by Roxo et al. [28] with suitable scars and great improvement to the contour to lower extremities.

In the accomplishment of the surgery other problems may be solved such as intense hair in the internal side of the thighs, especially in female, which cause unaesthetic appearance and physical discomfort.



**Fig. 16.11** Surgical result of medial thigh lifting on 59-year-old female patient. The operation was performed after 45 kg weight loss: (a, c) preoperative photos in front and lateral view; (b, d) post-operative photos showing the surgical result of medial thigh lipoplasty combined with liposuction on anterior side of the thigh and legs with skin resection on internal side of the knees. (e) Surgical demarcations before operation with continuous line the areas where skin resection would be done on medial thigh and knee, also the dotted lines show the areas of liposuction; (f, g) photos during surgery show the result of the operation already performed on right lower extremity. The skin resection was done on medial thigh and horizontally on internal aspect of the knees



**Fig. 16.12** Medial thigh lipoplasty afterward prosthesis inclusion was performed 3 months later in a 75-year-old female patient: (a) before operations; (b) 1 year after both procedures; photo of the patient after medial thigh lipoplasty operation with surgical demarcations for prosthesis implant procedure which was performed through the scars on gluteal sulcus on back (d, f) before operation; (e, g) same patient one year after medial thigh lipoplasty operation and prosthesis implant procedure which was performed through the scars on gluteal sulcus posteriorly 3 months later

The quality of the scars has direct relationship with the dressings, adhesive tapes placed on the wounds, and especially the patient must avoid abduction of the legs, not to do physical exercises that traction of the surgical wounds. Even patients with too much flaccidity and flabby skin may achieve good aesthetical result by using this technique (Fig. 16.12).

## Conclusions

Medial thigh lipoplasty must be performed in selected patients presenting skin flaccidity, and accumulated fat with unaesthetic appearance. The surgery is recommended for female and male patients with age ranging from 30 to 75 years. Weight loss patients presenting flabby skin are good candidates for operation. The procedure described above is an evolution of my previous publication [7] since it is performed without cutaneous or subcutaneous undermining which reduces surgical trauma, minimizes morbidity, provides comfort postoperatively. It reduces the rate of complications, with high levels of patient satisfaction. The scar resulting from surgery end is placed in the inguinal-crural, genitocrural, and gluteal-crural fold.

## References

1. Agris J (1977) Use of dermal-fat suspensions flaps for thigh and buttock lifts. *Plast Reconstr Surg* 59:817–822
2. Avelar JM (1985) Fat-suction versus abdominoplasty. *Aesth Plas Surg* 9:265–276
3. Avelar JM (1985) Combined liposuction with traditional surgery in abdomen lipodystrophy. XXIV Instructional Course of Aesthetic Plastic Surgery of the ISAPS. Madrid, 19 Sept
4. Avelar JM (1986) Surgical anatomy and distribution of celular tissue on human body (Anatomia cirúrgica e distribuição do tecido celular no organismo humano). In: Avelar JM, Illouz YG. *Lipoaspiração*, vol 9. Editora Hipócrates, São Paulo, pp:45–57
5. Avelar JM (1987) Study of the anatomy of the subcutaneous adipous tissue applied for fat-suction technique. In Maneksha RJ (ed) *Transactions of the IX International Congress of Plastic and Reconstructive Surgery*. New Delhi, 1–6 Mar, pp 377–379
6. Avelar JM (1989) (1989) Regional distribution and behavior of the subcutaneous tissue concerning selection and indication for liposuction. *Aesth Plast Surg* 13:155–165
7. Avelar JM (1996) Creation of a natural and definitive inguino-crural sulcus during medial thigh lifting. (Criação de natural e definitivo sulco inguino-crural no “lifting” da face interna da coxa). *Rev Bras Cir* 86:213–227
8. Avelar JM (1999) A new technique for abdominoplasty – closed vascular system of subdermal flap folded over itself combined to liposuction. *Rev Bras Cir* 88/89(1/6):3–20
9. Avelar JM (1999) Aesthetic plastic in inner side of the thigh – new concepts and technique without cutaneous or subcutaneous undermining. (Cirurgia Plástica de face Interna de Coxas – Novos Conceitos e técnica sem descolamento cutâneo ou subcutâneo). *Rev Bras Cir* 88/89(1/6): 57–67
10. Avelar JM (1999c) Plastic surgery on inner side of thigh – New Concepts and Technique without cutaneous or subcutaneous undermining. (Cirurgia plástica de face interna de coxas – Novos conceitos e técnica sem descolamento cutâneo ou subcutâneo). Ed Cidade científica Ltda. Rio de Janeiro (Brasil). *Rev Bras Cir* 88/89(1/6):57–67
11. Avelar JM (1999d) Flankplasty and Torsoplasty – New surgical approach. (Flancoplastia e Torsoplastia – Nova abordagem cirúrgica). Editora Cidade Científica Ltda. Rio de Janeiro (Brasil). *Rev Bras Cir* 88/89(1/6):21–35
12. Baroudi R (1975) Dermolipectomy of the upper arms. *Clin Plast Surg* 3:485
13. Delerm A, Cirotteau Y (1973) Plastie cruro-fémoro-fessière ou circumfessière. *Ann Chir Plast* 18:31–36

14. Farina R, Baroudi R, Golkeman B (1961) Riding-trousers like type of pelvicrural lipodystrophy (trochanteric lipomatosis). *Br J Plast* 13:174
15. Fournier P, Otteni FM, Avelar JM (1986) Introduction to the study of aesthetic semiology of the body. (Introdução ao estudo da semiologia estética do corpo). In: Avelar JM, Illouz YG. *Liposuction (Lipoaspiração)*, vol 12. Editora Hipócrates, São Paulo, pp 73–79
16. Franco T (1994) Aesthetic surgery of lower limbs (Cirurgia estética dos membros) In: *Teaching plastic surgery in Medical School. (Ensino da Cirurgia Plástica nas Faculdades de Medicina)*. Editor Juarez Avelar. Editora Hipócrates. São Paulo, pp 172–175
17. Grazer F (1976) The tuck and roll thigh plasty. Presented for Education Courses at the Annual Meeting of the American Society of Plastic and Reconstructive Surgery. Boston
18. Guerrero Santos J (1976) Lipectomies and body sculpture. Presented for Education Courses at the Annual Meeting of the American Society of Plastic Surgery. Boston
19. Illouz YG (1980) Une nouvelle technique pour les lipodystrophies localisées. *Rev Cir Esth Franc* 6(9)
20. Illouz YG (1982) Liposuction technique. First Instructional Course with surgical demonstrations at São Paulo Hospital, Prof. Andrews' Service. Organized by Brazilian Society of Plastic Surgery – Regional São Paulo, Endorsed by Brazilian Society of Plastic Surgery (BSPS), October
21. Illouz YG (1982) My technique of selective suction lipectomy. Presented at the annual meeting of the American Society of Plastic and Reconstructive Surgeons, Honolulu, October 1982
22. Illouz YG (1983) My technique of selective suction lipectomy. Presented at the Annual Meeting of the American Society of Plastic and Reconstructive Surgeons, Honolulu, Hawaii, October
23. Illouz YG (1983) Body contouring by lipolysis: 5 years experience with over 3,000 cases. *Plast Reconstr Surg* 72(5):591–597
24. Illouz YG (1986) Basic Principles of liposuction technique (Princípios básicos da técnica de lipoaspiração). *Liposuction (Lipoaspiração)*. Ed. by AvelarJM. & Illouz YG. Sao Paulo. Editora Hipócrates 3:13–18
25. Lookwood TE (1991) Transverse flank-thigh-buttock lift with superficial fascial suspension. *Plast Reconstr Surg* 87:1019
26. Pitanguy I (1964) Trochanteric lipodystrophy. *Plast Reconstr Surg* 34:280–6
27. Planas J (1975) The crural meloplasty for lifting of the thighs. *Clin Plast Surg* 2:495
28. Roxo CDP, Roxo ACW, Roxo CW (2012) Oblique thighplasty in patients after massive weight loss. *Rev Bras Cir Plast* 27(1)
29. Vilain R (1975) Some considerations in surgical alteration of the feminine silhouette. *Clin Plast Surg* 2:449

# Chapter 17

## Flanklipectomy and Torsolipoplasty

Juarez M. Avelar

### Introduction

The expressions flanklipectomy and torsolipoplasty are quite recent, for surgical correction of anatomical and unaesthetic alterations of the flanks and posterior regions of the torso. Both are very important segments for the aesthetic appearance of the body contour. Its surgical treatment has been a challenge to several generations of plastic surgeons and a constant search for adequate surgical result with acceptable scars.

The first tentative of surgical correction of the deformities on flanks was done through circular lipectomy by Somalo [23] and by Prudente [22]. Later, Gonzalles Ulloa [10] created the expression “belt lipectomy,” and some years later, Vilain and Dubousset [24] referred it as “lipectomie circulaire” since the operation is a prolongation of the horizontal incisions on the whole circumference of the body during abdominoplasty.

Ever since I developed new concepts for abdominolipectomy or lipoabdominoplasty [6] which is a combined procedure performed in a closed vascular system that is skin resection with liposuction technique, the posterior regions of the torso and flanks are treated, employing the same surgical principles according to my previous published [7].

Concerning body contouring, since I started to perform liposuction technique, it became necessary to combine it with panniculus resection [2, 3]. In fact, liposuction described and popularized by Illouz [13–15] was for the meantime performed to remove only localized adiposities. That situation required to combine a complemen-

---

J.M. Avelar, MD

Head of the Brazilian Scientific Institute of Plastic and Reconstructive Surgery,  
Al Gabriel Monteiro da Silva, 620 Jd Europa, São Paulo, SP 01442-000, Brazil  
e-mail: [juarezavelar@bol.com.br](mailto:juarezavelar@bol.com.br); [institutodaorelha@uol.com.br](mailto:institutodaorelha@uol.com.br)

tary procedure of panniculus or skin resection. Due to the associated procedures, several complications used to occur during and after operations which instigated me to devote much time performing anatomical dissections on cadaver to find out about the unknown compartment corresponding to the subcutaneous layers [4, 5]. Therefore, application of my surgical principles is the result of anatomical research and the necessity of removal of excess skin after performing liposuction to achieve adequate improvement on body contouring.

Direct approach to the flanks and torso to treat excess skin and/or excess localized adiposity is not a matter of routine for plastic surgeons due to the extensive procedure leaving permanent and visible scars. Patients after massive weight lost present redundancy of skin folded over it giving unaesthetic appearance on the posterior and lateral aspects of the torso. Most of the techniques are performed by block resection of full thickness of the panniculus combined with wide undermining of the lateral borders of the surgical wound as described by Grazer [11], Guerrero-Santos [12], Pitanguy [20], and later by Baroudi [8, 9]. A peculiar block resection proposed by Pontes [21] is performed without panniculus undermining. Usually, those procedures may present excess of bleeding during operation, and it is painful during post-operative recovery.

This operation is not a routine procedure since it is performed in selected persons with excess adipose fat and also on patients after weight loss. Nowadays, more patients undergoing bariatric surgeries are a significant group which requires body contouring operations. Nevertheless, some improvements on those deformities may be achieved during conventional abdominal lipectomy by lateral prolongation of the surgical incisions described by Pitanguy [19]. Few years after the beginning of my practice, I suggested to perform posterior-anterior rotation of the upper abdominal panniculus flap, looking for reshaping the silhouette of the body [1].

When Pitanguy [18] described his technique regarding surgical correction of trochanteric lipodystrophy, a new era was opened on body contouring surgery. In the use of his procedure, several deformities of the lateral and posterior regions may be treated simultaneously. However, flank regions were not treated specifically. This demands block resection of the whole panniculus which constitutes the skin and subjacent adipose tissue sectioning of all perforator vessels and wide undermining.

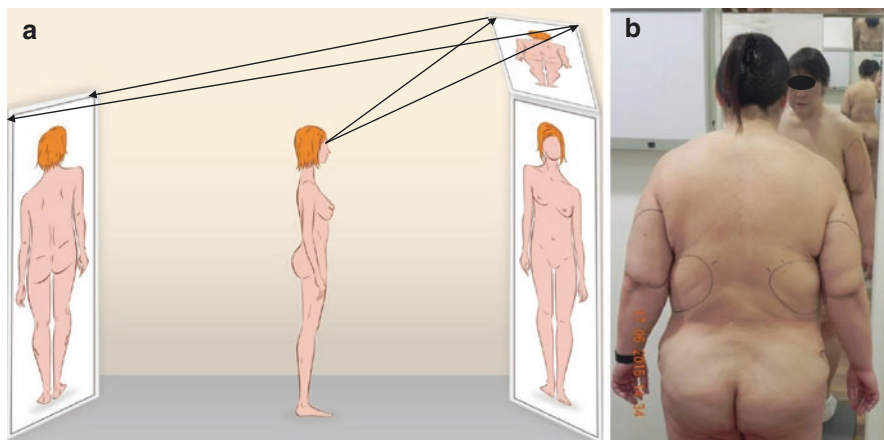
The methodology previously described [7] is another surgical procedure to repair deformities of the lateral and posterior aspects of the torso which is a combination of liposuction and cutaneous resection but without panniculus undermining nor block resection.

It is a nontraumatic technique since the vascular system is totally preserved, as to the whole arterial, venous, and lymphatic network of the subcutaneous panniculus. I have performed my procedure on patients from 40 to 75 years old without any local and systemic repercussions, as may happen when panniculus resection is performed as a block with panniculus undermining. It is not safe and also advisable to indicate and to do panniculus resection on whole circumference of the body on patients older than 50, since too much bleeding and risk of panniculus resection may cause local and systemic complications.

## Technique

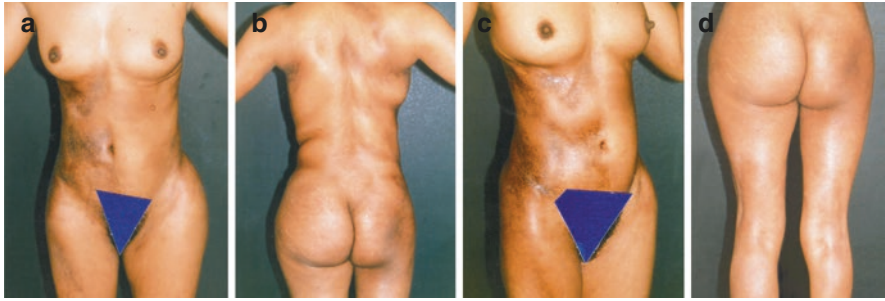In order to perform any procedure in plastic surgery, surgical planning is a fundamental step before operation. The physical examination must be carefully done with the patient in standing position as well as lying down for proper evaluation of the anatomical alterations of the regions. I have at my office a useful organization of mirrors vertically placed on the wall, one in front of the other (Fig. 17.1). When a patient stays in a standing position between those mirrors, she/he can see the whole body simultaneously in front and back views. The Illouz “pinching test” is a valuable maneuver to evaluate the presence of localized adiposity in all regions of the human body [15–17]. Therefore, on the lateral and posterior aspects of the torso, that maneuver is particularly useful to facilitate the surgical planning. The evaluation of the excess skin on those regions depends on the surgeons experience and adequate analysis of the cutaneous covering to judge how much it should be resected. In cases without skin flaccidity and without cutaneous excess, liposuction technique alone may achieve excellent results. Nevertheless, when there is excess skin and flaccidity, it is mandatory to perform a combined procedure according to my original description [7].

As in any field of plastic surgery, the surgeons should not make any operation without adequate photos of the patients before surgery. It is a very useful surgical orientation during operation as well as for legal aspects to protect the plastic surgeon.

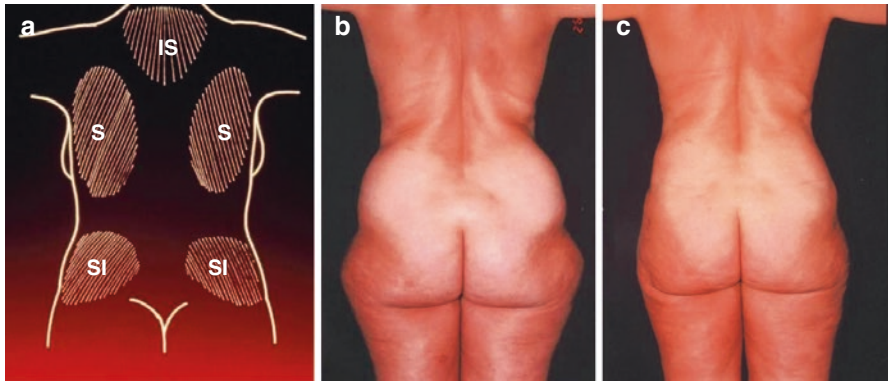


**Fig. 17.1** Scheme (a): examine room with two vertical mirrors, one is placed in front of the other and another one is placed obliquely 45° with the ceiling; photo (b): a patient can see her body in frontal view in one mirror and on back view on the other one due to the other one placed on 45°. This is my routinary photographic studio before and after torsolipoplasty and flanklipoplasty





**Fig. 17.2** A 22-year-old female patient with Romberg disease on her right side: (a) anterior view; (b) posterior view; (c) lateral view; (d) showing complex deformities on the right side of the body, hemifacial atrophy, and severe asymmetric torso, flank regions, and buttocks also on right

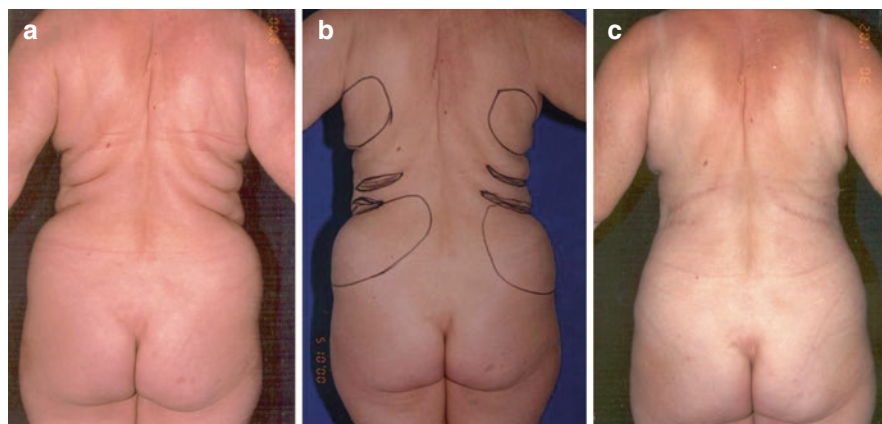


**Fig. 17.3** The most frequent regions of the torso to present localized adiposities: (a) drawing showing the interscapular (*IS*), scapular (*S*), and suprailiac (*SI*) regions; (b) a 57-year-old female patient presenting accumulated fat on scapulars and suprailiac regions. (c) Same patient after liposuction and flank lipoplasty without skin resection

## Surgical Demarcation

Surgical demarcation of the regions to be carried out is an important guideline for surgeon's orientation during operation. It is quite frequent asymmetry of the torso that must be identified and to show to patients before operation. Nevertheless, a patient came to me many years ago with Romberg disease (Fig. 17.2), presenting severe asymmetry of the torso, but she was not operated. Nowadays, torsolipoplasty would be done for her with liposuction on one side of the body and fat injection on the other as well.

During surgical demarcations, the two areas that must be carefully marked (Fig. 17.3) are as follows:



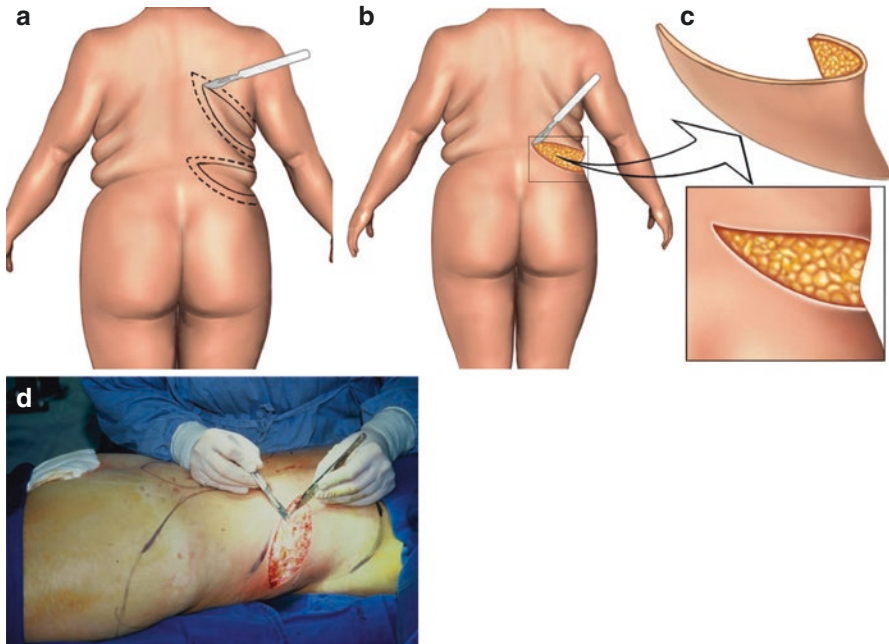
**Fig. 17.4** Surgical planning and demarcations before torsolipoplasty and flanklipoplasty: photos of a 56-year-old female patient who underwent torsolipoplasty performed with skin resection combined with flanklipoplasty without skin resection. (a) Preoperative photo showing asymmetry with three cutaneous folds on each side. (b) Surgical demarcations in the areas of skin resection on cutaneous depressions on the torso with localized adiposities between the folds and accumulated fat on flanks regions. (c) Same patient after surgery

- (a) The area where there is localized adiposity and consequently liposuction will be performed
- (b) The area where excess skin may present cutaneous folds which sometimes are the main motivation for operation

There are patients presenting asymmetry of the torso which must be well identified and to show to them during demarcations (Fig. 17.4). So, surgical demarcations are a mandatory procedure to identify localized adiposities and multiple folds on the posterior aspect of the torso that can be adequately treated without skin resection. Performing proper liposuction on the cutaneous folds where there is accumulated fat, it is possible to achieve harmonious results. Again, it is important to emphasize about precious surgical demarcations. I do one small incision for each fold where it is necessary to do liposuction. I avoid to do any communication from one segment of the cutaneous fold with the other one.

In the use of my concepts, liposuction procedure is performed on two levels: (a) on full thickness of the panniculus where skin resection is done with preservation of the perforator vessels and (b) below the fascia superficialis of the panniculus where skin resection is not performed which means without any damage to perforator vessels. Consequently, the vascular network of the remaining panniculus will provide its traction and suture since it slides over the musculature underneath. The combination of these surgical steps is done to reshape the silhouette harmonizing the abdomen with great improvement of the irregularities on the surface of the torso [7].

Frequently, flanklipoplasty and torsolipoplasty may be performed in combination with other procedures on the lower extremities and abdomen as well, in which



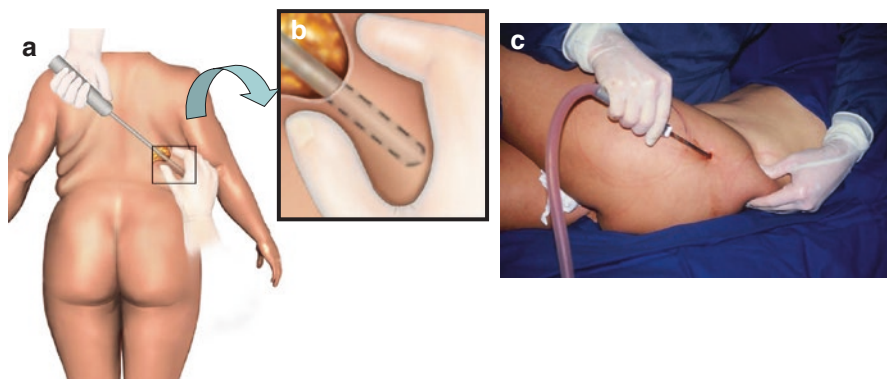
**Fig. 17.5** Torsolipoplasty with liposuction procedure with skin resection combined with flankli-poplasty without skin resection. (a, b) Drawings show cutaneous folds on the torso surgical demarcations; on the right side, it shows the central area where skin resection is done, and dotted lines indicate the area for liposuction and subcutaneous tunnelization; (c) on close up, it shows the segment of skin resection after liposuction was done; (d) peroperative photo showing resection of the skin during torsolipoplasty procedure

it is more comfortable to use epidural anesthesia combined with intravenous sedation under the care of an anesthesiologist. However, in isolated procedures on flanks and torso, it is possible to perform the operation under local anesthesia also in combination with intravenous sedation.

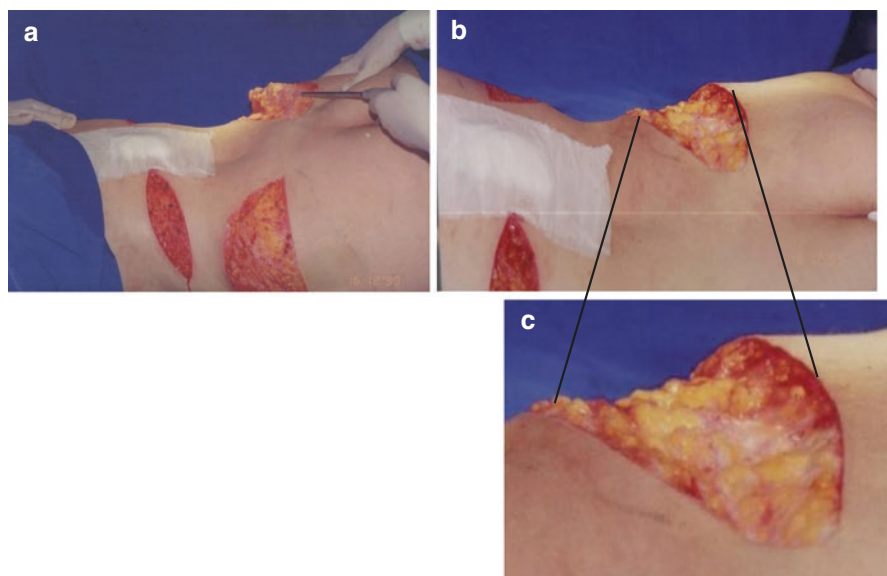
I prefer to keep the patient on prone position which requires warring of breath under care of anesthesiologist. Local infiltration is performed with saline solution (1.000 ml + epinephrine 2 mg).

The operation follows a sequential systematization of liposuction procedure, skin resection of the areas presenting cutaneous folds even severe depressions, and suture of the surgical wound.

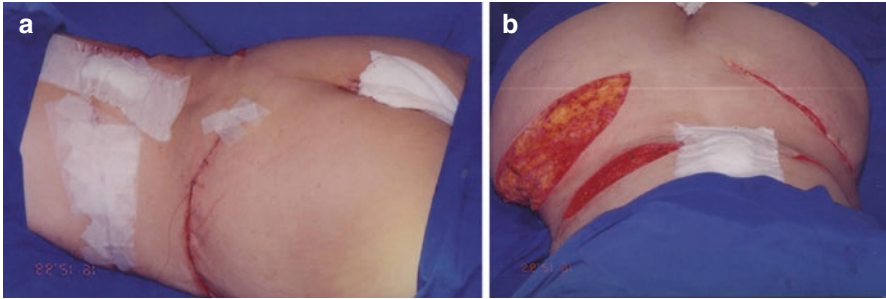
Liposuction is performed all over the demarcated areas in two different levels. In the area where cutaneous resection will be performed, it is done on the full thickness of the panniculus (Figs. 17.5, 17.6, and 17.7). This means on the deep lamellar layer and superficial one (areolar layer), preserving all vascular network (arteries, veins,



**Fig. 17.6** Lipotorsoplasty and flanklipoplasty procedures without skin resection. Liposuction is performed only on cutaneous folds presenting localized adiposities. Drawing (a) liposuction procedure on cutaneous fold; (b) close up showing the cannula underneath the skin. (c) Photo during operation on a patient in supine position wherein liposuction on flank on the left side is performed



**Fig. 17.7** Preoperative photos showing torsolipoplasty and flanklipoplasty in combined procedures of liposuction with skin resection on patients on prone position. (a) The raw areas show that both procedures were done on left side of the patient and the surgeon is pulling the connective tissue with a cannula on flank on right side; (b) one can see the depression on flank region on right side after liposuction; (c) close up to show the depression on the area after liposuction and skin resection. There is no bleeding during and after surgery



**Fig. 17.8** Photos during operation showing torsolipoplasty and flanklioplasty in combined procedures of liposuction with skin resection on patients on prone position. (a) Lateral view of the left side showing that the torsolipoplasty was done and the area is covered with adhesive tapes. Flanklioplasty was done and the wound has been sutured; (b) photo of the same patient from top view showing the operation on torso and flank was done and sutured on left side. The raw areas on right side show that liposuction was made on torso and flank and the wounds without any bleeding and they are not sutured

and lymphatic), nerves, and the connective tissue between them. However, on the neighboring regions where there is localized adiposity, liposuction is performed only on the deep level, which means below the fascia superficialis, preserving the areolar layer. After liposuction procedure, there is depression on the area due to absence of adipose tissue (Fig. 17.8).

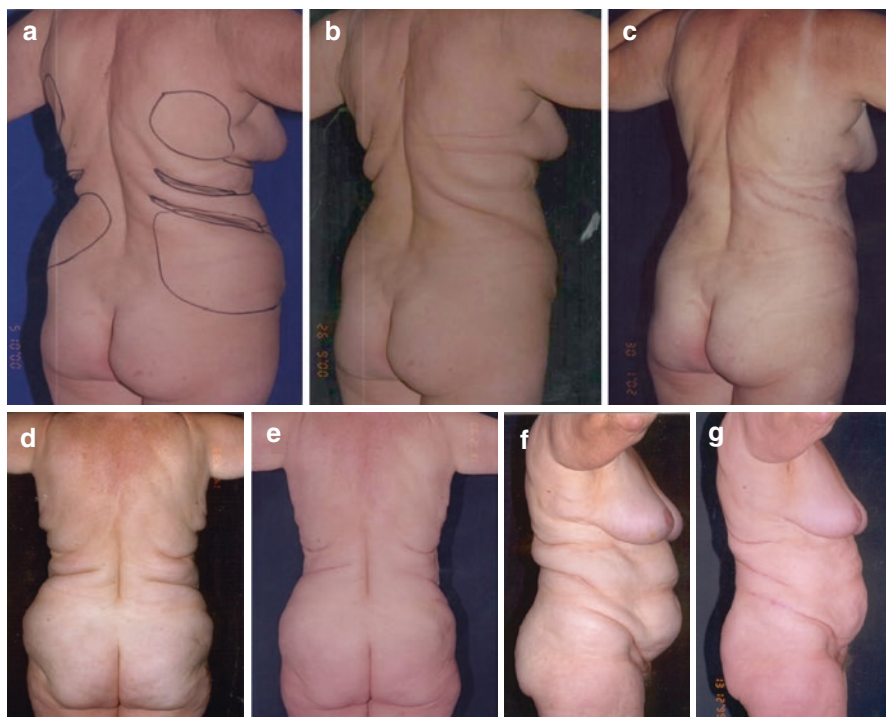
Afterward, full-thickness skin resection is done on deep folds on flanks and any other areas of the posterior side of the torso following the correct demarcations previously done. I use a knife for cutaneous incisions on the border of the elliptical area and below the skin without any damage on the vascular structures underneath (Figs. 17.9 and 17.10).

All histological elements of the skin must be removed specially hair follicles, sweat glands, and sebaceous glands. Although hair is less frequent on flanks and torso in females, it may occur in males (Fig. 17.11).

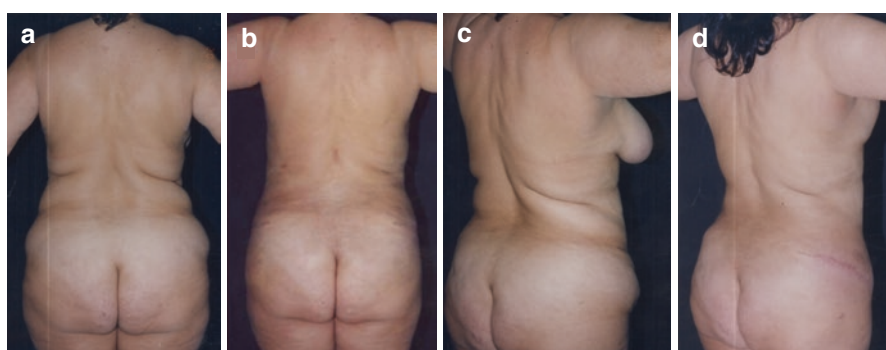
Very often, there are striae all over the flanks and neighboring regions. They may be resected if they are inside the marketed area (Fig. 17.12). During this procedure, there is no bleeding because the knife does not cut any vessels and consequently cauterization is not necessary.

Since there is no bleeding because there is no damage to the vascular networks, the suture is done in two or three levels. The fascia superficialis is an important anatomical element of neighboring regions of the cutaneous resection and it should be sutured as the deepest layer. I use absorbable material to suture all levels (Figs. 17.13, 17.14, and 17.15). Afterward, running suture is done to close the cutaneous wound.

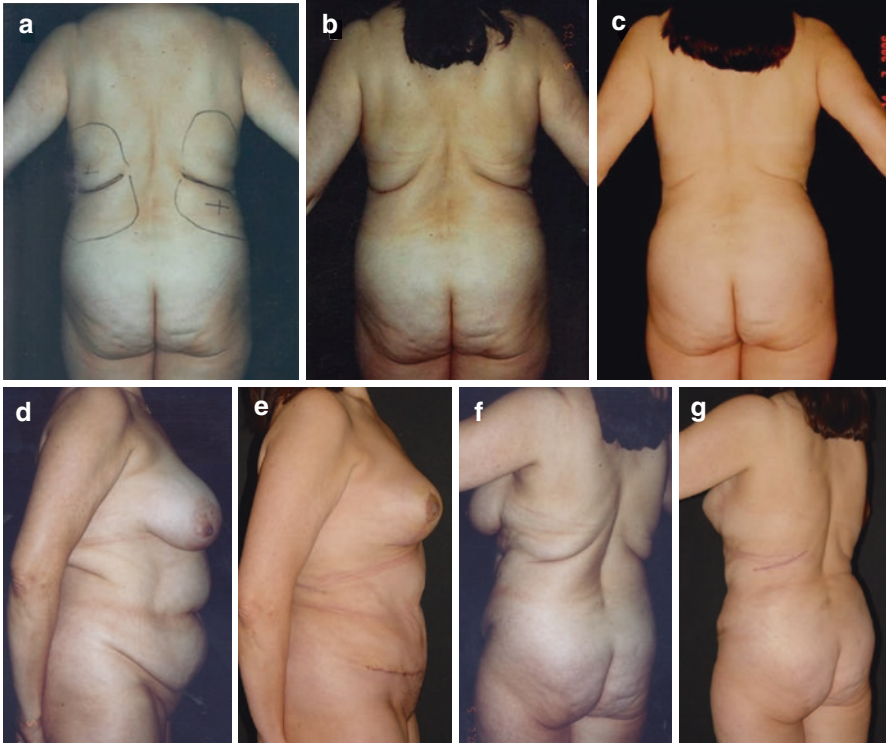The bandaging is done using a garment modeling the body with very light pressure all over the regions.



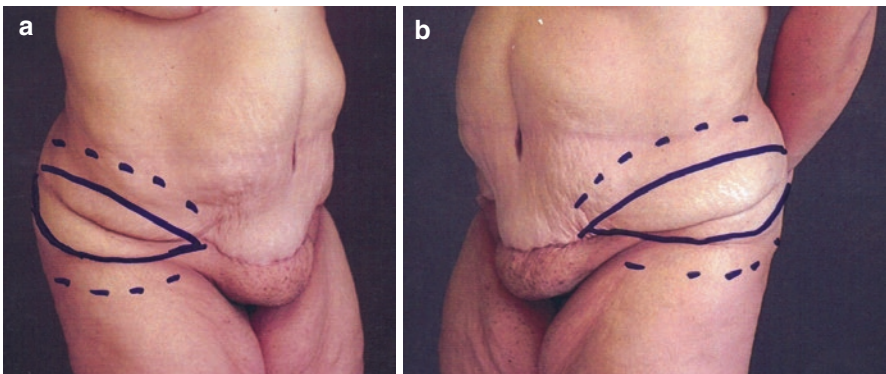
**Fig. 17.9** Torsolipoplasty with skin resection and flanklipoplasty without cutaneous excision. A 75-year-old female patient showing cutaneous folds on torso regions with adiposities and accumulated fat on flanks; photo (a): an oblique posterior view shows the surgical demarcations for skin resection on deep areas and the other one for liposuction; photos (b) before surgery and (c) after operations. Photos (d, f) before surgery; photos (e, g) show the surgical result



**Fig. 17.10** A 54-year-old female patient showing the result of the torsolipoplasty performed with skin resection combined with flanklipoplasty with skin resection: (a, c) preoperative photos showing cutaneous folds and adiposity; photos (b, d) after surgery

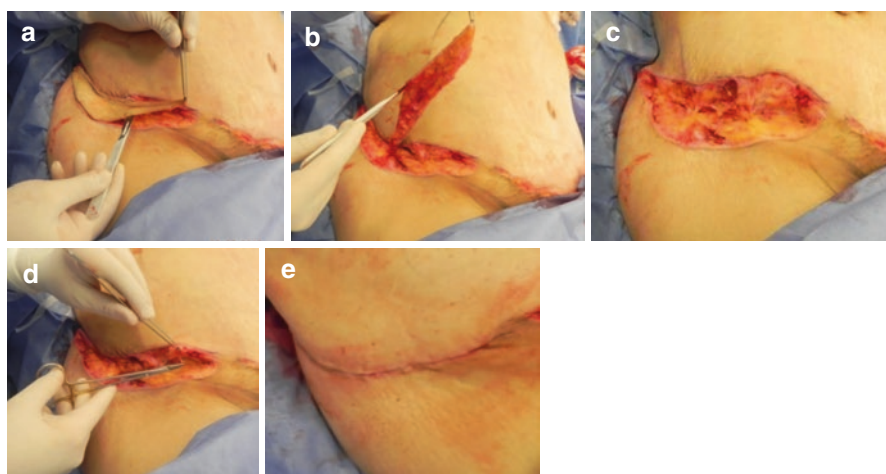
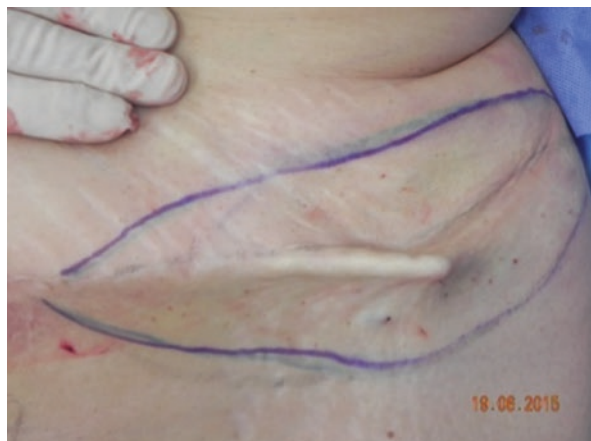

**Fig. 17.11** Torsolipoplasty with skin resection combined with flanklipectomy without cutaneous excision on a 47-year-old female patient with unaesthetic folds and asymmetric adiposities on torso regions: (a) photo on posterior view shows the surgical demarcations; (b) preoperative; (c) after operations. Photos (d, f) preoperative on profile and posterior oblique views. Photos (e, g) after torsolipoplasty with cutaneous resection associated with flanklipectomy without skin resection and lipoabdominoplasty

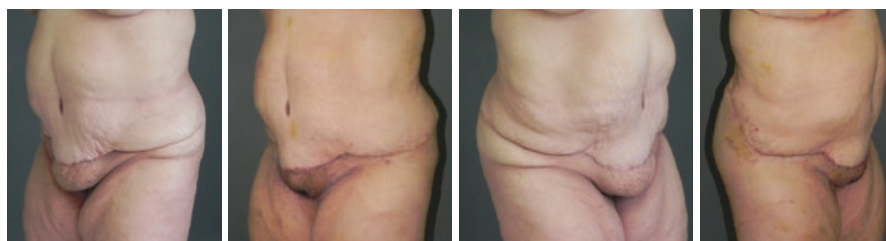


**Fig. 17.12** Surgical demarcations for flanklipectomy combined with cutaneous resection on right and left sides: photos (a, b) the continuous lines show the area for full-thickness liposuction and afterward skin resection will be done. The dotted lines demonstrate the area for deep liposuction, which is done below fascia superficialis

**Fig. 17.13** Flanklipoplasty – full-thickness liposuction on the area of skin resection on flanks: photo shows the cannula underneath of the skin removing all adipose tissue



**Fig. 17.14** Photos during operation showing flanklipoplasty technique on the right side of the patient on prone position. Following surgical demarcations, first liposuction procedure was performed. Photos (a, b) showing skin resection being done; (c) after skin resection, the raw area shows connective tissue and all perforator vessels are preserved; (d) shows the suture of the dermis to dermis with isolated stitches; (e) after suture



**Fig. 17.15** A female surgical demarcations for flanklipoplasty combined with cutaneous resection on right and left sides. The continuous lines show the area for full-thickness liposuction and afterward skin resection will be done. The dotted lines demonstrate the area for deep liposuction, which is done below fascia superficialis



## Complications

Torsoloplasty and flaneloplasty are very useful procedures with minimal complications as long as patients are good candidates, the operations are made under adequate indications and with proper demarcation, and the procedure is well performed.

The final scars are well acceptable by patients, since the surgeon gives all information and instruction about the operation and post-operative care.

There is no bleeding during operation or postoperatively. I have not had any cases of hematoma, seroma, dehiscence of the suture, or any other complications which frequently occur in other raw procedures. Post-operative drainage is not necessary since no undermining is done.

## Discussion

The main surgical principles of the operation are performed on two points: (a) skin resection after liposuction on full thickness of the panniculus which is folded to deep level and (b) to perform deep liposuction on areas with localized adiposities. These procedures are done without any panniculus undermining or resection. Therefore, there is no bleeding during operation. Electrocauterization usually is not necessary since there is no bleeding during or after surgery (Figs. 17.7, 17.8, and 17.14).

My anatomical researches show the peculiarities of the subcutaneous vascularization [4, 5] and where the fascia superficialis is an important element in the vascular architecture of the subcutaneous panniculus. Small vessels are present going directly from the fascia superficialis to the skin. The sophisticated vascular network offers adequate blood supply to the remaining tissue.

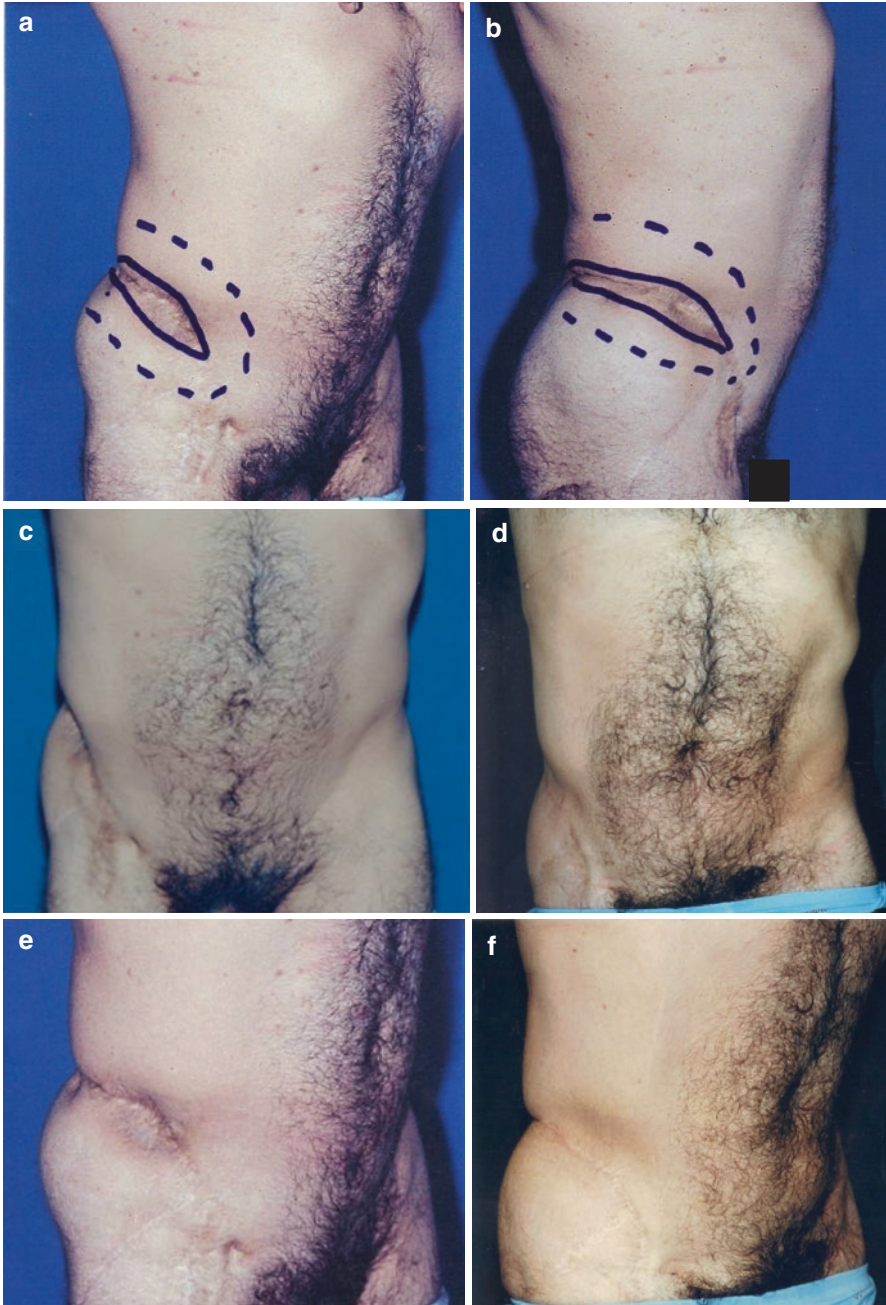
The aesthetic results give the patients a very high level of satisfaction with good scars (Figs. 17.9, 17.10, and 17.11). The post-operative period is very comfortable since there is no vascular trauma. The procedure preserves all anatomical structures removing only skin and fat tissue underneath.

Surgical demarcation is a mandatory step before operation in order to determine the areas for skin resection and the regions presenting localized adiposities. Such demarcation must be done with the patient in standing position before premedication in front of a mirror in order to follow the drawings performed by the surgeon, even to understand the location of the final scars.

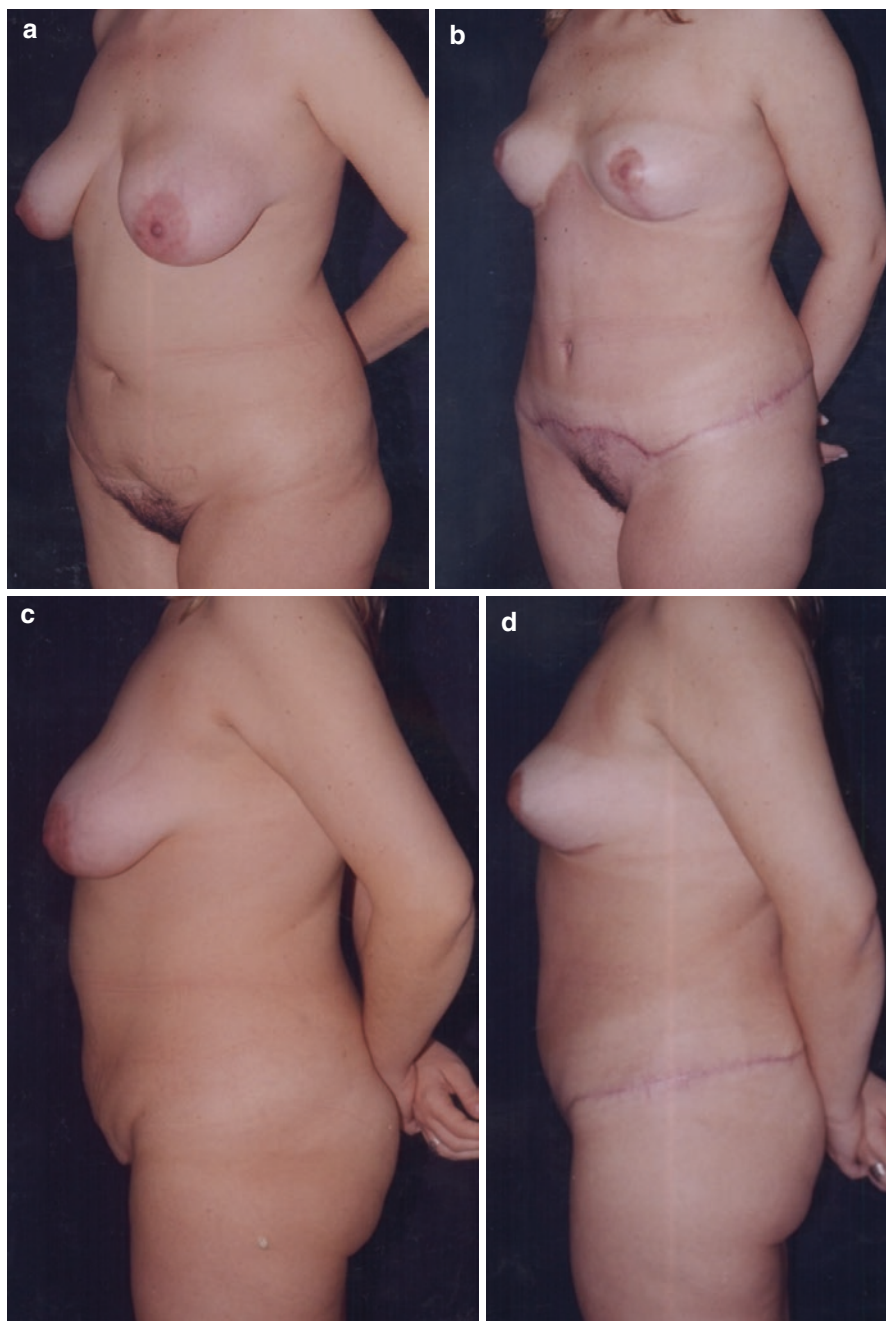
Quite often, aesthetic treatment of the flanks as well as several regions of the torso may be performed with isolated liposuction procedure when patient does not present excessive cutaneous flaccidity in which skin resection may not be done. This decision is a meter of surgeon's experience and adequate physical examination, proper evaluation, and meticulous surgical planning. Such situation is an important judgment since Illouz' "pinch test" is a fundamental procedure during evaluation. Usually, in patients under 40 years old, it is possible to achieve good surgical results without skin resection, avoiding scars after operation. The main surgical principle is to perform liposuction only on restrict areas where localized adiposities are evident in order to achieve similar thickness to the panniculus of cutaneous fold where liposuction will not be done (Figs. 17.7, 17.8, and 17.9). I recommend that in each area, it is necessary to do a small cutaneous incision to perform liposuction procedure in that specific area. Following such technical detail, each compartment does not present communication with areas of cutaneous folds.

Flanklipoplasty and torsolipoplasty operation may be performed in female and male patients, but in women, it is a more frequent procedure to improve body contouring. The average age of my patients is 49 years, between 36 and 75 years, presenting cutaneous flaccidity, excess skin, striae, and localized adiposity. After 6 months of post-operative evaluation, they show well-balanced aesthetic results on the flanks and torso with good scars (Fig. 17.9). It is necessary to use adhesive tapes covering the scars within 3 months, changing every 10–15 days. The patients can take a shower once a day. Physical exercises are not allowed within 3 months after surgery.

Flanklipoplasty and torsolipoplasty may be performed as isolated procedures even after trauma, since the scars and other deformities may be improved (Fig. 17.16). But quite often, they may be done in combination with other operations such as abdominoplasty, mastoplasty, or any other ones. Also, it is a very useful procedure for reparation of asymmetry of the torso, since accumulation of fat is quite often (Fig. 17.17).



**Fig. 17.16** A 49-year-old male patient presenting severe and deep surgical scar secondary to orthopedic operation due to complex fractures on the hip and iliac crest. Photos (a, b) surgical demarcations show the *continuous lines* delimitating the central area where skin resection will be done after deep liposuction. The *dotted lines* outside of the previous one show the area where tunnelization with cannula was one without liposuction procedure. Photos (c, e) in front and anterior oblique views showing the complex deformity on the right side of the flank. Photos (d, f) showing postoperative result following the surgical planning



**Fig. 17.17** Flanklipoplasty with skin resection was carried out in combination with lipoabdominoplasty in a 38-year-old female patient. Photos (a, c) before surgery; (b, d) after operation

## Conclusions

It is a nontraumatic method, without sectioning of veins and arteries on the regions of cutaneous resection and on areas of liposuction which are the main surgical principles. In the correct use of liposuction technique, there is no vascular trauma to the perforating vessels neither on the area of skin resection nor on the neighboring panniculus. The perforating vessels work as multiple pedicles giving normal blood supply, and the absence of fat tissue on the lamellar layer makes the panniculus slide easily to suture the surgical wound.

In cases of corporal asymmetry, cutaneous resection of one side of the torso may be done or even two resections on one side and one on the other (Fig. 17.9).

## References

1. Avelar JM (1983) Abdominoplasty: technical refinements and analysis of 130 cases in 8 years follow-up. *Aesthetic Plast Surg* 7:205
2. Avelar JM (1985) Fat-suction versus abdominoplasty. *Aesthetic Plast Surg* 9:265–276
3. Avelar JM (1985) Combined liposuction with traditional surgery in abdomen lipodystrophy. XIV Instructional Course of Aesthetic Plastic Surgery of the ISAPS, Madrid
4. Avelar JM (1986) Surgical anatomy and distribution of cellular tissue on human body (Anatomia cirurgica e distribuição do tecido celular no organismo humano). In: Avelar JM, Illouz YG (eds) *Liposuction (Lipoaspiração)*. Editora Hipocrates, Sao Paulo, pp 45–47
5. Avelar JM (1989) Regional distribution and behaviour of the subcutaneous tissue concerning selection and indication for liposuction. *Aesthetic Plast Surg* 13:155–156
6. Avelar JM (1999) A new technique for abdominoplasty – closed vascular system of subdermal flap folded over itself combined to liposuction. *Rev Bras Cir* 88/89(1/6):3–20
7. Avelar JM (1999) Flankplasty and torsoplasty – new surgical approach. *Flancoplastia e Torsoplastia- Nova abordagem cirúrgica*. *Rev Bras Cir* 88/89(1/6):21–35
8. Baroudi R (1986) Gluteo-trochanteric region – liposuction as modeling and reduction. *Região gluteo-trocanterica – Lipoaspiração como redução modeladora*. In: Avelar JM, Illouz IG (eds) *Lipoaspiração*. Editora Hipocrates, Sao Paulo, pp 187–200
9. Baroudi R (1988) Abdominoplasty, torsoplasty, extremities, liposuction. *Aesthetic plastic surgery : in five volumes/edited by Mario González-Ulloa et al*. Imprint Padova: Piccin Nuova Libreria; St. Louis, Mo.: CV Mosby, 1–2, c1987
10. Gonzalez-Ulloa M (1960) Belt lipectomy. *Br J Plast Surg* 13:179–186
11. Grazer F (1976) The tuck and roll tight plasty. Presented for Education Courses at the annual meeting of the American Society of Plastic and Reconstructive Surgery. Boston
12. Guerrero-Santos J (1976) Lipectomies and body sculpture. Presented for Education Courses at the annual meeting of the American Society of Plastic and Reconstructive Surgery. Boston
13. Illouz YG (1978) A new technique for localized fat deposit. *Les Nouvelles Esthetiques*, Paris
14. Illouz YG (1980) A new technique for localized lipodystrophy (Une nouvelle technique pour les lipodystrophies localisees). *Rev Chir Esthet* 4:19
15. Illouz YG (1982) Liposuction technique. First Instructional Course with surgical demonstrations at São Paulo Hospital, Prof. Andrews' Service. Organized by Brazilian Society of Plastic Surgery – Regional São Paulo, Endorsed by Brazilian Society of Plastic Surgery (BSPS)
16. Illouz YG (1983) Body contouring by lipolysis: a 5-year experience with over 3000 cases. *Plast Reconstr Surg* 72:591

17. Illouz YG (1982) My technique of selective suction lipectomy. Presented at the annual meeting of the American Society of Plastic and Reconstructive Surgeons, Honolulu, Hawaii
18. Pitanguy I (1964) Trochanteric lipodystrophy. *Plast Reconstr Surg* 34:280
19. Pitanguy I (1967) Abdominal lipectomy: an approach to it through an analysis of 300 consecutive cases. *Plast Reconstr Surg* 4(40):38
20. Pitanguy I (1977) Dermolipectomy of the abdominal wall, thighs, buttocks, and upper extremity. In: Converse JM (ed) *Reconstructive plastic surgery*, 2nd edn. Saunders, Philadelphia, pp 3800–3823
21. Pontes R. (2008) Abdominoplastia: ressecção em bloco e sua aplicação em lifting de coxa e torsoplastia. (Abdominoplasty: resection en bloc and its application in thigh lifting and torsoplasty) Rio de Janeiro: Revinter
22. Prudente A (1943) Dermolipectomia abdominal com conservação da cicatriz umbilical. *Anais II Congr. Latino-Americano de Cir Plast*, Guillermo Karast. B. Ayres
23. Somalo M (1940) Circular dermolipectomy of trunk. *La Semana Med* 24:1435–1443
24. Vilain R, Dubousset J (1964) Technique et indications de la lipectomie circulaire. 150 observations. *Ann Chir* 18:289

# Chapter 18

## Gluteus Lipoplasty: Improvement Results on Buttocks Through New Concepts on Abdominoplasty

Juarez M. Avelar

### Introduction

Aesthetic surgery of buttocks is a recent area in plastic surgery since the first description about reduction of fat is credited to Fernandez and Correa-Iturraspe [14, 17] for treatment of obese patients. Few years later, Lewis [24] described skin and fat resection for reduction of the thigh using a long vertical incision going from medial thigh to near the knee. Afterward Farina et al. [16] performed correction of trochanteric lipodystrophy by a long vertical incision down the lateral side of the thigh.

Nevertheless, the remarkable contribution was described by Pitanguy [26, 27] with extensive trochanteric dermolipectomy using an incision that followed the gluteal posterior crease, and laterally it extends toward the anterior superior iliac spine. The final scar is located on the natural fold and can be hidden in a bikini bathing suit. Afterward other procedures were published by Delerm and Giroteau [15], Vilain [28], Planas [25], Guerrero-Santos [19], and Grazer [18], and others have introduced some variations of Pitanguy's technique. Even de-epithelized procedure was described by Vilain et al. [29] from the excess skin of the lateral trochanteric bulge area to correct local lipodystrophy creating aesthetical buttock contour. A dermal-fat suspension flap was described by Agris [1] to suture anteriorly to the inguinal fascia and posteriorly to the fascia lata.

However, liposuction is the most revolutionary technique developed, published, and popularized by Illouz [20–22] through which it became possible to reduce the volume as well as to reshape the buttocks. Undoubtedly in few years, liposuction became the most frequent procedure performed all over the regions to improve body contour. Localized adiposities were removed by fat suction, but in some cases, it

---

J.M. Avelar, MD

Head of the Brazilian Scientific Institute of Plastic and Reconstructive Surgery,  
Al Gabriel Monteiro da Silva, 620 Jd Europa, São Paulo, SP 01442-000, Brazil  
e-mail: [juarezavelar@bol.com.br](mailto:juarezavelar@bol.com.br); [institutodaorelha@uol.com.br](mailto:institutodaorelha@uol.com.br)

was evident that some redundancy of the skin remained which require skin and panniculus resection.

Fat grafting is a useful procedure as a surgical complement to improve and remodel the shape and size of buttocks. It is another good surgical option when patients present adequate donor area of fat, such as the abdominal wall, flanks, and inner thigh. Lipografting procedure is not discussed in this chapter, since a very wide field has been devoted in order to improve surgical results [23].

Meantime flabby skin on buttocks used to demand for aesthetic surgery which may be carried out by skin removal, leaving ungraceful and quite often deep scars.

For reparation of abnormalities of buttocks concerning senility and weight loss which cause flabby skin, it has been useful to employ surgical principles of my new concepts of lipoabdominoplasty for removal of excess skin, reshaping the posterior aspect of the gluteus regions [9–11]. In fact, since the origin of my new surgical principles, the treatment of medial thigh lifting has been improved very much which was published employing the new concepts [12, 13].

In the last decades, more and more patients after massive weight loss and who underwent bariatric operations are looking for correction of the buttocks. Therefore, in a very short period of time due to a great scientific development, there are several surgical options for aesthetic and reconstructive surgery of the gluteus regions. To choose the adequate procedure is an important step before a surgeon performs surgery to his or her patients.

## Technique

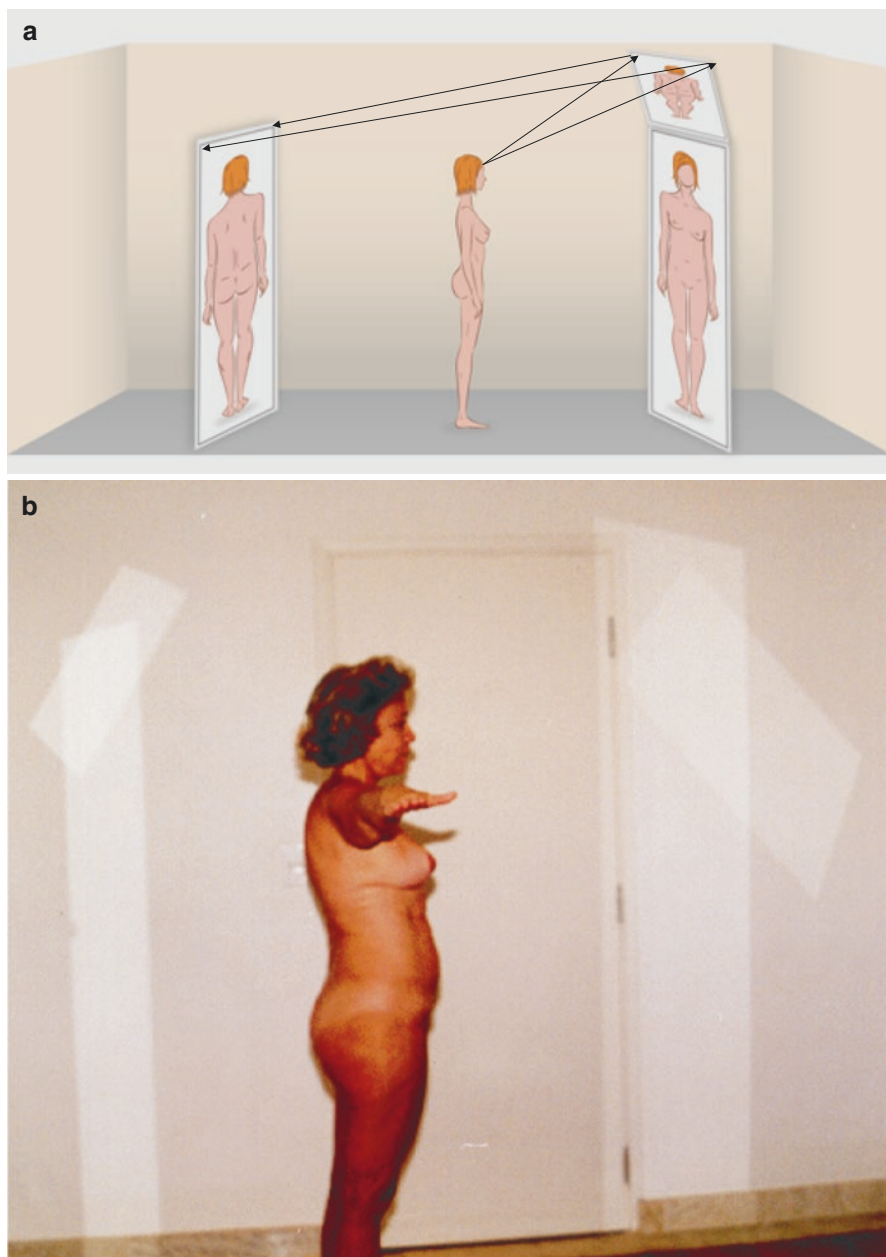
### *Patient Evaluation*

It is important to mention that a surgeon may ask about the past medical history of the patient and meticulous physical examination is an essential step to identify any systemic disease that may contraindicate buttock surgery. Examination from the waist to the ankles is essential to evaluate the full extent of the patients' deformity.

Localized adiposities on thighs, hips, and buttocks must be well evaluated if there is skin redundancy, laxity, and other abnormalities. Quite often patients present some asymmetry of the body which may not be noticed before. For this reason, it is very important for a surgeon to examine his or her patients in standing position in front of mirrors. My preference is to do physical examination with the patient in front of two vertical mirrors in conjunction with another one adequately placed on the ceiling of my examination room, making an angle of 45° through which patient can see the front and posterior view at the same time (Fig. 18.1).

Surgical planning is a mandatory procedure before operation which I do during first consultation to demonstrate to my patients the options of intervention to solve his or her problems. Always patients concern very much about extension and location of the scars as well as the final result of the body contour. If new patients ask to see my other surgical results, I do not show any preoperative and postoperative





**Fig. 18.1** (a) Drawing showing my examination room with two vertical mirrors and another one placed 45° through them; patient standing between them can see the front and back view simultaneously. (b) A female patient in standing position between two vertical mirrors; (c) she sees her body in frontal view; (d) when she looks at the superior mirror placed 45°, she can see the posterior aspect of her body



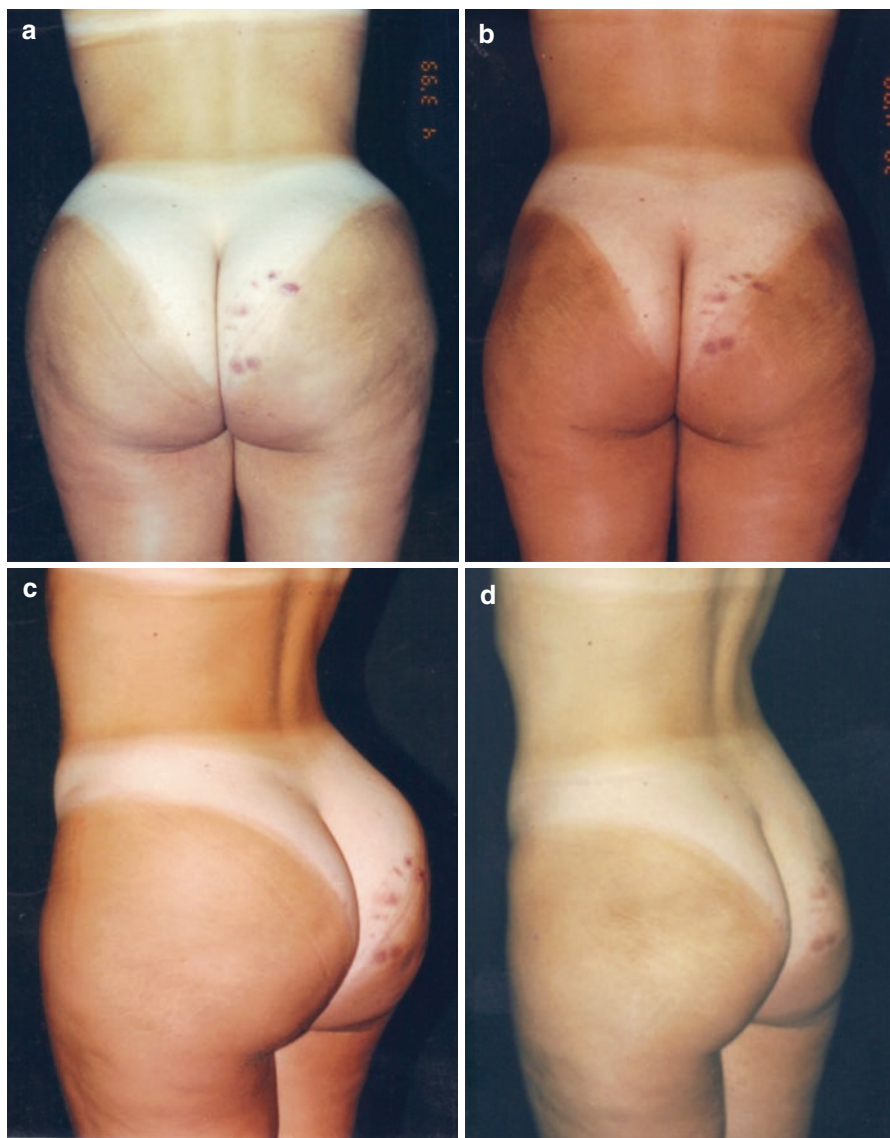
**Fig. 18.1** (continued)

photographs of my patients already operated. When they argue to see some results, I allow my nurses to show them some photos on my published books.

Patients should be specifically questioned about frequent aspirin ingestion as well as other continuous medications. No aspirin-containing compounds should be taken for at least 10 days prior to surgery to avoid bleeding during and after operation.

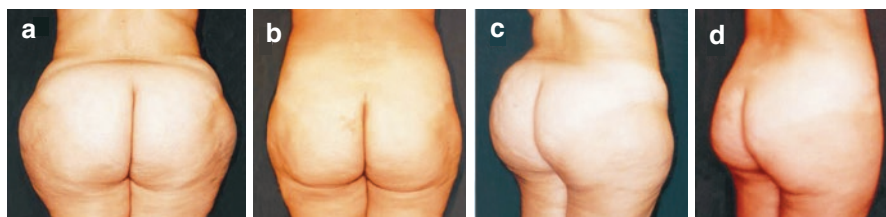
When patient presents localized adiposities on buttocks, liposuction procedure is the best choice for treatment to improve body contour (Fig. 18.2). Frequently, deformities of buttocks are associated with trochanteric lipodystrophy. Again liposuction technique of the trochanteric lipodystrophy associated with buttock adiposities may be performed (Fig. 18.3). On the other hand, correction of the flabby buttocks with cutaneous flaccidity can be operated by skin resection associated with subcutaneous tunnelization without liposuction also without panniculus undermining. Therefore, my new concepts for lipoabdominoplasty are employed for the removal of excess skin for remodeling the buttocks (Fig. 18.4).

Redundancy of the skin of buttocks, senility, weight loss, and ptosis may be due to aging and musculocutaneous laxity, or small flat gluteal muscles such that the

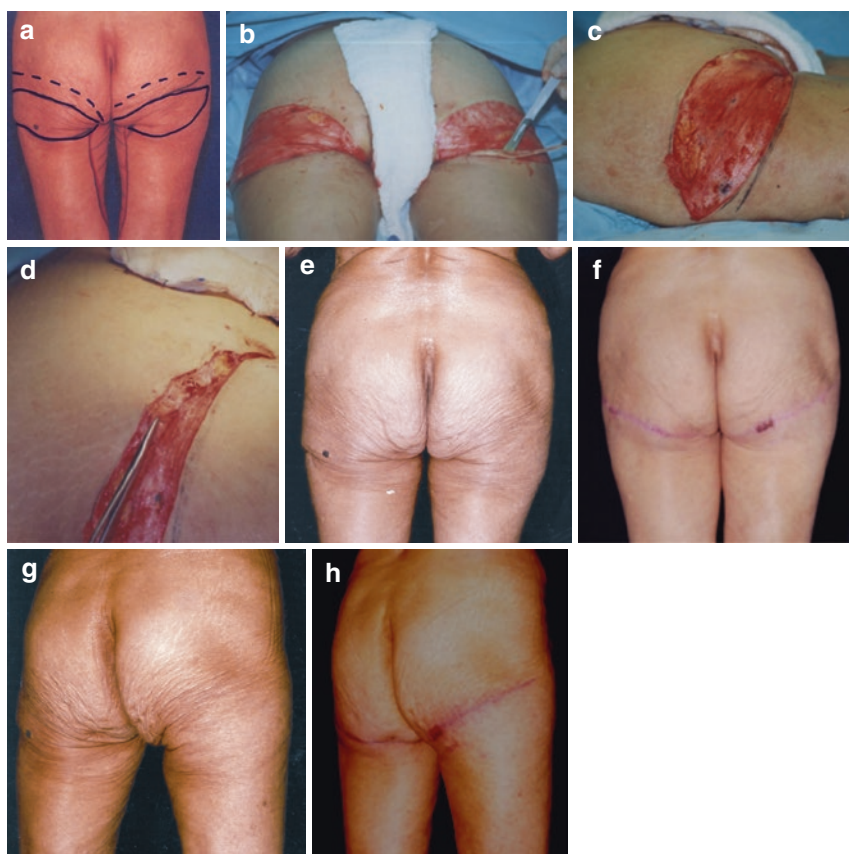


**Fig. 18.2** Liposuction of the buttocks and flanks without skin resection: (a, c) preoperative view of a 19-year-old female patient with abundant localized adiposity; (b, d) postoperative

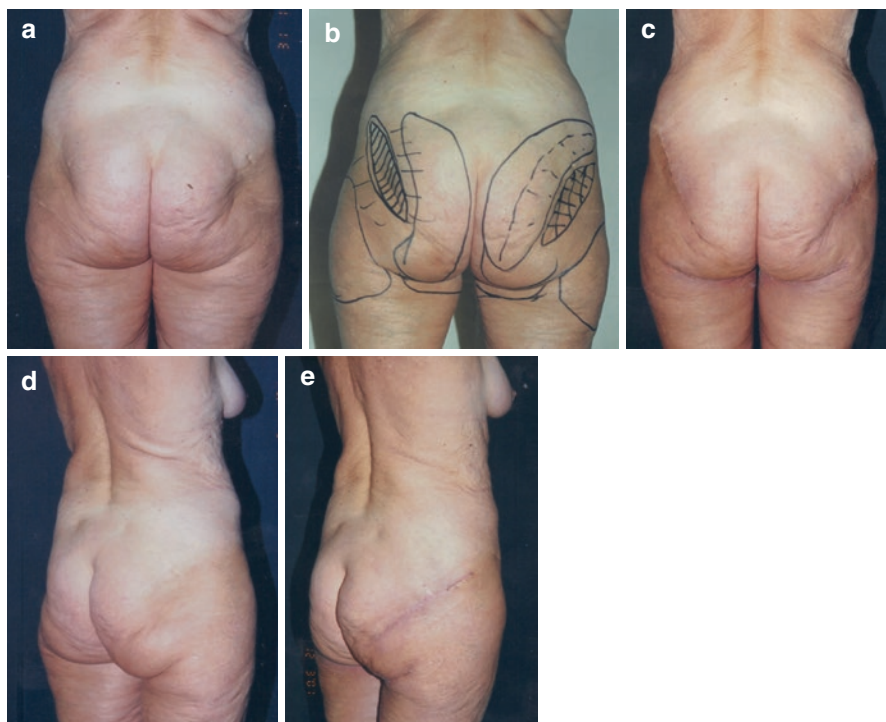
skin and subcutaneous tissue hang loosely in the area where the gluteal crease should be. Patients with this deformity are concerned with their appearance when nude or in thigh-fitting or revealing clothing such as bathing suits and slacks. Improvement of the body contour may achieve outstanding results in the use of silicone prosthesis implant which is an excellent surgical option for adequate candidates, but it is not described here.



**Fig. 18.3** Liposuction of the buttocks and flanks without skin resection of a 21-year-old female patient: (a, c) before operation; (b, d) postoperative view



**Fig. 18.4** Aesthetic surgery of buttocks to improve cutaneous flaccidity performed by surgical principles of new concepts on abdominoplasty: (a) photo of a patient with cutaneous flaccidity of the buttocks with surgical planning; continuous lines on gluteus fold demarcated the area of skin resection similar to Pitanguy's technique, and dotted lines show the area of subcutaneous tunnelization. Prosthesis inclusion is demarcated on the inner side of the thigh which was done afterward; (b) photo from back view showing both areas of skin resection being done following demarcation; (c) lateral view of the left side with wide raw area; (d) suture of the wound by plication of subdermal folded over itself prior the dermal suture. (e, g) Preoperative of aesthetic surgery of buttocks of a 75-year-old female patient presenting severe and unaesthetic cutaneous flaccidity; (f, h) post-operative photos of the same patient after operation. The silicone prosthesis inclusion on the inner side of the thigh was performed on another operation by Dr. Montellano who introduced the prosthesis through the scar of buttock lifting previously done



**Fig. 18.5** Aesthetic repair of buttocks performed by surgical principles of new concepts on abdominoplasty through demarcation similar to limited Pitanguy's approach: (a) preoperative photo of a 69-year-old female patient presenting bilateral unattractive depression on lateral aspect of the buttocks with adipose tissue and excessive cutaneous flaccidity; (b) surgical demarcations show the area for skin resection with full-thickness liposuction on the center and deep liposuction on flanks combined with tunnelization areas on each side; (c) Improvement of the depression areas and contour of the buttocks after surgery. Photos (d) of posterolateral view before operation; (e) after surgery

The buttock deformities are important and frequent problems on human body causing unaesthetic and unbalanced disturbances. According to the etiology of the abnormalities, there are origins among my patients which are the following:

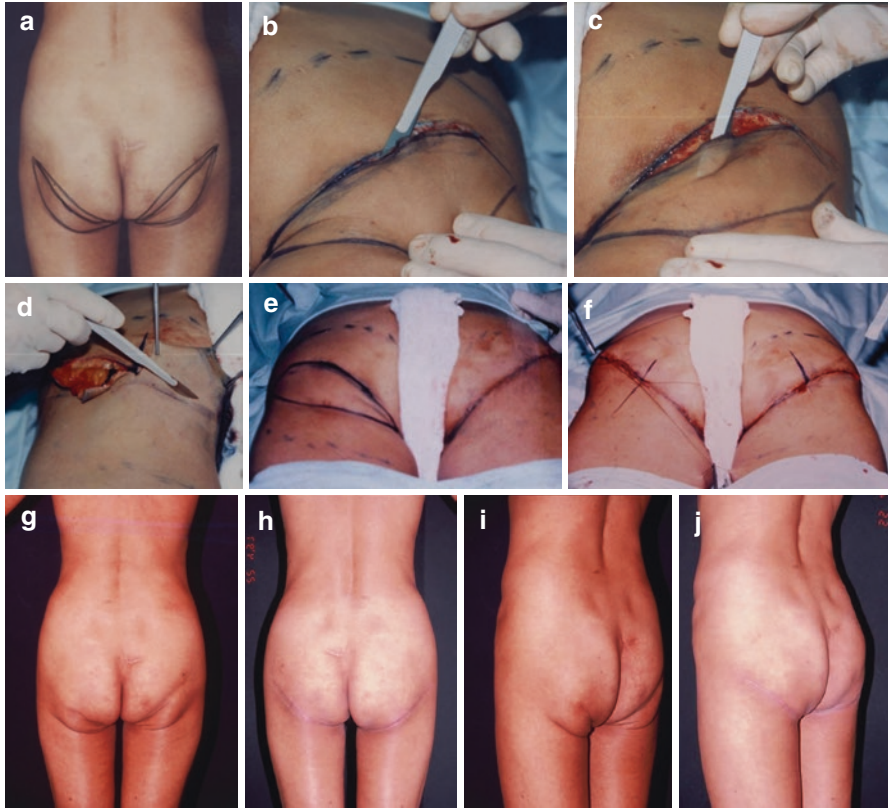
1. Localized lipodystrophy (Figs. 18.2 and 18.3)
2. Senility (Fig. 18.4)
3. Degenerative origin (Fig. 18.5)
4. Acquired origin

(a) Secondary to silicone prosthesis inclusion (Figs. 18.6 and 18.7)

(b) Infection after gluteus injection (Figs. 18.8 and 18.9)

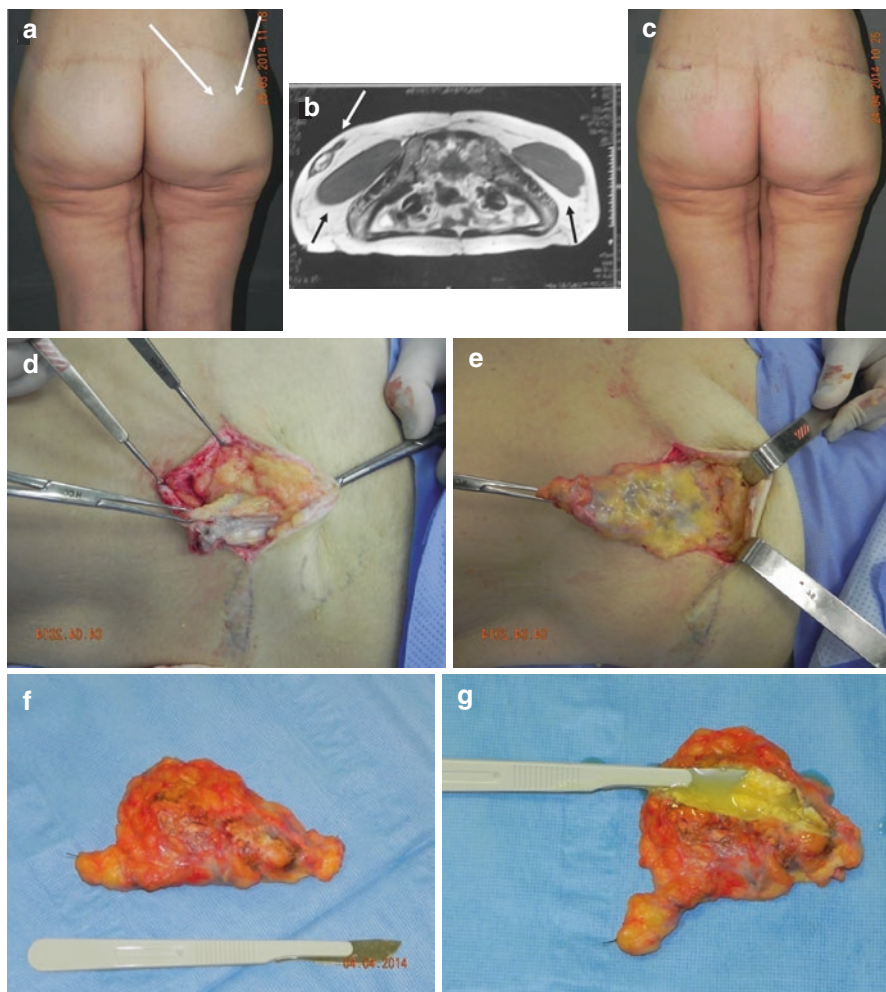
### *Surgical Demarcations*

My preference is to demarcate the incisions, localized adiposities, and other abnormalities on the patient's skin with indelible ink 1 day prior to the operation in order to inspect the location of the final scars and the areas with accumulated fat



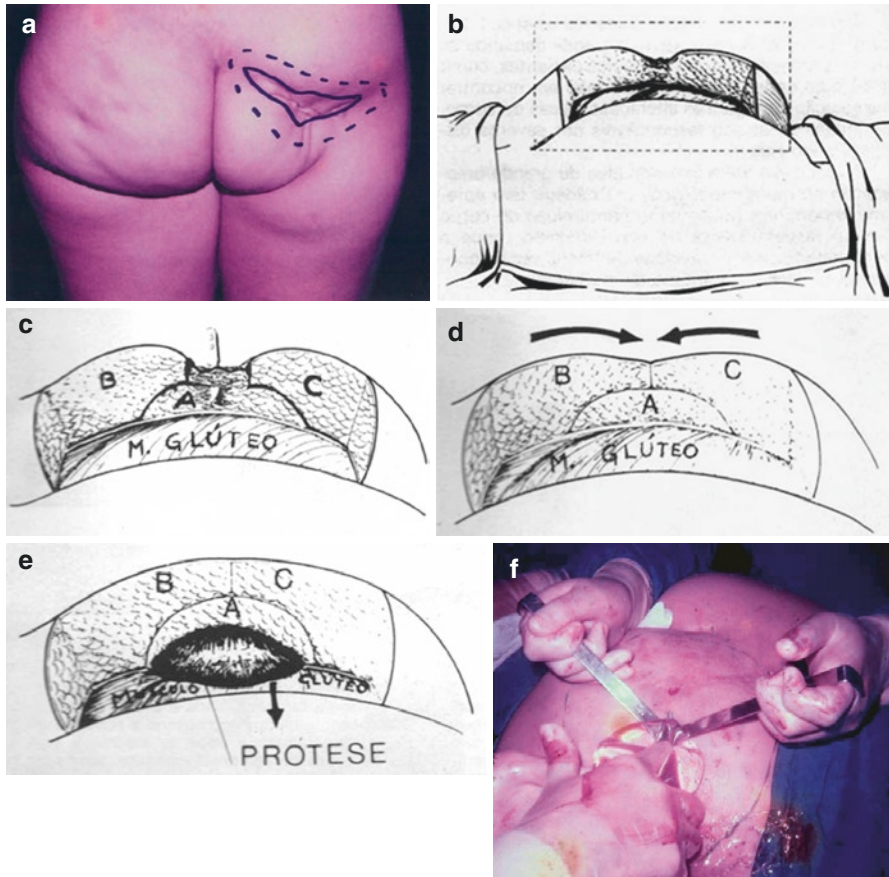
**Fig. 18.6** Aesthetic repair of buttocks performed by surgical principles of new concepts on abdominoplasty through demarcation similar to Pitanguy's approach: (a) surgical demarcations show the area for skin resection with full-thickness liposuction on the gluteus sulcus on each side; (b, c) preoperative photos showing full skin being incised after full-thickness liposuction combined with tunnelization on the upper area demarcated with dotted lines. Photos during surgery: (d) the excess skin is being resected on the right side of the patient; (e) posterior view showing the operation performed on the right side of the patient with final suture of the surgical wound; (f) one can see both sides already performed with buttock reparation. Photos (g, i) of preoperative view of a 49-year-old female patient presenting unaesthetic deformities with ungraceful scars on lower segment of the buttocks secondary to silastic prosthesis inclusion with extrusion; (h, j) postoperative photos after reparation of the buttocks employing surgical principles of new concepts on abdominoplasty

(Figs. 18.4a, 18.5b, 18.6a). The amount of skin redundancy responsible for the drooping buttocks is carefully evaluated by Illouz' "pinching test" [23]. Also rolling in the excess skin on the upper and lower sides of the gluteal crease is marked. When patients present accumulated adiposities on buttocks and other regions of the lower extremities, even on the torso, liposuction technique is the best one for remodeling the body contour (Figs. 18.2 and 18.3). Liposuction procedure is not described here since it is not the purpose of this chapter, but the readers will find meticulous technical information elsewhere in this book.



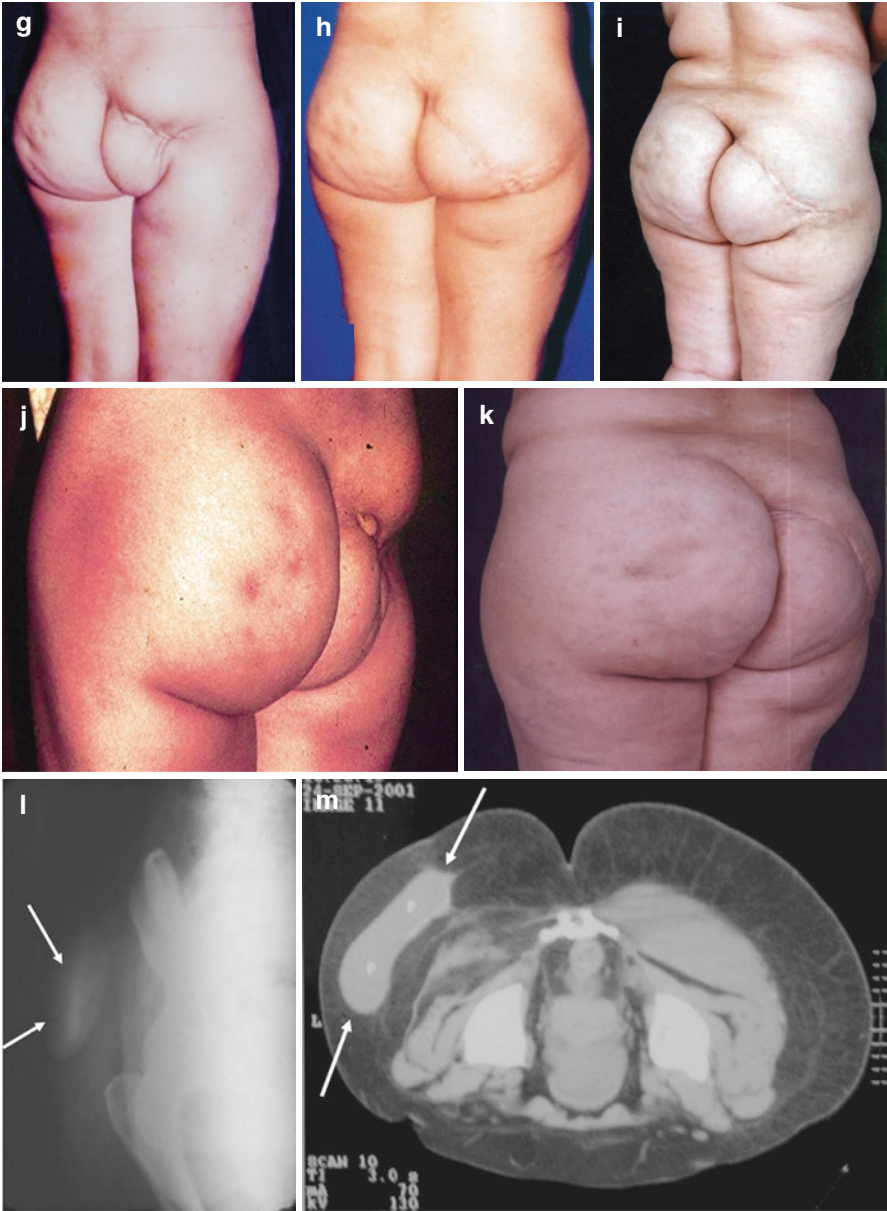
**Fig. 18.7** Steatonecrosis on the buttock after gluteus silastic prosthesis implant performed elsewhere: (a) a 32-year-old female patient after 45 kg weight loss underwent gluteoplasty, and few years later, gluteus prosthesis implant presented a tumor on her right buttock indicated by *arrows*; (b) computerized tomography shows a cyst between the prosthesis and the skin indicated by *white arrow*. The *black arrows* indicate the prosthesis placed on gluteus muscles; (c) same patient after tumor resection on right buttock. (d, e) Removal of the cyst through cutaneous incision during operation; (f) the tumor after removed; (g) incision with knife showed full of liquid oil with diagnosis of steatonecrosis

When localized adiposities are present with distortion of the silhouette, all regions must be well drawn. Thanks to liposuction technique, most of abnormalities regarding accumulation of fat on buttocks may be treated with smooth results (Figs. 18.2 and 18.3). Therefore, nowadays, Pitanguy's technique for reparation of trochanteric lipodystrophy through dermolipectomy on gluteus regions and the



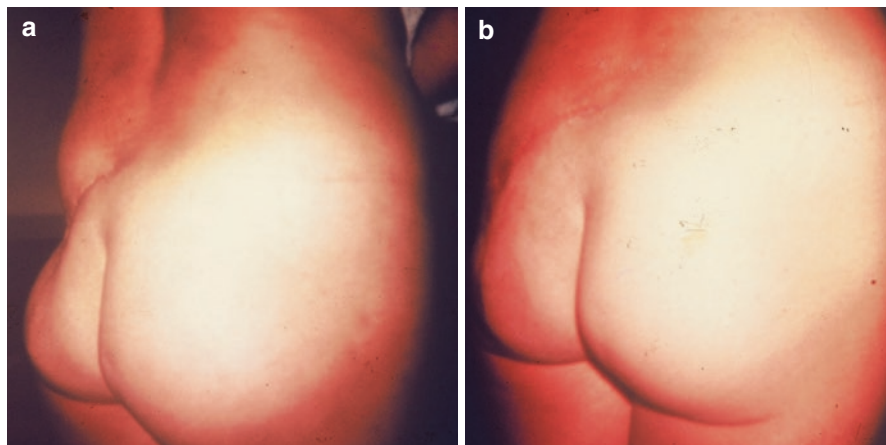
**Fig. 18.8** Reconstruction of the buttocks of the right side using round mammary prosthesis in two surgical stages: first stage, (a) surgical demarcations for resection of cutaneous scars with continuous lines and with dotted line of the area for cutaneous undermining since when the operation was performed in 1973 there was no liposuction; (b) schematic shows the buttock on the right side delimited with *dotted lines*; (c) drawing shows the scars being excised and creation of three subcutaneous flaps; (d) drawing shows that the panniculus flaps B and C being pulled over the flap A. Second surgical stage – (e) schematic shows that the prosthesis was inserted below the flaps A, B, and C. (f) Photo during operation showing the insertion of the round silastic prosthesis 2 months after the first stage of reconstruction. (g) Preoperative view of the right buttock of a 19-year-old girl with deep and severe scar secondary to local infection after injection in infancy; (h) the surgical result 2 years after two stages of reconstruction with mammary prosthesis; (i) same patient 29 years after surgery. It was indicated with liposuction as complementary procedure but she refused. (j) Preoperative in oblique view of the right buttock; (k) same patient 29 years after surgery. (l) X-ray of the same patient 2 years after operation showing the prosthesis located on the muscular plane and below the subcutaneous panniculus; (m) computerized tomography of the same patient 29 years after surgery. The *arrows* indicated the prosthesis





**Fig. 18.8** (continued)

thigh should not be the first surgical option. Nevertheless, in patients presenting skin flaccidity and also redundancy, the adequate surgical treatment is to employ similar demarcation of Pitanguy’s technique in order to resect the excess panniculus, but without panniculus undermining (Figs. 18.4, 18.5, and 18.6). Due to new



**Fig. 18.9** A 29-year-old female patient presenting severe deformity on left buttock caused by infection after injection in infancy; (a) preoperative photo; (b) postoperative photo of the patient 5 months after reconstruction in two surgical stages with round silastic prosthesis

concepts and knowledge I introduced on lipoabdominoplasty, it is possible to perform remodeling of the buttock region by lifting procedure with minimal trauma without bleeding during and after operation (Figs. 18.5 and 18.6).

### ***Buttock-Lifting Operation***

My operations are performed at the hospital under epidural or general anesthesia. With the patient in the operating room on prone position, all demarcated areas are again evaluated, and when it is necessary, another drawing is done (Figs. 18.4, 18.5, and 18.6). The exact amount of excess tissue is determined and outlined on buttocks in a fusiform area similar to demarcation of Pitanguy's technique. The medial and lateral lengths of the excision will depend on the amount of the skin that might be excised. Markings are done on the medial thigh due to laxity and skin redundancy and/or trochanteric lipodystrophy. The thickness of the tissue to be resected is determined by the thickness of the subcutaneous fat on demarcated area which is very thin since the description is concerning to flabby and ptotic buttocks.

First of all, local infiltration is done according to surgical planning on two levels: deep infiltration on the supramuscular plane on all regions for liposuction and superficial and deep infiltration inside the panniculus on the area for skin resection. The solution is 1,000 mL of sorum + 2 mg of epinephrine (1/1,000) which is a solution of 2/1,000,000 under local infiltration in all area of buttocks and medial thigh as well. When liposuction will be performed, it is mandatory to infiltrate the amount of accumulated fat that will be aspirated. However, this topic will not be discussed here, but only skin resection combined with tunnelization procedure with preservation of perforator vessels of the remaining panniculus.

The basic principles of my new concepts of lipoabdominoplasty to be employed are full-thickness liposuction of the area of skin resection, deep tunnelization of the remaining panniculus, full-thickness skin resection, no skin or panniculus undermining done, and finally suture of the panniculus.

Following surgical demarcations, the surgery starts with full-thickness liposuction of the panniculus corresponding to the skin area to be resected, even if it is very thin (Figs. 18.4, 18.5, and 18.6). At the end of liposuction, only connective tissue with perforator vessels will remain. The next step is to do tunnelization on the upper border of the panniculus to facilitate migration from upward to downward but without any panniculus undermining or resection (Figs. 18.4, 18.5, and 18.6).

The final step of the surgery is the suture of the wound which must be done with absorbent material always with isolated stitches in three levels. It is important to suture the fascia superficialis which is a very important anatomical structure according to my previous descriptions [5–7]. Fascia superficialis may be well identified on both borders of the wound where suture must be done from the lower border to the same anatomical structure of the upper border (Fig. 18.6). When patient presents flabby and excess skin, subcutaneous suture is done after skin resection on way to fold over itself without any cutaneous undermining (Fig. 18.4). On top, the dermis from one border is sutured with the dermis of the upper border. Drainage is not necessary since there is no bleeding during or after operation. Afterward adhesive tapes are placed on the border of the suture which is maintained during 7 days, and it is changed for another one and kept for 2 or 3 weeks.

Concerning reconstruction of the buttock is an updated field due to the demand from patients for better aesthetic body contour. Therefore, some acquired abnormalities of the buttocks damage very much the silhouette which requires reparation with special emphases for aesthetic improvement of the surgical results (Figs. 18.8 and 18.9) [3]. The buttocks have immense importance in harmony with the whole human body, especially in females, where the physical appearance and harmony are essential for intimate being of women. Nowadays, gluteus augmentation is a quite frequent operation, but some patients may present complications with extrusion of the prosthesis which leave ungraceful appearance which may be repaired by similar procedure as I use to do for buttock lifting (Figs. 18.7, 18.8, and 18.9).

During my training with Prof. Pitanguy, I learned his technique with much concern about selection of patients, indication, and surgical planning as well. That knowledge gave me opportunity to perform several operations since the beginning of my professional activities, employing his outstanding technique for remodeling trochanteric lipodystrophy as well as to treat variety of deformities on buttocks. I have had performed reconstruction of unusual deformities on buttocks when I started my practice in 1973. Meantime, I operated two female patients presenting severe acquired deformities on buttocks due to complications of gluteus injections in infancy. For reparation of those complex deformities, it was carried out with round mammary prosthesis implant [2] which was my thesis to become fellowship member at the Brazilian Society of Plastic Surgery. At that time, there was no gluteus silicone prosthesis implant, since my decision was directed to replace the volume of my patients' buttocks (Figs. 18.8 and 18.9). As both patients presented

severe and complex and deep scars, the deformities of the buttocks were great challenge. In order to improve the thickness of the panniculus, reconstruction was performed in two surgical stages. In the first one, the remaining panniculus was undermined laterally followed by traction in order to suture one dermal flap over the other one (Fig. 18.8).

Nowadays, there is a great improvement on this field that became possible to achieve good aesthetic results since a wide variety of prosthesis for buttock augmentation inclusion is available. Nevertheless, when I took that important decision for reparation of severe buttock deformities of my patients, there was only one unique surgical option, and that was to employ round mammary silicone prosthesis (Fig. 18.8).

## Complications

The most dreaded problem after operation following surgical correction of laxity of the buttocks in association with medial thighs is the final surgical scars. The position of the scars is such that they are under constant stress and tension and, therefore, have a tendency to widen and in very rare cases become hypertrophic. As this kind of operation is performed on patients, over 65 years old, usually they heal better than younger ones since for young patients the best choice is liposuction procedure. This is especially true for scars on the posterior lateral buttocks. Scars in the inguinocrural area have fewer tendencies to become hypertrophic but they may spread in width.

Even the scars in the inguinocrural area following medial thigh lifting should be well placed in order to avoid migration to the inferior level of the gluteus sulcus covered by normal swimwear. For this reason during demarcation and operation as well then, there is not a great deal of tension on the incision. On the inguinocrural area, the suture must be done on permanent anchoring in the deep fascia which may help and avoid the inferior migration, but in some cases, it may happen [8, 12]. During inguinocrural incisions, I create a dermal flap which is helpful to improve the scars since it gives a good support to suture the skin.

## Discussion

Among several deformities on the buttocks, the main subject described here is those caused by senility, after weight loss, and reconstruction of the buttocks after unsatisfactory results of silicone prosthesis inclusion. The treatment is to employ my new concepts for correction of ptotic and flabby buttocks; the final aesthetic results are satisfying since selection of patients, surgical demarcations, and the operation are adequately performed. Combination of liposuction with conventional procedures was a helpful improvement when accumulated adiposities are associated with

redundancy panniculus which was the beginning of the new concepts on abdominoplasty which can be employed for correction of buttock deformities [4]. Usually this operation is carrying out on patients over 65 years old which present nice scars. Nowadays, more and more young patients after weight loss or who underwent bariatric surgery complain about flabby buttocks. The incidence of hematoma does not happen, since there is no panniculus undermining or resection or even dead space beneath the flaps. I do not use drains under the resected area since there is no bleeding or hematoma. As far as the patients follow the surgeon's instructions during postoperative recovery, they do not complaint about pain even in the early period.

When traditional operation (dermolipectomy) with panniculus undermining and resection is performed, wound infection may follow buttock-lifting surgery. But under tunnelization without panniculus undermining which is the main surgical principle of new concepts on lipoabdominoplasty, such complication is very rare since blood supply to the remaining panniculus is well preserved. Also I have not had any case of wound dehiscence due to excellent vascularization on the border of the suture. I use to do only absorbable internal stitches, but adhesive tapes covering the sutured wound are my routine procedure during at least 2 months.

Besides the senility etiology and weight loss, other deformities of the buttocks caused by another origin may damage the body contour: sequel of intragluteus injection, sequel of poliomyelitis, degenerative diseases, and trauma are the most common to cause imperfection of the buttocks.

## Conclusion

Surgical treatment of buttocks is an important field in plastic surgery since very wide etiology may damage the region. Localized adiposities, cutaneous flaccidity, senility, trauma, degenerative process, and poliomyelitis may destroy partially the buttocks which require aesthetic and reconstructive reparation. The use of mammary silicone prosthesis was employed in my first patients when specific implant was not manufactured. Liposuction procedure is an excellent surgical option in cases of localized adiposities on gluteus and neighboring regions as well.

## References

1. Agris J (1977) The use of dermal-fat suspension flaps for thigh and buttock lifts. *Plast Reconstr Surg* 59:817
2. Avelar JM (1975) Buttocks repair by round mammary prosthesis. Abstracts Sixth International Congress of Plastic Surgery. Paris, p 78
3. Avelar JM (1977) Buttocks reconstruction. *Braz. Journ of Medicine (Reconstrução de nádega) Jornal Bras. De Medicina*. Fevereiro, 43–55
4. Avelar JM (1985) Combined liposuction with traditional surgery in abdomen Lipodystrophy. XXIV Instructional Course of Aesthetic Plastic Surgery of ISAPS, Madrid

5. Avelar JM (1986) Anatomia cirúrgica e distribuição do tecido celular no organismo humano (Surgical anatomy and distribution of the cellular tissue on human organism). In: Avelar JM Illouz IG (eds) *Lipoaspiração (Liposuction)*. Editora Hipócrates, São Paulo, pp 45–57
6. Avelar JM (1986) Fisiopatologia e Estudo Metabólico da Lipoaspiração (Physiopathology and Metabolic Study of the Liposuction). In: Avelar JM, Illouz IG (eds) *Lipoaspiração (Liposuction)*. Editora Hipócrates, São Paulo (Brasil), pp 42–44
7. Avelar JM (1989) Regional distribution and behavior of the subcutaneous tissue concerning selection and indication for liposuction. The best scientific work presented in Zurich, Suiss. X Congress of Intern. Soc Aesth Plast Surg 13:155–165
8. Avelar JM (1996) Creation of a natural and definitive inguino-crural crease during medial thigh lifting. (Criação de natural e definitivo sulco inguino-crural no “lifting” da face interna da coxa). *Rev Bras. Cirur setembro/outubro* 86(5):229–237
9. Avelar JM (1999) Uma nova técnica de abdominoplastia – sistema vascular fechado de retalho subdérmico dobrado sobre si mesmo combinado com lipoaspiração (A new technique for abdominoplasty – closed vascular system of subdermal flap folded over itself combined to liposuction). *Rev Bras Cir* 88/89(1/6):3–20
10. Avelar JM (1999) Novos conceitos para abdominoplastia (New concepts for abdominoplasty). Paper presented at the 36th Congress of the Brazilian Society of Plastic Surgery. Rio de Janeiro
11. Avelar JM (1999) Abdominoplastia: Nuevos conceptos para una nueva Técnica (Abdominoplasty: New concepts for a new technique). XXVI Annual International Symposium of Aesthetic Plastic Surgery, Chairman: Prof. Jose Guerrerosantos – Puerto Vallarta, Jalisco, pp 10–13
12. Avelar JM (1999) Cirurgia Plástica de Face Interna de Coxas/Aesthetic Plastic in the Inner Side of the Thigh – New Concepts and Technique without Cutaneous or Subcutaneous Undermining. *Rev Bras Cir* 88/89(1/6):57–67
13. Avelar JM (1999) Flancoplastia e Torsoplastia – Nova Abordagem Cirúrgica. Flankplasty and Torsoplasty – a new surgical approach. *Rev Bras Cir* 88/89(1/6):21–35
14. Correa IM (1952) Tratamiento quirúrgico de la obesidad. *Rev Med Argent* 66:340
15. Delerm A, Giroteau Y (1973) Plastic, Cruro'femoro'fessiere Ou Crum Fessiere. *Ann Chir Plast* 75:31
16. Farina F, Baroudi R, Goldman B (1961) Riding-trousers-like type of pelvicular lipodystrophy (trochanteric lipomatosis). *Br J Plast Surg* 13:174
17. Fernandez JC, Correa Iturraspe M (1951) Dermolipectomia vertical en el delantal grasoso. *Dia Med XXIII*:1483
18. Grazer F (1976) The tuck and roll tight plasty. Presented for education courses at the annual meeting of the American Society Plastic and Reconstructive Surgery. Boston
19. Guerrero-Santos J (1976) Lipectomies and body sculpture. Presented for education courses at the annual meeting of the American Society of Plastic and Reconstructive Surgery. Boston
20. Illouz YG (1980) Une nouvelle technique pour les lipodystrophies localisées. *Rev Cir Esth Franc* 6(9)
21. Illouz YG (1982) Liposuction technique. First Instructional Course with surgical demonstrations at São Paulo Hospital, Prof. Andrews' Service. Organized by Brazilian Society of Plastic Surgery – Regional São Paulo, Endorsed by Brazilian Society of Plastic Surgery (BSPS)
22. Illouz YG (1982) My technique of selective suction lipectomy. Annual meeting of the American Society of Plastic Reconstructive Surgeons. Honolulu
23. Illouz YG (1984) Refinements in Liposuction to improve body contour. Theory and Practical Course with surgical demonstrations at “Nove de Julho” Hospital. Organized by Brazilian Society of Plastic Surgery (BSPS) with collaboration of Regional São Paulo
24. Lewis JR (1957) The thigh lift. *J Int Coll Surg* 27:330
25. Planas J (1975) The crural meloplasty for lifting of the thighs. *Clin Plast Surg* 2:495
26. Pitanguy I (1964) Trochanteric lipodystrophy. *Plast Reconstr Surg* 34:280–286
27. Pitanguy I (1972) Dermolipectomies crurales. *Ann Chir Plast* 17:40
28. Vilain R (1975) Some considerations in surgical alteration of the feminine silhouette. *Clin Plast Surg* 2:449
29. Vilain RC, Dardour JC, Bzowski A (1977) Use of Dermal-fat flaps in treating abdominal scars, in abdominoplasty and in subtrochanteric lipectomy. *Plast Reconstr Surg* 60:876

# Chapter 19

## Plication of the Abdominal Wall in Lipoabdominoplasty

João Erfon and Claudio Maurício

### Introduction

According to Sinder, the first publication on abdominoplasty was made by Demars and Marx in 1960 [35, 40]. Since then, the advance of scientific knowledge allowed the development and improvement of the surgical technique.

Currently, abdominoplasty is one of the most frequent cosmetic surgeries performed in the world [7, 14, 17]. Some factors such as security and lasting results have contributed to the evolution of this procedure. According to the American Society for Aesthetic Plastic Surgery's 2004 Cosmetic Surgery National Data Bank, the number of abdominoplasty increased by 344% between 1997 and 2004 [20]. Several tactics and approaches were suggested and reproduced successfully by experts from around the world. One of the major contributions is credited to Avelar who opened a wide field performing important association of liposuction technique with abdominoplasty introducing new concepts which reduced the high incidence of complications during and after surgery [1]. In the beginning, he published mini-abdominoplasty combined with liposuction procedure, making this the full extent of the abdominal flap, without panniculus undermining [1]. Leão began plication of the aponeurosis above the navel on the preserved fascial and connective tissue [19]. Some years later, other authors following Avelar's surgical principles presented more contributions and even introduced the expression of "lipoabdominoplasty" to broaden the application of this

---

J. Erfon, MD (✉)

Director, Artclinic Ltda., Av Atilano de Moura, 530., Fortaleza, Ceará 60810180, Brazil  
e-mail: [erfon@artclinic.com.br](mailto:erfon@artclinic.com.br)

C. Maurício, MD

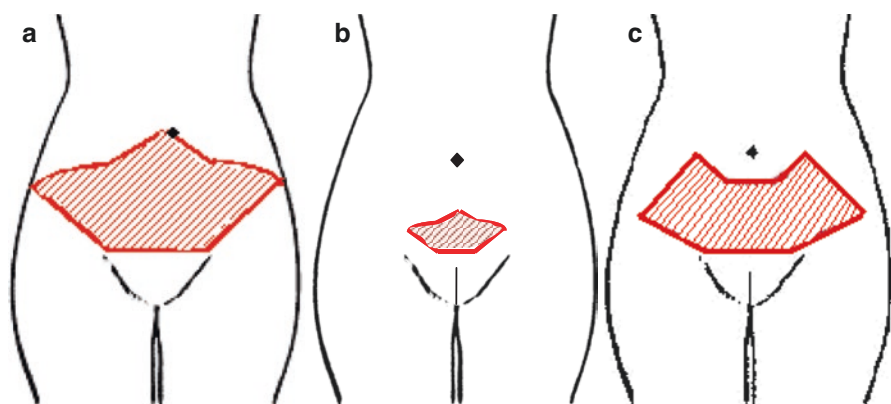
Preceptor of the Plastic Surgery Post-Graduate Course, Department of Surgery,  
Walter Cantídio Hosp of the Federal University of Ceará, Costa Mendes, 1608-Third floor,  
Fortaleza, Ceará 33368061, Brazil  
e-mail: [claudiomauriciomr11@hotmail.com](mailto:claudiomauriciomr11@hotmail.com)

association to full abdominoplasty [34]. The main surgical principle is to preserve the fascia superficialis without exposure to abdominal aponeurosis. I introduced a systematization of lipoabdominoplasty with determination of three segments in the lower abdomen (Fig. 19.2a). In both lateral segments, the fascia superficialis and all the important anatomical structures would be maintained, while in the central one, below the navel, the fascia superficialis is resected, exposing the aponeurosis and allowing safe plication of the *rectus abdominalis* muscles [9, 10]. This subject is the main topic of this chapter since the perforator vessels are preserved during operation which provide normal blood supply to the remaining abdominal panniculus.

## Technique

All patients with indication for abdominoplasty after careful clinical evaluation concerning the excess of the skin and accumulated adipose tissue provision are to be addressed, and hypotonia of the abdominal wall (Fig. 19.1) may be classified into three categories: (a) full abdominoplasty, (b) mid-abdominoplasty, and (c) mini-abdominoplasty [9, 10].

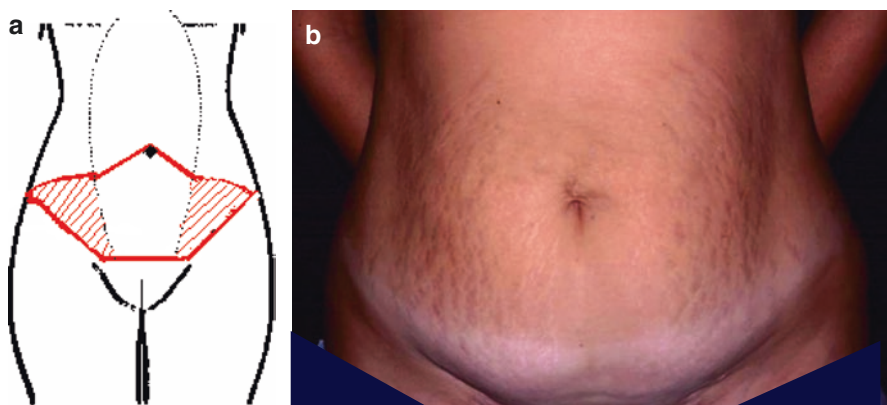
Full abdominoplasty – surgical demarcations are done with patient in standing position before going to the operating room. The areas of liposuction on the abdomen and flanks are marked as well as the incision lines. All surgeries are performed under general anesthesia. In the operating room with the patient in supine position, the incisions are marked again. They are positioned in order to keep the final scar at the hairline level following the abdominal groove laterally and the pubic region length do not exceed 6 cm (Fig. 19.1a). The navel is drawn as diamond-shaped incisions. Markings divide lower abdomen in three areas. Fascia superficialis must be resected at the central segment and maintained at the lateral ones (Fig. 19.2a, b).



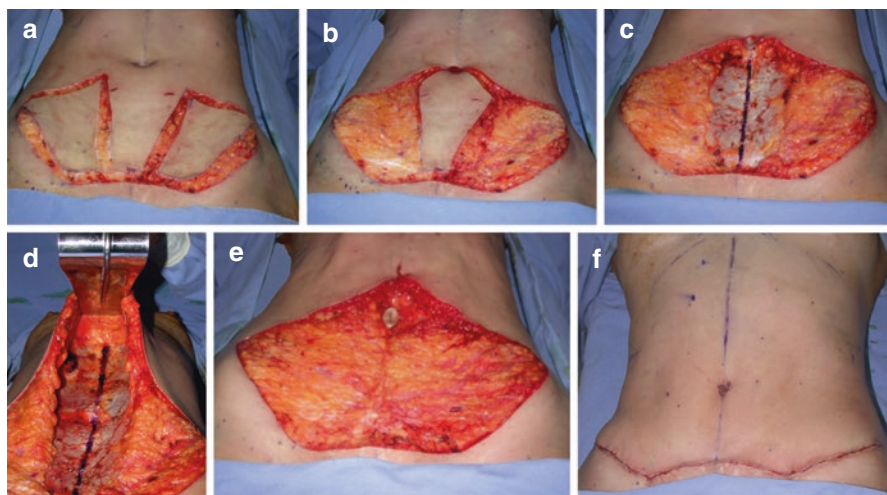
**Fig. 19.1** (a) Surgical demarcations of full abdominoplasty. From the top point of the umbilicus, two slightly inclined lines are marked with the same dimension of the demarcation on the pubis. Another line is marked laterally to join the ends of the lower abdominal crease. (b) Planning of mini-abdominoplasty (planning of mini-abdominoplasty). (c) Mid-abdominoplasty planning (planning of mid-abdominoplasty)



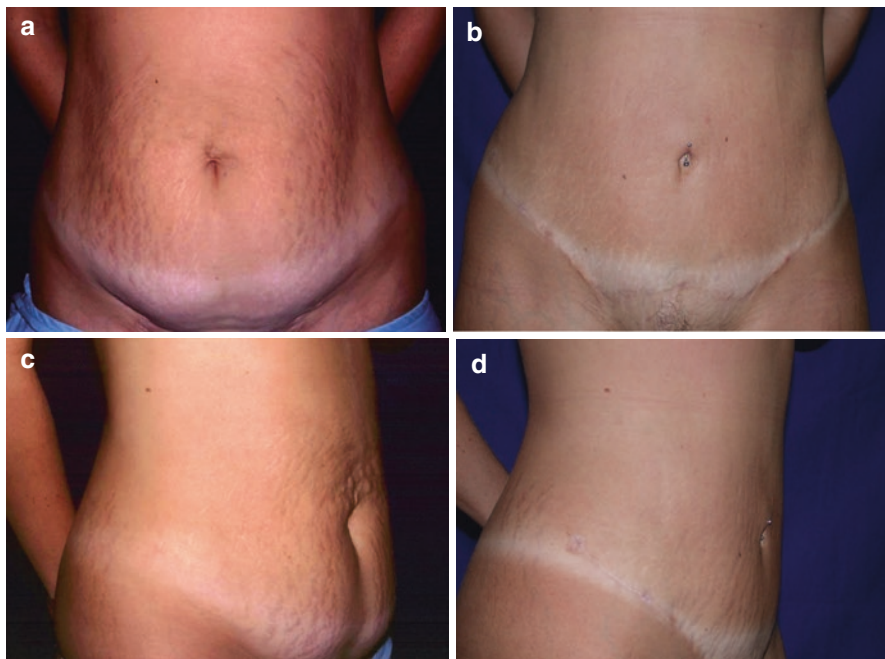
All areas are infiltrated with saline solution (1000 ml) with epinephrine (1 ml). The operation starts with superficial and/or deep liposuction throughout the demarcation area (Fig. 19.3b). The incisions are initiated and the skin resected, preserving the fascia superficialis, on lateral sides of the lower abdomen, while in the central



**Fig. 19.2** (a) Drawing showing an area of infraumbilical conjunctive tissue as well as the tunnel having already been demarcated for plication of the abdominal muscle fascia. (b) Surgical planning and demarcation on a female patient. Two areas for liposuction (L) laterally; liposuction and panniculus undermining on midline above the umbilicus (L-U); two areas laterally of liposuction and skin resection (L-R); skin and subcutaneous resection on midline below the umbilicus (RSS)



**Fig. 19.3** (a) Beginning of the surgery with liposuction of the previously illustrated marked areas and incision of the lateral inferior cutaneous flaps of the abdomen. (b) Excision of the entire skin of the lower side-cutaneous flaps, leaving intact the superficial fascia. (c) Resection of the medial infraumbilical area with the muscle fascia being exposed, preserving the superficial fascia side. (d) Undermining of the tunnel is plication from the umbilicus up to the xiphoid. (e) Occlusion of the superficial fascia plication keeping the whole lymphatic system and vascularization. (f) Final result leaving a nice body contour



**Fig. 19.4** (a, c) Preoperative full lipoabdominoplasty. (b, d) Postoperative 6 months

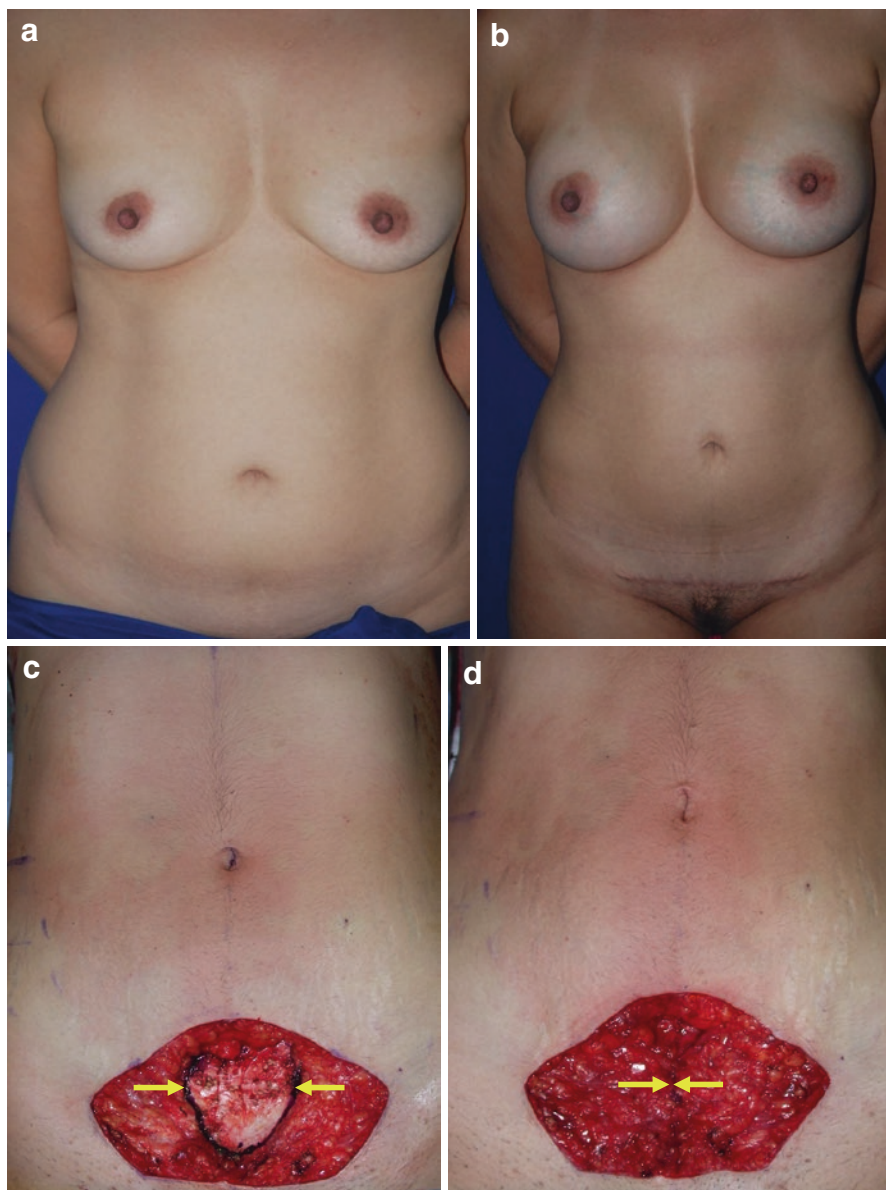
area, excision of tissue is made to muscle aponeurosis (Fig. 19.3c). The navel is incised all around, and a tunnel is undermined on the central area in the upper abdomen, limited to the muscle of the rectus, taking care to preserve the perforating vessels (Fig. 19.3d), as described by Avelar [1] initially and later by Saldanha [34] and other authors [10, 11, 34].

The plication of the *rectus abdominalis* muscles is performed with double isolated stitches in “X” on the midline of the abdomen from the xiphoid process to the pubis, using mononylon 0 (zero) for correcting muscle diastasis. The fascia superficialis on infraumbilical area is also plicated with colorless mononylon 3-0 (Fig. 19.3e) [10, 11, 25]. The association of infraumbilical muscular plication and approximation of the lateral segment of the Scarpa’s fascia allow mobilization of the peripheral tissue, providing improvement of body contouring with higher-definition waist and reducing the extent of the lower abdominal scar, as well as eliminating the “dead space” (Fig. 19.3f).

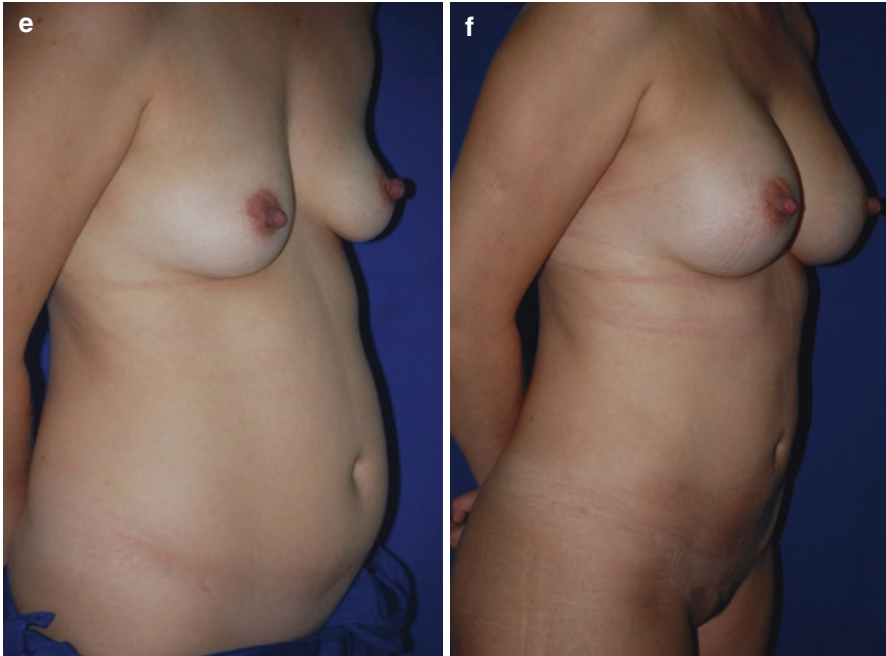
Afterward, the operating table is bent and the patient is flexed; the upper abdominal skin flap is pulled downward, and the suture starts with mononylon 2-0, using five internal points, separated, to suture it to the pubis. The suture is completed by internal separated stitches subcutaneously, using colorless mononylon 3-0. External sutures are not used (Fig. 19.4). The umbilicus is reestablished with internal points separated with colorless mononylon 4-0 being the vertical dimension longer than the transversal one [3]. Complementary liposuction may be carried out during this surgical procedure.

This technique has also been used in cases of mini-abdominoplasty (Fig. 19.5) and mid-abdominoplasty (Fig. 19.6).

Simple dressing with gauze and elastic garment is applied. The use of pneumatic compression device on the lower extremities is used from the beginning of surgery until lasting while the patient is in the hospital. Also the use of elastic socks during the 21 days postoperatively. According to the clinical indication following the risk assessment protocol for thrombotic events, Caprini [41] prescribed low molecular



**Fig. 19.5** (a, c, d, e) Pre- and trans-operative lipominiabdominoplasty. (b, f) Postoperative 6 months



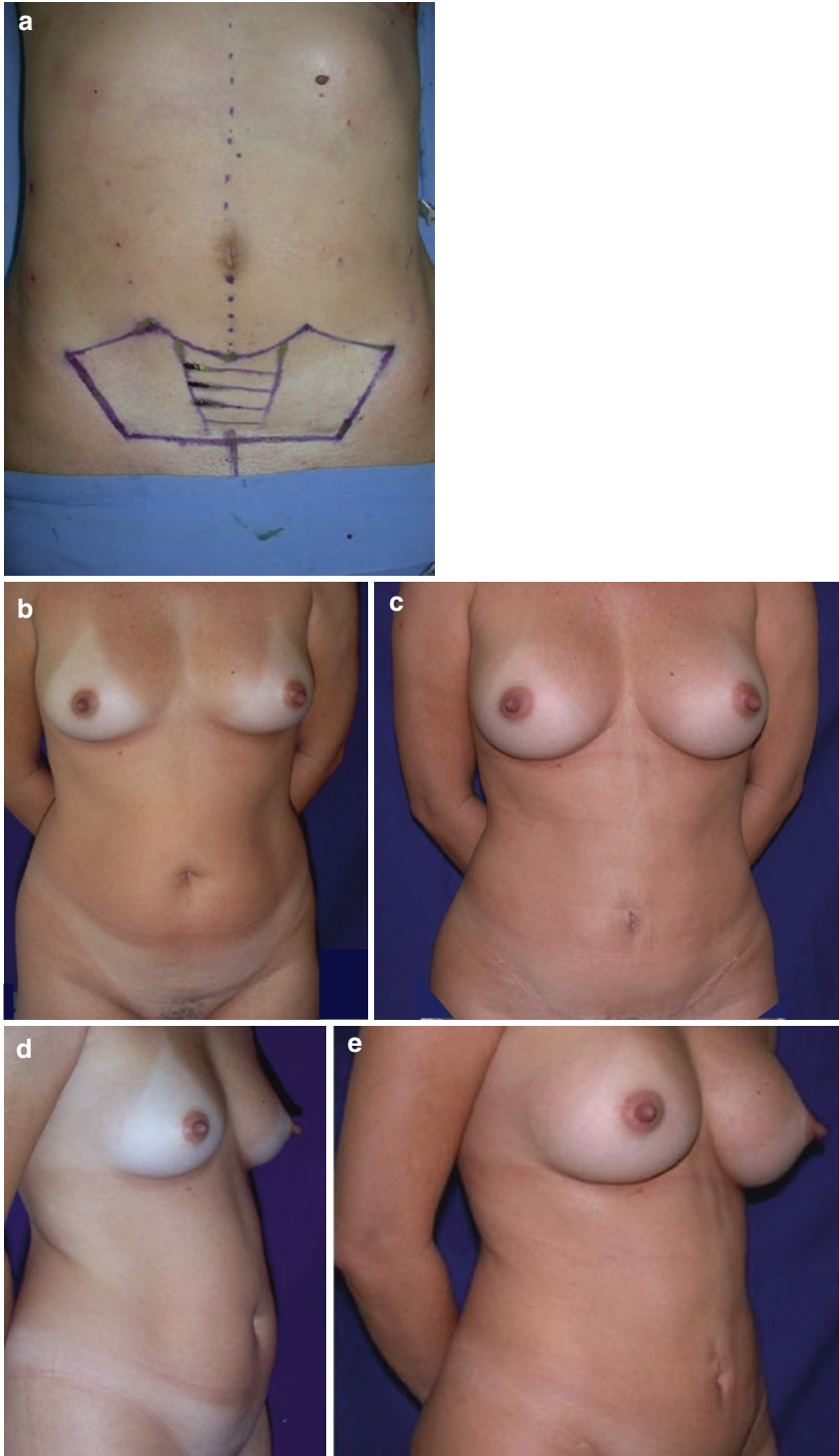
**Fig. 19.5** (continued)

weight heparin, 40 mg/day, for ten days [4, 21, 22, 30]. Patient can go home on the next day and may walk carefully.

## Complications

Many authors describe care to reduce complications in abdominoplasty: Uebel [39] with the recommendation of smaller detachment [39], Baroudi and Ferreira with the membership points to reduce seroma [5] Avelar [1], Saldanha [34], and Erfon [9] with lipoabdominoplasty able to significantly reduce both complications which was more common in abdominoplasty, skin necrosis and seroma [1, 9, 11, 34]. Fatos have been proven with studies by Graf et al. [13] and other authors [1, 2, 10, 11, 13, 21, 34]. Hurvitz et al. point out the infection as the second major complication in abdominoplasty and recommend the use of antibiotics while keeping the drain [14] in lipoabdominoplasty. As far as the operation is performed without panniculus undermining, I do not use any kind of drain [11]. The use of antibiotics is used for seven days postoperatively.

Comparing the observed data using the traditional technique [6] with the data published by Matarasso et al. [20], the number of complications proved to be extremely low using the lipoabdominoplasty [6, 20]. During 14 years, one single case of epidermolysis at the distal end of the flap (in mid-abdominoplasty) and one case of hematoma that was resolved with drainage and required secondary liposuction after 6 months are recorded. The two most common complications that were



**Fig. 19.6** (a, b, d) Planning preoperative lipomidabdominoplasty. (c) Postoperative 6 months

the seroma and secondary re-interventions occurring in 80% of cases, using the traditional technique, coinciding with other authors [2, 5, 14], were significantly reduced. The re-interventions used to be are of 4% after traditional abdominoplasty. In the use of lipoabdominoplasty, seroma is clinically insignificant at 0% (zero percent).

The literature describes other complications with the use of traditional abdominoplasty [14].

## Discussion

At the end of the twentieth century, Avelar [1] presented new surgical concepts for abdominoplasty which are highlights of the remarkable Kelly's [42] publication that described the basic fundamentals on "resection of the abdominal panniculus." Great improvement of the traditional abdominoplasty technique was introduced by Callia [6] through wide undermining of the abdominal flap. Later, Illouz [15] with his wonderful liposuction technique made an important contribution to the aesthetic treatment of body contour and also to the abdominal wall. Nevertheless, abdominoplasty has undergone a deep change with the advent of combination of traditional abdominoplasty with liposuction with limited panniculus undermining proposed by Avelar [1]. Following Avelar's concepts, Leão [19] performed reinforcement of the aponeurosis above the umbilicus, Erfon [9] presented plication of the abdominal aponeurotic wall below the umbilicus, and later Saldanha et al. [34] suggested the term lipoabdominoplasty.

The use of liposuction of the abdominal wall associated with mini-abdominoplasty and also a combination of mini-abdominoplasty with skin resection on submammary folds, without panniculus undermining and preservation of perforating vessels, was described by Avelar [1]. Later, the association of liposuction to full abdominoplasty was proposed by Saldanha et al. [34]. Therefore, the fundamental principles of modern abdominoplasty were introduced with minimum detachment of the abdominal skin flap, plication of the *rectus abdominalis* muscles, and preservation of fascia superficialis. These concepts brought great progress in the quality of results of abdominoplasty without damage to the blood supply of skin flaps and/or increase in the rate of complications described by Roostaeian et al. [33]. The mark of three segments in the lower abdomen, preserving the fascia superficialis on both sides and resecting the central segment, below the navel, exposing the muscle aponeurosis, enabling a safe plication under direct vision, and keeping the principles of those two authors, was introduced by Erfon [9] as a named set contribution. This new technique requires a short learning curve and allows the association of abdominoplasty and liposuction setting exceptional aesthetic results, more secure vascularization of the abdominal panniculus, as well as a drastic reduction of complications such as seroma and necrosis.

The Scarpa's fascia preservation became an effective mechanism for reducing the seroma rate and reduces the throughput early drain when applied as was mentioned by Costa Ferreira et al. [8].

According to Sinder [35], plication of the muscle diastasis is done since 1960, with suture of the anterior aponeurosis of the *rectus abdominalis* muscles as the most common procedure.

Different methods have been used in the abdominal wall plication [19, 23, 27, 39]; however, plication of the rectus abdominis muscles, as recommended by Pitanguy [31], has been routinely used by most authors.

For proper plication of the abdominal wall, some factors are important: (a) Knowledge of the anatomy. (b) Ultrasound of the abdominal wall must be a routine preoperatively and also Doppler echocardiography for evaluation of diastases of the rectus muscles and hernia, as well as the lower limbs in patients with high-risk factors for deep vascular thrombosis (DVT). (c) Body mass index less than 30. (d) Dissection of the tunnel for plication, for the pubis, up to 1 cm above the xiphoid process, keeping the musculocutaneous perforating vessels. Even the upper skin flap and the superficial fascia in the lower abdomen, the inferior epigastric vessels and superficial iliac circumflexes, lymph vessels, and nerves of the region must be preserved [11]. (e) "X" suture stitches separated using mononylon 0 (zero). (f) Eliminating the break of the aponeurosis at 0.5 cm intervals, 1 cm above the xiphoid process to the pubis, with maximum detachment up to 2 cm lateral to medial edges of the *rectus abdominalis* muscles.

It is essential to keep viable the musculocutaneous perforating vessels on the superior abdominal panniculus flap for adequate blood supply as well as the fascia superficialis in the lower abdomen (Fig. 19.3d), after plication of the aponeurosis.

Superficial fascia plication is carried out to avoid dead space formation and seroma (Fig. 19.3e), and reduces the extension of the final scar of abdominoplasty [9, 10]. Excellent aesthetic results may be achieved by reducing lower abdomen connective tissue amount (Fig. 19.4). It is not necessary to use drains after abdominoplasty as mentioned by Avelar [1] and Erfon [9]. Anatomical studies prove that maintaining the superficial fascia actually prevents seroma as reported by Koller and Hintringer [18] and Nahas [28].

Factors such as preoperative extent of diastasis of the *rectus abdominalis* or previous abdominal surgery do not seem to compromise the longevity of the correction plication [37].

The diastasis of the upright of recurrences is related to quality plication showing no relationship with the postoperative time [28].

The vertical suture is more resistant than the horizontal by virtue of the distribution and arrangement of muscle fibers [16].

Although there are standard techniques for the treatment of the navel Avelar [43], the lozenge umbilicoplasty [9] shows greater vertical extension than the horizontal and has been used with satisfactory results (Fig. 19.2). It should not be fixed to the deep aponeurosis, keeping at least 1 cm pedicle to avoid tension avoiding necrosis and ungraceful scars.

In patients with large diastases diagnosed preoperatively, the use of elastic straps is started one month before surgery, to avoid postoperative respiratory complications.

The term mid-abdominoplasty was used by Stuckey [36] to describe a surgery with transverse incision, involving the umbilical region. However, it has been used by Erfon [9] to describe his classification for abdominoplasty, in special cases where the incisions of the mini-abdominoplasty need to go beyond the pubis, with purpose of larger skin resection, and it is impossible on full abdominoplasty. He also recommends partial transverse pubectomy in order to keep the size of the pubis at most 6 cm [9].

Recently, Rodrigues studying the intra-abdominal pressure found that the increase in this pressure, resulting from muscle plications, was not significant and returns to the preoperative level in 15 days [32].

In healthy patients, plication may even improve lung function by the ability to optimize the forced vital capacity [38].

Beyond the plication of the aponeurosis, perform plication of the superficial fascia, excluding the “dead space” (Fig. 19.3e).

Nahas [24] ranked abdominoplasty according to aponeurosis deformity of the abdominal wall. Also, he demonstrated that the plication improves the definition of the waist [23] maintaining in the long term: whether used absorbable or nonabsorbable [28] or even post-pregnancy tummy tuck [26]. The same author also points out that the abdominal wall may be weakened by previous surgery, pregnancy, weight change, age, and congenital disorders and, in the latter case as well as in cases of recurrence of the plication, would require plication of the posterior sheath of the *rectus abdominalis* muscles [27, 28].

The plication of the anterior aponeurosis of the *rectus abdominalis* muscles, even in cases of recurrence, has been routinely used to separate points, reversed “X,” with double mononylon 0 (zero), with good distribution of voltage.

Some authors have proposed plication through videolaparoscopy procedure [2, 12, 29].

Murphy et al. [21] noted that the results found in studies about the chemoprophylaxis of postoperative deep vein thrombosis in patients undergoing orthopedic or abdominal surgery intracavitary could be extended to larger plastic surgeries such as abdominoplasty, because of anatomical areas, degree of invasion, and population profile [21].

Although there is no consensus in the literature as the absolute indication for prophylaxis of deep vein thrombosis in patients undergoing abdominoplasty, the use of enoxaparin 20–60 mg/day for a period of 1–4 weeks based on the risk assessment protocol Caprini [41] was effective in reducing thrombotic events [21, 22].

The use of the Caprini model (2010) also showed effective in reducing these events in patients undergoing plastic surgery [4, 30].

## Conclusions

The plication of the abdominal aponeurosis in abdominoplasty is one of the most important aspects of this surgery. It has been indicated in more than 90 % of our patients with better aesthetic and functional results. We have observed long term



excellent outcomes, even in adverse situations such as changes of weight and pregnancy and present recurrence in rare cases. The possibility of associating the lipoabdominoplasty [1, 2, 11, 34] with a safe plication and minimal undermining allows: a) preservation of noble anatomical structures; b) minimal dead space; c) better accommodation of lower abdominal preserved tissue; d) low seroma levels; e) reduction of re-interventions necessity. As observed above all these findings are undoubtedly important contributions of the final process of this technique [10, 11].

The classification of patients in three surgical groups – full abdominoplasty, mini-abdominoplasty, and mid-abdominoplasty – facilitates surgical indications, especially for beginners, using this technique.

The different marking – with the predetermination of three segments in the lower abdomen, preserving the superficial fascia on both sides and resecting the central block to the muscular aponeurosis, reducing the learning curve, and optimizing the development of lipoabdominoplasty – has also been an important facilitator in the use of this surgical technique.

Another important contribution is the partial transverse pubectomy to avoid high and unsightly scars, keeping the pubis of adequate size, around 6 cm.

## References

1. Avelar JM (1999) A new technique of abdominoplasty: closed vascular system of retail subdermal folded on itself, combined with lipoaspiração. *Rev Bras Cir* 6:3–20
2. Avelar JM (2000) Abdominoplasty – a new technique without detachment and without resection of the abdominal panniculus. *ACM* 29:147–149
3. Avelar JM (2002) Creation of the umbilical region. Surgical new instruments for abdominoplasty. *Hipócrates*, São Paulo, pp 111–121
4. Bahl V, Hu HM, Henke PK, Wakefield TW, Campbell DA Jr, Caprini JA (2010) A validation study of the venous thromboembolism retrospective risk scoring method. *Ann Surg* 251:344–350
5. Baroudi R, Ferreira CA (1998) Seroma: how to avoid it and how to treat it. *J Aesthet Surg* 18(6):439–441
6. Callia WEP (1965) Contribution to the study of surgical correction of the pendulum and distended abdomen: original technique (PhD Thesis). Sao Paulo, Faculty of Medicine, University of São Paulo
7. Castro EJ, Radwanski HN, Pitanguy I, Nahas F (2013) Long-term ultrasonographic evaluation of midline aponeurotic plication during abdominoplasty. *Plast Reconstr Surg* 132(2):333–338
8. Costa Ferreira A, Rebelo M, Silva A, Váscquez LO, Amarante J (2013) Scarpa fascia preservation during abdominoplasty: randomized clinical study of efficacy and safety. *Plast Reconstr Surg* 131(3):644–651
9. Erfon J (2001) Abdominoplasty by vascular closed system associated with liposuction. Presented at the XVI North-Northeast Surgery Day. *Plástica Costa do Sauípe*, Bahia. 13 1 15 September
10. Erfon J (2002) Abdominoplasty through the closed vascular system associated to liposuction: Avelar's technique. In: Avelar JM (ed) *Abdominoplasty*. Hippocrates, Sao Paulo, pp 299–307
11. Erfon J (2011) Tummy tuck with liposuction and minimal detachment (Abdominoplasty with liposuction and minimal undermining). *Rev Bras Cir Plást* 26(1):116–120
12. Faria-Corrêa MA (1992) Videoendoscopic abdominoplasty (subcutaneouscopy). *Rev Bras Cir Plást* 7:32–34

13. Graf R, Araujo LR, Rippel R, Neto LG, Pace DT, Cruz GA (2006) Lipoabdominoplasty: liposuction with reduced undermining and traditional abdominal skin flap resection. *Aesthetic Plast Surg* 30(1):1–8
14. Hurvitz KA, Olaya WA, Nguyen A, Wells JH (2014) Evidence-based medicine: abdominoplasty. *Plast Reconstr Surg* 133(5):1214–1221
15. Illouz YG (1980) Une nouvelle technique pour les lipodystrophies localisées. *Rev Chir Esthet Franc.* 6(9):ap 1980
16. Ishida LH, Gemperli R, Long MV, Alves HR, da Silva PH, Ishida LC, Ferreira MC (2011) Analysis of the strength of the abdominal fascia in different sutures used in abdominoplasties. *Aesthetic Plast Surg* 35(4):435–438
17. Kelly HA (1910) Excision of the abdominal wall. *Surg Gynec Obst.* p 229
18. Koller M, Hintringer T (2012) Scarpa fascia or rectus fascia in abdominoplasty flap elevation: a prospective clinical trial. *Aesthetic Plast Surg* 36:241–243
19. Leão C (2000) Abdominoplastia: a new abordagem. *Anais the XXXVII Brazilian Congress of Plastic Surgery.* Porto Alegre-RS. November 12–15
20. Matarasso A, Swift RW, Rankin M (2006) Abdominoplasty and abdominal contour surgery: a national plastic surgery survey. *Plast Reconstr Surg* 117:1797–1808
21. Murphy RX Jr, Peterson EA, Adkinson JM, Reed JF III (2010) Plastic surgeon compliance with national safety initiatives: clinical outcomes and “never events”. *Plast Reconstr Surg* 126:653–656
22. Murphy RX Jr, The Alderman, Gutowski K, Kerrigan C, Rosolowski K, Schechter L, Schmitz D, Wilkins E (2012) Evidence-based practices for thromboembolism prevention summary of the ASPS venous thromboembolism task force report. *Plast Reconstr Surg* 130(1):168e–175e.
23. Nahas FX (2001) Advancement of the external oblique muscle flap to improve waistline: a study in cadavers. *Plast Reconstr Surg* 108(2):550–555
24. Nahas FX (2001) An aesthetic classification of the abdomen based on the myoaponeurotic layer. *Plast Reconstr Surg* 108(6):1787–1795
25. Nahas FX, Augusto SM, Ghelfond C (2001) Nylon versus PDS (polydioxanone) in the correction of rectus diastasis. *Plast Reconstr Surg* 107:700–706
26. Nahas FX (2002) Pregnancy after abdominoplasty. *Plast Surg Aesth* 26:284–286
27. Nahas FX, Ferreira LM (2010) Concepts on correction of the musculoaponeurotic layer in abdominoplasty. *Clin Plast Surg* 37(3):527–538
28. Nahas FX (2012) Discussion: evaluation of the long-term stability of sheath plication using absorbable sutures in 51 patients with diastasis of the recti muscles: an ultrasonographic study. *Plast Reconstr Surg* 130(5):720e–721e. (Doc)
29. Nahas FX, Vasconez LO (1995) Diastasis correction of the abdominal muscles straight laparoscopically. *Rev Med Cir* 1:109–123
30. Pannucci CJ, Bailey HS, Dreszer G et al (2011) Validation of the Caprini risk assessment model in plastic and reconstructive surgery patients. *J Am Coll Surg* 212:105–112
31. Pitanguy I (1967) Abdominal lipectomy: an approach to it through an analysis of 300 cases consecutive. *Plast Reconstr Surg* 40(4):384–391
32. Rodrigues MA, Nahas FX, Gomes HC, Ferreira LM (2013) Ventilatory function and intra-abdominal pressure in patients who underwent abdominoplasty with plication of the external oblique aponeurosis. *Aesthetic Plast Surg* 37(5):993–999. (Doc)
33. Roostaeian J, Harris R, Farkas JP, Barton FE, Kenkel JM (2014) Comparison of limited-undermining lipoabdominoplasty and traditional abdominoplasty using laser fluorescence imaging. *Aesthet J Surg* 34(5):741–747
34. Saldanha OR, Pinto EB, Matos WN Jr, Lucon RL, Magellan F, Bello MS (2001) Lipoabdominoplasty without undermining. *J Aesthet Surg* 21(6):518–526
35. Sinder R (1979) Plastic surgery of the abdomen. Ed Ramil Sinder, Rio de Janeiro

36. Stuckey JG (1979) Midabdomen abdominoplasty. *Plast Reconstr Surg* 63:333–335
37. Tadiparthi S, Shokrollahi K, Doyle GS, Fahmy FS (2012) Rectus sheath plication in abdominoplasty: assessment of its longevity and a review of the literature. *J Plast Reconstr Aesthet Surg* 65(3):328–332
38. Tercan M, Bekerecioglu M, Dikensoy O, Kocoglu H, Atik B, Isik D, Tercan A (2002) Effects of abdominoplasty on respiratory functions: a prospective study. *Ann Plast Surg* 49(6): 617–620
39. Uebel CO (1994) Abdominal surgery associated with liposuction. In: Tourniex AAB (ed) *Update in aesthetic plastic surgery*. Editorial Robe, Sao Paulo, pp 483–489
40. Demars and Marx: As mentioned in Voloir P (1960) *Opérations plastiques sus-aponevrótiques sur la paroi abdominale antérieure*. These, Paris
41. Caprini JA (2005) Trombosis risk assessment as a guide to quality patient care. *Dis Mon* 51(2–3):70–78
42. Kelly HA (1899) Report of gynecological cases. *John Hopkins Med J* (10):197
43. Avelar JM (1976) Umpilicoplastia: Uma técnica sem cicatriz externa. *Anais do XIII Congr. Bras Cir Plast Porto Alegre* 81–82

# Chapter 20

## Dorsolipoabdominoplasty

Célio Ferreira Leão and Geisa Moura Leão

**Summary** In this text, the author describes the importance of aggregating the plication of the abdominal fascia after suturing the rectus abdominis muscles in order to improve aesthetic outcomes in body contours, notably in the waistline.

### Introduction

In 1999 at the Brazilian Congress of Plastic Surgery in Rio de Janeiro, we learned Avelar's technique of abdominal liposuction associated with classic abdominoplasty [1, 8] (1999), known as the closed vascular system of subdermal flap folded over itself, combined with liposuction.

In 2000, at the XXXVII Brazilian Congress of Plastic Surgery [2] in Porto Alegre, Rio Grande do Sul, we presented our study "Abdominoplasty: A new approach" [4], in which we showed how to create a xipho-umbilical surgical

---

This present study was carried out in the plastic surgery service of Santa Casa de Misericórdia de Goiânia Hospital in Goiás.

Email: [celioleao1@hotmail.com](mailto:celioleao1@hotmail.com)

C.F. Leão, MD (✉)

Members of the Brazilian Society of Plastic Surgery, UFG Goiás Medical School, PUC Goiás Medical School, Goiânia, GO, Brazil

Residency Service, Santa Casa de Misericórdia de Goiânia Hospital, Goiânia, GO, Brazil

e-mail: [celioleao1@hotmail.com](mailto:celioleao1@hotmail.com); [karlachaul@gmail.com](mailto:karlachaul@gmail.com)

G.M. Leão

Members of the Brazilian Society of Plastic Surgery, Marcos Vinícius Calazans de Sousa – R3 – Santa Casa de Misericórdia de Goiânia Hospital, Goiânia, GO, Brazil

Mário Junqueira de Souza – R2 – Santa Casa de Misericórdia de Goiânia Hospital, Goiânia, GO, Brazil

Célio Coelho Neto Leão – R2 – Plastic Surgery Hospital, Rio de Janeiro – RJ, Rio de Janeiro, Brazil

tunnel complementing Avelar's technique (1999) in suturing of rectus abdominis muscles. We also presented dorsal liposuction with fat grafts in the buttocks.

This study culminated, 15 years later [4, 5], in plication of the abdominal fascia [7] running from the xiphoid process to the pubis using a continuous suture, complementing the body sculpting with improvements, principally in the suture line [9].

## **Material and Methods**

From 2000 to 2014, a total of 784 patients underwent dorsolipoabdominoplasty, an average of 58 patients per year and 4.6 patients per month. However, it was only at the beginning of 2015 that we were able to conclude the study and plicate Scarpa's fascia with continuous suturing (which we called Leão's spiral suture) in a second continuous suture running from the xiphoid process to the pubis.

## **Surgical Technique**

### ***Marking***

Performed with the patient in a standing position and on a surgical table with the head elevated 30°. In these positions, measurements of the body contours were taken at the thorax, waist, and hip lines, as well as the excessive cutaneous flap to be excised from the inferior part of the abdomen.

### ***Anesthesia***

General or epidural, under the care, responsibility, and recommendation of an anesthesiologist.

## **Surgery**

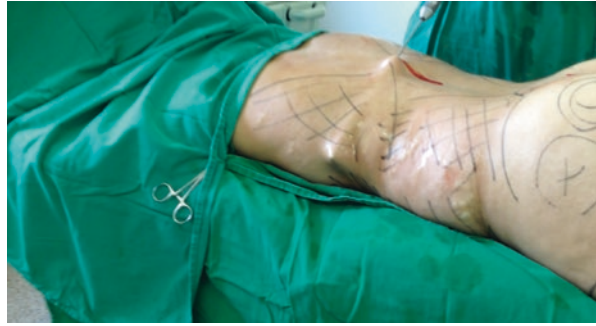### ***Phase 1***

Patient is positioned on the surgical table with the head elevated 30°. Measurements of body contours are taken with patient standing and lying down so that the waist-line and excess skin to be removed from the lower abdomen can be calculated. Dissection [1] from the umbilicus to the aponeurotic muscle plane is conducted, and the inferior abdominal flap is resected, as described in phase 2.

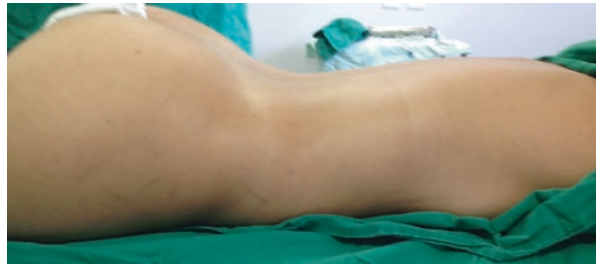## Phase 2

We begin the surgery with liposuction of the dorsal region and flanks and subsequent grafting of the fat into the buttocks (Figs. 20.1 and 20.2). Next, we construct a surgical tunnel [1] at the level of the aponeurosis running from the umbilicus to the xiphoid process, maintaining a 3–4 cm distance from the median line of the rectus abdominis muscles. This is followed by suturing from the xiphoid process to the pubis with double-tied 0 line and a 4.0 needle (Figs. 20.3 and 20.4). A second continuous suture [6] is then initiated, joining the fascia from the thoracic and abdominal regions in a

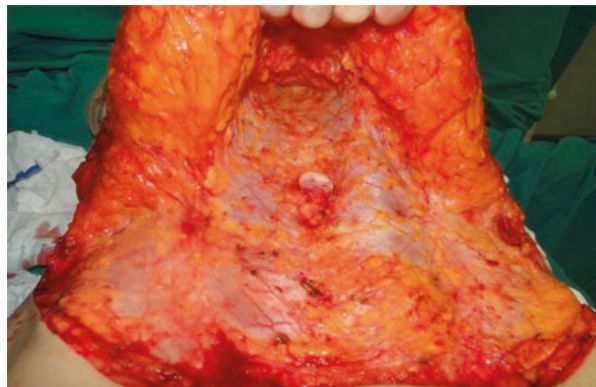
**Fig. 20.1** Liposuction of the dorsal area and flanks communicating with previously performed abdominal liposuction and fat transfer from this region to the buttocks



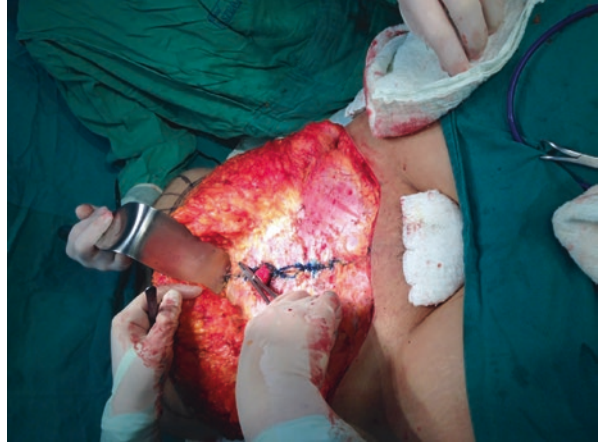
**Fig. 20.2** After liposuction and graft of resulting fat into the buttocks



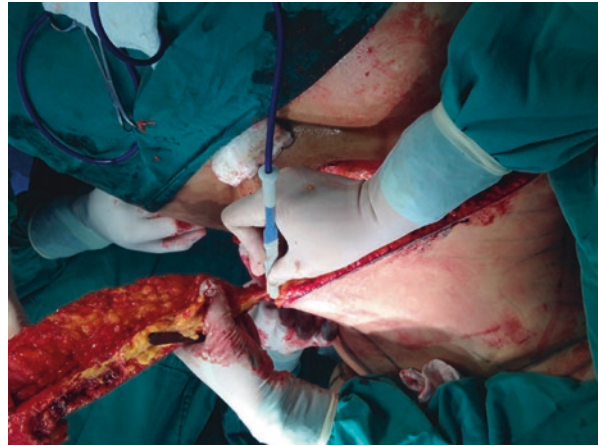**Fig. 20.3** Creation of xipho-umbilical surgical tunnel to allow plication of rectus abdominis muscles from the xiphoid process to the pubis while preserving the vascularization of the abdominal flap



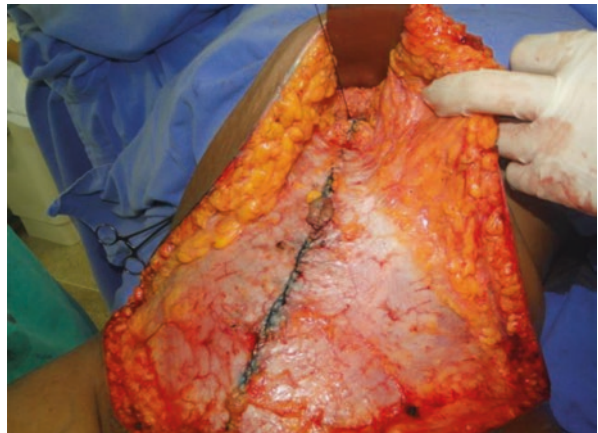
**Fig. 20.4** Plication using continuous running suture with 2.0 nylon line, utilizing the Mota Maia method (interruption every five stitches)



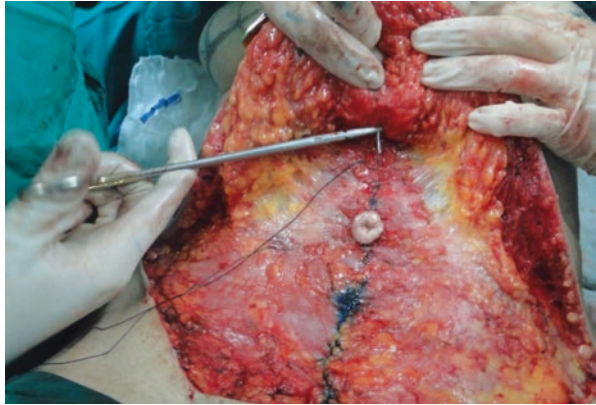**Fig. 20.5** Resection of excessive inferior abdominal flap



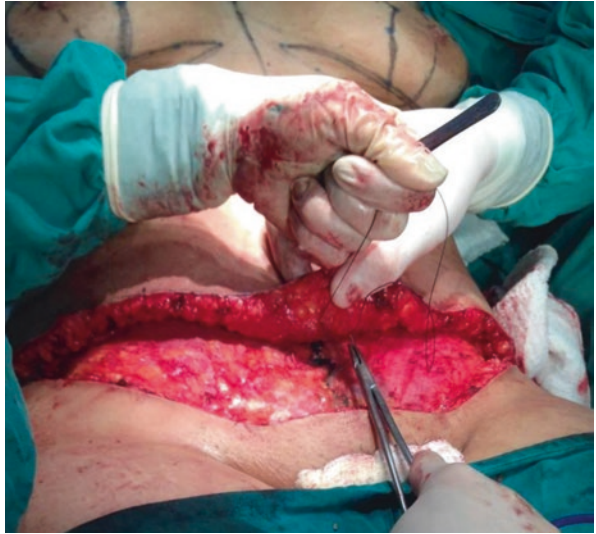**Fig. 20.6** Plication with 2.0 or 3.0 Vicryl suture, joining fat and fascia on the right side, transfixing the aponeurosis at the median line at the umbilicus level, and later reaching fat and fascia on the opposite side to improve the waistline at this level



**Fig. 20.7** A second continuous running suture is placed, besides plication of the rectus abdominis muscles, which joins the fat and fascia on the right side of the abdominal flap, passing along the median line in the muscular aponeurosis and the fat and fascia on the opposite side of the flap. This suture continues with interruptions every five stitches until reaching the pubic region, securing the remaining superior flap to the inferior flap



**Fig. 20.8** Securing the abdominal flap to the abdominal aponeurotic plane



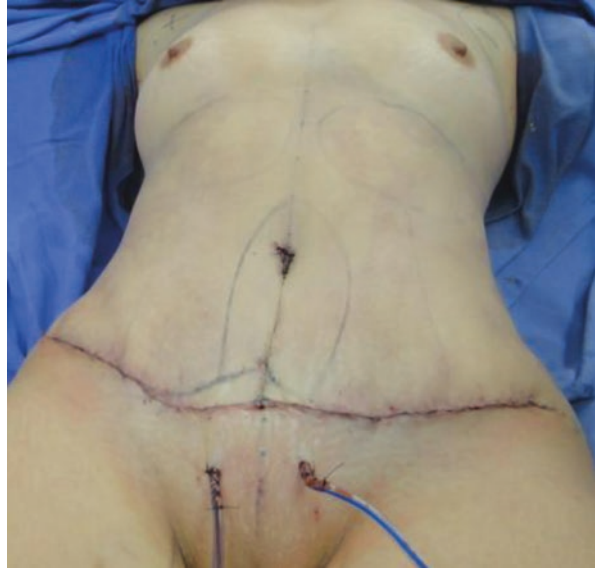xipho-pubic extension with 4.0 Vicryl line and a 3 cm needle, using what we call Leão's spiral suture. The excess abdominal flap is excised (Fig. 20.5), and the umbilicus is secured to the aponeurotic abdominal plane. Because of the tunnels created by liposuction, the superior thoracic flap descends more easily to the inferior edge of the abdomen, where it is sutured as described below (Figs. 20.6, 20.7 and 20.8).

### *Phase 3*

Separate stitches join the fascia of the inferior flap to the fascia of the superior abdominal flap, the aponeurosis, and the inferior abdominal flap, using 0 nylon line in separate stitches. Continuous suturing is conducted up and down the subdermal



**Fig. 20.9** Final suturing using nylon, Vicryl, and PDS line. After repositioning of the umbilicus, micropore, glue, and vacuum suction drains are used



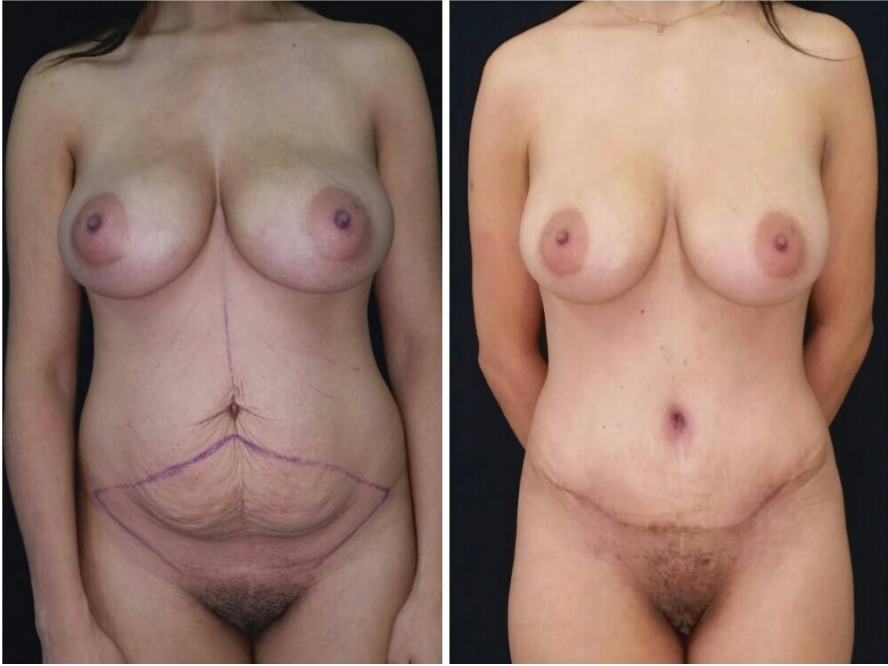
plane with Vicryl or Monocryl threads and finally using intradermal PDS 4.0 suture. To conclude the procedure, the umbilicus is exteriorized and sutured using nylon or PDS 4.0 line to join the dermis of the umbilicus, the aponeurosis, and the abdominal dermis with cardinal sutures. Only then can the skin of the umbilicus and abdomen, which is now less tense, be sutured.

#### ***Phase 4***

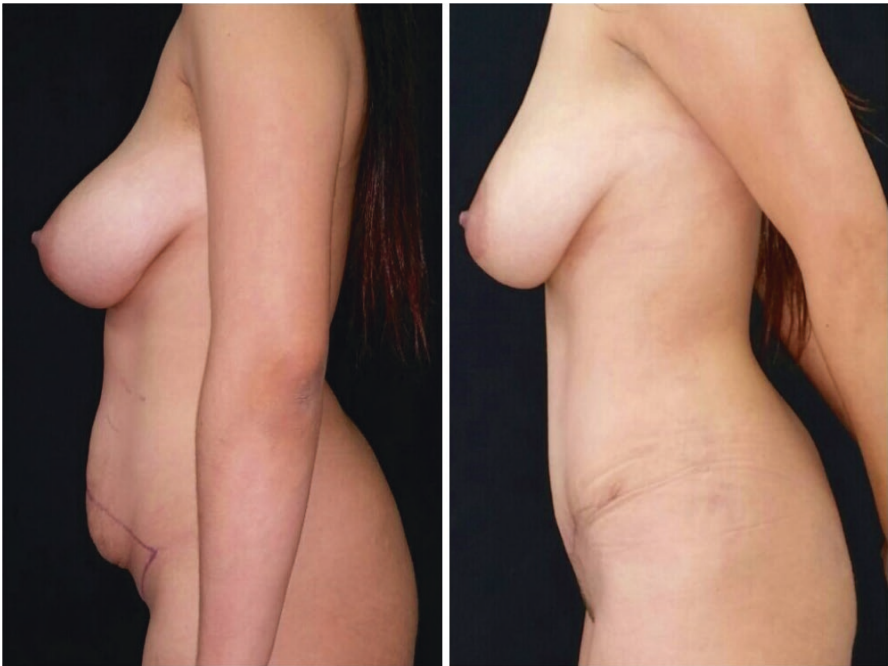
After the vacuum drain is placed, the incision is dressed with micropore tape, glue, and a surgical belt (Fig. 20.9).

### **Abdominoplasty in Morbid Obesity**

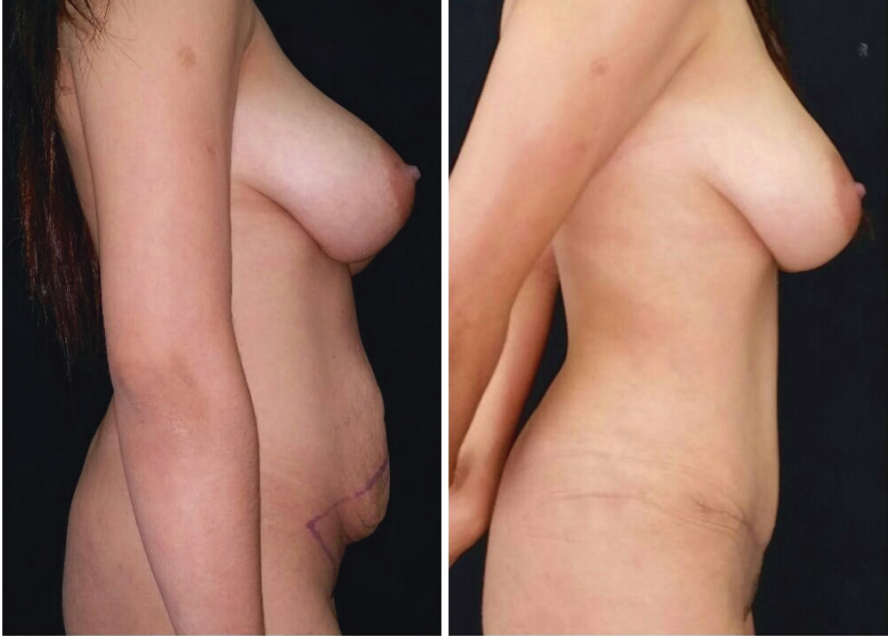For post-bariatric abdominal surgery, we have chosen the anchor lipoabdominoplasty technique, using the exact same plication of the muscular fasciae. It is important to stress that in this procedure, the operatory technique leads to the excision of the entire inferior flap along with the superior flap, making it easier to suture both the rectus abdominis muscles and the muscular fasciae, moving from xiphoid process to the pubis. In this way, better body contour and waist diameter outcomes are obtained in these patients. Lateral suturing in the inferior part of the abdomen is done with 3–4 separate stitches, joining the fascia of the inferior flap, the abdominal aponeurosis, and the fascia of the superior flap. From this point, the surgical incision is brought together (Figs. 20.10, 20.11, 20.12, 20.13, 20.14, 20.15, and 20.17).



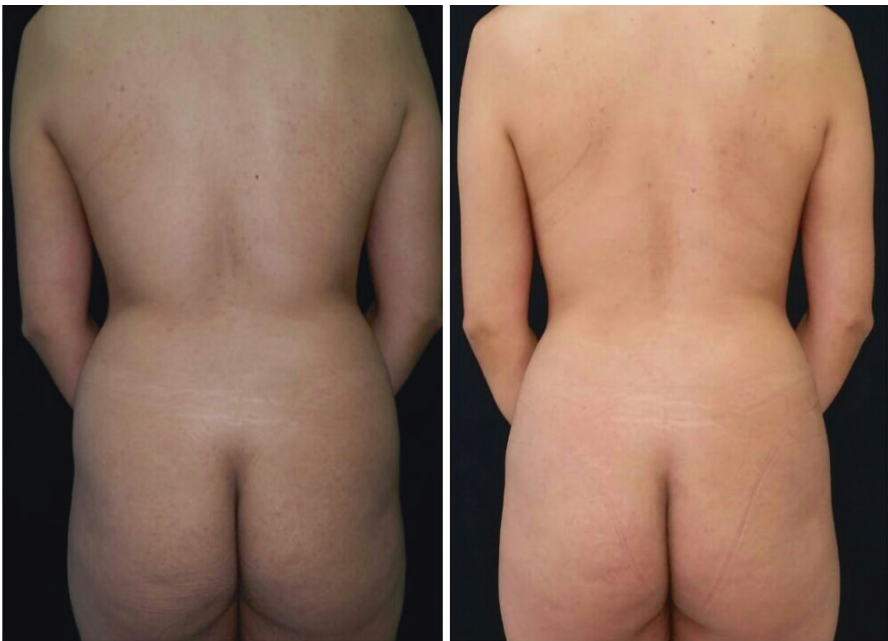**Fig. 20.10** Before and after dorsolipoabdominoplasty (30 days post-procedure), frontal view



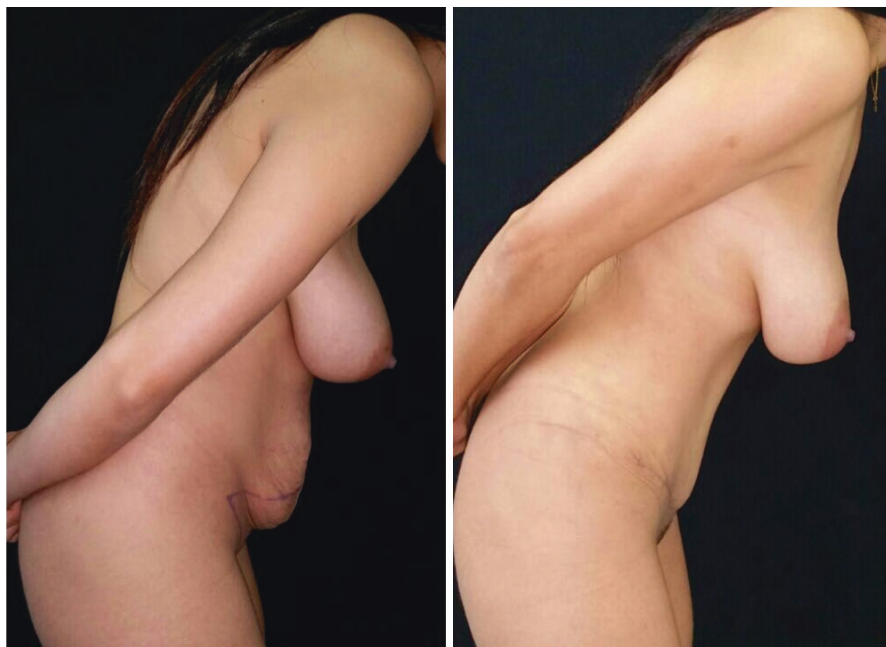
**Fig. 20.11** Before and after dorsolipoabdominoplasty (30 days post-procedure), left profile



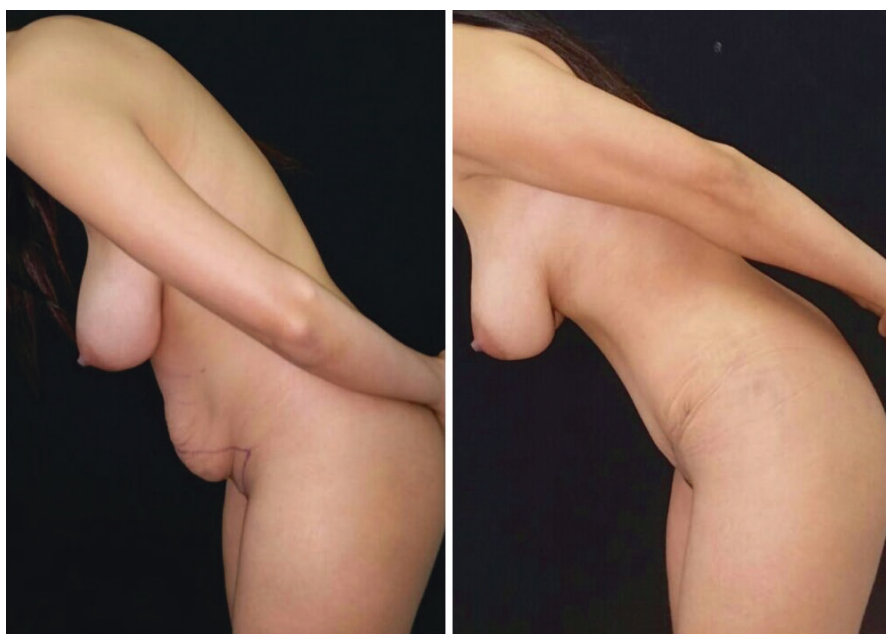**Fig. 20.12** Before and after dorsolipoabdominoplasty (30 days post-procedure), right side profile



**Fig. 20.13** Before and after dorsolipoabdominoplasty (30 days post-procedure), dorsal view



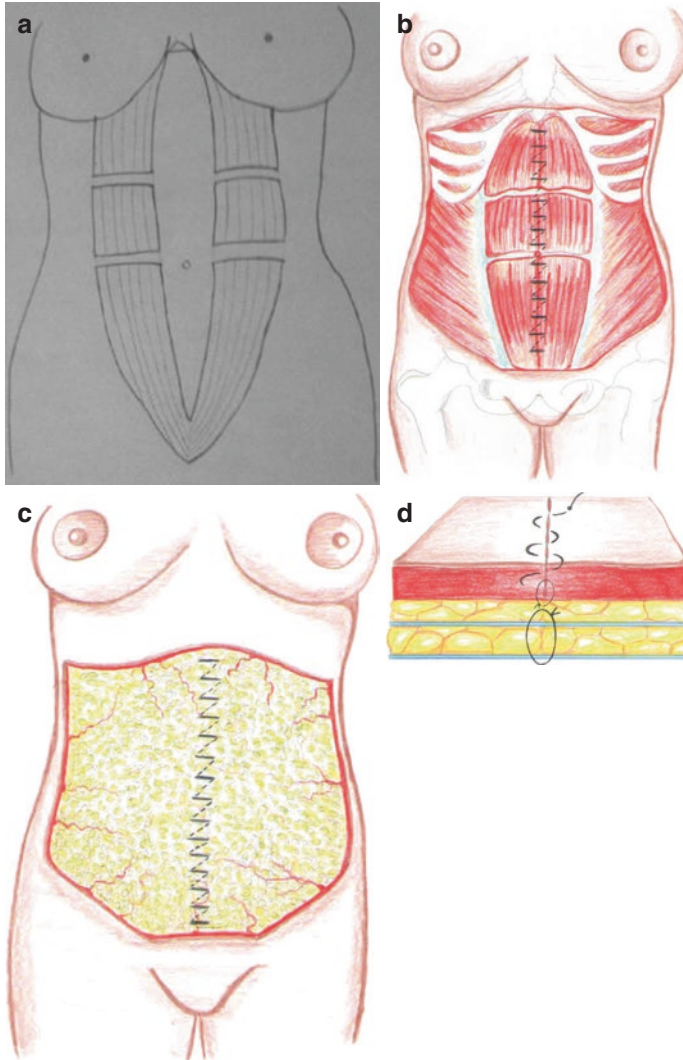
**Fig. 20.14** Before and after, curved position, right profile



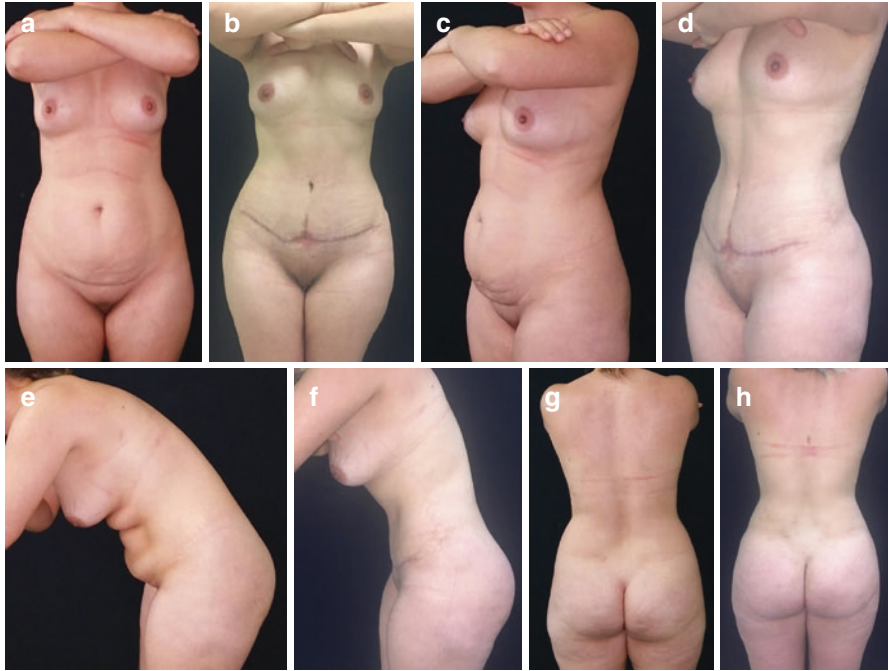
**Fig. 20.15** Before and after, curved position, left profile

## Discussion

First, it is necessary to differentiate surgical principle from operatory technique. This present study defines surgical principle as a new idea that arises from time to time, intermediated by various surgical techniques from different authors, which evolves and constitutes new findings, leading to advances in medical science. Based on historical references, we have listed surgical principles and operatory techniques (Fig. 20.16, Tables 20.1).



**Fig. 20.16** (a) Diastasis recti abdominis; (b) Plication of the rectus abdominis using continuous suturing with nylon line; (c) Plication with continuous 2.0 Vicryl spiral suture plicating the fascia to the aponeurotic plane, interrupted every five stitches, starting in the xiphoid process and ending in the pubic region; (d) Transverse view of suture



**Fig. 20.17** A 44 years old patient who underwent dorsolipoabdominoplasty. Photos ( **a**, **c**, **e**, and **g**) before operation. Photos ( **b**, **d**, **f** and **h**) after surgery. dorsolipoabdominoplasty (30 days post-procedure), frontal view. Photo ( **e**) another patient before and ( **d**) after dorsolipoabdominoplasty

**Table 20.1** Surgical principles

Surgical principle	Operatory techniques
Graft	Grafting of thin, average, and complete skin
Flap	Pedicle, bipedicle, crossed rotation
Myocutaneous flap	Cutaneous, fasciocutaneous, and microsurgical muscles
Liposuction	Dry, tumescent, ultrasonic, vibroliposuction, laser
Liposuction combined with surgery without undermining of the tissue	Subdermal flap folded over itself combined with liposuction. Abdominoplasty: a new surgical technique. Dorsolipoabdominoplasty. Dorsolipoabdominoplasty with suture of the muscular fasciae and fat graft into the buttocks. Creation and excision of the fasciocutaneous spindle in the inferior abdomen and suture of Scarpa's fascia

From Illouz's original liposuction (1980) [3], new techniques have been introduced, principally, subdermal flap folded over itself combined with liposuction [1], a new surgical technique for abdominoplasty [4], creation and excision of the fasciocutaneous spindle in the lower abdomen and suture of Scarpa's fascia [7], lipodorsoabdominoplasty [5], and dorsolipoabdominoplasty [6].

Since 1999, significant advances have been made in these surgical techniques. Based on the aforementioned studies, liposuction was combined with classic abdominoplasty and first performed by Avelar [1].

## Conclusion

Dorsolipoabdominoplasty [6] is the technical evolution of abdominal plastic surgery; adding continuous suturing to plicate Scarpa's fascia to classic abdominoplasty and lipoabdominoplasty aims to improve body contour sculpting.

## References

1. Avelar J (1999) Uma nova técnica de abdominoplastia - sistema vascular fechado de retalho subdérmico dobrado sobre si mesmo combinado com lipoaspiração. *Revista Brasileira de Cirurgia*, Rio de Janeiro - RJ 88/89(1/6):3–20
2. Avelar J (2002) Abdominoplasty without panniculus undermining and resection: analysis and 3-year follow-up of 97 consecutive cases. Accepted for publication October 2, 2001. Copyright 2002 by The American Society for Aesthetic Plastic Surgery
3. Baroudi R, Ferreira CA (1998) Seroma: how to avoid it and how to treat it. *Aesthet Surg J* 18(6):439–441
4. Bozola AR (1992) Abdominoplastias. In: Mélega JM et al outros. *Cirurgia Plástica. Reparadora e estética*. 2ª edição. MEDSI. pp 775–790
5. Illouz YG (1980) Une nouvelle technique pour lês lipodystrophies localisées. *Rev Chir Esth Paris, França*
6. Leão CF (2000) Abdominoplastia: uma nova abordagem. In: Congresso Brasileiro de Cirurgia Plástica, 37, Porto Alegre-RS. *Anais.Sociedade Brasileira de Cirurgia Plástica*
7. Leão CF (2010) Lipodorsoabdominoplastia: 10 anos de experiência. *Revista da Sociedade Brasileira de Cirurgia Plástica, São Paulo*, 25(4) out./dez. 2010.
8. Leão CF (2014) Dorsolipoabdominoplastia, abordagem circunferencial para melhorar resultados, como faço. In: Encontro da Associação dos Ex-Alunos do Prof. Pitanguy, 21, 2014, Costa do Saúipe-BA. *Trabalhos apresentados*
9. Ramos JAE (2002) Abdominoplasty through a closed vascular system associated to liposuction – Avelar's technique. In: Avelar J M (editor) *Abdominoplasty without panniculus undermining and resection*. Hipócrates, São Paulo. Capítulo 15

# Chapter 21

## Buttock Lipografting and Augmentation Combined with Avelar's Abdominoplasty

Marcelo Paulo Vaccari-Mazzetti and Ryane Schmidt Brock

### Introduction

The women's body has some attractive parts composed of the front view (breasts and abdomen) and back view (dorsum and buttocks). In the lower level, we could consider the abdomen and the buttocks together in the lateral view to make an aesthetic unit, and the harmonic shape between both is our target. In the back view, the buttocks are one of the most important aesthetic parts of the female body and give a healthy and sensual aspect to the women.

In our experience, from 2005 until today, we performed 104 surgeries with Avelar's lipoabdominoplasty technique [2, 3] (Avelar 1999, 2002) associated with liposuction and lipografts in the buttocks.

When the patient looks for us and asks about techniques to improve her or his body shape, we use personal criteria to indicate the need of skin resection in the abdomen, associated (Avelar's lipoabdominoplasty) or not with liposuction:

1. Older than 35 years old
2. Smoking habit in the past
3. Striae in the abdomen
4. History of pregnancy

---

The authors have no conflicts of interest.

The study had no financial support.

M.P. Vaccari-Mazzetti, MD, MSc (✉)

Department of Plastic Surgery, Brazilian Society of Plastic Surgery,  
Face Defects Research and Study Center, São Paulo, SP, Brazil  
e-mail: [dr.marcelovaccari@gmail.com](mailto:dr.marcelovaccari@gmail.com)

R.S. Brock, MD, MSc

Members of the Brazilian Society of Plastic Surgery, Department of Plastic Surgery,  
São Paulo, SP, Brazil



Liposuction volume (ml) (mean value)	Fat graft volume available (ml) (mean value)
1000	310
1500	455
2000	630
2500	780
3000	910
3500	1080
4000	1250
4500	1450
5000	1600
6000	2000

**Fig. 21.1** Tables with fat volume available from liposuction. This volume is increased when we used the abdomen as donor area. In the cases that we achieved 2,000 ml of liposuction volume or less, the use of the abdomen was fundamental to achieve a significant surgical result in the shape of the buttocks. The Avelar technique made it possible the use of the fat of the abdomen without consequent skin excess in postoperative period

5. Sagging skin in the abdomen
6. Sedentary lifestyle
7. Abdomen ptosis in moderate level or more

If the patient has two or more conditions above, our criteria which are offered together are to consider a skin resection (with or without lipoabdominoplasty) to improve the patient body shape and the lipograft techniques to improve the gluteus.

In this particular point of view, the indication of Avelar's technique ([2, 3], Avelar 2006) is mandatory because we can use the abdomen as donor area to obtain the fat tissue that will constitute the lipografts. Usually the patient may have other donor areas to give fat, but the use of the abdomen is very useful to improve fat volume and consequently the results in the new buttocks lipografted. The abdomen liposuction alone must be avoided in these conditions, under risk to cause skin excess in the abdomen especially around the umbilical scar (Fig. 21.1).

When we perform the surgery in a patient with poor amount of body fat, sagging skin in the abdomen, and a desire to improve her or his buttock, all available fat must be used, and the association of Avelar technique for lipoabdominoplasty ([2, 3], Avelar 1999, 2002) allowed to improve the amount of fat to perform lipografts in the buttocks (Fig. 21.2).

The principles of lipoabdominoplasty were described initially by Avelar in 1999 [2] and later complemented by himself ([3], Avelar 2000, 2006). The Avelar lipoabdominoplasty technique principles are discussed in other chapters (for this reason,

Year	Minimum volume (ml)	Mean volume (ml)	Maximum Volume (ml)
2006	1500	3500	5000
2007	800	3250	5250
2008	1450	3000	6100
2009	2000	3750	5800
2010	1550	3800	6000
2011	700	3450	5200
2012	1500	4100	5100
2013	2200	3500	4850
2014	1700	3700	5100

**Fig. 21.2** Tables of the volume of liposuction associated with Avelar’s lipoabdominoplasty technique. In the particular cases of the minimum volume of liposuction, the abdominal area was very useful to improve fat volume used for lipografts and achieved a better result in the buttock shape. Avelar’s technique has been useful to avoid an abdominal sagging after liposuction in a specific and numerous groups of patients

we won’t describe here). We’ll focus in the buttock augmentation with submuscular lipografts combined with subcutaneous lipografts to improve the body contour.

Plastic surgeons try to give the best function associated to the best shape in all parts of the human body, and the reconstructive aspect linked to the aesthetics and in buttocks couldn’t be different [5].

According to the Brazilian Society of Plastic Surgery and also the American Society of Plastic and Reconstructive Surgery, the liposuction is the most common procedure in plastic surgery in Brazil and the United States of America ([www.sbcpr.org](http://www.sbcpr.org) and [www.asprs.org](http://www.asprs.org)).

There are many liposuction techniques, this fat could be used or discarded. When it’s used at the same surgical procedure it’s usually named liposculpture [9].

Liposculpture is an important technique to improve the results of liposuction and needs such know-how in fat grafts biology. The donor site, the fat collection, the treatment of the fat, and the receiving site can change the results and decide the success or failure of the surgical procedure [9].

The results in buttock shape are related with the volume of graft fat; sometimes the amount of available fat is less than we desire to improve a shape and change it to be round and full.

Studies show that the best choice to manipulate fat is to purify fat cells and put these into the muscle to give a better vascular supply and improve the maintenance of the fat volume [11, 13, 14].

Different results in different studies create one question: What really occurs with the fat into the gluteus muscle at the postoperative period [13, 20]?

It's very important to be successful in this surgery and to have the knowledge of adequate and safe surgical technique to avoid complications. It will be possible to improve the body contour of our patients with satisfaction for both the patient and plastic surgeon.

## Technique

### *Anatomical and Image Studies (Magnetic Resonance and Intraoperative Ultrasonography)*

We made anatomical dissections in five cadavers, and we found an emerging ischiatic neurovascular major branch between the medium and minor gluteus muscles, in the middle of two osseous structures, confirmed in image studies.

The study with magnetic resonance was also performed too. There was an analysis of ten Caucasian female, between 25 and 35 years old, without any health problems, with the following inclusion criteria: nonsmokers; duplex venous exam of the legs without any degree of incompetence; no history of oral contraceptive use; two times a week of 30 min, at least, of physical activities; and more than 3 l of aspirated volume (we didn't aspirated more than 7% of the body weight).

The magnetic resonance was done between 2 and 7 days prior to the surgery and 7, 15, 30, and 180 days after the surgery. We used a fat subtraction technique in all the resonance studies, which were done in sagittal and axial incidences.

After the magnetic resonance imaging study, we performed the lipograft injection with simultaneous ultrasonography in the gluteus in two patients of our regular clinical series, and it was possible to identify the great vessels and nervous structures, and the lipografts were visible when they were put into the muscle, confirming the security of this procedure, when we avoid the dangerous areas determined by anatomical and resonance magnetic studies (Fig. 21.3).

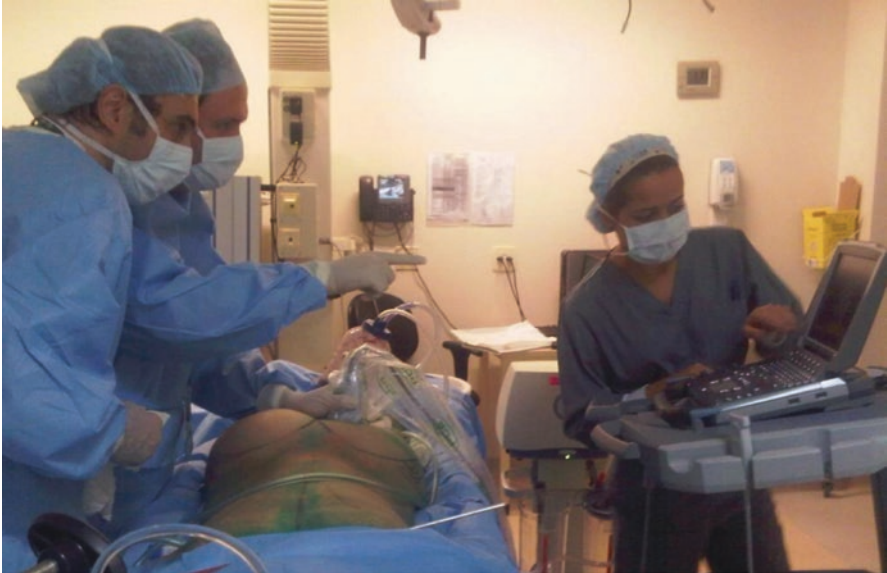The volume was calculated using the same anatomical marks in all exams: femoral acetabulum, ischiatic border, and the skin of the gluteus, with latero-lateral and anteroposterior measurement (Fig. 21.4).

The clinical evaluation of the patients showed a gluteus augmentation in all cases and a decrease of the pelvic circumference. Edema was present in all cases; two of them showed an important edema of the legs; they were submitted to a duplex exam, which excluded vascular problems.

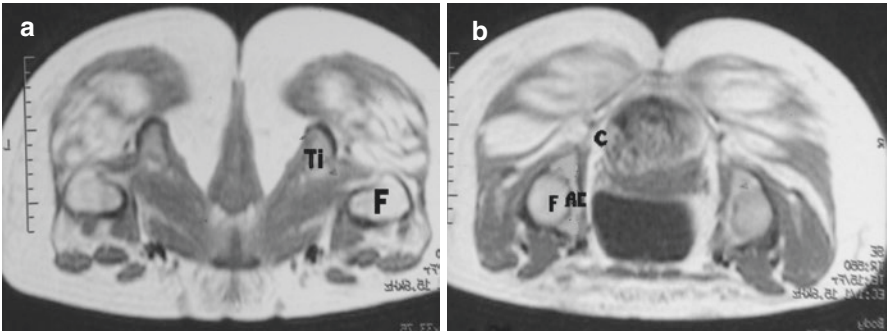
The clinical exams were done weekly and showed a complete decrease of the edema in 4 weeks. Similar results were observed in our regular clinical series.

### *Safety Triangles and Danger Triangle to Avoid Neurovascular Complications*

Vascular and nervous structures were observed in resonance exam in pre- and all postoperative images.



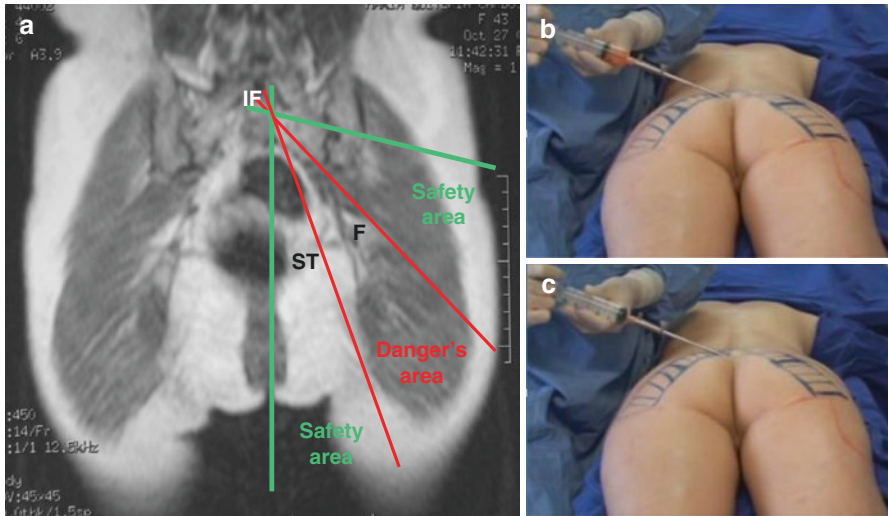
**Fig. 21.3** Submuscular injection of lipografts guided by ultrasound to avoid neurovascular injury



**Fig. 21.4** (a, b) image of resonance image of the gluteus. Some anatomical landmarks used in a study of the technique to perform lipografts with safety and calculate the volume of lipografts in submuscular area, femur (*F*), ischial tuberosity (*Ti*), acetabulum (*AC*), and (*d*) arise of sciatic nerve (*C*). The lipografts into the muscle have a white color, while gray is the color of the muscle

In anatomical and resonance magnetic studies, we observed two significant osseous landmarks: femoral acetabulum and ischial tuberosities.

The area where neurovascular structures give rise is made by three points: the end of sacral area in the beginning of the intergluteus groove (1 cm below), the skin projection of the femoral acetabulum, and the ischiatic bone. It is characterized as a triangle of danger and must be avoided for submuscular lipografting. At the same time that this danger triangle is made, two other triangles are made in lateral (with lateral border of the gluteus) and medial position (with intergluteus fold) of this one; these other two triangles were safe areas to introduce your submuscular lipografts (Fig. 21.5).



**Fig. 21.5** Coronal view of gluteus magnetic resonance image (a) with anatomical landmarks to determine two safety triangles (green) and one danger triangle (red): 1 cm below the beginning of the intergluteus fold (*ST*), the beginning of the natural Intergluteal fold (*IF*), ischial tuberosity osseous skin projection (TI), and head femoral osseous skin projection (*F*). During the submuscular lipograft injection in the gluteus, (b) the lateral safety area was filled with careful retro-injection technique without pressing with a number 5 cannula to an adequate distribution of the fat into the muscle. The submuscular lipograft technique was finished (c) and the subcutaneous lipograft in the danger triangle will be started

### *How to Avoid Buttock Asymmetry*

The first and more important fact is the patients, all of ours, had asymmetric buttocks, sometimes the asymmetry is small and the surgeon and the patient don't mention it before the surgical procedure, and it could cause an inconvenient situation for both, after the surgery, if the asymmetry remains. In another time, the asymmetry is evident in the preoperative pictures, and it must be considered in preoperative evaluation, and different volumes of lipografts must be used for each side, more volume in the small side. The difference in volume average of the two sides in our patients is usually 20%.

### *Surgical Technique*

The Avelar lipoabdominoplasty was described in other chapters. The anesthesia used is general. The operating room is prepared to give a pre-increase of temperature and to avoid hypothermia, and all the saline solution infusion is in 30 °C. The patient is covered by a thermal coat (warm touch®), to avoid excessive loss of corporal temperature. The fluid reposition used is the Ringer's lactate solution, using a formula of infusion volume = 2 × suction volume initially and changed during the

procedure according to the urinary volume and aspect. The urinary volume must be 0.5–1.0 ml/kg/h.

The clinical trials showed that the most common aspirated areas were the abdomen, flanks, dorsum, and internal and external thigh that correspond to an average of 40% of body surface.

When the patient was in prone position, we used cushions in the shoulders and the pelvic to improve lung airflow. To turn the patient position, we must be careful and perform it slowly.

We performed the liposuctions with wet technique, except in the lateral thighs, using a constant volume infusion of personal solution, which contains 1 l of Ringer's lactate, 30 ml of lidocaine 2%, and 3 amps of epinephrine; the same volume, 1 l, is used to the front and to the back. We started with the patient in prone position, to collect fat from the abdomen. This part of the procedure lasts no more than 25 min. We used a number 4 Mercedes cannula connected to a vacuum provided by a 60 cc liposuction aspirator, for fat aspiration and collection in a closed system. The fat collected from the abdomen is submitted to a carefully filter process to avoid cell damage; immediately after the fat became yellow and serum-free and macroscopic blood-free, it's put into a 60 cc closed syringe, and we wait for the change of position of the patient to introduce the fat into the muscle.

Prior to putting the fat graft into the muscle, we mark the dangerous triangle area and the safety triangle area.

The first point will be used to introduce carefully the number 5 cannula, with three sequential roles, each marked 5 cm, deep in the muscle, in the two safety triangles (lateral and medial). After this introduction, we wait for a few seconds and aspirate it to identify possible minor vascular injury, and after that we make a soft press in the syringe, associated to soft push movement and fat graft retro-injection, and repeat it several times in different parts of the gluteus, in order to complete depression areas or only to improve gluteus size. The syringe is completed only with 50 cc each.

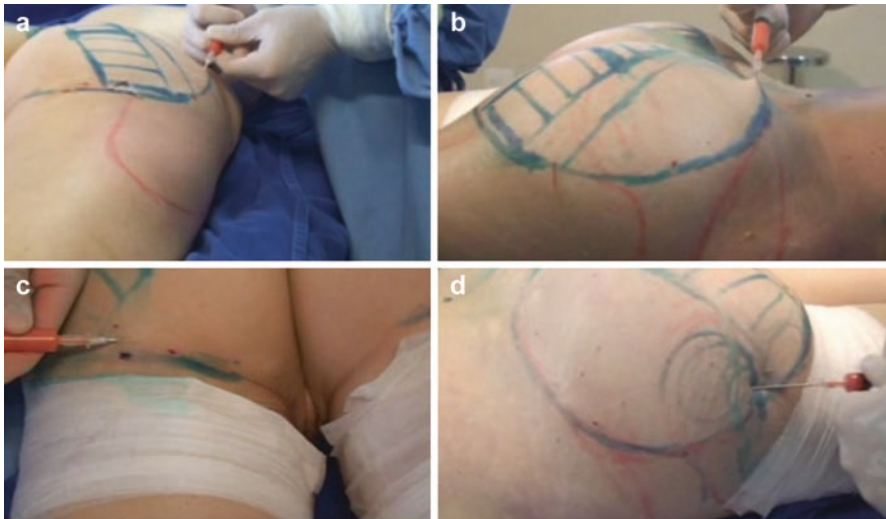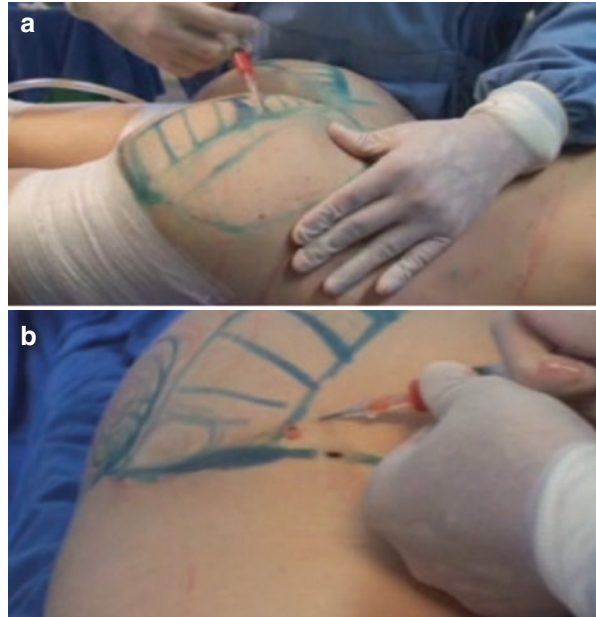
After the fat injection from the abdomen, we continue the liposuction from the dorsum and repeat the same treatment of the abdominal fat, stop the aspiration of each in 15 min, and inject the treated dorsum fat.

When the aspirated fat changes color, to a red pattern, we finish the collection period and start the technical refinement with a superficial use of a number 3 cannula connected to a lipoaspirator. At the end of the dorsum treatment, we return the patient to prone position and make the refinement in the abdomen.

### ***Technical Surgery to Improve Shape Results***

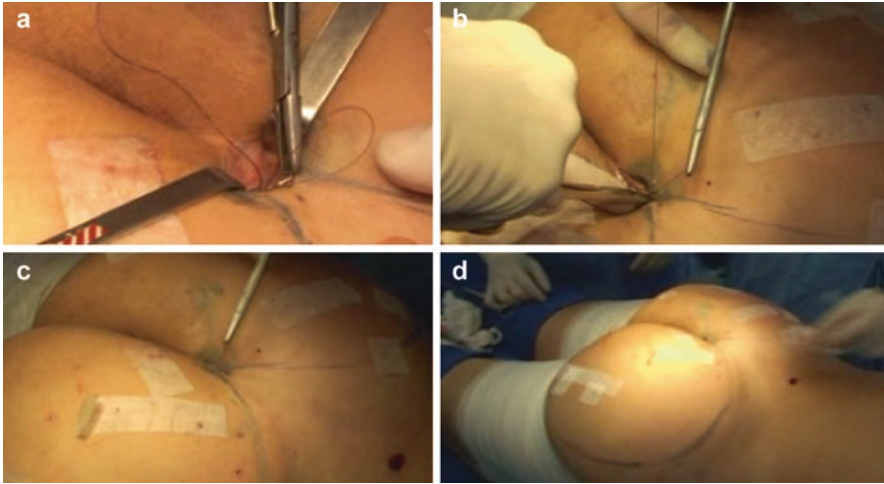
The use of triangles of safety to introduce submuscular lipografts and a nonuse of dangerous triangle made an area of no submuscular grafting, and this area must receive a subcutaneous lipografts. We recommended a subcutaneous lipografts in small mashed tunnels, performed with a 14 G cannula, with round point. The gluteus contour (border) could be subcutaneously grafted and improve the circle aspect of the gluteus (Fig. 21.6).

**Fig. 21.6** Complementary subcutaneous lipografts in the danger triangle, in a panoramic view in the middle of the triangle (a) and closed view in the basis of the triangle (b). This area must be avoided in the submuscular plane



**Fig. 21.7** Complementary subcutaneous lipografts in the lateral border of the buttocks (a), superior border of the buttocks (b), gluteus inferior fold (c) to improve buttocks, and improved filled achieved with submuscular lipograft in the lateral trochanteric depression (d)

The small depressions in the gluteus skin could receive the submuscular lipografts, without sub-excision, and overcorrection must be done with an immediate posterior manual massage, and some lateral areas between the gluteus and trochanteric fat could be grafted (Fig. 21.7).



**Fig. 21.8** The redundant sacral skin after liposuction could be correct by a sacral fixation, with a stitch involved skin and sacral fascia (a), fixation (b), final aspect with the skin “flatted,” (c) and a panoramic view (d)

When the patient has a high quantity of fat in the sacral area and the sagging skin is present, we recommend a resection of the skin to fuse under the fat into intergluteus fold and push a sacral skin into this fold, with a stitch using 3-0 Prolene in the sacral fascia to avoid excess skin in this area (Fig. 21.8).

### ***Technical Results***

The average volume of fat graft was 700 ml, the smallest volume was 500 ml, and the biggest was 950 ml. There were no intraoperative problems.

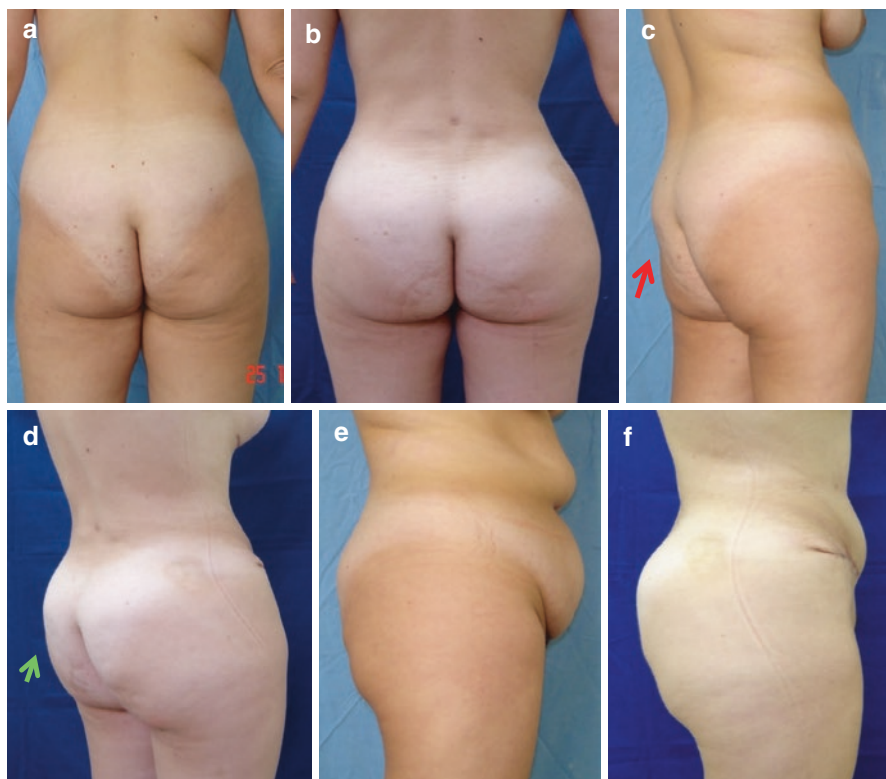
After magnetic resonance studies we concluded that almost 50 % of the volume lipografted was maintained when the patient doesn't changed the weight more than 5 %, which more or less could change the shape obtained by the surgical procedure (Figs. 21.9, 21.10, and 21.11).

### **Complications**

The complications observed by our team were neurologic, infection of the lipografts, hematoma, and gluteal asymmetry. The vascular complications could be present (Fig. 21.12).

The neurologic problems that could be present are leg pain and temporary walk disability, unilateral or bilateral. Usually it is auto-limited and the problem is solved in 1–3 months. A sensitive sensation as cold, warm, pricking, and paresthesia could occur because the nerve is on a temporary inflammatory process.





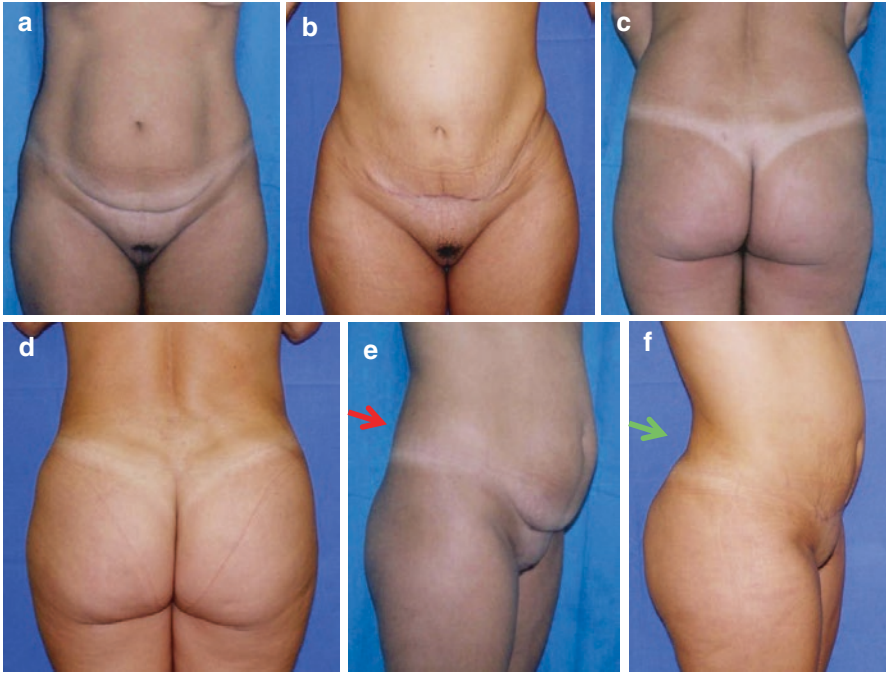
**Fig. 21.9** Patient underwent Avelar's lipoabdominoplasty type IV plus gluteoplasty performed by submuscular and subcutaneous lipografts derived from liposuction of the abdomen and dorsum. (a) In posteroanterior view, the buttocks had a square shape, and after surgery, (b) the shape was changed to a circular shape with an injection of 1,500 ml of lipografts. In a (c) preoperative postero-oblique view, a convex projection (*red arrow*) of the buttocks was changed to a (d) concave projection (*green arrow*). The preoperative lateral abdomen view showed a double fold (e) that was corrected by liposuction combined with abdominoplasty described by Avelar as shown in postoperative view (f)

The respect to dangerous triangle will avoid a direct neurologic lesion by the cannula.

Six patients had pain in thighs, four unilateral and two of them bilateral. These patients showed sciatic nerve edema at magnetic resonance at days 15 and 30. The symptoms decreased gradually and disappeared in 3 months; at day 180, magnetic resonance exam showed the disappearance of the sciatic nerve edema.

The infectious complication is serious because usually all the lipograft volume is lost and the infection could be systemic in few days. The initial symptoms as pain in the buttock, disability to walk, asymmetry of the two sides of the buttock, and, in an advanced condition, the inflammatory symptoms are present in the affected side.

When infection is presented the patient must return to the hospital and receive drainage procedure of the fat, with a lot of washing and endogenous antibiotics for gram-negative, gram-positive, and anaerobium flora while waiting for antibiogram. The bacterioscopic exam is useful at first moment. The infection by gram-positive



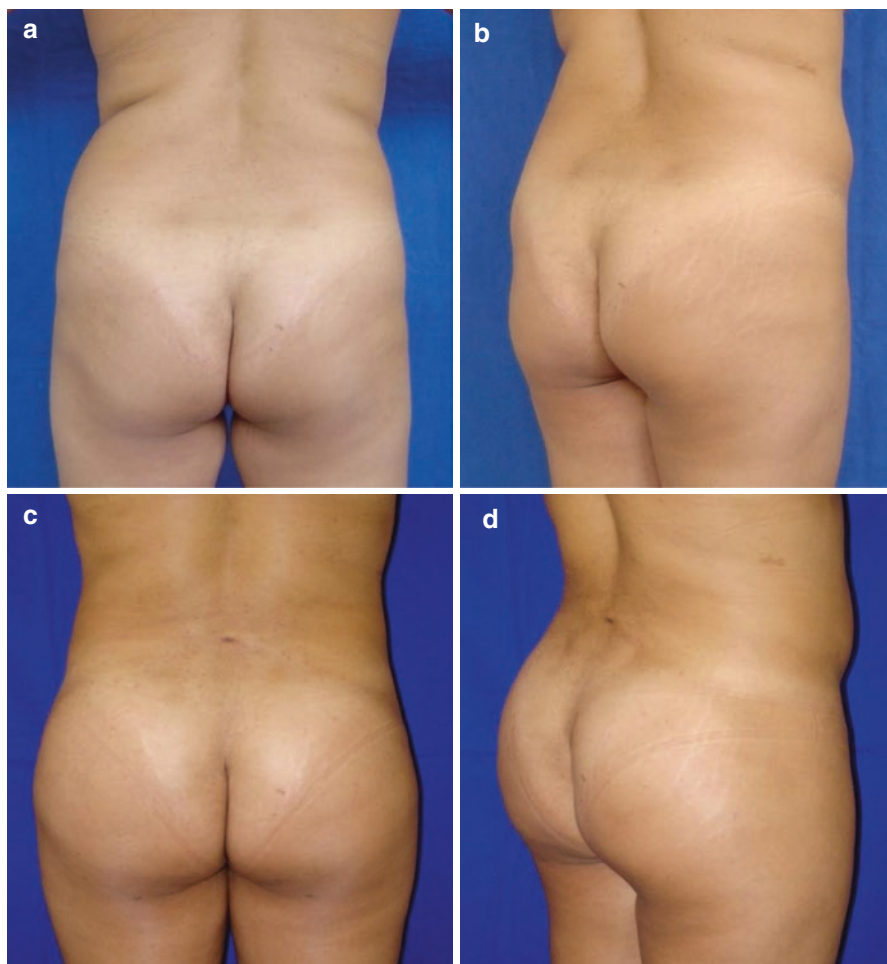**Fig. 21.10** Patient underwent Avelar's lipoabdominoplasty type I plus gluteoplasty performed by submuscular and subcutaneous lipografts derived from liposuction of the abdomen and waist. The abdomen in preoperative anteroposterior view with skin excess (**a**); in postoperative view (**b**), the rectus abdominalis muscles did not undergo correction because the patient had a desire to be pregnant again. In preoperative posteroanterior view, (**c**) the buttocks had a square shape, and after surgery (**d**) the shape was changed to a circular shape with an injection of 600 ml of lipografts. In a preoperative antero-oblique view, (**e**) a flat projection (*red arrow*) of the waist was changed to a concave projection (*green arrow*) improved by the high convexity of the buttocks achieved with lipografts as shown in postoperative antero-oblique view (**f**)

usually is less intense and responds well and fast to the antibiotic therapy. In all cases of suspected anaerobium flora, the diagnosis was made by exclusion, because the culture was inconclusive for this kind of bacteria.

The asymmetric buttock is caused specially by non-identification of a difference between one side and another at preoperative exam. In our patients, all of them were asymmetric in preoperative exam, and we believe that it's an important point to be discussed with your patient prior to the surgery. Another cause of asymmetry was a unilateral infection and a loss of a unilateral lipograft volume.

We observed two cases of gluteus unilateral hematoma after submuscular lipograft. These two cases were related with a trauma history in the postoperative time. Both were drained by local anesthesia and an aspiration with a liposuction number 3 cannula, guided by ultrasound.

The dangerous complication is a large fat embolism and its consequence: thromboembolic pulmonary disease and a respiratory distress. The intensive care unit will be necessary. This complication could be avoided by the use of safety triangles and non-intense pressure to put the submuscular lipografts.



**Fig. 21.11** Patient with quadrangular gluteus and a fold in the trochanteric position, before and after one-year postoperative images of a patient submitted to liposuction associated with sub-muscular and subcutaneous lipografts in the gluteus. It was injected with 700 ml of submuscular fat graft and 100 ml at the subcutaneous: **(a)** posteroanterior view with a quadrangular aspect and an asymmetry with more fat in the flank, **(b)** a preoperative concave format of the gluteus, **(c)** posterior image of the postoperative with a round format of the gluteus, **(d)** a convex gluteus format

## Discussion

The liposuction associated with fat graft in the buttocks increases the surgical results and promotes a very high level of patient's satisfaction with the corporal contour surgery [5, 9, 13].

The Brazil has one of the biggest and useful beach coast in the world. In our local culture the woman body shape is specially admired.

<b>Bienium</b>	<b>2005/2006</b> <b>(n = 40)</b>	<b>2007/2008</b> <b>(n = 110)</b>	<b>2009/2010</b> <b>(n = 112)</b>	<b>2011/2012</b> <b>(n = 60)</b>	<b>2013/2014</b> <b>(n = 56)</b>
<b>Complications</b>					
Paresthesia	–	–	1(0.8 %)	1(1.6 %)	–
Thigh pain	–	17 (15.4 %)	35 (31.2 %)	20 (33.3 %)	11 (19.6 %)
Asymmetry	1 (3.3 %)	–	–	–	–
Infection	1 (2.5 %)	2(1.8 %)	–	–	2(3.5 %)
Hematoma	–	1(0.9 %)	1(0.8 %)	–	–
Total	–	20(18.1 %)	37(32.8 %)	21(35 %)	13(23.2 %)

**Fig. 21.12** Tables of complications in submuscular fat grafts. The occurrence of infection needs return to the hospital for a surgical drainage, daily wash, and venous infusion of antibiotics. The pain in the thigh is due to the sciatic nerve inflammatory process; in all of our cases, it was temporarily and must be discussed to the patient in preoperative consultation. Hematoma cases were related with trauma in postoperative time

This technique avoids the necessity of implants into the gluteus to improve its size when the patient has a fat reserve sufficient to increase the buttock. The advantages of this technique are the use of autologous tissue, maintaining the possibility of receiving intramuscular medicine, no migration of the tissue injected, nerve damage is temporary, and more lipografts sessions could be done if the patients desire and increase weight [6, 12, 18].

The anatomical studies actually provide not only anatomical information but physiologic patterns of tension after subfascial augmentation [10]. In our studies, we were focused only in anatomical landmarks to avoid direct neurovascular damage. In our clinical series, we stopped to put submuscular lipografts when the fat reflows by the number 5 cannula injection; it’s our clinical pattern to consider a high excessive pressure in the submuscular layer, which is the signal that represents an intramuscular limit pressure; and no more lipografts must be performed at this locus.

When the surgeon associates procedures at the same surgery, the intra- and post-operative risks increase too, and the care in the preoperative time must be more intense. Special care during surgery, like bleeding and corporal temperature control, must be taken all the time. The aspirated volume has a maximum limit in Brazil of 7% of the corporal weight, and this limit can only be established if all clinical conditions are favorable [4, 15, 17].

When everything goes as planned, we can try to increase results with the association of liposuction technique with fat graft injection. The better results in maintenance of fat volume with intramuscular techniques were demonstrated, but the studies had no uniform pattern [1, 13, 20].

Some authors preferred implants to achieve a gluteal augmentation, but the autologous tissue is better, always as possible. Fortunately, we had this possibility in almost all cases [1, 5].

Once we used the fat graft in gluteal augmentation, it was important to understand what happens with this fat. Other authors were also concerned about this and used the magnetic resonance imaging to study the fat graft survival [1, 13, 19, 20].

The difficulties to access a useful exam to control the fat volume, like appropriate facilities, high costs, and different possible results, made uncommon the magnetic resonance imaging study in clinical series with a high number of patients [8, 13, 16, 20].

The magnetic resonance is very useful to provide images from the soft tissues like muscle, fat, and neurovascular structures. We needed to establish a method for analysis, and in the sagittal view, it was impossible for us, but in the axial views, the images could be studied, measured, and compared [7, 13, 20].

In other studies with magnetic resonance, the measurement methods were not described with sufficient details to provide reproducibility. In this study, we gave specific radiological technique information.

Our study provides a reasonable number of patients, studied in an immediate time after surgery, 7 and 15 days, and a later time when the fat graft biology was stable. The two initial times were idealized because we hoped to find differences between them due to a decrease of the inflammatory reaction. However, it was observed better with a longer time, 30 days.

One of the serious complications is the neurovascular injuries. When occur a neurologic damage of the sciatic nerve, it's usually temporary and the disability to walk and to run is treated in a few months with specific physiotherapy.

The vascular injury could result in venous thrombosis. Consequently resultant thromboembolic phenomena occur and it could result in a fatal prognosis. To avoid neurovascular injury, the dangerous triangle must be avoided when performing sub-muscular lipografts, and the two safety triangles are the best option. In the dangerous triangle, we recommend subcutaneous lipografts.

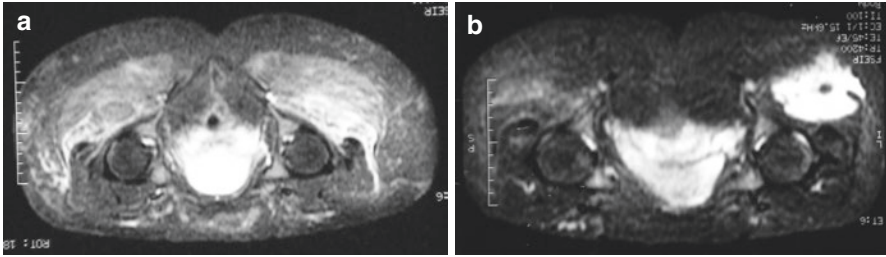
The infectious complications were the most important in our clinical series and all efforts must be done to avoid this clinical condition. The clinical suspect is made when the pain after the procedure remains specifically in the buttock. Two patterns of pain were observed: increase after the third day or decrease until the fifth and increase after this time. Is very important to distinguish the different kinds of pain. When the patient is able to indicate the exact place of the pain in the gluteus, it's a lipograft infection symptom, but if the pain is undefined and present in the thigh, it's probably a neurologic symptom.

The ultrasound was unable to show infected area and was frequently normal in the first week; in our experience, the clinical symptoms were more important to make a correct diagnosis and permit a fast drainage intervention. After drainage, a vacuum drainage was maintained until the secretion was eliminated by at least 2 days.

The culture most of the time was being unable to diagnose the bacteria, besides the suppurated drainage, and we conclude by anaerobic infection and the antibiotics were useful to solve the problem.

We consider fundamental surgical steps to avoid infectious problems:

1. Trichotomy of all anal regions with intense and careful degermation.
2. The use of closed system to collect fat and the maintenance of the fat almost without environmental air contact.
3. Limit the time of the fat out of the body for a maximum of 30 min.



**Fig. 21.13** Magnetic resonance technique of fat subtraction; this technique demonstrated that 1 week after the surgery almost 40 % of the volume grafted wasn't fat or at least viable fat. The view with 1 week (a) and 2 weeks (b)

4. Repeat degermation process every 2 h after the beginning of the surgical procedure.
5. Perform the surgery in institution with quality hospital accreditation.

During 5 years using the adopted protocols to avoid infectious complications, we didn't have any case lipograft contamination and we believe that this kind of surgery needs an adequate hospital structure support.

It is very important to know the volume of the lipograft. It was examined with a resonance magnetic study using fat subtraction technique and the result demonstrated very high volume of soft tissue, that could include high number of fat cell death (Fig. 21.13).

After the initial findings about the volume, the real fat volume integrated very well into the muscle environment and showed the maintenance average close to more than 80 %, some cases more than 90 % in 180 days.

The very important fact is the maintenance of corporal weight. After 3 l of liposuction, it is expected to have an approximated 2 kg of loss. When we reached this result and with the fact that the patient cannot change more than 5 % of corporal weight, we concluded that the increase or decrease of the gluteus form would change not because of the fat graft volume but because of the fat cell which is a live tissue into the muscle.

These findings permit a good way to improve a buttock size and shape during a liposuction associated to fat graft into the muscle, with a low rate of complications.

## Conclusions

The buttock lipografts associated to Avelar's lipoabdominoplasty were sufficient to allow an improvement in remodeling the shape and, with preventive maneuver techniques, provide acceptable and temporary complications. A high percentage (46 %) of the intraoperative volume of fat graft into the muscle is not a viable cell fat, but the maintenance in the gluteus muscle of the "real" fat is almost 90 %. This maintenance of lipografts permits a better shape contour with a low risk. This technique

needs a specific preoperative planning for each patient, carefully management in all surgical steps and close attention to the patient until the final result, at least after 6 months post-operative.

## References

1. Aiache AE (2006) Gluteal recontouring with combination treatments: Implants, liposuction and fat transfer. *Clin Plast Surg* 33:395–403
2. Avelar JM (1999) A new technique for abdominoplasty – closed vascular system of subdermal flap folded over itself combined to liposuction. (Uma nova técnica de abdominoplastia – sistema vascular fechado de retalho subdérmico dobrado sobre si mesmo combinado com lipoaspiração). Editora Cidade Científica Ltda. Rio de Janeiro (Brasil). *Rev Bras Cir* 88/89(1/6):3–20. Nov/Dec
3. Avelar JM (2002) Abdominoplasty without panniculus undermining and resection: analysis and 3-year follow-up of 97 consecutive cases. *Aesthet Surg J* 22:16–25
4. Cárdenas-Camarena L, Lacouture AM, Tobar-Losada A (1999) A combined gluteoplasty: liposuction and lipoinjection. *Plast Reconstr Surg* 104(5):1524–1531
5. Cardenas-Camarena L, Paillet JC (2007) Combined gluteoplasty: liposuction and gluteal implants. *Plast Reconstr Surg* 119(3):1067–1074
6. Cardenas JC, Muñoz Ahmed JÁ (2002) Large-volume lipoinjection for gluteal augmentation. *Aesthet Surg J* 22(1):33–38
7. Chamosa M (2004) Lipectomy of the ilio-lumbosacral region. *Plast Reconstr Surg* 113(1): 419–424
8. Cuenca-Guerra R, Quezada J (2004) What makes buttocks beautiful? A review and classification of the determinants of gluteal beauty and the surgical techniques to achieve them. *Aesthetic Plast Surg* 28:340–347
9. Harrison D, Selvaggi G (2007) Gluteal augmentation surgery: indications and surgical management. *J Plast Reconstr Aesthet Surg* 60(8):922–928
10. Hwang SW, Nam YS, Hwang K, Han SH (2012) Thickness and tension of the gluteal aponeurosis and the implications for subfascial gluteal augmentation. *J Anat* 221:69–72
11. Lewis CM (2004) Buttock augmentation: Case studies of fat injection monitored by magnetic resonance imaging. *Plast Reconstr Surg* 114:1015–1016
12. Mendieta CG (2007) Gluteal reshaping. *Aesthet Surg J* 27(6):641–655
13. Murillo WL (2004) Buttock augmentation: case studies of fat injection monitored by magnetic resonance imaging. *Plast Reconstr Surg* 114(6):1606–1614
14. Pu LLQ, Coleman SR, Cui X, Ferguson REH, Vasconez HC (2008) Autologous fat grafts harvested and refined by the Coleman technique: a comparative study. *Plast Reconstr Surg* 122(3):932–937
15. Roberts TL III, Toledo LS, Badin AZ (2001) Augmentation of the buttocks by micro fat grafting. *Aesthet Surg J* 21(4):311–319
16. Roberts TL III, Weinfeld AB, Bruner TW, Nguyen K (2006) Universal and ethnic ideals of beautiful buttocks are best obtained by autologous micro fat grafting and liposuction. *Clin Plast Surg* 33:371–394
17. Robles-Cervantes JA, Martínez-Molina R, Cardenas-Camarena L (2005) Heating infiltration solutions used in tumescent liposuction: minimizing surgical risk. *Plast Reconstr Surg* 116(4): 1077–1081
18. Smith P, Adams WP Jr, Lipschitz AH, Chau B, Sorokin E, Rorich RJ, Brown AS (2006) Autologous human fat grafting: effect of harvesting and preparation techniques on adipocyte graft survival. *Plast Reconstr Surg* 117(6):1836–1844
19. Viterbo F, Marques M, Valente M (1994) Fat-tissue injection versus graft: experimental study in rabbits. *Ann Plast Surg* 33:184–192
20. Wolf GA, Gallego S, Patron GAS, Ramirez ZF, Delgado BJA, Echeverri AA, Garcia GMM (2006) Magnetic resonance imaging assessment of gluteal fat grafts. *Aesthetic Plast Surg* 30(4):460–468

# Chapter 22

## Vertical Abdominoplasty: Indications and Refinements

Everardo Abramo de Oliveira and Fabio Neves

### Introduction

The vertical dermolipectomy is based on skin resection in both a vertical and horizontal component. It's been a well-known and widespread technique for many years, initially indicated for revision of scars with important incisional hernia, associated with excess skin in the midline of the abdomen [1]. Its indication has become more common since the mid-90s with the spread of surgical techniques for the treatment of obesity. The large weight loss obtained by these surgeries, which often represents more than 50 % of the patient's original weight, has generated a great challenge to our specialty. These patients' skin will not retract enough to allow it to accompany such reduction in fat content. Therefore flaccidity develops in the face, neck, breasts, arms, back, stomach, buttocks, and lower limbs. In the case of the abdomen, there is a huge discrepancy between the continent (skin) and the new contour. Resection of a horizontal skin band, even when performed circumferentially, does not correct the excess of the midline as there is no reduction in the perimeter. The surgeon needs to combine a horizontal to a

---

E.A. de Oliveira, MD (✉)  
Private Practice, Rio de Janeiro, RJ, Brazil

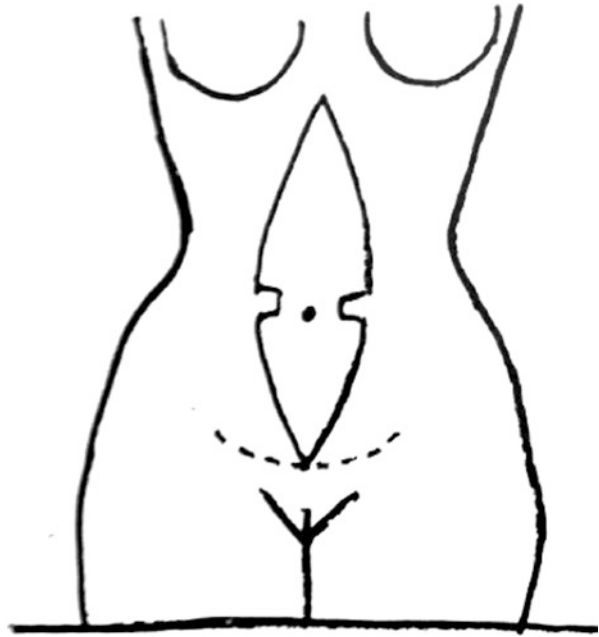
Prof. Ronaldo Pontes Plastic Surgery Service, Niterói D'Or Hospital, Niterói, RJ, Brazil  
e-mail: [everardoabramo@hotmail.com](mailto:everardoabramo@hotmail.com)

F. Neves, MD, MS, PhD  
Private Practice, Rio de Janeiro, RJ, Brazil

Members of the Brazilian Society of Plastic Surgery, Department of Plastic Surgery,  
Hospital Federal de Ipanema, Rio de Janeiro, RJ, Brazil  
e-mail: [fabio@fabioneves.com.br](mailto:fabio@fabioneves.com.br)



**Fig. 22.1** Neo-umbilicoplasty with rectangular dermoepidermal flaps described by Fernandes and Iturraspe in 1951 (Source: Sinder R. Plastic Surgery of the abdomen. Rio de Janeiro, 1979)



vertical skin resection extensive enough to properly envelop the new body. En bloc resection of the abdominal flap after previous marking as described by Pontes [2] is mandatory in this case. There should be no skin undermining. Sensibility and proper training of the plastic surgeon in prior marking of the skin dissection area are essential. Traditionally, vertical techniques maintain the umbilical cavity in place. However, in its junction with the vertical incision, a circumferential scar is created, subject to all kinds of unaesthetic results such as hypertrophy, stenosis, unnatural shapes, suture marks, and other distortions.

In 1951, two Argentine authors, Fernandes and Correa-Iturraspe [3], devised the making of a neo-umbilicus from two rectangular skin flaps with a lateral base (Fig. 22.1). The same flaps were used in various abdominoplasty techniques, including post-bariatric cases by several authors [4, 5]. Special situations such as moderate or large umbilical hernias, median scars with large deformation of the navel, or severe abdominal wall defects as in laparostomies may also call for this technique [1, 4]. Thus, neo-umbilicoplasty had been reserved for situations where maintenance of the original navel was compromised. Other authors also perform neo-umbilicoplasty routinely, but with different purposes and techniques [6, 7]. The neo-umbilicoplasty with lateral flaps provides predictable results that are aesthetically appropriate and without the drawbacks of a periumbilical scar. This has motivated the present authors to consider using it as a routine in vertical abdominoplasty [8].

One challenge was to position the flaps on the very point of the original umbilicus, as its correct position and shape are essential for a cosmetic appearance of the abdomen [9]. Because it calls for previous marking with en bloc resection, we conceived a 10 cm wide skin band on which we mark the flaps only after tractioning and advancing the sutures. This enables us to achieve excellent cosmetic results, accurate positioning and low complication rates.

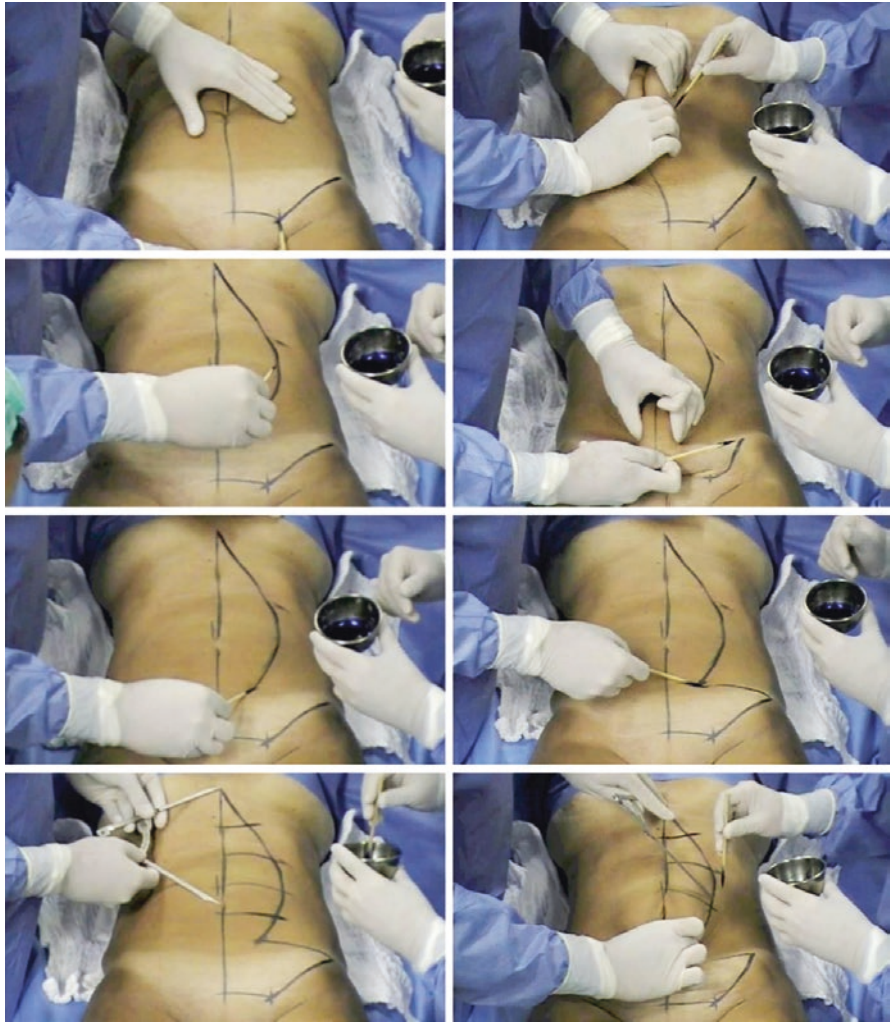
## Preoperative Preparation

Post weight loss patients represent the vast majority of current indications for vertical abdominoplasty. The surgeon must be careful to indicate the procedure only after weight loss is stable for at least 6 months and close to ideal. Physical examination should examine for hernias in the midline, especially in patients who have undergone open surgery. Ultrasound examination of the abdomen and abdominal wall is essential in the preoperative evaluation, as with the classic technique. Cholelithiasis is not an uncommon pathology in patients undergoing gastroplasty and must be corrected beforehand. In case of large incisional hernias, we indicate the use of compression garments preoperatively to reduce respiratory disorders. As a consequence of low absorption of nutrients, including iron, anemia is frequent and must be given special attention.

## Technique

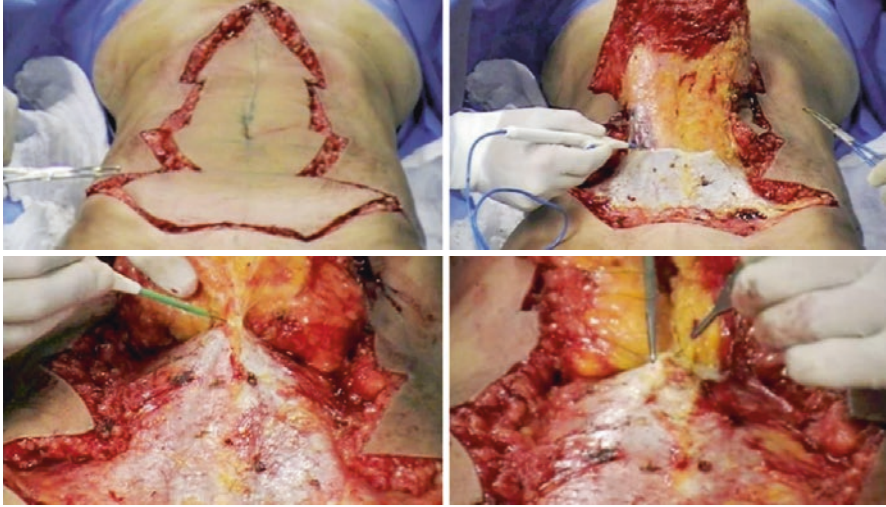
We prefer general anesthesia, which in recent years has presented great advances in quality and safety. Post-bariatric patients, who represent the majority of indications, often have incisional hernias. General anesthesia, combined or not with epidural analgesia, provides better muscle relaxation and comfort to the patient and medical staff to also correct these defects.

This is an en bloc resection technique with no undermining. Marking the resection area with the patient standing is more difficult and can lead to distortions. Thus, markings are done with the patient supine and anesthetized, which favors symmetry (Fig. 22.2). The abdominal midline is initially marked. We position the horizontal line along the suprapubic region, approximately 6 cm from the pubic symphysis. This line extends laterally up to 2 cm from the inguinal crease. From this point we draw an oblique line toward the anterior superior iliac spine. The final appearance is similar to a bicycle handlebar. Using a clamping maneuver, the width of the vertical flap is estimated. A large spindle-shaped strip is then drawn on one side and then copied on the other with the aid of a compass. We set the caudal end of the vertical incision by pulling the strip toward the pubic area. We routinely perform a neo-umbilicoplasty with lateral skin flaps. To do this, we estimate the location of the neo-navel measuring the distance between the xiphoid



**Fig. 22.2** Steps for marking the en bloc resection area

process and the original navel (to be amputated). This distance is transferred to the strip while keeping its traction toward the pubis. Thus we have, approximately, the point where the lateral flaps are designed for the reconstruction of the new navel. For more accurate fixation at the point where the original navel is, we conceived skin bands measuring  $10\text{ cm} \times 2.5\text{ cm}$  where the flaps for the neo-umbilicus will be drawn after abdominal traction. This tactic prevents possible positioning errors. Each band extends from 5 cm above to 5 cm below the point marked on the spindle-shaped strip. We mark symmetrical points on both sides of the strip, as well as across the base of the safety band.



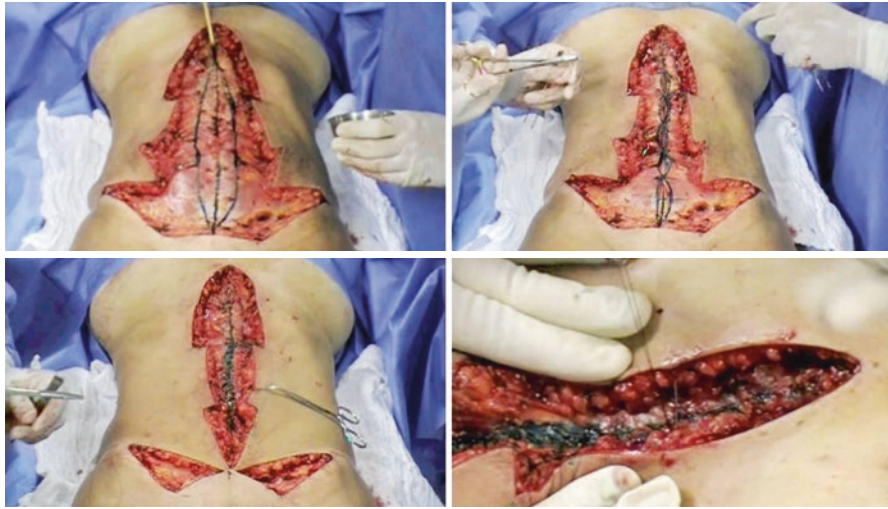
**Fig. 22.3** Flap removal with amputation of the navel and creation of the aperture for the new umbilicus

**Flap Resection** All incisions and flaps are infiltrated subcutaneously with anesthetic and vasoconstrictor solution (1000 ml 0.9 % saline solution, 20 ml Lidocaine 20%, 20 ml ropivacaine 7.5 %, 2 ml adrenaline 1:1000). The flap is then removed en bloc and the navel is severed at its base and included in the surgical specimen. We suture the umbilical hole with nylon 3-0 and leave enough thread to guide us as to the navel position. Careful and strict hemostasis is performed throughout the dissection. Special attention should be given to the perforating vessels that have greater caliber in this group of patients. We do not perform any kind of supra-aponeurotic undermining laterally (Fig. 22.3).

**Plication** We mark the plication zone, and the rectus abdominis muscles are brought together in the midline with strong inverted X sutures using polypropylene 0, followed by a running suture with the same thread (Fig. 22.4). At this moment, we correct eventual abdominal wall hernias.

**Traction** Drains are not use routinely. The remaining skin are pulled down and to the midline. By suturing with nylon 3-0 in the midline aponeurosis and subcutaneous (including the fascia of Scarpa) of both flaps, the formation of dead space is prevented. This procedure is performed throughout the suture, both at the midline and transversal line. We follow with subdermal separate stitches with monocryl or mononylon 4-0 and conclude with nylon 5-0 in Greek bar suture interspersed with running suture or monocryl 5-0 in intradermal suture (Fig. 22.4).

**Creating Flaps for the New Umbilicus** Once the suture reaches the base of the rectangular flaps, it is time to draw the side flaps for the new navel. We locate the long mononylon 3-0 thread left in the aponeurosis to mark the original location of



**Fig. 22.4** Plication of the rectus abdominis, traction, and tripod suture to prevent dead space

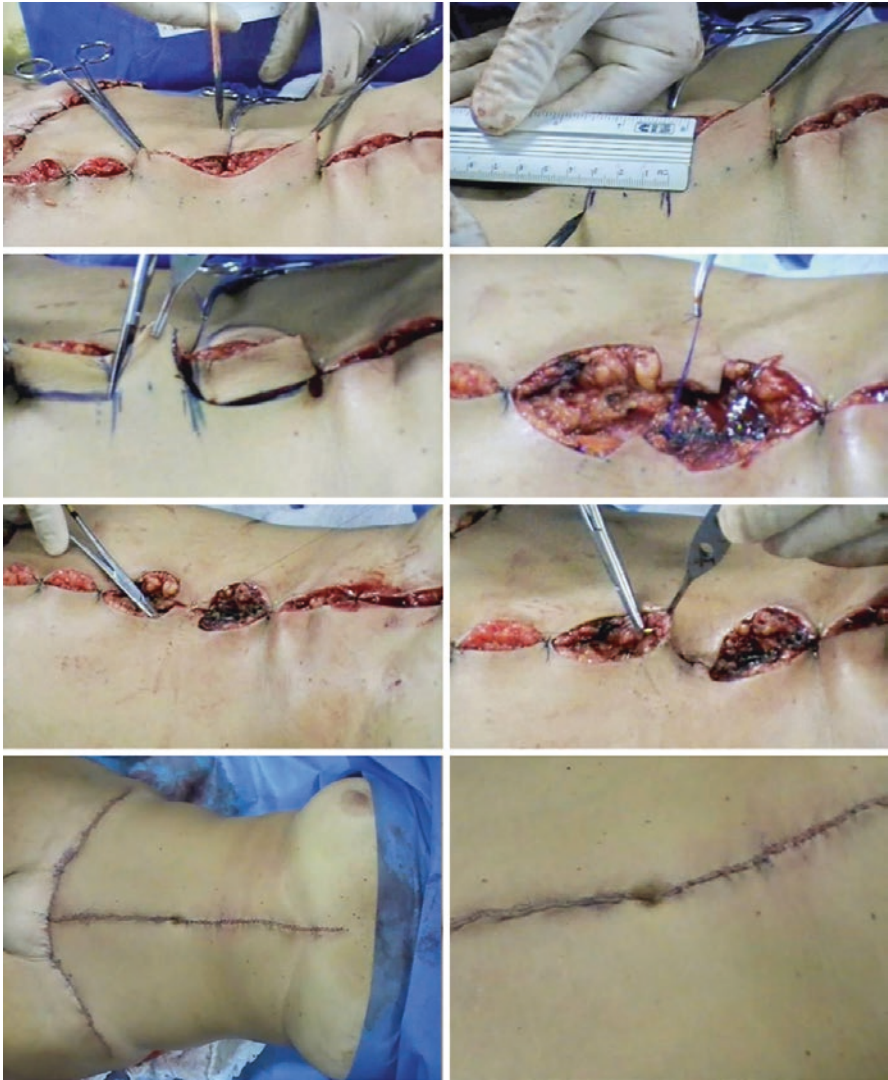
the navel and we draw in its projection two trapezoidal flaps (right and left) measuring 3 cm in their base. The height of the flaps depends on the thickness of the subcutaneous, from 2.0 to 2.5 cm. The rest of the rectangular band is finally resected, as well as all existing subcutaneous tissue below.

**Fixating the Flaps** Using three mononylon 3-0 sutures, we join the medial dermis of these flaps to the aponeurosis in the midline. Afterwards, we perform intradermic separate stitches with inverted knots, joining both flaps only at their cranial and caudal portions. In this way we create a “glove finger,” fixed to the aponeurosis, whose appearance resembles a navel. It is not necessary to suture the skin of these flaps (Fig. 22.5).

**Dressing** We insert a sphere of gauze that is replaced with every change of dressing until fully healed. Large padded restrictive dressings are applied, fixed with crepe bandages. This dressing is kept for 24 h, after which we introduce compression garments.

## Postoperative Care

For DVT prevention we routinely use pneumatic leg compressors placed at induction of anesthesia and maintained until the patient walks and wears compression garments. We encourage early deambulation, in the first day postoperative. We consider very important to appropriately guide patients as to the best way to stand up, sit, and lie, always on their side without bending forward. Antibiotic prophylaxis with first-generation cephalosporin is begun at induction of anesthesia and maintained postoperatively until discharge, which normally occurs in 24–48 h. Analgesics, anti-inflammatory, and antiemetics are prescribed in addition to the



**Fig. 22.5** Neo-umbilicoplasty and postoperative results

control of hydration and urinary output. We avoid occluding the incisions and prefer to cover them only with gauze and a light compression garment, seamless and wrinkle-free, with no brackets, full-torso, and comfortable. The hygiene of incisions should be done only with alcohol at 70% starting 4 day postoperative, when the patient is released for bathing and wetting the incisions. We always recommend patients to thoroughly dry all incisions, including the use of a cold air hairdryer. Return for revision is done after 6 days and garments must be worn for 45 days, after which we recommend they resume physical exercise progressively, taking until 2 months to begin exercise with heavy weights.

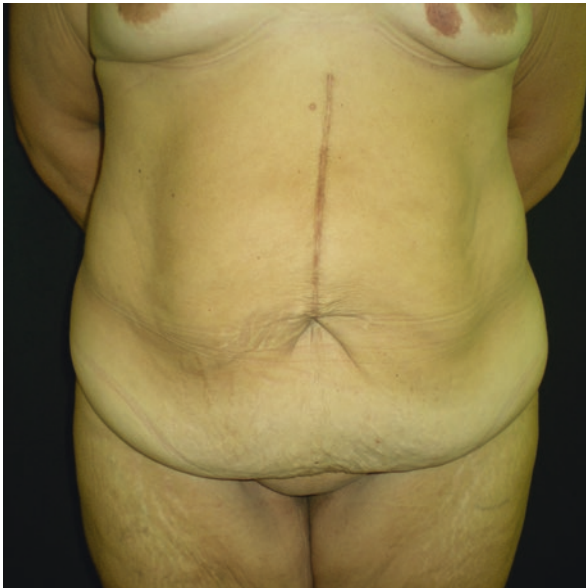
## Complications

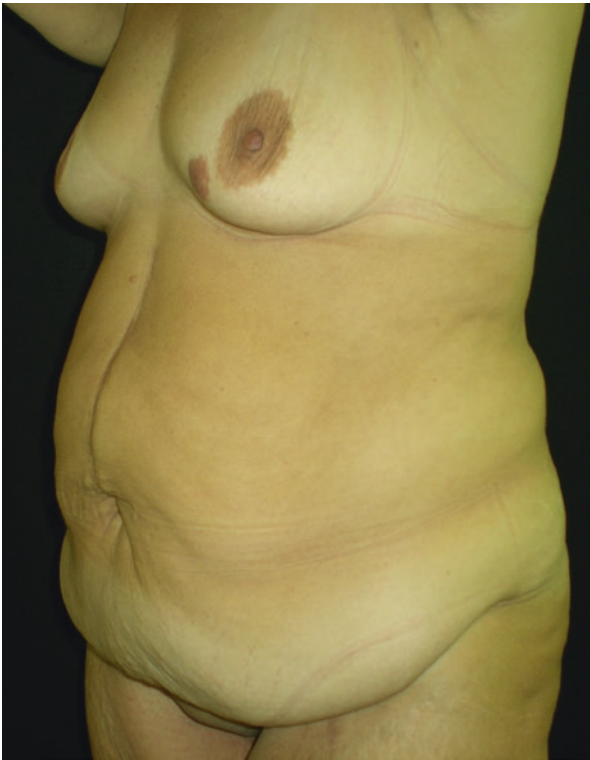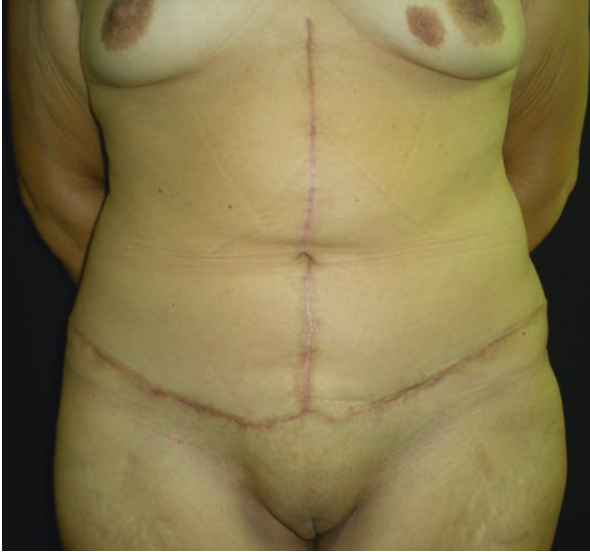In these surgical procedures in general, where there is no skin undermining or “dead spaces,” the occurrence of extensive areas of skin necrosis, fluid collections (hematoma and seroma formation), and infection is minimal. We do not use drains. More common, though not frequent, are small areas of dehiscence, reaction to the sutures, edge necrosis, local infections, changes in scar healing, and other minor complications inherent to any surgical procedure.

The statistics of seroma, especially on the flanks and sacral region, increase when liposuction is combined. The seroma should be suctioned as soon as diagnosed, even after relapse. By neglecting its early treatment, we risk allowing for the development of pseudocapsules, whose treatment is surgical [5]. Some patients may complain of aesthetic changes, whether as paresthesia, hyperesthesia, or areas of cutaneous hypoesthesia, which are usually self-limited.

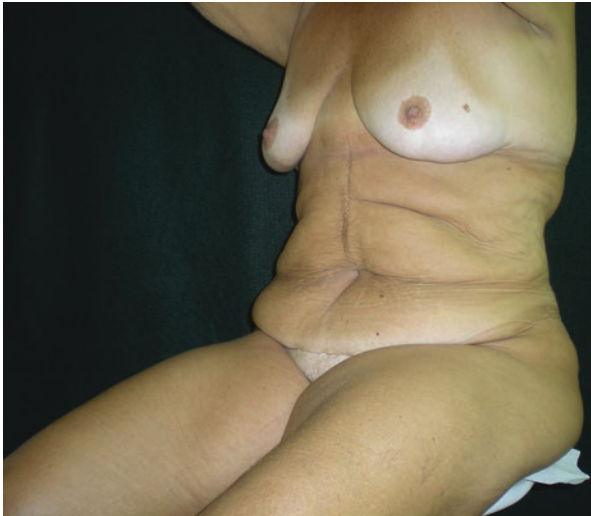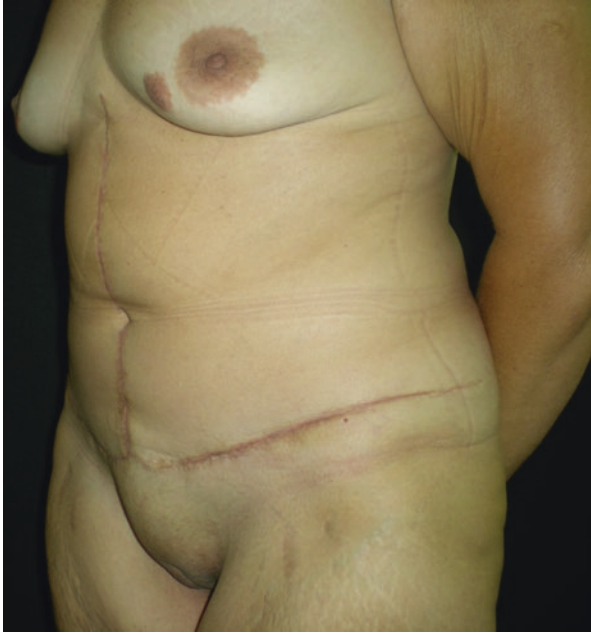Fortunately, serious complications, such as extensive infections and pulmonary embolism, are very rare. In both cases, rehospitalization and specific treatment is necessary.

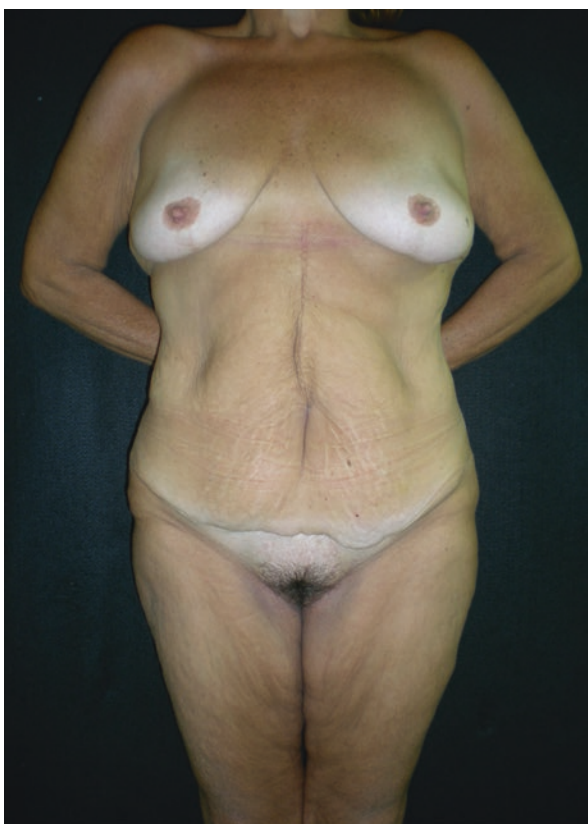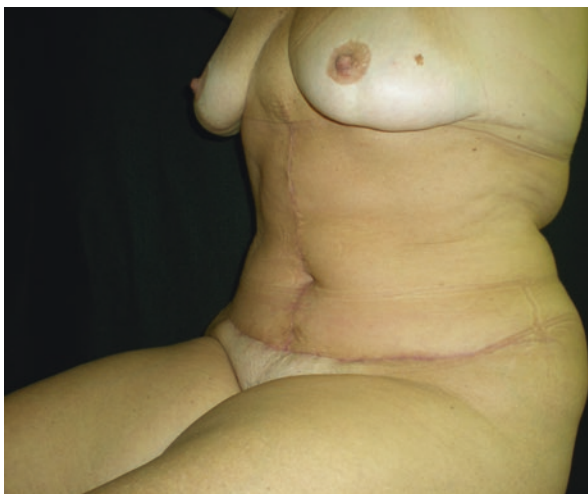The most common late complications are scarring defects, asymmetries, and incomplete resections. Hypertrophic scarring is to be initially treated with silicone sheets. Massage using heparin or corticosteroid-based lotions and/or local injection of steroids can also be used. Surgical correction of hypertrophic, expanded, or asymmetric scars should not occur in less than 6 months.

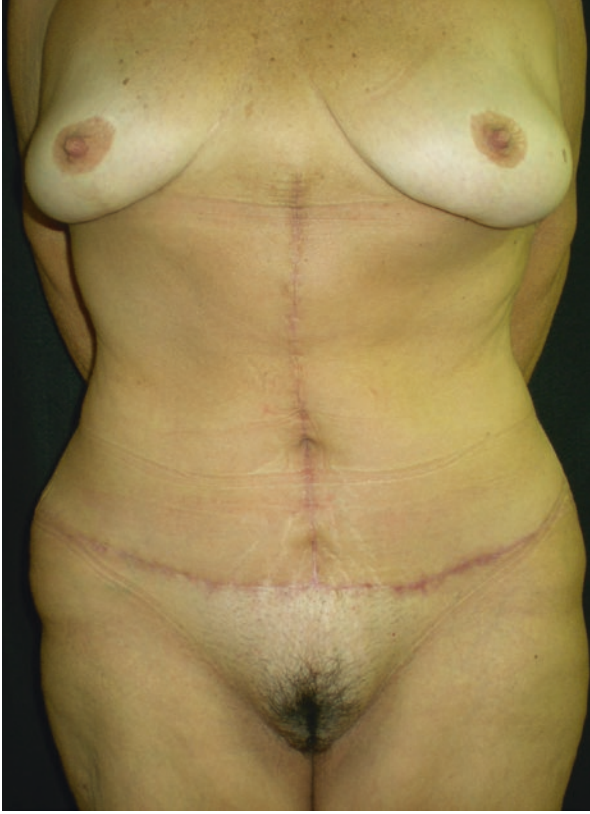


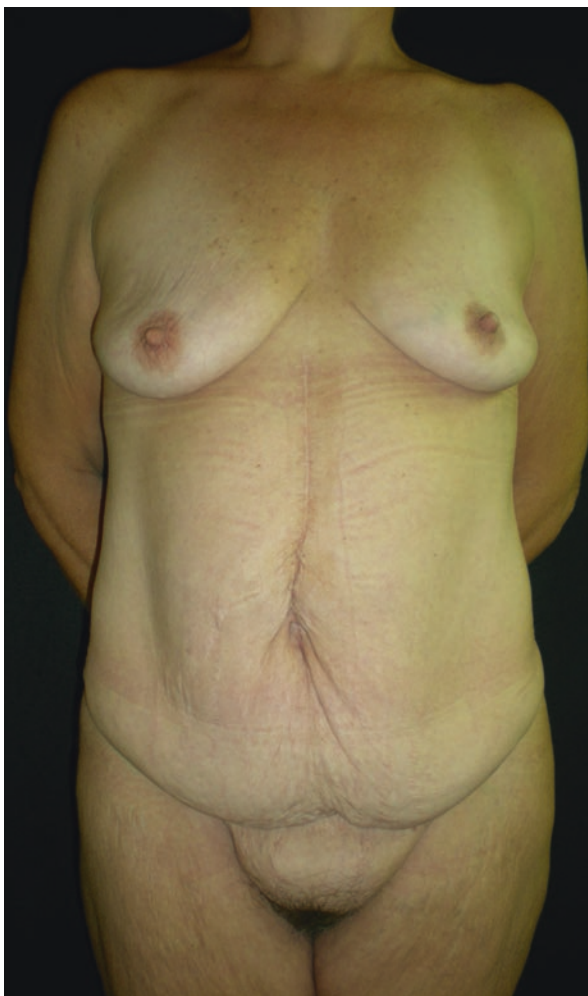
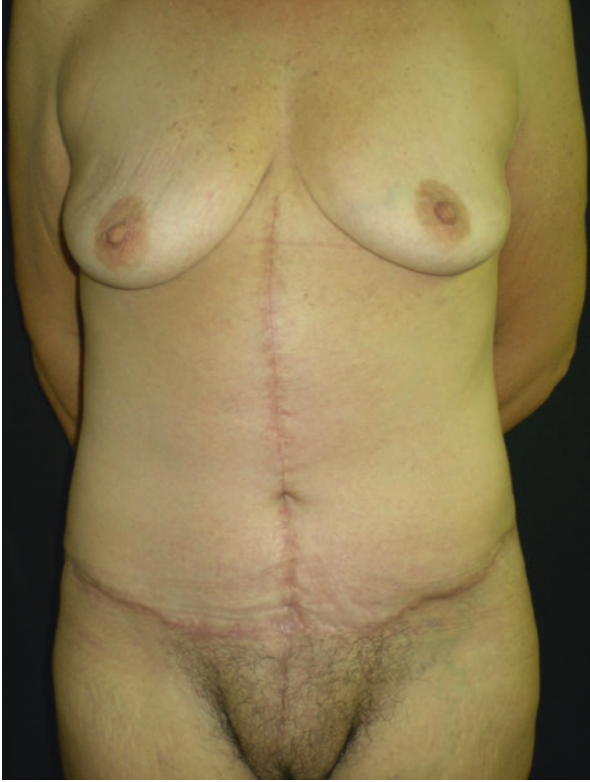




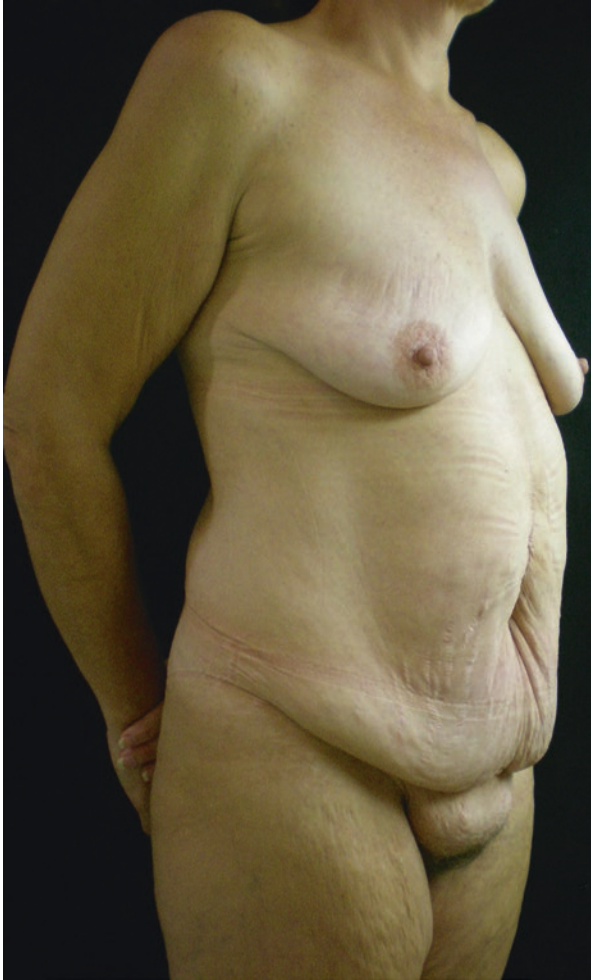

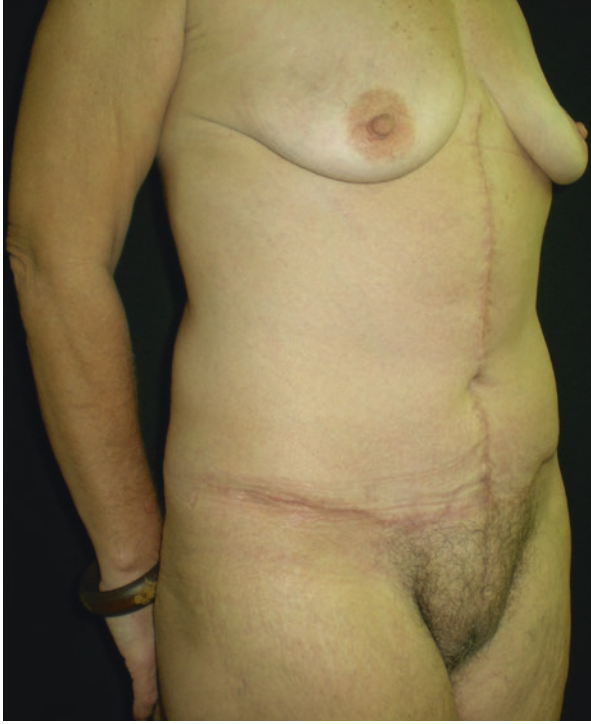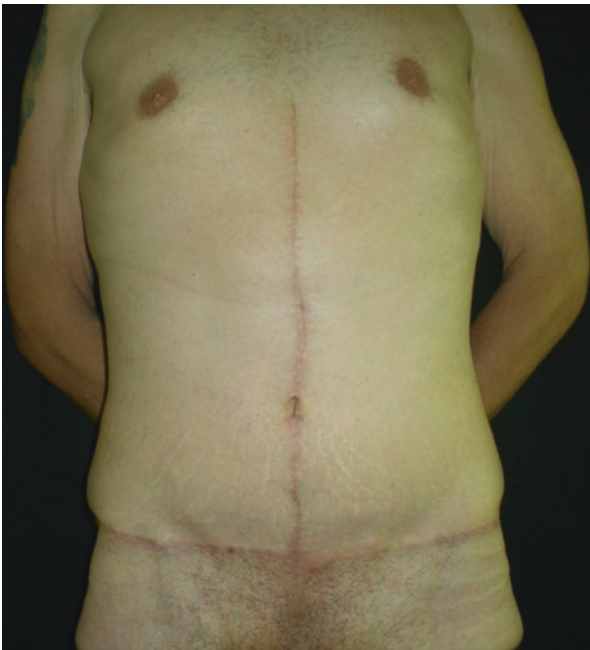




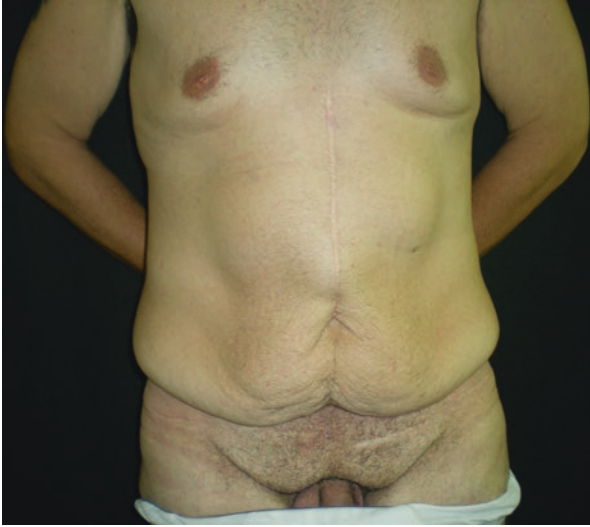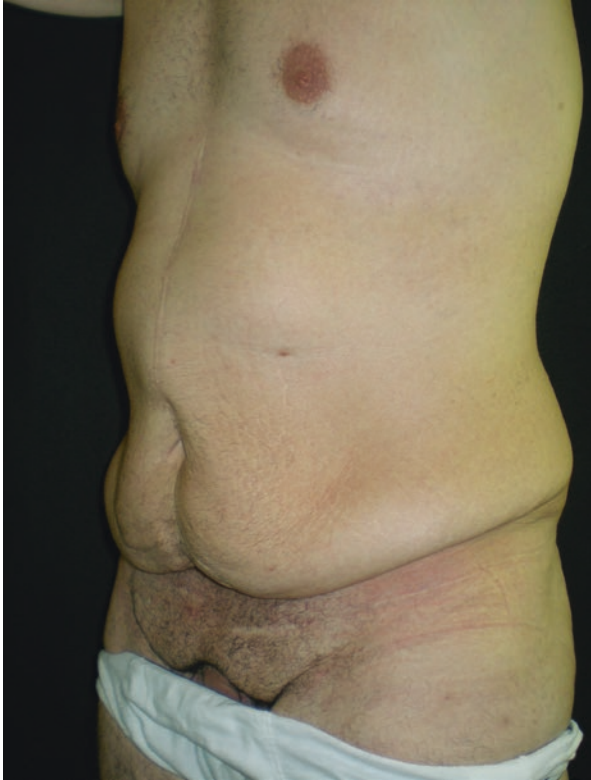


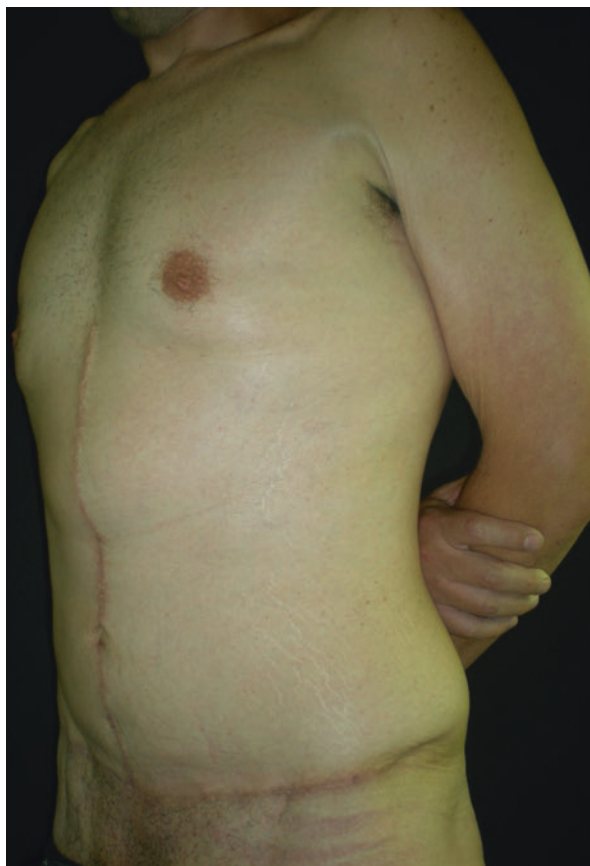












## References

1. Amud RJM (2008) Neo-umbilicoplasty without scarring. *Rev Bras Cir Plast* 23(1):37–40
2. Chang TN, Baroudi R (2006) Abdominoplasty techniques. In: Mathes SJ (ed) *Plastic surgery*, vol 6, 2nd edn. Philadelphia: Saunders, pp 168–170
3. Craig SB, Faller MS, Puckett CL (2000) In search of the ideal female umbilicus. *Plast Reconstr Surg* 105:389–392
4. Franco D, Medeiros J, Farias C, Franco T (2006) Umbilical reconstruction for patients with a midline scar. *Aesthetic Plast Surg* 30:595–598
5. Nogueira DSC (2008) Routine neo-umbilicoplasty in abdominoplasty. *Rev Bras Cir Plást* 23(3):207–213
6. Pontes R (2004) Lifting de coxa. In: *Abdominoplastia - Ressecção em Bloco e sua Aplicação em Lifting de Coxa e Torsoplastia*. *Revinter* 14:153–183
7. Rozen SM, Redett R (2007) The two-dermal-flap umbilical transposition: the natural and aesthetic umbilicus after abdominoplasty. *Plast Reconstr Surg* 119(7):2255–2262
8. Silva FN, Oliveira EA. Neo-onfaloplastia na abdominoplastia vertical. *Rev Bras Cir Plást*. 2010;25(2):330-6
9. Sinder R. Esquemas das Principais Técnicas de Plástica do Abdome. In: *Cirurgia Plástica do abdome*. Rio de Janeiro; 1979; 7:21:36

# Chapter 23

## Abdominoplasty After Massive Weight Loss

Flavio Mendes and Fausto Viterbo

### Introduction

The significant increase in patients undergoing surgical treatment for obesity has led to a new understanding of body contouring surgery. In recent years, this population of formerly obese individuals has appeared more frequently in plastic surgery clinics, seeking treatment for a new pattern of deformity which is completely different from those that have enhanced conventional surgical techniques and approaches over the decades [35]. The physiopathology of these deformities has taken on a very particular character, requiring careful observation on the part of the specialist in considering the anatomic changes and biodynamics of the involved tissues for improved diagnosis and surgical planning. For this to be possible, we must break away from some of the paradigms acquired over time, when procedures addressed abdominal deformities basically resulting from pregnancy, aging, and mild to moderate weight loss.

Furthermore, the new metabolic status of these patients who lose weight must be considered, because of the restrictive and/or malabsorbing effects of bariatric procedures. Although the general condition and clinical comorbidities of obese patients show significant improvement after massive weight loss, various patterns of nutritional deficits are often found in the preoperative approach to body contouring [41]. Special care should be taken with clinical and laboratorial assessment of these patients before surgery, because identifying and correcting these potential disorders are fundamental to ensuring better homeostasis and surgical wound healing [1]. Similarly, the psychological status of post-bariatric patients deserves special attention since specific disorders are often associated with this population and can

---

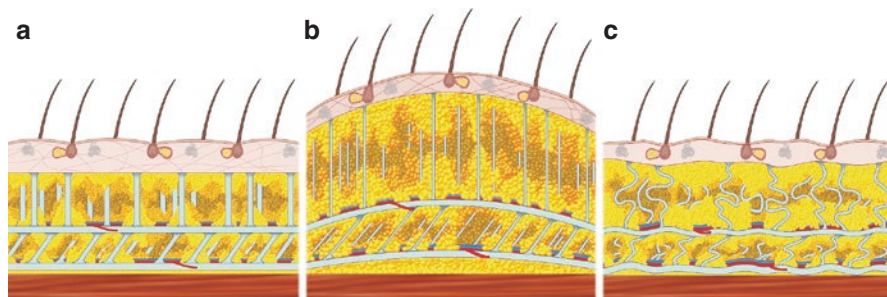
F. Mendes, MD (✉) • F. Viterbo, MD  
Division of Plastic Surgery, Botucatu Medical School – UNESP, Botucatu, SP, Brazil  
e-mail: [mendesmd@fhmendes.com.br](mailto:mendesmd@fhmendes.com.br); [faustoviterbo@hotmail.com](mailto:faustoviterbo@hotmail.com); [fv@faustoviterbo.com.br](mailto:fv@faustoviterbo.com.br);  
<http://www.fhmendes.com.br>; <http://www.faustoviterbo.com.br>

negatively impact postoperative recovery. A multidisciplinary team approach is the gold standard in treating these patients from the beginning of their struggle against obesity through weight stabilization and recovery of a better body shape [28].

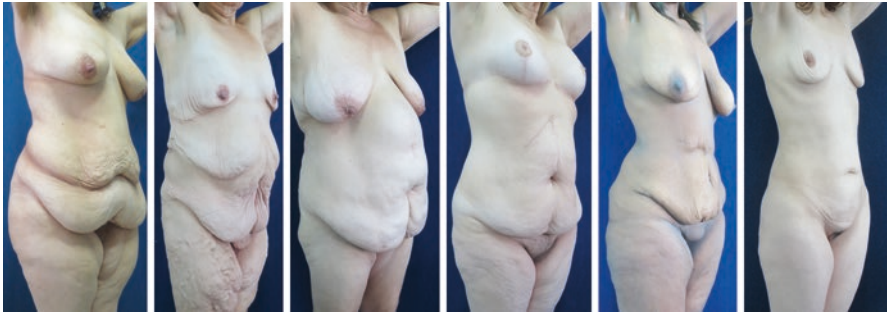## Physiopathology of Deformities

Unlike in most conventional patients, extreme obesity followed by massive weight loss causes anatomical changes that are not only restricted to the anterior abdominal wall, but are contiguously related to the lateral and posterior lower body including the flanks, the proximal base of the thighs, and the buttocks. Although similar to anterior aponeurotic muscle laxity resulting from pregnancy or distention of the intra-abdominal fat, these changes are most intense in the subcutaneous layer and are scattered in a generalized pattern. This is why the term “abdominoplasty” is less appropriate in dealing with post-bariatric patients, since diagnosis and planning must consider tissue readjustment throughout the lower body. Evaluating and treating only the abdominal area in these patients can lead to unsatisfactory results in terms of improved body contours. Patients often seek plastic surgeons to solve a problem that seems to be in the abdomen, without understanding the circumferential and diffuse nature of their deformity. It is up to the surgeon to guide the patient and to discuss all the aspects to be corrected in detail, explaining the variables of the different approaches, possible results, and limitations.

Markman and Barton [24] conducted a detailed study of the entire continuity of subcutaneous cellular tissue using tomographic slices; the superficial fascia was seen to be a constant structure, dividing superficial and deep fat compartments throughout nearly all of the trunk and limbs. Avelar [6] was the first to observe that the superficial fascia in different areas of the body consists of multiple layers separated by adipose tissue and that the thickness of these layers is indirectly proportional to the increase in the quantity of fat. In 1991 Lockwood [22] published new concepts that provided a better and more complete understanding of the entire three-dimensional structure of connective tissue between the dermis and muscle, defining and popularizing the so-called superficial fascial system (SFS), which is specifically responsible for supporting the skin and body fat (Fig. 23.1a). Large accumulations



**Fig. 23.1** Superficial fascial system. (a) Normal; (b) obesity; (c) massive weight loss



**Fig. 23.2** Different presentations in body contour of massive weight loss patients

in the adipocytes of obese patients create a generalized mechanical stretching effect in the SFS through volumetric increase of the whole subcutaneous space (Fig. 23.1b). Weight loss, meanwhile, causes a large-scale emptying of these adipocytes, producing a volumetric reduction of the subcutaneous tissue without a proportional retraction of the collagen fibers, which remain elongated and weak. This incompetency of the SFS inability leads to significant looseness of the skin (Fig. 23.1c).

Song et al. [39] presented the Pittsburgh scale as an attempt to classify deformities after massive weight loss and suggested specific treatment based on the deformities encountered. Although this classification was scientifically validated, it was based exclusively upon static observations of body contours; because it was based only on the action of gravity on the mass of thinned tissue and not dynamic assessment, it is insufficient and is further limited by zones of subcutaneous adherence. Possible variables also include factors such as age, sex, intensity of weight loss, presence of ventral hernia, and final rate of fat loss, which can cause very different presentations in the body contours (Fig. 23.2). Extensive training and frequent contact with patients who have lost large amounts of weight are necessary to decide what approach is the best in a certain case when only static observation is used. Furthermore, physical examination is required to truly understand the intensity of these deformities, including vigorous palpation and movement of the tissue, which generally reveals a looseness of the skin which far exceeds what is suggested in static examination alone.

After massive weight loss, the tissue exhibits generalized roundness and mobility which compromise the body silhouette due to the migration and descent of all the surrounding body segments. This is the fundamental anatomic variable that defines deformities in the body contours of post-bariatric patients, determining a completely different approach targeting the new biodynamics of these tissues.

## Tissue Biodynamics and Repair Vectors

We can state that the pattern of deformity after extensive weight loss will be determined by each individual's type of fat deposits (central or peripheral), the weight of the excess tissue (gravitational force), and the degree of mobility (cutaneous

translation) in the different areas of the body, which is directly related to the degree of subcutaneous emptying. This evaluation should also consider the effects of adherence zones and the spatial positioning of individuals. The qualitative and quantitative multiplicity of these variables explains why we so rarely encounter post-bariatric patients with identical body contour deformities. Consequently, each patient is unique, and assessments must be absolutely individualized in order to identify specific needs to be considered in the therapeutic plan [4].

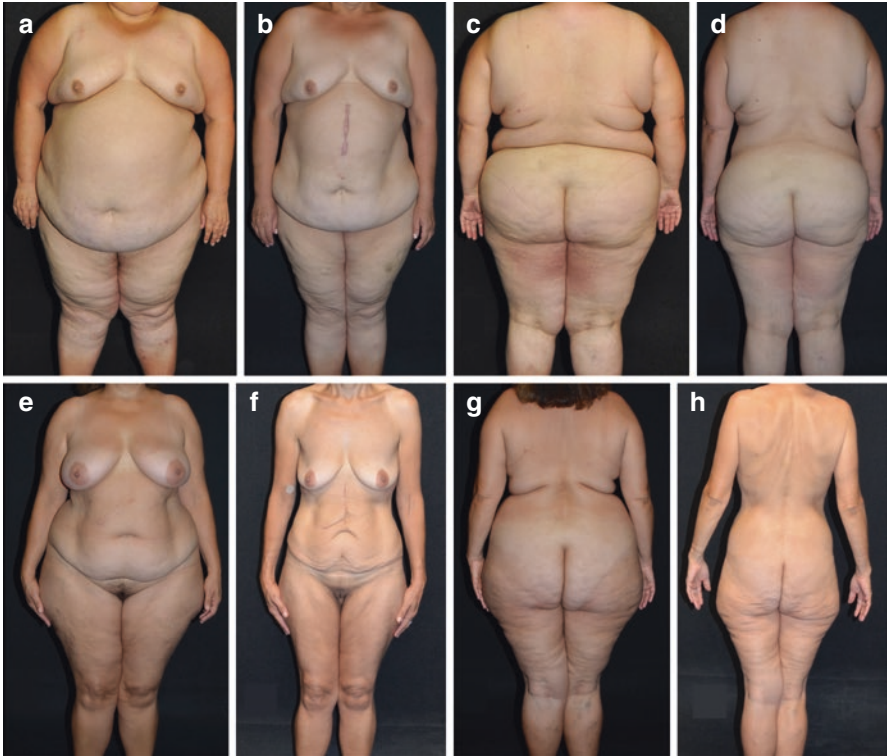### ***Pattern of Fat Deposits***

Regardless of sex, each person has a genetic preference determining how fat is deposited throughout the body, and this characteristic will be essential in determining post-weight loss deformities. In the central pattern (apple shape or android), fat is predominantly deposited above the waistline, and excess tissue is present in the anterior aspect of the lower body, with some preservation of the flanks, the lateral aspects of the thigh, and the buttocks. In the peripheral pattern (pear shape or gynoid), fat is deposited primarily below the waistline, leaving excess tissue more circumferentially distributed throughout the flanks, the base of the thighs, and the buttocks (Fig. 23.3).

In summary, patients with defined fat deposit patterns have a biodynamic mechanism for emptying these tissues, which along with adherence zones and gravity can create different types of deformities, affecting each area of the lower body with more or less intensity. We know that these typical fat deposit patterns (central and peripheral) are not always absolute or clearly defined in individuals. They may appear to be combined in certain bodies, but the physiopathology of each pattern will be responsible for establishing the deformities that can and should be identified and appropriately treated.

### ***Degree of Subcutaneous Tissue Reduction***

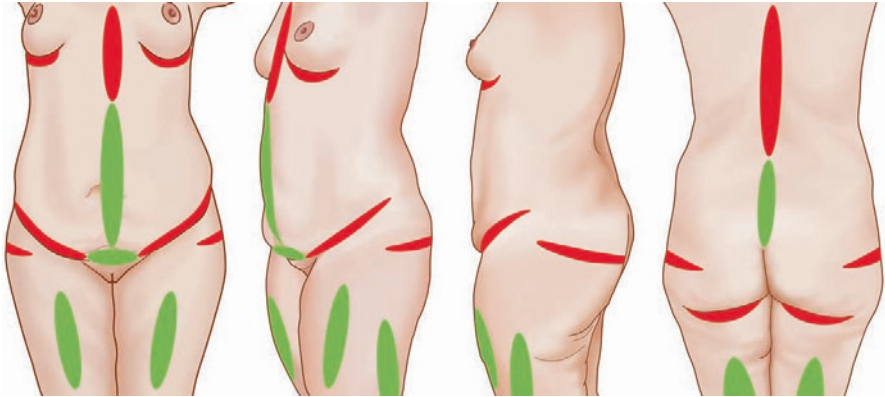
The reduction of fat in patients after weight loss is frequent, but not always sufficient for better execution of body contour treatments; even in a single patient, it may occur at different levels. This means that post-bariatric patients do not always attain ideal conditions for the best surgical recommendation. Regardless of the amount of weight lost, incomplete reduction of fatty tissue causes greater deformities due to the action of gravity and complicates the surgical maneuvers required to improve body contours. Just as conventional aesthetic procedures do not apply to patients who are significantly overweight, in post-bariatric patients, it is important to remember that the objective of plastic surgery is not weight loss, but the enhancement of body contouring by correcting deformities caused by massive weight loss. For this



**Fig. 23.3** (a, c) Central pattern obesity; (b, d) central pattern massive weight loss; (e, g) peripheral pattern obesity; (f, h) peripheral pattern massive weight loss

reason, reduction of mass (“deflation”) around the body is essential because it allows efficient surgical planning to readjust loose tissue, to the benefit of the silhouette. Without the reduction of fat, the superficial fascia system is not completely disordered and incompetent, significantly reducing the ability to move these tissues and proportionally increasing the chances of complications and failures [9]. In these cases, only “hygienic” surgeries can be considered as approaches to provide “relief” and very limited results.

Body mass index (BMI) is a good indicator of the patient’s degree of fat reduction and may guide the recommendations for body contour treatment. Besides technical difficulties in achieving expected results, the literature shows a higher incidence of complications in post-bariatric patients who still have elevated BMI (>32). This must be thoroughly explained to candidates even before their bariatric surgery, so that they can understand that the body contouring procedure has limitations and that the patient must no longer be considered obese to be a good candidate for surgery and have a favorable outcome. Similarly, extremely low BMI (<20) can be associated with severe nutritional deficit and low immunity [15].



**Fig. 23.4** Zones of adherence of the subcutaneous tissue. *Red* strong, *green* mild

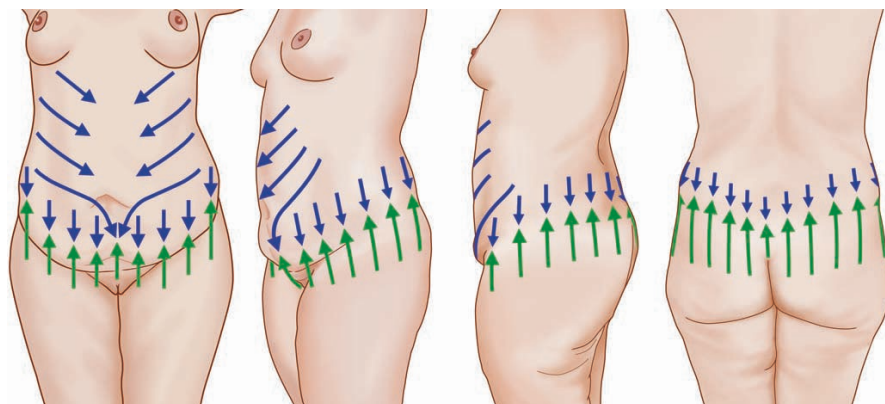
### ***Adherence Zones***

If we imagine the lower area of the body as a roughly cylindrical structure, without the adherence zones scattered throughout the subcutaneous tissue, we would have an absolutely standard behavior in the entire tegument after massive weight loss, which causes a uniform descent around its whole circumference. These adherence zones are extremely important in the final composition of a normal human silhouette, because they provide this “selective limitation” in the mobility of skin coverage around the body (Fig. 23.4). The location and intensity of these adherence zones remain relatively constant in different individuals of both sexes, so what determines contouring differences is the pattern of fat deposits, which along with their degree is determined by genetic and behavioral components. Reduction of the subcutaneous tissue results from large-scale weight loss, followed by the destructuring and incompetence of the superficial fascial system, which in turn provoke greater mobility of these tissues that are still restricted by the adherence zones. Ultimately, the effects of gravity on tissue which is more free compared to areas with greater deep fixation cause the deformities that plastic surgeons face in repairing the body contours of post-bariatric patients [4].

### ***Lower Body Readjustment Vectors***

“Post-bariatric body readjustment” implies complete anatomical and functional readjustment of the entire superficial fascial system. Once the physiopathological aspects leading to changes in the body contours of post-bariatric patients are understood, we suggest considering the body segments as “cylinders” to better understand the vectorial behavior of movements, considering the generalized and circumferential pattern of these deformities. These vectors should be considered





**Fig. 23.5** Vectors for tissue adjustment in post-bariatric body contouring

both vertically and horizontally, understanding that horizontal resections generally promote a lift of tissues, while vertical ones promote a tighter coverage along the longitudinal axis. The combination of these two approaches provides the concept of body readjustment: lift and tighten.

In this way, readjustment of the lower body means correcting vertical laxity and the consequent drop of the pubis and the infra- and supra-umbilical abdominal tissue (anterior), as well as lateral (flanks) and posterior (dorsum) connected areas, including the gluteal region. Circumferential resection at the waist reduces vertical laxity and promotes lift in the anterior, lateral, and posterior portions because of the greater vertical mobility occurring in this direction and upward. If necessary, longitudinal tightening of the tegument (reducing laxity) or transversal readjustment (through resections generally placed along the anterior median line) can also comprise this readjustment (Fig. 23.5). Palpation must be fully utilized to identify and quantify excess tissue, planning resection, and correction vectors with the full agreement and understanding of the patient.

In the gluteal region, besides potential lifting of structures that have truly fallen, an analysis should be conducted regarding whether it is appropriate to readjust the volume using methods that prioritize desirable body contours in patients of both sexes.

### ***Planning and Surgical Technique***

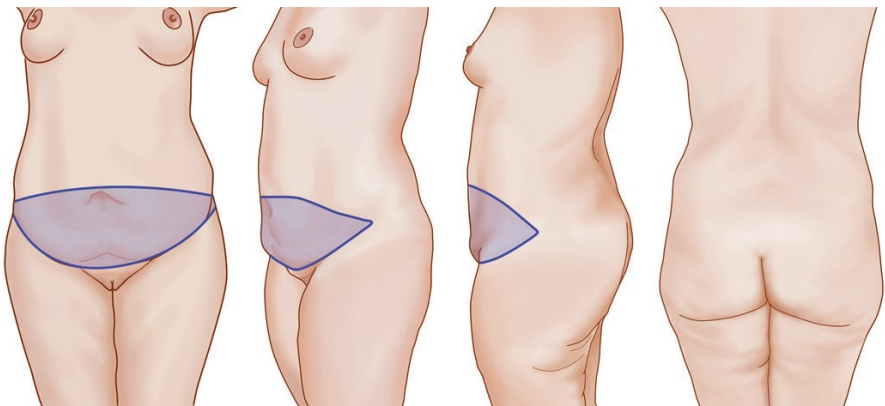
Physical examination of the lower body should begin with static inspection of the standing patient, with the examiner seated on a swiveling stool that permits movement around the patient. A mirror should always be present since it allows the examiner to show the patient the mobility, fall, and laxity of tissues, as well as the vectors recommended for tissue resection and contour correction resulting from adherence zones and gravity. Around the entire circumference of the body, folds and

sulci present in an orthostatic position should be identified to consider the need for resection, always bearing in mind the physiopathology of body contours after massive weight loss. Vigorous palpation of the involved tissues helps to simulate the effects to be obtained with resection and potential correction vectors. Previous identification of scars and hernias in the abdominal wall is also essential in the planning and safety of the proposed treatment. Plication of the anterior aponeurosis should be done using the same approach as conventional surgery and usually is necessary, considering prior distension resulting from the accumulation of intra-abdominal fat during obesity or even from past pregnancies. Cases of small and uncomplicated hernias with a ring of up to approximately 10 cm in diameter can only be corrected by previous plication, but when a direct approach cannot be safely achieved, the use of alloplastic material such as synthetic mesh is recommended. Generally, a plastic surgeon trained in general surgery is fully capable of conducting this treatment in a single surgery and will leave more complex cases to be executed with the cooperation of other specialists in abdominal wall reconstruction.

Modolin et al. [25] published a wide systematization of possible approaches to abdominoplasty after massive weight loss. Broadly, these same concepts are pertinent in systematizing the planning of lower body readjustment using four approaches: (1) anterior transverse (conventional), (2) anterior combined (anchor), (3) circumference (belt), and (4) combined circumference (anchor + belt). Each of these approaches as well as their possibilities and limitations will be further discussed in this chapter.

### *Anterior Transverse Approach*

This technique is used for abdominoplasty in conventional patients, but is rarely recommended in the post-bariatric population. Although this approach is efficient in patients with deformities resulting from multiple pregnancies and is restricted to the anterior aspect of the abdomen, the anterior transverse approach tends to be insufficient for treating more general loose and circumferential tissue (Fig. 23.6). Patients

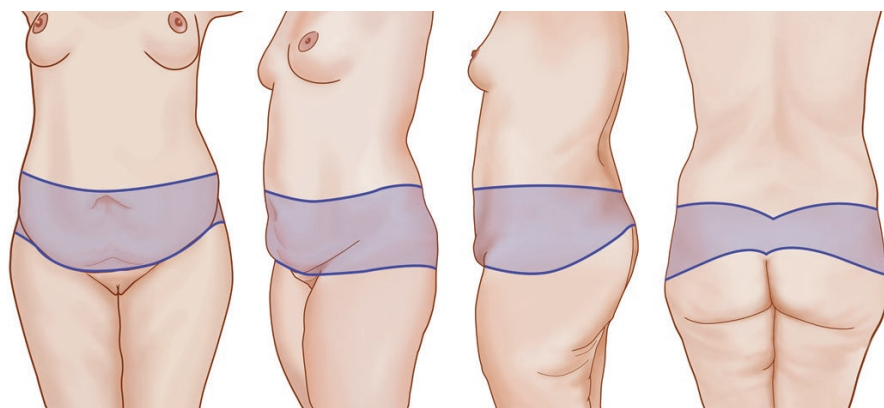


**Fig. 23.6** Conventional anterior transverse approach

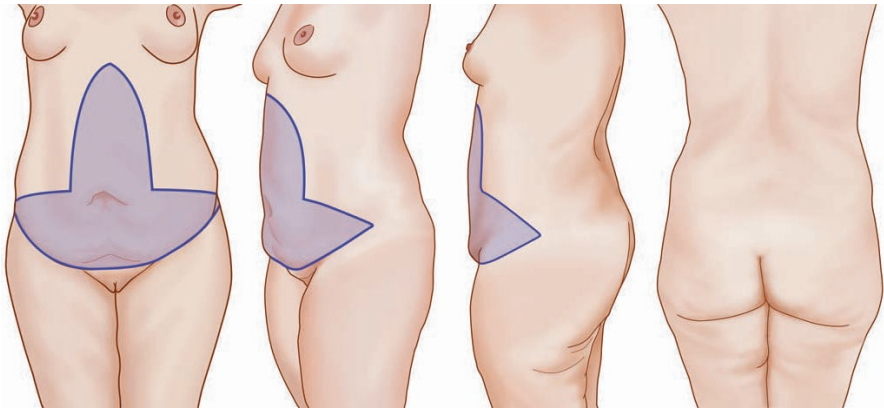
who lose large amount of weight and undergo this technique always appear to have an amputation of the abdomen in a single direction (vertical), with evident and aesthetically displeasing remaining tissue at the flanks and dorsum, also involving the base of the thigh and the buttocks. Even in cases where larger deposits of fat were located above the waistline, without significant excess tissue and lowering in the lateral and posterior structures of the lower body, the anterior transverse approach alone does not correct horizontal excess tissue in the upper abdomen, resulting in residual laxity that is extremely inconvenient after surgery when body contouring is evaluated as a whole.

### *Circumferential Approach*

The objective of this technique is to expand the anterior transverse resection of the lower abdomen to the flanks and lower dorsum, removing an actual belt of loose tissue in order to remove remaining tissue and also lift the anterior and lateral base of the thighs, as well as the gluteal region (Fig. 23.7). This procedure is especially indicated for patients with the peripheral pattern of fat deposits and cases where the reduction caused by weight loss provokes significant ptosis of the lateral and posterior structures of the lower body. In cases where fat is deposited mainly above the waistline (central obesity), there is a natural preservation of the lateral and posterior structures of the lower body, and the circumferential approach will be less useful, since there is no significant ptosis to be corrected at this level. When indicated, the circumferential approach offers excellent results with significant improvement in body contour. As with the anterior transverse approach, it should be remembered that the circumferential technique alone does not correct the horizontal excess of tissue in the upper abdomen and may result in greater or lesser levels of remaining anterior laxity.



**Fig. 23.7** Circumferential approach



**Fig. 23.8** Combined anterior approach

### ***Combined Anterior Approach***

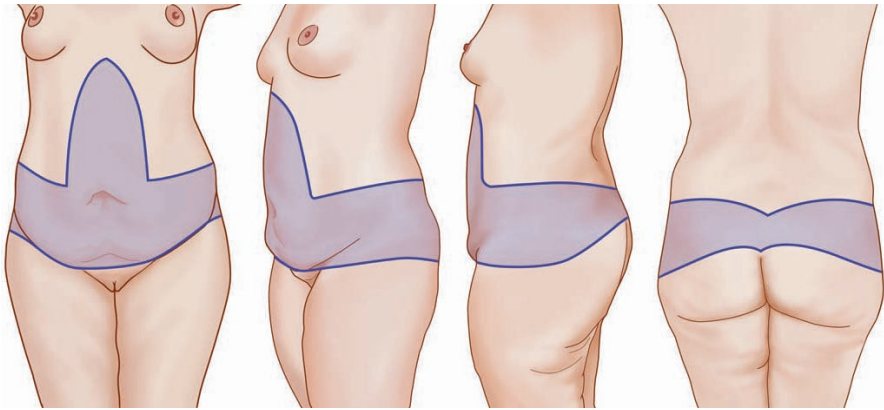
Also known as “anchor” or “fleur de lis” abdominoplasty, this technique combines longitudinal resection with the anterior transverse approach specifically to correct the horizontal excess abdominal tissue which is normally present in post-bariatric patients (Fig. 23.8). This technique is mainly indicated for central obesity, where fat is deposited above the waistline and significantly expands abdominal circumference. Because these cases generally do not present excess tissue or notable fallen lateral and posterior structures of the lower body, a combined anterior approach can provide better adjustment of the body contours by taking into account the recommended vectors for the required correction.

It is important to remember that although this technique can greatly improve contouring, this technique invariably leaves a visible and permanent median scar. It is up to the medical team to provide patients with detailed information about the pros and cons involved in this type of approach so that they can participate in their surgical planning.

### ***Combined Circumferential Approach***

This technique also combines anterior longitudinal resection with the circumferential approach specifically to correct horizontal excess abdominal tissue which is typically present in the post-bariatric population (Fig. 23.9).

This procedure is principally indicated in cases of peripheral obesity, where fat is mainly deposited below the waistline but significantly expands the abdominal circumference. Besides addressing significant remaining and fallen tissue in the lateral and posterior structures of lower body, the combination with an anterior



**Fig. 23.9** Combined circumferential approach

longitudinal resection can provide the best contouring readjustment while considering best vectors for the necessary corrections.

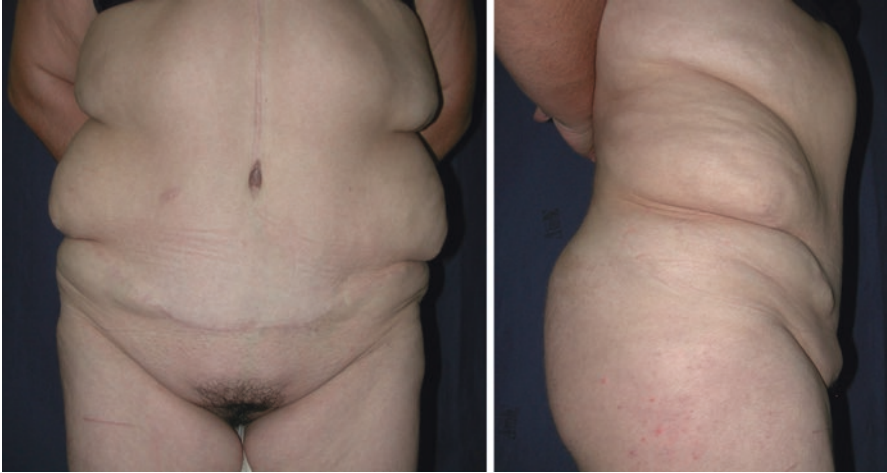Here it is also necessary to consider the visible and permanent median scar which results from this procedure. The patient should be very well informed about the limitations and possibilities of each approach to help plan the approach which provides the best contour/scar ratio.

## Results

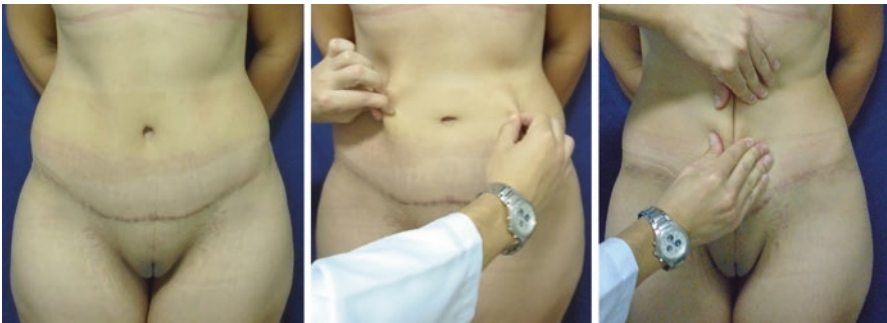We cannot imagine that a single approach could adequately correct all types of deformities, so each patient should be carefully evaluated to improve planning and, consequently, progress. Many of the unfavorable outcomes observed in the post-bariatric population result from indication of classical abdominoplasty procedures. Figure 23.10 shows one of these catastrophic results, where there was certainly no proper assessment of the patient's real needs; consequently, the patient received a completely inappropriate approach which was unable to provide adequate body contouring after surgery.

Appropriate indication for conventional abdominal surgery (anterior transverse approach) in patients who have lost massive amounts of weight tends to be not the rule, but the exception in the formerly obese population. Even in patients with less remaining tissue in the static examination, as in Fig. 23.11, this type of approach tends to result in residual laxity in the horizontal direction of the abdomen. This may be the price to be paid to avoid the anterior vertical scar, but the patient must be aware and recognize that, in this case, less scarring also means more flaccidity.

In post-weight loss patients with the central pattern of obesity, the combined anterior approach (anchor) generally offers better results because it corrects the vertical and horizontal laxity of the entire anterior abdomen. In these cases, the



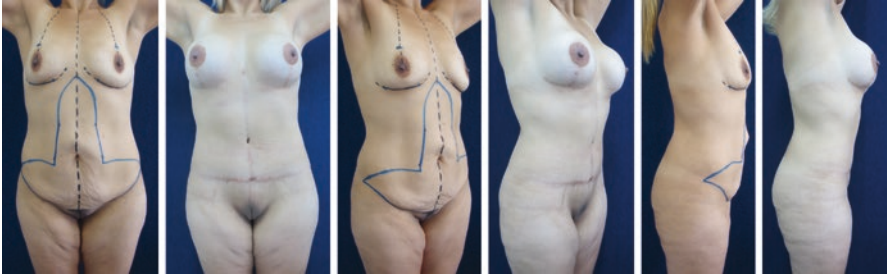**Fig. 23.10** Poor result of post-bariatric abdominoplasty due to a conventional approach, not considering the patient's particular deformities and needs



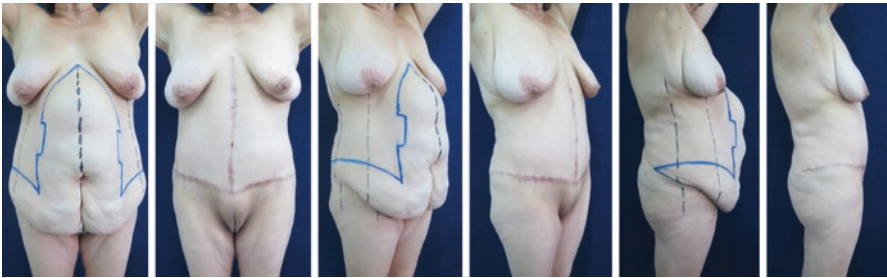
**Fig. 23.11** Residual laxity after conventional abdominal approach in massive weight loss patient

contours of the lateral and posterior areas of the lower body tend to be preserved and do not require the combined circumferential approach. Figures 23.12 and 23.13 show two separate cases with lesser and greater deformity after bariatric surgery; both cases benefited from the combined anterior approach without the need for additional circumferential resection.

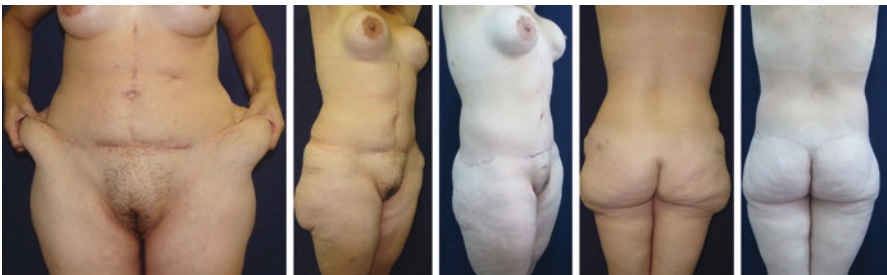It is also true that we will not always achieve completely satisfactory results using only the combined anterior approach. Figure 23.14 shows a case where anchor surgery resolved anterior abdominal laxity but did not provide adequate contouring because of residual tissue at the flanks, the thigh base, and the dorsum. The more peripheral type of fat deposits in this patient should have highlighted the need for a circumferential approach from the beginning; in this case, this procedure was successfully done in a second surgical procedure (Fig. 23.14). Although complementary resection can be scheduled for a separate procedure, it must be included in the



**Fig. 23.12** BMI=26. Anterior combined approach in massive weight loss patient. 12 months PO. Augmentation mastopexy associated



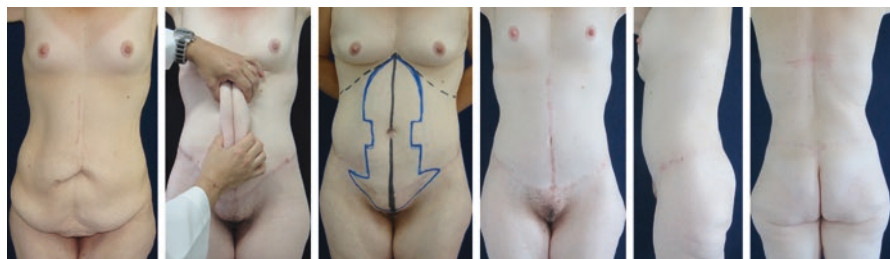
**Fig. 23.13** BMI=30. Anterior combined approach in massive weight loss patient. 6 months PO. Incisional hernia treated as well



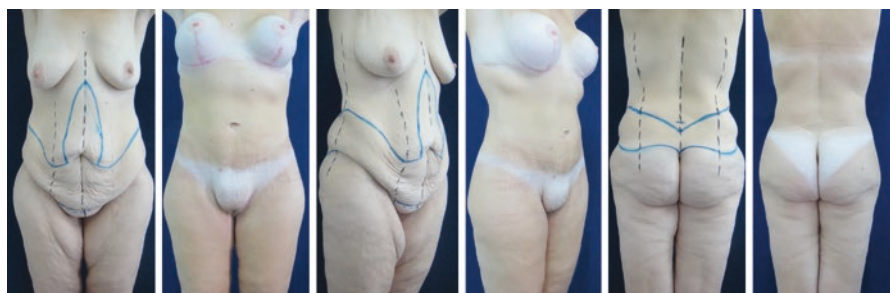**Fig. 23.14** Circumferential approach to correct lower body deformities which were not addressed by the previous anterior combined surgery

initial planning, and the patient must be informed of the possibilities from the pre-operative stage and not afterward, when the results are seen to be inadequate.

Similarly, an isolated circumferential approach cannot always offer completely satisfactory results. Figure 23.15 is a postoperative view of one circumferential approach that yielded significant horizontal flaccidity of the anterior abdomen, which was later corrected in a new procedure. Often this type of residual laxity is not seen in static images, but can significantly bother patients in their daily lives. Correction of this problem requires a resection of the transverse excess abdominal



**Fig. 23.15** Anterior vertical approach to correct residual abdominal laxity which was not addressed by the previous circumferential surgery



**Fig. 23.16** BMI=27. Combined circumferential approach. Twenty-four months PO. Augmentation mastopexy and inner thigh reduction were performed in a second procedure (6 months PO)

tissue with a visible and permanent vertical anterior scar. Again, the patient must be informed of these details and also be invited to share opinions and cooperate in the best recommendation for the case.

The combined circumferential approach provides the most complete level of correction for lower contouring. Suspension vectors (buttocks, flank, and thigh base) and tissue tightening (anterior abdomen) are associated through resections in the transverse and longitudinal planes of the lower body. This approach also is responsible for the most scarring among all of the possible approaches, which is why its benefits should be very greatly desired by the medical team and the patient despite the resulting scars. Figure 23.16 shows an extremely favorable result of this approach which resulted in a major improvement in body contouring with scars that are well positioned and not very evident.

## Complications

Generally, complications in plastic surgery can be compared to disasters that may be greater or smaller depending on the threat or harm they pose to the patient, regardless of the facts or sequence of facts that caused them. Consequently, we



consider the term “adverse effects” to be more appropriate, meaning injuries or harm resulting from a healthcare intervention, and in the case of surgeries, mistakes are not necessarily involved. Adverse effects can be divided into avoidable and non-avoidable; avoidable events are the main target in terms of surgical safety. In some cases, however, it is difficult to clearly define when an adverse event can be avoided or not because of the complexity and singularity of the human body in the face of the stimuli and choices that the medical team provokes during treatment. There are situations where preventing certain adverse effects may lead to the appearance of other ones. The medical team must be attentive to the possibilities, which should be discussed with and explained to the patient to achieve efficiency through better understanding and shared actions. In general, the current principles of surgical patient safety are more focused on the system than the individual, as shown in the “Swiss cheese” model proposed by the psychologist James Reason to explain the occurrence of system failures. As a mental model for patient safety, this analogy illustrates overlapping multiple layers of protection to reduce the probability that the holes will align, allowing avoidable adverse events to fall through the holes [34].

In this model, post-gastroplasty complications can be minimized if professionals recognize that patients vary in their physiology and morphology, identifying both individual risk factors and those related to the procedure itself. From this point, patients can be selected appropriately, and better treatment strategies can be established for each individual specifically within the planned procedure. Perhaps counterintuitively, the rates of complications in body contouring procedures in post-bariatric surgery patients are no greater than those in patients who lose weight through diet and exercises, which shows us that preventative measures based on the parameters described above seem to be sufficient for planning approaches within the limits of safety [15].

## Lesser Adverse Events

### *Seroma*

Some authors have considered seroma the most common postoperative complication in patients undergoing gastroplasty, occurring in 15–50% of cases [16]. Seromas form through subcutaneous accumulation of transudate liquid after surgeries with more significant detachments and may even lead to fibrosis in adjacent areas, compromising the results of body contouring. There is strong evidence that patients with higher BMI tend to present seromas more frequently, but their relationship with liposuction remains controversial. Seroma prevention requires a detailed surgical technique with reduced detachments and sutures in three or four planes in an attempt to avoid formation of dead space within the detached areas. In 1998, Baroudi and Ferreira [13] proposed closing abdominal dead space with “adherence stitches” that fix the superficial fascia of the flap to its deep aponeurotic fascia, constituting an excellent preventive technique. The placement of negative pressure drains to remove bleeding and transudate is a classic approach advocated

by several authors, who suggest maintaining the drain for a few days while there is active draining of secretion greater than 30 cc/day. A randomized study suggested that the action of drains and adherence sutures are equivalent [5], but both are recommended in procedures such as abdominoplasty. The use of fibrin glue in post-bariatric plastic surgery seems to be promising, although this option remains very expensive for patients and cannot completely eliminate the risk of serohematic collections. The use of compression wraps is also indicated as a positive measure for preventing this complication, especially in abdominoplasty.

The classic treatment for seroma is repeated aspiration punctures, which are standard treatment in most plastic surgery services and in most cases resolve the issue. However, patients who continuously accumulate serous secretions for more than 4–5 weeks may benefit from a new approach, introducing an ultrasound-guided drainage catheter and continuing local compression using belts. If the condition persists, an imaging exam must be repeated (ultrasound or computed tomography) to assess the formation of a pocket; if this is the case, it must be openly resected and adherence sutures applied [36].

## Dehiscence and Wound Separation

Some surgeons consider dehiscence and suture separation to be the most common complications in post-bariatric plastic surgery; they often occur in areas of greater tension above the scar in formerly obese patients. Part of the blame lies in the protein metabolism of the extracellular dermal matrix and increased inflammatory activity of the cytokines, metalloproteinase metabolism, and their inhibitors in the dermal matrix. An important consideration is the presence of hypoproteinemia as a contributing factor in the process of dehiscence (not only the albumin or prealbumin) and also other macro- and micronutrients such as vitamins and minerals. Other factors that can be related to increased dehiscence are elevated BMI at the time of body contouring surgery, prolonged surgical time, and the volume of tissue removed during the procedure. Diabetes, hypertension, and tobacco use are also cited as risk factors for dehiscence [2].

In most cases, areas of dehiscence are small and vary from 1 to 2 cm; areas larger than 3 cm are less common. Wound separation usually occurs early after the procedure and generally associated with intensive and premature body movements or excessive tissue removal. Dehiscence itself is more frequent and commonly occurs later, within 15 days after surgery, and is commonly associated with the presence of subjacent seromas [17].

Prevalence of this complication begins with good review of the preoperative exams and verification of protein levels (especially albumin), vitamins (such as B12, B6, and folic acid), and minerals (such as zinc and iron). Tobacco use must cease for at least 4 weeks prior to the surgical procedure, and control of diabetes and hypertension is also fundamental. Prior to the procedure, meticulous preoperative marking, especially in abdominoplasty, avoids tension on final sutures. Three-

layered sutures also help prevent dehiscence. Postoperative care and rest at home must be extensively discussed by the team and the patient.

Treatment of dehiscence or wound separation will depend on the size of the affected area and when it occurs (early or late). Normally, early occurrences can be referred to the surgical center for resuturing, but local treatment with bandages and closure in a secondary procedure is indicated, especially in chronic wounds, with adjustments only after 6 months. Whenever viable, primary suturing should be considered after cleaning and debriding as early as possible.

## Scar Alterations

Keloids or hypertrophic scarring can occur in any surgical procedures, even if they do not involve tension suturing and are done correctly. Scars cause devascularization of the affected area that can lead to a definitive loss of blood flow which was normal before the procedure. Obesity also seems to be related to scarring problems, since patients with very high BMI before bariatric surgery and even after weight loss tend to develop this type of problem. Body biotype, weight maintenance during the postoperative period, and tobacco use are also important factors affecting wound scarring after surgery. Scarring problems may also result from other complications such as infection, dehiscence, and fat necrosis.

The best action to prevent unsightly scarring is to carefully avoid excess tension in the suture thread. Several authors suggest marking the day before the surgery with the patient standing. All of the authors suggest checking and rechecking the resection while removing the segment, which is more prudent than excision and previous resection of the marked area. In 1993, Lockwood illustrated that sutures in the superficial fascial system improved tension on the suture thread, guaranteeing a longer-lasting result and better scar quality while avoiding scar migration.

Correction of unsightly scarring may be scheduled after the postoperative period when scarring is close to fully mature, usually 4–6 months after the procedure. Keloids and hypertrophic scars may benefit from massage, compression, triamcinolone infiltrations, or resection in combination with betatherapy. Scar asymmetry is also noteworthy, especially because most patients after significant weight loss have some asymmetry in the preoperative period. Scar migration can worsen the visibility of the problem and should be prevented using Lockwood's principles.

## Compressive Injuries from Intraoperative Placement

Correct positioning and protection of patients are important to reduce intraoperative morbidity. Poor positioning can cause neurological, vascular, and ocular damage, leading to large clinical repercussions. All this becomes especially important in cases of different decubitus during the procedure. Arms and elbows must be placed

at angles that avoid traction and injuries to the brachial plexus. The head, arms, legs, elbows, and region above the knees must be supported by pads to avoid nerve compression. It is also important to use ophthalmological lubricant cream in the eyes or to simply keep the eyes closed with bandages or a similar covering. In ventral decubitus, special care is needed to avoid the increase in intraocular pressure, which has been responsible for vision loss in rare reported cases [37].

## Major Adverse Effects

### *Hematomas*

Hematomas are not a common complication, but may assume alarming proportions; their appearance can be associated with impaired hemostasis, hypertensive peaks, coagulation disorders, or the use of anticoagulants such as aspirin or heparin. The presence of an expanding hematoma indicates a medical emergency due to the presence of an actively bleeding blood vessel, which can cause acute anemia and even hypovolemic shock in the patient. However, smaller and unidentified hematomas can lead to colonization and infection or even compromise the vascularization of the skin flaps, leading to ischemia and necrosis.

Good anamnesis and adequate laboratory testing can greatly reduce the possibility of bleeding and subsequent formation of hematomas by identifying coagulation problems. Suspending the use of medicines that can cause bleeding (coumarin, aspirin, nonsteroidal anti-inflammatories, heparin, and herbal medications) and preventing intraoperative hypotension are important preventive measures. Similarly, it is essential to take measures for efficient hemostasis: smaller vessels can be electrocauterized, while larger vessels should be closed with suture line. It is also very important to control nausea and vomiting in the postoperative period.

The main general treatment for hematomas is drainage. Large or expanding hematomas should be approached directly through surgical excision and removal, with hemostasis of the vessel responsible for the bleeding. Smaller and stabilized hematomas can be treated with closed drainage of the contents using a large needle or liposuction cannula, followed by compression with appropriate surgical bandaging [14].

### *Skin and Fat Necrosis*

Skin necrosis after surgery generally results from contributing factors implicated in reduced blood circulation, such as tobacco use, diabetes, and previously existing scars. In some studies, liposuction may be associated with the occurrence of skin necrosis. In abdominoplasty, blood circulation in the abdominal flap depends on the intercostal, subcostal, and lumbar vessels and may lead to risk of necrosis in the

infraumbilical and suprapubic area. In circumferential abdominoplasty, necrosis at the waistline and intergluteal sulcus may occur, but these are rare phenomena. We should respect vascular territories, utilize the concept of skin deflation, and avoid large detachments in body contouring surgeries after massive weight loss. As general prophylactic measures, we can avoid large detachments, use liposuction carefully, require at least 30 days without tobacco use, rigorously control diabetes, adopt good surgical techniques, and address large seromas and hematomas as early as possible. The best approach in skin necrosis, in our experience, is to debride the affected area with late primary sutures, whenever possible. Very large areas can be treated with skin grafts or surrounding flaps, while extremely small areas can be treated with debriding, bandaging, and secondary closure.

### *Hypothermia*

Post-bariatric plastic surgeries are often long, and patients may become hypothermic during the procedure or in the immediate postoperative period. Anesthesia may contribute to this condition, which can precipitate or aggravate coagulation disorders, causing thromboembolic phenomena or cutaneous vasoconstriction, which in turn further complicates blood intake to surgical flaps, increasing the risk of necrosis and scarring problems. Generally, a body temperature of 35 °C is the cutoff for more aggressive action to avoid complications. Whenever possible, patient temperature should be continuously monitored throughout the procedure. Prevention is combined with treatment, involving activities to warm the patient and maintain body temperature. Keeping this goal in mind, we can divide our approaches into passive warming methods, where the overall intention is to keep body temperature close to the physiologically normal level, and active methods, which are meant to effectively increase the patient's body temperature. Careful use of air conditioning in the room, blankets, heated mattresses, and heated intravenous solutions are some effective procedures in preventing and treating intraoperative hypothermia. Good communication between the surgical and anesthetic teams is fundamental to preventing this threat to the patient [19].

### *Infection*

Data in the literature show an increased rate of infections in surgical sites in post-bariatric surgery body contouring procedures compared to typical patients, suggesting a cause/effect relationship with vitamin deficiencies and the immunosuppressed state of this population. Among preventive measures, we can highlight careful disinfection and handwashing hygiene, preoperative showers with chlorhexidine gluconate, the use of disposable pens and markers, glove changes for the entire team every 90 min during surgery, bladeless trichotomy just before anesthetic induction,

Careful surgical technique, reduced hospital stay, and intravenous antibiotic prophylaxis, which should begin between 30 and 60 min before incision. Treatment should involve incision and drainage of collected fluids with a schedule of repeated bandage changes and antibiotic therapy based on culturing and antibiogram [18].

## ***Thromboembolism***

Pulmonary thromboembolism is a severe complication, greatly feared by the medical community because it represents a threat to the patient's life. Occurrence increases when related to well-defined risk factors and can affect formerly obese patients who undergo plastic surgery. Clinical diagnosis is difficult, and even imaging exams can be inconclusive, so all efforts must go toward preventing this adverse effect. The physiopathology of thromboembolism was described by Virchow as a triad: (1) stasis, (2) hypercoagulability, and (3) vascular injury. Nevertheless, an enormous set of circumstances can lead to the formation of an intravascular thrombus. Caprini's work in the early 1990s was a great contribution in this area [3]. After some reviews of risk stratification model, the most accepted by the majority of authors is based on the modified Davison-Caprini model [26].

Abdominoplasty has one of the highest rates of deep venous thrombosis (DVT) and pulmonary thromboembolism (PTE). Other significant risk factors for DVT and PTE are obesity (BMI > 30), use of hormonal birth control and hormone replacement therapy (estrogens), surgery time, age, and extremely tense plication of the aponeurosis of the rectus abdominus. Neuraxial blocks (epi-/peridural) seem to decrease the incidence of thromboembolic disease. Simple preventive measures are essential, including early ambulation and investigation of the patient's hematological history. The principal causes of hematological disorders can be related to hemophilia in men and factor V Leiden mutation (40%) and protein C and S and antithrombin III deficiency (5%) in women. The use of intermittent pneumatic compression on the lower limbs is obligatory in this type of surgery; it is recognized (in general surgery patients) that compression alone can decrease the incidence of DVT by 60%. This device must stay with the patient until discharge and can only be removed when the patient ambulates.

Chemical prevention of thromboembolism in plastic surgery based on risk factors is not a new concept, but it is an approach that has become more refined with the passage of time, especially due to the evolution in antithrombotic drugs. In 2012, the American College for Thoracic Surgery revised and published a practical, clinical, evidence-based guide to antithrombotic therapy and thromboembolism prevention. This guide recommends the use of intermittent mechanical compression *or* low molecular weight heparin for moderate-risk patients (Caprini score 3–4) and intermittent compression *and* low molecular weight heparin for high-risk patients (Caprini score > 5); mechanical compression instead of low molecular weight heparin is reserved only for patients with a recognizably high risk of bleeding [21]. Nevertheless, many issues are still the object of analysis and study with regard to chemical prophylaxis for thromboembolism, especially with relation to the possibility of bleeding and

formation of hematomas. Some central issues involving DVT chemical prophylaxis are when it should begin, when it should be used, and when it should be stopped.

A number of studies associate the use of heparin with increased incidence of bleeding and hematomas, although other recent studies have demonstrated that if an application routine is followed, the incidence of adverse events related to prophylaxis does not change [26, 27]. To date, there is no absolute consensus related to the prevention, diagnosis, and treatment of thromboembolism in plastic surgery, a fact which demands new and ongoing evidence-based medical studies.

## Discussion

Body contouring surgery has experienced a true resurgence with the popularization of surgical treatment for morbid obesity. In recent years, a new and growing population of patients with extremely challenging deformities has been visiting plastic surgery clinics, demanding a new approach to techniques in search of better results. Some procedures that had been practically abandoned with the advent of liposuction are now returning because of the devastating nature of these deformities. Suggestions by authors from the last century such as Somalo [38] and Gonzalez-Ulloa [20] have regained relevance and become even better known. Techniques published decades ago by pioneers in our field such as Professors Ivo Pitanguy [29–32] and Ricardo Baroudi [10–12] are regaining importance and guiding the evolution of new and necessary approaches. We are, after all, living in a historical period of readaptation, where the current generation of plastic surgeons is writing another important chapter in plastic surgery.

In this context, the main concept to be incorporated by plastic surgeons in abdominal approaches to post-bariatric patients is to avoid isolated evaluation and intervention in the abdomen without considering associated deformities in the lower body. Each patient has a different reality and even specific genetic characteristics, but the general and circumferential character of the physiopathology and biodynamic deformities will always influence body contouring as a whole. Even when isolated intervention is chosen by the medical team, this decision must result from full knowledge of the overall contouring situation. Preoperative planning is fundamental in this process and must be based on the complete physical exam, with vigorous palpation of tissues and simulation of probable correction vectors as well as the patient's opinion. All of this careful surgical planning becomes evident in surgical site marking, which should be done carefully and calmly, preferably the night before surgery to avoid stress and mistakes resulting from marking in the operating room before anesthesia. Photographic and video records of both the physical examination and site marking provide essential support for retrospective assessments of the results obtained. Preliminary procedures should also include laboratorial and clinical assessments specifically aimed at identifying pitfalls related to nutritional deficits and psychological disorders, which could significantly compromise the expected results [33].

Some details of the surgical technique may also make the difference in caring for this type of patient. Although tissue resection can be extensive in the lower body, there is no need for larger detachments of remaining flaps. This means that the mobility of the covering resulting from the reorganization of the superficial fascia system permits large tissue advances, when correction vectors are found, safely and with circulatory viability. This abdominal approach without detachment was originally proposed by Avelar [7, 8] and is naturally applicable in the post-bariatric patient since weight loss provokes the reduction of subcutaneous tissue and makes flap mobilization easier, with less risky maneuvers. If the superficial fascia system is incompetent because of the disproportionate content/continent ratio found in the tegument of the formerly obese patient, this subcutaneous ligament structure can still (and must) be used to repair this condition. Initial studies by Lockwood [22, 23] proposed using the SFS as anchors for tissue suspension, even before the popularization of bariatric surgeries and large increase of deformities resulting from massive weight loss. More recently, the Pittsburgh group [40] proved the viability and efficacy of using this tridimensional mesh of collagen to guarantee anchoring for sutures in the dermoadipose flaps, which generally proceed under great tension. In this way, the flaps should be approached on three planes, with an effectively deeper approach to the SFS using nonabsorbable sutures, releasing more superficial layers from excessive tension. Another critical factor in these large surgical resections is the ability to initially cut only one edge of the preoperative marking, normally the one on the more fixed region with less translational mobility of the skin, and only make the incision on the other marked edge after detaching the area to be resected and confirming that it will be possible to close the wound well and evenly. Although some very experienced surgeons can successfully perform all the incisions and detachments at the same time without needing to confirm the complete migration of the flaps, we strongly advise against this approach, especially for surgeons who are just beginning with this procedure, in order to avoid difficulties in closing the wounds due to exaggerated resections or even residual laxity resulting from insufficient resections.

The role of liposuction in body contouring after bariatric surgery is still a somewhat controversial issue. Some surgeons consider the technique as a direct, simultaneous coadjuvant during resections, while others prefer separate procedures for safety reasons. It is important to remember that a patient who has lost large amounts of weight can still present areas where fat has been incompletely reduced, where liposuction may be useful, never as a single approach, but as a complementary one. In this sense, there are two approaches: auxiliary liposuction of areas that will be effectively resected and liposuction of areas that will only be mobilized after the respective resections. These are different situations in which good sense should guide strategy; in other words, small- and medium-sized interventions in well-located areas can be associated with tissue resections, while larger approaches in areas with large quantities of fat to be aspirated should be scheduled at different times. The medical literature does not yet have statistical and evidence-based studies that can clarify this relationship. Therefore, in each case potential compromisation of the body after liposuction incorporated into the surgical timetable must be



considered to reduce the risk of local and systemic complications resulting from this association.

Without assuming it completely covers the subject, this chapter attempts to reveal the peculiarities of lower body contouring in patients after massive weight loss, emphasizing the new standard approach needed to face the dramatic and generalized aspect of the deformities presented. Great care should be taken in planning and executing treatment to enhance results and reduce complications.

## References

1. Agha Mohammadi S, Hurwitz DJ (2008) Potential impacts of nutritional deficiency of post-bariatric patients on body contouring surgery. *Plast Reconstr Surg* 122:1901–1914
2. Albino FP, Koltz PF, Gusenoff JA (2009) A comparative analysis and systematic review of the wound-healing milieu: implications for body contouring after massive weight loss. *Plast Reconstr Surg* 124:1675
3. Arcelus JI, Candocia S, Traverso CI, Fabrega F, Caprini JA, Hasty JH (1991) Venous thromboembolism prophylaxis and risk assessment in medical patients. *Semin Thromb Hemost* 17(Suppl 3):313–318
4. Aly AS (2006) Belt lipectomy. In: Aly AS (ed) *Body contouring after massive weight loss*. Quality Medical, St Louis, pp 71–145
5. Andrades P, Prado A, Danilla S et al (2007) Progressive tension sutures in the prevention of postabdominoplasty seroma: a prospective randomized, double-blind clinical trial. *Plast Reconstr Surg* 120:935–946; discussion 947–951
6. Avelar J (1989) Regional distribution and behaviour of the subcutaneous tissue concerning selection and indication for liposuction. *Aesthetic Plast Surg* 13:155
7. Avelar J (1999) A new technique for abdominoplasty – closed vascular system of subdermal flap folded over itself combined with liposuction. *Rev Bras Cir* 88/89(1/6):3–20
8. Avelar J (2002) Abdominoplasty without panniculus undermining and resection: analysis and 3-year follow-up of 97 consecutive cases. *Aesthet Surg J* 22(1):16–25
9. Au K et al (2008) Correlation of complications of body contouring surgery with increasing body mass index. *Aesthet Surg J* 28:425–429
10. Baroudi R et al (1974) Abdominoplasty. *Plast Reconstr Surg* 54(2):161–168
11. Baroudi R (1978) Thigh lift and buttocks-lift. In: Courtiss EH (ed) *Aesthetic surgery*. Mosby, St Louis, p 233
12. Baroudi R (1984) Body sculpting. *Clin Plast Surg* 11(3):119–143
13. Baroudi R, Ferreira C (1998) Seroma: how to avoid it and how to treat it. *Aesthet Surg J* 18:439–441
14. Blinder MA, Young VL (2009) Approach to venous thromboembolism and bleeding. In: Young VL, Botney R (eds) *Patient safety in plastic surgery*. QMP, St. Louis, pp 279–310
15. Coon D et al (2009) Body mass and surgical complications in the postbariatric reconstructive patient: analysis of 511 cases. *Ann Surg* 249(3):397–401
16. Colwell AS, Borud JL (2008) Optimization of patient safety in postbariatric body contouring: a current review. *Aesthet Surg J* 28:437–442
17. Consensus Panel (2006) Safety considerations and avoiding complications in the massive weight loss patient. *Plast Reconstr Surg* 117(1):74S–81S
18. Davinson SP, Clemens MW (2008) Safety first: precautions for the massive weight loss patient. *Clin Plast Surg* 35:173–183
19. Forstot RM (1995) The etiology and management of inadvertent perioperative hypothermia. *J Clin Anesth* 7:657–674

20. Gonzalez-Ulloa M (1960) Belt lipectomy. *Br J Plast Surg* 13:179
21. Guyatt GH, Aki EA, Crowther M et al (2012) Antithrombotic therapy and prevention of thrombosis: American College of Chest Physicians evidence-based clinical practice guidelines (9<sup>th</sup> Edition). *Chest* 141(Suppl 2):7S–47S
22. Lockwood TE (1991) Superficial fascial system (SFS) of the trunk and extremities: a new concept. *Plast Reconstr Surg* 87:1009–1018
23. Lockwood TE (1993) Lower body lift with superficial fascial suspension. *Plast Reconstr Surg* 92:1112–1122
24. Markman B, Barton F Jr (1980) Anatomy of the subcutaneous tissue of the trunk and lower extremities. *Plast Reconstr Surg* 80:248
25. Modolin M et al (2003) Circumferential abdominoplasty for sequential treatment after morbid obesity. *Obes Surg* 13:95–100
26. Pannucci CJ, Barta RJ, Portschy PR et al (2012) Assessment of postoperative venous thromboembolism risk in plastic surgery patients using the 2005 and 2010 Caprini Risk Score. *Plast Reconstr Surg* 130:343–351
27. Pannucci CJ, Watchman CF, Dreszer M et al (2012) The effect of postoperative enoxaparin on risk for reoperative hematoma. *Plast Reconstr Surg* 129:160–168
28. Pinho PR et al (2011) Psychological approach for post-bariatric plastic surgery. *Rev Bras Cir Plast* 26(4):685–690
29. Pitanguy I (1967) Abdominal lipectomy: an approach to it through an analysis of 300 consecutive cases. *Plast Reconstr Surg* 40(4):384–391
30. Pitanguy I (1972) Thigh lift and abdominal lipectomy. In: Goldwyn RM (ed) *Unfavorable results in plastic surgery*. Little Brown, Boston, p 387
31. Pitanguy I (1975) Abdominal lipectomy. *Clin Plast Surg* 2:401–410
32. Pitanguy I (1977) Dermolipectomy of the abdominal wall, thighs, buttocks and upper extremity. In: Converse JM (ed) *Reconstructive plastic surgery*, vol 7, 2nd edn. Saunders, Philadelphia, pp 3800–3823
33. Pitanguy I et al (2000) Contour surgery in the patient with great weight loss. *Aesthetic Plast Surg* 24(6):406–411
34. Reason JT (1990) *Human error*. Cambridge University Press, New York
35. Shermak MA (2012) Pearls and perils of caring for post bariatric body contouring patient. *Plast Reconstr Surg* 130:585–596
36. Shermak MA, Rotellini-Coltvet LA, Chang D (2008) Seroma development following body contouring surgery for massive weight loss: patient risk factors and treatment strategies. *Plast Reconstr Surg* 122:280
37. Shermak M, Shoo B, Deune EG (2006) Prone positioning precautions in plastic surgery. *Plast Reconstr Surg* 117:1584–1588; discussion 1589
38. Somalo M (1940) Dermolipectomia circular del tronco. *Sem Med* 47:1435–1443
39. Song AY et al (2005) A classification of weight loss deformities: the Pittsburgh rating scale. *Plast Reconstr Surg* 116:1535–1554
40. Song AY et al (2006) Biomechanical properties of the superficial fascial system. *Aesthet Surg J* 26(4):395–403
41. Wolf AM, Beisiegel U (2007) The effect of loss of excess weight on the metabolic risk factors after bariatric surgery in morbidly and super-obese patients. *Obes Surg* 17:910–919

# Chapter 24

## Silicon Breast Implant Inclusions Through Abdominal Approach

Helio Paoliello Jr and Ricardo Paoliello

### Introduction

The silicon breast implant inclusions through abdominal approach technique [5, 8, 9] offers, in selected patients, brilliant results on breast augmentation associated with abdominoplasty, without significantly prolonged surgical time [4]. With the evolution of the technique and the advent of liposuction [6] and higher-quality breast implants, especially regarding to texture, the proposed technique is easily performed and with fewer complications.

Carefully selected patients have a high level of satisfaction, which allows me to recommend it when indicated.

In 1982, during the III Jornada Paulista de Cirurgia Estética, at Campos do Jordão, São Paulo, organized by the illustrious colleague Dr Juarez M. Avelar, I first presented the results in plenary.

During the debate, it was said that “in longilineal people, it would be more difficult to insert the implants.” However, as time has gone by, I persisted with this conduct and today I can assure that the access to the mammary pockets when the dissection plane is ideal refutes this observation.

The abdominoplasty without undermining, idealized by Avelar [1, 2], brought a new and challenging moment to breast implant inclusions through the abdominal approach, which was doable, since some technical principles are obeyed.

The use of larger caliber cannulas unplugged from the liposuctioner and specific defractors makes the preparation of the tunnels easy. Saldanha’s lipoabdominoplasty [10] also enables silicon breast implant inclusion through abdominal

---

H. Paoliello Jr, MD (✉) • R. Paoliello, MD  
Plastic Surgery Discipline, Faculdade de Medicina de Marília (FAMEMA),  
Marília, SP, Brazil  
e-mail: [heliopaoliellojr@yahoo.com.br](mailto:heliopaoliellojr@yahoo.com.br); [drricardopaoliello@gmail.com](mailto:drricardopaoliello@gmail.com);  
[clinicapaoliello@gmail.com](mailto:clinicapaoliello@gmail.com); <http://www.clinicapaoliello.com>

approach, regarding attention to the preparation of the submammary tunnels in order to avoid unnecessary blood vessel lesions. At first, smooth silicon implants were used, being replaced by the textured ones in their advent. All patients received round high-profile implants; nowadays Ultrahigh Profile (UHP) is used.

UHP breast implants over 300 cc may, when the surgeon does not have enough technical training, offer some difficulty in the preparation of the submammary pockets; anyway there is no contraindication in using larger volume implants.

The adopted criteria to select patients were based on biotype, breast ptosis level, habits (smoking, medicines in use, etc.), and comorbidities.

Concerning the classification of the abdomen type, the indication of the technique, classical, Avelar's, or Saldanha's, must the principles that guide each one be followed [1, 2, 7–10]. Biotype does not interfere with technique. Only breasts with small degree of ptosis are submitted to surgery. Smokers that cannot withdraw the addiction, at least one week before the procedure, are dismissed, due to a higher risk of undermined abdominal tissue necrosis. Body mass index (BMI) between 20 and 25 is required, due to health standards and, in selected cases, some overweight patients between 26 and 28 without esthetic and anatomic deformities (corporal dimorphism). Medicines that interfere with blood coagulation (platelet adhesion inhibitors, birth control pills, etc.) were studied and, when necessary, discontinued or had their dosages adjusted. This surgery should not be performed in patients with diabetes or high blood pressure without proper control and correct use of medications; patients with coagulopathies that contraindicate elective surgery should not undergo surgery. All patients underwent noninvasive imaging examination (ultrasonography, mammography) aiming to exclude breast and abdominal pathologies. Exceptionally, CAT scan is required.

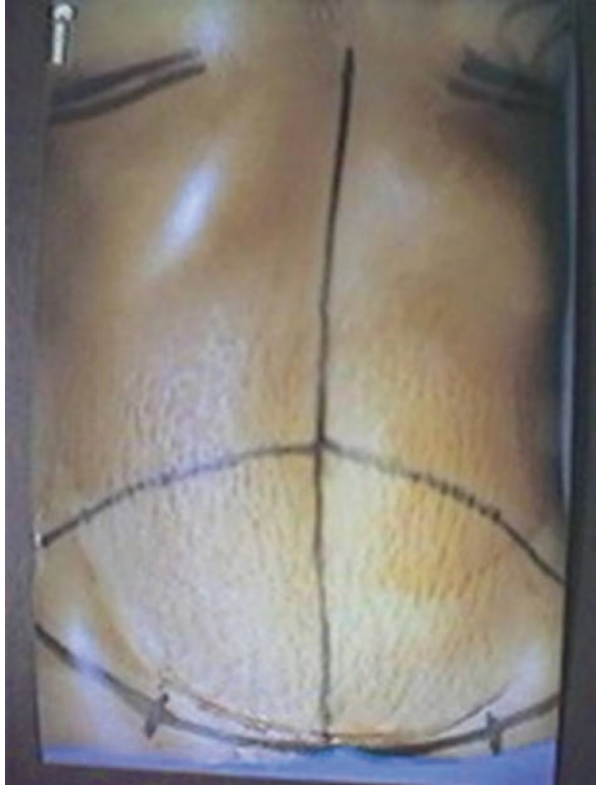## Technique

Silicon breast implants are placed subglandular, due its undermining facility and lower unexpected bleeding risk. Wallach [11] also proposed the submuscular and dual plane through abdominal approach.

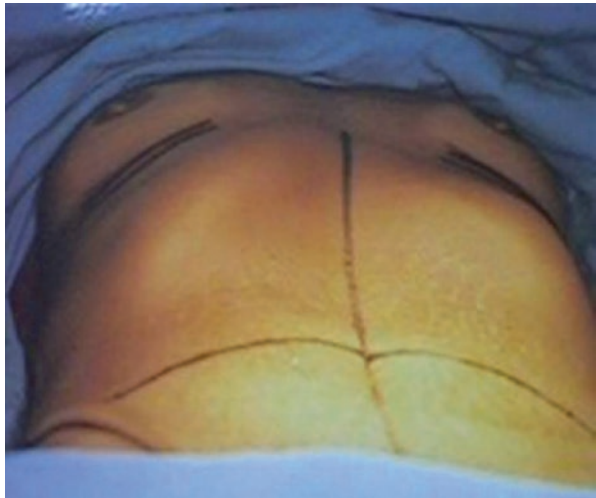The classical abdominoplasty is the most commonly performed surgery, also performing plication of the rectus abdominis using nonabsorbable polypropylene 0.0.

The access tunnel to the breasts is the same suprafascial plane using blunt scissors until the subglandular area, when blunt dissection using the fingers is performed. The width of the tunnel is equivalent to the implant size and surgeon's hand width, allowing a correct implant pocket size and implant allocation (Figs. 24.1 and 24.2). If smooth breast implants are chosen, one or two stitches using 2.0 absorbable sutures in the submammary tunnel, to fix the deep plane into the muscular fascia, avoiding implant sliding, are required. This maneuver is not always necessary when using textured implants, due to its roughness. The use of a bra after the surgery sets the inframammary fold in place again. Dini [4] always advocates the deep stitches to set the inframammary folds, but we believe that those are not necessary to set them in place, and when those stitches are performed asymmetrically, they may yet

**Fig. 24.1** Markings, front view supine (markings in the base of the breasts include the submammary fold in both standing and sitting positions)

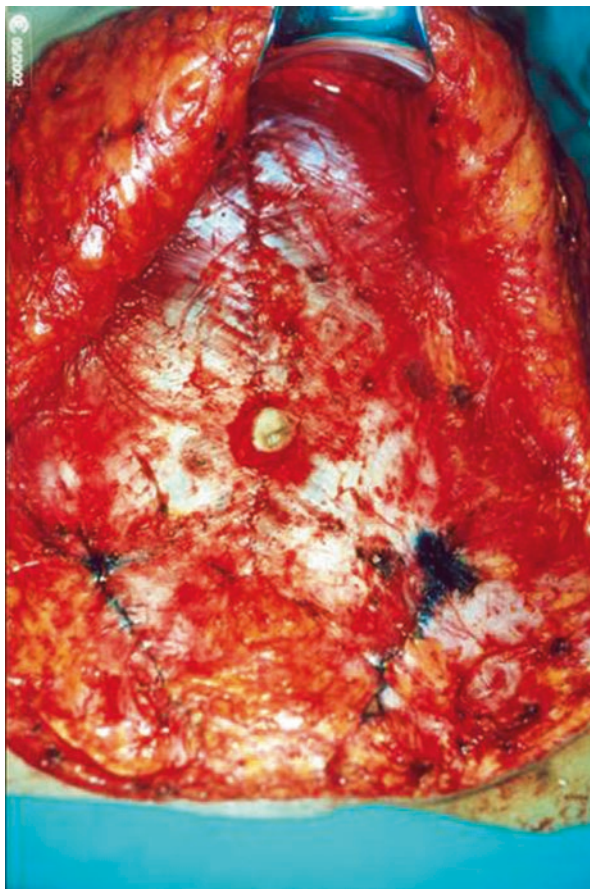

**Fig. 24.2** Supine podocephalic view of the markings



cause asymmetry of the folds, in supine position alter surgery. If chosen, to perform those stitches, the operating table must be set in a semi-Fowler's position to check the symmetry of the stitches with the inframammary fold. When using Avelar's

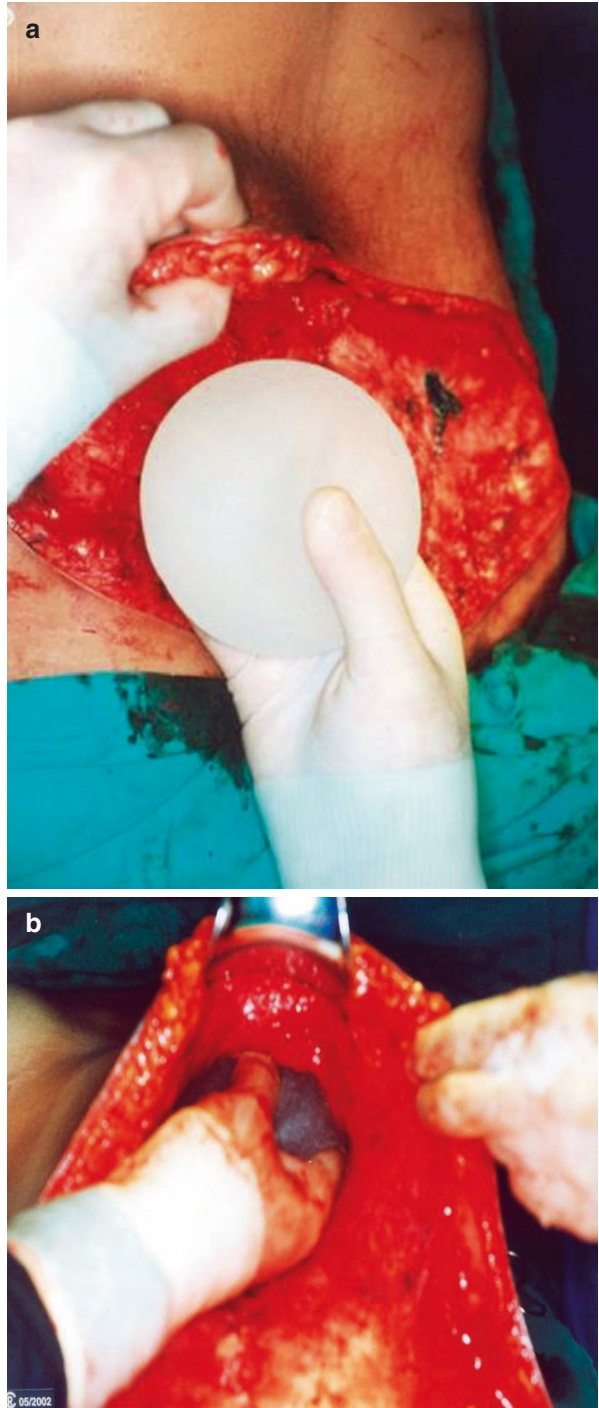
**Fig. 24.3** Undermined abdomen, plication of the rectus abdominis, and oblique muscles



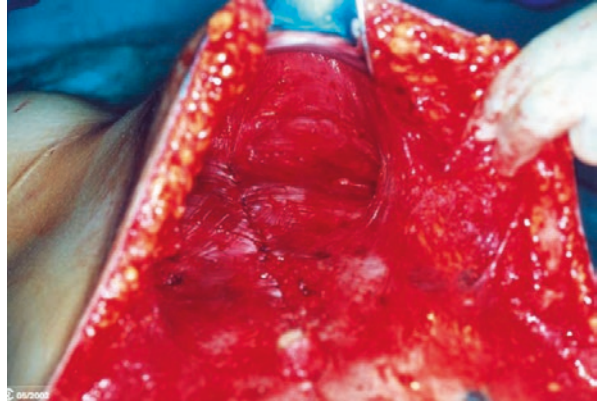
technique, the tunnels will be longer, although undermined using blunt 6 mm canulas, unplugged from the liposuctioner followed by the defractors. The maneuver to ease the subglandular pocket preparation consists of a pinch traction of the areolopapilla complex presenting a safer and easier dissection plane. The undermining should be carefully done, avoiding undesirable bleeding from tearing the pectoralis major muscle. In case of bleeding, in one or both pockets, even after the placement of sterile surgical towels embedded in saline with epinephrine (saline 500 ml, epinephrine 1:1000) for 10 min, video endoscopy is required. In the absence of such resource, submammary or periareolar incisions must be performed to stop the bleeding. Dressing with modeling elastic belts of mild compression kept the implants in site. The use of vacuum drains placed distal to the thoracoabdominal tunnels enables the identification of bleeding that, if insignificant, discard approach. Those drains are removed 24–48 h after surgery, avoiding the patient to take it home (Figs. 24.3, 24.4, and 24.5).

Patients must be kept in Fowler's position when classical abdominoplasty, and with a mold torso elevation (30°) when undergone Avelar's or Saldanha's. Usage of

**Fig. 24.4** (a, b) Breast implant placement



**Fig. 24.5** Tunnel closed; in this patient, 2.0 absorbable stitches were placed



progressive elastic stockings and early ambulation are recommended after surgery. When necessary, the usage of low molecular weight heparin is associated. Usage of IV antibiotics, 2 g cephalothin sodium 30 min before surgery and 1 g after 4 h, followed by 1 g oral cephalexin every 6 h after surgery while at hospital is recommended. Patient can be released from the hospital 24–48 h after procedure with analgesics and cefadroxil 500 mg every 12 h during 10 days, as a surgeon choice.

The anesthesia, general or epidural with IV sedation, is a patient/anesthetist indication, decided at the preanesthesia evaluation.

## Complications

Classified as immediate, mediate, and late.

Immediate: hemorrhage inside the implant pocket. Mediate: implant slide, seroma, infections, and asymmetry. Late: keloids, hypertrophic scars, belly button deformation, rippling, and capsular contracture

The most common complications related with this kind of surgery like hematoma, infections, seroma, dehiscence, and cutaneous flap suffering can and must be avoided by paying close attention to the operatory technique, surgical timing, careful maneuver of the abdominal flap, hemostasis, and antisepsis.

When performing hemostasis, a systolic blood pressure above the patient's usual pressure is asked to the anesthetist, so any bleeding can be easily identified and an effective hemostasis is made.

Even without reports of visceral perforations during liposuction with abdominoplasty and breast implants, those perforations that may happen [12] need immediate



confirmation and a quick surgical intervention to decrease the sequelae that, when ignored, may lead to death. Capsular contracture of the implants in several degrees may happen, especially with smooth implants.

In all patients, the final shape of the scar was horizontal (Figs. 24.8, 24.9, and 24.10); seroma, when present in variable volumes, is punctured through transcutaneous approach.

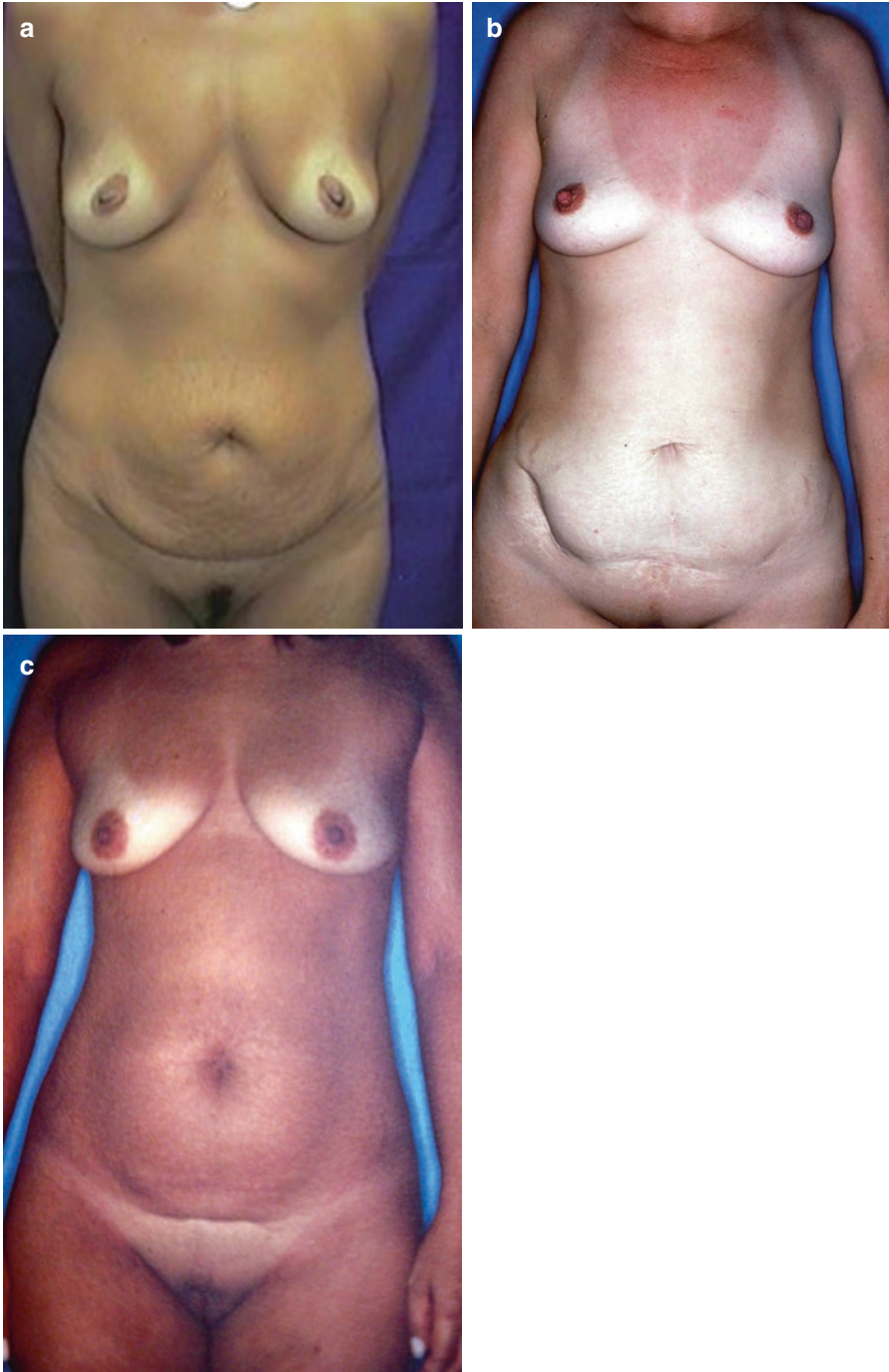Small areas of epidermis suffering (epidermolysis) may occur and heal without surgical interventions. If infraumbilical necrosis occurs (triangular necrosis of the abdominal wall), delimitation of the necrotic area must be patiently observed and a careful debridement must be done without removing healthy tissues; closure by first or second intention must be done considering the patient's level of anxiety. The surgeon must not haste to fix such complication, since a good relationship with the patient, explanations and demonstrations of similar cases with reasonable results can be shown, decreasing both surgeon and patient's emotional wear. As to the umbilical scar, dimorphism will be fixed following the primarily used technique. Scars and its deviations dismiss discussion, since their treatments and results are broadly known.

Rippling and capsular contractures that need intervention should be accessed through submammary incision, since it is easier to perform, and the implants must be placed in submuscular plane, or subglandular plane if chosen, after capsule incisions or removal.

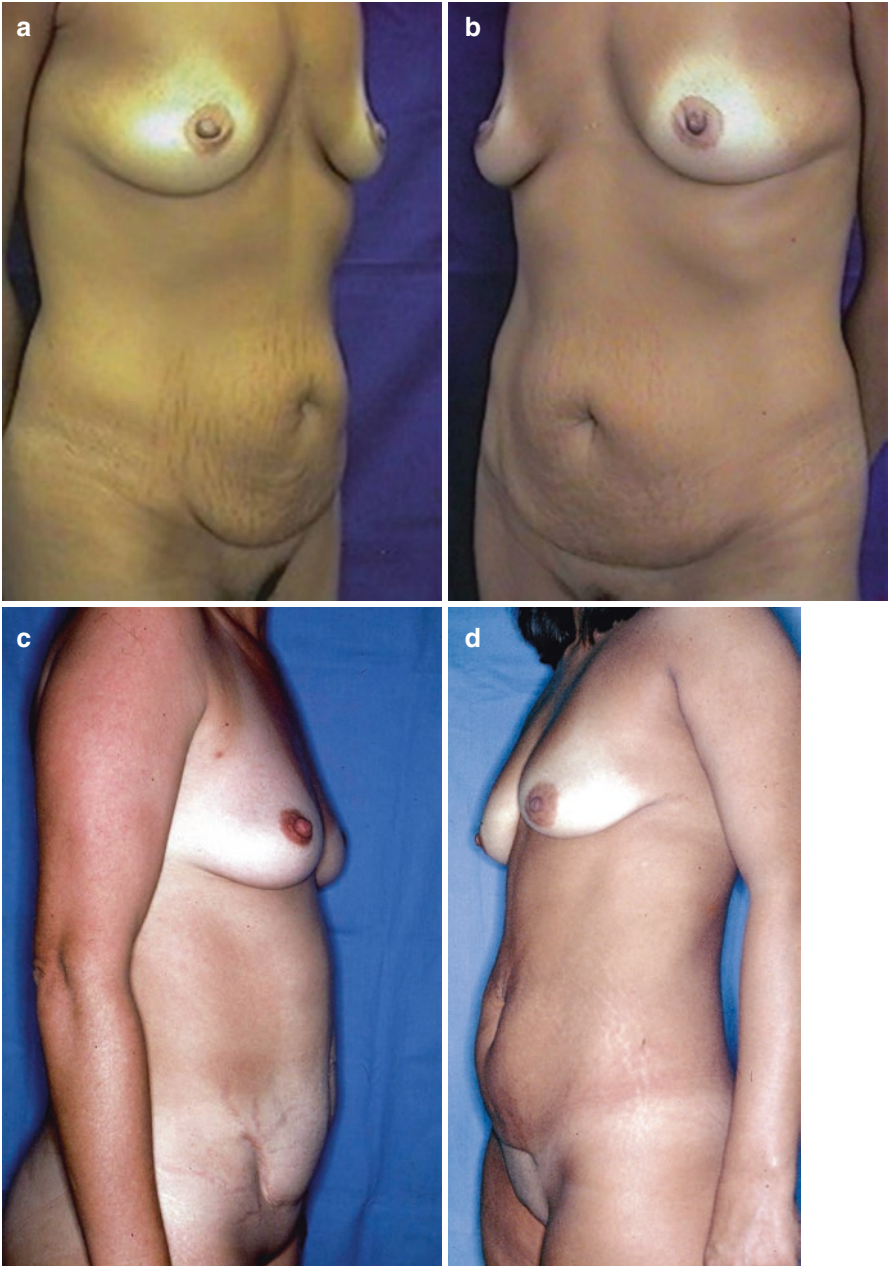
## Discussion

Due to the narrow indication of this silicon breast implant technique associated to conventional abdominoplasty or Avelar's technique, even today, there are only few surgeons willing to perform it. The results and satisfaction of the patient can and must be analyzed under two ways: the breasts and the abdomen. Patients show a high level of satisfaction concerning the breasts, since there are no scars; the same cannot be told about the abdomen. Scars are, undoubtedly, the higher obstacle, which continues to narrow the indications of this silicon breast implant technique, even with short scars and small undermining techniques published that make the access to breasts more difficult.

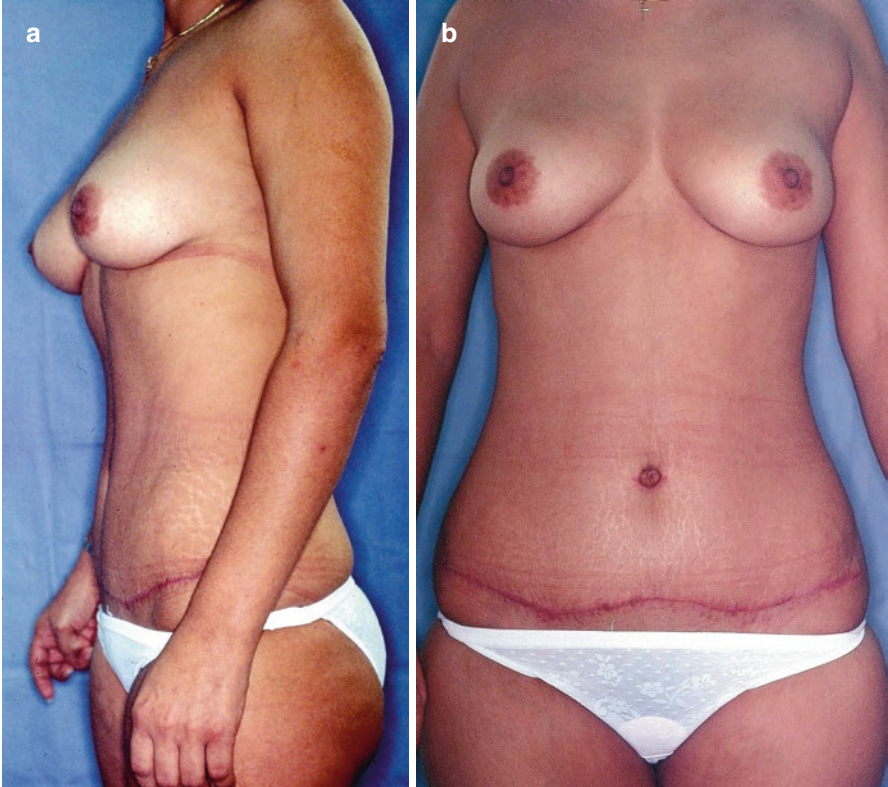
Breasts with lower degrees of ptosis show better results, due to the more gracious aspect and better projection of the superior pole. Increasing the volume of breast implants to lift breasts with higher degrees of ptosis is not always achieved, since the shape of breasts will not change, making the results unsatisfactory (Figs. 24.6, 24.7, 24.8, 24.9, and 24.10).



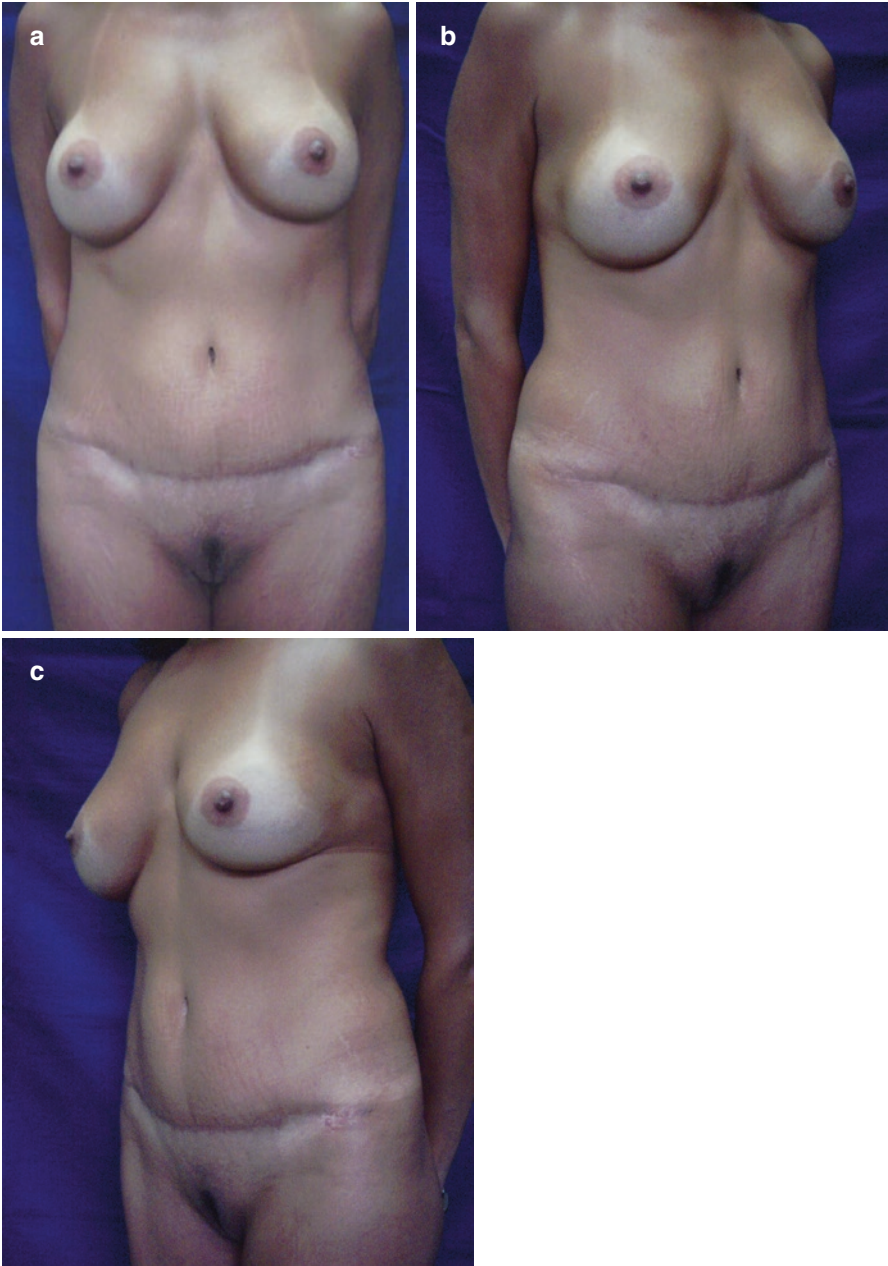**Fig. 24.6** (a) (Patient A), (b) (patient B) and (c) (patient C): before surgery, front view



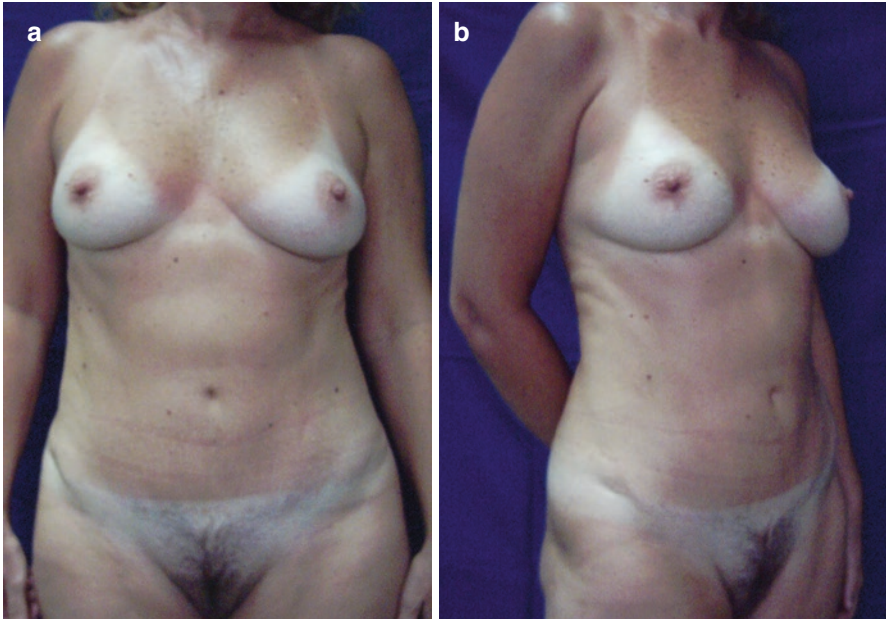
**Fig. 24.7** (a, b) (Patient A), (c) (patient B), (d) (patient C): before surgery, half-sided right view, half-sided left view, right-sided view, and left-sided view



**Fig. 24.8** (Patient C): 6 months after surgery, (a) left-sided view and (b) front view



**Fig. 24.9** (Patient A): 12 months after surgery, residual edema. (a) Front view, (b) half-sided right view, and (c) half-sided left view



**Fig. 24.10** (Patient B): post-op 18 years, (a) front view and (b) half-sided right view

## Conclusion

Considering the achieved results, lower rates of complications, and a relative low learning curve, this surgery, when properly indicated, presented itself as a good choice, adding another option to breast augmentation techniques.

The silicon breast implant inclusions through abdominal approach, since first publications by Planas, Ribeiro, and Henderer [5, 8, 9], have been the subject of discussion and created a variety of opinions among plastic surgeons. If some have those publications as ideal when the patient presents abdominal laxity, especially after pregnancy and atrophic breasts with or without mild ptosis, others argue that the technical difficulty does not justify the absence of a scar in the breasts inframammary fold. In this chapter, we discuss the original techniques and their evolution to abdominal surgery by new technique and inclusions through abdominal approach. It's up to the reader to choose his or her option, always basing on criterion indications.

## References

1. Avelar JM (2000) Abdominoplastia: uma nova técnica sem descolamento e sem ressecção do panículo abdominal. *Arq Catarin Med* 29(1):147–149
2. Avelar JM (2002) Abdominoplasty without panniculus undermining and resection: analysis and 3-year follow-up of 97 consecutive cases. *Aesthet Surg J* 22(1):16–25

3. Bozola AR, Psillakis JM (1988) Abdominoplasty: a new concept and classification for treatment. *Plast Reconstr Surg* 82:983–993
4. Dini GM, Jean M, Gianini L, Oliveira MF, Santos Filho IDAO, Iurk LK, Ferreira LM (2013) Aumento mamário por meio da incisão da abdominoplastia: estudo prospectivo de 100 casos. *Rev Bras Cir Plast* 28(1):105–113
5. Hinderer UT (1975) The dermolipectomy approach for augmentation mammoplasty. *Clin Plast Surg* 2(3):359–369
6. Illouz YG (1980) Une nouvelle technique pour les lipodystrophies localisées. *Rev Chir Esthet* 4:19
7. Paoliello HR Jr (2006) Inclusão mamária por via abdominal. Robe Editorial. In *Atualização em Cirurgia Plástica Estética e Reconstructiva*; Livraria e Editora Santa Isabel, São Paulo, pp 703–706
8. Planas J (1976) Introduction of breast implants through the abdominal route. *Plast Reconstr Surg* 57(4):434–437
9. Ribeiro L (1974) Inclusao de protesis de Cronin por via areolar e abdominal. *Transact. Annals of the II Congreso Argentino de Cirurgia Estética*. Buenos Aires, p 64
10. Saldanha OR, Federico R, Daher PF, Malheiros AA, Carneiro PR, Azevedo SF et al (2009) Lipoabdominoplasty. *Plast Reconstr Surg* 124(3):934–942
11. Wallach SG (2004) Transabdominoplasty breast augmentation. *Aesthet Surg J* 24(4):373–378
12. Zakine Z, Baruch J, Dardour JC, Flageul G (2015) Perforation of viscera, a dramatic complication of liposuction: a review of 19 cases evaluated by experts in France between 2000 and 2012. *Plast Reconstr Surg* 135(3):743–750

# Chapter 25

## Post-Bariatric Abdominoplasty

Paulo Kharmandayan, Marco Antonio de Camargo Bueno,  
and Jorge M. Psillakis

### Introduction

Although obese individuals have been considered the ones with the greatest chances of survival through natural selection, considering the extreme conditions in the beginning of humanity, obesity is now considered a disorder which is endemic across the world. Obesity-related conditions generate extremely high costs.

Obesity has become a syndrome that generates other conditions, as the human species is not subjected to high caloric expenditure activities and has increasingly adopted more sedentary habits. Consequently, great discrepancy has arisen between calorie intake and energy expenditure. In view of that, bariatric surgical techniques have been developed, with procedures involving stomach and intestine surgery in the attempt of restraining the damage and to promote weight loss. In this way, bariatric procedures allow *ex-obese* individuals an improvement in quality of life with the decrease in the number of comorbidities.

Individuals who undergo these procedures are faced with hanging excess soft tissue, especially of the abdominal wall. They begin to feel the need for a better

---

P. Kharmandayan, MD, PhD

Members of the Brazilian Society of Plastic Surgery, Department of Surgery, Division of Plastic and Reconstructive Surgery, School of Medical Sciences-UNICAMP, University of Campinas, Rua Apeninos, 429, room 709, São Paulo, SP 01533-000, Brazil  
e-mail: [pkharmand@gmail.com](mailto:pkharmand@gmail.com)

M.A. de Camargo Bueno, MD

Member of the Brazilian Society of Plastic Surgery, Plastic Surgeon, Staff Unicamp University Hospital, São Paulo, Brazil

J.M. Psillakis, MD

Members of the Brazilian Society of Plastic Surgery, Department of Plastic Surgery, Hospital “Alemão Oswaldo Cruz”, Av. Vereador José Diniz, 3457, Campo Belo, São Paulo 04616-003, Brazil  
e-mail: [jpsillos@gmail.com](mailto:jpsillos@gmail.com)

© Springer International Publishing Switzerland 2016

J.M. Avelar (ed.), *New Concepts on Abdominoplasty and Further Applications*,  
DOI 10.1007/978-3-319-27851-3\_25



appearance so as to feel better and consequently seek plastic surgery as a solution.

In general, *these patients* are most uncomfortable with the increase of sagging abdominal tissue, which can often limit their everyday activities. Therefore, a procedure in the abdominal area is the prime surgical act at this point.

A virtually new plastic surgery subspecialty was created: post-bariatric reconstructive surgery or massive weight loss surgery.

It should be taken into consideration that there are specific procedures in the whole body segment, with their peculiarities: apart from the weight loss, and with their comorbidities under control, *people with massive weight loss* are still risk patients, since all the changes produced by poor absorption in the reduced stomach have not yet been determined. *For this reason*, the surgeon must pay attention to the body changes and the risks they bring. A number of studies have been conducted on the organization of these modified adipose tissues after weight loss; often, the adipocyte layout observed is different from that of the normal tissue. Another important change that should be considered is the diameter of blood vessels, which, after bariatric surgery, will still keep their previous form.

Aspirations to ideal beauty standards should be thoroughly explained, so that the patient becomes aware that the surgery aims to improve body contour, but leaves permanent scars. Many patients may present psychological issues, and, due to the anxiety of improving their body contours, they may want surgery right away. It is due to the surgeon to determine the appropriate time for the procedure, as weight loss generally stabilizes 18 months after bariatric surgery.

Such changes should be addressed by a multidisciplinary team – plastic surgeon, general practitioner, endocrinologist, psychologist/psychiatrist, dietitian, physical therapist, and nurse – so that the patient can benefit from each area.

Even in their practices, surgeons are encouraged to have their own support group so as to plan the procedures well and so that the patients are well informed.

## Technique

### *Preoperative Care and Exams*

Routine blood testing before abdominoplasty surgeries after massive weight loss includes blood count, coagulation studies, blood typing, urea, total CK, glucose, total protein, and liver function tests.

Imaging tests such as abdominal echograms should be carried out for many of these patients who develop gallstones after undergoing bariatric surgery. Furthermore, it is necessary to visualize the abdominal wall, considering that on post-gastroplasty scars, small hernias may be found, which are not detectable during clinical exams and are often found during the intraoperative period. Supplementary X-rays and CT scans will be requested depending on preexisting comorbidities, with special attention to smokers, who may need pulmonary physical therapy before the procedure.

Preanesthetic, cardiac, and lung function assessments are routine and very useful.

## ***Surgical Planning***

The preferred technique for *post-bariatric abdominoplasty* in patients with excessive fatty skin tissue is the anchor or inverted T incision. This is true for patients with small post-laparoscopy scars as well as for those bearing large scars along the median epigastric line as a result from open surgery.

This approach allows for good results for body contour, because it makes possible the one-block removal of skin fatty tissue from the anterolateral portions of the abdomen, which would not be properly approached through the transversal abdominoplasty, with craniocaudal flap traction. It also facilitates the exposure of the aponeurotic muscles in the abdominal wall in its central portion, making it easier to correct hernias that may exist, as well as the plication of the rectus abdominis muscles (diastasis).

A *one-block* resection is performed, without detaching the lateral fat tissue from the aponeurosis. In certain situations, complementary liposuction can be performed simultaneously in the lumbar lateral portions, using the concepts described by Avelar [1].

## **The Umbilical Scar**

Most surgeons preserve the umbilical scar. However, in this kind of patient, it has long stalk, usually deformed by obesity, often leading to postsurgical complications. This is due to the difficulty in fixating it to the aponeurosis of the *rectus abdominis* muscles, from sutures dehiscence, tissue necrosis, and postoperative stenosis, producing unpleasant aesthetic results, which will motivate complaints from patients in the late postoperative period.

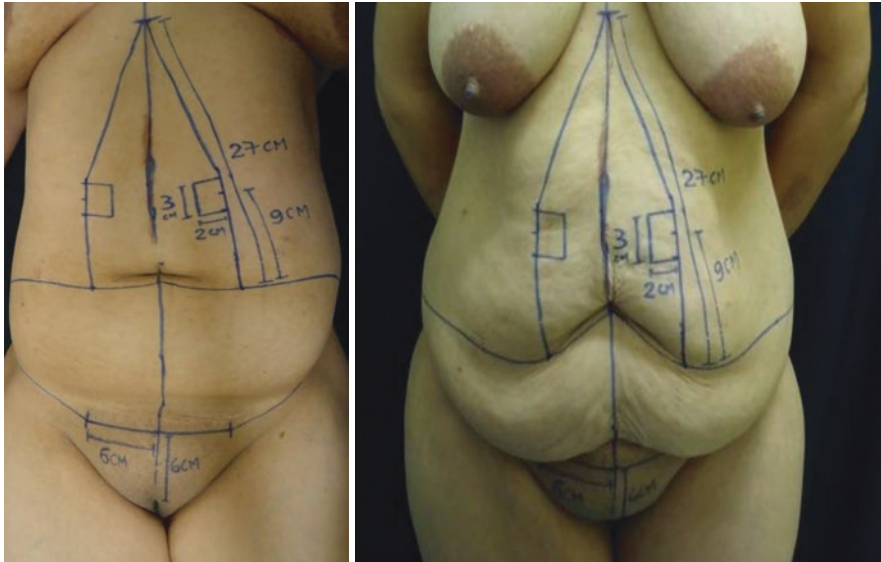
Many techniques have been proposed for umbilical reconstruction or neoumbilicoplasty. We chose total amputation of the umbilical scar at the same time with the one-block removal of the abdominal tissue, closing the stump at the aponeurosis.

To reconstruct the new navel, when we do the first incision for tissue resection, we prepare two small square fatty skin flaps, one on each side, pedicled at the flap margin. In our hands this technique produced a better aesthetic result, with less scar, for it is in continuity with the vertical xiphoid-pubic scar (Fig. 25.1).

## ***The External Oblique Muscular Aponeurotic Flap Approach***

Psillakis [2] in 1984 introduced the external oblique muscle aponeurosis and muscle detachment. This led to an improvement of body contour in abdominoplasty, as it created a more defined waistline and reinforced the lower abdominal wall.

This procedure is easy to accomplish; the detachment can reach close to the costal margin superiorly and to the anterior axillary line, laterally, without causing any bleeding, for the existing tissue between the external and internal oblique muscles



**Fig. 25.1** Presurgical marking

is loose; this makes possible an easy dissection and does not increase the surgical time, with lasting and pleasing results in women.

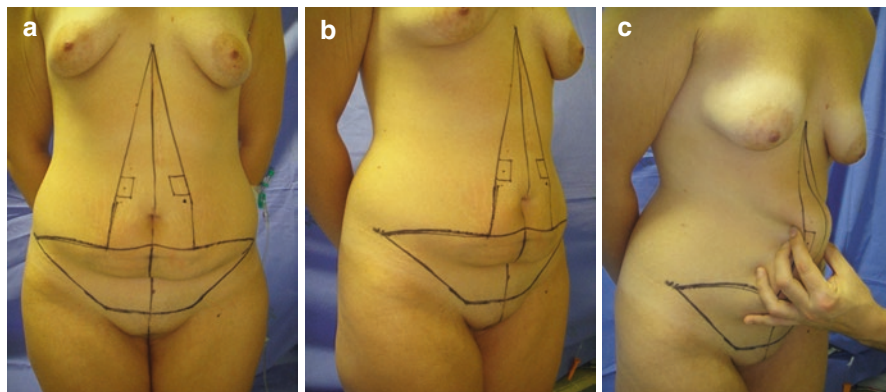
This technique begins with an incision at the aponeurosis of the external oblique muscle, near and parallel to the external margin of the *rectus abdominis*, and it continues with blunt dissection. This muscle aponeurosis set is pulled sideways to the center of the abdomen in an inferior medial direction and sutured at the new place, often advancing 3–4 cm toward the midline, with great improvement in body contour.

## Surgical Marking

We begin with the patient in the orthostatic position, taking as reference points the angle of the xiphoid appendix superiorly and inferiorly the anterior vulvar commissure in women or the base of the penis in men. A vertical line is drawn between the two points, which is called midline (Fig. 25.1).

With the patient in the dorsal horizontal decubitus position, we place a mark 6 cm above the anterior vulvar commissure in women or the base of the penis in men. A straight, 12-cm line is then drawn transversally on the pubis, 6 cm to each side of the midline, toward the iliac spine.

Then, with the patient sitting, we trace a line from the straight line described above, passing over the anterior superior iliac spine to the end of the fold generated by the excess abdominal tissue. Through this maneuver, we define the suprapubic line, where the lower incision will be made.



**Fig. 25.2** Presurgical marking, sequential photos. (a) front view (b) oblique view (c) bidigital maneuver

At the umbilical or supraumbilical region – according to the amount of tissue to be excised – while the patient is still sitting, with a bidigital maneuver on the fatty skin tissue, we draw a curved, vertical line extending caudally, up to the ends of the lower suprapubic line. Thus, in the lower abdomen, a large skin spindle is formed, which will be removed.

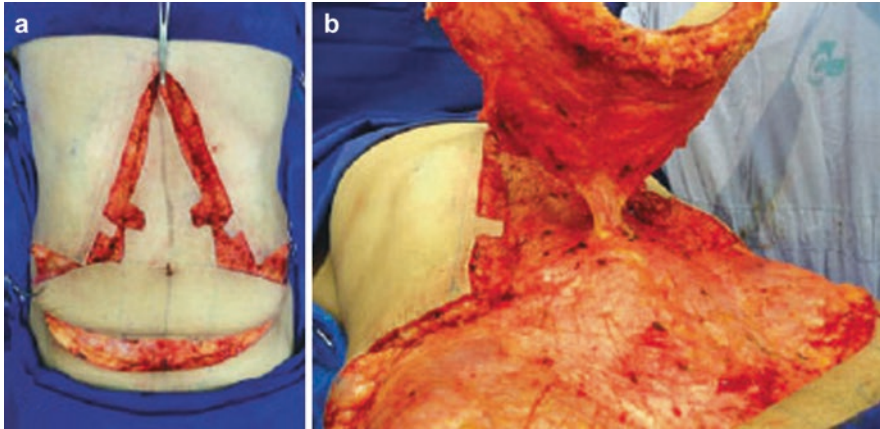
With the patient in the dorsal horizontal decubitus position, through another bidigital maneuver in the supraumbilical region, we define *the skin fatty excesses in the lateral-medial area* until the xiphoid appendix region, beginning with a wider pinch at the umbilical region, which becomes narrower as it approaches the xiphoid appendix, forming a large triangular spindle, which will be excised one block, with the one described above. With this marking, an “A” shape is formed, whose base is the transverse umbilical line, and to its sides, the amount of tissue to be removed. Normally, the distance between the sides of the “A,” from the xiphoid to the transverse supraumbilical line, is 27–30 cm. This information is important because the new cutaneous flaps that will form the neo-umbilicus will be at the upper portion of the lower medium third, i.e., 9 cm cranially from the transverse supraumbilical line. These flaps can also be marked from the xiphoid, approximately 18 cm on the side-line of the supraumbilical triangle (Figs. 25.1 and 25.2).

These flaps stand out symmetrically over the fatty subcutaneous tissue that will be removed, their bases being 3 and 2 cm long.

## The Operation

### *Surgical Technique*

General anesthesia is chosen; epidural is also possible, as well as a combination of both.



**Fig. 25.3** Perioperative period. One-block resection. (a) Incisions (b) detail of umbilical stump

Infiltration is performed with 0.9% saline solution and 1:1000 epinephrine, producing a 1:500,000 or dilution, i.e., one *epinephrine ampoule* in 500 ml of saline solution. This infiltration is performed only at the borders to be incised.

After the onset of the dilution, the one-block resection of the entire fatty skin tissue is performed (Fig. 25.3), with care at the midline, especially in the epigastric gastroplasty scar, due to the presence of small hernias. We include the umbilical scar in the resection and close its umbilical stump using 2-0 nylon thread. Thorough hemostasis of the whole exposed area is necessary.

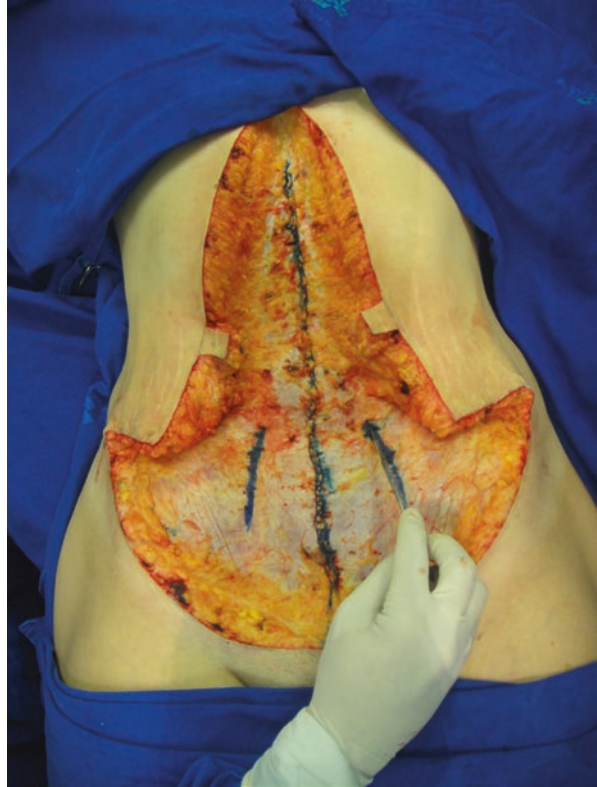The *rectus abdominis* muscles are plicated parallelly using 2-0 nylon thread sutures every 5 cm followed by 0 *polyglactin* continuous sutures from the xiphoid to the pubic region, in order to close the diastasis of the *rectus abdominis* muscles.

We then advance the muscle aponeurotic flaps of the external oblique muscles by way of a 5-cm incision in the aponeurosis of the same muscle parallel to the *rectus abdominis* muscle border, 3 cm from it. A blunt dissection is performed laterocranially between the external and internal oblique muscles, up to the costal margins (Figs. 25.4 and 25.5). These flaps are pulled and sutured as close as possible to the midline, to the aponeurosis of the *rectus abdominis* muscle with two 2-0 nylon thread isolated sutures, bilaterally (Figs. 25.6, 25.7, and 25.8).

If localized excess fat subcutaneous tissue remains in the lumbar lateral regions, liposuction can be performed according to the concepts quoted by Avelar which allow for better sliding of the flaps, without harming the blood supply [1].

The borders of the two skin flaps are sutured at the vertical midline with 0 polyvicryl isolated sutures. We proceed to closure by tissue planes, pulling the flaps close to the midline and attaching them with internal sutures to the aponeurosis of the *rectus abdominis* muscles, followed by the suture of the neo-umbilical flaps with three dermoaponeurotic sutures using 2-0 nylon thread, where the original navel was. The subcutaneous tissue of both vertical and lower transverse incisions

**Fig. 25.4** Perioperative period. Marking for the incision and for the dissection of the aponeurosis of the oblique muscles



is closed with 2-0 *polyglactin* isolated sutures. We make dermis stitches using colorless 4-0 nylon or 3-0 *poliglecaprone* thread and close the skin with intradermal 4-0 nylon thread.

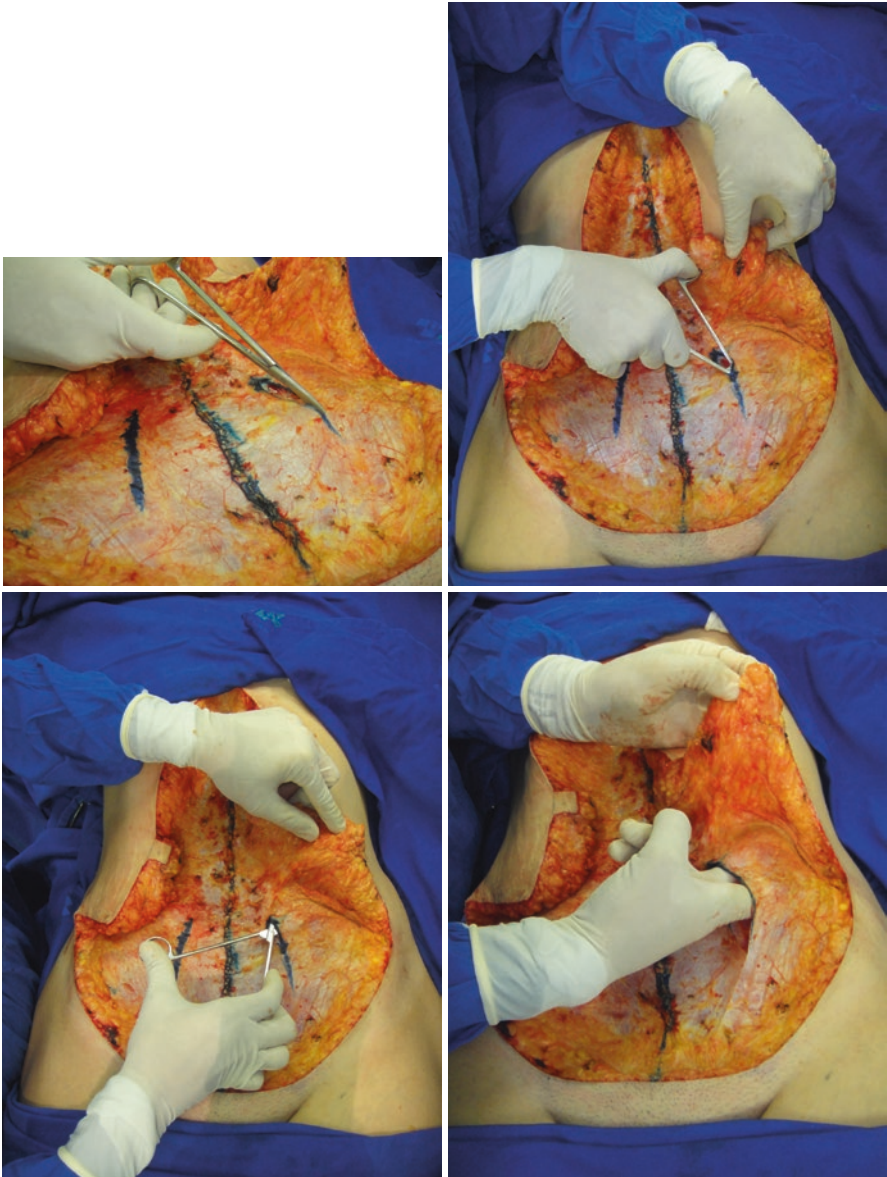
Suction drains are placed and maintain them for 7 days, in average.

Adhesive porous bandages are applied on the entire suture line and dressing covering the whole abdomen with cotton and a single piece of gauze inside the neoumbilical scar. Next, compressive or regular bandages complete the dressing (Fig. 25.9).

## Discussion

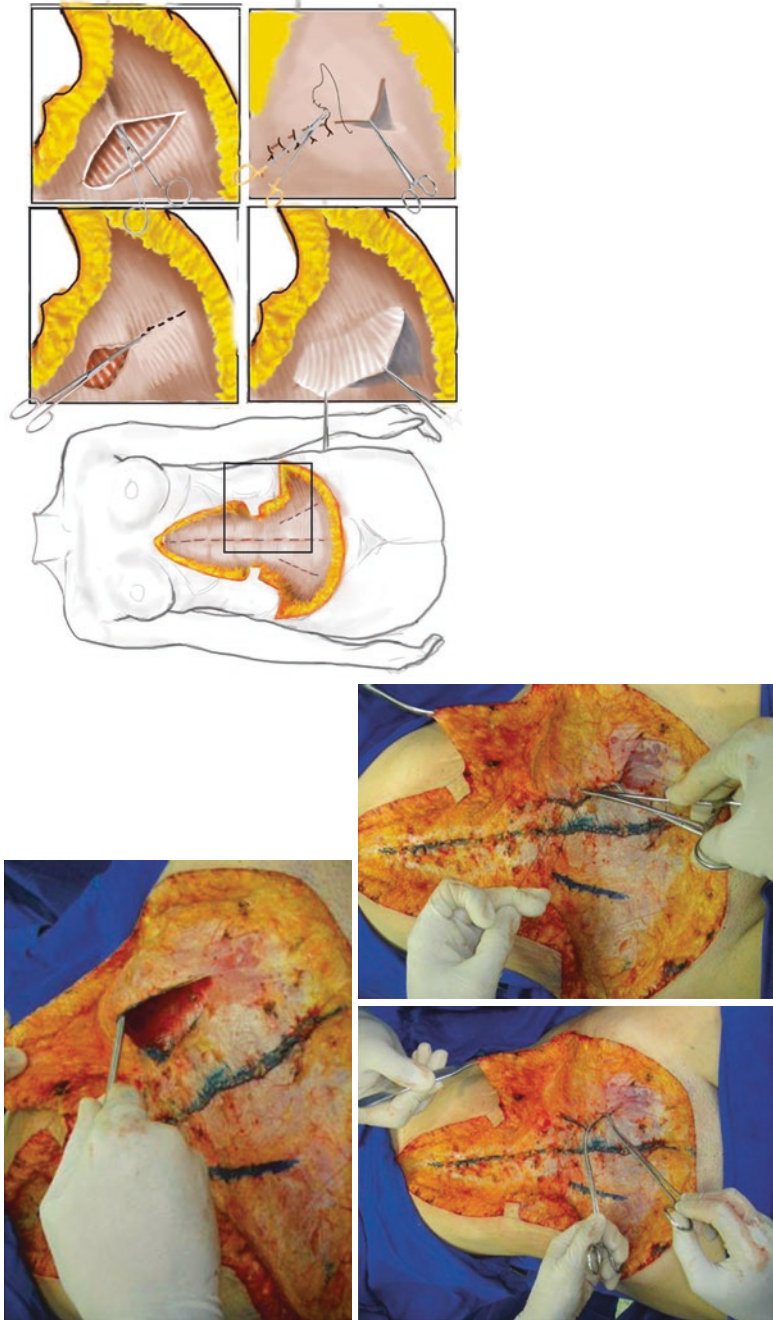
Post-bariatric *abdominoplasty* surgery demands a great deal of attention, a well-trained surgeon, and a relative quick performance of the surgical act, for that abdomen is not a typical one.

Sometimes it is better to do smaller and shorter surgeries than to risk surgical or postsurgical complications.



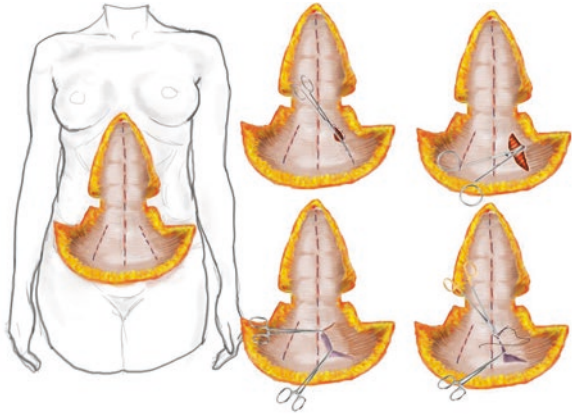
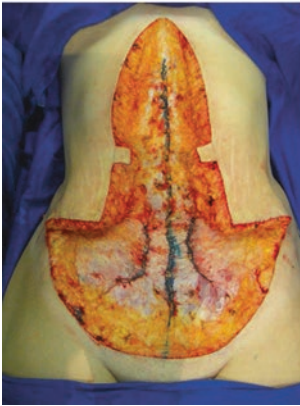**Fig. 25.5** Incision and dissection of the aponeurosis of the oblique muscle, sequential photos

Some *ex-obese* patients expect to finish the process without indelible, visible scars. It is relevant to remind them that the quality of resulting scars is associated not only to the technique used but also to various factors, including ethnic, skin color and texture and postsurgical care. These factors should be emphasized before surgery, in order to avoid their being called in question later. When addressing these

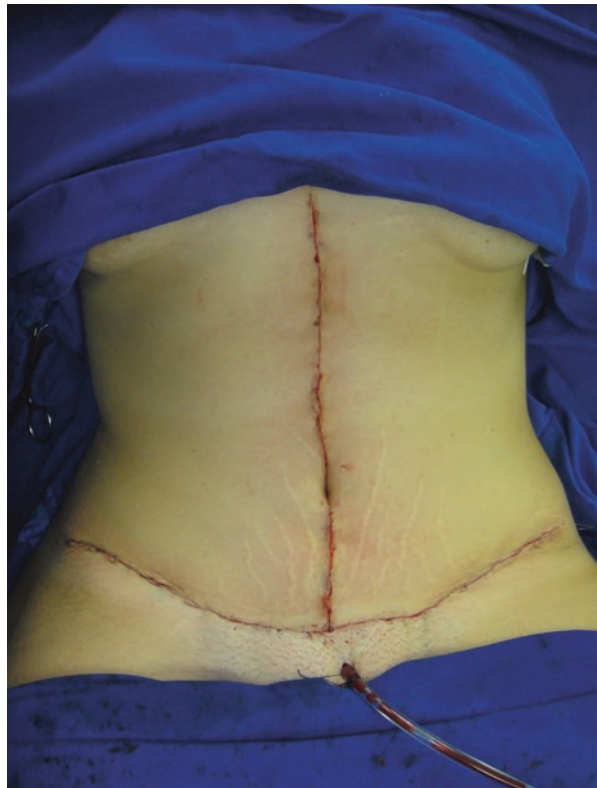


**Fig. 25.6** Advancement of the aoneurosis before plicature, sequential photos

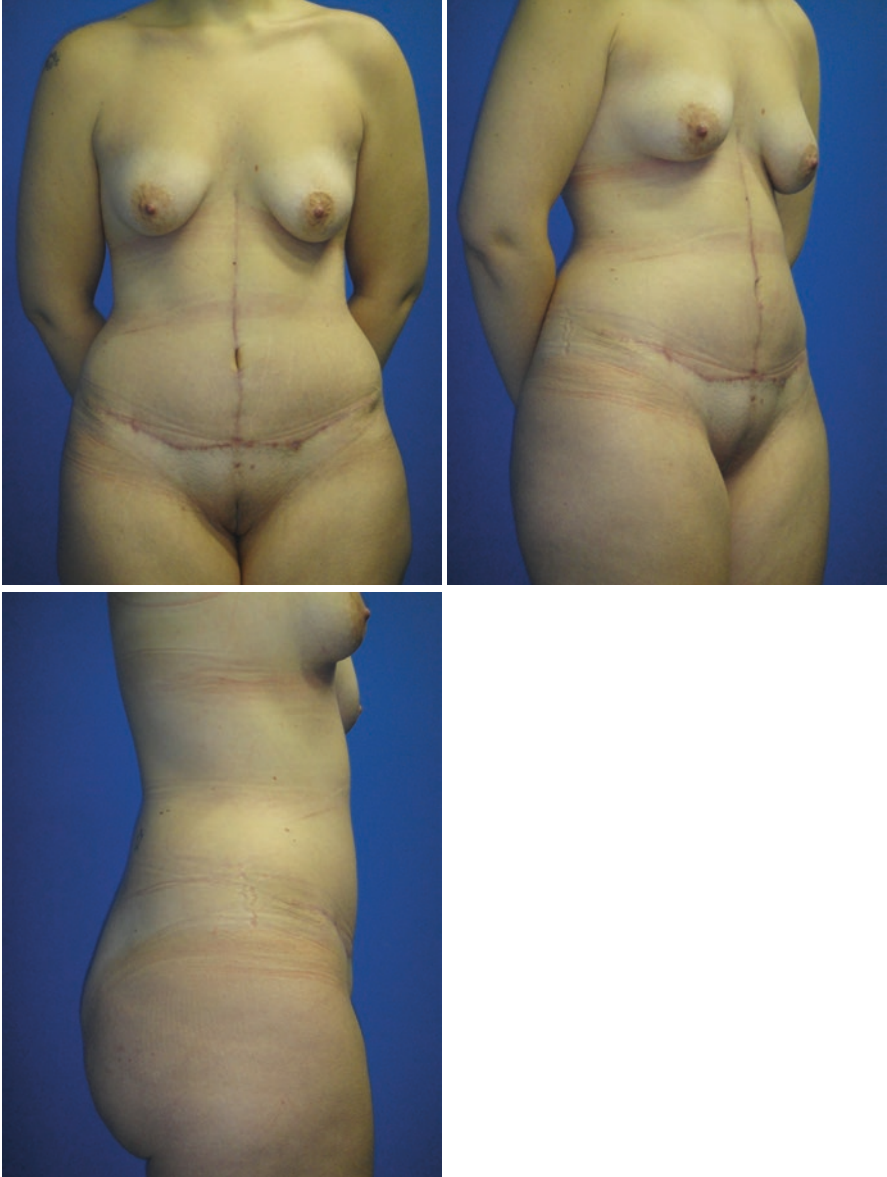



**Fig. 25.7** Performed plicatures



**Fig. 25.8** Immediate postoperative aspect



**Fig. 25.9** Postoperative, sequential photos

individuals, the surgeon should avoid giving false expectations, always showing what is actually possible in view of the present situation.

It is recommended prior to the surgery that the patient wears an abdominal compression garment, especially if they have a flaccid abdomen or hernia. This preoperative training will make the patient get used to feel the reduction of pulmonary

expansion that they will experience after surgery, due to the correction of the large diastasis of the *rectus abdominis* muscles and correction of possible incisional hernias. These maneuvers reduce the intra-abdominal space, with compression of the internal organs of the abdomen and elevation of the diaphragm, producing a reduction in lung expansion and risk of respiratory failure.

Plastic surgery residency training hospitals should be very careful about this kind of surgery due to its various peculiarities and avoid excessive detachment due to the risk of major bleeding as a consequence of the wide-caliber vessels and also certain deficiencies in blood coagulation that are not yet fully understood, or due to nutritional protein deficiency. Reducing surgical period is also important, as well as avoiding the removal of large amounts of tissue, due to the patient's expectations, preventing or reducing the occurrence of comorbidities.

In teaching services and schools, new surgeons should be warned that *massive weight loss patients/ex-obese* are a different kind of patients and that plastic surgery should be viewed as an opportunity of work and social reinsertion and not only as an aesthetic procedure.

Compressive stockings are used for prophylaxis against venous thromboembolism. Intraoperatively, we use intermittent sequential pneumatic compression.

Blood supply may be necessary. It is not convenient to operate on patients with hemoglobin levels under 12 g/dL.

## Conclusions

This surgical protocol standardization has been used in our unit since 2005, with good aesthetical results. This technique is easily learned, by training plastic surgeons.

We would like to stress the aesthetic contour improvement obtained by the use of median resection fulfilling patients' expectations in spite of the resulting long midline scar. This improvement could hardly be achieved through the craniocaudal traction on the transversal abdominoplasty.

We would also like to underline that the aesthetic results obtained with the neoumbilicus using the described flaps have eliminated problems of stenosis and necrosis frequently observed when the umbilical scar is maintained.

## References

1. Avelar JM (2000) Abdominoplasty: a new technique without undermining and fat layer removal. *Arq Catarinense de Med* 29:147–149
2. Psillakis JM (1984) Plastic surgery of the abdomen with improvement in the body contour. *Clin Plast Surg* 11:3

**Part III**  
**Surgical Principles on Abdominoplasty**

# Chapter 26

## Historical Evolution of Abdominoplasty

Ramil Sinder

Muscular hernia, obesity, lipodystrophy, flaccidity of assorted etiology of the abdominal wall (e.g., multiple gestations), and other reasons in minor frequency have been the indications for abdominoplasty since the last years of the nineteenth century.

A great number of techniques have been published since then and many of them with important surgical maneuvers like the aponeurotic muscle reinforcement, transposition or navel reconstruction became classical techniques and were adopted by the great majority of surgeries of this type. For the last 20 years, liposuction has been mostly indicated apart or associated to abdominoplasties.

Probably a great number of important assignments from highly regarded surgeons have not been mentioned here. The intention of the present publication is not to cover all aspects of such a vast subject, but to point out the great number of publications, demonstrating the great interest for the treatment of the abdominal deformities. Many techniques are still used even though more than a hundred years have passed.

I want to thank all my colleagues, even those not mentioned here, that have contributed with their own knowledge and experience and are still trying hard in one way or another to improve the resources of plastic surgery.

Next, in a chronological order is a list of important contributions in this field of plastic surgery.

1. 1890 – Demars and Marx – proximal concavity crescent-shaped excision (including the umbilical scar from one anterosuperior iliac spine to the other) [51].
2. 1899 – Kelly – described, at the Johns Hopkins Medical Society, transversal excision including the navel, similar to the technique of Demars and Marx (Fig. 26.1) [90].

---

R. Sinder, MD

Associated Professor of Plastic Surgery Department of Fluminense Medical School,  
Niteroi, Rio de Janeiro, Brazil

e-mail: [ramilsinder@hotmail.com](mailto:ramilsinder@hotmail.com); [institutodaorelha@uol.com.br](mailto:institutodaorelha@uol.com.br)

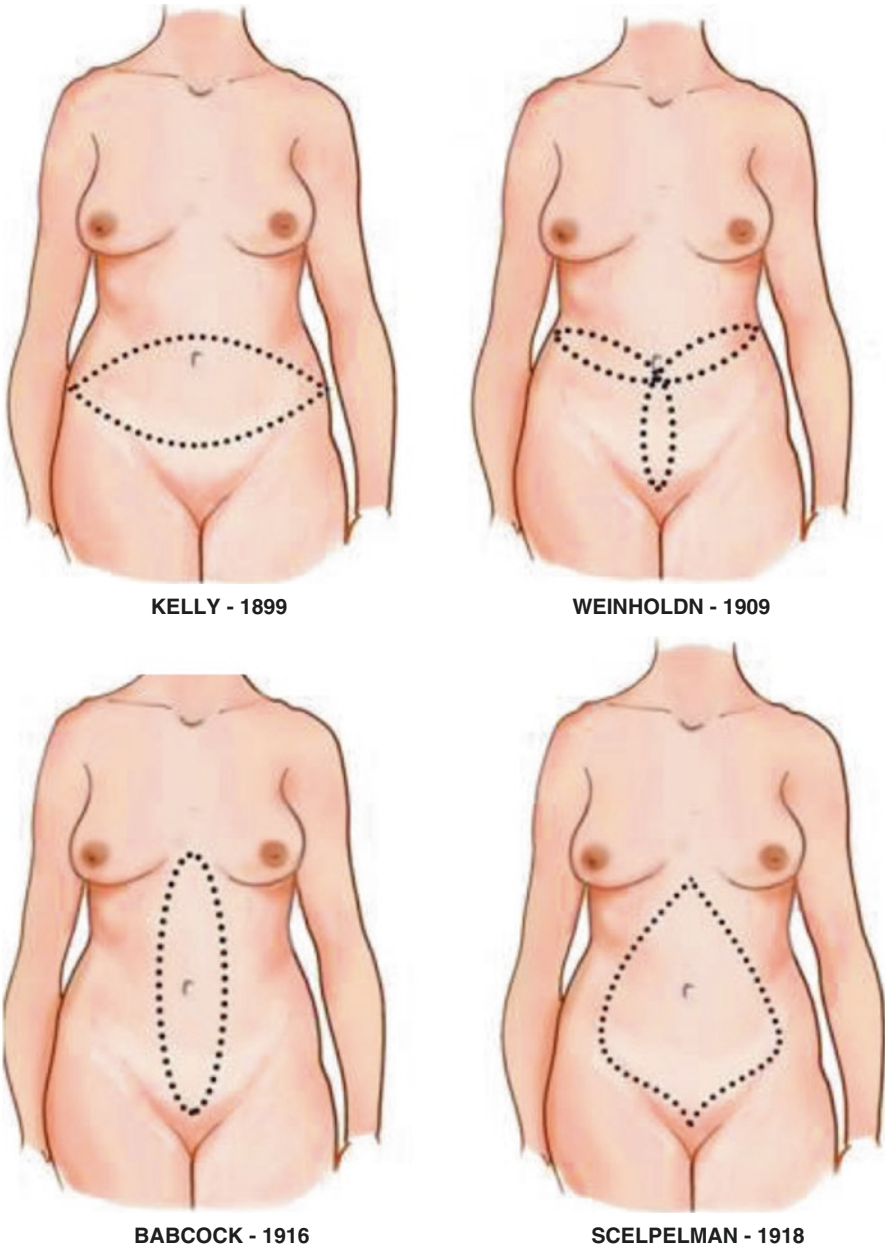
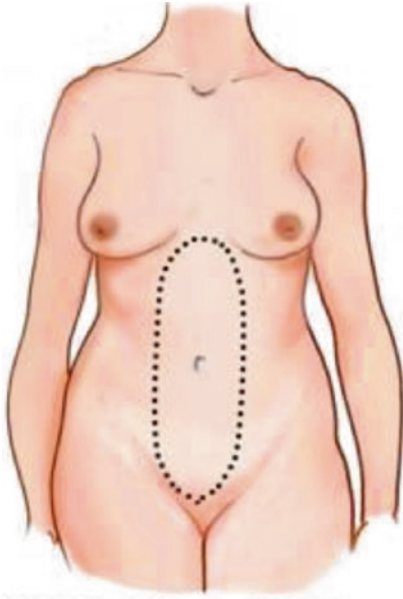


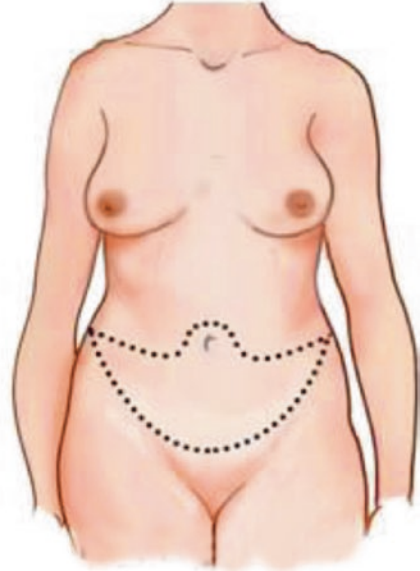
Fig. 26.1 Demarcations of the techniques [167]

3. 1901 – Peters – description of the surgery performed in 1899 by Kelly, using drawings as illustration [101].
4. 1901 – Macdonald, TL – dermoadipose tissue excision associated to incisional hernia surgery.

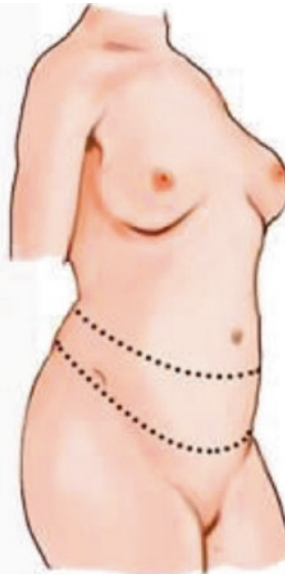
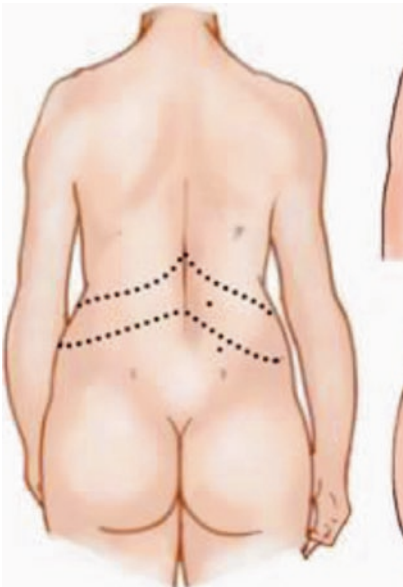
5. 1909 – Weinhold – excision of three fuses of dermo adipose tissue, two being paraumbilical oblique and one longitudinal infraumbilical, resulting in a scar resembling a three-tip star (Fig. 26.1) [167].
6. 1911 – Desjardins – according to Dartigues, he did longitudinal dermo adipose fusiform excision [50].
7. 1911 – Jolly – transversal infraumbilical cutaneous adipose excision, resembling a “slice of melon” or proximal concavity crescent [87].
8. 1912 – Mórestin and Ceballos – transversal dermolipectomy with vertical points for the aponeurosis reinforcement [97, 118].
9. 1916 – Babcock – xiphoid-pubic fusiform cutaneous adipose excision, including the navel (Fig. 26.1) [19].
10. 1917 – Beck, C – transversal abdominal dermolipectomy where the navel remains in the middle of the resulting scar [30].
11. 1918 – Schepelmann – (a) in the global abdomen: cutaneous adipose excision resembling a drop, transversal fusiform incision, and periumbilical longitudinal jacket of the aponeurosis. (b) In the pendulum abdomen: excision resembling a proximal concavity crescent, periumbilical longitudinal fusiform incision, and transversal jacket of the aponeurosis (Fig. 26.1).
12. 1924 – Thorek – transversal infraumbilical dermolipectomy resembling a crescent of proximal concavity.
13. 1926 – Kuster – longitudinal rectangular dermolipectomy (Fig. 26.2) [91].
14. 1931 – Flesch-Thebesii S-Weischeimer – cutaneous adipose excision resembling a transversal crescent of proximal concavity: navel transposition previously centralized in a skin triangle (Fig. 26.2) [66].
15. 1936 – Biesenberger – mixed abdominal dermolipectomy (longitudinal and transversal excision) [32].
16. 1936 – Ehrenfeld – mixed abdominal dermolipectomy.
17. 1939 – Thorek – transversal excision with navel graft (he called it: plastic lipectomy). He suggested the possibility of navel transposition [59, 152, 153, 156].
18. 1940 – Somalo – torso-circular (belt lipectomy). He was probably the first one to make use of the expression “abdominal dermolipectomy” (Fig. 26.2) [140, 143].
19. 1942 – Thorek – in cases of voluminous umbilical hernia “hiding” or deforming the navel, he makes its transplant with graft over the aponeurosis at the level of the new opening of the proximal flap (Fig. 26.3) [154, 155].
20. 1942 3 – Prudente – transversal fusiform dermolipectomy and torso-circular (belt lipectomy) [110, 111].
21. 1943 – Bankoff – mixed abdominal dermolipectomy [22].
22. 1974 – Cibils PLTG – tight infraumbilical transversal dermolipectomy complemented by excision of a longitudinal triangular segment [43].
23. 1946 – May – dermolipectomy resembling a transversal crescent with the excision of a triangle on each side [96].
24. 1946 – Somalo – mixed ventral dermolipectomy (cruciform).
25. 1946 – Talamas – transversal abdominal dermolipectomy [148].
26. 1948 – Malbec, EF – transversal fusiform excision (Morestin Ceballos technique, 1912, modified).
27. 1949 – Pick – (a) longitudinal infraumbilical triangular cutaneous adipose excision based on the suprapubic transversal incision at the extremities from where the



**KUSTER - 1926**



**FLESH - THEBESIOUS -  
WHEISHEIMER - 1931**



**SOMALO AND PRUDENTE - 1940**

**Fig. 26.2** Demarcations of the techniques [65, 141–143]



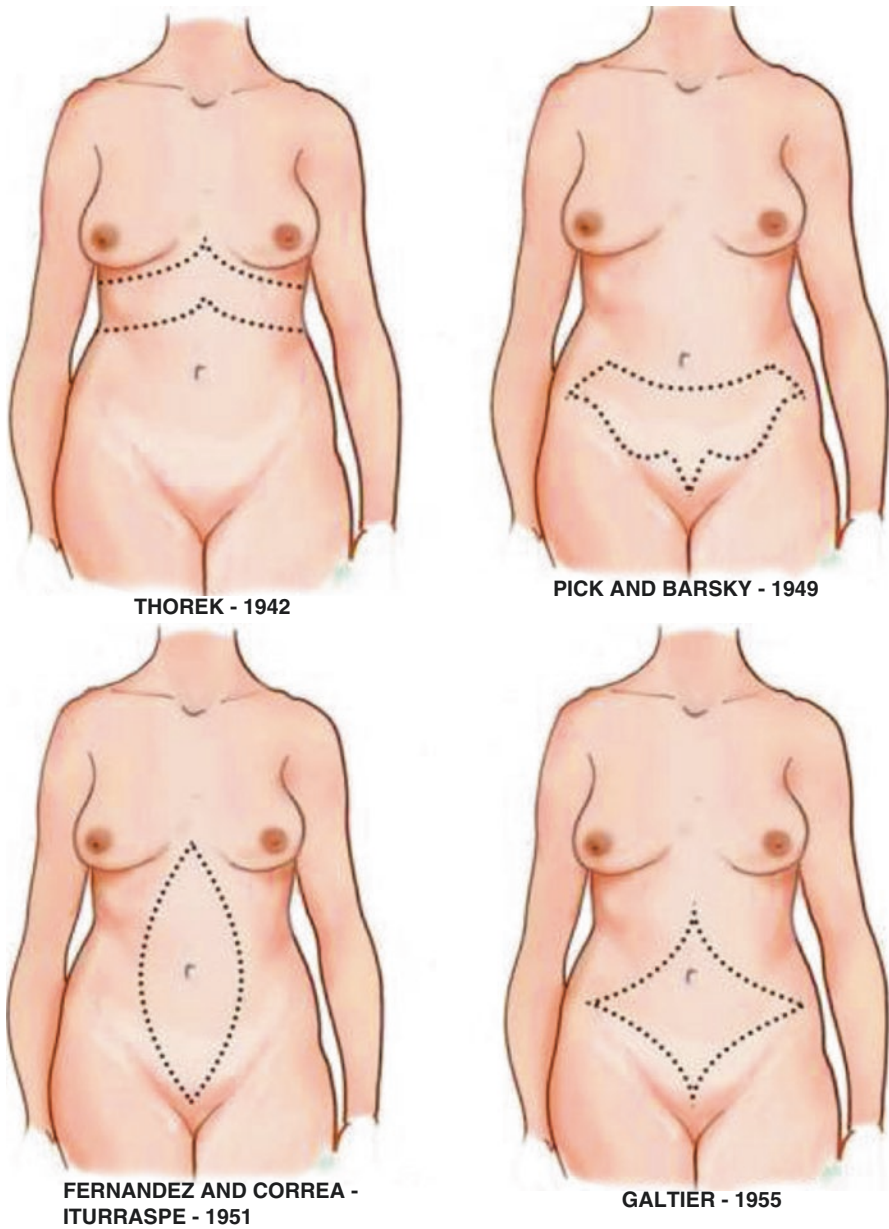
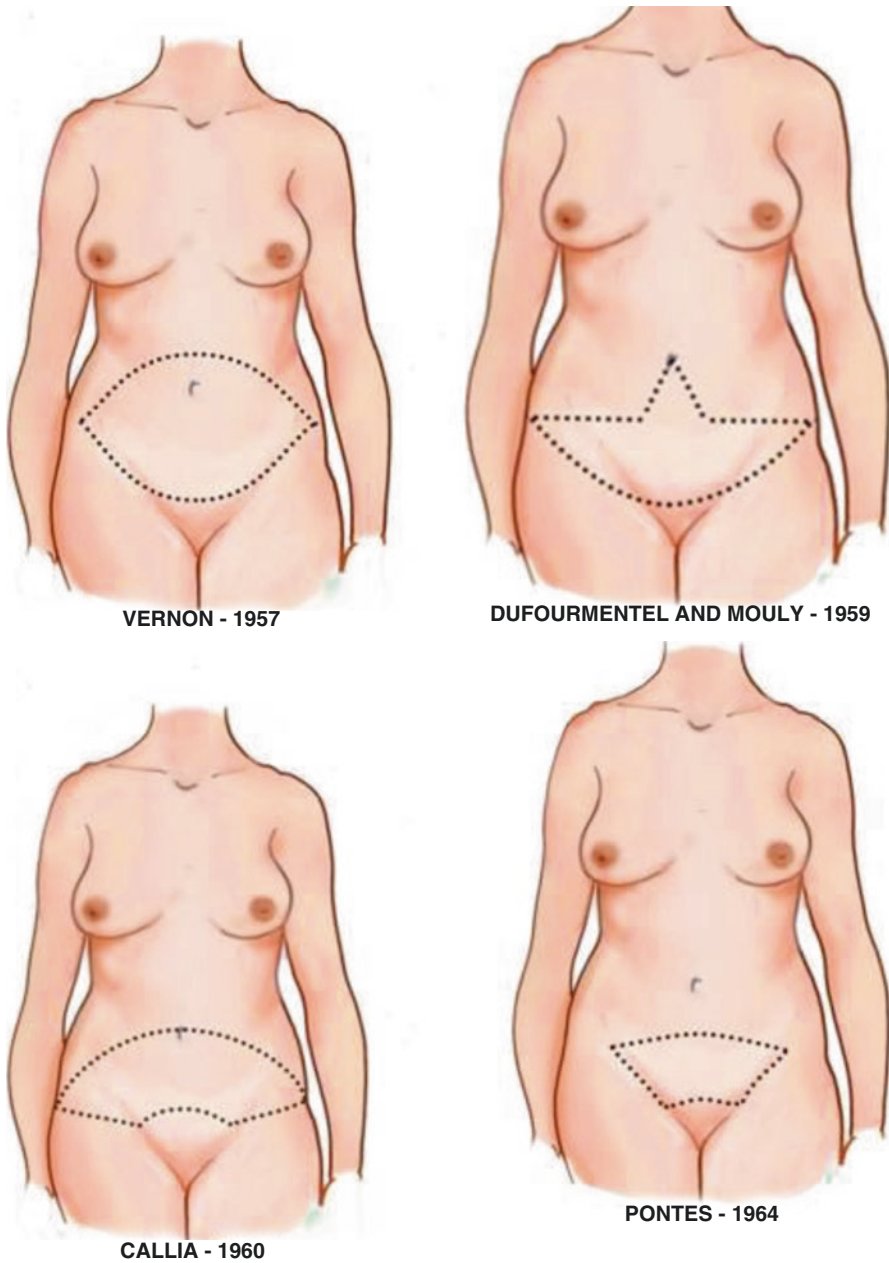


Fig. 26.3 Demarcations of the techniques [61–63, 69, 155]

compensation is done ( Bürow’s triangles) to avoid the forming of “ears (b) xiphoid-pubic fusiform dermolipectomy; each vertex ends in a transversal incision. The compensation is done at the extremities (Bürow’s triangles)” (Fig. 26.3).

28. 1950 – Barsky – suprapubic transversal dermolipectomy resembling a crescent of the cranial concavity [28].

29. 1951 – Fernandes and Iturraspe – xiphoid-pubic fusiform dermolipectomy” (Fig. 26.3).
30. 1951 – Fernandes and Irene Talamas – dermolipectomy resembling two transversal fuses, one being supra- and the other infraumbilical.
31. 1951 – Goldenberg – mixed abdominal dermolipectomy.
32. 1952 – Correa-Iturraspe – longitudinal dermolipectomy. He classified the abdominal dermolipectomies according to the longest axis of the incision: (a) transversal or horizontal, (b) longitudinal or vertical, and (c) mixed [45–47].
33. 1952 – Spina – longitudinal dermolipectomy [147].
34. 1953 – Fournier MM – (a) longitudinal fusiform, (b) transversal fusiform, and (c) mixed [67].
35. 1955 – Galtier – resembling a four-tip star (Fig. 26.3) [69].
36. 1956 – Andrews – suprapubic transversal incision of proximal concavity, the aponeurotic muscle reinforcement opening the sheaths of the rectum which are sutured in jacket, lipectomy of the supraumbilical flap at the level of the new opening for the navel, and neo-omphaloplasty if necessary [5–7].
37. 1957 – Baril LE – longitudinal dermolipectomy [23].
38. 1957 – Berson – inverted abdominal dermolipectomy with transversal epigastric incision or supraumbilical incision [31].
39. 1957 – Claolé -infraumbilical transversal dermolipectomy and longitudinal triangular dermolipectomy with suprapubic basis [44].
40. 1957 – Schrimpf -transversal abdominal dermolipectomy [126].
41. 1957 – Vernon – transversal dermolipectomy with navel transposition (Fig. 26.4) [157].
42. 1959 – Dufourmentel and Mouly – mixed dermolipectomy with the resulting scar having an anchor or inverted “J” shape (Fig. 26.4) [53].
43. 1959 – Gonzales Ulloa, M – dermolipectomy torso-circular (belt lipectomy) with excision of two dorsal triangles (proximal and distal) and one pubic-ventral (distal) [75].
44. 1959 – Ribeiro, E B – transversal dermolipectomy: infraumbilical excision shaped like a Prussian mustache.
45. 1960 – Callia W – dermolipectomy shaped like a bicycle handlebar + skin graft de-epithelialized over the aponeurosis to reinforce it + neo-omphaloplasty by excision of a little subcutaneous material and suture from the dermis to the aponeurosis. The median part of the incision will be over the pubis and its lateral prolongation a little below, parallel to the crural arcades (Fig. 26.4) [38].
46. 1961 – Ivanissevich – transversal dermolipectomy [84].
47. 1962 – Galtier – mixed dermolipectomy (transversal+longitudinal) [70].
48. 1962 – Spadafora – transversal dermolipectomy with the lateral branches of the excision obliquely ascending. Oblique “S”-shaped excision on the lateral parts of the abdomen (flanks) (Fig. 26.5) [144–146].
49. 1964 – Marchal and Lapeyrie – fusiform longitudinal dermolipectomy [95].
50. 1964 – Vilain and Dubouset – techniques and indications of torso-circular (belt lipectomy) [162].
51. 1964 – Pontes, R – transversal dermolipectomy with previous cutaneous adipose excision after establishing the limits (before the supraumbilical undermining flap) (Fig. 26.4) [108].



**Fig. 26.4** Demarcations of the techniques

- 52. 1963 – Callia – published a small book: “abdominal dermolipectomy”, with a detailed description of his technique [39].
- 53. 1965 – Ely – low transversal dermolipectomy complemented by longitudinal cutaneous adipose excision if necessary [58].

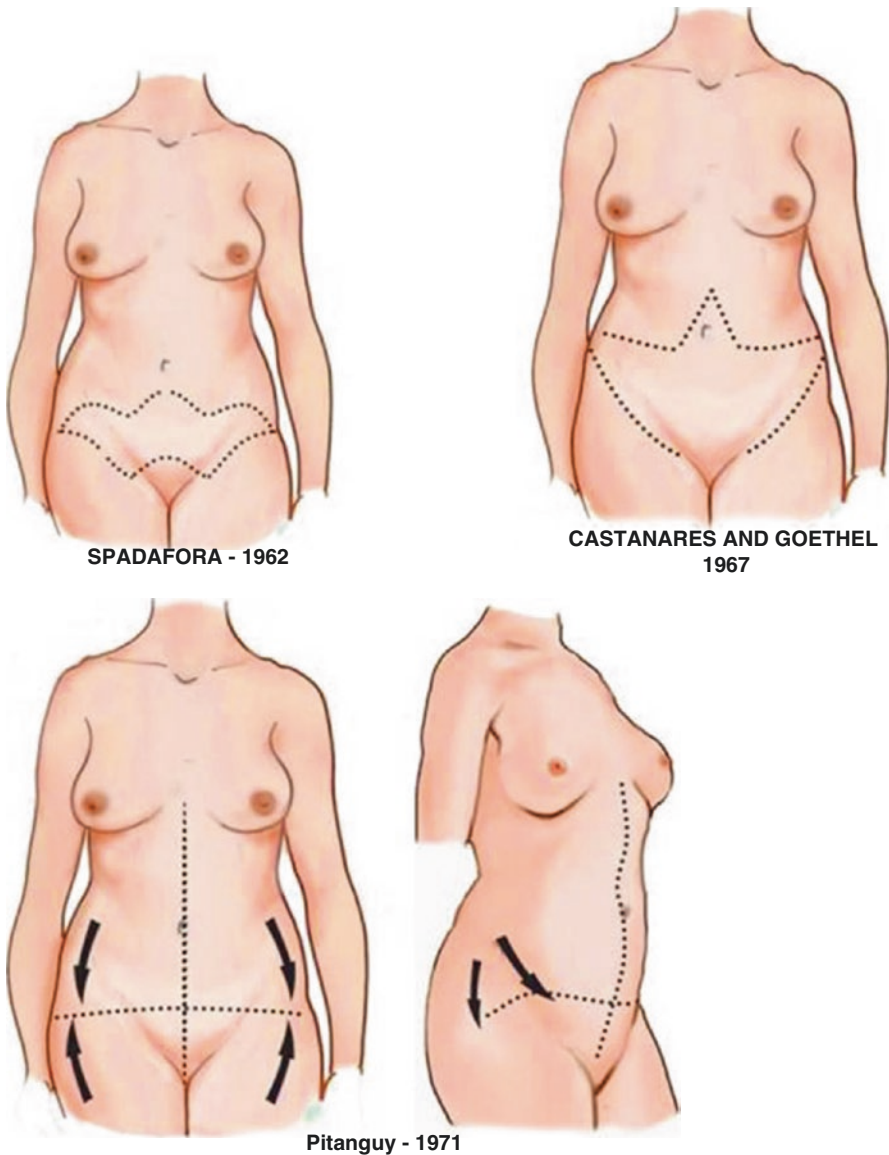
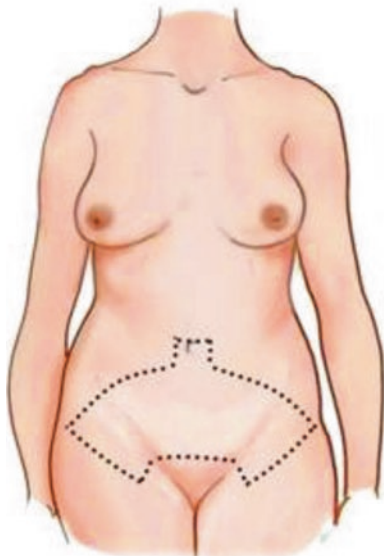


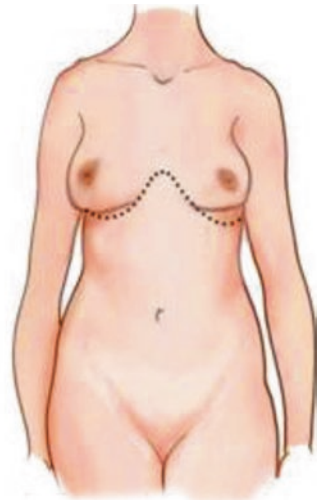
Fig. 26.5 Demarcations of the techniques [40, 102, 145]

54. 1965 – Pontes, R – the importance of the association of abdominoplasty with incision hernioplasty [108].
55. 1966 – Junqueira – cutaneous adipose excision resembling a crescent, from one costal border to another having the part at the level of the mons veneris.
56. 1967 – Barraya – mixed dermolipectomy preserving the navel “anchor” or “inverted-T”-shaped scar [26, 27].

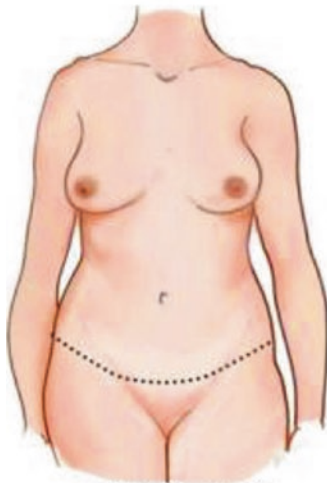
57. 1967 – Castañares and Goethel – mixed dermolipectomy almost without undermining of the flaps, which are approached due to their elasticity (Fig. 26.5) [40].
58. 1967 – Pitanguy, I – low horizontal dermolipectomy with the extremities of the incision being oblique going outward and downward. Reinforcement of the aponeurosis without opening the abdominal rectus muscle sheath. Incision of proximal concavity in direction of the navel. Makes use of a plaster shield in the dressing (bandaging) in order to better distribute the compression (Fig. 26.5) [103, 104].
59. 1968/75 – Hinderer – takes the transversal abdominoplasty as an access to include mammary silicone prosthesis [82, 83].
60. 1969 – Serson, D, and Martins LC. – geometric dermolipectomy with previous excision of the cutaneous adipose excess (before undermining the supraumbilical flap) (Fig. 26.6) [127].
61. 1971 – Fischl, R – median longitudinal fusiform dermolipectomy [64].
62. 1971 – Lagache and Vandenbusch Callia's technique modified: bilateral longitudinal extension of the transversal excision.
63. 1971 – Thomeret – mixed dermolipectomy: medial longitudinal cutaneous adipose excision and transversal circular-torso (belt lipectomy) [150, 151].
64. 1971 – Pontes, R – systematization and variations of the previous cutaneous adipose excess resection in abdominoplasties.
65. 1972 – Albuquerque, JS – suprapubic transversal dermolipectomy, cut in bevel, on the distal incision parallel to the inguinal fold [3].
66. 1972 – Kamper et al. – dermolipectomy or panniculectomy after great loss of weight in obese patients [89].
67. 1972 – Rebello, C; Lion, Franco T – inverted abdominal dermolipectomy with submammary incision, associated or not to the suprapubic transversal incision. The excess tissue may be used for mammary reconstruction (Fig. 26.6) [115, 116].
68. 1972 – Regnault – W-shaped transversal abdominal dermolipectomy [120].
69. 1973 – Baroudi, R – wrote about the details of the umbilical scar treatment [24].
70. 1973 – Grazer – retractor with optic fiber in order to position the navel. The incision is identical to the one developed by Pitanguy, but the lateral extremities do not exceed the anterosuperior iliac spine line (Fig. 26.6) [78].
71. 1973 – Sinder, R – the use of a triangular de-epithelialized flap or suprapubic trapezoidal flap in abdominoplasty. Personal technique of the abdominal wall plastic surgery [130–132].
72. 1974 – Baroudi, R et al. – different types of incisions (straight, curvilinear, “W” shaped), depending on each patient's abdomen. Transversal and longitudinal lines are previously outlined to guarantee the symmetry of the excisions [25].
73. 1974 – Elbaz, J S – excision resembling a periumbilical ring in patients with flaccidity in this part of the body. Horseshoe-shaped dermolipectomy with distal opening around the mons veneris (Fig. 26.6) [54].
74. 1974 – Oghoa – transversal dermo adipose excision with curvilinear proximal incision with the same length of the distal incision to avoid the lateral “ears.”.
75. 1975 – Baker – dermolipectomy using a plastic pattern to outline symmetric incisions (Fig. 26.7).



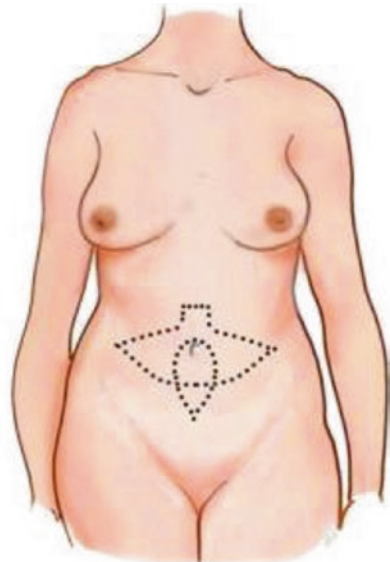
**SERSON NETO - MARTINS - 1971**



**REBELLO-FRANCO  
1972**

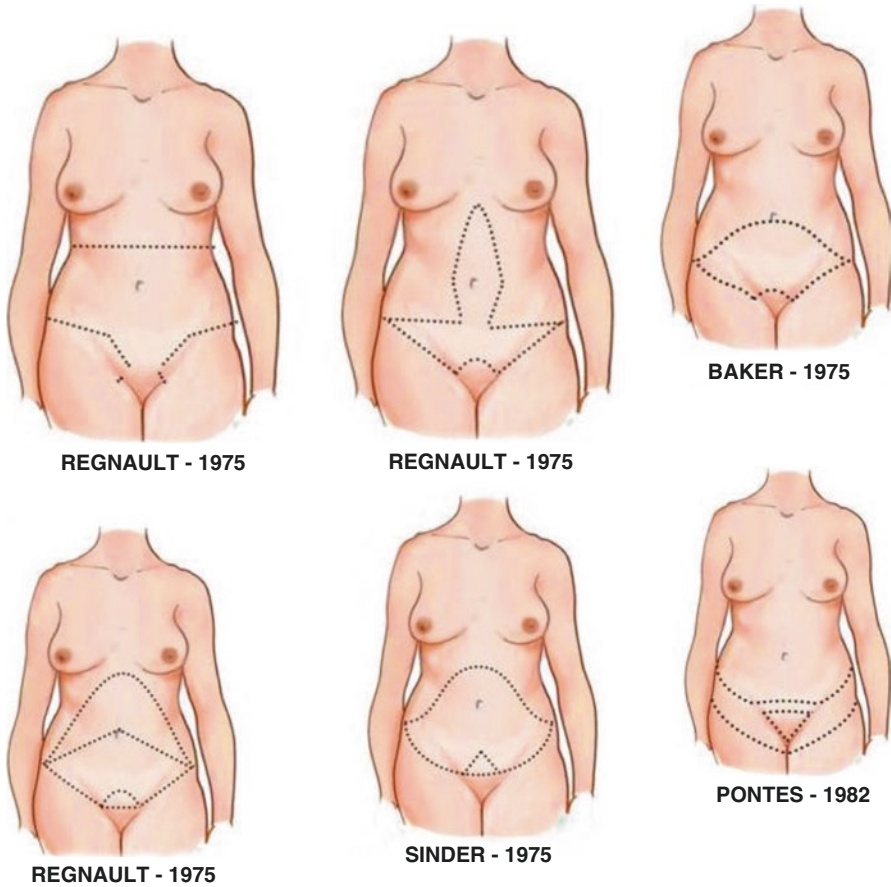


**GRAZER - 1973**



**ELBAZ-GLICENSTEIN AND LEWIS  
1974**

**Fig. 26.6** Demarcations of the techniques [121, 128]



**Fig. 26.7** Demarcations of the techniques

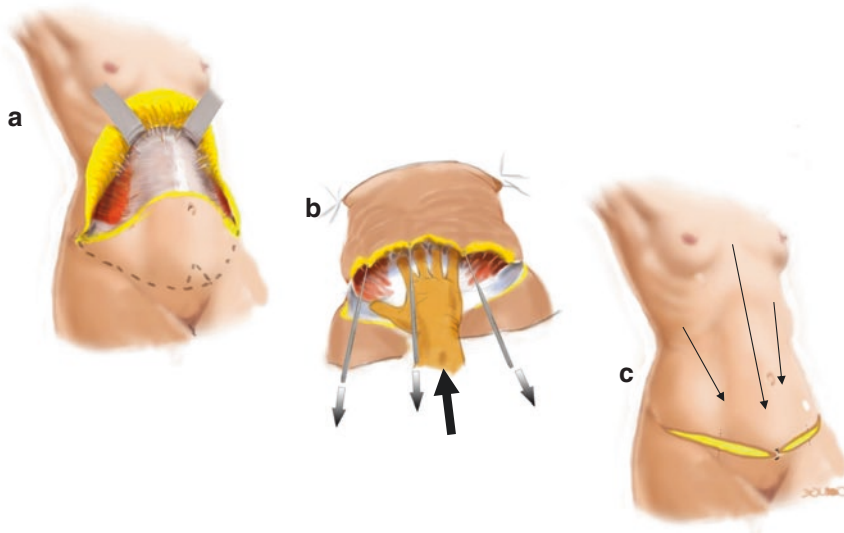
76. 1975 – Glicenstein – mixed infraumbilical dermolipectomy (inverted-T-shaped scar) and a suprapubic transversal one identical to Serson's ; in the proximal flap, the de-epithelialized two small flaps which after being sutured under the pubic skin reduce the tension on the scar.
77. 1975 – Hinderer – infraumbilical excision and inverted-“T”-shaped suture. Takes advantage of the same access used by the abdominoplasty to introduce the mammary prosthesis.
78. 1975 – Regnault – “W”-shaped low transversal dermolipectomy. Incision resembling a “fleur-de-lis”(modification of the Castañares technique). Torso-circular (belt lipectomy) associated to a small suprapubic longitudinal excision, without undermining, resulting in an inverted-“T”-shaped scar with three tips or extremities (Fig. 26.7) [119].
79. 1975 – Sinder, R – transversal abdominoplasty: The surgery begins with a proximal incision liberating the navel; undermining of the supraumbilical

flap which is drawn in the distal direction, verifying if it affects the distal incision line without much tension (this line can be undermined in a proximal direction if there is too much tension). Also de-epithelialization of a small triangular or trapezoidal flap on suprapubic region is created with preservation of adipose tissue for adequate suture of the superior abdominal flap. This technique is not indicated when a patient does not present excess of skin on the abdomen as well as enough cutaneous flaccidity. Lipectomy or liposuction is performed on midline in order to provide transposition of the umbilicus (Fig. 26.7). This technique became employed on breast reconstruction with transverse musculocutaneous rectus abdominalis TRAM [80].

80. 1975 – Vilain – dermolipectomy “en soleil cou-chanf” (sunset). Transversal suprapubic incision with reduced scar [160, 161].
81. 1976 – Avelar, JM – described a new technique of umbilicalplasty. The final umbilical scar resembling a three-tip star [9, 11].
82. 1976 – Sinder, R – thesis about abdominoplasty techniques.
83. 1977 – Agris -horizontal bar, with five hooks with field calipers, between two vertical rods, as a support of the dermoadipose flap to be excised during the abdominoplasty [2].
84. 1977 – Castro – abdominoplasty associated to gynecological surgeries [41].
85. 1975 – Elbaz, JS, and Flageul, G – published the book “Chirurgie Plastique de l’ abdomen” [55].
86. 1977 – Grazer and Goldwin – they reported 45% of periumbilical cicatricial retractions in the postoperative of abdominoplasties with navel transposition.
87. 1977 – Vilain – circular-torso dermolipectomy [160].
88. 1978 – Avelar, JM – abdominoplasty, systematization of a technique without external umbilical scar [10].
89. 1978 – Dubou and Gusterhout – they place the navel at the intersection of the medial line with the transversal line which passes along the most cranial part of the iliac crests [52].
90. 1978 – Freeman and Weimer – periumbilical dermolipectomy [68].
91. 1978 – Jackson – aponeurosis cruciform plication (transversal and horizontal) [88].
92. 1978 – Planas – “vest over pants” abdominoplasty (same as Ramil Sinder’s technique, 1975) [107].
93. 1978 – Psillakis – treatment of the largest oblique muscle in order to obtain better waist in abdominoplasties.
94. 1979 – Hakme, F – transversal dermolipectomy with peri- and supraumbilical lipectomy [79].
95. 1979 – Juri – transversal infraumbilical dermolipectomy with reduced scar.
96. 1979 – Lewis – cutaneous adipose excision below or above the navel, which will be inserted on the proximal or distal labium of the surgical wound.
97. 1979 – Nácul et al. – transversal abdominoplasty starting with the proximal incision and navel liberation, as described by Ramil Sinder in his technique, in 1975. However, it provisionally leaves a cutaneous adipose “flap” in the supra-umbilical material with orifices for the digital traction in distal direction which



- will be excised, totally or partially, just after confirming that the tension will not be exaggerated.
98. 1979 – Sinder, R – published the book “Cirurgia Plástica do Abdome”, in which he describes in details his personal technique.
  99. 1979 – Stuckey – central abdominal dermolipectomy: four small incisions forming a square around the navel, traction, excision of the cutaneous adipose tissue excess, and suture of the periumbilical skin.
  100. 1980 – Guerrero-Santos, J – secondary abdominoplasty with umbilicoplasty or neo-umbilicoplasty at the intersection of the medial line with a transversal plane which is 1cm above the iliac crest.
  101. 1980 – Guerrero-Santos, J – (a) makes two undermining planes: a deep one and a superficial one to avoid skin anesthesia. (b) Suprapubic incision resembling a bevel to avoid any depression on that area. (c) Fixing the subcutaneous web to the fascia in the medial part to avoid the excessive elevation of the mons veneris. (d) Semi-Fowler position to avoid necrosis of the medial distal part of the flap.
  102. 1980 – Ulloa – he classifies the abdominal wall deformities according to their gravity in three different degrees: 1st degree, makes a low transversal bikini incision (the lateral parts remain below the inguinal ligaments); 2nd degree, Pfannenstiel-type low and long incision; 3rd degree, torso-circular lipectomy (belt lipectomy) with triangular excision at the medial dorsal part of the cranial and caudal labium of the surgical wound.
  103. 1982 – Avelar, JM, and Padoyez, JC – abdominoplasty associated to mammoplasty.
  104. 1982 – D’assumpção – etiology, prophylaxis, and treatment of infection, seroma, and postabdominoplasty dehiscence.
  105. 1982 – Delerm – transversal dermolipectomy. Uses the de-epithelialized suprapubic flap described by Sinder in 1975. Presents details of the umbilical scar treatment.
  106. 1982 – Franco, T – Simultaneous correction of abdominal flaccidity and femoral lipodystrophy.
  107. 1982 – Martin, L C – prophylaxis and treatment of breathing problems after abdominoplasties.
  108. 1982 – Melega, JM – etiology, prophylaxis, and treatment of thromboembolism due to abdominoplasty complications.
  109. 1982 – Pítanguy, I – abdominoplasty: some historical, philosophical, and psychosocial considerations [105, 106].
  110. 1982 – Pontes, R – Unsatisfactory results in abdominal plastic surgery (Fig. 26.7) [109].
  111. 1982 – Ribeiro, L – abdominoplasty with supraumbilical, periumbilical lipectomy and at the distal part of the supraumbilical flap after dermoadipose excision.
  112. 1982 – Sinder, R – technical variations of abdominoplasties. Generalities about abdominal plastic surgery and personal contribution (transversal abdominoplasty starting with the proximal incision) (Fig. 26.8).
  113. 1983 – Avelar, M J – refinements of the technique used in transversal dermolipectomy; details of the umbilical scar treatment [12].

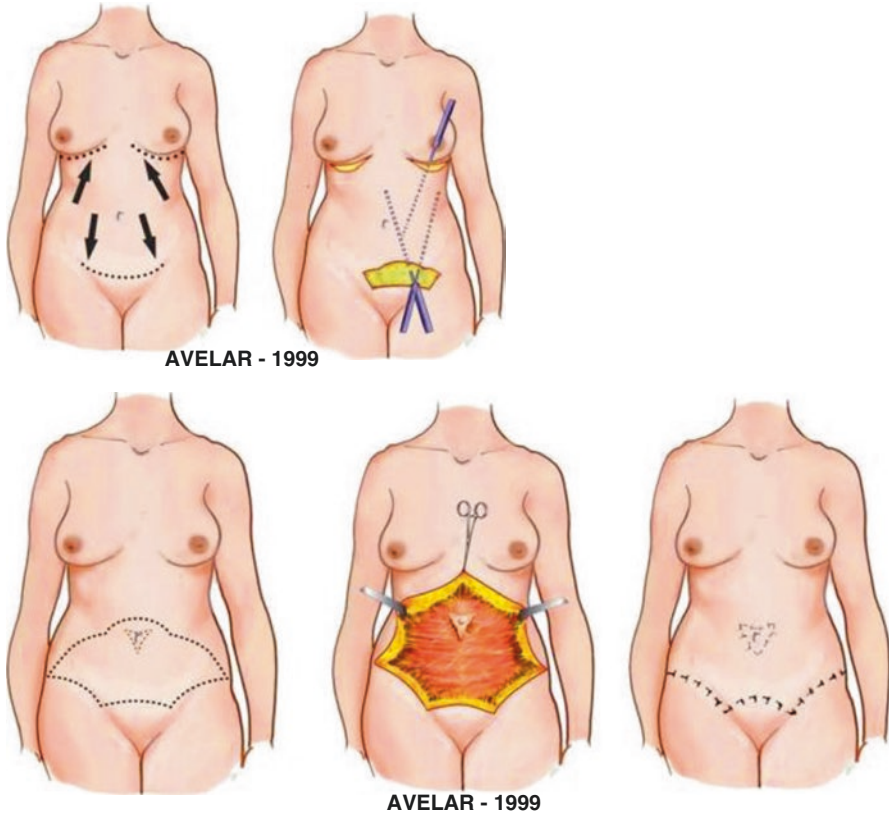


**Fig. 26.8** Sinder's technique – (a) the first incision is done on superior line of surgical demarcation following panniculus undermining up to the rib margin; (b) afterward the superior flap is pulled downward to evaluate the area of panniculus resection; (c) the excess panniculus was already resected and the upper flap is pulled downward and the final suture will be done [133–140]

114. 1983 – Casaubon – surgical treatment of the abdominal congenital bands.
115. 1983 – Hunter et al. – pulmonary complications are more frequent in obese people, smokers, and people with pneumonopathy. Thorax X-ray, vital capacity, and arterial gasometry are important preoperative exams in these cases.
116. 1983 – Savage – abdominoplasty after “bypass” gastrointestinal surgery.
117. 1984 – Appiani – (a) bilateral longitudinal jacket of the large oblique muscle, based on Coffey's hernioplasty technique (1910). (b) two aponeurotic muscle flaps of the large oblique muscle with cranial pedicle are sutured one to the other in front of the rectus muscles below the navel (waist) [8].
118. 1984 – Castro CC – mixed abdominoplasty in the excision of multiple scars of the abdominal wall, resulting in an anchor-shaped or inverted-“T”-shaped scar [42].
119. 1984 – Jaimovich et al. – different options for treatment and reconstruction in abdominal necrosis: Melleney's postoperative progressive synergic bacterial gangrene [86].
120. 1984 – Psillakis – liberates the aponeurosis of the large oblique muscle on the lateral border of the abdominal rectus up to the anterior axillar line and sutures it on the front of the rectus. When there is protrusion of the seventh and/or eighth rib or cartilage, a segment is resected.
121. 1986 – Avelar, JM – infraumbilical excision + liposuction + section and reimplantation of the umbilical pediculus (miniabdominoplasty) [13, 14].
122. 1986 – Avelar, JM – surgical anatomy and distribution of the subcutaneous fat tissue on the human body.

123. 1986 – Dardour – transversal abdominoplasty using different methods and techniques according to each patient’s characteristics, such as cutaneous flaccidity, thick adipose panniculus, and distance of the navel to the pubis [49].
124. 1986 – Wilkinson and Swartz – “limited abdominoplasty,” liposuction without navel transposition; aponeurosis plication. The incision can be curvilinear or angulated, very low. In small navel transpositions the primitive opening is sutured between the pubis and new opening itself.
125. 1987 – Bolivar, E et al. – abdominoplasty associated to liposuction. Sheath plication of the abdominal rectus muscles through a small incision on the proximal border of the navel, using a retractor with optic fiber illumination and Reverdin needle [33].
126. 1988 – Bozola and Psillakis – classify the abdominal wall deformities in five groups. Each group receives proper surgical technique [34].
127. 1989 – Heter et al. – studied the consequences of abdominoplasties in 530 patients. 230 of them had other associated surgeries. They concluded that obesity is the main factor of morbidity and pulmonary embolism [81].
128. 1989 – Avelar, JM – regional distribution and behavior of the subcutaneous tissue concerning selection and indication for liposuction [15].
129. 1989 – Mühlbauer – in selected cases, as great loss of weight, lipodystrophy, obesity, and excessive cutaneous flabbiness, he performs round abdominoplasty associated to inguinocrural and gluteal dermolipectomy [98].
130. 1989 – Teissourian B and Gotkin R – transversal abdominoplasty associated to torso-circular liposuction [149].
131. 1990 – Abramo et al. – H-shaped plication of the aponeurosis of the rectus abdominal muscles (longitudinal and transversal) [1].
132. 1990 – Caldeira et al. – classify the abdominal wall deformities and establish correlation with different procedures which can be associated to abdominoplasty as liposuction and lipograft [35, 36].
133. 1990 – Malcol Paul – wrote useful article to prevent seroma after abdominoplasty [100].
134. 1991 – Kamakura et al. – mixed abdominoplasty with an anchor-shaped scar for treatment of secondary abdominal deformities.
135. 1991 – Psillakis, Appiani, and De La Plaza – they published the book: “Color atlas of aesthetic surgery of the abdomen.” Details of Psillakis and Appiani techniques as well as the association of both (Dolphino) [113].
136. 1992 – Illouz, YG – performs abdominoplasties with neo-omphaloplasty associated to liposuction [85].
137. 1992 – Le Louarn – in order to avoid or reduce seroma formation in transversal abdominoplasties. He performs liposuction and dissection behind or below the superficial abdominal fascia [92].
138. 1994 – Rebello, C; Franco; and Jaimovich – atypical abdominoplasties due to preexistent scars and lesions on the abdominal wall [117].
139. 1994 – Wilkinson – abdominoplasty with reduced scar associated to liposuction; details of navel treatment.

140. 1995 – Almeida – abdominoplasty with double excision. Fixes the limits of the dermo adipose excision leaving on the proximal flap a distal band of security tissue, which is totally or partially excised after checking if the final resulting tension of the distal traction is not excessive (4a).
141. 1995 – Almeida – correction of the deformity resembling a suprapubic step (secondary to liposuction with cutaneous excision) making use of a de-epithelialized (4b).
142. 1995 – Lockwood, T – describes and emphasizes the importance of the abdominal superficial fascial system in abdominoplasties [93].
143. 1995 – Baroudi, R, and Morales – bicycle-handlebar-shaped incision in primary and secondary abdominoplasties.
144. 1995 – Correa – makes use of videoendoscopy in abdominoplasties (treatment of diastasis of the rectus muscles and periumbilical lipodystrophies due to minimal incisions) [60].
145. 1995 – Lockwood, T – abdominoplasty + high lateral liposuction with suspension of the superficial fascial system: flap undermining with scalpel just on the central and paramedian areas, undermining up to the costal margin and flanks using a liposuction cannula. Larger dermo adipose excision on the lateral part and then on the medial parts. The suture of the superficial fascial system reduces the tension of the skin suture.
146. 1995 – Matarasso – makes a study giving emphasis to the ventral abdominal wall and its importance when it comes to liposuction associated to abdominoplasty with reduced incisions.
147. 1995 – Pitanguy, I et al. – classification of the abdominal wall deformities in six groups. For each one he associates maneuvers to techniques (such as liposuction, the use of Marlex web, and so on).
148. 1996 – Gerow, Walter, and Spira – transversal abdominoplasty with short and oblique lateral incisions up to 2 cm above and medial to the anterosuperior iliac spines (French line abdominoplasty, strong aponeurosis plication) [72].
149. 1998 – Caldeira – transversal abdominoplasty associated to the treatment of intense aponeurotic muscle flaccidity which is reinforced with polyethylene web [37].
150. 1998 – Ribeiro L, Acorsi A, and Buss A – miniabdominoplasty indications and technique: small suprapubic fusiform cutaneous excision, dermo adipose undermining up to the xiphoid appendix, sectioning the deep implantation of the navel, aponeurosis plication, supraumbilical liposuction, or dermo adipose graft depending on the deformity [123].
151. 1998 – Zukowski et al. – revision of 85 cases of abdominoplasty associating liposuction to aponeurotic plication by endoscopy [168].
152. 1999 – Avelar, JM – superficial and deep liposuction associated to the excision of suprapubic and bilateral inframammary skin excess (as a full thickness of the skin); skin suture without navel transposition (Fig. 26.9).
153. 1999 – Avelar, JM – published a new procedure for flankplasty using his surgical principles without panniculus undermining and resection. He achieved good aesthetic results and suitable scars.



**Fig. 26.9** Demarcations of Avelar's technique. On top: it is demarcated upper lipoabdominoplasty and lower lipoabdominoplasty. On bottom: Avelar's technique for full lipoabdominoplasty

154. 1999 – Avelar, JM – his publication regarding thigh lifting is an important surgical evolution in this field performing the operation without panniculus undermining and resection, which is a useful method based on Avelar's principles of abdominoplasty.
155. 1999 – Avelar, JM – described a new technique of axillaplasty using his surgical principles of abdominoplasty without panniculus undermining (Fig. 26.9).
156. 1999 – Jaimovich, C A et al. – the importance of the abdominal wall, semiotics for abdominoplasty planning.
157. 1999 – Shestake – the increase of miniabdominoplasty indications by the association to liposuction [129].
158. 2000 – Ramirez – dermolipectomy associated to liposuction with distal incision resembling a “U”- and proximal “M”-shaped, a new “V”-shaped opening for the navel, aponeurotic muscle reinforcement opening the central wall of the rectus sheath + medial line suture [114].
159. 2000 – Avelar JM – emphasized the importance of abdominoplasty without panniculus undermining and resection with minimal morbidity and good

- aesthetic results. A half-moon skin resection on the submammary fold improves the aesthetic results on the upper abdomen (Fig. 26.9) [16].
160. 2001 – Avelar JM – introduced new concepts for abdominoplasty with special approach for plication of the musculoaponeurotic wall of the abdomen without panniculus undermining and resection. The diastasis on the upper abdomen is treated by reinforcement of the aponeurosis through umbilicus incision without panniculus undermining [17].
  161. 2001 – Nahas FX – aponeurotic muscle reinforcement by incision on the ventral wall of the rectum sheath and its suture on two different planes on the medial line [99].
  162. 2002 – Avelar JM – presented wide experience after 114 patients underwent abdominoplasty without panniculus undermining in the last 3 years. He also performed transposition of the umbilicus which means full abdominoplasty with reinforcement of the musculoaponeurotic structures of the abdomen without panniculus undermining [18].

## References

1. Abramo AC, Viola JC, Marques A (1990) The H approach to abdominal muscle aponeurosis for the improvement of body contour. *Plast Reconstr Surg* 86(5):1008–1013
2. Agris J (1977) Apparatus to hold the panniculus up during abdominoplasty. *Plast Reconstr Surg* 60(2):292–293
3. Albuquerque J (1975) Neonfaloplastia — comunicação pessoal, VIII Congresso Panamericano do Colégio Internacional de Cirurgiões—Rio de Janeiro—Brasil
4. Almeida R (1995) Abdominoplasty with double excision. *Plast Reconstr Surg* 95:610
5. Andrews JM (1956) Nova técnica de lipectomia abdominal, onfaloneoplastia. *Memoria do III Congresso Latino-Americano de Cirurgia Plástica, Cuba*, pp 143–157
6. Andrews JM (1956) Nova técnica de lipectomia abdominal e onfaloneoplastia, III Congresso Latino-Americano de Cirurgia Plástica, p 148
7. Andrews JM (1976) Dermolipectomia abdominal. *Anais do XIII Congresso Brasileiro de Cirurgia Plástica*. Ed. Meridional, Porto Alegre
8. Appiani E (1984) Muscular plastic for aesthetic conformation of abdominal girdle. *Ann Plast Surg* 13(2):97
9. Avelar JM (1976) Umbilicoplastia: uma técnica sem cicatriz externa. *Anais do XIII Congresso Brasileiro de Cirurgia Plástica*. Ed. Meridional, Porto Alegre
10. Avelar JM (1978) Abdominoplasty – systematization of a technique without external umbilical scar. *Aesthetic Plast Surg* 2:141–151
11. Avelar JM (1979) Cicatriz umbilical – da sua importância e da técnica de confecção nas abdominoplastias (Umbilical scar – its importance and technique for creating during abdominoplasty). *Rev Bras Cir* 1(2):41–52
12. Avelar JM (1983) Abdominoplasty: technical refinements and analysis of 130 cases in 8 years' follow-up. *Aesthetic Plast Surg* 7:205–212
13. Avelar JM (1985) Fat-suction versus abdominoplasty. *Aesthetic Plast Surg* 9:265–276
14. Avelar JM (1985) Combined liposuction with traditional surgery in abdomen Lipodystrophy. XXIV Instructional Course of Aesth Plast Surg of ISAPS, Madrid
15. Avelar JM (1999) Uma nova técnica de abdominoplastia – sistema vascular fechado de retalho subdérmico dobrado sobre si mesmo combinado com lipoaspiração (A new technique

- for abdominoplasty – closed vascular system of subdermal flap folded over itself combined to liposuction). *Rev Bras Cir* 88/89(1/6):3–20
16. Avelar JM (2000) Abdominoplasty: a new technique without undermining and fat layer removal (Abdominoplastia: uma nova técnica sem descolamento e remoção da camada de gordura). *Arq Catarinense de Med* 29:147–149
  17. Avelar JM (2001) The new abdominoplasty and derived technique. International course – American society for aesthetic plastic surgery annual meeting. The Aesthetic Meeting, New York
  18. Avelar JM (2002) Abdominoplasty without panniculus undermining and resection: analysis and 3-year follow-up of 97 consecutive cases. *Aesth Surg J* 22(Jan/Feb):16–25
  19. Babcock WW (1916) On diseases of women and children. *Am J Obst* 75:596
  20. Babcock WW (1939) Plastic reconstruction of the fern\* and abdome. *Am J Surg* 43:260
  21. Babcock WW (1953) A textbook for students. W. B. Saunders, Philadelphia
  22. Bankoff G (1943) Plastic surgery. Philadelphia. pp 343–346
  23. Barrile N (1957) Plastic surgery of enlarged abdomen. Editora Semana Méd-Buenos Aires 111(20): 997
  24. Baroudi R (1973) Management of the umbilicus in abdominoplasty Presented at Society Aesthetic Plastic Surgery Meeting. Newport Beat
  25. Baroudi R, Keppke EM, Tozzi Netto F (1974) Abdominoplasty. *Plast Reconstr Surg* 54:161–168
  26. Barraya L, Nakpane ET (1968) Abdomen moluscum. Abdomen pendulum. Reparations, Nouvel ambilic. *La Presse Med* 76(48):2287–2289
  27. Barraya L, Deleuze J (1967) Chirurgie abdominal. Reparations pariétales et dermolipectomies. *Nouvel ombilic Chir* 93(15/16):473–479
  28. Barsky AJ (1950) Principles and practice of plastic surgery. Williams and Wilkin Co., Baltimore
  29. Barsky AJ, Kahn S (1964) Principles and practice of plastic surgery. MacGraw-Hill Book Company. Inc, New York, pp 543–546
  30. Beck C (1917) pendulous abdomen. Cure by removal of the excess fat and obliteration of ventral hernias. *Surg Clin* 1:731–736
  31. Berson MJ (1948) Atlas of plastic surgery. Grune and Stratfl, New York
  32. Biesenberger H (1936) Abdomen pendulous. *ZBL Chir* 63:1399
  33. Bolivar E et al (1987) A new methodology in abdominal aesthetic surgery. *Aesthetic Plast Surg* 11:213–222
  34. Bozola AR, Psillakis JM (1988) Abdominoplasty: a new concept and classification for treatment. *Plast Reconstr Surg* 82(6):983–993
  35. Caldeira AML, Niéves A, Oliveira A (1990) Cirurgia do contorno corporal – Reflexões sobre um novo enfoque da cirurgia plástica do abdome. I – Classificações das derformidades abdominais e suas correlações cirúrgicas. *Rev Bras Cir* 80(2):95–104
  36. Caldeira AML, Niéves A, Oliveira A (1990) Cirurgia do contorno corporal – 2ª Parte. Reflexões sobre um novo enfoque da cirurgia plástica do abdome. *Rev Bras Cir* 80(3): 169–186
  37. Caldeira AML, Lucas A (1998) Flacidez músculo-aponeurótica abdominal intensa. Su tratamento. *Cir Plast Ibero-Latinoamericana*. Vol 24(1) Enero/Febrero; Marzo. pp 9–15
  38. Callia WEP (1960) Dermolipectomie abdominale. Opération de Callia du film réalisé para Benedito J. Duarte. Centre-cinematographique Carlo Erba
  39. Callia WEP (1963) Contribuição para o estudo da correção cirúrgica do abdome pêndulo e globoso — técnica original. Tese de Doutorado apresentada à Faculdade de Medicina da USP, São Paulo
  40. Castañares S, Goethel JA (1967) Abdominal lipectomy: a modification in technique. *Plast Reconstr Surg* 40:378–383
  41. Castro CC (1977) Estudo da Associação Cirúrgica da Plástica de Abdome com procedientos ginecológicos. *J Bras Gin* 83:137

42. Castro CC et al (1984) T Abdominoplasty to remove multiple scars from the abdomen. *Ann Plast Surg* 12(4):369–73
43. Cibils Puig JP (1974) Nuevo método de lipectomia abdominal, com conversación del ombigo em su posición normal. III Congreso Latino-Americano de Cir. Plástica 11:827. Santiago Del Chile
44. Claoué C (1957) Abdominal plástic surgery. *Clin Y Labor* 64:81–89
45. Correa Iturraspe M (1952) Dermolipectomia vertical del abdomen. *Bol y trab Soc Argent Cir* 13:698
46. Correa Iturraspe M (1952) Tratamiento quirúrgico de la obesidad. *Rev Ass Med Arg* 66:340–349
47. Correa Iturraspe M (1952) Resultados de la primera dermolipectomia abdominal vertical. *Bol Soc Argent Cirurg* 651
48. Correa Iturraspe M (1962) Vertical dermolipectomy of the abdomen. *Esthetic results. Sem Méd (Buenos Aires)* 121:1071
49. Dardour R, Vilain S (1986) Alternatives to the classic abdominoplasty. *Ann Plast Surg* 17(3):247
50. Desjardins P (1911) Résection de la couche adi d'obésité extrême (lipectomie). Rapport par Dartigues, Paris. *Chirurg* 3:466
51. Demars Marx (1890) Mentioned in Voloir P. *Operations plastiques sus-aponévrotique sur la paroi abdominale anterieieure. Thèse, Paris*
52. Dubou R, Gusterhout DK (1978) Placement of the umbilicus in an abdominoplasty. *Plast Reconstr Surg* 61(2):291–293
53. Dufourmentel C, Mooly R (1959) *Chirurgie Plastique. Collection médico-chirurgicale. Flammarion éd. Paris, pp 381–389*
54. Elbaz JS (1974) Technique du “fer à cheval” dans les plasties abdominales. *Ann Chir Plast* 19:155–158
55. Elbaz JS (1975) Panel (secrétariat) des abdominoplasties V Congrè de l' I. P.R.S., Paris, 29 août
56. Elbaz JS, Zumer L (1974) Maternité et préjudices esthétiques. *Les dossiers de l' obstétrique* 2:16–22
57. Elbaz JS, Dardour JC, Ricbouxc B (1975) Vascularisation artérielle de la paroi abominale. *Ann Chir Plast* 20(1):19–29
58. Ely JF (1965) *Cirurgia Plástica — Fundo Editorial Prociencx — São Paulo*
59. Enrenfeld H (1939) Abdomen pendulous – ZBI. *Chir* 63:556
60. Ferraro H et al (1977) Improving the efficiency ease and efficacy of endoscopic abdominoplasty. *Plast Reconstr Surg* 99:895
61. Fernandez JC, Correa-Itur Raspe M (1961) Lipectomia del abdomen. *Bol y Trab Soc Argent Cir* 22:591
62. Fernandez JC (1962) Vertical dermolipectomy of the abdomen. Detailed technique. *Sem Med Buenos Aires* 120:431–432, 22 nov 1962
63. Fernandez JC, Correa Iturraspe M (1951) Dermolipectomia vertical en el delantal grasoio. *Ed Dia Med* 18:23(36):1483–1488.
64. Fischl RA (1971) Vertical abdominoplasty. *Plast Reconstr Surg* 51(2):139–143
65. Flesch-Thebesús M, Weischeimer K (1968) Die Operation des Hangebauches. *Chirurg* 3:841. Apud Piçkrell K (1931) Reconstructive surgery of the abdominal wall and back. In: Converse JM (editor) *Reconstructive plastic surgery, vol 5. W. B. Saunders Co, Philadelphia/London, pp 1951–1956*
66. Flesch-Thebesús M, Weischeimer L (1931) Die operation des Hangebauches. *Chirurg* 3:841
67. Fournier MM (1953) Lipectomia abdominal. *Cirurgia Y Cirurg* 21:443–448
68. Freeman BS (1978) Panel des. Abdominoplasties. “V Congrès de l' I.P.R.S.” Paris, 29 août
69. Galtier M (1955) Traitement chirurgical de l' obésité de la paroi abdominale avec ptose. *Mem Acad Ch* 81:341
70. Galtier M (1962) Obésité de la paroi abdominale avec ptôse. *Presse Med* 70:135



71. Gautier-Benoit C, Quandalle P, Florim M, et Faillon JM (1968) Le traitement des eventrations postopératoires par plaque de mersilène. *Lille Chir* 13:17
72. Gerow F et al (1996) The french line abdominoplasty. *Ann Plast Surg* 36(530)
73. Goldecberg B, Salvo A (1948) Dermolipectomia abdominal. *Dia Med* (Buenos Aires) pp 36
74. Gonzalez-Ulloa M (1967) Belt lipectomy. *Br J Plast Surg* 13:179–186
75. Gonzalez-Ulloa M (1959) Circular lipectomy with transposition of the umbilicus and aponeurotic technic. *Cirurg Y Cirurj* 27:394–409
76. Gonzalez-Ulloa M, e Flores ES (1970) Reestruturacão total do corpo feminino deformado pela síndrome de negligênciaobstétrica. *Gaz Sanit Ano XIX*(9):2
77. Grazer FM (1971) Use of fiber optic bundles in plastic surgery. *Plast Reconstr Surg* 43:28
78. Grazer FM (1973) Abdominoplasty. *Plast Reconstr Surg* 51:617–623
79. Hakme F (1979) Lipectomia peri e supra-umbilical nas abdominoplastias. *Ver Bras Cir* 69:271
80. Hartrampf CR, Scheffan M, Black PW (1982) Breast reconstruction with a transverse abdominal island flap. *Plast Reconstr Surg* 69(2):216–225
81. Hetter TR et al (1989) Abdominoplasty combined with other major surgical procedures: safe or sorry? *Plast Reconstr Surg* 83:997
82. Hinderer U (1966) Tratamiento quirúrgico de la obesidad abdominal (Dermolipectomías). *Anales de la Acad Med Quir Esp* 5:51
83. Hinderer U (1968) Problemas psicológicos y psiquiátricos en el paciente de cirugía plástica. *Rev Esp de Psicol Anal* 1:31
84. Ivanishevich M (1961) Técnica de Velez Diaz Canseco. *Dermolipectomia*. *Sem Méd* (Buenos Aires) 118:535–538, 30 de maio de 1961
85. Illouz YG (1992) A new safe and aesthetic approach abdominoplasty. *Aesthetic Plast Surg* 16:237–245
86. Jaimovich CA et al (1984) Necroses abdominais – opções para reconstrução. 21st Congresso Brasileiro de Cirurgia Plástica – Rio de Janeiro – Brasil; 18 à 20 Novembro
87. Jolly R (1911) Die Operation des Fettbauches. *Berl Klin Wschr* 48:1317
88. Jackson I (1978) Abdominoplasty, the waistline stitch and other refinements. *Plast Reconstr Surg* 61:180
89. Kamper MJ, Dwight V, Gallomay DV, Aschley F (1972) Abdominal panniculectomy after massive weight loss. *Plast Reconstr Surg* 50:441–446
90. Kelly HA (1899) Report of gynecological cases. *Johns Hosp Bull* 10:197
91. Kuster H (1926) Operation bei Hängebrust and Hängeleib, *Mc tsschr. F Geburtsh Gynäk* 73:316
92. Le Louarn C (1992) La plastic abdominale sour-fasciale partielle. *Ann Chir Plast Esthet* 37(5):547–552
93. Lockwood T (1995) High lateral-tension abdominoplasty with superficial fascial system suspension. *Plast Reconstr Surg* 96:603
94. Malbec EF (1948) Lipectomia abdominal. *La Prensa Méd Arg.* 35:26.
95. Marchal G, Lapeyrie H, Amar E (1964) Sur un procédé de plastie cutanée dans le traitement des faiblesses et du tablier adipeux de la paroi abdominale. *Montpellier Chir* 10(4):315–318
96. May H (1947) *Reconstructive and reparative surgery*. F.A. Davis Co., Philadelphia, p 392
97. Morestin A (1911) La restauration de la paroi abdominale par résection étendue des téguments et de la graisse sous-cutanée e1 plissement des aponeévroses superficielles envisagé comme complément de la cure radicale des hernies umbilicales. Thèse, Paris
98. Muhlbauer W (1989) Radical abdominoplasty, including body shaping: representative cases. *Aesthetic Plast Surg* 13:105–110
99. Nahas FX (2001) Advancement of the external oblique muscle flap to improve waistline: a study in cadavers. *Plast Reconstr Surg* 108(2):550–555
100. Paul MD (1990) The American Society for Aesthetic Plastic Surgery, Inc. Asaps Interim. Board Meeting. *The Aesthetic Societh, Aesthetic Surgery - Journal - Fall* 10(3):12
101. Peters L (1901) Resection of the pendulous, fat abdominal wall in cases of extreme obesity. *Ann Surg* 33:299

102. Pitanguy I (1971) Surgical reduction of the abdomen thigh and buttocks. *Surg Clin North Am* 51:478–489
103. Pitanguy I (1967) Abdominal lipectomy: an approach to it trough an analysis of 300 consecutive cases. *Plast Reconstr Surg* 40(4):384–391
104. Pitanguy I (1967) Abdominoplastias. *O Hospital*, Rio de Janeiro 71(6):1541–1556
105. Pitanguy I, Yabar AA, Pires CEB, Motta SR (1974) Aspectos atuais em lipectomia abdominal. *Rev Bras Cir* 64(5/6):147–167
106. Pitanguy I (1982) Perspectivas Filosóficas e Psicológicas do Abdômen. Anais Simpósio Brasileiro de Abdominoplastia. Braz Society of Plastic Surgery. pp 15–24
107. Planas J (1978) The “vest over pants” abdominoplasty. *Plast Reconstr Surg* 61:694
108. Pontes R (1965) Plástica abdominal: importância de sua associação à correção das hérnias incisionais. *Rev Bras de Cir* 52(i):85–92, agosto
109. Pontes R (1982) Plástica abdominal – Resultados insatisfatórios. (Plastic of the abdomen – unsatisfactory results) In: Avelar (editor) Proceedings of the Brazilian Simposium of Abdominoplasty. Soc Bras Cir Plástica Reg. São Paulo, pp 47–51
110. Prudente A (1942) Dermolipectomia abdominal com conservação da cicatriz umbilical. In Trans. Second Congr. Lati no-Americano de Cir. Plásti, pp 468–470
111. Prudente A (1943) Dermolipectomia abdominal com conservação da cicatriz umbilical. Anais II Cong. Latino-Americano de Plást, Guillermo Karast. Buenos Aires
112. Psillakis JM (1978) Abdominoplasty: some ideas to improve results. *Aesthetic Plast Surg* 2:205–215
113. Psillakis JM, Appiany E, De La Plaza R (1991) Color atlas of aesthetic surgery of the abdomen. Thieme Medical Publishers, Inc., New York, pp 1–88
114. Ramirez O (2000) Abdominoplasty and abdominal wall rehabilitation: a comprehensible approach. *Plast Reconstr Surg* 245
115. Rebello C, e Franco T (1972) Abdominoplastia por incisão sub-mamária. *Rev Bras Cir* 62(7 e 8):49–252, julho/agosto 1972
116. Rebello C, Lion P, Franco T (1972) Abdominoplasty through submammary incision. Intern. Cong. — International Soc. of Aesthetic Plastic Surg, Rio de Janeiro. Ed. Publicaciones Controladas, 58, Madrid
117. Rebello C, Franco T, Jaimovich CA (1994) Abdominoplastias atípicas. “Cirurgia Plastica Reconstrutiva e Estética” vol IV, 2ª Edição. Editora Masson Salvat Medicina Cap 386:3143–3151
118. Reder F (1911) Remarks on the obese abdominal wall. *Trans Am Ass Obst Gyn* 24:175–181
119. Regnault P (1975) Abdominoplasty by the W technique. *Plast Reconstr Surg* 55(3):265–274
120. Regnault P (1972) Abdominal dermolipectomy. Internat Microfilm J Aesthet Plast Surg (Dr. J. Tamerim. 44 E. 67 Street, N.Y. N.Y)
121. Rebello C (1968) Plástica de abdome. *Rev Med Bras* 56(3):51–65
122. Ribeiro L (1974) Inclusão das próteses de Cronin por via areolar e abdominal. *Transact. II Congresso Argentino de Cirurgia Estética*, Buenos Aires, p 64
123. Ribeiro L, Acorsi A, Buss A (1998) Miniabdominoplasty indications and technique. *Aesthetic Plast Surg* 11:313–317
124. Saldanha OR (2001) Lipoabdominoplasty without undermining. *Aesthet Surg J* 21:518–526
125. Schepelmann E (1924) Ueber Brauchdeckenplastik mit besend Berück-sichtigung des Hängebauches. *Beitr Klin Chir* 3:1918. Also, *Zentralbl. f. Gynäk*, 2289
126. Schimpf H (1957) Expérience acquise dans la plastic de l’ abdom pendulum avec conservation de l’ ombilic. *Zbl Chir* 82(8):321
127. Serson Neto D (1970) Dermolipectomias abdominais (Abordagem geométrica) *Rev. CBC* 10:17–20, março-abril
128. Serson Neto D (1971) Planejamento geométrico. La dermolipectomia abdominal. *Rev Esp Cir Plast* 4:37–42
129. Shestak KC (1999) Marriage of abdominal and liposuction expands abdominoplasty concept. *Plast Reconst Surg* 103(3):1027

130. Sinder R (1973) Uso de retalho decorticado em plástica de abdome (técnica pessoal de abdominoplastia) IV Congresso Médico-Cirúrgico da Faculdade de Medicina de Teresópolis, TERESÓPOLIS, Estado do Rio de Janeiro
131. Sinder R (1973) Uso de retalho dermoadiposo em plástica de abdome. Comunicação de técnica pessoal de plástica da parede abdominal — VII Congresso da Associação Médica Brasileira e V Congresso da Sociedade de Medicina e Cirurgia do Rio de Janeiro. Rio de Janeiro
132. Sinder R (1974) Uso de retalho dermoadiposo em plástica de mamas e de abdome. (Técnicas pessoais). XI Congresso Brasileiro de Cirurgia Plástica – BELO HORIZONTE, Estado de Minas Gerais
133. Sinder R (1975) Plastic Surgery of the abdomen - Técnica pessoal de abdominoplastia, com prévio deslocamento de retalho supraumbilical (antes da ressecção infraumbilical) e uso de retalho dermoadiposo, – VI International congress of plastic and reconstructive surgery, Paris, França, 25 de agosto de 1975
134. Sinder R (1975) PLÁSTICA DE ABDOME – Técnica pessoal de abdominoplastia com prévio deslocamento do retalho supra-umbilical (antes da ressecção do excesso dermoadiposo infraumbilical) e uso de retalho dermoadiposo suprapúbico. VI CONGRESSO DA SOCIEDADE DE MEDICINA E CIRURGIA DO RIO DE JANEIRO, 23/28 de Novembro
135. Sinder, R. (1975 ) Use of a decorticated dermo-adipose flap in abdominoplasty. Abstracts of the sixth international congress of plastic and reconstructive surgery, Paris, 24–29 Aug 1975
136. Sinder R (1975) Conduta pessoal na plástica de abdome – X Congresso Médico-Cirúrgico do Hospital de Ipanema e IX Jornada de Administração Hospitalar promovido pelo Centro de Estudo do Hospital de Ipanema e pela Associação de Hospitais do Rio de Janeiro, 16 de Outubro
137. Sinder R (1976) CIRURGIA PLÁSTICA DO ABDOME – Tese sobre técnica pessoal de abdominoplastia, apresentada em 1975, para concurso de Livre Docência de Cirurgia Plástica da Faculdade de Medicina da Universidade Federal Fluminense, realizado em Niterói, Estado do Rio de Janeiro
138. Sinder R (1977) Detalhe de técnica citado no Livro de Cirurgia Estética de Talita Franco e Cláudio Rebello, Livraria Atheneu, Rio de Janeiro, São Paulo, Capítulo 9 (Abdominoplastia), 277
139. Sinder R (1979) Cirurgia Plástica do Abdomen. In: Editor Ramil Sinder; Niteroi, Rio de Janeiro, Brasil
140. Sinder R (2002) Historical evolution of abdominoplasty. In: Avelar JM (ed) Abdominoplasty without panniculus undermining and resection. Editora Hipocrates, São Paulo, pp 21–40
141. Somalo M (1940) Circular dermolipectomy of trunk: La Semana 1435–1443, June 13
142. Somalo M (1946) Cruciform ventral dermolipectomy: swallows – shaped incision. Prensa Med Argent 33:75–83
143. Somalo M (1941) Dermolipectomia abdominal. Anales del primero Congreso Latino-Americano de Cirugía Plástica 2:2104, Sao Paulo
144. Spadafora A, Y Torres Sanmarco JJM (1974 ) Cirurgia de Obesidade, Flaccidez cutanea y Envejecimiento. Buenos Aires López Libreros
145. Spadafora A (1962) Pendulous abdomen-antero-lateral dermo pectomy (Personal technic). Prensa Med Arg 49:949–499, 2 Mar 1962
146. Spadafora A (1965) Abdomen adiposo Y péndulo dermolipectomia ¡Ífaco-inguino-pubiana. Prensa Unversitaria (Buenos Aires) 114:1839–1842
147. Spina V (1952) Ventre em péndulo. An Paul Med Cir 64:425–429, dez., 1952
148. Talamas Vasquez J (1946) Transversal abdominal dermolipectomy. Prensa Méd Méx 11:69
149. Teissourian B, Gotkin R (1989) Contouring of the midtrunk in overweight patients. Aesthetic Plast Surg 13:145–153
150. Thomeret G (1967) Protése et traitement des hernies récidivées. Entretiens de Bichat 25–26
151. Thomeret G (1971) La lipectomie circulaire. Nouvelle pratique chirurgicale illustrée. Entretiens de Bichat; Paris, p 169
152. Thorek M (1939) Modern operative technique. J.P. Lippincott-Phil, London

153. Thorek M (1939) Plastic reconstruction of the female breasts and abdomen. *Ann J Surg* 43:269–278
154. Thorek M (1942) *Modern surgical technique, one volume war edition*. J. B. Lippincott Company, Philadelphia, pp 1264–1266
155. Thorek M (1942) *Plastic surgery of the breast and abdominal wall*. Ed. Charles C. Thomas, Springfield
156. Thorek M (1951) *Anatomy in surgery*. J. B. Lippincott Co., Philadelphia, pp 363–397
157. Vernon S (1957) Umbilical transplantation upward and abdominal contouring in lipectomy. *Am J Surg* 94:490–492
158. Vilain R (1958) *La Chirurgie des formes chez la femme*. Film médi-cal de la Cinematheque Diamant
159. Vilain R (1958) *Chirurgie raisonnable de l'obésité*. Entretiens de Bichat, chirurgie et spécialités. Expans Se Fr, p 161
160. Vilain R (1975) Technique dite “en soleil couchant” dans les der-mo-dystrophies abdominales. *Ann Chir Plast XX(2):239–242*
161. Vilain R (1975) Traitement des stéatomeries chez la femme: théorie et pratique. *Ann Chir Plast XX(2):135–146*
162. Vilain R (1964) A propos de la chirurgie réparatrice de la paroi abdominale. *Bul Mens Soc Chir Paris* 54:290–294
163. Vilain R, Dubousset J (1964) Technique de la lipectomia circulaire. *Ann Chir* 18(5–6):289–300
164. Vilain R, Elbaz J, Singier P, Gueriot J (1967) Etude critique des complications des laparotomies. *Ann Chir* 21:262
165. Vilain R, Monsaigeon J (1973) Rapport du XI colloque international de dermo-cirurgie sur le vieillissement de la peau. *Ann Chir Plast XVIII(1):92–93*
166. Vilain R, Soyer R (1964) Traitement chirurgical des eventrations. *Ann Chir* 18:277
167. Weinhold S (1909) Bauchdeckenplastik. *Zentralbl F Gynäk* 38:1332
168. Zukowski ML et al (1998) Endoscopic intracorporeal abdominoplasty: a review of 85 cases. *Plast Reconstr Surg* 102(2):516

# Chapter 27

## Abdominoplasties: Classification (Bozola and Psillakis) and Concepts of Treatment Strategies

Antonio Roberto Bozola

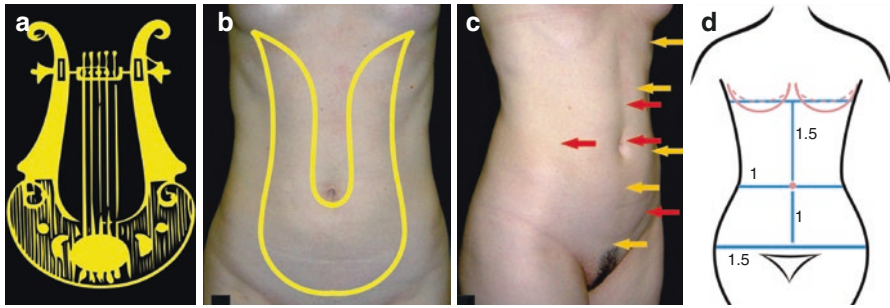
### Introduction

The recent history of abdominoplasty must consider the Brazilian collaboration. Callia [13] (1963) has defended a technique that uses a low suprapubic incision. Pitanguy [19] (1967) has modified the plications of the abdominal rectus muscles, without muscle detachment; he has also modified the design of the low incision. Baroudi and Moraes [5] (1995) have proposed a design that was called the “bicycle handlebar,” because it follows the natural folds of the human abdomen. Psillakis [21] (1984) has defended lateral plications of the external oblique muscles that reduce the waist circumference through an oblique incision of their aponeurosis. This is carried out from the inguinal ligament to the costal margin of the chest, accompanied by medial traction. Sinder [25] (1975) reversed the initial incision of the abdominoplasty through first detaching the supraumbilical flap, followed by its traction, and then a low umbilical excision of the skin could be executed. Bozola and Psillakis [8] (1988) have classified the esthetic alterations of the human abdomen, and they have proposed different diagnoses to reduce the amount of skin excision. Avelar [2] (1978) has described a triple-Z omphaloplasty strategy that has led to numerous other strategies. He developed a liposuction technique where liposuction is followed by a suprapubic and submammary fold excision without detachments, resulting in minimum extent of the excisions [3] (1985) [4] (1999). Célio Leão [16] (2000) has recognized detachment of the medial part of the liposuctioned flap positioned on the diastasis and has carried out plicature without vascular damage. Saldanha [23] (2003) has proposed lipoabdominoplasty followed by liposuction and resection of a low umbilical skin segment, umbilicus transposition, and plications of the rectus abdominis muscles that are

---

A.R. Bozola, MD

Members of the Brazilian Society of Plastic Surgery, CEPlástica – Centro de Estudos em Cirurgia Plástica, Av José Munia 7075, Sao Jose do Rio Preto, SP, Brazil  
e-mail: [zeze@bozola.com.br](mailto:zeze@bozola.com.br); [ceplastica@hotmail.com](mailto:ceplastica@hotmail.com)



**Fig. 27.1** (a) The “lyre”, (b) the lyre over the abdomen, (c) protrusions (yellow arrows) and depressions (red arrows) causing shining and shadows with the visual effects of a lyre, (d) 1/1.5 proportions between infra- and supraumbilical segments and between the waist and the hip

carried out through a central tunnel that is placed upon the diastasis. In this case vascularization is maintained because of maintenance of the perforating blood vessels of the muscles. Bozola [9] (2003) has proposed a large liposuction (the lumbar region, the flanks, the hypochondrium, the upper portion of the buttocks). This must be carried out with a low horizontal mammary line up to the inguinal pleats, including the dorsolateral part and replacement of skin, in accordance with their previous classifications. Bozola still proposes using three tunnels upon muscle diastasis: two of them for plications of the external oblique muscles, without aponeurosis incisions. In fact, today all abdominoplasties are followed by liposuction. That means less excision of the skin and less vascularization damage.

The word *beautiful* is an adjective, and it is used to express a feeling when the human eye identifies *beauty*. This beauty is anatomical and morphological; it depends on form, volume, measurement, proportion, relief, shine, shadow, color, dynamics of movement, and corporal posture that stimulate the human brain, more specifically the limbic system, through human eyesight. These factors are judged by optics, physics, and mathematics and are capable of being reproduced; this beauty is not subjective [12] (2013).

Besides classical anatomical and surgical techniques, the plastic surgeon must know the *anatomy of corporal beauty*. Recognizing beauty makes possible the diagnosis of *corporal esthetic pathology* and the employment of a suitable treatment. It is necessary to become critical in beauty. Diagnostic errors are responsible for a quarter of medical errors in plastic surgery.

In this chapter the author proposes the idea of *the beauty of abdominal anatomy*. Bozola and Psillakis in 1988 [8] defined the beautiful abdomen—that it is not a plane; it has a relief. The incidence of light on the saliencies and depressions makes points and lines of shining and shadows that together resemble a lyre (Fig. 27.1a, b).

The saliencies are the rectus abdominis muscles, the iliac crests, the pubis, the hypogastrium, and the inferior costal margins. The depressions are the supraumbilical medium line, umbilicus, iliac fossa, and semilunar lines (insertion of the oblique to the rectus muscles) (Fig. 27.1c).

It must be considered that there is a vertical medium line of the pubis to a horizontal line that tangents the submammary folds in the breast meridian, so the *normal* position of the umbilicus nearly divides the vertical line in a metric proportion of 1 on the inferior segment to 1.5 on the superior segment (Fig. 27.1d). Proportions of 1–1.4 or bigger can be considered as *high* implantation of the umbilicus, presenting a short supraumbilical segment of the skin, and the proportions of 1–1.6 or smaller are considered as *low* implantation of the umbilicus, presenting a long supraumbilical segment of the skin. These factors are important in the indications for skin resection and surgery. The perimeters of the waist and the hips have a 1/1.5 proportion, up to 1/1.6; this value was considered beautiful in the past, near the golden or divine proportion ( $\Phi = 1/1.618$ ) known in world history (Fig. 27.1d).[10] (2010) [12] (2013).

The Phi proportion has been studied and described by astrophysicists, [1] (2004) botanists, architects, mathematicians, musicians, psychologists, dentists, doctors, and others [17] 2005 [14] (2004). We can find it in nature, and it was observed by Aristotle and Euclid in Greece, 300 years before Christ. The psychologist Chris McManus demonstrated its influence when observers of a similar square collection chose figures that presented a measurement approximating the Phi proportion. Ricketts [22] (1982) and Marquardt [18] (2010) studied and applied the proportion to the human face. In accord with these authors, if Phi exists among face segments, the limbic system is stimulated, and attraction occurs. This sense of beauty has been marked in the human brain throughout time. This is the backup of the human brain. It is like an instinct and sometimes people confuse it with subjective feelings. This is wrong, because we are talking about numbers and measurements that are reproducible and objective.

Since 1982 the author has been studying abdominoplasties and in 2010 proposed Phi to observe the abdominal beauty, mainly in the umbilicus position of the abdomen. He suggests that a low umbilicus implantation, presenting a value near Phi between the superior and inferior segments, makes the abdomen more beautiful. He has also been studying Phi in breasts [11] (2011).

In 1988 a new concept and classification was proposed for abdominoplasties, offering appropriate treatment for each deformity.

Before this time, all abdominoplasties were realized with the resection of the infraumbilical segment skin and umbilical transposition, presenting bad results because of the excessive skin removal. The scars were large, high, or hypertrophic. They had an arch form and their concavity turned down toward the thighs; the extremes crossed the groin plates toward the thighs, so the pubis was high and artificial, and was separated from the abdominal anatomical collection, losing sensuality and abdominal beauty [7] (2011). These abdomens had excessive stretching and always presented a high umbilicus and short supraumbilical segment of the skin. Some authors proposed a supraumbilical transverse incision, firstly, to detach the superior segment, to stretch it toward the pubis, and to mark the position of the transverse inferior incision. This is a way of avoiding complications with stretched skin, but the suprapubic transverse scar was always very high.

Sometimes the scars finished in a vertical field form (mini inverted T) leaving part of the remaining infraumbilical area to cover the abdomen with skin. Did it need skin? No! It needed diagnosis. There was no skin excess but the skin was removed.

The abdominal fat did not have adequate treatment. Currently this fat is removed in the iliac fossa, under the fascia superficialis (lamellar layer), cone-shaped in the umbilicus exit, and in the supraumbilical medium line, removing a narrow fat segment with a fine layer from the umbilicus exit up to the xiphoid appendix. Muscular plication was always realized in the same way, after large displacements.

In the first study and all the others afterward, it was proposed to combine, in groups, several diagnoses relative to the: (1) excess skin, (2) excess subcutaneous fat, (3) laxity or not of the musculoaponeurotic layer, and (4) position of implantation of the umbilicus, dividing the abdomen into two segments--inferior and superior. So the extent of skin removal was reduced; the scars were smaller and placed lower, preserving the inferior part of the lyra through adequate skin stretching. Separation of the abdominal anatomical collection from the pubis segment was avoided.

Nowadays, enough skin is removed to leave the abdomen slightly stretched; the liposuction area is larger than before, and muscular plication is realized through selective tunnels where the muscular perforator vessels do not exist, or where they are not necessary to keep good vascularization of the abdominal flap. Before, abdominal sensitivity was damaged with large displacements, and now it is preserved either totally or partially.

The concept of miniabdominoplasty is known worldwide, but the present author regards it as inappropriate. Only if this classification is made by observation of the suprapubic scar extent when the skin excess is small could it make sense.

With the evolution of liposuction, treatment of the abdomen has increased in extent and intensity. Now, the conduct of abdominoplasties is characterized by a significant reduction of flap undermining, with a significant increase in the liposuction and tunneling areas without important perforator vessels for aponeurosis plication and the reduction of skin resection and traction, fixing the flap on the aponeurosis, and reducing the number of seromas. There is nothing "mini" in this treatment.

The Bozola and Psillakis classification (1988) contributes to the adjustment of different diagnoses in the same corporal segment that demand different treatments.

By observing the new strategies and using vibroliposuction equipment, nowadays the author still maintains the same classification, but changes the treatment with more liposuction and undermining in tunnels, and does not consider and treat only the anterolateral abdomen anymore. The author aims to treat the trunk circumference, from the inframammary fold to the inguinal crease, including the lower flank, the superior part of the buttocks, the lumbar area, and the inferior portion of the thorax (hypochondrium). The author has thus achieved a more natural abdominal and trunk form.

The strategies, techniques, and statistics described here result from observations of the author's last 500 patients operated on and followed.

The author proposes five different groups, as they were proposed 26 years ago, with their respective current treatments for esthetic deformities of the abdomen.

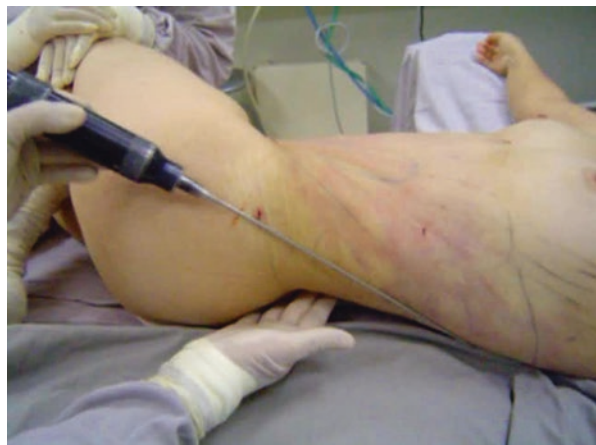

### ***Abdomen Classifications (“Esthetic Pathologies”) and Their Respective Treatments***

In general miniabdominoplasties are considered as minor surgery when compared with the classical abdominoplasty or with liposuction-abdominoplasty done with the resection of all the infraumbilical skin and transposition of the umbilicus. This classification does not reflect the real complexity and the extent of this surgery. Nothing is “mini.” Sometimes this surgery is equal to or greater than classical abdominoplasty. As stated above, the classification could make sense if it was made by observation of the suprapubic scar extent, when the skin excess is small. It is a classification that is simpler than the reality.

Thus, as stated above, and in accordance with the: (1) excess skin, (2) excess subcutaneous fat, (3) laxity or not of the musculoaponeurotic layer, (4) the position of implantation of the umbilicus, and dividing the abdomen into two segments, inferior and superior, it is possible to classify abdomen types into five groups and to treat them correctly, obtaining good final results.

**Group I** This group represents about 27% of the last 200 patients operated in a private clinic; this group usually consists of nulliparous women having normal skin and muscle tone, but an excess of fat in the subcutaneous tissue in all abdominal areas, flanks, lumbar region, and hypochondrium (the antero-latero-inferior area of the thorax), more evident in the lower and paraumbilical areas and lateral flanks. They were treated by liposuction [15] (1992) (vibroliposuction, pneumatic equipment), using cannulas with a diameter of 3 or 4 mm, with 0.5 cm incisions on the xiphoid appendix, the iliac fossa, on the flanks, and when necessary, on the hypochondrium. The patient must be on the operation table in the Trendelenburg position. It is not necessary to change the decubitus because we can cause surgical complications such as hemodynamic changes; then, to treat the flanks and lumbar region on the right side, it is enough to cross the right leg over the left leg, forcing the trunk dorsal decubitus laterally (Fig. 27.2). Then the surgeon does this other way round to treat the left side.



**Fig. 27.2** Position to liposuction the sides and the dorsum, without changing the dorsal recumbency

The operating room must have a temperature above 20 degrees C, because otherwise the corporal temperature is reduced, causing slow blood circulation and thrombosis.

In the intraoperative and postoperative periods the patients also remain with their legs in a high position. Postoperatively patients can use tight elastic clothes on the trunk.

Infiltration is performed with hypoosmolar solution, in general, 2 L, consisting of 1000 mL physiological saline and 1000 mL distilled water, containing 10 mg dexamethasone, 2 mL epinefrine 1:1000, and 5000 IU hyaluronidase. The patient remains under general anesthetic and with blood pressure 20% lower than her natural pressure. Vibroliposuction was done in all operative plans, preserving 0.5–1.0 cm of the most superficial layer, trying to thin more the areas that should be depressed to show the “lyre”. Compressive dressings with elastic waists are placed on the patient when she is still under general anesthetic and the blood pressure is 20% lower than her natural pressure. This dressing is removed every day and it is put on again after showering.

You should not resume liposuction in an area in which it has already been done because suction of clots is possible, causing the area to bleed again. Such a procedure is done only in restricted cases. At the beginning of the surgery 1 g intravenous hydrocortisone is given, and at the end of the surgery 10 mg intravenous dexamethasone is also administered. If necessary, 4 mg intravenous dexamethasone is administered after 12 h and after 24 h.

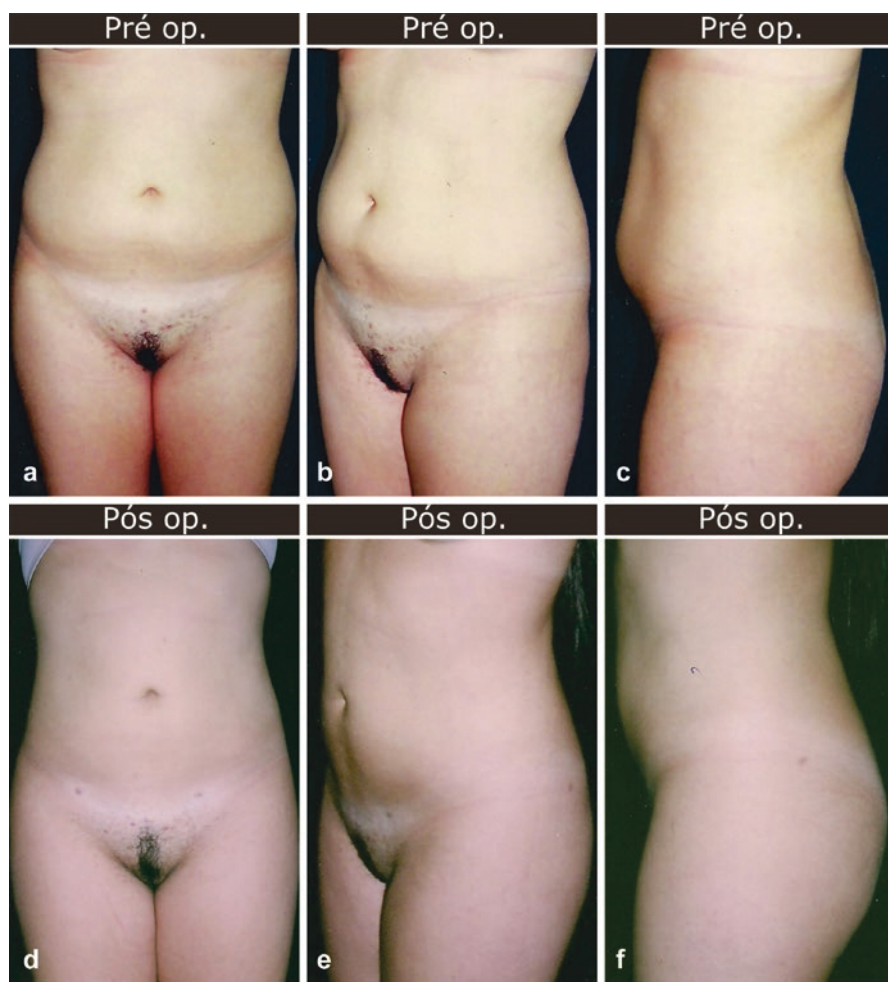In plastic surgery, corticosteroid is used to reduce edema and the inflammatory reaction that are enemies of final good results.

The production of antithrombin and activated protein C occurs when there is a large inflammatory process and insult to the endothelium, resulting in a hypercoagulation state. It is known that the inflammatory process activates the blood coagulation system.

Depending on the surgical extent and time, how great the corporal insult is, and how serious and complicated is the inflammatory process, activation of the blood coagulation system can occur without the natural inhibition of the endothelium. Any kind of tissue trauma (burns, liposuction, extensive surgery, injury) that affects 20% of the corporal area can be considered severe and causes systemic inflammatory response syndrome (SIRS), [24] (1999), resulting in equilibrium changes of blood hemostasis. The result is thrombosis.

Corticosteroids reduce edema, have known antiinflammatory effects, protect physiological activity, and block the SIRS.

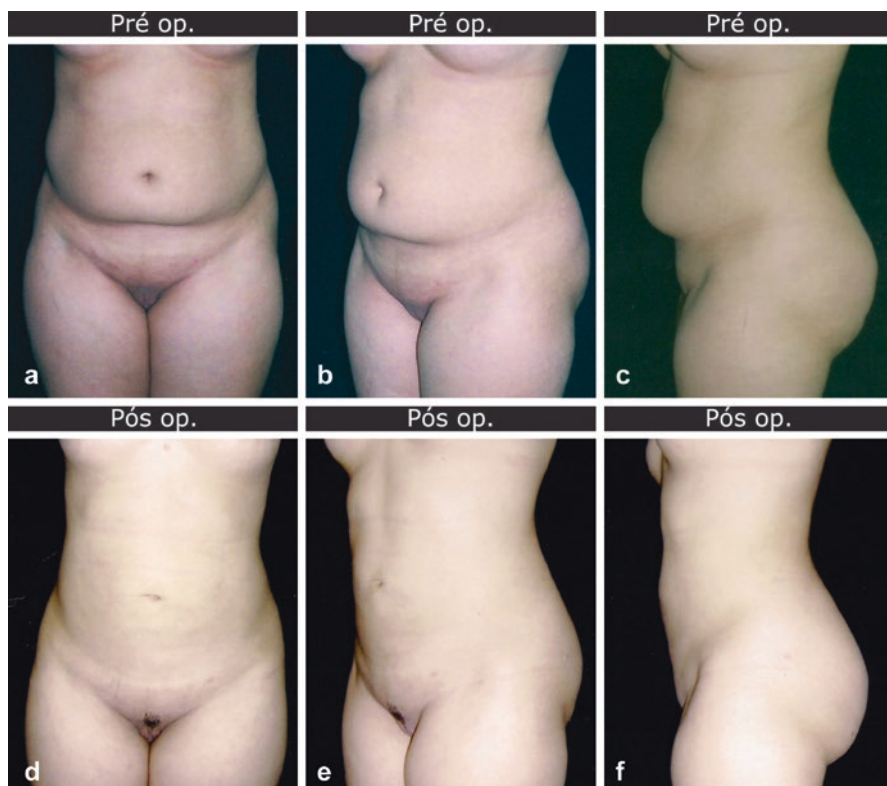
Corticosteroids also increase plasma volume and brain excitability, and they cause euphoria and a feeling of wellness. They increase motor activity and reduce platelet aggregation in spite of a platelet increase in the first 2 or 3 h. They reduce local swelling and inflammation, nausea and vomiting, leaving a normal appetite. Corticosteroids increase the power of analgesics and they act on infections, improving clinical aspects. They also stabilize the coagulation system and blood hemostasis. They cause facial blushing for 72 h, then their effects end. Corticosteroids also cause a “doping effect” and must not be used in people with diabetes or hypertension.



**Fig. 27.3** (a–f) Preoperative and postoperative characteristics of group I (G I; liposuction only)

With all these considerations, the author recommends a high dose of corticosteroid in plastic surgery, for a short time. The pharmacological effects of corticosteroids are important for achieving good patient recuperation (Figs. 27.3a–f and 27.4a–f).

**Group II** This group represented about 22% of the operated patients. In general there was a suprapubic transverse scar after the Pfannenstiel incision. When the *fascia superficialis* is not sutured, its contraction cambers the *hypogastrium* and the lower pubic region, and the scar becomes depressed. It was observed that there was good tone in the muscle-aponeurotic wall, normal implantation of the umbilicus (relationship close to 1–1.5 on the inferior segment for the superior), skin excess only in the infraumbilical segment, and fat excess similar to Group I. Vibroliposuction

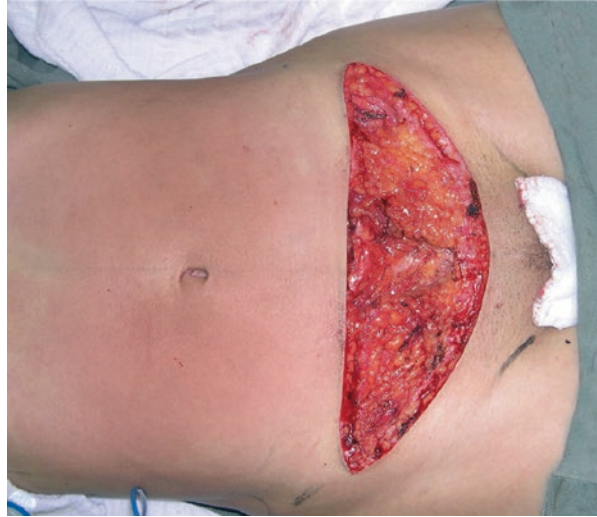


**Fig. 27.4** (a–f) Preoperative and postoperative characteristics of G I, with great change in body contouring

was realized in all segments, as described in Group I, and a spindle-shaped transverse suprapubic segment was resected [3] (1985) [4] (1999) (skin and subcutaneous tissue), up to the muscular aponeurosis, with an indigenous canoe shape and variable lateral extension as necessary. The vertical extension of this segment starts 12–14 cm below the umbilicus up to the pubic region with slightly tensioned skin (Fig. 27.5). The inferior demarcation is also determined with the skin tensioned upward and sufficiently lower than. The final scar will not cut the bottom of the “lyre”. It is sutured with non-absorbable stitches, and it was made firstly and always on the *fascia superficialis*. The final suture of the skin is curvilinear and follows the inguinal pleats, about 1.0–1.5 cm above them. No detachment is necessary. The proportion between the supraumbilical and infraumbilical segments remains the same as that preoperatively.

*The fascia superficialis* is elastic; it is able to contract when incised. Its phylogenetic origin in animals is the pilous layer of the erector pili muscles [26] (1910). After cesarean section, when the fascia is not sutured, it contracts towards the umbilicus, cambers the *hypogastrium* and the pubic region, and depresses the scar. In all

**Fig. 27.5** Skin spindle removed in GII, as described in the text



abdominoplasties this happens too. The wound must be always be sutured with non-absorbable stitches. And this also reduces the tension of the skin and obtains best quality scars (Figs. 27.6a–f and 27.7a–f).

**Group III** These patients represented about 7% of the operated patients; they all had alterations similar to Group II and diastasis of the external oblique muscles. There was a normal position for implantation of the umbilicus. The treatment was similar to the Group I patients for liposuction and similar to the Group II patients for resection of the skin and subcutaneous tissue. For the exposure of the aponeurosis insertions of the external oblique muscles in the lateral aponeurosis of the rectus muscle, two lateral tunnels were made from the iliac fossa up to the rib lateral edge. The width was sufficient to expose the diastasis. This region does not have important perforator vessels and there is a little bleeding during the undermining of the supraaponeurotic tunnels (Fig. 27.8). The suture of the aponeurosis begins in the rib lateral edge (with non-absorbable stitches), with anchored continuous suture, going down close to the inguinal ligaments, reinforced at the end with some separate stitches [12] (2013). The tunnels are closed by fastening the flap and attaching it to the muscular aponeurosis with absorbable stitches. The skin is tractioned smoothly towards the inferior edge of the removed skin, suturing the *fascia superficialis* and skin as described for Group II patients (Figs. 27.9a–f) and (27.10a–f).

**Group IV** These patients represented about 18% of the of the operated patients, possessed mild skin excess in the superior and inferior segments, and had a high position of the umbilicus implantation, a ratio of 1/1.4 between the infraumbilical and supraumbilical segments of skin, up to 1–1.2, or more. There was diastasis of the rectus abdominis muscles, and excess in the fat layers similar to Group I. The patients were treated by liposuction, the same as the Group I patients, skin resection

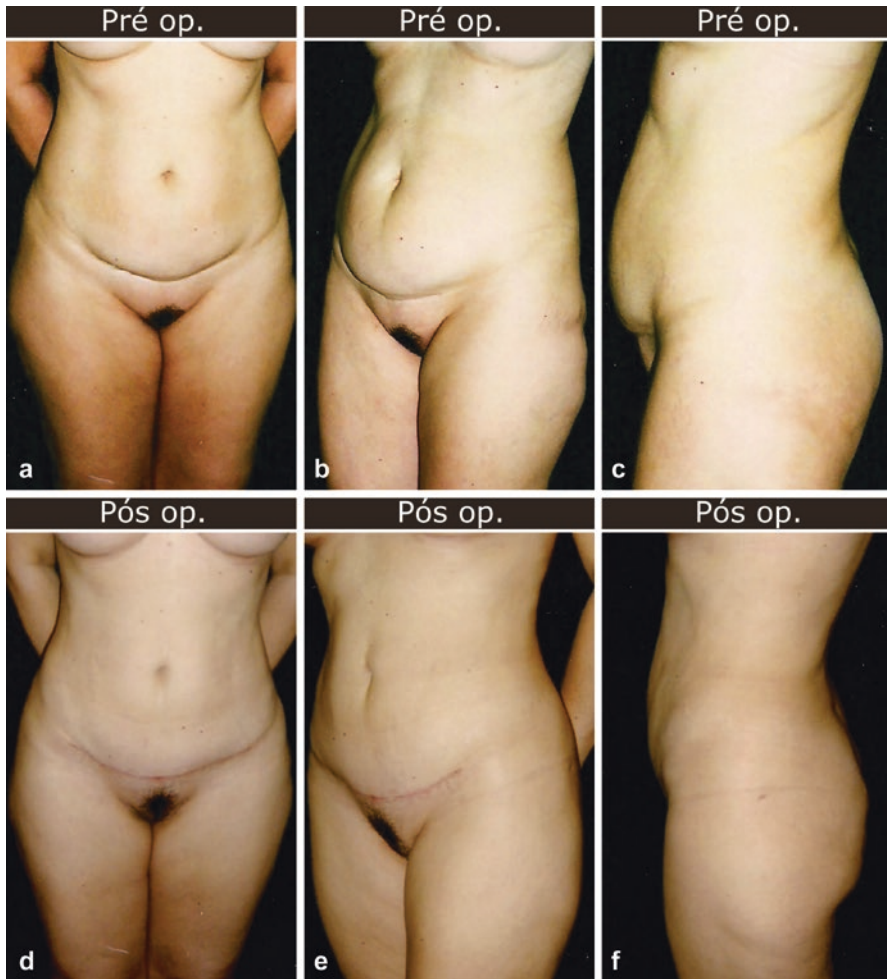
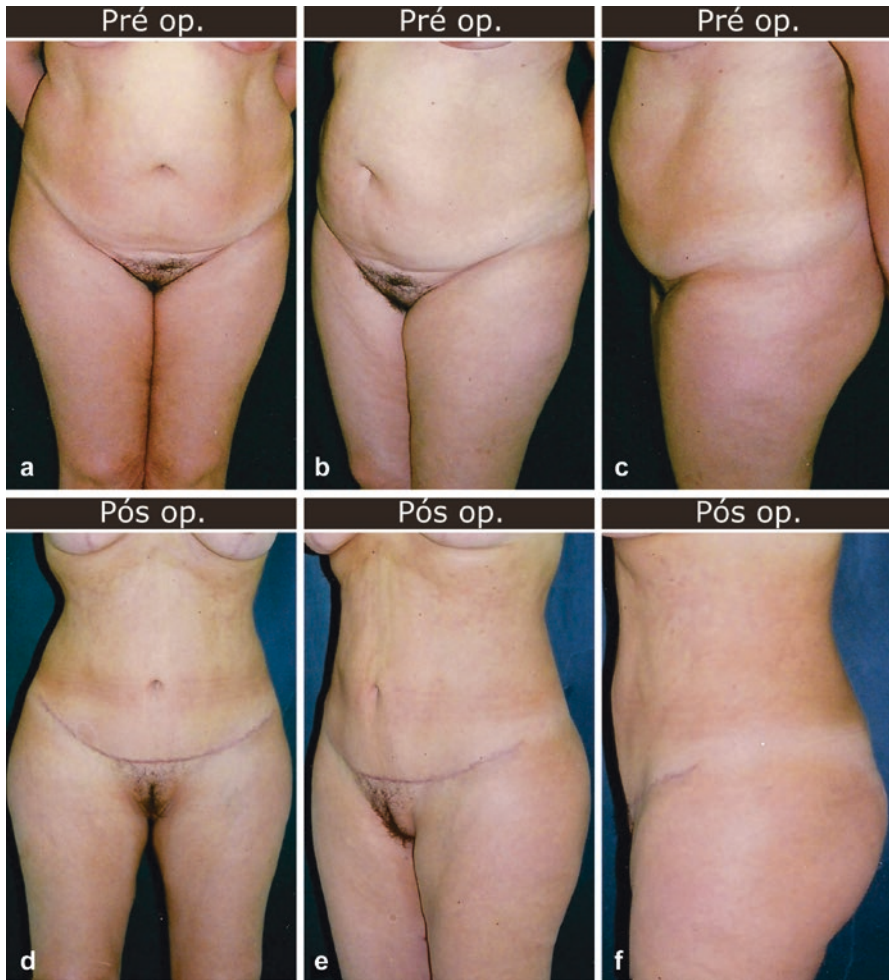

Fig. 27.6 (a–f) Preoperative and postoperative characteristics of G II

similar to the Group II patients, and suturing of the edges of the rectus muscle aponeurosis was done through a tunnel in the midline [8] (1988) [16] (2000) (Fig. 27.11), measured from the superior edge of the skin incision to the xiphoid appendix, detaching the umbilicus implantation from its aponeurotic implantation, attached to the flap. This area is also free of important perforator vessels, and the tunnel width is just enough to expose the medial edges of the rectus muscles; sometimes is possible to preserve two paraumbilical perforator vessels. The aponeurosis of the muscles is sutured with non-absorbable stitches, continuous suture, anchored, and reinforced with some separate stitches. The tunnel was closed from the xiphoid appendix with absorbable stitches, fastening the flap to the aponeurotic fascia, with gentle downward skin traction. The umbilicus was reattached with



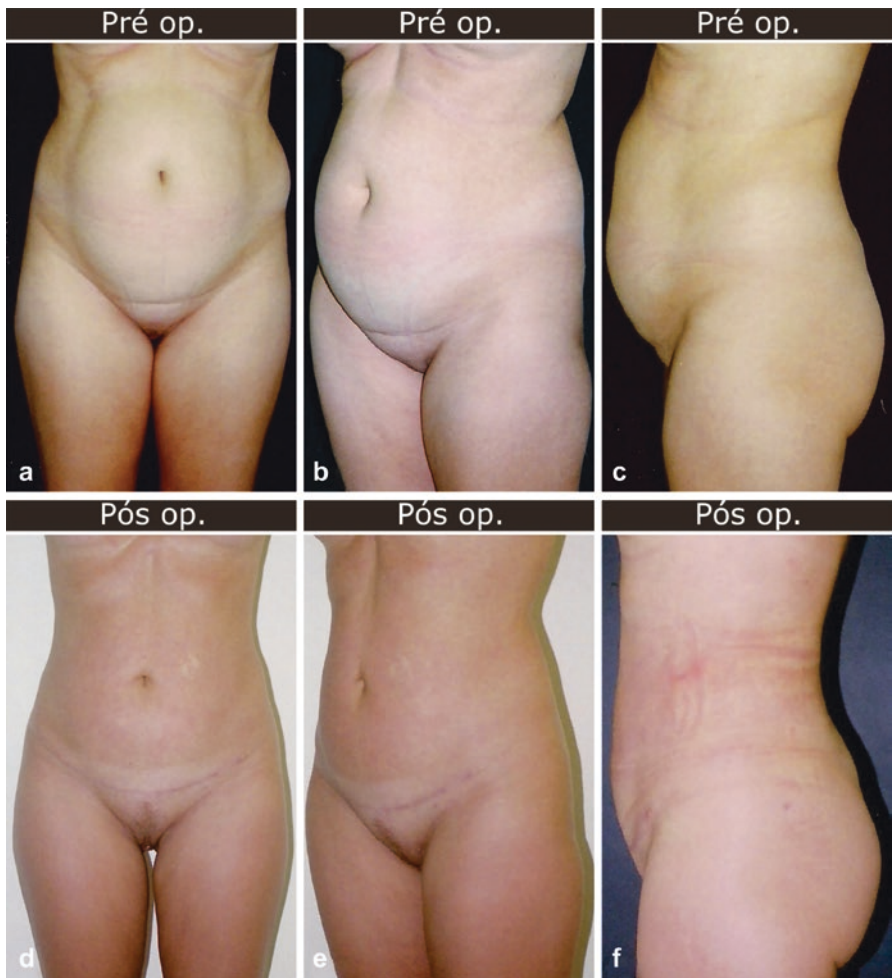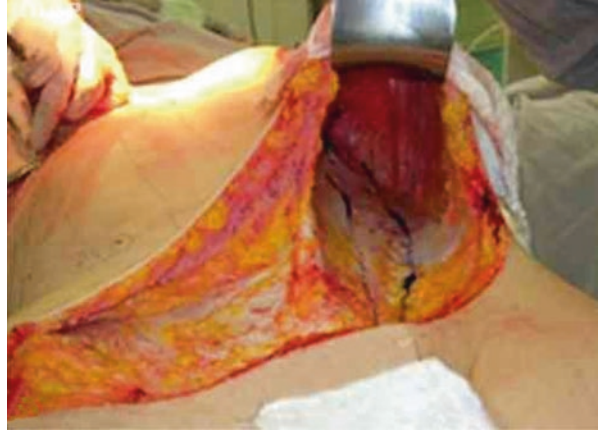
**Fig. 27.7** (a–f) Preoperative and postoperative characteristics of G II. Moderate obesity does not preclude surgery, which improves the body contour, stimulating posterior weight loss

bolster stitches through the skin on the bottom of it, fixed to the aponeurosis, 2–4 cm below the original implantation, altering the relationship between the infra- and supraumbilical segments, with a maximum of 1/1.6. The umbilicus with high implantation thus became a normal or lower implantation (Fig. 27.12). The remaining closure of the incisions was similar to the Group II and III patients.

The gauze fragment that compresses the bottom of the umbilicus to the aponeurosis (bolster stitch, Group IV) must stay in place for 2 weeks.

**Group V** Containing about 10% of the operated patients, this group had a large supraumbilical skin excess (long supraumbilical segment) with or without infraumbilical excess; low umbilicus implantation (proportion between infra- and

**Fig. 27.8** Lateral tunnel on the oblique muscles inserts to their plicatures



**Fig. 27.9** (a–f) Preoperative and postoperative characteristics of G III



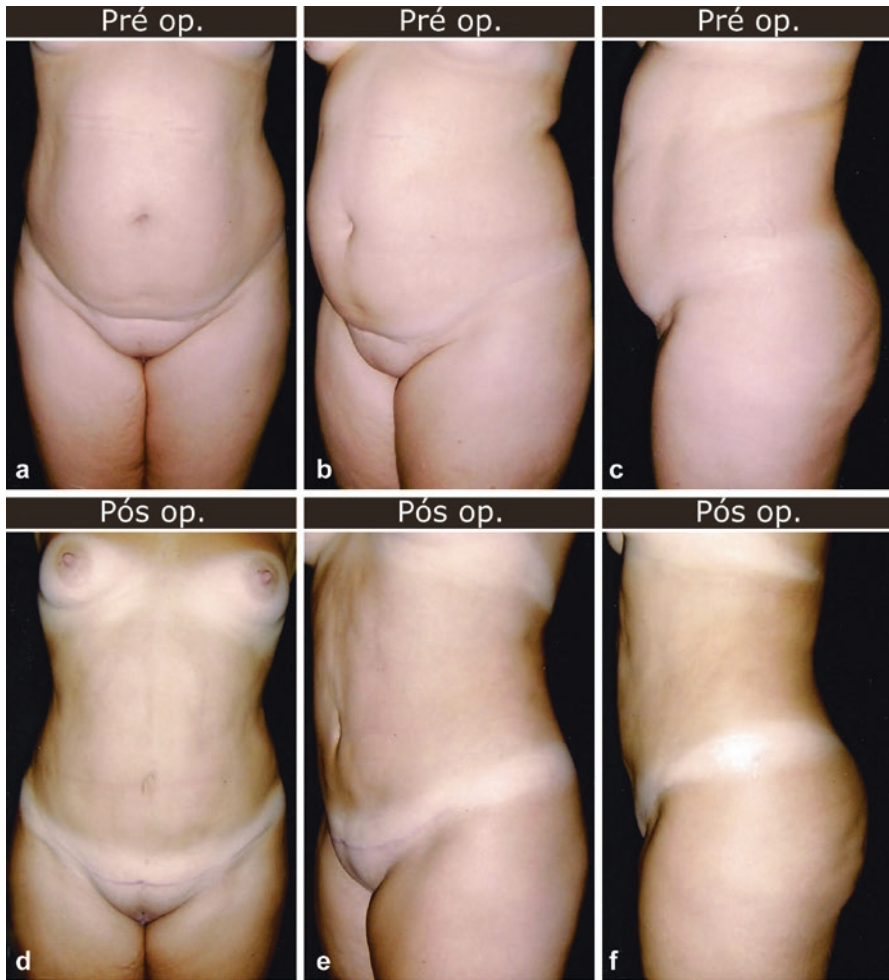
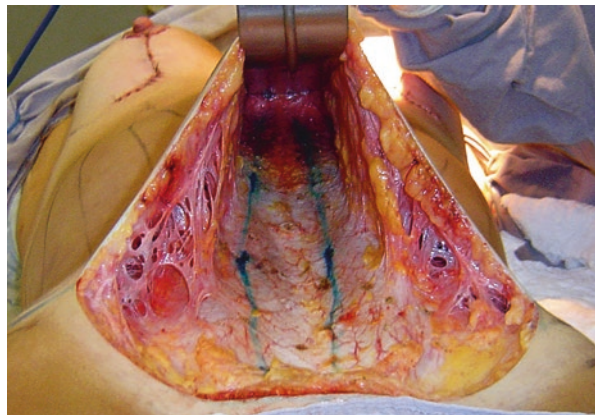
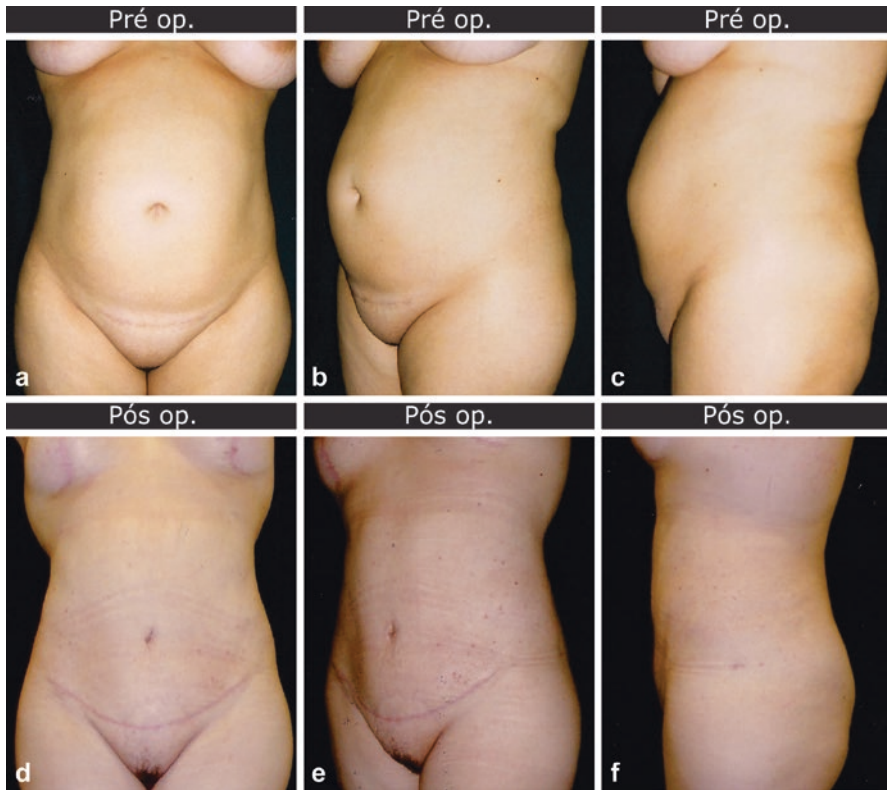


Fig. 27.10 Preoperative and postoperative characteristics of G III

Fig. 27.11 Central tunnel to rectus abdominis muscle plicature

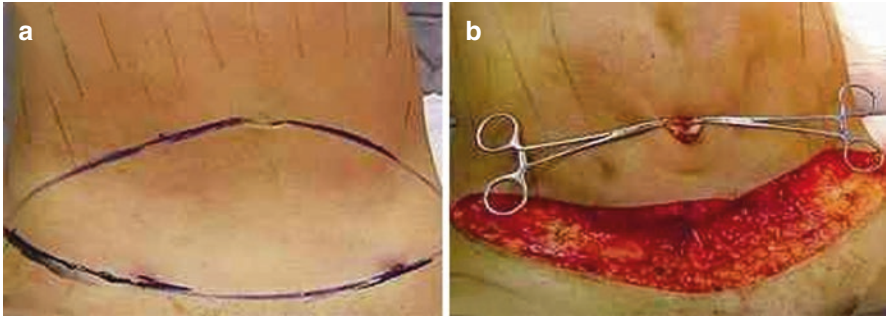




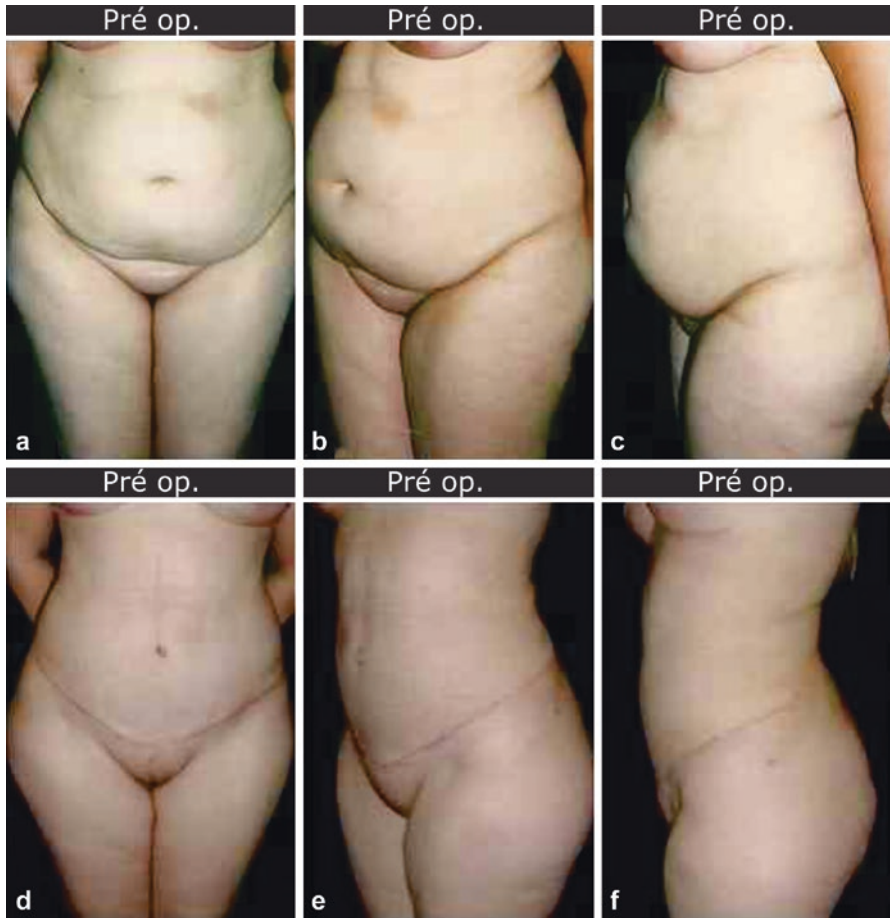
**Fig. 27.12** (a–f) Preoperative and postoperative characteristics of G IV. Lowest umbilical position postoperatively

supraumbilical segments equal to or smaller than 1–1.6), excesses of fat layers, and diastasis of the rectus and/or external oblique muscles. Liposuction was done as described for Group I patients, with transverse skin and subcutaneous resections, from the pubis to the umbilicus, a central tunnel to the umbilicus from the xiphoid appendix, suture of the aponeurosis of the rectus muscles from the xiphoid appendix to the pubis, and transposition of the umbilicus [23] (2003) (Fig. 27.13a, b). The scar must be low enough not to cut the bottom of the “lyre” and not to “disconnect” the pubis from the abdomen [7] (2011) (Figs. 27.14a–f and 27.15a–f).

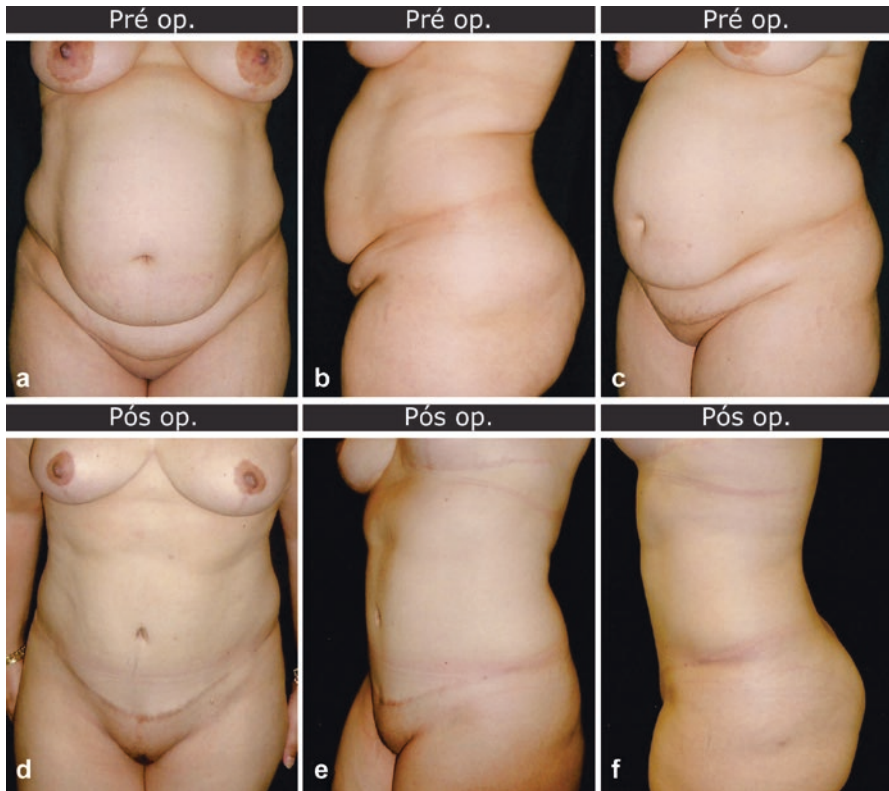
If there was also diastasis of the external oblique muscles, treatment was done as for the Group III patients, with two lateral tunnels, resulting in three tunnels where there were no important perforator vessels (Fig. 27.16) (2005) [12] (2013). The flap was fixed to the aponeurosis in areas of the tunnels, [6] (1998) [20] (2000) from top to bottom, similar to the Group III and IV patients. The *fascia superficialis* and the edges of the skin were sutured after small undermining of the edge of the liposuctioned flap. This is better to slide it towards the pubis, concluding with a demarcated omphaloplasty. In this case it is important to carry out zetaplasties at the suture place, averting stenosis of the umbilicus.



**Fig. 27.13** (a, b) Resection of skin up to the umbilicus, all the infraumbilical segment and umbilical transposition

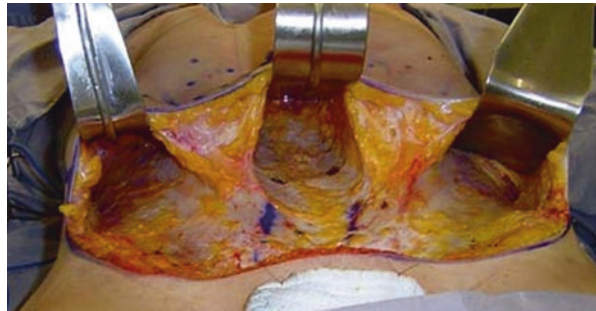

**Fig. 27.14** (a–f) Preoperative and postoperative characteristics of G V, low scar, without cutting the bottom of the lyre



**Fig. 27.15** (a–f) G V Lipoabdominoplasty

**Fig. 27.16** Three possible tunnels to muscular plicatures, one central and two lateral, preserving the perforators of all the “abdominal myocutaneous flap”



### *Comments*

About 16% of the cases were sequels and secondary abdominoplasties, of which 1% were the author’s cases, both were severe postoperative hospital infections. There were no deaths.

The percentages of patients in the different groups were modified with time, demonstrating that the views of abdominal surgery changed in the cases with diagnoses of small esthetic alterations (Groups I and II). And the tendency was to reduce skin resections that were performed with excessive traction of the abdominal flap, moving patients from Group V to Group IV, leaving the umbilicus lower postoperatively, without, however, exceeding the proportion of 1/1.6 described in the segment between the infra- and supraumbilical skin. The abdomen was less stretched and more natural, with shorter and better quality scars.

When there was no fat excess we used the same infiltration and vibroliposuction without suction to liberate the skin and the thin layer of fat of the aponeurosis. It made it easier and more comfortable for all the later procedures to be similar.

In the last abdominoplasties the scar could not be high, “cutting the bottom of the lyre”; after 6 months we could displace the flap over the *fascia superficialis* up to the umbilicus and perform traction downward, resecting the skin below the scar, recomposing the bottom of the lyre.

This scar will not be high if, preoperatively, the proportion between the infra- and supraumbilical segments is above 1/1.6.

The position of the umbilicus divides the abdomen into two segments and is the best parameter for the classification.

All of the tunnels for aponeurotic sutures are made in areas with no important perforator vessels in the medium line, and the procedure just exposes the edges of the rectus muscles on the diastasis. Sidelong it exposes the aponeurosis of the union of the external oblique and rectus muscles with the suture recomposing the semilunar lines.

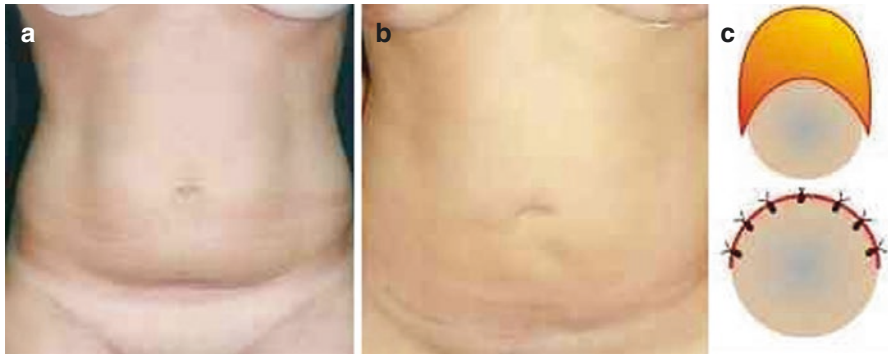
Sometimes, to correct *hypogastrium* cambers, it is necessary to suture the aponeurotic layer transversely joining the inferior extremities of the lateral sutures of the external oblique muscles that together compose the suture in the “lyre”.

The suture of the flap on the aponeurosis reduces the incidence of seromas and hematomas, and aids in postoperative drainage. Aspiration drainage may be needed for 18–24 h to remove excess liquid infiltration during surgery when liposuction is very intense. The more points of attachment of the flap in the abdominal aponeurosis, the less the need for drainage and the lower the drainage residence time. We should be careful not to strangle the random circulation of the flap, so the points should be distributed in a parallel cranio-caudal direction, leaving “vertical vascular corridors”. Depressions in the skin caused by the sutures disappear quickly if fast absorbable sutures are used. Because of the liposuction and reduction of the displacements, we started to compress the treated areas with elastic strips immediately after the conclusion of the surgical procedure with the patient still in hypotension 20 % below the initial arterial tension.

If there has been liposuction previously during another surgery, the flaps will not slide easily, needing greater care in diagnoses of the skin resections.

The scars should never cross the inguinal pleats; this is esthetically bad. Excessive traction of the skin with resections beyond the necessary level does not make the abdomen more beautiful, and the scars will be worse and longer.

Some authors, when removing the skin after liposuction, intend to leave the *fascia superficialis*, and fat residues of the lamellar layer just below it and they suture it on



**Fig. 27.17** (a–c) A skin half moon-shape resection in the upper part of the umbilicus

itself, folding it in three layers. The vascular and lymphatic systems are also folded. In the author's experience, infraumbilical edema was greater than when all the plans until the aponeurosis are removed, and there was no vascular damage to the flap. This edema only exists in Groups II, III and IV, where part of the infraumbilical segment remains, and when the lymphatic and venous vessel drainage is sectioned or bended toward the inguinal pleats. The edema does not exist in Groups I and V.

In patients in Group II or III, sometimes the form of the umbilicus leaves a transverse fold outlining it at the top, making it visually "sad". There are three options to overcome this: (a) removing a half moon skin above it, with a width more or less of 2 cm elevating its superior half, with consequent scar (Fig. 27.17a–c). (b) The infraumbilical flap is undermined up to the umbilicus base; this base is cut and re-implanted right below the umbilicus with a bolster stitch point, (the same as in Group IV) inverting the bottom, with the same proportion. (c) The umbilicus is liberated from the flap, leaving it fixed to the aponeurosis, and after flap traction and resection, omphaloplasty is done in the same way as in Group V, and the wound is closed with layers leaving an infraumbilical vertical scar almost always starting from the umbilicus (Fig. 27.18a, b).

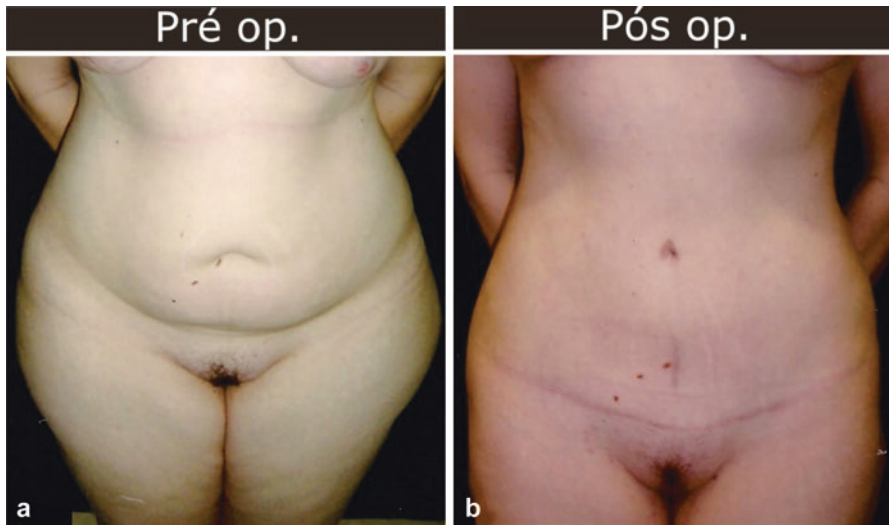Correct diagnosis depends on the abdominal esthetic pathology and the level of knowledge of the abdominal classification.

During abdominoplasty do not incise the infraumbilical flap vertically, because it is possible that the supraumbilical flap cannot extend easily toward to the pubis.

There are also Group III cases with diastasis of the rectus muscles. Three tunnels are made for suturing the aponeurosis of the diastasis of the muscles and reattaching the umbilicus in the same position or lightly lower. There are also Group V cases with diastasis of the oblique muscles. Three tunnels are also made in this group.

In Group II patients aspiration drainage is not necessary. For patients in the other groups it might be needed, but attaching the flap on the aponeurosis can avoid it or can reduce its residence time.

Positioning the umbilicus at a larger proportion than 1:1.6 between the infra- and supraumbilical segment makes the abdomen esthetically inadequate (Table 27.1).



**Fig. 27.18** (a, b) Borderline case between G IV and G V; the umbilicus is released as in the classical abdominoplasty (G V) and its cut is closed between the suprapubic scar and the new umbilicus, with no height

**Table 27.1** Classification of the abdomen in Group I, II, III, IV and V

Group	% patients	Alterations	Treatments
I	27%	No excess skin Fat excess in the abdomen, flanks, and lumbar region No muscle aponeurotic diastasis Umbilicus in normal position, near the metric relation of 1/1.5, up to 1/1.6, between the infra- and supraumbilical segments	Infiltrative vibroliposuction
II	22%	Infraumbilical skin excess Fascia superficialis sectioned (cesarean section) and no sutures Fat excess similar to G I A good muscle-aponeurotic layer Umbilicus implantation near 1/1.5 up to 1/1.6 between infra- and supraumbilical segments (normal)	Infiltrative vibroliposuction Resection of the transverse suprapubic spindle-shaped skin excess. Low curvilinear scar, no cutting the lyre's bottom, 1–1.5 cm above the inguinal pleats

(continued)

**Table 27.1** (continued)

Group	% patients	Alterations	Treatments
III	7%	Infraumbilical skin excess Fascia superficialis sectioned Fat excess similar to G I. Oblique muscle diastasis Umbilicus implantation with normal proportion (1/1.5 up to 1/1.6) between infra- and supraumbilical segments	Infiltrative vibroliposuction similar to G I Resection of the spindle-shaped skin excess similar to G II Plication of the oblique muscle aponeurosis through two lateral tunnels from the iliac drainage to the latero-costal margins; there are no important perforator vessels
IV	18%	Little or medium skin excess in the supra- and infraumbilical segments. Umbilicus with high implantation. Relation bigger than 1/1.4 between the infra- and supraumbilical segments Fat similar to G I Diastasis of the rectus muscles	Infiltrative vibroliposuction Spindle-shaped skin resection similar to G II and G III Plication of the rectus muscle diastasis through a medial tunnel up to the xiphoid appendix, detaching the umbilicus implantation, and reattaching with a bolster stitch 2–4 cm below (proportion up to 1/1.6 between the infra- and supraumbilical segments)
V	10%	Skin excess in the infra- and supraumbilical segments Umbilicus with low implantation; proportion 1/1.6 or more between the infra- and supraumbilical segments (this is a long segment) Fat excess similar to G I, II, III, and IV Diastasis of the rectus and or oblique muscles	Infiltrative vibroliposuction Transverse spindle-shaped skin resection from the pubis to the umbilicus Plication of the rectus muscle aponeurosis through a medial tunnel and the oblique muscles with a lateral tunnel when necessary. Umbilicus transposition and omphaloplasty
Re-interventions	16%	Other surgeons 15%	Author 1%

## References

1. Atalay B (2004) *Math and the Mona Lisa, the art and science of Leonardo da Vinci*. Harper Collins, New York, NY
2. Avelar JM (1978) Abdominoplasty: systematization of a technique without external umbilical scar. *Aesthetic Plast Surg* 2:141–151
3. Avelar JM (1985) Fat suction versus abdominoplasty. *Aesthetic Plast Surg* 9(4):265–275
4. Avelar JM (1999) Uma nova técnica de abdominoplastia- Sistema vascular fechado de retalho subdérmico dobrado sobre si mesmo combinado com lipoaspiração. *Rev Bras Cir* 88/89(1/6):3–20
5. Baroudi R, Moraes MA (1995) Bicycle-handlebar type incision or primary and secondary abdominoplasty. *Aesthetic Plast Surg* 19:307–320



6. Baroudi R, Ferreira C (1998) Seroma how to avoid it and how to treat it. *Aesthet Surg J* 18:439
7. Bernabei J (2011) Importância da área pubiana na abdominoplastia. Mesa Redonda 12 12/13 horas 48° Congresso Brasileiro de Cirurgia Plástica, Goiânia, 11/14 Nov
8. Bozola AR, Psillakis JM (1988) Abdominoplasty: a new concept and classification for treatment. *Plast Reconstr Surg* 82(6):983–993
9. Bozola AR, Bozola AC (2003) Abdominoplastias. In: Mélega JM (ed). *Cirurgia Plastica Fundamentos e Arte*, vol 42, 1st edn. Ed. Medsi cap, Rio de Janeiro, p 609
10. Bozola AR (2010) Abdominoplasty: same classification and a new treatment concept 20 years. *Aesthetic Plast Surg* 34(2):181–192
11. Bozola AR, Longato FM, Bozola AP (2011) Análise geométrica da forma da beleza da mama e da forma de prótese baseado na proporção Phi: aplicação prática. *Rev. Bras. Cir. Plást. (Impr.)* [online]. vol.26, n.1, pp.94-103. ISSN 1983-5175. <http://dx.doi.org/10.1590/S1983-51752011000100019>
12. Bozola AR (2013) Abdominoplasty: effectiveness of classification of Bozola and Psillakis – 27 years of note from the author. *Rev Bras Cir Plast* 28(4):632–641
13. Callia W (1963) Contribuição para o estudo da correção cirúrgica do abdome em pêndulo e glboso. Técnica original. Diss. Fac. Med. Univ, São Paulo
14. Eco H (2004) *Storia della bellezza*. RCS Libri S.p.A., Bompiani, Italy
15. IIouz YG (1992) A new safe and aesthetic approach to suction abdominoplasty. *Aesthetic Plast Surg* 16:237–245
16. Leão C (2000) Curso de Abdominoplastias. Chair man: Bozola A R. XXXVII Congr Bras Cir Plast. Porto Alegre, 12 a 15 novembro
17. Livio M (2005) La proporción áurea, la historia de PHI, el numero más sorprendente del mundo. Editorial Ariel. S.A, Barcelona
18. Marquardt SR (2010) Marquardt beauty analysis (website). Available at: Accessed 15 Mar 2010
19. Pitanguy I (1967) Abdominal lipectomy; an approach to it through an analyses of 300 consecutive cases. *Plast Reconstr Surg* 40:384
20. Pollock H, Pollock T (2000) Progressive tension sutures: a technique to reduce local complications in abdominoplasty. *Plast Reconstr Surg* 105(7):2583–2586
21. Psillakis JM (1984) Plastic surgery of the abdomen with improvement in the body contour – physiopathology and treatment of the aponeurotic musculature. *Clin Plast Surg* 11:465–477
22. Ricketts RM (1982) The biologic significance of the divine proportion and Fibonacci series. *Am J Orthod* 81(5):351–370
23. Saldanha OR, Pinto EBS, Mattos WN Jr, Pazzetti CE, Bello EML, Rojas Y, Santos MR, Carvalho ACO, Filho OR (2003) Lipoabdominoplasty with selective and safe undermining. *Aesthetic Plast Surg* 27(4):322–327
24. Salles MJC et al (1999) Síndrome da Resposta Inflamatória Sistêmica/Sepse- Revisão e estudo da terminologia e fisiopatologia. *Rev Assoc Med Bras* 45(1). São Paulo Jan/Mar
25. Sinder R (1975) Plastic surgery of the abdomen-personal technique. In: Abstracts of the 6th International Congress of plastic Reconstructive Surgery. Masson, Paris, p 53
26. Sterzi G (1910) “La Fascia Superficialis” in *Il Tessuto Sottocutaneo*. Luigi Nicolai Tipografo Editora, Firenze

# Chapter 28

## Abdominoplasty Planning

Rolf Gemperli, Cristina Pires Camargo, and Alexandre M. Munhoz

### Introduction

The abdominal region is characterized as an esthetic functional unit that is relevant to define the body contour. Contour affections from the abdominal wall can cause significant alterations from the esthetic and functional point of view and have negative impact in the quality of life. Between the most frequent causes of contour alteration, we can list obesity, skin and muscle flabbiness, localized lipodystrophy, multiple pregnancies and previous surgeries, and hernias in the abdominal wall [10, 11].

Currently, innumerable techniques and surgical tactics are established in the plastic surgery arsenal with the objective to treat and improve abdominal contour. Within the main ones that deserve emphasis are liposuction, mini abdominoplasty, and classic abdominoplasties and its varieties in terms of incision and dissection area [8, 9].

Abdominoplasty is one of the procedures from contour body surgeries. This procedure can be indicated as unique treatment or associated, for example, with the liposuction. Currently, there are innumerable surgical variations related to

---

R. Gemperli, MD (✉)

Chief of Plastic Surgery Division University of São Paulo (USP) Medical School,  
Rua Pedroso Alvarenga, 1046 – 2° Andar – cj-23, Bairro Itaim Bibi – São Paulo,  
SP 04531-004, Brazil  
e-mail: [rgemperli@sti.com.br](mailto:rgemperli@sti.com.br)

C.P. Camargo, MD

Plastic Division of São Paulo University (USP) School of Medicine, Assistant of Plastic  
Surgery lab (LIM04) School of Medicine, Rua Pedroso Alvarenga, 1046 – 2° Andar – cj-23,  
Bairro Itaim Bibi – São Paulo, SP 04531-004, Brazil  
e-mail: [consultoriodracruzina@gmail.com](mailto:consultoriodracruzina@gmail.com)

A.M. Munhoz, MD, PhD

Plastic Division of São Paulo University (USP) School of Medicine, Assistant of  
São Paulo Cancer Institute (ICESP), Rua Pedroso Alvarenga, 1046 – 2° Andar – cj-23,  
Bairro Itaim Bibi – São Paulo, SP 04531-004, Brazil

abdominoplasties. Usually, most of these procedures involve resection of the cutaneous integument and adipose tissue (dermolipectomy) and the treatment of the abdominal aponeurotic muscle layer (plicatures). In these techniques, the principle is relatively simple although the main differences are related to the type of incision and extension of the dissection. Within the main ones that deserve attention are classic transversal abdominoplasty, extended abdominoplasty, abdominoplasty “in anchor,” reverse abdominoplasty, simple circumferential abdominoplasty, and composed circumferential abdominoplasty [8, 9].

Planning abdominal surgery is fundamentally important for results [1–3]. The surgeon should analyze patients’ progressive history, conduct a physical exam, and evaluate risks for thromboembolism and habits (smoking, use of medications) [2, 6].

## Previous History

The patient’s complaint gives direction to the initial approach. Questioning big weight losses, time of weight stability, and previous and desired pregnancies should be in the initial approach. Some patients present recurrent weight variation that can lead to the loss of the abdominoplasty results. The surgeon should approach this subject asking about eating habits, exercise, and use of anorectic medications. Besides that, a multidisciplinary approach with a general clinician, endocrinologist, and nutritionist should be considered.

There are cases where overweight or obese patients (BMI >30) desire to have an abdominoplasty [6]. This condition entails an elevated risk of complications as seromas, thromboembolic events, and infections on the surgery site [4, 9].

In general, surgeries are considered median or large, with extensive dissection areas and detachment of skin flaps. This way, a rigorous clinic evaluation is indispensable with pertinent exams of the cardiovascular, hematologic, coagulation, and hemostasis systems. In the preoperative anamnesis, associated diseases (hypertension, heart diseases, lung diseases, diabetes, thyroid diseases) should be investigated, and when facing the findings, request an evaluation with a professional from the field and perform more specific exams. It is important to highlight that many techniques need decubitus change during trans-operative.

**Table 28.1** Possible surgical complications and its associations with comorbidities

Comorbidities	Consequences
Heart disease	Risk increase of local and systemic complications
Diabetes	Risk increase of local complications
Chronic obstructive lung disease	Risk of pulmonary insufficiency (Pickwick syndrome) after abdominoplasty
Coagulopathies	Risk of intra- and postsurgery bleeding. Increased risk of bruises

Because of these reasons, there is a preference for general intravenous or mixed anesthesia, keeping the air track monitored and avoiding postural hypotension during decubitus change.

The presence of diseases like diabetes, high blood pressure, and chronic obstructive lung disease can increase the risk of complications post surgery (Table 28.1) [4, 6]. For example, the occurrence of previous thrombotic event or varicose veins on the lower limbs can elevate the risk of thromboembolic episodes [3, 4, 12].

Normally, in every surgery considered median or large, it should have a routine in the surgical practice some preventive technical aspects. Thus, it is important to monitor the hydration and diuresis through catheterization with the objective to avoid hypovolemia or hyper hydration and its hemodynamic repercussions (hypotension, tissue and pulmonary edema, etc.). In prolonged surgeries, a thermal mattress should be placed routinely to prevent hypothermia and its repercussions for patient's coagulation, as well as discomfort and postoperative agitation. At last, an intermittent compression of the lower limbs should be performed during the transoperative period and the introduction of low-molecular-weight heparin 12 h before the beginning of surgery and maintenance until the fourth postoperative day to avoid thromboembolic phenomenon in lower limbs and lungs.

## Habits

Smoking should be investigated because it increases the risk of local complications not only in surgeries in general, but also in abdominoplasties. Thus, smoking investigation should be extended to the number of cigarettes smoked per day, the period that the person have or had this habit [12]. Araco et al., demonstrated that patients who interrupted use of cigarettes for four weeks before abdominoplasty presented 14,3% of local infections, while nonsmokers presented 1,2% incidence ( $p < 0.005$ ) [1].

Use of some medications can alter coagulations (as aspirins and derivatives) or scarring (isotretinoin, corticosteroids) [13, 14]. Although the use of systemic isotretinoin does not present scientific evidence determining its effects on scarring, because it is a non-essential drug to the patient's health, its suspension is indicated for six months before surgery [5]. From this data about patient's history and habits, physical exam is proceeded. For didactic reasons, semiotics of the abdominal wall is important for surgical planning.

## *Abdomen Anatomy*

The abdomen has as limits:

Upper – costal cartilages from the seventh to the tenth ribs and xiphoid appendix

Lower – iliac crests, pubic symphysis, pubic crests, and inguinal ligaments

**Table 28.2** Vascularization, innervation, and function of abdominal muscles

Muscle	Vascularization/innervation	Function
Abdominal rectus	Lower and upper epigastric arteries/median and lower intercostal nerves.	Trunk flexion, compress the abdomen.
External oblique	Intercostal and lumbar arteries/Inferior intercostal nerves and lumbar plexus branches	Abdominal girdle, thorax rotation to the opposite side of this muscle
Internal oblique	Intercostal, lumbar and epigastric arteries/ Branches from the genital femoral nerve	Agonist to the external oblique muscle
Transverse	Internal mammary artery and circumflexes/ Inferior intercostal nerves and lumbar plexus branches	Abdominal girdle <sup>a</sup>

<sup>a</sup>Abdominal girdle- abdominal distension and retraction

The skin is loosely attached to the fat tissue with exception of the umbilical scar that is fixed in the aponeurosis of the median line, localized at the L3–L4 level. The adipose tissue, in the upper umbilical region has a similar distribution to the rest of the body fat tissue. On the infraumbilical area, tissue is organized with elastic fibers forming two fasciae, the superior which is known as Camper fascia and the deep known as Scarpa fascia or membranous layer. The fascia involves the abdominal muscles. Following the stratigraphy, the next layer is the muscular. The abdomen presents the following muscle pairs: external oblique, internal oblique, and rectus transverse. Anatomic details are resumed in Table 28.2.

### ***Vascularization***

The skin is irrigated by two vascular plexuses: dermal and subdermal. The deeper plans, from the muscle and aponeurosis, are vascularized by the superior and inferior epigastric arteries. Vessels from dermal and subdermal plexus communicate with those arteries through perforating vessels [10]. Venous drainage is situated in the subdermal plan and it is directed to the auxiliary, femoral, and epigastric vessels. The lymphatic drainage is also composed by the superficial and deep system. The supraumbilical area drains to the axillary lymph nodes, while the infraumbilical area drains to the inguinal [10].

### ***Physical Exam***

The patient should be assessed on dorsal decubitus, sitting, and on orthostatic position. Each one of these positions provides important information for planning an abdominoplasty. On dorsal decubitus, muscles are palpated to investigate the level of flabbiness of the abdominal wall and occurrence of hernias (umbilical, Spieghel, epigastric, hypogastric). During investigation of hernias, the patient can be asked to perform a Valsalva maneuver.

On sitting position, exceeding skin and fat are observed.

On orthostatic position, the excess of skin and fat are observed. It is on this position that the surgeon does the pinching test, to assess how much skin and fat will be removed and to plan the incision level and the possibility to perform other incisions, as the vertical.

With this information, it is possible to classify the type of abdomen and organize what is the best technique to be performed.

### ***Abdomen Classification***

There are some abdominal classifications that provide support for surgical planning choice [11].

Lewis classification corresponds to three categories: pendulous, globose, and flaccid [10, 11].

Pitanguy et al., divides trunk alterations in six types, as:

Type I – Generalized abdominal lipodystrophy without cutaneous flabbiness without diastasis. Umbilical scar is in normal anatomic position.

Type II – Generalized abdominal lipodystrophy with discrete cutaneous flabbiness associated or not to the diastasis. Umbilical scar is in normal anatomic position.

Type III – Generalized abdominal lipodystrophy with moderate cutaneous flabbiness associated or not to the diastasis.

Type IIIa – Umbilical scar is in normal anatomic position

Type IIIb – Umbilical scar is in elevated position

Type IV – Generalized abdominal lipodystrophy with accentuated cutaneous flabbiness associated with diastasis or accumulated fat under the belly, with or without associated scar. Umbilical scar is in normal anatomic position.

Type V – Accentuated cutaneous flabbiness with or without lipodystrophy, presence of median scar on the abdomen. Umbilical scar is in normal or modified anatomical position.

Type 0 – Accentuated lipodystrophy, morbid obesity. In these cases, the patient has to lose weight for new assessment.

Facing these classifications, the following surgical modalities can be chosen [8]:

- Mini-abdomen or partial abdominoplasty – removal of small quantity of skin and fat tissue, with limited dissection below the umbilical scar. It is indicated for patients with infra-abdominal flabbiness with little skin and fat excesses on this region [10, 11].
- Total or classic abdominoplasty – an incision extended between the iliac crests. Dissection englobes the incision point until the xiphoid appendix, with plicatures of all the rectal abdominal muscles extension [10, 11]. This technique is normally the most used one to resect skin and fat excess in the abdomen, but it is little used for patients with big weight losses and who are post-bariatric. The lower incision point that will be very close to the resulting

postsurgery scar consists of the arched line with the concavity cranially turned and positioned close to the lower abdominal groove. The area that will be resected normally involves the abdominal flap until the umbilical scar level. After the lower incision until the fascia of abdominal muscles, the supra-aponeurotic detachment, in the cranial direction, until the xiphoid appendix, leaving the umbilical scar inserted in the aponeurotic level. For the folding for diastasis correction of the rectal abdominal muscles, skin excess is marked and resected, and the retail is mobilized inferiorly, until the lower incision. Umbilical scar is exposed outside in a new position, and the suture per surface is done, fixing the fat surface from the retail to the aponeurosis with some stitches in all its extensions. Alterations in incision marks were posteriorly proposed, having as a resulting scar the shape of a bike handlebar or “W,” focusing on esthetics as well as functional side.

- Circumferential abdominoplasty – the incision is extended from the abdomen anterior region, as the classic abdominoplasty, until above the buttocks, propitiating an elevation of those [7]. This technique is normally indicated for patients who present severe dysmorphic body, in which alterations are characterized by skin excesses in all anterior and posterior abdomen, and ptosis of the gluteus area. Better distribution of remaining tissues is obtained after removal of flank excesses, propitiating decrease of abdominal circumference and suspension of gluteus area. Another important advantage of this technique, especially for post-bariatric surgery patients through laparoscopy, is the proscription of the vertical incision on the anterior abdominal wall. The circumferential abdominoplasty consists of prolonged transverse incisions on the abdomen, above the superior, anterior, and posterior iliac crests, directed to the back until the spine projection.

In general, initially the superior posterior incision is marked and formed by two arches on the back region, above the gluteus, with concavity turned down and, being united at the center, forming an angle on the spine projection as a vertex turned down. Through flap bi-digital maneuver, to quantify the skin and fat excesses, an inferior, posterior incision is marked, symmetric and parallel to the superior incision, also with an angle in the central region with the vertex turned down. The superior and inferior posterior incisions are prolonged in direction to the anterior abdomen, passing on the anterior superior iliac spines, having between the points, the skin excess also quantified by bi-digital flap maneuver. The anterior marking of

**Table 28.3** Pitanguy’s classification and indication of different abdominoplasty’s techniques

Abdomen	Surgery
I	Liposuction
II	Mini-abdomen
III	Abdominoplasty
IV	Atypical Abdominoplasty
0	To lose weight or do treatment of other abdominal deformities for future abdominoplasty indication

the inferior incision consists of a transverse line in the inferior abdominal groove, arched with the concavity cranially turned, passing by the pubis, 5–7 cm above the vulvar rime. The superior anterior incision is performed through the transverse line, to resect the skin and fat excesses, whenever possible above the umbilical scar.

- Atypical abdominoplasty – in accordance with scars on the abdomen and/or other alterations, abdominoplasty incisions are different than the classic, for example, the inverted T (Table 28.3) [10, 11].

### ***Laboratory Exams***

The patients' planning and preparation for abdominoplasty needs investigation of clinical and physiological parameters interesting for the cardiovascular system, hematological and coagulation. Normally, cardiovascular investigation is done with ECG, thorax X-ray, echocardiogram with Doppler; the hematological investigation is done with complete blood count; the coagulation investigation with coagulation tests, bleeding time, and clotting; and the homeostasis investigation with electrolytes and kidney function tests, as urea, creatinine, sodium, and potassium. Cardiologic assessment is done by a specific professional and with an exercise test, depending on the patients' age and previous history.

### ***Photography***

The patient should be positioned in front, back, and on profile (right and left side) for the trunk photography documentation. This documentation has to be performed in the pre- and postoperative period.

### **References**

1. Araco A, Gravante G, Sorge R, Araco F, Delogu D, Cervelli V (2008) Wound infections in aesthetic abdominoplasties: the role of smoking. *Plast Reconstr Surg* 121:305e–310e
2. Friedland J, Maffy T (2008) MOC-PS(SM) CME article: abdominoplasty. *Plast Reconstr Surg* 121(4):1–11
3. Harinath G, St John PH (1998) Use of a thromboembolic risk score to improve thromboprophylaxis in surgical patients. *Ann R Coll Surg Engl* 80(5):347–349
4. Hurvitz KA, Olaya WA, Nguyen A, Wells JH (2014) Evidence-based medicine: abdominoplasty. *Plast Reconstr Surg* 133(5):1214–1221
5. Jaimovich CA, Mazzarone F, Parra JFN, Pitanguy I (1999) Semiologia da Parede Abdominal: Seu valor no planejamento das abdominoplastias. *Rev Soc Bras Cir Plast* 14(3):21–50
6. Koolen PG, Ibrahim AM, Kim K, Sinno HH, Lee BT, Schneider BE, Jones DB, Lin SJ (2014) Patient selection optimization following combined abdominal procedures: analysis of 4925 patients undergoing panniculectomy/abdominoplasty with or without concurrent hernia repair. *Plast Reconstr Surg* 134:539e



7. Marques M, Modolin M, Cintra W, Gemperli R, Ferreira MC (2012) Monsplasty for women after massive weight loss. *Aesthetic Plast Surg* 36(3):511–516
8. Matarasso A, Matarasso DM, Matarasso EJ (2014) Abdominoplasty: classic principles and technique. *Clin Plast Surg* 41(4):655–672
9. Matarasso A (1996) Classification and patient selection in abdominoplasty. *Oper Tech Plast Reconstr Surg* 3(1):7–14
10. Pitanguy I (1995) Abdominoplasty: classification and surgical techniques. *Rev Bras Cir* 85:23–44
11. Pitanguy I (2000) Evaluation of body contouring and facial cosmetic surgery today: a 30 year perspective. *Plast Reconstr Surg* 105:1499
12. Rohrich RJ, Coberly DM, Krueger JK, Brown S (2002) Planning elective operations on patients who smoke: survey of North American plastic surgeons. *Plast Reconstr Surg* 109(1): 350–355
13. Wang AS, Armstrong EJ, Armstrong AW (2013) Corticosteroids and wound healing: clinical considerations in the perioperative period. *Am J Surg* 206(3):410–417
14. Wootton CI, Cartwright RP, Manning P, Williams HC (2014) Should isotretinoin be stopped prior to surgery? A critically appraised topic. *Br J Dermatol* 170(2):239–244

# Chapter 29

## Abdominoplasty in Male Patients

Sérgio Carreirão

### Introduction

Plastic surgery still is a procedure mostly sought by women. But the number of men undergoing aesthetic plastic surgery is growing in an upsweep since the 1960s. Cultural and social changes have encouraged men to enjoy the benefits of these surgeries. Concerns with aging, health, and well-being could explain the growth of the aesthetic plastic surgery in men.

In this context, the abdominal contour surgery is becoming more and more popular among men, and liposuction and abdominoplasty are the more frequent procedures.

### Indications

First of all, the abdominal deformity in male patients should be well identified. The probability of a successful postoperative result should be high and the patient should be realistic about the limitations and drawbacks of the surgical procedure [1]. We review 111 cases of abdominoplasty in men over the last 20 years, and the main reasons for seeking the surgery were flaccidity and skin excess, lipodystrophy, and abdominal bulges including diastasis of the rectus abdominis muscles, eventrations, hernias, and, more recently, the dysmorphias after bariatric surgery and after a major weight loss (Table 29.1).

---

S. Carreirão, MD

Full Member of the Brazilian Society of Plastic Surgery (TSBCP), Full Member of the Brazilian College of Surgeons (ECBC), Fellow of the American College of Surgeons (FACS),  
Rua Barao de Lucena, 48 – Sala 12, Rio De Janeiro, RJ, Brazil  
e-mail: [scarreirao@hotmail.com](mailto:scarreirao@hotmail.com)

**Table 29.1** Main indications for abdominoplasty in men

Cases: 111	
Flaccidity, skin excess, and lipodystrophy	48
Abdominal bulges (hernias and eventrations)	32
Abdominal bulges (muscular diastasis)	17
Unaesthetic scars	05
Post-bariatric surgery dysmorphias	09

## What Is Different About Men?

Higher rates of cardiovascular diseases, arterial hypertension, smoking, alcohol ingestion, and regular medications are noticed in our patients. The prostatic hypertrophy needs attention when the use of vesical catheter is required. Men are more resistant to pre- and postoperative medical advices. Men tend to minimize the procedure and always hope for a fast recovery without any complications. Men are also not adept to postoperative rest [2]. Therefore, it is advisable to have a more detailed explanation preoperatively about the procedure and stages that are included, such as care and restrictions.

In men, lipodystrophy is typically in a rounded form, and fat is accumulated mainly in the flanks. With aging, lipodystrophy progresses through all the interior part of the abdomen. It is observed that the globular abdomen, which is more common in the male gender and more frequent than in women, is due to the fat intra-abdominal accumulation.

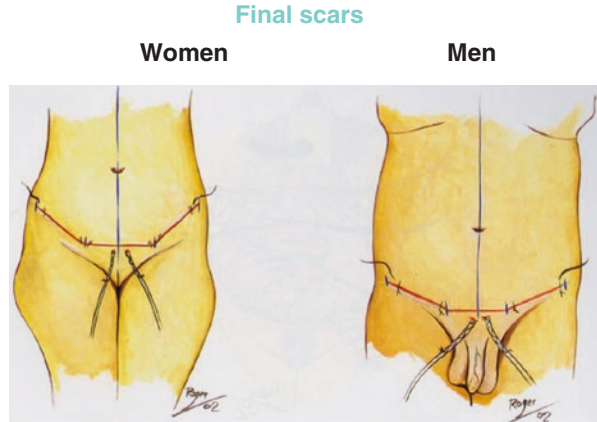
## Surgical Procedures

### *Classic Transversal Abdominoplasty*

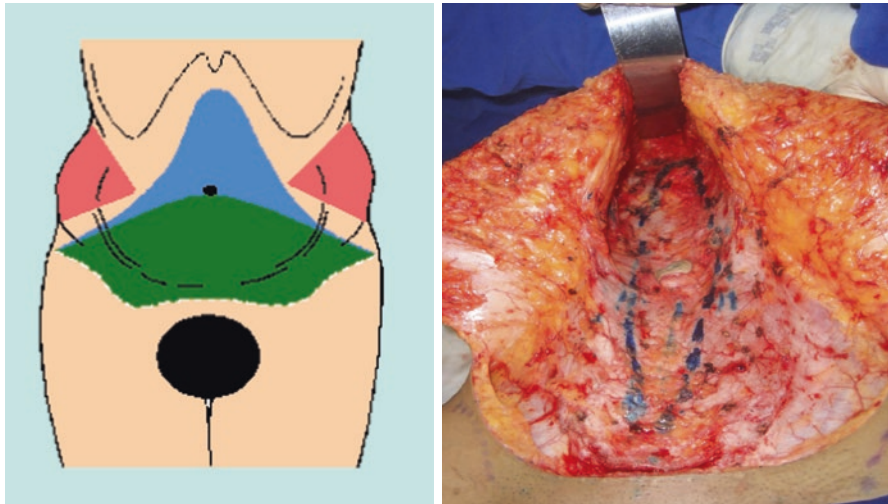
The abdominoplasty's incision in men is a bit different than the one made in women. The man is concerned that the final scar stays hidden when using swimsuits, being the lower extremes of the incisions lower than the ones in women (Fig. 29.1).

Undermining of the cephalic abdominal flap is identical in both genders, but it is more conservative in the lateral aspect in men (Fig. 29.2). In treatment of diastasis of the rectus muscles of the abdomen, we proceed by putting together the internal borders of the muscles as described by Pitanguy (Fig. 29.3) [3, 4]. We eliminate the procedures of additional muscular sutures that could cause narrowing at the midline. When indicated, we perform complementary liposuction on the lateral parts that are not detached. The abdominal flap is pulled in caudal direction without tension excesses. We use adhesion sutures to relieve the tension on the flap. Omphaloplasty is performed through transversal incision on the demarcation line of the future umbilical scar. We put carefully this scar as higher as possible, which helps the cosmetic result in men. Also when it is indicated, we perform a liposuction

**Fig. 29.1** Differences in the incisions and the final scars in transversal abdominoplasties between men and women



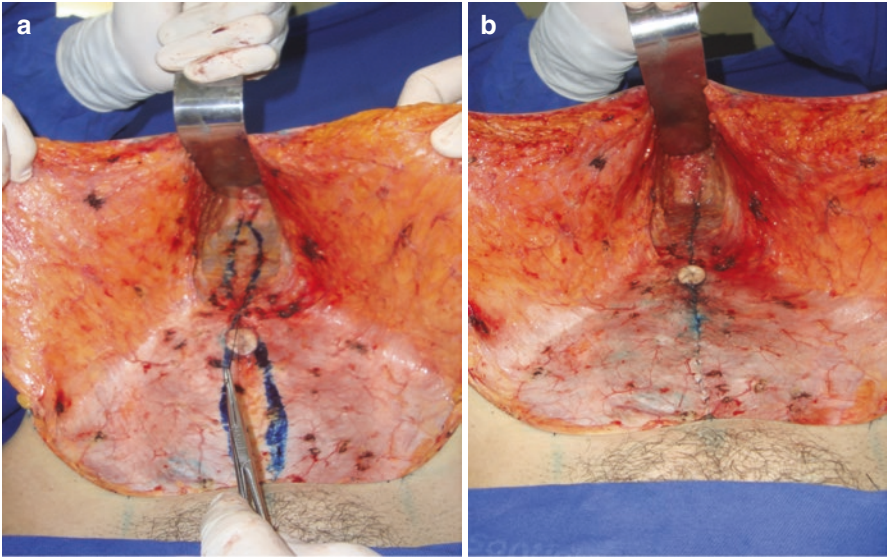
**Undermining and liposuction**



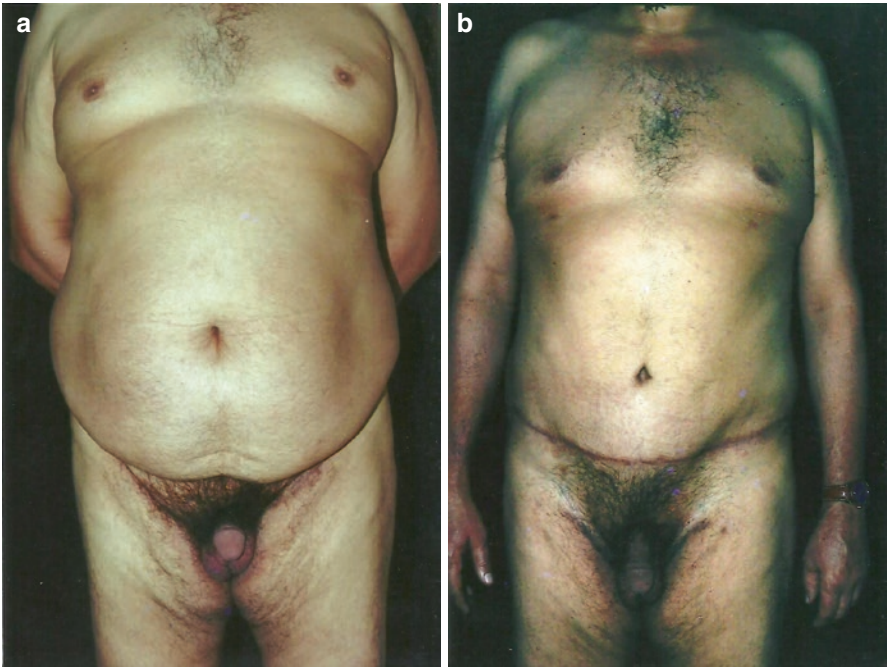**Fig. 29.2** Surgical technique. Detach of the flap in transversal abdominoplasty. Procedure adopted by the author. In *green*, the widely detached area. In *blue*, the area of direct undermining in tunnel for muscular plication. In *brown*, the liposuction area

in the inferior areas in flanks. Closing suture is performed in three plans with suction drains brought out below the incision (Fig.29.4).

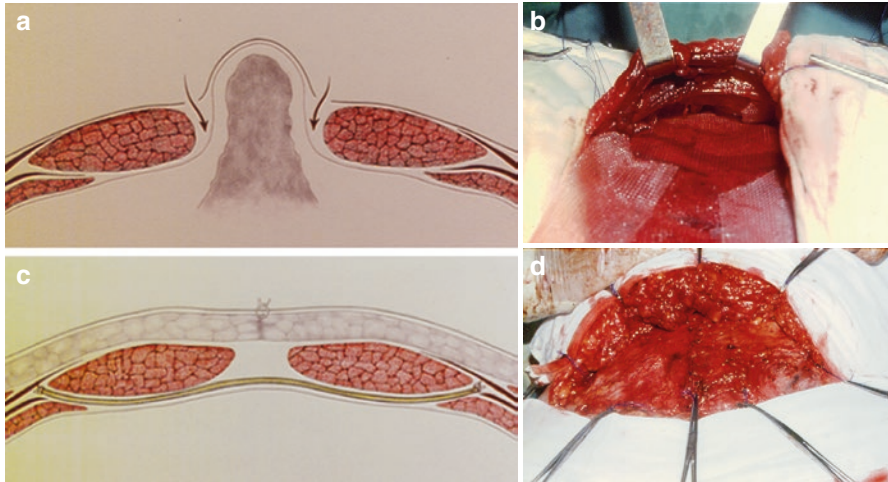
This kind of abdominoplasty is also performed for bulgings and hernias located mainly in the inferior abdomen. In these cases we adopt the Rives' procedure [5] as treatment of great eventrations. Once the deformity is identified through careful dissection, we open the anterior aponeurosis of the rectus muscles of the abdomen at its medial aspects. We proceed with a dissection underneath the muscular layer until the aponeurotical borders of the lateral musculature



**Fig. 29.3** (a, b) Plication of the musculature in rectus abdominis muscles, according to the techniques described by Pitanguy



**Fig. 29.4** (a, b) Pre- and postoperative in transversal abdominoplasty

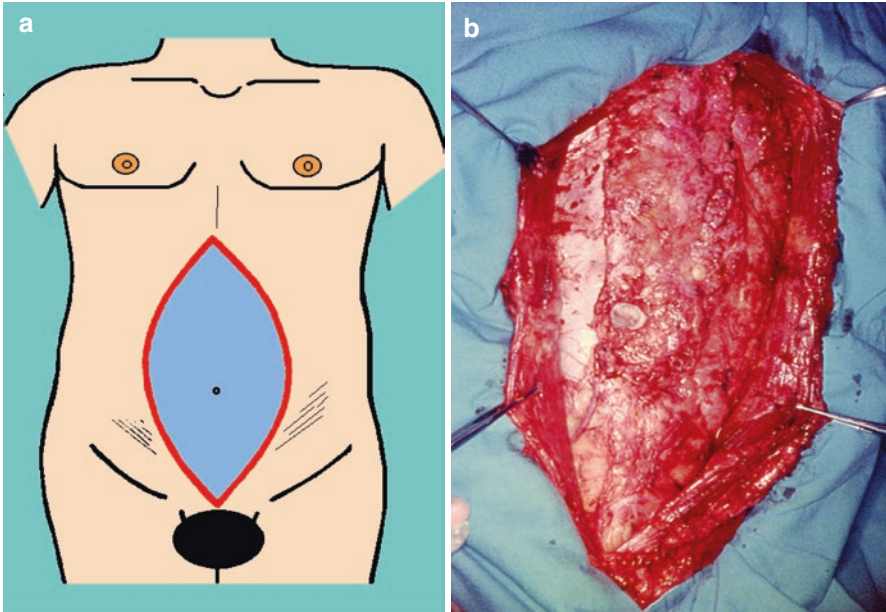


**Fig. 29.5 (a–d)** Adopted technique for the correction of infraumbilical bulging in transversal abdominoplasty. **(a)** Original deformity. **(b)** Fixation of the mesh underneath the rectus abdominis muscle. **(c)** Mesh is fixed in retromuscular level. **(d)** Final result

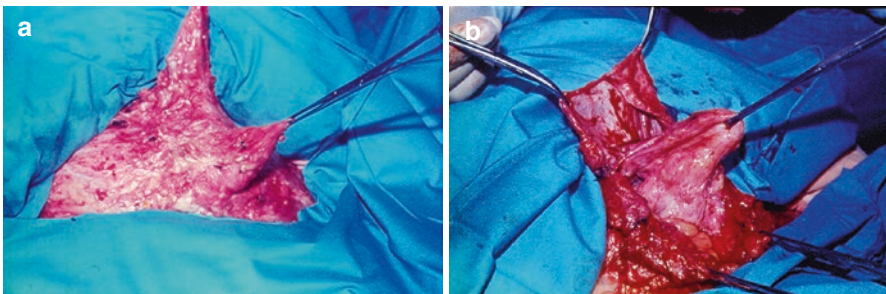
of the abdominal wall, where we fix the Prolene mesh in both sides, leaving the mesh placed over the peritoneum and under the rectus muscles of the abdomen (Fig. 29.5). The use of the Prolene mesh showed good cosmetic and functional results, with easy manipulation and minimal immunologic reaction. The size of the mesh must always be larger than the original defect. The abdominoplasty is then completed as it is described above.

### *Vertical Abdominoplasty*

This kind of approach can be performed in patients that already have median infra- and supraumbilical scars and with skin excess in the vertical direction. This procedure suits even better cases of xipho-pubic bulges or incisional hernias with hernial sacs with visceral content [6]. The xipho-pubic access is done through spindle resection of the skin excesses in midline preserving the umbilical scar. In case of a preexisting surgical scar, this scar is resected. When excess of skin is presented, its resection is calculated by manual pinching, forming a vertical spindle with a bigger diameter located in the periumbilical area (Fig. 29.6). In cases of bulging or hernias, the anterior borders of the rectus abdominis are exposed. The hernial sac is opened, reducing its contents when necessary. The wall is rebuilt by Rives' technique, as already described, with the placement of the mesh in the entire anterior abdominal wall, from the xiphoid until pubis (Figs. 29.7 and 29.8).



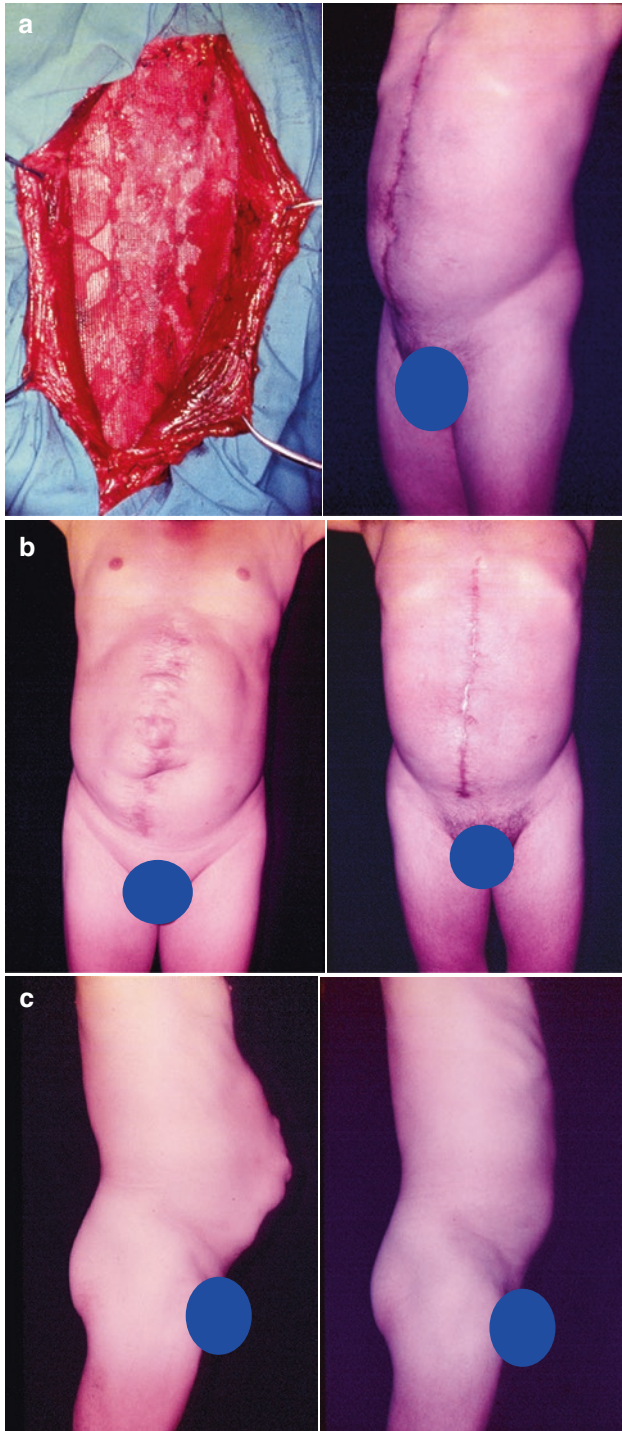
**Fig. 29.6** (a) Marking for removal of the skin excesses in vertical abdominoplasty. (b) Supraumbilical eventrations with xipho-pubic bulge



**Fig. 29.7** (a, b) Medial hernias with xipho-pubic bulge in the anterior abdominal wall. Treatment of the wall with Prolene mesh. Vertical abdominoplasty

### *Abdominoplasty in Inverted T*

Abdominoplasty in inverted T is also known as abdominoplasty in anchor. In recent years, it has been performed for treatment of patients that underwent bariatric surgery with skin excesses in both longitudinal and vertical directions. The excess of skin is calculated by pinching maneuvers and the marking of the resections is done with the patient standing up. The resections are in blocks, without detaching the soft tissue. The treatment of the musculature of the abdominal wall



**Fig. 29.8** (a) Method of affixing the Prolene mesh on xipho-pubic deformity. (b) Postoperative aspect. (b, c) Pre- and postoperative aspects



is optional. Nowadays, this technique is used on men who have been accepting quite well the replacement of the abdominal deformity for the final scar in inverted T (see specific chapter).

### ***Other Types of Abdominoplasty***

In male patients, depending on the type of the deformity, it is also possible to perform abdominoplasties in which the undermining of the flaps is replaced by liposuction of those. These techniques are described by Avelar [7] and later by Saldanha et al. [8] and are nowadays procedures widely performed in treatment of male abdominal lipodystrophy.

### **Results**

Taking in consideration the care already mentioned, the results of the abdominoplasty in male patients have been extremely positive when the indication and the type of treatment are considered. It is not always possible to take all the abdominal bulges off, but the body contour aspect is almost always granted (Fig 29.4). The cases of bulging and incisional hernias have more satisfying results and allow the patient to go back to normal activities, including sport activities.

There is a big trend to perform transversal abdominoplasties as it can be observed historically since the end of the twentieth century, when the first abdominal lipectomies started to be performed, with horizontal incisions. They are capable of offering better scars, because they stay hidden by lingerie or swimsuits. In the other hand, vertical abdominoplasty, whose scars are always questionable when it comes to its appearance, has advantages in cases of central or oval skin in excess, with a long vertical component.

### **Complications**

There are no differences between the complications in women or male patients nor the frequency between them. The main local complications noted are seroma, hematoma, infection, and necrosis of the flap. Systemic complications in abdominoplasties are almost always severe, including vein thrombosis, pulmonary embolism, and respiratory insufficiency.

## Conclusions

We believe that the surgery in male patients should always be more conservative and more careful so it does not leave any stigma. When it comes to male patients, the selection of the appropriate technique for the deformity is especially important in order to achieve the final satisfaction of the patient. More than ever, in these cases, the relation between deformity/final scar should be noticed.

The worse enemies for a good result in this topic are obesity, prolonged surgical time, and the number of associated surgeries that in our opinion should not pass one and should not include intracavitary surgeries.

The results are more than satisfactory, leading to an increased number of candidates to surgery (around 10% of the performed abdominoplasties).

We found that the increased search for aesthetic surgery by men does not find reciprocity in medical literature, since we noticed that articles, chapters, and books about aesthetic surgery in men have not grown in the same proportion. May this be our motivation for future publishing.

This chapter discusses the peculiarities of the abdominoplasty in male patients. It takes into account the main differences between abdominoplasty in male and in female patients, highlighting the pre- and postoperative aspects. The abdominoplasty's main techniques performed in male patients are described here. Results and complications from those techniques are also analyzed.

## References

1. Edgerton MT, Langman MW (1982) Psychiatric considerations. In: Courtiss EH (ed) Male aesthetic surgery. The C.V. Mosby Co, St Louis
2. Pitanguy I et al (1966) Cirurgias do contorno corporal masculino. *Rev Bras Cir* 68(3): 143–157
3. Pitanguy I et al (1974) Aspectos atuais em lipectomia abdominal. *Rev Bras Cir* 64(4/5): 149–164
4. Pitanguy I (1981) Aesthetic plastic surgery of head and body. Springer, Berlin/New York
5. Rives J et al (1973) Les grandes eventrations. *Mem Acad Chir* 99:547
6. Carreira S et al (1984) Treatment of abdominal wall eventrations with abdominoplasty techniques. *Aesthetic Plast Surg* 8:173–179
7. Avelar JM (1999) Uma nova técnica de abdominoplastia – sistema vascular fechado de retalho subdérmico dobrado sobre si mesmo combinado com lipoaspiração. *Rev Bras Cir* 88/89:3–20
8. Saldanha OR et al (2001) Lipoabdominoplasty without undermining. *Aesthet Surg J* 21(6): 518–526

# Chapter 30

## Challenges in Abdominoplasty

Alberto M. Lott Caldeira and Martin B.M. Robles

*Plastic Surgery is a constant battle between blood supply and beauty.*  
Sir Harold Guillies

### Introduction

The abdominal region represents one of the most important parts in the aesthetic balance of the body. The abdominal wall tissues are affected by diverse conditions that could lead to variable deformities. The surgical approach to the deformities in the abdominal wall represents one of the most important challenges in the scenario of plastic surgery [1].

The surgical technique of choice in the reconstruction will depend on the professional's knowledge and medical-surgical culture. Elaborating a surgical reconstruction plan involves numerous principle variables, including the repair and reconstitution of the involved tissues, determination of the real defect, and the most efficient usage of the adjacent tissues and substitution of the compromised area for tissue similar to the original [26, 20].

Giving priority to respecting the anatomic-physiological limits and developing multiple operatory time/sequences with discipline and precision will help with the desired outcome. In the first moment we must make sure that we're providing a wide volume of tissue to consecutively establish and act with discipline and method on the progressive gradual process of remodeling the affected segment so we reach its ideal and functional form [17].

---

A.M.L. Caldeira, MD, MSc, FICS (✉) • M.B.M. Robles, MD  
Plastic and Reconstructive Surgery Department, Advanced Plastic Surgery – Caldeira-Roth  
Institute, Rio de Janeiro, RJ, Brazil  
e-mail: [lottcaldeira@gmail.com](mailto:lottcaldeira@gmail.com)

The importance of orienting the patient about the necessities of multiple surgeries to achieve a definitive and satisfactory result together with the psychological preparation is a resource that the surgeon must use to maintain control, establishing a fruitful doctor-patient relationship to ensure the trust with him/her and his/her family [29, 30].

This chapter consists of the presentation of three complicated and challenging cases with defects in the abdominal wall to be worked on aiming not only at the reconstitution of the abdominal wall but also of the totality of the corporal outline, in the pursuit of harmonic and aesthetically gratifying results.

## Case by Case and Methods

### *Case #1*

This case deals with a female patient, 36 years old, with a history of abdominoplasty sequelae and neo-omphaloplasty with sizable scars, infraumbilical and unaesthetic transverse suprapubic, enlarged, and poorly located.

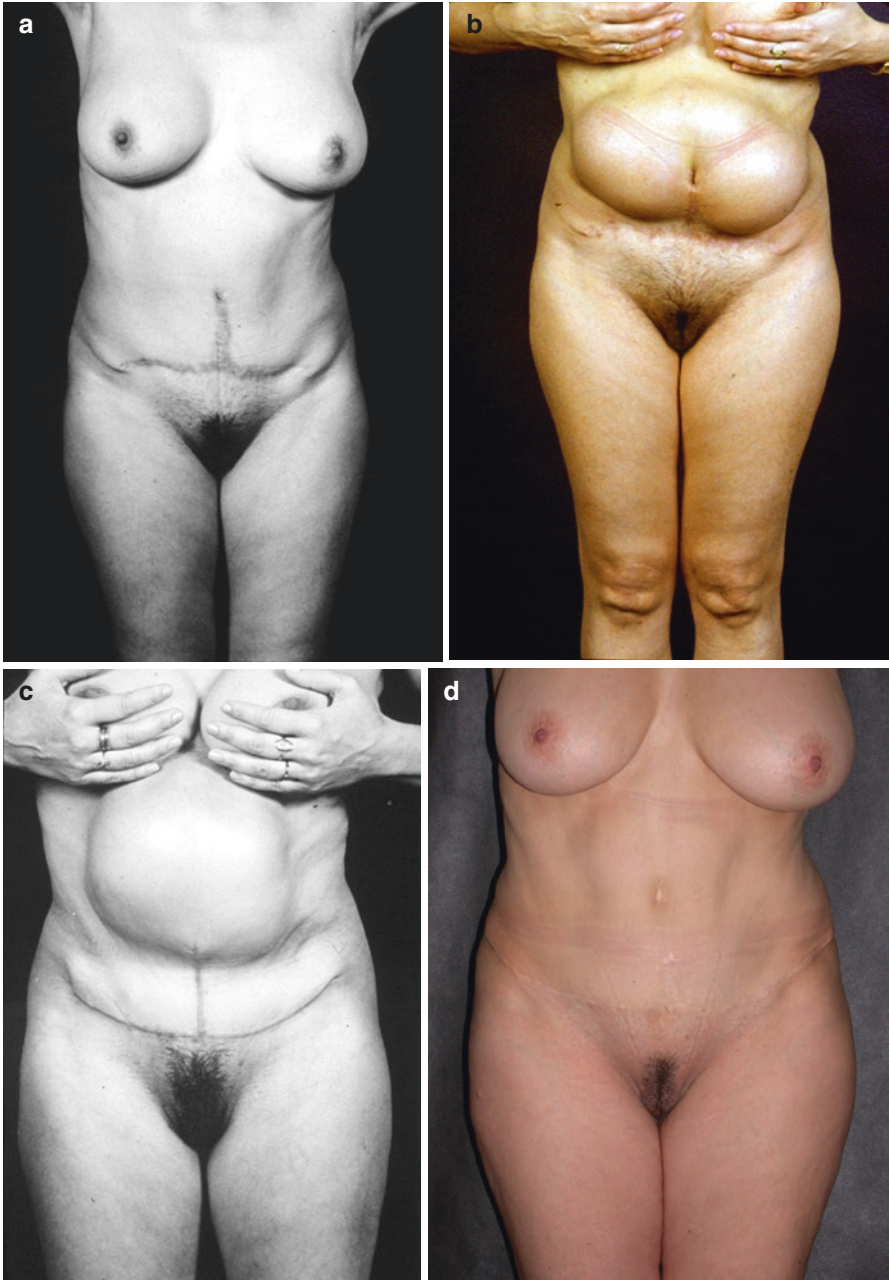
Therefore, as a result of the abovementioned and observable conditions cleared in the physical exam, the patient was oriented to undergo a surgical treatment in two to three sessions. In the first session the placement of three abdominal expanders was done, in first instance aiming at making a wide tissue volume available to consecutively remove and remodel the affected segment, transferring and relocating the resulting scars to unobtrusive and imperceptible locations (Fig. 30.1a–d).

Five months after the first intervention, the patient underwent an atypical abdominoplasty with the removal of the left expander in croissant, removal of the base of the capsule of all the expanders, and the median plication of the abdominal rectus. The Replacement of the 800 cc oval expander in the empty epigastric region for the re-expansion and transfer (rectangular – 600 cc) of the right-sided expander to the umbilical transverse position was made. Transverse relaxing incisions were made in the cutaneous flap capsule, associated with the traction and resection of the scars and location of the final abdominal transverse scar in low and convex form.

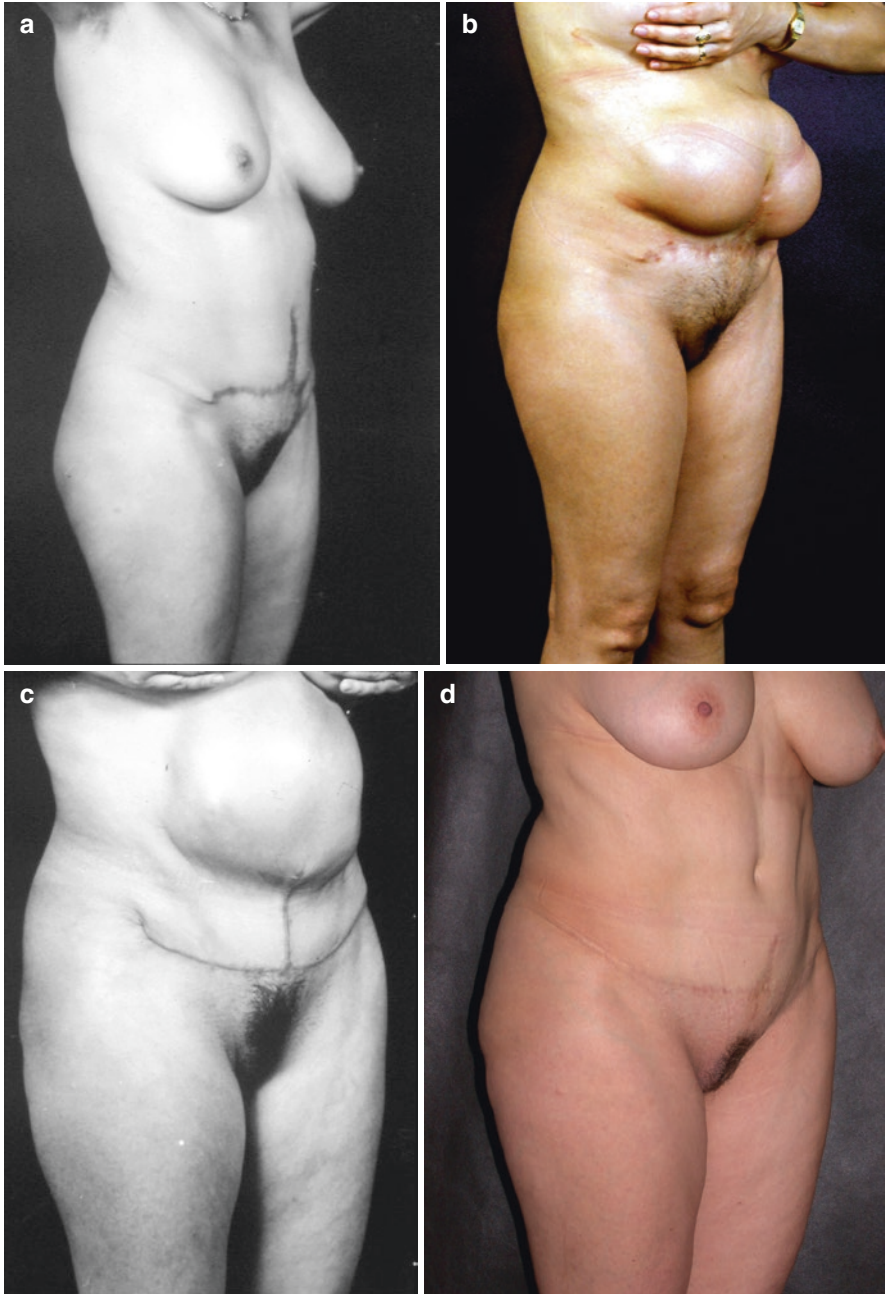
Three months after the second intervention, the patient was again submitted to a third operatory session, when a third abdominoplasty was made, with the removal of two expanders, 1° being oval 800 ml and 2° rectangular 600 ml, and inferior advancing of the flap with resection of  $\pm 8$  cm of width of the scarring suprapubic region. Associated with a neo-omphaloplasty with a modified Talita Franco technique [19] (Fig. 30.2a–d).

### *Case #2*

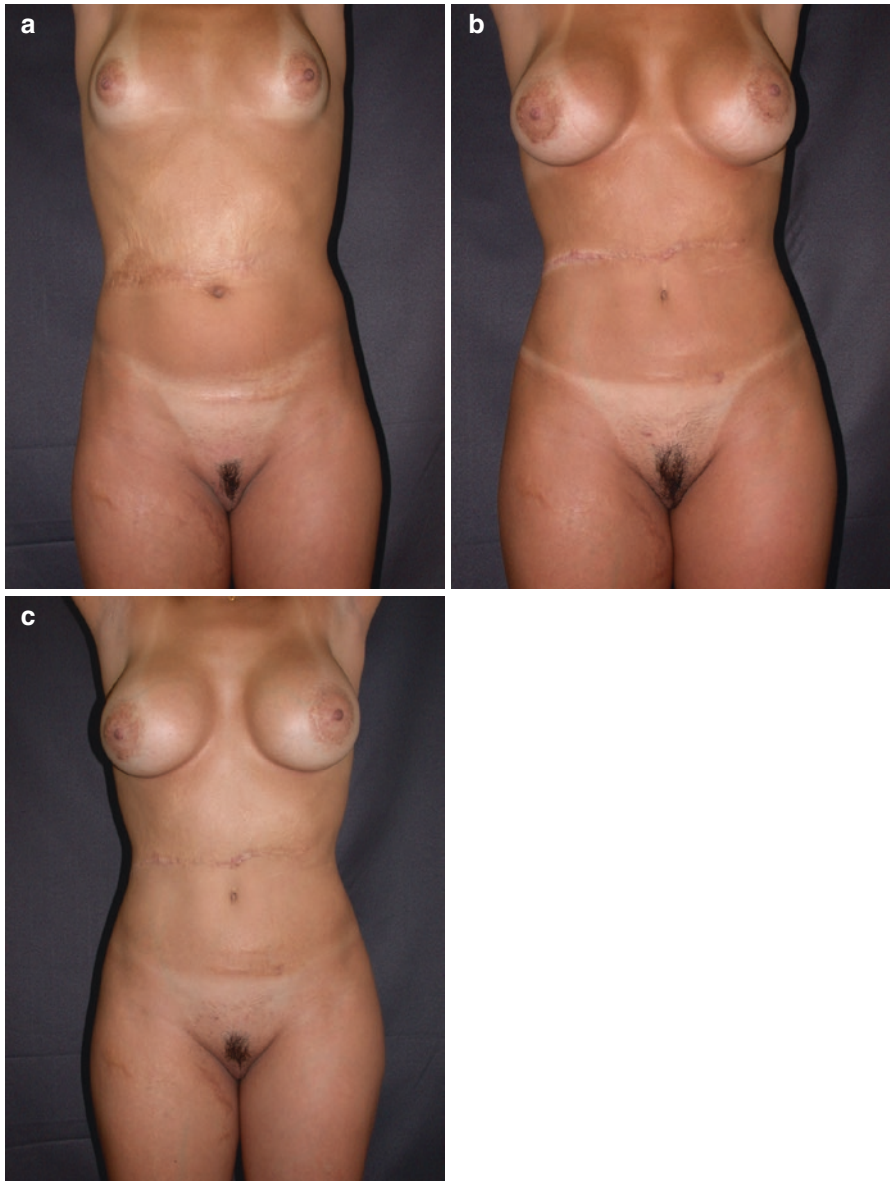
Female patient, 25 years old, with a history of burn sequelae on the face, abdomen, and 1/3 of superior thighs. The patient says that she was 4 years old when she suffered  $\pm 30\%$  body burns with incandescent alcohol which resulted in hypertrophic scars and keloids in the already mentioned areas (Fig. 30.3a–c).



**Fig. 30.1** (a) Pre-op of the 1st surgical session. (b) Five months after the 1st surgical session. (c) Three months after the 2nd surgical session. (d) Fourteen years after the 1st surgical session

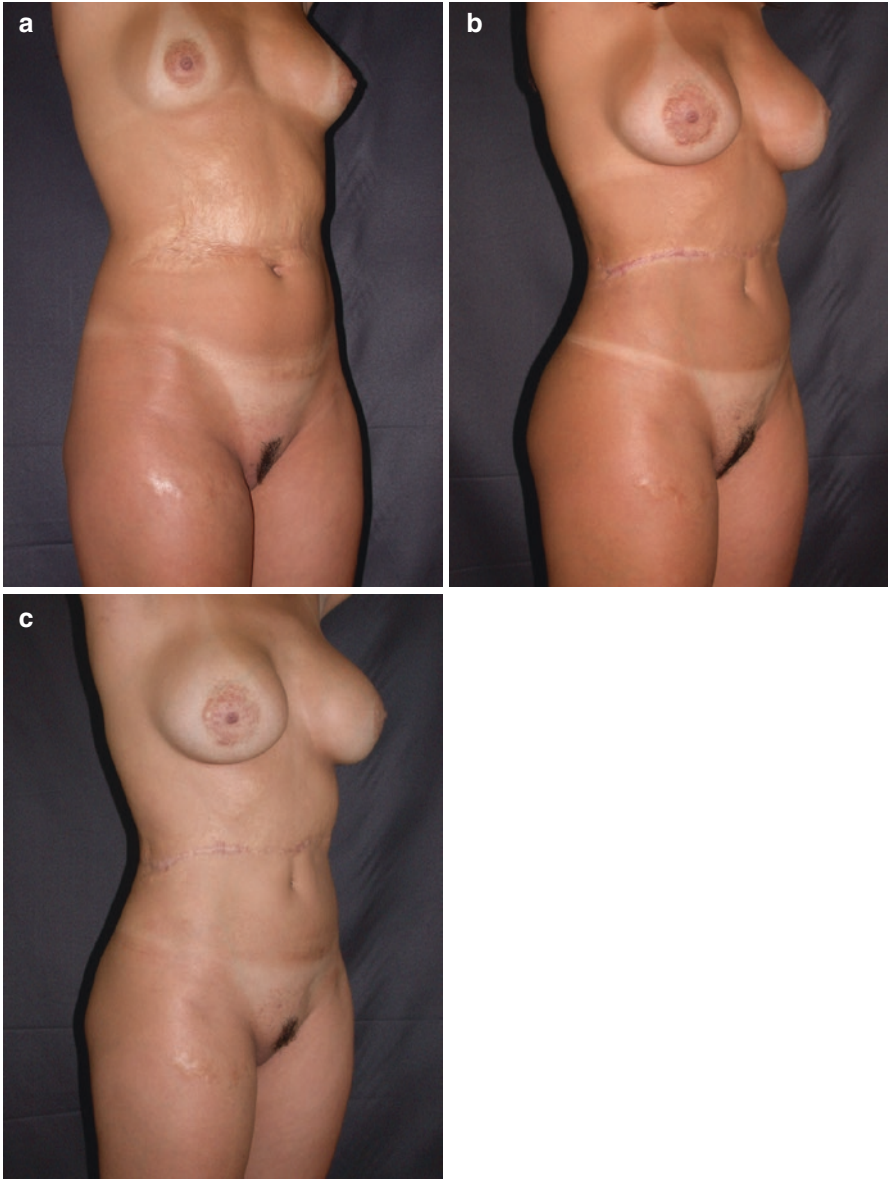


**Fig. 30.2** (a) Three-quarter view of the pre-op of the 1st surgical session. (b) Three-quarter view 5 months after the 1st surgical session. (c) Three-quarter view 3 months after the 2nd surgical session. (d) Three-quarter view 14 years after the 1st surgical session



**Fig. 30.3** (a) Pre-op of the 1st surgical session. (b) One year after the 1st surgical session. (c) Two years after the 1st surgical session

Although presenting herself in the beginning of adolescence, in a formative phase and corporal rescaling and without secondary adipose disposals, we were urged to request her to have the biggest weight gain possible that would allow the reutilization of a subsequent liposuction, with cutaneous mobilization and



**Fig. 30.4** (a) Right three-quarter view of the pre-op of the 1st surgical session. (b) Right three-quarter view 1 year after the 1st surgical session. (c) Right three-quarter view 2 years after the 1st surgical session

advancing, removal of the adjacent scars, and reutilization of the fat tissue in possible poor adipose areas (Fig. 30.4a–c).

So, in consequence of the abovementioned, 2 years after the initial check, the patient underwent a medial transverse supraumbilical lipoabdominoplasty with



the preservation of the pre-umbilical vascular pediculus bilaterally and discreet shift with top traction of the abdominal flap, partial decortication of the supra umbilical burned area, traction and reposition of the flap (Scarpa's fascia) over top subcutaneous skin after decortication of the top burn area, and fixation of the Scarpa's fascia of the decorticated area to the transposed periumbilical superficialis fascia and omphaloplasty with triangular umbilical remodeling [2, 4, 5, 6] associated with a body liposculpture in the sacral region; dorsum lumbar, back, and posterior flanks; and back and abdomen with total volume removal of 3,440 ml, 2,740 cc being of pure fat with 300 cc lipograft in the right buttocks and 280 cc in the left (Fig. 30.5a–c).

### *Case #3*

Female patient, 35 years old, with a history of back liposuction sequelae with deep adherences, diffused and transversal in the supraumbilical, cutaneous flaccidity localized in the supraumbilical abdomen, top traction of the umbilical scar locating itself 17–18 cm above the beginning of the pubic hair deployment, and sequelae of a reductive mammoplasty with vast horizontal scars, united in the medial external back region and surpassing the laterally back axillary lines.

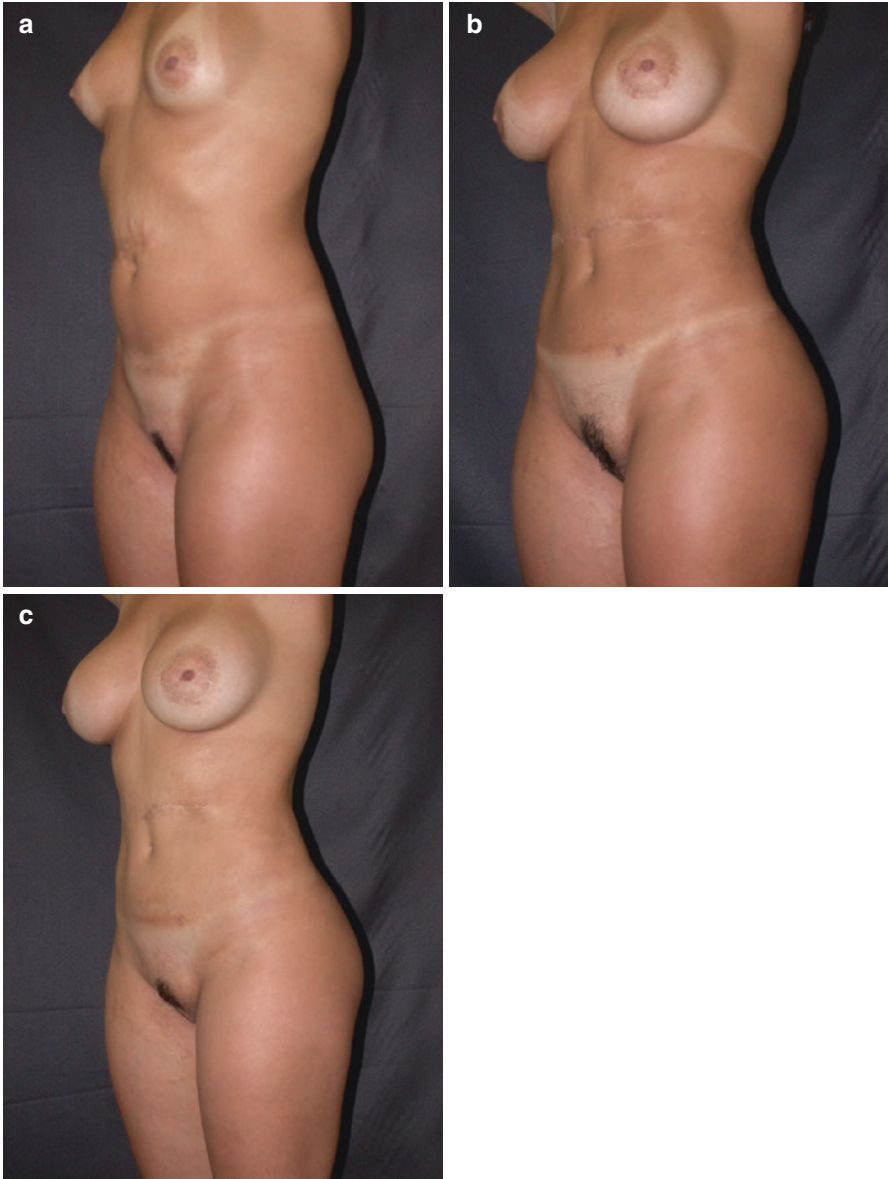
The patient declares that at the age of 19 she underwent a reductive mammoplasty with terrible results characterized by a practically bilateral mammary amputation. In 1998, she took a back abdominal liposculpture limited to this region, developing a strong cutaneous retraction with deep cutaneous adherences in the postoperative session.

In 1999 and 2000 she took two new localized liposuctions to correct the deformities without much therapeutic success and with punctuation of the presented deformities (Fig. 30.6a–c).

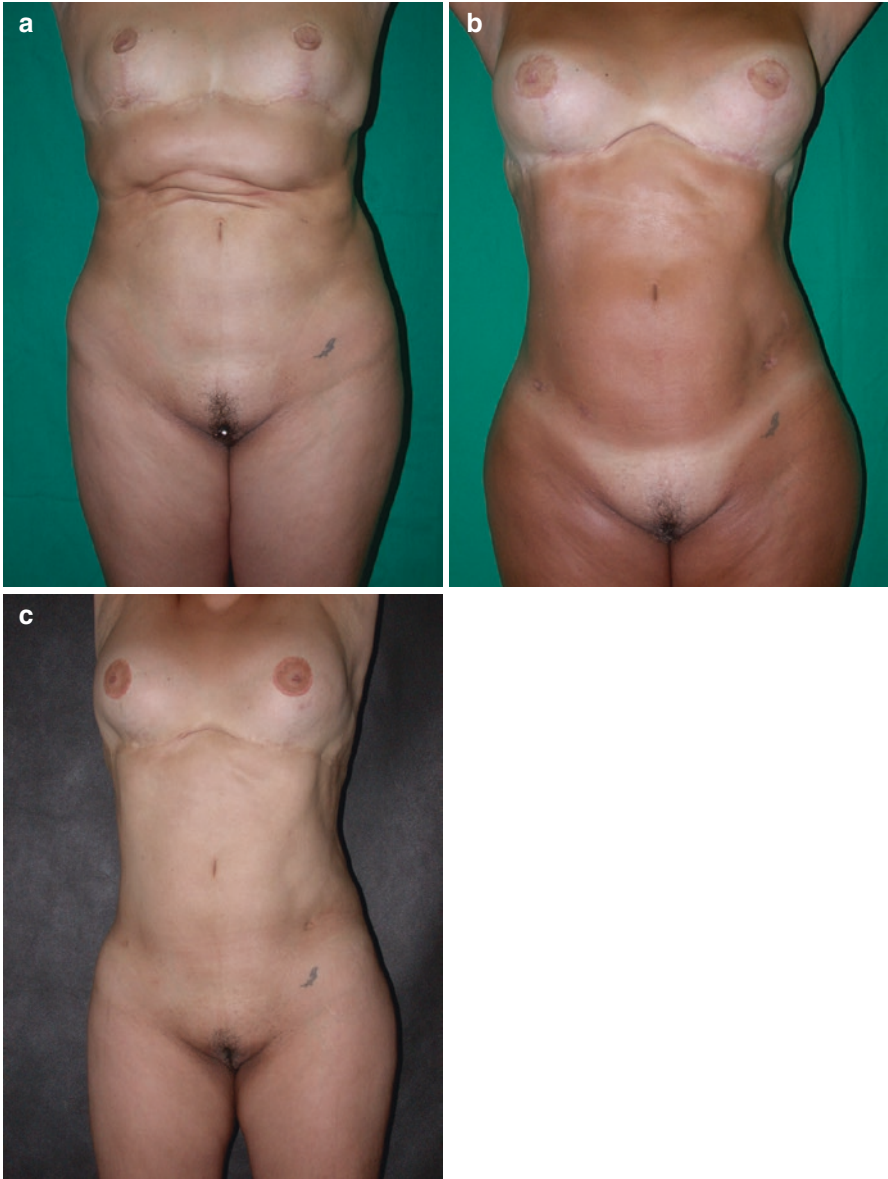In March of 2003 she underwent a reversal abdominoplasty by the longitudinal previous mammary incision with bipartition of the local fat flap and transposition of the hemi-bipartite flap to fill up the inferior adherence area mentioned.

After some months the following was observed: return to the anterior condition with worsening of the former deformities, with installation of voluminous and persistent storage of inframammary seroma (Fig. 30.7a–c).

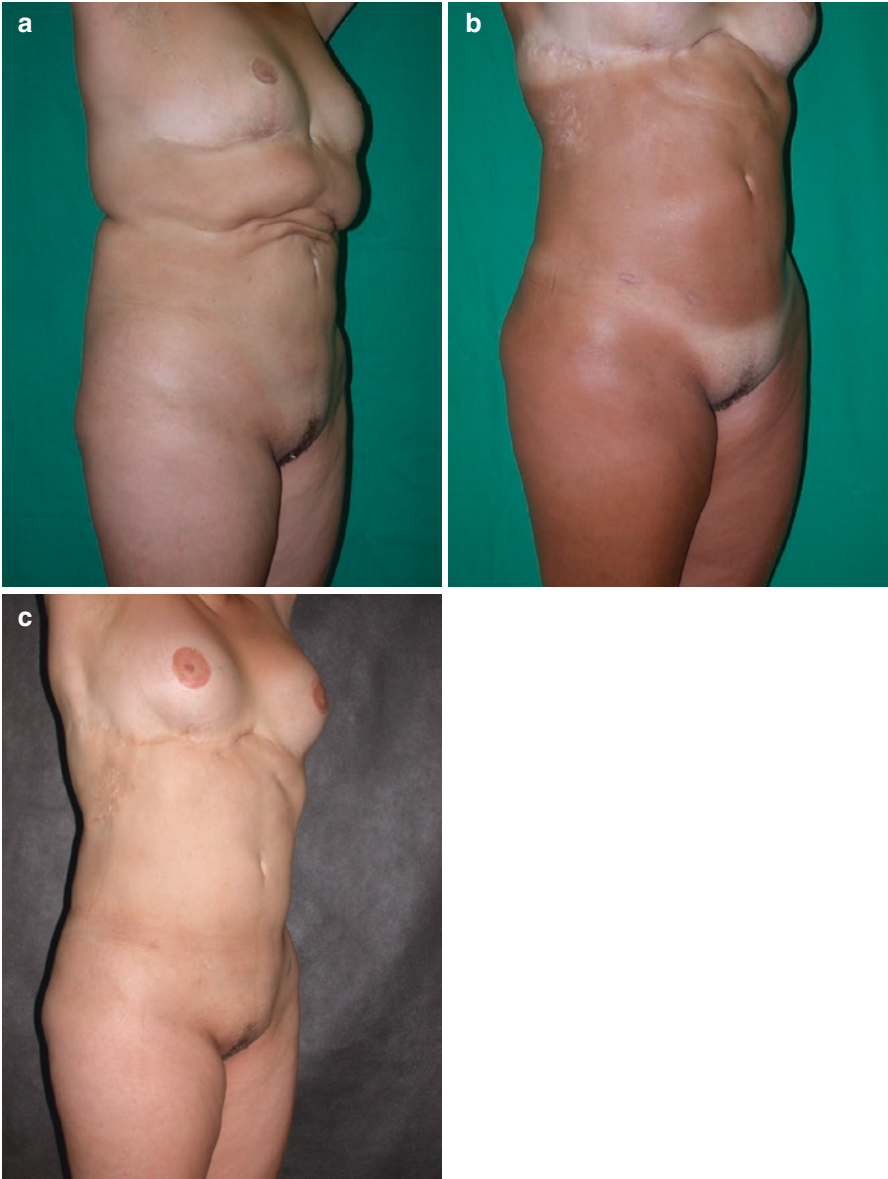So, in consequence of the abovementioned and observable conditions cleared in the physical exam, the patient was submitted to reversal abdominoplasty with bilateral reversal Holmstron flap confection and removal of an extensive supraumbilical seroma with resection of punctuated fibrosis scars and areas of diffuse retractions on the top abdomen. Associated to the mammary reconstruction with thoraco-medial flap confection of  $\pm 15$  cm length  $\times$  8 cm width, decorticated in its full extension, introduced under pectoralis major muscle (Caldeira II type) and fixation of the decorticated flap, followed by mammary remodeling [8, 10, 11 12] (Fig. 30.8a–c).



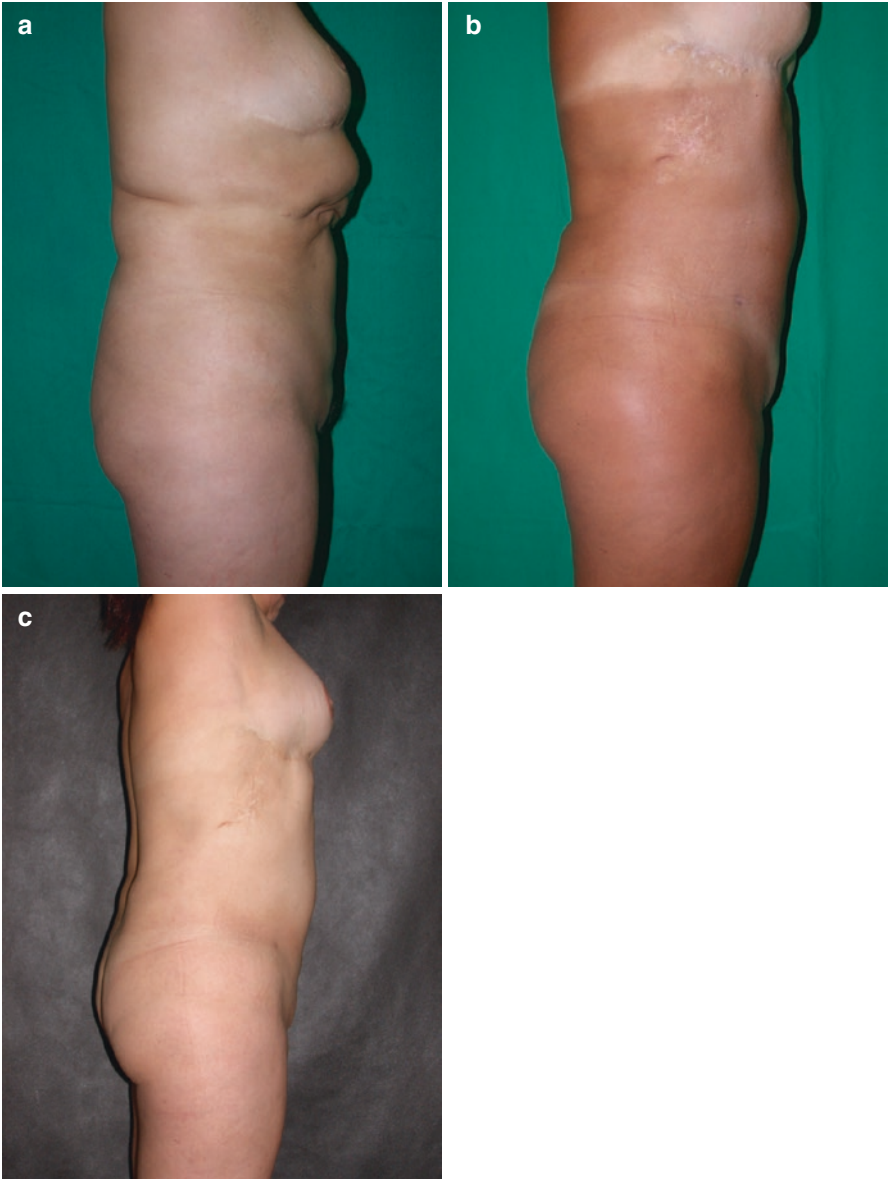
**Fig. 30.5** (a) Left three-quarter view of the pre-op of the 1st surgical session. (b) Left three-quarter view 1 year after the 1st surgical session. (c) Left three-quarter view 2 years after the 1st surgical session



**Fig. 30.6** (a) Pre-op of the 1st surgical session. (b) Eight months after the 1st surgical session. (c) Six years after the 1st surgical session



**Fig. 30.7** (a) Right three-quarter view of the pre-op of the 1st surgical session. (b) Right three-quarter view 8 months after the 1st surgical session. (c) Right three-quarter view 6 years after the 1st surgical session



**Fig. 30.8** (a) Right profile view of the pre-op of the 1st surgical session. (b) Right profile view 8 months after the 1st surgical session. (c) Right profile view 6 years after the 1st surgical session

## Discussion

Plastic surgery is usually divided into in two areas: aesthetic and reconstructive. However, this division with clear distinctions and peculiarities doesn't express any type of specialty. Every reconstructive surgery must attain a truly aesthetic benefit. Furthermore, any aesthetic surgery involves a type of reconstruction or restructuring in the body contour [13, 14].

Plastic surgeons must assume the role of natural innovators and experts in the identification of problems and development of unique solutions to solve them. This attitude is responsible for the appearance of new directions and advancements of the limits of the frontiers of knowledge in our specialization [16, 23].

More than following tendencies, the aesthetic abdominal plastic surgery needs a global focus in relation to the corporal outline. It's not reasonable to approach the abdomen without evaluating the surrounding regions and structures [13, 14, 21, 28].

The abdomen constitutes a focus of huge interest in the body outline. Therefore, the combined approach of all the thoracoabdominal areas and the adequate treatment of those modifications could allow us a better harmony of outline. Various deformities can be found in the abdominal region, arising from factors like obesity, large weight losses, multiple pregnancies, and previous surgical sequelae [24, 25].

As seen in [Case #1](#), the amplitude and extensions of the scars compromising all the infraumbilical segment of the abdomen, associated with remarkable cutaneous deficiencies and umbilical destruction, seemed to call for the usage of multiple and concomitant tissue expanders by consecutive cutaneous distensions that brought the effective transposition of the final scar to a transverse position, inferior concave, top sided, with well-elevated extremities, following the design of a bathing suit [9, 31, 32].

Certainly a simple procedure is the best for a simple problem, but in a more complex situation a simple method could not be the best or is simply inadequate [13, 14].

Choosing the umbilical scar placement to be positioned in the flap, we used the rule that the ideal distance between the umbilicus and the implantation of the pubic hair is 14–16 cm. The utilized technique for a neo-omphaloplasty was a modification of Talita Franco's technique [19] with effective defatting of the neo-umbilicus region and the circular central dermal aponeurotic fixation in the previously determined position.

There are a great number of surgical procedures that can be utilized to correct the abdominal deformities and nearby regions. The correct evaluation will allow the choice of the adequate procedures to every particular case. In recent times, the old abdominoplasty technique has been undergoing adaptation modifications to the new aesthetic tendencies. Thus, scars and displacements took different forms and amplitudes, reducing the number of complications and allowing better aesthetic results [22, 27, 34, 35].

The liposuction, lipograft, and the usage of tissue expanders complemented the number of procedures, treating the different alterations found more precisely [3, 33].

In [Case #2](#), the deficiency and skin restriction to the advancement of the secondary scars to the previous burn were supplanted by the stimulation of the gains in body

weight. With the increase in weight gained by the patient we achieved fat hypertrophy of the abdominal circumference area with cutaneous distention which showed itself sufficient after the liposuction of the body outline. The advancement of the tissue excess allowed us the resection of the hypertrophic scar areas by supraumbilical lipo-miniabdominoplasty and the exact amount of scar tissue, with omphaloplasty by Avelar's technique [5, 6].

We believe that the preservation and fixation of the superficialis fascia (side to side overlapping technique) in the relocation and cutaneous resection made possible an anatomic restructuring of the neo-periumbilical region [7].

Besides that, the removed fat tissue was utilized in an enhancement gluteoplasty by lipograft, playing a fundamental role in the redefinition of the new body outline [13, 14].

The dissemination and popularization of liposuction as an important procedure in corporal outline surgery, in recent years, has shown us very unsatisfactory results, motivated by improper or inadvertent conduct and procedures that presented serious or extensive changes in the abdominal dermal fat tegument [18].

Vicious and bad-quality surgical scars, adherences, saliences, and cutaneous retraction are some of the multiple factors that discourage the surgeon about cure prognostic and treatment success [1, 5, 6, 9].

The third case presents a deterioration of the abdominal wall due to three inadvertent previous liposuctions that resulted in an extensive depression area and supraumbilicus retraction. In a reversal abdominoplasty with bipartition of the supra-adjacent fat content in-block mobilized to fill the retraction area, it was composed of an absolutely empirical procedure, erroneous and inefficient, since the fat block suffered by its thickness and extension, as would be expected, total decomposition, steatonecrosis, and formation of large inclusion of oily cysts [36].

That evolution, however, promoted a big extension of the inframammary abdominal region and the autonomy gain of the upper-back abdominal flaps. In consequence of those changes, we were allowed to elaborate an abdominal and mammary reconstitution plan where:

1. A secondary reversal abdominoplasty with wide back abdominal covering skin repositioning that made possible a correction of the retraction area and supraumbilicus depression [19].
2. The top cutaneous segment to be neglected, already being autonomized, was utilized as two bilateral flaps, called RELAT flap (reverse lateral thoracodorsal flap), used in the bilateral mammary reconstitution internally supported by bipedicle pectoralis major muscular flaps [8, 11, 12, 15].
3. A broad liposuction of the back and posterior flanks was performed, with the aim of the rescaling of the corporal contour [13, 14].

The abdomen deformities must be treated together with the deformities or changes of areas like the thoracodorsal region, flanks, breast, and hip. Making illogical planning without taking into consideration areas that before abdominoplasty show an

acceptable appearance, after the procedure, could not harmonize as the new abdominal contour, being more evident and growing as a new source of serious concerns.

## Conclusion

Complex reconstitutions demand the mastering of the principles of plastic surgery. Those basic or fundamental principles represent the foundations as well as the starting and reference points, situating themselves as specialty canons.

There are cases that the deformities enforce limits and restrictions to the direct approach based on the classic parameters described in abdominoplasty. They demand, as shown in the presented cases, that the surgeon modify the approach standards and embody unusual conduct, therefore respecting the established principles to achieve more refined and surprising aesthetic results.

**Financial Disclosures** None of the authors have a financial interest in any of the products, devices, or drugs mentioned in this manuscript.

## References

1. Aly AS (2006) Body contouring after massive weight loss. QMP, St Louis
2. Avelar JM (1978) Abdominoplasty – systematization of a technique without external umbilical scar. *Aesthetic Plast Surg* 2:141–151
3. Avelar JM (1986) Study of the anatomy of the subcutaneous adipose tissue applied for fat suction technique. *Travail de l'Institute Scientifique Brésilien de Chirurgie Plastique*, São Paulo
4. Avelar JM (1999) Uma nova técnica de abdominoplastia – Sistema vascular fechado de retalho subdérmico dobrado sobre si mesmo combinado com lipoaspiração. *Rev Bras Cir* 88/89(1/6):3–20
5. Avelar JM (2002) Abdominoplasty. Without panniculus undermining and resection. Editora Hipócrates, São Paulo
6. Avelar JM (2002) Abdominoplasty. Without panniculus undermining and resection. Analysis and 3-Years follow up of 97 consecutive cases. *Aesthet Surg J* 22(1):16–25
7. Baroudi R, Ferreira CA (1998) Seroma: how to avoid it and how to treat it. *Aesthet Surg J* 18(6):439–441
8. Caldeira AML, Barral S, Araújo I, Thomaz D (2008) Aesthetic abdominal and breast reconstruction with reverse lateral thoracodorsal flap. *Plast Reconstr Surg* 121(5):346e–347e
9. Caldeira AML, Lucas A (1998) Flacidez músculo-aponeurótica abdominal intensa. Su tratamento. *Cir Plast Ibero Lat Am* 24(1):9–15
10. Caldeira AML, Lucas A (2000) Pectoralis major muscle flap: a new support approach to mammoplasty, personal technique. *Aesthetic Plast Surg* 24:58–70
11. Caldeira AML, Lucas A, Cajano P (1999) Lembi di muscolo gran pettorale nella mastoplastica. *Minerva Chir* 54(10):729–738
12. Caldeira AML, Lucas A, Grigalek G (1999) Mastoplasty: the triple-flap interposition technique. *Aesthetic Plast Surg* 23:51–60



13. Caldeira AML, Niéves A, Oliveira A (1990) Cirurgia do contorno corporal – Reflexões sobre um novo enfoque da cirurgia plástica do abdome. I – Classificações das dermofimidades abdominais e suas correlações cirúrgicas. *Rev Bras Cir* 80(2):95–104
14. Caldeira AML, Niéves A, Oliveira A (1990) Cirurgia do contorno corporal – 2ª Parte. Reflexões sobre um novo enfoque da cirurgia plástica do abdome. *Rev Bras Cir* 80(3):169–186
15. Caldeira AML, Roth GB (2009) Chapter 15. The triple flap interposition mammoplasty. In: Shiffman M (ed) *Mastopexy and breast reduction*. Springer, Berlin/Heidelberg, pp 103–113
16. Carreirão S, Pitanguy I, Correa WE, Caldeira AML (1983) Abdominoplastia Vertical – Uma técnica a ser lembrada. *Rev Bras Cir* 73(3):184–194
17. Elbaz JS, Flageul G (1989) *Liposucção et Chirurgie Plastique de L'Abdomen*. Masson, Paris
18. Fournier PF (1987) Body sculpturing through syringe liposuction and autologous fat re-injection. Samuel Rolf International
19. Franco T, Rebello C (1977) *Cirurgia Estética*. Livraria Atheneu, Rio de Janeiro
20. Gillies H, Millard R (1957) *The principles and art of plastic surgery*. Little Brown and Co., Boston, pp 291–420
21. Guerrero Santos I, Spaillat L, Morales F, Dicksheet S (1980) Some problems and solutions in abdominoplasty. *Aesthetic Plast Surg* 4:227–237
22. Hakme F (1979) Lipectomia peri e supra-umbilical nas abdominoplastias. *Rev Bras Cir* 69:271
23. Kesselring UK, Meyer R (1978) A suction curette for removal excessive local deposits of subcutaneous fat. *Plast Reconstr Surg* 62:305
24. Lázaro da Silva A (1971) Plástica com o saco herniário na correção das hérnias incisionais. *O Hospital* 79:123–124
25. Lázaro da Silva A (1974) Plástica com o saco herniário na correção das hérnias incisionais, longitudinais, medianas ou para-retais e nas diástases dos retos abdominais. *Rev Col Bras Cir* 1:113
26. Millard DR Jr (1986) *Principles of plastic surgery*, 1st edn. Little Brown and Company, Boston
27. Pitanguy I (1967) Abdominal lipectomy: an approach to it through an analysis of 300 consecutive cases. *Plast Reconstr Surg* 40(4):384–391
28. Pitanguy I (1977) Dermolipectomy of the abdominal wall, thighs, buttocks and upper extremity. In: *Reconstructive plastic surgery*. W.B. Saunders Co., Philadelphia
29. Pitanguy I (1981) *Aesthetic plastic surgery of head and body*. Springer, Berlin/Heidelberg
30. Pitanguy I, Caldeira AML, Almeida CC, Alexandrino A (1982) Abdominoplastia – Algumas considerações históricas, filosóficas e psicossociais. *Rev Bras Cir* 72(6):390–402
31. Psillakis JM (1978) Abdominoplasty: some ideas to improve results. *Aesthetic Plast Surg* 2:205–215
32. Psillakis JM (1984) Plastic surgery of the abdomen with improvement in the body contour. Physiopathology and treatment of the aponeurotic musculature. *Clin Plast Surg* 11(3):465–477
33. Saldanha OR (2001) Lipoabdominoplasty without undermining. *Aesthet Surg J* 21:518–526
34. Sinder R (1975) Plastic surgery of the abdomen – personal technique. In: *Abstracts of the 6th international Congress of plastic and reconstructive surgery*. Masson, Paris, p 58
35. Wilkinson TS, Swartz BE (1986) Individual modifications in body contour surgery: the “limited” abdominoplasty. *Plast Reconstr Surg* 77:779–784
36. Yoshimura K, Eto H, Kato H, Sugra H, Aoi N, Doi K, Kuno S (2012) The fate of adipocytes after nonvascularized fat grafting: evidence of early death and replacement of adipocytes. *Plastic Reconstr Surg* 129(5):1081–1092

# Chapter 31

## Abdominoplasty: The Role of the External Oblique Muscle

Jorge M. Psillakis

### Introduction

Aesthetic appearance of the abdomen has a variable form according to the spatial position of bone skeleton, the muscular system shape, the volume of viscera inside the abdominal cavity, and the volume of adipose tissue on the subcutaneous tissue [1].

In our days, an abdomen within the beauty standards has a “lyre” form [2], due to light reflections on prominences and shadows on the sulcus (Fig. 31.1).

This natural ideal form is the goal to be achieved by the surgeon.

On surgical planning, this goal predicts the work has to be done on the several layers of the abdominal wall: skin, subcutaneous tissue, and muscles.

The final result to be reached will depend on the preoperative situation of the patient; the higher the deformity, the more difficult and minor the possibility to achieve the ideal result.

Incision, skin and subcutaneous resection, localized subcutaneous defatting and remodeling, liposuction, treatment of the muscle layer, and treatment of the navel are the techniques to be planned and used.

Correction of muscle diastases is part of the treatment.

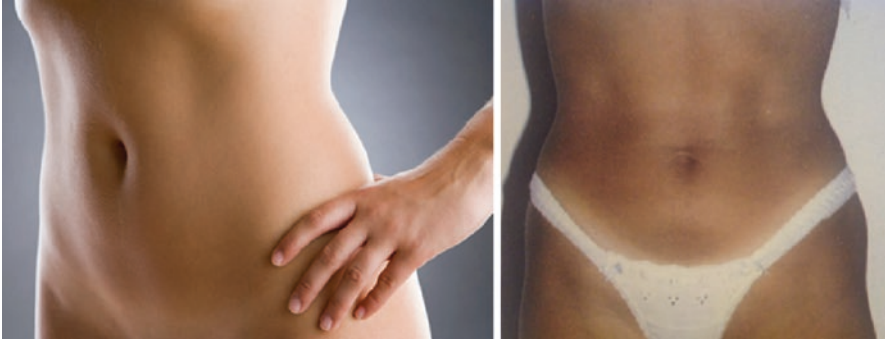Traditionally, treatment from the anterior rectus muscle diastasis [3–5] is the only technique used by surgeons in all cases, with suture of strong nonabsorbable stitches, from the xiphoid process up to the pubis. As result the anteroposterior projection of the abdomen are reduced [6] (Fig. 31.1), but in our experience, do not model and do not reduce the girth.

The diastase of the oblique muscles [7, 8] have had less attention from surgeons; this will be discussed in this chapter.

---

J.M. Psillakis, MD

Members of the Brazilian Society of Plastic Surgery, Department of Plastic Surgery, Hospital “Alemão Oswaldo Cruz”, Av. Vereador José Diniz, 3457, Campo Belo, São Paulo 04616-003, Brazil  
e-mail: [jpsillos@gmail.com](mailto:jpsillos@gmail.com)



**Fig. 31.1** Abdomen within the beauty standards as a “lyre” form, due to light reflections on prominences and shadows on the sulcus. Put attention carefully on the shadows and light reflections

### **Surgical Technique: Oblique Muscle Plication Technique [7]**

During surgery we can diagnose if there is diastases or not and its degree and indicate surgical correction.

This technique may be performed on cases with mild flaccidity.

After rectus muscles have been plicated, with forceps, we pull, in an inferior and medial direction, the aponeurosis of the oblique muscle just below the navel, to verify mobilization of this muscle.

If there is difficulty for this mobilization, it is a sign that there is no diastasis, and therefore, there is no need for plication.

If there is a mild mobilization, we begin to suture the oblique aponeurosis muscle over the rectus muscle aponeurosis with separate stitches.

The first two stitches are done at the level of the navel, one on each side to avoid distortion of the navel position.

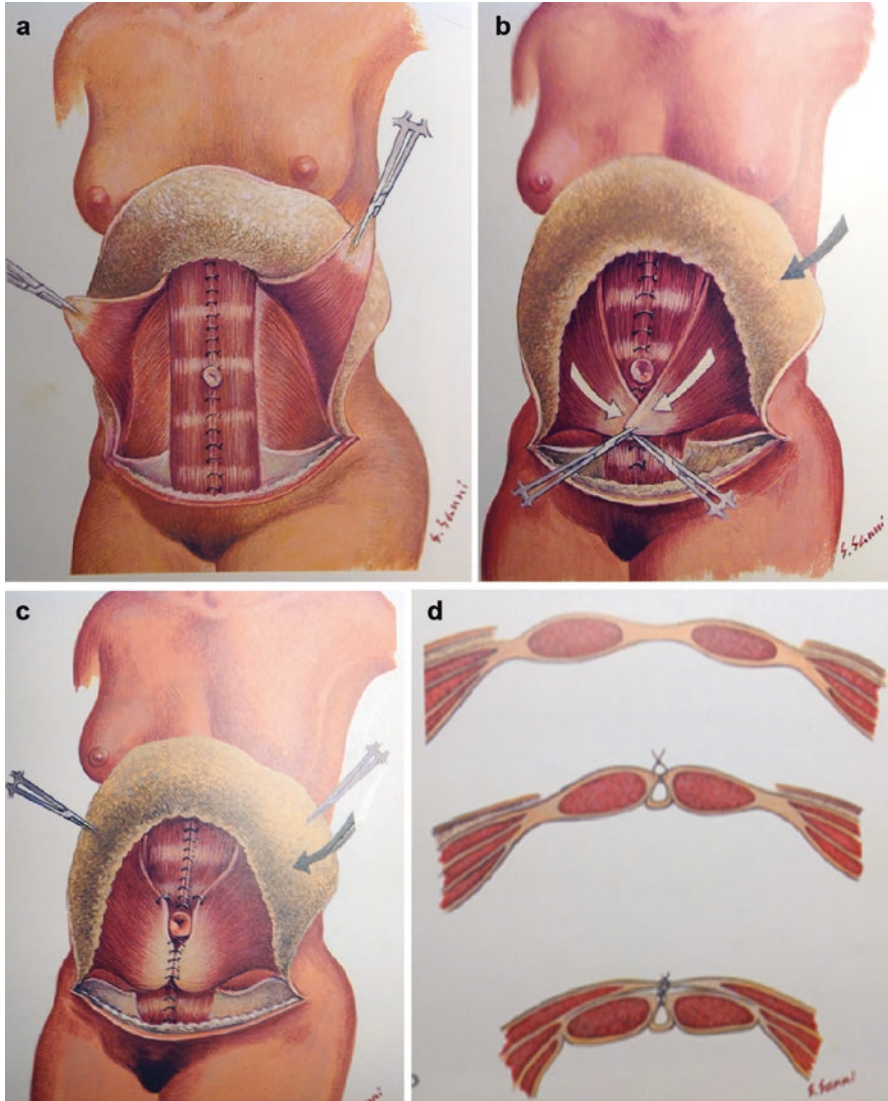
Sutures are completed in the overall margin of the oblique muscle, superimposing to the underlying abdominal fascia.

### **Surgical Technique: Oblique Muscle Advancement Technique [1, 8, 9] (Fig. 31.2)**

After rectus muscles have been plicated, with forceps, we pull, in an inferior and medial direction, the aponeurosis of the oblique muscle just below the navel, to verify mobilization of this muscle.

If there is a large mobilization, it is a sign of great flaccidity; in this case, we began the dissection of the external oblique muscle.

We begin with a small incision, made with scalpel at the aponeurosis of the oblique muscle, where it is attached to the lateral margin of the rectus muscle.



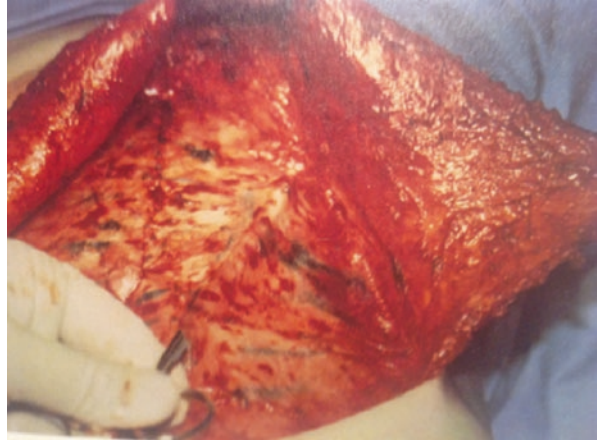
**Fig. 31.2** (a–d) Drawing of the oblique muscle advancement technique

A scissor is inserted into the avascular plane, finding the outside edge of the rectus muscle where the aponeurosis of the external oblique muscle is cut and separated (Fig. 31.3).

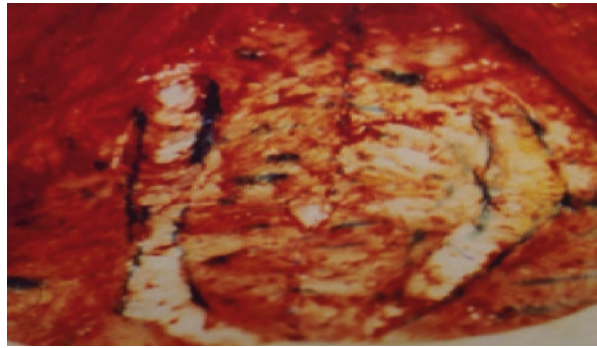
This incision extends from the most inferior extremity at the pubic area up to the ribs, in a curve shape with the convex side directed to the midline (Fig. 31.4).

Once the aponeurosis from the oblique muscles is separated, it is easily dissected up to the anterior axillary line.

**Fig. 31.3** Surgical technique: separation of the oblique aponeurosis from the rectus one



**Fig. 31.4** Total separation of the aponeurosis



At this point, care must be taken, to not damage the vascular pedicles, which are visible in a semilunar line.

At this point, traction is made over the oblique muscles, advancing them in a downward and inferior direction; with this maneuver it is possible to see what happens at the level of the waist.

We can see the remodeling of the waist in a concave shape in several degrees according to the flaccidity of each case. The waist reduction and remodeling is evident.

Pulling the oblique muscles in a downward and inferior direction, the sutures are placed at the level of the navel. Initially, one or two stitches are placed on both sides, to avoid distortion of the navel position (Fig. 31.5).

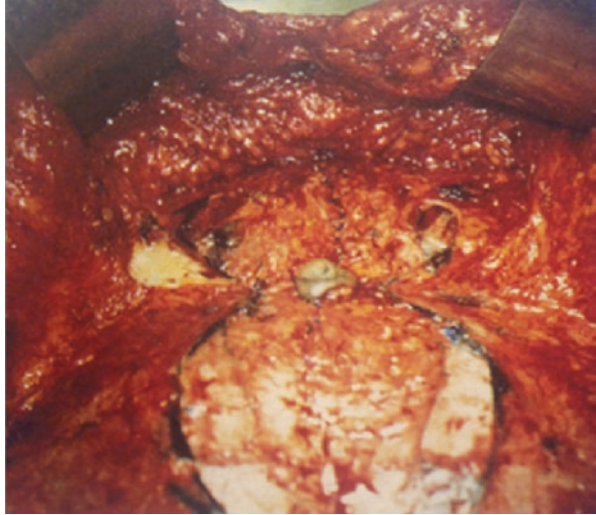
The fixation is completed by interrupted nonabsorbable stitches, fixing the overall oblique muscle to the underlying fascia. At the end, we have the suture line in a “Y” shape (Fig. 31.6).

In some cases, the flaccidity is so severe that the aponeurosis extends beyond the midline.

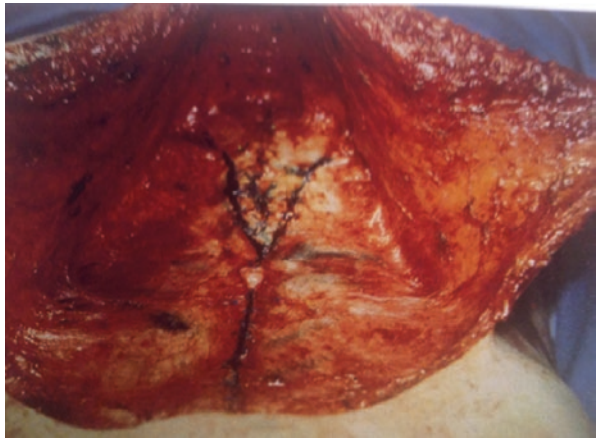
In this case, a hole is done at the aponeurosis to allow the exposition of the navel.

Abdominoplasty is completed as usual, with cutaneous tegument resection, pulling the flaps on a downward and medial direction (Figs. 31.7, 31.8, 31.9, 31.10,

**Fig. 31.5** The first two stitches are placed at the level of the navel



**Fig. 31.6** Surgical technique: final view of the suture line, in a “Y” shape



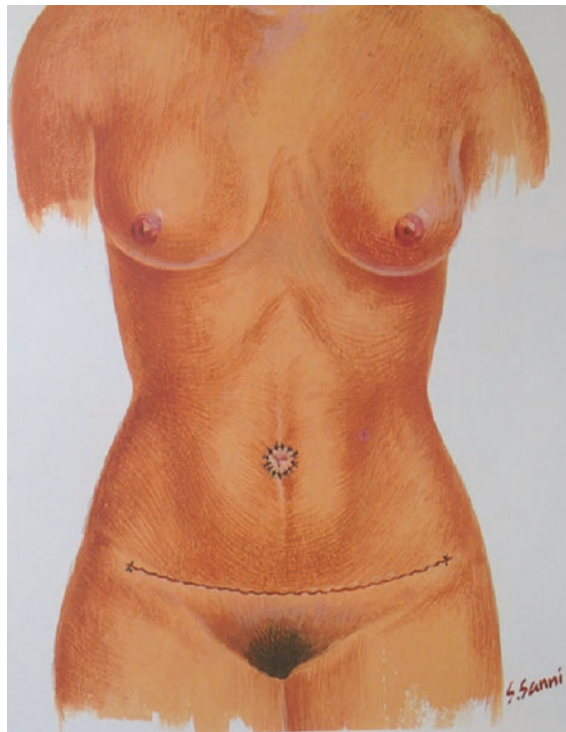
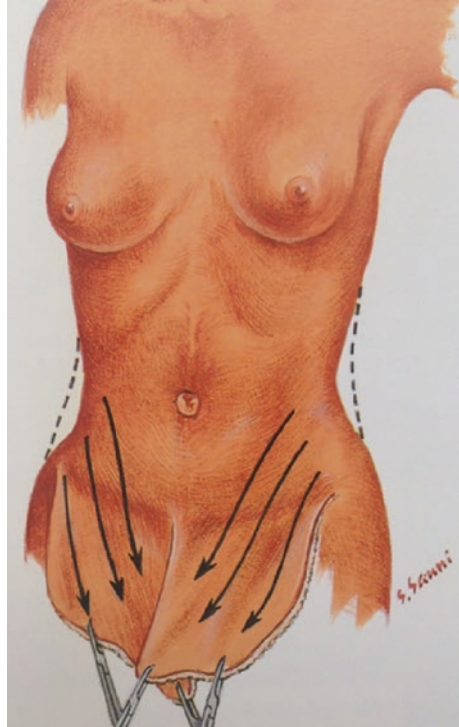
and 31.11), and suture of the wound margins in three planes, with the final intradermal suture with absorbable thread, to avoid the need to remove stitches.

Measures of the waist before and after this technique were made in a series of cases (Table 31.1).

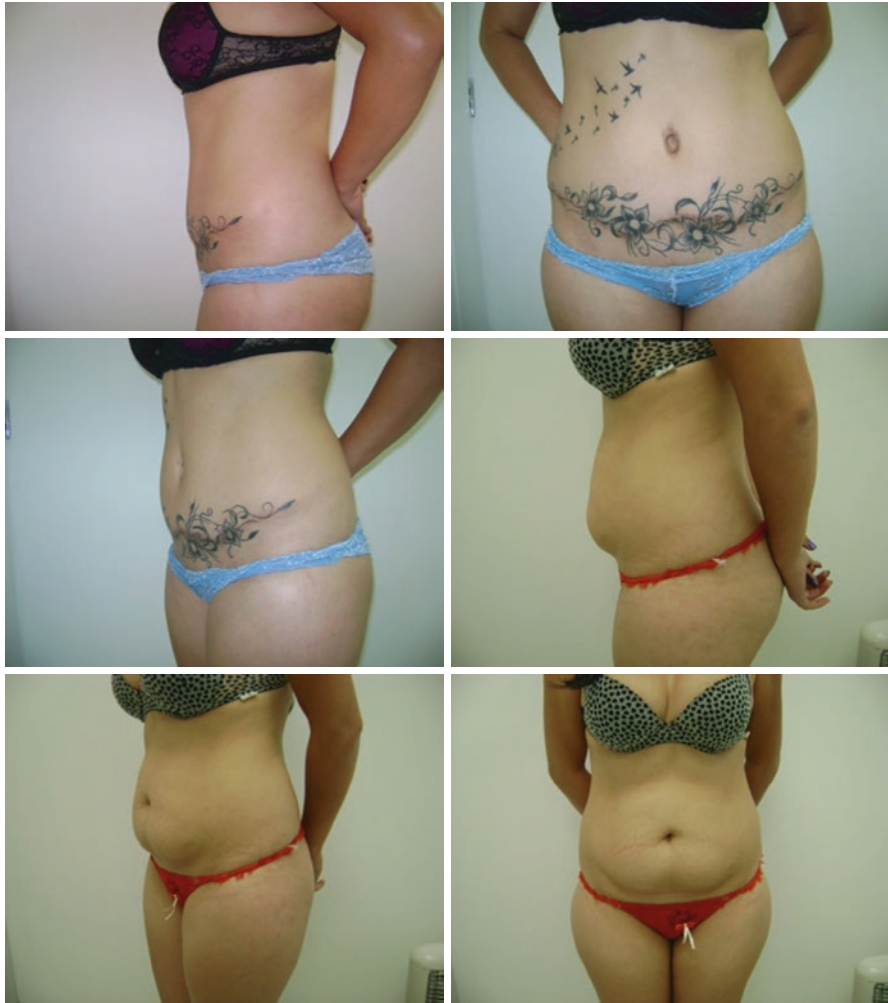## Complications

We began to treat the external oblique muscle in 1978 with simple plication and, after 1982, with dissection and advancement. No surgical complications occurred due to this technique. Complications are similar to the standard technique, described below.

**Fig. 31.7** Technical drawing: cutaneous tegument resection, pulling the flaps on a downward and medial direction



**Fig. 31.8** Technical drawing: final result with suture



**Fig. 31.9** Pre- and postoperative result: patient hides the horizontal scar with tattoo

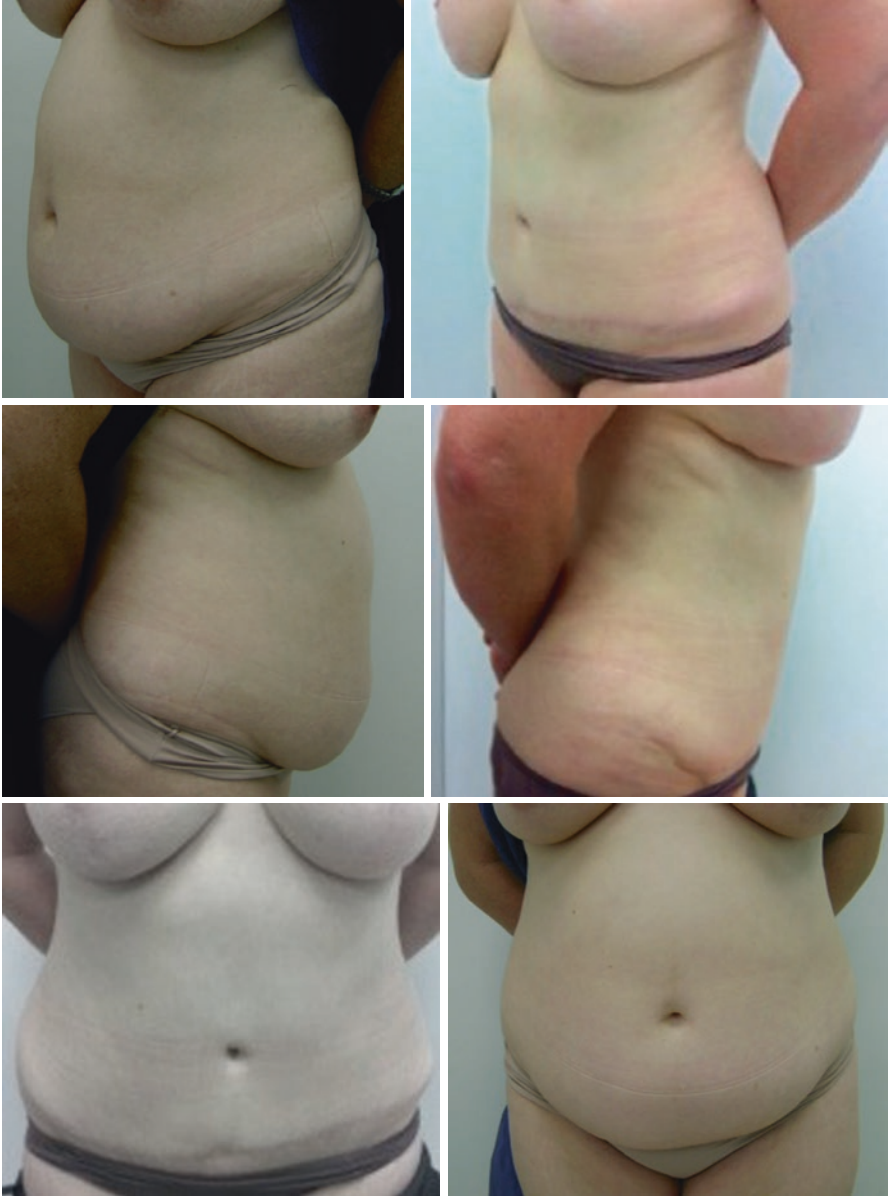Some colleagues mentioned to me that more sensitive patients had complained of more pain in the immediate postoperative, period than those who had performed only suture of the rectus muscles; these patients were treated with more analgesic.

A detailed description of complications in abdominoplasty with documentation is described in our book [18], but also experienced surgeons have well described them and how to avoid it [19–21].

The most frequent complication are seromas, especially in which SAL is associated to abdominoplasty and in obese patients. Seromas are difficult to avoid in 100% of cases but can be reduced, with some measures: a very careful hemostasis has to be performed progressively during the elevation of the abdominal flap and gentle manipulation of fat tissue.

At the end of surgery, close drainage is used, maintaining the suction drains up to the day that drainage is reduced to 35 cc/day.





**Fig. 31.10** Pre and postoperative result

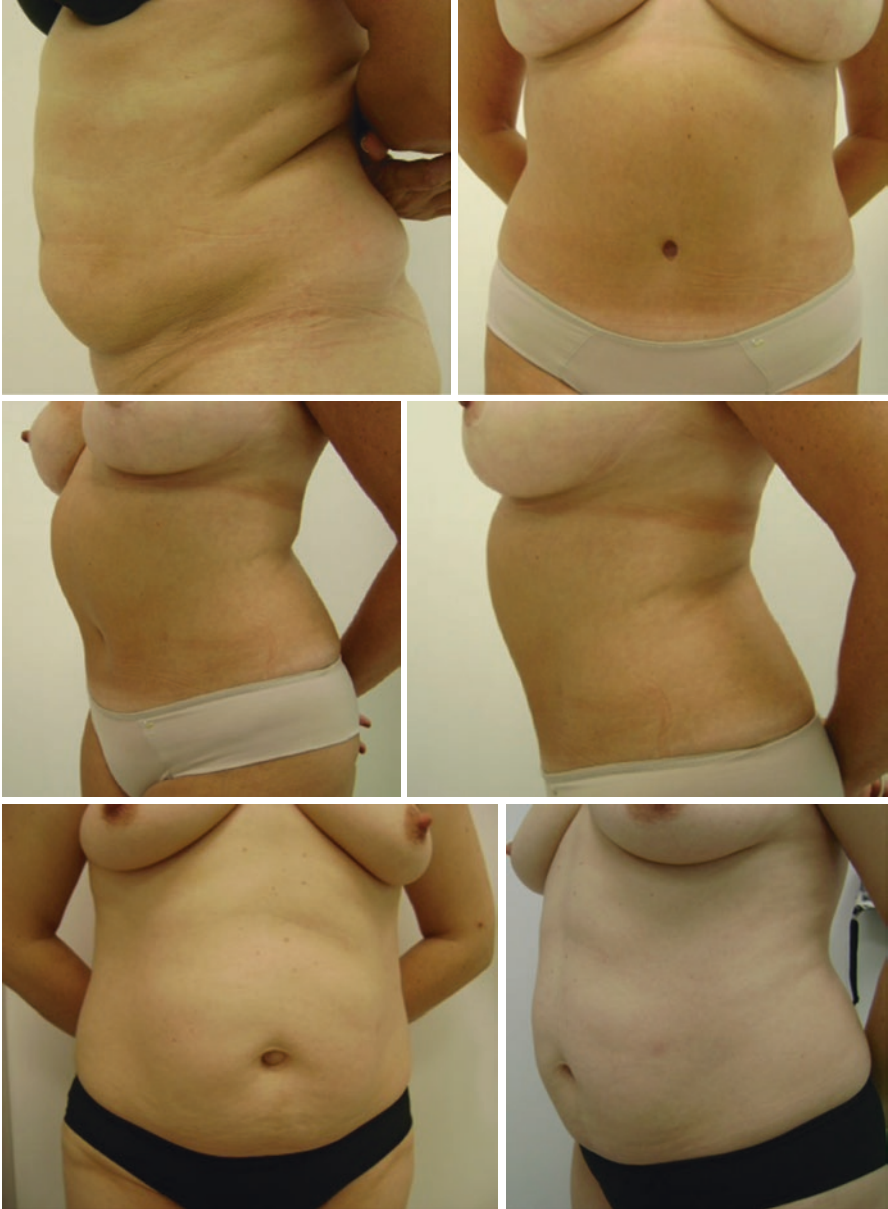

Fig. 31.11 Pre- and postoperative result

**Table 31.1** External Oblique Muscles technique: waist measurements before and after surgery

	Age	Pre-op waist (cm)	Post-op waist (cm)	Weight pre-op (kg)	Weight postoperative (kg)
1	25	85	78	69	63
2	26	87	75	56	58
3	28	101	80	73	66
4	36	96	80	71	64
5	36	80	80	52	57
6	36	81	78	65	69
7	36	75	73	56	52
8	37	75	73	57	57
9	38	92	82	69	73
10	40	77	73	53	51
11	43	90	83	68	66
12	44	78	73	54	53
13	44	75	71	56	56
14	45	80	78	58	58
15	47	81	76	61	55
16	48	80	73	62	63
17	48	92	81	60	59
18	50	91	77	57	55
19	51	86	85	51	63
20	55	83	76	66	63

The incidence of seromas is proportionate to the amount of fat in the subcutaneous tissue and to the surgical trauma over it. Aggressive maneuvers during the undermining of the flap, excessive burn by electrocautery, and liposuction are the main causes of large volumes, which can be seen up to the second postoperative week.

Ultrasound exam is the elective method to diagnose and control treatment of late seromas, which are treated with transcutaneous puncture with needle.

Another cause of complications are patients who do not obey the postoperative instructions, emotionally agitated patients who walk and move excessively in the first 12 days, or patients who had sexual relations before the third week. This can cause seromas, hematoma, and several degrees of skin necrosis at the suture line.

Hematomas are rare and will depend on the same measures taken to avoid seromas. We had two cases of late hematoma at the suprapubic area, due to sexual relations before the 15th day postoperative. This hematoma was produced by direct trauma at the infraumbilical area, where there is no sensibility.

Little skin losses at the margins of the suture line can occur, which heal by second intention, with more scarring. Large areas of skin necrosis were not seen in our series in the last 40 years. This complication is more frequent in the beginner's hands.

Pulmonary embolism may occur, especially in very obese patients and more frequent when combined to gynecological surgeries. The use of pneumatic stockings and the use of the medications protocol can prevent it. In our series we had one case

of pulmonary thrombosis 26 years ago in a very obese patient, who was carefully treated and survived.

Hypertrophic scars or keloids can occur, more commonly around the navel. Asymmetries of the suprapubic scar may occur due to a technical mistake. “Dog ears” may be seen at the late postoperative period in one or in both sides at the extremity of the scar.

Abdominoplasty appears to be an easy procedure, but it is not, and undesirable complications or unpleasant aesthetic results may occur due to mistakes at the preoperative evaluation, design of the incision, aggressive tissue management during surgery, ignorance of the anatomy with emphasis on the blood supply of the cutaneous tegument, lack of knowledge of the complication causes, and lack of sensibility to aesthetic details.

## Discussion

Abdominoplasty techniques have evolved progressively in these 50 years.

At the beginning, the goal was to reduce cutaneous and fat volumes only.

Progressively surgeons’ experience in all the world, with a great contribution of Brazilian surgeons, begin to introduce technical details to reach superior results.

Better correction of the muscles and aponeurosis was the first step on this path, followed by the knife-localized defatting of the abdominal flap. Defatting with knife was too limited because of the irregularities and the risk of skin necrosis.

Liposuction brought a great advancement and progressively was widely used with modifications on the tissue detachment, to better maintain the skin vascularization. This technique was made possible to have a great defatting of the subcutaneous tissue with blood supply safety, making possible a better remodeling of the overall abdominal wall [10–13].

The unaesthetic scar at the navel was also a problem, in the late postoperative results. Several techniques were described to reduce this problem [13, 17].

Recently an excellent technique was described, totally resecting the skin of the original navel and reconstructing a new umbilicus, without external scar. On the abdominal flap, at the level of the new umbilicus, all the fat of the subcutaneous tissue is removed up to the dermis, which is fixed to the aponeurosis [14–16]. Horizontal scar, recently, has been hidden by tattoo (Fig. 31.9).

The modeling of the waist depends on the thickness of the fat, the spatial position of the oblique muscles, and the distance from the ribs to the iliac crest.

Correction of the oblique muscle diastases has contributed in all patients, to reduce the waist that can be seen in our table; when patients lost weight, the reduction was higher; even in patients who gain weight, the measure of the girth has reduced, which is a definitive proof of the effect of the technique to achieve this goal.

The result of this technique also better models the grooves and bumps that will produce light reflections and shadows, as nuances of ideal abdomen.

Treatment of external oblique muscle diastases is important to better shape the abdomen.

## Conclusion

Treatment of the external oblique muscle diastases is useful, in many cases, to obtain a better aesthetic result on abdominoplasty, especially on cases with diastases of this muscle.

During surgery, we can diagnose if there is diastases or not and its degree and indicate surgical correction.

Oblique muscle plication technique may be performed on cases with mild flaccidity or diastases, to better remodel the abdomen.

Dissection and advancement in a downward and inferior direction of the external oblique muscles are used when we find a great flaccidity or diastases, which results in not only reduction of the waist but an overall better remodeling of the abdomen, with a superior aesthetic result.

Measurement confirms the reduction of the girth, due to the spatial modification of the muscle aponeurosis layer, by correction of the external oblique muscle diastases.

Loss of weight and liposuction also contribute to improve the waist reduction.

## References

1. Psillakis JM et al (1991) Color atlas of aesthetic surgery of the abdomen. Thieme Medical Publishers, Inc, New York, pp 1–88
2. Bozola AR, Psillakis JM (1988) Abdominoplasty: a new concept and classification for treatment. *Plast Reconstr Surg* 82:983–993
3. Callia WE (1965) Contributions for the surgical correction of the pendulous and globose abdomen: original technique. Doctor's thesis, Medicine Medical School, São Paulo University, Sao Paulo
4. Callia WE (1967) A plastic surgery technique for the general surgeon. *Med Hosp* 1:40–52
5. Pitaguy I (1967) Abdominal lipectomy: an approach to it through an analysis of 300 consecutive cases. *Plast Reconstr Surg* 40:384–391
6. Psillakis JM et al (1991) Color atlas of aesthetic surgery of the abdomen. Thieme Medical Publishers, Inc, New York, pp 43–45
7. Psillakis JM (1978) Abdominoplasty: some ideas to improve results. *Aesthetic Plast Surg* 2:205–215
8. Psillakis JM (1984) Plastic surgery of the abdomen with improvement in the body contour. *Clin Plast Surg* 11(3):465–477
9. Psillakis JM (1984) Abdominoplasty: treatment of the external oblique muscle to obtain a better waist. *Ann J Sul Bras Plast Surg SBCP* 1:85–89
10. Avelar JM (2000) Abdominoplasty: a new technique without undermining and fat layer removal. *Arq Catarin Med* 29:147–149
11. Saldanha OR, De Souza Pinto EB, Mattos WN Jr, Pazetti CE, Lopes Bello EM, Rojas Y et al (2003) Lipoabdominoplasty with selective and safe undermining. *Aesthetic Plast Surg* 27(4):322–327
12. Avelar JM (1978) Abdominoplasty: systematization of a technique without external umbilical scar. *Aesthetic Plast Surg* 2:141–151
13. Saldanha OR (2001) Lipoabdominoplasty without undermining. *Aesthet Surg J* 21:518–526
14. Avelar JM (2002) Abdominoplasty without panniculus undermining and resection: analysis and 3-year follow-up of 97 consecutive cases. *Aesthet Surg J* 22:16

15. Kirianoff TG (1978) Making a new umbilicus when none exists. *Plast Reconstr Surg* 61(4):603–604
16. Amud RJM (2008) Neo-onfaloplastia sem cicatriz. *Rev Bras Cir Plast* 23(1):37–40
17. Abreu JA (2010) Abdominoplasty: neomphaloplasty without scar or fat excision. *Rev Bras Cir Plást* 25:499–503
18. Psillakis JM et al (1991) Color atlas of aesthetic surgery of the abdomen. Thieme Medical Publishers, Inc, New York, pp 76–81
19. Grazer FM, Goldwyn RM (1977) Abdominoplasty assessed by the survey, with emphasis on complications. *Plast Reconstr Surg* 59(4):513–517
20. Teimourian B, Rogers WB 3rd (1989) A national survey of complications associated with suction lipectomy: a comparative study. *Plast Reconstr Surg* 84(4):628–631
21. Floros C, Davis PK (1991) Complications and long-term results following abdominoplasty: a retrospective study. *Br J Plast Surg* 44(3):190–194

# Chapter 32

## Correction of Minor Abdominal Diastasis and Acquired and Congenital Deformities of the Umbilicus

José Carlos Miranda and Lincoln Graça Neto

### Introduction

Plastic surgery of the abdomen shows a considerable development in recent years related to reducing the extent of the transverse scar, as well as compared to less undermining of the abdominal flap [3]. According to survey by Shestack [9] regarding abdominoplasty, he found about 5% of complications performed with wide undermining and long incisions. However, the use of reduced undermining and smaller incisions achieved poor results due to the presence of remaining adipose tissue in the upper abdomen and also lasting local edema in the lower abdomen above the scar.

With the advent of liposuction technique associated with segmented low transverse resections of the abdomen, new possibilities came up, but the results were not satisfied due to the presence of cutaneous flaccidity associated with lack of correction of the muscular diastases when patients present [6]. These aspects have caused even greater concern over surgical results. After Avelar's publications [1, 2, 4, 5] regarding abdominoplasty in a closed vascular system with the subdermal flap folded over itself, combined with liposuction, it opened new expectations for surgery of the abdominal wall [4, 5]. In fact, Avelar's surgical principles are based to preserve the perforator vessels of the abdominal panniculus which is essential to perform safe abdominoplasty. Based on these concepts, Saldanha (2001) introduced lipoabdominoplasty technique also allowed to do correction with reduced undermining and plication of the aponeurosis of the rectus abdominis [8].

In more modern times, new "ghost" came to annoy and cause concerns due to increase complications of these surgeries, especially deep vein thrombosis and

---

J.C. Miranda, MD (✉) • L.G. Neto, MD  
Members of the Brazilian Society of Plastic Surgery, ISAPS Member,  
Augusto Severo Street No. 80, Cep 80030-240, Curitiba, Paraná, Brazil  
e-mail: [j.miranda@uol.com.br](mailto:j.miranda@uol.com.br)

pulmonary embolism. These are due to several factors caused by early and prolonged use of contraceptives as well as increasing the average age of search for abdominal surgery, which previously patients were around 35 years of age and currently between 45 and 50 years.

Nowadays women care so much to maintain a well-balanced weight, as well as special care regarding skin hydration for preventing stretch marks even physical exercise during pregnancy and post-pregnancy which present less impact on the abdominal wall. Consequently the profile of patients with abdominal wall disorders has increased the demand for correction of minor changes due not only to pregnancy but also to constant weight loss and birth defects, which cause less scar and faster postoperative recovery.

In order to solve these abnormalities, I developed some procedures that may be useful for correcting localized changes of excess fat as well as in minor abdominal diastases and navel deformities. In the use of my procedures, the final results are more graceful abdomen and with minimal remaining scars.

## Technique

After careful clinical evaluation, three areas must be treated:

- (a) Localized adiposities in the abdominal wall, flanks, and other regions of the trunk, which are good indication for liposuction, to achieve harmonious result to the body contour
- (b) Acquired and congenital deformities of the umbilicus
- (c) Excess skin and transverse scar in the lower abdomen

## Surgical Demarcation and the Operation

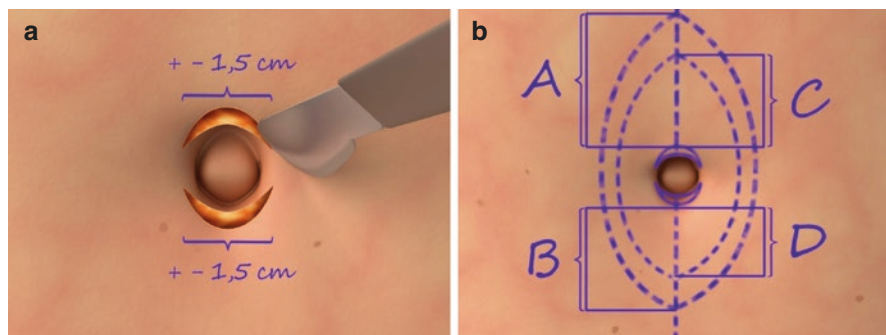
Firstly surgical demarcation must be well performed before surgery. All areas with fat deposits located in the abdominal wall and other regions of the trunk will be a useful guide for liposuction.

For patients presenting upper and lower diastases of rectus abdominis without previous scar on navel, two incisions of 1.5 cm long each are drawing on above and below the umbilical region (Fig. 32.1a).

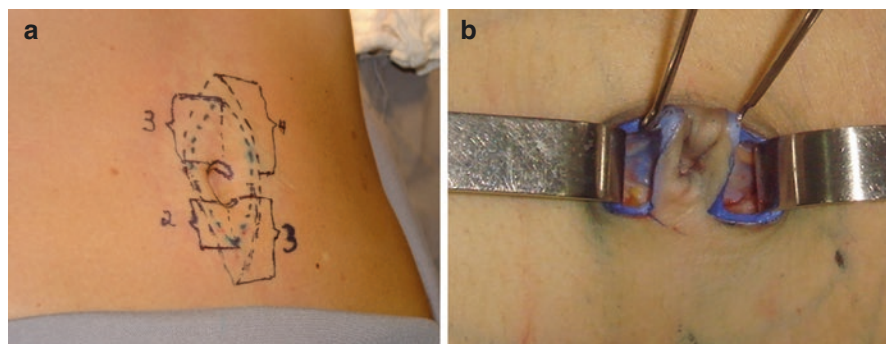
From these lines two elliptical areas to be undermined are drawing (Fig. 32.1b) a similar V and inverted V, with the base turned to the umbilicus. The superior area may be about 4–5 cm (A) and 3–4 cm at the bottom (B). Also the areas for plication, with 3–4 cm superiorly (C) and 2–3 cm inferiorly (D), are demarcated (Fig. 32.1b).

Skin incisions are done followed by cutaneous undermining of the demarcated areas on superior and inferior segments of the elliptical-shaped areas, with preservation of umbilical pedicle and two skin islands (Fig. 32.2a, b). When patient presents hernia, its correction is performed.





**Fig. 32.1** Surgical demarcation. (a) Drawing shows two curve incisions of 1.5 cm each, above and below the umbilicus. (b) Demarcation with dotted lines of two elliptical areas (one is smaller inside of the other). The superior segment (A) and the inferior one (B) indicate the areas to be undermined. The smaller areas represented by (C) and (D) show the segment for plication of the border of the rectus abdominis



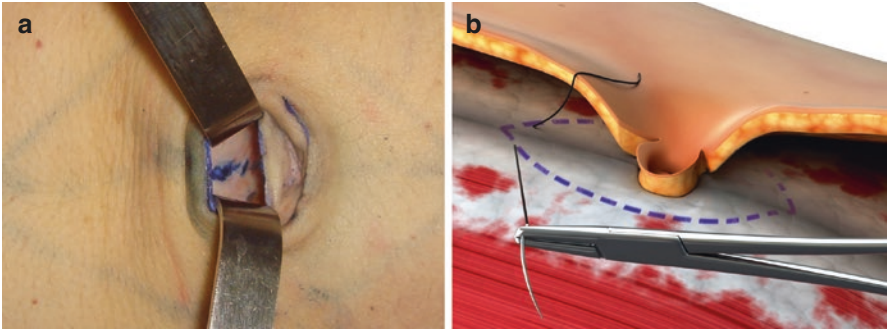
**Fig. 32.2** Demarcation and incisions during surgery. (a) Demarcation of *two dotted lines* according to description on Fig. 32.1b: the elliptical areas for cutaneous undermining and plication in cm. (b) Two horizontal skin incisions 1.5 cm each (above and below the umbilicus) without complete circumferential around the umbilicus

Following the operation, demarcation and plication of the aponeurosis of the rectus abdominis above and below of the umbilicus are done. Plication is performed with mononylon 0 (Fig. 32.3a, b). Afterward it is useful procedure to suture the subcutaneous tissue with two to three mononylons 3-0 (Fig. 32.4a, b).

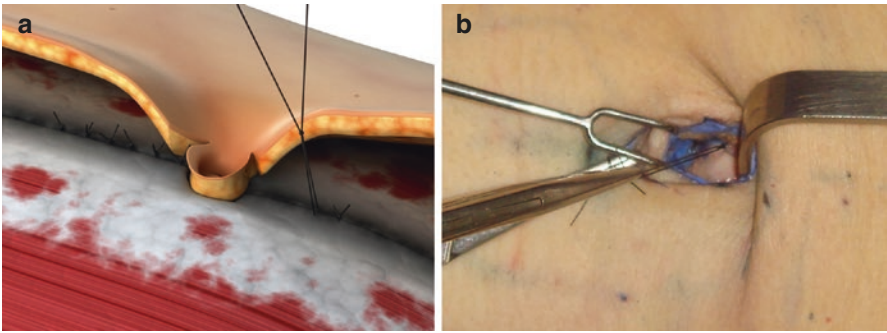
Next, the umbilical pedicle is sutured to the aponeurosis with three mononylons 3-0 in the upper and lower portion (Fig. 32.5).

Subdermal suture is done with mononylon 3-0 or 4-0 (similar to “round block”), using as reference the final diameter of the umbilicus, the surgeon’s fingertip itself (Fig. 32.6a, b). Finally the skin is sutured with nylon 5-0 (Fig. 32.7a, b).

The surgical technique efficiency results are shown in Figs. 32.8a, b, 32.9a, b, and 32.10a, b.

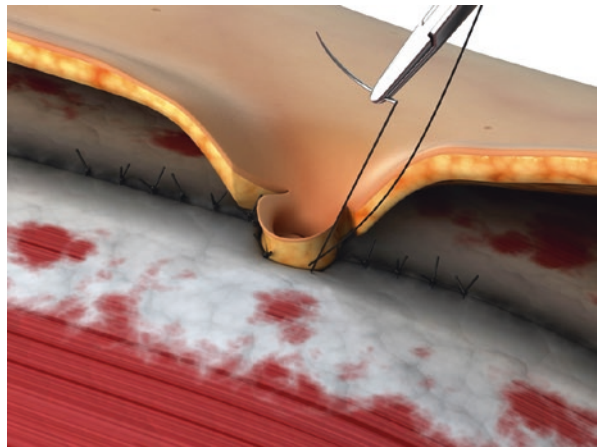


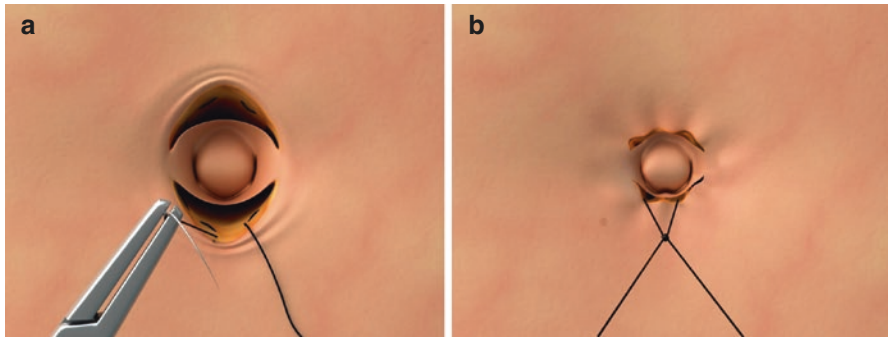
**Fig. 32.3** Skin undermining and plication of the rectus abdominis around the umbilicus. (a) Photo during operation shows cutaneous undermining already performed above and below the umbilicus. (b) Drawing demonstrates the cutaneous undermining around the umbilicus. An elliptical area is demarcated with *dotted line* for plication with 4–6 stitches with mononylon 0



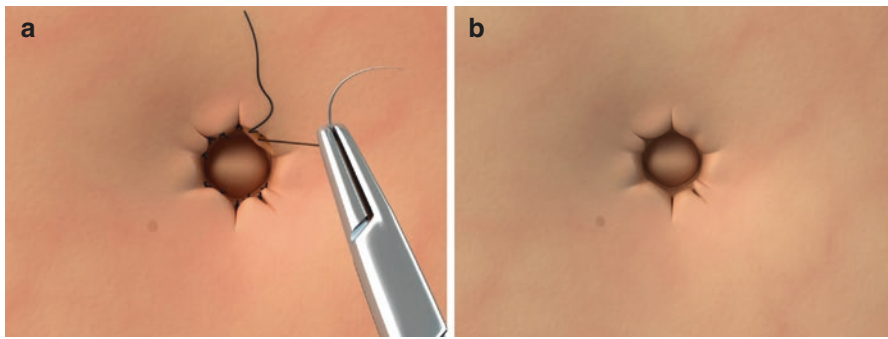
**Fig. 32.4** Plication of the minor diastases of the rectus abdominis. (a) Drawing shows the plication already performed. (b) Photo during surgery shows the plication with above and below the umbilicus with 4–5 stitches with mononylon 0. Subcutaneous tissue was sutured with mononylon 2

**Fig. 32.5** Drawing demonstrates the shortening of the umbilical pedicle close to the aponeurosis with three stitches superiorly and inferiorly

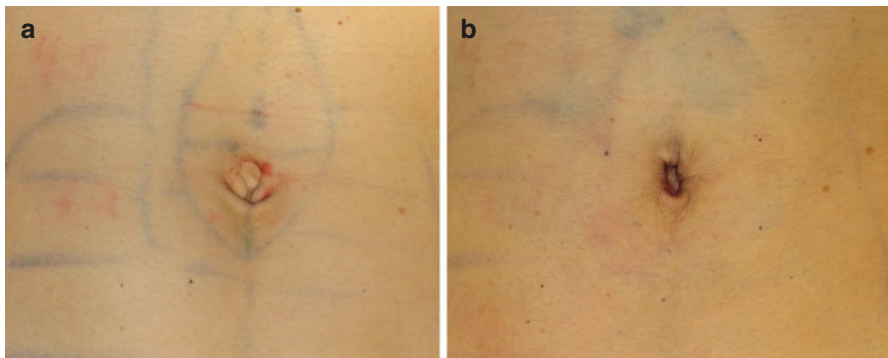




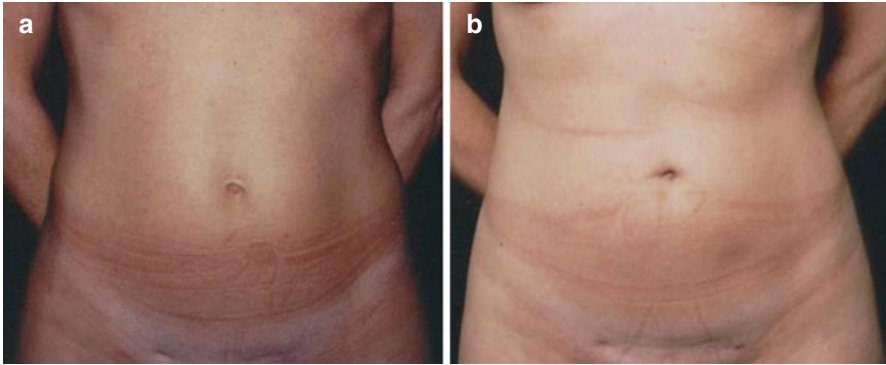
**Fig. 32.6** Drawings show the suture of the skin incisions on the abdominal flap. (a) “Round block” suture with purpose to reduce the final diameter near the fingertip of the fifth finger of the surgeon. (b) After suture of the incisions on the abdominal flap as a “round block”



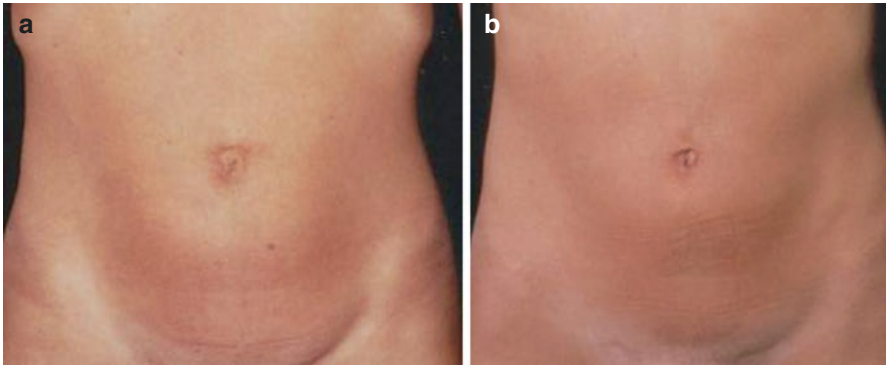
**Fig. 32.7** Drawings demonstrate the final suture around the umbilicus. (a) Umbilical suture with monofilament 5-0. (b) Final suture with a final diameter that matches the fingertip of the surgeon’s fifth finger



**Fig. 32.8** Preoperative photos showing correction of “sad” navel. (a) Photo before operation with demarcations of the areas for liposuction, correction of the muscle diastasis. (b) Final aspect after immediate postoperative view with the “round block” suture around the umbilicus



**Fig. 32.9** Correction of “sad navel” on a female patient. (a) Preoperative photo shows minor degree of diastases of the rectus abdominis and localized adiposities on each side of the umbilicus. (b) 1-year postoperative photo of the same patient after liposuction and plication of the diastasis of the rectus abdominis



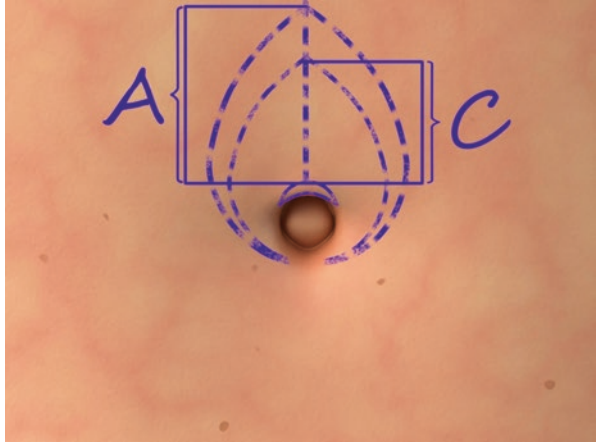
**Fig. 32.10** Correction of minor degree of muscular diastases and wide umbilicus. (a) Preoperative photo. (b) Same patient 1 year after plication of diastases of the muscles combined with liposuction and correction of the navel

In case of “sad navel,” usually only one single incision is done on the upper portion of the navel, and plication of the aponeurosis of the rectus abdominis near the umbilical pedicle is performed (Figs. 32.11 and 32.12). We can see an example of the result of the technique in Fig. 32.13a, b.

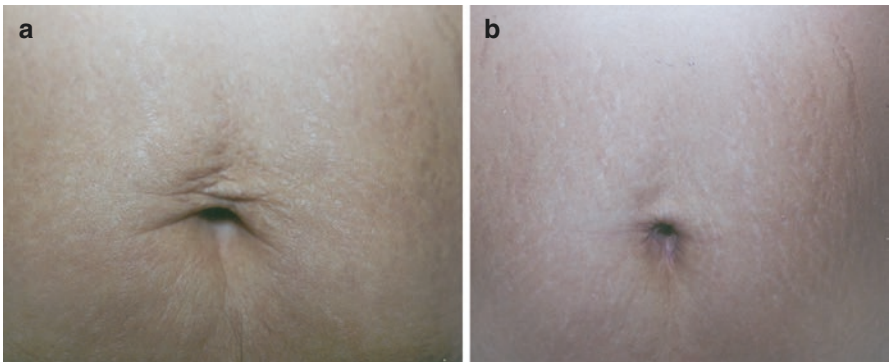
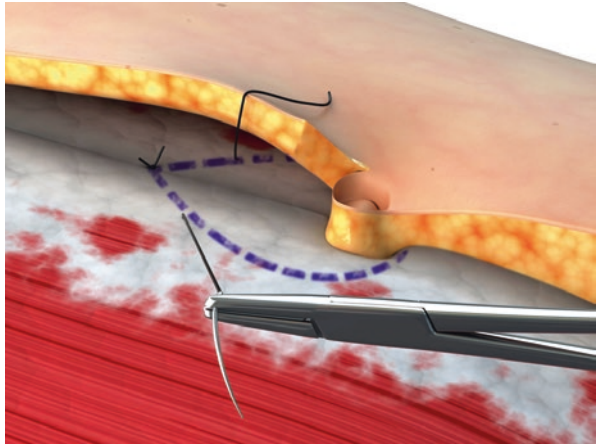
When a patient presents scars due to previous operations or navel with exaggerated diameter, circular incision all around the umbilicus is done with resection of the excess skin (Figs. 32.14a, b and 32.15a, b). The next steps of the operation are done on similar way as previously described above (Figs. 32.16 and 32.17).

When there is excess skin on the lower abdomen, unaesthetic scars can be corrected following Avelar’s principles [4], which means liposuction on the lower abdominal flap with resection of the excess skin, with preservation of vessels and nerves (Fig. 32.18a, b). The technical results are suitable for correction of the deformities (Figs. 32.19, 32.20, and 32.21).

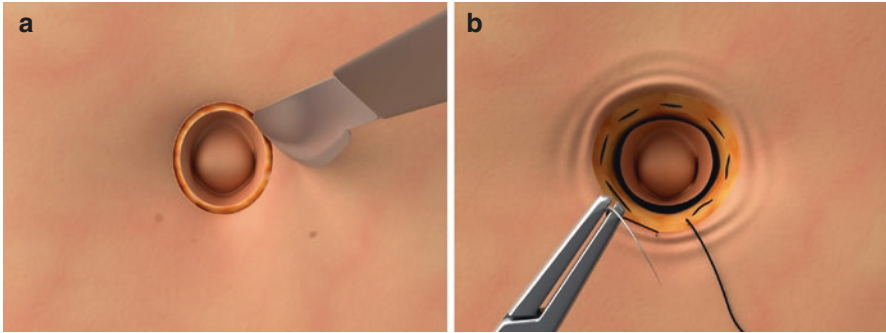
**Fig. 32.11** Drawing shows surgical demarcations for correction of “sad navel.” Two areas are demarcated above the umbilicus: the area for cutaneous undermining (A) with 3–4 cm and the area to be subjected to the aponeurosis plication (C) with about 2–3 cm and upper periumbilical incision of 1.5 cm



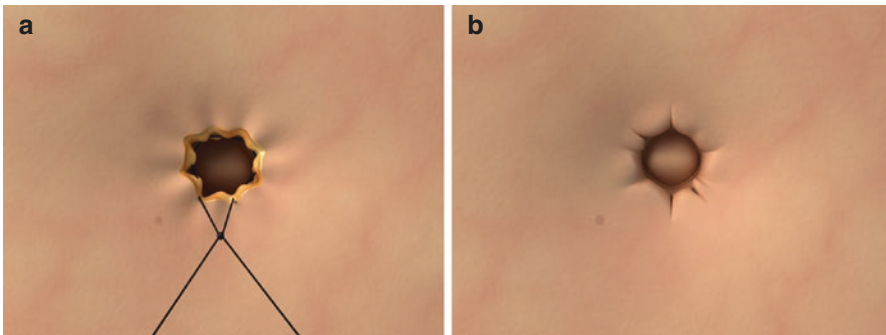
**Fig. 32.12** Drawing demonstrates the suture of the aponeurosis with two or four monofilament stitches



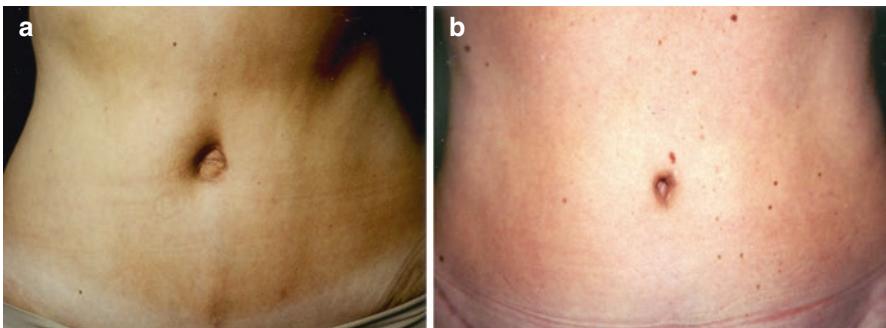
**Fig. 32.13** Correction of “sad navel.” (a) Photo before operation shows upper diastasis of the muscles. (b) Postoperative photo shows the surgical result 1 year after correction of “sad navel”



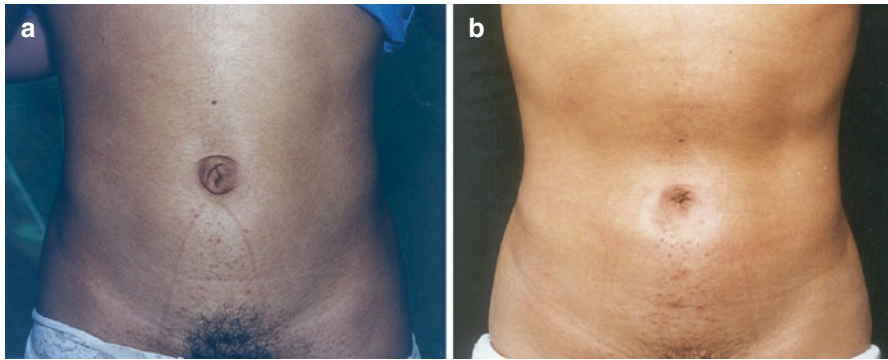
**Fig. 32.14** Drawings show circular incision around the umbilicus in case of presence of previous scars with wide umbilical diameter. (a) Skin incision. (b) Running suture of the cutaneous incision as a “round block” after treatment by the technique already described on Figs. 32.2, 32.3, 32.4, and 32.5



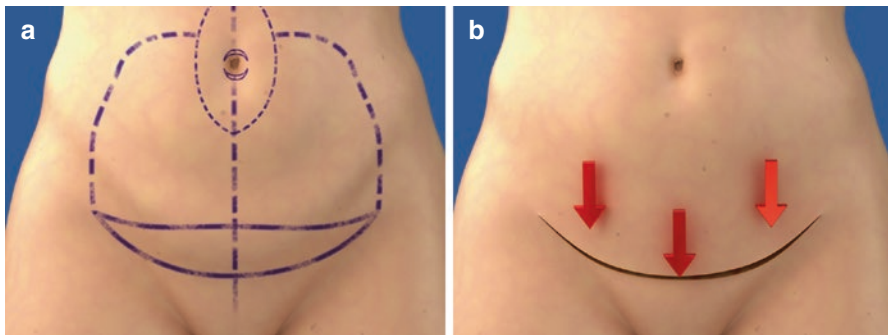
**Fig. 32.15** (a) “round block” suture (b) final aspect after suture as a “round block” of the abdominal flap, with nylon monofilament 5-0 with a diameter corresponding to the limit fingertip of the surgeon’s fifth finger



**Fig. 32.16** Correction of enlargement of the umbilicus by withdrawal of local skin in previous abdominoplasty. (a) Preoperative photo shows ungraceful appearance with scar all around the umbilicus. (b) Postoperative photo after correction with the described technique



**Fig. 32.17** Surgical correction of congenital abnormality of the umbilicus. (a) Preoperative photo shows excess of skin folded over itself inside the navel. (b) Postoperative photo of the same patient 4 months under correction by the described technique



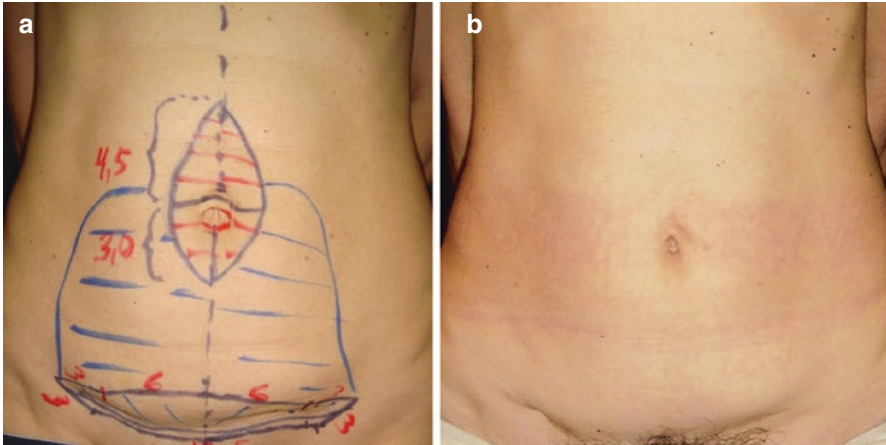
**Fig. 32.18** Correction of multiple abnormalities on the abdomen. (a) A photo of a female patient with excess adipose tissue, muscle diastasis, transverse scar, and lower umbilical change. The *dotted line* is the area to do liposuction (b) Postoperative photo of the same patient after correction of multiple changes. The *arrows* shows direction of traction

Postoperatively, after the removal of the stitches, one can use silicone mold inside the umbilicus for a few weeks, in order to preserve the scar and avoid retraction, contraction, even stenosis of the umbilicus.

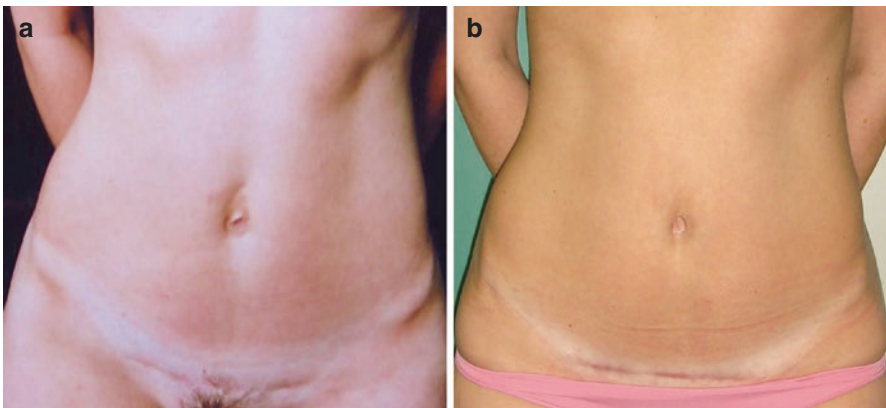
## Complications

From 2002 until 2014, 35 patients were operated and did not present any kind of local complications such as hematoma, seroma, infection, necrosis, or suture dehiscence.

As unfavorable outcome, we had insufficient traction suture in “round block” in a patient, resulting in a navel with slightly increased diameter. That situation was observed by us, and patient did not complaint about it.



**Fig. 32.19** A representative case of multiple corrections of deformities on the abdomen. **(a)** Preoperative photo with surgical demarcations: an elliptical area around the umbilicus and the area for liposuction. **(b)** Postoperative photo of the same patient 3 years after abdominal liposuction, corrections of “sad navel”, muscle diastasis, and lower abdominal step



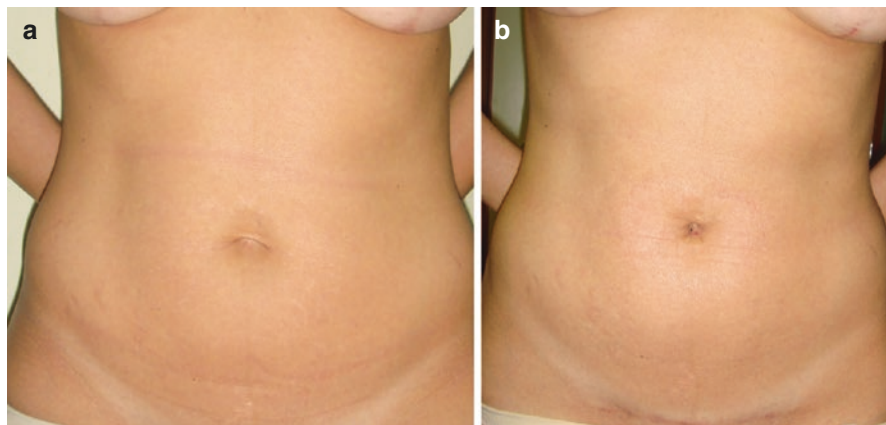
**Fig. 32.20** Correction of multiple deformities of the umbilical region. **(a)** Preoperative. **(b)** Same patient 1-year postoperative after abdominal liposuction, plication of diastasis of the rectus abdominis muscles, and lower scar revision

Additional procedures such as liposuction and resection of ellipses of dermal fat flaps were necessary for each particular case which had no complications.

## Discussion

Surgery for abdominal wall has showed significant progress in recent decades, related to reduce the area for undermining, as well as on the size of the final scars. We have observed cases of minor localized adiposities with reduced muscular





**Fig. 32.21** Illustrative case of correction of “sad navel” with multiple changes of the abdomen. **(a)** Preoperative photo shows local adiposities, diastases of the rectus abdominis, and unaesthetic appearance of the umbilicus as a “sad navel.” **(b)** Same patient 6 months after surgery: liposuction, muscle plication of diastasis, and correction of “sad navel”

diastases but with significant changes of the umbilicus which there is no indication for liposuction, traditional abdominoplasty, or lipoabdominoplasty.

Also there are patients who do not want to undergo operation that results to long final scars with quick return to normal activities.

We describe tactics that aim to correct:

- (a) The excess abdominal fat with small diastases medial muscles
- (b) Navel changes, including the so-called sad navel and the prominent navel
- (c) Small umbilical hernia, which may be present alone or together.
- (d) Other congenital changes in small proportion
- (e) Associations of the latter, with excess skin and fat of the lower abdomen and/or transverse scars of the lower abdomen and upper abdomen excesses and laxity

The elasticity of the skin is a favorable anatomical condition to make possible to perform the operation all around the umbilicus. Through two small curve cutaneous incisions, it is possible to undermine the local panniculus and also to perform plication of the rectus abdominis.

One of the fundamental aspects of the operation is the small amount of skin incisions which are inconspicuous after surgery. The incision should not be a complete circular all around the umbilicus, unless there is already prior scar or the navel area is very wide, as may occur on acquired or congenital deformities. The direction of the vectors may produce scar contraction, retraction, and even stenosis of the navel.

The surgical procedure for the treatment of umbilical changes congenital and/or acquired and associated or not with minor abdominal muscle diastases and with localized excesses of fat leaves less extensive scars. These procedures have proved adequate and lasting results.

Cases with fatty excesses of the abdomen and posterior trunk region may be associated with liposuction. Patients with low transverse scars are good candidates for skin resection using Avelar's surgical principles, thus providing improvement to body sculpting.

The cases of flaccidity of the upper abdomen can also be corrected by half-moon skin resection described by Avelar but should be the subject of a more accurate evaluation [4]. Proper surgical planning as well as adequate explanation to patients before operation is mandatory because the final scars on sub-mammary folds may be noticed afterward.

## Conclusion

In the use of this method, correction of minor abdominal and umbilical abnormalities, either congenital or acquired as small and medium complexity, is possible. It leaves fewer scars with graceful aesthetic results. In my hands this method is more and more employed which nowadays is very useful to attend to the desire of patients. Due to requirements of a modern life in a competitive world, more and more patients require the shortest time possible for recovering of surgeries.

When patients present questions about inappropriate scars and artificial aspects after full abdominoplasty with unaesthetic results, it is thankful to offer them smooth body contour with minimal surgical trauma. In the use of this procedure, it is possible to correct ungraceful abnormalities of the umbilicus and minor degree of diastases of the rectus abdominis with reduced risk. Therefore it is a safe procedure since the final scars are hidden in the umbilicus with very low rate of sequels which are essential for patients.

## References

1. Avelar J (1976) Umbilicoplasty: a technique without external scar. Proceedings of the 13rd congress of the Bras Society of Plastic Surgery. Edit South, Porto Alegre
2. Avelar J (1978) Abdominoplasty – systematization of a technique without external umbilical scar. *Aesthet Plast Surg* 2:141
3. Avelar J (1983) Abdominoplasty: technical refinement and analysis of 130 cases in 8 years follow-up. *Aesthet Plast Surg* 7:205
4. Avelar J (1999) A new technique for abdominoplasty – closed vascular system of subdermal flap folded over itself combined to liposuction. *Rev Bras Cir* 88/89(1/6):3–20
5. Avelar J (2000) A new technique without panniculus undermining and without panniculus resection. Presented at the international society of aesthetic plastic surgery. Postgraduate Course Instructions, Montreal, 7 Sept
6. Illouz Y (1980) Une nouvelle technique pour les lipodystrophies localisées. *Rev Chir Esthet* 4:19
7. Matarasso A (1997) Awareness and avoidance of abdominoplasty complications. *Aesthet J Surg* 17:256
8. Saldanha O, Pinto EB, Mattos WN et al (2003) Lipoabdominoplasty with selective and safe undermining. *Aesthet Plast Surg* 27(4):322–327
9. Shestack KC (2000) Liposuction an adjunct to the full abdominoplasty revisited. *Plast Reconstr Surg* 106:1197–1206

# Chapter 33

## Abdominoplasty on Patients with Previous Surgical Scars

João Medeiros Tavares Filho, Diogo Franco, and Talita Franco

### Introduction

The abdominal wall may be subject to alterations arising from age, pregnancy, massive weight loss, traumas, or surgery, causing morphological disorders and/or emotional stress, leading to a recommendation for correction through abdominoplasty.

This operation is basically designed to remove excess skin and correct the diastasis of the aponeurosis of the rectus abdominis muscles, while also reducing subcutaneous tissue thickness, with the resulting scar in a place that is barely or not visible [1].

In some situations, the abdomen may present scars that can hamper or limit the scope of the surgery and its aesthetic outcome (Fig. 33.1). The final position of the abdominoplasty scar will depend on the position of the old original scar and the amount of excess skin on the abdominal wall.

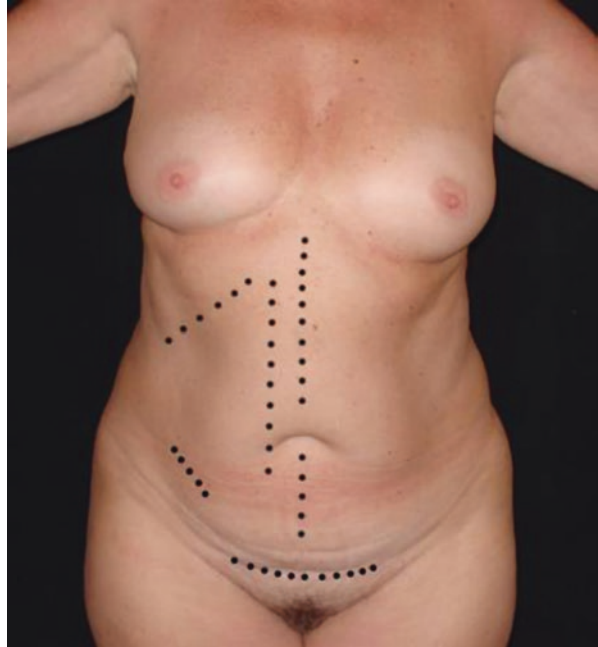
During the preoperative period, it is important to investigate these patients through clinical examinations and imaging tests, seeking the presence of incisional hernias while also assessing the need to use alloplastic mesh or to work together with a general surgeon.

When planning an abdominoplasty on patients with previous scars, four affected areas may be taken into consideration:

---

J.M.T. Filho, MD, PhD (✉) • D. Franco, MD, PhD • T. Franco, MD, PhD  
Plastic Surgery Division, Members of the Brazilian Society of Plastic Surgery,  
Federal University of Rio de Janeiro, Rio de Janeiro, Brazil  
e-mail: [jmedeiro@compuland.com.br](mailto:jmedeiro@compuland.com.br)

**Fig. 33.1** Usual abdominal scar positions



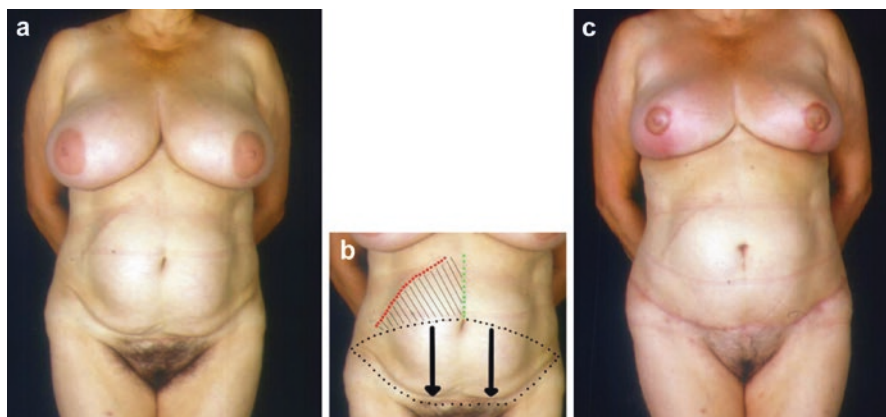
- A. Upper third
- B. Middle third and periumbilical area
- C. Lower third and flanks
- D. Extensive or multiple scars

### ***Scar on the Upper Third of the Abdomen***

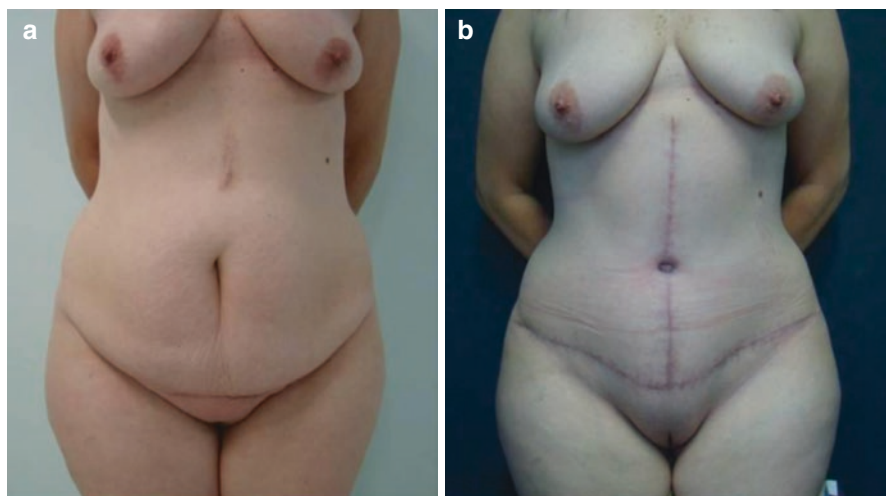
#### **May Be Vertical or Horizontal**

When there is flaccidity in the epigastric region, reverse abdominoplasty is performed, as described by Rebello and Franco [4, 6]. Depending on the amount of excess skin and its location, we may be able to remove the entire previous scar, or part of it, leaving a scar located in the inframammary sulcus.

Para-costal incisions frequently used prior to the advent of cholecystectomies through video surgery limited regular abdominoplasties due to the risk of necrosis in the triangular area between the previous scar, the midline, and the edge of the flap. The best option would be limited undermining associated with liposuction (Fig. 33.2).

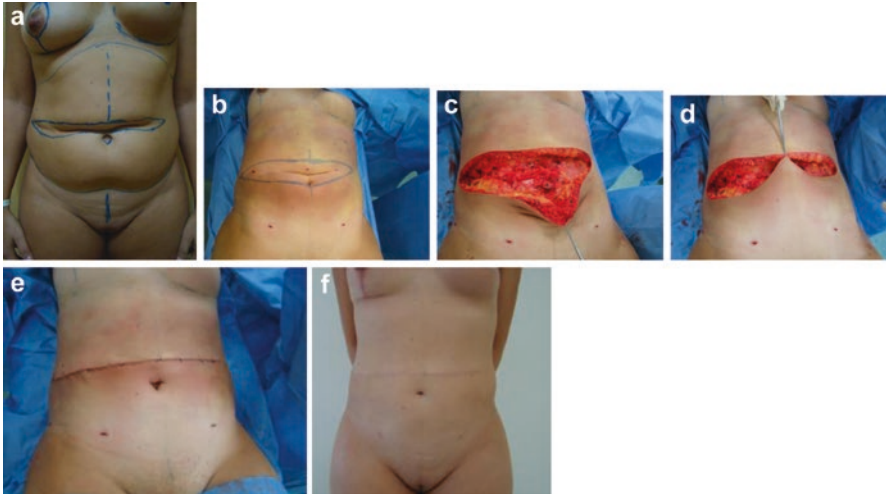


**Fig. 33.2** Patient presenting para-costal incision (a). Notice that if we perform a usual abdominoplasty traction and resection (*arrows*), an important amount of tissue would be under low blood flow condition (area between *red* and *green*) (b). Final result after limited undermining (c)



**Fig. 33.3** Vertical scar at the upper third associated with flaccidity of the lower half (a). Postoperative view after a classic abdominoplasty, improving and centralizing the scar and ending in an inverted T (b)

For vertical scars associated with discreet flaccidity on the upper third but accentuated on the lower half of the abdomen, we perform a classic abdominoplasty, improving and centralizing the scar or ending in an inverted T [5]. The preexistence of a vertical scar allows the surgeon to supplement its resection by removing a vertical strip and improving the waistline (Fig. 33.3).



**Fig. 33.4** Latero-lateral scar on the middle third of the abdomen. Abdominoplasty planning with navel repositioning and liposuction (a). Perioperative, after abdominal liposuction, scar excision and upward undermining of the flap for transposing the navel (b–d). Immediately postoperative and at 7 months (e, f)

### *Scar on the Middle Third of the Abdomen or Periumbilical Area*

#### **Horizontal**

Scars in this position are not common but, when they occur, it is hard to move them to a less obvious place, except when massive flaccidity is present. The best option is to remove some excess skin through the existing scar while improving its appearance. Liposuction may help with the outcome (Fig. 33.4).

#### **Vertical**

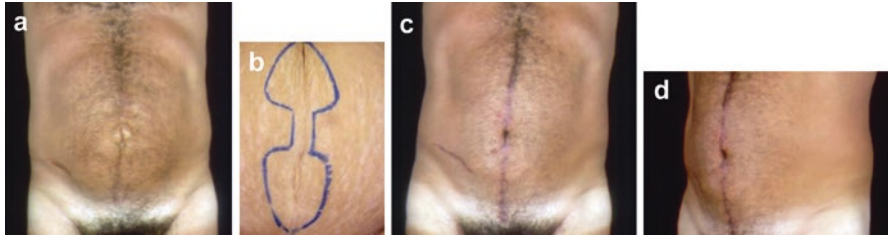
These scars generally affect both the upper and lower thirds to a greater or lesser extent and may be located on the midline or slightly lateral.

We essentially assign high priority to removing excess skin in a vertical direction, positioning the resulting scar on the midline.

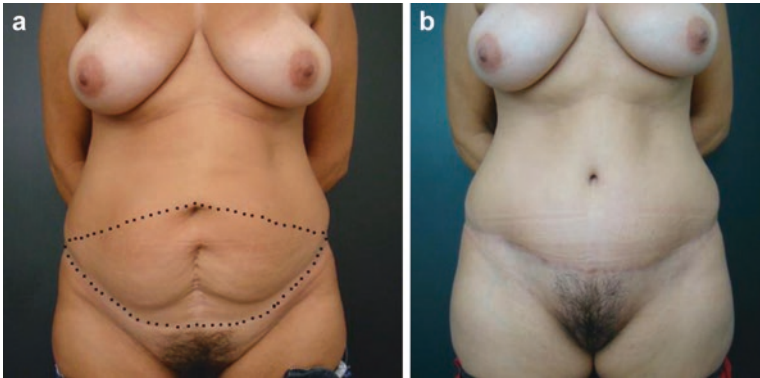
In these cases, we perform neo-omphaloplasty using two lateral flaps that will be fixed to the umbilical stump or to the aponeurosis, resulting in a navel with good depth and no surrounding scar (Fig. 33.5) [9].

### *Scar on Lower Third of the Abdomen (Infraumbilical)*

This is the most common presentation for existing scars and also usually leads to the best outcome, as the resulting abdominoplasty scar is located at the lower edge of the hypogastric region, where it is easily hidden by clothing.



**Fig. 33.5** Vertical scar splitting umbilicus in two segments (a). Neo-omphaloplasty using two lateral flaps (b). Postoperative view (c, d)



**Fig. 33.6** Classic abdominoplasty (a). Postoperative: 6 months (b)

This procedure is equivalent to a classic abdominoplasty: removal of the surplus infraumbilical segment, plication of the aponeurosis of the rectus abdominis muscle, navel repositioning, and a scar in the suprapubic region, running parallel to the inguinal folds. When necessary, this can be associated with liposuction (Fig. 33.6).

## *Extensive or Multiple Scars*

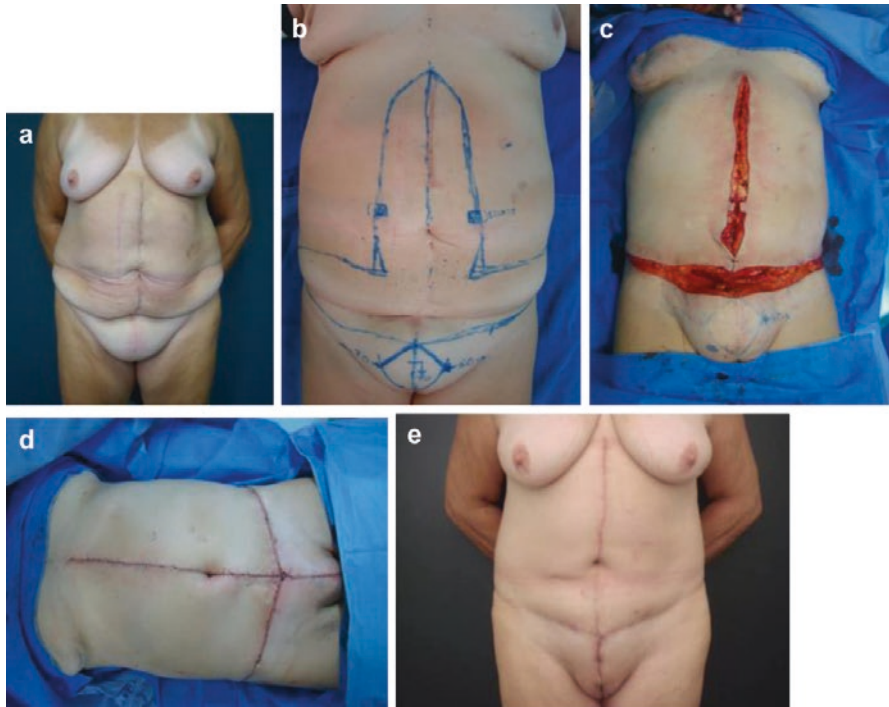
### **Xipho-Pubic Scar**

Abdominoplasty may be conducted through a vertical resection in an inverted T or H, locating the horizontal segments in the inframammary sulcus and the suprapubic region.

In these cases, incisional hernias are common, treated by repositioning the hernia content, closing the aponeurosis, and placement of mesh (Fig. 33.7) [2].

### **Lateral Scars (Costal Marginal, Flanks)**

Transverse or oblique scars may adversely affect the vascularization of segments that will undergo detachment and traction, with several reports of necrosis under these circumstances. This complication has been lessened using the techniques



**Fig. 33.7** Abdomen with large midline xipho-pubic and right upper para-midline scar in the pubic region (a). Inverted T abdominoplasty planning (b) and treatment associated with the pubic region and neo-umbilicoplasty with lateral flaps (c). Immediately postoperative, inverted T abdominoplasty, neo-omphaloplasty, and treatment of the pubic region (d). Late postoperative (e)

described by Avelar and Saldanha [3, 7, 8]. These authors recommend smaller flap detachment and association with liposuction in order to maintain better vascular and lymphatic flows, allowing for safer abdominoplasties when this type of scar is present.

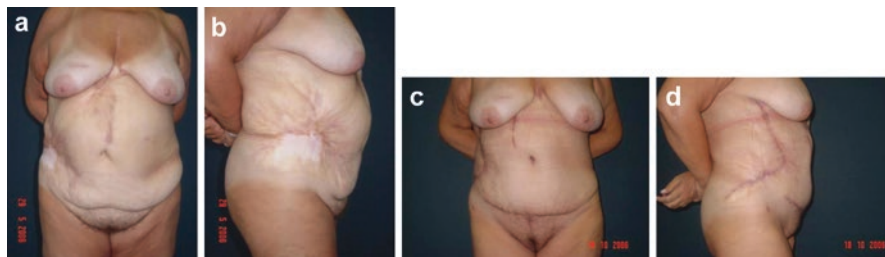
In some situations, we may recommend two-stage surgery: abdominoplasty followed by liposuction or vice versa.

### Abdomen with Major Scarring

These scars are usually seen in trauma victims or in patients who suffered abdominal wall infections leading to broad, depressed scars adhering to the aponeurosis or peritoneum. Each case is unique, and surgeons must deploy good sense and creative flair, paying close attention to possible alterations in vascularization around the scars.

Such cases are better treated using serial excisions or skin expansion (Fig. 33.8).





**Fig. 33.8** Bariatric surgery patient and burn sequelae (a, b). Reverse and lateral abdominoplasty, postoperative at 5 months (c, d)

## Complications

The most severe complication is flap necrosis.

In order to lessen this possibility, we must avoid excessive tension on the flap and around the scar region, besides reducing undermining in the plicature area, thus maintaining good lymphatic drainage and vascularization through this region.

When there is the possibility of umbilical necrosis, it is better to opt for neomphaloplasty, which is indicated mainly when the resulting scar is vertical.

Late unaesthetic deviation of vertical scar may occur mainly when there are different tensions on the lateral flaps that were sutured. These changes can be avoided by attaching the flap fascia to the midline aponeurosis.

Hypertrophy or broadening occurs frequently in vertical scars.

## References

1. Sinder R (1979) *Cirurgia Plástica do Abdome*. edição do autor, Rio de Janeiro
2. Aly AS (2006) *Body contouring after massive weight loss*. Quality Medical Publishing, Inc, St. Louis
3. Saldanha O (2004) *Lipoabdominoplastia*. Di-Livros Editora Ltda, Rio de Janeiro
4. Rebello C, Lion PM, Franco T (1974) Abdominoplasty through submammary incision. In: *Year book of plastic and reconstructive surgery*. Year Book Medical Publishers Inc, Chicago
5. Franco T (2002) *Princípios de Cirurgia Plástica*. Atheneu, Rio de Janeiro
6. Franco T, Franco D, Medeiros Tavares Filho J (2008) Dermolipectomia por incisão submamária, Cap 39, p. 303. In: Resende JH (eds) *Tratado de Cirurgia Plástica na Obesidade*. Editora Rubio, Rio de Janeiro, Brazil
7. Avelar MJ (2002) Abdominoplasty without panniculus undermining and resection: analysis and 3-year follow-up of 97 consecutive cases. *Aesth Surg J* 22(1):16–25
8. Avelar MJ (1999) A new technique for abdominoplasty – closed vascular system of subdermal flap folded over itself combined to liposuction. *Rev Bras Cir* 88/89(1/6):3–20
9. Franco D, Medeiros J, Farias C, Franco T (2006) Umbilical reconstruction for patients with midline scar. *Aesth Plast Surg* 30:595–598

# Chapter 34

## The “Lying” H-Shaped with Double Contour Plication of the Anterior Aponeurosis Wall in Abdominoplasty

Antonio Carlos Abramo

### Introduction

Age and pregnancy address physiological and anatomical changes that modify the cutaneous and adipose tissues and the muscle aponeurosis system. Abdominoplasty and lipoabdominoplasty are indicated to treat the abdominal deformities caused by these changes. Lipoabdominoplasty is indicated for patients with sagging skin, light to severe lipodystrophy, and with or without abdominal muscle diastasis [4]. It is performed through selective dissection at midline with partial or total plication of the recti diastasis and a wide liposuction of the abdominal wall [8]. Unlike lipoabdominoplasty, abdominoplasty is indicated for patients with large skin redundancy, extensive lipodystrophy, large or severe degree of recti diastasis, and severe muscle flaccidity. Recovery of severe physiological and anatomical changes requires an enlarged plication with extensive dissection of the skin flap for its accomplishment. Variants of the fusiform xiphoid-pubic median plication to abdominal muscle aponeurosis, such as the H approach with double contour and the two fusiform plications, have been widely employed to muscle reinforcement [1, 7]. Lateral and horizontal deviation of the umbilicus is a common finding that occurs with age and pregnancy. It is widely understood that proper repositioning the umbilicus is essential to a pleasant abdominoplasty. Anatomical landmarks to identify ideal umbilicus location have been subject of controversy in textbooks [9]. Repositioning lateral and horizontal umbilicus deviation to its proper location has been achieved through the H-shaped double contour plication [3]. Complications are commonplace to both abdominoplasty and

---

A.C. Abramo, MD, PhD

Division of Plastic and Reconstructive Surgery, Escola Paulista de Medicina,  
Federal University of São Paulo – UNIFESP, São Paulo, SP, Brazil

ACA – Institute of Assistance in Plastic Surgery of São Paulo, Brazilian Society  
of Plastic Surgery and Brazilian Association of Medicine,

Rua Afonso de Freitas, 641, São Paulo, SP 04006-052, Brazil

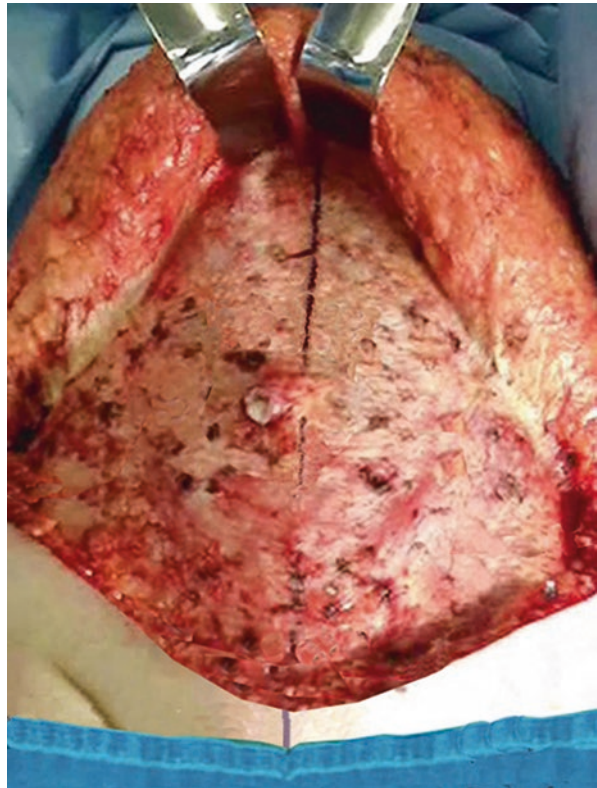
e-mail: [clinica@abramo.com.br](mailto:clinica@abramo.com.br)

lipoabdominoplasty, particularly wound dehiscence, redundant epigastric bulging, poor positioning of the umbilicus, and upward displacement of the pubis [5]. These occurrences take place when there is excessive tension of the flap along the suture, wide dissection, and inadequate plication of the abdominal muscles.

The “lying” H-shaped double contour plication described here is proposed in order to attempt longitudinal and transverse shortening of the anterior abdominal wall and umbilicus displacement. It decreases tension on the suture line, avoids upward advancement of the pubis, and mobilizes the umbilicus to an appropriate location.

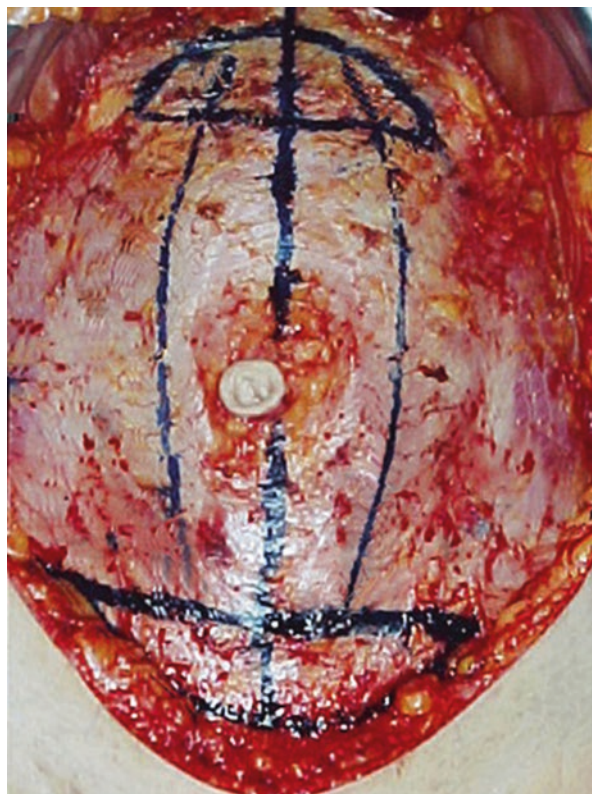
## Operative Technique

Abdominoplasty is done with total muscle relaxation under general anesthesia. Marking of the incision is made with the patient lying down and then standing to avoid distortions in the height of its lateral extension. The incision is a curved line with the concavity directed to the umbilicus centered 5 cm above the vulvar commissure and extended laterally toward the anterior superior iliac spine. The length of the incision follows the excess of the skin at the hypogastrium. Dissection of the skin flap has the shape of a reversed slightly rounded “V” from the anterior iliac spine ending 5 cm of the xiphoid as a smooth curved line following the lower rib edge (Fig. 34.1). The greater the width of the double contour of “lying” H, the greater the roundness of the



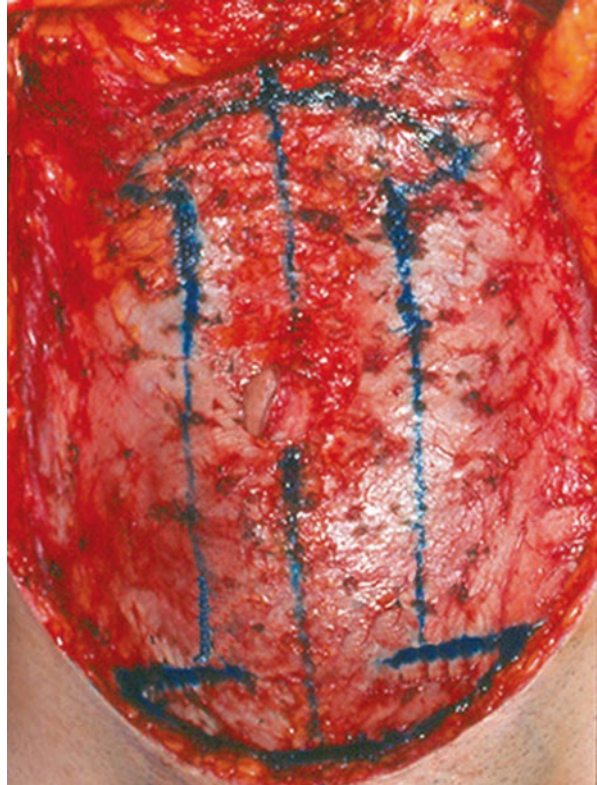**Fig. 34.1** Inverted “V” dissection from the xiphoid toward the anterior iliac spine. Abdominal midline from xiphoid to vulvar commissure shows the umbilicus deviated laterally to the right

**Fig. 34.2** A “lying” H-shaped with double contour is outlined on the anterior abdominal wall. The vertical branch has the shape of an ellipse centered on the abdominal midline, showing the right horizontal deviation of the umbilicus. The *lines* of the vertical branch are marked inside the medial border of the rectus muscle for adequate correction of the muscle flaccidity



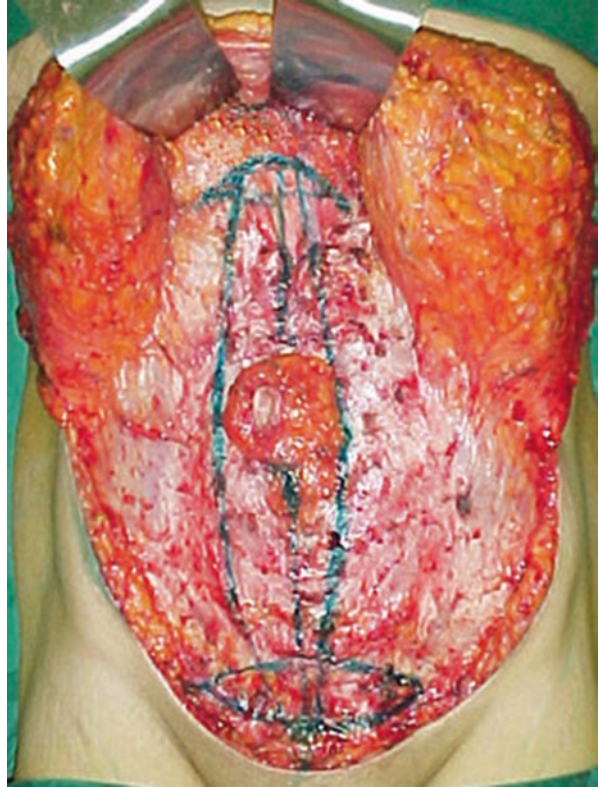
“V” apex, resulting in a more extensive dissection in the epigastrium. Afterward, a “lying” H-shaped with double contour is outlined on the exposed muscle aponeurosis defining the plication area (Fig. 34.2). Three circumstances must be considered in planning the “lying” H-shaped with double contour: its location on the aponeurotic wall, the shape and distance between the lines of the vertical branch, and the length and width of the ellipse of the horizontal branches. The “lying” H-shaped with double contour is centered on the midline of the abdominal wall from the xiphoid to the vulvar commissure. The vertical branch can be marked either as an ellipse (Fig. 34.2) or as two parallel lines (Fig. 34.3) from the medial border of the rectus with width of up to 12 cm between them, according to the rectus diastasis, degree of muscle flaccidity, and intra-abdominal pressure. The horizontal branches have a transverse elliptical shape centered on the midline of the abdominal wall located 2 cm from the end of the skin flap on the epigastrium and 1 cm from the incision line at the hypogastrium. Its length cannot be more than 15 cm, and width may vary from 2 to 6 cm, according to the muscle flaccidity and umbilicus location (Fig. 34.2). In addition, the width of the horizontal branches cannot be the same for upper and lower abdomen, to mobilize the umbilicus to its proper location on the anterior abdominal wall (Fig. 34.4). Plication is performed with separate stitches

**Fig. 34.3** The vertical branch can be also marked as two parallel lines advancing out of the diastasis of muscles, if necessary, to repair the muscle weakness. No lateral deviation of the umbilicus is observed



only involving the aponeurotic layer of the muscle aponeurosis system not including the underlying muscle. It begins at the epigastrium, bringing together the middle point of the upper line of the ellipse and the upper extremities of the vertical lines, following the same procedure in the hypogastrium, ending with the closure of the vertical lines. After the plication on upper and lower abdomen, a large bulging occurs around the umbilicus, showing the muscle reinforcement in these areas, highlighting the effectiveness of the transverse plication (Fig. 34.5). The approach of the vertical and horizontal branches modified the double contour of the “lying” H-shaped to a single contour (Fig. 34.6). Values of the intrapulmonary pressure before, during, and after the “lying” H-shaped double contour plication are analyzed to avoid excessive intra-abdominal pressure. Points of coaptation between the inner face of the flap and the anterior abdominal aponeurosis are carried out, intermittently, from the xiphoid process toward the incision in the hypogastrium. Abdominoplasty is completed in routine fashion. Pressure dressing with elastic tape is maintained for 5 days. Drainage is maintained for 24 h.

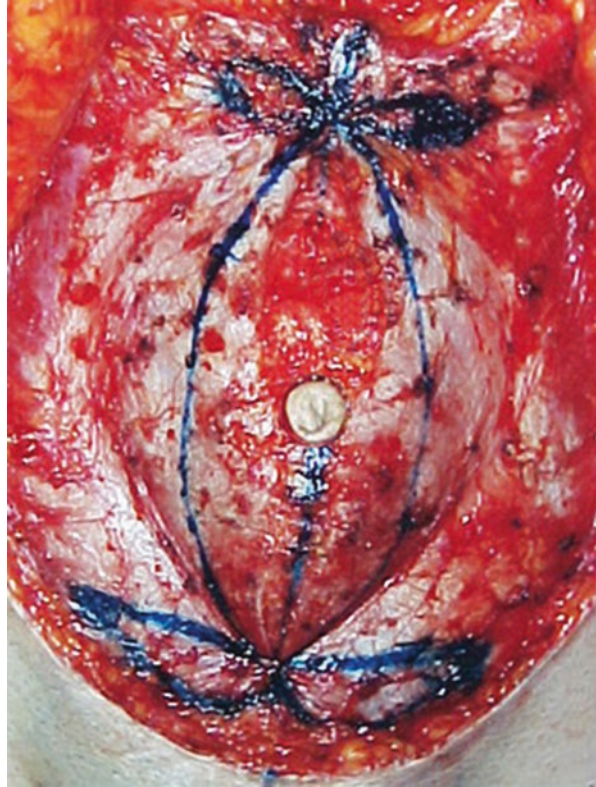**Fig. 34.4** The width of the horizontal branches is not the same for upper and lower abdomen. The width in the hypogastrium is 2 cm larger than in the epigastrium to mobilize the umbilicus to its proper location on the anterior abdominal wall



## Results and Complications

Long-term maintenance of the recovered abdominal contour characterized by an improved waist, reinforced epigastric and hypogastric areas, no pubis upward displacement, and a well-located umbilicus is achieved with the “lying” H-shaped double contour plication. In the presence of umbilicus deviation, longitudinal, transverse, or both, it is relocated 3 cm above the anterior iliac spine. Closure of the vertical and horizontal branches of the “lying” H reduced the transverse and longitudinal dimensions of the abdominal muscle aponeurosis system, allowing an easy accommodation and lowering of cutaneous flap toward the pubis without tension (Fig. 34.7). Shortening obtained in the anterior abdominal aponeurosis corresponds to the sum of the widths of each horizontal branch ellipse divided by two, ranging from 2 to 6 cm, mean range of 4.5 cm. Recurrence of abdominal projection and loss of the waistline is occasional with such plication, occurring when there is an excessive body weight gain after surgery. Two representative cases are presented in detail to illustrate late outcomes.

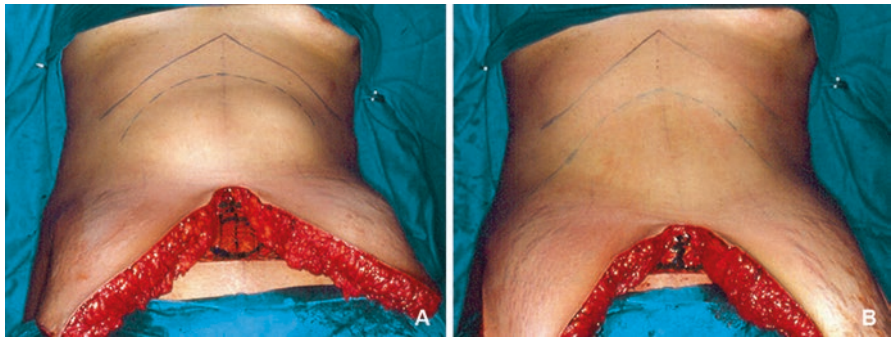
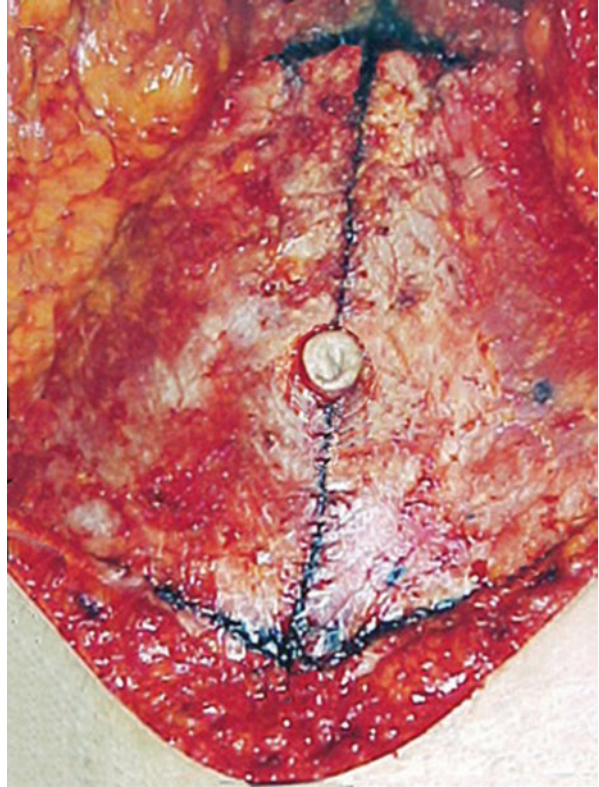
**Fig. 34.5** Approach of the horizontal branches at the epigastrium and hypogastrium. Reinforcement of the upper and lower abdomen increases the intra-abdominal pressure, addressing a large protrusion of the umbilical and periumbilical areas



**Case 1** A 45-year-old female, no pregnancy, underwent bariatric surgery losing 42 kg presented sagging skin, vertical scar on epigastrium, down displacement of the umbilicus, moderate fold in the lower abdomen, increased intracavity adiposity with wide rectus diastasis, and severe muscle flaccidity, resulting in a excessive projection of the entire abdominal wall (Fig. 34.8a, c). The “lying” H-shaped with double contour was performed using elliptical vertical branches with width of 9 cm at the umbilicus and 6 cm at the horizontal branches and horizontal branches with width of 4 cm at epigastrium and 1 cm at the hypogastrium. Reinforcement of the muscular wall, recovering the abdominal contour, and leading the umbilicus to its suitable location were achieved at 1 year postoperatively (Fig. 34.8b, d), remaining 10 years after surgery (Fig. 34.8e).

**Case 2** A 44-year-old female, three pregnancies, presented striations around the umbilicus, large rectus diastasis, moderate muscle flaccidity with a marked bulging around the umbilicus, and up displacement of the umbilicus (Fig. 34.9a, c). The “lying” H-shaped with double contour was performed using parallel vertical branches with 8 cm width and horizontal branches with 2 cm width in the epigastrium and 6 cm in the hypogastrium. It provided reinforcement of the muscular wall

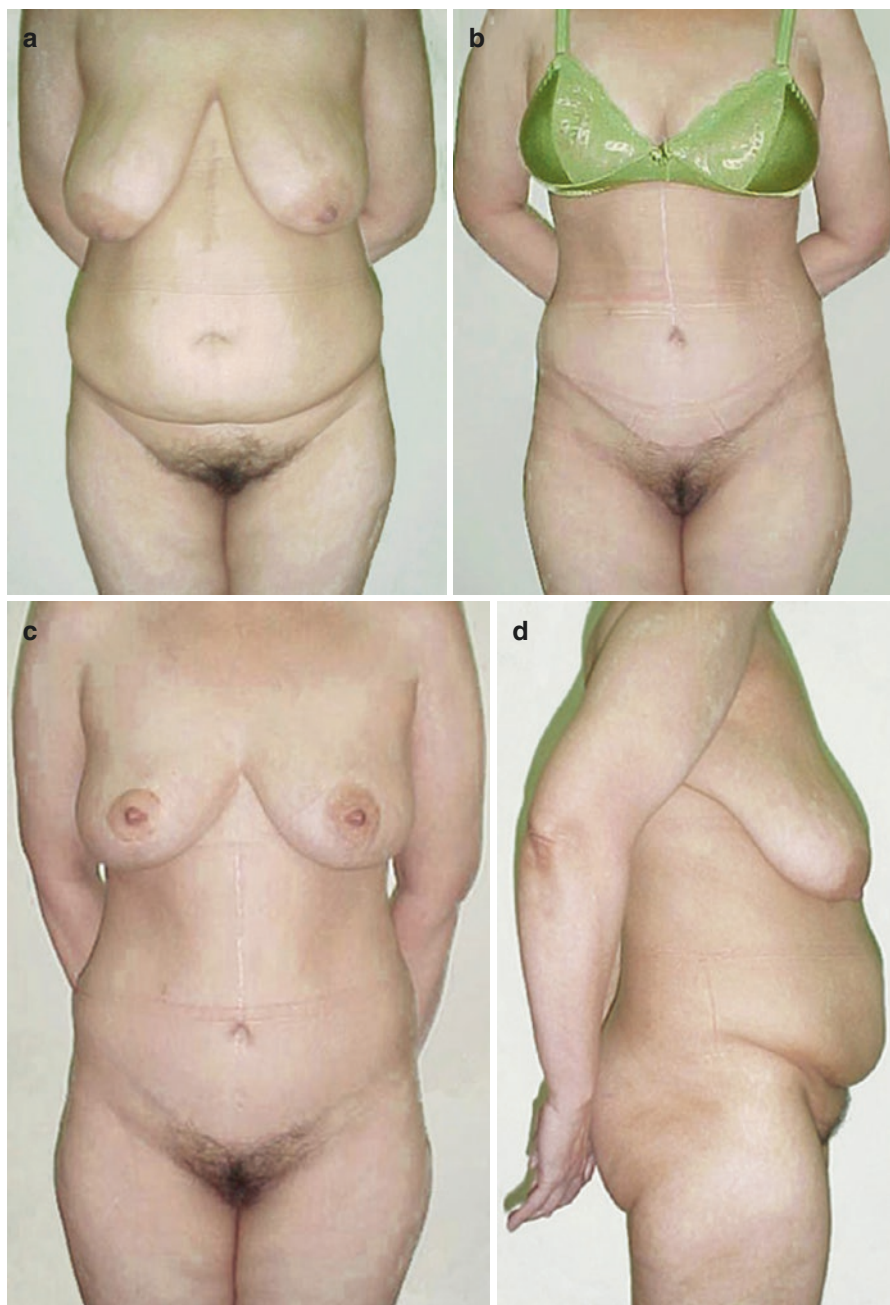
**Fig. 34.6** After plication the double contour of the “lying” H becomes a simple contour, repairing the strength of the muscle aponeurosis system on the entire abdominal wall

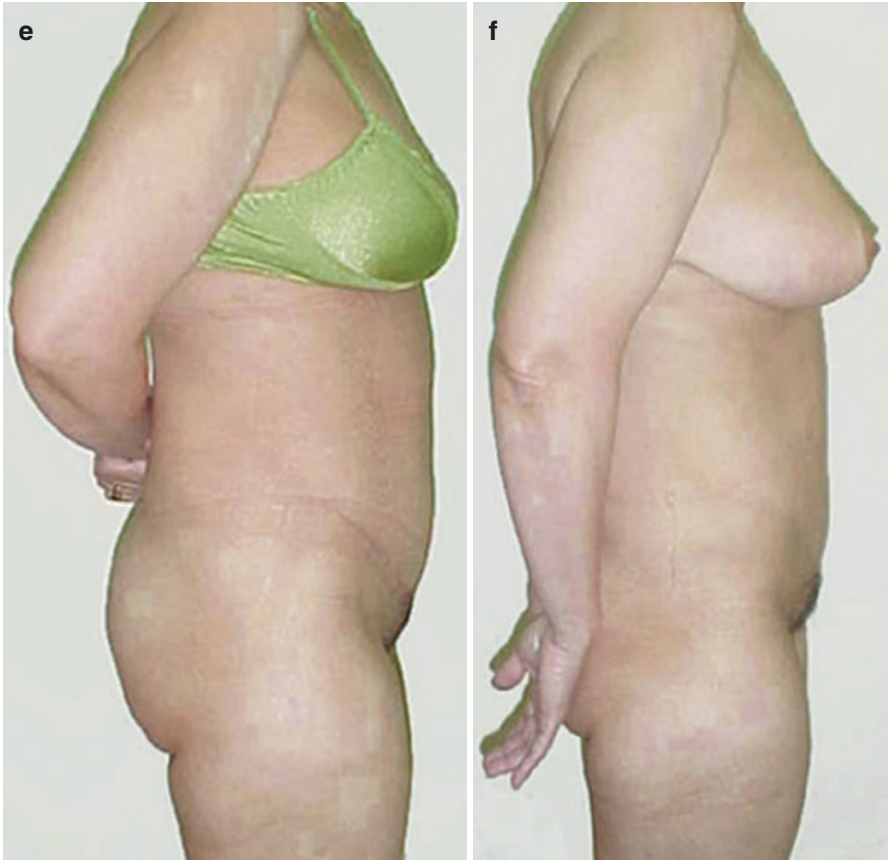

**Fig. 34.7** (a) Skin flap accommodation before plication. (b) Recovery of the waistline and a notorious improvement of the abdominal contour with an unquestionable lowering without tension of the skin flap are showed after the “lying” H-shaped with double contour plication

with recovery of the waist, well-marked “rectus valley” on the epigastrium, shortening of the longitudinal dimension of the anterior abdominal wall, and down displacement of the umbilicus (Fig. 34.9b, d).



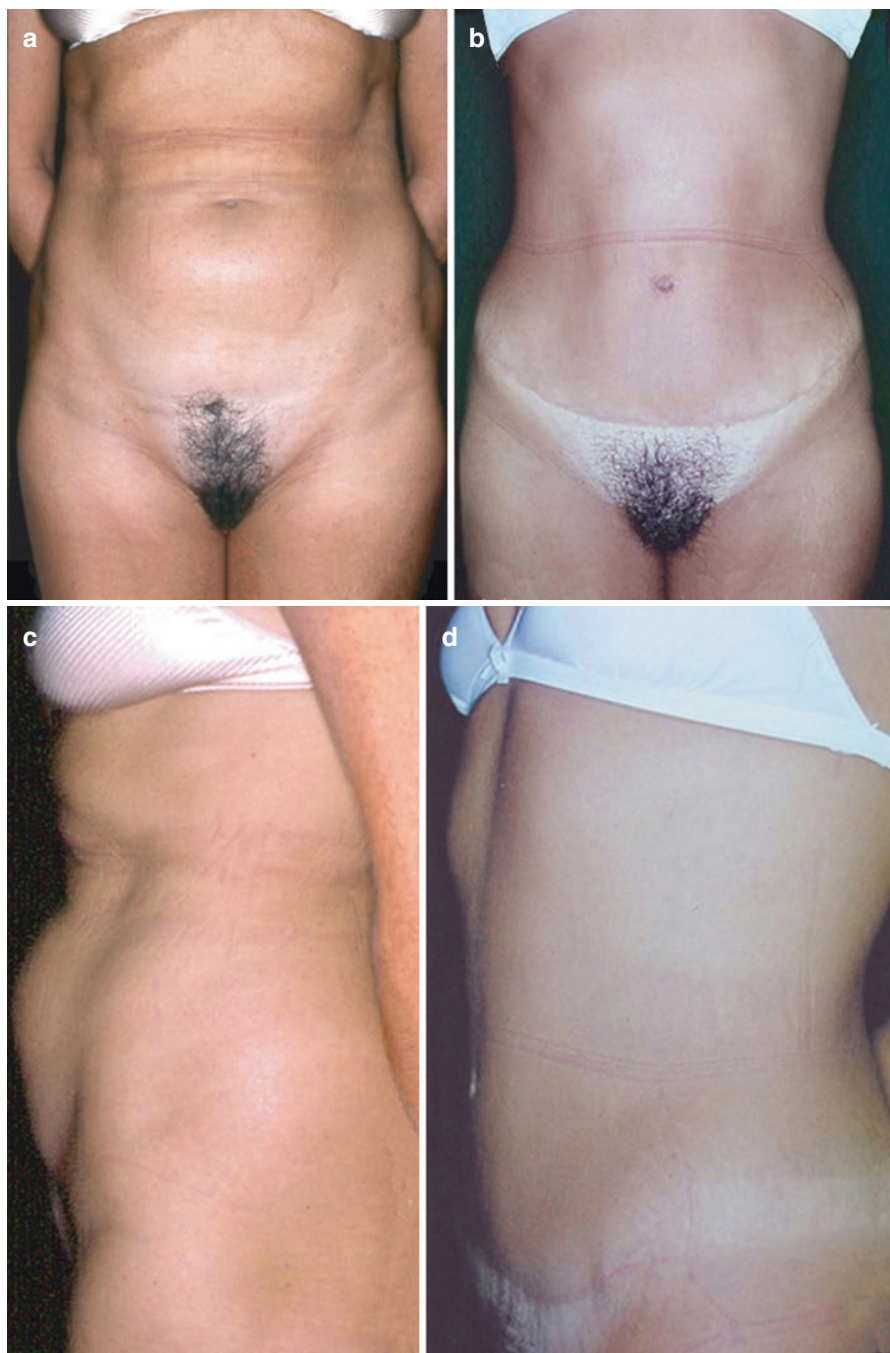



**Fig. 34.8** (continued)



**Fig. 34.8** Case 1. (a, d) Preoperative front and side views of a 45-year-old female with sagging skin, vertical scar resulting from bariatric surgery on epigastrium, down displacement of the umbilicus, moderate fold in the lower abdomen, increased intracavity adiposity, wide rectus diastasis, severe muscle flaccidity, and an overstate bulging of the entire abdominal wall. (b, e) Postoperative front and side views showing repair of muscle flaccidity, recovery of the abdominal contour, and suitable location for umbilicus achieved at 1 year postoperatively. (c, f) Postoperative front and side views showing that the reinforcement of the muscle aponeurosis system remained 10 years after surgery



Increase of the intrapulmonary pressure happens at the end of plication. It decreases in level at the end of the surgery, but remains from 15 to 20% higher in relation to the intrapulmonary pressure setting prior to the plication. No further respiratory distress is reported by the patients a day after the surgery or late postoperative period. Incidence of hematoma is similar to other aesthetic abdominal procedures, including lipoabdominoplasty. An accurate and careful hemostasis ensures reduced risk of hematoma. Seroma is not a common finding when points of the coaptation are employed, regardless of the extend of the dissection. Its incidence increases when abdominoplasty is associated to liposuction of the flanks and pubis, reducing gradually its volume to disappear around 30 days after the surgery. Treatment consists in serial punctures performed through the incision every 7 days. Suture dehiscence and skin necrosis are related to extensive dissection, excessive thinning of the skin flap in its middle portion, and tension on the suture line, mainly at the pubis. Reduction of the longitudinal dimension of the anterior abdominal wall provided by the “lying” H-shaped double contour plication is helpful to avoid these complications. Infection is random and is not dependent on the type of plication performed. Major complications due to increase of intra-abdominal pressure such as pulmonary embolism, leg vein thrombosis, and gastroesophageal reflux were not observed after the “lying” H-shaped double contour plication.

## Discussion

The contour and in particular the projection of the abdomen are indicators for the type and extent of the plication to be made in an abdominoplasty. Plication only involving the aponeurotic layer of the muscle aponeurosis system not including the muscle just beneath prevents vascular compromise of the muscular layer, which would impair the effectiveness of the reinforcement obtained in the muscle aponeurosis system over medium and long term. The “lying” H-shaped with double contour plication strengthens the entire abdominal muscle aponeurosis system, creating an adequate support to restrain the intra-abdominal pressure. Despite restoring the waistline, repairing the rectus diastasis, and reinforcing the muscle aponeurosis system, the goal of the “lying” H-shaped with double



**Fig. 34.9** Case 2. (a, c) Preoperative front and side views of a 44-year-old female with striations around the umbilicus, large rectus diastasis, moderate muscle flaccidity, marked bulging around the umbilicus, and up displacement of the umbilicus. (b, d) Postoperative front and side views showing reinforcement of the muscular wall with recovery of the waistline, well-defined “rectus valley” on the epigastrium, shortening of the abdominal longitudinal length, and proper location of the umbilicus

contour plication is to shorten the longitudinal and transverse dimensions of the anterior abdominal aponeurosis. The advantages of reducing the vertical and horizontal diameters of the anterior abdominal muscle aponeurotic wall are unquestionable [11]. Closure of the horizontal branches enables to shorten the longitudinal length of the anterior abdominal aponeurosis. The degree of shortening of the anterior abdominal aponeurosis can arrive up to 6 cm long, depending on the width of the horizontal branch ellipses. Reduction of the distance from the xiphoid to the pubis allows lowering of the skin flap toward the pubis without tension at this level and provides for better adjustment of the skin flap over the reinforced muscle aponeurosis system, improving the abdominal contour. Different widths of the horizontal branch ellipses at the epigastrium and hypogastrium allow the upper and lower displacement of the umbilicus leading it to its proper location [2]. A useful landmark to establish the umbilicus proper location is the iliac spine, more accurately 3 cm above the anterior iliac spine, ensuring a pleasant appearance to the abdominal contour [6]. The umbilicus is not in the same location in all patients; only 17 % have the umbilicus at midline, and 52 % have the umbilicus located more than 2 % lateral to the midline [10]. The vertical branch centered in the abdominal midline makes it possible to centralize the umbilicus in the midline of the abdomen. The approach of the lines of the vertical branch mobilizes the umbilicus transversally, repairing its lateral displacement, by attaching it at the abdominal midline. Approach of the upper portion of the vertical branch lines associated with the closure of the elliptical horizontal branch in the epigastrium avoids the recurrence of bulging in the upper abdomen. In addition, closure of the vertical branch associated with the closure of the horizontal branch creates a pleasing skin depression along the midline on the upper abdomen, named “rectus valley.” To repair a major flaccidity of the muscle aponeurosis system, an enlarged plication is necessary. The “lying” H-shaped with double contour plication provides the necessary means for this. To perform a plication with such greatness, a wide dissection in the epigastrium is required. However, reduction of both, transverse and longitudinal, abdominal diameters provided by the “lying” H-shaped with double contour plication allows the lowering of the skin flap toward the pubis without tension, reducing the risk of complications at this level. Large dissection of the skin flap especially in the epigastrium and skin closure under tension are described as being responsible for flap necrosis, suture dehiscence, and lift of the pubis [12]. Even though a wide dissection of the skin flap at the epigastrium is needed to perform the “lying” H-shaped with double contour plication, the aforementioned complications did not occur. This happens due to the longitudinal shortening of the muscle aponeurosis system which facilitates the down displacement and easy accommodation of the skin flap toward the pubis, where it is fixed without tension. Absence of tension at suprapubic area avoids pubis elevation, suture dehiscence, and skin necrosis after the skin closure. In addition, a wide dissection of the skin flap in the upper abdomen is necessary to avoid the formation of a skin bulge along the edge of the plication, particularly if the plication is very large.

## Conclusion

Although the wide dissection of the skin flap at the epigastrium needed to perform the “lying” H-shaped with double contour plication, the shortening of the distance from the xiphoid to the pubis provides an easy down displacement of the skin flap without vascular compromise of the flap. Lowering of the skin flap toward the pubis without tension avoided suture dehiscence, necrosis of the skin flap at the hypogastrium, and the up displacement of the pubis. The extension of the double contour of the “lying” H provided a strength reinforcement of the abdominal muscle aponeurosis system. In addition, closure of the horizontal branches of the “lying” H-shaped with double contour plication allowed a wide mobilization of the umbilicus carrying it to its correct location.

The “lying” H-shaped with double contour plication to muscle aponeurosis decreases longitudinal and transverse diameters of the anterior abdominal wall. Rather than the median xiphoid-pubic fusiform plication, the H-shaped plication recovers the waist and reinforces the epigastrium and hypogastrium, reducing the possibility of recurrent projection at these areas. The double contour of the transverse plication also allows the umbilicus mobilization taking it to an appropriate position in the abdominal wall. It also reduces the distance of the xiphoid-pubis allowing lowering and fixation of the cutaneous flap without tension, with better accommodation of the cutaneous flap. Long-term maintenance has been achieved with the “lying” H-shaped with double contour plication.

## References

1. Abramo AC, Viola JC, Marques A (1990) The H approach to abdominal muscle aponeurosis for the improvement of body contour. *Plast Reconstr Surg* 86(5):1008–1013
2. Abramo AC, Viola JC, Marquez A, Jung KS (1998) Abdominoplasty: a transversal and longitudinal pleating to muscle aponeurosis. *Word Plast* 2(1):52–58
3. Abramo AC, Casas SG, Oliveira VR, Marquez A (1999) H-shaped double contour plication in abdominoplasty. *Aesthetic Plast Surg* 23:260–266
4. Avelar JM (1999) A new technique for abdominoplasty-closed vascular system of subdermal flap folder over itself combined with liposuction. *Rev Bras Cir* 89:3–20
5. Heller JB, Teng E, Knoll BI, Persing J (2008) Outcome analysis of combined lipoabdominoplasty versus conventional abdominoplasty. *Plast Reconstr Surg* 121:1821–1829
6. Hinderer UT (1975) The dermolipectomy approach for augmentation mammoplasty. *Clin Plast Surg* 2:359–369
7. Marquez A, Brenda E, Pereira MD, de Castro M, Abramo AC (1996) Abdominoplasty with two fusiform plication. *Aesthetic Plast Surg* 20:249–251
8. Matos WN Jr, Ribeiro RC, Marujo RA, da Rocha RP, da Silva Ribeiro SM, Carrillo Jimenez FV (2003) Classification for indications of lipoabdominoplasty and its variations. *Aesthetic Plast Surg* 27(4):322–327
9. Rodriguez-Feliz JR, Makhijani S, Przybyla A, Hill D, Chao J (2012) Intraoperative assessment of the umbilicus distance: a reliable anatomic landmark for transposition of the umbilicus. *Aesthetic Plast Surg* 38:8–17

10. Rohrich RJ, Sorokin ES, Brow SA, Gibby DL (2003) Is the umbilicus truly midline? Clinical and medicolegal implications. *Plast Reconstr Surg* 112:259–263
11. Verissimo P, Nahas FX, Barbosa MVJ, Gomes HFC, Ferreira LM (2014) Is it possible to repair diastasis recti and shorten the aponeurosis at same time? *Aesthetic Plast Surg* 38:379–386
12. Villegas FJ (2014) A novel approach to abdominoplasty: TULUA modifications (transverse plication, no undermining, full liposuction, neoUmbilicoplasty, and lower transverse abdominal scar). *Aesthetic Plast Surg* 38:511–20

# Chapter 35

## Reverse Abdominoplasty

Talita Franco, Diogo Franco, and João Medeiros Tavares Filho

The abdominal wall is perhaps the part of the body that has most prompted the creation of surgical techniques. Initially, their purpose was mainly reparative, for correcting hernias or the after-effects of obesity. Until the mid-twentieth century, there was still some resistance to purely cosmetic surgery, and the reparative motivation was a strong argument for performing abdominoplasties. At that time, body displays were still discreet and were not of much concern to surgeons or even patients, when incisions were positioned in areas not commonly seen. The resulting scars could consequently cover central areas of the abdominal wall and navel resection was not uncommon.

From the 1950s onwards, changing fashions and more liberal customs affected incision placement, in order to conceal scars [1–6]. Naturally, with most aesthetic alterations to the abdomen located in the infraumbilical region, scars were also located there. The incision proposed by Callia [7], parallel and slightly above the inguinal folds and running along the edge of the pubic hair region, was very well accepted and has been widely used since then by Brazilian plastic surgeons.

The supraumbilical region did not warrant much attention, due mainly to limited demands for aesthetic corrections. This began to change when epigastric flaccidity starts to bother women eager to wear two-piece bathing suits and bikinis [8–14]. Thorek [13] and Berson (1957) had already proposed supraumbilical transverse resections. However, these options left scars half-way between the breast and the navel, which were not well accepted by increasingly more discerning patients.

In 1972, Rebello and Franco performed what became known as a reverse abdominoplasty, placing the incision in the inframammary fold, with the resulting scar being easily concealed (Fig. 35.1).

---

T. Franco, MD, PhD (✉) • D. Franco, MD, PhD • J.M. Tavares Filho, MD, PhD  
Plastic Surgery Division, Members of the Brazilian Society of Plastic Surgery,  
Federal University of Rio de Janeiro, Rio de Janeiro, Brazil  
e-mail: [talita@openlink.com.br](mailto:talita@openlink.com.br)



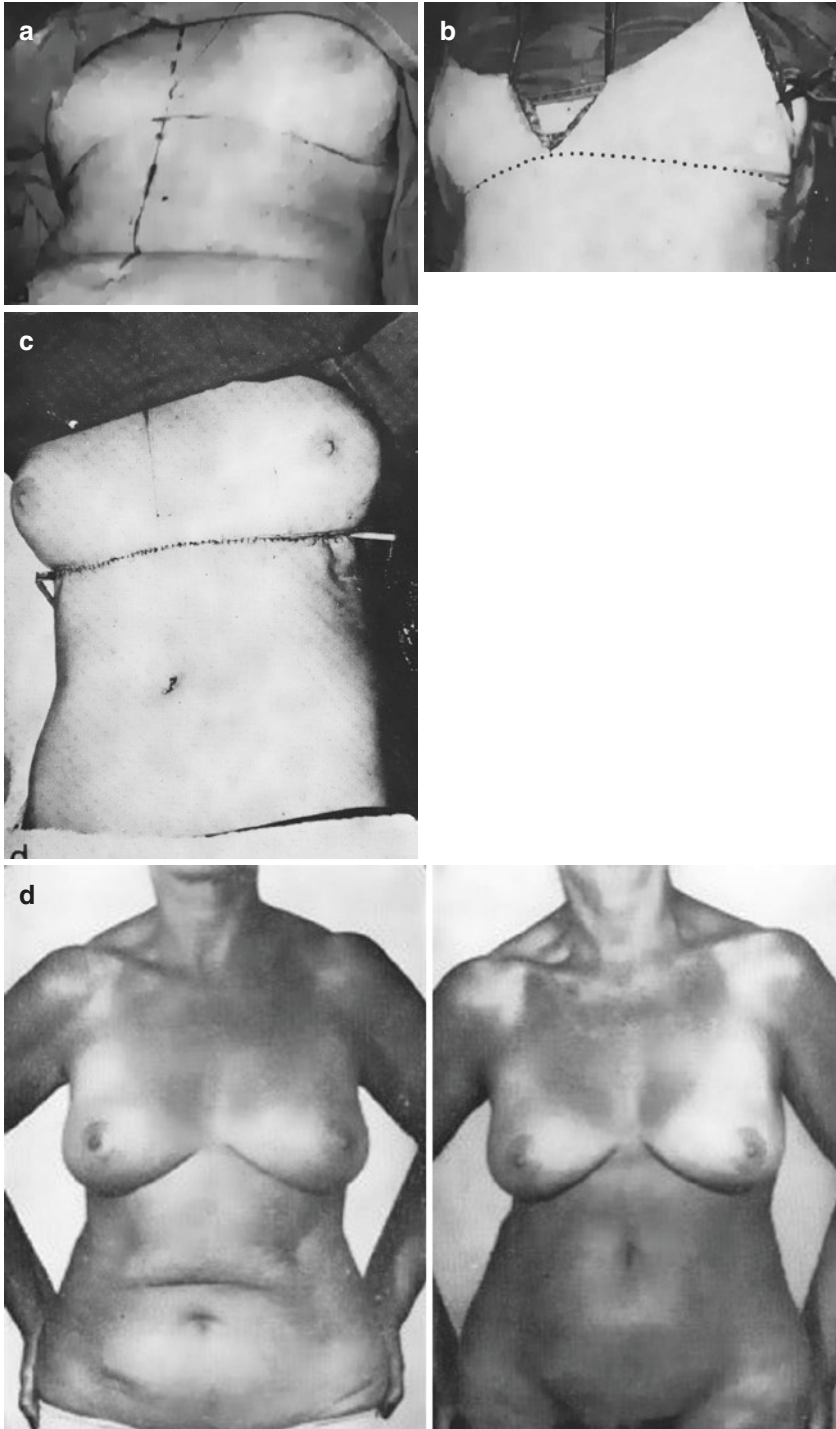


Fig. 35.1 (a–d) Photographic sequences of the first case of reverse abdominoplasty, published by [11]

This solution was welcomed by surgeons and their patients, with the authors describing variations in this technique, associated or not with abdominoplasty through infraumbilical incision, with or without navel detachment.

These variants are described below.

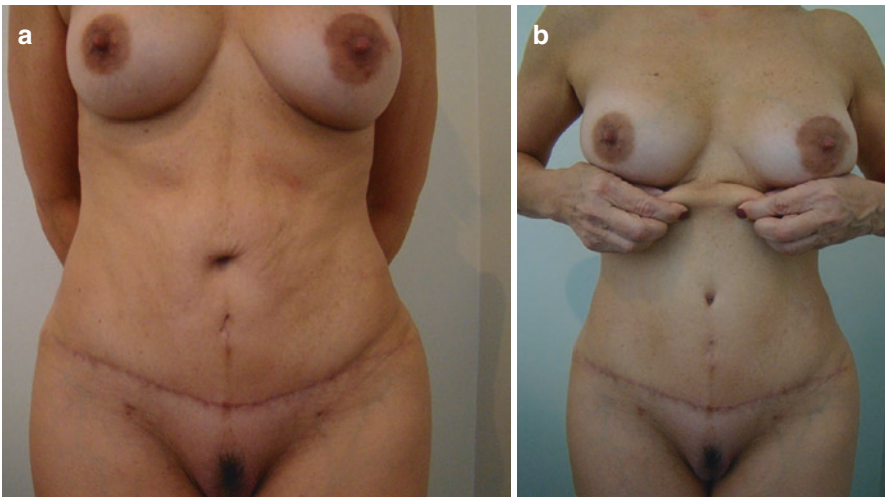
## Indications

The most frequent aesthetic alterations of the epigastrium are adiposity and flaccidity. Adiposity is resolved through liposuction that may supplement traditional abdominoplasties when necessary. Moderate levels of epigastric flaccidity also benefit from approaches based on infraumbilical access. However, when the flaccidity is predominantly supraumbilical, the reverse abdominoplasty is indicated, associated or not with a transverse infraumbilical incision (Fig. 35.2).

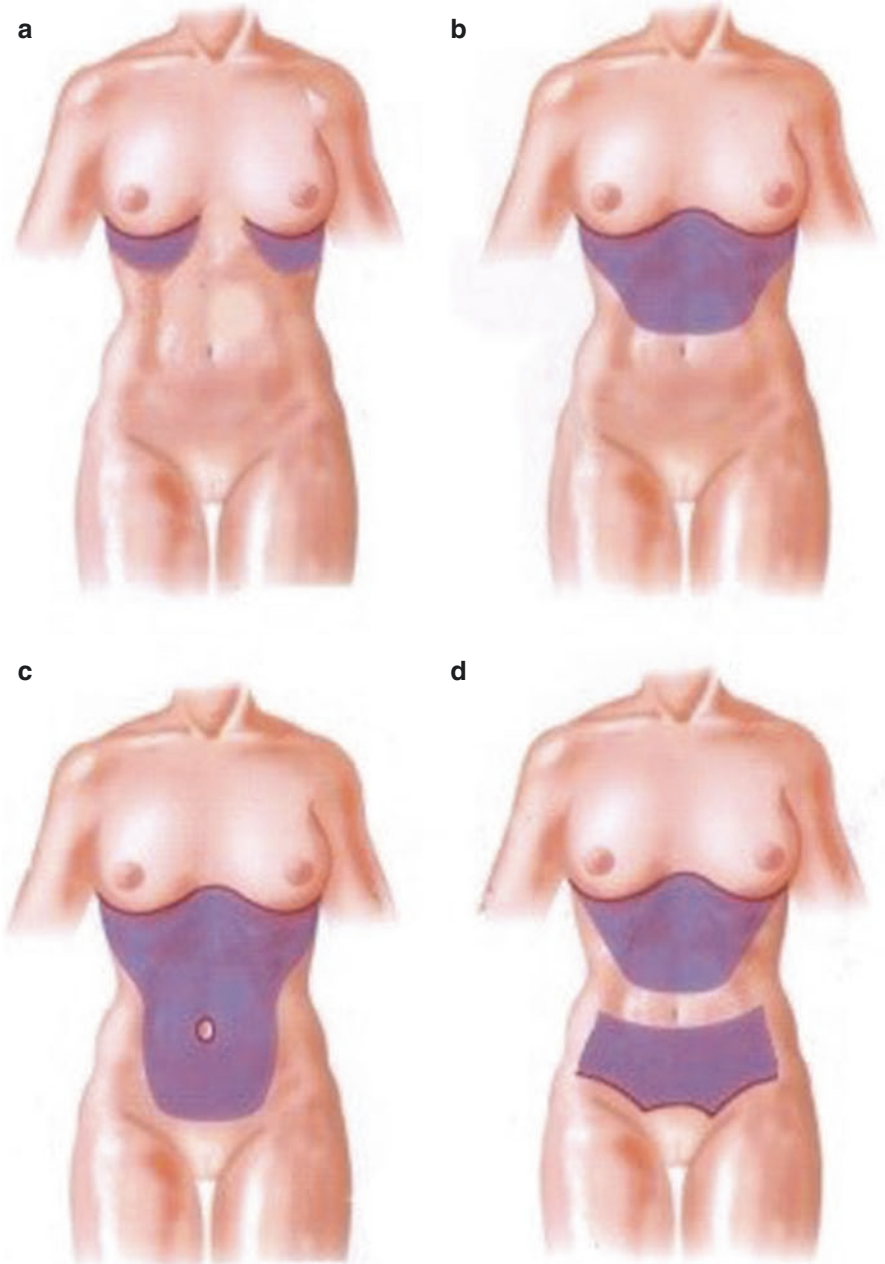
This submammary approach is also useful for enlarging small breasts, using surplus flaps from the upper abdomen that are decorticated and inserted behind the mammary glands.

The extent of reverse abdominoplasty varies, as shown (Fig. 35.3):

- (a) Resection of narrow strips under each breast, sometimes without crossing the midline, or of a narrow band, with no undermining. This is used for minor flaccidity and may be associated with liposuction.
- (b) Undermining of the entire supraumbilical region, including the costal margins and extending as far as the navel, with no detachment.
- (c) Extensive undermining as far as the infraumbilical segment after navel detachment, with no suprapubic incision. This downward undermining is a



**Fig. 35.2** Patient after traditional abdominoplasty (a) wishing to resection supraumbilical flaccidity (b)



**Fig. 35.3** Layout of the extent of the incisions and undermined areas, depending on the requirements of each case **(a)** Resection under each breast. **(b)** Undermining of the entire supraumbilical region, with no umbilical detachment. **(c)** Extensive undermining as far as the infraumbilical segment after navel detachment, with no suprapubic incision. **(d)** Dual access, with inframammary and suprapubic approaches.

difficult task, due to the presence of the ribcage that requires powerful retractors to hold the flap, whose blood supply may be adversely affected.

- (d) Dual access option, with inframammary and suprapubic approaches preserving a transversal strip with no undermining some 3–4 cm wide, without navel detachment. The abdominal blood supply is better protected, with more effective treatment of flaccidity in the epigastric and infraumbilical regions.

## Technique

Preoperative assessment in an orthostatic position with the body bent slightly forward allows a prior evaluation of tissue flexibility, helping with the resection calculation. The inframammary folds are indicated with surgical markers.

The operation is performed under general anesthesia in a supine position, with incisions in the marked folds that may be in a small W shape at the level of the sternum. The downward undermining process follows the aponeurotic level, as in regular abdominoplasties. The rest of the procedure depends on the type of conduct selected, with or without navel detachment and with or without undermining the lower abdomen. Aponeurotic plicature is used only when both upper and lower access paths are performed, as plicating only above or below the navel will result in greater protuberance of the non-plicated area.

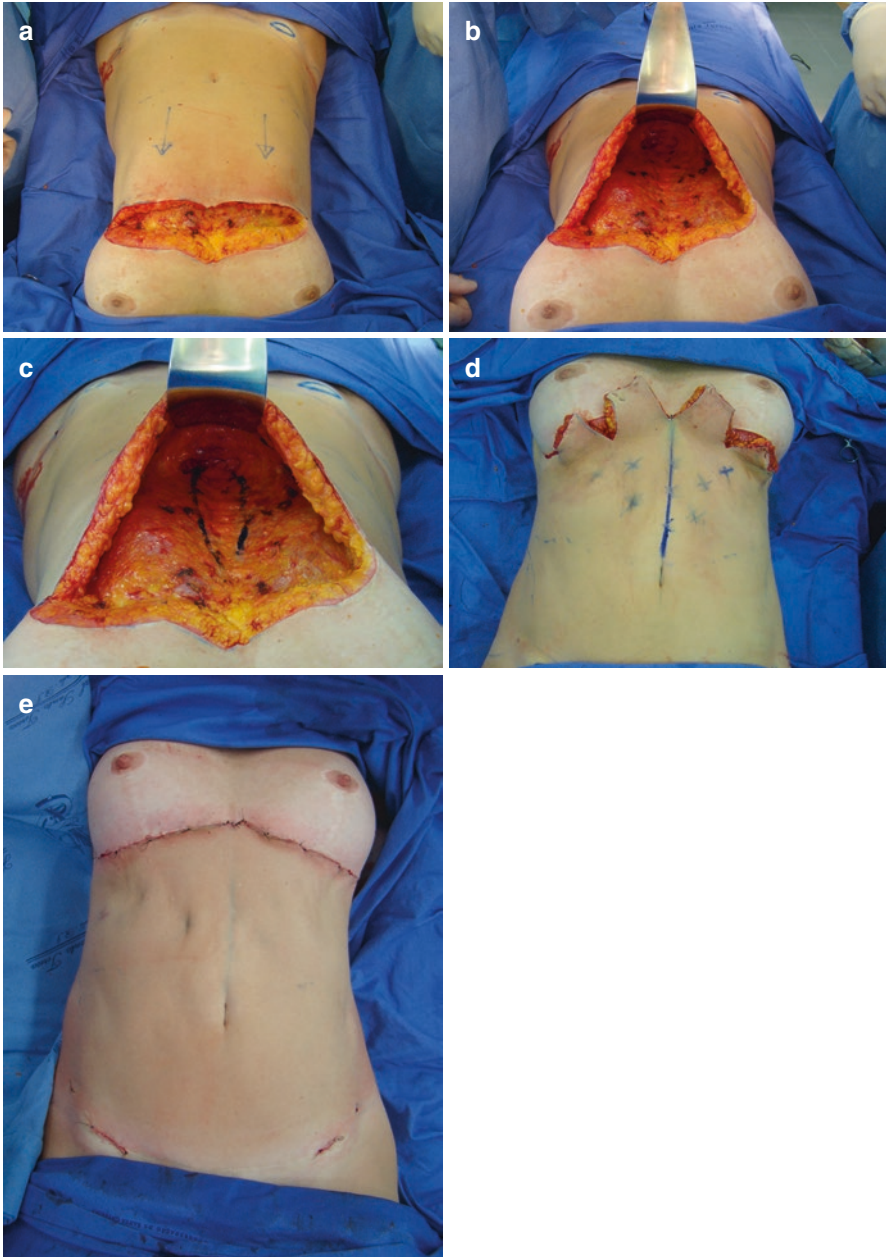
Once undermining has been completed, the upper flap will be split in half along the midline, as far as the planned resection location. A strong stitch placed here maintains traction and demarcates the two cutaneous-adipose segments that are normally resected, but which may also be used for breast augmentation. Some Baroudi adhesion sutures between the flap and deeper tissues enhance flap stability, reducing the possibility of seroma and suture line stress.

With resectioning completed, suturing takes place at three levels, with the fascia superficialis stitched to the deep fascia in order to accentuate the inframammary fold. A closed aspiration drain is used (Figs. 35.4, 35.5, and 35.6).

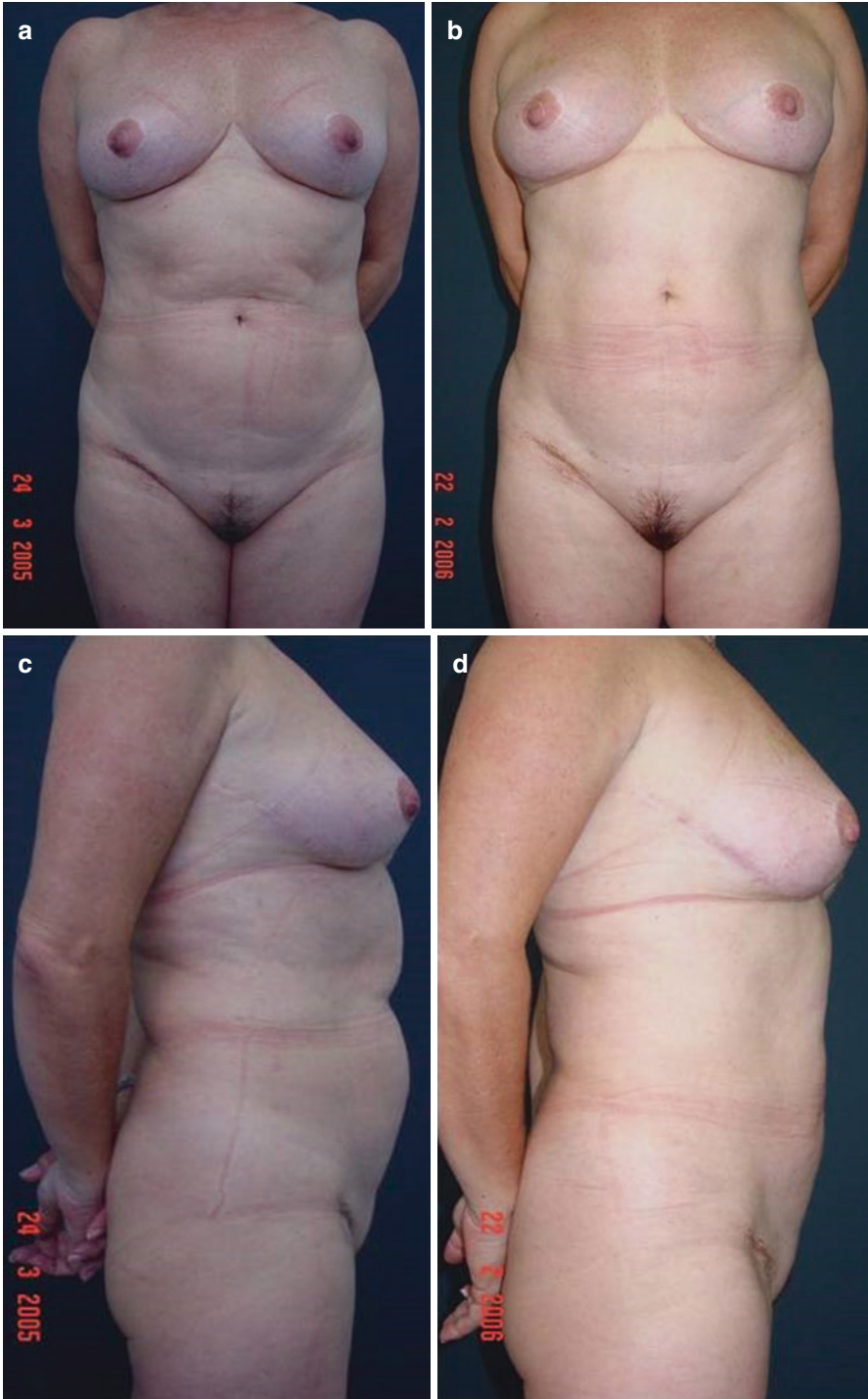## Conclusions

Reverse abdominoplasty does not replace the usual technique through suprapubic incision and must be used only for cases where the deformity is located mainly in the supraumbilical segment. However, the direct approach offered by this technique results in better outcomes for this region than a traditional abdominoplasty, with these two techniques forming an excellent combination in some cases.

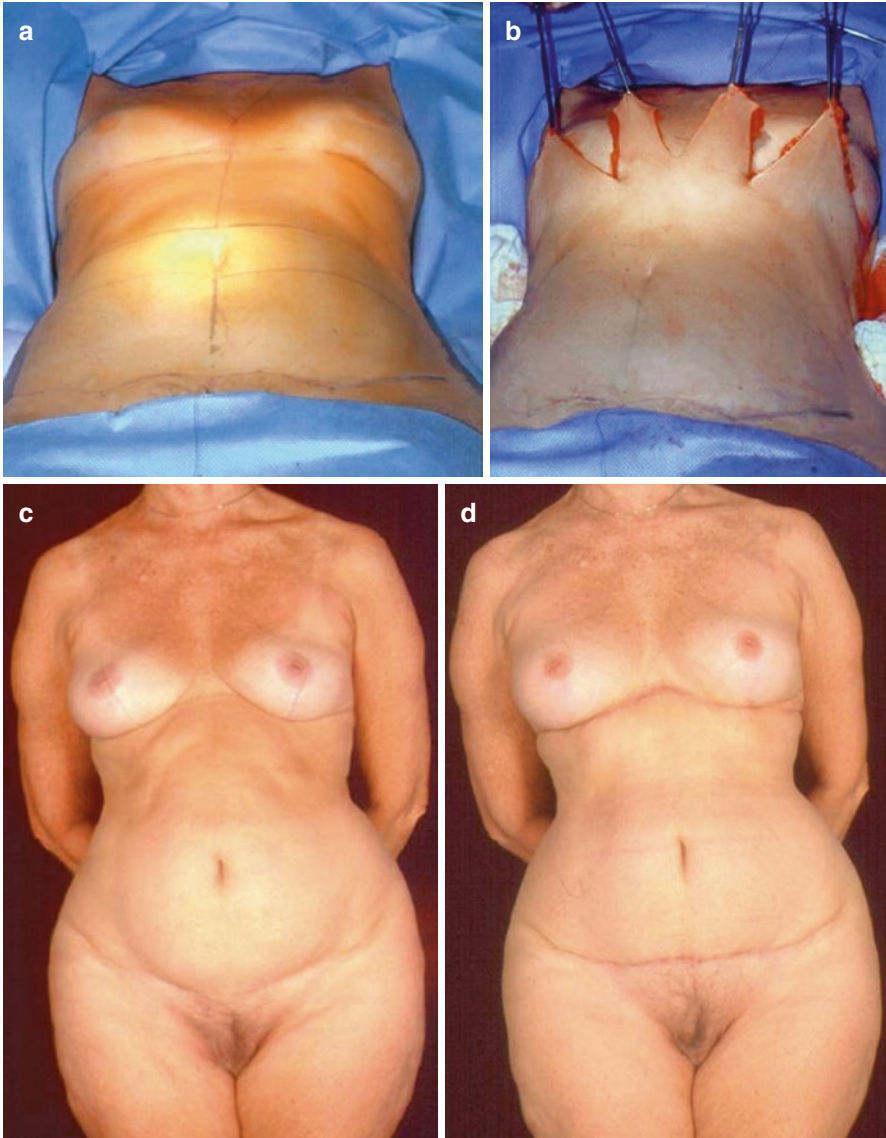
Patients with supraumbilical flaccidity and breast fold scars (usually resulting from reductive mammoplasty) may benefit from this technique.



**Fig. 35.4** Surgical sequence showing the inframammary incision (a), supraumbilical undermining (b), marking the plicatura (c), start of resectioning surplus flaps (d), and final sutures (e)



**Fig. 35.5** Patient after reverse abdominoplasty addressing only the supraumbilical area, associated with liposuction of the infraumbilical segment. (a, c) Preoperative; (b, d) postoperative



**Fig. 35.6** Peroperative reverse abdominoplasty together with the usual infraumbilical incision, with no connection between the two undermining areas and without detaching the navel. (a) Marking upper and lower incisions. (b) Completion of upper undermining showing the surplus flaps that were decorticated and inserted into the retromammary areas. (c) Preoperative. (d) Postoperative

Liposuction does not replace reverse abdominoplasty but rather supplements it. They are different indications and flaccidity may increase after liposuction, leading to a recommendation for inframammary resection.

The most common complications, although not frequent, are hematoma, seroma, loss of breast fold line, and hypertrophic scars in the sternum region.

Among the many resources currently available for ensuring better outcomes for our aesthetic operations, reverse abdominoplasty must be rated as an extremely useful tactic for atypical cases.

## References

1. Akbas H, Guneren E, Eroglu L, Demir A, Uysal A (2002) The combined use of classical and reverse abdominoplasty on the same patient. *Plast Reconstr Surg* 109:2595–2596
2. Avelar MJ (1999) A new technique for abdominoplasty – closed vascular system of subdermal flap folded over itself combined to liposuction. *Rev Bras Cir* 88/89(1/6):3–20
3. Avelar MJ (2002) Abdominoplasty without panniculus undermining and resection: analysis and 3-year follow-up of 97 consecutive cases. *Aesthet Surg J* 22(1):16–25
4. Baroudi R, Ferreira C (1998) How to avoid it and how to treat it. *Aesthet Surg J* 18:439–441
5. Baroudi R, Keppe EM, Carvalho CG (1979) Mammary reduction combined with reverse abdominoplasty. *Ann Plast Surg* 2:368–373
6. Berson MJ (1948) Atlas of plastic surgery. Grune & Stratton, New York
7. Callia WEP (1967) Uma plástica para o cirurgião geral. *Medicina hospitalar* 1:40–41
8. Deos MF, Arnt RA, Gus EI (2009) Tensioned reverse abdominoplasty. *Plast Reconstr Surg* 124(6):2134–2141
9. Franco T, Franco D, Medeiros Tavares Filho J (2008) Dermolipectomia por incisão submamária. In: *Tratado de Cirurgia Plástica na Obesidade*. Ed: José Humberto Resende. Rubio. Capitulo 39, pp 303–308
10. Halbesman GJ, van der Lei B (2008) The reverse abdominoplasty: a report of seven cases and a review of English-language literature. *Ann Plast Surg* 61:133–137
11. Rebello C, Franco T (1972) Abdominoplastia por incisão submamária. *Rev Bras Cir* 62(7-8):249–252
12. Rebello C, Franco T (1974) Abdominoplasty through submammary incision. In: *Year book of plastic and reconstructive surgery*. Year Book Medical Publisher Inc, Chicago
13. Thorek M (1942) Plastic surgery of the breast and abdominal wall. Charles C. Thomas Ed, Springfield
14. Yacoub CD, Baroudi R, Yacoub MB (2012) Abdominoplastia reversa estendida. *Rev Bras Cir Plast* 27(2):328–332



# Chapter 36

## Extended Reverse Abdominoplasty: A Technical Alternative for Breast Reconstruction

Cecin Daoud Yacoub

### Introduction

New knowledge of abdominal wall anatomy as to its circulatory hemodynamics has promoted a great technical evolution of this important chapter of plastic surgery over the last decades.

Studies of the microsurgical flap initiated by Holstrom, in 1979, followed by the development of the transverse rectus abdominis myocutaneous flap (TRAM) reported by Hartrampf, in 1982, represented important evolutionary marks in the history of abdominal wall surgery.

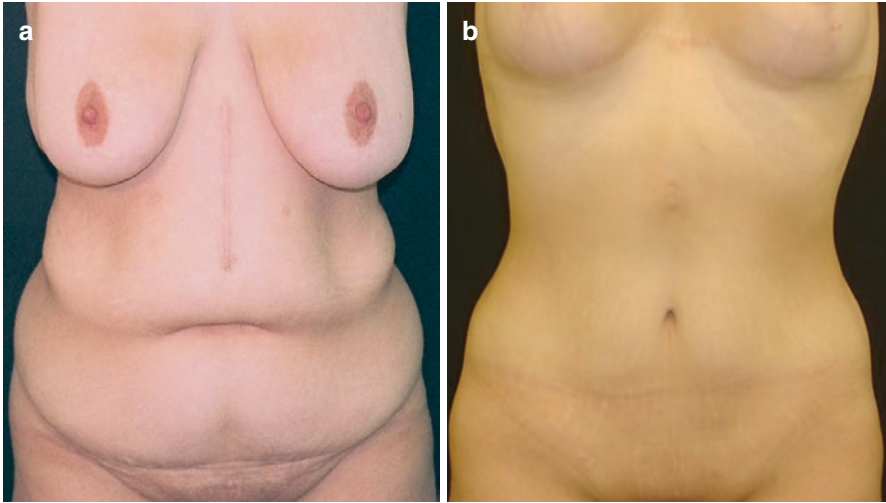
During this same period, liposuction appeared, as published by Illouz, in 1980, which revolutionized aesthetic procedures of body contours and led to various studies associating liposuction and abdominoplasty, but was abandoned at the end of that decade in face of the high rate of complications.

This fact led to a standstill and simultaneously promoted new incursions into the studies of abdominal wall circulation, without many answers. In 1999, Avelar brought a major contribution by publishing his technique of “closed vascular system of subdermal flap folded over itself, combined to liposuction,” which opened new horizons of knowledge about the limits of circulatory autonomy of the abdominal wall. Thus, he was able to reconcile the union of these two procedures.

---

C.D. Yacoub, MD  
Sociedade Brasileira de Cirurgia Plástica (Brazilian Society of Plastic Surgery),  
São Paulo, SP, Brazil

Plastic Surgery Department, Instituto de Cirurgia Plástica Santa Cruz  
(Dr. José Marcos Mélega), Av. Republica do Libano, 1268, Sao Paulo, SP, Brazil  
e-mail: [cecinyacoub@terra.com.br](mailto:cecinyacoub@terra.com.br)



**Fig. 36.1** (a) Example of an abdomen with a scar in the epigastric region due to bariatric surgery. (b) Postoperative phase of *extended reverse lipoabdominoplasty associated with mastopexy without prosthesis*, with total elimination of the median scar and migration of the scar of the former umbilicus in the same region

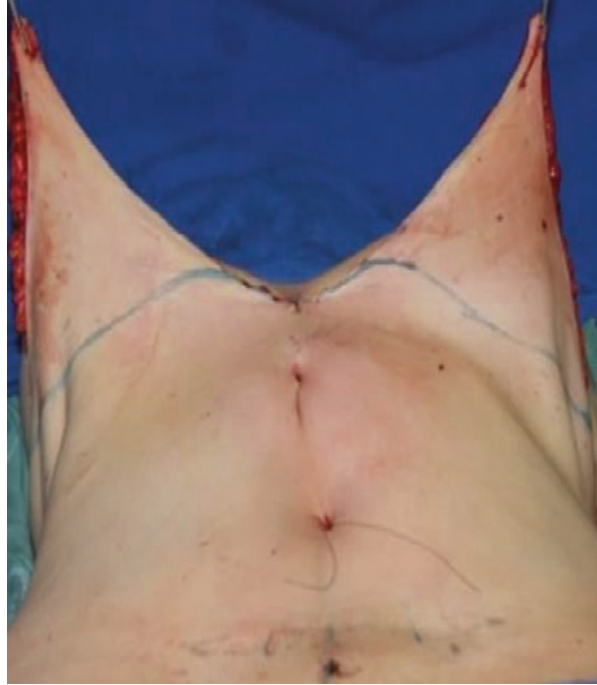
According to these principles, in 2001, Saldanha published his technique, “lipoabdominoplasty with selective detachment,” added all the conventional surgical maneuvers, and amplified its indications.

In 2012, Yacoub et al. published a study based on these new concepts in which a complete abdominoplasty is performed via inverted access with or without liposuction, by means of an incision in the submammarian sulcus, as described by Rebello and Franco, but extended by the isolation of the umbilicus, selective dissection from the umbilicus to the pubis, plicature of the rectus sheath, and onphaloplasty, in which the flap traction reflects throughout the entire abdomen as is done in conventional abdominoplasty.

This procedure was named “reverse extended abdominoplasty” and has the objective of being applied in patients with one or more scars in the upper segment of the abdomen to be reduced or eliminated, in exchange for a smaller and less apparent scar in the same region, resulting from the ascending and reducing skin that surrounded the umbilicus. However, it does not reach the superior transverse incision, thus avoiding the formation of an anchor-shaped scar if it were accessed by the conventional technique (Fig. 36.1).

Additionally, also noted was that this method offers an ample excess flap that advances over the chest region with signs of vitality to its extremity and allows it to be used in some cases of breast reconstruction and other repair procedures in the anterior and lateral chest regions reached by it (Fig. 36.2).

**Fig. 36.2** Excess flap with great advancement over the chest

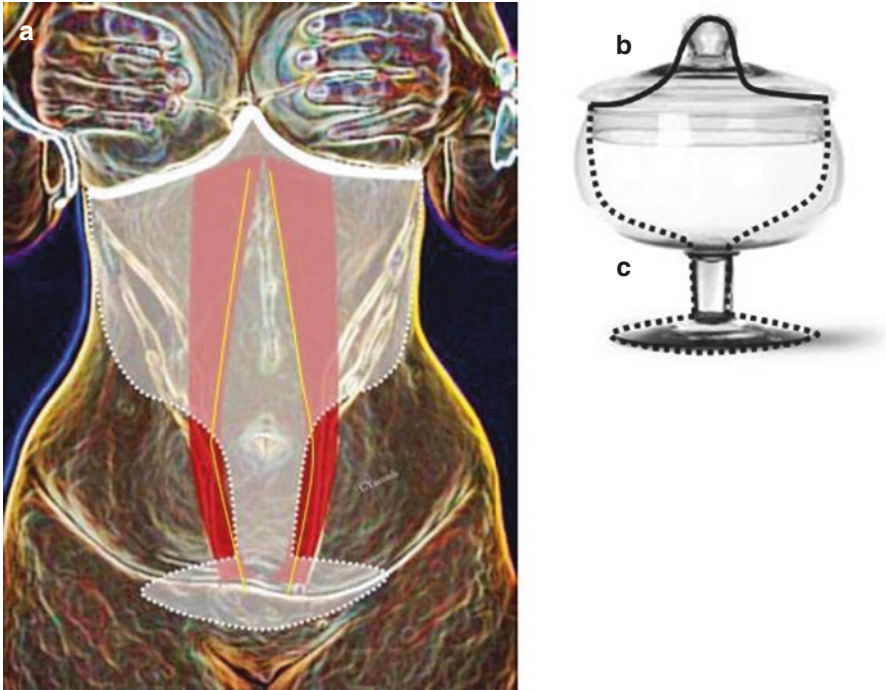


## Method

For better orientation, the tracing described below refers to extended reverse abdominal surgery without mammary reconstruction. In late reconstructions, the tracing follows a large portion of the preexisting scar. In immediate reconstructions, it may or may not follow the mastectomy incision.

## Marking

Initially, an approximate tracing is made over the internal margin of the rectus muscles along their extension. It marks the incision in the submammary sulcus up to the anterior axillary line, bilaterally, and the union of both along the midsternal line above the xiphoid process, with the tracing slightly forming a concave curve upward. For better orientation, an approximate tracing is also made of the limits of the dissection along the entire abdomen, starting from the lateral extremes of the incision, which drop in descending curves toward the median portion of the abdomen, approximately one centimeter from the umbilicus, to the limit of the internal

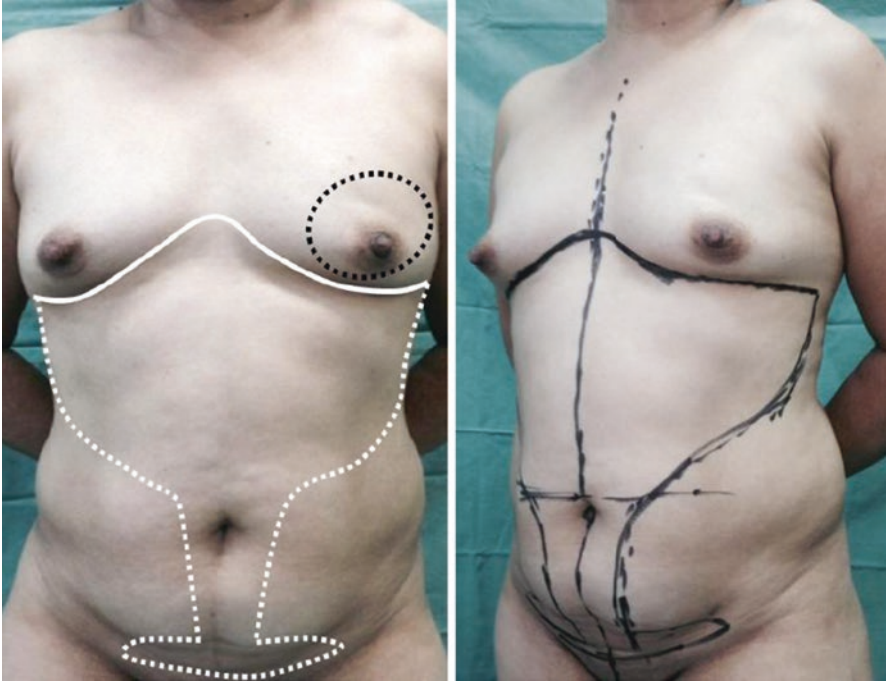


**Fig. 36.3** (a) Surgical planning; (b) continuous single-trace incision, corresponding to the “lid” of a “crystal compote”; (c) dissection in a dotted line, corresponding to the “body and base” of the “crystal compote”

borders of the abdominal rectus muscles, when they turn toward the caudal direction. Based on these points, the tracings descend parallel to the internal borders of the rectus sheaths and when reaching the pubis, diverge laterally in a semicircle form to the fold of the inner thigh, when they return to the midline involving the entire pubic region. At the end, a tracing in the form of an “imperial crystal compote with lid” is drawn (Figs. 36.3 and 36.4a), in which the “lid” corresponds to the incision line (Fig. 36.3b) and the “body” to the approximate limits of dissection (Fig. 36.3c).

## Dissection

Patient is on supine position with infiltration of saline solution with 1:250,000 adrenaline in the subcutaneous plane of the incision and preaponeurotic plane of the dissection. After the skin incision, the flap is dissected at the level of the said plane until reaching the umbilicus; when it is then isolated by an ellipsoid incision,



**Fig. 36.4** Mastectomy with immediate reconstruction: patient M.A.S. 51 years of age, carcinoma in the left breast, stage (T4)

followed by dissection in the caudal direction and along the trajectory, the flap is gradually split into two in order to facilitate access to the pubis (Fig. 36.2).

### **Plicature of the Abdominal Rectus Muscles**

This is performed with 2-0 monofilament nonabsorbable suture as is used in conventional abdominoplasty.

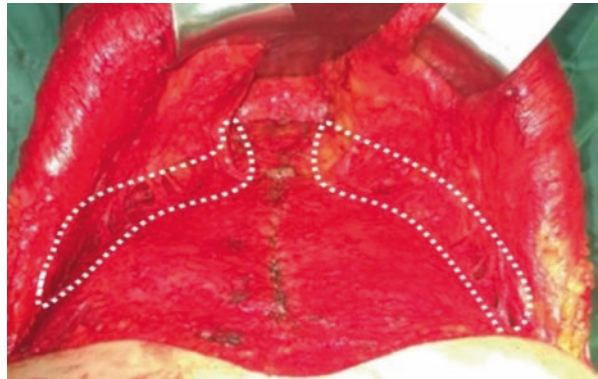
### **Progressive Tunneling**

These are maneuvers made with blunt detachers created by Dílson Luz, with progressive diameters, using movements similar to those of a liposuction, applied between the fat tissue and the subjacent aponeurosis in order to detach the inferolateral portion of the non-dissected flap, without damaging the perforating vessels (Figs. 36.5 and 36.6).

**Fig. 36.5** Set of Dílson Luz detachers



**Fig. 36.6** Plicature of the rectus sheath; inferolateral region of the flap (*dotted line*) released from the aponeurosis by progressive tunneling



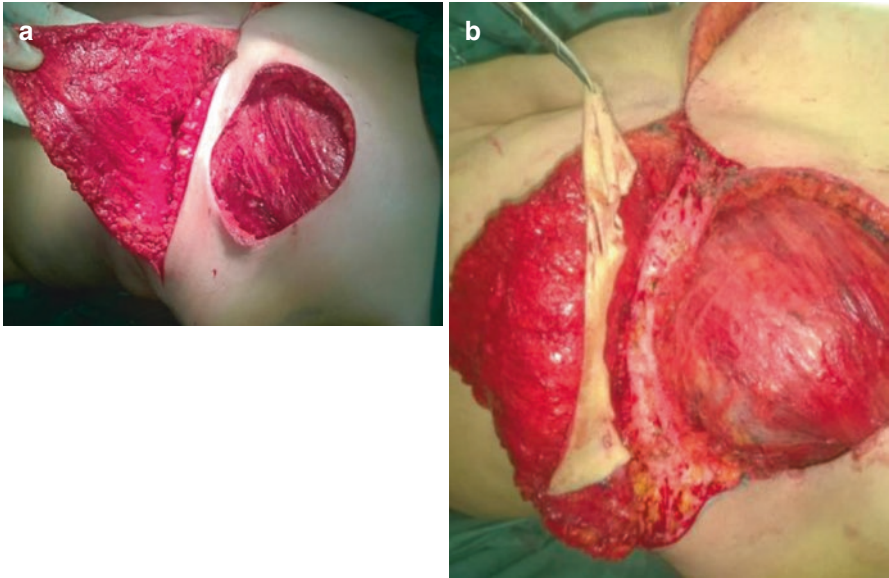
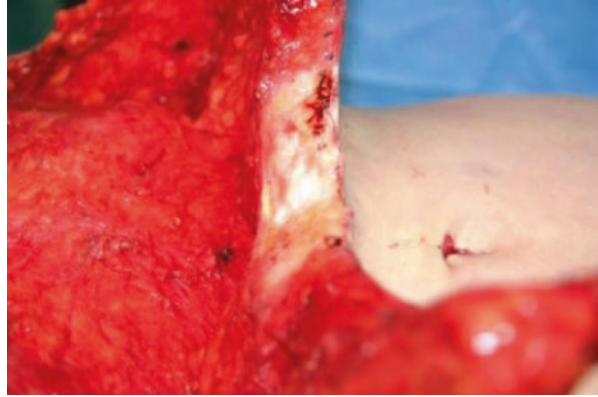
## Adhesion Points on the Abdominal Wall

The abdominal wall adhesion points recommended by Baroudi are considered mandatory in this method. Besides their habitual objective in preventing seroma, they exert an important function of gravitational containment of the flap during cephalad traction and also help to position it during the lateral rotation maneuver to the midline. For this, long-term 2-0 absorbable sutures are used, with long stitches to guarantee fixation (Fig. 36.7). Even so, active suction drains with opening toward the pubis are applied for preventive purposes.

## Omphaloplasty

Performed during the application of the adhesion points of the flap and when reaching the umbilicus, the subjacent skin is incised as per the starlike tracing of the Avelar technique, which adapts to the fusiform-incised umbilicus by means of synthesis with 3-0 and 4-0 nylon sutures (Fig. 36.7).

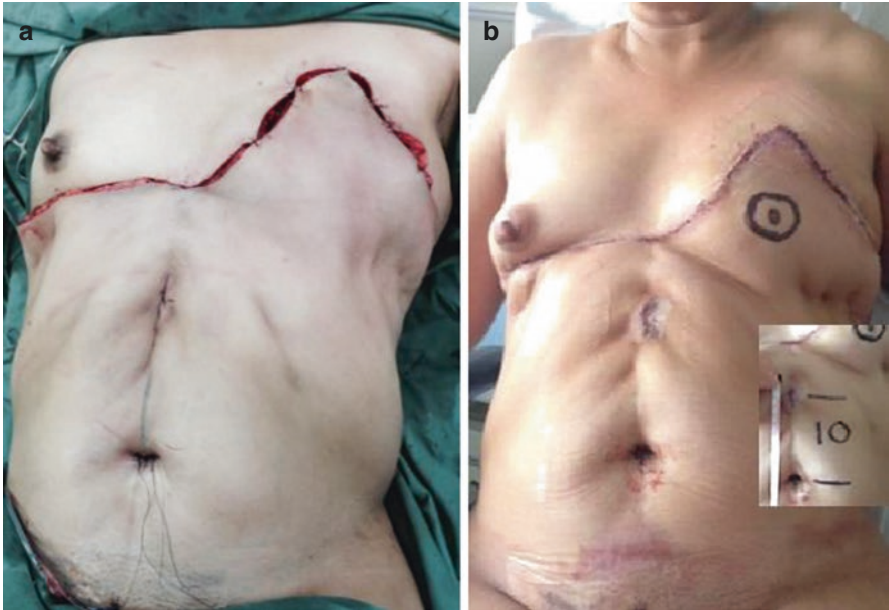**Fig. 36.7** Baroudi  
adhesion points and  
omphaloplasty by the  
Avelar technique



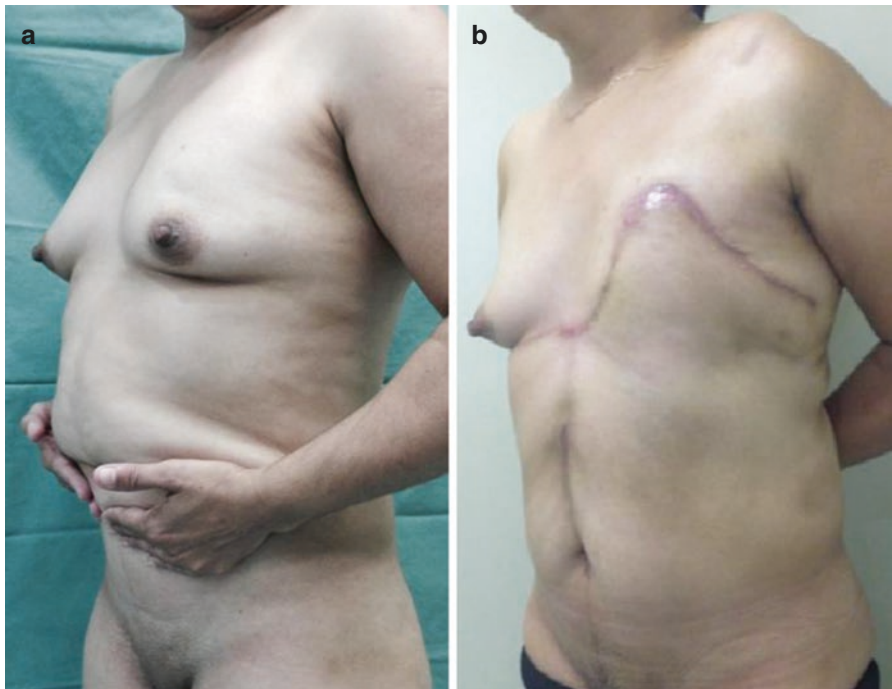
**Fig. 36.8** (a) Extended reverse abdominal flap fixed along the remaining previous sulcus; (b) disepithelialization of the old sulcus and implantation of the expanding prosthesis in the submuscular layer

## Skin Suture and Flap Definition for Breast Reconstruction

After removal of the excess skin and maintaining the flap for reconstruction, the suture is performed in three layers, with isolated stitches of monofilament 3.0 nylon in the deep layer to define the new mammary sulcus, 4.0 in the subcutaneous layer and dermis, and with 4.0 and 5.0 absorbable suture in the cuticular layer (Figs. 36.7a–c, 36.8, 36.9, and 36.10).

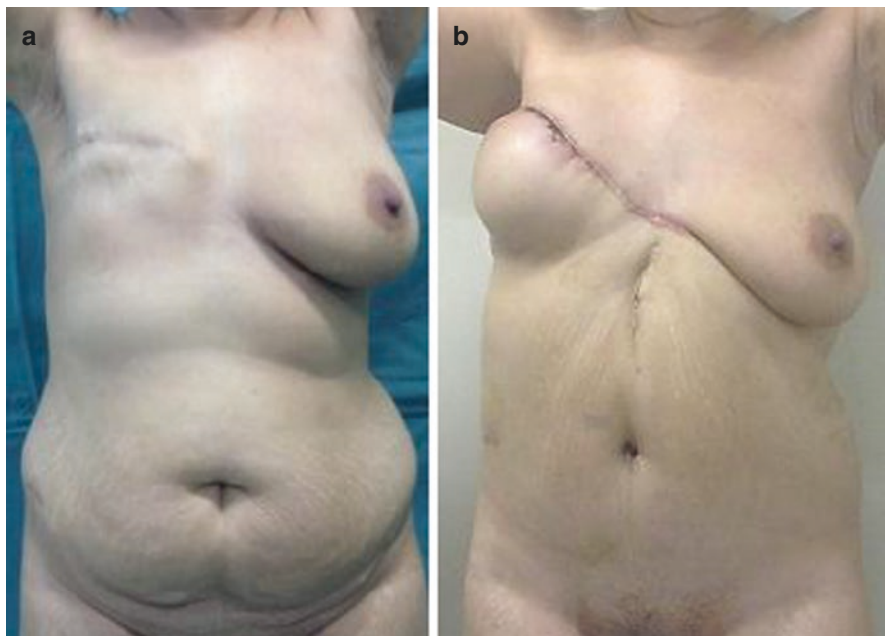


**Fig. 36.9** (a) Intraoperative phase during positioning of the flap; (b) 24 h postoperative. In this case, the *extended reverse abdominal technique* offered 10-cm advancement of the flap along the midline



**Fig. 36.10** (a, b) Pre- and postoperative aspects at 6 weeks





**Fig. 36.11** (a) Surgical planning, 38-year-old patient, with right mastectomy, radiation therapy, and chemotherapy 2 years ago. (b) 48-hour postoperative in the sitting position – implantation of supramuscular 285-mL prosthesis

## Late Breast Reconstruction

As described, the marking is made in the breast sulcus until the sternum, and from there the tracing follows over the mastectomy scar and ends at the same level of the contralateral limit. The other tracings and maneuvers obey the same description (Fig. 36.11).

## Anatomical Principles

In 1987, Taylor and Palmer described the angiosomes of the abdominal region divided into three main segments, superior, inferior, and lateral, considered as important topographic references for surgical planning. In the inferior region, the primary vascularization comes from the inferior epigastric vessels. In the superior region, the superior epigastric vessels are responsible for blood supply. In the lateral region, the supply is provided by lateral perforating vessels formed by anastomoses between the intercostal, subcostal, lumbar, and deep iliac circumflex vessels in the space between the internal oblique and

transverse muscles, from where they emerge through the internal and external oblique muscle, pass through the subcutaneous layer, and reach the skin subdermal plexus.

The inferior and lateral regions also receive supply from the femoral branches through the superficial epigastric, external superficial pudendal, and superficial iliac circumflex vessels (Fig. 36.2).

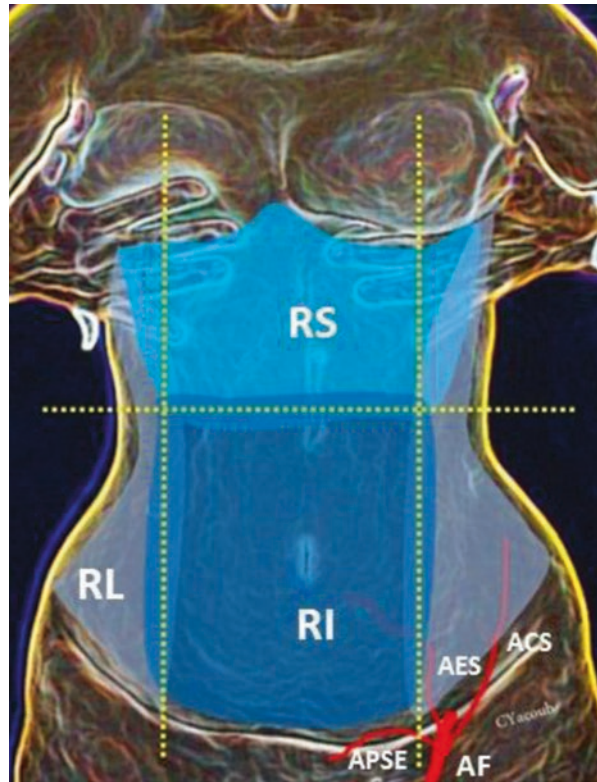
## Other Anatomical Considerations of Surgical Interest

- Spalteholz, in 1893, defined the concept of direct cutaneous vessels as those with the primary function of irrigating the skin and indirect vessels as those that irrigate the subjacent tissues, such as the subcutaneous layer and muscles.
- Taylor and Hamdy, in significant studies, concluded that 80% of blood supply of the abdominal wall comes from the perforating vessels.
- The inferior epigastric vessels have perforating branches up to half the distance of the superior segment of the abdomen, between the xiphoid process and the umbilicus, which corresponds to the area of anastomosis with the superior epigastric vessel; that is, the perforating arteries of the superior epigastric vessels never reach the umbilicus.
- The perforating arteries are closer to the lateral border of the rectus muscles than to the linea alba.
- Venous drainage occurs in a manner parallel to the arteries, with the drainage territory corresponding to that irrigated by the arteries.
- Superficial lymphatic drainage of the supraumbilical region drains toward the axillary lymph nodes, and those of the infraumbilical region drain toward the superficial inguinal lymph nodes. Deep drainage accompanies the perforating vessels.
- All the vessels that compose the circulatory network of the abdominal wall promote anastomoses in all levels of layers, with greater or lesser intensity according to distribution (Fig. 36.12).

## Inclusion Criteria

The inclusion criteria to indicate the extended reverse abdominoplasty in breast reconstruction follow the same criteria for analysis of the conventional method by means of Bozola classification and the reverse “pinch test.” Additionally, common sense should prevail in the decision for this method, which goes through a learning curve and offers advantages and disadvantages relative to the other well-known procedures.

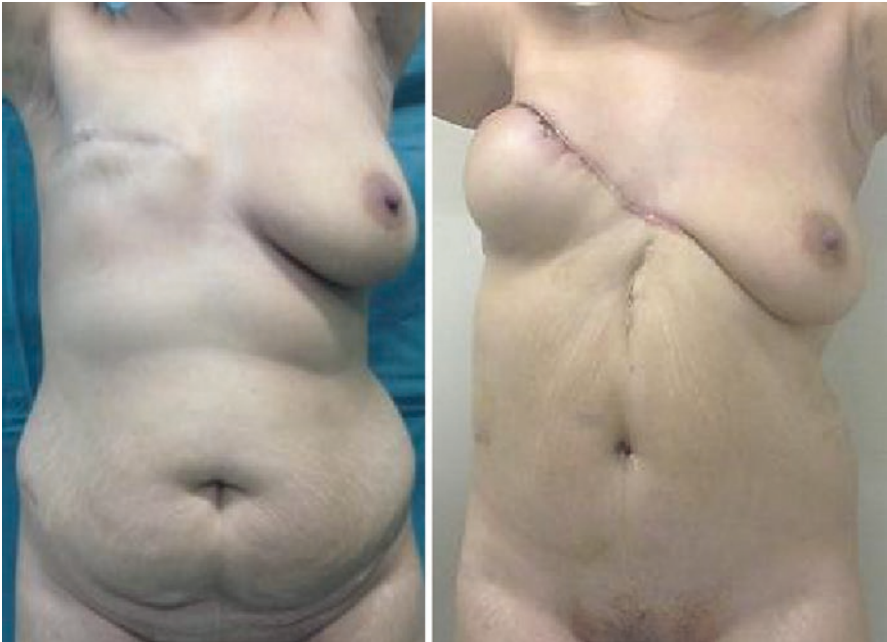**Fig. 36.12** Schematic drawing of the abdominal wall circulation as per Taylor classification, divided by regions supplied by angiosomes formed by the perforating vessels. *SR* superior region, perforating branches of the superior epigastric artery; *IR* inferior region, perforating branches of the inferior epigastric artery; *LR* lateral region, region of the lateral perforating vessels, formed by the anastomoses of the corresponding arteries. Schematic drawing of another vascular source formed by three branches of the femoral artery, *FA* in the inferior and lateral regions of the abdomen, *SEPA* superficial epigastric pudendal artery, *SEA* superficial epigastric artery, *SCA* superficial circumflex artery



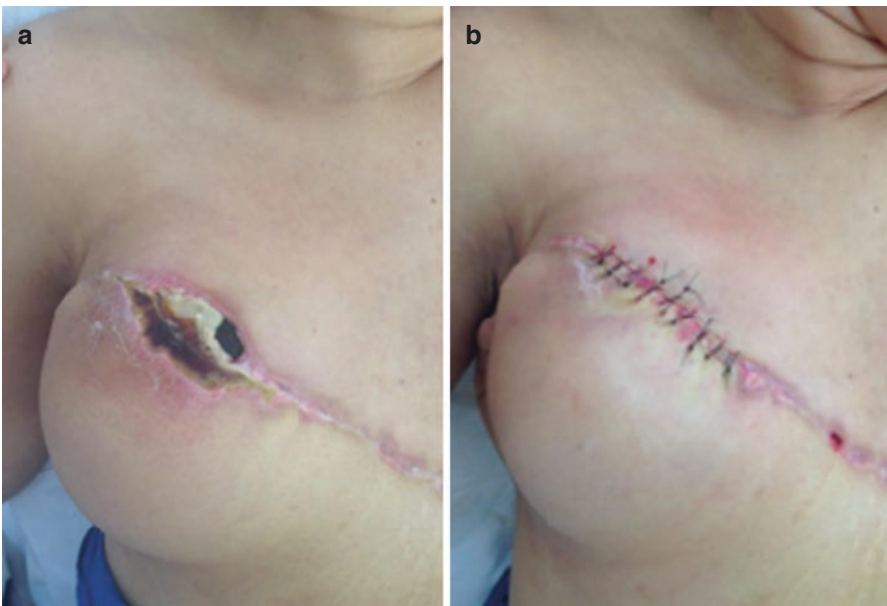
## Complications

During the period of August 2005 to March 2015, 16 patients were submitted to extended reverse abdominoplasty. Of these, seven patients were for esthetic purposes, age range of 22–57 years, and nine patients for repair purposes, aged 37–69 years.

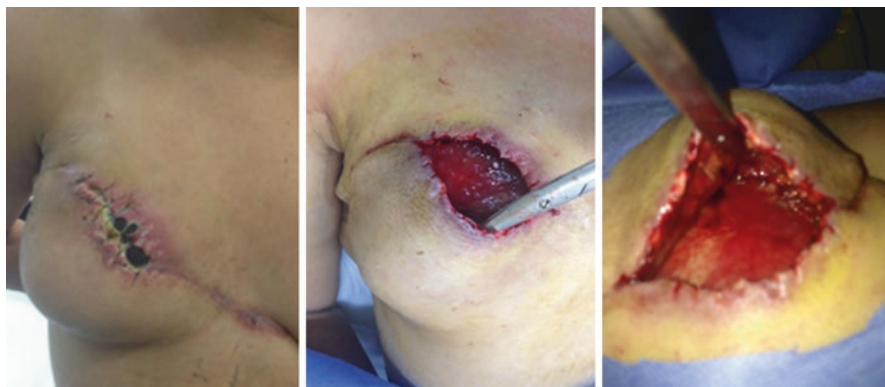In all cases, there were no relevant complications in the abdominal segment. The complications presented occurred in the reconstructions, in the segment of advancement of the flap that had undergone prior irradiation. Suture dehiscence, steatonecrosis, and partial skin necrosis occurred in more than 30% of cases. Of these, there were three cases of exposure to the prosthesis that had to be removed for posterior reimplantation. However, there was no case of total loss of the flap advanced over the chest, but the index considered, representative of the complications presented, led to contraindication of this technique in irradiated patients, until means are found to reduce this morbidity. Autonomization of the irradiated flap, lipograft sessions, and initial implantation with an expanding prosthesis, even if the technique offers space for the definitive implantation of the prosthesis into the submuscular layer whenever possible, are the alternatives currently under study (Figs. 36.13, 36.14, and 36.15).



**Fig. 36.13** Patient from example 01, pre- and postoperative at 4 weeks with beginning of distress in the upper portion of the scar



**Fig. 36.14** (a) Patient from example 01, 6 weeks postoperative with distress along the borders of the cephalad and caudal flaps with exposure of the prosthesis. (b) Debridement and suture



**Fig. 36.15** Patient from example 1, 8 weeks postoperative – removal of prosthesis

## Discussion

In 1979, Lewis was the first to publish on the use of the superior segment of the abdomen as a donor site for a breast reconstruction flap, in the article entitled “Use of a sliding flap from the abdomen to provide cover in breast reconstruction,” with dissection of the flap and without transposition of the umbilicus.

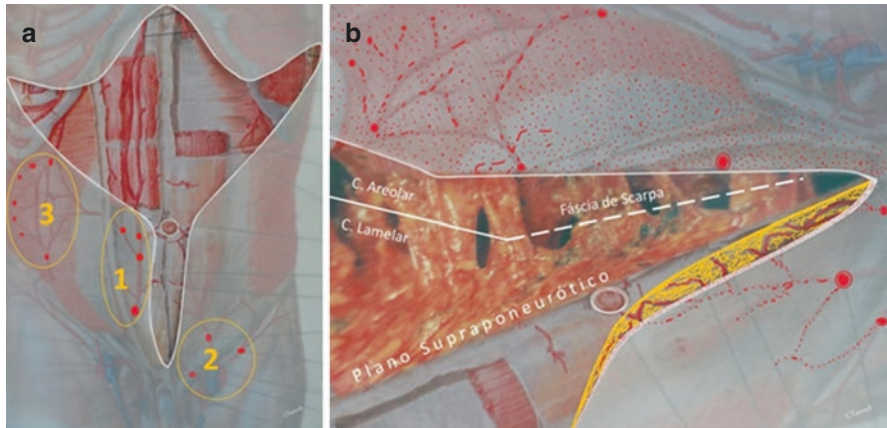
The flap formed by extended reverse abdominal surgery has the following characteristics:

- Simple cutaneous flap of the skin continuous with the recipient area and with moderate fat texture
- Peninsular flap, with dissection to the pubis, transposition of the umbilicus, followed by neo-omphaloplasty, which allows a greater advancement of this flap in comparison to what is offered by the conventional reverse abdominal technique
- Triaxial flap, maintained by the three sources of irrigation originated in the inferior segment of the abdomen (Figs. 36.14a, b and 36.16)

The major advantage of using this method for breast reconstruction was that of offering a large quantity of cutaneous tissue for the chest region without hindering the donor area; on the contrary, it leaves the donor site with no sequelae by using the extended reverse abdominoplasty with all maneuvers offered by conventional abdominoplasty, except for a small scar implanted in the epigastric region, reminiscent of the old umbilicus.

Even in cases of striated skin in the inferior segment that migrated to the epigastric region, the result was considered satisfactory when compared with the other alternatives and according to the degree of satisfaction demonstrated by the patients.

The indication of this method will depend on if the cutaneous tissue offered will be sufficient in size and texture to cover the recipient area or if there will be the need for a muscle reinforcement offered by the myocutaneous techniques.



**Fig. 36.16** (a) Schematic drawing of the sources of irrigation of the extended reverse abdominal flap: 1 median region, perforating myocutaneous branches of the inferior epigastric artery; 2 inferior region, septocutaneous branches of the femoral artery; 3 lateral region, perforating myocutaneous branches formed by the lateral anastomoses. (b) Schematic drawing of the horizontal view of the sources of irrigation of the flap, associated with a real image of the perforating “plug-flap”

The new mammary sulcus cannot be well defined in the first stage of reconstruction in order to not compromise irrigation of the distal portion of the flap, leaving it for the next phases along with the other complementary procedures.

Active suction drains are applied along the whole extension of the breast and abdomen with opening at the pubis. Extended reverse abdominal surgery proves favorable to the superficial and deep drainage systems, due to the low seroma output presented in the abdominal region and lasting no longer than 3 days. The presence of lipolysis occurred in complications of the irradiated patients, began on average on the seventh postoperative day, with output by the orifice opened spontaneously in some point along the surgical scar.

In general, we can conclude that the ample flap formed by the extended reverse abdominoplasty technique showed vitality and resistance to large dissections and tractions. However, it also showed fragility in the segment that suffered irradiation.

In this sense, various procedures have been analyzed in search of reducing the rate of complications and obtaining greater vascular autonomy of the entire irradiated territory. One of them is still in the phase of experimentation, and it is through the use of new knowledge offered by lipograft that it has demonstrated a gain in benefits in different pathological situations of the skin and its underlying tissue. Several studies demonstrated gain in texture of the adipose layer accompanied by angiogenesis, reduction of fibrosis, and subsequent gain in skin elasticity. Other studies of great interest for this chapter demonstrated to date that lipografting does not stimulate the cytogenesis of neoplastic cells.

Thus, it is believed that soon this method will again be indicated in reconstructions after preparation of the irradiated area.

## Further Reading

- Avelar JM (1976) Umbilicoplastia – uma técnica sem cicatriz externa. An do XIII Cong Bras de Cir PlastPorto Alegre, pp 81–82
- Avelar JM (1986) Surgical anatomy and distribution of the subcutaneous fat tissue on human body. In: Avelar JM, Illouz YG (eds) Lipoaspiração. Ed Hipócrates, São Paulo, pp 45–57
- Avelar JM (1999) Uma nova técnica de abdominoplastia: Sistema vascular fechado de retalho subdérmico dobrado sobre si, combinado com lipoaspiração. Rev Bras Cir 6:3–20
- Baroudi R, Keppke MK, Carvalho CG (1979) Mammary reduction combined with reverse abdominoplasty. Ann Plast Surg 2:368–373
- Baroudi R, Ferreira CA (1998) Seroma: how to avoid it and how to treat it. Aestet Plast Cirg J 18(6):439–441
- Boyd BJ, Taylor GI, Corlett R (1984) The vascular territories of the superior epigastric and deep inferior epigastric systems. Plast Reconstr Surg 73(1):1–16
- Bozola A, Psillakis J (1988) Abdominoplasty: a new concept and a classification for treatment. Plast Reconstr Surg 82:98
- Callia WEP (2012) Dermolipectomia abdominal. São Paulo: Carlos Erba. Claro F Jr, Figueiredo JC, Zampar AG, Pinto-Neto AM. Applicability and safety of autologous fat for reconstruction of the breast. Br J Surg 99(6):768–780. doi:10.1002/bjs8722
- Daher JC (1993) Breast Island flaps. Ann Plast Surg 30:217–223
- Deos MF (2009) Tensioned reverse abdominoplasty. Plast Reconstr Surg 12:2134–2141
- El-Mrakby HH, Milner RH (2002) The vascular anatomy of the lower anterior abdominal wall: a micro dissection study on the deep inferior epigastric vessels and the perforator blanches. Plast Reconstr Surg 109920:539–543
- Fischer M, Bark A, Loureiro ALRS, Pianowski R, Graf R, Grillo MA et al (2003) Estudo de Doppler fluxometria em retalho de abdominoplastia. ACM Arq Catarin Med 32(Supl 1): 173–178
- Gardner G, O’Rahilly (1967) Anatomy. Ed. Rio de Janeiro, Brazil: Guanabara Koogan, vol 8, pp 66–74; 40:407–422
- Hartrampf CR, Schefflan M, Black PW (1982) Breast reconstruction with a transverse abdominal island Flap. Plast Reconstr Surg 69:216–224
- Holstrom H (1979) The free abdominoplasty flap and its use in breast reconstruction. Scand J Plast Reconstr Surg 13:423
- Huger WE (1979) The anatomic rationale for abdominal lipectomy. Am Surg 45:612
- Illouz YG (1980) ne nouvelle technique pour les lipodistrophies localisées. Ver Chir Esthet 4:19
- Illouz YG (1992) A new safe and aesthetic approach to suction abdominoplasty. Aesth Plast Surg 16:237–245
- Inceoglu S (1998) Investigation of the effect of liposuction on the perforator vessels using color Doppler ultrasonography. Eur J Plast Surg 21:38
- Lewis JR Jr (1979) Use of a sliding flap from the abdomen to provide cover in the breast reconstruction. Plast Reconstr Surg 64(4):491–497
- Técnica LD, Luz D (2010) Tunelizações sucessivas: princípios aplicações e procedimentos complementares. DiLivro, São Paulo
- Matarasso A (1991) Abdominoplasty: a system of classification and treatment for combined abdominoplasty and suction-assisted lipectomy. Aesth Plast Surg 15:111
- Mathes SJ, Nahai F (1997) Reconstructive surgery. Principles, anatomy and technique. Churchill Livingstone and Quality Medical Publishing Inc, New York/St. Louis, USA
- Mélega JM, Viterbo F, Mendes FH (2011) Cirurgia Plástica os Princípios e a Atualidade. Guanabara Koogan, Rio de janeiro
- Munhoz AM, Ishida LH, Montag E, Sturtz G, Rodrigues L, Ferreira MC (2001) Perforator vessels anatomy and principal application in their inferior epigastric perforator (DIEP) flap. Kongs Verein Deutsch Plast Chirs 32(1):1–2
- Pitanguy I (1995) Abdominoplasty: classification and surgical techniques. Rev Bras Cir 85:23–44

- Rebello C, Franco T (1972) Abdominoplastia por incisão submamária. *Ver Bras Cir* 62:249–252
- Taylor GI, Palmer JH (1987) The vascular territories (angiosomes) of the body: experimental study and clinical applications. *Br J Plast Surg* 40(2):113–141
- Saldanha OR, Pinto EB, Matos WN Jr, Lucon RL, Magalhães F, Bello EM (2001) Lipoabdominoplasty without undermining. *Aesthet Surg J* 21(6):518–6
- Spalteholz W (1893) Die vertheilung der blutgefasse in der haut. *Arch Anatntwcklngs-gesch* 1:54
- Yacoub CD, Baroudi R, Yacoub MB (2012) Extended reverse abdominoplasty. *Rev Bras Cir Plast* 27(2):328–332



## Chapter 37

# Abdominoplasty: Pearls and Pitfalls

**Ithamar Nogueira Stocchero, Gustavo Flosi Stocchero,  
Guilherme Flosi Stocchero, and Alexandre Siqueira Franco Fonseca**

If the face is the full representation of the identity of humans, reflecting their age, feelings, and attitude toward circumstances, the abdomen is surely the body part that better shows the worry about aesthetics, physical aptness, healthy vanity, and even care about one's health.

Inadequacies in the aesthetics of this body area may originate from several factors, either genetic, weight related, or due to lack of physical activity. However, they are most frequently related to a history of pregnancies, which are events that lead to an increase in intra-abdominal pressure. The greater pressure exerted by the

---

I.N. Stocchero, MD (✉)

Department of Plastic Surgery, Centro Médico Viver Melhor, São Paulo, SP, Brazil

Hospital Santa Catarina, São Paulo, SP, Brazil

Sociedade Brasileira de Cirurgia Plástica, São Paulo, SP, Brazil

e-mail: [dr.ithamar@vivermelhor.com.br](mailto:dr.ithamar@vivermelhor.com.br)

G.F. Stocchero, MD, MBA

Department of Plastic Surgery, Centro Médico Viver Melhor, São Paulo, SP, Brazil

Sociedade Brasileira de Cirurgia Plástica, São Paulo, SP, Brazil

University of São Paulo Hospital, São Paulo, SP, Brazil

e-mail: [gustavo@vivermelhor.com.br](mailto:gustavo@vivermelhor.com.br)

G.F. Stocchero, MD

Department of Plastic Surgery, Centro Médico Viver Melhor, São Paulo, SP, Brazil

Sociedade Brasileira de Cirurgia Plástica, São Paulo, SP, Brazil

e-mail: [guilherme@vivermelhor.com.br](mailto:guilherme@vivermelhor.com.br)

A.S.F. Fonseca, MD, PhD

Department of Plastic Surgery, Centro Médico Viver Melhor, São Paulo, SP, Brazil

Sociedade Brasileira de Cirurgia Plástica, São Paulo, SP, Brazil

Plastic Surgeon at Instituto do Câncer do Estado de São Paulo, São Paulo, SP, Brazil

e-mail: [dr.alexandre@vivermelhor.com.br](mailto:dr.alexandre@vivermelhor.com.br)

pregnancy, together with hormonal alterations that promote tissue imbibition to facilitate abdominal distension, favors the changes that will result in projection, ptosis, and excess of tegument within the abdominal wall.

There are three factors that may be present in poor abdominal aesthetics, either isolated or combined. And it is these factors that will indicate the best treatment for each case. Excess fat will warrant liposuction, excess skin will require resection, and muscle laxity – or their separation (diastasis recti) – will need repositioning.

Abdominoplasty carries some apparently incoherent curiosities. Although it is a procedure that is subject to high rates of pitfalls and complications of either major or minor importance, it is also the plastic surgery which best keeps good results for longer periods, thus offering a satisfactory body contour for a long time. Another point to be noted is that, since it is often the first aesthetic procedure that women undergo, it is commonly performed in a moment when they are building their family structure. Therefore, the choice of a plastic surgeon will be made considering a budget that is compatible with this period. That makes abdominoplasty a procedure marked by certain difficulties in its postoperative evolution, by its great durability, and by being performed by surgeons starting their careers.

Despite the fact that it has been executed for 125 years since it was first done by Demars and Marx [1] and that it has undergone several modifications and improvements [2–8], we consider the classic surgery of abdominal dermolipectomy to be the one described and standardized by William Ermete Primo Callia [9, 10] in 1963, even though it has been altered ever since it was presented as his doctoral dissertation. Nevertheless, the aforementioned pitfalls and complications, which may be frequent, have led to the search for important technical changes which are now largely employed, such as the iconic changes idealized by Juarez M. Avelar [11–15] and their variations [16–18].

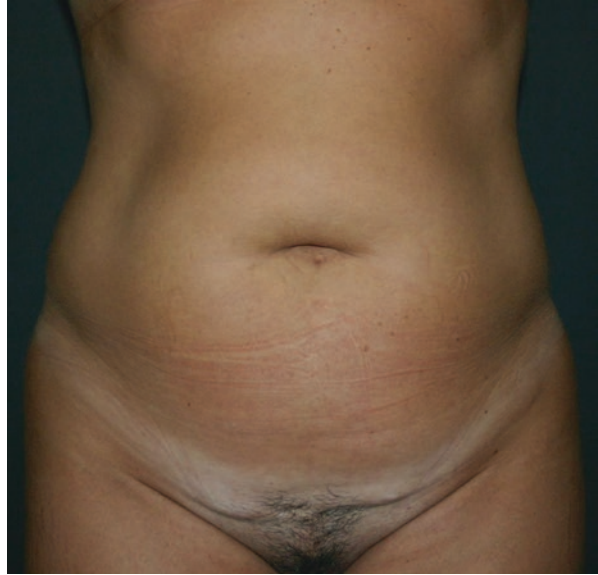## Choice of Surgical Technique

Notwithstanding the fact that the greatest source of nuisance for a patient is the skin apron that is usually present – sometimes hanging over the pubis and even the genitalia –, the ideal candidate for abdominoplasty is the one that presents with excess skin in the supraumbilical region, which will allow for tissue redraping down to a low point within the abdomen, thus leaving a more inconspicuous scar (Figs. 37.1 and 37.2).

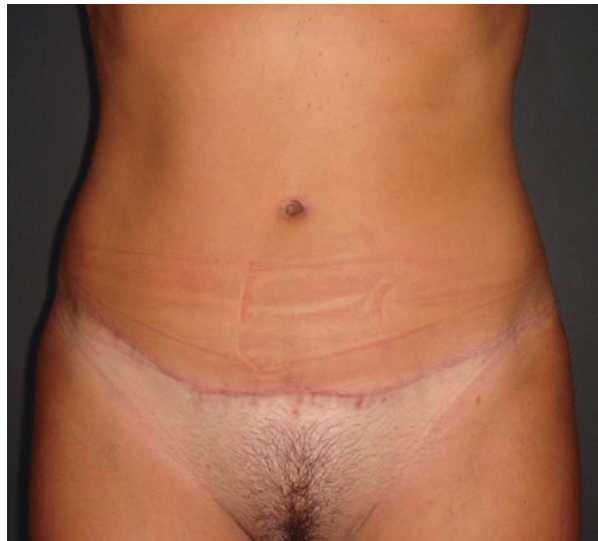Surgical outcome will be as better as is the quality of the patient's skin. Certainly, an excellent quality skin is usually linked to cases that do not need surgical treatment, requiring only liposuction, which is not the scope of this chapter [19].

Striae are the consequence of a rupture in the elastic fibers of the skin, leading to true intradermal scars, which limit harmonious traction of the skin. Alerting the patient about such limitation is relevant, although it is not a contraindication to abdominoplasty. Striae are usually more prevalent within the infraumbilical region, which facilitates their excision (Figs. 37.3 and 37.4).

**Fig. 37.1** Abdominoplasty before

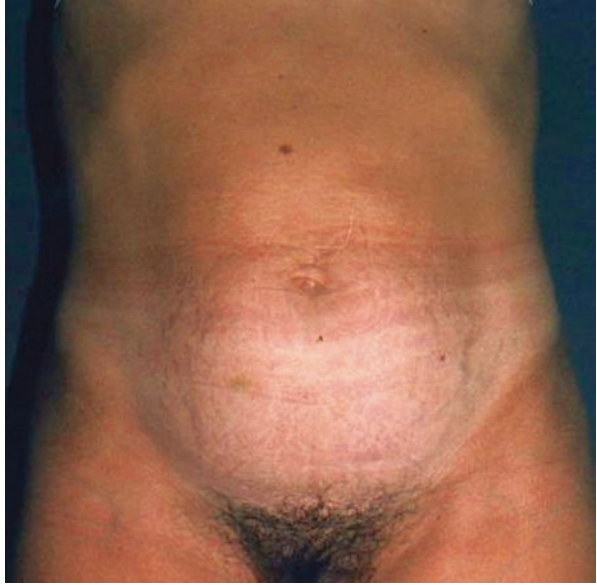

**Fig. 37.2** Abdominoplasty after

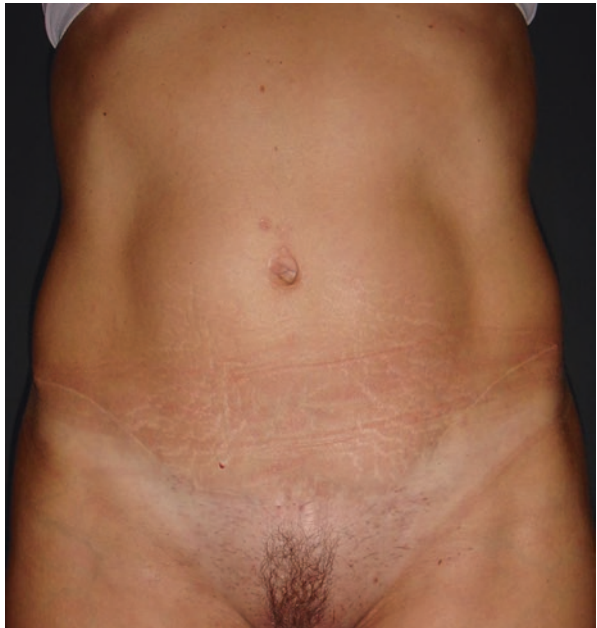

Pre-existing scars may limit the procedure, considering the risks involved in undermining. Even a small laparoscopy incision has already caused significant interference in the blood supply of the abdominal flap, originating relevant necrosis [20]. A method to show this vascular alteration is intraoperative photography. Flashlight can frequently make the subdermal plexus more clearly visible. This step should be a routine, given the accessibility of digital cameras, which may allow for an occasional correction of vascular deficiencies thus shown within the flap.

**Fig. 37.3** Striae before surgery

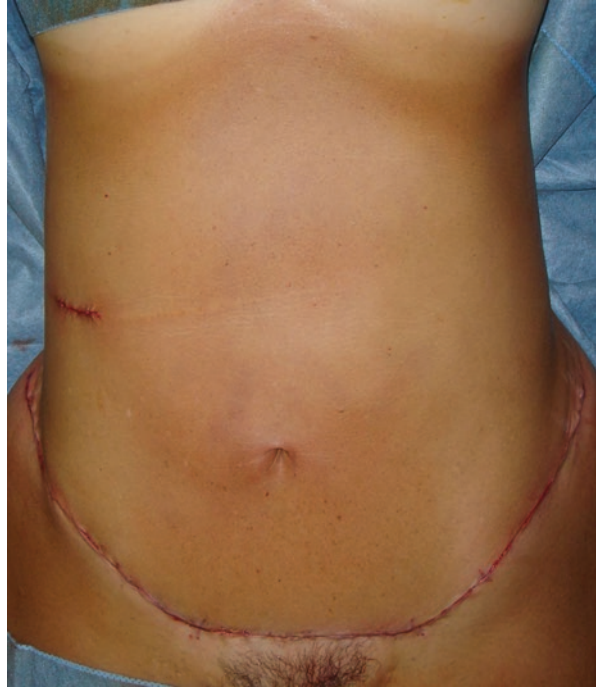

**Fig. 37.4** Striae 9 years after



When there is a lack of excess skin that would permit the redraping of the flap from the supraumbilical point down to the desired suprapubic point, the surgeon should not insist in pulling down the skin, due to the risk of serious complications – necrosis being the worst of them. In such cases, one choice is to resect the

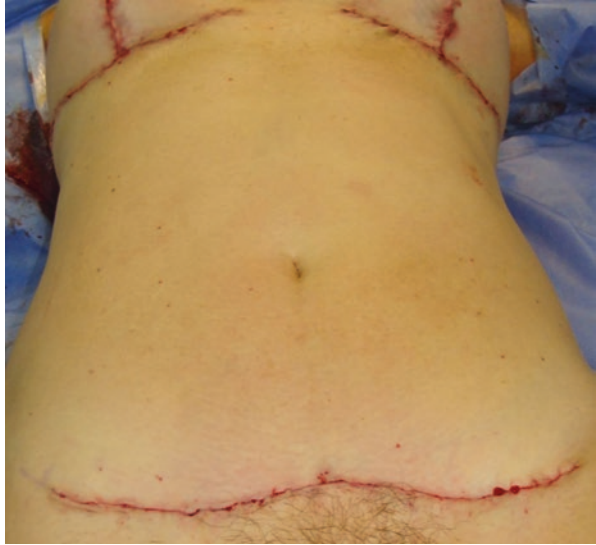
**Fig. 37.5** Umbilicus transposition



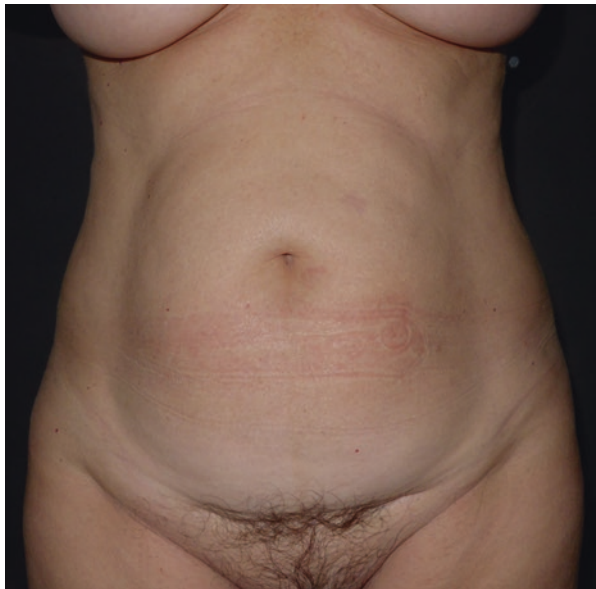caudal excess skin and, if necessary, transpose the umbilicus to a lower position (Fig. 37.5). It is important to note that the umbilicus is located at the midline, within a projection of the anterior superior iliac spines, with variations of 3 cm upward or downward, which allows for umbilical transposition. With this maneuver, excess skin within the inferior abdominal region will be treated. In case there is excess skin within the superior abdominal region, a reverse abdominoplasty may be warranted. That procedure will permit excision of the skin through the inframammary folds, which is highly prized when that surgery is associated with mammoplasties. It is important to preserve a septum that will be the anterior extension of the inframammary fold, hence preventing a low insertion of the breasts (Figs. 37.6, 37.7, and 37.8).

A very easy manner of marking the abdominal skin to avoid the need for lateral skin compensation is to demarcate the points where the abdominal fold starts, both to the left and to the right [8]. The patient should be in a sitting position and doing delicate lateral inclinations. Using a 40-cm flexible ruler, the midline is marked from the xiphoid process down to the vulvar commissure. After that, a second line is marked perpendicularly to the first one. Tan lines, pre-existing scars, or bikini bottoms preferred by the patient may be used as a reference. The second line is drawn bilaterally up to the points at which the tan lines, scars, or bikini sides end. The length of this line is measured and noted. Then, using the same ruler, a line is drawn starting at the initial point of the abdominal crease, running through the limit of the lateral mark and extending down to the midline

**Fig. 37.6** Superior and inferior abdominoplasty end of surgery



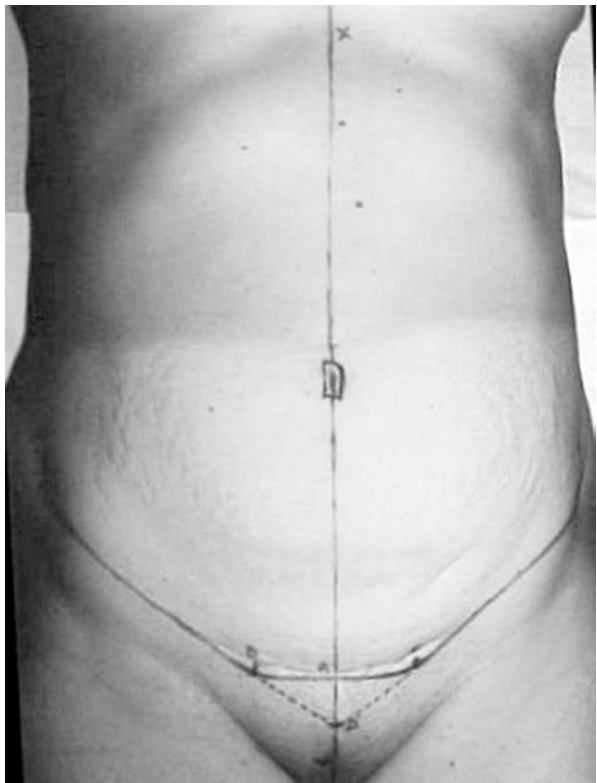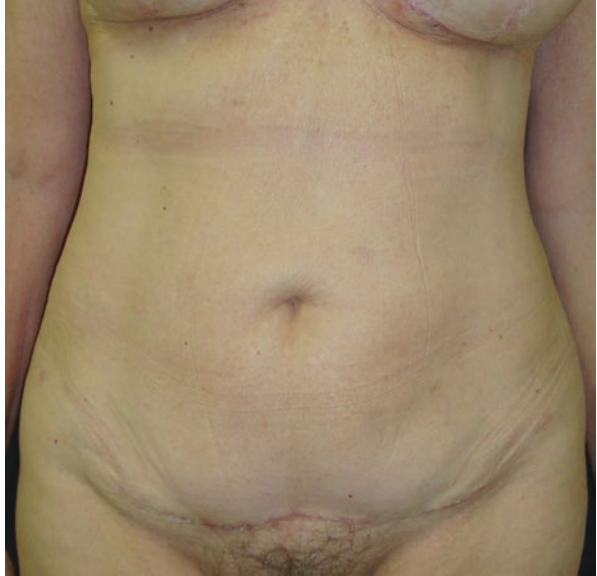**Fig. 37.7** Superior and inferior abdominoplasty before



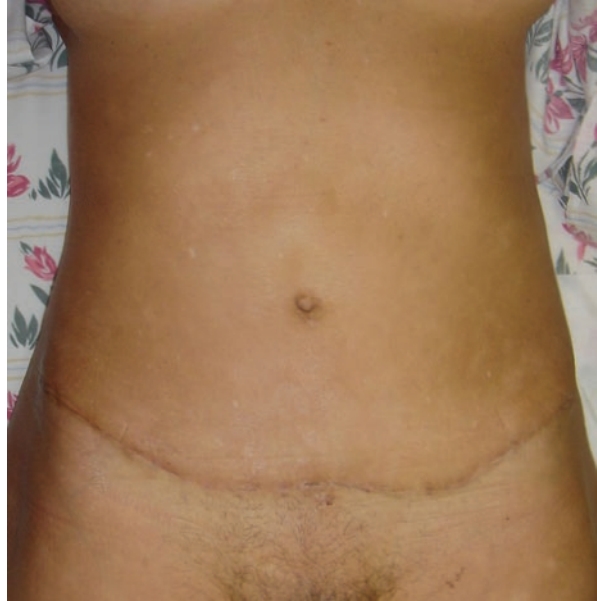above the pubis. The measure is then transferred to the other side. The length of the lateral branch is noted (Fig. 37.9).

Whenever there is an excessive or irregularly distributed panniculus, it should be treated with liposuction, leaving this layer uniform. It is very important to aspirate the hypochondrial and epigastric regions, where fat deposits are increased from the third decade on [21] (Fig. 37.10).

**Fig. 37.8** Superior and inferior abdominoplasty after



**Fig. 37.9** Markings

**Fig. 37.10** Good result

The skin is incised with a No. 22 blade, following the “bicycle handlebar” pattern drawing, leaving fat in the pubic region with a cranially inclined beveled shape, in order to avoid any depressions that might occur due to a lack of supraumbilical fat after the flap is redraped. If supra-aponeurotic dissection is chosen, it will be performed using a scalpel to prevent excessive use of electrosurgery. The undermining is carried out up to the xiphoid process, extending laterally just enough to accommodate the flap. Occasionally, the surgeon may forgo the undermining of the supra-aponeurotic fat.

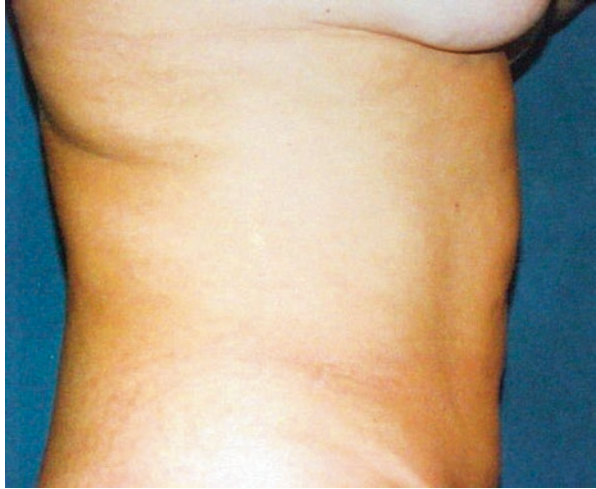When diastasis recti are present, it should be corrected by plication with sutures extending from the xiphoid process down to the pubis. Inadequate supraumbilical approximation of the muscles will lead to a “turkey gobbler” aspect, which will require reintervention (Figs. 37.11 and 37.12). There are cases in which plication of lax areas of the aponeuroses – either parallel or perpendicular to the greater axis of the abdomen – may be useful to achieve the desired contour, creating a firm base over which the dermal fat flap will be pulled down and redraped.

The umbilicus, which is normally circumcised in most techniques, leaves a stigma of the surgery that may be avoided by employing a neoumbilicus, which will be defatted and fixed to the aponeurosis with three sutures in a triangular fashion, in order to simulate the original umbilical grooves. A fixation suture is exteriorized through the skin by its central point and tied over sterile gauze pads, thus promoting an inflammatory reaction that will improve the aspect of the neoumbilicus [22] (Figs. 37.13, 37.14, and 37.15).

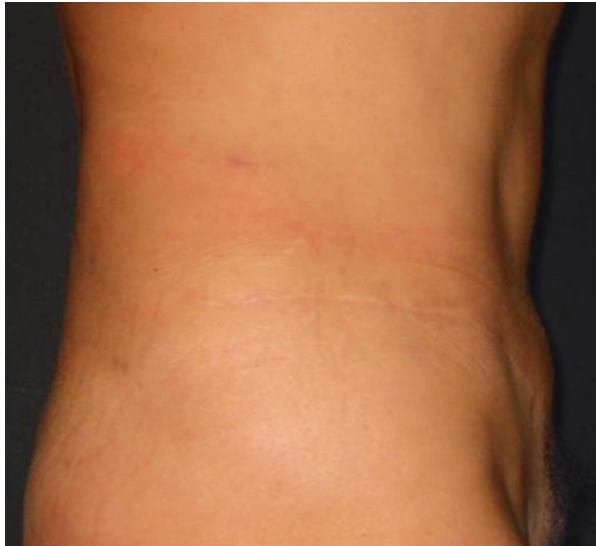With the patient preferably placed in a horizontal position, or using the least flexion possible, the abdominal flap is pulled down and sutured at its midpoint to the suprapubic border and then is harmoniously distributed with the purpose of not leaving dog ears. Measures previously taken in the initial demarcation are then



**Fig. 37.11** Turkey gobbler before

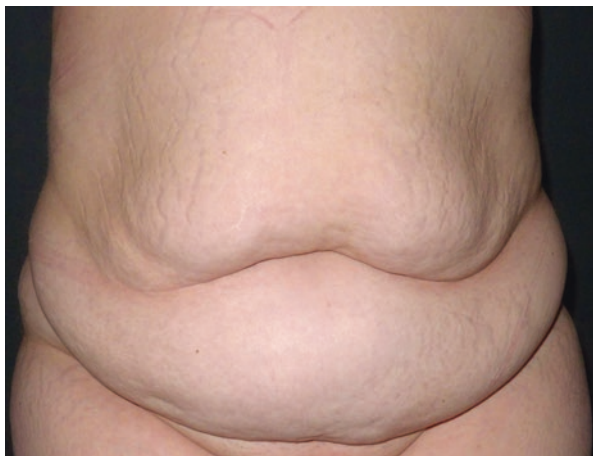

**Fig. 37.12** Turkey gobbler after

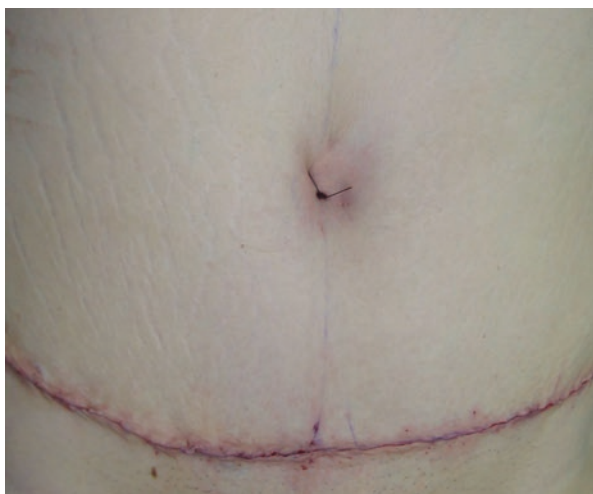


transferred. Care should be taken with incisions so that the panniculus is kept with a proper thickness over the beveled fat pad initially designed. Suturing the flap fat to the aponeurosis is an individual option [23, 24] (Millan RB, 1979, Personal communication; Millard DR, Jr, 1981, Personal communication), as is the use of suction drains [25]. A useful step for eliminating residual blood pools that may be present after flap dissection is to place two or three large-bore cut venous catheters under the undermined flap, exteriorize them through the skin at the pubic region, and pad them with sterile gauze pads. This will facilitate blood drainage in the postoperative period, when associated with a semirecumbent position of the patient [20].

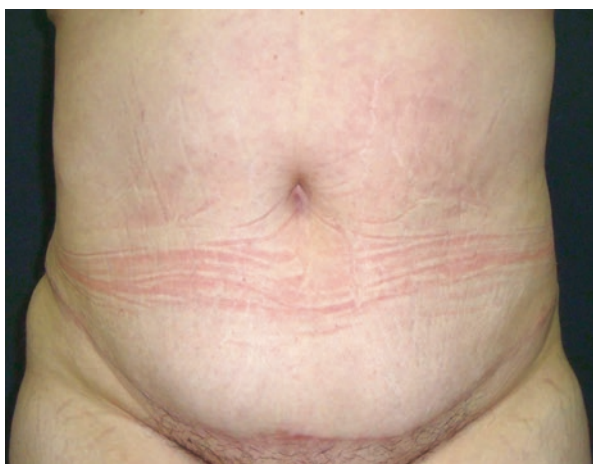**Fig. 37.13** Neo umbilicus before



**Fig. 37.14** Neo umbilicus end of surgery



**Fig. 37.15** Neo umbilicus 6 month after



Cushioned dressing pads are placed over the sutures and secured with elastic adhesive bandages, using moderated compression. The dressings are removed after 4 days, when the first ultrasound exam will be performed, in order to search for any preaponeurotic collections of liquid [26–31]. Such evaluation, first published by the senior author, is carried out every 3–4 days and, if any seromas are detected, they are readily aspirated, using ultrasound guidance.

The incisions are taped with microporous adhesive tape and thus kept for 6 weeks, to protect wounds against traction.

Overly tight compression garments should be avoided, since they can produce folds in the skin, which may hinder blood supply to the flap and, above all, difficult venous drainage. It is better to not employ any compression than impair blood flow, which is already diminished due to the interruptions imposed by the long transverse incision, together with the possible sections of perforators.

Restricting abrupt movements that involve the abdomen within the first ten postoperative days is important to avoid shear stress over neofomed vessels that result from inosculation, which occurs in the postoperative period. Such friction might rupture the vessels, hence promoting bleeding and, consequently, generating hematomas, collections of lymph, and, possibly, seromas.

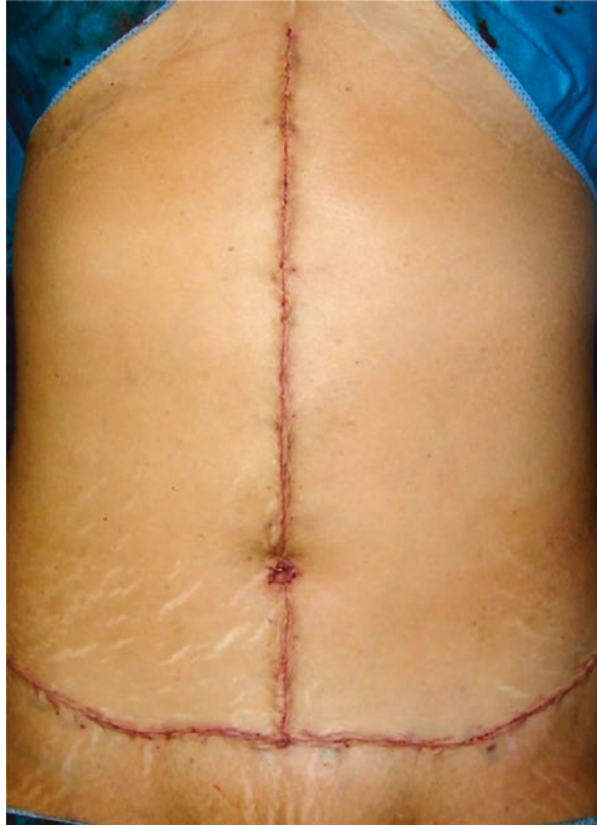Refraining from smoking for at least 5 days after surgery may be relevant, since the strong vasoconstrictive effects of nicotine can interfere with blood flow in smaller-bore vessels, leading to tissue necrosis.

In a few words, a successful abdominoplasty depends on good preoperative assessment, considering the diversity of surgical techniques available, preventing complications as much as possible<sup>m</sup>. When planning for surgery in patients after massive weight loss, it must be emphasized that these patients undergo an increase in vessel diameter, which persists after weight loss. Special care should be taken regarding hemostasis. Besides, patients with a history of bariatric surgery may present with nutritional deficiencies (protein and/or iron depletion) as well as abnormal blood counts and coagulation tests (Fig. 37.16).

## Summary

1. Do not try to do more than what is safely indicated.
2. Avoid unnecessary undermining. Preserve flap blood supply.
3. Avoid excessive traction over the flap.
4. Diagnose seromas early and fully treat them, thus preventing chronification, which will lead to bursae formation, a condition that is harder to treat. A persistent seroma may be related to high levels of serum prolactin. Once this condition is treated, seromas will tend to resolve.
5. The use of sequential compression devices during surgery is recommended, especially in patients older than 30 years.
6. It is important to preoperatively discuss with the patient about the possibility of a second procedure, in order to achieve better aesthetic results. It is better to perform two safe procedures than a single one that may carry higher risks.

**Fig. 37.16** After bariatric surgery



## References

1. Andrade P, Prado A, Danilla S, Guerra C, Benitez S, Sepulveda S, Sciarraffa C, De Carolis V (2007) Progressive tension sutures in the prevention of postabdominoplasty seroma: a prospective, randomized, double-blind clinical trial. *Plast Reconstr Surg* 120(4):935–946
2. Avelar JM (1999) A new technique for abdominoplasty – closed vascular system of subdermal flap folded over itself combined to liposuction. *Ver Bras Cir* 88/89(1/6):3–20
3. Avelar JM (2000) Abdominoplastia – Uma Nova Técnica sem Descolamento e sem Ressecção do Panículo Abdominal. *Arquivos Catarinenses de Medicina* 29(Supl 1):147–149
4. Avelar JM (2006) Abdominoplasty combined with lipoplasty without panniculus undermining: abdominolipoplasty – a safe technique. *Clin Plast Surg* 33(1):79–90
5. Avelar JM (2002) Abdominoplasty without panniculus undermining and resection: analysis and 3-year follow-up of 97 consecutive cases. *Aesthet Surg J* 22(1):16–25
6. Avelar JM (2002) Abdominoplasty without panniculus undermining. Editora Hipócrates, São Paulo, pp 123–136
7. Baroudi R, Ferreira CAA (1998) Seroma: how to avoid it and how to treat it. *Aesthet Surg J* 18(6):439–441
8. Bercial ME, Sabino Neto M, Calil JA, Rossetto LA, Ferreira LM (2012) Suction drains, quilting sutures, and fibrin sealant in the prevention of seroma formation in abdominoplasty: which is the best strategy? *Aesthet Plast Surg* 36(2):370–373
9. Bozzola AR (1988) Abdominoplastias. In: Mélega JM, Zanini AS, Psillakis JM (eds) *Cirurgia Plástica Reparadora e Estética*. Medsi, Rio de Janeiro, pp 801–818

10. Callia WEP (1963) Contribuição para o Estudo da Correção Cirúrgica do Abdome em Pêndulo e Globoso. Técnica Original. Tese de Doutorado apresentada à Fac. Med. Univ., São Paulo
11. Callia WEP (1965) Dermolipectomia Abdominal (Operação de Callia). Monografia, Dis Fac. Med. Univ, São Paulo
12. D'Assumpção EA (1982) Três Complicações Comuns em Abdominoplastia: Infecção, Deiscência e Seroma. In: Anais do Simpósio Brasileiro de Abdominoplastias. Soc. Bras. Cir. Plástica, São Paulo, pp 77–82
13. Demars M, Marx M (1890) Surgical treatment of obesity. *Proges' Med* 11:283
14. Di Martino M, Nahas FX, Barbosa MVJ, Ayaviri NAM, Kimura AK, Barella SM, Novo NF, Ferreira LM (2010) Seroma in lipoabdominoplasty and abdominoplasty: a comparative study using ultrasound. *Plast Reconstr Surg* 126(5):1742–1751
15. Farkas JP, Kenkel JM, Hatf DA, Davi G, Truong T, Rohrich RJ, Brown SA (2007) The effect of blood pressure on hematoma formation with perioperative lovenox in excisional body contouring surgery. *Aesthet Surg J* 27(6):589–593
16. Fonseca ASF, Stocchero GF, Araujo CAL (2014) Neo onfaloplastia em Cirurgia de Reconstrução Mamária com Retalhos Abdominais, in 51º Congresso Brasileiro de Cirurgia Plástica, Costa do Sauípe, BA, de 12 a 16 de novembro de 2014
17. Grazer FM, Goldwyn RM (1977) Abdominoplasty assessed by survey, with emphasis on complications. *Plast Reconstr Surg* 59(4):513–517
18. Hönig JF (2008) Abdominoplastik Prinzip und Technik. Ed. Springer, Darmstadt
19. Illouz YG (1980) Une Nouvelle Technique pour les Lipodystrophies Localisées. *Rev Chir Esthet* 6:9–14
20. Jaouen R (2011) Evidence-based approach to seroma. *Plast Reconstr Surg* 128(2):607–608
21. Lima JC (1993) Abdominoplastia Sob Anestesia Peridural, Anestesia Loco – Regional em Cirurgia Estética. Editora Hipócrates, São Paulo, pp 314–325
22. Matarasso A, Belsley K (2005) Abdominal contour procedures, evaluating the options. *Dermatol Clin* 23:475–493
23. Matarasso A et al (1995) Liposuction as an adjunct to a full abdominoplasty. *Plast Reconstr Surg* 95(5):829–836
24. Mélega JM (1982) Tromboembolismo como Complicação da Abdominoplastia: Etiologia, Profilaxia e Tratamento. In: Anais do Simpósio Brasileiro de Abdominoplastias. Soc. Bras. Cir. Plástica, São Paulo, pp 73–76
25. Nahas FN, Ferreira LM, Ghelfond C (2007) Does quilting suture prevent seroma in abdominoplasty. *Plast Reconstr Surg* 119(3):1060–1064
26. Nurkim MV et al (2002) Incidence of hematoma and seroma in abdominoplasty with and without the use of drains. *Rev Soc Bras Cir Plast* 17(1):69–74
27. Pitanguy I (1977) Dermolipectomy of the abdominal wall, thighs, buttocks, and upper extremity. In: Converse JM (ed) *Reconstructive plastic surgery*, 2nd edn. Saunders, Philadelphia, pp 3800–3823
28. Pontes R (1982) Plástica Abdominal – Resultados Insatisfatórios. In: Anais do Simpósio Brasileiro de Abdominoplastias. Soc. Bras. Cir. Plástica, São Paulo, pp 47–51
29. Stocchero IN (1996) Abdominoplastia: Conceito, Sistematização, Complicações. In: Tournieux AB, Curi MM (eds) *Atualização em Cirurgia Plástica II*. Robe, São Paulo, pp 431–436
30. Stocchero IN (2002) Complications in traditional abdominoplasty. In: Avelar JM *Abdominoplasty without panniculus undermining*. Editora Hipócrates, São Paulo, pp 123–136
31. Stocchero IN (1993) Ultrasound and seromas (brief communication). *Plast Reconstr Surg* 91(1):198
32. Stocchero IN (1992) Ultrasound: a valuable aid for diagnosis and management of seromas. *Rev Soc Bras Cir Plast* 7(1–3):108–114
33. Stocchero IN, Ex-Mohammad JA et al (1998) Ultrasound in the diagnosis and management of fluid collection complications following abdominoplasty. *Ann Plast Surg* 41(5):498–502
34. Sucena RC (1982) Dermolipectomias abdominais. In: Sucena RC (ed) *Cirurgia Plástica*. São Paulo, Roca, pp 1137–1153
35. Thorek M (1953) Operación para el abdomen péndulo. In: Thorek M (ed) *Técnica Quirúrgica Moderna*. Salvat, Barcelona, pp 1740–1741
36. Zimman OA (2001) Frequency of seroma in abdominal lipectomies. *Plast Reconstr Surg* 108(5):1449–1451

# Chapter 38

## Complications During and After Abdominoplasties

Paulo Roberto de Sousa Jatene and Maria Cristina Vargas Jatene

### Introduction

The harmony of body contouring is predominantly influenced by the aesthetics of the abdomen. So abdominoplasty is one of the most frequently performed aesthetic procedures in the world. However, the complication rate is considered greater than that of other aesthetic surgeries [10]. It is important to emphasize that, despite the technical developments in the last 50 years, the basic pillars of the technique remain unchanged. They are extensive detachment, resection of skin and subcutaneous, plication of aponeurosis of muscles, and umbilicus transposition.

Even if there has been a marked decrease in the score of complications, severe complications are still reported emphasizing the urgent need of caution and intensification of security measures. In this scope, complications resulting from abdominoplasties range from dissatisfaction with the result, prolonged convalescence, unexpected expenses, and physical and psychological suffering, until the occurrence of a lethal outcome. Such failures usually culminate in litigation and arbitrations in justice, extremely taxing event for everyone involved. However, many of the complications that occurred show they are not preventable and, once established, they be treated and solved in an efficient way.

In 1999, a new technique of abdominoplasty was described by Avelar, when was associated to the liposuction, the tuck technique. There was the least detachment of

---

P.R. de Sousa Jatene, MD (✉)

Member of the Brazilian Society of Plastic Surgery, Avenida Angélica,  
2530/cj 21 Higienópolis, São Paulo, SP CEP 01228-200, Brazil  
e-mail: [paulojatene@uol.com.br](mailto:paulojatene@uol.com.br); <http://www.paulojatene.com.br>

M.C. Vargas Jatene, MD

Master of Science of Anesthesiology, Pain Management Specialist,  
Avenida Angélica, 2530/cj 21 Higienópolis, São Paulo, SP CEP 01228-200, Brazil

the abdominal panniculus, preserving the local blood supply, which, in our view, has greatly contributed to the technique, minimizing much of postoperative complications, such as the occurrence of seroma and necrosis [2]. Therefore, the description of this method incurred an advent of lipoabdominoplasty, considered a great development of this technique.

It is essential to highlight that the anesthetic procedures used in abdominoplasty can also result in complications inherent to the technique. The most used methods are the spinal anesthesia (spinal or epidural) and/or general anesthesia. The spinal anesthetics have advantages over general events [12], and these propitiate better handling of postoperative pain favoring the early ambulation that is also a thromboembolism prevention factor.

## Method

The complications resulted from the abdominoplasty are widely commented and are subject to analysis under the scrutiny of several publicist services. In 2005, we disclose a study of the complications arising from the abdominoplasties, related to our casuistry, in a comparative study with world literature [5]. However, in this presentation, it is an approach most emblematic case and collected from our clinical experience, enriched with the casuistry of other services that kindly gave their data to us. Thus, based on the compilation made, we present the following results.

## Results

The global literature is unanimous in pointing out the most common complications of abdominoplasty: in Table 38.1 we see the rate of intraoperative complications, which are classified as related to anesthesia and surgery; in Table 38.2 we see the postoperative complication rate, which is classified into major and minor [7]. In Table 38.3, we have a discrimination of postoperative complications, and their incidence is referred to in the global literature, in relation to the total abdominoplasties performed [8].

**Table 38.1** Intraoperative complications

Referring to the anesthesia (0.2–26 %)	Drug interactions Clinical changes arising from previous diseases such as heart diseases, pneumopathy, blood dyscrasias, previous hydro-electrolytic abnormalities, allergies, etc. Complications resulting from the use and/or excessive absorption of local and/or systemic anesthetics Technical mistakes
Referring to surgery (0.8–30 %)	Excessive bleeding Excessive surgical time Excessive plication of the rectus abdominis

**Table 38.2** Major and minor postoperative complications

Complications	Incidence
Major	10.3–10.9%
Minor	40.1–43.2%

**Table 38.3** Postoperative complications

Complications	Incidence
<i>Major complications</i>	<i>Percentage</i>
Deep vein thrombosis	0.2–1.2%
Systemic infection	0.4–0.9%
Hematoma	10.0–22.2%
Wall dehiscence	0.9–1.6%
Tissue necrosis	0.2–1.0%
Death	0.2–0.7%
<i>Minor complications</i>	<i>Percentage</i>
Seroma	5.0–25.0%
Small dehiscences	16.0–41.0%
Local infection	0.5–6.2%
Unsightly scars	4.0–22.0%

## Discussion

Complication is any unexpected event that adversely affects the outcome of the procedure, as it slows the recovery or brings the need for additional procedures to correct the problem. Under the medical-surgical perspective, it is meaning and it is embracing an make it clear that every episode is harmful and unexpected; even under careful and diligent technique it occurs, oblivious to the fault or will of the agent and the complication can me from any the complication cam come from type of procedure.

As noted earlier, the complications can be classified as:

- Intraoperative complications:
  - From surgical procedures
  - Resulting from anesthesia
  
- Postoperative complications:
  - Major
  - Minor

It should be noted that minor complications are understood as those which are treated properly, resulting in a satisfactory outcome, leaving hardly any stigma.

However, the major complications consist of those that cause further stigma or cause risk to life, even leading to a lethal outcome.



Despite of technical advances in the technique of abdominoplasties, many complications still result from these aesthetic surgeries. As mentioned before, morbidity and mortality rates remain unacceptably high, even being lower when compared to the incidence reported in general surgery [13]. Especially when we approach the postoperative complications, catches the eye the rate of complications, since the aim of aesthetic procedure performance is precisely the improvement of the appearance. In this sense, in order to improve the technique, we put into discussion a number of complications of abdominoplasties, which appear as the most emblematic ones in our casuistry series and other professionals, who kindly gave up their data for this report.

Therefore, among the most representative, we will mention a few examples of *minor postoperative complications*, since those related to immediate care dressings, even those alluding to scarring complications, namely, the presence of epidermal bubbles due to the use of adherent dressing; small suture dehiscence, unsightly scars( enlarged, hypertrophic, asymmetrical, misplaced).

*Among the major postoperative complications*, we will mention large abdominal wall necrosis, umbilicus necrosis, large wall bruising, and extensive seroma, with formation of pseudo-bursa, thromboembolic events, and death.

#### A. *Minor postoperative complications*:

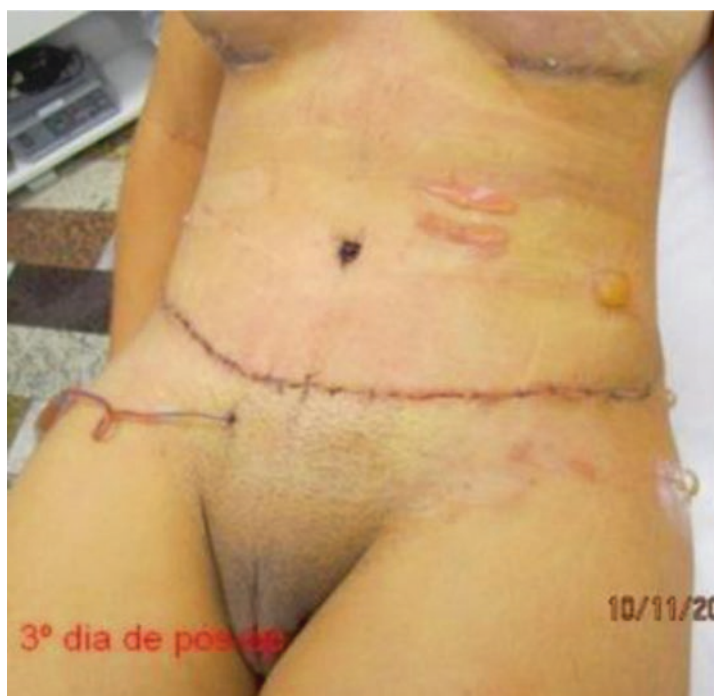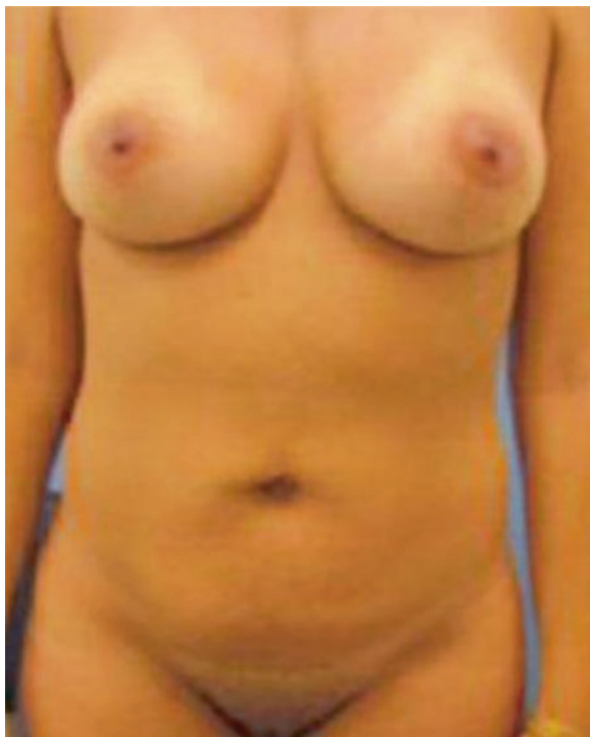1. *Epidermal bubbles due to adherent dressing sensitivity* under discussion, the 38-year-old patient had umbilical hernia and diastasis of rectus abdominis muscles (see Fig. 38.1).

Surgical correction for abdominoplasty went properly and the result was satisfactory. But in the immediate postoperative period, the patient presented epidermal bubbles due to the sensitivity of skin to adherent dressing used (micropore) (see Fig. 38.2). The lesions were treated as second-degree burns, and they showed good recovery without sequelae: however, they represented a source of extreme discomfort to the patient and great concern to the medical staff.

2. *Small suture dehiscence*: they can occur due to stress or local infection of operative wound antibiotic therapy, especially in cases of tummy tuck, where there is extensive detachment of tissues (Fig. 38.3).
3. *Unsightly scars (enlarged, hypertrophic, uneven, poorly positioned)*:

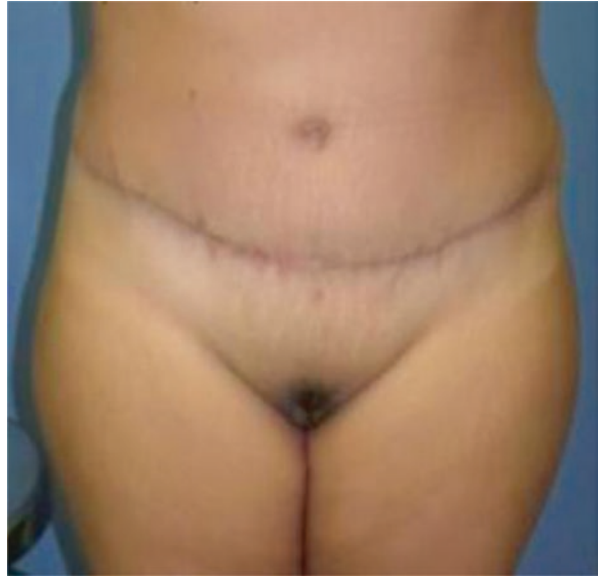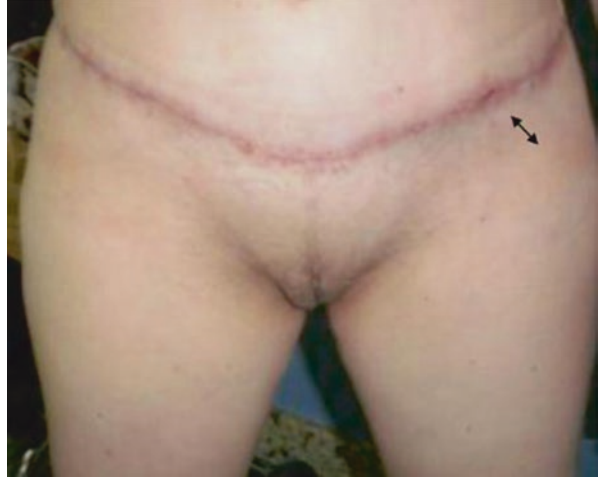The unsightly scars may occur by infection (often subclinical occurrence), local excess sutures, presence of necrotic material, dead space in the suture region, or individual organic reaction (keloid scars). Asymmetric unsightly scars often occur after seroma or hematoma drainage postoperatively, especially after repetitive drainages, which cause fibrosis and retraction of the dermo-skin flap to cranial portion giving an unpleasant aspect to the scarring. The treatment of unsightly scars consists of resection and new suture. In cases of keloid reactions, the postoperative beta therapy is indicated (Figs. 38.4 and 38.5).

**Fig. 38.1** Patient preoperative carrier of umbilical h ernia and diastasis of rectus abdominis muscles

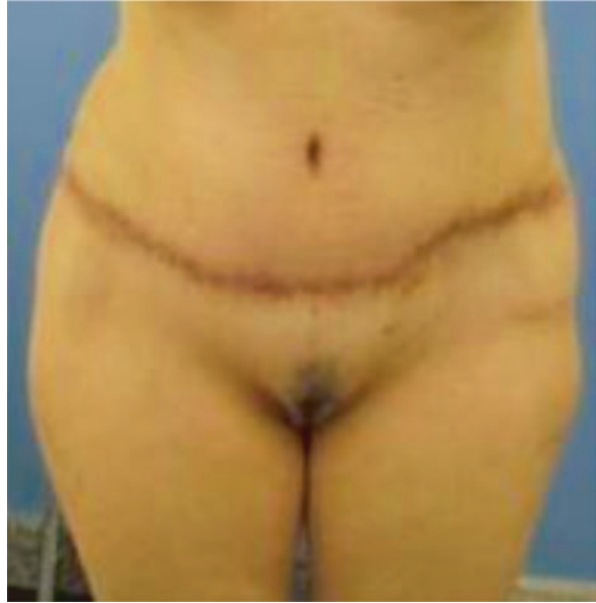

**Fig. 38.2** Epidermal bubbles in postoperative abdominoplasty, due to sensitivity of the skin to adhesive dressing (micropore)

**Fig. 38.3** Small suture dehiscence



**Fig. 38.4** Unsightly scar

**Fig. 38.5** Asymmetric scar

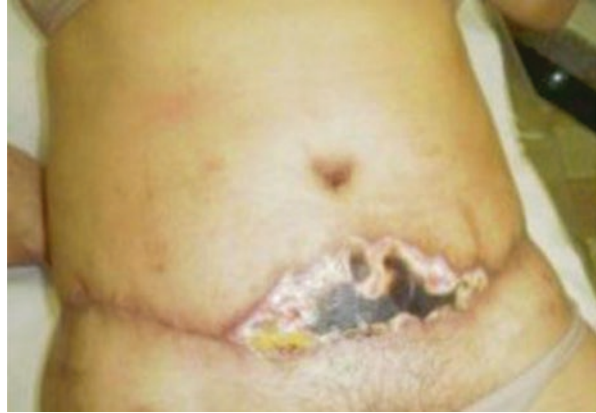*B. Major postoperative complications:*

1. Great necrosis of abdominal wall: the main factors liable to lead to skin and surrounding tissue necrosis are listed below.
  - Excessive tension of the abdominal flap
  - Previous liposuction in abdominal region
  - Large bruises
  - Loads of seroma
  - Localized infections
  - Smoking
  - Combinations of one more factor reported above

*Detailed*

A detailed medical history is of fundamental importance in preventing necrosis. Factors such as smoking and previous liposuction must be questioned since these elements are crucial in the evaluation of the integrity of local vascularization. The use of medication such as anticoagulants and antiplatelet adhesive should be discussed, since they can cause bleeding and large bruises, leading to distension and pain of the skin flap. The seroma, frequent occurrence in abdominoplasties, can also cause distension of tissues and impaired vascularization with subsequent tissue necrosis. Being of idiopathic etiology, prevention of seroma is practically impossible. The current recommendation would be to avoid manipulation of the abdominal wall tissues at the time of surgery.

**Fig. 38.6** Abdominal wall necrosis



The decrease in the vascularization of the dermal flap leads to the devitalization of the tissues and growth of microorganisms that cause infection and can lead to septicemia and death.

On the other hand, localize or systemic infection is also the cause of wall necrosis. This can be treated with the prophylactic use of broad-spectrum antibiotics.

Therefore, these would be some of the measures recommended to prevent this catastrophic adverse event, which is the abdominal wall necrosis (see Fig. 38.6).

Treatment of necrosis comprises antibiotic therapy, cicatrization by secondary intention, and new surgical approach for resection of unsightly scar arising.

However, one should pay attention to the quality of local vascularization before surgical rapprochement.

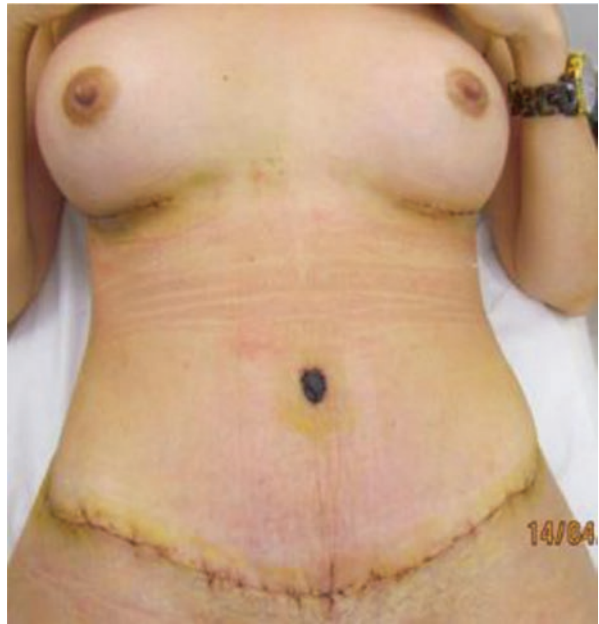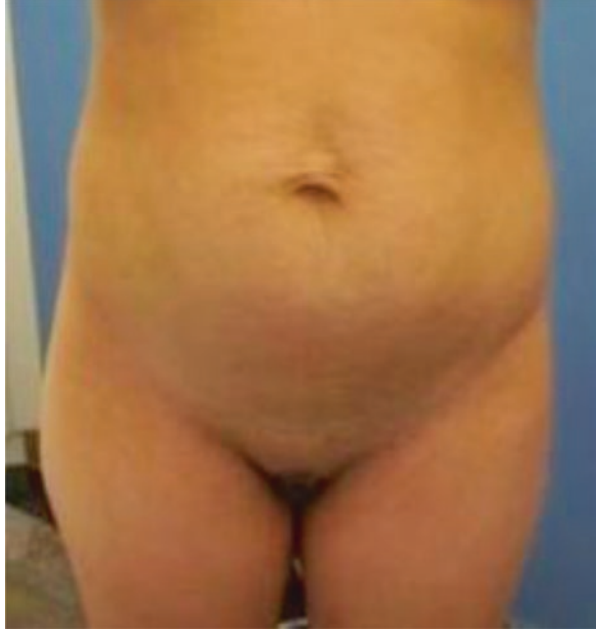2. *Necrosis of the umbilicus*: they frequently occur in cases of simultaneous correction of umbilical hernia. The treatment of umbilical hernias associated with abdominoplasty is a challenge for the plastic surgeon.

The umbilicus has the characteristic inherent to any other scar, which is scarce local vascularization. Thus, the great detachment resulting from abdominoplasty, coupled with strong sutures required for hernial restraint, causes important changes in circulatory demand and can lead to necrosis (see Figs. 38.7 and 38.8).

Treatment of umbilical necrosis involves carrying out neo-onfaloplastias.

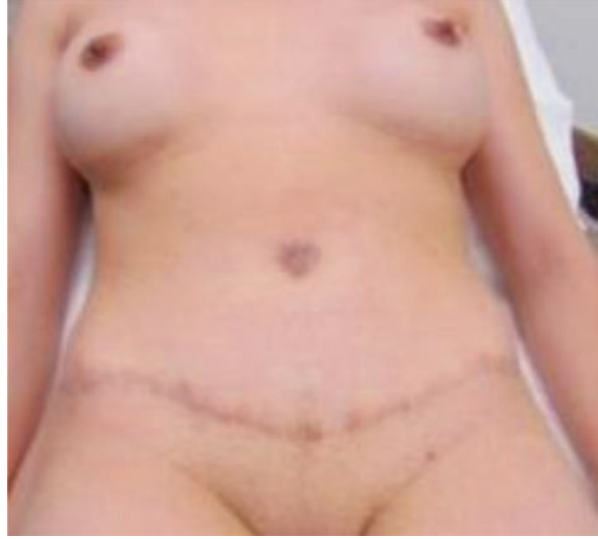According to the reconstruction techniques described by Avelar [3], we can reconstruct the region harmoniously, without damage to the abdominal aesthetics (see Figs. 38.7 and 38.9).

**Fig. 38.7** Preoperative umbilical hernia and diastasis of rectus abdominis



**Fig. 38.8** Umbilicus necrosis

**Fig. 38.9** Umbilicus after neo-onfaloplastia



### 3. *Large abdominal wall hematoma:*

The large abdominal wall hematoma resulting from abdominoplasties can occur due to inefficient local hemostasis or coagulation changes, as well as the occurrence of hypertensive crises in the postoperative period. It is known that the use of antiplatelet and anticoagulants should be discontinued before surgery: otherwise severe bleeding will occur and, postoperatively, cause a large proportion of bruises. According to Kaplan (2007) [6], there are also some antidepressants which cause changes in blood clotting or coagulation; question patients about the use of these drugs and establish interdisciplinary conduct with the head psychiatrist, regarding the possibility of suspension or substitution of the drug in the preoperative and immediate postoperative period.

It is very important to be careful in the immediate postoperative period, as the appearance of episodes of hypotension, tachycardia, paleness, and fainting (lipothymia unmistakable signs of acute anemia). If they occur, laboratory tests (hemoglobin, hematocrit) are indicated for tracking blood loss. If severe anemia and instability of the hemodynamic parameters are found, image studies are indicated. Among them, the most trusted for the wall hematoma diagnosis is computed tomography. Diagnosed wall hematoma, coupled with hemodynamic instability, in addition to volemic replacement by blood transfusions, it is mister surgical rapprochement and hemostatic review. It should be emphasized that evering cases of low blood flow by abdominal vacuum drain, whose use is recommended by many authors, one cannot rule out the occurrence of wall hematoma that is often found in collections with clots, which are not eliminated by draining. Therefore, the clinical parameters, in

this case, are necessary for tracking the complication which must be treated quickly, since it can lead to hemorrhagic shock and death.

4. *Extensive seroma with resulting formation of pseudo-bursa.*

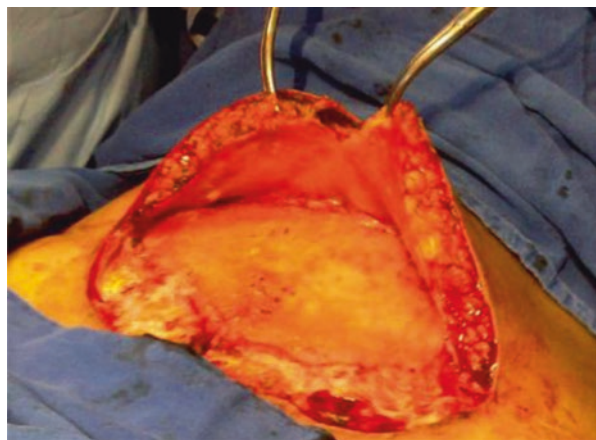
The seroma seems like one of the most frequent complications in abdominoplasties (5–25%) [8]. They are of idiopathic occurrence and self-limited with spontaneous resolution in a few weeks. However, exceptions can occur with extensive and long-term seroma, creating a dead space, which causes the formation of a capsule or *pseudo-bursa* [11].

In the case presented here, a 27-year-old patient presented seroma of major and difficult treatment, which lasted for months, when it was diagnosed the occurrence of pseudo-bursa by ultrasound. The treatment of this complication consists of surgical approach and removal of the capsule. In this case, the complete excision of the capsule was impossible once it stretched across the entire abdominal wall (Fig. 38.10). Therefore, its partial resection was performed and the remainder underwent a local scarification, for the purpose of subsequent adhesion of the flap to the muscle levels (Fig. 38.10).

Consequently, the treatment had a satisfactory outcome (Fig. 38.10).

In the case presented here, a 27-year-old patient presented seroma of major and difficult treatment, which lasted for months, when it was diagnosed the occurrence of pseudo-bursa by ultrasound. The treatment of this complication consists of surgical approach and removal of the capsule. In this case the complete excision of the capsule was impossible once it stretched across the entire abdominal wall (Fig. 38.10).

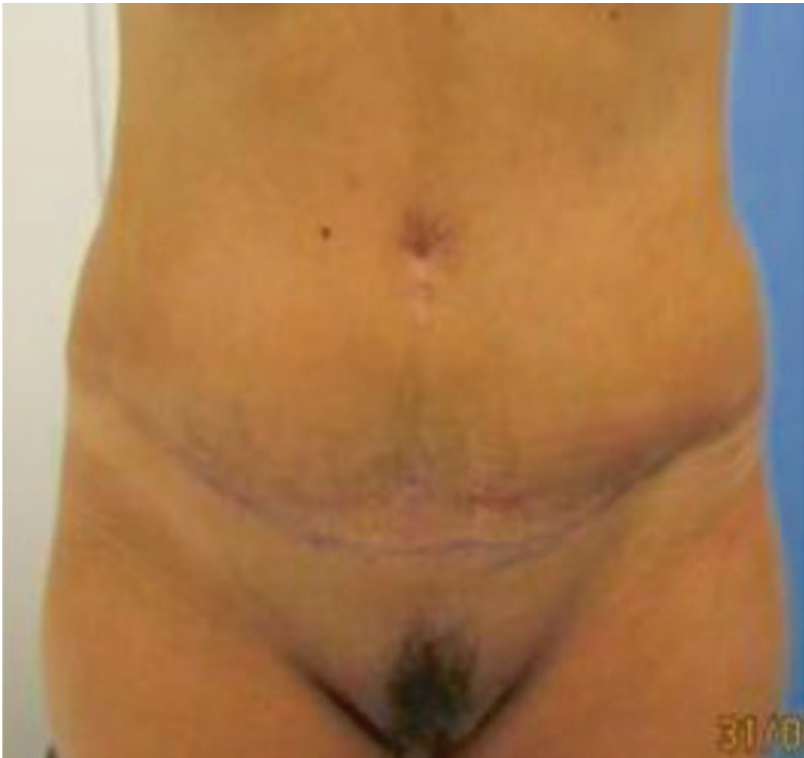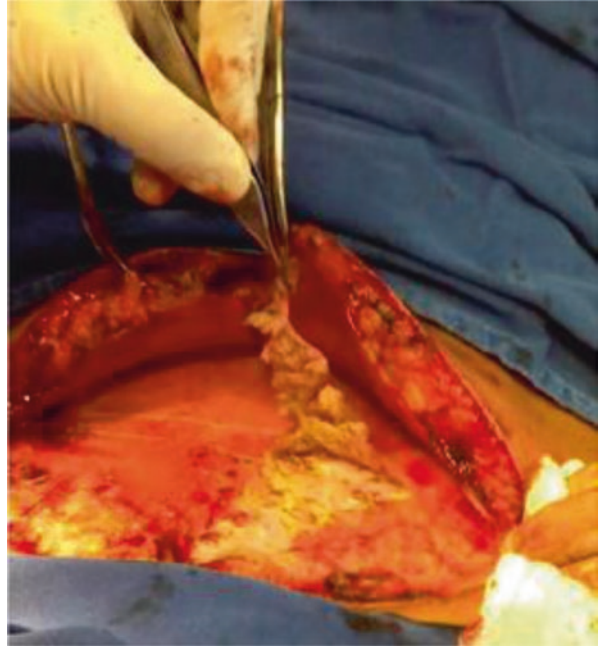
Therefore, its partial resection was performed and the remainder underwent a local scarification, for the purpose of subsequent adhesion of the flap to the muscle levels (Fig. 38.11). Consequently, the treatment had a satisfactory outcome (Fig. 38.12).



**Fig. 38.10** Pseudo-bursa of abdominal wall



**Fig. 38.11** Pseudo-bursa scarification



**Fig. 38.12** Postoperative resection of pseudo-bursa

5. *Thromboembolic events*: Among all the complications of abdominoplasties, thromboembolism with subsequent pulmonary embolism is the most fearsome.

This event can be avoided with knowledge of its pathophysiology and simply on the *Virchow triad*: venous stasis, endothelial injury, and hypercoagulability [1]. The presence of these factors can lead to deep vein thrombosis (DVT) and pulmonary embolism consequently, the latter with a mortality rate of 40–50%. Therefore, the prevention and early diagnosis of DVT are important.

The clinical diagnosis of DVT is done by the detection of unilateral local signs of the affected lower limb: edema, severe pain in the calf (Homans sign), increased skin temperature, and dilation of the superficial veins. There may be also general signs, such as mild fever, tachycardia, and anxiety [1].

Currently, the diagnosis of DVT is done by venous Doppler ultrasound of the lower limbs and dosage of D-dimer. Prophylaxis of thromboembolism is made with low molecular weight heparin and physical measures such as massage on lower limbs during surgery, early ambulation, and elastic stockings.

6. *Death*: according to the global literature, the occurrence of deaths in abdominoplasties varies between 0.2 and 0.7%. The main causes relate to *generalized infections* due to the contamination of necrotic tissue, hematoma, and seroma formation, as well as of *thromboembolic events*. Therefore, prevention of life of patients undergoing abdominoplasties. Based on that premise, it must be noted that the measures of prophylactic antibiotic therapy and prevention of thromboembolism are crucial to the safety and consequent success of the procedure.

## Conclusion

Several technical changes and concepts of abdominoplasty were developed in the last 15 years. Careful patient selection, stratification of risks, and prophylaxis, associated with meticulous technical improvement, have shown a decrease greatly in the rates of complications, resulting from the technique. The disclosure and discussion of complications greatly contribute to the satisfactory resolution of these, which is the purpose of this text.

## References

1. Abs R (2000) Accidents thromboemboliques em chirurgie plastique: revue de La litarature ET proposition d` un algorithme de prophylaxie. Ann Chir Plast Esthet 45(6):604–609
2. Avelar JM (1999) A new technique for abdominoplasty- closed vascular system of subdermal flap folded over itself combined to liposuction. Revista Brasileira de Cirurgia 88/89 (1/6):3–20

3. Avelar JM (1978) Abdominoplasty: systematization of a technique without external umbilical scar. *Aesthetic Plast Surg* 2(1):141–151
4. Jaimovich C, Mazzarone F, Navarro J, Pitanguy I (1999) Semiologia da Parede Abdominal: SEU VALOR NO PLANEJAMENTO das Abdominoplastias. *Revista Brasileira de Cirurgia Plástica* 14(3):21–50
5. Jatene PRS, Jatene MCV (2005) Abdominoplastia: Experiência clinica, Complicações e Revisão da Literatura. *Soc Bras Cir Plast* 20(2):65–71.
6. Kaplan e Sadock (2007) Precauções e efeitos adversos dos Antidepressivos (IRS). *Synopsis of psychiatry*, 10th edn. pp 130–134
7. Neaman KC, Hansen JE (2007) Analysis of complications from abdominoplasty: a review of 206 cases at a university hospital. *Ann Plast Surg* 58(3):292–298
8. Parvizi D, Friedl H, Wurzer P, Kamolz L, Lebo P, Tuca A, Rappl T, Wiedner M, Kuess K, Grohmann M, Koch H (2015) A multiple regression analysis of postoperative complications after body-contouring surgery: a retrospective analysis of 205 patients: regression analysis of complications. *Obses Surg* 25:1482–90
9. Pitanguy I (1981) Abdominoplasty. In: *Aesthetic plastic surgery of head and body*, 1st edn. Springer/Berlin, Berlin/Heidelberg/New York, pp 99–127
10. Rangaswamy M (2013) Minimising complications in abdominoplasty: Na approach based on the root cause analysis and focused preventive steps. *Indiam J Plast Surg* 46(2):365–376
11. Roje Z, Roje Z, Karanovic N, Utrobicic I (2006) Abdominoplasty complications: a comprehensive approach for the treatment of chronic seroma with pseudobursa. *Aesthetic Plast Surg* 30(5):611–615
12. Sigurdssons GH, Thomson D (1995) Anaesthesia and microvascular surgery. *Clinical practice and research. Eur J Anesthesiol* 12:101–122
13. Yoho RA, Romaine JJ, O'Neil D (2005) Review of the liposuction, abdominoplasty, and face-lift mortality and morbidity risk literature. *Dermatol Surg* 31(7 Pt 1):733–743

# Erratum to: New Concepts on Abdominoplasty and Further Applications

Juarez M. Avelar

## Erratum to:

J.M. Avelar (ed.), *New Concepts on Abdominoplasty and Further Applications*, DOI 10.1007/978-3-319-27851-3

In the original version for the below papers, the name of the author was incorrect. It should read as Alex Bosso Fioravanti.

Front Matter: On Table of Contents, Contributors list, pp. xvi, xx

Chapter 10: Importance of Concepts in Abdominoplasty and Liposuction in Breast Reduction, pp. 147

Chapter 12: Lipoabdominoplasty Combining a Wide Undermining of the Upper Abdomen with Complete Body Liposuction, pp. 179

---

The updated original online version for this chapter can be found at

DOI:[10.1007/978-3-319-27851-3](https://doi.org/10.1007/978-3-319-27851-3)

DOI:[10.1007/978-3-319-27851-3\\_10](https://doi.org/10.1007/978-3-319-27851-3_10)

DOI:[10.1007/978-3-319-27851-3\\_12](https://doi.org/10.1007/978-3-319-27851-3_12)

---

J.M. Avelar, MD

Head of the Brazilian Scientific Institute of Plastic and Reconstructive Surgery,  
Al Gabriel Monteiro da Silva, 620 Jd Europa, São Paulo, SP 01442-000, Brazil  
e-mail: [juarezavelar@bol.com.br](mailto:juarezavelar@bol.com.br)

# Index

## A

Abdomen/surgery, 3, 19, 33, 47, 59, 73, 85, 107, 127, 147, 161, 179, 209, 227, 241, 255, 271, 289, 305, 309, 319, 331, 347, 367, 391, 405, 419, 443, 465, 473, 483, 499, 513, 525, 533, 547, 557, 573, 587  
Abdome with previous scar, 55, 514, 525  
Abdominal approach, 378, 387, 388, 391–402  
Abdominal deformities, 167, 176, 367, 419, 470, 473, 480, 494, 533  
Abdominal laxity, 378, 380, 402  
Abdominal wall, 3, 19, 33, 47, 59, 73, 85, 107, 127, 147, 161, 179, 209, 227, 241, 255, 271, 289, 305, 309, 319, 331, 347, 367, 391, 405, 419, 443, 465, 473, 483, 499, 513, 525, 533, 547, 557, 573, 587  
Abdominoplasty, 19, 20, 31–43, 49–52, 54, 56–57, 61, 65, 66, 68, 70, 73–83, 85–103, 107–125, 127–142, 180, 209–223, 227, 264, 271  
Abdominoplasty; complications, 3, 19, 33, 47, 59, 73, 85, 107, 127, 147, 161, 179, 209, 227, 241, 255, 271, 289, 305, 309, 319, 331, 347, 367, 391, 405, 419, 443, 465, 473, 483, 499, 513, 525, 533, 547, 557, 573, 587  
Abdominoplasty, 3, 19, 33, 47, 59, 73, 85, 107, 127, 147, 161, 179, 209, 227, 241, 255, 271, 289, 305, 309, 319, 331, 347, 367, 391, 405, 419, 443, 465, 473, 483, 499, 513, 525, 533, 547, 557, 573, 587  
Abdominoplasty with scar, 380, 471, 520  
Abnormalities of the abdomen, 32  
Aesthetic treatment, 31, 33, 65, 85, 256, 283, 312

Anatomy, 3, 5, 8, 10, 19–29, 33, 101, 103, 128, 162, 165, 221, 241, 255, 264, 313, 432, 444, 467–468, 509, 557  
Anatomy of the abdomen, 3, 19–29, 33, 83, 103, 128–130, 241  
Aponeurotic wall plication, 172, 174, 184–185  
Areolar layer, 7, 8, 10, 20–29, 36, 40, 53, 76, 99, 138, 256, 259, 276, 278  
Atypical Abdominoplasty,  
Atraumatic rhytidoplasty, 5, 9, 11, 209–211, 213, 217–223  
Atrophic breasts, 402  
Augmentation of buttocks, 331–346  
Auricle, 9, 210, 212, 227–229, 231–235, 237–239  
Avelar abdominoplasty, 3–14, 147–159  
Avelar's concepts, 3–14

## B

Bariatric surgery, 32, 100, 114, 266, 272, 303, 371, 378, 381, 383, 385, 388, 406, 470, 473, 474, 478, 531, 538, 541, 558, 583, 584  
Blepharoplasty, 9, 11, 13, 36, 39, 210, 241–252  
Body contour, 10, 29, 31, 34, 40, 47, 48, 50, 60, 73, 87, 99, 128, 153, 155, 159, 179, 187, 189, 263, 271, 289, 290, 292, 293, 296, 301, 303, 307, 312, 324, 329, 333, 334, 369–371, 375, 406–408, 453, 465, 480, 494, 514, 524, 574  
Body contouring, 5, 12, 47, 56, 79, 86, 127, 128, 207, 256, 271, 272, 283, 308, 367, 370, 371, 373, 375, 377, 380–382, 385, 387–389, 430, 587

Breast implants, 101, 102, 391–402  
 Breast reconstructions,  
   59, 121, 147–159, 163, 188, 557–570  
 Buttocks, 36, 255, 263, 274, 289–303, 320,  
   321, 329, 331–347, 368, 370, 375, 380,  
   444, 446, 470, 489  
 Buttocks lipografting, 331–346

## C

Case study, 3, 19, 33, 47, 59, 73, 85, 107,  
   127, 147, 161, 179, 209, 227, 241, 255,  
   271, 289, 305, 309, 319, 331, 347, 367,  
   391, 405, 419, 443, 465, 473, 483, 499,  
   513, 525, 533, 547, 557, 573, 587, 596  
 Circumferential, 347, 348, 368, 370,  
   372–380, 385, 387, 466, 470, 515  
 Classification, 31–43, 75, 131, 228–230,  
   314, 315, 369, 392, 434, 437,  
   443–462, 469–471, 566, 567  
 Classification of the abdomen,  
   392, 469–471  
 Combined circumferential approach,  
   376–378, 380  
 Combined procedure, 5, 7, 8, 10–12, 19,  
   33, 41, 50, 75, 86, 87, 99, 210, 220,  
   257, 263, 264, 271, 273, 277, 278  
 Combined surgeries, 10, 379  
 Complete body, 179–206  
 Complications, 3, 19, 33, 47, 59, 73, 85,  
   107, 127, 147, 161, 179, 209, 227, 241,  
   255, 271, 289, 305, 309, 319, 331, 347,  
   367, 391, 405, 419, 443, 465, 473, 483,  
   499, 513, 525, 533, 547, 557, 573, 587  
 Corporal contour, 342, 495  
 Creation of umbilicus, 4, 107–124  
 Cutaneous fold, 229, 233, 243, 244,  
   249, 251, 252, 275–277, 279, 283

## D

Difficult abdominoplasty, 407  
 Double contour plication, 533–545

## E

Ear, 9, 11, 13, 36, 38, 204, 212, 215,  
   216, 218, 219, 221, 227–239  
 Ear reconstruction,  
   9, 11, 13, 36, 38, 227–239  
 Evolution of abdominoplasty, 419–436  
 External oblique muscle,  
   93, 407, 408, 410, 443, 444, 451,  
   456, 459, 468, 499–509, 566

## F

Face lighting, 9, 11, 13, 36, 209,  
   210, 216, 220, 242  
 Flabby buttocks, 292, 302, 303  
 Flank, 9, 11, 12, 26, 29, 36, 40, 49, 52, 86,  
   128, 134, 139, 180, 182, 241, 247, 255,  
   257, 271–286, 290, 293–295, 306, 321,  
   337, 342, 354, 368, 370, 373, 375, 378,  
   380, 444, 446, 447, 461, 470, 474, 475,  
   489, 495, 514, 526, 529, 543  
 Flankplasty, 12, 36  
 Full abdominoplasty, 41, 85–103, 109

## G

Gluteoplasty, 297, 340, 341, 495  
 Gluteus, 11, 289–303, 332–339, 341–345, 470

## H

History, 31, 73, 163–164, 180, 243,  
   290, 331, 334, 341, 386, 443, 445,  
   466–467, 471, 484, 489, 557, 573,  
   583, 593  
 Holmstrom bilateral reverse flap, 489  
 H-shaped plication, 545

## I

Importance of Avelar's concepts, 147–159  
 Inner tight, 448

## L

Lamellar layer, 23, 26  
 Lipoabdominoplasty, 10–12, 20, 31–43,  
   47–57, 59–70, 74, 76, 79, 80,  
   82, 85–103, 108–111, 125, 128,  
   138–140, 153, 179–206, 241, 244,  
   247, 271, 280, 285, 290, 292, 300,  
   301, 303, 305–314, 331–333, 336,  
   340, 345, 391, 435, 443, 458, 488,  
   513, 523, 533–534, 543, 558, 588  
 Lipografts, 290, 331–346, 489,  
   494, 495, 567, 570  
 Lipoplasty, 11, 34, 36, 39, 40, 49,  
   81, 86, 222, 247, 255–258,  
   261–269, 289–303  
 Liposuction, 3, 19, 33, 47, 59, 73, 85,  
   107, 127, 147, 161, 179, 209, 227,  
   241, 255, 271, 289, 305, 309, 319,  
   331, 347, 367, 391, 405, 419, 443,  
   465, 473, 483, 499, 513, 525, 533,  
   547, 557, 573, 587

Liposuction of the torso, 40  
 Lower abdomen, 49, 57, 82, 91, 100, 129, 133, 152, 153, 182–183, 199, 305–307, 312, 313, 315, 320, 329, 375, 409, 513, 514, 518, 523, 535–538, 541, 551  
 Lower abdominoplasty, 48, 56, 60, 74, 75, 79, 81, 82, 264  
 Lower and upper lipoabdominoplasty, 41, 47–57, 59–70, 74, 76, 79–82, 100, 435  
 Lower blepharoplasty, 9, 11, 13, 39, 241–252  
 Lower lid, 39, 241–252  
 Lower lipoabdominoplasty, 41, 47–57, 74, 76, 79–82, 435

**M**  
 Male, 21, 49, 56, 65, 115, 161, 176, 180, 222, 223, 237, 243, 249, 250, 263, 269, 278, 283, 284, 473–481  
 Male patient, 49, 65, 115, 223, 237, 249, 250, 284  
 Mastectomy, 49, 559, 561, 565  
 Medial lipoabdominoplasty, 11, 488  
 Medial tight, 258  
 Microtia, 228, 229, 232–236  
 Minimal complications, 8, 9, 220, 257, 282  
 Minimally invasive plastic surgery, 162, 165, 175  
 Minor diatesis, 516, 518, 524,  
 Muscle aponeurotic plication, 184–185

**N**  
 Neo-umbilicoplasty, 348, 349, 353, 407, 530  
 New abdominoplasty, 496  
 New concepts, 3–14, 19, 25, 29, 32–35, 37, 38, 50, 53, 59, 73, 75, 87, 94, 99, 102, 209–223, 227, 228, 232, 236, 238, 239, 241, 247, 255–269, 271, 289–303, 305, 368, 386, 436, 445, 558  
 New navel, 107, 350, 351, 407  
 New surgical principles, 33, 36, 290  
 New umbilicus, 4, 90, 92, 97, 107–125, 351, 361, 509

**O**  
 Obesity, 75, 324, 327, 347, 367, 368, 371, 374–377, 383, 386, 387, 405, 407, 419, 453, 465, 469, 481, 494, 547

**P**  
 Pathologies, 392, 447–458  
 Perforator vessels, 7–10, 12, 20–22, 25–28, 33–38, 41–43, 50, 53, 55, 56, 63, 76, 77, 86, 90–95, 99, 102, 103, 209, 210, 227–239, 241, 252, 256, 259, 264, 272, 275, 281, 300, 301, 306, 446, 451, 452, 456, 459, 462, 513  
 Plastic surgery/methods, 4, 5, 9, 11–13, 19, 31, 50, 73, 109, 122, 139, 141, 149, 163, 165, 175, 179, 209, 227, 242, 273, 289, 301, 303, 305, 314, 319, 320, 329, 333, 348, 367, 370, 380, 382, 385–387, 405, 406, 416, 419, 427, 431, 444, 448, 449, 465, 473, 483, 494, 496, 513, 557, 574  
 Plication, 9, 41, 55, 63, 77, 93, 111, 127, 151, 161–176, 184, 215, 294, 305–315, 319, 351, 374, 392, 407, 430, 443, 475, 484, 500, 513, 533–545, 580, 587  
 Post-bariatric, 324, 348, 349, 367–374, 376–378, 381, 382, 385, 387, 388, 405–416, 469, 470, 474  
 Preservation of perforator vessels, 90, 94, 209, 227–239, 252, 300, 312

**R**  
 Reconstruction of the buttocks, 301, 302  
 Rectus abdominalis, 7, 8, 10, 33–37, 41, 48, 55, 56, 114, 161, 171–172, 174, 184, 187, 306, 308, 312–314, 341  
 Rectus diastasis, 161, 162, 165, 168, 172, 174–176, 187, 535, 538, 541, 543  
 Reinforcement, 41, 48, 50, 55, 56, 81, 82, 85, 93–96, 100, 102, 110, 114, 116, 312, 419, 421, 424, 427, 435, 436, 533, 536, 538, 541, 543, 545, 569  
 Reinforcement of abdominal secular structures,  
 Reparation of buttocks, 263  
 Reverse abdominoplasty, 59, 466, 526, 547–555, 557–570, 577  
 Reverse lower lid, 246  
 Rhytidolipoplasty, 38, 209–223  
 Rhytidoplasty, 5, 9, 11, 209–211, 213, 217–223  
 Rhytidoplasty with selected cutaneous undermining, 9  
 Robotic plastic surgery, 163, 165, 175  
 Robotic rectus plication, 172  
 Robotic surgery, 162

**S**

- Safety, 4, 86, 223, 227, 334–337, 341, 344, 349, 350, 374, 381, 388, 509, 598
- Scars on abdome wall, 49
- Scars on umbilicus, 107, 140, 170, 171, 332, 348, 397, 407–408, 410, 411, 416, 419, 427, 430, 431, 468–471, 474, 477, 489, 494
- Skin expansion, 530
- Skin resection, 8, 32, 34, 36, 39–42, 49, 50, 52–55, 60–65, 76, 77, 79, 81, 85, 88–91, 93, 101, 110, 125, 139, 140, 241, 243–245, 251, 252, 256, 258–260, 262, 264, 266, 267, 271, 272, 274–286, 292–296, 300, 301, 307, 312, 314, 331, 332, 347, 348, 436, 445, 446, 451, 459, 462, 524
- Subcutaneous panniculus, 22–27, 40, 272, 282, 298
- Suprapubic skin resection, 41, 53, 76, 79, 81, 89, 125
- Surgical planning, 41, 42, 48, 50, 51, 53, 55, 59, 60, 68, 74, 76, 77, 83, 88, 90, 100, 109, 120–122, 213, 215, 228, 229, 236, 237, 246, 257, 263, 273, 275, 283, 284, 290, 294, 300, 301, 307, 367, 371, 376, 387, 407, 467, 469, 499, 524, 560, 565

**T**

- Torso, 5, 9, 11, 24, 28–29, 32, 40, 48, 50, 52, 53, 61, 62, 64, 75, 79, 86, 89, 241, 271–276, 278–280, 283, 286, 296, 354, 394, 421, 424, 427, 429–431, 433
- Torsolipoplasty, 29, 271–286
- Torsoplasty, 12, 36
- Transposition of the umbilicus, 4, 41, 51, 74, 107, 121, 122, 430, 436, 447, 456, 462, 569, 577, 587
- Traumatic amputation of the ear, 231

- Treatment, 8–10, 12, 28, 31–33, 36, 39, 43, 59, 60, 65, 85–88, 114, 116, 131, 133, 162, 165, 176, 215, 238, 243, 247, 250, 251, 255–257, 263, 266, 271, 283, 289, 290, 292, 299, 302, 303, 312, 333, 337, 347, 354, 367, 369–371, 374, 381–389, 397, 419, 427, 430–434, 443–462, 465, 466, 470, 474, 475, 478, 480, 484, 494, 495, 499, 508–510, 520, 523, 530, 543, 551, 574, 590, 593, 594, 596, 597
- Tummy tuck, 128, 133, 314, 590

**U**

- Umbilical deformities, 41, 75, 513–524
- Umbilical hernia, 48, 114, 116, 119, 120, 161, 165, 348, 523, 590, 591, 593, 594
- Umbilical scar, 107, 140, 170, 171, 332, 348, 397, 407–408, 410, 411, 416, 419, 427, 430, 431, 468–471, 474, 477, 489, 494
- Umbilicoplasty, 4, 108, 171, 313
- Umbilicus, 3, 22, 37, 51, 59, 74, 85, 107–125, 127, 149, 168, 180, 306, 321, 349, 430, 443, 494, 509, 513–524, 529, 533, 558, 577, 587
- Unaesthetic umbilicus, 120
- Upper abdomen, 20, 32, 42, 59–61, 65, 68, 70, 74, 77, 88, 100, 128, 179–207, 375, 436, 513, 523, 524, 544, 549
- Upper abdominoplasty, 41, 61, 62, 65–68, 70, 73–83, 125
- Upper lipoabdominoplasty, 41, 59–70, 100, 435

**V**

- Vascular network, 19, 20, 24, 34, 55, 101, 102, 215, 217, 221, 259, 275, 276, 278, 282
- Vertical tummy tuck,

**W**

- Weight loss, 10, 32, 47, 49, 65, 75, 109, 114, 266, 267, 269, 272, 290, 292, 297, 302, 303, 347, 349, 367–389, 405, 406, 416, 453, 466, 469, 473, 494, 514, 525, 583
- Wide undermining, 12, 28, 32, 179–207, 255, 272, 312, 513