

Chapter 10

Acute Pelvic Pain in Pediatric and Adolescent Patients

Paula C. Brady

Definitions

Adnexal Torsion Twisting of the ovary and/or fallopian tube leading to occlusion of vascular flow, resulting in pain and eventual necrosis. Adnexal torsion constitutes 3 % of gynecologic emergencies [1]. Risk factors for adnexal torsion include ovarian cysts greater than 5 cm and prior adnexal torsion. In children, 50 % of torsions occur in the absence of any other ovarian pathology (such as a mass) [2]. This is attributed to laxity of the utero-ovarian ligament, leading to ovarian hypermobility. Rarely, isolated tubal torsion may occur (often in association with hydrosalpinx or other adnexal pathology), which presents with symptoms indistinguishable from ovarian torsion.

P.C. Brady, MD (✉)

Department of Obstetrics, Gynecology and Reproductive Biology,
Brigham and Women's Hospital, 75 Francis Street,
Boston, MA 02115, USA
e-mail: Pbrady2@partners.org

Differential Diagnosis

Ovarian mass/cyst (with or without rupture)

Adnexal torsion

Uterine outflow obstruction

- Imperforate hymen
- Transverse vaginal septum
- Cervical agenesis
- Vaginal atresia
- Obstructed uterine horn
- Obstructed hemivagina with ipsilateral renal agenesis (OHVIRA)

Dysmenorrhea

Endometriosis

Mittelschmerz (ovulation pain)

Urologic (nephrolithiasis, cystitis, pyelonephritis, acute urinary retention), gastrointestinal (appendicitis, gastroenteritis, bowel obstruction), musculoskeletal, hematologic (sickle cell crisis, porphyria), and psychiatric

Postoperative complications (Chap. 16)

Sexual abuse (Chap. 9)

In sexually active patients: ectopic pregnancy (Chap. 3); sexually transmitted infections, pelvic inflammatory disease, and tubo-ovarian abscess (Chap. 6); and spontaneous abortion (Chap. 8).

Please see Chap. 1 for a full discussion of this differential diagnosis, including dysmenorrhea, endometriosis, and mittelschmerz, which are not discussed here.

When You Get the Call Ask for a full set of vital signs, and request an ultrasound (transabdominal in virginal patients) if one has not already been performed. Request that the patient not receive further pain medications prior to a physical

examination by gynecology, if possible, to allow for an accurate assessment.

When You Arrive Review the full vital signs flow sheet and whether the patient has received any pain medications, which may affect the patient's physical exam findings. Assess the patient's discomfort and distress.

History

Review the time course of the patient's symptoms, including whether the pain began acutely or developed over weeks to months, and whether she has associated symptoms, including fever, nausea, or emesis. Review the location and quality of her pain, including aching, sharp, continuous, or episodic. Review whether she has ever had this pain before or suffers from chronic pain. Ask whether the patient's abdomen feels or appears distended.

Review the patient's full medical and surgical history, including whether she recently had surgery. Inquire whether the patient has begun menstruating; in adolescents, review whether the patient has ever been sexually active, which broadens the differential diagnosis. Review whether she has a history of polycystic ovarian syndrome, ovarian cysts, or ovarian torsion.

Physical Examination

An abdominal exam should be performed, which may reveal distention or a pelvic mass, focal right lower quadrant pain due to appendicitis or adnexal torsion, flank pain due to nephrolithiasis or pyelonephritis, or suprapubic pain potentially due to cystitis. Peritoneal signs—including rebound (pain on the abrupt release of abdominal palpation), involuntary abdominal guarding, or shake tenderness (pain with shaking the patient's abdomen or bed)—indicate intra-abdominal infection, inflammation or hemorrhage, from such processes as appendicitis, adnexal torsion and ovarian cyst rupture, respectively.

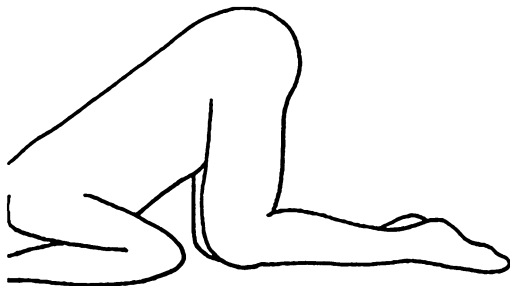


FIG. 10.1 Knee-chest position for pediatric gynecologic examination

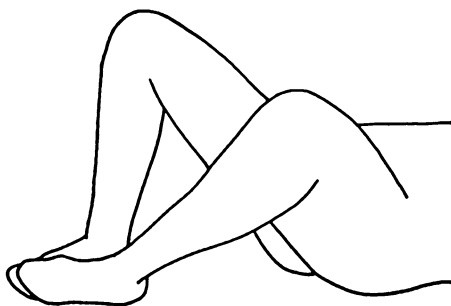


FIG. 10.2 Frog-leg position for pediatric gynecologic examination

Pelvic exams are not required for complaints of pelvic pain, particularly if the source is identified by history or imaging. If necessary, genital exams in children can be performed in the knee-chest (Fig. 10.1) or frog-leg positions (Fig. 10.2). The external genitalia can be inspected for evidence of hematocolpos (vaginal distension with menstrual blood). In children, a rectal exam may reveal hematocolpos or a pelvic mass [3]. In sexually active adolescents, a bimanual exam may reveal evidence of pelvic inflammatory disease, an adnexal mass concerning for an ovarian cyst or neoplasm, ectopic pregnancy or tubo-ovarian abscess, or an immobile uterus in patients with significant endometriosis or other pelvic adhesions.

Diagnosis

Tachycardia, tachypnea, and fever suggest systemic infection; any evidence of sepsis and/or hemodynamic instability requires urgent assessment and resuscitation by a pediatrician or pediatric emergency physician. A low-grade fever is nonspecific and can be associated with infection, ovarian torsion, ovarian cyst rupture, or genital outflow tract obstruction.

A complete blood count and urinalysis should be collected in children and adolescents with acute pelvic pain; leukocytosis may be present in patients with adnexal torsion, ovarian cyst rupture, outflow tract obstruction, or infection. Electrolytes can be checked in patients with nausea and emesis. A beta-human chorionic gonadotropin (hCG) should be checked in postmenarchal patients.

In patients with suspected gynecologic outflow tract obstructions, transperineal or transabdominal ultrasounds are a helpful first step to diagnosis. Magnetic resonance imaging (MRI) can be used to further clarify the patient's anatomy and identify any associated renal anomalies [4].

In patients with presentations suspicious for ovarian cysts or torsion, ultrasound is the first-line modality for diagnosis. Though usually not necessary, computed tomography or MRI may clarify cystic or complex components initially seen on ultrasound and evaluate for metastasis [6]. Please see Chap. 4, Adnexal Masses and Ovarian Cyst Rupture, for more information on the diagnosis of ovarian masses. Please refer to Chap. 5, Adnexal torsion, for more information on ovarian and tubal torsion.

Among patients found to have pelvic masses, tumor markers can be sent for complex ovarian masses concerning for malignancy. Endodermal sinus tumors, embryonal cell carcinomas, immature teratomas, and mixed germ cell tumors are associated with elevated levels of alpha-fetoprotein (AFP), while hCG is associated with choriocarcinoma, embryonal cell carcinoma, and mixed germ cell tumors [5, 6]. Lactate dehydrogenase (LDH) is associated with dysgerminomas [6].

Estradiol and inhibins are markers of granulosa cell tumors; estradiol produced by a granulosa cell tumor in a pediatric patient may result in signs of precocious puberty. Cancer antigen 125 (CA-125) is a marker of epithelial ovarian cancer, which is very uncommon in children and adolescents, and can also be elevated in benign gynecologic neoplasms or conditions (such as endometriosis), and systemic illness.

Management

Outflow Tract Obstruction

Imperforate Hymen

The hymen, which is the result in utero cannulation of the vaginal plate, can have varying degrees of obstruction, including imperforate (no opening), microperforate (very small opening), cribriform (multiple small openings), and septate (largely cannulated, though with a septation). Imperforate hymen is the most common congenital anomaly of the female reproductive tract, estimated to occur in 1 in 1,000–2,000 women [7]. These are sometimes diagnosed soon after birth, when vaginal mucous distends the membrane, though many others present after menarche [8]. An imperforate hymen is ideally repaired when the tissues are exposed to estrogen, in infancy or after puberty [8, 9].

After menarche, patients may present with pain, particularly cyclical pelvic pain and back pain, or urinary and bowel dysfunction due to pain or mass effect. Patients with completely imperforate hymens will have primary amenorrhea; patients with microperforate or cribriform hymens may have some menstrual bleeding, but may still present with symptoms of vaginal obstruction. Patients may present with vaginal distention with menstrual blood (hematocolpos) and uterine distension with blood (hematometra) or blood in the fallopian tubes (hematosalpinx); patients may also have hydronephrosis due to mass effect [8]. On exam, patients will

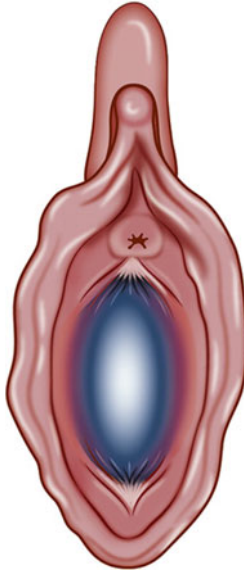


FIG. 10.3 Bulging imperforate hymen (Reprinted from Dietrich et al. [10], with permission from Elsevier and the North American Society for Pediatric and Adolescent Gynecology)

have a bulging membrane at the distal vagina, often blue tinged, and vaginal distension on rectal exam (Fig. 10.3) [10].

An imperforate hymen should be repaired definitively, and not just incised and drained, as the hymen may heal closed and symptoms may recur [8]. For the repair (performed under anesthesia), an elliptical incision should be made in the membrane and excess tissue excised, after which the hymeneal tissue is sutured to the hymeneal ring with a small diameter Vicryl or Chromic suture [11].

Transverse Vaginal Septum

Transverse vaginal septa are attributed to failure of the müllerian ducts and/or urogenital sinus to canalize normally; 46 % occur in the upper vagina, while 35 % occur

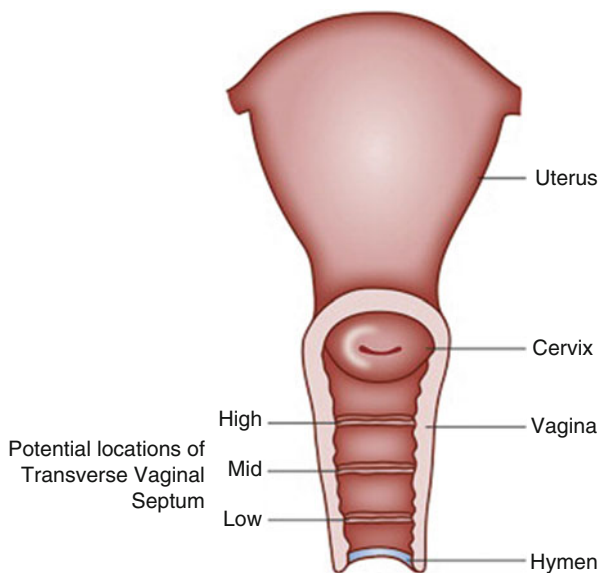


FIG. 10.4 Transverse vaginal septum (Reprinted from Dietrich et al. [10], with permission from Elsevier and the North American Society for Pediatric and Adolescent Gynecology)

in the midvagina (Fig. 10.4) [8, 12]. Patients present with symptoms similar to those with imperforate hymen. Patients with incomplete septa may have some menstrual bleeding, but may still present with symptoms of outflow tract obstruction. The vagina may appear shortened, or like a “blind pouch”; the proximal obstruction may be palpated by rectal exam [9]. The transverse vaginal septum should be visualized with MRI, to clarify the location and thickness—usually less than 1 centimeter (cm)—and to confirm the presence of a cervix [4].

Surgical repair is preferable at the time of distention of the septum by the hematocolpos, which acts as a tissue expander. Small septa can be resected and repaired in an end-to-end anastomosis of the vaginal mucosa. A Z-plasty, using vaginal mucosal flaps, may be performed to reduce the risk of vaginal stenosis (Fig. 10.5) [13, 14]. Thick septa require repair by a

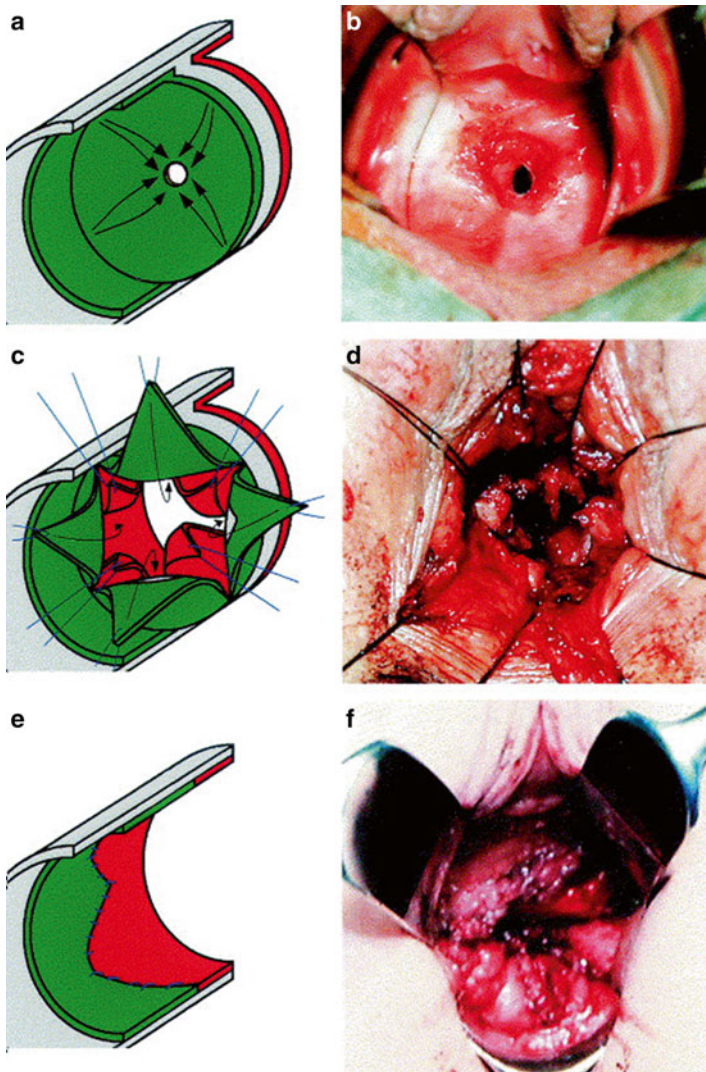


FIG. 10.5 Z-plasty for resection of a transverse vaginal septum. (a, c, and e) Show the basic principle of the operation. The mucosa of the vaginal vault (anterior portion of the barrier) is colored green. The mucosa of the upper pocket (where the cervix is located, posterior portion of the barrier) is colored red. There is a gray-colored midseptum. Stay sutures are blue. The corresponding intraoperative situation is demonstrated by photographs b, d, and f (Reprinted from Wierrani et al. [13], with permission from Elsevier and the American Society for Reproductive Medicine)

specialist and may require a skin graft [8]. Postoperative use of dilators is recommended to maintain vaginal patency [9].

Cervical Agenesis

Cervical agenesis, or the congenital absence of the cervix, is rare and presents similarly to a transverse vaginal septum (Fig. 10.6(I)). This diagnosis is confirmed by MRI. Hysterectomy is often recommended, as surgically created fistulous tracts between the uterus and vagina expose the patient to ascending infection that can result in sepsis and death [8, 15]. Alternatively, some patients are treated with menstrual suppression, with oral contraceptive pills or gonadotropin-releasing hormone agonists, to allow patients to participate in later decisions regarding their reproductive potential [16].

Vaginal Atresia

Vaginal atresia is the congenital absence of the lower vagina; the incidence is estimated at 1 in 5,000 women (Fig. 10.6(I)) [17]. Vaginal atresia results from failure of the urogenital sinus to contribute to the lower vagina; a normal upper vagina, cervix and uterus are present above the obstruction. Patients will present with primary amenorrhea and cyclical pelvic and back pain. The uterus, cervix and upper vagina (particularly if distended with menstrual blood) may be palpable by rectoabdominal exam. Physical exam reveals a dimple in the position of the vaginal introitus [18]. MRI should be obtained to clarify the thickness of the anomaly and assess for renal anomalies.

Like thick vaginal septa, surgical repair requires a specialist, at the time of vaginal distension with menstrual blood. Careful dissection is performed to the point of the upper vagina, after which the vaginal mucosa is pulled through, though a skin graft may be required [8]. Postoperative vaginal dilation is recommended to maintain vaginal patency.

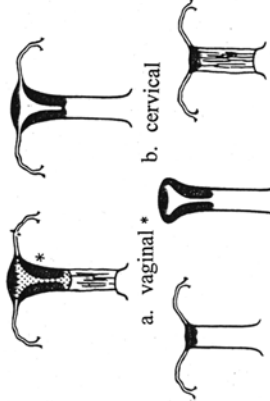
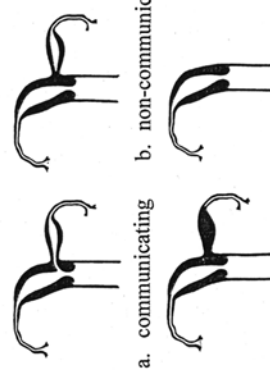


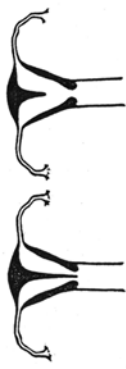


<p>I. Hypoplasia/Agenesis</p>  <p>a. vaginal* b. cervical c. fundal d. tubal e. combined</p>	<p>II. Unicornuate</p>  <p>a. communicating b. non-communicating c. no cavity d. no horn</p>	<p>III. Didelphus</p>  <p>IV. Bicornuate</p>  <p>a. complete b. partial</p>
<p>V. Septate</p>  <p>a. complete** b. partial</p>	<p>VI. Arcuate</p> 	<p>VII. DES Drug Related</p> 

Fig. 10.6 Müllerian anomalies. * Uterus may be normal or take a variety of abnormal forms. ** May have two distinct cervixes (Reprinted by permission from the American Society for Reproductive Medicine. (*Fertil Steril* [20]))

Obstructed Hemivagina with Ipsilateral Renal Agenesis (OHVIRA)

Patients may also present with symptoms of gynecologic out-flow tract obstruction due to a rare syndrome of an obstructed hemivagina with ipsilateral renal agenesis, called OHVIRA [19]. Patients with OHVIRA have uterus didelphys (2 uteri, each with a cervix) and a longitudinal vaginal septum, with one side obstructed (Fig. 10.7). These patients will have menstrual flow from one uterine cavity through the unobstructed hemivagina, but may eventually present with progressively worsening cyclical pelvic pain due to the second obstructed uterine cavity. On physical examination, patients will have a bulge in the vagina [18]. The diagnosis can be confirmed by MRI. Surgical repair entails excision of the vaginal wall of the obstructed hemivagina, to create a unified vaginal vault and allow for unobstructed menstrual flow [8, 11].

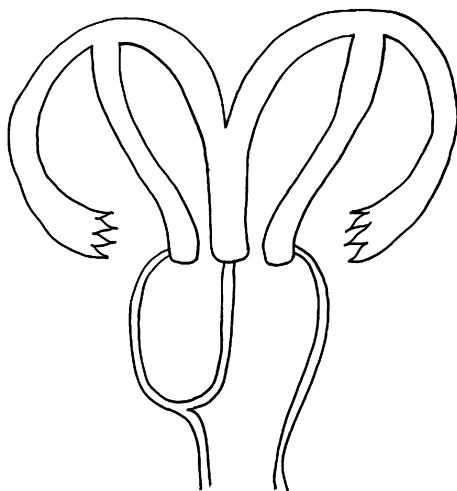


FIG. 10.7 Obstructed hemivagina with ipsilateral renal agenesis (OHVIRA). The ipsilateral renal agenesis is not shown in this image

Obstructed Uterine Horn

Most uterine anomalies—including arcuate, septate, unicornuate, bicornuate, or didelphys uteri—are asymptomatic and may only be diagnosed due to infertility, miscarriage, or obstetrical complications [8, 20]. A patient may, however, have a rudimentary uterine horn that does not communicate with the vagina or contralateral lower uterine segment, leading to obstruction (Fig. 10.6(IIb)). Like OHIVRA, patients may have menstrual bleeding from an unobstructed hemiuterus, but may complain of progressive dysmenorrhea. This diagnosis can be confirmed with ultrasound or MRI, and management is usually by hemihysterectomy [8].

Other uterine anomalies that do not usually present emergently, including nonobstructive longitudinal vaginal septa or müllerian agenesis (Mayer-Rokitansky-Küster-Hauser syndrome), which is the congenital absence of the upper vagina with absence or hypoplasia of the uterus, cervix and fallopian tubes, will not be covered here.

Adnexal Cysts and Masses

Ovarian cysts may be detected antenatally or within the first few weeks of life. Ovarian cysts in neonates are usually the result of hormonal stimulation in utero and generally regress in the first year of life, particularly those less than 5 cm in diameter [21–23]. Serial ultrasound, every 4–6 weeks, is recommended. Aspiration of simple cysts may be indicated for fetal or neonatal cysts greater than 4–5 cm [24]. Torsion may occur at any age; intestinal obstruction may also result from large ovarian cysts in neonates, due to mass effect and inflammation. Either of these is an indication for surgical management.

Simple cysts, representing functional cysts in the vast majority of patients, are the most common adnexal masses in pediatric and adolescent patients [6]. In patients without

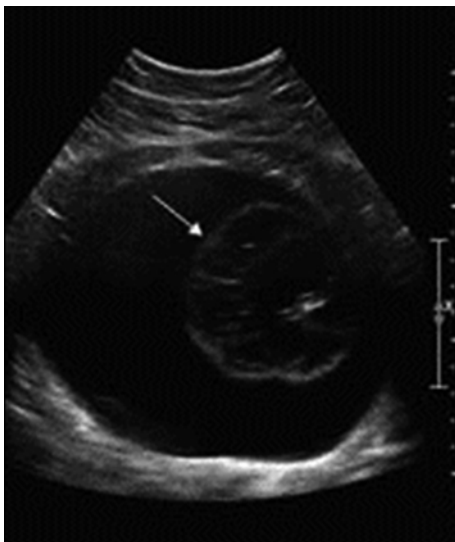


FIG. 10.8 Ovarian teratoma. The ultrasound shows a 14 cm cystic mass and 7 cm solid component (*arrow*), referred to as a Rokitansky nodule (Reprinted from Kelleher and Goldstein [6], with permission)

symptoms concerning for torsion, simple cysts can be followed with serial ultrasound and can take up to 3 months to resolve [6]. In postpubertal patients, hormonal suppression with oral contraceptive pills is often prescribed to prevent recurrence of simple cysts, though the efficacy of this intervention has not been confirmed [25].

Mature teratomas, also called dermoids, are benign germ cell tumors that represent up to 70 % of ovarian neoplasms in children [26]. These are bilateral in 10 % of patients [25]. On imaging, fat fluid levels, linear echogenic bands (hair fibers, also called dermoid mesh), and a “Rokitansky nodule” or “dermoid plug”—a central echogenic area—are suggestive of mature teratomas (Fig. 10.8) [27].

Ovarian cystectomy is recommended for the management of ovarian teratomas, and ovarian preservation is a priority

in this age group. Emergent intervention is only required in cases of suspected ovarian torsion, which can be performed by laparotomy or laparoscopy. Laparoscopy is associated with less pain, shorter hospital stay, and a lower complication rate than laparotomy [28]. Laparotomy may be chosen to reduce the risk of dermoid rupture, which is thought to result in adhesive disease and may rarely result in chemical peritonitis; laparoscopic technique can be adjusted (including use of a tissue recovery bag to remove the cyst from the abdomen) to limit spillage of cyst contents [29,30]. Intraoperatively, pelvic washings should be collected prior to the removal of a dermoid (or any ovarian mass with complex or otherwise concerning features) for staging purposes, in the rare event that malignant transformation is diagnosed [31]. If rupture of a dermoid occurs, copious irrigation is recommended to minimize the risk of chemical peritonitis [6]. Annual ultrasounds have been suggested postoperatively to assess for recurrence [32].

Epithelial neoplasms represent less than 20 % of ovarian neoplasms in children; these include serous and mucinous cystadenomas, and the vast majority are benign. Please refer to Chap. 4 for information on the ultrasound features of cystadenomas. [33]. Management is surgical, by either laparoscopy or laparotomy. Approximately 10 % of cystadenomas recur after cystectomy [34]. Following removal of a cystadenoma, follow-up every 6 months with physical exam and/or imaging has been recommended, though no formal guidelines have been published [28].

Malignant ovarian tumors account for only 1 % of pediatric and adolescent ovarian neoplasms; ovarian malignancies in this age group are usually germ cell or sex cord-stromal tumors, which are generally associated with a positive prognosis [35–37]. Please refer to Chap. 4 for information on the ultrasound features of ovarian malignancy. Tumor markers, discussed in “Diagnosis,” should be collected in patients with suspicious ovarian masses, prior to surgical removal. Surgical management is indicated for ovarian masses suspicious for malignancy; laparotomy is usually performed to allow for full

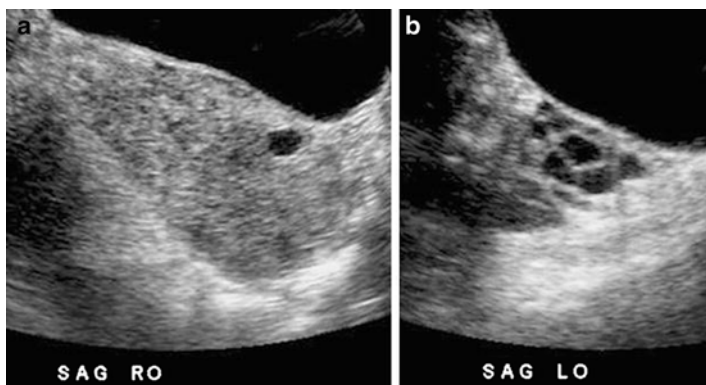


FIG. 10.9 Ovarian torsion by ultrasound in a prepubertal girl (**a**) The torsed ovary is enlarged and heterogeneous and measures $7.9 \times 3.8 \times 6.3$ cm corresponding to a volume of 361.6 cm^3 . (**b**) The contralateral normal ovary measures $2.8 \times 1.4 \times 1.9$ cm corresponding to a volume of 14.2 cm^3 (Reprinted from Servaes et al. [41], Fig. 10.1, with kind permission from Springer Science and Business Media)

exploration of the abdomen and to limit risk of rupture of the mass, which is thought to worsen prognosis [38, 39]. Any patient with malignancy should be managed by a surgical or gynecologic oncologist.

Adnexal Torsion

Children with torsion of the ovary and/or fallopian tube usually present with abdominal pain, nausea, and vomiting and may have low-grade fever or leukocytosis [40]. By ultrasound, half of pediatric patients with torsion will have an adnexal mass [2]. Even in the absence of a mass, a torsed ovary will appear more heterogeneous and significantly larger than the contralateral normal ovary (Fig. 10.9) Please refer to Chap. 5, Adnexal Torsion, for an in-depth discussion of ultrasound findings in patients with ovarian and tubal torsion. [41].

Management of suspected adnexal torsion is surgical, usually by laparoscopy. Every effort should be made to preserve the ovary, as over 94 % of discolored or hemorrhagic ovaries

will regain normal ovarian function and appearance by ultrasound [42, 43].

Oophoropexy, or surgical fixation of the ovary, can be considered to prevent recurrent torsion, though the practice is somewhat controversial [44]. Oophoropexy may be considered in a patient with only one ovary, torsion in the absence of risk factors or an ovarian mass, or recurrent torsion. Given the high rate of recurrence of ovarian torsion in children (>15 % in some series), some providers advocate for oophoropexy in all pediatric patients with ovarian torsion [45]. There are no randomized studies comparing recurrence rates or long-term effects on fertility following oophoropexy. Techniques include truncation of the utero-ovarian ligament and fixation of the ovary to the ipsilateral round ligament, pelvic sidewall, uterosacral ligament, or posterior uterus, using absorbable or permanent suture [46, 47].

Please see Chap. 5 for more information on the diagnosis and management of ovarian and tubal torsion.

References

1. Hibbard LT. Adnexal torsion. *Am J Obstet Gynecol.* 1985;152:456–61.
2. Beaunoyer M, Chapdelaine J, Bouchard S, Ouimet A. Asynchronous bilateral ovarian torsion. *J Pediatr Surg.* 2004;39:746–9.
3. Templeman CL, Fallat ME. Benign ovarian masses. *Semin Pediatr Surg.* 2005;14:93–9.
4. Hoffman BL, Schorge JO, Schaffer JI, Halvorson LM, Bradshaw KD, Cunningham F, Calver LE. Chapter 18. Anatomic disorders. In: Hoffman BL, Schorge JO, Schaffer JI, Halvorson LM, Bradshaw KD, Cunningham F, Calver LE, editors. *Williams gynecology*. 2nd ed. New York: McGraw-Hill; 2012. <http://accessmedicine.mhmedical.com.ezp-prod1.hul.harvard.edu/content.aspx?bookid=399&Sectionid=41722307>. Accessed 26 May 2015.
5. Pienkowski C, Cartault A, Carfagna L, Ernoult P, Vial J, Lemasson F, et al. Ovarian cysts in prepubertal girls. *Endocr Dev.* 2012;22:101–11.

6. Kelleher CM, Goldstein AM. Adnexal masses in children and adolescents. *Clin Obstet Gynecol.* 2015;58:76–92.
7. Parazzini F, Cecchetti G. The frequency of imperforate hymen in northern Italy. *Int J Epidemiol.* 1990;19:763–4.
8. Banerjee R, Laufer MR. Reproductive disorders associated with pelvic pain. *Semin Pediatr Surg.* 1998;7:52–61.
9. Quint EH, McCarthy JD, Smith YR. Vaginal surgery for congenital anomalies. *Clin Obstet Gynecol.* 2010;53:115–24.
10. Dietrich JE, Millar DM, Quint EH. Obstructive reproductive tract anomalies. *J Pediatr Adolesc Gynecol.* 2014;27:396–402.
11. Laufer MR. Chapter 12. Structural abnormalities of the female reproductive tract. In: Emans SJ, Laufer MR, editors. *Pediatric & adolescent gynecology.* 6th ed. Philadelphia: Lippincott Williams & Wilkins; 2012.
12. Rock JA, Schlaff WD, Zacur HA, Jones Jr HW. The clinical management of congenital absence of the uterine cervix. *Int J Gynaecol Obstet.* 1984;22:231–5.
13. Wierrani F, Bodner K, Spangler B, Grünberger W. “Z” plasty of the transverse vaginal septum, using Garcia’s procedure and the “grunberger modification. *Fertil Steril.* 2003;79:608–12.
14. Garcia RF. Z-plasty for correction of congenital transverse vaginal septum. *Am J Obstet Gynecol.* 1967;99:1164–5.
15. Rock JA, Roberts CP, Jones Jr HW. Congenital anomalies of the uterine cervix: lessons from 30 cases managed clinically by a common protocol. *Fertil Steril.* 2010;94:1858–63.
16. Doyle JO, Laufer MR. Mayer-Rokitansky-Kuster-Hauser (MRKH) syndrome with a single septate uterus: a novel anomaly and description of treatment options. *Fertil Steril.* 2009;92:391.e17–9.
17. Evans TN, Poland ML, Boving RL. Vaginal malformations. *Am J Obstet Gynecol.* 1981;141:910–20.
18. Miller RJ, Breech LL. Surgical correction of vaginal anomalies. *Clin Obstet Gynecol.* 2008;51:223–36.
19. Smith NA, Laufer MR. Obstructed hemivagina and ipsilateral renal anomaly (OHVIRA) syndrome: management and follow-up. *Fertil Steril.* 2007;87:918–22.
20. The American Fertility Society classifications of adnexal adhesions, distal tubal occlusion, tubal occlusion secondary to tubal ligation, tubal pregnancies, müllerian anomalies and intrauterine adhesions. *Fertil Steril.* 1988;49:944–55.
21. Giorlandino C, Bilancioni E, Bagolan P, Muzii L, Rivosecchi M, Nahom A. Antenatal ultrasonographic diagnosis and management of fetal ovarian cysts. *Int J Gynaecol Obstet.* 1994;44:27–31.

22. Brandt ML, Helmrath MA. Ovarian cysts in infants and children. *Semin Pediatr Surg.* 2005;14:78–85.
23. Pasic JC, Billmire DF, Rescorla FJ, Finnell SM, Leys CM. Management of neonatal ovarian cysts and its effect on ovarian preservation. *J Pediatr Surg.* 2014;49:990–3.
24. Bryant AE, Laufer MR. Fetal ovarian cysts: incidence, diagnosis and management. *J Reprod Med.* 2004;49:329–37.
25. Holt VL, Cushing-Haugen KL, Daling JR. Oral contraceptives, tubal sterilization, and functional ovarian cyst risk. *Obstet Gynecol.* 2003;102:252–8.
26. Caruso PA, Marsh MR, Minkowitz S, Karten G. An intense clinicopathologic study of 305 teratomas of the ovary. *Cancer.* 1971;27:343–8.
27. Choudhary S, Fasih N, Mc Innes M, Marginean C. Imaging of ovarian teratomas: appearances and complications. *J Med Imaging Radiat Oncol.* 2009;53:480–8.
28. Medeiros LR, Stein AT, Fachel J, Garry R, Furness S. Laparoscopy versus laparotomy for benign ovarian tumor: a systematic review and meta-analysis. *Int J Gynecol Oncol.* 2008;18:387–99.
29. Shiota M, Kotani Y, Umemoto M, Tobiume T, Hoshiai H. Study of the correlation between tumor size and cyst rupture in laparotomy and laparoscopy for benign ovarian tumor: is 10 cm the limit for laparoscopy? *J Obstet Gynaecol Res.* 2012;38:531–4.
30. Shamshirsaz AA, Shamshirsaz AA, Vibhakar JL, Broadwell C, Van Voorhis BJ. Laparoscopic management of chemical peritonitis caused by dermoid cyst spillage. *JSLs.* 2011;15:403–5.
31. Bal A, Mohan H, Singh SB, Sehgal A. Malignant transformation in mature cystic teratoma of the ovary: report of five cases and review of the literature. *Arch Gynecol Obstet.* 2007;275:179–82.
32. Templeman CL, Hertweck SP, Scheetz JP, Perlman SE, Fallat ME. The management of mature cystic teratomas in children and adolescents: a retrospective analysis. *Hum Reprod.* 2000;15:2669–72.
33. Grapsa D, Kairi-Vassilatou E, Kleanthis C, Dastamani C, Fillipidou A, Kondi-Pafiti A. Epithelial ovarian tumors in adolescents: a retrospective pathologic study and a critical review of the literature. *J Pediatr Adolesc Gynecol.* 2011;24:386–8.
34. Hazard FK, Longacre TA. Ovarian surface epithelial neoplasms in the pediatric population: incidence, histologic subtype, and natural history. *Am J Surg Pathol.* 2013;37:548–53.
35. Eskander RN, Bristow RE. Adnexal masses in pediatric and adolescent females: a review of the literature. *Curr Obstet Gynecol Rep.* 2012;1:25–32.

36. Oltmann SC, Garcia N, Barber R, Huang R, Hicks B, Fischer A. Can we preoperatively risk stratify ovarian masses for malignancy? *J Pediatr Surg.* 2010;45:130–4.
37. Stuart GC, Dawson LM. Update on granulosa cell tumours of the ovary. *Curr Opin Obstet Gynecol.* 2003;15:33–7.
38. Schorge JO, Eisenhauer EE, Chi DS. Current surgical management of ovarian cancer. *Hematol Oncol Clin North Am.* 2012;26:93–109.
39. Bakkum-Gamez JN, Richardson DL, Seamon LG, Aletti GD, Powless CA, Keeney GL, et al. Influence of intraoperative capsule rupture on outcomes in stage I epithelial ovarian cancer. *Obstet Gynecol.* 2009;113:11–7.
40. Spinelli C, Buti I, Pucci V, Liserre J, Alberti E, Nencini L, et al. Adnexal torsion in children and adolescents: new trends to conservative surgical approach – our experience and review of literature. *Gynecol Endocrinol.* 2013;29:54–8.
41. Servaes S, Zurakowski D, Laufer MR, Feins N, Chow JS. Sonographic findings of ovarian torsion in children. *Pediatr Radiol.* 2007;37:446–51.
42. Shalev E, Bustan M, Yarom I, Peleg D. Recovery of ovarian function after laparoscopic detorsion. *Hum Reprod.* 1995;10:2965–6.
43. Santos XM, Cass DL, Dietrich JE. Outcome following detorsion of torsed adnexa in children. *J Pediatr Adolesc Gynecol.* 2015;28:136–8.
44. Abeş M, Sarihan H. Oophoropexy in children with ovarian torsion. *Eur J Pediatr Surg.* 2004;14:168–71.
45. Ashwal E, Krissi H, Hirsch L, Less S, Eitan R, Peled Y. Presentation, diagnosis, and treatment of ovarian torsion in premenarchal girls. *J Pediatr Adolesc Gynecol.* 2015;28:526–9.
46. Pansky M, Smorgick N, Herman A, Schneider D, Halperin R. Torsion of normal adnexa in postmenarchal women and risk of recurrence. *Obstet Gynecol.* 2007;109:355–9.
47. Fuchs N, Smorgick N, Tovbin Y, Ben Ami I, Maymon R, Halperin R, et al. Oophoropexy to prevent adnexal torsion: how, when, and for whom? *J Minim Invasive Gynecol.* 2010;17:205–8.